

How to use the ophthalmoscope : being elementary instructions in ophthalmology ; arranged for the use of students / by Edgar A. Browne.

Contributors

Browne, Edgar A.
University College, London. Library Services

Publication/Creation

London : Trübner & Co., 1876.

Persistent URL

<https://wellcomecollection.org/works/t325dup6>

Provider

University College London

License and attribution

This material has been provided by This material has been provided by UCL Library Services. The original may be consulted at UCL (University College London) where the originals may be consulted.

This work has been identified as being free of known restrictions under copyright law, including all related and neighbouring rights and is being made available under the Creative Commons, Public Domain Mark.

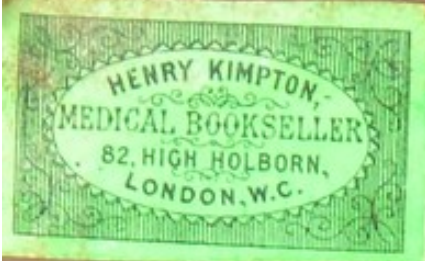
You can copy, modify, distribute and perform the work, even for commercial purposes, without asking permission.



Wellcome Collection
183 Euston Road
London NW1 2BE UK
T +44 (0)20 7611 8722
E library@wellcomecollection.org
<https://wellcomecollection.org>

HOW TO USE
THE
OPHTHALMOSCOPE

EDGAR A. BROWNE



HENRY KIMPTON,
MEDICAL BOOKSELLER
82, HIGH HOLBORN,
LONDON, W.C.



2811015667

OPHTHALMOLOGY HC BROWNE

August 1881

HOW TO USE
THE
OPHTHALMOSCOPE.

PRINTED BY BALLANTYNE, HANSON AND CO.
EDINBURGH AND LONDON

HOW TO USE
THE
OPHTHALMOSCOPE.

BEING

Elementary Instructions in Ophthalmoscopy.

ARRANGED FOR THE USE OF STUDENTS.

BY

EDGAR A. BROWNE,

SURGEON TO THE LIVERPOOL EYE AND EAR INFIRMARY AND TO THE
DISPENSARY FOR SKIN DISEASES ;
FORMERLY DEMONSTRATOR OF ANATOMY IN THE LIVERPOOL
ROYAL INFIRMARY SCHOOL OF MEDICINE.

LONDON:
TRÜBNER & CO., LUDGATE HILL.
1876.

[All rights reserved.]



Digitized by the Internet Archive
in 2014

<https://archive.org/details/b21284994>

PREFACE.

I HAVE endeavoured in the following pages to give a simple account of the mode in which the student should approach the physical diagnosis of eye-disease by means of the ophthalmoscope.

The existing accounts of the instrument are either adapted to the wants of the advanced student, or are imbedded in complete ophthalmic treatises, which, in the present state of science, are far from portable. I have therefore thrown together those elementary facts which are necessary to be known in a sufficiently compact form to serve as a constant companion (or veritable *vade mecum*) to the student in the days of his early difficulties.

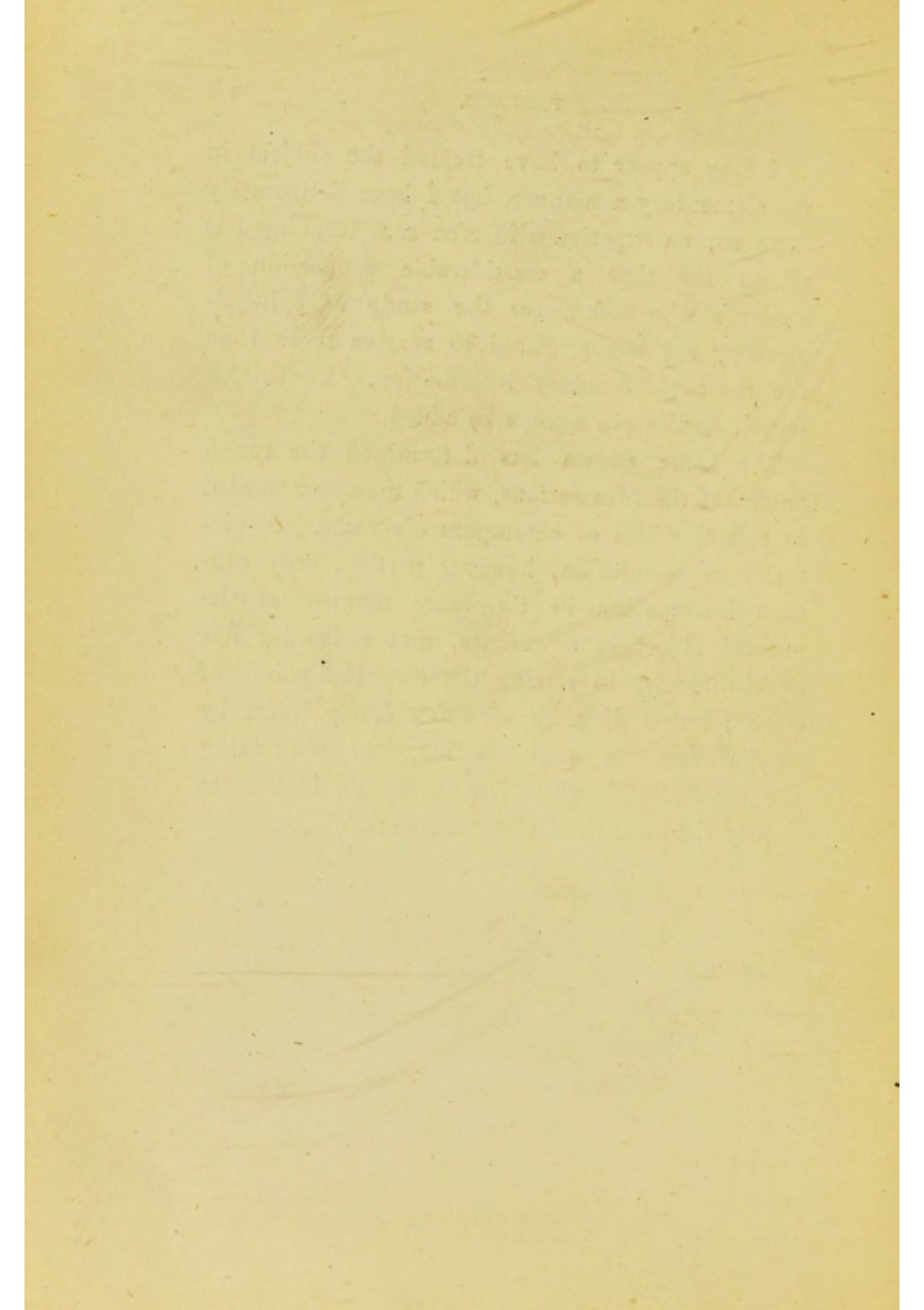
The arrangement has been dictated by what appear from personal experience to be the wants of the average student. He is generally anxious to learn, but distracted by a multitude of facts and theories, for the most part dimly and phantasma-

gorically seen. Harassed by the desire of acquiring a full complement of practical knowledge in the brief periods between the dreaded crises of his examinations, he (not unnaturally) loves short cuts, and is especially addicted to studying full-blown examples of disease rather than acquiring the art of observing the separate facts upon which the power of accurate diagnosis is dependent. For one who will patiently study the healthy structures of the eye, twenty will be found eager to flash the light unsteadily in front of a case of glaucoma, or other disease with a definite name, which may seem likely to be required of them.

I have endeavoured to reverse the process, and to inculcate a sounder, and, in the end, a shorter method of work. My scheme is therefore strictly limited to counselling the student how to acquire the art of seeing and the power of recognising and localising the commonest deviations from the normal standard in the individual structures. Furnished with this information, the student will proceed to the study of the separate diseases with the aid of one of the excellent systematic works at present available. To any of these my little book may be considered as bearing the same relationship that a dissecting-room manual does to the treatise on anatomy.

I may appear to have treated the subject in too elementary a manner, but I have deliberately done so, as experience in *viva voce* teaching has shown me that a considerable proportion of students who commence the study of ophthalmoscopy are not prepared to receive more than the most rudimentary information. To this, if sound, details can always be added.

The same reason has determined the rough nature of the illustrations, which may be regarded as reproductions of extempore diagrams. A pictorial representation, however perfect, only conveys information in the same manner as the natural object it represents, and a learner has equal difficulty in seizing the essential points of either; but a diagram of a few hasty lines, by emphasising one dominant fact, and suppressing the less material, will often convey an idea more clearly than the most elaborate work of art.



CONTENTS.

SECTION I.

OPTICAL PRINCIPLES.

	PAGE
Light—General Statements	1
Reflection	4
By Curved Surfaces	6
Focus—Real, Virtual, Principal, Conjugate	7
Refraction	9
By Prisms	12
By Lenses	14
Focus of Lenses	15
Images	19
Formation by Pinhole	20
„ by Mirror	21
„ by Lenses	22
Eye as an Optical Instrument	25
Why the Pupil of the Eye appears Black	30
How can the Fundus be rendered Luminous?	33
The Ophthalmoscope—Erect Image	35
„ Inverted	37

SECTION II.

Ophthalmoscope—Description of	PAGE 39
„ Mode of Using	41
Oblique Illumination	49

SECTION III.

Appearances of Healthy Structures	51
Media	52
Optic Disc	52
Vessels	54
Retina	55
Choroid	56


SECTION IV.

Appearances of Disease, &c.	57
Plan of an Examination	58
The Media	60
To Determine the Depth of Opacities in the Media	61
Opacities in Cornea and Lens	63
„ in Vitreous Humour	66
To Ascertain the Refraction of the Eye	68
Conical Cornea	76
Astigmatism	77
Optic Disc	80
Alterations in Colour	80

CONTENTS.

xi

	PAGE
Alterations in Surface-Level	82
Excavations { Physiological	83
{ Atrophic	85
{ Glaucomatous	85
Elevation—The Swollen Disc	86
The Margins of the Disc	91
The Vessels	96
The Retina	97
The Choroid	103
Table of Common Appearances	105



THE OPHTHALMOSCOPE.

THE student who desires to use the ophthalmoscope to good purpose must acquire (1) some knowledge of the optical principles upon which it is constructed, (2) the knack of using the instrument, and (3) the power of interpreting what is seen.

The two first steps may be easily and rapidly acquired by a moderate amount of attention; the third can only be mastered by reiterated personal observations and comparison of numerous facts, in the same manner as any other method of physical diagnosis.

SECTION I.

OPTICAL PRINCIPLES.

The laws of light necessary to be understood are a few of those concerned in reflection, refraction, and the formation of images. The student is

strongly advised to carry out the simple experiments mentioned in the text, as the best mode of comprehending the facts, and impressing them on the memory.

Every object we can see owes its visibility to rays of light proceeding from it to the retina.

The bodies which emit rays of light, as the sun, a candle-flame, &c., are termed *luminous*; those which only reflect rays, as the moon, a clock-face, a mirror, &c., are *illuminated*.

A single ray of light cannot be obtained, but a number together, termed a beam or pencil, may be easily demonstrated. Completely darken a room facing the sun, bore a small hole in the shutter, and a vivid, perfectly straight strip of light will be seen traversing the darkness, if the air of the room contain particles of solid matter, like dust or tobacco-smoke. The path pursued by the rays, whether from luminous or illuminated bodies, is a straight line, never a curve.

Luminous bodies are supposed to be composed of an infinite number of luminous points, giving off rays in all directions. From any one point in a luminous surface, the individual rays are separated in proportion to the distance from their origin. In other words, all rays of light in Nature are divergent.

Hence the divergence of rays received on a given surface is in proportion to the distance of that surface from the point whence the rays come.




Fig. 1.

In fig. 1, let the perpendiculars Pp Rr represent two surfaces of equal dimensions (quarter of an inch). Simple inspection shows that the divergence of the rays proceeding from a luminous point L to the surface Pp is greater than the divergence of the rays which are received on the surface Rr . If the student will enlarge the diagram by making the distance between L and Rr equal to twenty-four inches, keeping the other dimensions exactly the same, he will find the divergence of the lines Lr LR so slight, that on isolating any small portion they will almost appear parallel.

Hence it will be easily understood that any two rays of light from a luminous point in the sun, distant more than ninety-four millions of miles, and entering the pupillary aperture,—less than a quarter of an inch in diameter,—must form with one another

an inappreciable angle, and such rays are therefore always assumed to be, and treated in ordinary calculations as, parallel.

In physiological optics all rays proceeding from a distant source are said to be parallel, and those from a near to be divergent.

A ray of light moving through a homogeneous medium, such as the ether of space, continues in a straight line for ever. But if it meet with another body, it may either be absorbed or made to change its course at an angle. If the opposition be so great that it cannot pass through the interposing object, it is reflected; if the substance be traversible, it is refracted.

Reflection varies in degree, according to the quality of the surface upon which the light falls; rough, dark-coloured surfaces reflect light very imperfectly; light-coloured or polished surfaces reflect very perfectly.

Let the student in his darkened room hold a piece of dark cloth at an angle of 45° to the beam of light admitted by the minute hole in the shutter; it will disappear at the cloth. But let him place a looking-glass in the same position, and the beam will be seen to pass onwards at right angles to its original course.

If now a ruler be placed perpendicular to the surface of the mirror at the point where the beam

impinges, it will divide the angle made by the beam into two equal parts. In fig. 2, SAC represents the angle made by the incident and reflected rays, and the angles SAR RAC must be each equal to half a right angle.

If the mirror is more inclined, the angles

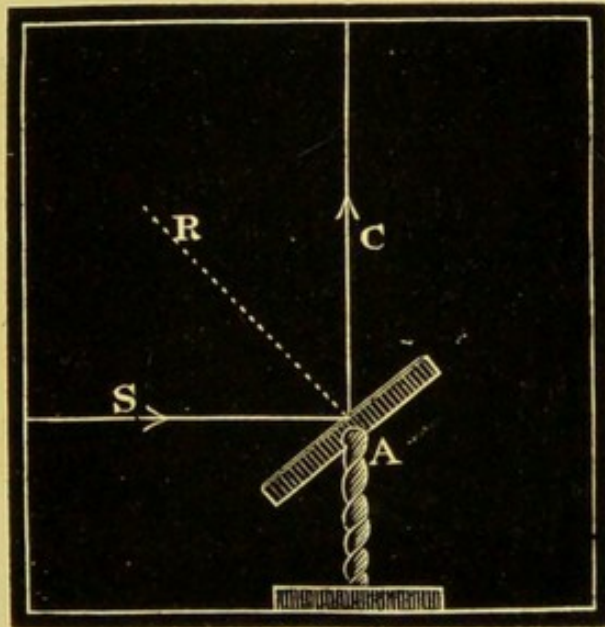


Fig. 2.

(with the ruler still placed perpendicularly to the surface) will be larger ; if the inclination is diminished, the angles will be smaller, but the angle on one side of the ruler is always equal to the angle on the other, or, stated as a law : The angle of reflection is equal to the angle of incidence. It will also be observed that the incident and reflected beams are in the same plane, which is at right angles to the plane of the mirror.

Reflection from Curved Surfaces.

A curved surface may be regarded as a number of infinitely small planes inclined to one another. Each plane would reflect a ray of light according to the law above stated. The mode in which a concave surface reflects can be easily understood by enlarging a few

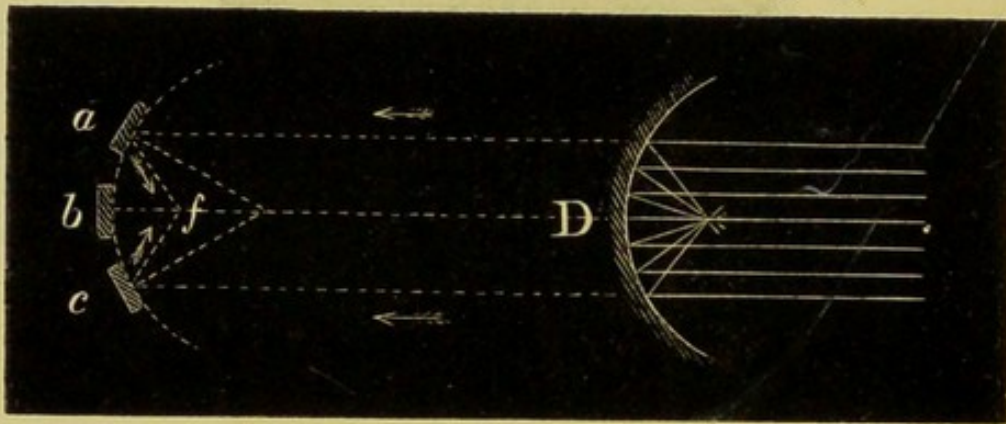


Fig. 3.*

of its planes, as shown by the dotted lines in fig. 3.

Consideration of the angle of incidence for each shows that parallel rays falling upon three planes inclined to one another, as *a*, *b*, *c*, would be reflected to a point situated as at *f*, and what is true of the three is approximately true of the infinity of surfaces contained in the curved surface at *D*.

Parallel rays falling upon a concave mirror are reflected to a point situated upon the axis.

* Practically the mirror would have to be of less curvature in order to bring rays to an approximate focus.

If the concavity is the segment of a sphere, rays issuing from a luminous point situated at its centre would be reflected back upon themselves, as the radii are obviously perpendicular to all parts of the surface. But if the impinging rays are parallel, they would be reflected to a point situated at about half the length of the radius from the mirror surface (by construction of fig. 3), and *vice versa* divergent rays from a point at f would be reflected as parallel.

This point is termed the *principal focus* of the

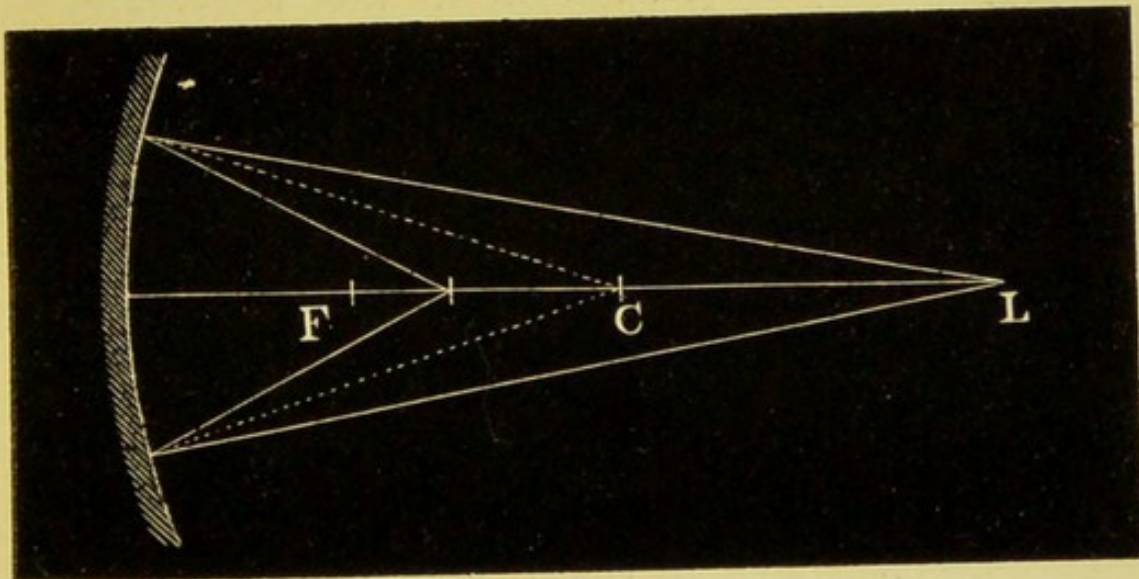


Fig. 4.

mirror. But if the incident rays are already divergent, they would be reflected to a point beyond the principal focus, and it is obvious the closer a luminous point L approaches the mirror (with consequent increasing divergence of rays), the further F will recede. And if the luminous

point were to be situated at F, the rays would be reflected to L. These two points are called *conjugate foci*, and have a constant relationship, so that (with the principal focal length known) when the distance of one is given the other can be found by a mathematical formula. Their relative positions may be easily remembered.

(α) If the luminous point is at the centre, the conjugate focus is also at the centre.

(β) If between principal focus and centre, the conjugate is beyond the centre.

(γ) If beyond the centre, the conjugate is between the principal focus and centre.

With convex mirrors all the above facts are reversed, but require attention as introducing a new and important principle. Hitherto we have followed the rays, and seen them converge to a real or positive focus. In the case of a convex, spherical surface, parallel rays are rendered divergent, and therefore no positive or real focus is formed. But if the divergent rays are produced by imaginary lines on the far side of the mirror, they will be found to meet in a point corresponding to the principal focus of a concave mirror of the same curvature.

As the focus is imaginary, and on the opposite side of the mirror from the actual rays, it is termed *negative*, and as the divergent rays have the

same optical properties *as if* they came from the negative point F (and not as they really do from the incident parallels), the focus is termed *virtual*.

The terms positive and negative, real and

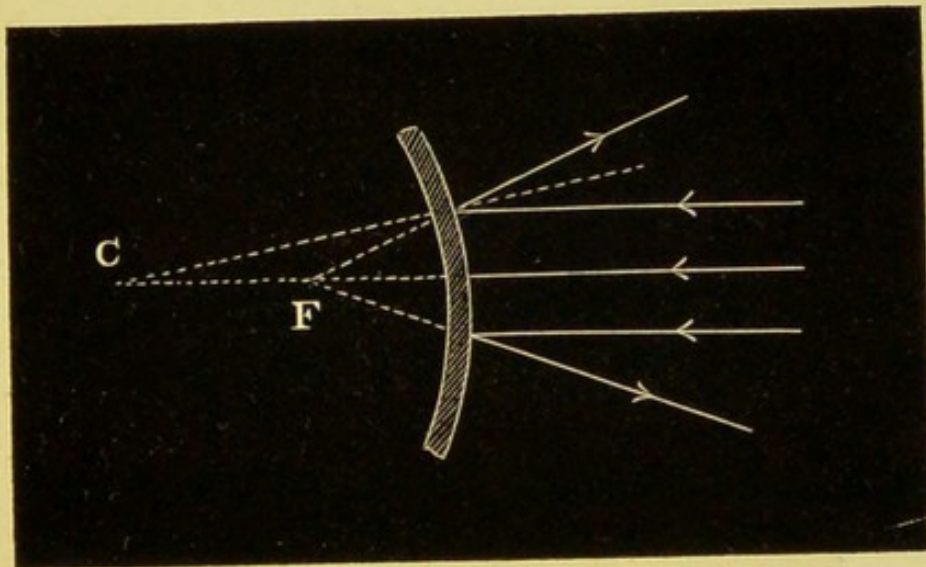


Fig. 5.

virtual, principal and conjugate, are of frequent occurrence, and must be thoroughly understood.

Refraction.—When a ray of light passes obliquely from one medium to another, as from the ether of space into air, or from air into water or glass, it is bent so that its course in the second medium is at an angle with its course in the first.

If the ray falls perpendicularly to the surface, separating the two media, it continues its original course.

Stand four microscopic slides perpendicularly on the page of a book as it lies flat on the table. Now read through them. The lines appear shifted to a lower level as they pass behind the glass. Thus:—

<p>“For we which Have eyes to</p>	<p>now behold these p wonder but lack ton W.</p>	<p>resent days gues to praise.” <i>Shakespeare.</i></p>
---------------------------------------	--	---

Inspection of fig. 6 shows a ray passing obliquely from the book to the surface of the

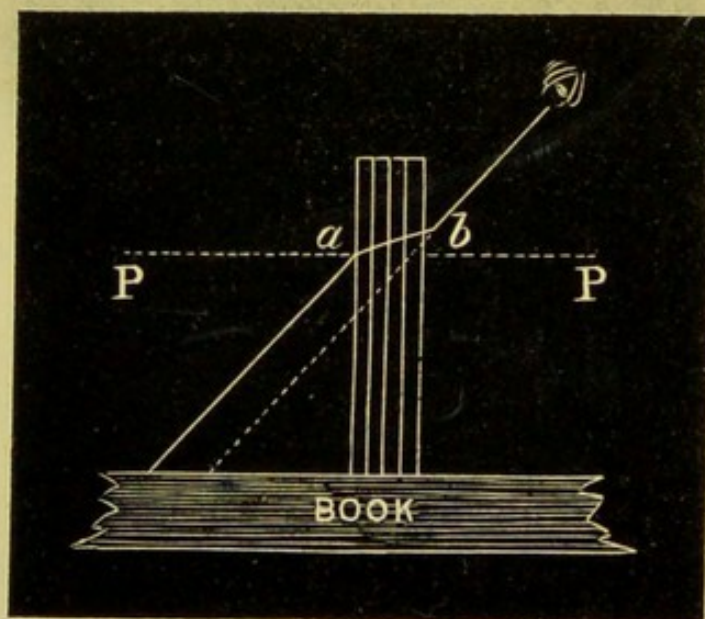


Fig. 6.

glass, where it is bent in the direction ab . On emerging from the surface at b , it is again refracted in a direction parallel to its original course. If the ray is produced as shown by the

dotted line, it will seem to come from a position nearer to the glass than its real starting-point, and will have the optical value of coming from that position; so that any given word seen through the glass would be virtually lower than the rest of the line.

The ray passing from the air to glass is shown as bent towards the perpendicular PP, and this is the general rule when light passes from a *rarer* to a *denser* medium.* The ray passing from glass to air is shown bent from the perpendicular, and this is the general rule with the passage from a *denser* to a *rarer* medium.

In all ordinary cases of refraction, the incident and refracted rays are in the same plane. It is easy to see that if the glass be inclined so that the ray coincides with the perpendicular, no refraction is possible, as it cannot be bent towards a line with which it is already identical, and on reading, no distortion of the lines will be apparent.

The amount of refraction varies with the medium and the obliquity of the rays, but is constant for the same medium at the same obliquity. That is to say, a ray falling on a sheet of plate-glass at an angle of 45° would be less refracted than a ray falling on the surface

* There are some few exceptions to this rule—*e.g.*, oil of turpentine is less dense, but more refractive than water.

of a diamond at the same angle. A ray falling on glass at 60° would be less refracted than the one at 45° . A ray falling on diamond at 60° would be less refracted than the one at 45° , but more than the ray at 60° on glass. And so on; the same proportion being always maintained till the ray falls perpendicularly to the surface, where it undergoes no refraction either by glass or diamond. The angle is measured by a method involving a slight acquaintance with mathematics for its comprehension.

If the surfaces of a refracting substance are inclined to one another, as in a prism, it is obvious a ray can never be perpendicular to more than

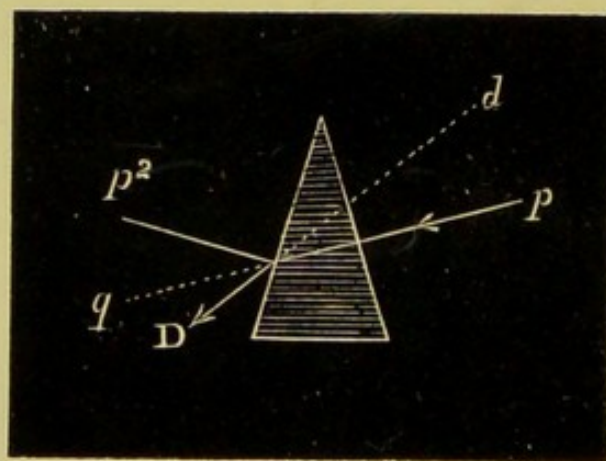


Fig. 7.

one surface at a time. A ray can therefore never fall upon a prism without being refracted.

Fig. 7 shows a ray from p falling perpendicularly to the first surface of the prism, and it

therefore undergoes no refraction; and, if the second surface were parallel to the first, the two perpendiculars would coincide, and the ray undergo no deviation. But on emerging from the second surface, it comes into relation with the second perpendicular p^2 , from which it is refracted according to the law of passage from a denser to a rarer medium. A ray from p would therefore not proceed to q , but to D , and would virtually come from a point situated as at d .

Rays of a moderate degree of obliquity are refracted towards the base of a prism, and this fact will enable us to understand the laws of refraction by curved surfaces, on which the main

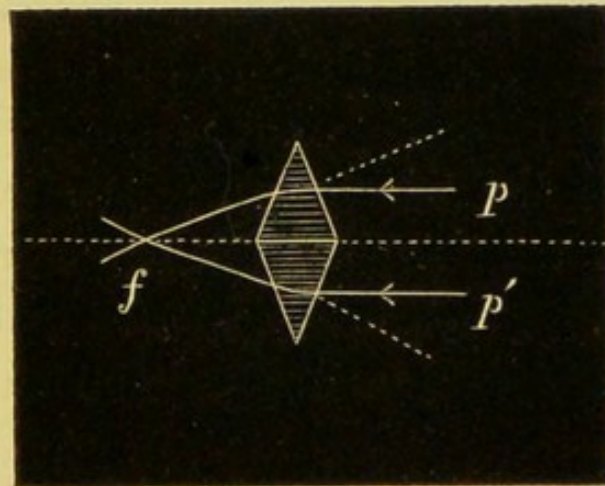


Fig. 8.

properties of the eye as an optical instrument depend.

If two prisms are placed base to base, any two parallel rays pp' falling upon corresponding points

in the surfaces, being equally refracted toward the base, would meet and cross at some point situated as f on the far side. This point may be termed the focus for the two rays; and as the reverse of every optical fact holds good, any two divergent rays proceeding from a luminous point at f would, in passing through the prisms, be rendered parallel as pp' .

If the surfaces of the prisms, instead of being plane, were curved equally from the centre to the edge, they would form an optical contrivance called a lens. When thickest in the centre with two curved surfaces, a lens is biconvex.

As a curve can be resolved into a number of small planes, it follows that a biconvex lens may be regarded as a number of truncated prisms arranged with their bases towards the centre. Prisms so arranged would refract parallel rays towards their bases; hence, parallel rays falling on one surface would be rendered convergent, and tend to meet in a point at some distance from the second surface. When the surfaces of a lens are segments of a sphere it is called a spherical lens.

Fig. 9, Cc are the centres of curvature.

A straight line AA drawn through the centre of the lens, and perpendicular to both surfaces, is the *principal axis*.

Oblique lines sa , sa , passing through the same point, are the *secondary axes*.

Rays of light coinciding with principal or secondary axes undergo no refraction—all other rays are refracted. Parallel rays are rendered convergent by a biconvex lens, and meet in a

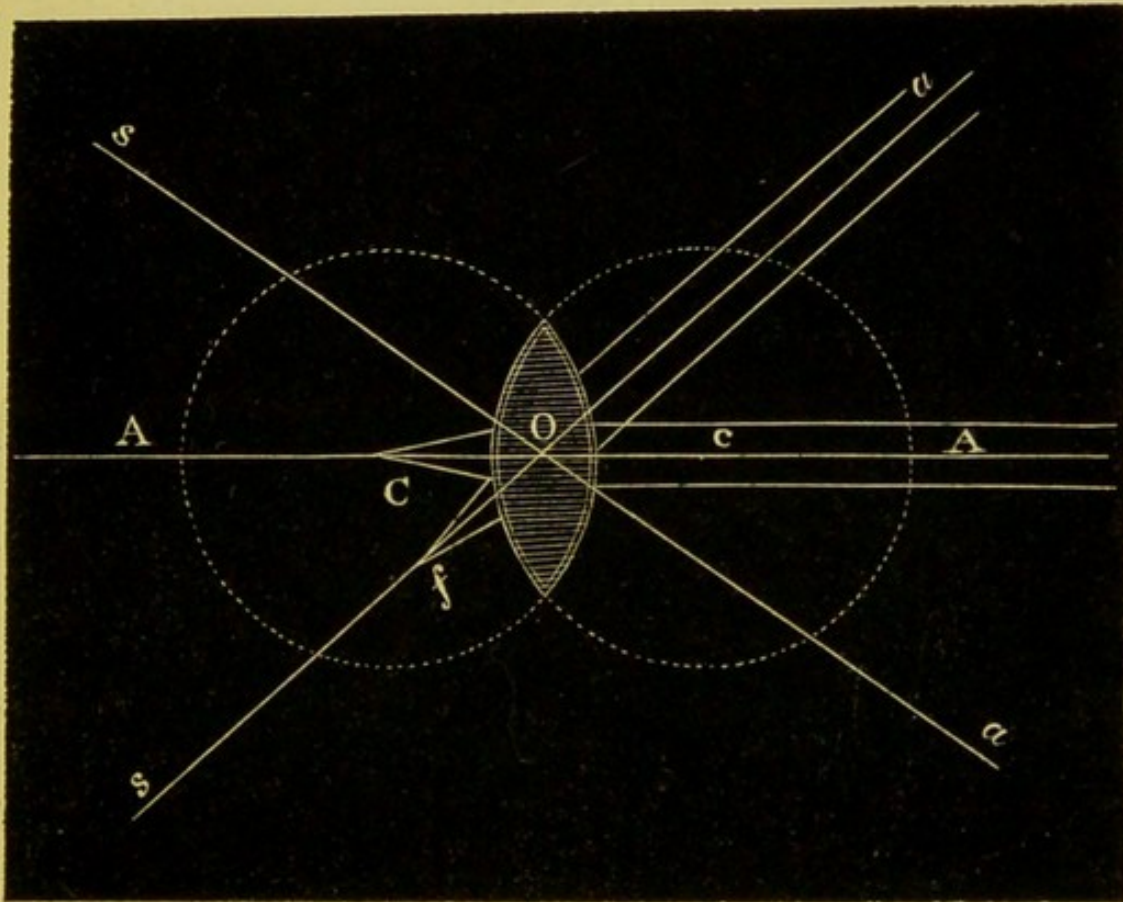


Fig. 9.

point at a fixed distance from the second surface.

Parallel rays are brought to a focus in a point on the axis to which they are parallel, if with the principal on that axis as at C , if with a secondary on that axis as at f .

The focus for parallel rays is termed the *principal focus*, and its distance from the optical centre of the lens its *principal focal distance*.

Lenses are spoken of, according to the focal lengths, as one, two, or three-inch lenses.

The divergent rays from a luminous point at the principal focus are rendered parallel; but rays from a more distant point are less divergent, and the refractive power of the lens is more than sufficient to render them parallel.

They are, therefore, rendered convergent in a point situated at a certain distance on the other

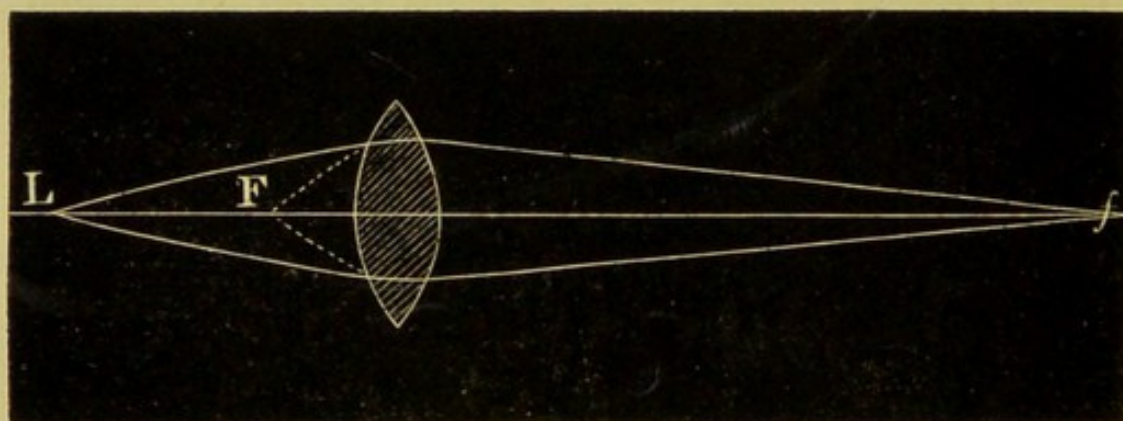


Fig. 10.

side of the lens. The closer the luminous point L approaches F, the further f will recede; and *vice versa*.

As the relationship of these is constant and interchangeable, they are termed *conjugate*; both are positive and real.

The rays from a luminous point closer than

the principal focus are too divergent to be rendered parallel by the refractive power of the lens, and consequently emerge from the other side divergent, though in a less degree than before passing through lens.

Fig. 11 shows rays diverging from a luminous

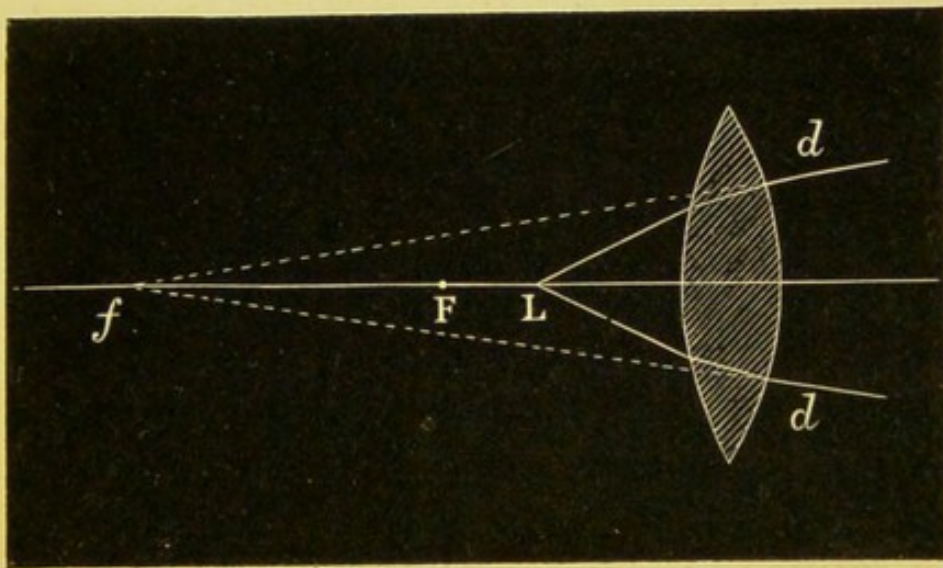


Fig. 11.

point L, situated on the axis between the lens and its principal focus F.

If the resulting diverging rays *dd* are produced by imaginary lines, they will meet in a point situated as at *f*, and the lines *dd* will have the optical value as if they proceeded from *f*, and not, as they really do, from L. The closer L is brought to F the further *f* recedes, and *vice versa*.

A luminous point situated as L has, therefore, a conjugate focus on the same side of the lens. It has no real existence, but represents the point

B*

whence the rays seem to come—it is negative or virtual.

A concave lens is thicker at the edge than at the centre, and may be regarded as an infinite number of truncated prisms with their bases turned away from the centre. As parallel rays would be refracted towards the bases, it follows that a concave lens renders parallel rays divergent.

A concave lens has no real or positive focus. But if the directions of the divergent rays are produced backwards, they will meet in a point on the axis called the principal focus. As the divergent rays have the optical value of proceeding from it, and not from the incident parallel rays, it is

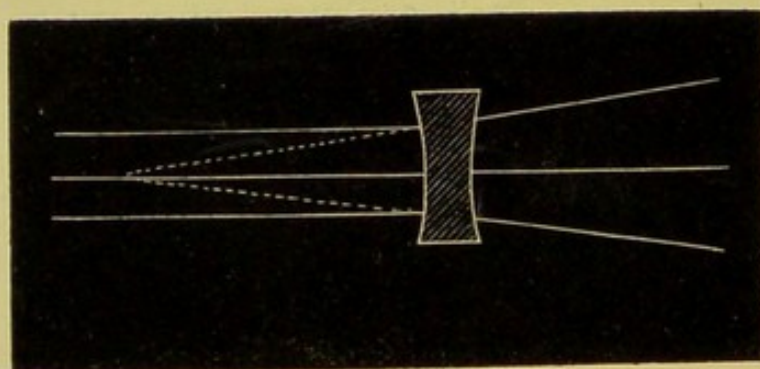


Fig. 12.

virtual or negative. Concave lenses are spoken of, according to their (negative) focal length, as one, two, or three, &c., inch lenses.

We are now in a position to understand the formation of images.

When you look into a looking-glass you see yourself; you can judge of your complexion, the state of your hair or clothes, or you can assume attitudes with the certainty that whatever you see in the glass is an exact optical reproduction of yourself. But you are aware that your *simulacrum* has no other existence, can neither touch nor be touched, is neither hot nor cold, solid nor gaseous, nor can it convey any impression to any other sense than sight—it is your *image*.

If you place a sheet of white paper six inches distant from a candle-flame, with a cardboard screen exactly midway between the two, and make a pin-hole in the screen, you will see the image of the flame on the paper. Its colour, shape, and movements are accurately reproduced, but it is inverted.

Inspection of fig. 13 shows numerous divergent rays proceeding from luminous points in the flame F. Most of them are intercepted by the screen, and it is plain (as they can only proceed in a straight line) that not more than a few rays from each point can pass through the pinhole at *c*, and must necessarily cross there. The ray from the uppermost point of E becomes the lowermost on the screen P, and *vice versa*; and as the rays from the right cross over to the left, and those from the left to the right, it follows that the image will be completely reversed.

The figure shows that if the screen is exactly midway between the candle and the paper, the image and the flame will be of the same size. But if you place the paper at a greater distance (say

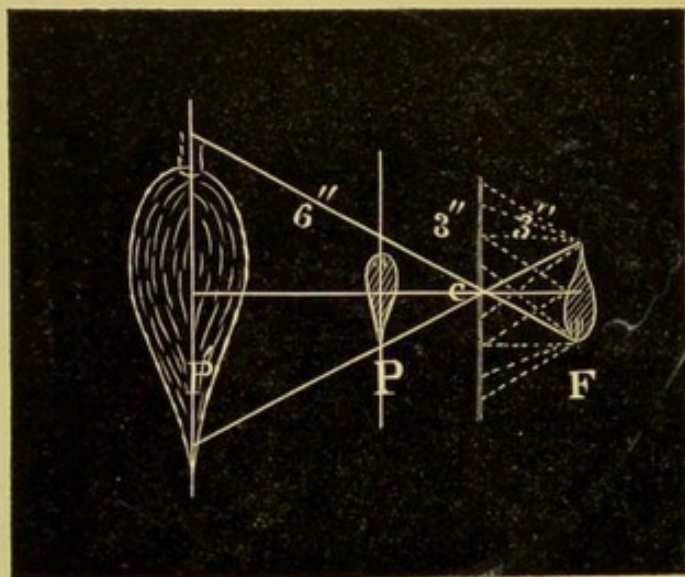


Fig. 13.

nine inches), the image will be enlarged, as at P'; if nearer, it will be decreased. In trying this experimentally, you will find the smaller the image the brighter it will be.

If you make a second pinhole in the screen, two images will be formed on the paper; with a third, three, and so on. If you make a number of pinholes close together, a corresponding number of images will be formed, but they will overlap, and present only the appearance of a blurred spot of light.

You will therefore have no difficulty in under-

standing that the reflection from a sheet of paper (or any visible object) is composed of the rays proceeding from a number of overlapping images of the sun, candle-flame, or other source of illumination. With a minute aperture in a screen all superfluous rays are cut off, and each point of the flame is represented by a point in the image, and it is therefore clearly defined.

You will have noticed that whereas the image of the flame appears *on* the screen and inverted, your own image appears to be *behind* the looking-glass and erect.

Fig. 14 shows the divergent rays from a point A

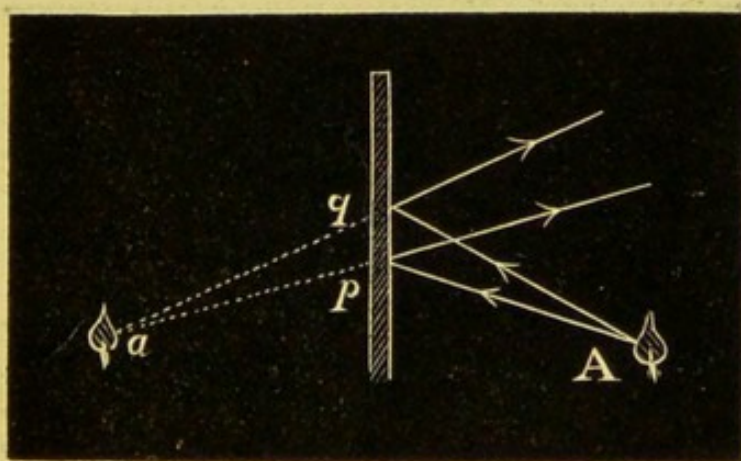


Fig. 14.

falling upon a plane mirror at pq . As the angle of reflection is equal to the angle of incidence, the rays will continue to diverge at the same rate as they did before reflection. If the lines are produced, they will be found to meet at a point a ,

exactly the same distance behind the mirror as A is in front of it. The same is true of rays proceeding from other points. Hence the reflected rays seem to come from the points behind the mirror, and not, as they really do, from those in front. Such an image is termed *virtual*, in contradistinction to one that can be thrown on a screen and is termed *real*.

The chief use of lenses is to produce images. Make the aperture in the screen the size of a shilling, and fasten a two-inch convex lens in it; place the flame at six inches, and as you move the sheet of paper, you will find at a distance over

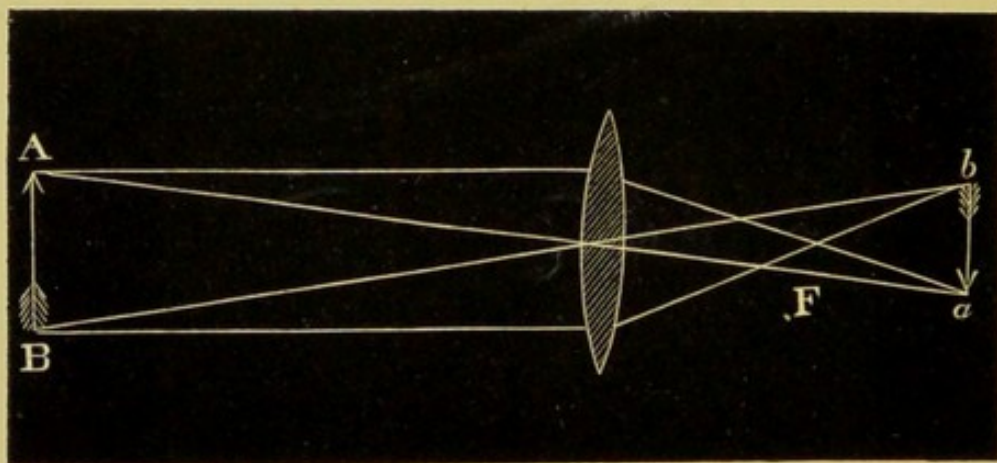


Fig. 15.

two inches from the lens you can obtain a clear, inverted and diminished image of the flame.

In fig. 15 let AB represent two points in front of the lens, at a distance greater than its focal length. To understand the formation of the

image, draw a line, parallel with the principal axis, from A, and a similar line from B. They will be refracted, and cross at F, the principal focus. Now from the same points draw lines corresponding with the secondary axes; they undergo no refraction, but meet and cross the former rays at *ab*. In other words, *ab* are the conjugate foci to AB.

From what has been said before, you can understand that the image of A will be formed at *a*, and of B at *b*, and so for other points in the object.

This image is inverted, and as it can be received on a screen, or seen suspended in the air, it is a real image. From the construction of the figure it is seen that the image is diminished. As *ab* are the conjugate foci of AB, it follows that if *ab* represented points in an object, the image would be formed at AB and enlarged.

Hold a (two-inch) convex lens at (six inches) a greater distance than its focal length from this page. The letters will appear inverted and diminished, and as if printed on the surface of the lens. It is really in the air, and its formation is represented by fig. 15. This inverted aerial image is of the utmost importance in practical ophthalmoscopy, and must be further studied.

Move the lens to double its focal length (four inches); you will observe the print is still inverted,

but the letters are no longer diminished, but of their natural size. At three inches, the letters are magnified, and continue to increase as you approach the principal focus (two inches), where you will notice the inverted image disappear. On approaching the lens with your eye you will be able to read, as the letters are in their natural position. The page being at the principal focal length (p. 5), you will remember the rays issue from the lens parallel, and have the optical value of proceeding from an infinite distance.

Now hold the two-inch lens at a less distance ($1\frac{1}{2}$ inches) than its focal length. The print will appear

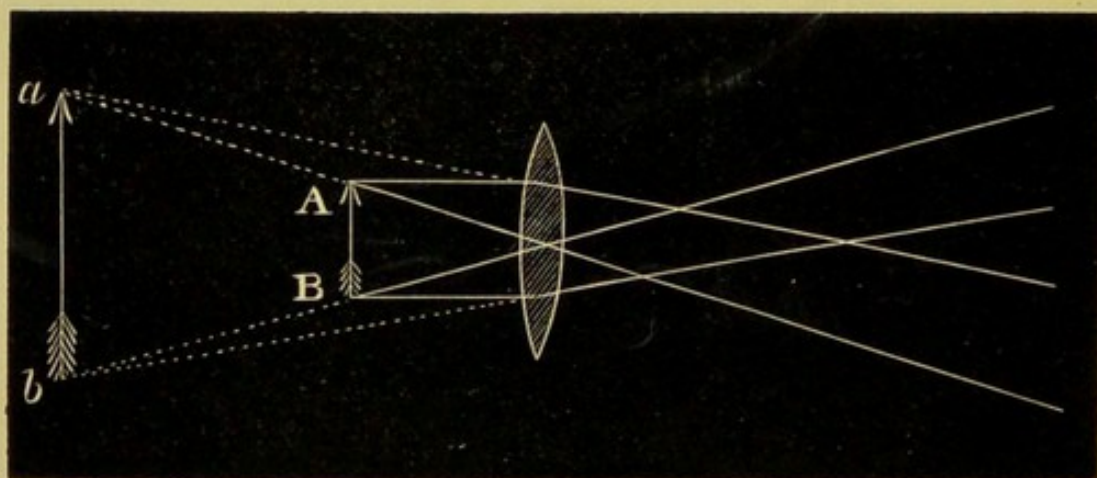


Fig. 16.

enlarged and erect. With a flame at the same distance no image can be thrown on a screen, but an enlarged image of the flame can be seen on looking through the lens. A convex lens gives an enlarged virtual image of an object placed

within its principal focal length. Inspection of fig. 16 shows divergent rays from a point A, continuing to diverge, though to less extent, after passing the lens. If produced backwards, they will have the optical value of coming from a point at *a*, further from the lens than the object. The same is true of divergent rays from B, which seem to emerge from a point at *b*. In other words, *a* and *b* are the virtual conjugate foci of AB, and the position of the image can be found by determining the conjugate foci for a few of its points.

The eye looking through the lens receives the divergent rays, not as from the points whence they really issue, but as coming from the virtual conjugate foci of these points, and therefore sees an enlarged, erect, and virtual image behind the object.

The foregoing facts may be thus tabulated. The image produced by a convex lens varies according as the object is placed at

More than Double Principal Focus.	Double the Principal Focus.	Between Principal Focus and Double.	The Principal Focus, or within.
Inverted. Real. Diminished. Same size. Magnified.	Erect. Virtual. Magnified.

We are now in a position to consider the eye as an optical instrument.

The cornea, aqueous and vitreous humours, with the crystalline lens, are the refractive media of the eye. Combined, they represent a bi-convex lens of (rather less than) one-inch focus. The optical centre of the combination is a little behind the crystalline lens. The retina is a sensitive screen placed at the focus (we shall hereafter find exceptions to this rule).

Our perception of the outer world is due to the formation of real inverted images on the retina.

We are unconscious of the inversion as we are of the music of the spheres.

To see objects distinctly, their images must be accurately focussed on the retina.

Hence it is obvious that to compare the figures on a church-clock a hundred yards off with those on our own watch at eight inches—the rays from one being parallel, from the other divergent—some power of adjustment must be possessed by the eye.

Supposing parallel rays brought to a focus on the retina, divergent rays would be focussed behind it (*v.* Conjugate Foci), and therefore the lens must either be removed further from the retina, or be of a shorter focus by becoming more convex. It has been proved experimentally that the latter process actually takes place.

In focussing near objects, the crystalline lens is

rendered more convex, the greater change taking place on the curve of the anterior surface. This power of altering the focal length to meet requirements is called the *accommodation* of the eye.

Let us assume you can see the number on a door across the street thirty or forty yards off, and can read print at seven inches. What increase in convexity has the crystalline lens undergone? You can paralyse your accommodation by dropping a little *liquor atropiæ sulphatis* on to your conjunctiva. In half an hour the pupil should be widely dilated, and you will be able to see as clearly as ever at a distance if you shade your eye to avoid dazzling by bright light.

But hold a book at seven inches—the letters are blurred and confused owing to the circles of dispersion formed on the retina.

Place a convex lens of seven inches focus before the eye; you can now read distinctly, but distant objects appear confused.

Hence, to accommodate from distance to seven inches, an increase in convexity equivalent to the addition of a seven-inch lens is required.

When the crystalline is at its least convexity, the eye is said to be accommodated for its *far point*.

When the crystalline is at its greatest convexity, the eye is said to be accommodated for its *near point*.

The distance between the two points is termed the *range of accommodation*.

In early life the near point lies at about three inches, but the power of accommodation diminishes with age. You observe old people either hold a newspaper at arm's length, or supplement the defect in accommodation with convex spectacles.

When the near point has receded beyond eight inches, the eyes are said to be *presbyopic*.

In ophthalmoscopic examinations the patient is assumed to relax his accommodation to the utmost, *i.e.*, for his far point. The accommodation of the surgeon has to be varied according to circumstances.

We estimate the size of objects by the angles enclosed by the two lines drawn from the extremity of the object through the optical centre of the eye on to the retina. Our impressions of size, therefore, depend partly on the actual magnitude of the object, and partly on its distance from the eye. Fig. 17 makes this evident. The lines drawn from the extremities AB of an object through the optical centre C enclose the angle subtended by the arc *bq*, and *bcq* is the visual angle of AB. But if an object of same size is at a greater distance, as XY, the lines passing through the optical centre would only enclose the smaller angle *xcy*.

In order that an object placed at the same distance as XY should seem as large as AB, it would require to have the dimension pq . As a

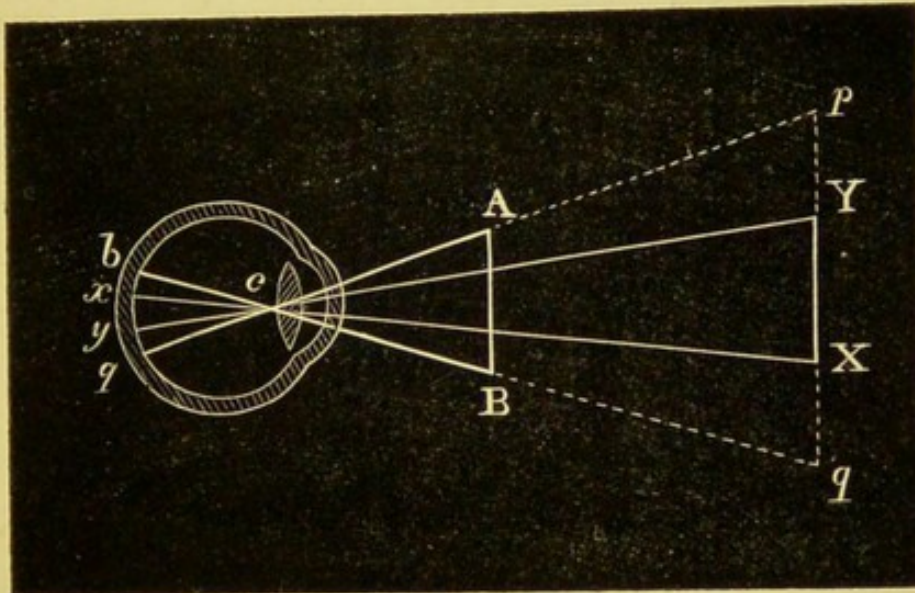


Fig 17.

familiar illustration of this fact, a threepenny-piece held at arm's length will appear as large as the moon's disc, which has an actual diameter of more than 2000 miles.

XY is therefore said to be viewed under a smaller angle than AB, and it would appear to be a smaller object.

By the unconscious estimation of objects of known size, such as men, sheep, carts, &c., we estimate distance. If AB and XY represented two men, we should judge the one to be farther off than the other by his inverted image occupying less space on our retina. It has been experimentally determined that (with the average acute-

ness of vision) we require letters to be seen under an angle of five minutes, and the strokes composing them at an angle of one minute, in order to read type fluently. Magnifying-glasses are contrivances for increasing the angle under which we view objects; as in telescopes, where the smallness of the angle is due to distance, or microscopes, where it is due to actual minuteness of the object.

Why the pupil of the eye appears black.

When we look into the eye through the pupil, we can see nothing. We know that the humours are perfectly transparent, that the injected choroid is red, and that the sclerotic behind all is brilliantly white; and yet we see nothing but inky blackness. We may move our head where we please, we may hold our light where we please, the result is the same—the interior of the eye appears pitch dark.

Take a common chip ointment-box rather more than an inch deep, blacken the inside with ink or paint, paste some printed matter on the inside of the bottom, cut a round hole half an inch in diameter in the lid, which replace.

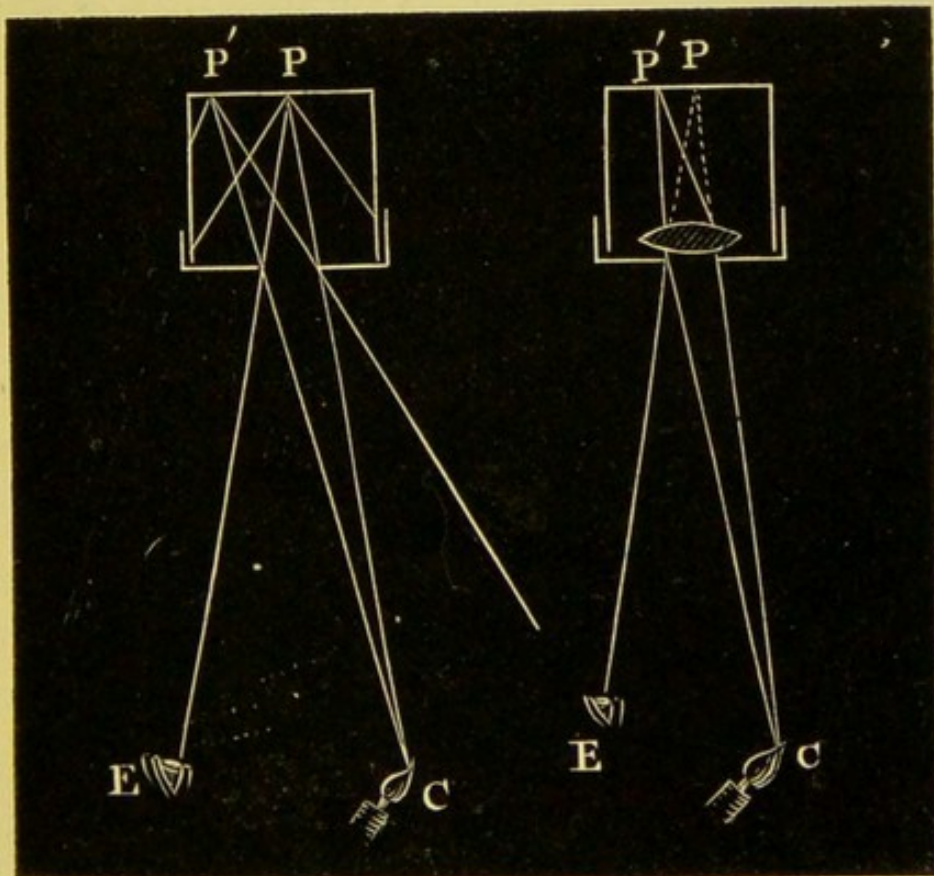
Now direct the light of a candle into the hole, and you will find with a little manœuvring you can read the print—the paper looks white and the letters black as usual.

But place a convex lens, one-inch focus, behind the opening, and you will find you can no longer read, you cannot even see the white paper—the opening looks black like the pupil.

The cause of this change is obviously the lens.

Examine figs. 18 and 19.

In fig. 18 the divergent rays passing from the candle C on to the surface PP' are scattered in all directions from the illuminated surface; those



Figs. 18, 19.

which strike the blackened interior of the box are absorbed, while others emerge through the hole in the lid as a divergent pencil. An eye placed

at E would therefore perceive the illuminated letters at P.

But in fig. 19 the rays, instead of passing in straight lines to the inner surface of the box, are refracted by the lens to P', and it is quite obvious that in returning from P' they will be again refracted on passing through the lens, and will converge to the point C whence the light came. No rays will pass in the direction PE.

Inspection of fig. 18 shows a pencil of straight ingoing rays and straight outcoming rays separated by an angle, and it is clear the diameter of the cone of light having its apex at P increases with the distance from the box. In our experiment the cone is about six inches in diameter at a foot from the bottom of the box. Thus there is plenty of room for the eye to receive the outcoming rays without the head of the observer intercepting the light from the candle, as it must do if the diameter of the cone were less than the distance between the pupil and the temporal side of his head.

The lens accomplishes this diminution. Inspection of fig. 19 shows a bent ingoing ray and a bent outgoing ray, and the refraction of the two being equal, a cone of light is formed having its apex at the luminous point C with the base at the lens. In this experiment the greatest width of the cone is only half an inch, and it is impossible for the

observer to place his pupil on the line of the returning ray without getting his own head "in the light." *

In the human eye the dioptric system (cornea, lens, and humours) is equivalent to our one-inch lens, and the foregoing conditions equally obtain, except that the cone is nowhere wider than the aperture of the pupil.

How can the fundus of the eye be rendered luminous?

As rays projected into the eye are returned to the point whence they came, we can understand that if it were possible to reflect a pencil of rays into the eye, the return-pencil would strike the reflector. Furthermore, if the reflector were transparent, so as to allow a portion of the return-rays to pass through it, the observer would perceive the fundus of the eye dimly illuminated, and the pupil would no longer appear black.

Hold four glass microscope-slides. You will find you can see through them, or you can reflect as with a mirror the light from a flame on to a screen. Here, then, is the transparent reflector sought.

Again have recourse to our artificial eye ; reflect

* If my youthful ideas of proportion are correct, it might have been possible for Gulliver to have studied the Brobdignagian retina without an ophthalmoscope, or for a Lilliputian to have studied Gulliver's.

the light from a flame placed at about eight inches, and look through the slides at the pupil. After a little practice, you will perceive a white glare

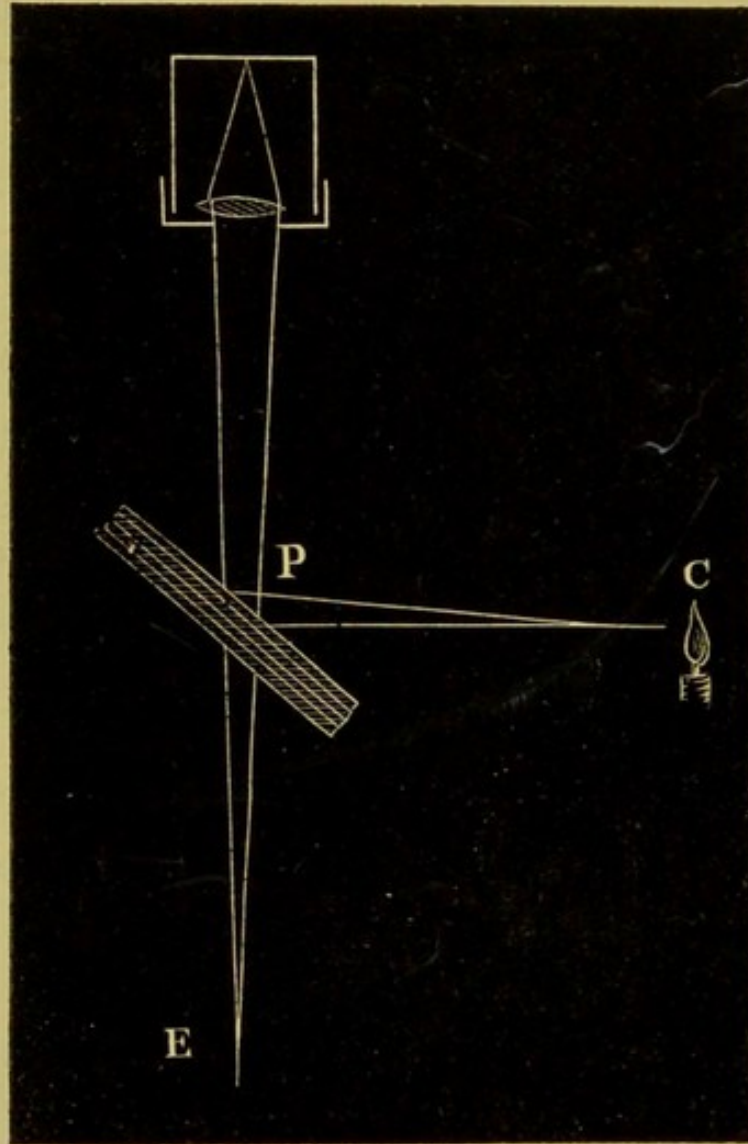


Fig. 20.

from the paper at the bottom of the box. Your own eye is in the line of reflection.

Inspection of fig. 20 shows the rays from the candle C reflected by the slides into the pupil,

and by the reverse action of the lens returned to the point P.

Of these rays, some will be reflected back to the candle, but others will penetrate the glass so as to be received by an eye placed at E.

This is the method by which Helmholtz solved the problem of placing the observer's eye within the reflected cone of light. His ophthalmoscope was constructed of four glass plates, with certain additions, which do not here concern us, for rendering details clearly visible.

As much light is lost with this form of reflector, it has not come into general use, but a mirror having a small central opening for the observer's eye has been almost universally adopted.

The manner in which a concave mirror renders the fundus of the eye visible may be readily understood.

A concave mirror of short focus receives the divergent rays from a flame placed at F, and rendering them convergent, reflects them into the eye so as to illuminate a portion of the fundus.

As the accommodation is relaxed, the rays on returning from the fundus are equivalent to the rays from an object exactly at the principal focus of a convex lens.

They issue parallel, and no real image is formed ;

but an erect, virtual, enlarged image, apparently

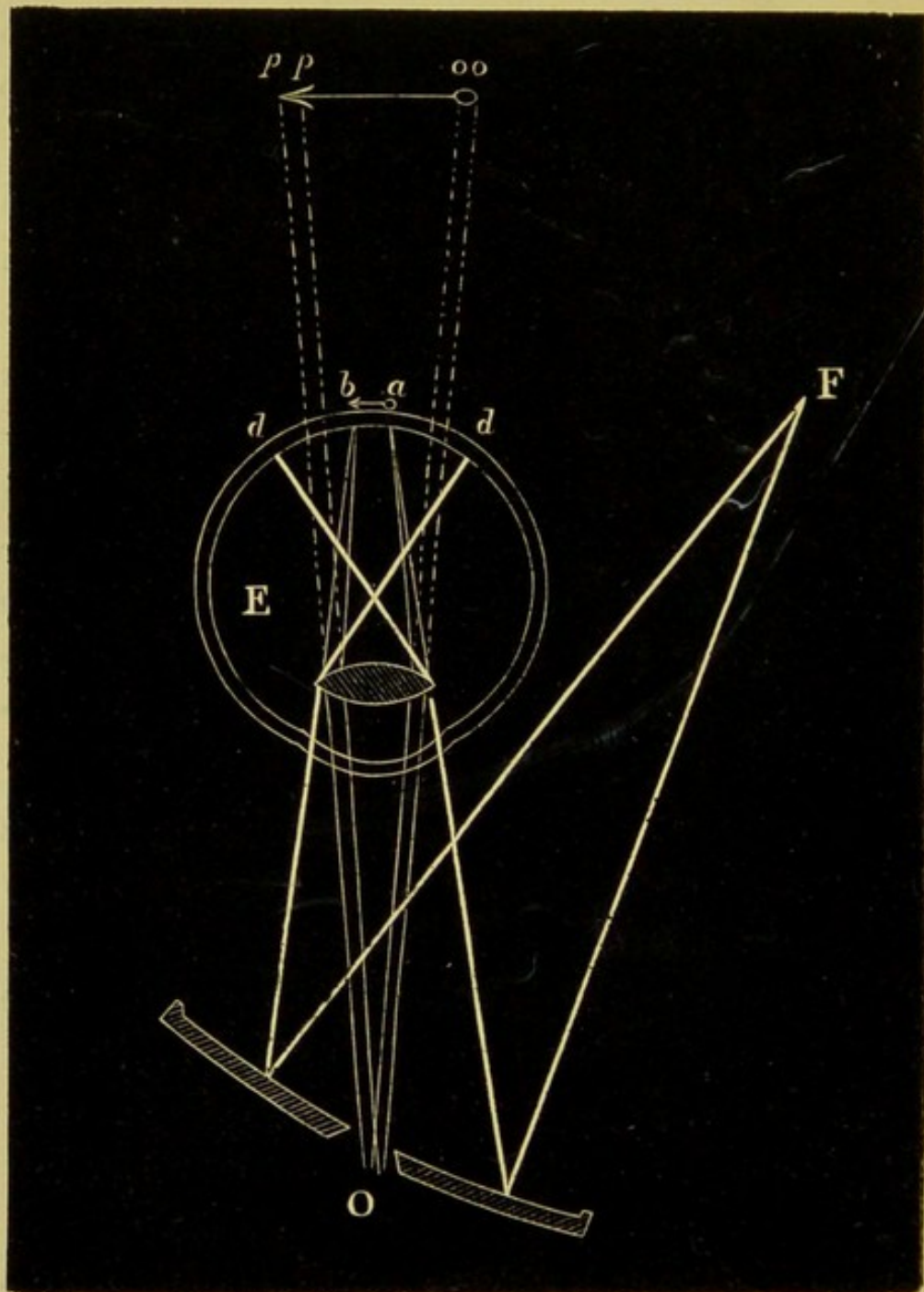


Fig. 21.

situated behind the fundus, can be seen by the

observer looking through the central aperture of the mirror.

Fig. 21 shows divergent rays from a flame *F*, rendered convergent by a concave mirror, and reflected into the eye at *E*.

The rays cross in the vitreous humour and form a circle of dispersion *dd* on the retina. The return divergent rays from a given point *a* would on emergence be rendered parallel, and have the optical value of proceeding from behind the eye in the direction of the dotted lines *oo*. In a similar manner the rays from a point *b* are shown as proceeding from *pp*. By the eye placed behind the mirror at *O*, an enlarged, erect, virtual image would be seen apparently situated behind the patient's eye.*

By this method of examination, details are seen greatly magnified, and nearly in their true colours, but only a small portion of the fundus is in view at one time. In order to obtain a general view of a larger surface, a convex lens is held a short distance from the patient's eye, so as to form a real inverted image in the air. This is termed the indirect method of examination.

Fig. 22 shows divergent rays from a flame *F*,

* In the diagram, the sight-hole is outrageously enlarged in order to allow the lines to be widely separated for the sake of ready apprehension.

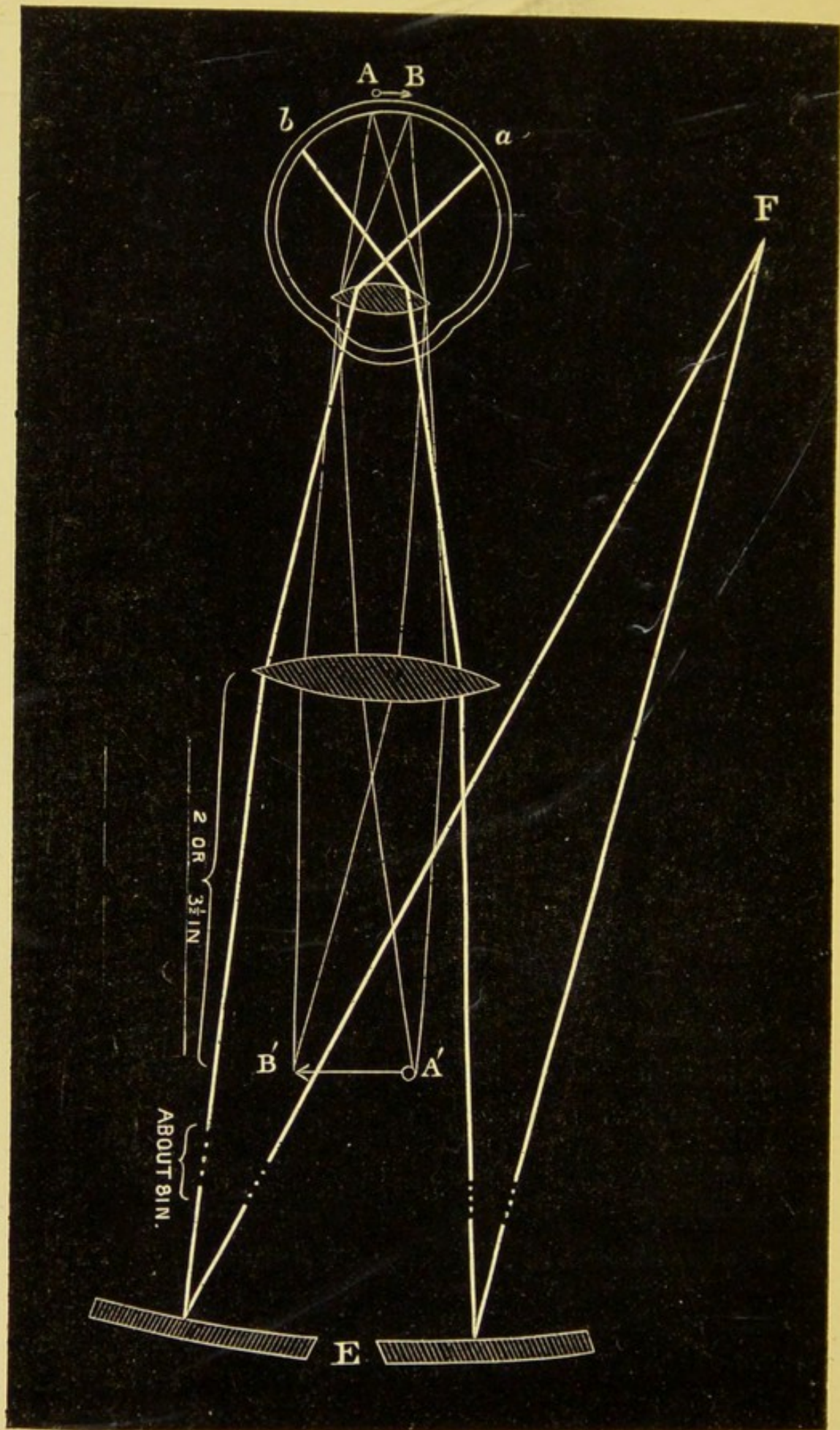


Fig. 22.

rendered convergent by the mirror, and still more so by the lens crossing in the vitreous, and forming a circle of dispersion *ba* on the retina. The return rays from any point *A* are refracted to its conjugate focus at *A'*, and so also the rays from *B* would be brought to a focus at *B'*. An eye placed behind the mirror at *E* would (at its proper distance for distinct vision) perceive the magnified image *BA'* in the air. The size of the image is influenced by the focal length of the lens. It is obvious that the more the rays are converged, the less the image must be; and the rule may be easily remembered as a sort of paradox—the stronger the objective, the less the image.

SECTION II.

The instrument known as Leibrieck's small ophthalmoscope is the best for a learner.

It consists of a concave mirror of from 8 to 12-inch focus; made, by preference, of silvered metal. The thick glass mirror now ordinarily sold has many disadvantages. The sight-hole is placed centrally, and to enable the light to pass when the mirror is inclined, its edge should be

bevelled at as great a slope as possible, so as to form a funnel-shaped opening, narrowest in the front. The anterior diameter of the aperture should not exceed one line. Two large convex lenses of respectively 2 and $3\frac{1}{2}$ inches focus are required for the examination of the inverted image. The first gives a small, clear image with a considerable extent of field; the second magnifies sufficiently for the examination of ordinary details, but only shows a limited portion of the fundus at one time. The 2-inch is the easier to manage, and should be employed at first.

Other lenses, small enough to fit into a clip behind the mirror, should be provided. Of these, one should be the correcting glass for your own eye if you are not emmetropic (see p. 68), and the others may be conveniently 8, 12, 20, and 30-inch convex and concave.

These are used as eye-pieces, and serve in estimating the refraction of the eye, and in examining elevations or depressions in the erect image (p. 82). The 8-inch convex may be used to magnify the inverted image. A 4-inch convex may be added for the examination of eyes after cataract operations.

The patient should be seated in the chair, with his back supported and his head erect. He should be cautioned not to move his head when

directed to look in this or that direction. The lamp should be placed on the same side as the eye to be examined, about three inches laterally from the patient's head, and sufficiently far back to leave the eye in shadow.

A gas-bracket with a parallel movement and a porcelain argand burner is the most convenient form of light; but any lamp with a clear, steady flame, and capable of being varied in height, will answer the purpose.

The room must be darkened.

The observer will find it convenient to sit upon a music-stool, as it enables him readily to arrange his height according to requirements. He should sit exactly opposite to and slightly above the level of his patient. If you are not pronouncedly right-handed, it is well to make a practice of using either eye indifferently from the first. The important point is to have your own and the observed eye exactly in the same line.

I should advise you to adopt the plan of examining the patient's left eye with your left, and *vice versa*, as shown in fig. 23. It has these advantages (which you will realise after working through this section)—that the little finger of the hand holding the mirror serves as a guide for the movements of the patient's eyeball; that the hand carrying the objective is out of the patient's

way; and you can vary from the indirect to direct examination with great rapidity.

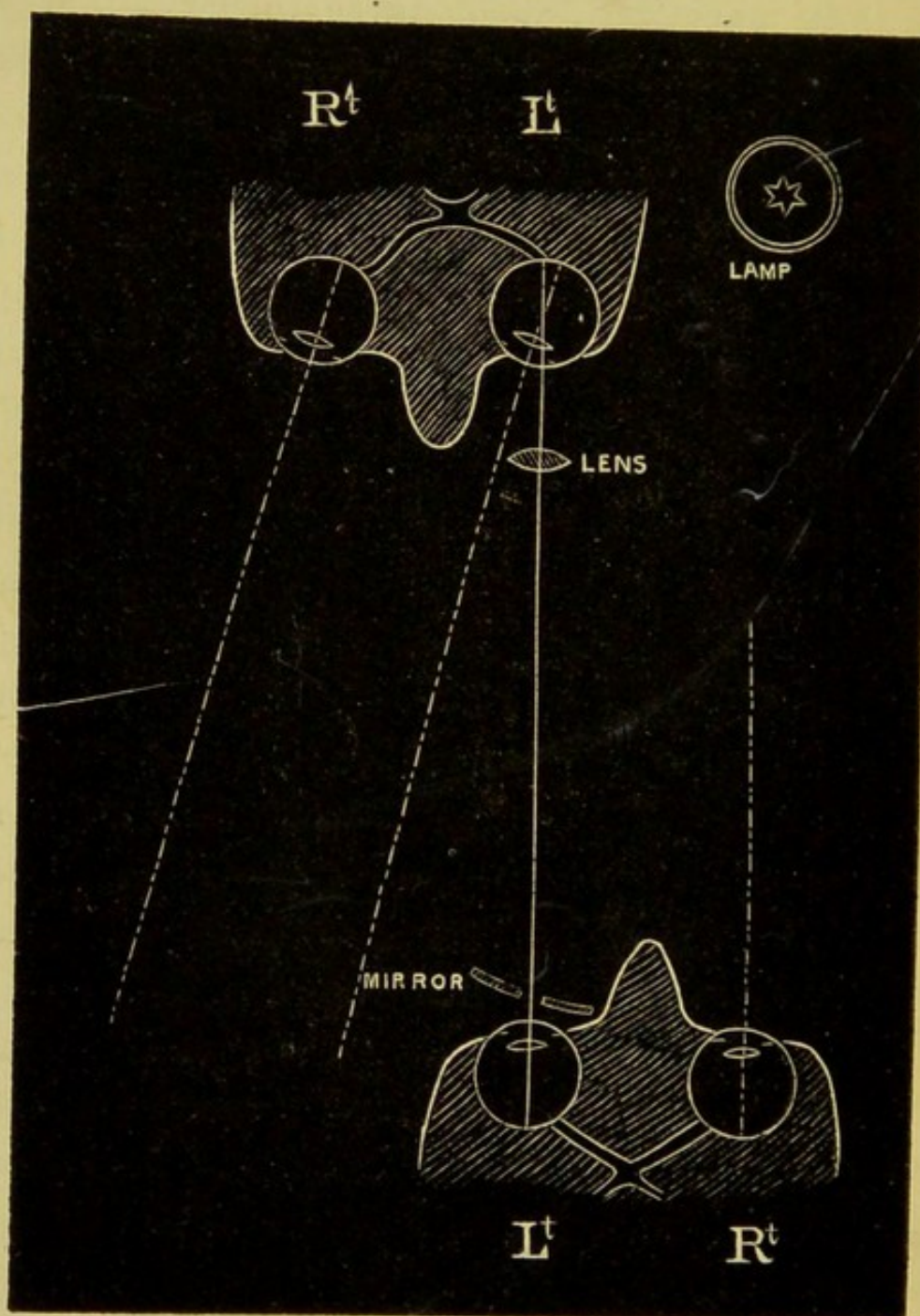


Fig. 23.

The patient's eye should be under the influence

of atropine, to enlarge the pupil and relax the accommodation.

[The patient must be warned of the effect of it upon the pupil and vision for near objects. The skilled observer can frequently do without it, but to the beginner it is essential.]

The first step consists in reflecting the light by the mirror into the pupil whilst looking through the sight-hole.

For this purpose take the mirror in your hand, and hold it with the reflecting surface turned towards the lamp, with the edge resting lightly against the superior margin of your orbit, much as you would hold an eyeglass.

By closing the unoccupied eye you can ascertain whether you are looking through the sight-hole. I have seen disappointment crown patient efforts from neglect of this simple precaution. Now vary the inclination of the mirror till you bring the bright spot of light on to the patient's pupil, which will change from black to glowing red. Continually practise bringing up the mirror and throwing the light into the pupil till you can do it with ease and precision.

Your next step should be to practise moving your head nearer to or further from the patient, still maintaining by an action of your fingers (that will soon become automatic) the light upon

the pupil. Finally, move your head from side to side three or four inches each way, keeping the light all the time on the pupil.

During the whole of these movements the pupil should present a red glare—if it look black, your light is astray.

Now direct the patient to look (*without moving his head*) at your upraised little finger. You should perceive the red glare from the pupil change to a yellowish white. By rotation of the eyeball inwards the optic disc has come into the axis of vision. As this is the chief landmark in all examinations, you should continually practise this manœuvre till you can do it perfectly. Do not proceed to the employment of the objective till you have thoroughly learned the knack of managing the light with the mirror, as above directed.

So far you have seen nothing distinctly; you have now to learn how to bring details into focus with the aid of the objective.

Take the lens (2-inch) between the thumb and forefinger of your disengaged hand, and hold it two inches in front of the patient's eye, so that the light from the mirror passing through the lens is concentrated on the pupil. You may steady your hand, if you choose, by resting your little finger against the upper margin of the orbit.

You should now see the inverted image of the

optic disc, and a portion of the surrounding fundus. Remember the image is in the air about two inches on your own side of the lens. You have therefore to overcome the difficulty of focussing with the objective so as to obtain a sharp, clear image, and of holding your head at such a distance as to see it plainly. In the beginning you will bungle, as you did when you first tried to row with a pair of sculls, or execute the associated movements of arms and legs in swimming; but if you have previously mastered the use of the mirror as advised, the period of struggle will be short. The distances you have to maintain are—(1) the lens must be two inches from the pupil, and (2) your own eye must be two inches farther from the lens than the distance at which you clearly read small type (^{brilliant}); say that is twelve inches, you will see the image clearly at fourteen.

The optic disc, pierced by the retinal vessels, should now be clearly in view. Its healthy aspect is described at p. 52. At this period you should give your whole attention to acquiring the power of focussing. Select as a test-object the edge of the disc or a vessel. Practise with this sole object over and over and over again, till you can bring out the details clear and sharp—with nothing blurred or foggy about the edges or colours—as

easily and precisely as you can focus the face of a beauty with an opera-glass. You may find the disc only partly in view. Bear in mind that the image moves in the opposite direction to your head, and in the same direction as the lens. You can therefore generally bring the disc completely into view, either by moving the lens a little sideways in the required direction, or by moving your head in the opposite.*

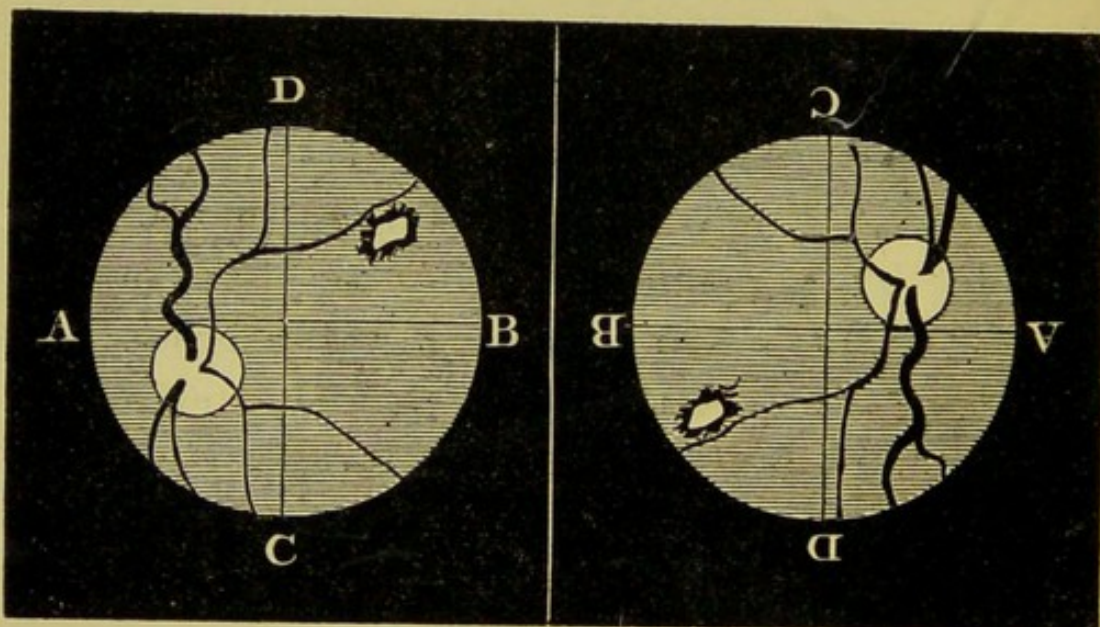


Fig. 24.

Fig. 25.

* Students do not readily understand the effect of inversion. Fig. 24 is a map of the left eye in the erect image, showing the position of a disc, with the largest vein curving upwards, and a diseased patch in the upper and inner quadrant of the field.

Fig. 25 is a map of same eye in the inverted image, showing the changed position of the disc. The largest vein apparently courses downwards, and the diseased patch is now in the lower and outer quadrant. The maps have been drawn of the same size for the sake of comparison, but the student will remember they should differ greatly in magnitude.

The last difficulty is caused by the reflections of the mirror on the lens and cornea. The former has not unfrequently been viewed with complacency as the disc. It may at once be distinguished by the little black dot in the centre. By inclining the lens a little from the perpendicular, it can be thrown beyond the margin of the field.

Do not imagine these early steps are easy. Even with a good teacher much difficulty will be experienced. You must spend time and take trouble before you can simultaneously perform the minute adjustments of hand and eye upon which focussing depends. But do not attempt to pass on to other portions of the subject till you have thoroughly mastered this; and above all, do not persuade yourself you can see when you cannot. I repeat the steps :

1. Throw the light into patient's eye with mirror.
2. Move your own head to and fro, still maintaining light upon the pupil.
3. Move your own head from side to side.
4. Direct your patient to look to one side, so as to bring optic disc into view.
5. With disengaged hand place objective, and focus details.

Now read over and *verify* the description of the healthy structures before proceeding to acquire the art of examining the *erect image*.

Ascertain, in the first place, that your own refraction is normal ; if not, a suitable correcting lens must be placed in the clip behind the mirror.

The direct method of examination, though exceedingly simple, requires much practice ; but the student should spare no pains to acquire facility, as certain important details cannot otherwise be seen in their true aspects.

The examination is made with the mirror alone. The lamp must be on the same side as the eye to be examined, rather more forward than for the indirect method.

The patient is directed to look at some distant object, and to pay no attention to the movements of the observer.

Throw the light into the pupil as before ; but remember you will have to approach very close to your patient, and therefore, to avoid interception of light and nasal bumps, use the right eye for examining the right, and the left for the left.

As soon as you see the whitish glare indicative of the optic nerve, approach the patient, still maintaining the light upon the pupil.

As you approach, the vessels will come into view as blotchy, red streaks, which will become clearer and clearer, till, having only a space of two or three inches between the eyes, you should see a

well-focussed, magnified image of the optic disc, or at least a portion of it. The main difficulty in doing this lies in the tendency to accommodate for a near point as you approach the eye. If you find you cannot focus clearly, place a concave lens in the clip behind the mirror. The rays will then fall upon your eye divergent as if from a point at a definite distance (whatever the negative focal length of the lens may be), and you will find no difficulty in accommodating accordingly. By degrees substitute weaker and weaker glasses, till you can altogether relax your accommodation. Some observers experience great difficulty in accomplishing this feat, and habitually use a weak concave. When the patient's eye is not thoroughly under the influence of atropine, its employment is generally advantageous.

As the field is very limited, you must hunt over the fundus bit by bit. Bear in mind that the image moves in the same direction as you do.

Oblique Illumination.

Changes in cornea, aqueous, lens, or capsules are most perfectly seen in their true aspect as regards position and colour by oblique illumination. This consists in concentrating the light on the parts to be examined by means of a lens. Diffused daylight or lamplight may be employed, but the

direct rays of the sun for obvious reasons must be avoided.

The lenses used as objectives are employed to concentrate the light.

The patient is seated facing a window or lamp. The latter should be about twelve inches laterally

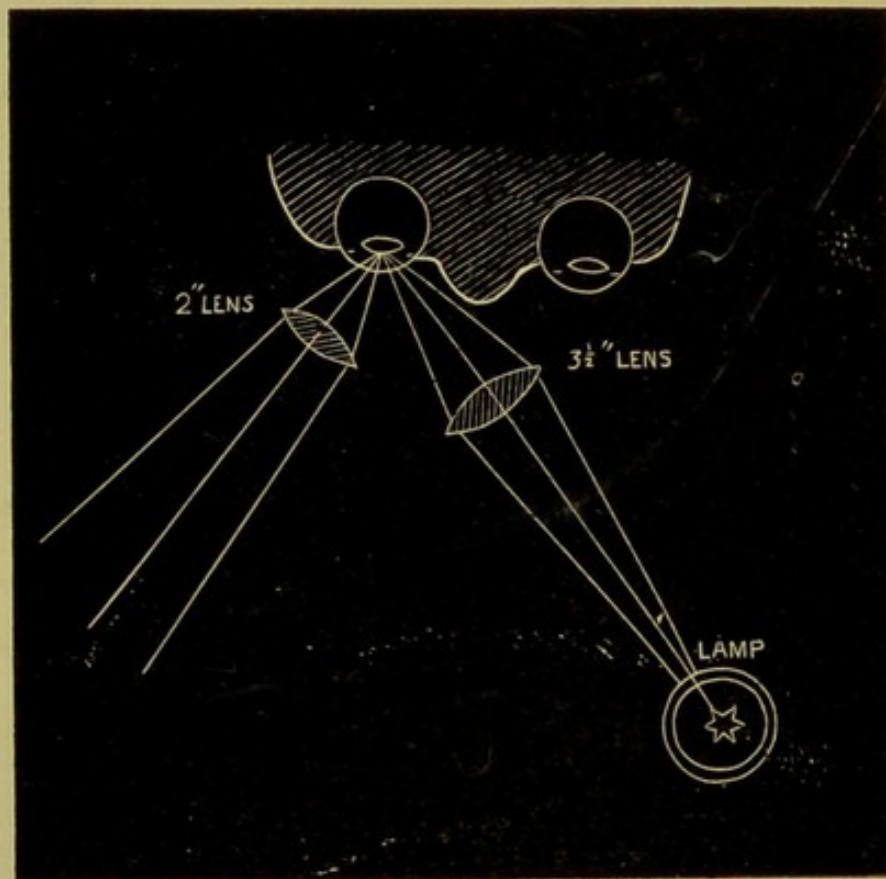


Fig. 26.

and six or eight in front of his eye, but the position should be varied from time to time, till a thorough exploration has been made. Standing in front of the patient and on the side opposite to the lamp, take the ($3\frac{1}{2}$ -inch) lens in hand, hold the lens

between the lamp and observed eye rather more than its focal length from the latter, so that a bright, circular spot of light is thrown into the pupil. By moving the lens slightly, and directing the patient to look successively in various directions, the faintest opacities are made visible.

The second lens (2-inch) can be held rather within its focal length from the eye, and used as a magnifying glass.

Two or three trials will suffice to make you complete master of the method.

SECTION III.

APPEARANCES OF HEALTHY STRUCTURES.

Having learned *how* to see fairly, you will have now to learn *what* you see. First, make yourself acquainted with the healthy appearances. Many students with good ears are slow in becoming competent auscultators from neglecting to master thoroughly the healthy respiratory sounds. From the same cause ophthalmoscopic appearances which are consistent with health, and are really proper to the individual's construction, are frequently mistaken for pathological signs by students who have

formed their idea of the healthy fundus from an atlas.

1. The media must be examined with a moderate light by the mirror alone, and the results checked by the oblique illumination. A strong light renders slight opacities transparent. Strings or bubbles of mucus on the cornea are occasionally misleading, but may be recognised by their changing their position when the patient winks.

[Slight turbidity of lens or vitreous is frequently mistaken for haziness of retina. By oblique illumination, a faintly striated appearance of lens is seen in some people, and the deeper reflection in the aged is seldom quite free from milkiness.]

2. The optic disc must be studied in the inverted image, but minute variations in colour are best made out by the direct examination.

The general aspect of the disc is circular or oval, with the long diameter vertical. The colour is compound, being derived from the following elements: (α) Red from the nutrient capillaries; (β) Glistening white from the connective tissue; and (γ) Transparent yellowish grey from the nerve tubules.

The whole produces the effect of a delicate cream-colour, warmed with a light rose-pink, but varying in different subjects. Some persons have naturally florid discs, as some have florid cheeks,

and *vice versa*. The effect of contrast also must not be overlooked, a well-pigmented fundus making the disc appear whiter than it does in a blonde.

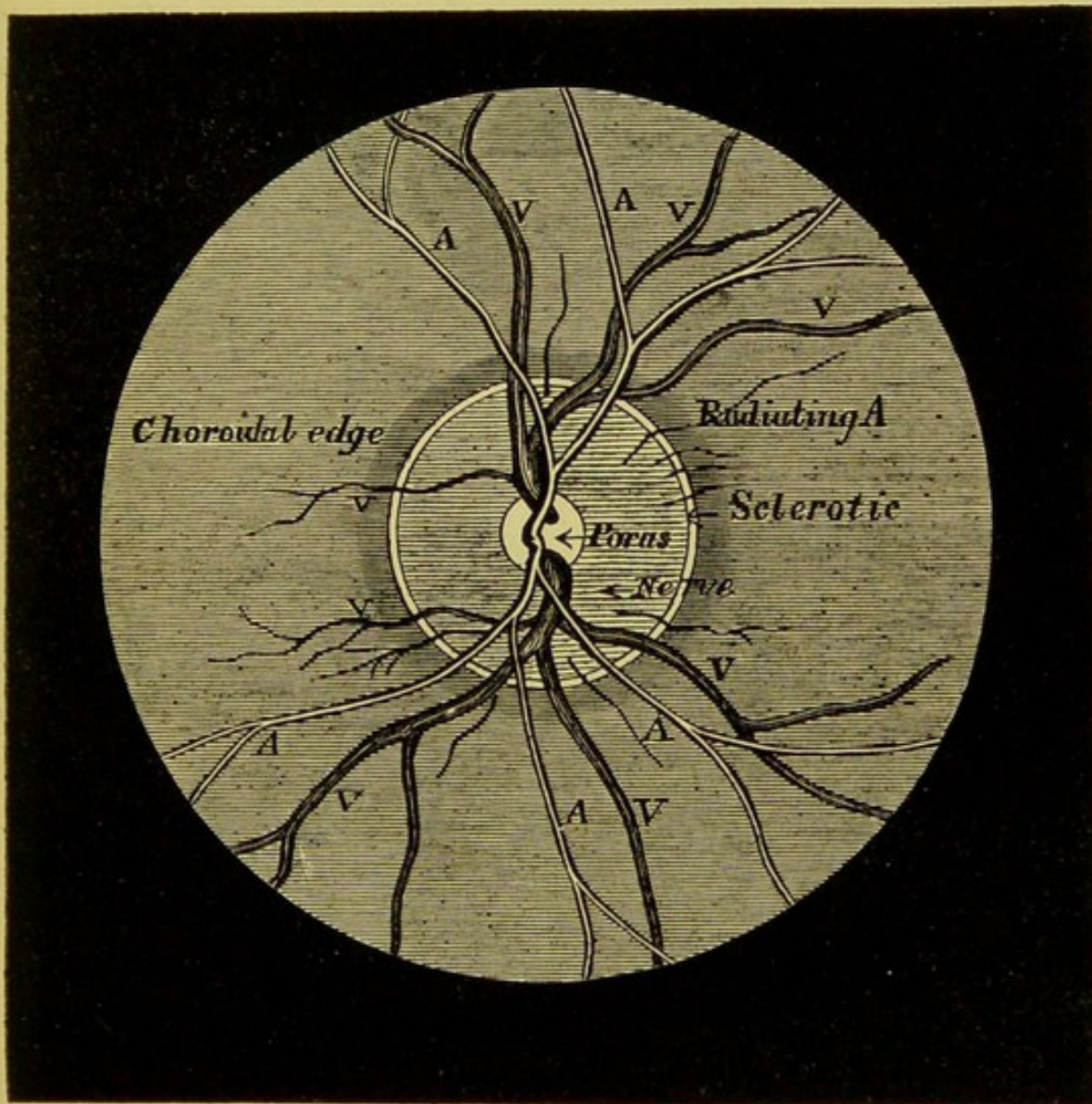


Fig. 27.—Scheme of Optic Disc.

The colour of the surface is not uniform. Proceeding from the edge towards the centre, we perceive—

(a) The border of the choroidal opening. This

varies from a light to a brownish grey, and is frequently marked on the outer side by a crescent of dark pigment.

(β) The border of the sclerotic opening and the internal sheath of the nerve together form a slender zone of glistening white. As the choroidal opening varies in size and shape, the amount of sclerotic visible varies from a scarcely perceptible line to a well-marked crescent, which is liable to be mistaken for the effects of disease.

(γ) Of the general surface, the inner half is the most decidedly pink; the outer (by contrast) often looks so white as to be mistaken by careful but inexperienced observers for commencing atrophy.

(δ) In the centre appears a small white patch, sometimes circular, sometimes irregular in form. This is the bundle of connective tissue surrounding the central vessels. The surface is depressed rather below the level of the true nerve substance. It is called the *porus opticus* (v. Physiological Pit, p. 83).

3. The vessels.

The central artery of the retina pierces the disc near its centre, and divides as it emerges into an upward and a downward branch, which, by repeated bifurcations, spread over the whole retina except the yellow spot.

The corresponding veins enter the disc separ-

ately, a short distance apart—sometimes two to each artery. They are larger than the arteries, and their course is more sinuous. In some eyes a spontaneous pulsation is seen as the veins enter the nerve, and slight pressure on the eyeball suffices to produce it as a rule.

A few small trunks derived from the short ciliary arteries pierce the disc and radiate on to the retina.

The vessels look like what they are—very fine, transparent tubes filled with red fluid. The light falls upon them so that their edges appear dark and their centres bright and shining. As the arteries are cylindrical, the central streak is well marked; but the veins, being somewhat flattened, show it more imperfectly. At the edge of the larger vessels also a faint white line can frequently be perceived on the retina.

You must learn to distinguish the vessels.

The following are the main differential points :—

ARTERIES.	VEINS.
Smaller.	Larger.
Bright red, tending to scarlet (approximate).	Dull red, tending to crimson (approximate).
Edge and bright central streak, well marked.	Colour more uniform.
Course straight.	Course sinuous.
Cross over veins.	Cross under arteries.
Pulsation very difficult to see.	Pulsation easily seen.

4. *The retina.*—The general expanse of the retina is not as a rule visible, but in some deeply

pigmented eyes it can just be seen like the "bloom" of a grape over the choroid.

The yellow spot is very difficult to see. It is situated on the axis of the eyeball, about two diameters of the disc to its outer side. The patient must look straight before him, and the observer must "dodge" a little from side to side, and hold the objective obliquely, so as to avoid the corneal reflex, which is just in the line of sight.

The appearance of the spot varies very much. It is generally oval, duller than the surrounding fundus, destitute of visible vessels. In the centre, after considerable practice in favourable cases, a small, bright spot can be distinguished. This is the *fovea centralis*.

5. The choroid gives the general red tint to the fundus of the eye. It varies from a bright pink in the blonde to a dull purplish-brown in the brunette. The details of the inner layers cannot be seen, but in the erect image the tessellated pigment layer causes the surface of the fundus to appear granular.

The appearance of the deeper layer of the choroid is mainly influenced by the amount of its pigmentation.

In very fair persons, where the pigment is scanty, the general choroidal glow is a beautiful, bright rose-colour, the intertwining of the choro-

dal vessels are plainly seen, and the ciliary arteries can be observed piercing the sclerotic.

In persons of a medium tint, the choroidal vessels form a meshwork of bright red with the interspaces filled with pigment more or less dark; the spaces are irregular in shape, but are small and round near the disc, larger and more elongated towards the periphery of the fundus.

In very dark persons, the details of the deeper layer cannot be seen, and the fundus presents a surface of a uniform dark reddish-brown. It is of the utmost importance to become practically acquainted with the pigmentation of the choroid, and not to fall into the error of mistaking its natural markings for the effects of proliferation.

SECTION IV.

APPEARANCES OF DISEASE AND STRUCTURAL DEFECTS.

It is no part of my purpose to teach you diseases of the eye, but I advise you to learn what to look for as pathological appearances before passing on to the study of the separate diseases described in systematic treatises. I cannot help thinking students would gain time if all physical diagnosis were attacked in this manner. A student who

has been previously well taught to distinguish the separate chest-sounds without an inkling of the diseases, is almost certain to become a more accurate auscultator than one who begins by mixing up the rational and physical signs, the general symptoms and morbid anatomy, so as to acquire a certain superficial skill in diagnosing one case from its family likeness to another. I shall enumerate the most important evidences of diseased action in the tissues of the eyeball, and give directions which will enable you with practice to distinguish those most likely to be confounded.

In making an examination, I should advise you to follow systematically the plan here appended. Pass on from structure to structure in regular order, till your attention is arrested by some appearance not according with your previous experience. By turning to the description of the structure under observation, you will probably be enabled to form a rough idea of the significance of what you see. In this way you can store up your early observations, till you can readily answer such questions as, Am I looking at an elevation or depression? Are those white patches deposits or atrophied spaces?

Plan of an Examination.

[Instil atropine twenty minutes beforehand.]

1. Examine the cornea, lens, and vitreous

with the mirror alone. Small *nebulæ*, opacities in the lens, or *flocculi* in the vitreous may be observed and their position noted before proceeding to view the inverted image. Dislocation of the crystalline will be thus seen, and sometimes a detached retina is visible.

Slight opacities are best seen with a moderate amount of illumination, as a strong light renders them semi-transparent.

Many experts reserve the examination by oblique illumination till the last, but the student will do well to employ it at this period if the media do not seem perfectly clear.

2. Estimate the condition of refraction, whether emmetropic, hypermetropic, or myopic. Hypermetropia is a frequent cause of defective vision, pain, and alarm. Ascertain if the lens be *in situ*.

3. Pass on to the optic disc. Note its shape; remember the effect of unequal refraction (astigmatism or conical cornea) on its form; its colour, whether it errs on the side of redness or pallor; the margins, whether sharp, clear, and even, or woolly, indistinct, or jagged; whether the level of the surface be above or below the rest of the fundus, and if the vessels show a sharp outline.

4. Distinguish between arteries and veins; note their relative size, straightness, or tortuosity; clearness with which they can be focussed; if hidden

at any portion of their course ; pulsation, if any ; and whether they are curved in passing over the margin of the disc.

5. Pass on to the retina ; observe if its transparency be impaired, especially if the edges of its vessels are blurred. Satisfy yourself that the want of transparency is in the retina and not in the media. I have seen incipient cataract diagnosed as retinitis. Look carefully, especially in the region of the yellow spot, for deposits or hæmorrhages, and at the periphery for spider-shaped pigmentation.

6. The choroid ; note its colour, and the size of the opening surrounding the optic disc, whether circular or atrophied, irregularly showing a "crescent" of sclerotic ; look for irregular patches of pigment or atrophied spaces, and whether the larger choroidal vessels are too plainly visible.

I.

The Media.—As the media are transparent in health, disease is shown by opacity either diffused or collected into spots. The first step in observing an opacity is to make sure of its position. As deep as the posterior capsule, opacities can be seen in their true colours by the oblique illumination. With the mirror, exceedingly minute opacities

can be seen at any depth. As they are rendered visible by the rays reflected from the fundus, they are in shadow and consequently appear black.

To Determine the Depth of an Opacity in the Media.

In looking at a moving eyeball with the mirror, the corneal reflex remains still, and may be used as a fixed object by which to measure the excursions of any moving spot. The pivot or turning-point around which the eye rotates coincides with the posterior pole of the lens, and in whatever direction the globe is moved, that point always remains stationary.

If we imagine a line drawn through this point, its ends would move, with the movements of the globe, in opposite directions, like a sea-saw. A glance at fig. 28 will make this apparent. A line is shown in the left eye passing through the turning-point and the corneal reflex.

Opacities are represented at A, B, C, situated at various depths on this imaginary axis. When the patient looks to the left, the parts assume the positions marked by the dotted lines. The opacity A (situated on the anterior capsule) moves to the left (A'), B in the vitreous moves to the right (B'), C (deeper in the vitreous) moves yet further to the right (C'), and a point on the retina would move most of all.

Therefore (in the erect image) opacities moving in the (*a*) same direction as the patient looks are in anterior portion of lens, aqueous, or cornea: in the (*b*) opposite direction are in the vitreous, and the extent of movement is in proportion to their depth. (*c*) Those remaining stationary are situated at the posterior pole of the lens.

To understand how, with the inverted image, the movements of an opacity would be affected by

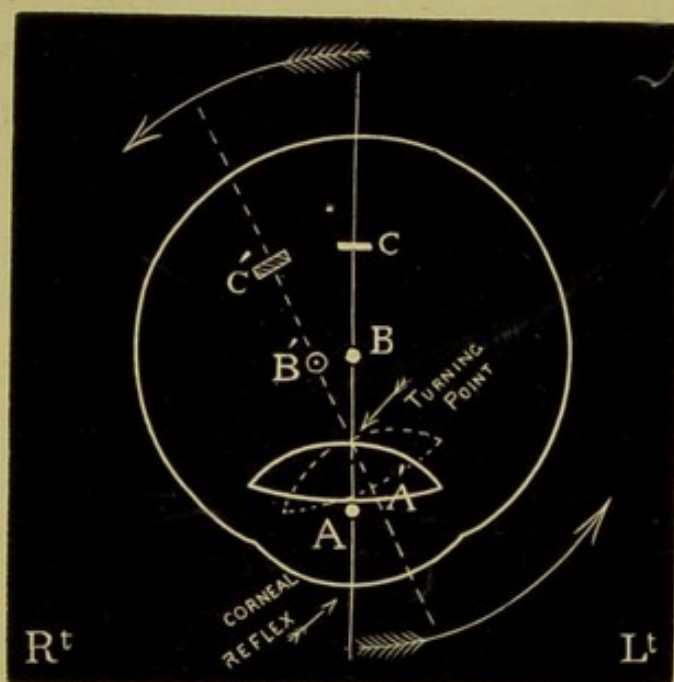


Fig. 28.

its depth, stick three pins in a row about two inches apart; look at them with one eye exactly on the same level—the foremost pin only will be visible. Interpose a convex lens between the eye and the first pin, so as to see its enlarged inverted image.

Move the lens to the right ; the image moves to the right also, more rapidly than the lens ; by continuing the movement, the inverted image of the second pin comes into view, and also moves to the right, but slower than the first ; and ultimately the third image is seen moving in the same direction, but slowest of all.

The Cornea.—Opacities in the cornea are easily seen to be superficial. With the mirror small nebulæ appear as black spots, and transparent ulcers have a black edge. With the oblique illumination very thin nebulæ and ulcers or inequalities of surface are easily seen.

The Lens.—On the anterior capsule opacities are, for the most part, due to disease of either cornea or iris. Small patches of lymph, threads tying the iris down to the capsule, and dots or streaks of uveal




Fig. 29.*

* Fig. 29.—A shows pupil tied down by adhesions to anterior capsule, with deposit of lymph in centre ; B, central capsular cataract ; C, cortical ; D, zonular—all as seen by oblique illumination.

pigment, present no difficulty in detection. A common form is seen in young children as the result of ulceration of the cornea. It appears by oblique illumination either as a small white spot, not more than about half a line in diameter, in the centre of the pupil, or as a whitish mass occupying a greater space, heaped up into a cone on the anterior capsule, and projecting forwards into the aqueous.

The former is termed a central capsular cataract, the latter pyramidal. In neither is the capsule itself supposed to actually become opaque.

The most common opacities of the proper lens substance are the following:—

1. Soft cataract of early life and traumatic cataract. With the mirror the fundus appears blurred, as if seen through tobacco-smoke or a diffused milkiness. By oblique illumination the whole lens appears a whitish grey. A few streaks or chalky dots and shining flakes of cholestearine may perhaps be seen on the under surface of the capsule.

2. Senile or hard cataract. The opacity is most marked in the centre. In incomplete cases the fundus is seen dimly as through a London fog, or no reflection may be seen in the centre, while the periphery appears as a dull red. By the oblique illumination the nucleus is seen to be of an amber

tint, and the remainder of the lens occupied by faint opalescent striæ.

3. Cortical cataract. Dark striæ are seen extending like spokes of a wheel from the periphery towards the centre of the lens, the red glow of the fundus shining through the interspaces. By oblique illumination the striæ appear grey or white, and the direction of their curves indicates their position in the anterior or posterior layers of the lens.

4. Zonular (laminar or lamellar) cataract is an opacity of certain layers of the lens, the centre and other layers remaining transparent. On section they might be compared to the layers of paste and jam in a rolypoly pudding, except that they are concentric. As the opacity is in no part very thick, a diffused reflex is generally visible, even in the centre, and the fundus can be made out through the clear margin of the lens. By oblique illumination a small white central disc is seen, with an ill-defined margin, or surrounded by concentric rings, dots, or interlacing lines. The opacity is readily perceived not to be in exact juxtaposition with the anterior capsule, but to be situated at a variable distance behind it.

The lens may have been dislocated or removed from the globe by operation. We have already learned that in looking through the lens it acts as a magnifying-glass, and we are therefore pre-

pared to find the image by either method of examination very small. The eye is of course highly hypermetropic. The virtual, erect image can be seen at some distance with the mirror alone, and details can be clearly focussed at a few inches' distance through a 4-inch convex eye-piece. By the oblique illumination a dislocated lens can generally be seen lying behind the iris, or it will float partly into view when the eyeball is moved.

Dislocation into the anterior chamber can be seen by the unaided eye.

The Vitreous Humour.—In examining the vitreous, the patient must be made to look quickly in various directions in obedience to orders. By this means opacities will be seen to tremble if the consistence of the vitreous is lost or is slightly reduced, or to float quickly to and fro if it is approaching a fluid condition. You may note the following:—

1. A diffused opacity or general fogginess; this is seen, either in the direct or indirect method, by causing a veil over the details of the fundus. It may be either the result of spontaneous inflammation of the vitreous (hyalitis,) but more commonly follows circulatory or inflammatory changes in the retina and choroid. Some little care is required to discriminate between opacity of the vitreous and lens.

2. Filamentous opacities, like spider-webs, are seen as very delicate threads traversing the vitreous. With the movements of the eyeball, they may be seen variously foreshortened, so as to change their shapes from dots to lines. These changes are subjectively visible to the patient, and are generally a source of great annoyance.

3. Membranous and flocculent opacities are seen as shadowy objects floating to and fro when the eye is moved. As they pass over the pupillary area, they often unfold and assume queer shapes, like leaves or paper blown about by the wind. They are frequently attached at one end. Heavier masses of lymph will be seen after rising to fall slowly down in a straight line.

4. Blood-clots from choroidal or retinal hæmorrhage, when recent, scarcely admit of mistake. As they break up and commence to become absorbed, they lose colour, become woolly at the edges, and can scarcely be distinguished from inflammatory flocculi.

5. Crystals of cholestearine are also unmistakable. When the eyeball is moved, they glitter and shine with an indescribable pyrotechnic brilliancy.

6. Foreign bodies, when recent, present their own proper appearance, but after a time the vitreous in immediate contact becomes grey and opaque. The whole vitreous may become foggy,

or the foreign body become closely encysted in a coating of yellowish-grey lymph. A dislocated lens frequently becomes encysted in this manner.

To Ascertain the Refraction of the Eye.

In a properly formed eye, parallel rays are brought to a focus exactly on the retina, without any effort of the accommodation. Such an eye is termed *Emmetropic*. But many eyes differ from this standard.

(A) In one class the length of the eyeball is greater than the focal length of the lens, &c. Parallel rays are therefore focussed at a point in front of the retina. We have already learned that the distance between the image and a lens is increased in proportion to the divergence of the incident rays (*v.* Conjugate Foci), and we can therefore understand that in this class of eyes only divergent rays can be focussed on the retina. Such eyes, in order to see distinctly, must either have the object within a certain distance (say ten inches), or parallel rays from distant objects must be rendered artificially divergent by concave spectacles.

These eyes are familiarly termed short-sighted, or technically, myopic.

We have already learned that rays proceeding from the retina are refracted by the lens, &c., and

we can therefore understand that in emmetropia, as the retina is exactly at the principal focus, the divergent rays proceeding from it would emerge from the eye parallel.

In myopia, the retina being beyond the principal focus, rays proceeding from it would have a less degree of divergence, and would therefore emerge as convergent rays, meeting at the conjugate focus of the retina.

(B) In another class the length of the eyeball is less than the focal length of the lens, &c. Parallel rays are therefore focussed at a point behind the retina.

We have already learned that the distance between a convex lens and the image produced by it is decreased if the incident rays are already convergent, and we can therefore understand that in this class of eyes only convergent rays can be focussed exactly on the retina. No such rays exist in nature, and these eyes require parallel rays to be rendered artificially convergent by convex spectacles in order to see anything distinctly. These eyes are termed oversighted, or hypermetropic.

How can we recognise these conditions by the ophthalmoscope?

You have already learned that, in order to see details of an emmetropic eye clearly, you must

approach within two or three inches. At that distance, and with your own and the patient's accommodation relaxed, details can be accurately made out.

Fig. 30 shows divergent rays proceeding from two points *ab* (say the upper and lower margin of the optic disc), traversing the lens *L*. They emerge parallel, and as if proceeding respectively from the virtual points *oo*, *pp*, producing an enlarged virtual image. Simple inspection shows that an eye situated at *E* would only see the portion of the image included in the angle *CED*; that if it approached so as to increase the angle, it would see more; if it receded so as to diminish the angle, it would see less (*v. Visual Angle*, p. 28). You may roughly demonstrate this by laying a convex lens (2-inch) on the optic disc in fig. 27.

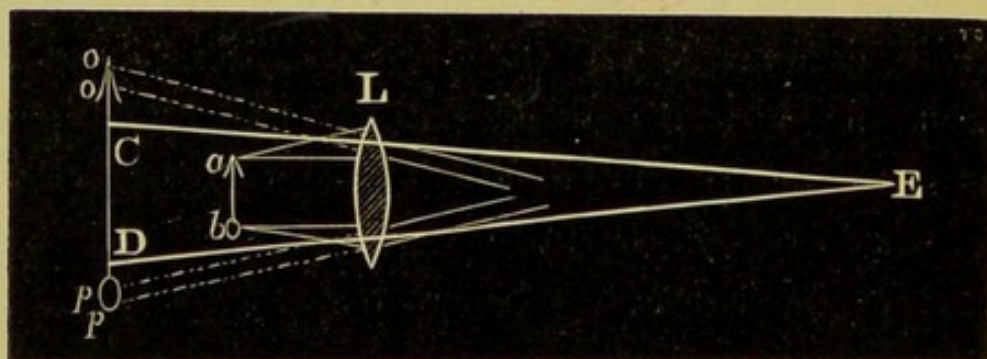


Fig. 30.

On looking through it at the diagram, a space equal to the diameter of your lens will be plainly seen at a distance of 15 inches. But gradually

raise the lens from the paper, the details become larger and larger, but less and less can be seen of the surface of the disc, till the lens, having arrived at 2 inches from the page, nothing can be seen distinctly but a glare of white and confused blotches of black (corresponding to the glare seen from the interior of the eye with the mirror alone). If now, still maintaining the position of the lens, you bring your eye to within 2 or 3 inches of the lens, you will be able to see all the details clearly magnified.

In myopia a clear image of the fundus cannot be seen by the naked eye at a few inches. Withdraw your head some distance (say 18 or 20 inches), and you will perceive the disc and vessels come more or less clearly into view. On moving your head slightly from side to side, you will observe the image move in the *opposite* direction,—it is an inverted image.

Suppose your patient has his far point at 10 inches, the rays from his retina would converge and meet at that distance to form an inverted image. You would be able to see this at your ordinary distance for small objects (say from 8 to 12 inches). Therefore at from 18 to 22 inches from the patient's eye you would see a real inverted image without using an objective. Fig. 31 shows the path of the rays and the position of

the image,—E, the observer's eye (emmetropic) ;
M, the myopic eye ; I, position of the image.*

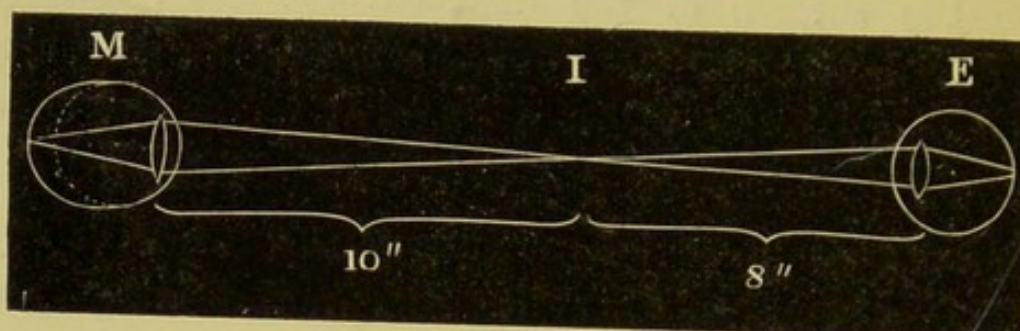


Fig. 31.

As the return rays are convergent, it follows that you cannot see the erect image of a myopic eye without the aid of a lens to render them parallel. In the above example, the rays cross at 10 inches from the myopic eye. Let us suppose you place your eye at 2 inches; the rays would cross at 8 inches behind the front of your cornea, supposing no refraction to take place. Therefore if a concave lens of 8-inch negative focal length be placed as an eye-piece behind the mirror, the rays will be rendered parallel, and focussed on your retina without accommodation.

In a few trials it is easy to determine what concave lens placed in the clip of the mirror gives

* Short-sighted persons are very common, and may be known by their inability to see objects (a church clock, names over shops, &c.) clearly at a distance; by their good sight for small objects held near the eye, and by concave glasses improving vision for distance. The statements in the text should be verified on such an one.

the clearest image at a few inches. By adding the distance between the eyes to the negative focal length of the eye-piece, an approximation is made to the glass required to correct the myopia. This is a valuable method of examining short-sighted children, who cannot be depended on to give accurate replies.

With the indirect examination it is less easy to diagnose myopia, except of a high degree. Arrange a biconvex lens (say 2 inches) vertically, with a visiting card a little beyond its focus (say $2\frac{1}{3}$ inches); you will be able to see an enlarged inverted image at about 18 inches. Now interpose an objective ($3\frac{1}{2}$ inches), and observe the resulting small inverted image. Move the objective to and fro some few inches, in a line between your eye and the 2-inch lens; you will note that the image becomes smaller as the objective approaches the lens, and *vice versa*. So in the indirect examination of a myopic eye, the image is rendered smaller by moving the objective closer.

In hypermetropia a more or less clear view of the fundus can be obtained at a distance with the mirror alone. On moving your head from side to side you will observe the disc move in the same direction; the image is enlarged, erect, and virtual. As the return rays are divergent, they have of course the optical value of coming from a virtual

focus behind the eye (say 10 inches), and could be rendered parallel by a convex lens of 10 inches principal focal length. Hence, with a 10-inch eye-piece we can approach within 2 or 3 inches of the patient's eye, and see the details perfectly clearly. [With an emmetropic eye the convex lens would render the return rays convergent, and consequently details would be blurred.]

The strongest glass (subtracting the distance between the eyes) with which we can see details clearly is approximately the one required to correct the hypermetropia.

With the indirect examination the image is increased by approaching the objective to the patient's eye, and *vice versa*.*

* Over-sighted or hypermetropic persons are not so easily detected for practice as myopic. They may generally be known by complaining of uneasiness or pain after reading, sewing, &c., by slightly imperfect sight for distant objects, imperfect or difficult vision for minute objects held close to the eye, and by improvement resulting from convex glasses. A young woman who likes to see in her mother's spectacles, and can see through them at a distance, is a safe subject.

THE FOLLOWING TABLE WILL ENABLE THE STUDENT READILY TO CONTRAST THE
FOREGOING FACTS.

	<i>Adapted in Rest for</i>	<i>Parallel Rays Focussed</i>	<i>Rays from Retina Emerge as</i>	<i>Image by Direct Method</i>	<i>Erect Image Seen Close</i>	<i>Image by Indirect Method</i>
EMMETROPIA . .	Parallel rays.	On the retina.	Parallel.	Erect, virtual, seen close.	Without cor- recting eye- pieces.	Not affected.
MYOPIA	Divergent rays.	In front of retina.	Convergent.	Inverted, real, seen at dis- tance.	With concave.	Made smaller.
HYPERMETROPIA .	Convergent rays.	Behind retina.	Divergent.	Erect, virtual, seen at dis- tance.	With convex.	Made larger by moving objective closer to eye.

Two errors of refraction due to faulty curvature of the cornea require a brief notice.

1. *Conical Cornea*.—The cornea may lose its normal curvature, and become more or less pointed in the centre, so that, viewed in profile, it appears somewhat conical. I say “somewhat,” as the term requires as much indulgence as the “triangle” and “square” of anatomical descriptions. The sides of the cone are, as might be expected, curved, and the apex is generally blunt.

Extreme degrees are easily recognised with the naked eye by the glittering appearance of the cornea and the visible projection of its central portion, but slighter degrees can only be diagnosed by the aid of the ophthalmoscope. With the mirror alone two facts may generally be noted: (*a*) The corneal reflex is distorted, and changes its shape when the patient moves his eye; (*b*) an ill-defined shadow is seen at the base of the cone on the side opposite to the direction whence the light proceeds. It is only seen in this and the following affection, and is easily overlooked. With the objective the disc appears distorted and the vessels strangely curved. The general appearance of the disc is heart or flame shaped, with the apex towards the apex of the cone. You will remember in the normal eye the

image follows the movement of the lens if shifted slightly from side to side, but no important change of shape occurs. But upon executing this manœuvre with a conical cornea the disc is seen to undergo the most violent changes of shape. The eye is, moreover, highly myopic, but no concave eye-piece will enable you to see the disc clearly in the erect image.

2. *Astigmatism*.—If you look at yourself in the back of a spoon, you note that your face is much altered, according to the direction in which you hold the bowl—if vertically, you appear preposterously long-faced; if horizontally, your cheeks are widely expanded. This is due to the fact that the long diameter of the spoon has a greater radius of curvature than the transverse, and the focal length of the curves consequently differ in proportion (*v. Reflections from Curved Surfaces*, p. 6). A normal cornea may be regarded as the segment of a transparent globe, but an astigmatic cornea as the segment of a transparent spoon. Now if we suppose the transverse curvature of such a cornea to be of the radius required (plus the other dioptric media) to bring parallel rays to a focus exactly on the retina, it is obvious that if the vertical curvature be of a shorter radius (*i.e.*, more convex), the refractive power of the

eye could be increased in that direction, and parallel rays could be brought to a focus in front of the retina.

In other words, such an eye would be emmetropic in a transverse direction, and myopic in the vertical. Or the curvature of the faulty meridian might be less than the normal, and then the eye would be emmetropic in the transverse and hypermetropic in the vertical direction.

This constitutes the simplest form of astigmatism. The complete estimation of astigmatism is quite beyond a beginner's powers, but you may readily learn to recognise its existence with sufficient precision for all ordinary purposes.

In the erect image the optic disc appears oval. If this be the actual shape of the disc, it will not alter as you approach or recede from the eye; but if it be due to unequal curvature, it will change its shape according to the distance at which you view it. A disc which appears oval with the long diameter vertical at two inches, and changes to an oval with the long diameter horizontal as you recede from the eye, is seen through an astigmatic cornea. Of course the change of shape varies according to the degree and nature of the curvatures, but the fact of a change occurring is diagnostic.

It is obvious that the vertical and horizontal vessels cannot be in focus at the same time. If the vertical meridian should be emmetropic, and the transverse myopic, the vessels passing upwards and downwards would be blurred in the erect image, while those passing horizontally would be seen clearly. If in the erect image certain vessels are blurred while others can be focussed clearly, astigmatism should always be suspected.

In the inverted image the disc can be made to vary its shape by moving the objective to and fro.

If the objective is first held exactly at its focal distance from the cornea, and gradually moved nearer, the optic disc will gradually become more and more oval. If the objective be gradually moved from the eye, it will become oval in the opposite direction when it has passed the focal length of the lens. When the lens is within its own focal length, the longest diameter of the disc corresponds with the meridian of least curvature; when it is beyond its own focal length, the longest diameter of the disc corresponds with the meridian of greatest curvature.

By the above tests a rough diagnosis of astigmatism is by no means difficult.

The Optic Disc.

In studying the optic disc the following facts must be borne in mind:—

1. The nerve accurately fills the unyielding sclerotic opening, and in the event of any swelling by soakage or cell-proliferation, the ring acts as a ligature on the distal extremity of the nerve.

2. The proper vascular supply of the disc is continuous with the intracranial, but anastomoses with the choroidal and retinal circulations.

3. The central artery and vein are not concerned in the nutrition of the disc, but are greatly influenced by the tightness with which the nerve fits the sclerotic ring.

Alterations in colour:—

The disc may be too red or too white.

The hyperæmic disc is unnaturally red.

The colour varies from pink in slight cases to violet in extreme degrees of congestion. It is more easy to estimate correctly in dark than fair people, as the normal discs of the latter always appear in the inverted image pinker than they really are. The surface of the hyperæmic disc is covered with minute red dots, and numerous small vessels can be seen radiating towards the retina. The sclerotic margin becomes obscured.

In high degrees of congestion the disc is almost undistinguishable by its colour from the surrounding fundus, and its situation has to be made out by the convergence of the central vessels.

The disc is unnaturally white in anæmia and atrophy. Some practice is required to distinguish the two conditions.

In anæmia the rest of the fundus is pale, and lights up badly. The central vessels are badly filled, but their relative size not affected. The surface of the disc not sunken, and the whiteness is due to the abstraction of pink alone, so that in the erect image the nerve can be distinguished from the porus opticus and sclerotic border. Both eyes are equally affected.

In atrophy the fundus (by contrast) looks even redder than normal. The arteries are small, and in late stages generally reduced in number, the veins in the early stage dilated, in the later shrunken, and undistinguishable from the arteries; the surface of the disc shelving (*v.* Atrophic Cup) with the margin, at first ragged (in the variety following inflammation), but afterwards sharp and even. The whiteness is due both to the abstraction of pink and the transparent grey of nerve-substance with the addition of tendinous glistening from increased connective

tissue, the whole resulting in a staring bluish-white, like skim-milk.

Alterations in Surface-Level.

1. *Depressions.*—By a well-known optical illusion, a concave disc looks as if it were convex, but a little practice enables us readily to place the right interpretation on what we see. With a binocular instrument things appear in their true relations, and the student may advantageously assist his judgment in the early part of his studies by an occasional peep through one, remembering, however, that for practical work the ordinary mirror is alone to be adopted.

To ascertain whether a space is depressed below the general level of the fundus, the vessels must be carefully examined. When the vessels pass from one level to another, they appear curved, or even bent at an angle. If the inclination is gradual, the trunk of the vessel can be continuously traced, but if the alteration of level is abrupt, the continuity of the vessel is broken—it seems to break off at the edge of the space, and then to start afresh at a little distance.

It is obvious also, that if the portion of the vessel on the higher level be accurately focussed, that on the lower must be seen more or less

indistinctly. If you are in doubt whether these indistinct portions of vessels are elevated or depressed, examine their refraction. If depressed, they will lie beyond the principal focus of the eye, and will answer the tests for myopia; if elevated, they will lie within the principal focus, and will answer the tests for hypermetropia. Small trunks form better guides than the larger vessels, as they require more accurate focussing, and hug the surface more closely.

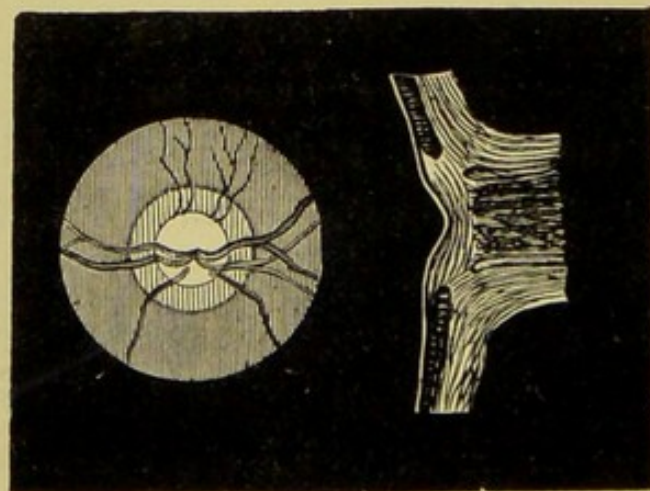
Three kinds of depression or excavations of the optic disc are to be distinguished. Of these, one is a congenital and innocent peculiarity, the others are pathological.

(1.) *The physiological pit* is an exaggeration of the *porus opticus*. It is most frequently round or oval, but sometimes irregular in shape, whiter than the rest of the surface, and only involving a portion of the nerve-surface. It has no precise margin, but shelves gradually into the higher level. The vessels as they pass over the surface of the disc are seen to bend as they approach the centre, and in well-marked cases their point of entrance is so much out of focus as to be scarcely visible.

Fig. 32 is a rough sketch of the appearances of a disc with a physiological depression in its centre, showing the mode in which the vessels dip down

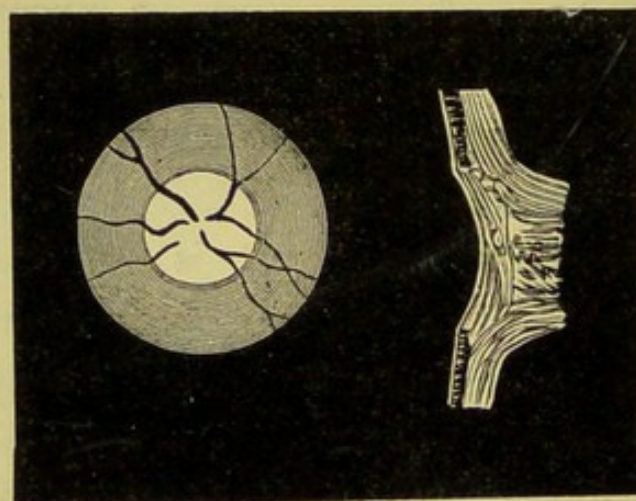
EXCAVATIONS OF THE OPTIC DISC.

Fig. 32.



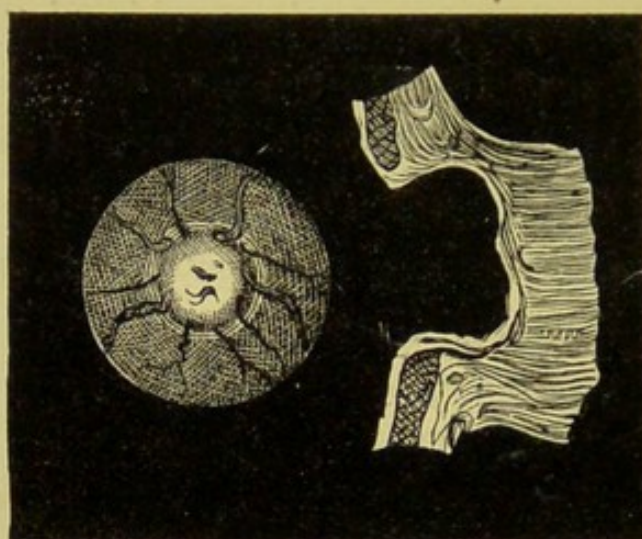
Physiological.

Fig. 33.



Atrophic.

Fig. 34.



Glaucomatous.

out of focus where the level of the nerve becomes depressed. Beneath is a sectional view showing the curve of the surface. The outer portions of the disc are seen to be on their normal level, and to slope downwards in the centre, forming a small conical pit.

(2.) *The depression from atrophy* extends more completely over the whole surface of the disc, but is shallow, and the declivity from the edge to the centre is a gentle curve. The vessels bend in a corresponding degree. The arteries are reduced in size, the veins in an early stage tortuous and dilated, but in complete atrophy greatly diminished in calibre, and undistinguishable from the arteries.

The colour of the surface is bluish-white (skim-milk or office-paper), and reflects light strongly.

Fig. 33 shows the ophthalmoscopic appearances fairly well, and the section beneath may be taken as fairly representing the gradient of the curve in an average case.

(3.) *The glaucomatous pit* is an excavation caused by increased intraocular pressure thrusting the nerve backwards through the sclerotic ring. The edge is always steep, and sometimes even overhanging. The vessels seem to climb over the edge, and disappear suddenly—isolated

portions of them can be seen towards the centre of the disc, dim, and out of focus. The surface of the disc is variously coloured bluish or greenish grey or white. The arteries are small, the veins much enlarged, knotted or beaded, and exceedingly tortuous. The disc is surrounded by a white halo of partially-exposed sclerotic. The floor of the pit can be seen to be considerably below the level of the fundus by your moving the objective slightly from side to side. The margin of the disc will move in the same direction as the lens at a greater rate than the floor of the disc, and will present the appearance of actually moving to and fro over it (p. 62). This is called the *glaucomatous parallax*.

Fig. 34 shows the sudden twist and abrupt termination of the vessels at the margin of the disc, with small portions faintly visible on the floor of the cup. The steep overhanging walls, seen in section, may be contrasted with the gradual shelving in the other excavations.

2. *Elevation of Surface.*

The Swollen Disc.—When you come to study this affection in detail, you will probably be much confused by the various opinions held as to its mechanism and nature, and distracted by the different names with which it has been invested. But

you will find all observers agree in the one point, that the disc is swollen, and projects forwards. Bearing in mind how tightly and rigidly the sclerotic ring encircles the optic nerve, you are prepared to find that any cause which tends to increase the diameter of the portion so encircled—whether by retardation of the venous flow by direct pressure, or the injection of intracranial fluid down the course of the nerve, or by active cell-proliferation—must cause the distal extremity of the nerve to swell up like the top of a champagne-cork. It is to this swollen condition you must give the closest attention, as it is of great importance in the diagnosis of coarse intracranial disease. With its pathology we have here no concern, but we may practically divide our cases of swollen disc into three classes, which differ in ophthalmoscopic appearances, though agreeing in the one common character of elevation. Although a cupped disc appears at first sight convex, the converse is not true. A swollen disc is not an obvious phenomenon, although by a little attention to signs it is easy of recognition.

1. It projects forwards, and can be seen at a little distance in the erect image.

The swelling is made up of new and congested blood-vessels, of serum, and of inflammatory products; and the apparent surface of the disc is

therefore advanced, so that its refraction is hypermetropic.

2. Its diameter is enlarged.

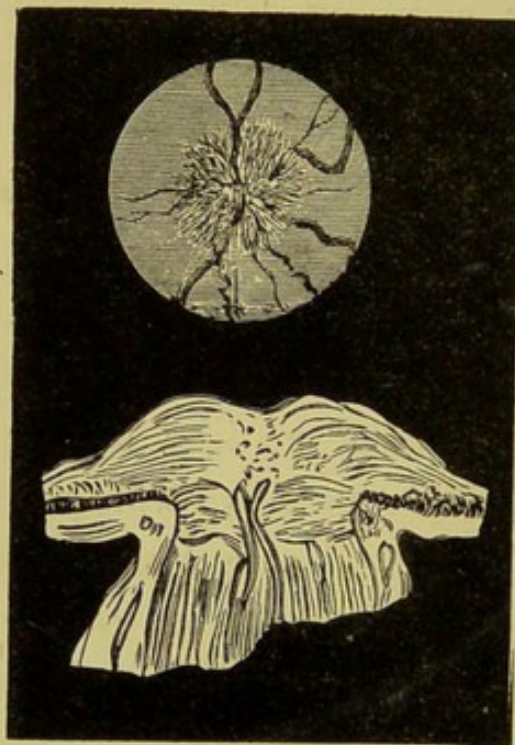


Fig. 35.—Swollen Disc.

The optic-nerve fibres, as they radiate from the centre of the disc, are infiltrated for some little distance beyond its margin, and rendered grey and opaque, so as to look like a continuation of the natural surface of the disc.

3. The margin is woolly.

The infiltration shades off with a fluffy or woolly edge into the unaffected retina. The natural margin of the disc is hidden.

4. The central veins are enlarged, arteries diminished.

The constriction at the sclerotic ring impedes both the ingress and egress of blood. The veins are greatly enlarged, tortuous, and knotted. As they pass on to the surface of the disc, they are more or less covered by the exudation, sometimes completely; sometimes a bend will appear to dip beneath the surface and then reappear again, like portions of a line of railings cropping up here and there above the surface of a snowdrift.

The arteries are reduced to mere threads, and are seen with difficulty, or not at all.

A swollen disc is observed in three different conditions.

(A.) When the predominant signs are those of vascular arrest.

The projection is very steep on one side, but slopes gradually down to the level of the disc on the other. The surface has a mossy look, and the margin of the disc is fringed with a fluffy grey border, which on close inspection can sometimes be made out as composed of innumerable small vessels and more or less semi-transparent effusion. The optic-nerve fibres are swollen and slightly opaque, so that they present a faint appearance of radiation. The colour varies from violet, reddish-grey, to a faint dusky grey scarcely tinged with colour. Numerous minute red spots are dotted over the

exudation; some are loops of distended vessels, others small extravasations.

This condition constitutes the first stage of the optic neuritis consequent upon tumours, &c., of the encephalon. It is frequently referred to under the names "Stauungs papille," choked disc, or ischæmia papillæ.

(B.) When the predominant signs are those of cell-proliferation.

The swelling of the disc is more uniform, and there is no steep, one-sided projection. The surface is less velvety, but has a more solid appearance, and presents less signs of undue vascularity. The exudation extends further beyond the margin than in the choked disc, and is far more opaque, hiding all subjacent details. The colour is less inclined towards red, and more a dirty grey, or the "stone-colour" of house-painters. The central vessels are more completely concealed. This condition constitutes optic neuritis proper.

(C.) When atrophy of the optic nerve has commenced, but the products of inflammation are not yet absorbed.

As the neuritis subsides, all signs of vascularity disappear, and the strangled nerve undergoes atrophic changes. But a quantity of exudation remains, and presents a prominent, irregular surface to view. The colour is intensely white, with a

grey border. The veins are still enlarged and contorted, the arteries seen with difficulty, or not at all.

This constitutes the declining stage of optic neuritis.

The Margins of the Disc.

You have already learned its normal contour, and made yourself familiar with the aspect of the choroidal edge and thin white sclerotic border. Sometimes the choroidal opening is disproportionately large, and the nerve is seen surrounded by a wider strip of white than usual. As the disc in these cases is not placed centrally in the opening, the band is broader on one side than the other, and presents the form of a sickle-shaped or crescentic patch of white. This, it must be remembered, is merely a structural peculiarity, and should be carefully distinguished from the pathological crescent found in cases of myopia.

A crescentic patch of black pigment is frequently seen at the margin of the choroidal opening in perfectly healthy eyes.

But the normal elements of the margin may be obscured, and the junction of the disc with the rest of the fundus appear blurred or "woolly." The edge is rendered especially woolly by exudation or infiltration of the optic-nerve fibres by

fluid in neuritis or swollen disc, and the margin in these cases is seen to extend beyond its normal dimensions, and to shade off softly like the edge of a cloud into the red of the surrounding fundus.

Conversely, the sharpness of the margin is also impaired (but in a less degree) by infiltration of the retina or choroid in the immediate neighbourhood of the disc. In intraocular pressure (glaucoma), the disc is surrounded by a narrow white halo of sclerotic, partially exposed by thinning of the choroid.

The margin may be irregular, jagged, and dotted here and there with white spots or small collections of pigment. This occurs after the disc has been swollen and is commencing to atrophy, the products of inflammation not yet being absorbed. When the atrophy is complete (or when it has not been preceded by neuritis), the margin is clear and even.

White patches may be seen at the margin of the disc extending in various directions over the fundus.

1. *Opaque Nerve-Fibres*.—In ordinary cases the neurilemma of the optic nerve ceases at the *lamina cribrosa*, and the transparent tubules are alone continued into the retina. But occasionally some of the fibres retain their sheaths, and a number

of them together present the appearance of a white patch which hides the subjacent choroid. These patches are very various in shape, but are generally either long and narrow like a tongue or fan-shaped, radiating outwards from the disc. The borders are clean, and distinct from the adjacent retina, which is perfectly transparent. The peripheral extremity has a frayed appearance, owing to the different lengths of the opaque fibres, and the surface of the patch (closely viewed in the erect image) is markedly striated. Some of the retinal vessels may be seen crossing the surface of the patch, but others will be observed emerging from beneath it. This shows the opacity to be in the inner layer of the retina, and enables it readily to be distinguished from a white patch of sclerotic seen through an atrophied space in the choroid.

The malformation is congenital and innocent, but the student must be aware of its existence, as, though by no means common, it is liable to be mistaken for a pathological product, and the unfortunate patient subjected to an energetic course of treatment and much restriction.*

2. *Inflammatory exudation*.—The retina is not

* In the rabbit a certain proportion of fibres are normally opaque, and radiate in four directions from the disc in the form of a Maltese cross. The student should carefully study the condition in one of these animals, who, by the way, submit with more philosophy to an ophthalmoscopic examination than many human beings.

unfrequently rendered opaque by exudation in the immediate vicinity of the disc. The opacity may vary from a slight cloudiness to a pronounced white. The edges of the patch are almost always bordered by a thin line of cloudy retina; the surface is not striated, the shape irregular, and the retinal vessels are covered or pushed on one side.

3. *Atrophy of the Choroid*.—In the majority of pronouncedly myopic eyes the choroid is atrophied on the outer side (real) of the disc, and a patch of sclerotic is visible through the opening. The opening varies from a small crescent (scarcely larger than the malformation already noted) to an irregular-shaped patch, which in extreme cases may entirely surround the disc, though its greatest width is always on the outer side, extending sometimes as far as the yellow spot. The surface of the patch is brilliantly white, and the disc by contrast appears pink. The retinal vessels pass *over* the surface, and are seen with unusual distinctness. There is no appearance of striation nor obscuration of vessels, as in the two previous affections.

In pronounced cases the optic disc loses its circular form, and becomes oval or irregularly pear-shaped. The sclerotic, in addition to being exposed, is thinned, and bulges backwards. The

surface of the patch is therefore beyond the focal length of the eyeballs, and details are well seen *inverted* at a distance with the mirror alone. The edge of the choroid must be carefully examined. If the edge is sharp and distinct, and merely marked by an increased deposit of pigment, the mischief is stationary. But frequently the adjacent choroid will be found to be thinned irregularly, to be dotted with small spaces through which the white gleam of the sclerotic is dimly visible, and small collections of granular pigment. Great care is required to detect these changes, which are indicative of still progressing mischief.

In distinguishing the foregoing conditions from one another, the student will find the following facts useful.

The myopic crescent is very common, exudation much less frequent, and opaque nerve-fibres rare. The vessels are unusually distinct in the crescent, but some will be altogether covered or obscured in the other conditions. The crescent extends most towards the yellow spot, the opaque fibres least towards it; exudation in any direction, but with a preference for the line of the large vessels. The surface of the crescent is brilliant white, of exudation faintly yellow or grey, of nerve-fibres striated.

The Vessels.—Venous pulsation is noticed in many eyes as a normal phenomenon, and can be produced in all by gentle pressure on the globe.

Arterial pulsation is never seen except in disease, and very seldom then.

When present in either vessel, it should not be lightly regarded, but the eye should be carefully examined for other signs of glaucoma.

The ingress and egress of blood are prevented either by tightening of the optic nerve in the sclerotic ring, or by direct pressure on the centre of the disc.

The veins are therefore enlarged, knotted, and tortuous in neuritis (swollen disc), and in glaucoma (intra-ocular pressure) the arteries at the same time are relatively and actually diminished in calibre, and straitened.

The veins remain enlarged in the early stage of atrophy following neuritis; but when the change is complete, both arteries and veins are much reduced in size.

Both vessels are reduced from the beginning in primary atrophy of the disc, and in atrophy of the retina. In the absence of the signs of mischief at the disc, enlarged tortuous veins, with relatively small arteries, are indicative of retinal hyperæmia.

The central artery may be plugged by a clot.

No arteries are visible, or they can be dimly

traced as slender grey lines on the surface of the retina. Coagula may perhaps be seen lying in some of the larger vessels, like the short column of mercury used as the register in a thermometer.

The veins are thin, and become less as they approach the disc. A peculiar undulatory movement, differing from pulsation, has been observed in recent cases, and on the restoration of circulation.

THE RETINA.

The signs of disease in the retina are—

Opacities.

Hæmorrhages.

Pigmentation.

Detachment.

1. *Opacities* vary from (*a*) slight films, just rendering the affected portions of the retina more than usually visible, like a thin layer of milk-arrowroot spread over the fundus, to (*b*) glaring white opaque patches absolutely hiding all beneath them.

Haziness of the retina, due to slight infiltration accompanying hyperæmia or early inflammatory action, is recognised by impairment of the full red glow of the choroid. This is not easily described, except as what a painter would term a

“chalkiness” in the red. It may easily escape observation in the indirect examination, or with too powerful illumination. If, therefore, in examining an eye you do not perceive any obvious signs of disease, never rest satisfied that the retina is unaffected till you have explored it by the direct method, with a feeble illumination. Care is required to discriminate between haziness in the retina and that due to slight turbidity of lens or vitreous.

The condition of the lens is ascertained by the oblique illumination.

A diffuse haziness in the vitreous is generally uniform in distribution, and the reflex appears equally cloudy in whatever direction the eye is turned; but you will almost always be able to make out certain parts of the retina to be more affected than others by carefully scrutinising the edges of the blood-vessels. In looking through a foggy vitreous, the amount of blurring is equal for vessels of equal size everywhere, and the obscurity will extend to the outlines of the vessels crossing the disc, as well as to those on the fundus; whereas in retinal haziness some vessels may be still focussed sharply, especially over the disc. As a rule, the periphery is the clearest part of the retina.

When the region surrounding the yellow spot

is affected, a peculiar appearance is observed. As the *macula* is considerably thinner than the rest of the retina, it does not obscure the choroidal reflex in an equal degree, and consequently in the centre of the pinkish-grey or whitish opacity is seen a small crimson spot. This is likely to be mistaken for a hæmorrhage.

Bear in mind that opacities of lens, vitreous, and retina not unfrequently coexist.

The denser opacities consist of inflammatory deposits, sclerosis, fatty degeneration, &c. They appear as buff, grey, or white patches, more or less opaque, varying in size from very minute discrete dots to broad masses, covering the greater part of the fundus.

The position of these deposits may be estimated by tracing the blood-vessels in their vicinity. If in the inner layers of the retina, the vessels will be pushed on one side, obscured, or altogether hidden; if in the outer, the vessels will be seen passing over the surface without alteration in their course or clearness.

The regions principally affected by deposits are in the neighbourhood of the disc, the yellow spot, and the periphery of the equator.

2. *Hæmorrhages* appear as well-defined red patches many degrees darker than the general hue of the fundus.

Recent spots are bright red. In a little time they become darker, passing into a dull brown. Ultimately they are decolourised, and remain as yellowish-grey patches; or they may be altogether absorbed, leaving no mark of their presence except a slight opacity of the retina.

Large hæmorrhages may escape forwards into the vitreous, obscuring the fundus, or, less extensive, may lie between the hyaloid membrane and the retina, as circular or dumb-bell shaped patches. Or they may escape backwards between retina and choroid, when they appear as variously-shaped patches, obscuring the details of the choroid, whilst the retina and any large vessels may be traced over the clot. The retina is of course detached.

In the layer of optic-nerve fibres hæmorrhages appear as fine linear streaks.

In some forms of retinitis (*e.g.*, that occurring in Bright's disease or diabetes) hæmorrhages are commonly seen mingled with the retinal opacities. They are for the most part irregularly-shaped splotches, and are generally in the immediate neighbourhood of larger or medium-sized vessels. In other forms the clots appear as small dots, and no connection can be traced between them and any vessel.

The only object that can possibly be mistaken

for a recent hæmorrhage is the *macula lutea*, surrounded by infiltrated retina (*v.* Opacities).

3. *Pigmentation*.—Under certain conditions pigment is deposited in the retina in the form of minute dots. The distribution follows the course of the smaller vessels. By coalescence black or dark-brown spots are formed. These are individually small in size, but very numerous, and generally grouped close together. A number of filiform processes radiate from each spot, rendering it in general form very like a bone-corpuscle or a spider. As the affection progresses, the “legs” become longer and anastomose, so that the spaces between the main deposits are filled with a fine black network.

The earliest appearance of this condition is at the extreme periphery of the retina, but in advanced cases the neighbourhood of the optic disc also becomes affected.

Compare Choroidal Pigmentation, p. 104.

4. *Detachment*.—Extensive detachment of the retina is easily seen and recognised. As you are examining the condition of the vitreous, and the patient moving his eye in various directions, the red glow of the fundus is suddenly interrupted by a dark shadow. Closer examination shows this to be caused by a grey substance which has floated, partly or entirely, across the area of the

pupil. This can be seen by the mirror alone (at six or eight inches from the eye) lying considerably in front of the normal fundus, and generally in the lower half (real). The surface is in folds or undulations, which change their shape with every movement of the eyeball.

With a little care the retinal vessels can always be made out on the surface. They have lost their characteristic tubular appearance and transparency, and appear as dark-red or dull-brownish flat streaks, like lines drawn on the membrane in bad red ink. They follow the contours of the folds, and undulate with the movement of the retina. If the detachment is small enough to allow the junction with the unaffected retina to be seen, these dark lines may be traced as the continuation of vessels proceeding from the optic disc, and in all cases you should attempt to do so. In a very extensive detachment the loose membrane flaps to and fro in the vitreous, and hides the optic disc, so that it is impossible to follow the vessel.

Smaller detachments are only seen when examining the details of the fundus. They appear as small "puckerings" or "rucks" of the retina of a silvery or pearly grey colour. At first sight these might be mistaken for exudations, but with a little care you can make out you are looking at a fold, and not at a solid opaque patch.

Look with extreme care at the vessels crossing the patch. They will be seen to be unduly tortuous at that part of their course, dark in colour, and flat, whereas the same vessels passing over the sound portions of the retina present their natural tubular appearance.

The retina at the edges of a detachment is always slightly opaque.

THE CHOROID.

The chief signs of disease in the choroid are—

Changes in colour.

Changes in pigmentation.

Patches of exudation.

Atrophic spaces.

1. *Changes in colour* are extremely difficult to recognise without great practice. Hyperæmia or slight inflammatory action, accompanied by serous infiltration, impairs the transparency of the choroid, and renders the red turbid or dirty. Less fluid exudation gives rise to a bluish tint or a pale grey, like the colour of a cigar ash. This may either be collected in one or two patches, or spread generally over the fundus. Assistance in recognising the quality of the tint is afforded by the retinal vessels, which stand out in greater contrast in proportion to the greyness of the fundus.

2. *Changes in Pigmentation.*—In old people the layer of hexagonal cells undergoes atrophy, and the pigmentation of the deeper layer of the choroid can be seen with unusual distinctness. You will be prevented from mistaking these natural markings for the effects of proliferation by having carefully studied the shapes of the pigmented spaces in the different regions of the normal fundus.

Almost all changes in the choroid give rise to deposition of pigment.

It appears as irregularly-shaped splotches, dark brown or black in colour, so that the fundus seems to be scattered with groups of ink-blots or cinders, some large, some small. These are very conspicuous, and cannot escape observation. They are easily distinguished from retinal pigmentation by their deep solid colour, their irregular shape, and by their deeper position, which is frequently indicated by retinal vessels being seen to pass clearly in front of them.

3. *Patches of Exudation.*—Inflammatory deposits in the choroid resemble similar conditions as observed in the iris. They appear as irregularly-shaped, ill-defined spots, varying in colour from a dull yellow to ash grey. They are distinguishable from retinal deposits by being less clearly seen by pigment changes in their immediate neighbourhood, and by their greater depth.

4. *Atrophied spaces* are the too frequent result of choroidal mischief. They appear as brilliant white patches of all possible shapes and sizes. They are distinguishable from retinal opacities by their sharply-defined borders, by being surrounded by irregular pigmentation, and by the vivid sharpness with which any retinal vessels which happen to cross may be seen.

The following table of some common appearances may be found useful in early examinations:—

Disc.

Surface depressed—

Physiological pit (congenital).

Atrophic (nerve-shrinking).

Glaucomatous (intra-ocular pressure).

Surface elevated—

“Choked disc” or “neuritis.”

Colour—

Red—Hyperæmia.

White—Anæmia.

Atrophy.

Margin obscured—

Hyperæmia of disc, retina, or choroid.

“Woolly”—Neuritis.

White patch in vicinity of disc—

Enlarged choroidal aperture (congenital).

Myopic crescent.

Opaque nerve-fibres.

Retinal exudation.

VESSELS.

Veins enlarged—Neuritis.

Glaucoma.

Retinal hyperæmia.

Consecutive atrophy (early).

Veins diminished—Atrophy of disc (either primary or complete consecutive).

Atrophy of retina.

Embolism.

Arteries diminished—Neuritis.

Atrophy (all stages).

Embolism.

FUNDUS.

Reflex hazy or milky—Retinitis.

Turbid vitreous (hyalitis, &c.)

Turbid lens (early cataract).

Diffuse nebulæ of cornea.

White or light-coloured patches—

Spaces of atrophied choroid.

Exudation (fatty degeneration, sclerosis, lymph, &c.)

Blood-clots decolourised.

Detached retina.

Dark patches—

Brown or black (stellate or spider-shaped)—retinal pigment.

Blotty—choroidal pigment.

Red (irregular, linear, dumb-bell, flame-shaped, circular)—recent hæmorrhages.

Yellow spot surrounded by hazy retina.

Conclusion.—You have been occupied hitherto in learning the individual structures, and the general aspect of the changes indicative of disease in each. You have studied the disc, or the retina, or the choroid separately, and for its own sake, without reference to its relationships. You have simply attempted to acquire the power of determining the actual condition of each structure without help from rational symptoms, or consideration of the concomitant changes in other parts of the eyeball. This is the first step.

You have now to proceed to study the changes wrought by diseased action more in detail, and to learn the significance of them in association. As it were, you have learned the shapes of your letters, and you have now to understand their combined powers of forming words. You pass from the appreciation of single symptoms in their simplest aspect to their variation under different conditions, and their significance, not as isolated facts, but as members of a group. For instruction in the diagnostic and ætiological value of symptoms, and for detailed accounts of actual diseases, I commend you to the guidance of other teachers, some of whom are here enumerated.

Authorities.—The plan of this little book precluded the advisability of marginal references, even were it possible to state with accuracy the

source whence elementary facts were originally derived. But I desire to express my indebtedness to the following writers, to whom the student is referred for further information in ophthalmoscopy :—

- Albutt, T. Clifford. The Ophthalmoscope in Diseases of the Nervous System, &c. 1871.
- Bader, Charles. Natural and Morbid Changes of the Human Eye. 1868.
- Carter, Brudenel. Annotated Translation of Zander on the Ophthalmoscope. 1864.
- Hulke, J. W. The Ophthalmoscope. 1861.
- Hutchinson, Jonathan. Royal Ophthalmic and London Hospital Reports, &c., *passim*.
- Jackson, Hughlings. Medical Times and Gazette, &c., *passim*.
- Macnamara, C. Manual of Diseases of the Eye. 1872.
- Von Carion, C. Stelwag. Treatise (Amer. trans.) 1868.
- Wells, Soelberg. Treatise. 1869. (New edition since.)
- Wecker, L. de, and Jaeger, E. de. Traité des Maladies du Fond de l'Œil et Atlas d'Ophthalmoscopie. 1870.

THE END.

