

Illustrations of some of the principal diseases of the eye : with a brief account of their symptoms, pathology, and treatment / by Henry Power.

Contributors

Meneses, Henry Power.
Brown, H. W.
University College, London. Library Services

Publication/Creation

London : John Churchill and Sons, MDCCCLXVII [1867]

Persistent URL

<https://wellcomecollection.org/works/zb5wdcsv>

Provider

University College London

License and attribution


This material has been provided by This material has been provided by UCL Library Services. The original may be consulted at UCL (University College London) where the originals may be consulted.

This work has been identified as being free of known restrictions under copyright law, including all related and neighbouring rights and is being made available under the Creative Commons, Public Domain Mark.

You can copy, modify, distribute and perform the work, even for commercial purposes, without asking permission.



Wellcome Collection
183 Euston Road
London NW1 2BE UK
T +44 (0)20 7611 8722
E library@wellcomecollection.org
<https://wellcomecollection.org>



J/-

2809396760

OPHTHALMOLOGY HC602 POWER

ILLUSTRATIONS

OF SOME OF THE PRINCIPAL

DISEASES OF THE EYE,

WITH

H.W. Brown

A BRIEF ACCOUNT OF THEIR
SYMPTOMS, PATHOLOGY, AND TREATMENT.

BY

HENRY POWER, F.R.C.S.,
M.B. LOND.,

SURGEON TO THE ROYAL WESTMINSTER OPHTHALMIC HOSPITAL; ASSISTANT SURGEON TO,
AND LECTURER ON, PHYSIOLOGY AT THE WESTMINSTER HOSPITAL.

LONDON:

JOHN CHURCHILL AND SONS, NEW BURLINGTON STREET.

MDCCCLXVII.

~~AM Brown~~



2809396760

EDINBURGH :
PRINTED BY SCHENCK AND M'FARLANE,
ST JAMES' SQUARE.

P R E F A C E.

DURING the last ten years, I have been in the habit of taking drawings of almost every interesting case that came under my observation at the Royal Westminster Ophthalmic Hospital. At first rude enough and mere sketches, I at length found that with pains and care I was able to make tolerably faithful transcripts of the various forms of disease that presented themselves; and having collected in this way some hundreds of drawings in water-colours, I thought I might make them of service to the profession by the aid of lithography. I have been obliged, however, materially to diminish the number of illustrations I originally intended to publish, on account of the great and unavoidable expense attendant on their being printed in colours; and also, from finding as I proceeded that, notwithstanding the excellence and ability of the artists employed by Messrs Hanhart, of Charlotte Street, Fitzroy Square, by whom the first six plates were printed, and also by Mr M'Farlane, of Edinburgh, to whose care I committed the rest, chromo-lithography was scarcely capable, without an expenditure totally disproportioned to the end in view, of expressing the fine shadings of colour which enable the practised eye to distinguish various yet similar forms of disease, and which are so easily attainable by the brush.

In the accompanying letterpress I have endeavoured to give a very concise view of the pathology and surgery of the eye, omitting generally such subjects as appeared to me to be matters of curiosity or rarity only, and also all details with which it seemed reasonable to suppose that every surgeon would be familiar.

HENRY POWER.

UPPER SEYMOUR STREET, PORTMAN SQUARE,

September 1867.

CONTENTS.

CHAPTER I.

GENERAL ANATOMY AND DISEASES OF THE ORBIT.

	PAGE
General Description of the Orbit and its Contents—Wounds and Injuries of the Orbit—Tumours in the Orbit—Caries and Necrosis of the Orbital Parietes—Inflammation of the Cellular Tissue of the Orbit—Protrusion of the Globe—Aneurism—Cancer,	1

CHAPTER II.

STRABISMUS.

Origin and Insertion of the several Muscles moving the Eye—Their Action—Causes of Strabismus—Diagnosis of the Different Forms of Strabismus—Symptoms of Strabismus from Paralysis of the Third Nerve—Of the Sixth Nerve—Of the Fourth Nerve—Treatment of Strabismus,	31
--	----

CHAPTER III.

DISEASES OF THE LACHRYMAL ORGANS.

General Anatomy of the Lachrymal Gland—Canaliculi—Lachrymal Sac and Nasal Duct—Inflammation of the Lachrymal Gland—Lachrymal Fistula—Obstructed Ducts and Lachrymal Abscess,	57
--	----

CHAPTER IV.

DISEASES OF THE EYELIDS.

General Anatomy of the Lids—Inflammation, Erysipelas, Abscess, Wounds, Contusions, and Injuries of the Lids—Ophthalmia Tarsi—Phtheiriasis Ciliarum—Hordeolum—Ulcers of the Lids—Epithelial	
--	--

	PAGE
Cancer of the Lids—Tumours of the Lids—Epicanthus—Chrom- hydrosis—Morbid Nictitation and Blepharospasm—Ptosis—Symble- pharon—Ectropion—Trichiasis, Distichiasis, and Entropion,	83

CHAPTER V.

DISEASES OF THE CONJUNCTIVA.

Structure of the Conjunctiva—Simple, Acute, and Chronic Inflamma- tion of the Conjunctiva—Catarrho-Rheumatic Ophthalmia—Phlyc- tenular Ophthalmia—Purulent Ophthalmia of Children—Contagious Ophthalmia—Gonorrhœal Ophthalmia—Diphtheritic Ophthalmia— Granular Lids—Pterygium—Ecchymosis of the Conjunctiva— Tumours of the Conjunctiva—Encanthis—Syphilitic Affections of the Conjunctiva,	161
--	-----

CHAPTER VI.

DISEASES OF THE CORNEA AND SCLEROTICA.

General Anatomy and Pathology of the Cornea and Sclerotica—Arcus Senilis—Inflammation of the Cornea or Keratitis—Chronic Inter- stitial Keratitis—Pannus—Ulcers of the Cornea—Opacities of the Cornea—Staphyloma of the Cornea—Conical Cornea—Neuro-Para- lytic Affections of the Cornea,	235
---	-----

CHAPTER VII.

DISEASES OF THE CHOROID, IRIS, AND VITREOUS.

General Anatomy of the Choroid, Iris, and Vitreous—Irideremia—Colo- boma Iridis—Mydriasis and Myosis—Effects of Atropine and of the Extract of Calabar Bean—Iritis: its several Forms, its Consequences, and Treatment—Modes of Operation for the Formation of Artificial Pupil—Coretomy—Corelysis—Iridectomy—Iridesis—Ophthalmos- copic Appearances of the Choroid—Irido-Choroiditis—Cyclitis and Sympathetic Ophthalmia—Choroiditis Serosa or Glaucoma—Choroid- itis Plastica—Various Morbid Conditions of the Choroid,	336
--	-----

CHAPTER VIII.

DISEASES OF THE RETINA.

General Anatomy of the Retina—Hyperæmia of the Retina—Ecchymosis of the Retina—Retinitis: its various Forms, Diffused, Nephritic, Syphilitic, and Glycœsuric—Pigmentary Degeneration of the Retina
--

CONTENTS.

vii

PAGE

—Detachment of Retina from the Choroid—Embolism of the Central Artery of the Retina—Morbid Conditions of the Optic Nerve—Amblyopia and Amaurosis,	439
---	-----

CHAPTER IX.

DISEASES OF THE LENS.

General Anatomy of the Lens—Ætiology and Pathology of Cataract—Principal Varieties of Cataract—Various Modes of Operation for the Removal of Cataract—Division and Solution—Depression—Extraction of the Lens by Flap Operation—Extraction by Linear Incision and by Modified Linear Incision—by Suction—Accidents and Evil Results of these Operations—Subsequent Treatment,	492
---	-----

CHAPTER X.

WOUNDS AND INJURIES OF THE EYE.

Injuries of the Conjunctiva and Exposed Surfaces of the Sclerotic and Cornea—Injuries Implicating the Iris, Lens, Choroid, and Retina—Panophthalmitis,	548
--	-----

CHAPTER XI.

DISEASES OF ACCOMMODATION AND REFRACTION.

Emmetropia—Ametropia—Nature of the Act of Accommodation, and Means by which it is Effected—Range of Accommodation—Sharpness of Vision—Hypermetropia—Presbyopia—Myopia—Astigmatism,	587
--	-----

ERRATA.

Page 274, line 29, *for* Plate IX. fig. 54, *read* Plate X. fig. 60.

Page 448, line 15, *for* figs. 53, 55, 56, *read* figs. 44, 50, 59.

Page 477, line 8, *for* fig. 56, *read* fig. 50.

„ line 17, *for* fig. 57, *read* fig. 51.

171

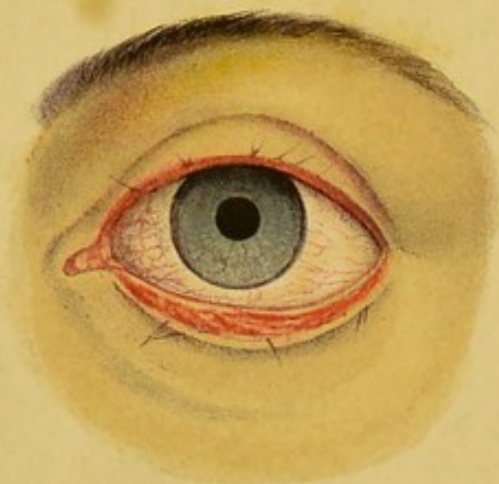
fig. 14, and Plate I. fig. 14

2, 3, and figs. 14, 20, 21

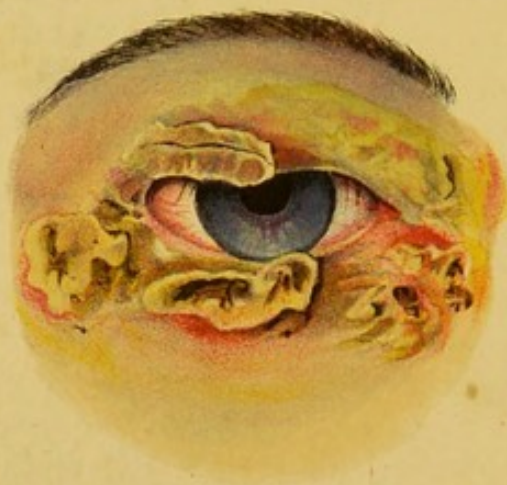4 fig. 20

and fig. 21

1.



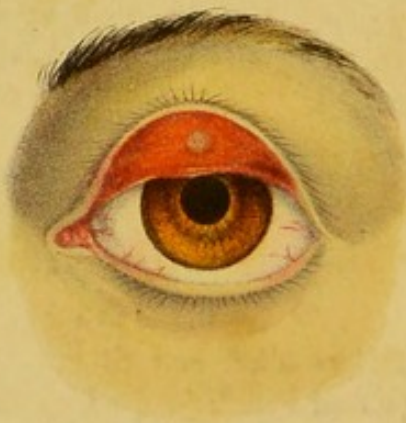2.



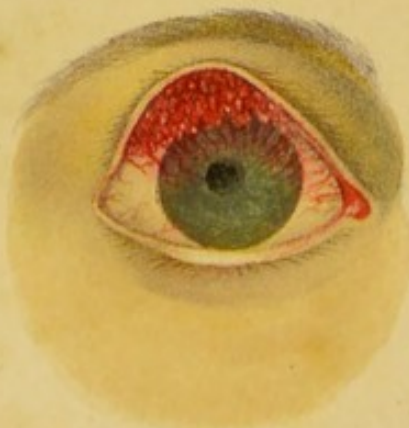3.



4.



5.



6.

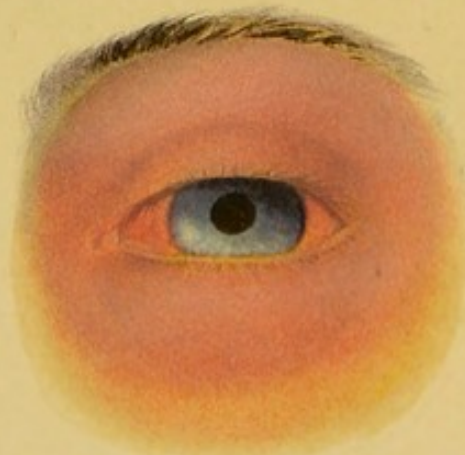

PLATE I.

FIG. 1.

A case of ophthalmia tarsi (blear eyes). The margins of the lids are red, sore, ulcerated, and thickened; the palpebral conjunctiva redder than natural. The cilia are few, having dropped out from ulceration of the follicles and sebaceous glands. Those that remain are short, stunted, agglutinated, and irregularly directed; the ocular conjunctiva is usually congested and watery, the tears being secreted in greater abundance than in the healthy state, and from the closure or eversion of the puncta, being imperfectly discharged into the nose. The Meibomian glands may often be seen to be perfectly healthy.—*V.* p. 111.

FIG. 2.

A case of impetigo of the lids, or crusta lactea. The child, *æt.* 5, had long been subject to ophthalmia tarsi, was ill-nourished, and very dirty. A week previously it had caught cold in the eye, and had been vigorously rubbing the lids to relieve the severe itching experienced. The scabs were large, thin, of various colours, yellow, ashen grey, brown, and green, partially detached from the skin, which beneath them was red, and somewhat moist, discharging a thin ichor. The cilia had almost all fallen off (*madarosis*), and those that remained were stunted.—*V.* p. 116.

FIGS. 3 and 4 (Chalazion).

A very common form of cyst of the eyelid. When the lids are closed, as in fig. 3, the tumour is smooth and uniform, and the skin, which in the early stages is freely moveable, is in no way discoloured; it is hard to the touch. On everting the lid a small bluish spot is perceived, not quite so defined as in fig. 4, surrounded by a little vascular zone. On pricking it with a needle, a little clear or opalescent fluid escapes, and healing follows.—*V.* p. 109.

FIG. 5.

A case of granular lids, such as may be frequently seen amongst the poor Irish, and those who have long suffered from conjunctival inflammation. The lids are more or less thickened (tylosis), and, on everting them, the papillae are seen red and hypertrophied, projecting from their inner surface. The largest are most distant from the palpebral margin. The irritation occasioned by these rough projections causes the development of vessels over the cornea, which is otherwise rendered more or less opaque by the formation of a thin membrane on its surface, and by the proliferation of its outer layers of cells (superficial keratitis). The eyelids are gummed together in the morning, and there is a considerable amount of puriform discharge. This form frequently follows, but is distinct from, the true "trachoma" or contagious ophthalmia of armies. In the latter form of disease the granulations are smaller, rounder, more scattered, and paler than in those represented in the Plate. They are said to be pearl or sago-like.—*V.* p. 209.

FIG. 6.

A case of erythema of the lids. The colour of the skin was bright red, the conjunctiva was congested, and the redness disappeared on slight pressure. No cause could be assigned for the occurrence of the disease beyond exposure to bright sunlight. An emetic, which was given because the breath was foetid and the tongue foul, and a little lead lotion, effected a perfect cure in forty-eight hours.—*V.* p. 92.

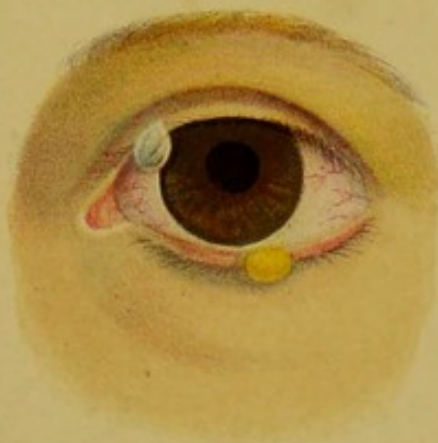FIG. 5.

as may be frequently seen amongst
have long suffered from conjunctival
more or less thickened (hypertrophied), and
are seen red and hypertrophied, pro-
n. The largest are most distant from
irritation occasioned by these rough-
ment of vessels over the cornea, which
or less opaque by the formation of a
, and by the proliferation of its outer
stratified). The epithelium is granular
there is a considerable amount of
m frequently follows, but is distinct
or contagious ophthalmia of acute
the granulations are smaller, rounder,
as in those represented in the Plate
go-like.—F. p. 209.

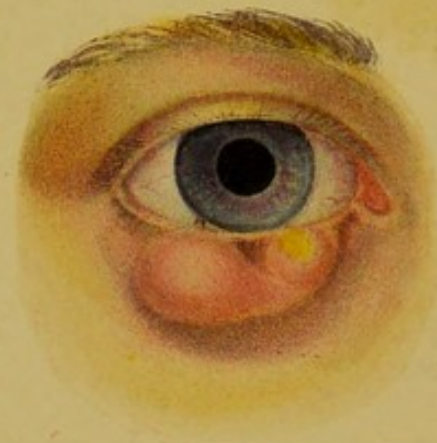
FIG. 6.

lids. The colour of the skin was
was congested, and the redness disap-
the cause could be assigned for the
and exposure to bright sunlight. An
cause the breath was fetid and the
action, effected a perfect cure in forty-

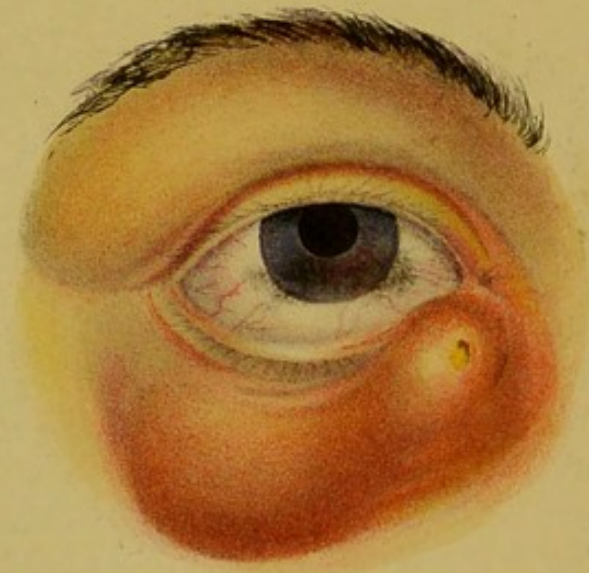7.



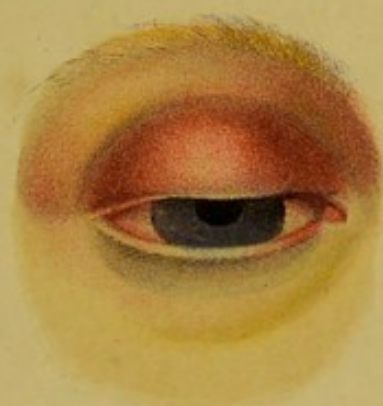8.



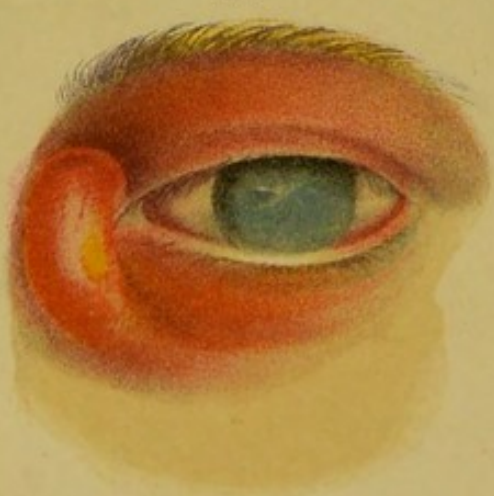10.



9.



11.



12.

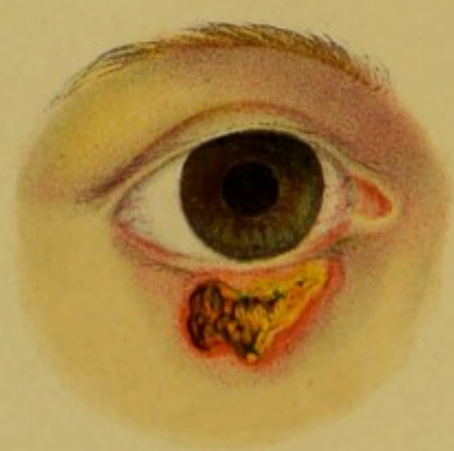

PLATE II.

FIG. 7.

Common forms of tarsal tumours. Though here represented of small size, they may grow indefinitely. That in the upper lid was covered by an extremely thin pellicle, contained watery fluid, and did not return after being snipped off with scissors, and the base touched with a point of nitrate of silver. That on the lower eyelid probably originated from the closure of the orifice of a sebaceous follicle, and the gradual dilatation of the tube. When the skin covering it had been divided, a thick, firm sac presented itself, the interior of which was filled with a pultaceous white fat. The sac and contents were both removed, and by careful adaptation of the lips of the little wound, healing by immediate union occurred.—*V.* p. 107.

FIG. 8.

A severe case of hordeolum or styne on the lid. The swelling was here double, of a dusky red colour. The inner pustule had burst; the outer was maturing, the pain was severe; lachrymation and agglutination of the lids were well marked. The patient was a dark-complexioned girl, 15 years of age, who had had no less than thirty-five in succession. The bowels were much disordered. The treatment adopted, which proved successful, was the steady administration of steel, with purgatives.—*V.* p. 117.

FIG. 9.

Abscess of the upper lid occurring in a child *æt.* 3. The lid was of a uniform dark red, or almost livid colour, the skin tense and shining, the pain and sense of throbbing distressing. There were moderate redness of the conjunctiva and lachrymation. On being opened, about half a drachm of well-formed pus escaped, with immediate relief to the symptoms, and no ill effects ensued, though in such instances it is by no means uncommon to find that the gradual contraction of the abscess induces eversion of the lid.—*V.* p. 90.

FIG. 10.

A case of abscess situated at the inner canthus of the eye, but not apparently connected with the lachrymal sac. There had been no previous obstruction to the flow of the tears, and none followed the subsidence of the disease. The abscess had just burst when the drawing was taken. The colour of the swelling was dusky-red, except at the apex, where the skin had sloughed, and there was considerable diffused red swelling of the loose connective tissue between the lid and the cheek. The duration of the disease had been ten days. It was only requisite here to apply poultices, and to adopt general tonic measures. It would have been highly improper to slit up the canaliculus.

FIG. 11.

A case of obstructed nasal duct, followed by inflammation of the lachrymal sac, and the formation of an abscess. The primary disease had existed many years; the secondary less than a week. The pain had been most intense. The form of the swelling and its position corresponded to that of the lachrymal sac, and it presented a slight constriction in the central part, where it was crossed by the tendo oculi. The cornea was opacified, and the pupil was invisible—the results of a former injury with lime. The canaliculus was slit up, and the contents of the abscess evacuated. A few days subsequently a large probe was with difficulty passed through the nasal duct, and considerable improvement resulted, though the tears, on exposure to cold air, still continued to flow over the cheek.—*V. p. 67, et seq.*

FIG. 12.

An ulcer, believed to be of specific nature, on the outer surface of the lower lid. The margins were somewhat raised, rounded, and of an angry red colour. The base was moist, but not discharging, and presented here and there a dirty, smutty, brown scab. It had existed for many months.—*V. p. 105.*

FIG. 10.

at the inner canthus of the eye, but the lachrymal sac. There had been flow of the tears, and some followed. The abscess had just burst when the hour of the swelling was dusky red, the skin had sloughed, and there was filling of the loose connective tissue. The duration of the disease had requisite here to apply position, and area. It would have been highly in-

FIG. 11.

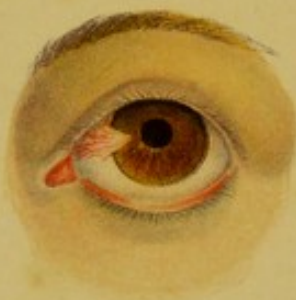duct, followed by inflammation of the nation of an abscess. The primary was; the secondary less than a week. The form of the swelling and its of the lachrymal sac, and it presented lateral part, where it was crossed by the squarish, and the pupil was invisible—y with time. The canaliculi were all because evacuated. A few days when difficulty passed through the usual moment resulted, though the tears, on turned to flow over the cheek.—F. p.

FIG. 12.

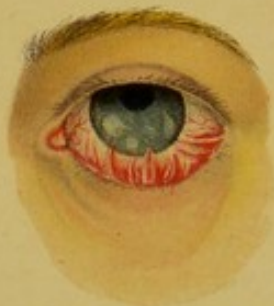of specific nature, on the outer surface as were somewhat raised, rounded, and the base was moist, but not discharging, a dirty, crusty, brown scale. It had C. p. 100.

PLATE III.

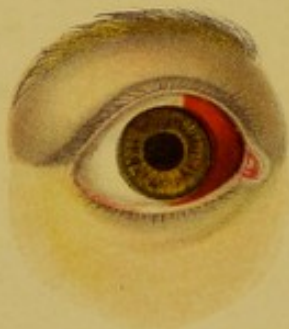13.



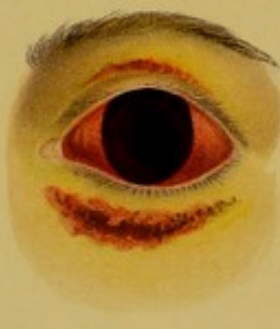14



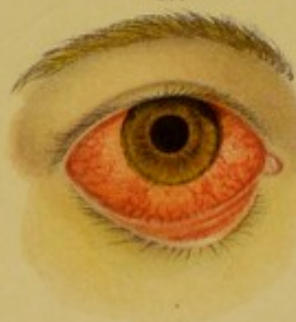1.5



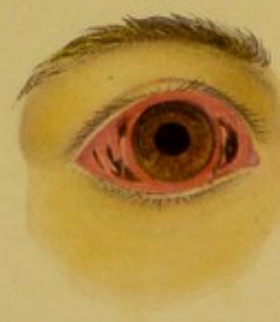16



17.



18.



PLATE

A case of pterygium, which is seen to correspond, is most frequently on internal nerves. A few vessels run above that of the adjoining conjunctiva and terminates in a rounded apex and centre of the cornea, being in no way interfere with vision, joining it near the apex with a pair, ending it off with a small, sharp seal close. On the reappearance of the a thin semi-transparent membrane of disease.—T. p. 219.

Fig. 1

An example of syphilis. The surfaces of the conjunctiva are un-
derlaid with a gradually obstructive
The cornea, when the drawing was
subsequently it became pannous (E
blindness followed—the result less
radically made of life of the man
of the upper lid.—F. p. 132.

11

An instance of simple ecchymosis by the rupture of a small vessel fully contracted with the next poured out is of dark colour, and red. The conjunctiva is slightly polished, but iridating or lobed often, especially towards the defect. Vision was unimpaired.

PLATE III.

FIG. 13.

A case of pterygium, which is seen to be of triangular form, and to correspond, as most frequently occurs, with the position of the internal rectus. A few vessels ramify on its surface, which is raised above that of the adjoining conjunctiva. It is smooth and opaque, and terminates in a rounded apex, about midway between the margin and centre of the cornea. It was not painful, nor did it in any way interfere with vision. Its removal was effected by seizing it near the apex with a pair of toothed forceps, and dissecting it off with a small, sharp scalpel. The cornea beneath was clear. On the reappearance of the patient, two years afterwards, a thin semi-transparent membrane occupied the original site of the disease.—*V.* p. 219.

FIG. 14.

An example of symblepharon. Here the palpebral and ocular surfaces of the conjunctiva are united by numerous tough bands of cicatricial tissue, greatly obstructing the movements of the globe. The cornea, when the drawing was taken, was merely nebulous, but subsequently it became pannous (fig. 5), opaque, and atrophied, and blindness followed—the result less of the symblepharon than of the uncleanly mode of life of the man, inducing a granular condition of the upper lid.—*V.* p. 132.

FIG. 15.

An instance of simple ecchymosis of the conjunctiva, occasioned by the rupture of a small vessel in coughing. It should be carefully contrasted with the next two drawings. Here the blood poured out is of dark colour, and obviously superficial to the sclerotic. The conjunctiva is slightly raised, and presents a smooth and polished, but undulating or lobulated surface. The limits of the effusion, especially towards the margin of the cornea, are well defined. Vision was unimpaired.—*V.* p. 223.

FIG. 22.

A case of ectropion, or eversion of the lid, occasioned by the bursting of an abscess, and the gradual contraction of the sac and cicatrix. The inner surface of the lid is seen to be everted and rugous, though its shape is tolerably well preserved. The globe of the eye, constantly exposed to the irritation of dust and foreign bodies, has undergone repeated attacks of inflammation, resulting in its almost complete opacity, the iris being only just perceptible at its lower part. A few vessels ramify on its surface.—*V. p. 137.*

FIG. 23.

Vesicular ulceration of the conjunctiva. The ulcers appear as a chain of small circular depressed spots, with clear or hazy bases, and a margin of clouded cornea. This cloudiness is due to the proliferation of nuclei and cells. The vessels of the conjunctiva advance over the margin of the cornea, constituting pannus. Lachrymation, intolerance of light, and pain, were all well marked in this case.—*V. p. 306.*

FIG. 24.

A strongly-marked example of pannus, the vessels of the conjunctiva being very numerous and closely arranged, presenting the appearance of a red rag over the cornea at its upper and outer part. There is also a well-marked circum-corneal zone of vessels, as the patient was suffering from rheumatic ophthalmia. The anterior chamber was remarkably deep. The subject of the disease was a man, by occupation a butcher, and 21 years of age. It had only lasted ten days, the eye being previously perfectly sound. He had only recently recovered from small-pox, and attributed the attack to exposure to cold during his convalescence. He was ordered to apply six leeches, and subsequently a hot linseed-meal poultice, to promote the bleeding; to take dec. cinchonæ, with ʒj. of the liq. hyd. bichlorid.; and I perforated the cornea with a broad needle, in the act of performing which I was much struck with its extremely soft condition at the pannous part. Recovery, though with the persistence of a nebula at the upper part of the cornea, slowly occurred.—*V. p. 292.*

FIG. 22

version of the lid, occasioned by the
the gradual contraction of the sac and
of the lid is seen to be everted and
tolerably well preserved. The globe
to the irritation of dust and foreign
attacks of inflammation, resulting in
the iris being only just perceptible at
the center of its surface.—Fig. 117.

FIG. 23

conjunctiva. The alveoli appear as a
red spots, with clear or hazy bases, and
This cloudiness is due to the prolifer-
the vessels of the conjunctiva advance
constituting papillae. Lachrymation,
were all well marked in this case.—

FIG. 24

of papillae, the vessels of the cor-
and closely arranged, presenting the
the cornea at its upper and outer part.
circum-circum-nose of vessels, as the
hemorrhagic ophthalmia. The interior

The subject of the disease was a
and 21 years of age. It had only
previously perfectly sound. He had
small-pox, and attributed the attack to
overexposure. He was ordered to
apply a hot linseed-meal poultice, to
the inner canthus, with 3j of the lip-
and the cornea with a lead pencil,
to I was much struck with its ex-
tensive part. Recovery, though with
the upper part of the cornea, slowly

FIG. 28.

A case of ulceration of the cornea, with formation of pus and development of vessels between the lamellæ, occurring in an old and ill-nourished rheumatic patient, and following a trifling abrasion of the cornea with the finger-nail of an infant. The circum-corneal zone was well defined, and of a dark tint. The cornea was hazy at the margins, so that the pupil could scarcely be seen, even upon lateral examination. The general surface was eroded, the ulcer being deep, with irregular margins, and with a larger vessel running from above downwards and outwards. The pain was severe. Opium and tonics were administered, and she recovered with only a moderately-dense leucoma, of considerably smaller size than the original ulcer.—*V.* p. 286.

FIG. 29.

A case of leucoma, just such as would be produced in the foregoing case, of which, however, it is not a copy. The accidental absence of the opacity opposite the pupil caused it to interfere very little with vision. The sclerotic is seen to be healthy. So much of the iris as could be observed was perfectly natural, and its movements free.—*V.* p. 315.

FIG. 30.

A very severe case of inflammation of the cornea, arising from a blow on the cornea with a piece of metal (tenth day). The conjunctiva is seen to be deeply congested, and to a certain extent chemosed, concealing the circum-corneal zone of redness, which would otherwise have been visible. The cornea is almost everywhere infiltrated with pus of a semi-solid tenacious nature. Neither the iris nor the pupil could be distinguished. The pain had been severe, but when the sketch was taken it was trifling. Dense leucomata followed, but the outer part of the cornea cleared sufficiently to allow iridectomy to be performed with good results.—*V.* p. 558.

FIG. 22.

cornea, with formation of pus and even the lamellae, coming in an old patient, and following a trifling abrasion of an infant. The cornea-normal a dark tint. The cornea was hazy at all could scarcely be seen, even upon normal surface was eroded, the sclerogenic, and with a larger vessel running outwards. The pain was severe, mistreated, and she recovered with only of considerably smaller size than the

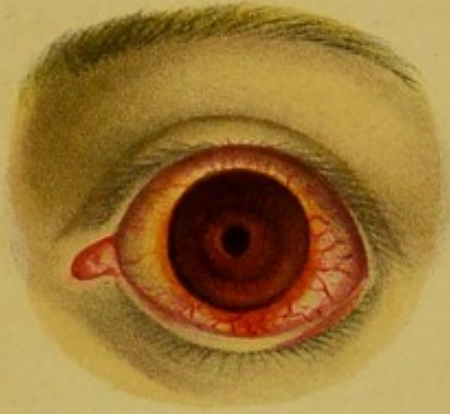FIG. 23.

it as would be produced in the face, it is not a copy. The accidental of the pupil caused it to interfere very it is seen to be healthy. So much of was perfectly natural, and its move-

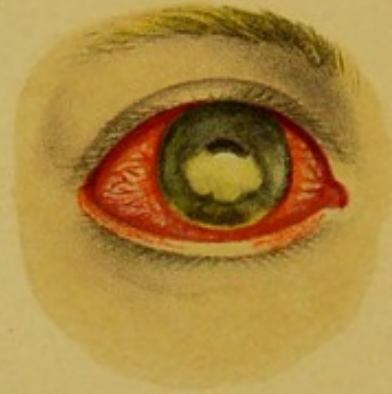FIG. 24.

operation of the cornea, arising from a use of metal (beach day). The cornea congested, and to a certain extent cornea-normal zone of redness, which visible. The cornea is almost everywhere semi-solid heretofore nature. Neither distinguished. The pain had been was taken it was trifling. Dense outer part of the cornea cleared out, be performed with good results.—V.

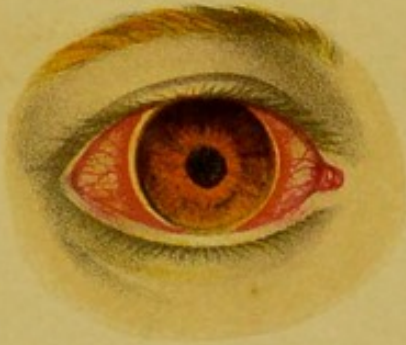31.



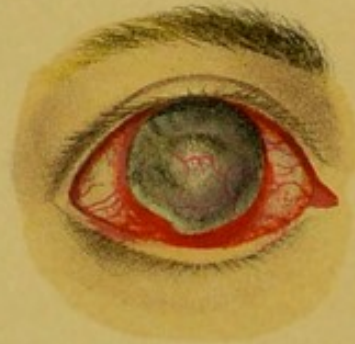32.



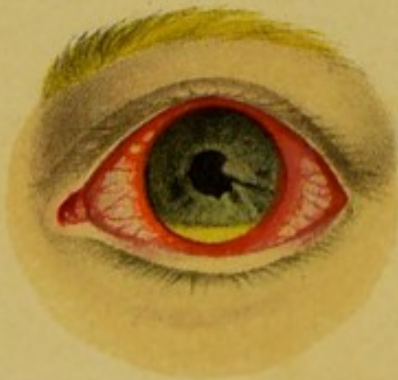33.



34.



35.



36.

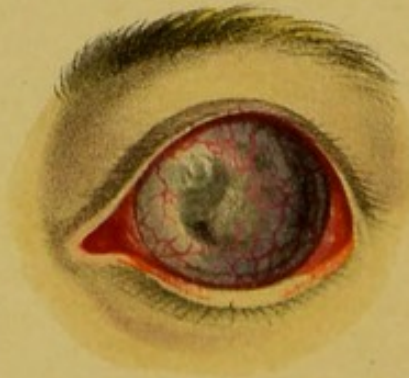

PLATE VI.

FIG. 31.

An illustration of a case of catarrho-rheumatic ophthalmia in a boy *æt.* 16. He had been apprenticed to a seal-engraver, and had worked very hard at the business for nine hours a-day. He had been exposed to wet and cold, and for the previous ten days had experienced pain in his eyes and over the brows. The conjunctiva is seen to be considerably injected. There is a tolerably well-defined circum-corneal zone of vessels. The cornea is clear. The markings on the iris are well defined. The pupil is small. Intolerance of light and lachrymation were present. Purging, a few doses of colchicum and aconite, and rest from his work, quickly effected a cure.—*V.* p. 257.

FIG. 32.

A case of hypopyon and onyx, arising from cold, occurring in a man *æt.* 36 (third week). The conjunctiva is deeply congested, the circum-corneal zone very well defined; the onyx nearly conceals the pupil, whilst the fluid forming the hypopyon has gravitated to the bottom of the anterior chamber. There were much pain, lachrymation, and headache. His habits had been extremely unsteady. A puncture was made with a broad needle through the lower part of the cornea, which permitted the escape of the aqueous, with the greater part of the puriform fluid forming the hypopyon. Eight leeches were applied to the temple, and the *mist. ferri aperiens* ordered to be taken thrice daily. Great relief to the pain and refreshing sleep followed, and recovery, with the persistence of a dense leucoma, which, however, considerably cleared in the course of the following year, occurred.—*V.* p. 286.

FIG. 33.

A case of rheumatic ophthalmia, on the fourth day of its occurrence, in a woman *æt.* 40. The drawing presents the white line between the circum-corneal zone of redness and the periphery of the cornea, which was at one time considered to be characteristic of rheumatic ophthalmia. The patient was an Irishwoman, had had many similar previous attacks, and was quickly cured by the application of a few leeches, the administration of colchicum and aconite, and the use of warm fomentations.—*V.* p. 257.

FIG. 34.

Partial staphyloma corneæ in a boy, æt. 5, following an attack of measles, which left him in an exceedingly reduced state. The lower segment of the cornea projects considerably, the base of the swelling softening off above into the healthy cornea, behind which the iris can be discerned. The circum-corneal zone of redness is well marked, especially below. A few vessels ramify on the opaque projecting part of the cornea, and at one point externally. This presents an attenuated spot, through which a little light enters. The staphyloma was no doubt in this instance the result of the gradual yielding of the cicatricial tissue, by which the repair of an ulcer was effected.—*V.* p. 316.

FIG. 35.

A case of hypopyon, occurring in a patient who was liable to such attacks, on exposure to cold, or to very bright light. An ulcer had formed and penetrated the cornea, which had been followed by cicatrization, and to the leucoma which marked the site of the ulcer the iris was adherent. The formation of pus no doubt proceeded from the iris, irritated by vain attempts to contract and dilate with variations of light. On two or three occasions the application of a few leeches, a purge, and the administration of the *mist. ferri aperiens* quickly subdued the inflammation, and the matter disappeared by absorption.

FIG. 36.

An old-standing and well-marked case of staphyloma corneæ, resulting, as is almost always the case, from destruction of the cornea by purulent ophthalmia. The cicatricial tissue, which replaces the natural membrane, and which is lined by the remains of iris, yields to the internal pressure, and forms a large projecting globular mass, that is comparatively insensible to touch, and is almost or completely impervious to light. Numerous vessels ramify over its surface. The disfigurement and the liability to inflammatory attacks from exposure to cold or to dust, and the tendency to sympathetic irritation of the opposite eye, are the chief reasons inducing these patients to apply for relief. Abscission, Mr Hancock's operation, or enucleation of the globe, should be adopted.

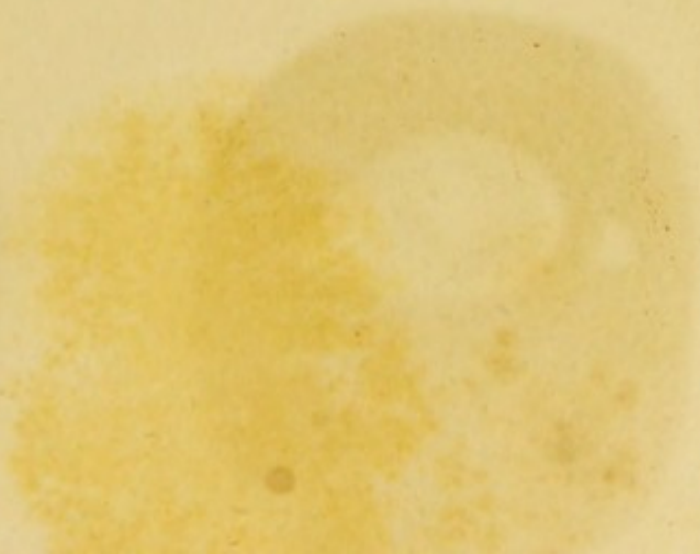
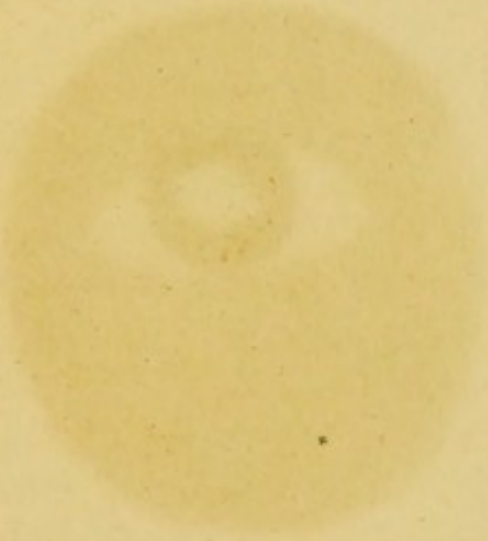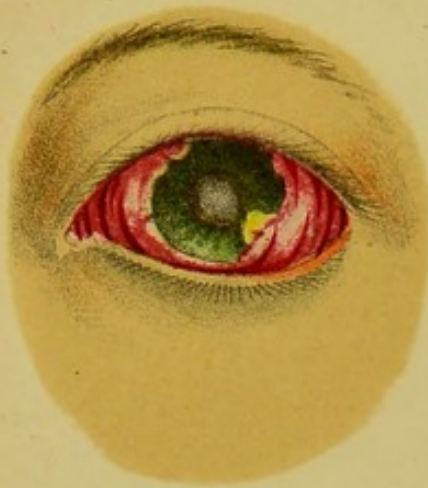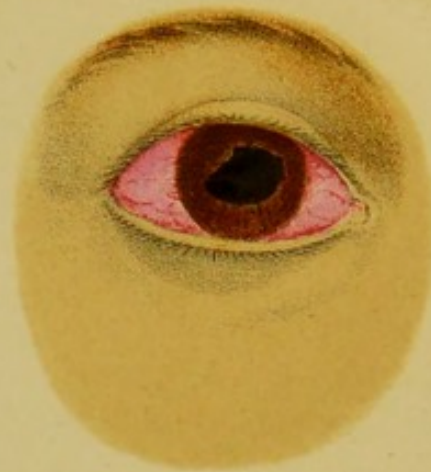


PLATE VII.

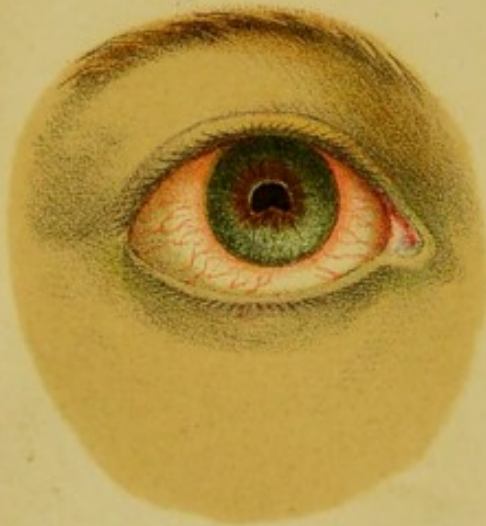37.



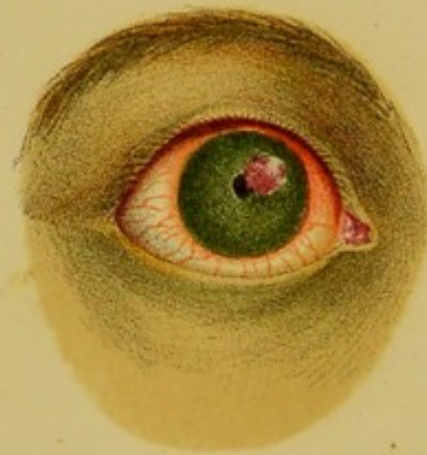38.



39.



40.



41.



42.

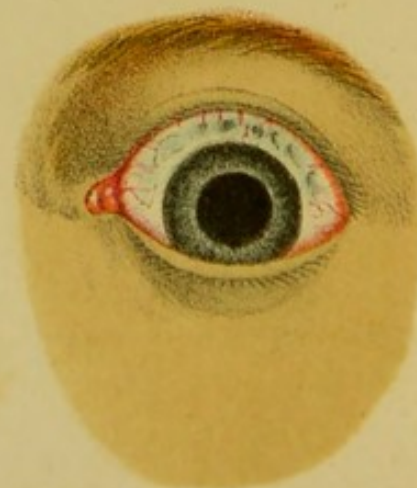

PLATE VII.

FIG. 37.

This case was the result of an accident. The patient was struck on the eye with a fragment of iron, which divided the cornea at the outer part. The cornea became sloughy at the seat of injury; a traumatic cataract formed in two days; intense pain and swelling of the lids followed. Pus appeared for a short time in the anterior chamber, and then vanished. Local bleeding and opium were freely employed, and poultices constantly applied. Three weeks after the accident, the distinction between light and darkness being perceived, a Schuett's operation for the removal of the lens was performed, but without avail, and complete blindness ensued in the eye.—*V.* p. 558.

FIG. 38.

The appearances presented by a case of syphilitic iritis, a very few hours after the first symptoms had been complained of, in a man of twenty-seven years of age. A drop of a weak solution of atropine had been instilled into the eye an hour before the drawing was taken. The sclerotic was pink, with a delicate circum-corneal zone. The conjunctival vessels only moderately congested; the cornea perfectly clear; the markings of the iris distinct, but the regularity of the pupil materially interfered with by effusion of lymph, partly into its substance, and partly glueing it to the capsule of the lens. Vision was considerably impaired. Prompt treatment produced a rapid and complete cure. Such cases are amongst the most satisfactory that are met with by the ophthalmic surgeon.—*V.* p. 357.

FIG. 39.

A case of iritis at a somewhat more advanced stage (third or fourth day). The sclerotic redness and circum-corneal zone are not so well marked as in the preceding case; but the iris is discoloured in the immediate vicinity of the pupil, and there is a distinct tag of adhesion to the capsule of the lens at the lower part. With vigorous and well-applied treatment, and especially by the methodic instillation of atropine, perfect recovery may even here take place.—*V.* p. 357, *et seq.*

FIG. 40.

A case of specific iritis on the seventh day, occurring in a girl *æt.* 20, three months after the primary sores, which had been followed by bad sore throat. The circum-corneal zone was strongly defined. The markings of the iris were very indistinct; its colour changed from blue to green; the pupil small and nearly immovable. A small vascular button of lymph is shown at the upper and inner part of the free margin of the iris. Vision much impaired. By appropriate treatment the lymph was absorbed, but the iris remained permanently attached to the capsule of the lens.—*V.* p. 357.

FIG. 41.

A case closely resembling the preceding, but more advanced. The button of lymph is larger, the circum-corneal zone better defined, the pupil irregular, from adhesions having formed between the margin of the iris and the capsule of the lens. The patient was a cachectic-looking man, *æt.* 24, a draper. The primary disease had occurred four months previously. The inflammation of the eye had lasted a fortnight. The pain was severe, and loss of vision almost complete. Solution of atropine was dropped into the eye. He was ordered to apply six leeches to the temple, and to take two grains of calomel and one of opium every six hours. On the following day, the pain continuing, he was cupped to $\frac{3}{4}$ vi., with immediate relief. The effused lymph underwent gradual absorption in the course of the following week, and the mouth becoming sore, the mercury was exchanged for iodide of potassium. The vision ultimately improved sufficiently to enable him to read No. 8 of Jager's Test Types; but firm adhesion remained between the iris and the capsule of the lens at the site previously occupied by the button of lymph.—*V.* p. 357.

FIG. 42.

A case of sclero-choroiditis anterior in an early stage. The conjunctiva, cornea, and iris are all healthy; but the sclerotic at the upper part, corresponding to the interval between the tips of the ciliary processes and the periphery of the iris, is attenuated, discoloured, and slightly lobulated.—*V.* p. 260.

Fig. 41.

the seventh day, occurring in a girl
primary case, which had been fol-
lowed by circum-corneal zone was strongly
inflamed; in color
the pupil small and nearly immovable.
As shown at the upper and lower
cornua. Vision much impaired. By
the 14th day the iris was absorbed, but the iris re-
mained in the capsule of the lens.—F. p. 357.

Fig. 42.

the preceding, but more advanced
stage, the circum-corneal zone better
defined, adhesions having formed between
the capsule of the lens. The patient
at 24, a deeper. The primary
stage previously. The inflammation
greater. The pain was severe, and less
action of atropine was dropped into
every six hours to the temple, and
and one of opium every six hours.
Continuing, he was cupped to 5 grs.,
effused lymph underwent gradual
absorption following week, and the month
changed for iodide of potassium
sufficiently to enable him to read
a firm adhesion remained between
lens and the site previously occupied
by the iris.—F. p. 357.

Fig. 43.

the anterior in an early stage. The cor-
nea healthy; but the sclerotic at the
anterior between the tips of the
cornua of the iris, is attenuated, dis-
tended.—F. p. 358.

PLATE VIII.

FIG. 43.

A case of sclero-choroiditis at a more advanced stage than that shown in the last illustration. The pupil is small, and adherent to the capsule of the lens; the iris discoloured and atrophied, its markings being scarcely distinguishable. The whole of the front of the eye was enlarged in volume, and the sclerotic attenuated with the choroid showing through it. Vision was greatly impaired, but not lost.—*V.* p. 260.

FIG. 44.

The early stage of cancer of the globe of the eye, as it appeared in a child *æt.* 2. The conjunctiva, sclerotic and cornea, and iris were healthy, the pupil of moderate size, acting well with reflex, but not by the direct action of light. At the fundus was a brownish-yellow reflecting surface, formed by the development of the cancer in the choroidal tissue, and its protrusion, covered by the retina, into the cavity of the vitreous. On close inspection, numerous minute red spots, and a vessel or two of small size, could be discerned. The eye was rather tense, but did not appear to be unusually tender or painful. Vision was evidently lost.—*V.* p. 583.

FIG. 45.

An advanced stage of the same disease in a child *æt.* 1½. The child was not unhealthy-looking or badly nourished, but it appeared to suffer much pain, crying frequently, and particularly at night. The history of the case was just that of fig. 44, and the cancer had evidently commenced within the globe, and had made its way through the sclerotic, and had subsequently invaded the connective tissue of the orbit and lids. No operation could with advantage be proposed or adopted in such a case. Dr Broadbent's plan of injecting with acetic acid might be tried.—*V.* p. 583.

FIG. 46.

A case of lenticular cataract and of capsular cataract. The small central white spot exhibits the latter, and it is probable was primarily produced by the perforation of a corneal ulcer in the course of purulent ophthalmia during infancy. It will be seen that the general opacity of the lens is distinctly behind the plane of the iris, and occupies the pupil, forming a strong contrast to such an opacity of the cornea as is seen in fig. 29.—*V.* p. 496.

FIG. 47.

A section of the cornea made for the extraction of cataract by the old or flap operation. The reparative powers of the patient were so feeble that the flap failed to unite for many days, yet, which is an event of extremely rare occurrence, they remained transparent, and finally united by secondary adhesion.—*V.* p. 535.

FIG. 48.

The appearance of the lids of the above case on the seventh day. They are pink, œdematous, with tears flowing from between them, and offer those characters which are usually considered to indicate non-union of the lips of the corneal section and prolapse of the iris. In such instances the wound should be carefully examined, any protrusion of the iris touched with a fine point of nitrate of silver, and a moderately firm compress applied for several days. One of the chief advantages of the modified linear operation is, that non-union from suppuration of the edges of the corneal wound, with prolapse of the iris, is exceedingly uncommon.—*V.* p. 535.

Fig. 66.

and of capsular extract. The small
letter, and it is probable was pri-
tion of a corneal ulcer in the course
infancy. It will be seen that the
distinctly behind the place of the
forming a strong contract to such as
in fig. 29.—*V.* p. 436.

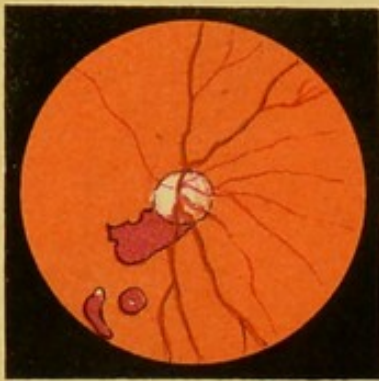
Fig. 67.

de for the extraction of cataract by
re reparative powers of the patient
billed to unite for many days, yet,
rare occurrence, they remained trans-
secondary adhesion.—*V.* p. 535.

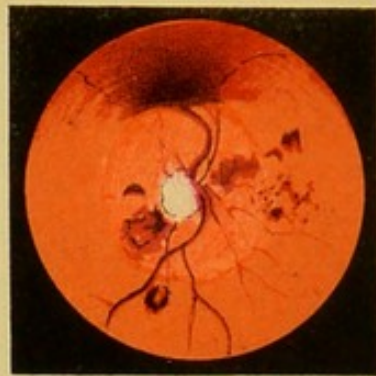Fig. 68.

of the above case on the seventh day,
the tears flowing from between them,
which are usually considered to indicate
corneal section and prolapse of the iris.
It should be carefully examined, and
with a fine point of nitrate of silver,
was applied for several days. One of
modified linear operation is, that no-
the edges of the corneal wound, with
ly uncommon.—*V.* p. 533.

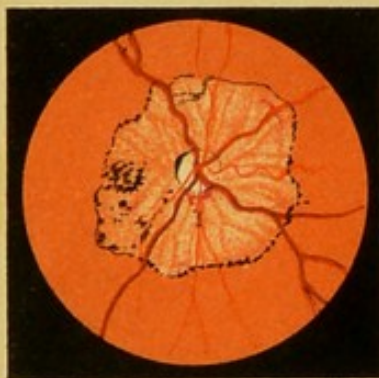49.



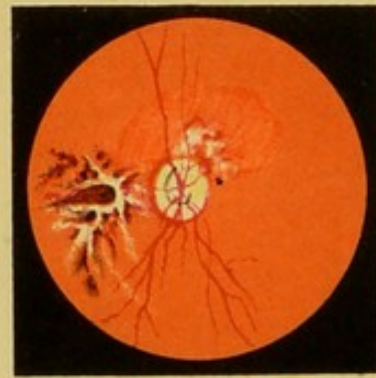
50.



51.



52.



53.



54.

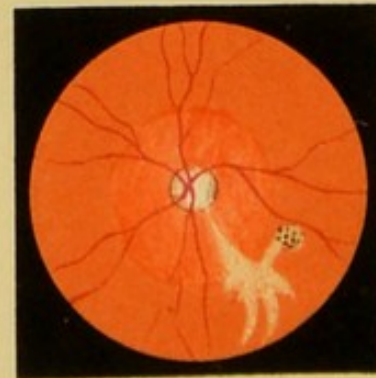


PLATE IX.

FIG. 49.

A case of hæmorrhage upon the choroid, in a man who had previously been subject to Bright's disease of the kidneys. The retinal veins were rather large, the arteries small. The hæmorrhagic spots were three in number, and were remarkably well defined, and had a dark, almost black, bordering line.—*V.* p. 486.

FIG. 50.

Hæmorrhage from the retinal vessels, occurring in an old man, whilst in the act of stooping, one month previously to the taking of the sketch. The descending vein is seen to have burst at a short distance from the optic disk, and the effused blood is very dark at and around the extremity of the vein, which it completely conceals. The outer parts of the clot are less defined, and pass gradually into the natural tint of the choroid. There are several other pigmentary spots and small extravasations. The effusion here is on the surface of the retina.—*V.* p. 448.

FIG. 51.

A case of old-standing syphilitic inflammation of the retina. The veins are large and dark, the arteries small. Around the optic disk is a discoloured halo of irregular form. The margins of this halo are strongly marked by a deposit of pigment. The chorio-capillaris has disappeared within its limits, and the larger arteries and veins, forming the outer layer of the choroid, are seen ramifying on the white sclerotic. The situation of the fovea centralis is marked by the little clump of pigment granules near the optic disk.—*V.* p. 487.

FIG. 52.

The appearances seen in a case of myopia. The optic disk, which is of small size, and apparently vertically elongated form, is surrounded by a white ring, indicating posterior staphyloma of limited extent. To the *apparent* inner side of the optic disk, and in the situation of the fovea centralis, the retina appeared puckered, with black spots of pigment in the angles of the elevations. Above the optic disk are some small white patches; both the puckered or shrivelled part, and the white spots, were in all probability the remains of previous hæmorrhages, and consisted of the retinal substance, and of fibrine deprived of hæmatin, both having undergone fatty degeneration.—*V.* p. 605.

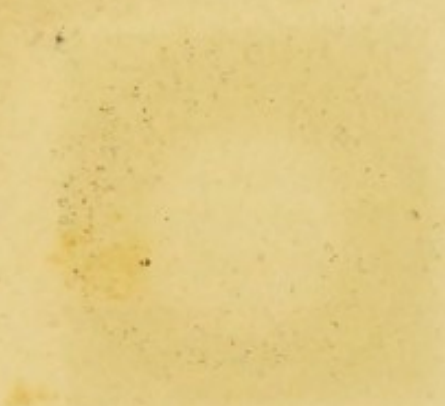
FIG. 53.

A case of separation of the retina from the choroid to a moderate extent. The shading is somewhat too dark. The retinal vessels are clearly seen to be superficial to the detached portion, and to follow the windings and sinuosities of the membrane.—*V.* p. 461.

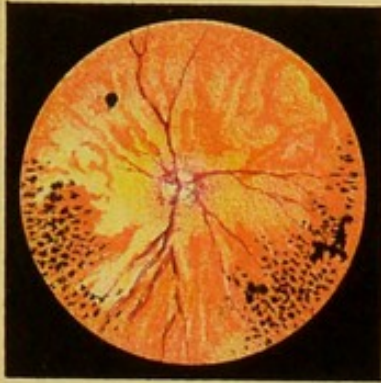
FIG. 54.

A remarkable case of retinal or subretinal effusion that was long under my observation. The patient was a girl of 22. Eyes apparently healthy, but vision of right materially impaired, XX. of Snellen's Test Types being only seen at two feet. There had been no pain nor other indication of inflammation, and the failure of sight had been gradual. On examination, the media were found to be clear, the vessels of the retina natural, but extending from the optic disk was the singularly-shaped effusion exhibited. The situation of the foramen centrale is probably marked by the few granules of pigment. No improvement resulted, nor was any change observed, after a great variety of treatment, extending over a period of nearly a year.—*V.* p. 461.

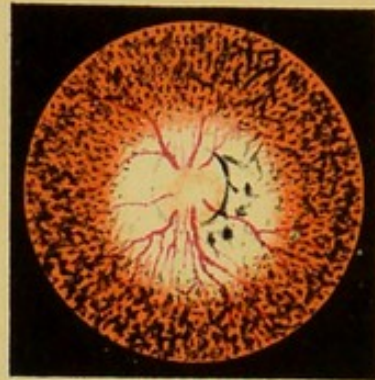
2430



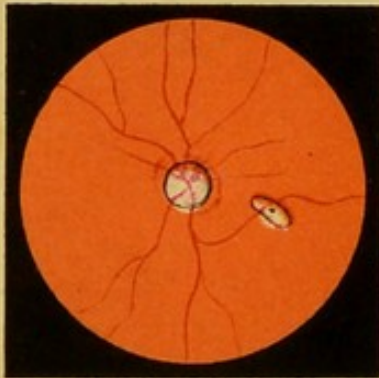
55.



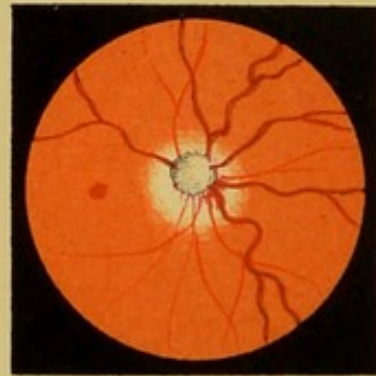
56.



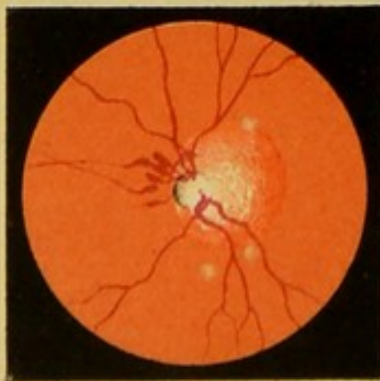
57.



58.



59.



60.



PLATE X.

FIG. 55.

A case of choroiditis disseminata, in which the retinal tissue was also probably implicated. The reflection from the fundus was paler than natural, and the choroid presented large and irregular patches, apparently of plastic effusion, conferring upon it a remarkable marbled appearance. Here and there were numerous spots of pigment, in some instances of considerable size. The optic disk was pink and ill defined, and the vessels were irregular in size, and at certain points appeared to be interrupted.—*V.* p. 427.

FIG. 56.

A case of retinitis pigmentosa. The media were beautifully clear. The optic disk was large, and bounded at its outer margin by a slight deposit of pigment. The choroid around the optic disk was atrophied, so that the white reflection from the sclerotic became apparent, over which the retinal vessels, of moderate size, could clearly be seen running. The more peripheral portions of the choroid presented innumerable black spots, arranged with great regularity, apparently between the branches of the choroidal vessels. More superficially placed, and probably situated in or on the retina, were other masses of pigment, of irregularly-branched, stellate, and anastomosing forms.—*V.* p. 458.

FIG. 57.

An apparently slight but really important affection of the fundus, consisting of a staphylomatous protrusion of the sclerotic, occupying precisely the situation of the foramen centrale. A slight ring of pigment surrounds both the optic disk and the protrusion. Central vision was destroyed in this case, but objects situated laterally could still be discerned.—*V.* p. 276.

FIG. 58.


A case of diffused retinitis, or effusion beneath and into the retinal tissue. The vessels are large, and do not advance beyond the edge of the optic disk. The tint of the choroid was in this instance very deep. Around the optic disk was a greyish halo, which only very gradually passed into the shade of the adjoining choroid.—*V.* p. 473.

FIG. 59.

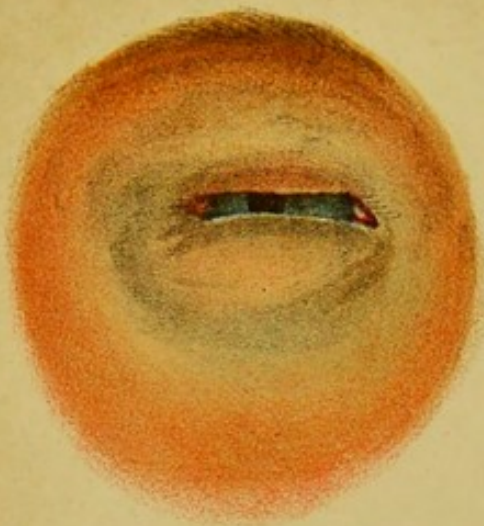
A case of retinitis albuminurica. The optic disk was ill defined ; the vessels were large and tortuous. On the apparent inner side were several small ecchymoses, evidently proceeding from the retinal vessels. On the apparent outer side was a hazy circle, indicating sub-retinal effusion, and at several points were white spots.—*V.* p. 479.

FIG. 60.

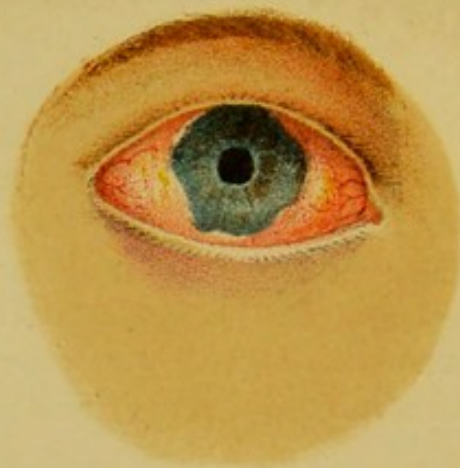A well-marked case of atrophy of the choroid and retinitis pigmentosa. The optic disk was large and pale, and bounded above by a black rim of pigment ; the vessels were rather large than otherwise. The choroid presented its natural red colour here and there. In the greater part of its extent it was so attenuated and transparent, that it permitted the bright white or yellowish reflection of the sclerotic to be seen through it. At various points considerable masses of pigment were deposited.—*V.* p. 451 and p. 274.



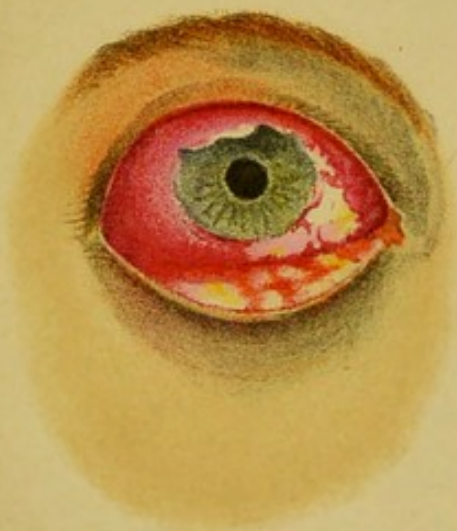61.



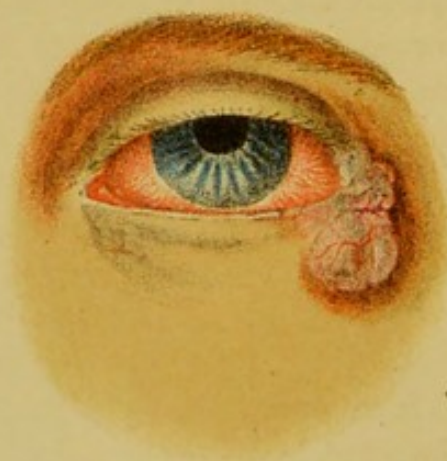62.



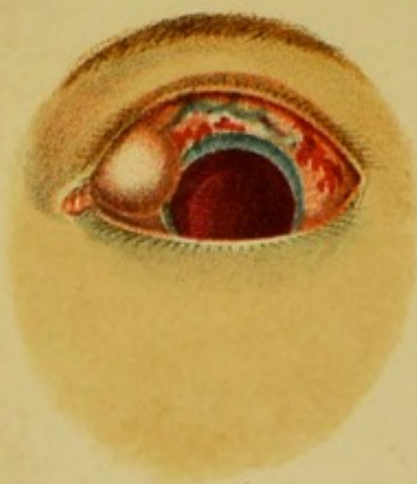
63.



64.



65.



66.

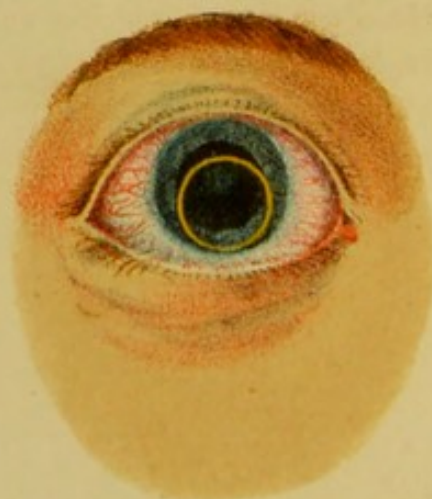

PLATE XI.

FIG. 61.

A case of erysipelas of the lids in a woman of 40 years of age. These are seen to be swollen, puffy, and œdematous. The palpebral fissure is nearly closed. The conjunctiva is usually, in such cases, chemosed. A thin watery fluid was discharged from the eye. An account of the case will be found at p. 93.

FIG. 62.

A case of gonorrhœal ophthalmia in its acute stage. The conjunctiva is chemosed, that is, infiltrated with a yellowish serum, and overlaps the margin of the cornea. A few vessels ramify on its surface, and there are some minute spots of ecchymosed blood. The cornea is as yet transparent, and the lens free and moveable; but the discharge of yellow matter was profuse, and the swelling of the lids considerable. At a later stage, and according to the success of the treatment, the inflammation may gradually subside, or the cornea may become hazy, then opaque, and may finally slough, followed by evacuation of the humours and atrophy of the globe.—*V.* p. 200.

FIG. 63.

A case which in many points bore a close similarity with those described by v. Gräfe and others as examples of diphtheritic conjunctivitis. When the drawing was taken, the patient was suffering intense pain. The lids were swollen, there was a profuse ichorous and sanious discharge. The conjunctiva was chemosed, and the lower part of both its ocular and palpebral surfaces were ulcerated, the ulcers creeping slowly along the membrane. The case resulted in loss of vision in that eye, from defective nutrition and consequent opacity of the cornea.—*V.* p. 229 and 204.

FIG. 64.

An illustration of epithelial cancer of the lids at their outer angle. The swelling is seen to be irregular, lobulated with one or two vessels ramifying on its surface ; it was tender but not painful. Its surface was moist. Dr Broadbent's plan of treatment was adopted with a very successful result, ten months having elapsed without any return.—*V.* p. 103.

FIG. 65.

A case of severe blow upon the eye, causing rupture of the sclerotic and dislocation of the lens. The injury was from a blow with the fist, rupturing the sclerotic above, the wound being about half an inch in length, of irregular form, and bluish colour. It was situated about a quarter of an inch from the margin of the cornea. The conjunctiva around was ecchymosed, the cornea was clear, the pupil widely dilated, and the interior of the globe filled with blood. At the inner angle of the eye was a smooth circular rounded swelling, which slightly overlapped the cornea. It proved to be the lens lying beneath the conjunctiva, which had escaped through the sclerotic wound. Vision was, of course, irrevocably lost.—*V.* p. 567.

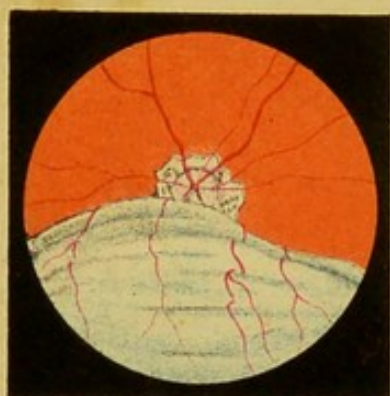FIG. 66.

A case of dislocation of the lens into the anterior chamber, where it appears as a ring of yellowish colour. There was surprisingly little inflammation, and the lens appeared to excite no irritation. The eye had not previously been a very healthy one, probably in consequence of a preceding attack of choroiditis, as his vision had been much obscured, and he had noticed that the iris always trembled on any movement of the eye or head, showing that the vitreous was fluid.—*V.* p. 568.

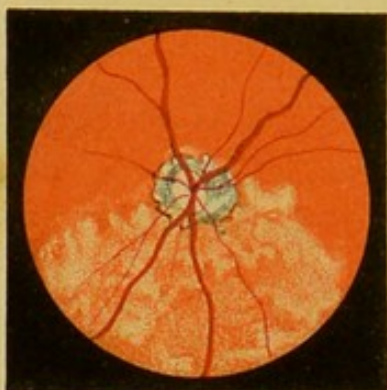


PLATE XII.

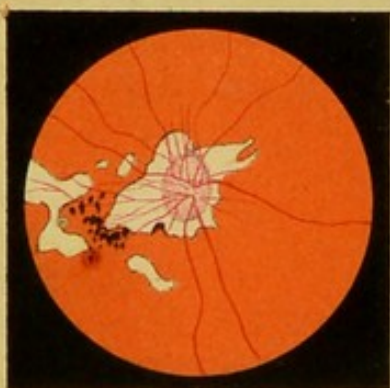67.



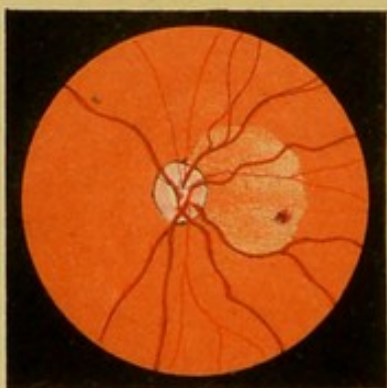
68.



69.



70.



71.



72.

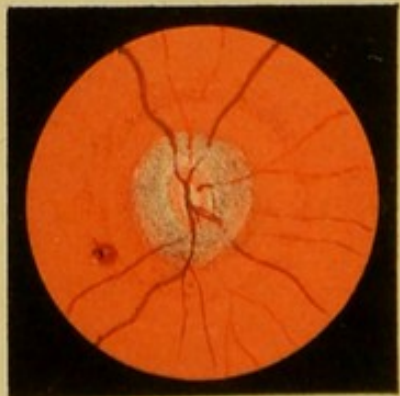

PLATE XII.

FIG. 67.

A case of extensive detachment of the retina from the choroid. The separated membrane appears as an exquisitely delicate grey or bluish film waving or floating in the vitreous at every movement of the eye. The optic disk could just be seen above it, with a staphylomatous ring around it. The retinal vessels could be distinctly observed following the inflections of the detached membrane,—*V.* p. 461.

FIG. 68.

The appearances presented by the same patient three days subsequently. The detached retina had become reapplied, probably in consequence of the bursting of the fluid into the vitreous, though no rent could be perceived. The portion which had been detached presented a patchy appearance, as though fibrin had been effused into or beneath it. The veins were particularly large and dark.—*V.* p. 464.

FIG. 69.

A case of advanced myopia. The optic disk is vertically elongated and pink, and it is surrounded by a staphylomatous protrusion of irregular form, but of which the longer diameter is nearly horizontal. Two or three other patches, where the choroid is atrophied and the sclerotic presents a white reflection, are also seen, but the foramen centrale appeared to have just escaped, which was in accordance with the fact that the vision, though myopic, was not materially impaired. The retinal vessels were seen with wonderful clearness crossing the atrophied parts of the choroid. A little pigment was deposited between the optic disk and fovea centralis.—*V.* p. 605.

FIG. 70.

An illustration of a case of syphilitic retinitis occurring in a woman *æt.* 31. The veins are large and numerous. The retina presents an *œdematous* patch on the outer side, the *œdema* just including the fovea centralis which is unusually distinct. The lower margin of the effusion is exactly bounded by the curve of one of the veins.—*V.* p. 488.

FIG. 71.

A case of embolism of the arteria centralis retinae. The optic disk is ill defined, its margin being surrounded by a disk or halo of *œdema*. The arteries and veins of the retina were reduced to the diameter of hairs. The chorio-capillaris or tunica Ruyschiana is atrophied, allowing the larger vessels of the choroid to be seen. In the account of the case, on p. 466, it has been accidentally omitted to state that the fovea centralis appeared to be the seat of a small hæmorrhage.

FIG. 72.

A well-marked case of specific retinitis. The veins are very large, the optic disk hyperæmic, and surrounded by an *œdematous* halo that partially obscures the vessels by which it is traversed. The foramen centrale was unusually distinct.—*V.* p. 490.

CHAPTER I.

General Anatomy and Diseases of the Orbit.

GENERAL DESCRIPTION OF THE ORBIT AND ITS CONTENTS—
WOUNDS AND INJURIES OF THE ORBIT—TUMOURS IN THE
ORBIT—CARIES AND NECROSIS OF THE ORBITAL PARIETES—
INFLAMMATION OF THE CELLULAR TISSUE OF THE ORBIT—
PROTRUSION OF THE GLOBE—ANEURISM—CANCER.

General Features of the Orbit.

THE orbits are two deep four-sided cavities, inclined to one another at a small angle. Behind, they narrow almost to a point, and the apex is perforated by an aperture through which the optic nerve and the ophthalmic artery enter. Immediately external to the optic foramen, and running forwards and outwards, are the sphenoidal and sphenomaxillary fissures, the former extending along the outer and upper angle, the latter along the outer and lower angle of the orbit. Through the sphenoidal fissure pass the third, fourth, first or ophthalmic branch of the fifth, sixth, and some branches of the sympathetic nerves, the ophthalmic vein and recurrent lachrymal artery, and a process of the dura mater.

The bones entering into the formation of the orbit are the frontal, the sphenoid, the ethmoid, the palate, the superior maxillary, malar, and lachrymal bones, seven in all; but as the first three are single, only eleven bones compose the two orbits. The frontal forms the chief part of the concave surface of the

roof, but is supplemented behind by the lesser wing of the sphenoid. The os planum of the ethmoid forms the greater portion of the straight and vertical inner wall, aided by the sphenoid behind, the lachrymal before, and the frontal above. The floor is formed, in the greater part of its extent, by the superior maxillary bone, but partly, behind, by the palate, and in the fore and outer part by the malar. And the outer wall is formed by the great wing of the sphenoid, constituting its major part, but in front by the malar. On the inner wall are the anterior and posterior ethmoidal foramina, both transmitting arteries and veins of the same name, and the former also the nasal branch of the fifth nerve. On the floor is a groove, gradually deepening till it becomes a passage or tunnel beneath the inferior border of the orbit, opening below by the infra-orbital foramen. It transmits the infra-orbital branch of the second division of the fifth, and the infra-orbital branch of the internal maxillary artery, which enter the orbit through the speno-maxillary fissure.

On the outer and fore part of the roof is a depression, which is occupied by the lachrymal gland, and internally is a depression for the fibrous ring of the superior oblique muscle. The superior, external, and inferior borders of the orbit are well marked, but the inner border is continuous with the surface of the nose, and cannot be exactly defined.

The depth of the orbits appears to differ slightly in different people, and the floor is usually longer than the other walls. The proportions given by M. Wecker¹ are the following:—

The distance of the optic foramen from the internal angle (insertion of the internal palpebral ligament) is	1·6 inch.
From the external angle (middle of the external orbital border) is	1·7 „
From the middle of the superior border,	1·7 „
From the middle of the inferior border,	1·84 „
The distance of the upper extremity of the sphenoidal fissure from the internal angle is	1·6 „

¹ Etudes Ophthal., vol. i. p. 749.

From the external angle,	1.32 inch.
From the middle of the superior border,	1.5 "
From the middle of the inferior border,	1.8 "
M. Wecker further remarks, that he has usually found the width of the anterior opening of the orbit greater than its height, in the proportion of	39 : 35
But M. Arlt gives it as	36 : 30
And M. Richet as	40-41 : 45-46.
Zander and Geissler give to the external wall a depth of 2 $\frac{1}{4}$ inches, whilst M. Arlt only considers that it amounts to	1.6 inch.

I have carefully measured the dimensions of the orbit in forty-eight skulls in the College of Surgeons, comprising those of several different nations. In making the measurements, I employed a rule accurately divided into English inches and tenths, the extremity of which was, in all instances, placed on the centre of the outer border of the optic foramen in the sphenoid bone, which in fact constitutes, in most instances, the exact apex of the orbit. The outer, upper, and lower walls were measured from this point to their respective middle points. The remaining inner wall is the only one about which any difficulty in determining the limit can exist, and I have taken the anterior border of the nasal duct as the guide; first, because it is generally conspicuous and well-defined; secondly, because it really forms the boundary of the orbit in this direction; and, lastly, because the transverse measurement of the base or external aperture of the orbit can readily be taken from the same point.

In twelve skulls, from the Mosambique, the proportions were:—

Outer Wall.	Inner Wall.	Upper Wall.	Lower Wall.	Transverse Diameter.	Vertical Diameter.
1.8	1.7	1.8	1.8	1.6	1.5
1.9	2	2.1	2.1	1.6	1.3
1.9	1.8	2	2	1.5	1.4
1.9	2	2	2	1.6	1.3
1.8	1.7	1.9	1.9	1.5	1.4
1.8	1.8	1.9	1.8	1.6	1.4

Outer Wall.	Inner Wall.	Upper Wall.	Lower Wall.	Transverse Diameter.	Vertical Diameter.
1.8	1.8	2	1.9	1.7	1.4
1.8	1.8	2	1.9	1.6	1.3
1.9	1.9	2	2	1.7	1.3
1.9	1.9	2	2.1	1.6	1.2
1.9	1.8	1.8	2.1	1.6	1.3
2	1.9	2.1	2	1.6	1.4

In six African Negroes.

2.1	2.1	2.2	2.2	1.7	1.3
2.1	1.9	2.2	2.1	1.7	1.5
2	2	2.2	2.1	1.7	1.4
2.1	2	2.2	2.1	1.7	1.4
2	1.9	2.1	2	1.7	1.5
1.9	1.9	1.9	1.9	1.7	1.7

In six Australians.

1.9	1.9	2.2	1.9	1.8	1.4
1.8	1.8	2.1	1.8	1.7	1.4
2.1	2	2.3	2.2	1.8	1.3
2.1	1.9	2.4	2.1	1.8	1.4
1.9	1.8	2.1	1.9	1.7	1.4
1.9	1.8	2.2	1.9	1.8	1.4

In a New Zealander.

1.9	1.9	2	2	1.7	1.3
-----	-----	---	---	-----	-----

In Malay Pirate.

1.9	1.8	2.1	1.8	1.8	1.4
-----	-----	-----	-----	-----	-----

In three Chinamen.

1.9	1.9	2.2	2.1	1.7	1.3
1.9	1.8	2	2	1.6	1.3
2	1.9	2.2	2	1.8	1.4

In an Inhabitant of Java.

2	1.9	2.1	2	1.7	1.5
---	-----	-----	---	-----	-----

In a Gentoo from the Ganges.

2	1.9	2.2	2.1	1.8	1.4
---	-----	-----	-----	-----	-----

In an Egyptian.

1.7	1.7	2	1.8	1.7	1.4
-----	-----	---	-----	-----	-----

MEASUREMENTS OF THE ORBIT.

5

Outer Wall.	Inner Wall.	Upper Wall.	Lower Wall.	Transverse Diameter.	Vertical Diameter.
In an Affghan.					
2.1	2	2.3	2.1	1.7	1.5
In two Asiatic Turks.					
1.8	1.9	2.1	1.8	1.7	1.5
1.9	1.6	1.8	1.9	1.7	1.6
In two Laplanders.					
2	1.9	2.1	2	1.7	1.3
1.9	2	2	2.1	1.7	1.3
In three Greenlanders.					
2.2	2	2.4	2.2	1.8	1.5
2.3	2.1	2.3	2.2	2	1.5
2.2	2.2	2.3	2.3	1.7	1.5
In Skull from Tennessee.					
1.9	1.9	2.1	2	1.8	1.4
From Columbia River.					
1.7	1.7	1.7	1.8	1.6	1.4
From Guiana.					
1.9	1.8	2.1	1.9	1.6	1.5
From Patagonia.					
2	1.8	2.1	1.9	1.8	1.6
In an Ancient Peruvian (Bolivia).					
1.9	1.8	2.1	1.9	1.7	1.4
In an Ancient Egyptian, from Tomb near Great Pyramid, Thebes.					
1.7	1.7	1.9	1.8	1.8	1.5
In an Ancient Roman.					
2.1	2	2.1	2.2	1.8	1.4
The averages given by M. Wecker are—					
1.7	1.6	1.7	1.84	1.6	1.56

It will thus be seen that, in all nations and at all eras, the dimensions of the orbit are and have been nearly the same. The large size of the orbits of the Greenlander and of the

Negro is, however, worthy of notice, especially in regard to the great length of their upper wall. Lining the surface of the bones which constitute the orbit, is a thick, firm, and resistant layer of periosteum, that is continuous behind with the sheath of the optic nerve, and through this with the dura mater, of which it may be considered an offset. In front it may be traced over the margins of the orbit in all directions, becoming continuous with the periosteum of the adjoining bones.

The contents of the orbit are, the globe of the eye, with the optic nerve passing forwards and outwards, to enter its posterior surface; the six muscles effecting the movements of the globe—viz., the four recti and the two obliqui—and the elevator of the upper lid, the orifices and insertions of which will hereafter be accurately described; the lachrymal gland, with its ducts, and the vessels and nerves distributed to these several organs. The space between the muscles and the globe of the eye is filled with fat, forming an elastic cushion on which (separated only by the capsule of Tenon) the eyeball rests and easily performs its rotatory movements. The yielding nature of this tissue also materially aids, with other protective arrangements, in reducing to a minimum the dangers that would otherwise threaten an organ so exposed, so delicate, and so important as the eye.

As regards the vessels of the orbit, they are derived from the ophthalmic, which enters the orbit through the optic foramen, lying below, and to the outer side of, the optic nerve, and, as it passes forwards to become the supra-orbital, gives off a large number of branches, which successively supply the muscles, the lachrymal gland, the globe of the eye itself, the nose (through the ethmoidal foramina), and finally terminates in branches to the forehead and lids. A few branches, supplying the floor of the orbit, are derived from the infra-orbital branch of the internal maxillary.

The third nerve supplies, by its upper division, the levator palpebræ and the superior rectus, and, by its inferior division,

the internal rectus, the inferior rectus, and the inferior oblique muscles.

The fourth nerve supplies the superior oblique, entering it on its orbital or external surface; and the sixth supplies the external rectus.

The branches of the ophthalmic division of the fifth pair of nerves are exclusively sensory, and supply sensory fibres to the various tissues and organs within the orbit, and to the eye itself. The terminal branches issue from the upper border of the orbit, and supply the skin of the lids and temple.

In the posterior part of the orbit, and lying between the optic nerve and the sixth, is the ciliary, lachrymal or lenticular ganglion, of small size yet important function. It receives, at its posterior aspect, a branch of the sympathetic nerve; a branch, called its short root, from that branch of the third which goes to supply the inferior oblique; and a branch, termed its long root, from the nasal twig of the fifth.

From the anterior extremity of the ganglion issue half a dozen or more small branches, which pierce the sclerotic around the optic entrance, and terminate in the ciliary muscle and iris, conferring exquisitely acute sensibility on these parts, whence they are called ciliary branches. The nasal nerve, as it crosses the optic nerve, gives off one or two separate and distinct branches, called the long ciliary nerves.

Having mentioned the distribution of the several nerves in the orbit, it will be advantageous briefly to point out the prominent features which render it possible to diagnose the paralysis of each.

Paralysis of the second nerve constitutes amaurosis, or loss of vision.

Paralysis of the third is indicated by loss of the power of raising the upper lid (ptosis), and of rotating the eye upwards, inwards, or downwards, though the movement downwards and outwards is still effected by the superior oblique: the pupil is widely dilated.

Paralysis of the fourth is recognised by the incapability of the patient to turn the eye downwards and outwards to the same extent as on the opposite side, though this movement can still be partially performed by the united action of the external and inferior recti.

Paralysis of the ophthalmic division of the fifth is shown by loss of sensibility of the same side of the brow and lid, and of the globe of the eye itself.

Paralysis of the sixth, by incapacity to turn the eye outwards.

Paralysis of the portio dura of the seventh, by the impossibility of closing the eye, that is, of bringing the orbicularis into action (*lagophthalmos*).

And, lastly, paralysis of the sympathetic nerve is exhibited by contraction of the pupil.

It is of importance to remember, also, that the paralysis of each of these nerves may be centric or excentric, direct or reflex, as the case may be,—sometimes arising from direct injury; sometimes from cold, as from the sudden or protracted exposure to a draught of air; at others, from necrosis of bone, or abscess in the neighbourhood of the course of the nerve; from the poisoned condition of the blood occasioned by syphilis or lead; from worms in the intestinal canal; from bad teeth; or, lastly, from some lesion of the brain itself. These various possibilities should be considered in all cases of paralysis, since an accurate diagnosis at once indicates and simplifies the treatment. It will be necessary to return to the consideration of some of these in the description of certain forms of disease.

Diseases of the Orbit.

1. *Wounds and Injuries of the Orbit.*

Cases of this description are more frequently met with at a general than at an ophthalmic hospital; and I find very few examples recorded in our books. From the proximity of

the brain, injuries involving any part of the orbit must always be regarded with suspicion; but many cases are upon record where accidents, apparently of the most grave character, have yet been followed by very slight inflammatory symptoms. Fragments of bone have been torn away, exposing the globe, and even the cerebrum itself, without fatal results; whilst foreign bodies, as pieces of metal, splinters of wood, shot, and other missiles, have penetrated and remained for considerable periods of time imbedded in the fat and connective tissue of the orbit, without giving any marked indication of their presence, until at length (perhaps after the lapse of years) abscesses have formed, and, with the discharge of the matter, the foreign body has made its appearance. Not unfrequently, however, though no attempt has been made to remove it, the presence of such substance has been diagnosed in consequence of more or less protrusion of the globe, attended with partial or complete loss of sight, and by neuralgic symptoms. But whilst some fortunate cases have recovered quickly and perfectly from what we are constrained to regard as severe accidents, others have but too frequently suffered for long periods of time, and have even died from injuries which were in the first instance neglected on account of their supposed trivial nature. Punctured wounds of the orbit in particular, even when of an apparently slight character, are often followed by erysipelas, by violent inflammation, leading to suppuration, and by extension of the inflammation to the brain, terminating fatally. From the thinness of the roof of the orbit, a thrust with a foil or stick has often been found to have fractured the bone and penetrated the brain.

In some instances, in consequence of the fracture of the nasal and lachrymal bones, emphysema results, producing rapid tumefaction of the loose connective tissue of the lids, owing to the escape of air into it from the respiratory passages. The swelling has a translucent appearance, like that of

œdema, from which it is distinguished by the feeling of crepitation produced by pressure. It is a rare accident, and there is little to be done for it, except that, if it become very tense, the swelling may be pricked in two or three places with a needle, and hot fomentations applied.

In all direct injuries of the orbit, as soon as the patient is seen, the wound should be carefully and gently explored with a probe, and any foreign body or fragment of bone removed with the forceps. The patient should then be put to bed, and kept at perfect rest, with the wound covered with water-dressing. The bowels should be kept open, and the first signs of inflammatory reaction suppressed by leeches and opium. Should, however, inflammation have become established, free incisions should be made at an early period, not only with the view of relieving the tension and pain, but to prevent the accumulation of matter, and, as a general rule, hot fomentations and poultices are then preferable to cold-water dressing.

2. *Tumours in the Orbit.*

The chief forms of tumour which have been observed in the orbit, and which, upon the whole, are exceptional diseases, are exostosis, enchondromata, syphilitic nodes, aneurisms, and erectile tumours, cysts of various kinds, hydatids, and cancerous growths.

Exostoses are very rare. Mr Guthrie¹ states that he had only seen two instances of it, both from the frontal bone; one was the size of a large marble, the other was much larger. Mr Lawrence does not even mention them. Dr Mackenzie has collected several cases, from different sources, but appears only to have seen one instance himself. He divides them into the cellular, the craggy, and the ivory varieties, of which the latter is the most frequent. Tumours of this nature are of slow growth, generally painless, at least in the early stages

¹ On the Operative Surgery of the Eye, p. 164. 1830.

of their development ; though sometimes very painful, occasion the protrusion of the globe, and, by pressure on the optic nerve, cause loss of sight.

The ivory form of exostosis is so hard that, in more than one instance, an operation, undertaken for its removal, has been left unfinished, from the difficulty experienced in sawing or cutting through the tumour.

Where the diagnosis has been satisfactorily made out, even though the functions of the eye have been lost from pressure on the optic nerve or globe, an operation may reasonably be undertaken. Mr Haynes Walton¹ gives the details of a case in which an osseous tumour was removed from the superior part of the orbital ridge, and where the sight, previously almost wholly lost, was completely recovered.

Nodes on the temple and orbital ridge are not unfrequent, but they rarely interfere with vision. I have seen, however, one case where the pain was very great in the evening, and was accompanied by lachrymation and conjunctival congestion to so great a degree that the patient, who was a young tailor, was unable to pursue his occupation. He was cured, alike of his node and of the affection of the eye occasioned by it, by iodide of potassium, given internally, and mercurial inunction.

3. *Cysts of the Orbit.*

These may be either hydatid cysts, or may contain serum, blood, or atheromatous substance. Of the first and second occurring successively in the same case, a good example has been recorded by Mr Poland,² in a girl of five years of age. The cyst occupied the floor of the orbit, presented a semi-transparent bluish colour, and, on being incised, turbid serum escaped. Hæmorrhage into the cyst followed, but was suppressed by cold applications. A year after, the child

¹ Surgical Diseases of the Eye, p. 286. 1861.

² Ophth. Hospital Reports, vol. i. p. 23.

reappeared with the cyst filled with blood, partially in a fluid state, and partially forming laminated coagula. It was opened, and a considerable portion of the cyst was removed. Little suppuration followed, fungous granulations sprang up, and the child was for some time in a dangerous state; ultimately, however, perfect recovery took place.

I have met with several cases of atheromatous cysts, one or two of which have been small, superficially placed, and easily removed. In one instance, however, the tumour presented at the inner canthus of the eye, and appeared to be small; but, on an attempt being made to remove it, it was found to extend far back into the orbit, and, after excision of all that portion which could be reached, a probe could be passed through the os planum of the ethmoid to the depth of nearly two inches into the ethmoidal and sphenoidal sinuses, or into the upper meatus of the nose. The discharge, which was at first of a thick atheromatous nature, soon became purulent, and a fistulous passage was formed, which continued to discharge for more than a year, though it ultimately dwindled to a very small size.

In undertaking operations for the removal of cysts, care should be taken to have all the instruments and appliances that may be needed at hand; and, as Mr Poland observes, they should never be lightly treated, as the act of removal is often tedious and difficult, and the results of the operation dangerous.

4. *Caries and Necrosis of the Orbit.*

These diseased conditions of the bones of the orbit occur chiefly at the orbital border, where the force of violent blows is received. They are less frequently observed in the deeper lying and more protected portions of the bones. They may be associated with syphilis and with scrofula, and are probably now much more rare than in days when mercury was largely and indiscriminately given for the cure of the former disease.

As a general rule, the progress of these affections, when situated in the deeper parts of the orbit, is chronic; and the symptoms consist of deep-seated pain, swelling of the lid, and the formation of an abscess that, bursting, leaves a fistulous track, through which, if a probe be passed, the exposed bone may be felt. As soon as a sequestrum is loose, an incision should be made through the lid or palpebral sinus, and its removal effected.

In those cases where the orbital border has been killed by a blow, the progress of events is much more rapid. A swelling, with diffused redness, and excessively tender to the touch, is perceived over the part struck, and, after a few days, an œdematous condition of the lids is established; a little matter forms in the connective tissue over and beneath the periosteum, and, after the bursting of the small abscess, a fragment of bone comes away. Considerable constitutional disturbance usually results from the pain.

The treatment consists in rest, hot applications, such as poultices or fomentations, and attention to the bowels. The patient should not be lowered, as erysipelas, at least in London hospital patients, is apt to spread over the face and head. When this occurs, the use of wine, quinine, and a general sustentative plan of treatment should be immediately commenced.

5. *Inflammation of the Cellular Tissue of the Orbit.*

This affection is one of a very dangerous character, and may be either acute or chronic. It has been observed to follow injuries to the eye from blows;¹ erysipelas of the face;² escape of caustic fluid injected through the canaliculi into the connective tissue of the orbit;³ extension of inflammation

¹ See cases by Guthrie, on Oper. Surg. of the Eye, p. 157. 1830. And by Mr Hulke, Ophth. Hosp. Rep., vol. iv. p. 88. 1863.

² Poland, Ophth. Hosp. Rep., vol. i, p. 26.

³ Gräfe, Klin. Monatsber, b. i. p. 49. 1862.

from the lachrymal sac, produced by the application of the actual cautery; and other injuries of the like nature. In other instances, again, it appears to be idiopathic in its origin,¹ but then often occurs in those who are convalescent from, or who have been debilitated by, some febrile or other constitutional affection;² and Tyrrell has known it to take place in scrofulous children, without any obvious reason. It commences with violent pain in the orbit and circumjacent parts, sometimes accompanied by rigors and vomiting, and soon followed by the effusion of fluid into the areolar tissue. The serous or sero-purulent effusion quickly produces protrusion of the globe, and, at once extending and compressing the various parts at the back of the orbit, abolishes their functions. Thus vision is impaired or altogether lost by the pressure and extension of the optic nerve; the muscles are no longer capable of contracting, and the rotation of the globe is either partially or completely prevented; the ciliary branches of nerves cease to serve as the channels of reflex communication between the retina and the iris, which consequently remains immovable when the eye is exposed to bright light; whilst the cedema of the conjunctiva and lids, followed by a more or less intense livid redness, indicate the effects of the pressure on the absorbents and veins. In favourable cases an abscess forms, the matter makes its way to the surface, and ultimately bursts through the conjunctiva, and partial or complete recovery may take place. There is, however, a marked tendency to pyæmia in this disease; and M.M. Warlomont and Testelin³ state that thromboses have been observed to extend from the ophthalmic veins to the cavernous, circular, petrosal, and lateral sinuses of one side or the other, and, finally, by the jugular vein to the innominate vein. When, in acute cases, pyæmia is not the cause of death, the fatal result

¹ Lawrence, *Treatise on Dis. of Eye*, p. 743.

² Hulke, *Ophth. H. Rep.*, vol. iv. p. 89; and Tyrrell on the Eye, vol. ii. p. 202.

³ Vol. iii. French transl. of Mackenzie's *Pract. Treat.*, p. 136.

appears to proceed from cerebral mischief; so, in Mr Poland's case, the disease ran a rapid course, cerebral symptoms supervened, the patient became rapidly prostrated, and death took place on the sixth day. In a case that was treated by Dr Mackenzie,¹ the patient showed symptoms of pressure on the brain, and died apoplectic.

As regards the treatment, the patient should be put to bed, and though cold applications have usually been employed, especially in those cases which have arisen from injury, I should be inclined to apply hot poultices, with a view of promoting suppuration, which, as soon as it can be perceived, or, from the protrusion of the globe, is rendered probable, should be laid open by plunging a lancet deeply through the swollen conjunctiva into the orbit, either above or below the globe, or in both situations.

Care should be taken at the same time to support the patient with wine, beef-tea, and farinaceous food, and with quinine. Mercury and antiphlogistic measures, unless indicated by the pulse and general constitutional symptoms, should be avoided.

In the chronic cases of the disease, the symptoms are generally similar, the most marked features being the protrusion of the eyeball and the swelling and redness of the lids. In some instances the progress of the disease is exceedingly slow. In a case recorded by Mackenzie, the matter which had formed as the result of an injury only pointed after the lapse of twelve years.

6. *Inflammation within the Capsule of Tenon.*

The external surface of the globe of the eye is not in direct contact with the cushion of fat on which it rolls, but is separated from it by a tolerably firm layer of connective tissue, termed the capsule of Tenon; it is most distinct behind, where it is perforated by the muscles which are running forwards to

¹ *Prac. Treat.*, p. 33. 1854.

their insertion. Anteriorly, at the angle of reflection of the conjunctiva, it divides, according to Mackenzie,¹ into two laminae, one of which blends with, and is lost in, the loose connective tissue of the eyelid, whilst the other is continuous with the delicate subconjunctival fascia. Attention was first directed to inflammation within this tissue by O'Ferrall,² who regarded it as of rheumatic origin, and considered it to be characterised by violent pain, great protrusion of the eye, and redness and œdema of the lids; that of the upper lid, however, not extending over its whole surface, but being limited by a line about half an inch below the border of the orbit, beyond which the skin retains nearly its natural colour; the conjunctiva is chemosed, but does not present any remarkable vascularisation; the cornea is clear, and the iris healthy. After the disease has lasted for some time, recovery may take place; but suppuration is frequent, and the abscess points in the conjunctival fold. M. Wecker,³ in reviewing these symptoms, whilst he admits the limitation of inflammation to the capsule of Tenon, denies that they are those characteristic of it, and considers that O'Ferrall has really described, under these symptoms, cases of inflammation of the adipose tissue of the orbit.

He notes the principal phenomena of the disease to be a well-marked subconjunctival redness, which can neither be attributed to rheumatic iritis, to choroiditis, nor to muco-purulent ophthalmia; slight protrusion of the globe; and, lastly, diminution, though only to a moderate extent, of the movements of the eye. Inflammation of the capsule of Tenon is said never to proceed to suppuration, unless accompanied by panophthalmitis. The only case that I have seen, or at least have been able to diagnose, of this disease, occurred in a man of forty-five years of age.

¹ Treatise on Diseases of the Eye, p. 294. 1854.

² Dublin Journal of Medical Science, vol. xix. p. 343.

³ Etudes Ophthal., vol. i. p. 696.

The general symptoms were precisely those above related; there was no line of limitation of the inflammation in the upper lid, and not much pain; he was subjected to a great variety of treatment,—mercury, iodide of potassium, leeches, blisters, quinine, pressure, etc.,—without obtaining the least advantage, and at length, tired of confinement, he left the hospital.

The progress of the disease is in general slow, but terminates favourably; and, as the above case testifies, remedies have in general but little effect upon it. Vision is, in general, not materially impaired, the elasticity of the optic nerve allowing a certain amount of extension to take place without impairment of its function.

7. *Protrusion of the Globe. Exophthalmos.*

In the valuable essays by Mr Poland,¹ various cases are recorded, and the following table given, which enumerates all, or nearly all, of the causes that may lead to protrusion of the globe:—

- | | | | |
|------------------------------|---|---|----------------------------|
| 1. <i>Congenital.</i> | { | 1. Real protrusion. | |
| | | 2. Apparent, from shortening of the levator palpebræ and lids. | |
| 2. <i>In the Eye itself.</i> | { | 1. Inflammation of the globe; ophthalmitis. | |
| | | 2. Phlebitic ophthalmitis. | { 1. Scrofulous. |
| | | 3. Hydrophthalmos. | { 2. Encephaloid. |
| | | 4. Tumours in the eye . . . | { 3. Melanotic. |
| | | | { 4. Osseous degeneration. |
| | | | { 5. Hydatid. |
| 3. <i>Within the Orbit.</i> | { | 1. Inflammation of the cellular tissue; idiopathic and traumatic. | |
| | | 2. Suppuration and abscess. | |
| | | 3. Erysipelatous and phlegmonous inflammation. | |
| | | 4. Foreign bodies. | |
| | | 5. Excessive development of fat. | { 1. Encysted. |
| | | 6. Tumours | { 2. Hydatid. |
| | | 7. Aneurisms and effusions of blood. | { 3. Encephaloid |
| | | 8. Venous congestion. | { 4. Osseous. |
| | | 9. Paralysis of muscles of eyeball; ophthalmoplegia. | |
| | | 10. Spasm of muscles of eyeball, as in tetanus. | |

¹ Ophthalmic Hospital Reports, vol. i. pp. 21 and 168, and vol. ii. p. 216.

- | | | |
|------------------------------|---|--|
| 4. <i>External to Orbit.</i> | { | 1. Above :—nodes ; hydrocephalus ; fungus of dura mater ; polypi in frontal cells and diseases thereof ; tumour of brain.
2. Below :—diseases of the antrum.
3. Internal :—nasal polypi and tumours.
4. External :—exostosis.
5. In front :—contraction of lids and eye slipping through : hernia oculi. |
|------------------------------|---|--|

A cause of protrusion of the globe, omitted by Mr Poland, but which I have seen, is direct injury to, and crushing in of, the outer wall of the orbit. In the case in which this occurred, the man had been thrown out of a cart, and the hoof of the horse had been planted on the temple, smashing the bone, and causing the eye to protrude upon the cheek. The other injuries which the man had received were so severe that death took place in a few hours, and no treatment was required or adopted. Had this not been the case, however, the fragment of the outer wall of the orbit should have been manipulated as far as possible into position, and the eye cleansed and replaced, and covered with a wet pad, and moderate pressure. After injury of so serious a nature as this, recovery of sight could scarcely be looked for.

Some of the diseases enumerated in Mr Poland's table, as hydrocephalus, diseases of the antrum, polypi of the nose, etc., belong rather to general than to ophthalmic surgery. Others, as aneurism and encephaloid disease, will presently be referred to ; and others, as hydrophthalmos, will receive consideration hereafter. Reference will only be made here to that form of exophthalmos which probably arises from venous congestion, is frequently associated with struma, and which is perhaps more frequent than any one of the other causes.

It occurs in pallid and debilitated persons, principally females, who have been brought down by protracted nursing or by excessive discharges. It is often associated with palpitation of the heart, enlargement of the thyroid gland, swelling of the feet and legs, especially at night, and with the occurrence of venous murmurs. The eyes project sufficiently to

be very unsightly, but vision is not generally impaired. Some excellent cases have been recorded by Dr Prael,¹ of which the following is an abstract:—

The disease does not necessarily occur in women; and the first example given by Dr Prael is that of a man, which shows also very well the injurious effects of depletion. The subject was of soft temperament and blue eyes, married, but without children. At the age of 50, he suffered from fever, which was followed by increased cardiac impulse and enlargement of the thyroid gland. When seen, he was unable to close the lids of the right eye, which were red and congested. Rotation of the eye was difficult, but vision was good, and there was no photophobia. After some time he became weaker and thinner, and complained of facial neuralgia. This was followed by an attack of bronchial catarrh, during which the eyes continually became more prominent. Both of the globes were exposed during sleep, and the respiration was then stertorous. Acetic tincture of iron and phosphoric acid were advantageously employed in the course of the disease; but, about a week or two before he died, he caused himself to be bled. On the following morning the cornea was opaque below the middle, and the iris was stiff and was not affected by atropia. The cornea soon became opaque throughout; but instead of ulceration occurring, it dried up to a horny mass, slight vision remaining. A few days after, death ensued. On making a *post-mortem* examination, the body was found emaciated; the brain softer than natural in several parts; the thyroid gland was enlarged; the right side of the heart dilated and hypertrophic; the mitral valve converted by atheromatous deposit into a bony ring; and the aorta so contracted as scarcely to admit a goose quill. The cornea and sclerotica were horny and dry, but the interior of the globe appeared to be normal, and no cause was observable in the orbit to which the protrusion could be assigned, the

¹ Archiv. f. Ophth., vol. iii. 2. p. 199.

adipose and connective tissues and the lachrymal gland being all natural.

Dr Prael had, in five years, seen nine cases, at ages varying from fifteen to fifty. I have made a brief abstract of the principal points in one or two of them, to which the others bear a general resemblance.

1. Brunette, with blue eyes, æt. nineteen, tall and active, suffered from irregular menstruation, palpitation of the heart, bleeding at the nose, and dental and facial neuralgia. After chlorosis of two years' duration, eyes began to protrude. The protrusion was considerably increased by any kind of excitement. Rest, vegetable and unstimulating diet, free use of milk and lactate of iron, effected a cure in four or five years.

2. Was a maid-servant, of fair complexion, æt. fifteen. She suffered from dysmenorrhœa and eclampsia, which were followed by chlorosis. This was cured by the administration of lactate of iron. Then protrusion of the globe occurred, with hæmatemesis and return of the chlorosis. The thyroid was enlarged, but there was no disease of the heart. The protrusion was relieved by the employment of Haller's acid elixir.

3. Was a lady, who suffered from irregular menstruation. At eighteen she became chlorotic, and had certain hysterical symptoms, palpitation of the heart, and bleeding at the nose. The protrusion of the globes which then occurred was completely cured by full diet, and the use of carbonate of iron. Eight years after, she was still suffering from the symptoms of cardiac hypertrophy, and the thyroid was somewhat enlarged.

The following case presented itself amongst my patients last year:—E. S., married woman, æt. twenty-six, has observed, during the past twelve months, that her eyes have gradually become more prominent, until they now attract attention in the street. The lids can be closed easily, but the whole of the circle of the cornea, and about one-eighth of an inch of

the adjoining portion of the sclerotic, are visible. There is no appearance of congestion about the globes; the sclerotic is of a transparent pearly-blue colour, and the tension is natural. The left eye is the more prominent one, and there is slight diminution both in the sharpness of vision and in the power of accommodation. She was able to read XL of Snellen's test-types at thirty feet with the right eye, but only L with the left at the same distance. She speaks with a thick voice, but there is no swelling of the tonsils. The thyroid is full, but can scarcely be called abnormal. She has been married six years, and has had three children. The bowels and catamenia are regular; she does not suffer from swelling of the feet or breasts. Though pallid, she speaks and moves with much vivacity. The prominence of the globes increases considerably when she holds her head down in working or reading, or on any excitement, mental or bodily. She cannot attribute it to any cause, except that one evening, when she thought she was alone in the house, a friend burst suddenly in and frightened her. She came to the hospital on the 6th of February, and was at once placed on *mist. ferri co.*, and was directed to take two glasses of wine daily, and use a moderately cold portable shower-bath every morning. She immediately began to improve, gained some colour in her face, and the prominence of the eyes diminished. On the 3d of May, having pursued this treatment with great steadiness and perseverance, she was almost well. Her medicine was changed to *mist. quinae*, containing two grains of quinine, thrice-a-day, and she ceased to attend on the 10th May.

In a second case, the symptoms of anæmia were much more strongly marked, the feet swelling considerably, severe and nearly constant pain being experienced in the vertex, and much enlargement of the thyroid and disturbance of the catamenia being present. Under a similar plan of treatment, continued for some months, partial recovery took place.

v. Gräfe¹ remarks that, though in M. Prael's cases organic disease of the heart and arteries appears to have been the starting-point of the disease, in other cases, though present, these affections were clearly secondary in point of time; and he suggests that it will be hereafter shown that this disease is connected with some affection of the sympathetic and vasomotor system of nerves. In eight cases that he had himself observed, there was no hypertrophy of the heart or valvular disease present. There was always more or less hypertrophy of the cushion of fat on which the eyes rest. In four out of the eight cases, v. Gräfe found gastric disturbance present. In three of M. Prael's cases, the right eye alone projected; in all of the remaining cases, both eyes were prominent.

The treatment of the affection has already been incidentally given in the account of the above cases. As it is generally coincident with struma, the ordinary remedial measures for that constitutional disease must be put in force: removal to a warmer climate, rest, good food, warm clothing, the administration of cod-liver oil alone or combined with some of the preparations of iron or zinc; or, if the heart be affected, the use of digitalis, and attention to the nature and quantity of food, the function of digestion, and to the action of the bowels, are some of the points which would naturally suggest themselves to every practitioner.

Where the cornea has become dry and opaque from exposure, consequent upon inability to close the lids, v. Gräfe recommends weak iodine lotions, and speaks highly of the cosmetic advantage to be derived from tarsorrhaphy, which consists in refreshing the edges of the lid at the outer canthus, and bringing them together by one or two sutures.

8. *Aneurism of the Orbit.*

Here, as in other parts of the body, various forms of aneurism have been observed, which sometimes arise idio-

¹ Archiv. f. Ophth., b. iii. 2. p. 278. 1857.

pathically from disease of the coats of the ophthalmic artery or one of its branches, and notably of the *arteria centralis retinae*, and sometimes are the result of injury to some vessel, and subsequent gradual development of either a mixed or false aneurismal tumour. More rarely, aneurisms by anastomosis and erectile tumours have been met with, and in the same group of cases may be enumerated, since they also constitute pulsatile tumours, thrombosis, and phlebitic inflammations, extending into the cavernous sinus. Only about thirty cases of aneurism are on record, of which one-half were true aneurisms. These last are consequently very rare, and have never been seen to attain a larger size than that of a nut. In the case described by Mr Guthrie,¹ no tumour could be perceived. The eye was gradually protruded until it seemed to be outside of the orbit, but vision was scarcely affected. There was a distinct bruit. After death, an aneurism was found to be seated on the ophthalmic artery, of the size of a large nut. The ophthalmic vein, before it passed through the sphenoidal fissure, was enlarged and obstructed, in consequence of the great increase of size in the four recti muscles.

In M. Giraudet's case,² the aneurism was seated at the origin of the ophthalmic artery, the middle tissue of which was thickened on its inner surface by osseous lamellæ. In a case recorded by v. Gräfe, the central artery of the retina was enlarged to the size of a straw, for some distance; and M. Schmidler possesses an anatomical preparation, showing an aneurism of the central artery of both eyes of a patient who could only see a little when she looked down. It is difficult to found a satisfactory diagnosis upon the symptoms presented in these cases, since little can be ascertained except

¹ *Operative Surgery of the Eye*, p. 168. 1830.

² See the excellent Memoir of M. Demarquay, in the *Gazette Hebdomadaire* for 1859, p. 597, on *Infra-orbital Aneurisms*, which contains a fund of information on this subject, and many references to cases.

that there is beating in the head, pain, and protrusion of the globe,—symptoms that, unless accompanied by a bruit (not always very perceptible in cases of aneurism), may be more or less closely simulated by encephaloid cancer, and by phlegmonous abscess of the connective tissues of the orbit.

In the mixed form of aneurism, or, as M. Demarquay terms it, the consecutive diffused aneurism, there is probably enlargement of the artery at some part, in consequence of disease of its coats, producing the above-mentioned symptoms in a degree more or less marked in different instances. At length, in consequence of some violent shock or exertion, a sudden severe pain is experienced, which is coincident with the bursting of the aneurism, and all the symptoms then become aggravated; the blood, escaping from the fissure in the arterial walls little by little, but steadily, distends the connective tissue with which the clots blend and confound themselves, so that ultimately an irregular cavity still communicating with the artery is produced, possessing an audible bruit and distinct pulsation, and having a tendency to increase indefinitely. In such cases, the death of the patient, if no remedial means are employed, is certain, either from repeated hæmorrhage, or from the patient being worn out with the pain. The causes of the primary aneurismal dilatation of the vessels have been referred to severe and long-continued straining, as in childbirth, to senile alteration of the vascular walls, and to changes in them, consecutive upon inflammatory fever.

Primary diffused, or false, aneurisms are perhaps the most frequent of all the forms. They commonly arise from falls, blows, and shocks effecting the direct and immediate rupture of the coats of the vessel. They are distinguished from the preceding form by the suddenness with which the symptoms supervene, and the absence of all previous evidence of disease, as headache, dimness of vision, etc.

After the blow, the patients suffer persistent pain, increased on hanging the head down. The lids begin to be

cedematous, and subsequently livid; the accumulation of blood in the back part of the orbit gradually causes the eye to protrude, till almost complete exophthalmos results; the movements of the eye are limited, and accomplished with pain; vision rapidly becomes impaired, and ultimately altogether lost. At length a tumour appears at some part of the orbit, dilating equably, or pulsating with each systole of the heart, and accompanied not only by certain hissing, humming, or beating sounds, perceptible to the patient himself, but by a loud bruit, audible with the stethoscope applied to the temple.

The existence of these symptoms have, however, more than once misled very practised observers.¹

In Mr Bowman's case, five months after a blow, pain was experienced, which lasted a fortnight, and was then followed by a bruit, strabismus and swelling of the orbitary region, and protrusion of the globe. Pulsation was distinctly perceived. Ligature of the common carotid was performed; but the woman unfortunately died from secondary hæmorrhage. A *post-mortem* examination showed only tumefaction and swelling of the dura mater forming the outer wall of the cavernous sinus, and evidence of phlebitis in the interior of the cavernous transverses, circular and petrosal sinuses, and a varicose condition of the ophthalmic vein, with obstruction of its calibre at the point of its junction with the cavernous sinus.

In Gendrin's case, the woman was thirty-two years of age, had an affection of the heart, and encephalitis. Suddenly, after severe pain had been felt in the left eye, it began to protrude. Sight was abolished; the eyelids became red and tumid; the globe of the eye immobile; and there was a distinct bruit and pulsation. After her death, no aneurism was found; the intra-orbital veins were gorged with blood,

¹ See the case of Mr Bowman (Ophth. Hosp. Rep., p. 6, 1859); and one by Gendrin (Lectures sur les Maladies du Cœur, t. i. p. 240).

and the cavernous sinus contained a clot of blood surrounding the internal carotid and ophthalmic veins as they passed through it.

These cases give a lesson of caution in respect to operations on the larger arteries for their cure.

Various modes of treatment have been suggested, but some which are or have been successful elsewhere are not applicable in the case of aneurism in the orbit. Thus pressure, either upon the globe of the eye or on the carotid in the neck, cannot be very well borne, on account of the sensibility of the part.¹ Ablation of the tumour, though successful in one case, is too dangerous a mode of treatment to be generally adopted; whilst acupuncture and galvanopuncture are difficult to apply, and have not been found to succeed. The injection of coagulating fluids, again, as the prechloride of iron, when we take into consideration the likelihood of the formation of a deep-seated abscess, and the proximity of the brain, does not, though one or two successful cases are recorded, recommend itself strongly to the operator. The best method, when the presence of an aneurismal tumour has been certainly diagnosed, is undoubtedly ligature of the carotid. This has been performed eleven times, according to M. Demarquay, writing in 1859. Of these one died; two were cases of partial success; one was a failure, but was subsequently cured by the injection of lactate of iron; and the remaining seven cases were cured. The statistics of this operation are therefore sufficiently encouraging.

A case has been recorded by Holmes,² in which a tumour, presenting all the symptoms of aneurism, and which formed after a gun-shot injury, was cured by the administration of tincture of green hellebore and liquid extract of ergot, combined with low diet and perfect rest. In the course of a

¹ See M. Szokalski's case in *Annal d'Ocul.*, p. 116, 1865, where it had to be relinquished on account of the formation of extravasations that were very painful.

² *Amer. Journ. of the Med. Sciences*, vol. xlviii. p. 44.

fortnight amendment was observed, and soon the bruit and pulsation entirely disappeared, whilst the protrusion of the globe was greatly diminished.

Aneurisms by anastomosis commence almost constantly in or near to the skin, are almost always congenital, and are not accompanied by pulsation or by any stethoscopic sounds. They form somewhat nodulated or irregular swellings, which increase in size to a remarkable degree when the head is congested by stooping, mental excitement, or crying, but which soon return to their original condition. I have at present a case under my care at the hospital of a child of the age of two years, on whom I have operated three times, but still only with partial success.

Ligature of the carotid, which is so successful in cases of true or false aneurism, has not here been found to be of service; and the most favourable results are obtained by including as much as possible of the tumour in a subcutaneous figure-of-eight ligature. After the removal of the silk, the enlargement will be found to have diminished; and, when the swelling is great, a second and third portion may be successively attacked.

9. *Cancer of the Orbit.*

The most common form of cancer met with in the orbit is the encephaloid. The seat of its origin varies, but when once commenced it progresses with rapidity to a fatal termination. Like other tumours occupying the back of the orbit, it causes protrusion of the globe; is accompanied with severe pain from pressure on the nerves; produces strabismus, or immobility of the globe, and rapidly occasions loss of sight. The following history will give the chief features of this disease:—

J. P., the son of a baker, a pallid, short youth of twenty years of age, was seen by me on 16th June 1865, with protrusion of the globe, which he had first noticed three weeks

before. He had experienced but little pain except during the last week, when it was chiefly felt in the upper part of the orbit, and was worst at night and in the early morning. He was accustomed to rise at five for his work, and the pain was then always very severe. There was considerable projection of the eye, rendered more conspicuous by congestion and swelling of the lids, and by redness and slight chemosis of the conjunctiva. The tension of the globes was not increased; the media were clear; the fundus of the eye apparently healthy, except that the larger vessels of the choroid were unnaturally distinct, the pigment and capillary layers being atrophied. His vision had been becoming misty during the previous week. He was, and had always been, slightly myopic, holding ordinary print at a distance of six inches from the eye. Below the globe, and to its inner side, was a well-defined, hard, rounded swelling, in which no fluctuation nor pulsation could be perceived, though, in consequence of his having experienced a sharp rigor a day or two previously, the former was carefully looked for. An exploratory puncture was made with a grooved needle, which passed into the tumour with but little resistance, but no fluid escaped. Poultices and hot fomentations were directed to be applied, which alleviated the pain, and small doses of iodide of potassium administered. Four days afterwards (20th June), the protrusion of the globe was found to have rapidly increased. I saw him in consultation with his ordinary medical attendant, Dr Battye. He was looking very sickly. Tongue coated; bowels confined; great depression of spirits. Tumour very distinct, more prominent, and giving an obscure fluctuating feeling. Lids much swollen and livid. It was again thought expedient to puncture the tumour; but as no fluid escaped, it was diagnosed as of malignant character. On 23d June he described the pain as of a dull aching character, and complained of roaring, humming, and pulsating sounds in the left ear. Sight had rapidly diminished during the last few days, and was now limited to a

general perception of light. The movements of the eye were almost completely abolished. The conjunctiva was congested with dark-coloured blood, and chemosed. He remarked that the lids and conjunctiva were numb on pressure, but were not painful, clearly owing to pressure on the lachrymal branch of the fifth. The tumour extended as far back as the commencement of the infra-orbital meatus, since the infra-orbital nerve, at its point of exit, and especially the two incisor teeth, were also very numb on pressure.

He was very desirous to have some operation performed for its removal; and having been admitted into the Westminster Hospital, and with the approval of my colleagues, it was determined to attempt its removal.

This was accordingly undertaken on the 27th June. The globe was easily extirpated. It was then found to rest on a bed of soft medullary cancer, closely resembling brain-substance. Much time was spent in clearing the orbit as completely as possible of the cancerous mass; but it was found to have corroded the walls of the orbit, especially the frontal and inferior maxillary, and to dip deeply into the fundus towards the optic foramen and sphenoidal fissure. It was, however, in spite of much bleeding, very thoroughly removed, small patches which appeared suspicious being touched with concentrated nitric acid.

On examination, the eye was found healthy, but the disease appeared to have originated in the optic nerve, which occupied nearly the centre of the mass, and was very thoroughly infiltrated with the cancerous material. Under the microscope, the tumour was found to consist of the usual constituents of medullary cancer, large cells, frequently candle-shaped, and now and then containing several nuclei; numerous blood-vessels, and a fluid in which many minute fat corpuscles were floating.

On the following day (29th June) he was quite free from pain, and he had slept well. He was ordered two grains of

bromide of potassium three times a-day, and was directed to apply a lotion, containing sixteen grains of bromide of potassium to one pint of water, frequently to the surface of the wound. He went on satisfactorily up to the 5th of July, no reappearance of the disease having taking place, and healthy cicatrization having been established. On that day he returned home. A few days afterwards, I was again called to see him, as a fungous mass had begun to appear from the bottom of the orbit. The tumour now progressed rapidly. In a few weeks it had become level with the surface of the orbit. At this time the glands on the left side of the neck began to enlarge; the cancerous deposit had obviously become established in them. The man's vitality was, however, very great. He was sent down into the country, and enjoined to live freely. I saw him again in November. The whole side of the face was then one immense, swollen, cancerous mass, discharging a thin, ill-smelling, ichorous fluid. The whole chain of glands beneath the sternomastoid was affected, forming irregularly nodulated, livid, and ulcerated cancerous masses. Death occurred in January from exhaustion. During the latter months little pain was experienced, and treatment was almost completely abandoned.

CHAPTER II.

Strabismus.

ORIGIN AND INSERTION OF THE SEVERAL MUSCLES MOVING THE EYE—THEIR ACTION—CAUSES OF STRABISMUS—DIAGNOSIS OF THE DIFFERENT FORMS OF STRABISMUS—SYMPTOMS OF STRABISMUS FROM PARALYSIS OF THE THIRD NERVE—OF THE SIXTH NERVE—OF THE FOURTH NERVE—TREATMENT OF STRABISMUS.

THE importance of the recti and obliqui muscles in the production of strabismus renders it requisite to enter into some details regarding their attachment and actions.¹

The four recti muscles arise from a tendinous ring around the optic foramen in the sphenoid bone, the external rectus having an additional superior small tendinous head of origin from the inner edge of the sphenoidal fissure. From this ring the recti muscles run forwards, diverging from one another, and becoming somewhat wider, until they are ultimately inserted, by broad and delicate tendons, into the sclerotic coat, at about the distance of a quarter of an inch

¹ For more extended descriptions of these points, and especially for details respecting the pathology of strabismus, the author refers to the instructive papers of Mr Soelberg Wells, in the Ophthalmic Hospital Reports, vols. i. and ii., to which he is much indebted in drawing up the following remarks to v. Gräfe's Essay in the Archiv. f. Ophth. B. and i. p. i.; to Donder's Essays in the Annales d'Oculistiques, t. i. pp. 205 and 258; to Holthouse on Squinting, 1858; to Warlomont's and Testelin's Translation of Mackenzie's Treatise (supplementary volume); and to Henle's Handbuch der Systemat. Anatomie des Menschen.

from the margin of the cornea. The attachment of the tendon of the superior rectus is slightly oblique, the line of insertion running backwards and outwards; and that of the inferior rectus is placed rather to the inner side of a vertical line dividing the cornea and sclerotic into two lateral halves. The tendon of the external rectus is remarkably wide. The internal rectus is the largest of these muscles, and its tendon is proportionately thick and strong. The edges of each tendon are by no means well defined, the fibres gradually blending with those of the adjacent connective tissue.

The superior oblique muscle arises from the orbital plate of the frontal bone, by a small tendon in the interval between, and a little in advance of, the superior and internal recti muscles. Running forward and lying on the internal rectus, it terminates in a round tendon that passes through the fibrous ring attached to the borders of the fossa at the anterior and inner part of the roof of the orbit, and, being reflected backwards, is inserted in the posterior and superior quadrant of the eye by a tendon a quarter of an inch in breadth. The line of insertion is parallel to the axis of the optic nerve, and the most anterior fibres are inserted at a point midway between the cornea and the entrance of the optic nerve.

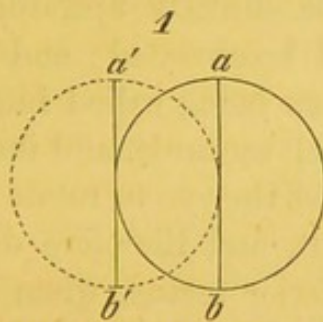
The inferior oblique muscle arises from a small depression situated on the orbital plate of the superior maxillary bone, close to the commencement of the lachrymal canal. It runs outwards beneath the inferior rectus, then between the external rectus and the globe of the eye, and is finally inserted into an obliquely ascending line between the external rectus and the optic entrance, for the space of one-third of an inch.

The superior, internal, and inferior recti, and the inferior oblique, are supplied by the third pair of nerves, the external rectus by the sixth, and the superior oblique by the fourth nerve.

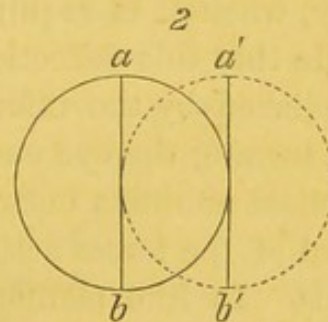
The principal action of the four recti muscles is doubtless

to rotate the eye—the superior upwards, the inferior downwards, the external outwards, and the internal inwards. The superior oblique directs the eye downwards and outwards, and the inferior oblique upwards and outwards. Further, when two of the adjoining recti act together, they rotate the eye in the diagonal between them. But in addition to these movements, and in consequence of the obliquity of the muscle planes, and of the oblique lines of insertion of the tendons of all these muscles, with the exception of the external and internal recti, accessory rotatory movements of the globe are effected, by which the vertical meridian of the eye is inclined in different instances inwards or outwards. I have endeavoured to render this effect apparent by the subjoined figures, in which the direction of the action of each of the muscles is indicated, as well as their action on the vertical meridian (*a b*), in the case of the right eye.

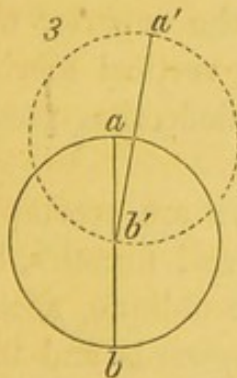
RIGHT EYE.



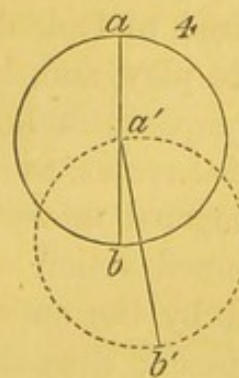
Action of External Rectus.



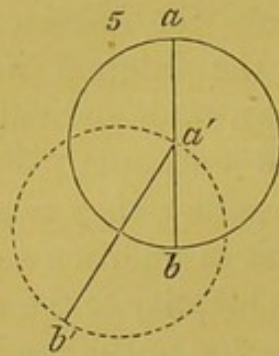
Action of Internal Rectus.



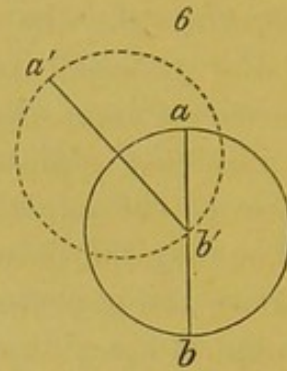
Action of Superior Rectus.



Action of Inferior Rectus.



Action of the Superior Oblique.



Action of the Inferior Oblique.

It will be seen that the external rectus simply turns the eye outwards, without altering the direction of the vertical meridian of the cornea, and that the internal rectus simply turns it inwards, also without altering the verticality of the meridian.

The superior rectus, however, not only turns the eye upwards, but gives it a slight inclination inwards, and also inclines the vertical meridian ($a b$) inwards ($a' b'$). Consequently, when it is required to look directly upwards, it is requisite that this deflection should be obviated; and this is accomplished by the inferior oblique being called into play, which, turning the eye outwards and upwards, and inclining the vertical meridian outwards, causes the eye to rotate in the diagonal of the forces acting upon it, and therefore directly upwards. In like manner, the inferior rectus, when acting alone, would rotate the eye downwards and a little inwards (fig. 4), inclining the vertical meridian inwards; but when it is desired to look directly down, the superior oblique is called into play, and, by inclining the vertical meridian outwards, compensates for the internal deflection produced by the internal rectus, as already stated.

The diagonal movements of the eye are accomplished by the conjoined action of two of the recti muscles, but these are aided by the superior or inferior oblique, according to circumstances; thus the movement upwards and inwards is effected by the united action of the superior and internal

recti, aided by the inferior oblique, to obviate the too great deflection of the vertical meridian inwards, occasioned by the superior rectus, and thus to render the vertical meridian parallel with that of the opposite eye.

Again, in the movement downwards and inwards, the inferior and internal recti act together; but as the inferior rectus would deflect the vertical meridian to too great an extent outwards, its action is therefore checked by the coincident contraction of the superior oblique, which has a tendency to deflect the vertical meridian outwards, and thus to keep it parallel with that of the opposite eye.

It must be remembered that the position of the vertical meridian in either eye alone is of no importance. From custom, however much it may be inclined, vertical objects are still seen to be vertical. The position of the vertical meridian is only of importance when that of one eye does not coincide with that of the other. Then, whilst a vertical image is seen to be vertical by one eye, it appears to the other to be slanting.

The following tabular statement will enable the actions of the several ocular muscles to be more easily understood:—

Movement.	Is affected by the
Upwards,	{ Superior rectus, aided by the inferior oblique.
Downwards,	{ Inferior rectus, aided by the superior oblique.
Inwards,	Internal rectus.
Outwards,	External rectus.
Upwards and inwards,	{ Superior rectus and internal rectus, aided by the inferior oblique muscle.
Upwards and outwards,	{ Superior rectus and external rectus, aided by the inferior oblique muscle.
Downwards and inwards,	{ Inferior and internal recti muscles, aided by the superior oblique.
Downwards and outwards,	{ Inferior and external rectus, aided by the superior oblique.

As regards the position of the vertical meridian in the different movements of the eye, the rules laid down by Donders are thus translated by Mr Wells :—

1. In looking in the horizontal meridian plane, straight-forward, to the right, or to the left, the vertical meridian suffers no inclination, but remains vertical.

2. In looking in the vertical meridian plane, straight-forward, upwards, or downwards, the vertical meridian also remains vertical.

3. In looking diagonally upwards to the left, the upper ends of the vertical meridians of both eyes are inclined parallelly to the left (that of the left eye outwards, that of the right inwards).

4. In looking diagonally downwards to the left, the upper ends of the vertical meridians of both eyes are inclined parallelly to the right (that of the left eye inwards, that of the right outwards).

5. In looking diagonally upwards to the right, the upper ends of the vertical meridians of both eyes are inclined parallelly to the right (that of the right eye outwards, that of the left inwards).

6. In looking diagonally downwards to the right, the upper ends of the vertical meridians of both eyes are inclined parallelly to the left (that of the right eye inwards, that of the left eye outwards). The reader will be able readily to follow these statements, by drawing a circle to represent the cornea on an india-rubber ball, and inscribing a cross within the circle, to represent the vertical and horizontal meridians.

In health, the movements of the two eyes are never independent nor opposed to one another in direction, and the muscles may be arranged in groups which affect what are called the associated movements of the eyes. Thus the two superior and two inferior recti act together; but the internal rectus of one eye is always associated in its contraction with the external rectus of the opposite eye; and, in like manner,

the movement downwards and outwards of one eye, effected by the inferior and external recti of one eye, aided by the superior oblique, is accompanied by a movement downwards and inwards of the opposite eye, effected by the inferior and internal recti, aided also by the superior oblique. These associated movements are always interfered with in squinting eyes, and the failure of their occurrence is the immediate cause of the remarkable phenomena observed.

The extent of voluntary movement of which each eye is susceptible is, from side to side, about 90° , and from above, downwards, about 60° .

The essential condition of strabismus is that, in consequence of some defect of the nervo-muscular apparatus, the patient is unable so to direct his eyes as to cause the image of any external object to fall upon the corresponding points of the two retinae; but either, if the image be received upon the central spot of one eye, it falls upon the outer side of this spot in the other, constituting a case of divergent squint in this eye, or upon the inner side, when it is a case of convergent squint. Abnormal deviations of the eye upwards or downwards are extremely rare. Donders shortly defines strabismus to be a deviation of the eyes, whereby the central spots of the two eyes simultaneously receive the impressions of different objects.

Whether the strabismus be convergent or divergent, diplopia, or double vision, is at first produced; but, after a while, the patients disregard the image received by the affected eye, which soon becomes the less vivid of the two, and attend only to that formed on the healthy side.

The forms which strabismus presents are various; and whilst some are recognised with facility, others require much care and attention for their diagnosis.

In some cases the affection is persistent, in others it is intermittent; though the latter case generally constitutes only the precursory stage of the persistent condition. In some

both eyes are affected; in others only one; and, lastly, the disease is sometimes congenital, but far more frequently acquired.

The circumstances which lead to the formation of strabismus have been materially elucidated during the last few years by Professor Donders, from whose investigations it may now be considered as established, that internal or convergent squint is a frequent concomitant and secondary result of moderate degrees of hypermetropia, or that condition of the refractive media in which parallel rays are brought to a focus behind or beyond the retina; whilst external or divergent squint is associated with myopia, in which parallel rays are brought to a focus in front of the retina. Convergent squint commonly appears as soon as the patient begins to use the eyes upon small objects, and therefore at about the age of five years; and Donders has ascertained the presence of hypermetropia in upwards of eighty per cent. of all cases of convergent squint.

The explanation given by Donders of the mode in which hypermetropia produces convergent strabismus is to this effect:—In normally constructed eyes, when the visual axes are parallel, as in looking at distant objects, these axes are cut at an acute angle of about 5° for each eye by the axis of the cornea, which is directed outwards to that extent; but, in the case of hypermetropic eyes, the axis of the cornea is directed outwards to the extent of 8° or 9° ; and consequently, when it becomes necessary to converge the axis, and to alter the accommodation of the eye in order to examine near objects, an unnaturally energetic nervous impulse is propagated to the internal recti, whence, in course of time, these muscles acquire undue strength, and predominate in their action over the external recti, which become elongated and correspondingly enfeebled.

Strabismus does not occur in very high degrees of hypermetropia, because the effort to converge the eyes to the extent requisite for single vision is so great, that pain and lachryma-

tion are produced, and the patient at length becomes content with the image of one eye strongly converged, whilst the other remains straight, and its images are unheeded.

The reason of the divergence of hypermetropic eyes in viewing distant objects appears to be due to an imperfect development of the eye. The outer portion being, as it were, arrested in its growth, it follows that the central spot is situated relatively too far externally as compared with the healthy eye; and as the axis of the cornea is also directed too far outwards, cutting the optic axis at an unnaturally wide angle, strong convergence of the axis is required to cause the images of near objects to fall on the macula lutea. In myopia, on the contrary, from the distension and pullulation of the outer parts of the globe which are associated with that affection, the yellow spot occupies a relatively more internal position, and the corneal axis is placed internally to its normal direction; and, further, from the elongated form of the globe, its movements are impeded, and the internal recti act at a mechanical disadvantage, whence greater efforts are required for the convergence requisite for the examination of near objects, which again induces unnatural fatigue and exhaustion of these muscles. As a consequence of this, the divergence of the axis follows, the external recti drawing the eyes outwards when the internal recti are exhausted and relaxed.

Donders¹ expresses his opinions on the mode of origin of strabismus in these cases, shortly, in these words:—

Hypermetropia occasions *accommodative* asthenopia, which is actively overcome by converging squint.

Myopia leads to *muscular* asthenopia, which passively results in diverging squint.

Other causes of strabismus, enumerated by Mr Soelberg Wells, are rheumatic and syphilitic affections, the latter constituting a large proportion of the cases;² inflammation and

¹ v. Gräfe's Archiv. f. Ophth., B. ix. 1, p. 154. 1863.

² One-third, v. Gräfe.

abscess, effusion of blood, and tumours within the orbit; intra-cranial and cephalic diseases and injuries; and it has sometimes been observed to accompany the debilitated states of the system remaining after an attack of one of the exanthematous fevers. All of the above-named causes may, and probably do, act by producing paralysis of the nerves.

In many cases, however, it appears to result from reflex irritation, as it is frequently associated with the presence of worms in the intestinal canal, and with mal-dentition. Dr Bader has observed it in connection with certain diseases of the retina, and Liebreich with an abnormal position of the optic nerve, and with cysticercus in the vitreous humour. It has not unfrequently been noticed as a consequence of leucomatous spots on the cornea, and occasionally, perhaps, it is the result of imitation.

v. Gräfe observes that, in all cases of persistent strabismus, a disproportion must exist in the mean length of the several muscles, that situated on the side towards which the affected eye is directed being shortened or contracted, and that on the opposite side being lengthened. The shortening or elongation depends either upon the point of insertion of the tendons of the muscles being abnormally situated, or upon some change having taken place in the structure of the muscle itself. In the former case, the muscle, though it may be of ordinary strength, acts at less advantage in the latter. Its proper energy and power are diminished.

Now, when we consider that in every case of persistent strabismus one muscle is shortened and its antagonist elongated, the question naturally arises, Does the contracted muscle pass into this condition of contraction in consequence of receiving an excess of nervous force, or is its contraction attributable to the antagonistic muscle receiving a deficient supply of nervous force? In other words, taking an internal squint as an example, is the deviation of the eye inwards due to unnatural activity of the internal rectus, or to paralysis of

the external rectus? According to v. Gräfe, the answer can be obtained by a careful determination of the amount of movement possessed by the eye. If the sum of its movements are equal to those of the sound eye, then it is the result of excessive innervation and energy of the affected muscle; but if, as is more frequently the case, the sum of its mobility is diminished, then it is the result of paralysis of the antagonistic muscle.

But, then, it may be asked, how is the amount of the movement possessed by the two eyes to be ascertained and compared? The plan to be adopted is the following, which, indeed, should be pursued in every case that presents itself:—The attention of the patient should be directed to some object placed in the median line, a short distance in front of him. It will then be found that he “fixes” the object with the sound eye, whilst the affected eye deviates more or less to the outer or inner side, according to the kind and degree of squint present.

This deviation is called the *primary* angle of deviation, and may be measured either by the plan adopted by v. Gräfe, of making a dot of ink below the centre of the cornea, on the lower lid of each eye, and measuring the distance of the dot on each side from the inner canthus; or by the plan of M.M. Testelin and Warlomont, of notching the border of an eyelet-hole in a piece of card, cut to the form and size of the palpebral fissure; or by the little instrument constructed by Mr J. Z. Lawrence, which consists of an arc of metal, divided at the edges into degrees, which can be applied to the lower lid; or by the more complicated and expensive instrument of Meyer; or, lastly, by the simple mode proposed by Dr Steffan,¹ in which a square piece of millboard, with an arc of 18 inches radius described upon it, to the degrees of which lines, emanating from one angle, radiate, is placed horizontally in front of the eye. The patient is then told to fix a

¹ Ophthalmic Review, vol. ii.

pin, inserted into the extremity of the arc, with the sound eye; and whilst the board is so held that one side corresponds to the direction the visual axis of the affected eye should possess if it occupied its natural position, the amount of deviation can easily be read off by carrying a taper round the arc till a reflection is obtained from the centre of the cornea on that side. Supposing this to be determined, the sound eye should now be covered with the hand, when the affected eye will immediately make an excursion and fix the object. On now removing the hand from the sound eye, it will be found that, whilst the affected eye has been directed to the object, the sound eye has rolled inwards or outwards, as the case may be; and the degree to which this has taken place constitutes what is known as the *secondary* angle of deviation. The primary angle of deviation, therefore, has reference to the affected, the secondary angle to the sound, eye.

In cases of paralysis, the secondary deviation is found to be constantly greater than the primary, whilst it is equal in those cases where paralysis does not exist.

The cause of the former phenomenon appears ascribable to the feeble innervation of the paralysed muscles requiring a stronger effort on the part of the nervous centres to rotate the eye in the required direction. But the same energetic impulse is propagated to the muscle of the opposite healthy eye with which it is ordinarily associated in action; hence this eye deviates through a larger angle.

When, on the contrary, the squint is due merely to a want of proportion in the length of the muscles, resulting from preternatural activity of the muscle on the side towards which the eye is drawn, the degree of primary and secondary deviation is always the same.

It is impossible, within the limits of this work, to give more than an outline of the chief varieties of strabismus, and our remarks will therefore be confined (1.) to convergent squint (*luscitas*), occasioned by paralysis of the sixth nerve and

external rectus muscle; (2.) to divergent squint, occasioned by paralysis of the third nerve and internal rectus; (3.) to that form of squint produced by paralysis of the fourth nerve and superior oblique muscle; and, lastly, to that form occasioned by paralysis of the inferior oblique muscle and the branch of the third nerve distributed to it.

1. *Convergent Squint.*

Of all the forms of strabismus, internal or converging squint, consequent upon paralysis of the sixth nerve and external rectus, from one of the foregoing causes, is most simple and uncomplicated. The action of this muscle, *per se*, is to turn the eye outwards; but when conjoined with the superior rectus and inferior oblique, it turns the eye diagonally upwards and outwards; and when conjoined with the inferior rectus and superior oblique, it turns the eye downwards and outwards—in the former case the vertical meridian being inclined outwards, and in the latter inwards. In order to diagnose the presence of paralysis of the sixth nerve, say on the left side, the patient is directed to follow any bright object, held in the first instance opposite to him, and then gradually moved to the left or outer side. It will be found that, after a certain point is reached, the affected eye ceases to turn outwards, and diplopia, or double vision, immediately begins to appear, the distance between the two images increasing as the object is moved further to the outer side. The reason of this is that, whilst the image of the object falls on the central spot of the sound eye which follows its movement, it falls continually more and more to the inner side of the macula of the diseased eye, and therefore gives the impression to the patient, by the law of projection, of the object lying to the outer side of its true position as revealed by the sound eye. The false image is consequently on the same side as the unhealthy eye, and is hence termed homonymous.

When the object is carried to the inner or right side, the

action of the muscles, supplied by the third nerve, enables the left to follow the movements of the right eye, and the diplopia disappears.

Another feature of the affection is, that if the patient be directed to look upwards and outwards with the affected eye, whilst the healthy eye, following the object, looks upwards and inwards, its vertical meridian being inclined inwards, the rotation upwards and outwards of the diseased eye is materially impeded, by reason of the paralysis of the external rectus, and its vertical meridian remains nearly straight. Vertical objects, consequently, appear slanting, since the vertical meridians of the two eyes are not parallel, and the mind judges of the position of external objects by the impressions made upon the healthy eye. Moreover, since the vertical meridians converge above (the right being inclined inwards, and the left remaining vertical), the double images appear to diverge above; and, lastly, in consequence of the rays from the object falling on the upper and inner quadrant of the eye, the false image appears to the patient to be beneath as well as on its own side of the true image, whilst, from the insufficient amount of inclination of its vertical meridian, it is also inclined to the left.

If, on the contrary, he attempts to follow an object downwards and outwards, the left eye being unable to follow the movement of the sound eye, and its vertical meridian remaining straight, the image is thrown on the lower and inner quadrant, and is therefore not only situated above the true image and homonymous, but, from the insufficient amount of inclination of its vertical meridian, is also inclined to the right. The patient also holds the head in a characteristic mode, turning it to the left in order to bring all objects into the right half of the field of vision.

Finally, if a small object, as a pencil, be placed before the patient, towards the affected side, and, the sound eye being

covered, he is told to strike it quickly, he will invariably strike too far to the affected side; for the nervous impulse propagated to the weakened muscle, and required to enable it to fix the object, is sufficient, were it healthy, to effect a greater rotation of the globe, for which the mind gives, so to speak, credit, and believes the object to be placed further towards the affected side than is really the case.

2. *Diverging Squint.*¹

When the trunk of the third nerve is completely paralysed, the pupil is widely dilated and immovable (mydriasis); the upper lid droops, and the patient is unable to raise it, except to a slight extent, through the agency of the occipits-frontalis (ptosis); and he cannot direct the eye upwards, inwards, or downwards. The external rectus and the superior oblique acting together, rotate the eye downwards and outwards, producing a divergent squint; and as the images of external objects fall on the outer side of the central spot, their position is referred by the patient to a point internal to their true one, and crossed diplopia occurs. So, when the patient attempts to follow an object moving upwards, whilst the sound eye continues to receive the impression of the object on its central spot, the affected eye, being unable to move upwards, receives the impression at a point below the central spot, and gives the idea of its being placed above the true image. The same holds for the downward movement; the false image falls on a higher part of the retina, and gives the impression of being beneath the true one.

The vertical meridians diverge above, that of the affected eye being inclined outwards. Objects appear, therefore, to the patient to slant to the right. He carries the head turned to the right, so that objects may fall on the left half of the field of vision, and the paralysed muscle be called into action as little as possible.

¹ Soelberg Wells, Ophth. Hosp. Reports, vol. ii. p. 192.

It is not necessary that the whole of the third nerve should be paralysed; and, in many cases, paralysis of one or other of the muscles takes place: thus, the internal rectus may alone be paralysed. In this case, supposing that of the left side to be affected, the left eye cannot follow an object made to move towards the right, and a divergent squint results with crossed diplopia. On covering the right eye, the left then will move inwards, in order to fix the object, in consequence of its having been previously left behind from the weakness of the internal rectus; and on then covering the left eye, the right will be found to make the secondary deviation (*déviatiou en retour*), which is, as in the former case, and for the same reason, greater than the primary deviation. When the sound eye is covered, and the patient is desired to strike at any object before him, he strikes too far to the side of the affected nerve; and, lastly, the image of the left eye slants inwards, so that the two images appear to the patient to converge at the top.

The absence of paralysis of the superior oblique (4th) can generally be ascertained by directing the patient to look downwards, when the action of this muscle will increase the divergence of the eye.¹

When paralysis of the third nerve occurs, in cases of hemiplegia, it is generally on the side opposite to that on which the limbs are paralysed.

v. Gräfe² observed, in some cases of paralysis of the third nerve, with immobility of the iris, that, on turning the eye outwards, contraction of the pupil occurred, though light had no influence. It does not seem clear whether this curious result was due to reflex action conveyed through a small twig, which is sometimes furnished to the ciliary ganglion from the sixth nerve, or whether it may not have been the

¹ For other evidences, see Soelberg Wells, *Ophth. Hosp. Rep.*, vol. ii. p. 194.

² *A. f. Ophth.*, vol. iii. 2. p. 363. 1858.

result of the mechanical irritation and elongation of the third, occasioned by the rolling of the globe. I have looked for this symptom in a good many cases, but have never yet observed it.

3. *Strabismus proceeding from Paralysis of the Fourth Nerve and the Obliquus Superior.*

At first sight, as v. Gräfe remarks, the position of the affected eye appears to be natural; but, if the attention of the patient be directed to an object in front of him, the cornea is seen to be somewhat higher and slightly more internal than on the sound side. On closing the sound eye, the affected one descends and rolls slightly outwards, in order to fix the object; whilst, if the movements of the sound eye under the lid be followed, it may be seen to roll downwards and inwards to a somewhat greater extent than the primary deviation, in accordance with the general rule, that the secondary deviation, in cases of paralysis, is greater than the primary. If the object be lowered, especially towards the outer side, the incorrect position of the affected eye becomes much more conspicuous, and it lags more and more behind and above, until at length the existence of a convergent squint becomes manifest. Yet, if the object be elevated above the middle line, all trace of strabismus vanishes, and the axes of the two eyes become parallel. As a consequence of these peculiarities, there is no diplopia when the object is above the horizontal meridian, but, when situated below that meridian, the diplopia occurs, and the false image is seen beneath the true one, and on the same side as the affected eye (homonymous diplopia). The vertical meridian of the affected eye will be inclined outwards, and the double images will therefore appear to the patient to converge at the top. A further peculiarity, stated by Mr Soelberg Wells to have been first observed by Dr Michaelis, is that the false image appears to the patient to be nearer to him than the true one; and if he

be told to strike an object held before him, he will aim too low, beyond, and too much to the left of it, and so miss it.

Paralysis of the *obliquus inferior* rarely occurs, *per se*, being almost always conjoined with paralysis of one or more of the muscles supplied by the third nerve. Mr Wells observes, however, that, in a case of pure or simple paralysis of this muscle, the symptoms presenting themselves would be, that, whilst in the lower half of the field of vision both eyes can be fixed upon the object when it is raised above the horizontal median line, the left, or paralysed eye, will lag behind, deviating downwards and inwards, thus causing a convergent squint; and if the right eye be closed, the left will make an excursion upwards and outwards. In aiming at the object, the patient will strike too high. The double images are only seen above the horizontal line, and are homonymous; and, as the left eye stands lower, will be projected above the true image, increasing as the object is moved inwards. The image appears to diverge, increasing as the object is moved outwards. The patient carries the head thrown back, to avoid diplopia.

Paralysis of the *superior rectus*, and of the *inferior rectus*, are very rare, and, after the extended consideration given to the paralysis of the other muscles, need not be particularly described.

M.M. Testelin and Warlomont observe, with truth, that, notwithstanding the precision of the signs above described, the immediate determination of the paralysed muscle is sufficiently difficult; and they give the following simple means, suggested by M. Desmarres, jun., as best facilitating this object:—

1. The patient is placed in front of a black board, on which are traced two lines in chalk, one quite vertical, and in the axis of his body; the other horizontal, on a level with his eyes.

2. A coloured glass is placed in front of the sound eye.

3. A taper is then moved across the field of vision, till the patient sees two images. He is then asked which of the two images appears most distant from the vertical line. The eye which perceives this image is that of which the muscles are paralysed. If the images are crossed, the strabismus is divergent; if homonymous, the strabismus is convergent.

Mr Holthouse¹ considers that the condition of the vision of the patient is the most certain and ready test of the squinting eye; and observes that, as a general rule, that eye should be selected for operation, the visual power of which is inferior. Another mode of diagnosis is founded on the fact that, when the sound eye is closed, the image of an external object moves, whilst, if the affected eye be closed, the image remains stationary.

A difficulty sometimes arises in the determination of the eye affected with squint, in consequence of the existence of a condition which is termed incongruence of the retinae.²

In these cases, crossed double images sometimes occur where homonymous diplopia ought to be present, as in cases of convergent squint. v. Gräfe has divided these cases into two categories:—

“1. The healthy eye fixes the object with its centre; upon closing this, the affected eye does not adjust its *macula lutea* upon the object, but upon a point of the retina lying internal or external to the central spot. This point acts, in fact, as a substitute for the centre of the retina, prevailing over it in the energy of perception, but being also identical in relation with the *macula lutea* of the healthy eye.

“2. Each eye, when tried separately, fixes the object with the *macula lutea*; but these two points are not identical, for, when both eyes are opened, diplopia arises.”

¹ Med. Times and Gaz., June 28, 1856. “On Strabismus,” p. 49. 1858.

² See Soelberg Wells, Ophth. Hosp. Rep., v. ii. p. 295, for fuller description of this condition.

4. *Treatment of Strabismus.*

Where the disease is of recent origin, and is associated with hypermetropia, or with myopia, the treatment obviously consists in the selection of glasses which will correct these defects; and the reader may refer to the sections on these subjects.

In slight cases, the employment of prismatic glasses is occasionally of service; the principle on which these act being, that rays of light, passing through a prism or plate of glass thicker at one side than at the other, are refracted towards the base of the prism. In convergent squint, therefore, the base of the prism should be placed towards the temple; for then the images which have been formed too excentrically towards the inner side of the *macula lutea*, for the patient to attempt to combine those of the affected with those of the sound eye, are now brought into closer proximity with one another, and the patient exerts the external rectus, which we presume to be paralysed, in order to combine them into a single image. Hence the two images should not be made to appear single when the glass is used, but only in close contiguity, or partially overlying one another, thus offering an inducement to the patient to bring the paralysed muscle into constant play. In cases of paralysis of the external rectus, the base of the prism should be placed externally; in paralysis of the internal rectus, internally. In paralysis of the superior oblique, the base should be placed below, and to the outer side; and in cases of paralysis of the internal oblique, above, and to the outer side.

Another mode of treatment, which will doubtless often prove successful in slight cases of strabismus, has been proposed by M. Emile Javal,¹ and consists in making the eyes undergo a series of stereoscopic exercises, the perception of

¹ See translation of his paper in *Ophth. Review*, vol. ii. p. 182. 1866.

the affected eye being first educated and improved by presenting to it a large black disc, and at the same time offering a smaller coloured one to the sound eye. Where both images are seen coincidently, the patient is instructed to endeavour to combine or superimpose the images ; and, finally, glasses are adapted to the defective condition of his vision, whether myopic or hypermetropic.

The employment of electricity in the treatment of strabismus, to arouse the torpid nerves and muscles, is so obvious that it has been applied by many surgeons, sometimes with considerable, at others with equivocal, success. In a paper communicated by M. Benedikt to v. Gräfe's Archives,¹ he appears to have obtained excellent results, and has not only used it in a somewhat different way from that usually adopted, but has also given a different explanation of its mode of action. He found that it was not often possible to produce contractions of the paralysed muscles, and that the cure was dependent, generally speaking, not upon direct electrical excitation of the several paralysed motor nerves, but upon reflex excitation through the fifth pair of nerves ; and, in fact, that a cure was only produced where the excitation was relatively weak, not usually exceeding three elements of a Daniell's battery, and of short duration, and where *no* traces of muscular contraction were observed. The improvement was instantaneous, as was shown by the increased mobility of the globe, and by the diminution of the field in which double images were perceived. In paralysis of the sixth nerve, he found by experience that, to obtain the best effects, the copper pole should be placed on the forehead, and the zinc pole over the malar bone.

In cases of paralysis of the other recti, or of the obliqui, the copper pole should be placed on the forehead, and the zinc on the inner side of the nose, near the inner canthus of the eye.

¹ See translation in Ophth. Review, vol. ii. p. 292. 1866.

In ptosis, the copper pole should be placed, as before, on the forehead, and the zinc on the lid itself; and in mydriasis, the copper pole on the closed lids, and the zinc pole on the cheek-bone.

In numerous cases, however, an operation is requisite, and this consists in dividing the tendon of the shortened muscle. After the division, the muscle immediately retracts, and subsequently forms fresh adhesions to the sclerotic at a point or line posterior to that which it previously occupied; as a consequence, it loses to a considerable extent the mechanical advantages and power which it previously possessed.

The amount of contraction and retraction which take place after tenotomy has been performed vary according to whether the tendon alone or some of the adjoining tissues have been divided; in the former case, a deviation of from one-and-a-half to two lines may be overcome; in the latter, deviations of from two to three lines. If more correction than this is required, the tissues must be very freely divided, and the operation repeated more than once.

Frequently it is necessary to perform a complementary operation on the corresponding muscle of the opposite and healthy eye; this, however, should never be undertaken coincidently, but the patient should be permitted to recover completely from the first operation.

In performing the operation, if the patient be young, or have little command over himself, chloroform may be administered, though its action renders it somewhat difficult to know whether the tendon has been sufficiently divided. The patient should either be recumbent or seated in a good light, with the head well supported against the chest of an assistant, who should raise the upper lid with a wire speculum, and, with a small hook implanted in the conjunctiva, close to the inner margin of the cornea, in cases of internal squint, roll the eye outwards, and depress the lower lid with his thumb. A small vertical fold of the conjunctiva should then

be picked up with a pair of forceps, and divided transversely with blunt-pointed scissors, about opposite the lower border of the tendon, and not more than a sixth of an inch from the border of the cornea. The opening need not be longer than two lines. A blunt-pointed hook is then to be introduced through the incision, and passed under the tendon of the muscle to be divided, the point of the hook being kept closely applied to the globe of the eye. With a little lateral movement, such as is used in passing an aneurism-needle under an artery, the tendon can be very neatly taken up, its white surface showing through the thin sclerotic conjunctiva; the points of the scissors are then entered by the opening, and with a few cuts the tendon is divided. More or less blood is immediately poured out, producing an ecchymosis, which sometimes extends into the connective tissue of the lower lid and cheek in persons of lax fibre, but which usually disappears entirely in the course of a month. The parts should be sponged with a little cold water, and then the patient may be allowed to use the eye.

The immediate effect of the operation should be the correction of the squint, so that, when the patient looks at some object at a little distance, the axes of the two eyes are parallel. If this is not the case, the tendon has been incompletely divided, and the hook must be reintroduced, and the remaining fibres severed. Care should be taken, in operating on internal squints, that the first incision be not made too far from the margin of the cornea; otherwise, from the more extensive division of the connective tissue, and the subsequent cicatrization, the caruncle is retracted, and almost disappears, giving a staring and unpleasing expression to the eye. When this has occurred, however, it may to a certain extent be remedied by a subsequent operation, which consists in dividing the cicatrized tissue, and bringing the conjunctiva of the inner canthus forwards, securing it in its new position by a suture.

Projection of the globe is an occasional result of the operation for strabismus. It results, according to v. Gräfe, from an enlargement of the palpebral fissure, and may be cured by removing the small piece of the skin from the edge of the lids at the outer canthi, and causing adherence by a suture.

The tendon of the external rectus is broader than that of the internal, and the operation does not in general succeed so perfectly as that for convergent squint.

v. Gräfe¹ considers the effect of tenotomy as twofold: (1.) It causes the rotation of the globe towards the antagonist of the divided muscle, which constitutes the *correction*; and (2.) it diminishes the action of the divided muscle, which occasions *muscular insufficiency*. He observes that the *immediate* correction which takes place after the operation of tenotomy should be carefully distinguished from the *definite*; for whilst the latter usually succeeds the former, it does not do so in cases of hypermetropia, of diplopia, or of divergent squint. He goes so far as to say that, if the action of one of the lateral muscles has been diminished by paralysis, the energy of all the other three lateral muscles (one of its own and two of the opposite eye) should theoretically, for perfect success, be correspondingly and proportionately weakened.

v. Gräfe further remarks that, when a squint results from an incomplete paralysis, or muscular atrophy, say of the internal rectus of the left eye, the section of the antagonistic muscle (external rectus) of its own side causes a useless insufficiency for the symmetry of the correction, but that the patient is placed under much more favourable conditions by tenotomy of the external rectus of the healthy side, since the associated muscles are then brought into identical conditions of action. Nevertheless, the excess of power which this gives to the internal rectus of the healthy or right eye is so great, and the secondary results are so disagreeable, that the practice cannot be inculcated.

¹ Klinische Monatsblätter, pp. 1-22. 1864.

In all cases where tenotomy has been performed for the relief of squint, it must be remembered that the extent of movement of which the eye is capable is diminished, since the divided muscle forms a new attachment, situated more posteriorly towards the equator of the globe, and therefore where it acts at a less mechanical advantage. When this is not excessive, little notice is taken of it by the patient; but when from any cause the muscular insufficiency becomes excessive, a squint in the opposite direction may occur, and it is then advisable to dissect down on the divided muscle, separate it from its attachment, and fix it to the sclerotic, in a new and more anterior position, by a thread or two of silk.

One of the advantages of restoring the parallelism of the optic axes by the operation for squint, consists in the visual improvement which commonly takes place if there be no retinal or other disease preventing it. The patient, who has hitherto disregarded the images received by the squinting eye, soon begins to perceive the advantages of stereoscopic vision, and after a few months finds the sight manifestly improved.

5. *Oscillation of the Globe. Nystagmus.*

These conditions, occasioned by alternating contractions of the recti or obliqui, vary greatly in degree, are usually horizontal or rotatory, but rarely vertical. They are not unfrequently seen in amaurosis, and often accompany other grave disorders of the nervous system, as epilepsy.

As Dr Mackenzie remarks, the former is often observed in myopic patients, and in albinos. It need not materially interfere with vision. I saw a near-sighted child, twelve years of age, some time ago, in which the frequency of the horizontal movement was very great, amounting, whilst I examined him, and when he was perhaps rather excited, to 160 per minute. There was an occasional intermittence for the

space of one second. The extent to which the globe rotated was rather more than one-tenth of an inch. He was not conscious of the movement. His general health was good, and no disease could be detected in the eye. It does not appear that any efficacious plan of treatment has been suggested for these cases.

CHAPTER III.

Diseases of the Lachrymal Organs.

GENERAL ANATOMY OF THE LACHRYMAL GLAND—CANALICULI—
LACHRYMAL SAC AND NASAL DUCT—INFLAMMATION OF THE
LACHRYMAL GLAND — LACHRYMAL FISTULA — OBSTRUCTED
DUCTS AND LACHRYMAL ABSCESS.

THE lachrymal apparatus consists of the lachrymal gland and its ducts, by which the tears are secreted and conveyed to the surface of the conjunctiva; and the canaliculi, lachrymal sac, and nasal duct, by which they are discharged into the inferior meatus of the nose.

The lachrymal gland is situated at the upper and external part of the orbit, occupying a small fossa in the orbital plate of the frontal bone. It belongs to the class of acinous glands, is of a yellow or pinkish colour, with a finely lobulated surface, and resembles a small portion of one of the salivary glands. Its weight is from nine to twelve grains. It discharges its secretion by four or five excretory ducts, the diameter of each of which does not exceed one-fiftieth of an inch, into the palpebral sinus of the upper lid. Separated from this principal gland by a process of fibrous tissue, given off from the tendon of the levator palpebræ, are a few isolated lobules, which lie just external to the conjunctiva, and the ducts of which partly open into the above-mentioned proper

lachrymal ducts, and partly by a few very minute and short tubes into the conjunctival fold.

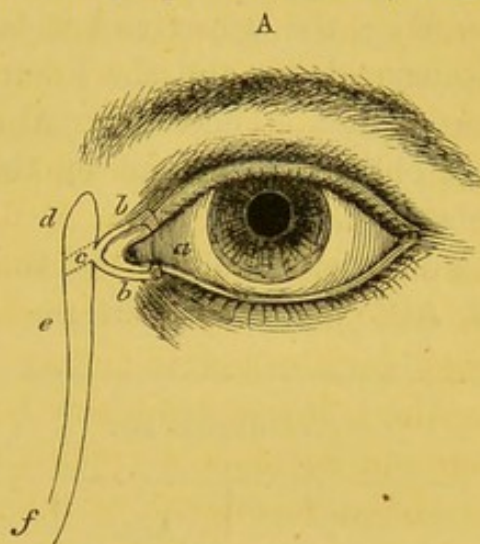
The gland is supplied by the fifth and sympathetic nerves, and, whilst constantly secreting an aqueous fluid, which lubricates the conjunctiva and facilitates the reciprocal movements of the lids and globe, may be readily excited to hypersecretion by reflex action. And this may be accomplished through one or other of several channels. Thus it may result from the sudden exposure of the eyes to a bright light; in which case the impression made upon the retina is reflected upon the gland, either through the sympathetic nerve, or through certain secreto-motory branches of the fifth nerve. Or, again, a flow of tears may be occasioned by the irritation of pungent substances applied to the conjunctiva, or to the Schneiderian membrane of the nose; in which case the impression is received by one set of branches of the fifth, and is reflected upon the gland through others proceeding from the same nerve; or, as in the former instance, perhaps through the branches of the sympathetic. It is doubtful whether the gland can be called into play by impressions made on the olfactory nerve, since pungent odours, as those of ammonia, undoubtedly act on the sensory branches of the fifth.

Finally, the gland may be readily excited to increased secretion by mental emotion, and by all circumstances occasioning an augmented flow of blood through the organ, as in the acts of coughing, sneezing, laughing, and vomiting.

According to Lerch, the composition of the tears in 1000 parts is—Of water, 982; of solids, 18 parts; and, of the solids, albumen constitutes 5 parts, whilst the remainder is composed of chloride of sodium, giving the fluid its saline taste; of a little free soda, which confers upon it its alkaline reaction; and of other ordinary salts.

Excepting during sleep, the tears are almost always secreted in excess of the evaporation taking place from the surface of the conjunctiva, and the superabundant fluid is carried off

by certain small channels into the lachrymal sac. The openings of these channels (*a*) are visible upon the margins of the upper and lower lids respectively, at about the distance of one line from the inner angle of the palpebral fissure, and are called the puncta lachrymalia. From these points two ducts proceed (*b*), the upper one of which, after ascending for a short distance, suddenly turns inwards, and runs with a slight inclination downwards towards the nose; whilst the lower one at first descends, and then runs inwards, with a slight inclination upwards; and both passages, termed the canaliculi, unite, just behind the internal palpebral ligament, to form a common tube, which opens into the lachrymal sac.¹



- a* Puncta.
- b* Canaliculi.
- c* Point where the sac is crossed by the tendon of the orbicularis muscle.
- d* Lachrymal sac.
- e* Nasal duct.
- f* Opening of nasal duct into inferior meatus of nose.

The length of the canaliculi is about one-third of an inch, and their diameter about one-twentieth; or at least they will admit, without laceration of the passage, of a sound of that diameter. These little tubes are surrounded, according to Henle, by a delicate, cavernous, and highly-vascular tissue, not distantly resembling that of the corpus spongiosum urethræ.

The osseous canal, by which the tears are conveyed from the eyes to the nose, extends from the inner and lower part of the orbit to the inferior meatus of the nose, and is formed by the lachrymal, superior maxillary, and inferior turbinal bones. Its length is about one-and-a-quarter inch; its

¹ See Foltz, *Ann. d'Ocul.*, p. 227. 1860.

greatest diameter is about one-third of an inch. It forms a gentle curve, and is directed downwards, backwards, and a little outwards.

It is lined by a membrane accurately applied to the surface of the bone, the upper and wider portion of which is called the lachrymal sac, and the lower and slightly narrower part the nasal duct. The lachrymal sac is pointed above, and is crossed obliquely in front by the tendon of the orbicularis palpebrarum.

The dimensions of the sac and of the duct are thus given by M. Arlt¹ and M. Weber²:—

LACHRYMAL SAC.			NASAL DUCT.	
	Arlt.	Weber.	Arlt.	Weber.
Length,	10 mm. ³	12-15 mm.	10-16 mm.	10-12 mm.
Breadth,	2 "	6 "	1½-2½ "	3 "
Antero-posterior diameter, . }	4 "	4 "	1½-2½ "	4 "

The walls of the membranous nasal duct, which, including the lachrymal sac, are about half-an-inch longer than the osseous canal, have been minutely described by R. Maier⁴ and by Henle, who show that they are lined by laminated epithelium, the cells of which are flattened, and only here and there ciliated. The subjacent mucous membrane contains, especially in its lower part, numerous acinous glands, and lies upon a kind of cavernous vascular tissue, that is separated from the bone by periosteum.

¹ Archiv. f. Augenheilk., i. 2, 135.

² Klinische Monatsblätter, p. 63. 1863.

³ A millimetre is equal to about 1-25th of an inch.

⁴ Über den Bau der Thränenorgane. Freiburg, p. 31. 1859.

Henle states that there are four localities in the lachrymal passages where folds of the mucous membrane (the so-called valves) exist, viz.: 1. At the commencement of the canaliculi, just where they change their direction. 2. Just before their point of opening into the lachrymal sac. 3. At the point of the junction of the lachrymal sac with the nasal duct, which is certainly the most important one, in a surgical point of view; and, 4. At the round, oval, or slit-like opening of the nasal duct into the inferior meatus. None of these can, however, be said to fulfil the function of a valve in the proper sense of the word. A narrowing of the tube appears constantly to take place, as has been particularly referred to by M. Arlt¹, at the point where it passes the turbinal bone.

Under ordinary circumstances, the puncta are always submerged in the lachrymal fluid; and the canaliculi and lachrymal sac are alike constantly filled with the secretion of the lachrymal and conjunctival glands. The agent and regulator of the discharge of the tears into the nose is no doubt the *musculus orbicularis palpebrarum*, through the medium of its tendon, which crosses somewhat obliquely the external surface of the lachrymal sac, and by the contraction of which, as in closing the lids whilst the tears are driven towards the corner of the eye, the lachrymal gland is expanded, producing a tendency to a vacuum which the tears rush in to fill.² The entrance of air and fluid from below is prevented, according to Henle, by the ordinarily distended state of the veins forming the cavernous tissue of the lower part of the nasal duct.

The importance of the action of the orbicularis muscle, and of the small portion of it known as Horner's muscle, *tensor tarsi*, or *musculus sacci lachrymalis*, is sufficiently indicated

¹ *Compt. Rend. du Congrès d'Ophth.*, p. 65. 1862.

² It is right to add, however, that some observers believe, with Arlt, that at the moment of closing the lids the lachrymal sac is not dilated but compressed, and the tears thus forced downwards into the nasal duct.

by the anatomical disposition of the parts, and by the absence of fluid in the lachrymal sac, consequent on paralysis of this muscle.¹

1. *Diseases of the Lachrymal Gland and Ducts.*

Inflammation of the lachrymal gland, whether of the acute or chronic form, is certainly of very rare occurrence. Mr Lawrence² observes that, though admitted and even represented to be common by some writers, it is so unusual, that he does not remember to have seen any instance in which he recognised its existence; and that on referring to records, embracing about 40,000 cases, the lachrymal gland was not even mentioned in the list of diseases; and in the reports of a large number of cases that I have myself looked over, I find only one instance to have occurred during the past few years, and this was in a boy æt. fifteen, who came under the care of Mr Hancock. Dr Mackenzie³ remarks that, though the disease is by no means a common one, the general subjects of it are children of a scrofulous diathesis; whilst Mr Todd,⁴ who has collected a number of cases, considers that it is rarely a primary affection, but generally secondary to inflammation of the conjunctiva, or some other form of ophthalmia. M. Wecker, after referring to the rarity of the acute form of inflammation, and the probability that some of the recorded cases were only examples of cellulitis, or of periosteal abscess, states that he has observed the chronic form in those who have long been the subjects of conjunctivitis, of pustular keratitis, and of iritis, accompanied with much lacrymation.

In a well-marked example of the acute form, the usual

¹ Arlt on the Lachrymal Sac, in v. Gräfe's Archiv. f. Ophth., p. 135, 1855; and Stellwag v. Carion. Zum Mechanismus der Thränen-leitung, etc., Wien. Med. Wochenschrift. Dec. 1864, Jan. and Feb. 1865.

² Treatise on Diseases of the Eye, p. 798. 1844.

³ Practical Treatise, p. 87. 1854.

⁴ Dublin Hosp. Rep., p. 408. 1822.

signs of local inflammation appear in the first instance, followed, according to the temperament of the patient, by more or less constitutional disturbance; and the treatment consists of local depletion, the application of poultices and hot fomentations, and, in the event of an abscess forming in its early evacuation, either by an incision through the lids or through the outer and upper part of the conjunctival fold.

The only case that has fallen under my notice was of a sub-acute type, and occurred in a tolerably healthy-looking woman, *æt.* 34. She was not aware of any cause to which the appearance of the disease could be assigned; but as she had been subject to fits of an epileptic character for sixteen years, and had had a very severe one about one month previous to her presenting herself at the hospital, she thought she might have injured herself in falling, especially as the symptoms commenced almost immediately afterwards; on the other hand, she stated that she had had a cold in the eye for some time previous to the fit, attended with the discharge of much yellow matter. At first there was only a feeling of soreness and tenderness over the outer part of the left lid, but subsequently the lid had become much swollen. When I saw her, her appearance immediately attracted my attention. The swelling of the upper lid, which was of an *œdematous* character, was almost entirely confined to the outer part; so that whilst the ciliary margins were separated to a natural extent internally, on looking outwards the cornea was almost wholly concealed; the outer side of the cheek was also somewhat swollen, the eye was very moist, and she stated that there were occasional gushes of hot tears, though they never ran down the cheek. On pressing the swelling, which was excessively tender as well as painful, the resistance of the *œdema* was first overcome; and then, at a greater depth, the swollen gland was distinctly perceptible, and it was slightly moveable. The pain during the previous

night had been so considerable as effectually to prevent her from sleeping. The constitutional symptoms were not very distinct. The tongue was clean; the bowels regular; the pulse rather frequent (90) and feeble. The duration of the disease had been one month, and she had never suffered from any affection of the eyes previously. The treatment adopted, which proved perfectly successful, was the application of two leeches to the temple, followed by the application of linseed-meal poultices, the *mist. quinae*, containing two grains of quinine, three times a-day, and a few compound soap pills. In the course of ten days the œdema and tenderness had vanished, but the deep swelling continued to be perceptible for a considerable period. In a very similar case, recorded by Heymann,¹ the disease appeared to be connected in its origin with an ulcer of the cornea. The symptoms presented were, that there was a moveable, bright-red rounded swelling, of considerable size, at the outer margin of the orbit, which was partly due to serous infiltration of the loose connective tissue of the lid, and partly to the enlargement of the gland itself, which last became more perceptible when the tissues of the lid had been softened by the application of poultices. The discharge of a little yellowish serous fluid was noticed to take place from the eye, but there was no puriform secretion.

In this case, the administration of iodide of potassium internally, and the application of mercurial inunctions, soon effected a cure.

The lachrymal gland is occasionally subject to chronic hypertrophy, to schirrus, cancer, and to encysted tumours, but these are so rare that they need not here occupy our attention, especially as, when they present themselves, they require only to be treated according to the general rules of surgery.

Small cysts sometimes form in the course of the lachrymal ducts, and, bursting externally, permit the constant discharge of a tear through the skin and down the outer surface of the

¹ *Archiv. f. Ophth. B.* vii. p. 142. 1860.

upper eyelid. In Mr Hulke's paper on this subject,¹ he remarks that these fistulae are commonly the result of mis-managed abscesses, or of neglected wounds, attended by prolonged suppuration in the upper lid, though they sometimes appear to be congenital in their origin; that, in the first instance, a small tumour, over which the skin freely glides, forms at the superior and outer part of the upper eyelid; and that on drawing the lid upwards, and at the same time pressing downwards and inwards, a tense elastic fluctuating swelling instantly starts out between the eyeball and the inner surface of the lid. The size of the tumour increases considerably and quickly when the patient cries. The treatment of cases of this kind is not always easy, nor are the results satisfactory. In one of Beer's cases, a cure was effected by the insertion of a red-hot needle. In other cases, injections of various stimulating fluids have been adopted, which, however, have in general only the effect of setting up considerable inflammation in the sac and its neighbourhood, without causing its obliteration. Sometimes attempts have been made to excise the cyst. If this plan be adopted, care must be taken that the whole of the sac is removed, as any part of it which remains behind forms, so to speak, the nucleus of another cyst. In one of the cases reported by Mr Hulke, a cure was effected by means of the following ingenious operation:—

“A single thread of silk was armed with a needle at each end, and one of the needles was introduced into the fistulous orifice in the skin on the outer surface of the eyelid, and carried for a short distance upwards; it was then made to pierce the fibro-cartilage of the lid and the conjunctiva, and the thread was drawn out at the inner surface of the lid. A similar manœuvre was repeated with the other needle, and the thread was drawn out at the inner surface of the lid at the distance of a quarter of an inch from the first, and a little

¹ On True Dacryops Fistulosus, Ophth. Hosp. Reports, vol. i. p. 286.

nearer the attached border of the lid. In this way the cyst was pierced at two points by the thread, which encircled in a loop the small intervening portion of tissue. The two ends of the thread were then brought out at the outer commissure, and secured upon the temple with a piece of sticking-plaster."

Little inconvenience followed. After ten days the thread was replaced by a thicker one, and the external fistulous orifice was closed by cutting it out, with a little of the healthy surrounding skin, and closing the wound carefully. Union followed, the little bridge of tissue encircled by the thread was divided, and the cure was complete.

The formation of calculous masses, or, as they may be termed, *dacryoliths*, in the lachrymal passages, has occasionally, though rarely, been observed. Mr R. H. Meade¹ has recorded a case in which twenty-three small rough, hard, dirty-white coloured calculi were discharged from the ducts in the course of four or five days. They were composed of phosphate, with a small admixture of the carbonate of lime, and traces of animal matter. If the presence of such calculi can be satisfactorily determined by the insertion of a probe, the treatment to be pursued consists in slitting up the canaliculus and scooping out the contents of the sac, followed by rest and cold applications.

Epiphora is a term applied to a condition of suractivity of the lachrymal gland, in which more tears are secreted than are requisite for the lubrication of the surfaces of the conjunctiva, or than the canaliculi can carry off into the lachrymal sac. Every one must have experienced this condition occasionally on sudden exposure to cold easterly winds, where the stinging impression made upon the conjunctiva causes an excessive secretion of tears, and at the same time affects the partial closure of the orifices of the canaliculi. The streaming of the tears down the cheeks of a crying child is a true case of epiphora. Where it arises from some disease of the gland,

¹ Med. Gaz. 1835.

probably the best proceeding to be adopted would be that of removal of the gland, which is sometimes indeed called for, when, from accident, such obliteration of the canaliculi has been produced as to abolish all hope of restoring the passages.¹ The operation may be easily accomplished by making a horizontal incision parallel with the orbital ridge through the outer and upper part of the upper lid.

2. *Obstructed Ducts and Lachrymal Abscess.*

(PLATE II., Figs. 10 and 11.)

These are amongst the most troublesome of the affections that present themselves in ophthalmic practice, and a great variety of surgical operations have been proposed for their relief. The seat of the obstruction, as well as its nature, varies in different instances, sometimes occupying the canaliculi; at others, the lower part of the lachrymal sac and nasal duct. In the former case, we may fairly hope to effect the cure of the disease; in the latter, the difficulty is much greater, and is in some cases so great that the total obliteration of the sac has been suggested as the only means by which relief can be obtained.

The principal causes which lead to obstruction of the ducts are chronic inflammation of the conjunctiva and blepharitis or ophthalmia tarsi, which, when of long standing, occasion the occlusion of the orifices of the canaliculi. Accidents, such as wounds or injuries from caustic chemical agents, are often followed by the same result, as well as by obliteration of these passages, to a greater or less extent. Obstructions in the lower part of the lachrymal sac, or in the nasal duct, whilst they may be induced by any of the foregoing causes, are not unfrequently occasioned by periostitis, or by necrosis of the bones forming the parietes of the lachrymal sac and nasal duct; the ascending process of the superior maxillary bone being generally, and the lachrymal and turbinal bones

¹ See Case recorded by Mr J. Z. Laurence, in the Trans. of the Path. Soc., vol. xvii. p. 271. 1866.

more rarely, affected. In many cases, again, the obstruction is induced by frequent or protracted catarrh of the mucous membrane of the nose, the inflammation gradually creeping up the nasal duct into the lachrymal sac, just as in other instances we find it producing deafness by extending into the Eustachian tube and tympanum.

Obstructions, whether of the canaliculi or of the nasal duct and lachrymal abscess, so often engendered by the latter, are diseases of adult age, very rarely occurring in childhood. In about 7200 cases recorded in the Hospital books during the year 1864-65, there were 108 cases of all forms of obstruction, 80 of which were females, and 28 males; the average age was 32, and only 6 were under ten years old.

In the early stages of all the forms of obstruction, the first and most prominent symptom is the accumulation of the tears at the inner corner of the eye, giving to the patient a peculiar appearance, well expressed by the common term "watery eye," and which is technically termed *stillicidium lachrymarum*, to distinguish it from *epiphora*, in which disease the tears are secreted in excess by the lachrymal gland. In *stillicidium*, the tears, after collecting for a minute or two, either flow over the edge of the lid, and, coursing down the cheek, produce more or less redness and irritation of the skin, or, by obscuring vision, oblige the patient perpetually to apply a handkerchief at short intervals.

It must not be forgotten, however, that an overflow of the tears may arise from slight eversion of the lids at their inner part, when, from the position of the orifices of the canaliculi, these tubes, though quite pervious, are rendered incapable of acting as conduits for the tears. The treatment of such cases will be appropriately considered under the head of *Ectropion*. On the other hand, it is not in every case even of complete occlusion of the canaliculi that the patient suffers from this inconvenience. Where none occurs, we must suppose that the evaporation from the surface of the globe is

exactly equivalent to the amount of fluid secreted by the lachrymal gland; and many instances may be observed where, although the eye presents a humid appearance for years, and the patient is obliged occasionally to wipe away the fluid which has collected, yet the discomfort experienced is not sufficient to lead him to apply for relief. Obstructions of the ducts are often accompanied by symptoms indicative of a strumous diathesis, but are not curable by any remedial means directed to the constitution alone.

When the obstruction has its seat in the nasal duct, the symptoms are usually sufficiently well marked to admit of easy diagnosis. In the early stages of the disease, no pain or inflammatory symptoms are complained of, but the patient notices the formation of a slight elastic swelling upon the side of the nose, close to the inner canthus of the eye, and corresponding to the position of the lachrymal sac, and sometimes experiences dryness of the corresponding nostril. On pressure, the tumour gradually yields, and a discharge of fluid takes place, either through the nasal duct into the nose, indicating that the obstruction has been overcome, or, less frequently, through the canaliculi into the conjunctival sac, or upon the cheek, showing that the closure of the nasal duct is complete. So long as the fluid can be pressed down into the nose, the tumour remains free from inflammation, and continues, though perhaps very slowly, to increase in size; but as soon as complete obstruction occurs, so that the fluid can neither be pressed down nor made to regurgitate, the occurrence of inflammation, as a result of a very slight determining cause, becomes imminent.

The fluid which thus regurgitates does not give the impression of its being composed of the tears alone or of the natural secretion of the conjunctival glands, inspissated by long retention in the sac, as Scarpa was disposed to admit, but seems to be secreted from the walls of the sac itself, the first portions which exude being of a clear mucous character, and subse-

quently, when the sac by firm pressure is nearly emptied, consisting of a little puriform fluid. As there appears to be little doubt that obstruction of the nasal duct may arise from simple turgor of the mucous membrane, and that, even when arising from other causes, it is generally associated with a congested state of the membrane, it may readily be conceived that the fluid contained in the sac is the product secreted from the unhealthy surface, which, having no means of passing downwards, gradually distends the sac, and may be made, on the application of slight pressure, to regurgitate through the canaliculi.

The patient may remain in this state for many months or years without experiencing any material change in the condition of the tumour; but at some time or other, in consequence either of an injury, or more frequently from cold and catarrh, inflammation is excited in the walls of the sac; and then commences a very painful, and sometimes even serious, disease, which in many instances, notwithstanding every attention that skill can suggest, long continues to trouble and harass the patient. The tumour becomes firmer, fuller, and more prominent; complaint is made of a feeling of tension, and of neuralgic pains down the nose. The surface of the skin soon becomes red and very tender, and presently the appearance of an abscess is offered. The swelling extends both upwards, towards the inner extremity of the eyebrow, and downwards towards the cheek. Occasionally the appearance of a double swelling is given, as in fig. 10, the upper and internal one being the inflamed sac, and the lower one, situated below the lower eyelid, being formed by infiltration of the lax cellular tissue there situated, and an erysipelatous redness of the skin; but more frequently the appearances are those of fig. 11, the swelling occupying a higher position, and being often indented near the centre by the tendo-oculi, which, by crossing the sac, prevents its dilatation at this part, whilst the tumefaction above and below is very distinct. At

this time the general malaise of the patient rises to a very high degree. He is unable to sleep, or to work during the day, in consequence of the violence of the pain, which extends over all that side of the head and face. The pulse is feeble and frequent. Febrile symptoms are present. The appetite is lost, the bowels are confined, and for some days the patient is sufficiently wretched. The conjunctiva is usually inflamed, but there is rarely more than a moderate amount of mucopurulent and lachrymal discharge. At length suppuration takes place in the lachrymal sac, and the abscess points sometimes above and sometimes below the tendo-oculi. If no surgical interference has taken place, a fistulous orifice is now formed, from which at first pus, afterwards a puriform, and subsequently a clear fluid is discharged; the swelling diminishes, the redness disappears, and partial recovery is effected; but the patient long remains liable to a recurrence of the affection, which passes through the same or nearly the same stages, whilst in many instances a permanent fistula is formed.

As regards the treatment of these affections, it will be expedient to consider them in the following order:—First, those cases where the obstruction is seated in the canaliculi; secondly, where there is an obstruction in the nasal duct; and, thirdly, where there is not only an obstruction in the nasal duct, but where there is an inflamed condition of that passage and of the lachrymal sac, producing the condition commonly known as lachrymal abscess.

Mr Bowman, in his instructive paper in the *Ophthalmic Hospital Reports*, has noticed the analogy that obtains between the mucous tract formed by the canaliculi and nasal ducts and that of the urethra, and has pointed out that the principles of treatment are the same in both. One of the cardinal maxims of this treatment is, that whilst we make every effort to regain and secure the patency of the canals, we should avoid with the utmost care the production of any injury, as

abrasion, false passage, or other mischief, to the walls of the canal in question.

Where the canaliculi are the seat of the obstruction, the obvious indication for treatment is to endeavour to restore the patency of these minute tubes, but this is by no means an easy task. Sometimes, indeed, the external orifice of the upper or lower passage on the margin of the lid, or the inner opening into the lachrymal sac, will be found closed only by a kind of hymen or thin fold of membrane, which, on being broken down by a fine probe, or pricked through with a needle, and afterwards kept open by the daily insertion of the same instrument for a week, will remain patulous; but these are only exceptional instances. In the majority of cases, the obliteration of the tube will be found to extend through nearly all the first or vertical part, or through a considerable portion of its horizontal course, and the passage of a probe or needle is impracticable, or, if accomplished, useless, so great is the tendency to heal up. In some cases, however, instead of total obliteration or atresia of the tube, there is only a contracted condition, resembling in fact a stricture of the urethra. Here considerable improvement may be effected by the careful and repeated introduction of a probe, or of a succession of probes, of gradually increasing diameter, though in but too many cases the complaint will return after the lapse of a longer or shorter period, and require the employment of the same means.

In order to introduce a probe into the nasal duct through the canaliculi, both patience and skill are required. The patient should be seated in a good light, and, unless the operator be ambidextrous, he should stand behind him for the right, and in front of him for the left, eye; the lid should be put moderately upon the stretch, and the probe, dipped in oil, made to enter the punctum vertically; its direction is then almost immediately exchanged for a horizontal one, and the instrument is slowly pushed inwards till the inner wall of the lachrymal sac is reached. When the point is felt to

touch this, it should be withdrawn to a very small extent, and, by a turn of the wrist, the part held should be made to sweep along the eyebrow, till it is about a quarter of an inch internal to the supra-orbital foramen. It is then in a nearly vertical position, with a slight inclination inwards, and, in the healthy condition of parts, can now be made to descend with facility through the nasal duct into the nose. Folds of mucous membrane, however, often interfere with its passage, and require much perseverance and some delicacy of manipulation to be overcome. When a stricture is really present, the probes, which can be introduced through the healthy puncta, are so pliable, on account of their small size, even when made of metal, and, *à fortiori*, when composed of whalebone, gutta-percha, or other elastic material, that they are quite inadequate to force a passage through the firm strictures which form in the nasal duct, and even when passed are of little service in effecting a dilatation of the canal. But this difficulty may sometimes be overcome by the employment of the probes recommended by Mr Critchett, composed of the fibres of the laminaria, which not only possess considerable firmness, but if, by a little humouring, they can be made to pass, immediately act as powerful dilators, their diameter quickly increasing by the imbibition of fluid. Care should be taken, however, that they are not allowed to remain in too long, as they may become so tightly impacted as to render it a matter of difficulty to effect their extraction; and though they possess considerable tenacity in the dry state, yet, when sodden with liquid, they will sometimes snap when firm traction is made upon them.

Where the employment of these means proves ineffectual, the canaliculi should be slit up in the mode first proposed by Mr Bowman; for thus not only is a freer passage for the tears into the lachrymal sac produced where any obstruction is present in the canaliculi, but room is obtained, without any perceptible disfiguration, for the application of sounds, or

other means required for the treatment of such obstructions as may be present in the nasal duct. The mode of performing this little operation may be thus described:—The patient being placed as before, a fine but grooved gold probe is introduced into the upper or lower canaliculus, and a small iris-knife is then run along the groove in the probe from without inwards, slitting up the canal to its point of entrance into the lachrymal sac, into which the point of the knife should be made to enter. A little mucous discharge from the sac usually takes place spontaneously through the opening thus made, or, on slight pressure on the sac, may be caused to flow in considerable quantity. A large probe may now be introduced at once, and be made by moderately firm pressure to pass down through the nasal duct. Little or no bleeding follows the operation; and the only after-treatment required is to keep the lips of the little wound separated by the daily introduction of a moderate-sized probe. In some instances no further treatment is necessary; in others, however, this operation can only be regarded as the preliminary to the adoption of other measures, as in those where a well-marked constriction of the nasal duct is present. Here, although the introduction of a large probe will sometimes break down the obstruction, it will often be found that this cannot be effected without the employment of an amount of force that threatens to tear the mucous membrane. In such cases the systematic introduction of graduated probes, or, still better, the probes of Mr Critchett, proves of great service; whilst in other cases a small bistoury, with a concealed blade, may be introduced, of the form suggested by Mr Bowman; or a small porte-caustique, of the construction recommended by M. Libbrecht; either instrument being passed as a sound down to the stricture, and the knife or caustic applied by means of pressure made upon a spring near the handle.

In the many cases I have myself treated in this way, the success has been very considerable. In some instances, how-

ever, it fails, and from causes that do not admit of a ready explanation. I believe, however, that in some instances it is due to the presence of small particles of diseased bone, which create much irritation and local disturbance. In other instances, it would seem rather to be connected with constitutional peculiarities, the mucous membrane in some strumous patients having a great tendency to be turgid and secrete glairy fluid. I have at present under my care a young lady, whose puncta I slit up, and through whose duct a large-sized probe passes with the utmost facility to the nose. Nor is there any eversion of the mouths of the canaliculi. Yet not only does a tear still continue to collect in the canthus, but she is subject to periodical accumulations of mucous and puriform fluid in the lachrymal sac, which I have found it necessary to open from time to time with a lancet; and I have seen several cases of a similar nature.

Mr Critchett¹ has suggested a means by which the slit-up canaliculus can be maintained patent in some cases where difficulty would otherwise occur, or where the circumstances under which the patient sees the surgeon do not admit of the after-treatment recommended by Mr Bowman—viz., of passing a probe, and breaking down the adhesions every morning for a few days, being carried out. After the canaliculus has been opened up, the lower lid is everted, and a small portion of the posterior lip of the wound near the caruncle is taken up with forceps and removed with scissors. Mr Critchett believes this additional proceeding to be useful also in cases where there is considerable thickening of the lower lid and eversion of the punctum, with consequent lachrymation, without any other lachrymal obstruction, and also in cases where the first operation has been performed on children and timid patients.

Weber² regards the following cases as curable by Mr Bowman's operation:—

¹ Ophth. Hosp. Rep., vol. i. p. 103.

² Dr A. Weber, on the Treatment of Lachrymal Strictures. A. f. O., viii. 1. p. 94.

1. All cases of strictures of the canaliculi, arising from inflammatory causes, which most frequently occur at their point of entrance into the lachrymal sac; but he observes, that cases arising from traumatic causes must often first be treated by a plastic operation, to rectify the effects of the cicatrization in producing inversion or eversion.

2. Cases of valvular obstruction at the entrance of the lachrymal sac into the nasal duct, providing these are not attended with abundant muco-purulent secretion.

3. Cases of obstruction at the inferior orifice of the nasal duct, especially where they have originated in catarrh.

4. Perhaps cases of complete obliteration of the lachrymal passages, where the membrane has lost its natural properties, and is only composed of cicatricial tissue, as occurs when the actual cautery has been applied.

On the other hand, the cases to which he believes Mr Bowman's method is inapplicable are:—

1. Atresia, *i.e.*, total obliteration of the canaliculi at their entrance into the sac.

2. Strictures of the nasal duct, if accompanied with much inflammatory action, producing secretion or ulceration.

3. Cases of callous stricture of the nasal duct.

4. Cases of hypertrophy and tumefaction of the mucous membrane.

5. Cases of polypous degeneration of the mucous membrane.

6. All cases of epiphora dependent upon caries; and,

7. All strictures and atresia which have occasioned dilatation of the sac.

Weber considers that the sounds employed by Mr Bowman are not sufficiently thick, nor sufficiently flexible, and that they have not the right form on transverse section properly to fill the canal. He recommends and employs elastic bougies of much larger size, 1.5–2 millimetres (= Bowman No. 5 probe) for the smallest, attaining a diameter of 4 millimetres

in the largest. When these will not pass, he uses a silver sound, which, at its commencement at one end, has a diameter of Mr Bowman's No. 1 probe, and after a course of 15''' (1¼ inch) enlarges to a thickness of 1·5 or 2 millimetres; at the other end, beginning with a diameter of 1 millimetre, it enlarges conically to a diameter of 3 to 3·5 millimetres at 15''' from the end. He uses a small tenotomy-knife for splitting up the superior canaliculus, and for dividing the ligamentum mediale, which he believes constitutes the chief hindrance to the entrance of the sound.

Foltz¹ recommends, for the treatment of lachrymal tumours and fistula, the employment of a kind of punch; and maintains that the cures effected by this means, when followed up for several years, will be found to be more numerous, more complete, and more radical, than those obtained by any other method.

The operation he proposes consists of three stages. In the first, an oblique incision is made into the sac, ten or twelve millimetres in length, below the tendon of the orbicularis; in the second, one branch of the instrument is passed down the lachrymal sac, the other upwards through the nostril and lower part of the nasal duct; and in the third, the branches are firmly compressed, when a cracking sound is heard, and section of the lachrymal nasal septum is completed. A canula, which forms part of the instrument, is rotated by the aid of a key, and on removal is found to contain a small circle of the os unguis and neighbouring bone, covered on one side by the mucous membrane of the lachrymal sac, and on the other by that of the nose. Though several surgeons have performed this operation, it is probable that few would select it for themselves, amongst the other methods that have been suggested, were they unfortunately the subjects of the disease.

In a case recorded by Mr Streatfield² of obliteration of the

¹ Ann. d'Ocul., p. 102, 1860; and p. 136, 1865.

² Ophth. Hosp. Rep., vol. iii. p. 4.

lower punctum, after various other measures had been unsuccessfully tried, he succeeded in re-establishing the channel for the tears in the lower lid, by entering a curved style through the upper canaliculus into the lachrymal sac, and then, by a "tour de maitre," altering its direction, and passing it in the opposite direction along the lower canaliculus till the point emerged at the inferior punctum. The inferior canaliculus was then slit up for a short distance, and its patency maintained by passing a probe a few times in the ordinary way.

Mr Guthrie was accustomed to treat all cases of obstructed duct, when no inflammatory symptoms were present, by firmly compressing the sac, and then instilling a drop or two of the *vinum opii*. It must be confessed that this was only a palliative proceeding, and seldom led to a cure; but that it produced relief was sufficiently proved by the persistent way in which the patients continued to attend, and it naturally suggests that in those cases where Mr Bowman's plan has been tried, and has failed of complete success, astringent injection might with advantage be employed. I have accordingly found that, as a secondary part of the treatment in point of time, the use of a somewhat diluted *vinum opii*, or a solution of alum (gr. ii-iv. ad. $\bar{3}$ i), with a small proportion ($\bar{3}$ i) of *vinum opii*, and a little mucilage, will very effectually stop the mucous discharge, and lead to considerable improvement in the state of the patient.

A plan of treatment, formerly very generally adopted, may be mentioned only to be condemned. It consisted in making an incision through the skin at the inner angle of the eye, and pushing on the point of the instrument till the lachrymal sac was opened, just below the *tendo-oculi*. A style was then introduced, and allowed to remain in the nasal duct. The objection to this plan is, that the style, gradually descending in the passage, oftentimes altogether disappears, and, producing no immediate inconvenience, is no longer thought of by

the patient, the tears continuing to descend by its side. The first time, however, the patient suffers from a cold in the head, the mucous membrane of the duct, swelling, tightly embraces the instrument, producing the most severe pain and the formation of an abscess, rendering its removal by operation imperative. No one who has not operated on such a case would readily believe the firmness with which the little style becomes impacted in the passages; but, deeply imbedded, coated with a tartar-like incrustation, and bent to the form of the canal, it resists very great efforts to drag it out, and is only removed by force, which inflicts great damage on the surrounding structures. Mr Bowman states that, when in the habit of performing this operation, he endeavoured to avoid this difficulty by using probes or styles of sufficient length to project from the upper orifice while resting on the floor of the nose; but even then the results of the operation were by no means satisfactory.

Where the disease is of long standing, and where the measures suggested by Mr Bowman have failed, it may perhaps be advisable, as a *dernier r  sорт*, to try to obliterate the sac, for the accomplishment of which various methods have been adopted. M. Desmarres, for instance, formerly employed the actual cautery; but finding it difficult to overcome the dread with which it inspired the patient, has lately,¹ with M. Delore, used the dry chloride of zinc, of which he inserts a small quantity into the upper part of the sac, in the form of a pat  , and covers it with charpie, after which cold or iced dressings should be applied. Dr Williams, of Cincinnati, still employs the actual cautery, if there be any carious bone. If not, however, he inserts into the sac portions of nitrate of silver, which he allows to dissolve slowly. The operation is repeated once a-week, and he has never seen any unpleasant consequences.

The closure and obliteration of the sac have also been

¹ Compt. Rend. du Congr  s d'Ophth., p. 141. 1862.

strongly advocated by Dr Delgado,¹ who has suggested the employment of an instrument on the principle of a porte-caustique, consisting of two limbs and a central staff, to which the caustic desired to be applied is attached. The instrument can readily be introduced through a small incision, or through the fistulous orifice, with the limbs closed and protecting the caustic. On then pressing a button, the limbs are separated, and the caustic protruded. It may now be effectually applied to the different surfaces of the sac. By this means, it is stated, very satisfactory results are obtained. The closure of the sac is complete, with the exception of a passage in the thickened tissue, through which the tears still course; and no overflow takes place, partly on this account, but partly also, he believes, because there is no longer existent that distension of the lachrymal sac which leads to excessive secretion of tears, by reflex irritation of the lachrymal branches of the fifth pair of nerves.

M.M. Sperino and Manfredi² have employed chloride of antimony for the destructive cauterization of the sac, which they have found not to occasion obliteration of the lachrymal passages, but, on the contrary, the re-establishment of their permeability.

The operation of obliteration of the sac is rarely undertaken in this country, and I have never seen an instance in which it has been adopted.

When an acute abscess of the lachrymal sac has taken place, there cannot be a moment's hesitation about the propriety of opening it at as early a period as possible. Nor can this be effected in any better mode than that suggested by Mr Bowman, of introducing his grooved probe into the canaliculus, and, after slitting up the passage, making a free opening into the lachrymal sac. The discharge of the pus and the application of poultices are immediately followed by relief of all the symptoms. A probe may be, either at once

¹ Ann. d'Ocul., t. lv. p. 236. 1866.

² *Ibid.*, Dec. 1864.

or after the lapse of a few days, passed down through the nasal duct, and, unless diseased bone be present, speedy recovery will take place. If not, recourse must be had to one or other of the methods of cure above described, directed to the removal of the primary cause. In most instances during convalescence tonics and wine may be freely administered.

It is not, however, every abscess near the inner canthus of the eye that is really connected with the lachrymal sac, and a certain degree of care is required to be exercised in the discrimination of each case. The proof of this assertion is evidenced by the facts, that not only do many of these cases of abscess arise, attain their acme, burst, and heal up without any internal obstruction of the sac having occurred, but in a still more satisfactory manner by the circumstance that, although in such cases the indications of an abscess may be perfectly clear, the canaliculus may be slit up, and a large probe passed down the nasal duct, without occasioning the discharge of any matter whatever, whilst even subsequently to this proceeding the matter will point and burst on the cheek. I do not think this distinction is sufficiently dwelt upon in works on ophthalmic diseases; but I have given drawings of two such cases in figs. 10 and 11, where such a difference actually existed. In fig. 10 the abscess was external, in fig. 11 it was internal, to the lachrymal sac. As regards the former of these two affections, it may be observed that the symptoms usually arise suddenly *without* any previous affection of the lachrymal passages, and generally after some exposure to cold and wet, when the patient has been debilitated by diarrhoea, or when the bowels have been otherwise disordered. Throbbing pain and swelling of a dull red colour, often attended with erysipelatous tumefaction in the lower lid, are observed. At this period the tears may flow over the cheek, partly from the pain and general congestion of all the adjoining parts, but principally, no doubt, from mechanical pressure exerted upon the canaliculi and

lachrymal sac by the inflammatory swelling. After a day or two of severe pain, the swelling becomes more defined; the centre and most prominent part assumes a yellowish colour; the little abscess forms a head usually about the point indicated in the figure, and may either be allowed to discharge of itself, or may be opened by a lancet. In either case a few drops of healthy pus are discharged, and, after a week or two, almost all traces of the disease have disappeared, nor is there much tendency to a relapse. The constitutional symptoms are slight; and beyond a purge, poultices, and fomentations, little treatment is required.

Polypi of the nasal duct are very rare. The following case, recorded by v. Gräfe¹ amongst several others, gives the salient points of the affection:—The patient was a girl, ten years of age, who had suffered from inflammation of the lachrymal sac and subsequent blennorrhœal discharge. The lachrymal sac was prominent, and on pressure, a gelatinous, transparent, coherent, and partly puriform mucus was discharged, but the complete evacuation of the cavity was not possible. When firm pressure was made, a sensation was felt as of a fatty tumour under the skin; an opening was made into the sac; and some fluid sprang out, with a pyriform polypus, of gelatinous consistence, and bearing a close resemblance to a nasal polypus. The pedicle was smooth, shining, and firmly adherent to the wall of the sac; and, after its removal, a tight stricture was found in the nasal duct, to which he applied the actual cautery.

¹ Archiv. f. Ophth., vol. i. p. 283. 1854.

CHAPTER IV.

Diseases of the Eyelids.

GENERAL ANATOMY OF THE LIDS—INFLAMMATION, ERYSIPELAS, ABSCESS, WOUNDS, CONTUSIONS, AND INJURIES OF THE LIDS—OPHTHALMIA TARSI-PHTHEIRIASIS CILIARUM—HORDEOLUM—ULCERS OF THE LIDS—EPITHELIAL CANCER OF THE LIDS—TUMOURS OF THE LIDS—EPICANTHUS—CHROMHYDROSIS—MORBID NICTITATION AND BLEPHAROSPASM—PTOSIS—SYMBLEPHARON—ECTROPION—TRICHIASIS, DISTICHIASIS, AND ENTROPION.

1. *General Anatomy of the Lids.*

THE structure of the eyelids, which fulfil such important purposes in preserving the eyes from injury, both during the waking state and when closed in sleep, is very complex, as the accompanying diagram, constructed by M. Moll¹ from five sections, examined under low powers of the microscope, testifies.

A vertical section through the middle of the upper eyelid, treated with acetic acid, and $\times 12$.

- A. External skin.
- B. Subcutaneous connective tissue.
- C. Palpebral part of the musc. orbicularis.
- D. Connective tissue containing fat between the orbicularis and the tarsus.
- E. The tarsal cartilage.
- F. Mucous membrane.
- G. Free border of the lid.

¹ Archiv. f. Ophth., Bd. iii. p. 258. 1857.

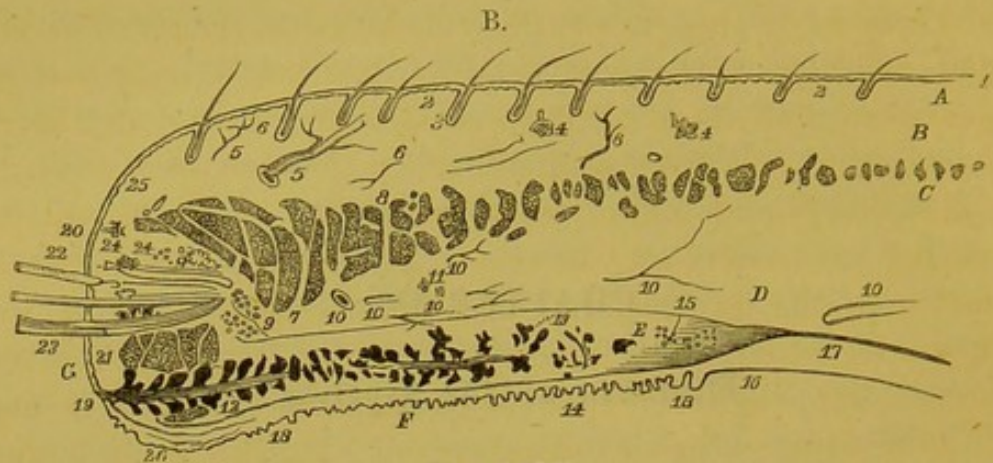


Fig. of Moll.

1. Epidermis.
2. Cutis, with papillae.
3. Hairs with their follicles.
4. Sweat glands.
5. Bloodvessels in the subcutaneous connective tissue.
6. Nerves in the same.
7. Pars ciliaris
8. Pars palpebralis
9. Fat.
10. Bloodvessels in the connective tissue between the musc. orbicularis and the tarsus.
11. Nerves in the same.
12. Lobuli of the Meibomian glands.
13. Termination of the same glands.
14. Section of an adjoining Meibomian gland.
15. Adipose tissue in the most superior part of the tarsus over the ends of the Meibomian glands.
16. Elastic tissue merging into the upper part of the tarsus.
17. Musculus levator palpebrae superior terminating in the above-named elastic tissue.
18. Papillae of the mucous membrane.
19. Opening of the excretory duct of the Meibomian follicle.
20. Glands of small hairs near the free border of the lid.
21. Tarsal portion of the orbicularis (Horner's muscle).
22. Cilia.
23. Two cilia in one follicle.
24. Sebaceous glands of the cilia.
25. Cutis of the free border of the lid.

The skin on the outer surface of the lid is seen to be thin and delicate; to be beset with a few small hairs having sebaceous follicles at their bases, and with here and there a sweat gland, and to be continuous with the mucous membrane at its free border. From near the centre of the margin of the lid, but usually a little nearer its anterior border than is shown in the drawing, the cilia (22) emerge, those of the upper lid being much longer and thicker than those of the lower. Into the root follicle of each cilium the ducts of one or more large sebaceous glands open. The posterior border (26) of the free margin of the lid, which rests upon the globe, is slightly bevelled off, and at this point the skin and mucous membrane blend with one another. The conjunctiva lining the lid is seen to be villous, the papillæ being small in front (18), but increasing in size towards the palpebral sinus, where the conjunctiva is reflected from the lid to the globe; and whilst some are purely vascular, others are nervous, and possess a high degree of sensibility.

The central part of each lid is occupied by the ciliary portion of the orbicularis muscle (7), the fibres of which increase in number and thickness towards the free border. The small fasciculus of muscular fibres (21) situated below the roots of the cilia, and through which the duct of the Meibomian gland is seen to run, corresponds to Horner's muscle, or the posterior lachrymal portion of the orbicularis palpebrarum. The tarsal cartilage (E) lies just beneath the conjunctiva, and in the upper lid is connected above with the tendon of the levator palpebræ (17). The ducts of the Meibomian follicles open near the inner margin of the edge of the lid, and their dilated extremities or acini lie in depressions on the tarsal cartilage, or are buried in its substance (12, 13). The vascular supply of the lids is derived from various sources—the ophthalmic, facial, and transverse facial arteries constituting the most important sources.

The sensory nerves are exclusively branches of the fifth,

which have been recently shown by Krause¹ to terminate in true *corpuscula tactûs*, which are of small size and oval form, and occupy the extremities of the papillæ. Their surface is transversely striated, the striæ being produced by pale nervous terminal fibres, and they are particularly numerous in the immediate vicinity of the ciliary border, accounting for the exquisite sensibility of this part, and for the pain occasioned by the entrance of the smallest particles of grit or dust.

The motor nerves, through the action of which the movements of the eyelids are performed, are the portio dura of the seventh and the superior division of the third,—the former supplying the orbicularis palpebrarum, which effects the closure—the latter, the levator palpebræ, which causes the opening—of the eyelids. The levator palpebræ arises from the base of the orbit, near the superior margin of the optic foramen, and immediately in front of the fibrous ring from which the recti muscles take their origin. It runs forwards, becoming gradually broader, and lying on the superior rectus. Stretching beyond this, it extends into the upper eyelid, and is inserted by a broad tendon into the superior border of the tarsal cartilage. As its name implies, it raises the upper lid and opens the eye. The orbicularis palpebrarum acts in the opposite direction, and closes the lids. It is divided into three parts:²—First, the orbicularis marginalis, or orbitalis, the fibres of which, arising from the contiguous parts of the superior maxillary and frontal bones, at the inner margin of the orbit, form the great circles of the muscle, and, after surrounding the orbit, return to the inner canthus, to be inserted just below the internal palpebral ligament. The second or ciliary portion, the mus-

¹ Archiv. f. Ophth., Bd. xii. p. 296. 1866.

² For very minute descriptions of this muscle, see Henke, v. Gräfe's Archiv. f. Ophth., 1859, and Arlt, *ibid.*, ix. 1864, whose accounts, however, do not agree very well together.

culus lachrymalis anterior of Henke, enters into the formation of the lids, lying immediately beneath the skin. The fibres arise from the upper and lower borders of the internal palpebral ligament, and, running horizontally with gentle curves, are inserted into the upper and lower borders respectively of the external palpebral ligament. The third portion of the orbicularis, called by Henke the musculus lachrymalis posterior, or Horner's muscle, arises partly from the crest of the lachrymal bone, and, after passing across and behind the lachrymal sac to the inner angle of the eye, is also connected with the outer end of the internal palpebral ligament, from whence it derives some accessory fibres. A tolerably thick fasciculus is thus formed, which divides at the inner canthus, the two subdivisions running outwards, close to the edges of the lids, and being finally lost in their outer part, or being continued to the ligamentum palpebrale externum.

The functions of these three portions of the orbicularis muscle, all of which are supplied by the portio dura, are essentially different. The first, or orbital portion, throws the skin into wrinkles at the outer and inner angles of the eye, and co-operates with the corrugator supercilii in frowning, and with the zygomatici in smiling. The second, or anterior lachrymal portion, is the active and principal agent in the closure of the lids; but it fulfils a second use in dilating the lachrymal sac, and thus aiding in the removal of the tears from the surface of the conjunctiva. This is accomplished by the intimate union which exists between the internal palpebral ligament and the anterior wall of the lachrymal sac, so that, when the muscle contracts, the anterior and posterior walls of the sac are separated from one another, and a tendency to a vacuum produced, causing the tears to be drawn in through the puncta and canaliculi. The third, or posterior lachrymal portion, Horner's muscle, is associated in its action with the levator palpebræ, co-operating with that

muscle in opening the lids, and at the same time, at the instant of its contraction, becoming tense, it compresses the lachrymal sac from behind forwards, and effects the propulsion of the lachrymal secretion from the lachrymal sac into the nasal duct.

The movements of the lids, though to a considerable extent under the control of the will, are yet automatically opened and shut. If they are voluntarily kept open, or are held apart for a few seconds, the mind being directed to the impressions received from them, a stinging or smarting sensation is experienced, accompanied by a strong desire to close them. If this be resisted, the feeling in great measure passes off, and they can be maintained open for a minute or more without inconvenience, as may be observed in many of the audience at a theatre or other representation, or in those who are intently engaged in microscopic examination, when, in consequence of the attention being strongly fixed, no regard is paid to the primary sensations of commencing dryness of the cornea, which usually induce nictitation. When the lids, however, are then closed, a feeling of dryness, soreness, and stiffness is usually experienced.

The movements of the lids may be called into play (1.) voluntarily ; (2.) by reflex action through the sensory branches of the fifth, in consequence of the cilia, lids, or conjunctiva being touched, or perhaps that which is the customary cause, incipient dryness of the cornea ; (3.) by reflex action through the optic nerve, as when a blow is aimed at the eye, or when a bright light falls upon the retina.

The lids are closed when severe mental or bodily pain is experienced ; they are widely opened under the emotions of surprise, fear, and wonder. During sleep the levatores palpebrarum are relaxed, and the orbiculares are slightly contracted, causing the lids to be approximated, but not firmly compressed against one another, the slightest force being suffi-

cient to separate them. The globe is at this time rotated upwards and inwards, by which means not only is the eye more perfectly protected from the action of light and from injury, but the formation of a line of inspissated mucus and lachrymal secretion across the front of the pupil is prevented.

As Sir P. Crampton¹ first observed, the levatores palpebrarum not only act *per se*, but have an associated action with the superior recti, in order that, when the latter muscles act, the upper eyelids may be removed from before the axes of vision.

The eyelids are fringed by stiff, slightly curved hairs, termed the cilia, the growth and characters of which have been minutely studied by Donders.² The upper eyelid has from 104 to 150; the lower, from 50 to 75. The length of the upper cilia varies from one-third to half-an-inch; of the lower, from one-fourth to one-third of an inch; and the upper ones are always thicker and stronger than those of the lower lid. Both sets form gentle curves, the convexities of which are opposed to one another, and, whilst thick and firm at the base, taper off to an extremely fine point. Each eyelash has a life of its own, grows slowly, and drops out at the end of from 100 to 150 days, to be succeeded by another, developed in and from the same hair-follicle. With a lens the young cilium destined to replace the old one may frequently be seen, towards the decline of the latter, projecting by its side from the follicle. The rate of growth is such that a cilium attains in three weeks a length of one-sixth of an inch; in seven weeks, of one-third of an inch; and in twenty weeks, of very nearly half-an-inch. Those of the lower lid are more slow in growing than those of the upper, and the cilia of old people do not increase with the same rapidity as those of young persons. Sebaceous glands, of moderate size, pour their

¹ Essay on the Entropion.

² Archiv. f. Ophth., b. iv. p. 286. 1858.

secretions into the follicles of the cilia, and are the frequent seat of inflammatory affections.

The cilia are so implanted upon the anterior border of the edges of the lids, that whilst no opposition is offered to the flat surfaces of the palpebral margins coming into immediate contact on closure of the lids, their separation is not interfered with by the roots or shafts of these hairs becoming crossed or interlaced with one another.

2. *Acute Inflammation and Abscess of the Lid.*

(PLATE II., Figs. 8 and 9.)

Both the upper and the lower lid may be the seat of acute inflammation, leading to the formation of an abscess, but it is most frequently seen in the upper lid. The causes to which it is attributable are either constitutional, as from cold and disordered bowels, as was the case in fig. 8, or traumatic, of which I have seen several examples. When of small size, it is scarcely distinguishable from hordeolum, the difference being probably in the mode of origin, hordeolum being in some way connected with the roots of the lashes, as is shown by its bursting, when left to itself, at the side of a hair, which then drops out; whilst in a well-marked case of abscess of the lid, as shown in fig. 9, the purulent collection occupies the connective tissue of the lid generally. In a remarkable case, recently under Mr Hancock's care, in the Westminster Ophthalmic Hospital, the patient, who was a girl of ten years of age, presented a large swelling, which not only involved the whole of the left lid, but extended far above the margin of the orbit, and formed a fluctuating tumour on the temple and forehead, one inch in breadth by two inches in height. The mother stated that the temple was first observed to be swollen about a fortnight before, and after it had remained so for a day or two, the lid quite suddenly became greatly swollen, red, and painful. The child was very unhealthy-looking, the face white, the front teeth all decayed, and with

matter oozing from the sockets; the bridge of the nose was broad and flattened, and she was nearly deaf. She had been delirious. The pulse was very small and feeble. An opening was immediately made into the abscess, just below the eyebrow. About three ounces of extremely foetid matter were evacuated. A poultice was directed to be applied. She was liberally supplied with food, wine, and iron, and complete recovery took place.

In almost all the cases I have seen, the patients have been children, and in one instance the child was only five weeks old. In this case the eyes had been weak and watery from birth, but there had not been an attack of purulent ophthalmia. The symptoms of the disease are sufficiently characteristic.

The lid at an early period becomes swollen, brawny, and hard, with a slight blush of redness upon the surface; the patient is restless and feverish; the swelling rapidly increases, and the redness becomes more and more pronounced, until it assumes a livid or purplish tint, and the surface becomes bright and glossy, and exquisitely tender to the touch; severe throbbing pain is complained of, and it is with difficulty that the lid can be sufficiently raised to enable the patient to see. The conjunctiva is usually moderately congested, and there is more or less lachrymation and puriform discharge. At length the most prominent part becomes yellowish and boggy to the feel, and finally, if left to itself, the matter, which has formed a circumscribed abscess, bursts through the skin by one or more small apertures. I have only seen one instance in which it burst through the conjunctiva, its extension in that direction being probably prevented by the firm texture of the tarsal cartilage and ligament to which the abscess is usually external in position. When left to themselves, abscesses of the upper lid are exceedingly apt to occasion ectropion, the cavity occupied by the matter gradually contracting, and either causing eversion of the lid, or tucking it up, as in fig. 22, Plate IV., till the ciliary margin of the lid is

in contact with the orbital border. A short time ago, however, I saw a boy where the opposite result had taken place. He had had an abscess of the lower lid, which had burst, after attaining a large size, over the malar bone; the subsequent contraction of the sac and cicatricial tissue produced a well-marked entropion of the lower lid.

Since these results are to be feared, abscesses of the lids should be carefully watched; and we should endeavour, in the first instance, to prevent the formation of matter by the application of one or two leeches, and cold or iced dressings, and the administration of a brisk purge; but if it be evident that resolution of the inflammation cannot be looked for, hot fomentations and poultices should be adopted, and as soon as it can be distinctly ascertained that a collection of matter is present, it should be opened by an incision directed parallel to the ciliary border, where the small cicatrix will be concealed by the natural transverse wrinkles of the skin of the lid. During convalescence a liberal diet may be allowed, and tonics administered. In the event of a disposition to ectropion being exhibited in the progress of cicatrization, a compress and bandage may be applied; but it is doubtful whether this would prevent its occurrence, however carefully adapted, and healing must then be allowed to proceed, in the hope that one or other of the measures to be afterwards detailed for the cure of eversion may effect the cure of the deformity.

3. *Erythema of the Lids.*

(PLATE I., Fig. 6.)

This affection is more serious in appearance than in reality. In the case from which the illustration was drawn, the conjunctiva was considerably congested, and the skin of the adjoining parts of the face on the same side presented a well-marked red appearance. On pressure, the redness disappeared, but returned immediately the finger was removed. The patient

complained of burning heat, but no special cause could be assigned for its occurrence. There were slight signs of constitutional disturbance. The bowels were confined; the tongue furred; the pulse frequent; the vision was unimpaired. The brilliancy of the coloration of the skin, and the absence of tumefaction or œdema, distinguished the case from one of erysipelas; and the freedom from throbbing or pain showed that no abscess was present. The treatment pursued was very simple; a brisk saline purge was administered. The patient was directed to bathe the parts with poppy fomentations and with lead lotion, and in three days scarcely any trace of the redness remained.

4. *Erysipelas.*

(PLATE XI., Fig. 61.)

This disease is usually the result of the action of cold on those who are debilitated by deficiency or improper quality of food, mental distress, night watching, or other depressing conditions, and is generally associated with disordered bowels. It is common in those who are much exposed to the night air, as watchmen, compositors, and prostitutes, and in those who gain their living in the streets, as costermongers, cabmen, etc.; and I have met with several cases in laundresses and washerwomen, owing, doubtless, to their being exposed to sudden and considerable variations of temperature. In many instances it follows injuries to the head, and is a not infrequent concomitant of lachrymal abscess, and of violent inflammations of the globe. It occurs at all ages, except, perhaps, in the newly born, and is, if neglected, likely to assume a very serious character. On the other hand, if seen at an early period, it constitutes one of those diseases which are fairly under the control of the surgeon, and pass away without leaving any trace of their former presence. The illustration was copied from a patient suffering from a well-marked attack, the description of which will give a good idea of the

general progress of the disease. The whole of the skin of the lid was in a peculiar cedematous condition, swollen, semi-transparent, and of a pinkish tint. The conjunctiva was red and watery, but was only beginning to be chemotic. The deep vessels of the sclerotic were not unnaturally congested; the pupil was of natural size; the markings of the iris were clear and distinct, and its movements, on exposure to light, were perfectly natural. There was no photophobia. The tongue was foul, the breath foetid. The patient led an irregular life, and was about forty years of age. She complained of burning heat of the skin, and of great stiffness of the lid. Her pulse was 100, and small and feeble. She was evidently extremely weak, and could scarcely stand whilst being examined. She was directed to go home and keep indoors, to foment the parts with poppy fomentations, to take an emetic of tartarised antimony, and then to commence a mixture containing cinchona and chlorate of potash. On the following day she sent for me to her own house. On calling there, I found that she had only bathed the eye with the poppy fomentation, being sure the emetic would make her worse. The lids were then much more swollen, and pitted on pressure, and her skin, near the outer angle, was raised into large vesicles, containing a clear serum. They could be separated only with some difficulty, and immediately the conjunctiva greatly chemosed, that is to say, swollen, and infiltrated with a thin serous fluid, conferring upon it a pale-pink or straw-yellow tint, protruded. Amongst these prominent folds, which advanced some distance upon the front of the cornea, the iris could be seen, still with well-defined markings, and vision was perfect. As the tongue was remarkably foul, I again directed the emetic to be taken, and this time with success. The contents of the stomach, with much bile, were discharged, and a brisk purgative effect followed. On the following day, the bathing having been assiduously maintained, the smarting and redness had considerably abated, the chemosis was diminished, and

the tongue was cleaning at the tip and edges. Full doses of decoction of cinchona, with tincture of cinchona and chlorate of potash, were ordered, and three or four glasses of port wine directed to be taken daily. From this time all the symptoms rapidly disappeared, and in a week the eyes had almost resumed their natural appearance.

Though in Hospital practice the administration of an emetic is usually adopted, yet this would be unnecessary when the tongue was clean, and the cause of the disease was clearly traceable to cold. Under such circumstances, the quinine and stimulant plan of treatment, or the administration of the sesquichloride of iron, in ten or fifteen minim doses, three times a-day, or more, may be at once advantageously commenced. As a general rule, hot fomentations are preferable to cold in erysipelatous affections, and the application of a warm poultice generally affords great relief to the smarting and feeling of tension.

When neglected, the result of the disease is usually the formation of an abscess; but sometimes, owing to the pressure exerted upon the vessels, and to the consequent interference with its nutrition, the cornea sloughs; of which I remember a well-marked instance that occurred in the late Mr Stanley's practice, and where, at Mr Lawrence's suggestion, though at too late a period to save the patient's eye, four or five deep radiating incisions were made through the conjunctiva; a proceeding that none of the cases that have come under my observation have been serious enough to lead me to adopt.

The following case is an example of erysipelas of the lid occurring consecutively to an injury of the head, and when, of course, it was only of secondary importance:—

A man of fifty years of age applied at the Westminster Hospital, with the left lids so swollen and cedematous, that the eye could scarcely be opened. He was in a bewildered condition, and could give no account of its cause. This circumstance, with the appearance of some redness and puffiness

of the forehead, led to further examination, and it was soon found that at the back of the head was a deep wound—which it was afterwards ascertained he had received three days previously in a drunken affray—surrounded by a wide zone of serous infiltration. He was at once admitted into the hospital, and the treatment was of course directed to the wound and general condition of the patient, rather than to the lids. These were, however, directed to be painted with collodion. Warm poultices were applied to the shaven scalp. Decoction of cinchona and chlorate of potash, with stimulants, were freely administered; and though considerable delirium was present at night, and extreme exhaustion during the day, the patient made a good recovery, the wound assuming a healthy appearance on the third day, coincidently with which the erysipelatous tumefaction subsided, and in fifteen days he was discharged well.

An occasional result observed in cases of erysipelas of the lids by v. Gräfe,¹ is amaurosis, dependent on atrophy of the optic nerve, which is in all probability attributable to the direct pressure exerted upon the nerve by the serous effusion in the orbit, and not to any blood poisoning, as in that case both optic nerves would be affected, which is not the case.

Erysipelas is, on the whole, a rare disease. Out of 15,000 cases, only sixty-seven presented themselves with this affection. The average age was thirty-four; as regards the sexes, thirty-seven were men and thirty were women.

5. *Wounds, Contusions, and Injuries of the Lids.*

Simple cuts of the lids, in whichever direction they may occur, and even though they may implicate the entire thickness of the lid, require no special surgical treatment beyond taking the greatest care that the edges of the wound are brought into accurate apposition, and retained there by

¹ Ophthalmic Review, p. 145. 1864.

several sutures, the threads of which may be very fine, as there is little or no traction upon them; union will thus take place, even where no attempt has been made to bring the parts together for twenty-four hours. In one or two cases, where a longer period than this has elapsed, the operation has failed in my hands, though the parts healed up very well without disfigurement by granulation.

The condition termed ecchymosis of the lids, or, in common parlance, "black eye," Plate III., fig. 16, is generally the result of a blow, and is due to the rupture of some small vessels. It is not unfrequently seen as a consequence of operations upon the eye, such as that for strabismus, and is then the consequence of the gravitation of the blood through the lax connective tissue of the part. I have seen one well-marked instance where it suddenly appeared after the action of an emetic, a vessel having given way during the congestion consequent upon the violent efforts of vomiting. From its position, the lower lid is usually the principal seat of the ecchymosis, and the blood often accumulates, especially in old people, in such quantity as to form a kind of bag in which fluctuation is clearly perceptible. The colour of a black eye is always livid, or dark purple, from the first; but after a few days it generally becomes still darker, and less defined at the edges. Its gradual changes of colour through green and yellow are well known. The rapidity with which the removal of an ecchymosis is effected differs considerably, according to the age of the patient and the quantity of blood effused. Where this forms a sac, it may be punctured with a fine grooved needle, and the contents allowed to escape; but in general its resorption must be left to nature; and it appears to be doubtful whether any of the ordinary applications, spirituous lotions, liniments, and the like, hasten in the smallest degree the disappearance of the discoloration. Pugilists puncture and then suck the wound, and are said to apply raw steak and arnica lotion; but if these act at all, it

is probably simply by their refrigerant action checking further effusion; and the rapid removal of effused blood in these persons is rather a consequence of the vigour and energy of their circulation and general nutritive powers than of any other cause. In young people, for the same reasons, effusions of blood soon disappear, whilst in the aged they are comparatively persistent. A well-marked black eye will scarcely have entirely disappeared at the end of a month.

After severe blows on the nose, attended with fracture of the bones and rupture of the mucous membrane, or even after violently blowing the nose, air sometimes enters the connective tissue, and causes considerable emphysematous swelling and a sensation of crepitation on pressure. Little treatment is required beyond, if the swelling be very tense, puncturing the semi-transparent and puffy tumour with a fine needle, and applying a poultice made of the species pro confectione aromaticâ of the London Pharmacopœia.

Injuries of the eyelids from the explosion of powder, and from particles of molten lead expelled with great force from the bottom of cavities in stone where a little water has unfortunately collected, are very common. In both classes of cases, considerable inflammation follows the accident; the lid swells to so great an extent, that unless seen immediately it is difficult to ascertain how far the globe of the eye has been injured. In accidents with powder, the parts should be cleansed as far as possible, and the larger and more accessible fragments of carbon may be at once removed, but it is better not to pick at them too much. The patient should be put to bed, and the eyes covered with a cold bread and water poultice, or some evaporating lotion, frequently renewed. When all inflammation has subsided, attempts may be made to remove some of the remaining portions, unless they are very deeply imbedded, in which case the patient is tattooed for life. In the French translation of Dr Mackenzie's work, it is stated that an application of a solution of the bichloride

of mercury, in the proportion of five grains to the ounce of water, may be made to the lids for several hours daily, so as to excite an eczematous eruption. The scab which succeeds to this will be found, on removal, to contain the greater part of the grains.

In explosions of molten lead, the lids should be separated, and all the fragments removed with forceps. Many of them will be found to adhere very firmly to the little eschar they have made.

Many cases are on record where injuries of the lids have been followed by amaurosis, and this has been attributed to reflex irritation conveyed through the supra-orbital or other branches of the fifth nerve. Where the loss of vision has been immediate, this explanation is not admissible; and there can be no doubt that in some of the instances adduced by the older authors, had the ophthalmoscope been in use, it would have led to the discovery of retinal detachment or other intra-ocular lesion. Still cases every now and then occur in which the eye itself has apparently escaped the immediate effects of the injury, and no impairment of vision has taken place, but where, in the act of cicatrisation, the infra-orbital nerves appear to have been subject to traction and irritation, which induces hypersecretion and increased tension of the intra-ocular structures; in fact, a kind of glaucoma which ultimately leads to complete blindness.

Mr Guthrie¹ remarks that, according to his observation, the eye, when amaurotic through injury of the supraorbital nerve, often shows little or no derangement of structure; the iris preserves more or less of its natural motions; and the information we acquire is from the patient's declaration of his loss of sight, which is generally unaccompanied by pain. When amaurosis, he continues, is the consequence of a direct injury to the eye itself, there are for the most part positive marks of the injury having been inflicted upon it, such as extravasation

¹ *Operative Surgery of the Eye*, p. 116. 1830.

in or lacerations of some of the internal parts. The motions of the iris are greatly impaired, the pupil is dilated, and the pain is considerable when the amaurosis is the consequence of concussion or of derangement within the head, such as extravasation of blood or deposition of matter; the eye of the side opposed to the injury is most frequently affected when both are not equally implicated.

Mr Hutchinson¹ has collected numerous interesting examples showing the influence of lesions of the sensory nerves upon the nutrition of the eye.

In the treatment of such cases we must be guided by circumstances. If inflammatory symptoms are established, it is almost needless to say that they must be combated by the application of leeches and other depletory measures, whilst in all cases the eyes should be kept at rest, in a subdued light, and all sources of irritation removed as far as practicable.

But if in consequence of the general transparency of the media, the absence of any retinal lesion or intraocular effusion of blood can be satisfactorily ascertained, whilst the increased tension of the globe and other symptoms show the progress of a glaucomatous process, after injuries of this nature, and if at the same time the cicatrix is the seat of pain, or becomes tender to the touch, the division of the nerve at the supra- or infra- orbital foramen should, as Bell and others have recommended, undoubtedly be tried, as several instances of recovery of failing sight have been placed on record when this operation has been performed. The source of irritation being thus cut off, it at all events seems reasonable to suppose that the effects should cease.

6. Ulcers of the Lids.

(PLATE II., Fig. 12; PLATE XI., Figs. 63, 64.)

Ulcers may make their appearance either on the inside (fig. 63) or on the outside (figs. 12, 64) of the lids. Putting the

¹ Ophth. Hosp. Rep., vol. iv. p. 120.

former aside, as they will hereafter be described when the diseases of the conjunctiva are under consideration, the chief forms of ulcer met with on the external or dermal surface of the lids are epithelial cancer, syphilitic ulcers, and ulcers following abscesses and injuries.

Epithelial cancer (fig. 64) presents itself, in the first instance, as a small pimple, generally situated on the margin of the lower eyelid, near the outer, or, less frequently, the inner canthus, which increases with extreme slowness, but gradually forms a lobulated swelling, advancing along the edge of the lid, the margin being ill defined at some points, but moderately elevated at others, and though, upon the whole, somewhat redder, yet passing by imperceptible shades of colour into the adjoining skin.

After the lapse of some months the tumour ulcerates on the surface, and then discharges a very little thin ichor. The borders of the ulcer are raised and rounded with some arborescent vessels distributed on their surface. The base is grey and destitute of granulations. Little or no pain is experienced in the course of the disease, unless it have begun to invade the conjunctiva, when more or less smarting and lancinating pains are felt, and the movements of the globe are considerably interfered with. If neglected, the cancerous degeneration gradually extends, and, as it were, infiltrates all the adjoining textures indiscriminately, until it at length attains a considerable size. In its earlier stages, whilst still small, it is quite loose and moveable; but when more advanced, especially when it has extended over the thin skin covering the malar bone, it becomes firmly attached to the subjacent periosteum, and almost immovable, and, by filling up the palpebral fold, causes the lid to become firmly adherent to the globe.

Epithelial cancer is essentially a disease of adult and even of advanced age, all the cases in which I have seen it having been in patients above fifty years of age. It progresses with

extreme slowness, and in several cases it has remained in the same condition for two or three years, until its activity has been excited by an accidental blow. The cause of its appearance is unknown. On examining specimens of this tumour after removal, the usual appearances characteristic of epithelial cancer are seen; uni- or multi-nucleated cells of various size, and of various shape, closely adherent to one another, and arranged in a somewhat concentric manner, with free nuclei and granular débris.

As regards the diagnosis of epithelial cancerous affections, Dr Mackenzie¹ observes that the edges of the ulcer are harder and more elevated than in syphilis, and that the sore is studded with roundish whitish tubercles, over which creep varicose vessels, appearances which are not seen in syphilitic ulcers.

In the latter the skin is more swollen, and of a darker colour, and the surface of the ulcer is more foul, generally presenting an ashy colour, with bloody points, and discharging an ichorous fluid. The pain is also severe in syphilitic ulcers, and they spread more rapidly than those of cancerous origin. Other constitutional evidence of the present or past existence of syphilis would naturally be carefully looked for in a doubtful case.

In the treatment of epithelial cancer, if the disease be seen at a very early period, when it is quite circumscribed, and freely moveable on the subjacent parts, probably the best mode of proceeding is to excise it, taking care that the incisions everywhere pass through healthy parts, for the disease has a very strong disposition to recur. Where, however, the disease has acquired a considerable size, some other plan must be adopted, since it is generally admitted that it is almost impossible to remove the whole of the disease, and the retention of the smallest quantity of the morbid tissue constitutes a fresh starting-point for the extension of the affection.

¹ Treatise, etc., p. 127.

Dr Mackenzie¹ states he has repeatedly found that extirpation, even when followed by a firm cicatrice, and an apparent cure, is succeeded after a time by a renewal of the schirrous hardness and intractable ulceration, and has recommended the destruction of the parts with sulphate of zinc as an escharotic. For this purpose the water of crystallization of the salt should be driven off by heat, and the residuum reduced to powder, and mingled with a little glycerine to the consistence of a thick paste, which may then be applied over the base and the hard edges of the ulcer, and repeated, if requisite, on two or three occasions.

Another mode of treatment has lately been proposed and warmly praised by M. Bergeron,² which consists in the local application of a concentrated solution of chlorate of potash to the ulcer, and the free administration of the same salt internally.

The following case was one in which Dr Broadbent's plan of injecting the cancerous mass with acetic acid was successfully employed, and is the subject of the drawing, fig. 64. John M., æt. 55, a tolerably healthy-looking man, applied on July 6, 1866, at the Hospital for the removal of a tumour from the outer canthus of the left eye. He stated that he was struck on this part several years ago, whilst working in Woolwich dockyards, with a piece of hot steel, that a swelling subsequently appeared, and that two years ago it was burnt off by a surgeon. The swelling had reappeared two months previously, and had been growing rather quickly since that time. It consisted of a lobulated mass of the size of three or four split peas, a little more red than the adjoining skin, into which the inner parts insensibly passed, with some red vessels ramifying on the surface. The apices of one or two of the lobules were ulcerated and bedewed with moisture. On the 8th July I excised the whole of the disease by a V-shaped incision; there was rather sharp bleeding; the edges of the

¹ Ophth. Hosp. Rep., vol. ii. p. 5.

² Bullétin de Therapeutique, t. lxvi. p. 12.

wound were brought together by wire sutures; rapid healing took place; and on the 17th he was discharged. On the 13th of October he reappeared. The disease had now apparently undermined the conjunctiva, interfering with and rendering painful the movements of the eye. In the course of a few days, whilst debating what line of treatment should be pursued, it could be clearly discovered that the disease was advancing; small reddish pimples appeared on the conjunctival fold, and symblepharon or adhesion of the ocular and palpebral conjunctiva appeared, at first sight, to have taken place; but on closer examination it could be seen that the appearance was due to the elevation of the conjunctival fold, in consequence of its being affected both superficially and in its deeper parts by the cancerous mass. Having read Dr Broadbent's paper, I determined to inject the swelling with a mixture of one part of strong acetic acid and four parts of water. The injection occasioned severe smarting pain, which lasted for an hour or two. On the following day the size of the swelling was manifestly reduced. The injection had not been followed by any inflammation, but there was a slight ecchymosis on the conjunctiva. A week after this, a few small pimples were observed to have formed near the previously healthy palpebral margin, the extension of which was promptly suppressed by a repetition of the injection. Five months have now elapsed, and there is at present no indication of a recurrence of the disease; the margin of the lid near the outer canthus is very thin, tightly adherent by cicatricial tissue to the globe of the eye, of its natural colour, and free from tenderness; and I am in great hopes that the disease is permanently cured, though undoubtedly the term is too short to speak with any degree of certainty.

Syphilitic ulcers are sometimes primary, sometimes secondary. If Ricord's doctrine be true, that chancroid, or soft chancre, never develops on the face, the only form of primary ulcer that can appear on the lids will be the true Hunterian

chancre. Desmarres, however,¹ relates a case which certainly does not resemble the progress of an Hunterian chancre. A young physician was cauterizing the fauces of a patient suffering from syphilitic ulceration, when he received some of the saliva of the patient, ejected in a violent effort at vomiting, on his cheek. A deep ulceration quickly developed, and penetrated to a great distance into the lid, but was ultimately cured. Similar cases have been observed by Mr Lawrence.²

When ulceration takes place, rapidly assuming almost a phagedænic type, the pain and inflammation are very severe, and the entire lid is often rapidly lost. The surface of the ulcer is grey or ash-coloured, with bloody points, and the edge towards the cheek, in one of Mr Lawrence's cases, was livid and sloughy, with ichorous discharge; the neighbouring integument was highly inflamed to a considerable distance, and the side of the face was generally swelled.

Primary syphilitic ulcers are usually limited to one eyelid, commonly attacking the free border; sometimes extending from without inwards, and effecting the destruction of the conjunctiva and tarsal cartilage, and at other times spreading in the opposite direction. In all cases, if the ulceration be not checked, the whole eyelid is lost, and very often the other eyelid is threatened with destruction. The pre-auricular lymphatic glands in these cases are, according to Desmarres, frequently enlarged.

The primary forms of syphilitic ulceration must be very rare, as I do not remember to have seen any case. The secondary forms are, however, more frequent, and Plate II., fig. 12, represents a not unfrequent type. In this instance, about a year after primary venereal disease had been contracted, a small pimple arose on the lower lid, the head of which was accidentally knocked off. From this time a slow process of ulceration commenced, which, with some intermis-

¹ *Maladies des Yeux*, vol. i. p. 621.

² *Treatise on Diseases of the Eye*, 3d edit., p. 109.

sion, had gradually extended till it reached the present size, and during the last two or three months it had appeared to be stationary. Little discharge had taken place from it, and he had scarcely suffered any pain. The whole ulcer was moveable, and somewhat raised above the level of the adjoining surface; the edges were rounded and red, and the base was brownish and moist. The patient was a pallid-complexioned man, forty years of age. About six months previously a surgeon had attempted to burn it off with some caustic; but this treatment had only caused it to increase in size from that of a split pea, which it had then attained, to its present diameter. The sore was treated with weak nitric-acid lotion, and mercury was freely administered internally. The surface of the ulcer quickly lost its grey aspect, and assumed a healthy appearance; granulations formed, that rapidly healed up, and the cure of the disease was complete within a month after the gums had been made sore.

In both of the forms of syphilitic ulcerations occurring on or within the lids, the only treatment that is required is the local application of black-wash or of nitrate of silver, or other ordinary application to venereal sores, and the administration of calomel and opium, till the gums are affected, the remedies being continued for some days after this has taken place, in smaller doses.

Desmarres¹ admits the presence, though they must be exceedingly rare, of condylomata on the lids. When their nature is recognised, they should be removed with scissors, and the solid nitrate of silver be freely applied to their base.

The remaining form of ulcer that is occasionally seen is of *traumatic origin*. In a case of this kind that came under my care during the present year, the child was twelve months of age, and had received a blow from a stone thrown by his brother a fortnight previously. No notice was taken of the

¹ *Maladies des Yeux*, vol. i. p. 624. 1854.

occurrence for a day or two, when considerable swelling came on. Some lotion was applied, and after the lapse of three days the child suffered from fits, and the swelling was lanced, after which cold-water dressing was applied. When the child appeared at the Hospital, a very large ulcer indeed occupied the whole extent of the outer surface of the swollen upper lid. The margin was raised, everted, and angry-looking. Its base was of a dirty-greyish hue, discharging freely thin sanious pus. The centre of the ulcer was covered by a thick brownish scab, or rather slough, consisting apparently of the dried skin and connective tissue of the lid, with some adherent matter. The lid was partially everted. With so large a loss of substance, it was impossible to attempt any approximation of the lips of the ulcer. Warm poultices were directed to be applied, and quinine given, after which the surface of the wound rapidly improved in its character, granulation sprang up, the slough separated, and the cicatrix formed was linear, but complete ectropion was the consequence.

7. *Tumours of the Eyelids.*

(PLATE I., Figs. 3, 4; PLATE II., Fig. 7.)

Tumours, for the most part of small size, are frequently seen upon the eyelids, sometimes presenting the appearance of small semi-transparent vesicles, covered with a delicate cuticular investment, as in the upper eyelid of fig. 7, which contain a watery fluid, and require no other treatment than that of pricking with a needle, or of snipping off at their contracted base with a pair of scissors, the minute wound being afterwards touched with a point of nitrate of silver. In other cases, as in the lower lid of the same figure, the tumour, which has a somewhat thicker investment, appears to be filled with a cheesy kind of substance, and is probably the result of some disease in the sebaceous follicles, which open into the hair sacs, and the same treatment may be adopted. Small warts are sometimes seen, which are best left un-

touched, but which, if troublesome, may also be removed by an oval incision, or by the application of nitric acid.

Nævi and aneurismal tumours have already been referred to; and certain other tumours, as lipoma and elephantiasis, are only curiosities, and need not here be discussed.

By far the most frequent form of tumour met with in the substance of the lids are (1.) sebaceous cysts and (2.) Meibomian cysts, or, as they are often termed, chalazion. The differences between these two forms of disease, though sufficiently well marked when attention is paid to them, are not so great as to lead to their being entered in Hospital books under their proper distinctive names. I find, accordingly, that in 7200 cases there were ninety cases of tarsal tumour, the greater number of which I have no doubt were of the second form. Of these forty-eight were males and forty-two females, and the average age was twenty-seven. The youngest patient was three months old, the most aged sixty-one years. It is rarely seen under ten and over forty years of age. Tumours of this nature are more frequent upon the upper than upon the lower lid.

Sebaceous cysts take their origin in the sebaceous follicles of the small hairs covering the lids, and are usually situated near the orbitary border. They are also immediately subjacent to the skin, possess a thin investing membrane of connective tissue, so that, with care, they can be dissected cleanly out, and contain a quantity of pultaceous, atheromatous, or sebaceous matter. On turning the eyelid inside out, no evidence of their presence can be observed, unless they are very large. The skin over them is moveable.

When they become troublesome, or spoil the appearance of the patient, they should be removed; and this may be accomplished by making a horizontal incision through the skin with a small sharp knife, and dissecting the tumour cleanly out; or it may be boldly cut through, and the two halves of the sac partly dragged and partly dissected out. In both

instances a good deal of bleeding takes place, which should be stopped by cold applications before uniting the edges of the wound; and in the last part of the operation, the adaptation of the edges, great nicety should be observed to prevent any puckering of the skin of the lid. The needles used should be small and curved, and the silk very fine, as there is little or no tension. If undue pinching of the skin between the forceps has been avoided, union by first intention will take place, which may be facilitated by the application of a piece of dry lint to the lid, kept in position by a bandage.

Meibomian cyst, chalazion, or tumor tarsi par excellence, is an affection arising in one of the follicles of the Meibomian gland, and the tumour is therefore imbedded in the substance of the tarsal cartilage. These cysts are usually solitary, but it is not unfrequent to meet with them occupying a symmetrical position on the right and left upper or lower eyelids, and two, or even three, are sometimes seen upon the same side. They seldom attain a larger size than that of a pea, or, at the outside, that of a bean, even where they have been neglected; but those who are subject to them commonly apply for relief whilst they are yet very small, for though they are almost or altogether painless, they impede to some extent the movements of the lids, produce a greater or less degree of disfigurement, and are believed to, and perhaps really do, render the eyes more liable than usual to attacks of inflammation. They are in general of very slow growth, though I have seen them attain the size of a large pea in two months. Although they appear to the touch to be circumscribed, any attempt to remove them by dissection is fruitless, as their parietes are in reality formed by the surrounding fibro-cartilage. They project, without causing discoloration (Plate I., fig. 3), as rounded eminences through the delicate skin of the eyelid, which moves easily over them, unless the patient has teased them by the application of ointments, or by frequent rubbing. Though usually painless, even when

firmly compressed between the fingers, they are sometimes tender, and the patients complain of occasional darting pains passing through them. On everting the eyelid their exact position can generally be easily recognised by a thinning of the palpebral mucous membrane, and the appearance of a small circular bluish or yellowish white disk. (Plate I., fig. 4.)

The contents of these small sacculi vary considerably. In many cases, on puncturing the cyst, a little thin transparent or slightly opalescent fluid alone escapes, whilst in others the material is clotted, as in sebaceous cysts, or puriform. If wholly left to themselves, they generally burst after two or three months, or sometimes after a much longer period, through the conjunctiva, and occasionally through the skin of the lid, a small fungous excrescence often appearing at the orifice of the sac.

The treatment of these cysts is very simple. It consists in everting the lid and introducing a sharp-edged flat needle through the palpebral conjunctiva. After enlarging the opening, the needle should be made to scrape or cut the inner surface of the tumour in several directions, with the object of setting up inflammation, by which the cavity may be obliterated. When the contents of the tumour are very fluid, an immediate reduction in its size is apparent; but in other instances very little matter escapes, and the cavity, becoming filled with coagulated blood, only slowly disappears.

When the disease is of recent formation, the interior may be lightly touched with a point of nitrate of silver, either pure or diluted with nitrate of potash, applied by means of a *porte-caustique*, carefully avoiding the extension of the caustic to the healthy conjunctiva, by the immediate application of salt and water to the cyst with a camel-hair brush.

8. *Epicanthus*.

This is for the most part a congenital affection, in which, owing to defective development and prominence of the bones

of the nose, the skin at the inner angle of the eye forms a fold which partly covers the globe. It is sometimes also seen as the result of caries and necrosis of the several bones entering into the formation of the nose. It is then accompanied by ozæna. The disease has been sometimes observed to disappear during the progress of growth, in consequence of the gradual elevation of the bridge of the nose. When this does not take place, a vertical fold may be pinched up in the middle line, of sufficient depth to obliterate the epicanthus. The fold should then be transfixed with a bistoury, and the edges brought together with sutures.

9. *Ophthalmia Tarsi. Ciliary Blepharitis. Blear Eyes.*

(PLATE I., Fig. 1.)

Ciliary blepharitis, or tinea tarsi, is a disease of such frequent occurrence, that out of a total number of 7200 cases registered at the Hospital in one year, no fewer than 700, or nearly ten per cent., were thus affected. It occurs at all ages and in both sexes. The causes to which it is attributable are want of cleanliness, inadequate supply of wholesome food, especially when accompanied by indulgence in fermented liquors, disordered bowels, cold, and the irritation of smoke, or the fine dust floating in the air to which some workpeople are exposed. It is not unfrequently seen as the result of old-standing conjunctivitis, from whatever cause that may arise, and is often associated, either as a cause or as a consequence, with obstructed ducts, and with stillicidium lachrymarum.

The disease is still more likely to occur when several of the above-mentioned causes are in operation at once; and hence it is not a matter of surprise to find that it is common amongst the Laplanders,¹ who live for many months in the year in low huts, having only a small hole at the top for the escape of smoke and vitiated air, and whose diet is scanty, and salted; amongst the lower classes of the Jew population

¹ Linnæus, quoted by Mackenzie, Treatise, etc., p. 144.

on the Continent, who live in utter disregard of all hygienic rules;¹ and amongst the poor, and especially the children of the poor, in our own country, who suffer alike from cold, want of cleanliness, and insufficient food. Cold and exposure to dirt or dust ought, perhaps, rather to be considered as predisposing causes, or as circumstances tending to perpetuate and render inveterate the disease than as exciting causes; for I have not observed it to be unusually prevalent in sweeps, blacksmiths, lightermen, or stokers, whose faces are nevertheless constantly begrimed with coal-dust and dirt; nor, again, in those whose occupations cause them to be habitually much exposed to the weather, as in the case of sailors, masons, and others who are well fed amongst the operative classes.

In the above 700 cases, the trades and occupations in which I found it to be most common were the following:—There were twenty-eight servants, fourteen day-labourers, thirteen tailors, eleven carpenters, six shoemakers, five painters, five compositors, and five porters. Solitary instances of the disease were observed in many other trades, and there were several cases of old people; but the great majority of the remainder were either married women, who had only housework to attend to, or children; the latter, indeed, under the age of 15, constituting just one-half of all the cases recorded. It is more frequent in females than in males in the proportion of 100:75, and those who possess strumous proclivities are especially liable. The frequency with which it occurs appears to be but little influenced by seasonal changes, the numbers presenting themselves during the spring quarter alone being somewhat in excess of the remaining divisions of the year.

In the earlier stage of the disease corresponding to M. Wecker's "simple ciliary blepharitis," which is not unfrequently observed to follow an attack of one of the exanthematous fevers, the symptoms are often so slight as almost to escape the attention of the patient, and he rarely at this

¹ Wecker, *Etudes Ophth.*, t. i. p. 610.

period applies for relief. They appear to be merely increased redness, accompanied by slight sensations of heat, pain, and itching about the edges of the lids, and some swelling, generally commencing near the angles. In the morning, on waking, the lids are found to be firmly adherent from the excessive and dried secretions of the sebaceous follicles of the cilia, and of the tears which the patient is compelled to rub away, as well as forcibly to separate the lids before he can see.

After the disease has lasted for some time, a limited but persistent inflammation is established along the borders of the lids, constituting M. Wecker's second stage of hypertrophic ciliary blepharitis, in which a condition analogous to a confluent and indurated acne of the ciliary border is produced. In this stage, small pustules form along the margin of the lid, either between the cilia or at their bases; and these, being imperfectly nourished, become brittle, and break off or fall out, and are not properly restored. The sebaceous glands which open into the follicles of the cilia, and which are of considerable size, secreting the oily material that gives to these large hairs their smooth and glossy surface, appear to be almost always inflamed; whilst, I am sure, from careful observation, that it is only very rarely that the Meibomian glands are in any way implicated. Occasionally, however, on everting the lids, the little jagged lines which correspond to these glands may be observed to be red and vascular.

At a still later period, the sebaceous follicles, and the hair sacs into which they open, become the seat of suppuration. Pustules are formed surrounding the bases of many of the cilia, which fall out as soon as the pustules burst, or remain clinging to the thick grey or brown crusts which result from the drying up of the matter; and, when these are detached, an ulcerated surface is left. This constitutes the "ulcerated ciliary blepharitis" of Wecker. At this time the eyelids often become, to some extent, everted; the conjunctiva of the globe

is more or less inflamed; the lashes are few in number, stunted in growth, and unnaturally directed either obliquely outwards or towards the globe, and then greatly add to the inconvenience and distress of the patient. Lastly, in very bad cases, the ulcerations are extensive and deep, and by their cicatrization lead to the closure of the orifices of the Meibomian ducts, and to the obliteration of the glands themselves.

Such was the state of the woman from whom fig. 1 was sketched, and in this condition the eye may long remain, now somewhat better, now worse, but always producing more or less inconvenience and discomfort, if not actual distress, and giving the patient an unsightly and dirty appearance. In children, especially in those of strumous or otherwise unhealthy constitution, or in those who, restless and impatient, are constantly rubbing the lids to relieve the itching, a high degree of inflammation may be set up, and the skin of the lids may be much swollen, hot, and painful, with sometimes a papular and sometimes an eczematous affection on its surface.

When the disease has been once established, and the patient is exposed to any cause which tends to perpetuate it, as in the case of railway guards and drivers, who are constantly exposed to powerful draughts of cold air, an inflamed condition of the lids, attended with more or less thickening and induration, and the frequent formation of small pustules, is persistent—a condition that is termed tylosis.

Dr Mackenzie¹ remarks that the more important consequences of ophthalmia tarsi are tylosis; excoriation of the edges of the lids; obliteration of the Meibomian follicles; madarosis, or loss of the eyelashes; lagophthalmos and entropion, from the contracted state of the skin consequent upon the healing up of the excoriated lids; trichiasis, or inversion of the lashes; distichiasis, or misplaced eyelashes; and entropion, from repeated ulceration of the edges of the

¹ On the Diseases of the Eye, 4th edition, p. 148. 1854.

lids, and contraction of the cartilages,—a sufficiently numerous and formidable series of sequelæ.

The essential points in the treatment of this disease are to subdue inflammation and heal ulceration, to remove and to prevent the reformation of scabs, and to promote the growth of the cilia. With these objects in view, the bowels should be well cleared, in the first instance, with two or three doses of the compound jalap powder. Some preparation of steel or of cinchona may then be given, and the patient should be directed to wash the lids with a little warm water, or milk and water, or poppy fomentation, in the morning before opening the eyes; whilst, to diminish the difficulty often experienced in separating them, a little glycerine, sweet oil, or weak citrine ointment (ung. hydrarg. nitratis 3j ad. adipis 3j) may be smeared along the edges of the lids at night before going to bed. In other cases, ointments containing one part of calomel or of red precipitate (binoxide of mercury) to 300 of simple cerate; or one part of nitrate of silver to seventy-five of cerate; or one part of oxide of zinc to two parts of cerate; or, lastly, one part of alum, or borax, to forty parts of cerate, may be beneficially applied.¹

I have found the plan suggested by Mr Streatfeild² very satisfactory in its results, namely, after thoroughly fomenting the lids with warm water, to detach the scabs gently with forceps, and then to cut off the cilia close to their roots. The raw surface, avoiding the openings of the Meibomian follicles, may then be touched with solid pure or diluted nitrate of silver. When the disease occurs amongst young men of the better classes of society, they should be recommended to avoid late hours, disordered bowels, and exposure of the eye to the fumes of tobacco, and should take active exercise, and, if practicable, sea-bathing. It need scarcely be added, that in all instances the most assiduous attention to cleanliness is

¹ See L. Gosselin, *Diction. de Med. et de Chir.*, t. v. p. 262. 1866.

² *Ophth. Hosp. Rep.*, vol. i. pp. 53, 54. 1857.

requisite, and that two or three times a-day the secretion and scabs should be washed away with warm water, applying a little glycerine on each occasion. When ulcerations are present, the employment of the citrine ointment proves unserviceable, if not prejudicial, and the minute sores will more readily heal if they are just touched with a point of nitrate of silver, and the lids be directed to be washed with a lotion containing two grains of alum to an ounce of water. The only disease with which ophthalmia tarsi is likely to be confounded, is that in which lice develop on the cilia, near their roots, occasioning by their irritation more or less redness of the ciliary margin, and presenting, from their numbers, some resemblance to the scabs which appear in the former disease, from which they can be immediately distinguished, on minute inspection, by the form and movement of the animals. This affection, termed *phtheiriasis ciliarum* is immediately cured by the application of the unguent. hydrargyri, either with or without clipping off the lashes with scissors close to the margin of the lid. It is a rare disease, and I have only noticed it two or three times during the past two years.

10. *Impetigo*.—*Porrigio larvalis*—*Crusta lactea*.

(PLATE I., Fig. 2.)

This affection, which is not very frequently seen at an Ophthalmic Hospital, since it rarely attacks the eyelid alone, but is almost always a part of a general pustular eruption on the face, is essentially an infantile disease. Crops of pustules appear on the brow, cheeks, and lids, which mature rather quickly, and then burst. The matter concreting forms large brown, grey, or greenish scabs, such as are shown in the drawing, which, after a certain time, peel or flake off, leaving either red, tender, and smooth skin beneath them, or presenting ulcerations, from which foetid matter escapes to concrete again on neighbouring scabs. In this way thick masses are formed, which give the child a most loathsome appearance, and which

for the time seriously impairs its health. The glands of the neck are usually enlarged, and the child is generally small, puny, and white.

The disease may generally be traced to some systematic error of diet, occasioning perpetual disorder of the bowels, and should therefore, so far as the treatment is concerned, be principally attacked from this side. The bowels should be thoroughly unloaded with calomel and jalap, or with the compound jalap powder, followed by the compound confection of senna, the syrup of senna, or the syrup of rhubarb, once or twice a-week. The diet should be of the most simple and unstimulating kind, and should be given at regular intervals; and as soon as the motions are healthy, the administration of tonics, as decoction of cinchona with the liquor arsenicalis, quinine, cod-liver oil, and iron, may be commenced. Locally, the parents should be directed to preserve the parts in as clean a condition as possible, the scabs being loosened with warm poppy fomentations, or with warm milk, and then gently removed with scissors and forceps. Any ulcerations that are present may be touched with the diluted nitrate of silver.

Mr Erasmus Wilson advocates the employment of emollient and sedative fomentations, and water dressing, during the inflamed stages; and, subsequently, when the inflammation has somewhat subsided, coating the parts with the benzoated oxide of zinc ointment, rubbed down with spirit of wine (3i. to ʒi.); whilst Mr Nayler¹ considers that the best application to the skin, after the scabs have been removed, is a sulphur ointment, containing from ten to fifteen grains of iodide of sulphur to one ounce of cerate.

11. *Hordeolum. Stye on the Eye.*

(PLATE II., Fig. 8.)

Hordeolum is one of those diseases of the eyelids which,

¹ On Diseases of the Skin, p. 142. 1866.

though of trifling import, is productive of considerable pain and inconvenience to the patient for several days. It consists of a small boil, which forms in the substance of the lid, close to the ciliary margin, and forms a dark-red swelling, which projects both on the outer and on the inner or ocular surface of the lid. It seems usually to take its origin in the connective tissue of the lid, in close relation with the hair follicles, through one of which it often bursts. It commences with a sense of heat, pain, and itching, the two former symptoms attaining a height, and producing an amount of distress, by no means commensurate with the size of the little swelling, and explicable only by referring it to the extreme sensibility of the fifth pair of nerves, by which the lids are supplied. The pain, which at first is smarting, soon becomes aching and throbbing, the tumour increases in size, a small yellowish head appears at the most prominent point, indicating the formation of pus, the skin gives way, a drop or two of matter escapes, and the swelling and pain immediately subside. When one hordeolum has appeared, it is probable that others will follow, since their formation is generally due to some vitiation of the blood, the result of confined or disordered bowels. I have known as many as forty appear successively, their eruption extending over a period of sixteen or eighteen months. In fig. 8 I have sketched a somewhat more severe example than usual, and have recently seen a case which was almost the exact counterpart, two hordeola making their appearance together, and attaining a size that almost entitled them to be called circumscribed abscesses of the lid. In both instances the pain had deprived the patient of rest for two or three nights, and both were feverish, with furred tongues, loss of appetite, and confined bowels.

The treatment of hordeolum, when only one has made its appearance, should consist in clearing the bowels with jalap and scammony, then ordering a little saline and tonic mixture, as the *mist. ferri co.*, with the addition of ten or twenty grains

of sulphate of magnesia for a dose; or in the administration of alterative pills of pil. hydrargyri and quinine, or of suitable doses of Gregory's powder. Bread-and-water poultices should be applied to the eye, especially at night. When the disordered condition of the system is more confirmed, and the disease returns again and again, still more careful attention should be paid to the condition of the alimentary canal, tonics and purgatives being simultaneously or alternately prescribed. The patients should be directed to avoid hot rooms, smoking, late hours, and unwholesome food, as raw vegetables or highly-seasoned dishes. Whilst the too free use of beer and other liquids should be avoided, a little wine may be administered with advantage, as the patient is generally in a depressed state of health. Early rising and active exercise should be enjoined. I have not found it expedient to lay open the swelling at any period of its development with a lancet, believing that it does not in any way either prevent or hasten the maturation of the abscess.

12. *Chrom-hydrosis.*

The various observations that have been made upon this remarkable but rare affection have been collected by M. Leroy de Méricourt.¹ It consists in the secretion, or rather excretion, of an indigo-blue material, which usually first appears upon the surface of the lower lids, spreading in some instances from thence to other parts of the face and body. It is easily removed by oil, with difficulty by glycerine, and scarcely, if at all, by water. The subcutaneous veins are much congested and very conspicuous. About five-and-twenty cases are on record, of which only three occurred in males. The women affected were almost all subject to disordered menstruation, and suffered from severe headache and

¹ Annales d'Oculistiques, t. I. p. 110; and the reader will find an excellent resumé of all that is as yet known upon the subject in M.M. Warlomont and Testelin's translation of Dr Mackenzie's Treatise, supplementary volume, pp. 44-59.

other symptoms, indicating serious derangement of the general health. The duration of the affection has been found to vary, with intermissions, from a few months to many years. On examining the colouring matter under the microscope, it has been found to consist of minute scales and particles, with irregular jagged margins, bearing some resemblance to small fragments of thin dried varnish. Its chemical nature has been examined by Ordonez, who states that it resembles the dark material of which melanotic deposits are composed, and that it dissolves readily in warm sulphuric acid, communicating to it a brown tint.

Local treatment of various kinds has not been attended with any advantage, and in those cases where a cure has been effected, attention has been chiefly paid to rectifying constitutional disturbances.

Some doubt and suspicion still hang over the real existence of the disease in question, and some good observers are inclined to think that the surgeons in attendance upon the supposed invalids have been deceived by the wily vagaries of hysterical patients.

13. *Nævus Maternus. Teleangiectasis.*

There appear to be two forms of this disease, the cutaneous or superficial, and the subcutaneous or deep, and both are rarely seen. In the former, a red or scarlet blotch, of greater or less brilliancy, and of variable size, appears upon the surface of the skin, sometimes affecting the eyelid above, sometimes extending over nearly the whole side of the face, and consisting in a minute injection of capillary vessels, rarely penetrating beyond the papillary layer of the skin. In the latter the tint is of a much duller purple or livid colour, the vessels being of larger size and more deeply situated, often indeed extending, as already stated (p. 27), far back into the orbit, and constituting a form of aneurism by anastomosis. This variety, though much less conspicuous, is far more for-

midable than the cutaneous form of the affection, as it is difficult or impossible to determine to what depth it extends, or at what rate it will progress. When of considerable size, it forms a lobulated swelling, which becomes very prominent when from any cause the return of blood from the head is temporarily interrupted. Whilst the cutaneous nævus, after having been once formed, is usually stationary, the subcutaneous variety sometimes develops with alarming rapidity, rendering an operation, having for its object either the destruction of the vascular plexus itself, or the stoppage of the supply of blood to it, imperative.

Mr Lawrence remarks that, in newly-born children, he has frequently seen red marks, sometimes of considerable extent, gradually disappear,—a statement that most surgeons can confirm, and which I have had an opportunity of observing in a child of my own, in whom a scarlet nævus, of about one-third of an inch in diameter at birth, has, in the course of five years, completely disappeared, apparently in consequence of the skin becoming thicker over it. For such cases, therefore, no treatment is demanded; but when the surface covered by the nævus is considerable, or found to enlarge, and in cases where the disease is of the subcutaneous form, one or other of many different plans of treatment may be selected.

Dr Mackenzie¹ enumerates the following:—1. Refrigerants, pressure, and astringents, as liquor plumbi, alum lotion, and creosote. 2. Vaccination. 3. Irritants, as tartar emetic and croton oil. 4. Escharotics, as nitrate of silver, caustic potash, or nitric acid. 5. Injection, with perchloride of iron, or other powerful astringent. 6. Actual cautery. 7. Subcutaneous division of the vessels, with a fine sharp knife or needle with cutting edge. 8. Subcutaneous section, followed by cauterization with a probe dipped in melted nitrate of silver. 9. Seton. 10. Ligature. 11. Tying the vessels of supply. 12. Excision of the entire mass. 13. Ob-

¹ Treatise on the Diseases of the Eye, 4th edition, p. 160.

literation of the carotid artery. To these methods may be added (14.) that of traversing the tumour with threads strongly impregnated with tincture of iodine, or with perchloride of iron. 15. Transfixing the tumour with a thread dipped in solution of perchloride of iron, then applying to the surface of the tumour a small disk of wood, over which the ends of the thread are carried and firmly tied together. The tumour is thus subjected to the combined action of a ligature, compression, and chemical action.¹ 16. Galvano-puncture, and the transfixion of the tumour with wires or needles, subsequently heated by the application of the flame of a candle to their extremities.

Most of these methods must be perfectly familiar to the practical surgeon, and need not here be fully discussed. The first six are almost exclusively applicable to the superficial variety of *nævus*; the others are rather adapted for the subcutaneous form. It may be remarked, that great care should be taken when it has been determined to inject the tumour subcutaneously with perchloride of iron, tincture of iodine, or solution of ammonia, as several almost instantaneous deaths have taken place under this plan of treatment. It is only requisite to inject one or two drops at a time, and a properly-constructed subcutaneous injection-needle, with screw syringe, should be employed; and a further important precaution is to hold the eyelid firmly with a pair of Desmarres's ring forceps, which isolates the circulation of the lid very perfectly.

The subcutaneous figure-of-eight ligature is perhaps the method of treatment most generally adopted, and which gives the most satisfactory results, providing the *nævus* does not dip very deeply into the orbit. By repeating the operation two or three times, very large *nævi* may be effectually checked in their growth, or be caused entirely to disappear, without any disfigurement beyond slight puckering of the skin.

¹ *Lancet*, p. 143. Aug. 7, 1857.

14. *Morbid Nictitation and Blepharospasm.*

The former of these affections consists in the rapid involuntary opening and closing of the lids, and is usually at first dependent upon reflex irritation, but after a time, especially in children, in whom it most frequently occurs, degenerates into a habit. I have, however, seen one instance of it in an adult, under Mr Holthouse's care, in the Westminster Hospital, where it appeared to be of centric origin, having first appeared after a fever, and being accompanied by violent pains in the head. The movements are so instantaneous that they do not interfere much with distinct vision. They vary in rapidity at different times, and cease altogether during sleep.

The disorder does not appear to be very amenable to treatment. M.M. Warlomont and Testelin recommend hot fomentations with water, or with a solution of bromide of potassium. When it occurs in children we should naturally endeavour to improve the general health, which is usually more or less impaired, by attention to the bowels, exposure to fresh air and exercise, regular diet, and the removal of all probable exciting causes.

Slight twinkling or twittering movements are often complained of by people somewhat depressed in health. They are chiefly experienced in the lower lid and near the inner canthus; and the proper treatment consists, in addition to the above-mentioned points, in the administration of tonics and stimulants, and relaxation for a time from work involving much straining of the eyes.

Blepharospasm consists in a violent and involuntary contraction of the fibres of the orbicularis muscle. It is sometimes intermittent and sometimes persistent. M. Wecker¹ refers to an instance which has recently fallen under his notice, in which the patient, on two or three occasions, narrowly

¹ Etudes Ophthalmologiques, t. i. p. 676.

escaped being run over in crossing the street, owing to the spasm which was probably induced at the moment by sudden impression of fear, occasioning complete closure of both lids and consequent helplessness. It is frequently seen in cases of strumous ophthalmia, and is then termed photophobia. The irritation exciting the spasm may either originate in a preternaturally acute sensibility of the retina, occasioned by worms in the bowels, or over-exertion of the eye, or of those branches of the fifth pair of nerves which are distributed to the cornea and conjunctiva, as we may generally discover in such cases some abrasion or ulceration of the cornea, or some redness and enlargement of the papillæ of the lids. From one or other of these causes, a state of morbid irritability is established in the ganglionic centres of the fifth and seventh nerves, resulting in the powerful and persistent contractions of the orbicularis muscle, not only where the rough or ulcerated surfaces are irritated by pressure, but whenever the associated and protective movements of the same are called into play in the ordinary mode.

The treatment of blepharospasm must in all cases be dependent upon the nature of the cause. When it originates from the ultimate branches of the fifth pair, by small ulcers on the cornea or conjunctiva, the patient should be placed under the influence of chloroform, and the ulcer touched with a fine point of nitrate of silver, which, deadening or destroying the sensibility of the nerve, will sometimes at once effect a cure. Foreign bodies, which have escaped notice in consequence of the energy of the spasm, and the difficulty of exploring the surface of the conjunctiva, may sometimes, by the same means, be brought into view, and should, of course, be removed.

When nothing is found to explain the symptoms in the eye itself, the other branches of the fifth, and the trunk of the seventh, should be, as far as possible, examined, and if any source of irritation be discovered, the treatment should be at

once directed towards its removal. Carious teeth should be extracted; the expulsion of ascarides in the rectum should be effected by a turpentine injection; and lumbrici, or tæniæ, destroyed by santonin, oil of male fern, or other anthelmintic. When there is reason to think that a congested state of the retina is the cause, of which I have seen one well-marked instance in a compositor, work of a lighter character should be undertaken, the patient kept in a subdued light, the employment of coloured glasses recommended, and the congestion diminished by the application of leeches to the temple, and the administration of quinine, sulphate of zinc, arsenic, or other nervine tonics.

Subcutaneous section of the fibres of the orbicularis has been sometimes tried, but Desmarres¹ states that it was always unsuccessful in his hands. In other instances, subcutaneous injection of morphia has been performed, though with only temporary advantage.

M. Wecker² recommends subcutaneous division of the infra-orbital nerve in cases where the affection has followed neuralgia in its branches, and where morphia has failed; and even when section has been unsuccessful, he has obtained good results from the application of powerful interrupted currents of electricity, applied either with both poles close to the affected part, or with one pole to the back of the neck and the other to the lid.

v. Gräfe³ gives the details of a most interesting case of blepharospasmos from injury, occurring in a young man æt. 19, who received a blow on the eye from a piece of apple, a small portion of which was imbedded for a quarter of an hour in the cornea. Soon after the accident, a violent contraction of the orbicularis set in, causing the eye to be kept constantly and permanently closed. Under chloroform the spasm

¹ *Maladies des Yeux*, t. iii. p. 611.

² *Etudes Ophthalmologiques*, vol. i. p. 681.

³ *Archiv. f. Ophth.*, p. 440. 1854.

relaxed, but on careful examination nothing could be found. The spasm returned on the recovery of sensibility. A great variety of remedies, including medicines, endermic applications, etc., were employed without effect, and the spasm extended, assuming an almost epileptiform character. At last v. Gräfe showed the patient to Romberg, who, regarding the case as one of reflex spasm from lesion of a sensory nerve, recommended section, not of the portio-dura, but of the supra-orbital nerve, which v. Gräfe accordingly performed with justifying success; for although the spasm recurred for a little while in the lower lid, it soon disappeared again altogether, and, after some months, dull sensibility returned in the lid.

v. Gräfe appears to regard this case as one of hyperæsthesia of the musculus orbicularis from contusion. I have seen protracted and violent contraction of the orbicularis follow in several instances the entrance of lime in the eye, though it was impossible to discover any fragment remaining, and the swelling and redness consequent upon the injury had disappeared. After some weeks, however, it gradually and spontaneously diminished.

15. *Ptosis.*

By the term ptosis a drooping of the upper lid is signified, due to paralysis of the branch of the third nerve supplying the levator palpebræ. A condition analogous to true ptosis is, however, frequently seen in old people, occasioned by simple relaxation of the skin, and again in inflammatory and erysipelatous swelling of the lids, and in cases of simple ecchymosis. Both sets of cases have this in common, that the upper lid falls over the cornea, and the patient is unable to raise it by a voluntary effort, and thus, while the visual organs and powers are perfectly preserved, he is deprived of the use of one or both eyes. The essential difference between them appears to be, that in the latter instances the difficulty is of a purely mechanical nature, whilst in the former it is

functional. In the latter, the energies of the nerve and muscle are unaffected, but either the resistance offered by the stiff and tumid tissues of the lid is too great to be overcome, or the contraction of the muscle, though taking place to its full extent, produces little effect upon the loose and dependent skin, the elasticity of which is in great measure lost. In the latter the power of movement is abrogated, and, in consequence of some change in the nerve or muscle, the dictates of the will can no longer be obeyed.

True ptosis, or palsy of the levator palpebræ, may arise from very various causes. Very frequently it follows exposure to cold. At other times it results from the growth of intra-orbital tumours pressing upon the nerve or muscle; from penetrating wounds, or severe contusions of the orbit; from syphilis; from cerebral lesion; from debility succeeding an attack of one of the exanthematous fevers; and perhaps occasionally from reflex paralysis, induced by the presence of worms in the intestinal canal, or from carious teeth.

In some instances the paralysis is limited to that branch of the third nerve which supplies the levator palpebræ; but in many cases the trunk of the nerve is affected, which is denoted by divergent strabismus, and by dilatation and immobility of the pupil; and, where cerebral lesion is present, other nerves will in all probability be also paralysed, the implication of the fifth being shown by loss of sensibility over the side of the face; of the fourth, by the patient being unable to roll the eye downwards and outwards; of the sixth, by the absence of divergent strabismus, and by inability to rotate the eye outwards; of the seventh, by facial palsy, and probably also by more or less well-marked symptoms of hemiplegia. In such cases the ptosis is a symptom of quite secondary importance; the prognosis is necessarily extremely guarded, and the treatment should be directed to the general condition of the patient. Where the fourth and sixth nerves are coincidently paralysed, and especially

if the globe is prominent, the symptoms point to the growth of some tumour within the orbit. Ptosis has been observed in some instances to be a congenital affection.

The most frequent cause of the disease in the cases that have come under my notice has undoubtedly been exposure to cold. Thus, in one instance, it arose from sleeping under an open window; in a second, from sleeping on damp grass; and in a third, from sleeping in a railway carriage, with the draught of air upon the face. Various considerations render it probable that the cold here acts, not directly on the branches of the third, but on the fifth, through which a kind of reflex influence is conveyed to the third nerve.

As regards the frequency of ptosis, I find that about twenty cases are recorded in the Hospital books as occurring out of 7200 patients in one year.

The prognosis of ptosis, where it has been ascertained to have originated in exposure to cold, is generally favourable, and recovery, though often slow, is in the end tolerably perfect. The remedies to be adopted are of a tonic or alterative nature, and operative proceedings are rarely requisite, and should not be resorted to at too early a period. The treatment of these cases now forms a curious contrast to that pursued but a few years ago, and might be adduced as evidence in favour of the occurrence of change of type in disease. Mr Lawrence, for instance, gives a case that was seen in the year 1827, in which a thin and broken-down woman, addicted to habits of intemperance, was, in the course of four or five days, bled to 32 oz., besides having eighteen leeches applied to the temples—a plan which, though it was followed by a successful result, few would now venture to employ.

On the contrary, with the object of restoring the lost function of the third nerve, at the present time the most reasonable treatment would appear to be the administration of decoction of cinchona, with a little compound tincture of cinchona, and 3j doses of the solution of the bichloride of

mercury; or two-grain doses of quinine, or of sulphate of zinc, given in the form of pill; or three or four minims of solution of strychnia, or of the liquor arsenicalis, or a few drops of the tincture of the sesqui-chloride of iron, repeated three times a-day. In addition to one or other of these remedies, blisters are certainly useful, possibly not so much from their derivative action as from their being stimulants to the sentient extremities of the fifth nerve. If the disease prove refractory, and the recovery tedious, improvement may sometimes be effected by the application of electrical currents, for which purpose the interrupted current of one of the rotatory electro-magnetic machines may be employed; or the method proposed by M. Benedikt¹, of weak excitation with continuous currents, as by two or three elements of a Daniel's battery, the positive pole being placed on the forehead, and the negative on the lid, may be tried.

In cases of very simple character, arising from relaxation of the skin in old people, or from exposure to cold in children, some benefit is obtained from the local application with a paint-brush to the outside of the lid of the tincture of iodine, or of collodion, or of the acetic tincture of cantharides, and by the application of strips of plaster made to adhere to the lid, and then brought up over the forehead. Where no benefit has been derived from any of these measures, an operation must be resorted to, and the most simple and efficacious consists in the removal of an oval piece of skin from the upper eyelid of about one-third of an inch in width, the line of the lower incision being about the distance of one line from the ciliary margin and parallel to it. Mr Haynes Walton and v. Gräfe recommend, in addition, that the fibres of the orbicularis should be divided, and a portion of about one-third or one-fourth of an inch excised, by which the power of the muscle is reduced.

If care be taken to divide the skin with a very sharp knife,

¹ Ophth. Rev., vol. ii. p. 292. 1866.

if all contusion of the margins of the cut with forceps, etc., be avoided, and if, with a fine sewing-needle and fine silk, the lips both of the skin and muscles are brought accurately into contact, union takes place in a very rapid and perfect manner. In a girl, upon whom I operated for purely cosmetic reasons, the ptosis being comparatively slight, union was complete in twenty-four hours, and there was scarcely any swelling of the lid. Some surgeons, however, consider that better results are obtained by abandoning the wound to itself, and allowing it to heal by granulation.

The following case is one of paralysis of several of the branches of the third nerve occasioning ptosis, apparently arising from cold, and the irritation of carious teeth, which furnishes a good example of the phenomena usually observed. Eliza A., æt. 22, came to the Hospital on the 27th November, complaining of drooping of the upper lid, and a diverging squint of the left eye, which had appeared rather suddenly about three weeks previously. She was a tolerably robust and fresh-coloured woman, and her occupation was that of a cook. The strabismus was very considerable, being to the extent of between two and three lines, and the ptosis was such that the upper lid, when she looked straight forward, just covered the pupil. She could, with considerable effort and pain, rotate the globe of the diverging eye a little beyond the middle line, and this was accomplished with much greater facility when the upper eyelid was held up with the finger, evidently because the double images were distressing to her, and she tried to overcome them by a violent effort. As soon as the lid was allowed to drop, the globe was seen to be rotated slowly outwards and a little downwards by the external rectus and superior oblique muscles. The pupil of the affected was of the same size as that of the healthy eye, and was equally active. She had had no accident, and her kitchen was warm; but she had caught a severe cold at the time the squint first appeared, and had then had sharp toothache, from which her

face was still swollen. She was ordered decoction of cinchona, and 3j of the solution of bichloride of mercury, three times a-day, and was directed to have the first and third molars of the upper jaw on the left side extracted. On the 4th December she was decidedly improved; the squint had diminished to about one line, and she could rotate the eye with effort, and when following an object held before her, quite into the inner canthus. On the 6th December a blister was applied, and the medicine repeated. On the 13th December, the recovery having apparently halted, I daily applied a rather strong current of interrupted electricity, one pole being placed on the temple, the other on the inner side of the nose and malar bone alternately. On the 15th, considerable improvement had taken place; and from this time her recovery proceeded uninterruptedly till, at the end of December, the ptosis had disappeared, and there was so slight a trace of external squint remaining that she ceased to attend.

The following case is probably an example of the origin of ptosis in syphilis, as no other cause for it could be discovered:—The patient was a wheelwright, æt. 28, who had suffered from a chancre three months previously. The ptosis was first observed eight weeks before he presented himself, and commenced with pain in the head and forehead. Very soon afterwards diplopia was noticed, and seriously interfered with his work. By closing the affected eye, however, he managed to go on for some time longer. On examination, the external strabismus was found to exist to a marked extent in the right eye; but by a strong effort, which occasioned him much pain, he was able to bring the eye into parallelism with the left. The effort soon ceased, and the eye was slowly rotated outwards by the external rectus. Vision was equally good in both eyes. He was ordered two grains of calomel, and a quarter of a grain of opium, three times a-day. A week later, it was observed that the iris was paralysed, the pupil being moderately dilated, and not acting on exposure to a bright light. Two

days afterwards the mercury had begun to affect the gums, and the pills were reduced to one a-day. Three days subsequently he began to recover the power of raising the lid, the mercury was stopped, and the iodide of potassium prescribed; and in the course of another week he was fast recovering the use of the muscle, and the iris had resumed its natural size and activity. At the expiration of one month from the time of his presenting himself at the Hospital, he was perfectly well.

As an instance of ptosis arising from injury, the following may be quoted:—A boy was sent to me by my friend Mr W. K. Parker, who, whilst playing, received a smart blow on the left eye with a stone. There was no bruise nor cut of the skin, but the lid immediately dropped, and he had been unable to raise it for a period of six weeks. On raising the lid, the conjunctiva was found perfectly natural, the cornea clear, and the vision unaffected. Under the combined use of calomel, quinine, and opium, and the application of a succession of blisters to the temple, improvement took place to a certain extent, and he regained the power of raising the lid about as far as the middle of the cornea; but I have been unable to ascertain the subsequent history of the case. In such an instance as this, the removal of a portion of the skin and muscle would be necessary to complete the cure.

16. *Symblepharon.*

(PLATE III., Fig. 14.)

The condition termed symblepharon consists in the unnatural adherence of the lids to the ocular conjunctiva. In by far the greater proportion of cases this occurs in the lower lid, because, being generally the result of accident, such as the entrance of lime, acids, or other chemical agents into the eye, or of burns, the stress of the injury falls upon the most exposed, and therefore upon the lower, part of the eye. The adhesion of the two surfaces of the conjunctiva is sometimes

so close, that no separation can be effected, and the movements of the eye are much interfered with; but frequently the connection is effected by means of bridles, or thin membranous vascular processes extending between the two surfaces, and a certain amount of lateral play is allowed, and occasionally a probe can be passed beneath them. The patient from whom the drawing was taken has been in occasional attendance at the Hospital for nearly ten years. He was an ostler, and the disease appeared to have originated merely in the irritation of the ammoniacal fumes and dirt in which he lived, causing frequent attacks of conjunctivitis and granular lids.

The disease, during the last three or four years, has steadily advanced. In one eye both lids are now almost completely adherent to the globe, and in the other the movement is only very limited; the conjunctiva over the cornea has become very vascular, the cornea nearly opaque, and vision is almost entirely abolished, although the perception of light is very distinct, indicating that the retina is not materially affected.

Some years ago I saw a remarkable case of symblepharon, of which I possess a drawing, in a miner. He was working in one of the mines in South America, and had prepared and lighted a fuse for blasting the rock. As, however, a few minutes elapsed without any explosion, he was incautious enough to look down the hole, which was partially filled with sand. At this moment the fuse ignited, and he was stunned by the injury on the face and head which he received. Violent inflammation of the lids followed, resulting not only in the complete adhesion of the lids to one another along their edges, but also to the surface of the globe, of which no trace could be at first sight perceived. On careful examination, however, the movements of the globe could be followed, both by the eye and by the finger pressed gently on the lids. He had come over to England to have some operation performed for the restoration of his sight, which he was quite certain was preserved, and he stated that he could still discern the bright

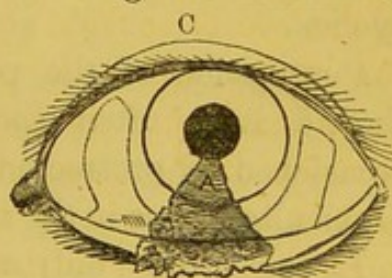
light of day from night. The hopelessness of any operative measure was plainly pointed out to him; but, moved by his importunity, and thinking it possible some part of the cornea might have escaped the general adhesion, I at length consented to make an attempt to remove the skin. He was accordingly placed under the influence of chloroform, and I made an incision near the line of union of the lids, but had no sooner divided the skin than the escape of fluid showed that I had opened the globe of the eye. The cornea here could not have been more than the thickness of a moderately stout sheet of paper, no line of separation between it and the skin could be distinguished, and the wound was therefore at once closed by two or three sutures, and no change occurred in the quantitative perception of light. Nothing would appear to be more simple than the treatment of ordinary cases of symblepharon, and to those who see them for the first time, simple division naturally suggests itself; but it is astonishing with what pertinacity the divided membrane reunites, unless the attachments are only in the form of bridles and isolated processes. By the operation, great relief is temporarily experienced, and the extent of motion afforded to the eye is considerably increased; but in the course of a few days or weeks the patient returns in almost precisely the same condition. In some instances I have found, after free division of the attachments, that daily touching the bottom of the wound with a fine point of the nitrate of silver, by preventing the cicatrization of this part, and affording time for the upper parts of the wound to heal, will relieve the state of the patient; but even here a slow process of contraction often occurs, and after the lapse of a few months the disease will be found to have returned. In other instances I have succeeded much more satisfactorily by freely dividing the adhesions, and immediately inserting a false eye or glass shell, as recommended by Mr J. C. Wordsworth,¹ and keeping

¹ Ophth. Hosp. Reports, vol. iii. p. 216.

the eyes firmly closed upon it by a pad and bandage, taking care to cleanse the parts thoroughly every morning and night. If the adhesions have been very firm and strong, it will be found, however, that by the gradual contraction of the parts the shell is at length shot out, and can no longer be replaced.

Dr Mackenzie's rule, which is supported by Mr Guthrie's observation, and by all practical experience, appears to be perfectly correct. When the symblepharon is insulated so that a probe can be passed round it, a cure is always accomplished by operation; but when the adhesion is continued back to the angle of reflection of the conjunctiva, the result of an operation is uncertain, and where the adhesion is very extensive, interference is useless. Various attempts have been made by different surgeons to insulate the attachment, as by passing a thread deeply through the affected parts, and, when the course of the thread has become a fistulous passage, dividing all the parts above. This will also occasionally succeed.

Mr Teale¹ has lately suggested a mode of relief for slight cases, by transplanting a portion of the conjunctiva, which is certainly efficacious. It consists in dividing the frænum at the margin of the cornea, and dissecting it back till the movements of the globe are perfectly free. The apex of the symblepharon formed of the skin of the lids thus remains isolated and adherent to the cornea.



In the next place, two flaps of conjunctiva are formed, one from the inner surface, the other from the outer surface, of the globe. These should be about two-thirds of an inch long and a quarter of an inch wide, and, when sufficiently detached, should be twisted a quarter of the way round, and laid down in the wound, the inner flap being the lowest; and both must then be secured in their new position by one or two fine

¹ Ophth. Hosp. Reports, vol. iii. p. 253.

sutures. The margins of the gap from which these flaps have been taken are also brought together by a suture, and rapid and perfect union of the displaced tissue occurs. A mucous surface being thus presented to the inner surface of the lid which has been dissected off, no tendency to union takes place, and the apex left isolated on the cornea soon atrophies, and becomes wholly or partially transparent.

17. *Anchyloblepharon and Blepharo-phymosis.*

In the former of these affections the edges of the eyelids are united by cicatricial tissue along either the whole or a part of their extent, seriously interfering with or entirely obstructing vision. In the latter there is a contraction of the palpebral fissure, not proceeding from the union of the eyelids, but from shortening of the mucous membrane and subcutaneous connective tissue, which is usually accompanied by an abnormal curvature of the tarsal cartilage.

Union of the edges of the lids rarely occurs without being associated with a greater or less degree of symblepharon ; and, like that affection, if it be not congenital, is almost always the consequence of direct injuries, burns, scalds, or cuts of the eyelids.

Contraction of the palpebral fissure, on the other hand, though it is often due to the same causes, is frequently occasioned by protracted inflammation of the lids where profound alterations in the structure of their tissues have occurred.

In cases where only a portion of the borders of the lid has become soldered together, and where the amount of symblepharon present is slight, a grooved probe may be passed under them, and the line of union divided by a bistoury. In other instances, where the contraction of the palpebral fissure is considerable, and especially where the adhesion has taken place towards the outer angle, a plan of treatment may be tried which has been proposed by M. Hamer.¹ One blade of

¹ Annal. d'Oculist., vol. liii. p. 177. 1865.

a sharp-pointed pair of scissors is made to enter at the outer canthus of the eye between the skin and conjunctiva, and on closing the blades the skin alone is divided for from one-third to one-half of an inch towards the temple. The lids are everted, and the conjunctiva detached from them, both above and below, to about the same extent; it is then still further dissected forwards and inwards towards the globe, by which means a large triangular flap of the conjunctiva is obtained. The wound made in the first instance with the scissors is now deepened with a bistoury till its edges can be fairly separated, the fibres of the orbicularis muscle being of necessity divided. Into this wound the raw surface of the conjunctival flap is laid, its retraction being prevented by a few points of suture. M. Hamer has operated on about eighteen cases, and M. Snellen on several others; and it has been found that the movements of the globe become more free, the shape of the eyelids improved, the pressure on the globe diminished, and that the chances of relapse, so frequent when simple division of the outer canthus is performed, are considerably diminished.

18. *Ectropion.*

(PLATE IV., Fig. 22.)

The term ectropion is employed to designate the condition in which one or both of the lids are everted. The circumstances to which it owes its origin are very various. One of the simplest forms occurs in the lower lid, and is simply the result of the relaxed and atonic condition of the skin, so frequently met with in old and debilitated persons, causing the lid to separate from the globe and become, along a portion or the whole of its length, everted. Another of the slighter forms results, as has been pointed out by Mr Guthrie,¹ from chronic inflammation, accompanied by contraction of the skin of the lids, without any marked cicatrix, as occurs in chronic cases of cilio-blepharitis or ophthalmia tarsi. In more severe

¹ On the Operative Surgery of the Eye, p. 42. 1830.

cases, and especially when it has arisen suddenly, it may depend, in the third place, on acute inflammation, accompanied by tumefaction of the conjunctiva, with relaxation or atrophy of the fibres of the orbicularis muscle, as is seen in the later stages of purulent or gonorrhœal ophthalmia. Or, fourthly—and this is by far the most common cause—it results either from direct injury or from abscesses consequent upon injury to the brow and cheek, or to the lids themselves; and it is especially common after burns, whether by fire or by one of the mineral acids, or by alkalies, the gradual contraction of the cicatrix which succeeds to such accidents producing in this way the most frightful disfigurements, and requiring much skill and judgment in selecting the mode of operation best adapted for their relief. In the same category of causes may also be enumerated syphilitic ulcers and small-pox, and erysipelas, or perhaps, more correctly speaking, the abscesses which occasionally form in the lids in the latter diseases.

Scarpa¹ describes a case which resulted from an abscess occasioned by the entrance of a piece of wheat-straw, which was retained beneath the lids for a period of eight months.

Fifthly, it may arise from spasm of the orbicularis, or from paralysis of the seventh pair of nerves; and, lastly, it almost always accompanies the growth of large intra-orbital or intra-ocular tumours. (*See Plate VIII., fig. 45.*)

Where the patient is from any cause unable to close the eyelids, the term *lagophthalmos* is sometimes applied to his condition. The term, however, is only appropriate to cases of paralysis of the seventh nerve and orbicularis muscle, and though frequently associated with *ectropion*, and especially with that form which is caused by the contraction of an abscess, is by no means necessarily accompanied by any disposition to eversion of the lids.

Ectropion is a disease of less frequent occurrence than the opposite condition of inversion of the lids. Amongst 7200

¹ *Pract. Observ., etc.*, p. 151. 1806.

cases, only five instances are recorded. The lower lids are more frequently subject to it than the upper. The effects of the disease, though more disfiguring, are certainly not so distressing to the patient, nor so destructive to vision, as those occasioned by inversion of the lids. It might at first be imagined that the absence of so important a covering as the lid would quickly lead, by permitting the entrance of foreign bodies into the eye, and by preventing its surface from being properly moistened, to inflammation of the conjunctiva, or of the cornea; but in general the conservative powers of nature, or rather the adaptability of the different organs to altered circumstances, is remarkably shown in such cases; for even when scarcely a vestige of the lid remains, the accumulation of dust and mucus on the surface of the cornea is effectually guarded against by the powerful action of the internal and superior recti and the inferior oblique muscles, which together roll the eye rapidly upwards, and, aided by the contraction of the orbicularis, cause whatever remains of the lid there may be to sweep clear and clean nearly the whole of the exposed ocular surface. In point of fact, the patients usually apply for relief, not on account of any discomfort that they experience in this respect, but because the internal surface of the conjunctiva, still retaining its red appearance, and usually becoming granular, spoils their appearance, and in certain occupations seriously interferes with their chance of gaining employment.

Nevertheless, cases every now and then present themselves where much lachrymation is present from the irritation of the air and light, and where a condition of chronic conjunctiva is established, leading either to ulceration and staphyloma, or to xerosis, *i. e.*, carnification and unnatural dryness of the surface of the cornea, ending, if neglected, in total loss of sight.

The treatment of cases of ectropion varies with their severity, and with the nature of the causes by which they have been produced.

Where the affection has followed chronic inflammation of long standing, and is only partial or incomplete, and where the conjunctiva lining the lids and forming the oculo-palpebral fold has become thickened and tumefied, whilst the external surface of the lid, as in many cases of ophthalmia tarsi, has been fretted by the passage over it of tears and altered secretions, the most assiduous care is demanded to keep the parts thoroughly clean: they should be bathed with poppy fomentation, or solution of alum, several times in the course of the day, and a little zinc ointment may be subsequently gently rubbed over the skin of the lid. If this prove insufficient, the tumefaction should be reduced by the direct application of nitric or sulphuric acid, the lid being thoroughly everted, perfectly dried, and freely touched with the acid, avoiding, however, the puncta and caruncle, and limiting the action of the escharotic entirely to the palpebral conjunctiva. When the membrane, by its change of colour to white or yellow, shows that it has been sufficiently acted on, olive oil may be freely brushed over the parts, or a stream of water may be directed upon the eye from a caoutchouc-bottle, and a little water-dressing subsequently applied. The same plan may be adopted with advantage in some of the cases of partial eversion, resulting from atony of the orbicularis or relaxation of the skin, in which only one-half, and usually the outer half, of the lower lid is everted. In other cases, where considerable tumefaction of the conjunctiva appears to be present, a fold may be raised with the forceps and removed with the scissors, the edges of the wound being united by two or three fine sutures.

Where the eversion is more extensive and complete, various modes of operation have been suggested. In one,¹ a triangular or wedge-shaped piece, including the whole thickness of the lid, is removed with a strong pair of scissors. (Woodcut D.)

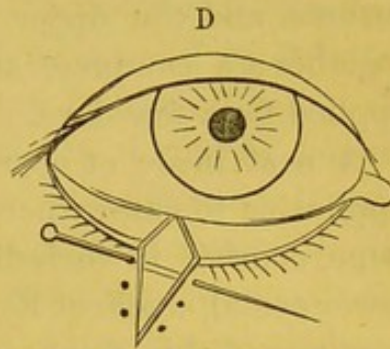
The section, which may be made either at the centre or

¹ Adams' Pract. Observat. p. 5. 1814.

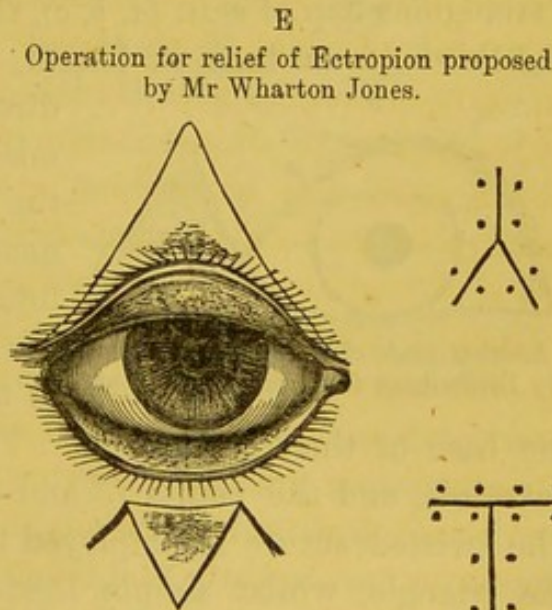
towards the outer canthus of the eyelid, should be closed with pins, as in harelip section, the first one being introduced close to the tarsal border, and over these collodion may be painted, or a pad of lint placed. The pins may be removed on the third or fourth day.

In another operation proposed by Dieffenbach,¹ an incision is made through the skin below the lower and everted eyelid, and is deepened until the conjunctival sac is reached. The conjunctiva uninjured is then seized from below, and brought down through the external wound to the edges of which it is attached, the lids being at the same time inverted by pressure. Adhesion soon takes place between the displaced conjunctiva and the lips of the wound, and the eversion is corrected.

The plan recommended by Mr Wharton Jones² is best adapted for cases similar to that from which the illustration (fig. 22) was taken. Two incisions are made, meeting above, and descending on either side to the outer and inner canthus respectively. (See upper eyelid of woodcut E.) The triangular portion of skin having the border of the lid for its base, which is thus



Operation for Ectropion proposed by Adams.



Operation for relief of Ectropion proposed by Dieffenbach.

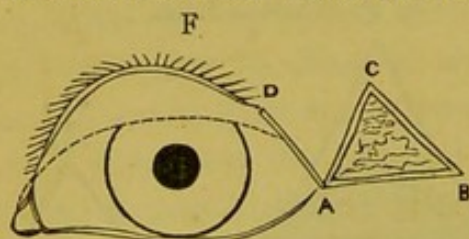
¹ Zeis. Handbuch der plast. Chirurgie, p. 380. Berlin, 1838, quoted by Wecker, Etudes Ophthalmol.

² Principles and Practice of Ophth. Surg., p. 412.

circumscribed, is dissected off from the subjacent tissues till the lid becomes free and the globe can be covered. The flap is then laid down again and secured in its new position by sutures, and the upper part of the wound are also brought together; a compress and bandage should be kept lightly applied for a few days.

A neat mode of operation, proposed by Dieffenbach, and applicable to cases where there are cicatrices adherent to the bone, consists in including the scar in a triangular cut (*see* lower eyelid, woodcut E), and separating the lateral and sound portions of skin freely from the adjoining parts; these may then be drawn together with harelip pins, after the excision of the scar, and a neat T-shaped cicatrix results, whilst the deformity is materially improved.

Another operation proposed by Dieffenbach¹ consists, in the event of the *upper* lid being everted, in removing altogether a triangular flap of skin (*a, b, c*), the sides of which are about one-third of an inch in length, and the apex of which is



Another mode of Operation proposed by Dieffenbach for relief of Ectropion.

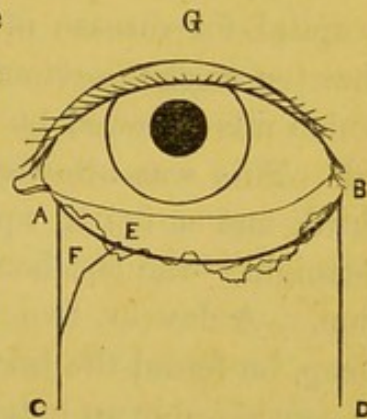
directed upwards. The commissure is then divided, and the lid freed from its attachments by an incision on its internal surface. The edge of the lid (*a d*) is next refreshed to an extent equal to that of

the base of the triangle (*a b*). The whole lid is now drawn outwards, and the points (*a* and *b*, *d* and *a*) are then united. The twisted suture is employed for the union of the sides of the triangle, whilst simple ligatures are sufficient for the coaptation of the palpebral border to the base of the triangle. The whole of the wound is thus closed, and even if union by the first intention do not take place, the relief or the cure of the ectropion may be hoped for from the contraction of the

¹ See Wecker, *Etudes Ophth.*, t. i. p. 633, where it is quoted from Zeis. *Handbuch der plast. Chirurgie*, p. 380. 1838.

cicatrix resulting from the removal of the triangular portion of skin (*a b c*).

When, in consequence of severe and protracted ulceration of the skin of the lower lid and cheek, the eversion is attended with considerable contraction, separating the lid by a large interval from the globe of the eye, and causing the line of junction between the conjunctiva and the skin to be drawn downwards, v. Gräfe¹ has recommended the following operation:—An incision is made along the part corresponding to the former edge of the lid, from the punctum lachrymale to the outer commissure of the lid (*a b*). From the extremities of this incision the vertical cuts (*a c*, *b d*) are made parallel to one another, and about three-quarters of an inch in length. The quadrangular flap thus marked out is dissected freely downwards. After being detached, the whole flap is drawn forcibly up, and fixed in its new position by sutures, commencing at *c* and *d*. The angle (*c, f, e*) is then formed by a curved or bent incision; the angle (*f*) can now be drawn up towards (*a*) and attached by a suture. It will be easily seen that, in proportion as the obtuse angle (*f*) is brought up towards the horizontal incision (*a b*), the palpebral fissure will be diminished, and to the smaller extent will the flap be elevated; whilst, in proportion as the angle (*f*) is drawn towards the vertical incision (*a c*), will the flap be raised, and to the less extent will the palpebral border be shortened. The lips of the horizontal wound should then be brought together by sutures, taking care to include as much of the skin and as little of the conjunctiva as possible. It is of great importance that union by the first intention should take place; for which reason all bleeding



Mode of operation recommended by v. Gräfe for the relief of Ectropion.

¹ Archiv. f. Ophth., Bd. x. ii. p. 229, 1864; and Warlomont and Mackenzie, t. iii. p. 74, from whom the following description is taken.

should be allowed to cease before the sutures are applied, and the parts kept perfectly immovable by the compress-bandage for twenty-four hours after the operation.

The method of transplanting a flap of skin taken from the temple or cheek, so as to form a new eyelid (blepharo-plasty), owes its origin to Dr Fricke of Hamburg. When successful, the result in improving the appearance of the patient is very good; but the cases require to be selected, or it will certainly fail, and leave the patient with an additional scar on the forehead. I have tried it in three cases. Of these one was quite successful, one was partially so, and the third entirely failed.

The successful case was that of a policeman, thirty-two years of age, who had been under treatment in a general hospital for disease of the kidneys and dropsy. He stated that ten weeks previously he received a blow on the forehead, which was followed by the formation of an abscess upon the lid. This was allowed to burst spontaneously. A second, third, and a fourth appeared successively, at intervals of a fortnight,—the last being opened by the surgeon of the division. A day or two before I saw him, on awaking from sleep, he found the lid everted. Since then it had swollen to so considerable an extent, that the tarsal edge nearly touched the brow. The surface of the exposed conjunctiva was smooth and polished, it was moist and slippery to the touch, and had the appearance of a bag containing fluid. In colour it was a light, semi-transparent pink, and here and there a slight ecchymosis had taken place, giving the surface a marbled appearance. The eye could just be seen beneath the lower border. There was no lachrymal discharge or pain, and the ocular conjunctiva and cornea were clear. Not having then seen such a case, I thought it would be possible, by gently pressing out the serous fluid and applying a pad and bandage, to effect a cure; and, on attempting to do so, found that the lid could, in the course of five minutes, be

restored to its original position, when it seemed to be healthy, except for a long cicatrix at its upper part. I immediately put on the pad and sent him home. The next day, however, he presented himself in the same state, and we attributed the failure to the bandage having become loose. After another attempt, however, I began to see that it was vain to hope for success by this means, and proposed the formation of a new lid, to which he gave willing assent. I accordingly admitted him into the Hospital, and, having placed him under chloroform, made a deep incision in the sulcus between the eyebrow and the tarsal cartilage, which at once freed the upper lid. An oval flap of skin was then, with the exception of a pedicle, detached from the temple, and being twisted at about a right angle to its original position, was laid down in the wound, and, as soon as the bleeding had ceased, fixed by sutures. Very satisfactory union took place, and the man left the Hospital well pleased with the result. The only drawbacks were, that a few hairs had been unavoidably included in the flap, and still continued to grow near the inner angle, requiring to be cut from time to time; and, secondly, in my anxiety that the flap should not slough, I had made it of considerable thickness, causing the new eyelid to be too heavy. He appeared a year or two after with this defect considerably diminished, and I have no doubt that still further improvement has taken place by this time.

The second partially successful case was that of the boy whose eye is depicted in fig. 22. He came to the Hospital in 1858, when the drawing was taken. The account then given was, that a short time previously he had received a kick from a horse on the brow. An abscess resulted, probably accompanied by caries of the frontal bone, and this was quickly followed by the ectropion. The boy's health not being good at the time, the father was recommended to take him into the country, and to return with him when he was stronger.

I saw no more of him till the Christmas of 1865, when he was fourteen years of age. The state of the eyelid had so far changed, that all the palpebral conjunctiva of the upper lid previously exposed had been drawn up and tucked in, so that the tarsal edge, instead of being everted, was now actually inverted, and the cilia touched the surface of the cornea, without, however, producing any irritation, and nearly the whole forepart of the globe was exposed. It was, in fact, now rather a case of lagophthalmos and inversion than one of eversion of the lid. The operation of transplantation, however, seemed feasible, and the requisite incisions were made, and the flap secured in its new position by stitches. In a few days contraction of the flap had taken place to so great an extent, that it only covered the outer half of the wound, in which state he was sent out of the Hospital. After a few days he was readmitted, in order that I might try to free the inner portion of the lid. This I attempted to do by the introduction of a narrow bistoury from above downwards, entering the point near the inner extremity of the eyebrow, and freely dividing all the tissues subcutaneously. But here an unexpected difficulty arose: the skin could readily be pressed downwards; but, upon doing so, the hæmorrhage was so great, in consequence of the supra-orbital arteries having been divided, that I was obliged to discontinue it. The following day, on depressing the skin again, and retaining it in position with a pad, the bleeding did not indeed recur, but an erysipelatous blush appeared, and I thought it prudent to desist; the boy was therefore dismissed, with only the outer half of the upper lid restored.

The third and wholly unsuccessful case was one where the disease had been produced by the contraction of the cicatrices of syphilitic sores, with which the face was everywhere marked. In this instance the disfigurement was very great. The cause of failure was the sloughing of the entire flap of transplanted skin, and this was due to the fact, that it was itself in some

measure only cicatricial tissue; for the temples and cheeks were so extensively seamed with the scars of old ulcers, that it was impossible to obtain a flap which did not touch upon some of the cicatrices. It was injudicious to attempt the operation in this case; but the man was urgent, had come from a considerable distance, and was anxious that some attempt should be made to remove the deformity.

19. *Entropion, Trichiasis, Distichiasis.*

Entropion signifies an inversion of the lids, as a consequence of which the cilia which fringe their borders fret and irritate the surface of the cornea.

In trichiasis, whilst the palpebral border retains its natural position, one or more of the cilia assumes an unnatural direction, and, instead of curving outwards, slants inwards towards the globe.

In distichiasis there are two or more rows of cilia, the anterior set occupying the natural position, and the posterior growing more or less irregularly, and being frequently directed towards the cornea.

Since in all these cases the essential feature of the disease is the irritation of the cornea by the lashes, they may well be associated together, and their symptoms, causes, and treatment collectively discussed.

Inversion of the lid may proceed from a variety of causes: sometimes being due merely to relaxation of the integuments, as is seen in some old people; at others, to undue and spasmodic action of the orbicularis muscle; or it may be the result of protracted inflammation of the conjunctiva, such as occurs in old cases of catarrhal-ophthalmia, and of tinea tarsi, and in the more severe forms of purulent and diphtheritic ophthalmia,—in all of which granular lids are frequently seen as a sequela, accompanied by the deposition of a fibrinous material beneath the mucous membrane, the contraction of

which, like the tissue of a cicatrix, gradually produces the inversion.

Lastly, it may be of traumatic origin, and follow blows or injuries to the lids, abscesses, and burns, or the entrance of caustic substances into the eye, as lime or the mineral acids.

The causes of trichiasis and distichiasis are less evident, and have as yet received no satisfactory explanation. In neither case does there appear to be any new formation of cilia, but simply an abnormal direction and curvature of the hairs springing from the old follicles.

The important influence which the orbicularis muscle may possess in the production of entropion, is well shown by such cases as those reported by Dr Mackenzie,¹ Mr Haynes Walton,² and M. Desmarres,³ where the inversion of the upper lids could be immediately induced by a powerful and perfectly voluntary contraction of the whole muscle; and it may occasionally be observed as a consequence of the spasmodic contraction of the muscle during the ordinary nictitating movements of the lids.

The first effects experienced, when the inversion has taken place, are sensations as of a foreign body beneath the lids, attended with much lacrymation, and more or less inflammation of the conjunctiva. In a very short time the conjunctival vessels begin to advance upon the margin of the cornea, the surface of which becomes troubled and hazy, and its natural polished surface covered by a thin vascular membrane.

The secretions of the sebaceous glands opening into the follicles of the cilia, of the Meibomian glands, of the mucous follicles of the conjunctiva, and of the tears, more or less altered in quantity and quality, concrete on the edges of the lids, and cause them to adhere with considerable firmness after sleep; and the efforts of the patient to open the lids,

¹ Ophth. Hosp. Rep., vol. ii. p. 176, 186.

² Operative Ophth. Surgery, p. 167. 1861.

³ Traité des Maladies des Yeux, vol. i. p. 483. 1854.

without due attention to cleanliness and ablution, often give rise to painful excoriations at the inner or outer canthus; whilst the cilia being placed under abnormal conditions, and receiving an insufficient supply of nourishment from the thickened and indurated lids, grow at oblique angles to one another and to the palpebral border, become brittle and break off, their stiff projecting root-portions pricking the eye, and causing acute pain. This state may persist for many months; the feeling of a foreign body in the eye, though dulled by being constantly endured, and by the gradual carnification of the surface of the cornea, being yet very distressing to the patient, and leading to spasmodic action of the orbicularis muscle, which reacts upon, and increases, all the symptoms.

The pathological changes which occur in the cornea in these cases have been carefully examined by Iwanoff;¹ and though they will be more fully detailed under the head of Pannus, of which entropion is a common cause, it may be remarked here that this observer has shown that the corneal epithelium long resists unchanged the irritation of the inverted lashes, and that the starting-point of the altered condition of the cornea consists in the new growth of round and delicate formative cells, which make their first appearance at the corneal margin, beneath the epithelial cells of the conjunctiva, and, gradually multiplying, advance over the surface of the cornea, and ultimately become converted into a kind of connective tissue; the anterior elastic lamina of Bowman, and the subjacent corneal tissue, long retaining their normal appearance and microscopical characters. In old cases, however, it is found that the deeper layers of the cornea almost always suffer from a low form of inflammation, accompanied by more or less interlamellar deposit and opacification, sometimes attended by ulceration, which may even proceed to perforation, prolapse of the iris, and staphyloma.

In other instances the cornea apparently contracts in

¹ Pagenstecher's *Klinische Beobachtungen*, p. 126. Wiesbaden, 1866.

diameter from the advance of the conjunctival connective tissue on all sides towards the centre, and often assumes a dry condition (xerosis), and almost a conical form, with facettèd margins. In such cases, if the lids be examined with care, it will be observed that their mucous lining is converted into a kind of cicatricial tissue, with irregular and puckered surface, the contraction of which occasions the vicious curvature of the tarsal cartilage, and the approximation of the angles of the palpebral fissure to one another, which constitute the essential features of the severer forms of this disease, and towards the removal of which most of the recent methods of operation that have been proposed are directed.

A form of entropion, which fortunately is only temporary, is often seen after operations for cataract, especially in those who are of lax fibre, and when, in consequence of the non-union of the wound, it has been thought expedient to maintain pressure with a cotton-wool pad and bandage for a fortnight or more after the usual period has elapsed. The appearance of the eye is then such as is shown in Plate XI., fig. 61. The lids will be found œdematous, of pink colour, and semi-transparent; a line of white deposit forms along their edges, and on separating them a copious flow of tears takes place. It will then be found that the lower eyelid is quite rolled in upon itself, so that the ciliary margin touches the cornea, which appears to be due to the œdematous fluid collecting on the outside of the tarsal cartilage, and pressing it inwards.

The ultimate results of entropion being of so formidable a character, almost invariably leading, if neglected, to loss of useful vision, it is of great importance that the malady should be recognised and treated in its earlier stages, before the form of the tarsal cartilage has become materially altered, the mucous membrane spoiled, and the structure of the cornea profoundly altered; and this may be the more earnestly insisted on, since the progress of the disease can be effectually

checked in its simple forms, whilst in the more advanced degrees, though the incurvation of the cartilage may be remedied, and the sufferings of the patient greatly mitigated, vision will be found to be permanently impaired.

For the sake of convenience, the treatment may be considered (1.) in reference to that form where the inversion arises from relaxation of the skin; (2.) when arising from spasm of the orbicularis; (3.) from contraction of the mucous membrane, leading to abnormal curvature of the tarsal cartilage; and (4.) when the inversion is combined with trichiasis or distichiasis.

1. When the affection is of recent origin, or where it seems to proceed, as in some old people, from a mere redundancy and flabbiness of the skin, it may sometimes be cured by causing one or two long pieces of strapping to adhere to the loose skin, and drawing it upwards or downwards, according to whether the upper or lower lid is affected. In that form of the disease which follows the use of the compress-bandage, this method succeeds perfectly. In other instances a cure may be effected by the application of collodion, of the tincture of iodine, of a blister, or of some stronger escharotic, as sulphuric or nitric acid, to the surface of the skin, a tendency to eversion being produced in each instance by the contraction and cicatrization which the integuments undergo. Great care should be taken, if the stronger acids are used, that none of the fluid creeps along the fissures of the skin towards the angles of the eye, and enters the conjunctival sac; to prevent which, it is well to paint the circumference of the lid with a little oil, and to apply the acid along a line of about one-third of an inch in breadth, and parallel to the ciliary border, in very small quantity at a time. The collodion and iodine paints may, however, be freely brushed over the surface.

2. Where these measures have been tried and have proved unsuccessful, and in cases where spasmodic action of the orbicularis is observed to take place, recourse must be had to

an operation, by which a portion of the skin, or of the skin and subjacent muscle together, may be removed. One mode of accomplishing this consists in pinching up a broad fold of the skin, parallel to the border of the lid, with a pair of entropion forceps, and dividing it with a sharp knife or scissors. The wound presents the form of a myrtle-leaf, being broad in the centre and pointed at its extremities. Its anterior edge should be about one line distant from the ciliary border, its breadth should be at least one-third of an inch, and its length nearly equal to that of the palpebral fissure. The edges of the wound may either be brought together by sutures or abandoned to themselves, the inversion being rectified by the contraction of the cicatrix. In some instances, especially in cases of entropion of the lower lid, instead of pinching up a fold parallel to the ciliary margin, the plan suggested by Jansen may be adopted, in which two or three oval portions of skin are pinched up from the cheek at right angles to the ciliary border, and removed with scissors, the edges of each wound being brought together by harelip pins and the twisted suture. When there is reason for believing that the occurrence of the inversion is occasioned or maintained by undue or spasmodic contraction of the orbicularis, some of the fibres of the muscle may be simultaneously removed in either of the above plans of treatment. In similar cases Cunier¹ recommends the subcutaneous vertical section of the orbicularis, by the introduction of a narrow-bladed knife, either near to or at some distance from the border of the lid, and the division of the fibres as the knife is withdrawn. A thick fold of the relaxed skin of the lid, including the fibres of the orbicularis, is now pinched up parallel to the border of the lid, and pierced with two or three needles armed with ligatures. These are drawn tight, and allowed to work themselves out by ulceration, which usually takes place in the course of a fortnight.

¹ *Annales d'Oculist.*, t. v. p. 264. 1841.

3. A great variety of operations have been suggested for those cases of entropion which are induced by cicatrization of the mucous membrane, occasioning abnormal curvature of the tarsal cartilage, attesting at once the frequency of the affection, the distress it occasions, and the imperfection of the means at our disposal for rectifying it.

Mr Streatfeild¹ has proposed a good plan of operation when the form and curvation of the cartilage of the lid are not materially altered. The lid being held by Desmarres' ring-forceps, so that the skin is made tense, and the edge of the lid exposed, an incision is made just through the skin, at the distance of a line from the border of the lid, exposing, but not dividing, the roots of the cilia. A second incision, farther from the palpebral margin, is now made, the cut being inclined at an angle to the first, so that a triangular piece of the tarsal cartilage is excised. This operation, which Mr Streatfeild terms "grooving the fibro-cartilage," effects a cure on the same principle as the removal of an oval portion of the skin, viz., by causing eversion during the process of granulation. To aid this, and to avoid the spasmodic action of the orbicularis, he has found it sometimes requisite to make a vertical incision through the fibres of the muscle at each extremity of the lid.

In all cases where the curvature of the tarsal cartilage is materially changed from long standing inflammation, the operation is quite useless if limited to the skin or muscle, and must invariably be directed to effecting an alteration in the tarsal cartilage. Mr Guthrie's operation, though severe, I have seen succeed very fairly. It consisted in dividing the whole lid vertically, avoiding the punctum lachrymale near the angles, with scissors or a sharp-pointed bistoury, to the extent of one-third of an inch. The central loose portion should be examined, and if the cartilage be viciously curved at its extremities, a small horizontal incision should be made

¹ Ophth. Hosp. Rep., vol. i. p. 121.

at the part abnormally bent. A horizontal portion of the skin of the upper lid, included between the two vertical incisions, should now be removed, and the edges brought together with sutures. The free central portion should then be completely everted by a thread passing through the edge of the lid, and kept applied to the forehead by a piece of sticking-plaster. Granulation of the edges of the wound is to be promoted by frequently touching them with sulphate of copper, and water-dressing kept constantly applied.

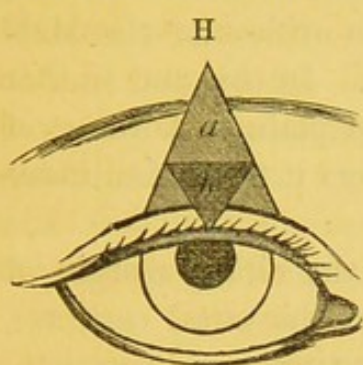
Sir P. Crampton's mode of operating was to enlarge the palpebral fissure by an incision passing obliquely upwards, both at the external and internal canthi, and of about three lines in length. The palpebral conjunctiva was then scored along its whole length, and the lid kept up by a suspensorium. The division of the superior lachrymal canaliculus, inevitable in this operation, he considered of no importance.

M. Pagenstecher¹ has suggested still another plan, which I have had no opportunity of trying, but which M. Wecker considers superior to every other. It consists in extending the external fissure of the lids by a horizontal incision, in such a way that the wound of the conjunctiva shall have a length of about one-fourth of an inch, and that of the skin about one-third of an inch. The horizontal direction of the wound is then converted into a vertical one by stretching the skin from above downwards, and the opposed surfaces of the mucous membrane and skin are then united by sutures. The palpebral fissure is thus enlarged, a slight degree of ectropion is produced, and, by the interposition of the mucous membrane between the fibres of the orbicularis muscle, the force of its contraction is diminished.

The mode of treatment recommended by v. Gräfe is exhibited in the accompanying diagram, where, at a distance of a line, or a line and a-half, from the ciliary border, an incision is made parallel to it, extending to within two lines of the two

¹ *Annales d'Oculistiques.* 1862.

canthi; a triangular flap of skin (*a*) is then entirely removed, and the sides of the triangle are dissected off from the



subjacent tissue, in order that they may be subsequently approximated. In the lower lid this is all that is required; but in the upper lid he further recommends the excision of a small triangular portion of the tarsal cartilage (*b*), the base of which is in the opposite direction to that of the flap removed

from the skin. The edges of the wound in the integuments are brought together by sutures, one of which should pass through and unite the two extremities of the base of the triangle removed from the tarsal cartilage.

When simple trichiasis or distichiasis exist, and especially if only one or two lashes have assumed a perverted direction, sufficient relief is often obtained by the mere removal of the offending cilia. The evulsion of these, however, should not be carelessly performed. A pair of well-made forceps, the blades of which are finely serrated and accurately fitted to one another, or, as some prefer, with perfectly smooth extremities, are required. Each hair should be seized separately near its base, and slowly drawn out, so that the bulbous root, surrounded by a little black pigment, may be seen in each case. If the hair be bent or twisted, or suddenly jerked, it is very likely to break, leaving a short stiff stump, that is much more injurious and painful to the patient than the inverted eyelash itself.

In cases, however, where many cilia are affected, some more radical means of removing the disease must be employed, and we must endeavour to prevent their growth by destroying their roots. Simple and easy as this appears to be, it will be found in practice that the complete obliteration of the hair follicles is a matter of considerable difficulty, and several operations have been suggested.

Jäger removed, by nice dissection, the anterior portion of the margin of the lid, which included the roots of the cilia, leaving the posterior part, containing the orifices of the Meibomian follicles, as far as possible entire. In this and similar operations, it is advisable to insert a thin plate of horn or of silver under the lid, which at once renders it tense, facilitates the operation, and protects the eye.

Mr Saunders removed the whole of the ciliary margin of the lid on a level with the free border of the tarsal cartilage, which is a very severe as well as an unsatisfactory operation.

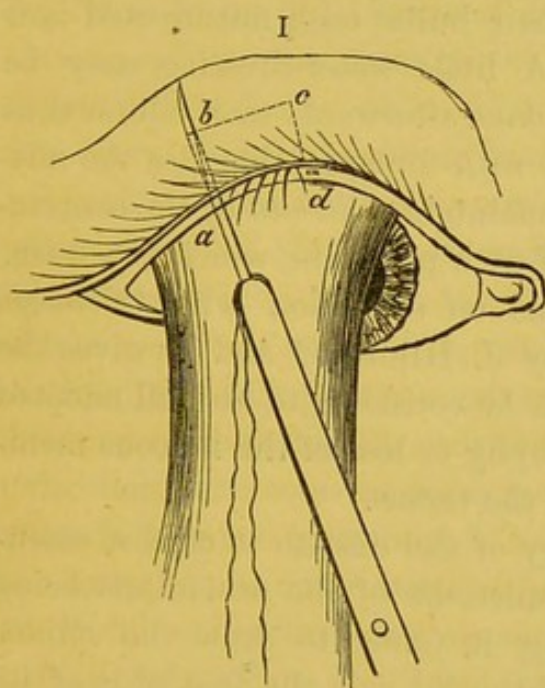
Dr Wright's method¹ seems likely to be successful, and is based on sound principles, but requires great delicacy and care in its performance. It consists in making an incision along the whole length of the margin of the lid between the Meibomian follicles and the cilia, taking care to stop short of the punctum lachrymale. A flap containing the roots of the cilia is then dissected off from the cartilage. An oval portion, two or three lines broad, of the loose skin of the upper eyelid, is then removed in the ordinary way, the lower incision being about the distance of two lines from the edge of the lid. The point of the knife is then thrust through the fibres of the orbicularis and the subcutaneous textures which intervene between the two wounds that have been made, and the flap containing the cilia is thus detached, except only at its extremities, and its position is shifted to the upper part of the wound resulting from the removal of the oval portion of skin from the upper lid, and fixed in its new position by sutures. According to Dr Wright, whose statements are corroborated by Dr Waldhauer,² who has operated on 200 patients, the results are exceedingly satisfactory, no deformity resulting.

A method of treating cases of partial trichiasis or distichiasis, where only a few cilia turn in, has been recently

¹ Dublin Quart. Jour., vol. xxxix. p. 90. 1865.

² St Petersburg. Med. Zeit., Bd. ii. p. 201.

proposed by U. Herzenstein,¹ and is superior to either of those just mentioned, since there is no loss of tissue involved in it. It consists in producing an artificial madarosis, or destruction of the roots of the hairs fringing the lids, the functional importance of which he thinks has been over-estimated. He accomplished this by entering a needle, threaded with fine silk, between the inner and outer margin of the border of the lid, as at *a*, and making it pierce the skin a little above the



ciliary margin (*b*), the thread is drawn through, and the needle is made to re-enter at the same orifice (*b*), and made to run parallel with the border of the lid for the space in which the cilia maintain the wrong direction (*to c*). The thread is again pulled through, and the needle again entered at the last point of emergence, and directed vertically till the point reappears between the edges of the border of the

lid (*a*). The two ends are then tied, and allowed to cut their way out. The suppuration excited thoroughly destroys the bulbs of the offending cilia, and no further trouble is experienced.

R. Schirmer² has recommended the application of the wire of the galvano-caustic apparatus to the skin immediately above or below the displaced cilia, the roots of which are then destroyed by the passage of a current which causes the thread of platina to become white hot.

Though it is not unfrequent to meet with cases of simple trichiasis, it far more frequently occurs in combination

¹ Gräfe's Archiv., Bd. xii. p. 76. 1866.

² Griefswalder Med. Beiträge, Bd. iii. p. 15, and Ophthal. Review, Bd. ii. p. 215.

with a greater or less degree of inversion of the lids. This complication of entropion with trichiasis appears to be a common affection amongst the poor Irish in Cork.¹ Dr Williams believes it to be a scrofulous affection, and recommends constitutional as well as local treatment. In regard to the latter, he employs the following means:—A little potassa fusa being allowed to liquify by exposure to the air, a needle should be dipped into it, and the tarsal border punctured to the depth of the hair bulbs, each misdirected hair being attacked in turn. A little water-dressing may be applied; and three or four days afterwards each cilium thus treated should be pulled out with forceps, otherwise the misdirected hairs will be firmly maintained *in situ* by the contraction of the minute cicatrix of each puncture, which is a burn.

Some sensible observations on entropion with trichiasis are contained in a paper by J. Hildreth,² and he gives the details of an operation which he considers to be well adapted for cases originating in atrophy or loss of the mucous membrane, or from alterations of the tarsus.

He considers the pathology of the disease to consist essentially in the position and functions of the orbicularis being such that, when contracting, it tends to draw the ciliary margin of the integument of the lid *over* the free edge of its cartilage; and, secondly, that the levator, when contracting, tends to draw the free edge of the cartilage *away* from the ciliary margin of the skin covering it,—and hence, that there are present two antagonistic forces, *both* tending to produce a projection of the ciliary border of the skin covering the lid over the corresponding edge of the tarsus, and thereby deviating the cilia inwards. The operation he recommends, with the object of counteracting these difficulties, consists in a kind of transplantation of the skin upwards without dividing

¹ See D. J. Williams' Paper in the Dublin Hosp. Gaz. for January 15, 1861, and Ophth. Hosp. Reports, vol. iii. p. 219.

² New York Med. Journal. April 1866.

it, and is performed in the following way:—He makes a horizontal incision along the border of the lid, between the openings of the Meibomian follicles and the insertion of the cilia, commencing a little external to the punctum, and extending to the outer commissure. The integuments and muscular fibres are then dissected off the tarsal cartilage. The former, therefore, remains now under the influence of the orbicularis only; the latter under that of the levator palpebræ. The lid must next be everted, and two separate coarse silk threads made to pass through the tendon of the levator close and parallel to the superior edge of the tarsus, and near both extremities of its separation from the external integuments. Both strands of each ligature must come through the mucous surface, and each loop should embrace horizontally about five millimètres of the tendon, taking care not to include any of the parts external to it. The four strands of the two cords thus left projecting from the aperture of the lids should be left four or six inches long, in order to insure their being fastened to the cheek, and so arranged as to avoid resting on the cornea. Sufficient traction must next be made on these cords to bring the ciliary edge of the tarsus in contact with or below the corresponding border of the opposite lid, and these must then be firmly secured to the cheek by strips of adhesive plaster. The skin and fibres of the orbicularis are now to be drawn upward, and fixed to the tarsus in proper position by two broad stitches inserted near the junction of the outer third with the inner third of the dissection of these parts from the tarsus. The advantages of this operation appear to be, that there is no wound of the external integument, and that the tendency of the transplanted parts to suppurate, to fail to unite well, or of the cilia to subsequently fall out on account of imperfect nutrition, is avoided, whilst the good result obtained is permanent.

The last proceeding suggested has been that by Dr Prince¹

¹ Hay's American Journal of the Med. Sci., p. 381. Oct. 1866.

of Jacksonville, who maintains that the disease commonly results from the shortening of the mucous membrane of the lid, converted by long-standing inflammation into a kind of cicatricial tissue, both in its transverse and vertical diameter, so that the cilia come to be inverted, whilst the loose skin slips or rolls downwards over the margin. The palpebral fissure appears smaller, owing to the encroachment of the external canthus; and to avoid this he adopts the following operation, by which a portion of integument is implanted behind or on the inner (ocular) surface of the upper eyelid, near the external canthus:—The point of a knife is entered at a short distance ($\frac{1}{16}$ -inch) from, and on a level with, the outer canthus, and carried outwards for the distance of about three lines; from this cut as a base, a triangular flap of skin, the apex of which is near the middle of the lower eyelid, is raised and turned back on itself, by transfixing the apex with a wire suture having a needle at both ends. The first horizontal cut is now made considerably deeper, so as to cut through the fibres of the orbicularis, and the mucous membrane is freely divided. The upper eyelid is now transfixed by one of the needles, and the triangular flap is tucked up under the upper lid, and maintained in position by transfixing the lid with the second needle at a little distance from the first, both needles passing through the wound in the mucous membrane, and the raw surfaces of the flap and membrane being approximated.

The wire is twisted over a compress, and union soon takes place. The removal of the loop of wire is provided for by attaching to it a small portion of silk or thin wire, which is allowed to hang from the palpebral fissure. The surface of skin thus turned inwards towards the globe soon becomes converted into mucous membrane, and the palpebral fissure is permanently enlarged. An objection to this mode of treatment appears to be, that some thickening of the outer canthus is in some instances the consequence.

CHAPTER V.

Diseases of the Conjunctiva.

STRUCTURE OF THE CONJUNCTIVA—SIMPLE, ACUTE, AND CHRONIC INFLAMMATION OF THE CONJUNCTIVA—CATARRHO-RHEUMATIC OPHTHALMIA—PHLYCTENULAR OPHTHALMIA—PURULENT OPHTHALMIA OF CHILDREN—CONTAGIOUS OPHTHALMIA—GONORRHOEAL OPHTHALMIA—DIPHTHERITIC OPHTHALMIA—GRANULAR LIDS—PTERYGIUM—ECCHYMOSIS OF THE CONJUNCTIVA—TUMOURS OF THE CONJUNCTIVA—ENCANTHIS—SYPHILITIC AFFECTIONS OF THE CONJUNCTIVA.

1. *Anatomy of the Conjunctiva.*

THE conjunctiva is a mucous membrane covering the fore part of the globe of the eye and the inner surface of the lids, and these two portions, termed respectively the ocular and palpebral divisions of the conjunctiva, freely glide over one another in the different movements that both are capable of performing. At the margins of the lids the conjunctiva is continuous with the skin,¹ from which it only differs by being thinner, possessing fewer and smaller papillæ, and being destitute of any epidermic layer of hard and flattened cells. The rete mucosum of the skin may, however, be readily traced into it, in the form of a laminated epithelium of about 1-100th of an inch in thickness, the superficial cells of which are slightly flattened, and the deeper columnar in form, with a large nucleus and finely granular contents. That portion of the

¹ See 26, Fig. of Moll, p. 84.

conjunctiva which rests upon the tarsal cartilage is tolerably smooth to the naked eye, on account of the small size of the papillæ, though these are clearly visible when sections of the membrane are examined with low powers of the microscope; and the surface may then also be seen to present numerous fine openings of minute follicles or depressions, resembling the Lieberkühnian follicles of the small intestine, and, like them, lined by columnar epithelium, and discharging a mucous fluid which facilitates the movements of the lids. Towards the posterior border of the tarsal cartilage the papillæ gradually become larger, till they attain their greatest size in the oculo-palpebral fold, where the conjunctiva forms a *cul-de-sac*, to be reflected forwards on the surface of the globe. At this part the cylindrical epithelium is stated to be exchanged for the laminated pavement form. The matrix of the conjunctival mucous membrane, as well as of the papillæ, is composed of connective tissue, the fibres of which, especially in the papillæ, radiate outwards, and, according to Krause, terminate in free extremities, amongst which the deeper layers of epithelial cells lie. It is well supplied with blood-vessels, and should always possess a pale rosy colour when it lines the tarsal cartilage, becoming deeper in tint near the posterior part.

The conjunctiva investing the globe (*conjunctiva bulbi*) differs in its sclerotic and corneal positions. In that part which covers the sclerotic it still retains a considerable degree of thickness, and possesses a submucous connective tissue, by means of which it is loosely attached to the underlying fibrous membrane. This portion is moderately supplied in the normal condition with blood-vessels and nerves, but, as a rule, possesses only a few papillæ and glands. In that part which covers the cornea the structure of the mucous membrane seems to be reduced to its simplest possible form. It possesses no blood-vessels, nor any subepithelial tissue, but consists merely of eight or nine layers of epithelium, of which

the superficial are flattened and imbricated, but so perfectly adapted to one another, and so delicate, as to give the most perfect brilliancy and polish to the surface; whilst the deeper ones are more columnar in form, and rest on the anterior elastic lamina of Mr Bowman.

The vessels of the sclerotic portion of the conjunctiva are superficial, of a bright tint, pursue a tortuous course, with frequent divisions and anastomosis, and, by pressing the edge of the lid against the globe with the finger, can be easily made to move over the subjacent membrane. In some delicate persons, and in children, they are very few and small, so that, except near the oculo-palpebral fold, they cannot be distinguished. In others, and even in the former, a few minutes after the entrance of any foreign body into the eye, their course may be followed quite up to the margin of the cornea, where they form numerous capillary communications with the branches of the ciliary arteries, and may even advance a little way over the edge of the cornea, though they soon turn or loop back into the proper conjunctival connective tissue. The vessels of the conjunctiva constitute terminal branches of the ophthalmic artery, and they return their blood into the ophthalmic vein, which is again continuous with the cavernous sinus. The condition of the conjunctival vessels, on this account, frequently proves of great service in directing attention to, or in aiding the diagnosis of, intra-orbital and intra-cranial tumours, which, by impeding the return of blood through the larger and concealed, cause congestion of the smaller and more conspicuous veins.

It has been shown by M.M. Donders¹ and Leber² that the portion of the conjunctiva immediately surrounding the cornea derives its blood from the anterior ciliary arteries, and that a communication is here established between the superficial and deep vessels of the eye, the veins being in all instances

¹ *Annales d'Oculistiques*, t. lii. p. 189. 1861.

² *Archiv. f. Ophth.*, Bd. xi. p. 1.

large, and the arteries remarkably delicate and small. Some of the blood of the circumcorneal portion of the conjunctiva is returned by branches discharging themselves into the canal of Schlemm. The remainder passes into the proper conjunctival veins.

The nerves of the conjunctiva are exclusively derived from the fifth pair.

Kleinschmidt¹ has enumerated no less than four varieties of glands that have been found distributed in various parts of the conjunctiva. These are:—1. The acinous glands; 2. The sweat glands; 3. The glands of Manz; and, 4. The lymph follicles, or trachoma glands.

The acinous glands chiefly occupy the inner part of the conjunctiva at the point of transition between its ocular and palpebral portions. They are about forty in number in the upper fold, and from two to six in the lower. They appear to be constant in man, and in the ox and dog. They form grape-like clusters of follicles, containing cells, nuclei, and fat drops, and possess small excretory ducts which open in the sinus. Henle considers that they collectively represent an accessory lachrymal gland, to which their structure bears an obvious resemblance. The sweat glands have been described by Meissner, and are situated at or near the corneal border, where in the ox they may be easily perceived, numbering from six to eight. It seems to be doubtful, however, whether they are present in man.

The glands of Manz are muciparous follicles, chiefly occupying the outer corneal border, and presenting the form of oval or rounded sacs with open mouths, and containing cells and finely granular matter. They are well supplied with vessels and nerves, and they have been observed by Stromeyer in man as well as in most animals, but Kleinschmidt has only been able to recognise them in the pig.

The lymph follicles, sometimes known as the follicles of

¹ Archiv. f. Ophth., Bd. ix. iii. p. 147.

Bruch, or as the trachoma glands, have been carefully examined by Huguenin and H. Frey.¹ Though present in the human subject, they found them most conspicuous on the inner surface of the lids in the eyes of oxen. They appear to be closed follicles, resembling the solitary glands of the intestine, and, like them, consisting of an investing membrane, composed of dense connective tissue, and a looser net-work of the same in their exterior, the delicate trabeculæ of which have nodal swellings at their points of intersection, and numerous lymph cells occupying their interstices. The capillaries are few and small. The glands lie in a bed of peculiar texture, to which they have assigned the name of "lymphoid mucous tissue," from its spongy character and the numerous lymph corpuscles it contains.

The lymphatics of the ocular conjunctiva are very numerous, form a close plexus around the margin of the cornea, and lie at a somewhat deeper level than that of the blood-vessels. They discharge themselves into the superficial sub-maxillary glands.

At the inner angle of the eye is a small swelling over which the conjunctiva is prolonged, termed the caruncle, and external to this is a fold of the membrane, the plica semilunaris. The caruncle is a thickened portion of the mucous membrane, from which a few fine hairs project, having large sebaceous glands, conspicuous even to the naked eye on section, opening into their root follicles. The plica semilunaris is a simple fold of the mucous membrane, the looseness of which facilitates the movements of the globe in the outward direction, and which is clearly the rudiment of the membrane nictitans seen in many of the lower animals.

¹ Siebold and Kolliker's Zeits, Bd. xvi. ii. p. 215.

2. *Acute or Catarrhal Conjunctivitis.*

(PLATE III., Fig. 17.)

This is a disease of such frequent occurrence that few people pass through life without suffering from it at one period or another. It is met with in both sexes, and at all ages, and is the most common of all the affections presenting themselves in the out-patients of an hospital.

The attack comes on in some instances in a remarkably sudden manner, so that the patient is firmly convinced an eyelash or some particle of dust has entered the eye, and there is much smarting pain and lachrymation. Generally however, its progress is slower, and the patient complains for a day or two of the eye feeling weak and frequently becoming filled with tears which to some extent obscure the vision, of more or less redness of the conjunctiva, and of the lids and lashes sticking together in the morning after sleep; but the pain is usually quite inconsiderable. A very short experience enables the surgeon to diagnose a case of catarrhal conjunctivitis from the deeper seated and more serious forms of inflammation. There may be present a very considerable amount of redness, and the eye may seem to be in a condition of great danger, but a careful examination soon shows that the congested vessels are quite superficial, and that the more important structures are unaffected. At the same time, such cases should never be neglected, since, although in general easily and quickly curable in the first instance, they may readily pass, by extension of the inflammation to other parts, into conditions fraught with the utmost danger to sight. The colour of the congested parts is characteristic. The vessels are large, quite superficial, and possess thin and delicate coats, permitting the tint of the blood to be distinctly visible, and conferring on the inflamed tissue a bright scarlet or vermilion hue.

The course and position of the vessels are also peculiar.

The larger trunks appear to spring from the upper and lower sinuses or folds of the conjunctival membrane, and especially from beneath the plica semilunaris at the inner angle. As they pass forward towards the cornea, they pursue a tortuous course, and become more minute as well as more superficial, dividing, subdividing, and anastomosing in every direction, but, upon the whole, gradually becoming less conspicuous near the margin of the cornea, so that, instead of there being a distinct zone around the corneal border, as in iritis, the colour is actually paler at this part than elsewhere. In many places the smaller arteries and veins form little knots or plexuses, giving a patchy appearance to the membrane, which is also very characteristic of the disease, and which is rendered still more conspicuous in cases where the attack is a sharp one, by minute ecchymosis taking place from the over-distended vessels. The larger vessels can easily be moved over the subjacent sclerotic by pressing on the lid, but it must not be supposed that none of the deeper vessels can be seen; for even in comparatively mild cases, the subconjunctival and sclerotic vessels sympathising with, and having been exposed to the same causes of disease as the more superficial ones traversing the conjunctiva, allow a freer current of blood to pass through them. The colour of these vessels is always of a darker and more purple hue, and their course is straighter. The result of the congestion of all these vessels is a considerable increase in the amount of lymph percolating through the splits and fissures of the connective tissue, and hence the whole membrane assumes a swollen semi-transparent watery appearance, which constitutes the incipient and slighter grades of chemosis.

In the earlier period of the disease lachrymation is often considerable, and complaints are made that the tears are hot and excoriate the cheek. A little later, as observed by Mr Wharton Jones, there may be found, on depressing the lower lid, a flake of puriform mucus and exfoliated epithelium,

occupying the oculo-palpebral fold. This soon increases in quantity, till it forms a considerable discharge, increasing at night, or after any unusual exertion of the eye has been made, and so firmly agglutinating the lids together in the morning, that much trouble is experienced in opening them, the rubbing to which the patient naturally resorts proving a fertile source of ophthalmia tarsi. A feeling of weight or heaviness in the lids is often complained of, and is probably attributable to the alteration in the character of the secretions, and the roughness of the conjunctiva occasioned by the enlarged vessels, but partly also from the circumstances that the lids are themselves swollen and congested, and their papillæ erect and filled with blood, as may be seen on everting them and examining their inner surface. Intolerance of light, indicating the participation of the retina in the general inflammation, is sometimes present in the early stages, but rarely to a marked extent, and vision is usually, except for the tears, perfect. Acute conjunctivitis may be either a primary affection or, what is too frequently overlooked, consecutive to some other disease. It need scarcely be remarked how important it is to recognise this distinction in practice, since it is obvious that, where it is of a secondary nature, it is hopeless to treat it with success without first removing the prime cause. It is most frequently brought on by imprudent exposure to cold, especially in those the tone of whose vessels has been lowered either by local or by constitutional disturbance. Thus it often occurs in persons who have been sitting in a crowded and heated assembly, and have suddenly gone out into a colder air; and the inflammation is much more likely to occur when some general disorder of the system is present, as in convalescence from fevers, in those suffering from confined bowels, or from fatigue and exhaustion. Such cases of conjunctivitis are usually termed catarrhal. But the disease may also arise from slight injuries, as from the irritation of an inverted lash, from the contact of floating particles of lime

or other caustic substance in the air, or from irritant vapours, as those of ammonia and ordinary coal-smoke. Thus M. Huss¹ observes that conjunctivitis is endemic amongst the inhabitants of the north of Sweden, its prevalence being clearly attributable to their mode of life, and particularly to their being cooped up during the winter months in the close and foul atmosphere of their huts, whence the smoke can only escape through an aperture in the roof. He adds, that during the open months of the year spontaneous cure takes place, though it is rare to meet with old Lapps whose palpebral conjunctiva is not red, tumefied, and rugous.

When conjunctivitis is consecutive, it is often found to follow over-use of the eye on small print, or on fine needlework; and I have known it follow excessive work with the microscope. In many of these cases careful examination will show that there is some defect in the sight of the eye, and that the patients are the subjects of hypermetropia, a condition in which, for the examination of near objects, a constant strain is made upon the recti and ciliary muscles, leading, perhaps mechanically, to a certain amount of congestion of the conjunctival veins. In such instances the adoption of appropriate glasses will rapidly relieve all the symptoms.

In other cases it follows inflammation either of the choroid and iris, or of the sclerotic and cornea, not so much in these instances from sympathetic irritation as from direct extension of the inflammation from the contiguous structures. There is good reason for believing it to be a contagious affection, and it certainly often appears as an epidemic. It is common in this country during the spring months, when easterly winds are prevalent, and when considerable alternations of atmospheric temperature and moisture occur.

When ordinary precautions are taken, or where the cause is no longer in operation, the disease, after attaining a certain degree of intensity, begins to subside, and in a few days, even

¹ *Annal. d'Oculist.*, p. 71. 1853.

when no treatment is adopted, providing the patient be otherwise healthy, passes away entirely. A certain disposition to recur under the influence of slight exciting causes is, however, usually observable for some time. The treatment of an ordinary case of catarrhal conjunctivitis is consequently in general very simple, and consists rather in avoiding further irritation than in carrying out any very active measures. It is prudent in all instances to adopt the recommendation of Dr Moorens, and to examine the under surface of the upper lid, so that the presence of any foreign body may not pass undetected. In a mild case the patient should be recommended, especially in the winter and spring months, to keep in-doors, to take a purge, and to bathe the eye with a little weak alum lotion, containing about two grains of alum to an ounce of water; and he may be directed to apply a little olive oil, simple cerate, or citrine ointment, to the edges of the lids at night, with a view to prevent their adhesion during sleep. Some difference of opinion exists as to the propriety of using hot or cold applications to the eye, some, as M. Wecker,¹ recommending the use of cold compresses, of a temperature of about 55° F., frequently wetted, and laid upon the eye for a quarter of an hour at a time every hour, or every other hour; whilst M. Arlt condemns their use, and employs hot fomentations. The latter are certainly in most cases more agreeable to the feelings of the patient; and if the former are used, care should be taken not to prolong their application beyond the above-mentioned time, lest they induce a rheumatic attack. The food should be good, and a glass or two of wine may be allowed. In more severe cases a blister, or two or three leeches, should be applied to the temple, and the bleeding maintained by a hot linseed-meal poultice. Besides the alum lotion, a solution of from one to two grains of nitrate of silver in an ounce of distilled water may be dropped into the eye two or three times a-day.

¹ *Etudes Ophthalmol.*, t. i. p. 24.

Snellen¹ remarks that the nitrate of cobalt and the sulphate of copper (gr. ii. ad. ʒj.) produce the same effects as the nitrate of silver (gr. i. ad. ʒj.), whilst the neutral acetate of lead is specially distinguished by the little pain it produces. These measures, or a repetition of the bleeding, are usually sufficient to cure any ordinary case of catarrhal conjunctivitis in the course of ten days or a fortnight. Should, however, the inflammation extend to the cornea, and occasion superficial keratitis, the treatment to be presently described under the head of that disease must be put into force; the most important measures being the scarification of the surface of the palpebral mucous membrane, or its cauterisation with mitigated nitrate of silver, or the removal of a band of conjunctiva from around the cornea (peritomy).

All employment of the eyes on fine work, as sewing, reading, or figures, should if possible be avoided. The poorer class of patients are apt to wrap up the inflamed eye with a handkerchief, or with flannel, which, by its heat, and by favouring the accumulation and the drying up of the secretions, tends to relax the vessels and to perpetuate the disease. No coverings are requisite, even if the patient be allowed, on account of the mildness of the weather, to take out-of-door exercise.

3. *Chronic Conjunctivitis.*

An ordinary attack of inflammation of the conjunctiva may subside into a condition in which, whilst some of the signs of inflammation are present, others, and in particular pain, are absent. The eye looks red and congested; the vessels are enlarged, and carry red blood over the margin of the cornea, upon the surface of which they may be seen forming fine striæ and plexuses, greatly impairing its polish and transparency at this part, and constituting the state known as superficial keratitis. The patients complain of the rough

¹ Ophth. Hosp. Rep., vol. iv. p. 60.

and sandy feeling which they experience on moving the eye, of sensations of heat and irritation, of weight and heaviness in the lids, especially at night, and of constant lachrymation; but unless the causes of conjunctivitis have long been in operation, and the central parts of the cornea have become vascular, there is no impairment of vision. The maintenance of a condition of chronic inflammation in the conjunctiva is very frequently due to some physical cause which, if discovered, should be as far as possible removed or remedied. Amongst the more common may be enumerated trichiasis or distichiasis, entropion or ectropion, and tumours on the lids. In other instances, as in chimney-sweepers and masons, amongst whom, Middlemore¹ states, it frequently occurs, it appears to arise from unavoidable exposure to dust and dirt; and in others, again, it appears to arise from an unhealthy constitution and loaded bowels, and follows an acute attack of inflammation in the same membrane. Hence it is much more frequently met with in the poor, who are not only more exposed to the influence of causes inducing acute conjunctivitis, but are less able than the better classes to give the time and attention requisite for the cure of the disease in its earlier and more curable state.

The treatment of cases of chronic inflammation should not be lightly or slovenly undertaken, for it is apt to produce disease of the hair and sebaceous follicles of the lashes, and of the Meibomian follicles, thickening of the margins of the lids (tylosis), granular lids, and sundry affections of the cornea, which remain amongst the most obstinate of all ophthalmic affections.

In cases where there is any reason to suspect the presence of a foreign body, the lids should be everted, and the inner surface of the lid, and especially the oculo-palpebral folds, carefully examined. Where the occupation of the patient appears to be the cause, sedulous attention to cleanliness

¹ Treatise on the Diseases of the Eye, vol. i. p. 338. 1835.

should be enjoined, and the eyes should be washed with tepid water after returning from work. When the persistence of the disease can be referred to defects of sight, as to hypermetropia, the proper glasses for the correction of the latter must be selected and employed. Where the constitution is at fault, exercise, and the avoidance of stimulants, must be recommended, and purgatives and tonics used, as the circumstances of the case may require.

As regards local treatment, the application of one or two leeches to the lids or temples will unload the vessels, and pave the way for local astringents. Of these an immense variety have been recommended at different times. Amongst the best are the *vinum opii*, solutions of alum, sulphate of zinc or of copper in the proportion of two grains to the ounce of water, and weak ointments of red, yellow, or white precipitate of mercury, of which a small quantity may be smeared over the inner surface of one or both lids once or twice a-day.

As a general rule, it is not advisable to use the solutions of nitrate of silver in chronic cases of conjunctivitis for more than a week or a fortnight together, as they are apt to occasion permanent discoloration of the membrane. In recent cases, a single application of Mr Guthrie's ten-grain ointment of nitrate of silver will sometimes effect an immediate cure. A safer mode of employing the nitrate of silver is, however, that recommended by M. Desmarres, of touching the surface of the palpebral conjunctiva with a stick of caustic, composed of one part of nitrate of silver and two of nitrate of potash, the parts being immediately washed over with a solution of common salt.

4. *Catarrho-Rheumatic Conjunctivitis.*

If an attack of ordinary catarrhal ophthalmia be neglected, or if the patient be exposed to great atmospheric vicissitudes, whilst his health is temporarily impaired by fatigue, watching, hunger, or a disordered condition of the alimentary canal,

and especially if he be advanced in years, the conjunctival inflammation is apt to extend to the underlying sclerotic. In such cases all the symptoms of conjunctivitis are considerably aggravated; the pain is more severe, and of an aching rather than of a smarting character; and, instead of being limited to the eyelids and eye, affects the temple and brow, whilst it is always most severe at night. The injection of the superficial conjunctival vessels is considerable; but the general scarlet tint of the eye is considerably lowered, and rendered of a pink or purplish colour, by the injection of the deeper-seated subconjunctival or episcleral veins, which run from the canthi and sinuses in tolerably straight and converging lines towards the border of the cornea. In many instances the distended vessels relieve themselves by an effusion of serous fluid into the subconjunctival tissue, producing smooth, semi-transparent, pale, pink, or yellowish cedematous folds, which overlap the cornea and constitute the state of chemosis. The amount of lachrymation is in general very considerable.

The pain and manifest redness of the eye generally cause even the poorer classes of patients to apply early for relief, and if care be taken the prognosis is in general favourable at this stage; but should the case be neglected, or the patient be exposed to much privation and cold, the continued violent inflammation of the conjunctiva and sclerotic at length interferes with the nutrition of the cornea, a haziness or troubling appears in its substance, and the impairment of vision becomes so considerable, that only large objects can be discerned. The formation of an ulcer is now frequently observed. This is usually situated near the periphery of the cornea, is of an elongated form, nearly transparent, or only moderately hazy at the base and borders, and shallow, but accompanied by very severe aching pain in the temples and brow, coming on at night, or in the early morning, and banishing sleep. Occasionally the ulcer is deep, with indented borders, and occupies

the centre of the cornea; and sometimes the formation of matter takes place between the lamellæ of the cornea (onyx), or collects at the bottom of the anterior chamber (hypopyon).

In severe cases, the deeper structures, as the choroid, iris, and retina, often sympathise with the superficial inflammation, or become affected through the general congestion of the vascular system of the eye; and intolerance of light, with more or less complete loss of sight, contraction of the pupil, and adhesion of the posterior surface of the iris to the capsule of the lens, are of common occurrence. Under these circumstances the prognosis is doubtful, if not unfavourable. A leucomatous opacity always occupies the former site of the ulcer, obstructing vision, according to its position in regard to the pupil, to a greater or less extent; and although it is frequently surprising to see how perfectly dispersion of the opacity takes place, even in old people, some amount of irregularity or facetting of the cornea usually remains, which considerably impairs the usefulness of the organ.

When the inflammation has extended to the iris, the chances of recovery of vision will materially depend upon the presence or absence of posterior synechiæ or adhesions, since, if these have taken place to any considerable extent, the eye is left in a condition which renders it peculiarly liable to fresh inflammation on exposure to sudden variations in the amount of light, or to great alternations of temperature.

In proportion as the inflammation in catarrho-rheumatic ophthalmia is more severe than in simple conjunctivitis, must the treatment adopted be more active and energetic. As confined bowels constitute a powerful predisposing cause of the disease, which occurs most frequently in elderly people, the treatment may in almost all instances be advantageously commenced by the administration of from one to five grains of calomel, and an equal quantity of compound colocyath pill, followed in the course of a few hours by a black draught. The simple unloading of the bowels which follows

these remedies often produces an immediately beneficial effect, the pain and inflammatory redness subside, and the condition and spirits of the patient are materially improved.

The application of a few leeches may now be recommended; and it is surprising to see the effects produced, both on the disease and on the patient, by so small a number as two or three, especially when the bleeding has been maintained for some hours by the application of hot linseed-meal poultices. Dr Mackenzie, writing so lately as 1854, proposes the removal of from ten to thirty ounces of blood from the arm, and the same quantity to be removed on the following day. The patients he treats must indeed be far stronger and healthier than the pallid Londoner of the lower class; for I have repeatedly been told that the application of from two to six leeches, even in well-grown and apparently healthy adults, was followed by complete prostration and a fainting condition lasting for hours; and I do not remember to have seen any case where it was thought necessary to direct that blood should be taken from the arm.

Where the patients have preferred it, I have often ordered cupping to the extent of six ounces, but have good reason for believing that not more than three to four ounces, even including the subsequent bleeding, are really taken away, and yet this invariably produces a powerful effect on the progress of the disease, and blanches the patient perceptibly for some days. The patient should be directed to foment the eyes with hot water and with poppy fomentations. Other local applications, as solutions of nitrate of silver, etc., appear to be of little service, and are on the whole seldom employed.

It is wise to keep the patient within doors for a few days, and a mixture of nitrate of potash (grx), tincture of colchicum (℥xx), tincture of aconite (℥iii) in camphor mixture (ʒi), may be advantageously ordered, especially when ulceration is present. On the decline of the disease, change of air, if possible, should be obtained, and the medicine may be altered

to decoction of cinchona, containing a little compound tincture of cinchona and a little chlorate of potash, or a few minims of nitromuriatic acid. When the disease has shown a tendency to run into the condition of onyx and hypopyon, and particularly in old and feeble persons, I have seen remarkable benefit obtained with great rapidity, by avoiding all lowering measures, as bleeding and purging, and commencing at once with a mixture containing ten to twenty minims of sesquichloride of iron, and a few grains of sulphate of magnesia, with a little tincture of ginger, capsicum, or compound tincture of cardamoms added to prevent griping. In such cases wine should be ordered to the extent of from six to eight or twelve ounces per diem.

Where ulceration is present, or even where there is only a little diffused opacity of the centre of the cornea, paracentesis of the cornea, allowing the escape of the aqueous humour, will often give an instantaneous relief to the pain. Poultices of hot linseed-meal or bread and water should then be applied, and full doses of opium ordered.

The collection of thick matter between the lamellæ of the cornea or onyx should be opened from below with a broad needle, as will be hereafter more fully treated of when the diseases of the cornea are under consideration.

In cases of perforating ulcer, where a portion of the internal margin of the iris has become attached to the cornea, so that the pupil is rendered linear, or is obscured by the cicatrix, Mr Critchett's operation of iridodesis, which will be subsequently described, is extremely useful.

5. *Phlyctenular, Pustular, or Scrofulous Ophthalmia.*

(PLATE IV., Figs. 19 and 20.)

This is one of the most common forms of ophthalmic disease, and is most frequently met with in the ill-fed children of the poor. Amongst 2000 patients who presented themselves indiscriminately at the Hospital during the last

year and a-half, and of whose cases I have preserved notes, 110 were subjects of this disease. Of these, fifty-seven were males and fifty-three were females. The average age was ten, and the prevailing ages were from three to twelve. The youngest was one, and the oldest forty-five.

In this affection one or more little vesicles, which subsequently become pustules, appear upon the conjunctiva, close to the margin of the cornea, and, after enduring for a while, burst, leaving small ulcers, which granulate up and leave no trace of their former existence. Though the disease is often protracted by relapses and the occurrence of fresh crops of pustules round the cornea, and though considerable inflammation of the conjunctiva is often present, it is seldom dangerous to sight, or occasions other ill effects than considerable discomfort and inconvenience to the patient.

In the milder cases, where only one or two vesicles or pustules appear, the early symptoms are very slight. After exposure to a cold draught of air, or some other trivial source of irritation, a small rounded or conical vascular swelling is seen on the conjunctiva close to the edge, and not unfrequently encroaching on the surface of the cornea. A single large vessel, or a triangular-shaped leash of smaller vessels, run up to it, and ramify on and around it. After a few days the centre begins to be semi-transparent, and a small vesicle makes its appearance, which, like a vesicle of herpes, assumes a grey or yellow colour before bursting. When this has taken place, a minute hollow ulcer is left, forming the apex of a red swelling, and usually round or oblong in form. When magnified, the surface of the ulcer appears rough and granular, with shreds of membrane adhering to it, and the edges are in the first instance sharp and well defined, though, when the healing process commences, they become smooth and rounded.

A little smarting pain and irritation, similar to that produced by the entrance of a foreign body under the lids, are usually present, and the patient often complains of increased

flow of tears, and more or less intolerance of light, especially when the pustule is partially seated on the cornea. A little muco-purulent discharge is often visible in the lower fold of the conjunctiva, if the lid be drawn down, and there is some difficulty in opening the eyes after sleep, in consequence of the lids being glued together by the dried secretions. The efforts of the patient to separate them by rubbing and by force, instead of washing them, often lays the foundation of ophthalmia tarsi.

The duration of the disease is very various; in some, all the stages will have run their course in from ten days to a fortnight, whilst in others I have known a single pustule to remain for several weeks, the maturation of the pustule and the healing of the ulcer being accomplished with extreme slowness.

In the more severe cases, which occasionally occur in children that are otherwise the picture of health, several vesicles form in close proximity to one another, presenting the appearance of a little ring of beads round the cornea; whilst in other instances three or four large ones form, generally at some distance from the edge of the cornea, their development giving rise to, or being accompanied by, considerable conjunctivitis. (*See Plate IV., fig. 20.*) Even here, however, the pain is not very great, probably owing to the facility with which the loose tissue of the conjunctiva permits swelling to take place, and the consequent freedom of the nerves from pressure; and the chief discomfort from which the patient appears to suffer, is the drying up of the muco-purulent discharge, which is considerable in quantity. In some few cases, however, severe smarting pain is complained of; and in some strumous children photophobia is present, although this does not constitute a characteristic feature of the affection, nor is it ever so severe as in cases of ulcers seated on the cornea.

Though the ulcers may occur at any part of the circum-

ference of the cornea, I find that, in a considerable proportion of the cases, they appeared on the outer side, and that in a great number of cases the affection was limited to one eye. In most instances it will be found that the bowels are disordered; and a special predisposing cause of the disease is a foregone attack of measles, or some other infantile disease, probably owing to the debility which is left in those who are not very carefully attended.

Amongst a great number of the above 110 cases, in which I could observe nothing remarkable, I noted that the disease was accompanied by herpes or eczema of the face in nine instances; by varicella in two; that it followed measles in six; that it was accompanied by a spongy condition of the gums, causing them to bleed on slight pressure, in two—the photophobia being intense in both; and that in four instances it was preceded by diarrhoea. In one instance it was attributed to a slight blow on the eye, and in one or two women it appeared to arise from the asthenic condition consequent upon severe labours. In 88 cases in which a note was made of the fact, the disease occurred in the left eye alone in 39, in the right eye alone in 30, and in both eyes in 19.

M. Wecker observes that it is only requisite to attend the clinique of M. Marjolin, at the Hospital of St Eugenie for children, situated in the midst of the poor population of the Quartier St Antoine, in Paris, to see how poverty, and its accompanying deficient supply of proper food and cleanliness, bad air, damp rooms, and insufficient exposure to sunlight, constitute predisposing causes of the disease, since one-half of all the children suffer from pustular ophthalmia.

The only diseases with which pustular conjunctivitis can be confounded are episcleritis and pinguecula, in the former of which the tumour is larger, rounded, seated at some distance from the edge of the cornea, having no tendency to ulcerate, and being generally of a duller colour, with the conjunctival vessels ramifying over its surface, and consisting of

an inflammation of the sclerotic coat proper; whilst the latter can only simulate it where the conjunctiva is inflamed, when it remains perfectly white (being non-vascular) amongst the red vessels, and evidently possesses a clear and non-ulcerated surface.

The treatment, when the patient is seen before the vesicle has formed, is to clear out the bowels with an aperient pill and a brisk saline purge. In children, the compound jalap and scammony powder, with one grain of calomel, acts exceedingly well, and the eye may be washed with a little weak alum lotion. If the vesicle has formed, or if it has burst, in either case it should be touched with a fine point of mitigated nitrate of silver, taking care to have a brush dipped in olive oil or solution of common salt, to apply immediately afterwards, so that the action of the caustic may not extend beyond the point originally touched. In more severe cases, where several ulcers and much conjunctival inflammation are present, the application of one or two leeches will effect a marked improvement. A warm poultice applied to the eye at night, and the instillation of two grains of nitrate of silver to one ounce of water, will generally cure the disease.

It is expedient, looking at the generally pallid and cachectic condition of the subjects of the disease, to administer tonics, and of these iron and cinchona are the most valuable. In children, especially of the fair type of strumous constitution, cod-liver oil sometimes answers admirably. The action of any of these tonics will be found to be materially aided by the addition of a glass of wine at dinner time. A mode of treatment for this affection, which has recently been introduced, consists in the insufflation of a small quantity of calomel in a state of impalpable powder, and quite free from the bichloride, into the eye; or it may be easily applied by everting the upper lid, and brushing it over with a dry camel-hair brush dipped in the powder. It is not advisable,

however, to employ this means if the ulcers are seated on the cornea, as it is apt to excite much inflammation.

M. Pagenstecher recommends the employment of the hydrated binocide of mercury, obtained by the addition of solution of potash to the solution of corrosive sublimate, taking care that there is always an excess of the former.¹ The precipitate is to be thoroughly washed, dried by a gentle heat in the dark, and should form an amorphous yellow powder, which is to be most carefully rubbed down with cold cream, in the proportion of from 30 to 60 grains of the precipitate to one ounce of the cold cream. A minute fragment, the size of a pin's head, may then be smeared over the surface of the lid, and allowed to remain for two or three minutes. It is stated that by this means the photophobia is rapidly diminished, and that an obliteration of the capillaries is effected, which prevents the recurrence of the disease. Where any obvious depressing cause, as diarrhoea, is present, it must be relieved by astringents, as the *mist. cret. co.*, followed up by decoction of cinchona and nitric acid.

6. *Purulent Ophthalmia of Infants.*

The purulent ophthalmia of infants must be regarded as a severe form of catarrhal ophthalmia, and we recognise two causes for its occurrence: the presence of a leucorrhœal or of a gonorrhœal discharge in the mother at the time of birth, and exposure to wet and cold, or to some other and unknown atmospheric influence, at a variable period after birth. It may possibly arise in some instances, as Dr Mackenzie suggests, from the entrance of soap or spirit into the eye of the newly-born infant.

The disease under consideration, and the gonorrhœal ophthalmia of adults, are the only forms of purulent ophthalmia common in this country, the so-called Egyptian or contagious ophthalmia of hot climates being, in the acute stage at least,

¹ See Lawrence and Moon's *Handy-Book of Ophth. Surgery*, p. 57, Note. 1866.

very seldom if ever seen, though it is not uncommon to meet with patients who are suffering from its consequences.

The formation and discharge of a little puriform matter from the eyes soon after birth is seen in many, perhaps even in the majority of infants, and is due probably to the mere exposure of the delicate conjunctival mucous membrane to the action of air and cold; but the ordinary attention to cleanliness which the child receives at the hands of the mother or nurse, is in general sufficient to check the progress of the affection, without any special medical treatment. A somewhat higher grade of inflammation is also not unfrequently seen, which is clearly of a catarrhal nature, presenting the usual symptoms of that affection in adults, and which, if neglected, may rapidly pass into a fully-developed attack of purulent ophthalmia.

When the disease arises from contamination of the eye by the mother in the act of birth, the discharge is almost uniformly first noticed within one week after birth. In 65 cases of which I took accurate notes, it was noticed on or before the seventh day in 54, the second, third, and fourth days being by far the most common; but the eyes were often stated to have been weak from birth. Those cases which occur after the second or third week, and are sometimes seen at a much later period, can scarcely be attributed to inoculation, but seem rather to be acute catarrhal cases, dependent upon atmospheric conditions, which, like other infantile affections, run their course with great rapidity and vehemence, but nevertheless agree in all essential particulars with the more frequently seen form of infantile ophthalmia arising from infection.

The number of cases of purulent ophthalmia occurring at the Hospital in infants during one year (1864-65) was 76, out of a total of 7200 cases, or rather more than one per cent. The number of males and females was equal. The frequency with which leucorrhœal or gonorrhœal discharges in

the mother are associated with purulent ophthalmia in the adult, may be judged by the observations of Dr Lederschold,¹ who found that, amongst 30 infants born in the Maternity Hospital at Stockholm, and affected with purulent ophthalmia, no less than 20 were born of mothers suffering from vaginal discharges, and 10 of mothers who had no discharge. Amongst the 65 cases above mentioned, I ascertained the presence of leucorrhœa in the mother in 27 cases, and of gonorrhœa in four; though these numbers certainly do not indicate the true proportion of cases, since in some instances the child was brought by the nurse or by friends, and no reliable information could be obtained.

The symptoms which present themselves in an ordinary case of purulent ophthalmia are, that in the course of the first two or three days after birth the eyes of the infant are observed to be weak and watery, and to discharge a little thin straw-coloured fluid; the lids, especially the upper ones, are slightly swollen and red at their ciliary margins, and there is more or less intolerance of light. On the third day the discharge has become more opaque and creamy, and, on microscopical examination, is found to consist partly of altered epithelium, partly of mucus, and partly of pus corpuscles. It collects in the palpebral sinuses and in the corners of the eyes, and, when the lids are separated, forms streaks and coherent laminae over the cornea. On everting the upper lid, its surface is found to be of a deeper red than natural, the papillæ enlarged, and a little of the discharge adhering to them. At this stage the affection is probably still curable by simple attention to cleanliness; but if it be neglected its violence rapidly increases. The lids in a few days become much swollen and œdematous, and of a light pink or rose colour; the discharge becomes very abundant, reappearing immediately after it has been wiped away, and during sleep dries along the edges of the lids, agglutinating them together,

¹ Med. Gaz., vol. xxvii. p. 382.

so that the child on awakening is unable to open the eyes. The pus is then removed with much less frequency, because less noticed. It collects under the closed lids, greatly distending them, yet not appearing to occasion very much pain or distress. Every now and then a burst of the discharge takes place at the inner canthus; or, if an attempt be made to separate the lids after they have been gently sponged with warm water, large drops of yellow pus ooze forth. On evert- ing the upper lid at this stage, the papillæ are found to have considerably increased in size, apparently from vascular congestion and serous infiltration. Either at this, or at a somewhat later period, serous effusion takes place into the texture of the ocular conjunctiva, probably in consequence of pressure on the veins producing the semi-transparent red swelling around the cornea known as chemosis; and this, by co- operating with the tumefaction of the mucous membrane lining the upper lid, occasions, in some instances, its spontaneous eversion, and, by interfering with the nutrition of the cornea, induces the ulceration or sloughing of that tunic. The vascular engorgement is so great in some cases, that the discharge assumes a reddish tint, and, more rarely, hæmorrhage occurs, which, by relieving the vessels, is generally followed by temporary diminution of the swelling and discharge.

In many instances the disease, having attained its height about the end of the second week, gradually declines in intensity; the redness and swelling diminish, the discharge becomes less abundant, and changes from a puriform to an opalescent serous fluid, and the child is again able to open the eyes. On examining the inner surface of the lids, the enlargement of the papillæ will be found to have in great measure disappeared, though some of those that are situated in the upper palpebral sinus, or on the inner surface of the lid, above the border of the tarsal cartilage, retain for many weeks a larger size and more brilliant colour than natural; and it is observable that, so long as this is present, there

is a liability to relapse on exposure to cold or other irritation.

In cases, on the other hand, where the disease is allowed to advance without any attempt being made to check its progress, the course of events is usually that, after the discharge has been abundant, and the lids much swollen and congested for about ten days, on separating the lids the surface of the cornea will be found to have lost its polish and transparency at some part generally near the margin, owing to separation of the epithelium and to commencing inflammatory changes. The cloudiness soon extends, and becomes so opaque that the pupil can no longer be seen through it, and the whole thickness of the cornea appears to be affected; its colour and consistence alter; it becomes of a yellowish or dull reddish tint, and more or less flaccid and depressed. The formation of a large central penetrating ulcer is coincident with these changes, and fine vessels advance over the surface of the cornea and between its layers. Sometimes perforation takes place at once, a portion of the cornea sloughing away; at others, a staphylomatous protrusion of the internal elastic lamina is visible for a short time, which at length gives way, and permits the escape of the aqueous humour and the prolapse of the iris; whilst in other instances, again, cicatrization takes place without perforation. In the former cases, as soon as the aqueous has escaped, the resiliency of the contents of the globe and of the external tissues presses the lens, and with it the iris, forwards, so that the anterior chamber, always small in children, is almost obliterated; the pupil soon becomes nearly or altogether closed by the adherence of the margin of the iris to the edges of the ulcer; and this, as will hereafter be shown, is the usual foundation and precursory stage of staphyloma corneæ, the weak cicatricial tissue closing the perforation and continuous with the attached iris being insufficient to withstand the pressure from behind. Coincidentally with the changes in the cornea, the discharge from

the conjunctiva usually becomes thinner and sanious, and less abundant. As a general rule, after perforation has taken place, a persistent and strongly-marked leucoma indicates the former position of the ulcer, and is occasioned by the presence of cicatricial tissue. It is nevertheless wonderful to see in how many instances deep opacities of the cornea occurring in very young children altogether disappear in the course of a few months or years, or leave only a faint nebulosity and slight facetting of its surface.

An occasional result of perforation of the cornea is the formation of a capsulo-lenticular cataract, in which a minute white dot appears upon the centre of the capsule of the lens, the substance of which remains either clear or more or less opaque. (*See Plate viii., fig. 46*). This is persistent through life.

Both eyes are almost always affected coincidently in purulent ophthalmia; occasionally, however, one is alone inflamed, or is affected for a considerable period before the other is attacked. When this is the case, every care should be taken, by shielding the sound eye with a compress and bandage, to prevent its becoming implicated in the disease.

The origin of the immense quantities of pus discharged from the conjunctiva in purulent ophthalmia is a subject of interest, and has been especially investigated by M. Prosoroff,¹ who has shown that, shortly after the introduction of any irritant substance into the eye, the epithelial cells undergo a series of changes, the superficial ones assuming a spherical, the deeper ones an oval, form. The nuclei of the cells then divide, and, after a short space, the cell-walls and the contents of the cells appear to break down, and the nuclei, which have already begun to possess well-defined nucleoli, are set free, and form the pus corpuscles. All these changes are effected with great rapidity.

As regards the treatment, it is scarcely too much to say

¹ Arch. f. Ophth. Bd. ii., Heft. xi. p. 135. 1865.

that, in private practice, no case, if seen sufficiently early by the surgeon, should ever be lost. In Hospital practice it is different. There the want of faith in the virtue of cleanliness so characteristic of the lower classes, the neglect to which the child is exposed from the necessity of the mother's attending to her household duties, and the late period to which the parents defer bringing the child to the Hospital, all militate against a perfect and speedy cure. But even here, unless the nurse or parents are exceedingly obtuse or careless, the disease is curable (providing no serious inflammatory changes have taken place in the cornea) in the course of from three weeks to a month, the discharge being materially relieved in a few days, though there still remains so much congestion that very brief neglect of cleanliness, or undue exposure to cold, will occasion a relapse.

The first and most essential part of the treatment consists in the constant removal of the discharges from the eye as soon as it is formed; and if the mode of accomplishing this be properly explained to the nurse, it may be safely left in her hands. She should be directed to obtain an india-rubber syringe, with ivory nozzle, and to direct a stream of tepid or of cold water every hour upon the eyes of the child, taking care that the concretions along the edges are thoroughly washed away, and that the stream gains entrance between the edges of the lids to the surface of the eye itself. When the whole of the matter has been thus removed, a few drops of a solution of alum, containing from two to ten grains to the ounce of water, should be dropped into the eye. Once a-day this process of ablution should be performed by the surgeon, after which a two, four, or ten grain solution of nitrate of silver, providing the cornea is not affected, may be instilled. An instrument that is still more convenient than the india-rubber syringe for Hospital use, where many cases have to be attended to, consists of a tin canister, into the lower part of which a pipe is soldered, connected with a yard

or two of india-rubber tubing, ending in a brass nozzle and stop-cock; if the vessel be filled with water, and placed on a shelf six or seven feet high, a little jet is obtained on turning the stop-cock, which, whilst it possesses any desired amount of force, is perfectly steady, and can be directed with the greatest facility to any part of the lids. In cases where the cornea is affected, and an ulcer is present, the stream of water directed against the eye should be very gentle, the use of the syringe by the nurse should be interdicted, and she should be directed simply to wipe away the secretion that is formed with a clean piece of cotton wool or lint. Throughout the whole course of the disease, it is advisable to touch the lids with a little sweet oil before the child sleeps, to prevent their adherence.

It is not superfluous to observe, that great care should always be taken by the person entrusted with the duty of removing the collection of matter from the eyes by injection, that none of the fluid enter his own eyes, as it is certain to excite severe inflammation, even when immediate measures are taken to remove it by directing a continuous stream of water on the everted lids and into the palpebral sinuses, as I have had several opportunities of observing.

A plan of treatment, followed by good results in the hands of Dr Macmillan,¹ and speedily affecting the arrest of the purulent discharge (four or five days), consists in the application to the inner surface of the lids of a solution of five grains of chloride of zinc in half-an-ounce of glycerine, with a camel-hair brush, thrice a-day, with the frequent use of warm ablution and pure glycerine to the edges of the lid.

Instead of solutions of nitrate of silver, or other astringent salts, v. Gräfe,² Wecker,³ Desmarres, and others, recommend the employment of a solid stick of nitrate of silver, the strength of which has been moderated or lowered by admixture with nitrate of potash, or other neutral salt, in the

¹ Med. Times and Gaz., vol. ii. p. 7. 1858.

² Archiv. f. Ophth., Bd. i. 1. ³ Etudes Ophthalmol., vol. i. p. 45.

proportion of one part of the former to two or three of the latter. This is applied to the inner surface of the lids, and to the superior and inferior *culs-de-sac* of the conjunctiva, when it occasions a thin white eschar; and the action of the caustic should be prevented from extending by painting the parts all over with a brush dipped in solution of common salt. Considerable pain and lachrymation succeed the application of the caustic. The temperature of the lids rises, and in the course of an hour or two the eschar has become detached, and separates in flakes and fragments. Then follows, according to M. Wecker, a period of remission of all the symptoms during which the epithelium is undergoing regeneration, but which, after lasting for a variable period, is itself followed by a third period of recrudescence, in which all the primary symptoms are apt to recur, unless a fresh cauterisation be made. Some judgment is required to determine the precise period when the second application of the caustic is requisite. It should be after the eschar produced by the first has separated, when the epithelial cells are regenerated, and before the period of recrudescence has attained its full intensity. Cold applications of iced water, frequently repeated, immediately after each cauterisation, are of essential service in promoting the contraction of the distended vessels of the mucous membrane. As a general rule, the lids may be touched with the caustic every twenty-four hours; but in severe cases it is required every twelve hours; and in mild cases, and when the violence of the disease is abated, every forty-eight hours is sufficient.

When, on examination, the cornea presents an opaque or ulcerated surface, the instillation of the solution of atropine should be at once commenced, which, by diminishing interocular pressure, and, consequently, the tension of the cornea, promotes granulation, and, in the event of perforation taking place, prevents the iris from becoming implicated in the lips of the wound, and the consequent formation of a staphyloma.

When perforation of the cornea appears imminent, it is expedient to pass a needle through some part which remains transparent, and thus to permit the escape of the aqueous humour. An immediate remission of the symptoms is always obtained by this means; and if the appearance of the ulcer does not rapidly improve, the tapping may be repeated two or three times. The actual perforation of the ulcer itself should always be avoided if possible; for not only is the iris almost certainly brought into contact with the edges of the ulcer, leading to anterior synechia and anterior staphyloma, but the lens and capsule being thrust forward by the elasticity of the contents of the globe, are also brought into immediate contact with the cornea, with the result, in many instances, as already stated, of the formation of a minute white spot on the centre of the capsule, the so-called capsulo-lenticular cataract.

In cases where a staphylomatous protrusion of the internal elastic lamina of the cornea is already present, little can be done beyond applying a fine point of nitrate of silver to it, and removing any excess by the application of a brush dipped in salt and water. A pad of cotton wool may then be placed on the eye, and kept in position by a firm compressing bandage, both of which, however, should be frequently removed, in order that the eye may be cleansed.

The evil results which may follow severe cases of purulent ophthalmia have already been incidentally mentioned, but may here be collectively given. They are: a congested state of the lids and enlargement of the papillæ upon them, leading to frequent relapses,—nebulæ and leucomata,—or, in other words, superficial and deep opacities of the cornea, superficial keratitis, perforating ulcers, or sloughing of the cornea, leading to escape of the aqueous, and even of the lens, of which most hospital surgeons must have had opportunities of observing instances; capsular cataract; and according to whether the iris has or has not formed adhesions to the margins of the

ulcer, anterior synechia, and anterior staphyloma; posterior synechia; and, lastly, collapse of the globe and general atrophy. For the treatment of some of these complications and terminations, the reader is referred to the sections on the diseases of the cornea and iris respectively.

The following notes will show the progress and termination of a severe case. A female child, ten days old, was brought to the Hospital with purulent ophthalmia. The discharge had been observed for five or six days, but the eyes had been weak from birth. The mother was a pale, delicate-looking woman, had given birth to two children within eleven months, and suffered severely from leucorrhœa. Both of the eyelids of the child were much swollen and congested. The discharge was copious, thick, and yellow. There was much difficulty in obtaining a view of the cornea, but that of the right eye appeared to be nearly opaque, and of the left perfectly clear. The eyes were thoroughly washed with cold water, and a drop of a weak solution of nitrate of silver (grii. ad. ʒj.) instilled into each eye. The nurse was directed to keep the eye thoroughly clean, and to wash it out with a small india-rubber injection bottle every hour. Two days after, the discharge was much less, and the congestion diminished. Finding that the eyes were much improved, the care and attention previously devoted to the child were relaxed, and after the lapse of three days she was again brought to the Hospital suffering from a relapse. The lids were now much swollen, the right to so great a degree that, without using more force than was justifiable, no examination of the cornea could be obtained. The left was still clear. The mother and nurse were again exhorted to wash the eyes assiduously with cold water, and to keep them thoroughly clean by removing any discharge as soon as it appeared. In a few days the swelling of the lids had again so far subsided as to permit the cornea to be examined, when the right was found to have a moderately dense, white, nebulous patch

occupying its lower segment, through which the pupil could be dimly seen; solution of belladonna was inserted. The next day, the ninth from the first attendance, a change for the worse occurred. The right cornea appeared flaccid and depressed, and its opacity had increased in extent and intensity, although the discharge had diminished; the left cornea still remained perfectly clear. On the thirteenth day of attendance, the flaccid cornea began to yield and form a staphylomatous protrusion, which, owing to the extension of vessels over and in the substance of the cornea, assumed a dim red colour. Solution of atropine and a compress were applied. The next day the softened portion of the cornea had become detached, and a small clear bead formed by a protrusion of the elastic lining membrane of the cornea appeared. This was touched with a point of nitrate of silver, and the pad and bandage again applied. On the nineteenth day, the nurse having omitted to bring the child in the intervening period, the staphylomatous protrusion was nearly the size of a large split-pea, and oval in form. The discharge from the right eye was still considerable, but that from the left had ceased, and the cornea was clear. The protrusion was again touched with nitrate of silver, a puncture was made through the lower part of the cornea, and alum solution directed to be frequently employed. In the course of the following fortnight, the protrusion gradually subsided, and the discharge ceased in the right eye; but a recurrence of the discharge occurred in the left, from exposure to cold and neglect. Thirty-five days from the child's first appearance, the note made was, "Little discharge from left eye; staphylomatous protrusion of right cornea now reduced to the size of a pin's head; the corneal tissue around the protrusion opaque; little or no discharge from the eye." On the forty-fifth day the child was brought again with recurrence of the discharge, having caught cold, and on the fifty-fifth day both eyes were discharging pus profusely. Some small aperient and alterative powders of rhu-

barb, carbonate of magnesia, and hydrargyrum cum cretâ were ordered to be given twice a-week; the washing of the eye and the instillation of alum lotion as before. Under this treatment the symptoms again quickly disappeared. In the last note taken, which was on the seventy-first day of attendance, it is stated that the child's eyes were then clear and free from discharge; the right eye wonderfully improved, presenting only a leucomatous patch on the lower segment of the cornea, to which the pupil is adherent through the greater part of its extent; the upper part, however, through which there is no doubt the child can see, remaining free.

It is not always that an issue so favourable as occurred in this case can be looked for; but it furnishes a good example of some of the more important complications that may occur in the progress of the disease, as the liability to relapse, the ulceration and staphylomatous protrusion of the cornea, the implication of the iris partially rescued no doubt by the instillation of the atropine, and the leucomatous opacity. It exhibits also clearly the extraordinary conservative powers of nature in clearing away opacities of the cornea, for on several occasions there appeared to be no doubt that the sight of the right eye was irretrievably lost.

7. *Contagious or Egyptian Ophthalmia.*

This disease, like the purulent ophthalmia of infants, may be regarded as an intense and exaggerated form of ordinary catarrhal ophthalmia, the inflammation commencing in, and for a considerable period being limited to, the conjunctiva; but from the enormous swelling, and consequent pressure upon the adjoining tissues, leading to impairment of the nutrition of the cornea, which frequently sloughs or ulcerates, the result being, in many instances, the partial or total abolition of sight in one or both eyes. Formerly it was one of the scourges of the army, and appears to have been brought over to this country by the soldiers returning from the Egyptian

campaigns in 1800-1-2, when large numbers of pensioners were thrown upon the public charity by the blindness thus occasioned. It is now, however, partly from the improvement in surgical knowledge of the diseases of the eye, leading to an early recognition and treatment of the disease when it appears, but chiefly, no doubt, to improved hygienic conditions, and especially enlarged barrack accommodation and purer supplies of water, almost unknown in this country. During the past ten years, I can scarcely recall half-a-dozen cases which have presented themselves in an hospital where six or seven thousand out-patients are annually treated; and these have been for the most part of a mild type, and have terminated favourably. It is not surprising, however, that considering the facility with which it can be communicated from man to man, it should rapidly spread amongst soldiers on active service, since it was stated, only a few years ago, that the ventilation of the sleeping wards of some of the troops, even in London, was of the most imperfect description, and that the men were accustomed to wash themselves in the chamber utensils.

The first symptoms that make their appearance are precisely similar to those of a severe attack of catarrhal ophthalmia. The patients complain of an itching or smarting sensation in the lids on moving the eye, comparable to that produced by the entrance of fine sand or dust, which is, no doubt, due to dryness of the palpebral mucous membrane, and to enlargement of the conjunctival vessels. The irritation thus produced, after lasting for a short period, excites an abundant discharge of hot tears, which flow over the cheeks. The lids begin to swell, and upon everting the upper lid, it is found to present a deep red colour. The papillæ, in particular, are large, red, and prominent, giving the surface a granular appearance, though no true granulations are present. The vessels of the conjunctiva and of the subconjunctival tissue enlarge, giving to the eye a brilliant red

colour, and effusion soon begins to take place, raising the membrane in large chemotic folds, which overlap and partially conceal the cornea, and ecchymoses, or even hæmorrhages, are frequently observed. The discharge, at first thin and watery, and chiefly consisting of the tears, soon becomes of a serous or slippery character, and lightly stained with blood; and this again rapidly changes into an opaline fluid, becoming hourly more thick, till at last it presents the character of true pus. The quantity of this which is discharged is noted by all observers as being extraordinary. Dr Veitch, who had extensive opportunities of observing the disease, states that it amounted, in some of the cases under his care, to several ounces in the twenty-four hours, and that after being thoroughly cleared away from the eyes, a few minutes sufficed to cause its reaccumulation. When the acute stage of the inflammation has passed away, the discharge becomes less abundant, and altered to a muco-purulent or blennorrhœal fluid, that continues to flow for a considerable period. This secretion is in the highest degree inoculable, and the smallest portion gaining entrance into the healthy eye, induces a disease which in general runs through a similar course, though, according to Wecker,¹ it may give rise to an attack of diphtheritic ophthalmia.

With the formation and discharge of pus from the eye the symptoms attain their acmé. The lids are then of a deep purple colour, and enormously swollen, and the mucous membrane is so tumefied that ectropion sometimes spontaneously takes place, whilst the chemosed folds of the conjunctiva protrude through the aperture of the lids. Their temperature is greatly increased, and the sufferings of the patient becomes considerably augmented, lancinating pains being experienced in the globe, which radiate to the brows and temple. With all this local inflammation, however, there is little or no constitutional disturbance; and if the lids

¹ *Etudes Ophthal.*, vol. i. p. 32.

can be separated, the vision may still be found to be perfect. A certain degree of intolerance of light is generally observed to be present, and is sometimes, as in the cases observed by v. Roosbröck,¹ intense. It seems probable, however, as Middlemore² suggests, that this symptom is not dependent on the sympathy of the retina with the inflammation of the conjunctiva, but that it is owing to the general excitement of the vascular system of the eye, and to a commencing participation in the inflammation on the part of either the cornea, the sclerotic, or the membrane of the aqueous humour.

At this period all the vessels are densely congested, and no separate trunks can be distinguished, and the disease quickly hastens on to one or other of its ordinary terminations.

In favourable cases, where a moderate degree of attention has been paid to cleanliness, the symptoms subside in the course of a few days; the pain, swelling, and redness diminish, the discharge decreases, and assumes a muco-purulent character, and the lids can again be opened, and sight returns. Such a termination in resolution of the inflammation may occur in the most severe cases, but the lids long remain swollen and hypertrophic, liable to relapses of the inflammatory symptoms, and, in the case of the lower lid, so relaxed that ectropion frequently takes place.

In too many cases, however, when the inflammation has run high, and when the knowledge or the means requisite for its cure in the early stages have not been at hand, as in the case of sailors, etc., a most serious train of symptoms supervenes, terminating in loss of sight. This disastrous termination is almost always due to the impairment of the nutrition of the cornea resulting from the pressure on the vessels supplying it, or from the stasis of the blood in their interior. The first appearance of disease presented by the cornea is, that its surface, especially near the margin, is dull, and its structure

¹ *Annales d'Oculist.*, t. xxx. p. 44. 1853.

² *Treatise on the Diseases of the Eye*, vol. i. p. 116. 1835.

rendered opaline, probably from an œdematous condition of, or serous infiltration between, the laminae. The clouded appearance assumes a deeper yellowish colour, exfoliation of the epithelium occurs, and an ulcer soon makes its appearance. This frequently extends in a circular direction round the margin of the cornea, and, deepening, may ultimately cause perforation, loss of the aqueous humour, protrusion of the iris, and collapse of the eye, or the gradual formation of an anterior staphyloma. In many cases, before perforation occurs, a deposit of pus occurs in the laminae of the cornea, of irregular form, constituting an onyx of variable size; whilst at others the matter accumulates in the anterior chamber, and forms an hypopyon.

Veitch observes that rupture of the cornea may take place whilst it is yet perfectly transparent and its structure unimpaired; but M. Wecker has shown that this statement is founded on a fallacy, and that in the cases where this anomalous occurrence presents itself, the cornea has in reality undergone profound alterations of structure; that its epithelial layer near the centre has separated; that the subjacent lamellæ have become eroded, till an ulcer of considerable depth has formed, the base still retaining its transparency, or only temporarily becoming yellowish and opaque; and that when the posterior surface is nearly reached, the intra-ocular pressure causes the deeper layers to protrude, till they attain the level of the rest of the surface; and thus, though extremely thin, and liable to rupture, the transparency of the part, and the retention of sight by the patient, may easily mislead the surgeon, unless he examines the cornea with the utmost care.

From some of these conditions, however, perfect recovery may take place, not, indeed, when a portion of the cornea has sloughed, or when the iris has protruded, but from the ulceration, onyx, and hypopyon, the matter disappearing by solution and absorption, and the ulcers filling up by granulation.

The whole course of the disease very closely resembles the purulent ophthalmia of infants, and the gonorrhœal ophthalmia of adults. It is distinguished from diphtheritic inflammation by the subconjunctival exudation being serous, and not of a fibrinous character, as in the latter affection, by the greater redness of the surface, and more complete vascular injection, causing bleeding to take place on the least touch. From an acute attack of granular lids it is recognised by the much greater swelling and more rapid progress of the whole affection, and by the absence of the peculiar whitish elevations on the mucous membrane, quite distinct in their appearance from enlarged papillæ, which characterise the true granular lids.

If the disease be seen in the early stage, assiduous attention to cleanliness, with the application of the mitigated nitrate of silver to the mucous membrane of the lids, and of mild astringent lotions, will, as in the analogous cases of purulent and gonorrhœal ophthalmia, effect a cure. When only one eye is affected, every care should be taken to preserve the other from inoculation. This may be accomplished either by applying a compress and bandage to the sound eye, or, which is preferable, since it allows the patient the use of the eye, the employment of a glass shield, fitting closely around the eye, as recommended by Snellen and Donders.

The remaining principles of treatment are so precisely similar to those recommended in the case of purulent ophthalmia of infants, that it has not been thought requisite to repeat them, and the reader is referred to that section. The only point to which attention may be directed is the recommendation recently made by v. Gräfe of the aqua chlori, which proves extremely serviceable in reducing the amount of discharge, and may be used, providing the conjunctival inflammation is not very severe, and there is no inflammation of the cornea present.

8. *Gonorrhœal Ophthalmia.*

(PLATE XI., Fig. 62.)

This is one of the most serious diseases to which the eye is subject. Violent in its onset, rapid in its progress, and quickly communicated from one to the other eye, it is, if neglected, invariably attended with loss of sight; and it is only a matter of surprise that, considering the frequency of gonorrhœa, so few cases of this disease should occur; yet, when seen at its commencement, it may be said to be fairly under our control, and blindness, if it ever occur, should at least be the exception to the rule.

The disease arises from the introduction of some of the urethral discharge into the eye, and is much more frequent in males than in females. A very few hours elapse after the contact of the poison with the mucous membrane before more or less smarting and pricking pain are experienced, with an increased flow of tears. The lids soon swell, a yellowish thin fluid is poured forth, which quickly becomes opaline and then purulent, and rapidly increases in quantity, at first collecting between the adherent lids and the globe, then bursting out at the inner canthus, and trickling in great drops down the cheek. Much burning heat and pain accompany these symptoms, though sometimes only a sense of tension is complained of. The lids attain a great size and assume a livid colour, whilst their internal surface is red, villous, and easily bleeds. On separating them, after they have been gently sponged, the cornea is seen in the early stages perfectly bright and clear, though its surface may be smirched with the purulent fluid; the conjunctiva is extremely red and vascular, and very soon passes into the condition of chemosis, the œdematous folds overlapping the margins of the cornea, and protruding between the lids. Where this state has continued for a period varying from a few hours to some days, according to the violence of the inflammation, the nutrition of the cornea begins to be

impaired; a portion of its surface presents a dull appearance, in consequence of the separation of the epithelium; or its substance, especially near the margin, appears hazy and troubled, from what was formerly considered to be a deposition of lymph, but is now attributed to the development of nuclei. At a later period, the discharge from the conjunctiva still continuing profuse, the formation of pus takes place, between the lamellæ of the cornea, giving rise to onyx, and ulceration or sloughing may then ensue. If the latter events occur, the humours of the eye escape, the lens is thrust forwards towards the cornea, pushing the iris before it, leading to obliteration of the anterior chamber of the eye, and to anterior or posterior synechiæ; the eye collapses, and relief of the pain and subsidence of the swelling of the lids follow; but with the shrinking of the globe all hope of restoration of sight is lost. Here, as in the purulent ophthalmia of children, it is not uncommon to meet with cases where, after the ulcer has penetrated through the substance of the cornea, the posterior elastic lamina still remains intact, and then protrudes as a transparent bead, permitting the patient to regain perception of external objects, and giving false hope of permanent improvement. After it has given way, the iris generally becomes attached to the edges of the ulcer, and, yielding to the intra-ocular pressure, forms a reddish brown button, on which some vessels may be seen ramifying, and which, on the decline of the disease, undergoes a gradual process of flattening. In general the ultimate result is, that the corneal surface becomes contracted in diameter, its texture more or less opacified and vascularised, and the anterior chamber entirely obliterated. In other instances the iris, instead of being withdrawn, continues to yield to the intra-ocular pressure, and a lobulated swelling forms, composed of the iris and the remains of the cornea, which was formerly, on account of its lobulated appearance, termed *staphyloma racemosum*.

In many cases the ulcer is seated near the periphery of the

cornea, and pursues a circular course round a part or the whole of its circumference, the central part soon dying for want of nourishment, and again leading to the conditions which have just been described.

In this disease, as in the other forms of purulent ophthalmia, the discharge when fresh is of the most dangerously infectious nature, and the abundance with which it is poured forth is most remarkable. Its introduction into the eyes of the attendants during the process of ablution, and, if the disease should fortunately be limited to one eye, its entrance into the opposite eye of the patient, should be most sedulously guarded against by the application of a pad of cotton wool, and of a broad linen bandage, or, still better, of a glass shell over the sound eye. The contagious character of the discharge, however, appears to be soon lost after exposure to the air, or to the action of water. Thus M. Wecker¹ observes that it is no longer capable of exciting inflammation if it have been mingled with from 50 to 100 times its bulk of water, and that it is rendered innocuous even by mere drying on linen, in the course of from 36 to 48 hours. The origin of the discharge has already been referred to, under the head of the Purulent Ophthalmia of Children.

In few affections has the treatment commonly adopted undergone a more complete revolution than in this. Formerly the antiphlogistic plan was carried to its fullest extent; the patient was freely bled, blistered, and purged, and calomel was liberally administered; but Mr Lawrence, writing in 1848, seems already to doubt the propriety of this practice, and speaks very guardedly of its advantages in the early stages of the malady, whilst protesting against its adoption if the cornea have begun to suffer.

The treatment now generally practised is very simple, and certainly more efficacious. Instead of depleting the patient, he is supported and stimulated, the good effects of which are

¹ *Etudes Ophthalmol.*, t. i. p. 68.

almost immediate in the pallid, cachectic, and half-starved men who are most commonly the subjects of the disease. The patient should at once be put to bed, and it should be the duty of an attendant to remove all collection of matter, and to prevent its reaccumulation by the injection from an india-rubber bottle of either pure cold water or a solution of alum, containing two grains to the ounce, regularly every quarter or every half hour throughout the day, dropping into the eye, after each ablution, a drop of nitrate of silver, of the strength of two grains to the ounce; or, as Mr Collis¹ recommends, one quarter of a grain to the ounce. The patient is at the same time allowed good diet, as half-a-pound of rump steak twice a-day, with a pint of beer; and he should be directed to take a mixture containing one or two grains of quinine every eight hours. Under this plan of treatment the purulent secretion quickly diminishes (when the nitrate of silver drops may be used more rarely), the swelling of the lids ceases, and in the course of a week the patient is convalescent.

If the cornea appear to be implicated in the first instance, whilst the same general measures are adopted, it is prudent to instil a solution of atropine, for the purpose alike of diminishing the intra-ocular pressure, and of lessening the chance of anterior synechiæ, in the event of a perforating ulcer occurring. If this have already taken place, and the iris protrudes, the staphyloma must be touched with nitrate of silver, either pure or in the mitigated form; but the utmost that can be looked or hoped for in these cases is, that a portion of the cornea may remain clear, permitting the performance, at a subsequent period, of one or other of the operations for artificial pupil.

According to M. Wecker, the disease we are now about to describe, diphtheritic ophthalmia, is an occasional result of the inoculation of the eye with purulent ophthalmia, the

¹ Dub. Quart. Journ. of Med. Sci., vol. xxxv. p. 5.

disease then running a very violent and destructive course, and requiring for its treatment bleeding and the local and general exhibition of mercury.

The treatment adopted by this writer consists in the application of from 24 to 36 leeches, one after the other, so as to keep up a continuous stream of blood, the application of iced compresses, and the administration of calomel till the gums are affected—measures which, it appears to us, are unnecessary, in view of the satisfactory results obtained by the simpler means above described. He also cautions against the use of nitrate of silver, lest a stasis of blood should be induced, and the conditions proper to diphtheritic ophthalmia be established.

9. *Diphtheritic Conjunctivitis.*

With the exception of a few scattered notices, the first accurate and detailed description of this disease was given by Prof. A. v. Gräfe.¹ It is almost unknown in this country, and scarcely any English works with which I am acquainted contain a full account of it; whilst it is so common in Germany, where it appears to occur both in a sporadic and epidemic form, that v. Gräfe, in 1855, had witnessed forty-eight cases, and Dr Jacobson had seen no fewer than sixty-two cases, in a total number of about 10,000 patients. It appears to be almost as rare in France and Belgium as it is in England.

It presents certain points of similarity to ordinary purulent ophthalmia; but there are many circumstances which show that the two affections are not identical. Some surgeons, however, with M. Marjolin, think that diphtheritic conjunctivitis is only a modification, or rather a complica-

¹ Archiv. f. Ophth., p. 168, 1854-5; but, more recently, excellent descriptions of the disease have been given by M. Wecker, *Etudes Ophthalmologiques*, t. i. p. 70; by J. Jacobson, *Archiv. f. Ophth. Bd. vi., Abtheil. ii.* p. 180, 1860; by M. Buisson, *Tribute à la Chirurgie*, 1861; and by Cyprien Raynaud, *Thesis.*, Paris, 1866,—from which authors the following account is derived.

tion, of purulent ophthalmia. Diphtheritic conjunctivitis is rarely seen in adults, and is most common in children of from two to eight years of age, affecting boys rather than girls. The strong and healthy, as well as the weak, the delicate, and the strumous, are exposed to its attacks; but the latter are most liable, and it is frequently seen in those convalescent from an attack of one of the eruptive fevers, and in children who are teething. According to v. Gräfe, inherited syphilis may be regarded as a predisposing cause, since he was able to ascertain its presence in eight of his forty-eight cases. It frequently appears when a sudden fall of temperature follows long continued heat, especially if there be much moisture in the air. Of its epidemic character there can be no doubt, as v. Gräfe himself has observed three or more epidemics of it in succession, at different seasons of the year; like other epidemic affections, the first cases are always the most severe, and its visitation has been observed to be concurrent with that of other diphtheritic diseases; but the question of its contagiousness is still undetermined. M. Cayraud is opposed to its being a contagious affection, on the ground that M. Peter applied a portion of the matter exuding from the conjunctiva to one of his own tonsils without observing any ill effect. The attack comes on with great suddenness, and usually makes its first appearance on the inner surface of the upper lid. If this be everted, which can only be accomplished at the cost of much suffering to the patient, the surface of the conjunctiva is seen to be smooth and comparatively dry, in this respect (unless it be of catarrhal origin, which is of rare occurrence) strongly contrasting with the condition of the lids in purulent ophthalmia. The tissues of the lids are infiltrated with a dense fibrinous exudation, which materially interferes with the circulation of the blood through its vessels, and causes such enormous swelling, as to lead a practised observer at once to form a diagnosis. The external surface of the lid is bright, glossy, and of a dark

purple colour, resembling an abscess, whilst the inner surface is pale, with a few irregularly distributed vessels cropping up, and then suddenly again descending, and in many cases distended to so great a degree as to rupture, leading to the formation of minute ecchymoses. The Meibomian follicles are not distinguishable. The disease soon extends to the lower lid, and both become so rigid and tense that they can only be separated from one another with the greatest difficulty. The conjunctiva oculi becomes chemotic at an early period, but the tumefaction is not due to serous but to fibrinous infiltration; and if incisions be made into it, no fluid escapes. The subjective symptoms are very characteristic. Pain of the most severe lancinating and burning character is almost always present, and the lids are exquisitely tender to the touch. The temperature of the parts is so remarkably elevated, that v. Gräfe describes it as *calor mordax*, and states that, in order to keep the parts at a moderate temperature, it is sometimes requisite to renew even iced cloths two or three times in the minute. The swelling and rigidity of the lids is so great that the patient finds it impossible to open the eye, and there is usually a marked degree of photophobia present.

In some instances, patches of fibrinous exudation make their appearance on the surface of the conjunctiva, at first in the form of small grey points, which become more and more numerous and larger, till at last they blend into a uniform, very thin and delicate, almost transparent, layer, which ultimately becomes converted into a hard opaque lardaceous mass, analogous to that which infiltrates the conjunctiva and all the tissues of the lids, obliterating their vessels, and conferring upon them a grey aspect, in striking contrast with the red and villous appearance of the conjunctiva in ordinary purulent ophthalmia. This exudation is composed of fibrinous and coagulable material.

In the earlier periods of the disease, a thin discharge occurs, which soon becomes of a smutty grey colour, and contains

many yellow fibrinous flocculi and pus-cells, with portions of necrosed tissue, mingled with tears, and finally, after the lapse of a few days, becomes almost entirely purulent. Coincidentally with this change in the character of the discharge, the lids lose much of their stiffness; the conjunctiva becomes looser in texture, and assumes a spongy character; softened fibrinous masses are frequently thrown off, and only a few isolated white patches remain, between which the vascular layer of the mucous membrane appears completely deprived of epithelium. Tolerably free bleeding from the denuded vessels frequently takes place at this stage. The membrane begins to assume some resemblance to that seen in cases of granular lids, except that the granulations are much firmer, more coherent, and less moveable.

A gradual process of contraction now begins to take place, accompanied by the formation of what may be termed "cicatricial tissue," and which is very apt to lead to ectropion or to entropion. The duration of the several stages is various, but upon the whole the disease is one which runs its course rapidly and energetically, extending from a few days to three weeks or more, the stage of shrinking varying considerably in its duration. The rapidity with which the fibrinous exudations are formed is in some instances surprising. v. Gräfe has seen cases where several times in the twenty-four hours membranes of nearly half-a-line in thickness, presenting a hole corresponding to the cornea, but otherwise constituting an exact impress of the surface of the conjunctiva, were thrown off. In describing these false membranes, M. Cayraud remarks that they constitute the pathognomonic symptom of the disease.

The chief danger of this form of disease is the effect that is likely to be produced upon the cornea, of which some part, at an early period, assumes a slightly hazy appearance from exudation, and from which, in the course of the following twenty-four hours, the epithelium separates. The cloudiness

then becomes more marked, and of a yellowish colour; the superficial ulcer deepens and extends, minute fragments of the corneal tissue slough, and are thrown off, and perforation ultimately takes place, leading to hernia of the iris and staphyloma corneæ. The results observed by Dr Jacobson in twenty-two eyes, occurring in seventeen patients, were, that five eyes were wholly destroyed; in four others, adherent leucomata took place, with very serious impairment of sight; in six, opacities of slighter grade occurred; in four, the cornea escaped altogether; and in three cases, actual improvement of vision resulted, in consequence of the removal and obliteration of vessels which had formed in consequence of previous superficial keratitis. Sharp febrile symptoms generally accompany the disease, the pulse being frequent, the appetite deficient, and the functions of the alimentary canal disturbed, all of which are probably due to the want of sleep and prostration occasioned by the severity of the pain.

The only disease with which it seems at all likely that diphtheritic conjunctivitis may be confounded, is purulent ophthalmia. From this it may be distinguished by the pain which accompanies it; the great heat, swelling, and stiffness of the lids; the comparatively slight redness of the mucous membrane, the absence of discharge in the earlier stages, and the presence of fibrinous exudations and of general febrile disturbance.

As regards the treatment, it would appear that diphtheritic conjunctivitis is a disease over which therapeutic measures have comparatively little power.

An important feature in the history of the disease to be remembered, is its aptitude to attack the two eyes consecutively; and Jacobson especially refers to the advantage obtained from the application of a pad and bandage to the affected eye in preserving the other from an attack. The presence of the bandage, however, should not be allowed to interfere with the most minute attention to cleanliness.

The treatment recommended by v. Gräfe consists in placing the patient upon an antiphlogistic regimen, in the administration of mercury with quinine or cinchona, and in the local application of strong solutions of nitrate of silver. The period at which cauterisation of the membrane should be performed is a moot point. M. M. v. Gräfe and Wecker consider the second stage as that at which its results are most beneficial, whilst M. Cayraud, following M. Giralvés, recommends its use in the first stage, or at the outset of the disease. In either case, however, its effects should be carefully watched, and the cornea thoroughly protected from injury. The caustic employed should be the mitigated caustic, composed of one-third of nitrate of silver, and two-thirds of nitrate of potash; and, after a short space of time, a stream of weak salt and water should be directed upon the part to which it has been applied. M. Wecker strongly recommends the imposition upon the lids of iced compresses, frequently changed during the first period of the disease. At a later period they may be advantageously exchanged for hot applications.

Leeches and scarifications are of use in the second stage, when the conjunctiva has begun again to be vascular; but they are of little service in the first period, as the quantity of blood obtained, even when the scarifications are deep, is extremely small.

A variety of other remedies have been employed by different practitioners in this disease, amongst which it will be sufficient to mention the vinum opii and solution of atropine, and solutions of citric and of carbolic acids, whilst the general and topical employment of chlorate of potash has been strongly recommended by M. Giralvés.

10. *Granular Lids. Trachoma.*

(PLATE I., Fig. 5.)

The preternatural growth and development of the papillæ, and of the layers of epithelium covering them, were formerly

supposed exclusively to constitute the condition termed "granular lids;" but it would appear, from the observations and inquiries of numerous writers,¹ some of whom have enjoyed large fields of observation, that there are in reality two forms of granulations, the nature of which is essentially different. In one, there is simply an hypertrophy of the papillæ naturally present; in the other, there is a growth, or rather a development, of new tissue. In the first form, where the pre-existent papillary tissue is only exaggerated, the granulations, like the papillæ themselves, are arranged in rows, and attain their greatest size opposite the upper edge of the tarsal cartilage. They are composed of connective tissue, interpenetrated with capillaries, and covered by many layers of epithelium. Such enlarged papillæ are frequently seen as a result of long-continued inflammation, and are especially familiar to military surgeons, after the subsidence of the contagious form of purulent ophthalmia already described. They are obviously due to the increased flow of blood which occurs in such affections, but, as a rule, produce no ill effects upon the cornea, require no treatment beyond cleanliness, free exposure to air and light, and active bodily exercise, and soon spontaneously disappear.

The second form to which the term true or trachomatous granulations is now generally restricted, on the other hand, first appears in the form of small whitish spots, scattered irregularly over the inner surface of the lid, but frequently also occupying the oculo-palpebral fold, which soon becomes elevated and prominent, acquiring, at the same time, a translucent appearance, as though they contained fluid, which has caused them to be compared to frogs' spawn, or to grains of

¹ See, for an excellent account of this disease, a paper by Dr J. A. Marston, in Beales' Archives of Medicine, vol. ii. p. 183; also the section on Trachoma, in Wecker's Etudes Ophthalmologiques, t. i. p. 98; and the Essays of Binard, in the Annales d'Oculistiques, p. 157, 1853; of Arlt, in the Vierteljahrsschrift, v. Soc., Prague, 1850; of Roosbröck, in the Archiv. de Med. Militaire, 1853; and of Stellwag v. Carion, in his Augenheilkunde.

boiled sago or tapioca. On puncturing them they are found to be solid, and no escape of fluid occurs. They are composed, according to Dr Marston and M. Wecker, in their incipient condition, of numerous nuclei proceeding from the proliferation of the submucous connective tissue corpuscles with a few fibres, and therefore, to a certain extent, present some analogy to miliary tubercles; from which, however, they differ essentially in having little tendency to undergo fatty degeneration and to break down themselves, or to excite suppuration and ulceration in the adjoining textures. On the contrary, the fibrous tissue soon increases in quantity, and becomes translucent, whilst the nuclei disappear; and at a still later period, the whole mass becomes hard, dense, and fibrous, and, contracting, resembles the tissue of which a cicatrix is formed.

M. Wecker seems to doubt, but several good authorities admit, that the trachomatous granulations may proceed, not only in the manner stated—from the proliferation of the connective tissue corpuscles in certain centres or foci—but that they may also be the result of the hypertrophy and development of the minute lymphatic follicles, described by Krause as existing in the submucous layer of the lids.

The true granulations are often caused by, or follow, comparatively slight grades of inflammation, but are destroyed and abolished by higher degrees; a circumstance of which advantage is taken in the treatment.

The mode in which moderately acute inflammation effects a cure, appears to be by causing an effusion of lymph, which compresses and obliterates the vessels supplying the neoplastic formation. Very high degrees of inflammation, however, act prejudicially, by causing an increased and fresh development of vessels, which, in their turn, induce a return of the granulations in their worst and most intractable form. In many instances both the papillary and trachomatous forms of granulations co-exist.

The causes of true granular diseases of the lids are probably to be looked for in exposure to great variations of temperature, and hygrometrical conditions of the air. Poor living, dirt, and intemperance, are powerful predisposing, if they be not exciting, causes, as the few cases which appear in London commonly occur in Irish labourers, in whom these conditions are united. It is by some believed to be epidemic, and is certainly readily communicable by contagion; hence its propagation in great military establishments and asylums, where many are crowded together, and where small attention is paid to washing utensils, towels, etc. According to Dr Marston it is endemic in Denmark, Belgium, and Ireland, and is common at Malta.

M. Wecker divides the disease into two stages, the acute and the chronic. In the early stage of acute true trachoma, the ordinary symptoms of catarrhal ophthalmia—smarting pain, redness of the conjunctiva, swelling of the lids, and lachrymation, accompanied by more or less photophobia—are present. On everting the upper lid, the semi-transparent rounded granulations are visible; at first small in size, but subsequently increasing, and, by their enlargement, exciting much irritation of the corresponding and opposite parts of the ocular conjunctiva, and causing the discharge to assume a purulent character. In the course of a week or ten days, in consequence of the inflammation thus excited, the granulations atrophy and disappear—the papillæ, however, frequently becoming hypertrophied—and then one of two or three events may occur: either recovery may take place, with gradual subsidence of all the symptoms; or the disease may pass into the chronic stage, in which the granulations gradually reappear; or, as occurs in some rare cases, the granules never disappear at all, but continue to multiply and increase in size throughout the whole course of the disease. A marked feature of the trachomatous affection is the tendency which it has to injure the cornea. In many instances the formation

of phlyctenulæ around the margin of the cornea is observed; whilst in others a fringe of delicate semi-transparent membrane is occasioned, which advances upon the upper segment of the cornea, and is composed of connective tissue, with many minute vessels, covered by epithelium. In course of time, with the persistence of the cause of irritation, the vessels become more numerous and crowded, and at length form a well-marked pannus, such as is displayed in Plate IV., fig. 24, only covering the upper segment of the cornea.

As regards the prognosis and treatment, nearly all the most experienced observers agree in the opinion that the disease has a natural tendency to a favourable termination, and that the treatment should consist rather in the removal of hurtful agencies than in the applications of powerful caustics, astringents, or irritants to the mucous membrane. Time, therefore, as Dr Marston observes, is an important element in the treatment; and our endeavour should be, so to regulate the amount of inflammation as to cause the obliteration of the granulations, whilst, at the same time, they should not be permitted to attain so high a degree as to run the risk of the chronic form being established. In all instances the ordinary hygienic measures recommended by common sense should be adopted, as good air and food, moderate exercise, cleanliness, and frequent ablution of the eye with cold water, or with weak astringent lotions.

Dr Marston observes that a sudden check may be sometimes given to the progress of a threatened epidemic by finding out and removing the exciting cause, as in the following instance:—The 2d battalion, 23d Regiment, removed to barracks in Malta called "Polverista Gate," the name sufficiently indicating the prevalence of dust. Ophthalmia commenced among the men,—of the presence of which, however, in a latent state, Dr Marston had previously convinced himself,—and made rapid progress, but was promptly suppressed by the common-sense suggestion of Dr Tydd, the

regimental surgeon, viz., to water the roads and neighbourhood of the barracks.

In cases where the inflammation appears to be passing beyond the natural limits, so as to incur the danger of the re-establishment of the granulations, and where, at the same time, profuse purulent discharge is present, leeches may be applied to the temples, iced or cold compresses to the lids; whilst the surface may be cauterised with the mitigated nitrate of silver two or three times in the course of a week, followed by cold compresses, as recommended in purulent ophthalmia. On the other hand, if the reaction be slight, and it is desired to excite a higher degree of inflammation for the removal of the granulations, the surface of the lids may be lightly touched with the sulphate of copper, or with a solution of citric acid.

In acute cases of granular lids, attended with much swelling of the lids, lachrymation, and photophobia, Pagenstecher¹ recommends scarification and the methodic application of cold, followed, as soon as the inflammation is reduced, by light cauterization of the surface of the lid with mitigated nitrate of silver, the action of the escharotic being immediately neutralised with solution of salt. In other instances, the liquor plumbi acetatis may be used, and the cure completed in either case by the application of the sulphate of copper. Care should be taken, he observes, in the employment of the nitrate of silver or acetate of lead, that the corneal tissue is not materially affected, as their use is apt to be followed by extension of the mischief, ulceration, and sloughing.

In the chronic form of the disease, the development of the granulations takes place with much less irritation of the conjunctiva than in the acute. It is in these cases that both forms of granulations, the papillary and the trachomatous, are most frequently seen together; but it is not uncommon to find the trachomatous granulations alone present, whilst in others both forms are so numerous and so closely packed,

¹ *Klinische Beobachtungen*, Heft. ii. p. 4. 1862.

that they cause the conjunctiva to present a generally swollen and granular character, in which it is impossible to distinguish which are hypertrophied papillæ, and which are true granulations.

In chronic cases of trachoma the cornea is almost always affected, and pannus is produced upon its upper portion, and it becomes faceted and prominent; whilst in other cases, ulcerations and abscesses, often leading to perforation and staphyloma, are observed. It is a remarkable circumstance, however, that the granulations may long remain in a latent state, exciting no irritation or inflammation, and their presence being wholly unperceived by the patient, until a direct examination of the inner surface of the lids is made.

In the later stages of chronic trachoma, the fibrous tissue, of which the granulations are composed, undergoes a kind of contraction and condensation, becoming converted into a cicatricial tissue, giving to the inner surface of the lids a puckered or nodulated appearance, that acts most injuriously upon the corneal texture, and leads to its opacity and vascularization, and to its becoming dry, and covered by a membrane-like tissue (xerosis); whilst in many cases entropion and trichiasis, or, more rarely, symblepharon, with all their attendant trains of symptoms, are induced.

Nothing furnishes better evidence of the persistent and intractable nature of chronic trachomatous granulations, when fully formed, than the fact that many soldiers, especially in the troops of foreign powers, are annually discharged on account of their being the subjects of this disease,—in many instances, it is believed, established by the application of irritating ointments, applied by themselves with this object in view, but succeeded by the heavy penalty of retaining the disease, or of suffering from its effects throughout life.

As regards the treatment of the chronic condition of trachomatous granulations, the remarks of Dr Marston are so opposite, and so thoroughly in accordance with those of the best

foreign observers, that I shall merely transcribe his observations. After pointing out the importance of the hygienic measures already recommended in the acute form, as segregation from other cases, removal from hospital air, and a strong faith in time as an element for goods, he remarks, "that as to the various collyria, caustics, and special modes of treatment so strongly recommended and vaunted at different times, all I can say is, that I have never observed any facts warranting the slightest reliance in any one of them. As to burning down and repressing redundant granulations by sulphate of copper, lunar caustic, etc., I firmly believe that we prolong the disease and complicate it by new morbid phenomena of our own production." "At the same time, during the whole treatment, we must be upon the watch that the deeper tissues do not become implicated, that a syphilitic iritis is not also making progress, or that a scleritis or an irido-choroiditis is not set up; for then, in addition to mercury, copious local depletion and division of the cornea, with evacuation of the aqueous humour, may be required."

The treatment suggested by M. Wecker, whilst agreeing with that proposed by Dr Marston in mild cases, differs in so far as he places more faith in topical remedies, when the disease assumes a severe and obstinate character. When the conjunctiva is but slightly vascular, and the inflammation is insufficient to effect the obliteration of the granulations, he recommends the cauterization of the lid with sulphate of copper, at rare intervals, with free use of cold ablutions to assuage the pain. When this has lost its effect, he employs the solution of nitrate of silver (gr. viii. ad. 3j.), or of the subacetate of lead, which may be advantageously applied by means of a pulveriser, affording a refreshing coolness to the lids. He strongly condemns the use of strong caustics—as nitrate of silver in substance, and nitric acid—as being certain to cause cicatrices.

As regards the mode of treatment of granular lids by in-

oculating the eye with pus taken from the purulent ophthalmia of infants, which, by producing violent inflammation, leads to the deposit of lymph in the tissues, and atrophy of the vessels supplying the mucous membrane and papillæ, I have not tried it in a sufficient number of cases to be able to give a decided opinion; but it has appeared to me that the effects produced were not of such advantage to the patient as to lead me to adopt its frequent employment. Where it is carried out, care should be taken that the surface of the cornea is thoroughly vascularised, as sloughing of its texture may otherwise occur.

A more promising method of treatment for obstinate cases of granular lids, whether accompanied by pannus or not, has been suggested by v. Gräfe,¹ and consists in the application of hot fomentations at a temperature of 100° Fahr., or more, every five minutes, for an hour at a time; then intermitting their application for a quarter of an hour, and again applying them. This proceeding establishes a hyperæmic condition of the lids, attended with discharge of pus, and acts as the foregoing method of inoculation is supposed to act, by promoting the absorption of the hypertrophied papillæ and trachomatous granulations.

Sämisch, whilst approving of the hot fomentations, employs them only of a temperature of 76° Fahr., but keeps them constantly on the eye.

In the Congrès d'Ophthalmologie of 1862,¹ M. Coursserant stated that he was accustomed, in chronic cases of trachoma, to abrade not only the surface of the conjunctiva, but the internal surface of the tarsal fibro cartilage; and M. Borelli exhibited an instrument resembling a harrow, termed a scar-dasso, with which he rakes the inner surface of the lid either daily or every two, three, or four days, until the granulations

¹ Archiv. f. Ophth., Bd. vi., ii. p. 133. See also Sämisch, in Pagenstecher's Klin. Beobacht., Heft. ii. p. 98. 1862.

² See Comptes Rendus du Congrès, p. 49.

are flattened and disappear by suppuration and absorption. He then applies the solid sulphate of copper, or chromic acid, to reproduce the polished surface of the conjunctiva! and completes the cure with laudanum. We cannot but regard these proceedings as unnecessarily severe, and are disposed to agree with M. Anagnostakis in thinking that the remedy is worse than the disease.

The reply made to the paper by M. Hairion gives a good *resumé* of the mode of treatment adopted by those who are advocates for more active measures than those which we believe to be best adapted for the cure of the disease, and we shall therefore give an outline of his remarks. M. Hairion admits four periods in the progress of the disease, in each of which he believes special treatment to be appropriate. In the first, when the granulations are vesicular or semi-transparent, and are seated upon healthy conjunctiva, he applies tannic acid, dissolved in a solution of gum in water, or solid sulphate of copper, or acetate of lead in powder, the application of which last is admissible in this stage only. In the second stage, when the granulations have become vascular, and the conjunctiva is thickened, inflamed, and thrown into folds, corresponding to the period of purulent discharge above described, he applies a solution of nitrate of silver, dissolved in an equal weight of distilled water, once a-week; and where the inflammation runs high, he scarifies the granulations freely. In the third stage, when fibro-plastic tissue of fleshy aspect replaces the granulations, and occupies the greater part of the conjunctiva, he uses a strong solution of chromic acid, to destroy the new tissue equally and uniformly; and considers the same remedy may be employed in the fourth stage, when the inner surface of the lid is nodulated, irregular, and rough. The solution of chromic acid, in the proportion of one drachm to a fluid drachm of distilled water, applied with a brush to the lids, produces immediately an eschar, which soon disintegrates, and is replaced by an exudation of lymph. This

again soon separates, leaving the surface of the conjunctiva of a vivid red, dotted with black points, which are clots filling the mouths of small vessels, destroyed by the acid. Granular lids, including both forms, the papillary and the trachomatous, are a rather common disease, the former variety however constituting in London by far the greater proportion of cases. Out of a total of 7200 patients who presented themselves indiscriminately at the Hospital in 1864-65, 75 were cases of granular lids. Of these 48 were males. The majority (40) were under 30 years of age, the most common age being between 20 and 30, which may be regarded as the period of life most subject to the disease. The youngest patient was 16 years of age, and it is rare to see a well-marked case before that period. The oldest patient was 70; and several were 50 and upwards.

11. *Pterygium.*

(PLATE III., Fig. 13.)

This is an affection of a very curious and anomalous nature, the ætiology and pathology of which have not yet received a very satisfactory explanation. It consists apparently in the growth of a portion of the sub-conjunctival tissue, and in its extension over the surface of the cornea. Its shape is triangular, with a rounded apex directed towards the pupil. It is somewhat raised above the level of the adjoining parts, and presents a smooth polished appearance. Its colour varies from yellowish white to red, according to the proportion of blood-vessels and connective tissue entering into its formation. It varies in consistence, sometimes being easily torn, and bleeding readily; at others, possessing considerable toughness, but always being very firmly connected with the cornea, with which its deeper surface insensibly blends. It is usually of considerable thickness, and opaque, but the subjacent cornea retains its transparency. It is generally single, but I have met with several instances where it has been double,

affecting both eyes; and one instance in which it was quadruple, one being situated on each side of each eye. Velpeau gives a case where five pterygia existed on the same bulb. Rognetta,¹ Tavignot,² and others, have noticed that its position almost always corresponds to that of one of the four recti-muscles. The frequency with which pterygium occurs, as respects the various parts of the eye, takes place, according to Middlemore,³ in the following order:—First, at the inner canthus of one eye; secondly, at the inner canthi of both eyes; thirdly, at the outer and inner canthi of the same eye; and, lastly, at the outer canthus, or at the upper or lower border of one eye alone. The cause of its being most frequently seated at the inner canthus is, according to Pétrequin,⁴ partly on account of the greater number and size of the vessels naturally present at this part, partly on account of the greater thickness of the conjunctiva on the inner portion of the globe, and partly owing to the circumstance that there is a certain disposition of the conjunctiva to develope here in order to form the *membrana nictitans* or third eyelid, so remarkably prominent in some animals. Mackenzie⁵ has noted cases in which it originated in accident to the eye, and is certain that the disease often begins by the formation of what ultimately forms its apex, close to the edge of the cornea, before any thickening or unnatural vascularity of the conjunctiva is observable. Arlt attributes its origin to the gradual traction exerted upon the conjunctiva by the cicatrization of superficial abscesses at the border of the cornea. Very recently, M. Alex. Winther⁶ believes that he has been able to prove that pterygium proceeds from a thrombosis, causing obliteration of, or contraction in, either a corneal vein or one

¹ *Annal. d'Oculist.*, t. iii. p. 237.

² *Annal. d'Oculist.*, t. xxxviii. p. 100.

³ *Treatise on the Diseases of the Eye*, vol. i. p. 366. 1835.

⁴ *Annal. d'Oculist.*, t. i. p. 467.

⁵ *Pract. Treatise, etc.*, p. 246.

Experimental Studies upon Pterygium. 1866.

of the *venæ vorticosæ*, which induces a disturbance of the circulation in that region of the cornea supplied by the corresponding ciliary artery, proceeding along and penetrating the tendon of the adjoining rectus muscle. According to Middlemore, the growth is always rapid prior to its approach to the margin of the cornea, stationary for a certain period when it arrives there, and much slower upon the cornea than upon the sclerotic.

The disease appears to be most frequent in those who have resided in warm climates. In this country, and in France,¹ it is comparatively rare; but in certain parts of America it must be exceedingly common. M. J. F. Carron du Villards,² who practised for seventeen years in Mexico, and dates from Maracaibo, states that he has operated upon no less than 400 cases, and Pétrequin observes that the disease was well known to the Arabian writers. G. Tradescant Lay³ found this disease very common in Borneo Proper.

Pterygia are more unsightly than painful, and, if neglected, gradually but very slowly attain a considerable size, impede the natural movements of the eye, interfere with vision, perhaps render the eye more liable than usual to inflammation, and lead to trichiasis. The only affection with which it is likely to be confounded is pannus, from which it is distinguished by its fresh colour, well-defined edges, freedom from pain or other inflammatory symptoms, and by its lateral position.

The object to be effected in the treatment is the permanent removal of the thickened mass; and various methods have been adopted, of which the following is the best:—The patient should be directed to turn the eye in that direction by which the fold of membrane, constituting the pterygium, is relaxed. The eyelids being then separated by an assistant, or by means

¹ Cuvier, *Ann. d'Oc.*, t. xlv. p. 150.

² *Ann. d'Oc.*, t. xxxviii. p. 222.

³ *Lancet*, vol. ii. p. 300. 1838.

of the spring speculum, the membrane is to be seized with a small but well-toothed pair of forceps, and either transfixed with a sharp-pointed bistoury, or dissected off with a small-bladed, blunt-pointed knife; the bleeding surface of the cornea should be covered with a drop of oil, to relieve the smarting, and if much of the conjunctiva has been removed, the edges may be brought together with a fine suture, or left to heal by granulation.

The proceeding recommended by M. Desmarres¹ is, to dissect off the thickened membrane from the apex towards the base by which it is left attached; the lower border of the wound in the conjunctiva is then incised in a direction parallel to the circumference of the cornea, for about a quarter of an inch, and the loose flap of the pterygium itself is then imbedded in the wound, with the edges of which it is united by sutures. These should be introduced at some distance from the line of incision, and consist of silk of considerable thickness, in order that they may not be lost sight of in the inflammation and swelling which follow.

M. Carron du Villards, whose large experience entitles his mode of operating to be regarded with attention, seizes the pterygium as near as possible to its insertion into the cornea, and with a pair of scissors, curved on the flat, incises the base, and then immediately commences a movement of torsion until the pterygium is completely separated. He believes that he thus avoids all lesion of the cornea, and all danger of consecutive cicatrices, as there is no necessity for employing caustics.

M. Tavignot's² method is very neat, but requires the patient to be very steady. It consists in seizing the pterygium with toothed forceps by the summit of the triangle, directing the patient to turn his eyes to the opposite side; the base is then seized with a second pair of forceps, and through the fold

¹ Ann. d'Ocul., t. xxv. p. 207.

² *Idem*, t. xxxviii. p. 100.

thus produced three fine threads are passed; the whole of the part in front of the threads is now removed by curved scissors, and the edges of the wound brought together by the threads, so as to form a linear cicatrix.

Szokalski¹ has succeeded in curing a case with ligature, and M. Decondé cured another by the direct application of acetate of lead in powder, while Mr Tradescant Lay obtained great credit from the natives of Borneo by the cure of the disease from the direct application of calomel, combined with general treatment.²

12. *Ecchymosis of the Conjunctiva.*

(PLATE II., Fig. 15.)

This and the two following illustrations, one representing the effects of a violent blow on the eye, followed by hæmorrhage into the anterior chamber, and the other representing a sharp attack of conjunctivitis, have been placed in juxtaposition in order that they may be compared with one another, and the essential differences between them as they have appeared in typical examples of each clearly recognised. It must, however, be understood, that many cases are seen in which the characters of these affections are mixed, and where, consequently, the treatment must be correspondingly modified.

Ecchymosis of the conjunctiva is sometimes produced by the most trivial causes: a slight blow either on the eye or forehead; a severe fit of coughing or of sneezing; sleeping with the head hanging over the bedside; straining, as in pulling on tight boots, and even stooping to pick up some small object, may all lead to its occurrence; and though in itself it is perfectly harmless, and will pass away without leaving any trace of its former presence, yet no patient thus affected should be allowed to leave without a careful examina-

¹ Ann. d'Ocul., Supplement iii.

² Op. Cit., p. 300.

tion of his general condition, and, unless the rupture of the capillaries have been the result of some accidental blow, without a caution that the vessels within the brain might have given way instead of those without.

The affection is recognised immediately by the uniformity of its tint, which is usually of a dark red; the surface of the conjunctiva is raised by the blood beneath, but is bright and polished. The rupture usually takes place upon the inner side of the eye, where the vessels ramifying on the conjunctiva are largest and most numerous, and the membrane surrounding them most loose. Little or no pain is experienced, and the patients complain only of slight stiffness in moving the eye, and of the disfigurement. The border of the effusion is soft, but well defined. When the quantity that has escaped from the vessels is considerable, the conjunctiva is sometimes thrown into large folds or sacs, which contain a little fluid and much coagulated blood. Usually, however, the blood is so far coagulated, or at least is so retained within the meshes of the connective tissue, that little or none flows out when the membrane is pricked. The treatment to be adopted is of the simplest possible kind, and consists merely in bathing the eye with weak alum lotion, and in the avoidance of all violent exertion. If straining has occasioned the rupture of the vessels, the bowels may be opened by castor oil.

The rapidity with which absorption is effected varies greatly in different instances. In children, and when the amount that has escaped is moderate, a fortnight, or a little more, suffices entirely to remove the stain; but in old people, and in some full-bodied men, it may remain for a month or more.

13. *Tumours of the Conjunctiva.*

Of these some are innocent, whilst others are malignant. Amongst the innocent tumours may be enumerated pinguecula, watery cysts of the conjunctiva, dermoid tumour, lipoma, and tuberculous tumours.

The chief forms of malignant tumours, on the other hand, are epithelioma, medullary cancer, colloid, and melanosis.

Watery cysts of the conjunctiva are only occasionally seen, and are usually of small size, not exceeding that of a millet seed. After being once formed, they appear to remain without change, or to grow with extreme slowness. In one case that has recently come under my observation, no enlargement was observed for four months. The contents are quite clear, thin, and transparent, like water. The little vesicles are sometimes double, or multiple. They are invested by a thin web of tissue or sac, which is moveable on the subjacent tissue, for on attempting to raise them with the forceps, they slip from the grasp of the instrument, and sometimes burst and disappear. The treatment consists in raising them or the adjoining tissue with forceps, and snipping them away with a small pair of scissors, curved on the flat, and they will seldom be found to reappear.

Pinguecula presents the form of a small yellow or yellowish white patch, seated on the sclerotic, beneath or in the substance of the conjunctiva, and near the edge of the cornea. Under ordinary circumstances, from their small size, and the slight difference of their colour from that of the adjoining sclerotic, they attract little or no attention; but when from any cause the conjunctiva becomes at all congested, these little bodies, possessing no vessels, do not partake of the general scarlet tint, and their yellow colour then stands out in strong contrast with the adjoining tissue, and renders them exceedingly conspicuous. In some instances they might almost be mistaken for the base of an ulcer. From their appearance they were formerly considered to consist of fat, but Weller first stated that they contained no adipose tissue. In order to resolve this point, M. Desmarres¹ states that he excised one, and transmitted it to M. Charles Robin, with a request that he would examine it microscopically. The reply

¹ *Maladies des Yeux*, vol. ii. p. 233.

of M. Robin was to the following effect:—The tumour is rounded, hard, and polished on the surface, and of a yellowish colour. It is composed exclusively of the pavement epithelium of the conjunctiva, slightly hypertrophied. It is entirely destitute of vessels. The subconjunctival connective tissue is scarcely thickened. The epithelial cells are small at the deep, and augment in size towards the superficial, surface. They are remarkable for their regularity, delicacy of form and outline, and for their granular character, which last is most obvious in the vicinity of the ovoid nucleus which they contain. As M. Desmarres observes, pinguecula can scarcely be considered as a disease of the eye, and, in fact, requires no treatment unless it becomes so prominent as to attract attention; it may then, however, be excised. The largest one of which I have met with an account, was removed by M. Magne, when the tumour had attained the size of a small nut. It was situated on the outer side of the right eye, which he believes to be the most frequent position occupied by pinguecula. It had been slowly growing for some years, and so far interfered with the movement of the globe that diplopia was produced. After removal it was examined by M. Homolle, who found the contents to be composed of epithelial lamellæ and pigmentary corpuscles, with a small quantity of a fatty substance resembling margarine.

Lipoma, or true fatty tumour in the conjunctiva or in the subconjunctival tumour, is occasionally seen. It presents the appearance of a smooth, yellow enlargement, usually situated at the upper and outer part of the eye. It gives rise to no pain, but is inconvenient in consequence of its interfering with the movements of the eye, and on account of its unsightly appearance. In such cases it should be removed, the conjunctiva being divided over it, and the tumour dissected out; the redundant portion of the conjunctiva may then be cut away, and the edges of the wound brought together by sutures. Water-dressing may be afterwards applied.

Dermoid tumours, or verrucæ of the conjunctiva, consist of tumours sometimes of considerable size, equalling that of a cherry, which occupy the conjunctiva at the margin of the cornea, or cover the sclerotic, in immediate proximity with the cornea, with both of which the base of the tumour is often continuous. Their colour, according to M. Wecker,¹ who has given a good connected account of them, is yellowish grey, their surface smooth, with many little sinuosities; and they are often, though by no means always, beset with hairs and sebaceous follicles. They are covered on their outer part by the conjunctiva, but this is insensibly lost towards the corneal border. They occasion little or no pain, but impede the movements of the eye, and lead to inflammation of the conjunctiva. Microscopically examined, they have been found to consist of connective tissue, free from corpuscles, but mingled with much elastic tissue, especially at their base. They are hard and firm, and give an impression, on section, of their being semi-cartilaginous. A few vessels, chiefly running towards the hair follicles, when these are present, and a little fat, are generally found to be constituents of the tumours.

The treatment of these peculiar swellings, the ætiology of which is still obscure, consists in removing them from the subjacent tissues by dissection, taking care not to penetrate too deeply into the substance of either the cornea or sclera, with which the base of the tumour is continuous.

Dr Mackenzie states that he has seen several cases of *scrofulous tumours*, which grew slowly till they attained the size of a hazel nut, presented a whitish or yellowish colour, and were composed of fibres and cells. The only treatment to be adopted is to remove them whilst they are yet of small size.

¹ Etudes Ophthalmologiques, t. i. p. 186. See also an account of the microscopical examination of one made by Mr Hulke, Ophth. Hosp. Rep., vol. iii. p. 333.

14. *Cancer of the Conjunctiva.*

As regards the malignant affections of the conjunctiva, the subject of *epithelioma*, after what has been already stated in reference to it (p. 101), need not again engage our attention.

Cases of *gelatinous or colloid cancer* have been observed in a few instances, but present no features characterising them from the same disease occurring in other parts of the body, or from those which have already been described at p. 27.

It is still a disputed point whether *melanosis* is to be included under the head of malignant affections or not. On the one hand, its development is generally unaccompanied by pain. It does not appear to affect the neighbouring glands to any notable extent, it has little tendency to ulcerate, it often remains quiescent for long periods of time, and even when growing rapidly, appears to produce comparatively trifling constitutional disturbance. In many instances it is quite solitary, and, when removed by excision, betrays no tendency to recur.

On the other hand, in the majority of cases, it extends, though often slowly, yet with exceedingly great steadiness. It frequently occurs in small masses, scattered over different parts of the body; it appears to infiltrate the tissues it affects, and there are scarcely any which may not become the seat of the deposit; whilst it exhibits, in many instances, after its removal, a remarkable tendency to recur, and the presence of true cancer cells in the mass has been substantiated by numerous observers. The black appearance presented by the disease is so characteristic that no error in diagnosis is likely to be made, though I have seen one case where it was closely simulated for many months by blood extravasated into the subconjunctival tissue in an old person. And there can be as little doubt about the treatment. As long as the deposit is small in quantity, and gives no indications of development, no treatment beyond attention to the general health should be adopted. But if

the disease appears to be extending, the smaller spots coalescing, or new ones appearing, the whole of the affected structures should be excised, and many instances are reported where perfect recovery has followed this procedure.

15. *Ulcers of the Conjunctiva.*

(PLATE XI., Fig. 63.)

The most common form of ulcer of the conjunctiva is that which is seen in pustular ophthalmia, the characters of which have already been described. Other forms are sometimes seen consequent upon burns and injuries, but occasionally anomalous forms present themselves, of which the following is an example, and which I have considered sufficiently remarkable to give an illustration of:—

Samuel Puddlephatt, æt. 33, a coachman, came to the Hospital on the 11th September 1866, complaining of the ordinary symptoms of an attack of acute conjunctivitis. He was a short, thick-set, but tolerably healthy-looking man. The disease was limited to the right eye, which induced me to examine the under surface of the upper lid. On eversion, there appeared a number of small whitish granulations scattered over the mucous membrane, and interspersed with enlarged papillæ. Considering the case to be one of incipient granular lids, and the tongue being foul and the breath offensive, I ordered him an emetic powder, containing one grain of tartarised antimony; a mixture containing ʒj. of decoct. of cinchona, ʒj. of the compound tinct. of cinchona, and ʒj. of the solution of bichloride of mercury, three times a-day; alum lotion to be frequently applied, and a drop of the tincture of opium to be instilled into the eye. On the 13th he was in much the same state, except that considerable chemosis was present, and he complained of violent pain in the eye and brow. On the 15th the lids were considerably swollen and painful, and withal red and stiff, so that it was with great difficulty that a glimpse of the clear cornea and chemosed conjunctiva could be ob-

tained. However, on firmly depressing the lower lid, a superficial ulcer was exposed, of yellowish colour, with irregular not very well defined edges, and of considerable extent, occupying the sulcus and portions of the ocular and palpebral conjunctiva. The rest of the conjunctiva was highly inflamed, except near the margin of the lower lid, where were two or three minute ulcers presenting the same characters as the larger one. He stated that a day or two previously the pain had been very intense in the eyeball, and that there had been profuse lachrymation, but that during the last twenty-four hours the discharge had become puriform, and the pain had much diminished in severity. He also stated that he had observed some swellings in the neck at the commencement of the attack, apparently of a glandular nature. He was now questioned minutely respecting the origin of the disease, but could give no other account than that his eye being already inflamed to a slight degree, he was travelling by railway the day before he came to the Hospital, and thought a piece of grit had entered the eye when looking out of the window, as sharp pain came on. He had had no venereal disease. After I examined the eye in the first instance, the sensation of a foreign body under the lid left him. He was directed to continue with the mixture, and to apply hot fomentations and compresses continually. On the 18th September it appeared that great benefit had been derived from these means. The chemosis had much diminished, the lids were less stiff, the cornea could be seen to be clear and the iris healthy, and when the lids were separated vision was good. The margin of the ulcers was better defined, and its colour of a deeper red than the adjoining parts, which had not previously been the case. On the 20th, the ulcer had extended towards the outer canthus, especially over the sclerotic surface, but there was not much pain. Vision began to be impaired at this time, as on this day he could only read C of Snellen at thirty feet. He looked pale and ill, and the pulse was small and

feeble. He was directed to continue the hot fomentations, and the bichloride of mercury was withdrawn, and chlorate of potash substituted for it in the same mixture. He was directed also to bathe the eye with a lotion containing chlorate of potash 5 grs. to the ℥j., and to take a moderate amount of alcohol. On the 25th of September hypopyon appeared, the pus occupying about one-sixth of the anterior chamber. On the 27th, the quantity of pus had increased to nearly double the former amount; the ball was tense, and very tender and painful, but the ulcer was looking healthier and showed no disposition to extend. I tapped the hypopyon with the point of a Wenzel's knife, and drew off nearly all the pus. The cornea was clear. He now stated that he recollected being struck across the eye, a day or two before his railway trip, with the dirty tail of a horse, which caused acute pain for a short time; but he thought no more about it. On the 29th September the cornea, which up to this time had remained clear, became rough and finely granulated on the surface; the iris was contracted; pus had again collected in the anterior chamber to the extent of one-fourth of the total height of the anterior chamber, but he was nearly free from pain, and had experienced none after the tapping. On the 4th October the surface of the cornea was deprived, through nearly its whole extent, of epithelium, which gave it a dull granular appearance on the surface, but its substance was clear. The conjunctival ulcer had quite healed, and the chemosis was fast disappearing. No cicatrix was visible, but the original seat of the ulcer looked pulpy and œdematous, and was of rather a lighter tint than the rest of the conjunctiva. He still took the cinchona and chlorate of potash. On the 9th of October the cornea was extensively ulcerated, and an onyx had formed; the hypopyon had remained stationary. On the 16th the hypopyon had vanished; the onyx was also less thick, and the pupil could be dimly seen; the chemosis was still considerable. On the 20th October he

was free from pain, but a superficial fleshy growth or pannus began slowly to advance over the upper edge of the cornea, and the vision became very indifferent, only the shade of the hand passed in front of the eye being ultimately perceptible.

Syphilitic ulcers of the conjunctiva are exceedingly rare. One of the few cases on record is contained in the work of Desmarres,¹ and occurred in a midwife, æt. 30, who was otherwise in good health. When first seen the inferior lid of the left eye had been swollen for a fortnight, but she had experienced no pain. On examining the eye there was found, occupying the centre of the inferior *cul-de-sac*, an elongated tumour of the size of a pea, at the summit of which was an ulcer, with jagged and excavated edges, and with slight purulent discharge. This elongated tumour was continuous with the conjunctiva, underneath which it lay, presenting just the appearance of a primary specific ulcer on the prepuce. The eye was very red, and discharged a little pus. The diagnosis was assisted by the presence of a large preauricular ganglion, the size of a filbert. As, however, the patient denied having recently delivered any infected woman, or having been herself exposed to infection, M. Desmarres sent her to M. Ricord, who returned the following letter:—
 “Comme diagnostic rationnel, je crois que c’est un chancre de la conjonctive avec son adénopathie symptomatique. C’est un accident qui ne *saute* que rarement *aux yeux*, et ce n’est pas, dans tous les cas, celui qui rend le plus ordinairement *l’amour aveugle*. Pour le moment, voici ce que je conseille: 1, Toucher l’ulcération avec le nitrate de l’argent; 2, collyre émollient; 3, dix sangsues sur le ganglion; 4, un purgatif salin; 5, regime doux et pas de fatigue. Il faut attendre un peu les resultats de cette medication avant de recourir aux spécifiques.” These suggestions were carried out, but Desmarres was unable to ascertain in what manner the case progressed or terminated.

¹ *Maladies des Yeux*, t. ii. p. 215.

The development of *cysticerci* under the conjunctiva has been seen in a few instances. Arlt¹ refers to two instances which fell under his notice where the tumour was of the size of a lentil, with transparent walls and clear contents, and was moveable on the sclerotic; both occurred in young persons.

By others the *Filaria medinensis* has been observed, and M. Bouilhet² removed ten or a dozen small maggots from the conjunctiva of a young woman, which had been deposited by some kind of fly; but such observations are quite exceptional.

16. *Encanthis*.

The usual appearance presented in this affection is that of a small tumour, formed by an enlargement of the caruncle and plica semilunaris. It occupies, in consequence, the inner angle of the eye, and rarely attains a size larger than that of a pea or bean. The surface is granulated, so that it resembles a raspberry; like which fruit, also, it possesses a lighter or darker rosy tint, and a semi-transparent aspect. Its development is not accompanied by any pain; but by causing irritation it occasions increased secretion of tears, and by separating and slightly everting the lids, it prevents the canaliculi from discharging their function, and epiphora results.

The proper treatment consists in removing it by operation, and this may be best accomplished by seizing it with a pair of toothed forceps, after the lids have been separated by an assistant, and cutting it away with one or two strokes of a pair of curved scissors, avoiding the removal of more conjunctiva than is absolutely requisite. A little bleeding follows the operation, which may be stopped with cold applications, and a pad and bandage may be worn for a day or two.

A malignant form of the disease has been described by Beer, Scarpa, and others, when a tumour of considerable size forms at the inner canthus of the eye, which assumes a

¹ Krankheiten des Auges., p. 170.

² Ann. d'Oculist., t. xv. p. 133.

fungous appearance, implicates the surrounding tissues, ulcerates on the surface, discharges a foetid fluid, and presents other characteristics of a cancerous nature, though its precise nature does not appear to have been ascertained. In such cases no operative proceedings appear to be advisable, but the disease must be kept in check as far as possible by astringent lotions and attention to the general health.

CHAPTER VI.

Diseases of the Cornea and Sclerotica.

GENERAL ANATOMY AND PATHOLOGY OF THE CORNEA AND SCLEROTICA—ARCUS SENILIS—INFLAMMATION OF THE CORNEA OR KERATITIS—CHRONIC INTERSTITIAL KERATITIS—PANNUS—ULCERS OF THE CORNEA—OPACITIES OF THE CORNEA—STAPHYLOMA OF THE CORNEA—CONICAL CORNEA—NEURO-PARALYTIC AFFECTIONS OF THE CORNEA.

1. *General Anatomy and Pathology of the Cornea and Sclerotica.*

THE globe of the eye is composed of three tunics enclosing three humours. The first and outermost tunic is composed of the sclerotic, or, as it is now frequently termed, the sclera and the cornea; the second is formed by the choroid and iris; and the third and most internal is constituted by the retina. The three humours are the aqueous, the lens, and the vitreous. Of the three tunics, the first is destined for the support and protection of the more delicate internal structures, and its anterior or corneal portion is transparent, to admit of the entrance of light into the interior of the eye. The second is composed of a plexus of vessels, and of pigment cells, the former ministering to the nutrition of the organ, and the latter converting it into a camera obscura, and preventing the reflection and dispersion of light; whilst the anterior portion—the iris—forms a muscular septum, per-

forated in the centre, which plays an important part in regulating the quantity of light admitted. The third is the essential part of the organ, and is formed by an expansion of the optic nerve, on which the form, position, and colours of external objects are accurately depicted, and which, by its excitation, gives rise to impulses that, conveyed through the fibres of the optic nerve to the brain, brings the mind into relation with the outer world, and is, under ordinary circumstances, the source of by far the larger proportion of our ideas. Yet, when the retina is deficient, its place in this latter respect may be supplied to a wonderful extent, in all save colour, by the perceptions connected with the sense of touch.

The globe of the eye varies slightly in size in different individuals, and in the sexes; but, according to the exact measurements of Mr Nunneley,¹ its circumference may in general be estimated at about three inches, and its diameter, therefore, at rather less than one inch.

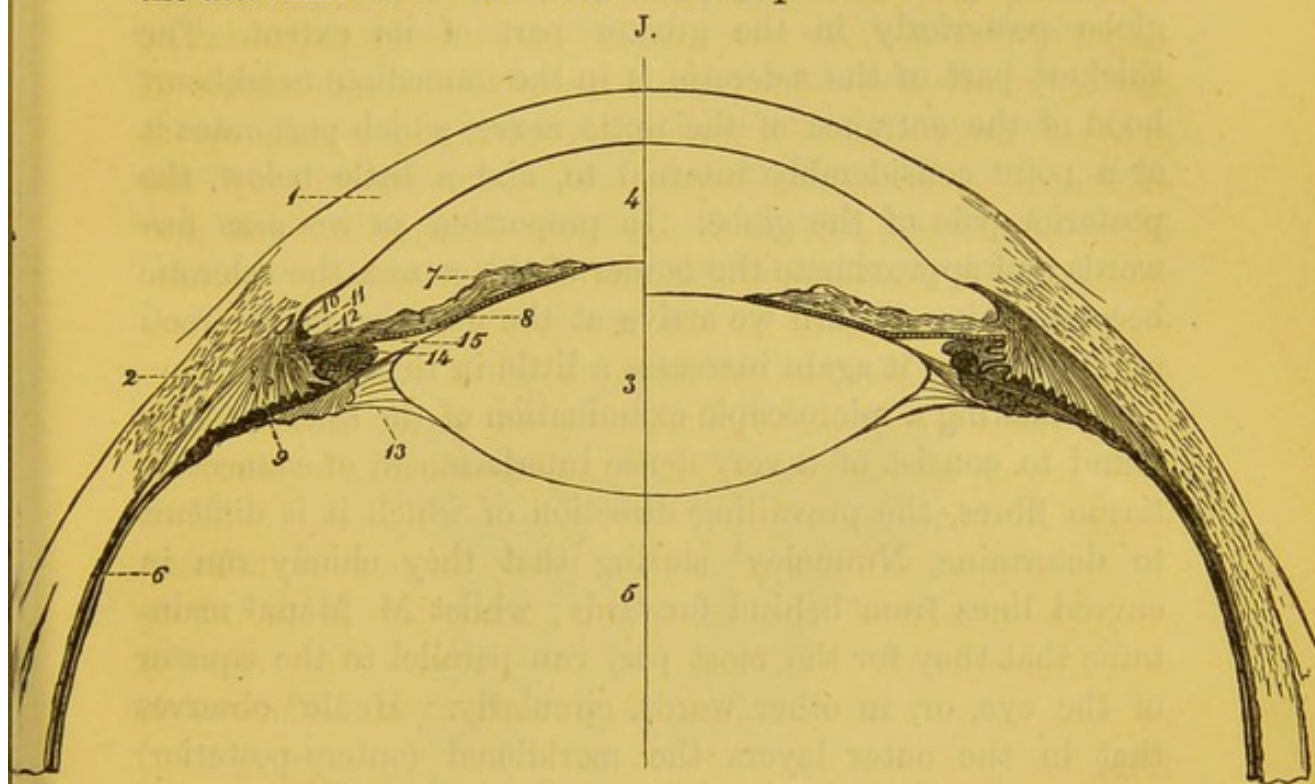
The accompanying diagram will render intelligible the arrangement of the parts occupying the fore part of the eye, to which reference will immediately be made.

That half of the eye which is lettered shows the disposition of the parts when accommodated for near objects; the blank half when at rest, or rather when accommodated for objects at an infinite distance.

The sclerotic and cornea, however much they may apparently differ, are continuous with one another, and the structure of one is only slightly modified as it passes into the other. The sclerotic, which forms nearly five-sixths of the external coat of the eye, is a very firm and dense membrane, composed of connective tissue, and closely resembles in structure and function the tunica albuginea of the testis. Anteriorly, for a considerable part of its extent, it is covered by the thin conjunctival membrane, shining through which it forms the

¹ On the Organs of Vision, pp. 131-134. 1858.

"white of the eye." Beneath the conjunctival covering are the attachments of the recti and obliqui muscles, which are



Section of the Anterior part of the Eye, after v. Jäger.¹

1. Cornea.
2. Sclerotic.
3. Lens.
4. Aqueous humour and anterior chamber of the eye.
5. Vitreous.
6. Choroid at the point where the ciliary processes commence. It is lined internally by the retina, and the fig. is opposite the point where the sclerotic become thickened by the insertion of one of the recti muscles.
7. Iris.
8. Uvea.
9. Ciliary muscle.
10. Canal of Schlemm.
11. The ligamentum pectinatum iridis.
12. A few circular fibres of the ciliary muscle seen in section.
13. Layer of membrane proceeding from the ciliary processes, and constituting the posterior boundary of the canal of Petit.
14. Apex of one of the ciliary processes.
15. Posterior chamber of the eye, filled with aqueous humour.

¹ Ueber die Einstellungen des Dioptrischen Apparatus in Menschlichen Auge. Taf. iv. 1861.

inserted close to the cornea, and from whose edges a membranous expansion or capsule is given off, which invests the globe posteriorly in the greater part of its extent. The thickest part of the sclerotic is in the immediate neighbourhood of the entrance of the optic nerve, which perforates it at a point considerably internal to, and a little below, the posterior pole of the globe. In proportion as we pass forwards and approximate the border of the cornea, the sclerotic becomes thinner, until we arrive at the insertion of the recti muscles, when it again increases a little in thickness.

On making a microscopic examination of the sclerotic, it is found to consist of a very dense interlacement of connective tissue fibres, the prevailing direction of which it is difficult to determine, Nunneley¹ stating that they chiefly run in curved lines from behind forwards; whilst M. Manz² maintains that they for the most part run parallel to the equator of the eye, or, in other words, circularly. Henle³ observes that in the outer layers the meridional (antero-posterior) fibres predominate; in the inner, the æquatorial. Mingled with the straight and rectangularly crossing fibres of the connective tissue, is a network of fine elastic fibres, which confers that elasticity upon the sclerotic which, though slight, is yet perceptible when the globe is gently pressed with the fingers.

Internally the sclerotic is grooved by branches of the ciliary nerves and arteries passing forwards to the ciliary muscle and iris, and is connected with the choroid coat by a delicate layer of connective tissue, in which are many pigment cells.

Anteriorly, under the microscope, the sclerotic may be seen to pass almost insensibly into the cornea; the change from the one into the other, which is effected by the tissue assuming a laminated aspect, and becoming transparent, being effected first usually in the deeper parts, so that the sclerotic

¹ Op. Cit, p. 151.

² Wecker, *Etudes Ophthalmol.*, vol. i. p. 211.

³ *Anatomie des Menschen*, vol. ii. p. 589. 1866.

appears to overlap the cornea. Where the sclerotic is perforated by the optic nerve, it is continuous with the neurilemma; and near the point of junction a few fibres are given off, which, interlacing with one another, and leaving openings through which the fasciculi of the nerves pass, constitute the cribriform fascia. The arrangement of the parts in question has been carefully examined by M. Giraud-Teulon,¹ and is exhibited in the accompanying woodcut.

K.

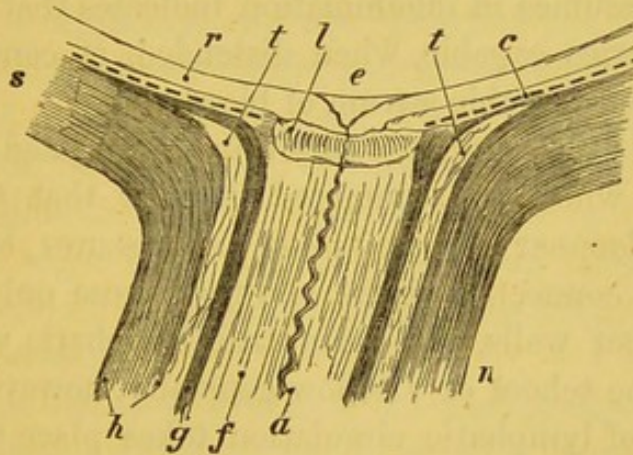


Diagram of the disposition of parts at the point where the sclerotic is perforated by the optic nerve (after M. Giraud-Teulon).

- | | |
|---------------------|-------------------------------------|
| (r) Retina. | (n) Optic nerve. |
| (c) Choroid. | (l) Cribriform plate. |
| (s) Sclerotic. | (e) Physiological excavation. |
| (f) Nervous fibres. | (t) Interstitial connective tissue. |
| (a) Central artery. | |

According to this observer, the sclerotic is composed in its posterior region of two fibrous laminae separated by a very distinct zone of connective tissue (*t*), which forms around and a little behind the cribriform lamella (*l*) a kind of disk, though only of small extent. The neurilemma of the optic nerve presents an analogous disposition: it is likewise formed of two annular fibrous laminae, separated also by a continuation of the same intervening layer of connective tissue (*t*). Of these

¹ *Annales d'Oculistiques*, t. lvi. p. 201.

two fibrous investments of the nerve, the most internal (*g*) is intimately connected with the cribriform lamella, with the choroid, and lastly with the internal fibrous lamina of the sclerotic. The most external (*n*) passes forwards to blend with the external lamina of the sclerotic.

The sclerotic coat is fairly supplied with blood-vessels, derived chiefly from the posterior and partly from the anterior ciliary arteries; and though, under ordinary circumstances, the membrane is nearly white, yet the deep lake-tint which it speedily assumes in inflammation indicates that it contains many capillaries capable, when distended, of conveying collectively a considerable stream of blood.

The lymphatics have been carefully investigated by Ludwig and Tomsa, who have attempted to show that their origin lies in the lacunar spaces, splits, and fissures between the fibres of the connective tissue, and that these only gradually acquire proper walls, and form true lymphatic vessels. M. Manz and the school of Virchow generally, however, consider that a kind of lymphatic circulation takes place through the numerous connective tissue corpuscles, and those anastomosing prolongations that are found in the substance of the sclerotic. In this they also hold that the elastic fibres take a prominent part.

The nerves of the sclerotic are little known. The intense pain which is experienced when the intra-ocular pressure is much increased, may be explained by attributing it to pressure on, and irritation of, the ciliary nerves internal to the sclerotic. It is probable, however, that these nerves give off branches to the membrane as they penetrate its substance.

The cornea is one of the most remarkable textures in the body. It is exceedingly tough, highly polished on its surface, and perfectly transparent. When viewed from within, it is exactly circular, which has an important bearing on the uniform contraction of the ciliary muscle with which it is so closely connected; its anterior surface, however, is oval

from side to side, the conjunctiva always advancing a little way upon it both above and below. Its thickness is generally stated to be equal throughout; but Krause's measurements show that it is rather thicker towards the periphery in the proportion of 0·9 millimètres to 1·12 millimètres. Its index of refraction is 1·3525; its weight is 2·7 grains; its average diameter is half-an-inch. In chemical composition it is analogous to cartilage, since it yields chondrin on boiling. According to the researches of Helmholtz, the curvature of the cornea is ellipsoidal and not spherical, and in its several meridians it has almost always a different radius of curvature, the vertical having the shortest, which is a fact of capital importance in the production of regular astigmatism. Knapp,¹ however, maintains that the external surface of the cornea is neither the segment of a sphere nor of an ellipsoid of revolution, but should be regarded as the summit of an ellipsoid with three axes.

When the cornea is examined microscopically, it is found to consist of a number of branched cells, lying in an inter-cellular substance. The arrangement of these two component parts, in respect to one another, is such as to admit of two explanations. According to some observers,² the greater part of the substance of the cornea is made up of a great number of lamellæ,—Henle counted as many as 300,—superimposed one upon the other, yet not arranged quite uniformly in a concentric manner, since none of them are coequal in point of extent with the surface of the cornea itself, but may be seen on vertical sections to terminate at various points by greatly attenuated margins, dipping down or ascending between those situated above and below. Dr Lightbody³ observes, that although it is difficult to state with certainty the length of the bundles, he has been able to trace them,

¹ *Comptes Rend. d. Congres. Ophthal.*, p. 37. 1862.

² See Henle, *Anatomie des Menschen*, Bd. ii. p. 593. 1866.

³ *Humphry and Turner's Journal of Anatomy*, vol. i. p. 17.

distinct and separate, in a radial direction, in a sheep, for about one-third of the radius, after which they fined off and lost themselves amidst other bundles, or divided either in the direction of their thickness or breadth, giving origin to, or joining, two or more bundles. Henle terms these primitive lamellæ, and describes them as connected together by a web of fibres, but separated from one another at certain points, so as to leave an anastomosing network of lacunar spaces, constituting the canal system by which the nutrition fluids are conveyed to all parts of the cornea. On this view, the walls of the canals are simply formed by the surfaces of the lamellæ themselves.

A different explanation of the appearances presented on making a vertical section has been offered by Virchow,¹ His,² and others, who regard the cornea as a coherent, uniform mass, composed of intercellular substance, in which spindle-shaped cells, with irregularly-disposed branched processes—though for the most part of a quadripolar type—are so placed that they produce a lamellar or plate-like appearance. The cells and their prolongations are alike hollow, and, since they freely anastomose with one another, form a system of communicating tubes, by which the pabulum is conveyed for those parts of the tissue which are most remote from the blood-vessels.

M. His observes, in reference to Henle's views, that the supposed lamellæ of the latter author are nothing else than the expression of a fibrillar cleaving of the vertical section, pursuing a parallel course to the surfaces of the cornea; and there can be no question that the corneal texture, under certain circumstances, has a disposition to split up into bundles of fibres, rather than into lamellæ.

The presence of nuclei in many of the lacunar spaces, which is now generally admitted, is certainly in favour of the opinion held by Virchow; whilst it must be allowed, on the

¹ Cellular Pathology, p. 304. 1860.

² Beiträge zur Normal und Path. Anatomie der Cornea, p. 12, *et seq.* 1856.

other hand, that the lamellar arrangement on vertical section is almost too uniform and well defined to be attributed to the distribution of the cells alone which are found in the substance of the membrane. According to Dr Lightbody, the form of the cells becomes less regular towards the edge of the cornea, gradually merging into the connective tissue corpuscles of the sclerotic. They are far more abundant in young than in old animals; and in the foetus of four or five months the cornea appears to be almost made up of these cell-like bodies, which then appear as oval masses of protoplasm or "germinal matter." At a later period, whilst still retaining the character of protoplasm, destitute of any confining cell wall, they send out processes which sometimes do, and sometimes do not, communicate with those of other corpuscles; whilst the inner cell is capable, according to Kühne, of undergoing slow movements, analogous to those performed by the white corpuscles of the blood, and by amœbiform cells. In adult and aged persons, the corpuscles of the middle and posterior lamellæ are few and scattered; while in the anterior layers, where active nutrition is still going on for the production of the conjunctival epithelium, they are almost as numerous as in the mature foetus.

The cornea is bounded in front and behind by transparent and homogeneous membranes, named by Mr Bowman respectively the anterior and posterior elastic laminae. The former of these was described by him as being tied down to the surface of the cornea proper by a system of fibres crossing the lamellæ at right angles, and becoming continuous at the periphery with the basement membrane of the conjunctiva. It has recently been carefully examined by M. Iwanoff,¹ by whom it is described as presenting remarkably varying degrees of thickness in different animals, being very thick in man and the ox, thinner in rabbits, and reduced to a minimum in dogs. He considers it to be only a slightly modified

¹ Pagenstecher's *Klin. Beobacht.* Wiesbaden, Heft. iii. p. 120. 1866.

and condensed tissue, of the same nature as that of which the rest of the cornea is composed, from which it is impossible, without tearing, to separate it. Solution of permanganate of potash ($\text{Mn}_2 \text{O}_7 \text{ KO.}$), which loosens and dissolves the connective substance of the cornea, dissolves also the membrane of Bowman, leaving, however, a fibrous stroma, which is identical with that of the corneal stroma. An additional reason for regarding it as only a modification of the corneal substance is, that it presents the same features in the pathological changes which it undergoes.

When, as sometimes happens, the anterior elastic lamina is deficient, the fibres near the front of the cornea simply seem to spring from the surface, diminishing slightly its transparency at this part.

The anterior surface of this membrane, and therefore the exposed surface of the cornea, is covered by several layers of epithelium, which have been carefully examined by Dr C. Schalygen,¹ who admits three principal series. The deepest of these consist of one or two layers of columnar cells, resting immediately on the anterior elastic lamina of the cornea. The middle series is the thickest, and consists of several rows of roundish, roundish-oval, or angular cells; and the external consist of flattened roundish cells, which become more and more compressed as they reach the surface, till at length they only form scales. The number of layers is difficult to determine, but he estimates it, for the external, middle, and internal layers respectively, at 3, 6, 1, or as 3, 5, 1. The cells of the conjunctival epithelium, over the sclerotic coat, are usually more round. The nuclei of the corneal epithelium are of considerable proportional size, and are roundish, oval, or flat, according to the shape of the cell in which they lie.

Posteriorly the cornea is also bounded by an elastic membrane, the so-called posterior elastic lamina, or membrane of Descemet. This becomes thicker and denser with advancing

¹ Arch. f. Ophth. Bd. xii., Heft. i. p. 83.

age, but always shows a tendency to roll up in an opposite direction to that in which it is laid down, or with the natural convex surface inwards. It strongly resists the action of most chemical re-agents, and possesses little or no indications of structure. It is usually considered to divide into three portions at the margin of the cornea, the most internal curving inwards to the iris, and forming a series of pillars which bound the anterior chamber of the eye laterally; the most external dipping into the substance of the sclerotic, and bounding the canal of Schlemm; and the median fibres become blended or continuous with the fibres of the tendon of origin of the ciliary muscle. The latter termination is, however, according to Dr Lightbody, its only true one. The posterior elastic lamina is lined internally by a single layer of polygonal and somewhat flattened epithelium, which forms the wall of the anterior chamber of the eye, and is in contact with the aqueous humour.

The cornea is very thick, much thicker indeed than the sclerotic with which it is continuous; a fact to be remembered in introducing cutting instruments from without, otherwise the point of the knife or needle is apt, especially in flat corneæ, to travel amongst the lamellæ, and never gain entrance into the anterior chambers at all.

Vessels are only found in the cornea of the foetus, at which period they may be traced under the anterior elastic lamina, forming a tolerably close network reaching to near the centre of the cornea. Towards the end of foetal life they vanish, and the only trace that is left of them in adult life consists in certain capillary arches that extend over the extreme margin of the cornea for a short distance, though nothing is more common in disease than to see vessels prolonged in and upon it from the adjoining textures.

The relations of the surface of the cornea to the sense of touch are remarkable. The pain and irritation excited by the pressure of a foreign body, or of a slight abrasion, are of

a very severe character, though no doubt the sensations are often materially aggravated by the sensibility of the inner surface of the palpebral conjunctiva. Yet the cornea may be touched with the finger, and even cut with a knife, with scarcely any sensation of pain. The distribution of the nerves has recently been made the subject of special study by Hoyer,¹ who states that nerve-fibres run through the deeper layers of the cornea, and then suddenly changing their direction, pass forwards and terminate in fine extremities, which are either connected with the cells covering the cornea, or run up between them. Numerous writers maintain that they terminate in plexuses and looped networks, and Kühne² considers that they are continuous with the prolongations of the connective tissue corpuscles.

Just at the point of fusion of the sclerotic and cornea, at the outer border of the anterior chamber of the eye, is a small sinus (fig. J. 10, p. 237), termed the canal of Schlemm, which runs round the inner border of the cornea. It does not appear to be a perfectly smooth and regular sinus, but, according to Leber³ and Rouget, is a circular plexus of veins receiving many small venous trunks from the ciliary muscle, and communicating, by many branches which traverse the sclerotic, with the anterior ciliary veins.

As the vascular system of the eye is very complex, it will be expedient here to give a short general account of it, which will render the changes that occur in inflammation more intelligible, and avoid the necessity of frequent repetition. In the drawing and the description, I have followed the excellent account given by Dr Th. Leber.⁴

From an examination of the following diagram it may be seen that the branches of the ophthalmic artery form three divisions

¹ Reichert and Dubois Reymond's Archives, p. 180. 1866.

² Gaz. Hebdomadaire, t. ix. p. 15.

³ Ann. d'Ocul., p. 46. 1865.

⁴ Archiv. f. Ophth., Bd. xi. i. p. 1.

or systems, namely, (1.), The vascular system of the retina; (2.), of the choroid and ciliary region; and (3.) of the conjunctiva.

1. The *retinal vascular system* is composed of the central artery and vein of the retina (*z*), which gain entrance into the globe through the optic foramen. This system is remarkably independent, only communicating with the ciliary vascular system at the point where the short posterior ciliary arteries form a circular plexus in the sclerotica around the entrance of the optic nerve (3).

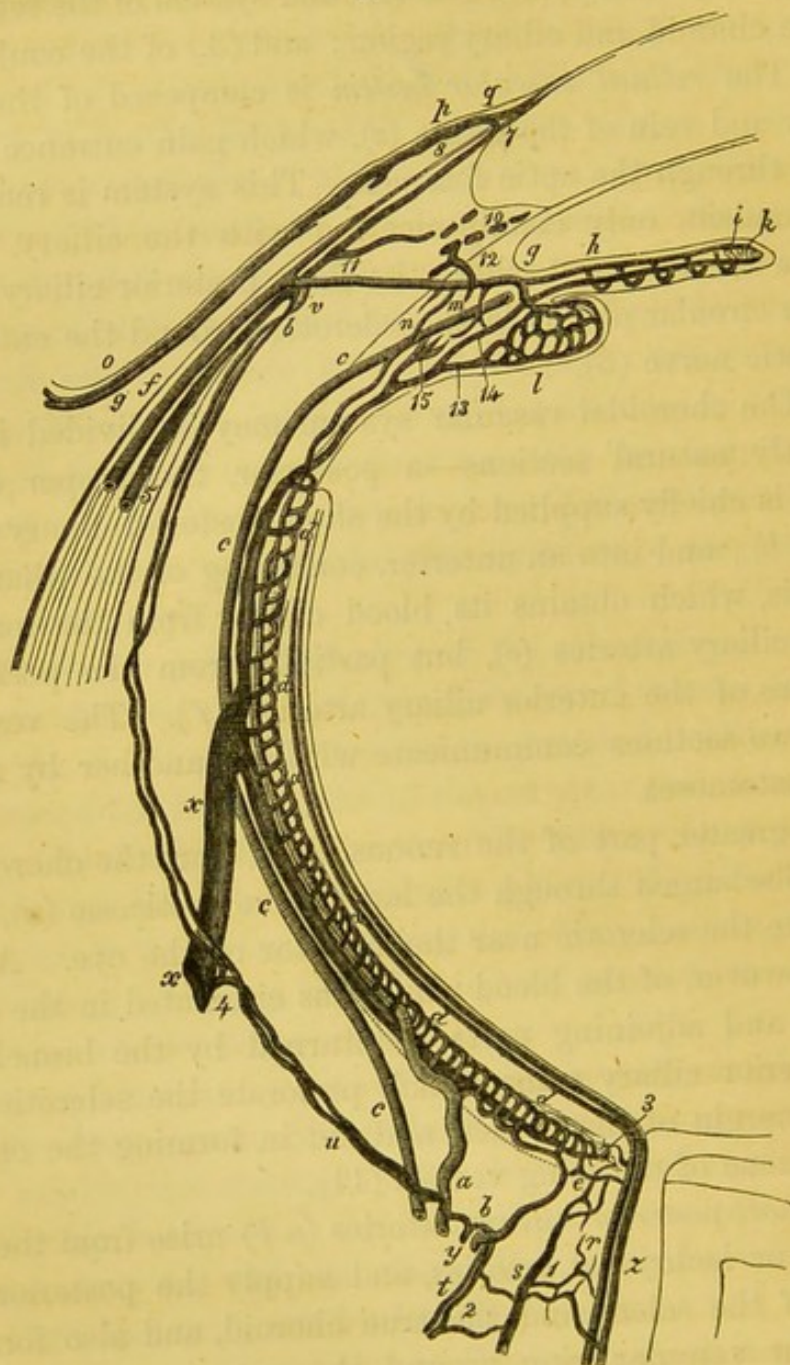
2. The choroidal vascular system may be divided into two perfectly natural sections—a posterior, the proper choroid, which is chiefly supplied by the short posterior ciliary arteries (*a* and *b*); and into an anterior, consisting of the ciliary body and iris, which obtains its blood chiefly from the long posterior ciliary arteries (*c*), but partially from the perforating branches of the anterior ciliary arteries (*f*). The vessels of these two sections communicate with one another by numerous anastomoses.

The greater part of the venous blood from the choroid and iris is discharged through the large *venæ vorticosæ* (*x*), which perforate the sclerotic near the æquator of the eye. A small part, however, of the blood which has circulated in the ciliary muscle and adjoining parts is returned by the branches of the anterior ciliary veins, which perforate the sclerotic close to the margin of the cornea, and aid in forming the circumcorneal zone of radiating vessels (11).

The *short posterior ciliary* arteries (*a b*) arise from the ophthalmic or lachrymal arteries, and supply the posterior segments of the sclera and the true choroid, and also form an important vascular ring around the entrance of the optic nerve, in the substance of the sclerotic, which communicates with the branches of the *arteria centralis retinae*.

The *long posterior ciliary* arteries (*c*) have the same origin as the preceding, and supply the ciliary body, the iris, and the anterior part of the choroid.

L.



This figure is a diagrammatic representation of the arrangement of the vessels of the eye, after Leber.¹

ARTERIES.

- (a.) Larger. } Branches of the short posterior ciliary arteries.
 (b.) Smaller. }

¹ Archiv. f. Ophth., Bd. xi. 1865.

- (c.) Long posterior ciliary arteries (which end abruptly, since, properly speaking, they do not run in the plane of the section. If their actual course were indicated, they should enter the great iris-circle *g*, instead of the anterior ciliary arteries, and give off exactly the same branches).
- (d.) Chorio capillaris.
- (e.) Arterial vascular circle around the optic nerve, giving off branches which penetrate its substance.
- (f.) Anterior ciliary artery.
- (g.) Greater circle of the iris.
- (h.) Artery of the iris.
- (i.) Smaller circle of the iris.
- (k.) Capillary plexus in the sphincter papillæ.
- (l.) Arteries of the ciliary processes.
- (m.) Arteries of the ciliary muscle.
- (n.) Recurrent artery to the choroid.
- (o.) Posterior artery of the conjunctiva.
- (p.) Anterior artery of the conjunctiva.
- (q.) Arterial branch to the loop-like plexus around the margin of the cornea.
- (r.) Central artery of the retina.
- (s.) Artery of the internal sheath of the optic nerve.
- (t.) Artery of the external sheath of the optic nerve.
- (u.) Branch of the short ciliary artery to the sclera.
- (v.) Branch of the anterior ciliary artery to the sclera.

VEINS.

- (x.) One of the venæ vorticosæ.
- (y.) Posterior ciliary vein.
- (z.) Central vein of the retina.
- 1. Veins of the inner sheath of the optic nerve.
- 2. Veins of the external sheath of the optic nerve.
- 3. Veins (and arteries) of the choroid entering the optic nerve.
- 4. Scleral vein passing to the vena vorticosa.
- 5. Anterior ciliary veins; and
- 6. Their branches to the sclera.
- 7. Veins of the looped plexus around the cornea.
- 8. Anterior conjunctival veins.
- 9. Posterior conjunctival veins.
- 10. Ciliary plexus.
- 11. Branch uniting the ciliary plexus with the anterior ciliary veins.

12. Veins of the ciliary muscle passing to the ciliary plexus.
13. Veins of the ciliary process.
14. Veins of the iris.
15. Veins of the ciliary muscle passing to the vena vorticosæ.

The venæ vorticosæ return the greater part of the blood conveyed by these arteries, and at the point where they perforate the sclera receive some of the veins belonging to that tunic. The remainder of the sclerotic veins, however, unite to form small trunks, which are termed the *posterior ciliary veins*. These receive no branches from the choroid.

3. The external vessels of the eye are divisible into two layers—a superficial, including the vessels of the conjunctiva, and of the subconjunctival connective tissue; and a deep, formed by the distribution of the anterior ciliary vessels upon the sclera. The *posterior*, or proper, *superficial conjunctival vessels*, are derived from the palpebral and lachrymal arteries, and may easily be seen, running forwards from the conjunctival fold, as small, bright red, slightly tortuous branches, which may be made to glide over the subjacent tissue by slight pressure. They divide and form arches, from which smaller branches pass forwards till they attain a distance of about one-sixth of an inch from the corneal border, where they blend with the branches of the circum-corneal zone, formed by the division of the anterior ciliary arteries. These are the vessels which are so deeply congested in the ordinary catarrhal affections of the eye, and are entirely distinct from the subjacent branches of the anterior ciliary arteries.

The *anterior ciliary arteries* (*f*) take origin from the arteries of the four recti, the tendons of which they penetrate. There are usually two to each rectus, except the external, which has only one. They supply the outer part of the sclerotic, and run in a tortuous manner towards the border of the cornea, near which they divide into many branches, that, after giving off delicate episcleral twigs, perforate the sclerotic directly from before backwards, whilst others radiate out-

wards, to join the proper conjunctival vessels. Occasionally an anterior ciliary artery is given off from a palpebral artery, near the outer part of the eye. These are the most conspicuous arteries under ordinary circumstances, and are those which, on examination of the healthy eye, first attract attention. At the point where they perforate the sclerotic a little pigment matter is usually deposited.

The anterior ciliary veins correspond to the arteries, but are rather more numerous. At the same time, since they are only required to return a portion of the blood transmitted by the arteries, they are small and delicate, and are scarcely visible unless the eye is somewhat congested. As the arteries give off, so do the anterior ciliary veins receive branches—(1.), From the capillary network of the sclera; (2.), from the looped plexus of vessels around the margin of the cornea; (3.), from the anterior conjunctival veins; and (4.) from the vessels distributed to the ciliary muscle. The anterior ciliary arteries and veins constitute the greater portion of the episcleral plexus of vessels, and of that circum-corneal zone of blood-vessels so remarkably prominent in inflammation of the iris.

Arcus senilis.—At the age of fifty, a bluish-white ring generally begins to make its appearance round the periphery of the cornea, termed the arcus senilis, the pathological import and relations of which have been exhaustively investigated by Mr Canton.¹ Its formation is the result of a process of fatty degeneration taking place in the corneal tissue, the change first occupying the upper and subsequently the lower segment of the cornea, the two arcs continuing to increase till they at length unite a little below the horizontal meridian of the cornea, and form a complete circle.

The presence of the arcus senilis is an indication of impaired nutritive functions, and generally of enfeebled vital powers, and is coincident with other changes indicative of the

¹ On the Arcus Senilis, by Edwin Canton. Lond., 1863.

accession of old age, as the presence of grey hair, ossification of the laryngeal and costal cartilages, and calcification of the arteries. It is also frequently associated with fatty degeneration of other organs, as of the heart, liver, kidneys, various muscles, bones, arteries, and other parts. If a thin section be made through the portion of cornea thus affected, the appearances presented are, according to Mr Canton, that the lamellæ, at a short distance from the sclerotic, are of a light brownish hue, with the fibres confused or matted together. The depth of this tint is ordinarily greatest towards the anterior elastic lamina, and thence declines more and more as it approaches the membrane of Descemet. On examination of the specimen with a power of 200 diameters, the arcus will be found to be constituted by myriads of fine oil-globules, intermingled with some of larger size. "These oil-drops are arranged in two ways—first, in the direction of such of the lamellæ as have disappeared, and which they replace, constituting a fatty degeneration or conversion; and, secondly, in the interstices, or between the lamellæ, forming a fatty deposition. The slight elevation which the cornea presents at the site of the arcus is due to this latter condition." In the early stages of the change, the oil-globules will be found in the interior of the corneal cells, and in their prolongations.

The presence of the arcus senilis does not in any way interfere with the healing of the lips of the wound in the section made for the extraction of cataract.

The general pathology of the cornea includes essentially the alterations that take place in its structure as a consequence of inflammation. These have been carefully studied by His¹ and by Iwanoff.²

His examined microscopically sections of cornea through

¹ Beiträge zur Norm. und Pathol. Histologie der Cornea. Baasl, p. 109. 1856.

² Essay on the Pathological Anatomy of the Corneal and Lenticular Epithelium, in Pagenstecher's Klinische Beobacht. Wiesbaden, Heft. iii. 1866.

which threads had previously been passed, and agrees with Virchow in believing that there is no such thing as a free and independent exudation in corneal inflammation. The changes which really occur are—that (1.) the cells of the cornea increase in size, and become finely granular, whilst (2.) the nuclei divide and multiply; (3.) the cell-wall becomes separated from the contents, and the latter divide, exhibiting (4.) the process of endogenous multiplication of cells; (5.) the young cells thus generated continue to enlarge either with or without destruction of the mother cell; (6.) fatty degeneration of the brood of young cells, which are incapable of further development, then takes place; (7.) the granular contents of the cells become reapplied to the walls coincidentally with enlargement of the old-cell nuclei and the appearance of nucleoli; this is followed by (8.) diminution of the volume of these cells; and finally terminates in (9.) the shrinking up or mortification of the young cells.

The stages numbered above, 1, 2, and 3, correspond to the period that is ordinarily termed the stage of exudation or deposition; 4 and 5, to the stage of organisation of the deposit; and the remainder to the stage of reabsorption of the exudation.

The appearances which are presented in inflammatory affections of the cornea are essentially the following:—
1. Cloudiness. 2. The development of vessels in, or more frequently on, its surface, from the union of spindle-shaped cells and the extensions of capillary loops from the adjoining textures. 3. Softening and disintegration of its texture. 4. The formation of matter, occasioning, if it be included between the lamellæ, an abscess, or if the anterior lamellæ have given way, an ulcer; and, lastly, the restitution of loss of substance by regeneration or cicatrization, sometimes into proper transparent corneal tissue, and sometimes into a new tissue resembling connective tissue, which is formed on the surface of the cornea between the epithelial layers and Bowman's elastic

lamina, by the conversion of the cells into connective tissue corpuscles, and the fibrillation of the blastema.

M. Iwanoff, who has paid much attention to the pathological changes occurring in the cornea after mechanical or other injury, remarks that the corneal epithelium reacts very slightly to an amount of chemical or mechanical irritation, which, when applied to the corneal substance, excites a remarkable degree of perturbation, at most only occasioning its disappearance by fatty degeneration.

If we corrode the surface of the cornea with nitrate of silver in substance, we remark, in the first instance, the occurrence of a serous exudation from the corneal tissue, raising the epithelium into a transparent vesicle. The corneal corpuscles proliferate abundantly, pus forms, the little vesicles lose their transparency, and gradually become converted into pustules. The epithelium offers only the indications of regressive metamorphosis, the cells becoming filled with fat drops, the nuclei shrinking, and the whole cell, in some instances, shrivelling up. The pus now either escapes by the bursting of the pustule, or its fluid constituents are re-absorbed, whilst dried and distorted cells remain, which, with the débris of epithelium, form a kind of crust or scab. This is soon rubbed off by the movements of the lids and the flow of tears, and there remains a shallow suppurating surface, with loss of substance, in fact a corneal ulcer. After a time the depressed surface becomes covered by cell-formation, forming a kind of granulation tissue. From this moment the healing process commences at the surface of the ulcer, whilst at its edges oval and spindle-formed cells make their appearance, which are frequently met with in active process of multiplication, and from which, at a subsequent period, the true epithelial cells differentiate themselves, the process commencing first at the borders, and gradually extending over the entire surface of the ulcer. The restitution of the destroyed corneal tissue begins somewhat later and proceeds more slowly. In the first instance, the

spaces between the round newly-formed cells become larger, and filled up with an homogeneous or slightly granular mass, and the cells themselves become oval, puriform, or stellate in form. The intervening spaces still continue to increase, and the homogeneous substance, in the later stages of reparation, acquires a fibrous appearance.

It is remarkable that, whatever may be the position of the ulcer on the cornea, whether centric or peripheric, there is always a circum-corneal conjunctival zone of increased redness, with slight tumefaction; and if these parts are examined microscopically, a process of cell-proliferation in the sub-epithelial connective tissue will always be found to have taken place; and an interesting point is, that also at this part the epithelial layers partake in the proliferation process. Similar but more superficial effects are produced by the instillation of strong solutions of nitrate of silver. Under these circumstances, indeed, it has been shown by M. Schalygen,¹ that the epithelial cells covering the general surface of the cornea may undergo proliferation, the middle layers showing the most remarkable increase, so early even as the fourth day after the application of the irritant. The changes above described, after M. Iwanoff, are stated by him to take place with different degrees of rapidity in different animals, the energy of the process apparently standing in close relation with the thickness of the anterior elastic lamina: where this is thick, as in the ox, and especially in man, the changes being slow and gradual; where it is thin, as in the rabbit and dog, the development of cells taking place with much rapidity.

¹ Archiv. für Ophthal., Bd. xii. i. p. 89.

I. DISEASES OF THE SCLEROTICA.

(PLATE VI., Figs. 31 and 33.)

The diseases proper to the sclerotic coat are comparatively few, though it frequently participates in the inflammatory conditions that affect neighbouring parts, as the iris, the choroid, and the cornea; nor is this surprising, when it is remembered that, on the one hand, it is a fibrous membrane, possessing relatively few vessels and nerves, and on the other, that its vascular and nervous supplies are closely connected with those of each of the above-mentioned tissues.

The simplest, and at the same time not very uncommon form of inflammation of the sclerotic, is termed *episcleritis*. This affection offers the following symptoms:—A smooth, reddish swelling makes its appearance on the surface of the sclerotic at some distance from the edge of the cornea; and, as M. Wecker¹ remarks, usually in the space between the insertions of the recti. It progresses very slowly, and gives rise to no pain or other inconvenience. On minute examination, it clearly contains two sets of vessels, some proceeding from the conjunctiva, which are superficial and scarlet, and ramify all over its surface, whilst others are more deeply seated, are of larger size, and emerge from or run upon the sclerotic itself, conferring on the tumour a dull red tint. The conjunctiva covering it is smooth and polished, and usually a little chemosed, but presents, as a general rule, no tendency to suppuration or ulceration, by which it is distinguished from cases of phlyctenular disease of the conjunctiva, attended with considerable inflammation, to which it otherwise bears some resemblance. In some exceptional and severe cases, however, ulceration, even proceeding to perforation of the sclerotic, has been observed to take place. The swelling rarely attains a greater elevation than that of a split-pea, and from being of a yellowish amber colour, and semi-transparent at the apex,

¹ Etudes Ophthal., vol. i. p. 241.

gives the impression of being produced by the effusion of serum and lymph beneath the conjunctiva. Except in the immediate vicinity of the tumour, the remainder of this membrane presents its natural appearance. The progress of the affection is almost always chronic, especially if left to itself.

Regarding it as a rheumatic affection, the treatment which I have adopted has been the administration of iodide of potassium in three-grain doses, with three minims of tincture of aconite, and twenty of tincture of colchicum; and recovery has invariably taken place in the course of three or four weeks, the swelling entirely disappearing, the vessels resuming their natural diameter, and no trace of the former presence of the disease being left. In any case where it grows intractable, leeches may be applied to the temple, and warm compresses placed on the eye.

1. *Rheumatic Inflammation of the Sclerotica.*

(PLATE VI., Figs. 31 and 33.)

Few affections present themselves more frequently in hospital practice than simple rheumatic or catarrho-rheumatic ophthalmia, in which the sclerotic is the principal tissue implicated. It is a disease that is rarely met with in young persons, but becomes more frequent as life advances, and is perhaps the most common affection from which old people suffer. It is almost always referred to atmospheric changes, as to exposure to wet and cold, or to a cold draught of air, or to sleeping in a damp bed, or to some other cause which may occasion a suppression of the functions of the skin. The disease has been induced by Dr Richardson in dogs, by injecting a small quantity of lactic acid into their veins; and it is not improbable that it may arise, in some instances, from the development of this acid in the body. The disease generally commences with a feeling of stiffness and soreness in the eye, accompanied by some lachrymation and slight vascular injection (Plate VI., fig. 31). The vessels thus congested, which

are chiefly branches of the anterior and short ciliaries (*f* and *u*, fig. L, p. 248), are small and delicate, and deeply seated, conferring on the sclerotic a delicate pink hue, and run in straight lines from the conjunctival fold towards the cornea. Such typical cases are, however, very uncommon; in the majority of instances, the conjunctival vessels are also affected, either from the first or in the later stages, and in consequence a second and more superficial plexus becomes visible (*o*, fig. L.), the branches of which are larger, more tortuous, more freely anastomosing with one another, of a brighter hue, and capable of being freely moved over the subjacent vessels, when the eyelid is pressed on the ball in different directions. The disease is then called catarrho-rheumatic ophthalmia, and some puriform discharge usually takes place.

The cornea is sometimes surrounded by a whitish ring (fig. 33), which was formerly considered characteristic of rheumatic ophthalmia. It is, however, only due to the circumstance that the portion of the sclerotic which advances upon the margin of the cornea is ill supplied with vessels, and therefore, when the conjunctival and sclerotic vessels are highly congested and of a deep colour, this portion appears by contrast white.

The character of the pain is very peculiar in rheumatic inflammation of the eye. In the catarrho-rheumatic form, it is smarting at first, but soon becomes, especially in old and debilitated persons, dull, heavy, and aching, running up the brow and temple, or down the side of the nose, or affecting the superior maxillary division of the fifth nerve. The patients are often tolerably free from suffering by day, but the pain comes on with distressing severity at night, or in the early morning, probably in connection with the depression of all the nervous and vascular functions at this period of the day. The globe of the eye is often complained of as feeling tight and ready to burst, and pressure upon it, made through the closed lid, is borne with impatience and shrinking. In the majority of cases, however, the patients refer the pain

rather to the brow and temple than to the eye itself. The cornea usually remains clear, so that the details of the iris can be distinctly seen, unless ulceration occurs, the course and termination of which will hereafter be described, and respecting which it need only be stated here, that the ulcer is usually laterally situated on the cornea, which presents a cloudy halo around it; that it is deep, with depressed and irregular margins, and is accompanied by great pain. Chemosis is rarely seen, except in a very slight degree (fig. 18). Vision is rendered obscure and dim at a very early stage of the disease, partly, perhaps, from concomitant congestion of the iris and choroid, leading to increase of the intra-ocular pressure, and disturbing the functions of the retina, and partly owing to slight turbidity of the humours. In many instances the patient, who could see XXX of Snellen's test-types perfectly with the sound eye at 30 feet, has been unable to distinguish XL satisfactorily, and has even found it difficult to read L or LXX at the same distance. Sometimes one eye alone, more generally both eyes, are affected. Photophobia, though occasionally well marked, cannot be considered a prominent feature of this complaint.

When the disease affects a person strongly predisposed to rheumatic affections, or when the cause has been both potent and persistent, the inflammation does not remain limited to the sclerotic, but implicates the cornea, or still more frequently extends to the iris and choroid, and is not an uncommon cause of blindness, by occasioning adhesion of the iris to the capsule of the lens, and a closure of the pupil by lymph; and even if the latter event does not supervene, the foundation is often laid for a subsequent attack of glaucoma, the adhesions which form between the back of the iris and the lens being often so complete as to entirely shut off the two chambers from all communication with one another, and to lead to those recurring attacks of iritis which will hereafter be shown to culminate in an attack of this formidable disease.

The treatment to be adopted in rheumatic ophthalmia, limited to the sclerotic, is first to apply leeches in sufficient numbers (four or six), to produce an immediate influence on the vessels of the globe; and the bleeding should be maintained by poultices, which, when applied as hot as the patient can conveniently bear them, are almost always effectual in lulling the pain. The local, or in the case of robust country people general, bleeding should be followed by purge of a from two to five grains of calomel and a manna and sulphate of magnesia draught. After the bowels have been cleared by this proceeding, which in most instances is an essential part of the treatment, opium may be at once given, either alone in one-grain doses three times a-day, or, in the case of old people, in combination with quinine and with sulphate of iron. In out-patient practice I have found the mist. ferri aperiens, composed of two grains of sulphate of iron, ten or twenty grains of sulphate of magnesia, and a little tincture of ginger in camphor mixture, exceedingly useful. When these means fail, and often from the first, the patient may be ordered a mixture containing three minims of tincture of aconite, and twenty of tincture of colchicum, three times a-day, which sometimes acts almost magically in removing the pain. Lastly, turpentine, in small or moderate doses, will sometimes afford relief when other remedies have been tried in vain. In very persistent cases, calomel and opium must be given till the mouth is sore, and the action maintained for some days by lowering the dose. When, as often occurs, the iris is affected, atropine must be employed (*see* section on Rheumatic Iritis).

2. *Staphyloma Scleroticæ. Sclero-Choroiditis Anterior.*
Cirsophthalmia.

(PLATE VII., Fig. 42; and PLATE VIII., Fig. 43.)

The protrusion of the sclerotic coat, which, from the form and colour it presents, is termed *staphyloma scleroticæ*, may affect either its anterior or posterior segment. In the former

case it is more or less apparent to a superficial examination, though it is frequently concealed beneath the upper lid, and may thus for some time escape observation. In the latter it is only rendered visible by the employment of the ophthalmoscope, by which instrument, however, its position, extent, and progress can be most satisfactorily determined.

In sclero-choroiditis anterior the disease presents itself in the form of a dull leaden or purplish-coloured protrusion of the sclerotic, generally situated in the position corresponding to the interval between the posterior border of the iris and the ciliary processes of the choroid, though sometimes encroaching on the cornea, and sometimes being seated near the æquator of the eye. The sclerotic is obviously thinned, and permits, as it were, the dark choroid to be seen through it. The discoloured surface is at first but slightly elevated, but at a later period it forms a more or less rounded or lobulated swelling, or series of swellings, encircling the cornea, which, from being covered by the conjunctiva, are always glossy and polished on their surface, where numerous vessels of dark colour and tortuous course may generally be seen to ramify.

In recent cases, or when the swelling is rapidly increasing in size, the signs of inflammation are always present; the vessels of the conjunctiva are congested; there is a more or less well-marked circumcorneal zone; the tumour is extremely tender to the touch; and the whole globe is tense firm, resistant of pressure, and acutely painful. Other marks of an inflammatory condition of the choroid, in which the iris participates, are also generally present. The iris is dull coloured and sluggish; the aqueous is turbid; the vitreous is so hazy that the fundus can only be explored imperfectly; the vision is greatly impaired; the patient generally complains, as in glaucoma and other affections where the intra-ocular pressure is materially increased, of ciliary neuroses, or pains in the brow, temple, cheek, and nose. The size to which the protrusion may attain is very various, and is per-

haps dependent upon the greater or less rapidity of its growth, and the violence of the inflammatory symptoms. Generally speaking, it does not exceed that of a pea or of a bean; but sometimes the whole globe seems to yield to the increased intra-ocular pressure, and the condition of hydrophthalmia, or buphthalmia (ox-eye), is produced. The margins of the tumour are sometimes sharply defined, the livid bulging appearing to rise directly from the surface of white and healthy sclerotic; whilst at others the tumours blend gradually with the surrounding tissue, and it is difficult to say where the discoloration and attenuation of the sclerotic commences.

The thinning sometimes proceeds to so great an extent that it spontaneously gives way, permitting the escape of the vitreous, which, in old-standing cases, is often fluid. I had a remarkable example of this under my care some months ago, in an old woman with well-marked anterior staphyloma on the inner side of both eyes, but most marked in the left. Whilst walking in the street, and making no particular exertion, she suddenly felt something give way in the left eye, and a gelatinous fluid streamed down her cheek. She came at once to the Hospital, and I found that a rent had taken place through the summit of the swelling, from which thin vitreous was still oozing. The conjunctiva, anterior chamber, and the vitreous itself, contained much blood, which even now, six months after the accident, has not entirely disappeared, but has become converted into a black mass, that is strikingly similar to melanosis. A little excentric vision is still retained.

The rapidity with which anterior staphylomata develop is very remarkable. I have seen one or two instances where the thinning of the sclerotic and swelling has attained the size of a bean within the space of six weeks; and in such cases it has appeared to be a sequela of extreme debility, night-watching, and a rheumatic habit of body.

The pathology of the affection is rather obscure, but some interesting examinations of eyes affected with partial and general anterior staphyloma of the sclerotic have been made by M. Schiess-Gemuseus.¹ In one instance, where the disease was partial and of small extent, and where the eye had been removed from a child of twelve years of age, the principal points noticed were, that posteriorly, where the globe had preserved its normal form, the choroid and retina were healthy, but were rather firmly adherent to one another, so that some of the pigment of the choroid remained attached to the retina when attempts were made to separate them, and a little loose pigment was found amongst the rods and cones of the retina, indicating an incipient breaking up of the choroidal pigment cells. More anteriorly, the adhesion was less strong between the two membranes. The connective tissue corpuscles of the choroidal stroma were more numerous than natural, and many of them contained two nuclei. The ciliary processes opposite the projection were diminished in height, as though by the stretching of the tissue. The tumour itself was formed by the sclerotic greatly attenuated; and the interior was lined throughout by a thin and delicate layer of connective tissue, with pigment cells. The cornea was hazy, and apparently greatly increased in thickness; but, upon closer inspection, this was found to be occasioned by the presence of a clear, semi-transparent, indistinctly striated mass, destitute of cellular elements, which was intimately connected with the cornea, and included the iris in its substance. The stroma of the iris was thickened by serous effusion, and by fibrinous deposit. The lens was cataractous and shrunken. The anterior capsule was thickened, and, to a certain extent, blended with the above-mentioned mass; but the posterior capsule and vitreous humour were natural.

In another case, the patient was a woman *æt.* 19, and had been short-sighted from her childhood. At about seven

¹ *Archiv. f. Ophth.*, Bd. xi. p. 47. 1865.

years of age she had a "brain fever," after which the globe underwent considerable enlargement, and presented the same appearances as when she offered herself for examination. She had not suffered from pain or any other symptom of inflammation. The left eye was very short-sighted, and to some extent amblyopic. Even when the lids were closed, it was obvious that the right eye was considerably enlarged. On opening it, the dilatation in all dimensions, but especially above, became conspicuous. The sclerotic above the cornea appeared bluish and semi-transparent. The cornea, with the exception of a narrow hazy segment below, was natural in appearance. The pupil was of moderate size, and immovable; the anterior chamber flattened; the iris apparently healthy. On examination with the ophthalmoscope, a small excavated papilla was seen. The eye was removed on cosmetic grounds, in the usual manner, and it was remarked that the fat of the orbit was atrophied, in consequence of the pressure of the enlarged globe. Immediately after removal, the measurement of the eye gave for its antero-posterior diameter, 38 millimètres; for its vertical, 31.5 millimètres; and for its horizontal, 31 millimètres (instead of about 25 millimètres in each direction). After being hardened for a short time, the globe was opened. It was then found that the vitreous was in great part fluid. In the vicinity of the ora serrata, where its connection with the choroid and retina is most intimate, a flocculent mass was present. The whole cavity of the bulb was greatly enlarged. The iris was separated from the processus ciliares by a broad zone, containing a small quantity of pigment, and was coated behind by the pigment of the uvea, which, however, was not adherent to it at any part. The lens had fallen to the lower part of the globe. The choroid was easily torn, was poor in pigment, and almost transparent; its several layers could easily be separated from one another, and it was nowhere very firmly adherent to the retina. The pigment epithelium was

still perfectly preserved as a single layer of cells of natural size; but the cells themselves contained very little pigment, and what there was, was chiefly accumulated at their periphery. The nuclei were very distinct, and normal in appearance. The chorio-capillaris was very beautifully seen, many of the vessels containing blood-corpuscles. The pigmentary cells of the stroma were very pale, rendering this part of the choroid almost transparent, and the outer layer of vessels was less thick than natural. Thus the whole choroid might be said to be in a state of moderate atrophy. In the most anterior portion of the vitreous, which still retained somewhat of its original characters, there were numerous large roundish cells, with one or more nuclei. At the *pars ciliaris choroideæ*, the adhesion between the sclera and choroid was remarkably firm; but even here the *corpus ciliare*, with its anterior highly-pigmented portion stretching towards the iris, could be separated from the sclerotic. The thickness of the pigmentary layer increased here, as usual; but the capillary layer was deficient, and there was only left on the outer side an apparently fibrous membrane, destitute of pigment, but containing large branched vessels. The ciliary processes were separated from one another to a much greater extent than natural, and were in a condition of extreme atrophy. Of the ciliary muscle there were no traces, except a few connective-tissue fibres. From the anterior portion of the *corpus ciliare* to the origin of the iris, the sclerotic was remarkably attenuated, and covered only by thin connective-tissue laminae, in which were a few pigment corpuscles. This part corresponded to the dilated portion of the sclerotic. Where the sclerectasy was the greatest, there was the greatest space between the ciliary processes; and where it was smallest, the folds of the ciliary processes were seen as faint elevations, running forwards over the intervening territory of the sclerotic.

Here and there, between the ciliary processes, small round vesicles were observed, possessing a peduncle, and invested

by a structureless membrane, presenting a simple pavement epithelium on its interior, and apparently forming small cysts of the choroid.

The iris, attached to the cornea by its periphery, was thinner than natural, and appeared to be moderately atrophied.

The cornea was normal, except below, where a little epithelial thickening and haziness existed, and where a few vessels advanced upon it.

The retina was normal. The optic papilla was deeply excavated, probably as a consequence of the increased and persistent intra-ocular pressure.

The sclerotic generally was much attenuated, but in no part to so remarkable a degree as between the corpus ciliare and iris.

Similar changes, more or less strongly marked, were seen in other instances,—the choroid always becoming atrophied; the retina, the seat of pigmentary deposits; the lenticular system almost completely disappearing, and the vitreous becoming fluid; whilst in all instances the protrusion itself was formed by the sclerotic greatly thinned, and lined by a pigmented layer. In all the cases examined by M. Schiess-Gemuseus, the disease appears to have commenced just between the ciliary processes and the level surface of the iris; and from the above account it seems probable that it is primarily an inflammatory affection of the choroid, implicating the adjoining part of the sclerotic, which, becoming enfeebled, yields to the intra-ocular pressure, itself somewhat increased, and thus forms the sclerectasia. This view is supported by the fact that v. Gräfe has ascertained that there is generally an excavation of the optic disc.

The treatment of cases of anterior staphyloma of the sclerotic, to be attended with success, should be undertaken at as early a period as possible, and whilst inflammatory symptoms are still present. If at this time the various means capable of effecting a reduction in the intra-ocular pressure

be put in force, whilst the general health of the patient is supported, good vision may be retained, though I do not remember ever having seen an instance in which an actual protrusion completely disappeared under treatment.

Following these indications, therefore, six or eight leeches should be applied to the temple; the bowels, which are generally confined, should be opened by a brisk saline and calomel purge, and the performance of either iridectomy, or division of the ciliary muscle, in the mode recommended by Mr Hancock, adopted. When the intra-ocular pressure has been relieved by these means, the inflammatory condition of the choroid may best be subdued by the administration of decoction of cinchona, with either the bichloride or the biniodide of mercury, in 1-16th to 1-8th grain doses, repeated thrice daily. In the following case, such marked benefit occurred from the adoption of division of the ciliary region of the sclerotic, that I am induced to give my notes of the case.

Jane C., æt. 47, applied for relief at the Hospital on the 18th of January 1867. She complained of persistent and severe pain in the right eye, on which a staphylomatous projection of the sclerotic had recently appeared. She was a small, pallid woman, following the occupation of a laundress, and had been for several months past in constant attendance, day and night, upon a child who was dying of phthisis. She had been able to see perfectly up to six weeks previously, when one evening, after an unusually hard day's work, as she was sitting down to read, sudden dimness of vision came on, with giddiness, the candle appearing like a revolving wheel, accompanied by severe pain, which had continually increased till it had almost become intolerable. It had almost entirely prevented sleep for the previous week. She was just able to count the fingers with the right eye when held up before the light, at six inches distance. The globe was dull-coloured, and generally congested; the cornea dull; the iris naturally of a blue colour, greyish; the pupil widely dilated; the mark-

ings of the iris indistinct; the aqueous turbid; the vitreous so hazy that the fundus could not be seen (on the left side it was healthy). On the upper and outer part of the sclerotic of the right eye was an elongated swelling running circularly round the cornea for the distance of rather more than half-an-inch, most prominent externally and below, and gradually subsiding above and internally. It was of a purplish colour, most prominent at the most projecting part, and there was a narrow seam or band of deep-red colour intervening between it and the margin of the cornea. The tension of the globe was moderately increased, and it was extremely tender. She was certain the swelling had not been more than six weeks in developing itself. She had never suffered from rheumatism or from specific disease. Her bowels were and had been much confined throughout the whole of the attack.

Whilst examining her, Mr Hancock happened to come in, and on consultation it was agreed at once to perform his operation of dividing the ciliary muscle. This was accordingly done on both sides of the sclerotic, without chloroform; very little fluid escaped, though the anterior chamber was certainly opened by the edge of the knife. The pain was severe, and considerable faintness followed the operation. I ordered her m. xl. of tincture of opium with m. x. of chloric ether immediately, and a second dose to be taken at night; two leeches to be applied to the temple, with a hot linseed-meal poultice to keep up the bleeding, and a cathartic pill at bed-time, with the *mist. ferri aperiens* (containing 3j. of sulphate of magnesia in each dose), three times a-day. On the following day, as the patient was unable to come into the Hospital, I called upon her at her own house, and found her greatly improved, and in high spirits, as the pain had entirely left her. She had passed an excellent night, and had for the first time for many days eaten a hearty breakfast. The leeches had bled very freely. The improvement of vision was manifest, as she could count my fingers at three feet. On the 22d January, the iron

and sulphate of magnesia mixture having been continued, she could read Snellen's test-types LXX at five feet; there had been little or no pain; the pupil was quite round and smaller, and reacted sluggishly on exposure to light. On the 30th, she could read CC of Snellen at thirty feet distinctly; all inflammation had subsided; the turbidity of the humours had vanished, and the fundus could be clearly seen; the optic disc was rather whiter than natural; the retinal arteries unusually few in number, but the veins of considerable size. The choroid presented no abnormal appearance. No further improvement in the vision occurred, even after two months, but the swelling gradually became less prominent, and of a whiter colour, whilst the tension of the globe became normal.

The vision of those who are affected with extensive staphyloma of the sclerotic, especially if of long duration, being always seriously affected, if not altogether lost, the treatment is not very hopeful, and is almost limited to the endeavour to obtain a well-formed stump for the adaptation of an artificial eye.

With this object in view, various means have been suggested to cause moderate collapse of the eye, such as will hereafter be mentioned in treating of staphylomatous protrusion of the cornea, as abscission of the projection with the knife or scissors, the edges of the wound being brought together by sutures; the excitement of suppurative choroiditis by passing threads through the globe, a plan by no means to be adopted; transfixion of the base of the tumour with hare-lip needles, and strangulation of the tumour below them with a silk or metallic thread. In some cases the latter of these methods will answer very satisfactorily, whilst in others the most violent inflammation is induced, and both patient and surgeon find sufficient reason to regret that the globe was not wholly extirpated.

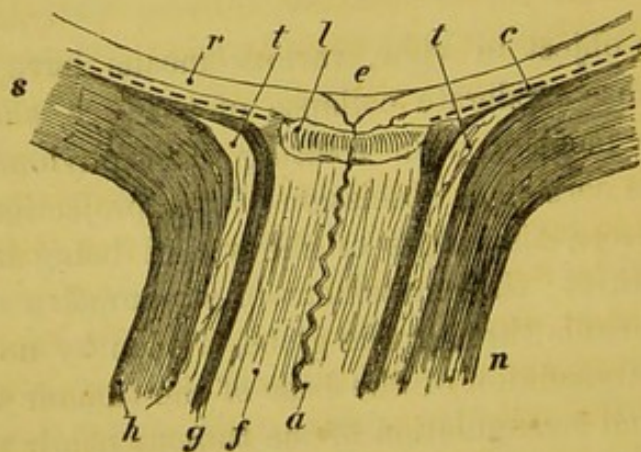
3. *Staphyloma posterior. Sclero-choroiditis posterior.*

(PLATE XII., Fig. 69.)

In this affection, a portion of the sclerotic at the fundus of the eye is attenuated and protruded, carrying with it the retina and choroid. The antero-posterior diameter of the eye is consequently increased; parallel rays of light falling on the cornea are no longer brought to a focus on the retinal plane; the conditions of myopia are established; and this change in the visual power, together with the circumstance that the earlier and slighter degrees of the protrusion can easily be distinguished by the ophthalmoscope, constitute the only reasons for considering this in a separate section from the disease we have just described,—the pathology, cause, and treatment of both being in many respects identical.

The pathology of the disease has been carefully investigated by M. Giraud-Teulon,¹ according to whose observations, as

M.



Anatomical disposition of parts at the entrance of the optic nerve:—(r) retina, (c) choroid, (s) sclerotic, (f) nervous fibres, (a) central artery of the retina, (n) optic nerve, (l) cribriform plate, (e) physiological excavation, (t) interstitial cellular tissue lamina,—after Giraud-Teulon.

shown in the adjoining woodcut, the sclerotic in its posterior region is composed of two fibrous laminae, separated by a zone

¹ Annales d'Oculist., t. lvi. p. 201.

of connective tissue (*t*), which forms around and a little behind the cribriform lamina a flat and narrow disk. The neurilemma of the optic nerve presents an analogous disposition. It is likewise formed of two annular fibrous layers (*g* and *h*), separated by a layer of connective tissue. The inner fibrous layer (*g*) is closely connected with the cribriform lamella (*l*), and with the choroid (*c*), and is ultimately continuous with the internal fibrous lamina of the sclerotic. The outer fibrous layer (*h*) of the nerve is continuous with the outer layer of the sclerotic, and in like manner the intermediate layer of loose connective tissue blends with that lying between the two layers of the sclerotic (at *t*).

Now, in the disease the symptoms of which we are about to describe, a gradual process of distension, thinning, and atrophy takes place, not only of the choroid (*c*), but of the internal lamina of the sclerotic (continuous with *g*), and subsequently of the intermediary lamina of connective tissue on which they rest. After a time the attenuated membranes yield to the intra-ocular pressure, causing a condensation of the intermediate lamina, and come at last to apply themselves to, and blend with, the external layer of the sclerotic (*n*). This again yielding, occasions the formation of a prominence posteriorly in close proximity with, and partially or completely surrounding, the optic entrance, and the true staphyloma described by Scarpa is formed.

In the slightest degrees of the malady, the protrusion is exceedingly small, and almost always limited either to the circumference of the optic nerve, or to the macula lutea, and is scarcely visible from the outer side. In extreme cases, on the other hand, the whole of the posterior segment of the sclerotic is prominent; the eye assumes a pear-shape; and a case is on record where the antero-posterior diameter of the eye, which is normally one inch in length, had increased till it amounted to one inch and a-half.

The first appearance of the disease under the ophthalmo-

scope, consists in a white crescent, partially investing the optic disk, such as is represented in Plate X., fig. 58, and almost always situated towards its outer side; and therefore, bearing in mind the inversion which objects situated at the fundus of the eye undergo when examined with the ophthalmoscope, occupying *apparently* the inner or nasal margin of the disk. The white crescent, which includes a very variable amount of the disk, sometimes completely encircling it, gives so strong a pseudoscopic impression of projection, that it was formerly considered to be occasioned by an exudation of lymph. Accurate dissections have, however, shown the incorrectness of this view, and that it is really due to a deficiency or an atrophy of the choroid at this part, permitting the white surface of the sclerotic to reflect brilliantly the entering light, consequently that the apparent elevation is in reality a depression. There appears to be little doubt that the extacy of the sclerotic may be sometimes congenital; and it is certain that in some instances it is quiescent, whilst in others it is slowly or rapidly progressive. In the former class of cases, where the protrusion is slight, only partially surrounds the optic disk, and does not implicate the central spot of the retina, no inconvenience may be experienced by the patient, (though it is frequently observed in cases of myopia), and he may pass through life without being aware of his suffering from any defect in the eye.

The white crescent, or more or less complete ring in these cases, is always very well defined at its margins (Plate XII., fig. 69), which are frequently dotted with black pigment (Plate X., 57); and it would appear as though, in the process of development of the eye, the rapidity of growth in the choroid had not been commensurate with that of the sclerotic and retina, and had therefore not attained, or had become detached from, the circumference of the papilla, the outline of which is always distinct, and the surface characterised by its natural pink or reddish colour. In progressive cases, which,

according to Dr Noizet,¹ are apt to make their first start at the age of puberty, and to occur in those addicted to literary pursuits, composers, engravers, and jewellers, the early symptoms are principally those of asthenopia, the eyes being easily fatigued, even when moderately used, and pain, dimness of vision, and conjunctival congestion, being experienced on any protracted or over exertion.

In the second stage, coincidently with the gradual protrusion of the sclerotic and retraction of the retina, myopia becomes a more or less well-marked symptom, increasing with the extension of the disease, and accompanied by extreme asthenopia, whilst little or no improvement results from the employment of concave glasses. M. Giraud-Teulon attributes the further progress of the disease from this point—that is, after the globe has become ovoid in form—in great measure to insufficiency of the internal recti muscles, and to the circumstance, that whenever the eyes are converged for the examination of near objects, an increased and unnatural pressure is exerted upon the globe by the external and oblique muscles, since the globe in the act of rotation continually offers longer diameters to their surface, and the reaction which it presents is the cause of the posterior protrusion. In cases where the protrusion is rapidly taking place in consequence of impairment of the general health, with continued close attention to minute objects, the symptoms are closely analogous to those observed in sub-acute glaucoma, and probably proceed from the same cause, namely, an increase in the intra-ocular pressure in consequence of hypersecretion from the choroidal vessels. Vision becomes misty and obscured; there are feelings of tension and fulness in the globe, which becomes more resistant to pressure; neuralgic pains are felt in the terminal branches of the fifth nerve; the iris becomes dull-coloured and sluggish, and its plane retracted, so that the anterior chamber is enlarged and deepened, the cornea still

¹ Gaz. Hebdomad., p. 399. 1858.

preserving its natural curvature; the pupil is dilated; the rotation of the globe outwards is impeded, in some instances to such an extent that the characters of a convergent squint are produced, and this appears to be the result of the alteration in the form of the eye, causing the external rectus to act at a mechanical disadvantage. Under the ophthalmoscope, when the progression of the disease is slow, the media remain clear; but the white reflection, indicating the extent of the staphyloma, will be found to have increased, till it approximates to, or involves, the macula lutea—vision in such cases often remaining almost unimpaired. But in the more rapidly progressive cases the media are more or less turbid, indications of the vitreous being fluid may be noticed, and the edges of the protrusion are less clearly defined, and often indented and jagged.

In the later stages of the disease, the patient complains of increasing dimness and obscurations of vision, rendering it difficult for him to discern even near objects, though there is at the same time an unnatural sensibility to light, which is, as Dr Noizet suggests, probably due to the internal reflection from the white sclerotic. Subjective luminous sensations are perceived with *muscæ*. The pupil is much dilated, and the iris is sluggish. In some cases, however, the vision remains acute up to a late period, showing the integrity of the retina.

On examination with the ophthalmoscope, the protrusion is found to have still further advanced, often occupying a very considerable portion of the fundus. The surface appears variously marbled or mottled (Plate IX., fig. 54), a few of the larger choroidal vessels and patches of the chorio-capillaris coming into beautiful relief against the white ground of the sclerotic, and dotted here and there, or abundantly, with pigment.

In those cases where the staphylomatous protrusion surrounds, crescent-like, only the outer portion of the optic

papilla, the form of that spot, as was first shown by Liebreich,¹ presents characteristic changes, though these are less obvious, or wholly disappear, when the protrusion entirely embraces the entrance of the optic nerve. In the former case the papilla assumes an oval contour, the long diameter of which is sometimes twice as great as the short, being invariably at right angles to the line of greatest extension of the staphyloma; and, consequently, as this is usually directed to the outer side, and horizontally, the oval appears with its long diameter vertical. In extreme cases, also, as he observes, that portion of the surface and margin of the papilla lying next to the staphyloma seems to incline away from the observer.

The retinal vessels are also remarkably affected. They are stretched and elongated, in consequence of the protrusion of the globe, but near the optic papilla undergo one or two sharp curves or bendings, in consequence of the papilla itself being converted by the intra-ocular pressure into a funnel-shaped depression, from the bottom of which the vessels emerge. Liebreich observes, that in some cases as many as three curves within a very small space may be seen to occur,—the first at the point of emergence itself, the second in order that the vessel may rise from the level of the lamina cribrosa to the margin of the protrusion, and the third at the scleral margin; and he adds, that it is not surprising that the passage of arterial blood is interfered with, and that a considerable stasis of blood and enlargement of their calibre takes place in the veins.

In the later stages of the disease, liquefaction of the vitreous is almost constantly present, the lens becomes cataractous, and the retina may even become detached from the choroid, though this is rarely observed.

The term sclero-choroiditis, applied to this disease, and implying inflammation of those tissues, whilst it appears to

¹ Archiv. f. Ophth., vii. 2, p. 124. 1860.

be appropriate to the rapidly-progressive forms, is of somewhat doubtful applicability when employed to designate the white crescent so frequently observed to accompany moderate degrees of myopia; and even in the slowly-progressive forms, there are few or no evidences of inflammation; for, as has been already shown in speaking of anterior sclerectasy, the disease is characterised by great atrophy of the sclerotic and of the choroid, the stroma and pigment cells of the latter losing their colour, and ultimately disappearing, the vessels diminishing in size, and the whole membrane becoming reduced to a thin and delicate web of connective tissue, firmly adherent to, and tightly stretched over, the hollow cavity formed by the bulging sclerotic. The retina, in consequence of its possessing a system of vessels proper to itself, long remains intact; but such serious changes as those above described in the choroid, from which it is probable its nutrition is to a certain extent derived, cannot take place without more or less functional disturbance; and we find, accordingly, that not only is myopia present, but that the patient experiences a degree of amblyopia, or diminished sharpness of vision, which at an early period causes considerable embarrassment. This is especially the case when the staphylomatous protrusion either commences at or extends to the macula lutea; and in two patients that I have now under my care it is particularly well marked. In one there is certain, in the other doubtful, history of specific taint; and in the former the disease is progressing rapidly, whilst in the latter it has been five years in extending from the size of a pin's point to about the magnitude of one-half of the optic disk.

As regards the treatment of cases of sclero-choroiditis posterior, it appears to be rather of a preventive than of a curative nature. When the protrusion has once formed, the eye never again recovers its original form. In cases, therefore, where the white ring or crescent is apparent, and where it exhibits any tendency to increase, all circumstances leading

to exertion of the eye should be avoided. The age of puberty seems to be that at which the disease is peculiarly liable to make sudden extension. Hence, close attention to books, drawing, and especially to figures, should be discountenanced; active exercise in the country should be enjoined, and every means taken to improve the general health. When any inflammatory symptoms appear, such as turbidity of the vitreous, pain in and tension of the globe, leeches should be applied; and I have frequently divided the ciliary muscle, in the manner recommended by Mr Hancock, with advantage. Cinchona and the bichloride of mercury, in small doses, may be given at the same time.

II. DISEASES OF THE CORNEA.

1. *Inflammation of the Cornea. Keratitis Parenchymatosa.*

(PLATE V., Fig. 25.)

Inflammation of the cornea forms rather a large proportion of all diseases of the eye. On examining the records of the Hospital, I find that out of 7200 patients applying for relief in the course of one year, 241 were cases of keratitis. Of these, 127 were males and 124 females; the average age was 20 years.

The usual cause of the simpler and less severe forms of keratitis is exposure to wet and cold, in a constitution already enfeebled and predisposed to disease, as during convalescence from measles, or other febrile ailment; whilst the more serious forms, terminating in abscess, generally result from direct injury, as from blows with chips of metal or stone, or from the entrance of lime or other caustic into the eye, and not unfrequently follow mere abrasions of the corneal epithelium. (*See section on Keratitis Suppurativa*, p. 286.)

Keratitis, again, is not unfrequently a secondary affection, complicating the course, and often forming the chief source

of danger in the more violent forms of conjunctival inflammation. It is common in those of a strumous, of a rheumatic, and of a gouty habit of body; and, as has been shown by Mr Hutchinson, it is frequently observed in those who are the victims of inherited syphilis, to which form we shall devote a separate section.

A peculiar form of keratitis, which will be described under the head of neuro-paralytic affections of the eye, has been observed in cases of lesion of the fifth nerve.

The usual symptoms presented in a mild case of inflammation of the substance of the cornea, the so-called keratitis parenchymatosa, are, that with the formation of a delicate pink circum-corneal zone of vessels, and a moderate degree of pain, the cornea begins to be hazy, either in patches or generally throughout its whole texture. The surface occasionally preserves its natural polish and brilliancy, but generally assumes a dull, tarnished, or ground-glass appearance, which may be very closely imitated by firmly compressing the eye of an animal recently removed from the body. Sometimes numerous dotted or punctated opacities may be seen, the yellowish points being evidently situated in the deeper corneal layers. Such cases are essentially chronic in their course, and many instances may be observed where comparatively little congestion of the conjunctival or episcleral vessels occurs; whilst in others this condition is strongly marked, and there is then usually present a greater or less degree of photophobia and lachrymation. Vision is generally very considerably impaired.

The usual subjects of this form of disease are weakly and delicate children, especially those of a strumous habit of body; and Tyrrell remarks, that he does not recollect to have seen a single case of pure corneitis in a subject possessing a proper degree of general power. The progress of the affection varies remarkably in different instances. Sometimes only the centre, or some circumscribed portion near the periphery, presents

the ground-glass appearance; and this, after remaining stationary for some days or weeks, especially if judicious treatment have been adopted, gradually disappears. In other instances the inflammation extends until a dense vascular opacity of the cornea is formed, wholly obscuring the pupil and iris, and constituting a very formidable variety of pannus. More rarely, suppuration takes place between the lamellæ of the cornea, which termination will be considered in the next section.

As regards the treatment, perhaps it may be said that, providing all hurtful agencies are removed, cases of simple keratitis tend naturally to recovery. In conformity with the general condition of the patient, tonic and sustentative treatment are usually indicated. The child should be allowed to play in the fields, away from the glare and dust of roads; mild aperient medicine should be given, followed by the administration of quinine and wine, either at once or after slight local depletion. As in so many other instances, however, each case is a study in itself; and generally, with the discovery of the cause, the disease, if that cause can be removed, is cured. The following case affords a good illustration in point, and will give an outline of the general treatment that may be pursued:—

G. S., a boy æt. 10, applied at the Hospital on the 6th February 1866, with keratitis of the left eye. The cornea was dull and hazy throughout its whole extent, and there was a slight superficial pannus upon its upper edge. There was a well-defined pink circum-corneal zone. Vision was very imperfect; he could just make out CC of Snellen at 10 feet. He was a delicate-looking boy, but had had no febrile affection, and only dated the commencement of the disease from being thoroughly wetted in going to school about a fortnight previously. His tongue was perfectly clean, and the teeth sound and well formed. He was ordered one leech to the temple, and a powder containing one grain of quinine and

three of hydrargyrum cum creta, three times a-day. On the 13th he was no better, and as the powders purged him, one-sixth of a grain of opium was added to each. On the 24th of February the condition of the eye was not improved, but the appetite was good, and the child was always lively. The alterative powders were now exchanged for mist. quinae ʒss . ter die. At the close of the following month he was rather worse, though he had been regularly in attendance at the Hospital. On the 20th of March cod-liver oil was prescribed for him, with m. xxx. of tinct. ferri iodidi. This was immediately followed by a good effect, and on the 3d of April the improvement was so great that he could distinguish C of Snellen at 30 feet. On the 10th a relapse took place, and, from the presence of an eruption about the nose, I was induced to make particular inquiries respecting the presence of worms in the intestinal canal. Some thread-worms had been seen, and he was therefore ordered a full dose of the oleum filicis maris, with half-an-ounce of castor oil. He was briskly purged, and several round worms, as well as numerous thread-worms, came away. Great improvement now took place, and on the 1st of May there was only a nebula left, the circum-corneal zone had disappeared, and vision was nearly as good as in the opposite eye. He now ceased to attend the Hospital, but on the 22d May returned again with a recurrence of all the symptoms. The mother had not observed any more worms, but on the same treatment being repeated, improvement ensued; but some haziness about the cornea, attended with a slight circum-corneal zone, rendered it evident that the inflammation was not entirely subdued. Powdered calomel was now applied to the internal surface of the upper lid, with the best effects, removing in a few days some slight hypertrophy of the papillæ, which probably had maintained the irritation, and in a month the boy was dismissed well.

The following is a characteristic case of this form of keratitis, occurring in a strumous subject:—A young man,

a pianoforte maker by trade, of pallid complexion, small stature, and scrofulous habit of body, 19 years of age, came to the Hospital on the 27th of March 1866, complaining of inflammation in the eyes, great lachrymation and photophobia, which he had endured for five weeks, but he had not experienced much pain. Previously to this period his sight had been excellent. The teeth were irregular but large, and were not notched. Both corneæ were rough and hazy, and were surrounded by a well-marked circum-corneal zone. His appetite was bad, his tongue furred, and the bowels confined. He was ordered an emetic powder, containing a grain of tartarised antimony, and a powder containing one grain of quinine and three grains of mercury and chalk, three times a-day. On the 3d of April, considerable inflammation being still present, a leech was applied, and the powders were exchanged for the decoction of cinchona, with the solution of the bichloride of mercury, which was followed by immediate and marked amelioration of all the symptoms, and on the 16th of April only a slight nebula remained. In the middle of May he again appeared with a recurrence of the symptoms, which gave way to the same remedies, continued for a fortnight. On the 14th June the cinchona and mercury were replaced by the iodide of potassium in three-grain doses, and in a fortnight only a nebula remained. He then left for the country, and wrote to me saying that he had never felt, or been able to see, better in his life. It often occurs, as in this instance, that remedies which in one form appear to exert little influence over the progress of a disease, will, if the mode in which they are administered be altered, quickly accomplish a cure.

2. *Chronic Interstitial (Syphilitic) Keratitis.*

This form of disease has been most carefully and excellently described by Mr Jonathan Hutchinson.¹ It usually com-

¹ Ophth. Hosp. Rep., vol. i. p. 229.

mences, he observes, as a diffused haziness in the centre of the cornea of one eye. There is at this stage no increased vascularity, nor any tendency to ulceration, though the sight is necessarily somewhat misty. On close inspection, the general impression of haziness may be seen to proceed from the presence of a number of minute roundish specks of various size lying in the substance of the cornea. Sometimes quickly, sometimes slowly, this haziness extends and deepens, till the cornea resembles ground glass, or tissue paper on which a drop of oil has fallen. A circum-corneal zone of inflammation of a delicate pink hue now becomes apparent, and is accompanied by more or less intolerance of light and pain about the orbit. After a month or two the cornea of the opposite eye becomes infiltrated, and runs through the same stages. The cornea now remains granular and rough for a considerable period, perhaps even for months, and the vision is often so misty, that only a quantitative perception of light remains. After a time, however, the substance of the cornea begins to clear, and in most instances a fair amount of vision is regained, though patches of opacity often remain for many years. Ulcers are rare, and Mr Hutchinson has never observed the existence of pustules on the surface of the cornea.

The circumstances which have led Mr Hutchinson to believe that chronic interstitial keratitis is the expression of an inherited syphilitic taint are,—

1. That certain patients, to his knowledge affected with an inherited taint, have been, whilst under his observation, attacked with this form of keratitis.

2. That, in a large number of cases, he obtained from the parents of the patient a free confession as regarded themselves, and distinct history of specific symptoms in the child during infancy.

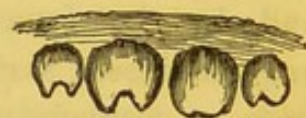3. That in almost all cases the subjects presented a peculiar physiognomy, of which a coarse flabby skin, pits and

scars on the face and forehead, cicatrices of old fissures at the angles of the mouth, a sunken bridge to the nose, and a set of permanent teeth, peculiar for their smallness, bad colour, and vertically notched edges, are the most striking.

4. The presence of various suspicious forms of disease in the skin, bones, and mucous membranes. In confirmation of which, I may refer to one well-marked case now under my care, occurring in a boy of twelve, in whom a considerable portion of the hard palate has necrosed, and sinuses extend in every direction into the floor of the nose.

5. The beneficial effects of specific treatment; and, lastly, the frequent association of the disease with iritis.

The peculiar form of the teeth, on which Mr Hutchinson lays so much stress, is shown in the accompanying little woodcut, copied from his paper in the Ophthalmic Hospital Reports, and which represents what he considers to be a typical form in such cases.



The disease, according to Mr Hutchinson's observation, occurs most frequently between the ages of ten and fifteen years. It is rare to meet with it in patients after twenty, or before two years of age. Girls appear to be more subject to the disease than boys, in the proportion of nearly two to one.

The term strumous keratitis was and still is, in many cases, applied indiscriminately to this and the preceding form of keratitis; but the true syphilitic, inherited keratitis, is characterised by the absence of phthisis, enlargement of the lymphatic glands, or other tuberculous affection; whilst an additional reason for considering it as an altogether separate and distinct disease, is to be found in the large and white teeth which are frequently associated with the strumous diathesis.

The treatment which should be adopted in a well-marked case, consists in placing the patient under favourable hygienic conditions as regards air, exercise, and food. Specific treat-

ment should then be at once commenced, by the administration of the decoction of cinchona and the bichloride of mercury, or of quinine and grey powder in small doses, frequently repeated, which may be subsequently exchanged for the iodide of potassium. Mr Hutchinson recommends a mixture containing iodide of iron, iodide of potassium, and tincture of nux vomica, some mild mercurial ointment being at the same time rubbed in behind the ears, in the neck, or under the axillæ. When the patient is very much debilitated, wine should be ordered in moderate quantities, with iron in one or other of its soluble forms, especially in that of the ferro-citrate of quinine. As regards local treatment, it is usually inadvisable to employ stimulants or irritants of any kind; but hot fomentations, or the methodical application of lint compresses steeped in hot water, as recommended by v. Gräfe, at temperatures varying from 88° Fahr. to 104° Fahr., prove of essential service. At the later periods of the disease, when little inflammation is present, and opacity of the cornea remains, the insufflation of calomel may be resorted to with advantage, especially if there be any tendency to the formation of vessels on its surface. A form of inflammation of the cornea, in some respects resembling the foregoing, but by no means necessarily associated with syphilitic taint of the system, is occasionally met with, and has been termed *aquocapsulitis* or *descemitis*, in consequence of the remarkable changes which occur on the posterior surface of the cornea. It is always or nearly always accompanied by iritis or iridochoroiditis. The characteristic feature of the affection is the appearance of a number of well-defined yellowish spots, which can clearly be discerned, by oblique illumination, to occupy the posterior surface, and usually the inferior segment, of the cornea. They vary in size from that of the head of a large pin to an almost imperceptible point, and increase very slowly, though ultimately, by multiplication and approximation, they may come to obscure the pupil and the iris to a

very considerable extent. Pathologically speaking, they consist of a number of cells, accumulated in certain centres or foci, and seated on the posterior elastic lamina, which appears, in most instances at least, to undergo no alteration. After a variable period, the cells undergo fatty degeneration, break down, and disappear, or become detached and float as shreds in the aqueous humour, which is always more or less turbid. The treatment is so similar to that recommended for simple keratitis, of which it appears to be only a peculiar form, that it is unnecessary to repeat it.

The most marked example of it that has hitherto come under my notice, was in an old woman, apparently healthy and well nourished, but in whom, after the operation of cataract, the wound failed to unite by first intention, the flap long remaining transparent (*see* Plate VIII., fig. 47). About three months after the operation she returned to the Hospital, complaining of pain in the left eye, which distressed her exceedingly at night, and was attended with much lachrymation. I examined the eye carefully, and found a circum-corneal vascular zone, with some turbidity of the aqueous, and dullness in the colour and markings of the iris. Considering the case to be one of ordinary rheumatic ophthalmia, I directed her to apply hot fomentations, and to take small doses of colchicum and quinine. As she lived at some distance from town, I did not again see her for a fortnight. The disease had then made considerable progress. The sclerotic was of a dull colour, the circum-corneal zone strongly defined, and the cornea dotted with the most distinct and well-marked spots, from fifteen to twenty in number, and varying in size from that of a large pin's head to the most minute dot. The iris had contracted adhesions to the capsule, and the aqueous was very turbid, and she was only able to see the shadow of the hand passed before the eyes. The symptoms, however, are by no means so marked in all instances, nor the ultimate results so unfavourable, as the following, to which I could

adduce several parallel cases, will show:—J. M'T., æt. 12, a somewhat pallid girl, but with sound teeth, presented herself with inflammation of the cornea of both eyes, on the posterior surface of which were numerous minute yellowish spots. The tongue was foul, the bowels out of order, the breath offensive, and she frequently grated her teeth at night. On the supposition of worms being present, the *ol. filicis maris* was ordered, to be followed by a dose of castor-oil; but though no worms came away, an immediate improvement followed the purging. She was then placed on the decoction of cinchona, with intro-muriatic acid, to which, after the lapse of a few days, 3ss. of the solution of the bichloride of mercury was added. In one month the spots had almost entirely disappeared, and, the mixture being exchanged for cod-liver oil, she was soon perfectly well.

3. *Keratitis Suppurativa. Inflammation of the Cornea, with Suppuration between the Lamellæ.*

(PLATE V., Figs. 28 and 30; PLATE VI., Fig. 32.)

Suppurative keratitis is almost always induced by direct injury to the eye, though often of the most trivial kind; the abrasion of the epithelium, occasioned by a sudden movement of the finger of an infant, or by the corner of a sheet of paper, or of the leaf of a tree, have all produced, in persons of an unhealthy habit of body, this serious disease; but it is far more frequently met with as the result of severe blows, as from a chip of iron or a fragment of stone. In whatever manner it may be induced, the accompanying symptoms vary in their severity to a remarkable extent, sometimes advancing so insidiously that, unless the organ were directly under observation, scarcely any attention would be directed to it on account of pain, redness, or other symptom of inflammation; whilst, in other instances, the most violent and unbearable suffering is experienced, accompanied by febrile symptoms

and great prostration of strength. If a case of accident be examined in which the cornea has just been struck a severe blow with a piece of stone or metal, it will generally be found that the epithelium is abraded to a greater or less extent, destroying the natural polish of the surface. The conjunctival and episcleral vessels are more or less congested, and vision, from the eye being as it were stunned with the shock, is greatly impaired; the iris is motionless, and often dilated, and more or less blood is generally effused into the anterior chamber. After the lapse of twenty-four hours, unceasing pain having been experienced, the whole substance of the cornea may present a dull, hazy, and clouded appearance, whilst the conjunctival congestion has considerably increased. In strong and plethoric patients, in those of a rheumatic habit of body, and also in the weakly and scrofulous, the formation of a yellow purulent deposit may now be observed to take place with rapidity, a few days being sufficient for the purpose. In the cases arising from cold, however, its progress is generally more gradual, and two or three weeks may elapse before the purulent deposit occurs. The matter forms a yellowish white mass or layer between the lamellæ of the cornea, and though, for the most part, occupying only a limited portion (fig. 32), it sometimes involves the whole extent of the membrane (fig. 30). This condition is termed *onyx*, and results, as has been already stated, from the multiplication of the corneal corpuscles and their nuclei, and their subsequent fatty degeneration. The margins of the purulent deposit are generally thinner than the central portion, but well defined, and usually irregular in their outline. The adjoining substance of the cornea is sometimes clear, but more frequently hazy and troubled. It appears principally to occupy the middle of the thickness of the membrane, but may approximate more to the anterior or to the posterior surface, which influences the subsequent course of the disease. The cornea is sometimes raised over

the seat of the abscess. The consistence of the purulent deposit varies at different periods. At first it is firm and semi-solid, consisting only of the hypertrophied cells and nuclei heaped together; but subsequently, when true pus has been formed, and the adjoining lamellæ have broken down, it becomes more fluid, and will sometimes, though not always, flow out, when the anterior lamellæ have been pierced with a broad cataract-needle, or the point of a Wenzel's knife. When the formation of matter between the lamellæ has taken place, the eye rarely regains its original transparency; sometimes, however, in young and healthy subjects, a process of reabsorption of the pus, and the formation of new tissue, which probably in such instances is of small extent, does occur, effecting a spontaneous and perfect cure of the disease. In other cases, the deposit appears to undergo a kind of calcareous degeneration, as in the analogous atheromatous deposit in the walls of arteries; and the cornea then, in course of time, often shrinks considerably in diameter, remaining, of course, completely opaque. As a general rule, however, the abscess bursts either anteriorly or posteriorly through the few remaining lamellæ of the cornea and the anterior or posterior elastic laminæ, which for the most part retain their transparency, and undergo no morbid change.

If it have been deeply seated, the rupture will probably take place posteriorly, and the matter is then slowly or suddenly discharged into the anterior chamber, where it quickly gravitates to the lower part (as in fig. 32), occupying the angle between the iris and the cornea, and constituting the condition known as hypopyon. The purulent, mingled with the aqueous fluid, is often so reduced in consistence, that it can be made to change its position by varying the inclination of the head. But by far the most frequent termination of corneal abscess is, that it bursts through the anterior lamellæ, leading to the formation of an ulcer. The further progress of the case, under these circumstances, is

very various. Amongst the more important terminations are the following:—The ulcer may heal with or without the formation of an opaque cicatrix or leucoma. Alteration of the curvature of the cornea may take place, the contraction of the cicatrix, if the ulcer have been extensive, at first flattening the cornea, but subsequently giving rise, in consequence of its yielding to the intra-ocular pressure, to unnatural prominence of the cornea, and constituting the disease termed staphyloma corneæ. If the abscess have been of small size but deeply situated, and have burst forwards, a transparent protrusion occurs, formed by the posterior elastic lamina, and a few of the posterior corneal lamellæ. And lastly, if the ulcer or abscess have perforated the whole substance of the cornea, and have been of considerable size, prolapsus of the iris will probably result, leading to anterior synechia and anterior staphyloma.

Dr E. Junge,¹ in examinations of the fluid forming hypopyon in keratitis, found in one case, where it proceeded from a central ulcer, that the aqueous humour was tolerably clear, but contained floating in it a considerable number of round, sharply-defined pus cells, of equal size, with from two to four nuclei in each. On the addition of a little distilled water to the fluid, a precipitate took place, which was not soluble in acetic acid. The yellow mass forming the hypopyon itself, consisted of a tenacious and coherent mass, composed of a homogeneous matrix, in which variously-formed cells were imbedded, some being evidently pus cells analogous to those in the anterior chamber; others, and especially those more deeply seated, being smaller, and filled with fat molecules; and others, again, being very large, and containing two nuclei, which last, he believes, were epithelial cells.

In another case of corneal ulceration, the hypopyon consisted chiefly of mucous corpuscles, cells with two and three nuclei being only scattered here and there. A matrix was

¹ Archiv. f. Ophth., Bd. v. Heft. ii. p. 200. 1859.

here also present, and contained in various parts nests of these cells.

The results of these and two other observations led him to conclude that the matrix of the hypopyon, whether the disease be accompanied with high inflammatory symptoms or not, is composed essentially of a mucous, and not of a fibrous exudation, and that sometimes pus cells, and sometimes mucous corpuscles, preponderate. The origin of these is not ascertained, but, from experiments made on rabbits, Dr Junge is inclined to think that they proceed from the cells lining the membrane of Descemet.

It is obvious that the treatment of suppurative keratitis must be guided by the severity of the attack, and must in all instances be materially modified by the changes that have been wrought in the structure of the cornea at the time when the case first comes under observation. In cases of blows upon the eye, when the cornea already presents a misty aspect, but where the patient is weak and debilitated, and comparatively little pain is felt, the general powers of the system must be judiciously maintained by good diet and free allowance of wine; warm fomentations should be applied to the eye, and perfect rest enjoined. Under these circumstances we may hope to see the opacity disappear altogether, or become circumscribed, and the abscess may then be opened in the manner that will be immediately described in speaking of the inflammatory form.

In cases of acute abscess of the cornea arising from injury, especially when occurring in old and rheumatic subjects, and attended with violent pain, increased tension of the globe, and chemosis, the patient should be confined to bed, and the bowels opened by a brisk purgative of compound jalap powder and calomel, followed by a black draught. In the meanwhile, from six to twelve leeches may be applied to the temple, and hot fomentations will generally be found to prove soothing and agreeable, whilst they increase the flow of blood. They may

either be applied by means of a large sponge, or of flannel wrung out of hot water, or decoction of poppy-heads; or they may be methodically applied by means of compress and bandage. No caustic solutions should be dropped into the eye, since these only add to the existing irritation; but the instillation of atropine may be adopted, partly on account of its diminishing intra-ocular pressure, and partly on account of its tendency to prevent prolapse of the iris in cases where the onyx is central and seems about to perforate the cornea.

The employment of opium or of morphia is almost always indicated, to allay pain and procure sleep. It should be given in full doses, as a grain of the powder, or 3ss. of the liquor morphia acetatis, three or four times a-day, after the leeches have been applied. If, in spite of these remedies, the opacity of the cornea seems hourly increasing, whilst the pain is severe and the tension great, paracentesis of the globe must be performed. It is immaterial how this is accomplished, whether through the cornea with a broad needle, or with a Wenzel's knife through the sclerotic in the ciliary region, as recommended by Mr Hancock. I have myself generally adopted the latter plan, and have had every reason to be satisfied with the results. I have usually endeavoured to make the section so that the edge of the knife should just open the margin of the anterior chamber, and have found that, with the escape of the aqueous, of a small portion of the vitreous, and of a few drops of blood,—probably proceeding from the canal of Schlemm, as well as from the vessels of the ciliary region,—the tension and the pain are alike relieved; and I have only once found it requisite to repeat the operation on the opposite side of the eye. When a circumscribed abscess has already formed, however, and even where it has burst into the posterior chamber, causing an hypopyon, I have usually adopted the plan suggested by Weber in his essay on corneal abscesses,¹ of passing a broad needle, or lance-shaped

¹ Archiv. f. Ophth., Bd. viii. 1861.

knife, through the cornea obliquely from below upwards, so that the point enters at the lowest part of the abscess, and emerges from the tissue of the cornea into the anterior chamber at the highest part of the abscess. The issuing stream of the aqueous humour aids the discharge of the thick purulent matter, washing out, as it were, the cavity in which it is contained.

In the later stages of the disease, where maculæ on or in the substance of the cornea, or staphylomatous protrusion have occurred, the treatment to be adopted must be such as is recommended in the sections devoted to those subjects respectively.

4. *Keratitis Vasculosa. Pannus.*

(PLATE I., Fig. 5; PLATE IV., Figs. 21, 23, and 24.)

These two forms of disease are essentially similar in their nature. In the former, slight superficial haziness or troubling of the cornea occurs, generally proceeding from some long-standing cause of irritation, followed by the development of vessels, which ramify on the surface just beneath the epithelial layers. In the latter, which is of a much more serious nature, the substance of the cornea becomes swollen, softened, and opacified by inflammatory action, attended with the pathological changes to be presently described; and vessels then not only, as in the former case, extend over its surface, but penetrate between the lamellæ, converting the whole, or a portion only, of the cornea into a red mass of uniform colour, in which it is impossible, unless with the aid of a lens, to distinguish the several vessels.

Keratitis vasculosa, the slighter form of the disease, is often occasioned by very trivial causes, such as the fretting of the surface of the cornea by one or two inverted lashes, which, by reason of their fineness and light colour, may easily escape observation; or by a few enlarged papillæ or granulations on the under surface of the lid, which may not be detected

unless it be thoroughly everted, in consequence of their occupying the oculo-palpebral fold. In other instances it is a consequence of slight abrasions of the epithelium and surface of the cornea, or of the entrance of some foreign body into the eye. It may often be seen accompanying, or rather succeeding, the development of minute phlyctenular ulcers on the cornea, and here, as in the foregoing cases, generally presents an acute type, and only affects a limited portion of the surface. In the last mentioned cases the mode of formation of the vessels may be very well seen. The surface of the cornea, at some point near the periphery, becomes hazy, and loses its natural polish, closely resembling glass that has been breathed upon; the troubling gradually extends as a streak or patch towards the ulcer; and, after a day or two, minute vessels, proceeding from a subconjunctival or conjunctival trunk, may be seen to overstep the limits of the corneal border, and divide and anastomose on its surface, forming a triangular leash, and continually increasing in number and size. In old cases of granular lids, trichiasis, or entropion, the disease assumes a chronic form, the whole or the upper half of the cornea becoming vascularised, and covered by a thin semi-transparent membrane-like tissue. In the more acute cases, as those arising from the entrance of foreign bodies, or from ulcerations, the usual symptoms of congestion of the conjunctival vessels—smarting pain, lachrymation, and photophobia—are present. In the chronic forms, as those succeeding granular lids or cicatrices of the lids, impairment of vision is the circumstance which induces the patients to apply for relief.

The further progress of the affection depends on circumstances. If the formation of the vessels have accompanied ulceration of the cornea, with the healing of that ulceration they gradually dwindle and disappear; and although a slight nebula is left for a short time, this also soon vanishes, and the transparency of the cornea is completely restored. The

same occurs if the inverted lashes in trichiasis have been removed. There is then a spontaneous tendency to cure, providing the cause can be removed. To attain this end, however, much skill and attention are required, especially in those cases arising from entropion, and occurring in unhealthy subjects, where the general substance of the cornea has become implicated; whilst in some cases, where the disease arises from cicatrices of burns, etc., the cause being irremovable, the disease is of necessity persistent.

For the treatment of the more acute cases, the reader is referred to the section on the several conditions which may induce its occurrence, especially to those on trichiasis, ulcers of the cornea, and on the entry of foreign bodies into the eye; whilst as regards the treatment of the chronic cases, resulting chiefly from granular lids, it may be advantageously deferred till we have described pannus, with the treatment of which affection that of keratitis vasculosa essentially agrees.

Pannus consists in the formation of a strongly-marked, red, and vascular growth, which spreads to a greater or less extent over the surface of the cornea. The pathological changes which occur in this disease have been carefully examined by Ritter¹ and Iwanoff,² who state that it consists in an inflammatory process, occasioning an abundant proliferation of the formative or deeper-lying cells of the sub-epithelial connective tissue at the conjunctival border, which subsequently, if the term may be used, infiltrate the substance of the cornea. Iwanoff states that the newly-formed cells constantly press forward between the epithelium and the anterior elastic lamina, which last, in the earlier periods of the affection at least, always remains completely intact. Ritter, however, has observed instances where the hypergenesis of cells occurred beneath the healthy conjunctival layer of epithelium and anterior elastic lamina, and occupied

¹ Archiv. f. Augenheilkunde, Bd. iv. p. 365.

² Pagenstecher's Klinische Beobachtungen, Heft. iii. p. 130. Wiesbaden, 1866.

one-eighth of the remaining thickness of the cornea; and even Iwanoff admits that, where the causes producing pannus are, as in the case of cicatrices, very persistent, the mechanical irritation may be so great as to excite the corneal tissue itself to the active proliferation of cells. In most of the cases which he examined, vessels soon began to develop in the newly-formed cell mass, lying, like that, between the epithelium and the anterior elastic lamina. The walls of these vessels, when first developed, are so extraordinarily thin, that, if indeed they are present, they can scarcely ever be distinctly perceived, even with high magnifying powers; and there is every reason to believe that they originate in the longitudinal apposition of fusiform cells, the opposed extremities of which break down and permit the passage of blood corpuscles through them: hence, on making vertical sections, the blood seems to be simply extravasated on the surface of the cornea. In old cases of pannus, however, the vascular walls are well developed. It does not appear that the already formed epithelial cells of the conjunctival layer of the cornea take any part in the development of the new cell mass, though occasionally two nuclei may be seen in the same cell. Coincidentally with the formation of vessels, a change begins to be observable in the new growth; the more superficial cells assume the characters of ordinary epithelium, though they are at first somewhat larger, rounder, and less distinctly defined than the normal cells, possess larger nuclei, and exhibit constant changes of form when examined with Schultze's warmed stage. After a time they can no longer be distinguished from the true epithelial cells, and this layer, therefore, becomes from two to three times thicker than natural. The deeper-lying cell mass, on the contrary, undergoes a transformation into connective tissue, the cells becoming spindle-shaped and stellate, the intervening substance undergoing fibrillation, and being everywhere penetrated by vessels. The deep layers of the cornea, and the posterior

elastic lamina, even in old cases, are generally found quite intact and healthy.

The extremely small amount of pain or irritation which in many cases accompanies these pathological changes, is a noteworthy circumstance, and is probably due to the absence of pressure on the nerves, in consequence of the external epithelial layers readily yielding to the swelling produced by the neoplastic formation beneath. The disease commonly occurs in weakly and delicate subjects, and even where, as in a case recently under my care, the patient presents ruddy cheeks and the outward signs of health, it will generally be found that the food has been insufficient in quantity or improper in quality, or that he has been living in the midst of hygienic conditions unfavourable to the preservation of sound health. The redness in severe cases is very remarkable, and has often been compared to a red rag laid upon the surface of the cornea. The margin of the redness, though well defined, is yet soft and rounded, and generally has a narrow hazy border just in advance of it. During the last few weeks I have had three cases where the disease was limited to a very small extent of the cornea, not exceeding that of a hemp seed, and formed by the division of a single episcleral vessel of large size, which ran up to the border of the cornea, and at once split, brush-like, into the innumerable scarlet vessels of a minute pannous tissue. In some cases lachrymation and photophobia, though often with little or no pain, are present.

There is no increase in the tension of the globe; and in one well-marked instance, wishing to ascertain whether a paracentesis of the cornea would have any effect in checking the disease, I was struck with the extreme softness of all the tissues, permitting the needle to enter the anterior chamber with the greatest possible ease. In some cases, however, a good deal of smarting pain, with ciliary neuroses, lachrymation, and photophobia, are present. In all instances impairment of vision is complained of. Yet even at the acmé of

the redness and vascularization, quantitative perception of light is always present.

The causes of pannus are sometimes purely constitutional, proceeding from the action of cold and wet on a debilitated and strumous patient; at others it is the result of the persistent irritation of the cornea produced by granular lids, and cicatrices on the lids, which at first producing only vascular keratitis, after a while, if neglected, excite the deeper layers of the cornea to hypergenesis; and, lastly, it may follow direct injuries of the cornea. It is almost always chronic in its course, and though, especially in the milder form, it may disappear without leaving any trace, too often permanently impairs vision by the formation of a dense leucoma, resulting from the cicatrization and condensation of the connective tissue, developed in the sub-epithelial layers. In many cases, also, the tissue of the cornea having been weakened by the inflammatory process, yields to the intra-ocular pressure, and a more or less prominent staphyloma occurs.

The treatment of cases of pannus, when dependent upon granular lids, or upon ulcers of the cornea, should be directed first to the removal of the cause, and then to the obliteration of the vessels.¹ In the latter case, when it is clearly due to abnormal curvature of the tarsal cartilage, the palpebral fissure may be enlarged by the plan of operation proposed by M. Pagenstecher, and already described under the head of Entropion (p. 154). When it arises from constitutional causes,—and, indeed, in all instances,—the general condition of the system should be carefully attended to in the mode to which attention has already been so frequently directed, and which need not here be repeated, save to observe that the administration of bichloride of mercury, iodide of potassium, quinine or iron, is generally required, and that when the pulse is feeble and frequent, and the progress of the disease very slow, wine is indicated.

For the obliteration of the vessels, and the removal of the

¹ Wecker, p. 278.

skin-like membrane, one or other of the following methods may be adopted:—1. The employment of caustics. 2. Inoculation of the eye with pus taken from the eye of a child suffering from simple purulent ophthalmia. 3. Syndectomy.

1. As regards the employment of caustics or irritants, a great variety have been suggested and used at different times, though the mode in which they act is not very obvious. Some appear to constrict the vessels, or perhaps even to destroy these walls; others seem to act principally on the inter-vascular tissue, and to promote its disintegration or absorption; and others, again, appear to occasion the coagulation of albumen, and thus to check the formation of new cells. Amongst the more important agents of this kind may be mentioned solutions of nitrate of silver and acetate of lead, which, however, are apt to stain the cornea, or give rise to metallic deposits, and sulphate of copper, which may advantageously be employed in the solid form; tincture of opium instilled into the eye once or twice in the course of the day; and the introduction of minute portions of the ointments of red or white precipitate of mercury under the lids. The application of calomel in fine powder, applied with a camel-hair brush to the interior of the lids, has lately received strong commendation, which it has appeared to me to deserve. Solutions of citric acid, of tannin and of the perchloride of iron, have also been extensively used; and Snellen recommends the application of the *ol. terebinthinæ* in very chronic cases. All of these remedies prove useful in the later stages of the complaint, and should rarely be employed in the earlier, unless the disease assumes a thoroughly asthenic type.

The operation of "syndectomy"¹ consists in the removal of a large zone of conjunctival tissue from around the cornea. It was first suggested by Dr Furnari.² The instruments re-

¹ See the account of this operation by C. Bader, *Ophth. Hosp. Reports*, vol. iv. p. 19.

² *Gazette Medicale*, Nos. 4, 6, 8, 10, 12, and 14. 1862.

quired are toothed forceps, blunt-pointed scissors, curved on the flat, one of the rings of which has a contrivance for holding a sponge, and a small blunt-pointed hook, the concavity of which is sharp, for the purpose of cutting through the vessels that have been hooked up, and a small scarifier. The patient being seated, the lids are opened by a speculum, and the excision commenced near the outer canthus. M. Furnari removes a broad ring of the ocular conjunctiva, extending from the margin of the cornea to within one-eighth of an inch of the line, where the reflection of the conjunctiva from the globe to the lid takes place. It is not safe to pass beyond this limit, lest symblepharon should ensue. A small flap of conjunctiva is retained at the upper part during the earlier steps of the operation, for the purpose of fixing and turning the globe, but is subsequently removed. It is important that the sub-conjunctival tissue should be cleanly dissected off the sclerotic, together with all the bloodvessels it contains, any which escape the scissors being caught up and cut with the sharp hook. The vessels upon the cornea are now to be freely scarified, and their ends, if projecting, cut off with the scissors. After the bleeding has somewhat subsided, the raw surface, carefully avoiding any remaining transparent portion of the cornea, is to be touched with a moistened camel-hair brush, which has been rubbed on a solid stick of nitrate of silver; and some judgment is required to determine the amount of cauterization demanded, since, if too severe, corneal opacities are apt to be left, and, if too slight, are insufficient, exfoliation of the corneal epithelium occurs, and the formation of fresh vascular webs is likely to take place. A strong irritation (but no inflammation) follows the operation, which may be relieved by cold applications. The pain, photophobia, and lachrymation cease in about twenty-four hours after the operation. The separation of the corneal epithelium follows about a week later, the bloodvessels upon the cornea atrophy, and the transparent membrane reappears. A few days after

the operation a thick plastic material covers the exposed surface of the sclerotica, and a week later a conjunctival border again appears around the edge of the cornea, and the other margin of the conjunctiva, swollen and granular, may be observed advancing towards the cornea. In from one to two months all trace of the loss of the conjunctiva has disappeared, being replaced by new and similar tissue. It may be as well to state here, that the operation is indicated in,— 1. Membranous and fleshy pannus; 2. Phlebectasiæ of the conjunctiva and cornea; 3. In simple vascular keratitis; 4. In partial vascularities of the cornea; 5. In inter-lamellar infiltration of blood or lymph; 6. In corneal lesions, resulting from entropion, ectropion, and trichiasis, after these conditions have been relieved by appropriate measures; and, lastly, in staphylomatous conditions of the cornea consecutive to softening of its substance. M. Bader, who states that he has frequently performed this operation, dispenses with the use of the caustic, as he found it likely to produce abscess of the iris, sloughing of the sclerotic coat, and abscess or severe inflammation in the cornea. He found it to be most serviceable in pannus, but available also in cases of cornical cornea, of which it cured two cases out of four that were operated on.

Inoculation, as a means of curing vascular keratitis, has been chiefly recommended by v. Roosbröck,¹ who has performed the operation on upwards of one hundred patients without ill effects. It succeeds best in those cases where the disease is of comparatively recent origin, and should never be undertaken unless the whole surface of the conjunctiva is covered by the vascularized membrane, which must not be too dense and thick. It is contra-indicated in cases where ulceration of the cornea is present.

¹ See v. Roosbröck's excellent paper on Pannus, in the *Annales d'Oculistiques*, p. 262. 1853.

5. *Ulcers of the Cornea.*

(PLATE V., Fig. 27 ; PLATE IV., Fig. 23.)

Ulcers of the cornea are for the most part only an indication of some general disorder of the system; yet they frequently constitute so important a symptom, that the treatment must be essentially directed to their removal, though the systemic affection should in no instance be neglected. In the following section, the characteristic phenomena of some of the most common forms—the herpetic, the rheumatic, and the variolous—are detailed, with the treatment most appropriate for each. The form of ulceration which results from the bursting of an abscess has been already considered under the head of suppurative keratitis, and certain rare forms of ulceration, depending upon defective or abnormal nervous influence, will be described under the head of neuro-paralytic affections of the cornea.

In a total of 1300 cases, of which I took notes indiscriminately, there are 151 cases in which ulceration of the cornea was present, and the proportions of the phlyctenular and rheumatic varieties, which constitute the bulk of the cases, are about as 4 : 1.

The phlyctenular or herpetic form of ulceration is therefore by very far the most common. It occurs in pallid, anæmic children, though it may occasionally be seen in those of florid complexion, and who are in apparent health. It is remarkably frequent as a sequela of measles, or of one of the other exanthemata. The pulse is generally frequent, the skin moist and flabby, the appetite bad, the bowels somewhat confined, and the energy, both of the mind and body, considerably impaired. The ulcer may occupy any part of the cornea, and may be either single or multiple; it is not unfrequently seen just at the point when the cornea and sclerotica are continuous with one another; and sometimes the cornea appears to be encircled by a chain of such small ulcers. The

first appearance of the disease is in the form of a minute granule imbedded in the substance of the cornea, on the surface of which a small vesicle or blister, filled with a transparent fluid, and covered by the corneal epithelium, develops. On the bursting of this, a shallow ulcer of circular, or more rarely of linear, form, with a grey or yellowish base, remains, surrounded by a cloudy halo of greater or less extent. In unhealthy children, the little ulcer may undergo considerable enlargement, or may penetrate deeply through the laminae of the cornea; but usually it quickly heals up, and leaves no trace of its existence. If the patient be not subjected to medical treatment, successive crops of the vesicles appear and heal up, each vesicle or series of vesicles, however, increasing the inflammatory symptoms, until the margins of the cornea become overrun with vessels, and a condition of superficial keratitis is established. The formation of the vesicles is attended with considerable irritation of the eye, evidenced by redness of the conjunctiva, lachrymation, and intolerance of light, which appear to be occasioned, in the early stages of the affection, by the elevation being hard and prominent, giving the sensation as of a foreign body in the eye, and in the later, by the exposure and irritation of the corneal nerves. Both the superficial conjunctival and the episcleral vessels are injected, and one or two of considerable size usually run up to the margin of the cornea nearest to the ulcer, and, overstepping this limit, traverse the membrane till they reach the ulcer itself. On opening the eyes an abundant flow of tears takes place, and a little puriform mucus collects at night in the corners, and along the edges of the lids, causing them to adhere.

An asthenic form of herpetic ulceration is occasionally met with in delicate children, in which scarcely any redness or pain are present, and the ulcer only appears as a slight indentation on the surface of the cornea, without any haziness at its base or around its border. Intolerance of light is some-

times a very conspicuous symptom, and at others wholly absent. M. Desmarres,¹ in speaking of a form of ulcer apparently identical with this, remarks, that so long as the base of the ulcer is quite clear and transparent, the photophobia is intense; but that as soon as the base becomes yellowish or grey, the intolerance of light diminishes. The treatment of these cases may be divided into the local and constitutional. As regards the former, the following sound observations occur in Messrs Lawrence and Moon's recently published work on the Diseases of the Eye:—"It is essential that the eye should be excluded from light and air, and, as far as possible, be kept in a state of repose. The best means of fulfilling these requirements is the application of a cotton-wool compress. The eyelids having been closed, the superficial parts of the orbit should be evenly padded with cotton-wool, and a bandage so applied as to maintain a slight and uniform pressure upon the eye." And they add, in a note, "The healing of a corneal ulcer is a purely natural process; but how can we expect this to go on, if the raw surface is being constantly irritated by the friction of the lids in the act of winking?" It may be remarked, however, that the application of a bandage should in nowise be allowed to interfere with cleanliness; and that, if a considerable amount of conjunctivitis be present, it should frequently be removed to prevent the accumulation of muco-purulent fluid.

The use of calomel applied directly to the cornea, or to the interior of the lids, has been highly spoken of by M. Pagenstecher² and others in this affection. Care should be taken that it is free from the bichloride, and that it contains no particles large enough to give the impression of sand or grit when the lids are closed. In order to apply it, the upper lid should be everted, lightly touched with a soft cambric handkerchief to remove superfluous moisture, and the powder

¹ *Maladies des Yeux*, t. ii. p. 275. 1855.

² *Ophthalmic Review*, 1865; and Giraud-Teulon, *Ann. d'Oculistiques*, 1865.

should then be dusted on with a camel-hair brush. It appears to act by exerting a stimulant or tonic action on the vessels, and by promoting granulation. Its use is contra-indicated when it excites much irritation, and when the ulcer appears to increase in depth and extent.

The application of lotions containing belladonna, conium, or hyoscyamus, is very commonly employed, and of these the first is perhaps the most efficacious in allaying irritation, whilst at the same time it fulfils a second purpose in preventing the prolapse of the iris in the event of perforation of the cornea taking place. As regards blisters, which are very commonly employed in this disease, I cannot say that I have seen much benefit derived from their use; they may, however, prove of service where there is a considerable amount of intolerance of light.

As regards constitutional treatment, which I believe to be of considerable importance, the chief points to be attended to are, to promote the general health by active exercise, by a due supply of wholesome food, and by the administration of purgatives and tonics. In winter, when the affection is certainly most common, care should be taken to keep the feet dry and warm. The bowels are generally more or less disordered; and the treatment may in most instances be advantageously commenced by a full dose of the compound jalap powder, with one or two grains of calomel. If ascarides be present, an injection of turpentine may be administered; and tapeworms may be killed and dislodged by the use of the oil of male fern, followed by a dose of castor-oil. If, as occurs in many cases, the appetite be impaired, or altogether lost, we must endeavour to restore the general tone of the constitution by the employment of cod-liver oil, quinine, or of one of the preparations of iron. The last, for the sake of economy, is most generally employed in hospital practice, and, especially in fair-haired children, answers exceedingly well. It should be given either in the form of Griffith's mixture,

or of the tincture of the sesquichloride, half an ounce of the former, or ten or fifteen drops of the latter, being taken daily. In the dull-complexioned, dark-haired children of strumous diathesis, who frequently suffer from this disease, cod-liver oil succeeds well; but both of these remedies must yield in value to quinine, which, given in doses of one grain thrice daily, either with or without a grain or two of the hydrargyrum cum cretâ, almost always effects a cure. In cases where a very great degree of irritability and intolerance of light are present, two or three grains of hyoscyamus or of conium may be given with the quinine and mercury; and where the strumous diathesis is unquestionably present, a quarter of a grain of the extract of belladonna may be given with the best possible results. Its effects should, however, be carefully watched. If the child refuses to take the quinine, which is not unfrequently the case, the compound decoction of cinchona, and from ℥xx. to ℥xxx. of the liquor hydrargyri bichloridi, may be substituted for the above.

When the inflammation is severe, and the child is in an unhealthy state of body, and when the ulcer daily extends both superficially and in depth, threatening to perforate the cornea, recourse should be had at once to the operation of *paracentesis corneæ*. For this purpose a broad needle may be employed, and, the head being steadied by an assistant, the point should be entered near the lower part of the periphery of the cornea, and the aqueous humour allowed to discharge itself slowly by its side. Care should be taken to introduce the instrument with sufficient obliquity of direction to avoid wounding the iris or capsule of the lens, yet not so great as to cause it to travel between the laminae of the cornea. The intra-ocular tension being in this way diminished, the ulcer is placed under favourable circumstances for granulation, and recovery soon takes place. It is requisite in some instances to repeat the paracentesis two or three times.

A peculiar form of phlyctenular ulceration has been

described by Mr Bowman under the term of Vesicular Ulceration of the Cornea, of which an illustration is given in Plate IV., fig. 23. It consists in the formation of a chain of small vesicles or blisters on the surface of the cornea. The fluid is thrown out just beneath the epithelium, as in the ordinary form of phlyctenular ulceration, and there is always a high degree of irritation, occasioning much lachrymation and intolerance of light. It is a somewhat rare form of disease, only one or two cases coming under observation in the course of a year. In most of the cases that I have seen, the vesicles have been of different sizes, and whilst some may be observed in the incipient stage, others are filled with clear or slightly turbid fluid; and here and there one may be found to have burst, leaving a small ulcer with grey or yellow base, and a well-marked cloudy halo around it. On healing, a slight nebula is left for a short time, but soon entirely disappears. The following case will give some idea of the general progress of these cases:—M. A., æt. 40, came to the Hospital, stating that the right eye had been inflamed for a week; that there had been considerable pain in it, which was always most severe at night; that the eyes were always watering, the tears feeling very hot, and excoriating the cheek. The lids were slightly swollen, the tongue was furred, and the bowels confined. The right cornea was surrounded by a well-marked vascular zone; and on the surface of the lower segment was a semicircle of minute vesications, seven or eight in number, some very small, others as large as a pin's head, and evidently filled with a limpid fluid. The subjective sensation of a foreign body under the lids was very distinct when the eyes were closed. On the margin of the lids was a considerable accumulation of the whitish secretion, so often observed to accompany rheumatic inflammation of the eye; and she stated that, though not subject to rheumatism, she thought she could trace the present attack to sleeping in a thorough draught between an open door and

window. The principal vesicles were at once touched with a fine point of nitrate of silver, and she was directed to bathe the eyes with poppy fomentations; a purge was administered, and a mixture containing tinctures of aconite and colchicum was ordered to be taken three times a-day. In one week the ulcers had healed up, leaving only slight nebulæ, and she ceased to attend.

Rheumatic Ulcer of the Cornea.—In the second form of ulcer—the rheumatic—after the usual symptoms of rheumatic ophthalmia have endured for a few days, a vesicle forms near the margin of the cornea, accompanied by severe pain over the brow of an aching character, and exasperated at night, at which time it comes on with great regularity, wearing the patient out with want of sleep, and occasioning more or less pyrexia. The conjunctival and episcleral vessels are highly congested, the colour being of a deep and sometimes of an almost livid red, and tolerably uniform over the whole surface of the sclerotica, though certainly more pronounced around the margin of the cornea. There is not in general any great degree of serous infiltration or chemosis present. In many cases a small quantity of whitish secretion, consisting of epithelial scales, and perhaps of urate of soda, accumulates along the borders and at the angles of the lids. The ulcer is generally deep, of an elongated form, with irregularly but sharply defined edges, and situated a little within the margin of the cornea. The base of the ulcer is usually clear, and the corneal tissue around it moderately hazy. Sometimes, especially in aged persons, it is broad and shallow, and occupies either the centre or lateral portion of the cornea. This form of ulcer is accompanied by sufficient inflammation to lead in many instances to the development of pus between the lamellæ of the cornea, constituting an onyx, which may either burst internally, forming an hypopyon, or, more frequently, makes its way outwards, and leads either to the formation of a dense leucoma, to keratocele, or to staphyloma

of the cornea. Occasionally the ulcer pursues a circular course round the margin of the cornea with considerable rapidity, producing such interference with its nutritive supply as to lead to its general opacification and detachment as a slough, followed by escape of the humours and collapse of the globe.

As ulcers of the cornea of the rheumatic type usually occur in the aged and debilitated, and have been induced by exposure to cold, whilst they are almost always accompanied by a costive state of the bowels, the remedies to be administered may be anticipated to consist in the maintenance of a uniform temperature, the unloading of the bowels, and local depletion, with general sustentative measures. If the weather be unfavourable, the patient should be kept strictly indoors, with avoidance of cold draughts of air. The amount of purgation to which he should be subjected must of course have reference to his age and strength; but in ordinary cases two pills, containing five grains of pil. hydrargyri and five of colocynth, followed by a black draught, may be given, the free action of which produces immediate relief to the pain. If, however, it still continues, opiates must be employed, considerable doses, as a grain of the extract of opium every eight, six, or even four hours, being well borne. The plan of treatment which I have found of most service in hospital cases has been the following:—After the bowels have been thoroughly cleared, the patient is ordered to take a draught containing twenty minims of tincture of colchicum and three minims of tincture of aconite, in camphor mixture, thrice daily, and at night a pill containing five grains of the compound soap pill. If the inflammation be severe, this treatment may be accompanied by the application of from four to eight leeches on the temples, maintaining the flow of blood after their removal by a succession of hot linseed-meal poultices. The effects of the aconite should be watched, and if any numbness or tingling of the extremities be felt, the

dose should be diminished, or the use of the remedy suspended. Yet another plan, which sometimes proves exceedingly serviceable, is the administration of turpentine in twenty-minim doses, mixed with mucilage, three or four times a-day. It has appeared to me to be of most use in the later stages or more chronic forms of the disease, but should be discontinued if the urinary organs become affected. During convalescence, the *mist. ferri. co.* may be taken with advantage. Throughout the whole course of the disease, beer should be interdicted, and replaced by a little brandy or gin and water. The patients should not be too much restricted in their diet, and one or two glasses of wine may be allowed with the dinner. Upon the whole, local applications are not of very great service in this form of ulceration, if we except that of moist heat, which is in general very soothing to the pain, and may be applied by means of lint dipped in hot water, or liquor in which poppy-heads have been boiled. In this as in the last-described form of ulcer, paracentesis of the cornea is sometimes requisite to relieve the tension of the globe, and should always be adopted where the ulceration appears to be penetrating deeply through the lamellæ of the cornea. The employment of atropine or belladonna is requisite at every stage of the disease.

Out of 100 cases of ulceration of the cornea, whilst 76 were phlyctenular, only 19 were rheumatic, and the average age of these was 45; the oldest was 67, and the youngest was 24. The following case will give some idea of the usual progress of a case of rheumatic ulceration of the cornea:—J. B., æt. 31, a cowshed cleaner, presented himself at the Hospital suffering from severe ulceration of both corneæ. The ulcer on the right cornea was nearly central; that on the left was elongated and laterally situated. The base of both of these ulcers was nearly transparent; their margins were irregular, indented, and sharply defined; and around each was a halo of grey colour and semi-opaque, indicating an hypertrophy of

the corneal corpuscles. The redness of the conjunctiva, both on the ocular and palpebral surfaces, was intense and almost uniform. The pain was constant and severe, but at night it became almost unbearable, totally preventing sleep after twelve or one o'clock in the morning. The tongue was slightly furred, and the bowels were confined. The duration of the disease had been seven or eight weeks. At one time, being able to lie up, he got better, but during the preceding week all the symptoms had been gradually increasing in severity. Atropine was instilled into both eyes. He was directed to keep indoors, to foment the eyes with flannel dipped in hot water, to apply four leeches to each temple, and to keep up the bleeding with a linseed-meal poultice. He was ordered a scruple of compound jalap powder, with two grains of calomel, to clear out the bowels, and a draught containing one ounce of decoction of cinchona, one drachm of the tincture of cinchona, and one drachm of the liquor hydrargyri bichloride, to be taken three times a-day. Two days after the condition of the eyes was unaltered. He had been unable to get the leeches, and they had not been supplied by the Hospital. He was now directed to be cupped to ʒiv. from each temple. Three days after this he was in all respects better. The pain had diminished, the redness was much less, and the progress of the ulcers had evidently been checked. On the seventh day after he was first seen, the right eye was much better, the ulcer beginning to granulate up, but the left was still very painful and red. The cinchona mixture was exchanged for the *pil. saponis co. gr. v.*, three times a-day, and he was ordered to repeat the purge. A great improvement followed. On the ninth day the redness had almost gone from the right eye, and the ulcer was quite shallow, with rounded smooth edges. The left presented a leash of fine vessels on its surface, which appeared to proceed chiefly, not from the margin of the cornea, but from a slight tag of adhesion that had formed between its

posterior surface and the iris, and which was now for the first time perceived; a few branches were, however, also derived from the conjunctival vessels. From this time steady improvement, under the same line of treatment, continued to take place; and when the last note was taken, on the twenty-first day of his attendance, it is stated that the ulcers had granulated up to the general level of the cornea; that their position was only indicated by the presence of a faint, soft nebula, which would probably soon disappear. The pupil was a little elongated towards the ulcer on the left side, in consequence of the persistence of the tag of adhesion.

Symptomatic or Exanthematous Ulceration of the Cornea.—

A peculiar kind of ulceration of the cornea has been observed to occur in those debilitated conditions of the system which follow severe attacks of small-pox, measles, scarlatina, erysipelas, and typhus, which appears to be due to a deficient supply of nervous power, and is hence analogous to that ulceration which follows division of the fifth pair of nerves.

The best observations that have been made upon the peculiar inflammations of the eye accompanying or following small-pox, which will here be taken as a type of the others, are those of Mr Marson,¹ who, as surgeon to the Small-Pox Hospital, enjoyed extensive opportunities of observing these diseases. He remarks that he has never seen a small-pox pustule form on the conjunctival mucous membrane. A sharp attack of what might almost be called *catarrhal ophthalmia*, attended with considerable redness and chemosis of the conjunctiva, is not uncommon during the first few days, evidently coincident with the general congestion of the skin, which is then present; but this subsides without producing any serious effects. The common *abscess* of small-pox, again, forms on the eye between the conjunctival and sclerotic coats, and also occasionally between the layers of the cornea. It is usually small, takes place contemporaneously with abscesses

¹ In the *Lancet*, p. 234. 1839.

in other parts of the body, and the eyes recover unimpaired.

Mr Marson also refers to a *deep-seated inflammation*, which rapidly destroys sight without producing ulceration of the cornea, and is met with in those cases of small-pox which are so severe as to occasion death on the seventh or eighth day. Various circumstances tend to show that all the deep-seated structures are here implicated, the disease being probably a form of irido-choroiditis. But the most important of the affections consecutive upon small-pox, in a practical point of view, is a peculiar kind of *ulceration of the cornea*, which is the effect of the state of body consequent upon a severe attack of small-pox, followed by violent secondary fever. In all instances the pustules are beginning to subside on the body generally before the eye is attacked. The ulcer may appear at any time from the tenth to the thirtieth day after the date of the first appearance of the eruption, and the proportion of cases attacked is 1 in 39. The disease commences on the tenth or twelfth day with redness and slight pain in the affected eye, and very soon an ulcer appears at the inner or outer margin of the cornea, or sometimes on both sides at once, and spreads with more or less rapidity, according to the degree of secondary fever present. In the more severe cases, perforation of the cornea, with escape of the aqueous and prolapse of the iris, occurs. Pus collects in the anterior chamber, and ultimately the sloughing of the cornea permits the escape of the lens and vitreous humour, followed by collapse of the globe. This destructive ulceration or sloughing never takes place in a severe degree except when there is a high state of secondary fever present, and is, as Mr Marson points out, probably analogous to the sloughing of the cellular tissue and abscesses in various parts, which are no uncommon events of this state.

As regards the treatment of variolous ulceration of the cornea, Mr Marson recommends cupping, or the application

of leeches to the temple,—though, as the patients are already much debilitated, very little abstraction of blood can be borne,—warm fomentations, attention to the bowels, and, in some instances, the direct application of nitrate of silver to the ulcer. In many instances the patient is unable to sustain any depletion whatever, and then cinchona and stimulants, in one form or other, must be freely administered. The use of mercury should be avoided.

Mr Marson states, as the result of his experience, that although the appearance of the eye may be very unfavourable in cases where the inflammation and ulceration have been severe, but not so violent as to cause the discharge of the humours, in a few months after the patient has otherwise recovered his health, very great reparation usually takes place also in the eye, the leucomatous state will in great measure disappear, and, unless the ulcer have been deep and exactly in the line of vision, very useful sight may be regained.

v. Gräfe¹ has called attention to certain forms of corneal ulceration occurring in infantile encephalitis, which have often been referred, together with those that occur in certain forms of typhus, to neuroparalytic ophthalmia, the functions of the nerves ministering to nutrition being supposed to be affected, as in those cases where artificial division of the fifth has been performed in animals, or after paralysis of this nerve in man. v. Gräfe has observed in these cases that usually both eyes are affected, one generally a few weeks after the other. The affected eye becomes intolerant of light, weeps, and presents moderate conjunctival congestion, especially around the cornea, which itself becomes dull and hazy near the centre, where an ulceration commences, leading to destruction of the membrane either wholly or up to a narrow margin or seam.

The lower part of the conjunctiva bulbi becomes dull, dry, and covered with fine scales, and forms perpendicular folds

¹ Corneal Ulceration in Infantile Encephalitis, *Archiv. f. Ophth.*, Bd. xii. Heft. ii. p. 250. 1866.

when the eye is rotated. The condition, in fact, may be termed one of acute xerosis. The palpebral conjunctiva, except in being slightly congested, is normal; the secretion is deficient, or only consists of a few mucous flocculi. The disease cannot apparently be cured, though it may be held in check for a few days by appropriate treatment, as aromatic and warm poultices, atropine, and the pressure bandage. Sooner or later the iris becomes affected, assuming a yellowish swollen appearance, and no longer dilating under the influence of mydriatics. The lids are scarcely swollen till the later stages of the disease, when the cornea is spoiled, and panophthalmitis sets in with suppuration of the globe, before which, however, death often occurs. In the second eye the process is usually slower and more tedious. The disease only occurred once in the first week; in all his other cases, it appeared during the second, third, or fourth month of life. The children showed general debility, loss of appetite, and pallor, but no strongly-marked brain symptoms. They died from diarrhoea, or bronchial complications. In one case there were convulsions;¹ little was observed in the brain on general inspection in another, but on microscopical examination Klebs found much fatty degeneration of the neuroglial tissue; the perivascular spaces were strongly marked, and the case appeared to be one of chronic encephalitis passing into shrivelling, atrophy, and induration of the cerebral substance.

There is, moreover, a form of ulceration of the cornea, which has been described by M. Reindorf² as occurring in, and indeed constituting, one form of sympathetic ophthalmia. He states that he has observed it on three occasions, and that he is convinced of its sympathetic nature. The appearances presented are these:—"There form," he says, "in the tissue of the cornea circumscribed infiltrations, which soon pass

¹ v. Gräfe, iii.

² De l'Ophthalmic Sympathique, Memoire couronné par la Soc. cent. de Lille. Bull. Med. du Nord. de la France. 1865.

into the condition of superficial ulceration. As soon as some of these heal up, others make their appearance, until frequently the whole surface of the cornea is slightly troubled and softened. The iris always participates in the inflammation in these cases, and an hypopyon is not unfrequently seen. These morbid conditions are accompanied by an extreme photophobia and ciliary neuroses. If the disease be not checked, the ulcerations become deeper, and may even proceed to perforation. The patient is then in danger of losing his eye, either by the formation of a staphyloma, or by an irido-choroiditis, with consecutive glaucoma.

6. *Opacities of the Cornea.*

(PLATE III., Fig. 14; PLATE V., Fig. 29.)

Opacities of the cornea vary considerably in degree; the slighter forms are termed *nebulæ*, the more dense *albugo* and *leucoma*. In some instances they constitute a mere dot; in others, as in Plate IV., fig. 22, the tissue of the cornea throughout its whole extent seems to have undergone a change into a kind of a cicatrix, hard, dense, dry, and insensible. *Leucomata* are sometimes complicated by the adhesion of the iris, and, when extensive, often lay the foundation for the formation of a staphyloma.

Nebulæ generally result from slight and superficial inflammation of the cornea, such as occurs in the less severe grades of pannus, and from phlyctenular ulcers; they are sometimes so faint as only to be seen in a good light, and appear to consist of a thickening and multiplication of the deeper layers of epithelial cells on the surface of the cornea, many of which have become granular and semi-opaque, probably from fatty degeneration.

Leucomata only differ from *nebulæ* in being of a much denser white or opaque colour, and in affecting the substance of the cornea instead of its surface only; but, like *nebulæ*, they are composed of numerous granular cells and nuclei

which have in part undergone fatty degeneration, and have in some instances developed into a kind of fibrous or connective tissue, or have even undergone calcification. Their opacity is very considerable, so that it is impossible to discern the colour of the iris through them, and they are often very sharply defined at the edges. Leucomata commonly result from severe inflammation of the substance of the cornea, such as may be produced by direct mechanical injury, or by the entrance of lime into the eye. If in such cases an abscess has formed, and has burst into the anterior chamber, the iris frequently becomes attached to the margins of the wound, constituting a case of anterior synechia. The progress of these cases has been well given by M. Stellwag v. Carion,¹ from whose work the accompanying little drawing has been borrowed. If the posterior aperture be very small, the portion of iris which cleaves to the corneal surface presents a stalked or pedunculated form; and as contraction of the cicatricial tissue around occurs, it gradually becomes compressed on all sides, till at last the only remains of it are found in a little black pigment in the centre of the cicatrix, the posterior extremity of which expands into the iris. The same occurs in cases of penetrating ulcers of small size, except that here the iris protrudes as a little button or knot on the forepart of the cornea, called, from its resemblance to the head of

H.

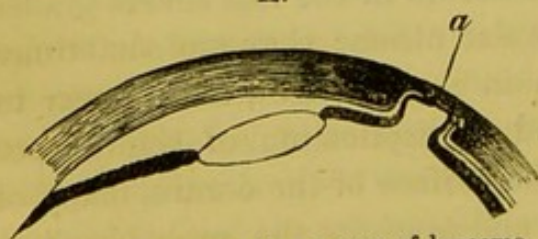


Diagram representing a case of leucoma complicated with anterior synechia.

whilst the anterior surface of the cornea preserves its natural convexity. The projecting portion of iris lines the cavity in an attenuated condition (*a*), and is firmly adherent to the

a fly, *myocephalon*. When the opening into the posterior chamber, formed by the bursting of the abscess, is of larger size, as in the figure, the cicatrix is often found to be hollowed out,

¹ Lehrbuch der Augenheilkunde, Abtheil. ii. p. 101.

margin of the depression, where some remains of the posterior elastic lamina may usually be found. In some instances the iris breaks down before the whole cavity is lined by it, and it is easy to understand how in some instances the lens may become implicated, and capsular or lenticular cataract result.

A form of leucoma is sometimes seen, resulting from the injudicious employment of acetate of lead or nitrate of silver lotions in superficial ulcerations of the cornea; a dense white or grey incrustation forms, which is firmly adherent to the cornea, and is destitute of organization; it appears to consist of the substance of the tissue in combination with an oxide or some salt of the metal, and rests, according to v. Carion, on a clouded layer, which covers or fills up the original depression of the ulcer, and is often permeated by vessels. According to M. Wecker,¹ in the case of nitrate of silver the metal first precipitates itself in the intercellular substance, and becomes redissolved, that it may be deposited anew in the cells, probably by the action of the phosphates which they contain, and under the influence of light.

Leucomata, under some circumstances, may become inflamed, and they then are frequently pervaded by vessels; but even without any inflammatory symptoms, large vessels may be gradually developed in them, and they are then termed vascular nebulæ.

The importance of nebulæ, and other opacities of the cornea, is partly owing to their unsightliness, but chiefly on account of the great disturbance and imperfection of vision they occasion. A very faint nebulæ will often be productive of more inconvenience than an opaque leucoma, if the latter be a little excentrically placed, and even if it be central, providing it be small; and this seems to be owing to the circumstance that, in the former class of cases, the diffusion of light is much greater, rendering the definition of objects much less clear

¹ *Etudes Ophthalmologiques*, t. i. p. 232.

than in the latter. To diminish this diffusion of light as far as possible, the patients turn their back to the light when examining any object, shade the brows, and hold it as near to the eye as possible. But the straining of the eye which is thus induced not unfrequently leads to myopia, to asthenopia, and to posterior staphyloma; whilst, in other instances, strabismus and nystagmus are engendered. The reparative power of nature is very remarkably shown in many cases of corneal opacity, and here, as elsewhere, it is always most distinct in the young. In many instances of opacity of the cornea resulting from purulent ophthalmia in infants and from perforating ulcers in children, the newly-formed cells and nuclei, possessing of themselves great developmental powers, and aided no doubt by the abundant vascular supply at this period of life, and perhaps also by the growth of the whole organ, form new tissue and become perfectly transparent. In adolescence the same process will still take place, but more slowly, and we rarely see in adult life a well-marked leucoma wholly disappear.

The treatment of these affections must be directed to assisting the natural powers of absorption as far as possible, or to effecting the removal of the opacity by operation, where this is superficial, and has been produced by the calcification of the new cells, or by metallic incrustation. When the opacity is persistent, considerable improvement may be effected by the judicious employment of mechanical means, by which the entrance of diffused light into the interior of the eye is prevented, and in other cases by the formation of a new pupil.

To fulfil the first indication, the promotion of absorption, an immense variety of substances, either in the solid or fluid state, have been recommended to be instilled into or applied to the eye, all of them, however, having for their effect irritation and slight inflammation of the conjunctiva and cornea, thus occasioning an increased vascularity of the parts, and

exalting their nutrition to a level with that of the early months or years of life. Amongst the most efficacious of these remedies may be enumerated solutions of alum, or sulphate of copper, in the proportion of from two to four grains to the ounce of distilled water; corrosive sublimate, one quarter to one-half grain ad. ʒj.; tincture of opium; oxgall; the *vapour* of bi-sulphide of carbon, applied by means of a bottle with expanded neck, fitting round the orbit, care being taken that none of the fluid enters the eye; powdered sugar and calomel have also been employed. Abroad, perhaps more than in this country, ointments of various kinds are in use, especially containing the red and yellow precipitatis of mercury. v. Carion, who gives a long list of various substances that have at different times been celebrated for their power in effecting the removal of corneal opacities, recommends the following:—Red precipitate of mercury, gr. i.–iv.; oxide of zinc, gr. iii; iodide of potassium, gr. ii.–iv.; pure iodine, gr. one-eighth, rubbed up with one drachm of lard, fresh butter, or palm-oil, the ingredients to be very accurately mixed.

Solutions of nitrate of silver are apt, it should be remembered, to stain the conjunctiva an exceedingly unpleasant brown colour, and therefore, if used, should not be continued for more than a week at a time.

Most of these preparations may be applied once or twice in the course of the day; their effects should, however, be watched, and their use immediately stopped if any permanent inflammation of the eye appears to be established.

In cases where the opacity proceeds from the action of lime, M. Gosselin,¹ taking advantage of the solubility of saccharate of lime, has suggested the employment of syrup as a lotion, and with, it is said, excellent effects.

In the slighter forms of opacity which are too deeply situated to yield to the above measures, but where, owing to the inter-

¹ Archives Generales de Medicin, p. 513. 1855.

ference and diffusion of the rays of light, great impairment of vision results, stenopœic glasses may be used, as recommended by Donders, with great advantage. These consist of two deep concavo-convex shells, fitting around each eye, blackened in their interior, and having a small hole at their centre through which alone light can enter the eye. The size of the aperture which produces the greatest improvement in vision varies in different instances, and even in the same instance, according to the intensity of the light, but in general is from one thirty-sixth to one-twelfth of an inch in diameter. A small circular disk, with various-sized apertures, similar to that commonly attached to microscopes to moderate the amount of light, may be adapted to the stenopœic glasses, and the patient can then alter the aperture through which the light is admitted to suit his own convenience. The chief inconveniences attending their use are, that they are unsightly to wear, and that they considerably limit the field of vision; to so great an extent, indeed, that it is scarcely safe for the patient to go into the streets alone, though the vision of both near and distant objects may be tolerably distinct.

In cases of extensive leucomata leaving some portion of the cornea clear, if the iris be healthy, excellent sight may be regained by the formation of an artificial pupil in one or other of the modes to be afterwards detailed. When practicable, the natural border of the pupil should be retained, as in Mr Critchett's operation of iridesis, and the new pupil should always be as near as possible to the centre of the eye; whilst, if the choice of making it near the outer or inner margin of the cornea be open to the surgeon, the latter should invariably be selected. It is important to notice, however, that there is little chance of success if extensive anterior synechiæ have formed; for the violence that is necessary to detach the iris from the cornea, the frequent introduction of the forceps through the wound, and the unhealthy condition of the parts, generally render the attempt nugatory; whilst, even

if successful, the lens is often found to be misplaced or cataractous, requiring therefore to be removed by the scoop, and much increasing the dangers of the operation, and the likelihood of the new pupil becoming closed by the fragments which remain, and by the products of the inflammation which is sure to succeed. Nor is it of much use to perform iridectomy or other similar operation when the natural curvature of the cornea is materially altered, nor when the pupil must necessarily be made at the extreme periphery of the cornea, as under these circumstances the images of external objects falling upon the retina are so distorted as to cease to prove of any advantage to the patient.

Attempts have been made at various times, in cases where the whole cornea has been rendered opaque, to make an artificial pupil through the sclerotica, by removing a small portion of that membrane with a circular trephine, analogous to Mohr's cork borer; but such openings invariably soon close up by the formation of an opaque fibrous cicatrix. Others have suggested the removal of the entire circle of the cornea, and the substitution of the same membrane freshly removed from an animal, or even the introduction of a glass cover in the form of a stud (Nussbaum); but in the former instance it is impossible to obtain union in parts so feebly supplied by blood, and in the latter, for various obvious reasons, failure is inevitable.

7. *Conical Cornea.*

(PLATE V., Fig. 26.)

This affection, as its name imports, consists in the gradual projection of the cornea, which, at first almost imperceptible, may at length interfere with the closure of the lids. Both eyes may be affected at the same time, and to the same degree; or the disease may make considerably greater progress in one eye than in the other; or, lastly, it may be limited to one eye. The ætiology and pathology of the disease are

still involved in much obscurity; but it would appear that the yielding of the cornea is rather occasioned by the membrane losing its natural strength and capability of resisting the ordinary pressure exerted against it by the contents of the globe, than by any increase of the intra-ocular pressure itself, since the tension of the globe never seems to be materially increased. The disease usually occurs in young and delicate adults, from sixteen to twenty years of age. The oldest patient I have seen was thirty-seven; but Mr Bowman¹ states that it may commence as late as fifty.

The development of conical cornea is unattended by any symptoms of inflammation, and the membrane remains for a long period perfectly clear, bright, and polished. Impairment of vision, especially in viewing distant objects, is always complained of, even where the alteration of the curvature is so slight as to be scarcely perceptible without minute attention being paid to it. The diagnosis, however, at this period is materially aided by ophthalmoscopic examination, when, as Mr Bowman has noticed, a certain shade appears on one or the other side of the cone that can be made to shift its position by slight alteration in the direction in which the light is caused to be reflected from the mirror.

The course of the disease is essentially chronic and slowly progressive, the cone ultimately becoming very sharp or steep, and frequently hazy at the apex, where it is more or less thinned;² but, according to Mr Bowman, it never advances to bursting, either by extreme stretching, or by ulceration, or by sloughing, which is attributable to the circumstance that, when the attenuation of the apex is carried to a certain extent, the escape of fluid by exosmosis is facilitated to so great an extent, that the internal pressure is reduced to a degree at which it is no longer in excess of the diminished

¹ Ophth. Hosp. Reports, vol. ii. p. 154.

² See M. Hulke's Dissection of an Eye affected with Conical Cornea, appended to Mr Bowman's paper above cited.

resistency of the cornea; and this accords well with the fact, that such eyes are usually unduly soft. In the case examined by M. Hulke, the apex of the cone was hazy; and on a microscopical examination of this part, it was found that the anterior elastic lamina was perfect, but thinner than elsewhere, and wrinkled, whilst under it was a stratum of crowded club-like nuclei; and beneath these the proper lamellar tissue was replaced by a web of caudate and nuclear fibres, amongst the meshes of which were clusters of oval and fusiform cells. The posterior elastic lamina and the epithelium, both on the back and front of the cornea at this part, as well as the whole structure of the cornea elsewhere, were perfectly normal. His and Wecker produced the disease artificially in rabbits, by introducing a needle through the peripheral part of the cornea or the sclerotica, and lacerating the posterior elastic lamina from within; the opacity which followed the operation soon disappeared, but gradually increasing conical malformation of the cornea succeeded.

The treatment of cases of conical cornea is eminently unsatisfactory in its results. From the absence of inflammation, from the retention of the transparency and brilliancy of the membrane, and from the slow progress of the disease, it gives the impression of being the indication of some constitutional affection—a symptom of some more general disease; yet it often occurs in apparently strong and healthy children, in whom no strumous or other specific taint of constitution can be ascertained to exist, and the administration of tonics, as iron, quinine, and cod-liver oil, appear to exert no influence whatever on its progress. The attention of inquirers, therefore, in consequence of the failure of such general remedies, has been directed to the local treatment of the affection, and the most important of the many plans that have been tried are the following:—1. In the early stages, concave glasses are of great service in correcting the myopia resulting from the unnatural curvature of the cornea. In the later stages,

however, when the form of the projection has become really conical, they are useless. 2. Paracentesis of the cornea, the eye being tapped two or three times a-week with a broad needle, and the aqueous humour drawn off; a plan that I have on several occasions systematically carried out under Mr Guthrie's direction, though with little advantage to the patient, as was to be anticipated if the disease really result from yielding of the cornea under normal pressure, and not from increased intra-ocular pressure. 3. The application of stenopæic glasses, by which the light is only permitted to enter the eye through the apex of the cone; a plan which is attended with some success if the prominence be not very great, and retain its transparency. 4. A similar condition may be physiologically produced by the instillation of the solution of Calabar bean in glycerine,¹ which, by causing contraction of the pupil, temporarily improves the vision. 5. In view of the advantages resulting from the use of these means, Mr Bowman has suggested the alteration of the form of the pupil from a circle to a slit-like aperture. This may be accomplished by making a small puncture at the margin of the cornea, introducing a blunt hook, seizing with it the edge of the iris, and withdrawing it through the opening. It may either be left here, or, as recommended by Mr Critchett, it may be tied with a fine piece of silk, by which its retraction is prevented. This constitutes the operation of iridesis, or iridodesis. After a few days the operation should be repeated on the opposite side of the cornea, and the pupil will then be found to be converted from a round into a narrow slit-like aperture, which should always, if possible, be made vertical in direction, since this best fulfils the object in view, and at the same time is less noticeable from without. v. Gräfe² formerly recommended iridectomy, but has only seen a cure effected by this means in two cases. He refers to

¹ Prepared by Messrs Hanbury.

² Arch. f. Ophth., Bd. xii. Heft. ii. p. 215. 1866.

Critchett's iridesis, and to Bowman's slit-like pupil, obtained by double iridesis; but believes that in all these cases, from the unnatural condition of the refractive medium formed by the cornea, comparatively slight advantage is gained. He considers that a better mode of proceeding is to cause opacity of the central part of the projecting cornea, since such a condition is known to flatten the normal cornea. This condition can be induced by touching the cornea with nitrate of silver, after cutting off a little flake with a cataract needle; an artificial ulcer succeeds, which penetrates deeply, and the floor of which is pierced two or three times by a needle. Healing is then allowed to take place, and a cicatrix is formed. In a patient in whom this was done, and who previously could not read more than 16 of Jäger's Test Types at one-and-a-half inches, after the operation she could read 7 fluently at the same distance, and her excentric vision was much improved, the cornea being at the same time considerably flattened.¹

8. *Staphyloma Corneæ.*

(PLATE VI., Figs. 34 and 36.)

Where the cornea has been for a long time the seat of inflammatory processes, whether of a strumous, rheumatic, or syphilitic type, or where cicatrices have formed as a result of mechanical or chemical injuries, or of ulceration, the resisting power of the cornea is, as in the foregoing disease, diminished; and whilst the iris, lens, and other contents of the globe retain their natural characters, a partial or general protrusion takes place to a greater or less extent, constituting the affection known as *staphyloma corneæ*. The formation of the staphyloma in this case is exactly analogous to the ruptures that are so frequently seen in military practice to follow cuts across the abdominal muscles. In both instances the cica-

¹ For cases of Conical Cornea treated by iridodesis, the reader is referred to the Ophth. Hosp. Rep., vol. iii. p. 338, and to Pagenstecher's mode of performing this operation, do. do., p. 321.

tricial tissue laid down for the repair of the lesion, yields to the pressure *à tergo*, and may continue to enlarge to an indefinite extent. In by far the greater number of cases, however, the disease does not present this simple character, and the mode of formation is that which was first intelligibly

O.

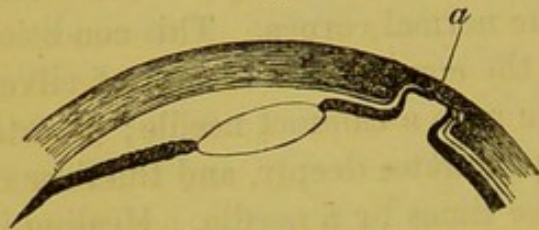


Diagram showing the effects of an onyx or abscess bursting posteriorly, and the incipient stage of a staphyloma corneae.

P.

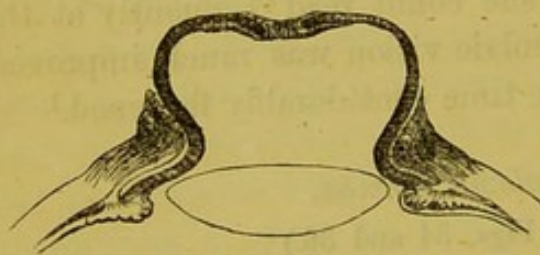


Diagram showing the effects of a central perforating ulcer, and the nature of an anterior staphyloma of the cornea, after Stellwag v. Carion.

described by Mr Wharton Jones,¹ and may be easily understood from an examination of the accompanying figures.

Here, in consequence of the perforation of the cornea by an ulcer, or of the bursting of an abscess, as in fig. O, through the posterior lamella, adhesion of the iris to the margins of the ulcer, or depression, takes place, and protrusion of this membrane gradually occurs, either covered with a few of the remaining anterior or posterior lamella of the cornea, or by a new cicatricial tissue. The time at which the projection may begin to take place varies considerably; sometimes as in a case recorded by Mr Haynes Walton,² as many as twenty years elapsing between the original lesion and the staphylomatous protrusion; whilst in other instances, as may frequently be seen after attacks of purulent ophthalmia in children, a few weeks are sufficient to permit of a very serious amount of projection taking place. The extent to which this projection may proceed likewise differs in different instances, sometimes proceeding gradually,

¹ Med. Gaz., Feb. 1838, and Principles and Practice of Ophthalmic Surgery.

² Surgical Diseases of the Eye, p. 322. 1861.

till, as in fig. P, it attains a large size; more frequently, however, progressing rapidly at first, and then becoming stationary as soon as an equilibrium is established between the density of the membrane and the intra-ocular pressure. That this last is augmented in the early stages of the affection is evidenced, as stated by Wecker,¹ by the impairment of vision at this period, which is greater than can be attributed to the alterations observable in the curvature of the cornea alone, and also by the fact that ophthalmoscopic examination shows that the posterior parts of the eye are suffering in a similar manner to the anterior—excavation of the optic papilla being frequently observable. The cause of the increased intra-ocular pressure is probably due, either, as Gräfe maintains, to an inflammatory condition of the iris, which partially or wholly adherent to the posterior surface of the cornea, leads to effusion of fluid, or, as Donders suggests, to the irritation excited by this adhesion being reflected down upon the secretory nerves supplying the choroid and ciliary processes. When the globe has once become tense, the further progress of the disease is no doubt increased by the action of the recti muscles compressing the globe from without. When the swelling is very large, and is general or complete, involving the whole of the cornea, the iris rarely lines the entire extent of its internal surface, but cleaves to the edges of the protrusion, and may be traced, together with the posterior elastic lamina, for some distance into its interior, in a greatly attenuated state. The major part of the swelling is then formed of the cicatricial tissue, which is incorporated at the base of the tumour with the sound cornea. Occasionally, however, the iris seems to form the greater part of the tumour, conferring upon it a livid colour (fig. 30) and a lobulated appearance, which formerly obtained for it the name of *staphyloma racemosum*. In such cases, the iris and the false membrane covering it present a considerable amount of

¹ *Etudes Ophthal.*, vol. i. p. 334.

vascularity, and the lenticular system, though sometimes normal, is often displaced to a greater or less extent forwards, and rendered cataractous. In most instances the prominent part of the cornea is rendered extremely thin, and the tension of the globe may become considerably diminished; then, on the occurrence of some slight blow or exertion, rupture may take place, leading to the collapse of the globe, which shrinks, and ultimately becomes squared by the action of the recti.

The treatment of staphyloma of the cornea depends in each case on the stage at which it has arrived. In the earlier periods, especially if the lens be clear, attempts may be made to stay its progress; but when it has attained a large size, one or other of the methods proposed for the removal of the projecting part must be adopted. Amongst the best means for arresting the progress of the disease whilst it is yet incipient, I consider that the operation of dividing the ciliary muscle must be enumerated. Not that I am disposed to attribute the good effects observed to the fact of the fibres of the ciliary muscle having been divided, but because the wound made is of considerable size, and has a greater tendency to gape than when made through other parts of the globe,—thus allowing a drain on the contents of the globe to take place for some days, which effectually relieves the undue tension which exists, and allows the vessels to relieve themselves to a proportionate degree. The operation, moreover, in many instances, by dividing the extreme edge of the iris, establishes a communication between the anterior and posterior chambers, when these have, by closure of the pupil, become entirely separated. The operation is simply effected by entering the point of a Wenzel's double-bladed knife at a distance of about one-sixth of an inch from the margin of the cornea, and allowing it to penetrate about to the depth of two or three lines.

In other cases, iridectomy may be performed, and has proved extremely useful.

When the projection has become extensive, and is yet limited to one part of the cornea (fig. 34), it may be reduced by ligaturing the anterior portion in the manner proposed by M. Borelli,¹ which consists in transfixing the base with two needles, passed at right angles to one another, and surrounding the transfixed part with a firm silk ligature, which is prevented by the needles from slipping off. These last should be very fine, and may either be cut through close to the point of puncture, or may be brought outside the lid and twisted together. A light pad and bandage should be applied, and retained in position for three or four days; the ligatured portion then falls off, and a good stump remains for the application of an artificial eye.

In similar cases, Mr Tyrrell² states that he has successfully employed nitrate of silver and hydrate of potash, applying a fine point of these escharotics, and especially of the latter, to the base of the tumour, and gradually passing by successive operations towards the apex.

When the staphyloma is complete and extensive,—in such a case, for example, as is represented in fig. 36,—the one object in undertaking any operative proceeding is so far to reduce its volume as to permit the eyelids to close over it, and to allow of the application of a false eye. For when the swelling is very large, the extent of surface exposed to the influence of changes of temperature, and to the action of foreign bodies, is so great as to occasion the patient considerable and often-recurring annoyances. Inflammation is established by very slight causes, constant lachrymation is experienced, and the opposite eye, sympathising more or less in the irritation set up, renders operative interference requisite.

Several modes of treatment may be adopted, and, amongst others, the plan adopted by Mr Critchett of abscission answers very well. The lids being separated by specula, the eye

¹ *Compte Rendu du Congrès d'Ophthalmologie de Bruxelles.* 1858.

² *On the Diseases of the Eye*, vol. i. p. 273.

should be steadied by seizing the conjunctiva with forceps. Three or four needles, threaded with silk, are now to be made to transfix the eye, the points entering and emerging through the adjacent sound sclerotica. The staphylomatous projection is then removed by making an elliptical incision, or by transfixion with a double-edged knife; and the needles are now pulled through, and the edges of the wound brought together. Water-dressing may be applied, union soon takes place, and a very good stump is generally left.

When staphyloma is the result of accident, as from a blow with a chip of iron, followed by violent inflammation and suppuration within the globe, extirpation of the globe should be undertaken, especially if a wound be or has been present; as, in several instances in which I have removed the projection by abscission, it has been afterwards requisite to eradicate the entire globe, from the amount of pain and inflammation set up; and it has then been found that a particle of the foreign body (iron or stone) was imbedded in the remains of the lens, or in the vitreous, or in an organised and tenacious mass of lymph occupying the position of the lens.

9. *Neuro-paralytic Affections of the Cornea.*¹

The consideration of the effects produced by the paralysis or division of the fifth pair of nerves is of great interest in a physiological point of view, since it bears on the question of the existence of nerve fibres exercising a direct influence upon the nutrition of the tissues,—a question that can better be solved here than elsewhere, since the transparency of the cornea enables us to observe not only the superficial, but the more deeply-seated changes of structure that follow the

¹ The materials for this section have been derived from Longet, Schiff, and Budge's Physiologies; from v. Gräfe's Paper, in *Archiv. f. Ophth.*, p. 306, 1854-55; from that of Szokalsky, in Roser and Wunderlich's *Archiv. v. Jahrgang*, p. 214, quoted in Arlt, *Krankheiten des Auges*; from Dr Alcock's Essay on the Fifth Nerve, in the *Cyclopædia of Anatomy and Physiology*, vol. ii.

lesion of the nerve. That constant and well-marked alterations do occur in the parts supplied by it, is admitted by all, but the cause of these changes is explained upon different grounds by different experimenters. The chief phenomena that have been noticed where the nerve has been divided on one side by the introduction of a sharp-pointed style through the temporal fossa and base of the cranium, in the manner recommended by Majendie, are the following:—Immediately after the section, the globe appears to have lost all its sensibility; the iris in rabbits becomes strongly contracted and immovable, but in dogs and cats dilated; the vessels of the conjunctiva and iris rapidly enlarge, and the eye becomes unnaturally prominent; the tears cease to be secreted; the surface of the cornea becomes dry, dull, and non-reflecting; epithelial scales accumulate along the line of closure of the lids, especially near the centre of the cornea; very soon the inner surface of the lids becomes red and inflamed; the mucous secretion becomes more abundant, and so modified that it readily dries into crusts and scales, which glue the lids together; or if this do not occur, they remain widely separated and immovable, since the necessity for moisture and protection are not perceived. Even at so early a period as twenty-four hours after the division, the cornea begins to opacify near the centre, and on the third day it has generally acquired a well-marked yellowish hue, so as to obscure the changes occurring in the iris. Previously, however, to this taking place, the iris may be noticed to be inflamed, a false membrane forms on its anterior surface, and products of exudation may be seen floating in the anterior chamber. On the third or fourth day, the vessels begin to advance over the edge of the cornea, forming a well-marked circumcorneal zone, and soon afterwards an exudation occurs, raising the above-mentioned vascular zone gradually above the level of the cornea, so as to form a firm sarcomatous wall. About the sixth day, the cornea, which has been gradually becoming more

and more troubled, assumes a perfectly opaque and white colour, and the injection of the vessels of the conjunctiva and episcleral tissue continually increases; the white opaque cornea becomes softer, and incrustations of mucus cling to it, and these sometimes separating with portions of the superficial lamella of the cornea, give rise to appearances which have been described as ulcerations upon its surface. In the course of two or three days more the cornea detaches itself from the sclerotica at the circumference, and a penetrating ulcer forms at its centre, the fluids escape, and the whole bulb contracts to a misshapen stump or tubercle.

Longet observes that he has always found the lens and vitreous preserve their transparency; and both he and v. Gräfe remark, that though the pupil in rabbits is extremely contracted after the section, it will yet contract still further on exposure to a very bright light. v. Gräfe further states, that the pupil of the healthy eye undergoes no sympathetic or rather associated contraction when the eye of the affected side is exposed to a bright light, as indeed might have been anticipated from the absence of sympathetic contraction of the pupils in animals possessing lateral vision. Atropine, when instilled into the eye, remains for some time inoperative, or at most only hastening the accession of the spontaneous relaxation of the iris, which always occurs after from four to six hours. If the pupil be first dilated with atropine before the section is made, contraction still occurs. Longet noticed that the reflex act of winking, on exposure of the eye to bright light, was always performed, indicating the preservation of the functions of the optic and seventh pair of nerves.

The pathological changes above described do not take place with equal rapidity or intensity in all animals, being always more energetic in the young than in the old. If the trunk of the fifth is not completely divided, the eye may become completely insensible, and yet none of these symptoms of disturbance in the circulation and nutrition occur, or only in

an incipient grade. In other cases, where the partially-divided nerve began to regenerate itself and unite, Schiff observed that in every instance the disturbances of nutrition disappeared before the sensibility of the globe returned. He states also that, in man, cases of anæsthesia of the fifth nerve have been recorded without any disturbance of the nutritive functions, which he considers *proves that the nerves of common sensibility can be paralysed without any alteration taking place in the vasomotor nerves.*

Even at a very early period an objection was made to Magendie's observations as proving the existence of nerves ministering to nutrition, to the effect that the observed changes might be due to the loss of sensibility of the conjunctiva and diminution of the tears, which prevented the eye from perceiving the entrance of dust, or of protecting it by closure of the lids when requisite. But these objections were met by the counter arguments, first, that similar effects do not follow paralysis of the portio dura, though then the surface of the eye is similarly exposed, from inability of the animal to close the lids, nor even after total ablation of the eyelids, as was practised by Longet,¹ nor after extirpation of the lachrymal gland, though the eye is then much drier than is natural; and, secondly, that if such irritation as is supposed to be the efficient cause of the changes observed is prevented by sewing the eyelids together, the same morbid processes still take place.

Now, as in other parts to which the fifth is distributed, the effects observed after its division are only enlargement of the vessels, or, as in the case of the mucous membranes, some alteration in the character of the secretion, it seems natural to admit that we must seek for the more important changes which take place in the eye, in the greater delicacy of its structures, and in the consequent greater necessity, not only for the right state and composition of the blood, so ably

¹ Physiologie, vol. ii. p. 486.

pointed out by Mr Paget in his Lectures on Nutrition, but also for a due supply of that blood.

Hence it has been endeavoured to be shown, that the effects observed are in reality due to the loss of blood, and interference with the vascular supply, which is certain to be produced by an operation so severe as that by which the intra-cranial section of the fifth nerve is accomplished; whilst by others it is contended that the effects may be occasioned, not by injury of the fifth, but of the sympathetic branches which are in connection with the ganglion, since, if instead of dividing the nerve through the temporal fossa, and at the level of the semilunar ganglion, the section be made nearer to the origin of the nerve, the above-described symptoms are slower in their development, and much less marked. Schiff, however, states expressly that he observed no difference in the results of the operation, whether the nerve was divided in front of or behind the ganglion Gasserianum, and consequently does not hold with Bernard, that the vascular nerves take origin in this ganglionic enlargement. It is certain, however, that one or more branches of the sympathetic unite with the fifth at this point, and that the section of these fibres may account to some extent at least, if not altogether, for the enlargement of the vessels. Lastly, it has been attempted to be shown, especially by Snellen, that the lesions observed after section of the fifth do not proceed from within, or from any alteration of the nutrition of the part, but are due to the influence of injurious agencies acting from without; and he believes he has been able to show that, if the surface of the globe is very carefully protected from all sources of external irritation, the changes noticed as occurring in the cornea are often partial, limited, and comparatively slight. Even if this be true, however, there still seems reason for believing that the defective nervous supply causes the eye to be more inclined to disease, and to inflame under the operation of causes which would otherwise produce no effect. In

support of his theory, M. Snellen¹ gives the details of a case of kerato-conjunctivitis proceeding from paralysis of the fifth nerve, which was cured by the simple employment of protective measures. The redness of the conjunctiva and the troubling of the cornea disappeared after the eye was covered by a stenopœic shell, and after general means had been adopted to remove all mechanical causes of irritation. M. Snellen concludes his report of this case by observing, that *there is not the least reason to admit a direct influence of the fifth nerve on the ocular inflammation which supervenes in the paralysis of this nerve.* He adds a few words on the *great softness* of the ocular bulb in man after the paralysis or after the section of the fifth, a remarkable fact when compared with the hardness and the excessive tension of the eye in glaucoma, and which he thinks may lead some day to the discovery of another kind of influence of the fifth on nutrition, namely, that which it exercises on the secretion of the humours of the eye.

D. E. Junge¹ has also described a similar form of keratitis, concomitant with paralysis of the fifth, occurring in a child one-and-a-half years old. In this case the conjunctivæ were not much congested; the corneæ were hazy at the centre, and had lost their brilliancy, owing to irregularities of the epithelial layer. At the border of the corneæ were some opaque white deposits which could easily be removed, and consisted of epithelial cells. The corneæ gradually became dryer, resembling more and more xerophthalmos; the lachrymation was considerable. There was a diminution of sensibility in both corneæ, and over brow and temple. The child died from hydrocephalus, and the fifth pair on both sides was found to have undergone fatty degeneration.

¹ Annales d'Oculistiques, t. liii. p. 178. 1865.

² Microscopical Observations on Various Diseases of the Eye, Archiv. f. Ophth., Bd. v. ii. p. 191.

CHAPTER VII.

Diseases of the Choroid, Iris, and Vitreous.

GENERAL ANATOMY OF THE CHOROID, IRIS, AND VITREOUS—
IRIDEREMIA—COLOBOMA IRIDIS—MYDRIASIS AND MYOSIS—
EFFECTS OF ATROPINE AND OF THE EXTRACT OF CALABAR
BEAN—IRITIS: ITS SEVERAL FORMS, ITS CONSEQUENCES, AND
TREATMENT—MODES OF OPERATION FOR THE FORMATION OF
ARTIFICIAL PUPIL—CORETOMIA—CORELYSIS—IRIDECTOMY—
IRIDESIS—OPHTHALMOSCOPIC APPEARANCES OF THE CHOROID
—IRIDO-CHOROIDITIS—CYCLITIS AND SYMPATHETIC OPHTHAL-
MIA—CHOROIDITIS SEROSA OR GLAUCOMA—CHOROIDITIS
PLASTICA—VARIOUS MORBID CONDITIONS OF THE CHOROID.

1. *General Anatomy of the Choroid, Iris, and Vitreous.*

THE choroid is the vascular tunic of the eye. It occupies an intermediate position between the sclerotica and the retina. It is perforated by the optic nerve posteriorly, and is continuous with the iris in front. At its anterior part, and on its inner surface, it is thrown into a number of folds,—the ciliary processes,—and on the outer surface of the same part it is closely connected with the cornea and sclerotica by means of the ciliary muscle. Its internal surface is lined throughout, and its very substance is, so to speak, infiltrated with pigment matter and cells, giving it in many animals a black colour, but in man only a moderately deep-brown tint.

Externally it is connected with the sclerotic coat by a layer of delicate and highly-elastic connective tissue, termed the *membrana fusca*, consisting of fine fibres, connective tissue corpuscles, and a variable number of branched pigment cells. Coursing through this tissue, and often imbedded in the sclerotica, are the ciliary nerves supplying the iris and ciliary muscle.

The choroid is generally described as consisting of three layers of tissue,¹ the most external being *the choroid proper*, to which succeeds a *basement membrane* that is again lined by a layer of *pigment cells*.

The *proper choroid*, as shown in the figure on p. 248, is composed of two layers of vessels—an *outer*, consisting of the larger arteries (*c*) and veins (*x*), which, after dividing and subdividing, terminate in the *internal* or capillary layer (*d*), sometimes called the *chorio capillaris*. The arteries forming the outer layer, and supplying the whole of the choroid, as far as the *ora serrata*, are the posterior or short ciliaries (*a*). Anteriorly these form anastomoses with the long posterior ciliaries (*c*), and with the anterior ciliaries (*f*), which last perforate the sclerotica near the border of the cornea (11). The posterior ciliaries are from fifteen to twenty in number, and perforate the sclerotica in a zone immediately surrounding the entrance of the optic nerve, to which they give branches (*e*). The large veins (*x*), the tributaries of which are beautifully arched, forming the *venæ vorticosæ*, emerge at four or five openings in the sclerotica, situated about midway between the optic entrance and æquator of the globe. A part of the choroidal venous blood is, however, returned by the posterior short ciliary veins (*e*), by the anterior ciliary (5), and by the posterior long ciliary veins (10, 11, *b*). The arteries possess a thick circularly-arranged muscular-fibre coat, and are said by H. Müller,² whose observations are confirmed

¹ See Henle, *Anatomie des Menschen*, Bd. ii. p. 614. 1866.

² Würzburg, *Virchow*, Bd. x. Heft. i. p. 107.

by Schweigger,¹ to be accompanied on each side by longitudinal bundles of smooth muscular-fibre cells, which confer a contractile power upon the whole coat. The capillary layer (*d, d*) is an extremely close and delicate network of minute vessels, co-equal in extent with the retina, and formerly called the *tunica Ruyschiana*, after the anatomist who, by nice dissection, separated it from the more external or superficial and larger vessels with which it is continuous. In animals possessing a tapetum, the two vascular layers are really distinct, and are separated from one another by the tapetum; and this being perforated at definite intervals by branches from the outer layer, which immediately radiate and divide into capillaries, gives a kind of stellar arrangement to the latter, which is well shown in Mr Nunneley's drawings.² The capillary layer contains little or no pigment, but a considerable number of large, irregularly-branched pigment cells and masses lie scattered between the larger vessels of the outer layer.

H. Müller, Schweigger, and Bolling Pope, have described a close plexus of nerve fibres in the choroid proper, lying externally to the vessels. The fibres of this plexus are frequently varicose, and are for the most part pale and delicate, but numerous double-contoured ones may also be seen. They take origin in those branches proceeding from the ciliary ganglion, which are termed the short ciliary nerves. Interspersed amongst the nerve fibres are numerous ganglionic nerve cells, from which one or two prolongations are given off, and the number of the cells seems to stand in relation to the development of the muscular fibres.

The *Basal membrane* is transparent, structureless, and highly elastic, rolling inwards when detached. It bears upon its smooth internal surface a single layer of flattened hexagonal pigment cells. These contain a central transparent nucleus,

¹ Archiv. f. Ophth., Bd. vi. Heft. ii. p. 320. 1860.

² On the Organs of Vision, 1858. Plate IV., fig. 5.

around which, and especially on the retinal or inner side, a quantity of fine granular pigment matter is accumulated. The cells are connected with one another by a clear transparent material, but can scarcely be said to possess proper cell-walls. In the vicinity of the fovea centralis they are rather larger, more columnar in form, and contain more pigment than elsewhere. The forepart of the choroid, including that portion which extends, when viewed from within, from the termination of the retina or *ora serrata* to the tips of the ciliary processes and periphery of the iris, presents various points of interest. Just beyond the *ora serrata*, the choroid becomes thinner, and the vessels of the outer layer run parallel to one another in a stroma of fine connective tissue. On reaching the commencement of the ciliary processes (*pars striata*), they begin to divide and subdivide, and, ultimately uniting with the large and numerous ramifications of the anterior ciliary arteries, form the close capillary network of the ciliary processes themselves.

The term *ciliary processes* is applied to a number of folds projecting towards the centre of the eye from the anterior and inner part of the choroid, just behind the iris. Their number is from seventy to ninety or more, and some are more prominent than others. They contain much pigmentary matter, and are received into corresponding indentations in the hyaloid membrane and vitreous. The elevations and depressions of these two membranes together constitute the Zonule of Zinn, the position of which is indicated, when the two are forcibly separated, by the pigment of the ciliary processes remaining here and there attached to the hyaloid membrane, in lines radiating from the margin of the lens. Whether the pices of the ciliary processes touch the border of the lens or no, is a disputed point. M. Becker¹ states that at every age they are placed to the outer and anterior side of the edge of the lens, but do not touch it; and, further, that when the

¹ Ophth. Hosp. Rep., vol. iv. p. 306.

pupil contracts, either during accommodation or from the use of Calabar bean, the tips of the ciliary processes recede from the edge of the lens; and that when the pupil dilates, either during change of the optic axes and accommodation, or from atropine, they press forward towards the optic axis. Yet, even in the latter case, he maintains that they do not touch the lens, but lie between the iris and the lens, separated from the latter by a distinct space. He considers, moreover, that the size and projection of the ciliary processes stand in a certain antagonistic relation to the iris. If the pupil be small, the blood streams freely into the vessels of the iris, and the ciliary processes are small. If the pupil is dilated, the vessels of the iris are compressed, the circulation is impeded, and the ciliary processes enlarge.

The *iris* is a contractile diaphragm, placed nearly vertically in the aqueous humour. It is perforated, a little to the inner side of its centre, by the circular aperture constituting the pupil. It rests upon the anterior capsule of the lens throughout nearly the whole of its extent, and, following the curvature of that organ, is slightly arched forward. Whilst the central or papillary margin of the iris is free and unattached, the periphery is connected with the cornea and with the choroid—with the latter by direct continuity of tissue, and with the former by fibres proceeding from the posterior elastic lamina, which, forming small isolated bundles, separated from one another by minute intervals, run from the back of the cornea to the front and extreme margin of the iris, where they are lost. These fibres collectively constitute the *ligamentum iridis pectinatum*. The substance of the iris is made up of vessels arranged irregularly, two or three deep, lying in a stroma of connective tissue, with branched corpuscles, and possessing remarkably thick external tunics. The anterior surface of the iris is covered by a layer of cells,¹ though these are not always visible in the adult, and varies in colour from

¹ Arnold, Virchow's Archiv., Bd. xxvii. p. 366.

light to deep blue, olive green, and various shades of brown. According to Henle,¹ the colour of the blue iris, like the tapetum of the ox and other animals, is the result of the interference of light, and is produced by the peculiar arrangement of small spiculæ or rods, which are themselves colourless. The colour of the brown eye, on the contrary, is due to the presence of granular pigment, which is present in various quantity, and of varying intensity of colour, either in the superficial cells or distributed through the whole thickness of the iris. The posterior surface of the iris, termed the uvea, is covered by a layer of pigment cells of deep hue, which, projecting beyond the anterior margin of the iris, gives a crenulated margin to the pupil. Two sets of smooth *muscular-fibre cells* exist in the iris, a posterior radiating and an anterior circular set. The latter forms a tolerably well-defined zone, arranged concentrically in close proximity to the pupillary margin. The former are not very well defined in man, and are represented by a few small and scattered fasciculi, that are chiefly found near the periphery.

The *vessels of the iris* are partially derived from the short posterior ciliaries supplying the choroid (*d, d*, fig. L, p. 248), but chiefly from the long posterior ciliaries (*c, c*), aided by branches which perforate the sclerotica from the outside, and are the terminal branches of the anterior ciliaries (11, 12). The anastomoses of these vessels are very frequent and close, and it is to their arrangement that the peculiar markings observable on the front of the iris are partially due. It may be remarked of these, that they appear in most eyes to form two more or less well-marked zones, are internal, sometimes called the *circulus arteriosus iridis minor*, with radiating striæ; and an external, more irregular, called the *circulus art. iridis major*. The venous blood is returned by corresponding channels, but is partly discharged into the *canal of Schlemm*, from which the anterior ciliary veins take origin.

¹ Anatomie des Menschen, vol. ii. p. 631.

The iris is endowed with exquisite sensibility, pinching or laceration of its substance always occasioning acute pain. Its nervous supply is derived from the ciliary ganglion, which may here be briefly described. The ciliary ganglion is of small size, and forms a reddish mass, lying in the fat of the orbit, about a quarter-of-an-inch in front of the optic foramen, between the optic nerve and external rectus muscle. It is formed by the junction of branches from three nerves, with the addition of numerous ganglionic cells. The three nerves are a short and thick branch or root from the third; a long root, often double, from the nasal branch of the fifth; and one or two small branches from the sympathetic nerves surrounding the carotid artery. A small twig from the sixth has also occasionally been observed. The ganglion is of ovoid shape, and gives off from its anterior extremity ten or twelve filaments, called the *short ciliary nerves*, that pass forwards and penetrate the sclerotica near the optic entrance. On gaining the interval between the sclerotica and choroid, they traverse the fibres of the *membrana fusca*, to terminate partly in the choroid, but chiefly in the ciliary muscle and iris, though in what manner, whether in loops or free extremities, has not been quite satisfactorily determined.

In addition to these branches, the iris and ciliary muscle also receive the two *long ciliary nerves*, which take origin from the nasal branch of the fifth just after it has crossed the optic nerve. Whilst the short ciliary nerves are chiefly motor in their function, the long ciliaries are principally, if not exclusively, sensory branches.

The medium size of the pupil varies considerably in different eyes, in some not exceeding one-twentieth to one-thirtieth of an inch, and in others being as much as a quarter-of-an-inch in diameter. It is almost always larger in children than in adults; and the movements of the iris, with the play of light and shade, are in general much more active and extensive in young than in old people.

The contraction and relaxation of the muscular fibres entering into its structure, effecting the contraction and dilatation of the pupil, can only be induced in man by reflex action. This reflex action may, however, be called into play, not only by the incidence of light of varying intensity upon the retina, but also to a certain limited extent by or during accommodation of the eye for different distances. In many animals, however, and exceptionally in man, the power of exercising voluntary control over the movements of the iris is possessed. It may be well seen in some birds. In some of the lower animals, as shown by M. Brown Sèquard, the muscular-fibre cells of the iris, or the scattered nerve cells which enter into its formation, are capable of being excited by the direct action of light, since movements have been observed on exposure of the iris to bright light, even when the eye had been divided into an anterior and posterior half, and had long been removed from the body.¹

The contraction of the two irides takes place consensually in the healthy eye, so that if one eye alone be exposed to light, the other, though shaded, also contracts. According to Listing, the sympathetic contraction commences about two-fifths of a second after exposure of the opposite eye to light, and lasts about one-fifth of a second. According to Wecker,² the whole time occupied in consensual contraction of the right pupil, after suddenly opening the previously closed left eye, and in dilatation of the right pupil after occlusion of the left eye, is about six seconds.

The vitreous humour constitutes the greater part of the eye, and fills up all the space between the lens, which is received into a depression on its anterior surface and the retina. Chemically, it is composed of water, with rather less than two per cent. of solids. It is enclosed by a delicate sac, termed the hyaloid membrane, which is in contact externally

¹ See Brown Sèquard, *Journal de l'Anatomie*, t. ii. 1859.

² *Etudes Ophthalmologiques*, t. ii. p. 860.

with the retina, and is, according to Ritter, lined on its internal surface by a single layer of epithelial cells, of polygonal form and finely granular aspect, that separates it from the vitreous itself. The cells are only deficient at the part corresponding to the posterior capsule of the lens.

The adhesion between the hyaloid membrane and the retina is firm at the entrance of the optic nerve and at the ora serrata, but elsewhere they may be easily separated from one another. In the greater part of its extent, the hyaloid membrane is perfectly clear and homogeneous, but at the ora serrata it increases in thickness, and presents a fibrous character, the fibres resembling those of elastic tissue. At the posterior part of the ciliary processes, it divides into two layers; one of these separates from the external tunics, curves forwards and inwards towards the back of the lens, and after forming the posterior wall of the canal of Petit, lines the deep fossa into which the lens is received, when it again becomes transparent and homogeneous, the fibres being for the most part attached to the posterior surface of the capsule. The other layer continues forwards till, having arrived at the tip of the ciliary processes, it also is reflected inwards, forming the *ligamentum suspensorium lentis* and the anterior wall of the canal of Petit. The fibres, which are more numerous than the former set, are attached to the anterior surface of the capsule, and pursue a less regular course than those just mentioned; for, springing from the ciliary processes, they are attached to the margin of the lens, and, by dividing the canal of Petit with irregular septa, confer upon it that moniliform character which it presents when injected with air or coloured fluids. The divisions of the hyaloid membrane just described are collectively known under the name of the Zonule of Zinn. According to Henle, the fibres are quite peculiar, being flat, smooth, transparent, well-defined at their edges, and of very various diameter. Dr Hjalmar Heiberg,¹ how-

¹ Archiv. f. Ophthalmologie, Bd. xi. Heft. iii. p. 168. 1865.

ever, who has recently devoted much attention to them, considers that two varieties may be distinguished, one of which divides both anteriorly and posteriorly into numerous anastomosing fibres, whilst the other is *transversely striated*, and appears to be of the nature of muscular fibres. The latter variety is not well-marked in man, but is very distinct in the horse and some other mammals; and M. Heiberg believes that these fibres fulfil the important function of flattening the lens by their contraction, and that they thus constitute the active agents in the accommodation of the eye for distant objects. Weber¹ describes a third set of fibres which are situated more posteriorly than either of the foregoing, and which form the boundaries of a circular sinus, called the canal of Hannover, which lies just behind the canal of Petit.

The structure of the vitreous itself has not yet been fully elucidated, though much laborious microscopical investigation has been expended upon it. By Virchow, whose opinions are shared and supported by Donders, Doncan, and Weber, the vitreous has been included in a class of tissues of very limited extent and simple composition, to which he has applied the term "mucous," and of which the tissue of the umbilical cord affords another good instance in man. Both of these textures he regards as consisting of a network of fibres proceeding from connective tissue corpuscles which are scattered through its substance, the interstices being filled with a glairy fluid. Others, however, as Coccia and Ritter,² consider that the cellular elements are not disseminated through the substance of the humour, but only exist as an epithelium lining the investing membrane; whilst others, again, as Brücke, have been unable to perceive any cellular elements whatever. Here, however, as in other instances, negative must yield to positive testimony, and the evidence

¹ Virchow's Archiv., Bd. xix. p. 367. 1860.

² Archiv. f. Ophthalmol., Bd. xi. Heft. i. p. 99.

of M. Iwanoff¹ on this point seems to be decisive, especially since it receives confirmation from the changes observed in disease. He has described three forms of cells as being natural constituents of the vitreous. The first are small and round, with the cell-wall closely applied to the nucleus, their number diminishing with advancing age; the second form are stellate, with moniliform prolongations, and these are numerous at all ages, often contain two or three nuclei, and possess very granular contents; the third form, termed "physaliphores," by Virchow, are large cells containing one, two, or more small clear and rounded vesicles. These cellules may be regarded as the organs by which the peculiar mucous tissue of the vitreous is generated, and they have been observed to present remarkable amæbiform movements even for an hour after removal from the living body. Many attempts have been made to exhibit a definite lamellar or trabecular structure in the vitreous, by soaking it in solutions of various kinds; and M. Coccia² has particularly insisted on the differences presented by the aqueous and vitreous humours on congelation, as affording evidence of structure in the latter; for whilst the aqueous presents a perfectly homogeneous mass of ice, the vitreous is marked by numerous fine transparent and ramified striæ. Still no true septa or membranous divisions have been satisfactorily seen, and it does not seem improbable that the isolated fibres and shreds of connective tissue which may now and then be detected, are merely the remains of the capsular artery—a small vessel which in foetal life runs from the arteria centralis retinae to the posterior surface of the capsule.

M. Iwanoff states that, even with the utmost care, he has been unable to discover any cells with *anastomosing* prolongations analogous to those described by Weber and Virchow, nor has he been more fortunate in observing the layer

¹ Ann. d'Ocul., p. 114. 1865.

² *Idem*, p. 56. 1865.

of epithelial cells described by Ritter as lining the hyaloid membrane. The peculiar viscosity of the vitreous, and the manner in which, when divided, it gradually subsides, affords strong evidence of the presence of membranous septa, dividing it into spaces that intercommunicate with one another, and are filled with a fluid—a structure not dissimilar to that known to exist in the medusæ. It must be admitted, however, that the whole subject is open to further investigation.

DISEASES OF THE IRIS.

The iris is occasionally congenitally deficient, a condition that is termed *irideremia*, and the defect may be hereditary. I saw a man in whose eyes no iris could be observed, and in whom capsulo-lenticular cataracts had slowly formed. Both globes oscillated to a small extent. In one of his daughters the same conditions existed. Absence of the iris is almost always accompanied by dimness of vision, from the retinal images not being well defined. M. Hulme has given a good description of an instance that fell under his notice.¹ The cornea and sclerotica were here healthy, but both lenses had capsular opacities. The globes oscillated, but vision was sufficiently good to enable him to read No. 6 of Jäger's Test Types, and to follow his occupation as a sailor.

A slit or fissure is also occasionally present in the pupillary margin of the iris, giving the pupil a pear or guitar shape. Such a condition is termed *coloboma iridis*. The deficiency is generally single, and situated at the lower border; but there may be two or three fissures, though they are then usually only of small size, and do not extend to the periphery of the iris. The condition of coloboma may be induced by accident, and is always produced in the operation of iridectomy.

¹ In the forty-fourth vol. of the Med. Chirurg. Transactions.

It has been shown by v. Ammon¹ that congenital coloboma is the remains of a foetal fissure of the sclerotica, choroid, and retina; and, indeed, in many instances the deficiency of the choroid can be shown to be persistent with the ophthalmoscope. In such cases the sclerotica usually presents a staphylomatous protrusion of greater or less extent, with well defined borders, and, in consequence of the deficiency of the choroid and retina, reflecting light strongly of a white or greenish colour. In a case described by Arlt,² the place of the choroid and retina was occupied by a delicate membrane, which lined the interior of the protrusion; the ciliary processes just anterior to it were drawn to one side and backwards, and were stunted in their growth, and a linear raphe was traceable from the anterior border of the ciliary muscle to the forepart of the protrusion. The retinal vessels can always be seen in strong relief against the white ground formed by the atrophied part, and are usually straight, as though stretched.

The pigment of the eye is sometimes deficient, as in albinos, giving it a peculiar reddish appearance, such as is seen in white mice or rabbits. The difficulty such persons experience in seeing during the bright light of day, is an excellent proof of the value of the pigment in diminishing or preventing the frequent reflection of light in the interior of the eye. It has been noticed by many observers that here, as in the case of deficiency of the iris, there is a remarkable tendency to the formation of cataract. There is also an hereditary predisposition to its occurrence.

Up to the seventh month of intra-uterine life, the pupil is closed by a membrane, which originally intervened between the lens and the cornea, and closely invested the former. It is supplied by vessels derived from those of the iris, with the anterior surface of which it is connected. Instead of atrophy-

¹ Archiv. f. Ophth., vol. iv. 1858.

² Krankheiten des Auges, Bd. ii. p. 121

ing and becoming absorbed, it occasionally remains till after birth, and is then termed persistent membrana pupillaris, and appears as a grey, thin, striated membrane, in which vessels may or may not be traceable. If it exist in one eye only, no treatment is required; nor would it be wise to interfere when it is thin and delicate, even if it exist in both. If, however, it seriously interfere with vision, the membrane and lens must be broken up with needles; or an iridectomy may be performed, with the view of obtaining an artificial pupil through the clear margin of the lens.

Mydriasis and Myosis.—In certain pathological conditions, and under the influence of belladonna, hyoscyamus, or stramonium, the pupil becomes widely dilated, no longer responds to variations of light and shade, and the condition termed *mydriasis* is established. It is the result of the complete relaxation of the sphincter, accompanied by the contraction of the dilatator pupillæ. On the other hand, in some forms of disease, and under the influence of opium, nicotine, and notably of the Calabar bean, the action of the circular preponderates over that of the radiating muscular fibres of the iris, the pupil is reduced to a minute point, and the condition termed *myosis* is said to be present.

The contraction of the pupil is induced by excitation of the third nerve; very feebly, also, by excitation of the ophthalmic branch of the fifth, and occasionally by excitation of the sixth.

The dilatation of the pupil is effected by stimuli conveyed through the branches of the sympathetic nerve.

In reference to the action of belladonna, it appears from the observations of Donders and Kuyper that a solution of atropine, which is the active principle of the plant, when dropped into the eye, begins to act in fifteen minutes, the pupil attaining its maximum of dilatation in from twenty to twenty-five minutes. In forty-two hours the pupil is rather smaller, but a slight increase in its diameter may be perceived

even after the lapse of thirteen days. The strength of the solution used was about four grains to the ounce. With stronger solutions the action is still more prolonged; with weaker, it is more tardy in making its appearance, and is much less persistent; but, even with a very weak solution, the amount of atropine not exceeding one-fifth of a grain to an ounce, very complete, though transitory, enlargement of the pupil will be produced. That the active principle really undergoes absorption, is shown by the fact that a little of the aqueous humour, carefully withdrawn from an eye, the pupil of which is dilated with atropine, and dropped into the eye of another animal, will here also occasion dilatation of the pupil.¹

An important effect of the instillation of atropine into the eye was pointed out by Dr Schnellen,² viz., that it paralyses the ciliary muscle and the accommodation of the eye, causing near objects to appear misty, but not interfering with the vision of distant ones, except in so far as the dilatation of the pupil permits the entrance of too great an amount of light, and favours the formation of circles of dispersion. The loss of the power of accommodation begins to take place a little while after the commencement of the dilatation of the pupil, the near point gradually receding, till, at the expiration of an hour and forty-three minutes, it is identical with the remote point. Another remarkable effect sometimes observed to follow instillation of atropine, is that all things appear smaller than natural (micropsy);³ ordinary handwriting, for instance, looking microscopical, the clothes of an adult like those of an infant, and persons of ordinary stature appearing like dwarfs. The cause of this is, according to M. Wecker,⁴ that the visual angle does not augment when efforts at accommodation are made. The field of vision, owing to the larger amount of light admitted, is generally brighter than natural.

¹ v. Gräfe. ² Archiv. f. Ophth., Bd. iii. Heft. ii. p. 160.

³ See Warlomont, Annales d'Oculistiques, p. 277. 1853.

⁴ Etudes Ophthalmol., vol. ii. p. 875.

As regards the action of the extract of the Calabar bean, it has been shown by Dr Argyll Robertson and Donders, that it begins to act in from five to ten minutes, attains its maximum in from thirty to forty minutes, begins to diminish at the end of three days, and that its effects have entirely disappeared at the end of four days.¹ v. Gräfe remarks that, after the instillation of a solution of the Calabar bean, the visual field appears rather darker than natural, and the sharpness of vision is somewhat diminished. It interferes with the accommodation of the eye, diminishing its extent by approximating both the near and far points to the eye—in other words, inducing a myopic condition equalling $\frac{1}{4}$. This, however, is but transitory, not lasting more than two or three hours. Dr Argyll Robertson has observed that it causes objects to appear larger than natural (macropsy), which probably admits of an analogous explanation to that above given for the micropsy observed in atropinized eyes.

The precise mode in which these mydriatics and myotics affect the dilatation or contraction of the pupil, has not been quite satisfactorily cleared up even at the present time. As it has been ascertained that the sphincter pupillæ is called into play by the third nerve, whilst the dilatator is under the influence of the sympathetic, it would appear easy to explain the phenomena observed, by considering that the action of atropine is to paralyse the extremities of the third nerve and splenectic muscle, permitting the sympathetic nerve to exert an unopposed action in dilating the pupil; whilst the Calabar bean paralyzes the sympathetic nerve, and consequently renders the dilatator inactive. This view is indeed held by the most recent observer, M. J. Bernstein.² Nevertheless, it

¹ See Dr Argyll Robertson's Pamphlet, and Ophth. Hosp. Rep., vol. iv. p. 38; v. Gräfe, Archiv. für Ophth., Bd. ix. Heft. iii. p. 87, 1863; and Dr Soelberg Wells, Med. Times and Gaz., 1863.

² Zur Irisbewegung, in Henle and Pfeuffer's Zeitschrift für rat. Med., Bd. xxix. Heft. i. p. 35. 1867.

does not appear to satisfy all the conditions of the case, and, in particular, is not capable of explaining the observation of v. Ruete, who found that in complete paralysis of the third nerve, with dilatation of the pupil, the instillation of atropine caused further dilatation. The only mode in which this can be explained, seems to be by admitting that the atropine not only acts as a paralysing agent upon the third nerve, but exerts a stimulating effect upon the sympathetic; and, by going a step further, we might even suppose that it exerts no paralysing agency at all upon the third, but only a powerful stimulant action on the sympathetic. So with Calabar bean we may hold that it simply paralyses the sympathetic, or that it both paralyses the sympathetic and excites the third nerve; or, lastly, that it has no action on the sympathetic, but only excites the third. All these views have in fact been maintained by different observers. Thus Bernstein and Dogiel¹ consider that the action of the Calabar bean is exclusively exerted in producing paralysis of the sympathetic nerve, and therefore of the dilatator muscle. Rosenthal, on the other hand, maintains that, though essentially paralysing the sympathetic, it yet exerts a stimulant action on the third nerve; in proof of which he urges (1.) that excitation of the sympathetic can only induce a very small, if any, expansion of a pupil contracted by Calabar bean; and (2.) that, after previous paralysis of the sphincter by the instillation of atropine, the introduction of Calabar bean will cause the pupil to become of about a medium diameter. Robertson and v. Gräfe appear to hold the same opinion, the latter observing that it scarcely seems possible to explain the occurrence of so great a degree of myosis as actually occurs, without admitting that the third nerve and sphincter muscle are also excited to action.

Grünhagen and Rogow, again,—the latter of whom is the

¹ See the essay of Dr Rogow, "On the Action of the Extract of Calabar Bean and of Nicotine upon the Iris," in Henle and Pfeuffer's *Zeitschrift*, Bd. xxix. p. 1. 1867.

latest authority on the subject,—attribute the action of Calabar bean exclusively to stimulation of the third nerve, and doubt the occurrence of any paralysis of the sympathetic at all. In a series of experiments undertaken with nicotine, Rogow found that this, the active principle of tobacco, which likewise produces myosis, acts in a different manner from Calabar bean, and that, as is the case with creasote, nitrate of silver, and some other agents, it acts primarily upon the branches of the fifth, distributed to the cornea and conjunctiva, and therefore reflectorially through the third upon the sphincter, without occasioning any paralysis of the sympathetic; but as soon as absorption has taken place, paralysis of the sympathetic, occasioning still further contraction, is secondarily produced.

On the whole, the probability seems to be in favour of the view which attributes to atropine and Calabar bean a double action, each of these remedies paralysing one and stimulating the other nerve—atropine paralysing the third and stimulating the sympathetic, and Calabar bean paralysing the sympathetic and stimulating the third nerve.

The influence of the *fifth nerve* on the pupil has not been very satisfactorily determined. The ophthalmic division of the fifth, from the nasal branch of which the long root to the ciliary ganglion is supplied, contains, so far as is known, only sensory fibres; consequently any contraction of the pupil which follows its irritation must be of a reflex nature, and must take place either through the third, in inducing contraction of the sphincter, or, which is less likely, through the sympathetic, in paralysing or producing an inhibitory effect upon the dilatator. There seems to be reason for supposing that this reflexion takes place in the ciliary ganglion, where the branches of the fifth are probably in communication with the other nerves, and not in the great nervous centres, since the contraction still occurs when the trunks of both the third and sympathetic nerves are divided.

It has already been stated that mydriasis and myosis are occasionally met with in association with certain pathological conditions. The chief of these, observed to precede or accompany *mydriasis*, are compression of the brain, syphilitic taint of the constitution, and debility, however produced, whether by loss of blood, by inanition, or by disease. As a result of the latter causes, it may often be seen in typhus and in diphtheria. It is commonly observed also in cases where the third has been paralysed, either by the action of cold, or by a violent blow upon the eye. It accompanies and is one of the most important symptoms of increased intra-ocular pressure, such as is observed in glaucomatous affections. It is a frequent concomitant of amaurosis, or loss of sensibility of the retina.

It may also result from any cause stimulating the sympathetic. Such irritation is very frequently occasioned by the presence of worms in the intestinal canal. According to M. Wecker, the dilated pupils of hysteria, epilepsy, and certain forms of monomania (ambitious) are to be referred to the same condition. Where the affection is idiopathic, and is unconnected with retinal disease, appearing to arise from cold, debility, or exhaustion, the usual symptoms complained of are, that there is more or less dimness of vision in the affected eye, especially for near objects, arising from a loss of the power of accommodation, and from the occurrence of circles of diffusion. This symptom is much more prominent in normal, and yet more in hypermetropic eyes, than in those that are myopic. In the latter, the near point coinciding with the remote is attended with little or no inconvenience; but in the former, remote objects can alone be seen with distinctness. There is usually little or no pain, nor any redness of the eye; but the pupil is moderately or considerably dilated, and quite insensible to the direct action of light. It has appeared to me to occur with unusual frequency in those who have been recently married, and in such cases is probably de-

pendent upon debility consequent on excessive sexual intercourse.

The treatment consists in paying attention to the general health by the administration of tonics, purgatives, or alteratives, according to circumstances. The forms resulting from exposure to cold, and from debility, spontaneously, though very slowly, disappear, the pupil being sometimes visibly dilated, and responding sluggishly to the action of light for a period as long as a year after the original attack. For the specific form, cinchona and the bichloride of mercury, calomel and opium, the iodide of mercury, or the iodide or bromide of potassium, may be prescribed. Worms should be expelled by injections of turpentine and castor-oil, or by the administration of the oil of male-fern, kousso, or santalin. In some instances, advantage will be obtained by the local employment of the solution in glycerine of the extract of Calabar bean; and, in others, stenopœic glasses may be used.

The following case will show the tedious and protracted course which this affection pursues, the inefficacy of a variety of remedies upon its progress, and the ultimately favourable termination it sometimes offers:—

A gentleman, previously in perfect health, was compelled to work in an office undergoing repair, where he was exposed to strong draughts of air. After a few days he experienced a feeling of mistiness in the left eye, unaccompanied by pain or other inconvenience. The pupil was dilated to about double the size of that of the right eye, the media were clear, and the fundus healthy. There was no strabismus, nor was double vision complained of. The iris was quite immovable, both when directly and when sympathetically excited through the right eye. Distant objects could be discerned clearly enough; but he was unable to read ordinary print with the left eye, on account of the confusion and running together of the letters. He was ordered a blister behind the left ear, a purge of calomel and colocynth, and a solution of bicarbonate

of potash, with tinct. of hyoscyamus. No improvement following this treatment, he was placed on calomel and opium for ten days, at the expiration of which time the gums were slightly tender, but the pupil was as large and as fixed as before. It was now ascertained that he had been recently married; and instead of attributing the affection to cold and to the inflammatory condition of the third or of the ciliary ganglion, it was considered that it might arise from debility. The treatment was accordingly exchanged for cinchona, general tonic measures, and a liberal allowance of wine. This plan, carried out for a fortnight, though it improved his general health, caused no change in the condition of the eye. An examination of the teeth was now made, and two carious stumps in the upper jaw of the left side, with a badly stopped tooth, which was frequently painful, were directed to be removed. The carious canine was found to have a large sac at its root, and its removal occasioned a copious gush of tears. Cinchona and strychnia were then ordered, after which the patient, finding himself in no wise better, ceased to pay any further attention to the eye. About a year afterwards, I saw him again, and found that the pupil had regained its normal size, and, though it still reacted sluggishly to light, vision was good.

The pathological conditions under which *myosis* is established are less accurately known, but it is believed to be commonly associated with serious disease of the sympathetic system. It has been observed also in the early stages of locomotive ataxy and of meningeal inflammation. The treatment must depend upon the nature of the cause, when this can be discovered.

Remarkable alternate contractions and dilatations of the pupil are occasionally observed, and have been described under the term of *hippus*.

2. *Iritis. Inflammation of the Iris.*

(PLATE VII., Figs. 38-48.)

Inflammation of the iris is rightly considered one of the most important diseases to which the eye is liable, not only because its regular and uniform march leads, if unchecked by treatment, invariably to impairment, and often to total loss of vision, but because, while its strongly-marked features render its diagnosis comparatively easy, great and permanent amelioration of all the symptoms may be effected, both in its earlier and later stages, by well-directed medical and surgical treatment. Under these circumstances, it is surprising to find that, as Mr Lawrence observes, it had scarcely been recognised or described in treatises on ophthalmic surgery before the commencement of the present century. It occurs at all ages, though more frequently in adults than in children, and appears to be more common in men than in women. It is not usual to see both eyes affected coincidently.

The subject of iritis may be discussed in various ways. English writers, Mr Lawrence and Dr Mackenzie for example, giving in the first instance a general description of the disease, and then referring to the characters it presents in different constitutions, as the syphilitic, arthritic, and scrofulous; whilst M. Wecker, in common with Professor v. Gräfe, and some other authorities, classifies the forms of the affection upon a physiological basis, and divides it into simple or plastic iritis, serous iritis, and parenchymatous or suppurative iritis, of which last he considers syphilitic iritis to be a variety.

In pursuing the former method of considering the subject, it must be remembered that the differences observed in the several forms are quite subsidiary, and only present slight modifications of the broad and characteristic features of the disease; and that, though we might suspect, it would be scarcely possible, from an inspection of the eye alone, to be

certain of the existence of any particular constitutional taint. Nor does such knowledge, even when actually obtained, materially modify the treatment.

In the latter method, it seems doubtful whether the several forms can be satisfactorily diagnosed from one another.

In pleurisy, few pathologists would rank as distinct forms that in which serous fluid is poured forth abundantly, and that in which a fibrinous exudation occurs, since the proportion between these two products varies in every possible degree, and certainly only modifies the treatment secondarily and to a minor extent.

In the following observations, the leading features of the disease will be fully described, and the peculiarities presented by rheumatic, syphilitic, and strumous iritis lightly sketched.

The structures essentially engaged in the inflammatory process in iritis are the connective tissue corpuscles of the stroma of the iris. These, especially in the neighbourhood of the vessels, divide and multiply, and often also become granular, and undergo a process of fatty degeneration, or become converted into pus cells, or develop into new tissue of a low type of organisation (areolar, fibrous, or cellulo-fibrous). Besides the connective tissue cells, however, the pigment cells of the iris and the smooth muscular-fibre cells play a subordinate part, and undergo various pathological changes, the former becoming increased in size or atrophied, and either unnaturally deep in colour, or free from pigment, or filled with fatty molecules. The latter also not unfrequently undergo fatty degeneration, whilst finally the intercellular substance becomes, in almost all instances, the seat of serous or fibrinous effusion, followed by fatty degeneration.

It is difficult to say what is the first symptom observable in an attack of iritis, but one of the first is unquestionably a *change in the colour and appearance of the iris itself*. (See fig. 39, Plate VII.) The natural markings on its surface become, in consequence of the serous infiltration and swelling

of the tissue, blurred and indistinct, the colour undergoing such an alteration that, in the case of blue eyes, it becomes grey, muddy grey, dull olive green, or bright green in tint; and in the case of brown eyes, varying from a dull or deep brown to a rusty red hue. This discoloration appears to be due, on the one hand, to the congestion of the vessels of the iris, which in fact may sometimes be seen with the aid of a lens advancing upon the surface, and dividing near the border of the pupil; and, on the other, to incipient fibrinous deposit, and to a partial transudation of the colouring matter of the blood delayed in its transit through the vessels which, staining the aqueous of a yellow tint, alters the colour of the objects seen through it.

At a very early period, also, a *circumcorneal zone of blood-vessels* becomes apparent, occasioned by the congestion of the anterior ciliary arteries. These are extremely fine and delicate branches, which, pursuing for the most part a radiary direction, confer a delicate pink tint on the sclerotica at this part (*see f* and 5, fig. L. p. 248). Somewhat later in point of time, the conjunctival vessels, easily known by their larger size (*o, p*), more superficial position, brighter tint, greater tortuosity, and more frequent anastomoses, become congested, and occasion more or less chemosis and general redness of the globe of the eye.

The pain in cases of iritis varies considerably in degree, the progress of the disease being, in some instances, so insidious, that the inflammatory condition is wholly overlooked by the patient; whilst in others, it is of a severe aching, throbbing, or lancinating character. In rheumatic cases it is generally tensive, nocturnal, and severe, and extends over the temple, brow, nose, and cheek. Exacerbations and remissions are common in all forms of the disease. The differences observed are probably due to differences in the physical constitution and nervous irritability of the patient.

The pupil is generally much contracted, and presents but

little play of movement on the admission or obstruction of light. On the instillation of a drop of atropine, or on the application of belladonna to the brow, it may often be remarked that, though no adhesions are present, and considerable dilatation succeeds, yet that the enlargement does not take place with equal facility in every direction (fig. 37); the margin of the pupil consequently presents more or less irregularity, which may be explained on the supposition that the congestion, or possibly the exudation present, is not sufficient to hinder altogether, but only to impede at certain parts, the action of the dilatation and of the sphincter papillæ.

Amblyopia, or dimness of vision, is always complained of to a greater or less extent, objects appearing with dark and misty outlines. This condition is probably attributable to the disturbance of the circulation in the irido-choroidal vessels, which produces turbidity of the aqueous, and perhaps even of the vitreous humours, with impairment of the power of accommodation. In addition to the amblyopia, *intolerance of light*, causing the patient to keep the eye partly closed or covered with the hand, and *lachrymation*, are almost constant symptoms. They are both in all probability of a reflex character, and are occasioned by the hyperæmic and excited condition of the retina, to which also may be attributed the contracted condition of the pupil generally observable at the commencement of the attack.

As the disease advances, all the symptoms become more marked, the circumcorneal zone of redness becomes more pronounced, the pain more intense, the alteration of colour, especially in the inner circle of the membrane, more evident, the surface of the cornea dull, and the impairment of vision so great, that the hand or any moving object can be distinguished only at the distance of a few feet. In robust and florid patients, febrile symptoms are often present, the tongue being furred, the bowels confined, the appetite lost,

the skin hot and dry, with watchfulness and thirst, and frequent pulse. Under favourable circumstances, and with judicious treatment, resolution of the inflammation may easily occur at this stage, and in a few days all signs of disease will have passed away. But, if neglected, a variety of morbid conditions are apt to be produced, each of which requires special attention to be devoted to it. In the first place, some small vessel having given way, blood may occasionally be found to have gravitated to the bottom of the anterior chamber, an appearance which has been termed *hyphæma*. More frequently pus cells are developed at or near the surface of the iris, or from the membrane and cell-layer lining the posterior surface of the cornea, and becoming diffused through the aqueous, render it turbid, or, if more abundant, collect at the lower part of the anterior chamber, between the cornea and iris, forming a layer or smaller *hypopyon*. A still more common result of the inflammatory process is the production of what used to be termed fibrinous exudation on the surface, and usually near the pupillary margin of the iris.

This sometimes appears as a single warty growth (fig. 40); at others as a series or chain of such growths surrounding the pupil, and projecting into the anterior chamber. In other instances, again, it appears rather to rise from the surface of the iris near its periphery, or to infiltrate its substance, causing the membrane to appear greatly thickened, and wholly preventing it from acting under the influence of light, or even under that of strong solutions of atropine, or of Calabar bean. Sometimes the outgrowth occupies the pupillary aperture, appearing as though it partly originated from the anterior surface of the capsule of the lens. It then forms a whitish or greyish mass, which rapidly abolishes vision, and subsequently, by its contraction, causes the edge of the iris to adhere to the capsule, diminishing the pupil to a point, or obliterating it altogether; whilst finally, in many instances, it is chiefly accumulated behind the iris, glueing it to the

capsule of the lens, and constituting the condition known as *synechia posterior*, or exclusion of the pupil.

It would appear, from microscopical investigation, that these outgrowths consist of a structureless, finely granular, or radially striated matrix, in which are present a considerable number of delicate capillary vessels, cells, nuclei surrounded by blastema but not possessing a cell-wall, and other cell-like structures.¹ The latter are, for the most part, strongly charged with pigment, sometimes of quite irregular form, partially ramified, and of variable size; at others, strictly analogous to the ordinary stroma cells of the iris. Small heaps of pigment molecules may also be found scattered through the matrix. Similar structures may be found in every part of the substance of the iris. The newly-formed vessels may often be seen in the granulations, conferring upon them a yellowish, brownish, rust-coloured red, or rosy appearance (figs. 39 and 40). The granulations themselves give the impression to the eye of being composed of a soft, pulpy, or semi-gelatinous tissue, the edges being softened off, translucent, and of a lighter hue than the rest of the mass. In unhealthy subjects, the newly-formed growths quickly increase in size and coalesce (fig. 41), sometimes extend over one-half of the iris, or project forwards till they nearly touch the cornea. Under these circumstances, the central cells sometimes break down or degenerate into pus, and an *abscess of the iris* is thus formed, which, bursting, may discharge its contents into the anterior chamber.

Far more frequently, however, the lymph thrown out in front of or behind the iris causes this membrane to adhere either to the cornea or to the capsule of the lens. When the iris is adherent to the cornea, the condition is termed *synechia anterior*; but where, as is much more common, the posterior surface of the iris has formed adhesion with the capsule of

¹ See case of v. Gräfe, examined after extirpation by M. Colbey, *Archiv. f. Ophth.*, Bd. viii. p. 288.

the lens, it is named *synechia posterior*. The attachment thus produced may, in either case, be partial or complete. When it is partial, the instillation of atropine causes the pupil, which may previously have appeared quite circular, to assume a great variety of forms. It is then seen that certain parts of the pupillary margin of the iris are bound down by bridles or tags of adhesion, which are put strongly upon the stretch by the contraction of the dilatator. When the adhesion is complete, the instillation of the atropine fails to produce any alteration in the size of the pupil.

Even in the most favourable cases, when complete recovery has taken place after an attack of iritis, the eye long remains irritable, and subject, on slight exposure to cold or to any other exciting cause of inflammation, to a recurrence of all the symptoms; but the presence of adhesions, such as have just been described, are peculiarly adapted to render the eye liable to frequent attacks of inflammation, for since the iris of the affected eye strives to contract or dilate according to the amount of light which plays upon it, or sympathetically with the amount of light entering the healthy eye, a constant strain is exerted upon the tissues of the diseased iris. So long as these attachments are few and small, permitting free communication to take place between the anterior and posterior chambers, no bad effects may be perceived; but when the occlusion of the pupil is complete, or an annular adhesion of the iris to the capsule of the lens is present, so that the communication between the two chambers is shut off, inflammatory attacks are of constant occurrence. The iris is then often found to form a funnel-like depression, or, in some instances, to form a projecting ring around the margin of the pupil, the middle part of its plane being arched forwards, a condition termed *iridauxesis*, and due apparently to the accumulation of fluid in the posterior chamber. In such cases, as well as in those where the aperture of the contracted pupil is closed by a plug of lymph, a condition termed *atresia*

iridis, the supervention of iritis and of irido-choroiditis, is eminently likely to ensue. In a few happily rare cases, the disease may still pursue a further course; the whole anterior chamber may become filled with fibrinous deposit, violent general inflammation of the eye, or panophthalmitis may supervene, accompanied with the most intense pain, the development of pus in the interior of the globe, sloughing of the cornea, followed by the evacuation of the contents of the globe, and its collapse into an irregular button.

In other cases, when the inflammation of the iris has been less severe indeed, but more protracted, its tissue becomes atrophied, its tension is diminished, so that it trembles or flutters in the aqueous humour, a condition that is termed *iridodonesis*. It then often approximates the cornea, and for a while is tender and friable, easily breaking down and tearing when seized by the forceps. At a later period, however, fibres of almost tendinous firmness form in it, which, according to Stellwag v. Carion,¹ present quite the characters of obsolescent connective tissue, from which they differ only in the circumstance of their containing a greater or less amount of free pigment matter, and some few shrunken pigment cells. The proper tissue of the iris is then found to have almost disappeared, with the exception of the above mentioned bundles of connective tissue. It is doubtful whether any muscular or nervous fibres remain. In the more severe grades of the disease they certainly vanish altogether. As regards the vessels, only a few can be discovered, scattered irregularly through the membrane; but these are so enormously distended, that they may be seen even with the naked eye in the living subject, as large, irregularly coursing trunks, of venous appearance, lying on the surface of the iris. They sometimes occasion, when the iris is cut or otherwise injured, profuse hæmorrhage. Moreover, there not unfrequently appear in the atrophied iris obliterated or atheroma-

¹ Lehrbuch der Prakt., Augenheilkunde, p. 162. 1867.

tous vascular trunks. The pigment in the substance of the iris is much diminished, and often fails altogether, with the exception of a few heaps of pigment granules. Even the tapetum generally disappears, and only a few masses of pigment can be found at the posterior surface of the basement membrane, which is often thickened. The epithelium sometimes shows itself in such cases, changed into a uniform brownish coloured granular substance, which is here and there collected into roundish knots, that dip into the substance of the atrophic iris. When the iris is pushed forwards till it comes into contact with the membrane of Descemet, there may be found covering the altered epithelium a newly-formed, often much plaited, vitreous membrane, which unites the two just mentioned membranes intimately together. The ciliary muscle undergoes in many instances fatty degeneration, and changes, either wholly or partially, into a stiff, dense tendinous-like structure.

It is difficult to give any statistics upon the proportion which cases of iritis bear to other general diseases of the eye, since this membrane is frequently inflamed in diseases entered in hospital books under other names, especially in the case of rheumatic ophthalmia. In 3500 cases, however, it constituted the principal symptom in 113 instances; of which 70 were males and 43 females, and the average age was 31. The greater frequency in males than in females is undoubtedly due to their greater exposure to wet and cold, and to accidents in the pursuit of their occupations, as is shown by its greater prevalence in those who live out of doors, as salesmen in open markets, porters, labourers, masons, and policemen. It is, however, frequent in tailors and in shoemakers.

That iritis is very frequently associated with *syphilitic* constitutional taint is admitted by all observers. It is usually concomitant with the papular, tubercular or leprous disease of the skin, and appears some months after the primary sore. The fibrinous exudations are usually considerable in quantity

and of a rusty hue (figs. 39, 40, 41). They have been described by Virchow under the term "gummous masses," and by others as "neoplastic formations." In the syphilitic form of iritis the inflammatory process has a great tendency to extend to the ciliary processes, and to the choroid (iridocyclitis and irido-choroiditis), and even to the retina (syphilitic retinitis), and upon the whole the disease runs a more rapid course, and more frequently terminates disastrously, than in the other forms of iritis.

Though most frequent in the adult period of life, Mr Jon. Hutchinson¹ has collected and observed a series of cases in which syphilitic iritis occurred in infants. It is, however, unquestionably rare at this period of life. The age of these little patients varied from six weeks to sixteen months. In the majority of instances females were the subjects of the disease, and in a majority also of the cases only one eye was attacked. Various other syphilitic affections, as condylomata, psoriasis, "snuffles," and cachexia were remarked in different instances. When the child was seen at a sufficiently early period, the treatment, conducted upon the ordinary principles hereafter to be described, was sufficiently successful; for out of sixteen cases, in six the cure was complete; in two, only slender adhesions were left; whilst in the remainder one pupil was occluded by organised false membrane. Mr Hutchinson was only able to ascertain in a few instances the length of time which had elapsed between the date of the primary disease in the contaminating parent and the birth of the infected child. In one instance, the mother had been affected with primary syphilis three, in another six, months previously. In three cases it seemed probable that a period of somewhat less than a year had elapsed, whilst in five it had been at least two years. Of eight cases in which some history of the family was obtained, the affected infant was the only living child of the two parents.

¹ Ophth. Hosp. Rep., vol. i. p. 27.

As regards the *rheumatic* form of iritis, it has been already stated, in the section on catarrho-rheumatic ophthalmia, that the inflammation, though sometimes limited to the sclerotica, not unfrequently extends to the iris, constituting a form of iritis, the special symptoms of which have been very clearly given by Mr Rouse.¹ In rheumatic iritis there is usually not much tendency to the formation of plastic exudations, or at least there is much less tendency to their formation than in the case of syphilitic iritis. The disease is often observed to remain stationary for some time in the condition exhibited in Plate VII., fig. 39, the pain being considerable, particularly at night, and generally referred to the brow or nose; the redness round the cornea of a deep colour; the vision more or less obscured, with turbidity of the humours, and with remissions and exacerbations, which are evidently dependent upon changes of temperature, exertion of the eyes upon fine work, or exposure to bright light. Sooner or later, however, if the disease be allowed to progress, lymph is thrown out between the uvea and the capsule of the lens, and oftentimes complete posterior synechia is produced. The iris then becomes wholly and permanently immovable, but not unfrequently the adhesion between the uvea and the capsule is not complete, consisting of a few tags or bridles only. In this case, although at first the movements of the iris may be much limited, subsequently, in consequence of the bands yielding, considerable play may be observed; and we not unfrequently meet with cases where a small circle of black pigment-dots on the surface of the capsule show where these adhesions have formerly existed, but where, in course of time, by their atrophy and rupture, the iris has regained its freedom.

A peculiar, and also rare, form of iritis, accompanying *gonorrhœa*, has been described by various authors, whose accounts have been collated in an interesting paper by Mr C.

¹ In a Paper contained in the first volume of the St George's Hospital Reports. 1866.

Wordsworth.¹ According to this writer, cases of gonorrhœal iritis are characterised by the subjective symptoms; the pain and photophobia being severe, and out of all proportion to the objective. The lachrymation is profuse, there is little tendency to exudation, but the pupil at an early period becomes contracted and fixed by attachment to the capsule of the lens. In three cases which he records, the cornea was involved, and there was a disposition to relapse. In the disease as described by Mackenzie, however, effusion of lymph in considerable quantity is stated to be a characteristic symptom. The treatment of this affection should be conducted on the same principles as those recommended for the simple and specific form of the disease.

The form of iritis sometimes termed *scrofulous* iritis, is principally characterised by its very chronic character, and by the comparatively little disposition that exists to the formation of the neoplastic growths, so strongly marked in cases of syphilitic iritis. Nevertheless, according to Arlt, adhesion of the iris to the cornea (anterior synechia) is peculiarly liable to occur in this form, and extension of the inflammation to the choroid is very common. On exposure to cold or other exciting cause, the disease is apt to become acute, and may then pass through the same stages as the ordinary form.

Treatment.—The treatment of iritis may be divided into two periods; the first of which embraces the period during which certain remedies are administered, having for their object the prevention of the exudation of lymph, and the resolution of inflammation, without the formation of adhesions between the iris and the capsule, or posterior surface of the cornea; and the second period includes that during which a variety of operative measures are adopted for the purpose of removing the effects, more or less injurious to sight, of the effusions and adhesions which have taken place.

¹ Ophth. Hosp. Reports, vol. iii. p. 301.

If the diagnosis of iritis be made at an early period, the disease may really be said to be almost completely under the control of the surgeon. The patient should be kept in a room of uniform temperature, neither too hot nor too cold, and free from draughts. The bowels, if confined, should at once be opened by a few grains of blue pill and black draught, or by castor-oil, or by half a drachm of the compound jalap powder, with one or two grains of calomel. The diet, during the first few days at least, should be low, especially in robust or country patients. In Londoners, however, meat can seldom be withheld for any length of time, and it often becomes necessary to allow a little wine, or weak brandy and water. Here, however, the practitioner must be guided by the strength of the pulse, and the presence or absence of pyrexia. All exertion of the eye upon fine work, reading, or brilliant objects, should be interdicted.

With the view of effecting a dilatation of the pupil, and therefore of diminishing the quantity of blood circulating in its vessels, and the probability of fibrinous effusion and of adhesions to the capsule of the lens, the room in which he sits should be moderately darkened, and the use of belladonna commenced, either by smearing the brow and temple with the liniment, or by the systematic instillation of a solution of atropine, containing from one to four grains in the ounce of distilled water. The frequency with which this application should be repeated depends on the manner in which the iris responds to its action. If dilatation quickly follows, the weaker solution need only be instilled every morning; but if adhesions have already formed, the stronger solution should be dropped into the eye three or four times a-day, by which means so powerful a strain is exerted on the neoplastic formations, that they may oftentimes be seen to yield successively, till the whole border is again free, the position of the points of adhesion, however, frequently remaining visible on the capsule of the lens.

If the pain and redness be considerable, and the patient of a full habit of body, ten or twelve ounces of blood may be taken from the arm; but more frequently the abstraction of three or four ounces of blood from the temple, either by cupping, which leaves an ugly mark, or by leeches, is quite sufficient. In either case, a warm linseed-meal poultice may be subsequently applied with advantage. Great relief may frequently be given to the pain by puncturing the cornea with a broad needle, and allowing the aqueous humour to drain off, repeating the operation if the pain recur notwithstanding the use of other remedies. This little operation should especially be performed when there is a distinct collection of matter, or hypopyon, in the anterior chamber.

And now, according to his state, either calomel and opium alone, or combined with quinine, must be commenced, the ordinary doses being, calomel gr. ii., opium gr. $\frac{1}{4}$ to $\frac{1}{2}$, or even 1 grain, repeated thrice daily. In some cases the decoction of cinchona and solution of the bichloride of mercury, in half-drachm or drachm doses, are better than the calomel and opium, which last, if required, can be administered in the form of Dover's powder. Though denied by some, I cannot for a moment doubt the efficacy of mercury in clearing away exudations from the surface of the iris. I have often tried the experiment of stopping it when the patient was improving under its use, and have as often seen the advantage of recommencing it when he was worse in consequence of its discontinuance. When the mercury has once been commenced, it should not be given up as soon as the gums become tender, but the quantity may be diminished to one or two grains per diem, so that the action may be kept up for some days; otherwise, in many instances, a relapse will take place. Opium and quinine are powerful adjuvants, but the essential remedy is calomel. When, however, from any cause the use of mercury is contra-indicated, good substitutes for it may be found in iodide of potassium and

in the oil of turpentine, both of which possess a powerful influence in subduing inflammatory attacks of the iris. The iodide of potassium, in three-grain doses, thrice a-day, is often a useful adjunct in clearing away the remains of foregoing iritis which has been treated with mercury. The oil of turpentine is particularly useful in the rheumatic form of iritis, and should be given in the mucilage of acacia, in twenty or thirty minim doses, thrice a-day.

In traumatic cases, occasioned by a blow on the eye with a chip of stone or metal, whether with or without perforation of the cornea, the reaction is sure to be severe, and half-a-dozen leeches may at once be placed on the eye, and mercury and opium commenced, with a view of preventing, as far as possible, the supervention of inflammation. A warm bread-and-water poultice placed over the eye will generally aid in lulling the pain, which is always sharp. In the chronic form, or later periods of the disease, blisters are sometimes very useful; but they are an uncertain remedy, and sometimes fail in effecting any improvement.

When anterior or posterior synechia has occurred, or where the pupil has become occluded, and the adhesions are sufficiently strong to resist the dilating influence of belladonna, it is necessary to resort to some operative proceeding, by which an artificial pupil may be produced. The three modes of operation formerly adopted, with this object in view, were the simple division of the iris (coretomy), the removal of a piece of the iris (corectomy), and the tearing away of the iris from its peripheric attachments (coredialysis). The latter operation has now fallen rightly into disuse, and the first is only occasionally undertaken. It is, however, well adapted for those cases where the lens has been removed either by operation or by the natural process of absorption. After operations for cataract, however skilfully performed, a portion of the capsule often becomes opaque, and, together with fibrinous effusion from the margin of the iris, completely

obstructs the passage of light to the retina, to the mortification both of the operator and of his patient. In such cases the treatment may consist of the entrance of a narrow-bladed iris knife through the cornea at its lower or upper margin, and the transfixion of the iris near the contracted pupillary border. A slight sawing movement effects the section of the iris to the extent desired, and retraction of the fibres sometimes follows immediately, or may be induced by the instillation of atropine. A little blood sometimes escapes, which, though usually of no importance, as it gravitates to the lower part of the anterior chamber and is soon absorbed, yet occasionally becomes troublesome, by forming a coagulum in the new pupil, requiring a second operation for its removal. It is not advisable to undertake this operation in cases where the lens is still present, whether clear or opaque and adherent; for in the former instance other operations can be performed in which the lens, here necessarily divided and lost, may be preserved; whilst in the latter case the iris, when divided, will not contract, and the broken-up lens is very likely to become a stimulus inducing inflammation in the iris.

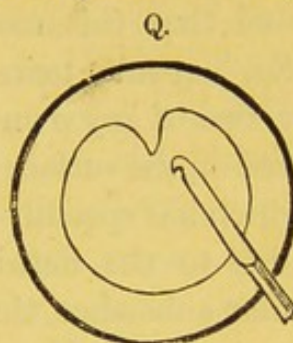
In cases where only partial adhesions between the iris and lens capsule have taken place, or where the pupil is filled by a membrane which has not formed very close adhesions to the capsule, the iris being otherwise healthy, Mr Streatfield¹ has proposed an operation which he has termed *corelysis*, the object of which is to reinstate the pupil, and one therefore which of necessity demands that the lens shall be transparent.

The operation should not be undertaken so long as any inflammatory symptoms are present, nor when any important retinal or choroidal disease can be diagnosed. The pupil should be dilated as far as possible with atropine. Chloroform should be administered, and the operator should stand behind the patient. A fold of the conjunctiva should then be seized close to the corneal margin, on the side opposite to

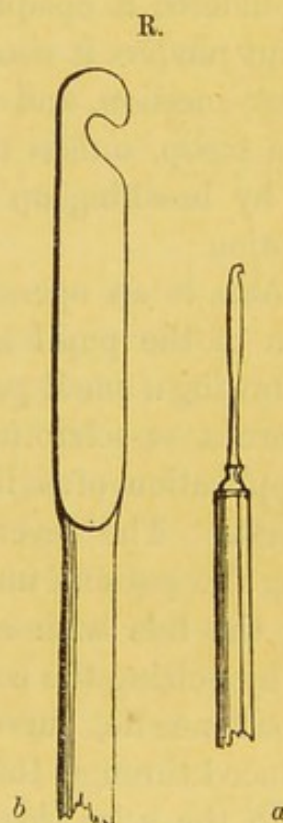
¹ Ophth. Hosp. Rep., vol. ii. p. 309.

that on which the puncture is to be made, in order to steady the globe. A broad needle is now to be passed through the cornea; and on its withdrawal the instrument represented in the adjoining figure is to be quickly introduced through the same opening, but due care should be taken that it does not press upon the lens. When the adhesion is reached, an attempt should first be made to detach it from the capsule, by pressing against it with the blunt spatula-like edge of the instrument below the hook; but if this be unsuccessful, it should then be seized by the hook and made to yield, or be divided by firm pressure.

Mr Streatfield states that he has obtained good results from his operation, not only in cases of partial adhesion, but also in cases of occlusion of the pupil, where the iris occupies its natural plane, and appears still to retain some amount of contractility, and where the false membrane is not very opaque. The broad needle, after piercing the cornea, should be made to transfix the false membrane near the opposite or distal margin of the iris, and raise it from the surface of the lens. The spatula hook should then be made to penetrate the same point, and the membrane rolled back or torn open with the hook.



Mode of introducing the hook in Mr Streatfield's operation.



Streatfield's Spatula Hook for Corelysis.

(a) Natural size.

(b) Enlarged, after Warlomont and Testelin.

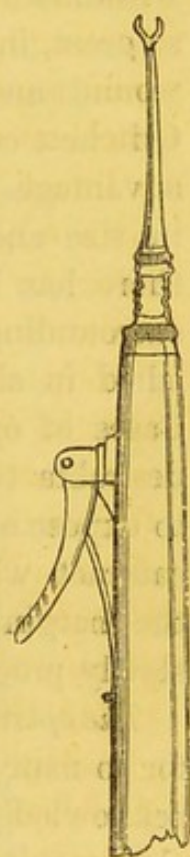
When the adhesions between the iris and the capsule of the lens are very firm and extensive, however, it will be found that this mode of operating is not applicable, and that the capsule tears in preference to the adhesion. In one or two of my own cases, a delicate pearly projection has appeared on the surface of the lens a day or two after the operation, which has speedily become quite opaque, and has evidently been due to the hernia of a small quantity of the proper lenticular substance, through a minute aperture in the capsule. In one instance the vesicle appeared to burst, the margins floating in the aqueous, which, gaining admission to the lens, soon rendered it opaque throughout. The occurrence of this accident renders it necessary to open the anterior chamber by a linear incision, and to extract the remainder of the lens with a scoop, unless the patient be so young that we may hope, by breaking up the lens with a needle, to effect its absorption.

Iridesis is an operation in which, whilst the natural free margin of the pupil is preserved, its position is altered by withdrawing a small portion of the iris through an opening in the cornea or sclerotica, retaining it in its new position by the application of a ligature. It was first proposed by Mr Critchett.¹ The several steps of the operation consist in placing the patient under the influence of chloroform, separating the lids with a wire stop speculum, and fixing the globe by seizing the conjunctiva with a small pair of forceps. A broad needle, curved at an angle upon the flat, is then introduced through the margin of the cornea at its clear part, close to the sclerotica, slightly encroaching upon the latter, and if possible on the inner or nasal side. "A small loop of fine black silk is then placed over the opening that has been made. A fine blunt hook, made of silver, so as to allow of being curved conveniently for entering at the nasal side of the eye, is then passed through the loop of silk and the

¹ Ophth. Hosp. Rep., vol. i. p. 220; vol. ii. p. 145; and vol. iv. p. 156.

opening into the anterior chamber to the margin of the pupil, which is thus drawn out through the opening by means of the hook. An assistant then seizes each end of the loop of silk with small broad-pointed forceps, and tightens them carefully so as to enclose the portion of iris that has been caught in the hook and pulled out. Care should be taken to include the iris only in the tie, and not any of the conjunctiva, as it detaches more readily. Some little management is also necessary in bringing the hook out through the small wound, otherwise it is apt to entangle itself in the opening as it is drawn out. This is done by turning it on the flat as it emerges. In the course of two or three days, the little knot of silk, together with the portion of iris that has been included in the ligature, drops off; or, if this do not occur, it may be lifted off with a pair of forceps."

In his earlier mode of performing the operation on withdrawing the broad needle, which was accomplished, if possible, without permitting the escape of the aqueous humour, the small cannula forceps were passed through the minute aperture made in the cornea by the needle, and the iris was seized near but not close to its ciliary attachment, and drawn out to the extent considered necessary. A piece of fine floss silk, previously tied in a small loop round the cannula, was slipped down, and the operation completed as before. This last described, but first performed, operation of Mr Critchett was essentially the same as the old one of iridenkleisis, and the advantages claimed for it over iridectomy were, that it can be accomplished without any laceration of the fibres of the iris; that the form and position of the pupil are alone altered; that it retains permanently a definite size, clearly-defined margins



Cannula forceps.

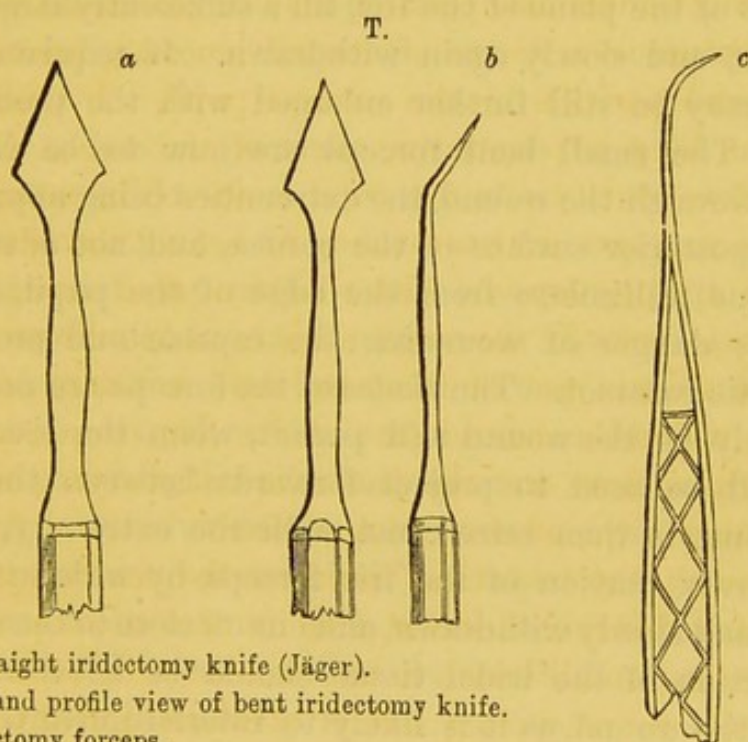
and contractility under the influence of light; and, finally, that its position can be exactly regulated. It will be seen, however, that some of these advantages can no longer be claimed for Mr Critchett's later operation, since the margin of the iris is seized with the hook, and it appears to be in effect only another mode of performing iridectomy with a small opening. Stellwag v. Carion¹ states that the application of the ligature does not always prevent the return of the protruded portion of iris; and I have found great difficulty in withdrawing the hook with the portion of iris seized by it—so great, in one instance, that it was requisite to enlarge the wound and perform iridectomy. The cases in which Mr Critchett considers his operation may be performed with most advantage are:—1. Cases of central leucoma, corresponding in size and position to the natural pupil. 2. Cases where there has been a penetrating ulcer of the cornea with some surrounding opacity, and the pupil is altered in shape, diminished in size, and drawn towards or behind the opacity. 3. Cases of opaque capsule, with adherent pupil, in which it is desirable to enlarge the pupil slightly in one direction, so as to expose a clear part of the lens; and, 4. Cases of nuclear cataract, where the central part of the lens is opaque, whilst the margin is clear, and the disease is stationary, or only very slowly progressive, as in congenital cases.

*The operation of iridectomy*² is now so frequently undertaken for so many different diseases, and its performance has been acknowledged on all hands to be attended with such remarkable results in recovering lost or seriously impaired vision,

¹ Lehrbuch der Augenheilkunde, p. 259. 1867.

² For good accounts of the mode of performing this operation, and of the indications for its performance, see T. Windsor, *Ophthalmic Review*, vol. i., 1865; v. Gräfe, *Archiv. f. Ophthalmol.*, Bd. ii. Heft. iii. iv., and the Papers translated for the New Sydenham Society; Desmarres, *Traité des Maladies des Yeux*, vol. ii.; W. Bowman, *British Med. Journal*, 1862; Wecker, *Etudes Ophthalmologiques*, p. 430, 1864; and Sichel (fils), *Treatise on the Indications for Iridectomy*, whose mode of treating the subject I have followed in this section.

that it is advisable to describe somewhat more fully the indications by which we should be guided in adopting it. Before proceeding to consider these, however, the several steps of the operation, as it is now usually performed, may be briefly given. The patient should be brought into as favourable a state as possible for the operation, by attention to the bowels, and the administration of tonics, etc., if required and if time be of no object. If chloroform is to be administered, the quantity of food previously taken should be small. The instruments required are a pair of toothed forceps, for seizing the conjunctiva and fixing the globe; a lance-shaped knife of Jäger, either straight (*a*), or bent on the flat surface (*b*), with



- (*a*) A straight iridectomy knife (Jäger).
 (*b*) Flat and profile view of bent iridectomy knife.
 (*c*) Iridectomy forceps.

the blade at an angle of 140° to the shaft; a pair of fine iris forceps (*c*), with the extremities bent at a similar angle. A small blunt-pointed knife or bistoury, to enlarge the corneal wound if necessary, and a pair of small scissors, curved on the flat. The operator should stand, according to M. Sichel, in front of the patient when operating on the outer side of the

right eye, or the inner of the left, and behind him for the opposite sides. The lids should be separated by the fingers of assistants, and not with a spring speculum, since the pressure of this may cause the extrusion of the lens. A large fold of the conjunctiva should now be seized with toothed forceps, and the eye drawn fairly over to the opposite side to that on which the incision is about to be made. The point of the knife is to be introduced through the sclerotica at a distance of from one millimètre to one-and-a-half millimètres from the border of the cornea, and the wound should be four or five millimètres (one-fifth inch) in length. The blade of the instrument should be pushed steadily forwards parallel to and in front of the plane of the iris, till a sufficiently large opening is made, and slowly again withdrawn. If requisite, the incision may be still further enlarged with the probe-pointed knife. The small bent forceps are now to be introduced closed through the wound, the extremities being approximated to the posterior surface of the cornea, and not advanced beyond one millimètre from the edge of the pupil, otherwise there is danger of wounding the capsule and producing a traumatic cataract. The blades of the forceps are now opened as widely as the wound will permit, when the tissue of the iris will be seen to project forwards between them. The membrane is then seized, not with the extremity, but with the convex portion of the iris forceps, by which it is to be gently and slowly withdrawn, and cut off close to the sclerotica. No portion of the iridal tissue should be left between the lips of the wound, as it is likely to interfere with the process of cicatrization. If any blood have collected in the anterior chamber, it should be evacuated; but if after two or three efforts this cannot be accomplished, it may be left, as it is usually absorbed in a few days. The operation being completed, a simple bandage may be applied to the eye. Usually the inflammation which succeeds is trifling and transitory; should it, however, become severe, as occurs when the capsule

has been injured, and the lens swells and opacifies from the imbibition of fluid, leeches should be applied to the temple, and the bichloride of mercury with cinchona or calomel and opium may be ordered; and if still no relief is obtained, it becomes necessary, in many instances, to reopen the wound and extract the lens with a scoop—a proceeding that is sometimes followed by immediate and permanent relief of the pain, and at others by violent inflammation and loss of the organ.

Where extensive anterior synechiæ have formed, and where the tissue of the iris has become atrophied and friable, breaking away piecemeal as it is seized by the forceps, the result of the operation is generally of little service to the patient, since the surface of the cornea, from whence the iris has been torn, generally becomes opacified by the formation of false membranes.

Where extensive posterior synechiæ have formed, it is almost impossible to remove a portion of the iris without injuring the capsule of the lens and inducing cataract. In such cases, we may either content ourselves with removing a very small portion of the iris with the utmost care and gentleness, trusting that the synechia may have been annular, and that the margin of the lens is sufficiently clear to permit the passage of light, or we may at once practise a large iridectomy, and either at the same time, or by a subsequent operation, remove the lens with a scoop.

In some instances, especially where the intra-ocular pressure has previously been considerable, the healing of the wound does not take place kindly, but the cicatrix is formed of a delicate semi-transparent membrane, strengthened here and there by a few threads of fibrous tissue, between which the thinner portion of the cicatrix bulges. This form of union has received the name of cystoid cicatrization. Whilst of small extent, it is best treated by the application for some weeks of a compressive bandage; but if the protrusion be considerable, and accompanied by much conjunctival redness, v. Gräfe

recommends the membrane to be divided with a cataract-knife, and the thin portion to be cut away with scissors, after which the patient is to be treated in the same way as subsequent to the operation for cataract.

It is recommended by the same author to perform the operation of iridectomy at the upper part of the iris, since the deformity of the pupil is then covered by the lid, and the pressure of the lid tends, in some measure, to prevent the above-mentioned cystoid cicatrization. In those, however, whose eyes are deeply set, and in those in whom the palpebral fissure is small, it is extremely difficult, even when the globe is well rotated downwards, to enter the bent knife, so that it shall pass in front of and parallel to the plane of the iris, as I have more than once had an opportunity of experiencing. On this ground, Arlt prefers the inferior section to the upper or inner one, and recommends the point of the knife to be introduced perpendicularly to the surface of the globe, just at the point of junction of the cornea and sclerotica, the handle of the knife being depressed as soon as the blade appears in the anterior chamber, when it is pushed forward to the requisite extent.

Indications for the performance of iridectomy.—The operation of iridectomy, says M. Sichel, may be undertaken either, first, to admit the passage of light into the interior of the eye, which has been prevented by various affections, such as leucomata of the cornea, adhesion of the iris to the anterior capsule of the lens, or closure of the pupil by a false membrane; or, secondly, as a prophylactic or curative means for diseases like glaucoma, against which ordinary remedial measures have been found to be inoperative; or, thirdly, as a means of augmenting the chances of success of another operation, with which object it has been recommended by v. Gräfe in his recently-suggested mode of operation for cataract (modified linear extraction).

When the operation is performed for the first of these,

or for purely optical reasons, M. Sichel terms it *optical iridectomy*; when for the second or third, *therapeutical iridectomy*.

The indications for *optical* iridectomy are, first, opacities of the cornea; and, second, occlusions of the pupil by false membranes. In either case the general rule holds, that the pupil formed by the operation should be as *small* and as *central* as possible, and if the choice can be made, the inner is preferable to the outer side; whilst if only the upper part of the cornea be clear, it should be made here, the superior rectus being afterwards divided if requisite.

Where the opacity of the cornea is small and central, whilst the pupil is free, iridesis is preferable to iridectomy; but where the opacity is complicated with anterior synechiæ, iridectomy should be adopted—that part of the iris being excised which is situated behind the largest surface of transparent cornea, and where it is least stretched. The adhesions should not be broken down, since they are frequently double, the iris adhering both to the anterior capsule and to the cornea, owing to which circumstance a traumatic cataract may easily be produced. Mr Windsor states that a hook has sometimes been advantageously used in cases of anterior synechia, the instrument being introduced through the sclerotica, and therefore posterior to the plane of the iris.

When iridectomy is employed as a *therapeutical* means,—*i.e.*, as a means of arresting the progress of inflammation, or of disease of the iris or of some other structure,—the portion of iris removed should be as large as possible, and it should be excised to its extreme marginal attachment, the object being to diminish intra-ocular pressure as far as possible, and thus to enable it to exert its special curative action.

The conditions for which iridectomy is undertaken as a *therapeutical* means are—(1.) For certain diseases of the cornea and sclerotica; (2.) for certain affections of the iris and choroid.

The diseases of the cornea and sclerotica for which it has

been proposed are—(1.) Ulcers, (2.) conical cornea, and (3.) staphyloma of the cornea or sclerotica. 1. Much difference of opinion exists as to the propriety of performing it in cases of ulceration of the cornea. M. Wecker¹ makes the following observations on this point:—"When a considerable hypopyon has formed, whether iritis be present or not, the matter should be evacuated by a large opening made with a lance-shaped knife through the sclerotica, in close proximity to the margin of the cornea. If, on the second or third repetition of this operation, the rapid progress of the affection is not checked, an extensive iridectomy should be practised, in order to relax the cornea and to facilitate the cure. Moreover, since we must ultimately perform this operation, on account of the extensive opacification which follows a large ulcer with so great an amount of suppuration, why should not the patient enjoy the benefits that this operation can afford as an anti-phlogistic during the acute period of the keratitis?" Mr Hulke,² who has reported several successful cases where this practice was pursued, takes up the same line of argument. M. Sichel considers, on the other hand, and I am disposed to think justly, that its value is not sufficiently demonstrated in these affections to permit it to be recommended as a measure to be generally adopted; and he prefers simple paracentesis with a needle, followed by the instillation of atropine, which may be repeated as often as necessary without fear of injury to the eye. 2. In cases of conical cornea, either a vertical or a horizontal double iridectomy may be performed, as Mr Bowman has recommended, the operation being followed by the employment of suitable stenopæic glasses. 3. In cases of staphyloma of the cornea and of sclero-choroiditis, either anterior or posterior, there can be no question of the value of iridectomy, and of its beneficial effect in reducing the increased intra-ocular pressure, providing it be performed in

¹ *Etudes Ophthal.*, vol. i. p. 311.

² *Ophth. Hosp. Rep.*, vol. iii. p. 174.

the earlier periods of the malady, before the protrusion has become strongly pronounced.

As regards the advisability of performing iridectomy in iritis, considerable diversity of opinion exists, some maintaining that it proves of great service even in acute cases, when, notwithstanding the employment of antiphlogistic remedies, there is a strong tendency to the formation of false membranes; whilst others, amongst whom M. Sichel may be distinguished, hold that the required diminution of intra-ocular pressure may be obtained by the more simple operation of paracentesis, and that the operation is contra-indicated during the acute stages of iritis, and especially in the acute stages of syphilitic iritis, in which there is a great tendency to the production of false membranes. It is certain that, to be of any service in such cases, the portion of iris removed should be large; but even under these circumstances I have found, in several instances, that, on the healing up of the wound, the pain and inflammation have recurred, rendering it requisite to resort to paracentesis, which has completely produced the desired effect, but which it has appeared to me might, had it been used earlier, have rendered the operation of iridectomy unnecessary.

The worst and most unsatisfactory cases in which to perform iridectomy are undoubtedly those in which the preceding iritis has been of specific origin, and where, as a consequence of frequent and protracted attacks of inflammation, firm adhesions have formed between the lens and the posterior surface of the iris. I have had many such cases to treat, in common with all ophthalmic surgeons. They are generally pallid and cachectic patients, in whom mercury and opium have already been pushed to the utmost extent. Atropine produces not the slightest effect on the pupil. Leeches only temporarily relieve the pain, which is paroxysmal, frequently leaving the patients for a few hours, and then returning with almost unbearable severity. Quinine and tonics are of little

service while the tongue is furred and the breath foul. Purgatives are ill borne, and the patient and the surgeon alike look for relief to some operative proceeding. Iridectomy naturally suggests itself, and I have many times removed a large segment of the iris. However carefully the operation may be performed, the capsule is in general torn, or the lens injured; and I have tried both the plan of allowing it to remain, in the hope that it may have escaped, as well as that of removing it at once with a scoop, and have met with but little success in either case.

If the lens be left, and the good effects of iridectomy be alone trusted in, it will generally be found that the lens undergoes opacification, swells up, and that the pain and inflammatory symptoms, which had subsided immediately after the operation, again return, necessitating the reopening of the old wound and the extraction of the lens. And even after this has been accomplished, inflammation may still continue, and the eye at best remain a seriously-impaired organ, probably with only a quantitative perception of sight. On the other hand, if it be attempted to remove the lens at the same time that the iridectomy is performed, one of two results occurs. In young people the chief portion of the soft lens is indeed easily removed, but fragments always remain adherent to the inflamed iris, and become the centres of suppuration, which causes the eye to be utterly destroyed; whilst in older people (æ. 40 to 50) the adhesions will be found to be very firm, to require strong pressure in order fully to break them down, and so much injury is inflicted on the iris that again the eye is rendered a useless organ.

In the chronic stages of iritis, and in irido-cyclitis, especially when this is kept up by the presence of a foreign body, or even by a depressed lens, which acts as a foreign body, it is generally admitted that iridectomy proves a very valuable operation, at once reducing intra-ocular pressure, and thus effectually quelling the pain and inflammation; whilst, by the

formation of an artificial pupil, a considerable amount of vision is in many instances regained.

The value of iridectomy in various affections of the choroid, and especially in glaucomatous affections, has been fully established by the observations of v. Gräfe and numerous other operators, and will be referred to hereafter in treating of that disease. M. Sichel, however, thinks that its beneficial effects have not been satisfactorily established in cases of choroiditis parenchymatosa, serosa, disseminata, plastica, and suppurativa. It is always indicated in cases where, in consequence of adhesions between the iris and capsule of the lens, the communication between the anterior and posterior chambers of the eye has ceased to exist. Such a condition is a fertile source of subacute irido-choroidal inflammation, attended with considerable pain in the affected eye, and very frequently proving the cause of impairment of vision in the opposite one.¹ We shall conclude by enumerating the conditions under which, according to M. Stellwag v. Carion, it is right and justifiable to practise the operation of iridectomy, or rather an operation for the formation of artificial pupil.

1. Cases of extensive leucomata of the cornea, where a portion of this membrane still remains transparent, whether associated with anterior synechia of the iris or not.
2. Cases of atresia of the pupil, or false cataract, especially if the iris be adherent to the capsule of the lens (synechia posterior), and whether accompanied or not with cloudiness of the capsule and coincident chronic iritis, irido-choroiditis, or panophthalmitis, or with sympathetic ophthalmia of the opposite eye.
3. The various forms of corneal and sclerotic ectasies.
4. Glaucoma.
5. Cases of partial dislocation of the lens.
6. Cases of partial, capsular, or lenticular opacities of a stationary or very slowly progressive character, but seriously interfering with vision.
7. Cases where, in consequence of the capsule of the lens having been injured, the lens substance becomes

¹ See Sympathetic or Reflex Ophthalmia.

swollen by the imbibition of fluid, and, pressing upon the iris, threatens to induce inflammation of the tissue. 8. As an accessory to the operation for cataract. 9. To effect the extraction of foreign bodies lying in the anterior chamber, or imbedded in the iris, and which cannot be removed without laceration or contusion of its substance. And lastly, in cases of obstinate contraction of the pupil (myosis).

The general symptoms of a case of iritis arising from cold are exhibited in the following case:—

J. C., æt. 23, a navvie working on the Thames embankment, and previously in perfect health, was exposed to severe cold and was thoroughly wetted on 3d December 1865. On the following day the glands under his jaw swelled, and were very painful, obliging him to give up work. He stayed at home for three or four days, and then resumed work, though still feeling ill, and that he had a bad cold hanging about him. On the 12th December, he was told that his eyes were red, and they watered a good deal. Pain soon came on in the right eye, which was so severe that he again discontinued work. He took a purge, which opened the bowels freely, but was in no way improved. When he presented himself at the Hospital, on the 19th December, the tongue was furred and white, his pulse quick, but small for so large and strong a man, which he accounted for by saying he had had little to eat or drink for the two preceding days. The right conjunctiva was deeply injected; there was a strongly-marked circumcorneal zone. The cornea was rather dull, especially towards the centre. The iris was of a brilliant green (that of the left eye being of a bright blue), and contracted, and no movement could be observed when the light was allowed suddenly to fall upon it. The pupillary space was dull. The vision was remarkably impaired, as he could not see the largest of Jäger's Test Types at a greater distance than three feet, and even here very imperfectly. The pain was severe, and extended over the brow. It was always worst at night, evidenc-

ing a rheumatic character. He was ordered to have six leeches applied, and a linseed-meal poultice placed on the temple. Some belladonna linament was placed on the brow, and the decoction of cinchona, with an eighth of a grain of bichloride of mercury every six hours. On the 21st December he returned. The leeches had immediately relieved the pain. A small button of lymph, of yellowish colour, had made its appearance on the inner side of the pupil. The circumcorneal zone was somewhat fainter, but the vision was very obscure. The medicine was repeated, and he was directed to have six more leeches, followed as before by the poultice. A drop of solution of atropine (gr. ii. ad. ʒj.) was dropped into the eye. On the 23d, the button of lymph had manifestly diminished in size, its edges were soft and translucent, and the general appearance of the eye was much paler, whilst there was but little pain. On the 26th, the button of lymph had disappeared; the haziness of the cornea had also entirely vanished, and the conjunctiva and sclerotica had almost regained their original colour. He could now see C of Snellen's Test Types at 30 feet with the right eye. The mixture was repeated. On the instillation of atropine, it was observed that there was a slight adhesion of the iris to the capsule of the lens on the inner side. On the 6th January 1866, he considered himself well. The redness had disappeared. He stated that he could see as well with one eye as with the other. A small tag of adhesion still remained on the inner side.

The following is the history of the case represented in fig. 39, and will give the principal features of a case of syphilitic iritis:—

H. B., æt. 23, a pallid, unhealthy-looking man of small stature, came to me, on the 6th March 1860, with a well-marked attack of iritis in the right eye only, the left being perfectly healthy and natural, and of a clear blue colour. He stated that about six months previously he had contracted

syphilis, and then suffered from hard chancres, for which he had been under regular treatment. They lasted for three months before they healed up. The cicatrices were still present, and very distinct. About three weeks previously he had again become infected, and had now two small ulcers, with soft base, situated upon the corona glandis. There was a copper-coloured eruption of thin scaly variety over the arms, legs, chest, and abdomen. About eight or ten days previously his attention had been directed to the eyes, in consequence of their feeling dim, and painful, and watery in the evening, as soon as he began to read. The pain was slight in the morning, but severe at night. The lid was swollen, and was kept partially closed. The sclerotica was of a uniform pink, with large conjunctival vessels running tortuously over it, and there was a strongly-defined circumcorneal zone. The cornea was perfectly clear and transparent. The iris was of dull greenish hue, strongly marked near the pupillary border, with radiating striæ of rusty-coloured exudation, which formed a marked contrast to the clear tint of the opposite eye. The pupil was smaller than the other, irregular in form, with a very distinct bridge of adhesion at its lower part. The vision was so misty that he stated he could only see a glimmer of light, yet the pupil seemed clear. Hence, though I was not then aware of the diagnosis of that disease, I have no doubt now that he was also suffering from syphilitic retinitis.

The treatment adopted was the application of four leeches to the temple, the instillation of atropine (gr. iv. ad. ʒj.), and the administration of calomel (gr. ii.), with opium (gr. ss.), three times a-day. On the 11th of March I saw him again, when he was manifestly improved; the mouth had been sore for forty-eight hours, but he had still continued the use of the pills; the vascularity of the sclerotica and conjunctiva had much diminished; the pain had almost entirely disappeared; and it is stated in the notes that the colour of the iris was almost if not completely restored. The dimness of vision

was still considerable; he was, however, able to distinguish a pencil-case in a good light. On the 16th of March the pupil dilated well with atropine, except below, where the tag of adhesion was too firm to admit of it. Vision was much improved, as the larger types of Jäger could be just made out. He considered himself, however, so well that he ceased to attend.

The case represented in fig. 41 was almost precisely similar to the foregoing, occurring in a young woman, æt. 20, who was servant in a coffee-house three months previously to her appearance on the 10th August 1858. She had had sores in the vagina, and subsequently a bad sore throat. The affection of the eyes had commenced about a week previously. She had placed herself under the care of a surgeon, who had treated her with calomel and opium. The button of lymph was very conspicuous, and the inflammatory symptoms severe. As she looked cachectic, and had had but little sleep, the calomel was ordered to be continued in small doses. The opium was increased to a grain, three times a-day, and a grain of quinine was added to each pill. The mouth was soon affected, and much improvement took place in the course of a day or two, when the medicine was exchanged for the mixture of iodide of potassium, three grains of the salt being given for a dose. In this case vision was only moderately affected. Belladonna liniment applied over the brow caused the pupil to dilate everywhere but at the point at which the effusion had taken place. She was dismissed cured on the 23d August, the disease having run its course in thirteen days—an unusually short period, which was probably attributable to the early and judicious employment of calomel and opium by the surgeon who first saw her.

The following case is the only one I have space to cite as an instance of iritis proceeding from an injury:—

Ed. H., a mason, applied at the Hospital on the 28th July 1860, stating that about six weeks previously he had caught

a severe cold, which caused the eyes to be very red and inflamed, with copious lachrymation, though he had not suffered much pain, and the vision had been perfectly good. About three weeks previously, his eyes being still inflamed, a piece of stone struck him upon the right eye. The sight was immediately greatly impaired, and from that time he had suffered severe pain in the eye, brow, and temple, had only slept by snatches, and was at length induced to apply for relief. The iris was much contracted and irregular, and its surface around the pupillary margin was infiltrated with a reddish-brown exudation, whilst the markings on the rest of its surface were dull and indistinct. Atropine caused no dilatation. There was a slight ecchymosis on the sclerotica near the cornea, showing where the eye had been struck. The circumcorneal zone was strongly defined. A small quantity of pus had gravitated to the bottom of the anterior chamber. He had only quantitative perception of light. Being of plethoric appearance, he was ordered to be cupped to 3xii., to take a pill containing four grains of calomel and one of opium three times a-day, and to avoid beer or alcohol. He did not return to the Hospital till the 6th August, but he was then greatly improved in all respects, and could see the shadow of the hand passing before the eyes; and in a few more days the inflammatory symptoms had subsided, though a complete posterior synechia existed. On the 18th October he returned to the Hospital, complaining of recurrent inflammatory attacks having taken place on two or three occasions, and I admitted him into the Hospital, and removed a portion of the iris by iridectomy, with sufficient advantage to enable him to see his way about.

Before proceeding to consider the diseases to which the choroid is liable, it will be advisable to describe the appearances which it presents in the healthy eye when examined with the ophthalmoscope.

DISEASES OF THE CHOROID COAT.

The diseases of the choroid coat constituted, before the application of the ophthalmoscope to the surgery of the eye, some of the most obscure of the internal affections to which this organ is liable. In fact it was formerly almost impossible to give any positive diagnosis respecting them. Now, however, with the aid of this invaluable instrument, though much remains to be cleared up by subsequent research, and though we are still ignorant of the nature of some of the conditions which can be clearly discerned through the transparent media, enough has been ascertained to enable us to form a very sound opinion on the nature and probable course of the greater number of the various diseases revealed to us, and even in some instances to state, with some approach to accuracy, the causes by which they have been produced. As in the following pages reference will frequently be made to the abnormal conditions presented by the eye when examined with the ophthalmoscope, it has been thought advisable to commence this section with a brief description of the mode of using the instrument, and of the appearances ordinarily presented by the healthy fundus.¹

The use of the ophthalmoscope requires considerable practice, and its rudiments may be better acquired by a few lessons from a competent teacher than by the most lengthened verbal description. The ordinary ophthalmoscopes, consisting of a plane or concave mirror, with a central aperture and a convex lens, or, still better, the binocular ophthalmoscope, are by far the most serviceable for general purposes, and may be obtained from any surgical instrument maker. The patient, into whose eye solution of atropine should previously have been dropped, should be seated, with the head well supported, and a good

¹ For a much more full and a very excellent account of the ophthalmoscopic appearances of the fundus, see Mr Carter's Translation of Dr Zander's Work on the Ophthalmoscope, 1864; also the Essay of Mr Hulke on the same subject.

steady light on his left hand, or, when the binocular instrument is used, over his head. The observer should be seated opposite to him and nearly on the same level, and should hold the mirror in his left hand. The patient is then told to look a little inwards towards the observer's left ear or temple, when the left eye is under examination, and towards his right ear when the right eye is examined. As soon as the reflection from the mirror falls on the eye of the patient, the observer, looking through the aperture in the mirror, sees a strong red reflection of the light from the fundus; and in some instances, as in myopic patients, it is even possible to discern the larger vessels.

The management of the mirror, so as to direct the light properly upon the eye of the patient, and at the same time to look through the aperture, is soon acquired. The next step is to recognise the optic disk, or point of entrance of the optic nerve. For this purpose a convex lens of three or four inches focus must be used. It should be held lightly between the thumb and fore-finger of the left hand, an inch or more in front of the eye of the patient, the hand being steadied by allowing the little finger to rest on the forehead. After a little practice, the pearly pink or slightly yellowish circle of the optic disk or entrance is perceived, together with the branches of the central artery and vein of the retina, which usually perforate the disk near its centre or at its margin. When once seen, the entrance of the optic nerve is easily recognised again; and when the observer has familiarised himself with its appearance, he may next proceed to examine and endeavour to describe the appearances presented by the choroid coat, as the presence or absence of pigment, atrophy of its tissue, the existence of deposits, etc. Lastly, we may try to observe the central point of the eye, or foramen of Soemmering, which is in general difficult for a beginner, partly because it is really inconspicuous, being small and of only slightly different colour from the rest of the fundus, and

partly because the reflections of light from the cornea and lens are in the way, and must, so to speak, be evaded by slightly altering the position of the mirror. In order to see the foramen centrale, the patient must look at the central aperture of the mirror. It will then occupy the centre of the pupil, and appears as a small spot of darker colour than the rest of the choroid, owing to accumulation of the choroidal pigment, not defined at the periphery, but blending insensibly with the adjacent parts of the membrane. Oftentimes there is a minute yellow spot to be seen in the centre of the red stain, and sometimes the whole is surrounded by a soft whitish line, which is the reflection of the rim of the mirror from the surface of the retina. When the observer has accomplished the feat of perceiving the foramen centrale satisfactorily to himself, he may consider himself qualified for observing any of the diseases of the retina or choroid.

The colour of the fundus of the healthy eye varies considerably. It depends essentially on two circumstances, the vascularity of the choroid, and the amount of pigment contained in its superficial layer of hexagonal cells. In the majority of cases it presents a uniform deep orange vermilion tint, and a soft villous appearance, difficult to represent on paper. When the pigment cells are filled with pigment, as in very dark eyes, or as in the eyes of negroes, the reflection is of a deep blackish red, chocolate or smutty colour, and this is always best marked around the foramen centrale and the entrance of the optic nerve, sometimes giving to the former, in fair people, so deep a colour that, by contrast with the adjoining parts, it resembles a stain of blood.

In many cases the amount of pigment in the cells is so small that they become almost transparent, and the structures lying behind them, as the *venæ vorticosæ* and larger vessels, can be distinctly perceived (figs. 71 and 50). The capillary layer of the choroid, according to Liebreich, is scarcely perceptible in the healthy eye, and influences only to a slight

extent the colour of the fundus. When all the layers of the choroid are atrophied, the sclerotica shines through with a fine white porcellaneous lustre. Such an appearance is frequently seen in myopic eyes (fig. 69), in the immediate vicinity of the optic disk.

The optic papilla disk or entrance usually presents the appearance of a small projecting button of a pearly yellowish pink or bluish tint. It is in reality rather depressed below the adjoining surface of the retina and choroid, the impression of its elevation being pseudoscopic. The edges are clearly

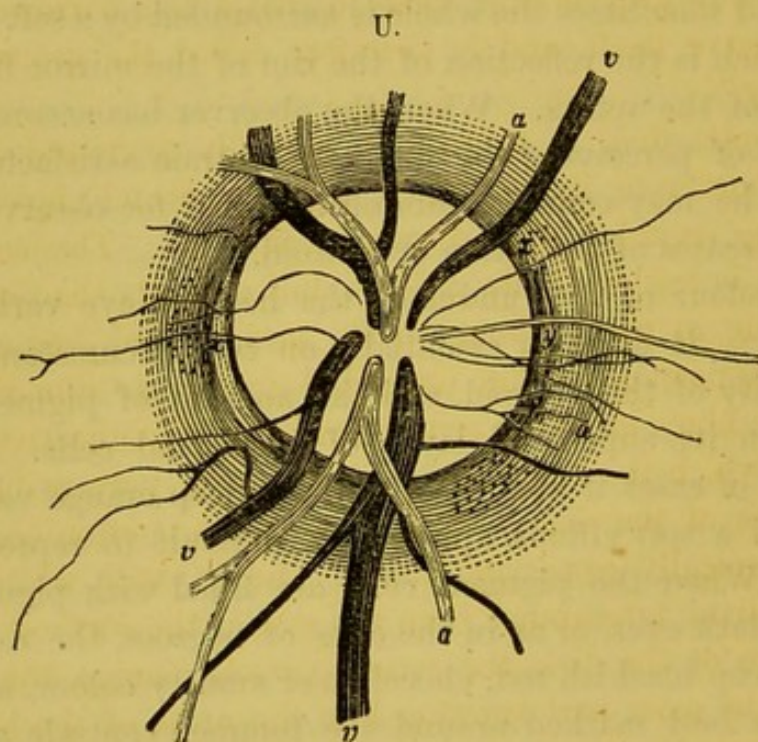


Diagram showing the general arrangement of the vessels at the optic entrance. (a a) Arteries. (v) Veins. (x) Double boundary of the papilla. (y) Choroidal vessels (after Zander).

but softly defined against the red choroid. Upon close inspection, the margin of the disk appears to be bordered by a faint whitish line (*x, y*), respecting which Zander makes the following remarks:—"At the point where the lamina cribrosa ceases, the nerve is contracted, and the opening in the choroid is narrow, and in a certain measure compresses the trunk.

For this reason, a sort of double border (x) is often seen around the nerve entrance; and between the limits of this border it is still surrounded by the choroid, in which, at this part, Donders has sometimes seen a choroidal vessel (y). With regard to the limits of the nerve, the following description is quoted from Liebreich: Under the choroidal margin is the line, more or less dark, that indicates the border of the opening in the choroid; under the sclerotic margin is a bright crescent or circle, formed by the curving round of the sclerotic fibres, and appearing between the choroidal margin and the fine greyish line that indicates the narrowest part of the nerve itself, and is therefore called the proper nerve boundary."

The optic disk is frequently partially surrounded by a curved border or line of black pigment, which, however, is not to be regarded as a diseased condition. The surface of the disk is seldom quite smooth, but presents shadings, corresponding to undulations, on its surface, and frequently a net-like appearance of fine elongated grey dots—due either to the nerve fibres or to the cribriform layer of connective tissue through which the nerve fibres pass—being perceptible. At the centre of the disk a small depression is often seen, also pseudoscopically appearing raised, and of still whiter and more brilliant appearance than the rest of the surface. Near the centre of the disk, the retinal vessels emerge, the larger ones for the most part running like the arms of the letter x , either vertically upwards and downwards, or towards the inner side. The part near the foramen centrale is usually sparingly supplied with vessels, though, as Niemetschek¹ has shown, the old opinion that it is quite free from blood-vessels is to a certain extent incorrect, since he has observed a capillary net-work covering it.

The arteries are at once distinguished from the veins by their smaller size, brighter tint, and straighter course. The

¹ Prager Viertel Jahrschrift, Bd. i. p. 132. 1866.

veins are conspicuous, large, and dark, and form easy curves as they traverse the fundus. They often run some distance before giving off any branches. The arteries, on the contrary, soon break up and are lost. The larger vessels reflect the light from the most convex part of their surface, causing the appearance of a central lighter-coloured part, bounded by two darker lines. Pulsation may be seen under favourable circumstances both in the arteries and in the veins. It is stated, indeed, that it is always visible in the veins under normal conditions (Zander). I cannot say that I have been able to perceive it; but in many cases slight pressure with the finger will cause it to appear in both the veins and in the arteries.

A series of pathological conditions have been collected from different writers, and described by M. Stellwag v. Carion under the term of *senile* alterations, of which the following is an abstract, and many of which can easily be discovered by a proficient in the use of the ophthalmoscope¹:—These senile changes, he remarks, occur, as in the case of other pathological alterations, at different periods of life in different people, but may be regarded as essentially of an atrophic nature. The matrix or parenchyma of the choroid and of the ciliary processes becomes drier, firmer, and more friable. A few of the larger vascular trunks are frequently atheromatous, and the degeneration may even proceed so far as to occasion their complete obliteration. The capillary network is atrophied in streaks and patches. The basement membrane appears at certain spots, or over the whole extent of the choroid, thickened, roughened, and hazy with colloid deposits, and remarkably dry and withered. The pigment cells are curiously altered, losing their colour, and partially disappearing; whilst the tapetum becomes transparent, allowing the larger vessels to be seen with singular clearness, and even permitting the sclerotica to be

¹ Lehrbuch der Augenheilkunde, p. 265. 1867.

easily seen through the whole remaining thickness of the choroid.

As regards the several histological elements of which the membrane is composed, the *stroma cells* long retain their natural characters, but at length they also become clouded and filled with fat molecules; the *pigment cells* lose their colouring matter, or disappear entirely, and fat or colloid vesicles appear in the interstices.

The *atheromatous vessels* may often be seen with the naked eye as thick-branched white cords, either separate or forming net-works, whilst in other instances they disappear entirely. Their walls often appear increased in thickness, and infiltrated with fat, calcareous matter, and pigment molecules.

The *capillary layer of the choroid* is often free from blood for spaces of considerable extent, or is reduced to a feebly-marked net-work of fine vessels, which is scarcely separable from the surrounding and subjacent deposit of finely granular and fatty molecular deposit. In other cases, the obliterated remains of these impervious vessels may be seen as a delicate trellis-work, looking like cords and bands of connective tissue.

The thickening of the *basement membrane* is the consequence of the deposit of hyaline masses, which, originally soft, gradually stiffen and become more condensed, and blend with the substance of the membrane. These present the form of undulating or more defined and even pedunculated swellings, resembling particles of fine sand, and either quite transparent, or containing calcareous and pigment molecules. These deposits raise the superjacent pigmentary layer, and often push it to one side and project through it, so that their base is surrounded by a ring of pigment cells and molecules. The changes that have just been described appear either in patches, or generally over the whole surface of the membrane, and are frequently very distinct in the immediate neighbourhood of the foramen opticum.

The *cells of the tapetum* undergo more or less fatty degene-

ration. In the clearer parts the pigment is remarkably diminished and discoloured, in some instances altogether disappearing, and becoming replaced by fat—the nuclei, as well as the clear polygonal lines, being no longer capable of being distinguished; and in some cases all traces of cell structure vanish, and the basement membrane is laid bare, or is covered only by a few scattered molecules of fat or pigment.

Changes essentially similar to these have been observed in the ciliary processes and muscle, the latter undergoing, in particular, marked fatty degeneration.

3. *Irido-choroiditis, or Irido-cyclitis, and Sympathetic Ophthalmia.*

Inflammation of the choroid and iris together may arise idiopathically without any apparent or demonstrable cause, but far more frequently owes its origin to the irritation occasioned by the presence of posterior synechiæ, that have formed in the course of a previous attack of iritis. It may also follow incised or lacerated wounds of the ciliary region, especially if some particle of foreign body have become impacted in the choroid or iris. And, lastly, it may be consequent on grave lesion of the opposite eye; in which case it is generally known under the name first applied to it by Dr Mackenzie, of sympathetic or reflex ophthalmia.

The cases in which the cause is referable to the presence of posterior synechia are perhaps the most frequent. The disease here commences in the iris, and extends to the choroid. The mode of origin appears to be, that where, in consequence of an attack of iritis, complete adhesion of the iris to the capsule of the lens has taken place, so that the communication between the two chambers is entirely cut off, whilst the iris is firmly bound down, and prevented from dilating and contracting under the influence of variations in the amount of light, a constant striving takes place on the

part of the muscular tissue of the iris to overcome the resistance thus occasioned, and an amount of irritation is produced which leads to congestion of the parts, and to increased secretion into the anterior and posterior chambers. The tension of the globe then becomes perceptibly augmented; a well-marked circumcorneal zone, chiefly consisting of veins conveying dark-coloured blood, appears; the iris becomes altered in colour, its vessels being evidently congested, whilst effusions of blood or pus, which gravitate to the bottom of the anterior chamber (hyphæma and hypopyon) are not unfrequently seen. In many instances the pupil is occluded by false membranes, and no ophthalmoscopic investigation can be made; but where this is practicable, the vitreous is often found to be hazy with floating shreds and flocculi. The choroid of dark colour, and sometimes the optic disk, can be observed to be excavated. The vision is always materially impaired, partly owing to the turbidity of the humours, but partly also from functional disturbance of the retina and of the ciliary muscle, consequent upon the increased intra-ocular pressure. In many instances, also, the cornea suffers from inflammatory condition of the surrounding tissues, and presents more or less opacity, often of a dotted or punctated character, the spots being evidently situated on the posterior surface of the membrane (aquocapsulitis).

In that form of irido-choroiditis which arises from injury, the progress of the disease is acute, and the inflammatory symptoms usually run high. There is considerably-augmented vascularity, the globe is very tender to the touch, and the patient complains of ciliary neuroses and subjective sensations of sparks and flashes of light, with rapid failure of vision. It often, however, even here pursues a subacute course, the patient in great measure recovering from the immediate effects of the wound, though more or less of a ciliary zone of redness remains; and it is only after the lapse of some weeks that the inflammatory symptoms above de-

scribed gradually develop themselves. The acute form sets in usually within a week or two after the occurrence of the accident, and commences with symptoms of asthenopia, the patient being unable to accommodate the eye for any length of time, and fine work, or reading, soon causing redness and lachrymation. From this condition recovery, under favourable circumstances, may take place, but very frequently further changes are perceived. The sclerotica in the ciliary region, weakened by the persistent inflammation of the surrounding parts, yields to the intra-ocular pressure, and a staphylomatous protrusion appears. In other instances, after the occurrence of more or less severe inflammation of a glaucomatous nature, implicating almost all the tissues of the eye, and either presenting alternate periods of quiescence and exacerbation, or pursuing a steady onward course, a process of atrophy of the organ commences, which terminates in its total destruction, the aqueous and vitreous undergoing absorption, and the sclerotica becoming folded upon itself, and squared by the action of the recti muscles. According to Stellwag v. Carion, the vitreous in such cases becomes traversed by bands and fibres of connective tissue, which gradually contract; and ultimately the whole of this humour presents the appearance of a pediculated cup, on the anterior rounded borders of which the ciliary processes lie, whilst the lens occupies its concavity. The retina, adhering to the vitreous and detached from the choroid, presents a similar funnel-like form, and the irregular space between the retina and the choroid is filled by a watery or semi-gelatinous, yellowish, reddish, or brown fluid, constituting the so-called *hydrops retinalis*. Coincidentally with these changes, or at a somewhat later period, fibrinous often very well defined masses are deposited upon the surface of the choroid, especially in the vicinity of the optic entrance, which may ultimately become vascular, converted into connective tissue, and may even undergo ossification.

Sympathetic Ophthalmia.—If the disease be of a sympathetic character, that is, if it arise in one eye in consequence of injury to the other, the inflammatory symptoms take origin on the side of the choroid, and extend from thence to the iris and other tissues.

The sequence of symptoms has been well given by Mr Critchett, and by M.M. Warlomont and Testelin. It occurs usually, as the former writer has shown, as a consequence of a wound implicating the iris or ciliary body; and the first manifestations of the inflammatory process appear ordinarily in about from four to six weeks after the accident—rarely sooner, but often much later; and I find that, in one instance recorded by Pagenstecher, no less than seven years had elapsed from the receipt of the primary injury. The patient complains of being unable to accommodate the uninjured eye for near objects, or for any length of time. He is consequently unable to read without lachrymation and confusion of the letters and lines. M. Wecker observes that a characteristic feature of this form of the disease is a remarkable diminution of the sharpness of the central part of the field of vision, or the absolute loss of perception of some parts of the field, due probably to partial separations of the retina—a condition which only rarely occurs when the malady originates in the diseased conditions of the iris on its own side. The cornea loses its brilliancy and polish, and becomes surrounded by a circumcorneal zone. Effusion now takes place from the congested vessels of the choroid, or rather, perhaps, of the ciliary processes into the vitreous, rendering it more or less turbid, whilst the iris long retains its natural appearance, though responding sluggishly to the action of light. The globe becomes hard, and the patient suffers from pains in the brow, temple, and nose. If the inflammation increase, detachments of the retina are apt to occur; the globe becomes softer; the iris is pushed forward, diminishing the depth of the anterior chamber; the lens becomes opaque, and adhesions form be-

tween the iris and the capsule. The globe finally undergoes atrophy; the aqueous and vitreous are alike absorbed; the sclerotica becomes misshapen, folded, and squared by the action of the muscles; and the various degenerative changes which have already been described may then supervene.

The mode in which this sympathetic irritation leading to inflammation is conveyed, is unknown. M. Pagenstecher¹ considers that it is probably conducted through the sympathetic system; and remarks that, independently of the improbability of the optic as a nerve of special sense propagating an injurious influence in a retrogressive direction, the primary effects of the sympathetic ophthalmia would in such circumstances undoubtedly first appear in the retina, and not in the choroid as here seen, where the phenomena of the disturbance of the accommodative activity, the asthenopia, injection of the ciliary vessels, hyperæmia of the iris, muddiness of the aqueous, and, at a later period, of the vitreous, constantly precede the symptoms of retinal affection, and form a picture of disease having close analogies to those presented by serous choroiditis. M. Wecker, however, remarks that, whilst the sympathetic irritation can scarcely be supposed to act through the optic nerve, it is equally difficult to explain it as occurring through the ciliary nerves, since these have been frequently observed to be completely atrophied, and therefore to constitute unlikely channels for the conduction of such noxious agency. It has also been observed by M. Vose Solomon to take place after extirpation of the primarily diseased globe, which must be considered as opposed to M. Pagenstecher's views. On the other hand, these are supported by the observations of Mr Critchett, who, as already stated, believes that sympathetic ophthalmia is peculiarly liable to occur when the primary injury has affected the parts to which the sympathetic nerves are essentially distributed,—namely, the ciliary processes and muscle,—and the

¹ Klinische Beobachtungen, Heft. ii. p. 48. Wiesbaden, 1862.

adjoining region of the cornea and sclerotica, choroid, and iris.

The pathological conditions which may be found in the eye first affected after its excision, may be of the most varied character. The form of the globe is often altered, with irregular staphylomatous protrusions, and its size diminished, presenting, as already stated, a shrunken or atrophied appearance. If the loss of the eye has been occasioned by injury, the cicatrix is always visible. The tissue of the iris is either friable and rotten, or, in consequence of the effusion of lymph behind it, thick, coriaceous, and inelastic. It is frequently discoloured. It is often firmly adherent to the cornea or to the capsule of the lens, or to both, so that the anterior and posterior chambers of the eye are alike obliterated. The pupil is small and angular, and often filled with false membrane. The cornea is hazy; the choroid is attenuated. In one instance I found it œdematous, and presenting a gelatinous appearance, with large flakes of blood between it and the sclerotica. A neuroma was found, in another instance,¹ on a ciliary nerve. Other conditions that have been seen are, effusions of blood on or beneath the choroid, separating it from the sclerotica, or detaching the retina; atrophy of the retinal elements; and, in consequence of the liquefaction and absorption of the vitreous, funnel-shaped displacement of the retina. Colloid changes in the choroid have been noticed, and occasionally the whole globe has been found filled with pus.²

The *treatment* of irido-choroiditis, in those forms where it arises spontaneously, or where it is the result of posterior synechiæ consequent upon a previous attack of iritis, should first be directed to the subjection of the inflammation and reduction of the intra-ocular pressure. For this purpose the general and local antiphlogistic measures should be adopted which have been already fully detailed under the head of

¹ Bader, Ophth. Hosp. Rep., vol. i. p. 216.

² See section on Panophthalmitis.

Iritis. The patient should be kept in a darkened room, at perfect rest. All exertion of the eyes should be interdicted. The food should be light, and small in quantity. Leeches and cooling evaporating lotions may be applied to the temple, and a solution of atropine (gr. iv. ad. ʒj.) frequently dropped into the eye. The bowels should be thoroughly opened, and the use of calomel and opium commenced, whilst, if the tension of the globe be considerable, iridectomy is strongly indicated. Mr Hancock's operation is also well adapted for these cases, the relief to the pain, probably produced by the hæmorrhage from the anterior ciliary vessels, being almost immediate. Where firm posterior synechiæ exist, however, its effects are certainly not so permanent as the operation of iridectomy; for as soon as cicatrization of the wound occurs, the parts return to their original condition, and are liable to a recurrence of the inflammation. For the same reason, when iridectomy is performed, a considerable portion of the iris should be removed, and every care taken to prevent violent inflammation succeeding to the operation. It is believed by M. Wecker that the spontaneous forms are most likely to occur in females at the critical periods of life; and attention should therefore in such cases be carefully given to the due performance of the catamenial functions, and any disturbance rectified as far as possible.

In the cases of sympathetic ophthalmia, it is admitted on all hands that the only chance of safety for the remaining sound eye consists in the removal of the primarily injured or diseased eye at as early a period as possible, when there is clear evidence that the second one is becoming inflamed. The question as to whether, when the second eye is affected, the removal of the first, in all instances, effects a cure, is a very important one, and must be answered in the negative, since a case has been placed on record by M. Vose Solomon, where sympathetic ophthalmia supervened after enucleation of the primarily injured eye had been performed. If inflam-

matory symptoms do present themselves, iridectomy should be performed without delay, and the greatest possible care should be taken in the after-treatment.

4. *Glaucoma*.¹

By the careful clinical observations of v. Gräfe and others, the term glaucoma, which was formerly loosely applied to very various affections of the eye, is now limited to the different stages and forms of a well-marked inflammatory disease of the choroid and iris, the symptoms and progress of which are accurately known, whilst the treatment, if practised during the earlier stages of the disease, is fairly successful.

The forms of the disease that are now generally admitted are:—1. Acute glaucoma. 2. Chronic glaucoma. 3. Glaucoma consecutive upon other diseases of the eye. And, 4. Simple glaucoma, with excavation of the nerve.

Acute Glaucoma.—In the acute form of the disease, the outset of the inflammation is usually preceded by the occurrence of certain premonitory symptoms, for the most part of a subjective nature, which, according to v. Gräfe, are absent or unnoticed in only about from 25 to 30 per cent. of all the cases. Of these *precursory symptoms*, some only are present in any particular case, and they vary considerably in their severity in different instances. They present this point in common, that they may all be referred to increase in the intra-ocular pressure, occasioned, there is every reason for believing,

¹ v. Gräfe, in the Papers translated by Mr Windsor for the Sydenham Society; R. Förster, Archiv. f. Ophth., vol. iii.; Haffmans, *idem.*, Bd. viii. Ab. ii. p. 124; Coccinus, Archiv. f. Ophth., vol. ix. p. 1; Donders, Annal. d'Oculist, t. liv.; Wecker, Etudes Ophthalmologiques, vol. i. p. 451; Hulke, Medico-Chir. Transact., vol. xliii.; Stellwag v. Carion, Lehrbuch der Pract. Augenheilkunde, p. 295, 1867; Warlomont and Testelin, Translation of Dr Mackenzie's Treatise, vol. iii. p. 317; Dr Magawly, Contribution to the Clinical History of Glaucoma, Ophthalmic Rev., p. 233, Oct. 1864. Besides the above, the reader will find numerous contributions to the clinical history of glaucoma in the Ophthalmic Hospital Reports, Lancet, British Med. Journal, and Medical Gazette, during the last two years, by Bowman, Crichtett, Hulke, Bader, and others.

by congestion of the choroidal vessels, and excessive secretion into the aqueous and vitreous humours. Amongst the more important are—1. Presbyopia, or hypermetropia, partly arising from flattening of the whole globe in the antero-posterior direction, and partly from functional disturbance of the ciliary muscle, occasioning loss of the power of accommodation for near objects; 2. The appearance of coloured rings or haloes surrounding well-defined bright objects, such as a candle or gas-jet; 3. Periodical or intermittent obscuration of the field of vision, the patients complaining that they feel as though a dark veil or mist were gradually drawn before the eyes, exactly similar to the sensation produced when the finger is firmly pressed for a few seconds on the ball of a healthy eye. Limitation of the field of vision belongs to the same series of phenomena, the patient being only able to see, besides the point on which he fixes the eye, a very small circle of surrounding objects; at other times, certain portions of the field of vision are incapable of being perceived at all. The obscurations can be induced at any moment in the affected eye by slight pressure on the globe, or by any cause leading to an increase of the intra-ocular pressure, as by hanging the head down or straining. This symptom is often accompanied by sparks or flashes of light, or by sensations as of a revolving wheel, which are very distressing to the patient. 4. At this period the pupil is usually somewhat dilated and sluggish, but the media are clear, and no perceptible alterations can be distinguished in the choroid or optic papilla, excepting that the colour of the former is deep, and that the vessels of the latter, and especially the veins, are large and tortuous, and can be made to exhibit, 5. pulsation on slight pressure. The phenomenon of pulsation which occurred spontaneously in seventeen out of seventy-nine of Arlt's cases,¹ is clearly due to the circumstance that, on account of the increased intra-

¹ Rydel, in Bericht über der Augenklinik der Wiener Universität, p. 137. 1867.

ocular pressure, little or no blood enters the retinal vessels during the diastole of the heart, or rather during the elastic recoil of the arteries more centrally situated. It is only at the moment of the ventricular systole that the blood is propelled with sufficient force to overcome the resistance offered to its entrance into the globe, and consequently to give the impression of a wave. 6. Some pain is usually experienced over the brow and temple, as well as in the eyes themselves, in consequence of the pressure exerted upon the ciliary nerves, on which account the pains are termed by v. Gräfe ciliary neuroses. Besides the above symptoms, the sclerotic generally looks dull and congested, and the tension of the globe is decidedly increased.

These various premonitory symptoms are often perceived and complained of by the patients for many weeks, or even months, before the accession of the disease itself, which may indeed be considered as only a violent exacerbation of them all. In many cases, however, the whole train of symptoms suddenly lights up without any precursory signs, and in an otherwise apparently healthy eye.

In such sudden fulminating cases as they have been termed, the inflammation often commences at night, after more or less protracted want of sleep, with most severe pain in the brow and eye. The tension of the globe is greatly increased; the conjunctival and subconjunctival vessels are congested, but there is seldom any vivid redness or chemosis. The sclerotica is dull and yellowish; the cornea loses its polish and transparency, presenting the same appearance that may be produced by compressing the globe when recently removed from the body. The sensibility of the surface is also considerably diminished. The aqueous and vitreous are sufficiently turbid in most instances to prevent the fundus of the eye from being explored with the ophthalmoscope, though the optic entrance may occasionally be dimly perceived. M. Wecker states that in some instances a deposit of punctated character may be

observed on the posterior surface of the cornea or membrane of Descemet. The pupil is dilated and immovable, in consequence of the paralysis from pressure of the third pair of nerves (mydriasis and iridoplegia), and its colour becomes of a dull or olive green tint, from which the disease has received its name. It is believed by Dr Mackenzie¹ to depend not upon any turbid or discoloured condition of the humours, but upon a diplo-chromatic state of the crystalline lens, by which it absorbs the extreme prismatic rays, and reflects the middle ones. The depth of the anterior chamber of the eye is always considerably diminished. The vision is rapidly impaired, or even altogether lost, so that not even the quantitative perception of light remains. A single day is not uncommonly sufficient for this effect to be produced; and cases are recorded where it has occurred in so short a time as half-an-hour. This exceedingly violent form of the disease usually attacks elderly persons, or, according to Stellwag, those who have passed their fifty-fifth year. It leads invariably to glaucomatous excavation of the optic nerve, and to degenerative atrophy of the internal tunics of the eye, and in some instances has been observed to rise to such a pitch of intensity that general supuration of the globe has taken place.

In many cases, again, the acute inflammatory symptoms subside. The haziness of the aqueous and vitreous diminish, but the globe remains more tense than natural, the anterior chamber shallower, the pupil wider, and only very sluggishly responding to the action of light. Vision is then more or less perfectly regained.

On examining the fundus in such cases, retinal ecchymoses may frequently be seen in the form of round red spots, together with excavation of the optic papilla and arterial pulsation. In one case, recorded by v. Gräfe,² in which the attack was very violent and sudden, there were enormous

¹ Ophth. Hosp. Rep., vol. ii. p. 252.

² *Idem.*, vol. iv. p. 45, translation by Mr Bowman.

retinal ecchymoses in various parts of the eye, partly in the inner plane of the retina (where they were darkest), in the form of large opaque cherry-red flakes, completely covering the retinal vessels; partly along the vessels themselves in irregular stripes or spots, forming larger figures where the vessels divided; and partly also, which is the most common form in acute glaucoma after iridectomy, behind the visible vessels, in the shape of round light-red transparent spots. At last suffusions appeared, more connected, of a bright-red colour, but not opaque, which, judging from their free diffusion, and their relation to the coarse choroidal veins, originated on the surface of the retina. These last, in the progress of absorption, were more slowly removed than the foregoing.

The excavation at the nerve entrance is recognised by the bending of the retinal vessels at the external border of the papilla, and by there appearing to be a break in their course at this point, since those portions of the vessels which run from the point of entrance to the margin of the papilla are situated on a different and posterior plane to the remainder. As each bends forwards, therefore, to reach the general plane of the choroid, it is for a moment lost sight of, and, in accordance with the laws of perspective, the two extremities of the vessel do not exactly join or fit on one to the other. (*See fig. X, p. 410.*)

The central portion of the vessels present, according to Stellwag v. Carion, in the earlier stages of the disease, quite clear and well-defined borders. The arteries are of normal diameter, or somewhat narrowed; the veins remarkably broader, in consequence of their being flattened, and frequently surrounded by a net-work of small anastomosing branches. At a subsequent period of the disease, all the central portions of the vessels—*i.e.*, those occupying the region of the papilla—become paler and indistinctly defined, as though veiled by a thin greyish haze, and ultimately

almost wholly disappear. The retinal veins and arteries then appear to spring directly from the margin of the papilla.

X.

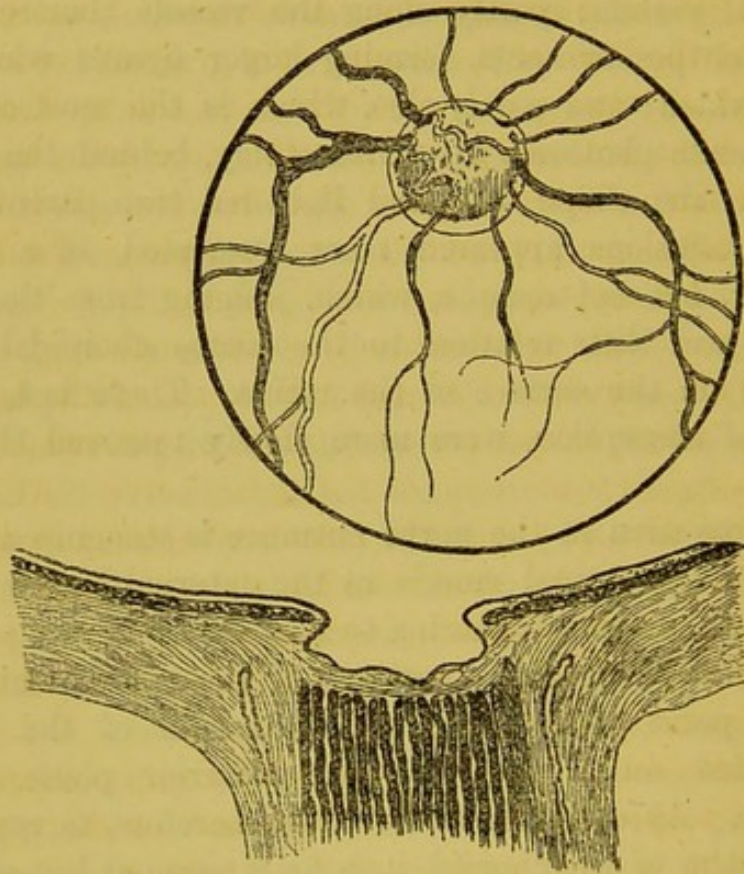


Figure of an excavated optic entrance, showing the mode in which the vessels curve over the excavated border.

Under these circumstances, the larger veins seem to end in a roundish point, of a much darker tint than the rest of the vessel, evidently in consequence of its suddenly changing in its direction from a horizontal to a vertical one.

The existence of excavation of the papilla is further shown by its being surrounded throughout its whole extent with a broad clear annulus, which appears to be due to the atrophy, or shrinking of the choroid from the margin of the optic papilla, permitting the sclerotic margin, which does not partake in the excavation, to be seen.

It is important to remember that the depression of the

optic papilla presents a pseudoscopic appearance of prominence, so that it appears as a button projecting from the fundus. The concavity really present is, however, easily recognised by the binocular ophthalmoscope, or, as Stellwag observes, by the form of the shadow, the greatest breadth and depth of which always occur on the same side as that from which the light is thrown, varying, therefore, with the position of the mirror and the eye of the observer. It is always annular in form, sharply defined at the periphery, but becoming softer and disappearing towards the centre.

The colour of the optic entrance in the early stages of the disease is pink or reddish, owing to the stasis of the blood in the vessels, but, at a later period, whitish or yellowish white, from the atrophic condition of the optic nerve. After the lapse of some days or weeks, the former symptoms recur with more or less violence; and though these remissions and exacerbations may sometimes alternate for several weeks or months, sight is ultimately, with the occurrence of an attack of greater intensity than usual, lost.

When the disease has thus run its course, the sclerotic is often found to present a peculiar brownish or dirty yellow colour, whilst on its surface run tortuous dark-coloured vessels, formed by the branches of the anterior ciliary veins, which appear to perforate this tunic near the margin of the cornea, and carry off a portion of the blood from the irido-choroidal region, relieving the *venæ vorticosæ*. The tension of the globe is so greatly increased, that it feels almost as hard as a stone. The iris, projecting forwards, and widely dilated, as well as altered in colour and consistence, not unfrequently forms firm adhesions to the capsule of the lens. The lens may then become opaque; and this condition may remain without material alteration for many months. At length, however, the hardness diminishes, and the globe becomes squared by atrophy and the action of the recti muscles.

Of the *chronic form* of the disease it is hardly requisite to say

more than that all the symptoms above described as existing in the acute form are present, though less strongly marked. The conjunctiva, for example, is slightly injected. The colour of the sclerotica, the diminished sensibility of the cornea, the altered position and appearance and activity of the iris, and the hardness of the globe, are all less distinct indeed, but still clearly present. The two symptoms which, according to M. Wecker, may be unfailingly observed, and which differentiate this form from the preceding, are progressive and gradual contraction of the field of vision, and the excavation of the optic papilla. In the acute form, the violence of the inflammation produces so much and such sudden turbidity of the humours, that the sight is quickly impaired to a serious extent, and the excavation cannot be distinguished. In chronic glaucoma, the inner part of the field of vision is that which usually first fails, then the upper and lower portions, and finally the outer part; the order of failure being apparently connected with the distribution of the retinal vessels, that are always most numerous towards the inner or nasal side, which consequently retains its functional activity longest. The best mode of determining the extent of the field of vision consists in desiring the patient to fix his eye on a small spot in the centre of a black drawing-board, and then making a series of points with a piece of chalk, just within the field of vision. On joining the spots with a line, a tolerably accurate boundary or contour line of the field of vision will be obtained. Small ecchymoses are not unfrequently observable, which, after enduring for some time, change their colour, become paler, and ultimately disappear.

Consecutive glaucoma presents no essential distinguishing feature from the chronic form, beyond that, as its name implies, it appears in the course of some other diseases. Thus it is not an unusual concomitant of staphyloma of the cornea or sclerotica, when these are sudden in their onset and violent in their attack. The increased tension of the

globe becomes apparent to the touch, and with this condition all those symptoms supervene which have been already detailed as characteristic of acute glaucoma. In like manner, iritis and irido-choroiditis, by the effusion of fluid which takes place from their over-congested vessels into the aqueous and vitreous,—and still more frequently by the traction and irritation of the iris in cases of synechia posterior, when the eye is exposed to varying degrees of light,—often induce an attack of glaucoma; but, as Stellwag observes, consecutive glaucoma must not be confounded with glaucoma complicatum, in which the glaucomatous affection occurs in an already diseased organ without causal relation between the two being observable. Thus it is not unfrequently observed in eyes affected with simple cataract, and is sometimes combined with amaurosis of cerebral origin. In the latter class of cases it is termed pseudo-glaucoma by Sichel (père).¹ This writer observes that glaucoma is sometimes symptomatic of an organic and incurable cerebral malady, but at others of a cerebral amaurosis, which is not organic, but is still accessible to ordinary therapeutic measures. He states also that a peculiar and not very infrequent variety of pseudo-glaucoma depends upon the use of convex lenses of too great power, and, whilst remaining unimproved by iridectomy, is capable of being cured by a rational medical treatment, repose of the eyes, and the use of glasses of lower power.

There is yet another form of glaucoma, which was originally described by v. Gräfe as amaurosis with excavation or cupping of the optic nerve, but which is now more generally designated simple chronic glaucoma, in accordance with the views of M. Donders, by whom this is considered as the really typical form of glaucoma—glaucoma simplex. The symptoms are those of ordinary glaucoma, except that no inflammation is present. In most instances the globe becomes

¹ Introduction to the Thesis of his son, on the "Indications of Iridectomy." 1866.

very hard and tense, though sometimes even this is not a marked feature; the pupil becomes dilated and sluggish, and the field of vision concentrically limited; but the media retain their natural and perfect transparency, permitting the optic disk—*apparently* projecting as a pearly button, with the changes noted by Förster, and already described as occurring in the form and position of the blood-vessels—to be distinctly and beautifully seen. There is no pain; the arteries do not exhibit pulsation unless the globe be pressed; and the disease is always chronic in its course.

The pathology of glaucoma is still obscure. v. Gräfe, with most modern ophthalmologists, regards the forms of the disease which have just been described under the terms of acute and chronic glaucoma as the true types, and consequently maintains that it is essentially an inflammatory affection, the choroid being the membrane primarily and chiefly affected. On the other hand, M. Donders, with whom M. Wecker appears to coincide, considers that simple glaucoma, or that form in which excavation of the optic nerve with preservation of the transparency of the media occurs, is really the type, to which inflammation may or may not be superadded, and that it essentially consists in a neurosis or functional disturbance of the secretory nerves of the eye, in many instances maintained and intensified by tension and traction exerted upon the iris. He remarks that, in simple glaucoma (the last of the above-described forms), the eye acquires a remarkable degree of hardness, which is clearly due to hypersecretion of the humours of the eye, and which is yet unaccompanied by the least trace of inflammation. He believes that these secretions are under the influence of the nervous system, and supports his view by reference to the effects of section of the fifth pair of nerves, which induces an excessive softness of the globe, and is accompanied by a singular diminution of the secretion of tears. On the contrary, when from any cause the secretory nerves are irritated,

the secretion of the vitreous is augmented, and the lens and iris are pushed forwards, but the traction and tension of the latter again react as irritants upon the secretory nerves, causing a further increase of secretion and of intra-ocular tension. It is to be remarked, however, that though diminution of the intra-ocular pressure is well-marked after section of the fifth, it is by no means constant after pathological changes, involving destruction of the nerve.

Another view of the pathology of glaucoma, to the effect that it is primarily associated with *rigidity of the sclerotic*, has been advanced and ably supported by M. Stellwag v. Carion, who considers that the increased tension of the globe observed in some cases of glaucoma, where no inflammatory processes have been or can be shown to be present, is opposed to v. Gräfe's view, and that M. Donders' theory is supported by no matters of fact, but rests only on analogy.

M. Stellwag v. Carion¹ observes that the hardness of the globe had long ago been pointed out by Dr Mackenzie as a fundamental feature of the disease, but that up to the present time no clear perception of its nosological significance has been obtained, whilst it has been erroneously considered as an expression of and synonymous with increased intra-ocular pressure. In point of fact, however, the perceptible resistance of the globe to pressure is no simple phenomenon, but results on the one hand from the amount of intra-ocular pressure, and on the other from the degree of elastic extensibility (resilience) possessed by the ocular capsule. It is impossible to consider the two factors separately. It can only be said that any augmentation of the pressure in the interior of the eye increases the tension of the capsule, and consequently the perceptible resistance; but at the same time the eye must, with unchanged internal pressure, appear so much the harder in proportion as the sclerotica is less yielding and extensile. Similar conditions are present in the

¹ Lehrbuch der Prakt., Augenheilkunde, p. 270. 1867.

case of the hardness of the pulse in the larger arteries, the hardness being always greater in stiff atheromatous arteries than in normal arteries, especially in those of childhood.

Now, rigidity of the sclerotic and consequent unusual hardness of the eye (so v. Carion continues to argue) is not infrequent as a natural condition, perhaps inherited and congenital, and tending to increase with age, but still more frequently as an acquired condition due to senile changes and atheromatous degenerations. That in such cases the hardness does not proceed from any increase of the intra-ocular pressure, is abundantly shown by the circumstance that, as a rule, neither subjective nor objective functional disturbances are present, and that both eyes may even permanently retain their full integrity of function.

The physical changes occurring in the sclerotic, and occasioning its rigidity, have not been very accurately ascertained; but Coccius has observed the presence of fatty, and Donders of calcareous degeneration. But if now the increase in hardness of the globe be not necessarily combined with an increase of the intra-ocular pressure, but is attributable to other causes, it is difficult to admit the latter as constituting an integral constituent of the glaucomatous process; rather it would appear that the increased resistance of the bulb in simple glaucoma, and in the remissions of the inflammatory form, is to be referred purely to the rigidity of the capsule of the bulb; and the circumstance that the resistance which the globe offers to external pressure in indubitable cases of glaucomatous affections is frequently not greater than that which is met with in perfectly sound eyes, with rigid capsule, is a strong argument in favour of this view. The constant occurrence of excavation of the optic disk in glaucoma cannot be considered as a valid proof of the temporary or permanent augmentation of the intra-ocular pressure, since this may well result from diminution of the resistance of the cribriform layer, which may, *per se*, without any alteration of the normal pressure,

occasion the excavation; and such diminution of its resistant power may be induced by simple neuritis, atrophy, or inflammatory change, such as is frequently observed to accompany the acute glaucomatous processes.

In conclusion, M. Stellwag observes that, if an increase in the amount of intra-ocular pressure ceases to be an essential element in the production of glaucoma, the rigidity of the sclerotic capsule alone remains, which accounts for the rare occurrence of glaucoma in young subjects, and likewise for the curative results of the modes of operation found effective in obtaining relief; since in these the sclerotic is divided through a considerable arc, and the wound is closed by a yielding cicatrix, which in some degree supplies the absence of elasticity of the ocular capsule itself. He then goes on to show how the various changes above noted may result from the circulatory disturbances induced by the rigidity of the sclerotica.

It is generally admitted that glaucoma is more frequent in women than in men. According to the statistics of Dr Magawly,¹ the proportion of women to men is as 6·41:3·64; and he has furnished the following table, showing the augmented tendency to the disease which exists after the fortieth years. The affection occurred

	Men.	Women.	Total.
Between 10 and 20 years in	1	...	1
" 20 " 30	1	...	1
" 30 " 40	1	2	3
" 40 " 50	7	11	18
" 50 " 60	12	23	35
" 60 " 70	13	15	28
" 70 " 80	3	5	8
" 80 " 90	1	...	1
	<hr/> 39	<hr/> 56	<hr/> 95

Arlt states that in 110 cases there were sixty-five women

¹ Ophthalmic Review, No. 3. 1864.

and forty-five men. Dr Lucian Rydel¹ more recently found that in Arlt's practice there were seventy-nine cases, of which forty-six were men and only thirty-three women. He explains this discrepancy, however, by the circumstance that more men were under observation than women, and states that, if the numbers were reduced proportionately, the ratio was only 6·5 per cent. in men, to 7 per cent. in women. Dr Rydel agrees with various older writers in thinking that the disease is remarkably frequent amongst the Jews, as many as 23 per cent. of all the cases being Israelites. The simple form of glaucoma is always most common in men.

The treatment of glaucoma pursued in the present day may be summed up in a few words. It consists in relieving the intra-ocular pressure by operation, either by iridectomy as recommended by v. Gräfe, or by the division of the ciliary muscle as practised by Mr Hancock; in relieving the neuralgic pains in the temple and forehead by the subcutaneous injection of morphia, and in the judicious employment of local depletion, combined with general stimulants and tonics. There can be little doubt but that the operation of iridectomy, as well as that of division of the ciliary muscle, act by giving exit to a portion of the contents of the globe, and by permitting the overcharged vessels to relieve themselves of their contained blood. "Its advantages," say M. Sichel, "are that it produces an immediate intra-ocular depletion of blood; that is to say, that it effects a considerable diminution of the quantity of blood in the deep vessels of the globe, and thus decreases in a prompt, direct, and very efficacious manner the fulness of the organ, as well as the intra-ocular tension and pressure."

Where iridectomy is performed with these objects in view, the corneal section should be of considerable extent, and if possible occupy the upper segment; a large fold of the iris

¹ Bericht über der Augenklunik der Wiener Universität, p. 132. 1867.

should be excised, comprising one-fifth or more of its whole surface, and be repeated should the symptoms continue, whilst care should be taken that it is removed quite to the ciliary margin.

We have followed the practice of v. Gräfe in recommending the removal of the upper part of the iris, partly because by the pressure of the upper eyelid the natural curvature is better preserved, and partly because the altered form of the pupil and the line of incision are concealed. It cannot be denied, however, that the danger of wounding the capsule is very great, especially where the anterior chamber is shallow and the eye deeply set. On this account Arlt usually operates on the lower segment of the iris, which is much more accessible, and finds that the patient soon learns to elevate the lower eyelid sufficiently to cover the inferior part of the artificial pupil, and thus to avoid the inconveniences of irregular refraction of light.

The period at which iridectomy should be performed is a subject of much difference of opinion. Sichel (fils) is opposed to operating in the acute inflammatory stage of glaucoma, but operates immediately after this has subsided. v. Gräfe makes the following remarks upon this point:—If iridectomy be performed during or immediately after the occurrence of the primary acute inflammatory symptoms, it hastens in a large proportion of cases the supervention of an attack of the same disease in the opposite eye, presupposing that this has already shown more or fewer of the precursory symptoms of an attack, and even possibly when it is perfectly sound. Whilst, for example, in acute inflammatory glaucoma the first manifestations of inflammation in the other eye occur after the lapse in most cases of some months, or even of some years, *after* iridectomy has been performed, the second eye is not unfrequently attacked within the first month, or even within the first fortnight. This disadvantage, however, v. Gräfe believes to be outweighed by the circumstance that the curative

effect of iridectomy is always greatest when it is employed in the very first stages of the inflammatory process, whether in the eye first affected or in the second eye, whilst every moment of delay is hostile to success. In another place, also, he remarks that iridectomy is so much the more efficacious against glaucoma in proportion as it is practised earlier, and the less the internal organs of the globe have undergone material alterations of structure or function.

The operation of iridectomy has been sometimes followed by success, even when performed in quite the later stages of the acute form, but in general it then proves useless. It is indicated in the chronic form for the same reasons which have been given for practising it in the acute; but in that form of the disease which accompanies cerebral amaurosis, it is never followed by any beneficial result.

The object attained by iridectomy—that, namely, of reducing the intra-ocular pressure—may also be obtained by Mr Hancock's operation of cyclicotomy, or division of the ciliary muscle. Mr Hancock¹ considers that in acute glaucoma the eyeball is constricted and marked by a circular depression at the point corresponding to the ciliary muscle, whilst the vessels round this point are gorged to a great degree; and he is of opinion that the disease is essentially occasioned by undue and excessive constriction exerted on the bloodvessels by the spasmodic or extreme contraction of the ciliary muscle, analogous to the spasm so often observed in the muscular fibres of the urethra, as well as in the sphincter ani muscle, in certain affections of those parts. The operation which he has proposed for the relief of these conditions, consists in the introduction of a cataract-knife, or, still better, of a double-edged lance-shaped knife, through the sclerotica, just without, and in a radial direction from, the margin of the cornea to the depth of about one-sixth of an inch. The length of the cut should be about the same. By this incision, especially if the

¹ See *Lancet*. 1860.

knife be held obliquely to the meridional lines of the eye, both the circular and radiating fibres of the ciliary muscle will be divided. The knife must not be introduced too deeply lest the lens be injured. If introduced too far outwards, only the vitreous will be penetrated. This is sufficient, if the vitreous, as occasionally happens, be fluid. An oozing of the vitreous takes place for a day or two, and great and permanent relief is occasioned. Where the vitreous is firm, little or none will escape; and then I think, by a slight alteration in the direction of the point of the knife, the anterior chamber may be opened, and the tension relieved by permitting the aqueous to escape. That in some cases of acute glaucoma this mode of operation is attended by satisfactory results I cannot doubt, as I have seen several permanently successful cases, both under Mr Hancock's and my own care. I think, however, it is most successful in the earliest stages of the acute forms of the affection. It is useless where the iris has formed adhesions to the capsule of the lens; but in the chronic form, where this complication has not occurred, it is also very useful.

In comparing the two operations, the relative dangers of the two must not be overlooked. In the division of the sclerotica in the ciliary region there are scarcely any; and I do not remember one instance out of a large number in which the patient has been placed in a worse position than that in which he was previously to the operation. No doubt that it sometimes fails in effecting any relief, but the same is also observed in cases where iridectomy has been performed.

The dangers of iridectomy, on the other hand, are by no means slight, as all who have frequently performed the operation will admit. v. Gräfe gives a caution, that the aqueous should not be allowed to flow too rapidly through the wound, otherwise retinal ecchymoses are apt to occur; nor is this the only effect. Cataract is a very frequent result of the operation; and though this not unfrequently results from laceration of

the capsule in the act of seizing the iris with the forceps, or is made by the point of the knife in the corneal section, which may happen in very practised hands, yet v. Gräfe himself observes that the same laceration may be occasioned by the sudden escape of the aqueous, and gives this as an additional reason why the knife should be withdrawn slowly and carefully after the corneal section has been completed. In some cases, again, violent inflammation of the globe succeeds, and in not a few cases the new pupil becomes filled by exudation and neoplastic formations, which gradually obscure and finally abolish vision.

Lastly, in about one-fifth of all the cases, the wound in the sclerotic does not heal by a uniform line of cicatrix, but in isolated patches, or by bridles, the interspaces of which are filled only with a very fine tissue, which readily yields to the intra-ocular pressure, forming cyst-like protrusions that from time to time give way, permitting the escape of the fluids of the eye into the subconjunctival tissue. To avoid the occurrence of this imperfect cicatrization of the wound, great care should be taken in applying the compressive bandage, and in causing the pressure to be exerted evenly and uniformly on the globe. Should this prove inefficacious, the projecting part may be snipped off with a pair of curved scissors, and the pad and bandage carefully reapplied.

A slight modification of Mr Hancock's operation has been suggested by M. Vose Solomon,¹ which consists in entering "a Beer's cataract-knife at the corneo-sclerotic union, and then pushing it through the pillars of the iris into the muscle; the flat surfaces of the blade being opposed on one side to the sclerotic, and on the other to the rim of the lens. The incision in the muscle is limited to one-sixth of an inch." M. Solomon terms his operation intra-ocular myotomy.

Besides the operative proceedings, the general health of the patient should be carefully attended to. The pain and incon-

¹ Med. Times and Gazette, vol. i. p. 54. 1861.

venience which attend the exertion of the eye on minute objects are usually sufficient to deter the patient from using it for these purposes, even in the chronic forms of the complaint; if not, however, he should be directed carefully to abstain from reading or needle-work; he should be kept in a darkened room, and as quiet as circumstances will permit. The diet should be sustentative, especially if the patient is very debilitated, when a little wine may be allowed, the quantity being regulated by the effects produced. Cooling, evaporating lotions may be applied on linen to the eye, the cloth being frequently changed. The advantages of injections of morphia have been already alluded to. In the case of women, the due performance of the catamenial functions should be carefully inquired into, and, if deficient, promoted by warm hip-baths, leeches to the os uteri, and the administration of the preparations of iron and of aloes.

Although inflammation of the choroid, attended with effusion into the vitreous, commonly occasions the symptoms of glaucoma, I possess notes of three or four cases in which, whilst there was good evidence of choroiditis being present, no glaucomatous symptoms exhibited themselves. There was never at any time severe pain, nor increased tension of the globe, nor dilatation of the pupil; but the striking symptoms were—rapidly increasing dimness of vision, till only the largest objects were perceived; liquefaction of the vitreous, with large masses of floating pigment distinctly visible in it; a tendency to deposition upon or opacification of the posterior capsule of the lens; and a disposition to the formation of posterior synechiæ.

The two following cases appeared to me to be examples of this form of inflammation:—Julia C., æt. 19, a remarkably healthy-looking and well-grown woman, came to the Hospital complaining of dimness in the right eye. She stated that she had been married for three years, and had had one child. The surface of the cornea near the outer angle of the eye was

cloudy, and there was a trifling inflammation of the conjunctiva. On examining the lids, one or two fine cilia were found to be misplaced in direction, and they were removed. Two days afterwards she returned, complaining still of the dimness, and the eyes were now examined with the ophthalmoscope. The fundus of the left was perfectly natural, the colour of the choroid around the foramen centrale being strongly marked; the media quite clear. The fundus of the right could only be discerned with great difficulty, on account of muddiness of the vitreous, in which floating shreds and particles could be plainly discerned. As far as could be seen, however, the choroid was of its natural colour, and the retinal vessels did not appear to be unduly dilated or tortuous. The iris, previous to the instillation of atropine into the eye, was of moderate diameter, contracted sluggishly on the admission of light, but dilated freely with the atropine. The vision was very obscure, so that she could scarcely discern the hand held and moved between the window and the light, and she was quite unable to see the largest type of Snellen at any distance. The eye, looked at from without, appeared perfectly natural; the conjunctiva was not congested; the sclerotic was of a pearly clear blue; the iris markings were quite distinct and clear. She was at once placed on good diet, and ordered to take three or four glasses of wine daily, and a draught containing 3j. of decoction of cinchona, 3j. of compound tincture of cinchona, and 3j. of solution of the bichloride of mercury (1·16th gr.), three times a-day.

The attack appeared to have come on suddenly, as it was not noticed until the day before she came to the Hospital, on the 6th December. On the 11th December great improvement in the symptoms had taken place. She could dimly discern the bars of the window-frame, and even CC of Snellen, at three feet distance. She had had no pain nor inconvenience about the eye, nor had she suffered from any subjective symptoms of light. The tension of the globe was normal, or

only slightly increased. On ophthalmoscopic examination, the fundus could be much more distinctly seen. The choroid appeared darker than that of the opposite eye, but none of the *venæ vorticosæ* or larger ciliary vessels could be seen. The margin of the optic disk was hazy and ill-defined (resembling the appearances shown in fig. 72); the optic disk itself was paler than natural, and the retinal vessels were decidedly smaller than those of the opposite eye. On the 5th January, vision had so materially improved that she was able to distinguish C of Snellen at thirty feet; and the vitreous had become clearer, though still very hazy as compared with the other. The tension of the globe was thought to be a little greater than natural. On the 12th February the vision was still in the same state, but she had suffered from severe headache for the last fortnight over the brow; and as she lived at some distance from town, had been unable to come up. I again examined the eye on the 29th March, and was unable to discover any pathological change, except that the retinal vessels were large, and that the choroid was of a deep colour. The pupil was round; the media was clear, with the exception of one or two large floating shreds; the tension of the globe was nearly the same as that of the opposite eye. The iris acted readily with atropine, but sluggishly to the action of light, and the vision was in precisely the same condition.

The cause of such an attack as this occurring in a young and apparently healthy married woman must always be obscure. I ascertained from the husband that about a year previously he had contracted gonorrhœa, which he had communicated to her, but was certain that neither he nor she had suffered from syphilis. There had been some trifling irregularity of the menstrual functions, the quantity and frequency of the discharge having been somewhat less than usual.

The case represented in fig. 60, which appears to be a more advanced stage of the same affection, occurred in a married

man, æt. 40, who came to the Hospital complaining of great dimness of vision. The failure of sight had commenced about two years previously, the whole field of vision becoming obscure, or, as he expressed it, he "appeared to be looking through steam or a white fog." He had never experienced much pain in the eye, though he had suffered occasionally from headache. Soon after the dimness of vision commenced, he was much troubled with large *muscæ volitantes*, some appearing as large as pigeons; and about the same time he had constantly the perception of irides and bright halos round lights. During last year, however, the *muscæ* and *chromatopsiæ* had almost entirely disappeared. When he presented himself, the vision in both eyes was so dim that he could only see the largest of Jäger's Test Types with difficulty; the left, which is the one depicted, being the worst of the two. There was no increase in the tension of the globes, and the humours were perfectly clear. The pulse was rather slow and feeble; the appetite bad. He could assign no cause for the disease, except that he had undergone much anxiety of mind and distress in consequence of domestic events. Ophthalmoscopic examination showed the optic disk nearly natural in form and colour, its apparent inner margin encircled with a black crescent; the retinal vessels rather small, but beautifully defined. The choroid presented a remarkable marbled appearance, large patches having a yellowish tint, due apparently to the atrophy of its texture, and to its permitting the light to be reflected from the sclerotic. Here and there portions of the choroid retained their natural hue, passing sometimes abruptly, but more generally gradually, into the lighter-coloured parts. Scattered very irregularly over the whole fundus were dots and patches of pigment.

The treatment adopted was the *mist. ferri. co.*, but no improvement followed whilst he was under observation; and such cases may in general be set down as incurable.

5. *Choroiditis Disseminata, Plastica, vel Exsudativa.*

(PLATE X., Fig. 55.)

This form of choroiditis, the choroidite disseminée of the French authors,¹ has been subdivided by M. Wecker into a simple and syphilitic variety. Both are characterised by the deposition of masses of plastic lymph on the surface and in the substance of the choroid coat. In the *simple form*, and in the earlier stages of the disease, these masses are usually of a yellowish colour, with soft and ill-defined borders, becoming subsequently more defined and prominent. It is not always easy to distinguish these deposits from retinal exudations, or from those atrophic patches of the choroid which permit the brilliant reflection of the sclerotic to be perceived on ophthalmoscopic examination. (Compare fig. 49 with fig. 69.) But the diagnosis may in general be established by the duller colour of the choroidal as compared with the retinal exudations, by the fact that when the effusion is on the retina, or in its substance, the branches of the central artery and vein are more or less veiled, or even for a short space completely lost; whilst, in cases of choroidal effusion, the retinal vessels pass over it with clearly-defined borders; and lastly, according to Wecker, by the circumstance that the deposits on the choroid, although ill defined, are surrounded by tolerably healthy choroidal tissue; whilst the spots in retinitis are the centres of a diffused opacity or haziness, which exhibits itself in the form of small points or faint striæ for some distance around them. Moreover, hæmorrhages (compare fig. 50) from the retinal vessels frequently precede or accompany the spots seen on the retina; and the vessels, which are large and tortuous, may be seen to terminate abruptly at the spot where the ecchymosis has taken place.

¹ Wecker, *Etudes Ophthal.*, vol. i. p. 483; Warlomont and Testelin, *Supplementary Volume to their Translation of Mackenzie's Treatise*, p. 322.

When the inflammatory conditions occasioning the choroiditis have lasted some time, the deposits often coalesce to form plates of considerable dimensions, and an increased formation of pigment then takes place around them (*see* fig. 49), appearing in the form of dots or rings, by which they are encircled.

In the simple form of the disease, the deposits appear in the first instance, and by preference, near the equatorial parts of the globe, and gradually advance towards the posterior pole of the eye; whilst in the specific form—and this is the chief distinguishing characteristic between them—the opposite holds good.¹ If the disease pursue an active course, effusion is apt to take place into the vitreous, producing more or less turbidity, and obscuring the changes occurring in the tunics. In a dissection of a case of this kind made by Pagenstecher, the choroid and retina were firmly attached to and blended with one another at the seat of the deposits, though easily separable elsewhere. The choroidal vessels and pigment cells, and the retina, were alike atrophied, and their situation was occupied by a mass of lymph containing numerous nuclei, which infiltrated the remains of these tissues.

The symptoms of this disease are somewhat obscure, and could not enable a diagnosis to be made without the use of the ophthalmoscope. They chiefly consist in mistiness or cloudiness of vision, partly arising from the effusion into the vitreous, and partly from the functional disturbance of the retina, which reposes on the inflamed membrane. The patients complain of dark spots floating before the eye, and of gradual concentric limitation of the field of vision. In many instances the inflammation extends to the iris, and then posterior synechiæ are apt to occur. In general there is little pain or tenderness of the globe, and there are few or no outward marks of the serious form of inflammation that is progressing within.

¹ Wecker.

The causes of this affection are very obscure, if we except the syphilitic form; but they have been referred to grave constitutional disturbance, occasioned by puerperal fever, severe hæmorrhages, menorrhagia, or uterine disturbance.

The following case will show the principal symptoms of a well-marked form of the disease, and the treatment that may be adopted in it, though in this instance it did not prove very efficacious. I may premise that, although the figure (55) is a good illustration of the general appearances of the disease, I regret that I had no opportunity of taking notes of the case in its earlier period. The patient was a labourer, æt. 30, whose vision had been perfectly good up to December 1855, when he was exposed for some time to intense heat, from the burning of a hut. Immediately after this the sight began to deteriorate, until he was unable to see more than the general outline and position of objects before him. I found he could read the largest letters of Jäger's Test Types (No. 20) at the distance of one foot from the left eye. The globe was of natural tension. The iris was healthy in appearance, and dilated well with atropine. The media were perfectly clear. The optic disk appeared small (myopia), with a blurred margin. The retinal vessels were remarkably clear and distinct, and could be followed throughout their whole extent. The choroid presented many yellowish patches, of very irregular form, the edges in some parts being sharply defined, and at others softened off into the natural colour of the choroid. The venæ vorticosæ and ciliary arteries were very perceptible, and at some distance from the optic disk were numerous patches and dots of pigmentary deposit. Decoction of cinchona and iodide of mercury were in the first instance prescribed for him without effect, and subsequently iodide of potassium, which he continued to take for some time. As, however, it effected no improvement, it was exchanged for the iodide of iron, from which for a time he thought he derived benefit; but I did not find that he read the Test

Types with greater facility than at first. Indeed, it can scarcely be expected, when the organic changes are so profound as in cases similar to the above, and where the functions of the retina have long been impaired, that it can ever again acquire its original powers. The most that can be done is, by judicious prophylactic measures, to avoid the increase and extension of the disease.

The subject of suppurative choroiditis will be appropriately considered under the head of Panophthalmitis.

Hæmorrhage from the Choroidal Vessels.—This condition is generally the result of accident, following severe blows upon the eye, or is consequent upon such intense congestion of the vessels of the choroid as occurs in glaucoma. It has also been observed to occur when, in cataract or in glaucomatous affections, the requisite incisions have been too rapidly performed, the vessels previously loaded with blood having been suddenly relieved from pressure. Under such circumstances the blood may be either effused into the vitreous, making its way through the retina, or it may be extravasated between the choroid and the sclerotica. If it occur in any quantity, the eye may be considered as irretrievably lost. If, however, only a small quantity escape, it may in process of time undergo absorption, though, as Mr Frank¹ has shown, the mark or cicatrix of the lesion often remains, and may be recognised by the ophthalmoscope. When the hæmorrhage has once taken place, no treatment can be directed to the eye beyond rest and the application of cold; but general measures should be adopted for the prevention of a recurrence of the effusion, as moderation in diet, the free action of the bowels, and avoidance of all violent exertion; whilst in old and debilitated patients the strength should be supported by wine and the preparations of iron.

In addition to the foregoing affections of the choroid, a number of pathological conditions have been described by

¹ Ophth. Hosp. Rep., vol. iii. p. 84.

different authors, which for the most part possess but little general interest. Amongst the most important may be enumerated—

1. *Tubercular Deposits in the Choroid*.—Three cases of this disease have been described by Manz¹ and one by F. Busch,² all of which bear a striking similarity to one another. They all occurred in young persons, the several ages of these four cases being six months, one and a-half years, fifteen years, and twenty-nine years. No affection of the sight was known to exist in any of them during life. In all the cases miliary tubercular deposits were found widely distributed through the other organs of the body, as the lungs, liver, kidney, and serous membrane; and in one case hydrocephalus was the cause of death. In Busch's case, there were about three-and-twenty small, clear, grey, transparent nodules, distributed over the posterior portion of the choroid, the largest being about the size of a pin's head, and the smallest very minute. On microscopical investigation, the cells of the choroid contained very little pigment, and in some parts none, and were intermingled with an immense number of nuclei, the origin of which was referred by Manz to the tunica adventitia of the vessels; but Busch could trace no connection between the two. The tubercular nodules occupied the whole thickness of the choroid, and projected from its inner surface. Their external portions consisted of a great number of small sharply-defined nuclei, the outline of which became indistinct in the more central parts, without presenting any trace of fatty degeneration, or of breaking up of their substance.

2. *Colloid Disease of the Choroid*.—In this disease, which has been described by Wedl³ and Donders,⁴ H. Müller⁵ and

¹ See v. Gräfe's Archiv. f. Ophth., vol. ii. Heft. ii. p. 120, and vol. iii. p. 133.

² Virchow's Archiv., vol. xxxvi. p. 448.

³ Syd. Soc. Translat., p. 282. 1855.

⁴ Archiv. f. Ophth., Bd. i. Heft. ii. p. 107. 1855.

⁵ Anatomische Beiträge, Bd. ii. Heft. ii.

Hulke,¹ a number of clear, transparent bodies are found distributed through the inner layer of the choroid. In Donders' case, which was that of a woman aged seventy, they constituted a double girdle or zone near the ora serrata. In most cases, when the inner surface of the choroid is examined with a strong lens, the darker parts may be seen to consist of ordinary pigment cells, arranged in a net-like manner, whilst the clearer intervening parts are usually completely destitute of them, and present in their stead a number of bright, quite transparent, round, smooth, and colourless bodies. These are irregularly distributed on the surface of the choroid, are highly refractile, possess no cell-wall nor nucleus, and resist compression. Scarcely any of the ordinary re-agents have any action upon them, and they therefore appear to consist of a material which is neither starch, amyloid, nor colloid, but which resembles in some respects the walls of cartilage cells when thickened. Many opinions have been put forward as to their nature, some considering that they may be pigment cells destitute of pigment; others, as Donders, that they may proceed from the *nuclei* of the pigment cells, which first increase in size, and then lose their cell-wall, leaving the enlarged nucleus behind. H. Müller regarded them as a modification and outgrowth of the elastic lamina. Mr Hulke has, however, seen the elastic lamina pass over them, and states that stellate pigment cells are often found adhering to their outer, and either a few scattered cells or a sheet of pavement hexagonal cells to their internal, surface, which favours the supposition that they take their origin in the chorio-capillary layer. By their coalescence they often form masses of considerable size, and they are prone to undergo fatty degeneration and to calcify. They occur for the most part in adults, and are not easily recognisable during life with the ophthalmoscope. Mr Hulke is disposed to think that the appearance of these colloid globules is always

¹ Ophth. Hosp. Rep., vol. i. pp. 70, 180.

associated with inflammatory conditions of the choroidal tunic.

The symptoms which these bodies produce are probably inappreciable unless they are numerous and large, when more or less amblyopia will result. Their usual seat is midway between the entrance of the optic nerve and the ora serrata, a part that naturally participates but little in the perception of external objects.

No line of treatment can be suggested for this disease except that of general support and local depletion.

3. *Formation of Cartilage and Bone in the Choroid.*—Wedl¹ observed on the inner side of the choroid coat, in an atrophied eye, numerous more or less extensive isolated grey nodules, which consisted of bone substance, the corpuscles in which were large, oval, or elongated, and presented a jagged outline. The inter-corpuscular substance was composed of thick fibres, decussating in various directions, and leaving everywhere minute vacuities between them. In other parts, the fibres composing this substance were already fused into a homogeneous, finely-perforated mass. Contiguous to the ossified part, a yellowish fibro-cartilaginous tissue could be perceived, beneath and close to which granular, flattened, oval, elementary structures, aggregated into layers, were apparent, together with shreds of the membrana limitans.

4. *Cancer*, both of the melanotic and medullary character. As, however, other symptoms of these are identical with the same diseases when taking origin in the retina, their description will be deferred till the diseases of the retina are under consideration.

Lastly, one or two isolated cases are on record of cysts and of fibro-plastic tumours of the choroid, the gradual progress of which in all instances proves totally destructive of vision.

¹ Pathological Histology, Translated by Busk, p. 506. 1855.

DISEASES OF THE VITREOUS.

Though occupying so large a proportion of the volume of the eye, the importance of the vitreous, in a pathological point of view, falls far below that of the several investing tunics which surround and enclose it. This results in part from its peculiar structure, which renders it little liable to inflammatory processes, and indeed leaves it doubtful whether the term inflammation can be properly applied to any of the pathological changes that take place in its substance, and partly to the circumstance that almost every cause which might be supposed capable of inducing inflammation in it acts also upon the adjoining textures, to the inflammation of which the various changes seen in the vitreous may reasonably be attributed. Nothing can illustrate this better than the results of the old operation of reclinatio, in which the substance of the vitreous inevitably suffers serious injury, and yet in which suppuration is a rare event ; or, again, in cases of the entrance of foreign bodies into the eye, and their lodgment in the vitreous, where the morbid processes observed appear to be essentially due to the damage inflicted on the sclerotic, choroid, or retina. The following remarks will, on this account, be limited to a brief consideration of liquefaction of the vitreous, and of the opacities which are so frequently noticed, either with or without such diminution of its consistency. (*See section on Panophthalmitis.*)

Liquefaction of the Vitreous. Synchysis.—Under certain pathological conditions, generally affecting all the tunics of the eye, the vitreous becomes converted from a gelatinous or semi-solid to a perfectly fluid consistence, a change that is usually made apparent by the trembling of the iris on slight movements of the eye or body, and by unnatural softness of the globe. The transparency of the humour is sometimes perfectly retained, but not unfrequently floating spots and membranous flocculi may be observed both by the patient and

on ophthalmoscopic observation. The fluidification of the humour may either affect the whole or may be limited to a part, and even to a very small part, of its substance. It often follows iritis, choroiditis, and irido-choroiditis, especially when these affections are consequent upon injury, and then affects the entire mass; but after reclamation of cataract, that part which has been broken down by the pressure of the lens alone becomes fluid. It frequently accompanies that condition in which the whole globe is enlarged,—the so-called *hydrops oculi*,—and is often observed in cases of cataract occurring in those who have been always strongly myopic and amblyopic previously to the formation of the cataract.

For its treatment nothing can be done, and the less the eye is interfered with by operation the better. Its presence constitutes a very decided contra-indication against the flap operation for cataract. If, through continuous secretion of the fluid, the globe begin to enlarge, it may be tapped through the cornea, or Mr Hancock's operation may be performed.

Opacities of the vitreous present many varieties from those which are wholly subjective, and cannot be discerned by the most careful ophthalmoscopic investigations, to degrees of turbidity which are easily recognised by that instrument, and in which the form and position of the floating particles can be diagnosed with tolerable accuracy. The slighter forms must have been occasionally noticed by every intelligent observer in his own person, appearing as beaded striæ and pearly structures,¹ which continue to move for an instant after the movement of the eye has been arrested, and then slowly sink below the field of vision. These appearances are probably due to some small transparent cellular structures, possibly the remains of the capsular artery, which, from their

¹ For a full description of the varieties of which, see the section on *Myodesopia* in Dr Mackenzie's *Treatise on Diseases of the Eye*, p. 949.

refractive power for light being different from that of the medium in which they float, cast a shadow on the retina, though, like bubbles in water, they may be perfectly transparent. In other instances they are much more opaque, and then probably consist of one or more pigment cells which have become detached from the choroid or uvea, and have made their way through the hyaloid membrane into the substance of the vitreous. Or they may originate, as v. Gräfe believes, in slight hæmorrhagic effusions, especially if, on moving the eye, they may be seen gradually to rise to the apparent upper part when it is brought to rest. Such spots and flocculent or membranous-like bodies have received the name of *muscæ volitantes*. The looped and filamentous forms, as well as minute black specks, may be observed in perfectly healthy eyes, and for the most part, after lasting for some weeks or months, gradually become fainter and disappear. When they are numerous, or of large size and constant, they are of bad augury, indicating in many instances the accession of glaucoma, though they are oftentimes associated with dyspepsia, prolonged exercise of the eyes on minute objects, sustained mental exertion, or any circumstance occasioning congestion of the cerebral vessels. The amount of movement which these spots undergo in the changes of position of the eye afford some evidence of the degree of liquidity of the vitreous. Their position may also be approximately ascertained by causing the patient to look through a small opening, as a pin-hole in a card, at the sky. If the card be moved upwards, and the objects appear to move in the same direction, they are situated behind the pupil; and the greater the extent of movement they appear to possess, the more distant must they be from the surface of the retina. If they appear to move in the opposite direction to the card, their position is in front of the iris.¹ Sir David Brewster's plan for determining the position of

¹ Wecker.

muscæ consists in looking at two flames through a minute aperture, by which means double images of the moving objects are thrown upon the retina. Those situated in the fore part of the vitreous throw very distinct double images; those near the retina will have their double images situated close to one another, or overlapping; whilst any object on the retina will have only a single image. From measurements made of the shadows of these objects, Dr Mackenzie and Sir David Brewster arrived at the conclusion that their size was from 1-600th to 1-800th of an inch in diameter.¹

Such floating bodies as these are rather troublesome and annoying to the patient than positively injurious to sight, unless they exist in large numbers; and in such cases the choroid is usually the seat of inflammation.

As regards the treatment, the patient should be counselled to refrain from employing the eye on minute objects, to take active exercise in the open air, and to avoid all conditions that may tend to cause cerebral congestion. If debilitated by night-watching and mental anxiety, rest, liberal diet, mild tonics, and purgatives are obviously indicated.

Another form of hyaloid opacity occasionally seen, is that in which minute glittering scales fill the vitreous, giving it the appearance of eau de vie de Dantzic; and as it is always accompanied by liquefaction of the vitreous, it has been termed by Desmarres *synchisis scintillans*. In one well-marked example that I have lately seen, this condition was present in a woman of middle age, whose eye had long been lost from injury in youth. Nothing remarkable was observed on external inspection, but on examining it with the ophthalmoscope the light was brilliantly reflected from numerous

¹ The reader will find some instructive remarks on the depth and position of objects in the vitreous in Dr Rainy's Paper on the Causes of Apparent Motions of the Images of Objects situated in different planes within the Eye, when viewed by means of the Ophthalmoscope, Ophth. Hosp. Rep., vol. iii. p. 91.

minute scales, which have been ascertained to be cholesterine, and which fell like a shower through the vitreous when the eye was moved upwards.

Crystals of hæmatin have been occasionally observed to form in the vitreous after intra-ocular hæmorrhage.

CHAPTER VIII.

Diseases of the Retina.

GENERAL ANATOMY OF THE RETINA—HYPERÆMIA OF THE RETINA—ECCHYMOSIS OF THE RETINA—RETINITIS: ITS VARIOUS FORMS, DIFFUSED, NEPHRITIC, SYPHILITIC, AND GLYCOSURIC—PIGMENTARY DEGENERATION OF THE RETINA—DETACHMENT OF RETINA FROM THE CHOROID—EMBOLISM OF THE CENTRAL ARTERY OF THE RETINA—MORBID CONDITIONS OF THE OPTIC NERVE—AMBLYOPIA AND AMAUROSIS.

1. *General Anatomy of the Retina.*

CONTINUOUS with the optic nerve, resting on the choroid behind, and supported by the vitreous in front, is the retina. The structure of this membrane has received great attention at the hands of microscopists during the last few years,¹ though some points are still open to investigation, and are differently interpreted by exact observers.

The retina consists of an expansion of nervous tissue, with certain appendages, apparently of a sensory character, the whole being interpenetrated, and as it were supported, by a delicate web of connective tissue. In its recent state it is transparent; but very soon after removal from the body, and still more quickly if it have been exposed to the action of chromic acid, iodine-water, alcohol, solution of bichloride of

¹ See Henle's *Systematic Anatomy of Man*; Schultze' *Monograph on the Retina*; and Mr Hulke's *Papers*, in the *Proceedings of the Royal Society*, from which sources the following account is partly drawn.

mercury, or other hardening agent, it becomes semi-opaque and of a delicate grey colour. Its average thickness is about 1-25th of an inch. On examining a thin vertical section, hardened in chromic acid in the manner recommended by Mr Lockhart Clarke, and subsequently moistened with a drop of solution of gum mixed with glycerine, the following layers may be distinguished from the outer towards the inner surface, though it must be remembered that considerable difference exists in their relative thickness and development in different parts of the retina:—

1. The layer of *rods and cones*, sometimes called the bacillar layer (*b*, fig. Y; *a*, fig. Z). This layer is about 1-500th of an inch in thickness. The rods, which are much more numerous than the cones, except near the macula lutea, are round, flat topped externally, where they are received into slight depressions of the choroid, and pointed internally. The cones are somewhat shorter and thicker than the rods. The inner-pointed extremities of both the rods and the cones are believed by some to be articulated to the outer cylindrical portion, and to have a different composition.¹ Ritter² has observed that, in specimens preserved in chromic acid, each of the rods contains a fine thread continuous with a nerve fibre, resembling an axis cylinder. After perforating the *membrana limitans externa*, the inner extremity of every rod and cone expands into a nuclear-like body, from which again a fibre may be traced for some distance in the substance of the retina. As regards the proportion of the rods and cones, the former diminish in number from the ora serrata towards the fovea centralis, where they altogether fail, and are replaced by the cones which are here in direct contact with one another.

2. The second layer is the *membrana limitans externa* (*le*, fig. Y, and *b*, fig. Z), composed of a delicate transparent

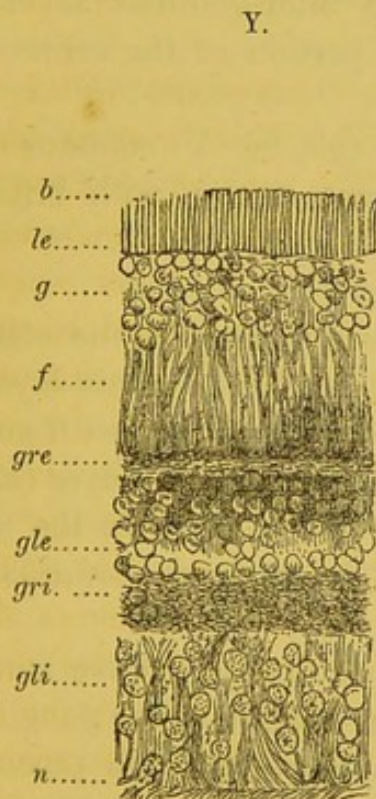
¹ Krause Zeit. f. rat. Med. Bd. vi. and xi.

² Archiv. f. Ophthalmol., Bd. v. Heft. ii. p. 101.

material, which appears to be a modification of connective tissue.

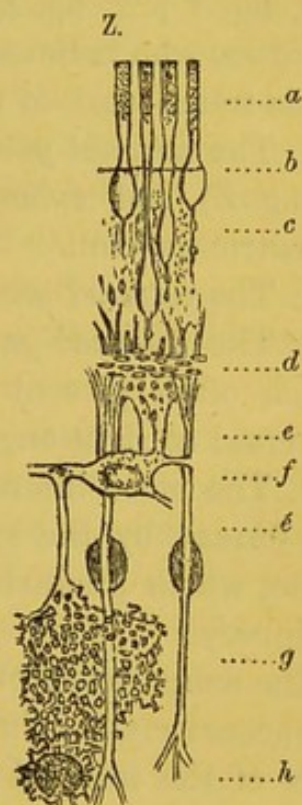
3. To this succeeds in general, but not always, the layer, composed of the nuclei belonging to the *rods* and *cones* (*c*, fig. Z), which, when present, are again followed by

4. A remarkable layer of *oval nuclei*, termed by Henle striated or striped nuclei, because each presents an equatorial and two polar dark bands (*g*, fig. Y).



Vertical section of the Retina of a newly-born Child.

- (*b*) Bacillar layer.
- (*le*) External limiting membrane.
- (*g*) Nuclear layer.
- (*f*) External fibrous layer.
- (*gre*) External granular layer.
- (*gle*) External ganglionic layer.
- (*gri*) Internal granular layer.
- (*gli*) Internal ganglionic layer.
- (*n*) Fibrous nervous layer, after Henle.



Vertical section of the Retina, to show the arrangement of the Connective Tissue.

- (*a*) Bacillar layer.
- (*b*) Membrana limitans externa.
- (*c*) External granular layer.
- (*d*) Inter-granular layer.
- (*e* and *e'*) Fibres of Müller.
- (*f*) Inter-granular layer with large cells.
- (*g*) Molecular layer.
- (*h*) Nerve cell. $\times 600$, after Schultze.

5. The fifth forms the *external fibrous* and *granular* layer (*f*, fig. Y), which is most distinct near the fovea centralis. The fibres for the most part run perpendicularly to the general plane of the retina, are very delicate, and, after death or in hardened preparations, become rough, branched, and tangled from the contraction of the vitreous. The granular appearance is generally diffused throughout this layer, but the inner part is so modified as to constitute almost a separate layer (*gre*, fig. Y; *d*, fig. Z), termed the inter-granular layer by Schultze, who believes it to be a portion of the connective tissue frame-work of the retina.

6. The *external ganglionic* layer (*gle*, fig. Y) contains cells (*f*, fig. Z) and spherical transparent nuclei, with brilliant excentric nucleoli.

7. The *internal granular* layer (*gri*, fig. Y), and

8. The *internal ganglionic* layer (*gli*, fig. Y), the cells of which often present caudate prolongations. This layer is traversed at right angles by numerous fibres derived from

9. The more internally placed *fibrous* nervous layer (*n*, fig. Y), formed by the spreading out of the fibres of the optic nerve, which gradually diminishes in thickness towards the periphery.

The actual mode of termination of the optic nerve fibres is not accurately known; but Kolliker holds that the ganglionic cells of the internal ganglionic layer possess two processes, one continuous with a fibre of the internal fibrous layer, and therefore running parallel to the plane of the retina, and the other passing outwards at right angles to this towards the bacillar layers, with a rod or cone of which it may possibly be continuous. Besides these layers, and extending vertically between the two membrana limitantes, is a system of connective tissue fibres which pervades the whole retina (shown in fig. Z). In the centre of the thickness of the retina, the trabeculae are exceedingly fine, delicate, and transparent, filling up the interspaces of the other elements; but near the

limiting membranes they are collected into well-marked brushes or bundles, the so-called fibres of Müller (*e é*, fig. Z).

The *macula lutea*, *fovea centralis*, or foramen of Sömmering, is a circular or transversely elliptical spot, presenting a central bright yellow slightly depressed disk, of 1-12th of an-inch in diameter, surrounded by a yellowish halo. The colour depends on pigment diffused through the several layers of the retina that are here present. The characteristic feature of the macula lutea is the great comparative development of the external fibrous layer, of which it might almost be considered as the centre, just as the optic nerve is the centre of the internal fibrous layer. The bacillar layer here consists only of cones, and the remainder of the retina seems to consist merely of cells and nuclei, the layers elsewhere seen having coalesced into a uniform mass, and the whole thickness of the retina being much reduced.

As regards the vascular supply of the retina, though it is probable that it obtains nourishment from the great plexus of the choroid on which it lies, yet no blood-vessels enter it that spring from this source. The single artery which passes directly to the retina, is the *arteria centralis retinæ*; and Leber has shown (*see* fig. L., p. 248) that its only communication is with the posterior short ciliaries in the substance of the sclerotic itself, where they together form a ring around the entrance of the optic nerve.

The branches of the central artery lie on the surface of the retina, between it and the hyaloid membrane. They may clearly be seen under the ophthalmoscope to spring from the centre of the optic disk, and divide into numerous branches, always of brighter colour and smaller calibre than the veins, and pursue a more or less wavy course, dividing and subdividing till they can no longer be followed. The veins are large and dark-coloured, with beautifully defined borders, and cross either over or under the arteries they accompany. As

a general rule, two large ones ascend, and two or three descend, diverging from one another.

The retina, when healthy, being transparent, is not perceptible under the ophthalmoscope, or only appears as the faintest possible haze in the immediate vicinity of the optic disk, where its thickness is greatest; but when diseased, the presence of deposits in its substance, or upon its internal surface, betray themselves by their colour, and by altering in some way the course of the vessels.

The appearances presented by the optic disk in health have already been described (p. 394), and those which it presents in white atrophy will be hereafter considered. But a brief account may here be introduced of the principal changes in the retinal vessels recognisable by the ophthalmoscope, and which have been so well given by M. Bouchut,¹ that I have made an abstract of the section of his work bearing on this subject, and have also included the principal cerebral affections in which he has found the changes in the vessels to occur, though they are also seen in many other morbid states.

1. The first and simplest condition is that of *papillary congestion*, in which the optic disk appears rosy, and as though covered with a red veil, and with a blurred outline. This state is always associated with congestion of the choroid, and is seen in cases of severe cerebral hæmorrhage, in certain cases of erysipelas, and in typhoid fever.

2. *Peripapillary Congestion*.—This consists of a hyperæmic condition of the choroid, and of the periphery of the disk, sufficient to mark the whole or part of its contour. It is seen in simple acute tubercular or rheumatismal meningitis, and in some forms of tumour of the brain.

3. *General or partial anæmia*, which occurs in chronic meningitis, and in some cases of senile cerebral romollissement. It is also consecutive upon congested states of the retina.

¹ On the Diagnosis of the Diseases of the Nervous System by means of the Ophthalmoscope. Paris, 1866.

4. *Tortuous course of the retinal veins*, or phlebo-retinal flexuosities. This state is often natural; but after severe cerebral injury, as fracture of the skull or apoplexy, the degree of tortuosity varies from day to day, and then indicates the presence of inflammatory condition of the cerebral veins and sinuses.

5 and 6. *Dilatation of the retinal veins*, or retinal phlebec-tasies, and varicosities of the veins, as well as of

7. *Venous hæmorrhages*, are conditions commonly observed in all those diseases in which there is any hindrance to the intra-cranial venous circulation, such as may occur in tubercular meningitis, in phlebitis of the sinuses, fracture of the skull, with compression of the brain, etc.

8 and 9. When clots form in the vessels, the conditions termed phlebo-retinal *hæmostasis* and *thrombosis* are said to be established.

10. One case is on record of *aneurism* of a retinal vein.

11. *Œdema*, or serous infiltration of the nervous texture, may affect either the optic disk itself or the peripapillary region. Here, coincidently with the redness, there often appears a pale opaline infiltration veiling the papilla, and there may be especially remarked a greater or less dilatation of the veins external to the papilla. A difference in the diameter of the same vessel—small on the papilla and large on the retina—is the main feature of peripapillary œdema. Besides being the characteristic of various inflammatory states of the retina, this condition is met with in fractures, apoplexy, and meningitis.

To these numerous vascular changes enumerated by Bouchut may be added fatty degeneration of the vessels and sclerosis, or thickening of their walls by hyaline deposit, and, finally, embolism of the *arteria centralis retinae*.

Diseases of the retina constitute, according to Dr Mandelstamm's observations,¹ about 3·3 per cent. of all the affections

¹ Pagenstecher's *Klin. Beobacht*, Heft. iii. p. 47. 1866.

of the eye. They are most frequent in adults, and the proportion of males to females is about as three to one. The forms of disease most frequently observed by this writer were retinal detachment from the choroid and atrophy of the optic nerve, the latter especially in young people. Amongst the aged, retinal apoplexies were very common. At the Westminster Ophthalmic Hospital the proportion has been rather less than 3 per cent. amongst about 3000 patients, of whose cases I have taken notes. Of these the chief forms of disease have been, in the order of their frequency, œdema of the papilla and surrounding portion of the retina, atrophy of the optic nerve, separation of the retina from the choroid, syphilitic retinitis, and Bright's disease, attended with retinitis.

2. *Hyperæmia of the Retina.*

Hyperæmia, or congestion of the retina, may chiefly affect either the arteries or the veins. In the former case it is active; in the latter, passive. In active congestion, the arteries as well as the veins are of large size and numerous; the optic disk is pink, but still easily defined from the neighbouring portion of the choroid. Active hyperæmia may be immediately induced in animals by section of the sympathetic in the neck. Besides being associated with the diseases already enumerated (p. 444), it may result from protracted close attention to fine work, or exertion of the eye upon brilliant objects, and is probably a constant antecedent of acute inflammatory diseases. I have lately seen a good example of it in a jeweller under twenty years of age, who had been engaged for some time in working with a powerful lens.

The passive form of congestion is frequently met with in those who from any cause are asthenic, or in whom the return of the blood from the globe is hindered by the growth of a tumour in the orbit, or by thrombosis of the cavernous sinus; or it may even be temporarily produced by simple

pressure on the globe of the eye with the finger. The veins after some time become of large size and tortuous, whilst the arteries may be extremely small; and there is usually more or less cedema of the retina around the optic entrance.

In the acute form of hyperæmia the retina becomes preternaturally sensitive to light; the tension of the globe is slightly increased; the pupil is small, the brows contracted; darkness and shade are sought as a relief, and sparks and flashes of light are often experienced. In the passive form, the functions of the retina are more or less interfered with; the tension of the globe is more or less increased; the pupil is dilated, and dimness of vision, as though produced by the presence of a veil, or of the slow or quick advent of a twilight gloom over the whole or part of the field of vision, is complained of.

Both the active and passive forms of hyperæmia, though often but slightly marked and transitory, should never be lightly regarded, since they constitute in many instances the forerunners or premonitory symptoms of serious inflammatory mischief, which, if recognised before material organic changes have occurred, may be successfully treated, but which, if allowed to progress, too often terminates in the permanent impairment of the organ.

In the majority of cases, both local and general treatment may be advantageously adopted, the local consisting in the daily, or alternate daily application of one or two leeches to the temple, for which the employment of Heurteloup's artificial leech may be substituted. This instrument consists of a circular knife and exhausting syringe, by which any required amount of blood can be readily and almost painlessly withdrawn. In some instances blisters may be applied, but they are dirty, disfiguring, and less effectual than leeches. In the acute form of hyperæmia, tinted glasses prove extremely grateful to the patient, by moderating the amount and lowering the tone of the light admitted.

The general treatment is also very important. The habits and occupation of the patients should be carefully inquired into, and all circumstances which may be supposed to induce congestion of the cerebral or ocular vessels avoided. Fine work, reading or writing, attendance upon hot fires, the employment of unsuitable glasses, confined bowels, violent straining or stooping, tight lacing, and a variety of other conditions, which would naturally suggest themselves to the intelligent surgeon in any given case, should be inquired into and, where seen to be harmful, avoided. In many cases attention should be paid to the condition of the heart, liver, lungs, and kidney, with diseases of each of which retinal congestion and inflammation have been observed to occur.

3. *Retinal Ecchymoses.*

(PLATES IX. and X., Figs. 53, 55, and 56.)

One of the diseased conditions of the retina, which can be most easily recognised with the ophthalmoscope, is an effusion of blood from the retinal vessels. It is always a serious symptom, and may result from various circumstances requiring careful discrimination, both for their prognosis and treatment. Sometimes it is the result of Bright's disease; at others it is a consequence of blows or injuries of the eye, especially if the vessels are already congested. Hence it is not unfrequently seen to follow the sudden escape of the aqueous in the operation of iridectomy for glaucoma. Sometimes, again, it is the consequence of violent fits of coughing, or proceeds from straining or stooping in old persons, whose arteries are more or less diseased. It has been seen to occur in purpura.

The subjective symptoms usually observed may be briefly stated to be sudden loss or great impairment of sight, coincident with some violent exertion, the whole field of vision being sometimes dull and misty; and at other, dark spots or scoloinata existing, corresponding more or less accurately in

form and position to the effusions observable with the ophthalmoscope. In some cases sharp pain is experienced at the time of the rupture of the vessel, but in others this symptom is absent.

The characters which hæmorrhages present differ in different instances. In the case of Bright's disease, and sometimes in glaucoma, they are small, round, or angular, or form fine striæ, as though produced by the rupture of a capillary. (*See* Plate IX., fig. 49, and Plate X., fig. 59.) When they result from coughing or straining, on the other hand, they are often, as in fig. 56, very large.

It is important to determine whether the hæmorrhage has taken place from a retinal or from a choroidal vessel; and this may be accomplished in some instances by observing that, in the case of a retinal hæmorrhage, the vessel which has burst (usually a vein) runs up to the ecchymosis, and is then lost, though in some instances it may be traced beyond it; whereas in choroidal ecchymoses the retinal vessels may be distinctly traced over them. Zander¹ also observes that choroidal effusions are usually circumscribed, rarely forming a continuously extended layer, and that they are frequently concealed partially by pigment spots in the retina, which lie in the same plane with its vessels, and therefore in front of the effusion.

The disappearance of blood-clots in or on the retina takes place with great slowness; remains, in the form of various blackish discolorations, or of shrivelled white fibrinous dots and striæ, being often observable for some months after the occurrence of the symptoms indicating the rupture of the vessel. Fig. 52 shows this condition. In some instances the ecchymoses appear to undergo fatty degeneration, assuming a brilliant white or yellowish colour. After some time the hæmorrhagic patches often become surrounded by, or even the seat of, pigmentary deposits.

¹ On the Ophthalmoscope, Translated by Carter, p. 147.

No local treatment can be applied to the effusion itself when it has once occurred; it must be directed in all instances exclusively to the general condition of the patient. The appropriate treatment for bronchitis, albuminuria, etc., must be put in force, and all circumstances tending to induce congestion of the cerebral vessels must be carefully avoided.

The following case (Plate IX., fig. 50) will give the principal symptoms observed in a case of simple retinal ecchymosis, without other disease of the eye:—

J. S., æt. 74, an artist, was in possession of perfectly good vision one month before I saw him. He appeared to be a hale old man, with ruddy complexion, but with extraordinarily gouty fingers. He was stooping down one day, when he suddenly felt his vision become dull and misty. He was positive he had had no fit nor any even momentary loss of consciousness. There was no pain at the time in the eye, nor had he suffered from any afterwards. He was annoyed, however, by the appearance of a large green, leaf-like body, which constantly floated before the eyes. He compared its form to that of a vine-leaf, but stated that its borders were not very definite. It seriously interfered with his perception of external objects. He did not experience any double vision, and was able to read the largest of Jäger's Test Types. On examination with the ophthalmoscope, the choroid appeared generally rather pale. The margins of the optic disks were ill-defined, though no peripapillary œdema could be distinguished, and the disks themselves, especially on the right side, were pink. The arteries were small; the veins very large. On the right side the hæmorrhagic spots, though numerous, were small. On the left (that represented), there was with the inverted image a large ecchymosis at the upper part, evidently proceeding from the vein which is depicted as entering it. There were numerous other spots and blotches, some of very minute, others of considerable size, and one in particular which occupied the position of the macula lutea,

or rather the space between it and the optic disk. I saw this patient a month afterwards. The ecchymoses were still plainly visible, though somewhat fainter, and the margins of the effusion at the upper part of the right eye had become considerably softened off. The subjective appearance of a leaf and of floating corpuscles had materially diminished, but the whole field of vision was complained of as being misty. This patient died in the course of a few months after I saw him, from apoplexy. The only treatment which was or could be adopted in this case was of a general nature, and directed to the prevention of an attack of that affection, to which he actually succumbed.

Another case that came under my care occurred in a waterman, æt. 58, in whom the vessel burst whilst he was bending to the oar. He was a rubicund man, and suffered from chronic bronchitis. The hæmorrhage had chiefly taken place around the macula lutea, and central vision was entirely lost. The disks were hyperæmic, the veins large, the arteries small. In another case the ecchymosis occurred during an epileptic fit, was very large, and presented the yellow tint indicative of fatty degeneration in a very striking manner.

4. *Retinitis Pigmentosa. Retinitis Nyctalopia and Hemeralopia.*
Night and Day Blindness.

The terms nyctalopia and hemeralopia have received opposite significations from different writers. Dr Copland¹ gives the following definition:—"Obscuration or loss of vision by night only (nyctalopia); or by day only (hemeralopia)"—the *a* in the middle of each of the words being manifestly viewed as privative.

The hemeralopic form of disease is rare, and seems to be understood in a sense synonymous with photophobia, or intolerance of light. It is described as occurring in albinos, in consequence of the deficiency of choroidal pigment, and

¹ Dictionary of Pract. Med., vol. ii. p. 896.

in those who are suffering from retinal irritation, however produced; whether directly, by over-exertion of the eyes, or by exposure to bright glaring light; or indirectly, as by the presence of worms in the intestinal canal, or hysteria. F. Arlt,¹ who has seen numerous cases of this disease, states that the patients thus affected see distant objects badly in broad daylight, are unable to distinguish the features of their friends at the distance of a few yards, and can no longer read; whilst after sundown, on dull days, or by the light of the moon, they either see quite well, or feel that their powers of vision are manifestly improved. The patients often complain of the presence, when the light is strong, of a mist or veil drawn over the eyes; at others, of a net-work, or of numerous black spots, or of a trembling similar to that of air rising from a heated surface. Examination made with test types showed that only a moderate diminution in the sharpness of the central portion of the field of vision existed, the majority being able to read No. 11-14 of Jäger's Test Types, and the amount of deterioration did not appear to bear any reference to the duration of the affection. The diminished sharpness of vision seemed to be tolerably uniform over the whole field, and there was no absolutely insensible part, nor any narrowing of the field. Both eyes were affected coincidently, and to the same or nearly the same degree. No indications of disease were perceptible on external examination; with the ophthalmoscope, the media were found to be clear. The optic disk in most instances, but not always in the earlier stages, hyperæmic; and occasionally it was even paler than natural. It usually became pale in the later stages. Well-marked inflammatory symptoms of the retina were only observed in 10 out of 33 cases, though it is likely they existed in so slight a degree as to escape observation in many of the others. The appearances were slight opacification of the retina, either uniformly diffused or of a striated character,

¹ Bericht über der Augenklinik der Wiener Universität, p. 123. 1863-1865.

and blurring of the margin of the optic disk. In no instance was distinct prominence of the optic disk observed, nor any ecchymoses in the retina.

The disease is chronic in its course, and may even remain for years without inducing complete blindness. The prognosis, unless the obscurity of vision is very great, is not unfavourable. Arlt states that the proportion in which it occurs is about 1 in 900 or 1000 cases. He thinks its essential cause is blinding of the eyes with bright reflected or diffused sunlight. The treatment which he found most beneficial, and which cured 17 out of 33, and relieved 9 of the remainder, was perfect rest of the eye, diminution of the amount of light by the use of smoked glasses, the application of eight or ten leeches behind the ears, and the systematic use of mercury, either in the form of corrosive sublimate or by inunction.

Nyctalopia, or night-blindness, on the other hand, is comparatively frequent. During the bright daylight the vision of those who are subject to it is good, even to reading the finest print or threading a small needle; whilst, as the sun declines, the field of vision becomes more and more gloomy, till at length it passes into a condition of obscurity so deep that the flame of a candle or lamp can only just be discerned, and all other objects are unperceived. With the rising of the sun, vision is restored. It must be owned that in many cases the vision is exceedingly obscure even by daylight; the patients are, in fact, amblyopic for a long time before they become nyctalopic. This affection appears to arise from several causes, and to be sometimes purely functional, and at others organic, in its nature. Thus it may originate from excessive stimulation of the eyes, as is seen in those who have been exposed to the reflection of the sun from snow or sand or water, in consequence of which the retinae are left in a state of exhaustion, which renders them incapable of perceiving objects that are feebly illuminated. This state

may be temporarily induced by looking for a few seconds at a bright cloud or at the sun's disk. It may be produced also by imperfect nutrition of the retina, as is shown by the following account given by Dr Meissner, and quoted by Dr Copland:—In a small town of Podolia, Meissner met with more than one hundred cases of the complaint. It was then the time of the Greek fast, when the inhabitants use no animal food, but live chiefly on bread and groats prepared with oil. He was assured that, at the same period every year, a great many people were seized with nyctalopia, but that when Easter came they ate the liver of a black cock or black swine, and were cured in a few days. He examined, by day and by night, several of those affected with the disorder, but could perceive nothing particular in their eyes, except great immobility of the pupils. In other respects they were in perfect health, and would submit to no other treatment, assuring him that they should be free from their malady within fourteen days without any medicines. On Easter-day they began to eat liver and animal food, and two of those he had examined saw as well as ever on the third day, and on the following Sunday all were completely cured. Here the affection was obviously purely functional, and dependent on temporary anæmia of the blood-vessels of the retina; and there can be little question that some of the cases that occur among the pauper population of large towns, and chiefly amongst the women, are traceable to similar causes.

I have seen several instances of the disease in weak and debilitated nursing-women amongst the poor, but have been unable, with the most careful examination of the eyes with the ophthalmoscope, to discover any physical cause to which the dimness of vision might be referred. Such cases have always quickly recovered when the child has been weaned, and the mother received into hospital and placed upon good diet.

But that the disease may be associated with organic disease of the retina is unquestionable; and this may either chiefly

affect the arteries or be accompanied by the formation of pigmentary deposit in or on the surface of the retina.

In the most marked case that has come under my notice dependent upon the former cause, the symptoms were very remarkable, and appeared to be complicated with embolism of one eye. I subjoin, briefly, the notes I took of his case:—

W. H., æt. 41, a pallid-looking man, engaged as a milkman, states that his general health is good, though his dusky, colourless face and feeble pulse belie his words; is married, with two children; is perfectly sober and steady, and has never suffered from syphilis or rheumatism. Has always been subject to night-blindness, even from a child, and he has never been able to see any but the morning star. Lately this has become invisible, and the shape of the moon is irregular. About three years ago, on awaking from sleep, he found that in the course of the previous night the sight of the right eye had entirely gone; but as he experienced no pain or inflammatory symptoms, he had no advice. In the course of the following year, sufficient vision had returned to enable him to see the largest of the bills printed on the walls as advertisements. In the month of October, precisely a year after the original attack, loss of vision again occurred in the right eye, followed by partial recovery, so that moving objects, and those lying to the outer side, could be discerned. After the lapse of another year, he had a violent bilious attack, and, whilst vomiting, the loss of vision in the right eye once more became complete (? retinal ecchymosis). Still, improvement took place, and the vision became sufficiently good to enable him to see moving objects again, until a fortnight previously, when another relapse had occurred, and he could then only just distinguish the position of the window with the right eye. He applied for relief, on account of the failure of the left eye, which for some months had been getting gradually worse. He could only see CC of Snellen at five feet. His perception of primary colours from one another was accurate, but he was

unable to distinguish dark-brown from red, and confused orange with yellow. He stated that, on looking at any horizontal straight line, it formed exactly at the point of fixation a small arch with the convexity above, the two extremities of which are continuous with the rest of the line. Fifteen or eighteen years ago, magnifying glasses improved his sight materially, but latterly they have been unserviceable.

His father had good vision up to an advanced age, but his mother and one sister were also subject to nyctalopia, but a second sister was free from any defect of vision.

On ophthalmoscopic examination of the left eye, the whole choroid was obscured by a dusky veil, causing it to assume a pale colour in all parts. The optic disk was blurred at the margins, and surrounded by an œdematous circle of moderate extent. The central artery scarcely perceptible, and the veins extremely small.

The humours of the right eye were too muddy to permit the fundus to be seen.

Extending from the optic disk in all directions were brilliant white anastomosing cords, thicker near the disk, and fining off towards the periphery; they came out in strong relief against the dark reddish-grey choroidal ground. There was no obvious pigmentary deposit. The foramen centrale was dark-red, and around it was some crumpling of the retinal tissue. Neither convex, concave, nor cylindrical glasses were of any service to him.

Dr Quaglino of Milan made the following observations on thirty soldiers¹ affected with nyctalopia:—

The predisposing causes of the disease seemed to be, undoubtedly, certain pathological conditions of the abdominal viscera, favouring venous stasis in the vessels forming the vena cava, as intermittant and gastric fevers and scurvy. The exciting causes were the direct glare of the sun, strong reflection of the sun's rays from a white soil, and the glittering

¹ Ann. d'Ocul., p. 97. 1866.

of water. Suppression of the perspiration, and disposition to rheumatism, appeared in some instances to play an important part in the production of this singular affection. The subjects were commonly leucophlegmatic, with yellowish skins and scorbutic gums. Recurrence of the disease after exposure to the exciting causes was not unfrequent.

The following ophthalmoscopic symptoms were observed:—1. Grey tint of the retina generally, especially marked around the pupil and along the vessels. 2. Congestion of the retinal veins. 3. The retinal arteries, when the disease was of recent date, were congested and enlarged, but when of long standing were smaller than natural, and lost here and there in the retinal parenchyma, which appeared thickened and hypertrophied. 4. Roseate injection of the papilla, with indistinct limitation of its periphery. Lastly, in old and recurrent cases, the papilla assumed a dead white colour. From these appearances Dr Quaglino is induced to hold that the essence of the disease is in a venous stasis, accompanied by a serous infiltration into the substance of the retina and between the fibres of optic papilla, whence follows pressure on the bacillar layer, rendering its elements less apt to receive the impressions of objects feebly illuminated, such as those seen at night or by twilight.

As regards the treatment, the most rational and successful consists in keeping the patient in a darkened apartment, and so giving the eye perfect rest; clearing the bowels well with calomel, scammony, and jalap or aloes; the administration of quinine, when the spleen is enlarged, and of cod-liver oil, combined with a light but nourishing diet. Blisters have been recommended by Mr Bampffield, who is stated to have observed great benefit derived from their employment.

A peculiar organic change with which nyctalopia has been observed to be associated, is the deposit of pigment in the retina—a condition which has been supposed to be constantly the result of inflammation, and has hitherto received the

name of retinitis pigmentosa. The frequency of occurrence, as well as the importance of this form of disease amongst retinal affections, are such as to demand for it consideration in a separate section, especially since, though commonly, it does not appear to be always or necessarily concomitant with night-blindness.

5. *Retinitis Pigmentosa.*

(PLATE IX., Fig. 56.)

The first observer who gave a detailed description of this form of disease was Donders, in the case of which the following is an abstract:¹—The patient was 35 years of age, had been blinded by smallpox in infancy, and had died from typhus. On examining the eyes, the corneæ were found to be opaque, and had contracted strong adhesions to the iris. The ciliary muscle had undergone fatty degeneration. After immersion for two days in spirit of wine, the retina in each eye was found to be firmly adherent to the choroid, and exhibited a fine irregular net-work of pigment in its tissue, visible to the naked eye, affecting all the layers, and in general and especially surrounding the vessels. The deposit commenced near the optic papilla, and appeared to cover the foramen of Sœmmering. The papilla was atrophic, small, and depressed. Here and there considerable thickenings or accumulations of pigment were visible, which gave off processes often intercommunicating with one another, forming a wide-meshed net-work intersected by smaller processes. Appearances exactly resembling those just described are frequently seen in patients suffering from night-blindness, in whom there has been a gradually increasing concentric limitation of the field of vision. The deposition or the development of the pigment generally occurs in or near the æquatorial region of the eye, and gradually spreads towards the posterior pole, proportionately interfering with vision as it advances.

¹ Archiv. für Ophthalmologie, Bd. iii. p. 139. 1859.

The central part of the field of vision, even when reduced to 10° or 15° , often remains remarkably good, enabling the patient to read fine letterpress, and distinguishing the disease from cerebral amaurosis, in which, with concentric limitation, there is also marked diminution in the sharpness of vision throughout the whole field. v. Gräfe¹ observes that a similar preservation of good central vision, with limitation of the field, occurs in excavation of the optic nerve, but that it is not here concentric but slit-like, and after such fashion that the point of fixation is to the inner side of the slit. Nevertheless, it must be admitted that, in many cases of retinal pigmentation, the central unpigmented portion is amblyopic, the optic disk becoming whiter and duller, with its diameters (especially the transverse) diminished, and the arteries both absolutely and relatively smaller than the veins.

v. Trigt first showed that the deposit took place in the retina, and not in the choroid. Donders asks, Is this condition the result of an inflammatory process? and states that both he and v. Gräfe have repeatedly seen it accompanied by incipient cataract, and rarely with flocculi in the vitreous. Donders also noticed this condition associated with constitutional syphilis (though not with syphilitic iritis), and also with acquired myopia and sclero-choroiditis. From these circumstances he is induced to believe that it does not proceed from simple disturbance of nutrition without any inflammatory process, but that there is an exudation standing in causal relation to the pigmentary deposit; and this is corroborated by the subjective phenomena of flashes of light and unpleasant sensations of pressure which never fail to appear, both of which point to the occurrence of some form of inflammation.

In an essay upon this form of disease by Mr Bolling Pope,² the same view as that taken by Donders of the inflammatory

¹ Archiv. f. Ophth., Bd. vi. Heft. ii. p. 250. 1858.

² Würzburg, Med. Zeits., Heft. iii., 1862; and Ophth. Hosp. Rep., pt. xviii. p. 76. 1863.

origin of the pigment is maintained. In the earlier stages, serous exudation, followed by hypertrophy of the connective tissue entering into the structure of the retina, takes place, especially of its outer granular layers, which gradually leads to atrophy of the nervous portion of the retina and fusion of the remains of the membrane with the choroid. A process of contraction then takes place of the newly-formed and hypertrophied connective tissue, which results in the displacement of the pigment, all of which, according to Mr Bolling Pope, proceeds from the choroid, and is not itself a new formation. In the majority of the cases of this disease, the arteries are sclerosed, their walls being thickened by a hyaline deposit. The very slow progress of the disease is a remarkable feature in it; and there seems, in most instances, to be a greater or less degree of hereditary tendency to its development.

M. Wecker¹ considers that it is always a congenital defect, and has noticed it in conjunction with the development of extra fingers and toes. It has also been supposed to be connected with and to result from marriages of consanguinity, and to be associated with idiocy and deaf-mutism. Dr Laycock² states that he has observed five cases of night-blindness in the same family, and that in each instance the affection was associated with partial deafness. Mr Hutchinson³ has noticed that deposits of pigment are not unfrequently visible in the eyes of those who present unmistakable signs of being the victims of hereditary syphilis.

No treatment is of any service in this disease, and its recognition is consequently only valuable as a means of determining the cause and probable course of the existing obscurity of vision.

¹ *Etudes Ophthalmol.*, vol. ii. p. 351.

² *Med. Times and Gaz.*, April 21, 1866, and March 1867.

³ *Ophth. Hosp. Rep.*, vol. ii. pp. 261, 276, etc.

6. *Detachment of the Retina from the Choroid.*

(PLATE X., Fig. 53; PLATE XII., Figs. 67 and 68.)

Separation of the retina from the choroid may be the result either of a direct blow or succussion of the eye, or of an inflammatory condition of the membrane itself. Myopia, and the changes in the form and structure of the globe which occur in this affection, constitute collectively a powerful predisposing cause for subretinal dropsy. It consequently not unfrequently appears in the course of the sudden development of sclero-choroiditis posterior, which is often also associated with myopia. It has been observed to accompany the formation of choroidal tumours.

Mandelstamm¹ found that retinal separations occurred in 99 out of 347 cases of retinal disease. There were 76 males and 23 females. The right eye alone was affected in 47, the left in 44, and both coincidently in 8 cases.

The extent of the detachment varies considerably, being sometimes restricted, as in fig. 53, to comparatively narrow limits, and sometimes affecting nearly the whole of the membrane. When of small extent, the retina may retain its natural transparency, and the alteration may only be made visible by the peculiar course of the retinal vessels; generally, however, it is indicated by a light-grey or whitish shading. When more extensive, the colour of the separated membrane is usually whitish or pearly white.

The nature of the fluid producing the detachment differs much in different instances. Sometimes, when it has originated from a blow, it is blood, or serum stained with blood; but when it owes its origin to inflammation, a fluid is exuded containing albumen or fibrine in solution, which coagulates on exposure to the air, is more or less discoloured with blood or pigment, and may contain cells, nuclei, fat molecules, or cholestearine.

When the effusion results, as is most commonly the case,

¹ Pagenstecher's Klin. Beobacht, Heft. iii. p. 48. 1866.

from disease, as in sclero-choroiditis posterior and extreme myopia, the premonitory symptoms, though generally present, are often overlooked. They consist of dimness of vision, of sparks and flashes of light, or of dark spots floating before the eye, with headache, tension of the globe, and other evidences of intra-ocular pressure. The vitreous is in such cases more or less hazy; perhaps, as v. Gräfe has suggested, from the perforation of the retina by the subjacent turbid fluid. In the more advanced stages, the acuteness of vision is still more impaired, and objects are seen as though broken or distorted, and a considerable portion of the field of vision, corresponding to the seat of the effusion, is dark. If it be the lower part of the retina that is detached, all the upper segment of the field of vision is void; if the lower, the upper portion of the field. Finally, in extreme cases the perception of light is altogether abolished, or reduced to a mere quantitative perception of light. When, on the other hand, the disease results from a blow, the loss or great impairment of vision is immediate, blood is effused beneath the retina, and more or less inflammation of the choroid and iris, and of the external tunics, is likely to supervene. In most instances, even upon a superficial examination, but quite certainly with the ophthalmoscope, the separated retina can be distinctly perceived behind the iris, waving or floating in the vitreous with the movements of the head or eye. The detachment usually, but not always, takes place in the lower part of the retina, and this is especially likely to occur where it is of idiopathic origin; for even if the effusion commence above, the fluid is likely to gravitate to the lower parts of the fundus oculi. The floating membrane of course obscures the red reflection of the choroidal vessels. Here and there a dark-red retinal vessel, a branch of the arteria or vena centralis retinae, may be traced, following with wavy course the folds and inflections of the separated membrane. Cataract and atrophy of the globe are frequent sequelæ.

As regards the treatment of cases of separation of the retina, those of ancient date may be at once dismissed as incurable; but some remarkable results have been obtained by v. Gräfe,¹ Bowman,² and others, in recent cases, by tapping the sclerotic over the seat of the detachment. It has been found by microscopical examination that the retina retains its organic structure unchanged for some time after separation from its vascular bed; and when by the removal of the fluid its reapplication is permitted, it may in favourable cases regain its functional powers. The tapping may either be performed with a simple double-edged needle (v. Gräfe), or with two needles, so as to tear the retina, and allow of the escape of the subretinal fluid into the vitreous (Bowman), or by the introduction of a fine trocar, as adopted by Wecker, who, however, remarks, that none of his cases have retained the sensibility of their retinae for more than a year after the operation.

The following cases will give the ordinary symptoms presented in separation of the retina from the choroid:—

1. T. H., æt. 69, night-watchman. About six weeks ago he noticed that he was gradually becoming blind with the left eye, the vision of which was previously perfectly good. The appearance of the eye is now healthy, and corresponds precisely to that of the sound eye. The vision of the left eye is so obscure that he can only just discern the position of the window, and this only when the light falls on the inner part of the retina; that of the right eye is natural. He cannot attribute the loss of sight to any particular cause. During the last seven years he has been temperate and steady, but before that was a hard drinker. He has had no pain. On examination with the ophthalmoscope, it was found that there was almost complete separation of the retina, except at the inner part. The iris expanded fairly under the action of

¹ Archiv. f. Ophth., Bd. ix. p. 85. 1863.

² Ophth. Hosp. Rep., vol. iv. p. 135.

atropine, but there appeared to be some slight attachments of the uvea to the capsule of the lens. The vitreous was hazy and turbid. The retina presented the usual greyish semi-transparent appearance, but did not float or wave, except on quick movements of the head, when a tremor ran through it. It gave an impression of greater solidity than usual. No distinct margin could be traced at any part. A vessel or two followed the inflections and sinuosities of the raised membrane. The optic entrance could not be distinctly seen, but the vessels radiating from it were easily traceable, and were of large size. He was ordered decoct. cinchon. $\bar{3}$ j. and the liq. hyd. bichlor. $\bar{3}$ j. t. d. A fortnight after, it was found that the vitreous was clearer, and the vision correspondingly improved, as he could see the houses on the opposite side of the street. The outer limit of the retinal separation was well defined. Though a variety of medicines were afterwards employed, the vision did not improve beyond this point.

2. S. B., æt. 35 (Plate XII., figs. 67 and 68), came to the Hospital on the 18th of Sept. 1866, complaining of dimness of sight of the right eye. She has always been near-sighted, but was able to see the most minute objects. The dimness came on quickly last week. External examination of the eye revealed nothing of importance, except that the iris was tremulous, and of a deeper brown colour than that of the opposite side. The corneæ were both remarkably brilliant. The right eye was sometimes tender and ached, and she had only a quantitative perception of light in it. On examination with the ophthalmoscope, the left eye presented the general symptoms of myopia, with posterior staphyloma, and the choroid was very atrophic and pale. The right eye presented a hazy vitreous, with floating membranes and grey spots and fragments. Only the upper half of the optic disk could be discerned, the lower being obscured by the detached retina, which presented a most beautiful silvery appearance, with well-marked

folds, the sinuosities of which were followed by several small but very distinctly-visible vessels. The margin of that portion of the optic disk which could be seen was hazy and ill defined, as though there was some effusion under it, and the vessels were rather small. After careful inquiry, I could obtain no evidence of any specific disease, nor had she had any blow or injury to the eye. The glimmering of light that she perceived was on the inner side. She was and had been married for eight years to a smith. I ordered her decoct. of cinchona, with the solution of the bichloride of mercury. On the 21st September she was again examined, when, to my great surprise, the floating retina had entirely vanished, and had become reapplied throughout its whole extent to the subjacent choroid. The vitreous, though still turbid, was very much clearer. The optic disk was perfectly visible. The surface of the choroid, over which the separation had taken place, presented a curious appearance, not smooth and uniform in colour as in the rest of the membrane, but hazy, with yellowish or whitish-yellow patches, very numerous, of small size, and apparently situated between the choroid and the retina. They were, without doubt, little flakes of fibrinous exudation, analogous to those seen on serous membranes when inflamed. The retinal vessels could at certain points be distinctly traced passing over them, but did not appear to be deflected in doing so. She stated to-day that she had not been regular for five months, and has lately grown very stout, but does not believe herself to be pregnant. On the 24th I took the drawing, fig. 68. She thinks her vision has in all respects improved during the last few days. The iris remains of a very dark hue. On the 2d October the margin of the optic disk was very hazy and indistinct from effusion, but the other features of the affection are unchanged. 4th October.—Vision has so decidedly improved, that she can see CC of Snellen at four feet. She is still continuing the cinchona and bichloride of mercury. 9th October.—Adhesions have

taken place between the iris and the lens capsule, so that the pupil becomes vertically oval on the instillation of atropine. After this period it was extremely difficult to obtain a view of the fundus, partly on account of the obstruction caused by the contracted pupil, and partly from her unsteadiness and want of command over the eye. On the 30th of October the iris was everywhere firmly adherent to the capsule; the anterior chamber was very deep; vision remained as before.

7. *Embolism of the Arteria Centralis Retinæ.*

(PLATE XII; Fig. 71.)

The following case will give the principal features of this remarkable affection:—

H. H., æt. 42, a tailor, came to the Hospital in July 1866, stating that, shortly after an attack of rheumatic fever, he had been taking a long walk on a very hot day, and on his return home saw everything perfectly well till he had opened the front door of his own house. He then felt suddenly blinded, but at first thought it only due to his entering a dark passage from the bright sunlight, vivid green and yellow colours, however, appearing before the eyes. He felt his way up-stairs, and burst open his room door, exclaiming to his wife, "Good God, I am blinded!" She recommended him to lie down, and he fell asleep for half-an-hour. On waking, the sight of his left eye had perfectly returned, and had remained good up to the time of his coming to the Hospital, which was about one month after the attack. The vision of the right eye had undergone gradual improvement, so that he was now able to discern the bars on the window, to count his fingers at the distance of a foot, and to pronounce correctly upon the colour of different objects. No pain had been at any time experienced in the eyes. On examination with the ophthalmoscope, the media were found to be perfectly clear, the colour of the choroid natural, but the larger vessels unusually distinct, indicating atrophy of the chorio-

capillaris. The optic disk was white, and for a considerable distance around it the retina was hazy, and of a bluish-white colour, indicating serous effusion into its structure. The retinal vessels were extremely small, the arteries being scarcely distinguishable, and the veins reduced to the diameter of hairs. There was a small extravasation of blood on the foramen centrale. An examination of the heart was made, but with unsatisfactory results, as there was much noise in the adjoining street, and he was a stout man. He was ordered iodide of iron, but no material change occurred in his condition during the short period he attended at the Hospital.

The above case shows well enough the chief symptoms produced by the sudden occlusion of the arteria centralis retinae—namely, the prior attack of rheumatism, probably occasioning deposits on the auriculo-ventricular or aortic valves—the sudden occurrence of blindness—the œdematous or sub-inflammatory condition of the retina around the optic disk—the minute size of the vessels, both arteries and veins—and the persistent character of the disease, uninfluenced by remedies, which collectively constitute an almost unmistakable type of disease.

8. *White Atrophy of the Optic Nerve. Amaurosis.*

The use of the ophthalmoscope has permitted a large number of diseases that were formerly classed together under the head of amaurosis to be accurately distinguished from one another, and many of those which have been described in the foregoing pages would have formerly received this appellation. Though much restricted in its signification, the term may, however, still be retained with advantage to express that condition of loss of sight which is accompanied by a white appearance of the papilla, and is now commonly termed white atrophy of the optic nerve.

The causes which may lead to this state are very various,

and amongst the most important the following may be mentioned:—Inflammatory conditions within the eye, as in glaucoma, occasioning pressure upon the nerve; inflammation of the optic nerve; pressure exerted by the growth of tumours upon the optic nerve, the chiasma, optic tract, or cerebral ganglia from whence the optic nerves arise; anæmic conditions either of the body generally or of the vascular system of the eye in particular, which may be induced by disease of the kidneys or liver, leading to hypertrophy of the left ventricle, and atheromatous degeneration of the walls of the vessels, by over-nursing, or by the excessive use of alcohol, or of tobacco (Wordsworth). It also occurs in meningitis, in sunstroke (of which I have myself seen two examples), after typhoid fever, and during convalescence from the exanthemata, and in the more chronic affections of epilepsy and paralysis. It may result from excentric causes, the paralyzing influence originating in some irritation of the fifth, or of the sympathetic, as in cases where it has appeared coincidently with carious teeth. Lastly, it has been not unfrequently found to follow locomotive ataxy or tabes dorsalis. In some instances the atrophy is preceded by various indications of irritation of the retina, and inflammation of the optic nerve itself. In such cases intolerance of light and pain are complained of, with the occurrence of flashes of light, or photopsiæ; and subsequently there is a gradual contraction of the field of vision, ending in total blindness.

When the disease is preceded by an inflammatory or sub-inflammatory state of the retina, ophthalmoscopic examination shows, in the earlier periods, papillary and peripapillary congestion, with serous effusion, affecting the disk itself and the part of the retina immediately adjoining. The veins are large and tortuous, indicating the difficulty that the blood finds in escaping from the globe, owing to the pressure exerted upon them by the inflamed tissue. In many instances hæmorrhages from the over-distended vessels are seen, the

blood clearly escaping from the retinal vessels, which may be observed to lose themselves, as in fig. 50, in the mass, and to reappear beyond it. At a later period the vessels become small and delicate, and ultimately converted into whitish cords; whilst the optic disk is pale, as in fig. 60, and more or less excavated. Mr Wordsworth, in reply to inquiries made by Zander¹ respecting the diagnosis of tobacco amaurosis, when the fundus was under examination with the ophthalmoscope, gave the following statement:—"I believe that the earliest changes observed in tobacco cases are those of increased vascularity of part or the whole of the optic disk. After an uncertain period, the nerve is very unequally coloured, part being over-vascular and part anæmic. In several cases that I have seen, this has been very palpable, about one-half of each nerve being so changed. In more advanced stages the outlines of the disk have been observed to be undefined, the choroidal margin being blurred, and the area of a bluish-grey colour. Lastly, the conditions of white atrophy are approached. I say approached, for I have never seen this appearance so distinctly marked from tobacco as from cerebral disease; nor have I met with any case that has ended in *total* loss of sight. In many smokers that I have examined I have almost invariably found the optic disk hyperæmic, even when this physiological condition has not prejudiced vision."

In many cases, however, there is no evidence of a premonitory stage of inflammation of the retina around the papilla. The disk, especially on its outer segment, becomes gradually converted into a glistening white spot, of silky or tendinous lustre, and well-defined borders, on which various delicate shadings are observable, which appear to be the cribriform layer of the sclerotic, brought into view by the gradual wasting and retraction of the nerve fibres. A certain degree of excavation is constantly present, which is distinguished

¹ The Ophthalmoscope, Translated by Carter, p. 132.

from a natural or physiological excavation essentially by the circumstance that the margin of the white line surrounding the optic disk indicative of the excavation is not well defined, and also by the circumstance that in abnormal excavation the vessels pass straight across the excavated part. The vessels, both arteries and veins, are always small and inconspicuous, though never altogether obliterated. Various changes, as deposit of pigment, atrophy of the chorio-capillaris, etc., are frequently found to accompany the progress of the atrophy. They are not, however, necessarily connected with it.

In cases where the atrophy has been caused by the pressure of a tumour, as of an aneurism, an hydatid cyst or cancerous mass upon the optic nerve or tract, symptoms are produced which enable us to determine with some approach to accuracy the part to which the pressure is applied; for since, by the decussation of the optic nerves at the chiasma, the outer part of one eye and the inner of the other are supplied by the same nerve, it follows that, if the pressure be applied to the *optic tract* of one side, there will be loss of sensibility of the corresponding portions of the two retinæ, and the condition termed *hemioptia*, in which only one-half of an object can be seen, and of which Drs Wollaston and Abernethy presented notable examples, will be produced. If, on the other hand, the *chiasma* be affected, the vision of both eyes will be more or less seriously impaired. And lastly, if the optic nerve of one side be implicated, more or less complete amaurosis of that same side will be occasioned.

It may be remarked here, that Liebreich, in his article on amaurosis, in the "Dictionnaire de Medecine,"¹ admits three degrees of amaurosis, viz., first, amaurotic amblyopia, where only large objects are distinguished, or where the visual field is so limited that the patient is unable to guide himself from place to place; secondly, amaurosis where distinct vision of

¹ Bailliere, vol. i. p. 785.

all objects is abolished, but where there remains a general or quantitative perception of light; and lastly, absolute amaurosis, where the blindness is total.

The probability of recovery in a well-marked case of white atrophy of the optic nerve, with complete amaurosis, is infinitesimally small. The most favourable cases are those arising from alcoholism, from the abuse of tobacco, and in those which appear to result from anaemia, especially in young subjects, even when vision has been reduced to mere quantitative perception of light. The treatment must be modified according to circumstances. Tonics are frequently indicated, and especially those which have been called nervine tonics, as quinine, arsenic, sulphate of zinc, and strychnia, which may be variously combined. When the primary cause is the development of a tumour in the cranium, of course no treatment will prove of any avail, beyond giving such directions as may tend to improve the general health of the patient, and prevent cerebral congestion.

The optic nerves occasionally become the seat of a soft gelatiniform tumour, giving the sensation of fluctuation when compressed with the finger, which is of the same nature as that termed myxoma by M. Virchow. It appears to be formed by the growth of the delicate connective or mucous tissue which surrounds the fibres of the nerve. If the soft white-of-egg-like tissue be traversed by numerous fibrous bands, and contains many polymorphous cells, it is termed a glioma; and by a still further condensation of tissue and diminution of the structureless albuminous portion, it passes into a glio-sarcomatous or myxo-sarcomatous tumour, which may again become vascular, and closely simulate, at certain periods of its progress, fungus hæmatodes. The pressure which such tumours gradually exert—for they usually grow slowly—abolishes the functions of the eye, whilst their growth occasions its protrusion from the orbit. On ophthalmoscopic examination, the usual appearances of interference

with the return of venous blood may be seen, owing to the pressure exerted upon the ophthalmic vessels. The arteries are small, the veins large, and there is more or less œdema of the retina around the optic entrance. The only remedy that can be adopted is the enucleation of the eye and the removal of the tumour, which in general shows no tendency to recur.

9. *Retinitis.*

(PLATES IX., X., and XII., Figs. 49 to 60, and 67 to 72.)

In commencing the description of this disease, it may be as well, perhaps, to give here the forms of retinitis admitted by the two most recent systematic writers on ophthalmic diseases—M. Wecker and M. Stellwag v. Carion.

The forms of retinitis admitted by M. Wecker are—

1. Acute serous retinitis ;
2. Parenchymatous retinitis, which he subdivides into (1.) diffused interstitial, (2.) perivascular, and (3.) neuro-retinitis ;
3. Apoplectic ;
4. Syphilitic ;
5. Nephritic ; and, lastly,
6. Pigmentary retinitis.

Besides which he admits a subacute inflammation of the optic nerve itself.

M. Stellwag v. Carion's arrangement is much more simple. He admits only—

1. Diffused neuro-dictyitis, or retinitis with serous effusion.
2. Exudative retinitis.
3. Nephritic retinitis.
4. Suppurative retinitis.

Evidently considering that such forms as apoplectic and pigmentary retinitis are rather to be considered as ordinary inflammation, accompanied or followed by these changes, than as separate and distinct types of disease.

The form of retinitis to which he has applied the name of exsudative retinitis seems to be identical with that which has been already described under the head of Choroiditis Dis-seminata (p. 427), and represented in Plate X., figs. 55 and 60; his definition of the disease being that it consists of an inflammation of the retina, attended with the exudation, first of serum and subsequently of yellowish masses of fibrine and pigment, followed at a later period by the atrophy of the several layers of the choroid.

In the following remarks a general view of retinitis will first be given, to which will succeed a brief description of the principal features it presents when occurring in those suffering from Bright's disease and syphilis. Finally, an account will be added of the disease known as retinitis nyctalopica, or pigmentosa.

A. *Retinitis Diffusa. Neuro-dictyitis Diffusa.*

(PLATE X., Fig. 58.)

In this disease inflammatory processes are set up in the connective tissue, which forms the supporting framework of the retina. Changes similar to those which occur in the same tissue in other parts of the body are produced, which may to some extent be observed by ophthalmoscopic examination, and which, by their effects on the adjoining delicate nervous texture, soon seriously interfere with vision.

Ætiology.—The causes inducing an attack of retinitis are, amongst others, direct injuries, long-continued over-exertion of the eye on minute objects, or sudden exposure of the eye to brilliant light. Still more frequently, it seems to be the result of the tainted or impoverished condition of the blood accompanying syphilis, diabetes, hepatic affections, and leucœmia, whether produced by disordered menstrual functions or from other causes. It is very commonly associated with choroiditis or irido-choroiditis. It has been observed to result from cerebral tumours and diseases in the neighbourhood of the optic

nerves, as abscesses and caries of the bones of the orbit, occasioning in some instances an inflammatory, and in others an atrophic, influence to be propagated along the course of the nerve fibres to the retina, whence the term *retinitis descendens*.

Pathology.—As regards the pathology of retinitis, M. Iwanoff,¹ who has devoted much attention to this inquiry, remarks, that inflammation of the retina in its simplest form does not present any very well-marked organic lesions besides those of hyperæmia, ecchymoses, and tumefaction of the retinal layers generally. In the more advanced stages, however, deposition of lymph occurs, either in the retinal tissue or between the hyaloid and the internal limiting membrane, with the formation of new nuclei in the nervous fibre layer, which sometimes, even when the inflammatory process has presented but little intensity, passes on to purulent retinal infiltration. Retinitis, he further observes, commences generally at the periphery, and, when once established, may either undergo resolution, the membrane recovering its functional activity, or may present two kinds of alterations. In one, the violence of the inflammation is concentrated in the space between the internal limiting membrane and the hyaloid; the outer layers of the retina are but slightly attacked; and the disease terminates in hypertrophy and proliferation of the fibres of Müller, which project beyond the internal limiting membrane into the vitreous, forming delicate pediculated excrescences or condylomata. In the other, the outermost layers of the retina are the parts chiefly affected; resulting in hypertrophy and proliferation of the external granular layer,—a condition corresponding to M. Wecker's interstitial parenchymatous retinitis. In both instances the exudation of fluid into the meshes of the retinal tissue confers upon the membrane a soft grey colour, obscuring the subjacent choroid, and rendering the margin of the optic disk obscure; whilst the veins are large and tortuous, and the arteries small, and both

¹ *Annales d'Ocul.*, p. 111. 1865.

are partially concealed by the retinal swelling and infiltration. In the earlier stages the elements of the bacillary layer undergo little change, though at a more advanced period they become granular and disappear. At the same time, the other elements of the retina undergo a gradual process of atrophy; sometimes by fatty degeneration, followed by the deposition of masses of pigment; whilst at others the fibres of Müller become less transparent, and reflect the light strongly, constituting the condition which has sometimes been described as one of sclerosis of the retina.

Symptoms.—Retinitis may attack both eyes simultaneously or successively, or be limited to one. In either case it may be acute or chronic in its progress. In acute cases, severe pain is experienced in the globe of the eye, radiating to the temple and brow, with intense photophobia and distressing subjective sensations of light,—sparks, flashes, and coloured rings being constantly perceived. The visual powers undergo rapid diminution, the whole field becoming more and more dark until the perception of external objects is entirely lost. The globe is usually somewhat increased in hardness, and tender to the touch, and the conjunctiva and sclerotic slightly congested, but by no means to so great a degree as to afford any indication at first sight of the serious changes which are occurring within. In other, and especially in syphilitic cases, whilst the disease is acute in its progress, the most prominent symptom is the failure of vision, the ciliary neuroses and subjective symptoms of light being comparatively slight. In both cases, but more especially when the choroid or choroid and iris are implicated, the vitreous may be observed to be hazy and troubled. In the chronic forms of retinitis which accompany the development of cerebral disease, or persistent exertion of the eyes on bright or minute objects, the subjective symptoms, so far as regards the globe, are slight, and but little pain is experienced. The patients complain of black spots floating before the eye, and of misti-

ness or dimness of vision; at the same time the symptoms of the primary disease of the brain inducing the retinitis, if any be present, are more or less obvious, though in some instances it is betrayed by the alterations in the visual powers alone.

As regards the ophthalmoscopic appearances, considerable experience in the use of the instrument is required to distinguish them in the earlier stages at least, for then the only change that is perceptible consists in an opacification of the retinal tissue of the most delicate character, so that, instead of presenting an almost perfect transparency, it offers the appearance of a haze or greyish troubling, most conspicuous in the immediate vicinity of the optic papilla and macula lutea, obscuring to some extent the normal well-defined margin of the disk. At a later period, and when the inflammatory changes have become more marked, the papillary border becomes still less defined, and the appearances presented are those which have been well described by Stellwag v. Carion, in the following terms:—"The retina is frequently seen as a more or less thick and not always quite uniformly troubled whitish, yellowish, or greyish layer, extended like a veil over the surface of the choroid, which only glimmers through it of a dull-reddish or smutty tint. Hence the optic nerve is very ill defined, and can scarcely, except by its somewhat brighter colour and the position of the vessels, be differentiated from the adjoining structures. The disturbance in the retinal circulation is frequently indicated by well-marked, radially-streaked redness of the papilla and the parts immediately around it, but still more frequently, and especially in cases of long standing, by remarkable dilatation and tortuosity of the venous trunks. The arteries, on the other hand, appear of normal diameter, or somewhat constricted. Not seldom the veins present brighter and darker tracts in their course, due apparently to the different parts occupying different planes, and being seen here lying flat upon the retina, and there more or less projecting and fore-

shortened. Both arteries and veins are sometimes clearly defined, and sometimes much obscured by deposits, either in the anterior layers of the retina or in the vitreous, and both sets are often bordered by white lines or striæ, indicating hypertrophy of the vascular walls." Sometimes (as in a case I have lately seen) the arteries are only apparent as bright white lines on a dull grey ground; hæmorrhagic extravasations (fig. 50), though not constant, are yet of very common occurrence, and, if extensive, have occasioned a separate form of the disease, to be recognised under the term of *retinitis apoplectica*. In the later periods of the affection, atrophy of the optic nerve occurs, indicated by its dull white colour, silky or satiny lustre, and the small size of the vessels. The extent to which the inflammatory mischief has extended is marked, I have reason to believe, after or during the progress of recovery, by a line of pigment such as is shown in fig. 51, the pigmentary layer of the choroid and the chorio-capillaris being atrophied within that boundary.

Treatment.—In the treatment of diffused retinitis, a due regard should be paid to the cause which has operated in inducing the attack; but in all instances the patient should be carefully guarded from exposure to bright light, or to great alternations of light and shade; and this may be effected either by keeping him in a room artificially darkened, or by covering the eyes with a carefully-adapted pad and bandage. In chronic cases, and in those in which the symptoms are not very strongly marked, great relief will be obtained from the use of tinted glasses, which will not interfere with out-of-door exercise. A few leeches may be applied to the temples, and repeated after the lapse of two or three days, if their application has been followed by any benefit. When the inflammatory symptoms run high, calomel and opium may be at once commenced, two grains of the former and half-a-grain of the latter being taken three or four times a-day. The decoction of cinchona, with the 1-16th of a grain of the bi-

chloride, or 1-8th of a grain of the iodide, for a dose, may, if preferred, be substituted for the calomel and opium. The same treatment may be pursued in cases where the retinitis is of a secondary character, and appears to originate either in intra-cranial or intra-orbital disease. In these cases, however, the affection is scarcely under control. The use of opium in considerable doses, and frequently repeated, so as to exert a decided sedative action on the nervous system, is sometimes very serviceable in such cases; but when it produces feverishness, dry tongue, and disturbed rest, with distressing dreams, it should be at once withdrawn, and conium or hyoscyamus substituted for it, with or without local depletion. A woman is at present under the care of Mr Hancock, in whom all the symptoms of retinitis of sub-acute character—as the smutty grey colour of the fundus, the absence of outline in the papilla, the large size and tortuous course of the retinal veins, with considerable photophobia and great obscurity of vision—were present, apparently in consequence of the development of a tumour on the outer and back part of the orbit; or, as Mr Hancock believed, of an enlargement and congestion of the orbital veins of a gouty character, since the conjunctival and episcleral veins, of which there were eight or nine large purple and tortuous trunks, ran up to the margin of the cornea, where they suddenly terminated by perforating the sclerotic. There was also strabismus convergers to the extent of a line and a-half, with a moderate degree of protrusion of the globe. In this woman the employment of aconite and colchicum has proved of signal service, materially reducing the size of the veins and the protrusion of the eye, and enabling her to read No. 1 of Jäger's Test Types with ease.

When all symptoms of irritation have passed away, it is usually expedient to prescribe some of the nervine tonics, as quinine, sulphate of zinc, arsenic, or iron, and to recommend country air and exercise.

B. *Nephritic Retinitis. Retinitis Albuminurica.*

(PLATE IX., Fig. 49; PLATE X., Fig. 59.)

In this form of retinitis, which is not an uncommon accompaniment of Bright's disease, though it may also occur under other circumstances, the characteristic features are a high degree of hyperæmia of the retinal vessels, accompanied by serous infiltration of the retina, and often by hæmorrhages, succeeded sooner or later by the formation of white brilliant spots, which have been shown to consist, for the most part, of a fatty degeneration of the retinal tissues. The principal subjective symptom is a sudden or gradual deterioration of sight, which, though generally bearing a direct relation to the changes observable in the retina, appears to be in no way dependent upon the degree or stage of the renal affection, and may, in fact, precede the appearance of albumen in the urine. The disease is sometimes so rapid in its progress, that the patient is reduced to a state of almost complete blindness in the course of a few days; whilst in other instances it progresses very gradually, now better and now worse, sometimes terminating in complete recovery. Throughout the whole course of the disease, the external symptoms are very slight, consisting only of pallor of the conjunctiva and dilatation of the pupil. With the ophthalmoscope, however, a series of very interesting changes in the retina may be followed, since the media retain their clearness and transparency to the end. The first changes visible are a pink suffusion of the papilla, and enlargement and increased tortuosity of the retinal veins. This is soon followed, as shown in figs. 58, 59, or 72, by the effusion of a serous fluid into the texture of the surrounding retina. That this is not subretinal is shown by the circumstance that the vessels may lose themselves in it for a short space, again emerging and becoming distinct beyond the limits of the œdema. The arteries are usually smaller and less injected than natural. The venous congestion may

attain to so great a degree that the walls give way, and small angular ecchymoses, usually situated near the optic disk, may make their appearance, surrounding or concealing the vessels, as in fig. 59.

v. Gräfe¹ remarks that the diffused infiltration of nephritic retinitis may also be observed in syphilitic retinitis; but in that form of disease it is less uniform and circumscribed, occupies frequently only a segment of the circumference of the papilla, and extends irregularly along the course of the larger vessels. The same symptom is also observed in neuroretinitis; but here the presence of fibres or striæ in the connective tissue can generally be observed, whilst the papilla is itself swollen and prominent.

After the œdematous condition of the retina around the papilla has lasted for some time, pathological changes are observed, which result in the formation of white, or yellowish, or bluish-white spots, as in fig. 59. These are at first separate and small, but gradually increase in size, and blend to form large irregular plates surrounding the optic disk, the outline of which becomes ill marked and distinguishable only by its more deeply-tinted pink colour. The margins of the coalesced white spots are seldom if ever surrounded by any red or inflamed border, but are sometimes very irregular, resembling those seen in fig. 69, and present an appearance which Stellwag v. Carion not inaptly compares to tongues of flame. Another lesion, which has been particularly pointed out by v. Gräfe, is the formation of small punctated or starred figures around the macula lutea, which appear to be of frequent occurrence. In the earlier and slighter grades of the disease, the observed changes may long remain unaltered; and in favourable cases, as occurred in the subject of fig. 59, no trace of the disease, either functional or organic, may remain after the lapse of two or three years.

¹ *Annal. d'Oculist*, t. li. p. 121. 1864.

As regards the nature of the pathological changes which occur in the retinal tissue, their microscopical characters have been worked out by many observers. Heymann,¹ who was one of the first who examined eyes after death in which the foregoing morbid changes had been observed during life, gives the following description, as presenting the chief features of one of his cases:—The patient was an intemperate man, æt. 56, who had suffered from albuminuria for several months. Dropsy supervened, followed by maniacal symptoms, diminution of sight, leading to total blindness, and death. On *post-mortem* examination the kidneys were found diseased, the heart had undergone fatty degeneration, and the left ventricle was hypertrophied. On dividing the left eye through the æquator, the vitreous was found to be firm, and apparently healthy. The anterior half of the sclerotic, which during life presented a bluish appearance, was found to be destitute of pigment within. The retina was throughout the greater part of its extent greyish-white and transparent. At a distance of from one to two lines from the optic papilla, it exhibited a ring of about twenty various-sized whitish-yellow spots, with well-defined margins, of which the largest lay below the optic papilla, and was crossed by a vessel. The choroid could easily be separated from the retina, even at the spots, and here, as elsewhere, preserved its normal features. With an ordinary hand-lens the white spots presented a punctated white appearance, but under higher powers it could clearly be seen that the retina, and especially its ganglionic cell-layer, had undergone fatty degeneration. Subjacent to the cells which were thus altered were other bodies resembling nerve-cells, but characterised by the presence of highly refractile bodies in their interior, occupying the position of the nuclei, and apparently corresponding with Virchow's corpora amylacea, though they offered no concentric striæ. The rods and cones did not appear to be abnormal,

¹ Archiv. f. Ophth., p. 137. 1856.

nor was any diseased condition remarked in the retinal vascular layer. The nervus opticus, both to the naked eye and on examination with the microscope, appeared healthy, except that numerous corpora amylacea were found between the fibres. The substance of the corpora striata was also found to have undergone fatty degeneration.

As in some respects a contrast to the above case, the following one may be cited, which has been reported by v. Gräfe:¹—The patient was sent to him by M. Traube, and was affected with albuminuria. He had suddenly become blind, quantitative perception of light alone remaining. At this time no disease of the retina could be detected with the ophthalmoscope. He then suffered from epileptiform fits; after which recovery of vision took place, and was retained for a month. The convulsions then recurred, and loss of sight followed; but partial recovery again took place. At length, however, he was only able to count the fingers at a distance of four feet. The visual field was not contracted, though somewhat obscure in the upper segment. At this time the retinal veins appeared congested and tortuous, whilst the arteries were relatively small. The retina around the optic entrance was tumid, with a diffused bluish-grey infiltration concealing the pigment layer, which gradually came into view at a distance of about four lines from the periphery of the optic disk. Within the limits of the infiltrated part, spotted and streaked ecchymoses or apoplexies occurred, many of them being clearly situated behind the vessels. No actual separation of the retina from the choroid could be distinguished. These symptoms might be considered as the first stage of retinal degeneration in nephritis; and the appearances may be summed up by stating that there were passive or venous hyperæmia, and serous effusion into and under the retina. About two months after this period, the visual powers were found to be materially deteriorated, as

¹ Archiv. f. Ophth., vi. 1860.

the fingers could only be counted at two feet. On ophthalmoscopic examination, the diffused bluish opacity around the optic disk had become contracted, forming a zone of only about three lines in breadth, and incomplete above. It did not now appear quite so homogeneous as before, but presented a striated character, especially towards the periphery; whilst internally were some whitish spots, though not reflecting light quite so strongly as those of fatty degeneration. Nothing remarkable was observed in the parts of the retina around the macula lutea. A few days after, the patient was moribund; the sight had entirely failed. The uræmic symptoms were strongly marked, and the dropsy so great, that v. Gräfe was unwilling to distress the patient by compelling him to submit to another examination. After death, diffused nephritis was found, and hypertrophy of the left ventricle of the heart. The eyes were examined by C. Schweigger,—one, the left, being opened at once, and the other after being hardened. In the left the optic papilla was surrounded by a circular elevation, incomplete on the side of the macula lutea. In and near the elevation were striated ecchymoses. Just on the outer side of the macula lutea was a white spot, striated in the direction of the fibres of the nervous tissue, and, when highly magnified, showing only linear rows of points. The white material seemed *not* to consist chiefly of fat, but of fine filamentous tissue, for the most part accumulated in the granular layers. A little fat was, however, present. There was also hypertrophy of the connective tissue, forming the trabecular framework of the nervous fibrous layer. The fibres of the optic nerves were sclerosed; and the retinal vessels in and near the papilla were likewise thickened and sclerosed, especially as regards the tunica adventitia.

In yet another case, examined by Heinrich Müller,¹ the

¹ See Translation of his Paper by Dr Soelberg Wells, in *Ophth. Hosp. Rep.*, vol. iii. p. 51.

walls of the choroidal vessels were thickened by a homogeneous mass, which refracted light very strongly, but affecting them so irregularly that they presented a beaded appearance, the calibre being at certain points either greatly narrowed or completely blocked up; a condition that was still further increased by the hypertrophy of the layers of cells forming their internal tunic. These cells were evidently in a state of fatty degeneration, and, becoming detached, formed numerous emboli, that obstructed the smaller vessels. In the vitreous he observed an increase in the number and size of the hyaloid cells, and the presence of a number of transparent, pliable, sharp-pointed rods, varying in length, and not acted on by ether, glycerine, or acetic acid. The retina presented a number of spots, some of which were white and others red. Its elements were sclerosed, that is to say, that the rods and cones and the radial fibres, with the nuclear fibres appertaining to them, were firm and resistant, and capable of being easily isolated. Upon the surface, and sometimes penetrating some distance into the retinal tissue, were ecchymoses, and in various parts were nests of ganglion cell-like bodies, proceeding from hypertrophied nerve fibres, with numerous granular globules, containing fat drops and dim granules. In other parts, extensive masses of new formation were found embedded, especially in the inter-granular layer, which consisted of hyaline globules and drops, darkly-granulated colloid lumps, and a confused mass of very distinct small fibres.

It is not easy to determine whether the retinitis accompanying renal disease is due to the charging of the blood with urea or other product of disintegration, or whether it is not rather, as Traube believes, a consequence of the secondarily-produced increased tension of the aortic system of vessels; but there can be no question of the existence of a wide-spread and serious alteration in the walls of the vascular system, as is abundantly testified, not only by the hypertrophy of the left ventricle of the heart, but by the

atheromatous condition of the small vessels leading to the retinal ecchymoses.

As regards the impairment of vision in renal retinitis, Liebreich¹ is of opinion that it does not necessarily depend on any organic lesion of the retina, but on uræmic intoxication. M. Wecker,² however, is opposed to this view, observing that when, in consequence of the progress of the renal disease, the urinary secretion is more and more abnormal, the general circulatory troubles increase; the tension of the arterial vascular system augments; morbid alterations take place in the vessels: and it is to these conditions that he is disposed to attribute the coincidence of retinitis with nephritis. Schweigger³ has also noticed that the concurrence of retinitis with disease of the kidneys is almost always associated with hypertrophy of the left ventricle.

The treatment of nephritic retinitis must obviously be subordinate to that adopted for the renal affection, to which reference must be made to the works of Drs Basham, Johnson, and others, who have devoted especial attention to this subject. It may, however, be observed, that as a hyperæmic condition of the retina has been observed to be present in the earlier periods of the disease, the patient should avoid exertion of the eyes on bright or small objects. Leeches in small numbers (two or three) at a time may be applied to the temple; and Horner⁴ has recently recommended the employment of ice. Mercury, which would probably otherwise be used for the local affection, is not advisable in the state of dyscrasia usually present in those who are suffering from Bright's disease. The bowels should be kept freely open with the compound jalap powder, fifteen or twenty grains of which may be given every other day, and some one of the

¹ Dict. de Medecine, Bailliere, t. i. p. 785.

² Etudes Ophthal., t. ii. p. 342.

³ Archiv. f. Ophthal., Bd. vi. p. 294. 1860.

⁴ Klinische Monatsblätter, p. 11. 1863.

preparations of iron, as the ammonio-citrate or potassio-tartrate, given in appropriate doses, three or four times a-day.

The case represented in fig. 49 of Plate IX. presents a somewhat unusual form of retinal hæmorrhage. The patient was 56 years of age, and had suffered from renal dropsy two years previously. One morning having gone to bed with perfectly clear vision, he awoke blind. In the course of a few hours imperfect vision returned, and he was able to see his way about the house, and at length was enabled to do a little work; but the vision again deteriorated, and at the same time the water became scanty, and the dropsy reappeared. During the previous year he had been blind for all useful purposes, though he could still make his way about in districts with which he was well acquainted, and could just discern the moon. On superficial examination the eyes appeared healthy; the pupils were small. With the ophthalmoscope the choroids were of natural colour, and the retinal veins and arteries presented no peculiarity of size or arrangement. The optic disks were clearly defined in both eyes. On the apparent inner side of the right optic disk was an irregular, elongated red spot, contrasting strongly with the tint of the choroid, its hue being much deeper. The spot appeared to be below the level of the adjoining choroid, and its surface was perfectly smooth. Its size was rather larger than that of the optic disk. The foramen centrale presented an extremely minute central black spot, surrounded by a white halo, which was again invested by a small red circle, bounded externally by a black line of pigment. Another small hæmorrhagic spot of elongate form was situated close to the foramen centrale. The urine, at the time I saw him, was of sp. gr. 1010, and contained a small quantity of albumen. The treatment above recommended was adopted; but during three months that he remained under my observation, no change took place in the amount of vision present, nor in the appearance of the spot.

C. Glycosuric Retinitis.

A peculiar form of retinitis has been observed in some rare instances to accompany diabetes. The following case, reported by M. Galezowski,¹ will give a good idea of the symptoms that present themselves in this form of secondary disease. The patient was a gentleman, æt. 49. The eyes were normal to outward appearance, except that the pupils were sluggish. He could only read No. 18 of Jäger with considerable difficulty. The field of vision was contracted. The optic papilla was atrophied, and its limits well-defined. The arteries were small. There was no diffused infiltration of the retina, as in retinitis albuminurica, but there were numerous small apoplectic ecchymoses appearing to proceed from the smaller arteries, and some white spots of fatty degeneration, both visible over the great part of the fundus of the eyes. The patient suffered from a curious form of colour blindness, being unable to distinguish blue and red tints.

The treatment must in such cases be directed to the constitutional affection.

D. Syphilitic Retinitis.

(PLATES IX. and XII., Figs. 51, 70, and 72.)

The inflammation of the retina, sometimes termed syphilitic retinitis, is a form which is always associated with other manifest signs of syphilitic taint of the constitution. It is essentially chronic in its course, and in its earlier stages at least the prognosis is favourable, though when it has progressed to atrophy of the choroid and retina, no improvement under treatment can be anticipated. Amongst the earliest symptoms that have been noticed are dimness of sight, which extends over the whole field of vision, whilst occasionally particular spots are entirely insensible to light. On ophthalmoscopic examination at this time, the veins will be found

¹ *Compte Rendu du Congrès Ophth. de Paris*, p. 110. 1862.

enlarged and dark, and the fundus presents a smoked or clouded appearance, similar to that observed in those whose eyes are strongly pigmented. The margins of the optic disk soon become obscured by an oedematous condition of the adjoining portions of the retina, and at a later period a fibrinous effusion appears to take place chiefly in the external layers of the retina. v. Gräfe¹ remarks that the appearance presented by the effusion is less uniform and regular than that which occurs in the retinitis accompanying albuminuria; and whilst it extends to a greater distance from the papilla, it only partially surrounds it. The vessels have been noticed frequently to be partially covered by striæ of white material, which follow their course for a greater or less distance, radiating therefore from the papillæ outward in all directions. The choroid is sometimes affected, the margin of the deposit being surrounded by deposits of pigment irregularly scattered. The macula lutea is often the centre of a similar serous effusion, followed by fibrinous deposit. Hæmorrhagic effusions into or upon the retina are not uncommon, and the vitreous sometimes presents a clouded and troubled appearance, but at others remains perfectly clear. In one of Dr Bader's cases,² a quantity of small grey and white flocculi, of the size of a very small pin's head, were seen suspended in the vitreous, which slightly changed their relative position when the eye was moved.

The treatment of this affection would in almost all instances merge into that appropriate to the cure of the constitutional affection, and would consist chiefly in local depletion, and in the well-directed administration of mercury either internally or by inunction.

The following is the history of the case represented in fig. 70:—

E. P., married, and 31 years of age, contracted syphilis

¹ *Annales d'Oculistiques*, t. li. p. 121. 1864.

² *Ophth. Hosp. Rep.*, vol. i. p. 245.

from her husband 15 months previously to her attendance at the hospital, of which she was never properly cured. She was then suffering from discharge and soft chancres in the vagina, sore throat, and superficial ulceration on the tongue. On the 21st of Oct., on rising in the morning, she first noticed that the sight of the right eye was misty and confused. It daily became worse, and on the 25th of Oct. she applied for relief. She did not complain of any pain in the eye. On external examination nothing remarkable was observed; there was no conjunctival or scleral redness; the iris was healthy, but acted more slowly than the opposite one. On closing the left eye, with which she saw fairly, and, desiring her to read, she was unable to make out even the largest letters, stating that the centre of vision was obscured to the extent of a vertical oval of from eight to twelve inches in diameter. Lateral vision was preserved sufficiently to enable her to recognise large objects, as a book, especially when the images occupied the lower part of the field of vision. On examination with the ophthalmoscope, the media were slightly hazy, and the retinal vessels were large. Situated at the fundus of the eye, including the apparent inner half of the optic disk and the foramen centrale, was a whitish cedematous patch, the margin of which was rather irregular, but which did not appear to obscure the vessels. The arteries, however, just as they passed over the border between the healthy retina and the inflamed patch, were slightly inflected, as were also, though to a less marked degree, the veins.

She was ordered decoction of cinchona and the bichloride of mercury, in doses of 1-16th of a grain; then leeches to the temple, and a gargle of chlorate of potash. On the 30th October the appearance of an cedematous patch had almost gone, and would scarcely have been noticed had not the previous notes been taken. The vision, however, was not improved. On the 13th November no change nor any improvement in the sight had occurred, though she had been continuing the

medicine in reduced doses. The bichloride was accordingly exchanged for the mist. potass. iodidi, which produced an immediate good effect; for on the 20th November she could see C of Snellen at 30 feet; on the 15th December she could read LXX at 30 feet; and the last note, taken on the 31st January, states: "No trace of former disease remaining; general health much improved; can read as well with the right as with the left eye, viz., L at 30 feet."

The following is the history of fig. 72, Plate XII.:—

A married woman, æt. 40, came to my house, stating that about five weeks previously she had suffered from inflammation in the right eye, accompanied with redness, intolerance of light, much lachrymation, and intense pain. The vision became rapidly obscured; "everything appeared as if it were enveloped in smoke." She had to give up reading and working. In the course of the following week similar symptoms appeared in the left eye. She then went to a physician, by whom she was directed, in the first instance, to take some iodide of potassium, which was soon exchanged for the bichloride of mercury, and then for the biniodide in decoction of cinchona. A blister was applied to her forehead. Under this treatment considerable improvement took place; but, from exposure to cold, a relapse occurred, and she came to me. Both eyes were of dull colour, the episcleral vessels being slightly congested, and the sclerotics yellowish. The globes were full, and their tension slightly increased. The corneæ were clear, the markings upon the irides slightly obscured, and their movement sluggish on exposure to light, which was borne with some impatience. The aqueous humour was not quite clear, imparting a dull appearance to the anterior chamber; the pupils were small. On ophthalmoscopic examination, dots of pigment were found on the capsule; the vitreous was found to be like the aqueous, somewhat turbid. The margins of the optic disks were obscured in both eyes by a well-marked grey halo, as repre-

sented in the drawing, which gradually fined off, and became imperceptible at a distance of about twice the diameter of the disk itself. The veins were large, and the arteries rather small, and both were obviously partially concealed by the serous effusion beneath the retina.

Feeling confident it was a case of syphilitic retinitis, I took the husband aside and asked him when he had suffered from syphilis. He denied ever having had anything the matter with him from boyhood, when he had once contracted gonorrhœa. Being unable to pursue the inquiry farther, I at once ordered six leeches to the temples, to be followed by a linseed-meal poultice, and began the administration of decoction of cinchona, with full doses of bichloride of mercury. Atropine was dropped into the eye. Two days afterwards she called by herself, and I then taxed her with having exposed herself to contagion, which she strenuously denied. However, it came out by degrees, that six months previously she had had a sharp attack of rheumatism in her legs and head; that a leprous eruption, the coffee-coloured remains of which were still perceptible on her arms, had broken out two months subsequently, which had again been followed by severe sore throat and falling off of her hair.

This accumulation of proofs rendered the matter no longer doubtful, and she admitted the fact. The treatment was steadily persisted in for 15 days, with great improvement of the vision. She derived great benefit at this time from the use of smoked glasses; and from being only able to read No. 16 of Jäger, which was her condition when I first saw her, she could read the smallest print of Snellen's Test Types. The bark and bichloride were now exchanged for the mist. potass. iodidi, which she continued to take for another fortnight; at the end of which period the following prescription was given her, and she was dismissed well—Quinæ disulph. gr. i.; acid sulph. dil. ℥i.; tinct. aurantii, 3; aquæ, 3j., ter die sumend. In the following month she went to America.

CHAPTER IX.

Diseases of the Lens.

GENERAL ANATOMY OF THE LENS—ÆTIOLOGY AND PATHOLOGY OF CATARACT—PRINCIPAL VARIETIES OF CATARACT—VARIOUS MODES OF OPERATION FOR THE REMOVAL OF CATARACT—DIVISION AND SOLUTION—DEPRESSION—EXTRACTION OF THE LENS BY FLAP OPERATION—EXTRACTION BY LINEAR INCISION AND BY MODIFIED LINEAR INCISION—BY SUCTION—ACCIDENTS AND EVIL RESULTS OF THESE OPERATIONS—SUBSEQUENT TREATMENT.

1. *Structure of the Lens.*¹

THE lens of the eye is circular and biconvex, having a diameter of rather more than one-third of an inch. Its thickness, or the length of its axis, is one-fifth of an inch; and it is now generally admitted to be slightly thicker after death, so that it appears to be kept during life in a constant state of compression. The posterior curvature is more convex than the anterior, and is a segment of a parabola, whilst the anterior is a segment of an ellipse.² From the period of foetal exist-

¹ For good recent accounts of the structure of the lens the reader is referred to Mr Nunneley's excellent work on the Organs of Vision; to the section on the Eye in Quain and Sharpey's Anatomy; Henle's Anatomie des Menschen, Bd. ii. p. 678, 1866; Kolliker's Handbook of Human Microscopical Anatomy; Meyer, Archiv. f. Anat. v. Phys., 1851; H. Müller, Beiträge, etc., in Archiv. f. Ophth., Bd. iii., 1856; T. F. Becker's Essay in the Archiv. f. Ophth., Bd. ix. Abth. ii. p. 1; and Wecker, Etudes Ophth., t. ii. Fas. I.

² Krause.

ence to extreme old age, the lens undergoes a gradual process of flattening, induration, and loss of transparency; but at all ages its consistence progressively increases from the outer surface, where it is as soft as jelly, to the centre, where it is almost as firm, especially in old people, as gelatine or soft cartilage. Its refractive index, as regards light, amounts upon the whole, according to Helmholtz, from 1.44 to 1.45, pure water being 1.3354, and its weight in the adult is about $4\frac{1}{2}$ grains. The lens is invested by a perfectly transparent and homogeneous capsule; and when confined by this, as remarked by Henle, possesses a high degree of elasticity, though when removed from it, it is soft and easily broken down. Hence we may conclude, that the elasticity in the former case is due to the tension of the capsule, its cavity being completely and tightly filled by the lens substance. The lens lies in a depression on the anterior part of the vitreous humour, to the membrane covering which the posterior portion of the capsule is firmly adherent. The anterior layer of the capsule is at least twice as thick as the posterior, and its inner surface is separated from the lens substance by a single layer of hexagonal cells, each containing a large spherical nucleus. In the central region the cells are larger and well-defined, but near the margin nuclei alone are present, which are smaller than the cells, more closely packed

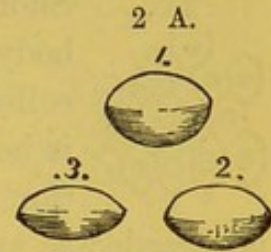


Diagram showing the changes in form of the lens with advancing age—1, Lens of foetus; 2, of adult life; 3, of old age.

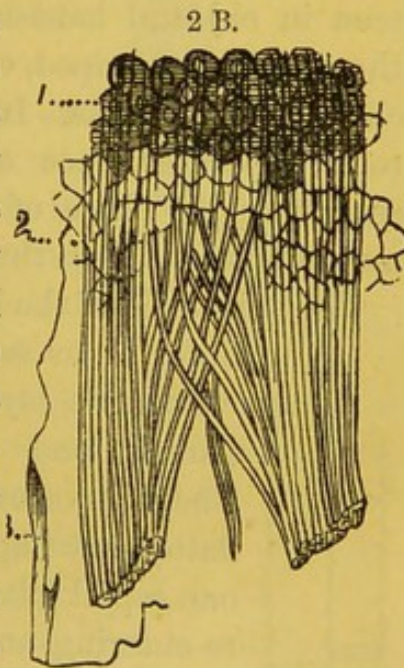
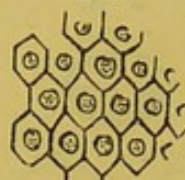

Diagram showing the marginal portion of the anterior wall of the capsule of the lens. 1. Epithelium shown detached in fig. 2 C; 2. Impressions of the boundaries of the epithelial cells left on the lens substance; 3. Structureless membrane; 4. Insertion of the fibres of the zonule, after Henle.

together, and, according to Mr Hulke,¹ are arranged in several layers, which collectively constitute the matrix of the lens.

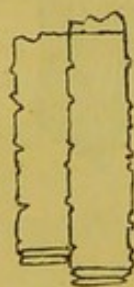
2 C. Shortly after the removal of the eye from the body, a little fluid, termed the liquor Morgagni, collects between the capsule and the lens. This is believed by some to proceed from the liquefaction of the cells in question; whilst by others it is regarded as an effusion from the ends of the delicate young fibres of the lens.²



The posterior capsule of the lens is in direct contact with the lens substance, no layer of cells existing at this part. The lens presents a disposition to break up or split in certain planes, radiating from the poles, which are most distinctly seen in old and hardened specimens. The type of these is the mammalian tripod, which, according to Nunneley, is most obvious in the foetus. In the adult the planes are more numerous in consequence of the primary planes immediately subdividing. Those of the posterior surface are frequently more numerous than those of the anterior.

The substance of the lens is made up of flattened hexagonal fibres, or, as some maintain, of flat tubes arranged in concentric layers. The fibres are perfectly trans-

2 D.



parent, and present serrations at their edges. They curve over the border of the lens, when they flatten out (fig. 2 E), and pass from the extremity of one septal plane on one surface of the lens to the re-entering angle between two septal planes on the opposite surface, or in corresponding intermediate position. Their number is very great. Leeuwenhoek³ estimated the number of layers in the lens of a cod at 2000, and Sir David Brewster the number of fibres in each layer at 2500. Each fibre in the infant at least contains a well-marked nucleus (fig. 2 F).

¹ Ophth. Hosp. Rep., vol. i. p. 185.

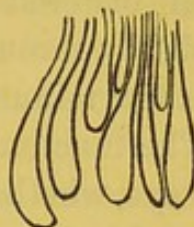
² Becker.

³ Nunneley, Organs of Vision, p. 252.

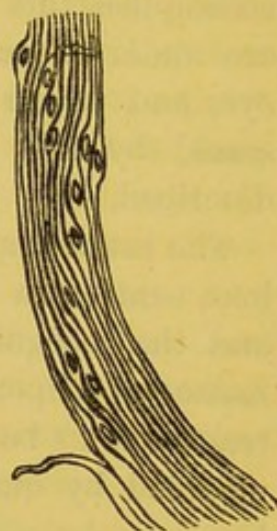The lens is retained in its place, partly by being imbedded in the cup-shaped depression of the vitreous and the adhesion existing between the posterior capsule of the lens and the hyaloid membrane, and partly by a ligament termed the suspensory ligament of the lens, or Zonule of Zinn, which, proceeding from the inner surface of the ciliary processes, passes to the anterior surface of the lens, forming in this passage a small part of the posterior chamber of the eyes. This suspensory ligament appears to be a continuation of the hyaloid membrane, but is intimately connected on the outside with a membrane continuous with the retina, and known as the lamina ciliaris retinae. The proper ligament is composed of remarkably delicate, smooth, and well-defined fibres, which divide into brushes of still finer filaments as they pass towards the lens (fig. 2 B, p. 493), and are intermingled near their origin with a little connective tissue. Around the border of the lens is a small space of triangular form, the base of which is formed by the edge of the lens, the anterior boundary by the suspensory ligament of the lens, and the posterior by the hyaloid membrane. This is the canal of Petit (15, fig. J, p. 237).

The lens is extra-vascular, and its nutrition is effected in the adult by the process of imbibition from the neighbouring textures alone, the materials being in great measure derived from the numerous blood-vessels in the ciliary processes of the choroid. In the foetus, however, a branch of the central artery of the retina passes directly forwards through the vitreous to the posterior surface of the lens, on which it forms a close anastomosing net-work of capillaries. The experiments of Dr Bence Jones and M.

2 E.



2 F.



Dupré¹ on the rapidity with which lithia and quinine appear in the lens, show that the nutritive processes are not sluggishly performed in health, since even in old animals, when such material is taken into the blood, it enters the lens, probably through the medium of the aqueous, in the course of a few minutes.

The function of the lens is to collect rays of light entering the eye, whether parallel or divergent, into a focus which shall correspond to the central spot of the retina. It is enabled to accomplish this by its elasticity and compressibility, which are under the control of muscular fibres placed within the eye, and which constitute that accommodative power possessed by the eye, which will hereafter be more fully described.

The interest attached to the pathological conditions of the lens, centres in those which accompany or produce cataract; and the recognition of the chief varieties of cataract is a matter of importance, in a practical point of view, since the treatment to be adopted in any particular case is essentially modified by our knowledge of the exact condition of the lens.

Taken as a whole, cataract may be said to constitute about 10 per cent. of all ophthalmic diseases; and it occurs with nearly equal frequency in the two sexes.

Cataracts may be divided, first, into lenticular, or those occasioned by opacity of the substance of the lens; and capsular, or those affecting the investing membrane. Lenticular cataracts are subdivided into hard, soft, and zonular or perinuclear. Capsular cataracts are either anterior or posterior. A combination of capsular and lenticular cataract in the same eye is not unfrequent. Besides these may be mentioned traumatic cataracts, or those arising from injury; and false or secondary cataracts, arising from the presence and opacification of lymph, lens substance, or portions of

¹ *Proceed. of Royal Society.*

capsule in the area of the pupil, an event of not unfrequent occurrence after the operation for the extraction of cataract.

Other forms, which have been admitted or described by writers on ophthalmic surgery, but which are either extremely rare or capable of being classed under one or other of the foregoing heads, are congenital, black, osseous, and trabecular cataracts.

Ætiology of Cataract.—The formation of a cataract, in consequence of injury of the capsule, and the admission of the aqueous to the lens substance, is an event of daily occurrence. It has also been satisfactorily shown by Mr Lawson,¹ that cataract may be formed after blows upon the eye without the rupture of the capsule; and it may even result from violent shocks to the system generally, as by a railway collision, without any other appreciable injury having been inflicted upon the globe. In such cases it would appear to be merely the result of the violent succussion of the substance of the lens causing some alteration in its nutrition. A similar mechanical explanation of the origin of the opacity may also be given in the peri-nuclear cataracts of infants who have suffered from fits, and in the capsulo-lenticular cataracts of those who have suffered from purulent ophthalmia with perforating ulcer of the cornea. But in the majority of cases the ætiology of cataract is exceedingly obscure, and for the most part no information can be obtained from the patient as to the period of its first appearance, though it may sometimes be reasonably attributed to a period of mental distress or other cause occasioning great debility. It is most common about the age of 60, and especially in those who have at an early period become grey, wrinkled, and enfeebled. In many cases an hereditary tendency has been shown to exist.

In some instances it appears to be referrible to inflammatory states of the eye, as glaucoma, which are obviously unfavourable to the due performance of the nutritive functions in the

¹ Ophth. Hosp. Rep., vol. iv. p. 179.

several tunics and humours. Kunde¹ has adduced many observations showing that opacity of the lens can be caused in animals—as in frogs, cats, and dogs—by the establishment of conditions interfering with the exosmotic processes that minister to the healthy nutrition of the lens, the activity of which is well shown by the interesting experiments of Dr Bence Jones and M. Dupré. Thus the administration of sugar, and of various mineral salts, in large quantity, occasions the formation of a cataract resembling that which occurs in the later stage of diabetes, and which may be attributed to the same cause—an excessive density of the blood, leading to exosmosis of fluid from the lens, and the formation of vacuolæ in its substance, accompanied by the deposition, in an insoluble state, of calcareous and other salts.

Similar conditions may reasonably be supposed to be present in old age, and may also be induced in animals by long exposure to extreme cold. The facts just mentioned in regard to the action of certain salts and of sugar, coupled with the almost endemic distribution of some forms of cataract, seem to point to some peculiarity in the soil or water, or to some error of diet, as the efficient cause of cataract, but no certain information has been gained upon the point. J. Meyer has indeed lately shown that the use of bread containing ergot is an occasional cause of cataract, which for the most part occurs in young people, develops slowly, and is usually of soft consistence; but whether the cataract proceeds from any specific influence of the poison on the nutrition of the eye, or is the result of the convulsions that accompany its use, is, according to Stellwag v. Carion, not satisfactorily determined.

In a paper by Dr E. Müller,² it is stated that capsular cataract is very rare in southern and middle Germany, Jäger having only seen it four times in 910 cases of cataract; Arlt

¹ Zeitschrift f. Wiss. Zool., Bd. viii. p. 466. 1857.

² v. Gräfe's Archiv. f. Ophthalmol., p. 166. 1856.

had only noticed it from sixteen to twenty times, and Schauenburg had scarcely seen it at all. On the contrary, in northern Germany it is so frequent that v. Gräfe considers it to be one of the most common forms of cataract; and M. Müller had himself seen, in the course of fifteen months, upwards of eighty cases. It appears to be a common affection in Egypt. Still the facts obtained are not sufficiently numerous to enable any definite conclusions respecting the ætiology of cataract to be drawn.

Pathology of Cataract.—There can be no doubt that cataractous loss of transparency occurring in the lens is sometimes the result of an inflammatory process. M. Moers, in particular,¹ has made various experiments with the view of establishing inflammation in the lens; in some cases by injecting a strong solution of nitrate of silver into the lens, after evacuation of the aqueous humour; in others, by pricking the lens with a needle; and in others, again, by passing a thread through it, smeared with unguentum cantharidis. In all instances the inflammation seemed to originate, and to be most marked, in the cells lining the posterior surface of the crystalloid. These became swollen, the nuclei underwent division, and endogenous multiplication of cells occurred; at length the parent cell burst, and the imperfectly developed daughter cells, closely resembling pus globules, were set free. The accumulation of these in some instances took place to so great an extent as to cause the rupture of the anterior capsule and the escape of the puriform fluid into the anterior chamber; and in fortunate cases this was succeeded by the closure of the ruptured capsule and the recovery of its transparency. More frequently, however, the puriform sub-capsular fluid became inspissated, underwent all the phases of fatty degeneration, and was the seat of various deposits, giving rise to the formation of capsular cataract.

¹ Virchow's Archiv., Bd. xxxii. p. 45; and M. Wecker, Recherches sur l'etiologie de la Cataracte, Ann. d'Oculist., t. iv. p. 16. 1865.

In some cases the lens may even become vascularized, and this is effected, according to Ritter, by a connection becoming established between the elongated nuclei of the sub-capsular layer of cells and similar fusiform nuclei of the connective tissue, forming the tunica adventitia of the vessels of the iris. These communications permit the passage, first of lymph-like fluids, and subsequently of blood; and finally a system of capillaries appears between the iris and the lens, penetrating into the very substance of the latter.

When the inflammation has extended from the sub-capsular layer of cells to the more central parts of the lens, the fibres are found to lose their homogeneity, fat molecules accumulate around their nuclei, which enlarge, lose their transparency, and divide. From this period either improvement may take place, the inflammation subsiding and the fibres resuming their transparency, or, becoming more intense, may lead to continual subdivision of the nuclei, till they fill the interior of the swollen fibres, and ultimately cause their disruption. The imperfectly formed nuclei, resembling pus corpuscles, now insinuate themselves between the natural planes of the lens, and effect its complete destruction. The physical cause of the opacity in cataract is generally attributed¹ to the presence of olein, cholesterin, earthy salts, or of a fine molecular material, which, when of some thickness, presents a dirty yellowish-brown colour. The seat of these deposits, where the lens is affected, as Müller, Förster,² and others have shown, is usually in the layers occupying an intermediate position between the cortical and nuclear portions of the lens substance; and it may perhaps be truly said, that the opacity never affects the precise central nor the peripheral portions of the lens—these remaining clear to the last. Amongst 72 lenses examined by Förster with incipient cataract, in patients varying in age from 54 to 87, only one was found

¹ See Wedl, *Patholog. Histology*. Syd. Soc. Transl., p. 182. 1855.

² *Archiv. f. Ophth.*, Bd. iii. 1857.

with nuclear opacity, and Malgaigne did not find one in 60 cases that he examined in which the nucleus was the part primarily affected. According to Förster, lenticular opacities present themselves under four forms.

(1.) As short and small white striæ interruptedly inclosing the æquator of the nucleus, of brownish colour, well-defined edges, and pointed extremities; (2.) as thin white clouds composed of fine granules; (3.) as radiating lines, thickest and broadest at the æquator of the nucleus, but not chiefly occupying, as maintained by Stellwag v. Carion, the septal planes of the lens; and (4.) as a cloudy layer of small fat drops encircling the nucleus like a girdle.

In almost all instances, but especially in the nuclear cataracts of old people, the fibres of the lens themselves, as observed by Nunneley, appear to have undergone a kind of degeneration, losing their well-defined form of transparency, and becoming granular and friable, irregularly swollen, and more or less separated from one another. In the more cortically situated opacities of young persons, according to Ritter,¹ the fibres become, in the first instance, finely punctated, the dots dissolving in acetic acid, and being therefore of an albuminous and not of a fatty nature. The fibres then increase in volume, and finally break down with fatty degeneration.

Soft cataracts are usually found in young people, and are sometimes congenital. After the age of thirty, from the natural increase of hardness in the lens, they are very rare; they are usually of large size, causing the iris to project forwards, and give the impression of semi-transparency; the colour is bluish-white or greyish-blue, and has been compared to starch, paste,² cream, or pus.³ Mr Guthrie states that the lens substance is sometimes so soft that, when the eye is at rest for a little while, a kind of separation takes place, the denser particles falling like a precipitate to the

¹ Wecker, *Etudes Ophth.*, vol. ii. p. 18.

² v. Carion.

³ Tyrrell.

bottom. Sometimes fine striæ are seen when the cataract is of somewhat firmer consistence. It is not uncommon for absorption of the lens substance to take place in the course of some months or years; and then, though the external appearance of the cataract is not materially altered, the operator, on introducing the needle, is surprised to find no resistance beyond that presented by the capsule and the attachments which this has formed with the iris. On the breaking up and depression of these, a clear pupil is immediately left; such cases are sometimes called discoid cataracts. In soft cataracts, the whole substance of the lens having undergone pathological changes and become opacified, the part which under the ophthalmoscope presents the most marked opacity, is that which occupies the centre of the pupillary area, because there the greatest thickness of the opacity is looked at. As a rule, this form of cataract develops quickly. M. Sichel, M. Wecker, and others, admit a form of cataract to which they apply the term *cortical* or *semi-soft* cataract, and which they consider to be the most common of all. In this form the opacity commences in the peri-nuclear layers of the lens with small dots or striæ arranged in a radial manner, and gradually increasing in number and size with a rapidity proportionate to the youth of the patient,—in old age with extreme slowness. The striæ are usually whitish, but the whole substance of the lens assumes a more or less brown tint as the disease advances. So long as the nucleus remains clear, the apparent opacity, in opposition to what is observed in soft cataracts, is least marked at the centre of the pupillary area, whilst the marginal portion is quite opaque.

Hard cataracts are almost exclusively met with in patients who are over forty years of age. They vary in consistence to a considerable degree, the lens becoming, in some old standing cases, of an almost stony hardness, and being really converted into a calcareous mass, which it is

impossible to divide with a needle or knife. The hard and usually dark-coloured opacity is generally confined to the more central parts of the lens, excluding the nucleus itself, and, as is rendered evident by oblique illumination, is long surrounded by a tolerably clear zone of the lens substance. It often commences by striæ of whitish colour, which converge towards the centre of the lens. Under all circumstances its progress is slow, but the whole mass of the lens ultimately becomes opaque, and its size is usually somewhat diminished.

Of late years the term *zonular* or stratified has been employed to distinguish a form of cataract which usually occurs in the eyes of both sides coincidently in young subjects. It is stated by M. Stellwag v. Carion¹ to be the most common form of cataract in youth, exceeding in number, at that period, all the others put together. It is characterised by the opacity being limited to those layers of the lens which occupy an intermediate position between the nucleus and the periphery, and by having little tendency to spread either towards the cortical or nuclear portions. Hence it is sometimes called peri-nuclear cataract. The centre of the opacity is frequently occupied by a little white spot, such as is shown in Plate VIII., fig. 46. I have seen one example of this form of cataract, in which the opacity presented the appearance of a perfectly white and very dense ring, with sharply-defined edges, the capsule and lens substance being perfectly clear both in its outer and inner edges, and allowing the fundus to be perfectly explored with the ophthalmoscope. It occurred in a man aged thirty.

M. Rydel² states that, in the practice of M. Arlt, the zonular form of cataract occurred 29 times in a total number of 10,668 patients, 17 of the cases being men, and 12 women. M. Arlt has met with it so frequently in children who have suffered

¹ Lehrbuch der Augenheilkunde, p. 621. 1867.

² Ann. d'Ocul., p. 244. 1865.

from convulsions, that he is inclined to believe there exists between them a relation of cause and effect, and that in the violent muscular movements some slight displacement takes place between the central and firmer portions of the lens, and the softer external parts, leading to imperfect nutrition and altered physical properties of the intermediate layers; and this is in accordance with the observation of M. v. Gräfe, that it sometimes follows blows on the eyes and luxation of the crystalline lens. The form of cataract termed *black* or *cataracta nigra* is exceedingly rare, but scattered cases will be found in both English and foreign journals. In some instances the colour seems only to have been an exaggeration of that brown tint, which has been already referred to as coincident with advancing age. In a case, however, recorded by v. Gräfe,¹ the nucleus was surrounded by striæ, which appeared of a blood-red by transmitted light, and which, under the microscope, presented minute crystals, resembling those of hæmatoidin, with which their micro-chemical reactions were identical. It is therefore probable that, in some of the instances where well-marked black cataract has been present, it has originated in a blow or injury by which blood has been forced into the texture of the lens, and has undergone the usual changes which occur in blood extravasates.

Capsular Cataract.—From the united testimony of various observers,² it seems now to be well ascertained that the clear, transparent, and homogeneous membrane constituting the capsule of the lens, rarely if ever becomes opaque. H. Müller states, as the result of his microscopical investigations, that in capsular cataracts the opacities do not in general result from a metamorphosis of the original capsule, but are due to

¹ Archiv. f. Ophth., Bd. i. p. 333.

² See H. Müller, Bd. ii. Heft. ii. p. 166, and Bd. iii. Heft. i. p. 55; Schweigger, Archiv. f. Ophth., Bd. viii. Heft. i. p. 192; Hulke, Ophth. Hosp. Rep., i. p. 182.

the deposit of layers of new material of various kinds, frequently of a colloid or hyaline character, which, blending with altered lens substance on the one side, and with the capsule on the other, appear to the eye as transformations of the latter, though under the microscope the original capsule may frequently be discovered unaltered, save in having undergone some increase in consistence. Whilst the new-formed layers are frequently closely analogous to the capsule itself, in the homogeneity of their structure, they often undergo conversion into connective or fibrous tissue, or become the seats of the deposit of fat or calcareous salts, and they then appear as uniform or as punctated, stippled, clouded, netlike, or trabecular opacities, and, occasionally, even a bony investment to the lens may be formed.

The deposits that are found *on* the surface of the capsule are often composed of fibres of connective tissue and pigment, probably derived from the breaking down of old inflammatory adhesions between the posterior surface of the iris and the capsule. After the instillation of atropine they may often be seen as a ring, occupying the position corresponding to the margin of the iris. Sometimes, again, they assume the form of a small white central spot, such as is depicted in Plate VIII., fig. 46. These are frequently the result, as Mackenzie states, of purulent ophthalmia, with perforating central ulceration, and are formed by the deposition of lymph between the cornea and lens, which, in the infant, are in very close proximity with one another. The deposit sometimes forms a little conical whitish mass, occupying the centre of the pupil, and dipping into the substance of the lens by its posterior clubbed extremity. Its anterior pointed extremity is intimately blended with the anterior capsule of the lens, which is drawn forwards and thrown into folds, and this, coupled with an obvious diminution in the size or atrophy of the lens, has occasioned this form of cataract to be termed *pyramidal cataract*. In other cases the deposit

is most marked at the margin of the lens, where it appears as a white zone when the pupil is dilated with atropine,—a condition that has been termed *cataracta siliquata*.

The posterior part of the capsule is rarely observed to be the seat of opacities, which may perhaps be attributed partly to the absence of epithelial cells lining its inner surface and its greater tenuity, and partly to the less active nutritive processes that take place in it through the vitreous.

Traumatic cataracts are in general recognised by the uniformity of the opacity as compared with the striated appearance of senile cataracts, and by the presence of some evidence of the injury in the lids, sclerotica and cornea, iris, or capsule of the lens. The changes that take place in the lens substance when, through an injury to the capsule, the aqueous humour gains admission to the substance of the lens, are that the fibres swell, separate from one another, curl up, and assume a beaded appearance, finally becoming opaque, and breaking down into an emulsion.

Very slight injuries of the capsule or lens may heal up without leaving any trace, or only a white cicatrix, which is then termed a partial traumatic cataract; but in the majority of cases general cataract is the result, the lens usually undergoing an increase in size, and becoming opaque throughout its mass,—a condition that is often coincident with violent general inflammation of the several tunics, which may lead to entire destruction of the eye, or, in less severe cases, may cause anterior and posterior synechiæ.

Occasionally, as a result of violent succussion of the head or body, or occurring as a congenital defect, a greater or less degree of dislocation of the lens and capsule is observed. When complete, as shown in Plate XI., fig. 66, the lens may long remain in the anterior chamber, preserving its natural transparency, and setting up no inflammation. A similar accident sometimes happens to a cataractous lens. In both instances the appearances presented are very striking. In the former,

the lens betrays its presence by a bright yellow rim, owing to its refractive power being different from the aqueous; and in the latter, the white, disk-like mass can be very distinctly seen lying between the iris and cornea, and can be made to move on slightly altering the position of the head.

A lesser degree of dislocation, always congenital, and usually upwards and inwards, the lens being still embraced by the ciliary processes, has been termed ectopia. It is difficult to determine without the use of the atropine and of the ophthalmoscope, which enables any deviation from its normal position to be easily ascertained by the shadowed border of the lens. The eyes thus affected are extremely myopic and astigmatic; they sometimes see objects fringed with prismatic colours, or double.

Symptoms of Cataract.—The earliest symptoms of an ordinary case of nuclear cataract are, that the patient complains of bright objects, such as the flame of a candle or lamp, being misty and surrounded by a halo. Occasionally there are some indications of inflammation in the eye; but generally the disease advances without occasioning any marked symptoms; and in many cases it is only on closing the healthier of the two that the patient suddenly discovers how far the disease has progressed. The rapidity with which it advances is often considerable, and most surgeons must have had opportunities of observing cases where almost complete blindness had resulted from the development of cataract in the course of a few weeks. Tyrrell gives a case in which in twenty-four hours the patient was reduced from being able to read, to mere quantitative perception of light. In the earlier periods of the affection the patient can uniformly see better by the dim light of evening than in the broad daylight, the more widely-dilated pupil in the former case allowing the light to pass through the lateral and more transparent parts of the lens. The same effect is produced by the instillation of atropine.

The colour of hard nuclear cataracts is generally of a more or less dull brown or brownish-green colour.

On examining the eye at an early stage, the opacity appears as a dark greyish or brownish cloud or haze in the centre of the pupil, around and between which and the margin of the lens is a clear black space. This condition is, however, frequently simulated by other states, where the lens preserves its transparency; and no positive conclusion can therefore be drawn from a consideration of this symptom alone. In elderly persons especially, the pupil is never of so deep and clear a black as in the young, and sometimes so much light, of a dull brown or reddish colour, is reflected, as to occasion a deceptive appearance of cataract. Considerable assistance may in such cases be derived from the employment of the ophthalmoscope, by which very slight degrees of opacity may be recognised, and, still better, when conjoined with the method of oblique illumination. For this last method of observation the patient is seated as in ophthalmoscopic examination; but the light of the lamp, placed in front or at the side of the patient, is concentrated on the pupil, dilated with atropine, by means of a lens of one or two inches focus. The observer then examines the media with a second lens as far as he can, in regular order, from without inwards, focussing successively the cornea, then the anterior capsule, the body, and the posterior capsule of the lens. As the disease progresses, the opacification becomes more and more obvious. Striæ of larger or smaller size, or dots, may be observed at the margin of the lens, which gradually increase in number and thickness till the lens assumes a general bluish, greyish, brownish, or even greenish tint, in which state it may remain for long periods of time apparently unaltered. In many cases, however, a process of contraction ultimately takes place, and the lens and iris may be seen to float and quiver in the media.

It has been a question whether the existence of a cataract

for many years necessarily induces amblyopia or loss of functional activity of the retina. It may be considered as tolerably certain that where vision has been seriously impaired by opacities of the transparent media at an early age, the retina will have become so dulled to external impressions, and its development so interfered with, as to permit it to recover its natural sensibility with difficulty when these have been at a long subsequent period cleared away by operation.¹

Diagnosis.—The diagnosis of cataract, respecting which so much was formerly written, is now capable of being almost completely determined by a single careful examination of the eye, after the instillation of atropine, with the ophthalmoscope and oblique illumination. With these aids very slight opacities may be recognised, whilst at the same time valuable information may be gained respecting the condition of the fundus, and of the propriety of performing some one of the various operations proposed for cataract in preference to another.

Treatment.—The question whether cataract can be cured by medicinal agents must be answered in the negative. It is indeed true that a certain degree of haziness of the lens, which accompanies some forms of disease, as glaucoma, may, by attention to the general health and judicious local treatment, be made to disappear; but no means are as yet known by which a fully-developed cataractous opacity can be removed without operation.

In the early stages of the affection, great benefit may be derived from the employment of atropine, or of belladonna liniment, especially in cases of nuclear or peri-nuclear cataract, the dilatation of the iris allowing the rays of light to enter through the marginal and as yet transparent portions of the lens; but when the disease has so far progressed that the whole lens is opaque, an operation is required, the object of which is in all instances to effect its removal from the axis of vision.

¹ v. Gräfe; Arlt.

Before any operation for the removal of cataract is performed, the utmost care should be taken to place the patient in the circumstances which may prove most favourable to his subsequent recovery. Attention or non-attention to apparently trifling points proves oftentimes of vital importance to the success of the operation; and when it is remembered how long and anxiously it has been previously dwelt upon by the patient, and how great is the disappointment attendant upon an unsuccessful operation, it is inexcusable in the surgeon if he neglects those precautions which are well known to exert a powerful influence in promoting a cure. If possible, the operation should neither be undertaken in the hottest nor in the coldest periods of the year,—the former making the patient restless at night, the latter rendering him liable to rheumatic inflammation. If the patient suffer from cough or chronic bronchitis, it must be relieved by stimulants, expectorants, rest in-doors in an equable temperature, leeches, blisters, opium, or such other means as are found to be effectual. A severe cough is a direct contra-indication to the flap operation, and necessitates, if it cannot be cured, the performance of depression, or of one of the other methods of extraction. The bowels, especially in old people, in whom they are apt to become clogged, should be freely opened two or three days previously. If requisite, the patient's health, strength, and spirits must be raised by the employment of wine and tonics, and by cheerful and encouraging conversation. The presence of any grave constitutional affection, diabetes, syphilis, gout, rheumatism, or scurvy, are contra-indications to any operation. The pupil should be moderately, but not widely, dilated with atropine; and care should be taken that the eye is free from any inflammation, or from any condition like those of inversion of the lid or trichiasis, which may induce inflammation.

When the patient has, by attention to these points, been placed in a satisfactory state, the mode of operation must be determined upon according to the age of the individual and

the nature of the cataract. The several operations which are now commonly practised, may be reduced to the following:—first, division or solution, applicable only to soft or semi-soft cataracts; secondly, suction, also adapted only for soft cataracts; thirdly, depression or reclination, chiefly employed in cases of old persons with hard cataracts; fourthly, extraction by flap operation, the proceeding which is now most generally performed on all cataracts occurring in persons over forty years of age; fifthly, linear incision and removal of the lens with a scoop or spoon; and, lastly, the operation lately introduced by Prof. v. Gräfe, termed the modified linear extraction, both of which last are adapted for all forms of cataract, except the soft, though even in this the linear extraction may be adopted.

Treatment of Cataract by Division.—This operation appears to have been first systematically performed in this country by Pott,¹ and probably originated in observation of the changes which not unfrequently take place in cases of injury of the lens by sharp instruments, where, after the formation of a cataract, the opaque substance of the lens is again gradually removed by the solvent action of the aqueous humour. The operation consists in the introduction of a needle either through the sclerotic (discission), or through the cornea (keratonyxis), and the breaking up of the capsule and lens substance, so as to admit the free access of the aqueous humour. Formerly, the operation was limited to soft cataract, and therefore almost exclusively to young persons, as it was found that the fragments of harder lenses were but slowly absorbed, and frequently acted like foreign bodies in the eye, and were exceedingly apt to induce inflammation. Of late years, however, the length of time occupied in the cure has been often advantageously shortened, and the risk of inflammation considerably reduced, by making a linear incision through the cornea, and

¹ Chirurgical Works, vol. iii. p. 156.

permitting the escape of the broken-up substance of the lens, or by preceding the operation of division by one of iridectomy, as recommended by v. Gräfe. Either of these plans may be adopted in cases of older people with moderately hard cataract, in whom the ordinary flap operation is unadvisable, whether from a strongly-marked rheumatic diathesis, or from the circumstance of one eye having already been lost.

In an ordinary case of soft cataract, before proceeding to the operation, care should be taken that the pupil is widely dilated with atropine, not only to enable the operator to see the movements of his instruments clearly, but to keep the margin of the iris as far as possible from the fragments of the divided crystalline.

The patient must be placed in a semi-recumbent position, in a good light, the operator standing in front of or behind him, according to the eye operated on, and raising or depressing one lid, whilst an assistant takes charge of the other. If chloroform be given, however, both lids may be entrusted to the assistant, who holds them apart; whilst the operator seizes a fold of the conjunctiva with a pair of forceps, rotates the eye downwards, and holds it steady. A sharp spear-pointed, double-edged needle, with a round body, to prevent the issue of the aqueous, and a stop or thicker part, at the distance of 4-10ths of an inch from the point, to prevent its entering too deeply, is now made to penetrate either the sclerotic or the cornea. In the former case, the needle should enter at a point a little above the horizontal meridian of the eye, and about one-sixth of an inch from the margin of the cornea, and, passing behind the iris, should be thrust obliquely forward into the anterior chamber, the division of the lens being then accomplished by bringing the handle forwards, and rotating, or, if the expression may be used, circumducting it freely. The puncture through the cornea is frequently preferred at the present time, because less important parts are perforated, because the point of the needle can be followed

through its whole course, because the long ciliary arteries and choroid escape injury, and because the degree to which the capsule shall be opened can be determined with far greater nicety. Experience has shown that the minute puncture through the cornea heals up readily, leaves no mark, and is rarely followed by any inflammation. In soft cataracts, as soon as the needle ruptures the capsule, the fluid or semi-fluid substance of the lens gushes through the rent in the capsule into the aqueous humour; and in such cases the rapidity with which absorption takes place is astonishing, a few days sufficing to lessen the opacity to a manifest extent, whilst the greater part may disappear in the course of three weeks or a month. Some fragments of the capsule, recognisable by their white opacity, however, generally remain for a longer period, and require to be subsequently dealt with, either by extraction with the cannula forceps through a small linear opening, or by depressing them from the axis of vision by a second needle operation.

Where the cataract is of firmer consistence, it has been found by experience that the free admission of the aqueous to it, through a large rent in the capsule, occasions such a swelling of the lens substance by imbibition, as greatly to increase the intra-ocular tension, and to be a fruitful source of consecutive inflammation. With a view of avoiding this difficulty, v. Gräfe¹ recommends that the capsule should, in the first instance, be opened only to a small extent—in fact, should be little more than punctured. The inflammation which follows is slight, and can be easily subdued, whilst the portion of lens substance which protrudes into the anterior chamber through the rent in the capsule gradually undergoes absorption; and a second operation may then be performed, and repeated till complete solution is effected. In cases of moderately-soft lens, especially occurring in persons of from twenty to thirty years of age, however, free division of the

¹ Arch. f. Ophth., Bd. v. p. 173.

lens is frequently performed without any bad results accruing. The fragments are soon observed to become semi-transparent at the edges, and recall the appearance of a portion of albumen undergoing solution in artificial gastric fluid.

It is interesting to the physiologist to see the almost instantaneous injection of the conjunctival and subconjunctival vessels that occurs when the puncture is made, either through the sclerotic or through the cornea. The redness, in the form of a more or less complete circum-corneal zone, lasts for a day or two, and is attended with more or less pain, lachrymation, and photophobia. The escape of the aqueous upon the introduction of the needle should, if possible, be avoided, as the lens is immediately advanced towards the cornea, and the subsequent steps of the operation are much impeded, if not altogether prevented. If it happen, the patient had better be put to bed, and the operation postponed for a few days. No harm in general results from the entrance of portions even of moderately-hard lens into the anterior chamber; indeed, Guthrie¹ expressly directs that the fragments should be pressed into the anterior chamber. Care should, however, be taken that no portion rests just upon the margin of the iris, as it is in this position exceedingly liable to produce iritis. Though the operation is a slight one, inflammation of a severe nature may be very easily lighted up, and due attention should therefore be paid to the patient. A drop of solution of atropine should be instilled immediately after the operation is completed. The eye should be covered with a pad and bandage, and the patient should be kept in bed for from twenty-four to forty-eight hours, with a moderate allowance of food. After this period he may get up and walk about in a shaded room. A little belladonna liniment may be applied to the brow every morning, to maintain the dilatation of the pupil.

The objections to the selection of this operation in old

¹ Operative Surgery of the Eye, p. 353. 1830.

persons are, that iritis and choroiditis of a rheumatic or glaucomatous character are apt to supervene, if not immediately, yet after the lapse of a few months, leading to gradual contraction of the field of vision, and ultimate blindness; whilst in other cases general ophthalmitis, with suppuration of the globe, have been observed. These effects are probably due to the presence of hard fragments of the lens, which are incapable of being absorbed, and which consequently act as foreign bodies within the globe. The treatment of these complications must be conducted on the principles already laid down for iritis and glaucoma; and in some instances iridectomy has proved a most valuable remedy. Usually, however, the organic changes which have taken place are so great, that very imperfect vision is retained. In a case in which I operated on a young woman of 28, the iris retracted to so great an extent as to become almost invisible, and became fixed in that position by inflammation.

Treatment of Cataract by Depression or Reclination.—The essential feature of these operations is the removal of the cataractous lens from the line of sight, either by simply depressing it in the globe of the eye below the level of the lower border of the pupil, or by turning it half over, so that the anterior surface shall look upwards. In performing the operation of depression, which is now but rarely employed, the pupil should be well dilated with atropine, and the patient should be placed as recommended for division. A rather broad and straight or slightly curved needle should be introduced a little behind the junction of the cornea and sclerotic, near the horizontal meridian of the eye. After traversing the space between the lens and the ciliary processes, it should be made to appear in the pupillary area in front of the lens. Some operators now divide the capsule; others at once proceed to press the lens backwards, and then to effect its depression. It should be fairly pushed out of sight, and yet not be allowed to press against the retina. In this position it should

be retained for some seconds, or longer, if on raising the needle there seem to be any disposition in it, as is sometimes the case, to rise again. Mackenzie¹ recommends the point of the needle to be entered behind the cataract, and a division of the posterior part of the capsule to be made, as well as subsequently of the anterior portion of the capsule, before effecting either depression or reclamation of the cataract. In the few cases in which I have depressed a cataract, I have generally pursued the plan recommended by Mr Lawrence, and which, I think, is generally adopted, where simple, steady pressure is employed, and the anterior and posterior layers of the capsule are torn through.

Mr Vose Solomon² has suggested the employment of two needles in the operation of reclination—an operation which he believes to be undertaken under the most favourable circumstances when the globe is large, and the cataractous lens of mixed consistence, that is, composed of a hard nucleus, with soft cortex. As this form of cataract is voluminous, and presses the iris forwards, it is difficult to introduce a single needle through the sclerotic, and between the iris and lens. Mr Solomon therefore recommends that the outer and lower part of the lens should be pressed backwards from the iris by a fine needle passed through the nasal side of the cornea, thus making a free space for the sclerotic needle to pass to the front of the cataract. He believes, also, that the employment of two needles enables the lens to be more easily and methodically reclined, and is attended by other advantages.

The after-treatment is simple, consisting only of keeping the patient in bed for a day or two, and in the avoidance of all sudden movements, such as coughing or sneezing, by which the lens may be dislodged from its new position, and again occlude the pupil. If moderate inflammation supervene, it may be combated by leeches and purging.

¹ Treatise, p. 779.

² Ophth. Hosp. Rep., vol. i. p. 219.

One of the bad results of this mode of operating is the occurrence of violent vomiting, probably occasioned by the pressure of the lens against the retina, for the relief of which Middlemore and other authorities recommend that the corneal section should be performed, and the depressed lens removed, as in the ordinary method of extraction. Hæmorrhage may also occur after the operation, either with or without vomiting, in which case the sight may be considered as being irretrievably lost. In almost all instances, if the eye in which the operation has been performed be examined some years subsequently, it will be found that the vitreous is fluid, and the vision very imperfect, the patient frequently complaining of clouds and muscæ.

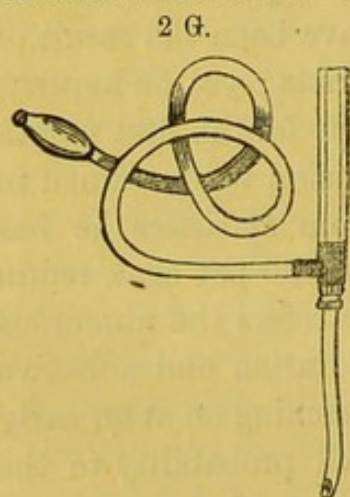
Professor v. Gräfe strongly condemns the treatment of cataract by this treatment.¹ The results of the operation, he remarks, cannot be satisfactorily determined for some months after the patients have been discharged from the care of the surgeon. In his own practice, nearly 20 per cent. of the failures in the first eye operated on have been the result of depression performed in the country districts; yet, on inquiry, he found that half of these could see fairly for the first month or two after the operation, whilst good vision was retained in others for as long as six months. From statistics he has collected, he believes that not more than 60 per cent. retain good vision for any length of time. He refers the numerous failures to three chief causes—to suppuration and adhesive inflammation of the internal membranes coming on at an early period after the operation, and due in all probability to the irritation set up by the unabsorbed nucleus of the cataract; to infiltrations of the vitreous, due to the proliferation of the cellular elements diffused through its substance, such proliferation being consequent upon the irritation of the dislocated lens; and, lastly, to certain peculiar inflammations presenting

¹ See A. v. Gräfe, *Clinique Ophthalmologique*, par Ed. Meyer. *Du Traitement de la Cataracte par l'Extraction Linéaire Modifiée*. 1866.

a glaucomatous character which supervene at a much later period. In these, owing to organic changes in the choroid and other parts, an excessive secretion of the intra-ocular fluids occurs, followed by excavation and atrophy of the optic nerve. Scarcely any of these affections are curable, and all occasion a liability, on the occurrence of the least injury, to serious and destructive inflammation.

It must be acknowledged, however, that one cause of the greater likelihood of some of these evils occurring in cases where depression has been performed, is, that this operation is undertaken by many surgeons in cases when, from the presence of some constitutional disease, as gout or rheumatism, or from the existence of chronic cough, the success of the flap operation is rendered doubtful. It was considerations of this kind that led v. Gräfe to adopt his method of linear extraction, which will presently be described.

Treatment of Cataract by Suction.—A mode of treating cataract where the lens is nearly diffuent, has been recently



Suction Curette of Mr Teale.

proposed or rather re-introduced by Mr Pridgin Teale.¹ Mr Teale employs an instrument which he has termed a "suction curette," the construction of which is essentially similar to one suggested by Mr Greenway for the purpose of making an artificial pupil by sucking out a piece of iris. Its nature will be readily understood from the following description and figure :—

"The *suction curette* consists of three parts—a curette, a handle, and a suction-tube. The curette is of the size of the ordinary curette, but differs from it in being roofed in to within one line of its extremity, thus forming a tube flattened on its upper surface, and terminating, as it were, in a small

¹ Ophth. Hosp. Rep., vol. iv. p. 197.

cup. The curette is screwed on to the handle. The handle receives the curette, and is hollow for a short distance, thus being a continuation of the tube of the curette. Passing out at right angles from this portion of the handle, is a further continuation of the tube, to which the suction-tube can be fixed. The suction-tube is a piece of india-rubber tubing, ten or twelve inches long, having an ivory or metal mouth-piece at one end, and fitting on to the projecting part of the handle by the other." To use the instrument, the cornea should be punctured by a broad needle, and the anterior capsule of the lens freely broken down. The open extremity of the instrument should be made to penetrate the soft lens substance, the removal of which is effected by the operator's exerting gentle suction with his mouth through the tube. An improvement upon this instrument has been made by Mr Greenway,¹ by the addition of an india-rubber valve within the mouth-piece, opening towards the mouth when the slightest degree of suction is made, and closing spontaneously as soon as the suction ceases. This arrangement prevents the entrance of any accidental back-current of air. It need scarcely be said that the suction force employed at first should be extremely gentle, and that, in the event of the tube becoming choked with fragments of capsule, the instrument should at once be removed, cleansed, and re-introduced. I have had no experience of the operation further than that I have seen it once or twice successfully adopted by M. Rouse, and it appears to me to be well adapted for those cases where, from any cause, time is an important object.

Treatment of Cataract by frequently-repeated Paracentesis Corneæ.—This method has been proposed by M. Sperino, under the impression that the frequent renewal of the aqueous humour, consequent upon its evacuation by repeated punctures of the cornea, is capable of effecting a solution of

¹ Lancet, p. 693. June 8, 1867.

the opaque particles deposited in the substance of the lens. Considerable discussion respecting the merits and disadvantages of this plan took place at the Ophthalmological Congress held at Paris in 1862. At this meeting M. Reymond stated that, in selected cases, and especially in those where the cataractous change had invaded the whole lens, presented a finely-punctated appearance, and had made rapid progress, as well as in the hard, uniform, well-defined cataracts of old people, the operation had generally been followed by success, or at least by important improvement. M. Riccardo Secondi declared that he had also operated in several instances with great advantage. In one case the patient had previously only been able to see No. 20 of Jäger's Test Types, whilst, after sixteen tapplings, he could read No. 10 with the unassisted eye, and No. 4 with a glass. On the other hand, it was argued by MM. Rivaud, Landrau, Torresini, Borelli, and Desmarres, that, in their experience, whilst paracentesis corneæ had been fairly tried, thirty or forty tapplings having been sometimes performed, and in one instance the patient having submitted to the puncture every other or every third day for no less a period than nine months, no improvement whatever, far less entire disappearance of the cataract, had taken place. It was, moreover, urged that this apparently simple operation is not by any means to be regarded as altogether free from danger, since, amongst other accidents which had actually occurred, might be enumerated leucomata, produced by frequently puncturing the cornea at the same spot, iritis, anterior synechia with deformity of the pupil, prolapse of the iris, hæmorrhage into the anterior chamber, synchysis or liquefaction of the vitreous, periorbital and ocular neuralgia, and even general inflammation and supuration of the globe. Now, as the patient is more or less exposed at each repetition of the operation to these several complications, when it has to be frequently performed, they deserve serious consideration; and it may therefore be con-

cluded that at present this can scarcely be recognised as a legitimate mode of treatment.

Extraction of Cataract by Flap Operation.—For the removal of a hard cataractous lens, the superior or inferior semicircular division of the cornea is the method at present most generally practised; for where the patient is in good health, where no accident occurs during the operation, and where the healing process is perfect, it leaves nothing to be desired. The eye appears almost perfectly natural, the cornea being clear, the pupil round, and the cicatrix almost invisible. Vision, even without glasses, is sufficiently good to enable the patient easily to make his way about; and with them, is so clear that he can read any ordinary print without difficulty. It is, too, in practised hands, a very successful operation, v. Gräfe and others reckoning the proportion of total failures at not more than ten per cent. It is best adapted for the hard cataracts of old people. A circumstance which gives a great superiority to the flap operation over that for depression, is, that it is rarely followed by any inflammatory symptom after recovery from the operation is once completed. A thin fluid probably takes the place of the lens removed, which has no tendency to induce the secondary and subacute inflammatory processes characteristic of the operation by depression, to which attention has already been directed.

In every case of flap operation, the preliminary measures for the improvement of the general health should be carefully attended to, and, in particular, any rheumatic or gouty symptoms, as far as circumstances will admit, should be removed. Both of these constitutional affections, when well marked, render success at best doubtful; and where the operation has failed, lead to many weeks of severe suffering. The presence of cough, in like manner, must be regarded as a positive contra-indication, and the more so, as by judicious treatment it can generally be materially alleviated or altogether removed. Amongst local affections, entropion, inflammation of the con-

junctiva, ophthalmia tarsi, and indeed any inflammatory condition of the globe, render it unadvisable to undertake the operation. Where posterior synechiæ exist, it is better to substitute linear extraction, with or without previous iridectomy, in place of the flap operation.

Before operating upon a case of cataract, it is expedient, especially in those who come to town from the country, to allow them a few days' rest, and to permit them to become accustomed to the noises of London. I have known a restless night lead to loss of vision. An old Irish woman was operated on for extraction by the ordinary flap method. On making the section, the knife carried off the lens, the corneal wound closed admirably, the pupil was perfectly round and clear, and she was instantly put to bed. For two days everything went well,—there was no pain, nor any swelling,—and I anticipated a quick and perfect cure. On the evening of the second day after the operation, a little child was admitted into the Hospital, and sent into the female ward with the mother. Its eye was the seat of a cancerous tumour, and very painful, and its screams and cries were incessant, keeping every one awake throughout the night. On the following morning the eyelids of my patient were swollen and red, and in the course of the next day the globe suppurated.

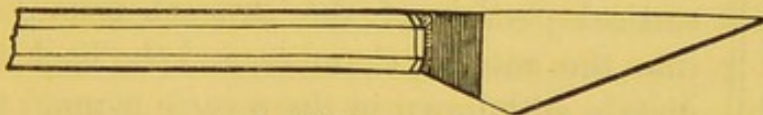
When determined upon, the operation is thus conducted. The patient should be placed in the semi-recumbent position, in a good light, with the head well supported. He should be encouraged to be steady by a few words from the surgeon to the effect that the pain is not very severe and is quickly over. Unless the operator be ambidextrous, which is rarely the case, he must stand behind the patient when about to operate on the right eye, and in front of him when operating on the left. The eye not under operation should be closed with a pad and bandage. Some surgeons prefer to operate with the pupil in its natural state; others where it has been dilated with atropine. When the pupil is naturally very

small, moderate dilatation, such as is produced by instilling one drop of a weak solution (1 gr. ad. ʒj.) of atropine into the eye over night, is certainly advantageous. Suppose the right eye to be the one about to be operated on, the surgeon, standing behind the patient, raises the lid with the forefinger of the left hand, whilst an assistant gently draws down the lower lid, avoiding all pressure on the globe. The patient should now be directed to turn the eye downwards, and the tip of the middle finger is then applied lightly but firmly to the inner surface of the globe, so as to prevent it from turning inwards at the moment that the section is made.

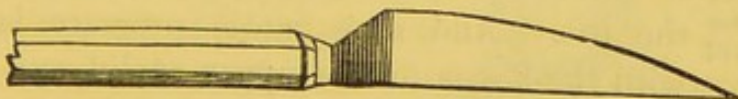
A triangular-bladed cataract-knife, the point of which has been previously ascertained to be extremely sharp by passing it through thin leather, which it should perforate without noise, is made to penetrate the cornea at its outer margin, and enter the anterior chamber a little above the horizontal meridian.

The instrument, of which the following cuts show good forms, should be held so as to pierce the cornea nearly vertically, and

2 H.



Beer's Cataract Knife.



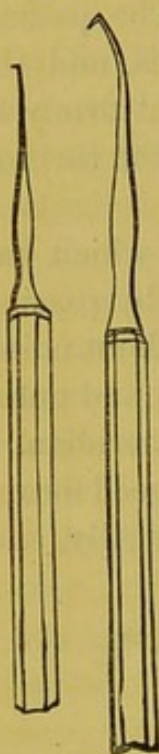
Zehender's Cataract Knife.¹

be then made to traverse the anterior chamber parallel to the plane of the iris, and transfix the cornea on the opposite side, at the same level, without the slightest stop or even hesitation. The steady onward movement of the knife being continued, it cuts its way out, and the flap is made. The superior, free, curved border of this flap, or, in other words, the line of incision,

¹ See Lawrence and Windsor's *Ophth. Rev.*, p. 9. In this knife the cutting edge is curved with a radius of four inches, and the blade has a maximum breadth of three lines.

should be close to the junction of the cornea and sclerotic, and nearly, but not quite, parallel to it, forming a segment of a somewhat smaller circle. As soon as the flap is completed, the lid is allowed to fall, and the patient to rest for a few moments, whilst the aqueous which has flowed over the

2 I.



Cystitomes,
or hooks for
the division of
the capsule.

cheek should be wiped away with a soft sponge and a cambric handkerchief. He may now be told that the pain is over, that everything has gone well, and that he is to endeavour to avoid straining. The lid being now again cautiously raised, the curved needle, or sharp hook (cystitome), 2 I., is to be gently introduced, with its back or angle foremost, through the wound, till it reaches the centre of the pupil, which is now small and contracted, a condition which always occurs as soon the aqueous has escaped. The point is then turned backwards, and, with a circular movement, is made to break up the anterior capsule. As soon as this is accomplished, a little of the softer cortical portion of the cataract usually escapes into the anterior chamber, and the hook is immediately withdrawn in the reverse manner to which it was introduced, that its point may not catch in the iris. And now gentle pressure is applied with the finger to the upper eyelid, and with the curette (fig. 2 K) to the globe, either directly or through the lower lid. The pressure should be very moderate, and should alternate in degree between the fingers and the curette. If the lens remain immovable, the pressure may within certain limits be increased, but beyond these it is probable that its reticence depends either on the opening being too small, or upon the anterior capsule having been insufficiently lacerated. In the former case, the wound must be enlarged; and in the latter, the needle must be re-introduced, and the capsule more freely divided. As soon as the lens has escaped, care must

be taken to remove any portion of the soft cortical layers that may be adherent to the lips of the wound, or that may still remain within the globe. It is better, however, to leave very minute or very soft portions of the lens substance in the anterior chamber, than incur the risk of breaking down the hyaloid membrane and vitreous, in what frequently proves a vain attempt to remove by instrumental means that which would be easily effected by the natural process of absorption.

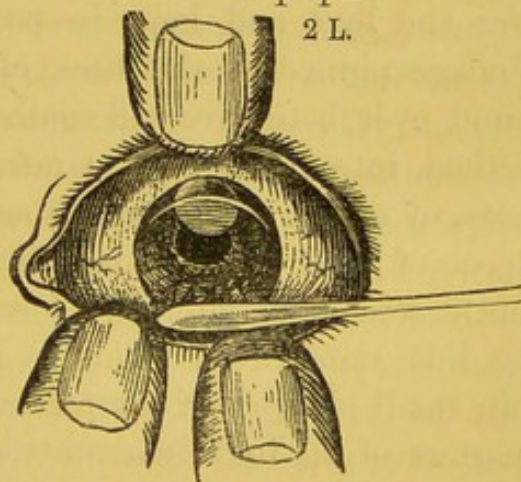
If the iris is in any degree prolapsed, it must be replaced by the curette with the utmost delicacy, and the edges of the wound should be as perfectly adapted to one another as possible. This is best accomplished, especially when the flap is inclined to turn outwards, by introducing a curette between the inner surface of the lid and the cornea, and moving it once or twice from side to side. The patient should then be directed to look downwards, and the eyelid cautiously yet sufficiently raised to enable the operator to see whether the pupil is round and the adaptation perfect. This being accomplished, the lid should at once be allowed to fall, and a soft portion of sponge gently moved in a circular direction on its surface, thus lightly pressing the lips of the wound together, and securing their adaptation by squeezing out any still remaining minute fragment of lens substance existing between them. A pad of carded

2 K.



Curette.

2 L.



In this diagram, after S. v. Carion, the section of the cornea has been made, the capsule has been ruptured with the needle, pressure is being made on the globe with the curette and the points of the fingers, and the lens is escaping through the wound.

wool should then be smoothly arranged over the lid, separated from it only by a piece of fine cambric, and kept in position by a bandage, the middle of which is pinned to the back of the night-cap, and the ends brought round over the ears and the pad. The pad may be replaced in the course of a few hours, before it has had time to become agglutinated to the lid and occasion any difficulty in its detachment; or it may be left without being touched for three or four days. Whichever plan is adopted, great care should be taken not to exert any force in detaching the pad, as by pulling the wool sharply from the eyelid a separation of the lips of the wound may result, an accident that immediately causes sharp pain, and is the sure prelude to a long and tedious recovery by secondary adhesion, even if it be not followed by total loss of vision.

As regards the modes of keeping the eyes closed after the operation of extraction, various plans have been adopted. Formerly one or two narrow strips of black sticking-plaster were placed over the centre of the lids, or near the angles of the eye; a pad of linen, of fine texture, and about four inches long by two or three in width, was then placed over the eye, and kept in position by a calico or linen bandage pinned at the back of the nightcap, and brought round over both eyes and again pinned in front. A superior method, introduced by v. Gräfe, has been employed of late years, of which the following account is a description.¹ The object of v. Gräfe's bandage is to cause the upper lid to be gently stretched (laterally) across the eyeball, and to keep the lids immovable. This is accomplished by using very thin small pledgets of charpie or cotton wool, of about three-quarters of an inch in diameter, which, after the closed eye has been covered with a piece of fine linen, are placed in the hollow at the inner canthus of the eye, then between the

¹ Taken from the abridged Translation of v. Gräfe's Paper, by Mr Soelberg Wells, *Ophth. Hosp. Rep.*, v. iv. p. 207.

globe and the upper edge of the orbit, and finally on the outer canthus, till all these depressions are filled up to the level of the eyeball, over the convexity of which a thin layer may be placed. If only a temporary bandage be required, a knitted cotton bandage, fifteen inches in length and one and three-quarter inch in breadth, is to be applied over the cushion of charpie, and passed to the back of the head; the strings which are attached to its extremity are then brought round and tied in front. Where firmer pressure is required, the *regular compress* bandage may be used, which is about one and three-quarter yard in length and one and a-half inch in breadth. The outer two-thirds consists of fine and very elastic flannel; the central third of knitted cotton. After the charpie or wool cushion has been well arranged, one end is to be applied to the forehead, just above the affected eye, and is then to be passed to the opposite side of the forehead to the back of the head. The knitted portion is then to be carried on below the ear, and brought upwards over the compress, the bandage being passed across the forehead, and its end firmly pinned.

In the third form of bandage, termed the *pressure compress*, which is intended to produce the strictest immobility, and to exert the greatest amount of graduated pressure, the bandage consists of three ascending turns instead of one. The bandage, which is to be made of fine, very elastic flannel, should be about three and a-half yards in length and one and a-quarter inch in width. One end of the bandage being placed between the angle of the jaw and the ear of the affected side, it is to be brought over the compress (but not applied too lightly), and carried across the forehead to the back of the head, and then, passing again beneath the ear, a second turn is to ascend (somewhat more vertically) over the compress, pressing firmly upon the latter; the bandage is then again carried across the forehead to the back of the head, and brought finally once more beneath the ear over the compress; but this time it is

not to be pulled tight. The object of this last turn being to prevent the displacement of the pad by the firm pressure of the second turn of the bandage, it should be made as little ascending as the ear on the one hand and the bridge of the nose on the other will permit. Here, as in the last case, the opposite eye should be closed by a strip of court-plaster.

The regular compress may be, and is usually, applied immediately after the operation, but should not be applied too tightly. The first one may be left on for six hours, but subsequently the bandage need only be changed once a-day, the lids being gently sponged on each occasion. On the second or third day, when the state of irritation is most considerable, it should be somewhat relaxed. If everything has gone on favourably after the operation, v. Gräfe generally leaves it off at the end of a week, reapplying it, however, at night-time. But if the patients prefer the bandage, or are restless, it may be employed for another week.

As soon as the operation is completed, the patient should be placed in bed, and kept at rest in a quiet and well-ventilated, but not necessarily darkened, room, as the pad of cotton wool effectually prevents the access of light. In healthy subjects, and under favourable circumstances, the symptoms which follow the operation of extraction are very slight. A little smarting pain is generally experienced, which is often relieved by a gush of tears. After a few hours, if it still persist and threatens an uneasy and restless night, twenty minims of tincture of opium and ten of chloric ether may be given with advantage. The pain gradually subsides; and the entire process of healing may then take place without any inconvenience whatever.

A little puffiness of the lids and slight cedematous redness is often observable for a few days, and if the skin near the inner canthus has been pricked by the point of the knife at the moment of the corneal section, an ecchymosis may appear; but these conditions need excite no alarm, provided

the eye is easy, as they soon spontaneously disappear. The diet of feeble old persons should be good. On the day after the operation they may be allowed two or three slices of bread with the crust cut off, and an egg, for their breakfast, or, if it agree with them, a basin of boiled bread and milk; for dinner they may have a chop, finely minced, with potatoes and a glass of wine; and, finally, for tea, bread and milk, arrowroot, or some other bland food requiring no mastication. In younger and more robust patients the meat and wine may be omitted, and beef-tea or soup substituted; but here, as elsewhere, the operator must be guided by the state of the patient, his habits, and by the general rules of surgery.

If everything go on well, the eye may be opened about the fourth or fifth day; and, if the patient be quiet and calm, it is usual to allow the pad and bandage to remain untouched till that time; if, however, he be restless, it is better to apply a fresh pad every six or eight hours, before time has elapsed to permit of the agglutination of the pad to the surface of the lids. When the eye is opened for the examination of the wound, the edges of the lids should be gently moistened with a very soft sponge and warm water; and the lower lid may then be depressed, in order to separate the edges. I have seen an injudicious effort at separating the lids by raising the upper lid and depressing the lower simultaneously, followed by breaking asunder of the lips of the corneal wound and the loss of the eye. When the lids have been carefully detached from one another along the whole length, the patient should be told to look downwards, and the upper lid may then be cautiously raised to a sufficient extent to enable the operator to see that the wound has healed. Care should be taken that, at the moment of raising the lid, the light be moderate, as in some instances the retina is remarkably sensitive, and the sudden access of bright light occasions such a violent reflex or spasmodic closure of the

lids, as to separate the edges of the feebly-united corneal wound.

When the patient is steady, the eye prominent, and the operator moderately expert, no artificial means need be employed to maintain the eye in position during the operation; nor is it requisite to use chloroform: but when the patient is nervous, the eye deep-seated, the anterior chamber shallow, or when from any other circumstances the difficulties of the operation are increased, chloroform should be administered; and when the patient is thoroughly under its influence, the conjunctiva should be seized at the lower part by a pair of toothed forceps, which may be held by the operator himself, or be entrusted to the hand of an assistant; these, by keeping the eye perfectly fixed and under control, will be found materially to facilitate the various steps of the operation.

In performing the first step of the operation, to wit, the section of the cornea, the two most common errors that I have seen occur in the hands of others, and have felt that I have fallen into myself, have been first making the flap of improper size, either too small or too large; and, secondly, failing to continue the onward movement of the knife, or slightly twisting it on its axis, thus permitting the escape of the aqueous humour. This is almost always followed by the iris folding over the edge of the knife, unavoidably compelling the operator, unless he withdraws the instrument and postpones the operation, to cut away a larger or smaller portion of its tissue, and to form an irregular pupil. The formation of a flap so small that it will not permit the escape of a moderately-hard lens, is an error that can to a certain extent be remedied by enlarging the wound with scissors or with a blunt-pointed knife, and this should invariably be done in preference to any attempt at squeezing or forcing the cataract through the small aperture, as the suspensory ligament is apt to rupture and permit the

escape of the vitreous, whilst the lens slips down to the lower part of the globe. In the event of this accident occurring, the proper mode of treatment must depend upon circumstances. If the patient is tolerably steady, or is insensible from chloroform, a curette or spoon should be gently introduced, and slipped under the lens, which may then be lifted out, the assistant aiding its removal, if requisite, by inserting the cystitome into its substance. If, on the contrary, the involuntary movements of the eye are very energetic, or if the vitreous be very fluid, after one or two ineffectual attempts have been made, it is better to desist from endeavours which will probably only lead to the evacuation of the whole contents of the globe, and leave the lens in the eye. I have at least seen several instances in which good vision was obtained when this plan was adopted.

A second and very important result of the formation of too small a section of the cornea is, that in endeavouring to force the hard lens through the small opening, the iris, posterior surface of the cornea, and the edges of the wound, are more or less bruised and injured, and constitute so many *points de départ* or foci of inflammatory processes, accompanied by the proliferation of cells, which, by closing the pupil, may ultimately occasion the complete failure of the operation.

The formation of too large a flap may arise in two ways, either by the knife being entered too low through the cornea, the line of incision being still contained within the periphery of the cornea, or the knife being entered at the right height, the cut may extend beyond the cornea, and implicate the sclerotic. In the former instance the danger to be feared is, that a large portion of the cornea being severed from its supply of nourishment, it may not obtain sufficient by imbibition to maintain its vitality; sloughing consequently occurs, and the eye is irretrievably lost.

On the other hand, in the latter instance, hæmorrhage into

the anterior chamber is not unfrequent, and prolapsus of the iris is almost sure to occur, which it is difficult to prevent, and which is certain seriously to interfere with the progress of recovery. If the section extend a little beyond the margin of the cornea, encroaching on the sclerotic, it often happens that the edge of the knife, blunted with the fibrous tissue it has divided, instead of cutting cleanly through the conjunctiva, raises it in the form of a large fold, and divides it to an extent considerably greater than the cut in the sclerotic. Such cases generally do well, providing the flap of conjunctiva can be smoothly laid down, and has no tendency to roll in; the large raw surfaces rapidly unite, and earlier and better adhesion takes place under these than under other circumstances. I have more than once seen difficulty arise from the cornea being penetrated so obliquely that the point of the knife traversed the lamellæ for a considerable distance without entering the anterior chamber at all. The internal wound was consequently much smaller than the external, and it was only with much difficulty and pressure, leading to the retention of the soft cortical portions of the cataract in the eye, and the escape of the nuclear parts alone, that the operation was completed.

In some cases, after the section has been made, it is found that the vitreous is extremely fluid, and escapes in considerable quantities, causing the eye to collapse. Experience has shown, however, that this accident is not followed by such serious effects as might have been anticipated. If the lens, which has a great tendency to fall towards the fundus, can be got out, the globe soon plumps up again, and, in many cases, good vision is retained. I have generally looked upon it as an indication for supporting the patient well, after the operation, with food and wine.

Slight conjunctivitis is not an unfrequent consequence of the operation, the patient complaining of a feeling as of grit or sand in the eye. Little treatment is required, as it usually

spontaneously disappears as soon as the bandages are removed and the eye is allowed to be opened.

Intra-ocular hæmorrhage is a rarer accident now than formerly, perhaps because the ophthalmoscope enables a better diagnosis to be made of some forms of disease simulating cataract. I have only seen one case, but in this it appeared to take place partly from the choroidal vessels, and partly from the sclerotic wound. After some weeks nearly the whole was absorbed, and the iris regained its natural colour, but the globe was somewhat shrunken.

One of the most frequent causes of failure, or at least of imperfect success of the flap operation, is prolapse of the iris. The course of events in that case is, that everything appears to go on well till the expiration of the first twenty-four or forty-eight hours, no pain being experienced, and the lids looking natural, when suddenly, without apparent cause, the patient complains of a sharp stabbing pain, which lasts for a few minutes, and then gradually passes off. I have known this to be occasioned by an accumulation of tears beneath the lids, which at length exerts sufficient pressure to separate their agglutinated edges, and producing momentary pain and a gush of tears. More frequently, however, it indicates the separation of the lips of the wound; and if a careful examination be now made, the iris will be found protruding in the form of a black fold or prominence between the edges of the cut, which are usually of a grey or yellowish colour. If no treatment be adopted, this continues to enlarge, and ultimately forms an extensive staphyloma, drawing the pupil up to so great an extent as to abolish all useful vision, and by the protracted inflammation which succeeds, so seriously impairing the functions of the retina, as to hold out but slight prospect of success by the formation of an artificial pupil. The best mode of treating this affection is by the steady employment for several weeks of a well-adapted pad and bandage, by touching the protrusion with a point of nitrate of silver,

by removing it with the scissors if it have attained a considerable size, and finally by supporting the patient well with food and wine. The strength may also be maintained by the administration of quinine, a good mode of exhibiting it being that of a pill containing one grain of quinine, and two of sulphate of iron, with two of the pil. hydrargyri, three times a-day.

Good results may often be attained by a subsequent iridectomy. Next to prolapse of the iris, the most frequent cause of failure of the flap operation is the suppuration of the cornea. This usually occurs in old and ill-nourished persons, and in those suffering from diabetes, which is one of the reasons that this constitutional affection is a contra-indication for the performance of the operation for extraction. The suppurative process commences at the edges of the wound, which do not unite by the first intention; and the greyish or yellowish appearance which they present soon extends over the whole cornea, which appears like a piece of wet, white-kid leather. This state is sometimes accompanied by intolerable pain, at others it appears to be simply the result of asthenia, and the pain is comparatively trifling. In the former case the inflammatory symptoms run high; the lids are much swollen, red, and cedematous. The patient complains of constant violent throbbing and burning heat, no doubt occasioned by the extension of the inflammation to the iris, choroid, and deeper structures of the eye, which completely deprives him of rest. There is at first weeping, but subsequently a considerable discharge of puriform mucus. These symptoms portend the loss of the eye. After the lapse of some days the cornea sloughs, the intra-ocular fluids escape, and collapse of the globe succeeds. For this sequence of events it is distressing to feel that little can be done in the way of treatment. In the earlier period, that recommended for prolapse of the iris should be adopted; but when it is obvious that the sloughing of the cornea is extending, the greatest benefit will

be derived from warm fomentations, poultices, or sponges dipped in water at a temperature of 100° Fahr., and the use of frequent doses of quinine and opium.

Though never so satisfactory in its results as union by first intention, secondary adhesion of the lips of the wound is often observed, and is well exemplified in the drawings (figs. 47 and 48, Plate VIII.) taken from one of my patients, who was a source of great anxiety and trouble to me. She was a healthy-looking woman, of 56 years of age, with good pulse, appetite, and apparent strength. The operation went off extremely well, and for two days no bad symptoms were observed. About this time, however, the patient began to complain of a feeling of grittiness under the lid, and of some heat and fulness about the eye. The pad and bandage were removed, and the eyelids sponged, but the eye was not examined. On the following day, the same complaint being made, on the removal of the pad the lid was found œdematous, and rather tender. This condition continued for a week, when the lids were cautiously separated, and the appearances depicted were presented.

The flap was almost perfectly transparent to within a very short distance of its free edge; above it the vitreous, undamaged, and included in the hyaloid membrane, protruded. The iris was quite free from inflammation. The surface of the lids presented the appearance shown in the second figure, and I drew them, not as being of any importance in this particular case, but because the peculiar tumidity and semi-transparent congestion are signs of very bad omen in all cases of extraction, almost always indicating extensive separation of the lips of the wound. After the drawing was taken, pads of wool and moderate pressure were applied, and wine and quinine freely administered, and, after three weeks unceasing attention, I had the satisfaction of finding that she had moderately-good vision, being able to discern 20 of Jäger's Test Types. Gradually, however, the iris and pupil were

drawn up towards the wound, and at the expiration of three months the latter was altogether obliterated. The lower three-fourths of the cornea, nevertheless, remained perfectly transparent, and the iris of its natural clear blue. After some weeks it was determined to perform an iridectomy; but on the day appointed, an acute attack of glaucoma, with singularly well-marked aquo-capsulitis occurred, for which she declined to have any operation performed, and which resulted in the total loss of vision in that eye. Again, after the lapse of some months, iridectomy was proposed for the eye which had been operated on for cataract. It was performed, and for a week or two she could read No. 18 of Jäger's Test Types. Gradually, however, a deposit of lymph occurred upon the remaining edges of the iris, which, in spite of various remedies, terminated in the loss of all but the quantitative perception of light.

After all the steps of the operation have been successfully performed, one of the most annoying results is the formation of what is termed *secondary cataract*, which may result either from some of the soft cortical substance of the lens having been left behind, or from the deposit of lymph, or, more properly speaking, the development and opacification of nuclei and cells on the remains of the capsule. Mr Bowman,¹ in a paper on these secondary or capsular opacities, remarks, that their thickness or density is oftentimes quite insufficient to explain the imperfection of vision present, which is not improved by any kind of glasses. In such cases, ophthalmoscopic examination, especially when aided by oblique illumination, exhibits the presence of a very delicate film, the wrinklins and striæ of which are sufficient to produce so great a distortion of the forms of external objects, as entirely to prevent the patient recognising any but the largest, although the retina may preserve its normal sensibility. Where this result has occurred, the eye should be allowed to resume its natural condition, and no effort made for the removal of the

¹ Ophth. Hosp. Rep., vol. i. p. 360.

opacity, until after the lapse of six or eight weeks, or until all signs of inflammation have subsided. A fine needle may then be entered through the outer part of the sclerotic and behind the iris, until the point is seen in the pupillary area, when the false membrane may be slowly and steadily torn through, or depressed into the vitreous. Where the fibres are unusually dense or adherent, or where the remains of the capsule have been reduced to one or two tough strings, which cannot be divided by a single needle, Mr Bowman has advocated the use of two needles, with the following recommendations. The needles should be spear-pointed, and cutting for the terminal twentieth of an inch, and their stems should be cylindrical, to permit their being easily moved without loss of the aqueous. They should be made to penetrate the cornea near its edge, at an angle of about 60° to 70° to the perpendicular, the second needle being inserted "in such a position as may best secure the rupture of these bands in the usual way, their points crossing, one in front and the other behind the band, and revolving a few turns round each other, and then, perhaps, being separated." The greatest gentleness should be employed throughout, both to avoid undue traction on the iris, to which such remains of the capsule are often firmly adherent, and also to avoid unnecessary injury to the vitreous. A moderately-strong solution of atropine is then to be dropped into the eye, and every precaution taken to prevent the access of inflammation.

If the remains of the capsule are obviously exciting considerable inflammation, instead of waiting, it is sometimes advisable to make a linear incision through the cornea, and to extract the fragment with the simple curved, or with the cannula, forceps; and occasionally it may be expedient to perform a large iridectomy. As a rule, however, it is to be remembered that eyes requiring these secondary operations rarely succeed well, or give any better result than that the patient is able to distinguish very large type.

From the foregoing observations it will be seen, that al-

though the operation by superior or inferior division of the cornea, laceration of the capsule, and extraction of the lens by pressure, is frequently very satisfactory; yet that it is liable, even in the most expert and practised hands, to various accidents and ill results, which seriously impair or altogether destroy vision. v. Gräfe estimates that in every 100 cases thus operated upon, about 65 enjoy good vision, and are able with the aid of glasses to read ordinary or rather large type; about 25 can only be said to be improved, vision being inadequate to the perception of small objects; and in the remaining 10 per cent., no vision, or at least no useful vision, is retained. The two essential conditions inducing failure are undoubtedly suppuration in the edges of the corneal wound preventing adhesion, and iritis. The corneal mischief may arise from constitutional causes, and from injury in the act of extracting the lens. The iritic inflammation may likewise owe its origin to constitutional disorder, or more frequently to bruising or laceration of its substance during the act of extraction, and still more frequently, perhaps, to irritation after the extraction has been successfully performed, occasioned by the presence of fragments of the capsule and lens substance.

A careful consideration of these causes of failure has led to various suggestions, by which it has been hoped that they might be more or less effectually avoided. Thus the section has been made to traverse the sclerotic instead of the corneal tissue, and has been made of large size, by which, on the one hand, all bruising of the tissues in the act of extraction is prevented, whilst the edges of the wound being comparatively well supplied by blood, have a much greater tendency to unite. Again, with a view of preventing the iritis, it was proposed by M. Moorens to perform iridectomy a month or two before the extraction of the cataract is undertaken, and this suggestion of removing the large portion of the iris has been carried into effect by Jacobson, who combined it with

the flap operation, and it now forms a conspicuous feature of nearly all the more recently proposed plans for the operation of extraction. The three methods, which will now be described, are—(1.) The linear extraction, (2.) the modified linear extraction, and (3.) the method of extraction adopted by M. Pagenstecher.

Linear Extraction of Cataract.—The mode of removing the lens in cataract, termed “operation by linear incision,” and sometimes the “scoop, or Schuft’s operation,” appears to have originated with Mr Gibson of Manchester, who broke down the lens with a needle, and, after the lapse of a few days, allowed the *débris* to escape through an opening made at the margin of the cornea. When the lens is soft throughout, this method may still be practised with advantage. When, however, the nucleus of the cataract is hard, it cannot be evacuated from the anterior chamber without so much violence as to risk setting up severe inflammation of the iris and cornea, and of preventing that very union by the first intention which constitutes the chief point of superiority of this method over the old flap operation. v. Gräfe attempted to obviate these difficulties by removing a portion of the iris before proceeding to extract the lens; the capsule of the lens was then extensively lacerated, and a kind of spoon was afterwards passed behind the lens and between it and the posterior capsule, and gentle traction and leverage exerted. The operation proposed by Schuft is essentially the same as that adopted by Gräfe, except in the form of the instrument he employs, which is a scoop of peculiar form, the surface being flat and elongated or oval in form, with an edge or rim of small elevation running round its extremity, and standing at right angles to it. In the act of extraction the greatest possible care should be taken not to press the hard nucleus against the cornea, and to clear all the remains of the soft cortical layers of the cataract away from the lips of the wound.

This plan has received the support of Mr Critchett and of Mr Bowman,¹ the latter of whom observes that it is especially applicable to those in whom a rapid recovery is desirable, as in old, weak, or nervous persons, in those of an irritable habit, and in inflammatory subjects; also in cases complicated by the presence of diabetes or other morbid conditions of the system generally; in myopics, and in those in whom the eye itself is not perfectly healthy; and lastly, in cases which are unfavourable for the performance of a flap operation, as when the eye is deeply set or very prominent, the anterior chamber shallow, the pupil small, rigid, or adherent.

The operation consists essentially of two parts—first, the performance of an iridectomy, the portion of iris removed being of moderate size; and, secondly, of the extraction of the cataract.

As regards the iridectomy, after the description that has already been given of this operation (p. 377), nothing further need here be said, beyond remarking that, if possible, the section with the bent knife should be made at the upper segment of the cornea, at its junction with the sclerotic, so that the loss of the iris may be subsequently concealed by the upper lid, and that the opening should be made sufficiently large to admit of the passage of the hard nuclear portion of the lens without the necessity of exerting strong pressure against the cornea with the spoon or traction instrument. In many instances the corneal section should occupy one-third of its circumference. If bleeding occur, the operation should be stayed till it has ceased, as the subsequent steps of the operation require that a good view of the parts concerned should be obtained.

After the completion of the iridectomy, the second step of the operation must be commenced. With this object in view, the anterior capsule must be freely divided with the rectangular bent needle or pricker, avoiding as far as possible any

¹ *Ophth. Hosp. Rep.*, vol. iv. pp. 318 and 332.

dislocation of the lens or injury to the iris or suspensory ligament. On the withdrawal of the needle, if the lens do not start forward, when it may be gently removed or assisted by the pricker or curette, the scoop or traction instrument must be carefully introduced. This consists of a blade, represented in the adjoining figure, more or less hollowed out into a spoon-like cavity at its extremity, slight modifications of which have been made to suit the taste or convenience of different operators; though there really does not appear to be much in favour of one rather than of another, the essential form being small, shallow, broad, and slightly excavated or hooked at the extremity. The instrument, whatever the form selected may be, is made to pass backwards, so as to reach the interval between the lens and the posterior capsule; then cautiously depressed, so as to lift the lens out of its bed; and finally, slowly withdrawn, carrying the lens with it. If any fragments of the peripheral portion of the lens remain, they should be cleared away by the re-introduction of the scoop, taking especial care that no portion stick between the edges of the wound. When the fragments are troublesome to seize or extract, Mr Bowman has recommended the use of the suction syringe, with a larger orifice than usual, the extremity of which admits of being turned in every direction, without in any way interfering with the iris.

The combination of discission with linear extraction I have adopted in many instances with very favourable results, but it can only be used when the lens substance is sufficiently soft to issue through the linear opening without the employment of any but the most gentle pressure, and without the frequent separation of the lips of the corneal wound by the curette or scoop. In removing the lens by this method, after the rupture of the capsule with the needle, the semi-solid

2 M.

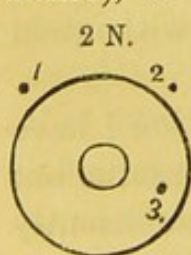


Spoon.

cataractous substance may be pressed forward into the anterior chamber. A double-edged Wenzel's knife may then be thrust through the cornea at the lower part; the greater part of the lens escapes on separating the edges of the wound with the curette; and the remainder may be extracted with the same instrument, none being allowed to remain in the wound itself. Very little inflammation follows this operation.

In cases where the substance of the lens is much more firm, and particularly when the iris has formed extensive adhesions to the capsule, the prospects of success under any method of operation are not encouraging, inflammation of the iris being often set up, or the pupil closed by a plug of false membrane. In such cases, however, the linear extraction, preceded by a large iridectomy, affords, in all probability, the best chance of success. I have had one or two successful cases where the ordinary flap operation has been performed, the presence of the adhesions being, so to speak, ignored; but I have, generally speaking, preferred to perform a large iridectomy, the lens being immediately removed with the scoop.

The *modified linear extraction* practised by v. Gräfe may be thus described:¹—The patient being placed in the reclining posture, the lids separated with a spring speculum, and the eye fixed by seizure of the conjunctiva with toothed forceps (chloroform being administered or not, as the patient may desire), a narrow-bladed, sharp-pointed knife is entered

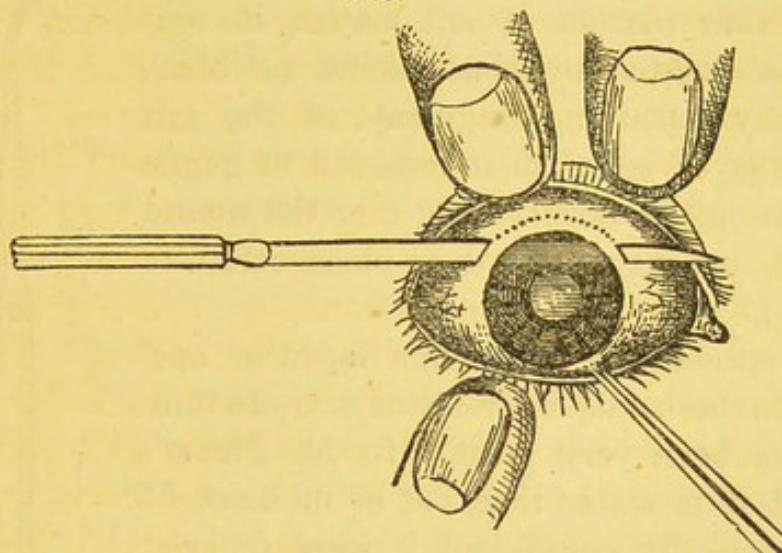


through the sclerotic at the dot 1, which is two-thirds of a millimètre from the edge of the cornea. At the instant of penetration, the flat surface of the knife should look forwards and its edge upwards. In order to make the section as large internally as externally, the point of instrument is at first directed downwards towards the dot 3. It is then raised in front of the iris, and the counter-puncture

¹ See Clinique Ophthalmologique, par A. de Gräfe, Traduction par Ed. Meyer. 1866.

made from within at 2. The edge of the knife is then turned forwards and made to cut straight out. A slight sawing movement is required to divide the sclerotic, and afterwards

2 O.



Section of the Cornea made in the operation described by v. Gräfe as the
"Modified Linear Extraction" (after S. v. Carion).

the conjunctiva. The length of the incision thus obtained he believes to be equal to four and a-half to five millimètres, —equal to one-fifth of an inch. If, as is usual, the iris now prolapses, it is to be seized by a small pair of straight forceps, a triangular portion drawn out, and cut away with the scissors. In the event of its not prolapsing, a pair of curved forceps must be introduced through the wound, as in iridec-tomy, and the anterior surface of the iris seized, withdrawn, and a portion of moderate extent excised. The formation of a coloboma thus completes the second act.

The third consists in a free division of the capsule by means of a cystitome (2 P), the point of the instrument running across the face of the lens from below upwards and inwards, and by a second movement from below upwards and outwards, quite to the edge of the lens. The removal of the lens is next accomplished by exercising gentle pressure on the globe, near the centre of the wound, with a curved curette, the back

being applied to the sclerotic, and lightly passed with a gliding movement from one side of the wound towards the other, when, if the cataract be at all soft, it will readily escape, whilst if it be hard throughout, or with a very thin coating of soft matter, its exit must be assisted by the crochet or blunt hook, any remaining fragments of the soft cortical layer being then removed by gentle pressure on the lids, the edges of the wound adapted, and any pigment or blood carefully removed.

The success attending this mode of operating, in the hands of Professor v. Gräfe himself, has been very great. In M. Meyer's account it is stated that, out of 69 cases, 62 were perfectly cured and 7 were relieved. In none was there total loss of vision. In the ordinary flap operation, on the other hand, he estimates that the average number of total failures is about 10 per cent., and that about 10 per cent. are only improved. Mr Windsor,¹ however, states that the results in about 300 operations have been, that in 90 per cent. the success was complete, eight being from one-sixth to five-sixths, whilst of the remaining 10 per cent. at least four gave promise of improvement by the performance of some secondary operation.

I have only tried the operation in three cases, in two of which it succeeded fairly, one of the patients being able to read No. 8, and the other No. 10, of Jäger's Test Types; whilst the third was scarcely a fair one to test the merits of a new operation, as the patient was an instance of total iridderemia, and his eye consequently not a very healthy one for operation of any kind. Nevertheless, the failure here was not immediately connected with the operation, healing

2 P.



v. Gräfe's
Cystitome.

¹ Syd. Soc. Year-book for 1865-66, p. 364.

taking place perfectly, and loss of vision only taking place from the gradual extension of a fibrinous deposit along the whole of the posterior surface of the cornea.

The chief objections to the operation appeared to me to be the difficulty of seizing the iris for the performance of iridectomy, and the almost certain escape of a large amount of vitreous.

Yet another modification of the flap operation has been practised by M. Pagenstecher,¹ who gives the following description of his operation:—

The patient is rendered completely insensible with chloroform, and the globe is fixed in the desired position by forceps. An inferior flap is made by penetrating the sclerotic with the point of the cataract-knife, about three-quarters of a line from the corneal border, and a little below the horizontal meridian of the eye. The blade is now steadily pushed through the anterior chamber in front of the plane of the iris, and the counter-puncture made on the opposite side, also through the sclerotic. Care should be taken that the edge of the knife, as the section extends, maintains the same distance from the margin of the cornea. The sclerotic section being completed, the conjunctiva should be allowed to remain uncut. A broad iridectomy is now performed towards the inferior and outer side, after which the conjunctival bridge is divided with scissors. Up to this point the operation is the same for all kinds of nuclear cataracts; but afterwards certain modifications are introduced according to whether the cataract is over-mature, or has recently become mature, or is immature, or is complicated with posterior synechia. In over-ripe cataracts, where the lens lies shrunk, the capsule is also generally only loosely connected with the surrounding textures, and by manipulation and pressure on the upper part of the cornea, both the lens and capsule can generally be pressed out of the wound without the rupture of the latter.

¹ Klin. Beobacht., Wiesbaden, Heft. iii. p. 22. 1866.

In cases of recently-matured cataracts, the same manœuvres are to be tried, but if found unsuccessful, the spoon is to be introduced below and behind the lens to free its attachments, and subsequently to gently press it out (a portion of the vitreous always escaping), its exit being further aided by a Daviel's spoon, if requisite. When any difficulty is experienced in passing the spoon behind the lens, the hyaloid membrane may be opened with a small silver hook.

When posterior synechiæ are present, the attachments must be broken down by a hook.

The spoon employed by Pagenstecher in the above operation is of large size, being nine millimètres in length, six millimètres in breadth, and one millimètre in depth, at the deepest part of its concavity. It is slightly broader at its free extremity, with a curvature corresponding to that of the lens; the margins are thin, and very slightly curved forwards, so that in the introduction of the instrument there is no risk of injuring the capsule or lens.

Pagenstecher has operated on 63 cases, some of which were complicated with irido-choroiditis, atresia iridis, leucoma, etc., with extraordinarily good results. He states that 20 could read No. 1 of Jäger's Test Types; 9, No. 2; 12, No. 5; 2, No. 8; 3, No. 16. Four, who were unable to read, could count the fingers with facility at 20 inches' distance, and two only retained but a quantitative perception of light.

The advantages of his operation he considers to be, that there is no chance of the formation of secondary cataract, or of primary iritis, or of non-adhesion of the lips of the wound, resulting from the presence of fragments of the lens or of the capsule. The disadvantages are the escape of the vitreous, which is scarcely to be so regarded, and the occurrence of acute inflammation in the vitreous, which he has twice seen.

As regards the treatment of *zonular* or *stratified cataract*, v. Gräfe,¹ founding his suggestion upon the known trans-

¹ Ann. d'Ocul., p. 118. 1856.

parency of the cortical portion of the lens in this form, proposes to remove a portion of the iris, in order to form an artificial pupil, by which means the lens is preserved intact, the accommodative power is preserved, and the operation is one from which speedy recovery may be anticipated. Nevertheless, as observed by M. Rydel,¹ the opaque disk must be sharply defined and quite stationary, and must not exceed in such cases two and a-half to three millimètres in diameter, otherwise so small a portion of the lens remains transparent, that it can hardly be expected that iridectomy will prove serviceable. The amount of good to be obtained from an operation of this kind can be approximately determined by the instillation of atropine, though it must be remembered that this destroys the accommodative power, and by dilating the pupil, and admitting a large quantity of light, confuses the vision to an extent that would certainly not follow a successful operation. Iridesis, in consequence of its simply altering the position of the pupil, whilst retaining its small diameter, is likely to prove more beneficial in these cases. When the concentric circles are numerous, and the lens generally opaque, M. Rydel recommends discission.

The treatment of *capsular cataracts* is identical with that already described under the head of Secondary Cataract, p. 536. v. Gräfe² has recommended the employment of some common term of comparison for the results of cataract operations, and has suggested the following scale:—1. Complete success, when the patients are capable of reading the smallest print with appropriate glasses. 2. Moderate success, when the patients can read large characters, and make their way about with facility. 3. Imperfect success, when the patients can count the fingers at the distance of at least a foot. 4. Failure, when only quantitative perception of light, or total blindness, results.

¹ Ann. d'Ocul., p. 245. 1865.

² Idem, p. 73. 1865.

CHAPTER X.

Wounds and Injuries of the Eye.

INJURIES OF THE CONJUNCTIVA AND EXPOSED SURFACES OF THE
SCLEROTIC AND CORNEA—INJURIES IMPLICATING THE IRIS,
LENS, CHOROID, AND RETINA—PANOPHTHALMITIS.

THE number and variety of the injuries affecting the eye, and the different results by which they may be followed, are so manifold, that it is impossible to do more, in such space as is here at disposal, than indicate the chief of those that are likely to present themselves, and to state briefly the mode of treatment to be adopted.

Injuries of the eye may conveniently be considered in the following order:—(1.) Those affecting the conjunctiva, the cornea, and the exposed surface of the sclerotic; (2.) those affecting the iris; (3.) those affecting the lens, and its capsule, and the vitreous; and lastly, those implicating the choroid and retina.

1. *Injuries of the Conjunctiva, and of the Exposed Surfaces of the Sclerotic and Cornea.*

The most common injuries affecting the conjunctiva are produced by the entrance of particles of grit, coal-dust, or of insects, between the opposed surfaces of the lids and globe, which are sometimes driven with sufficient force to imbed themselves firmly in the membrane, and even in the subjacent

tissue of the cornea and sclerotic. At the moment of entrance, the lids are spasmodically closed, acute pain is experienced, with a copious gush of tears, by which the offending substance is often washed away. If this do not occur, the conjunctival vessels rapidly become congested, and a condition precisely similar to that of catarrhal ophthalmia is quickly established. In many instances, the violent rubbing to which the patient resorts in order to relieve the pain, breaks down the particle, and the symptoms disappear; but when it is of a more consistent nature, and especially if it be smooth and polished, like the elytra of a beetle—a piece of the stem or the husk of the seed of one of the cereals—the only effect is to press it under the lid, where, not being easily seen, it may long remain, and be slowly productive of serious corneal mischief. Such particles are usually found, when a few days have elapsed from the time of the accident, adhering to the centre of a little round, red spot or ulcer on the inner surface of the upper lid, surrounded and partially concealed by tenacious mucus. In order to discover them, the upper lid must be everted; and, to accomplish this, the patient should be directed to close the eye gently, as in sleep. A probe, or an ordinary pencil-case, held in the right hand, should be placed on the outer surface, at the upper border of the tarsal cartilage; and if the eyelashes are seized with the left hand and drawn up, while the probe is at the same time pressed down, eversion immediately takes place. A little difficulty sometimes occurs when the cartilage is very soft, or when the patient resists strongly; but this can in general be overcome with patience and address. If, however, the lids be spasmodically closed, as sometimes occurs in very nervous patients, or when the pain is great, it is better to use chloroform than to run the risk of injuring the eye. The foreign body, which is seldom firmly adherent to the surface, may be easily wiped away with a camel-hair brush, and with its detachment all the symptoms speedily vanish.

Smiths, engine-fitters, and those who are frequently engaged in hammering iron, are very liable to the entrance of minute spiculæ of metal, which may penetrate the conjunctival cornea or sclerotic tissue to a considerable depth; and many persons suffer in a similar manner from particles of coke, in looking out of railway carriages when travelling at the end of a long train.

In all such cases the foreign body appears as a minute black spot, that, when the light is favourable, is seen to project slightly from the surface, and which, if it have been impacted for a day or two, is surrounded by a grey halo of inflammation. Minute inspection, or the use of a lens, is sometimes requisite to enable the particle to be distinguished. To remove it, the patient should be seated in a good light, and whilst one lid is raised or depressed by the operator, an assistant should separate the other; a light touch with a curved needle, held nearly horizontally to the surface, will then, in most cases, dislodge the fragment; but if it be more firmly imbedded, a small round-ended but sharp-edged instrument, resembling a gouge, may be employed to scoop or dig it out. The most difficult cases are those which are quite recent, and in which the momentum has been considerable. The corneal tissue then tightly embraces the particle; but after a few days inflammation occurs, the corneal tissue is rendered loose and soft, and the fragments can be easily detached. Care should be taken not to continue picking at a mere stain, which is often left by particles of iron; otherwise it is by no means improbable that the anterior chamber may be opened and a permanent leucoma result. As in the act of removal the surface of the cornea is more or less abraded and roughened, it is expedient to instil a drop of castor-oil, which lubricates the part and allows the lids to glide smoothly over them. The patient should be recommended to abstain from using the eye for a day or two, and the application of a bread-and-water poultice, by keeping the

eye at rest, will frequently materially aid in preventing the occurrence of any subsequent inflammation. When no foreign body can be discerned, the eye should be thoroughly washed out with a syringe and warm water, and a drop of oil instilled into it. Rest, and the application of a pad and bandage for twenty-four hours, will generally remove the symptoms.

In cases of gunpowder accident, the exposed surface of the globe is often completely tattooed, the grains being very deeply imbedded. Here it is almost impossible to pick the grains out with a needle, and the best plan is to pinch the larger ones up separately with a pair of small forceps, and cut them away with small curved scissors. Two or three may thus be removed at a time, and no mark will be left. Acute inflammation usually follows accidents with gunpowder, the lids swell, the conjunctiva becomes chemosed, and a considerable quantity of puriform fluid is discharged. Under these circumstances the patient should be kept in bed, the bowels should be well cleared, and cold applications maintained to the eyelids. It is sometimes requisite to apply leeches. Amongst bricklayers, masons, and the like, the entrance of lime into the eye is of frequent occurrence, the particles of which adhere to the surface with great tenacity, burning their way in, as it were, and converting the subjacent tissue into a slough. The injury produced by lime is peculiar also in the circumstance that it is progressive, reminding one of the gradual contraction of the œsophagus that not unfrequently follows poisoning with soap lye, or other strongly-alkaline fluid. It not unfrequently happens that an amount of injury with this substance, which at first sight appeared trifling, produces, after the lapse of a few days, slight nebula of the cornea, gradually deepening into an opacity, affecting all the layers, and presenting a marbled, pink appearance, indicative of deep-seated keratitis, which may be either quite persistent, or may only very

gradually and partially pass away. Within the first few hours of the entrance of lime into the eye, the appearances offered are often strikingly similar to those exhibited in Plate XI., fig. 63, the conjunctiva being inflamed, chemosed, and at certain points ulcerated. When the burn is so severe as this, symblepharon, or adhesion of the lid to the globe, is almost certain to occur. The proper treatment for these cases is to wash the eye out immediately and thoroughly with a weak solution of acetic acid in water (a drachm to a pint), and to remove with the utmost care every solid particle that can be seen. The inflammatory symptoms should be subdued by means of iced applications and leeches, and the eye frequently bathed with the weak acetic solution.

In cases where the conjunctiva has been burned with acids, if the case be seen directly, weak alkaline lotions may be used, otherwise they are of little service, as the acid will have been already washed away with the tears. The entrance of molten metal between the ocular and palpebral surfaces of the lid is not an unfrequent accident in plumbers, and though often destructive to vision, occasionally produces less mischief than might have been expected. I have recently seen a case where two men engaged in fixing iron railings with fused lead were thus injured, an explosion having resulted from the accidental presence of moisture in one of the holes. I removed several large flattened fragments from the palpebral sinuses of both of these patients, and no ill effects, beyond slight inflammation, followed. Burns with coal or red-hot substances are, however, very apt to produce symblepharon. In the following instance, an apparently serious accident was followed by comparatively slight results:—

A coachmaker, 56 years old, was struck fairly on the centre of the cornea with a piece of hot iron, six days before he presented himself at the Hospital. When seen, there was a depressed ulcer of considerable size, with a white base on the

centre of the cornea. The anterior chamber contained much blood, the circum-corneal zone was strongly defined, but he was of a phlegmatic constitution, and said that the pain was only trifling. Vision was so greatly impaired that he could scarcely see the fingers of his hand. He was ordered two leeches, a linseed-meal poultice, perfect rest, and the *mist. ferri aperiens* ʒj. (sulphate of iron, gr. ii.; sulphate of magnesia, gr. xx. in camphor mixture) three times a-day. Ten days afterwards the ulcer was fast healing, and the blood had been in great measure absorbed; and in the course of a month only a small dense leucoma remained, whilst the sight was unimpaired.

Wounds of the sclerotic portions of the conjunctiva, as is daily seen after operations for strabismus, ectropion, etc., heal with surprising rapidity, and leave scarcely any trace of their former existence. For their treatment little is required beyond warm or cold applications, according to the feelings of the patient, and rest, which is best secured by placing a cotton-wool compress and linen bandage over the eye.

Foreign bodies sometimes strike the cornea with sufficient force to penetrate it, and then fall through the aqueous to the bottom of the anterior chamber, where they may be easily recognised. They sometimes become surrounded or encysted in a capsule of lymph, whilst in other cases they remain free and moveable; but in both instances they may remain quiescent for many months or years, or may induce sooner or later inflammatory reaction. If the case be seen immediately, or soon after the accident, the proper treatment would be to make an incision through the margin of the cornea with a broad needle or narrow knife, carefully avoiding the escape of the aqueous. The cannula forceps should then be introduced, and the foreign body, if possible, seized and extracted. The same treatment may be adopted where the force of the projectile has caused it to become fixed in the substance of the iris, all precautions being taken to avoid injuring the lens, or to remove more of the iridal tissue than is absolutely

necessary. The inflammation, which is almost certain to follow, should be combated by rest, leeches, calomel, and opium, and the instillation of atropine.

Even where iritis has been already established as a consequence of the injury, and especially where hypopyon has occurred, it is better to open the anterior chamber, and extract the foreign body. When, however, the accident is of old date, and the fragment has become encapsuled with lymph, unless it prove a source of irritation, it is better to leave it untouched.

The most remarkable case of this kind that has come under my observation, was that of a young sailor-boy who presented himself at the Hospital, and was seen by Mr Hancock. He complained of great irritation in one eye, and stated that about three months previously he was descending the mast, with an open knife in his hand, when he slipped, and, in doing so, ran the point of the knife into the eye. Great inflammation followed, but he was judiciously treated; and the lens not having been injured, he was able to see to read ordinary print. He complained, however, of a dimness in the eye, and of its constantly watering. On examining it, the lids were found slightly swollen, and the tears readily flowed. There was a small cicatrix on the inner part of the lower lid. The cornea was clear, except at the lower and inner, and at the upper and outer part, where were two leucomata, so that it appeared that the blade had transfixed the cornea. The cicatrices were surrounded by a nebulous halo, and the pupil was oval. On the upper and outer segment of the iris, and close to its periphery, was a greyish semi-transparent bulb or vesicle, from the centre of which projected a black hair, which, crossing the outer part of the pupil, curved gently downwards and outwards, till the point was lost in the fissure formed by the attachment of the iris to the cornea and sclerotic below. Its length was 4-10ths of an inch, and it was about double the thickness of the cilia on the upper lid.

of the boy, and much darker in colour. It was at once recognised to be a cilium which had been transplanted by the accident, and which, grafted on a more vascular tissue, where it received a more abundant supply of nourishment, had taken on vigorous growth, and had occasioned no inconvenience until it had begun to irritate the iris by its point. Mr Hancock inserted a double-edged knife through the upper cicatrix, and with a pair of iris forceps withdrew the hair with great facility. At its base a small bulb was found, and the eye was well two days afterwards.

Clean cuts of the cornea with fragments of glass or sharp instruments, as knives or scissors, which are oftentimes thoughtlessly thrown by young people to one another, sometimes heal up without any ill result, except the formation of a linear cicatrix; but more frequently the iris becomes engaged in the wound, and still more frequently a traumatic cataract also forms. As already stated, these forms of injury, especially when implicating the ciliary region, are peculiarly liable to be followed by irido-choroiditis of the same, and by sympathetic ophthalmia of the opposite eye.¹ As regards the treatment of simple cuts of the cornea, atropine should be at once instilled into the eye, or belladonna applied to the forehead, to prevent the iris from becoming attached to the edges of the wound; a pad and bandage should be applied, and the patient kept at rest for some days in a darkened room. Local depletion must be practised in proportion to the degree of reaction present.

If the accident be quite recent, and the iris protrude through the wound, an attempt may be made to reduce it by gentle pressure with a curette, and by the instillation of a four-grain solution of atropine every six hours. At a later period, when firm adhesions have formed between the iris and the edges of the wound, the treatment should be directed to the removal of all inflammatory symptoms, and as soon as the eye is

¹ See Section on Sympathetic Ophthalmia, p. 401.

tolerably clear, a small opening may be made at the border of the cornea, and a curette or Mr Streatfeild's hook introduced, by means of which the attachment may be broken through. In other cases, an iridectomy may be performed, which, in such cases, succeeds extremely well, on account of the iris being everywhere perfectly healthy, except at the seat of adhesion.

Fistulæ of the cornea occasionally follow wounds and penetrating ulcers of the cornea. A depression is seen, in the centre of which is a small orifice, from which, either constantly or at intervals, the aqueous humour is discharged. The general treatment requisite for ulcers of the cornea is usually sufficient to effect a cure of the fistula. When, however, this does not take place, the external orifice may be touched with a fine point of nitrate of silver, and a pad and light compressive bandage subsequently applied. If this prove ineffectual, the base of the ulcer may be penetrated by a broad needle, and a small pair of cannula forceps introduced, with which the iris may be seized, and, as in Mr Critchett's operation for iridesis, drawn out and retained between the lips of the little wound. The inflammation which is thus set up has been found to be sufficient to effect the closure of the opening.¹ In obstinate cases, iridectomy would probably prove of service by diminishing the intra-ocular pressure, and giving time for the ulcer to heal by granulation.

Injuries of the Lens.—Some difference of opinion exists as to the possibility of the occurrence of wound of the capsule of the lens without subsequent formation of cataract. Mr Lawrence, with many others, is of opinion that, in every case where the capsule has been injured, the lens becomes opaque, and that the slightest mechanical injury is sufficient to produce that effect, such as a puncture of the part with the finest needle.² Dieterich, however, in experiments on animals,

¹ See case reported by Businelli, *Ann. d'Ocul.*, t. li. p. 30. 1864.

² *Treatise on the Diseases of the Eye*, p. 153. 1844.

found in many cases that, if the wound was limited to the capsule, no opacification of the lens followed; and MM. Warlomont and Testelin and Donders¹ cite several instances where spontaneous cure followed similar injuries.

I have recently seen a good instance of such repair of wound without cicatrix, in the case of a boy who, playing with an india-rubber catapult and steel pen, drove it forcibly through the sclerotic, just behind the attachment of the iris. It penetrated the lens, causing a well-marked black stain, that might have been ink, with which the pen was charged at the time of the accident, but which was more probably a portion of the pigment of the ciliary processes. After a short time three striæ radiated through the inner segment of the lens, plainly visible under the ophthalmoscope as whitish lines; and I predicted that a fully-formed cataract would soon appear. My forecast was, however, happily falsified by the event; for, after an absence of about three months, the boy returned with scarcely a trace of the original injury.

In another case which came under my observation some years ago, the blade of a pair of scissors entered the eye just at the junction of the sclerotic and cornea, penetrated the iris, and wounded the lens. On dilating the pupil with belladonna over the brow, a large white patch, with numerous striæ emanating from it, could be plainly seen, both with the naked eye and with the ophthalmoscope. The patient was a delicate girl and very quiet, and the inflammation which succeeded was not severe. She was confined to her room, but was allowed to be up. A few leeches were applied, and belladonna liniment kept constantly applied to the brow and temple. This patient called to see me a year after the accident, when I found, on an examination of the eye, and a comparison of its present condition with a drawing I had made at the time, that the opacity had remained absolutely stationary.

¹ Archiv. f. Ophth., Bd. iii. Abt. i. p. 151.

That foreign bodies sometimes remain for a long time in the interior of the eye without setting up any serious amount of inflammation, is sufficiently shown by the following, amongst many other similar cases:—A man, æt. 31, whilst shooting, received a shot in the eye from the gun of another man standing at a distance of eighty yards. Great inflammation and pain followed the accident, and the mark of a wound in the sclerotic was apparent. He was leeches and blistered, and took medicine, and the inflammatory symptoms were soon subdued, and he remained well for six months. He was then one day engaged in trussing hay, when he felt something fall in his eye; sharp pain came on, and a dark spot appeared at the lower part of the iris, which he recognised to be a shot. Up to this time he had been able to see light, but the inflammation which now supervened completely deprived him of vision. The surgeon by whom he was attended counselled him not to have it removed by operation, and by degrees this second attack of inflammation subsided. He remained well for many months, except that the eye was tender, and became painful with changes in the weather. At length his sound eye began to be sympathetically affected, and I admitted him into the Hospital for operation. A double-edged knife was introduced through the lower edge of the cornea, and as soon as the scoop was introduced to remove the opaque lens, the shot dropped out. This patient speedily recovered, but no sight was regained.

Every writer on the anatomy of the eye has expatiated on the wonderful provisions which protect the eye from direct injury without impeding the range of vision. The rapid and instinctive movements of the head when danger threatens; the movements of the orbicularis and other muscles; the projection of the malar, frontal, nasal, and superior maxillary bones; and, lastly, the mobility of the eye itself; the capability of the four recti, when acting simultaneously, to retract the globe (an act which is more perfectly accomplished in

various animals by a special retractor bulbi); and the presence of the elastic cushion of fat on which the eye rotates—are all circumstances which contribute materially to diminish the effect of direct blows and injuries. Nevertheless, instances not unfrequently occur in which all these fail in their object, and where the full force of a sudden and violent blow from some blunt instrument, as the fist, the ferrule of an umbrella or walking-stick, or a large fragment of metal or stone, is sustained by the globe. The effects are almost always of a serious nature, and may perhaps be best given by reference to cases. Amongst the most common results are abscess, ulceration, or sloughing of the cornea, frequently accompanied by hypopyon, rupture of the sclerotic, iritis, traumatic cataract, displacement of the lens, intra-ocular hæmorrhage, and amaurosis, this last being often produced by separation of the retina from the choroid.

The following is an example of ulceration of the cornea and hypopyon, following a blow:—

A carpenter, æt. 48, was struck, on the 3d of March, on the eye by a piece of wood. He paid little attention to it for some days, though it was painful and interfered with his work. On the 12th he came to the Hospital. The lids were then swollen and œdematous. The cornea was hazy throughout, with a small central ulcer. Vision so greatly impaired that he could only see CC of Snellen's Test Types at the distance of a foot, and then only indistinctly. The inflammation present appeared to be of a rheumatic type, the deeper vessels of the conjunctiva being congested, the circum-corneal zone of a livid colour, and the pain being always worst at night. He was ordered four leeches and a linseed-meal poultice, a purgative draught and pill, and the mist. aconiti c. colchico three times a-day. He did not again make his appearance till the 20th, as all the symptoms had been relieved for the first few days after the application of the above remedies, and he thought it was getting well.

During the previous two days, however, he had been exposed to cold, and the inflammation had returned with considerable severity. On examining the eye it was found that, the other appearances being nearly the same, the anterior chamber was nearly half filled with pus (hypopyon). A broad needle was at once introduced through the margin of the cornea, and the greater portion of the matter flowed away by its side. The other measures were repeated. On the 22d, he stated that the tapping had effected great relief to the pain, but the matter had again collected to nearly the same extent. The anterior chamber was again tapped, and he was ordered quinine mixture three times a-day. On the 27th, the pus had again re-collected to so considerable an extent as to half fill the anterior chamber, but he was unwilling to have it punctured. On the 29th, the central ulcer, which had increased in diameter, penetrated the cornea, and permitted the spontaneous escape of the aqueous and of the pus. He came to the Hospital a few hours after this had occurred. The iris was close behind the cornea, but the pupil was still visible, and to prevent any adhesion of the margin to the ulcer, atropine was instilled, and a compress and bandage applied. On the 3d of April, considerable conjunctivitis being still present, leeches were applied, and the *mist. ferri co.* ordered. On the 10th, considerable improvement had taken place, the ulcer was filling up, and he was able to see dimly a little light, as though through ground glass. After this the cornea continued to clear, the iris was healthy, and the pupil distinct; but sight was permanently impaired from the presence of a white leucoma, situated exactly over the centre of the pupil, the removal of which by any kind of stimulant, as the *vinum opii*, or the bisulphide of carbon, was hopeless. In such a case as this, iridectomy at a subsequent period will probably prove of great advantage.

In some cases, where severe blows have been received upon the eye, the immediate or apparent effects are com-

paratively slight, and nothing may be observed beyond the abrasion of the corneal epithelium, and some redness of the conjunctiva. In young people, however, violent inflammation is soon lighted up; the conjunctiva becomes chemosed, the lids swollen, the pain, lachrymation, and photophobia intense. In some old persons, on the other hand, so little inconvenience is felt, that they do not give up their ordinary avocations. In both, however, after the lapse of a few days, the cornea becomes dull and hazy, and then yellowish matter appears between its laminae and in the anterior chamber; and, finally, the cornea sloughs, the humours escape, and the eye collapses. (Plate V., fig. 30.) In other and still worse cases (if, indeed, anything can be worse), such as are represented by the drawing, fig. 16, Plate III., a considerable quantity of blood may be extravasated into and around the eye, and loss of vision is immediate, complete, and permanent.

The following is a case of rupture of the cornea and sclerotic attended with intra-ocular hæmorrhage:—On the 1st of May a man came to the Hospital who had been struck on the eye, two days previously, by the fragments of a seltzer-water bottle, which exploded as he was in the act of opening it. On examining the eye, a clean cut was found extending transversely across the centre of the right cornea, and through the sclerotic, for the space of one-fourth of an inch on each side of the cornea. The eye was filled with blood. After the shock of the accident little pain had been experienced. The conjunctiva was moderately inflamed, and there was a slight oozing of blood from the eye. Vision was entirely lost. Nevertheless, there was a considerable amount of photophobia. The left eye was not struck, but it was slightly inflamed, and sympathised very strongly with the injured one. He was admitted into the Hospital at once, put to bed in a darkened room, a cold compress was applied, and he was gently purged. On the 10th of May the inflammation in the injured eye was subsiding,—the wound had

healed; but no pupil could be seen, nor could the iris be distinguished; everything behind the cornea appeared of a bluish-black colour. The left eye was tender, there was some lachrymation, and he thought the vision was impaired. These symptoms were combated by various means, as leeches, belladonna, tonics, etc., but without effect; and, after a consultation with Mr Hancock, it was determined to remove the injured globe. This was accomplished on the 9th of June, and was followed by immediate disappearance of all the sympathetic inflammation and irritation in the left eye; and in a week he was discharged quite able to resume his duties as butler. On examination of the eye, it was found to contain a considerable quantity of partially coagulated and partly fluid blood, or broken-down vitreous and blood of dark colour, which obscured the iris, but the choroid and retina did not appear to be materially altered in structure.

In some instances the loss of vision is less immediate than in the foregoing case, the patient being at first able to distinguish light from darkness, but, subsequently, even this quantitative perception of light disappearing, and total blindness succeeding. The causes which lead to this result are either the effusion of blood beneath the retina, effecting its extensive separation from the choroid, or the occurrence of inflammation and suppuration in the vitreous. (*See Panophthalmitis.*)

It is difficult to give any positive directions respecting the treatment of cases in which minute fragments of steel have penetrated the cornea and become imbedded in the capsule or substance of the lens. The patients, in the first instance, are naturally unwilling to have the operation for cataract performed whilst they can as yet see perfectly; whilst, in some instances, a very minute spiculum may remain for a long period without inducing cataract. Sooner or later, however, the lens does, in almost every case, become opaque, and the opacification is then attended with various signs of inflam-

mation of the iris and choroid. If the operation for cataract be now performed, it will almost surely fail, in spite of the utmost care and attention, and it is in this class of cases that sympathetic ophthalmia is exceedingly likely to be set up, requiring the removal of the injured globe. The following case will exemplify these remarks:—

W. G., æt. 36, a boiler-maker, whilst engaged on his work, was struck on the right eye with a piece of iron. He went to the Surrey Ophthalmic Hospital, and a fragment was removed from the surface of the cornea by Mr Laurence, who told him that a minute spiculum had entered the eye and was imbedded in the lens, advising him, at the same time, to keep the eye at rest, and to wait the event. He came to the Westminster Ophthalmic Hospital on the 27th Nov., eight weeks after the accident. The eye then looked natural; both irides were blue, the right of rather a deeper colour than the left, but not remarkably so. He complained of pain in the right eye when at work, and of dimness of vision coming on at intervals. The tension of the globe was moderately increased (T. 1). The sharpness of vision with the right eye was 1-5th, with the left 1. On examination with the ophthalmoscope the humours of the right eye were found to be cloudy. The black spot could be plainly perceived on the outer and lower part of the lens, but was not surrounded by any halo of opacity, though the whole lens was hazy. The retinal vessels were large, and the papilla was hyperæmic. The choroidal reflection was dark. Near the centre of the retina, though not occupying precisely the position of the foramen centrale, was an elongated patch of whitish colour, of the form of a comma, inclined to the nose, with well-defined and reddish margins. He was told that inflammatory changes were occurring, but that it would be better to wait till the cataract was more mature before any operation was undertaken for its removal. On the 14th February he returned to the Hospital. The iris was then

noted to be clearly in a state of low inflammation. The pupil was dilated and motionless. The colour of the healthy iris was of a clear grey-blue, with slightly brown striation at the pupillary margin; that of the affected iris was olive-green, but the striations were strongly marked and quite clearly defined, no exudation having taken place. No circumcorneal zone of redness was perceptible. The cataract had increased slightly in opacity, but the vision was not worse than when last seen. He was admitted into the Hospital on the 21st February, and, with the view of checking the inflammatory changes taking place in the iris and choroid, it was determined to perform a large iridectomy, and to remove the lens with a scoop. This was accordingly done on the 23d, a considerable segment of the iris being removed from the upper part, and the lens successfully extracted. No blood escaped. The particle of foreign body could not be discovered in the lens substance removed. In consequence of the softness of the external layers of the lens, the scoop had to be introduced two or three times to remove fragments from the anterior chamber. Severe pain was experienced during the night, which was not relieved by opium; and on the following morning the conjunctiva was considerably chemosed. On opening the eye the cornea appeared rather dull, the globe was full and tense, and exquisitely tender, the anterior chamber was filled with fluid, pressing the iris back, and some faintly-nebulous fragments of the lens filled the aperture of the pupil. He was at once placed under chloroform, and I performed Hancock's operation, opening the anterior chamber. Great relief followed this operation. He was ordered twenty drops of tinct. opii. and twenty of chloric ether every half-hour till sleep was obtained. On the 26th the haziness of the cornea was diminished, except near the line at which the iridectomy was performed, where it was yellow. The pain was less, but the eye was very tender, and the chemosis still great. He was ordered ʒiii. of brandy, as

the pulse was small, and his general condition much depressed. On the 28th he was much improved,—the cornea quite clear, the chemosis subsiding, the lids scarcely swollen or red. He could discern the shadow of the hand passed before the eye. On the 8th of March the artificial pupil was found to be filled with a yellowish mass occluding vision; and as the globe retained its natural tension, it was determined to make a small linear opening, and to endeavour to remove the false membrane with the cannula forceps. This opening was accordingly made on the inner side, and the membrane was readily seized, and came away with unexpected facility. Little pain or swelling followed the operation, and for a few days his sight was somewhat improved. On the 16th March, however, it was observed that the pupil had again become filled up with false membrane; yet he could still see the shadow of the hand. Under these circumstances it was thought best to allow some months to elapse, in order that the plug occluding the pupil might become firm, and all inflammatory conditions subside, before any further attempt at operating was made. Unfortunately, on the 10th April, symptoms of sympathetic irritation of the left eye came on, the globe becoming tense and tender, the conjunctival vessels congested, the pupil dilated and sluggish, and the vision dim. For this reason it was determined to extirpate the globe of the right eye. The sympathetic symptoms gradually subsided, and the left eye again acquired its normal powers. On opening the globe the greater part of the vitreous was found to have become absorbed, and a considerable quantity of fluid, containing glittering cholesterin scales, to have collected between the choroid and the retina. The retina itself was entirely detached from the choroid, coarctate, and adherent to the remains of the vitreous. The iris was thickened by the deposit of much tenacious lymph, both on its anterior and posterior surfaces, and the pupil was filled with a similar material.

Fragments of stone or metal not unfrequently penetrate the cornea or sclerotic, and become fixed in the vitreous. For a short time, if the irritability of the eye be not too great, they may be seen suspended in the humour by ophthalmoscopic investigations, but soon a grey opacity begins to surround and obscure them, and they often become, as it were, imbedded or encysted in a kind of capsule. The structure of this capsule presents close analogies to connective tissue; and the opinion of Virchow regarding the structure of the vitreous is no doubt strongly corroborated by such changes. In other cases, the weight of these fragments, and the atrophy and softening of the parts in their proximity, cause them to fall gradually to the most dependent part of the eye, on touching which they not unfrequently set up so much irritation and pain as to call for some operation by which their removal may be effected, or even for extirpation of the globe. In other instances, genuine suppuration appears to occur. Suppuration in the vitreous is by no means a rare phenomenon. It is seen but too frequently after operations for cataract; but it has been maintained that such suppuration does not take place primarily in the vitreous, but in the inflamed tissues around, in the choroid, iris, or cornea, as the case may be, and that the pus cells developed from these sources gradually insinuate themselves into the substance of the vitreous; but these objections have been met by an ingenious experiment of M. Donders, who has drawn through the eyes of animals a fine thread of caoutchouc. This was then extended to the utmost, and divided close to the sclerotic. The retraction of the rubber caused it to become lodged in the vitreous, without material damage to other parts. In these experiments Donders substantiated the existence of distinct suppuration around the foreign body, though the choroid and adjoining textures were not inflamed. When once formed, it is probable that these alterations of texture are very persistent; and as at an early period they interfere with sight, so

by becoming condensed, and the seat of further changes, as of fatty or calcareous degeneration, or of atrophy, their ill effects are progressive rather than stationary or recuperative.

The prognosis of such cases is in general unfavourable. If the eye be not at once lost by the supervention of violent inflammation, slowly progressive inflammatory changes are always, or almost always, set up, which surely end in the destruction of sight.

In cases where the position of the foreign body can be clearly discerned with the ophthalmoscope, an attempt may be made to remove it by the proceeding recommended by v. Gräfe, which consists in making a section through the sclerotic, about midway between the cornea and the equator of the eye, avoiding as far as possible the attachments of the recti muscles. As soon as the wound, which should be of considerable extent, is made, the foreign body escapes, with more or less of the vitreous.

2. *Displacement of the Lens.*

(PLATE XI., Figs. 65 and 66.)

This condition is occasionally congenital and hereditary, as in Mr Dixon's case,¹ where partial displacement was noticed in a mother and three sons. They came to the Hospital complaining of shortsightedness, and one was really so. It is obvious, however, that in all such cases the edge of the lens being the part situated in the axis of vision, the condition of the eye must rather approximate that of hypermetropia than of myopia, unless alteration in the form of the globe has occurred as a secondary change; hence, whilst one of Mr Dixon's patients saw better with a convex glass, the one who was myopic, or rather who simulated their condition, was not improved by concave glasses. As a general rule, however, cases of displacement of the lens are occasioned by accident, as by violent succussion of the body, or by a

¹ Ophth. Hosp. Rep., vol. i. p. 55.

direct blow on the eye, and the displacement may be partial or complete. Of the former I have seen two or three examples, all characterised by the iris being pressed forward by the central and thickest portion of the lens, and by the remainder of the iris being tremulous, and apparently receding, as Mr Dixon observed in his cases. In such cases, iridesis has been proposed and adopted with success.¹ Sometimes the lens, with its capsule entire, is dislocated into the anterior chamber, where it occupies a position intermediate between the iris and cornea, and may remain perfectly transparent for a considerable period. It is, however, extremely likely to become opaque, and to be a source of iritis and of glaucoma, and should invariably be removed by a linear incision through the margin of the cornea at its lower part.

The case represented in Plate XI., fig. 66, was an instance of this accident. The man had received a sudden blow upon the head, and his vision had immediately become obscured. He saw objects double and broken with this eye (monocular diplopia). He experienced no pain, and there was very little redness or mark of inflammation. The form of the lens was quite distinct, its upper border appearing as a ring of golden colour. On inclining the head in different directions, the dislocated lens followed to some extent the movement, though it did not gravitate quite to the bottom of the chamber, except when the head was vertical. As there was no pain, he declined to submit to any operation.

I have met with several instances where an opaque calcareous or over-ripe cataractous lens has escaped from its capsule into the anterior chamber, in consequence of slight accidents, and in which it has been easily removed by a linear section through the cornea, very little inflammation succeeding, and the patient being quite well in three or four days.

When the blow upon the eye has been of such severity as

¹ Wecker, *Gazette des Hospitaux*, No. 22. 1863.

to rupture the sclerotic, the lens may present itself under the conjunctiva, Plate XI., fig. 65, where it appears as a swelling of a semi-transparent nature, somewhat resembling a chemosed portion of the conjunctiva. The pupil is often widely dilated in these cases, through paralysis of the third nerve, and the aqueous and vitreous more or less deeply coloured with blood. The wound of the sclerotic is always more or less distinctly visible. The usual practice is to cut down upon and remove it; but this, as MM. Warlomont and Testelin observe, should be done with care, and with as small and valvular an opening as possible, as otherwise the contents of the globe may escape through the rupture of the sclerotic. When the injury has been so violent as this, sight is generally irrevocably lost. The following case is one which lately came under my care:—A. R., æt. 67, presented herself at the Hospital on the 20th September 1866, stating that one month previously she had received a severe blow on the right eye from a thrust with the end of a stick. The eyes were very deeply set, and the lids of the right eye were kept firmly closed. There was much lachrymation and pain, and it was very difficult to examine the eye; but it was noted that there appeared to be iritis and posterior synechia, and it was added, "The iris is very dark-coloured, and the pupil is not clearly visible." Around the cornea was a strongly-marked circum-corneal zone, and the sclerotic generally seemed inflamed. Vision was abolished. Not noticing anything further, I regarded it as inflammation of a rheumatic type occurring after accident in an old person, and ordered her to apply two leeches, a linseed-meal poultice, and to take a mixture containing colchicum and aconite. On the 3d October she was in the same state, and was directed to repeat the remedies. On the 11th, as no improvement had taken place, the eye was more carefully examined. It was then found that immediately above the cornea, and in the middle line, was a swelling of circular outline, semi-transparent appearance, reddish-yellow

colour, the base of which was surrounded by a red zone of vessels. The remainder of the sclerotic generally was much inflamed, and the anterior chamber was partially filled with clots of blood. The form and smoothness of the tumour at once suggested the probability of its being the dislocated lens; and this opinion was corroborated by the presence of a dark line on its inner side, which was evidently a rupture of the sclerotic. I ventured, therefore, to make a linear incision, with a double-edged knife, at the lower part of the tumour, of about 1-6th of an inch in length, but nothing escaped. Still feeling convinced that it was the lens, I enlarged the opening to the extent of one-third of an inch; and then, on slightly pressing the tumour with the lid, and directing the patient to look down, the nucleus of the lens slipped out, and a little further pressure effected the removal of the external portion, which was of much softer consistence, though both had preserved their transparency, or were not more yellow than would have been natural at the patient's age. A pad and bandage were applied, and she was allowed to go home. The inflammation soon subsided, and no further ill effects were experienced.

In rare instances, luxation of the entire globe has been observed as a consequence of violent pressure or blows upon the eye; and it is remarkable that on the replacement of the globe in the orbit, vision has been occasionally restored. This fortunate result can only be attributed to the elasticity of the optic nerve. In most instances, amaurosis would probably be the consequence; but in the hope of such recovery of sight taking place, the eye should be immediately replaced, and kept in position by a pad and bandage.

As regards retinal injuries, if they have been made with a sharp-cutting instrument, they do not appear to be necessarily followed by any serious results; the retinal wound heals, and the cicatrix being always, or almost always, quite laterally situated, in no way interferes with vision. It has already been mentioned that Mr Bowman has even proposed and

successfully practised the operation of perforating the retina with one or two needles in cases of its detachment from the choroid, in order to permit the passage of the subretinal fluid into the vitreous. It has been observed, in many cases, that this is not followed by any symptoms of inflammation, and that in the event of its becoming reapplied, a linear cicatrix is alone left. Similar cicatrices are occasionally seen in cases of accident; but if the blow have been a severe one, blood is usually effused; it is impossible to explore the fundus; and the disease, which will be described in the next section, often supervenes.

3. *Panophthalmitis.*

It is not uncommon to meet with cases where the whole contents of the globe appear to have undergone suppurative inflammation, the place of the vitreous being occupied by a yellow mass, obviously consisting of the substance of that humour infiltrated with pus, so that the eye may be regarded almost as a circumscribed abscess.

Such cases are not unfrequently seen after severe injuries to the eye, as by blows or punctured wounds, especially when any foreign body has gained entrance and has been retained in the interior of the globe, or even in cases of syphilitic injuries, where the constitution of the patient has been greatly impaired by excesses, or when the most ordinary precautions have been neglected. In this way it is often seen to follow slight abrasion of the surface of the eye, the inflammation excited in the conjunctival tissue, cornea, or iris being, as it were, propagated by continuity, as well as by contiguity to the choroid and internal textures. It is sometimes a disastrous consequence of operations undertaken for the relief of other diseases of the eye. It has been observed to occur in consequence of the irritation excited by the presence of a cysticercus in the vitreous. It has sometimes supervened in the course of pyæmia or puerperal disease. It has been

particularly described by D. J. Jacobi,¹ as occurring in the course of the epidemic form of meningitis cerebro-spinalis, between the fourth week and the eighth month after the commencement of the attack. Lastly, it has been observed during the development and progress of intra-ocular tumours, especially in those of a tuberculous nature.

Under whichever of these processes the inflammation, leading to general suppuration of the globe, may set in, the patient usually experiences intense pain in the eye, which rapidly extends to the temple, brow, or cheek; the lids become swollen, red, and œdematous; the eyeball bulges forward; the conjunctiva becomes chemosed; the subconjunctival vessels are large and numerous, giving the eye a dull appearance, and a circum-corneal zone becomes more or less marked; the surface of the cornea loses its polish, and it presents a nebulous appearance throughout its whole thickness; the iris is pressed forwards, diminishing the depth of the anterior chamber; its markings are confused, and the pupil is either small or, more generally, widely dilated. In the latter case, especially after severe blows, blood may be frequently discovered in the vitreous, which, even without this, is so hazy as to render an examination of the fundus difficult. The tension of the globe increases; it becomes exquisitely tender; and violent throbbing is experienced, coincidently with which the formation of pus takes place in its interior.

Where the primary injury has been a blow, the sight is usually immediately lost; but when it is the consequence of inflammation, extending from the outer tunics, vision is only gradually lost by intra-ocular pressure, and sparks, flashes, and other subjective symptoms of irritation of the optic nerve, are complained of.

In the cases which occur after an attack of the epidemic cerebro-spinal meningitis, as well as in the metastatic form

¹ Arch. f. Ophth., Bd. xi. Heft. iii. p. 156.

seen in pyæmic conditions of the system, both eyes are almost always simultaneously affected. This occurred in nine out of eleven cases observed by Jacobi, and in every instance the eye or eyes affected were completely lost.

In traumatic cases, the disease is, of course, limited to the one that has received the injury, but the other is extremely likely to suffer from sympathetic ophthalmia.

The pathological changes which occur in these cases have been the subject of much discussion and of many inquiries, of which those of Schweigger,¹ Ritter,² Schiess,³ and Weber,⁴ are most deserving of perusal, and constitute the greater part of what is at present known respecting the microscopic changes which take place in the several humours and tunics in the progress of acute inflammation.

C. Schweigger observes that, in advanced cases of choroiditis, where the whole of the choroidal stroma is infiltrated with pus, the exact starting-point of the suppurative process is very obscure; but in cases of more recent date, the formation of small collections of pus may not unfrequently be found to be limited to the internal vascular layer of the choroidal *stroma*, where they may be easily overlooked on account of the strong adhesion of this layer to the true capillary layer of the choroid, or chorio-capillaris. Hence we have here an exemplification of the general fact that the earliest occurrence of suppurative changes takes place by the side of vessels; and M. Schweigger has assured himself that the pus cells proceed from alterations and proliferations of the corpuscles of the connective tissue with which the vessels are so abundantly accompanied. Very frequently, however, purulent collections take place between the choroid and the retina, accumulating till these membranes are completely detached from one another. The retina then becomes coarctate, or extends like a cord, column, or funnel-shaped body, from

¹ Archiv. f. Ophth., Bd. v. Heft. ii. p. 216. ² *Idem*, Bd. viii. p. 18.

³ *Idem*, Bd. ix. p. 22.

⁴ Virchow's Archiv., Bd. xix. p. 367.

the optic disk towards the surface of the lens, against which it may even be compressed, as a grey semi-transparent, pul-taceous mass, by the rupture of its continuity with the papilla. The lens is pushed forwards by the gradual increase in the purulent mass, and the anterior chamber is reduced to extremely small dimensions. Besides the alterations which occur in the connective-tissue corpuscles, attended by the formation of pus, considerable changes take place both in the stellate pigmentary cells of the choroidal stroma, and to a less degree in the hexagonal cells of the internal pigmentary layer, which in some parts lose their pigment, and in others contain pigment of an unnaturally dark hue. Here and there, in both portions of the membrane, cells may be seen, which appear to be passing into a condition of fatty degeneration. M. Schweigger believes that the development of pus cells may take place in the substance of the retina, and, by gradually breaking down its elements and diffusing themselves into the vitreous, may lead to atrophy and pigmentation of that tunic. As regards the vitreous, he has observed in acute cases an active process of cell-development in its structure, some of the new cells being large, branched, anastomosing with one another, and nucleated; others smaller, and presenting intermediate forms between these and pus corpuscles. They sometimes develop pigment in their anterior. As regards the lens, he only observes that its opacity commences in the outer layers.

Dr Ritter's experiments, made with a view of determining the progress of violent general inflammation of the eye, and the origin of the pus, were performed on rabbits. He introduced a needle, and pressed the lens against the choroid with considerable violence. The results which he obtained may be best understood by describing successively the changes observed in the several tissues.

As regards the vitreous, it must be remembered, Ritter holds, that in the normal condition no cellular structures are

to be found distributed through its tissue. Cells occasionally appear in inflammation, but are then, he believes, derived from the choroid. In his opinion, simple injury to the vitreous, even though extensive, never leads to the formation of pus within it, nor has he ever observed any extravasation of blood. The first appearance of pus always appeared just within or without the lower part of the hyaloid membrane, and, gradually increasing in amount, pressed towards the centre of the vitreous, the upper part of which usually remained clear to the later stages. He considers that although, as Schweigger had previously stated, pus cells may be found alike in the vitreous, retina, and choroid, they can only be developed in the latter membrane, since in the two former tissues the anatomical elements fail, out of which pus corpuscles can originate. The real origin of the pus cells is to be looked for in the unpigmented stroma cells of the choroid, and in the nuclei of the muscular-fibre investment of the vessels, which enlarge and divide. The branched pigment-holding cells of the stroma, on the other hand, long remain quite unaltered, though they ultimately break down, and leave only little clumps of pigment. As soon as inflammation is established in the choroid, its vessels increase in diameter, and subsequently the connective-tissue cells enlarge, and, together with the nuclei, increase in number, exerting so much pressure upon the vessels as to effect their obliteration. A fibrinous exudation is poured forth, diffusing itself equally through all the intra-ocular tunics. In the meanwhile, the inner layer of pigment cells has undergone various changes. Many lose their hexagonal form, become enlarged, pouched, and pressed together, so that the clear lines of separation normally present are lost; the pigment becomes distributed in a thin layer beneath the cell-membrane, whilst the central and larger part of the cell remains clear, and often contains two nuclei. Some of these cells, breaking down, permit the passage of the pus cells, hitherto lying on their outer side, into

the space between the choroid and retina, where they form thin layers.

The retina still opposes a certain resistance to their entrance into the vitreous, but soon they may be seen lying between the elements of the retina, which are separated from one another, and broken down, and at length they gain admission by one or many points into the vitreous. Fragments of the *membranæ limitantes*, nerve cells, radial fibres, and elements of the bacillar layer may then be found near the centre of the globe; but, even at this stage, isolated patches of the retina may be seen presenting its natural structure. In some instances, it would appear that the pus may enter the vitreous by another path, viz., through the separation of the retina at the *ora serrata* from the zonula of Zinn, but this does not occur to any great extent.

The vitreous, in most instances, becomes at an early period so reduced in consistence as to be almost or completely fluid, whilst its transparency is greatly impaired by the presence of minute granules, and by degenerated epithelial cells. It is ultimately absorbed and the whole posterior chamber of the eye becomes filled with pus, with which event this stage of the process terminates.

The part played by the iris is important. Often at first it is only slightly affected, the cells slowly undergoing changes analogous to those already described in the choroid. Sometimes, however, the inflammatory symptoms are more active, pus, in the formation of which the muscular-fibre cells of the vessels may be distinctly seen to take a part, being developed, which, falling to the bottom of the anterior chamber, constitutes an hypopyon, or, as more frequently occurs in rabbits, on account of the viscosity of the liquor puris, forms a consistent mass projecting into the anterior chamber. The epithelial cells of the uvea, and the pigment cells of the iris, are very resistant of change.

The changes occurring in the retina during the suppurative

process are that the radial fibres enlarge, become granular, and the nuclei multiply. The nerve cells also become granular, and their contents frequently undergo fatty degeneration. In the external granular layer, hyaline spherical bodies may occasionally be seen, often three times as large as pus corpuscles. They resemble mucus corpuscles, possess no investing membrane, but strongly refract light. M. Ritter considers that they are formed by the contents of the bacilli, pressed out by the pressure of the surrounding pus cells. The inner portions of the bacilli cannot in general be traced.

The capsule of the lens, and the epithelial cells of the anterior capsule, never exhibit any pathological change, even to the very last. For some time the separated portions of the lens remain clear, but subsequently they become cloudy, the outer layers of fibres being detached from one another, irregularly crumpled and infiltrated with pus, whilst the more deeply-seated fibres are scarcely altered, being only lightly punctated with irregular swellings on their edges. Remains of the lens are always found, even in atrophic eyes.

As regards the outer tunics, the sclerotic always remains unchanged, but the conjunctiva becomes vascular and chemosed. A well-marked circum-corneal zone is formed, and the cornea is covered with vessels, which Ritter found on the twenty-fifth day had nearly reached the centre, and the corneal tissue is much softened; the nuclei are enlarged but not multiplied. When these processes have run their course, the eye begins to shrink, and its complete atrophy is the final result. As regards the time occupied in these processes, M. Ritter's examinations showed that from the sixth to the tenth day pus had already been formed in considerable quantity, breaking down the retina, and penetrating into the vitreous. On the twelfth day the pus occupied about one-half of the posterior part of the bulb, and by the sixteenth to the twenty-fifth day, the whole of the vitreous was infiltrated. The globe, however, had at the same time lost but little of

its tension. The later stages were not noted, all the eyes being removed for examination at this period.

I venture to give one more account of the pathological changes observed in panophthalmitis—that of M. Schiess, who also experimented on rabbits, and established general inflammation by dividing the middle of the cornea in several directions with scissors. The iris soon protruded through the wound, the centre of which formed a kind of funnel-shaped cavity, occupied by a plug of coherent pus that constantly underwent renewal. The whole eye assumed a conical form, and diminished in size and firmness. The conjunctiva became œdematous, and there was considerable purulent discharge. In one case, where the eye was removed on the twenty-ninth day after the injury had been inflicted, and was examined after eighteen days' immersion in chromic acid, it appeared like a utricle filled with pus, the anterior swollen edges of which consisted of the iris fused with the altered corneal tissue, and infiltrated with pigment. The central opening formed a channel by which the pus, so long as it was developed in the interior of the globe, could be discharged—until, in fact, complete atrophy or phthisis bulbi took place, no traces of the lens nor of the vitreous, except near the optic entrance, could be discerned. The sclerotic appeared somewhat thickened, and in consequence of a condensation of the fibres of the lamina fusca, was intimately attached to the choroid. Posteriorly, the limits of the two were clearly defined; but in the neighbourhood of the ciliary processes they appeared to be fused together. At this part some increase in the connective-tissue corpuscles of the sclerotic was noticed, especially near the corneal margin. The same was observed in the superjacent connective tissue, where a little pus had formed. The proper stroma of the choroid was decidedly thickened, the interstices were filled with nuclei or small cells, without any very definite cell-wall, and there were numerous fusiform bodies, each of which appeared to contain

several nuclei. M. Schiess does not entirely agree with Ritter in thinking that the pus cells originate from choroidal stroma cells destitute of pigment, but their endogenous formation from other cells is perfectly obvious. The number of pus cells constantly increased towards the inner surface of the choroid. The condition of the bloodvessels was very remarkable, as they appeared to have atrophied in consequence of pressure made upon them by the process of cell development. M. Schiess appears to think that the real seat of origin of the suppurative process is in the connective tissue surrounding the vessels, and is of opinion that Ritter's preliminary stage of dilatation of the bloodvessels is doubtful. The focus or chief seat of the purulent deposit was in the chorio-capillaris, nearly one-half of the entire increase in thickness of the membrane being due to the changes occurring in this layer, the cell proliferation being in truth enormous. The internal layer of pigment cells retained for the most part the regularity of their arrangement, though in some places they appeared to have given way under the pressure of the new formations. Every part of the inner portion of the choroid was thoroughly infiltrated with pus cells, but no evidence could be obtained of the endogenous formation of pus cells from the pigment cells. In no instance was the basement membrane of the choroid recognisable. The retina presented different appearances according to the local intensity of the production of pus cells, and of the serous exudation. Although nowhere healthy, its elements here and there preserved their normal relations to other parts, and especially in those cases where it was still covered by any remains of the vitreous. An especially active proliferation process appeared to have taken place near the entrance of the optic nerve, which was distinctly excavated. Around the optic papilla the retinal fibres appeared torn, and were directed straight forwards in bundles, which were thoroughly impregnated with pus. The whole retinal tissue appeared dull and

hazy, and in parts was converted into fibrous or granular heaps, lying on the choroid. In other parts the tissue was infiltrated with serum, and radiating fibres were seen, together with large pale nuclei, a few ganglionic cells, and elements of the granular layer. The radial fibres generally appeared swollen, broad, and with fibrous structure. The outer limitation against the choroid was more distinct than the inner against the vitreous, in which last, fragments of the retina lay loose; or perhaps, more correctly speaking, the place of the vitreous was occupied by a chaotic mass of retinal tissue, disintegrated choroid, and pus cells. He saw no remains of the membranæ limitantes.

The treatment of general inflammation of the globe of the eye can only be undertaken, with any chance of success, in the earlier stages of the affection; in the later, it is almost exclusively palliative, and little hope can be entertained, when pus has once made its appearance in the vitreous, that the organ will again become a useful one. If the case be seen before this has occurred, active local depletory measures may be practised. Leeches should be applied to the temple, cold compresses placed on the eye, and frequently changed, and if great tension of the globe be present, the aqueous may be tapped through the cornea, or the sclerotic may be divided at the ciliary region. In the event of any foreign body being present, and imbedded in the iris or lens, immediate steps should be taken for its removal, by performing a large iridectomy, and, if requisite, removing the lens. This, however, as the details of numerous cases show, is a very dangerous proceeding. It need scarcely be added that attention should be paid to the general health of the patient, and that if the eye remain, as it is apt to do, tender and painful, enucleation should be adopted, lest sympathetic ophthalmia be established in the other.

Enucleation of the Globe.—This operation consists in removing the globe alone, leaving the conjunctiva, the muscles,

and the adipose tissue of the orbit, in order that a false eye, to be subsequently inserted, may have a cushion to rest upon, may be moved in directions associated with those of the opposite eye, and may come into contact with a surface naturally exposed.

To effect this, after the administration of chloroform, the lids should be separated by a wire-stop speculum; the operator should then pinch up a fold of the conjunctiva near the margin of the cornea, with a pair of toothed forceps, and by successive strokes of the scissors divide it all around the cornea. A curved strabismus hook, or grooved director, is to be passed under the internal rectus, and its tendon divided. By a repetition of the same movement, the other recti and the oblique are to be successively cut through. The eye being now released from all its attachments except the optic nerve, and the small vessels and nerves entering it behind, is to be completely enucleated by their section. Immediately after the division of the optic nerve, the eye starts forward, and can easily be removed. Moderately free bleeding generally takes place from the branches of the ophthalmic artery, which may be arrested by short exposure to the air, or by the application of a little iced water. As soon as the bleeding has ceased, the cut edges of the conjunctiva may be brought together at three or four points, by picking them up with a sharp aneurism needle, and a pad and bandage may be subsequently applied. Some operators fill the cavity of the orbit with strips of wet lint, but they are rather difficult to remove, without producing pain, during the first two or three days, and, if allowed to remain longer, become very offensive. It is rarely requisite to apply a ligature to any artery.

If in the course of the operation, from flaccidity of the eye, a portion of the sclerotic has been left behind,—the scissors dividing this membrane instead of the optic nerve,—it is better to remove it at once, as it occasionally becomes a

source of irritation, and retards the cure. When the operation is undertaken in a distended eye, it is sometimes requisite to enlarge the palpebral fissure by dividing the skin on the outer side of the orbit, to afford room for the succeeding slips of the operation, a manœuvre that was formerly very generally adopted. A suture must be subsequently inserted. When this is objected to, the distended globe may first be reduced in size by tapping the sclerotic or cornea, or by abscission of the fore part.

Pagenstecher considers that enucleation of the eye may be advantageously undertaken under the following circumstances:—

1. Traumatic irido-choroiditis occasioned by—
 - (a.) Lesion of the iris, resulting from its being nipped between the edges of the wound;
 - (b.) Lesion of the choroid;
 - (c.) Suppurative choroiditis, or suppuration in the vitreous;
 - (d.) Presence of a foreign body within the eye;
 - (e.) Lesion of the capsule of the lens;
 - (f.) Choroiditis after reclinacion, or depression of the lens.
2. Incipient exudative irido-choroiditis and hæmorrhage from the choroid.
3. Processes leading to staphyloma (choroiditis serosa).
4. Extensive separation of the retina.
5. Tumours developing from the choroid or sclerotic.
6. Formation of bone within the choroid.

The adaptation of the artificial eye should take place at as early a period as the patient can bear its insertion, as it prevents the eyelids from becoming contracted or falling in. The upper edge should first be introduced under the upper lid, and the lower edge may then be easily slipped over the lower lid.

4. *Cancer of the Globe.*

(PLATE VIII., Figs. 44 and 45.)

This formidable disease is almost invariably met with in children. In its earlier period it progresses slowly and painlessly, but in its later, after invading and destroying all the tissues of the globe, and extending to those of the orbit, it advances with rapidity, and differs in no respect in its features from those which have been already described in the case given under the head of Cancer of the Orbit (p. 27). Its original seat appears, in a great majority of instances, to be in the space between the retina and the choroid,¹ from whence, extending outwards, it may gradually perforate the sclerotic, or, as almost always occurs, developing forwards, it may at first separate the retina from the choroid, and then invade the nervous tissue, projecting into the vitreous, and approximating gradually the anterior portions of the eye. Sometimes, deposited no doubt by the vessels, it is found without any perforation having taking place on the outer side of the sclerotic; and in one case observed by v. Gräfe,² the optic nerve itself appeared to have been the conductor of the cancerous induration, the whole nerve having been found impregnated with cancerous deposit, whilst the neurilemma was only thickened.

The appearances presented by the disease are highly

¹ In some remarks appended by Mr Cowell, in the *Ophth. Hosp. Rep.*, vol. v. p. 188, to the report of an interesting case of cancer of the eyeball, it is stated that in 17 cases of this disease occurring in preparations presented to the Royal College of Surgeons by Dr Bader, where the tunics of the eye were not obliterated, and it was possible to determine the primary seat of the disease, in all the tumour was situated within the choroid, and the retina was more or less detached, and in all but one of these cases the fundus of the eye was the original seat; whilst in 11 cases of cancer of the globe reported by Mr Hulke in the *Ophth. Hosp. Rep.*, vols. iii. and iv., in none was the tumour external to the choroid. In Mr Cowell's case, the disease commenced exceptionally in the neighbourhood of the ciliary region, arising apparently from the inner surface of the sclerotic.

² *Archiv. f. Ophth.*, p. 413. 1854.

characteristic. Within the first year or two after birth, the parents find reason to believe that the child is blind with one eye, or observe an unnatural appearance in it which leads them to seek for advice. On examination, the eye presents the aspect depicted in fig. 44. The form and size of the globe are natural, and there are no evidences of intra-ocular congestion. The pupil retains its natural dimensions, or is only slightly enlarged, and the colour and movements of the iris are unaltered; but, on close examination in various lights, it will be seen that there is a metallic reflection from the fundus, which is believed by v. Gräfe to be due to the retina pressed forward by the tumour, and in a state of fatty degeneration. The colour of this reflection is yellowish, or clear brown, dotted over with minute red points, the whole being very clearly seen through the perfectly-transparent media, especially when the ophthalmoscope is used. At this period the child gives no indication of pain, and the globe preserves its normal tension.

The disease advances, in most instances, with moderate rapidity. After the lapse of two or three months its growth may be clearly discerned. The yellowish mass can be seen to have reached the posterior surface of the lens, pushing it forward together with the iris against the cornea. The movements of the iris are rendered sluggish, its colour is deepened or altered, indicating the presence of chronic inflammation, and the pupils are usually dilated. The globe is now often tense, and the presence of enlarged anterior ciliary veins ramifying over the sclerotic show that the escape of the blood by the ordinary channels from the interior of the eye is impeded, additional proof of which is often afforded by the effusion of blood into the anterior chamber. At a still later period the globe begins to undergo alterations of form, the sclerotic bulging irregularly at different parts, the iris becoming quite flattened, and apparently coalesced with the distended and opacified cornea, which at length ulcerates

through and permits the rapid development of the cancerous mass (fig. 45). Hæmorrhage now usually takes place from the surface, and the general appearance of fungus hæmatodes is presented. The child's health is quite broken down by this time. Severe pain, frequently of a paroxysmal character, is experienced. Sleep is much interfered with, the appetite is lost, the cancerous cachexia is established, the lymphatic glands of the pre-auricular and cervical regions are affected, and the cancerous mass spreading to the lids, which become greatly enlarged, and to all the adjoining tissues, and forming a frightful protrusion from the orbit, ultimately proves fatal, either by pure asthenia, or by implicating the brain substance and inducing convulsions.

The disease appears in many instances to be purely idiopathic, and to arise from constitutional and probably hereditary disease. Its colour, the transparency of the media and its deep-seated position, at once and certainly distinguish it in its early stages from cataract.

The only treatment that can be recommended for this disease is the immediate extirpation of the globe, as soon as its nature has been satisfactorily diagnosed; and it is consolatory to know that in many instances life has been permanently preserved by resorting to this operation at a sufficiently early period, that is, whilst the disease is limited to the globe, and has not had time to extend to the neighbouring glands. After it has once penetrated the sclerotic, no operation should be undertaken, as the only effect is the more rapid development of the tumour, and the more speedy advent of the fatal termination.

5. *Entozoa in the Globe.*

Several forms of entozoa have been noted as occurring in the eye. That most frequently seen has been the cysticercus cellulosus. More rarely, a single species of the genera filaria, monostoma or distoma has been observed; and besides these,

the *echinococcus hominis* and the *filaria medinensis* have been found either under the conjunctiva or in the connective tissue of the orbit.

Even the most frequent of these, the *cysticercus cellulosa*, is extremely rare. I have only seen one instance of it during the fifteen years I have been in attendance at the Westminster Ophthalmic Hospital. It was in that case lying free in the anterior chamber, but its more common position is in the vitreous. It has occasionally been found in or on the choroid or retina.

The presence and development of the *cysticercus* almost always occasions more or less acute inflammatory symptoms, leading to exudations and inflammatory deposits in its vicinity. If it occupy the anterior chamber, it can be easily discerned as a delicate sac with a neck at one point, of a pearly-grey colour and translucent appearance, moving in accordance with the position of the head. When situated in the posterior segment of the bulb, it can be recognised with equal facility with the ophthalmoscope, and in some instances, as Liebreich has shown, the little circlet of hooks around the head can be distinguished.

Vision is generally seriously impaired, and if no treatment be adopted, repeated attacks of irido-choroiditis set in, which ultimately destroy the eye.

If the *cysticercus* occupy the anterior chamber, the treatment is very simple. It is only requisite to make a linear incision, with such a knife as is shown on page 377, through the lower part of the cornea, and the worm will either escape with the aqueous, or may easily be extracted with iris forceps; but if it occupy the vitreous it is more difficult to remove. An attempt may however be made, which proved successful with Liebreich, by directing a ray of light from an ophthalmoscopic mirror into the eye, and seizing the animal through a sclerotic wound with a pair of cannula forceps. When it is imbedded in the retina or choroid, the eye must be extirpated.

CHAPTER XI.

Diseases of Accommodation and Refraction.

EMMETROPIA—AMETROPIA—NATURE OF THE ACT OF ACCOMMODATION, AND MEANS BY WHICH IT IS EFFECTED—RANGE OF ACCOMMODATION—SHARPNESS OF VISION—HYPERMETROPIA—PRESBYOPIA—MYOPIA—ASTIGMATISM.

WITHOUT attempting to give a full account of the various anomalies of refraction and accommodation of the eye,¹ I have thought it expedient to introduce here a short section explaining the principal terms which are now in use, and which have for the most part resulted from the extension of our knowledge of these subjects during the past few years.

The healthy eye, when perfectly at rest, possesses such an organisation that parallel rays of light, or those proceeding from a luminous object at an infinite distance, are brought to an exact, or almost exact, focus on the retina. Such a healthy or normally-constructed eye is said to be emmetropic. When parallel rays of light are not brought to a focus on the retina, ametropia is said to be present; and of this there are two

¹ For which the reader is referred to the works of Donders, published by the Sydenham Society; of Giraud Teulon, prefixed to the French translation of Dr Mackenzie's Treatise; to Mr J. Z. Laurence's Lectures; Liebreich, in *Nouveau Dictionnaire de Medecine*, Bailliere, t. i. 1864; Art. Accommodation; and to various papers, or rather treatises, in the *Ann. d'Ocul.* and the *Archiv. f. Ophth.*

forms—one in which the focus is in front of the retina (myopia), and the other in which it is behind (hypermetropia).

It may be observed that parallel rays of light are usually considered to be those which emanate from the sun, moon, or stars, or from any small luminous object, as a candle at a distance of thirty or forty yards, though it must be admitted that in none of these instances are the rays really perfectly parallel, but more or less divergent; and in proportion as the luminous object is approximated more and more nearly to the eye, the more divergent will the rays become, and, consequently, were the internal arrangements even of the emmetropic or normally-constructed eye to remain unchanged, the farther behind the plane of the retina would such divergent rays be combined into a focus, and therefore the more blurred and indistinct would be the retinal image. But, so far as relates to parallel rays of light, the vision of emmetropic eyes is not improved either by concave or convex glasses, for, when perfectly at rest, the images of all distant objects are brought to an exact focus on the retina.

On the other hand, in the case of the myopic eye, whilst parallel rays are brought to a focus too soon, or in front of the retinal plane, rays of a certain degree of divergence, differing for each case, are exactly focussed upon the retina. Hence myopic patients approximate objects more or less closely to their eyes, and are benefited by concave glasses, both of which conditions cause the rays to be divergent. The myopic eye is constructed, therefore, when at rest, to focus divergent rays.

Hypermetropic eyes, again, differ from normal eyes in their inability to focus parallel rays of light on the retina, their principal focus being behind it; and in order to obtain correct and sharp images of external objects, the rays must be either convergent or must be rendered so by convex glasses. Hypermetropic eyes are constructed to focus, when at rest, rays of a greater or less degree of convergence.

In order that a clear image should be obtained in an emmetropic eye, when near objects or those giving off divergent rays are examined, it is obvious that the eye must have a power of adaptation by which, whilst under some circumstances parallel, under others divergent, rays can be exactly focussed upon the retina. This power is called the *faculty of accommodation*, and though the means by which it is effected are completely under the control of the will, yet the power is exerted so constantly that it becomes an habitual act, and is almost unconsciously performed. The existence of such a faculty of adjustment is shown at once by looking through a window at any distant object, as a tree. It will then be found that, if the surface of the window be examined, the outline of the tree becomes confused, whilst a certain degree of exertion or tension is maintained in the eye; whilst, if the attention be fixed on the tree, any spots or marks that may happen to be on the window almost entirely vanish, and all exertion of the eye ceases; it is at rest.

It is easy to perceive that if—supposing the dioptric system of the eye to be arranged for focussing parallel rays of light upon the retina—it were required to focus divergent rays upon the same membrane, two methods might be employed,—the lens might be caused to increase in thickness, *i.e.*, to become more spherical, or the whole eye might be elongated in its antero-posterior direction. In the former case, the luminous rays would be brought to a focus sooner; in the latter, the position of the focus remaining unaltered, the retina, following the sclerotic, would retreat till it arrived at the focus. In reality, there is reason to believe that both these means are employed, and that whilst the chief agent in effecting the accommodation of the eye for near objects is the ciliary muscles, some assistance is obtained from the contraction of the recti and oblique muscles, when very strong efforts at accommodation are made.

It is proper to mention that an observation, to some extent militating against the view that the adjustment of the eye for

distinct vision of near objects results from muscular action, has been made by Helmholtz, who believes it can be shown by exact measurement, that after death the thickness of the lens is somewhat greater than during life, which tends to prove that the living muscle exerts a certain power of flattening the lens, since all muscular energy relaxes in death. If so, it is difficult to see how its contraction during life can occasion increased convexity of the lens. Strong evidence that the act of accommodation is in reality a muscular act, is, however, afforded by the fatigue that is experienced after a short time when any small object is attentively examined and held close to the eye, as well as by the fact that the faculty can be altogether abolished by the agency of certain neuro-muscular poisons, as belladonna. Distant objects, on the other hand, may be long regarded without the occurrence of any such symptom of fatigue, apparently because no exertion of muscular power is made.

The effects believed to be produced by the contraction of the ciliary muscle are shown on the left or numbered side of the opposite figure.

When the ciliary muscle contracts, the anterior surface of the lens becomes more convex, probably from direct compression of its margin. The posterior remains with its convexity unchanged. The pupil is slightly contracted, in order to cut off the outermost rays, and to prevent spherical aberration. The iris resting on the capsule of the lens is slightly advanced towards the posterior surface of the cornea.

That the iris plays only a subordinate *rôle* in the acts of accommodation, is shown by a remarkable case¹ in which v. Gräfe removed the whole of the iris, and yet the sharpness of vision and the accommodative power of the eye were but little if at all interfered with, whilst the instillation of atropine completely paralysed the power of accommodation,—a result clearly due to its action on the ciliary muscle.

¹ See Dr Soelberg Wells, in *Ophth. Hosp. Rep.*, vol. ii. p. 199.

I have also preserved notes of two cases of total deficiency of the iris, in which, nevertheless, though the sharpness of vision was materially diminished, in one instance, from cata-

2 Q.

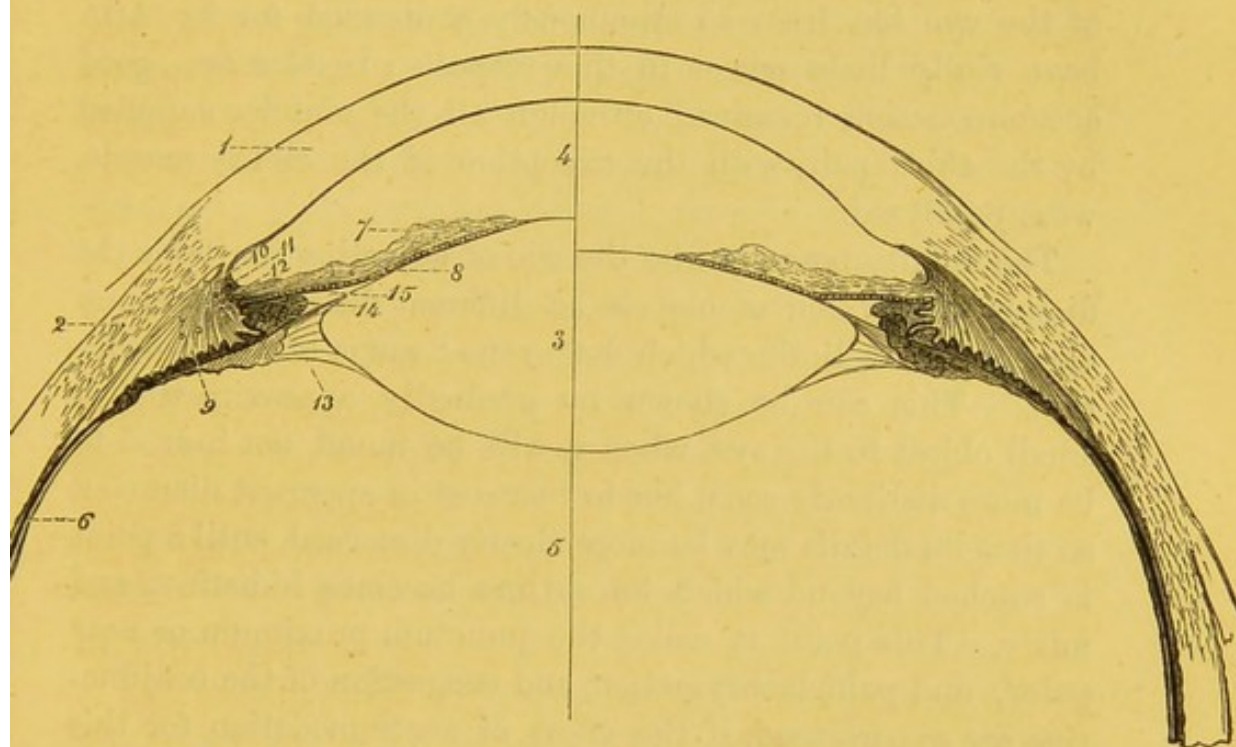


Diagram showing the action of the ciliary muscle. The numbered side shows the arrangement of the parts in accommodation for near objects, and the blank side when accommodated for distant objects.

- | | | |
|---|---------------|--------------------|
| 1. Cornea. | 2. Sclerotic. | 3. Lens. |
| 4. Aqueous humour and anterior chamber of the eye. | | |
| 5. Vitreous. | | |
| 6. Choroid at the point where the ciliary processes commence. It is lined internally by the retina, and the fig. is opposite the point where the sclerotic become thickened by the insertion of one of the recti muscles. | | |
| 7. Iris. | 8. Uvea. | 9. Ciliary muscle. |
| 10. Canal of Schlemm. | | |
| 11. The ligamentum pectinatum iridis. | | |
| 12. A few circular fibres of the ciliary muscle seen in section. | | |
| 13. Layer of membrane proceeding from the ciliary processes, and constituting the posterior boundary of the canal of Petit. | | |
| 14. Apex of one of the ciliary processes. | | |
| 15. Posterior chamber of the eye, filled with aqueous humour. | | |

ract, and in the other from myopia, yet within small limits the power of accommodation appeared to be fairly preserved.

Another case, observed by v. Gräfe, shows that the recti and obliqui muscles, whose agency in affecting the accommodation of the eye has been so strenuously contended for by Arlt, have really little power in this respect. In this case, good accommodation remained, although all the muscles supplied by the third pair, with the exception of the ciliary muscle, were paralysed.

The faculty possessed by the eye of adjusting itself for the distinct perception of objects at different distances, does not exceed certain limits which define the "range of accommodation." This can be shown by gradually approximating a small object to the eye, when it will be found, not indeed to be more distinctly seen, but to increase in apparent diameter, so that its details may be more clearly discerned, until a point is reached beyond which its outline becomes indistinct and misty. This point is called the *punctum proximum* or *near point*; and pain, lachrymation, and congestion of the conjunctiva are experienced, if the effort of accommodation for this point be long continued. If the object be gradually removed from the eye, its outline remains distinct, until it is at such a distance that the rays of light emanating from it may be considered to be parallel,—that is, at infinity,—and hence the *far point*, or *punctum remotum* of the emmetropic eye is said to be infinity.

The range or extent of accommodation in the healthy eye may be therefore represented by the distance between infinity and the near point. The determination of the latter may be accomplished by gradually approximating to the eye an optometer, or small oblong metal frame, across which six or eight fine silk threads or hairs are carried, and which is mounted on a slide rule. The frame is approximated to the eye until the threads begin to be ill defined, when the near point is reached. The distance of this from the eye can then

be read off on the rule. In proportion as age advances, the power and range of accommodation diminish ; and it has been shown by Donders that the diminution follows a tolerably regular march.

At fifteen years of age the range of accommodation is very great, extending in a healthy eye from three inches (the near point) to infinity (the far point), the eye being capable of accommodation for distinct vision of objects at all intervening distances ; at twenty-five years, it extends from four inches to infinity ; at thirty-five years, from six inches to infinity ; at fifty years, from twelve inches to infinity ; at the age of sixty or seventy, the power of accommodation almost wholly fails, and then supervenes a slight amount of hypermetropia, the near and far point almost coinciding, and both being beyond infinity ; or, in other words, the eye is incapable of focussing parallel rays proceeding from infinitely distant objects, unless those rays have been rendered more or less convergent by convex glasses.

The causes to which this loss of the power of accommodation and recedence of the near point with advancing age are due, are doubtless the gradual flattening of the lens which is known to occur, accompanied by an increase in its density and consistence, and an atrophic condition of the ciliary muscle.

Donders considers that the far-sightedness or presbyopia of old age begins at about the age of forty, when the near point retreats to beyond eight inches.

In hypermetropic patients, the whole range of accommodation is placed farther off than in the normal eye. In an extreme case, the near point may be infinity, or, in other words, with the utmost tension of accommodation (and the activity of the ciliary muscle may be quite as great in the hypermetropic as in the emmetropic eye), only parallel rays can be brought to a focus on the retina ; nay, it may even be that, before they can be so focussed, a convergent direction must be given to them. Such, indeed, is the condition of a

patient from whom the lens has been removed by operation (aphakia).

In myopia, on the contrary, the whole range of accommodation is situated nearer to the eye than natural, the near point being often at a distance of three or four inches, and the far point at twenty or thirty inches. Yet even here the activity of the ciliary muscle may be as great as in the emmetropic eye, since it requires as great an effort to accommodate the eye from objects at twelve inches to those at eight inches, or from eight to six inches, as for adjusting the eye from infinity to a distance of twenty-four inches, or from twenty-four inches to twelve, the difference in the divergence of the rays, and the consequent necessity for vigorous contraction of the ciliary muscle, increasing rapidly as the objects are approximated to the eye.

The sharpness of vision in any case is estimated by a comparison of the definiteness with which some small object taken as unity can be seen at a given distance. In the Test Types of MM. Snellen and Giraud Teulon, letters are printed, the size of the retinal image of which, when held at the distance of about a foot, is just equal to the diameter of one of the rods of the bacillary layer, subtending an angle of one minute, or an arc of 5000ths of a millimètre, which is equal to about 1-5000th of an inch. Each of these letters (No. I.) is taken as unity. No. II. are exactly twice as large, casting the same sized image at two feet, No. XX. at twenty feet, and so on.¹ Consequently, the greater the distance a given type can be read, the greater the sharpness of vision. If the experimenter can read I. at one foot, or X. at ten feet, his sharpness of vision is $\frac{1}{1}$ or $\frac{10}{10} = 1$ or $S = 1$. If he can only read type XXX. at twenty feet, his sharpness of vision is expressed by the fraction $\frac{20}{30}$ or $\frac{2}{3}$. If he can read it at forty feet, it is $\frac{40}{30}$.

¹ Giraud Teulon. Introduction to the Supplement of MM. Warlomont and Testelin's Translation of Dr Mackenzie's Treatise on Diseases of the Eye, p. 19. 1865.

M. Donders¹ and M. de Haan, from examinations of the healthy eyes of a considerable number of patients, have ascertained that the sharpness of vision undergoes scarcely any alteration before the age of twenty-seven years, but that it then begins to diminish slowly, so that at fifty it is $\frac{1}{2}$, and between seventy and eighty it falls to about $\frac{1}{10}$, the patient being only able to see an object at one-half the distance at which he was able when young.

Slight variations occur not only between different healthy individuals of the same age, but also in the same person, in connection with the clearness of the day, the condition of the general health, etc. The cause of the diminished sharpness of vision with advancing age is no doubt attributable to the diminished transparency of the several media, as may indeed be naturally concluded from the inferior clearness with which the fundus can be explored with the ophthalmoscope in old as compared with young people. The lens, moreover, reflects much more light in old age; the sutures of its sectors become more apparent; irregular astigmatism augments; monocular polyopia becomes more or less marked and irregular; the vitreous becomes hazy, and shreds and membranes may be sometimes discerned in it with the microscope; lastly, a structural alteration, of considerable importance and frequency, consists in the development of warty thickenings of the elastic lamina of the choroid, which, projecting forwards, seriously impair the organic and functional perfection of the outer layers of the retina.

The sharpness of vision diminishes with age much more rapidly in high degrees of myopia than in emmetropia, which is probably due to the progressive atrophy of the membranes, and to a chronic inflammation of the vitreous, leading to cloudiness and loss of transparency.

In hypermetropia the decrease of sharpness of vision follows nearly the same law as that of the healthy eye.

¹ Ann. d'Ocul., p. 204. 1865.

For the clinical examination of the eyes, and to determine whether they are emmetropic or affected with myopia or with hypermetropia, Snellen's Test Types, and a series of concave and convex glasses, are required. The several types are placed before the patient at their corresponding distances, I. at one foot, II. at two feet, XX. at twenty feet. If he can read all these, there is *prima facie* evidence that he is emmetropic; but slight degrees of myopia or of hypermetropia may still be present. To prove the absence of the former, a concave glass of low power ($\frac{1}{40}$) is applied. If there be no improvement he is not myopic. A convex glass of similar focal distance is applied. If he still sees no better, there is no manifest hypermetropia. There may, however, be some amount of latent hypermetropia. This can be ascertained, if thought requisite, by paralysing the ciliary muscle with atropine, and then applying the low power of convex glasses, when, if hypermetropia exist, considerable improvement in the perception of distant objects will be obtained.

1. *Hypermetropia.*

When, owing either to the globe of the eye being flattened in the antero-posterior direction, or to the refractive media, cornea, aqueous, vitreous, and especially the lens, being of too low a refractive power, the images of external objects are not brought to a focus soon enough to be sharply defined upon the retina, but fall, or would fall, were the sclerotic transparent, behind it, the eye is termed hypermetropic.

The diagnosis of hypermetropia is accomplished by observing that the affected eyes are small, sunken, and widely separated, the sclerotic around the cornea presenting a flattened appearance, whilst in the æquatorial regions the meridians are strongly curved. The anterior chamber is generally shallow, the pupil small, and diverging strabismus frequently occurs in one or the other eye, or may be induced if an object held in the middle line be gradually approximated, so that

strong convergence of the optic axes is required. Donders considers that the whole physiognomy offers peculiar features, the face being flattened, and the nose but slightly prominent, so that it can scarcely give support to ordinary spectacles. These physiognomical characters are frequently hereditary, and are thus also probably congenital. On ophthalmoscopic examination, a little care will enable the observer to see without the lens a distinct upright image of the fundus, in opposition to what is seen in myopia, where the image is inverted; and the diagnosis may be materially assisted by following the plan recommended by Mr Cowell,¹ in which "a finger of the hand not employed in holding the ophthalmoscope is held up as an object for the patient to fix with the eye not under examination, and in such a position that the observer may get an image of one of the retinal vessels. If the finger be then slightly moved to and fro in a direction perpendicular to the vessel, the image will be seen to move with the finger when myopia is present, and in the opposite direction when the eye is hypermetropic." In the same paper by Mr Cowell, a plan of Mr Hutchinson's is mentioned for distinguishing between these conditions by means of the ordinary convex object lens. By approximating the lens to the eye, the image increases in size if hypermetropia be present, and diminishes if myopia exist.

Hypermetropic eyes are almost always asthenopic, that is, soon become fatigued when engaged on minute objects; and this is usually due to excessive exertion, and consequent exhaustion, of the ciliary muscle in accommodating the eye for near objects; whence the term, "accommodative asthenopia." The acuteness of vision is also generally more or less impaired, so that even when the defect is neutralised by appropriate glasses, the several test types are not well seen at their proper and corresponding distances.

The eye in hypermetropia is not adapted for parallel but

¹ Ophth. Hosp. Rep., vol. v. p. 227.

for convergent rays, and therefore, so to speak, for objects beyond infinity, since all objects on this side of infinity give off divergent rays. A distinct act or effort of accommodation is consequently required to enable distant objects to be clearly discerned. The hypermetropic eye, in fact, accommodates itself for parallel rays proceeding from infinitely distant objects, exactly in the same way that the normal eye accommodates itself for the examination of near objects. In hypermetropia the entire range of the accommodative power of the eye is situated at a greater distance from the eye than in the normal eye, and at a still greater distance than in the myopic eye.

The degree of hypermetropia actually present in any case may be divided into two factors,—that which is *manifest*, and which the patient is unable to overcome by any effort of tension on the part of his ciliary muscle; and that which is *latent*, or which, by more or less exertion of the accommodative power, he is able to conceal. The amount of manifest hypermetropia present is easily ascertained. The patient is placed at a distance of twenty feet from No. XX. of Snellen's Test Types, and convex glasses, beginning with the weakest, are successively given to him, until a pair of sufficient strength are obtained to produce considerable improvement in vision, the letters appearing blacker and better defined. The fraction, of which the denominator is the focal length of the glass in inches, expresses the degree of hypermetropia present. If the lens required be of 24-inch focus, the hypermetropia is $\frac{1}{24}$; if 36, $\frac{1}{36}$; and so on. The action of such glasses is to bring parallel rays to a focus on the retina.

In people of about fifty years of age no further investigation need be made, since all latent hypermetropia disappears about that period of life, and is replaced by manifest hypermetropia, because then the power of accommodation, in consequence of the increased consistency of the lens, and diminished activity and vigour of the ciliary muscle, is almost entirely lost. In

younger people, however, it is frequently necessary to determine the degree of latent hypermetropia present; and this is accomplished by the instillation of atropine, which, by paralyzing the ciliary muscle, and incapacitating the patient from making the slightest exertion of accommodation, renders evident the entire amount of hypermetropia present. It will then be found, not only that no near objects can be focussed, but that a stronger convex glass than was previously sufficient must be employed in order to render distant objects clearly visible.

Donders has employed the term *facultative* hypermetropia to indicate that condition, when the power of accommodation is sufficiently strong to enable objects to be accurately seen at an infinite distance, both with and without convex glasses. The hypermetropia is *absolute* when, even with the strongest convergence of the visual lines, accommodation for parallel or converging rays is not to be attained.

The slighter degrees of hypermetropia are those most frequently met with. Donders remarks that degrees of one-sixth are already sufficiently rare, and those of one-fourth or one-third are quite exceptional. The highest degree of hypermetropia is that in which the lens is absent, a condition to which the term aphakia has been applied.

The treatment of hypermetropia is determined at the moment of its exact appreciation, and consists in the adoption of those glasses which neutralise it. In practice, it is expedient not to give, at least in the first instance, those which neutralise the whole amount of hypermetropia present, but to begin with those which neutralise the manifest hypermetropia, and then to proceed by degrees to those which neutralise the latent hypermetropia. Donders observes that, with the spectacles, advice should be given to the patient never to work without them, to interrupt his work every half-hour for some minutes, to avoid excessive fatigue, and, in about eight days, to report himself. It will then be found

that, if the glasses have been too weak, the asthenopia, which arises from excessive tension of the ciliary muscle (accommodative asthenopia), is not removed; whilst, if they have been too strong, he will have been compelled to hold the work too near to his eyes, and a new form of asthenopia (muscular asthenopia), due to over-exertion of the internal recti muscles, will have been induced. According to the statements made, stronger or weaker glasses may then be chosen.

2. *Presbyopia.*

Presbyopia, termed by Donders hypermetropia acquisita, is a condition which results from the increase in the density and consistence of the lens, and from the diminution in the range and power of accommodation that accompany advancing age. As these changes are, however, progressive throughout life, even from childhood, no precise or natural symptom can be given by which it can be shown that presbyopia has commenced. An artificial line must be drawn, and Donders has conveniently indicated it, by considering that presbyopia has commenced when objects can no longer be clearly distinguished at the distance of eight inches, which shows that the near point has receded beyond that point. This usually occurs about the age of fifty, in normal or emmetropic eyes, and quite independently of whether they have been much used or not. To see ordinary print, the presbyopic patient removes it to 10, 12, or 14 inches from the eye, and coincidentally seeks a good light, partly because there is usually some concurrent loss of transparency in the media, and partly because, with a bright light, the pupil contracts, the circles of diffusion become smaller, and the retinal images less diffused.

The degree of presbyopia can easily be deduced from the formula, $Pr. = \frac{1}{8} - \frac{1}{n}$, when n represents the number of inches at which the near point lies from the eye. Thus, supposing

that the nearest point of binocular vision, for ordinary print, is 20 inches, by this formula we find $Pr. = \frac{1}{8} - \frac{1}{20} = \frac{1}{13\frac{1}{2}}$ *convex* glasses, of about 13 or 14 inch focus, will supply the deficiency, and produce that amount of convergence of the rays proceeding from near objects which will enable him to see easily all objects at a moderate distance.

We not unfrequently meet with cases in which presbyopia is conjoined with hypermetropia. The presence of the former can be rendered evident by the patient being still unable to see objects at eight inches distinctly when the hypermetropia has been neutralised by a glass. When hypermetropia is present, therefore, it is requisite to ascertain and correct its amount in addition to the presbyopia.

Presbyopia may coincide with low degrees of myopia, but never with the higher. If, for instance, the near point be more remote from the eye than 8 inches, say at 12 inches, so that we have a presbyopia of $\frac{1}{8} - \frac{1}{12} = \frac{1}{24}$, we may easily have a condition, at the same time, in which the far point is at 20 inches, so that there is a myopia of $\frac{1}{20}$ combined with a presbyopia of $\frac{1}{24}$, and his range of accommodation would only be $\frac{1}{30}$. But it is obviously impossible that presbyopia should ever be combined with high degrees of myopia, as $\frac{1}{8}$ or $\frac{1}{6}$, for, if the remote point be 8 or 6 inches, even if there were entire loss of accommodation, and the near point were to retreat to the far point, they would still both be within 8 inches, beyond which the near point of a presbyopic patient lies.

When the symptoms of presbyopia, viz., recession of the near point, and the necessity of using convex glasses for distinct vision at ordinary distances, quickly increase in intensity, and are accompanied by increased tension of the globe of the eye, sparks and periodical obscurations, the supervention of glaucoma is likely to take place, and active and immediate treatment is required.

Donders has given the following table, showing the number

of the convex glasses required to produce distinct vision at the distances stated, which distances are such as are in ordinary life found convenient:—

Age.	No. of Convex Glasses.	Distance of Distinct Vision.
48	1-60	14
50	1-40	14
55	1-30	14
58	1-22	13
60	1-18	13
62	1-14	13
65	1-13	12
70	1-10	10
75	1-9	9
78	1-8	8
80	1-7	7

The approximation made at the more advanced age is simply on account of the sharpness of vision at this period being diminished, as well as the power of accommodation. For distant objects, glasses of lower power are required. The first glasses worn should be as weak as may prove effectual in improving the vision, and should at first be only used in the evening. When stronger glasses are required, those previously used should be kept for the day.

3. *Aphakia.*

The condition termed aphakia is established when the lens has been removed, either by operation or by absorption, after an injury, and when, therefore, parallel rays of light can no longer, by any exertion of the power of accommodation, be brought to a focus on the retina. Such an eye is in the highest degree hypermetropic; and in order that correct images of external objects should be thrown upon the retina, that membrane should be distant from 30·58 millimètres,¹ to 31·69 millimètres² (or about one and a-quarter inch), from

¹ Donders.

² Giraud Teulon.

the anterior surface of the cornea. As its real distance is only about 23 millimètres (or nearly one inch), a convex glass is required to be placed in front of the eye, of such strength as shall enable the eye to bring parallel rays to a focus at this distance.

Considerations of a theoretical nature, as well as practical trials, show that the glass required usually ranges from three to four inches focus, which places the eye exactly in the position of a healthy eye, the accommodative power of which has been neutralised by atropine. In this case, however, a kind of accommodation can be exercised for distant and near objects, by altering the distance at which the glass is held before the eye, so that, supposing distant objects are seen well with a glass of three-inch focus, placed at half-an-inch from the cornea, if it be removed to one inch, vision is adapted for a distance of twenty-two inches, and when removed to one and a-half inch, it is adapted for objects situated at thirteen and a-half inches from the eye. Donders remarks that there is usually some diminution in the sharpness of vision, owing to slight deposit on the inner surface of the capsule of the lens. As a general rule, two pairs of spectacles are recommended to be used after operation for cataract, one of three and a-half inches focus, adapted for near objects, and one of rather lower power, as from four to six inches focus, for more distant objects.

4. *Myopia.*

This condition is essentially dependent upon an elongation of the globe of the eye in the antero-posterior direction; as a consequence of which, parallel rays of light falling upon the cornea are brought to a focus in the vitreous, in front of the retina, and, continuing their onward course, form circles of diffusion, which render the outlines of all objects confused and indistinct.

Another cause of myopia, which has been less accurately

determined, is an increased convexity and consequent refractive power of the lens.

Myopia is rare, as was shown by Ware, amongst soldiers, sailors, and those employed in agricultural pursuits. On the contrary, it is not infrequent in those who are constantly engaged in examining minute objects, reading, writing, and the like. It is therefore generally observed amongst the more highly cultivated classes, which may be attributed partly to the compression of the globe of the eye, which occurs in strong convergence of the visual axes, and partly to increased congestion of the head, in which the eye partakes, leading primarily to increased secretion of the humours and tension of the globe, and, secondarily, to yielding of the sclerotic and other tunics near the posterior pole.

The disease is frequently hereditary, and may show itself at a very early age.

Myopic eyes present, both to an external and to an ophthalmoscopic examination, certain characteristic features. They are often concomitant with other symptoms of scrofula. They are usually of large size, and the patients acquire a peculiar habit of nearly closing the lids, which is believed to be partly for the suppression of the vertical diameters or the circles of diffusion, so that horizontal lines are better seen, and partly for the purpose of forming a kind of concave lens of the fluids lubricating the cornea. When examined with an ordinary ophthalmoscopic mirror alone, in the higher degrees at least, an enlarged inverted image of a small portion of the retinal vessels can be distinctly seen; but when a convex lens is used in addition, a large portion of the fundus can be seen at once, and generally presents a greater or less amount of disease.

The most important abnormal appearances presented, as stated by Donders, are atrophy of the choroid on the outer side of the optic nerve, combined with change of form of the nerve surface; a straight-lined course of the vessels of the

retina; incomplete diffuse atrophy of the choroid in other places; and morbid changes in the region of the yellow spot.

Some of these changes are represented in Plate XII., fig. 69, and Plate IX., fig. 51.

The atrophy of the choroid usually commences as a white semicircle, embracing the outer part of the optic disk, and the colour is due to the absence of the choroidal layers permitting the light to be brilliantly reflected from the surface of the sclerotic. A second white crescent gradually forms on the inner border of the optic nerve, and at length the two crescents unite and form a larger or smaller oval, the long axis of which, in the great majority of cases, is nearly horizontal, its outer extremity approximating to or (very rarely) including the yellow spot. The yellow spot is often, however, separately affected, becoming the centre of a similar atrophy of the choroid. Over these white, highly-reflecting surfaces, the vessels of the retina may be seen with extreme clearness and definition, pursuing a nearly straight course, as though they had been stretched. The nerve surface of the optic papilla is somewhat congested in the young, but white and reflecting in old cases, and almost always presents both an apparent and real elongation in a direction perpendicular to the axis of the atrophy.

Choroiditis disseminata, fluidification of the vitreous with floating particles of pigment, and other more serious diseases of the eye, as separation of the retina, irido-choroiditis, etc., are not infrequently seen as accompaniments of advanced degrees of myopia. If the degree of myopia do not exceed $\frac{1}{16}$ to $\frac{1}{14}$, the liability to disease does not appear to be materially increased.

Since, as already stated, the focus of a myopic eye for parallel rays is in front of the retina, *a fortiori*, convergent rays are brought to a focus at a point still more distant from the retina and nearer the posterior surface of the lens. But convergent rays are never or scarcely ever met with in nature,

though they can be immediately produced by the use of a convex glass. Hence the use even of weak convex glasses, in consequence of their producing such a convergent direction of the rays of light, effects a marked deterioration of the powers of vision in a myopic patient, and are rejected by him. Divergent rays, on the contrary, can, within certain limits, be focussed; but these proceed from all near objects; and hence the myope can see distinctly objects in such proximity to the eye as would render them, even with the utmost tension of the accommodative power, very indistinct to the normal eye. On the other hand, in proportion to the distance of an object from the eye, do the rays emanating from it assume a more parallel direction to one another. But the myopic eye is incapable of bringing parallel rays to a focus. A point is consequently sooner or later reached before the rays become parallel, *i.e.*, short of infinity, at which the outlines of objects begin to be confused. This is the far point; and the degree of myopia present may be conveniently indicated by employing, as Donders has done, a fraction representing this far point in inches. Thus a myope, whose far point is situated at thirty-six inches, suffers from myopia of $\frac{1}{36}$; and the concave glasses, which possess this focal distance, will compensate his myopia, or, in other words, will make the luminous rays from all objects beyond thirty-six inches as divergent as they would be if they were situated at the distance of thirty-six inches. If his far point is at six inches, his myopia is $\frac{1}{6}$, and the concave glass required to correct his defect will have a focal length of six inches.

The range of accommodation in young myopes is not materially diminished, except in the highest degrees, where atrophy of the ciliary muscle occurs, and the power of accommodation wholly, or almost wholly, fails with advancing age.

The diminution in the range of accommodation follows nearly the same steps as in emmetropic eyes. It is only in the highest degrees that it decreases rapidly. Myopia is

almost without exception progressive in youth, augmenting, moreover, with a rapidity proportionate to its degree. In very high degrees it never ceases to progress, but the slighter grades often remain stationary after they have reached a certain point. The supposition that myopia decreases with advancing years is erroneous, and is partly due to the circumstance that the near point recedes gradually, as in normally-constructed eyes, and partly because the pupil contracts to some extent, and hence the circles of diffusion are less conspicuous. Slight degrees of myopia do not exclude presbyopia, which, in fact, occurs in myopics as soon as their near point is situated beyond eight inches.

In selecting glasses for myopes, care should be taken not to give them too strong ones at first, since considerably weaker glasses than those first selected are often found to be sufficient. As a general rule, the easiest method of determining the glass required consists in desiring the patient to read rather small print, as No. II. or III. of Jäger's Test Types. He will for the most part hold it at about the distance of his far point. By measuring this distance, and giving him concave glasses of the same focal length, he will experience great improvement. The nearer concave glasses are placed to the eye, the more powerful is their effect.

5. *Asthenopia.*

The term asthenopia has been applied to a peculiar condition of impaired vision, in which, whilst the eyes preserve their natural healthy appearance, and the vision both for near and distant objects, but especially for the latter, is preserved with perfect acuteness, the patient complains that he is unable to work or read for more than a few minutes at a time, and this more particularly when the light is indifferent. He is obliged frequently to rest for a few moments and rub the eyelids. The relief which follows is of short duration, and, if he still continue to work, sensations of fulness and

pain over the brow, and rarely in the eyes themselves, are experienced; lachrymation and congestion of the conjunctiva succeed; the forms of external objects become blurred and misty; printed letters appear confused, and run into one another; and, lastly, strabismus often occurs, with crossed images.

The researches of Donders¹ and v. Gräfe² have shown that these symptoms may accompany both hypermetropia and myopia, but that the disease presents somewhat different features in the two cases, and arises from different causes. When it is associated with hypermetropia, it is essentially occasioned by the modification of the refractive powers of the eye, leading to atony or deficiency of energy from over-exertion of the ciliary muscle; whereas, when it is associated with myopia, it proceeds from over-fatigue and insufficient power of the internal recti muscles. In the former case, the disease is often distinguished as accommodative asthenopia; in the latter, it is termed muscular or motor asthenopia.

In accommodative asthenopia the eyes are generally found to be affected with moderate degrees of hypermetropia, in consequence of which the patient is obliged, in looking at ordinary print, to exert the power of accommodation, or, in other words, the ciliary muscle, to a very high degree. Fatigue naturally succeeds, and the patient experiences a sensation that is precisely similar to that felt by a healthy person after wearing concave glasses of moderately low power for a short time. Such accommodative asthenopia sometimes supervenes suddenly after the eyes have been strained for too long a period on minute objects. It has also been observed to occur in cases of paralysis of the third nerve, whether by disease or by the constant instillation of atropine; and it occasionally

¹ See "Accommodation and Refraction of the Eye," by F. C. Donders, N. Syd. Soc. Trans., p. 259.

² See Windsor's Abstract of v. Gräfe's Paper on Muscular Asthenopia, in Laurence's Ophthal. Review, vol. ii. p. 303.

occurs as the result of simple debility, as during convalescence from fever.

In those cases which are associated with hypermetropia, the asthenopia, being dependent upon an abnormal form of the globe, which is frequently an hereditary defect, is itself often observed to be transmitted from parent to child. In this form of the disease, the internal recti preserve their natural power; and if any small object, as a pencil held vertically in the middle line, be slowly approximated to the eye, the gradual convergence of the optic axes can be properly performed and maintained without any tendency to the production of strabismus.

In muscular asthenopia, on the other hand, which accompanies myopia, the insufficiency of the internal recti consequent on over-exertion can be readily made apparent by the above experiment. As the pencil is gradually brought closer to the face, one or the other eye begins to lag behind, then stops in its convergent movement, and finally is drawn outwards, in consequence of the action of the external rectus preponderating over that of the internal.

A still better method of exhibiting the insufficiency of the internal recti muscles consists in directing the patient to fix both eyes on an object at the distance of from eight to ten inches, and then excluding one eye by passing a screen upwards before it. "If the internal rectus has been abnormally tense, the eye under the screen will pass outwards, and again inwards when the screen is removed. The degree of divergence measures the excess of tension." The insufficient power of the muscle may be also rendered evident by placing a prismatic glass before the eye, with its angle either directly upwards or downwards. This necessarily occasions two images of any small object, which in the normal eye would be placed one above the other; but in the asthenopic condition of the eyes we are now considering, the muscles being set free, as it were, to take up their own position, and being

no longer influenced, as they were previously to the application of the prism, by the strong natural disposition that always exists of avoiding double vision by fusing closely-approximating images, contract only to such a degree as can be accomplished without unnatural effort. The weaker one of the two internal recti consequently contracts less than the stronger, and the appearance of crossed diplopia immediately results, the image perceived by the eye whose internal rectus is most feeble being above and on the opposite or outer side of that perceived by the stronger eye. The degree of insufficiency can be expressed by the prism which, placed with its angle *outwards* before the second eye, corrects the divergence, *i.e.*, brings the two dots into the same vertical plane.

The successful treatment of these two forms of asthenopia must naturally depend upon a just appreciation of their cause. In both forms the patient should be enjoined to rest the eye as far as possible. If an asthenic condition of the system generally be present, suitable tonic remedies must be prescribed. Any paralysis of the third nerve, rendered evident by other symptoms, must be treated by mercury, blisters, electricity, etc. But above all, in accommodative asthenopia, the defects of the refractive media must be rectified by the selection of appropriate glasses, care being taken not to wholly neutralise the hypermetropia, lest a feeling of tension, almost as unpleasant as the previous asthenopia, be induced.


In motor asthenopia, on the other hand, it has been proposed by v. Gräfe to rectify the insufficiency of the internal recti by dividing the tendon of the external rectus. Considerable care should be taken, and a very thorough knowledge of the case in all its bearings be possessed, before this proceeding is resorted to, since, if the tenotomy be too extensive, a convergent squint is likely to be produced.

6. *Astigmatism*.¹

When the refractive powers of the eye differ to a marked extent in different meridians, a defect of vision becomes apparent, to which the term astigmatism has been applied. Donders remarks, that the asymmetry on which this difference depends is proper to all eyes, but that it usually exists to so slight a degree that the acuteness of vision is not essentially impaired by it. Exceptionally, it becomes considerable, and then occasions an aberration of the rays of light which seriously interferes with the sharpness of vision.

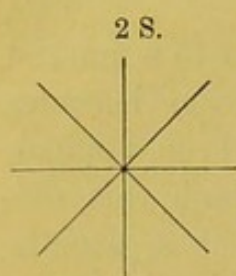
This aberration betrays itself even in perfectly normal eyes, when a cross, formed by the intersection of fine lines, is examined at different distances. It will be found that, in the great majority of persons, the far point at which the vertical line is distinctly seen is more distant than that for the horizontal line. The same holds for the near point, and for every intermediate degree of tension of accommodation. Hence, if the horizontal line can be distinctly seen, the vertical one is slightly misty, and, to be acutely seen, must be slightly removed from the eye. If, on the contrary, the eye is accommodated for the vertical line, the horizontal line must, in order to obtain equal sharpness, be brought nearer to the eye. It follows from these facts, that the refractive media of the eye have a shorter focal distance in the vertical than in the horizontal meridian. But this rule is liable to numerous exceptions, and it can easily be rendered evident that the maximum and minimum refractile power frequently lie in other meridians than the vertical and horizontal. For

2 R.



¹ Besides the work of Donders, already mentioned, which contains references to all previous writers, the reader will find much information on the subject of Astigmatism in the papers of M. Javal, in the *Annales d'Oculistiques* for 1865-1866.

if a star, formed by fine lines radiating from a point, be



carefully examined, it will be found that, at different distances and with different degrees of accommodation, one or other of the lines comes out in strong relief, or, in other words, is more distinctly perceived than the rest; and "were we so perfectly conscious of our accommodation that we could accurately state

what lines in the above figure are seen quite sharply at the maximum and what at the minimum of augmented tension, the direction of the maximum and minimum of curvature would at the same time be known. That consciousness, however, is seldom very accurate."

Another easy means of recognising astigmatism consists in directing the patient to look at a minute point of light, such as may be produced by making a small hole in a copper or opaque chimney of a gas lamp. Such a circular source of light is invariably perceived by an astigmatic eye as a line of greater or less length.

The aberration of the rays of light dependent upon the difference in focal length of the different meridians of the light-refracting media, is termed by Donders *regular* astigmatism, and appears to be chiefly due to the different radii of curvature which the cornea presents in its different meridians, aided to a minor extent by differences in the curvature of the lens. A second form of astigmatism has been constituted by Donders, under the head of *irregular* astigmatism, in which abnormal refraction takes place in one and the same meridian of the eye. This form is sometimes dependent upon limited alterations in the curvature, and perhaps, as Mr Bowman has suggested, in the consistence of the lens, causing it to be unequally acted on by the ciliary muscle, and sometimes upon ulcers of the cornea, nebula, etc.

The treatment of astigmatism consists in the correction of the abnormal curvature by the selection of appropriate

glasses. For this purpose it is found that the ordinary concave or convex glasses (for the anomaly may co-exist either with myopia or hypermetropia) are inadequate, and it is necessary to use cylindrical glasses. The existing myopia or hypermetropia should first be determined, and then the degree and direction of the astigmatism. The application of a cylindrical glass, fulfilling the indications obtained, and placed in the proper position, will then effect an immediate and considerable improvement in the sight.

The position and amount, as well as the treatment, of astigmatism in any given case has been thus proposed to be ascertained by M. Javal:¹—

1. "*Monocular Demonstration*.—Draw a circle with radii 15° from each other, and let the patient view this figure through a lens, which, for the sake of precision, I will suppose to be a three-inch one. Withdraw the figure gradually till all the lines become dim or disappear excepting one. Then try all the cylindrical concaves, one after another, beginning with the lowest powers, with their axes perpendicular to the radius which has remained black, till you have found the glass which makes all the radii equally black. You have then at once diagnosed astigmatism, and determined the number and position of the correcting glass."

For every person with binocular vision, the following procedure is preferable:—

2. "*Binocular Demonstration*.—We now add, before the other eye, a lens and a circle, identical with the preceding ones, the circle being first at the focal lengths of the glasses, with their centres as far apart as the distance between the two eyes. The circles cannot be fixed except the visual lines are parallel and the head straight. The relative position of the visual lines being a fixed one, this sufficiently guards against any changes of accommodation."


¹ Ann. d'Ocul., 1865, quoted in Laurence and Moon's Handy-book of Ophthalmic Surgery.

That the patient may readily say what he sees, the position of the radii are marked on the second disk by the same numbers as the hours of a watch, and these numbers not being seen by the same eye as the radii, afford a constant test of binocular vision.

M. Nachet has constructed an apparatus realising the above conditions. By a simple mechanism, the circles may be moved backwards or forwards, or the lenses may be decentrated so as to always face the two images, and in less than a minute the whole series of cylindrical glasses may be submitted to the eye in any desired position.

M. Knapp has pointed out the following features as characteristic of irregular astigmatism:—1. A dazzling haze—objects not being seen distinctly on account of the unequal diffusion of the light. 2. Amblyopia—which may be most conspicuous either in looking directly at any object or in indirect vision. 3. Metamorphopsy—straight lines appearing curved, and the curved contour of a circle presenting irregular projections and depressions. This peculiarity appears, from the researches of Professor Förster, to be due to irregular contraction of the retina, and has not been observed by M. Knapp in cases of astigmatism having their seat in the lens. 4. Diplopia and monocular polyopia—the image of a single object being seen double or multiple, a symptom that can be brought prominently into notice by the application of stenopœic glasses. Besides the above, which may be termed subjective symptoms, he enumerates others of an objective character, as distortion of the image of a luminous surface, reflected from the surface of the cornea, as seen by an observer; apparent undulations of the surface of the iris; irregularities and spots on the surface of the cornea, and certain ophthalmoscopic peculiarities, amongst which may be mentioned, the appearance of double images of the retinal vessels, in cases when the patient complained of monocular diplopia; the appearance of shades in the forms of rings and disks, analogous to those so well seen

in conical cornea; and, lastly, the appearance of what is termed ophthalmoscopic parallax, when on slight movement of the patient or observer, whilst one part of the retinal vessels remains nearly stationary, another part undergoes remarkable change in its relative position.



INDEX.

- A.
Abscess of cornea, 286.
— of the globe, 571.
— of iris, 362.
— of lachrymal sac, 67.
— of lids, 90.
— of orbit, 13.
Absorption, cure of cataract by, 511.
Accidental injuries of the eye, 548.
Accidents of operation of extraction of lens, 530.
Accommodation, nature of faculty of, 589.
— action of atropine upon, 351.
— action of Calabar bean upon, 351.
— cause of loss of, 593.
— loss of from disease, 354.
— range of, 593.
Accommodative asthenopia, 608.
Acetate of lead, stain on cornea, 317.
Acinous glands of conjunctiva, 164.
Acuteness of vision, 594.
Adams, Sir W., operation for ectropion, 140.
Affghan, measurements of orbit in, 5.
Albino, deficiency of pigment in, 348.
Albugo, a white spot, or opacity on the cornea, 315.
Albuminuria, a cause of retinitis, 479.
Amaurosis (*αμαυρωσις*, obfusco, to dim—loss of vision from pathological conditions of the optic nerve and retina), 99, 467.
Amblyopia (*αμβλυωσις*, obtusus; *οπτομας*, video—dimness of vision), 360.
Ametropia (*ἀμετρος*, extra modum; and *ὀψ*, oculus,—an abnormal condition of the dioptric media of the eye, in which parallel rays of light are not exactly focussed on the retina when the eye is at rest), 587.
Ammon, v., on coloboma iridis, 348.
Anatomy of the choroid, 336.
— of the conjunctiva, 161.
— of the cornea, 240.
— of the lachrymal organs, 57.
— of the lens, 492.
— of the lids, 85.
— of the muscles of the eye, 31.
— of the orbit, 1.
— of the retina, 439.
— of the sclerotic, 236.
— of the vitreous, 343.
Anchyloblepharon (*ανχι, prope; βλεφαρον*, palpebra—union of the edges of the lids), 136.
Ancient Egyptian, measurements of orbit in, 5.
— Peruvian, measurements of orbit in, 5.
— Roman, measurements of orbit in, 5.
Aneurism of the orbit, 22.
Anterior chamber, foreign bodies in, 553.
Aphakia (*α, priv.; φακος*, lentil—absence of the lens), 602.
Aqua chlori, v. Gräfe on the use of, 199.
Aqueous humour, cure of cataract by repeated evacuation of, 519.
Aquo capsulitis (inflammation of the aqueous membrane), 284.
Arcus senilis, 256.
Arll, Prof., hemeralopia, 452.
— on operation of iridectomy, 419.
— on proportions of the orbit, 3.
— on the lachrymal sac and nasal duct, 60.
— on the treatment of conjunctivitis, 170.
Artificial eye, mode of insertion, 582.
Asiatic Turk, proportion of orbit in, 5.

- Asthenopia (α , not, and $\sigmaθενης$, strength; $\omega\psi$, the eye — weakness of sight), 607.
 — accommodative, 608.
 — muscular, 608.
 Astigmatism (α , priv., and $\sigmaτιγμα$, from $\sigmaτιζω$, to point—a condition of the eye in which rays derived from a luminous point are not again united or focussed into one point on the retina), 612.
 Atheromatous vessels of retina, appearances of, 397.
 Atresia iridis ($\alphaτρεσιω$, immotus maneo — obliteration of the pupil), 363.
 Atrophy ($\alphaτρεφω$, to waste—to want nourishment), 403, 578.
 — white, of the optic nerve, 467.
 Atropine, action of, on the pupil, 349.
 Australian, proportions of orbit in, 4.
- B.
- Bader, M.*, on syndectomy, 300.
 Bandages, different forms of, 527.
Becker, M., on ciliary processes, 339.
Beer, M., on lachrymal fistula, 65.
Bell, Sir C., on the effects of section of the fifth nerve, 100.
 Belladonna, action of, 349.
Benedikt, M., on cure of strabismus by electricity, 51.
 — on cure of ptosis by electricity, 129.
Bergeron, M., on treatment of epithelial cancer of lids, 103.
Bernstein, M., on the action of belladonna, 352.
 Binoxide of mercury, formula for ointment containing, 182.
 Blear eyes, 111.
 Bleorrhoea ($\betaλερρωα$, mucus; $\rhoω$, to flow—a thick puriform discharge from the eye), 182.
 Blepharo-plasty ($\betaλεφαρον$, the eyelid; $\πλασσω$, to form—the formation of a new eyelid), 144.
 Blepharo-spasm ($\betaλεφαρον$, the eyelid; and $\σπασμος$, a convulsion), 123.
 Blood effused from the retinal vessels, 449.
 — effused into the eye, 561.
 Blows on the eye, 559.
 Bone, formation of, in the choroid, 433.
- Borelli, M.*, on cure of cataract by paracentesis corneæ, 520.
 — on cure of granular lids, 217.
 — on staphyloma corneæ, 329.
Bouchut, M., on the pathology of the retina, 445.
Bouilhet, M., case of larvæ under the conjunctiva, 233.
Bowman, Mr., case of aneurism in the orbit, 25.
 — on structure of the cornea, 243.
 — on conical cornea, 322.
 — on treatment of capsular opacities, 536.
 — on treatment of obstructed ducts, 74.
 — on treatment of detached retina, 463.
Brewster, Sir D., on muscæ volitantes, 437.
Broadbent, Dr., on treatment of cancer by injection of acetic acid, 103.
Bruch, M., on the follicles of the conjunctiva, 165.
 Burns of the conjunctiva with gunpowder and lime, 551.
Busch, M., on tubercular deposits in the choroid, 431.
- C.
- Calabar bean, action of, 351.
 Calculi in lachrymal ducts, 66.
 Canal of Hannover, 345.
 Canaliculi, their course, 59.
 — obstructions in, 67.
 Cancer of choroid, 433.
 — of conjunctiva, 228.
 — of globe, 583.
 — of orbit, 27.
 — epithelial of lids, 100.
 Cannula-forceps, 375.
Canton, Mr., on the arcus senilis, 251.
 Capsule of Tenon, inflammation in, 15.
 Capsular cataract, 504, 547.
 Caries of the orbit, symptoms of, 12.
 Cartilaginous formations in choroid, 433.
 Caruncula, anatomy of, 165.
 Cataract, 496.
 — ætiology of, 497.
 — diagnosis of, 509.
 — pathology of, 499.
 — symptoms of, 507.
 — treatment of, 509.

- Cataract, treatment of, by depression, 515.
 —, „ by division, 511.
 —, „ by flap operation, 521.
 —, „ by linear operation, 539.
 —, „ by modified linear, 542.
 —, „ by frequently repeated paracentesis corneæ, 519.
 —, „ by suction, 518.
 — varieties of, 501.
 Catarrhal conjunctivitis, 166.
 Catarrho-rheumatic conjunctivitis, 173.
 Caustics, moderated, on use of, 190.
 Cayraud, M., on diphtheritic conjunctivitis, 205.
 Cellular tissue of the orbit, inflammation of, 13.
 Ceratocele (κερας, horn; κηλη, a swelling—a protrusion of the internal elastic lamina of the cornea), 326, 186.
 Chalazion (χαλαζα, hail—a small hard tumour in the eyelid), 109.
 Chemosis (χαινω, to gape—an effusion of serum into the conjunctiva, preventing the lids from closing), 94.
 Chinaman, measurements of orbit in, 4.
 Chlari, aqua, v. Græfe on use of, 199.
 Cholestearine in the eye, 565.
 Choroid, general anatomy of, 336.
 — ophthalmoscopic examination of, 391.
 — diseases of, 391.
 — tubercular deposits in, 431.
 — colloid disease of, 431.
 — cancer of, 433.
 — formation of bone in, 433.
 Choroiditis, 427.
 Choroidal vessels, hæmorrhage from, 430.
 Chrom-hydrosis (χρωμα, colour; υδωρ, water), 119.
 Cicatrices, contraction of, causing ectropion, 144.
 Cilia, 89.
 Ciliary blepharitis, 111.
 — vessels, 247, 337.
 — nerves, 338.
 — processes, 337.
 Cilium, transplantation of, 554.
 Cirsophthalmia (κίρσος, a varicose vein; οφθαλμος, the eye—a bluish swelling formed by a thinning and protrusion of the sclerotic, 260.
 Coccius, M., on the pathology of glaucoma, 416.
 Collis, Dr., on treatment of gonorrhœal ophthalmia, 203.
 Coloboma iridis (κολοβωα, to mutilate—a fissure of the iris), 347.
 Colloid disease of the conjunctiva, 228.
 — „ of the choroid, 431.
 Columbian, measurements of orbit in, 5.
 Condylomata of lids, 106.
 Conical cornea, 321.
 Conjunctiva, anatomy of, 161.
 — acinous glands of, 164.
 — cancer of, 228.
 — cyst of, 225.
 — cysticerci in, 233.
 — dermoid tumour of, 227.
 — ecchymosis of, 223.
 — lymph glands of, 165.
 — Manz glands of, 164.
 — melanosis of, 228.
 — scrofulous tumour of, 227.
 — sweat glands of, 164.
 — tumours of, 224.
 — ulcers of, 229.
 — verrucæ of, 227.
 Conjunctivitis, catarrhal, 166.
 — chronic, 171.
 — catarrho-rheumatic, 173.
 — diphtheritic, 204.
 — phlyctenular, 177.
 — pustular, 177.
 — scrofulous, 177.
 Contagious ophthalmia, 194.
 Contusions of eyelids, 96.
 Copland, Dr., on hemeralopia and nyctalopia, 451.
 Corectomia (κορη, the pupil; εκτομη, excision—the removal of a portion of the iris to form an artificial pupil), 371.
 Coredialysis (κορη, the pupil, and διαλυσις, separation—detachment of the iris from its peripheral attachments), 371.
 Corelysis (κορη, the pupil, and λυω, to separate—the operation of freeing the iris from the capsule), 373.
 Coremorphosis (κορη, the pupil, and

- μορφῶν, to form—the formation of an artificial pupil), 371.
- Coretomy (κορη, the pupil, and τεμνω, to cut—section of the iris to make an artificial pupil), 371.
- Cornea, structure of, 240.
- fistula of, 556.
- general pathology of, 252.
- conical, 321.
- inflammation of, 277.
- neuro-paralytic affections of, 330.
- opacities of, 315.
- paracentesis of, 305, 519.
- suppuration of after flap operation, 534.
- staphyloma of, 325.
- ulceration of, 301.
- vesicular ulceration of, 301.
- vascularity of, 292.
- Coursserant, M.*, on treatment of granular lids, 217.
- Cowell, Mr.*, on the diagnosis of hypermetropia, 597.
- on cancer of the globe, 583.
- Crampton, Sir P.*, on treatment of entropion, 154.
- Critchett, Mr.*, his operation of iridectomy, 374.
- on treatment of staphyloma corneæ, 329.
- on treatment of obstructed ducts, 73, 75.
- on sympathetic ophthalmia, 401.
- Crusta lactea on lids, 116.
- Cunier, M.*, on treatment of entropion, 152.
- Cyclitis (κυκλος, a circle—inflammation of the tissues around the cornea), 398.
- Cysticerci of the conjunctiva, 229.
- of the globe, 586.
- Cystitomes, 544.
- Cysts, sebaceous, of the eyelid, 108.
- Meibomian, of the eyelid, 109.
- in the orbit, 11.
- of conjunctiva, 225.
- D.
- Dacryocystitis (δακρυ, a tear; κυστις, a sac—inflammation of the lachrymal sac), 67.
- Dacryoliths (δακρυ, a tear; λιθος, a stone—calcareous concretions in the lachrymal passages), 66.
- Dacryops fistulosus (δακρυ, a tear; ωψ, the eye), 65.
- Day-blindness, 451.
- Debility a cause of blindness, 454.
- Delgado, M.*, on the treatment of obstructed ducts, 80.
- Delore, M.*, on the treatment of obstructed ducts, 79.
- Demarquay, M.*, on aneurisms in the orbit, 23, 26.
- Depression of cataract, 515.
- Dermoid tumours of conjunctiva, 227.
- Descemitis, 284.
- Desmarres M.*, on treatment of cataract by paracentesis corneæ, 520.
- on the treatment of chronic conjunctivitis, 173.
- on the treatment of obstructed ducts, 79.
- on treatment of entropion, 148.
- on treatment of pinguecula, 226.
- on treatment of pterygia, 222.
- on the treatment of syphilitic ulcers of conjunctiva, 232.
- on the treatment of syphilitic ulcers of lids, 105.
- on the treatment of ulcers of the cornea, 303.
- on the determination of strabismus, 48.
- Detachment of the retina from the choroid, 461.
- Dieffenbach, M.*, his operations for the cure of ectropion, 141.
- Dieterich, M.*, on wounds of the lens, 556.
- Diphtheritic conjunctivitis, 204.
- Diplopia (διπλος, double; ωψ, the eye—double vision), 37.
- homonymous, 43.
- crossed, 46, 610.
- Dislocation of eye, 570.
- of lens, 567.
- Distichiasis (δισ, double; στοιχος, row—the arrangement of the cilia in a double row, one of which turns inwards), 147.
- Divergent squint, 45.
- Division of cataract, 511.
- Dixon, Mr.*, cases of dislocation of the lens, 567.
- Dogiel, Dr.*, on the action of belladonna, 352.
- Donders, Prof.*, on asthenopia, 608.
- on astigmatism, 612.

- Donders, Prof.*, on the action of belladonna, 349.
 — on action of Calabar bean, 351.
 — on the conjunctival vessels, 163.
 — on glaucoma, 413.
 — on hypermetropia, 597.
 — on myopia, 604.
 — on presbyopia, 600.
 — on the recti muscles, 31.
 — on retinitis pigmentosa, 458.
 — on staphyloma corneæ, 327.
 Duct, nasal, anatomy of, 59.
 Ducts, lachrymal, 57.
 — obstructed, causes of, 67.
 — obstructed, symptoms of, 69.
 — Bowman's treatment of, 71.
 — Critchett's treatment of, 73.
 — Foltz's treatment of, 77.
 — Guthrie's treatment of, 78.
 — Delore's treatment of, 79.
 — Desmarres' treatment of, 79.
 — Sperino's treatment of, 80.
 — Streatfeild's treatment of, 77.
 — Williams' treatment of, 79.
Duprè, M. Aug., on the rapidity of absorption by lens, 496.
- E.
 Ecchymosis (εκκομιζω, to throw out—
 an effusion of blood), 223.
 — of the conjunctiva, 97.
 — of the lids, 97.
 — of the retina, 409.
 Ectopia (εκτοπος, displaced—disloca-
 tion of the lens), 507.
 Ectropion (εξ, out, and τρεπω, to turn
 —eversion of the eyelids), 137.
 — Dieffenbach's operation for, 142.
 — v. Gräfe's operation for, 143.
 — Wharton Jones' operation for,
 141.
 Effusion of blood into the eye, 560.
 — upon the retina, 409.
 Egyptian, measurements of orbit in, 4.
 — ophthalmia, 194.
 Electricity, employment of, in strabismus and ptosis, 51, 129.
 Embolism of retinal artery (εμβολον, a
 plug—obstruction of an artery
 by a fragment of coagulable
 lymph), 466.
 Emmetropia (εμμετρος, observing an
 exact measure—a term applied
 to denote a healthy eye; paral-
 lel rays of light being exactly
 focussed on the retina when the
 eye is at rest), 587.
 Emphysema (εμφυσω, to blow into—
 the entrance of air into the lacunæ of connective tissue), 9, 98.
 Encanthis (εν, in; κανθος, the angle of
 the eye—an enlargement of the
 caruncle), 233.
 Encysted tumours of the orbit, 11.
 Entozoa in the globe, 585 (εν, in;
 ζω, to live—a parasite), 585.
 Entropion (εν, in; τρεπω, to turn—in-
 version of the eyelid), 147.
 — Crampton's, Sir P., operation
 for, 154.
 — Guthrie's, 153.
 — v. Gräfe's, 155.
 — Hildreth's, 158.
 — Jäger's, 156.
 — Jansen's, 152.
 — Pagenstecher's, 154.
 — Prince's, 159.
 — Saunders', 156.
 — Streatfeild's, 153.
 — Williams', 158.
 — Wright's, 156.
 Enucleation of the globe, 580.
 Epicanthus (επι, upon; κανθος, the
 angle of the eye—a fold of skin
 between the nose and the
 angle of the eye), 110.
 Epiphora (επι, upon; φερω, to carry—
 too active secretion of the lachrymal
 gland), 68.
 Episcleritis (επι, upon; σκληρος, hard
 —a small inflammatory swell-
 ing on the sclerotic), 256.
 Epithelioma (επι, upon; θαλλω, to bud
 forth—a form of cancer com-
 posed of epithelial scales and
 cells), 101, 228.
 Erectile tumours of the orbit, 23.
 Erysipelas of the lids (ερυσιπιλας, St
 Anthony's fire), 93.
 Erythema of the lids (ερυθημα, a red-
 ness), 92.
 Eversion of eyelids, 137.
 — of puncta, 68.
 Exanthematous ulceration of the cor-
 nea (εξανθημα, a blossom), 311.
 Excavation of the optic papilla, 409.
 Exophthalmos (εξ, out; οφθαλμος, the
 eye—protrusion of the globe),
 17.
 Exostosis of the orbital bones (εξ, out;

- οστέον*, the bone—a bony tumour), 10.
 Extirpation of globe, 580.
 — of lachrymal gland, 67.
 Extraction of cataract by flap operation, 521.
 — by linear operation, 539.
 — by modified linear, 542.
 Eye, general inflammation of, 571.
 — rupture of, 549.
 Eyebrow, wounds of, 99.
 Eyelashes, growth of, 89.
 — inversion of, 147.
 — transplantation of, 554.
 Eyelids, abscess of, 90.
 — anatomy of, 83.
 — contusions of, 96.
 — ecchymosis of, 98.
 — emphysema of, 9, 98.
 — epithelial cancer of, 101.
 — erythema of, 92.
 — erysipelas of, 93.
 — eversion of, 137.
 — formation of new, 144.
 — inflammation of, 90.
 — injuries of, 96.
 — inversion of, 147.
 — tumours of, 107.
 — ulcers of, 100.
 — wounds of, 96.
- F.
- Faculty of accommodation, 589.
 Far point, 592.
 Far-sightedness, 600.
 Fatty degeneration of the retina in retinitis albuminurica, 481.
 Fifth nerve, influence of on pupil, 353.
 Filaria in the conjunctiva, 233, 586.
 Fistula of the cornea, 556.
 — of the lachrymal sac, 65.
 Flap operation for the extraction of cataract, 521.
 Foltz, M., treatment of obstructed ducts by, 77.
 Foreign bodies in aqueous, 553.
 — in orbit, 9.
 — imbedded in the cornea, 550.
 — „ in the lens, 562.
 — „ in the iris, 553.
 — „ in the vitreous, 566.
 Formation of cartilage and bone in the choroid, 433.
 Förster, M., on the pathology of cataract, 500.
- Frey, M., on the glands of the conjunctiva, 165.
 Fricke, M., on blepharoplasty, 144.
 Furnari, M., on syndectomy, 298.
- G.
- Galezowski, M., on glycosuric retinitis, 487.
 Ganglionic layers of the retina, 442.
 Geissler, M., on the proportions of the orbit, 3.
 Gelatinous cancer of conjunctiva, 228.
 Gendrin, M., case of aneurism in the orbit, 25.
 Gentoo, measurements of orbit in, 4.
 Gerontoxon (*γερων*, an old man; *τόξον*, a bow—the arcus senilis), 251.
 Gibson, Mr, his operation for removal of cataract, 539.
 Giraldès, M., on treatment of diphtheritic conjunctivitis, 209.
 Giraudet, M., on aneurism in orbit, 23.
 Giraud-Teulon, on structure of parts at optic entrance, 239.
 Glands of the conjunctiva, 164.
 Glaucoma, acute (*γλαυκος*, green, from the colour of the pupil), 405.
 — consecutive, 412.
 — simple, 413.
 — pathology of, 414.
 Glycosuric retinitis, 487.
 Gonorrhœal ophthalmia, 200.
 Gosselin, M., on treatment of tinea tarsi, 115.
 — on treatment of opacities of the cornea, 319.
 Gräfe, v., on use of aqua-chlori, 199.
 — on nature of black cataract, 504.
 — on blepharo-spasm, 125.
 — on various modes of bandaging the eye, 526.
 — on treatment of cataract by division, 513.
 — on treatment of cataract by depression, 517.
 — on treatment of cataract by modified linear operation, 542.
 — on action of Calabar bean, 351.
 — on inflammation of the cellular tissue of the orbit, 14.
 — on diphtheritic conjunctivitis, 204.
 — on treatment of ectropion, 143.
 — „ of entropion, 155.
 — „ of glaucoma, 405.

- Gräfe, v.*, on treatment of chronic keratitis, 284.
 — „ of staphyloma corneæ, 327.
 — „ of separation of the retina, 463.
 — „ of retinitis albuminurica, 480.
 — „ of retinitis syphilitica, 488.
 — „ of ulceration of the cornea in infantile encephalitis, 313.
 — on the recti muscles, 31.
 — on polypi of the nasal duct, 82.
 — on protrusion of the globe, 22.
 Granular layers of the retina, 442.
 — lids, 209.
 Greenlander, measurements of orbit in, 5.
Greenway, Mr., his suction instrument for removal of cataract, 519.
 Grooving the tarsal cartilage, Mr Streatfeild's operation of, 153.
 Guianese, measurements of orbit in, 5.
Guthrie, Mr., on aneurism of the orbit, 23.
 — on ectropion, 137.
 — on entropion, 153.
 — on inflammation of the cellular tissue of the orbit, 13.
 — on obstructed ducts, 78.
 — on treatment of cataract, 514.
 Gummata, 366.
 Gunpowder accidents, 551.
- H.
- Haan, M. de*, on sharpness of vision, 595.
 Hæmorrhage into globe, 560.
 — on retina, 449.
 — from choroidal vessels, 430.
Hairion, M., on granular lids, 218.
Hamer on treatment of anchyloblepharon, 136.
Hancock, Mr., his operation of division of the ciliary muscle, 420, 267, 277, 291, 328, 404, 418.
Heiberg, M., on the ligament of the lens, 345.
Helmholtz, M., on the curvature of the cornea, 241.
 — on the accommodation of the eye, 590.
 Hemeralopia (*ημερα*, day; *α*, not; and *οπτομαι*, to see—loss of vision by day), 451.
 Hemiopia (*ημισυς*, half; *οπτομαι*, to see—perception of only one lateral half of any object), 470.
Henle, M., on the structure of the cornea, 241.
 — on the structure of the glands of the conjunctiva, 164.
 — on the lachrymal passages, 61.
 — on the recti muscles, 31.
 — on the cause of the colour of the iris, 341.
 Herpes of the conjunctiva, 178.
 — of the cornea, 301.
Herzenstein, M. U., on the treatment of entropion, 157.
Heurteloup's artificial leech, 447.
Hildreth, Dr S., on treatment of entropion, 158.
His, M., on the structure and pathology of the cornea, 242, 252.
Holmes, Mr., case of aneurism of the orbit, 26.
Holthouse, Mr., on the recti muscles, 31, 49.
Homolle, M., on pinguecula, 226.
 Hordeolum (*hordeum*, barley), 117.
Horner, Mr., on treatment of retinitis, 485.
Horner's muscle, 87.
Hoyer, M., on the nerves of the cornea, 246.
Huguenin, M., on the glands of the conjunctiva, 165.
Hulke, Mr J. W., on colloid disease of the choroid, 432.
 — on conical cornea, 323.
 — on true lachrymal fistula, 65.
Hulme's, M., case of irideremia, 347.
 — on cellulitis of orbit, 13.
Huss, M., on an endemic form of conjunctivitis, 169.
Hutchinson, Mr Jon., on syphilitic keratitis, 281.
 — on iritis in infants, 366.
 — on nyctalopia, 460.
 — on lesions of sensory nerves, 100.
 Hydatids in the eye, 585.
 Hydrophthalmia (*υδωρ*, water; *οφθαλμος*, the eye—dropsy of the eye), 260.
 Hyperæmia of retina (*υπερ*, above; *αιμα*, blood—excessive supply

- of blood to, or congestion of a part with blood), 446.
- Hypermetropia (*υπερ*, above; *μετρον*, a measure; *οπτομαι*, to see—a condition in which parallel rays of light, when the eyes are at rest, are brought to a focus behind the retina), 596.
- definition of, 588.
- characters of, 596.
- absolute, 599.
- facultative, 599.
- latent, 599.
- manifest, 598.
- range of accommodation in, 593.
- a cause of convergent squint, 38.
- Hyphæma (*υπο*, below; *αιμα*, blood—effusion of blood into the anterior chamber, where it gravitates to the lower part), 361.
- Hypopyon (*υπο*, below; *πυον*, pus—effusion of pus into the anterior chamber, where it gravitates to the lower part), 361.
- I.
- Impetigo of the lids, 116.
- Inflammation of the cellular tissue of the orbit, 13.
- of the conjunctiva, 166.
- of the cornea, 277.
- of the eye generally, 571.
- of the iris, 357.
- of the iris and choroid, 398.
- of the lachrymal gland, 62.
- of the lachrymal sac, 70.
- of the lids, 90, 113.
- of the retina, 472.
- of the sclerotic, 257, 261.
- Injuries of the eye, 548.
- of the cornea, 548.
- of the conjunctiva, 551.
- of the lens, 562.
- of the lids, 96.
- of the orbit, 8.
- of the sclerotic, 548.
- Inoculation, treatment of granular lids by, 217.
- Interstitial keratitis, 277.
- syphilitic, 281.
- Inversion of the lid, 147.
- Iridauesis (*ιρις*, the iris; *αυξη*, growth—a bulging forward of the plane of the iris), 363.
- Irides and iridodesis (*ιρις*, the iris; *δειω*, to bind—the act of ligaturing a small portion of the iris drawn through a wound in the cornea or sclerotic, to prevent its return), 324, 374, 320, 376.
- Iridectomy (*ιρις*, the iris; *εκτεμνω*, to cut out—the removal of a portion of the iris), 376, 419.
- Irideremia (*ιρις*, the iris; *ιρημια*, deprivation—deficiency of the iris), 347.
- Iridodonesis (*ιρις*, the iris; *δονησις*, the act of agitating—trembling of the iris), 364.
- Irido-choroiditis (*ιρις*, the iris; *χωριον*, a foetal membrane—inflammation of the iris and choroid), 398.
- Irido-cyclitis (*ιρις*, the iris; *κυκλος*, a circle—inflammation of the parts around the cornea), 398.
- Iris, anatomy of, 340.
- abscess of, 362.
- coloboma of, 347.
- inflammation of, 357.
- influence of, on accommodation, 590.
- prolapse of, 533, 555.
- Iritis, idiopathic, 357.
- gonorrhœal, 367.
- rheumatic, 367.
- syphilitic, 365.
- Iwanoff, M., on the pathology of the cornea, 252.
- on the pathology of pannus, 294.
- on the pathology of retinitis, 474.
- on the effects of entropion on the cornea, 149.
- on the structure of the cornea, 243.
- on the structure of vitreous, 346.
- J.
- Jacobi, M., on panophthalmitis, 572.
- Jacobson, Dr., on diphtheritic conjunctivitis, 208.
- Jäger, M., on treatment of entropion, 156.
- Jansen, M., on treatment of entropion, 152.
- Javal, M., on astigmatism, 613.
- on treatment of strabismus, 50.
- Javanese, measurements of orbit in, 4.
- Jones, Dr Bence, on rapidity of absorption by lens, 495.

- Jones, Mr Wharton*, on treatment of catarrhal conjunctivitis, 167.
 — on treatment of ectropion, 141.
Junge, Dr J., on the nature of the fluid in hypopyon, 289.
 — on neuroparalytic affections of the cornea, 335.

K.

- Keratitis (κίρας, a horn—inflammation of the cornea), 277.
 — chronic interstitial, 281.
 — suppurative, 286.
 — syphilitic, 281.
 — vascular (pannus), 292.
 Keratome (κίρας, a horn; τμήνω, to cut—an instrument for making a linear incision of the cornea), 377.
 Keratonyxis (κίρας, horn; νύττω, to puncture—a division of cataract through a puncture in the cornea), 512.
Kleinschmidt, M., on the glands of the conjunctiva, 164.
Knapp, M., on curvature of the cornea, 241.
 — on astigmatism, 614.
Krause, M., on the thickness of the cornea, 241.
Kühne M., on the nerves of the cornea, 246.
Kunde, M., on the ætiology of cataract, 498.

L.

- Lachrymal abscess, 67.
 — calculi, 66.
 — fistula, 65.
 — gland, anatomy of, 57.
 — „ inflammation of, 62.
 — secretion, composition of, 58.
 — sac, anatomy of, 60.
 Lagophthalmos (λαγώς, a hare; οφθαλμός, the eye—paralysis of the branch of the 7th, supplying the orbicularis palpebrarum, so that the eyelids cannot be closed), 8.
Landrau, M., on treatment of cataract by repeated paracentesis cornea, 520.
Laplanders, measurements of orbit in, 5.
 — endemic form of conjunctivitis amongst, 169.

- Lateral illumination, mode of employing, 508.
Laurence, Mr J. Z., strabismometer devised by, 41.
 — on treatment of epiphora, 67.
 — on treatment of ulcers of the cornea, 303.
Lawrence, Sir W., on cellulitis of the orbit, 14.
 — on gonorrhœal ophthalmia, 203.
 — on inflammation of the lachrymal gland, 62.
 — on wounds of the capsule and lens, 556.
 — on syphilitic ulcers of the lids, 105.
Lawson, Mr, on traumatic cataract, 497.
Lay, M. Tradescant, on pterygium, 221.
Laycock, Dr, on nyctalopia, 460.
Leber, M., on the vascular system of the eye, 163.
Lederschold, M., on purulent ophthalmia in Stockholm, 184.
 Lens, diseases of, 492.
 — displacement of, 567.
 — function of, 496.
 — injuries of, 556.
 — rapidity of absorption by, 496.
 — structure of, 492.
 Leucoma (λεικωμα, a white surface—an opacity of the cornea), 315, 191.
 Lice on the eyelashes, 116.
 Lids, anatomy of, 85.
 — abscess of, 90.
 — crusta lactea on, 116.
 — cysts of, 107.
 — ecchymosis of, 97.
 — emphysema of, 98.
 — epithelial cancer of, 101.
 — impetigo of, 116.
 — injuries of, 96.
 — porrigo larvalis on, 116.
 — tumours of, 107.
 — granular, 209.
Liebreich, M., on posterior staphyloma, 275.
 — on retinitis albuminurica, 485.
 Ligamentum pectinatum iridis, 340.
 — suspensorium lentis, 344.
Lightbody, Dr, on the structure of the cornea, 241.
 Lime in the eye, 551.

- Linear extraction of cataract, 539.
 — extraction of, modified by Gräfe, 542.
 — extraction of, modified by Pagenstecher, 545.
Linnaeus on liability of Laplanders to ophthalmia tarsi, 111.
Lipoma (λίπος, fat—true fatty tumour of the lids), 226.
Lippitudo (a watery running from the eye—blear eyes), 111.
 Liquefaction of the vitreous, 434.
Liquor Morgagni, 494.
Longet, M., on neuro-paralytic affections of the cornea, 333.
 Lymph follicles of the conjunctiva, 165.
- M.
- Macula lutea*, appearance of, under the ophthalmoscope, 393.
 — structure of, 443.
Mackenzie, Dr, on cellulitis of orbit, 15.
 — on cancer of lids, 102.
 — on catarrho-rheumatic conjunctivitis, 176.
 — on conjunctival tumours, 227.
 — on entropion, 148.
 — on glaucoma, 408.
 — on inflammation of the lachrymal glands, 62.
 — on myodesopia, 435.
 — on consequences of ophthalmia tarsi, 114.
 — on oscillation of the globe, 55.
 — on pterygium, 220.
 — on symblepharon, 135.
 — on sympathetic ophthalmia, 398.
 — on teleangiectasis, 121.
Macmillan, Dr, on treatment of purulent ophthalmia, 189.
Madarosis (μαδάσσω, to render bald—a falling out of the eye-lashes),
Magawly, Dr, on glaucoma, 417.
 Maggots beneath the conjunctiva, 233.
Magné, M., on pinguecula, 226.
Maier, M., on the lachrymal sac and duct, 60.
Majendie, M., on neuro-paralytic affections of the cornea, 332.
 Malay, measurements of orbit in, 4.
Mandelstamm, M., on separation of the retina, 461.
Manfredi, M., on obstruction of lachrymal sac, 80.
Manz, M., on the structure of the sclerotic, 238.
 — on the glands of the conjunctiva, 164.
 — on tubercular deposits in the choroid, 431.
Marjolin, M., on diphtheritic conjunctivitis, 204.
Marson, Mr, on exanthematous ophthalmia, 311.
Marston, Dr, on granular lids, 210.
Meade, Mr, on lachrymal calculi, 66.
 Meibomian cysts of the eyelids, 109.
Meissner, M., on the glands of the conjunctiva, 165.
 — on nyctalopia, 454.
 Melanosis of the conjunctiva (μύλας, black), 228.
 Meningitis cerebro-spinalis, general inflammation of the eye in, 572.
Méricourt, M. *Leroy de*, on chromhydrosis, 119.
 Meridian of the eye, action of the several muscles on vertical, 33.
Meyer, M., on the ætiology of cataract, 498.
Middlemore, Mr, on contagious ophthalmia, 197.
 — on chronic conjunctivitis, 172.
 — on pterygium, 220.
 Moderated nitrate of silver, use of, 189.
Moers, M., on the pathology of cataract, 499.
Moorens, M., on treatment of cataract, 538.
 — on treatment of conjunctivitis, 170.
 Mosambique, proportions of orbit in skulls from, 3.
 Movements of the eye, 35-37.
 — of the lids, 88.
Musæ volitantes (musca, a fly), 435.
 Muscles of the eye, anatomy of, 31.
Müller, M. H., on frequency of capsular cataract, 498.
 — on the structure of the choroid, 338.
 — on colloid disease of the choroid, 431.
 — on retinitis albuminurica, 483.
 Mydriasis (μυδρίασις, unnatural dilatation of the pupil), 349, 354.
Myocephalon (μύια, a fly; κεφαλή,

the head—a protrusion of the iris through a wound in the cornea or sclerotic resembling the black head of a fly), 316.

Myodesopia (*μυια*, a fly; *ιδος*, like; *οπτομαι*, to see—floating objects before the eyes), 435.

Myopia (*μυω*, to close; *ωψ*, the eye—shortsightedness), 588.

— characters of, 603.

— pathology of, 605.

— range of accommodation in, 594.

Myosis (*μυω*, to close—unnatural contraction of the pupil), 349.

N.

Nævus maternus, 120.

Nasal duct, anatomy of, 59.

— treatment of obstructions in, 71.

Naylor, Mr, on the treatment of por-rigo larvalis, 117.

Near point, 592.

Nebulæ (*nebula*, a cloud—a slight opacity of the cornea,) 315, 191.

Necrosis of the orbital bones, 12.

Negroes, measurements of orbit in, 4.

Nephritic retinitis, 479.

Nerves of the cornea, 246.

Neuro-paralytic affections of the cornea, 330.

Nictitation, 123.

Night-blindness, 453.

Nitrate of silver, effects of moderated, 190.

Noizet, Dr, on posterior staphyloma, 273.

Nunneley, Mr, on measurements of the eye, 236.

— on structure of the choroid, 338.

— on structure of the sclerotic, 238.

— on pathology of cataract, 501.

Nyctalopia (*νυξ*, night, *α*, priv.; *οπτομαι*, to see—loss of sight by night), 453.

Nystagmus (*νυσταγμος*, sleep—an involuntary motion of the globe), 55.

O.

Oblique illumination, mode of employing, 508.

— muscles of the eye, 32.

Obliteration of lachrymal sac, 79.

Obstruction of canaliculi, 67.

— of nasal duct, 69.

Ocular capsule, inflammation of, 15.

O'Ferrall on inflammation of the capsule of Tenon, 16.

Œdema of conjunctiva (*οιδεω*, to swell up), 185.

— of retina, 445, 479.

Onyx (*ονυξ*, the nail—pus between the lamellæ of the cornea), 287.

Opacities of the cornea, 315.

— of the lens, 496.

— of the vitreous, 435.

— cataract, 496.

Ophthalmia tarsi (*οφθαλμος*, the eye), 111.

— purulent of infants, 182.

— „ of adults, 194.

— contagious, or Egyptian, 194.

— gonorrhœal, 200.

Ophthalmoscope, mode of using, 391.

Optometer (*ωψ*, the eye; *μετρον*, a measure—an instrument for measuring the nearest point of distinct vision), 592.

Orbicularis muscle, 85.

Orbit, general anatomy of, 1.

— aneurism of, 22.

— caries and necrosis of, 12.

— cancer of, 27.

— cysts of, 11.

— cellulitis of, 13.

— exostosis of, 10.

— inflammation of capsule of Tenon in, 15.

— proportions of, in different races, 4, 5.

— tumours of, 10.

Ordóñez on chrom-hydrosis, 120.

Oscillation of globe, 55.

Osseous formation in choroid, 438.

P.

Pagenstecher, M., operation for the extraction of cataract, 545.

— on choroiditis disseminata, 429.

— on sympathetic ophthalmia, 402.

— on treatment of entropion, 154.

— on treatment of pannus, 297.

— ointment containing binocide of mercury, 182.

— on treatment of ulcers of the cornea, 303.

Pannus (*pannus*, coarse rag—vascularisation of the cornea), 293, 215.

Panophthalmitis (*πας*, the whole;

- οφθαλμος, the eye—inflammation of all the tissues of the globe), 571.
- Papilla optica, its normal appearance, 394.
- excavation of, 409.
- atrophy of, 469.
- Paracentesis corneæ, 305.
- treatment of ulcers of the cornea by, 305.
- treatment of conical cornea by, 324.
- treatment of cataract by, 519.
- Paralysis of the third nerve, effects of, 45.
- of the fourth, 47.
- of the sixth, 43.
- of the portio dura of the seventh, 8.
- Peritomy (περι, around; τιμνω, to cut—removal of a band of conjunctiva round the cornea), 298.
- treatment of superficial keratitis by, 171.
- Petit, canal of, 495.
- Pétriquin on pterygium, 220.
- Phlyctenular conjunctivitis, 177.
- Photophobia (φως, light; φοβος, dread—intolerance of light), 360, 451.
- Phtheiriasis ciliarum (φθειρα, a louse—lice on the lashes), 116.
- Pinguecula (*pinguis*, fat—small tumour on the ocular conjunctiva), 225.
- Plica semilunaris, structure of, 165.
- Poland, Mr, on cellulitis of the orbit, 13.
- on cysts of the orbit, 11.
- on protrusion of the globe, 17.
- Polypi of the nasal duct, 82.
- Pope, Mr Bolling, on the structure of the choroid, 338.
- on retinitis pigmentosa, 459.
- Porriago larvalis on lids, 116.
- Prael, M., on protrusion of the eye, 19.
- Presbyopia (πρεσβυα, senile; ωψ, the eye—the condition in which the vision resembles that of old people, in whom the near point retreats from the eye, and the power of accommodation is nearly lost), 600.
- Pressure compress bandage, mode of applying, 527.
- Prince, Dr, on treatment of entropion, 159.
- Prismatic glasses, application of, 50.
- Probes, mode of introducing through canaliculi, 72.
- Mr Critchett's laminaria, 73.
- Prolapse of iris, 555.
- Prozoroff on origin of pus in purulent ophthalmia, 187.
- Protrusion of the globe, 17.
- Pseudo-glaucoma of M. Sichel, 413.
- Pterygium (πτερυξ, a wing—a triangular growth of the conjunctiva over the cornea), 219.
- Ptosis (πτωσις, to fall—a drooping of the upper lid, occasioned by paralysis of the branch of the third nerve, supplied to the levator palpebræ), 126, 52.
- Punctum proximum, 592.
- Punctum remotum, 592.
- Purulent ophthalmia of adults, 194.
- of infants, 182.
- Pustular conjunctivitis, 177.
- R.
- Range of accommodation, 592.
- Recti muscles, origin of, 31.
- functions of, 31.
- Refraction, diseases of, 587.
- Refractive index of lens, 493.
- Reflex ophthalmia, 398, 555.
- Retina, anatomy of, 439.
- detachment of, from choroid, 461.
- ecchymoses from vessels of, 448.
- hyperæmia of, 446.
- injuries of, 570.
- Retinitis, 472.
- albuminurica, 479.
- diffusa, 473.
- glycosurica, 487.
- hemeralopica, 451.
- nyctalopica, 453.
- pigmentosa, 451, 458.
- syphilitica, 487.
- Reymond, M., on cure of cataract by paracentesis corneæ, 520.
- Rheumatic inflammation of the sclerotic, 257.
- ulceration of the cornea, 307.
- Richardson, Dr, on artificial production of scleritis, 257.
- Richet, M., on proportions of orbit, 3.
- Ricord, M., on syphilitic ulcer of the conjunctiva, 232.

- Ritter, M.*, on the ætiology of cataract, 500.
 — on panophthalmitis, 577.
 — on pathology of pannus, 294.
 — on structure of vitreous, 345.
Rivaud, M., on cure of cataract by paracentesis corneæ, 520.
Robertson, Dr Argyll, on the action of Calabar bean, 351.
Robin, M., on pinguecula, 225.
Roosbröck, M., on contagious ophthalmia, 197.
 — on treatment of pannus by inoculation, 300.
 Rupture of cornea, 561.
Rydel, M., on treatment of zonular cataract, 547.
- S.
- Saunders, Mr*, on treatment of entropion, 156.
Scarpa on ectropion, 138.
Schalygen, Dr, on the structure of the cornea, 244.
 — on the pathology of the cornea, 255.
Schiess, M., on panophthalmitis, 579.
Schiess-Gemuseus, on the pathology of anterior staphyloma, 263.
Schiff, M., on neuroparalytic affections of the cornea, 344.
Schirmer, M., on treatment of entropion, 157.
Schlemm, canal of, 341.
Schmidler, M., on aneurism in the orbit, 23.
Schnellen, M., on the action of belladonna, 350.
Schuft, M., operation for extraction of cataract, 539.
Schweigger, M., on panophthalmitis, 573.
 — on the structure of choroid, 338.
 Sclerotic, anatomy of, 236.
 — inflammation of, 257.
 — rigidity of, in glaucoma, 415.
 Sclero-choroiditis anterior, 260.
 — posterior, 270.
 Scotomata, (*σκοτος*, darkness; or *σκοτασμα*, giddiness — fixed black spots, 435.
 Scrofulous tumours of conjunctiva, 227.
 — conjunctivitis, 177.
 Sebaceous cysts of the eyelids (*seba*, fat), 108.
- Secondary cataract, 536.
Secondi, M., on treatment of cataract by paracentesis corneæ, 520.
 Sharpness of vision, 594.
Sichel, M., on cataract, 502.
 — on iridectomy, 418, 383.
Snellen, M., on treatment of anchyloblepharon, 137.
 — on treatment of conjunctivitis, 171.
 — on neuro-paralytic affections of the cornea, 334.
Solomon, Mr Vose, on treatment of cataract by declination, 516.
 — his modification of Hancock's operation, 422.
 — on sympathetic ophthalmia, 402.
 Solution, cure of cataract by, 511.
Sperino, M., on cure of cataract by frequently-repeated paracentesis corneæ, 519.
 — on treatment of obstructed ducts, 80.
 Staphyloma anterior, 260.
 — corneæ, 325.
 — posterior, 270.
 — racemosum, 201.
Steffan, M., strabismometer, 41.
Stellwag v. Carion on abscess of the cornea, 316.
 — on cataract, 503.
 — on glaucoma, 409.
 — on iridectomy, 385.
 — on retinitis, 472, 396.
 Stenopæic glasses, 320.
 Stereoscope, use of, in strabismus (*στρεβισμος*, solid; *σκοπία*, to see — the appearance of solidity resulting from the fusion of two plane images of the same object, taken at a different angle, seen simultaneously), 50.
 Stillicidium lachrymarum (an overflow of tears from obstructed ducts), 68.
 Strabismus (*στρεβισμος*, a squint), 31.
 — definition of, 37.
 — convergent, 43.
 — divergent, 45, 609.
 — ætiology, 38.
 — treatment of, 50.
 Strabismometer, Mr Z. Laurence's, 41.
 — Dr Steffan's, 41.
Streatfeild, Mr, on treatment of entropion, 153.

- Streatfeild, Mr.*, on treatment of obliterated canaliculi, 77.
 — on treatment of ophthalmia tarsi, 115.
 — operation of corelysis, 373.
 — M. M. Testelin and Warlomont's, 41.
Stromeyer, M., on the glands of the conjunctiva, 164.
 Styte on the eye, 116.
 Style, introduction of into the nasal duct, 72.
 Suction instrument of Mr Teale for the extraction of cataract, 519.
 Suppuration in the eye, 571.
 — in the cornea, 286.
 Sweat glands of the conjunctiva, 164.
 Symblepharon (συν, together; βλεφαρον, the eyelid—adhesion of the lids to the globe of the eye), 132.
 Sympathetic ophthalmia, 401.
 Synchysis (συγχυσις, mixture—fluidification of the vitreous), 434, 576.
 — scintillans, 437.
 Syndectomy, (συν, together; εκτεμνω, to cut out—the removal of a circular band of the conjunctiva), 298.
 Synechia anterior (συνεχω, to hold together—adhesion of the iris, either to the cornea or the capsule of the lens), 362.
 — posterior, 363.
 Syphilitic iritis, 365.
 — retinitis, 487.
 — keratitis, 281.
 — ulcers of the lids, 102, 104.
 — ulcers of the conjunctiva, 232.
Szokalski, M., case of aneurism in the orbit, 26.
- T.
- Tarsal tumours, 107.
Tavignot on pterygium, 220.
Teale, Mr., on treatment of cataract by suction, 518.
 — treatment of symblepharon, 135.
 Tears, composition of, 58.
 — causes occasioning discharge of, 58.
 Teleangiectasis, 120.
 Tennessee, measurements of orbit in, 5.
Tenon, inflammation within capsule of, 15.
- Tenotomy for strabismus, 52.
Tinea tarsi (*tinea*, the grub of a moth—ulceration of the margins of the lids), 111.
Todd, Mr., on inflammation of the lachrymal gland, 62.
Torresini, M., on cure of cataract by paracentesis corneæ, 520.
 Trachoma (τραχος, rough—a granular condition of the inner surface of the lids), 209.
 — glands of the conjunctiva, 165.
 Transplantation of cilium, case of, 554.
 Traumatic ulcer of the lids (τραυμα, a wound), 106.
 — cataract, 497.
 Trichiasis (τριχ, the hair—the inversion of one or more cilia), 147.
Trigt, v., on retinitis pigmentosa, 459.
 Tubercular deposits in the choroid, 431.
 Tumours of the conjunctiva, 224.
 — of the lids, 107.
 — of the orbit, 10.
 Tylosis (τυλος, a callosity—thickening and induration of the lids from protracted inflammation), 114, 172.
Tyrrell, Mr., on cellulitis of the orbit, 14.
 — on keratitis, 278.
 — on staphyloma corneæ, 329.
 — on rapidity of development of cataract, 507.
- U.
- Ulcers of conjunctiva, 229.
 — of cornea, 301, 311.
 — of lids, 100.
 — „ cancerous, 101.
 — „ syphilitic, 104.
 — „ traumatic, 106.
 Upper lid, mode of everting, 549.
- V.
- Variolous ulceration of the cornea, 311.
 Vascular system of the eye, 246.
Veitch, Dr., on contagious ophthalmia, 196.
Velpeau, M., on pterygium, 220.
 Verrucæ of the conjunctiva (verruca, a wart), 227.
 Vesicular ulceration of the cornea, 306.
 Vessels of the conjunctiva, 163.
 — of the choroid, 337.
 — of the eye, 248.

- Vessels of the iris, 341.
 — of the orbit, 6.
 — of the retina, 443.
Villards, M. Carron de, on pterygium, 221.
Virchow, M., on the structure of the cornea, 242.
 — on the structure of the vitreous, 345.
 Vitreous, anatomy of, 343.
 — diseases of, 435.
 — liquefaction of, 434.
 — injuries of, 566.
 — opacities of, 435.
- W.
- Waldhauer, Dr.*, on treatment of entropion, 156.
Walton, Mr Haynes, on entropion, 148.
 — case of exostosis of orbit, 11.
 — on treatment of ptosis, 129.
 — on staphyloma corneæ, 326.
Ware, Mr., on rarity of myopia amongst soldiers, 604.
Warlomont and Testelin on cellulitis of the orbit, 14.
 — on sympathetic ophthalmia, 401.
 — on treatment of dislocated lens, 569.
 Warts on conjunctiva, 227.
Weber, M., on the ligament of the lens, 345.
 — on the lachrymal sac and duct, 60.
 — on the treatment of lachrymal strictures, 75.
Wecker, M., on blepharospasm, 125.
 — on conjunctivitis, 170.
 — on choroiditis disseminata, 429.
 — on conjunctival tumours, 227.
 — on corneal ulceration in contagious ophthalmia, 191.
 — on diphtheritic conjunctivitis, 209.
 — on gonorrhœal ophthalmia, 202.
 — on granular lids, 212.
 — on metallic stains of cornea, 317.
 — on treatment of hypopyon, 382.
 — on retinitis, 472.
- Wecker, M.*, on staphyloma corneæ, 327.
 — on treatment of detached retina, 463.
 — on effects of the application of moderated nitrate of silver, 190.
 — on frequency of pustular ophthalmia, 180.
 — on ophthalmia tarsi, 112.
 — on the proportion of the orbit, 2.
Wedl, M., on colloid disease of the choroid, 430.
Weller, M., on pinguecula, 225.
Wells, Dr S., on the recti muscles, 31.
 — on strabismus, 39.
Williams, Dr., on treatment of entropion, 158.
 — on treatment of obstructed ducts, 79.
Wilson, M. Erasmus, on impetigo, 117.
Winther, M., on pterygium, 220.
Wordsworth, Mr., on amaurosis produced by the abuse of tobacco, 469.
 — on gonorrhœal iritis, 368.
 — on treatment of symblepharon, 135.
 Wounds of the cornea, 553.
 — of the eye, 549.
 — of the lens, 556.
 — of the lids, 96.
 — of the sclerotic, 561.
Wright, Dr., on the treatment of entropion, 156.
- X.
- Xerosis (*ξερὸς*, dry—deficiency of tears), 139, 150, 215.
- Z.
- Zander* on proportions of orbit, 3.
 — on the optic papilla, 395.
 — on choroidal and retinal effusions, 449.
Zealand, New, measurement of orbit in, 4.
 Zonular cataract, 503.
 — treatment of, 547.
 Zonule of Zinn, 495.

Schenck & M^r Farlane, Printers, Edinburgh.

