

A treatise on the principal diseases of the eyes / by Antonio Scarpa ; translated from the Italian, with notes, by James Briggs.

Contributors

Scarpa, Antonio, 1752-1832.
Briggs, James
Jay, Barrie
Classics of Medicine Library.
University College, London. Library Services

Publication/Creation

London : printed for T. Cadell and W. Davies, Strand, 1806.

Persistent URL

<https://wellcomecollection.org/works/gfc7vu8c>

Provider

University College London

License and attribution

This material has been provided by This material has been provided by UCL Library Services. The original may be consulted at UCL (University College London) where the originals may be consulted.


Conditions of use: it is possible this item is protected by copyright and/or related rights. You are free to use this item in any way that is permitted by the copyright and related rights legislation that applies to your use. For other uses you need to obtain permission from the rights-holder(s).




Wellcome Collection
183 Euston Road
London NW1 2BE UK
T +44 (0)20 7611 8722
E library@wellcomecollection.org
<https://wellcomecollection.org>



Chromolaena



OPHTHALMOLOGY
HCGSI SCARPA



**THE INSTITUTE
OF
OPHTHALMOLOGY
LONDON
PRESENTED BY**

Professor Barrie Jay

S/287

H



THE INSTITUTE
OF
OPHTHALMOLOGY
LONDON


EX LIBRIS

STITUTE
MOLOGY
BOOK
BY

ie Jay



THIS SPECIAL EDITION OF




PRACTICAL OBSERVATIONS

ON THE

Diseases of the Eyes

BY ANTONIO SCARPA



HAS BEEN PRIVATELY PRINTED

FOR THE MEMBERS OF

THE CLASSICS OF MEDICINE LIBRARY

THE CLASSICS OF MEDICINE LIBRARY

EDITORIAL ADVISORY BOARD

Morton D. Bogdonoff, M.D.
John K. Crellin, Ph.D., M.R.C.S.
Robert A. Good, Ph.D., M.D., D.Sc.
John P. McGovern, M.D., Sc.D.
Morris H. Saffron, Ph.D., M.D.
Eugene A. Stead, Jr., M.D., D.Sc.
Frank Vellios, M.D.
Richard J. Wolfe, M.L.S.
Norman R. Zinner, M.D., M.S., F.A.C.S.

PUBLISHER

Leslie B. Adams, Jr.

Special Edition Copyright © 1980
The Classics of Medicine Library,
Division of Gryphon Editions, Ltd.,
P.O. Box 76108, Birmingham, Alabama 35223
All Rights Reserved
Printed in the United States of America

PRACTICAL OBSERVATIONS
ON THE
PRINCIPAL DISEASES
OF THE
EYES:
ILLUSTRATED WITH CASES.

TRANSLATED FROM THE ITALIAN

OF

ANTONIO SCARPA,

PROFESSOR OF ANATOMY AND PRACTICAL SURGERY IN THE UNIVERSITY
OF PAVIA, FELLOW OF THE ROYAL ACADEMY OF BERLIN, OF THE
ROYAL SOCIETY OF LONDON, OF THE JOSEPHINE MEDICO-
CHIRURGICAL SOCIETY OF VIENNA, AND OF THE
MEDICAL SOCIETY OF EDINBURGH, &c. &c.

WITH NOTES,

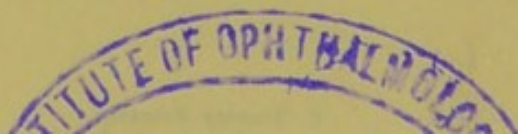
BY JAMES BRIGGS,

MEMBER OF THE ROYAL COLLEGE OF SURGEONS IN LONDON,
AND ASSISTANT-SURGEON OF THE PUBLIC DISPENSARY.

LONDON:

PRINTED FOR T. CADELL AND W. DAVIES, STRAND.

1806.



Je sçais que la plupart des chirurgiens négligent de s'appliquer aux maladies des yeux; parceque elles sont si nombreuses qu'on s'en fait un monstre, et que l'on croit qu'elles demandent toute l'application d'un homme, et une adresse toute singuliere pour exercer les opérations qui leurs conviennent. Il n'est rien de tout cela; elles sont nombreuses à la verité, mais elles sont très-faciles à apprendre à un chirurgien déjà éclairé dans sa profession: elles n'ont point d'autres regles pour leur traitement que celles que l'on suit pour guérir les autres maladies; pourvû seulement que l'on ait égard à la nature de l'œil; et il n'est besoin que d'une adresse médiocre, et d'un peu de jugement pour en faire les plus difficiles opérations. *Maître-Jean Traité des maladies de l'œil.*

TO
JOHN PEARSON, Esq. F. R. S.

SENIOR SURGEON OF THE LOCK HOSPITAL AND ASYLUM,
SURGEON OF THE PUBLIC DISPENSARY, AND OF
THE INSTITUTION FOR INVESTIGATING
THE NATURE OF CANCER,
&c. &c.

As a small Tribute of Gratitude for the useful Instructions,
and friendly Assistance which he has derived
from him in the Pursuit of his Studies,

And as a Testimony of Respect for his Talents and Erudition,
and of Esteem for his Integrity,

THIS WORK

IS INSCRIBED BY

THE TRANSLATOR.

THE HISTORY OF THE UNITED STATES

OF THE
NORTH AMERICAN CONTINENT
FROM THE FIRST DISCOVERY
TO THE PRESENT TIME

BY
JOHN F. JOHNSON
OF THE
NEW YORK PUBLIC LIBRARY

NEW YORK
PUBLISHED BY
JOHN F. JOHNSON
12 NASSAU ST. N.Y.

THE HISTORY

OF THE

UNITED STATES

THE
TRANSLATOR'S PREFACE.

THE comparatively slow advancement of surgery, in common with the other branch of medicine, is principally to be attributed to the great diversity and extent of the facts upon which it is founded, and to their irregular and uncertain occurrence. But, independently of these obstacles to its improvement, which are naturally inseparable from the study of it, it would seem as if the slow progress of this department of the healing art had been in no inconsiderable degree owing to an imperfection in the manner of cultivating it; by surgeons either limiting their observations to the diseases of some particular part of the body, or by directing their sole attention to some particular disease.

Those who have applied themselves to the study of diseases of the eye, have too frequently confined

themselves to the mere consideration of such affections, without any regard to surgical diseases generally; as if the disorders of the eye had something in their nature totally distinct from those of other parts; or as if there were no analogy between similar diseases affecting different parts of the body. It has been frequently imagined likewise, that the operations which are performed upon the eye require greater skill or dexterity, than those which are executed upon other parts of the body. And it has been rather upon some fancied improvement in the methods of operating, than upon any acknowledged peculiarity in the nature of the diseases which affect this organ, that those who have termed themselves oculists, have generally rested their pretensions. Whether there be, however, any greater difficulty in these operations, than in those which are executed upon the body generally, those who have had the most extensive opportunities of performing both, are best able to determine. It ought also to be recollected, that the term dexterity can scarcely be applied with propriety to surgical operations, in the same sense

sense in which it is employed in the mechanic arts; the success of an operation depending more upon a distinct knowledge of what ought to be done, than upon any adroitness in the performance of it.

The custom of considering the diseases of the eye as a distinct province of the healing art, and of confining the study of them to a few individuals, appears to be no less unfounded in nature, than prejudicial to the general advancement of surgery. Nor can any thing analogous to this be discovered in the other departments of science, the principles upon which they are formed, being drawn from the most comprehensive view of the objects which they embrace. If, indeed, we take a view of the improvements which have been introduced into this branch of surgery, we shall find that, they have been almost exclusively confined to those, who, with extensive opportunities of investigating the morbid affections of the eye, have united an enlarged knowledge of other diseases. And it is to this application of the general principles of surgery, and to a more correct anatomy, both of the

natural and disordered state of this organ, than has been hitherto attained, that the greater part of the discoveries contained in this work are to be attributed.

In attempting, therefore, to render the writings of an author more generally known, who has so greatly contributed to enlarge our knowledge of the diseases of the eye, and to establish the treatment of them upon the most rational principles, the translator is unwilling to believe that any particular apology is necessary, or that his labour has been useless or misapplied. His principal solicitude in the execution of it, has been to render it as close an imitation of the original as the genius of the two languages would admit.

It has not been thought necessary to distinguish the notes which the translator has added to it by any particular designation, since they are neither numerous nor important; and are in no danger of being confounded with those of the very able author.

It was originally the translator's intention to have subjoined to the work, the "additional observations"

observations" of the French editor, *Monf. Leveillé*. Further consideration, however, convinced him, that the greater part of the remarks contained in them, are to be found in writings which are accessible to most English readers; and that in this respect he would have departed from the author's original plan, who does not propose to offer a complete treatise of the diseases of the eye, but only such facts and observations as his extensive practice has afforded him an opportunity of making in the most important of those disorders which affect the organ of vision. The translator, however, has availed himself of that gentleman's notes, which he has distinguished by affixing his name to them.

As most of the names of the pharmaceutical preparations which the author has used in the course of the work are falling gradually into disuse, it has been thought proper, for the sake of uniformity, to employ those which are at present adopted by the London College.

It may be proper to mention, that the two principal errata which occur in the original
work

work, and which should have been incorporated in the translation; unfortunately were not discovered, until that part of it was printed off in which they ought to have been inserted.

THE
AUTHOR'S PREFACE.

IN the practice of surgery, I have been uniformly in the habit of comparing my own observations with those of the most eminent writers of every age; and I have been frequently gratified to find, in their writings, facts and observations which my own experience confirmed. It was only on the diseases of the eyes, that in a very considerable number of cases and variety of circumstances, the results of my practice did not accord with their fair promises and specious instructions, by following which I was very frequently disappointed of the success which I had expected. It has appeared to me also, that the greater part of modern surgeons who have written complete systems of surgery, or treatises on the diseases of the eyes, have rather employed themselves in collecting a number of formulæ of medicines, or in minutely detailing all the methods of operating which have been at any time proposed for the cure of those diseases, than in determining, from observation and experience, which of the numerous remedies and
variety

variety of operative methods ought to have the preference. Professed oculists, who have entirely devoted themselves to this department of surgery, from whom great and important improvements might justly have been expected, have only contributed new theories, which for the most part have been disproved by a minute anatomical investigation of the eye, or they have merely furnished us with histories of cures little less than miraculous. And it is to be regretted, that, even in the present day, some who have been regularly educated in surgery, no sooner aspire to the celebrity of oculists, than they immediately attach themselves to the marvellous, and cannot be withheld from inserting in their writings some trait less characteristic of the surgeon than the empiric; than which nothing can be more injurious to the welfare of mankind, to the advancement of surgery, and to the honour of him who practises it. These inconsiderate promises being readily embraced by the young and inexperienced, who ignorant of the many, and sometimes insuperable difficulties which they have to encounter, proceed with ardour and intrepidity, and in the end embarrass themselves, to the prejudice of their own reputation and the safety of others.

The following observations, therefore, which are the result of my own practice and experience, have been published with a view to separate
rate

rate from this important branch of surgery whatever is untrue or exaggerated, and to assist the young surgeon in the treatment of the more important diseases of the eyes, not only by a selection of the most efficacious remedies hitherto known, but, as far as the present state of our knowledge admits, of the most simple and useful methods of operating, in the several cases in which they are requisite. Divested of every prejudice, and having frequent opportunities of employing the most approved remedies, and the various modes of operating which have been hitherto proposed for the cure of those diseases, which most frequently affect the organ of vision, I have been made fully acquainted with the utility of some of these methods of treatment, and the inefficacy or imperfection of others, though equally commended and extolled; and on these points, therefore, I am enabled to pronounce definitively. In making these researches I ought to confess, that on several occasions I could not but acknowledge the justness of some of the practical doctrines transmitted to us by the ancients, which have been entirely neglected by the moderns; as well as observe how unjustly some of their methods of operating have been discredited and laid aside, to give place to others which experience proves to be greatly inferior.

Relin-

Relinquishing every hypothesis which is inconsistent with the anatomical structure of the eye; and practical observations on the diseases of this organ, I have endeavoured to explain with conciseness and perspicuity those appearances which I have observed to be most certain and constant, with respect to the nature of the diseases that affect this important part of the human body, as well as the safest method of treating them. And, in order to render the methods of operating more intelligible to the young surgeon, I have thought it proper to add to the greater part of the chapters contained in the work, the detail of a small number of cases; expressly selecting from the great number, which I might have adduced under several of the heads, the histories of such as have been registered in my practical school of surgery, in the presence of a great number of pupils. Examples without precepts are generally uninteresting, and precepts without examples are for the most part obscure, and of little utility. I entertain, however, the fullest confidence, that whoever will exactly follow the plan of cure which I have laid down in the treatment of this class of diseases, both with respect to the remedies and operations, will not only easily understand what I have advanced, but will also find that the event will generally, if not always, accord with what I have asserted; which,

which, in the healing art, is the most that can be promised.

Nor am I disposed to believe that the most able practitioners of the present day will regard this work as useless, merely because it may probably not contain any thing which to them may be sufficiently important or novel. Their correct judgment in the knowledge of diseases, as well as the operations which are best suited to each of them, and the frequent opportunities which they have had of comparing, at the bedside of the patient, the numerous remedies and methods of operating which have been proposed for the cure of diseases of the eyes, have doubtless led them, as well as myself, to establish their practice on a solid basis, and to make a selection of whatever is most certain and useful in the exercise of this branch of surgical science. But this is not the case with the student who enters on this career, and stands in need of a faithful guide, to prevent him from being seduced by the ostentatious promises of some, and the magisterial precepts of others, who, attached to some particular opinion, founded only upon theory, or upon some particular and extraordinary case, have established upon it a general rule.

It ought to be observed, however, that in writing this work I have not proposed to give a complete treatise of the diseases of the eyes, but
only

only to speak of the principal affections of this organ, which I have sedulously and repeatedly attended to, since there are some which I have never met with; such are, for instance, the prolapsus of the eye-ball, from external violence, the hypopion, without being preceded by an evident inflammation of the internal membranes of the eye, and, as it is called by metastasis, the union of the internal membrane of the eye-lids with the eye-ball. I have not mentioned, besides, the congenital or accidental coalescence of the eye-lids, the carbuncle of the eye-lids, wounds dividing the cartilage of the tarsus, extraneous substances introduced between the eye-lids or fixed in the eye, and other similar accidents; because, from the simple nature of these subjects, they do not admit of discussion, and because they have been already explained with the greatest precision and clearness by almost all the writers who have treated of them.

It will be seen, in many instances, that I have included diseases in the same chapter, which, although treated of by the greater number of writers under separate heads, are not in reality essentially different, and, notwithstanding the distinct denominations which have been given to them, are nevertheless cured by the same remedies and the same operations. In speaking of the artificial pupil alone, I have confined myself to the consideration of
that

that particular case of contracted or obliterated pupil, which occasionally takes place, after the extraction or depression of the cataract ; principally in consequence of the violent *internal* ophthalmia, excited by those operations, because my experience has not yet sufficiently instructed me in the best method to be pursued in the other cases of that disease.

For the same reason I have not entered into a description of the cancer of the eye, since I have never met with more than two instances of this disease, which only serve to establish a fact already sufficiently known, the inefficacy of extirpating the eye-ball, whenever the cancerous diathesis has, in the smallest degree, extended beyond the ball itself, or its appendages. The first of these cases occurred in a boy 13 years of age, in other respects strong and healthy, in whom, besides the eye-ball being scirrhous and projecting out of the orbit, there was a tubercle of the same nature situated between the internal angle of the eye-brow, and the root of the nose. I extirpated the eye and removed every part within the orbit which was indurated, or diseased, in the most careful manner, together with the tubercle situated between the supercilium and root of the nose : every thing went on well, and the wound was completely healed. Two months after the child had returned home, which was in the province of Cremona, two

new indurated tubercles appeared in the cellular membrane of the supercilium of that side, towards the temples, and fungus afterwards germinated from the bottom of the orbit. This unfortunate child was then seized with continual pain in the head, afterwards with slow fever and general convulsions, which shortly terminated in death. The second case was that of a man 50 years old, strong, and in every other respect perfectly healthy, in whom the cancerous fungus had attacked, not only the eye-ball, but also a portion of the upper eyelid. I removed the eye-lid with the greatest possible exactness, close to the arch of the orbit, where it appeared perfectly sound, and along with it the globe of the eye, and all the other parts contained in the orbital fossa. The cure went on very well until the 40th day, and the cicatrix gradually advanced from the external margin of the orbit towards the bottom of that cavity. In the midst, however, of the most promising hopes the wound became stationary; a fungus began to appear in various points of the bottom of the orbit, which I endeavoured, but in vain, to destroy, first with the favin-powder, afterwards with the caustic; the patient was ultimately attacked with acute pains in the head, and by a kind of nervous fever, he became insensible and died.

For

For the greater advantage of students I have thought it necessary to add three plates. The first represents the *via lachrymalia*, and particularly the exact situation and extent of the lachrymal sac. For as the perfect success of the operation for the fistula lachrymalis depends greatly on the lachrymal sac being laid open freely through its whole extent, from below the tendon or ligament of the *orbicularis palpebrarum* to the lowest part of it, and on the incision being made exactly in the direction of its axis; it is necessary that the young surgeon should know precisely the true situation and direction of these parts; which perhaps would not be easily learnt from the plates which we have at present, since they consist at most of small sections of the face, in which the relative situation of the *via lachrymalia* with the surrounding parts and the rest of the head is lost. The second plate gives a representation of some diseases of the eyes, which appear to me never to have been accurately delineated. The third plate shows the instruments, which with the syringe of Anel, and those of the pocket case, with which every surgeon is provided, form, in my opinion, the whole apparatus that the surgeon-oculist requires.

With the hope that this work may not prove useless or uninteresting, especially to young surgeons, for whose use it is principally intended,

I propose, upon the same plan, to communicate successively to the public, such important observations or useful researches, as I may hereafter make in the other departments of surgery.

C O N T E N T S.

Chap.	Page
Preface	xi
I. Of the puriform discharge of the palpebræ and fistula lachrymalis	I
II. Hordeolum	72
III. Encysted tumours of the eye-lids	78
IV. Cilia which irritate the eye.	96
V. Relaxation of the upper eye-lid	126
VI. Everfion of the eye-lids	133
VII. Ophthalmia	160
VIII. Nebula of the cornea	203
IX. Albugo and of the Leucoma	226
X. Ulcer of the cornea.	233
XI. Pterygium.	256
XII. Encanthis	280
XIII. Hypopion	292
XIV. Procidentia iridis.	322
XV. Cataract	352
XVI. Artificial pupil	405
XVII. Staphyloma	425
XVIII. Dropsy of the eye	453
XIX. Amaurofis and of the hemeralopia	481
XX. Calculous concretion of the internal part of the eye	532

PRACTICAL OBSERVATIONS, &c.

CHAP I.

OF THE PURIFORM DISCHARGE OF THE PALPEBRÆ, AND OF THE FISTULA LACHRYMALIS.

SURGEONS are generally agreed that a *fistula lachrymalis* exists, whenever a discharge of a viscid, curdly, yellowish matter, resembling pus and mixed with tears, issues from the *puncta lachrymalia*, on compressing the space situated between the internal canthus of the eye and the nose.

If the term *fistula lachrymalis*, when applied to the disease of which I am about to treat, were a mere verbal inaccuracy, and had no influence on the diagnosis and treatment of the complaint, it would be a matter of little importance : but, since it involves a real error, and one which may easily mislead the young surgeon in the diagnosis and treatment of this and other diseases of the *via lachrymalia*, I think it necessary that some distinction should be made between these two morbid affections. Whenever, therefore, on pressing the lachrymal sac, though in other respects in a sound state, a viscid, curdly, yellowish matter, resembling pus, flows from the *puncta lachrymalia*, I give to

that morbid state of the *via lachrymalis* the appellation of the puriform discharge of the palpebræ; and I would restrict the term *fistula lachrymalis* to that form of disease, in which the lachrymal sac is not only greatly distended, but ulcerated, and in a fungous state on its internal surface, where there is likewise an external opening, which is sometimes accompanied with a caries of the *os unguis*.

The viscid, curdly, yellowish humour mixed with the tears, which in the first instance flows back again through the *puncta lachrymalia*, is not wholly produced by the sac, as is commonly believed; but is for the most part transmitted to it from the eye-lids by the *puncta lachrymalia*, from which it regurgitates, and consequently appears again upon the eye and eye-lids whenever the sac, which is gradually filled with this humour, happens to be pressed upon. This puriform humour is principally furnished by the internal membrane of the palpebræ; and comes more particularly from the lower eye-lid along the tarsus, and from the glands of Meibomius: the sebaceous matter peculiar to these glands being not only secreted in larger quantity, but also acquiring an acrid and irritating quality. This morbid state of the sebaceous glands is very frequently derived from a catarrhal flux, from a scrofulous taint, from the small pox, and from cutaneous eruptions improperly repelled. In addition

tion to the sebaceous matter which is copiously secreted by these glands, a quantity of thin mucus is poured out from the internal membrane of the palpebræ, which greatly contributes to increase the quantity of viscid humour which, in these cases, is diffused over the eye and eye-lids.*

That the puriform humour which issues from the lachrymal sac on the application of pressure originates from these sources, is rendered evident by everting the affected eye-lids, particularly the inferior one, and comparing them with those of the sound side. For the internal membrane of the former is invariably found redder than natural, and presents a villous appearance, especially along the tarsus; the edge of the eyelid is tumefied and discoloured with innumerable small varicose vessels; the glands of Meibomius are more turgid and projecting than in a natural state, and not unfrequently, when examined with a powerful glass, appear to be slightly ulcerated.

This villous structure, then, which the surface of the internal membrane of the palpebræ assumes in these cases, becomes an organ, secreting a larger quantity of fluid than usual, resembling viscid lymph, which being mixed with the sebaceous matter, copiously effused from the glands of Meibomius, constitutes the

* Rudolphus Vehrens has called this disease *Epiphora Sebacea*. See Haller's address to Boerhaave's *Methodus Studii Medici*.

whole of that tenacious fluid with which the eye-lids are imbued, and which is continually carried by the *puncta lachrymalia* into the sac, so as to fill, and sometimes even distend, that cavity enormously.

If indeed the lachrymal sac is emptied of this matter, by means of compression, and the eye and internal surface of the palpebræ are carefully washed, so that none of the glutinous humour pressed from the sac shall remain upon them, and the eye-lids are everted half an hour afterwards, the internal surface, especially of the lower one, will be found covered with a fresh effusion of mucus mixed with sebaceous matter, which has evidently not flowed back from the lachrymal sac towards the eye, but has been generated between the eye and the palpebræ, having been there poured out by the villous surface of their internal membrane, and the glands of Meibomius. That the internal membrane of the palpebræ assuming a fungous or villous appearance, changes its natural functions, and becomes an organ secreting an immoderate quantity of mucus, we have an instance in that species of puriform discharge of the palpebræ, produced by the incautious application of the matter of gonorrhœa to the edges of the eye-lids. For in this case the eye and palpebræ are first of all inflamed, the internal membrane of the latter then becomes tumefied, and assumes a vil-

lous

lous appearance, and a prodigious quantity of viscid, yellowish humour, is afterwards poured out, similar to that which is discharged from the urethra in a venereal gonorrhœa.

In the puriform discharge of the palpebræ, however, of which I am treating, and which is commonly met with in practice, the secretion of mucus from the internal membrane of the eye-lids, and the glands of Meibomius, is not so considerable as in that arising from the application of the matter of gonorrhœa; nor is it always preceded like that with symptoms of the most violent inflammation. In general it takes place slowly, and in proportion as the puriform fluid is secreted, it partly lodges upon the eye and palpebræ, and partly descends through the *puncta lachrymalia* into the sac, where being accumulated, it instantly flows back upon the eye when any pressure is made upon that cavity.

As a further proof that the lachrymal sac has no other share in this disease than that of receiving, together with the tears, the puriform humour which is transmitted to it from the affected palpebræ, it is sufficient to observe, that if the morbid secretion of the eye-lids is retarded or suppressed, either accidentally or by means of external applications, little or none of this viscid curdly humour is collected in the lachrymal sac, or can be forced from the *puncta lachrymalia* by the application of pressure. In-

deed, if in the highest degree of this disease the eye-lids are accidentally attacked with inflammation, as in the case of erysipelas of the face, the effect of which, as of all other inflammations, is to suppress every kind of secretion in the parts affected with it, the accumulation of puriform matter in the sac ceases altogether, which returns as soon as the inflammation of the palpebræ has abated, and the morbid secretion of their internal membrane, and of the glands of Meibomius, is reproduced. I have frequently ascertained that the same effect is produced when an inflammation of these parts is artificially excited, by the introduction of any strongly-irritating substance between the palpebræ and the ball of the eye: as I have also constantly observed that the puriform discharge may be radically cured by merely correcting, at an early period, the morbid secretion of the internal membrane of the palpebræ, and of the sebaceous glands situated along the tarsus.

If, however, notwithstanding what has been advanced, some may yet be inclined to believe that the puriform humour in this disease is rather formed by the internal membrane of the sac than the palpebræ, it may not be improper for them to consider, that the internal membrane of the lachrymal sac is exactly similar to that which lines the frontal and ethmoidal sinuses, being a very delicate membrane entirely desti-

tute

tute of sebaceous glands, and fitted to secrete a thin mucus, but not a sebaceous, unctuous matter, such as that which in this disease forms so considerable a part of the fluid which issues from the lachrymal sac. It is not, indeed, improbable that a small part of the thin mucus which lubricates the internal membrane of the sac may be mixed with the puriform humour transmitted to it by the *puncta lachrymalia*; but we are not warranted to assert from thence that the principal part of the puriform humour is formed in the sac.

If the origin therefore of this disease be not principally in the lachrymal sac, but in the internal membrane of the palpebræ, and in the sebaceous glands of Meibomius, it is very evident how much they are mistaken who confound this disease of the *via lachrymalia* with the *fistula lachrymalis*; and consequently, how improperly they propose in the treatment of the puriform discharge of the palpebræ to heal an ulcer of the internal membrane of the sac, which does not exist, or to open a passage for the tears into the nose by the dilatation of the nasal canal, which they imagine to be entirely, or in a great measure, obstructed. For in these cases, the nasal canal cannot properly be said to be obstructed, unless either relatively with respect to the density and tenacity of the puriform matter, which attempts to pass from the

B 4

palpebræ

palpebræ towards the cavity of the nostrils, or because the irritation which this matter produces, in the course of the *via lachrymalia*, occasions a slight degree of thickening, or tumefaction of the membrane of the nostrils which lines the nasal canal.

And in order to proceed with this subject in as clear a manner as possible, upon which, it seems unfortunately, the more that has been written, the greater has been the obscurity and doubt which has been introduced into it, I have thought it proper to divide the puriform discharge of the palpebræ into four stages. The first, is that in which the puriform oily mucous matter, secreted by the internal membrane of the palpebræ and the glands of Meibomius, is carried into the lachrymal sac, and accumulates there; but descending easily through the nasal canal is for the most part discharged into the nose, and occasions no manifest distension of the sac, which, when compressed, only gives issue to a moderate quantity of viscid matter. The second stage of the puriform discharge of the palpebræ, is that in which the matter flowing from the eye-lids not being entirely discharged, or without great difficulty into the nose, from its excessive quantity and density, as well as from the tumefaction of the internal membrane of the nasal canal, produces gradually, and in the course of some years,
a con-

a considerable distension of the lachrymal sac, so as to destroy its natural elasticity, and cause it to project in the form of a tumour. The third stage, is that in which the viscid matter, in consequence of its abundance, density, and acrimony, and perhaps still more from its excessively distending the parietes of the lachrymal sac, causes an inflammation, erosion, and suppuration of that cavity, and of the integuments covering it; and thereby occasions an ulcer of the *via lachrymalia*, extensive internally, but narrow externally, from which is discharged a mixture of puriform matter and true pus. This third stage of the puriform discharge of the palpebræ; is that to which the term *fistula lachrymalis* properly belongs, especially if the ulceration has been for a long time neglected, or improperly treated. Lastly, the fourth stage of this disease, is the same as the *fistula lachrymalis*, but accompanied with a caries of the *os unguis*.

From the consideration of this series of progressive stages of the puriform discharge of the palpebræ, the difference between this disease and the *fistula lachrymalis* must be very obvious, and consequently what is the true and principal origin of the latter. And since, from what has been stated, the primary and principal cause of the *fistula lachrymalis* does not exist either in the sac or the nasal canal, as it has been hitherto believed,

believed, but in the morbid state of the palpebræ, it must necessarily follow that every method of treatment of the *fistula lachrymalis*, which is merely directed to heal the ulceration of the sac, or to overcome the obstruction of the nasal canal, can never effect a permanent cure of this disease, unless such practice be conjoined with other measures which are calculated to correct effectually the morbid secretion of the palpebræ, from which the *fistula lachrymalis* is derived.

With respect to the treatment of the first stage of the puriform discharge of the palpebræ, when it is recent, and when the viscid humour transmitted from the palpebræ through the *puncta lachrymalia* into the sac, though it is somewhat detained in the latter, does not however distend it sensibly, nor elevate it externally, the cure may be effected without having recourse to the division of the sac, or any other painful operation. The plan of treatment under such circumstances consists in restraining the immoderate secretion of the glands of Meibomius, and internal membrane of the palpebræ, and at the same time in assiduously washing the *via lachrymalia* through their whole extent, in order to prevent any of the acrid, sebaceous, and grumous matter from lodging in them.

This may be obtained by means of stimulating and astringent medicaments applied to
the

the margin and internal membrane of the palpebræ, and by deterfive injections thrown into the *puncta lachrymalia*. The best local, stimulating, and astringent remedy in this case, is the opthalmic ointment of Janin,* employed at first with a larger quantity of lard than is directed in the formula, until the patient's eye is accustomed to this kind of stimulant; a portion of this ointment, equal to the size of a barley-corn, should be introduced upon the point of a blunt probe morning and evening, between the palpebræ and ball of the eye, near the external angle, and the whole margin of the eye-lid smeared with it; the patient should then be directed to close the eye, and rub the palpebræ gently, so that the ointment may be equally distributed upon the whole of their internal surface; a compress and bandage should be applied over it, and the patient desired to keep his eye-lids closed in this manner during two hours. At the expiration of this time, the eye should be washed with cold water, and a few drops of a collyrium, consisting of four ounces of plantain water, five grains of vitriolated zinc, and half an ounce of the mucilage

* Take of hog's lard half an ounce, prepared tutty and armenian bole, of each two drams, white precipitate, (calx hydrarg. alba) a dram. The hog's lard, having been washed three times in rose water, should be intimately mixed in a glass mortar, with the other ingredients previously reduced to a fine powder.

of quince-seed, should be instilled into the eye three or four times in the course of the day.

When, in addition to the affection of the glands of Meibomius, and the villous appearance of the internal membrane of the palpebræ, there are small superficial excoriations upon the edges of the eye-lids, it will be advantageous to employ at the same time the *unguentum nitratis hydrargyri* of the Edinburgh Pharmacopœia. This remedy should be used by warming it a little in a small vessel till it liquifies, and then with the point of the finger smearing it upon the edges of the eye-lids at the time when the patient goes to bed. If this should be insufficient, recourse must be had to the *argentum nitratum*, as employed by S. Yves, which should be drawn gently along the edges of the palpebræ, washing the eye immediately afterwards with new milk.

In order to preserve the canal in a permeable state, the surgeon, previously to the use of the stimulant and astringent applications, should inject distilled plantain water, rendered more active by the addition of a little spirit of wine, through the *puncta lachrymalia*, morning and evening, by means of Anel's small syringe; and this injection should be repeated at each time of dressing the eye, until it is evident that the fluid thrown into the *puncta lachrymalia* has passed into the nostril.

The phænomena which usually present themselves

felves during the treatment of the first stage of the puriform discharge of the palpebræ, are the following: The secretion of puriform matter is at first more copious than before, provided the irritation produced by the ointment does not exceed certain limits, and occasion an inflammation of the palpebræ.* The edges of the eye-lids, especially of the inferior, which before were tumefied and rigid, now become gradually thin, soft, and flexible; the glands of Meibomius insensibly diminish, and the internal surface of the palpebræ, which had previously a villous appearance, and was almost in a fungous state towards the margin of the eye-lid, gradually recovers its natural smoothness, and becomes pale. As these favourable changes succeed each other on the internal surface of the palpebræ, the puriform discharge diminishes in quantity, and from being viscid, tenacious, and grumous, becomes thinner and more fluid, and no longer imbues the palpebræ and cilia. If the sac be compressed afterwards at different intervals, there only issues from the *puncta lachrymalia*, a discharge of turbid tears; and finally, when the natural secretion of the palpebræ is

* In order that this remedy may produce its proper effect, however, it is necessary that it should induce a certain degree of irritation exciting a little warmth and redness in the palpebræ and *conjunctiva*, during the whole time it remains upon the eye:

entirely restored, the regurgitation of puriform matter ceases altogether, or there is only a discharge of a few pure and limpid tears. These advantages are obtained for the most part in six weeks, if there be no obstinate causes depending on the patient's general constitution, which, towards the end of the treatment, occasion a return of the disease, as too frequently happens in those who are in the last stage of scrofula, especially on the approach of spring and autumn, or in those who are otherwise unhealthy, or who have been affected with a severe *variolous metastasis* to the eyes. These cases require a longer continuance of the treatment than the others, although a cure may be ultimately obtained, if, in conjunction with the external means already mentioned, a seton is made in the neck, and such internal remedies employed as are suited to correct the morbid predisposition. Of these I shall have occasion to speak in the chapter on Ophthalmia.

From these principles relative to the first stage of the puriform discharge of the palpebræ and the method of treating it, we are enabled to form a correct judgment of the case related by Fabricius Hildanus, in his Cent. IV. Obs. XX. of a lady about thirty years of age, who had been afflicted with a *fistula lachrymalis* for two years, which he cured in four months, merely by making a seton in the neck, and by the frequent
use

use of an appropriate collyrium. This case of *fistula lachrymalis* of which Fabricius speaks, appears to have been only a puriform discharge of the palpebræ, which, although of two years standing, had not proceeded beyond the first stage; and in consequence of the determination made to the neck and the action of the collyrium, which was probably astringent, applied to the eye-lids, the puriform discharge was suppressed, and consequently ceased to taint the eye, and obstruct the *via lachrymalia*. A great number of similar examples may be met with both among ancient and modern writers on the diseases of the eyes, which have been improperly considered as cases of *fistula lachrymalis*.*

As the disease in this first stage does not produce any remarkable pain or tumefaction in that part of the integuments situated between the internal angle of the eye and the nose, and only occasions a slight weeping of the eye in the day-time, and during the night, some degree of cohesion of the eye-lids; and as this discharge of tears becomes even more tolerable to the patient, if he have the precaution to press occasionally upon the internal canthus of the eye,

* I have very frequently seen, says Pott, cases of incipient *fistula lachrymalis* cured merely by means of a good diet, and the application of the vitriolic collyrium.

and to force the puriform matter confined in the sac back again through the *puncta*; so it very frequently happens, that not only the lower classes of people, but also the more opulent, neglect this form of the disease 'for a considerable length of time, and seldom have recourse to surgical assistance, until the disease has arrived at the second stage, or when it is accompanied with distention and manifest tumefaction of the lachrymal sac; for the cure of which, besides the local remedies already enumerated, it is requisite to perform a surgical operation.

For, in the second stage of the puriform discharge of the palpebræ, when the viscid matter, secreted by the eye-lids, has gradually, and, in the course of some years, distended the sac, and elevated it externally in the form of a tumour, although the primary indication which the surgeon ought to fulfil, be, in every period of this disease, to correct the morbid secretion of the palpebræ, yet the fulfilment of it, under these circumstances, is not alone sufficient to effect a complete cure of the disease; on account of the atony or flaccidity superinduced upon the membranes of the lachrymal sac, which requires the employment of appropriate means. This circumstance demands the greater care and attention, as in the first place the diminished vitality of the membranes of the lachrymal sac, in consequence of the distention

tenſion which they have ſuffered diſpoſes them, as well as the integuments, to ulcerate from the ſlighteſt attack of inflammation in the ſurrounding parts ; becauſe, in the ſecond place, although the morbid ſecretion of the palpebræ be perfectly corrected, yet, whenever the lachrymal ſac remains conſiderably dilated, ſo that the tears are retarded in it, the further diſtention and dilatation of it, and conſequently the perpetual weeping of the eye, are inconveniences abſolutely inevitable. It is evident, that to avoid this diſcharge of tears, it is not only neceſſary that the naſal canal ſhould be ſufficiently open into the cavity of the noſtrils, but alſo that there ſhould be a certain proportion between the caliber of this canal and the capacity of the lachrymal ſac ; otherwiſe, if the latter exceed its uſual dimenſions, the tears poured into it from the *puncta lachrymalia*, as all fluids propelled through narrow tubes into large ones loſe much of the motion originally communicated to them, are retarded, accumulate in the preternaturally dilated ſac, and conſequently flow back upon the eye ; nor is the weight of the tears alone ſufficient to make them deſcend through the naſal canal and diſcharge themſelves into the noſe, in the ſame quantity in which they are abſorbed and poured by the *puncta lachrymalia* into the ſac.

To fulfil this indication, that is, to prevent

the accumulation of the puriform matter and tears in the distended sac, which all surgical writers have considered as important, it has been proposed to make use of astringent lotions, consisting of a strong solution of alum in the infusion of oak-bark; others have suggested a firm and long-continued pressure upon the dilated sac, by means of a small instrument resembling a tourniquet. Both these methods are, however, altogether inadequate to the purpose, for several reasons, which it is of little importance at present to examine. The only method of treatment which has been found really efficacious, is that of making an incision into the sac, and introducing into it such remedies as are calculated to constrict its cavity, either by restoring the actions of its membranes, or diminishing their extent, principally by the use of caustic applications.*

For

* A case of this second form of the disease lately occurred at the Public Dispensary, in which the lachrymal sac was immoderately distended, and the integuments covering it discoloured and tender to the touch, yet by merely employing the *unguentum hydrarg. nitrat. mitius*, which was introduced between the eye-lids twice a-day, and directing the patient to empty the sac as often as there was any accumulation of matter in it, by pressing upon it with the finger, the symptoms gradually disappeared, and the disease in the course of some weeks was removed; a slight discharge of tears, however, occasionally took place whenever the eye was exposed to cold air.

For the cure then of the second stage of the puriform discharge of the palpebræ, or when it is attended with a considerable dilatation of the lachrymal sac, the patient being seated, and his head properly held by an assistant, the surgeon should direct him to close his eye-lids, and gently pressing upon those of the affected side with the index and middle finger of one hand, with the other he should carry the point of a straight bistoury immediately below that small whitish spot of the integuments, which is naturally seen on the side of the nose, a little below the internal commissure of the palpebræ, covering the tendon or ligament* of the orbicular muscle; and pressing the knife freely forwards, must penetrate the cavity of the lachrymal sac; he should then continue the incision from above downwards, in the direction of the fold which the lower eye-lid makes at that part, and which nearly corresponds to that of the *osseous sulcus* in which the lachrymal sac is situated.†

And, to make the operation fully succeed, if the surgeon is ambidextrous, he should open the lachrymal sac of the left side with his right

air. This instance would seem to prove that, however judicious the operation here proposed by Professor Scarpa may be, in the generality of cases, it is not absolutely necessary in all. And the propriety of proceeding to any operation before such measures have been employed, may be reasonably doubted.

* Plate I. c.

† Plate I. c. b.

hand, and *vice versa* that of the right side with his left hand, when the disease is on that side : always taking particular care that the point of the bistoury fall perpendicularly upon the *os unguis*, and never pass obliquely from without inwards, between the margin of the orbit and the globe of the eye. In performing this operation the young surgeon should, in no instance, depart from the rule here laid down, of commencing the incision of the sac, by plunging the point of the bistoury immediately below the whitish spot of the integuments, which is seen between the internal angle of the eye and the nose. For in morbid dilatations of the sac, which are always attended with tumefaction of the neighbouring parts, the uncertainty of penetrating with precision into that cavity, and of extending the incision accurately in the course of it is so great, that even the best anatomists may, by not paying attention to this circumstance, easily get out of the direction of the sac, or not open it in the most convenient manner requisite. Under this small whitish spot of the integuments, the sac never deviates from its natural position, however distended and altered by disease, since it is firmly confined in its situation at this part by the ligament of the orbicularis muscle. When the point of the bistoury has fairly penetrated the upper part of the cavity of the sac, the rest of the incision
may

may be executed without difficulty, by following the direction of the inferior arch of the orbit where the natural fold of the eye-lid has been effaced by the tumefaction of the sac. The practice of laying the sac open through its whole extent * is of the greater importance for obtaining a complete cure of the disease, as by this method only are we enabled to make such applications to it as are necessary; and experience has proved, that a small incision of the sac, only sufficient to admit a seton or tent through it into the nose, does not fulfil the original intention for which it ought to be made.

The sac being divided longitudinally, so as to expose the whole of its internal surface, the surgeon should introduce into the lowest part of it a moderate sized probe, which he should push through the nasal canal into the corresponding nostril, giving the instrument a slight inclination from without, inwards. After having withdrawn the probe, he should introduce into the nasal canal a bougie of a proper thickness, an inch and a half long in the case of an adult, pressing it gently forwards, until the extremity which has entered the nostril, is incurvated towards the fauces, and the other end being secured by a waxed thread, has descended so deeply as to be concealed at the lowest part of the lachrymal sac, and precisely at the entrance

* Plate I. c. b.

of the nasal canal; in short, that the bougie may preserve the dilatation of the nasal canal without occupying any part of the cavity of the lachrymal sac. A piece of elastic gum tent, of an equal length and thickness, answers extremely well, instead of the bougie, both on account of its great smoothness and flexibility. A bougie, or elastic gum tent, an inch and a half long, for an adult, is preferable to one shorter, and only proportioned to the length of the nasal canal; as the one being incurvated in the nostril towards the fauces, remains constantly in its situation at the lowest part of the sac, and is entirely concealed in the nasal canal, while the other by its shortness is easily forced upwards and outwards through the incision, and prevents the dressings from remaining long at the bottom of the sac. Nor is it a matter of indifference whether the passage of the nasal duct be preserved open or not, during the whole time required for the cure of the distended and flaccid sac; as we know from experience the great tendency which there is in the canals and excretory ducts of the animal body, to contract and become obliterated, when the fluid which they are accustomed to convey ceases, even for a short time, to pass through them. Of this we have an instance in the fistula of the parotid duct, the anterior portion of which, no longer

longer receiving any saliva from its appropriate gland, very soon contracts and closes itself.

Having thus filled the nasal canal, the surgeon should examine the whole preternatural extent of the lachrymal sac, with a bent probe, especially that part of it which is situated above the tendon of the orbicular muscle,* and which has not been included in the incision; this will serve him as a guide for calculating afterwards the progress of the contraction of the whole sac, which is the principal object in the treatment of the second stage of the puriform discharge of the palpebræ. Lastly, the whole cavity of the lachrymal sac should be filled with soft lint, which should be retained in its situation by means of a compress and the monocular bandage.†

On the third day, if the lips of the wound have begun to suppurate, the dressing should be renewed; and this should consist in washing the wound, and filling again in the most exact manner the bottom of the cavity of the dilated lachrymal sac, with soft lint dipped in a liniment, consisting of the hydrargyrusnitratus ruber and mucilage of gum-arabic. This escharotic is very gentle in its action, and corresponds to what are commonly called mild or *indolent caustics*:

* Plate I. a.

† For the description and method of applying this bandage, see Heister's Surgery, Part III. sect. i. p. 357.

it gives the patient little uneasiness, and produces daily a greater contraction of the lachrymal sac; whether it effects this by simply stimulating it, or by promoting an abundant discharge of humour, with which, in this second stage of the disease, the membrane forming the sac is loaded, the fact is, that at every application the doffel of lint, introduced into the cavity of the sac, is covered with a whitish slough resembling cotton; and that by persisting in this treatment the capacity of the sac is gradually diminished.

If it should appear to resist these applications the whole cavity of the sac should be filled with the hydrarg. nitrat. ruber, either alone or mixed with a little alum, and should be also repeatedly touched with the argentum nitratum, if necessary. By means of these powerful escharotics the internal surface of the sac will be reduced to the state of a simple ulcer, the healing of which must be necessarily attended with a corresponding contraction of its cavity.

The most scrupulous attention ought to be paid at each dressing, that the external edges of the wound are kept open, and only suffered to contract in proportion to the rest of the sac, either by the introduction of lint or sponge. While these means are employed for the purpose of reducing the sac to its natural size, it will be proper to introduce between
the

the eye-lids, morning and evening, the ophthalmic ointment of Janin, and to direct the patient to instil into the eye a few drops of the vitriolic collyrium three or four times a-day, in order to correct the morbid state of the palpebræ; without which a complete cure of the disease cannot be obtained in any of its stages.

As soon as the sac is nearly reduced to its natural capacity, which may be ascertained by examination with the point of a probe, the use of escharotics should be suspended, and lint dipped in a mixture of aqua calcis and mel rosæ substituted in the place of them. Afterwards when the process of cicatrization has evidently proceeded from the edges of the incision to the bottom of the sac, and the discharge of matter from it has ceased; in short, when the internal surface of the sac is healed, it will be proper to withdraw the bougie or elastic gum tent from the nasal canal, in which it had been placed from the beginning of the treatment, and to substitute in its place a tent formed of lead, the upper extremity of which should have affixed to it a small plate of the same metal,* about four lines in breadth and rather more than one in thickness. The body of this tent being perfectly solid will continue to keep the nasal canal open for some time, and by its weight cause the small plate resting on the whole external surface of the sac

* Plate III. fig. 9.

to make a continual pressure upon it from without inwards.

This important part of the treatment was not neglected by the ancient surgeons, I mean the application of a moderate degree of pressure upon the sac, after its contraction and complete cicatrization internally. Among the moderns Gucrin* appears to be the only one who has properly appreciated this practice of the ancients. For although the passage for the tears into the nose may have been sufficiently kept open, and caustic applications have also been employed to restore the sac to its natural size, and to obtain on its internal surface a perfect and solid cicatrix; nevertheless it may easily happen that the sac, from having been greatly dilated, (notwithstanding the means which have been employed) may not have acquired sufficient power, towards the end of the cure, to resist a new impulse of the tears from any little difficulty which they may meet with in passing into the nose. In order therefore to prevent such an accident, nothing is more advantageous, towards the end of the treatment of this form of the disease, than the application of a gentle degree of pressure upon the external surface of the sac, in order to restore its natural tone, and enable it to resist any accidental impulse of the tears, after every

* *Essai sur les maladies des yeux*, p. 160.

kind of application has been removed. I have observed, however, that pressure made upon the sac, by means of graduated compresses and the monocular bandage, or by the small machine of *Aquapendente*, however altered and improved, does not speedily answer the purpose; since both these methods are very inconvenient to the patient, are easily removed from the point of compression, and, however carefully applied, never exercise an uniform degree of pressure upon the external parietes of the sac. By means of the small plate, affixed to the extremity of the leaden tent, this intention is answered in the most complete and simple manner; since, as I have before stated, it rests precisely in the direction of the sac, and being constantly pressed downwards by the weight of the tent, makes a gentle and equable pressure upon its external part, without occasioning the smallest inconvenience to the patient.

So great is the advantage derived from a constant and regular pressure made upon the external part of the sac, whether simply dilated, or accompanied with ulceration, by means of this instrument, that in a lady in whom the lachrymal sac was very much dilated, and had recently suppurated and burst externally, but who had not courage to submit to an operation, after having enlarged the aperture of the sinus,

nus, by means of a piece of catgut, and passed into the nose a tent of a large size furnished with an external plate, I succeeded in the course of eight months in lessening the lachrymal sac, so as to reduce it to its natural size; and, by destroying at the same time the fungus which formed around the fistulous opening, and within its cavity, sometimes by the hydrargyrus nitratus ruber, at other times by the argentum nitratum, the disease was perfectly cured: which I am certain would not have been effected by the mere dilatation of the nasal canal, or it would have relapsed shortly afterwards, from the permanent dilatation and flaccidity of the lachrymal sac.

When after some time the surgeon shall perceive that by means of this plate the lachrymal sac, instead of projecting outwards, on the contrary sinks within the sulcus of the *os unguis*, the leaden tent should be completely withdrawn, and the external aperture of the lachrymal sac, now reduced to a size only large enough to admit it, be suffered to close, without employing any means to remove the callus which surrounds the margin of the opening; and that for the following reasons: if the tears, no longer mixed with the puriform humour of the palpebræ, pass directly through the nasal canal, and descending without any considerable obstruction are discharged into the nose, the cure is completed;

pleted; and no vestige of this opening remains externally, as its edges, although callous, approximate and contract so as scarcely to be perceptible. If, on the contrary, notwithstanding the nasal canal having been kept dilated, the tears meet some obstruction, in consequence of any unusual foldings of the *via lachrymalia*, they neither accumulate in the sac, so as to distend it, nor flow back upon the eye, but pass partly through the nasal canal and partly through this small external aperture, which has been left conveniently open, from which they issue at intervals in the form of small drops, without even the patient, or those around him, perceiving it; this small discharge, added to that by the nasal canal, being sufficient to preserve the eye constantly clear and free from tears. In process of time, however, the whole of the tears resume their course through the nasal canal, and the external aperture disappears. Some years ago a medical student informed me that he had had, from his earliest infancy, a small aperture upon each lachrymal sac, sufficient to admit the point of a needle, and so small as to be scarcely perceptible to the naked eye. He told me that whenever the secretion of tears was greatly augmented by exposure to very cold air, smoke, or other similar causes, a small quantity of tears issued from this aperture in the form of dew or drops of sweat;

sweat; but that it was not attended with any inconvenience, and that when it took place no defect could be perceived in the part. I am possessed of an extensive series of facts, which point out the advantages of this practice. For, as I have said, either the tears pass freely through the nasal canal into the cavity of the nostrils, and the external aperture, although callous, contracts so closely as to be no longer distinguishable; or the tears for some time are slightly obstructed in their passage through the nasal canal; and, although, they accumulate in the sac, do not distend it immoderately or occasion a relapse of the disease; or, lastly, the disease of the *via lachrymalis* is such, that even after the most methodical treatment, their passage from the bottom of the sac into the nose is altogether, or in a great measure, permanently intercepted; and, in this case, it is better for the patient that a few drops of tears should occasionally escape from the external aperture of the sac, as in the case of the student before mentioned, than that he should be subject to a new distention and ulceration of the sac, and a perpetual reflux and inundation of the tears upon the eye. I can, however, assert that in the greater number of cases which have come under my observation, in which, after the treatment of the *fistula lachrymalis*, a passage has remained open for a few small drops of tears through the

the callous aperture of the sac, it has produced no remarkable inconvenience to the patient, and has ceased spontaneously after a few months. From what has been stated it will be easy for the student to comprehend what I have to say respecting the treatment of the third and fourth stages of the *puriform discharge of the palpebræ*, or rather of the *fistula lachrymalis*.

When the *puriform discharge of the palpebræ* is accompanied with an abscess of the parietes of the lachrymal sac, or an ulceration of its membranes opening externally, this constitutes the true *fistula lachrymalis*. If we recollect that this disease derives its origin from the puriform humour which is abundantly secreted by the glands of Meibomius, and the internal membrane of the palpebræ, and that this thick and tenacious humour being retained and accumulated in the sac, partly by distending and partly by irritating it, has produced an inflammation and consequent suppuration and ulceration of its membranes, and the integuments covering it; the method of treating the *fistula lachrymalis* will not be different from that laid down in the second stage of the puriform discharge of the palpebræ. The primary indication, therefore, in the treatment of the *fistula lachrymalis* will be invariably to correct the morbid secretion of the palpebræ; to lay open the lachrymal sac through its whole extent, and to place
a bou-

a bougie or elastic gum tent in the nasal canal, so that it shall occupy no part of the cavity of the sac; and, lastly, to remedy the flaccidity, suppuration, and ulceration, by escharotic and detergent applications, and by compression. As the spontaneous rupture of the abscess or the ulceration most frequently takes place in a part not favourably situated for dividing the lachrymal sac, with precision, through its whole extent, in such cases, therefore, the surgeon should not attend to the orifice formed by the abscess or ulcer, but should lay it open longitudinally, precisely according to the rules already delivered. In such cases, especially in ulcerations of the internal membrane of the lachrymal sac of long standing, this membrane is constantly found converted into a fungous substance, and in some parts of it hard and callous. The surgeon having therefore placed the bougie or elastic gum tent, secured by a waxed thread, in such a manner as to occupy the nasal canal only, should immediately have recourse to escharotics, such as the hydrargyrus nitratus ruber, either alone, or conjoined with a small quantity of alum, or to the argentum nitratum, with which the cavity of the sac should be sprinkled and filled at each dressing, until the fungus and callus are entirely destroyed, and the ulcer
which

which remains is susceptible of a solid cicatrization.

To this very important part of the treatment of the *fistula lachrymalis* the ancient writers in surgery paid the most scrupulous attention: *Ægnetia*, *Ætius*, *Avicenna*, and the most celebrated practitioners of the succeeding age, have spoken of it diffusely, and have, with much reason, regarded it as one of the most essential points in the cure of the disease. The caustics which they employed for this purpose were the unguentum *isis*,* an ointment composed of ceruse and the hydrarg. nitrat. rub. the unguentum *ægyptiacum* (bxy mel æruginis), the trochisci de minio and the cuprum vitriolatum. This practice, however prudent or advantageous, fell into disuse when the new theory came into vogue, which taught that the *fistula lachrymalis* was derived from no other cause than the obstruction of the nasal canal; and that therefore, in order to effect a radical cure of it, it was only necessary to clear and dilate this canal, or to make a new passage for the tears into the nose. The frequent relapses which have taken place since the introduction of this mode of treatment, and the doubts which even at the present time are occasionally raised by surgical writers of the

* The two principal ingredients in this ointment, according to *Cullen*, are the ærugo æris (cuprum vitriolatum) and alumen ustum.

highest repute, of the possibility of the radical cure of the *fistula lachrymalis*, sufficiently demonstrate the contrary, and prove how improperly the ancient method of employing caustics in a prudent manner has been abandoned in the treatment of this disease. This very useful practice of the ancients has been revived among us by the elder Nannoni,* with this difference, however, that this able surgeon has, in my opinion, proposed too free an use of the caustic, in the treatment of the *fistula lachrymalis*, that is so as to destroy the sac entirely, and convert it into a completely solid and callous body; and this he attempted to do the more confidently, from a persuasion, that, “*when the lachrymal sac is converted into a solid body, the tears occasion little or no inconvenience:*” an opinion, which indeed stands in perfect opposition to observation and the anatomical structure of the parts. But as he adduces instances of persons, in whom, after such treatment, there remained no weeping of the eye, it is reasonable to conclude that the caustic in these cases had destroyed the fungus of the sac, and facilitated the healing of its internal surface, not that it had obliterated the cavity, which, notwithstanding such destruction, had preserved its continuity with the nasal canal.

This is precisely what the surgeon ought

* Trattato Chirurg. sulla semplicità del med. Osserv. xxxi.

to have in view in the treatment of the *fistula lachrymalis*, otherwise, by the total destruction and obliteration of the lachrymal sac, he would only be converting it into another disease equally troublesome, the perpetual reflux and accumulation of tears and matter upon the corresponding eye. The action of the caustic should be therefore regulated in such a manner as only to destroy the fungus, and dispose the internal surface of the sac to heal. After this has been accomplished, the bougie or elastic gum tent should be withdrawn from the nasal canal, and the rest of the treatment conducted in the manner before directed, by compressing the external part of the sac, by means of the plate affixed to the tent of lead, and after it is withdrawn, allowing the tears the greatest possible opportunity of discharging themselves into the nose.

The fourth stage of the puriform discharge of the palpebræ, commonly called by surgeons *fistula lachrymalis cum carie*, is a disease less common than was formerly imagined, but which, however, I have had frequent opportunities of seeing, in the course of my practice; and from my own observations on this subject, it appears to me that this stage of the *fistula lachrymalis* presents itself under two distinct forms. The first is that in which the sac, having been for a considerable time enormously distended,

and filled with a mixture of matter, tears, and the puriform humour of the palpebræ, is entire externally, but opens internally into the corresponding nostril through the *os unguis*, which is carious and eroded, and in which the destruction of the *via lachrymalia* is so great that the nasal canal is obliterated and destroyed, and may be considered as having no connection with the lachrymal sac. The other form of the disease is that in which the ulcerated sac opens externally, and the *os unguis* in its posterior part is denuded and carious, but not perforated, and where the nasal canal is indurated and filled with fungus, so as to be nearly closed and separated from the rest of the *via lachrymalia*.

The first form of this disease may be known, by observing, that when the sac, which is very large, is even gently compressed, a small portion only of the purulent humour contained in it issues through the *puncta lachrymalia* upon the eye, while the greater part of that fluid is discharged into the nose, and the capacious sac at the same time subsides and disappears, and the matter which issues abundantly from the corresponding nostril emits a foetid odour which is peculiar to carious bone. The second form of this disease is rendered evident by the introduction of a probe into the sac, by which the *os unguis* is found denuded, and which being pressed downwards in all directions, instead of entering the nasal canal,

canal, comes in contact only with fungous, indurated, and contracted parts.

The first of these forms of the *fistula lachrymalis*, is not beyond the reach of art, and allows us to hope for a perfect cure, provided the disease only includes the *os unguis*, with a small part of the ethmoidal cells. For if the sac be laid open through its whole extent, without any regard to the restoration of the nasal canal, and its cavity cleared by means of escharotic and detergent applications, as the aqua calcis with mel rosæ, the separation of the carious and perforated bone, and the contraction of the cavity of the sac, are necessary consequences. The puriform discharge of the palpebræ ceases by applying upon the internal surface of the eye-lids, from the commencement of the treatment, the unguentum ophthalmicum, the action of which remedy may be assisted, according to circumstances, by the internal use of such medicines as are adapted to correct the particular diathesis, by which the morbid secretion of the palpebræ has been produced or kept up. These advantages being obtained, and the internal surface of the sac healed, and nearly reduced to its natural size, if the edges of the external wound are permitted to approximate and contract, so that there is no longer any vestige of it, the opening which remains in the posterior part of the lachrymal sac, communicating with the corresponding nostril, is so large, from the defi-

ciency of the *os unguis* and the pituitary membrane which covers it on the side of the nose, that the tears carried by the *puncta lachrymalia* and lachrymal canals into the sac are immediately discharged into the nose, so that the cure may be considered as complete, since the patient is no longer incommoded by the overflowing of the tears.

The same method of treatment is attended with equal success in the second form of the *fistula lachrymalis*, accompanied with denudation of the *os unguis*; with this difference, that as the *os unguis* is only denuded and not perforated, and the pituitary membrane covering it on the side of the nostril is entire, and as there is no hope of being able to restore the office of the nasal canal, in this case it becomes absolutely necessary to make a new and permanent passage for the tears into the nose, by perforating and destroying the denuded *os unguis* and the corresponding portion of the pituitary membrane. Experience has shown, that the mere perforation of the *os unguis* and pituitary membrane, without a destruction of a portion of the latter to some extent around the place of perforation or separation of the bone, does not sufficiently answer the purpose, since this opening in process of time becomes too small for the discharge of the tears, and continues gradually contracting until it is entirely closed. A very common exemplification

fication of this presents itself in the caries of the palate from a venereal cause. When the carious portion of bone is separated, a communication sometimes remains between the nose and mouth, sufficient to admit the point of the finger; this aperture, however, gradually contracts itself, so as scarcely to admit a writing quill, and it sometimes even closes up entirely, in consequence of the approximation of the membrane of the palate, which has been divided, but not much injured by the preceding ulceration attending the caries of the subjacent bone. If this takes place under such circumstances the closing of the pituitary membrane is much more to be expected after the simple perforation of it by the trocar, which is employed for the purpose of piercing the *os unguis*. The tubes, which have been proposed for keeping this perforation of the pituitary membrane constantly open are not to be confided in, since even those which are best constructed for producing such an effect are very frequently, after a short time, forced upwards against the anterior part of the lachrymal sac, or they fall into the nostrils too soon, or in the space of a few months they are filled with an earthy substance which renders them completely impervious and useless. The perforation and separation of the denuded *os unguis*, therefore, as well as the destruction of a portion of the pituitary membrane around the

part where *os unguis* has been detached, are the only certain and efficacious means hitherto discovered, which can secure a permanent passage for the tears into the nose: to answer which purpose no mode of treatment appears better adapted than the application of the actual cautery, which, though certainly too freely employed by the older surgeons, has been too hastily rejected by the moderns.* Men's opinions generally run into extremes. The ancients cauterized the *os unguis* and pituitary membrane, in every case of *fistula lachrymalis*, and very frequently without necessity; the moderns, notwithstanding its evident utility and necessity, neglect it altogether.

For the purpose of applying the cautery, the sac should be divided through its whole extent, and its cavity filled with soft lint, which should be retained in its place by means of a compress and bandage. At the end of two days the dressing should be removed, and the cavity of the sac and denuded bone made perfectly dry. A canula† being introduced within the sac, and placed upon the *os unguis* in a direction a little oblique from above downwards, and the patient's head firmly supported, the surgeon with one hand should hold the canula, and with the other pass the cautery‡ as far as the *os*

* Of this opinion also is Richter. *Obs. Med. Chirurg.* ch. x.

† Plate III. fig. 5.

‡ Plate III. fig. 6.

unguis, upon which he should make a moderate degree of pressure, in order that the point of the cautery may not only pass beyond it, but also destroy the pituitary membrane which covers it internally. And as it is a matter of the greatest importance for the complete success of the operation, that this part of the membrane should form an eschar, and be completely detached around the opening in the bone, if the surgeon therefore perceive that the point of the cautery cools too quickly, he should carefully apply a second, which he should have in readiness for that purpose. The cavity of the sac should be afterwards filled with soft lint spread with an emollient ointment, such as that consisting of wax and oil, and the patient be directed to draw up his nostrils frequently in the course of the day the *aqua malvæ* in a tepid state. If, on the following day, the patient feel much pain and there be considerable tumefaction of the nose and palpebræ, they should be covered with a poultice of bread and new milk. As soon as a suppuration is established between the sound and cauterized parts, the eschar of the pituitary membrane will be discharged through the nose, and the fragments of the *os unguis* will pass partly along with the matter by the external opening of the sac, and partly by the nostril. Through this new opening into the nose the surgeon should now introduce

introduce either a bougie or a small sondon of fine linen tied with a waxed thread, to prevent its falling into the nostrils, the size of which should be increased in proportion as the new opening becomes larger by the loosening of other portions of the eschar of the pituitary membrane or particles of bone. Besides the application of the ophthalmic ointment of Janin, in order to suppress the puriform discharge of the palpebræ, escharotics should be employed at the same time, with a view to destroy the fungous and indurated parts of the sac, and to obtain a contraction of its cavity nearly to its natural size. When the whole internal surface of the sac is nearly healed, if there be any appearance of fungus around the artificial opening in the nose, it should be repressed by touching it frequently with the *argentum nitratum*; nor should this be omitted until the margin of this internal opening be as perfectly healed as the rest of the cavity of the sac. After which the lips of the external wound should be suffered to close without scarifying their edges, *

It may not be unnecessary to observe here, that the treatment of this, as well as of the second stage of the puriform discharge of the palpebræ is of long duration, and that the cure is seldom completed in less than four months, even where the most diligent attention is paid, and the patient, in other respects, is perfectly healthy.

healthy. But this delay is sufficiently compensated by a perfect and lasting cure.

From what has been delivered in this chapter we are enabled to draw the following conclusions.

1. That the disease generally termed *fistula lachrymalis*, which is divided by some very accurate writers into the *simple*, the *compound*, with atony or flaccidity of the sac, and the *complicated* with caries of the *os unguis*, is principally derived from the morbid secretion of the glands of Meibomius and the internal membrane of the palpebræ.

2. That it is impossible to obtain a perfect cure of this disease in any degree, stage, or complication, unless the morbid secretion of the palpebræ be at the same time permanently corrected by the application of topical remedies upon the margin and internal surface of the affected eye-lids, and by the use of such internal medicines as are calculated to correct the particular predisposition from which the morbid secretion of the palpebræ is derived.

3. That in the second stage of the disease attended with atony and evident distention of the sac, although the morbid secretion of the palpebræ be corrected, and the action of the nasal canal perfectly restored, the weeping of the eye will nevertheless continue, unless the sac be reduced to its natural size, by laying it
open

open through its whole extent, and by applying upon its internal surface escharotics, and afterwards detergent and astringent remedies, so as to reestablish a certain proportion between the capacity of the sac and the caliber of the nasal canal.

4. That the *fistula lachrymalis*, accompanied with caries and perforation of the *os unguis*, and of that portion of the pituitary membrane which covers it, together with an obliteration of the nasal canal, provided the caries has not penetrated too deeply within the ethmoidal cells, particularly in unhealthy constitutions, admits of a perfect cure, without any inconvenience remaining from the weeping of the eye, by merely destroying the fungus within the cavity of the sac, by promoting the separation of the edges of the carious and eroded bone, and by restoring the cavity of the sac to its natural size, and healing it internally.

5. That in the *fistula lachrymalis*, with denudation of the *os unguis*, and an insuperable obstruction of the nasal canal, in which it becomes necessary, in order to effect a perfect cure of the disease, to make a new passage for the tears from the sac into the nose, the application of the cautery is preferable to the simple perforation of the bone and pituitary membrane by means of the trocar; since the passage in the *os unguis* does not remain sufficiently and constantly

stantly open, unless the portion of pituitary membrane which covers it be also destroyed.

6. That at the end of the treatment of the second, as well as of the third and fourth stages of the disease, it is an useful precaution not to scarify the edges of the external orifice of the sac, which is now healed internally, but to suffer them to contract spontaneously, until at least there are the most certain indications that the tears meet with no obstruction in the sac, and either pass completely through the nasal canal, or through the artificial opening made in the *os unguis* and pituitary membrane.

CASE I.

A young lady of Pavia, 17 years of age, of a delicate and sensible fibre, began to experience an unusual difficulty in opening the right eye, in consequence of a preternatural tumefaction of the palpebræ of that side, accompanied with a weeping of the eye, and an accumulation of gum, especially in the morning. She was directed to wash the eye frequently with elder-flower water. After four months the disease had greatly increased, and on being consulted, I found, that on pressing the lachrymal sac a very considerable quantity of puriform matter issued from the *puncta*. On everting the palpebræ of the right side, the internal surface, especially of the inferior eye-lid, near its margin, was

was evidently more tumefied than natural, and had a villous appearance, the glands of Meibomius were more turgid and elevated than usual, and interwoven with small varicose vessels: which appearances were not perceptible, or in a very small degree, upon the internal surface of the left side. The right ala of the nose in this young lady also had been for several months very red and swollen, and the internal surface of the corresponding nostril incrusted and dry.

Having pressed out all the puriform matter contained in the sac, I attempted to inject some water through one of the *puncta lachrymalia*, and at the fourth attempt the water passed into the nose and fauces. And as the lachrymal sac was not perceptibly more distended than natural, I directed all my attention to divert the discharge, to diminish and correct the morbid secretion, and at the same time to strengthen the varicose vessels of the internal membrane of the affected eye-lids.

I therefore ordered the patient to take, in the course of the day, a pint of milk whey, with a dram of the crystals of tartar, and half a grain of tartarized antimony, which did not disagree with the stomach, and procured one, and sometimes two copious evacuations every day.

As a local application, a small quantity of the ophthalmic ointment of Janin was introduced between the eye-lids, prepared exactly according
to

to the author's formula. The irritation which this remedy produced in the present case was so violent, that in little more than an hour, notwithstanding the parts were repeatedly washed with milk, the eye-lids became enormously swollen and inflamed. During the inflammation, which continued four or five days, the puriform discharge was entirely suppressed, nor could any thing be forced from the sac, though pressed upon at different intervals, except pure tears. On the subsidence of the inflammation the puriform discharge of the palpebræ returned nearly as before. The ophthalmic ointment was again applied, which was rendered less active by adding a double quantity of lard, of which a portion equal to a grain and a half of wheat was applied morning and evening, the *via lachrymalis* being previously cleared by an injection of plantain water with a small quantity of spirit of wine added to it, and a few drops of the vitriolic collyrium were instilled into the eye three or four times a day.

By this treatment, at the end of three weeks the puriform discharged was greatly diminished, and consisted of little more than tears rendered turbid by mucus, and the right ala of the nose was no longer incrusted, but resumed its natural appearance. The internal membrane of the eye-lids became gradually pale and smooth, the glands of Meibomius recovered their natural

size, and the varicose vessels disappeared; the use of the whey with the antimon. tart. was now suspended.

About the fortieth day, on pressing upon the sac, there only issued from it pure tears, and the injection passed with the greatest facility from the *puncta lachrymalia* into the nose. The tears, however, continued to meet with some obstruction, and the patient, on exposing herself to cold air, or reading by the light of the candle, was obliged to wipe the eye frequently. As this inconvenience did not appear to arise from an atony of the sac, and as the patient constantly complained of a fullness of the pituitary membrane of the right nostril, by which the extremity of the nasal canal suffered some degree of constriction, I ordered her to draw up her nostril frequently in the course of the day the vapour of vinegar and water, and to take a little snuff. This expedient succeeded very well, for in ten days the discharge from the nose was reestablished, and the weeping of the eye entirely ceased.

CASE II.

Maria Bordoni, of S^a Christina, a girl 12 years old, who had been subject in her infancy to frequent attacks of ophthalmia, in one and sometimes both eyes, was affected for eight weeks with a weeping of the right eye, and a considerable

able discharge of apparently purulent matter. She was brought by her parents to the hospital, not so much on this account, as in consequence of a small hard, red, and painful tumour which had made its appearance, within six days, between the internal angle of the eye and the nose.

The edges of the eye-lids, of the right side were considerably tumefied, their internal surface red, and presenting a fungous appearance, and the glands of Meibomius greatly increased in size.

A poultice of bread and milk was applied upon the tumour, as the membrane of the sac appeared to be in a state approaching to suppuration; in a few days, however, the inflammation was dissipated, the tumour subsided, and the *puncta lachrymalia*, which before appeared to be retracted towards the caruncle and were concealed, now separated from the commissure of the palpebræ, and resumed their natural position. On pressing now upon the lachrymal sac the puriform matter issued in great abundance from the *puncta lachrymalia* upon the eye.

I began immediately to employ the ophthalmic ointment of Janin night and morning in a quantity not exceeding the size of a barley-corn. By this application the puriform discharge of the palpebræ was at first increased, but in the course of a month diminished so considerably, that there only issued from the sac a diluted

mucus. As soon as the edges and internal surface of the eye-lids had recovered their natural state, I began to inject through the *puncta lachrymalia*, plantain water, with a little of the vitriolic collyrium, added to it, which had been filtered, and the injection passed into the nose. The child was treated in this manner for twenty days more, and then discharged from the hospital perfectly cured.

CASE III.

A country boy, 10 years of age, after a variolous metastasis to the eyes, with which he had been attacked two years before, was affected with a weeping of both eyes and a gumming of the eye-lids. The palpebræ were thickened and deprived of their lashes, and their internal surface was of a dark red colour, and had a villous appearance; the glands of Meibomius were more elevated than usual, and on pressing the sac on each side, which, however, did not appear to be more distended or elevated than natural, a considerable quantity of curdly, yellowish, puriform matter issued from the *puncta*. This child had, what is commonly called, a gross habit of body.

I began the treatment, by ordering ten ounces of the decoction of the triticum repens, a dram of the cryſtalli tartari, and half a grain of the antimonium tartarizatum, to be taken every day
at

at intervals; and if the medicine should purge him too much, he was directed to take only half the quantity for a few days following. I directed also that the ophthalmic ointment of Janin should be applied morning and evening between the palpebræ of both eyes, which, as usual, considerably increased the secretion of puriform matter. Finding that at the end of two weeks the discharge did not diminish, I made a seton in the neck which presently suppurated and greatly relieved the eyes. From this period, by continuing the application of the ophthalmic ointment, and frequently purging the patient with small doses of the antimonium tartarizatum, the puriform discharge gradually diminished, the edges of the eye-lids subsided and recovered their natural flexibility, and the internal surface began to assume a pale colour, and to lose its villous appearance. The daily and frequent use of the vitriolic collyrium, and the injection of plantain water with a little spirit of wine through the *puncta lachrymalia* was never omitted. The injection at the first passed with some difficulty, but it afterwards descended freely into the nose on both sides; and towards the end of the third month the child left the hospital completely cured.

CASE IV.

A girl, four years of age, of Parpanese, was affected after the small-pox with an habitual ophthalmia of the right eye, accompanied with a turgescence of the edges of the eye-lids, a copious discharge of puriform matter, and great sensibility of the eye to a very moderate degree of light. After an ineffectual treatment of several months, the child was brought to Pavia, in the beginning of December 1798. The internal surface of the palpebræ was red and villous, and on compressing the sac a thick, yellowish matter mixed with tears, issued from the *puncta lachrymalia*, similar to that with which the eye-lids were continually imbued. The lachrymal sac, however, did not appear larger or more elevated than natural. It is proper to remark that the lymphatic glands of the neck were enlarged and indurated, the abdomen turgid, and that the child had an extraordinary voracity for every kind of food. Added to this, there was a constant discharge of a whitish matter from the parts of generation, similar to the *fluor albus*.

I ordered, at first, a good diet, and directed that the child should take every day, in small doses, a pint of the decoction of the *triticum repens*, with a dram of the *crystalli tartari*, and half a grain of the *antimonium tartarizatum*. This remedy occasioned at first a copious vomiting
of

of viscid, yellowish matter, but afterwards it excited only a slight nausea, and two or three evacuations in the course of the day, without inducing debility. A few days afterwards I directed three drops of the *Tinctura Thebaïca* of the London Pharmacopœia to be instilled into the eye for several successive nights, which excited great pain at the first, but after a few minutes it ceased entirely, and left the eye in a better state than before, having rendered it less impatient of the light. After pursuing this treatment for two weeks, I made a seton in the neck, which presently produced a copious suppuration, and was attended with a considerable diminution of the chronic ophthalmia. The use of the antimonium tartarizatum was continued in small doses, and the ophthalmic ointment of Janin substituted for the Thebaïc tincture, at first only in the evening, but afterwards morning and evening, and the vitriolic collyrium was dropped into the eye every three hours in the day.

By the use of these remedies the chronic ophthalmia was entirely dissipated, the edges of the eye-lids recovered their form and natural state, and the quantity of puriform matter which issued from the *puncta lachrymalia* upon the eye, by pressing upon the sac, was gradually lessened. Towards the end of February of the same year, the regurgitation of matter ceased altogether, as

well as the cohesion of the eye-lids during the night. The tumefaction of the abdomen and lymphatic glands of the neck was very much diminished; the child improved in its appearance; and was satisfied with a moderate quantity of food; there was yet, however, a little discharge from the genitals. In the beginning of March I ordered the child to take two ounces of the tincture of the cinchona three times a day.* Towards the middle of April she was dismissed perfectly cured, without any fear of the puriform discharge of the eye-lids degenerating into the *fistula lachrymalis*. The seton was kept open for several months afterwards.

CASE V.

Signora Angiola P. . . , a lady, 40 years of age, living in the vicinity of this city, neglected a puriform discharge of the palpebræ for more than 11 years, which by degrees produced an enormous dilatation of the lachrymal sac. When I examined her the first time, the lachrymal sac was full, the tumour which it formed externally was rather larger than a filbert, and on being pressed gave issue to a large quantity of viscid, curdly, greenish matter. The edges of the eye-lids of the same side were tumid, and

* I suspect the author here means a watery tincture or infusion of the bark, as such a quantity of the spirituous tincture could not fail to have been attended with unpleasant effects.

internally red and fungous, and the sebaceous glands greatly enlarged.

I laid open the lachrymal sac through its whole extent, from the ligament of the orbicularis muscle to the lowest part of it, and having passed a fine probe through the nasal canal, and afterwards one of a larger size, I introduced into it a bougie an inch and a half long, tied with a waxed thread, in such a manner that its upper extremity should remain entirely concealed in the nasal canal; and I filled the whole cavity of the sac very exactly with soft lint, which I confined in its situation by means of a compress and the *monoculus* bandage.

At the end of two days I took off the dressings, without removing the bougie from the nasal canal. I found the whole internal surface of the sac in a fungous state. I filled its cavity with a doffel of lint spread with a liniment, consisting of the hydrargyrus nitratus ruber, and mucilage of gum arabic. On the following day the doffel of lint came away covered with a thick whitish or cottony crust, and this substance continued to come away in an increased quantity by the use of the hydrargyrus nitratus ruber, with which the cavity of the sac was filled several times in the course of three weeks. From this time, by the repeated application of the caustic powder, the fungus of the internal surface of the sac

began to disappear, and its cavity to contract. I withdrew the bougie for the first time from the nasal canal in order to clean it and immediately replaced it.

This treatment was continued during twenty days longer, occasionally increasing the activity of the hydrargyrus nitrat. rub. by the addition of a small quantity of alum, and keeping the external opening of the sac dilated by the introduction of lint, and sometimes sponge, and that with the same advantage as before, with respect to the destruction of the fungus and the contraction of the atonic and flaccid sac. The dressing afterwards consisted in filling the cavity of the sac very exactly with lint moistened in the aqua calcis and mel rosæ. I then withdrew the bougie from the nasal canal for the second time, for the purpose of cleaning it, and immediately replaced it as before.

The cicatrix began to extend from the edges of the external opening of the sac towards its internal surface, which in a month after this period was nearly reduced to its natural capacity. There remained, however, here and there some points not healed, which appeared rather disposed to throw out a fungus; and that part of the sac situated above the tendon of the orbicularis muscle,* which had not been included in the incision, was not yet diminished, in pro-

* Plate I. a.

portion to the rest of the sac. The cure was completed three weeks afterwards, by the occasional application of the *argentum nitrat.* and dry lint.

At the expiration of this time the bougie was entirely withdrawn from the nasal canal, and the leaden tent with its plate* intended to compress the anterior part of the sac substituted in its place. I directed her to wear this for a full month, and to clean it every day, and wash the eye with plantain water mixed with a little spirit of wine.

The palpebræ having recovered their natural state by the application of the ophthalmic ointment of Janin, which had been employed from the beginning of the treatment, and there being only a discharge of limpid tears from the orifice of the sac, I removed the leaden tent entirely, the plate of which had so completely compressed the sac, that instead of threatening a new elevation, it was even more depressed within the *fulcus* of the bone than natural. The edges of the orifice of the sac, which before were callous and elevated around the cylinder of the tent, immediately contracted, although they had neither been stimulated nor scarified, without leaving scarcely any vestige of the incision made in the sac; and the tears immediately passed into the nasal canal. It is proper to remark that,

* Plate III. fig. 9.

except during the first fifteen days from the operation, the patient constantly attended her family affairs as usual, and that she has now enjoyed five years of the most perfect health, suffering no inconvenience either from the weeping of the eye or the discharge of matter.

CASE VI.

Signor Francesco Bochioli, of S. Angelo Lodigiano, a robust man 50 years of age, was affected for about 10 years with a puriform discharge of the palpebræ of the right eye, attended with atony and great dilatation of the lachrymal sac, which occasioned a continual discharge of tears, and frequent attacks of acute ophthalmia on that side. When I saw him, the tumour formed by the lachrymal sac was the size of a nut, slightly inflamed and painful; the edges of the eye-lids were tumefied as usual, their internal surface was florid and villous, and the glands of Meibomius enlarged.

A poultice of bread and milk was applied for two days upon the affected palpebræ and lachrymal sac, to diminish the rigidity of these parts, and at the same time to lessen the slight degree of inflammation and tension of the integuments. The operation was then performed as in the preceding case, by laying the sac open through its whole extent, from the tendon of the orbicularis muscle to the lowest part of it, and introducing

roducing a bougie an inch and a half in length into the nasal canal, without its upper extremity projecting into the cavity of the sac.

The fungus of the internal surface of the lachrymal sac was very considerable, in order to destroy which I was under the necessity of employing, for thirty successive days, sometimes the escharotic liniment abovementioned, occasionally the hydrarg. nitrat. rub. alone or mixed with alum, by means of which there came away at each dressing a stratum of a white thick substance resembling cotton.

Having destroyed the fungus, the ulcer which occupied the internal surface of the sac produced healthy granulations, and the sac was disposed to contract in every direction. As the opening was too narrow, and prevented the commodious introduction of the doffel of lint into the cavity of the sac, it consequently became necessary to have recourse for a few days to the prepared sponge.

On attempting to withdraw the bougie for the first time from the nasal canal, the thread with which it was tied broke, probably from being too much macerated, and the bougie was left in the canal and entirely forgotten, until the cavity of the sac was perfectly healed and contracted. This was obtained in the course of 40 days, by only introducing dry lint into the sac, and occasionally touching the bottom of
the

the wound with the argent. nitrat. The cicatrix, as usual, commenced from the edges of the wound, and by degrees extended over the internal surface of the sac, which was now reduced nearly to its natural capacity. The edges of the palpebræ of the right side had also recovered their natural state and flexibility from the uninterrupted use of the ophthalmic ointment of Janin.

The internal surface of the sac being now completely healed, I introduced a thick probe through the sac into the nasal canal, in order to push the bougie downwards, and make it pass out by the nose or fauces; but, contrary to my expectation, the probe passed freely into the nose, and the injection even more so, which led me to suspect that the bougie had recently descended into the fauces and stomach during the patient's sleep, without his having perceived it. I substituted in its place a leaden tent furnished with the small plate for compressing the anterior part of the sac, which the patient wore for 50 days; during this time he attended his business, and took it out and replaced it himself occasionally. The plate by means of the weight of the leaden cylinder, having depressed the anterior part of the sac considerably towards the sulcus of the bone, I withdrew the tent entirely, and the external orifice of the sac closed without

out its edges being scarified, and the tears passed through the nasal canal.

CASE VII.

Dominica Roffi, a female peasant 30 years of age, a native of the Genoese Mountains who lived in this city in the capacity of a servant, of a strong and sanguineous temperament, but who had been formerly subject to herpetic eruptions and erysipelas of the face, had during several years a weeping of the left eye and a gumming of the eye-lids, with tumefaction of their edges and enlargement of the corresponding sebaceous glands. The lachrymal sac of that side had gradually increased to the size of a filbert, and on being pressed gave issue to a considerable quantity of puriform matter. In this state she was admitted into the practical school of surgery, the 9th of December 1796.

Although, from the great distension and tumefaction of the lachrymal sac, no doubt could be entertained of the necessity of commencing the treatment by laying it open, yet in order fully to convince the students that the puriform matter which issued copiously from the sac upon the eye, was not generated in the sac itself, but was principally transmitted to it from the increased morbid secretion of the palpebræ, I merely endeavoured to correct or restrain this morbid secretion of the eye-lids, by the application

tion of the opthalmic ointment of Jarin, and the frequent use of the vitriolic collyrium. At the end of three weeks, the discharge having been almost entirely suppressed by these local remedies, there only issued from the distended sac limpid tears, or which were rendered slightly turbid by a small quantity of thin mucus.

I then proceeded to the radical cure, by laying the sac open through its whole extent, and introducing a bougie into the nasal canal in the manner before mentioned, and lastly by filling the cavity of the sac with dry lint, which was maintained in its situation by a compress and bandage.

Two days after, the dressings were removed and the cavity of the sac filled with a dossil of lint spread with the liniment, consisting of the hydrarg. nitrat. rub. and mucilage of gum arabic. This remedy gave the patient a good deal of pain, which is not the case in general, and occasioned a considerable tumefaction of the cheek; in consequence of which I was under the necessity of desisting from it for some days. It was, however, afterwards renewed with a larger proportion of mucilage. By the corroding action of this application I obtained in the course of a month a sloughing of the internal membrane of the sac, and a considerable contraction of its cavity, the internal surface of which showed a very favourable disposition to heal.

heal. The lips of the orifice were carefully prevented from closing too quickly by the frequent introduction of sponge instead of lint. As soon as the cavity of the sac was reduced to its natural size, and completely healed internally, the bougie was withdrawn from the nasal canal, and the leaden tent with its compressing plate introduced in the place of it. The sac and the rest of the *via lachrymalis* were daily washed, sometimes with plantain water and spirit of wine, at other times with the aqua calcis and mel rosæ.

Towards the middle of May, the external part of the sac being so much depressed by the plate as to leave no fear of its yielding to the impulse of the tears, every application was removed from it, and its external orifice suffered to close. The tears were discharged into the nose; with this difference, however, that if by any accident the lachrymal fluid was secreted in larger quantity than usual, a few drops issued from this small and almost imperceptible aperture in the sac, and thus preserved the eye constantly dry. This occasional discharge continued during some months after the patient had left the hospital; it afterwards disappeared entirely, and she has remained perfectly well ever since. It is proper to observe, that, before the operation, and for several weeks afterwards the ophthalmic ointment of Janini was made use of

at night until the morbid secretion of the palpebræ was completely suppressed; and that during the treatment the patient was frequently purged either with small doses of the tartarized antimony and crystals of tartar, or with the solvent pills of Schmucker.*

CASE VIII.

Maddalena Marinoni of Scaldasole, a girl 19 years of age, was admitted into this hospital in January 1792, on account of a puriform discharge of the eye-lids, attended with a small degree of elevation of the lachrymal sac. By the constant use of the ophthalmic ointment of Janin morning and evening, and occasionally of the collyrium vitriolicum, the morbid secretion of the eye-lids entirely ceased, but the eye remained constantly watery, and the sac as much elevated as at first, which, on being pressed, discharged by the *puncta* an abundant quantity of limpid tears. The puriform discharge of the palpebræ was changed into that disease, which is generally called by surgeons *the dropsy of the lachrymal sac*. Being perfectly satisfied, that, in order to restore to the sac its natural elasticity and size, little advantage would be derived either from astringent injections, or compression, I determined to lay it open longitudinally, which I found internally smooth, and without the least

* See the Chapter on Amaurosis.

appearance of fungus. After having examined the nasal canal I introduced into it a silver tube, which was to remain there permanently, exactly similar to that recommended by Bell;* and having injected some warm water, in order to cleanse the inside of the sac and canula, I brought the lips of the wound together, and retained them in contact by means of some strips of adhesive plaster, a compress, and the *monoculus* bandage.

The subsequent inflammation of the sac and palpebræ was very considerable, and it was necessary to take away blood copiously, to cover the parts with an emollient and anodyne plaster, and to confine the patient to a low diet. In a week the inflammation abated, and the lips of the wound were united and consolidated; in short every thing went on surprisingly well; there was no longer any weeping of the eye, and three weeks after the operation the patient was discharged from the hospital perfectly cured. After continuing well for a year, she began to complain of a sense of weight and pricking between the internal angle of the left eye and the nose, and the weeping of the eye again returned. A small tumour appeared in the situation of the lachrymal sac, which on being pressed gave pain, and gradually inflamed.

* A System of Surgery, vol. iv. plate 42. fig. 5, 6.

It ultimately suppurated and burst externally, discharging matter mixed with tears. In this state the girl returned to the hospital about 19 months after the division of the sac and introduction of the tube into the nasal canal.

On pressing this tumour, even slightly, it was easy to discover that it contained an extraneous body, and I had no doubt that this was the metallic tube which had been formerly placed in the nasal canal. Without therefore regarding the opening formed by the abscess, I laid the sac again completely open, from the tendon of the *orbicularis palpebrarum* to the lowest part, and found the tube lying across it; I extracted it and found that it was completely filled with a compact calcareous substance; after which I only filled the sac with soft lint and covered it with a compress and bandage.

On removing the first dressing, which was two days after, the whole internal surface of the sac exhibited a florid, irregular, and fungous appearance. The probe however passed with perfect facility through the nasal canal into the corresponding nostril, and I therefore introduced into it without delay a bougie one inch and a half in length, tied with a waxed thread, and pushed so far downwards that its upper end might not project into the cavity of the sac. For the purpose of destroying the fungus formed by the internal surface of the sac, I employed at first,

first, for several days, a doffel of lint dipped in the liniment, consisting of the hydrarg. nitrat. rub. and mucilage of gum arabic; I afterwards filled the whole cavity of the sac repeatedly with the hydrarg. nitrat. rub. in powder.

At the end of seven weeks the cicatrix began to extend from the margin of the wound towards the bottom of the sac, which was now almost reduced to its natural size. The dressing only consisted of dry lint, or sometimes of lint dipped in the aqua calcis and mel rosæ, with a few drops of spirit of wine added to them. In 20 days more the cavity of the sac was completely healed, nor was it necessary to use the argentum nitratum more than twice or three times. I now withdrew the bougie from the nasal canal and introduced a leaden tent mounted with a plate, which the patient wore for a month, when it was removed, and the external orifice of the sac suffered to close without scarifying the edges.

The tears passed into the nostril and no longer regurgitated from the *puncta*, and collected upon the eye. Injections also thrown into the *puncta* passed freely into the nose. If, however, from any cause the secretion of tears was increased, a small portion of that fluid issued from the contracted aperture remaining in the sac, which occasioned no sensible inconvenience, as the eye remained constantly clear. This small

and occasional discharge from the almost imperceptible aperture in the sac gradually diminished, and after four months completely disappeared. To this last instance I might add a great number of similar histories, which I omit, not only for the sake of brevity, but because they would not afford a clearer illustration of what has been advanced on this subject.

CASE IX.

An elderly woman, 55 years of age, was admitted into the practical school of surgery from the country, on account of a small and somewhat indolent tumour, the size of a small nut, which she had had for a considerable time, situated between the internal angle of the right eye and the nose. In pressing upon this tumour, which readily yielded, a considerable quantity of greenish offensive matter issued from the corresponding nostril; and a small quantity of the same viscid fluid from the *puncta lachrymalia*, upon the eye.

The woman stated, that she had been affected with this disease during 15 years, and that it began with an immoderate gumming of the eye, which she had never attended to; that the tumour had frequently burst externally, attended with relief, and closed again spontaneously; that within the last year, after much swelling of the whole face and violent pains within the
root

root of the nose, she was relieved by the discharge of a considerable quantity of fetid matter from the right nostril, but that notwithstanding the tumour continued to increase every day more and more. The edges of the eye-lids of the right side were rigid, indurated, red, and in a fungous state internally, and the sebaceous glands enlarged.

I pushed the point of a bistoury immediately below the tendon of the *orbicularis palpebrarum*, and directed the instrument against the *os unguis*; then, following the fold of the inferior eyelid, I laid the sac completely open. In the act of dividing it a considerable quantity of matter gushed out; opposite the incision I found the *os unguis* wanting, and round this part there were portions of the ethmoid bone denuded. The opening which was formed by the deficiency of the *os unguis*, was large enough to admit a thick writing quill, and communicated directly with the right nostril. The pituitary membrane around this opening was equally destroyed; I took great pains to discover the nasal canal, but without success. The cavity of the tumour was filled with lint, and a poultice of bread and milk applied upon the eye-lids, in order to soften their hard and rigid edges.

On removing the dressings the following day, I found the whole internal surface of the sac converted into a fungous ulcer. I filled the

cavity very exactly with lint dipped in the caustic liniment mentioned in the preceding case; and, in order to prevent it from passing into the nostril, I previously introduced into the opening formed by the deficiency of the bone, a small findon with a waxed thread passed through the centre of it, similar to that which is used after the operation of trepanning the cranium. Besides a copious discharge of matter from the enlarged sac, pieces of slough and sometimes particles of carious bone came away at each dressing. The parts where the fungus was more prominent than the rest, were sprinkled with the hydrargyrus nitratus ruber alone, or mixed with alum, and occasionally touched with the argentum nitratum.

By continuing this treatment for 30 days the ulcer assumed a healthy and granulating appearance, and had a tendency to contract in every direction. The treatment afterwards consisted in dressing the wound with dry lint, and occasionally touching the edges of the large orifice, leading from the sac into the nostril, with the argentum nitratum.

Towards the 60th day the ulcer was completely healed, and the sac nearly reduced to its natural size, and by the uninterrupted use of the ophthalmic ointment of Janin, morning and evening, and the vitriolic collyrium three or four times a day, the palpebræ had recovered
their

their natural healthy condition. The edges of the external orifice of the sac were now permitted to close, the tears being directly discharged into the nostril through the large opening formed in the posterior part of the sac by the deficiency of the *os unguis*, and the woman left the hospital perfectly cured.

CHAP. II.

OF THE HORDEOLUM.*

THE hordeolum, strictly speaking, is only a small bile which forms upon the margin of the palpebræ, most frequently towards the great angle of the eye.

Like the furuncle, this small tumour is of a dark red colour, highly inflamed and much more painful than might be expected from the smallness of its size; which arises partly from the violence of the inflammation, by which it is produced, and partly from the exquisite sensibility and tension of the skin which covers the edges of the eye-lids. Hence it is that the hordeolum, in persons of delicate and sensible habits, frequently occasions fever and restlessness; its suppuration is slow and imperfect, and when matter is formed in it, it does not appear disposed to burst.

This particular form of inflammation, which might be called *furuncular*, differs in several respects from common *phlegmonous* inflammation. The former commences in the skin, extends itself downwards into the subjacent cellular membrane, and produces a more or less extensive destruction of it; the *phlegmonous* in-

* Κριθη, χαλαζα, grando, stye, stithe, or stian.

inflammation

flammation, on the contrary, originates in the cellular membrane, the vitality of which it does not destroy, and is afterwards propagated externally to the skin. The *furuncular* inflammation is quickly arrested, and forms a small, circumscribed, hard, and very painful tumour, which, though elevated upon the skin, does not contain extravasated coagulable lymph, but is completely filled with mortified or disorganized cellular membrane; while on the other hand the *phlegmonous* inflammation is disposed to propagate itself extensively through the cellular membrane, into the cells of which a considerable quantity of coagulable lymph is incessantly poured, which occasions the tumefaction. In consequence of the furunculus being completely filled with mortified or disorganized cellular membrane, suppuration either does not take place in it, or very imperfectly, and never in the centre of the tumour, but at its circumference where it is in contact with the sound parts; while in the phlegmon a true and complete suppuration is formed precisely in the centre of the inflamed cellular membrane, which, when the matter is discharged, spontaneously contracts and recovers its natural state and functions. In the second stage of the furunculus, the skin which covers it ulcerates and bursts in one or more points, and discharges a very small quantity of serous fluid, afterwards the small portion of
mortified

mortified cellular membrane, which formed the body and base of the tumour, comes away in the form of an extraneous substance, and the cavity which remains closes and heals in a short time. All these phenomena, peculiar to the *furuncular* inflammation, are common to the Hordeolum, the nature of which does not consequently differ from that of the furunculus.

The treatment of the Hordeolum therefore, as well as that of the furunculus, when the tumour occupies the subjacent cellular membrane, forms an exception to the general rule, that the best termination of inflammatory tumours is that of resolution. For whenever the *furuncular* inflammation has extended so deeply as to destroy a portion of the cellular membrane, the resolution of the tumour cannot in any manner be effected, or at most imperfectly; hence this mode of termination would be rather injurious, since a greater or smaller portion of the cellular substance deprived of vitality would be left; which sooner or later must occasion a reproduction of the hordeolum, or degenerate into a hard and indolent substance, which would deform the margin of the eye-lid.

The resolution of the incipient hordeolum may be accomplished in that stage of it, in which the inflammation affects only the skin, and not the subjacent cellular membrane, as happens on the first appearance of the disease;
in

in which case repellent applications are advantageous, especially the repeated application of cold to that part of the margin of the eye-lid, which is beginning to appear red, by means of a convenient piece of metal, as the extremity of a key, a piece of money, or what is still preferable, ice. But if the disease has already affected and destroyed a small portion of the subjacent cellular membrane, every repellent application is not only useless but injurious, and recourse should be had to the assiduous use of local emollient and anodyne remedies.

In the second stage of the disease therefore the hordeolum and palpebræ should be covered with a warm poultice made of bread-crumbs boiled in new milk, with a little saffron or melon-pulp added to it, and renewed every two hours, and even oftener in the winter season.

The appearance of a white spot upon the most elevated part of the hordeolum should not induce the surgeon to be hasty in opening it, in order to give issue to the very small quantity of ferous matter which is formed between the skin and the diseased and mortified cellular membrane. It will be better that he should wait until the skin surrounding this whitish speck become considerably thinner, that it may burst and open itself sufficiently to allow of the small quantity of serum, and of the whole of the small portion of corrupted cellular membrane, which formed
the

the principal part of the tumour, being easily discharged. If the portion of membrane be slow in coming away through this aperture, the surgeon, by pressing lightly upon the eye-lid, at the base of the small tumour, should force it out; by this means all the symptoms of the disease will disappear, and the cavity left by the mortified cellular membrane, which formed the centre of the tumour, will be entirely closed and healed in 24 hours.

It sometimes, though rarely, happens, that this process of nature, designed to separate the mortified portion of the cellular membrane from that which is sound, is but imperfectly performed, and that a small portion of yellowish disorganized cellular substance still remains at the bottom of this small cavity, which by adhering prevents the small tubercle from being completely healed. In these cases, in which little or no advantage can be derived from continuing the application of the emollient poultice, the surgeon should touch the bottom of the cavity with the point of a camel's hair pencil dipped in the sulphuric acid, one or more times, until this remaining portion of cellular membrane deprived of life be also completely detached from the sound parts and expelled; after which the small cavity that remains will very speedily close.

If,

If, after the cure of the hordeolum the eyelid upon which it was situated, remain a little tumefied and edematose, it may be easily removed by the application of the aqua lytharg. acet. comp. with a little spirit of wine added to it.

There are some persons who are particularly subject to this disease. This arises most frequently from fordes in the primæ viæ, in consequence of their living on acrid and irritating food, and indulging in spirituous liquors. Such persons should observe a better regimen than that which they have been accustomed to, and should take occasionally a pint of the decoction of the triticum repens, or of milk whey with a grain of the antimon. tartariz. in divided doses, particularly when symptoms of indigestion of the stomach are present. As a local and preservative remedy, the vitriolic collyrium may be dropped into the eyes, and the eye-lids washed with it once a day.

CHAP III.

OF ENCYSTED TUMOURS OF THE EYE-LIDS.

ENCYSTED tumours are very frequently formed in the eye-lids. Some writers indeed pretend that they are more frequently met with in the eye-lids than in other parts of the body, in consequence of the former being more abundantly furnished with sebaceous glands, as those of Meibomius, from the preternatural increase of some of which they have presumed these follicular tumours to originate.

As such a discussion is of no practical advantage, I willingly omit it, and shall merely observe that the glands of Meibomius occupy the edges of the palpebræ, while small encysted tumours do not appear more frequently in this than in other parts of the eye-lids, where these glands do not exist; and that it is also proved that follicular tumours originate as well from the cells of the reticular membrane, as from these glandular bodies.

An encysted tumour of the eye-lids in its commencement is not larger than a millet-feed
or

or a small pea, and it is only after a considerable time that it arrives at the magnitude of a bean, and sometimes of a filbert. These tumours do not in general excite pain, but only occasion some uneasiness, when having acquired a considerable bulk they prevent the free motion of the eye-lid, produce a partial depression of it, or press upon the globe of the eye.

With respect to the seat of these tumours it appears to me, from numerous observations, that they are, from their commencement, most frequently less covered by the internal membrane of the eye-lids, than by the integuments and muscular fibres; so that their bases are in general so superficially placed upon the internal surface of the eye-lids, that when the latter are everted, these tumours are seen as it were uncovered, and the yellowish follicle appears transparent through the fine internal membrane of the palpebræ which covers them.

The frequent unavailing attempts which I have made to obtain a resolution of these encysted tumours on their first appearance, sometimes by employing the remedy so much extolled by Morgagni,* consisting of the aqua reginæ, or elder-flower water, and a moderate quantity of the aqua ammoniæ, so as not to excite any heat or uneasiness in the skin of the

* *Epist. anat. xiii. 2.*

eye-lids; at other times by applications of resolvent gums and local mercurial frictions; have convinced me that the only effectual method of curing this disease, especially when it has existed for some months, is the extirpation of the tumour.

And as these follicular tubercles are generally much more superficially situated towards the internal than the external surface of the palpebræ, so I am authorized, from observation and experience, to believe that the best method of removing these tumours is to extract them from the internal surface of the eye-lid, although it has been even lately asserted to the contrary by surgeons of high and deserved reputation. For, by extracting the small follicular body from the internal surface of the eye-lid, the incision which is required is entirely superficial; the separation of the cyst from the surrounding parts is easily effected; the after-treatment is of no importance; and there does not remain the smallest vestige upon the integuments of the palpebræ, either of the preceding disease, or of the operation which has been performed.

The only exception of any importance which can be offered to this method of treatment, is in the case where the encysted tumour is so situated upon either of the palpebræ, that the eye-lid cannot be everted sufficiently to expose the base of the tumour, and to admit of its

being completely removed : as in the case where the tumour is situated immediately under the external or internal commissure of the eye-lids, so as to extend under the arch of the orbit, a circumstance which has occurred to me oftener than once.

It may not be improper on this occasion to relate the history of a case of encysted tumour situated deeply in the orbit which was treated by Messrs. Bromfield and Ingram. This tumour, after having caused pain at the bottom of the orbit of the eye during several years, diminution of sight, and afterwards total blindness, ultimately forced the eye-ball out of its socket, and produced an eversion of the lower eye-lid. On examining the protruded eye-ball with the finger, these surgeons perceived, on the external and lower side, a fluctuation, which they imagined to arise from an encysted tumour; and it was agreed that it ought to be opened. For this purpose Mr. Bromfield, having directed that the lower eye-lid should be pressed upwards as much as possible, and held very firmly in that position, divided the integuments with a scalpel, in the direction of the inferior edge of the orbit, beyond the conjunctiva, and of a sufficient extent to enable him to introduce his finger behind the ball of the eye, precisely upon the seat of the cyst. The operator guided by his finger penetrated the cyst, and there issued from it a pellu-

cid fluid, sufficient in quantity to fill a small wine glass. Having paused a little he drew the empty cyst towards him by means of two small hooks, removed it and filled the wound with soft lint. In 24 hours the head and neck became enormously swollen; this symptom however was relieved, by the use of internal antiphlogistic remedies and mild applications, and the wound healed in less than a month. The lower eye-lid gradually returned to its natural position, and the eye-ball retired within the orbit. The narrator adds, that having an opportunity of seeing this patient again, five months afterwards, he found that he could distinguish, with the eye which had been so dangerously affected, a strong light from darkness. *Medical Observ. and Enquiries, vol. iv. page 371.* A case similar to this is related in the treatise on the diseases of the eyes, by Saint-Yves, chap. 21, under the title, *Opération d'une tumeur singulière dans l'orbit.*

But these are rather to be regarded as encysted tumours of the parts in the vicinity of the eye-lids, than of the eye-lids themselves; and even if it were desirable to class these particular cases with the latter, they would not in the least detract from the propriety and utility of the method of treatment here recommended.

Supposing then the encysted tumour to occupy the upper eye-lid, the patient being seated

seated and his head firmly supported, an able assistant, placed behind or on one side of him, should turn out the upper eye-lid, in such a manner that by placing the point of the fore-finger of one hand upon the tumour, and the fore-finger of the other covered with a piece of fine rag, upon the everted margin of the palpebra, the follicle may be made to project as much as possible from its internal surface. The surgeon standing before the patient, with a lancet or small convex-edged scalpel * should, with the hand unsupported, divide the fine internal membrane of the palpebra covering the follicle, in the direction of the edge of the eye-lid, and for a sufficient extent to allow of the tumour passing easily out and projecting beyond its internal membrane: the follicle being then taken hold of with the forceps, † or a small hook, should be drawn out and completely separated from all its attachments to the surrounding parts, either by the scalpel or by a stroke of the curved scissors. ‡ The eye-lid then being returned to its situation should be covered with a compress dipped in the aqua lythargyri acetati comp. supported by the *monoculus* bandage.

If the encysted tumour be situated in the lower eye-lid, the assistant should place himself before the patient, and the surgeon behind, or

* Tab. III. fig. 12.

† Tab. III. fig. 8.

‡ Tab. III. fig. 4.

on one side, as he may find most convenient, and proceed to the operation in the manner already described. In operating on children, whether on the upper or lower eye-lid, the most convenient position is to lay them on a table of a convenient height, with the head raised by a pillow, and the hands and feet firmly held by assistants.

When the surgeon is deprived of an intelligent assistant, the operation may be performed in the following manner. The operator should turn out the eye-lid with the point of the fore-finger of his left-hand, and place the extremity of the thumb of the same hand upon its everted margin, in order to hold it more securely, and to make the root or base of the follicle project as much as possible from the internal surface of the eye-lid. Then, with a lancet or small convex-edged scalpel in the right hand, he should make a slight incision through the internal membrane upon the tumour, in the direction from one canthus of the eye towards the other, and with the point of the same instrument, insinuated obliquely between the cyst and internal membrane of the palpebra, should separate it from all its surrounding adhesions. Having done this, with the point of the index finger of the left hand, which had been placed from the beginning behind the tumour, he should press upon it so as

to make the cyst pass completely through the incision made in the internal membrane of the eye-lid, which had before covered it. Then laying aside the scalpel, and taking hold of the curved scissars, he should include the base of the follicle in them, and at one stroke separate it entirely from its remaining attachments, and immediately return the eye-lid to its natural position.

In employing this method of extirpating encysted tumours of the eye-lids, it is not necessary to be scrupulous about the separation of the very minute particles of the cyst, when it is opened or bursts during the operation. For when the principal part of the follicle is removed, and the eye-lid restored to its situation, the tears, especially if the lower eye-lid be operated on, enter and fill the cavity left by the tumour, and consequently prevent the lips of the wound from uniting by the first intention. When the process of suppuration therefore is established, there is no necessity to employ any other means, as the small particles of the follicle which have accidentally remained behind, adhering to the bottom of the ulcer, are gradually loosened and thrown off with the matter which is discharged from it. If, however, this process of nature should not speedily take place, and the integuments be not readily depressed and contracted, in consequence of hav-

ing been too much distended during the continuance of the disease, the cure may be accelerated by everting the eye-lid, and touching the bottom of the cavity of the wound with the *argentum nitratum*, taking care to wash the eye immediately afterwards with new milk. In general, however, this expedient is unnecessary, as every external vestige of the disease commonly disappears in the course of four days from the operation, and on everting the eye-lid, the part where the incision was made is found covered with a mucous matter, the bottom of the small cavity nearly on a level with the internal surface of the eye-lid, and in the course of eight days it becomes perfectly healed.

It is very singular that some of the most distinguished writers in surgery of the present day should seem so adverse to this method of removing encysted tumours of the eye-lids, while they recommend the extirpation of similar follicular tumours of the cheek from the inside of the mouth, not only to avoid an external wound of the parotid duct, but, because, according to their own observations, these tumours are much more speedily cured when they are removed from the inside of the mouth, than when the operation is performed externally. The same advantage of a speedy cure is equally obtained in the extirpation of encysted tumours from the internal surface of the palpebræ, which is not
less

less authorized by practice, and is more easily executed.

I shall conclude this chapter with subjoining some observations relative to a particular species of encysted tumour of the eye-lid, which in some respects differs materially from that which I have already spoken of, and which is not unfrequently met with in practice. This is a small, hard, and indolent tubercle, generally rather larger than a millet-seed, which arises precisely upon some part of the edge of the eye-lid among the cilia, and is of a white colour, resembling the white of a boiled egg. When this tubercle is of long standing it contains a substance exactly similar to that of the albumen ovi when boiled, and is merely covered with a very thin and transparent skin, which is closely united with the dense matter contained within it.

M. Aurelius Severinus,* who has given a more accurate description of this disease than any other writer, says: *Tuberculi cujusdam exigui in clivo palpebræ ciliari nascentis, et se cum pilis oblique proferentis; quo magnitudine, duritieque mihi sementulam refert, si tantummodo flavum hujus colorem in exquisitum alborem intelligas mutatum.—Corticulam duriores, ac ferme corneolam huic tuberculo adverti; usque adeo ut medicamentis acer-*

* De novis observ. absces. § De miliolo exterioris palpebræ tuberculo.

rimis, id est liquidis causticis, tentatum, nullam vel tactus vel coloris mutationem senserit.—Continet molleculam chartæ bobbicinæ madidæ similem portiunculam.

The situation of this tumour on the very edge of the eye-lid, the extreme fineness of the pellicle which covers it, as well as the smallness of its size, and the hardness of the matter which it contains, render it most convenient to remove it from the external surface of the eye-lid. This may be easily executed by including it exactly at its base, with the curved scissors, or by passing the point of a lancet through the root of it, so as to remove the whole tubercle close to the edge of the eye-lid. When the bleeding has ceased the divided parts may be covered with a small piece of court plaster. On the following day the wound may be touched with the argenteum nitratum and the rest of the cure left to nature. On the exfoliation of the eschar the part will be found completely healed.

CASE X.

A child, the daughter of a nobleman of Pavia, had had for a year and a half an encysted tumour of the upper eye-lid of the right side, the size of a small pea.

For the purpose of extirpating it, I placed the child upon a table of a convenient height, with the head supported upon a pillow, and the arms
and

and legs firmly held by two assistants. I desired the assistant situated behind the head of the child to evert the eye-lid by placing the point of the fore-finger of his left hand upon the integuments and the tumour, and one finger of the right hand covered with a piece of fine cloth upon its everted margin.

Having placed myself on the side of the patient, with the hand unsupported I divided the internal membrane of the palpebra longitudinally, at the part covering the base of the tumour, which was distinguishable by its yellowish colour. Through this incision, which was little more than three lines in length, almost the whole of the follicle immediately passed out; I took hold of it with the forceps, and having raised it, completely detached it. The eye-lid was then replaced, and covered with a compress dipped in the aqua lytharg. acetat. comp. and a bandage.

The child, which had been unruly, became quiet, and almost immediately fell asleep. On the third day the eye-lid was a little tumefied and inflamed; I directed a small bag of emollient herbs boiled in milk, to be applied upon it, and the child remained out of bed as usual, and was perfectly cheerful. On the seventh day the tumefaction of the eye-lid had entirely subsided, and on carefully everting it I found the wound perfectly healed. There was not
the

the smallest vestige of the disease on the external part of the eye-lid.

CASE XI.

Signor Luigi Gozzani, of Novara, a medical student in this university, desirous of being freed from the inconvenience and deformity occasioned by an encysted tumour, nearly the size of a bean, situated upon the left superior eye-lid, submitted to the operation in the presence of a great number of his fellow-students in medicine and surgery.

Having placed himself in a chair, I turned out the upper eye-lid with the point of the fore-finger of my left hand, and retained it in this position by applying the point of my thumb upon its internal margin. I made an incision with a lancet in that part of the internal membrane of the palpebra, which covered the base or root of the yellow follicular humour, and carrying the point of it circularly between the tumour and the internal membrane of the eye-lid, separated it entirely; then, by making a greater degree of pressure on the tumour with the point of the fore-finger of my left hand, I forced it almost entirely out through the incision, and by including its base in the curved scissors, removed it at a single stroke, and returned the eye-lid to its situation.

This

This gentleman said, that the pain attending the operation was very trifling, and not greater than that occasioned by bleeding: during the two following days the eye-lid was slightly inflamed and swollen, and bags of emollient herbs were applied upon it. On the fifth day the patient found himself completely well, without its being possible to distinguish in which of the upper eye-lids the tumour had been situated; and on the seventh he returned to his studies as usual.

CASE XII.

A poor woman, 40 years of age, came to the practical school to consult me on account of an encysted tumour, the size of the end of the finger, which she had had for several years upon the left superior eye-lid towards the external angle, and which for some weeks had occasioned an unusual sense of weight, and prevented the eye from being sufficiently opened. I proposed the operation, to which she assented, but for some particular reasons refused to remain in the hospital after the operation, proposing to follow in other respects whatever I might direct.

The patient being seated, I everted the upper eye-lid with the fore-finger and thumb of my left hand, holding the point of the fore-finger firmly against the tumour, in order to make it project as much as possible towards the internal membrane

brane of the eye-lid, and having slightly divided the internal membrane upon the base of the tumour with a convex-edged scalpel, the follicle immediately passed out of the incision. I carefully separated it from the surrounding parts, by insinuating the point of the scalpel obliquely, and carrying it round between the follicle and internal membrane of the palpebra, and then embracing the tumour as closely as possible to the substance of the eye-lid with the curved scissors, I removed it at one stroke. The eye-lid was then returned to its situation, and covered with a dry compress and bandage, and the patient returned home.

I waited in vain for a week, flattering myself that the patient would give some account of herself, and at length she was found, and appeared perfectly well. On being asked what inconvenience she had suffered after the operation, she replied none, except a little swelling and inflammation of the eye-lid during the first three days; which, however, had not prevented her from attending her family affairs.

CASE XIII.

In the act of dividing the internal membrane of the palpebra for extracting an encysted tumour, of a size rather larger than a pea, situated on the lower eye-lid of a child 10 years of age, I accidentally opened the cyst at the same time,

from which the whole of its contents, consisting of a little milky concrete substance was immediately discharged. I laid hold of the cyst in several places with the forceps, first freeing it as much as possible from its attachments to the surrounding parts; but it eluded me, nor could I by any means detach it with such exactness, or remove it with the curved scissors close to the substance of the eye-lid, as not to leave some small particles of it adhering to the bottom and sides of the cavity. After having removed, however, a small portion of the edges of the incision made in the internal membrane, the eye-lid was returned to its situation.

During the two first days the eye-lid was a little tumefied and inflamed as usual, and on everting it, towards the end of the fourth day, I found the bottom of the wound covered with a glutinous matter. On the seventh day the cavity was quite superficial, contracted, and nearly healed; and on the ninth the patient was perfectly cured, without any elevation or deformity of the eye lid remaining externally. I might here have related a very considerable number of cases similar to this.

CASE XIV.

A shoe-maker's boy had for several years an encysted tumour, nearly in the centre of the right inferior eye-lid, which gradually increased
to

to the size of a nutmeg. It began also to produce an eversion of the eye-lid and a weeping of the eye.

I removed it from the internal surface of the eye-lid in the manner above-mentioned; but as the tumour was full of a milky substance, half concrete and half fluid, in making the incision the cyst was punctured, and the whole of the matter contained in it was immediately discharged. I was unable to separate the cyst from the neighbouring parts with the exactness that I could have wished; I removed, however, as much of it as I could, and returned the eye-lid to its situation, in expectation that nature by means of suppuration would complete the rest of the cure. During the two following days the eye-lid was swollen and inflamed, upon which I applied a poultice of bread and milk. On the fifth day the mucous suppuration appeared, the bottom of the cavity then began to assume a florid appearance, to contract and approach the internal surface of the eye-lid. After some days the ulcer became stationary, and there yet remained a little elevation of the eye-lid at the part where the tumour had been situated. I turned out the eye-lid and touched the cavity with the *argentum nitratum* which only occasioned a temporary heat in the patient's eye, as I took care to drop a little milk immediately afterwards between the palpebræ and eye-ball, and continued

nued the use of it for half an hour. On the following day the eye-lid became again tumefied and inflamed, and the mucous suppuration appeared again in greater quantity than at first. In the course of eight days more the cavity left by the encysted tumour closed and entirely disappeared, both externally and internally; and the patient was discharged from the hospital perfectly cured, without the least trace of the disease by which he had before been disfigured.

CHAP. IV.

OF THE CILIA WHICH IRRITATE THE EYE.

THIS disease, which is termed *Trichiasis*, presents itself under two distinct forms: the first is where the cilia are turned inwards, without the tarsus having changed its natural position and direction; the second consists in a morbid inclination of the tarsus, and consequently of the eye-lash towards the ball of the eye.

The first form of this disease is very rare, nor has it come under my own observation more than once, and in this instance only some of the hairs had changed their direction. The second species or form of *Trichiasis*, or that which consists in a folding inwards of the tarsus and cilia at the same time, is that which is commonly met with in practice. This may be either complete, affecting the whole of the tarsus; or incomplete, occupying only a certain portion of the edge of the eye-lid, and most frequently near the external angle of the eye; sometimes the disease is confined to one eye-lid only, at other times it affects both, and occasionally the patient is afflicted with it in both eyes.

To these two species of *Trichiasis* some writers have added a third, which they call *distichiasis*,

chiafis, and which they suppose to be produced by a double and unusual row of hairs. But this third species is only imaginary, and the reason of such subdivision seems to have arisen from a want of recollecting what was long ago remarked by Winslow* and Albinus† on the natural arrangement of the cilia; that although their roots appear to be disposed in one line only, they nevertheless form two, three, and in the upper eye-lid even four ranges of hairs, unequally situated, and as it were confused. Whenever, therefore, in consequence of disease a certain number of hairs are separated from each other in a contrary direction and disorderly manner, the eye-lash will appear to be composed of a new and unusual row of them, while in fact there has been no change either with respect to their number or natural implantation.‡

It is not an easy matter to determine precisely what are the causes which sometimes occasion a small number of the hairs to deviate from their natural direction, while the tarsus remains in its position. They are generally attributed to cicatrices which take place upon the tarsus in consequence of previous ulceration, by which the cilia fall off, and those which are naturally

* Exposition Anatom. Trait. de la tête, § 278.

† Acad. Annotat. lib. iii. cap. 7.

‡ Maître-Jan made the same observation, a long time ago, as may be seen in his *Traité des maladies de l'œil*, p. 494.

Léveillé.

growing are prevented from taking their proper direction. But it is proper to remark, that this cause is not the only one, since in the case which occurred to me, two or three hairs were turned inwards against the eye-ball, although there had been neither ulceration, nor cicatrization of any part of the tarsus.

For my own part I am inclined to think, that the small ulcers and cicatrices, which are occasionally formed on the internal margin of the tarsus, rather give rise to the second form of the disease, or the inversion of the edge of the eye-lid, and consequently of the cilia towards the ball of the eye. As these ulcers are of a corroding nature, and when neglected destroy the substance of the internal membrane of the palpebræ near the tarsus, it necessarily follows, that in proportion as they heal and contract themselves, they draw along with them and turn inwards the tarsus, and consequently the hairs which are implanted in it. And as these small ulcers do not always occupy the whole extent of the internal margin of the eye-lid, but are sometimes confined to a few lines in the middle or extremity, near the external angle of the eye-lid, so after the cicatrices are formed, the whole of the hairs are not always turned inwards, but only a certain number of them which correspond to the extent of the ulcers previously situated along the internal margin of the tarsus.

Indeed

Indeed in every case of imperfect trichiasis, in consequence of a cicatrix of the internal surface of the edge of the eye-lid, a very slight examination will shew, that the tarsus and cilia are every where in their natural situation, except opposite the part where the ulcers had formerly existed; and if the eye-lid be everted, it will be evident that the internal membrane near that part of the margin corresponding to the seat of the trichiasis is pale, rigid, and callous, and that from this contraction the inversion of its cartilaginous border is evidently derived, as well as the morbid inclination of the hairs towards the globe of the eye.

Besides these causes, there are others capable of producing the same injurious effect. In the first place the chronic ophthalmia of long standing, as that which arises from serofula or the small-pox, which becoming gradually worse and worse, keeps the integuments of the eye-lid for a considerable time in a state of distension and œdema, and induces a relaxation of them, by which the cartilaginous border of the eye-lid ultimately losing a proper and firm support in the integuments, inclines towards the eye-ball, and afterwards turns inwards, and draws the cilia along with it in the same improper direction. The same unpleasant effect, independently of the relaxation of the integuments, is frequently produced by a softening of the cartilage of the tarsus, in consequence of a

copious and long continued puriform discharge from the ciliary glands, by which the cartilage of the tarsus becomes either wholly or partially incapable of supporting itself erect, or of preserving the curve necessary to its perfect coaptation with the tarsus of the other eye-lid; hence the cartilage, either in the whole, or a part of its extent becomes relaxed and folded inwards, and draws along with it the corresponding hairs against the ball of the eye.

These causes are not unfrequently found combined together, and they are also often accompanied with cicatrices of the membrane which invests the internal margin of the tarsus. * Some pretend that the trichiasis is occasionally produced by a spasmodic contraction of the orbicularis palpebrarum. But I must confess that this has never come under my own observation, and it is difficult to believe that the spasm of this muscle, however violent, can produce a folding inwards of the tarsus and cilia, much less that it should continue to act as a permanent cause of the disease.

The degree of uneasiness which must necessarily result from the hairs perpetually pressing upon the cornea and white of the eye, may be easily calculated even by those who are little acquainted with surgery. To aggravate this evil still more, it very frequently happens, that

* Bell's System of Surgery, vol. iii. p. 276.

the hairs bent inwards acquire a much greater length and thickness than those which retain their natural position. And although the disease be confined to one eye, yet from consent, both are usually affected, and the sound eye cannot be moved without occasioning pain in that which is subjected to the irritation and friction of the inflected hairs. In general it may be said that both the eyes in persons affected with this disease are very irritable and impatient of the light. As the patient, in cases of incomplete trichiasis, retains some little power of opening the eye-lids for the purpose of seeing, and that most frequently towards the internal angle of the eye, the head and neck are frequently inclined in an awkward manner, producing in children, at length, a distortion of the neck and shoulders, which is with difficulty corrected, even after the trichiasis is cured. Children besides, impatient of the irritation which the inflected cilia produce, are incessantly rubbing the eye-lids, which contributes in no small degree to increase the evils consequent on the trichiasis; such are the *varicose chronic ophthalmia*, the *nebula*, and the *ulceration of the cornea*.

The cure of the second species of this disease, or that which is commonly met with in practice, and which consists in a morbid inclination of the tarsus, and consequently of the cilia towards the ball of the eye, whether in consequence of a cicatrix and contraction of the in-

ternal membrane of the palpebra in the proximity of the tarsus, from ulceration of the internal margin of the edge of the eye-lid, or in consequence of a relaxation of the integuments, a softening of the tarsal cartilage, or from all these causes combined; is effected by artificially everting the tarsus, and re-establishing it firmly in its natural position, together with the cilia, which were irritating the ball of the eye. This indication is completely answered by the excision of a portion of the skin close to the edge of the eye-lid, of such a breadth and extent that when the cicatrix is formed, the tarsus and margin of the eye-lid may be turned outwards, and sufficiently separated from the eye-ball, and may find a point of support in the cicatrix of the integuments sufficiently firm to retain them in their natural position and direction. After so many useless attempts, I do not believe that there are any among modern surgeons, who, with a view to the radical cure of this disease, place any confidence of success, either in the mere evulsion of the morbidly inflected hairs, in bending them outwards, and retaining them by means of adhesive plasters, or in plucking them out and destroying their roots with caustic or the actual cautery; much less in extirpating the edge of the eye-lid along with the hairs, or dividing the orbicularis muscle on the internal surface of the eye-lid, under the supposition that the disease is sometimes produced by a spasmodic contraction

tion of it. All these hypothetical methods have been rejected from practice, either as insufficient, or dangerous, and rather calculated to aggravate than cure the disease, or to occasion affections of the eye-lids, no less serious than the trichiasis itself.*

The most efficacious method for the complete cure of this disease, which has been hitherto employed, not excluding that recommended by Kokler,† and known as far back as the time of Rhases, consists, as I have already stated, in the excision of a certain portion of the skin of the affected eye-lid, close to the tarsus; an operation which, when reduced to the simplicity which I shall propose, by excluding from it not only the apparatus of instruments formerly in use, but the employment of the bloody future, is easily executed by the surgeon, attended with little inconvenience to the patient, and is invariably followed with immediate and certain success.

The patient being seated in a chair, if an adult, or, if a child, laid on a table of a conve-

* I am certain that those who have proposed to confine the application of the actual cautery to cases in which two or three hairs only were turned inwards towards the eye-ball, have never performed it. For besides the great difficulty, after the hair has been extracted, of introducing the heated needle precisely into the foraminula from which the hair has been plucked, it is still more difficult to find the root of the extirpated hair, which may be at some distance from the point which the surgeon proposes to cauterize.

† Versuch einer neuen Heilart der trichiasis. Leipzig, 1796.

nient height, with the head raised, and firmly held by an assistant placed behind, the surgeon should turn out the hairs which irritate the eye with the point of a probe, then with the forceps, such as are used for anatomical purposes, or with the point of the fore-finger and thumb, which answers equally well, and in many cases even better, he should raise a fold of the integuments of the affected eye-lid, being particularly careful that the part taken hold of correspond exactly to the middle of the space occupied by the trichiasis; since, as I have already observed, the whole of the tarsus is sometimes turned inwards, at other times one half of it, and occasionally only a third part of it. The surgeon should raise the fold of the integuments with his left hand, more or less, according to the greater or less degree of relaxation of the integuments of the eye-lid, and inversion of the tarsus, and for this evident reason, that the extent of the incision is always proportionate to the quantity of skin raised. If the patient be an adult, when the fold of the skin has been raised to a certain extent, he should be desired to open the eye, and if in this state the tarsus and cilia resume their natural situation, the fold of the integuments will be sufficiently elevated for the purpose. As children very seldom submit to such an experiment, we are under the necessity of doing it by guess. The forceps of Bartisch of Verduin, and those

those improved by Rau, which were formerly in use, have the inconvenience of raising the integuments of the eye-lid equally from one end to the other, and therefore of occasioning too much skin to be removed towards the angles of the eye, and not a sufficient quantity in the middle of it. On the contrary by using the dissecting forceps and raising the skin precisely in the centre of the whole extent of the trichiasis, it necessarily follows that the incision made in the integuments forms an oval, the broadest part of which is exactly in the middle, or nearly so, of the eye-lid, the narrowest towards the angles or commissures of it. This contributes very materially to make the cicatrix correspond to the natural fold of the eye-lid, and prevents a disease contrary to that which it is intended to remedy from taking place in the angles of the eye-lid, namely, an eversion of the commissures of the palpebræ.

Besides this caution relative to the situation and figure of the fold of the integuments to be removed, particular attention should be paid, that the division of the skin be made sufficiently near the inverted tarsus. Without attention to this circumstance, the surgeon may be disappointed after the healing of the wound to find the eye-lid shortened upon the whole from the eye-brow to the place of excision, but not in an equal proportion in the space between the edge
of

of the eye-lid and the cicatrix of the integuments; consequently, the tarsus will remain folded inwards as before, or not sufficiently everted to prevent the hairs from coming in contact with the eye; which inconvenience would subject the patient to a second excision of the integuments of the eye-lid lower than the first.

Matters being thus arranged, the surgeon holding the fold of the integuments with his left hand, by means of the forceps, should carefully include it in the crooked (probe) scissars * well sharpened, and being certain that one of the blades of the scissars is applied close upon the external margin of the tarsus, should remove it at one stroke. If both the eye-lids, or both eyes be affected, the operation should be repeated upon each severally, without delay, with such precautions and in such proportion as the extent of the disease, and the degree of inversion of the tarsus of each eye-lid may require. Afterwards, laying aside the method employed by the greater part of surgeons, of uniting the wound by futures, it will be sufficient to keep the supercilium depressed, if the operation have been performed upon the upper eye-lid, or if upon the lower, to support it upon the inferior arch of the orbit by pressing it from be-

* Plate III. fig. 2.

low upwards, to prevent the lips of the wound from separating; which should then be placed in perfect contact by means of strips of adhesive plaster, which ought to extend from the superior arch of the orbit to the zygoma; and for the greater security they should be maintained in that position by means of two small compresses, one applied upon the eye-brow the other upon the zygoma, and covered with the *uniting** bandage, which should be applied in the direction of the *monoculus*.

It appears to me that surgeons have been induced to employ the future, from observing that after the excision of the fold of skin, of the upper eye-lid for instance, the integuments were drawn so much upwards towards the supercilium, and downwards towards the tarsus, that the eye-lid might be said at the moment to be denuded, and entirely deprived of skin. But this is merely so in appearance, for when the supercilium is depressed by means of small compresses and the *uniting* bandage, the eye-lid is immediately covered with skin as before, and the lips of the wound are easily brought into perfect contact without the necessity of employing futures. Gendron † is one of the few, who in these cases prefer the strips of adhesive plaster to the use of futures, having very fre-

* See Heister's Surgery, Part III. sect. 1. chap. ii. p. 355.

† *Traité des maladies des yeux*, tom. i. p. 243.

quently observed that the use of the latter is followed by a violent tension and inflammation, which cause a laceration of the parts. Of the justness of his opinion, as well as the simplicity and the speediness of the operation I am satisfied from my own experience.

On removing the first dressings, the third day after the operation, the surgeon will find that the patient opens his eye without difficulty, and that the inflected tarsus and cilia have recovered their natural position and direction. In the partial or incomplete trichiasis, or that which occupies only one half or a third of the length of the tarsus in persons whose skins are very distensible, I have frequently had the satisfaction to find, on removing the first dressings, the wound perfectly united.

When, however, the wound has only united in part, and the remainder has suppurated and formed granulations, it should be covered with a small strip of lint spread with the ung. cerussæ. If there be fungus it should be occasionally touched with the argentum nitratum until the cicatrix is perfectly formed. In general the cure does not exceed the fourteenth day from the operation.

Hitherto I have spoken of the radical cure of the second and most frequent species of trichiasis. As to the first form of the disease, which fortunately is very rare, in which the hairs are pointed

pointed against the ball of the eye, without the tarsus having altered its natural position, the treatment, if there be any, is exceedingly difficult, since it is demonstrated that neither the plucking out, nor burning the roots of the hairs is adequate to the complete cure of the disease; and that the eversion of the tarsus, contrary to its natural direction, would equally subject the patient to the risk of a perpetual weeping of the eye, and chronic tumefaction of the internal membrane of the eye-lid. Upon this point the art of surgery is yet imperfect, and the subject merits a more diligent attention, than practitioners have hitherto bestowed on it. In the case hinted at in the beginning of the chapter which came under my own observation, there only appeared two or three hairs directed against the eye-ball. Having however bent outwards a small part of the tarsus, opposite the seat of the disease, I saw indeed that I should not succeed in replacing the two or three morbidly inclined hairs in their natural direction; but that I should be able to separate them sufficiently from the cornea, and prevent their pressing upon it without the tarsus being so much turned out as to allow the tears to fall upon the cheek. And as in this case * the skin near the tarsus was very

* Case XLX.

tense, I departed from the preceding rule, by making an external incision with the back of the lancet near the tarsus three lines in extent, and removing a piece of skin of the same length, and rather more than a line in breadth. When the cicatrix was complete, the operation was as successful as the nature of the disease admitted of, but not such that this method of treatment could be said to be perfect and exempt from inconvenience in cases of greater magnitude than the one here adduced.*

The trichiasis being cured something remains to be done, in order to correct the disease from which it has originated, as well as to repair the injury which the ball of the eye has sustained from the friction and irritation of the inflected

* Dr. Crampton proposes the following operation which he states to have performed in one instance, with a success which answered his warmest expectations. "Let the eye-lid be well turned outwards by an assistant; let the operator then with a lancet divide the broad margin of the tarsus completely through, by two perpendicular incisions, one on each side of the inverted hair or hairs: let him then, by a transverse section of the conjunctiva of the eye-lid, unite the extremities of the perpendicular incisions. The portion of cartilage contained within the incisions, can then, if inverted, with ease be restored to its original situation, and retained there by small strips of adhesive plaster, or (perhaps what is better) by a suspensorium palpebræ, adapted to the length of the portion of the tarsus which it is intended to sustain, should one or two hairs be displaced without inversion of the tarsus." *Essay on the Entropion*, p. 55.

hairs. The indications in general are to strengthen the vessels of the conjunctiva, to diminish the enlargement of the ciliary glands, and to remove the opacity of the cornea. Of these we shall treat distinctly in the chapters on *ophthalmia* and the *nebula* of the cornea.

The celebrated Albinus* is the only person, as far as I know, who has noticed the *trichiasis* of the *caruncula lachrymalis*. For the greater advantage of the student I have thought proper to subjoin the history which he has delivered. *In subtilibus illis pilis, quos Morgagnus in caruncula lachrymali animadvertit, trichiasis speciem vidi. Unus eorum increverat præter naturam, crassior longiorque atque ita se incurvans, ut globum oculi extrema parte attingeret.* Consecuta est oculi inflammatio dira, cruciatu tetro, et quod causa non intelligebatur, pertinax. Adhibita fuerant quæcunque suggerere ars potuerat, et empiria: collyria, epispastica, purgantia, sanguinis missiones, fonticuli, diæta. Quum nihil proficeretur, forte itum adme. In causam si invenire possem, inquirens, ecce pilus. Quo evulso, subsedit malum. The author leaves us, however, to wish for an important elucidation; whether the hair which was plucked from the caruncle was afterwards reproduced or not, and if it were in what direction it grew.

* Acad. annot. lib. iii. cap. 8.

CASE XV.

Teresa Ballerini, of Trumello, a country woman, 35 years of age, was afflicted with an obstinate chronic ophthalmia during five years, in consequence of which her sight was nearly destroyed. She was unable to raise the upper eyelid of either eye, on account of their extreme relaxed and corrugated state, and the tarsus and cilia of both eyes were seen folded inwards, and irritating the eye. A small degree of light was admitted at the internal angle of the eye, as the tarsus was less depressed and folded inwards at this part than any other. The cornea of the right eye appeared profoundly opaque, that of the left was only a little cloudy. The hairs had been several times plucked out by a surgeon in the country, one by one, but without advantage.

The patient being received into the practical school, and seated in a chair, I made a fold of the integuments of the upper eye-lid of the left side, with my fingers, near the margin, taking care to raise it more towards the external than the internal angle of the eye-lid; and finding it sufficient to draw the tarsus and cilia outwards, I removed it with one stroke of the crooked scissors. I immediately brought the lips of the wound together, and retained them in contact by strips of adhesive plaster, and more especially by the application

application of a compress upon the supercilium and the *uniting* bandage in the direction of the *monoculus*. I immediately repeated the same operation on the upper eye-lid of the right side.

On removing the first dressings, three days after the operation, the woman was able to open her eyes, and I found that the tarfi and cilia of both eye-lids had recovered their natural position.

A small wound remained at the divided part on both sides, the greatest breadth of which did not exceed two lines. By the application of the unguent. cerussæ, spread upon a strip of lint, and the occasional use of the argentum nitratum it healed in the course of twelve days. The effects of the chronic inflammation and the slight opacity of the left eye were removed in the course of a month by the use of the vitriolic collyrium, and the ophthalmic ointment of Janin; as to the right the *leucoma* was so dense as to be incurable.

CASE XVI.

Signor Count N. . . . of Pavia, had been subject from his infancy to a discharge from the eyes; at the age of ten he was unable to raise the upper eye-lid of the left eye, and in a very slight degree that of the right, or only for two or three lines towards the external angle, on which account he was obliged, for the purpose

of seeing, to hold his neck sidewise and look obliquely with the right eye. The tarsus and cilia of the superior palpebra of the left eye were folded inwards, and pressed almost entirely upon the ball of the eye, and particularly upon the cornea which they violently irritated: the cartilaginous border and the cilia of the right superior eye-lid, near the external angle, remained in their situation, while the rest of the hairs of the same row stimulated the cornea. On the left side the cornea was very dark, and marked here and there with small dense spots: that of the right side was merely cloudy.

The cilia were extirpated from this child five different times, and their roots touched with caustic; but, as they always grew again more pointed and bristly than before, it was proposed to remove along with them the edges of the affected eye-lids. Such were the circumstances of the case when he came under my care.

As the boy was very unmanageable, principally because he had been frequently tormented to no purpose, I was obliged to confine him more securely, by placing him upon a small bed where he could be easily held. I raised the skin of the superior palpebra of the right eye near the tarsus, by means of the forceps, making the most elevated centre or point of the wound towards the internal angle, for the reasons before assigned, and with the crooked
scissars

scissars divided it at one stroke; I then repeated the same operation upon the upper eye-lid of the left side, making the most elevated point of the wound on this side, precisely in the middle of the eye-lid. The retraction of the integuments and the denudation of the eye-lids had a frightful appearance to the bystanders. But by depressing the supercilium, and applying strips of adhesive plaster, with the compresses and *uniting* bandage upon each side, the integuments were made to cover the eye-lids, and the lips of the two wounds were held in perfect contact. The boy took 3 ounces of emulsion with 9 drops of the tincture of opium, he slept a little afterwards, and was sufficiently quiet during the remainder of the treatment.

The dressings were removed on the fifth day, and the boy was able to open his eyes sufficiently well: the tarfi and cilia of both eye-lids were now turned outwards, and so far separated from the ball of the eye as not to come in contact with it, though they could not yet be said to be in their proper and natural position. This was occasioned by the wounds having suppurated more than usual, and having a tendency to become fungous which prevented the perfect approximation of the divided edges of the skin. By repressing the fungus with the *argentum nitratum*, and covering it with the *unguent. cerussæ*, the sores healed in the course of two weeks; and

in proportion as they contracted, the tarsus and cilia of each eye-lid were separated at a greater distance from the eye-ball, and ultimately returned to their natural position.

By means of Janin's ophthalmic ointment, applied between the eye-lids morning and evening for forty days, and the vitriolic collyrium instilled into the eye several times in the course of the day, the varicose vessels of the conjunctiva recovered their tone. The slight opacity of the cornea of the right eye was entirely dissipated; that of the left only in part, as there were many opake spots irremovable.

CASE XVII.

I undertook the treatment of an old woman who for several years had been regarded by her friends as completely blind, in consequence of an extraordinary relaxation of the upper eye-lid of both eyes, produced by repeated attacks of ophthalmia, and an inversion of the edges of the eye-lids. The palpebræ being forcibly separated, the tarfi and cilia of both the upper eye-lids were seen pressing upon the eye-ball, and the cornea of each eye had in a great measure lost its natural transparency. In making this examination I did not perceive that on the left side there was also an inversion of a small part of the tarsus and hairs of the lower eye-lid.

So great was the relaxation of the integuments of the two upper eye lids, that instead of the forceps I used the thumb and finger of my left hand, with which I raised a considerable fold of the skin near the margin of the right superior eye-lid, which I divided with the scissors, removing a portion of the integuments of an oval figure, the transverse diameter of which corresponded precisely to the middle of the palpebra, the longitudinal to its two angles. The operation was repeated in the same manner upon the left superior eye-lid. I then applied upon each the usual dressings, consisting of a few strips of adhesive plaster, compresses upon the supercilium and zygoma, and the *uniting* bandage.

At the end of three days I removed the dressings for the first time, and found the whole in a good state, as the woman was able to open her eyes without difficulty, the tarsus and cilia of each eye-lid had returned to their situation, and the wound, though not yet cicatrized, had a healthy appearance: I observed, however, that in the act of opening and shutting the left eye a few tears escaped from it, and that the patient complained of a little pain in it, which was not the case in the right eye. I presently discovered that towards the external angle of the lower eye-lid of the left side there was a small number of hairs, which, together with the tarsus, to the extent of two lines, was folded inwards

and wounded the eye. Upon everting this part of the lower eye-lid, some white indurated spots were distinctly observed, opposite the inverted portion of the tarsus, which indicated the previous existence of some small corroding ulcers, the cicatrices of which had drawn inwards this small portion of the tarsus, together with its corresponding cilia.

I immediately divided the skin of the lower eye-lid with the back of a lancet, to the extent of nearly four lines along the inverted tarsus, and having insinuated through this opening the point of a fine pair of forceps,* I elevated and removed a small portion of the skin of an oval figure, and of a size proportioned to the degree of depression and inversion of the tarsus and hairs, and covered the wound with a strip of simple diachylon. The wound suppurated, and it was necessary to touch it frequently with the *argentum nitratum*. As soon as the wound was healed the portion of the edge of the eye-lid folded inwards recovered its natural position. The great age of the patient, who was near 60, and the tenacity of the humour collected in the substance of both the corneæ, notwithstanding the continual use of the ophthalmic ointment, and the vitriolic collyrium for a month, did not admit of that membrane being restored, but in a

* Plate III. fig. 8.

small degree, to its former transparency. The patient however towards the end of the treatment was able to distinguish the figures and colours of bodies, and left the hospital very well satisfied in having been freed from this painful disease.

CASE XVIII.

The daughter of Signor Giovanni R... of Rovescalla, a child nine years of age, of a scrofulous habit, who had contracted the *scabies* while at the breast, was seized in the seventh year of her age with a chronic inflammation of the palpebræ of both eyes, especially of the right, attended with exulceration of the internal margin of the tarsus, and of the boundary of the sclerotic coat with the cornea in some points of it. In the course of two years the ophthalmia, especially of the right eye, resisting the use of a variety of remedies, both internal and external, which had been prescribed for it, the child gradually lost the power of opening this eye, except a small part of it towards the external angle. The tarsi on both sides were indurated, incrusted, and gummed, but those of the right eye were also drawn inwards, together with the cilia both in the upper and lower eye-lid; the inversion in the lower however was confined to a small part towards its external angle. The irritation which

the cilia excited in the right eye was so troublesome that the child was incessantly carrying its hand to it.

The child was laid upon a table with her head a little raised, and firmly held by assistants, particularly by Signor Gianni, a skilful surgeon of this hospital. I formed a fold of the integuments of the upper eye-lid of the right eye with my fingers, in such a manner as to elevate it more towards the external than the internal angle of the eye, and with a pair of very sharp scissars removed a convenient portion of it, of an oval figure, close to the inverted portion of the tarsus, and in a direction parallel to it. A similar division was then made of the integuments of the lower eye-lid, but of a less extent, as the inversion of the tarsus and hairs was not so considerable in this as in the upper eye-lid.

The wound was wiped dry and covered in the usual manner with strips of adhesive plaster, extending from one arch of the orbit to the other; compresses were applied upon the supercilium and zygoma, and the whole secured by the *uniting* bandage applied in the direction of the *monoculus*.

Although immediately after the operation it was impossible to keep the child in bed, in order that she might take some rest, for which purpose some drops of laudanum had been given to her, yet no bad symptom occurred. When
the

the first dressings were removed on the third day, to the great astonishment of those around, the child opened the right eye without difficulty: the tarsus and cilia had regained their natural situation, and the wound in the upper as well as the lower eye-lid was perfectly healed. The great length to which the hairs that had pressed upon the eye-ball were grown, contrasted with those situated towards the internal angle which had preserved their natural direction, was very remarkable.

To complete the cure, it was only necessary to cover the two cicatrices with a strip of linen spread with the unguent. cerussæ, to strengthen the varicose vessels of the conjunctiva, and to remove the opacity of the cornea of the right eye, which was obtained as far as possible, considering the great and long continued thickening which had taken place, in the space of forty days, by employing at first the Thebaïc tincture of the *London Pharmacopæia*, afterwards the ophthalmic ointment, and at intervals during the day the vitriolic collyrium.

CASE XIX.

Lorenzo Crivelli, of Montalto, a strong peasant, 26 years of age, who had never been subject to discharges of the eyes, in the beginning of May 1798, arose from bed with a pruritus of
the

the right eye, so intolerable that he could not refrain a moment from rubbing it. This inconvenience, accompanied with heat and redness of the whole eye, increased in a few days to such a degree, that fearing he should lose the sight of the eye, he came to the hospital.

About the middle of the lower eye-lid of the right side, to the extent of two lines, there was evidently an irregularity of the hairs, which grew in different directions. Three of these arose distinctly from the internal surface of the tarsus, were directed obliquely towards the ball of the eye, and pressed partly upon the lower portion of the cornea, and partly upon the conjunctiva near to it, which had an impression on it at that part, and was tinged with a spot of blood. This had taken place without the tarsus, either in that or any other part of it, having changed its natural situation.

Being sufficiently aware of the inutility of plucking out the hairs in this disease, as well as the inefficacy of the means hitherto proposed for confining them outwards by adhesive plaster, fine ligatures, and other similar measures; and observing in this case that a moderate eversion of the small portion of the tarsus to which the disease was confined, would be sufficient to separate the hairs from the eye-ball without producing any remarkable deformity; I determined on this occasion, as the only means left to me,

to remove a small portion of the integuments of the lower eye-lid near the inverted hairs.

The patient being seated with his head bent backwards, and the eye-lid firmly fixed by an assistant pressing upon the angles, I made an incision in the integuments with the back of a lancet, four lines in extent, immediately below the edge of the eye-lid, and close to the tarsus; then having raised the divided skin with the forceps, I removed a small portion of an oval figure exactly of the same length, and about two lines and a half in its greatest breadth: The wound was covered with a strip of linen spread with digestive ointment, a compress was placed upon the zygoma, and the *uniting* bandage applied in the direction of the *monoculus*.

On removing the dressing two days afterwards I found the lips of the wound considerably approximated, and the edge of the eye-lid proportionately drawn outwards, with the three hairs corresponding to it which had been inverted, by which the patient found himself gradually relieved from this inconvenience. One hair only, the longest of the three, pressed yet slightly upon the cornea; I say slightly, because the patient did not complain of it, and the mark of the conjunctiva was now almost entirely dissipated. The wound was touched on that day and the three following with the *argentum nitratum*, in order to destroy a little more of the substance of the eye-lid,

lid, and to cause a still greater eversion of its edge opposite this small point of the *trichiasis*. Five days afterwards the wound was completely healed. The long hair which alone remained out of its natural direction no longer touched the cornea, but laid in the longitudinal direction of the internal edge of the lower eye-lid, without occasioning any uneasiness or weeping of the eye. I therefore believed that I had accomplished all that the case seemed to require, and permitted the man to return home.*

* In an essay on the Entropion lately published by Dr. Crampton of Dublin, the author endeavours to show, from a series of facts, that this disease, but particularly the inversion of the upper eye-lid, is owing to a thickened and contracted state of the conjunctiva. As this is a subject upon which observation alone must decide, I have thought it proper to subjoin his account of the nature of the disease, and the operation which he proposes for its removal. "When the eye is voluntarily opened (says this gentleman) the upper eye-lid is not drawn vertically upwards, but backwards, describing a line parallel to the anterior and superior surface of the eye, over which it moves. When the eye is completely open, the eye-lid is lodged in the space contained between the roof of the orbit and the superior surface of the eye. But should this space be filled up by the thickened or contracted conjunctiva, the levator palpebræ cannot execute its functions. Every accession of inflammation contracts the conjunctiva; the conjunctiva terminates upon the margin of the eye-lids; which deriving no support from without, and being constantly acted upon from within, readily yield and become permanently inverted." In order to remove this stricture formed by the conjunctiva, and to restore the parts to their natural position,

Dr.

Dr. Crampton recommends that the extremities of the *tarsi* should be divided with a sharp-pointed bistoury introduced between the eye-ball and *palpebræ*, and a transverse incision made in the internal membrane of the eye-lid, from one angle of the *tarsus* to the other, and that the eye-lid thus liberated should be supported in its natural position by means of a *suspenforium palpebræ*, till by recovering its original healthy state it is enabled to perform its functions.

CHAP. V.

OF THE RELAXATION OF THE UPPER EYE-LID.

THE operation detailed in the preceding chapter, is also employed for the cure of the relaxation of the upper eye-lid, when it is simple or unaccompanied with a morbid inversion of the cilia towards the eye-ball. This disease does not injure the organ of vision, except in as much as it prevents those who are affected with it from being able to see, without raising the upper eye-lid with the finger.

The excessive elongation of the upper eye-lid is sometimes, though rarely, a congenital disease: most frequently it arises from a morbid thickening of the parts, in consequence of obstinate chronic ophthalmia, in persons of a lax and unhealthy fibre, or from the long continued use of emollient and relaxing applications. It is sometimes occasioned by an atony of the elevator muscle, peculiar to the upper eye-lid, either simple or accompanied with a paralysis of the optic nerve, as usually happens in consequence of violent blows upon the eye-ball, when the eye-lids are closed, with or without laceration of
of

of the upper eye-lid and extensive ecchymosis of the conjunctiva. It sometimes takes place during short intervals, in consequence of a spasm of the orbicular muscle of the eye-lids.

The congenital elongation of the upper eye-lid, and the relaxation which takes place from a morbid thickening of the parts, in consequence of the too long continued use of emollient applications, or of the eye being kept too long closed and compressed by bandages, is a disease easily characterized by the combination of circumstances which have preceded it. If the atony or complete paralysis of the elevator muscle of the eye-lid have had any share in producing the relaxation of it, it may be known by making a transverse fold of the integuments with the fingers or forceps, near the superior arch of the orbit. For if this muscle have not lost its power of contraction, when it is relieved as it were from the superincumbent weight of the integuments, the patient is able to raise the eye-lid and open his eye sufficiently, if otherwise the eye remains half closed. That depression of the eye-lid, with inability of raising it, which recurs at short intervals, which comes on and disappears suddenly, and which depends on a temporary spasm of the *orbicularis palpebrarum*, is not properly a disease, but a symptom of some other general spasmodic affection, as of hypochondriasis, hysteria, chlorosis, or of diseases of the stomach, occasioned by indigestion

gestion or the presence of worms: the causes of which affections it is not difficult to ascertain.

Among the causes of this imperfection writers on surgery have also reckoned transverse wounds of the upper eye-lid or corresponding supercilium; of which however they have not treated with sufficient perspicuity. For if they intend to speak of those transverse wounds of the upper eye-lid or supercilium, which destroy or violently contuse the elevator muscle, or which greatly injure the supraorbital nerve, the relaxation of the upper eye-lid may certainly be the consequence, but not the only one, as they are very frequently succeeded by a much more serious accident, the total loss of sight. If they mean to include every other species of transverse wound of the upper eye-lid or supercilium, it is evident that if this be unattended with loss of substance and heal by the first intention, it cannot produce a relaxation of the eye-lid, and if it be accompanied with a loss of substance of the integuments or subjacent parts, and proceed to suppuration, instead of occasioning a relaxation, when healed, it would rather produce a contrary disease, the shortening of the eye-lid.

When the disease is purely local and recent, in persons not advanced in age, or affected with hemiplegia, or paralysis of the muscles of the face, and when it is derived from a morbid thickening of the parts which before were soft
and

and flaccid: some advantage may be expected from the use of local corroborant remedies, of which cold water, with a small quantity of spirit of wine added to it, frictions upon the relaxed eye-lid with the anodyne liquor, or tincture of cantharides, and the application of the soap liniment with camphor, merit a preference.

The relaxation which is symptomatic of hypochondriasis, hysteria, and of morbid stimuli in the stomach, is cured by the administration of internal antispasmodic and antihysterical remedies, by emetics and anthelmintics.

The congenital relaxation of the upper eye-lid, the inveterate humoral, and that which is accompanied with atony of the levator muscle, provided in this last case the immediate organ of vision remain sound, can only be cured by means of an operation. It is true, that in the case of atony or debility of the elevator muscle, the eye can never be so completely opened as the sound one, even after the operation; the patient, however, will be able to look at objects without being under the necessity of raising the eye-lid with his finger.

This disease is cured, as I have said, in the same manner as the trichiasis: by raising the superabundant portion of the integuments of the eye-lid between the finger and thumb, and removing it by means of the scissors; observing however not to take away a greater or less quantity

of skin than is necessary, that the eye-lid may yield to the action of the elevator muscle, and by obeying it, may conveniently uncover the eye-ball. In the most common case of trichiasis, or **that** which is derived from a relaxation of the eye-lid, together with a morbid inversion of the tarsus and hairs, it is of the greatest importance, as I have stated, for the complete success of the operation, to make the fold of the integuments as near as possible to the inflected tarsus, that the edge of the palpebra may be gradually drawn outwards; but in the case of simple relaxation of the upper eye-lid, of which I am now treating, without any morbid inclination of the edge of the palpebra or hairs, as there is no indication to be fulfilled but that of shortening the integuments of the eye-lid, it is more advantageous to make the fold and excision in the proximity and direction of the superior arch of the orbit, than near the tarsus.

The excess of the integuments of the relaxed eye-lid, compared with the sound one, is easily ascertained, by directing the patient to look steadfastly at an object in a line horizontal to the height of his eye; for the sound and open eye being held firmly in that position, will show clearly how much less the relaxed eye-lid is raised than the sound one. The surgeon, therefore, having made a transverse fold of the integuments at the upper part of the relaxed eye-lid,
in

in the vicinity and direction of the superior arch of the orbit, proportionate to the disparity of its length; and the fold of skin being firmly held by means of the forceps, he should direct the patient to open his eyes. If this be performed as well on the affected as the sound side, it will be a certain indication, as I have said, of the integrity and aptitude of the elevator muscle, to contract and exert its power upon the relaxed eye-lid; and if at the same time both eye-lids are raised to the same height, it will be also a sufficient proof of the exact quantity of integuments comprehended in the transverse fold to be removed; in the contrary case the fold must be increased or diminished accordingly. Having done this, the surgeon should remove this fold of the integuments with one stroke of the scissors, which being more elevated in the middle of the upper part of the eye-lid, than at its extremities will leave a wound of the figure of a myrtle leaf. The lips of the wound should then be placed in contact, and retained by means of strips of adhesive plaster, but especially by applying a compress upon the supercilium, and another upon the inferior margin of the orbit, and over these the *uniting* bandage in the direction of the *monoculus*. The cure is generally completed in a few days, provided, as in the case of trichiasis, the compresses and *uniting* bandage

are exactly applied, and the latter has a proper degree of tightness given to it.

The cases which I have related in the preceding chapter on trichiasis, render it the less necessary for me to adduce any instances in support of this operation, although I could have introduced several. To the young surgeon, however, it will be useful to read upon this subject the case published by Morand, in the second volume of his *Opuscules de Chirurgie*.

CHAP. VI.

● OF THE EVERSION OF THE EYE-LIDS.

As the excessive relaxation of the integuments of the palpebræ, and the morbid abbreviation of their internal membrane near the edge of the eye-lid, in consequence of small corroding ulcers, and the cicatrices consequent on them, occasion a morbid inclination of the tarsus and cilia towards the eye-ball; so, occasionally, the too great relaxation and tumefaction of their internal membrane, or the too great contraction and shortening of the skin of the eye-lids, or of the integuments of the surrounding parts, produce a disease contrary to that of trichiasis; the turning outwards or eversion of the eye-lids, termed *ectropion*.

With regard to the causes, therefore, there are two distinct species of this disease; the one arising from a preternatural tumefaction of the palpebra, which not only separates its edge from the eye-ball, but also presses upon it in such a degree as ultimately to evert it; the other produced by a shortening of the skin which covers

the eye-lid, or that of the neighbouring parts, by which the ciliary edge is, in the first instance, separated from the ball of the eye, and afterwards gradually turned outwards, together with the whole of the eye-lid.

The morbid tumefaction of the internal membrane of the palpebræ, which occasions the first species of eversion, not considering at present that of a similar kind, which takes place in old age, is generally derived from a congenital laxity of the conjunctiva, increased by attacks of obstinate chronic ophthalmia, especially of the scrofulous kind, in persons of a weak and unhealthy fibre; or is the consequence of a variolous metastasis to the eyes, accompanied with a relaxation of the vessels of the conjunctiva; of the crusta lactea, impetigo, or other eruptive diseases of the skin imprudently repelled.

While the disease occupies the lower eye-lid only, which is most frequently the case, its internal membrane is elevated in the form of a semilunar fold, of a pale red colour, resembling the fungous flesh of wounds, interposed between the ball of the eye and the eye-lid, which it everts to a certain extent. But when the morbid tumefaction has extended to both the eye-lids, the disease presents a circular appearance, in the centre of which the eye-ball lies as if imbedded, while the circumference presses upon, and turns out the edges of both the eye-lids, occasioning

occasioning considerable uneasiness and deformity. In either case, if the integuments of the eye-lids are pressed upon with the point of the finger, it is evident that they readily admit of being elongated, and that the eye-lids would yield so as to cover the eye-ball completely, if they were not prevented by this intermediate tumefaction of their internal membrane.

Besides the great deformity which this disease occasions, it produces a continual discharge of tears upon the cheek, aridity of the ball of the eye, frequent attacks of chronic ophthalmia, intolerance of light, and in the end *nebulæ* and ulceration of the cornea.

The second species of *everſion*, or that occasioned by a shortening of the skin which covers the eye-lid or surrounding parts, is not unfrequently a consequence of contractions produced by the confluent small-pox in the integuments of the face near the eye-lids, or in those of the eye-lids themselves; of deep burns accidentally inflicted on the same parts; of the extirpation of cancerous warts or encysted tumours of the eye-lids or circumjacent parts, where a sufficient quantity of skin has not been saved; of the malignant carbuncle; and lastly of lacerations of these parts, attended with considerable loss of substance. Each of these causes is sufficient to produce such a contraction and shortening of the integuments of the eye-lids,

lids, as to draw them towards either of the arches of the orbit; and conſequently to ſeparate them from the eye-ball, and cauſe an everſion of their edges. This effect no ſooner takes place than it is ſucceeded by another no leſs inconvenient, the tumefaction of the internal membrane of the eye-lid, which alſo greatly contributes to complete the everſion. For the internal membrane of the eye-lid, though flightly everted, being inceſſantly expoſed to the contact of the air, and continually irritated by extraneous ſubſtances, in a ſhort time ſwells and is elevated in the form of a fungus; one part of which by degrees covers a portion of the eye-ball, the other preſſes the eye-lid outwards, and produces ſo conſiderable an everſion of it, that its edge is not unfrequently brought in contact with the margin of the orbit. This ſecond ſpecies of the diſeaſe is attended with the ſame unpleaſant effects as the firſt, to which it may be added, that when either form of the diſeaſe has been of long ſtanding, the fungous tumefaction of the internal membrane of the eye-lids becomes indurated, coriaceous, and almoſt callous.

Although the internal membrane of the eye-lid, in both theſe ſpecies of everſion, appears equally tumefied, yet the ſurgeon may eaſily determine to which of the two ſpecies the diſeaſe belongs. For, in the firſt form of the diſeaſe, as I have ſtated, the ſkin of the eye-lid, or ſurrounding

rounding parts, is not disfigured with scars, and the everted eye-lid, on being pressed upon with the point of the finger, would rise again without difficulty, so as to cover the eye completely, if this carnous substance were not interposed; while, in the second species of eversion, besides the evident scars and contractions which are seen upon the skin of the eye-lid or neighbouring parts, if an attempt be made to restore the eye-lid to its situation, it either does not yield so as to cover the eye-ball entirely, or it can only be reduced to a certain extent, or, from the edge of the eye-lid having contracted an adhesion to the arch of the orbit, in consequence of a very considerable destruction of the integuments, it does not admit of being removed in any degree from its unnatural position.

From comparing therefore these two species of eversion, it must be evident that a perfect cure of this disease cannot be effected equally in both forms of it, and that the latter species in some instances is absolutely incurable. For as the treatment of the first species of eversion, which depends only on a morbid tumefaction of the internal membrane of the palpebræ, merely consists in removing that which is superfluous, the art of surgery possesses many efficacious means perfectly adequate to the fulfilment of this indication. But in the second species of the disease, in which the principal

cial cause consists in the loss of a portion of the skin of the eye-lid or surrounding parts, which no artifice hitherto known can restore, a complete cure of the disease cannot be obtained. The surgeon must be therefore content to remedy as far as possible the evils attendant on it, and that in a more or less satisfactory manner, according to the greater or less destruction of the integuments, and to abandon as incurable those cases in which the edge of the eye-lid is found to be united to the arch of the orbit. *Si nimium palpebræ deest*, says Celsus,* *nulla id restituere curatio potest*. In the treatment then of the second species of eversion, the degree of success must be determined in every case by the surgeon's observing to what extent the eye-lid, can be reduced by gently pressing it towards the eye-ball with the point of the finger, both before and after the employment of such means as are calculated to produce an elongation of its integuments, since it is to this point only that it can be reduced and maintained in its position permanently.

With respect to the treatment of the first species of eversion, if the disease be recent, the fungous state of the internal membrane not considerable, and consequently the eversion of the edge of the eye-lid small, of two lines in extent

* Book VII. chap. 7.

or little more, and in young persons, (for in those advanced in years the eye-lids are so flaccid that the disease is altogether incurable,) it may be removed by destroying the superficial fungus of the internal membrane of the eye-lid with the *argentum nitratum*, which ought to be executed in the following manner. The surgeon should completely evert the affected eye-lid with his left hand, and with his right wipe it dry by means of a piece of linen cloth; he should then rub the caustic strongly upon the whole extent of the superficial fungus, so as to produce an eschar. In order that it may occasion the patient as little pain as possible, at the moment the caustic is withdrawn an assistant should instantly cover the cauterized part with a little oil, which will prevent the tears from readily dissolving the *argentum nitratum*, and diffusing it over the eye-ball. If, however, any portion of the dissolved caustic should occasion uneasiness, it ought to be washed off, by frequently dropping into the eye a little new milk. This application of the caustic should be repeated for several successive days, until it has produced a sufficient ulceration and destruction of the superficial fungus of the conjunctiva, especially near the tarsus; after which lotions of simple water, or barley water with *mel rosæ*, will be sufficient to promote the suppuration and cicatrization of the wound. The result of this treatment will be,
that

that in proportion as the internal surface of the eye-lid heals, the eversion will gradually diminish, and the edge of the eye-lid will finally regain its natural position.

This method of treatment, as I have just stated, is only practicable with perfect success in cases of recent and very slight eversion.* Where the disease is considerable and of long standing, the most expeditious and certain method of remedying it, is that of extirpating the whole fungus, close to the internal muscular substance of the eye-lid. The patient being therefore seated, and his head bent somewhat backwards, the surgeon should hold the everted eye-lid firmly with the point of the fore and middle finger of his left hand, and with the curved scissors† in his right should include the excrescence of the internal membrane of the palpebra, as near to its base as possible, and remove it completely; the same operation should then be repeated on the other eye-lid, when both are affected; and if the excrescence be of such a figure that it cannot be exactly included between the scissors, it should be raised as much as possible with the forceps, or a double-pointed hook, and divided at its base by means of a small convex-edged

* In these instances, I believe, the disease may in general be effectually and more speedily removed by scarifying the internal membrane of the eye-lid with the point of a lancet.

† Plate III. fig. 3 and 4.

bistoury.* The hæmorrhage, which at the commencement of the operation is considerable, either ceases spontaneously or may be checked by washing the eye with cold water. The dressing should consist of two compresses, one placed upon the superior the other upon the inferior arch of the orbit, and over these the uniting bandage in the form of the *monoculus*, or applied in such a manner as to press upon and replace the edge of the eye-lid, so that it may cover the eye-ball again. When the first dressings are removed, which ought to be 24 or 30 hours after the operation, the eye-lid will be found to have recovered entirely, or nearly so, its natural position. The dressing should afterwards consist in washing the fore twice a day, either with simple water, with the aqua malvæ, or with barley water and mel rosæ, until it is completely healed. If towards the end of this period, the wound assume a fungous appearance, or if the surgeon perceive that the eye-lid is yet too far separated from the eye-ball, it should be frequently touched with the argenti nitratum, in order to destroy a little more of the internal membrane of the eye-lid, so that when the cicatrization is completed, the contraction may be such as to draw the edge of the palpebra nearer to the ball of the eye. In the mean time proper measures

* Plate III. fig. 12.

should be employed to remove the causes by which the eversion has been produced; as the chronic ophthalmia, the morbid determination of humours to the eye, and the weakness and varicose state of the vessels of the conjunctiva, of which I shall have occasion to speak in the chapter on ophthalmia.

The indication of cure in the second species of eversion, or that which is produced by an accidental shortening of the integuments of the eye-lids or of the surrounding parts, is not different from that already mentioned. If the shortening of the integuments has been capable of everting the eye-lid, the extirpation of a portion of its internal membrane, and the cicatrix which must ensue from it, may, for the same reasons, restore the eye-lid to its former position. But since that portion of the integuments which is lost can never be reproduced, and in whatever degree the whole eye-lid is shortened, so it must always remain, even after the most successful operation; consequently the treatment of the second species of eversion can never succeed so perfectly as that of the first species, and the eye-lid, though replaced, will always remain shorter than natural, in a degree proportionate to the greater or smaller quantity of integuments lost. In a considerable number of cases, indeed, the eversion appears greater than it is in reality, with regard to the small quantity of skin which is destroyed

destroyed; for, when the disease has once taken place, however small the contraction of the integuments may be, the tumefaction of the internal membrane gradually increases, so as to produce a complete eversion of the eye-lid. The operation in these cases is attended with a degree of success which could not have been expected by those unacquainted with the nature of the subject; for after the fungus of the internal membrane of the diseased eye-lid has been extirpated, and its edge brought towards the ball of the eye, the shortening of the eye-lid which remains is so inconsiderable, that in comparison with the deformity and inconvenience which it occasioned in a state of eversion, the cure may be considered as perfect; of this we have an example in the annexed figure.* Whenever therefore the retraction of the integuments of the everted eye-lid, and consequent shortness of it is not so considerable as to prevent it from rising again and covering the eye, if not perfectly, at least in a tolerable degree, the surgeon should undertake the operation in the manner already explained, employing, according to circumstances, sometimes the curved scissors, at other times the convex-edged bistoury, or both. When the disease has existed for a considerable time, and the in-

* Plate II. fig. 1, 2.

ternal membrane has become hard and almost callous, the everted eye-lid should be covered with a soft poultice of bread and milk for some days previous to the operation, in order to render it flexible and more easily separable than in its former rigid state.

It is one of the most certain and demonstrable facts, that the division of the cicatrices of the integuments, which have given rise to the contraction and eversion of the eye-lid, does not produce a permanent elongation of it, and therefore is attended with no advantage in the treatment of this disease. We see the same thing happen after deep and extensive burns of the skin of the palm of the hand and fingers, in consequence of which, whatever diligence be employed during the treatment to keep the hand and fingers in an extended state, as soon as the cicatrix is complete, the fingers are found irremediably bent. The same thing takes place after extensive burns of the face and neck. Fabricius ab Aquapendente,* who was well aware of the inutility of the semilunar division of the integuments of the eye-lids, in order to remedy their shortening and eversion, proposes, as the best expedient, that of stretching them by means of adhesive plasters applied upon the eye-lid and the supercilium, and tied firmly to-

* De Chirurg. Operat. cap. xv.

gether. Experience has taught me that whatever advantage may be derived from this practice, is equally obtained by the application of a bread and milk poultice for several days, afterwards of oily embrocations, and lastly of the *uniting* bandage, so applied as to extend the shortened eye-lid in a direction contrary to that produced by the cicatrix: which practice ought to be diligently employed in every case previously to the operation being undertaken.

When the operation is determined upon, the patient, if an adult, being seated in a chair, or if a child, laid upon a table with the head a little raised, and held by proper assistants, the surgeon, by means of a convex-edged bistoury, should make an incision of a sufficient depth in the internal membrane of the eye-lid along the tarsus, carefully avoiding the *puncta lachrymalia*, then with the forceps he should elevate the edge of the divided membrane, and continue to separate it with the knife from the whole of the internal surface of the eye-lid, in the manner usually employed in the anatomical dissection of it, until the separation be completed, as far as the point where this membrane is about to leave the eye-lid, to reach the anterior hemisphere of the eye-ball, receiving the name of conjunctiva. The separation being carried to this point, the surgeon, raising the membrane with the forceps still higher, should entirely remove it by one or two
L strokes

strokes of the scissars close to the deepest part of the eye-lid. The dressing should consist as usual in the application of a compress and the uniting bandage, in order to facilitate the return of the everted eye-lid towards the ball of the eye. On changing the dressings, one or two days after the operation, the eye-lid will be found in a great degree reinstated, and the deformity which it occasioned considerably lessened.

It is seldom that the operation is followed by any unpleasant symptoms, as vomiting, great pain, or violent inflammation. If, however, they should take place, the vomiting may be relieved by means of an opiate clyster, and the pain and inflammation with great tumefaction of the eye-lid lessened by the application of a poultice, or bags of emollient herbs, employing at the same time internal antiphlogistic remedies, until these symptoms have entirely subsided, and suppuration has commenced upon the internal surface of the eye-lid. When the suppuration has taken place, the part should be washed twice a day with barley water and mel rosæ, and the wound touched occasionally with the *argentum nitratum*, in order to keep the granulations within certain bounds, and to promote a solid cicatrix capable of retaining the reduced eye-lid in its situation.

CASE XX.

A young woman, 20 years of age, of a delicate constitution, and of a lax and chlorotic fibre, after an obstinate ophthalmia, had both the lower eye-lids turned outwards to the extent of about two lines. The disease, besides disfiguring the patient's countenance, occasioned a discharge upon the cheek of a mixture of tears and puriform matter. The everted edge of both eye-lids had a florid appearance, and was a little elevated and fungous.

After having tried the use of astringent collyria for a week, without advantage, I formed the resolution of destroying deeply the internal margin of both eye-lids by means of caustic. For this purpose having separated the eye-lids, one after the other from the eye-ball, and carefully wiped them, I applied the *argentum nitratum* upon the superficial fungus of their internal margin, and pressed it upon it so strongly as to produce an eschar, which was immediately covered with a layer of oil, and the patient's eyes washed successively with new milk. This application of the caustic was repeated six times at different intervals, and always with evident advantage; so that in 26 days I had the satisfaction to see the edges of both eye-lids raised to their situation. The *collyrium vitriolicum*

was employed for a considerable time after the cure, in order to prevent a return of the disease.

CASE XXI.

Giuseppa Mileri, a girl 9 years of age, a native of Pavia, of an unhealthy constitution, incautiously ran the point of a knife across the cornea of the right eye. This accident left a deformed cicatrix, and occasioned a chronic ophthalmia, which by degrees degenerated into an enormous swelling of the internal membrane of the lower eye-lid, producing an eversion of it, and giving the child's countenance a disgusting appearance. At the time of her admission into this school of clinical surgery, which was some months after the appearance of the ectropion, the child complained of no pain when the fungus was touched with the point of the finger.

I proceeded to remove the fungus with the curved scissors, and covered the part with a piece of linen spread with an ointment consisting of wax and oil, over which I applied a compress and the uniting bandage. When the dressings were removed, four days afterwards, the eye-lid had already risen up considerably, and on the following day the suppuration was completely established. The eye-lid remained nearly
stationary

stationary for a week. As soon, however, as the wound began to heal, and consequently to contract, the eye-lid rose up in an equal degree, and when the cicatrix was complete it recovered its natural position.

During the whole of the treatment, which took up about a month, no other external remedy was employed than a lotion of barley water and honey of roses, with some applications of the *argentum nitratum*, when the granulations were too prominent. Afterwards an electuary, consisting of cinchona and the antimonial *æthiops*, was employed with advantage. When the wound was completely healed I directed the ophthalmic ointment of Janin to be used morning and evening for some weeks, in order to strengthen the varicose vessels of the conjunctiva, which was attended with the best success. The extensive scar upon the cornea had entirely deprived the child of the sight of the eye, but the ectropion was completely cured.

CASE XXII.

A countryman, 38 years of age, was attacked with an erysipelas of the face, in consequence of which the eye-lid and supercilium of the left side were greatly swollen, and the inflammation terminated in suppuration. The matter discharged itself by bursting at three distinct places

in the upper eye-lid, near the superciliary arch. The furgeon, in order to expedite the healing of the ulcers, determined to divide and remove by the knife the apertures from which the matter was difcharged; and whether in this operation he had extirpated a portion of the integuments of the eye-lid, 'or they had been too much destroyed by the ulceration, in proportion as the ulcer healed, the upper eye-lid was obferved to be more and more drawn upwards and everted, and ultimately ceafed to cover the eye-ball. In confequence of which the internal membrane of the eye-lid, from being long expofed to the air, became greatly tumefied and by degrees degenerated into a fungous fubftance. In order to remedy this inconvenience in the beft poffible manner, I made the patient fit in the fame pofition as in the operation for the cataract, and with a fmall convex-edged fcalpel I began to feparate the internal fungous membrane, commencing the incifion near the external, and continuing to divide it nearly as far as the internal angle of the eye, taking care to avoid the part occupied by the *punctum lachrymale*. Having done this, I took hold of the membrane with the forceps, and then, continuing the incifion, I feparated it from the whole internal furface of the eye-lid, as far as where this membrane is about to reach the anterior hemisphere of the eye-ball, and form the conjunctiva.

As

As soon as the membrane was separated, the eye-lid fell upon the ball of the eye, and almost entirely recovered its former appearance. The loss of blood was inconsiderable; but a little after the operation the patient was seized with a violent vomiting, which continued for two hours, and was checked by administering opium freely by the mouth and by clyster.

For a few days the eye-lid was moderately swollen, but subsided on the commencement of the suppuration on its internal surface, and in 14 days from the operation the patient was completely well, as far as the nature of the case admitted.

The eye was not disfigured, although the eye-lid in reality was a little shorter than the right. He could raise it and depress it at pleasure, and apply it upon the eye-ball. When he wished to close his left eye entirely, the lower eye-lid was carried upwards beyond its usual limits, and so supplied the defect of length in the upper one.

CASE XXIII.

A boy, 10 years of age, in the beginning of October 1790, having lain during the night wrapt in a sheet upon which ears of corn had been beaten, awoke in the morning with the eye-lids of his left eye swollen and painful. Notwithstanding the use of emollient topics,

an abscess formed in the upper eye-lid, which burst below the supercilium towards the temples, and left an opening which could not be healed by any methods of treatment which were employed. In process of time the upper eye-lid began to be turned outwards, and its internal membrane to swell and protrude, and to increase the eversion of it prodigiously.

Towards the middle of June 1791, about eight months from the first appearance of any disease, the fungous excrescence formed by the internal membrane of the eye-lid, covered a considerable part of the upper hemisphere of the eye-ball, and the eversion was so considerable that the margin of the eye-lid, especially towards the temples, was almost close to the eyebrow. The eye-lid, however, readily yielded on being pressed upon with the point of the finger, and appeared as if it would have descended and covered the eye had it not been for the intervention of this fungous substance formed by its internal membrane.

As the fungus was dry and indurated, I ordered that a bread and milk poultice should be applied upon it for 24 hours; I then removed the whole of it with the curved scissors at one stroke, carefully avoiding the superior lachrymal punctum.

After the extirpation it was discovered that there was a piece of wheaten straw almost an
inch

inch long and half a line thick, contained in the fold of the fungus. The whole of the superfluous part of the internal membrane being now removed, the eye-lid descended over the eye so as to cover it conveniently. The operation was not followed by any unpleasant symptom, and 10 days afterwards the child left the hospital, so far cured that no defect remained, except a small elevation of the eye-lid near the external opening where the abscess had burst.

As there can be no doubt that this piece of straw had prevented the ulcer of the eye-lid from healing, during eight months after the bursting of the abscess, so it is singular that this extraneous body should have been forced through the internal membrane of the eye-lid, without the child having been awaked by it.

CASE XXIV.

Giuseppe Antonia Scanarotti, aged 36 years, living in the vicinity of Stradella, had a wart for a considerable time near the inferior orbital arch of the right side, which in January 1795 began to be painful. A surgeon in that neighbourhood applied a cerate upon it, the effect of which was, that two days afterwards he was seized with an erysipelas, which extended over the whole of the right side of the face. The surgeon then altered his plan, and as soon as
the

the eryfipelas began to difappear he applied the actual cautery upon the tubercle, and deftroyed it deeply, covering the efchar with a poultice of bread and milk, which was continued for feveral days. On the loofening of the efchar the part was found in the ftate of a fimple wound, and healed in the courfe of two months.* In confequence of this cicatrix the lower eye-lid was drawn a little downwards and outwards. In procefs of time the internal membrane of the eye-lid began to be elevated, and to affume a fungous appearance, and in about two years from the time of the accident, the fungus became fo exuberant as to evert the whole of the eye-lid in the manner reprefented in the 1ft figure of the 2d plate. The great deformity of the countenance, and the perpetual weeping of the eye which the difeafe occafioned, induced the patient to come into the hofpital the 29th of December 1797.†

On preffing the lower eye-lid upwards with the point of the finger, I found that the fkin yielded fufficiently to allow of its being nearly reftored to its natural pofition, and was therefore induced to hope that this poor man's

* Plate II. fig. 1.

† This cafe is recorded in the 1ft vol. 4th part, p. 806, of a journal tranflated from the German, by Thomas Volpi, entitled, *Biblioteca della più recente letteratura medico-chirurgica. Léveillé.*

condition might be ameliorated. And, as the fungus of the everted eye-lid was hard and coriaceous, I covered it for three days with an ointment consisting of oil and wax spread upon linen, over which was applied a poultice of bread and milk.

On the 3d of January 1798, the patient being placed in a chair, with the small convex-edged bistoury I made an incision along the internal margin of the tarsus of the lower eye-lid, from one canthus to the other, avoiding the punctum lachrymale; and by continuing to separate the internal membrane downwards, I removed along with it the whole of the fungus. After having covered the part with a piece of linen spread with oil and wax, I applied a very high compress upon the zygoma and eye-lid, and over it the *uniting* bandage in the direction of the *monoculus*.

On the 6th the dressing was removed for the first time, and the eye-lid was found to have advanced more than two-thirds towards its natural position. I washed the parts with the aqua malvæ made tepid, and renewed the dressing as at first.

On the 9th the eye-lid had risen up towards the eye-ball more than on the preceding days. The granulations being too luxuriant, were touched with the argentum nitratum, and the eschar was immediately smeared with oil.

On

On the 10th, 11th, and 12th, nothing particularly occurred, except that the cicatrix began to be formed near the internal margin of the tarsus.

On the 13th, 14th, and 15th, it was necessary to touch the ulcer towards the internal angle of the eye with the *argentum nitratum*.

On 21st the wound was completely healed, by employing a wash, consisting of the *aqua calcis* and *mel rosæ*, three times a day. The eye-lid had gained the highest degree of elevation it was capable of attaining, and precisely as it is seen in the 2d figure of the 2d plate. The difference, though very inconsiderable, which is also observable in the figure, was proportionate to the loss of integuments before sustained in the part where the cicatrix was formed, a loss not reparable by any ingenuity hitherto devised. By this operation, however, the deformity and weeping of the eye were removed.

CASE XXV.

Maria Teresa Zeccone, of Marcignago, was afflicted at the age of six years with a malignant carbuncle on the inferior and somewhat lateral external part of the lower eye-lid of the right side, which produced a considerable destruction of the integuments. The deformed and tense cicatrix which succeeded it, occasioned afterwards

wards an enormous eversion of the eye-lid. I examined this girl's eye when she had attained the 16th year of her age. The everted portion was at least five lines in breadth; the tears were incessantly discharged over the cheek. The eye-lid could be pushed upwards only in a very small degree, in consequence of the contraction of the integuments, especially towards the external angle of the eye. The great deficiency of integuments, and the rigidity of the cicatrix, did not permit me to hope for a perfect cure; however, I was desirous of alleviating her condition, and a bed was therefore allotted to her in the hospital, on the 17th of December 1799. In order to render the integuments of the eye-lid and the cicatrix as flexible as possible, I directed that the part should be anointed several times with lard, and that the uniting bandage should be applied in such a manner as might tend to elongate the skin of the cheek and affected eye-lid from below upwards; which was employed until the 22d day of the same month with great advantage.

The following day I performed the operation, by making an incision with the convex-edged bistoury upon the internal fungous membrane of the everted eye-lid, close to the tarsus, from the external towards the internal angle, avoiding the inferior *punctum lachrymale*, and having separated it in a great measure, and detached it

as far as where it begins to receive the name of conjunctiva, I raised it with the forceps and completely removed it by a single stroke of the curved scissors. I desired the patient to close her eye as much as possible, and having covered the part with a doffel of dry lint, to repress the bleeding, I applied the uniting bandage upon the eye-lid. The dressing was removed two days afterwards, and the eye-lid found straightened and considerably elevated towards the eyeball. The wound was washed with warm water, and covered with a piece of linen spread with the ointment, consisting of oil and wax, and the uniting bandage reapplied so as to press the integuments of the eye-lid still more upwards.

On the 27th the suppuration was very copious, and the wound had a tendency to become fungous. On the 29th this fungus had increased so as evidently to oppose the farther elevation of the eye-lid, I therefore removed it at once with the curved scissors.

On the 1st of January 1800, the suppuration was again abundant. The wound was washed several times a day with barley water and mel rosæ. On the 5th I ordered the ophthalmic ointment of Janin to be applied upon the internal surface of the eye-lid at bed-time, in order to repress the tendency which the wound always

had to the formation of fungus. This application was continued until the 10th.

At this period the eye-lid had almost attained the greatest degree of elevation of which it was capable, and embraced the lower hemisphere of the eye-ball, so that the tears were no longer discharged over the cheek.

From the 10th to the 20th the wound was occasionally touched with the *argentum nitratum*, and washed with barley-water and honey; by means of which it was perfectly healed.

On the 22d the girl left the hospital very well satisfied with her improved appearance. For no other defect remained than that depending on the shortness of the lower eye-lid, which, however, was not very evident, unless when she looked upwards.

CHAP. VII.

OF THE OPHTHALMIA.

THERE are two species of ophthalmia: the one acute and truly inflammatory, arising from an excess of stimulus and reaction of the living solid; the other chronic, from debility which is most frequently confined to the vessels of the eye or those of the eye-lids, but occasionally is connected with a weakness of the general constitution at the same time. The Arabian physicians have not improperly denominated the one ophthalmia *calida*, the other *frigida*.

This distinction, founded on observation and experience, is the most certain guide which we have in the treatment of the ophthalmia. For the first species of this disease invariably requires the use of general antiphlogistic remedies, and mild emollient applications; the other that of astringent and corroborant remedies, either alone or conjoined with the internal administration of tonics, in order to strengthen the patient's general constitution.

Besides

Besides this distinction, it is in my opinion of the greatest importance, in the treatment of this disease, to know that the truly acute inflammatory ophthalmia, even when treated in the most effectual manner, is scarcely ever so completely resolved, that a certain period having elapsed, and the inflammation entirely ceased, some small degree of chronic ophthalmia does not remain in the conjunctiva and surrounding parts from local debility. This takes place either in consequence of the distension of the vessels of the eye, during the period of inflammation, or of the increased morbid sensibility of the whole organ of vision; which increased sensibility continuing in the eye, after the acute inflammatory ophthalmia has ceased, keeps up in that organ, and the parts surrounding it, a morbid determination of blood, which may readily lead the inexperienced to believe that the inflammation of the eyes is not subdued.

Of the great importance of this observation, in determining with precision, at the bed-side of the patient, not only the species, but also the different stages of the disease, and consequently the selection of remedies best adapted to each of them, I have been over and over again convinced, from the result of my own practice and that of others. For I have frequently remarked, that those surgeons, who, whether guided by these principles or by an extensive experience only, know how to avail themselves

of the precise moment in which the *acute* ophthalmia changes into the *chronic* from local debility, speedily conduct the disease to a termination by substituting astringent and corroborant, for emollient and relaxing applications; while others, who either from ignorance or inattention are deceived by the appearances, continue the use of emollient and mild remedies, and thus perpetuate the turgescency of the vessels and the redness of the conjunctiva, which they suppose to be as much inflamed as at the beginning. It is precisely on this account that every empiric can boast of having cured obstinate cases of ophthalmia with his *aqua mirabilis*, while he imposes upon the public in vending it as a specific for ophthalmia in general; since this collyrium, which quickly dissipates the disease in the second stage, greatly aggravates it in the first. On this subject, says Hoffman;* *ausim dicere, plures visu privari ex imperitia applicandi topica, quam ex ipsa morbi vi ac magnitudine*; which is particularly applicable to the ophthalmia.

In order to place these general principles relative to the ophthalmia in the clearest light, and to render them intelligible to the young surgeon, I have thought it necessary to enter into a minute detail of the phænomena of this otherwise frequent and well known disease.

* Differtat. de erroribus vulgaribus circa usum topicorum in praxi, § 7.

The *acute* inflammatory ophthalmia is either mild or violent; both are accompanied with the same symptoms which characterize the inflammation of other parts, with the addition however of a series of other unpleasant effects depending upon the disturbed function of the organ of vision.

In cases of the mild acute ophthalmia, the internal surface of the palpebræ and the white of the eye become unusually red, the patient feels a sense of heat in the eyes greater than natural, accompanied with heaviness, pruritus, and pricking, as if small particles of sand had accidentally got into them. In that part of the eye-ball where the sensation of pricking is most complained of, a small fasciculus of blood vessels is constantly met with upon the conjunctiva more elevated and turgid than the rest of the small vessels of the same order. The patient voluntarily keeps his eye-lids half closed, on account of the stiffness and difficulty which he finds in opening them, and because by this means he moderates the impulse of the light, to which he cannot expose himself, in any considerable degree, without feeling the sense of heat, the pricking, and discharge of tears increased. If the patient possess much sensibility, his pulse becomes a little quick, especially towards the evening, or he is affected with lassitude, dryness

of the skin, slight shiverings, and in some cases with nausea and inclination to vomit.

This disease is frequently of a catarrhal character, or what is commonly called a cold in the head, attended with a defluxion, in which the eyes as well as the frontal sinuses are affected, and sometimes also the fauces and trachea. This affection is very often occasioned by frequent variations of the atmosphere; by imprudent transitions from heat to cold; by the predominance of north winds; by journies performed in the summer through moist, unhealthy, or sandy countries; by long exposure of the eyes to the vivid rays of the sun; and similar other causes. It is not surprising therefore that this disease should be frequently observed to be epidemical, and to attack persons of every age and sex. In some particular cases this affection arises principally from the stomach and primæ viæ, being stimulated by unwholesome matters, as is frequently the case with those who are debilitated, or badly nourished, or who are greatly addicted to intoxication, or the use of coarse and indigestible food. The presence of such causes is indicated by the patient's habit of body and manner of living, the nausea which he complains of, the tendency to vomit, or repugnance to every kind of animal food, pain in the head resembling hemicrania, the furred state of the tongue, fetid breath, and continual flatulency.

To

To these causes may be added, the suppression of some periodical sanguineous evacuation, as the menstrual flux in women, the hemorrhoidal in men, or that which takes place from the nostrils.

The mild acute ophthalmia may be speedily cured by a proper regimen, and by purging the patient gently with a grain of the antimonium tartarizatum dissolved in a pint and a half of the decoction of the root of the triticum repens (dog-grass) taken in divided doses, and occasionally repeated for some days, provided it does not occasion excessive purging. The external treatment, supposing it to be carefully ascertained that the disease does not arise from the introduction of any extraneous substance between the palpebræ and eye, consists in washing the part frequently with the aqua malvæ made tepid, and in the repeated application of bags of emollient herbs boiled in new milk.* If, however, from the symptoms before enumerated the disease should appear to arise, either wholly or in part, from fordes in the stomach or primæ viæ, nothing will contribute more to remove the disease than the timely administration of an emetic. Whenever likewise the ophthalmia shall have been produced, either entirely or partly, by the suppression of the menstrual or hemorrhoidal

* These bags should be made of the finest gauze instead of linen.

flux, or of the periodical discharge of blood from the nose, great advantage will be derived from the application of leeches to the labia pudendi, or to the hemorrhoidal vessels, or in the last case to the pinnæ nasi, never omitting the use of mild and emollient applications to the eyes; and that the more assiduously in proportion to the obstinacy of the inflammatory symptoms, particularly the pain and heat.

By means of this treatment the inflammatory stage of the mild acute ophthalmia generally ceases in the course of four or five days; which is rendered evident by observing, that, independently of what usually takes place towards the termination of inflammation in parts which partake of the nature and actions of mucous membranes, the patient no longer complains of the troublesome sense of heat, heaviness, stiffness, and pricking in the eyes, which he felt at first; and that, on the contrary, he can open his eyes without pain or difficulty, and bear a moderate degree of light, without its increasing the discharge of tears or gumming of the eyelids.

Although, under these circumstances, the white of the eye still continues red, and appears inflamed, it is not so in reality. The ophthalmia is now to be considered as having passed from the inflammatory stage into that arising from laxity or debility of the vessels of
the

the conjunctiva and internal membrane of the palpebræ, and the surgeon in such cases would commit an egregious error if he were to continue the use of the emollient applications. On the contrary, he will speedily free himself from all embarrassment, if in place of these local emollient remedies those of an astringent and corroborant nature be substituted, as the collyrium vitriolicum, or that consisting of eight grains of the cerussa acetata, six ounces of plantain water, and a few drops of the camphorated spirit of wine, dropping it into the eyes every two hours, or immersing them in it by means of an eye-glass. By these means the relaxed vessels of the conjunctiva, as well as those of the internal surface of the palpebræ, very quickly recover their former vigour and the ophthalmia entirely disappears.

In some of these cases of the benign acute ophthalmia, especially in those which are epidemic, from intemperance of season, the inflammatory stage is extremely mild, and terminates so quickly as to be scarcely observed. And this is therefore perhaps the only case of erysipelatous inflammation, as the ophthalmia is in general, in which cold and repellent applications are advantageous on its first appearance, as cold water with lemon-juice or vinegar, or the white of an egg beaten with rose-water and a little alum. These remedies employed in

other cases of acute ophthalmia, though mild, but in which the truly inflammatory stage continues for some days, are exceedingly injurious.

The violent *acute* ophthalmia is attended with the same concurrence of symptoms as the mild, but they are far more malignant and severe. In this form of the disease there is a sense of burning heat in the eyes, spasmodic constriction of the whole eye-ball and supercilium, and an intolerance even of the weakest light. The weeping is sometimes continual, copious, acrid, and mixed with mucus which tends to produce a cohesion of the eye-lids; at other times this is altogether wanting, and there is a complete aridity of the eye; the fever is smart; the pain in the whole head, and especially the neck, is insupportable; accompanied with incessant watchfulness. The pupil is also more contracted than natural, the conjunctiva appears in every part of it of a deep red colour, and the very delicate net-work of smaller vessels, which, in the mild acute ophthalmia, is observable upon the anterior hemisphere of the eye, among the more elevated *fasciculi* of blood vessels, passing from one fasciculus to another, cannot be distinguished, but all are equally turgid, and as it were twisted together, composing one excrescence, which is elevated upon the eye-ball, and has a tendency to project between the palpebræ.

If,

If, unfortunately, the disease make further progress, and one or more vessels, by the blood being violently thrown into them, are lacerated on the side next the eye-ball, a quantity of blood is effused into the cellular membrane, which connects the conjunctiva to the anterior hemisphere of the eye; in consequence of which the conjunctiva becomes gradually elevated upon the eye-ball, and projects towards the eye-lids, so as to conceal within it the cornea, which appears as if it were depressed. This highest degree of the acute ophthalmia is that which is called by surgeons *chemosis*.

In general, the violent *acute* ophthalmia is principally confined to the external part of the eye-ball. Occasionally the internal part of the eye is affected alone, or at least in a greater degree than the external parts of it. When the disease affects the internal part of the eye, it is indicated by the violence of the pain felt at the bottom of the orbit, not corresponding at the moment to the changes which take place in the conjunctiva and eye-lids. I say at the moment, because the internal ophthalmia is in general very soon succeeded by an inflammation of the external parts of the eye also. From considering, therefore, the small alteration which appears externally, the great aversion which the patient has, even to the weakest light, the red appearance of the iris, the great contraction of the

the

the pupil, and occasionally the red and turbid state of the aqueous humour, it is not unreasonable to suspect, that in the highest degree of this disease, as in that which affects the external parts, there is an extravasation of blood into the chambers of the eye, more particularly between the choroid and sclerotic coats, to which cause the generally unhappy issue of the internal ophthalmia ought to be attributed, rather than to any other, which, unless it produce a supuration of the eye, generally terminates in amaurosis.

The violent acute ophthalmia demands the most rigorous prosecution of the antiphlogistic plan of treatment in its full extent. Experience has shown that a delay in the employment of evacuations, and especially the neglect of taking away a sufficient quantity of blood, are the principal causes of the disease attaining the state of chemosis, and threatening either the formation of matter, or the effusion of coagulable lymph within the eye, or at least degenerating into the obstinate *chronic* ophthalmia, from the excessive distension of the vessels of the conjunctiva during the inflammatory stage.* In all cases, therefore, of the violent acute ophthalmia, blood should be taken away quickly

* See upon this subject the precepts and practical observations of Galen. De curat. rar. par sanguinis missiones. Cap. 17.

and abundantly from the veins of the arm or foot, in proportion to the age and temperament of the patient, and afterwards, according to circumstances, from the neighbourhood of the eyes, by means of leeches applied in the proximity of the eye-lids, especially near the internal angle of the eye upon the angular vein at its junction with the *vena frontalis, orbitalis profunda, and transversalis faciei*; always premising, however, the previous abundant evacuations of blood from the arm or foot.* And if the disease shall have appeared in consequence of the suppression of some periodical sanguineous discharge, as that of the nose, uterus, or hemorrhoidal vessels, instead of applying the leeches round the eye-lids, it will be more advantageous to apply them in the first case upon the *pinnae nasi*, and in the others to the internal part of the *labia pudendi*, or to the hemorrhoidal veins. In the case of a young woman, 19 years of age, who not long since was attacked with a violent inflammation in both her eyes, a little after the sudden suppression of the menses, the application of leeches to the internal part of the *labia pudendi*, after a copious evacuation of blood from the arm, pro-

* It appears not a little extraordinary, that no mention is made of the division of the anterior branch of the temporal artery, or rather that this mode of taking away blood should not have superseded the employment of general bleeding from the veins of the arm or foot.

duced so good an effect, that in less than 24 hours the inflammation abated, and the patient was greatly relieved. I have frequently had occasion to remark the same thing in cases of the violent acute ophthalmia, in consequence of the suppression of the periodical hemorrhoidal flux, as well as that of the nose.

The general and local abstraction of blood, although copious, is not always sufficient to produce a speedy diminution of that highest degree of the disease, which is termed chemosis. In such urgent cases recourse must be had to some other expedient, in order to produce a speedy discharge of the blood which is extravasated in the cellular membrane, connecting the conjunctiva to the anterior hemisphere of the eye, by which this membrane is enormously elevated and distended. This consists in the circular excision of the projecting portion of the conjunctiva with the curved scissors, at the part where the cornea and sclerotica unite; by means of which not only the whole of the blood which is extravasated under the conjunctiva is discharged, and with immediate relief to the patient, but also that, which, notwithstanding the abundant general evacuations of blood, might still greatly distend the vessels of this membrane. This operation is infinitely preferable to scarification, which is practised in such cases by the greater part of surgeons; since
the

the latter is not sufficient to discharge the blood which is extravasated under the conjunctiva, and rather increases than diminishes the irritation, and the determination of blood to the eye.

After the abundant general and local bleedings, the patient's bowels should be purged by mild antiphlogistic aperients, as the pulp of the tamarind, crystals of tartar, tartarized kali, or vitriolated magnesia; and in cases of torpor of the stomach an emetic should be given without hesitation; that is, for an adult, two scruples of ipecacuanha with a grain of the antimonium tartarizatum; the patient should afterwards be directed to take for several successive days, in divided doses, a grain of tartarized antimony, with two drams of crystals of tartar, dissolved in a pint of the decoction of the radix tritici repent. (dog grass) or milk whey.

Among the best external remedies, especially in plethoric subjects, and after a sufficient quantity of blood has been taken away and the bowels opened,* is deservedly ranked the application of a blister to the neck. Not, however, because the blister produces a discharge of serum from the part to which it is applied, but because

* Hoffman Medicinæ ration. system, T. 4. part 1. sect. 2. Setacea et vesicatoria non facile applicanda in plethoricis, nisi soluta prius plethora; et alvo præsertim in cacoehymicis, subducta.

it excites a consensual irritation, which suspends, as it were, the morbid process, by transferring it to the part which is artificially stimulated; and it is known, from observation, that the neck and back part of the ear are the parts which more readily sympathize with the eyes than any other part of the head; in the same manner as the lobe of the ear with the teeth, the peritonæum with the urinary bladder, and the skin of the abdomen with the viscera contained in it, &c.

With respect to the local remedies to be applied upon the inflamed eyes, the use of mild and emollient applications should never be departed from, as bags of mallows boiled in new milk, or a poultice of bread and milk with saffron, the pulp of roasted apples, and others of that class, which ought to be renewed every two hours or oftener. In order to moderate the excessive heat which is felt in the eyes, nothing is more advantageous than introducing with the point of a probe between the eye-lids and ball, the white of a fresh egg, or the mucilage of the psyllium prepared in the distilled water of mallows. The patient should be recommended to lie in bed with his head as much raised as possible, and not to do any thing which may impede or interrupt his perspiration. If the edges of the eye-lids should have much tendency to cohere, especially during the night,
they

they should be smeared at bed-time with a liniment consisting of oil and wax; as nothing contributes more to aggravate the painful effects of the disease, than the confinement and redundancy of the scalding tears between the ball of the eye and the palpebræ.

By the timely employment of these efficacious means, the inflammatory stage of the violent acute ophthalmia is in general subdued by the 5th, 7th, or 11th day. This is marked by the entire cessation of the fever, by the patient no longer complaining of the burning heat or lancinating pains in the eyes; by the subsidence and flaccidity of the eye-lids, and by the patient in general becoming easy, and having a return of his appetite. The eyes, which before were either entirely dry or poured out a thin and acrid serum, now discharge a quantity of mucous matter, which affords relief, the patient opens and shuts the eye-lids without much difficulty or aversion to a moderate degree of light, and, lastly, the humours are not rendered turbid by extraneous matters.

On the appearance of these symptoms, notwithstanding the redness and tumefaction of the conjunctiva still continue, it will be proper to desist from debilitating the patient any further, and instead of emollient and relaxing applications, (except in cases where the excision of the conjunctiva has been requisite, of which I shall

shall speak afterwards) it will be proper to substitute those of an astringent and corroborant nature, as a collyrium consisting of the acetated cerus and distilled plantain water, or composed of 6 grains of vitriolated zinc, 6 ounces of distilled water, one ounce of the mucilage of quince-seed, and a few drops of camphorated spirit of wine, which should be insinuated between the eye-lids every two hours, and the eyes immersed in it by means of an eye-glass. It should be observed that persons are occasionally met with who cannot bear cold applications to the eyes, especially in winter. In such cases the collyria should be used at first tepid, and the temperature gradually diminished, until the patient's excessive sensibility is allayed, and they can be employed entirely cold.

A very efficacious remedy in this state of the disease, or when after blood has been taken away copiously, and the bowels evacuated, the violent acute ophthalmia has passed into the second stage, or that arising from local debility, is the *Tinctura Thebaïca* of the London Pharmacopœia,* two or three drops of which may be in-

* *Rec. Opii colati unciam unam.*

Cinnamom.

Caryophyl. arom. an. drachmam semis.

Vin. alb. merac. libram semis.

Macera per hebdomadam sine calore; deinde per chartam cola. Adde, postquam colata sunt, spiritus vini tenuioris viceffimam circiter partem, ut tutiora sint a fermentatione. Repondere oportet vitreis ampullis accurate obturatis.

stilled

ftilled between the eye-lids twice á day, or only at night for feveral fucceffive days, and till the patient is completely cured. At the moment this remedy is diffufed over the eye, it generally produces confiderable heat and uneafinefs; but this quickly fubfides, and on the following morning the eye is found in a clearer and much better ftate. It is neceffary, however, to obferve again, that this application, which is fo useful in the fecond ftage of the difeafe, is exceedingly injurious in the firft, or inflammatory ftage, and that confequently it ought never to be employed until after copious general and local bleeding, and evacuation of the bowels, and in fhort until the inflammation has entirely ceafed.* I can aver, from my own experience, that what Mr. Ware has afferted of the utility of this remedy, when employed with caution, and at a proper period, is not at all exaggerated.

When the furgeon has been under the neceffity of making a circular excifion of the conjunctiva, in order to prevent the progrefs of the chemofis, he fhould recollect that after the in-

* Chirurgical obfervations on the ophthalmia by James Ware. But the speedy advantage of this remedy is not to be expected in all cafes indifcriminately. In fome the amendment is more flow and gradual, requiring the tincture to be made ufe of for a much longer time; and a few instances have occurred in which no relief at all was obtained from its firft application. In cafes of the latter kind, in which the complaint is generally recent, the eyes appear fhining and gloffy, and feel exquisite pain from the rays of light. P. 52.

flammatory stage of the disease is over, the ulceration which he has produced upon the eye-ball, at the junction of the cornea and sclerotic coat, must contra-indicate the use of irritating and astringent collyria, since they would exasperate the disease, and give occasion to a renewal of the inflammation. In such cases he must be satisfied, after the inflammation has been dissipated, with promoting the suppuration of the wound, by washing the eye frequently in the course of the day with mallow-water or new milk. The suppuration will present itself by a layer of mucus spread over the whole of the whitish circular zone, which remains after the division of the conjunctiva; which zone, towards the decline of the second stage of the disease, will gradually contract and heal, without leaving any vestige of the wound made in the conjunctiva.

Lastly, as soon as the patient is in a state to support a moderate degree of light without inconvenience, every kind of covering and incumbrance should be removed from the eyes, except a piece of green, or black taffeta, which should be suspended from his forehead, in order that under this defence he may be at liberty to open and shut his eye-lids at pleasure, and move the eye-ball freely. Those who are about the patient should be also directed gradually to admit a greater degree of light every day into his chamber, that he may habituate himself to it
as

as quickly as possible, and be able to face the full light. For it is a certain fact, confirmed by experience, that nothing contributes more to keep up and increase the morbid sensibility of the organ of vision, and consequently to prolong the disease, than obliging the patient to lie unnecessarily in a room completely dark, or with his eyes closed and covered with a bandage, a longer time than the nature of the case requires.

What has been already delivered, relative to the phenomena and treatment of the violent acute ophthalmia in both its stages, will be sufficient, in my opinion, to serve as a certain guide to the young surgeon in the management of this disease, although it should occasionally be attended with some other symptom which is not usual; I cannot, however, omit to mention a particular species of the violent acute ophthalmia, which is distinct from the common in this respect, that although the inflammation and swelling of the eyelids and conjunctiva come on with great intensity, like the other cases of ophthalmia of this species; yet a short time afterwards it is attended with an extraordinary copious discharge of matter from the eyes of a puriform appearance. This disease, as it is most commonly met with in infants, a little after their birth, or attacks adults in consequence of a sudden suppression of the virulent gonorrhœa, or of a translation of the venereal poi-

son in some other manner to the eyes, is called in the first case the puriform ophthalmia of infants, in the second the acute gonorrhœal ophthalmia.

The first, as I have said, attacks infants a little after their birth, or those of an early age, while at the breast. On the appearance of this alarming disease, the eye-lids become at once enormously swollen, and in such a degree that they cannot be separated from each other, much less turned outwards. And if this is effected with difficulty, the internal membrane of the palpebræ is found converted into a villous, fungous substance, similar in some degree to the *intestinum rectum*, when it is forced out and everted in children from excessive straining. The eye-lids, during the crying of the infant, are occasionally everted of themselves, and remain in that state until they are returned by force. When the first shock of the inflammation is over, which is of short duration, a most extraordinary quantity of puriform mucus is continually discharged from the eyes, which is partly secreted by the ciliary glands, but the greater part of it by the villous and fungous substance into which the internal membrane of the eye-lids and conjunctiva is converted. The fever, at the commencement of the disease is smart, the cries of the infant, the restlessness, and tremors of the whole body are incessant; and with these symptoms

symptoms is frequently associated a vomiting or purging of very offensive yellowish matter.

If a prompt and efficacious treatment be not employed to restrain this immoderate discharge of puriform mucus from the eye-lids and conjunctiva of infants, the cornea in a short time loses its transparency, becomes thickened, and a *staphyloma* is produced. On the first appearance of the disease, therefore, the antiphlogistic plan of treatment should be put in practice, by taking away blood from the infant, either by means of the lancet, or by the application of leeches to the temples. Afterwards a blister applied to the neck will be found very useful, especially if the disease have been preceded by the retropulsion of any eruption upon the head. It will be proper also to purge the infant with syrup of succory, conjoined with rhubarb and a little magnesia, directing the nurse at the same time not to overload the child's stomach with milk or other food as is usual, nor to swathe the child tightly, and dress it in heavy clothes, as is the custom with our ladies, even in the hottest weather. And if there be any reason to believe that it is in part occasioned by the nurse's milk being bad, she ought to be changed, or the disease, whether depending on the state of her stomach or constitution corrected.

In the poorer class of people this disease is most frequently met with in the second stage,

or after the inflammatory period is over, and the copious puriform discharge has taken place. If it should happen to be observed on its first invasion, besides the general remedies already mentioned, the eye-lids should be covered with bags of very fine gauze filled with emollient herbs boiled in milk and sprinkled with camphire; or with bread and milk with saffron, or the pulp of roasted apples sprinkled with camphor, in order to moderate the violence of the inflammation. As soon as the puriform mucus is copiously discharged from the eyes, which marks the commencement of the second stage of the disease, recourse must be had to astringent and corroborant applications, in order to restore the vessels of the eye-lids and conjunctiva to their former vigour, to repress the fungous and villous state of the internal membrane of the eye-lids, and thereby check the morbid and immoderate puriform secretion, from which it is principally derived. For this purpose the most useful and efficacious application is the introduction of the *aqua camphorata* between the eye-lids and ball of the eye. This water is composed of equal parts of the cuprum vitriolatum and armenian bole, and of a fourth part of camphire, well pulverized and mixed together. One ounce of this powder is put into a pint of boiling water; it is then taken from the fire, and after being allowed to stand a little until the
heaviest

heaviest parts subside, is decanted. The camhorated water thus prepared is used at first, by putting a dram of it into two ounces of cold distilled plantain water, and afterwards increasing the dose of it according to circumstances. This collyrium is injected by means of a small ivory syringe, the point of which is carefully introduced between the eye-lids at the external angle of the eye. In the worst cases it ought to be employed every hour, and in those of less magnitude two or three times a day. The eye-lids are afterwards covered with a piece of linen spread with the white of an egg beaten and inspissated with alum, and the cohesion of the tarfi is prevented by frequently anointing the edges of the eye-lids with pommade, or oil and wax.

By this method of treatment, in the course of two weeks the copious discharge of puriform mucus from the eyes generally ceases, the eye-lids subside, and the surgeon is now able to determine precisely the state of the eye, and particularly that of the cornea. If there should be any opacity of the latter, the most proper remedy for removing it is the Tinctura Thebaïca of the London Pharmacopœia, or if this is not at hand the ophthalmic ointment of Janin.

The violent acute *gonorrhæal* ophthalmia is very similar to the ophthalmia of infants, with respect to the violence of the inflammation, the

copious discharge of puriform mucus from the eyes which shortly succeeds it, and the tendency which the disease has to destroy the organ of vision; but it differs from it essentially, with regard to the cause by which it is produced.

This disease is occasioned in two ways. The one takes place in consequence, or at least after the sudden suppression of the virulent gonorrhœa; although every suppression of gonorrhœa is not constantly succeeded by the appearance of such ophthalmia. The other is produced by the insertion of the matter of gonorrhœa, which is inadvertently carried from the genitals to the eyes.

On the sudden suppression of the gonorrhœa, which usually takes place in consequence of violent exertions of the whole body, the abuse of spirituous liquors, long exposure of the whole body to an excessive degree of cold, and of acrid and astringent injections thrown into the urethra, or other similar causes, the ophthalmia appears with great tumefaction of the conjunctiva rather than of the eye-lids; not long after, a copious and continual discharge of greenish yellow matter issues from the eyes, similar to that of the virulent gonorrhœa; the disease is attended with great feverishness, restlessness, a burning heat, and acute pain in the eyes and head, and an intolerance of light, and in some cases also an incipient hypopion appears shortly afterwards in the

anterior chamber of the aqueous tumour. In the second case the same effects are produced when the patient incautiously inserts the virus, by rubbing his eyes with his fingers, or a cloth imbued with the matter of gonorrhœa; with this difference however, that the symptoms before enumerated are not so violent, and the inflammation so excessive in this instance as the former.

The greater part of surgeons are of opinion that in the first case there is a true metastasis of the matter of gonorrhœa from the urethra to the eyes. But to others this theory has appeared unsatisfactory, and in my opinion with much reason. For the puriform ophthalmia does not always succeed the sudden suppression of the gonorrhœa; on the contrary, this accident may be considered as rare, in proportion to the frequency of cases in which the disease is suddenly suppressed or repelled. In the second place the confirmed lues is never seen to succeed such metastasis of the gonorrhœa to the eyes.* In the third place the gonorrhœal ophthalmia from inoculation with the virus, in which case no doubt can be entertained that the venereal poison is the cause of the disease in the eyes, has never the same powerful and immediate tendency to destroy the organ of vision, as that which is de-

* The same thing is remarked by Bell, on gonorrhœa virul. v. 1. chap. 1.

rived from the gonorrhœal metastasis. Perhaps they approach nearer the truth, who regard this phænomenon rather as the effect of a direct consent between the urethra and eyes, than as a real translation of matter; the internal membrane of the urethra and of the palpebræ, as well as those of the fauces and rectum, being productions of the cutis; and if this effect does not take place in every case of sudden suppression of gonorrhœa, it is because all individuals are not endowed with the same degree of consensual sensibility.*

However

* The reasons which have led Professor Scarpa to doubt the opinion of the particular manner in which the gonorrhœa produces this affection of the eyes, would also I think lead one to suspect the existence of such a cause altogether; but the following communication, for which I am indebted to Mr. Pearson, forms a more satisfactory argument than any presumptive evidence that can be offered.

“ The venereal ophthalmia, or what Professor Scarpa calls the gonorrhœal ophthalmia, whether ascribed to metastasis, sympathy, or the application of the matter of gonorrhœa to the eye, is a disease which has been described by a considerable number of those writers who have treated professedly on venereal complaints; but whether the greater part of them have given the result of their own observations, or have merely transcribed from the works of their predecessors, is a question deserving some consideration.

“ Although I am fully disposed to treat the talents and accuracy of Professor Scarpa with the utmost deference, yet I cannot help entertaining some doubts of the propriety of assigning the gonorrhœa as a cause of ophthalmia; since, during a pretty extensive experience of twenty-five years, I have never seen one single instance of an inflammation of the eyes, which was evidently derived from a gonorrhœa. I am sufficiently aware of the nature and force of negative evidence in matters depending on testimony, not to over-rate it; and certainly, to deny the existence of any attested fact, merely because it has not occurred in the course of a man's own experience, would be hasty and unjustifiable.

However this matter may be, on the appearance of this violent acute ophthalmia, the primary indication is to subdue the violence of the inflammation as quickly as possible, in order to prevent the destruction of the eye or the opacity of the cornea. Consequently, as I have said before, blood should be taken away abundantly, not only generally but locally, by means of leeches, allowing it to flow in sufficient quantity; and in case of *chemosis*, the excision of the

justifiable. In the instance now before us, there are two points to be considered; the testimony of a respectable Professor, and the validity of his opinion; for it is not only asserted, that those who are infected with a gonorrhœa may be attacked by a violent ophthalmia, but that the gonorrhœa is some how or other the cause of that ophthalmia. It is with reference to the latter proposition that I express my doubts, which are founded upon the fact mentioned before, that, of the many thousand cases of gonorrhœa which have fallen under my notice, I never could, in any one instance, trace such a connexion between the eye and the urethra, as that to which Professor Scarpa alludes.

“The puriform ophthalmia of infants, was, within my recollection, generally regarded as an indication of a venereal taint; and much unnecessary distress was often excited in families, and very improper treatment was frequently pursued, in consequence of this erroneous opinion. The nature of that complaint, and the proper method of treating it, are now much better understood, and I conceive, that mistakes in these cases are not very common at this time.

“In that form of the secondary symptoms of syphilis, where the skin is the part chiefly affected, a disease resembling the ophthalmia tarfi sometimes appears. It is not commonly attended with much redness of the tunica conjunctiva, nor is the sensibility of the eye to light remarkably increased: yet I have seen it, in a few instances, in the form of an acute ophthalmia, resisting all the common modes of treatment, but yielding immediately to a course of mercury.

“The venereal ophthalmia resembles, in its appearance, those diseases of the tarfi and tunica conjunctiva, which are derived from scrofula: and, I believe, there are no specific characters by which diseases of the eye, or eye-lids, produced by the action of the venereal virus, can be distinguished from those which are excited by other causes.”

conjunctiva

conjunctiva ought to be performed; * it will be also proper to employ mild laxatives, cooling drinks, emulsions of gum arabic, the warm bath, or at least the pediluvium, and blisters to the neck. The patient ought to lie in bed with his head raised, and his eyes should be frequently fomented with bags of emollient herbs. A small quantity of mallow-water should be injected between the eye-lids and ball of the eye, two or three times a day, by means of a small ivory syringe, in order to cleanse the parts; and the white of a fresh egg, or the mucilage of the seeds of the psyllium, extracted with mallow-water, afterwards introduced with the point of a probe, in order to moderate the heat and pain which the patient so much complains of; the edges of the eye-lids should be also anointed, especially at night, with the ointment of wax and oil. The surgeon should also direct that a large poultice of bread and milk with saffron be applied upon the perinæum, and renewed every two hours, and that warm oil be injected

* Some pretend, that, in this particular case, scarifications of the conjunctiva are rather injurious than beneficial. This may be true with regard to scarifications, but with respect to the excision of the conjunctiva, I can assert that it is as advantageous in the case of *chemosis* from this species of ophthalmia as in the others. Some assert, that they ought never to be employed until the highest degree of the inflammation is mitigated by means of general remedies and emollient applications.

into

into the urethra several times a day, introducing after each injection a simple bougie, with the view of reproducing the gonorrhœal discharge.

When the inflammatory stage of the disease is subdued, which, as I have several times observed, is indicated by the cessation of fever, the burning heat and acute pain in the eyes, and by the diminished tumefaction of the eye-lids, although the fulness of the vessels of the conjunctiva, and the abundant discharge of puriform mucus from the eyes continue as at first, the surgeon, nevertheless, laying aside the use of emollient applications, ought to exchange them for a collyrium, consisting of one grain of the hydrargyrus muriatus dissolved in ten ounces of the aqua plantaginis, which should be instilled between the eye-lids every two hours; and if this application be too irritating, it ought to be diluted by adding a little mucilage of the seeds of the psyllium: this treatment, however, is proper only in cases where the excision of the conjunctiva has not been requisite, for when this operation has been executed, the use of stimulant and astringent applications, at least those of the strongest kind, ought to be desisted from in the second stage of this, as well as of every other species of ophthalmia. The same treatment is equally applicable to the gonorrhœal ophthalmia, when it is produced by the insertion of the matter; except that in the latter, no applications

applications are necessary to cause a return of the discharge from the urethra, and that the local stimulant and astringent remedies succeed better in this case in the solid than in the liquid form, as the common mercurial ointment smeared upon the edges of the eye-lids, or instead of it, the ophthalmic ointment of *Janin*.

Hitherto I have spoken of the two stages of the benign and violent *acute* ophthalmia, and of the treatment which each of these periods requires. But although the second stage of the violent acute ophthalmia, or that which consists in the atony of the vessels of the conjunctiva, and of the palpebræ, is most frequently speedily cured by the use of astringent and corroborant applications; yet cases are occasionally met with in practice, in which, from an unfavourable combination of causes, the second stage of this disease is protracted to a length of time, until it becomes in the strictest sense *chronic*, and slowly threatens the destruction of the organ of vision.

This unfavourable combination proceeds from three principal sources; either from an increased sensibility and irritability remaining in the eye, after the cessation of the *acute* stage of the ophthalmia; from some other disease in the eye, of which the ophthalmia is only a consequence; or, lastly, from some particular predisposition of the patient's general constitution.

That

That the morbid increase of sensibility in the eye is the cause of the disease being kept up, is inferred from the discharge not only resisting the use of astringent and corroborant applications, which produce such speedy and beneficial effects in cases of simple debility of the vessels of the conjunctiva and eye-lids, but also from the disease being aggravated by the use of these remedies, or even by cold water alone, from the patient's constantly complaining of a weight and great difficulty in raising the upper eye-lid, from the conjunctiva having always a yellow appearance, and from its becoming instantly bloodshot, on the patient's exposing himself to a moist and cold air, or to a more vivid light than usual, or on using his eyes a little in reading or writing by candle light. If, in addition to all this, the patient's habit is weak and irritable, if he is subject to frequent attacks of hemicrania, to restlessness, convulsions, spasmodic tension of the hypochondria, or flatulency, under these circumstances it is evident that the chronic ophthalmia is not only kept up by a morbid increase of sensibility in the organ of vision, but also by a general nervous affection, in which the eyes participate.

With respect to the diseases of the eye, from which the chronic ophthalmia is derived; besides the presence of an extraneous body between the palpebræ and ball of the eye, which has passed unobserved

unobserved by the surgeon, are reckoned the inversion of one or more hairs of the eye-lids, or caruncula lachrymalis, a small abscess or ulcer in some part of the cornea, the protrusion of a portion of the iris, the ulcerous herpes of the edges of the eye-lids, the tinea of the eye-lids, the vitiated secretion of the ciliary glands, the morbid enlargement of the cornea or of the whole eye-ball.

As to the diseases of the general constitution, the cure of the second stage of the violent acute ophthalmia is most frequently retarded or prevented, either by a scrofulous predisposition, or by an obstinate variolous metastasis to the eyes, and occasionally by the inveterate lues venerea. The symptoms of these are so well known, even by students in surgery, that it would be unnecessary here to repeat them.

In cases where the disease is kept up by an excess of partial or general sensibility, the internal administration of the bark, conjoined with valerian root, animal food of easy digestion, gelatinous and farinaceous broths, immersion in the cold bath, the moderate use of wine,* gentle

* Hippocrates says: oculorum dolores meri potio, aut balneum, aut fomentum, aut venæsectio, aut medicamentum purgans exhibitum solvit. Aph. 31. sect. vi., aph. 46. sect. vii. Celsus has given the true sense of this aphorism in the following words: solet enim evenire nonnunquam, sive tempestatum

the exercise, and the breathing a pure and temperate air are attended with peculiar advantage. Of the external applications, those which are of a sedative and corroborant nature are very useful, but particularly the aromatic-spirituuous vapour. This is employed by putting two ounces of boiling water, and two drams of the volatile aromatic spirit,* into a vessel capable of holding three ounces, then wrapping the vessel in a hot cloth, and conducting the vapour to the eye by means of a small funnel, or by merely bringing the vessel close to the eye. This should be repeated three or four times a day, for at least half an hour, and the eye-lids and eye-brow gently rubbed with the volatile aromatic spirit.

The patient should be cautious, both during the treatment and afterwards, not to fatigue his eyes, and should desist from looking as soon as

pestatum vitio five corporis, ut pluribus diebus neque dolor, neque inflammatio, et minime pituitæ cursus finiatur. Quod ubi incidit, jamque ipsa vetustate res matura est, ab iis eisdem auxilium petendum est, id est balneo, ac vino. Hæc enim, ut in recentibus malis aliena sunt, quia concitare ea possunt, et accendere: sic in veteribus, quæ nullis aliis auxiliis cesserunt, admodum efficacia esse consueverunt. Lib. VII. cap. vi. art. 8.

* Rec. Essentiæ limonum.

Ol. nucis moschatæ essentialis. an. drachmas duas.

Ol. caryophyllorum aromat. essentialis drachmam dimidiam.

Spiritus salis ammoniaci dulcis libras duas.

Distilla igne lenissimo.

he feels the smallest uneasiness or sense of heat in them. In reading or writing he should place himself in such a manner as to have uniformly the same degree of light; as the too strong or too weak a light in these cases is equally injurious. When the patient has once accustomed himself to the use of spectacles, he ought never to attempt to read or write, or to look at minute objects without them.

When the chronic ophthalmia is the consequence of some other disease of the eye, it is evident that the plan of treatment ought to be directed to remove the primary affection.

Of these diseases, some have been already spoken of in the preceding chapters, and the rest will be detailed hereafter. I shall only add here what my observation and experience have taught me with respect to the treatment of the chronic ophthalmia, when connected with those diseases of the general constitution which are most frequent. As no specific has been yet discovered for the cure of scrofula, the treatment of the chronic ophthalmia, when connected with that affection of the general system is exceedingly limited, and is rather confined to a knowledge of what aggravates this disease of the eyes, than of any means adapted to the radical cure of it. The chronic scrofulous ophthalmia is exasperated by whatever debilitates the patient: as the abstraction of blood, the frequent use of saline purgatives, termed

termed antiphlogistic, food of difficult digestion, as hard, salted, smoked, or fat meats, raw vegetables, acid fruits; also intense study, a sedentary life, moist and marshy habitations, uncleanness and frequent variations of temperature. On the contrary the disease is mitigated, as well as its effects upon the eyes diminished, by the use of detergents continued for some time, especially rhubarb, the tartarized kali conjoined with the tartarized antimony in small and divided doses, and if the eyes are not in a truly inflammatory and excessively irritable state, the internal use of tonics, particularly the cinchona in powder, decoction, or cold infusion; or the decoction of bark conjoined with the volatile tincture of guaiacum;* or the electuary, consisting of bark, cinnabar of antimony, and gum guaiacum.† The antimonial æthiops, in doses of half a grain a day, afterwards of 2, 3, 4 up to 20, taken for fifty days or more. The second water of quick

* Rec. Decoct. cinchon. unc. 9.

Aq. melis unc. 1.

A third part of this may be taken three times a day, to each dose of which 4 or 5 drops of the tincture of guaiacum may be added for a child 10 years of age.

† Rec. Cinchon. unc. 11.

Cinab. antimon. unc. 1.

Gumm. guaiac. unc. 11.

Syr. cort. aurant. q. s. f. electuar.

Of which half a teaspoonful may be taken three times a day, by a child of 10 years old.

lime with chicken broth, in doses of three ounces each, every morning fasting, and afterwards morning and evening for some months; constantly observing a proper regimen. Besides these, sea-bathing in the summer, and frictions with flannel, morning and evening, are attended with great advantage.

And with respect to the external means, the scrofulous chronic ophthalmia is exasperated by emollient and relaxing applications, and by the patient being confined in a room perfectly dark. On the contrary, those which afford relief are slightly astringent collyria, as lotions consisting of a decoction of henbane (*hyoscyamus niger*) and the flowers of mallow boiled in milk, with the addition of a few drops of the aqua lithargyri acetati comp.; the Thebaic Tincture of the *London Pharmacopæia*; ointments composed of tutty, armenian bole, or aloes, in such proportion as not to cause too much irritation. It is also advantageous to take away from the patient's eyes, every kind of covering, except a piece of taffeta suspended from the forehead, and at a distance from the eyes; to accustom him by insensible degrees to bear a moderately strong light, and to allow him to breathe a pure air, and to take exercise. In this manner the want of specific remedies is in some measure compensated by the disease being moderated, or at least rendered supportable.

I might

I might here adduce a considerable number of instances of patients confined for several months in a dark room, and abandoned as incurable, who have quickly recovered under the use of these remedies; but particularly I think from their having been very gradually accustomed to bear a greater degree of light. It is not unworthy of remark that the scrofulous diathesis very frequently disappears spontaneously at the age of puberty, when the body is completely developed; and when this fortunate change takes place in those who are affected with the chronic ophthalmia, the disease, as I have frequently had occasion to remark, disappears also at the same time with the general affection of the system.

Not less difficult of cure is the chronic stage of the acute ophthalmia from a variolous metastasis to the eyes; or that which takes place in consequence of the small-pox, and not unfrequently some weeks after the falling off of the crusts. This disease passes through a severe inflammatory stage; and even after the most judicious employment of antiphlogistic remedies, resists the use of corroborant and astringent applications, which appear best adapted to it.

One of the most efficacious remedies in this disease is a seton in the neck,* kept open for several months. Afterwards, when the stomach

* T. Hildanus Centur. I. observ. 41. exempl. ii. iii.
Journal de Médecin. de Paris, Février 1789.

and primæ viæ have been cleared by the opening powders,* I have found it very useful to order the patient, supposing a child 10 years old, to take morning and evening a pill, consisting of one grain of calomel, one of the golden sulphur of antimony, and four of the powder of cicuta. If the patient is possessed of exquisite local and general sensibility, besides this remedy I have found it advantageous to employ a mixture composed of three drams of Huxam's antimonial wine, and half a dram of the Thebaïc Tincture; five or six drops of which taken in any convenient vehicle twice a day, is a sufficient dose for a child of the same age; and as an external application the aromatic spirituous vapour, in the manner before recommended. Where, however, there is no increased local sensibility, it may be sufficient to immerse the eyes frequently in distilled plantain water, with a little cerussa acetata, or camphorated spirit of wine added to it; to apply the white of an egg with a little sugar; the Thebaïc Tincture of the *London Pharmacopæia*; or Janin's ophthalmic ointment, observing in every other respect the rules already laid down, not to keep the patient's

* Rec. Cryst. tar pulver. unciam dimidiam.

Antimon. tartariz. granum unum.

Misce, et divide in sex partes æquales.

One of these taken twice a day will be sufficient for a child of 10 years old.

eyes covered with bandages, nor to confine him for too long a time in a dark room. The same treatment is proper in cases of chronic ophthalmia, in consequence of the measles.

The venereal chronic ophthalmia is strictly speaking only a symptom of the confirmed lues. This disease is peculiar; in as much as it does not make its appearance with manifest symptoms of inflammation, but comes on insidiously, slowly, and without much uneasiness. It afterwards produces a gradual relaxation of the vessels of the conjunctiva, and internal membrane of the palpebræ, perverts the secretion of the ciliary glands; causes an ulceration of the edges of the eye-lids by which the hairs fall off, and finally renders the cornea opaque. In its highest degree, it excites a pruritus in the eyes, which increases particularly towards the evening, and during the night, and diminishes on the approach of morn, in the same manner as almost all the other secondary symptoms of lues venerea; lastly, it never arrives at the state of *chemosis*.*

As the inflammatory stage of this species of ophthalmia is trifling, being so mild as to pass unobserved, it is never necessary to employ the antiphlogistic plan of treatment. The same means, therefore, which are adopted in the cure

* See note, p. 187.

of the lues venerea, may, in general, be employed in this case, without the smallest delay; that is, general mercurial frictions, and at the same time the decoction of *mezereon* bark and *sarsaparilla*.* A few drops of the collyrium before mentioned, consisting of a grain of the hydrargyrus muriatus dissolved in 6 or 8 ounces of mallow, or distilled plantain water, with the addition of a little mucilage of the seeds of psyllium, may be introduced between the eyelids every two hours, and at night Janin's ophthalmic ointment. Cullen recommended, in this particular case, the *unguentum citrinum* of the *Edinburgh Pharmacopœia*, lowered with a double or triple quantity of lard; but I have observed that the same advantages are obtained from the ointment before mentioned. If much circumspection in the use of mercury be required in any case of complicated lues venerea, it is certainly in that of which I am now treating. For if it be administered in too large doses the violent shock which it gives to the head, never fails to aggravate the ophthalmia, and accelerate the total loss of sight. If therefore such an

* Rec. Cort. rad. mezereon drachmam unam et semis.

Rad. sarsaparill. unc. I.

Coque in aq. font. lib. III. ad reman. lib. II.

adde

Lactis vaccini recentis unc. VI.

To be taken in small doses in the course of 24 hours.

effect

effect should take place, the use of mercury ought to be suspended for some time, the patient should be gently purged, his skin should be washed, and he should be removed into another apartment.

Lastly, it is proper to remark, that although the disease with which the chronic ophthalmia is connected be removed, and no traces of the latter remain upon any part of the conjunctiva which invests the eye-ball, nevertheless, the edges of the eye-lids very frequently continue marked here and there with small ulcers; which, in order that they may heal perfectly, require to be frequently touched with the *argentum nitratum*, covering the eschar immediately afterwards with a little oil.

In some particular cases, and especially in consequence of the *crusta lactea*, these small ulcers are situated around the root or bulb of the hairs, as in the *tinea capitis*. In order to apply the caustic to these ulcers accurately, and to draw it with precision along the edge of the eye-lid, it is previously necessary to pluck out the hairs with the greatest possible care one by one, in the same manner as in the treatment of the *tinea capitis*. This being done, and the part fomented for some days, in order to obviate the effects occasioned by the irritation of plucking out the hairs, and to promote the suppuration of some small pustules which appear upon the
edge

edge of the eye-lids, in consequence of this operation, the argentum nitratum should be drawn once or twice along the tarsus; and the eschar covered with a pencil stroke of oil.

After the exfoliation of the eschar, it will be sufficient to anoint the edge of the eye-lids for some nights with the unguent. hydrarg. nitrat. or the ophthalmic ointment of Janin, in order that the whole series of small ulcers which occupied the roots of the hairs may be speedily healed. It is proper to observe, that the hairs which are plucked out, are reproduced, but not those which fall off spontaneously in consequence of the disease itself.*

* See on this subject the memoir of the surgeon oculist Euzzi, inserted in No. X. of the Mem. de Medic. of Dr. Giannini. The author considers the evulsion of the hairs as the principal object in the treatment of the *tinea* of the eye-lids, and says, that the ulcers may be readily healed by introducing three or four grains of the *unguentum cerussæ*, between the eye-lids, at bed-time, for five or six times, so as to penetrate underneath them. If, after some months, he adds, there be any appearance of the *tinea* re-attacking only some of the new cilia, the affected hairs should be carefully extirpated, in order to prevent the disease from being propagated to the others, and occasioning a complete relapse.

CHAP. VIII.

OF THE NEBULA OF THE CORNEA.

ONE of the evil consequences of the obstinate *chronic* ophthalmia is the nebula of the cornea. I have chosen to call the disease which I am now treating of by this name, in order to distinguish it accurately from the *albugo* and *leucoma*, or from that dense spot of the cornea which is seldom attended with ophthalmia, which is sometimes almost callous, coriaceous, and of the colour of pearl; which affects the substance of the cornea, and consists in a thickening of the intimate texture of that membrane from the stagnation of gluten, or which is formed by a cicatrix in consequence of an ulcer or wound of the cornea,* attended with loss of substance. The nebula, of which I am about to treat, differs from the dense and dark spot forming the *albugo* or *leucoma*, in as much as it is only a re-

* Avicenna, lib. iii. tract. 2. cap. 4. Scias quod albugo in oculo alia est subtilis, proveniens in superficie apparente, et nominatur *nebula*; et alia est grossa, et nominatur *albugo* absolute.

cent, flight, and superficial opacity * of the cornea, preceded and accompanied by chronic ophthalmia, through which the iris and pupil are seen, and which does not therefore entirely take away from the patient the power of seeing, but only causes the surrounding objects to be seen as if covered with a veil or cloud.

This disease is a consequence, as I have said, of the chronic ophthalmia, which has been long neglected, or improperly treated, in persons of a lax fibre, and whose eyes are weak and easily fatigued. The veins of the conjunctiva, which is greatly relaxed in this stage of the ophthalmia, yielding every day more and more to the blood which is retarded in them, become gradually more turgid and elevated than natural, assume an irregular and knotty appearance, first of all in their trunks, then in their branches at the junction of the cornea with the sclerotic coat, and ultimately in their minute ramifications, which are distributed upon the fine lamina of the conjunctiva, covering the external surface of the cornea. Whether a similar dilatation takes place also in the minute ramifications of the arteries corresponding to these veins, it is not an easy matter to determine. All that can be affirmed as certain, is, that the return of blood through the veins of the conjunctiva, which

* Plate II. fig. 5. a.

have become varicose, is greatly retarded by their flaccidity, their knotty and tortuous course, as well as by the folds which the relaxed conjunctiva forms in the different motions of the eye-ball.

The minute ramifications of these veins upon the cornea are fortunately the last to become varicose, not only on account of their small diameter in their origin upon the lamina of the conjunctiva which externally covers it, but because the lamina of the conjunctiva, being closely united to the cornea, confines and prevents them from being so easily distended by the obstructed blood, as where they are situated upon the white of the eye, and where the conjunctiva is naturally very distensible, and loosely connected to the anterior hemisphere of the eye-ball. Hence it is, that although what are strictly called the trunks of the veins of the conjunctiva, are, in all cases of long continued chronic ophthalmia, dilated, varicose, and knotty, the minute ramifications of these veins upon the fine lamina of the conjunctiva which covers the cornea externally, are not equally so; and this only happens in those cases where the relaxation of the whole conjunctiva, including that portion of it which passes over the cornea, and the flaccidity of its veins approaches to the highest degree.

How considerable the resistance is, which the lamina of the conjunctiva almost inseparably united to the surface of the cornea, offers to the
preternatural

preternatural dilatation of these venous ramifications may be inferred from cases of violent inflammation, particularly of *chemosis*, in which, in a very considerable number of instances, the cornea preserves its transparency, notwithstanding that the trunks of the veins of the conjunctiva, which are extremely turgid and twisted together upon the white of the eye, are raised in a mass above the level of the cornea, without the blood forcing the boundary between the cornea and the sclerotica.

In cases, however, where not only the trunks and branches of the veins distributed upon the white of the eye, but also their very minute ramifications upon the cornea have become preternaturally dilated, some small reddish lines begin to appear upon that part of its surface, around which, shortly afterwards, a thin, milky, or albuminous humour is diffused, which destroys its transparency in that part. The thin, whitish, superficial spot which is thereby produced, is precisely that to which I have given the name of nebula of the cornea. And as this sometimes takes place in one part only, at other times in several parts of the circumference of the cornea, consequently the disease is in some cases solitary, in others it is produced by a number of opaque points distinct from each other; but which, collectively, darken the cornea either partially or entirely.

The

The speck of the cornea, which is sometimes formed in the inflammatory stage of the violent acute ophthalmia, differs essentially from that kind of opacity, which constitutes the nebula. In the first case there is an effusion of coagulable lymph from the extremities of the arteries into the intimate cavernous texture of the cornea, which tends to thicken and subvert its structure; or else an inflammatory pustule is formed in the cornea, which afterwards suppurates and produces an ulcer; the nebula, on the contrary, is formed slowly upon the external surface of the cornea, in the long protracted chronic stage of the ophthalmia; is preceded by a varicose state of the trunks of the veins distributed upon the conjunctiva of the white of the eye, and afterwards by a dilatation of their minute ramifications situated upon the surface of the cornea; and, lastly, by an effusion of transparent or albuminous serum, into the texture of the fine lamina of the conjunctiva, which invests the external surface of the cornea; which effusion never causes any external elevation in the form of a pustule.

In whatever part of the cornea, therefore, the nebula is situated, there is always a fasciculus of varicose veins * corresponding to it upon the white of the eye, more elevated and knotty

* Plate II. fig. 5. b.

than the rest of the blood vessels of the same order. And if the cornea is cloudy in several points of its circumference, there are so many distinct fasciculi of varicose veins, projecting upon the white of the eye, which exactly correspond to the different opake points formed upon it. One would say, at first sight, that in each of these fasciculi of veins, which are so prominent and distinct from the others, the blood had forced itself a passage from the border of the sclerotic coat upon the cornea. I have a preparation of an eye taken from the body of a man affected with chronic varicose ophthalmia and nebula of the cornea, who died from an inflammation of the chest. After having injected the head by the arteries and veins, I found that the wax with which the veins of the conjunctiva were completely filled, had not only passed freely into the most elevated fasciculus of these veins, but into its minute ramifications distributed upon the surface of the cornea, at the part precisely corresponding to the *nebula*; while in all the rest of the circumference of the cornea the injection had stopped, from its having met with an insuperable obstruction. In this eye it is astonishing to see, by the help of a glass, the exceedingly fine net-work which the numerous small branches of veins form at the termination of the sclerotic coat, where they elegantly anastomose in endless variety, without
any

any of them, except those corresponding to the *nebula*, surpassing the boundary formed by the strong adhesion of the lamina of the conjunctiva at the part where it advances to cover the external surface of the cornea.

The *nebula* of the cornea demands from its commencement the most effectual method of treatment; for although at first it occupies only a small part of the circumference of the cornea, yet when left to itself it proceeds towards the centre of it, and the minute branches of the dilated veins, which ramify upon it, augmenting in number and extent, ultimately cause the delicate lamina of the conjunctiva to degenerate into a dense and opaque membrane, which greatly obstructs the vision, or tends to destroy it altogether.

The indication of treatment in this disease consists in causing the varicose vessels of the conjunctiva to contract, so as to recover their natural dimensions; and if this should not succeed in destroying the communication between the trunks of these vessels, and their minute branches which are distributed upon that part of the surface of the cornea where the *nebula* is situated, the former of these indications may be fulfilled by means of the astringent and corroborant applications mentioned in the preceding chapter, particularly the ophthalmic ointment of Janin, provided the disease be incipient,

and of small extent. But when it has advanced near the centre of the cornea and the relaxation of the conjunctiva and its vessels is very considerable, the most speedy and effectual method of treatment which has been hitherto proposed, is that of extirpating the fasciculus of varicose veins* near their origin, that is, close to the nebula of the cornea. By means of this excision the blood retarded in the dilated ramifications of the veins upon the surface of the cornea, is immediately discharged; the varicose vessels are enabled to recover their natural tone and dimensions; and a sort of drain is opened at the part where the cornea and sclerotic coat unite, by which the serous or albuminous fluid which is effused into the texture of the lamina of the conjunctiva spread upon the cornea, or into the cellular tissue which connects these two membranes together is gradually discharged. The rapidity with which the *nebula* of the cornea is dissipated by means of this operation is truly surprising, as the dimness in that part of the cornea where it is situated generally disappears in the course of 24 hours.

The extent of the excision in these cases must be determined by the expansion of the nebula upon the cornea, and by the number of fasciculi of varicose and knotty veins, more elevated and

* Plate II. fig. 5. b.

distinct than the others which proceed from the shade or cloud of the cornea, so that if the nebula is of moderate extent, and there is only one fasciculus of varicose vessels * corresponding to it, the extirpation of that alone will be sufficient. If, however, there are several opaque points upon the cornea, and consequently several fasciculi of varicose veins, forming a circle at different distances from each other upon the circumference of the white of the eye, the surgeon ought to remove the whole circle of the conjunctiva at the part where the cornea and sclerotic coat unite, since in this manner he will be certain of including the whole of the varicose vessels. On this occasion it ought to be observed, that the mere division of the vascular fasciculus does not fulfil the indication of permanently destroying the direct communication between the trunks of the vessels and their minute ramifications upon the cornea. For when an incision is made, for instance, with the back of a lancet, it is true that both portions of the divided vessel separate in a contrary direction, and leave an evident space between them; but it is equally certain that a few days afterwards the mouths of these vessels approach and inosculate, so as to recover their former continuity. In order, therefore, to derive the greatest possible advantage from this

* Plate II. fig. 5. b.

operation it is requisite to remove a small portion of the fasciculus of varicose veins, together with an equal portion of the conjunctiva upon which it is situated.

In order to perform this operation in the most expeditious manner, and with as little inconvenience to the patient as possible, setting aside the usual method of passing a needle and thread through the fasciculus of varicose vessels, an operation which is tedious, embarrassing, and unnecessary, an able assistant should hold the patient's head against his breast, and at the same time separate the eye-lids; the surgeon then taking hold of the fasciculus of vessels with a fine pair of forceps,* close to the margin of the cornea, and raising it a little, which, from the flaccid state of the conjunctiva, it readily admits of, should remove it by means of the small curved scissors, together with a small portion of the conjunctiva, making the section of a semilunar figure, and as much as possible concentric and close to the circle of the cornea. If, however, the case require that more than one fasciculus of vessels should be removed, and that these are placed at some distance from each other, the surgeon should raise them expeditiously, one after another, and extirpate them in succession; or if they are situated near to

* Plate III. fig. 8.

each other, and occupy the whole circumference of the eye, the excision should be carried completely round, following the edge of the cornea, and thus including, together with the conjunctiva, the whole of the varicose vessels.

The divided vessels should be allowed to bleed freely, and their discharge even promoted by applying a sponge dipped in warm water upon the eye-lids, with which they should be fomented until the blood cease to flow of itself; the eye should then be covered with a cloth and bandage, and ought not to be opened until 24 hours after the operation, when the *nebula* will be found either to have disappeared entirely, or to be so much diminished that the cornea may be said to have recovered its former transparency. During the succeeding days the patient should be directed to keep his eye closed and covered with a piece of soft rag and bandage, and to wash it three or four times a day with a little warm mallow-water. When the inflammation takes place upon the conjunctiva covering the white of the eye, which usually happens on the second or third day from the operation, it is curious to observe, particularly in cases where the conjunctiva has been divided circularly, that while the greater circumference of the eye-ball becomes red, a small whitish circle in the divided part forms a boundary, which prevents the redness of the conjunctiva

from extending to the cornea. By the use of internal antiphlogistic remedies and emollient applications this inflammatory state of the conjunctiva subsides in a few days, and that part of the conjunctiva which has been divided appears covered with a layer of mucus. From this period the wound contracts more and more, until it is completely healed. A lotion of mallow-water, used at first warm, and afterwards cold, is the only local remedy which it is necessary to employ in these cases; since every species of collyrium or stimulating ointment retards the cure.

When the wound is healed, it will not only be found that the cornea has recovered its transparency, but also, especially when the excision has been carried completely round the eye, that the preternatural flaccidity of the conjunctiva is considerably diminished or entirely removed; for after a portion of this membrane has been removed in a direction concentric to the margin of the cornea, the cicatrix by its closing draws the conjunctiva forwards, and as it were stretches it upon the eye-ball. If, however, the conjunctiva covering the white of the eye should remain afterwards a little more flabby than natural, yellow, and marked here and there with veins which threaten to become varicose, astringent and corroborant applications may be employed with advantage, and the ophthalmic

thalmic ointment of Janin in the manner recommended in the preceding chapter on the subject of *chronic* ophthalmia.

CASE XXVI.

Chlara Bellinzoni, of Belgiojoso, a robust woman, 33 years of age, subject from her infancy to cutaneous eruptions, especially in the spring, was attacked some years ago with a redness of the right eye, which extended from the internal angle towards the cornea, and which resisted every kind of application. In the course of three years, this redness, which evidently depended upon a fasciculus of varicose veins of the conjunctiva, extended so far upon the surface of the cornea as ultimately to render it opaque for a certain extent, and to occupy even more than two thirds of the pupil. Independently of the patient's indistinct vision, the continual sense of burning in the eye, occasioned by the disease; and particularly the fear of losing the sight of that eye entirely, induced her to come into the hospital.

On the 3d of April 1797, while an assistant separated the eye-lids, I took hold of the fasciculus of veins which extended in the direction of the internal angle of the eye towards the cornea upon the fine lamina of the conjunctiva which covers it; and collecting the whole of

the fasciculus into one fold, I raised it a little, and removed it with the curved scissors in the form of the letter C at the parts where the cornea and sclerotic coat unite. I allowed the blood to flow, and even encouraged it, by applying a soft sponge upon the eye-lids, squeezed out of warm water; and afterwards covered the whole with a compress and bandage.

On the following day, the eye-lids were attacked with an erysipelas, which extended over the right side of the face, accompanied with feverishness, and a greater degree of heat in the whole body than natural; an affection to which the patient had been frequently subject for several years, but which she had never mentioned before.

I ordered her to observe a rigorous diet, and to take a pint of the decoction of the triticum repens, with a grain of the antimonium tartarizatum, in divided doses, for several days; and upon the eye-lids I applied bags of emollient herbs. The great tumefaction and tension of the eye-lids prevented me from examining the state of the cornea.

The 8th day from the operation the erysipelas terminated by a desquamation of the cuticle. The patient was now able to open her right eye freely, and I found, with much satisfaction, that the cornea was entirely clear, and that she could distinguish objects distinctly. The divided part
suppurated

suppurated kindly, no other application being employed, until the conjunctiva was perfectly healed, than a lotion of the aqua malvæ. When the wound was healed, I ordered the patient to use the vitriolic collyrium with a little spirit of wine several times a day, by means of which the conjunctiva recovered its former tone, and the cornea its perfect transparency. The woman was discharged from the hospital, perfectly cured, in the beginning of May, which was little more than a month from the time of the operation,

CASE XXVII.

Giovanni Bonfasani, of S. Lanfranco, 50 years of age, 15 years before the appearance of the disease of which I am about to speak, was afflicted with a violent *acute* ophthalmia in both eyes; on the disappearance of which there remained on the lower part of the cornea of the right eye, a small but dense and irremediable *albugo*. The left eye remained in a good state, but the conjunctiva of the right was always marked in several parts with small varicose vessels. One cluster of these vessels, more turgid and elevated than the rest, was situated towards the external angle, and in the course of some years extended upon the cornea, and produced in that part a *nebula* through which the patient could

could with difficulty distinguish objects; the other small vessels of the conjunctiva also threatened to become varicose, which occasioned a troublesome sense of smarting, and a perpetual weeping of the eye.

The operation before described was undertaken the 8th of May, and the blood was encouraged to flow by fomenting the parts with warm water.

The day following I found the nebula almost entirely dissipated, the patient complained of a load at his stomach, and a bitter taste in his mouth; I therefore ordered him to take, in small doses, a pint and a half of the *triticum repens*, with a dram of the *kali tartarizatum*, and a grain of the *antimonium tartarizatum*, which procured some evacuations from the bowels, and relieved him.

The wound was healed in the course of 15 days, by merely washing the parts frequently with the *aqua malvæ*. I then ordered the patient to inject the vitriolic collyrium with a little spirit of wine several times a day, which he continued to do for two weeks with great advantage; as the cornea entirely recovered its former transparency, except at the part occupied by the *albugo*; the patient, however, saw sufficiently well with this eye, and left the hospital 36 days after the operation, during which
time

time it is proper to remark, he had only been confined to his bed for the first four days.

CASE XXVIII.

Nunciata Raffa, of Genzone, 17 years of age, of a weakly constitution, irregular in her menstruation, and who had been formerly very subject to discharges from the eyes, was admitted into the hospital the 2d of January 1799, on account of a *nebula* upon the cornea of the left eye, which for two months had occasioned some degree of smarting, weeping of the eye, and dimness of sight.

The *nebula* occupied about two thirds of the whole cornea, and was evidently connected with a large and very elevated cluster of varicose vessels, extending from the external angle of the eye to the part upon which it was situated. One part of this superficial speck was more dense, white, and opaque than all the rest. The fasciculus of varicose vessels was elevated with the forceps, and removed by means of the curved scissors, at the part where the cornea unites with the sclerotic coat, and the part was fomented with warm water to encourage the bleeding.

Twenty-four hours had scarcely elapsed, when on removing the first dressings the nebula was found almost entirely dissipated. The eye was afterwards covered and washed frequently in
the

the course of the day, with tepid mallow-water.

On the 3d day the wound began to suppurate, without any bad symptom taking place, and in the space of 14 days was healed. The vitriolic collyrium was employed for some weeks afterwards, which contributed to perfect the cure by completely restoring the transparency of the cornea, except in that part of the *nebula* which had been always more dense and opaque than the rest.

CASE XXIX.

Giacopo Deamici, of Pavia, 52 years of age, by trade a weaver, a thin and deformed man, was affected for several years with a chronic inflammation of the right eye, which terminated by almost entirely taking away the power of seeing on that side. When he came into the hospital, which was on the 2d of December 1794, his eye appeared to be in too hopeless a state to permit him to expect any particular benefit. The cornea of the right eye was completely cloudy, and marked in several places with deeply opaque white points, the vessels of the conjunctiva were relaxed and varicose in the whole circumference of the eye, from whence they extended upon the cornea in the form of reddish lines.

The

The operation, however, was undertaken, and a portion of the flaccid conjunctiva was removed from the whole circumference of the eye, at the part where the cornea and sclerotica join. The blood flowed abundantly from the wound. The next day the cornea was found much less cloudy than before.

From the 4th of December to the 29th the patient used no other external application than a lotion of mallow-water; the eye was defended from the contact of the air and light, by means of a piece of linen cloth, and he remained out of bed, as is usual with those who are in a state of convalescence.

At this period the wound was completely healed, and the cornea had almost entirely recovered its transparency, except that there remained upon it two dense white spots, neither of which was larger than the point of a needle. The patient used the collyrium vitriolicum for some time with advantage, and was then dismissed from the hospital.

CASE XXX.

Domenico Robola, aged 40, a shoemaker of Pavia, excessively addicted to wine, was admitted into the hospital on the 22d of May 1795; on account of a chronic ophthalmia in both his eyes,

eyes, which had rendered him completely incapable of following his business.

The disease began six years before, by an itching and redness in the eyes, with tumefaction and pustules upon the edges of the eye-lids; and from that indolence which is very common among this class of persons, especially those addicted to drinking, he neglected his disease until his sight was almost entirely destroyed. The conjunctiva on both sides was very much relaxed, and the blood-vessels in every part of the circumference of the eye were varicose and turgid, and passed every where beyond the border of the cornea, evidently extending for some way upon the fine lamina of the conjunctiva which covers it. The cornea also was completely cloudy; the eye-lids tumefied, and the ciliary glands more enlarged than usual.

The circular excision of the conjunctiva was performed upon both eyes, an operation, which in these cases, is easily executed, in as much as the relaxed state of the conjunctiva readily admits of its being laid hold of with the forceps, and elevated in the form of a fold around the whole of the border of the cornea. The blood was encouraged to flow, at first by fomentations of warm-water, afterwards by the application of bags of emollient herbs.

The following day I found the cornea of both eyes very much brighter. Two days after, the patient

patient complained of nausea, and a bitter taste in his mouth, I therefore ordered him a pint of the decoction of the root of the triticum repens with two drams of the crystals of tartar, and one grain of tartarized antimony, in small doses, which was repeated the two following days with advantage.

The mucous suppuration upon the white circle left by the excision of the conjunctiva, did not appear until the 8th day after the operation. By employing only a lotion of mallow-water, and keeping the eyes covered by a piece of linen suspended from the forehead, the wound healed in the course of 22 days more. I then began the use of the ophthalmic ointment of Janin morning and evening, and the camphorated vitriolic collyrium during the day. In two weeks more the cornea of both eyes, but especially that of the left, was so much amended that the man could see distinctly even the smallest objects, and was now able to return to his former occupation.

CASE XXXI.

A mendicant, 50 years of age, was admitted into the hospital on the 12th of April 1796, with the cornea of the right eye completely darkened by a *nebula*, in consequence of an obstinate chronic inflammation of the eye, which for two months had been exasperated by a cutaneous eruption

eruption upon the whole of the right side of the face. The whole of the cornea not only appeared superficially cloudy, but presented, a little above the centre of it, a point whiter and more opake than the rest. The blood-vessels of the conjunctiva appeared highly turgid, varicose, and relaxed, and were seen rising upon the cornea from every part of the circumference of the white of the eye. The edges of the eye-lids were also tumefied, and the eye watery and gummed.

A small portion of the conjunctiva, and its vessels, were removed around the white of the eye, near the margin of the cornea. A considerable quantity of blood flowed, which greatly relieved the patient of the troublesome sense of burning which he had before complained of. Bags of emollient herbs were applied upon the eye.

The next day the cornea presented a degree of brightness which exceeded all expectation.

Three days after, an abundant discharge of mucus took place from the ciliary glands, and that part of the conjunctiva which had been divided, which rendered it necessary to wash the eye frequently with mallow-water. The cornea acquired a greater degree of clearness; and, in order to divert more effectually the discharge from the eye-lids, I formed a seton in the neck.

In

In three weeks more, the circular wound of the conjunctiva was perfectly healed, and I was then able to employ the vitriolic collyrium, and the ophthalmic ointment of Janin; which perfected the cure by removing the morbid state of the ciliary glands, and strengthening the conjunctiva. The white opake spot, which was situated a little above the centre of the cornea, remained unaltered, but did not greatly obstruct the sight.

CHAP. IX.

OF THE ALBUGO AND LEUCOMA.

THE *albugo* and *leucoma*, as I have hinted in the preceding chapter, are essentially different from the *nebula* of the cornea, in as much as the former are not produced by a slow chronic inflammation, attended with a varicose state of the veins, and an effusion of thin, lacteous serum into the texture of the fine lamina of the conjunctiva, covering the cornea; but are the effect of the violent acute inflammatory ophthalmia, in consequence of which a dense coagulable lymph is poured out from the extremities of the arteries, sometimes superficially, at other times more deeply into the substance of the cornea: or else the disease consists in a firm, callous cicatrix of the cornea, produced by an ulcer or wound, accompanied with loss of substance. The term *albugo* more properly belongs to the first of these, that of *leucoma* to the latter, especially if the cicatrix or dense coriaceous spot occupy

occupy the whole or the greater part of the cornea.

The recent albugo, produced by the violent acute inflammation of the eye, and left upon the cornea after that affection has been dissipated by the use of general remedies and emollient applications, is of a clear milky colour; but when inveterate it acquires the colour of white cretaceous earth, or of pearl. Of those which are inveterate, some appear to have no further dependence on the vascular system of the cornea; since they remain insulated in the middle of the transparent part of that membrane, without occasioning any smarting or sense of uneasiness, without having any connection with the vessels of the conjunctiva, without the rest of the eyeball appearing in any degree diseased, and without nature attempting any dissolution of it by absorption.

The recent albugo, provided the coagulable lymph, extravasated by the action of the extremities of the inflamed arteries, has not disorganized the intimate structure of the cornea, is most frequently dissipated by the same means which are employed in the treatment of the first and second stage of the violent acute ophthalmia; that is, in the first stage, by general and local bleeding, by internal antiphlogistic remedies, and emollient applications; and in the second stage, by astringent applications of a

gently irritating and corroborant nature. For if, after the inflammatory stage has terminated, the action of the vascular absorbent system of the cornea is excited and restored, by means of these local remedies, the coagulable lymph stagnating in that membrane, and forming the albugo, is absorbed, and the cornea recovers its former transparency. The cornea has a considerable affinity to parts of a ligamentous structure. Like ligament it is endowed with little vitality, is not furnished with red vessels, and only appears to be exquisitely sensible when it is inflamed. The inflammation of the cornea, as that of ligamentous parts possessing little vitality, is slowly resolved, and therefore readily leaves behind it a portion of coagulable lymph, which, during the inflammatory stage, is effused into its substance, and produces opacity; this is not necessarily removed in any other manner, after the inflammation disappears, than by absorption, which can only be promoted by means of stimulant applications.

But although this is frequently obtained in the recent albugo, it is not so easily effected, when, from the long continuance of the disease, the action of the absorbent system of the cornea, in the affected part, has become torpid; or when the intimate texture of the cornea has been disorganized by an extravasation of dense and tenacious lymph from the extremities of
3 the

the arteries. For whether the humour forming the albugo be absorbed or not, the injury which has been done to the internal structure of the cornea in this part always renders it opake.

The circumstances, therefore, which are most favourable to the cure of the albugo, are, the disease being recent, without disorganization of the texture of the cornea, or of the lamina of the conjunctiva covering it, and its taking place in subjects of an early age, in whom the lymphatic system is most active, and in whom its action is more capable of being excited by external stimuli. I have seen innumerable instances in young children, where, in consequence of the violent *acute* ophthalmia, the specks or albugines, which have remained insulated in the middle of the transparent part of the cornea, after the disappearance of the ophthalmia, have vanished insensibly in the course of some months, and sometimes spontaneously, contrary to all expectation. Heister,* Langguth,† and Richter,‡ have made the same observation. This phænomenon certainly, can only be attributed to the vigorous action of the absorbent system in children, and to the intimate texture of the cornea, in such cases, not being disorganized in

* Institut. chirurg. tom. i. cap. 58.

† Differt. de oculorum integritate improvidæ puerorum statim sollicite custodienda. § xxi.

‡ Elem. di chirurg, tom. iii. cap. 4.

the part where the effusion of coagulable lymph has taken place.

Of the local remedies which are calculated to promote absorption, whether in the recent albugo, where the inflammation has ceased, or in that which is inveterate, those from which I have found the greatest advantage, are, the sapphirine collyrium,* the ointment consisting of tutty, aloes, calomel, and fresh butter,† that of Janin, the gall of the ox, sheep, pike, and barbel, applied upon the cornea, by means of a small hair pencil, two or three times a day, provided it does not cause too much irritation. The ox and sheep's gall is more stimulating than that of fish.‡ In some cases where the eyes were so irritable as not to bear the action of these remedies, I have employed with advantage the oil of walnuts a little rancid, directing

* This is a solution of 2 scruples of sal ammoniacus, and 4 grains of ærugo in 8 ounces of aqua calcis, allowed to stand for 24 hours, and then filtered.

† Rec. Tuticæ s. p. drachmam I.

Aloes s. p.

Calomelan. an. gr. duo.

Butyr. recent. unc. semis. M. f. unguent.

‡ Stimulant applications have been advantageously employed in the treatment of the albugo for more than 2500 years, but it was not until the present time that the rational principles of this mode of treatment were understood. These have been deduced from the correct notions which we have at present concerning the action of the sanguineous and absorbent systems in a state of health and disease.

two or three drops of it to be infilled into the eye every two hours, and continued for some months. In others I have found the juice of the lesser centaury with honey useful.

In general, however unfavourable the case may appear, it is proper to persist in the use of such local and general remedies as are judged most appropriate to the nature of the case, and particular sensibility of the patient's eye, with the utmost diligence, for at least three or four months before it is given over as hopeless, and the patient declared incurable.

All the expedients which have been hitherto proposed for the cure of the inveterate coriaceous albugo, or rather leucoma, and of that which is the consequence of a cicatrix, and which consist in the scraping of the laminæ of the cornea, the perforation of it, or the formation of an artificial ulcer upon a portion of the leucoma, are methods entirely useless, invented by those who are ignorant of the structure of the parts interested in the disease, and extolled by empiricism. For whether the thickness of the cornea be diminished by means of scraping, or by cutting it with an instrument, such methods cannot in any manner restore to that membrane the transparency which it has lost; and although, even immediately after the operation, a small degree of light should be admitted into the eye, this advantage would be only momentary; since

the ulcer produced by the operation on healing and becoming callous again, would reproduce on the cornea its former state of opacity. The artificial ulceration also excited on the leucoma would be useless, if the disease merely depended on a stagnation of dense lymph; but the fact shows the contrary, and proves that the leucoma, which is not produced by a cicatrix, is not only formed by a dense humour, but by a disorganization of the intimate texture of the cornea, in which consists, as I before stated, the difference between the *albugo* and the *leucoma*.

CHAP. X.

OF THE ULCER OF THE CORNEA.

THE ulcer of the cornea is a very frequent consequence of the bursting of a small abscess, which not unfrequently forms under the fine lamina of the conjunctiva, which covers the cornea, or in the substance of the cornea itself, in cases of violent acute ophthalmia. At other times the ulcer of the cornea is produced by the contact of corroding, cutting, or pricking substances, introduced into the eyes, as quick lime, particles of glass or iron, thorns, or other similar matters, capable of producing a solution of continuity.

The small abscess of the cornea is accompanied with the same symptoms as the violent inflammatory ophthalmia, particularly a troublesome sense of tension in the eye, eye-brow, and neck; a burning heat, copious discharge of tears, aversion to the light, and an intense redness of the conjunctiva, especially opposite and near the seat of the abscess.

This

This small inflammatory pustule, in comparison with those which form upon other parts of the body, is in general very slow in bursting after it has suppurated. Experience, however, has proved, that it is improper to open it with the point of a lancet or other instrument, in order to procure a discharge of the matter contained in it, as is practised by the generality of surgeons; for although this abscess seems to have arrived at its highest degree of maturity, the matter which it contains is so tenacious and rooted, as it were, in the substance of the cornea, that no part of it is discharged by the artificial aperture, and the orifice, on the contrary, which is made, rather aggravates the disease, increases the opacity of the cornea, and frequently occasions the formation of another small abscess in the vicinity of the first. In such cases the most certain method is to wait until the abscess opens externally of itself, promoting its rupture by frequently fomenting and washing the eye with tepid mallow-water, and by the application of bags of emollient herbs.

The spontaneous rupture of the small abscess of the cornea, is most frequently announced by a sudden increase of all the symptoms of ophthalmia, particularly by an intolerable sense of burning in that part of the cornea where the abscess previously existed, which is augmented by the patient's moving the affected eye-ball,
or

or even the eye-lids. This circumstance, however, is rendered evident by an excavation which may be observed in the part of the cornea where the whitish pustule was situated, and which may be still more distinctly seen by looking at the eye in profile.

The introduction of extraneous bodies into the eye, which have simply divided a part of the cornea, or are fixed in it, provided they are immediately withdrawn, do not in general leave an ulcer, the injured part being consolidated by the first intention. Those which abrade or burn the surface of this membrane, or which being fixed in it, are not immediately removed, occasion the acute ophthalmia, afterwards a suppuration round the injured part, and lastly ulceration.

The ulcer of the cornea has this in common with ulcerous solutions of continuity of the skin, where this integument is fine, tense, and possessed of exquisite sensibility; that on its first appearance it assumes a livid and cineritious colour; its circumference is red, its margin is tumid and irregular, it is exquisitely painful, discharges an acrid serum instead of pus, and has a tendency to spread and become deeper rapidly. Such is precisely the character of the ulcer of the cornea, and of those of the nipples, glans penis, lips, of the tip of the tongue, which are called aphthæ, of the tarſi, of the entrance of the auditory canal and of the nostrils, and other parts,

parts, where the thin tense and very sensible skin is inflected inwards.

The ulcers of this class, when left to themselves, or improperly treated, spread rapidly, become deep, and destroy the parts which they occupy; if that of the cornea extend superficially it presently destroys the transparency of this membrane, and if it spread deeply in the form of a small tube, and penetrate into the anterior chamber of the aqueous humour, it occasions a discharge of this fluid, and afterwards a fistula of the cornea; if the aperture become larger, besides the discharge of the aqueous humour, it gives rise to another disease much more serious than the ulceration itself, the protrusion of a portion of the iris, the discharge of the crystalline and vitreous humours, and in short the total destruction of the organ of vision. This most serious accident is not unfrequently the consequence of the violent acute gonorrhœal ophthalmia, complicated with atony or defect of vitality in the cornea; in consequence of which this membrane is no longer sensible to the action of the internal and external remedies, which are directed to arrest the progress of the ulceration, which, notwithstanding the most efficacious measures extends with the greatest celerity over the cornea, until it has completely destroyed it.

It is therefore of the greatest importance, as soon as an ulcer appears upon the cornea to
arrest

arrest its progress instantly, as far as the nature of the disease permits; or so to change the morbid process, that instead of tending to the destruction of the cornea, it may be disposed to heal; and this should be aimed at the more solicitously, as the difficulty of converting this morbid process into a healthy one, increases in proportion to the extent and depth of the ulcer; and although the healing of a large ulcer should be speedily obtained, the injury which the vision receives, in consequence of the extensive cicatrix which results from it, is irreparable.

With regard to the treatment of the ulcer of the cornea, the writers who have taught that no external application can be employed with advantage, for the purpose of healing the ulcer, before the acute ophthalmia has been either entirely, or in a great measure subdued, appear to me to have fallen into a considerable error. Experience shows precisely the contrary, and teaches that the application of such local remedies as are capable of quickly removing or mitigating the increased morbid sensibility of the ulcer, and at the same time arresting its destructive progress, should be employed in the first instance, and afterwards those which are proper in the ophthalmia, provided it should not disappear of itself in proportion as the ulcer heals. It is a fact, established by certain and repeated observations, that the ulcer is the cause
of

of the ophthalmia, and not the ophthalmia of the ulcer.* It is true, that on the bursting of the abscess of the cornea, the symptoms of the violent acute ophthalmia are exasperated; that the redness of the conjunctiva is increased, as well as the turgescency of its vessels; but it is equally certain that this arises only from an augmented determination of blood to it, occasioned by the increased sensibility of the ulcerated part of the cornea. On the contrary, as this irritable state of the ulcer is allayed or diminished, the ophthalmia in like manner subsides in an equal degree, and on the ulcer becoming clean, and proceeding towards cicatrization, the inflammation is gradually resolved and disappears, or at most requires only for some days the use of an astringent and corroborant collyrium.

Similar examples come under our daily observation in ulcers of other parts besides the cornea, particularly in the small fordid sores before mentioned, which take place upon the internal surface of the lips, the tip of the tongue, the nipples, and glans penis, which, on their first appearance, as I before said, are covered with an ash-

* Except the case in which the ulcer appears in the highest degree of the violent *acute* ophthalmia; where the primary indication must be always that of abating the violence of the inflammation as quickly as possible, previously to the treatment of the ulcer.

coloured surface, excite inflammation in the surrounding parts, and occasion a sense of pricking, and a very troublesome burning heat; in order to remove the inflammation, we do nothing more than speedily allay the excessive irritability of these sores, and change the ulcerative process into that which conduces to their cicatrization; after which the surrounding inflammation is immediately dissipated, without the necessity of recurring to other remedies, which are peculiarly directed in the treatment of that disease.

The remedy, which in all these cases produces so speedy and good an effect is the caustic. This immediately destroys the naked extremities of the nerves in the ulcerated part, and quickly removes the morbid excess of sensibility; converts the cineritious surface of the ulcer and the acrid humour with which it is imbued into a crust or eschar, which in the same manner as the epidermis moderates the contact of the surrounding parts upon the ulcer, and finally changes its destructive process into that of granulation and cicatrization.

For the purpose of cauterizing the ulcer of the cornea, the caustic which is preferable to every other is the *argentum nitratum*. This should be cut in the form of a crayon pencil, with the point of which, the eye-lids being well separated, and the upper one fixed by means of

Pellier's

Pellier's elevator,* the ulcer of the cornea should be touched, and the caustic held in contact with it a sufficient length of time to form an eschar. If any part of the caustic should be dissolved by the tears, it ought to be washed off by dropping a little milk into the eye.

During the application of the caustic, the patient complains of very acute pain, but this excessive uneasiness is amply compensated by the ease which is felt a few minutes afterwards. For the burning heat in the eye ceases, as if by a charm, the eye-ball and eye-lids can be moved without difficulty, the discharge of tears and turgescency of the vessels of the conjunctiva diminish; and the patient is able to support a moderate degree of light and to take rest.

These advantages continue as long as the eschar adheres to the surface of the ulcer, but as soon as the exfoliation takes place, which is on the 2d, 3d, or 4th day, the former symptoms of the disease return, particularly the sense of pricking and burning in the ulcerated part of the cornea, the copious discharge of tears, the difficulty of moving the eye-ball and eye-lids, and the intolerance of light; but these symptoms are always less violent than before. On the reappearance of these the surgeon should apply the caustic again without delay,

* Plate III. fig. 1.

taking care to produce an eschar equally strong and adherent upon the whole surface of the ulcer, which will be succeeded by the same relief as before. And this should be repeated a third time, if necessary; that is, if on the exfoliation of the second eschar, the excessive sensibility of the ulcer is not sufficiently destroyed, and its corroding and destructive progress arrested. If things go on favourably it will be constantly found, that after every exfoliation of the slough, the morbid sensibility of the eye is diminished and the ulcer less extensive and deep than before, and that, instead of its former livid and ash-coloured appearance, it assumes a light flesh-colour, a certain indication that its destructive process is checked, and that it is disposed to heal. In proportion also as the ulcer diminishes, the turgescency of the vessels of the conjunctiva and the ophthalmia gradually subside.

At this period, when the process of granulation has commenced, the further application of the caustic, which has been hitherto so beneficial, would be improper, since instead of accelerating the healing of the ulcer, it would, on the contrary, repress the granulations, reproduce the pain, inflammation, and weeping of the eye, and the ulcer would again assume a sloughy and cineritious aspect, and its edges become irregular and tumefied. This fact has also been

noticed by Platner.* *Neceſſe eſt*, ſays he, *ut hoc temperata manu, nec crebrius fiat, ne nova inflammatio, novaque lachryma his acrioribus concitetur*. As ſoon as the eye becomes eaſy and the proceſs of granulation has commenced, whether after the firſt, ſecond, or third cauterization, the ſurgeon ought entirely to deſiſt from the further uſe of any powerful cauſtic, and confine himſelf to the application of the vitriolic collyrium; or that which conſiſts of four grains of the vitriolated zinc, 4 ounces of plantain water, and half an ounce of the mucilage of quince-feed, or of pſilium, which ſhould be employed every two hours, and the patient's eye defended from the contact of the air and light by means of a ſoft comprefs and bandage. In caſes, however, where, beſides the ulceration of the cornea, the conjunctiva and its veſſels are in ſome degree relaxed, it is uſeful towards the end of the treatment to introduce Janin's ointment between the eye-ball and eye-lids, proportioning the quantity and ſtrength of the remedy to the particular ſenſibility of the ſubject.

With reſpect to the treatment of thoſe very ſuperficial excoriations of the cornea, in which there appears to be no excavation of the ſubſtance of that membrane, and which in reality conſiſt only in an abraſion of the cuticle, from

* *Inſtitutiones chirurg.* § 314.

the lamina of the conjunctiva, which covers the cornea, the use of the caustic is unnecessary. It is sufficient in these cases to employ the vitriolic collyrium with mucilage, or that consisting of vitriolated zinc and the white of an egg beaten together, with the addition of rose or plantain water. The symptoms which accompany these slight excoriations, or rather deprivations of the epidermis, are inconsiderable; and provided the patient take care to inject either of these collyria every two or three hours, and to defend his eyes from too vivid a light, and from vicissitudes of the atmosphere, they are generally removed in a short time.

Hitherto I have spoken of the ulcer of the cornea, and of the best method of treating it, in cases which are most frequently met with in practice. Occasionally, however, whether in consequence of the violence of the disease, or of improper treatment, the ulcer, already of considerable extent, assumes the form of a fungus elevated upon the surface of the cornea, which appears to derive its nourishment from a small fasciculus of blood vessels belonging to the conjunctiva, and on this account not unfrequently gives rise to a very serious error, the disease being mistaken for a *pterygium*. This disease, when left to itself, or treated with slight astringents, generally terminates in the destruction of the whole eye-ball; it demands, on the contrary,

the speedy use of some efficacious method capable of destroying, in a short time, the whole of the fungus of the cornea, as well as the vessels which pass to it from the conjunctiva, and which has also the power of arresting its destructive progress. This method consists, in the first place, in removing with the curved scissors the whole of the fungus close to the surface of the cornea, continuing the incision at the same time upon the conjunctiva, so as to include along with it the fasciculus of blood-vessels, from which it appeared to derive its support. Afterwards, when the blood has been allowed to flow, the *argentum nitratum* should be freely applied upon all that part of the cornea which had been previously occupied by the fungus, so as to leave a deep eschar; on the exfoliation of which, if the whole of the morbid part should not have been destroyed, it will be necessary to repeat the application of the caustic, until the ulcer of the cornea assume a healthy and granulating appearance.

In order to execute properly so deep a cauterization, it is not sufficient, in general, that the upper eye-lid should be firmly held by an assistant, and the lower one depressed; but it is also requisite that the operator should keep the upper eye-lid raised by means of a small spatula introduced between it and the eye-ball, and held in his left hand, while with his right he
applies

applies the caustic upon the fungous surface of the ulcer, and retains it there a sufficient length of time to form a firm and deep eschar.

It must be admitted that in very severe cases of this kind, the action of the caustic cannot be always calculated with precision; and it consequently happens, that together with the fungus a portion of the whole thickness of the cornea is destroyed. When this accident occurs it is always followed by a protrusion of the iris through the perforation made in the cornea. This accident, however serious it may appear to some, is not, however, such as to admit of no relief, as will be shown in the chapter on the procidentia of the iris, and provided the surgeon is able to obtain a solid cicatrix, in the part occupied by the excrescence, which must necessarily prevent a return of the fungus, and the total destruction of the eye-ball, he will have completely fulfilled the proposed indication.

CASE XXXII.

Antonio Carovo, of Pavia, a boy, 14 years old, was admitted into the practical school of surgery, who suffered great pain in his right eye, and was in danger of losing it, from two small ulcers upon the cornea, which had supervened in consequence of a violent acute ophthalmia.

One of these small ulcers occupied the inferior segment of the cornea, the other that towards the external angle of the eye; both were sloughy and of a cineritious colour. The blood-vessels of the conjunctiva, especially those which corresponded to the ulcerated part of the cornea, were extremely turgid. The boy complained of acute pain in the eye and head, and could not bear even the most moderate degree of light.

Having placed him in a supine posture, with his head a little elevated, I directed an assistant to raise the upper eye-lid, by means of *Pellier's elevator*, while with my left hand I depressed the lower. This is the only method, especially in children, of fixing the eye-ball sufficiently for the purpose of applying the caustic with precision to the ulcerated points of the cornea. Then with the *argentum nitratum*, cut in the form of a crayon, I cauterized both the ulcers so as to produce upon them a sufficiently deep and adherent eschar, washing the eye frequently afterwards with new milk. The patient complained at the moment of very acute pain, but half an hour after he was perfectly easy in every respect.

On the following day, he was able to support a moderate degree of light, and the blood-vessels of the conjunctiva appeared very much less turgid than before the application of the caustic.

Three

Three days after, on the exfoliation of the eschar, the former pains in the eye returned, but were less violent than at first. The ulcers were again touched with the caustic, which occasioned less uneasiness than before. It was repeated four days afterwards.

On the detachment of the last eschar, the ulcers were much diminished, and their surface, which was of a pale red colour, was raised on a level with the surface of the cornea. The vitriolic collyrium, with mucilage of quince-seed, was now substituted for the caustic, and instilled into the eye every two hours.

In the course of ten days more the ulcers were perfectly healed, and the ophthalmia entirely dissipated. And to render the cure more perfect, I ordered the patient to continue the collyrium for a month longer, and to introduce between the eye-lids, at bed-time, a small quantity of the ophthalmic ointment of Janin.

CASE XXXIII.

A beggar boy, 11 years old, of a weak constitution, and occasionally subject to periodical fever, some years after the small-pox, which had left a morbid sensibility in the left eye, was seized with a violent acute inflammation of it; in consequence of which a small abscess formed between the laminae of the cornea,

which burst spontaneously, and left a small sloughy ash-coloured ulcer, of an oval figure, which extended from the margin of the cornea, corresponding to the internal angle of the eye, almost as far as the part opposite the centre of the pupil. The boy complained very much, especially on being exposed to the light, and there was a copious weeping of the eye. The vessels of the conjunctiva also were exceedingly turgid, especially towards the internal angle of the eye. The *argentum nitratum* was applied to the ulcer, and its action limited, by repeatedly washing the parts with milk, and applying upon them bags of emollient herbs. The very acute pain produced by the caustic continued about half an hour; it then ceased, and the patient passed the rest of the day comfortably, and slept soundly the whole of the following night. The next day he opened his eye freely, and supported a moderate degree of light without uneasiness. The ophthalmia and weeping of the eye were greatly diminished.

On the separation of the eschar, the acute pain in the eye, the aversion to light, and the discharge of tears returned. The caustic was therefore repeated, and was attended with the same advantage as before.

Three days afterwards, on the separation of the second eschar, I found the ulcer very much contracted, attended with little pain, and the
bottom

bottom of it presenting a pale red, and granulating appearance. I ordered the collyrium vitriolicum, with mucilage, to be dropped into the eye every two hours, and the part to be constantly defended from the contact of the air and light, by means of a compress and bandage, and in a few days the sore healed. The blood-vessels of the conjunctiva, which were a little varicose, still kept up some degree of redness upon the white of the eye, and the boy was attacked with a tertian fever, attended with violent shiverings. I gave him the cinchona, with a few drops of the tincture of opium; the use of which was continued in small doses for a considerable time after the fever was subdued. Besides the vitriolic collyrium, the ointment of Janin was employed, which contributed materially to invigorate the vessels of the conjunctiva, and to remove entirely the chronic redness of the white of the eye. The cicatrix, though certainly very near the pupil, did not cover it, and consequently did not prevent the child from seeing with the left eye.

CASE XXXIV.

Giuseppe Reale, of S. Leonardo, a strong plethoric countryman, 22 years of age, was attacked with a violent acute ophthalmia in both his eyes, attended with fever and violent pain.

On

On the 7th day he came to the school of surgery, after having been once bled. His right eye was greatly inflamed, and there was an ulcer upon the inferior margin of the cornea, but not very deep; the left, which was equally inflamed, had an ulcer upon the external margin of the cornea, not larger in extent than a millet-feed, but excavated and deep. The patient's pulse was hard and vibrating, the fever continual, and he had an inclination to vomit. I immediately ordered 18 ounces of blood to be drawn from the arm, and at night 10 ounces more from the foot, and directed that bags of emollient herbs should be applied upon the eyes. He had a less uneasy night than the preceding, his pulse became soft and undulating, and his skin moist. As he complained of nausea I ordered him an emetic, which procured a copious and salutary evacuation of bilious matter; so that on the 4th day from the patient's entrance into the hospital, the inflammatory stage of the ophthalmia might be considered as having terminated. Both the ulcers were now touched with the *argentum nitratum*. In order to keep the patient's bowels open, and to encourage a state of perspiration, I ordered him, the following day, a pint of the decoction of the *triticum repens*, with two drams of the crystals of tartar, and a grain of tartarized antimony, to be taken in divided doses, and continued for several days. The applica-
tion

tion of the cautery allayed the violence of the pain in the eyes. When the eschars came away the ulcers were again touched with the *argentum nitratum*, and this was repeated three times in the course of eight days; by means of which the ophthalmia diminished, the granulating surface of the ulcer of the left eye arose on a level with the surface of the cornea, and that of the right eye was almost entirely healed. The *collyrium vitriolicum*, with the mucilage of *psyllium* dropped into the eyes every two hours, was afterwards sufficient to complete the cure; and as the cicatrices of the corneæ did not extend opposite the pupil, they did not obstruct the vision.

CASE XXXV.

Celestina Pacchiarotti, a child, two years and a half old, was brought by her mother to the school of surgery, in order that I might examine the right eye, which after a recent and severe attack of the small-pox had remained swollen, red, painful, and watery. I found upon the cornea, on the side next the nose, a small ulcer of a cineritious colour of the size of a millet-seed, and on the opposite side of the cornea, that is, towards the temples, a small incipient abscess.

I ordered that the ulcer should be immediately touched with the *argentum nitratum*.

The

The mother was charged to drop into the eye a little milk, and to bring the child every morning at the hour of dressing.

After the application of the caustic, the child remained easy for three days, but when the eschar separated she again showed signs of great pain and heat in the eye. The ulcer was again touched with the *argentum nitratum*, and on the detachment of the second eschar, which was four days after, I found it so small and superficial that it might be considered as on the point of closing. In four days more indeed, by merely dropping into the eye the *vitriolic collyrium*, with mucilage, it was completely healed.

The small abscess which occupied the margin of the cornea on the side of the temples, and which had hitherto remained stationary, increased and caused a return of the pain and tension in the eye; it afterwards burst and degenerated into an ulcer similar to the first. I instantly applied the caustic to this sore also, as I had done to the preceding. A blister was also put upon the neck, and the child was repeatedly purged with the syrup of succory and rhubarb. It was necessary to touch the ulcer a second time with *argentum nitratum* before it appeared disposed to produce healthy granulations, and to contract; which effects were obtained in six weeks from the exfoliation of the second eschar. The cure was completed by the
regular

regular use of the vitriolic collyrium and mucilage for two weeks; which not only contributed in a great degree to heal the second ulcer, but also to strengthen the vessels of the conjunctiva, and to clear the whole of the white of the eye,

CASE XXXVI.

Giuseppe Barbieri, of Pavia, aged 23, a saddler by trade, of a slender constitution, and occasionally subject to intermittent fever, was attacked, towards the end of September 1796, with an erysipelas on the right side of the face, which caused a considerable tumefaction of the eye-lids and conjunctiva of the right eye. This affection disappeared in ten days, by observing a proper diet, and by applying upon the face, as is the practice among the common people, the inner bark of the elder.

A month after, on being exposed to a sharp and cold wind, the right eye became very much inflamed. He repeated the same remedies as before, but finding however that the pain, heat, watchfulness, discharge of tears, fever, and intolerance of light increased, he came to the hospital. I found upon the lateral external part of the right eye, an ulcer, a line in length, and a quarter of a line in breadth, but very deep.

As

As I had not at that moment an opportunity of allowing him a bed in the hospital, I touched the ulcer with the caustic and gave him proper instructions for prosecuting the treatment at home. He did not return for advice till ten days after, consequently long after the exfoliation of the eschar, and I found him in a worse state than before. A bed was allotted to him, and I began by ordering him a bread and milk poultice to be applied upon the eye-lids, for the purpose of diminishing the excessive tension of the eye and surrounding parts, and to be repeatedly purged with the *opening* powders, composed of crystals of tartar and tartarized antimony.

In less than three days the tumefaction of the eye-lids subsided, and I immediately touched the ulcer with the *argentum nitratum*, and produced a deep eschar. It was necessary to apply the caustic three times more in the course of eleven days, before the ulcer lost its cineritious appearance, and was disposed to granulate and heal. By this treatment the pain in the eye, and the chronic ophthalmia, from relaxation of the vessels of the conjunctiva, gradually diminished, in proportion as the ulcer contracted.

When the bottom of the wound was nearly on a level with the surface of the cornea, I
ordered

ordered the patient to instil the vitriolic collyrium with mucilage of quince-seed every two hours, by means of which the ulcer was perfectly healed, and the patient regained the entire use of his eye.

CHAP. XI.

OF THE PTERYGIUM.

THE term *pterygium* is applied by surgeons to that small preternatural membrane of a reddish ash-colour, and of a triangular figure,* which arises in general from the internal angle of the eye, near the caruncula lachrymalis, and extends by little and little upon the cornea, attended with considerable injury to the sight.

Although this small membrane most frequently originates from the internal angle of the eye, it is sometimes seen to proceed also from the external angle,† and in some cases from the superior or inferior hemisphere of the eye-ball. From whatever part it may arise, however, it is a constant fact that this membrane is always formed of a triangular shape, the base of which is situated upon the white of the eye, and the apex upon the cornea, sometimes at a greater sometimes at a smaller distance from the centre of the cornea and of the pupil. In some cases,

* Plate II. fig. 3. a.

† Plate II. fig. 3. b.

though

though rarely, two or three pterygia of different sizes are met with upon the same eye, placed at different distances from each other around the circumference of the ball, with their apices directed to the centre of the cornea, where, if unfortunately they unite together, they cover the whole of its surface with a dense veil, and produce a complete loss of sight. This complicated case appears to me to be precisely what the ancient physicians have called the *pannus* of the eye.

The *chronic varicose* ophthalmia, with relaxation and thickening of the conjunctiva, the *nebula* of the cornea, and the pterygium, differ from each other only in as much as they are but greater or less degrees of the same disease. For all the three consist in a varicose, relaxed, and atonic state of a certain portion of the conjunctiva. In the *chronic varicose* ophthalmia, the præternatural fulness and nodosity of the veins, as well as the flaccidity and thickening of the conjunctiva, are confined to the white of the eye; in the *nebula* of the cornea, a certain order of varicose veins is dilated and knotty for a limited extent, upon the fine lamina of the conjunctiva, which covers the external surface of the cornea; and in the *pterygium*, in addition to the varicose state of the vessels, which are extended over a certain part of the cornea, there is a præternatural thickening

s

ing

ing of the thin lamina of the conjunctiva which covers it, upon which these small varicose veins are situated. Hence it arises that the *pterygium* appears at first to be a new membrane formed upon the cornea, while it is nothing more than the fine lamina of the conjunctiva, forming its natural external covering, which in consequence of the chronic ophthalmia has degenerated from a transparent into a thick and opaque tunic interwoven with varicose vessels. In cases of pterygium therefore no new production is formed upon the eye, the disease only consisting in a perversion of some one of the fine and transparent membranes which cover it. And a convincing proof of it, which I shall afterwards detail, is this, that the *incipient pterygium* may be cured in the same manner as the nebula of the cornea; that is, not by detaching it from the surface of the cornea, but merely by extirpating it at the part where the cornea and sclerotica unite, in the manner employed for destroying the communication between the minute ramifications of the varicose veins of the conjunctiva and their trunks, from the former of which the *nebula* is produced and nourished.

The pterygium, as I have said on the subject of the nebula of the cornea, would be a disease no less frequent than the *varicose chronic ophthalmia*, which so often occupies the white of the eye, if the fine and transparent lamina of
the

the conjunctiva, which invests the cornea externally, were not of a texture far more dense and compact than the rest of that membrane which corresponds to the white of the eye, and if the small vessels, which are distributed upon it, were not very fine, tense, and not so easily distended as their trunks, which are situated upon the rest of the conjunctiva, covering the anterior hemisphere of the eye-ball. Hence it is, that considering the frequent occurrence of the chronic varicose ophthalmia, the pterygium is rather an unusual disease. If, however, the very delicate vessels of the lamina of the conjunctiva covering the cornea, once yield to the impulse of the fluid propelled into them, and become varicose, it necessarily follows that the cellular membrane, which envelopes these vessels becoming gradually tumefied, the fine and transparent lamina, situated upon the cornea, is converted into a pulpy and reddish coloured tunic, which is precisely that of the *pterygium*.

That the *pterygium* is, in reality, nothing more than the natural expansion of the thin transparent lamina of the conjunctiva converted, for a certain extent upon the cornea, into a pulpy, flaccid, varicose membrane, is rendered probable from the folds which the pterygium and the conjunctiva corresponding to it form, whenever the eye-ball is rolled on the side on which the

disease is situated; and, on the contrary, from the tension which takes place in the *pterygium* and conjunctiva, when the ball of the eye is turned in the contrary direction. And this is still further confirmed, from observing, that in the former position of the eye-ball the *pterygium* may be as easily laid hold of by the forceps, and raised in the form of a fold, as the part of the conjunctiva corresponding to it, which is equally relaxed, varicose, and red.

In the dead bodies of those who have had this disease, when the flaccid and thickened part of the conjunctiva of the white of the eye, corresponding to the part of the cornea, which is rendered opake by the *pterygium*, has been carefully separated and removed, I have constantly found that the pterygium* was as easily detached from the cornea, as from the white of the eye, leaving the former in the part which it occupied denuded, and evidently deprived of the covering which it naturally receives from the fine transparent lamina of the conjunctiva. Nor have I been able in any instance to divest the cornea of its natural covering, beyond the seat of the disease. When besides there are several pterygia upon the same eye, at different distances from each other, there are so many flaccid, varicose, pulpy portions of the

* Plate II. fig. 4. a. b.

conjunctiva met with forming the base of each of them; while the rest of that membrane, covering the white of the eye, remains closely united to the eye-ball, without there being any appearance of varicose vessels upon the anterior hemisphere of the eye, except in those parts where the relaxation of the conjunctiva, and the nodosity of the vessels have, as it were, thrown to a distance the roots and rudiments of the pterygium.

It is worthy of observation, that whether the pterygium be great or small, and in whatever part of the circumference of the eye-ball it is formed, it constantly retains its triangular figure; having its base situated upon the white of the eye, and its apex upon the cornea. The constancy of this fact ought to be referred, in my opinion, to the adhesion of the lamina of the conjunctiva becoming stronger, in proportion as it advances from the circumference towards the centre of the cornea. For in consequence of such structure and different degree of cohesion which actually exists in the sound eye, it should necessarily follow, that in the first place the progress of the pterygium ought to be in every case of such disease much slower upon the cornea than upon the white of the eye; secondly, that from the greater resistance which the pterygium always meets with, in proportion as it extends towards the centre of the cornea, it

ought, from mechanical necessity, to assume a triangular form, the base of which corresponds to the white of the eye, the apex to the centre of the cornea. Forestus* has particularly remarked the constancy of this phænomenon, and speaking of the *pterygium*, he adds, *non cooperit oculum nisi in forma sagittæ*.

From this appearance and figure, which the disease invariably assumes, arises one of its principal diagnostic characters, by which the true *pterygium* is distinguished from the spurious, or from any other soft, fungous, reddish coloured excrescence, which externally darkens the cornea. For excrescences are sometimes formed upon the cornea, which, from their colour and soft membranous consistence, very much resemble the pterygium, although they are very different from it, being formed in reality by the substance of the cornea itself, which has degenerated into a soft and fungous substance. But these species of false pellicles independently of their being almost always more elevated upon the cornea than the *pterygium*, have constantly an irregular and tuberculated figure, and never represent a triangle with the apex directed from the margin towards the centre of the cornea.

Another distinguishing character of the pterygium is, the facility with which the whole of

* Oper. Med. lib. ii. Observ. 6.

it may be collected and raised in a fold upon the cornea by means of the forceps; while every other species of excrescence attached to this membrane remains firmly adherent to it, and does not admit of being folded in any manner, or elevated from the surface of the cornea. This peculiarity is of the greatest importance in the treatment of this disease, since the true and genuine pterygium may be cured in the simplest manner; while, as I have stated at the end of the preceding chapter, the fungous excrescence of the cornea cannot be radically extirpated and perfectly healed without the greatest difficulty. Plenck * remarks with much propriety: *pterygia, quæ filamentis solummodo adhærent, facile, abscinduntur, difficillimè quæ ubique accreta sunt corneæ, ac in plicam elevari non possunt.* But if this excrescence, although of a triangular figure, and constituting the true pterygium, adheres firmly to the cornea, and is of a deep red colour, resembling lac, bleeds readily on being touched, and occasions lancinating pains, which shoot through the eye and temples, the disease threatens to become of a malignant cancerous nature, or is so already; and therefore ought

* Ce morb. ocul. page 97.

Avicenna, lib. iii. fen. 3. cap. 23, says; duræ, speaking of the cornea, denudatio quando non est facilis, perducit ad nocumentum.

only to be treated by palliative means, or by the extirpation of the whole eye.

The cure of the true benign pterygium, or that which is of a triangular figure, of a cineritious or pale red colour, unattended with pain, and which may be raised in the form of a fold, is obtained by removing this small triangular opaque membrane in an exact manner from the surface of the cornea. But since, from what has been stated, the pterygium consists in an alteration of the transparent lamina of the conjunctiva into a dense and opaque tunic, in consequence of the varicose chronic ophthalmia, it necessarily follows that this disease cannot be removed by any means of art, without that part of the cornea which it occupies being deprived of its natural exterior integument. And as this deprivation of the natural covering of the cornea renders a cicatrix in that part inevitable, it follows also, that it is impossible to cure this disease by an operation, without the cornea remaining more or less dark in the part which was occupied by the pterygium. The young surgeon, therefore, for whom these observations are intended, should not suffer himself to be imposed upon by the specious relations of those who assert that they have removed pterygia by the knife, and completely restored the cornea to its original natural transparency. The cornea certainly appears less opaque in that part than
before;

before ; but it always remains dark, and clouded by an indelible, though superficial cicatrix. The advantage derived from the operation is, however, always considerable, in as much as it prevents the progress of the disease, or the further increase of the varicose and thickened state of the thin pellucid lamina of the conjunctiva covering the cornea, and at the same time removes the local cause of irritation and afflux to the eye, and thereby prevents the complete opacity of the cornea. If, therefore, it has happened that after the excision of an extensive pterygium the patient has recovered his sight, it ought to be understood some degree of sight, or in that proportion which there is between a dense membrane, which entirely obstructs the passage of the light, and a thin superficial cicatrix, which does not intercept it altogether.

All that I am able to assert, from repeated observation, as certain and invariable, is, that after the excision of the pterygium, the superficial and indelible speck which remains upon the cornea is always less extensive than the space which was previously occupied by the pterygium. Whether this arise in consequence of the fine transparent lamina of the conjunctiva at the circumference of the pterygium, not being entirely disorganized, but only filled with a thick humour, and merely affected with *nebula*, which, by means of the excision, unloads itself
of

of the tenacious humour which it contained, and consequently recovers its former transparency; or because the cicatrix in the part from which the *pterygium* has been extirpated, as generally takes place in all wounds, becomes actually less extensive than the parts which have been removed; certain it is, that this phænomenon is invariable, and that in a great number of cases in which I have performed the operation, of which some extended two lines, others two lines and a half upon the cornea towards its centre, in all, after the cure was complete, the cicatrix and offuscation of the cornea were less, and did not exceed one line and a half, or little more, in cases where the pterygium was two lines in extent.

The excision of the pterygium is an operation easily executed. It is not necessary for such purpose to have recourse to the curved needle, threaded with silk, with which the greater part of surgeons direct the small membrane to be pierced, for the purpose of forming a noose, by which this pellicle may be raised, and then divided at its base. This method is inconvenient, not only because it greatly prolongs the operation, but because the blood which flows from the perforations prevents the extent of the parts which are intended to be removed from being seen with the precision which is requisite.

The

The forceps * and very sharp scissars † are quite sufficient for the purpose.

The pterygium is in general removed by beginning the excision upon the cornea, and continuing it upon the white of the eye, as far as the whole extent of its base in the conjunctiva, so that when the disease proceeds from the internal angle of the eye, the incision is prolonged by the generality of surgeons as far as the caruncle. The disadvantage attending this practice is, in the first place, that the white of the eye is denuded to too great an extent; secondly, that in consequence of the great quantity of substance of the conjunctiva, which is removed in the base of the pterygium, and the direction in which it is executed, the cicatrix which takes place upon the white of the eye, forms an elevated ridge, which, like a small cord, confines the ball of the eye to the caruncula lachrymalis, and prevents the freedom of its motions, particularly in the direction from the internal towards the external angle. In order to avoid this inconvenience in the treatment of pterygia, which have a very extensive base upon the white of the eye, I have found it convenient to divide them, from the apex only, as far as the part where the cornea and sclerotica unite; and then to separate them at their base

* Plate III. fig. 8.

† Plate III. fig. 3.

by a femicircular incision,* including about a line in breadth of the substance of the conjunctiva, in a direction concentric to the margin of the cornea. By operating in this manner I have found that the after-treatment is much shorter than when it is executed after the common method, that the cicatrix does not form a ridge or frænum, and that the conjunctiva being stretched circularly and equably upon the white of the eye by the cicatrix, loses that relaxation and varicose state of its vessels which formed the base of the *pterygium*. This nicety is not, however, necessary where the *pterygium* is small, and does not extend much upon the white of the eye.

The patient being seated for this purpose, an assistant behind him should raise the upper eyelid, with the middle and forefinger of one hand, and depress the lower one with those of the other. The operator, supposing the affected eye is the right, should place himself before the patient, either sitting or standing, as shall be most agreeable to him; then desiring the patient to turn his eye a little from the side corresponding to the base of the pterygium, with the forceps held in his left hand a little open, he should take hold of the pterygium at about a line from its apex, and press it in the form of a fold, which

* Plate III. fig. 3. a.

he should then raise and draw gently upwards towards him, until he shall perceive a small crackling, indicating the detachment of the pterygium from the fine cellular membrane which connects it to the subjacent cornea. Then, with the scissors in his right hand, he should divide the fold as close to the cornea as possible, in the direction from the apex to the base; and having carried the incision as far as the part where the cornea and sclerotica unite, should raise the fold again still higher, and with one stroke of the scissors, as concentric and close to the margin of the cornea as possible, remove the pterygium, together with a portion of the relaxed conjunctiva, which formed the base of it. This second incision should have the figure of a crescent,* the points of which ought to extend a few lines beyond the relaxed portion of the conjunctiva, following the curve of the eyeball.

After the operation the blood should be encouraged to flow, by washing the parts with warm water, and the eye covered by a compress, either dry, or moistened with the aqua litharg. acetat. comp. and supported by a bandage, which should not compress the parts too much.

If no remarkable symptoms should arise, as pain, tension of the eye, and considerable tume-

* Plate II. fig. 3.

faction of the eye-lids, it will be sufficient that the eye-ball and internal surface of the eye-lids be washed three or four times a day, with tepid mallow-water, and the parts carefully defended from the contact of the air, without being compressed. If, however, such symptoms should occur, it will be necessary to have recourse to the antiphlogistic regimen, the application of bags of emollient herbs to the eye, and the introduction between the eye-lids of the white of egg, or mucilage of the seeds of the *psyllium* extracted with mallow-water.

On the 5th or 6th day, in general, from the operation, the surface of the wound appears of a yellow colour, and covered with mucus; a form of suppuration peculiar to membranes in general, and the eye-ball in particular, while its edges, and the rest of the conjunctiva surrounding them, are red. Afterwards the wound gradually contracts itself every day more and more, until it entirely disappears, and the cicatrix is complete.

During the whole of the treatment, from the time of the operation, it is not necessary to use any other application than a lotion of mallow-water three or four times a day. I have been convinced, from repeated observation, that astringent collyria, and the powders which are so highly extolled as that composed of the Florentine
tine

tine orris and alum, occasion great irritation in the eye, and a tumefied and fungous state of the conjunctiva; all of which directly oppose the healing of the wound. And what is more disagreeable they give rise to little tufts of fungus in the centre of the sore, which are with difficulty repressed and healed. I have seen all these inconveniences produced by a single unnecessary application of the *argentum nitratum*. On the contrary, by simply washing the parts with the *aqua malvæ*, the cure proceeds regularly, the yellowish surface of the wound contracts daily, and the cicatrization is completed in the mildest manner in the space of three, or at most four weeks. Afterwards it may be useful to drop into the eye three or four times a day the vitriolic collyrium, with a few drops of camphorated spirit of wine added to it, in order to strengthen the conjunctiva and its vessels.

I have remarked at the commencement, that the *incipient pterygium* is in reality nothing more than the nebula of the cornea, in which the veins of the conjunctiva, investing that part of the cornea where the disease is situated, are a little more dilated than in cases of the latter; and that the fine lamina of the conjunctiva acquires a greater degree of density and opacity in that part, than when it is simply affected with

with the *nebula*.* To express myself more clearly, the pterygium in this case is not a dense and opaque membrane, but a pellicule of the fineness of a spider's web, interwoven here and there with varicose blood-vessels, behind which the iris is yet sufficiently perceptible. In this state of the disease, it is not necessary to deprive that part of the cornea of its natural covering. It is sufficient, as in the treatment of the nebula of the cornea, to destroy by excision the communication between the dilated ramifications of the veins of the pterygium, and the varicose venous trunks situated upon the white of the eye. This is obtained by removing a small portion of the conjunctiva of a semilunar figure, by means of the forceps and scissors, at the part where the cornea and sclerotica unite, precisely at the base of the incipient pterygium, in the same manner as in the treatment of the nebula. After this operation the *incipient pterygium* is observed to be gradually dissipated, or there only remains a slight opacity of the cornea, for a certain extent of the part which it occupied, which, however, is most frequently far less considerable than that which is left by a cicatrix of the cornea.

* This middle state between the nebula of the cornea, and the confirmed *pterygium*, is denominated, by the Arabian writers, *Sabel*. *Sabel*, says Avicenna, est panniculus accidens in oculo ex inflatione venarum ejus apparentium in superficie conjunctivæ et corneæ; et textitur quiddam in eo, quod est inter eas, sicut fumus. Lib. iii. fen. 3. tract 2. cap. 19.

Acrell, in his *chirurgical observations*, relates his having cured an *incipient pterygium* in this manner; which I have also frequently attempted with perfect success, but which I have thought it more proper to detail among the cases of *nebula* of the cornea than those of the *pterygium*, for the reasons already assigned, and principally because the morbid state of the lamina of the conjunctiva in these cases very little exceeds that in which this covering of the cornea is found, when it is only affected with the *nebula*.

CASE XXXVII.

Antonio Cantoni, of Casorati, a young countryman, 19 years of age, presented himself at the practical school of surgery on the 12th of November 1792, with a *pterygium*, which extended from the external canthus of the right eye, upon the cornea, very near to the pupil.

On the 14th of the same month, the patient being seated, and the triangular membrane taken hold of with the forceps, at the distance of a line and a half from its apex, and properly raised, I carefully separated it from the whole of the cornea; then taking hold of the varicose and relaxed conjunctiva, which formed the base of the pterygium upon the white of the eye, and elevating it a little, I removed it in the

form of a crescent close to the margin of the cornea, and in the same direction.

As there was no remarkable swelling of the eye, or eye-lids on the succeeding days, the parts were merely washed with the aqua malvæ, and covered with a compress and bandage.

The surface of the wound, as well upon the cornea as upon the white of the eye, diminished daily, and on the 10th of December was completely healed. It was observable, that the cicatrix of the cornea did not approach so near the pupil as the apex of the pterygium.

CASE XXXVIII.

Mauro Pisani, a robust countryman, 45 years of age, was affected with a pterygium in the internal canthus of his right eye, which he had neglected so long, that it ultimately covered two thirds of the pupil, occasioning a great diminution of sight.

The operation was performed on the 22d of January 1793. The little membrane was very exactly separated, by means of the forceps and scissars, from the cornea, and a portion of the tumid varicose conjunctiva, which formed the base of the pterygium upon the white of the eye, was removed, in the form of a crescent. A greater quantity of blood flowed from the incision

incision than might have been expected from the size of it.

On the 5th day after the operation, the yellowish layer of mucus, which is a certain indication of suppuration, appeared upon the surface of the wound. During the whole of the treatment the patient used no other external remedy than a lotion of aqua malvæ three times a day, and was scarcely at all confined to his bed.

In 26 days the wound was perfectly healed. All that part of the cornea which had been obscured by the pterygium remained cloudy as before, but with this difference, that when completely healed it occupied rather less of the pupil, and the patient therefore saw more distinctly than before the operation.

CASE XXXIX.

A strong man, 34 years old, a carpenter by trade, had, for several years, a *pterygium* upon the right eye, which extended from the inferior hemisphere of the eye-ball, where it is covered by the lower eye-lid, towards the centre of the cornea, so as to cover about a fourth part of the pupil in a moderate light.

On the 12th of March 1794, the patient being seated in the practical school, and the eye-lids separated, particularly the lower, I took hold of the pterygium at a line and a half from

its apex, and having raised it completely in the form of a fold, I divided it a little beyond the margin of the cornea; then taking hold of the conjunctiva with the forceps, where it covers the white of the eye, I removed the base of the pterygium, together with a segment of that membrane, in a direction concentric to the margin of the cornea.

The blood was allowed to flow, and the eye was covered with a fold of lint, moistened in the aqua litharg. acetat. comp. which was supported by a bandage.

The day after, the eye-lids appeared swollen, red, and painful. I ordered blood to be taken from the patient abundantly, and the eye to be covered with bags of emollient herbs. The following day he was purged. The inflammation was dissipated on the 7th day. The conjunctiva remained, however, exceedingly tumefied and red, and the surface of the wound did not yet appear covered with mucus.

On the 12th day from the operation, the mucous suppuration began to take place, and from that time the wound gradually diminished.

During the whole of the treatment, except the application of bags of emollient herbs at the commencement, no other external remedy was employed than the aqua malvæ. At the end of five weeks the wound was healed. The patient, however, used the vitriolic collyrium, with

with the mucilage of quince-feed, four times a day, for fifteen days afterwards, and anointed the edges of the eye-lids at night with the ophthalmic ointment of Janin. In this case also the cicatrix obstructed the pupil considerably less than the pterygium had done.

CASE XL.

Francesco Vecchi, of Calignano, a countryman, 57 years of age, of a weak constitution, in the beginning of March 1795, made application on account of two large pterygia, one upon each eye, which had occasioned a deformity for several years, and finally threatened to produce blindness; for that of the right eye, in a moderate light, covered two thirds of the pupil, the other one half of the left. Both arose near the caruncula lachrymalis. This man was likewise affected with an habitual chronic ophthalmia in both his eyes.

These pterygia were removed in the manner related in the preceding cases. On the following day the eye-lids and conjunctiva of both sides were enormously swollen, accompanied with redness, pain, and fever. I directed blood to be taken from his arm, and also from the neighbourhood of the eye-lids, by means of leeches; he was restricted to a low diet, and ordered to take a pint of the *triticum repens*, with

a grain of tartarized antimony in small doses, and to apply upon the eye-lids bags of emollient herbs.

On the 8th day of this treatment he became easy, the inflammatory stage of the ophthalmia having ceased, and the eye-lids greatly subsided. The conjunctiva, however, was exceedingly red, tumefied, and almost in a fungous state, and the yellowish surface of the wound was not yet covered with mucus. Being satisfied that the delay of the suppuration was partly owing to the atonic state of the vessels of the conjunctiva, I should have been tempted to employ some astringent application, had I not been warned by similar cases, in which the use of astringent collyria, instead of removing the chronic ophthalmia arising from relaxation of the conjunctiva, had, on the contrary, reproduced the inflammation. In this case, therefore, and as it is now my usual practice, I was satisfied with using merely a lotion of mallow-water, and exciting an irritation in the neck, by the application of a large blister, which was kept open for some time, and also repeating it behind the ears.

On the 19th day from the operation, the tumefaction of the conjunctiva being very much diminished, the surface of the wound of both eyes began to suppurate, and to be covered with mucus. From this time the wound gradually contracted,

contracted, until the 53d day, when it was completely healed.

The collyrium vitriolicum was now directed to be instilled into the eye several times a day, at first alone, but afterwards with a little camphorated spirit of wine added to it; and the ophthalmic ointment of Janin to be used at night: by continuing these remedies for two weeks the conjunctiva recovered its vigour, and the chronic redness of the eyes, proceeding from the relaxation of this membrane and its vessels, disappeared.

The cicatrix of the cornea of the right eye covered only a third, or little more, of the circumference of the pupil in a moderate light; and that of the cornea of the left eye only a fourth part of the pupil.

CHAP. XII.

OF THE ENCANTHIS.

THE *encanthis*, in its commencement, is a small soft, reddish, or sometimes slightly livid excrescence, which arises from the caruncula lachrymalis, and neighbouring *semilunar* fold of the conjunctiva. The inveterate *encanthis* is commonly of a very considerable size,* and extends its roots beyond the caruncula lachrymalis, and *semilunar* fold, as far as the internal mem-

* *Purmannus*, in his *Chirurgia curiosa*, page 133, has left us the description and figure of a tumour as large as the fist, proceeding from the internal angle of the left eye by a very slender peduncle, and hanging upon the cheek; the obscurity, however, which pervades the whole of the description of this disease, and the little accuracy displayed in the drawing, leave room to doubt whether this large tumour originated from the caruncula lachrymalis and neighbouring *semilunar* fold, or rather from the integuments immediately on the outside of the internal commissure of the eye lids. *Purmannus* says, that he extirpated this tumour with success, by first employing a ligature near its root, and afterwards applying upon the root itself the small button of a cautery, included in a canula.

brane of either eye-lid, or of both. In consequence of its originating and being placed between the eye-lids at their internal commissure, which it necessarily keeps separated on the side next the nose, it occasions no inconsiderable inconvenience to the patient, by keeping up the *chronic* ophthalmia, and impeding the action of the eye-lids, particularly that of completely closing the eye; and partly by compressing, and partly removing the apertures of the puncta lachrymalia from their natural direction, it presents an obstacle to the free course of the tears from the eye into the nose.

This excrescence, in its early state, has generally a granulated appearance, resembling a mulberry; or it is formed of small fringe-like pieces. But when it has arrived at a considerable magnitude, a certain part of it presents a granulated appearance, while the rest offers only a smooth substance of a whitish or cineritious colour, streaked with varicose vessels, which occasionally advances so far upon the conjunctiva covering the eye-ball on the side next the nose, as to reach the part where the cornea and sclerotica unite. When the excrescence has arrived at an advanced state, it not only constantly involves the caruncula lachrymalis and *semilunar* fold, but the internal membrane of one or other of the eye-lids, or of both; besides the attachment, therefore, which the *encanthis* has, in such cases,

cases, to the caruncula lachrymalis, *semilunar* fold, and conjunctiva of the eye-ball, it is observed to give off a firm and projecting appendix or process, along the internal surface of the upper or lower eye-lid, in the direction of their edges; or the middle or body of the *encanthis* is, as it were, divided near the cornea, into two appendices or processes, resembling a swallow's tail, one of which extends along the upper eye-lid covered by its margin; the other runs along the internal surface of the lower eye-lid, concealed also by its margin, in the direction from the internal towards the external canthus of the eye.

The body of the *encanthis*, or that middle portion of the excrescence, which extends from the caruncula lachrymalis and *semilunar* fold inclusively, upon the conjunctiva of the eye-ball, almost as far as the junction of the cornea and sclerotic coat, is sometimes as prominent as a hazel, or ches-nut, at other times it is of this magnitude, but depressed, and as if it were flattened. The body of the excrescence, however, preserves the granulated appearance which it had at first, while one or other, or both its appendices, which are continued upon the internal surface of either or both eye-lids, present, as I have said, rather the aspect of a lipomatose than a granulated substance. If the eye-lids are everted, these appendices or processes of the *encanthis*

this make an elevated projection, and when this takes place in both the eye-lids, on their being everted, these lipomatose appendices form almost a ring, which is closely applied upon the eye-ball. This disease was known, and successfully treated by Fabricius Hildanus, who has called it *ficus schirrosus ad majorem oculi canthum*.*

It

* Centur. I. observ. 2. anno 1598, 20 Febr. ad ædes D. Petri Dumantii verbi divini ministri ad quadragenarium, habentem tumorem schirrhosum ad magnum oculi canthum castaneæ magnitudine colore livido, et multis venis capillaribus intertextum vocatus fui. Ille autem tumor ab una parte adhærebat conjunctivæ membranæ usque ad iridem; ab altera vero hærebat palpebræ superiori, et lachrymali glandulæ; ita ut ad oculi motum totam cooperiret pupillam scirrhus ille. Nos (ægro purgato, prout in præcedente observatione fufius declaravimus) incisa item cephalica in sinistro brachio, institutaque optima victus rationes præfente M. Nicolao Fevotto, et Daniele le Clerc. Laufannensibus, forcipe nostra oculari hic delineata tumorem apprehendimus. Tum attracta paulatim forcipe, et inversa superiori palpebra, tumorem cultello seperatorio ad id aptato commode seperavimus. Postea albumen ovi aqua rosacea mixtum imposuimus. Inde collyriis anodynis, et abstersivis et tandem exsicantibus oculum intra septimanas tres, visu plane illæso, perfanavimus. Interim tamen purgationes aliquoties interavimus, et cucurbitulas cum largiori flamma scapulis et nuchæ admovimus. Defensivum item fronti et temporibus applicuimus.

Collyrium anodynum. Rec. Mucilag. sem. cydon, plantag. cum aqua rosacea extractæ, lactis muliebris ana uncias II. camphoræ, croci ana scrupulum dimidium, misce et applica tepide.

Collyrium

It appears, however, that in the case related by Hildanus, the encanthis had only one appendix situated upon the internal surface of the upper eye-lid, below its margin.

The encanthis, as well as the pterygium, sometimes assumes a cancerous malignity, which is characterized by the dark red or leaden colour of the excrescence; its extraordinary hardness; the lancinating pains which accompany it, and which extend to the forehead, the whole of the eye and the temples, especially after it has been even slightly touched; by its disposition to bleed; and by its ulcerating in several points which throw out a fungous substance, and discharge a thin and very acrid humour. This worst species, or rather degeneration of the encanthis, admits only of a palliative treatment, unless the total extirpation of it should be attempted, together with all the parts contained in the cavity of the orbit; the success of which must be also very doubtful.

* Collyrium exsicicans. Rec. Aquarum plantag. rosar. ana uncias quatuor, tutiæ preparatæ, cornu cervi usti et preparati, cerussæ lotæ ana drachmam unam. Misce fiat collyrium. Hic monitos velim chirurgos; collyria in quæ ingreditur lac, æstate singulis, hyæme vero alternis diebus iteranda esse. Acescit enim lac, et acre efficitur: hinc dolores, et inflammationes excitat.

The

The benign encanthis, whether small or large, may be cured by means of excision. The small incipient encanthis, whether of a granulated or fringe-like appearance, which arises from the caruncula lachrymalis and *semilunar* fold, or from a small part of the edges of the eye-lids also, where they form the internal angle or commissure, may be elevated by the forceps, and by means of the curved scissars, separated close to its base from the whole extent of its origin. For the purpose of executing this operation, it is not necessary, as is practised by some, to pass a needle and thread through the small excrescence, in order to raise it and detach it with precision from all the parts to which it adheres; as this intention may be obtained by means of the forceps, without incommoding the patient by the punctures and introduction of a thread for the purpose of forming a noose. In the removal of that part of the small encanthis, however, which originates from the caruncula lachrymalis, it is necessary not to include more of the substance of the caruncle than is requisite for completely eradicating the disease, lest by removing too much of it, an irremediable weeping of the eye should be produced.

After the small excrescence is extirpated, the eye should be repeatedly washed with cold water, in order to clear away the blood, and should be covered with a linen cloth and bandage.

On the 5th, 6th, or 7th day, when the inflammation occasioned by the operation has entirely ceased, and the mucous suppuration is established, the divided parts should be touched with a small button of alum, cut in the form of a crayon pencil, and the vitriolic collyrium, with mucilage of quince-seed, instilled into the eye several times a day. If these means do not produce the desired effect of healing the wounds, but on the contrary, those of the caruncle and internal commissure of the eye-lids become fungous and stationary, they should be frequently touched with the argentum nitratum, taking care to avoid the conjunctiva as much as possible, especially if any part of it have been included in the incision. When the fungus has been destroyed, the treatment may be completed by the vitriolic collyrium, or by introducing an ointment consisting of fresh butter, the powder of tutty, and armenian bole, between the eye-ball and internal angle of the eye-lids three times a day. Bidloo greatly extols the application of the powder of chalk, either simple, or combined, with burnt alum. *Exercit. Anat. Chir. decad II.*

The large inveterate encanthis, whether flattened in its body, or projecting in the form of a hazel or ches-nut, with one or two lipomatose appendices along the internal membrane of either or both eye-lids, is equally cured by means of excision

cision. The ligature cannot be employed in this case advantageously, since the neck or peduncle of the excrescence is never sufficiently narrow to admit of its application; the encanthis on the contrary, when very voluminous, having constantly extensive attachments to the caruncula lachrymalis, femilunar fold, to the conjunctiva almost as far as the vicinity of the cornea, and also one or two lipomatose appendices along the internal membrane of either or both of the eye-lids. If, therefore, the body of the encanthis should be removed by the ligature, either one or both the lipomatose processes would always remain to be extirpated, which second operation could only be executed by means of excision. The fear of hæmorrhage, in this operation, upon which the advocates for the ligature appear to lay so much stress, is unfounded, since the cases of large and inveterate encanthis, which have been removed, are now so numerous, without any unfavourable accident having happened on account of the loss of blood (to which I could add some of my own) that upon this point* there cannot be any room for doubt or discussion.

* Pellier, Recueil d'observ. sur les malad. de l'oeil, part II. observ. 118, relates a case of excision of the encanthis, which although executed, as he says, by an able oculist, was, however, followed by a dangerous hæmorrhage. He does not enter, however, into any detail of the nature of the disease,
nor

discussion. Fabricius Hildanus, in the case of the large and inveterate encanthis before cited, in which there was only one lipomatose process along the internal membrane of the upper eyelid, after having taken hold of the body of the tumour with the tenaculum, and drawn it towards him, and having everted the upper eyelid, so that this appendage might project forwards through its whole extent, with a small bistoury separated this process from the internal surface of the eye-lid, and by continuing the incision divided the body of the encanthis from the conjunctiva covering the eye-ball, the semilunar fold, and caruncula lachrymalis. This operation was attended with the happiest success, and therefore ought to serve as a model and guide to surgeons in the treatment of this disease.

When, however, the inveterate, and very large *encanthis* has two lipomatose appendices, one along the internal surface of the upper, the other of the lower eye-lid, it is then necessary to proceed in the following manner: the patient should be placed in a chair, and the upper eyelid everted by an assistant, so that one of the

nor of the method of operating, from which one might have been enabled to deduce the causes of so unusual an occurrence. Indeed, he adds: *J'ai souvent fait cette operation a des excroissances de cette nature, et jamais je n'ai éprouvé un pareil accident.*

processes

processes of the encanthis may project outwards. This being deeply divided in the direction of the edge of the eye-lid, by means of a small bistoury, and then taken hold of and drawn out by the forceps,* should be entirely separated from the internal surface of the upper eye-lid, longitudinally, proceeding from the external towards the internal angle of the eye, as far as the body or middle portion of the encanthis. The lipomatose process, situated upon the internal surface of the lower eye-lid, should be separated in the same manner. The body of the encanthis should be afterwards elevated by means of the forceps, or, if this is not practicable, by a double hook, and then partly by means of the small bistoury, and partly by the curved scissors, completely detached from the subjacent conjunctiva which covers the eye-ball, from the semilunar fold and caruncula lachrymalis, penetrating more or less deeply into the substance of the latter, as the firmness and depth of the roots of the disease may render it necessary, since it ought to be openly acknowledged that in the treatment of the inveterate and very large encanthis, which is deeply rooted in the caruncle, it is not always in the surgeon's power to avoid the substance of that part so carefully that when the wound is healed, some little weeping of the

* Plate III. 12. 8.

eye may not remain in consequence of the operation.

The eye should be frequently washed with cold water, and the after treatment in this case conducted nearly in the manner recommended in the extirpation of the small incipient encanthis. Frequent lotions of the aqua malvæ and anodyne and detergent collyria are the most proper applications, until the mucous suppuration in the divided parts be fully established; afterwards slight astringents, and the ointment before recommended, may be used with advantage. In general, the mildest applications are the most useful, not only in the stage preceding the suppuration, but afterwards; especially when, together with the encanthis, a considerable portion of the conjunctiva, covering the white of the eye on the side towards the nose, has been removed, to which the body of the excrescence was closely united.

The whole of this chapter will be greatly illustrated by the following case of Marchetti.*
Curavi quemdam canonicum polonum laborantem meliceride magnitudinis jujubæ, quæ a caruncula anguli majoris oculi ad totam pupillam porrigebatur. A multis tentata curatio medicamentis, decoctis scilicet, collyriis et aliis hujusmodi; omnia tamen octo mensium spatio incassum adhibita. Cum vero

* Observ. med. Chirurg. Sylloge, obs. 21.

me consulisset, ipsum tumorem evellendum censui; quod cum reformidaret spe tamen salutis operationem admisit, quam statim molitus sum, corpore prius expurgato accuratissime ab aliis medicis. Paravi itaque hamulum, quo ipsam meliceridem perforavi, et manu apprehendi, altera vero forcipe eandem cum folliculo sectione separavi tum a caruncula, tum a tunica adnata, et ipsa pupilla; atque ita totum tumorem eduxi sine ulla offensa ipsius oculi; a quibus statim applicui gossypium imbutum aqua rosacea cum ovi albumine agitata, et portiuncula croci, patiente tres dies hoc modo fascia victo; adhibito postmodum collyrio cum aqua rosarum, et pulvere tutiæ præparatæ; quibus spatio octo dierum omnino convaleuit æger; increpante licet meam præceptore meo ab Aquapendente audaciam, curæ tamen brevi spatio temporis id præstiterim, quod alii medici non potuerunt perficere: idque præsentibus præclarissimo Joanne Dominico Sala cum multis studiofis.

C H A P. XIII.

OF THE HYPOPION

By the term hypopion, I mean with the generality of surgeons, that collection of yellowish glutinous humour, similar to matter which takes place in the anterior chamber of the aqueous humour, and not unfrequently also in the posterior chamber, in consequence of the violent *acute* ophthalmia, particularly where it is internal. For, as I have said, in speaking of the inflammation of the eyes, although the violent *acute* ophthalmia is, in the greater number of cases, principally confined to the external parts of the eye, it nevertheless occasionally attacks with an equal degree of violence both the external and internal membranes of this organ, particularly the choroidea and uvea. If, in the latter case, the inflammation, which affects the interior part of the eye, is not speedily arrested by the most effectual means, a coagulable lymph transudes from the choroid membrane and uvea, which, in proportion as it is poured into the cavity of the eye, is carried into the chambers

chambers of the aqueous humour, passes before the pupil, and falls to the bottom of the anterior chamber, sometimes filling a third part of it, at other times half, and occasionally reaching so high as entirely to obscure and conceal the iris and pupil.

This tenacious humour of the *hypopion* is generally called, not only by the common people, but also by surgeons, *matter*; but, in my opinion, very improperly, in the sense at least in which the term *matter* is generally received. For in this case it is not the product of an abscess or ulceration of the internal or external membranes of the eye-ball, but simply the result of a transfusion of coagulable lymph from the internal surface of the inflamed choroidea and uvea; precisely as takes place in all other membranes of the body affected with violent inflammation, as the dura and pia mater, for instance, the pericardium, the pleura, the peritoneum, and the membrane proper to the viscera; all of which, under such circumstances, are covered with a glutinous surface, or thin layer of coagulable lymph, exactly similar to the viscid matter which is collected in the chambers of the aqueous humour constituting the *hypopion*. In the most frequent cases of *hypopion* at least, no one among the most accurate and experienced surgeons has hitherto demonstrated

that this disease has been preceded by an abscess of the internal membranes of the eye; or, has ever observed the *hypopion* in consequence of an ulcer of the choroidea or uvea. If, however, notwithstanding this, it should be insisted that there is no essential difference between coagulable lymph effused from a membrane violently inflamed, and *matter*, it must then be conceded that there are cases in which matter is formed without abscess or ulceration, and that the *hypopion* is a disease precisely of this description.

The symptoms which would induce one to fear a transudation of coagulable lymph within the eye, or the formation of an hypopion, are those of the violent *acute* ophthalmia in the most excessive degree; as great swelling of the eye-lids, redness and tumefaction of the conjunctiva, as in the *chemosis*; burning heat in the eye with acute pain in it, as well as in the supercilium and neck; fever, watchfulness, aversion to the weakest light, and contraction of the pupil.

As soon as the hypopion begins to be formed, a small yellow line, in the form of a crescent, is seen at the bottom of the anterior chamber of the aqueous humour, which, in proportion as the glutinous humour transudes from the inflamed internal membranes of the eye, passes forwards through the pupil, and is precipitated in the aqueous humour, increasing in all its dimensions

minished; the patient's sleep and general ease are restored; that the eye can be easily moved; and lastly, that the collection of tenacious humour forming the hypopion has become stationary. It is not uncommon, especially among the lower classes of people, to see patients in the second stage of the violent acute ophthalmia, who carry this collection of coagulable lymph deposited in the chambers of the aqueous humour with the utmost indifference, and without complaining of any of those symptoms which characterize the acute stage of the disease. It is only at this period, I have said, or when the acute stage of the violent ophthalmia is over, that the hypopion ceases to augment, and the glutinous matter of which it is formed begins to be dissolved, and in a state to be absorbed, provided this salutary operation of nature is not prevented or retarded by the improper conduct of the patient.

To those who are little acquainted with the treatment of diseases of the eyes, it would certainly appear that the most expeditious and effectual method of treating the hypopion, which has become stationary in the second stage of the violent acute ophthalmia, would be that of making an incision in the lower part of the cornea, in order to give a speedy issue to the matter contained in the chambers of the aqueous humour; particularly as this is the doctrine
which

which is commonly taught in the schools of surgery. Yet experience proves the contrary, and demonstrates that the division of the cornea in these cases is seldom attended with success, and that, on the contrary, it most frequently gives rise to evils of greater magnitude than the hypopion itself, notwithstanding the modification suggested by Richter;* that is, of not evacuating the matter of the hypopion all at once, nor of promoting the discharge of it through the incision in the cornea, by means of repeated pressure or injections, but of allowing the tenacious lymph to be slowly discharged of itself. From a very considerable number of observations made upon this point, I have found, that however small the wound made in the lower part of the cornea may be for the purpose of giving issue to the matter of the hypopion, it most frequently reproduces the inflammation and occasions a greater effusion of coagulable lymph into the chambers of the eye than before. And if, even after the division of the cornea, the matter of the hypopion be permitted to flow out gradually and by drops, in consequence of its tenacity some days elapse before it is entirely evacuated; and the glutinous lymph by keeping open, in the mean time, the lips of the wound of the cornea, causes it to sup-

* *Observ. Chirurgicarum fasciculus primus, cap. 12.*

purate and degenerate into an ulcer, through which, after the tenacious fluid is evacuated, a discharge of the aqueous humour takes place, and afterwards a protrusion of a portion of the iris; by the division of the cornea therefore nothing more is generally effected than changing the hypopion into an ulcer of the cornea, with procedentia of the iris, and sometimes even of the crystalline.* Nor can any particular instance of success, in which the matter of the hypopion has been spontaneously discharged from a narrow fissure in the cornea, be adduced as an argument in favour of an artificial division of this membrane by the knife, in cases of stationary hypopion in the second stage of the violent acute ophthalmia. For it is known, by experience, that there is a material difference between the effects of the opening of a natural or preternatural cavity of the animal body, spontaneously, or procured by caustic, and that made by the knife; since in the two former, the consecutive symptoms are constantly milder than in the latter, or that of incision; independently of the spontaneous bursting of the hypopion through the cornea, being also not unfrequently followed by a discharge of

* Richter says in the same place. Aliquando vero cum operationem, hypopii post ophthalmiam vehementem orti instituerem, accidit ut incisa cornea, et elapso humore aqueo, lens crystallina in cameram oculi anteriorem prolaberetur, et dilatatio corneæ vulnuscule eximi ex oculo deberet.

the aqueous humour, and afterwards by a precedentia of the iris; and therefore the spontaneous rupture of the hypopion cannot in any respect serve as a rule in the treatment of this disease.

I know only one case in which the incision of the cornea, for giving issue to the matter of the hypopion may be considered, not only as useful, but even necessary, that is, where the accumulation of coagulable lymph poured into the cavity of the eye is so considerable, that from the excessive distention which it produces upon all the membranes of the eye-ball, it occasions symptoms of such magnitude as to threaten, not only the complete destruction of the organ of vision, but also the patient's life, as I shall have occasion to show towards the end of the chapter. This particular case, however, cannot serve as a model for the treatment of the common hypopion, or that which is most frequently met with in practice.

If it is certain besides, as it indubitably is, that blood extravasated in the eye, in consequence of any violence, and that even collections of membranous flocculi of the *capsular* cataract, pushed by the point of the needle from the posterior into the anterior chamber of the aqueous humour, insensibly dissolve, and are ultimately entirely absorbed, as I shall prove in the chapter on cataract; and that the same thing

thing happens to the *milky or caseous* cataract when broken down, and even to the crystalline lens itself deprived of its capsule and lodged in the vitreous humour by means of the operation; there is no cause to doubt that the same absorption can take place also in cases of collections of coagulable lymph, extravasated in the chambers of the aqueous humour, when the source from which the glutinous humour is derived has been suppressed, and the power of the absorbing system of the eye at the same time restored.

It appears clearly from these facts, in my opinion, that the resolution of the hypopion, by means of absorption, forms the primary indication, which ought to direct the surgeon in the treatment of this disease. I have remarked, that in order to arrest the progress of this disease, the only efficacious method is that of resisting the violence of the inflammation, and shortening the acute stage of the ophthalmia, by the rigorous employment of the antiphlogistic treatment, and by mild and emollient applications. If this method of treatment succeed, as it does in the greater number of cases, the incipient collection of coagulable lymph poured into the bottom of the anterior chamber of the aqueous humour, not only ceases to augment, but in proportion as the ophthalmia disappears the absorbent system takes up the heterogeneous

rogeous humour, and the white or yellowish spot, of a crescent-like form, situated at the bottom of the anterior chamber of the eye, gradually diminishes, and ultimately disappears altogether. *Janin** considered an infusion of the flowers of the mallow applied upon the affected eye, as a specific solvent for the hypopion, but it is now known that any external emollient application, provided it be combined with the most exact and efficacious internal antiphlogistic treatment, in order to repress the acute stage of the violent ophthalmia, is productive of the same beneficial effect as the decoction of the flowers of mallows. Warm water alone is attended with the same advantage.

“ A young woman,” says the celebrated practitioner *Nannoni*, “ was struck upon the eye with an ear of corn; in consequence of which it inflamed and produced a white matter, which presented itself behind the cornea, in the form of a crescent, without its being possible to determine whether it was contained in the laminæ of the cornea, or in the anterior chamber; whence I was asked, whether it could be evacuated by an incision; especially as the patient complained of great pain in the eye and forehead. I said, in the presence of Dr. Lulli and a number of surgical students, this patient being

* Mémoires et observ. sur l'œil, sect. 9. page 405.

in the hospital, that the great pain which she complained of was not occasioned by the matter, but by the cause from which the matter originated. Which cause consisted in an inflammation that would be probably increased by giving a more free access to the external air than it has with the internal parts, where there is no external wound. By fomenting the eye and forehead with warm water, the inflammation ceased, and the matter disappeared; a circumstance which we have now so frequently observed to follow, that even in this instance, we may boast of the simplicity of the healing art."

Such indeed is the happy termination of the hypopion, when the disease has been attended to from its commencement, and when the internal antiphlogistic treatment, and the emollient applications to the eye, speedily arrest and repress the *acute* stage of the violent ophthalmia. But it occasionally happens, either in consequence of the inflammatory period of the ophthalmia having resisted more than usual the means which are employed, or because they have been adopted too late, that the quantity of coagulable lymph poured into the eye, and collected in the chambers of the aqueous humour, is so considerable that it continues for a long time, even after the acute stage of the ophthalmia has entirely ceased to obscure the eye, and intercept
the

the vision. I have repeatedly seen patients, particularly in the lower class of people, as I have before observed, in whom the inflammatory stage of the violent ophthalmia having subsided very slowly, either from negligence or improper treatment, the anterior chamber of the aqueous humour has remained, for a long time, almost entirely filled with the viscid matter of the hypopion, which, the inflammation having ceased, they have carried about almost with indifference, without complaining of any considerable pain, or of any inconvenience in the eye, except the difficulty of seeing with it. It is evident, that in this second stage of the ophthalmia, the dissolution of the hypopion can neither be obtained by the same means, nor with the same celerity, as in the first. For in the second stage of the ophthalmia, both on account of the quantity and density of the viscid matter effused, as well as of the atony of the vascular system of the eye, it is not only necessary to allow nature time to effect a dissolution of it in the aqueous humour, and thereby dispose it to be insensibly absorbed along with this fluid, which is incessantly renewed; but also to invigorate the diminished power of the vascular system of the globe of the eye, particularly that of the absorbents, by artificial means; which must require more or less time, according

according to the age and constitution of the patient.

In the second stage of the violent acute ophthalmia, accompanied with hypopion, the surgeon's attention therefore, should be confined to remove from the eye whatever may irritate it, or reproduce the inflammation in it; and he should only employ those means which may contribute to dissipate the second stage of the ophthalmia, arising from a laxity of the conjunctiva and its vessels, and to excite, at the same time, the action of the absorbents. Under these circumstances, therefore, he should, in the first place, carefully ascertain the degree of sensibility of the affected eye, by introducing between the eye-lids and ball, some drops of the vitriolic collyrium, with mucilage of quince-seed; and if he should find that this application causes too great an irritation in the eye, he should immediately desist from it, and confine himself for some time to bags of tepid mallows, with the addition of a few grains of camphire, and at intervals the spirituous aromatic vapour mentioned in the chapter on ophthalmia, and the blister to the neck should be repeated. When the excessive morbid sensibility of the eye has ceased, he should return again to the use of the vitriolic collyrium, at first simple, but afterwards conjoined with a little camphorated spirit of wine. During this treatment,
the

the surgeon will perceive, that in proportion as the chronic ophthalmia is dissipated, and the action of the absorbent system of the eye excited, the tenacious matter of the hypopion is first divided into several parts, or small masses; that it afterwards becomes more dilute, diminishes in quantity, and subsides towards the lower segment of the cornea, and ultimately disappears altogether.

The surgeon cannot always promise himself to obtain the same success in the treatment of the hypopion, whether this disease be in the first or second stage of the violent acute ophthalmia, when the tenacious lymph, which is rapidly poured into the eye, is in so considerable a quantity as not only to fill completely both the chambers of the aqueous humour, but also to distend them violently, and to produce considerable pressure, particularly upon the cornea. This unfortunate circumstance, notwithstanding the most effectual efforts of art, adapted to the peculiar state of the disease, is frequently followed by another accident of still greater magnitude than the hypopion itself, I mean the ulceration, offuscation, and rupture of the cornea, either in its circumference or centre opposite the pupil; or in that part of it which offers the least resistance.

The proximate cause of this accident, is not so much to be attributed to the acrid quality of

the matter of the hypopion, as some pretend, as to the excessive degree of pressure which it makes upon the cornea from within outwards. Mr. John Hunter,* who has left us some important reflections upon this part of surgical pathology, has remarked, that extraneous substances lodged in any part of the animal body, although from their nature and figure not injurious, are continually determined and propelled by the powers of nature towards the surface of the body ; and that the same, or even a less degree of pressure, which, applied to the animal body externally, does not produce ulceration of the skin, when directed from within outwards, excites in the part which is compressed, the ulcerative process, and that constantly from within, towards the surface of the body. The matter of the ciliary glands for instance, collected in large quantity, and distending the lachrymal sac, which might easily force a passage through the nasal canal, rather occasions by its pressure, from within outwards, the ulceration of the sac, while the same degree of pressure applied upon the external part of it, would certainly not be sufficient to produce the same effect. Matter confined in the frontal sinuses rather occasions a corrosion of the bones and integuments of the forehead, by its pressure

* A Treatise on the blood, inflammation, and gun-shot wounds.

from within outwards, than forces its natural way into the nose. A musket-ball lodged among the muscles, in process of time is pushed, without any inconvenience, towards the surface of the body; but no sooner does it press upon the skin from within outwards, than it occasions it to ulcerate and open a passage for it. Precisely in the same manner, and in conformity with the same law, the coagulable lymph poured into the eye, forming the hypopion, is continually directed towards the cornea; and if this matter is in such quantity, as to press upon the cornea from within outwards, beyond a certain degree not easily determinable, the texture of this membrane is immediately acted on by the absorbents, ulcerated and corroded.

When this happens, the ulceration of the cornea in general proceeds with such rapidity that the surgeon has seldom sufficient time to prevent it. And when the corrosion and rupture of the cornea has taken place in any part of it, the redundant quantity of coagulable lymph confined in the eye* begins to be discharged through this opening, with great relief to the patient. This advantage, however, is not of long duration; for when the glutinous humour, which distended the whole of the eye enor-

* It is on this account that this highest degree of the hypopion, is called, by the greater part of surgeons, the *empyema of the eye*.

mously, and particularly the cornea, is entirely, or in a great measure, evacuated, it is very frequently followed by a fold of the iris, which passes across the ulcer or fissure of the cornea; from which it projects externally, constituting the disease denominated the procidentia of the iris, of which I shall speak fully in the next chapter.

If, under such urgent circumstances, the cornea already ulcerated, darkened, and in a great measure disorganized, is slow in bursting, the violence of the symptoms, which arise from the excessive distension of the eye-ball, obliges the surgeon to open this membrane artificially, in order to free the patient from the violent pain, as well as the danger of losing his life,* which may be

* *Memoires de l'Acad.* vol. xiii. 8. page 279. I passed some days in a garrison-town, where two sisters, ladies of quality, had, at the same time, the small-pox, one of them 20 the other 24 years of age: the variolous matter had been transferred to the eyes; the pustules upon the whole of the body had dried, and no doubt would have been entertained of the happy termination of the disease, if the eyes had not been affected. Their tumefaction occasioned fever, violent pains, accompanied with heat and throbbing. Being called into consultation with several surgeons of the town, and two or three surgeon-majors of the garrison, I proposed to open the eyes in order to save the patient's lives. My advice was not relished; in vain I represented that these organs were irrecoverably lost; the strongest objection which was urged to me, was, that they had never heard of such an operation. A physician, in particular, thought it exceedingly strange that I should

be executed with the less exactness, as, in these cases, he can scarcely reckon on the preservation of the organ of vision. The acuteness of the pain in the eye and the whole head in these cases is so great that it very frequently produces delirium, and excites an apprehension that the brain may be also affected by it.

If, after the evacuation of the tenacious humour, by means of the incision of the cornea, there were any hope of restoring to the patient, even in part, the transparency of this membrane, together with the action and use of the other parts, which constitute the principal organ of vision, it would be certainly prudent, that the surgeon should make the incision at the lower part of the cornea, as is practised in the extraction of the cataract. But in the case of *empyema* of the eye, of which I am now treating, where the cornea is every where injured by the ulcerative process, opaque, and ready to fall into a species of putridity, and where no hope can be entertained of being able to restore any

should propose to burst the eyes; but the very speedy death of one of these ladies gave the parents some regret that they had yielded to the more general opinion. The other sister had the good fortune to escape, through the beneficence of nature; a spontaneous opening taking place, through which the matter formed between the tunics of the eye was evacuated. Her eyes preserved their globular form and natural size, but she remained blind, after having run the greatest risk of her life.

part of it to its former transparency, the best method of speedily relieving the patient from the intolerable pain which he suffers, is to divide the centre of the cornea to the extent of a line and a half with a small bistoury, then to raise the divided edge with the forceps, and remove it circularly with a stroke of the scissars, leaving in the centre of the cornea an aperture of the circumference of a lentil-feed.

Through this opening, the lips of which do not come in contact, like those of a simple incision, the most fluid part of the matter, which distended the eye-ball, immediately escapes; the dense coagulable lymph, by little and little, takes the same rout; then the crystalline, and in a few days afterwards the vitreous humour also. It is very necessary, therefore, that the surgeon should abstain from compressing the eye-ball strongly, in order to accelerate the evacuation of the vitreous humour, as experience proves that it is advantageous in these cases that this humour should be gradually and spontaneously discharged.

Immediately after the operation the surgeon should cover the affected eye with a poultice of bread and milk, which he should renew every two hours, not omitting the use of those general remedies which are calculated to arrest the acute inflammation, and quiet the disturbed state of the nervous system. In proportion as the suppuration takes place in the internal part
of

of the eye, the eye-ball diminishes, retires to the bottom of the orbit, and finally heals, allowing every advantage for the apposition of an artificial eye. From what has been advanced, therefore, it must be concluded that the incision of the cornea is as necessary and useful in the case of *emphema* of the eye, accompanied with the very alarming symptoms above-mentioned, and the irremediable opacity of the cornea, which is in a great measure disorganized, as it is contraindicated and dangerous in the case of *hypopion*, which is most frequently met with in practice.

CASE XLI.

A strong country-woman, 35 years old, was brought into this hospital towards the end of April 1796, on account of a violent acute ophthalmia in both her eyes, with which she had been afflicted three days, with great tumefaction of the eye-lids, redness of the conjunctiva, acute pain, fever, and watchfulness. She was unable to assign any cause from which the disease had arisen.

I took away blood abundantly from the arm and foot, and also locally by means of leeches applied near both the angles of the eyes, and I also purged her. These remedies were attended with some advantage, in as much as they contributed

tributed to abate the inflammatory stage of the violent ophthalmia. Nevertheless an extravasation of yellowish glutinous lymph appeared in the anterior chamber of the aqueous humour, which filled about one third of that cavity.

By frequently washing the parts with the aqua malvæ made tepid, and the uninterrupted application of small bags of gauze filled with emollient herbs boiled in milk, by diet, and repeated mild purges with a grain of the antimonium tartarizatum dissolved in a pint of the decoction of the root of the triticum repens, the symptoms of the ophthalmia were entirely relieved, and on the 11th day the patient was able to bear a moderate degree of light.

By persisting in the use of these emollient applications the matter of the hypopion began to diminish, and by degrees, in the course of 12 days more, almost entirely disappeared. I now thought it proper to increase the strength of the local remedies, by introducing a few grains of camphire into the bags of mallows, which produced the best effect. For in less than a week the redness of the conjunctiva was entirely dissipated, as well as the small whitish line of a crescent-like figure, which had remained at the bottom of the cornea, depending upon the remaining part of the humour of the hypopion.

CASE XLII.

Maddalena Bignani, the wife of a gardener, in the vicinity of Pavia, 40 years of age, of a delicate constitution, was seized with a violent acute ophthalmia in her left eye, which, notwithstanding some evacuations of blood, occasioned an *hypopion* in the anterior chamber of the aqueous humour, so that the cornea of that side appeared almost entirely opaque. The patient was admitted into this practical school on the 7th day from the attack of the ophthalmia. She complained of acute and lancinating pain in the eye and corresponding temple.

I ordered leeches to be applied to the angles of the eye-lids, and I purged her gently with two drams of crystals of tartar, and a grain of the tartarized antimony, in a pint of the decoction of the root of the *triticum repens*, taken in divided doses. A poultice of bread and milk with a little saffron was applied upon the eye. In four days the acute stage of the ophthalmia ceased, together with the lancinating pain in the eye and temple; but the *hypopion* continued stationary. Nothing more was now prescribed to the patient than food of easy digestion, and the application of bags of mallows upon the eye, to be renewed as often as they became cold. By this simple treatment the matter of the *hypopion*,

pion, which filled the greater part of the anterior chamber of the aqueous humour, began to be dissolved and absorbed; and in the course of 18 days, reckoning from the time of the cessation of the inflammatory stage of the ophthalmia, the pupil was clear.

Some of the tenacious matter yet remained at the bottom of the anterior chamber, and some redness of the conjunctiva, produced by the ophthalmia, from relaxation. I ordered a few grains of camphire to be added to the bags of mallows, which evidently contributed to accelerate the absorption, and in the space of 13 days, to clear the white of the eye. When the hypopion was entirely dissipated, the patient used with advantage a collyrium, composed of the acetated ceruse dissolved in plantain water, with the addition of the mucilage of quince-seed, in order to constrict and strengthen still more the conjunctiva and its vessels.

CASE XLIII.

A robust country-woman, 20 years of age, was struck upon the right eye with a piece of wood; a violent inflammation ensued, and afterwards an hypopion, which occupied about one half of the anterior chamber of the aqueous humour. There was also on the external and lower side of the cornea, and apparently in the
part

part where she had been struck, a small ash-coloured and deep ulcer, of the circumference of a millet-seed, and the conjunctiva appeared excessively red and tumefied. The patient was admitted into this hospital the 5th day after the accident.

I ordered blood to be taken abundantly from the arm and foot, her bowels to be purged with small doses of the crystals of tartar, and the tartarized antimony, and a poultice of bread and milk, with saffron applied upon the eyelids.

On the 4th day from the patient's admission into the hospital, the inflammatory stage of the ophthalmia might be considered as having ceased, except that there was a slight pricking in the eye.

On the 6th day I found the patient more than usually tranquil. When the bag of gauze containing the poultice was raised, and the eye opened, I found the hypopion greatly diminished, and observed a small drop of the same tenacious matter ready to issue from the small ulcer upon the cornea, which, as I have remarked, had not been formed from within outwards, but from without inwards. I avoided every kind of pressure upon the eye ball, which might contribute to the too speedy evacuation of that humour, lest the iris should follow it. I continued to foment the eye with bags of emollient herbs until the whole of the matter of the hypopion

was

was insensibly evacuated by this opening; which was completed in seven days. I now touched the ulcer with the *argentum nitratum*, so as to produce a deep and firm eschar. The acute pain which the patient felt, and the sudden increase of the redness of the conjunctiva, led me to fear a return of the inflammation; but by repeated ablutions with warm milk, and emollient applications, together with an opiate emulsion at night, she became perfectly easy. The eschar continued to adhere for four days. On its exfoliation, I touched the ulcer again with the *argentum nitratum*, and the symptoms were much less severe than the first time. On the separation of the second eschar the bottom of the small ulcer was filled with granulations, and had a tendency to heal. The vitriolic collyrium, with mucilage, employed for two weeks longer, was sufficient to complete the cure.*

CASE

* I might have extracted from my journal, a very extensive series of cases, similar to the three preceding, had I believed that a great number of histories, nearly similar to each other, could have afforded a clearer elucidation of the method of treatment which I have recommended. I shall only observe that the hypopion in the first stage of the violent *acute ophthalmia* is rarely met with in the hospitals, as it is customary, particularly among the country people, to be copiously and repeatedly bled in inflammations of the eyes, and to employ diligently emollient cataplasms, with the hope of getting rid of the disease by these means, as it frequently happens. But in the case of hypopion, after the violence of the inflammation

CASE XLIV.

Mauro Spagnoli, a peasant, 60 years of age, was received into this practical school of surgery, the 20th of March 1793, who had one half of the anterior chamber of the aqueous humour of the left eye occupied by a collection of glutinous matter, which, according to his account, took place three weeks after a violent inflammation of that eye, which was removed by bleeding and emollient applications. He did not complain of any remarkable pain in the affected eye, and could bear a moderate degree of light without repugnance. The conjunctiva was red from the relaxation of its vessels.

The great age of the patient, the small degree of sensibility of the eye, and the slow and almost imperceptible diminution of the hypopion, sufficiently indicated the necessity in this case of exciting the action of the absorbent system, and strengthening the vessels of the conjunctiva, in order to dissipate the collection of tenacious lymph poured into the anterior chamber of the aqueous humour. Instead of employing, there-

tion has ceased, they find an extraneous matter poured into the anterior chamber of the aqueous humour, which obstructs the vision; and it is at this period, although the disease does not cause considerable pain, that they come into the hospital, especially if they are advanced in age.

fore,

fore, the antiphlogistic method of treatment, and the emollient applications, as in the preceding cases, I ordered the patient a nourishing diet, proportioned to the strength of his stomach, and the decoction of cinchona to be taken three times a day in doses of three ounces. I directed the vitriolic collyrium, with the mucilage of quince-seed, to be instilled into the eye every two hours, and a blister to be applied to the neck. In eight days the hypopion was reduced to one half, and the conjunctiva had lost the dark red colour which it had at the commencement. The action of the collyrium was increased by adding a little camphorated spirit of wine to it; and in ten days more the hypopion disappeared altogether, as well as the chronic ophthalmia from relaxation.

CASE XLV.

Giovanni Nuvola, a peasant, 45 years of age, a weak sickly man, labouring in the rice-field, was struck upon the right eye with an ear of rice, with such violence that his eye became inflamed the same day, attended with the most acute pain; and, in a few days after, a third part of the anterior chamber of the aqueous humour was filled with a tenacious yellowish lymph. The surgeon under whose care he was, bled him abundantly, purged him, and ordered the eye
to

to be assiduously fomented with an infusion of elder flowers and leaves of mallows.

On the 7th day, the inflammatory stage of the ophthalmia ceased, and the hypopion became stationary. The patient no longer felt any considerable uneasiness in the eye, and therefore kept it only defended from the air and light by means of a piece of linen suspended from his forehead. He now left the house, and attempted to pursue his labour in the fields; but finding that, two weeks after the inflammation had subsided, the sight remained obstructed by this yellowish matter, he came to the hospital. The conjunctiva was affected with ophthalmia from relaxation, and the cornea, besides the opacity depending on the matter of the hypopion, was, in two points, slightly excoriated, as if the epidermis had been removed.

On account of the patient's general and local debility, I ordered him to take the cinchona, and to observe a nourishing and strengthening diet, and to use the vitriolic collyrium externally every two hours, which he could not bear unless warmed. In a few days the vessels of the conjunctiva recovered their former vigour and the chronic ophthalmia disappeared. The hypopion also gradually diminished, and in fifteen days, the cornea having recovered its natural state of transparency, the patient used the ophthalmic ointment of Janin for a few times
only

only at night, and then left the hospital perfectly cured.

CASE XLVI.

Filippo Saletta, a miller, of Calignano, 56 years of age, was received into the practical school of surgery, on the 26th of December 1794, on account of an hypopion which occupied two thirds of the anterior chamber of the aqueous humour of the right eye. The blood-vessels of the conjunctiva were very much dilated and varicose, the eye-lids gummed, and there were superficial excoriations in some points of the cornea. He did not, however, complain of much pain in the eye, and exposed himself freely to the light. He related that at the commencement of the disease, which had continued for a month, he had found relief from being bled; but that afterwards, notwithstanding the application of warm fomentations of mallow-water, the disease had remained nearly in the same state as a few days after the bleeding.

I directed the patient in this case, as in a great variety of others similar to it, to take two drams of the cinchona three times a day, and to observe a strengthening animal diet. Externally, I ordered the vitriolic collyrium, composed of five grains of the vitriolated zinc, four ounces of
plaintain

plantain water and half an ounce of the mucilage of quince-feed, to be dropped into the eye every two hours. And as the eye appeared very little sensible to the stimulant and astringent action of this remedy a small quantity of camphorated spirit of wine was added to it. In 18 days, the hypopion, as well as the chronic ophthalmia, from relaxation, disappeared. In order to strengthen the part, and correct the morbid secretion of gum, the ophthalmic ointment of Janin * was afterwards introduced morning and evening, between the eye-lids of the affected eye, and continued for 12 days.

* With regard to this remedy, I ought again to caution the young surgeon not to use it at first except with a larger quantity of lard than is directed in the formula; otherwise it generally occasions too much irritation, and instead of being useful is injurious.

CHAP. XIV.

OF THE PROCIDENTIA IRIDIS.

THE *iris* preserves its natural position, and is kept at a proper distance from the cornea, as long as the humours which fill the cavity of the eye, in which that body is immersed and suspended, remain in perfect equilibrium with each other, during which the *iris*, although of the most delicate and distensible texture, contracts or relaxes itself without forming any unnatural fold. But if, after the effusion of the aqueous humour, in consequence of any accidental or artificial opening in the cornea, the pressure made by the humours of the eye behind the *iris*, is not balanced by the fluid contained in the anterior chamber, the *iris* is necessarily pushed forwards by little and little towards the cornea, and is in part gradually forced out of the eye, through the same opening by which the aqueous humour was evacuated. Hence, under such circumstances, a small tumour is formed upon the cornea, of the peculiar colour of the *iris*, which, by the greater part of surgeons,

geons, is termed *staphyloma* of the iris, but which I have thought proper to call with Galen * *Procidencia Iridis*, in order to distinguish it from another disease to which the word *staphyloma* more particularly applies.

The *procidencia iridis* is occasioned by wounds and ulcers of the cornea, penetrating for some extent into the anterior chamber of the aqueous humour, and also by violent contusions of the eye-ball with rupture of the cornea. If, immediately after an accidental or artificial wound of the cornea, as that which is made in the extraction of the cataract, or for the purpose of evacuating the matter of the hypopion, as is practised by some, the lips of the wound do not immediately return into mutual contact, and are not maintained in sufficient union to prevent the aqueous humour in proportion as it is renewed from flowing out of the anterior chamber; the iris being drawn along by the current of the aqueous humour, which is incessantly di-

* De differentiis morborum, class III. cap. 13. Contingit vero nonnunquam, ut tunica cornea appellata profundum habeat ulcus, qua deinceps exisa tota, aliquid ex ea tunica *procidat*, quæ secunda post corneam ordine sita est, uvea appellata, et ipsa pupillæ una divulsionem patiatur. Atque ex his tribus quælibet passio oculi existimatur: quodvis ulcus et erosio ad solam corneam pertinet, *procidencia* ad uveam, et divulsio ad pupillam.

Et tunica uvea, ut plurimum, relaxatur, cum corneam nimium erodi contigerit. De causis morbor. class III. cap. 10.

rected towards the wound of the cornea, infinuates itself between the lips of the wound, elongates, and by degrees a portion of it is protruded, and projects upon the cornea in the form of a small tumour. The same thing takes place when there is a recent wound of the cornea, and the eye-ball is unfortunately struck, or too much compressed by the bandage; or the patient is seized with a spasm of the muscles of the eye, with excessive and repeated vomiting, or with violent and frequent fits of coughing. This disease is still more frequently the consequence of ulcers penetrating into the anterior chamber of the aqueous humour, than of wounds of the cornea, inasmuch as the solution of continuity of the cornea, in consequence of ulceration, is accompanied with loss of substance, and the lips of the ulcer do not admit of being placed in mutual contact, in a membrane so tense and compact as the cornea. The small tumour is necessarily of the colour of the iris, that is, brown or grey, and is surrounded at its base by a small opaque circle* of the cornea, which is ulcerated, or has been for some time divided.

As the cornea is in general only perforated in one part of its circumference, whether in consequence of wound or ulcer, so most frequently

* Plate II. fig. 6.

there is only one *procidencia* of the iris met with in the same eye. But if it happen that the cornea has been wounded or eroded in several distinct places, more protrusions of the iris take place in consequence of them in the same eye, and there are as many small tumours projecting upon the surface of the cornea as there are apertures. I have seen a case in which there were three distinct *procidenciæ* of the iris upon the same cornea, in consequence of three separate ulcers penetrating into the anterior chamber of the aqueous humour, one of these being situated in the upper, and two in the lower segment of the cornea.

If we consider for a moment the delicate structure of this membrane, the great number of blood vessels with which it is supplied, the numerous filaments of nerves which are directed towards it, as to a common centre, and distributed upon it, it is easy to conclude how violent the symptoms which usually accompany this disease must be, although the portion of the iris projecting out of the cornea be small, and not larger than the head of a fly. The harsh and repeated friction to which this delicate membrane is exposed, from the motion of the eye-lids, from the access of the air, of tears, and of matter, are sufficient causes of continual and inevitable irritation. Added to this, that the small portion of the iris, which is protruded,

in consequence of the increased afflux of blood towards the part most irritated, acquires shortly after its appearance a larger size than at the time when it was forced out of the cornea; on which account it is more compressed and irritated a little after its appearance out of the cornea, than before. In the commencement of this disease the patient complains of a pain, as if a thorn were fixed in the eye; this is afterwards accompanied with an uneasy sense of tightness or constriction of the eye-ball, which is succeeded by an inflammation of the conjunctiva and eye-lids, a discharge of scalding tears, and a complete aversion to the light. And as the protruded fold of the *iris* draws the rest of the same membrane towards that part, the pupil, from mechanical necessity, assumes an oval figure,* and is removed from the centre of the iris towards the seat of the protrusion. The intensity of the pain, inflammation, and other symptoms which accompany the *procidencia iridis*, do not, however, always continue to increase; for cases are very frequently met with in practice of long standing, in which the disease having been left to itself, the pain and inflammation have spontaneously ceased, and the small tumour formed by the iris has become almost entirely insensible. I lately

* Plate II. fig. 6.

saw a man, 50 years of age, who had a procidencia of the iris, during 10 weeks, in the right eye, of twice the size of a millet-feed, which he bore with the greatest indifference, and without any other inconvenience, than a little chronic redness of the conjunctiva, and difficulty of moving the eye-ball freely, in consequence of the friction which the lower eye-lid made against the projecting portion of the iris. When the little tumour was touched with the point of the finger it felt hard and almost callos. This circumstance arises partly from the constriction, which, after some time, the lips of the wound, or ulcer, make around the base of the protruded portion of the iris, in consequence of which it is deprived of its natural exquisite sensibility; and partly in consequence of this tender membrane losing its vitality, from the induration and callosity induced upon it, by its long exposure to the air, and tears.

With respect to the treatment of this disease in its commencement, some recommend that the iris should be pushed back into its situation by means of a whalebone probe, and if there should be any difficulty in this, that even the wound or ulcer of the cornea should be dilated, by making an incision of a sufficient length, in the same manner as in the reduction of the strangulated intestinal hernia. Others advise, that the portion of the iris projecting from the

eye should be merely irritated, in order that it may contract and retire; or that the affected eye should be suddenly exposed to a very vivid light, from a hope, that by the forcible contraction of the pupil, the fold of the iris confined between the lips of the wound, or ulcer of the cornea, may return to its position. Experience, however, has clearly proved, that all these methods are absolutely useless, if not dangerous. For, supposing it were possible, by any of these methods, to replace the iris in its situation, without tearing or injuring it in any manner, as a passage would always remain open for the aqueous humour through the wound, or ulcer of the cornea, as at first, the iris, when replaced, would descend immediately afterwards, and protrude through the cornea, as it did previously to the operation.

It cannot be denied that the *procidencia iridis* is a serious accident. But whoever considers that we are not at present in possession of any means capable of instantly suppressing, or even of suspending, the discharge of the aqueous humour through the wound, and much less through an ulcer of the cornea, when either of these exceed certain limits, will find that in circumstances so unfavourable, the *procidencia* of the iris, instead of being a disease is rather a fortunate occurrence, and perhaps the only one which can prevent the complete destruction of
the

the organ of vision. For the fold of the iris, by insinuating itself in the form of a plug, between the lips of the wound, or ulcer of the cornea, puts a stop to the complete evacuation of the aqueous humour, which by being speedily collected anew in the anterior chamber, and no longer able to flow through the cornea, prevents the further protrusion of the iris, separates the rest of this membrane from the cornea, and by restoring the equilibrium between it and the other humours of the eye, prevents the total destruction of that organ. This being evident, it must be obvious, that any of those methods hitherto proposed for pushing back the *procidencia iridis*, can only be, as I have said, useless or dangerous.

Consistently with these principles, there are two principal indications which the surgeon ought to fulfil in the treatment of the *procidencia iridis*, when it is recent; the one, is that of allaying the highly exquisite sensibility of the portion of the iris, which projects out of the cornea; the other, of gradually destroying it to such a depth on this side the cornea, that without taking away the adhesion which it has contracted with the bottom of the wound, on the side next the anterior chamber of the aqueous humour, it may not keep the external lips of the wound, or ulcer of
the

the cornea, immoderately separated, and thereby prevent their healing.

Nothing answers these two indications better, than touching the portion of the iris, projecting out of the cornea, with the antimonium muriatum, or, what is more commodious and expeditious, with the argentum nitratum, so as to produce an eschar of sufficient depth. And, in order that this may be executed promptly, and with exactness, it is necessary that an assistant placed behind the patient's head, should keep the upper eye-lid suspended by means of the elevator of Pellier; and the patient, if he has attained the age of reason, should hold the eye-ball steady, by fixing it attentively upon one object. While the assistant gently raises the upper eye-lid, the surgeon should depress the lower with the fore and middle finger of his left hand, and with his right expeditiously touch the small tumour formed by the iris, with the argentum nitratum, cut in the form of a *crayon*, and press it upon the centre of the protruded portion, so as to produce an eschar of a proper depth. The pain which the patient feels at the moment is very acute; but by immediately washing the eye with warm milk, it quickly ceases. The caustic speedily destroys the sensibility of the protruded portion of iris, and by producing a sufficiently deep eschar, defends it from the friction

friction of the eye-lids, and the contact of the air and tears. And it is precisely on this account, that after the cauterization, the sense of pricking and constriction of the eye, of which patients so much complain, is not only relieved, but the inflammation also is considerably diminished, and at the same time the copious discharge of scalding tears.

These advantages, as in the case of ulceration of the cornea, continue precisely as long as the eschar adheres to the small tumour formed by the iris. On its exfoliation, which sometimes takes place on the second, sometimes on the third day from the cauterization, all the symptoms above enumerated return; with this difference, that they are less intense and acute than before, and the small tumour of the iris is less elevated upon the cornea, than it was before the application of the caustic. On the reappearance of these symptoms, the surgeon should again have recourse to the *argentum nitratum*, with the cautions already delivered, and he should repeat it a third or fourth time if necessary, that is, until the protruded portion of the iris be sufficiently depressed below the level of the external lips of the wound, or ulcer of the cornea, so as to be no longer an obstacle to their granulation and cicatrization.

It may be advantageous to repeat here what has been said on the treatment of deep ulcers of
the

the cornea. There is, as it has been remarked, when treating on ulcers of the cornea, a certain point beyond which the application of the caustic, at first highly useful, becomes exceedingly injurious, and the eschar which before allayed the pain afterwards aggravates it, and causes the inflammation to return, with nearly the same violence as at the commencement of the disease. This takes place, according to my observation, whenever the surgeon continues to apply the caustic, after the small tumour formed by the iris has been destroyed, below the level of the external lips of the wound, or ulcer of the cornea, and the caustic tends to destroy the granulation which has already commenced. In the treatment of this disease, therefore, as soon as the surgeon perceives that the projecting portion of the iris is sufficiently depressed, and that the application of the caustic, instead of relieving aggravates the disease, he should entirely desist from the use of it, and merely introduce between the eye-lids, every two hours, the vitriolic collyrium with mucilage of quince-seed, or that composed of the vitriolated zinc, and the white of an egg; and afterwards he should also employ the ophthalmic ointment of Janin, morning and evening, lowered by a double or triple quantity of lard. If the stimulus produced by these applications does not disturb the process of nature,

the ulcer will be constantly found to contract itself by little and little, and in the course of two weeks to be completely cicatrized.

The adhesion which the protruded portion of the iris contracts during the treatment, with the internal lips of the wound, or ulcer of the cornea, continues the same after the formation of the external cicatrix, and consequently during the rest of the patient's life. The pupil, therefore, even after the most successful treatment of the *procidencia iridis*, is found a little inclined towards the cicatrix of the cornea, and of an oval figure. This change of the situation and figure of the pupil, however, diminishes very little, if at all, the power of distinguishing, even the most minute objects, and injures the vision much less than might naturally be expected; provided the cicatrix of the cornea is not too extensive, and situated precisely opposite the centre of the cornea. And, in the first case, the vision is still less impeded by it, as the pupil, which, at the commencement of the disease, was narrow and oblong, and very much drawn towards the wound or ulcer, gradually enlarges after the formation of the cicatrix, and in the course of time, forms an oval less compressed,* and in some measure tends to occupy the situation which it formerly had towards the centre of

* Plate II. fig. 7.

the *iris*. This fact has been also remarked by Richter.*

The method of treating the *procidencia iridis*, here recommended, is that which I have found more certain and useful than any other which has been yet proposed, not excluding that of removing the small tumour formed by the *iris* beyond the surface of the cornea, by a stroke of the scissars:

If the perfect success of this excision corresponded in all cases to what some have promised, nothing would unquestionably contribute more to the speediness of the cure of the *procidencia* of the *iris*, than such an operation. But I am convinced, from experience, that this operation can only be executed with the hope of perfect success, in that individual case, in which the *iris* has contracted a strong adhesion to the internal lips of the wound, or ulcer of the cornea; and more particularly in that *procidencia* of the *iris* of long standing, in which the protruded portion has become in time almost insensible, hard, and callous, and where its base being strangulated between the lips of the wound,

* Observ. chirurg. fascicul. I. page 80. Omni tamen plerumque hoc vitium periculo, vel damno caret, partim cum raro visui obfit, partim quia sponte plerumque pristinam suam figuram pupillæ induit, citius quidem aliquando, interdum vero tardius. Minor pupilla sensim latior fit, oblonga fit rotunda, deorsum tracta sensim ad pristinum locum ascendit; atque hæc omnia sponte plerumque fiunt.

or ulcer of the cornea, has not only contracted an adhesion with them, but has also assumed the form of a fine peduncle.* Under these circumstances the excision of the inveterate procidentia of the iris is useful, and exempt from all danger, since the prominent portion of it, which has now formed an adhesion internally to the ulcerated edges of the cornea, being removed by a stroke of the scissars, on a level with the external lips of the ulcer, there is no risk of renewing the effusion of the aqueous humour, or of giving room to the protrusion of any other portion of the iris; and one or two applications of the caustic afterwards are sufficient to excite the process of granulation, and heal the ulcer of the cornea. But this is not the case in the recent procidentia iridis, which has not yet contracted an adhesion to the internal lips of the wound, or ulcer of the cornea. In four subjects affected with recent procidentia iridis, after having extirpated the protruded portion of the iris, of the size of the head of a fly, with the curved scissars, although I touched the divided part, as well as the lips of the ulcer of the cornea, immediately afterwards, with the *argentum nitratum*, I found the next day, not without regret, that another portion of the iris, of the same size

* I have seen a case, in which the small tumour of the iris, from being long compressed between the edges of the ulcer of the cornea, ultimately fell off spontaneously.

as the first, had made its way through the ulcer of the cornea, and that the pupil, which was exceedingly contracted in it, approached still nearer the ulcer of the cornea. I had, therefore, reason to fear that if I had persisted in removing the small tumour a second time, it would have appeared again, and always with a greater protrusion of the iris, and ulterior stretching of the pupil; I therefore contented myself after the first experiment, with treating the disease by the caustic, in the manner before recommended; which was attended, in all the four cases now mentioned, with success, except that the pupil having been too much drawn towards the ulcer of the cornea, remained covered more than usual by the cicatrix.

Before I finish this chapter, I shall take an opportunity of directing the attention of surgeons to a particular species of procidentia, much less frequent indeed than that of the iris, but which, however, is occasionally met with in practice, to which modern oculists have improperly, in my opinion, given the name of the *procidentia of the tunic of the aqueous humour*.*

This disease consists in a small pellucid vesicle, full of water, formed by a very fine membrane, which protrudes from the wound, or

* Chute de la tunique de l'humeur aqueuse. See Janin, Pellier, Guérin, Gleize, &c. &c.

ulcer of the cornea, nearly in the same manner as the iris does under similar circumstances. I have frequently seen this small vesicle, full of water, projecting out of the cornea a little after the extraction of the cataract, and sometimes also in cases of ulcer of the cornea, particularly after the excision of the prolapsed iris.

Oculists are, for the most part, of opinion, that this small pellucid tumour is formed by that subtle, elastic, transparent membrane, which invests the cornea internally, and which has been described by Descemet and Demours. As soon, say they, as the division or erosion of the cornea has exposed the thin membrane which lines its internal surface, as this pellicle is unable to resist the impulse of the humours which press upon it from behind forwards, it must of necessity insensibly yield, elongate, and ultimately project out of the wound, or ulcer of the cornea, precisely in the form of a small pellucid vesicle. But how remote this opinion is from the truth, must appear to any one who will for a moment reflect upon the following circumstances. In the 1st place, the fine and elastic pellicle, described by Descemet and Demours, cannot be separated by any artificial means from the internal surface of the cornea, except near the part where the sclerotica and cornea unite, and as *vesicular procidentiæ* are met

with in every part of the cornea, and in the very centre of it, where this pellicle is not separable and distinct from the compact texture of the cornea; it must at least be admitted, that the tunic of the aqueous humour is not always that which constitutes the disease here spoken of. 2dly. It is an admitted fact, that this *vesicular procidencia* more frequently happens after the extraction of the cataract, than on any other occasion; in which case, as the tunic of the aqueous humour must certainly have been divided, to allow of the passage of the crystalline humour, no one can be of opinion that the pellucid vesicle which projects from the cornea, after this operation, ought to be referred to the distension or protrusion of the tunic of the aqueous humour. 3dly. If, in cases of ulcer of the cornea, the small pellucid vesicle sometimes appears after the excision of the prolapsed iris, it is clear, that if it were formed by the tunic of the aqueous humour, it ought constantly to appear before that disease. 4thly. If the surgeon remove this *vesicular* body, by a stroke of the scissars, on a level with the cornea, a small quantity of limpid fluid is observed to spirt out in the act of dividing it, without the aqueous humour of the anterior chamber being evacuated; which inconvenience would be inevitable, if this *vesicle* were formed by the fine elastic pellicle which is said to invest

invest the cornea internally. Besides, although the small pellucid tumour be taken away by excision, yet it very frequently happens, that the next day another tumour, exactly similar to that which has been removed, is found in the same place. Now if this small tumour were formed by the tunic of the aqueous humour, protruding through the wound or ulcer, it could not be reproduced, as it is, at least in the same part of the cornea. These considerations have satisfied me that what has been commonly imagined to be a *procidencia of the tunic of the aqueous humour*, is in reality nothing more than the protrusion of a portion of the vitreous humour, which, after the extraction of the cataract, either from the too violent compression made upon the eye-ball, during or after the operation, or from the spasmodic action of the muscles, insinuates itself between the lips of the wound of the cornea, and appears externally, in the form now described.

The same thing happens likewise in cases of ulcer of the cornea, when the aqueous humour being evacuated, a powerful compression has forced a portion of the vitreous humour towards the ulcer situated opposite the pupil; or when the prolapsed portion of the iris being extirpated, an elongation of the vitreous humour has directly insinuated itself between the edges of the ulcer of the cornea, without passing through

the pupil. Hence it is evident why the small pellucid vesicle is formed in both cases, although the tunic of the aqueous humour has been divided or destroyed by the ulcer, and why this vesicle, even after it has been removed on a level with the cornea, very frequently reappears in the same place; it is because one or more cells of the vitreous humour forming it being removed, other cells of the same humour filled with limpid fluid enter in succession between the lips of the wound, or ulcer of the cornea, in the place of the first.

The treatment of this species of *procidencia* consists in removing by excision the small pellucid vesicle which emerges from the wound or ulcer, and in replacing the lips of the wound of the cornea in perfect contact immediately afterwards, in order that they may unite as exactly as possible. In cases of ulcer of the cornea, however, immediately after the removal of the vesicle, the ulcer ought to be touched with the *argentum nitratum*; and in such a manner that the eschar produced by the caustic, may resist a fresh escape of the vitreous humour, and the ulcer of the cornea at the same time be disposed to granulate and heal.

In this species of *procidencia*, that which projects out of the cornea is only a fine membrane filled with water, and entirely destitute of sensibility, the separation of which from the parts contained

contained in the eye is of very little importance; while on the contrary, by its presence, it produces all the disadvantages of any extraneous body which might oppose the union of a wound, or the granulation and healing of an ulcer. The division of this *vesicular* body, therefore, is clearly indicated, and experience confirms the success of it. It is in general speedily removed by a stroke of the curved scissors. But if in any particular case the small tumour should not project sufficiently out of the wound or ulcer to be included by the scissors, the intention may be obtained by pricking it with the point of a lancet or cataract needle; for the limpid fluid which it contains being discharged, the membrane of which it is formed retires within the lips of the wound, or ulcer of the cornea, and is no longer an obstacle to the approximation of the former, or the cauterization of the latter.

If it should happen that the day after the excision or puncture, the small pellucid tumour should reappear in the same part as before, it will be necessary to repeat the operation, and to take further measures to keep the wound of the cornea in contact; or if there be an ulcer, to make the eschar adhere more firmly to the bottom and sides of it, and present a more powerful barrier than before to the escape of the vitreous humour. In such cases, therefore,

the surgeon should guard against every thing with the greatest possible care, which might press the vitreous humour towards the wound, or ulcer of the cornea, and particularly the too violent compression of the eye-lids, spasm of the muscles of the eye, cough, sneezing, costiveness, and other similar causes, at the same time taking care to prevent the progress of the inflammation.

Upon the treatment of this species of pellucid *vescicular procidentia*, the two cases of Pellier * deserve to be read, to which, if further proofs were necessary, I might add several others similar to them, which I have met with in consequence of ulcer of the cornea, penetrating into the anterior chamber of the aqueous humour; the success of which has been as complete as in the two cases described by the French oculist.

Lastly, the *procidentia* is a disease from which the choroid coat is not wholly exempted; I have seen and treated this accident, in the person of Signor Giovanni Bressanini, an apothecary of Bescape. In consequence of a violent *acute* internal and external ophthalmia, which was treated at the beginning with repellents, a small abscess formed between the sclerotic and choroid coats, at the distance of two lines from the junction of the cornea with the sclerotica,

* Observ. sur l'œil, p. 350. observ. 99, 100.

on the inferior hemisphere of the eye-ball. The small abscess burst, and discharged a little dense and tenacious lymph; a small blackish body afterwards protruded from this ulcer of the sclerótica, which was formed by the choroid coat. The treatment consisted in repeatedly touching this prominent portion of the choroid with the *argentum nitratum*, until it was destroyed, and reduced to a level with the bottom of the ulcer of the sclerotic coat; after which the ulcer healed. This eye remained, however, very weak, and the pupil afterwards contracted, so as to be almost entirely closed.

CASE XLVII.

Angiola Mária Porta, a robust country woman, 30 years of age, after having been afflicted with a wandering gout, was attacked with a violent acute ophthalmia in the right eye, which occasioned the formation of an hypopion, and afterwards an ulcer of the cornea, with a *procidentia iridis*, of the size of a fly's head, accompanied with very acute pain in the eye, and a discharge of scalding tears.

The patient was admitted into the hospital on the 25th of May 1795. The small ulcer was immediately cauterized with the *argentum nitratum*, and in a few minutes the woman found her pain greatly relieved. As the

eschar did not adhere to the small tumour longer than 24 hours, I continued to apply the caustic to it every day until the 8th of June; that is, until the protruded portion of the iris was destroyed beyond the external lips of the ulcer of the cornea. Afterwards, I employed the ophthalmic ointment of Janin for the space of 15 days, in which time the small ulcer was perfectly healed.

CASE XLVIII.

Giuseppe Borghi, of Pavia, a boy 9 years old, was brought into the practical school on the 22d of January 1796, on account of a *procidencia* of the iris, of the size of a small lentil seed, which had formed itself through an ulcer situated on the lateral and external part of the cornea of the right eye, accompanied with chronic ophthalmia, edematose swelling of the eye-lids of that side, and excoriation of the tarfi; to all which evils the poor child had been long abandoned by the excessive negligence of his parents. Although he could not bear the light with the right eye; he gave no signs of pain when the small tumour, formed by the iris, was touched with the point of a probe, in consequence of this protruded portion being in some measure callous.

The

The small tumour was touched every day, for a week, with the *argentum nitratum*; as the eschar produced upon it did not adhere longer than 24 hours. At the end of this time the *procidencia* of the iris was destroyed as far as the bottom of the ulcer of the cornea. On account of the tumefaction and afflux to the eye-lids, I applied, in the mean time, a seton in the neck, and purged him frequently with the tincture of rhubarb. In order to accelerate the healing of the ulcer of the cornea, after the protuberant portion of the iris was destroyed, as well as the excoriations of the tarsus, I employed, locally, the ophthalmic ointment of Janin, morning and evening, and during the day the vitriolic collyrium with mucilage. In 26 days the boy was perfectly cured, as he could distinguish with this eye the most minute objects; the pupil, however, preserved an oval figure.

CASE XLIX.

A. Catterina Cartosi, an inhabitant of Valleggio, aged 21 years, a weak and thin woman, in attempting on the 20th of March 1797 to break a piece of wood, by bending it against her knee, a splinter struck the left eye, which divided the lateral and external part of the cornea perpendicularly. The iris situated behind passed through this fissure, and appeared externally in
the

the form of a blackish line, projecting upon the cornea in the direction from above downwards. The eye inflamed greatly, and it was not till the 8th day from the accident that she was brought to the hospital, after having been bled.

The acute pain in the eye continuing, I directed a bread and milk poultice to be applied, which gave her relief. I afterwards proceeded to touch this prominent line, formed by the iris, with the *argentum nitratum*. The eschar separated a few hours afterwards, and the pain in the eye therefore returned as acutely as before, on which account I was under the necessity of giving the patient at night an opiate draught. I repeated the application of the caustic for three successive days; which was sufficient to destroy the blackish line, formed by the iris, projecting upon the cornea. The ophthalmic ointment of Janin was afterwards used morning and evening, reduced by a double quantity of lard; by the action of which remedy the ulcer of the cornea contracted and healed, in the direction from the upper to the lower part of the fissure. The lower extremity of the wound, however, remained stationary, on account of the small portion of the iris corresponding to that part, not being destroyed to a sufficient depth below the external lips of the ulcer of the cornea. I therefore touched this part with the caustic twice in the space of three days; and afterwards
applied

applied the ophthalmic ointment, by which it was completely healed. As the perpendicular spot remaining upon the cornea, in consequence of the cicatrix, was situated on one side of the pupil, and as the latter being drawn towards the cicatrix, allowed a sufficient opening for the passage of the light, it did not prevent the woman from recovering the sight of the eye.

CASE L.

Signor Mauro R. . . of Pavia, 40 years of age, a thin man, in the month of August 1795, accidentally received a stroke with the lash of a whip in the external angle of the left eye, precisely at the junction of the cornea with the sclerotica. The violent contusion occasioned a small tumour in this part, with inflammation of the whole eye, which tumour shortly afterwards burst, and allowed a quantity of the aqueous humour to pass out, and after it a small portion of the iris, of the size of two millet seeds put together. The relaxation of the conjunctiva near to it, and the turgescency of its vessels formed an elevation in the external angle of the eye, which, in the form of a valve, covered a part of the *procidencia iridis*. It was particularly worthy of remark, that, although the pupil was of an oblong figure, as in all other
similar

similar cases, it appeared more dilated than that of the sound eye.

Two weeks had passed from the time of the formation of the *procidencia iridis*, before the patient consulted me. He did not at this time complain of much pain in the eye, and notwithstanding the disease, frequently went out of the house to attend to his affairs.

I ordered that the projecting portion of the iris should be touched with the *argentum nitratum*; which was repeatedly executed, until the whole of it disappeared, and the ulcer was disposed to heal; which was accomplished in 18 days. The vitriolic collyrium, employed for two weeks more, completed the cure, by perfectly healing the ulcer of the cornea, and restoring to the vessels of the conjunctiva their former vigour. The pupil remained, as usual, of an oval figure, but from a singularity, which I have not met with in any other instance, continued, as at the commencement of the disease, more dilated than that of the sound eye; on this account, after the patient was cured of the *procidencia iridis*, he saw better in the dark with the left than with the right eye.

CASE LI.

A postillion, 20 years of age, afflicted from his infancy with scrofulous tumours in the neck, and with ophthalmia, was attacked with a violent inflammation of the right eye, which occasioned an abscess and ulcer of the cornea, and afterwards a *procidencia iridis* of the size of a small lentil seed. At the time I saw him, which was five days from the appearance of the *procidencia*, he complained exceedingly on the slightest motion of the eye-lids. The cure was undertaken on the 11th of January 1792, by touching the small tumour, formed by the iris, with the *argentum nitratum*, and endeavouring to produce a deep eschar upon, and within it.

When the eschar was detached, the caustic was again applied and repeated, five times in the course of nine days, carefully washing the eye each time with warm milk. At this period the portion of the iris, which protruded through the ulcer of the cornea, was destroyed, and reduced below the level of the external lips of the ulcer. I now confined myself to the application of the vitriolic collyrium, which was dropped into the affected eye every two hours, by which on the 30th of the same month the ulcer was perfectly healed. The pupil appeared

peared of an oval figure, but this was not attended with any defect of vision.

CASE LII.

Giuseppe Gaggi, of Pavia, a robust man, much addicted to wine, being rendered nearly blind by an obstinate chronic ophthalmia, which had continued 40 days with *procidencia* of the iris, was brought into the practical school of surgery on the 6th of November 1795.

There were two distinct *procidentiæ* of the iris, each the size of a millet-feed, situated upon the inferior hemisphere of the cornea of the left eye, and to complete his misfortune, the cornea of this eye was rendered completely opaque by a dense nebula. Upon the upper hemisphere of the cornea of the right eye, there was also a *procidencia* of the iris, the size of the head of a fly, in other respects it preserved its natural transparency. The patient complained of intense heat in the eyes, but not of acute pain.

On the 6th, 7th, and 9th of November, the prolapsus of the iris of the left, as well as of the right eye, was touched with the *argentum nitratum*, and a deep eschar was produced, which, however, did not excite much pain.

On the 10th the eschar of the right side separated, and the *procidencia* of the iris was found very much diminished.

On the 18th, after three more applications of the caustic, the two *procidentiæ* of the iris of the left eye also were reduced to a level with the ulcers of the cornea. Being desirous, in this state of things, to stimulate the edges of the ulcers a little by another application of the *argentum nitratum*, the patient made some unusual contortions, and gave signs of acute pain; to relieve which, it was necessary to wash the eyes frequently with warm milk, and to cover them at night with a poultice of bread and milk. This sufficiently indicated the necessity of desisting from the use of the caustic. When the last eschar was detached, I therefore confined myself to the use of the vitriolic collyrium, which was introduced every two hours.

On the 13th of December, the patient being perfectly cured of the *procidentiæ* of the iris, and ulcers of the cornea, went into the convalescent ward. The ophthalmic ointment of Janin was introduced morning and evening, with a view, if possible, of dissipating the dense nebula of the left eye; but this was not attended with the desired success. The left eye, though freed from the *procidentiæ* of the iris, remained useless to him, but the right was preserved.

CHAP. XV.

OF THE CATARACT.

THERE are two methods of treating the cataract, the one by removing the opaque crystalline, from the visual axis of the eye, by means of a needle; the other, by extracting it from the eye, by making a semicircular incision in the base of the cornea.

It has long been disputed which of these two methods ought to have the preference; and in the warmth of discussion, the advantages of the one, and the disadvantages of the other, have been exaggerated by both parties. Observation and experience, however, the great teachers in all things, seem to have pronounced in favour of the ancient method of treating the cataract, or that of *depression*; not only because *depression* is more easily executed than *extraction*, and can be equally employed in every species of cataract, whether crystalline or membranous, solid or fluid; but because *depression* is attended with symptoms far less violent and dangerous than

than those which very frequently happen after extraction; and if from any accidental cause this operation should occasionally prove unsuccessful, it may be repeated two or three times upon the same eye without any risk; a circumstance which *extraction* does not admit of, when that operation has not had the desired success.

Influenced by these facts, I have for a considerable time laid aside the method of treating the cataract by extraction, and have applied myself entirely to the practice of depression, and I see continually great reason to be satisfied with the choice which I have made. The very frequent occasions which I have had of performing this operation, have afforded me an opportunity of making some useful alterations relative to the means which are employed previously to its execution; of which I shall now proceed to give a detail.

It is easy to determine whether the operation can be performed with a prospect of success or not. A favourable issue may be expected, whenever the cataract is simple, or without any other disease of the eye-ball, in a subject not quite unhealthy or decrepid, and in whom the opacity of the crystalline humour has been gradually formed, without having originated from any external violence, or habitual ophthalmia, especially the *internal*: where there has not been frequent

pain in the head, eye-ball, and supercilium : where the pupil, notwithstanding the cataract, has preserved its free and quick motion, as well as its circular figure, in different degrees of light : and lastly, where, notwithstanding the opacity of the crystalline lens, the patient retains the power, not only of distinguishing light from darkness, but also of perceiving vivid colours, and the principal outlines of bodies which are presented to him, and where the pupil has that degree of dilatation which it is usually found to have in a moderate light.

It is not equally easy to pronounce concerning that which regards the other part of the diagnosis ; that is, whether the cataract be hard or soft, caseous or fluid ; and whether, together with the opacity of the crystalline lens, the capsular membrane which envelopes it be also opaque. All that has been hitherto written and taught upon this subject, has not that degree of certainty which can serve as a guide in practice, and the most experienced oculist of the present day is not able to determine with precision what the nature and consistence of the cataract is, upon which he proposes to operate,* nor whether the capsule be yet transparent or not, although the lens be evidently opaque. For

* Mr. Hey states, that he has generally found a dark coloured cataract in old persons of a firm consistence.

Practical Observ. in Surg. page 49.

it is an indisputable fact, that the capsule sometimes preserves its transparency, when the lens does not. The want of accurate notions, however, upon this subject does not materially influence the success of the operation; as the surgeon ought in every case to be prepared to employ such means as the particular species of cataract which presents itself to him may require, during the performance of the operation, whether it be hard or soft, accompanied by opacity of the capsule, which invests it, or not. The firm crystalline cataract undoubtedly admits of being more easily removed by the needle from the axis of vision than any other; and does not rise again to its former place, if the surgeon in removing it from the pupil use the precaution of burying it in the vitreous humour. The *soft*, the *milky*, or the *membranous cataract*, however, when met with in the operation, may be also removed from the pupil, effused or lacerated with the same needle, without the necessity of introducing any other instrument into the eye.

With respect to the hard consistent cataract, it should be observed that the word *depression*, used in the schools of surgery to express the manner in which this operation is executed, readily produces in the mind of the student an erroneous idea, that this merely consists in pressing the opaque crystalline with the needle, from above downwards, until it descends below the

pupil. If this were the case, as there is not a sufficient space for firmly lodging the crystalline lens, between the corpus ciliare and the iris, it would constantly follow, that immediately after the operation, the cataract would rise up again, either entirely or partially, opposite the pupil. But the word *depression*, in this case, has a much more extensive signification than that which is commonly given to it. It includes two motions which the surgeon makes with the needle; one of pressing down the opaque crystalline, the other of burying it in the vitreous humour, by carrying it from before, backwards, out of the axis of vision. By this precaution only, is the opaque lens prevented from rising again, and in this sense only ought the term *depression* of the *cataract* to be explained and understood. There is upon this point a circumstance noticed by Parè,* which has not been mentioned by any writer, either before or since his time; that, after the depression of the cataract, and before the needle is withdrawn, the patient should be directed to turn the eyeball upwards. For by this means, says he, the depressed crystalline, upon which the needle yet rests, must be carried from before, backwards, and buried in the vitreous humour, a circum-

* Livre II. chap. xxii. Et étant ainsi abaissée, la lui fait laisser, la tenant sujette de l'aiguille par l'espace de dire une paternostre, ou environ, de peur qu'elle ne remonte, et pendant faire mouvoir vers le ciel l'oeil au malade.

stance of the greatest importance to prevent the cataract from rising again, and which deserves to be carefully attended to by the young surgeon.

Besides this precaution of lodging the firm cataract, which is to be depressed, in the vitreous humour, there is another of no less importance to the success of this operation. This consists in lacerating the anterior convexity of the capsule of the crystalline lens, at the time the latter is depressed, so that whether the capsule be opake or not, the sight cannot afterwards be obstructed by it. For it not unfrequently happens, that those who have not had sufficient instruction or experience in this part of surgery, after the needle has been made to penetrate between the anterior convexity of the capsule, which is yet transparent and the cataract, remove the opake crystalline from the axis of vision, and leave the anterior portion of the pellucid capsule in its situation, which becoming opake a few days after the operation, presents the appearance of a dense whitish veil behind the pupil, which either entirely, or in part, deprives the patient of the power of seeing, and which has very properly received the name of *secondary membranous cataract*.

To be more explicit, the most common cause of failure in the operation for the cataract, whatever be the method of performing it, is not owing to the crystalline lens, however dense it may

be, but to the capsule of the lens, and more particularly its anterior convexity. It is to be wished that the art of surgery were in possession of some easy and efficacious means, by which the surgeon, in every method of operating, might be able to separate with exactness, together with the opaque crystalline, the entire capsule of the lens from the *zona ciliaris* to which it is attached, an event which occasionally happens from a happy, but unforeseen combination of circumstances. But this fortunate occurrence * is very rare; as the *zona ciliaris*

* Richter Obs. Chirurg. Fasc. II. page 96. * Quater in-
ficius, saltem inopinatus, extraxi lentem capsula sua obvolutam.
See Janin, Pellier, Gleize, The Edinburgh Essays, vol. 5.
It once happened to Monro, in dissecting an eye affected with
cataract, to observe, after having removed the cornea and iris,
that by merely inclining the eye-ball in different directions,
the crystalline with its capsule separated by its own weight
from the *zona ciliaris*, so slight was the union of these parts
with each other in this particular and very rare case.

Monro's Works, Num. XXV.

* It should be observed, however, that this observation of Richter's applies
only to the extraction of the cataract, for he states immediately afterwards, as
will be seen by the following passage, that the capsule is most frequently re-
moved along with the opaque lens in the operation of couching. His experi-
ments, however, must be less decisive, in as much as they were made upon
brutes.

Qui deprimunt cataractam, lentem solummodo deprimere sibi videntur, cap-
sulamque in loco suo remanere putant. Ego vero puto, plurimisque experi-
mentis persuasus sum, hac operatione plerumque capsulam cum lente deprimi.
Sique itaque deprimatur facile capsula cur non extrahatur? Deprimi autem,
sequentia probare videntur. Sæpiissime coram auditoribus operationem de-
pressionis legitimo modo peregi in oculis suillis, dissectisque dein illis lentem
capsula sua integra indutam semper reperi. Ibid. page 97.—T.

most

most frequently connects the capsule of the crystalline lens so closely to the vitreous humour around the *annulus* of Petit, that even in dissecting the eye it is impossible to separate the capsule of the crystalline lens from the vitreous humour without considerable laceration. On account of the extreme difficulty, therefore, of obtaining a complete separation of the membranous capsule of the crystalline from its attachments, the surgeon in the greater number of cases has no better means left him to pursue, than to lacerate the anterior convexity of the capsule, through the whole circuit, which corresponds to the pupil in its greatest degree of dilatation at the moment when he removes the opaque lens from the axis of vision; for with respect to the rest of the anterior convexity of the lacerated capsule, which continues to adhere to the *zona ciliaris* beyond the greatest disk of the pupil when it is dilated, although it be opaque, or should become so after the operation, it can never afterwards prove any obstacle to vision, even in the weakest light; as it will always remain beyond the margin of the iris.

Nor let it be objected that, although this be obtained, the posterior capsule of the crystalline remains in its situation, which, by becoming opaque, may occasion the same obstruction to vision as the anterior convexity of the capsule, when that

has not been sufficiently lacerated opposite the pupil. For not to insist on the impossibility of depressing and forcing the opaque lens backwards, and deeply into the vitreous humour, without the posterior convexity of the capsule being also lacerated, in order to give passage to the crystalline lens, experience teaches us that, although this portion of the capsule of the crystalline lose its transparency, it is very seldom in so considerable a degree as to injure the sight materially. This fact is proved by the daily practice of extracting the cataract, in which operation the surgeon, after making the incision in the cornea, has only to divide the anterior part of the capsule, in order to make the crystalline pass out; without regarding the posterior convexity of this small membranous bag, which he leaves in its situation, without its giving rise, or but very seldom, to any considerable diminution of sight. Anatomy also teaches us that there are remarkable differences, in several respects, between the anterior and posterior portions of the capsule of the crystalline lens. One of the principal differences is, that the anterior convexity of this membranous bag is in its natural state, at least three or four times thicker and firmer than the posterior. The second difference, equally remarkable, is that the delicate posterior hemisphere of the capsule

fule is furnished with a set of vessels peculiar to it, and altogether distinct from that which is transmitted to the anterior convexity of this sac, as the first is formed by the extremity of the *arteria centralis*, which, as if from a centre, distributes branches to the circumference, while the anterior hemisphere of the capsule of the crystalline, which, as I have already said, is more compact than the posterior, receives its blood-vessels from those of the vitreous humour, which, having passed over the *zona ciliaris*, are irregularly incurvated, and ramify upon the anterior surface of the capsule. I do not, however, pretend from all this to infer that the posterior portion of the capsule of the crystalline never loses its natural transparency, but only to prove, from observation and experience, that even when it does become so, it is seldom the cause of perfect blindness. It is proper to repeat, that the principal obstacle to the favourable success of the operation for the cataract, in both methods, arises most frequently from the anterior convexity of the capsule of the crystalline becoming opake, and sometimes more dense than in its natural state, or from its being converted into a soft and pulpy substance.

A fact of no less importance to be known than the preceding, but which more particularly relates to the operation of the cataract by depression, is that the opake crystalline removed from
the

the axis of vision and lodged in the vitreous humour, provided it is deprived of its investing membrane, gradually diminishes in size from its circumference towards its centre, and ultimately disappears altogether. This phænomenon is unquestionable, and is proved by a very extensive series of observations made by men of the greatest accuracy and impartiality, to which I can add three other instances of my own upon this subject. The first was in a nobleman of Pavia, aged 60, who died precisely a year after he had undergone the operation of couching for a cataract in the right eye; the other was in a woman, 43 years of age, who died three years after the depression of the cataract; and the third in a man, 57 years of age, who died about three years and a half after the same operation had been performed. In the first of these three subjects I found the crystalline deeply imbedded in the vitreous humour, and reduced to about one third its natural size; and in the other two, in which the crystalline was deeply situated in the vitreous humour below the axis of vision, there was only the nucleus remaining of a size little larger than the head of a common pin.

The depressed crystalline disappears even in a shorter time, that is, in a few weeks, when it has degenerated into a pultaceous, cheesy, or milky substance. And when it is divided, reduced to fragments, and dissolved in the aqueous humour,

humour, it is finally absorbed, together with the aqueous fluid, which is continually renewed. This circumstance relative to the dissolution and absorption of the depressed crystalline, as it is beyond all doubt,* furnishes a powerful argument for asserting, in opposition to those who think unfavourably of this method of operating, that there is no species of *cataract* which may not be cured by *depression*.

This dissolution and absorption takes place, not only with respect to the crystalline lens, but also with regard to the membranous particles of the capsule of the crystalline; when they are detached from the surrounding parts, broken down by the needle, and float freely in the aqueous humour suspended in the form of small flakes, or fall to the bottom of the two chambers of that humour. It is constantly observed, in this case, that these membranous fragments of the capsule, deposited behind the cornea, first assume the whiteness of milk, they then become of a yellowish colour, and afterwards liquify and dis-

* Many celebrated modern surgeons might be cited, who have observed, and recorded this very important fact; but I shall content myself with merely quoting the words of Barbette on this subject, one of the oldest writers. *Licet*, says he, *cataracta non satis intra pupillæ regionem sit depressa, dummodo in particulas sit divisa, perfecta visio intra sex aut octo septimanas sæpissime, licet tota operatio absque ullo fructu peracta videatur; quod aliquoties experientia edoctus loquor.* CHIRURGIA BARBETTIANA, cap. xvi. part I.

solve in the aqueous humour; finally, that they diminish in quantity, and disappear entirely, leaving the cornea and the whole of the eye in the most perfect state of transparency. Any one may easily trace this salutary process of nature, step by step, whenever he meets with a case, where, either accidentally or by design, some membranous shreds of the capsule of the crystalline have been pushed through the pupil, and deposited in the anterior chamber of the aqueous humour, that is, between the iris and the concavity of the cornea. I have had frequent opportunities of repeating this observation. For in several cases of membranous cataract, as I shall afterwards show, I have pushed these membranous flocculi into the anterior chamber of the aqueous humour, in such quantity as to fill it on a level with the lower margin of the pupil, so as to form the appearance of an hypopion in it. I have observed, in these cases, that this collection of flocculi and particles of the capsule confined between the iris and concavity of the cornea, has never occasioned the patient any inconvenience, that is, either inflammation or pain; and that it is also constantly dissolved and removed by absorption, in a month or little more, and sometimes sooner. It is to be observed, also, that the absorption of the membranous flakes takes place more rapidly in the anterior than the posterior chamber of
of

of the aqueous humour, which may depend on the greater quantity of aqueous humour in the anterior chamber, by which the membranous particles are more easily dissolved than in the posterior; or may be owing to the greater quantity of absorbent vessels in the anterior chamber of the aqueous than the posterior. If it be true, therefore, as it indisputably is, that when the membranous cataract, or that formed merely by the opaque capsule of the crystalline, remaining opposite the pupil, after the removal of the lens, is broken into small particles by the needle, and pushed through the pupil into the anterior chamber of the aqueous humour, it may, by the powers of nature, be dissolved and removed in the same manner as the depressed lens is dissolved, and finally absorbed; it is evidently proved, I think, that the *membranous cataract* can be also cured by the needle, notwithstanding the assertion of those who affirm that this species of cataract can only be removed by means of extraction.

The apparatus of instruments necessary for performing the operation of the cataract, by depression, consists of a needle for that purpose, and an elevator of the upper eye-lid, which is employed particularly in those cases in which the eye to be operated on is small, deeply sunk, and where the patient is very unmanageable.

The

The elevator of *Pellier* * is preferable to all others, as it collects the eye-lid, and raises it against the superior arch of the orbit, making little or no compression upon the eye-ball.

With respect to the needle, most proper for the depression of the cataract, experience has taught me, that of the great number which have been proposed for this purpose, we ought generally to prefer that which unites to the greatest fineness, such a degree of firmness as will enable it to penetrate the membranes of the eye without bending: since I have used a very fine needle, I have never had to contend with any consecutive symptoms of importance after the operation of depression, not even with suppuration of the membranes of the eye at the place of the puncture. If, indeed, the symptoms consequent on this operation are in proportion as might be expected to the injury and solution of continuity, which takes place in the parts of the eye-ball, and particularly of those which are endowed with exquisite sensibility; it is certain that when the needle is of the finest kind, if, after it has penetrated the eye, it is merely conducted upon the capsule of the crystalline, the lens, and the vitreous humour, parts which are insensible, the operation must be always attended with very little pain, and the consequences

* Plate III. fig. 1.

of the puncture constantly, or in the greater number of cases, of little or no moment.

With respect to the form of the needle, I have had an opportunity of observing, that the one with a straight point, which is commonly used in this operation, is not the best calculated for conveniently lacerating the anterior convexity of the capsule of the crystalline, and of removing the cataract, at the same time, easily and expeditiously out of the axis of vision, and lodging it deeply in the vitreous humour. For whatever part of the eye-ball is pierced beyond the *corpus ciliare*, whether at a line from the union of the cornea with the sclerotica, at two, or two lines and a half, as some advise, the point of the straight needle, which is made to advance upon the anterior convexity of the capsule passes directly against the iris, and when it has reached it, presses only upon one point of the circumference of the capsule and lens in the manner of a tangent. In the motion which the surgeon gives to the point of the needle from before backwards, in order to press it firmly upon the centre of the capsule and lens, the pressure which he applies upon these parts is in reality only made by the body of the needle, the point of the instrument not penetrating the anterior convexity of the capsule and the crystalline lens, until these parts have been so far removed from the pupil towards the bottom of the eye by the
body

body of the needle, that its point, with respect to the part of the eye-ball which it has penetrated, has taken a direction from before, backwards. But since, as I have said, in removing the capsule and lens from the pupil, the pressure is not made by the point, but the shank of the needle; hence it very frequently happens, that in this movement, the anterior convexity of the capsule, however small its resistance is not lacerated, and the cataract being compressed, revolves round the instrument, and makes various gyrations above and below the pupil, and cannot after all be firmly fixed by the point of the needle, until after having been by different motions, and repeated pressure, removed from the pupil towards the bottom of the eye, it can be directly pierced by the point of the instrument, which is sufficiently inclined for that purpose from before backwards. But if the cataract be of a milky, soft, or cheesy consistence, and consequently its capsule flaccid and yielding, the shank of the straight needle is only imbedded in the capsule, without opening or lacerating it, and the surgeon is then obliged to make several motions with the needle, in order to remove it from the pupil, to retract the instrument, and turn the point of it backwards, that he may pierce the fore part of the capsule and lacerate it. Maître-Jan, speaking of the milky cataract, has made the same observation.

“ Many fruitless attempts are frequently made, because the needle glides only upon the membrane which covers the crystalline, which, in such attempts always remains entire, unless the instrument be a little withdrawn, in order to carry the point of it towards the middle of the cataract, for the purpose of pressing it upwards to break this membrane.”*

These difficulties are entirely, or for the most part avoided, by using a very fine needle, moderately curved at the point, such as that which I employ.† The curved extremity of this
needle

* *Traité des maladies de l'oeil*, chap. xiii.

† Plate III. fig. 10. Besides the reasons before assigned, an accident happened to me in performing the operation for the cataract with a straight needle, badly tempered, which proved to me the advantage of the *curved* needle over the *straight* one. In introducing the needle, through a very firm sclerotic coat, it happened that its point bent in the form of a *small hook*; which I perceived as soon as the instrument appeared between the pupil and the capsule of the crystalline lens. I proceeded, however, with the operation, and having pushed the point of the small hook through the capsule into the firm substance of the crystalline lens, I removed both from the axis of vision with the greatest facility, and afterwards withdrew the needle very cautiously from the eye, without producing any laceration. This circumstance happened to me in the practical school, in the presence of a great number of students, and the event was as favourable as possible.

Dr. Morigi, senior surgeon of the hospital of Piacenza, one of the most expert and able operators at present in Italy, has now adopted the use of this curved needle for several years in

needle is flat upon its convex surface, sharp at the edges, and has a concavity consisting of two oblique planes, forming a slightly elevated line in the middle, which is prolonged as far as the extreme point of the instrument, similar to the curved needle for stitching wounds. The handle is marked in the direction corresponding to the convexity of the curved point.*

The needle now described penetrates the eyeball with the same facility as a straight one of an equal degree of fineness. When it is cautiously pushed forwards, and is placed between the iris and the anterior convexity of the capsule of the crystalline, it is situated with its convexity towards the iris, and its point in the opposite direction towards the capsule and opake

the depression of the cataract, and with so much ease and success, that he takes every opportunity of recommending and promoting the use of it.

* Freytag, in his dissertation inserted in the 2d volume of the Chirurgical Dissertations, published by Haller, mentions, that his father employed a needle with a curved point for depressing a membranous cataract; and he adds, that he extracted the membranous cataract from the eye with the same instrument. The latter is certainly an exaggeration.

Bell, in the 3d volume of his system of surgery, Plate XXXII. fig. 4, has given the figure of a curved needle for the depression of the cataract. He says, he has frequently thought that the cataract might be more easily depressed by means of this needle than the straight one; but that he has not yet had sufficient opportunities of using it to be able to speak decisively of its advantages.

lens,

lens, which it easily and deeply pierces by the smallest motion from before backwards, without the lens having been previously removed from the pupil. By means of this instrument the surgeon readily succeeds in lacerating the anterior convexity of the capsule extensively, in deeply and firmly piercing the opaque lens, conducting it out of the axis of-vision and lodging it securely in the vitreous humour. In cases of the caseous, milky, or membranous cataract, the soft pulp of the crystalline may be broken into small parts, by means of the curved point of the needle, with the utmost facility, and the anterior convexity of the capsule torn into small flakes; which membranous flocculi may, with equal ease, by turning the point of the instrument forward, be pushed through the pupil into the anterior chamber of the aqueous humour, where being precipitated they are, as will be afterwards seen, dissolved, and absorbed by the powers of nature.

Having premised these general observations on the depression of the cataract, I now pass to a detail of the operation itself, according to the method which I have adopted.

In general the best surgeons do not now prepare patients indiscriminately, as was formerly the case, for any of the great operations, without manifest indications for doing it; and much less that which is employed in the case of ca-

taract, unless the term preparation be applied to the diet which is for some days prescribed to the patient, or the administration of a clyster the night previous to the operation. There are, however, in the case of cataract, particular circumstances, whatever be the mode of operating, which oblige the surgeon to depart from the general rule, and to subject the patient to some method of treatment preparatory to the operation. These circumstances occur in persons who are dyspeptic, or hypochondriacal, in women subject to hysterics, and in those whose eyes, independently of the cataract, are at the same time affected with tumefaction of the edges of the eye-lids, chronic redness of the conjunctiva, and a copious gumming.

In cases of dyspepsia, hypochondriasis, and hysteria, it is proper, two or three weeks before the operation, to order the patient strong, farinaceous, aromatic broths, and at the same time stomachic bitters and corroborants, of which, the infusion of quassia, in such cases, is particularly useful, either with the addition of a few drops of the vitriolic æther, or without, according to the particular constitution and sensibility of the patient. As a sedative and corroborant remedy, one of the most useful is a powder, consisting of a dram of the cinchona, and a scruple of the radix valerianæ sylvestris taken two or three times

times a day, the patient observing, in every other respect, a proper regulation of diet. It is a most certain and constant fact, that the less timid and nervous the patient is, the milder are the symptoms consequent on the operation.

Where the edges of the eye-lids are tumefied, incrusted, and gummed, with relaxation of the conjunctiva, chronic redness, and weeping of the eye, it is highly advantageous, two or three weeks before the operation, to apply a large blistering plaster to the neck, and to introduce between the eye-lids, morning and evening, the ophthalmic ointment of Janin, with a double or triple quantity of lard; and during the day, the vitriolic collyrium with mucilage of quince-feed, every two hours, in order to restrain the morbid secretion of the ciliary glands, and internal membrane of the palpebræ; to strengthen the conjunctiva and its vessels, and to restore the edges of the eye-lids to their natural state and flexibility, before proceeding to the depression of the cataract.

Every thing being arranged for performing the operation, the surgeon should place his patient on a low seat, on the side of a window, which has a northern aspect, so that the light coming from it may only fall upon the eye which is to be operated on laterally. The patient's other eye being covered, although affected

with cataract, the surgeon ought to place himself directly opposite the patient, upon a seat of such a height, that when he is prepared to operate, his mouth shall be on a level with the patient's eye. And, in order to give his hand a greater degree of steadiness in the several motions which the depression of the cataract requires, the elbow corresponding to this hand should be supported upon the knee of the same side, which for this purpose he should raise sufficiently by resting his foot upon a stool, and according to circumstances also, by placing a small hard pillow upon his knee. An able assistant situated behind the patient, with one hand fixed under the chin, should support the patient's head against his breast, and with the other placed on the forehead, gently raise the upper eye-lid by means of Pellier's elevator, carefully observing to gather the eye-lid against the arch of the orbit, without pressing upon the globe of the eye.

Supposing then the eye to be operated on is the left, the surgeon taking the curved needle in his right hand, as he would a writing pen, with the convexity of the hook forwards, the point backs, and the handle in a direction parallel to the patient's left temple; should rest his fingers upon the temple, and boldly perforate the eye-ball in its external angle, at rather more than a line from the union of the cornea
and

and sclerotica,* a little below the transverse diameter of the pupil, gradually moving the extremity of the handle of the needle from behind forwards from the patient's left temple, and consequently giving the whole instrument a curved motion, until its bent point has entirely penetrated the eye-ball; which is effected with the greatest readiness and ease. The operator should then conduct the convexity of the needle upon the summit of the opake crystalline, and by pressing upon it from above downwards, cause it to descend a little, carefully passing the curved point at the same time between the corpus ciliare and the capsule of the crystalline lens, until it be visible before the pupil, between the anterior convexity of the capsule of the lens and the iris. Having done this he should cautiously push the hook with its point turned backwards towards the internal angle of the eye, passing it horizontally between the posterior surface of the iris, and the anterior convexity of the capsule, until the point of the needle has arrived as near the margin of the crystalline and capsule as possible, which is

* Albucasis. Tantum recedendum a cornea, quantum specilli cuspis spatii contineat.

F. d'Acquapendente. Si aliqua datur in suffusione operatio tuta, eam forte futuram, ut vel acus prope corneam immittatur, vel si aliquanto longius ab illa, non tantum tamen quantum vulgo faciunt. De Chirurg. Operat. cap. xvii.

next the internal angle of the eye, and consequently beyond the centre of the opake lens. The operator then inclining the handle of the instrument more towards himself, should press the curved point of it deeply into the anterior convexity of the capsule, and substance of the opake crystalline, and by moving it in the arc of a circle, should lacerate the anterior convexity of the capsule extensively, remove the cataract from the axis of vision, and lodge it deeply in the vitreous humour, leaving the pupil perfectly round, black, and free from every obstacle to the vision. The needle being retained in this position for a short time, if no portion of opake membrane appear behind the pupil, which would require the point of the instrument to be turned towards it, in order to remove such obstacle, (for with respect to the crystalline depressed, in the manner now described, it never rises again,) the surgeon should give the instrument a small degree of rotatory motion, in order to disentangle it easily from the depressed cataract, and should withdraw it from the eye in a direction opposite to that in which it had been introduced, that is, gently inclining and turning the handle towards the patient's left temple.

In every species of cataract, with considerable opacity and density of the anterior hemisphere of the capsule of the crystalline, the surgeon may
very

very easily know, during the operation, whether the curved point of the needle, insinuated between the corpus ciliare and the capsule, is exposed between the pupil and the anterior hemisphere of that membrane; or, whether having penetrated into the membranous sac of the crystalline, it has only advanced between the anterior hemisphere of the capsule and the opake lens. But when the capsule, notwithstanding the opacity of the crystalline lens, preserves in a great measure, or entirely, its transparency, it is an easy matter for a young surgeon, not sufficiently conversant with this operation, to commit an error, and one of great importance, that is, to remove the cataract from the axis of vision, and lodge it in the vitreous humour, leaving the anterior convexity of the capsule untouched, which afterwards gives rise to the *secondary membranous cataract*.

To avoid this serious inconvenience, every operator should be particularly careful to satisfy himself before making any movement with the point of the needle for depressing the cataract, that the curved extremity of the instrument is really, and not apparently, situated between the pupil and the anterior portion of the capsule, of which he will be convinced by the degree of light which the convexity of the hook presents to him, and the facility which he finds in pushing it forwards through the pupil towards the
anterior

anterior chamber of the aqueous humour, and in moving it horizontally between the iris and anterior hemisphere of the capsule. In the opposite case he may be certain that the curved point is within the membranous sac of the crystalline, by observing that the extremity of the needle is obscured and covered by a more or less transparent veil; that he meets with some resistance in pushing it through the pupil into the anterior chamber of the aqueous humour; and that in doing it, this membranous veil which covers the hook is elevated towards the pupil; and lastly, that the point of the needle is with difficulty conducted horizontally between the iris and the cataract, from the external towards the internal angle of the eye.

The surgeon will remedy this inconvenience, by giving a slight rotatory motion to the needle, by which the point being turned forwards will pass through the anterior convexity of the capsule opposite the pupil; the point of the instrument being then turned backwards again, should be passed horizontally between the iris and the anterior hemisphere of the capsule towards the internal angle of the eye; and having reached this part should be boldly plunged into the capsule, and the substance of the opaque lens, in order to lacerate the former extensively, and to carry the latter deeply into the vitreous humour

mour out of the axis of vision, and thus complete the operation.

When, without observing this precept, the opake lens is removed, or, more strictly speaking, enucleated from its capsule and lodged in the vitreous humour; and the anterior convexity of this membrane being left entire, is slightly opake, the pupil will appear black, and so free from obstruction to the light as easily to deceive the young surgeon, and induce him to believe that the operation has been properly executed. But persons experienced in this part of surgery, will instantly perceive, that the pupil, under such circumstances, has not that just and perfect degree of blackness which it ought to have, and that this slight dimness is caused by an imperfectly transparent membranous veil, placed between the pupil and the bottom of the eye, which, when suffered to remain, never fails, in process of time, to give rise to the *secondary membranous cataract*. In this case, the expert operator having depressed the opake lens, should immediately turn the curved point of the needle forward, and pass it through the pupil into the anterior chamber of the aqueous humour, in order to perforate this semitransparent membranous veil with the greater certainty; then turning the point of the needle backwards and making it pass as far as possible between the posterior
surface

surface of the iris and this membrane, should press the point of the instrument into it and lacerate it from before backwards, making a movement as if he had to depress the lens again. In doing this he will have the satisfaction to see the pupil assume the deep black colour of velvet, and a degree of clearness which it had not before, although the opaque lens had been completely removed from the axis of vision.

Hitherto I have supposed the cataract to be of a firm consistence, and to resist the pressure of the needle. But if the operator should meet with a fluid cataract, the milky for instance, which is not an unfrequent occurrence,* when he has passed the needle between the corpus ciliare and the capsule, until it appears uncovered between the pupil and the anterior hemisphere of the membranous sac of the crystalline lens, and the curved point has been cautiously advanced between the iris and the margin of the capsule, nearest the internal angle of the eye; at the moment that the point of the needle is deeply pressed into the capsule and cataract, a whitish milky fluid will be seen to issue from the capsule, which, extending itself in the form of a

* In the greater number of cases which have fallen under Mr. Hey's care, the cataract has been found so soft as to permit the needle to pass through it in all directions.

cloud or smoke, will be diffused through both the chambers of the aqueous humour, and obscure the pupil and the whole of the eye. The surgeon should not on this account lose his confidence, but, guided by his anatomical knowledge, should make the small hook describe the arc of a circle from the internal towards the external angle of the eye, and from before backwards, as if he were depressing a solid cataract, with a view of lacerating, as much as possible, the anterior hemisphere of the capsule, upon which the favourable success of the operation principally depends, not only in this, but in every other species of cataract. For as to the effusion of the milky fluid into the chambers of the aqueous humour, it disappears spontaneously a few days after the operation, and permits the pupil and the whole of the eye to resume their former natural brightness.

The method of operating which the surgeon should employ will be little different from this, if, during its performance, he should meet with a soft or cheesy cataract. The anterior convexity of the capsule should be lacerated as much as possible opposite the pupil, so that the opening may equal the diameter of the pupil in its ordinary dilatation. And with respect to the pulpy substance of the cataract, which, in such cases, remains behind, partly diffused in the aqueous humour, and partly swimming beyond

the pupil, all that is necessary, is to divide the most tenacious parts of that substance, that they may be more easily dissolved in the aqueous humour, and to push those molleculæ of the caseous substance of the crystalline, which cannot be sufficiently divided, through the pupil into the anterior chamber of the aqueous humour, in order that they may not be carried opposite the pupil, but being situated at the bottom of the anterior chamber, may be gradually dissolved and absorbed without obstructing the sight.

The *secondary membranous cataract*, from what has been already stated, is not so much a distinct species of cataract as a consequence of the operation imperfectly executed, or which from some particular accident has not been attended with complete success. For this disease is most frequently formed by the anterior convexity of the capsule of the crystalline remaining entire in its situation, after the opaque lens has been removed, or which has not been sufficiently lacerated to allow a free passage to the light through the pupil.

The *secondary membranous cataract* sometimes appears behind the pupil in the form of membranous flocculi suspended in the aqueous humour of the posterior chamber, filling up the pupil; at other times it represents triangular membranous borders; the bases of which are attached

tached to the *ciliary zone*, the apices **extending** opposite the pupil. When it consists merely of a single small membranous flake, suspended in the posterior chamber of the aqueous humour, or fine triangular membranous process, 'it is not necessary on this account to subject the patient to a second operation, since it does not materially obstruct the sight, and in process of time disappears spontaneously. But when the *secondary membranous cataract* is formed by a mass of membranous particles, collected in the posterior chamber of the aqueous humour opposite the pupil, in such a degree as entirely or in a great measure to close it up (an occurrence which also happens when the anterior chamber of the aqueous humour is so unusually small and confined as not to be capable of containing the whole of the membranous flocculi of the capsule, a considerable part of which must necessarily remain behind in the posterior chamber closing up the pupil;) or when the disease consists in the anterior hemisphere of the opaque capsule, not being sufficiently lacerated, and adhering to the whole of the ciliary zone; then it becomes necessary to have recourse to another operation. For although, in the first case, there is sufficient ground to believe that the mass of membranous flocculi may in time dissolve and disappear; yet it is not proper to leave the patient in a state of perplexity, deprived of sight
for

for weeks or months, when it can be speedily obtained by a safe and easy operation; and in the second case the operation is absolutely necessary, as the lacerated capsule adhering every where to the *ciliary zone*, seldom or ever disappears; and in time rather increases in bulk and becomes more opake than at first.

In both these cases of *secondary membranous cataract*, the operation is performed in the following manner. In the first case where the mass of the particles of the capsule loosened from the ciliary zone close up the pupil, the surgeon having introduced the curved needle into the eye with the usual cautions, and pushed it into the posterior chamber, in contact with the mass of membranous flakes which obstructs it, should turn the instrument towards it, and press the whole of the membranous flocculi through the pupil one after another into the anterior chamber of the aqueous humour, precipitating them into the bottom of this chamber, between the concavity of the cornea and the iris. I am convinced from experience that any attempts made to remove these portions of membrane from the pupil, although perfectly loose, and to immerse them in the vitreous humour, in the same manner as the lens, are quite useless; for no sooner is the needle withdrawn from the eye, than the whole of the membranous particles, as if conducted by a current, appear filling up the pupil again.

On

On the contrary, when they are pushed through the pupil into the anterior chamber of the aqueous humour, they can no longer obstruct the pupil, but are macerated at the bottom of this cavity without occasioning the patient any inconvenience, and in a few weeks dissolve and disappear altogether.

In the second case, when the *secondary membranous cataract* is formed by the whole of the anterior portion of the capsule, or by several portions of it adhering to the *ciliary zone*, the surgeon having turned the point of the curved needle towards the pupil, should perforate the membranous cataract from behind forwards: or if its borders leave any interval between them, sufficient to admit the convexity of the instrument he should pass the hook through this opening; then turning the point of it backwards, should conduct it horizontally between the iris and the membranous cataract, as near as possible to its attachment with the *zona ciliaris*, and pressing the point of the hook into it, and into each border of it in succession, sometimes rotating the instrument between the fingers, as if to twist the portion of capsule round the point of it, he should lacerate it as much as possible, in every part of its circumference, so as to clear the whole ambit of the pupil; and having collected all the pellicles or flocculi together, should push them with the point of the needle

c c

through

through the pupil into the anterior chamber of the aqueous humour, as has been just stated. In doing this the greatest care should be taken by the operator not to touch the iris, for on this precaution principally depends the prevention of any consecutive symptoms of importance, notwithstanding the length of the operation, and the various movements which it may be necessary for him to make with the needle in the eye, in order to lacerate these membranes, and push them into the anterior chamber of the aqueous humour. And if a portion of the membranous cataract should be found adhering to the posterior surface of the iris, which will be known by this circumstance, that in stretching the small opaque membrane with the needle the pupil changes its figure, and from being round becomes oval or irregular; he should proceed with even greater caution than in the preceding case, making repeated, but small and gentle movements with the needle in every direction, in order to obtain the separation of it, without endangering the laceration of the iris at its union with the ciliary ligament.

Nor will it be necessary to vary, in any manner, the method of operating, when the secondary membranous cataract is formed by the posterior convexity of the capsule having become opaque at any period after the operation.

For

For after the crystalline is removed this delicate membrane is forced forwards, so as to be in contact with the posterior surface of the iris, and is pushed, as it were, almost within the pupil. In order to precipitate it into the anterior chamber of the aqueous humour, and thereby remove the obstruction, it is only necessary to press it from behind forward with the point of the needle; which is the more easy as the posterior hemisphere of the capsule of the crystalline loosened from the *ciliary zone*, has no considerable adhesion to the concavity of the vitreous humour, except from the very small trunk of the *central* artery.

Nor will the method of operating be different from this, in those uncommon cases in which the cataract is entirely, or in a great measure, *primitively membranous*. I design to speak of that particular species of cataract in which the crystalline wastes, or is dissolved and disappears, leaving only its opake capsule, or at most a small nucleus not larger than a pin's head within it. This singular species of cataract is most frequently met with in children, or persons who have not exceeded their 20th year, and may be distinguished from the others by a certain transparency and resemblance to a spider's web, or by a sort of reticulated structure, interrupted with a whitish opake spot in its centre or circumference. Any attempt in this case to

lodge this membrane in the vitreous humour would prove fruitless, as it would rise again and reappear behind the pupil immediately after the operation. The best and surest practice yet proposed, therefore, is to lacerate it with the point of the curved needle, and to push the different particles composing it successively through the pupil into the anterior chamber of the aqueous humour, where, as it has been before observed, it is dissolved, and in the course of three weeks is removed by absorption.

With respect to the after treatment of the operation of couching, it is only necessary, in general, that the patient should lie in bed, with his head a little raised, and in a dark room, and that the eye operated on should be covered with a piece of dry linen pinned to his night-cap. If he should complain of vivid heat in the eye and eye-lids immediately after the operation, it will be proper to cover them with a compress of soft lint, dipped in the white of an egg and rose water, beaten to a froth, with a small piece of alum. And if, notwithstanding this, the pain and tumefaction of the eye-lids increase, it will be necessary to cover the eye with bags of emollient herbs, and by these, as well as by general remedies, prevent the progress of the inflammation.

In persons of exquisite general sensibility, in those affected with hypochondriasis or hysteria, notwith-

notwithstanding the precautions above mentioned are taken previously to the operation, nervous affections are occasionally excited shortly after the operation, as vomiting, violent headach, shivering, and coldness of the whole body. In these cases I have found nothing allay this perturbed state of the nervous system more speedily than a clyster, consisting of 8 ounces of the infusion of chamomile, and 2 grains of opium dissolved in it, as the opium, when given by the mouth, is constantly rejected.

In very weak and timorous persons it very frequently happens that on the 3d or 4th day from the operation, they are seized with symptoms of indigestion, accompanied with an increase of general heat, especially during the night, as a bitter taste, nausea, disposition to vomit, pain in the head, tension of the hypochondrium, flatulency, universal uneasiness, and watchfulness. A gentle purgative, and the repeated use of clysters are in general sufficient to remove all these inconveniences, and consequently prevent the secondary ophthalmia.

With respect to the diet, this ought, in the greater number of patients, to be of the lowest kind, and for the first 24 hours should consist of broths only. Persons, however, who are much debilitated, or subject to convulsions, and elderly people, are exceptions to this rule, as a very ri-

gorous diet in such cases might occasion a return, or aggravation of the nervous symptoms. In these instances, therefore, it is necessary to allow some soup in addition, and liquid food, which should be given at short intervals.

It is not necessary, without particular reasons for doing it, to open the eye which has been operated on, and consequently expose it to the light before the 3d day after the operation. It is useful, however, to separate the eye-lids gently, morning and evening, and to wash the margins and cilia with a sponge dipped in pure water, in order to prevent their cohesion.

In cases of cataract in both eyes, I have learnt from experience, that it is not advantageous to operate upon them immediately one after the other; but that it is better to wait till the first is well, before the operation is attempted upon the other; the delay makes little difference in the time required for the cure of both. Upon this point I have had frequent occasion to remark that, the symptoms of the second operation, whether upon the same eye, or upon that which has not been operated on, are constantly less considerable than those of the first operation. Whether this arises from the tranquillity of the patient's mind, from having experienced the little inconvenience consequent on the operation of couching, or that each eye becomes less sensible to the puncture of the needle, and the motions

motions of the instrument, after one of them has once suffered the irritation produced by it, I am unable to decide. This I know, that I have frequently seen in women subject to hysteria, and in hypochondriacs, after the easiest and most successful depression of the cataract in one eye, convulsive symptoms excited either general or confined to the head, and the eye which had been operated on; and these, in some cases, so violent, as in a short time to leave the pupil dilated and immoveable, with almost total insensibility of the optic nerve of that side; while in the same patients, when the other eye has been operated on two weeks afterwards, it has not been followed by any remarkable accident.

If there be no symptoms of any consequence to combat, which is most commonly the case when the operation is executed in the manner here recommended, in general, on the 10th or 12th day from the operation, the patient is in a state to make use of his eye; which, however, he should do with caution, particularly at first, that is, without fatiguing it too much, or exposing it suddenly to a vivid light.

I consider it useless here to relate any history of cases of cataract, which have been perfectly cured by means of couching, and by the method here recommended; as well as to deliver a detail of facts relative to the cure of caseous or milky cataracts, which, after the operation, have been

dissolved in the aqueous humour, and then absorbed by the powers of nature; since a great number of these facts are to be found in surgical works, in which these subjects are particularly treated. I shall only add a few cases of *secondary membranous cataract*, the result of which may not be useless in proving the efficacy of the means which I have proposed in the treatment of this species of the disease; which I do the more willingly, as it is to this point that the arguments of those principally refer, who instruct, that in the treatment of the cataract, the operation of *extraction* ought to be preferred to that of *depression*.

CASE LIII.

A peasant, 50 years old, whom I had couched three years before, with complete success, for a cataract of the left eye, requested to have the operation performed upon the right. This cataract appeared to be of a favourable kind, that is, firm and resisting to the needle, as that of the left eye had been; the pupil moved freely, and the patient, notwithstanding the disease, could distinguish the figures of bodies with this eye. The anterior chamber of the aqueous humour of each eye was almost the largest I ever saw. As the palpebræ of this eye were a little tumefied and gummed, I directed a blistering
plaster

plaster to be applied upon the neck, and prescribed the frequent use of the vitriolic collyrium for a fortnight; by means of which remedies the eye-lids recovered their natural state.

I then proceeded to the operation, and although contrary to my expectation, I found the crySTALLINE somewhat soft, yet by employing some care I was enabled to remove it from the axis of vision, and to bury it deeply in the vitreous humour, freeing the pupil, as far at least as I could discover, from every obstacle to vision.

The operation was unattended with any particular accident; but on the 11th day, when the patient was permitted to leave his bed, and to begin to make use of his right eye, he told me that he could not see so distinctly with it as he had done the first days after the operation. I examined it in a clear light, and found more than half the pupil occupied by a whitish irregular body, of a nature evidently membranous. The iris of this eye presented this peculiarity, that at each motion of the eye-ball it oscillated and waved backwards and forwards in a peculiar manner.

Without further delay I introduced the needle again into the right eye, and having raised this membranous mass with its point, I found that it was larger than it had appeared to be
through

through the pupil. As it was loosened from every attachment, when I had collected the whole with the point of the needle opposite the pupil, I pressed it forwards, and with the greatest ease made it pass into the anterior chamber of the aqueous humour, which, in this subject, as I have stated, was very large, to the bottom of which it was immediately precipitated, leaving the pupil perfectly clear. The whole of this membranous substance was as large as a barley-corn. In the course of 25 days, however, it was dissolved and absorbed, without having occasioned, during its lodgment in the anterior chamber of the aqueous humour, any inconvenience or any impediment to the sight.

From the size and figure of this membranous body, I am inclined to believe, that it was the whole, or the greatest part of the capsule of the crystalline, which, by an unusual combination of circumstances, had been completely detached from the *ciliary zone*, but which, in making the cataract describe a portion of a circle, in order to lodge it in the vitreous humour, had been separated from the needle, and remaining behind had afterwards reappeared beyond the pupil.

CASE LIV.

A poor woman, very much emaciated, and subject to hysteria, was received into this practical school on account of a cataract in each eye, which she had had for several years. The colour of the cataract was blue, but interrupted here and there with whitish streaks, and there was not that convexity behind the pupil which the opaque crystalline usually presents. The pupil of each eye was moveable, and the patient could discern the figures of surrounding objects. The circumstances most unfavourable to the operation in this case, were the extraordinary smallness of the eyes, and their being deeply sunk, and more particularly the extreme narrowness of the anterior chamber of the aqueous humour; for with respect to the general morbid sensibility, I flattered myself it might be allayed by the use of the cinchona with valerian root for some time, and a more nourishing and strengthening diet than this poor woman had been accustomed to.

After a month's preparation I performed the operation upon the left eye, and having passed the needle between the posterior surface of the iris and the cataract, I perceived, on first fixing and pressing the point of it upon the anterior convexity of the capsule, that this
membrane

membrane became corrugated, and folded under the instrument; in short, that instead of the crystalline there was only its membranous bag, containing a small quantity of glutinous fluid, which, when discharged, was not in sufficient quantity to render the aqueous humour so turbid as to prevent my proceeding with the operation. This disease would have been denominated by some, *atrophy* of the crystalline. As there was no crystalline lens then, I merely reduced the capsule into small pieces opposite the pupil, making as many of the fragments as I could pass through the pupil into the anterior chamber of the aqueous humour, but I could not succeed in depositing the whole of them in it, on account of its unusual straitness.

Immediately after the operation, the patient, as frequently happens in cases of hysteria, was seized with a violent spasmodic affection of the head; but no sooner was a clyster of the decoction of chamomile flowers, with two grains of opium administered, than all her pains ceased, nor did any considerable inflammation take place in the eye afterwards.

On the 4th day the patient could see sufficiently well; but her sight afterwards diminished daily, till the 18th day after the operation, when she was completely blind, in consequence of the pupil being entirely occupied by a whitish membranous body, formed by the particles

particles and flakes of the capsule, which I had not been able to pass into the anterior chamber of the aqueous humour, on account of its extreme smallness. I then waited a week longer, until the membranous particles and flocculi, which had before been precipitated into the anterior chamber, were nearly dissolved, and left room for the others. I then introduced the needle again into the eye, and very soon freed the pupil from this impediment, by pushing all the membranous flakes into the anterior chamber, so as to fill it on a level with the inferior margin of the pupil. It is a constant fact, worthy of observation here, that those membranous fragments, which, during the first operation, can hardly be caught by the point of the needle, on account of their smallness, after they have been macerated some time in the aqueous humour, swell, and allow of being easily removed or pushed forwards with the instrument.

After the operation the pain in the head recurred as before, and was relieved in the same manner, by means of an opiate clyster.

About 28 days after the second operation, during which time the woman could distinguish surrounding objects very well, the fragments and membranous flocculi, with which the anterior chamber of the aqueous humour had been filled for the second time, were entirely dissolved and dissipated,

diffipated, leaving the whole extent of the pupil in its ordinary dilatation, black, clear, and free from every obstacle to the light.

CASE LV.

Bartolomeo Zucchi, of Calvairate, a robust man, 45 years of age, affected with cataract in both eyes, underwent the operation in this school of surgery on the 28th of April 1793. His eyes were rather small, and sunk in the orbits.

I operated upon the left eye, in which I met with a soft cheesy cataract. Having broken the soft pultaceous substance of the crystalline to pieces, I lacerated the capsule very freely all around the pupil; I then passed the whole of the fragments and membranous flakes through the pupil into the anterior chamber of the aqueous humour, which they filled on a level with the inferior margin of the pupil. The operation was not succeeded by any remarkable symptom, and on the 10th day these fragments and flakes were diminished more than one half, and the patient saw distinctly with the left eye.

I now operated upon the right eye, in which having found a cataract sufficiently firm, I was able to lacerate with precision the anterior convexity of the capsule extensively, and to lodge the
lens

lens deeply in the vitreous humour. Two weeks after the operation on the right eye, the membranous particles deposited in the anterior chamber of the left eye disappeared entirely, and the right eye was also capable of bearing the light. The patient was therefore soon afterwards discharged from the hospital perfectly cured in both his eyes.

CASE LVI.

Maria Spigoletti, 40 years of age, had had a cataract in the left eye for two years, and the crystalline of the right was becoming rapidly opake, the eye-lids were swollen and gummed.

She was purged with the *magnesia vitriolata*, a large blister was directed to be applied upon the neck, and the edges of the eye-lids to be anointed morning and evening with the ophthalmic ointment of Janin.

After three weeks preparation I attempted to depress the cataract of the left eye, which I found not dissimilar to mucus. Having therefore broken the anterior portion of the capsule, as well as the whole of the membranous sac of the crystalline into small pieces through the whole extent of the pupil, I made all the membranous fragments pass through it into the anterior chamber of the aqueous humour, and succeeded so as to render it free from every
impediment

impediment to vision. A slight inflammation ensued, which was in a great measure confined to the eye-lids, but subsided in a week, by merely employing at first bags of emollient herbs, and afterwards the aqua lithargyri acetati composita.

In the course of a month all the membranous fragments deposited in the anterior chamber of the aqueous humour, which had given the appearance of an hypopion, were dissolved and entirely removed, and the woman having recovered the sight of this eye was discharged from the hospital.

CASE LVII.

Giovanni Alberti, a country-man 66 years of age, affected with cataract in both his eyes, was admitted into this practical school of surgery for the purpose of undergoing the operation.

I attempted it on the left eye, and found the crystalline sufficiently firm to admit of being easily removed from the axis of vision, and immersed in the vitreous humour. Having accomplished this, I perceived, before the needle was withdrawn from the eye, that there was a portion of opake membrane, or a considerable part of the anterior convexity of the capsule, which had not been sufficiently lacerated, floating behind the pupil. I turned the point of
the

the needle backwards again, and having carefully broken this membrane as far as the circumference of the pupil admitted, I forced the whole of the fragments through the pupil into the anterior chamber of the aqueous humour. The patient had no bad symptom, and saw very well with this eye.

Twelve days afterwards I operated on the right eye, and the same thing occurred precisely; I was able to dislodge the opake lens readily, but a border of the anterior portion of the capsule remained behind, opposite the pupil, that is to say, the capsule was lacerated with the needle, but not so completely as to remove this portion of membranous veil. I therefore turned the point of the needle, as in the first instance, towards the membranous border, which I lacerated in pieces, and as I detached the portions of it, I pushed them through the pupil, and precipitated them into the anterior chamber of the aqueous humour; and this I repeated until the whole circumference of the pupil appeared black. About a month after the operation on the second eye, there was no vestige of membranous particles in the anterior chamber of either eye, and the patient completely recovered his sight.

CASE LVIII.

Paola Guagnini, of Sale, aged 45, weak, and subject to violent attacks of hysteria, had been affected for several years with a cataract of the left eye, and saw indistinctly with the right, from an incipient opacity of the crystalline on that side. The conjunctiva of both eyes was also in some degree relaxed, and the eye-lids tumefied and gummed. I therefore directed a blistering plaster to be applied upon the neck, and the vitriolic collyrium to be frequently instilled into the eyes for a fortnight; by these means the eye-lids subsided, and the immoderate viscid discharge ceased. On account of the patient's great irritability and weakness, I ordered her to take ʒj of the cinchona, and ℥j of valerian root, twice a day, during the whole of this time.

On the 21st of November 1795, she submitted to the operation. At the moment the point of the needle was pressed upon the cataract, in order to remove it from the axis of vision, it burst like a small bladder, and a milky fluid gushed out, which rendered both the chambers of the aqueous humour turbid. Notwithstanding this I could distinguish the nucleus of the opaque crystalline through this cloudy fluid

fluid, which I conveyed deeply into the vitreous humour; then conducting the point of the needle again towards the pupil I detached and lacerated the anterior hemisphere of the capsule into several pieces, and passed these membranous portions in succession through the pupil into the anterior chamber of the aqueous humour.

The patient did not complain of any acute pain during the operation, and passed the three following days without uneasiness. On the 4th day she was seized with a violent hysterical paroxysm, with a sense of suffocation, agitation of the whole body, delirium, and incoherent talking, which made me fear some unfavourable effect on the eye operated upon. There was, however, no alteration, and contrary to my expectation, I found the day after this accident that the pupil was clear, and that the woman could distinguish the most minute objects.

On the 10th day from the operation the patient was in a state to leave her bed, and to begin to use her eye in a moderate light.

The mass of membranous flakes precipitated into the anterior chamber of the aqueous humour, which resembled an hypopion, began to be dissipated, and in the space of 32 days the whole sediment of the particles was entirely absorbed, and the patient was discharged from the school of surgery perfectly cured. The un-

interrupted use of the cinchona with valerian root, and a few spoonsful a day of the infusion of chamomile, with the aqua ammon. succinat. and the aqua canellæ, had rendered the hysterical attacks less violent and frequent than before.

CHAP. XVI.

OF THE ARTIFICIAL PUPIL.

AN accident, not frequent indeed, but which, however, occasionally happens, in consequence of the operation for the cataract, by *depression* or *extraction*, is that of the contraction of the pupil, which becomes entirely, or in a great measure, closed, attended at first with a great diminution, and afterwards an entire loss of sight.

This disagreeable occurrence is most frequently produced by a violent inflammation of the internal membranes of the eye, and particularly of the iris, excited by the operation of depressing or extracting the cataract. In some particular instances, however, it takes place after the operation, but without the inflammation of the internal parts of the eye, or of the iris in particular, having had any evident share in its production; in which cases, at an indeterminate length of time from the depression or extraction of the cataract, the pupil is observed without any evident cause to be-

come daily more and more contracted, until it is almost entirely obliterated, and that without the patient complaining of any uneasiness; in a few instances, however, a degree of sensibility rather greater than natural is felt in the immediate organ of vision, even in a moderate degree of light.

In both cases the pupil in general contracts to such a degree as scarcely to admit the head of a small pin, and remains immoveable; the iris around the pupil assumes a rugose and stellated appearance, having an irregular aperture in the middle, behind which, the cataract having been depressed or extracted, the bottom of the eye either appears black, or a small spot, or whitish shade is observable, if, after either of these operations, a portion of the anterior convexity of the capsule of the opaque crystalline lens has accidentally remained behind, and contracted an adhesion to the iris.

Some surgical writers have been led from theory to suppose, that when this morbid contraction of the pupil is derived from an excessive distension of the vessels of the iris, in consequence of violent inflammation of this membrane, it might be remedied by the use of local resolvent and corroborant applications, and at the same time revulsives, as local and general bleeding, purgatives, blisters, and a seton in the neck. On the other hand, they have thought that

that emollients, and external as well as internal antispasmodic remedies, would be useful, in cases of constriction of the pupil produced by a spasm of the iris, and an increased morbid consensual sensibility of the immediate organ of vision with that membrane. But however plausible these indications, in the treatment of the contracted pupil, may seem, experience has shown their inefficacy, and has fully convinced us that this disease can only be remedied by making an artificial aperture in the iris, which may perform the office of the natural pupil.

Chefelden, as far as I know, was the first who ventured to propose and make a division of the iris, with the intention of forming an *artificial pupil*. He introduced a couching needle, with a cutting edge on one side only, through the sclerotic coat into the eye, at the distance of a line and a half from the cornea; then perforating the iris on the side next the external angle, and carrying the point of the needle through the anterior chamber of the aqueous humour, until it reached the side next the nose, he turned the cutting edge backwards, and retracting it, divided the iris transversely.

It has been said that this operation has had the happiest success; but Janin* has assured

* Mémoires sur l'œil, page 182, 183.

us, that having performed it in two instances with the greatest care, no advantage was derived from it; for after the symptoms produced by the operation had subsided, he found that in both patients the transverse opening made in the iris with the cutting edge of the needle had reunited and healed. The same thing nearly happened to Sharp,* long before Janin, "for," says he, "I once performed this operation with tolerable success, but a few months afterwards the very orifice I had made contracted and brought on blindness again."

Janin, in using Daviel's scissors for the extraction of a cataract, accidentally included the iris at the same time with the cornea, and divided it from below upwards, on the side of the pupil, which instructed him, as he expresses it, that the perpendicular division of this membrane, on the side of the pupil, was the only effectual method of preventing the lips of the wound made in the iris from healing, and consequently of establishing an *artificial pupil*. It was this circumstance which led this oculist to invent a method of operating, and to propose as the best means of forming an artificial pupil, that of opening the cornea, as is practised in the extraction of the cataract; and afterwards of dividing the iris with the

* Operations of Surgery, chap. 29.

scissars from below upwards, near the pupil on the side next the nose; for in doing it on the external side, he asserts, that he had observed it to give rise to a strabismus, in consequence of the too great divergency of the optical axis.

In the small number of cases of contraction of the pupil, which has fallen within my observation and practice, supervening to the operation for the cataract, by extraction or deprefion, I could never persuade myself to open the cornea, in order to make the perpendicular division of the iris, with the scissars proposed by Janin, or any other, by means of the knife, being aware of the frequent serious accidents which accompany the opening of the cornea, in cases where the eyes have been affected after the first operation with violent internal ophthalmia, spasm, or a morbidly increased sensibility of the immediate organ of vision. Nor could I ever induce myself to divide the cornea again, upon which, after the extraction of the cataract, there had remained an irregular cicatrix; and I have been still less inclined to do it, knowing that it is not so easy a matter as some may perhaps imagine, to divide the iris with the scissars, when it has become flaccid from the discharge of the aqueous humour.

I have more than once had occasion to see a portion of the margin of the iris two lines in extent, separated from the ciliary ligament, without

without laceration of the body of this membrane, in consequence of blows upon the eyeball; and that at the part where the iris was detached from the ligamentum ciliare there remained, during the rest of the patient's life, an oval fissure, which might, in all these cases, have performed the office of an *artificial pupil*, if the immediate organ of vision and the crystalline humour had not been too much injured by the violence of the stroke. I remember in a case of *proidentia iridis*, from a small ulcer of the cornea, where the iris was greatly stretched, in consequence of a considerable portion of it projecting out of the eye and having contracted an adhesion with the margins of the ulcer of the cornea, that this membrane, instead of being lacerated in its middle, was detached for a certain extent of its circumference from the ciliary ligament, producing an artificial pupil in that part, which was very useful to the patient after the *proidentia iridis* was cured. In depressing a cataract likewise, I have had the misfortune of seeing a similar detachment of the margin of the iris from the ciliary ligament occur, from my having pushed the opaque crystalline a little inadvertently against the internal margin of this membrane, at the time that it was rolling obstinately round the point of the straight needle, without my being able to catch it, in order to lodge it deeply in the vitreous humour and depress

press it. In different dissections of the eye likewise, I have very frequently had an opportunity of observing, that on taking hold of the iris with the forceps, not only at a small distance from its greater circumference, but also at the very edge of the pupil, this membrane, although certainly of the most delicate texture, instead of lacerating in the middle, has rather separated at its union with the ligamentum ciliare.* Lastly, it is beyond doubt, that the iris is a membrane entirely distinct from the choroid coat, and has a peculiar kind of connection, though very slight, with the ciliary ligament, independently of the union of the choroid coat with this ligament.

All these considerations collectively, but particularly that of the weak attachment of the iris to the ciliary ligament, and consequently of

* Guerin appears to me to have been better acquainted with this important circumstance, of the easy detachment of the iris from the ciliary ligament, than any other modern oculist.

“ *The separation of the iris from the ciliary ligament is easily effected; an observation which ought never to be lost sight of in the extraction of the cataract, for by forcibly extracting a large crystalline the iris might be entirely, or in part, detached and cause serious injury, loc. cit. page 218.*” All the advocates for extraction caution us, in cases where the membranous cataract adheres to the iris, to draw this small opaque membrane gently, otherwise there is a risk of separating the iris from the ciliary ligament; this accident being considered as more probable than the laceration of the substance of the iris.

the greater facility of separating the margin of the iris from the ligament to which it is united, than of lacerating the membrane itself, induced me to attempt a new method of making the artificial pupil in those cases, in which, after the extraction or depression of the cataract, the natural pupil might be too much contracted or obliterated; which method of operating consists in separating the outer edge of the iris from the ciliary ligament, for a certain extent, without previously dividing the cornea. The event answered my expectation, as will appear from the annexed cases. The following is a detail of the mode of performing this operation.

The patient being seated, and there held, as in the operation for the cataract, with a straight couching needle, not the thick one, which is used by the greater part of surgeons, but a very fine one,* to which I give the preference, the sclerotic coat is perforated at the external angle of the eye, about two lines from the union of the tunica sclerotica with the cornea, and the point of the needle is made to advance as far as the upper and internal part of the margin of the iris, that is, on the side next the nose. The instrument is then made to pierce the upper part of the internal margin of the iris, close to the

* Plate III. fig. II.

ciliary ligament, until its point is just perceptible in the anterior chamber of the aqueous humour; I say just perceptible, because that part of the anterior chamber being very narrow, if the point of the needle be made to advance ever so little before the iris it must pass into the substance of the cornea. As soon as the point of the needle can be seen in the anterior chamber of the aqueous humour, it should be pressed upon the iris from above downwards, and from the internal towards the external angle, as if with a view of carrying the instrument in a line parallel to the anterior surface of the iris, in order that a portion of its margin may be separated from the ligamentum ciliare. This separation being obtained, the point of the needle must be depressed, in order to place it upon the inferior angle of the commenced fissure, which may be prolonged at pleasure, by drawing the iris towards the temple, and by carrying the instrument from before backwards, in a line parallel to the anterior surface of the iris, and the greater axis of the eye.

Having done this, if the bottom of the eye, beyond the artificial pupil, does not appear obstructed by any opaque body, the needle may be withdrawn from the eye entirely. If, however, any portion of the opaque capsule present itself behind the new pupil, which has remained after the depression or extraction of the cataract, this

this small opaque membrane, being broken in pieces with the point of the needle, must be made to pass before the artificial pupil, and deposited in the anterior chamber of the aqueous humour, where, as I have shown in the preceding chapter, these membranous fragments and flakes of the capsule are gradually dissolved and absorbed with the aqueous humour, which is incessantly renewed.

In consequence of the detachment of the iris from the ciliary ligament, it constantly happens, that the aqueous humour is rendered more or less turbid by the effusion of a small quantity of blood into it; but this discoloured fluid is afterwards absorbed, and the eye recovers its former transparency.

During the operation the patient complains of much more uneasiness than in the depression or extraction of the cataract; nor can it be otherwise, since by separating a portion of the margin of the iris from the ciliary ligament, some of the filaments of the ciliary nerves which pass through it to be distributed to the iris must be stretched and lacerated. The symptoms which ensued from this operation in the two cases, which I have related, were neither of long continuance nor alarming. From some experiments made upon the dead subject, I am of opinion, that the curved needle which I employ for the depression of the cataract, may
be

be also preferable to the straight one in the formation of the artificial pupil; which I intend to ascertain on the first favourable opportunity.

CASE LIX.

Some years ago, I performed the operation for the cataract before a number of surgical students, upon the left eye of a countryman of Borgo S. Siro, 50 years of age; it was at the time when I used the straight pointed needle. In the act of depressing the crystalline, I found some difficulty in making a firm pressure upon it with the instrument, round the point of which the opaque crystalline, while rolling, was carried sidewise against the margin of the iris next the nose, separated this membrane for a certain extent from the ciliary ligament, and was ready to pass into the anterior chamber of the aqueous humour. I retracted it in the best manner I could, and notwithstanding a little turbidness produced by the effused blood, after some attempts, I caught the firm crystalline with the point of the needle, and buried it deeply in the vitreous humour out of the axis of vision. The eye was merely covered with a dry compress, and the patient was put to bed.

Towards the evening of the same day, the patient felt considerable pain and heat in the eye.

eye. I ordered him to lose blood from the arm plentifully, and the eye to be covered with bags of gauze filled with emollient herbs boiled in milk. The following day he was purged with crystals of tartar, and confined to a rigorous diet. The eye-lids and conjunctiva, however, were considerably swollen until the 5th day, and it was therefore necessary to repeat the bleeding; the tumefaction afterwards gradually subsided, and on the 14th day had entirely disappeared.

Upon examining the eye attentively, I found that the aqueous humour had not yet regained its former transparency, that the natural pupil, which was exceedingly contracted and almost obliterated, was removed from the internal towards the external angle of the eye, by the depression of the portion of the iris, which had been separated from the ciliary ligament; that, lastly, at the part where the separation had taken place there was an oval fissure two lines and a half in extent, through which the patient could distinguish objects sufficiently well. In two weeks more the eye recovered its natural transparency. There being a cataract in the right eye also, I performed the operation upon it a few days afterwards, and with the best possible success.

CASE LX.

Maria Guerini, an inhabitant of the Genoese mountains, a strong woman, 45 years old, but occasionally subject to rheumatism, which affected her sometimes in the back, at other times in the neck and head, had for a long time lost the use of her left eye, in consequence of cataract, and finding that she was likely to experience a similar misfortune also in the right, she was admitted into this school of surgery to undergo the operation.

I depressed the cataract of the left eye with success, and all went on very well till the 4th day, when the patient was suddenly seized with a ptyalism, rheumatism in the neck and the whole of the left side of the head, with acute pain, violent inflammation, and swelling of the eye-lids and ball of the eye; the conjunctiva was tumid and prominent as in the *chemosis*. I ordered blood to be drawn copiously from the patient's foot, as well as locally by means of leeches, and I directed a blister to be applied upon the neck. She was repeatedly purged with a grain of tartarized antimony dissolved in a pint of the decoction of the radix tritici repent. and during the day she made use of a tepid infusion of elder flowers. The eye was fo-

mented with small bags of emollient herbs. The inflammation both of the external and internal parts of the eye was such that an hypopion seemed inevitable. This state of perplexity continued a week, when the rheumatism and ophthalmia gradually disappeared. The patient, however, had no more sight with the left eye than before the operation. The pupil was so much contracted as to appear obliterated. I did not think it proper to meddle with the eye again at that time, but advised the patient to return to the hospital in a few months, which she did.

The patient having been purged with small doses of the antim. tart. and confined for some days to a proper diet, was subjected to the operation for the artificial pupil. Having pierced the sclerotic coat with a very fine straight needle, I passed the point against the summit of the margin of the iris next the nose, and as soon as I could just discern the point of the instrument I pressed it downwards, and drawing the iris towards the temple, I separated a portion of its margin from the ciliary ligament, and I continued to do this, descending to the extent of two lines and a half; I then withdrew the needle from the eye. The woman gave signs of acute pain, and the aqueous humour was rendered a little turbid.

As soon as she was put to bed I ordered blood to be drawn from the foot, and the eye to be

covered with bags of gauze, filled with emollient herbs boiled in milk, and I directed an emulsion with twelve drops of the tincture of opium, to be taken at bedtime. She passed a comfortable night.

There was afterwards a slight inflammation of the conjunctiva and eye-lids, which was subdued in a few days by emollient applications only, and on the entire cessation of the inflammatory stage, the aqua lithar. acet. comp. was employed with advantage.

On the 11th day from the operation I could examine the eye commodiously. The aqueous humour had not yet entirely regained its perfect clearness. The perpendicular fissure formed between the internal margin of the iris and the ciliary ligament, performed the office of a pupil; by which the woman distinguished the surrounding objects. After a months convalescence, the obscurity produced by the blood effused into the aqueous humour was dissipated, and the woman left the hospital cured.

CASE LXI.

A mendicant who had lost his left eye from the extraction of a cataract, in one of the hospitals of Piedmont, and the pupil of whose right eye was so contracted, after a violent inflammation, as scarcely to admit the head of a

small pin, and was therefore of little use to him, was brought into this practical school of surgery, in consequence of a fall upon the ice, by which he had dislocated his left hand. After he had recovered from this accident, I proposed to him to make some attempt to better his sight, to which he assented.

Having introduced a straight needle into the right eye, as in the operation of couching, I passed the point of it to the internal and superior margin of the iris, which I pierced as near its edge as possible; then partly by pressing the iris from above downwards, and partly by drawing it towards the temple, I separated it from the ciliary ligament to the extent of more than two lines; after which I withdrew the needle, leaving the aqueous humour somewhat turbid.

In the act of detaching the iris from the ciliary ligament, the patient gave signs of exquisite pain, but as soon as the eye was covered with a small bag of gauze filled with emollient herbs boiled in milk, he became easy.

On the 3d day the eye-lids and conjunctiva were considerably inflamed. He was bled largely, and purged with the crystals of tartar; and the emollient applications were continued. On the 10th day the acute ophthalmia was dissipated, and was succeeded by that from local debility, which was removed by means of the vitriolic collyrium, with mucilage of quince seed.

On

On the 20th day from the operation I found that the artificial pupil perfectly answered the intention for which it had been made; as the patient could distinguish objects sufficiently well. In less than a month afterwards the slight tinge which the aqueous humour had received from the blood entirely disappeared.

CASE LXII.*

In the year 1788, a woman came to me who had had a cataract extracted from the left eye. The pupil had closed, in consequence of a violent inflammation, which, according to her account, continued 50 days. She had been deprived of the right eye in her infancy, by a supuration of the cornea after the small-pox. Under these circumstances, there was no other means of restoring sight to this unfortunate woman, than by the formation of an *artificial pupil* in the left eye, which was executed in the following manner.

* This case has been communicated to me by Signor *Francesco Buzzi*, a very able surgeon and oculist of Milan, already known as an anatomist by his discovery of the *yellow spot* at the bottom of the eye, since described by *Soemmerring*. Persuaded of the imperfection of the common methods of making the artificial pupil, he had for a long time adopted and practised the new mode of operating which is here described.

The patient being placed in a chair, an assistant, situated behind, held the head, supported against his breast, by placing his right hand under the chin. With the fore and middle fingers of his left hand, he elevated the upper eyelid of the left eye, while I in the same manner depressed the lower. With a spear-pointed needle in the right hand I pierced the sclerotic coat at about the distance of two lines from the circumference of the iris, and afterwards pushing the instrument forwards, I penetrated the iris towards its upper part, about a line from the contracted pupil; and after having passed the needle in a direction parallel to the anterior surface of the iris, I inclined its point downwards, and at the same time pressed it backwards towards the centre of the vitreous humour, separating the iris forcibly at the upper part, for at least a third part of its circumference. This I executed with as much quickness as in the depression of the cataract, otherwise the blood which is discharged from the ruptured vessels of the iris, fills the anterior chamber, and prevents the iris from being seen; and therefore, if this precaution is neglected, the operation may be rendered imperfect, or perhaps even useless.

A few hours afterwards the patient felt a painful tension in the eye-ball, which extended to the orbit, the cheek, and one half of the head. I now employed the general remedies, in order
to

to prevent a violent inflammation. After 35 days confinement to bed, the blood, extravasated in the anterior chamber, was entirely removed; and I could perceive that this detached portion of the iris was so far removed towards the temple, that at the part where it had been separated there was a large oblong *artificial pupil*. The patient was afterwards able to walk freely by herself, and to read and write with the assistance of cataract spectacles.

I have hitherto spoken of the artificial pupil, in cases where the natural pupil is unusually contracted or obliterated, in consequence of the operation for the cataract.

I have not much difficulty in persuading myself that that species of contraction of the pupil, which is accompanied with an adhesion of the anterior convexity of the capsule of the opaque crystalline, may be also remedied by means of the needle. For, besides a very considerable number of cases recorded by authentic writers on these subjects, I might relate some of my own, relative to the cataract, complicated with considerable contraction and immobility of the pupil, which have been successfully displaced by the needle, so that after the operation, the pupil, which had been contracted and immoveable, has recovered its natural size

and mobility. But if even, in some particular cases, the adhesion of the anterior convexity of the capsule of the opaque crystalline to the posterior surface of the iris were such as to elude every possible attempt to separate it by means of the needle, I am of opinion that it could not be productive of any other consequence than that of separating the iris for a certain part of its circumference from the ciliary ligament, and consequently of producing an artificial pupil.* The elucidation of this point must, however, depend upon further observation and experience, as I have proposed to assert nothing upon these subjects which has not been dictated by practice, and confirmed by a sufficient number of facts.

* It is lately asserted that, in this particular case, the celebrated oculist Demours has fortunately succeeded in making an artificial pupil, by piercing the cornea and iris with a bistoury, near the sclerotic coat, and removing a portion of the iris, with the scissors, of the size and figure of a forrel-seed, and that without at all displacing the sound and transparent crystalline.

CHAP. XVII.

OF THE STAPHYLOMA.

THAT disease of the eye-ball is termed staphyloma, in which the cornea loses its natural transparency, is elevated upon the eye, and gradually projects beyond the eye-lids in the form of an oblong tumour of a whitish or pearl colour, which is sometimes smooth, at other times tuberculated, attended with a total loss of sight.

This disease not unfrequently attacks infants a little after their birth, and is most commonly a sequela of the puriform ophthalmia; or it appears in consequence of the small-pox, and what is extraordinary, never during the eruptive or suppurative stage of that disease, but on the desiccation of the pustules, and even after the crusts have desquamated.

In a great number of cases, when the staphyloma has arrived at a certain elevation upon the cornea, it becomes stationary, or only increases in exact proportion with the eye-ball; in
others

others the small tumour gradually increases in all its dimensions, and in such a disproportion, with respect to the rest of the eye-ball, that it ultimately projects considerably beyond the eye-lids, occasioning great uneasiness and deformity.*

This disease is justly ranked among the most dangerous to which the eye-ball is subject; since to the total and irremediable loss of sight which accompanies it, are added the evils which necessarily arise from the augmentation and protuberance of the staphyloma, when the tumour

* I had lately occasion to see a singular disease of the cornea, in a woman 35 years of age, which if it be not referable to the staphyloma, I do not know in what class of diseases to place it. The eyes were naturally prominent; the cornea of each side, without any evident cause, became elevated in the centre and gradually projected outwards, so that it no longer formed a regular segment of a sphere applied upon the sclerotica, but a pointed cone. When the cornea was viewed sidewise it resembled a small transparent funnel with its base applied upon the sclerotica. In particular motions of the eye-ball, the point of this cone appeared rather less transparent than its base, in others not so; but even where it appeared least transparent, it was not in such a degree as to present any considerable obstacle to the sight. When the eyes were placed directly opposite a window, the apex of the cone reflected the light so powerfully, that it had the appearance of a luminous point: and as this took place precisely opposite the pupil, which was now contracted, the woman could only see objects distinctly in a moderate light, in which the pupil was sufficiently dilated; in a strong light her vision was weak and confused.

of the cornea has acquired such a magnitude as not to admit of being enclosed and covered by the eye-lids. For in such cases, the continual exposure of the eye-ball to the contact of the air, and the particles floating in it, the friction which the cilia make upon it, and the incessant discharge of tears upon the adjacent cheek, are causes sufficient to occasion the eye to become gradually painful and inflamed, and sympathetically to affect the sound one; and finally to produce an ulceration of it, together with the lower eye-lid and the cheek upon which it rests.

It has long been the opinion of surgeons, that in the formation of the staphyloma, the cornea yields to the distension produced by the turgescence of the proper humours of the eye, in the same manner, nearly, as the peritoneum yields to the pressure of the viscera contained in the abdomen when an intestinal hernia is formed. Richter* has opposed this theory, by remarking that the staphyloma is most frequently formed without its having been preceded by any of those morbid predispositions which are generally regarded as capable of weakening the texture and elasticity of the cornea; that the cornea, degenerated into staphyloma, acquires a much greater thickness than

* *Observ. Chirurg. Fascicul. II.*

that which it possesses in a natural state, and that consequently the staphyloma, instead of being internally concave, is quite compact and solid, while it ought to be precisely the contrary if this tumour were the effect of an excessive distension of the cornea from within outwards, with an attenuation of its natural texture.

In conceding to Richter the encomiums to which he is entitled for his distinguished merits in all the branches of the healing art, I cannot but remark on this occasion, that the illustrious author in advancing, as he has done, a matter of fact, relative to the origin and nature of staphyloma, has extended his doctrine too far, in admitting no difference between the staphyloma recently appearing in infants, and that of adult subjects, in which last, the staphyloma, has acquired such a magnitude as to project considerably beyond the eye-lids. I fully agree with Richter as to the certain and demonstrable fact, that the recent staphyloma in infants is entirely compact and solid from the increased thickness which the cornea assumes in this disease; but it is equally certain, as I have found from repeated observation, that in the staphyloma, which originally is perfectly solid and compact, after a series of years, and in persons of a mature age, where the tumour has acquired such a size as to project out of
the

the eye-lids, the cornea, properly so called, is constantly thinner, or certainly not thicker than natural, that is to say, the tumour is not perfectly solid internally, unless with regard to its state of fulness, as it contains the iris and the crystalline and not unfrequently also a portion of the vitreous humour; which parts leaving their natural situation, are pushed gradually forwards to occupy the concavity of the cornea, which is proportionally formed and enlarged.

The cornea of infants, in its natural state, is in proportion, at least twice as thick and pulpy as that of adults; and consequently the anterior chamber of the aqueous humour is proportionally so contracted, in comparison with that of adults, that in very young infants the cornea may be considered as almost in contact with the iris. Such also is the natural softness, flexibility, and succulency of the cornea in infants at an early age, that when separated from the rest of the eye in the dead subject, and rubbed between the fingers, it loses at least one half of its bulk and thickness, which does not take place in adults. And the cornea is so pliant and distensible at this early period, that, if in the fine injections of the head, the injected substance is extravasated in large quantity within the eye-ball, the cornea, compressed from behind forwards, is considerably elevated in the body of the infant towards the eye-lids,

which, under such circumstances, never happens in the eyes of adults.

In consequence of this natural softness, succulency, and flexibility of the cornea of infants, as well as from the natural straightness of the anterior chamber of the aqueous humour, it not unfrequently happens, that when they are attacked soon after birth with the *puriform* ophthalmia, or variolous metastasis, their cornea, more readily than that of adults, gives admission within its spongy texture to the thick and tenacious humour which is propelled into it; by the stagnation and condensation of which, the cornea at that early period not only loses its natural organization and transparency, but also swells, becomes much thicker than natural, and in a short time degenerates into an acuminate, whitish, or pearly tumour, completely solid, without any internal vacuity, and perfectly in contact, and adhering to the iris, to which the cornea of infants, as I before observed, is naturally very closely situated.

In the course of some years, however, the disease undergoes new modifications. For the whole eye increasing in volume in proportion to the age, the iris and crystalline, from causes not fully known, abandon their natural situation, and are continually forced forwards; to which perhaps the preternatural fluidity and
turgescency

turgescency of the vitreous humour contributes, which, when the disease is of long standing, is constantly found in large quantity, and of a watery consistence. Now these parts, the crystalline and iris, when the cornea is not perfectly hardened and firm, gradually press this membrane from within outwards, and in time distend it in all its dimensions, so as to cause it to project beyond the eye-lids, rendering it at the same time thinner in proportion to the volume and capacity which it acquires. I have never met with a large staphyloma protruding out of the eye-lids in adult persons, which had not originated in infancy; and I have constantly found that the thickness and density of the cornea, both in the living and dead bodies of those who were affected with this disease were in an inverse proportion to the age. In the inveterate staphyloma, which projects considerably beyond the eye-lids, the iris may be distinctly seen in different parts of it contained within it; and if this is not equally evident in all the parts of the tumour, it is because the conjunctiva which externally covers the cornea, and the vessels of this membrane having become varicose, throw over it a stratum of substance of unequal density and opacity. And it is precisely this dense stratum of the lamina of the conjunctiva covering the cornea, which in the staphyloma that has arrived at a considerable size
and

and amplitude may easily deceive, the substance of the cornea appearing to acquire greater density and thickness, in proportion to the increase of the tumour, whereas quite the contrary takes place, the increased density of the lamina of the conjunctiva, which covers it externally, only supplying in part the diminished thickness of the true texture of the cornea; a means which nature providently employs on many occasions, in order to prevent the injuries which some important parts might receive, when deprived of their natural covering, and exposed to the action of external agents. It is not to be presumed, that of the many able surgeons and accurate observers of every age, who have frequently, in the course of their practice, destroyed inveterate staphylomata of the largest size, no one should have perceived that in this highest degree of the disease, the cornea instead of being diminished in thickness, according to the common opinion, is, on the contrary, a body entirely compact and solid internally. On the contrary I find them, when speaking of the destruction of large staphylomata, projecting much beyond the eye-lids, by means of the ligature, delivering cautions to draw the thread only lightly for fear of the cornea, rendered thin in these cases, being easily lacerated. And Gunz*

* De Staphilom. dissert. see the Disput. Chirurg. of Haller.
relates

relates his having been an ocular witness of such an unfortunate accident, in a case where a ligature had been applied upon the staphyloma, by means of a needle and thread.

The doctrine of Richter, therefore, upon the nature of this disease is true, when it is confined to the recent staphyloma of infants. But it appears to me to admit of exceptions as it regards the thickness of the cornea, in the staphyloma of long standing, which has arrived at a considerable size, and projects out of the eye-lids.

Some pretend that the sclerotic coat also is subject to staphyloma, that is, to a partial distension and elevation of its anterior hemisphere in the white of the eye; others entertain a doubt of the existence of this disease. It has never occurred to me, indeed, even once, to see any tumour or elevation of the sclerotica on its anterior surface, corresponding to the white of the eye, in the form of staphyloma; and on the contrary, what may seem extraordinary, I have twice happened to meet with the staphyloma of the sclerotic coat in its posterior hemisphere, in the dead subject, where I do not know that it has been seen or described by any other. The first time was in an eye taken from the body of a woman 40 years old, for another purpose. This eye* was of an oval figure, and

* Plate II. fig. 9.

upon the whole, larger than the sound one of the opposite side. On the posterior hemisphere of this eye, and on the external side of the entrance of the optic nerve, or on the part corresponding to the temple of that side, the sclerotica was elevated in the form of an oblong * tumour of the size of a small nut. And as the cornea was sound and pellucid, and the humours still preserved their transparency, on looking through the pupil, there appeared within it, towards the bottom, an unusual brightness, produced by the light penetrating that part of the sclerotica, which had become thin and transparent where it was occupied by the staphyloma. When the eye was opened, I found the vitreous humour entirely disorganized and converted into limpid water, and the crystalline lens rather yellowish, but not opaque. When the posterior hemisphere of the eye was immersed in spirit of wine, with a few drops of nitrous acid added to it, in order to give the retina consistence and opacity, I could perceive distinctly, that there was a deficiency of the nervous expansion of the retina within the cavity of the staphyloma; that the choroid coat was very thin and discoloured at this part, and wanted its usual vascular plexus; and that the sclerotica, particularly at the apex of the staphyloma, was

* Plate II. fig. 9. a.

rendered so thin as scarcely to equal the thickness of writing paper. I knew that the woman from whom the eye had been taken, had lost the faculty of seeing on that side some years before, during an obstinate ophthalmia, attended with a most acute and almost habitual pain in the head.

The same observation I had an opportunity of making on an eye, accidentally taken from the body of a woman 35 years of age, and politely sent to me from Milan by Dr. Monteggia, who has distinguished himself by his excellent medical and surgical writings. This eye was also of an oval figure, and larger than the opposite one.* The staphyloma of the sclerotic coat † occupied its posterior hemisphere on the external side of the entrance of the optic nerve, or on the side next the temple. The vitreous humour was converted into water; the capsule of the crystalline was exceedingly turgid, with a whitish diluted fluid; the crystalline, yellowish and less than natural; the retina, deficient within the staphyloma; the choroid and sclerotic coats, forming the tumour, were rendered so thin as to admit the light. Dr. Monteggia could not furnish me with any thing positive respecting this woman's sight before her death. It is remarkable, that in both the cases now described, the staphyloma

* Plate II. fig. 10.

† Plate II. fig. 10. a.

of the sclerotic coat was situated on the external side of the entrance of the optic nerve. Further observations may, perhaps, hereafter enable surgeons to establish the diagnostic symptoms of the staphyloma of the sclerotic coat; but from its deep situation and the nature of the disease, I doubt very much whether the art will ever arrive at an effectual method of arresting its progress, much less of curing it.

Returning to the staphyloma of the cornea, as this part of the eye-ball, in such cases, is rendered irremediably opake, the aim of the surgeon in the treatment of this disease, when recent, and in infants, must be necessarily confined to prevent the disorganized tumour of the cornea from increasing in size, and to depress and flatten it as much as possible; and in the large inveterate staphyloma projecting beyond the eye-lids, to effect such a reduction of its size, that it may re-enter and be deeply lodged within the orbit, so as to allow an artificial eye to be fixed, and thereby lessen the deformity of the countenance.

In recent cases of staphyloma, Richter proposes to produce an artificial ulcer upon the base of the tumour of the cornea, by means of the reiterated application of the *argentum nitratum* or the *antimonium muriatum*, and to keep it open by the repeated use of these caustics; in order to evacuate by means of this small cauterization,

terization the thick and tenacious humour, which is the immediate cause of the opacity and preternatural tumefaction of the cornea. The author asserts, that he has frequently obtained a diminution of the staphyloma by means of this small drain made in the substance of the cornea, and in one particular case, that he has even restored the transparency of the cornea; which has always appeared to me one of the most extraordinary and wonderful cures of the many which are found recorded on the diseases of the eyes; particularly as it was completed in 14 days. “*Ter repetita operatione, quarto scilicet, septimo et decimo die, ne vestigium quidem morbi die decimo quarto supererat.*”*

I am sorry to be obliged to declare, that although I have frequently adopted this method of treatment in the recent staphyloma of infants, and that with the fullest confidence of success, not only from a persuasion that this plan of treatment proceeded from certain and evident premises founded on the nature of this disease, when recent and in subjects of an early age, but because in so doing I was guided by one of the most authentic writers in surgery; yet I have never had the gratification to obtain such success, either with regard to restoring the transparency of the cornea, or diminishing the size of the sta-

* Observ. Chirurg. Fascic. II.

phyloma, as in any degree to equal that obtained and related by Richter. In three children, one a year and a half old, and the other two, little more than three years of age, recently attacked with staphyloma in one of the eyes, in consequence of the small-pox, in which I excited and kept open a small ulcer at the basis of the cornea, by means of the *argentum nitratum*, for more than 30 days, I derived no advantage from it with respect to the diminution of the tumour, and still less with regard to the opacity of the cornea. In a boy five years of age, who had been a short time affected with a staphyloma in one eye, after a violent *chemosis*, having produced an ulcer upon the basis of the cornea, by penetrating a small depth into the substance of the disorganized and tumid cornea with a lancet, and afterwards keeping the ulcer open for five weeks, by means of a solution of the *argent. nitrat.* I observed that the staphyloma was a little depressed, and had lost the acute point which it had in the centre,* but the cornea remained every where opaque as at first. In two other subjects, nearly of the same age, under the same circumstances, and treated in the same manner, although the ulcer of the cor-

* The conical figure which the cornea assumes in this disease, is a characteristic mark by which the staphyloma may be distinguished from the leucoma with complete opacity of the cornea.

nea was kept open for 50 days I could obtain no depression or diminution of the staphyloma, and consequently the pointed tumour in both remained of a pearl colour, as at first.

If, however, by means of further trials made by persons of ability, this plan of treatment should be found to be advantageous, not with a view to reestablish the transparency of the cornea, but merely to restrain and depress the recent staphyloma of infants, I am of opinion that no one will persuade himself that this mode of treatment can be of any utility in obtaining a diminution of the size of the inveterate staphyloma in adult persons; or that which protrudes beyond the eye-lids and presses upon the cheek. For what advantage can be expected from an artificial ulcer made in the substance of the cornea, which is no longer soft and pulpy, nor thickened merely by a tenacious humour effused into its cavernous texture, but which, in process of time, has become arid, coriaceous, prominent by the excessive distension from within outwards, and covered by a callous stratum formed by the lamina of the conjunctiva, and its varicose vessels? It is certain, that whenever the inveterate staphyloma, projecting beyond the eye-lids, happens to become accidentally ulcerated from external violence, from the acrimony of the tears, or from the long continued pressure of the parts upon which it rests, a

diminution in its size has never been observable in consequence of such ulceration; on the contrary, it is stated to have happened frequently in such cases, that the exulcerated inveterate staphyloma has degenerated into a fungus of a malignant nature.

In the highest degree of this disease, therefore, when the staphyloma projects out of the eye-lids, the most effectual means of arresting the progress of the disease, and removing the deformity, which we are at present in possession of, is the excision of the staphyloma, and when the wound is healed, the application of an artificial eye.

Of this operation Celsus* expresses himself in the following manner. *Curatio duplex est. Altera ad ipsas radices per medium transuere acu duo lina ducente; deinde alterius lini duo capita ex superiore parte, alterius ex inferiore adstringere inter se, quæ paulatim secando id excidant. Altera in summa parte ejus ad lenticulæ magnitudinem excindere; deinde spodium; aut cadmiam infricare. Introlibet autem factò, album ovi lana excipiendum, et imponendum; posteaque vapore aquæ calidæ foveendus oculus, et lenibus medicamentis unguendus est.*

Although the first method, or that of deligation, is at present laid aside, as admitted by all to be less proper; the greater part of surgeons,

* De Medicin. lib. vii. cap. 7.

nevertheless,

nevertheless, continue to pierce the base of the staphyloma with a needle and thread, not indeed with a view of making a ligature upon the tumour, but to form a loop, by which a commodious hold may be taken, for the purpose of retaining the eye-ball firmly at the time when the extirpation is performed. But since this advantage, as I shall hereafter show, may be obtained by a more simple, expeditious, and less inconvenient method to the patient; I am persuaded that the apparatus of the needle and thread will, ere long, be abandoned, not only as a method of treatment, but as an auxiliary in the operation.

With respect to the second mode of removing the *staphyloma*, or that by excision, it appears to me that sufficient attention has not been paid to what has been delivered by Celsus on this subject. For he does not direct that the staphyloma should be divided circularly at its base, as is practised in the present day, but that the excision should be made in the centre or extreme point of the tumour, and that a circular portion of the summit or apex of the staphyloma, equal in size to a lentil-feed, should be removed. *In summa parte ejus ad lenticulæ magnitudinem excindere.* The great importance of this precept of Celsus, in the treatment of the staphyloma, can only be estimated by those who have had frequent opportunities of comparing

paring the advantages of his mode of operating, with the very serious inconveniences which arise from the common practice of removing the staphyloma circularly at its base, and the still greater evils which are produced by the circular division of this tumour, including the sclerotica, according to the practice of Wolhouse; as such a mode of treatment is invariably followed by violent inflammation of the eye-ball and eye-lids, the most acute pain in the head, watchfulness, convulsions, copious suppuration, and sometimes gangrene of the eye and eye lids. It is, in my opinion, a certain fact, established by an extensive series of observations, that the further the semicircular excision of the staphyloma is made from the centre or apex of the tumour towards its base, and consequently the nearer the sclerotic coat, the more considerable are the symptoms consequent on this operation; and vice versa.

Consistently with these facts, the following is the method of effecting the destruction of the inveterate staphyloma, which I have adopted. The patient being seated, I direct the head to be properly held by an assistant, then with the small knife,* which is used for the extraction of the cataract, I pierce through the staphyloma at a line and a half or two lines from the centre or

* Plate III. fig. 7.

apex of the tumour, in the direction from the external to the internal angle of the eye; and passing the knife precisely in the same direction as in the extraction of the cataract, I divide the apex of the tumour downwards in a semicircular manner. Having done this, I take hold of this segment of the staphyloma with the forceps,* and turning the cutting edge of the scalpel upwards, I finish the operation by removing the apex of the staphyloma circularly; so that the detached portion is two, three, and sometimes four lines in diameter, according to the size of the staphyloma. And as a portion of the iris is generally included in the section of the apex of the staphyloma, from this membrane having contracted an adhesion to the cornea at the commencement of the disease, as soon as the circular division of the summit of the staphyloma is completed, the crystalline, or its nucleus, is immediately discharged from the eye, and after it a portion of the dissolved vitreous humour. In consequence of this evacuation the eye-ball is frequently so much diminished as to admit of being covered by the eye-lids, over which I immediately apply a dry compress and bandage.

The pain produced by the excision is trifling, and it is common to see patients very easy

* Plate III. fig. 8.

during

during the three or four first days after the operation. On the 4th day, in general, the eye and eye-lids begin to be painful, inflamed, and tumefied. On the appearance of these symptoms the eye should be covered with a bread and milk poultice, with a view of promoting and accelerating the suppuration of its internal membranes. Indeed, where the progress is regular, the swelling of the eye-lids subsides towards the 7th or 9th day, and some puriform matter is seen upon the poultice, mixed with the dissolved vitreous humour, which slowly issues from the bottom of the eye; these are succeeded by the matter becoming thicker and whiter, the patient becoming easy, and by a manifest diminution of the whole eye-ball, which not only retires within the eye-lids, but deeply within the orbit.

If the eye-lids be gently separated at this period, the conjunctiva is found tumid and reddish, and the edge of the divided portion of the staphyloma appears as if it were formed by a small circle of white skin. On the separation of this gelatinous circle, which seldom exceeds the 12th or 14th day from the operation, the margin of the wound becomes florid; it then contracts daily more and more, and lastly closes entirely. A small fleshy prominence remains only for a few days in the centre of it, resembling a small reddish papilla, which, by a few applications,

applications of the *argentum nitratum*, retires completely and heals.

The symptoms occasioned by this operation, are so far from being considerable, that in the greater number of cases, the surgeon is obliged to irritate the eye for several days after the operation, in order that it may inflame, partly by leaving it for a long time uncovered and exposed to the air, and partly by enlarging the wound made in the centre of the staphyloma, by removing another circular portion half a line in breadth, and thus facilitating still further the discharge of the humours, and the admission of the air to the cavity of the eye. When the inflammation has once commenced in the internal part of the eye, and is succeeded by suppuration, the rest of the treatment proceeds regularly, by the use of emollient applications only, and is speedily completed. And as, by adopting the method of destroying the staphyloma here recommended, the consequent contraction of the eye-ball takes place equally around the greater axis of this organ, the mutilated part which remains is also regular in its whole circumference, and offers an easy and convenient support to the artificial eye.

CASE LXIII.

Regina Fedele, a female peasant, 19 years of age, living in Cassanmagnago, had, from her infancy, a staphyloma of the left eye, in consequence of the small-pox, which gradually increased, so as to project without the eye-lids for more than an inch. The deformity, as well as the inconveniences arising from the perpetual weeping, and the frequent attacks of ophthalmia, which, by consent, were also propagated to the sound eye, induced the poor girl to apply to this hospital for relief on the 20th of November 1785.

I ingenuously acknowledge, that experience had not then sufficiently instructed me in the best method of operating in cases of staphyloma, and although I was of opinion that the removal of a portion of the sclerotic coat with the tumour ought to be proscribed from practice, yet it appeared to me a matter of little consequence that the excision should be made in the very borders of the cornea with the sclerotic coat. With the knife, therefore, which is used for the extraction of the cataract, I pierced through the base of the staphyloma, at the part where the cornea and sclerotica unite, and divided it downwards; then with the forceps and scissors I removed the whole tumour of the cornea circularly. The
6 eye-ball

eye-ball was presently emptied of the humours, and retired within the eye-lids. On examining the detached cornea, which had formed the staphyloma, attentively, I found that this membrane was entirely distinct from the callous stratum of the conjunctiva covering it; and that it was not thicker than natural, but in some parts even thinner. At the moment the staphyloma was extirpated, the patient felt acute pain. After the operation the eye-lids were covered with a dry compress and bandage; and as the patient was plethoric I ordered blood to be taken from the arm. Half an hour afterwards the patient was seized with vomiting and universal shiverings, which returned at intervals during the day and following night, notwithstanding the use of Riverius's mixture and opiate enemata.

The following day the eye-lids and ball of the eye appeared unusually tumid, and of a dark red colour, threatening gangrene. The fever was very smart, the pulse hard, with redness of the countenance, and very acute pain in the head. I therefore ordered blood to be taken away from the foot, and at night directed that leeches should be applied upon the left temple, and the eye-lids covered with a poultice of bread, milk, and saffron. During the night of the 2d day the patient was delirious, and was seized at intervals with universal rigors.

On

On the 3d day, observing that a blackish substance presented itself between the edges of the tumefied eye-lids, resembling clotted blood, I carefully separated them, and there gushed out half a table-spoonful of grumous blood mixed with aqueous humour, which was attended with relief to the patient and a diminution of the general symptoms.

On the 6th day, as the excessive tumefaction of the eye-lids was a little diminished, I found the eye-ball fullied with matter which was diluted and fetid. The edge of the wound was sloughy, and a small abscess the size of a pea was also formed in the conjunctiva, corresponding to the external angle of the eye, which I opened with a lancet. From the bottom of this small abscess arose shortly afterwards a fungus which gave me some uneasiness. I continued, however, the application of the emollient poultices, and the internal use of a grain of the tartarized antimony in a pint of the decoction of the triticum repens, taken in small doses, which kept up the perspiration, and procured one or two motions daily.

It was not till the 13th day after the operation, that the suppuration began to assume a healthy appearance, and the fever, and the pain in the head to abate. The eye-lids and ball of the eye afterwards subsided gradually, and the fungus of the conjunctiva became stationary.

The

The healthy suppuration continued copious for a month, during which the margin of the wound of the staphyloma remained dark and sloughy. When the suppuration of the internal part of the eye was greatly diminished, this sloughy margin separated in the form of an eschar, and left a small wound of a healthy aspect. The fungus of the conjunctiva in the external angle of the eye disappeared, and the diminished eye-ball retired towards the bottom of the orbit. In three weeks more the small wound in the centre of the remaining part of the eye-ball was perfectly healed.

By means of the decoction of the cinchona, and a proper diet, the young woman recovered her former strength, and about ten weeks from the operation, after having suffered the most acute pain, with great hazard of her life, returned home perfectly cured, as far as the nature of the disease admitted.

CASE LXIV.

Maria Antonia Bariola, of the valley Salinbeni, 30 years of age, of a delicate complexion, was disfigured from her infancy with a staphyloma of the right eye. The tumour had gradually increased, so as to protrude out of the eye-lids, particularly from the age of four years, after receiving a blow upon that eye. The sta-

phyloma frequently inflamed, and produced a corresponding affection of the left eye also, which, on her admission into the hospital, was not only inflamed, but ulcerated upon the cornea.

After some time had been taken up in the treatment of the ulcer and ophthalmia of the left eye; I proposed to the patient to submit to the excision of the staphyloma, which occupied the right eye, lest the left eye, which frequently participated in the inflammation with which the other eye was affected, should be ultimately lost also. The patient assented to it, and on the 6th of February 1796 I pierced the most pointed part of the staphyloma, with the knife used for the extraction of the cataract, at the distance of a line and a half from the centre or apex of the tumour, forming a semicircular border at the lower part, which being raised with the forceps and turned upwards I removed circularly with the same instrument, taking away a portion of the apex of the tumour of the cornea three lines in diameter. The brown and disorganized lens passed through this aperture, and afterwards a considerable portion of the dissolved vitreous humour. On carefully examining this circular portion of the cornea, separated from the rest of the staphyloma, I found it thinner than that membrane is in a sound state, except that some parts of it were thickened
by

by the induration and callosity of the lamina of the conjunctiva, which covered it. The eye-ball was a little diminished, and the eye-lids being closed, I directed them to be covered with a dry compress and bandage.

The patient did not seem to feel much pain from the operation, nor during the five following days, neither were the eye-lids or eye-ball at all inflamed. A small quantity of mucilaginous humour only, issued from the eye daily. As the inflammation and suppuration of the internal part of the eye, however, was necessary to obtain the proposed intention, and seeing that after six days from the excision of the staphyloma there was no appearance of its taking place, I ordered the patient to remove the bandage, and expose this eye as freely to the air as the sound one. It was thirty hours after this expedient before the eye and eye-lids began to inflame and tumefy, which was attended with moderate pain and slight feverishness. A poultice of bread and milk was now applied, and after three days the suppuration was seen to proceed from the internal part of the eye-ball, at first of a serous, but afterwards of a good quality. The margin of the wound was pale and floughy.

In eight days the suppuration abated, and shortly afterwards, on the separation of this small floughy circle, the wound contracted so

G G 2

that

that there was no longer any aperture in its centre, but a small reddish fleshy papilla, which I touched several times with the *argentum nitratum*. The emollient poultice was now discontinued, and the vitriolic collyrium substituted in its stead, which was dropped into the eye several times a day. The eye-ball very much diminished, and flattened at the part previously occupied by the staphyloma, preserved its motion, and presented a very good support for the application of the artificial eye. The cure was completed in little more than a month from the period at which the eye began to be inflamed.

In comparing this case with the preceding, the advantage which results from the small circular excision of the apex or summit of the staphyloma, in the manner taught by Celsus, must be obvious, contrasted with the alarming symptoms which succeed the removal of this tumour at the line where the cornea and sclerotica unite, and more particularly if it be executed in the sclerotic coat itself.

I shall not subjoin any other cases on this subject, to these now delivered, since those which I shall relate at the end of the next chapter, will equally contribute to a fuller confirmation of this practical point.

CHAP. XVIII.

OF THE DROPSY OF THE EYE.

IN all the cavities of the animal body, moistened by a ferous vapour, as in those destined to contain a certain and determinate quantity of aqueous and limpid fluid, there is such a reciprocity of action between the secreting extremities of the arteries, and the mouths of the absorbent vessels, that the fluid poured into these cavities is held in circulation, and incessantly renewed, without ever accumulating beyond a certain degree, or a determinate quantity. If this relation of action between these two vascular systems be interrupted or destroyed, in consequence of general or local indisposition, the cavities, no longer lubricated by the ferous vapour, contract and are obliterated; or, on the contrary, become unusually distended by the excessive quantity of ferous or watery fluid incessantly collecting and stagnating in them, and acquire an immoderate and much greater size than any one unacquainted with these subjects might imagine.

The eye, conſidered merely as a cavity deſtined to contain a certain and determinate quantity of ſerous, limpid, aqueous fluid, is ſometimes ſubject to one and ſometimes to the other of theſe two diſeaſes, the firſt of which is denominated *atrophy*, the latter *dropſy* of the eye. In the firſt caſe, the eye-ball gradually diminſhes, ſo as to contract itſelf and waſte away; and as the abſorbent ſyſtem never ceases to act ſo, where there is a defect of fluid to be abſorbed, it takes up, by little and little, the ſolid parts of the eye-ball, which it inſenſibly diminſhes, and in proceſs of time even deſtroys. In the ſecond caſe the eye becomes of a ſize greater than natural, and ſometimes ſo extraordinary in its bulk as to protrude out of the eyelids, at firſt with great weakneſs, and afterwards with complete loſs of ſight.

The generality of ſurgeons teach, that the immediate cauſe of the dropſy of the eye is ſometimes the increaſe of the vitreous, at other times of the aqueous humour. In all the caſes of dropſy of the eye which I have operated upon, or have examined in the dead body, in different ſtages of the diſeaſe, I have conſtantly found the vitreous humour, as the diſeaſe was inveterate or recent, more or leſs diſorganized and in a ſtate of diſſolution; nor have I been able, in any inſtance, to diſtinguiſh, on account of the increaſed quantity,
which

which of these two humours, vitreous or aqueous, had had the greater share in the formation of the disease. Among the most esteemed modern oculists there are some who believe that the principal cause of this disease ought to be referred to the contraction of the inorganic pores of the cornea, through which the aqueous humour being no longer able to transude, stagnates within the eye, and there produces the dropfy. In asserting this, they appear not sufficiently acquainted with the activity of the absorbent system in the animal œconomy, and seem not to have considered, that in conformity with their theory, the dropfy of the eye ought constantly to succeed the *pannus* of this organ, the *leucoma*, and extensive cicatrices of the cornea, a circumstance which is contradicted by daily observation and experience.

Lastly, I have dissected an eye affected with dropfy, in a child about three years and a half old, who died of marasmus. In this eye, the vitreous humour was not only wanting, and the cavity which it occupied filled with water, but the membrane of the vitreous humour was also converted into a substance, partly spongy, and partly lipomatose. This eye was a third part larger than the sound one. The sclerotic coat was not thinner than that of the sound eye, but was flaccid and yielding, and when separated from the choroid coat could not support itself or pre-

serve the globular form. The cornea was a third part larger than that of the sound eye, had lost its natural pulpy quality, and was sensibly thinner than that of the sound eye. Between the cornea and the iris there was a considerable quantity of aqueous humour of a faint red colour. The crystalline lens, with its opaque capsule, was pushed a little into the anterior chamber of the aqueous humour, where it could not advance further in consequence of its capsule having contracted a firm adhesion with the iris around the edge of the pupil. When this capsule was opened the crystalline passed out, one half of which was dissolved, and the rest very soft. It was impossible to separate the posterior capsule of the crystalline from a hard substance, which appeared to be, as it was in reality, the membrane of the vitreous humour altered in its texture. On dividing the choroid coat from the ligamentum ciliare to the bottom of the eye, a considerable quantity of reddish water issued from the posterior part of the eye, but not a particle of vitreous humour. Instead of vitreous humour there was a small cylindrical substance, partly fungous, partly lipomatose, surrounded by a considerable quantity of water, which ran through the longitudinal axis from the entrance of the optic nerve to the corpus ciliare, or to that hard substance to which the posterior convexity of the capsule of the crystalline

talline

talline strongly adhered. This small cylinder, for two lines and a half from the entrance of the optic nerve forwards, was covered by a stratum of whitish substance folded upon itself, as the omentum is, when it is drawn upwards towards the fundus of the stomach. I suppose that this stratum of whitish substance was the remains of the disorganized retina; for on pouring some rectified spirit of wine upon the whole internal surface of the choroid coat, and upon this little cylinder, I found no trace of retina upon the internal surface of the choroid, and this white substance, folded upon itself, acquired a considerable degree of firmness, precisely as the retina does when immersed in spirit of wine. The little cylinder, as well as the hard substance which occupied the place of the corpus ciliare, was evidently the membrane of the vitreous humour, emptied of water, and converted into a mass, partly spongy, as I have said, and partly lipomatose. It is not easy to determine whether this fungous and lipomatose degeneration of the membrane of the vitreous humour had preceded the dropsey of the eye, or had been the consequence of it. This case, however, added to several others of dropfical eyes which I have examined, in which no vitreous humour was found in the posterior part of the eye, but only some water or bloody lymph, contributes greatly to prove, that this disease consists principally
in

in a morbid secretion of fluid from the small cells of the vitreous humour, and sometimes, also, in a singular degeneration of the alveolar membrane, of which the vitreous humour is composed.*

The increased secretion of aqueous fluid, both into the small cells composing the vitreous humour, and into other parts of the eye-ball; the rupture of those cells from excessive distension; and at the same time the diminished energy of the absorbent system of the affected eye, are most probably the causes of the morbid accumulation of the humours of the eye. From the stagnation and gradual increase of the vitreous and aqueous humours, it necessarily follows, that the eye-ball assumes at first an oval figure, terminating in a point at the cornea; then, by enlarging in all its dimensions, it arrives at a size greater than the other, and ultimately protrudes out of the orbit, so as no longer to admit of being covered by the eye-lids, disfiguring the patient's countenance, as if an ox's eye had been inserted in the place of the natural one.

* A case, nearly similar to this, is related in the *Medical Observations and Inquiries*, vol. iii. art. 14. It is to be observed, however, that in the child mentioned in this work, the eye first began to diminish in size, and afterwards to become dropfical, and to acquire a very considerable bulk, which, if it had taken place in the case that came under my observation, could not have been known.

This

This disease is sometimes preceded by blows upon the eye or corresponding temple, or by an obstinate internal ophthalmia; at other times by no other inconvenience than a troublesome sense of swelling and distension in the orbit, difficulty in moving the eye-ball, and considerable diminution of sight: and lastly, by none of these causes, nor by any other sufficiently evident; especially if the disease happens in children at a very early age, from whom no account can be obtained. As soon as the eye has assumed the oval figure, and the anterior chamber has become larger than natural, the iris appears placed more backwards than usual, and is in a singular manner tremulous on the slightest motion of the eye-ball. The pupil remains dilated in every degree of light; and the crystalline is sometimes brown from the commencement of the disease, at other times it only becomes so in the highest degree of it. When the disease becomes stationary, and the crystalline lens is not profoundly opaque, the patient can distinguish light from darkness, and, in a small degree, the figures of bodies, and the most vivid colours; but when the eye increases still more in bulk, and the crystalline is entirely opaque, the retina is, as it were, rendered paralytic, by the excessive distension, and consequently is no longer sensible to the few rays of
light

light which pass through the edges of the opaque crystalline to reach the bottom of the eye.

In the last stage of this disease, or when the dropfical eye-ball protrudes out of the orbit, and can no longer be covered by the eye-lids, to the ill effects already enumerated, are added those which arise from the aridity of the eye-ball, the contact of extraneous bodies, the friction of the cilia, the discharge of matter and tears, the ulceration of the lower eye-lid, upon which the eye-ball presses, and the excoriation of the eye-ball itself; in consequence of which, the dropfical eye is occasionally attacked with violent ophthalmia and severe pain in the affected part, and the whole of the head. Nor does the ulceration always keep within certain bounds, but spreads, first rendering the cornea opaque, and afterwards destroying the sclerotica, and, in proportion, the other component parts of the eye-ball.

On the first appearance of the dropsy of the eye, surgical writers advise the internal administration of mercurials, the extract of cicuta, that of the *pulsatilla nigricans* (*anemone pratensis*); and externally, astringent and corroborant collyria, a seton in the neck, and compression upon the protruding eye-ball. As far, however, as I have consulted the result of the observations of the best practitioners upon this subject, I have not met with a single history

correctly detailed of a cure of the dropfy of the eye by means of these internal remedies. And, with respect to the external applications, I know from my own experience, that when the disease is manifest, astringent and corroborant collyria, as well as pressure upon the protuberant eye, are highly injurious. In these cases, I have succeeded in quieting, for some time, the uneasy sense of distension within the orbit, and upon the forehead and temple of the same side, of which patients in this state complain so much, particularly when they are affected with recurrent ophthalmia, by means of a seton in the neck, frequent ablutions with the aqua malvæ, and the application of a plaster made of the same plant. But as soon as the eye-ball begins to protrude from the orbit, and to pass beyond the eye-lids, there is no means of preventing the unhappy consequences of the disease, but by an operation which consists in evacuating the superabundant humours of the eye, by means of an incision, and thereby obliging its membranes, in consequence of a mild inflammation and suppuration of the internal part of the eye, to contract themselves, and retire to the bottom of the orbit. To defer this operation longer, would be to abandon the patient to the inconveniences of an habitual ophthalmia, the danger of ulceration of the eye-ball and
subjacent

subjacent eye-lid, and even to the carcinoma of the whole eye, with the hazard of his life.

To fulfil this indication of emptying the eye-ball of the superabundance of aqueous humour stagnating in it, the *paracentesis* of the eye-ball was formerly highly commended. *Nuck*,* one of the advocates for this operation, punctured the eye by means of a small trocar, precisely in the centre of the cornea. Afterwards it was judged more proper to puncture the eye-ball through the sclerotic coat, at about two lines from its union with the cornea, for the purpose of more easily evacuating the vitreous humour also, together with the aqueous, in such quantity as might be thought sufficient to diminish the morbid enlargement of the eye-ball.

This method of operating in the dropsy of the eye, notwithstanding the approbation it received from the most celebrated surgeons, is at present fallen into disuse, as ineffectual and inadequate to the purpose. Nor will this appear surprising to those who are acquainted with our present notions upon the animal œconomy, particularly with respect to the absorbent system, and who are not unaware how little can be reckoned upon the favourable success of the *paracentesis*, as a mode of treatment in chronic

* *De Duct. Ocul. Aquos*, page 120.

dropfies in general, but particularly that of the tunica vaginalis, or *hydrocele*. For the radical cure of the latter is never obtained, unless, after the water is evacuated, the adhesive inflammation takes place in the tunica vaginalis and albuginea, or when both these membranes suppurate, ulcerate, and contract a firm adhesion to each other, by which the possibility is taken away of any further collections of water in the scrotum. And if it has occasionally happened that the puncture has effected a radical cure of the hydrocele, it is because by an unforeseen accident it has excited an inflammation of the tunica vaginalis and albuginea, and has thereby produced a coalescence of these two membranes.

According to these principles, the paracentesis of the eye, directed only to evacuate the superabundant quantity of fluid contained in it, cannot be a means of curing the dropfy of this organ, unless the puncture made by the trocar excite an inflammation and suppuration, and afterwards a coalescence between the membranes composing it. Nuck relates, that, in a young man of Breda, on whom he performed the operation, he was obliged to puncture the eye five times at different periods; that at the 6th time it was necessary to employ suction through the canula, in order to evacuate the greatest possible quantity of vitreous humour; and lastly, that

he was under the necessity of introducing a plate of lead between the palpebræ and eye, for the purpose of maintaining a continual pressure upon the empty and diminished eye-ball. In a woman of the Hague, he says, that he punctured the eye twice without advantage, and that she was two or three times more subjected to the same operation, without, however, adding what was the result of it. I have not much difficulty in believing, that the radical cure of the dropsy of the eye may have been sometimes obtained by means of the puncture, after repeated introductions of the trocar, and other similar harsh modes of treatment with the canula of this instrument, introduced into the eye-ball; but this success cannot be attributed to the simple evacuation of the superabundant quantity of vitreous and aqueous humour; but to the irritation produced by the canula, and to the consequent adhesive inflammation or suppuration excited in the internal membranes of the eye. It is not surprising that Woolhouse, after having learnt this from experience, wishing to secure the perfect success of the *paracentesis*, for the radical cure of the dropsy of the eye, should afterwards have taught that when the canula has been introduced into the eye, it ought to be rotated between the fingers at least six times; and, according to the same rule, Platner should have proposed, that after the humours of the
eye

eye have been discharged by means of the trocar, a tepid fluid should be injected into the eye through the canula; and Mauchart, that the aperture made in the eye should be kept open by means of a small tent of lint. If all these circumstances prove on the one hand the insufficiency of the paracentesis in the radical treatment of the dropfy of the eye, they evidently shew on the other, that the perfect cure of this disease can only be obtained by emptying the eye of its humours, and at the same time exciting in its internal membranes, a certain degree of inflammation and suppuration.

In order to obtain this completely, the most easy and expeditious method hitherto proposed, is, without doubt, that which I have detailed in the preceding chapter on the radical treatment of the inveterate staphyloma, which projects beyond the eye-lids. Upon which I cannot but repeat also upon the present occasion, that the circular excision of the dropfical eye-ball in the sclerotic coat is highly disadvantageous, if not dangerous. For this operation is constantly followed by the most alarming symptoms, as repeated hæmorrhages, collections of grumous blood in the bottom of the eye-ball, violent inflammation of the eye-ball, of the eye-lids, and head; incessant vomiting, convulsions, and delirium, with great hazard of the patient's life. Those modern writers indeed, who have faith-

fully communicated to the public the result of their practice upon this subject, in the number of whom, after Louis,* Marchan,† and Terras,‡ deserve much praise, have ingenuously declared that in some cases of dropsy of the eye, in which they have performed this operation, they have had much reason to regret their attempt.

The circular incision made in the upper part or centre of the cornea of the dropical eye, of the circumference of a large lentil-seed, or rather more, in the manner described by Celsus on the subject of staphyloma, is exempted from these very unpleasant consequences. By means of this operation, which is in no degree painful, an opening is made for the discharge of the humours, and an inflammation is promoted in the internal parts of the eye. And this is obtained without occasioning that sudden evacuation and subsidence of the membranes of the eye, which necessarily happens when the circular incision is made in the sclerotic coat, which greatly affects the nerves of this organ, and the parts which sympathize with it, as the head and stomach; this intimate consent not being perhaps the least of the causes from which the unhappy consequences before mentioned are produced; independently of those which necessarily arise from

* Mémoires de Chirurg. T. xiii page 286. 290.

† Journal de Med. Paris. Janvier 1770. Sur deux exophthalmies ou grosseurs contre nature du globe de l'œil.

‡ Ibidem Mars 1776. Sur l'hydrophthalmie.

the almost sudden exposure of a large surface of the bottom of the eye to the contact of the air, and the frequent use of lotions which are employed in these cases.

With respect to the method of operating, it is precisely the same as that detailed in the preceding chapter. The surgeon, therefore, whether the cornea be transparent or not (since, as I have said, the immediate organ of vision, in these cases, is irremediably lost) should pierce this membrane with the small knife, at the distance of a line and a half from its summit or centre, and passing the instrument from one canthus of the eye to the other, should divide it downwards in the form of a semicircle, then having raised this segment of it with the forceps, and turned the cutting edge of the knife upwards, he should complete the operation by removing a circular portion of the centre of the cornea, of the size of a large lentil-seed, or three lines in diameter in the case of an adult. Through this circular opening in the centre of the cornea, the surgeon, by a gentle pressure, should force out as much of the superabundant humours of the eye, as may be sufficient to allow the diminished eye-ball to re-enter the orbit, and be covered by the eye-lids. For the remainder, which is left stagnating in the eye, will gradually flow out through this circular aperture in the centre of the cornea,

without the assistance of further pressure. Until the appearance of the inflammation on the 3d or 5th day from the operation, the eye should be covered by a dry compress and bandage. But as soon as the eye and eye-lids begin to be inflamed and swollen, the surgeon should, if necessary, employ the internal remedies suited to moderate the inflammation, and should cover the eye-lids with a poultice of bread and milk, which ought to be renewed every two hours at furthest. It very frequently happens, both in the case of staphyloma and in the dropsy of the eye, that on the first appearance of the inflammation, the eye which has been operated on increases in size, and protrudes out of the eye-lids again, nearly as much as before the operation. In this case it will be useful to cover the projecting portion of the eye-ball with a small piece of fine linen spread with a liniment composed of oil and wax, or with the yolk of an egg and the oil of St. John's wort, over which the poultice of bread and milk should be applied.

When the suppuration of the internal part of the eye has commenced, which will be evident by the dressings being moistened with a tenacious lymph mixed with a portion of the humours of the eye, which will incessantly flow from the opening in the cornea, and by the margin of the incision assuming a pale sloughy appearance, the eye-lids will subside, the eye-ball diminish

diminish in size and gradually re-enter the orbit, and will continue to contract itself more and more. The small sloughy margin of the wound in the cornea will afterwards separate in the form of an eschar, and leave a small ulcer of a healthy colour, which in the same manner as the eye-ball will gradually contract till it is closed and entirely healed, leaving sufficient room between the eye-lids, and the mutilated portion of the eye-ball, for the apposition of an artificial eye.

Although the circular excision of the centre of the cornea of the size of a large lentil-seed, be sufficient in the adult to excite a mild inflammation and suppuration in the internal part of the eye; yet if this should not manifest itself before the 5th day, it will be necessary to expose the eye to the air, or as I have said, in speaking of the staphyloma, to remove a circular portion of the cornea, by means of the forceps and curved scissors, a line or rather more in breadth; which occasions the patient no inconvenience or pain, and produces the desired effect of ultimately exciting an inflammation and mild suppuration of the internal part of the eye, without which a complete cure cannot be obtained.

CASE LXV.

A peasant boy, 13 years of age, of a healthy and robust constitution, had no other complaint,

except an immoderate enlargement of the right eye, which projected so much out of the orbit that the eye-lids were not sufficient to cover it. The cornea of this eye, although not clear, allowed the deeply-seated iris to be yet seen through it, the pupil dilated, and the crystalline of a dark colour. His mother informed me that at two years of age, a little after the desiccation of the small-pox, he was afflicted with a violent inflammation in both his eyes with a dense cloud, particularly in the right eye; that by means of repeated blisters to the neck and behind the ears, and other external and internal remedies, he finally recovered the use of his left eye; but that the right remained in the same state; and that it afterwards enlarged gradually till it acquired the enormous size which it had when I saw him; without his having ever complained of violent pain in it. The boy being taken into the hospital I agreed to perform the operation upon him, which was on the 8th of June 1797.

Having pierced through the middle part of the cornea with the small knife which is used for the extraction of the cataract, and elevated the lower segment of it with the forceps, I removed a circular portion of the centre of the cornea with Daviel's scissors, rather more than two lines in diameter; and as the crystalline did not advance by a slight pressure, I opened
its

its capfulè with the point of the knife, from which a milky humour immediately escaped, and afterwards the dark coloured nucleus of the crySTALLINE, and by a moderate degree of pressure, a considerable quantity of vitreous humour in a state of dissolution, by which the eye-ball was so much diminished, that on directing the patient to close his eye-lids, they were sufficient to cover it completely.

The boy did not seem to feel much pain during the operation, and passed the first and second day out of bed, without experiencing any inconvenience. On removing the compress and bandage from time to time, they were moistened with a glutinous humour, which had all the appearance of being the dissolved vitreous humour. On the 4th day I found the eye-lids swollen, red, painful, and a little separated, and the eye-ball inflamed, with a slight pain in the head, and a little fever. I ordered a poultice of bread and milk to be applied upon them, and to be renewed every two hours.

On the 7th day the suppuration commenced in the internal part of the eye-ball, at first of a ferous, and afterwards of a mucous and good quality, with a diminution of the fever and pain. The suppuration continued in larger or smaller quantity for two weeks, and in the mean time the palpebræ and eye-ball subsided greatly, and the latter very much diminished in

size, retired towards the bottom of the orbit. The small floughy circle which furrounded the incision in the centre of the cornea, separated entirely, and left a small wound of a florid colour, which in a week closed, and by a few applications of the *argentum nitratum* healed entirely. The deficiency of the eye might have been easily supplied by an artificial one.

CASE LXVI.

A young lady, 16 years of age, of a delicate constitution, in other respects healthy and regular, was affected with an enlargement of the left eye, which increased in all its dimensions, so as in the course of nine years to become twice the size of the opposite one, projected out of the orbit, and did not admit of being covered by the eye-lids.

Her parents attributed this disease to a fall which she had had when a child upon a heap of wood and rubbish, by which she struck and violently bruised her left eye, which was greatly discoloured externally. The cornea of this eye was, to some extent, become opake; but the pupil, notwithstanding, could be seen beyond it irregularly dilated, and the crystalline dark.

While the eye-ball remained on a level with the orbit, the patient complained of no greater inconvenience than that of blindness, but as soon

as it could be no longer covered by the eye lids an ophthalmia supervened, which became habitual, and was occasionally communicated to the sound eye; and this was accompanied with a very troublesome sense of tension in the enlarged eye, and in the temple of the same side. Astringent applications, compression, and the internal use of the *pulsatilla nigricans* had, as far as it appeared, augmented the pain in the head and eye, and had rendered the attacks of ophthalmia more frequent than before.

On being consulted, I proposed to empty the dropical eye by the excision of a portion of the cornea, as the only expedient capable of arresting the progress of the disease, and preserving the sound eye. The patient, as well as her friends, rejected this project as too violent and extreme. In order to allay the pain in the eye and head, and the troublesome sense of tension in the orbit, I prescribed to the patient the application of small bags of mallows with a little camphire, and the emulsion of gum arabic with a few drops of the tincture of opium to be taken at night.

Two months after the consultation, the same inconveniences returned with so much violence, that the patient demanded to have the operation instantly performed; which was executed precisely as in the preceding case, that is, by removing a circular portion in the centre of the

the

the cornea, of the size of a large lentil-seed. Some aqueous, and a large quantity of thin vitreous humour flowed out, and also the dark crystalline in a state of dissolution. The eye-ball retired a little within the orbit, so as to be covered by the eye-lids.

The patient found great relief from this evacuation of the eye, and continued perfectly easy till the 5th day. Finding, however, that the eye was slow in inflaming, I directed the patient to keep it exposed to the air the whole of the 6th day. On the night of the 7th the eye-lids were tumefied, and the eye-ball began to inflame, and gradually to enlarge so much as to be ready to project out of the eye-lids again. The fever, however, and the pain in the eye and head were moderate. The eye-lids and eye were covered with a cloth spread with the yolk of an egg and oil of St. John's wort; and over it was applied a poultice of bread and milk. The general treatment was limited to some emollient clysters and a low diet.

On the 11th day the ferous suppuration appeared, and afterwards the mucous, which continued abundant for 20 days longer, on the appearance of which, the fever and pain in the eye entirely abated, and the tumefaction of the palpebræ and eye-ball gradually subsided. The small sloughy circle around the incision in the cornea was afterwards detached as usual; the
little

little ulcer of a good colour contracted, forming in the centre a kind of fleshy papilla, which was repressed by the *argentum nitratum*, and finally healed entirely. The young lady, though cured, could not bear the application of the artificial eye, till eight months after the evacuation of the eye-ball.

CASE LXVII.

In the beginning of June 1799, Signor Vincenzo Visconti, a very able apothecary of this city, came to me with his infant son, about a year and a half old, who had been just brought to him from the country, where he had been nursed, that I might examine the left eye, which had become considerably more turgid and prominent than the right, with tumefaction of the eye-lids of that side, and a species of fugillation of the conjunctiva, particularly towards the internal angle. The father conjectured that it had arisen from a fall or blow upon the left eye; but the nurse strongly denied it. The child did not seem to be in pain, and appeared as if he could see with this eye. I ordered the little patient to be gently purged, and resolvent fomentations to be applied externally.

These remedies were of no advantage, and the eye-ball increased in size with such rapidity, that by the middle of November of the same year it projected out of the orbit prodigiously,
and

and was so large as not to admit of being covered by the eye-lids; which, as well as the conjunctiva, were occasionally inflamed, without any evident cause, on which account it was sometimes necessary to take away blood locally, by means of leeches. At this period the sight of the left eye was greatly diminished, if not entirely lost.

The rapid enlargement of the eye-ball, the inutility of the remedies hitherto employed, the deformity of the countenance, and more particularly the danger of the sound eye being affected by it, or the dropsy degenerating into a much worse disease, determined me, together with Signor Volpi, surgeon of this hospital, to empty and diminish the size of the dropical eye.

On the 21st of November, therefore, the child being placed upon a table, and held by proper assistants, with the small knife, which is used for the extraction of the cataract, I pierced through the cornea of the dropical eye, near the centre of it, and taking hold of the divided semicircular border with the forceps, and turning the cutting edge of the knife upwards, I removed a circular portion of the centre of the cornea, of the diameter of a small lentil-seed. I chose, in this, case, to remove as little of the centre of the cornea as possible, not only as I was desirous of ascertaining again, whether the
symptoms

symptoms consequent on the evacuation of the eye-ball, are in proportion to the extent of the circular incision made in the cornea, but because I greatly feared, that in so young a child, a sudden and violent inflammation of the eye and eye-lids might be attended with fatal consequences.

Through this small aperture formed in the centre of the cornea, the semifluid and dissolved crystalline escaped, and a large quantity of thin vitreous humour; so that the eye-ball instantly retired within the eye-lids, which were covered with a compress and bandage. The child slept a little after the operation, and afterwards got up and passed the rest of the day as usual, in play, without shewing any sign of pain.

From the 21st to the 28th, some fluid resembling the dissolved vitreous humour flowed from the eye, and the eye-ball and palpebræ subsided daily; but no appearance of inflammation presenting itself in the internal part of the eye, I ordered that the child's eye should be uncovered, with the precise view of causing it to inflame; which, however, had no effect.

On the 30th of November, I observed that a portion of the vitreous humour, not dissolved, but consistent and globose, protruded out of the circular aperture formed in the centre of the cornea, and the eye-ball appeared less diminished than it was on the preceding days. With a
stroke

stroke of the scissars I removed this obstacle formed by the vitreous humour, and on pressing upon the eye-ball gently, a considerable quantity of bloody serum flowed out, after which the eye-ball became as small as on the preceding days.

On the 2d of December some signs of inflammation in the eye-lids and conjunctiva appeared. The child seemed desirous to lie-in bed. I ordered a bread and milk poultice to be applied upon the tumid eye-lids.

On the 8th of December, the inflammation of the eye-lids and conjunctiva, instead of extending, as I had hoped, within the eye-ball, had, on the contrary, entirely ceased, and a portion of the iris presented itself at the small opening made in the centre of the cornea, which completely closed up this aperture, and the eye-ball, in the mean time, became again turgid. I pushed back this procidentia of the iris with the point of a probe, and immediately a remarkable quantity of bloody serosity flowed out.

Convinced now, that the circular aperture formed in the centre of the cornea was too small, and less than was requisite for exciting an inflammation of the internal membranes of the eye; by means of the forceps and curved scissars I removed a circular portion from the border of the cornea, so as to render this opening of a circumference

ference equal to a large lentil feed. After this an inflammation was speedily excited in the internal parts of the eye-ball, which had a very mild course, never obliging the child to lie in bed, nor causing it any acute pain. The internal inflammation having terminated in suppuration, true pus began to appear upon the poul-tice: from this time the cure proceeded with the greatest regularity to the end, without the child's ordinary mode of living, or its usual good humour being interrupted.

In proportion as the discharge of matter proceeding from the internal part of the eye diminished in quantity, the eye-lids subsided, and the eye diminished in size, and sunk towards the bottom of the orbit, leaving at last a regular surface, which would serve at pleasure for the convenient support of an artificial eye.

The result of this history proves, in the most convincing manner, what has been asserted in the two last chapters; that the violence of the symptoms consequent on the operation of the *staphyloma* and dropsey of the eye, are in proportion to the extent of the circular incision made in the eye-ball, for the evacuation of the humours. That therefore the very useful precept of Celsus, of removing only a circular portion of the centre of the cornea, of the size of a lentil-feed, admits of some exceptions. For if this incision be too small to allow the humours to

be readily discharged, and the blood which afterwards collects within the eye-ball, or be such as to be easily closed up by some portion of the vitreous humour, which is not dissolved, by a portion of the iris, or by grumous blood, it gives occasion to new collections of bloody serosity within the cavity of the dropical eye, and prevents the inflammation and suppuration of its internal membranes; a circumstance absolutely necessary to obtain the end which the surgeon proposes in the treatment of this disease.

C H A P. XIX.

OF THE AMAUROSIS AND OF THE HEMERALOPIA.

THE celebrated surgeons Schmucker and Richter, guided by observation and experience, have treated this subject with so much precision and clearness, that it only remains for me at present to add some reflections and facts, which tend to confirm the truth and utility of the doctrine of these two illustrious writers, and thus facilitate the studies of the young surgeon.

The amaurosis is *perfect or imperfect, inveterate or recent, continual or periodical*. The *perfect inveterate amaurosis*, with organic injury of the substance constituting the immediate organ of vision, is a disease absolutely incurable. The *imperfect recent amaurosis*, particularly that which is *periodical*, generally admits of a cure, since it is most frequently connected with a disordered state of the stomach and primæ viæ, or is dependent on causes, which though they affect the immediate organ of vision, may be removed

without leaving any trace of disorganization, either in the optic nerve or retina.

In general, those cases of amaurosis may be regarded as incurable which have existed for several years, in persons advanced in age, and whose sight has been weak from their youth; those which have been slowly formed, at first with a morbid increase of sensibility in the immediate organ of vision, and afterwards with a gradual diminution of perception in this organ to complete blindness; those in which the pupil is immoveable, without being much dilated, but where it has lost its circular figure, or when it is so much dilated as to appear as if the iris were wanting, having also an unequal or fringe-like margin; in which the bottom of the eye, independently of the opacity of the crystalline lens, has an unusual paleness, similar to horn, sometimes inclining to green, reflected from the retina as if from a mirror;* which are accompanied with pain of the whole head, and with a constant sense of tension in the eye-

* The retina of a sound eye is transparent, and, therefore, in any degree of dilatation of the pupil, the bottom of the eye is of a deep black colour. This unusual pallor then which accompanies the amaurosis, indicates that a considerable change has taken place in the substance of the optic nerve forming the retina, which, according to all appearance, is become thickened, and rendered permanently incapable of transmitting the impressions of light. This sign, therefore, is one of the most unfavourable.

ball;

ball; which have been preceded by great and protracted incitement of the whole nervous system, and afterwards by general debility and languor of the whole constitution, as after the long abuse of spirituous liquors, masturbation, or premature venery; those which have been preceded or accompanied by attacks of epilepsy, or by frequent and violent hemicrania; which have come on in consequence of violent and obstinate internal ophthalmia, at first with an increased, but afterwards diminished sensibility of the retina, and slowness of motion in the pupil; which, besides being inveterate, are the consequence of blows upon the head; which have been occasioned by direct blows upon the eye-ball; which have appeared after violent contusion and laceration of the *supraorbital* nerve,* whether this has taken place immediately after the blow, or some weeks after the healing of the wound of the supercilium; which have been occasioned by extraneous bodies penetrating the eye-ball, as leaden shot,† &c.; those which are derived from the confirmed lues venerea, in which the presence of one or more exostoses upon the forehead, upon the sides of the nose, or upon the maxillary bone,

* Of the numerous cases of amaurosis of this kind, I do not know that any one has been cured, except that related by Valsalva, in his Differt. II. § XI.

† Netti, *Instituzioni de Chirurgia*, T. iii. page 282.

lead to the suspicion that there may be also similar exostoses within the orbit: lastly, those which are conjoined with a manifest change of figure and dimension of the whole eye ball, as when it is of a long oval figure, or of a preternatural bulk or smallness. Maitre-Jan certainly alluded to these causes of amaurosis, when he said, *c'est rechercher la pierre philosophale que de vouloir chercher des remedes pour guérir le goutte seréine; cette maladie est absolument incurable.*

On the contrary, those cases of *recent imperfect amaurosis*, most frequently at least, if not always, admit of a cure, which, although the patient be almost, or even completely deprived of sight, have not been produced by any of those causes which are capable of contusing, or destroying, the organic texture of the optic nerve or retina; in which the immediate organ of vision preserves some, though little, sensibility to the light, whether in the direction of the axis of vision or laterally; those cases of sudden or recent amaurosis, in which, although the pupil is preternaturally dilated, it is not excessively so, and is regular in its circumference; behind which the bottom of the eye is of a deep black colour, as in a natural state; which have not been preceded or accompanied by violent and continual pain in the head and eye-brow, nor by a sense of constriction in the eye-ball; which have originated from violent anger, excessive
grief

grief or terror; those which have succeeded an excessive fulness and crudity of the stomach, plethora either general or confined to the head, the suppression of accustomed sanguineous discharges from the nose, uterus or hæmorrhoids; those occasioned by an evident metastasis of variolous, rheumatic, herpetic, or gouty matter; which are the consequence of profuse loss of blood; which are to be referred to a nervous debility not inveterate, in persons who are young, and which is consequently yet susceptible of being remedied; those produced by convulsions and violent efforts during a laborious parturition; those which accompany the course or decline of acute or intermittent fevers; and those, lastly, which are *periodical*, or which come on and disappear at intervals, every day, every three days, every month, or at a certain season of the year.

By an attentive examination of the nature and causes of the imperfect amaurosis which admits of a cure, it is found, from the careful observations of Schmucker and Richter, that this disease is most frequently derived from a morbid excitement or irritation in the digestive organs, either alone or accompanied with general nervous debility, in which the eyes participate sympathetically. According to these principles, in the greater number of cases of *recent imperfect amaurosis*, the principal indication of cure which the

surgeon ought to fulfil in the treatment of this disease, is that of unloading the stomach and primæ viæ of the saburræ and morbidic stimuli; and afterwards of strengthening the gastric system, facilitating the digestion, and at the same time exciting the whole nervous system, and particularly that of the eyes, which are affected and rendered torpid by a sympathetic connection.

With respect to the first part of the treatment of the *imperfect amaurosis*, the intention is perfectly answered by emetics and internal resolvents. In the class of emetics, experience has taught that the *antimonium tartarizatum* is preferable to every other, and that when given afterwards in small and divided doses, it answers the purpose of a resolvent medicine, the action of which may be increased by conjoining it with gummy or saponaceous substances. In the treatment of the imperfect amaurosis, therefore, which is most frequently sympathetic, and depending on acrid matters in the primæ viæ, it will be proper at first, in the greater number of cases, to dissolve for an adult, 3 grains of tartarized antimony in 4 ounces of water, of which 2 table-spoonsful may be taken every half hour, until it produces nausea, and afterwards abundant vomiting. On the following day he should be ordered to take the resolvent powders, composed of one ounce of the crystals of tartar and
one

one grain of the tartarized antimony, divided into six equal parts, of which the patient should take one in the morning, another four hours afterwards, and the third in the evening, during eight or ten successive days. This medicine will produce a slight nausea, and some evacuations of the bowels more than usual, and perhaps, after some days, even vomiting. But if, during the use of this opening powder, the patient make ineffectual efforts to vomit, and complain of a bitter taste and want of appetite, without any amendment of the sight, the emetic should be repeated, and even a third and fourth time, if the presence of the morbid stimuli in the stomach, bitter taste, tension of the hypochondria, acid eructations, and tendency to vomit require it. For it not unfrequently happens, that the patient, on the first evomition, throws up only water with a little mucus, but on repeating the emetic, after the nauseating powder has been used for some days, a considerable quantity of yellowish green matter will be thrown up, which will greatly relieve the stomach, head, and eyes.

The stomach being cleared, the opening pills of Schmucker should be prescribed,* or those of Richter,

* R. Gum. Sagapen.

Galban.

Sap. venet. an. drachmam j.

Rhei opt. drachmam unam et semis.

Richter.* The phænomena which are usually observed to happen in consequence of this treatment, are the following: the patient, after having vomited copiously, feels more easy and comfortable than before. Sometimes on the same day on which he has taken the emetic he begins to distinguish the surrounding objects; at other times this advantage is not obtained till the 5th, the 7th, or 10th day; and in some cases not till some weeks after the adhibition of the emetic, and the uninterrupted use of the opening powders or pills. As soon as the patient begins to recover his sight the pupil is found less dilated than before, and is also more contracted when exposed to the vivid light of a candle; and in proportion as the power of vision augments, this contraction and mobility of the pupil increases. Upon the whole, the cure

Antim. tartariz. grana xvj.

Suc. liquirit. drachmam unam F. Pilul. gran. unius.

The patient should take 15 of these pills, morning and evening, for the space of 4 or even 6 weeks.

* R. Gumm. Ammoniac.

Aff. fœtid.

Sap. venet.

Rad. Valerian, s. p.

Summit. arnicæ an. drachmas duas.

Antim. tartariz. gran. xvij. F. pilulæ granorum duorum.

The patient should take 15 of these pills 3 times a day for some weeks.

is seldom completed in less than a month, during which time the use of local remedies calculated to excite the languid action of the nerves of the eye should not be neglected, as will be hereafter mentioned.

When the surgeon shall have sufficient reason to believe, that by means of these remedies the offending matters which stimulated the stomach have been perfectly eliminated, and especially after the patient has, in a great measure, regained his sight, the plan of treatment should be directed to strengthen the stomach, and invigorate the nervous system in general, and that of the nerves of the eye in particular. He should therefore prescribe a powder composed of one ounce of the cinchona and half an ounce of valerian root, divided into six equal parts; of which the convalescent should take one in the morning and another at night, in any convenient vehicle, and should continue the use of this medicine for at least five weeks. In the mean time he should live on tender succulent food, and cooling broths, should take a moderate quantity of wine, and use gentle exercise in a salubrious air.

As a local application, both during the continuance and decline of the imperfect amaurosis, in order to rouse the languid action of the nerves of the eye, the vapour of the aqua ammoniæ puræ properly applied to the affected eye is of the highest

highest advantage. This remedy is employed by placing a small vessel containing it near the patient's eye; so that the very penetrating vapour with which it is surrounded may excite a pricking sensation in that organ; by the action of which, in less than half an hour, the eye which is exposed to it, becomes red and waters copiously. It is then proper to desist from it, and repeat it three or four hours afterwards, and continue it in this manner until the amaurosis is perfectly cured. If both the eyes are affected with this disease, it is unnecessary to observe that it is requisite to have two small vessels filled with the *aqua ammoniæ puræ*, or if one only be employed, that it will be necessary to hold it first to one eye and then to the other, until both water abundantly, and become red. It is necessary to renew the *aqua ammoniæ puræ* every 3d day, in order to preserve its activity. This very useful application ought to be employed from the commencement of the treatment of the imperfect amaurosis, or at least immediately after the patient's stomach has been unloaded of the offending matters, by means of an emetic, and continued for a length of time, even after the amaurosis is dissipated. Thilen,* besides many others, assures us, that he has also used this local remedy in such cases

* *Medicinische und chirurgische Bemerkungen* § Amaurosis.

with advantage. The action of the vapour of the caustic volatile alkali applied to the eyes affected with incomplete amaurosis, may be also assisted by other external stimuli applied to parts of the body which have a close consent with the eyes, as blisters to the neck, friction upon the eye-brow with the anodyne liquor, and irritation of the nerves of the internal nostrils by means of sternutatory powders, as that composed of two grains of the hydrargyrus vitriolatus, and a scruple of the powder of the leaves of betony; and lastly, the electric fluid. Electricity has been proposed as one of the principal means of curing the amaurosis, but experience has shown that no confidence is to be placed in it, except as a secondary remedy; and Mr. Hey,* one of the most zealous promoters of this practice, confesses, that electricity is only useful in cases of recent amaurosis, and most frequently only when combined with appropriate internal remedies, among which, resolvers are the principal.

With respect to the *imperfect periodical amaurosis*, every practitioner would be disposed to believe that the cinchona ought to be the specific; experience, however, has proved the contrary, and convinced us that this excellent remedy, which is so efficacious in intermittent

* Medical Observations and Enquiries, vol. v. page 26.

fevers and other periodical diseases, rather aggravates the *imperfect periodical amaurosis*, and renders its attacks more frequent, and of longer duration than before. This disease, on the contrary, is most frequently cured in a short time, by emetics and internal resolvents; and lastly, by corroborants and the cinchona, which before was useless or injurious.

This plan of treatment in the *imperfect amaurosis* of recent date, is, in the greater number of cases, employed with perfect success, since the disease, as it has been remarked before, is only sympathetic, and principally dependent upon the morbid state of the digestive organs. There are, however, as I have also observed, cases of imperfect amaurosis, to the formation of which, besides the more common causes enumerated, others concur, which require the employment of particular methods of treatment, besides those which I have mentioned. Such is, for instance, the *imperfect amaurosis*, which takes place suddenly, in consequence of excessive heat, insolation, violent anger in plethoric persons, which demands, before every other measure, the general and partial abstraction of blood, cold fomentations to the eyes, and the whole head; afterwards an emetic, or the purges with the kali tartarizatum, or antimonium tartarizatum, in small doses. Schmucker relates, that he had frequently, by means of bleeding and an emetic, restored

restored the sight to soldiers who had lost it by making forced marches, when heavily loaded, in very hot weather. An emetic, after the evacuation of blood, is the more indicated, as in all these cases the patient complains at the same time of a bitter taste, of tension of the hypochondria, and continual nausea. Richter mentions a priest, who being violently enraged, became instantly blind, and to whom having given an emetic the next day, on account of his having evident symptoms of bilious saburræ, he recovered his sight the same day.

So likewise, in the treatment of the recent imperfect amaurosis, from a sudden suppression of the catamenia, the principal indication previously to the use of an emetic, is evidently that of reproducing the discharge of blood from the uterus, by means of leeches applied to the internal surface of the labia pudendi, and by pediluvia; and afterwards that of a vomit, of the opening pills before mentioned, or those of Bekker, or those composed of a grain of aloes and two of myrrh and saffron. If these should not succeed in reproducing the menstrual flux, much confidence may be placed in electric shocks passed from the loins through the pelvis in all directions, and from that part to the thighs and feet repeatedly, and without abandoning the hope of success, although the good effects of this treatment should not be evident for some weeks,

weeks, since I am persuaded from experience, that it is one of the most powerful means which we possess, both of reproducing and accelerating the discharge of blood from the uterus.

In the treatment of the imperfect amaurosis also, occasioned by the suppression of an habitual profuse hæmorrhoidal flux, and accompanied with tension of the hypochondria, congestion of blood in the head and eyes, difficult respiration and crudities of the stomach, previously to the use of an emetic, the most efficacious method of treating the blindness is that of the application of leeches and warm fomentations, to the hæmorrhoidal veins, in order to obtain a copious discharge of blood from them; afterwards an emetic will be necessary, and the opening pills of Schmucker, or instead of them, those composed of aloes.

So in the treatment of the recent imperfect amaurosis produced by the variolous, rheumatic, herpetic, or gouty metastasis, or from the impetigo of the head imprudently repelled, the surgeon's attention should be directed to eliminate the æcid matters stimulating the stomach, and at the same time determine the peccant humour from the eyes to some other part, by means of a consensual irritation excited in the neck by blisters or setons, or blisters to the arms, hands, or feet; and in the case of impetigo of the head, or of herpetic eruptions imprudently repelled,

pelled, after the stomach has been unloaded of the *faburræ*, it will be very useful to give Huxham's antimonial wine, with the extract of aconite, the extract of aconite with calomel, and the golden sulphur of antimony (sulph. antimon. præcip.) of the third precipitation, in divided doses, the kermes mineral, the decoction of the woods, and the warm-bath.

The method of curing the imperfect amaurosis, in consequence of fevers improperly treated; that derived from deep grief, fear, profuse hæmorrhage, profound meditation, or forced and intense exercise of the eyes upon very minute or bright objects, does not differ at all, or very little, from that which has been already delivered; and consists principally in removing the forces of the stomach, and afterwards in strengthening the nervous system in general, and particularly that of the eyes.

Indeed, in this consensual *imperfect amaurosis*, in consequence of fevers improperly treated, the the practitioner's attention is immediately called to the morbid state of the organs of digestion; as in this disease, besides the blindness or great diminution of sight, the countenance appears pale and tumid, the digestion is slow, the appetite wanting or depraved, there is a bitter taste in the mouth, vertigo of the head, disturbed sleep, and a turgid abdomen with flatulence. In this combination of circumstances, nothing contributes more to

the restitution of the patient's sight than the use of an emetic, and the resolvent pills; afterwards the cinchona, bitters, preparations of steel, and externally the vapour of the aqua ammoniæ puræ.

Deep grief and terror have a direct action, as it were, at the same time, upon the nerves of the eyes and the organs of digestion, the function of which latter is so perverted by these affections, that bilious acrid saburræ speedily accumulate in them, from the stimulus of which the nervous system in general, and particularly that of the eyes, is consensually affected, and, I might say, almost rendered torpid. If, therefore, an emetic be indicated in any case of recent *imperfect amaurosis*, as one of the principal means of dissipating incomplete blindness, it is certainly in the case where the disease is derived from grief or terror; the good effects of which have been repeatedly confirmed by experience. When the stomach and intestines are unloaded of the bilious acrid matters, by means of the tartarized antimony, or resolvent pills, the treatment in this case also is completed by the cinchona, conjoined with valerian root; and by fumigations of the aqua ammoniæ puræ; by nourishing and easily-digestible food; by diverting the mind and directing it to agreeable objects; and by moderate exercise of the whole body. It is to be observed only, that the im-

perfect

perfect amaurosis, occasioned by fear, demands the continuation of these remedies for a much longer time than that produced by grief.

The *incomplete amaurosis*, which arises from general nervous debility, in consequence of profuse hæmorrhage, convulsions from *inanition*, or long continued application to deep studies, especially by candle-light, is less in reality an *amaurosis* than a weakness of sight, from exhausted energy of the nerves, particularly of those which constitute the immediate organ of vision. This inconvenience is cured or diminished, if recent and in young persons, by small and divided doses of the tincture of rhubarb, in order to cleanse the stomach and primæ viæ; afterwards by corroborant and cardiac remedies, and by the patient desisting from whatever debilitates the nervous system, and consequently the sight. Lastly, when the stomach is cleared of the *faburræ*; the decoction of cinchona with valerian may be prescribed with advantage, the infusion of quassia, with the addition of a few drops of vitriolic æther in each dose, nutritious animal food of easy digestion, and viper broth. The aromatic spirituous vapour mentioned in the chapter on ophthalmia may be usefully employed as a local application, and if this should not succeed, much advantage may be derived from that of the aqua ammoniæ puræ. The patient should take exercise on foot, horseback,

or in a carriage, in a pure and dry air, and in warm weather he should use sea-bathing. He should avoid as much as possible mental anxiety, and should not fix his eyes on very minute or lucid objects.* In proportion as he takes nourishment and regains strength, and the action of the nervous system in general is invigorated, his sight will gradually amend; to preserve and improve which, he should keep in mind, above all, to maintain the tone and vigour of the stomach, and to moderate the impression of light upon the eyes, which he may easily do by never exposing himself to a vivid light, unless when they are defended by plain green glasses.

* It occasionally happens that patients, in these cases, cannot look at a very near object, with one or both the eyes, without experiencing fatigue and pain in one or both of them, while they feel no inconvenience from looking at an object at a certain distance. And when the difficulty which they find in looking at a near object is confined to one eye, it is accompanied with strabismus and double sight. This depends upon a debilitated state of the muscles of the eyes, in consequence of which the patient cannot conveniently accommodate the eye-ball to very near objects, or maintain it for a length of time in this position; and when the debility is confined to the muscles of one eye, this being unable to concur in the actions of the other, strabismus and double vision are the necessary consequences. This inconvenience is also remedied by the general and local corroborants before mentioned, and by avoiding to strain the muscles of the eyes. And if the debility be confined to one eye only, and occasion the strabismus, it will be advantageous to keep the affected eye covered for some time.

The

The *hemeralopia* or *nocturnal blindness* is, strictly speaking, only an *imperfect periodical amaurosis*, most frequently sympathetic of disorder of the stomach, the attacks of which supervene towards the evening, and disappear in the morning. This disease is in some countries endemical, and in others epidemical at certain seasons of the year.

Those who are affected with this disease, see objects at sun-set as if covered with a greyish veil, which by little and little is converted into a dense cloud, interposed between them and the surrounding objects. The pupil both during the day and the night is more dilated and less moveable than it is usually in a state of health. In the greater number of cases, however, the pupil is more or less moveable in the day, and always enlarged and immoveable during the night. If the patient be placed in a room faintly lighted by a candle, where other persons can see sufficiently well, the objects are either discerned with difficulty, or cannot be seen at all, or he can only distinguish light from darkness; much less is he able to distinguish any thing by moonlight. On the approach of morning he recovers his sight, which remains perfect during the whole day, until sun-set.

The disease is generally cured, and frequently also in a short time, by treating it in the same manner as the imperfect amaurosis; by emetics,

the opening powders or pills, and by blisters to the neck; and locally, by the vapour of the caustic volatile alkali; and lastly, by the cinchona conjoined with the valerian root. In cases where the disease has been preceded by plethora or suppressed perspiration, bleeding, and sudorifics are also indicated.

By this method of treatment I succeeded in curing three patients attacked with it. The first was a boy 14 years of age, who, for several weeks, had used fumigations of boiled sheep's liver without advantage. The second was a waterman, and the third a husbandman of our neighbouring rice-fields. They were between 30 and 40 years old, each meagre, with a yellowish tumid countenance. The boy after having vomited copiously, by means of a grain and a half of tartarized antimony, dissolved in four ounces of water, and taken in small quantities in the space of two hours, made use of the opening powders during the following days; which occasioned some nausea, and two, or sometimes three copious motions every day. On the 5th day at night, he began to distinguish the surrounding objects by the very weak light of a lantern. The vapour of the caustic volatile alkali was used constantly from the first day after the emetic, and on the 16th day he was perfectly cured. The waterman, after three doses, vomited a large quantity of yellowish viscid matter. He afterwards used the opening
ing

ing powders, which, on the third day, produced a second vomiting, and exposed his eyes regularly every four hours in the day to the action of the vapour of the caustic volatile alkali. He did not begin till the 11th day to distinguish objects at night by the weak light of a candle. The husbandman vomited only once in large quantity, but was afterwards greatly nauseated by the opening powders for nine successive days, and had every day a copious evacuation from the bowels of greenish matter; he used also the vapour of the caustic volatile alkali, as a local application, and on the 14th day, at night, began to see by the light of a candle, and continued to acquire a greater power of seeing objects at night, until he was perfectly well. Towards the end of the treatment I ordered this patient to take the cinchona with valerian root.

But the most speedy recovery that I have known, was in the spring of the present year, in the case of Mauro Bonini, of Donelasco, a robust farmer, 22 years of age. In the month of March he began to discover, that at sun-set he could only distinguish objects very imperfectly. This indisposition increased to such a degree, that in the beginning of May, he became, towards night, almost entirely blind. On the 10th of May he came to this hospital. On examining him in the day-time I found the pupil of both his eyes unusually dilated, and al-

most immoveable; and towards night I made the experiment, and satisfied myself that he was blind. The patient complained of a bitter taste, heaviness of the head, and his tongue was furred. On the 11th of May I prescribed an emetic, which did not produce all the effect that I expected; on the following day, therefore, I gave him one more powerful, composed of $\mathfrak{z}\mathfrak{j}\mathfrak{s}$ of ipecacuanha, and gr. ij of tartarized antimony. This caused him to vomit a large quantity of yellowish green matter; the patient immediately afterwards found his head relieved, and the bitter taste removed; the pupil of both eyes was a little contracted, and appeared to be in a slight degree sensible to the impression of a vivid light. He began to use the vapour of the caustic volatile alkali externally. On the evening of the same day the patient's sight appeared to be improved. On the 13th no remedy was employed, except the vapour. On the 14th the patient complained again of a bitter taste, and his tongue appeared furred. I ordered him to take the opening powders every three hours, which produced nausea and repeated evacuations from the bowels. The use of the vapour was continued. Towards the evening the patient distinguished very well all the objects which were presented to him. On the 16th the symptoms of indigestion entirely disappeared, and the pupil of both eyes was contracted,

disease, recommended bleeding, the use of emetics, when the patient is fasting, or the evacuation of the bowels by purgatives or clysters, and sternutatories. This practice was followed by all the physicians who succeeded them, and was the same at the time of Forestus* and Timeus.† Hildanus,‡ who attributed much efficacy in the treatment of this disease to a seton made in the neck, states, however, that he had only employed this method after the repeated use of cathartics. The same thing is met with in the works of Smetius,§ Platerus,|| Adolphus,¶ and Trew.**

St. Yves,†† one of the most distinguished oculists of his time, mentions an ecclesiastic, who, a few days after he had lost his sight, having given him an emetic, and opened the jugular vein, recovered his sight; which was afterwards strengthened by means of the vapour of the spirit of wine, properly directed to the eyes. He also states, that he restored the sight of a young canon by the repeated use of purges, cooling broths, and the application of spirituous va-

* Obs. et cur. med. lib. xi. obs. 32. schol. obs. 38.

† Casus medicinal. lib. i. cas. 24.

‡ Centur. 1 observ. 24. Centur. 5. obs. 13.

§ Miscellan. med. page 546.

|| Praxis. med. page 104.

¶ Act. n. c. vol. ii. obs. 87.

** Commerc. Norimberg. T. 7. an. 1737. N. 1.

†† Traité des Maladies des yeux, chap. 27, 28.

Celsus,* in the chapter on the Mydriasis, adds the following words. *Quidam sine ulla manifesta causa subito obcæcati sunt. Ex quibus nonnulli cum aliquandiu nihil vidissent, repentina profusione alvi lumen receperunt. Quo minus alienum videtur et recenti re, et interposito tempore, medicamentis quoque moliri dejectiones, quæ omniam noxiam materiam per inferiora depellant.* This passage of Celsus relates, in my opinion, not only to the treatment of the dilated pupil, but also to that of the imperfect amaurosis, which takes place suddenly; and it appears to me to merit the attention of practitioners.

The first of these observations made by Celsus, that persons affected with amaurosis for some time, have recovered their sight on the supervention of a diarrhœa, appears to be con-

sufficient for a radical cure. I have known obstinate soldiers who have been unwilling to do any thing for three weeks: and I have sometimes even permitted it, in order to ascertain whether the remedy was as efficacious in an inveterate as a recent affection. I have found no difference, and as I now believe, I have made every necessary experiment to convince myself, I oblige them to submit to this treatment whenever I am aware of it. I shall not subjoin the names of those who have been cured in this manner. There are at present in the regiment more than 250 men who have been treated in this manner, and even more than 60 at the end of March, and the beginning of last April, 1787.

Dupont Mémoire sur la goutte sereine nocturne épidémique, ou nyctalopie.

* De Medicin. lib. vi. cap. 37.

firmed by a case related by Dr. Pye,* of a man 40 years old, who had been afflicted for two months with a periodical amaurosis, which, for a certain length of time, attacked him regularly every evening, afterwards irregularly and at different intervals, with great dilatation of the pupil, and such obscurity of vision towards night that he could not even distinguish the light of a candle. The man was seized with a diarrhœa. Dr. Pye ordered him the saline mixture, which he took for nine days; and afterwards an electuary, composed of the cinchona, nux moschata, and syr. e cort. aurant. These two articles were added to the cinchona on account of the diarrhœa, which still continued. On the second day of using this electuary the diarrhœa increased, and the patient vomited copiously; after which he recovered his sight almost instantly, so as to distinguish objects as well in the night as in the day. The diarrhœa continued, and after having employed the electuary for two days it was necessary to suspend the use of it. The diarrhœa was accompanied with a very violent fever, and it was remarked, that in the acme of the fever, although the patient became extremely deaf, he did not lose his sight either day or night. Dr. Pye does not state what means were employed for moderating the fever, but only that it proved

* Med. Observ. and Enquiries, vol. i. art. 13.

fatal. The fact, however, is certain, that this spontaneous evacuation of the bowels had entirely relieved the patient of the periodical imperfect amaurosis. I have no doubt, that if an attentive examination were made of the numerous cases recorded in medicine, a great number of similar facts might be met with, proving the influence which offensive substances, stimulating the stomach, have upon the organ of vision, and consequently of how much advantage the spontaneous evacuations of the bowels may be in the cure of this disease.

But, however rare or little noticed may be the examples of incomplete amaurosis disappearing, in consequence of spontaneous vomiting or copious dejections, promoted merely by the powers of nature; we are now in possession of so many cases of the successful treatment of this disease, by means of such evacuations procured artificially with emetics and internal resolvents, that no doubt can be longer entertained of the justness of the second part of Celsus's observation, relative to their propriety in this disease, *et recenti re, et interposito tempore, medicamentis quoque moliri dejectiones, quæ omnem noxiam materiam per inferiora depellant.*

The accurate cases related by Schmucker and Richter, afford numerous certain and satisfactory proofs of this; but the confidence which

we repose in the method of treating the imperfect and the periodical amaurosis now delivered, must be increased, if we reflect that the most authentic of the ancient writers, in the greater number of these cases, have also cured this disease, by no other means than those of emetics and purgatives, although in their writings they have attributed the success of the treatment to other causes, or to the efficacy of other remedies which they prescribed conjointly with the emetics and resolvents. Galen,* Ætius,† Ægineta,‡ Actuarius,§ Rhazes,|| Avicenna,¶ in speaking of the treatment of this

* Lib. de oculis, part iv. cap. 11, 12.

† Sermo septimus, cap. 48. 52. cap. 46. de nemeralopia. Si vero per hæc non successerit, rursus purgatorium dandum est, quale est hoc. Scammonia obol. iij, castorei obol. ij, salis obol. iij. In debilioribus autem scammonia obol. ij, injice. Talis autem purgatio sæpe et vestigio liberavit, aut multo meliorem conditionem induxit. Post paucos dies dandum est purgatorium pituitam et bilem ducens.

‡ Lib. iii. cap. 48.

§ De method. med. lib. iv. cap. 11. post sanguinis missionem sternutationes movendæ sunt, et ante cibum vomitibus utendum.

|| De ægritud. ocul. cap. 4. Cum prolongatur status morbi, provocentur sternutationes, et vomitus jejuno stomacho; deinde curetur cum collyriis valentibus ad hoc.

¶ Lib. iii. fen. 3. tractat. 4. Quandoque hoc fit propter communitatem stomachi et cerebri. Quod si fuerit ab humiditate, administrantibus tunc illud quod resolvit post evacuationes. Vomitus autem qui fit cum facilitate, est ex iis, quæ conferunt.

disease,

contracted, as in a state of health. On the 17th the patient left the hospital perfectly cured.

The ancients have very highly commended, in the treatment of this disease, fumigations of sheep's liver roasted, conveyed to the eyes by means of a funnel, as well as the eating of the liver thus prepared. This remedy, even at the present time is generally accredited, not only on the assertions of the vulgar, but also of professional persons; and some writers add, that it succeeds in a surprising manner among the Chinese, where this disease is said to be very frequent. I cannot relate any case of my own in confirmation of this; in the boy before mentioned, it appeared to me to be of no advantage. If, however, the efficacy of this remedy is a matter of fact, we may boast of having another means of curing the *nocturnal blindness*,* besides that which I have delivered.

Celsus,

* It was an old soldier who imparted to his comrades the remedy which I am about to describe, when there was so large a number affected with nocturnal blindness at Strasbourg in 1762. The soldiers cook a slice of ox's liver, weighing about half a pound, in an earthen pot newly varnished, and just large enough to hold four pints of water. When the liver is done, so as to be fit to eat, and the vapour is of a supportable heat, they place the pot upon the bed, and inclining the head very near it, they throw over a covering so as exactly to enclose them. They remain there until the liver ceases to produce any vapour, or the difficulty of breathing obliges the patient to come out. One application only, is, in general,

pours; and expressly states, that he had frequently succeeded in curing the *amaurosis* whenever he had undertaken the treatment of it, immediately on its accession, by taking away blood, and ordering an emetic to be taken once or twice in the interval of two days.

Heister* imagines that he had cured an *amaurosis* by means of salivation only. From the narration which he gives, however, it appears, that previously to the patient's using mercury, he ordered him an hydrogogue purgative; and that the following day, on his complaining of nausea and inclination to vomit, an emetic composed of two grains of tartarized antimony and a scruple of sugar, by means of which he vomited copiously, and his nausea was relieved; that after all this he ordered him some pills made with calomel and the extract of fumaria, and the size of a bean of mercurial ointment to be rubbed into the parotid glands; and that on the 9th day, the salivation having scarcely commenced, the patient could distinguish light from darkness. Now from this account, and from comparing it with what we know at present, of the efficacy of emetics and purgatives in the cure of this disease, it is easy to infer, that the cure of the imperfect *amaurosis* obtained by Heister is not to be attributed to

* System of Surgery, T. 1.

the mercurial salivation, but to the removal of the offensive matters stimulating the stomach.

The same writer* also, in a woman affected with amaurosis, and threatened with complete blindness from excessive grief, and from having fixed her eyes too long on lucid objects, obtained a cure by means of a single bleeding, and some cathartic pills composed of calomel and jalap. He† likewise restored the sight of a servant, which had gradually diminished without any apparent disease in the eye, but who complained of continual nausea, by prescribing to him a powder composed of 25 grains of ipecacuanha, and ten grains of vitriolated kali, to be taken in the morning; and an infusion of Euphrasia, hyssop, and saffron during the day, besides a blister to the neck, and a stimulant resolute collyrium.

Ribe‡ mentions a young man, 22 years of age, who had lost his sight three months before he was examined by him, which was restored by the use of an emetic repeated seven times at different intervals. Helvig§ and Schroëk|| have transmitted to us several histories of the imperfect amaurosis, sympathetic of the

* Med. chirurg. u. anat. Wahrnehm. 1. Band.

† Loc. cit. Band 75.

‡ Act. Svecic. vol. i. Trim. 1. N. 1.

§ Observ. physic. med. obs. 33.

|| Miscellan. nat. eur. decad. 2. an. 5. obs. 217.

stomach, and primæ viæ, cured by resolvent purgatives only.

Vandermonde* relates the history of a girl, eight years old, who, from saburræ and worms in the stomach, had recently lost her vision and speech. The presence of worms in this case was indicated by a rapid movement of the tongue, like that of a serpent; and continual expiration by the nose, great anxiety, and copious perspiration of the head. The girl took an emetic, and brought up, with other matters, a round worm half a foot long; she then took purgatives, conjoined with anthelmintics, and very quickly recovered her sight and speech.

Fabre† mentions a certain Jean Barricot, who, ten days after he had been afflicted with the colic, lost the sight of both his eyes, and who had lost blood twice without advantage, and had used a collyrium of rose water and the white of eggs. Fabre prescribed to the patient four grains of tartarized antimony, and two days afterwards, a draught made with half an ounce of fenna, half a dram of the *pulvis e tribus*, and one ounce of manna; in two days more four grains, as before, of the tartarized antimony, and so for nine days following; afterwards some pills composed of calomel and scammony, an infusion of euphrasia, and the sudorific and laxative

* Journal de med. de Paris. T. x.

† Ibidem T. xx. 8

ptisan of the Paris pharmacopæia for eight days. The vapour of spirit of wine and coffee was applied externally, directed to the eyes by means of a funnel. On the 4th day of this treatment, Barricot began to distinguish the light from darkness; on the 12th day he could distinguish colours at a small distance; and by the 20th, recovered his sight entirely.

Thilen * relates two very interesting cases of imperfect amaurosis, cured by the use of the tartarized antimony, first as an emetic, and afterwards as an opening medicine, sometimes given alone, at other times conjoined with saponaceous substances, and the extract of *arnica*.

Whytt † mentions a woman, whose sight was greatly diminished whenever she had acidity of the stomach. She was relieved from this inconvenience by means of an emetic, some absorbent powders, and bitter stomachic corroborants. I know also a very respectable person, who happened frequently, before he was aware of the cause, to experience for some hours after dinner a great dimness of sight, approaching to a degree of blindness, in consequence of eating fish fried in olive oil. It is very remarkable that the *digitalis purpurea*, the *stramonium*, the infusion of tobacco, and many other similar articles,

* Medicinische und chirurgische Bemerkung. § Amaurosis.

† Delle affez. ipocond. ed ister. cap. 1.

produce blindness almost as soon as they are taken into the stomach.

In the *French Mercury* for the year 1756,* there is an account of a cure performed by Fournier, of several persons affected with *hemeralopia*. The first were three soldiers, to whom, after being bled, he gave an emetic. On the following day, as they yet complained of heaviness of the head and nausea, he repeated the bleeding and emetic. By these means all the symptoms were removed, and the three soldiers were cured. Fournier employed the same method of treatment, with equal success, in eight other soldiers, belonging to the same garrison, attacked with this disease.

Pellier † cured the *hemeralopia* in the captain of the ship Micetti, with small doses of tartarized antimony, blisters to the neck and cooling aperient ptisans. The same writer asserts, ‡ that he had frequently cured the recent imperfect amaurosis, by small doses of tartarized antimony only (*émétique en lavage*), and by local aromatic fumigations.

To this series of facts, and many others which may be found recorded on this subject, not only by the ancient but by modern surgeons, I shall add some cases of my own, to prove, in the most

* Fevrier, page 168.

† Recueil de mem. et. obs. sur l'œil, obs. 132.

‡ Ibidem, observ. 136. 138.

convincing manner the utility and efficacy of the method of treating the recent imperfect amaurosis here recommended, which, as I have already stated, is only an affection derived from sympathy with the stomach,* depending upon morbid stimuli in the organ of digestion, with nervous debility, either general or confined to the eye.

It is to be remarked, that in the treatment of the recent imperfect amaurosis, both among the ancients and the greater part of the moderns, the general, or partial, evacuation of blood is very frequently and indiscriminately made to precede the use of an emetic or cathartic. Further observation on the treatment of this disease has taught us that it is not to be regarded as a general rule, and that the abstraction of blood ought only to be employed in those cases, in which it is clearly indicated by particular circumstances; as in cases of recent imperfect amaurosis accompanied with affections of the stomach, and at the same time plethora, either general, or confined to the head, in young and strong subjects, or in persons in whom the amaurosis has been produced or kept up by the suppression of some accustomed sanguineous evacuation. In other cases the abstraction of

* *Experientiæ suffragium firmum est, ut in omnibus capitis et nervorum morbis, sic etiam in iis qui oculos detinent, ventriculi et virtutis ipsius digestivæ rationem esse habendam. Hoffman Dissert. de morbis præcipuis recta medendi ratione.*

blood is not indicated; and in persons extenuated and affected with general nervous debility, afflicted with excessive grief, or where there is a disposition to convulsions, it may rather prove injurious.

So likewise with respect to the selection of remedies proper for unloading the stomach and intestines of the *morbific fomes*, and at the same time rousing the activity of the nervous system generally, it is worthy of remark, that, except the case above mentioned, of persons very delicate and extenuated, in whom the tincture of rhubarb is more properly indicated, the antimony tartarizatum as a vomit, or in divided doses as a resolvent, either alone or combined with gummy and saponaceous substances, so as to excite nausea, and gently open the bowels, is preferable to the drastic medicines, and acrid purging clysters, which were formerly in use. It is not improbable, that in the treatment of the recent *imperfect amaurosis*, produced by *faburræ*, and accompanied by suppression of perspiration, with metastasis to the eyes, the tartarized antimony given in small and repeated doses is preferable to every other internal purgative, from its particular mode of action upon the stomach, and sympathetically upon the whole system; not only by expelling from the stomach and intestines the acrid bilious impurities, but by its peculiar stimulus, strengthening

the activity of the nervous system, and restoring the perspiration and the action of the absorbent vessels.

CASE LXVIII.

Giacomo Migliavacca, of Pavia, 32 years of age, by trade a carpenter, of a weak constitution and emaciated, towards the middle of March 1798, after excessive grief, began to feel an obtuse pain in the eye-brow, general lassitude, tension of the abdomen, and loss of appetite. On the 7th of April following, three hours after rising out of bed, he suddenly lost the sight of both his eyes.

The next day he was admitted into the practical school of surgery. On examining his eyes, I found the pupils very much dilated and immoveable to the strongest light, but regular in their circumference, and the bottom of the eye behind the pupil of a deep black colour.

I ordered the patient, without delay, two grains of tartarized antimony, dissolved in four ounces of water, to be taken by spoonful at short intervals, until it produced nausea and vomiting. The patient having taken the whole of the solution, vomited at three times a very considerable quantity of mucus and bilious greenish matter, so acrid, that for some hours afterwards he complained of an intolerable heat
in

in the tongue and fauces. He had also, on the same day, two colliquative motions; he afterwards passed a good night, and the following day found himself relieved of the pain in the head and supercilium. I ordered him to take the opening powder, composed of one ounce of crystals of tartar and a grain of tartarized antimony, divided into six equal parts, one of which was taken three times a day, and continued for several successive days. The powder produced each time nausea, and one or two abundant evacuations from the bowels every day, with great relief, not only to his head, but his general constitution; since after the use of these opening powders for a few days, he ceased to complain of prostration of strength, and tension of the hypochondria. In the mean time I directed him to hold a small vessel, containing the aqua ammoniæ puræ near his eyes three times a day, until at each time they should begin to water and become red.

During the first four days there was no sensible alteration in the patient's eyes; but on the 5th day (13th of April) he said, that he could see the candle distinctly, which was brought near him. The pupils being then examined, I found them a little contracted. The opening powders were continued, but only twice a day.

On the 19th of April, the patient could sufficiently discern the surrounding objects in a

moderate light. I found the pupils, also more contracted than on the 13th, and as the patient had been hitherto kept on a low diet, and found his appetite returning, I allowed him the diet of convalescents. In order to strengthen his stomach and invigorate his nervous system, instead of the opening powders, I ordered him those composed of \mathfrak{zj} of the cinchona, and \mathfrak{zfs} of the valerian root, divided into six equal parts, of which he took one morning and evening, without ever omitting the use of the vapour of the caustic volatile alkali. From the 19th of April the patient's sight improved daily, and on the 22d of May he was discharged from the hospital in a state capable of following his business, which he also presently pursued.

CASE LXIX.

Stefano Barbieri, a pale weakly boy, 14 years of age, belonging to the hospital for orphans in this city, was attacked in March 1797 with a peripneumony, for which he was freely bled. While he was recovering, he complained that he could scarcely discern any thing with the right eye, and that he felt occasionally violent and deep pains in that eye, and the corresponding supercilium. Antispasmodics and tonics were prescribed for him; but without advantage, as the sight of this eye diminished daily;
the

the pupil was contracted and become immovable, and a small whitish line presented itself beyond the pupil, which appeared to be an incipient opacity of the capsule of the crystalline lens.

He remained in this state two years, as his left eye served him sufficiently well; when, in the beginning of September 1799, he was suddenly deprived of almost the entire sight of his left eye, with this peculiarity, that on his first waking in the morning, he could, with difficulty, distinguish light from darkness. Having examined him, I found the pupil of the left eye greatly dilated and immovable, while, as I have said, the pupil of the right, already greatly deteriorated, was immovable and contracted.

I chose, in this case, to try the effect of the *pulsatilla nigricans*. I ordered the patient to take three grains of it morning and evening; I then increased it half a grain twice a day, until the boy took nine grains of it night and morning. At the end of 15 days I was obliged to omit this remedy, as it was attended with no advantage to the sight, and occasioned violent pains in the head, vertigo, and little less than general convulsions. I was contented to do nothing till the 24th of December of the same year, when I pursued the following plan of treatment.

I prescribed two grains of tartarized antimony dissolved in four ounces of water, of which the boy took a table spoonful every half hour. After he had taken about three parts of the medicine, he vomited half a basin full of greenish, bilious, tenacious matter, and towards night had two alvine evacuations. He passed a good night, and on awaking the following morning distinguished the objects near him, and the persons who passed through the ward; which he had not been able to do for some months before. I immediately put him upon the use of the opening powders, composed of ʒj of crystals of tartar, and gr. ij of tartarized antimony, divided into eight equal parts, of which he took three a day; and these powders produced nausea and two evacuations regularly every day. The vapour of the caustic volatile alkali was used with the greatest diligence three or four times a day.

On the 1st of January, an hour after having taken the first opening powder, the boy vomited violently, and threw up a large quantity, as at first, of greenish viscid bilious matter. The medicine was suspended for that day, and was afterwards reduced to two doses only of the powder, one morning and evening, until the 8th of January.

At this time the boy could distinguish objects very well with the left eye, the pupil of which was less dilated than before, and showed some mobility on being exposed to a strong light.

The

The pupil of the right eye remained as at first, contracted and immoveable; and the boy could distinguish light from darkness. He had not the yellowish livid appearance in his countenance that he had before, and felt a good appetite.

I had now recourse to Schmucker's opening pills, of which the boy took four morning and evening, without omitting the frequent use of the vapour of the caustic volatile alkali. The pills produced nausea for a few minutes, and afterwards purged him twice a day, without occasioning debility.

On the 16th of January he was seized with a diarrhœa, without any evident cause; it was therefore necessary to suspend the opening pills, which were, however, resumed on the 22d, but in half the dose; and as these also purged him too much, they were employed every second day, without omitting the use of the vapour of the aqua ammoniæ puræ.

On the 9th of February, the boy finding the sight of his left eye tolerably re-established, left the house without leave, on a very rainy day, and returned completely wet from head to foot. This occasioned, two days afterwards, a continued fever of the remittent type, which was removed with the cinchona conjoined with valerian. The left eye, however, even in the
strongest

strongest paroxysms of the fever, retained its vigour.

On the 26th of February I left the boy in a good state of health, both with respect to his general habit and the sight of the left eye, with which he could distinguish the smallest objects. The right eye remained imperfect, as it was at the commencement of the treatment.

CASE LXX.

Giovanni Sciguagni, a carrier, about 30 years of age, a man of a strong temperament and good habit of body, in 1791 was seized one morning, as he was going out of church, with a weakness of sight in both his eyes, which progressively increased to such a degree, that in a few minutes he found himself completely blind.

Being brought to the hospital, his countenance appeared flushed, his pulse was hard and full, the conjunctiva was streaked with some blood vessels, and the pupil dilated and immovable; he complained of no inconvenience except the blindness.

Blood was taken from the arm, and afterwards 14 leeches were applied to the temples, and the anterior circumference of the neck, from which an abundant discharge of blood was obtained; the patient was at the same time ordered

dered a proper diet, aqueous drinks, and a purgative. By these measures a diminution of the strength of the body generally was obtained, but no advantage with respect to the blindness.

The next day two sinapisms were applied to the feet, and a large blister to the neck, which were of no benefit. On the 4th day of the disease he took, in small quantities, a pint of the decoction of arnica, and at night a pill made with the extract of arnica and the *pulsatilla nigricans*. But as these remedies, which were daily increased in dose, produced no advantage in the space of 15 days, although continued with diligence and exactness, recourse was had to Schmucker's pills.

At the end of six days, the patient experienced a small degree of relief from these pills, which gradually increased every day, and in the space of 27 days he recovered his sight perfectly, which remained good for two months; but afterwards relapsed in consequence of his indulging in indigestible food and spirituous liquors.

This second time, after having a small quantity of blood taken from him, he resumed the use of Schmucker's pills, and by those only, without any external application, except cold lotions to the eye, he recovered in the course of 32 days, and had no further relapse.

CASE LXXI.

Giuseppe Antonio Goffi, of Stradella, 60 years old, of a lively and strong temperament, was attacked towards the end of 1794, with an obstinate quartan fever, with which he was so afflicted for 13 months, notwithstanding the means which were employed, that on the final cessation of it, five months of good living were scarcely sufficient to put him in a tolerable state of health. At this time, his former strength not being yet perfectly re-established, he began to see black streaks before the left eye, which gradually increasing, in the space of 15 days he was completely deprived of the power of seeing with that eye. Some medicines which were prescribed for him rendered his sight a little better, but it was of short duration; and he continued sometimes losing almost entirely the sight of the left eye, at other times regaining it so as to be able to walk without danger.

He passed several weeks in this state, alternately better and worse, and in the hope that nothing further would ensue: the right eye remaining sound, he was unwilling to submit to any further treatment; when suddenly the sight of the right eye also became so diminished, that in a few days he found himself reduced to the necessity

necessity of being conducted, in order to walk with safety.

All the remedies which are administered on these occasions being found ineffectual, and the patient reduced also to the greatest distress, by being deprived of the employment by which he gained a livelihood, he came on the 8th of June 1796 to this city for relief.

On an attentive examination the pupils were found exceedingly dilated and immoveable, and the bottom of the right eye, beyond the pupil, was very dark.

On account of the disorder, principally of the organs of digestion, increased by violent affections of the mind, with which the patient for some months had been excessively agitated, four grains of tartarized antimony dissolved in eight ounces of water were prescribed for him, of which a large table-spoonful was to be taken every two hours. The first dose of this solution excited only nausea. It was repeated the following day, and he had scarcely taken six spoonful of it when he was seized with a violent vomiting, by which he threw up a large quantity of very bitter yellowish-green mucus, and had two alvine evacuations.

On the 11th I prescribed 16 grains of the antimonium tartarizatum dissolved in 12 ounces of peppermint water, with the addition of 3ss. of the syrup of orange-peel; of which a
spoonful

spoonful or two was to be taken three times a day. He was also ordered to drink, now and then, in small quantities, during the day, an infusion of a dram of the folia arnicæ in a pint and a half of water. On the two first days, a few hours after having taken one or two spoonfuls of the solution of tartarized antimony, he vomited more or less bile; but afterwards the medicine only excited nausea.

On the 14th the black streaks which appeared before the left eye began to be dissipated, and in a few days were entirely lost. The pupil of both eyes became a little moveable, and on the 12th day from the commencement of the treatment, he was already able to distinguish very large objects.

The solution of the tartarized antimony was now omitted, and he was ordered Richter's opening pills, of which at first he took 15 three times a day; afterwards 18, and lastly 24, never omitting, however, the use of the infusion.

He had not taken the pills 15 days before his sight was strong enough to enable him to walk without a guide; and in about six weeks, by the uninterrupted use of these pills, and the assistance of spectacles, which he used before he was affected with the imperfect amaurosis, he was able to read and write. On examining his eyes at this period, there was no appearance of disease,

disease, except that the sight was rather less perfect in the left than in the right eye.

The pills produced only nausea occasionally, and regularly every day a loose motion. He was allowed to return home at his own request, upon condition that he would continue to take, at intervals, another entire dose of the pills. He was not subject afterwards to any alteration in his sight.*

CASE LXXII.

Giuseppa Pizzi, a girl 16 years of age, of Belgiojosa, of a delicate constitution, who had not yet menstruated, towards the end of May of this year, 1801, was affected with a morbid appetite, so distressing that she could scarcely satisfy herself by eating every kind of gross food in large quantity, especially bread made with Indian corn (*zea mays*). The girl being also fatigued by the hard labour of the country, to which she had not yet been sufficiently accustomed, perceived that her sight became dim. Her immoderate appetite suddenly ceased; she had a bitter taste, and began to feel a sense of weight in the region of the stomach, accom-

* The progress and treatment of this disease is perfectly known to *Volpi*, a skilful and expert surgeon of this hospital.

panied with nausea and continual head-ach; she then lost the sight of the right eye entirely, and in a great degree that of the left. The pupil of both eyes was exceedingly dilated, and almost immovable to the strongest light, and she also appeared as if she had an incipient strabismus. In this state she was brought into the practical school of surgery, on the 4th of June 1801.

On the 4th of June the girl took a table spoonful of a solution of four grains of tartarized antimony in five ounces of distilled water, which occasioned great nausea for a long time; but she only vomited a little viscid whitish matter.

On the 5th, the emetic was repeated, and given in the same manner. It produced a more copious vomiting than on the preceding day; but always of mucous whitish matter. The pain in the head was, however, greatly diminished, as well as the sense of weight in the region of the stomach. The nausea, however, and furred tongue still continued. The pupil appeared a little moveable to a very vivid light, and when the left eye was covered, the patient could distinguish whether it was light or dark. She began to use the vapour of the aqua ammoniæ puræ, which was repeated every two or three hours.

On

6th. Little pain in the head; the taste less bitter than on the preceding days; the pupil acquires some mobility. The opening powders are prescribed, of which the patient takes three in the day, and continues to apply the vapour of the caustic volatile alkali to the eyes every two or three hours.

7th. Very little pain in the head. The opening powders produce nausea for a few hours; afterwards two abundant evacuations in the course of the day. The pupil contracts a little, and the patient can distinguish the figures of large objects.

8th. The pain in the head is entirely gone, as well as the bitter taste and furred state of the tongue. The pupil is more sensible to the impression of the light than on the preceding day.

9th, 10th, 11th, and 12th. The patient continues to take the opening powders, and to use the vapour of the caustic volatile alkali externally.

13th. The patient complains again of headache and bitter taste, and the tongue is furred. Instead of the opening powders I ordered her an emetic, composed of half a dram of ipecacuanha, and one grain of tartarized antimony, to be taken at once. The patient vomited much yellowish-green matter. The head-

ach immediately ceased, and the girl could then distinguish sufficiently well the objects that were presented to her. She continues the use of the vapour.

14th. She is very well. The pupil of the right eye, or of that most affected with amaurosis, is even more contracted than that of the left.

15th. The patient resumes the use of the opening powders, and continues to employ the vapour of the caustic volatile alkali externally.

16th. There is a gradual amendment. The patient can distinguish a small needle with the right eye.

17th, 18th, 19th, and 20th. The opening powders produce daily two abundant evacuations, without debilitating the patient. She has a good appetite and digestion.

21st. The use of the opening powders is omitted, and the decoction of cinchona with the infusion of valerian root, taken in doses of three ounces three times a day, substituted in place of them.

22d, 23d, 24th, 25th, 26th, and 27th. The girl can see the most minute objects as well with her left as her right eye. She acquires a healthy complexion; and the strabismus has almost entirely disappeared.

28th. She leaves the hospital perfectly cured. She is advised, however, to continue the use
of

of the vapour for a week longer, and internally, morning and evening, a powder composed of a ʒj of the cinchona, and ʒfs of valerian; and also to observe a regular diet, and to avoid the burning rays of the sun.

CHAP. XX.

OF A CALCULOUS CONCRETION OF THE INTERNAL PART OF THE EYE.

AMONG the very considerable number of diseased eyes, which the friendly condescension of Dr. Monteggia, a celebrated physician and surgeon of Milan, has afforded me an opportunity of examining, I have found one almost entirely transformed into a stony substance.*

This eye, taken from the body of an elderly woman, was about one half the size of the sound one. The cornea was dusky, behind which the iris appeared of a singular figure, being concave, and without foramen or pupil in the middle. The rest of the eye-ball, from the termination of the cornea backwards, felt unusually hard to the touch.

By making an incision I found the sclerotica† and the choroidea‡ nearly in a natural state, and a small quantity of limpid fluid issued from the

* Plate II. fig. 8.

† Plate II. a. a.

‡ Plate II. b.

anterior

anterior chamber of the aqueous humour. Beneath the choroid coat there appeared two hard calculous *scutellæ*, united together by means of a compact membranous substance; one of which was situated posteriorly, the other anteriorly. The former * occupied the bottom of the eye; the latter † the situation of the corpus ciliare and the crystalline lens.

Having made an incision through the compact membrane, which united the margins of the two calculous *scutellæ*, I found within this cavity, instead of the vitreous humour, some drops of a glutinous bloody fluid, and along the axis of it a small soft cylinder, ‡ which running anteriorly from the bottom of the eye along the greater axis of the ball, went to be implanted in an elastic cartilaginous substance, situated in the centre of the anterior calculous *scutella*, precisely at the part, which, in a natural state, is occupied by the crystalline lens and its capsule; both of which parts were entirely wanting.

The posterior surface of the iris had contracted a firm adhesion with the middle part of this cartilaginous substance, situated in the centre of the anterior calculous *scutella*; consequently when the iris was viewed on the side next the cornea and anterior chamber of the aqueous hu-

* Plate II. c. c.

† Plate II. d. d.

‡ Plate II. f.

mour, it appeared, as it was in reality, concave in the middle.

The optic nerve degenerated into a thread, passed through the sclerotic and choroid coats,* advanced through the centre or bottom of the posterior calculous *scutella*, and was lost in the small soft cylinder,† which, as I have stated, went to be inserted in the cartilaginous substance, situated in the centre of the anterior calculous *scutella*, or in the part which is naturally occupied by the crystalline lens and its capsule. The greater part of this small cylinder, especially near the ciliary body, was apparently nothing more than the membrane of the vitreous humour emptied of its fluid, wasted, contracted, and converted into a compact substance. The same thing was observed in the dissection of the dropical eye before mentioned.‡

Haller has met with a fact similar to this, and has given us the description of it, which, from its great resemblance to the one here detailed, is worthy of being related and confronted with it.

In furis cadavere, says he, § quod an. 1752, dissecuimus, diritas quidem non tanta, raritas autem etiam major fuit. Cum enim in eo homine nervos oculi solícite pararemus, cæcum fuisse eo la-

* Plate II. e. † Plate II. f. ‡ Page 294.

§ Observ. Patholog. oper. min. observ. 65.

tere, atque in cicatricem in cornea esse, et duritatem in oculo ipso adparuit. Cum dissectione defuncti essemus, adparuit mira mali causa. Choroideæ membranæ suberat, retinæ loco, lamina ossea, aut lapidea (nam fibras osseas nullus vidimus), cui ipsa choroidea adhærebat, ut alias retinæ solet concentrica, hemispherio cavo similis, nisi quod duplici lamina fieret, et in altero latere duobus quasi loculis excavaretur. Is quasi scyphus accurati rotundo foramine perforabatur, qua nervus opticus subit, ut eo magis induratum retinam esse adpareret.

Intra hanc osseam caveam multum vitreum legitimum corpus, sed nervum, quasi albam nempe cylindrum riperimus quæ per foramen ossei cyathi transmissa metiens ejus diametrum denique adhærebat osseo confuso corpori, quod potuisses pro corrupta lente crystallina habere. Ei corpori undique et iris, et processus ciliorum cognomines connascebantur, et cornea denique, ad quam iris pariter conferbuerat. Nunc sive retinam, ut ego persuadeor, sive quidquam aliud fuisse velis, quod in os cavum et hemisphæricum mutatum sit, in oculo tamen tenerrima parte corporis humani indurationem perfectam natam esse adparet; nihil ergo in corpore nostro dari, quod indurari nequeat. Lapillos aliquos in lente crystallina repertos fuisse legi; ejusmodi autem morbus, nescio an visus sit, qualem hæc opportunitas nobis obtulit.

Distinct mention is made of calculous concretions of the internal part of the eye, by F. d'Hildanus,* Lancisi, as quoted by Heister,† Morgagni,‡ Morand,§ Zinn,|| and Pellier.¶

* Centur. I. observ. 1.

† Vindiciæ de cataracta, page 97.

‡ De sed. et caus. morb. Epist. 13. 9. Epist. 52. 30.

§ Mem. de l'Acad. R. de sciences an. 1730.

|| Hamburg, Magaz. De retina offuscata, 19. B.

¶ Recueil de mem, et obs. sur l'œil, obs. 239.

I N D E X.



A.

- ACRELL, 273.
 Actuarii, 507.
 Adolphus, 508.
 Ægineta, 33, 507.
 Ætius, 33, 507.
 Æthiops antimonial, 195.
 Albinus, 97, 111.
 Albucasis, 375 note.
 Albugo and Leucoma, 226.
 Albugo, recent treatment of the, 227.
 Amaurosis, 481.
 —— Cases of, which are curable, 482.
 —— ————— incurable, 484.
 —— Cases of, 516.
 Artificial Pupil, 405.
 —— Operation for the, by Cheselden, 407.
 —— ————— Janin, 408.
 —— ————— P. Scarpa, 412.
 —— Additional remarks on the, 423.
 —— Cases of, 415.
 Avicenna, 33, 203, 263, 507.
 Aqua ammoniæ puræ, its use in the amaurosis, 489.
 —— camphorata, 182.

Bandage,

INDEX.

B.

- Bandage, uniting, 107.
- monocus, 23.
- Barbette, 363 note.
- Bartisch, 104.
- Bell, 65, 185 note, 370 note.
- Bidloo, 286.
- Blindness, nocturnal, 499.
- Buzzi, 202 note, on the artificial pupil, 421.

C.

- Calculous concretion of the internal part of the eye, 532.
- Capsule of the crystalline, the most frequent cause of failure in operations for the cataract, 357.
- Caruncula lachrymalis, trichiasis of the, 111.
- Cataract, 352.
- operation for, 373.
- soft or caseous, 381.
- fluid, 380.
- secondary membranous, 382.
- secondary membranous, how produced, 257.
- secondary membranous, cases of, 392.
- primitively membranous, 387.
- Cautics employed by the ancients in the fistula lachrymalis, 33.
- Cautery, actual, mode of applying it in the fistula lachrymalis, 40.
- preferable to simple perforation, 38.
- Celsus, 138, 192 note, 440, 504.
- Chemosis, 169.
- treatment of the, 187.
- Chefelden, his method of making the artificial pupil, 407.
- Choroid coat, procidentia of, 342.

Cilia

I N D E X.

- Cilia which irritate the eye, 96.
- cases of, 112.
- Collyrium sapphirine, 230.
- vitriolicum, 11.
- Conjunctiva, circular excision preferable to scarification, 172.
- Cornea, difference between that of infants and adults, 429.
- method of opening it in the hypopion, 310.
- Couching needle, on the, 366.
- Crampton, Dr. note, 110, 124 note.
- CrySTALLINE lens, state of the depressed, 362.
- posterior convexity of its capsule seldom the cause of failure in the operation for the cataract, 360.
- Cullen, 200.

D.

- Demours on the artificial pupil, 424 note.
- Depression of the cataract preferable to extraction, 352.
- detail of the operation, 371.
- Descemet and Demours, 337.
- Digitalis purpurea, its power of producing amaurosis, 512.
- Distichiasis, 96.
- Dropical eye, dissection of a, 455.
- Dropsy of the eye, 453.
- causes of the, 454.
- treatment of the, 460.
- — cases of, 469.
- operation for the, 467.
- Dupont, 504 note.

E.

- Ectropeon, 133.
- species of, 133.

Ectropion,

I N D E X.

- Entropion, description of the, 134.
 ——— treatment of the 1st species, 138.
 ——— ——— ——— 2d species, 142.
 Edinburgh essays, 358 note.
 Electricity, of what use in the amaurosis, 491.
 Elevator muscle, atony of, a cause of the relaxation of the
 upper eye-lid, 126.
 Elevator of Pellier, 240.
 Empyema of the eye, 307 note.
 Encanthis, 280.
 ——— case of one related by F. Hildanus, 283.
 ——— benign, operation for, 285.
 ——— inveterate, 287.
 ——— excision of one followed by a dangerous hæ-
 morrhage, 287 note.
 Encysted tumours of the eye-lids, 78.
 ——— method of removing, 83.
 ——— account of a particular species of, 87.
 ——— case of one by Bromfield and Ingram, 81.
 ——— cases of, 88.
 Entropion, Dr. Crampton on the, 124 note.
 Epiphora sebacea, 3 note.
 Erysipelas, causes a suppression of the puriform discharge of
 the palpebræ, 6.
 Eversion of the eye-lids, 133.
 ——— treatment of the, 138.
 ——— cases of the, 147.
 Eye-lid, upper, relaxation of the, 126.
 Extraction of the cataract compared with couching, 352.

F.

- Fabre, 511.
 Fabricius ab Aquapendente, 144, 375 note.
 Fabricius Hildanus, case of encanthis by, 283.
 Fistula lachrymalis, 31.

I N D E X.

- Fistula lachrymalis cum carie, two forms of it, 5.
 ————— treatment of the, 37.
 ————— distinction between this and the puri-
 form discharge of the palpebræ, 1.
 ————— cases of, 45.
 Forestus, 262, 508.
 Fournier, 513.
 French Mercury, 515.
 Freytag, 370 note.
 Furuncular inflammation, what, 72.
 ————— treatment of the, 74.

G.

- Galen, 170 note, 323, 507.
 Gendron, 107.
 Gianhi, Signor, 120,
 Gleize, 358 note.
 Gonorrhœa, Metastasis of the, to the eyes, 185.
 Guerin on the easy separation of the iris from the ciliary
 ligament, 411 note.
 Gunz, 432.

H.

- Haller, case of concretion of the eye related by, 534.
 Heister, 229, 509.
 Helvig, 510.
 Hemeralopia, 481, 499.
 ————— case of, speedily cured, 500.
 Hey, Mr. 354 note, 380 note, 491.
 Hildanus, 197 note, 508.
 Hippocrates, 192 note.
 Hoffman, 162, 173 note, on the amaurosis, 514 note.
 Hordeolum, 72.
 Hunter, Mr. 306.

I N D E X.

Hypopion, 292.

——— treatment of the, 295.

——— method of opening the cornea for the discharge
of the matter, 310.

——— cases of, 311.

Hyoscyamus niger, 196.

I. J.

Inflammation of the eye. . See Ophthalmia.

Iris, its easy detachment from the ciliary ligament, 409.

—— a membrane distinct from the choroid coat, 411.

Janin, operation for the artificial pupil, 408.

——'s ophthalmic ointment, 11.

K.

Kokler, 103.

L.

Lachrymal sac, method of laying it open, 19.

——— structure of its internal membrane, 6.

Langguth, 229.

Léveillé, Mon. note 97, 154 note.

Leucoma, 226.

Louis, 466.

M.

Maître-Jan, note 97, 368, 484.

Marchan, 466.

Marchetti, case of encanthis by, 290.

M. Aurelius Severinus, his account of a particular species
of encysted tumour, 87.

Mauchart,

I N D E X.

Mauchart, 465.
 Medical observations and inquiries, 453 note.
 Memoires de l'Acad. cases of hypopion quoted from, 308
 note.
 Monoculus bandage, 23.
 Monro, 358 note.
 Monteggia, Dr. 5, 435.
 Morand, 132.
 Morgagni, 79.
 Morigi, Dr. 369 note.

N.

Nannoni, '34.
 ——— case of hypopion by, 301.
 Nebula of the cornea, 203.
 ——— treatment of the, 209.
 ——— cases of, 215.
 Needle, curved, description of the, 369.
 Neffi, 483 note.
 Nuck, 462.

O.

Ophthalmia, species of, 160.
 ——— mild acute, 163.
 ——— treatment of the, 165.
 ——— violent acute, 168.
 ——— treatment of the, 170.
 ——— puriform of infants, 180.
 ——— acute gonorrhœal, 183.
 ——— how occasioned, 184.
 ——— treatment of the, 187.
 ——— chronic, 190.
 ——— causes of the, 190.
 ——— treatment of the, 190.

Ophthalmia,

I N D E X.

- Ophthalmia, chronic, scrofulous, 194.
 ————— from a variolous metastasis, 197.
 ————— venereal, 199.
 Ophthalmic ointment of Janin, 11.
 Opuscles de chirurgie, 132.

P.

- Palpebræ, puriform discharge of the, 1.
 Pannus of the eye, 257.
 Paracentesis of the eye-ball, 462.
 Parè, 55.
 Pearson, Mr. 186 note.
 Pellier, 217, 343, 358, 513.
 Platerus, 508.
 Platner, 242.
 Plenk, 263.
 Pot, 15 note.
 Procidencia iridis, 322.
 ————— causes of the, 323.
 ————— treatment of the, 327.
 ————— method of applying the caustic, 330.
 ————— in what cases excision is proper, 334.
 ————— cases of, 343.
 ————— of the tunic of the aqueous humour, 336.
 ————— choroid coat, 342.
 Psyllium, mucilage of, 188.
 Pterygium, 256.
 ————— benign treatment of the, 264.
 ————— incipient, what, 257.
 ————— diagnostic characters of the, 261.
 ————— cases of, 273.
 Pupil, state of the, in the Procidencia iridis, 326.
 ————— its disposition to regain its original size and figure
 remarked by Richter, 334.

Puriform

I N D E X.

Puriform discharge of the Palpebræ, 1.
 _____ division into four stages, 8.
 _____ treatment of the first stage of the, 10.
 _____ case of, recorded by Fabricius Hil-
 danus, 14.
 _____ treatment of the 2d stage of the, 16.
 Purmannus, 280 note.
 Pye, Dr. 505.

R.

Raw, 105.
 Rhazes, 103. 507.
 Relaxation of the upper eye-lid, 126.
 _____ causes of the, 126.
 _____ treatment of the, 128.
 Resolvent pills of Schmucker, 487.
 _____ Richter, 488.
 Ribe, 510.
 Richter, 229. 297. 298 note. 358 note.
 _____ on the proclivencia iridis, 334.
 _____ on the nature of staphyloma, 427.
 _____'s opening pills, 488.
 Rudolphus Verhens, 3 note.
 Rupture of the cornea, cause of in the hypopion, 305.

S.

Sabel, 272 note.
 Saburræ of the stomach the most frequent cause of amauro-
 rosis, 485.
 St. Yves, 82.
 Schmucker, 64. 481. Opening pills, 487.
 Schroëk, 510.
 Sharp, 408.
 Sheep's liver, fumigations of in the amaurosis, 503.

I N D E X.

- Scissors, crooked or probe, 106.
 Smetius, 508.
 Staphyloma, 181.
 ——— its nature and formation, 430.
 ——— two singular cases of it affecting the sclerotic coat, 433.
 ——— singular disease of the cornea resembling it, 425 note.
 ——— Richter's method of treating it, 436.
 ——— operation for the, 442.
 ——— cases of, 446.
 Stramonium, its power of producing amaurosis, 512.

T.

- Tent for compressing the lachrymal sac, 25.
 Terras, 466.
 Thilen, 490. 512.
 Timeus, 508.
 Tinctura Thebäica, its use in the ophthalmia, 176.
 Tobacco, infusion of, its power of producing amaurosis, 512.
 Trew, 508.
 Trichiasis, forms of, 96.
 ——— causes of the, 97.
 ——— treatment of the, 101.
 ——— operation for the, 103.
 ——— rare variety of, 108.
 ——— ——— ——— treatment of, 109.
 ——— of the caruncula lachrymalis mentioned by Albinus, 111.
 Tubes for the fistula lachrymalis not to be confided in, 39.

U

- Ulcer of the cornea, 233.
 ——— ——— ——— treatment of, 237.

Ulcer

I N D E X.

- Ulcer of the cornea, mistaken for the pterygium, 243.
——— cases of, 245.
——— artificial proposed by Richter in the
 staphyloma, 436.
Ulcers of the edges of the eye-lids, 201.
Unguentum citrinum, 200.
Uniting bandage, 107.

V.

- Valsalva, 483 note.
Vandermonde, 511.
Vapour, aromatic spirituous, 193.
Verduin, 104.
Volpi, 527.

W.

- Ware, Mr. 177.
Whytt, 512.
Winflow, 97.
Woolhouse, 442. 464.

There is a great deal of interest in the
subject of the history of the
country.

The history of the country is
very interesting and
important.

The history of the country is
very interesting and
important.

The history of the country is
very interesting and
important.

The history of the country is
very interesting and
important.

The history of the country is
very interesting and
important.

The history of the country is
very interesting and
important.

The history of the country is
very interesting and
important.

The history of the country is
very interesting and
important.

The history of the country is
very interesting and
important.

The history of the country is
very interesting and
important.

The history of the country is
very interesting and
important.

The history of the country is
very interesting and
important.

The history of the country is
very interesting and
important.

The history of the country is
very interesting and
important.

The history of the country is
very interesting and
important.

EXPLANATION

OF THE

PLATES.

PLATE I.

- a. b. The lachrymal sac.
- c. The tendon or ligament of the *orbicularis* muscle of the eye-lids.
- d. The superior lachrymal punctum.
- e. The inferior lachrymal punctum.
- f. The caruncula lachrymalis.
- g. A portion of the *orbicularis palpebrarum* which covered the lachrymal sac, separated in a great measure from the ligament c. and everted.

PLATE II.

Fig. 1. The eversion of the lower eye-lid, occasioned by a shortening of the integuments, in consequence of an extensive cicatrix formed a little below it.

Fig. 2. The state of the lower eye-lid (fig. 1.) after the operation. In consequence of the greater shortening of the integuments towards the temples than the nose, the lower eye-lid is seen to be less elevated towards the external than the internal angle. It embraced the lower part of the eye-ball

EXPLANATION OF THE PLATES.

ball however, sufficiently to prevent the descent of the tears upon the cheek, and to correct the deformity.

Fig. 3. Two pterygia of different sizes upon the same eye, taken from a dead subject.

a. The larger pterygium situated upon the eye-ball on the side next the nose.

b. The smaller pterygium on the side next the temples. The two lines, one straight, the other semicircular, marked upon the pterygium a, denote the double direction which ought to be given to the incision in the extirpation of the disease.

Fig. 4. Dissection of the conjunctiva of the eye (fig. 3.) which evidently proves that the pterygium is nothing more than a morbid thickening of the fine lamina of this membrane, which naturally covers the external surface of the cornea.

Fig. 5. a. The nebula of the cornea.

b. The fasciculus of varicose blood vessels of the conjunctiva, by which the nebula of the cornea is, as it were, nourished and kept up.

Fig. 6. a. Procidencia of the iris through a small ulcer of the cornea. In this figure is seen the whitish margin of the ulcer, the contracted and preternaturally displaced state of the pupil, and the oblong figure which it assumes in such cases.

Fig. 7. The state of the eye (fig. 6.) after the cure of the procidencia of the iris. The pupil in some degree recovers its natural figure.

Fig. 8. Calculous concretion of the internal part of the eye.

a. a. The sclerotica turned back.

b. A portion of the choroidea.

c. c. Calculous concretion in the form of a small cup or *scutella*, which occupied the bottom of the eye precisely in the situation of the vitreous humour.

d. d. The

EXPLANATION OF THE PLATES.

d. The other calculous concretion in the situation of the corpus ciliare.

e. The entrance of the optic nerve into the cavity of the eye-ball through the centre of the calculous scutella c. c.

f. The soft funnel-shaped body, which extended from the bottom of the eye as far as the situation of the capsule of the crystalline lens.

Fig. 9. Staphyloma of the sclerotic and choroid coats situated at the bottom of the eye.

Fig. 10. Another staphyloma of the sclerotic and choroid coats similar to it.

PLATE III.

Fig. 1. An elevator for the upper eye-lid.

Fig. 2. Crooked or probe-scissors for the division of the integuments of the eye-lids in cases of Trichiasis, or of excessive relaxations of them.

Fig. 3. Small scissors very convenient for removing any portion of the internal part of the eye-lids, or of the conjunctiva.

Fig. 4. Scissors curved upon the back, commonly called by the French *ciseaux à cuiller*.

Fig. 5. 6. Apparatus for cauterizing the os unguis and pituitary membrane which covers this bone on the side of the cavity of the nostril.

Fig. 7. Small knife for the division of the cornea.

Fig. 8. Forceps very useful in the various operations which are performed upon the eye-lids, conjunctiva, and eye-ball.

Fig. 9. A solid leaden tent, furnished with a small plate, for the purpose of compressing the external part of the lachrymal sac.

Fig.

EXPLANATION OF THE PLATES.

Fig. 10. The needle with a curved point, for the depression of the cataract.

* The point of the instrument magnified.

Fig. 11. The same needle with a straight point.

Fig. 12. A small convex-edged bistoury, very useful in removing the fungosities of the internal surface of the eyelids, and encysted tumours of those parts.

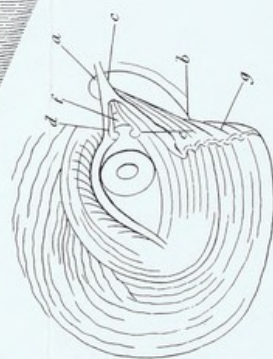
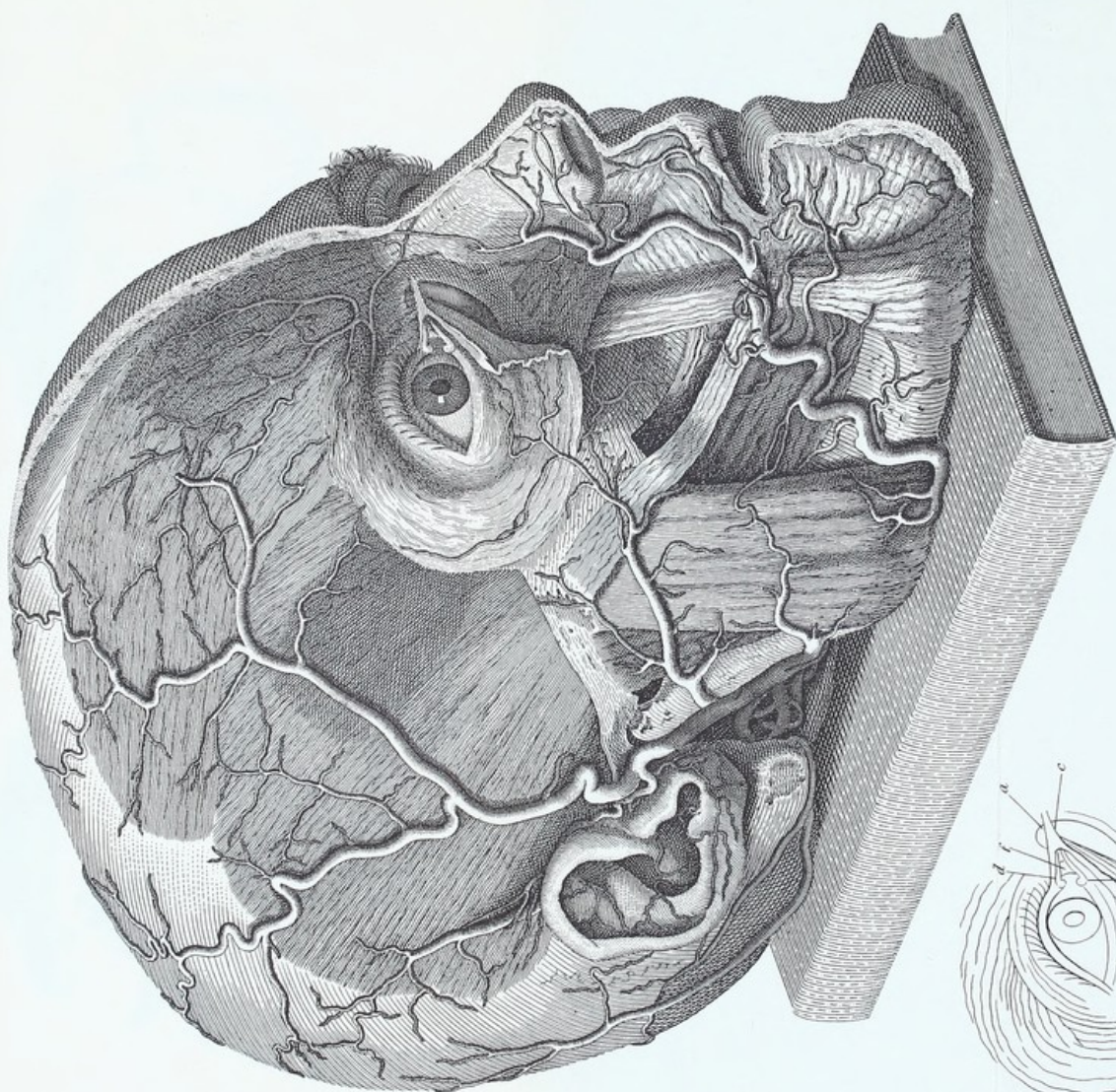




Fig. I.

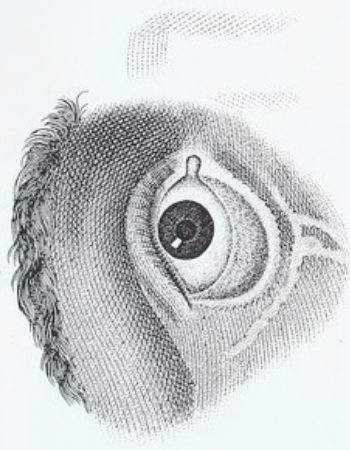


Fig. II.

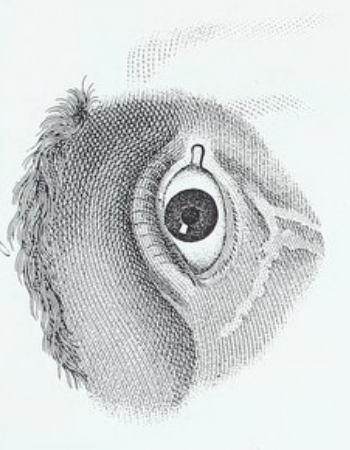


Fig. III.

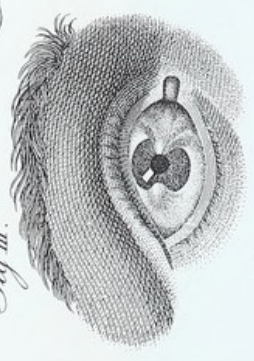


Fig. IV.



Fig. V.

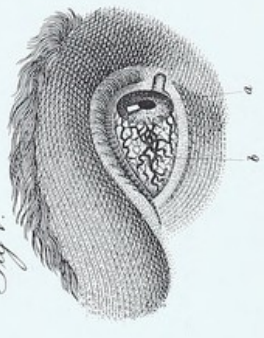

Fig. VI.

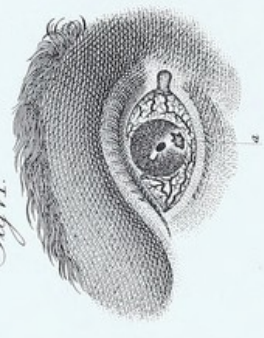


Fig. VII.

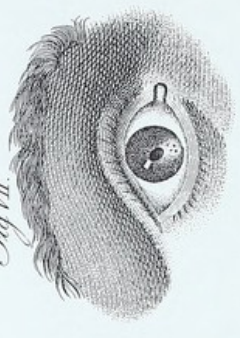

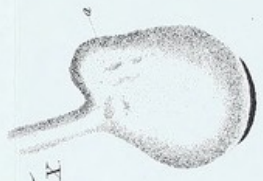
Fig. VIII.

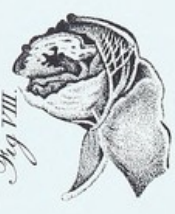

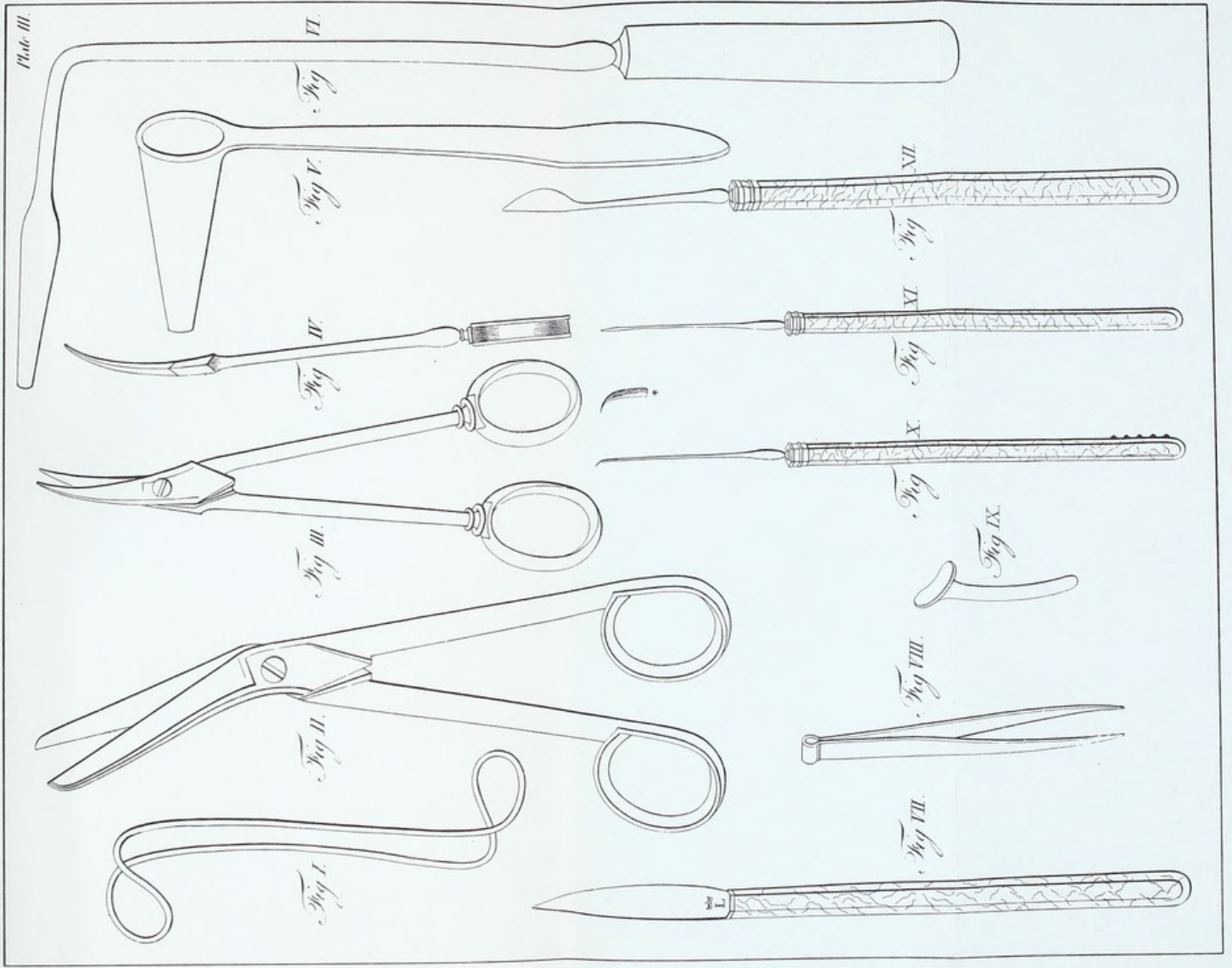
Fig. IX.

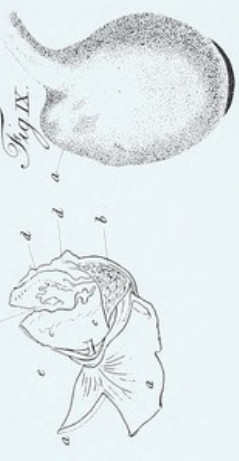



Fig. X.











CORRIGENDA.

P. 24. l. 9. *after* slough *dele* resembling cotton.

— 55. l. 6. f.b. — whitish *dele* or cottony.

— 59. l. 12. — substance *dele* resembling cotton.

— 33. l. 6. *for* Ægnieta *read* Ægineta.

— 263. l. 4. f.b. — Ce morb. — De morb.

— 188. l. 4. *after the words* blisters to the neck, *add*, Schmucker imagines that a powder consisting of gr. vj of Rhubarb and ℥j of nitre, taken every three hours, contributes greatly to reproduce the gonorrhœa, in consequence of the diuretic property of these medicines.

P. 194. l. 20. *after the words* most frequent, *add*: A fact which for its constancy merits the attention of practitioners, is, that every *chronic ophtbalmia*, whether scrofulous, variolous, morbillous, herpetic, or venereal, invariably affects the internal membrane of the eye-lids and the ciliary glands, in preference to the conjunctiva, which covers the anterior hemisphere of the eye, while on the contrary the *acute ophtbalmia*, from whatever cause or predisposition it may be derived, constantly occupies in preference the conjunctiva of the eye-ball.

This special edition of

PRACTICAL OBSERVATIONS ON THE

Diseases of the Eyes

has been privately printed for the members of The Classics of Medicine Library by the Rae Publishing Co. Engravings were printed by the Meriden Gravure Co. Film was prepared from the first English edition of 1806. New type matter was composed by Eastern Typesetting Co. in Baskerville. The text paper was especially made for this edition by The Monadnock Paper Mills. The volume has been bound in top grain genuine cowhide, with end leaves in a marbled design, by the Tapley-Rutter Co., Bookbinders. Edges are gilded, and covers are brass die stamped in 22-karat gold. Cover stampings, design and production of the edition by Max M. Stein.

THE [illegible] OF [illegible]

BY [illegible]

LONDON: [illegible]

[The following text is extremely faint and largely illegible due to the quality of the scan. It appears to be a multi-paragraph work, possibly a preface or an introductory chapter, discussing various topics. The text is arranged in several paragraphs, with some lines indented. The language is formal and academic in style, typical of 19th-century printed works.]





