

## **The diagnosis of nervous diseases.**

### **Contributors**

Purves Stewart, James, Sir.  
University College, London. Library Services

### **Publication/Creation**

London : Arnold, 1911.

### **Persistent URL**

<https://wellcomecollection.org/works/ne23uxv8>

### **Provider**

University College London

### **License and attribution**


This material has been provided by This material has been provided by UCL Library Services. The original may be consulted at UCL (University College London) where the originals may be consulted.

Conditions of use: it is possible this item is protected by copyright and/or related rights. You are free to use this item in any way that is permitted by the copyright and related rights legislation that applies to your use. For other uses you need to obtain permission from the rights-holder(s).



Wellcome Collection  
183 Euston Road  
London NW1 2BE UK  
T +44 (0)20 7611 8722  
E [library@wellcomecollection.org](mailto:library@wellcomecollection.org)  
<https://wellcomecollection.org>







INSTITUTE OF NEUROLOGY  
The  
ROCKEFELLER  
MEDICAL LIBRARY



Presented to the Library by

*Dr Margoles*


JOHN F. MACKENZIE  
Medical Bookshop,  
11 Teniel Place, Edinburgh



J. Toderico

10,620







THE DIAGNOSIS  
OF  
NERVOUS DISEASES

BY

PURVES STEWART, M.A., M.D. EDIN., F.R.C.P.

PHYSICIAN TO OUT-PATIENTS AT THE WESTMINSTER HOSPITAL; JOINT-LECTURER ON  
MEDICINE IN THE MEDICAL SCHOOL; PHYSICIAN TO THE WEST END  
HOSPITAL FOR NERVOUS DISEASES, AND TO THE ROYAL  
NATIONAL ORTHOPÆDIC HOSPITAL; CONSULTING  
PHYSICIAN TO THE CENTRAL LONDON  
THROAT HOSPITAL

*THIRD EDITION, REVISED AND ENLARGED*

LONDON  
EDWARD ARNOLD  
41 & 43 MADDOX STREET, BOND STREET, W.  
1911

[All rights reserved]



ROCKEFELLER MEDICAL LIBRARY  
INSTITUTE OF NEUROLOGY  
THE NATIONAL HOSPITAL  
QUEEN SQUARE, LONDON, WC1N 3BG

CLASS

Q8

ACC. No.

10,620

SOURCE

Dr Margolis

DATE

March 1984

## PREFACE TO THE THIRD EDITION

It is seldom in practice that we meet with diseases in their fully-developed, so-called "typical" forms; more often we have to deal with patients who exhibit signs and symptoms common to several diseases. This volume approaches the subject of diagnosis of nervous diseases from the clinical standpoint, avoiding abstruse details of purely theoretical interest.

The last edition, published in 1908, reappeared in 1910 in French and German translations, the work of the late Professor Gustave Scherb (Algiers) and of Dr. Karl Hein (Bad Schönfliess) respectively. These foreign editions have had the advantage of introductory prefaces by Dr. F. Helme of Paris and Professor Eduard Müller of Marburg. To all these gentlemen I would here express my grateful appreciation.

The present edition has been revised throughout, and a number of new figures have been added, together with a considerable amount of fresh material in the text.

The subject of the work is mainly that of diagnosis; treatment is not discussed save incidentally here and there. The order pursued is that in which it is convenient to study phenomena during the process of diagnosis. All the clinical illustrations are from cases which I have observed personally in hospital or private practice.

I hope that the book, despite imperfections of which I am conscious, will continue to be useful to the advanced student and to the practitioner, not to replace but to supplement the text-books already in use.

Once more I have to express my gratitude to my colleagues, both at Westminster and at the West End Hospital, for their kindness in permitting me to study various cases



under their charge. In particular I would acknowledge the kindness of my colleague Dr. Harry Campbell, who allowed me to photograph the brain shown in Fig. 223. I am also indebted to Dr. James Mackenzie and to Dr. Dundas Grant for many useful suggestions.

Lastly, my warmest thanks are again due to Dr. S. A. Kinnier Wilson for his invaluable criticism and help in the correction of the proof-sheets.

PURVES STEWART.

94 HARLEY STREET, LONDON, W.,  
*September 1911.*

# CONTENTS

CHAP.	PAGE
I. ANATOMY AND PHYSIOLOGY . . . . .	1
II. ANATOMY AND PHYSIOLOGY ( <i>continued</i> ) . . . . .	27
III. METHOD OF CASE-TAKING . . . . .	48
IV. COMA . . . . .	55
V. FITS AND OTHER CONVULSIVE PHENOMENA . . . . .	65
VI. INVOLUNTARY MOVEMENTS . . . . .	79
VII. APHASIA . . . . .	95
VIII. DISORDERS OF ARTICULATION . . . . .	109
IX. CRANIAL NERVES . . . . .	118
X. CRANIAL NERVES ( <i>continued</i> ) . . . . .	148
XI. PAIN AND OTHER ABNORMAL SUBJECTIVE SENSATIONS . . . . .	173
XII. ABNORMALITIES OF SENSATION : HYPERÆSTHESIA, PAR- ÆSTHESIA, ANÆSTHESIA . . . . .	190
XIII. ORGANIC MOTOR PARALYSIS OF UPPER NEURONE TYPE . . . . .	206
XIV. ORGANIC MOTOR PARALYSIS OF LOWER NEURONE TYPE . . . . .	222
XV. RECURRENT AND TRANSIENT PALSIES . . . . .	248
XVI. INCO-ORDINATION . . . . .	257
XVII. POSTURES AND GAITS . . . . .	267
XVIII. TROPHO-NEUROSES . . . . .	290
XIX. REFLEXES . . . . .	316
XX. AFFECTIONS OF THE SYMPATHETIC. ANGIO-NEUROSES . . . . .	334
XXI. THE NEUROSES . . . . .	355
XXII. ELECTRO-DIAGNOSIS AND ELECTRO-PROGNOSIS . . . . .	389
XXIII. THE CEREBRO-SPINAL FLUID . . . . .	403
XXIV. DISORDERS OF SLEEP . . . . .	423
XXV. INTRA-CRANIAL TUMOURS . . . . .	434
INDEX . . . . .	455





## PLATES

I. Sub-ungual hæmorrhages of the hand . . . . .	<i>To face page</i>	304
II. Erythromelalgia . . . . .	” ”	350



TABLE

1. The number of specimens of each species . . . . .

2. The number of specimens of each species . . . . .

# THE DIAGNOSIS OF NERVOUS DISEASES

## CHAPTER I

### ANATOMY AND PHYSIOLOGY

THERE is no department of medicine where an accurate knowledge of anatomy is of greater importance than in the diagnosis of nervous diseases. Let us therefore, at the outset, recall some of the main points in the anatomy and physiology of the nervous system.

The nervous system consists of two main divisions:—(1) the cerebro-spinal, comprising the brain and spinal cord, together with the cranial and spinal nerves, and (2) the sympathetic, constituted by two chains of pre-vertebral ganglia, one on each side of the spine. These two, the cerebro-spinal and sympathetic, intercommunicate.

For teaching purposes it is convenient to regard the nervous system as built up of nerve-cells, and their processes the nerve-fibres. Both are excitable. But whereas the nerve-cell has been commonly assumed to originate impulses as does the cell of an electric battery, the nerve-fibres serving merely as conductors, it is unusual for an impulse to arise within a nerve-cell, except as the result of a transmitted impulse.<sup>1</sup> Each nerve-fibre is made up of a bundle of extremely fine neuro-fibrillæ which traverse the nerve-cell, entering it through one process and leaving it through another. In this way the nerve-cell acts as a convenient shunt for impulses, receiving them from one quarter and transmitting them to another. The nerve-cell also

<sup>1</sup> The cardiac and respiratory nuclei in the medulla are exceptions to this rule. These automatic centres can be stimulated, not only by transmitted nerve-impulses, but also by chemical changes in the blood, *e.g.* by deficiency of oxygen and excess of CO<sub>2</sub> or of lactic acid.



exerts a trophic influence over the nerve-fibre and is intimately concerned with its nutrition, so that the nerve-fibre degenerates if separated from its trophic nerve-cell.

In a **reflex motor act**, which is the simplest manifestation of nervous energy, as for example in the plantar reflex, the impulse or stimulus starts from a sensory end-organ, in this instance the skin of the sole. The impulse travels up a sensory nerve-fibre, through the corresponding posterior nerve-root into the spinal cord, and there, through the intermediation of another inter-communicating nerve-fibre and cell in the grey matter of the cord,

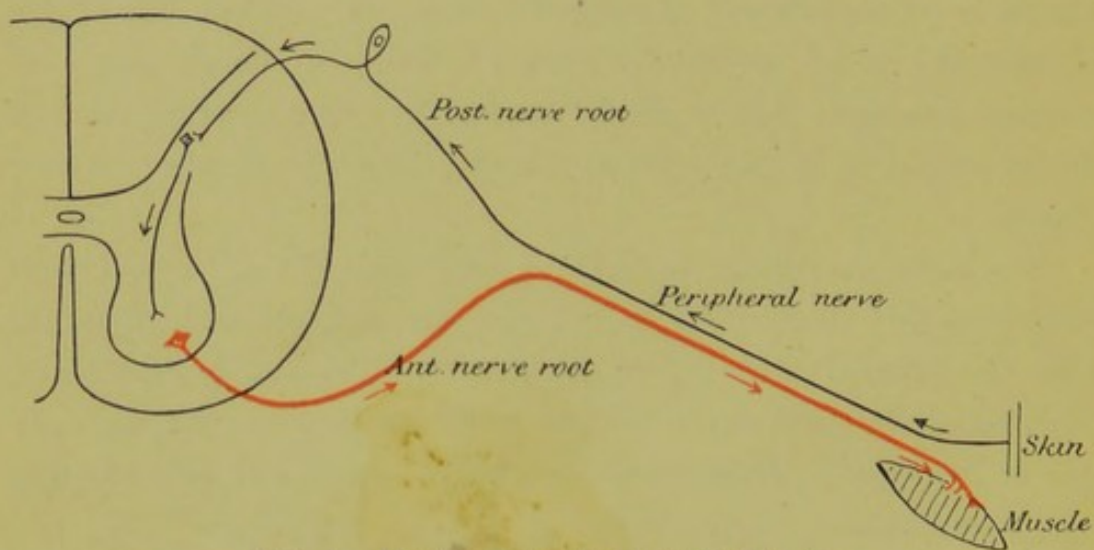


FIG. 1.—Diagram of a Simple Spinal Reflex.

it reaches an anterior cornual cell. From this motor-cell an efferent impulse starts, travelling outwards along an anterior nerve-root into a peripheral nerve and thus reaching a muscle-fibre in the flexor muscle of the toes. The muscle contracts and withdraws the sole of the foot from the original irritant.

The accompanying diagram (Fig. 1) will serve to recall the chief components of a simple spinal reflex, such as we have just described.

Some reflexes occur unconsciously, as for example the reflex contraction of the pupil when the retina is stimulated by light, or again, the normal movements of the stomach and intestines. But in other cases the afferent impulse, besides exciting a reflex motor action, sends part of its impulse upwards to the higher centres of the opposite cerebral cortex, where it produces a conscious sensation. This is accomplished by means of a sensory fibre

passing upwards in the substance of the spinal cord, as indicated in the other diagram (Fig. 2), through relays of nerve-cells and fibres in the medulla, pons, and so on, to the perceiving centre in the cortex.

Moreover, a discharge of motor energy from the motor cell in

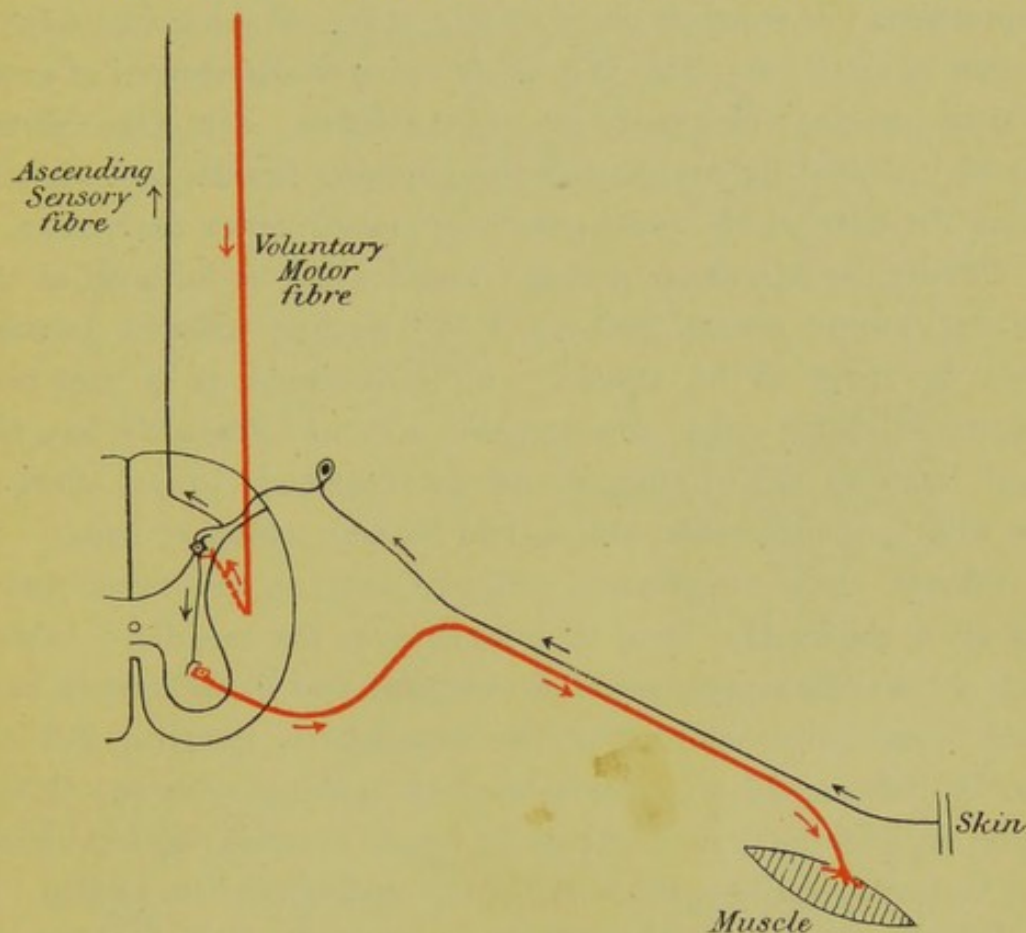


FIG. 2.—Diagram of a Voluntary Motor Act.

the anterior cornu can be produced not only reflexly, from below, but also voluntarily, from above. This is achieved by an impulse descending from the cortical motor centre of the opposite side, through the crossed pyramidal tract down the cord to the anterior cornual cell (see Fig. 2). A discharge can also be voluntarily inhibited from above.

Confining ourselves now to the consideration of a cerebro-spinal reflex motor action, we must bear in mind that afferent impulses, on reaching the cortical sensory centres, do not necessarily produce a descending impulse along the pyramidal tract. If they do, this is simply an automatic action, or a longer variety of reflex. There

\*



exist in the cortex perceiving-centres which take cognisance of the source and nature of the stimulus, and determine whether or not any active notice shall be taken of it, that is to say, whether a voluntary (and not merely an automatic) movement shall or shall not take place.

Some reflexes, even though associated with conscious sensory impressions (for example the vomiting reflex, or the sexual reflex), cannot be inhibited. This is possibly owing to the absence of antagonistic muscles which could prevent the reflex. But other reflexes can be inhibited by contracting the opposing muscles and thereby fixing the part which would otherwise make a reflex movement.

Finally, by education, a motor impulse can be initiated at the cortical motor centre, without any preceding afferent impulse from the part to be moved. All movements in a new-born infant are either reflex or automatic, and only gradually does the child learn to call in antagonistic muscles, and, by an effort of the will, to inhibit reflex acts and to initiate voluntary ones.

Certain more complicated reflexes, such as the reflex movements of respiration, have their centres in the medulla; others, such as the reflex movements of the heart and blood-vessels, have their lower reflex centres in the sympathetic ganglia, but can also be influenced by the cerebro-spinal nervous system. Others again, such as the movements of the heart, stomach, and intestine, can be performed independently of the central nervous system.

Figs. 3 and 4 are diagrams of the cerebral cortex, both on its convex and its mesial aspect. It is unnecessary here to enumerate in detail the various fissures and sulci, or the different lobes and convolutions.

When we look at a brain, the first landmarks to be identified are the Sylvian and Rolandic fissures. The central or Rolandic fissure starts at the middle line above, from a point half an inch behind the mid-point between the nasion and the external occipital protuberance. It runs downwards and forwards, along the convex surface of the brain, in the direction of the anterior part of the horizontal limb of the Sylvian fissure, making an angle of about  $67\frac{1}{2}$  degrees *i.e.* three-quarters of a right angle, with the middle line.

These two figures also show diagrammatically our present



views on cerebral localisation. It should be particularly observed that the motor areas in the pre-central convolution extend back as far as the Rolandic fissure but not behind it, as was formerly taught. Not only by experimental stimulation in anthropoid apes,<sup>1</sup> and in certain cases in man, but also by histological research,<sup>2</sup> it

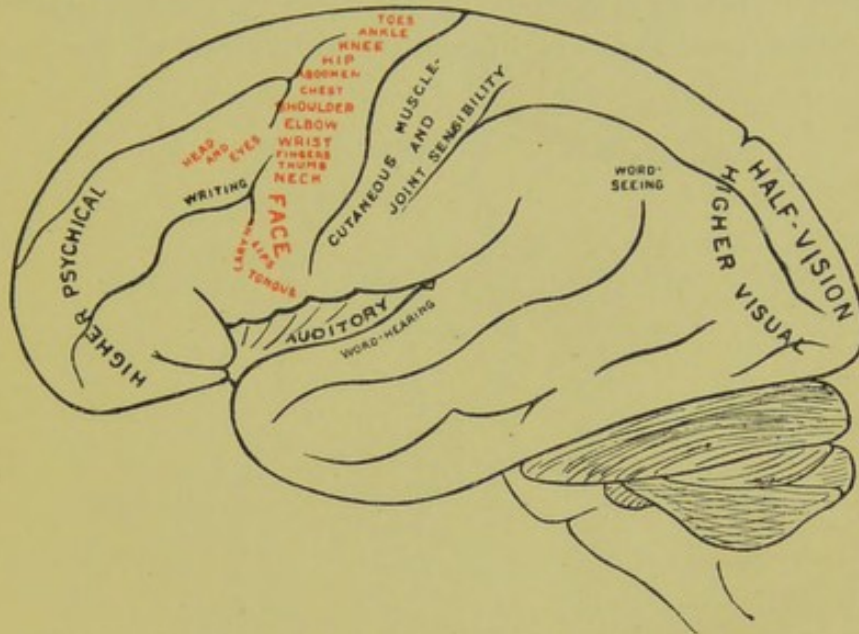


FIG. 3.—Scheme of Cerebral Localisation (outer surface).

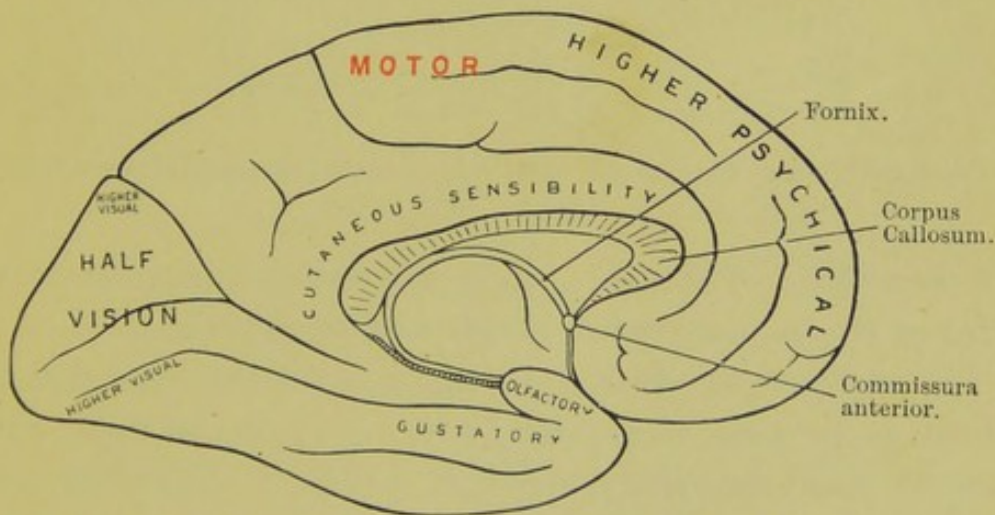


FIG. 4.—Scheme of Cerebral Localisation (mesial surface).

has been shown that the posterior wall of the Rolandic fissure differs in function and structure from the anterior or motor wall. The

<sup>1</sup> Sherrington and Grünbaum, *Trans. Path. Soc. Lond.*, 1902, vol. liii. p. 127.

<sup>2</sup> Campbell, A. W., *Histological Studies on the Localisation of Cerebral Function*, 1905.

Brodmann, K., *Journ. f. Psychologie und Neurologic*, Bd. ii. p. 80

anterior wall possesses giant pyramidal cells, and has no granular layer, whilst the posterior wall has a distinct granular layer, with no giant cells (see Fig. 5).

Another point to remember is that the different so-called motor areas are not sharply marked off from one another like a mosaic, but overlap, each area in Figs. 3 and 4 signifying that stimulation of that point produces the maximum movement of the particular

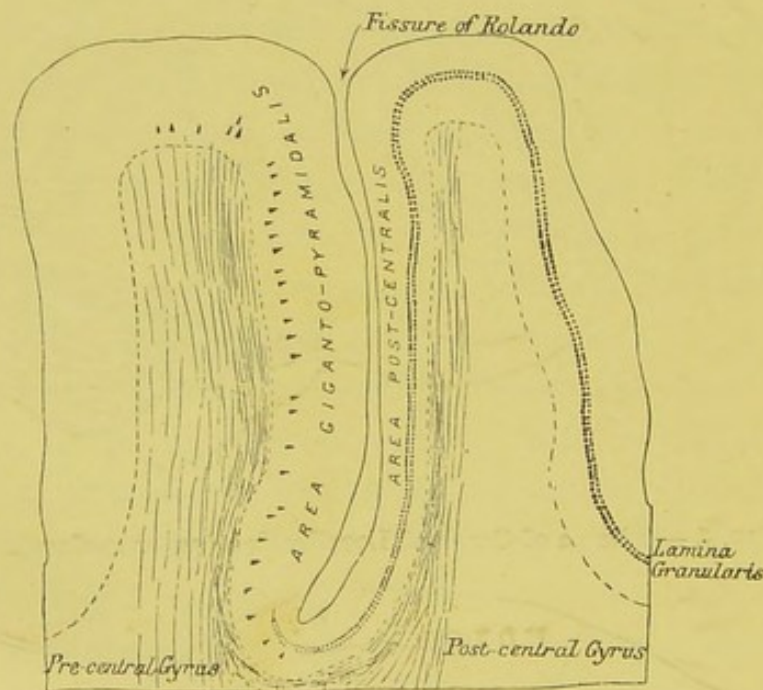


FIG. 5.—Diagram of cellular structure of pre- and post-central convolutions (after Vogt).

part mentioned. Moreover, there are minor variations in the extent of the various centres in different individuals.

The chief path by which motor impulses are conducted from the cortical motor areas to the muscles is the pyramidal tract, whose course is diagrammatically indicated in Fig. 6. From the motor cells in the cortex the fibres converge through the *corona radiata* into the great strand of nerve-fibres between the lenticular nucleus externally and the optic thalamus and caudate nucleus internally, namely, the internal capsule. Fig. 7 shows a horizontal section through the internal capsule, in which we notice that it has an anterior and a posterior limb, joining each other at an obtuse angle, the *genu* or knee. The motor fibres for the leg and arm



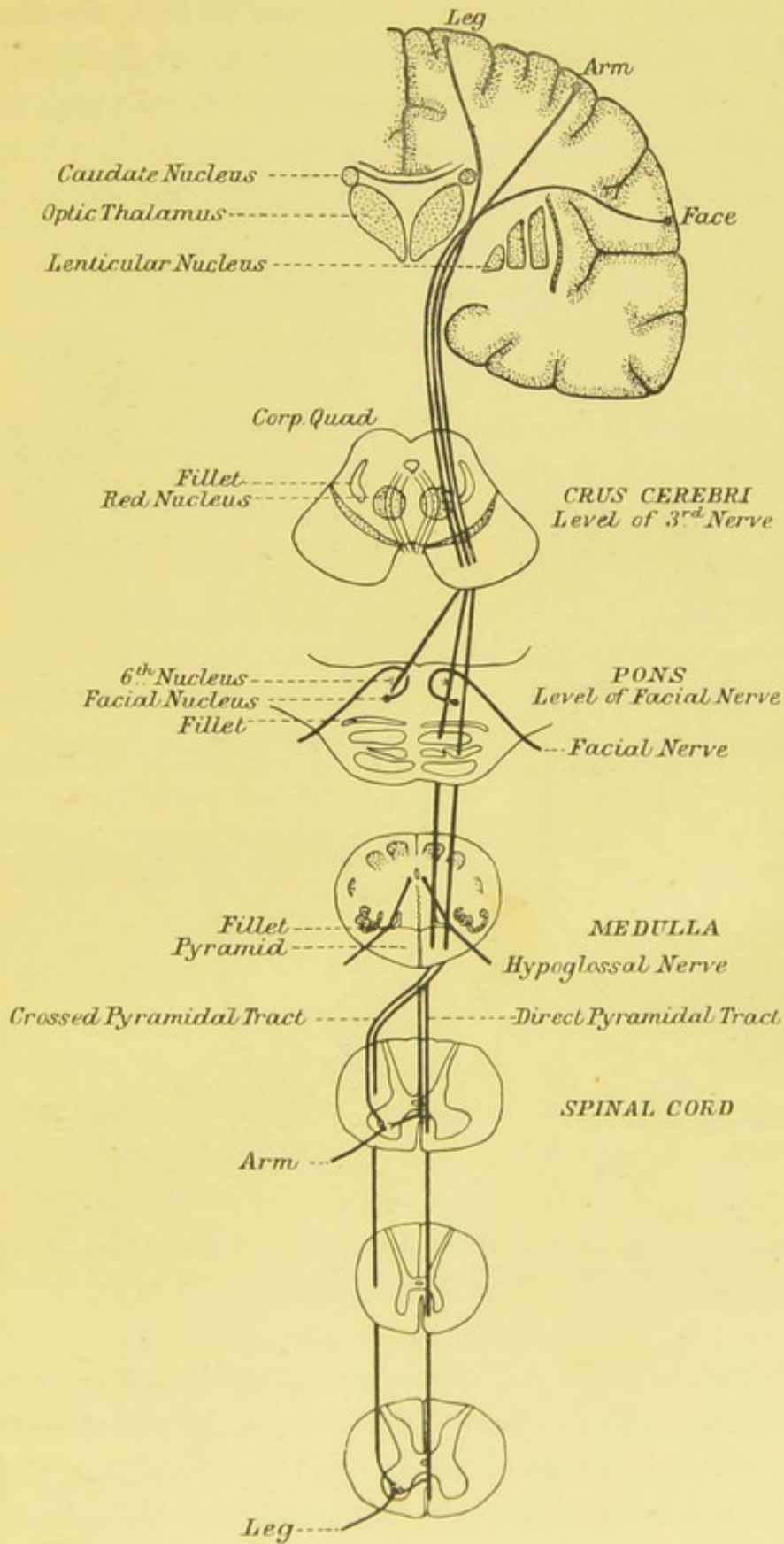


FIG. 6.—Diagram of Pyramidal Tract and its course through the brain and cord.



occupy the anterior two-thirds of the posterior limb, the fibres for the tongue and mouth are at the genu, those for the face just in front. But the order in which these different strands pass through the internal capsule is not quite the same as that in which they

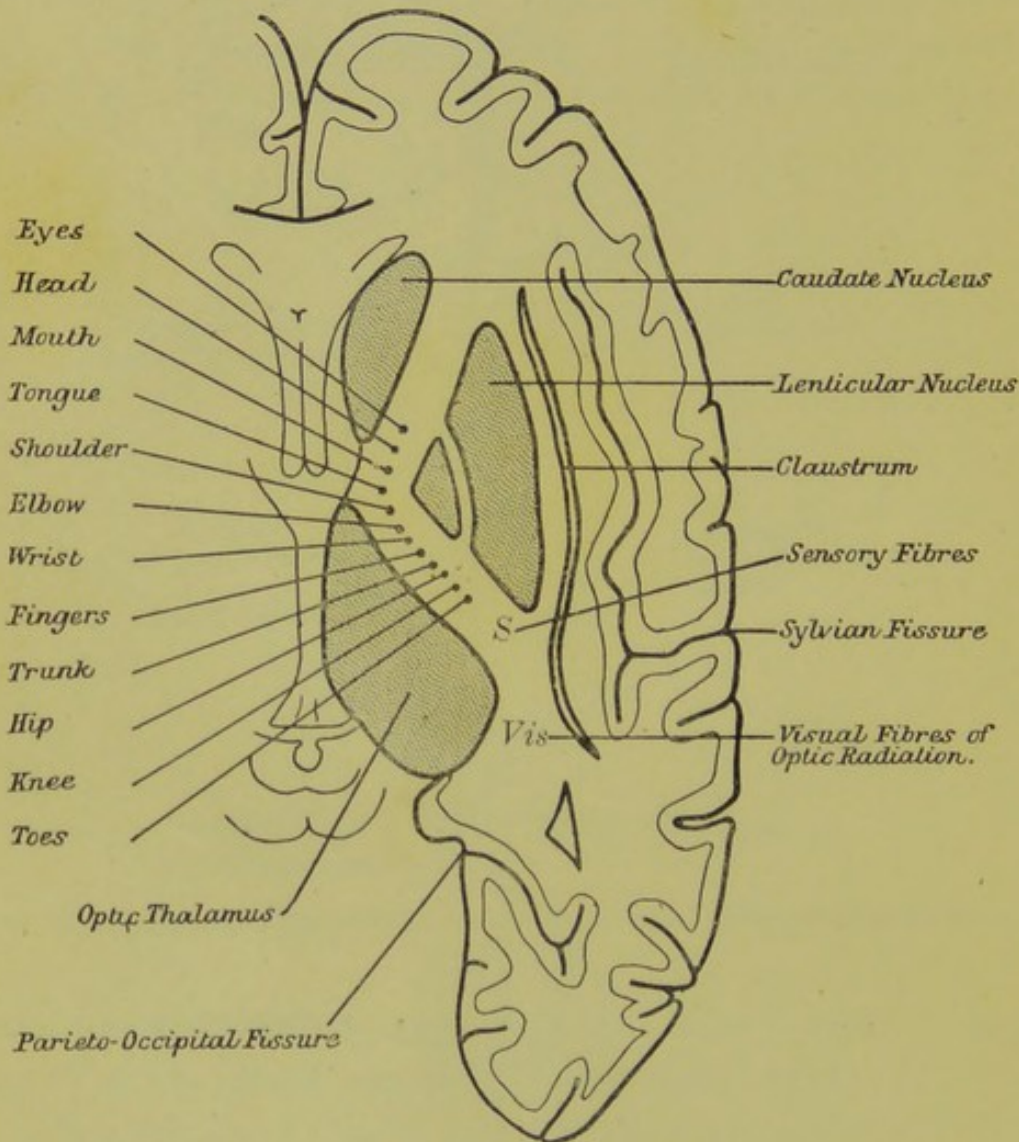


FIG. 7.—Horizontal section through right cerebral hemisphere, showing position of the various strands in the internal capsule. (After Beevor and Horsley.)

started from the cortex. Thus we notice that immediately behind the fibres for the lips we have, from before backwards, those for the shoulder, elbow, and fingers (not fingers, elbow, shoulder), then for the trunk, and lastly for the hip, knee, and toes. We also notice, in passing, that the pathway (thalamo-cortical) of the sensory fibres traverses the posterior part of the capsule, and that behind them



again are the visual fibres. The sensory fibres probably do not form a separate, compact bundle, but are partially mingled with some of the motor fibres for the leg.

Before leaving Figs. 6 and 7, it is of interest to study briefly, with their help, the different effects produced by lesions of the pyramidal motor tract at various levels.

*A lesion in or near the motor cortex*, if moderate in size, will produce, according to its situation, a monoplegia of the face, arm, or leg, on the opposite side of the body. A somewhat larger lesion will produce a brachio-facial or a brachio-crural monoplegia. From the proximity to the middle line of the cortical centres for the leg, a mesial, or bilaterally symmetrical, lesion may implicate the leg centres of both sides, producing a diplegia, mainly affecting the legs. (We observe that facio-crural monoplegia without implication of the arm is impossible from a single lesion.) For the production of a complete hemiplegia of face, arm, and leg a cortical lesion must be very extensive. But in the *internal capsule* all these strands are closely crowded together, so that a moderate-sized capsular lesion can produce a complete hemiplegia, whereas a capsular lesion small enough to cause a mere monoplegia is well-nigh impossible.

If the capsular lesion be in the region of the *genu* we have hemiplegia of face, arm, and leg. And moreover, from paralysis of the muscles which rotate the head and eyes to the opposite side, the patient has "conjugate deviation" of the head and eyes towards the side of the lesion, owing to unopposed action of the muscles supplied by the intact hemisphere.

If, on the other hand, the capsular lesion be farther back along the posterior limb of the capsule, the hemiplegia will affect the leg much more than the arm, and the face only slightly; whilst, owing to interference with the sensory tract, which lies between the motor and the visual fibres, there will now be hemianæsthesia also.

Lastly, if the lesion be at the extreme posterior end of the capsule, there will be not only hemianæsthesia but also hemianopia from interruption of the visual fibres. Here again we note that it is impossible for a single capsular lesion to produce



at the same time hemiplegia and hemianopia without also producing hemianæsthesia.

A lesion of the *crus cerebri* will tend to implicate the third cranial nerve on the side of the lesion, producing at the same time a hemiplegia of face, arm, and leg on the opposite side. This so-called "Weber's syndrome" is one variety of "crossed paralysis."

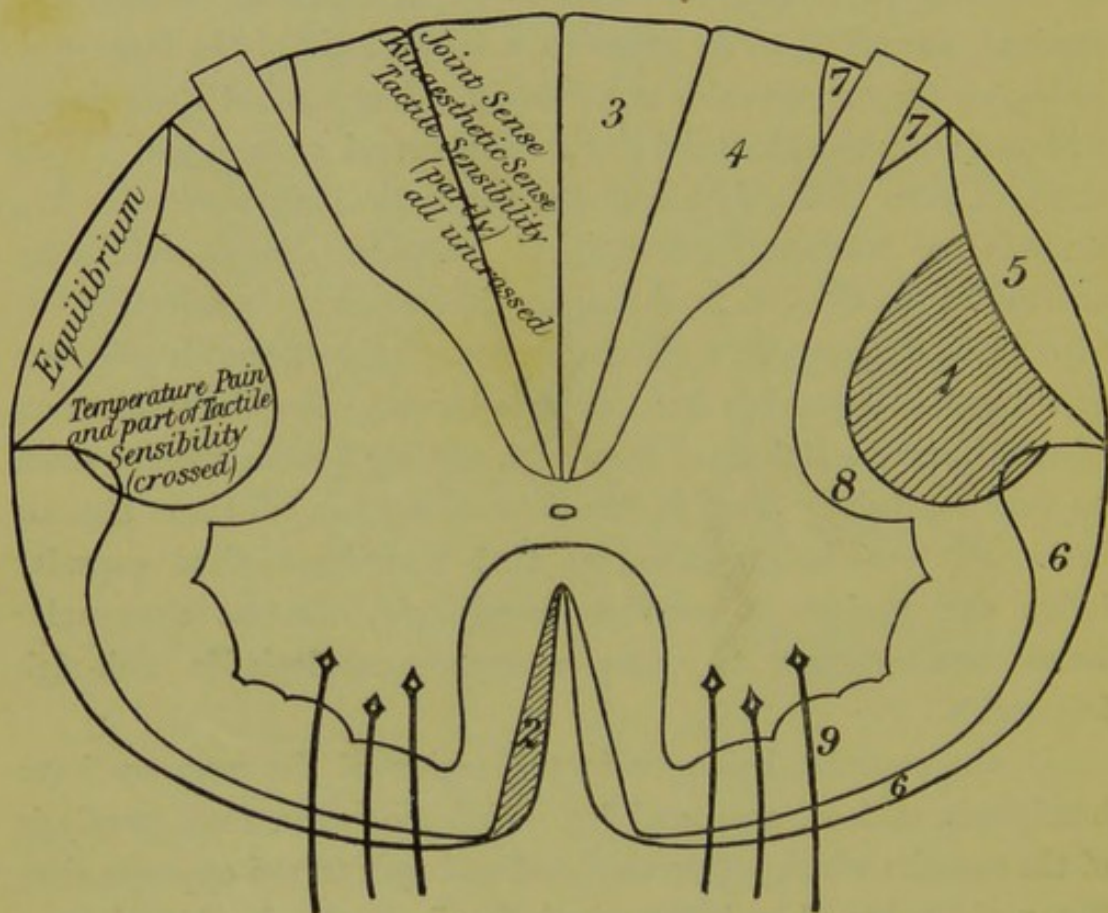


FIG. 8.—Diagram of Tracts in the Spinal Cord.

- |   |                                       |
|---|---------------------------------------|
| 1. Crossed pyramidal tract (descending) and Spino-thalamic tract (ascending). | 5. Direct or dorsal cerebellar tract. |
| 2. Direct pyramidal tract.  | 6. Ventral cerebellar tract (Gowers). |
| 3. Postero-internal tract (Goll).   | 7. Lissauer's marginal zone.          |
| 4. Postero-external tract (Burdach).  | 8. Lateral ground-bundle.             |
|   | 9. Anterior ground-bundle.            |

A unilateral lesion of the pons at the level of exit of the facial nerve will produce another "crossed paralysis," viz. :—facial palsy on the side of the lesion with hemiplegia of the arm and leg of the opposite side. And if at the same time the nucleus of the sixth cranial nerve be implicated (which is not unusual, since the facial nerve hooks round the sixth nucleus within the pons), we have nuclear palsy of the sixth nerve, facial palsy on the same side,



and hemiplegia of the arm and leg on the opposite side:—the “Millard-Gubler syndrome.”

*Unilateral lesions of the pons or medulla below the level of the facial nerve* leave the face unaffected and produce only a hemiplegia of arm and leg. And a *unilateral lesion of the spinal cord* below the cervical enlargement will produce a monoplegia of the leg on the side of the lesion without affection of the arm. It will also produce some anæsthesia of the opposite leg. Such motor paralysis of one leg and sensory paralysis of the other is called “Brown-Séquad paralysis,” to which we shall return later (p. 19).

Fig. 8 is a diagram representing the tracts in the spinal cord of chief clinical interest. There are also other ascending and descending tracts of minor importance, which we have omitted from the diagram for the sake of simplicity.

The pyramidal tracts are by far the most important descending tracts in the cord, for they convey voluntary motor impulses downwards from the motor cortex towards the anterior cornua. The pyramidal fibre does not actually join the anterior cornu, but ends in the region of the posterior cornu, whence a short intermediate connecting-cell and fibre run forward, linking it to the anterior cornual cell (see Fig. 2). Most of the voluntary motor impulses decussate at the lower end of the medulla and traverse the crossed pyramidal tract in the lateral column; a few run in the direct pyramidal tract and cross over later within the cord itself. A few pyramidal fibres also run down in the ipso-lateral pyramidal tract (which we might, somewhat paradoxically, call the uncrossed crossed-pyramidal tract). These fibres probably do not cross over, but supply motor impulses to the ipso-lateral leg. They account for the occurrence in hemiplegia of certain phenomena on the opposite, “non-paralysed” side, such as paresis, increased deep reflexes, and sometimes contractures in the “healthy” lower limb.

In addition to the great pyramidal or cortico-spinal tracts, there are other minor tracts which enter the spinal cord from above. These are derived from sub-cortical centres, and constitute subsidiary **subcortico-spinal tracts**. They end among the cells of the anterior horns, and provide a mechanism for the performance of

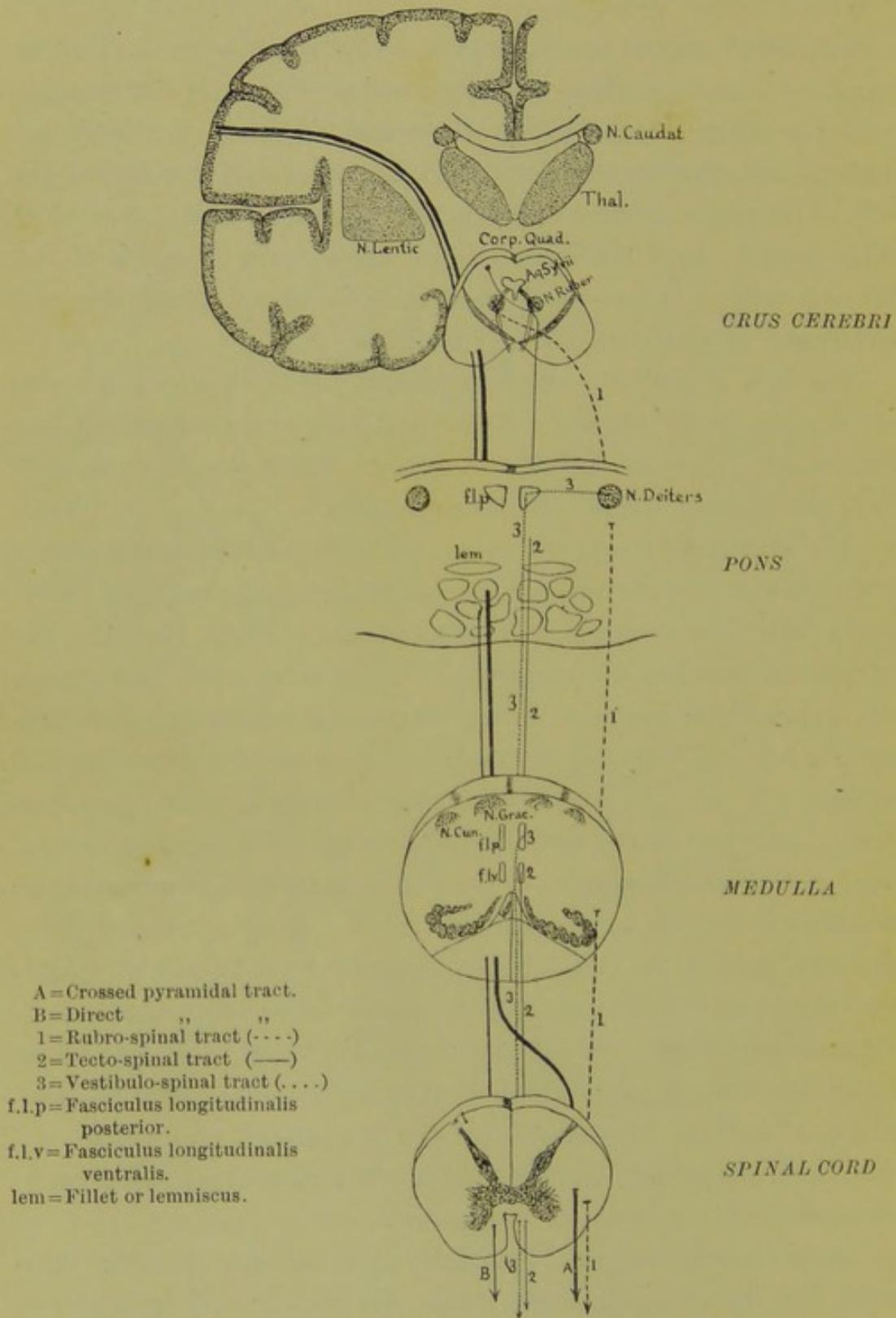


FIG. 9.—Cortico-spinal and sub-cortico-spinal tracts.



certain automatic acts which may still be possible when voluntary motor power is lost, as in pyramidal disease. Of these, the most important are the following (see Fig. 9):—

1. The *rubro-spinal* or *pre-pyramidal* tract (Monakow's bundle).—This tract arises in the red nucleus of the crus cerebri, decussates almost at once in the tegmentum, and descends in the contra-lateral side of the pons and medulla to the lateral column of the spinal cord, where it lies ventral to the crossed pyramidal tract.

2. The *tecto-spinal* tract or *ventral longitudinal bundle*.—This arises in the mid-brain from the anterior corpus quadrigeminum, crosses over in Meynert's "fountain" decussation beneath the Sylvian aqueduct, and then runs down the contra-lateral side of the formatio reticularis to the ventral column of the spinal cord.

3. The *vestibulo-spinal* tract or *dorsal longitudinal bundle*.—This arises from the accessory vestibular nucleus of Deiters within the pons, and passing downwards mainly on the ipso-lateral side of the spinal cord in the ventral column, ends amongst the anterior cornual cells.

In the adult the ventral and dorsal longitudinal bundles are indistinguishable from each other on section of the medulla or spinal cord, but they myelinate at different periods of development, and can thus readily be differentiated in the fœtus.

4. The *ponto-spinal* tract.—This is derived from cells of the formatio reticularis of the pons. Part of it runs down the ventral column of the ipso-lateral side, whilst part decussates in the raphé of the medulla and enters the opposite lateral column of the spinal cord.

**Sensory Paths.**—According to Head, Rivers, and Sherren,<sup>1</sup> the various afferent impulses from the periphery, on their way towards the spinal cord, do not run indiscriminately along the afferent nerves but are conducted along several distinct classes of nerve fibres. According to these observers, common sensation is a complex affair, based on three kinds of sensibility:—

1. *Deep sensibility*, a variety which takes cognisance of deep pressure, and which, if that pressure be excessive, is capable of producing a sensation of pain—"pressure-pain." Deep sensi-

<sup>1</sup> *Brain*, 1905, pp. 99-115.



bility also includes sensations from muscles, from joints, and the vibration-sense (see later, p. 195). The fibres conducting deep sensibility run along with the muscular nerves and are not destroyed by division of all the sensory nerves to the skin.

2. *Protopathic* cutaneous sensibility, a variety which responds

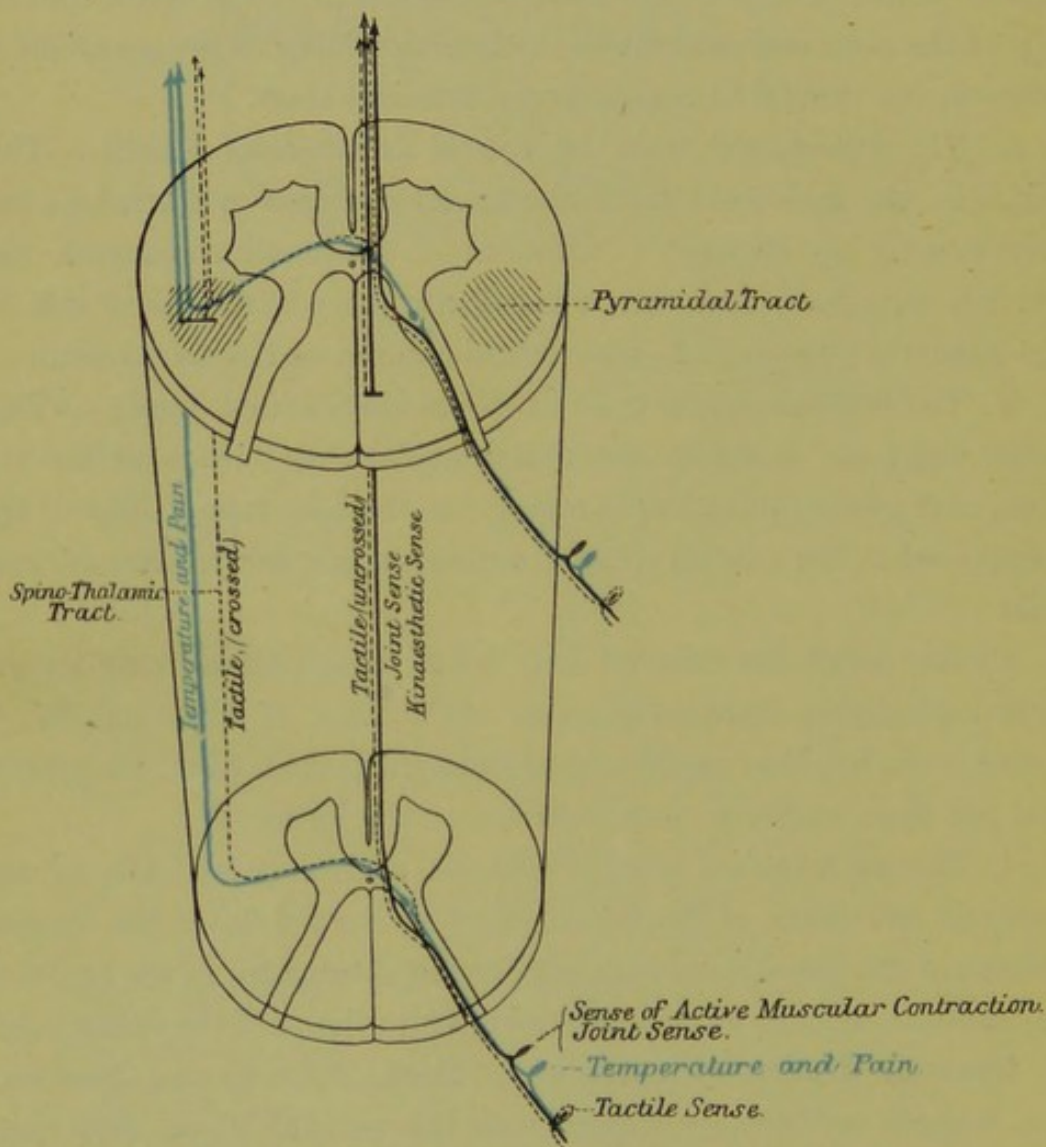


FIG. 10.—Diagram illustrating the course of the various sensory paths in the spinal cord.

to painful cutaneous stimuli (pricking, faradic stimulation), also to extremes of cold and heat, like freezing and burning (temperatures of  $45^{\circ}$  C. and over, and of  $10^{\circ}$  C. and under). These protopathic fibres from the skin are the first to regenerate after injury to a cutaneous nerve, so that the protopathic sensations are the earliest to recover as a cutaneous nerve heals.

3. *Epicritic* cutaneous sensibility, whose fibres are the slowest to recover after injury. This group includes the appreciation of light touches, of cutaneous localisation, the recognition of finer differences of temperature—not merely between hot and cold, but between warm and cool.

These differences, it should be noted, apply only to the extra-spinal portion of the sensory paths, *i.e.* to the peripheral nerves.

All the sensory impulses, whether conveying sensations of touch, temperature, or pain from the skin, sensation of active muscular contraction from the muscles (kinæsthetic sense), or sensations from the joints or bones, enter the spinal cord through the posterior roots, as indicated in Fig. 10.

Once the afferent impulses enter the spinal cord, it is no longer a question of deep, epicritic, or protopathic sensation ; they now become redistributed in simpler fashion. Thus all sensations of temperature run together in one tract, whether they reached the cord by the protopathic or the epicritic route : similarly all sensations of pain run together in the cord, whether they were protopathic or “ deep ” in the peripheral nerves, and so on. This is indicated in the following scheme :—

PATHS IN SPINAL CORD.		PATHS IN PERIPHERAL NERVES.		
Posterior Column } Tactile	$\left\{ \begin{array}{l} \alpha \\ \beta \\ \gamma \\ \delta \end{array} \right.$	Deep . . .	$\left\{ \begin{array}{l} \alpha \text{ Pressure.} \\ \beta \text{ Light Touches.} \\ \gamma \text{ Localisation.} \\ \delta \text{ Differences in Size.} \end{array} \right.$	
Lateral Column }		Epicritic . . .		
Lateral Column	$\left\{ \begin{array}{l} \text{Temperature} \\ \text{Pain} \end{array} \right.$	$\left\{ \begin{array}{l} \epsilon \\ \zeta \\ \eta \\ \theta \end{array} \right.$	Protopathic	$\left\{ \begin{array}{l} \epsilon \text{ Moderate differences of Temperature.} \\ \zeta \text{ Extreme differences of Temperature.} \\ \eta \text{ Cutaneous Pain (pricks, freezing, burns electricity).} \\ \theta \text{ Pressure-Pain.} \end{array} \right.$
			Deep . . .	$\left\{ \begin{array}{l} \iota \text{ Lengthening or Shortening of Muscles.} \\ \kappa \text{ Joints—passive movements.} \\ \lambda \text{ Vibration (tuning-fork).} \end{array} \right.$
Posterior Column	$\left\{ \begin{array}{l} \text{Muscles} \\ \text{Joints} \\ \text{Vibration (Bone).} \end{array} \right.$	$\left\{ \begin{array}{l} \iota \\ \kappa \\ \lambda \end{array} \right.$		

Of these various impulses, the fibres conveying sensations from the muscles and joints, together with the smaller part of the fibres for tactile sensation, ascend in the posterior column to the gracile and cuneate nuclei of the same side of the medulla. Most of the fibres for tactile sense, together with those for temperature and pain, cross in the anterior commissure to the opposite side



(these crossed fibres not coming directly from the posterior root, but through the relay of another cell in the posterior horn) and ascend the cord in the opposite lateral column, in the *spino-thalamic tract*. Thus the lateral column conducts not only pyramidal motor impulses coming down, but also spino-thalamic ascending impulses of touch, temperature, and pain.

The upward course of the various sensory fibres through the medulla and pons is somewhat complicated, and not yet entirely settled, but the most probable arrangement is shown in Fig. 11.

Most of the fibres for *touch* cross the middle line in the spinal cord, as already explained, and then pass directly upwards in the spino-thalamic tract of the lateral column and into that part of the medulla called the *formatio reticularis*. The *formatio reticularis* leads the fibres up through the pons and crus to the optic thalamus, and thence they pass through the posterior limb of the internal capsule to the sensory cortex behind the fissure of Rolando.

As the sensory tract traverses the pons it passes along the inner side of the sensory spinal root of the trigeminal nerve of the same side. Thus a *unilateral lesion of the formatio reticularis* just below the exit of the fifth or trigeminal nerve will produce a "crossed anæsthesia," *i.e.* anæsthesia of the face on the side of the lesion, and of the arm, leg, and trunk of the opposite side. But higher up the pons the sensory fibres from the face also cross the middle line, so that a lesion of the *formatio reticularis* in the crus cerebri will now cause complete hemianæsthesia of face, arm, and leg (see Fig. 12).

The fibres for *temperature* and *pain*, entering by the posterior root, pass into the grey matter of the posterior cornu. There they start afresh and cross to the opposite side of the cord, ascending in the opposite lateral column near the crossed tactile fibres. On reaching the medulla, they diverge from the tactile fibres and pass to the outer side of the olivary body, close to the lateral margin of the medulla and intermingled with the fibres of Gowers' tract. They then leave the region of Gowers' tract and pass upwards through the pons, gradually inclining towards the other sensory tracts and ultimately ascending with them



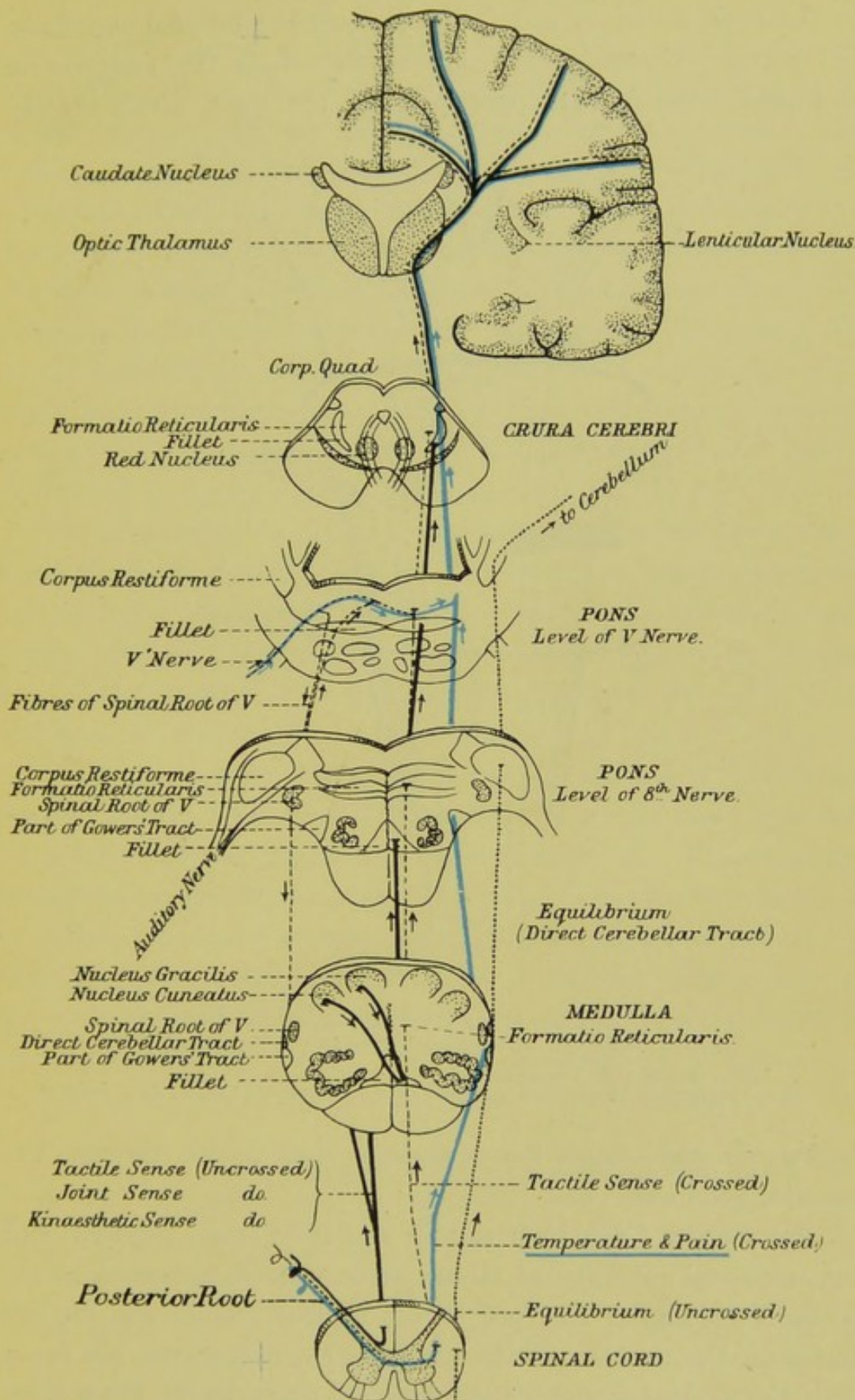


FIG. 11.—Diagram of Chief Sensory Tracts in Spinal Cord, Medulla, Pons, and Cerebrum.



to the optic thalamus and thence through the internal capsule to the cortex. Gowers' tract, now separate from the temperature and pain fibres in the upper part of the pons, hooks sharply

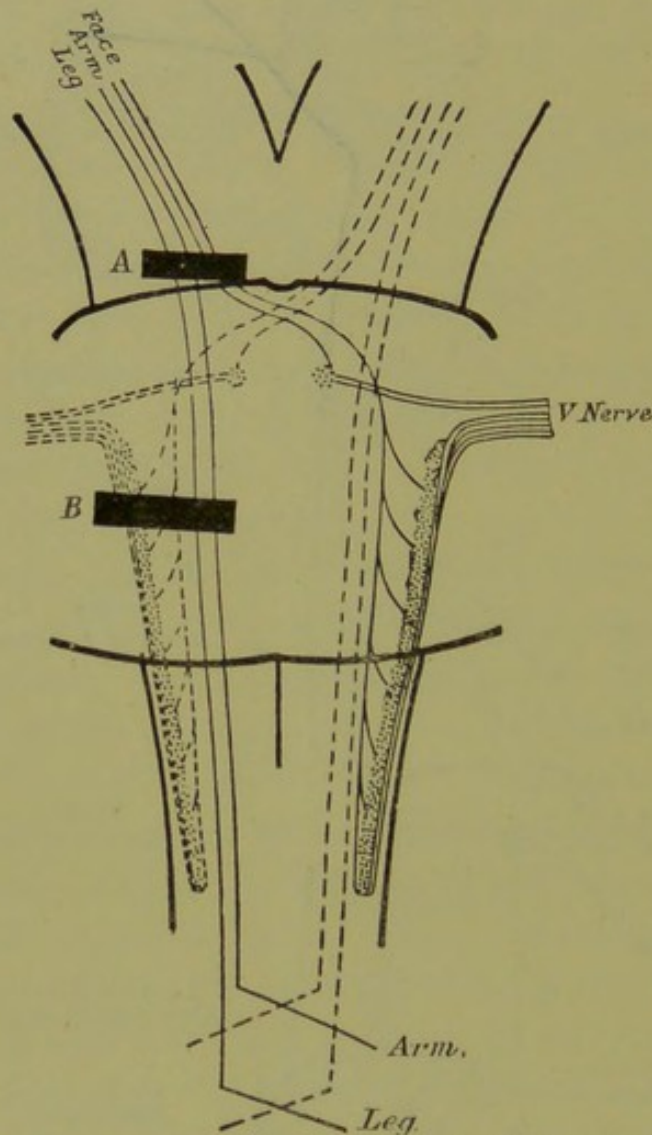


FIG. 12.—Course of Sensory Fibres in the Pons (Starr).

A. Lesion causing right hemianæsthesia.

B. Lesion causing "alternate hemianæsthesia" of left face and right side of body.

backwards and enters the cerebellum from above, through the superior peduncle.

The sensory fibres from *muscles* and from *bones*, together with the uncrossed minority of tactile fibres, ascend uncrossed in the posterior column of the cord to the nucleus gracilis and nucleus cuneatus, the nucleus gracilis receiving the fibres from the lower limb, the nucleus cuneatus those from the upper limb. From these two nuclei, nerve fibres pass upwards, and cross the middle



line in the internal arcuate fibres, forming the superior sensory decussation of the fillet (contrast this with the spinal decussation of the thermal, pain, and the majority of the tactile fibres). The sensory fibres from the leg, passing through the nucleus gracilis cross lower down than those from the arm, which go through the nucleus cuneatus. Having crossed to the opposite side and reached the fillet, a flattened strand of fibres, they pass upwards in that tract not far from the thermal and pain fibres. The main mass of the tactile fibres ascends through the crus cerebri to the optic thalamus, and passes on through the internal capsule to the sensory cortex, which lies mainly behind the Rolandic fissure,<sup>1</sup> and partly also in the gyrus fornicatus, on the mesial aspect of the brain.

We have still to consider another tract, which conducts sensory fibres for the *sense of equilibrium*. This tract does not commence in the posterior root-ganglion but arises as an "endogenous" tract within the cord. Arising from the cells of Clarke's column at the base of the posterior horn, it constitutes the direct cerebellar tract and ascends, uncrossed, into the restiform body and cerebellum.

Before leaving the motor and sensory tracts within the central nervous system it will be useful to mention the symptoms produced by a lesion of one lateral half of the spinal cord. Such a lesion is most commonly the result of a stab in the back; less commonly it is produced by bullet-wounds, fractured spine, caries, or by chronic diseases of the spinal cord itself. The syndrome which results is known as **Brown-Séguard paralysis**, and it will be readily understood by reference to Figs. 10 and 13. The symptoms are as follows:—

(1) *On the side of the lesion* we have, from interruption of the

<sup>1</sup> Sensory impulses run up not only to the post-central convolutions, but also to the motor areas. Thus a lesion of the motor cortex, besides causing a monoplegia of the corresponding limb, produces slight anæsthesia of the affected limb, with deficient sense of position in the weakened parts and diminished kinæsthetic sense in the affected muscles. It is to be borne in mind that the pyramidal motor cells do not lie in the most superficial layer of the cortex, but are covered by a layer of cells which are probably sensory in function. A striking evidence of this was afforded by a case of Negro and Oliva. These observers had the opportunity of stimulating the motor cortex of a woman who had been trephined. They found that with feeble stimulation only sensory symptoms were produced, a stronger stimulus being required to cause motor spasms.



motor tract, motor paralysis of the corresponding leg, with an extensor plantar reflex from the outset and, later on, exaggeration of the deep reflexes. There is a slight and transient elevation of

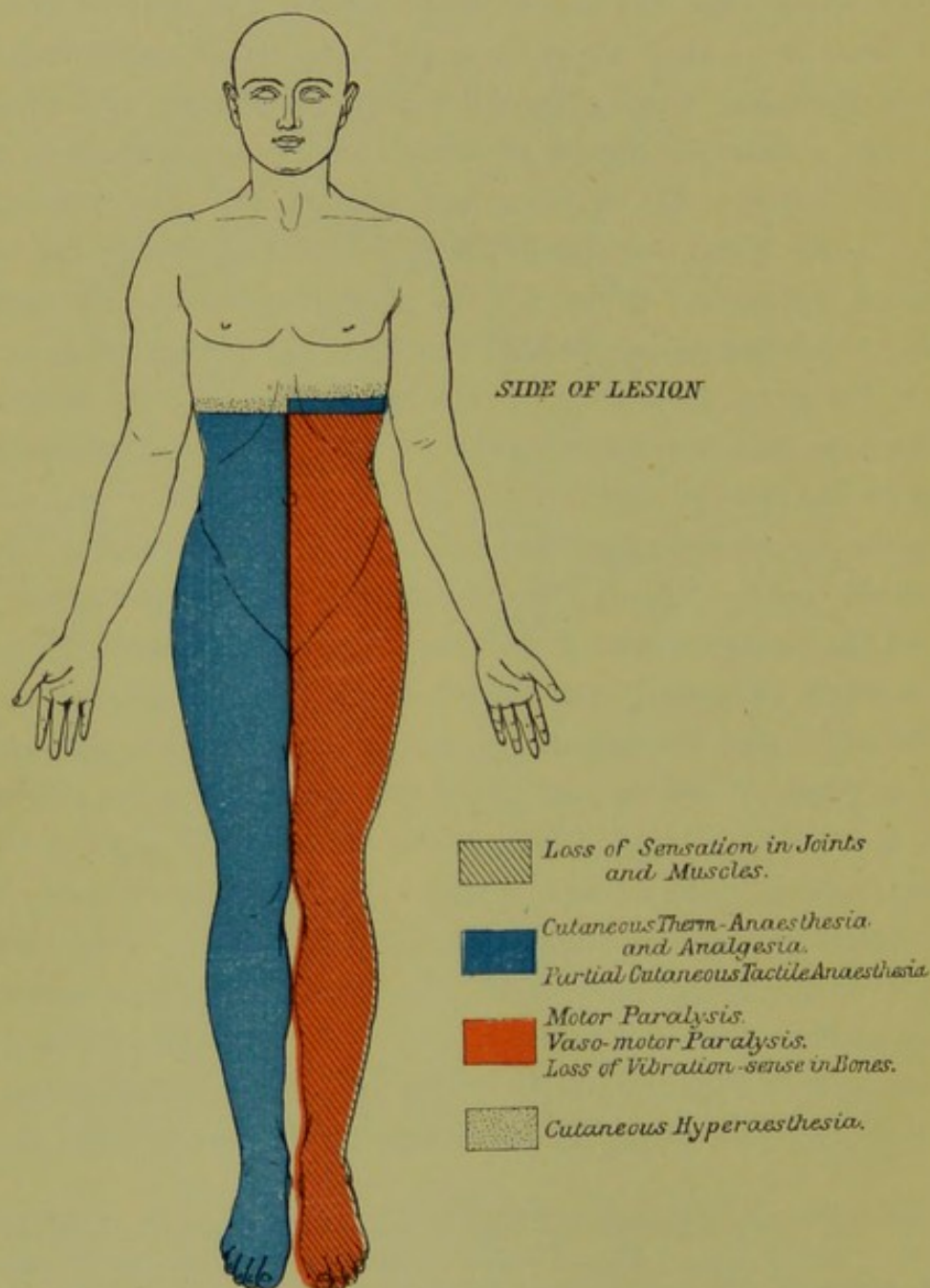


FIG. 13.—Diagram illustrating the symptoms resulting from a left-sided hemi-section of the spinal cord (Brown-Séquard syndrome).

temperature, owing to the interruption of vaso-motor fibres which descend in the lateral column. There is loss of sense of position on passive movement of the limb and loss of "vibration sense" (tested by a tuning-fork) in the bones of the paralysed leg,



due to interruption of the uncrossed fibres from the posterior roots below the lesion, which ascend in the posterior column. The paralysed leg is not anæsthetic, but, just at the level of the lesion, there is around the trunk a narrow zone of anæsthesia to touch, temperature, and pain, from severance of a few sensory fibres cut across before they have succeeded in crossing to the other side. Finally, there is a narrow zone of hyperæsthesia above the anæsthetic zone, perhaps due to local irritation of the lowest unsevered posterior-root fibres in the cord, close above the lesion; but this explanation is in dispute.

(2) *On the side opposite to the lesion* there is no motor paralysis. But there is loss of cutaneous sensation to temperature and pain (completely), and to touch (partially), in the non-paralysed lower limb and in the corresponding half of the trunk up to the level of the lesion. There is a zone of hyperæsthesia above the anæsthetic area, as on the side of the injury. Motor power is unimpaired, so also is the sensation of position on active or passive movement of the limb.

**Cerebellum.**—The cerebellum consists of a middle lobe or *vermis*, with a lateral lobe on each side, and its cortex is finely folded into leaves or lamellæ. Within the white matter, at a distance from the cortex and analogous in some respects to the basal ganglia of the cerebrum, there are several important masses of grey matter, of which the chief are the *corpora dentata*, two hollow crumpled sacs, one within each lateral lobe; the *roof nuclei* within the middle lobe; the *nuclei globosi* and the *nuclei emboliformes*, bilaterally situated, between the roof nucleus and the dentate nucleus (see Fig. 14); and the *nuclei of Deiters*, or accessory vestibular nuclei, within the pons, one on each lateral aspect. Deiters' nucleus has several highly important connections, with the cerebellar cortex, with the ocular nuclei (third and sixth), and with the anterior cornual cells of the same side of the cord, through the vestibulo-spinal tract. This centre in Deiters' nucleus, with its various connections, is probably the lower reflex mechanism whereby, when we hear a sound, the head and eyes are



promptly turned towards the side on which the auditory stimulus was received.

Each lateral lobe has three peduncles (Fig. 15). Of these, the superior peduncle contains fibres which are chiefly cerebello-fugal and are derived mainly from the dentate nucleus, this nucleus in turn being connected with the cerebellar cortex. The cerebello-fugal fibres of the superior peduncle pass up ventral to the corpora quadrigemina, cross the middle line and reach the red nucleus in the crus cerebri of the opposite side. Starting again

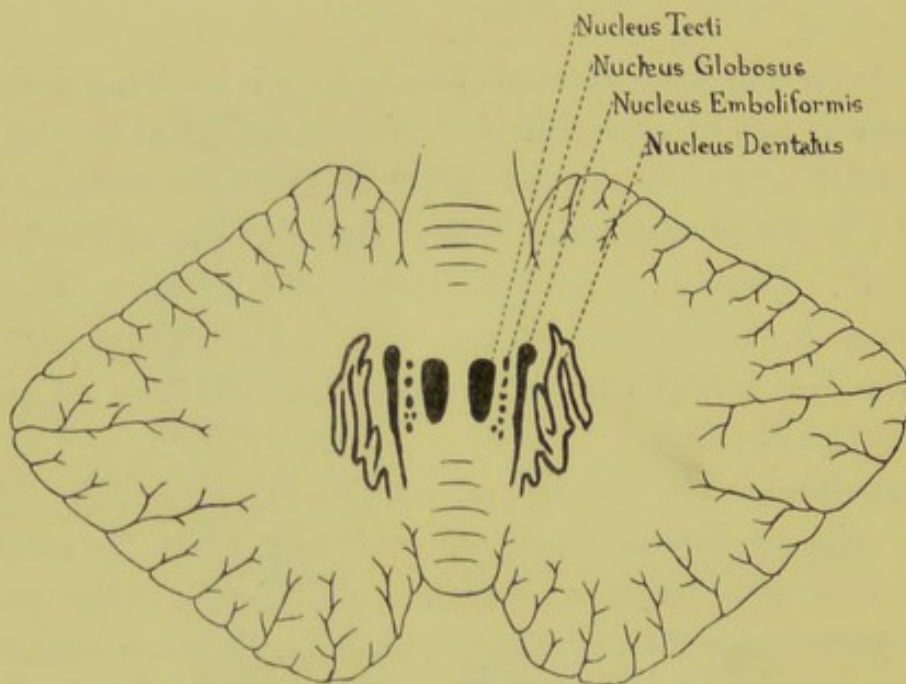


FIG. 14.—Horizontal section through cerebellum.

from this station, fibres run forwards along the anterior limb of the internal capsule, and pass to the optic thalamus and to the cortex of the frontal lobe. In this way the cerebellar hemisphere of one side is connected with the opposite side of the cerebrum, such connection being not a direct one, from cortex to cortex, but indirect, by the intermediation of intra-cerebellar and intra-cerebral nuclei.

The middle peduncle constitutes the greater part of the transverse fibres of the pons. And here again its fibres are not mere commissural strands running from one lateral lobe to the other. Fibres from each lateral lobe cross the middle line, it is true, but they end in cells in the *formatio reticularis* of the opposite side

of the pons. These new fibres arise and pass up the superior peduncle through the crus cerebri and internal capsule to the

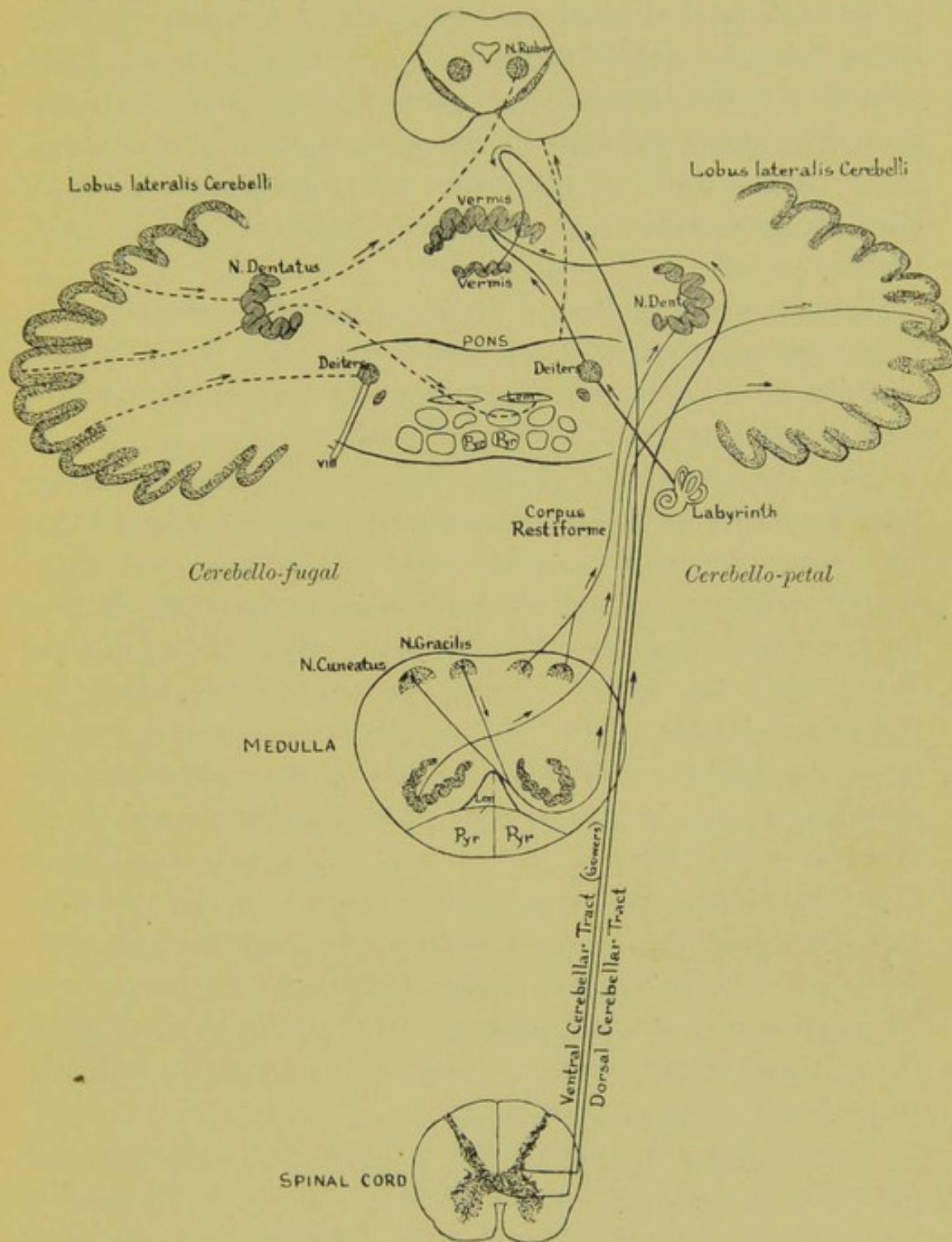


FIG. 15.—Cerebello-petal (—) and cerebello-fugal (---) paths.

frontal, temporal, and occipital lobes of the cerebrum. Important afferent, cerebello-petal fibres in the middle peduncle connect Deiters' nucleus with the vermis and the corresponding side



of the cerebellar cortex in the region of the flocculus, conveying impulses to the cerebellum from the semicircular canals.

The inferior peduncle or restiform body connects the cerebellum with the medulla and spinal cord. It contains the direct cerebellar tract, conveying impulses of equilibration from the same side of the spinal cord, also arcuate fibres from the posterior column nuclei of both sides, and fibres from the inferior olive of the opposite side. All these fibres are cerebello-petal, leading upwards.

Broadly speaking, then, each lateral half of the cerebellum is in connection mainly with the cerebral hemisphere of the opposite or contra-lateral side, with both sides of the medulla, and with the same or ipso-lateral side of the spinal cord.

Thus the cerebellum receives impulses from various sources:— from the cerebrum through the superior peduncles, from the skin and muscles through the inferior peduncles, and from most of the cranial nerve nuclei through the middle peduncles, especially from the semicircular canals, by the vestibular nerve. And in turn the cerebellum sends efferent impulses to the cerebrum, reinforcing the general muscular tonus and co-ordinating the motor impulses proceeding from the cerebrum. In most voluntary movements the centre of gravity of the body requires to be altered and certain muscular groups have to co-ordinate to maintain equilibrium. For this purpose the tonus of these muscular groups has to be augmented, and this is accomplished by the cerebellum, the great centre for co-ordination and equilibration, partly by the action of the dentate, roof, and emboliform nuclei on the cerebral motor cortex, partly by the nuclei of Deiters and the descending vestibulo-spinal tracts to the spinal cord.

Experiments<sup>1</sup> have shown that although the cerebellum as a whole—comprising cortex and nuclei—responds to stimulation, the cerebellar cortex, compared with the cerebral, is relatively very resistant to excitation. On the other hand, the sub-cortical cerebellar nuclei are highly excitable, and it is probable that stimulation of the cerebellum produces motor phenomena mainly

<sup>1</sup> Horsley and Clark, *Brain*, 1908, p. 45.



by excitation of these nuclei. If we stimulate one lateral half of the vermis or the lateral cerebellar hemisphere, we produce movements of the ipso-lateral limbs and also rotation of the body around its own longitudinal spinal axis. Thus excitation of the right side of the cerebellum produces a rotation in the direction of unscrewing an ordinary screw (the animal's head representing the head of the screw). Conversely, removal or division of the right lateral lobe produces rotation in the reverse direction—namely, that of screwing in a screw—since the intact side of the cerebellum maintains its tonic action, and is no longer opposed by the affected side whose muscles have lost their tonus (hypotonia). In such unilateral destructive lesions loss of co-ordinating influence also causes asynergia of the ipso-lateral arm and leg, together with various ocular phenomena, including nystagmus, owing to loss of cerebellar influence on the ocular nuclei through Deiters' nucleus.

Stimulation of the vermis in the middle line produces bilateral movements. Thus, if the posterior end of the vermis be stimulated, the animal rotates violently forwards, whilst if the anterior part of the vermis be stimulated, the animal rotates violently backwards. Destruction of the middle lobe produces opposite effects, the animal tending to fall forwards from an anterior lesion of the vermis, and conversely.

The movements of the trunk and limbs which result from stimulation of the cerebellar cortex are apparently not produced by direct action of the cerebellum on the spinal cord. Not only is there no direct tract leading downwards from the cerebellum into the cord but only indirect paths through Deiters' nucleus and the vestibulo-spinal tract, but Pagano<sup>1</sup> has shown that if the contra-lateral cerebral cortex be extirpated, stimulation of the lateral lobe of the cerebellum no longer induces movements in the ipso-lateral limbs. The motor action of the cerebellar nuclei is exercised indirectly, through the intermediation of the superior peduncles and the cerebral cortex.

The **pituitary gland** is a small oval body whose longest diameter

<sup>1</sup> *Rivista di patologia nervosa e mentale*, 1902, p. 145.



lies transversely. It occupies the sella turcica of the sphenoid bone. It is enclosed within a special covering of dura mater, and is connected with the floor of the third ventricle by a narrow, hollow stalk—the infundibulum, which leads upwards through a special aperture in the dura. The pituitary gland consists of two lobes:—(1) a larger *anterior lobe*, purely epithelial in structure and containing many chromophile cells of active, secreting nature; (2) a smaller *posterior lobe* which is subdivided into a *pars intermedia*, epithelial in structure, but without chromophile cells and a *pars nervosa*, the continuation of the infundibulum, and consisting of ependymal and neuroglial cells. The *pars nervosa* is developed by outgrowth from the primitive brain, whereas the *pars intermedia* and anterior lobe are developed as a backward diverticulum from the primitive ectoderm of the pharynx. In fact, a small longitudinal patch of pituitary tissue often persists in the submucous tissue of the pharyngeal roof, outside the cranial cavity.<sup>1</sup> The secretion of the anterior lobe enters the blood-stream of the venous sinuses around the gland, whereas the secretion of the *pars intermedia* and *pars nervosa* probably passes directly between the ependymal cells into the cerebro-spinal fluid of the third ventricle, and thence enters the blood-stream, *viâ* the dural sinuses. The secretion of the *pars nervosa* has a marked effect in raising the general vascular pressure.

<sup>1</sup> Civalleri, *Giornate dell' Accademia di Torino*, 1907.

Haberfeld, *Ziegler's Beiträge zur path. Anat.*, 1909, xlvi.



## CHAPTER II

### ANATOMY AND PHYSIOLOGY (*continued*)

HAVING considered the chief motor and sensory tracts within the central nervous system, let us now pass to the peripheral paths whereby the central nervous system is connected with the various end-organs.

Firstly, as to the motor system. Motor fibres starting in the cortex, and passing down the pyramidal tract, as already described, reach the nuclei of the various motor cranial nerves in the crura, pons, and medulla. Then, passing along the spinal cord, the pyramidal tract gives off fibres to the anterior cornua at various levels all the way down. This portion of the motor tract, from the motor cortex to the extremity of the pyramidal fibres, is called the *upper motor neurone*, and if the cortical motor cell or its axon, the pyramidal motor fibre, be destroyed, we have degeneration of the whole length of the pyramidal fibre below the level of the lesion, stopping short when it reaches the anterior cornual cell. This so-called "descending degeneration" does not, as the name might suggest, begin at the lesion and spread downwards, but affects simultaneously the whole motor fibre below the lesion, on the side remote from the nerve-cell which is its trophic centre.

From each anterior cornual cell a new motor fibre passes out of the cord along an anterior nerve-root, enters into the formation of a peripheral motor nerve, and thereby is conducted to a muscle-fibre. This lower segment of the motor path, starting at the anterior cornual cell and ending in the muscle-fibre, is called the *lower motor neurone*. Here also, if the anterior cornual cell or its axon, the peripheral motor nerve, be destroyed, we again have a "descending degeneration" of the whole fibre on the distal side of the point of injury, and of the muscle-fibre also. We note that degeneration of the upper motor neurone does not spread into the lower neurone, nor *vice versa*. It is particularly to be remembered



that a lesion of the upper motor neurone leaves the lower reflex arc intact, whilst a lesion of the lower motor neurone not only severs the reflex arc, but also causes the muscle-fibre in that reflex arc to degenerate and waste away.

Therefore in diagnosing the position of the lesion, in any given case of motor paralysis due to organic disease, the first question we must ask ourselves is whether the lesion is in the upper (cortico-spinal) or in the lower (spino-muscular) motor neurone. There is usually little difficulty in answering this question, if we bear the following points in mind :—

Lesion of Upper (Cortico-Spinal) Motor Neurone.	Lesion of Lower (Spino-muscular) Motor Neurone.
1. Motor Paralysis.	1. Motor Paralysis.
2. Spasticity.	2. Flaccidity.
3. No muscular wasting (apart from disuse).	3. Muscular Atrophy.
4. Electrical reactions normal.	4. R.D. (reactions of degeneration).
5. Deep reflexes present and often increased.	5. Deep reflexes absent or diminished.
6. Extensor plantar reflex (if leg affected).	6. Plantar reflex, if present, of normal flexor type (unless lesion paralyzes flexor muscles themselves).

Having thus recognised which motor neurone, upper or lower, is affected, we have then to decide at what level in the affected neurone the lesion is situated. To that point we shall come later (p. 215).

Returning for a moment to the sensory fibres; these may also be regarded as arranged in *sensory neurones*. The lowest sensory neurone starts from a sensory end-organ, in the skin or elsewhere, and extends up to the nerve-cell in the intervertebral ganglion on the posterior spinal root. This ganglion-cell is the trophic centre for the peripheral sensory fibre, and a lesion at or below this cell will cause "descending degeneration" of the distal segment of the fibre and of the peripheral end-organ. There is, however, one sensory end-organ, the muscle-spindle, which is an exception to this rule, and does not degenerate when the afferent fibre leading from it to the ganglion-cell is destroyed. The muscle-spindle thus has its trophic centre within itself.

But the ganglion-cell of the posterior root is also the trophic centre for the fibre which passes upwards from it along the pos-



terior root and enters the posterior column of the spinal cord. And therefore a lesion at or above the intervertebral ganglion-cell, in the posterior root, or in its intra-spinal prolongation in the posterior column, will cause an "ascending degeneration" of the fibre through its whole course within the spinal cord. Here again this so-called "ascending" degeneration occurs simultaneously throughout the entire extent of the nerve-fibre, on the side remote from its trophic centre in the intervertebral ganglion; and this degeneration extends as far as, but does not implicate, the next nerve-cell whose axon leads upwards towards the brain. Similarly a lesion of this second sensory neurone causes ascending degeneration in the fibre of the fillet above, as far as, but not including, the optic thalamus. There a third neurone starts, leading up to the sensory area of the cerebral cortex. In the case of the ordinary sensory tract, the path traverses the internal capsule.

In the case of an impulse which traverses the cerebellum, the chain of successive neurones is more complex, and consists, firstly of a posterior-root neurone, secondly of an ascending spino-cerebellar neurone, thirdly of a cerebello-dentate, fourthly of a dentato-thalamic, and lastly of a thalamo-cortical neurone.

The so-called "Wallerian degeneration"—"ascending" or "descending" as the case may be—signifies that a nerve-fibre, separated from its trophic cell, degenerates on the side remote from that cell. It should also be remembered that after lesions of a cranial or spinal nerve, especially in a young animal, marked chromatolytic changes are produced in the nerve cells of the corresponding motor nucleus in the bulb or spinal cord.

The anterior and posterior nerve-roots join to form mixed nerve-trunks. These again branch and intermingle to form plexuses in the cervical, lumbar, and sacral regions. The distribution of the different nerves, motor and sensory, is represented in Figs. 16, 17, and 18.

**Root Lesions.**—But what is perhaps less familiar, though of equal diagnostic importance, is the distribution of the anterior and posterior spinal roots. In lesions of the lower motor neurone, we have often to decide whether the distribution of symptoms









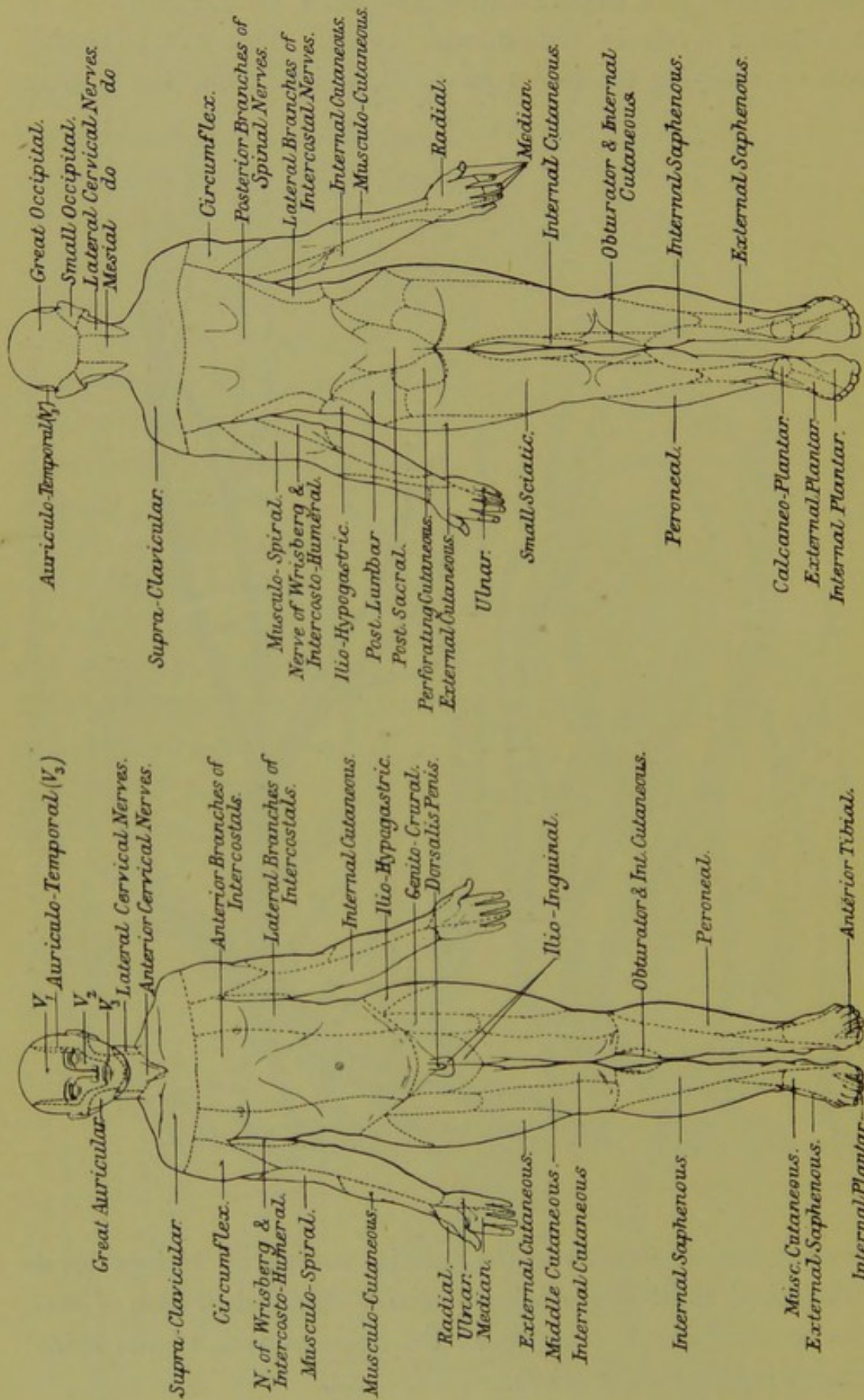


FIG. 18.—Diagram of Cutaneous Areas of Peripheral Nerves.



fibres, it is interesting to note that in each embryonic segment or metamere, the muscular territory (myotome) of the segment corresponds more or less closely with the cutaneous distribution (dermatome) and with a zone of the bony skeleton (sclerotome). In the trunk this segmental or metameric arrangement is comparatively easy to recognise, especially in the thorax, and even in the limbs, though more complex, a similar arrangement can be made out. Thus, as Bolk has shown, in the limbs there is for

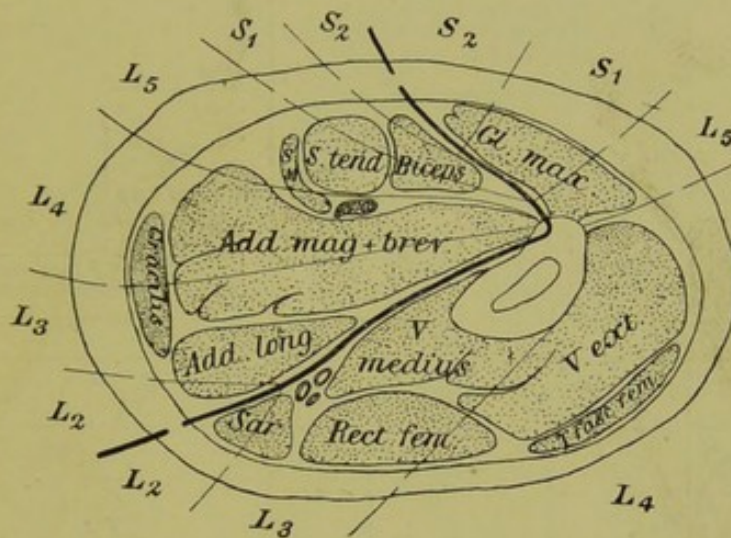


FIG. 19.—Transverse section through upper third of thigh. The thick black line indicates the boundary between the pre-axial and post-axial regions of the limb. The fine black lines mark the segmental distribution. (After Bolk.)

every spinal segment a corresponding dermatome, myotome, and sclerotome, but they are subdivided into a pre-axial and a post-axial division in each case (see Fig. 19).

We observe that comparatively few muscles are confined to a single segment, but that most of them are represented in two or more segments. If, therefore, a cord lesion be limited to one segment, it will cause complete paralysis of the muscles confined to that particular segment and partial paralysis of muscles whose motor nuclei extend up or down into other segments. This explains the apparent irregularity in the distribution and degree of paralysis in certain cases of infantile paralysis and other diseases of the anterior horns.



C1	C2	C3	C4	C5	C6	C7	C8	Th1		
Sterno- Omo- Thyro- Genio- Di-	no-hyoid -hyoid ro-hyoid io-hyoid gastricus	deus deus deus deus us				MUSCULAR LOCALISATION IN CERVICAL ENLARGEMENT				
	Trapezius Levat. Anguli Scap. Diaphragma Scleni Rhomboidei									
				Serratus magnus Pectoralis (clavicular) Supra-Spinat. Infra-Scapularis Terres minor		Pectoralis (sternal) Latiss. dorsi Pectoralis minor				SHOULDER
			Deltoides Biceps brachii Brachialis Anticus Supinator longus		Triceps brachii Flexors & Extensors of Wrist Pronators					ARM
						Flexors and Extensors of Fingers				FOREARM
							Interossei & Thenar & Hypothenar	Lumbricales		HAND

Th12	L1	L2	L3	L4	L5	S1	S2	S3	S4	
Quadratus Lumborum Cremaster	Psoas Iliacus			Tensor fasciae latae Gluteus medius Gluteus minimus Quadratus femoris Gemelli Gluteus maximus Obturator internus						HIP
		Pectinitor longus Gracilis Adductor brevis Sartorius Obturator externus Quadriceps Adductor magnus			Semi-membranosus Semi-tendinosus Biceps femoris					THIGH
				Tibialis Anticus Extensor proprius Extensor longus digitorum		Gastrocnemius Soleus Plantaris Popliteus Peroneus longus Peron. brev. Tibialis posticus Flex. long. digitorum Flex. long. halluc.				LEG
MUSCULAR LOCALISATION IN LUMBO-SACRAL CORD						Extens. brev. digitor. Abductor hallucis Flex. brev. halluc. Lumbricales Interossei				FOOT
						Sphincter Ani Levator Perinealis Ani Muscles				

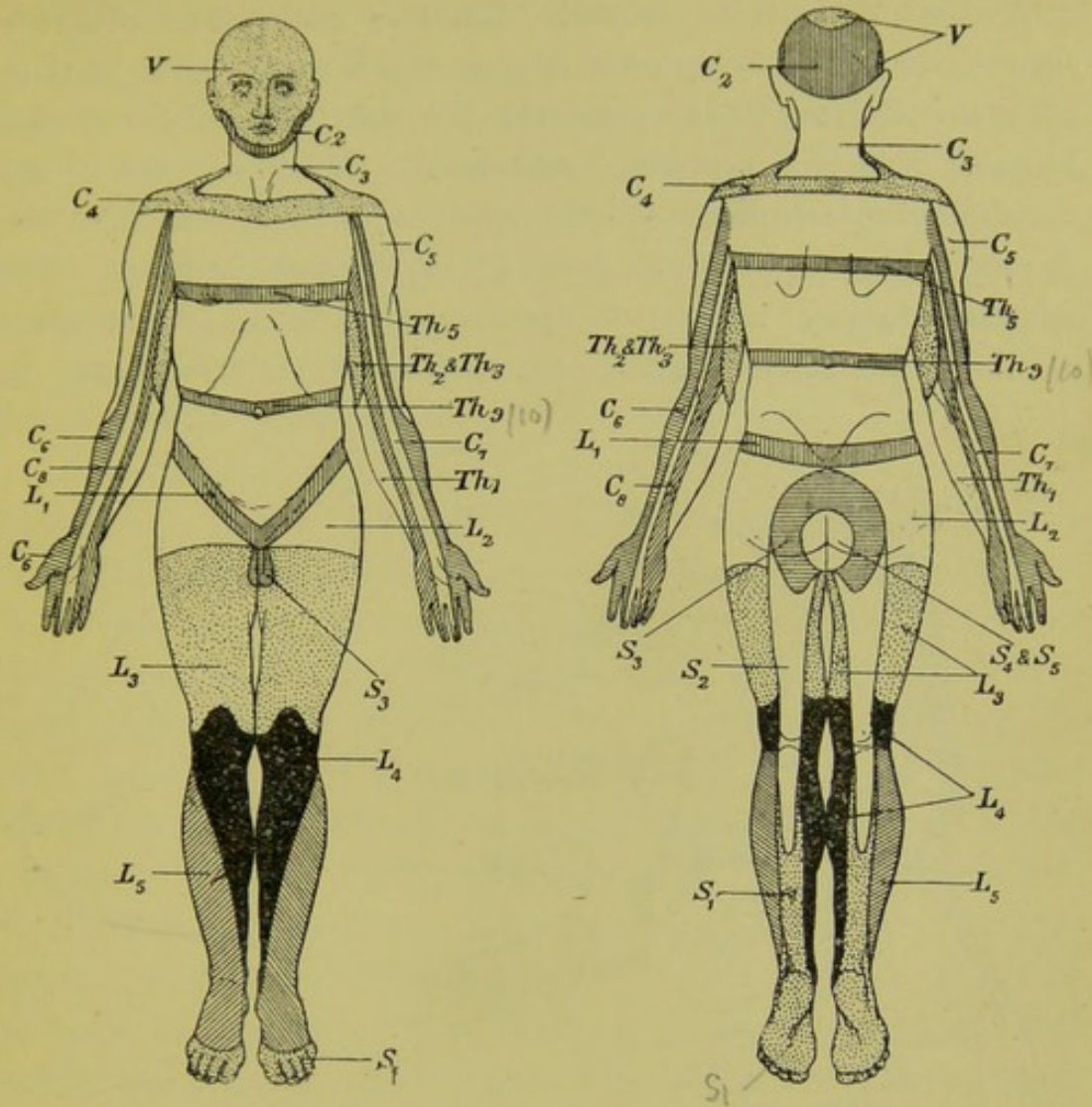


FIG. 20.—Diagram of Cutaneous Areas of Posterior Roots. (After Collier and Purves Stewart.)

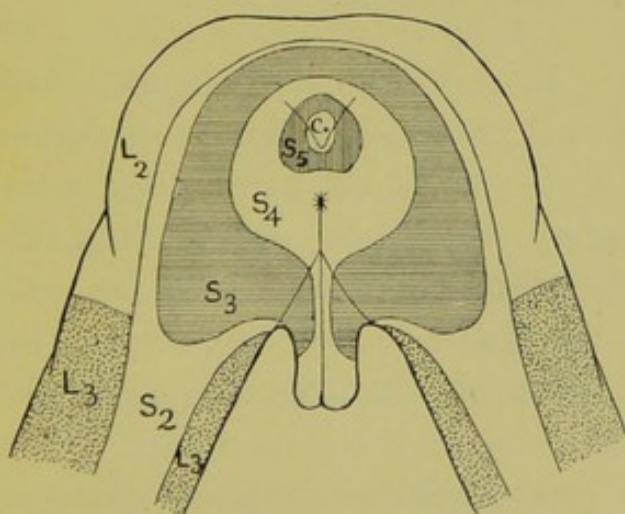


FIG. 21.—Sacro-coccygeal Root-areas.

Similarly in a case of cutaneous anæsthesia it is important to distinguish between a posterior-root lesion and a lesion of a peripheral nerve-trunk such as the radial or ulnar. The distribution of the posterior nerve-roots is indicated diagrammatically in Figs. 20 and 21.



**Paths of Special Senses.—Olfactory Path.**—The olfactory nerves, about twenty on each side, arising from the under surface of each olfactory bulb, perforate the cribriform plate of the ethmoid bone and are distributed to the olfactory region of the nasal mucous membrane on the superior turbinal body and the corresponding uppermost part of the nasal septum. The central olfactory tract has various connections, not of great clinical importance, leading to the optic thalamus and to

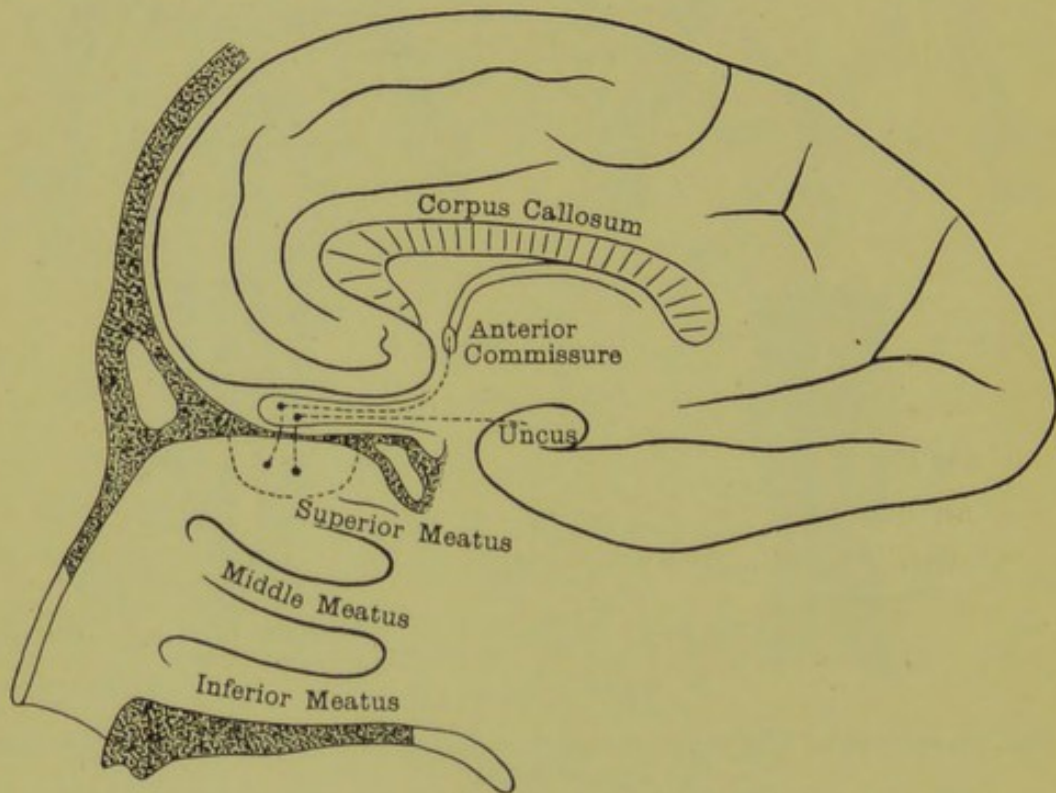


FIG. 22.—Diagram of Connections of Olfactory Nerves.

other sub-cortical ganglia. It connects the olfactory bulb with the cortical centre for smell, situated, as we have already seen, in the uncinatè gyrus at the tip of the temporo-sphenoidal lobe (Fig. 4). The olfactory tract does not traverse the internal capsule. Each olfactory bulb is connected not only with the uncinatè gyrus of the same side, but also, through the anterior commissure, with that of the opposite side. (See Fig. 22.)

**Visual Path.**—This is of great clinical importance. Starting from the retina, the visual fibres run backwards along the optic



nerve. At the optic chiasma there is a partial decussation, so that the fibres from the left halves of both retinae (corresponding to the right halves of the visual fields) run together in the left optic tract, and *vice versa*. The central visual impulses, from each macula lutea, pass into both optic tracts. The fibres of each optic tract run backwards, winding around the outer side of the crus cerebri, to the primary optic centres, viz. :—the posterior part of the optic thalamus, the external geniculate body, and the anterior corpus quadrigeminum.

From these three stations new fibres arise, forming the “optic radiation,” passing through the internal capsule behind the fibres for common sensation (Fig. 7) and so reaching the cortical half-vision centre. This centre, mainly on the mesial aspect of the hemisphere, is divided into an upper and a lower part by the calcarine fissure (Fig. 4). Above the fissure is the cuneate lobe, below it is the lingual gyrus. The half-vision centre also extends on to the convexity of the occipital lobe at its posterior extremity (Fig. 3). The calcarine fissure forms a boundary-line between the cortical representations of the upper and lower quadrants of the corresponding half of the visual field. Therefore a lesion of the left occipital lobe, or of the whole of the left cuneus and lingual gyrus, or of the fibres of the left optic radiation, will cause a right-sided hemianopia in both visual fields; a lesion of the left cuneus, *i.e.* limited to the part *above* the calcarine fissure, will cause blindness of the *right lower quadrant* of both visual fields; whilst if the lesion be *below* the left calcarine fissure, in the lingual gyrus, it will produce blindness of the *right upper quadrant* of both fields. These are varieties of “quadrantic hemianopia.”

Besides the half-vision centre, there is a higher centre on the convex surface of the occipital cortex, where a lesion, if sufficiently superficial (so as to miss the subjacent optic radiations), may cause, not hemianopia, but what is called “crossed amblyopia.” This means a concentric contraction of both visual fields, more marked in the eye of the side opposite to the side of the



lesion. Such a lesion has not been conclusively demonstrated in gross organic disease, but crossed amblyopia is one of the most frequent symptoms in hysteria.

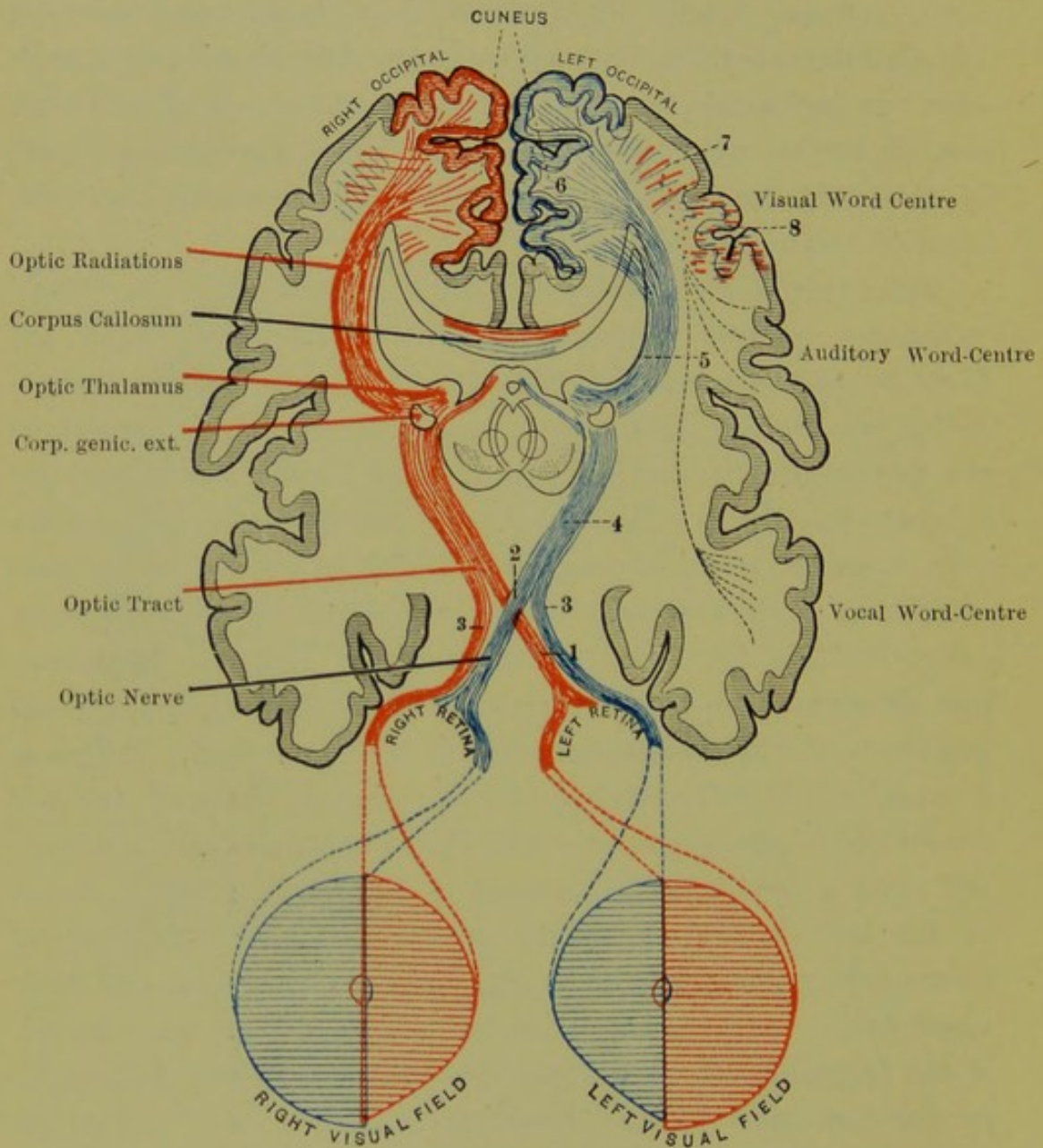


FIG. 23.—Diagram of Visual Paths (after Vialet).

Lesion at 1	produces	Blindness of one eye.
" at 2	"	Bi-temporal Hemianopia.
" " 3 and 3	"	Bi-nasal Hemianopia.
" " 4	"	R. Hemianopia with Hemiopic Pupil Reaction.
" " 5	"	" with Normal Pupil Reaction.
" " 6	"	Crossed Amblyopia. " "
" " 7	"	" " " "
" " 8	"	Word-Blindness.

Finally, in right-handed people there is in the left angular gyrus a centre for the storage of visual memories of written and



printed speech. If this centre be destroyed, we have word-blindness, which may or may not be associated with right hemianopia, according as the subjacent optic radiations are affected or not. Fig. 23 indicates diagrammatically these various fibres and centres, and also shows the effects upon the visual fields of lesions in various parts of the visual path.

**Gustatory Path.**—The course of the taste-fibres outside the brain is somewhat complex, and we shall study it again later when we consider the cranial nerves. It is probable that some of the taste impulses, chiefly those from the front of the tongue, enter the brain through the sensory root of the fifth cranial nerve, some through the glosso-pharyngeal nerve, and some through the *nervus intermedius* or sensory root of the facial. The cortical centre for taste is in the front part of the temporal lobe, close to the olfactory centre (Fig. 4). The intra-cerebral course of the gustatory fibres is not definitely settled, but it is probable that they do not traverse the internal capsule.

**Auditory Path.**—This is of some practical importance (Fig. 24). Entering the medulla in the cochlear division of the eighth nerve, the auditory fibres embrace the restiform body, some passing along its inner side to the ventral auditory nucleus, others passing along its outer side to the dorsal auditory nucleus. From these two nuclei new fibres pass upwards towards the cortex. A few run up uncrossed in the fillet of the same side, but most of the fibres decussate and ascend in the fillet of the opposite side. Some end in the posterior corpus quadrigeminum, others go on to the corpus geniculatum mediale, and finally the bulk of them, passing through the sub-lenticular region of the internal capsule behind the sensory fibres, reach the cortical auditory centre in the superior temporal convolution (Fig. 3), and in the anterior transverse temporal convolution of Heschl:—Flechsig's "auditory gyrus"<sup>1</sup> (situated on the upper surface of the temporal lobe, at the bottom of the Sylvian fossa, immediately behind the insula), with which the superior temporal is continuous. We note that each cortical centre receives auditory messages from both

<sup>1</sup> *Neurologisches Centralblatt*, 1908, p. 1.



ears, though more extensively from the ear of the opposite side, and that therefore a lesion limited to one temporal lobe will not cause deafness. In right-handed people there is a specially differentiated portion of the left auditory centre where memories of word-sounds are stored up (Fig. 3).

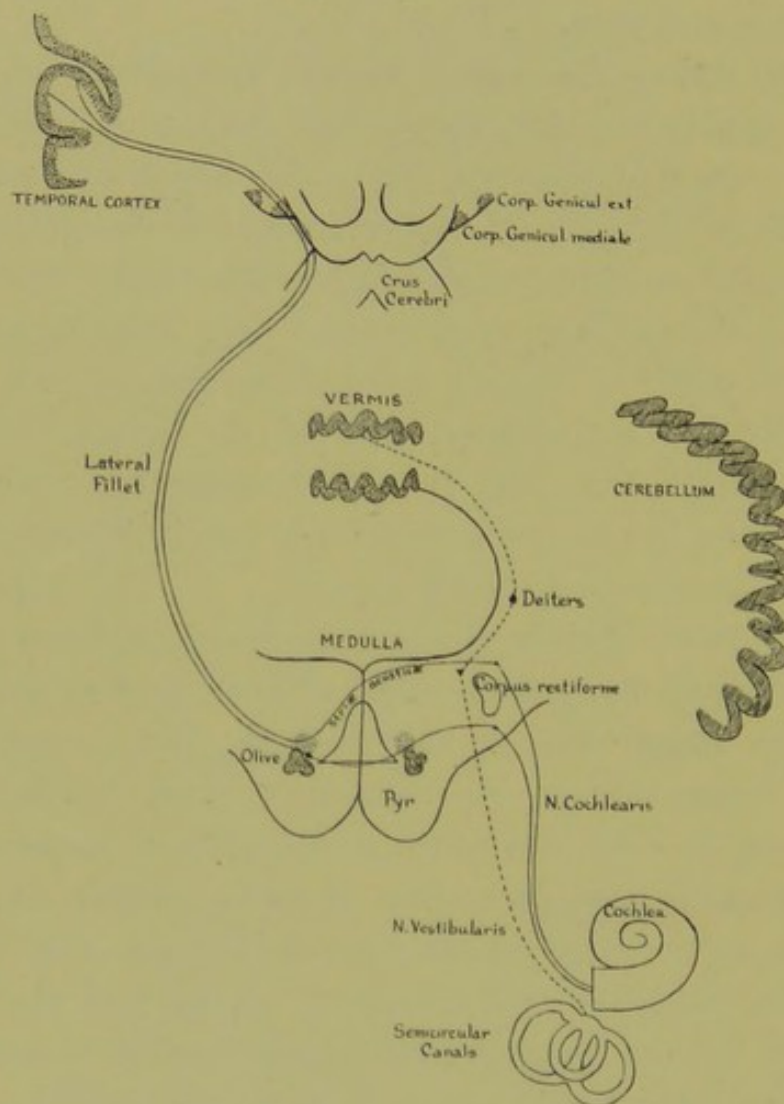


FIG. 24.—Diagram of Connections of Cochlear and Vestibular Nerves.

A certain amount of clinical evidence<sup>1</sup> supports the view that there is a special cortical centre associated with the sensations of *hunger* and *thirst*. It would appear to be in the temporal lobe, at or near the olfactory centre. Abscesses, injuries and tumours in this region have been associated with voracious appetite and intense thirst, persisting for weeks or months.

<sup>1</sup> Stephen Paget, *Essays for Students*, 1898.

**Arteries of the Brain.**—Most cases of acute brain disease which we meet with in practice are the direct result of some vascular disease, *e.g.* hæmorrhage, thrombosis, or embolism. It is therefore important to understand certain facts about the cerebral circulation.

The brain is supplied by two pairs of arteries—the internal carotids and the vertebrals, as shown in Fig. 25. The two vertebral arteries join to form the basilar artery which runs forwards in the middle line along the front of the pons, supply-

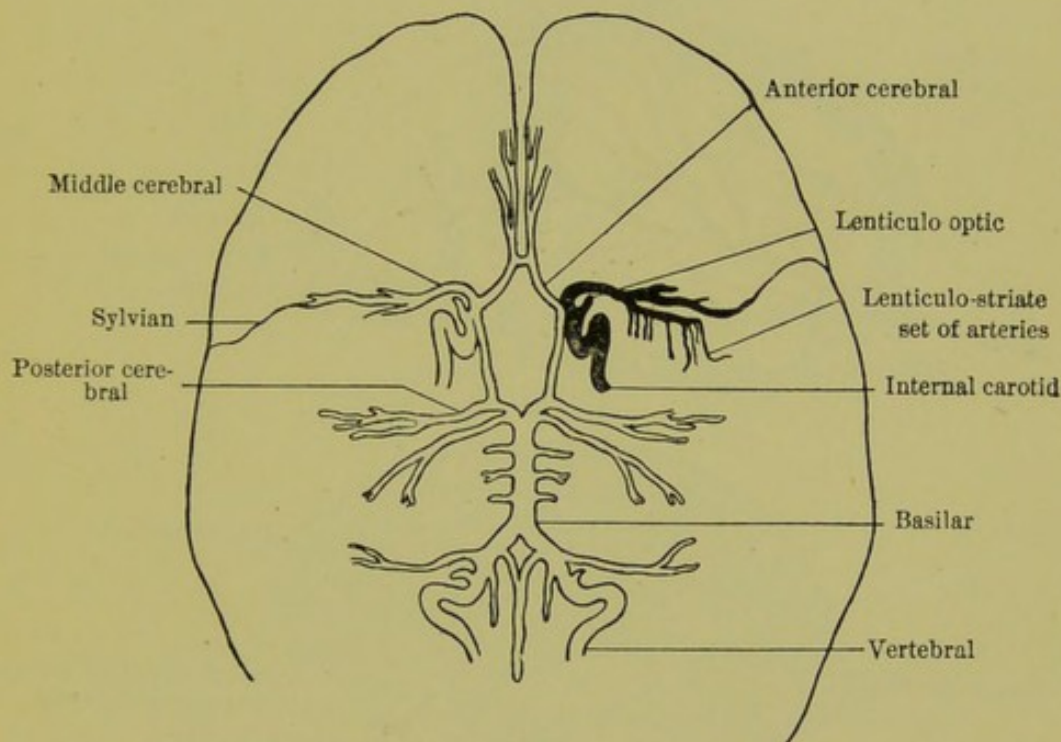


FIG. 25.—Arteries at the Base of the Brain. One, the lenticulo-striate, is called the artery of cerebral hæmorrhage. (After Dercum.)

ing perforating branches to the pons and arteries to the cerebellum. Between the crura cerebri the basilar divides into the two *posterior cerebral* arteries, each of which winds round the outer side of the crus, supplying it as it passes, and also giving branches to the optic thalamus and the corpora quadrigemina. Finally it reaches and supplies the lower part of the temporo-occipital cortex (Figs. 26 and 27). Each posterior cerebral artery sends a posterior communicating artery forwards to join the internal carotid.



The internal carotid, close to its termination, gives off an important branch—the *anterior choroid* artery, which passes backwards to enter the descending horn of the lateral ventricle. The area supplied by the anterior choroid (see Figs. 26 and 27) includes the posterior two-thirds of the posterior limb of the internal capsule, part of the choroid plexus of the lateral ventricle, and also the uncinus gyrus of the temporal lobe.<sup>1</sup> Finally, the internal carotid divides into three main branches—*anterior cerebral*, *middle cerebral*, and *posterior communicating*. The two

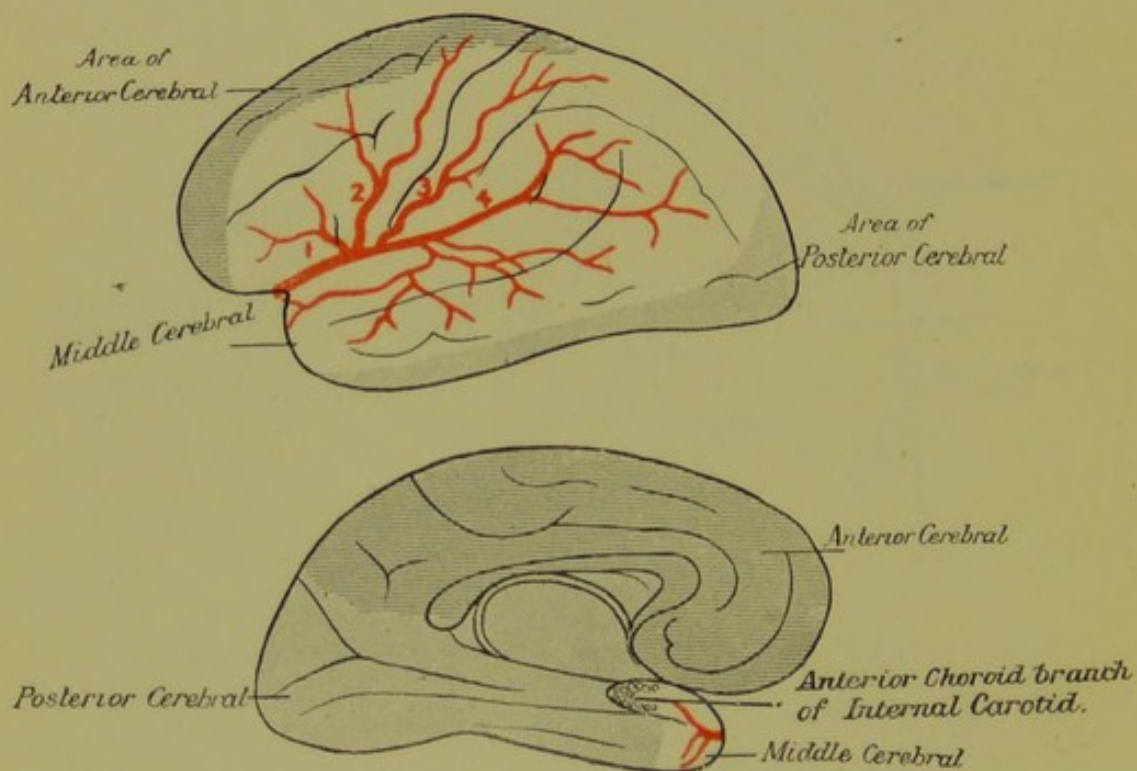


FIG. 26.—Diagram of arterial supply of cortex.

anterior cerebral arteries are connected by the short anterior communicating artery, thus completing the "circle of Willis." The *anterior cerebral* artery passes forward, and then, curving round to the top of the corpus callosum, turns backwards, parallel with its fellow of the opposite side, between the mesial surfaces of the two hemispheres. Most of the mesial surface of the cerebral hemisphere, as far back as the parieto-occipital fissure, is supplied by the anterior cerebral artery (Figs. 26 and 27). It also sends

<sup>1</sup> Beevor, *Brain*, 1907, p. 403.

branches over the edge of the hemisphere to its convex surface, supplying the anterior and mesial part of the frontal lobe and a small part of the parietal lobule. And at the beginning of its course, it sends a few perforating branches inwards to the caudate nucleus.

The *middle cerebral* artery, or *arteria fossæ Sylvii*, is clinically the most important of the three. Its main trunk passes upwards and outwards along the Sylvian fissure to the surface of the island of Reil, where it divides into its terminal branches. At its be-

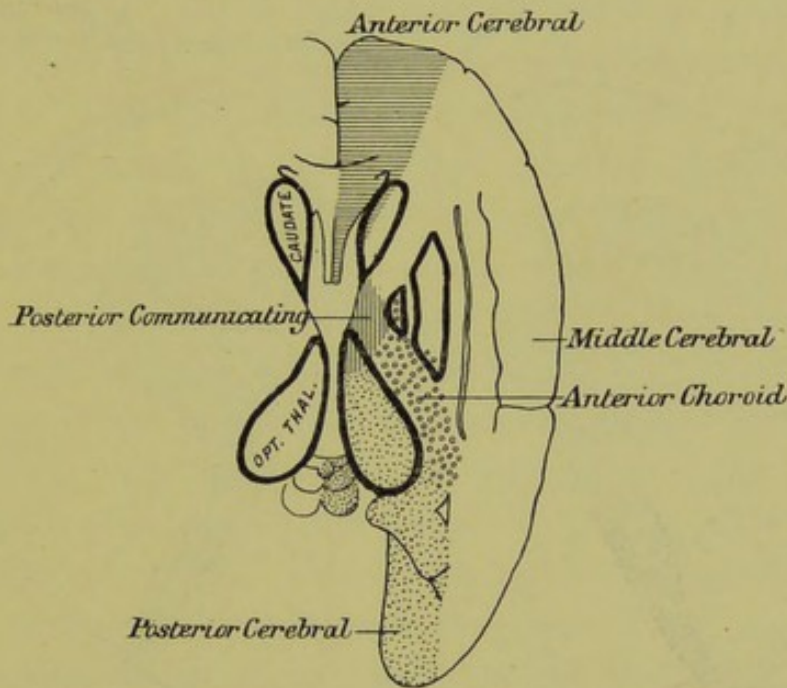


FIG. 27.—Arterial supply of basal ganglia and cortex.  
(After Beevor.)

ginning it gives off numerous basal perforating arteries, which enter the anterior perforated space and ascend to the caudate and lenticular nucleus (which together constitute the corpus striatum), also to the optic thalamus. These branches are called lenticular, lenticulo-striate, and lenticulo-optic, according to their distribution. All these, and especially one of the lenticulo-striate arteries, are frequently the seat of cerebral hæmorrhage. The main trunk of the middle cerebral runs along the Sylvian fissure, where it divides into four terminal branches (Figs. 26 and 27). One goes to Broca's convolution (the third inferior frontal); another to



the lower two-thirds of the pre-central convolution and to the adjacent part of the second frontal convolution; another to the post-central convolution and the adjacent superior parietal convolution; and a fourth to the supra-marginal convolution, the angular convolution and the upper temporal convolutions, and so to the tip of the lobe on its mesial aspect.

The cortical arteries anastomose with one another, but not so

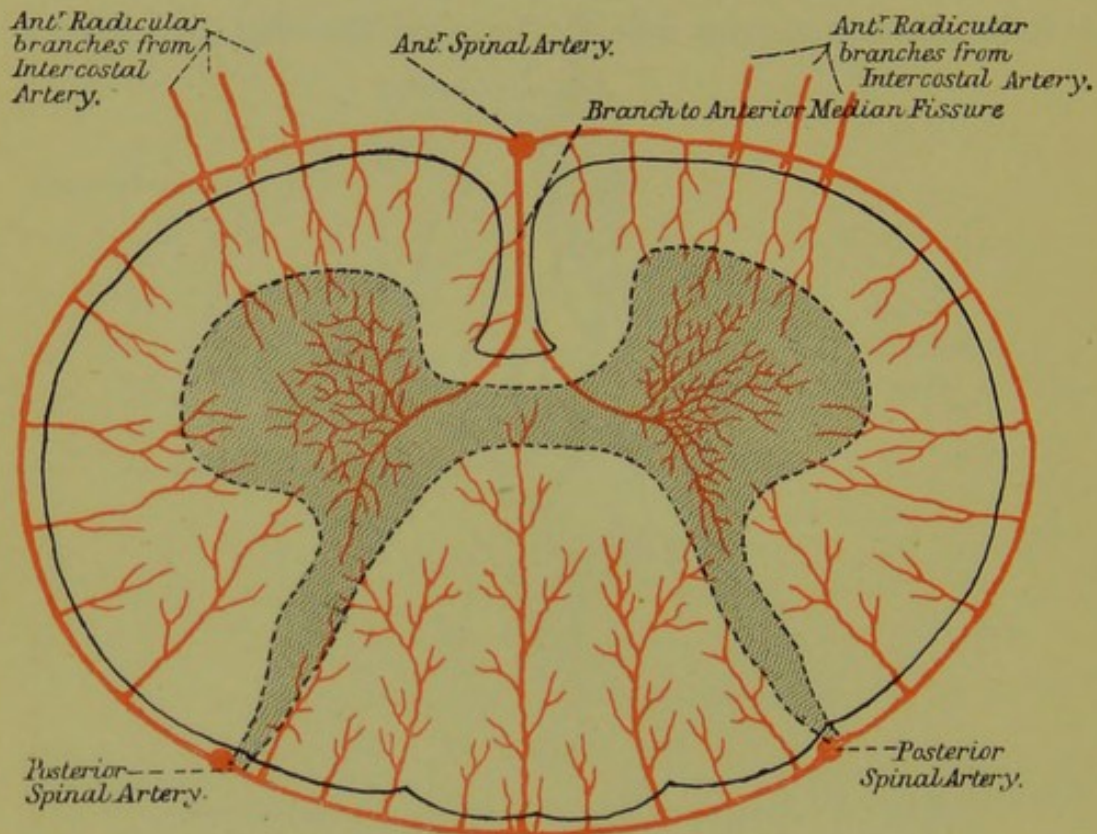


FIG. 28.—Diagram of the course and distribution of the terminal arteries of the spinal cord. (After Van Gehuchten.)

the perforating basal vessels. They are "terminal" arteries, and do not anastomose either with each other or with the cortical vessels. Therefore if a basal artery becomes blocked by thrombosis or embolism, a permanent area of necrosis results. On the other hand, the blocking of a cortical artery admits of a more favourable prognosis, since a collateral circulation may develop and the necrotic process be arrested.

The *cerebellum* is supplied by the anterior cerebellar and superior cerebellar arteries from the basilar, and by the posterior



cerebellar arteries from the vertebral. The posterior inferior cerebellar artery, which supplies the lateral aspect of the medulla, is of some clinical importance inasmuch as when it is thrombosed the resulting area of destruction (including the inferior olive, the restiform body, and the intervening nuclei of the vagus and glosso-pharyngeal) produces a characteristic unilateral bulbar syndrome (see later, p. 262).

The *spinal cord* is supplied by three main arteries, one anterior and two posterior, running on the surface along the entire extent of the cord. The anterior spinal artery arises from one or other vertebral, receiving a small communicating branch from the opposite vertebral. As it runs down the front of the cord, it is reinforced by a series of smaller vessels, derived from the intercostal and lumbar arteries, which enter here and there along the anterior roots. The anterior spinal artery sends numerous branches deeply along the pia mater lining the median fissure, dipping alternately into the right and left sides of the fissure, and supplying the grey matter of the cord. The two posterior spinal arteries, one on each side, also arise from the vertebral arteries and run downwards on the back of the cord, close to the posterior roots, being reinforced by small branches entering here and there along the posterior roots. Fig. 28 shows diagrammatically the position of these various spinal arteries, and it should be observed that the grey matter and the white receive their blood-supply from different vessels. Moreover, like the perforating basal arteries of the brain, all the spinal arteries, once they have penetrated the cord, are terminal arteries and do not anastomose. Therefore embolism or thrombosis of a spinal artery always produces an area of necrosis.

The **Venous Circulation** in the brain is peculiar, inasmuch as the direction of the blood-stream in the cortex is the same in the arteries as in the veins, *i.e.* from before backwards. The superior longitudinal sinus receives not only the superior cerebral veins from the cortex, but also some veins from the scalp, and through its starting-point at the foramen cæcum it receives branches from the nasal vein, though after childhood this foramen often becomes



closed. Therefore when *thrombosis of the superior longitudinal sinus* occurs in a marasmic child, we expect epistaxis, convulsions, and distension of the nasal veins, together with distension of the veins of the scalp. Posteriorly the superior longitudinal sinus ends at the torcular Herophili.

The inferior longitudinal sinus is quite small, and, like the superior, lies between the layers of the falx cerebri, but at its lower edge. It runs backwards to the anterior edge of the tentorium, receiving branches from the mesial surface of the hemispheres, and

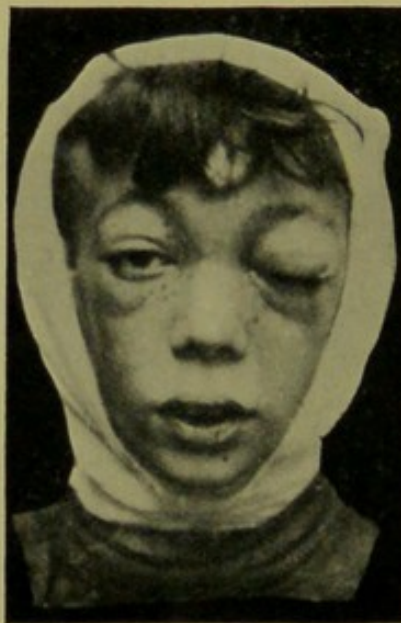

FIG. 29.—Thrombosis of left cavernous sinus.

ends in the straight sinus. The straight sinus receives some cerebellar veins and the veins of Galen from the velum interpositum and interior of the brain, and passes backwards either into the torcular Herophili or into one of the lateral sinuses. When the veins of Galen are thrombosed the cerebral ventricles become distended with fluid.

The lateral sinuses begin at the internal occipital protuberance and arch outwards, one on each side, to open through the jugular foramen into the internal jugular vein. The sinus passes close to the mastoid portion of the temporal bone. Here it receives



the superior petrosal sinus, and also emissary veins from the scalp in the mastoid region. Just before it empties into the jugular, it receives the inferior petrosal sinus and sometimes the occipital sinus from the torcular. *Lateral sinus thrombosis* is a well-known and dangerous complication of suppuration in the middle ear. It is recognised by distension of the mastoid veins, œdema of that region, and hardness and tenderness of the internal jugular vein. Together with this we may have rigidity of the neck, tinnitus, vertigo, and even signs of compression of the vagus, such as dyspnœa, dysphagia, bradycardia, and palatal paresis. It is not uncommon to find swelling and œdema of the ipso-lateral optic disc.

The cavernous sinuses lie one on each side between the sphenoidal fissure and the apex of the temporal bone. Each sinus receives the ophthalmic veins from the orbit and communicates by means of the circular sinus with its fellow of the opposite side. The sinus ends posteriorly by opening into the two petrosal sinuses. *Thrombosis of the cavernous sinus* is generally secondary to some septic condition of the orbit, naso-pharynx, or sphenoidal sinus. It is recognised by the presence of chemosis (œdema of the conjunctiva), proptosis (bulging forwards of the eyeball), and œdema of the upper lid and root of the nose (see Fig. 29). There may be paralysis of certain of the external ocular muscles from affection of the third, fourth, or sixth nerves which lie in the outer wall of the cavernous sinus.

Nearly all the intra-cranial venous blood leaves the skull by the internal jugular veins, so that in an infective thrombosis of any of the cerebral sinuses it may become necessary to ligature the internal jugular vein to prevent a general pyæmia.



## CHAPTER III

### METHOD OF CASE-TAKING

IN no class of maladies is a thorough examination of the patient of greater importance than in cases of nervous disease. One cannot urge too strongly the value of systematic examination, though it matters little what particular scheme of case-taking be adopted, so long as it is one which ensures that the investigation is complete, and that no point of importance is overlooked. Sometimes, it is true, we may make a diagnosis at a glance, as for example in paralysis agitans, or chorea. But more usually the patient presents symptoms or signs which are common to several diseases, and we have to decide from which of these diseases he is suffering. The chief causes of wrong diagnosis are insufficient examination, inaccurate observation, and, less commonly, false conclusions from correct and sufficient facts. But if we pursue a good routine method of examination, gross errors of diagnosis can generally be avoided.

Examination of a nervous case should not be confined to the nervous system alone. All the systems of the body should be investigated. An accomplished neurologist must be in the first place a sound physician.

The value of negative as well as positive facts cannot be over-estimated. The neurological student should accustom himself from the outset not only to chronicle deviations from the normal, but also, if he finds that certain other functions are normal, to record the fact and not to pass them over without reference.

As in any other case, a careful history should first be obtained. It is comparatively seldom that a patient, however willing he may be, provides us spontaneously with an accurate history of his case. We generally have to guide his tale by suitable questions, and in many cases we have to supplement the patient's account



by inquiring for corroborative or correcting facts from the patient's friends.

We first inquire as to the *mode of onset* of the patient's symptoms, whether such onset was sudden or gradual, and, if gradual, the exact order in which the various symptoms appeared. In the *family history*, inquiry should be made as to the occurrence of nervous or mental disease in other members of the family, also as to a family history of gout, asthma, tuberculosis, cancer, &c. In certain cases, consanguinity of the parents should be inquired for. In the account of the patient's *previous health*, it is important to inquire as to syphilis, kidney disease, gout, rheumatic fever, or any previous nervous disease, and a note should be made as to the patient's occupation and habits of life, and as to his temperance in alcohol, tobacco, &c. When inquiring about venereal disease, if the patient is a man, we should put our questions straightforwardly, but in female patients considerable delicacy is necessary, and it is advisable simply to inquire for collateral symptoms, *e.g.* rashes, falling out of hair, sore throat and, especially in married women, a succession of premature or dead children. In any case we should never interrogate a male patient on the subject of venereal disease in the presence of his wife, nor *vice versa*.

Having thus noted the chief points in the history of the case, we proceed to the examination of the patient's *present state*. The following scheme will be found useful:—

### **Scheme for Routine Examination of Nervous System.**

#### **Higher Cerebral and Mental Functions.**

Intellectual functions—Emotional state—Memory—Hallucinations or delusions—Delirium—Coma—Drowsiness—Insomnia.

#### **Fits or other Abnormal Movements.**

Fits — Tremors — Fibrillary movements — Chorea — Athetosis — Tic — Myoclonus, &c. Description of each.

#### **Speech and Articulation.**

Aphasia—Is patient right or left handed?

#### **Cranial Nerves.**

1. Smell—Anosmia—Parosmia.
2. Visual acuity—Fields of vision: Hemianopia, &c.—Colour-blindness—Ophthalmoscopic examination—optic discs, atrophy, neuritis—retinal hæmorrhages, choroiditis, &c.



3. } Pupils: Size, shape, reaction to light (direct and consensual), and  
 4. } to accommodation—External ocular movements—Ptosis—Move-  
 6. } ments of eyes in all directions—Convergence—Squint—Diplopia  
 —Nystagmus.
5. Sensation—Face: Conjunctival, nasal, and buccal mucous membranes  
 —Taste.  
 Motor—masseters, temporals, pterygoids, &c.
7. Facial muscles, upper and lower—Chorda tympani: taste in anterior  
 two-thirds of tongue—Nerve to stapedius—hyperacousis.
8. Hearing: Aerial and bone conduction—Examination of meatus and  
 tympanic membrane—Tinnitus—Vertigo.
9. Taste: Posterior third of tongue—Anæsthesia of pharynx—Difficulty  
 in swallowing.
10. Palate—Recurrent laryngeal branch—Laryngoscopic examination—  
 Heart, respiration, digestion.
11. Sterno-mastoid and Trapezius.
12. Tongue (motor only).

### Sensory Functions.

Subjective sensations: Pain:—site, direction of radiation, character,  
 frequency—Headache—Vertigo—Tingling—"Pins and Needles"  
 —Formication, &c.

Sensibility to touch—pain—temperature—Localisation of the spot  
 touched—Vibration-sense (with tuning-fork)—Anæsthesia—Par-  
 æsthesia—Hyperæsthesia—Tenderness on pressure over nerve-  
 trunks, muscles, or skin—Joint-sense—Sense of active muscular  
 contraction with different weights—Stereognosis.

### Motor Functions.

Paralysis or Paresis:—In head and neck, upper limbs, diaphragm, inter-  
 costals, spinal and abdominal muscles, lower limbs.

Monoplegia—Hemiplegia—Diplegia—Paraplegia—Hemi - para-  
 plegia—"Crossed paralysis," &c.

Co-ordination:—Unsteadiness of upper or lower limbs on voluntary move-  
 ment—Gait.

Muscular Atrophy or Hypertrophy: Rigidity—Flaccidity—Hypotonia.

### Reflexes.

**Superficial.**—Conjunctival, palatal, epigastric, abdominal, cremasteric,  
 plantar (flexion or extension of hallux)—bulbo-cavernosus—anal.

**Deep.**—Jaw, wrist, elbow, knee, ankle-jerks. Ankle-clonus—knee-  
 clonus, &c.

**Organic.**—Micturition—Retention—Retention with overflow incontinence  
 —Intermittent incontinence—Constant paralytic dribbling—  
 Defæcation—Control of sphincters—Priapism.

### Trophic Functions.

Muscles.—Electrical reactions—Faradic—Galvanic.

Skin.—Bullæ—Herpes—Bed-sores—Perforating ulcers—Glossy skin, &c.

Joints and Bones.—Charcot's arthropathy—Spontaneous fractures—Pes  
 cavus, &c.



**Examination of Skull and Vertebral Column.**

Abnormal projections or depressions—Tenderness, &c., on percussion.

**Cerebro-spinal Fluid.**

Naked-eye characters of fluid—Microscopic examination—Bacteriological characters—Chemical reactions, &c.

**Sympathetic Nervous System.**

Cervical sympathetic—Dilatation of pupil to shade and cocaine—Cilio-spinal reflex—Proptosis—Exophthalmos—Enophthalmos—Retraction of upper lid—Pseudo-ptosis—Flushing or sweating of face, neck, upper extremity.

Angio-neuroses—Raynaud's disease—Erythromelalgia—Angio-neurotic œdema—Localised hyperidrosis or anidrosis—Intermittent claudication, &c.

Several points should be noticed in the foregoing scheme. We begin with the higher cerebral and mental functions, for this reason, that if a patient be mentally obtuse, or worse, if he be delirious, then any statement he may make is open to doubt, and for our diagnosis we must rely mainly, and in cases of coma entirely, upon physical signs and upon the history supplied by the patient's friends.

The patient's emotional state is sometimes of diagnostic significance. Not only are many hysterical patients unduly emotional, but a similar condition is observed in certain cases of disseminated sclerosis, where there is a tendency to smile and giggle upon slight provocation, whilst, on the other hand, cases of aphasia and of advanced bulbar palsy are often lachrymose.

The statements of a patient who is addicted to alcoholic intemperance or to chronic poisoning with opium, cocaine or other drug, must also be received with considerable scepticism. There is a special variety of loss of memory, called *Korsakow's psychosis*, which occurs chiefly in chronic alcoholics, where the patient, who is usually a woman and the subject of peripheral neuritis (most commonly alcoholic, but sometimes due to other causes, such as arsenic, septic absorption, &c.), has a faulty conception of time and place and a specially deficient memory for recent events. Moreover she frequently has what are euphemistically called "pseudo-memories," so that "the truth is not in her." This is one of the toxic varieties of insanity, and is commoner in women than in men. Male alcoholics seldom show Korsakow's



psychosis, but tend rather to suffer from the more violent and dramatic "delirium tremens," with the tremors, acute distress, and hallucinations of rats, beetles, devils, &c. (zoopsia), so familiar to the lay writer.

Passing from the patient's mental condition, we should carefully observe and describe any fits, tremors, or other spontaneous abnormal movements that may be present. Disorders of speech and articulation should next be studied, and the cranial nerves examined in due order.

It will be observed that, in our scheme of case-taking, sensory functions are investigated before motor. As a matter of experience, this order of examination is found to be of considerable practical advantage. The discovery of an area of anæsthesia often puts us rapidly on the track of a correct diagnosis and enables us to select with greater ease the salient points in the motor and other phenomena.

Certain accessory methods of examination, such as the testing of electrical reactions and lumbar puncture, are required only in special circumstances, where they may throw a flood of light on an otherwise obscure case. Inspection, palpation, and percussion of the skull are of considerable value in some cases of tumour of the brain, especially in cases of cerebellar growths. Sometimes it is advisable to have the scalp shaved, in order to detect abnormalities in the shape of the cranium.

Having collected our facts, comprising the history and the present state of the patient, we are now in a position to make our diagnosis. And in the process of diagnosis we have, first of all, to ask ourselves—Is the disease an organic one, due to a gross irritative or destructive lesion in the nervous system, for example cerebral hæmorrhage, alcoholic neuritis or tuberculous meningitis? Or is it one of the so-called "functional" diseases, that is to say, without known morbid anatomy, for example hysteria, migraine, neurasthenia? <sup>1</sup>

If the evidence points to an organic lesion, we have then to

<sup>1</sup> The boundary-line between functional and organic diseases is not so definite as might at first sight be supposed. At the present day, many



ask ourselves two further questions: (1) Where is the lesion? (2) What is its pathological nature? The answer to the first question, which constitutes the *anatomical diagnosis*, is derived mainly from a study of the distribution and grouping of the signs and symptoms. The answer to the second, constituting the *pathological diagnosis*, is attained mainly by a study of the history of the mode of onset.

In making an anatomical diagnosis we should always endeavour to think of a single lesion which will account for all the symptoms. Thus, for example, if a patient comes to us with hemiplegia of the left arm and leg, of the "upper motor neurone" type (see p. 28), and at the same time a right-sided facial palsy of the "lower motor neurone" type, instead of diagnosing two lesions, one in the right side of the brain causing left hemiplegia and another in the right facial nerve causing right facial palsy, we prefer to diagnose a single lesion in the right side of the pons, implicating simultaneously the right facial nerve and the pyramidal tract (see Fig. 6).

As an example of pathological diagnosis, suppose we have a patient with spastic paraplegia of both lower limbs and anæsthesia up to the level of the umbilicus, the anatomical position of the lesion is comparatively easy to fix, namely in the lower thoracic region of the cord, implicating both sensory and motor tracts. If the symptoms appeared suddenly, we think of a vascular lesion such

diseases are classified as functional, for no better reason than that in them no constant anatomical changes have yet been recognised. In such diseases as epilepsy, paralysis agitans, exophthalmic goitre, and Raynaud's disease, there can be little doubt that profound molecular changes exist—in the two former instances in the central nervous system, in the two latter in the sympathetic system—but these changes have not yet been recognised. Other diseases again, due to poisoning by microbes or their toxins, or by other poisons—*e.g.* chorea, hydrophobia, tetanus, certain varieties of epileptiform fits, &c.—are undoubtedly the result of pathological changes affecting various groups of nerve elements. And yet, because at present these changes are not visible histologically, they have been classed as "functional." Even hysteria itself, the prototype of functional diseases, has some profound underlying bio-chemical change. The term "functional," then, is a confession of our etiological ignorance, and is by no means synonymous with "curable," as the steady and progressive advance of such a disease as paralysis agitans readily shows.



as hæmorrhage or thrombosis; if they developed within a day or two, some inflammatory condition such as myelitis is probable; whilst if they only appeared very slowly, taking many months to reach their present intensity, we have to think of a slowly progressive lesion, such as a tumour.

We must never diagnose hysteria or neurasthenia until we have excluded gross organic disease. And, finally, we should remember that the presence of certain hysterical or neurasthenic symptoms does not exclude a co-existent organic lesion, nor *vice versa*. Functional and organic disease may be combined in the same patient, and this combination increases the difficulty of diagnosis.

## CHAPTER IV

### COMA

WE are not infrequently called to see a patient who is found to be unconscious. In such cases it is of great importance to make a correct diagnosis as to the probable cause. There are different degrees of unconsciousness. For example, there are conditions in which the patient can be roused from his unconsciousness by shaking, shouting, or other stimuli, as in the case of ordinary sleep. When this degree of unconsciousness occurs in pathological conditions, as in a patient stupefied by various poisons (whether produced within the body or introduced from without), or from mechanical compression of the brain, for example by hæmorrhage, we call the condition *stupor*.

**Cerebral Concussion**, resulting from head-injury, is a condition in which the patient is pale and collapsed, with a low blood-pressure. He may be stuporose or even comatose. In a slight case there is merely temporary unconsciousness or giddiness, with pallor and a little mental confusion, often followed by headache. In more severe cases there is an *initial stage* of collapse with unconsciousness lasting for hours or even for days. But in most cases the patient can be roused by strong stimuli. His face is pale, his breathing is slow, shallow, and irregular; his pulse is weak and his temperature subnormal. He lies with flaccid limbs, like a drunken man. Trendelenburg has aptly named this condition "traumatic narcosis." Then comes the *stage of reaction*, often ushered in by vomiting, sometimes even by an epileptiform convulsion. Consciousness begins to return; the temperature rises and may mount to 100° F. or higher, the pulse is now full and bounding, and the respirations become deeper. There is usually headache. Such a patient generally has a "retrograde amnesia," *i.e.* he has no recollection of the incidents which occurred within the last few hours immediately prior to his accident. As a rule, although the



memory of these incidents returns later, the remembrance of the accident itself is permanently lost.

**Coma** is that degree of unconsciousness which is so deep that we are unable, by any ordinary stimulus, to rouse the patient. A deeply comatose patient does not swallow fluids placed in his mouth, his conjunctival reflexes are absent and his pupils insensitive to light, as in deep chloroform anæsthesia.

How are we to proceed when called to see a patient whom we find comatose? Firstly, we inquire into the history, as to the patient's previous health, whether the coma was sudden or gradual in onset and whether it was preceded by other symptoms, such as convulsions or headache. We then examine the patient, feel the head for signs of injury, smell the breath, examine the pupils, noting their size, equality or inequality, and their reaction to light; we listen to the heart and note the character and frequency of the pulse and respirations. We note the radial blood-pressure and, if possible, measure it by means of a Riva-Rocci sphygmomanometer. We observe whether the face is symmetrical or not, and whether there is conjugate deviation of the head and eyes in any direction. The optic discs in all cases should be examined. We lift the limbs in turn and let them fall, observing whether there is any difference between the flaccidity of the two sides. We also test the knee-jerks and examine the abdominal and plantar reflexes on both sides. Then we pass a catheter, draw off the urine, note its specific gravity and test it for albumen and for sugar. Finally we note the temperature in both axillæ, and in certain cases we perform lumbar puncture and examine the cerebro-spinal fluid.

The first question is whether the coma is due to a general toxæmia, such as poisoning by alcohol or opium, uræmia, diabetes, &c., or whether it is the result of some gross intra-cranial lesion, such as hæmorrhage, meningitis, abscess, tumour, &c.

As a general maxim we may state that, if coma be toxæmic in origin, practically all the signs and symptoms will be bilaterally symmetrical. On the contrary, most cases of gross intra-cranial disease being unilateral, or at least asymmetrical, there will there-



fore be a corresponding preponderance of symptoms on one side of the body, so that, in addition to coma, we have a number of unilateral signs. Let us consider these unilateral cases first.

The commonest case is that of **spontaneous cerebral hæmorrhage**. Here the onset of unconsciousness is generally sudden; the patient's face is flushed or cyanosed, his skin sweats profusely, he breathes stertorously, his blood-pressure is high, and his pulse is slow, full and bounding. All his limbs are flaccid, but on comparing the two sides, we find that the flaccidity is more absolute on the hemiplegic side. For example, the elbow of the affected side can be passively flexed to a greater degree than that of the healthy side. The arm and leg on the paralysed side also fall more "dead" than do those of the sound side when lifted up in turn and allowed to drop. The paralysed leg lies extended, whereas the healthy one tends to be semi-flexed. The head and eyes are often turned to one side, generally away from the paralysed limbs, unless the hæmorrhage be cortical or intra-ventricular, in which cases the deviation may be toward the paralysed limbs, and is associated with other irritative phenomena, *e.g.* spasticity instead of flaccidity. The face is asymmetrical, especially its lower part, the paralysed cheek flaps loosely during respiration and the mouth is distorted like a mark of exclamation laid on its side (!--), as if the patient were "puffing his pipe" at the paralysed angle of the mouth. The pupils are generally dilated and sometimes unequal, the larger pupil being on the side of the brain lesion. In pontine hæmorrhage, however, the pupils are often contracted to pin-points. At the onset of an ordinary apoplexy, whilst we get little help from the deep reflexes, which may or may not be diminished or lost on the affected side, there is, from the very outset, an extensor plantar reflex in the toes of the hemiplegic foot, and all the other superficial reflexes on that side are diminished or absent. The skin of the abdomen can be pinched or pricked on the paralysed side without eliciting an abdominal reflex—(Rosenbach's sign). The corneal reflex is abolished on the hemiplegic side instead of on both sides as in toxic coma. The



temperature on the paralysed side is usually higher than on the other, although the general temperature of the whole body falls at first. If the coma has lasted several hours, the bladder becomes distended and may develop an overflow incontinence. Afterwards, the temperature rises above normal, and in bad cases may go on to hyper-pyrexia.

Most cases of spontaneous cerebral hæmorrhage occur in patients past middle-age, in whom the arteries are no longer elastic and healthy, and there is often a history of kidney disease, with its resultant cardiac hypertrophy and high-tension pulse, conditions particularly liable to result in the bursting of a cerebral artery. The actual attack of hæmorrhage not uncommonly occurs during some slight physical exertion or mental excitement, as in public speakers, such as clergymen, politicians, or after-dinner orators, or in old men with brittle arteries, during straining at stool. In most cases of intra-dural cerebral hæmorrhage from whatever cause, the cerebro-spinal fluid is tinged with blood in greater or smaller amount (see later, p. 407).

But cerebral hæmorrhage may also, in rare cases, occur in young people having healthy vessels, as, for example, in a child during violent convulsions or during a paroxysm of whooping-cough, where the hæmorrhage is commonly venous and due to passive congestion with rupture of the cortical veins, or it may occur in any of the so-called "bleeding diseases"—purpura, hæmophilia, leukæmia, &c.

Cerebral hæmorrhage often occurs in cases of general paralysis of the insane, and in fact may be the first symptom calling attention to the disease. The symptoms are those already described, but there is usually a history of previous mental failure, grandiose ideas, loss of memory, attacks of emotional excitement, and slight indistinctness of articulation. In the absence of such history, we may be unable at the time to diagnose anything more than the fact of a cerebral hæmorrhage. But afterwards, when the patient recovers from his apoplexy—and the general paralytic recovers much more rapidly than the non-insane patient—we can generally recognise the characteristic evidences of the disease, both psychological and physical.



Coma may also be due to traumatic cerebral "compression," where there is a hæmorrhage on the surface of the brain, either intra- or extra-dural. The signs are practically the same as in spontaneous apoplexy but the onset is different, for there is a history of a head injury. The symptoms develop gradually, especially if the hæmorrhage be extra-dural, beginning with local paralysis and perhaps localised convulsions. The paralysis gradually increases, the patient becomes drowsy, stupid, and finally comatose, the blood-pressure meanwhile rising to an excessive degree. There may be, before the onset of coma, a "lucid interval" of several hours or even a whole day, during which the patient, who was perhaps only stunned by the original blow, recovers consciousness and is apparently normal. A lucid interval, when followed by the above symptoms, generally indicates that the hæmorrhage is extra-dural. In intra-cranial hæmorrhage œdema of the retina often supervenes within a few hours.<sup>1</sup> This œdema is more intense in the eye on the same side as the focal compression, and the fact may be of diagnostic value in obscure cases of coma following head-injuries. This retinal œdema rapidly subsides if the intra-cranial tension be relieved by operation. It is uncommon for symptoms of compression to come on immediately after the head injury, and when they do so, they suggest a depressed fracture pressing directly on the brain. This can generally be detected by examination of the cranium.

**Pontine Hæmorrhage** is generally near the middle line, and therefore tends to produce bilateral symptoms. Pontine cases generally (but not always) have strongly contracted pupils owing to irritation of the third nerve nuclei. There is often hyperpyrexia and most cases are fatal.

**Thrombosis of the Cerebral Sinuses** is a rarer cause of coma. Here the diagnosis rests chiefly on the history. Cases secondary to suppurative conditions of the middle ear or frontal sinuses will have a corresponding history and the other signs of intra-cranial venous obstruction. Primary thrombosis of a sinus, occurring without infection, as in marasmus, profound anæmia, &c., is ex-

<sup>1</sup> Cushing, *New York Medical Journal*, January 19, 1907.



cessively difficult to recognise. Thrombosis of cerebral arteries, producing cerebral softening, often causes hemiplegia, but its onset is slower than is that of hæmorrhage; it more often comes on during ordinary sleep and is rarely associated with coma. In young patients it is generally syphilitic in origin.

Amongst the other gross intra-cranial diseases producing coma, there is cerebral meningitis. Here again our diagnosis depends on the history. Most frequently the patient is a child. Instead of a history of sudden coma or of head injury we learn that there have been, for some days, headache, vomiting, photophobia and head-retraction, and often the characteristic "hydrocephalic cry." The

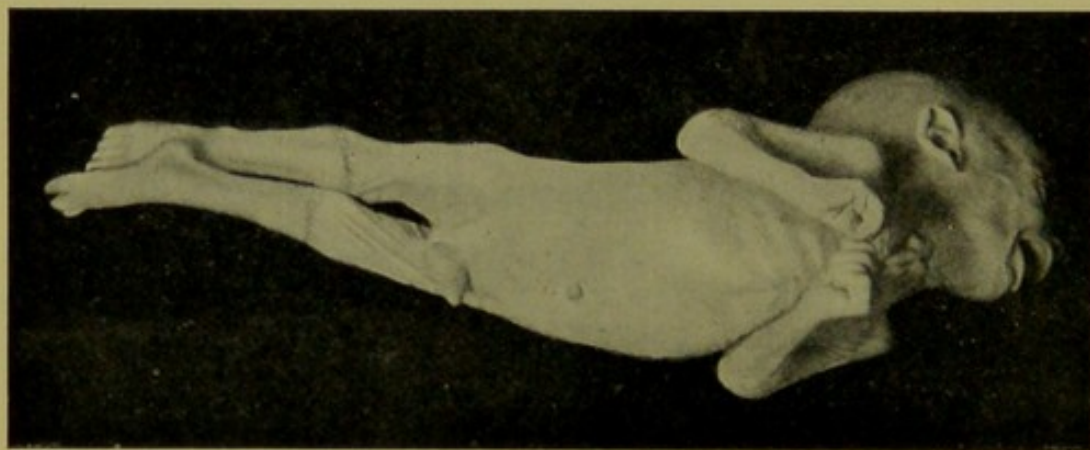


FIG. 30.—Case of posterior basic meningitis, showing head-retraction and posture of limbs.

child gradually becomes drowsy, apathetic, and finally comatose. Rigidity of the neck muscles and head-retraction persist during the coma (Fig. 30). Kernig's sign and Brudzinski's "neck" and "leg" signs are often of value. *Kernig's sign* consists in a reflex contraction of the hamstring muscles and a wince of pain when an attempt is made to put the sacral nerve-roots on the stretch by flexing the hip to a right angle and at the same time extending the knee. *Brudzinski's neck-sign*, which is even more frequently present than Kernig's sign, is elicited by first flexing the arms and legs on the trunk to their full extent and then passively flexing the head on the chest. The patient at once cries out. *Brudzinski's leg-sign* is elicited by passively flexing one lower limb on the abdomen to its full extent, when the other leg is at once drawn up by the



patient to a similar position. If the meningitis be chiefly on the convexity of the brain, there are commonly convulsions preceding or accompanying the coma. On the other hand, if the meningitis be mainly basal, there are cranial nerve paralyses, especially of the ocular muscles. Examination of the cerebro-spinal fluid obtained by lumbar puncture gives conclusive evidence in cases of suspected meningitis. Optic neuritis, if present, will indicate that the coma is not due to mere hæmorrhage, but that there is increased intra-cranial pressure, either due to meningitis, **cerebral abscess**, or possibly, if the history be a matter of weeks or months, to **intra-cranial growths**, syphilitic, tuberculous, or neoplastic.

Let us now pass to the other class of cases of coma, due not to a gross intra-cranial lesion, but to some general toxic condition of the higher cerebral centres. In this group the important point to notice is the absence of unilateral signs.

In the coma of **opium poisoning** there may be a history of laudanum swallowed or morphine injected hypodermically. An empty laudanum-bottle or a hypodermic-syringe may be found by the patient's side when he is discovered. If laudanum has been taken by the mouth, its odour may be detected in the breath. A chemical analysis of the stomach-contents obtained by the stomach-tube, will also help in the diagnosis. In the comatose patient we notice the excessive slowness of respiration, the slow and feeble pulse, the cold clammy skin, and, most striking of all, the pupils contracted to pin-points. These symptoms might be confused with those of pontine hæmorrhage. But there is not the pyrexia of a pontine apoplexy, and the coma of opium is not so deep as that of hæmorrhage. Moreover, in opium-poisoning the plantar reflexes are of the normal flexor type.

The coma of **acute alcoholic poisoning** is not so deep as that of apoplexy, for the patient can generally be roused, temporarily at least, by energetic stimulation. The typical stertor of apoplexy is not present, the pupils are dilated and react to light, and the corneal reflexes are preserved. The temperature is subnormal, the breath and stomach-contents smell of alcohol, and if we mix a specimen of the urine with potassium-bichromate solution and



then allow strong sulphuric acid to flow to the bottom of the test-tube, a green colour appears if alcohol be present in the urine.

We must be careful, however, not to diagnose alcoholic poisoning simply because the patient's breath smells of alcohol. In the first place, a patient with cerebral hæmorrhage may have had alcohol given him, just at the onset of his symptoms. Or secondly, a patient who has been drinking alcohol may have an attack of apoplexy, or he may fall and sustain a head injury causing compression. Therefore every patient with apparent alcoholic coma should be carefully watched for about twenty-four hours, in case unilateral paralysis, an extensor plantar reflex, or inequality of the pupils should supervene.

**Post-epileptic Coma** may be mistaken for apoplexy, if we do not happen to know that the patient is epileptic. But generally we have the history of preceding fits, and in a chronic epileptic there may be old scars about the scalp, tongue, or face, the result of injuries during previous fits. There is no preponderance of unilateral symptoms after a general epileptic fit, nor is there inequality of the pupils. The tongue may have been bitten during the fit and may be still bleeding during the stage of coma. Within an hour or less, the epileptic recovers consciousness without paralytic sequelæ. If, however, some transient localised motor weakness follows, this points rather to a Jacksonian fit due to a focal lesion.

In the **Stokes-Adams syndrome** we have profound coma and stertorous breathing, with or without epileptiform convulsions. The condition is readily diagnosed by recognition of the extremely slow pulse-rate. Acceleration of the pulse precedes recovery from the coma.

**Uræmic Coma** is not uncommon, occurring as it does in patients who are the subjects of nephritis, acute or chronic. The coma is usually preceded by uræmic headaches, vomiting, and convulsions, local or general. A history of previous renal disease is here of great value. And there may be obvious signs of renal dropsy about the face and legs. Respiration is frequently of the Cheyne-Stokes type. The breath often has a urinous odour, and a catheter specimen of urine will show albumen



together with various kinds of casts, and, in acute nephritis, blood. But we must not forget that a patient with chronic renal disease, a high-tension pulse and a hypertrophied heart, is just the one in whom cerebral hæmorrhage may fairly be expected. Therefore in a case of coma, mere albuminuria should not lead us to diagnose uræmic coma. We must always be on the look-out for symptoms of unilateral paralysis.

**Diabetic Coma** is easy to recognise, if we know that the patient has been suffering from diabetes. Even if there be no history of diabetes, examination of the urine shows the characteristic high specific gravity, together with the presence of sugar in large amount as shown by the ordinary tests. The addition of a few drops of liq. ferri perchloridi to the urine produces a deep brownish-red colour, due to di-acetic acid. The "acetone" smell of the breath is unmistakable and occurs only in diabetes, in the rare condition of "delayed poisoning by anæsthetics,"<sup>1</sup> and in the "cyclical or periodic vomiting" with acetonuria seen in children,<sup>2</sup> both of which latter conditions are associated with acute fatty changes in the liver. Further, diabetic coma is not sudden in onset, but is commonly preceded by headache, irritability and uncontrollable drowsiness, merging into profound coma with remarkably deep noisy breathing. The pulse is usually small and rapid, unlike the full, slow pulse of cerebral hæmorrhage. Rise of temperature, which is so common in cerebral hæmorrhage, does not occur in diabetic coma.

**Sunstroke** sometimes causes coma. Here, of course, it is essential that there should be a history of exposure to a hot sun, of a previously healthy patient. Alcoholic patients are more liable to sunstroke than teetotalers. A patient who is comatose from sunstroke often has extraordinary hyperpyrexia—108° F. and upwards. General convulsions may occur. The cerebrospinal fluid in such cases often shows evidences of acute meningeal reaction, in the form of a polynuclear leucocytosis, passing on subsequently to lymphocytosis.

<sup>1</sup> Guthrie, *Clinical Journal*, June 12, 1907.

<sup>2</sup> Langmead, *British Medical Journal*, 1905, p. 350.



In malarial climates we must also be prepared to meet with a comatose variety of **pernicious malaria**, where the parasites produce thrombosis of the smaller cortical vessels. A malarious patient may rapidly become comatose and die within a few hours, as happened to a friend of my own. In such cases the malarious history and the examination of the blood for the plasmodium will settle the diagnosis. A patient dying from cancer may become comatose shortly before death—the so-called **coma carcinomatosum**.

We need not do more than mention the terminal coma of such diseases as acute yellow atrophy, or the “coma-vigil” of typhus and of severe enteric fever.

**Hysterical Trance**, by a careless observer, might be mistaken for true coma. The hysterical patient, however, has neither stertor nor cyanosis, the breathing and heart's action are regular, though perhaps very faint, the pupils react to light and the patient generally resists forcible opening of the eyes. Thus a young man of twenty-two who had sudden attacks of apparent sleep (narcolepsy) coming on in the middle of meals or when playing cards, refused to be roused by ordinary stimuli in the form of shaking or shouting, but yielded at last to forcible digging in the ribs. He passed through a stage of “grande hystérie” before waking up, and for some time afterwards had hysterical blindness and other hysterical stigmata.

The **hypnotic trance** may be regarded as an artificially-induced form of hysteria, the result of suggestion in a highly sensitive subject.





attacks are hysterical or epileptiform. In reference to this the age and sex of the patient are often of importance. We do not meet with hysteria in infants, and rarely in children below the age of puberty. Epilepsy is of equal frequency in both sexes, whereas hysteria is twenty times commoner in females than in males. Hysterical attacks in male patients are most frequent in lads at about the age of puberty.

#### Scheme of Investigation in Cases of Fits

Exciting cause. Nature of warning, if any. Onset, sudden or gradual. Scream. Injuries during falling. Movements, tonic, clonic, purposive. Starting-point of movements, and exact order of spread. Biting of tongue. Micturition or defæcation. Colour of face, pale, flushed, cyanosed. Pupils. Conjunctival reflexes. Knee-jerks immediately after attack. Duration of attack. After-symptoms (coma, vomiting, headache, sleep, &c.).

Pursuing the foregoing scheme, we should inquire whether there was any apparent cause for the attack. Hysterical attacks generally follow some emotional disturbance. **Epilepsy** comes on without exciting cause. A warning or *aura* before an attack of epilepsy may be of the most varied character. Perhaps the commonest is the "epigastric" aura, or there may be an indescribable feeling of terror, subjective auditory or visual phenomena (visual auræ being most frequently red in colour), unilateral tingling or twitching of the face or one of the limbs, or a "dreamy" mental state (sometimes associated with subjective sensations of smell or taste), and so on, according to the particular cortical area whence the epileptic explosion happens to start. But often the epileptic has no aura; he falls suddenly as if struck down by an unseen hand. If we happen to be feeling the pulse of an epileptic at the moment of onset of a fit, it will sometimes be noticed that the heart suddenly stops for a few seconds. Such cardiac arrest, however, is not invariable. **Hysterical attacks** usually come on gradually, and are often preceded by the hysterical "globus" or ball in the throat, or by feelings of palpitation, excitement, giddiness, tingling in the feet, &c. Sometimes at the onset of the attack the epileptic, as he falls, utters a weird epileptic cry or moan, which is not repeated. By this time he is already unconscious and does not hear his own cry. Frequently he injures



himself in falling especially by striking his head. Many chronic epileptics may be recognised by the presence of numerous scars on the scalp and face. The hysterical patient, on the contrary, never injures herself when falling. She comes down carefully, often on a sofa or easy-chair. She not uncommonly screams, and may continue to scream or shout throughout the attack.

The nature of the movements during the attack is of importance. In epilepsy we have the tonic stage, in which all the voluntary muscles, including those of respiration, become suddenly rigid. The patient, therefore, falls like a log, and his lips and face become cyanosed, his pupils dilating and becoming insensitive to light. The tonic stage passes into the clonic, in which violent jerking occurs in all the voluntary muscles, at first rapid, and gradually becoming slower and of greater range. The eyes, which during the tonic stage have been drawn to one side (the side on which the tonic spasm was more intense), now show rapid clonic jerks towards that side. The face loses its cyanotic hue, air re-enters the lungs, and is jerked out in short puffs mixed with saliva, forming a froth which is not infrequently blood-stained, since the jerking tongue may be bitten by the clonic movements of the jaws. During this stage the patient often empties the bladder and sometimes the rectum. Within two or three minutes from their onset the movements gradually cease, and the patient remains in a state of coma, with stertorous breathing, flaccid limbs, and sometimes profuse sweating, the eyes being now turned to the side opposite to that towards which they originally deviated, and the pupils being now contracted. Then, after ten minutes or so, the coma passes off, and the patient may vomit, or may wake up, perhaps with a headache, or may pass into a sound sleep.

In a hysterical attack, on the other hand, the patient's face is natural in colour, never cyanosed, though later it may become flushed from physical exertion. The voluntary muscles are usually contracted, the fists clenched, the eyes tightly closed and resistant to opening, but if the eyes be forcibly opened the eyeballs roll upwards. Then, after a stage of general tremor totally unlike the clonic stage of epilepsy, the patient makes violent "purposive"



movements, kicking, pushing, biting, rolling about, banging her head on the floor, beating her own face, pulling her hair, &c. During this stage various grotesque postures may be assumed; of these, the most characteristic is one in which the back is arched (opisthotonos) and the patient rests on her head and heels. Or there may be curving of the trunk laterally (pleurosthotonos), or forwards (emprosthotonos), "crucifixion" attitude, &c. The patient may talk, scream, or sing during the attack, which may last for many minutes. But throughout the attack the pupils generally react to light, and the conjunctival reflex is usually preserved. The hysterical patient never bites her tongue, though she may bite her lips or fingers, or snap at the fingers of bystanders. She never empties the bladder or rectum during the attack, and after it is over she may or may not have any recollection of what has happened, and is sometimes in a semi-dazed condition. The hysterical patient is more likely to clear up suddenly after the fit than the epileptic; also she is more likely to "feel better" after the fit than in the case of an epileptic.

The knee-jerks, during the stage of flaccid coma terminating a severe epileptic fit, may be temporarily abolished, but soon they become exaggerated, and, for a few minutes, ankle-clonus may often be elicited, and the plantar reflex may be extensor in type. In hysteria the deep reflexes are unaltered.

If we bear in mind the foregoing points, the diagnosis between a severe epileptic fit and an attack of "grande hystérie" is generally easy.

*Catalepsy*, another variety of hysterical attack, is easily recognised by the peculiar immobility of the limbs. The patient during the attack, though not unconscious, is unable to move a muscle, but her limbs are plastic like those of a lay figure, and if placed passively in any posture, remain there.

There are also many varieties of *minor hysterical attacks*, easy of recognition, of which the commonest consist merely in emotional outbursts of uncontrollable laughing or crying, or a feeling of a lump in the throat—"globus hystericus"—which causes the patient to swallow.

Supposing, then, that we have come to the conclusion that



the patient's attacks are hysterical and not epileptiform, we should not rest content until we have settled the further point as to whether the hysterical attack was preceded by an attack of minor epilepsy or *petit mal*.

Attacks of *petit mal* are often overlooked. It is well to remember that in true epilepsy (whether major or minor) the one essential phenomenon is not convulsions but loss of consciousness. In *petit mal* it may be the only phenomenon, so transient, perhaps, that the patient does not even fall; he simply pauses for an instant during conversation, looks strange, and then goes on with what he was saying. Or he may fall down and get up again immediately, a variety of epilepsy which is often mistaken for syncope, but is distinguished by the suddenness of onset and of recovery. If we happen to observe a patient at the moment of his attack of *petit mal*, we generally notice that the pupils dilate and his face turns momentarily pale, the pallor being followed by flushing. It is immediately after such a minor attack that some patients go on to a *post-epileptic hysterical attack*, and if the initial epilepsy be not recognised, treatment will fail.

Attacks of minor epilepsy are, now and then, associated with *post-epileptic automatism*, in which the patient has an attack of *petit mal* which perhaps passes unnoticed; he then proceeds to perform some unusual or inappropriate act, of which he has no recollection afterwards. Perhaps the commonest automatic action is that of undressing; or he may proceed to empty his bladder, as in the oft-quoted instance of the judge who did so in the corner of his court of justice; or he may perform some still more complicated action. Thus a case of mine was that of a well-known financier who had several attacks of loss of memory. During one of these, lasting two and a half hours, he attended an important board-meeting and proposed certain resolutions to which, both before and after, he was strongly opposed. He then took a friend out to lunch and returned to his office. He finally woke up and asked his confidential clerk where he had been. The medico-legal significance of these cases is of importance, since such a patient, in a condition of post-epileptic automatism, may commit serious and



complicated crimes, of which he has afterwards no recollection. This condition is sometimes called "*masked*" or "*larval*" *epilepsy*. It is possible that attacks of automatism or psychic epilepsy may occasionally actually replace the ordinary epileptic fit without an antecedent attack of *petit mal*, may in fact be "epileptic equivalents." But the more carefully such cases are observed, the oftener is some indication found of minor epilepsy immediately before the eccentric action, in the form perhaps of initial transient pallor. This was so in the case of the financier above referred to. Other cases of ambulatory automatism are hysterical in nature (see later, p. 378). A previous history of epilepsy, either major or minor, is of great diagnostic value.

Supposing that, having excluded hysteria, we arrive at the conclusion that a patient's fits are epileptiform, we must still remember that other conditions besides idiopathic epilepsy can produce epileptiform fits. Sudden obstruction of the larynx, *e.g.* by a piece of meat, bolted in a hurry, becoming impacted at the top of the larynx, may cause immediate unconsciousness followed by a typical epileptiform fit and by death unless the offending foreign body be promptly extracted. Similar *asphyxial fits* sometimes occur in cases of attempted suicide by hanging, where the unconscious person is cut down in time. Fits may also be of toxic origin. Acute *alcoholic* or *absinthe poisoning* may produce coma and convulsions. The history and the smell of the breath will usually guide us in such cases. The sudden withdrawal of alcohol from a chronic drunkard is sometimes followed by an epileptiform fit. In patients suffering from the convulsions of *lead poisoning* there are usually other signs of plumbism, such as the blue line in the gums, high arterial tension, weakness of the extensors of the wrist, optic neuritis. Toxins produced within the body may also cause fits exactly similar to epilepsy, witness the *uræmic convulsions* of Bright's disease and of puerperal eclampsia. In every case of fits appearing in a previously healthy individual, the urine should be tested and the optic discs examined. In the case of a young officer who was brought into hospital at Pretoria suffering from a succession of fits typically epileptic in



character, acute nephritis was the cause. In chronic renal disease, besides the cardio-vascular changes, there not uncommonly exists albuminuric retinitis, which is of great diagnostic significance. When we come to the subject of infantile convulsions we shall find that many of them are toxic in origin.

Epileptiform fits may occur during the course of *general paralysis of the insane*; they may, in fact, be the first symptom of the disease. Epileptic fits appearing for the first time in a middle-aged patient should always suggest the possibility of paralytic dementia. In such cases we look for inequality or irregularity of the pupils, and especially loss of the light reflex, mental changes, facial tremors, and slurring articulation, and a history of syphilis should be sought. Lumbar puncture may show lymphocytosis of the cerebro-spinal fluid, a condition which is constant in general paralysis but does not occur in idiopathic epilepsy.

Epileptiform or hystero-epileptiform fits may also occur in *psychasthenic* individuals. Such patients have stigmata of psychasthenia in the form of phobias, tics, obsessions, &c. (see p. 358). Epileptiform fits in psychasthenia, unlike true epilepsy, occur only after some direct exciting cause, such as physical or mental over-exertion, excitement, &c. The attacks, as a rule, are few in number and may be limited to a single one.

Intra-cranial tumours anywhere, even deep within the substance of the brain, may cause general epileptiform fits, from *increased intra-cranial pressure*. Here we are usually guided by the cardinal signs of intra-cranial tumour—headache, vomiting, optic neuritis, &c.

All the epileptiform fits to which we have as yet alluded have a bilateral general distribution, and are not succeeded by any localised paralysis. But when fits are produced by gross focal irritation of the cortex their onset is a local one, and they are not necessarily associated with loss of consciousness. Such "*Jacksonian*" fits are usually followed by weakness of the part which is primarily convulsed. Jacksonian fits may occur as often as fifty or a hundred times a day. They usually begin with a subjective sensory aura, such as tingling, numbness or twitching, localised in some particular part, *e.g.* the thumb or big toe. Then



there is tonic spasm of that part, followed by clonic jerking. This may remain confined to the muscles where it began, or it may spread to others. If it spreads, it does so by a deliberate march from one cortical centre to another (Fig. 3, p. 5). Thus a fit commencing in the big toe would occur successively in the ankle, knee, hip, shoulder, elbow, hand, &c., and would affect the face last of all. Or a fit beginning in the elbow would spread *viâ* the shoulder, hip and knee, to the toes, and simultaneously *viâ* the wrist, fingers and neck, to the face and tongue, as the ripples produced by dropping a stone into a pool spread



FIG. 31.



FIG. 32.

Cortical gumma of the face-centre of the right cerebral cortex.

Fig. 31 shows patient during a Jacksonian fit of the left face.

Fig. 32 shows weakness of the left face on voluntary movement.

in ever-widening circles. A patient who has Jacksonian fits may remain conscious throughout the fit and may even be able to speak, though he is usually somewhat confused and excited. But if the convulsion spreads to the opposite cortical area, thus becoming bilateral, consciousness is lost as the fit crosses over. Jacksonian fits are followed by local weakness and increased deep reflexes in the convulsed part. Fig. 31 shows a patient during a localised fit in the left face, due to a gumma in the cortical facial centre. Fig. 32 shows the maximum voluntary movement of the face after an attack. It will be seen that the left lower face is markedly weaker than the right. The localised paralysis



passes off in the reverse order from that in which the spasm appeared, the muscles first convulsed being the last to recover power.

Of course, cortical lesions will produce localised motor phenomena only if they affect the motor centres in the region of the pre-central gyrus. A focal lesion of a sensory cortical area produces, not a motor, but a *sensory fit*. Thus disease of the tip of the temporal lobe (Fig. 4, p. 5) causes a sudden subjective sensation of smell or taste (often associated with a characteristic "dreamy" mental state), occipital lesions cause subjective visual hallucinations such as flashes of light, and so on. Moreover, after the sensory fit it is not uncommon to find temporary sensory paralysis, *e.g.* anosmia after a temporal fit, or hemianopia after an occipital fit.

A Jacksonian fit, of whatever variety, is the result of a local lesion in the neighbourhood either of the cortex or of its superjacent meninges or bones. If the lesion be in the substance of the cortex, not merely superficial to it, there is often some local paralysis even before the fit occurs.

Localised fits may be produced by any irritative cortical lesion. The commonest causes are tumours, syphilitic or otherwise, abscesses, meningitis of any variety, local hæmorrhages, depressed fractures, and so on. Localised fits may also be produced by *sub-cortical tumours* in the pre-central region. In such cases we observe muscular paresis in the affected limb, together with recurring convulsive phenomena in the limb; but the point of onset of the successive fits is less constant than in a true cortical convulsion, and the fit begins sometimes in one, sometimes in another muscle-group of the affected limb.<sup>1</sup> We should also bear in mind that Jacksonian fits may occur in certain cases of general paralysis of the insane, and sometimes even in uræmia.

**Infantile Convulsions** are epileptiform attacks occurring in infancy. The symptoms are similar to those of true epilepsy, but less violent. When called to see a child with convulsions, we should first examine for rickets, since rickety and hereditarily

<sup>1</sup> Cf. van Valkenburg, *Neurologisches Centralblatt*, 1906, p. 594.



neurotic children are especially prone to convulsions. We should also try to determine whether the fits are reflex, toxic, or organic in origin. In rickety infants of neurotic inheritance *reflex convulsions* may be set up by peripheral irritation such as the cutting of a tooth, round-worms in the intestine (thread-worms do not cause convulsions), a tight prepuce, &c. Moreover, rickety children often have other nervous symptoms, such as tetany, laryngismus stridulus, and the well-known inversion of the thumbs towards the palms, a phenomenon which sometimes precedes a convulsion. *Toxic* conditions may produce convulsions in previously healthy children. Thus any acute fever such as pneumonia, measles, scarlet fever or influenza, may be ushered in by a convulsion instead of by a rigor as in the adult. The convulsions produced by round-worms may be partly toxic in origin. Uræmic convulsions occur in children, though less often than in adults, and in cases with recurring convulsions the urine should always be examined. Asphyxial convulsions, due to deficient oxygenation of the brain, occur in dyspnoea from any cause, *e.g.* during pneumonia and diphtheria, during a paroxysm of whooping-cough, or in the cyanosis of congenital heart disease. Intra-cranial *organic* lesions may cause infantile convulsions. Thus, for example, polio-encephalitis superior, an acute inflammatory affection of the cortex, has a febrile onset with vomiting and convulsions, usually more marked on one side than on the other. After the convulsions have passed off, the child is often left permanently hemiplegic or diplegic. If the cortex of the frontal region is affected, permanent mental dulness may remain. Local disease or injury of the bones or membranes may produce infantile convulsions. Convulsions appearing within a few hours after birth are not unfrequently the result of compression of the brain by a meningeal hæmorrhage. Meningitis, whether due to the tubercle bacillus, to syphilis, or to other organisms, may produce convulsions, not only when cortical, in which case convulsions appear early, but also in basal cases, where the fits are due to increased intra-cranial pressure.

Epileptiform fits also occur in one variety of the **Stokes-Adams'**



**syndrome**, a condition which occurs after middle life, usually in male patients with degenerate arteries, and is characterised by paroxysmal attacks of abnormal slowness of the ventricular beat, the rate sinking as low as twenty per minute or even less, together with excessive pulsation in the veins at the root of the neck, more rapid than the ventricular beats, and corresponding with the auricular contractions. Such a patient is liable to syncopal attacks, to which may be superadded epileptiform fits or attacks of coma without convulsions. Fits do not occur unless the heart-block is complete, where the ventricle no longer responds to auricular stimulation. More or less slowness of pulse usually persists between the paroxysms, as a permanent phenomenon. The condition is frequently due to disease, syphilitic or otherwise, of the auriculo-ventricular muscle-bundle of Stanley Kent<sup>1</sup> and His, which arises in the right auricle, traverses the inter-ventricular septum and is distributed to both ventricles. When this bridge is diseased, the normal stimulus from auricle to ventricle is delayed or may even be completely blocked. This is known as heart-block, in which the auricles go on contracting normally, but the ventricle only responds to every second or every third stimulus. There is thus a dissociation between auricular and ventricular rhythm.<sup>2</sup>

**Strychnine Convulsions** should never be confounded with epileptiform fits, since they begin with clonic spasms, and shortly become tonic with opisthotonos, the tonic spasms recurring again and again with increasing severity. A patient poisoned by strychnine is not unconscious. Moreover, there are periods of intermission, lasting for several minutes at a time, during which the muscles are relaxed. The tonic spasms of **tetanus** might be mistaken for strychnine-poisoning, but they have no initial clonic stage. The earliest symptom of tetanus is the well-known tonic spasm of the jaw muscles, producing "lock-jaw." To this there are superadded paroxysms of tonic spasm in the face (*risus sardonicus*), trunk and limbs, with opisthotonos, somewhat like

<sup>1</sup> Kent, *Journal of Physiology*, 1893, vol. xiv. p. 233.

<sup>2</sup> Mackenzie, *Diseases of the Heart*, 1908, p. 169.



those of the tonic stage of strychnine-poisoning. Between the tetanic paroxysms there is no complete muscular relaxation as in strychnine-poisoning, but simply a remission in the degree of spasm, the jaw muscles remaining partially contracted.

A patient suffering from rabies exhibits great mental excitement, with tonic spasm of the muscles of deglutition, especially on attempting to swallow liquids (hence the misnomer hydrophobia).

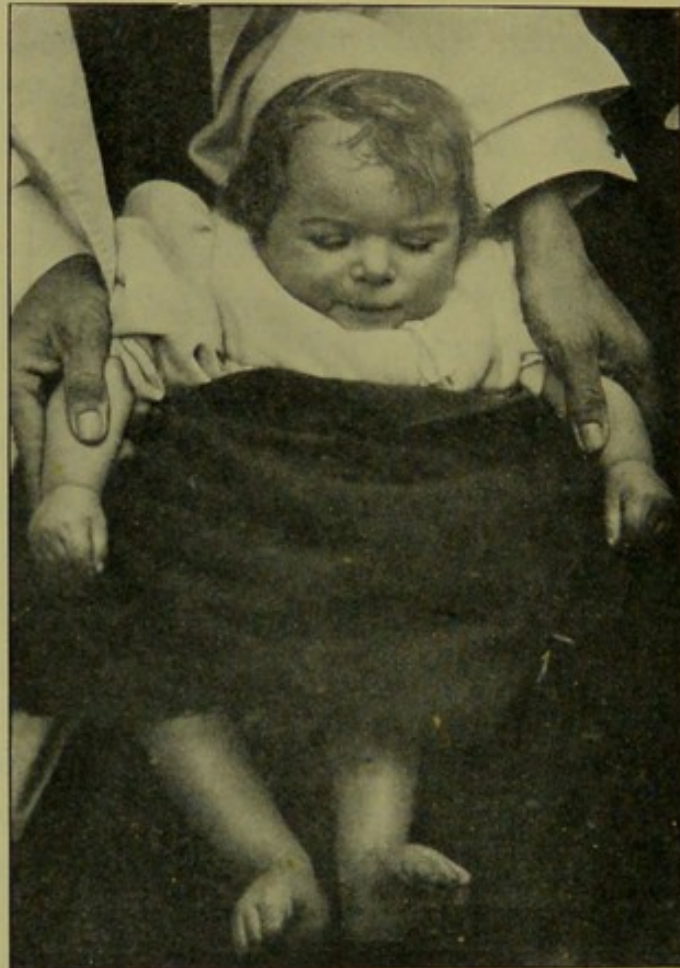

FIG. 33.—Tetany.

The spasm may also be induced by other stimuli such as a bright light or a loud sound. The spasm spreads to other muscles, especially those of respiration, and severe opisthotonos may supervene at the end, the patient dying either of respiratory spasm or from syncope. Hydrophobia may be simulated by hysterical patients who have been bitten by a non-rabid dog, and in such cases globus hystericus and hysterical opisthotonos may both occur, but true respiratory spasm does not occur in



hysterical attacks, though there may be hysterical rapidity of breathing.

During an attack of **tetany** the posture is very characteristic. There is a bilateral tonic spasm, usually painful, of the hands and feet, the hand assuming a conical shape ("main d'accoucheur"), the fingers being extended at the inter-phalangeal joints, slightly flexed at the metacarpo-phalangeal joints and pressed together with the thumb usually tucked inside the fingers; at the same time the muscles of the thenar and hypothenar eminences are contracted, so that the hollow of the palm is deepened. In the feet, the toes are flexed towards the sole, the ankle is dorsiflexed and the foot is sometimes inverted. These postures may persist during sleep. Pressure on the nerve-trunks of the affected limb induces a typical spasm (Trousseau's sign), and the muscles and nerves are unduly irritable both to faradism and to galvanism (Erb's sign). Tetany is most commonly met with in rickety children (Fig. 33), in whom it is often associated with laryngismus stridulus and with excessive irritability on percussion of the facial nerve (Chvostek's sign). But it occasionally occurs in adults, *e.g.* after extirpation of the thyroid gland, or rather of the parathyroids. The parathyroid glands produce an internal secretion which neutralises certain toxic products of metabolism. Tetany is, therefore, sometimes a symptom of parathyroid deficiency, whether arising from disease or from artificial removal of the gland. Tetany also occurs sometimes during pregnancy or lactation, and as a grave terminal symptom in dilatation of the stomach. This variety of tetany is probably toxic in origin: so also are the rare cases of tetany associated with congenital dilatation of the large intestine in children.<sup>1</sup> Cataract is a curiously frequent concomitant of the gastric form of tetany. An endemic form of tetany also occurs in certain Continental towns, chiefly in the winter months. It is especially common amongst shoemakers.

**Cerebellar Fits.**—Irritative lesions of the cerebellum are occasionally associated with cerebellar fits. These are never clonic, but consist of tonic spasms, sudden in onset. In *unilateral* cere-

<sup>1</sup> Langmead, *Lancet*, Jan. 19, 1907.



bellar disease the spasms are more marked in the ipso-lateral limbs than in those of the opposite side. The face is usually unaffected. The ipso-lateral limbs become rigidly adducted to the trunk, the contra-lateral limbs are abducted, whilst at the same time there is a screw-like rotation of the limbs, trunk and head around their own long axes, from the side of the lesion towards the healthy side,<sup>1</sup> and a deviation of the eyes towards the healthy side. Hughlings Jackson has described another variety of cerebellar fit occurring in cases of tumour of the *middle lobe*. Here also, as in tumours of the lateral lobe, the fits are tonic, not clonic. They consist of head-retraction with arching of the back, flexion of the elbows, supination of the hands, and rigid extension of the legs, with pointing of the toes.

But let us not forget that epileptiform fits, cerebral in type, may also occur in cerebellar tumours, due either to the general increase of intra-cranial pressure, or to a fulminating meningitis superadded to an old tuberculous tumour.

<sup>1</sup> Grainger Stewart and Holmes, *Brain*, 1904.



## CHAPTER VI

### INVOLUNTARY MOVEMENTS

BESIDES fits, which we have already considered, there are many other conditions in which involuntary contractions occur in the voluntary muscles. But our knowledge of the mechanism of their causation is so incomplete that it is impossible at present to classify them accurately. We must therefore content ourselves, in the meanwhile, with referring to some of their chief clinical varieties.

In studying involuntary movements occurring in striated muscles, it is important to observe whether the movement is confined to an individual muscle or part of a muscle, or whether, on the other hand, it consists in alternate contraction of muscles and of their antagonists. We should also observe whether the abnormal muscular contractions produce movements of a joint, or whether they are so localised, either to a small muscle or to part of a larger one, that we merely see or feel the muscle fibres contracting beneath the skin.

The muscular phenomenon known as **shivering** or **rigor** is sometimes physiological. For example, when a healthy person becomes chilled, as by prolonged swimming, he often shivers on coming out of the water. The involuntary muscular contractions of which shivering consists are for the purpose of producing heat and thereby raising the depressed body-temperature. But often rigors are toxic in origin, as are those occurring at the onset of certain acute fevers. Thus we have rigors in pneumonia, ague, influenza, scarlet fever, &c. And the rigor which sometimes follows catheterisation is probably also toxic in origin, since it rarely occurs except when there is a raw surface in a urinary tract which is not aseptic. In all these toxic rigors, although the shivering patient has a sensation of cold, his temperature meanwhile is rising, and it continues to rise until the rigor stops. He has the sensa-



tion of cold because by vasomotor action the blood is driven out of his skin, which is therefore cooled and is actually cold, although the temperature of the blood is raised.

Transient flickering or quivering of a muscle, a condition known as *myokymia* (or more popularly as "live flesh"), affecting a few muscle-bundles of a single muscle, without producing movement of a joint, is not uncommon in people who are anæmic or out of health. It is specially common in the orbicularis oculi and in some of the larger muscles of the limbs, *e.g.* the deltoid and biceps in the upper limb, the glutei and quadriceps in the lower. This variety of myokymia is not associated with muscular atrophy, nor with any alteration of electrical excitability. It is unaffected by rest or by voluntary exertion, and has no serious significance.

Sometimes, however, fibrillary movement occurs in organic lesions of the lower motor neurone. Thus in the muscular atrophy of *chronic anterior poliomyelitis*, of *amyotrophic lateral sclerosis*, and of some cases of *syringomyelia*, diseases in which the cells of the anterior cornua are undergoing slow degeneration, there may be seen fibrillary or fascicular tremors in the wasting muscles. This quivering myokymia can often be elicited by gentle flicking, or by a breath of cold air blown over the skin. A precisely similar fibrillary tremor occurs in the wasting tongue of *bulbar paralysis*, when the degenerative process has involved the hypoglossal nuclei. Fibrillary tremor does not occur in the primary myopathies, whether atrophic or pseudo-hypertrophic in type. In other cases fibrillary tremor occurs in the distribution of a motor nerve which has begun to recover from previous paralysis. It is not uncommon in the face during convalescence from facial palsy, and sometimes it persists for months and years after voluntary power has returned, as in the case of a professional friend of my own who is otherwise perfectly well. More usually the myokymia passes off when motor power has been restored.

Somewhat different in appearance is the condition known as *myoclonus*, a rare disease, characterised by paroxysms of sudden shock-like contractions in various muscles, lasting for several minutes at a time, irregular in rhythm and varying in



rapidity from ten to fifty per minute. In slight cases the twitches may be insufficient to produce movements in the affected parts. The muscles affected are usually those of the limbs, especially the lower limbs, often symmetrically on the two sides, but contractions may also occur in the trunk and even in the face. Sometimes the

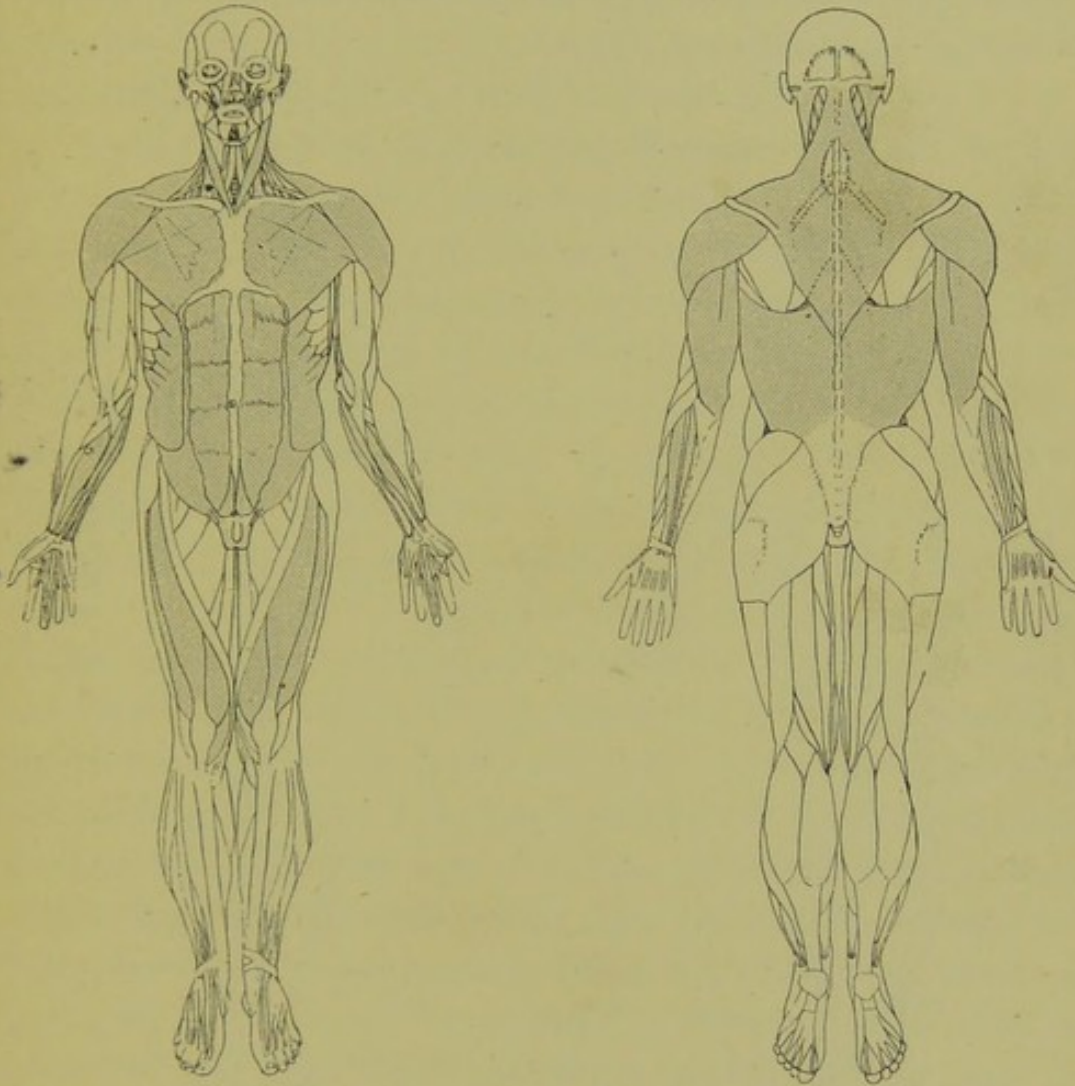


FIG. 34.—Unverricht's family myoclonus or "myoclonus epilepticus" in a boy aged 13. Besides the muscles indicated by shading in the diagram, the soft palate was also affected.

diaphragm and the larynx are affected, so that curious grunting respiratory sounds are produced. There is no muscular atrophy or alteration in electrical excitability. The spasms cease during sleep. Several varieties of myoclonus have been observed; in one—Friedreich's *paramyoclonus multiplex*, usually a disease of adult life—the myoclonus ceases on voluntary movement.



Another variety is Unverricht's *family myoclonus* or *myoclonus epilepticus*, in which several members of a family are affected, all belonging to the same generation, though the disease is not handed down from parent to child. In addition to the myoclonus, these patients have epileptiform fits, and they tend ultimately to become more or less demented. Moreover, the muscular contractions in

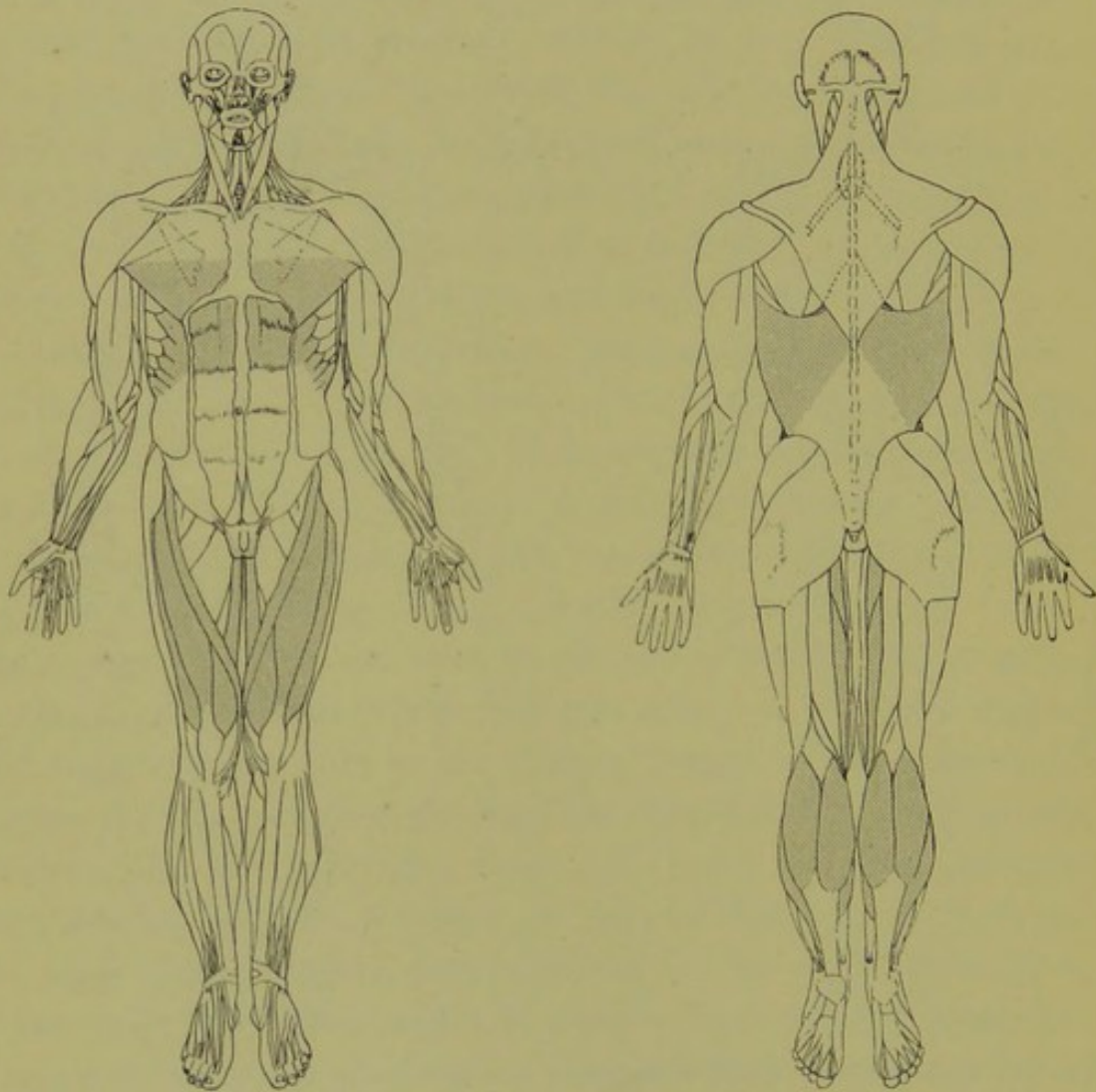


FIG. 35.—Friedreich's paramyoclonus multiplex in a man aged 50 (the affected muscles are indicated by shading).

family myoclonus are intensified by voluntary movement and by psychological excitement. Family myoclonus usually manifests itself in early life, often at or before puberty. Thus in a little boy of thirteen suffering from myoclonus affecting the muscles of the neck, shoulders, trunk, thighs and cremasters (see Fig. 34), the condition had existed since the age of four, and he had also epileptiform fits. Two elder brothers were similarly affected, both of whom,



as the patient graphically put it, began to "click" at the age of seven. On the other hand, another patient suffering from Friedreich's paramyoclonus showed no symptoms of the disease till the age of forty-seven. He never had fits, and at the age of fifty, when he came under observation, he had myoclonic shocks limited to the muscles indicated in the accompanying diagram (Fig. 35). Another variety is the *nystagmus-myoclonus* of Lenoble and Aubineau, to which we shall refer later (see p. 134).

We next pass to the consideration of **tremors**. The term "tremor" is applied to involuntary rhythmic oscillations of one or more parts of the body, resulting from the alternate contraction of muscle-groups and of their antagonists. A *simple* tremor is one which affects a single muscle-group and its antagonists, whilst in a *compound* tremor several groups with their antagonists are in action, producing a complex movement, *e.g.* flexion and extension of the fingers combined with pronation and supination of the forearm. Tremors may be rapid or slow; they may be diminished or increased by voluntary exertion, and they generally cease during sleep.

We must not forget that an ordinary voluntary muscular movement is not the result of a continuous muscular contraction, but is constituted by the fusion of a rapid succession of short single contractions, averaging from ten to twelve per second. In conditions of temporary *fatigue* or of chronic *asthenia* the rate of these muscle discharges becomes slower and less regular, so that the individual muscular contractions fuse less perfectly and the result is a very fine tremor. In *emotional* excitement—more often in states of fear than from pleasurable emotion—there may be a fine rhythmic tremor of about eight or nine oscillations per second, familiar to the knees of many a public speaker. The same occurs in *exophthalmic goitre*. This tremor is made more apparent by voluntary exertion. It is best elicited by making the patient hold his hands horizontally in front of him, with the fingers widely spread. We can then feel the tremor even better than see it, by placing our own fingers lightly on the dorsum of the patient's hand. This fine tremor affects all the limbs, and in many cases can be detected by simply placing one's hand on the patient's shoulder.



Similar fine tremors also occur in certain toxic conditions. The tremor of chronic alcoholic poisoning is familiar to the lay observer, and when an alcoholic patient becomes delirious and maniacal, his tremors are so evident that the condition is termed "delirium tremens." But other poisons besides alcohol produce fine tremors: for example, nicotine poisoning from excessive cigarette-smoking, also chronic poisoning by lead, mercury, chloral, cocaine, tea, coffee, tobacco, &c.

In cases of suspected alcoholism a valuable corroborative sign, known as *Quinquaud's finger-crepitation*, may often be elicited. In testing for this, we make the patient extend the fingers at the interphalangeal joints and press them at right angles to the palm of our own hand, which we hold in a vertical position. For the first two or three seconds nothing particular is noticed, but if the patient be a chronic alcoholic, we soon begin to feel a series of slight shocks, as if the phalanges of each finger were knocking, one against the other, trying to reach our palm.

The tremor of *paralysis agitans* occurs at rest and is generally rather coarse, varying in different cases from four to seven oscillations per second. It produces joint movements, *e.g.* the well-known "pill-rolling" movement of the thumb and fingers, flexion-extension movement of the wrists, pronation-supination of the forearm, flexion-extension of the ankle, &c. The coarser the movement, the slower is the rhythm. *Paralysis agitans* generally begins unilaterally, and may remain confined to one side for some time before ultimately becoming bilateral, as may be seen in Figs. 36 and 37, which are taken from the same patient at an interval of three years. Usually the tremor of *paralysis agitans* can be temporarily controlled by voluntary exertion. But this is not always so; indeed, cases occur in which voluntary movement increases the tremor. *Paralysis agitans* is always accompanied by rigidity in the affected muscles; in fact, rigidity may be well marked without tremor, in the so-called "*paralysis agitans sine agitatione*." An attack of ordinary hemiplegia occurring in a patient with *paralysis agitans* arrests the tremor in the hemiplegic limbs, but if the hemiplegia be not complete or permanent, the tremor may subsequently reappear.

**Senile tremor** is not unlike the tremor of *paralysis agitans*,



but its onset occurs much later in life. Moreover, it begins bilaterally, especially in the head, jaw, and lips, and is unaccompanied by the characteristic rigidity of Parkinson's disease. Thus in a famous old admiral it began at the age of eighty-four as a gentle antero-posterior tremor of the tongue, with a synchronous movement of the orbicularis oris. Both his hands had tremor and an interosseal attitude like that of paralysis agitans, but without rigidity.

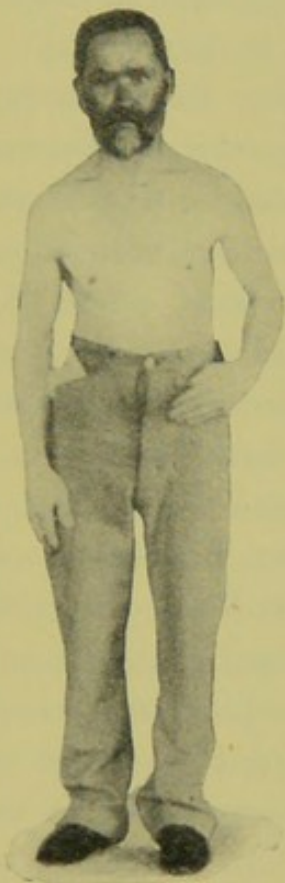

FIG. 36.—Paralysis Agitans, left-sided.

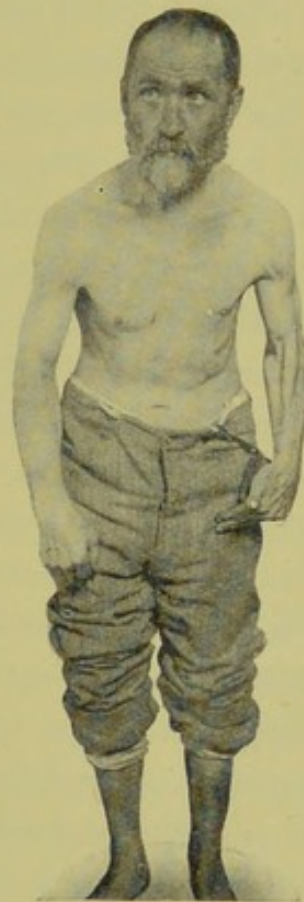


FIG. 37.—Paralysis Agitans:—the same patient as in Fig. 36, three years later.

In rickety children, especially during the second six months after birth, we sometimes observe a peculiar involuntary rotatory or nodding tremor of the head which usually comes on quite suddenly in winter-time and is known as *spasmus nutans*. It is generally accompanied by fine, rapid nystagmus, which may be more marked in one eye than in the other. If we fix the child's head, the nystagmus increases. The head movement is more often a lateral rotation than an antero-posterior nodding. It stops when the child's eyes are closed, either voluntarily or artificially. The



symptom persists for six or eight weeks or longer, and then passes off, perhaps to return again in the following winter. It is not associated with any mental defect.

**Head-rolling** is another variety of involuntary rhythmic movement met with in children, chiefly below the age of two years. Many of the patients are rickety and a large proportion have otitis media, latent or evident.<sup>1</sup> The movement is more vigorous than that of spasmus nutans, it is unassociated with nystagmus, and it ceases when the child sits up, only occurring when he lies down.

Rhythmic tremor sometimes occurs in gross brain disease. Thus, for example, in cases of lesions in the tegmental region of the pons or crus cerebri,<sup>2</sup> affecting the *rubro-spinal tract* (which descends from the red nucleus into the lateral column of the opposite side), or in lesions of the *lenticular nucleus*, we occasionally observe a slow rhythmic tremor of the limbs of the opposite side, chiefly in the hand and foot. This tremor is increased by excitement or voluntary movement, but ceases during sleep. In the diagnosis of such cases we have, besides the tremor, the other localising signs of a gross destructive lesion. Thus if the ocular nuclei (which lie dorsal to the red nucleus) be affected, there is ocular palsy of the nuclear type; if the pyramidal tract be affected there is spastic hemiplegia; and if the sensory tract, traversing the internal capsule and optic thalamus, be implicated, we have hemianæsthesia. When a unilateral lesion of one crus cerebri produces oculomotor paralysis of one side with tremor of the opposite arm and leg, this is known as *Benedikt's syndrome*. Moreover, certain lesions of the optic thalamus cause loss of emotional mobility in the opposite side of the face, with little or no weakness on voluntary movement.

In some cases of tumour of the frontal lobe, there is a fine tremor in the upper limb when it is held horizontally forwards. The tremor in such cases affects the ipso-lateral limb; thus in a right-sided frontal tumour we may find tremor in the right hand.

Let us now pass to the irregular, non-rhythmic, spontaneous

<sup>1</sup> Still *Clinical Journal*, Nov. 28, 1906.

<sup>2</sup> Holmes, *Brain*, 1904, vol. xxvii. p. 327.



movements. Of these, ordinary "rheumatic" chorea furnishes one of the most striking examples. All are familiar with the irregular, jerking, wriggling, grimacing movements of a choreic child. They may affect the face, soft palate, tongue, trunk, limbs, and even the muscles of respiration. The movements of the limbs are often more marked on one side than on the other, and may be confined to one side—so-called hemi-chorea. Choreic movements occur spontaneously but are increased by emotion or by voluntary movements. They cease during sleep. The muscles of choreic limbs have a tonus which is less than normal—hypotonia. A good method of eliciting choreic movements in a slight case of the disease, is to make the child hold both hands above the head, when after a few seconds slight involuntary movements appear in the fingers of one or both sides.

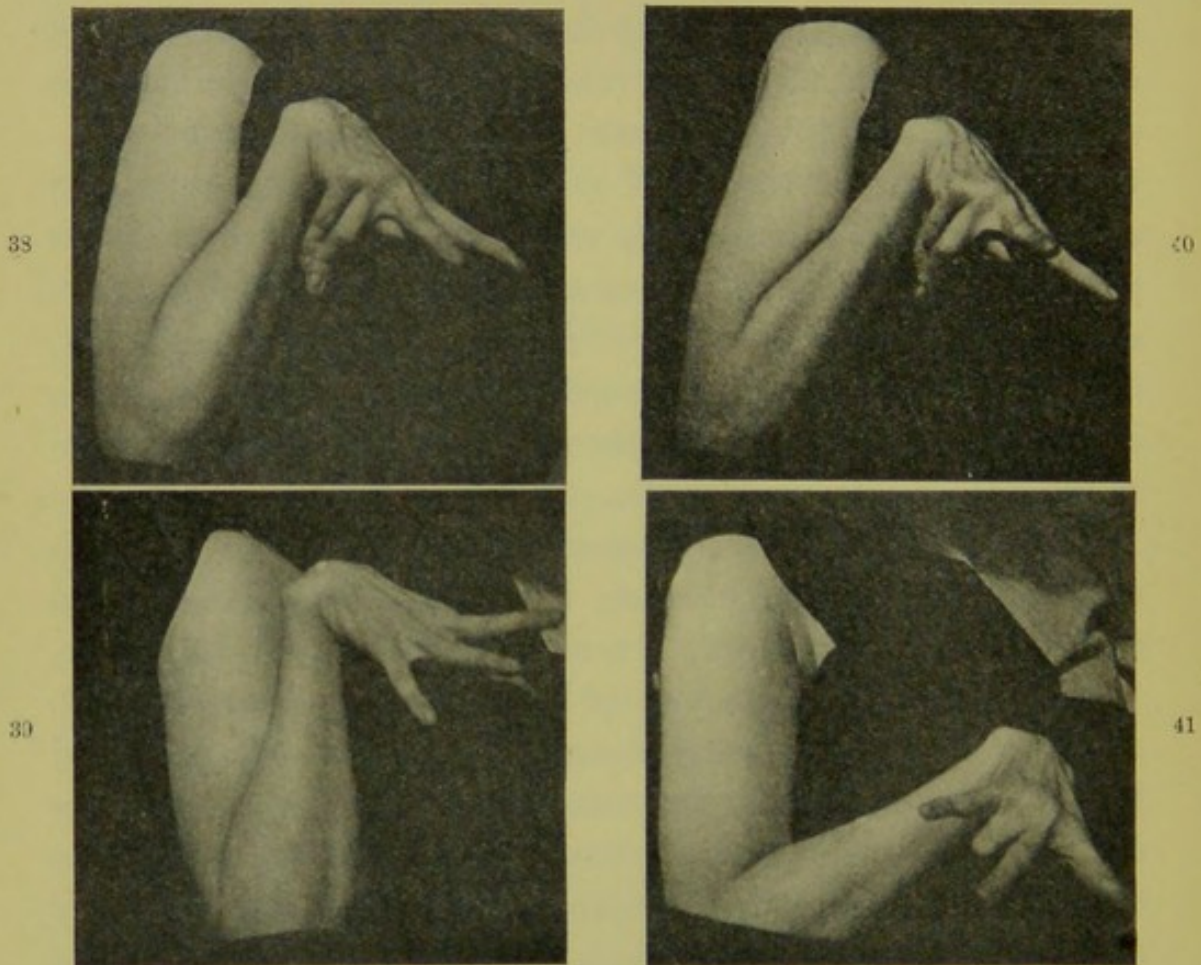
**Huntington's chorea** is a hereditary variety of chorea which comes on after middle life and becomes steadily worse. It is associated with progressive dementia.

*Hyoscine chorea*, whose symptoms are similar to those of ordinary chorea, occurs during acute intoxication with hyoscine, and is sometimes, but not invariably, associated with mild delusions.

The movements of **athetosis** or "mobile spasm" are different, occurring as they do most commonly in the spastic limbs of old hemiplegics (chiefly after infantile hemiplegia). Athetosis never occurs in a limb which is completely paralysed, but only when some degree of voluntary power survives. The movements are usually confined to the upper limb, and consist of very slow, irregular, twisting movements, most marked in the fingers and wrist, but in severe cases affecting the forearm, elbow, shoulder, and even the lower limb, where the most common involuntary movement is a hyper-extension of the great toe. Only in bilateral athetosis (generally, though not always, following diplegia) do the movements affect the face, causing hideous grimacing (see Fig. 48, p. 114). In a typical case the hand movements consist of slow flexion, then hyper-extension and spreading out of the fingers, irregularly, one after another. Combined with this, there is alternate abduction and opposition of the thumb, with flexion or extension of the wrist, and pronation or



supination of the forearm. Figs. 38 to 41 are taken from a well-marked case of athetosis in which the movements affected all the joints of the upper limb. Athetosis is intensified by voluntary movement whether of the paralysed limb or of the opposite unaffected hand. It cannot be controlled by voluntary effort, and sometimes persists even during sleep.



FIGS. 38 to 41.—Athetosis in a woman aged 29, the subject of right-sided hemiplegia of nineteen years duration. There was severe paralysis of the right upper limb from the shoulder downwards. The figures show athetosis of fingers, wrist, and elbow.

Spontaneous “associated movements” occur involuntarily in many cases of hemiplegia where the paralysis is incomplete. Thus the patient, when attempting to draw up the hemiplegic leg, involuntarily dorsiflexes the ankle and hyper-extends the hallux, or when flexing the fingers, he involuntarily dorsiflexes the wrist, and so on. (See later, p. 214.)

Many healthy people make automatic extension movements of



the upper limbs during the act of yawning. By the ancients these were termed **pandiculation**. Such movements are often well seen in the paralysed limbs of a case of severe hemiplegia when the patient yawns or is tickled, and the patient may harbour vain hopes of a return of motor power by observing extension movements of his paralysed fingers or elevation of the paralysed arm. Unfortunately these movements are not a hopeful sign in hemiplegia; on the contrary, the more severe the lesion of the pyramidal tract, the more marked is the pandiculation. It does not occur in limbs which are the subjects of athetosis or other involuntary movements. Pandiculation has been ascribed by Bertolotti<sup>1</sup> to irritation of the thalamic centres.

Spontaneous movements also occur in cases of advanced **Friedreich's ataxia**, being most marked in the head, neck, and face. They commonly consist in irregular nodding movements of the head or grimacing, which



FIG. 42.—Tabetic pseudo-athetosis on closing the eyes.

has been called "nystagmus of the face." But in Friedreich's ataxia the most outstanding feature is inco-ordination of voluntary movements. The absence of the knee-jerks, the deformity of the feet, the scoliosis, &c., will all point to a correct diagnosis.

Spontaneous movements, **pseudo-athetosis**, also occur in certain cases of **tabes** where there is severe impairment of joint-sense and ataxia of the muscular tonus. The movements are chiefly seen in the fingers and wrists, and can best be demonstrated by making the patient close his eyes and hold his hands steadily in the air with the fingers extended. In a few seconds we observe slow

<sup>1</sup> *Revue neurologique*, 1905, p. 953.



irregular flexion or extension movements of the fingers, which gradually assume curiously distorted attitudes, of which the patient is totally unaware. (See Fig. 42, also Fig. 164, p. 308, where similar movements have occurred in the lower limbs.)

Again, in **general paralysis of the insane**, spontaneous tremors of an irregular type are frequently observed, even when the patient is at rest. They occur chiefly in the face, especially if the patient be emotionally excited or just about to speak. Waves of fibrillary tremor appear, rippling along the muscles of the lips, tongue, and face. Irregular tremors of an intentional type are also frequently present, especially in the upper limbs. Their rhythm varies from 5 to 9 per second. They can often be demonstrated by asking the patient to write. Here we have other physical signs to guide us, *e.g.* the slurring articulation, the irregular or unequal pupils, frequently of Argyll-Robertson type, exaggeration or loss of the knee-jerks, the condition of the cerebro-spinal fluid, and the characteristic mental symptoms.

There is another great group of involuntary movements which includes the habit spasms, the tics, and the reflex spasms. A proper classification of these is well-nigh impossible, since the different varieties merge into each other. All are most common in people of "nervous" constitution, all are increased by emotion, and they cease during sleep. Slight degrees of **habit-spasm** may occur without any other sign of functional disease. Public speakers, such as clergymen, barristers, actors, and even medical lecturers, occasionally have little unconscious "tricks" of movement. A distinguished university professor has frequent clonic jerks of the frontalis muscles, which suddenly elevate his eyebrows; a popular comedian makes rapid blinking movements of both eyes (blepharo-spasm) when he advances towards the foot-lights; a young lady has clonic spasms of both platysmata when her neck is exposed in evening dress at dinner parties, and so on. Such minor degrees of habit-spasm are usually bilateral and occur without any local exciting cause.

More severe varieties of habit-spasm are included under the term "**Tic**." A tic is of cortical, not reflex origin, and consists



in the frequent explosive repetition of the same motor act—generally a violent, irregular one, such as rapid shaking or tossing of the head, grimacing, wriggling of the shoulder, &c. It passes off as suddenly as it comes on. Moreover, it does not interfere with voluntary movements. For example, however violent a tic of the right shoulder or arm may be, the patient's handwriting shows no abnormality. As Patrick<sup>1</sup> has put it, when the impulse to tic can no longer be controlled, the patient takes pen from paper, executes his tic and then resumes writing. At first sight, tic might be confounded with chorea. But chorea does not repeat the same movement regularly again and again. Patients who have severe tic usually show signs of mental degeneracy. This does not mean that they are necessarily deficient in intelligence. On the contrary, they are often "superior degenerates," bright and lively, but mentally immature, capricious, emotional, psychasthenic, and frequently the subjects of obsessions and various forms of "phobia." The greater the psychical abnormality, the more inveterate is the tic. "Tiqueurs" often have explosive articulation, "word-swallowing," sudden stoppage of speech, disordered respiration, echolalia (repetition of a particular word or phrase), or coprolalia (repetition of a blasphemous or obscene word).

*Spasmodic torticollis* is one of the commonest and most severe varieties of tic. Though the movement of the head is apparently a unilateral one, the head being jerked constantly to one side, commonly to the left (see Fig. 43), it is really a bilateral affair, since muscles on both sides of the neck are employed to produce




FIG. 43.—Spasmodic torticollis, with secondary hypertrophy of right sterno-mastoid.

<sup>1</sup> *Journal of American Med. Assoc.*, Feb. 21, 1905.



the movement, and it is sometimes combined with a backward jerk, a so-called retro-colic spasm. The movement may be tonic, clonic, or a combination of the two—tonico-clonic. The patient can often curb the movement by means of some antagonistic gesture of his own invention, *e.g.* by light pressure on the chin with his finger. Severe torticollis usually begins after middle life. At first occurring in paroxysms, it ultimately becomes continuous during waking hours, and the affected muscles become hypertrophied from over-use.

Besides idiopathic spasmodic torticollis, which comes on apparently spontaneously, certain cases have a definite exciting cause and should be classed, not with the tics, but with the reflex spasms which we shall consider presently. Thus, for example, we may have *neuralgic torticollis*,<sup>1</sup> in which an occipital neuralgia or a painful tooth is followed by spasmodic torticollis, usually tonic in form. When the neuralgia passes off, the muscular spasm ceases also. Again, we may have *labyrinthine torticollis*,<sup>2</sup> due to chronic irritation of one of the semicircular canals. In such cases the torticollis spasm has the object of mitigating vertigo, which would occur if the head were not kept leaning over to the opposite side. A torticollis thus initiated may become inveterate, but some cases are cured by the administration of quinine. A small proportion of cases are examples of *professional torticollis*, occurring only at the moment of performing a special act, especially in cobblers and tailors, who have to turn the head and eyes to follow the needle. Such cases are more properly to be classed with the occupation-neuroses (see p. 253). Spasmus nutans, head-rolling, and other rhythmic movements (see p. 86), must not be confounded with true torticollis, in which the spasms are either tonic or irregularly clonic.

There is another group of movements which, originally excited by some peripheral irritation, are classed as **reflex spasms**. A spasm, unlike a tic, begins locally, perhaps in a single muscle, and spreads to adjacent muscles. When the exciting stimulus

<sup>1</sup> Cruchet, *Traité des Torticolis Spasmodiques*, Paris, 1907.

<sup>2</sup> Curschmann, *Deutsche Zeitschrift für Nervenheilkunde*, 1907, p. 305.



is unilateral, the reflex spasm is usually unilateral also, but not invariably so, for bilateral reflex spasms also occur, as in tonic and clonic contraction of the orbiculares oculorum (blepharospasm), the result of corneal or conjunctival inflammation, or as in the case where a vaginal caruncle or anal fissure produces vaginismus with bilateral adductor spasm. Of the unilateral reflex spasms one of the most striking is the intense facial spasm which occurs in severe cases of trigeminal neuralgia or *tic douloureux*, which is not a true tic but a reflex spasm. In this disease the patient has paroxysms of agonising pain in one or more divisions of the trigeminal nerve. During a paroxysm, the face on the side of the pain is thrown into strong tonic contraction, the eye is closed, the mouth is drawn up on the affected side, and the patient often presses his hand desperately over the site of pain. Only when the acute stage of the paroxysm passes off do the facial muscles relax. Less severe *facial hemispasm*, either tonic or clonic, implicating some or all of the facial muscles, may arise from other reflex causes, generally in the territory of the fifth nerve, such as a decayed tooth, a non-erupted wisdom-tooth, a nasal polypus, &c. Facial hemispasm, unlike *tic douloureux*, is painless. It also occurs, less frequently, in lesions of the facial nerve itself, as, for example, when tumours or abscesses compress the nerve. Sometimes it follows an attack of ordinary facial palsy, less commonly it may precede its onset, so that in every case of facial hemispasm we should search for local lesions in the territory not only of the trigeminal but also of the facial nerve.

Sometimes a reflex spasm may persist as a habit-spasm, long after the original exciting cause has passed away. Such cases can usually be diagnosed by their history. For example, a lad lost his left arm by avulsion in a machinery accident. The stump was amputated at the shoulder-joint, but clonic spasms appeared in the trapezius and scapular muscles, and these persisted after all the posterior nerve-roots in that region were divided by operation. But other cases occur, even of unilateral spasm, without any reflex exciting cause or the history of one, and they



are difficult to classify. Thus a lady whose menopause occurred at the age of forty-five, at the same time also lost most of her property through the failure of a bank. She gradually developed clonic spasm of the left facial muscles. At first, this consisted merely in a slight flickering of the lower lid for a second or two, every few days, but the condition gradually increased in severity until, when she came under observation thirteen years later, the spasms affected all the facial muscles on one side, beginning as a flickering movement, and then becoming tonic and lasting from twenty to thirty seconds at a time, the eye being closed, the eyebrow elevated, the angle of the mouth drawn outwards, and the platysma thrown into strong contraction. In the intervals between attacks the face was symmetrical. Under treatment by bromides and galvanism this case became rapidly better.

Finally, there are numberless varieties of **hysterical spasms**, apart from the hysterical "fits," which have already been discussed. We can only refer to some of the commoner types. Thus *saltatory spasm* consists of a series of jumping or skipping movements, which occur whenever the patient assumes the erect posture. A similar spasm, less severe in degree, may produce paroxysms of trembling in the legs, as in a hysterical girl of nineteen with many other stigmata of hysteria, in whom the spasms ceased at once when she lay down. All sorts of movement, however, may occur in hysteria, simulating almost any kind of tremor. For instance, a hysterical woman of twenty-one had constant movements of the face, left arm, and both legs, resembling those of athetosis but very much faster. In her case typical hysterical contractures and segmental anæsthesia of the hysterical type, together with the normal state of the reflexes, aided in the diagnosis of hysteria, which disease will be further considered in a subsequent chapter.



## CHAPTER VII

### APHASIA

WE exchange ideas with our fellow-men chiefly by means of speech. Speech is an arbitrary code of signals, vocal or written. These signals are perceived by our auditory or visual centres. Every country has its own particular code or language, which is learned by each of its inhabitants. Gestures and mimic movements, as a means of communication, although international, have a very limited field of usefulness as compared with speech. Two individuals, each ignorant of the other's language, can certainly communicate with each other after a fashion by means of gestures alone, yet they cannot express many ideas in this way, but only simple primitive emotions such as pleasure, anger, surprise, and so on, or pantomimic imitations of certain acts.

There are three chief classes of cases in which the functions of articulate speech may be lost. Firstly, there are conditions in which the patient's higher intellectual functions are in abeyance, either congenitally as in idiots, or from disease as in acquired dementia, coma, stupor, or in certain cases of hysteria. Such patients are speechless, but they are not aphasics. Secondly, there are the cases where the higher intellectual centres are capable of function, but the cortical speech-centres which control the motor acts of speaking and writing, or the sensory processes of recognising spoken or written words, are diseased, and yet the patient has not necessarily any paralysis of the peripheral organs of speech, nor is he necessarily deaf or blind. To this group the term "aphasia" is applied. Lastly, there are the cases where, with intact intellectual functions and normal cortical speech-centres, there are defects in the peripheral organs of articulation, so that the patient is unable to articulate distinctly—for example, cases of cleft palate, post-diphtheritic palsy of the palate, facial or hypo-



glossal paralysis, bulbar paralysis, and so on. These are affections, not of speech proper, but of articulation.

**Aphasia** may be defined as impairment or loss of speech due to the loss of memory for those signs, vocal or written, by means of which we exchange ideas with our fellow-men. An aphasic, unless his higher intellectual centres are impaired, usually preserves his powers of gesture and of pantomime. Aphasia is due to disease, organic or functional, of certain well-defined special centres in or near the cortex of the brain. These cortical centres

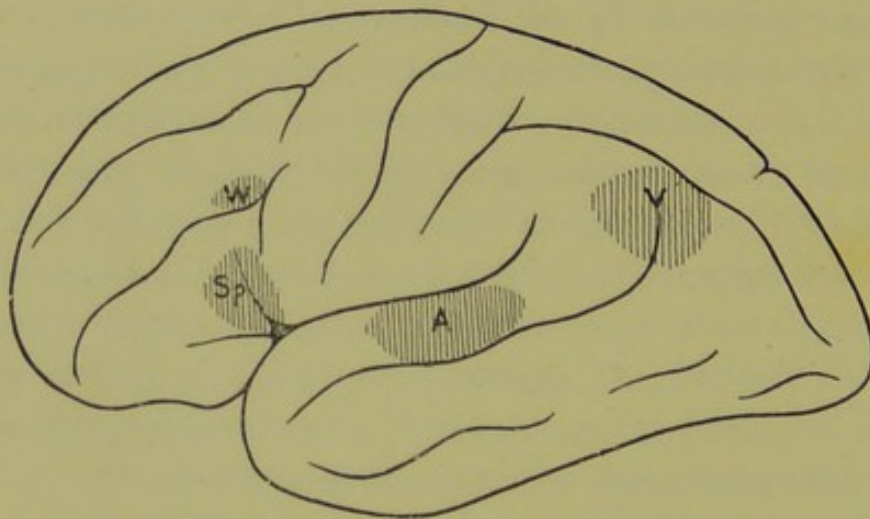


FIG. 44.—Diagram of left cerebral hemisphere, showing approximate positions of the centres concerned in speech.

A. Auditory word-centre.	} Sensory.
V. Visual word-centre.	
Sp. Vocal word-centre.	} Motor.
W. Motor centre for writing.	

exist on both sides of the brain, but ordinarily in right-handed people the speech-centres on the left side of the brain are predominant.

Let us consider the speech-centres somewhat more in detail. For the interchange of ideas two distinct processes are required—one sensory, the other motor. The sensory process includes the hearing and understanding of spoken words, and also the seeing and understanding of written or printed letters. The memories of words heard and seen are stored up in specialised parts of the auditory and visual centres, named respectively the auditory word-centre and the visual word-centre (Fig. 44). The auditory word-centre is at the upper or Sylvian surface of the temporal lobe (anterior transverse gyrus of Heschl, Flechsig's "auditory gyrus")



and in the adjacent posterior end of the first temporal convolution ; the visual word-centre is in the angular gyrus. Either centre may be diseased ; so that we have two varieties of sensory aphasia, viz.—**auditory aphasia** and **visual aphasia**. Then there is in speech the motor element, consisting of the motor act of expressing ourselves in words, either vocally or by means of writing. The memories of these motor acts of vocal speech are ordinarily supposed to be stored up at the posterior end of the inferior frontal (Broca's) convolution, and in the adjacent part of the pre-central convolution and of the insula. If this centre be destroyed, **motor aphasia** or **aphemia** is said to result, the patient being unable to utter words of which his motor memories have been destroyed. Marie, however, has recorded cases of destruction of Broca's convolution without any speech defect, and denies that it has any special importance in the mechanism of speech. He considers that cases of so-called motor aphasia are really examples of ordinary sensory aphasia combined with articulative difficulty (anarthria or dysarthria) due to a lesion of the lenticular nucleus and its surrounding white matter, and maintains that isolated lesions of Broca's convolution are accidental and of minor significance. Earlier writers used also to describe a separate centre for writing (independent of the vocal word-centre), a lesion of which would produce loss of the faculty of writing—**agraphia**. But no case has been verified pathologically in which a focal lesion has produced pure agraphia without affection of vocal speech, so that the writing-centre, although it may be represented diagrammatically in a theoretical scheme of cortical speech-centres, is probably merely a part of the ordinary psychomotor centre for the upper extremity.

Fig. 45 is a scheme of the connection of the various centres concerned in speech. Let us first notice that the motor vocal word-centre is subservient to the auditory word-centre, and that the writing-centre is similarly subservient to the visual word-centre. A child learns to speak first by hearing spoken words and then imitating them. Therefore speech at first is entirely auditory in origin. Later, in learning to read, the meaning of each word is learned by associating the letters seen with words heard



spoken, so that the auditory word-centre acts as the instructor of the visual word-centre.

In most people, during the process of silent thought, words are revived primarily in the auditory word-centre, and there is usually a simultaneous revival of the same words in the visual word-centre. But in other people the revival in the visual word-centre comes to be of greater importance. Accordingly we may classify people into "auditives" and "visuals" according to their mode of revival of words in thought. Most of us are "auditives."

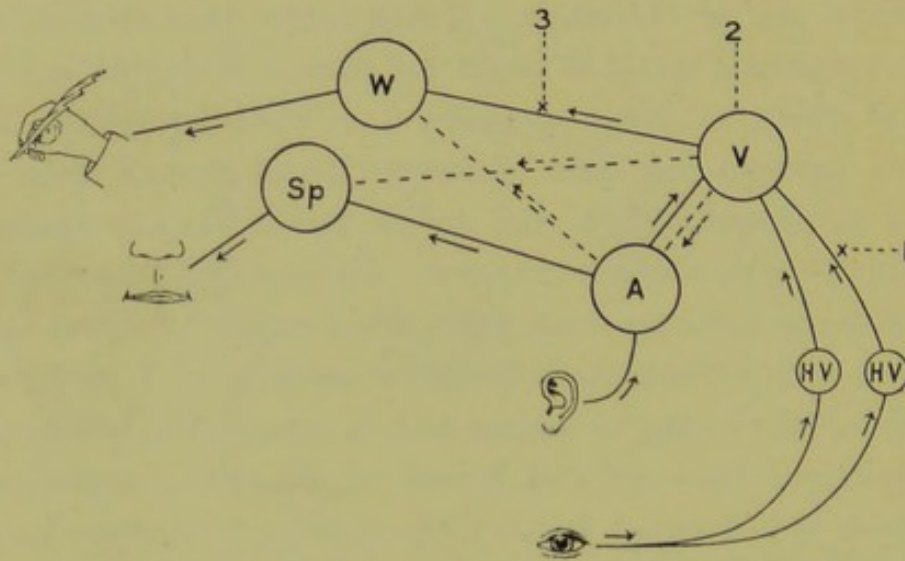


FIG. 45.—Diagram of Speech-Centres (after Bramwell).

A. Auditory word-centre. V. Visual word-centre.  
Sp. Motor vocal word-centre. W. Motor centre for writing.  
HV. Half-vision centre.

The interrupted lines indicate possible but less habitual routes for transmission of impulses.

Simultaneous revival of word-images in several speech-centres makes our comprehension of the idea more perfect. Thus a difficult concept is better understood if we read it aloud, because this involves the activity of the visual, auditory and vocal word-centres.

Aphasia commonly results from organic disease of one or more of the cortical speech-centres, or of the sub-cortical fibres connecting them. The most frequent organic causes are embolism, hæmorrhage, or thrombosis, cerebral abscesses and cerebral tumours. The differential diagnosis between these various conditions depends largely on the history; embolism producing the symptoms suddenly, hæmorrhage taking several minutes, thrombosis taking perhaps hours, abscess and tumours being still more gradual in onset. But



we also meet with cases of temporary or functional aphasia, sometimes from mere debility or exhaustion, sometimes from localised vascular spasm, sometimes following a "congestive attack" in general paralysis, or accompanying a paroxysm of migraine, or an attack of uræmia, or after an epileptic fit.

In investigating a case of aphasia we should first note whether the patient has other signs of gross cerebral lesion, such as hemianopia, or hemiplegia, and should inquire whether he is naturally right- or left-handed. Most children are taught to write with the right hand, whether they are right-handed or not, and therefore in determining this point we inquire with which hand a man draws a cork, throws a stone, &c.; or if a woman, with which hand she combs her hair or threads a needle; or, in either sex, which hand is used in cutting bread.

The following series of inquiries (based on Beevor's scheme) should then be made. The capital letters in parenthesis indicate the parts of the brain involved in each case.

1. Can the patient spontaneously utter intelligible words? (**Sp.**) Note the extent of his vocabulary. Can he pronounce all words or only a few? Get the patient to talk spontaneously, and observe whether he talks fluently or misplaces words or syllables, whether he talks in disjointed phrases, ("telegraphic" type of speech,) or whether he talks unintelligible jargon.

2. Can he understand words which he hears? (**A.**) Ask him to touch his nose, ear, eye, chin, &c., in turn, thus testing his interpretation of nouns. Then ask him to smile, whistle, shut his eyes, &c., thus testing his comprehension of verbs. Sometimes we find that the patient executes the first command correctly, but continues to repeat the same act in response to different commands. A patient can sometimes sing the words and air of a song, when he is unable to repeat the words in a speaking voice.

3. Can he understand written questions or commands which he sees? (**V.**) Write down and show him simple sentences, such as "How old are you?" "Put out your tongue." "Give me your left hand."

4. Can he write spontaneously? (**W.**) If his right hand is



paralysed, let him try with the left. Observe whether he writes intelligibly, whether he misplaces words or syllables, or whether he scribbles meaningless signs.

5. Can he copy from printed to written letters? (**V**→**W**.) Print some word such as "Hospital" or "Monday," and get him to copy this.

6. Can he write to dictation words which he hears? (**A**→**V**→**W**.)

7. Can he pick out objects of which he hears the name? (**A**→**V**.) Place in front of him a heap of objects, such as a key, a shilling, a match, a pencil, and ask him to pick out each in turn.

8. Can he repeat words heard? (**A**→**Sp**.) Try him first with simple words and phrases; *e.g.* "cat," "dog," "nurse," "good-morning," &c.

9. Can he name objects seen, and can he read aloud from words shown to him? (**V**→**A**→**Sp**.) Point to different objects and ask him what they are.

10. Does he understand gestures and pantomimic movements? Without speaking to him, get him to imitate you when touching the nose, spreading out the fingers, protruding the tongue, &c.

**Auditory Aphasia, or Word-Deafness.**—The patient in this case is not deaf, but simply word-deaf. He hears ordinary sounds and noises, but spoken words are not understood; they sound to him like an unknown tongue. The character of the symptoms varies according as the lesion is subcortical or cortical in position.

(*a*) **Subcortical, or Pure Auditory Aphasia.**—This is extremely rare (Marie, in fact, denies its existence). Here the lesion simply blocks the way-in for spoken words. The patient therefore has word-deafness—*i.e.* he is unable to understand what is said to him; he is also unable to repeat spoken words or to write from dictation. But the auditory word-centre being still intact, he possesses all his memories of auditory speech, and therefore spontaneous speech is perfect. Moreover, the visual word-centre being in normal working order, he is still able to read, and, as a matter of fact, reading is his only means of receiving messages from other people.



(b) **Cortical Word-Deafness.**—This is much commoner than the other variety. Here the lesion involves the cortical centre itself, and the auditory memories of spoken words are obliterated. And therefore, in addition to the previous defects of word-deafness with inability to repeat spoken words or to write from dictation, there are other symptoms due to the fact that the motor speech-centre is no longer controlled by the auditory word-centre. Internal speech and thought are impaired, and so the patient makes mistakes whether in speaking spontaneously or in reading aloud. He also makes mistakes in writing, especially in spelling. He talks fluently enough, it is true, but he tends to mix up his words or syllables, and in a severe case may jabber unintelligible jargon. Word-deafness renders the patient unaware of his own errors. This, as we shall see, is in marked contrast with motor aphasia, where the patient recognises his own mistakes as soon as he has uttered them. If the lesion of the auditory word-centre be incomplete, the word-deafness and resulting errors of speech are also partial. These latter may, in a slight case, be confined to inability to name objects, *i.e.* nouns, the patient being still able to express abstract ideas. Thus a partially word-deaf patient, who is unable to name a knife shown him, may say, "It is for cutting." Or again, partial word-deafness may produce simply confusion of words; the patient may say one word when he means another (*paraphasia*). It rarely happens that word-deafness remains permanent and complete; the auditory word-centre in the opposite hemisphere generally compensates, to some extent, as time goes on.

The extent of mental disturbance in word-deafness varies according to whether the patient be a strong "auditive" or a strong "visual." In the latter case the mental impairment is much less than in the former, and the disturbances of motor speech are but slight.

The auditory and visual word-centres are fairly close together, and more than this, they are supplied by the same branch of the middle cerebral artery (see Fig. 26, p. 42); so that it is not uncommon for a single arterial lesion, *e.g.* a thrombosis, to affect both centres together and to produce a combination of word-deafness and word-blindness.



**Visual Aphasia, or Word-Blindness (Alexia).**—In word-blindness the patient can see, but cannot understand printed or written characters. They appear to him like strange hieroglyphics. He sees the shape of the letters, but they convey no meaning to his mind.

Here, as in word-deafness, the symptoms vary in degree. The patient may be unable to recognise a single letter (letter-blindness), or he may be able to spell out the letters singly but unable to read syllables or words. Often a patient who is unable to read any other word, can recognise his own name. Frequently he retains

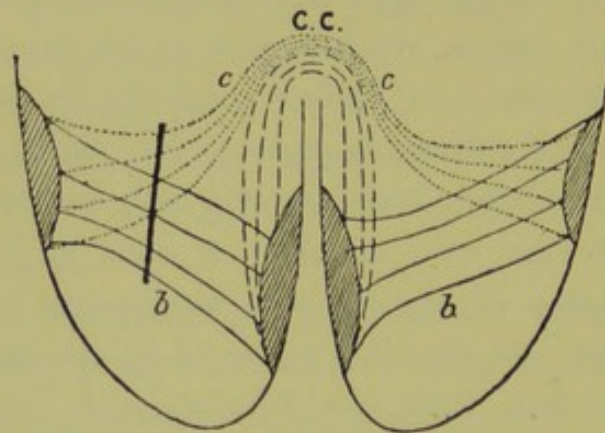


FIG. 46.—Diagram representing a lesion (indicated by thick black line) which produces pure word-blindness (Bastian).

C. C. Posterior extremity of corpus callosum.

c. c. Commissural fibres connecting the two visual word-centres.

b. b. Fibres connecting each half-vision centre with the visual word-centre of the same side.

the power of recognising numbers and of doing addition, subtraction, and multiplication sums. We have to recognise two varieties of word-blindness, according as the lesion is cortical or subcortical in position.

(a) **Subcortical, or Pure Word-Blindness.**—Here the way-in for visual word-impulsion is destroyed, the visual word-centre remaining intact. The patient cannot understand written or printed words, nor can he read aloud, but he still retains the power of writing spontaneously and from dictation; and therefore he can express his thoughts perfectly in writing, but is unable to read what he has himself written. Inasmuch as a subcortical lesion, in order to produce word-blindness, must be beneath the angular gyrus and in such a position as to cut off the afferent visual impulses from both half-vision centres to the visual



word-centre in the angular gyrus, it will necessarily implicate the optic radiation to some extent. And therefore a pure or subcortical word-blindness is always associated with hemianopia or, when partial, with hemi-achromatopsia (Fig. 46).

(b) **Cortical Word-Blindness.**—In this variety, in addition to the symptoms just described, there is loss of the memories of written or printed words, and therefore, inasmuch as the visual word-centre, which controls the writing-centre, is destroyed, the patient has **agraphia**. He is unable to write spontaneously, to copy from printed into written characters, or to write from dictation. If the lesion of the visual word-centre be partial the alexia and agraphia are also incomplete, and mistakes in writing may amount simply to the writing of wrong words, syllables or letters—so-called "*paragraphia*."

These points are illustrated by Bramwell's well-known diagram (Fig. 45), in which a lesion at the position marked 1, destroying fibres passing from one half-vision centre to the visual speech-centre, would not produce word-blindness. A lesion at 1, destroying fibres passing from both half-vision centres to the visual speech-centre, would produce word-blindness but not agraphia, since the visual speech-centre is unaffected and is able to influence the motor writing-centre. A lesion at 2, destroying the visual speech-centre, would produce word-blindness and agraphia. A lesion at 3 would produce agraphia (unless the motor writing-centre could be brought into action in some roundabout way), but not word-blindness, the visual speech-centre being intact.

**Motor Aphasia.**—In this variety the patient has lost the power of expressing himself by spoken words. He can neither speak spontaneously nor can he read aloud. And yet (unless the motor speech-centres on both sides of the brain are destroyed) he is not absolutely dumb. As Hughlings Jackson puts it, the patient is speechless, but as a rule not wordless. He can usually utter intelligently a few words, such as "yes" and "no," by means of the speech-centre on the uninjured side, and in addition he may have other words or phrases, mostly interjections, such as "oh my!" "come on!" "damn!" "by Jove!"—so-called



“recurrent utterances”—which he utters automatically when excited, or when making an effort to speak. A patient who has motor aphasia, unlike a word-deaf person, is conscious of his own errors.

(a) **Subcortical, or Pure Motor Aphasia.**—Here the patient, though intelligent and able to understand spoken and written language (by means of his uninjured auditory and visual word-centres), cannot utter spoken language, either spontaneously by reading aloud or by repeating what he hears. This is because the way-out for spoken speech is blocked. But his mental speech-processes are unimpaired, and if the outgoing fibres from the writing centre are unimpaired, he is able to express himself in writing, as in the scriptural case of Zacharias, the father of John the Baptist (St. Luke, i. 62, 63), and in many cases the patient can indicate by signs how many syllables or letters are in the word which he desires to speak but cannot utter. This variety of aphasia sometimes occurs in hysteria. The hysterical aphasic cannot utter any sound whatever, whether articulate or not. Zacharias was probably a hysterical aphasic.<sup>1</sup>

(b) **Cortical Motor Aphasia.**—This type, in which the lesion is supposed to be limited to the cortical motor speech-centre in the inferior frontal gyrus and adjacent grey matter of the insula and pre-central gyrus, is less securely established than the other varieties. (Marie denies its existence altogether.) The patient in this variety has not only all the defects of a subcortical case, which we have just considered, but, in addition, his mental processes of internal thought are impaired, since the co-ordination of memories of words spoken and written by himself is impaired. He has therefore difficulty in understanding complicated sentences, whether spoken or written. Together with difficulty in vocal speech there is often (though not always) associated a similar difficulty in writing—*agraphia*—proportional to the defect of speech.

Pure isolated *agraphia*, without any other symptom, does not occur, and as we have seen, the commonest variety of *agraphia*

<sup>1</sup> “And his mouth was opened immediately, and his tongue loosed, and he spake, and praised God.”



is that due to cortical word-blindness. The study of agraphia due to sensory aphasia is easier than that associated with motor aphasia, because in sensory aphasia there is no necessary motor paralysis of the right arm or hand, whereas sometimes in motor aphasia the patient has to make his attempts at writing with the left hand.

Such are the chief types of aphasia. Clinically, however, it is commoner to meet, not with pure auditory, visual, or motor aphasia, due to a small focal lesion, but with combinations of these, or with total aphasia, the result of a larger destructive lesion implicating several or all of the speech-centres. Such severe aphasias, of course, produce a more profound degree of mental deficiency, and inasmuch as the same artery, the middle cerebral, supplies not only the speech-centres, but also the other cortical motor areas and the corpus striatum (see Figs. 26 and 27), total aphasia is usually combined with severe right hemiplegia.

Hysterical aphasia is usually accompanied by other stigmata of hysteria, and especially by hysterical hemiplegia. It is paradoxical and polymorphic, and usually differs from organic aphasia in some curious fashion, according to the caprice of the patient. Thus, for example, a patient with hysterical aphasia may also have peculiar tricks of intonation or of accent.

Marie,<sup>1</sup> whilst admitting the existence of visual, auditory and motor aphasia as clinical syndromes, denies the existence of diagrammatic visual, auditory and motor speech-centres, and attributes all aphasic phenomena to intellectual deficiency from disintegration of some part of Wernicke's zone (which consists of the gyri surrounding the extremities of the Sylvian and the parallel fissure), which zone he regards as an intellectual area. According to Marie the essential fact of aphasia, of whatever variety, is insufficient comprehension of speech. He adduces evidence to show that Broca's convolution plays no special part in the function of speech except in so far as it contains certain motor centres for the face, tongue and larynx. In fact he discards a special vocal-word-centre just as others discard a motor centre for writing. The syndrome of motor aphasia is explained by him as due to intellectual deficiency *plus* articulative anarthria, this latter being due to a lesion of the lenticular zone (comprising the lenticular nucleus and its surrounding white matter). In other words, he regards motor aphasia simply as a sensory aphasia *minus* the power of speech. The intellectual processes of speech in right-handed patients are localised in the left hemisphere, whereas anarthria may be produced by a lesion of either lenticular zone.

<sup>1</sup> *Semaine Médicale*, 1906, Nos. 21, 42, and 48.



But though Marie's views are seductive in their simplicity, there are certain obstacles to accepting them in their entirety. Even supposing that the only real varieties of aphasia are sensory, and that some defect of intelligence is present in every case, it seems none the less probable that visual and auditory speech-centres do exist, and that lesions of these centres, rather than mere intellectual deficiency, are the cause of the well-defined clinical types of sensory aphasia. As Dejerine has urged, we may have advanced dementia from undoubted cortical disease, as in general paralysis, without any aphasia, sensory or motor. It therefore seems probable that the diminution of intelligence which is seen in aphasic patients is due to interference with cortical sensorial processes, producing disruption of the cerebral mechanism of speech, rather than that the aphasic phenomena should be regarded as secondary to intellectual deficit. With regard to Marie's conception of motor aphasia as a mere combination of intellectual deficiency with anarthria, it may be objected that this fails to account for the presence of well-articulated "recurrent utterances" such as are present in most patients with complete motor aphasia. If anarthria alone were the cause of the speech-loss, it ought to render the articulation of all words difficult. Moreover, the cortical vocal-word-centre is not limited to Broca's convolution, but probably extends into the insula and to the neighbouring part of the pre-central gyrus. So that there is no insuperable difficulty in the existence of a lesion limited to Broca's convolution unaccompanied by aphasia.

**Apraxia** is the inability to execute certain familiar purposive movements with the limbs, when there is neither motor paralysis, sensory disturbance, nor ataxia of the limb, nor any intellectual impairment. Apraxia of the muscles of the limbs is therefore analogous to motor aphasia of the speech muscles. Certain functions, comparable to the functions of speech, have their cortical centres situated in the first and second frontal gyri of the left hemisphere, these centres being connected with the corresponding centres in the right hemisphere by means of the anterior fibres of the corpus callosum.

Apraxia may be either sensory or motor in type. Thus if an apraxic patient be handed a tooth-brush and asked to use it, he may put it in his mouth and try to smoke it like a cigar. Such apraxia is *sensory* in origin, due to failure of recognition. On the other hand, suppose he recognises it as a tooth-brush and may even name it and tell what it is for, but when asked to use it he fumbles aimlessly with it, his apraxia is *motor* in type. To take another example, motor apraxia of the tongue is often seen in a hemiplegic patient who fails to protrude his tongue when told to do



so, but can still lick his lips unconsciously. Sometimes the apraxic patient cannot perform a given series of purposive movements unless he has the sensory stimulus of the object in his hand, with which the movements are associated. For example, an apraxic cornet-player could not purse up his lips to blow the instrument unless he had the actual mouthpiece at his lips.

Over 95 per cent. of people are right-handed. In them the left cerebral hemisphere is the dominant one and, besides controlling

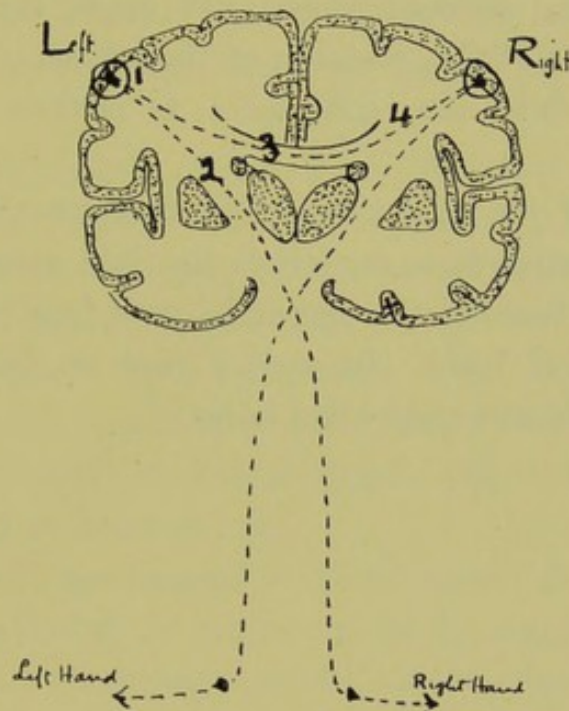


FIG. 47.—Diagram illustrating relation of corpus callosum to apraxia.

the limbs of the right side of the body, it exercises a potent influence upon the right cerebral hemisphere by means of the commissural fibres of the corpus callosum. Thus many movements of the left limbs are initiated by the left hemisphere, so that a left-sided cortical or subcortical lesion, if implicating the corpus callosum, may produce not only right-sided hemiplegia or monoplegia, but also apraxia of the non-paralysed left hand. Such apraxia of the ipso-lateral hand is evidence of a lesion of the fibres of the corpus callosum. Apraxia is associated with lesions of the left hemisphere much oftener than with right-sided lesions.



Fig. 47 is a diagrammatic representation of the above-mentioned points, which shows that :—

1. A lesion at or close beneath the left arm-centre produces paresis or paralysis of the right arm, whilst the left arm, deprived of the guidance of that centre, becomes apraxic.
2. A lesion of the left internal capsule, where the commissural fibres are uninjured, causes right-sided hemiplegia, without left-sided apraxia.
3. A lesion of the corpus callosum, or of the left centrum ovale implicating callosal fibres, will cause left-sided apraxia (from loss of the guidance of the left arm-centre over the right), whilst the right hand is neither paralysed nor apraxic.
4. A lesion of the right frontal lobe may interrupt the callosal fibres passing from the left to the right arm-centre without injuring those of the pyramidal path from the right centre to the left hand. In such a case we have a left-sided apraxia from a right-sided lesion.



## CHAPTER VIII

### DISORDERS OF ARTICULATION

It is necessary to distinguish clearly between speech and articulation. Speech is a cortical function, articulation is mainly bulbar.

Disordered articulation, or **dysarthria**, signifies difficulty in performing the co-ordinated muscular movements necessary for the production of the consonants and vowels which go to form syllables and words.

In simple dysarthria there is no affection of the cortical centres or paths which are concerned in the processes of speech proper. A patient, for example, who has advanced bulbar palsy, even when he is unable to articulate a single word, is not, strictly speaking, speechless. He is inarticulate, which is quite a different thing. His mental speech-processes remain normal, he can still express himself fluently in written speech, and he is able to understand everything he hears or sees.

The peripheral mechanism of vocal speech is partly musical (or voiced), consisting in vibration of the approximated vocal cords. It is also partly consonantal (or voiceless), consisting in the co-ordinated action of numerous muscles of the lips, tongue, palate, and pharynx. The term "articulation" is specially applied to the mechanism of consonantal pronunciation.

To test a patient's power of articulation, we listen to his ordinary conversation, or we ask him to read aloud a passage from a book or newspaper, and notice how he pronounces his words. Then, if he shows any abnormality in connection with particular consonants, we ask him to repeat "catch" words, chosen so as to present special difficulties, *e.g.* "British constitution," "biblical criticism," "West Register Street," "hippopotamus," "Burgess's fish-sauce shop," &c.

Difficulties of articulation are the result of defects, consisting



either in paralysis or inco-ordination, of certain groups of muscles in the lips, tongue, palate, pharynx, or larynx. The underlying defect may either be in the bulbo-muscular neurones (comprising the pontine and medullary nuclei, the peripheral motor nerves and the muscles), or it may be due to supra-nuclear affections in the cortico-bulbar neurones, at some point between the higher speech-centres and the bulbar nuclei. Or it may be due to ataxia of the organs of speech.

**Infra-nuclear and Nuclear Affections of Articulation.**—Articulation may be impaired as a result of paralysis of any of the motor nerves or nuclei supplying the articulative muscles.

*Unilateral hypoglossal paralysis* (as in the case of a business man shown in Fig. 81, in whom this nerve was divided by a stab in the neck dealt by a discharged employé) produces motor paralysis followed by atrophy of the corresponding half of the tongue. The paralysed half-tongue feels to the patient as if he had a foreign body in his mouth. This makes his articulation clumsy, lipping and indistinct, especially in the case of linguo-dental (S, Z, Th) and of anterior linguo-palatal consonants (T, D, L, R). But after a few days the patient becomes accustomed to the feeling of his palsied half-tongue, and his articulative difficulty to a large extent disappears.

*Facial palsy*, from its affection of the lips, renders labials (P, B) and labio-dentals (F, V) indistinct, especially so when the palsy is bilateral.

*Bilateral paralysis of the palate*, e.g. post-diphtheritic paralysis, congenital cleft palate, and syphilitic perforation of the palate, all produce the same articulative difficulty, inasmuch as the nasal cavity cannot be shut off from the mouth. As a result the voice is nasal, and certain consonants are altered (B becomes M, D becomes N, K becomes Ng, and so on), so that articulation as a whole is indistinct. This indistinctness of articulation is increased when the patient stoops forwards: it diminishes or even disappears on lying with the head thrown backwards, since in the latter position the soft palate tends to fall back by its own weight and shuts off the naso-pharynx.<sup>1</sup>

<sup>1</sup> Schlesinger, *Neurologisches Centralblatt*, 1906, p. 50.



Total paralysis of the palate is also associated with difficulty in deglutition, especially with fluids, which during the act of swallowing regurgitate into the naso-pharynx and escape through the anterior nares.

Unilateral paralysis of the recurrent laryngeal nerve renders the voice hoarse, by paralyzing one vocal cord, and so interfering with the phonation of vowels, but not with the articulation of consonants. If the vagus root be affected at its point of exit from the medulla, the soft palate is often paralysed on the same side (see later, Cranial Nerves). But unilateral palatal palsy, unlike bilateral, does not affect the articulation of consonants.

Articulation may also become indistinct from disease of the bulbar nuclei—so-called glosso-labio-laryngeal paralysis, or *bulbar palsy*. In this disease there is a diffuse, progressive weakness of the muscles of articulation, with atrophy and fibrillary tremors of the muscle fibres, especially those of the tongue and lips. Articulation becomes more and more indistinct, saliva dribbles from the patient's trembling lips, and in advanced cases there is interference with swallowing and coughing. If, as is often the case, bulbar palsy is an upward extension of an amyotrophic lateral sclerosis, there may be a concomitant muscular atrophy and fibrillary tremor in the muscles of the upper limbs, especially in the intrinsic hand muscles. Owing to affection of the pyramidal tracts, there is also exaggeration of the deep reflexes and general spasticity, especially of the lower limbs.

There is a form of *myopathy*—the *facio-scapulo-humeral type* of Landouzy and Dejerine, in which the facial muscles are atrophied. This affection is a bilateral one and the patient's lower lip protrudes in a characteristic fashion which has been termed the "tapir" type of lip. He has also a peculiar "transverse" smile. In severe cases of this disease the articulation of labial consonants becomes impaired just as it does in double facial palsy.

*Myasthenia gravis*, when it affects the bulbar muscles, reproduces all the features of bulbar palsy, with this difference, that the paralysis varies in its degree from time to time, becoming



accentuated by fatigue. After a period of rest a patient so affected may resume with normal articulation, but, if he continues to speak, his muscles gradually become exhausted, and his articulation becomes more and more indistinct. Not only the lips and tongue, but the ocular muscles, the muscles of mastication and various muscles of the trunk and limbs, show evidence of temporary paralysis or fatigue, and ultimately the patient succumbs to fatigue of his respiratory muscles.

**Articulative Ataxia.**—There are some diseases in which articulation becomes indistinct, not from paralysis of the muscles but from ataxia.

In *Friedreich's ataxia*, for example, the articulation becomes slow, thick, and clumsy, and the patient talks as if he had a foreign body in his mouth, so that his speech has been aptly termed the "hot-potato" speech. The pitch of the voice in this disease may vary from word to word, and in advanced cases a certain degree of mental feebleness is often superadded.

In laryngeal *tabes* where the larynx is affected by ataxy the voice is tremulous, and when a tabetic patient has ataxia of the tongue his articulation becomes laboured. This lingual trouble in *tabes* is often associated with a peculiar constant rolling movement of the tongue on the floor of the mouth, even when the patient is not speaking. The patient often has an annoying subjective sensation in his tongue, as if it were covered with blotting-paper, which he tries to get rid of by the restless rolling of his tongue.

**Supra-nuclear, or Cortico-bulbar Affections of Articulation.**—Articulation may be affected where the upper or cortico-nuclear neurones are involved. The slurring articulation of many cases of acute *alcoholic intoxication* is familiar to lay observers, being especially marked in the pronunciation of labial and of anterior linguo-dental consonants. In rare instances alcoholic dysarthria persists for days after the alcoholic celebration. Tollmer and other French authorities ascribe this circumstance to cerebellar intoxication. Many alcoholic patients realise their own articulative difficulty, and in endeavouring to compensate for it, they utter certain



words with a deliberation and undue emphasis that betrays them.

Very similar to the alcoholic articulation is that of *general paralysis of the insane*. But the typical general paralytic shows also a characteristic fibrillary tremor of all the muscles around the lips and nose.

Both in acute alcoholism and in general paralysis there is often a tendency to choose an occasional wrong word, or to misplace syllables. Such defects are not bulbar but cortical in origin. In the later stages of general paralysis, articulation may be totally unintelligible, reduced to a mere mumble.

After an attack of right-sided hemiplegia, the patient is often aphasic. But even in a left-sided hemiplegia where no true aphasia exists, it is not uncommon to find a temporary change in the articulation, which loses its crispness, and becomes a little laboured and indistinct. This dysarthria usually passes off after a few days, but sometimes persists permanently, varying in degree, especially if the lesion involves the lenticular nucleus. A lesion of the left lenticular produces greater dysarthria than one of the right nucleus.<sup>1</sup> The dysarthria of lenticular disease is due mainly to spasticity.<sup>2</sup>

In cases where a patient has a bilateral hemiplegia we often meet with "*pseudo-bulbar*" *paralysis*. The most common history is that there have been one or more hemiplegic attacks, all confined to the same side, but at last the patient has an attack on the opposite side. This now produces, in addition to the classic signs of a double hemiplegia, pseudo-bulbar paralysis, with thick, indistinct articulation, closely resembling that of true bulbar palsy and with the same dribbling of saliva, difficulty in swallowing, coughing, &c., but without atrophy or fibrillary tremors of the affected muscles. The pseudo-bulbar patient is emotionally irritable; he laughs, or more often cries, on slight provocation, and, unlike the subject of true bulbar paralysis, he is generally somewhat deficient mentally. There is usually a history of

<sup>1</sup> Mingazzini, *Sulla sintomatologia delle lesione del nucleo lenticolare*, 1902.

<sup>2</sup> Wilson, "Progressive Lenticular Degeneration," *Brain*, 1911.



successive (more rarely of simultaneous) attacks of hemiplegia on opposite sides of the body.

*Double athetosis* is a disease which is usually congenital. It is characterised by wild wriggling and twisting movements of all the limbs, chiefly on attempted voluntary movements, and by grimacing of the face, together with spastic rigidity of the affected muscles (see Figs. 48 and 49). There is generally a certain degree of mental deficiency. In this disease articulation is often affected. The grimaces of the face and of the tongue muscles interfere con-

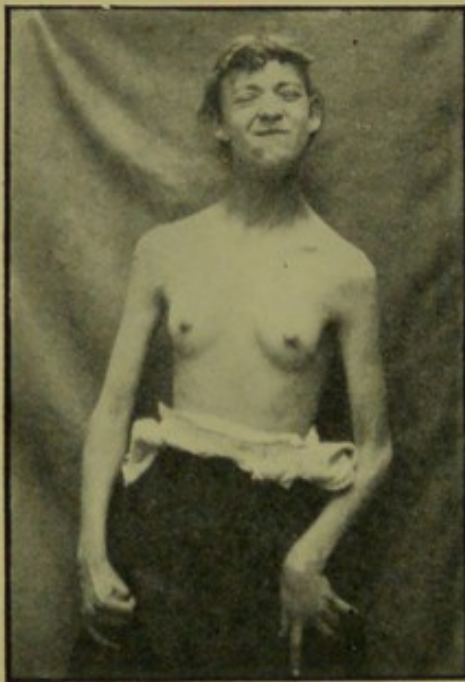


FIG. 48.

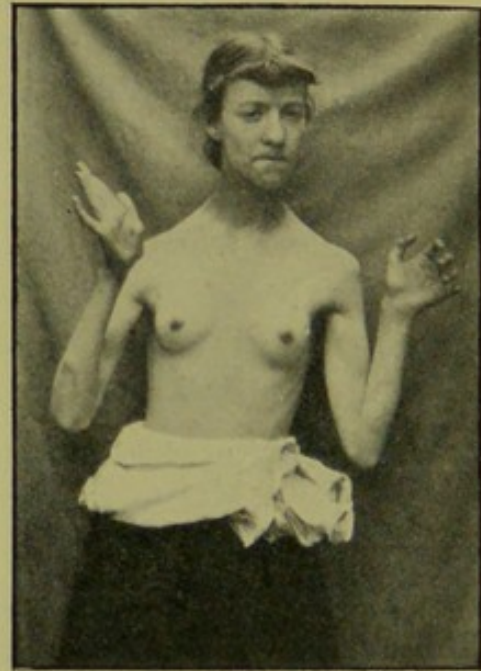

FIG. 49.

Figs. 48 and 49.—Double athetosis in a girl of 17. The patient was a 7½ months' child. She had also signs of stenosis of the pulmonary artery.

siderably with articulation. Moreover, irregular spasmodic contractions of the diaphragm and other respiratory muscles give the voice a curiously jerky or groaning character, due to sudden interruptions of breathing.

Patients suffering from *disseminated sclerosis* frequently have a peculiar so-called "staccato" speech, in which the words are enunciated in a jerky mincing fashion, very difficult to describe, but easy to recognise once it has been heard. This is sometimes called the "scanning" speech, from its fancied resemblance to the scansion of Latin or Greek verse.



In *paralysis agitans*, as the disease advances, the patient's voice becomes thin, feeble and reduced almost to a monotone, whilst his articulation, like his gait, acquires a "festinant" character. When speaking, he begins slowly, but towards the ends of sentences or long words he tends to hurry, so that the final syllables are pronounced hastily. Together with this we have the characteristic "starched," expressionless face, the Parkinsonian mask, commencing unilaterally and ultimately becoming bilateral.

Severe cases of *chorea* may have the articulation interfered with, owing to sudden violent movements of the face, tongue, and respiratory muscles. Speech becomes hesitating and jerky, and in very bad cases the voice may be reduced to a whisper.

There are also affections of articulation due to functional cortical disturbances. Of these the most familiar is **stammering**, which consists in a want of co-ordination between the vocal (laryngeal) and consonantal (oral) mechanisms of speech, so that, in the common type, the patient sticks at a consonant, which he often continues to repeat, over and over again, before he finally succeeds in enunciating the rest of the word. He misdirects his energy on the consonants, instead of touching them lightly and passing on to the vowel sounds. Most stammerers lose their stammer when they sing, their attention being then directed to the vocal part of speech.

A rarer variety of stammering is that in which the patient sticks at initial vowels. This is due to temporary spasm of the false vocal cords, and the patient remains with his mouth wide open until the spasm relaxes, when his words suddenly rush forth in a hurried stream until he has no breath left. He then takes another breath and the precipitate rush again occurs.<sup>1</sup>

Many stammerers acquire various tricks, chiefly through their efforts to overcome the stammer. Thus extra noises may be thrown

<sup>1</sup> Cathcart has pointed out that this variety of stammering is described in Shakespeare's "As You Like It" (Act iii. Scene 2) as follows:—

"I would thou couldst stammer, that thou mightst pour out this concealed man out of thy mouth, as wine comes out of a narrow-necked bottle, either too much at once, or none at all. I prithee, take the cork out of thy mouth that I may drink thy tidings."



in, *e.g.* sudden inspiratory grunting or whooping noises, or the patient may make grimaces or curious contortions of the limbs.

This leads us to recall the various *articulative tics* or habit-spasms which are met with in psychasthenic patients, either in conjunction with stammering or independently of it, and these may be of the most varied character. The patient's speech may be interrupted by weird pharyngeal barking or grunting noises. Or the articulation may be monosyllabic, a whole breath being taken for each syllable. Or, again, it may be jumbled up in the most extraordinary ways, though the "tiqueur" usually interpolates, now and then, a clearly articulated sentence or phrase amongst the other unintelligible ones. Hysterical aphonia is fairly common, and can usually be recognised by the history, together with the characteristic laryngeal appearances. We also meet with cases of hysterical mutism, where the patient does not utter even a whispered word.

**Deaf-mutes** are the patients who are popularly known as "deaf and dumb." A normal child learns to speak by imitating words which he hears, but if a child be congenitally deaf, he does not learn to speak, but remains deaf and dumb. Moreover, if he is born with normal hearing, but subsequently becomes deaf, *e.g.* from middle ear disease or from meningitis, should this occur before the age of about six years, he usually loses his power of speech. Deaf-mutes can generally be taught to speak again by the oral or "lip-reading" method, where the child imitates the movements of his teacher's muscles of articulation and also learns to phonate, though usually with a harsh, discordant voice. But even deaf-mutes who have never been taught to speak usually make noises of some sort or other, often pharyngeal snorts and grunts, or spluttering labial noises, and less frequently laryngeal sounds. They do this especially when excited. This was the case with a deaf-mute who used to make weird snorting noises when playing football. These doubtless helped to smite terror into the hearts of the opposite side. The congenital deaf-mute is usually brighter and more clever than the acquired deaf-mute. Deaf-mutes generally have a wonderful command of gestures and signs.



The dumbness which is present in profound degrees of idiocy is not an articulative difficulty, but a true speech affection due to mal-development of the cortical speech-centres. An imbecile child is speechless because he has no ideas to express; in this respect he differs from the deaf-mute, who is often bright and intelligent.

Certain varieties of deficient articulation are met with in children or in adults who are mentally more or less childish. The condition known as *lalling* consists in a want of precision in the pronunciation of certain consonants. Thus a patient may substitute the uvular R for the ordinary linguo-palatal R, or he may substitute V for Th or W for R, so that "broken reed" becomes "bwokeu weed." Or, again, the patient may substitute Th for S and is then said to *lisp*. These last two varieties are sometimes voluntarily assumed, as a fashionable affectation, by young men not overburdened with brain power. More serious varieties of *lalling* are where the letter L is replaced by some other consonant, so that "elephant" may be pronounced as "edephant," "esephant," "enephant," "erephant," &c. Still worse is it when the patient has difficulty with K or G, their places being taken by T and D respectively.

As a general rule, it may be stated that *lalling* on a single consonant does not necessarily indicate defective intellect, whereas *lalling* on many consonants, if the patient has passed the age of childhood, should arouse the suspicion of mental deficiency, although *lalling* is a normal stage in the process of learning to speak.

Finally, there is the condition known as *idioglossia*, where from difficulty in pronouncing his consonants a child retains the correct vowels, but substitutes other consonants and seems to speak a new language of his own. In the course of time the child usually completely outgrows this weakness.



## CHAPTER IX

### CRANIAL NERVES

THE recognition of cranial nerve palsies is, diagnostically, of the utmost importance, nor is it a matter of such difficulty as is commonly imagined.

**First, or Olfactory Nerves.**—From the under surface of the olfactory bulb on each side there arise some twenty minute nerves which perforate the cribriform plate of the ethmoid to be distributed to the upper part of the nose. To test the sense of smell, we direct the patient to close his eyes. We then hold aromatic substances, such as oil of cloves, peppermint, or asafoetida, in front of each nostril in turn, closing the other nostril with the finger. Ammonia or acetic acid must not be used to test the sense of smell, since these stimulate the fifth nerve (common sensation), and may produce a pungent sensation in the nose, even when the sense of smell is lost.

*Anosmia*, or loss of the sense of smell, is sometimes of diagnostic value. It may occur, for example, in congenital absence of the olfactory nerves, in some frontal tumours, in lesions of the olfactory bulb or olfactory tract, in injuries of the anterior fossa of the skull, and when there is atrophy of the olfactory nerves in tabes. It also occurs unilaterally very often in hysterical hemiplegia and is then associated with diminution of the other special senses on the hemiplegic side. But the value of anosmia as a symptom is lessened by the fact that numerous local obstructive conditions in the nose also produce loss of smell, *e.g.* nasal polypi or even a simple cold in the head.

*Parosmia*, or perverted sense of smell, is always cortical in origin. Various subjective *hallucinations of smell* occur not only in mental disease but also in gross lesions of the uncinate gyrus, which is the cortical olfactory centre. But here again local nasal



conditions may also cause olfactory sensations, *e.g.* the unpleasant odour perceived by a patient suffering from empyema of the antrum of Highmore, from which horribly offensive pus is escaping into the nose. On the other hand, in ozæna from chronic atrophic rhinitis the offensive smell is not perceived by the patient, though it is painfully evident to his neighbours.

Paroxysmal parosmia, preceded by a disagreeable feeling of irritation at the root of the nose, and sometimes followed by violent sneezing and by sudden secretion of nasal mucus, may occur as a *nasal crisis* in tabes.<sup>1</sup>

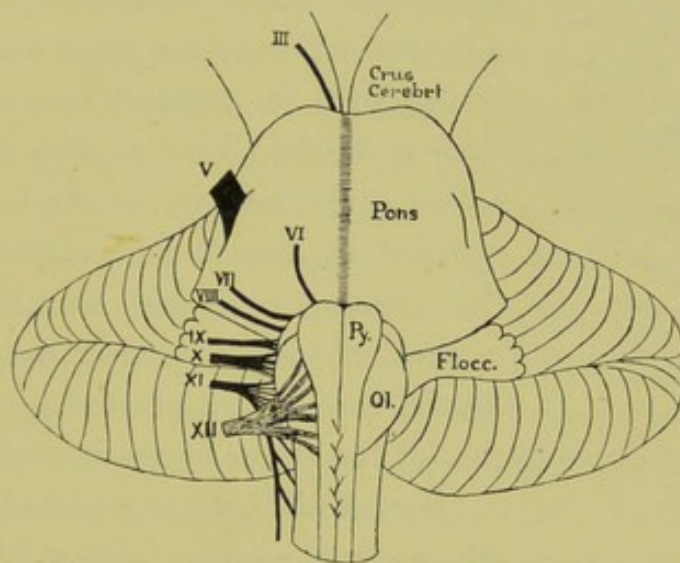


FIG. 50.—Diagram of pons and medulla, showing cranial nerves.

**Second, or Optic Nerve.**—This contains not only visual fibres, but also the afferent fibres or the pupillary reflex.

We have already referred to the course of the visual path from retina to cortex (Fig. 23, p. 38). In testing vision we should determine *visual acuity* by means of test types at a fixed distance, such as six metres. Using Snellen's types, of which the largest should be readable at sixty metres, and the smallest at six metres, we direct the patient to read the letters from above downwards. If his vision is normal he will be able to read the smallest type at six metres. His visual acuity is then represented as  $V = \frac{6}{6}$ . But if he can only read down as far as the type which ought to be visible at thirty metres, then  $V = \frac{6}{30}$ . Each eye should be tested separately,

<sup>1</sup> Klippel and Lhermitte, *Semaine Médicale*, Feb. 17, 1909.



the test types being well illuminated and the patient standing with his back to the light. When the visual acuity is much impaired, the patient may not see even the largest type, but can only count fingers at a short distance, or perhaps can only tell light from darkness. Temporary diminution of visual acuity may occur in myasthenia gravis.<sup>1</sup>

*Hemeralopia*, or day-blindness, is a condition in which the power of vision is bad during the day or in a bright light, whilst the patient sees better in a dim light. The phenomenon is not uncommon in tobacco amblyopia, where there is usually present a central scotoma for green and red. The hemeralopia is probably due to the fact that a bright light rapidly fatigues the retina and also, by producing pupillary contraction, causes the peripheral part of the retina to be less in use than the central, whereas in a dim light the pupil dilates and the unaffected peripheral portion of the retina comes into play.

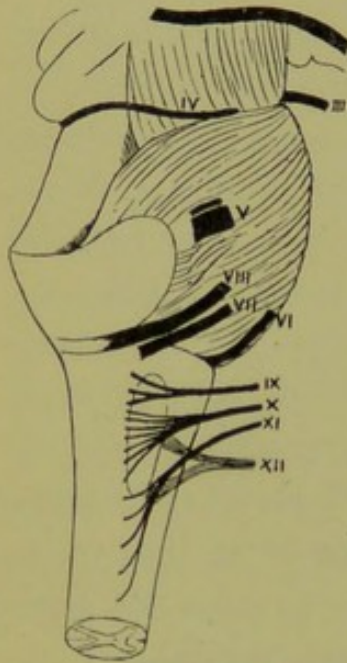


FIG. 51.—Lateral view of brain-stem with cranial nerves.

*Nyctalopia*, or night-blindness, where the patient becomes almost blind at dusk or in a dim light, is associated with various conditions, of which the most interesting is congenital *retinitis pigmentosa*, a disease easily recognised on ophthalmoscopic examination. It also occurs to a lesser degree in certain cases of "cortical" cataract, where the lenticular opacity acts as a permanent diaphragm.

*Colour vision* is most conveniently tested by means of Holmgren's wools. These are thrown on a table well lit by daylight, and the patient is given one particular test-skein of wool which is kept separate from the heap, and told, not to name the colour, but to match it, selecting from the heap of coloured skeins all those which are like the test-skein, whether lighter or darker in shade. The

<sup>1</sup> Tilney and Mitchell Smith, *Neurographs*, 1911, vol. i. p. 178.



patient is given a pale green test-skein. If his colour vision is normal, he will pick out all the pale greens correctly, but if he is red-green colour-blind he will select a grey or straw-coloured skein. Congenital red-green colour-blindness is the commonest variety. Yellow-blue colour-blindness is less common. If a patient be totally colour-blind he will confuse with the test-skein all those of similar brightness, no matter what their colour may be.

The size of the *field of vision* in each eye is of great importance, and for its accurate measurement a perimeter is required. This, however, is a large and expensive apparatus. For clinical purposes the following method is sufficient, presuming that the physician's own visual fields are normal. The physician sits exactly opposite the patient, about a yard away from him, and tests each eye separately. To test the patient's *right* eye direct him to cover up his left and to gaze steadily at the physician's left eye. Meanwhile the physician closes his own right eye and looks steadily at the patient's pupil, watching that the patient's eye does not wander from the fixation point. Then, holding his own left hand in a plane midway between himself and the patient, and beginning almost at arm's-length, he brings his hand inwards from the patient's ear towards the middle line, meanwhile moving his own fingers. If the patient's visual field is normal, he will catch sight of the moving fingers at the same time that the physician does so. If he does not, that visual field is contracted and the physician then brings his moving fingers inwards until the patient does catch sight of them. In this way we test both the upper and lower quadrants of the field on the temporal and nasal sides, in turn. If we find the visual field diminished in one or other eye, it is well to take a careful perimetric chart.

We may find a *central scotoma* or blind patch in one or both visual fields. This is detected by attaching a small white object to the end of a thin rod and holding it in the centre of the visual field, midway between one's own and the patient's eye. In this situation it is not seen by the patient. We gradually move the white object radially outwards in various directions until the patient catches sight of it. Central scotoma may occur in various



organic diseases of the optic nerve or retina, such as early optic atrophy, central retinal hæmorrhage, &c., or it may result, in a minor degree, from obstruction to central vision, *e.g.* by central opacities in the lens or cornea. It may also occur, as a temporary phenomenon, in some cases of migraine. Such conditions are easy

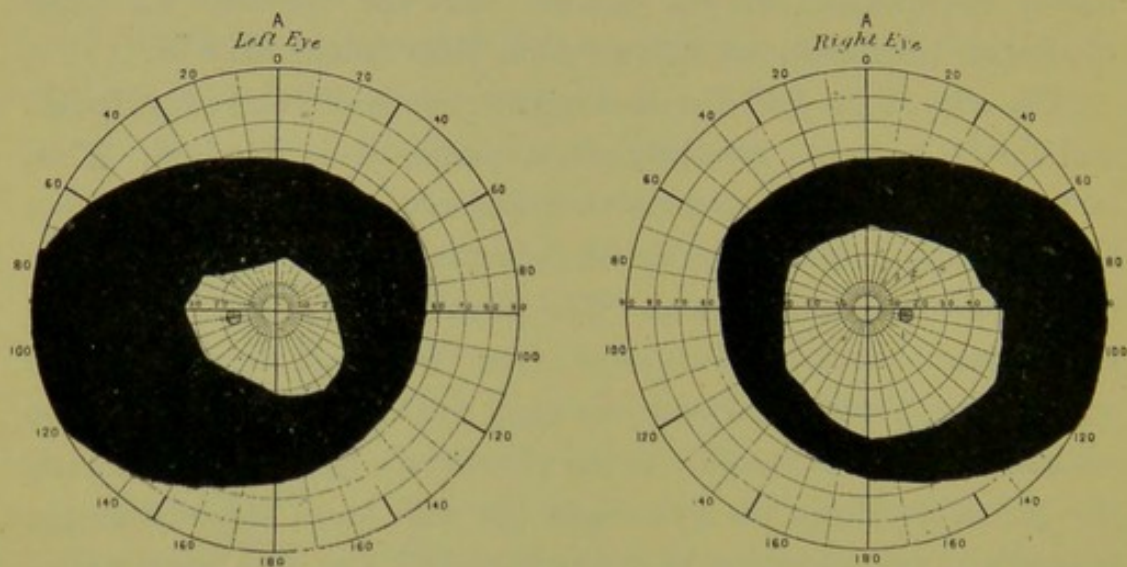


FIG. 52.—Crossed amblyopia, in a case of hysteria.

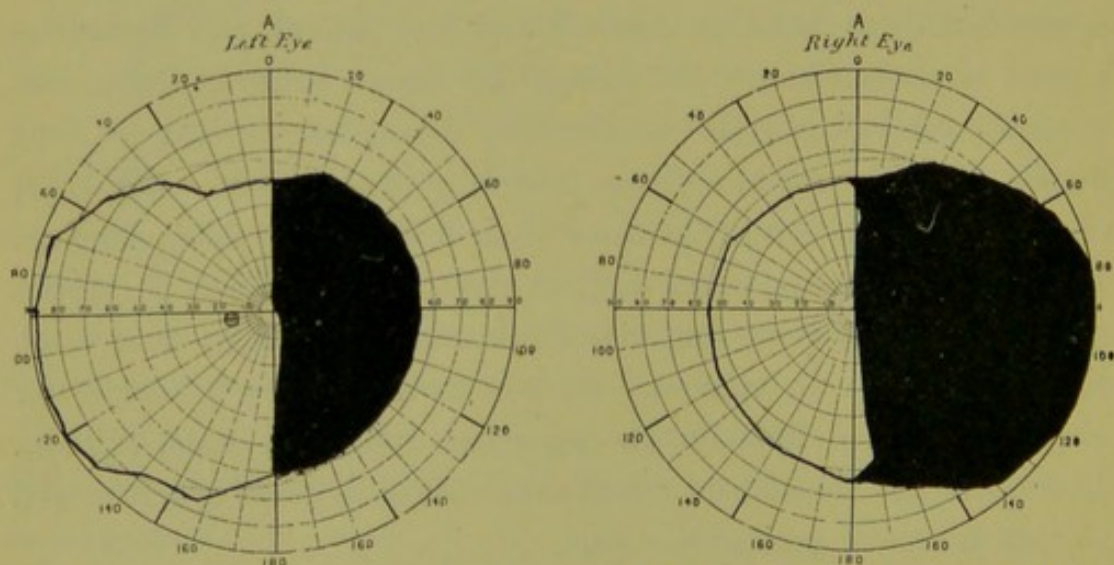


FIG. 53.—Right homonymous hemianopia, in a case of softening of the left occipital lobe.

of recognition. Central colour scotoma to red and green (detected in a similar fashion with coloured objects) together with deficient visual acuity, is highly suggestive of *tobacco amblyopia*. In such cases, besides a history of chronic excess in tobacco, we look for corroborative signs such as fine tremor of the hands, cardiac



irregularity, cardiac pain, &c. An almost identical amblyopia may also occur from chronic *alcoholism*.

The visual field may be *concentrically contracted*. This condition is sometimes due to optic atrophy, the field being reduced to a small area surrounding the fixation-point, so that the patient looks at the outer world as though through a narrow tube. More commonly concentric contraction of the visual field occurs in hysteria, the field on the hemiplegic side of the body being more contracted than that on the other side (Fig. 52). Temporary contraction of the visual field may occur in myasthenia gravis. Less frequently a cortical lesion of the angular gyrus, not implicating the subjacent optic radiation (Fig. 23), causes a similar concentric contraction of both fields, more marked in the eye of the side opposite to that of the brain lesion. This is somewhat clumsily named *crossed amblyopia*, but, as previously observed, it is much commoner in hysteria than in organic brain disease, and in hysteria it is frequently associated with diminution or loss of other special senses on the side of the more contracted field whose colour sense is frequently lost (achromatopsia). Hysterical amblyopia is unknown to the patient, and is only discovered on examination by the physician.

*Hemianopia* (Fig. 53) means blindness of half the visual field, right or left as the case may be, from causes other than retinal disease. It usually affects the visual field of both eyes, and is due to a lesion of the visual fibres at or behind the *optic chiasma*. Such chiasmic lesions may result from pressure by tumours, syphilitic or inflammatory affections of the basi-sphenoid, from tumours of the brain or of its membranes, and especially from pituitary tumours, as in acromegaly. We have already considered the signs of lesions of the optic tracts, and it is convenient here to recall the effects of lesions of the *optic chiasma*.

(A) If the lesion be in the central part of the chiasma, interrupting the decussating optic fibres (belonging to the nasal halves of both retinae), there is blindness in the outer half of each visual field:—*bi-temporal hemianopia* (Fig. 54). This sometimes occurs in pituitary tumours.



(B) If the lesion be situated at one or other lateral extremity of the chiasma, it will interrupt merely the non-decussating fibres of the optic nerve and optic tract on that side, causing *unilateral nasal hemianopia* in the corresponding eye. To produce bilateral nasal hemianopia there must be two separate lesions, one at each end of the chiasma, a condition which very seldom occurs. A lesion involving the central part of the chiasma and extending to one or other side (Fig. 54, A *plus* B) will produce the sum of these two, namely *bi-temporal hemianopia plus unilateral nasal hemi-*

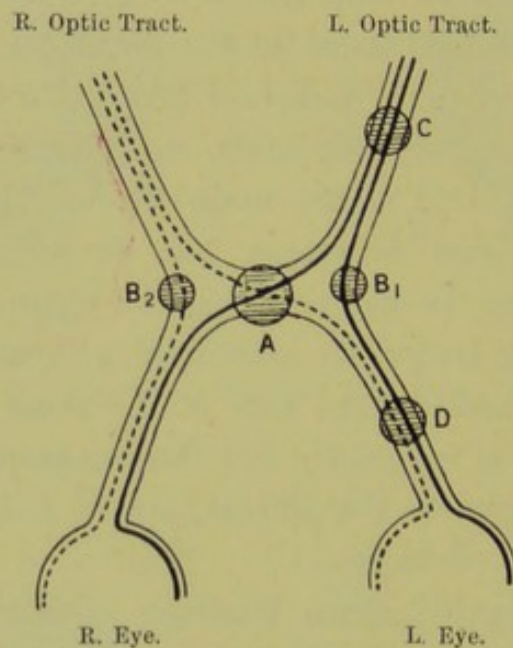


FIG. 54.—Diagram of course of visual fibres in optic chiasma. (Hamilton.)

anopia, *i.e.* total blindness of one eye with temporal hemianopia of the other.

(C) A lesion of the left optic tract behind the chiasma produces, as already seen, hemianopia in the right halves of both fields of vision.

(D) A lesion of one optic nerve simply causes blindness in the corresponding eye.

In rare cases we may have a *quadrantic hemianopia* in which only one quadrant (instead of one-half) of both visual fields is blind. This is generally due to a lesion limited to part of the cortical half-vision centre in the cuneate lobule and lingual gyrus. The calcarine fissure divides the half-vision centre into an upper and a lower part.



A lesion above the calcarine fissure, *i.e.* in the cuneate lobule, causes blindness of the lower quadrant, whilst a lesion below the calcarine fissure, *i.e.* in the lingual gyrus, causes blindness of the upper quadrant of the corresponding half-fields.<sup>1</sup>

The optic discs and retinae should be examined with the ophthalmoscope in every case of nervous disease. The most important conditions to look for are optic neuritis and optic atrophy. *Optic neuritis* occurs in numerous pathological conditions within the skull, especially in intra-cranial tumours and in tuberculous meningitis. But it also occurs in nephritis, in lead poisoning, in diabetes, and in severe anæmia ; and these four common conditions must always be excluded before we diagnose gross intra-cranial disease. We may also meet with optic neuritis in certain cases of cervical myelitis. *Optic atrophy* may occur primarily, as in tabes and disseminated sclerosis, or it may be a secondary post-neuritic process. Sometimes it follows a *retro-bulbar neuritis*, whether occurring spontaneously, or in disseminated sclerosis, or in chronic alcohol or tobacco poisoning. Pallor of the temporal halves of the optic discs is often an early sign of disseminated sclerosis. The combination of optic atrophy, blindness, and mental deficiency occurs in the *amaurotic family idiocy* of Tay and Sachs, an affection of certain Jewish children, coming on in infancy. In these cases, on ophthalmoscopic examination there is a characteristic cherry-red spot seen at the macula lutea, due to local œdema and atrophy of the retina, whereby the vascular choroid shines through. Apart from optic neuritis and optic atrophy, we must be on the lookout for other pathological conditions of the fundus, such as choroiditis, albuminuric retinitis, tubercle of the choroid, occlusion of the central retinal artery, retinal hæmorrhage, &c.

It must be remembered that a patient may have severe optic neuritis without any impairment of vision. Optic atrophy, on the other hand, causes the visual field to contract concentrically to a greater or less extent, whilst the visual acuity diminishes and ultimately the eye becomes blind. The atrophy of retro-bulbar

<sup>1</sup> Henschen, *Le Centre cortical de la Vision*. Internat. Med. Congress, Paris, 1900.



neuritis often produces central scotoma from affection of the papillo-macular bundle of optic nerve fibres. Scotoma is often the first sign of retro-bulbar neuritis, long before atrophy is visible by the ophthalmoscope.

**Third, Fourth, and Sixth Nerves.**—It is convenient to study together these three nerves which, between them, innervate all the voluntary muscles of the eye. The distribution of each is as follows:—The *third* nerve (oculo-motorius) supplies all the external ocular muscles except two:—the superior oblique supplied by the fourth nerve, and the external rectus supplied by the sixth. It also supplies the voluntary part of the levator palpebræ superioris (the involuntary part being supplied by the cervical sympathetic), and it contains fibres which indirectly, through the ciliary ganglion and short ciliary nerves, supply the non-striated sphincter pupillæ and ciliary muscle. The *fourth* nerve (patheticus) supplies the superior oblique alone, the *sixth* nerve (abducens) the external rectus alone.

Until comparatively recently, the motor nucleus for the pupil was generally considered to be located in the third nucleus, and in a special part of it near its anterior end (the so-called Edinger-Westphal nuclei, situated close to the middle line, one on each side, consisting of small nerve cells embedded amongst the larger cells of the oculomotor nucleus). To explain the occurrence of loss of the light-reflex various theoretical lesions were assumed, sometimes in these Edinger-Westphal nuclei (Bernheimer<sup>1</sup>), sometimes in Meynert's fibres leading from the anterior corpora quadrigemina to the supposed pupillary centre in the third nucleus. But against the first of these theories, cases have been recorded of tumour of the mid-brain completely destroying the oculomotor nuclei and so producing ophthalmoplegia externa, and yet the pupillary reflex still remained (Biancone,<sup>2</sup> Jacobsen<sup>3</sup>). Moreover, total ophthalmoplegia, internal and external, has occurred without any affection of the Edinger-Westphal nuclei (Monakow<sup>4</sup>). Further, degeneration of Meynert's fibres has not been demonstrated, even in cases of tabes or

<sup>1</sup> v. Graefe's *Archiv*, 1897.

<sup>2</sup> *Rivista di Freniatria*, 1899.

<sup>3</sup> *Deutsche Med. Wochensch.*, 1900.

<sup>4</sup> *Gehirn-pathologie*, 4te Aufl. 1905, s. 1053.



general paralysis where loss of the pupillary light-reflex is one of the commonest clinical phenomena. Lastly, experimental and clinical evidence (Piltz,<sup>1</sup> Bach<sup>2</sup>) has shown that the *ciliary ganglion* is the peripheral motor nucleus controlling the sphincter pupillæ, and Marina,<sup>3</sup> in a series of twenty-eight cases of tabes and general paralysis exhibiting the Argyll-Robertson pupil, found this ganglion invariably degenerated. In one of them where the Argyll-Robertson phenomenon was confined to one eye, the ciliary

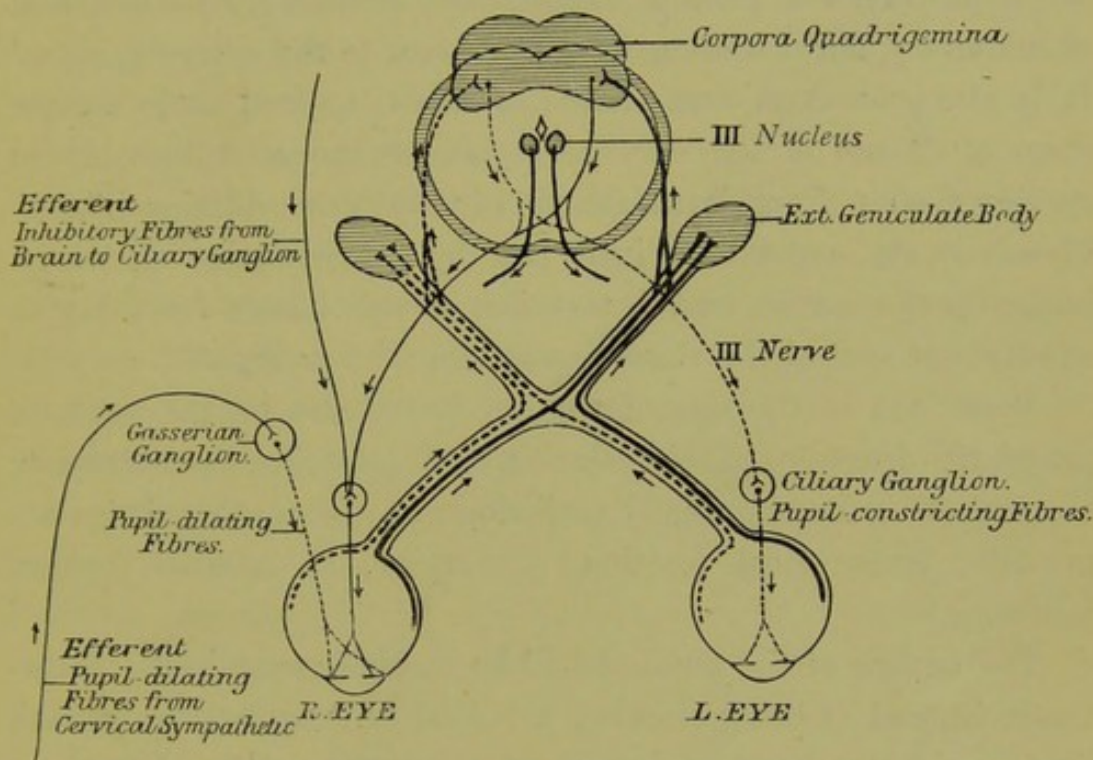


FIG. 55.—Diagram of the path of the pupil-reflex (modified from Bach).

ganglion was degenerated on that side alone, the ganglion of the other side being normal. It is therefore probable that degeneration renders the ciliary ganglion inexcitable to the stimulus of light, whereas it can still respond to the stronger stimulus of voluntary impulses transmitted along the third nerve. The connection between the anterior corpus quadrigeminum and the third nerves is *viâ* the fasciculus sublongitudinalis.<sup>4</sup>

**The Pupil.**—We note the size of the pupil, both in a bright and in a dim light, and we observe whether the pupils are equal in

<sup>1</sup> *Neurologisches Centralblatt*, 1903.    <sup>2</sup> *Zeitsch. für Augenhil. und e.*, 1904.

<sup>3</sup> *Annali di Neurologia*, 1901.

<sup>4</sup> Majano, *Monatschrift für Psychiatrie und Neurologie*, 1903, Bd. xiii. Heft 1.



diameter. Abnormal dilatation of the pupil (*mydriasis*) is often present in anæmia and neurasthenia, but it may occur, on one or both sides, in organic nervous disease. Mydriasis may be either paralytic, from paralysis of the sphincter pupillæ, as in disease of the third nerve or ciliary ganglion, or it may be irritative, as when due to stimulation of the dilator pupillæ. It also occurs when optic atrophy has caused blindness, and is then due to the absence of visual impressions. *Myosis* or abnormal contraction of the pupil occurs in pontine hæmorrhage, probably from irritation of inhibitory fibres leading from the brain to the ciliary ganglia.<sup>1</sup> It is also present in many cases of tabes, as well as in certain cases of disease of the cervical region of the cord (notably in syringomyelia) from interruption of the pupil-dilating fibres.<sup>2</sup> Myosis is also caused by iritis and by the irritation of foreign bodies in the cornea, and a transient myosis occurs for a day or so after excision of the Gasserian ganglion<sup>3</sup> (see Fig. 55).

Variations in the size of the pupil may also be the result of mydriatic drugs, either locally instilled (atropine, homatropine, cocaine) or taken internally (belladonna), whilst other drugs are myotics, either local (eserine, pilocarpine) or internal (opium, jaborandi).

The outline of the pupil should be carefully examined. Sometimes, instead of being circular, it is oval or irregularly polygonal. Such variations have an important diagnostic value. For if we exclude congenital malformation such as coloboma, operative procedures such as iridectomy, and disease such as iritis and synechiæ, then it may be taken as a general rule that irregularity of the pupils signifies either tabes, general paralysis, or old syphilis, the lesion being either in the short ciliary nerves or in the ciliary ganglion itself. *Ectopia pupillæ* is a condition in which the pupil is not in the centre of the iris. Sometimes it occurs in lesions of the mid-brain;<sup>4</sup> in other cases, however, it appears to have no pathological significance. Irregularity of the pupil can be pro-

<sup>1</sup> Bach, *Zeitschrift für Augenheilkunde*, 1904, s. 105.

<sup>2</sup> See later, *Cervical Sympathetic*, p. 335. <sup>3</sup> H. M. Davies, *Brain*, 1907, p. 265.

<sup>4</sup> S. A. K. Wilson, *Brain*, 1906, p. 524.



duced experimentally by stimulation or division of the short ciliary nerves. Each eye must be tested separately, noting the effect on the pupil of shading and uncovering, first the same eye and then the opposite eye.

The *pupillary reflex to light* should always be observed. Normally the iris contracts when light falls on the retina, whether of the same eye (direct reflex) or of the opposite eye (consensual reflex). The light-reflex depends upon the integrity of a reflex arc, whose afferent limb is the peri-macular fibres of the retina and optic nerve, whose intermediate station is in the mid-brain and whose efferent limb passes through the third nerve and ciliary ganglion to the pupillary sphincter (Fig. 55).

If the healthy pupil be strongly illuminated and examined with a magnifying lens (say  $\times 10$ ), we observe that it is not stationary but in a continuous state of fine irregular movement, slight alternate narrowing and widening, varying both in rhythm and amplitude. This normal *pupillary unrest*<sup>1</sup> must not be confounded with *hippus*, which is a pathological condition consisting in rhythmic clonic contractions of the iris, regular in their periodicity, much coarser in range, and visible to the naked eye. Loss of the normal pupillary unrest is always pathological, and may be one of the earliest signs of organic affection of the reflex visual path, *e.g.* in tabes or general paralysis.

Loss of reaction to light occurs in optic atrophy, in paralysis of the third nerve, and in degeneration of the ciliary ganglion. Loss of the light-reflex with preservation of contraction during accommodation for near objects—the classic *Argyll - Robertson phenomenon*—occurs typically in tabes and in general paralysis of the insane. Marina has shown this to be associated with degeneration of the ciliary ganglion. It also occurs in blindness from optic atrophy. In the early stages of optic atrophy the pupil of the affected eye may contract to light fairly well for a moment, but under continued exposure it dilates again, unlike a healthy pupil.<sup>2</sup> If this phenomenon be associated with diminution of

<sup>1</sup> Hübner, *Archiv für Psychiatrie*, 1906, Band 41, s. 1016.

<sup>2</sup> Gunn, *Brit. Med. Journal*, 1907, p. 353.



visual acuity or with failure to distinguish between red and green in the centre of the visual field, we should be suspicious of early optic atrophy (even though the optic disc be normal in appearance), which in many cases is due to commencing disseminated sclerosis. *Wernicke's hemiopic pupillary reaction*, in certain cases of hemianopia, is absence of pupillary contraction when a ray of light is thrown on the blind side of the retina. It signifies a lesion of the visual path behind the chiasma, and below or at the corpora quadrigemina. In retro-quadrigeminal hemianopia, where the lesion is anywhere between the corpora quadrigemina and the visual cortex, the pupillary reaction is normal (Fig. 23, p. 38).

The *reaction of the pupil to accommodation* is the contraction of the pupil which occurs when the patient converges the eyes to look at a near object. We test this by holding a finger close to the patient's face, first telling him to look at some distant object, and then suddenly to look at the finger. If he is blind, he can nevertheless converge by attempting to look at his own finger. In paralysis of the third nerve there is total immobility of the corresponding pupil, both to light and on convergence. Loss of the contraction on accommodation with preservation of the light-reflex—a condition the converse of the Argyll-Robertson phenomenon—is not uncommon after diphtheria, and is often accompanied by other evidences of post-diphtheritic neuritis, such as paralysis of external ocular muscles or of the palate, loss of knee-jerks, &c. *Paradoxical pupillary reaction* is when the pupil dilates instead of contracting on accommodation. This phenomenon, which is not uncommon in tabes (occurring, according to Pilez, in 40 per cent. of cases), can be demonstrated in two ways. Firstly, energetic voluntary closure of the eye produces a synergic contraction of the pupil, which dilates again when the eye is re-exposed to light. Secondly, if we tell the patient to depress the upper lid whilst we forcibly prevent it from descending, we see the pupil contract, whilst the eye moves upwards and outwards to get under cover of the upper lid. The *reaction of the pupil to painful stimulation* of the skin of the neck, causing the pupil to dilate, is important with regard to the cervical sympathetic.



It is often absent in the early stages of tabes. A *psychical dilatation* of the pupil also occurs, temporarily, under the influence of lively emotion, such as fear, intense interest, sexual orgasm, &c. The pupil may even contract or dilate when the individual thinks of a dark object or a luminous one.

Let us now consider **paralysis of external ocular muscles.**

To detect paralysis of the ocular muscles, having first examined the pupils, noting their size and any irregularity of outline, and having tested their reaction to light and on accommodation, we then ask the patient to follow our finger with his eye, making him look alternately up, down, to the right and left, and making him

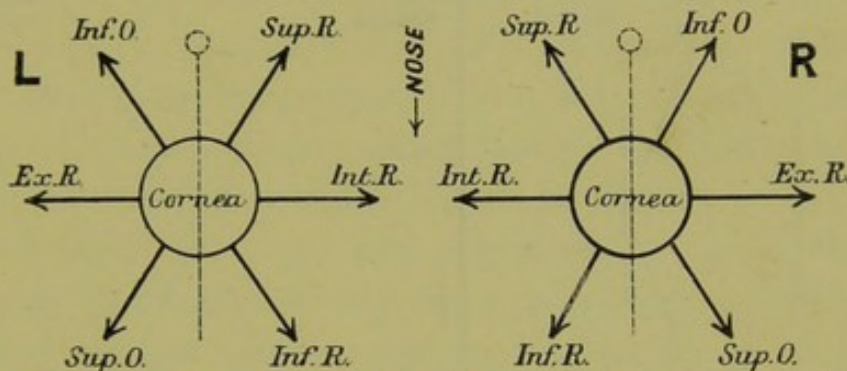


FIG. 56.—N. Bishop Harman's chart to show (1) *Movements of ocular muscles*, and (2) *Position of false image* in paralysis.

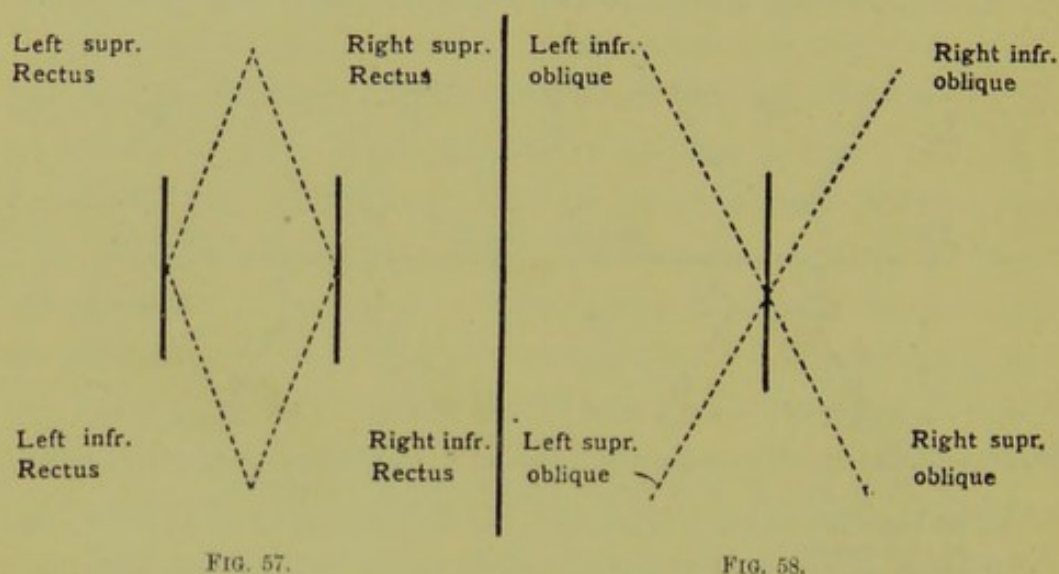
1. (a) Rectangular movements. The arrows point to the direction in which the eye is turned by each muscle.
- (b) Rotation. Put a match, head upwards, on each of the dotted lines indicating the vertical meridians. Muscles that rotate eye inwards turn the match-head towards nose (Sup. Rectus and Sup. Oblique); those that rotate it outwards turn match in the opposite direction (Inf. Oblique and Inf. Rectus).
2. Put matches on diagram again. The match will represent the true image. The four rays marked Sup. R., Inf. R., Sup. O., and Inf. O. will represent the relative position (in vertical and lateral displacement and tilting) of the false image produced in paralysis of each of these muscles. In paralysis of Int. or Ext. Rectus the false image will run vertically through the corresponding arrow-head.

converge. Meanwhile we observe whether there be any squint, deficient movement in any direction, diplopia, or nystagmus.

If an individual muscle is paralysed, there is diplopia, squint, and deficiency of movement of the affected eye towards the direction of traction of the affected muscle. Fig. 56 is Bishop Harman's diagram indicating the action of the individual muscles. A simple rule, worth remembering in all cases of ocular paralysis, is that the affected eye is displaced (by the unopposed antagonists) in a direction opposite to the direction of traction of the paralysed muscle, whilst the false image, seen by the affected eye, is displaced in the direction



of traction of the paralysed muscle. Figs. 57 and 58 are Werner's well-known "memoria technica," showing the position of the false image in the various ocular paralyses. Fig. 57 shows the position of the false image in paralysis of any of the recti; Fig. 58 in paralysis of the oblique muscles. For example, Fig. 57 shows that in diplopia from paralysis of the left inferior rectus, (1) the false image is on the right of the true (*i.e.* it is crossed); (2) the false image has its upper end inclined towards the true; (3) the false image is lower than the true; and (4) the diplopia occurs on downward movement of the eyes. To test diplopia we



Figs. 57 and 58.—Werner's "artificial memory" for the double images in ocular paralyses (*Ophthalmic Review*, 1886). Fig. 57 shows the position of the images in paralysis of the recti muscles. Fig. 58 in paralysis of the oblique muscles. The dotted lines indicate "false" images, the thick black lines "true" images.

use a long, lighted candle, at a distance of about three yards from the patient, holding it, first, exactly opposite the patient and moving it gradually from side to side and then from above downwards. One of the patient's eyes is covered with a red and the other with a green glass, to differentiate the two images, and the patient has to tell us the relative position of the red and of the green candle. It is necessary to ensure that the patient keeps his head fixed during the process of testing. The false image is that seen by the paralysed eye, the true image by the sound one.

Diplopia is a more delicate test than paralytic squint, for where



there is slight paresis of an ocular muscle there may be no noticeable squint, and yet the diplopia may be quite appreciable to the patient. To detect a paralytic squint we direct the patient to follow our finger, moving it laterally from side to side, and then vertically up and down, and observe whether there is deficiency of movement of one or both eyes in any particular direction or directions.

**Nystagmus** is an involuntary rhythmic tremor of the eyeballs, generally bilateral and symmetrical. The movement consists of an oscillation usually horizontal, from side to side, but sometimes vertical or even rotatory. Nystagmus may be either *oscillating* (where the movements to both sides are equal in range and of equal speed) or *rhythmic*, the commoner type, where both movements are equal in range but the one is fast and the other slow. In most cases nystagmus occurs only when the eyes are voluntarily moved to an extreme degree either laterally or, less commonly, vertically; in rhythmic horizontal nystagmus the rapid jerk is to the side towards which the eyes are directed. But sometimes, especially in the rotatory variety, nystagmus occurs when the eyes are directed straight forward. In cases where an ocular muscle has been paralysed but is in process of recovery, if we make the patient look steadily in a direction which necessitates the active movement of the formerly paralysed muscle, slight rhythmic nystagmus may develop, analogous to tremulousness of the hand after carrying a heavy weight. Nystagmus occurs in various organic diseases, notably in disseminated sclerosis, Friedreich's ataxia and cerebellar disease. It is present also in certain patients who have become more or less blind (though in complete blindness the movement is more often a slow rolling of the eyes), also in albinism, and a well-recognised form is miner's nystagmus, due to persistent ocular strain in a dim light. Miner's nystagmus is oscillating, generally vertical and accompanied by spasm of the levator palpebræ.

Another variety is *aural* or *vestibular nystagmus*. This, together with violent vertigo, may be produced experimentally in healthy subjects by syringing the drum of the ear with water, either distinctly above or distinctly below the temperature of the body.



Bárány<sup>1</sup> regards this nystagmus as a result of convection currents in the endolymph produced by warming or cooling of the labyrinth. The presence of such thermic nystagmus can be used as a test of the integrity of the vestibular nerve. The objective phenomena vary according to the position of the patient's head. Thus, for example, if the patient be standing up, with the head turned face downwards, and if the left ear be irrigated with cold water, the nystagmus which is produced is horizontal in type with the quick jerk to the left and most marked when the patient looks towards the left side. Meanwhile the head and eyes, and even the trunk, tend to rotate strongly, around the long axis of the body, towards the right side. If the patient's head be erect when his left ear is syringed with cold water, the nystagmus is rotatory in type and to the right, and the forced movement of the head and trunk is a lateral bending towards the left side. If hot water be used instead of cold, the direction of nystagmus and of forced movement of the head, eyes, and trunk is in each case reversed.<sup>2</sup>

There is also a rare congenital affection known as *nystagmus-myoclonus*, in which, together with nystagmus, commonly of the lateral oscillating variety, there are involuntary jerking movements of the limbs or trunk. These movements are aggravated by cold or by tapping the muscles, but can be controlled by an effort of will. The deep reflexes are often exaggerated, and it is not unusual to have other co-existing deformities, such as hypospadias, flat-foot, facial asymmetry, persistent branchial cleft, &c.<sup>3</sup>

Nystagmus can be produced in a normal person by placing him on a rotating stool and spinning him rapidly around the long axis of his own body; in such a case, if the stool be suddenly stopped, a temporary after-nystagmus appears, horizontal and rhythmic, the rapid phase of the nystagmus being in the opposite direction from the previous rotation. If a patient who already has a horizontal nystagmus be similarly revolved around his own long axis, on suddenly stopping the rotation we find that the original nystagmus towards the direction of rotation has temporarily ceased whilst that in the opposite direction is exaggerated.<sup>4</sup> In such a case, the experimental after-nystagmus has for the time over-compensated the pre-existing nystagmus.

<sup>1</sup> *Centralblatt für Augenheilkunde*, August 1905.

<sup>2</sup> Scott, *Lancet*, June 11, 1910.

<sup>3</sup> Lenoble and Aubineau, *Revue de Médecine*, July 16, 1906.

<sup>4</sup> Cassirer and Loeser, *Neurologisches Centralblatt*, 1908, s. 252.



We are now in a position to recognise the signs of paralysis of any of the ocular nerves. In a case of complete **third nerve paralysis** (Figs. 59 and 60) there is ptosis or drooping of the upper lid, from paralysis of the levator palpebræ, with over-action of the frontalis on that side, so that the eyebrow stands higher than normal. In hysterical ptosis (Fig. 61), on the other hand, there is no over-action of the frontalis, nor is there in the ptosis of myasthenia gravis, where the frontalis is usually partially paralysed as well. In third nerve paralysis there is also external strabismus from unopposed action of the external rectus, and there is inability



FIG. 59.

FIG. 60.

Fig. 59.—Total paralysis of right third nerve from syphilitic disease.

Fig. 60.—The same patient, the right eyelid being passively lifted to show the external strabismus and dilatation of pupil on the paralysed side.

to move the eye upwards, directly downwards, or directly inwards, although a slight downward and inward movement can be executed by the superior oblique. The pupil is dilated owing to paralysis of the sphincter iridis, and does not contract either to light or on attempted accommodation. Complete paralysis of the third nerve is less common than is a partial paralysis, affecting one or more muscles. Weakness of the internal recti sometimes occurs in exophthalmic goitre (constituting *Moebius's sign*). We make the patient look upwards to the ceiling and then ask him to look at the tip of his



own nose, when we observe that only one eye converges, the other eye becoming divergent.

**Paralysis of the Fourth Nerve** produces paralysis of the superior oblique muscle of the corresponding eye. This muscle

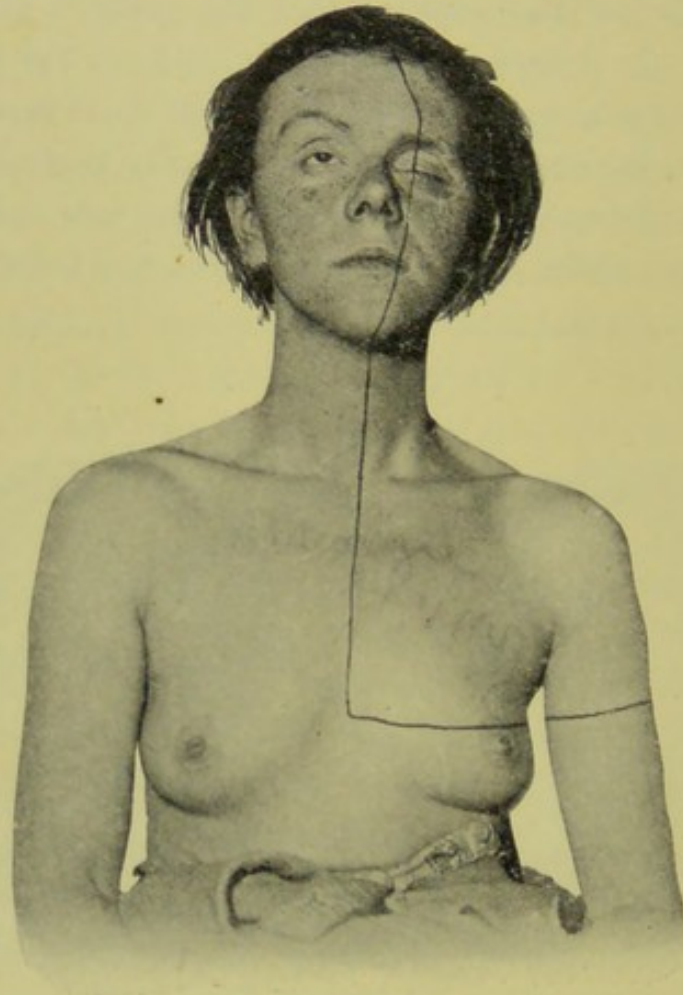


FIG. 61.—Case of left-sided *hysterical ptosis* in a woman of 25, showing absence of frontalis over-action on paralysed side. The area on the left side of the head, neck, trunk and shoulder, within the black line, was totally anæsthetic to all forms of stimuli. There was loss of smell and taste on the left side: contraction of the left visual field and diminution of hearing in the left ear. The figure also shows the presence of “dermographism.” The patient’s name having been traced on the chest with the head of a pin, a hard, cord-like pattern was produced, capable of being photographed.

has a threefold action: it turns the anterior pole of the eye downwards and outwards and at the same time rotates its vertical meridian slightly inwards (see Fig. 56). The deficiency of movement is difficult to see, and the paralysis is recognised mainly by the characteristic diplopia which occurs when the patient gazes in the direction in which the superior oblique ought to come



into action, *i.e.* downwards and outwards. When the patient looks horizontally forwards or upwards there is no diplopia. But when he looks downwards and outwards, diplopia appears, the false image standing lower than the true, and having its upper end tilted towards the other (Fig. 58). The false image also appears to the patient nearer to him than the true, the reason for which is obscure. Moreover the patient feels giddy, especially when he looks downwards, as in walking downstairs, and he habitually inclines his head forward and towards the sound side.

**Paralysis of the Sixth Nerve** is particularly easy to recognise.



FIG. 62.



FIG. 62A.

Case of paralysis of the left sixth nerve, of six weeks' duration, in a girl of 20, the subject of juvenile tabes.

Fig. 62 shows the normal movement of both eyes on looking to the right. Fig. 62A shows attempted movement of eyes to the left. The left eye is arrested at the mid-position.

There is merely paralysis of the external rectus, with inability to turn the eye outwards beyond the mid-point, all other movements being normal (Figs. 62 and 62A), and there is diplopia on looking outwards. In old cases in which contraction of the non-paralysed internal rectus has supervened, an internal strabismus results.

Sometimes an external ocular muscle is attacked by rheumatic myositis, which causes an ocular palsy of benign form. The muscle most frequently thus affected is the external rectus.

Ocular paralyses differ in type according as they are due to a supra-nuclear lesion (between the second frontal gyrus and the ocular nuclei), a nuclear lesion in the mid-brain, or an infra-nuclear lesion of the individual nerves such as we have just described.

Ocular paralysis from a supra-nuclear lesion never attacks a



single ocular muscle or even a single eye. On the contrary, associated muscles of both eyes are affected. The common type of paralysis from a destructive lesion at or above the internal capsule is one in which the patient loses the power of turning both eyes towards the contra-lateral side. Therefore the unopposed antagonists draw both eyes over towards the side of the lesion; this is called *conjugate deviation*. In certain cases of conjugate deviation, although the patient can no longer turn his eyes voluntarily to one side, say the right, he can do so reflexly by fixing some object directly in front with his eyes, this object being then moved towards the right or the patient's head being passively rotated to the left.<sup>1</sup> Curiously enough, conjugate deviation upwards or downwards does not occur from a paralytic lesion of the internal capsule, unless a bilateral lesion is present. In supra-nuclear lesions *reflex nystagmus* is still preserved. Bárány<sup>2</sup> has shown that reflex nystagmus can be produced in normal individuals in two ways. Firstly, there is *optic nystagmus*, produced by making the patient watch a rapidly-moving landscape when looking out of the window of a railway carriage, or by making him watch a series of vertical bars on a horizontally revolving cylinder. Secondly, there is *vestibular nystagmus*, produced either by rapid rotation of the individual on a revolving chair (rotation to the right producing horizontal nystagmus to the left and *vice versa*), or by syringing the ear with cold water, stimulation of the right ear producing nystagmus, partly horizontal but mainly rotatory, to the left and *vice versa* (see above, p. 134). If the vestibular nerve be diseased, reflex vestibular nystagmus is abolished.<sup>2</sup>

*Skew deviation* of the eyes occurs in certain lesions of the lateral lobe of the cerebellum or of its middle peduncle. Thus in a woman with a fatal hæmorrhage in the right half of the cerebellum and pons, the right eye was directed downwards and inwards, and the left eye upwards and outwards.

A nuclear lesion of the third, fourth, or sixth nuclei in the floor of the Sylvian aqueduct may be partial or complete, and the type

<sup>1</sup> Bielschowsky, *Münchener medizinische Wochenschrift*, 1903, s. 1666.

<sup>2</sup> Bárány, *ibid.*, 1907, s. 1072.



of ocular palsy which results is called **nuclear ophthalmoplegia**. In some cases the fibres for the ciliary ganglia or the ganglia themselves or short ciliary nerves to the internal ocular muscles (iris and ciliary muscle) are alone affected, and not the external muscles of the globe. The result is *ophthalmoplegia interna*, in which the pupils are dilated and immobile both to light and on convergence. This condition may be unilateral or bilateral, according as the ciliary ganglia or short ciliary nerves are affected on one or both sides. It often occurs as a transient result of post-diphtheritic neuritis. *Ophthalmoplegia externa* is a nuclear disease of the Sylvian aqueduct affecting numerous external ocular muscles, generally of both eyes and often symmetrically. A fairly common type is where the power of upward rotation of the eyes is lost, lateral movements being still possible. *Ophthalmoplegia externa* usually occurs alone, less commonly it is associated with the internal variety. When both varieties are combined we have *total ophthalmoplegia*, in which the eyes are fixed and motionless, the pupils being immobile, both varieties of reflex nystagmus (optic and vestibular) being lost, and the patient can look in any particular direction only by facing his head that way *en bloc*. Nuclear ophthalmoplegia, especially external ophthalmoplegia, may be associated with motor paralysis of the limbs if the lesion extends ventrally and implicates one or other pyramidal tract, or it may be associated with involuntary tremors if the lesion affects the red nucleus or rubrospinal tract (Fig. 15, p. 23).

Sometimes it is possible to differentiate between a nuclear and an infra-nuclear ocular lesion. In the case of *paralysis of the sixth nucleus* in the pons, there is not merely weakness of the external rectus of the same side, as in paralysis of the sixth nerve trunk, but in addition the internal rectus of the opposite eye is paralysed, so that conjugate movement of both eyes towards the affected side is impaired. The weakness of the contra-lateral internal rectus is only in connection with its associated movement with the external rectus of the ipso-lateral eye. This is proved by the fact that, in paralysis limited to the sixth nucleus, both internal recti can still act normally during convergence. Again,



since the facial motor root loops round the sixth nucleus within the pons, a lesion of the sixth nucleus is not infrequently accompanied by facial paralysis on the same side. The sixth nucleus is essentially an oculo-gyre centre, turning both eyes to the corresponding side, and therefore controlling not only the external rectus of the ipso-lateral side, but also the internal rectus of the contra-lateral side.

With regard to the diagnosis between nuclear and infra-nuclear paralysis of the third nerve, if in a doubtful case the orbicularis oculi is found to be affected together with the external ocular muscles, then the lesion is in the region of the nucleus, since the orbicularis is innervated by a group of cells which are in anatomical proximity to the oculomotor nucleus (but which really belong to the facial).

Mendel's theory<sup>1</sup> assumed that these cells belonged to the oculomotor nucleus and reached the orbicularis through the facial, but Bishop Harman<sup>2</sup> has shown that all the facial muscles, from orbicularis oculi downwards, are innervated from the group of cells comprising the facial nucleus, the upper end of this group extending as high as the oculomotor, and the lower end reaching to the level of the hypoglossal.

Sometimes transient ocular palsy affects the third nerve in whole or in part, recurring in the same eye without apparent cause at intervals of weeks or months, and clearing up completely between the attacks. This condition, known as Charcot's *migraine ophthalmoplégique*, is generally associated with headache, most intense in the eye and forehead of the affected side, and with vomiting. Its pathology is obscure; probably some cases are due to an inflammatory affection of the meninges at the point where the third nerve pierces them to enter the sphenoidal fissure. This is all the more probable inasmuch as the first division of the fifth nerve, which traverses the sphenoidal fissure, is often simultaneously affected, with the result that there is blunting of sensation in its area of distribution.

Now and then we meet with *congenital ptosis*, in which there is paralysis of the superior rectus and levator palpebræ superioris

<sup>1</sup> *International Med. Congress, Washington, 1887, vol. 5, p. 311.*

<sup>2</sup> *Transactions of Ophthalmological Society, 1903, p. 356.*



of one eye. In some of these cases, although the patient cannot raise his upper lid voluntarily, yet, curiously enough, the lid is jerked up when certain jaw movements are made, particularly when the patient throws into action the external pterygoid muscle of the same side, in depressing the lower jaw towards the opposite side.

This so-called "jaw-winking" movement has been shown by Harman to be the survival of a movement in fishes whereby, when the mouth is opened for breathing or eating, the gill swings open. In man the pterygoid and orbicularis oculi muscles are homologous

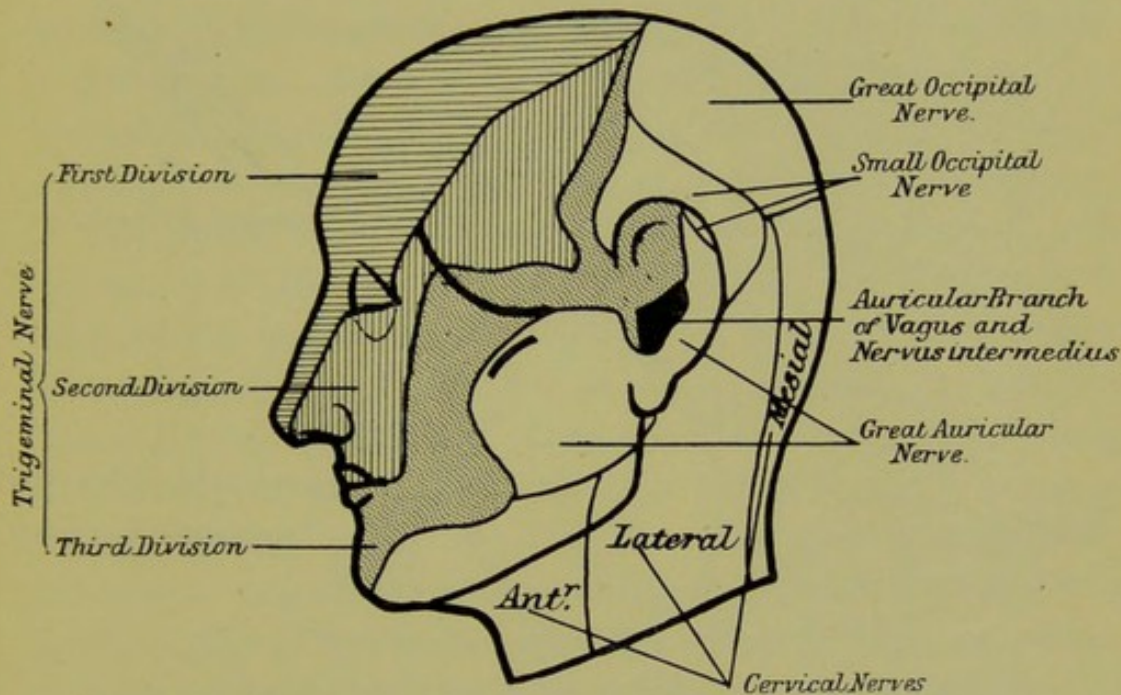


FIG. 63.—Cutaneous supply of head (modified from Frohse).

with the deep and superficial muscles of the branchial arch of the fish's spiracle, and when the one is contracted the other tends to relax and "the weak levator, taking advantage of the quiescence of its too powerful opponent, lifts the eyelid."

Jaw-winking movements generally disappear before adult life.

The **Fifth** or **Trigeminal Nerve** has a most extensive distribution, the main points of which are as follows:—The nerve consists of two distinct parts, sensory and motor. The sensory root, the one on which is the Gasserian ganglion, divides below the ganglion into three divisions, of which the first two are entirely sensory. The motor root courses beneath the Gasserian ganglion,



and then joins the third division, which thus becomes a mixed nerve.

The *first or ophthalmic division* passes through the sphenoidal fissure into the orbit and supplies the eyeball and lachrymal gland, the conjunctiva (except that of the lower lid), the skin of the forehead and scalp up to the vertex (Fig. 63), the mesial part of the skin of the nose, and the mucous membrane of the upper part of the nasal cavity. It also contains efferent pupil-dilating fibres

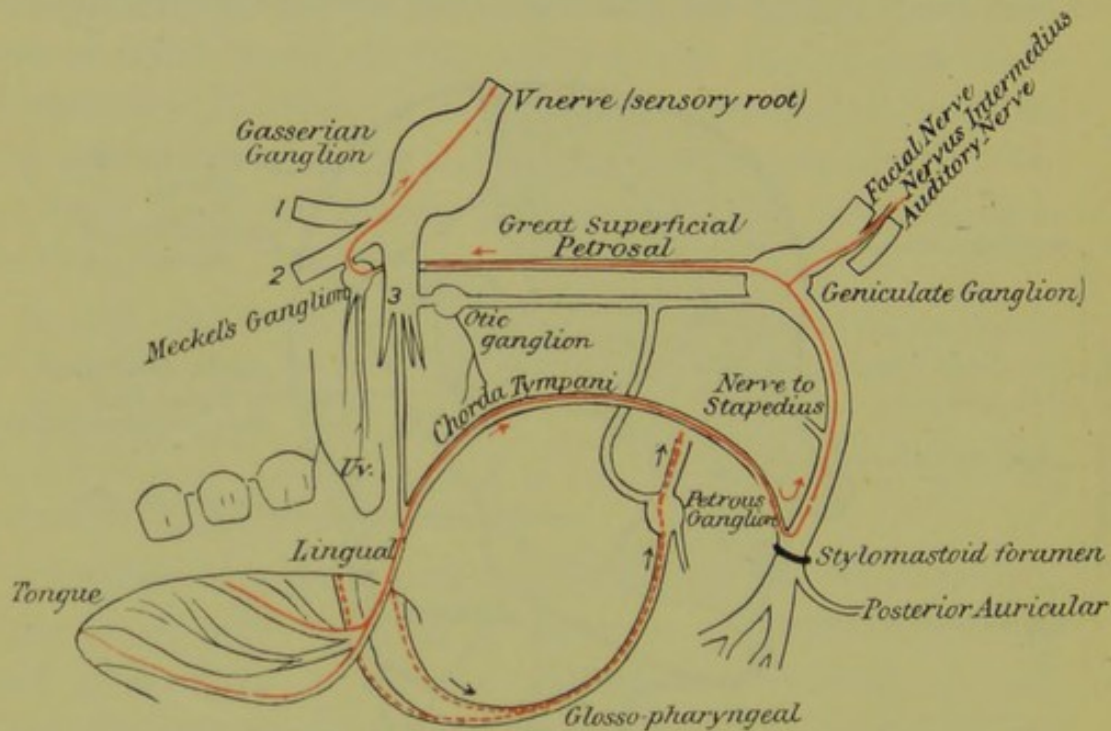


FIG. 64.—Diagram of trigeminal, facial, and glosso-pharyngeal nerves, showing course of taste fibres.

derived from the cervical sympathetic, joining it at the Gasserian ganglion, and going to the iris (Fig. 55).

The *second or superior maxillary division* passes through the foramen rotundum across the speno-maxillary fossa to the infra-orbital canal. In the speno-maxillary fossa it is connected with Meckel's ganglion, which gives off amongst other branches the Vidian nerve. This latter runs backwards to join the facial nerve, the posterior end of the Vidian being named the great superficial petrosal (Fig. 64). The superior maxillary division supplies the skin of the upper lip, the side of the nose and adjacent part of the cheek, the lower eyelid and part of the temple. It also supplies the



conjunctiva of the lower lid, the upper teeth, the mucous membrane of the upper lip, the upper part of the cheek, upper jaw, uvula, tonsil, naso-pharynx, middle ear and lower part of nasal cavity. It also contains some taste fibres to which we shall refer presently.

The *third or inferior maxillary division* is a mixed nerve. It emerges through the foramen ovale. The motor fibres supply the masseter, temporal, and both pterygoid muscles, also the tensor tympani, mylo-hyoid and anterior belly of the digastric. The sensory fibres supply the skin of the posterior part of the temple and adjacent part of the pinna, the anterior and upper wall of the external auditory meatus, as far as and including the anterior part of the drum, part of the cheek, the lower lip and chin, also the lower teeth and gums, the tongue (as far back as the circumvallate papillæ), floor of mouth, inner surface of cheek, and salivary glands.

The **Course of the Taste Fibres** is a complicated one and still much disputed<sup>1</sup> (Fig. 64). Those for the anterior two-thirds of the tongue are contained in the lingual nerve—a branch of the third division. But they do not run straight up from the lingual into the fifth nerve. They leave the lingual, course along the chorda tympani, and reach the facial within the Fallopian aqueduct. They run in the facial as far as the geniculate ganglion, where some pass off along the great superficial petrosal to Meckel's ganglion, ultimately rejoining the fifth nerve through its second division. Other taste fibres leave the geniculate ganglion to enter the nervus intermedius, passing thence to the glosso-pharyngeal nucleus.

The taste fibres for the posterior third of the tongue and the palate, which are supplied by the glosso-pharyngeal nerve, probably enter the brain through the glosso-pharyngeal. They do not join the fifth nerve, since division of the fifth nerve by the operation of removal of the Gasserian ganglion causes impairment of taste only in the anterior two-thirds of the tongue, and not constantly in that. Taste is not abolished in fifth nerve palsy, as was formerly thought, for in several cases of my own I have

<sup>1</sup> Cushing, *Johns Hopkins Hospital Bulletin*, 1903, Nos. 144-145. Davies, *Brain*, 1907, p. 219.



found that the patient, though unable to feel the contact of food or other objects on one side, still retained acute sense of taste at the back of the tongue.

To examine the sense of taste we direct the patient to protrude the tongue, and we rub on it various substances such as sugar, salt, quinine, and citric acid, preferably in white powders, which the patient cannot distinguish at sight one from the other. The patient must keep his tongue protruded throughout each test, and as

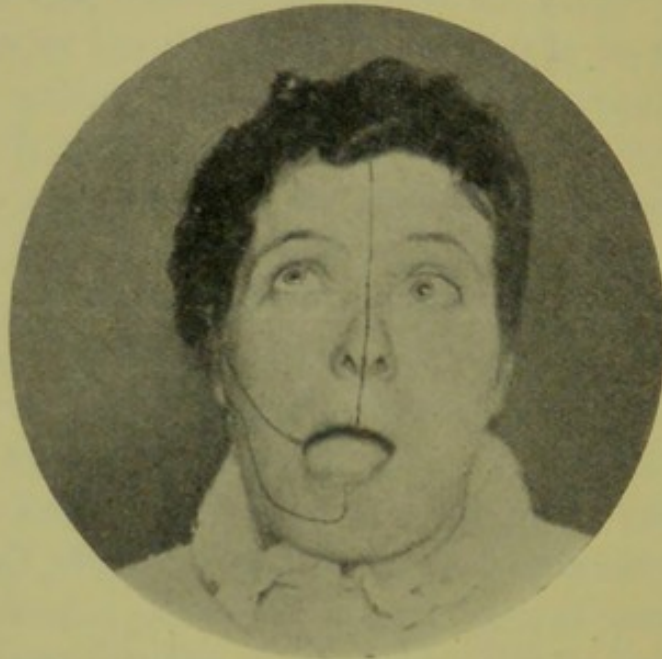

FIG. 65.—Paralysis of *Left third* and of *Right fifth* nerve. The patient is looking upwards and opening the jaw. Showing dilatation of pupil on left side with deficient upward movement of left eye. Also showing the deviation of the lower jaw towards the right side. The black line indicates area of anæsthesia on the right side of the face.

soon as he feels a taste he should make a sign and also determine in his mind what the taste is, before taking the tongue in. It is convenient to have a card with the following words printed on it:—"sweet," "sour," "bitter," "salt," "coppery." The patient can then point with his finger to indicate which taste he perceives. If he be allowed to pull the tongue in while waiting for the sensation to arrive, fallacies may occur owing to movements of the tongue and the flow of saliva carrying the substance to other parts. To map out exactly an area of loss of taste (*ageusia*) the most accurate method is to use a weak galvanic current with a wire electrode, which produces a coppery or metallic taste.



When the fifth nerve is totally paralysed there is anæsthesia of the corresponding half of the face and scalp, not extending as far as the angle of the jaw, this part being supplied by the cervical plexus (Fig. 63). The cornea and conjunctiva on the affected side are anæsthetic, and also the mucous membrane of the corresponding side of the nose, mouth, part of the soft palate and tongue, as far back as the circumvallate papillæ which, with the area behind, are innervated by the glosso-pharyngeal. This defect extends exactly to the middle line, and therefore the patient when drinking feels as if the cup were broken. Food tends to collect within the anæsthetic cheek, the buccinator muscle being anæsthetic, though its motor power is unaffected. Taste is impaired in the anterior two-thirds of the tongue, but does not remain totally lost. The trigeminal nerve has also sensory fibres for the facial muscles. Hence there is a degree of awkwardness and apparent weakness of the face—a pseudo-facial palsy, due to loss of the sense of active muscular contraction. All the muscles supplied by the motor root undergo atrophic paralysis and develop the electrical reactions of degeneration. There is hollowing of the temporal fossa above the zygoma, and wasting of the masseter below it, so that the zygoma becomes abnormally prominent. When the patient clenches his teeth, neither the temporal nor the masseter can be felt to harden as on the normal side, and when he opens his mouth the mandible is pushed over towards the paralysed side (Fig. 65). This is owing to paralysis of the external pterygoid, which fails to draw the condyle forwards on the affected side. The deflected mandible carries with it the tongue, but there is no real deviation of the tongue, when measured from the middle line of the lower incisors. It is stated that paralysis of the tensor tympani causes a difficulty in hearing notes of low pitch, but this is not easy to determine. Secretion of tears on the paralysed side is diminished, as is also the secretion of nasal mucus and of saliva. Consequently these mucous membranes become abnormally dry, and may show secondary trophic changes. Thus stimulation of the nasal mucous membrane by snuff no longer causes sneezing. Smell at first is unimpaired, but later, from



dryness and secondary trophic changes in the Schneiderian membrane, there may be anosmia in the affected nostril. The corneal and lachrymal reflexes are lost, also the palatal reflex, and the tongue on the paralysed side becomes excessively furred, probably because on the anæsthetic side there is deficient friction by food. The teeth on the paralysed side are anæsthetic and tend to drop out; this has been ascribed to a trophic change, but more probably it is mainly traumatic, the patient biting clumsily with

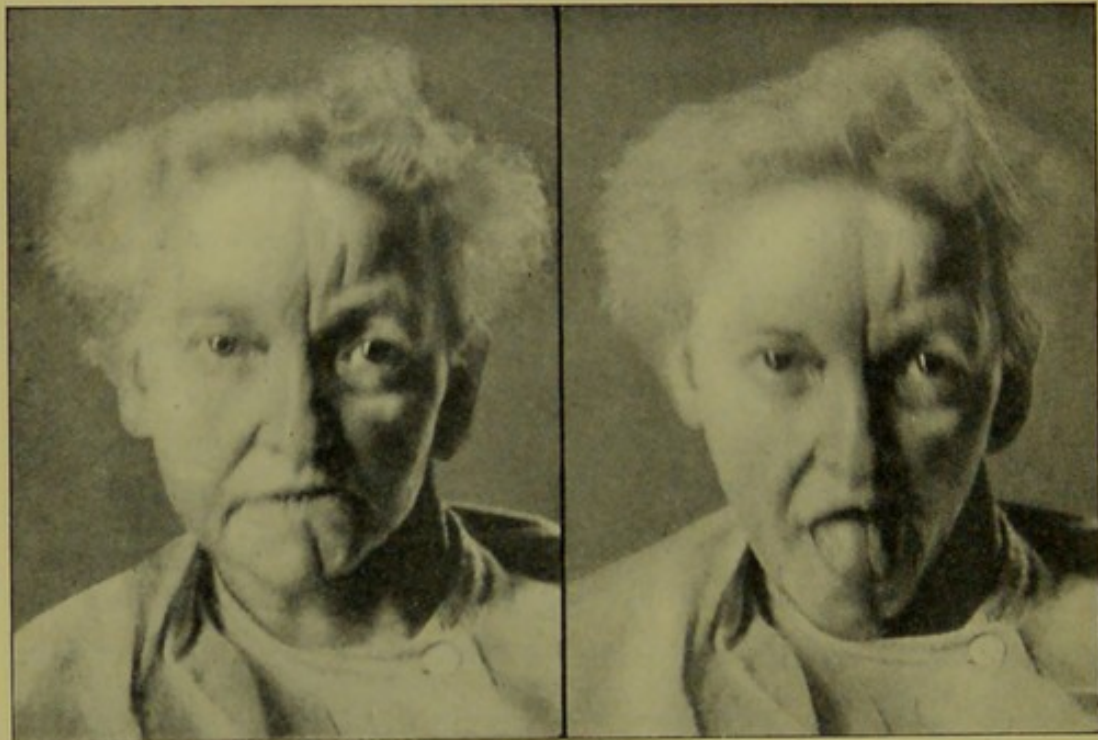

FIG. 66.

FIG. 67.

From a case of left-sided facial hemiatrophy. Showing atrophy of corresponding half of tongue.

his anæsthetic teeth. It used to be stated that neuro-paralytic keratitis occurred in total trigeminal palsy, owing to trophic changes. But this is not invariably so; when it does occur, it appears to be due to the presence of a special bacillus<sup>1</sup> in the anæsthetic eye, where, moreover, there is a deficiency of lachrymal secretion. Further, if the anæsthetic lids be kept closed by a suture, keratitis does not occur, even though the special bacillus be present.

There is another disease which occurs in the territory of the

<sup>1</sup> Davies and Hall, *British Medical Journal*, 1908, p. 72.



fifth nerve, viz., **progressive facial hemiatrophy**. This disease, which commences in early life—usually before puberty, and more often in females than in males—shows itself first in the skin of the face, either near the orbit or over the upper or lower jaw, gradually spreading over the whole face on one side. The skin becomes thinned from atrophy of its papillary layer, the subcutaneous fat disappears, and thus the affected side of the face becomes wrinkled and furrowed, in marked contrast with the healthy side. Later the subjacent muscles, cartilages, and bones become atrophic, but without motor paralysis or reaction of degeneration. The corresponding side of the tongue (Figs. 67 and 160), and occasionally that of the soft palate, also become wasted. But the hemi-atrophied tongue, when protruded, comes out straight, unlike that of a case of atrophy from hypoglossal palsy (Fig. 81, p. 170). The hair on the affected side of the face may fall out or become white, and the sebaceous glands may atrophy. The scalp is rarely affected. There is no anæsthesia.

The area of this disease corresponds accurately with that of the distribution of the fifth nerve, and in certain cases pathological changes have been found either in the nerve itself or in its nucleus of origin. Thus Mendel found signs of neuritis in the nerve, together with changes in the spinal root of the fifth within the medulla. More recently Loebel and Wiesel<sup>1</sup> found an interstitial neuritis of the Gasserian ganglion and of the parts distal to it. Removal of the Gasserian ganglion does not produce hemiatrophy. Facial hemiatrophy may also be a symptom of syringobulbia.

<sup>1</sup> *Deutsche Zeitschrift für Nervenheilkunde*, 1904, Bd. 27, s. 355.



## CHAPTER X

### CRANIAL NERVES (*continued*)

OF all the peripheral nerves in the body, cranial or spinal, the **Seventh** or **Facial nerve** is by far the most frequently paralysed, hence the importance of knowing its anatomical course and distribution. Like the trigeminal, it is a mixed nerve, possessing a motor root—the facial nerve proper, and a sensory root—the *nervus intermedius* of Wrisberg. These two roots meet at the geniculate ganglion.

Let us first consider the motor root. Arising from a nucleus situated mainly in the lower part of the pons, but some of whose cells (namely, those for the *orbicularis oculi*) extend as high as the nucleus of the third nerve, and others (namely, those for the *orbicularis oris*) are as low as the hypoglossal nucleus, the motor root of the facial pursues a tortuous course. Firstly, within the substance of the pons it forms a loop which hooks round the nucleus of the sixth nerve. Then, leaving the ventral surface of the brain-stem, it enters the internal auditory meatus, and passes along a winding bony canal in the temporal bone—the aqueduct of Fallopius. In the upper part of this canal it traverses a swelling, the *geniculate ganglion*, which is joined by the sensory root or *portio intermedia* of Wrisberg, also by the great superficial petrosal nerve from Meckel's ganglion, and by the small superficial petrosal from the otic ganglion (see Fig. 64). The geniculate ganglion is similar in structure to a posterior root ganglion and is sensory in function. Inflammation of this ganglion is accompanied by herpes of the external auditory canal and adjacent part of the auricle, exactly analogous to herpes zoster<sup>1</sup> (see Fig. 63, p. 141). Within the aqueduct the facial gives off a branch to the stapedius, and, lower down, the *chorda tympani* leaves it to join the lingual nerve. It then emerges from the skull through the stylo-mastoid foramen,

<sup>1</sup> J. Ramsay Hunt, *Journal of Nervous and Mental Diseases*, 1907, p. 73.



giving off a posterior auricular branch to the muscles of the pinna and to the occipital belly of the occipito-frontalis. The main trunk then divides into its terminal branches supplying all the muscles of the face (except the levator palpebræ superioris) from the frontalis above to the platysma below. It also supplies the stylo-hyoid and posterior belly of the digastric.

Although the facial nerve is largely motor, the geniculate ganglion is a sensory ganglion. The facial also contains certain secretory

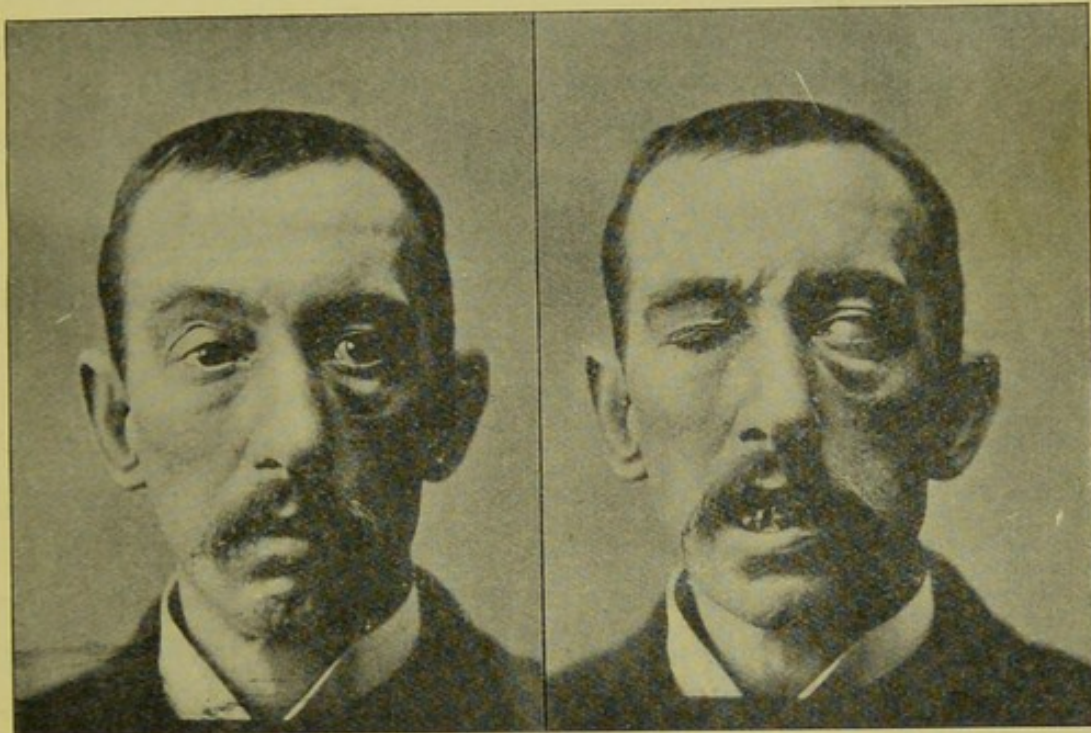

FIG. 68.

FIG. 69.

Case of left-sided facial palsy. Fig. 68 at rest. Fig. 69 on attempt to close eyes and retract angles of mouth.

fibres, whilst the taste-fibres of the chorda tympani accompany the motor portion of the nerve in part of its course. Thus lesions at different levels can be distinguished one from the other.

1. If the facial nerve is affected *after its exit from the stylo-mastoid foramen*, e.g. by cold, or by injuries or tumours in that region, the result (**Bell's Paralysis**) is complete palsy of that side of the face, which is therefore asymmetrical at rest, and the asymmetry is exaggerated on voluntary movement. The patient has neither emotional nor voluntary movement of the affected side (Figs. 68 and 69).



Voluntary movement of the integument by the platysma, as in forcible depression of the chin against resistance, is abolished on the

The furrows of the forehead are wiped out, and the patient cannot wrinkle the brow nor frown on that side. The eye is more widely open on the affected side and cannot be shut. The tears run down the cheek instead of into the lachrymal duct, and may produce excoriation of the skin or eczema. When the patient tries to shut the eye he merely rolls the eyeball upwards and outwards, or upwards and inwards, sometimes with a zig-zag movement, until the cornea passes under cover of the upper lid. An additional sign pointed out by Dutemps and Cestan<sup>1</sup> is as follows:—When the patient looks down and then attempts to shut both eyes slowly, the upper lid on the paralysed side is seen to move up a little, owing to contraction of the levator palpebræ, which normally acts synergically with the orbicularis but is now no longer antagonised by it.

This inability to close the eye allows the entrance of foreign bodies, and consequently conduces to conjunctivitis. The conjunctival reflex is abolished, and the regular involuntary blinking of health no longer occurs on the paralysed side. The eye brims over with tears, so that vision on the affected side is rendered less acute. Curiously enough, though the eye cannot be shut during waking hours, during sleep it often closes almost completely, probably from relaxation of the levator palpebræ.

The tip of the nose is drawn somewhat towards the sound side, the naso-labial fold on the affected side is flattened out, the ala nasi sinks in and shows no active movement, voluntary or respiratory, though it may flap passively during forcible nasal breathing. The mouth is drawn towards the sound side, but on the affected side its angle droops and saliva dribbles from it. When the patient smiles or shows the upper teeth, the healthy side moves alone; he cannot whistle, and the articulation of labial consonants is impaired. During mastication food accumulates between the teeth and the paralysed cheek. The patient often bites his cheek or lower lip, and during forcible blowing expiration the paralysed cheek flaps loosely.

<sup>1</sup> *Journal de Neurologie*, 1904, p. 48.



affected side. In those patients who were previously able to move the ear voluntarily, that power is also lost. All the paralysed muscles

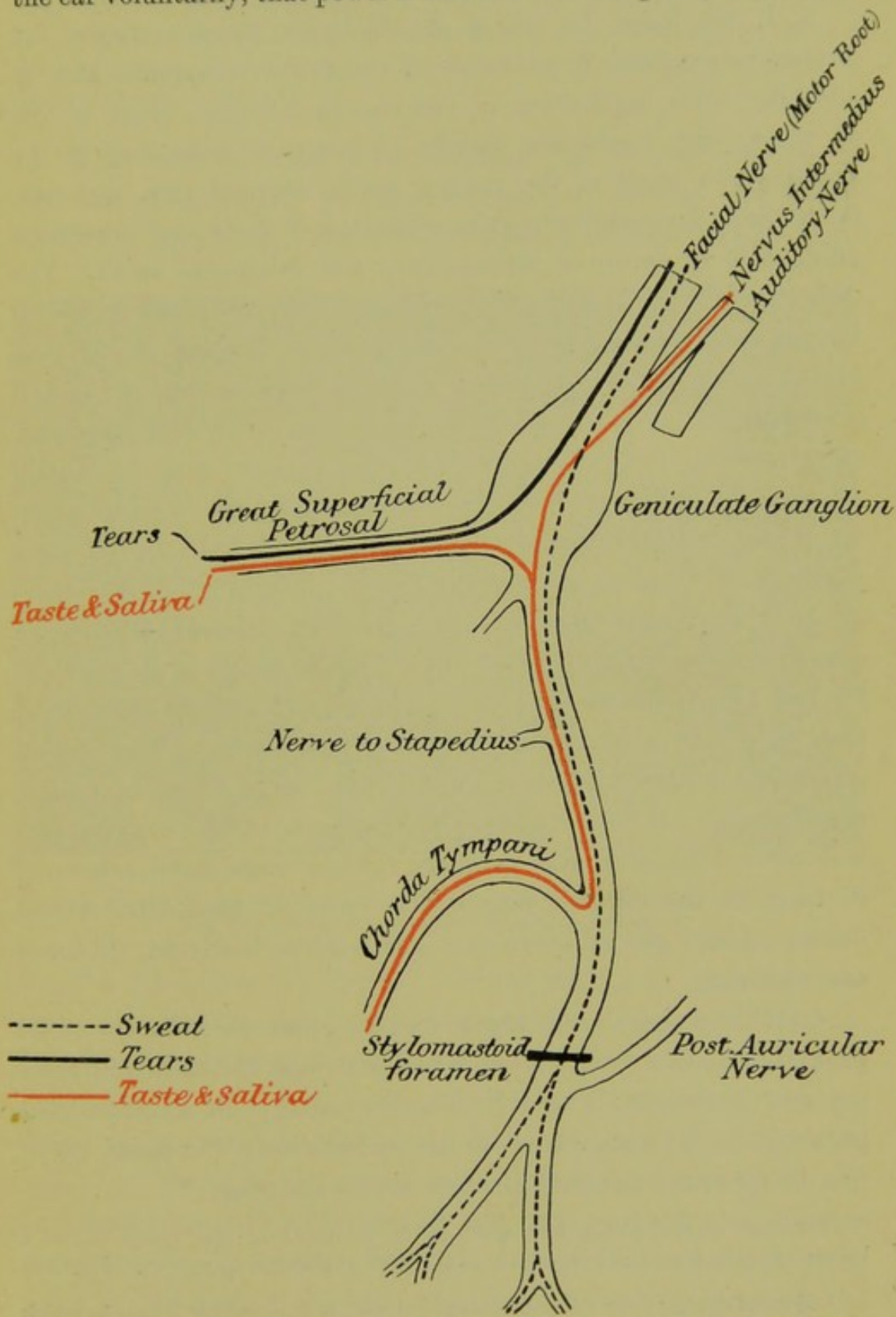


FIG. 70.—Diagram of Facial Nerve, showing course of secretory and of taste-fibres.



gradually develop the electrical reactions of degeneration. The affected side of the face generally sweats less than the healthy side.

2. If the lesion be *within the Fallopian aqueduct* below the geniculate ganglion, it produces all the above symptoms, and, in addition, from implication of the chorda tympani, there is loss of taste (and sometimes slightly of common sensation) in the anterior two-thirds of the tongue on the affected side, and also occasionally abnormal subjective sensations of taste, and sometimes diminution or excess of submaxillary and sublingual saliva. The deficiency of taste and of saliva may cause this part of the tongue to be abnormally furred up to the middle line. If there be paralysis of the nerve to the stapedius, there is *hyperacousis* or painful sensitiveness to loud sounds<sup>1</sup> (presuming that the auditory apparatus is not affected), and the patient can no longer produce the subjective noise in the ear, which we normally hear on attempting very forcibly to innervate the facial muscles, especially the orbicularis palpebrarum.

3. If the motor root of the nerve be affected *between its emergence from the pons and the geniculate ganglion*, it produces the same symptoms as in Bell's paralysis, but without affection of taste in the front of the tongue. And since disease in this region almost invariably implicates the auditory nerve, there is usually deafness also. If the auditory nerve chances to escape, hyperacousis will occur from stapedius paralysis. Many cases have deficiency of tears on the affected side. Most cases of basal intra-cranial disease present general symptoms also, such as headache, giddiness and vomiting.

4. If the lesion of the motor root be *within the substance of the pons*, facial palsy results as in Bell's paralysis, but taste and hearing are unaffected. There is, however, usually an accompanying paralysis of the sixth nerve or its nucleus, since the facial motor root hooks round the sixth nucleus within the pons.

Paralysis of the soft palate used to be included in the symptoms of a lesion of the facial nerve at or above the geniculate ganglion. But the

<sup>1</sup> Moos (*Zeitschrift für Ohrenheilkunde*, vol. viii. p. 221) records a case in which the hyperacousis was specially for low-pitched notes.



weight of evidence goes to prove that the facial has no share in the innervation of the palate. Chvostek,<sup>1</sup> in 1883, published a case of sarcoma of the facial nerve in which paralysis of the palate had been observed, but that was before the days of the Marchi method, and it is impossible to be sure that the lower roots of the vagus were un-legenerated. In his case there was also a cancer in the tongue.

Slight cases of facial palsy, whether due to cold, middle-ear affection, compression, or other causes, may recover completely in one or two weeks. More severe cases last from two to eight




FIG. 71.

FIG. 71A.

Case of left-sided facial palsy with contracture. Fig. 71 shows position at rest. Fig. 71A shows maximum voluntary movement.

months before recovery begins. Or the palsy may remain permanent. In severe cases, where improvement does not begin for three months or more, a spastic or contracted condition usually comes on as voluntary power reappears. The mouth becomes drawn back again towards the paralysed side, the palpebral fissure instead of being wider, is narrower than on the healthy side, and the naso-labial and other furrows not only reappear, but become exaggerated. The result is that, when at rest, the healthy side may seem the weaker of the two, though when voluntary movement

<sup>1</sup> *Wiener Medizinische Presse*, 1883, s. 34.



takes place it is easy to see which is the affected side (see Figs. 71 and 71A). Together with this contracture there is always in the spastic muscles a tendency to over-action, imperfect recovery being associated with imperfect control. One variety of facial hemi-spasm results (see p. 93). Thus, on closing the eye on the affected side, the angle of the mouth becomes drawn outwards; or again, on showing the upper teeth, the eye becomes

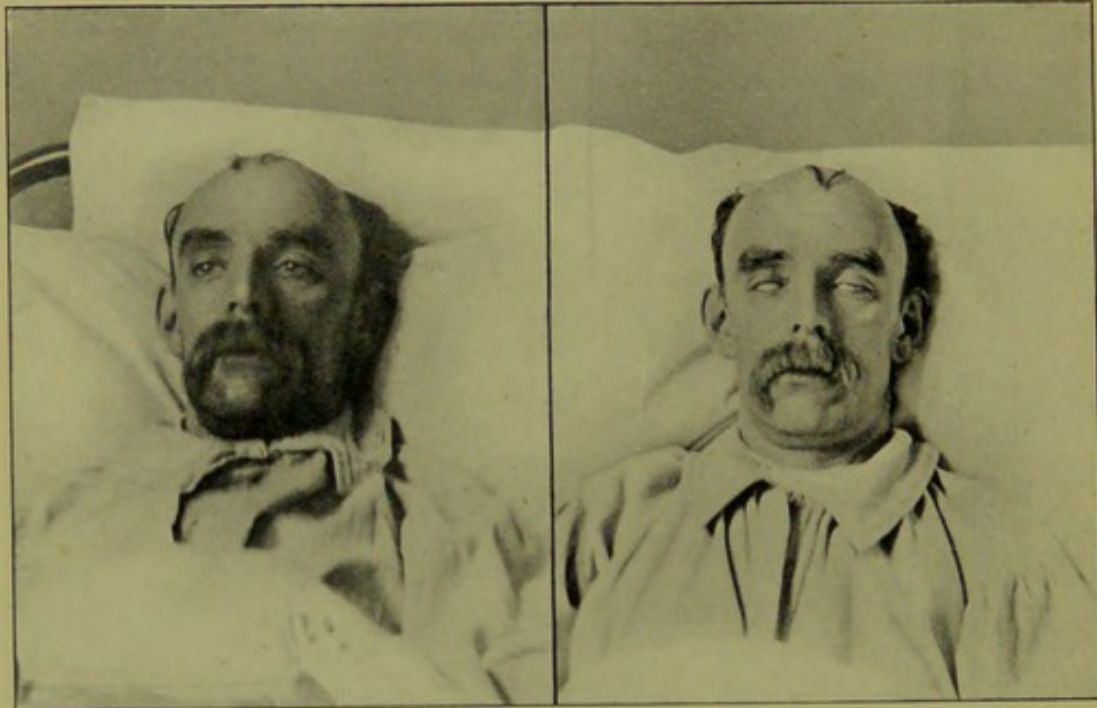


FIG. 72.

FIG. 72A.

Fig. 72.—Bilateral facial palsy, alcoholic in origin, associated with peripheral neuritis of upper and lower limbs.

Fig. 72A.—Maximum voluntary movement of face, on attempt to close the eyes and to retract angles of mouth.

closed. Sudden flickers of involuntary fibrillary tremors may sometimes be seen on the affected side. The spastic facial muscles can also be made to contract reflexly by tapping lightly over the point of emergence of the most accessible branch of the fifth, viz., the supraorbital nerve.<sup>1</sup>

Secondary contracture occurs only in cases of incomplete recovery. During the stage of total paralysis, when no impulses are reaching the muscles, they are quite flaccid. The development of contracture indicates that muscular regeneration has been imperfect.

<sup>1</sup> Mondino, *Rivista di patologia nervosa e mentale*, 1907, p. 49.



*Bilateral facial palsy* is rare. It may be due either to intra- or extra-cranial causes, the commonest intra-cranial cause being gummatous basal meningitis. Of the extra-cranial causes, the most important are double otitis media, cold, and post-diphtheritic paralysis. Alcoholic paralysis rarely attacks the facial nerve, but when it does, the affection is bilateral, as in the case of the man shown in Figs. 72 and 72A, who also had typical alcoholic neuritis of the limbs.

In bilateral facial palsy there is no asymmetry of the face, but it hangs like a fixed expressionless mask, incapable of evincing the slightest emotion.

Bilateral facial weakness also occurs in the "facio-scapulo-humeral" type of myopathy, to which we shall refer in a later chapter.

**Nervus Intermedius of Wrisberg, or Sensory Root of the Facial.**—Between the facial motor root and the auditory nerve at the floor of the cranial cavity, and entering the internal auditory meatus along with them, there is a slender fasciculus, known as the *portio intermedia*. The fibres of this nerve are remarkably small in calibre. Their trophic centre is in the cells of the geniculate ganglion. Centrally the fibres run into the bulb, alongside the fibres of the auditory nerve, to join a nucleus closely connected with that of the glosso-pharyngeal. Peripherally from the geniculate ganglion fibres run along the great and small superficial petrosal nerves; others along the trunk of the facial, in the chorda tympani. The nervus intermedius probably conveys taste impulses upwards to the brain, by way of the glosso-pharyngeal nucleus (Fig. 70, p. 151). And it appears to contain also efferent fibres which join the submaxillary ganglion. *Inflammation of the geniculate ganglion*, analogous to inflammation of the posterior root ganglion in herpes zoster, as Hunt has pointed out, produces characteristic symptoms. These consist in pain and herpes of the auricle and external auditory canal. If the inflammation be intense enough to implicate the motor fibres of the facial there is facial palsy also, with loss of taste in the chorda tympani distribution. If the auditory nerve be



implicated there is vertigo, tinnitus, deafness and even nausea and vomiting.

The **Eighth** or **Auditory Nerve** comprises two entirely different sets of fibres. (See Fig. 24, p. 40.) Firstly, there are *cochlear fibres* for the function of hearing. Secondly, there are *vestibular fibres* which supply the semicircular canals and constitute the most important nerve of equilibration, informing us of the position of our head in space. Affections of the cochlear fibres produce one form phenomena, while disease of the vestibular fibres causes auditory of vertigo, though vertigo and other auditory symptoms often result not only from disease of the labyrinth or vestibular fibres, but from affections of the middle or even of the outer ear.

The chief symptoms referable to the auditory nerve are deafness, tinnitus and vertigo.

In a patient who is apparently deaf we should always, before proceeding to test the hearing, examine the external auditory meatus, to make sure that it is not blocked, *e.g.* by wax. We then test *aerial conduction* by the ticking of a watch, the patient's eyes being shut and one ear closed while the other is being tested. Holding the watch at some distance from the ear, we slowly bring it nearer until the patient can just detect the tick. If there is **deafness**, we have to determine whether this is due to middle-ear disease or to affection of the labyrinth or auditory nerve. The *tuning-fork tests* help us here. Normally a vibrating tuning-fork, preferably C<sup>1</sup> (= 256 vibrations per second) placed on the vertex or centre of the forehead is heard equally in both ears (Weber's test), and if one ear be temporarily closed by the finger, the note is heard louder on that side. If the tuning-fork be placed on the mastoid process, we wait till it is no longer heard through the bone, and find normally that it is still audible when held close to the external meatus (Rinne's test). If the middle ear be diseased, or if the outer ear be blocked up, there is loss of aerial conduction, but bone-conduction is still preserved. The tuning-fork on the vertex is then heard louder on the affected side ("positive-Weber,") and Rinne's test is negative, *i.e.* the tuning-fork is no longer heard aurally after fading away on



bone-conduction. But if the deafness be due to affection of the internal ear or of the auditory nerve—so-called “nerve-deafness,” a tuning-fork on the vertex is not heard on the affected side (“negative-Weber”), whilst as a rule there is “positive-Rinne,” though not always. In deafness from chronic middle-ear catarrh, the hearing is generally better in the midst of a noise (*e.g.* in an omnibus or railway carriage), than in a quiet place:—so called *paracousis*,<sup>1</sup> whereas in nerve-deafness the reverse is the case. Additional localising evidence may also be obtained from the other concomitant symptoms. Thus gross disease of the auditory nerve within the skull, *e.g.* in a case of lateral extra-cerebellar tumour, is often accompanied by facial paralysis, though this conjunction is of value only when middle-ear disease can be excluded. On the other hand, disease of the labyrinth is often associated with tinnitus or vertigo, and labyrinthine deafness is specially characterised by loss of perception for high-pitched tones, as tested by Galton’s whistle. Disease of the auditory nuclei within the pons may be associated with weakness of the motor facial nerve of the same side and paralysis of the opposite arm and leg.

**Tinnitus**, or ringing in the ears, is a subjective symptom. It signifies irritation of some part of the auditory apparatus. The term does not include elaborate auditory hallucinations of cortical origin, such as distinct melodies or voices uttering intelligible words. The nature of the sound in tinnitus varies in different cases; for example, it may be buzzing, hissing or whistling. Broadly speaking, we recognise two main kinds of tinnitus—the pulsating and the continuous. *Pulsating* sounds, synchronous with the pulse, occur in a few intra-cranial aneurisms (sometimes audible by the physician on auscultation of the skull), but are also not infrequent in simple neurasthenia in the “silent watches of the night,” and in temporary Eustachian obstruction, as in some cases of coryza. Curious “clicking” sounds in the ear may result from

<sup>1</sup> Paracousis, according to some observers, is associated with abnormally low labyrinthine pressure, and the temporary improvement of hearing in such patients during a noisy journey, in a railway carriage or motor car, is due to a reflex contraction of the stapedius muscle pushing inwards the foot of the stapes and raising, for the time being, the pressure of the endolymph (see A. Cheatle, *Trans. Otol. Soc.*, 1900, vol. i. p. 52; also C. Heath).



clonic spasm of the tensor tympani muscle. *Continuous* sounds may be of high or low pitch. We should always notice whether they are increased or diminished by the recumbent posture. Low-pitched continuous tinnitus may be the result of venous hyperæmia, in which case it is aggravated by recumbency, or of simple anæmia, which is relieved by lying down. Nitrite of amyl aggravates tinnitus when due to hyperæmia and relieves it when due to anæmia. High-pitched continuous tinnitus is generally due to labyrinthine stimulation, either from outer or middle-ear affection (perhaps merely wax or water in the external meatus, an obstructed Eustachian tube, or an indrawn tympanic membrane), or from actual labyrinthine disease. It is also caused by certain drugs, notably by quinine and salicylates. Such drugs induce deafness as well as tinnitus, and the tinnitus may persist for weeks after the deafness has cleared up. Pulsating tinnitus due to arterial congestion can often be arrested temporarily by compression of the vertebral artery supplying the labyrinth, or of the carotid supplying the external or middle ear.<sup>1</sup>

**Vertigo**, or giddiness, is the peculiar disagreeable sensation which results if our sense of secure equilibration is disturbed. The process of equilibration is a muscular act, where all the muscles are innervated, of course, by the cerebral cortex, this latter being again largely influenced by the cerebellum. The cerebellum is a co-ordinating centre for equilibration. It receives afferent impulses from various sources, of which the semicircular canals of the inner ear are by far the most important, the others coming from the skin of those parts on which the body happens to be resting, from the muscles and joints concerned in maintaining our balance, and from the muscles of the head and eyes concerned in looking towards surrounding objects. Each half of the cerebellum exercises a co-ordinating influence, through the corresponding superior cerebellar peduncle, upon the contra-lateral cerebral cortex, and thus upon the muscles of the ipso-lateral limbs.

Giddiness is often accompanied by a feeling of movement either in the patient himself (subjective vertigo) or in external

<sup>1</sup> Dundas Grant, *Brit. Med. Journal*, Dec. 24, 1887.



objects (objective vertigo). Severe giddiness usually produces the motor phenomenon of reeling or staggering.

Vertigo may result from affection either of the higher cerebral centres or of the co-ordinating cerebellar centres, or from affection of any of the afferent paths to which we have already referred. Severe vertigo is often accompanied by nausea and vomiting, as in sea-sickness.

Vertigo may occur in healthy people. Thus, for example, a galvanic current of 10 to 15 milliamperes passed transversely through the head produces a variety of giddiness probably due to labyrinthine stimulation. In this the patient tends to fall towards the side of the positive pole, and his head and eyes are also rotated in that direction, accompanied by a rotatory nystagmus, until the moment of stopping the current, when he tends to fall towards the side of the negative pole. Rapid rotation of the body round its own axis, as in waltzing, or rapid changes in our position in space, as in swinging, produce giddiness which is probably due to variations in the pressure of the endolymph within the semicircular canals. Some people feel giddy when stepping unexpectedly from a firm surface on to a piece of boggy turf, or, as in a famous Edinburgh street, on to a piece of indiarubber pavement, this variety of vertigo being due to deficient sense of resistance conveyed from the skin of the soles and from the muscles and joints of the lower limbs. The giddiness produced by standing near the edge of a cliff or of a high tower is most probably due to loss of muscular impression from the ocular muscles. Ordinarily we have surrounding objects at or above our own level with which to compare our position in space, and if such objects are absent vertigo may result.

Vertigo is also associated with various pathological conditions. Among the intra-cranial causes we may mention blows on the head (this variety is often relieved by repeated small doses, about  $\frac{1}{9}$  grain, of perchloride of mercury),<sup>1</sup> and sudden *cerebral anæmia* or *hyperæmia*. A distinguished member of the medical profession who was the subject of aortic regurgitation used to have attacks of

<sup>1</sup> Dundas Grant, *Clinical Journal*, Oct. 9, 1907.



intense vertigo if he took a saline aperient. Probably in his case the withdrawal of a considerable amount of fluid from the circulation rendered the brain anæmic—hence the vertigo. It was always relieved by the recumbent posture, while cardiac tonics and the avoidance of hydragogue cathartics prevented its recurrence. Vertigo from cerebral hyperæmia is very common in women about the menopause, also in the arterio-sclerosis of chronic renal disease. In the latter class, relief is often obtained by the administration of iodides. It is still more marked in many cases of cerebral hæmorrhage or thrombosis, of which it may be a premonitory signal. Giddiness in old people with atheromatous arteries, if it be associated with headache, and especially if there be no sign of labyrinthine disease, should always be regarded with caution. Intra-cranial tumours may cause giddiness by raising the general pressure within the skull, and cerebellar tumours are especially associated with vertigo, even apart from increased intra-cranial pressure. *Intra-cerebellar tumours* of the lateral lobe produce a vertigo in which the subjective sense of rotation of the body is in the same direction as that of the apparent movement of surrounding objects, *i.e.* away from the side of the lesion. In *extra-cerebellar tumours*, while external objects appear to move away from the side of the lesion, the sense of subjective rotation is reversed, *i.e.* towards the side of the lesion.

A characteristic form of vertigo has also been described by Bruns,<sup>1</sup> and confirmed by various other observers.<sup>2</sup> It is produced by the presence of a *cysticercus in the fourth ventricle*. Sometimes the worm is anchored to the ependyma, sometimes it is swimming free. The patient, who otherwise shows no sign of intra-cranial organic disease, has paroxysms of violent vertigo, chiefly on sudden movement of the head, either active or passive, causing a temporary shifting of the position of the worm. He also has attacks of occipito-frontal headache with vomiting; his gait is tottering and unsteady, and glycosuria is not uncommonly present. There may be intervals during which he is ap-

<sup>1</sup> *Centralblatt für Neurologie*, 1902, s. 565.

<sup>2</sup> Osterwald, *Neurologisches Centralblatt*, 1906, s. 265.



parently well, and the case may be mistaken for hysteria. Death usually occurs suddenly from respiratory paralysis.

Vertigo is associated with certain degenerative diseases, notably with disseminated sclerosis. Vertigo is frequently the "aura" of an epileptic fit, or may accompany the headache of an attack of migraine. A hereditary family form of giddiness has also been described.

*Toxic vertigo* from alcohol or tobacco is a familiar type, and to the toxic class we may also refer cases produced by gastric disorder, by constipation, and by some cases of intestinal parasites, though in the last instance a reflex element may also be present. Giddiness is often present in neurasthenic and hysterical patients, in whom it may be elicited by the slightest exciting cause, for example by rectal examination.

*Ocular vertigo* occurs in cases of paralysis of any of the external ocular muscles, and is associated with diplopia. The visual field being erroneously projected, the patient judges wrongly as to the relation of his body to what he sees. "Objects appear to be in certain positions where the patient's feet, as a matter of fact, fail to find them" (Hughlings Jackson). The giddiness in such cases is not due directly to the diplopia, for it persists when the sound eye is covered. The condition can be imitated in health by closing one eye and displacing the other eye inwards by pressure with the finger, when if the subject tries to walk along a straight line his gait becomes very unsteady.

But in the vast majority of cases vertigo is associated with some disorder of the ear. It may result from wax, or foreign bodies in the meatus, or it may supervene during ear-syringing, especially if there is a perforation of the drum. The pathological cause may also be in the middle ear, as in otitis media or obstruction of the Eustachian tube, or the condition may result merely from sneezing or blowing the nose, also from spasm of the tensor tympani muscle.

Lastly, there is what is known as **Ménière's disease**, or labyrinthine vertigo. This has three main classes of symptoms: firstly, giddiness and reeling, due to affection of the semicircular canals; secondly, deafness and tinnitus, due to affection of the



auditory fibres; and thirdly, associated bulbar phenomena, such as nausea and vomiting, cardiac failure, cold clammy sweat, &c., due to affection of adjacent medullary centres.

The vertigo of Ménière's disease is paroxysmal, and comes on with such suddenness that the patient may fall to the ground as if struck down by an unseen hand. In other cases he reels, but has time to clutch at some neighbouring object to prevent himself from falling. The giddiness lasts sometimes for hours; slighter attacks may pass off in a few minutes. It is increased by movement, and the slightest attempt to raise the head may induce vomiting. The direction in which the patient falls is usually forwards or towards one side, and commonly away from the side of the affected ear. Not infrequently nystagmoid jerks of the eyes occur during the attack, and double vision has also been observed. The vertigo is frequently accompanied or followed by headache, nausea and vomiting, lasting sometimes for hours. Together with these there are characteristic auditory phenomena, generally a sudden loud noise, usually unilateral. There is also deafness, more or less complete, on the same side as the tinnitus, with diminution or loss of bone-conduction. A certain degree of deafness remains between the attacks, but is rarely absolute.

Such symptoms, occurring with apoplectiform suddenness, constitute the typical picture of Ménière's disease. But frequently the paroxysms are much slighter, and unassociated with nausea or vomiting, so that the patient may simply have sudden transient giddiness. But the attacks tend to recur; rarely does a patient escape with a single attack. The intervals between them vary; they may gradually decrease in frequency, or may progressively increase until after successive attacks the deafness becomes absolute. The vertigo then usually ceases.

Ménière's disease is distinguished from epileptic vertigo by the coexistence of vertigo with tinnitus and deafness. Loss of consciousness, which is the rule in epilepsy, is rare in labyrinthine vertigo. Labyrinthine vertigo often yields to small doses ( $\frac{1}{2}$  to 1 grain) of quinine. From cerebral hæmorrhage or thrombosis it is distinguished by the presence of auditory phenomena, and by the



absence of signs of a focal brain lesion. The pathology of Ménière's syndrome is obscure. Ménière himself described a hæmorrhagic effusion in the inner ear. But as Arthur Cheate<sup>1</sup> has luminously suggested, the phenomena are in many respects closely analogous to those of glaucoma, and may possibly be due to a sudden rise of tension in the endolymph or perilymph, whether produced by hæmorrhage or other causes in the labyrinth or by sclerosis of the middle ear, whereby the *fenestra ovalis* and *fenestra rotunda* become fixed, thereby depriving the inner ear of safety-valves which normally permit of compensation for sudden changes in labyrinthine pressure.

A focal lesion of Deiters' nucleus (as has been shown by Bruce and by Bonnier) produces sudden vertigo and reeling, together with nausea, acute distress, transient tinnitus or deafness, nystagmus, and sometimes pain in the distribution of the trigeminal nerve. All these phenomena are easily explicable when we remember the connection of Deiters' nucleus with the cerebellum and with the oculomotor nerves, and its close proximity to the sensory nucleus of the trigeminal.

No case of isolated palsy of the **Ninth** or **Glosso-pharyngeal Nerve** has yet been observed in man, so that its exact functions are not completely determined. We know that it supplies taste-fibres to the posterior third of the tongue and to the soft palate. It probably also supplies the taste buds which exist on the epiglottis and on the arytenoid cartilage. The glosso-pharyngeal is also a nerve of common sensation for the back of the tongue, part of the soft palate and upper part of the pharynx, whilst it has motor fibres for the middle constrictor of the pharynx, and for the stylopharyngeus.

Paralysis of the nerve causes anæsthesia of the back of the tongue and pharynx, difficulty in swallowing and deficient taste in the posterior third of the tongue. In animals where this nerve has been divided experimentally, the pharynx and œsophagus remain tonically contracted, owing to paralysis of the inhibitory fibres contained in the glosso-pharyngeal.

<sup>1</sup> *Archives of Otolaryngology*, vol. xxvi., 1897, p. 185.



The **Tenth Nerve, Vagus, or Pneumogastric Nerve**, according to modern nomenclature, is held to include those roots which used to be called the "bulbar part of the spinal accessory." Nowadays the term "spinal accessory" is limited to the spinal part of the accessorius which arises from an entirely separate nucleus, whereas the old "bulbar part" is derived from, and belongs to, a continuation of the vagus nucleus (nucleus ambiguus) in the medulla.

The vagus has a most extensive distribution. It supplies the pharynx, larynx, œsophagus, heart, lungs, stomach, and partly even the intestines and spleen. By its auricular branch it also

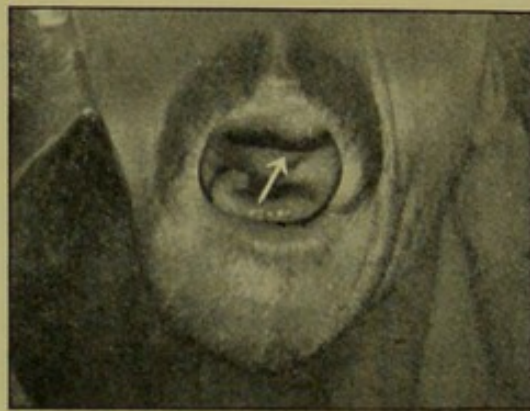


FIG. 73.—Paralysis of the right side of the palate. The patient is saying "Ah," and the palate is pulled up towards the left side. The arrow points to the centre of the uvula.

supplies part of the skin of the outer ear. Its pulmonary fibres are motor for the bronchial muscles and sensory for the respiratory passages. The vagus is both motor and sensory for the œsophagus, sensory for the stomach, and partly motor for the stomach and intestines. Its lowest roots of origin are those which are of the greatest diagnostic importance, for they contain motor fibres for the levator palati and the larynx, together with inhibitory fibres for the heart. With the exception of the crico-thyroid muscle, which is innervated by the superior laryngeal branch, all the laryngeal muscles are supplied through the inferior or recurrent laryngeal nerve.

The symptoms of vagus paralysis vary according to the site of the lesion. Intra-cranial lesions may affect all its roots of origin, or may attack the upper or the lower roots alone. In the latter



case there is often a concomitant affection of the adjacent hypoglossal nerve.

If the whole of one vagus trunk be affected, there is unilateral paralysis of the palate and larynx (Avellis's syndrome), together with anæsthesia of the larynx on the affected side. The only way to recognise a unilateral paralysis of the palate is to watch the movement of its median raphé when the patient utters a long

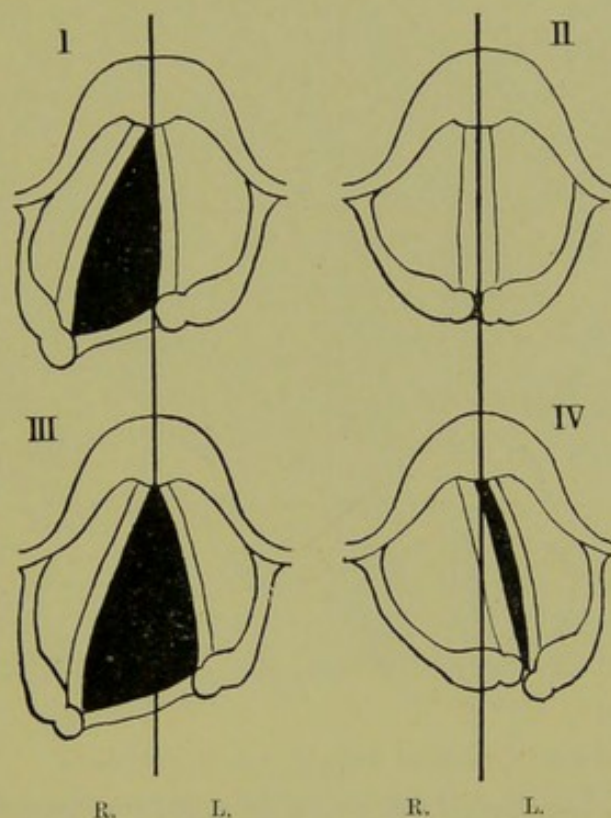


FIG. 74.—Organic laryngeal paralyses (Barwell).

- I. Left abductor paralysis, during inspiration.
- II. Left abductor paralysis, during phonation.
- III. Left recurrent laryngeal paralysis, during inspiration.
- IV. Left recurrent laryngeal paralysis, during phonation.

“Ah.” Normally the raphé rises straight up. But if one side of the palate be paralysed, the healthy side alone pulls upwards and the raphé deviates to the sound side, forming a characteristic dimple (Fig. 73).

If both vagi be paralysed, there is tachycardia and irregularity of the heart, from paralysis of the cardio-inhibitory fibres. There are also slowness and irregularity of respiration. These do not occur in unilateral vagus palsy. Gastric symptoms have also been observed even in unilateral cases, such as gastric dilatation,



vomiting, gastric pain, and loss of the sensations of hunger and thirst.

Of all these symptoms, the most constant and easiest to recognise are the affection of the soft palate and the laryngeal palsy. Paralysis of the recurrent laryngeal nerve may occur alone. The commonest cause is aortic aneurism, which frequently compresses the nerve on the left side. Mediastinal growths

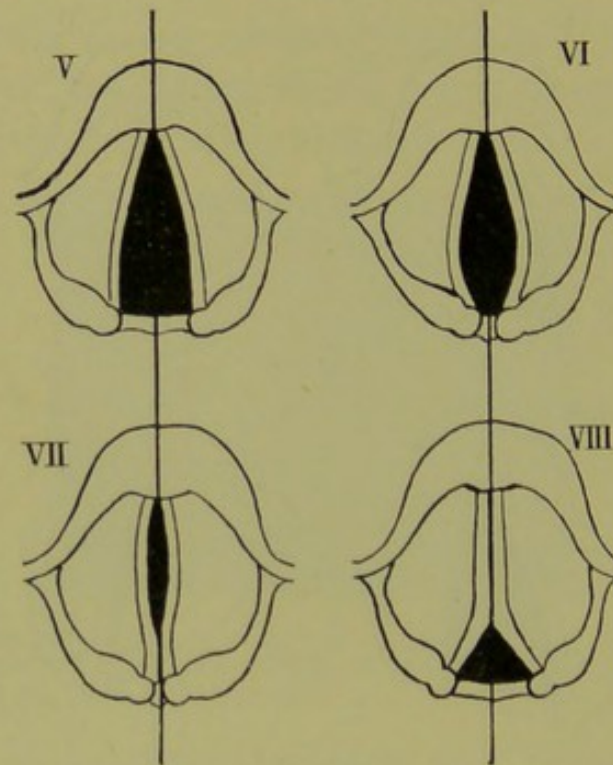


FIG. 75.—Functional laryngeal paralyses (Barwell).

- V. Adductor paresis—all the adductors affected—phonation.  
 VI. Adductor paresis—arytenoideus unaffected—phonation.  
 VII. Paralysis of the thyro-arytenoidei—phonation.  
 VIII. Paralysis of the arytenoideus—phonation.

may also compress it, or its paralysis may even be the result of mitral stenosis, where the left auricle becomes dilated and thus compresses the nerve directly against the pulmonary artery, or the auricle may force the left bronchus upwards and compress the nerve against the aortic arch.<sup>1</sup> In *recurrent laryngeal paralysis* the vocal cord on the affected side is immobile, fixed in the cadaveric position, *i.e.* midway between abduction and adduction, and the voice is generally hoarse though not absent, since during phonation the healthy cord can cross the middle line to meet the paralysed

<sup>1</sup> Frischauer, *Wiener Klin. Wochenschrift*, Dec. 28, 1905.



one. If *both recurrent laryngeals* be paralysed, both vocal cords are motionless and in the cadaveric position, and phonation is impossible since the cords cannot be brought together. There is no stridor except on deep inspiration.

It is here convenient to recall some of the chief diagnostic features of laryngeal palsies (Figs. 74 and 75). Abductor palsy,

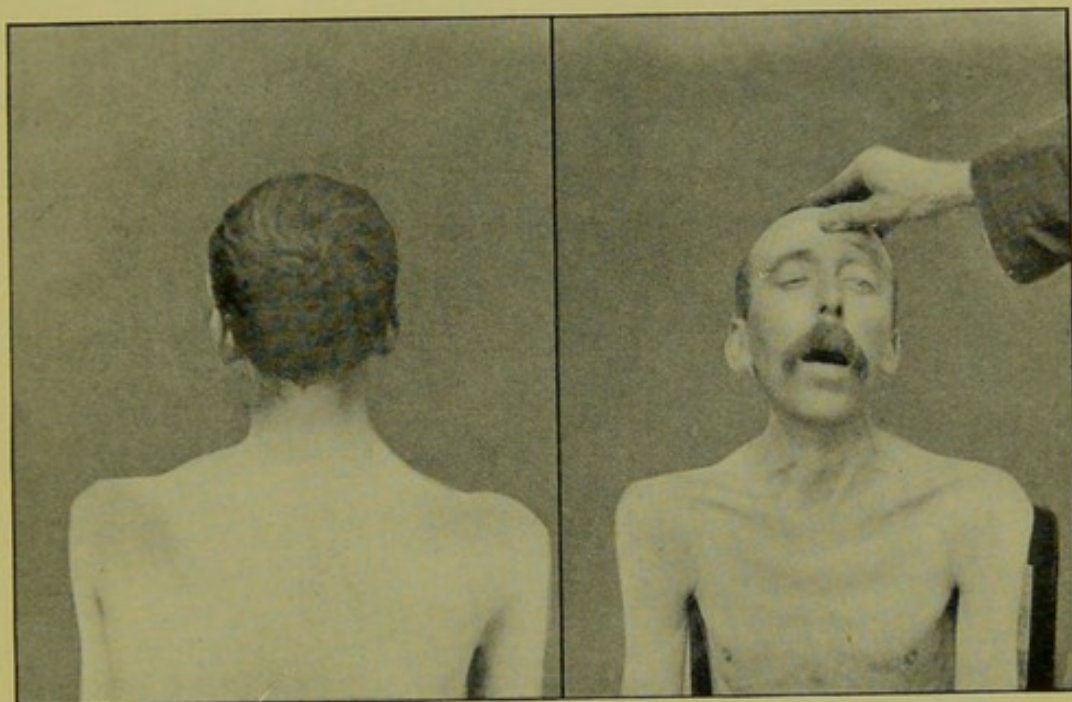


FIG. 76.

FIG. 77.

Paralysis of right spinal accessory nerve.

Fig. 76 shows the downward and outward displacement of the right scapula. Observe alteration in the lateral outlines of the neck. On the paralysed side the outline is formed by the levator anguli scapulae; on the normal side by the trapezius.

Fig. 77 shows the patient attempting to depress the head against resistance. Observe the absence of the right sterno-mastoid, the right omo-hyoid being now subcutaneous.

unilateral or bilateral, is always organic, and is often the earliest sign of a commencing recurrent laryngeal nerve affection. In *unilateral abductor palsy* the voice is unaffected, but on laryngoscopic examination the paralysed cord is seen to be immobile during inspiration, not moving outwards like its healthy fellow. On phonation the cords meet normally. In *bilateral abductor palsy* the voice is also unaffected, since both cords come together on phonation. And since they no longer move outwards during inspiration, but on the contrary are sucked together, inspiration is laboured and stridulous, and the patient is in danger, since the



slightest swelling of the cords may completely block the glottis. *Paralysis of the internal thyro-arytenoid muscle*, which occurs in some cases of early bulbar paralysis, is characterised by an oval instead of a linear appearance of the glottis on attempted phonation, owing to loss of the support of these muscles. The voice is therefore hoarse, but abduction and adduction are otherwise unaffected. *Adductor paralysis* is always bilateral and generally

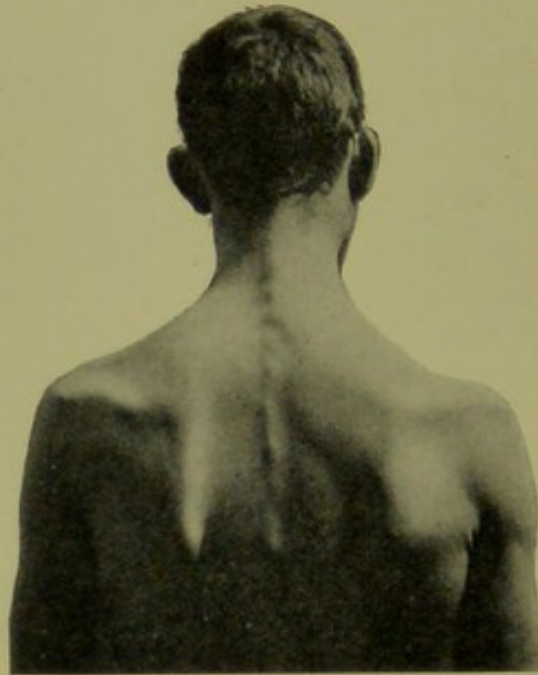


FIG. 78.—Paralysis of right spinal accessory nerve, showing downward and outward displacement of scapula. Owing to absence of the trapezius, the rhomboid muscles on the right side have become subcutaneous.

hysterical. It is common in hysterical aphonia. The patient loses her voice, often suddenly, and talks in a whisper. There is no stridor, and on inspiration the cords move normally outwards. But on attempted phonation they do not reach the middle line. The condition often disappears suddenly, sometimes as a result of the process of laryngoscopy, or of the application of strong faradic shocks to the larynx.

The **Eleventh** or **Spinal Accessory Nerve** is distributed to the sterno-mastoid and to part of the trapezius. It is exclusively a motor nerve. When it is paralysed, we have paralysis and atrophy of the sterno-mastoid, which no longer stands out on rotation of



the head to the opposite shoulder, nor on depressing the head against resistance (Figs. 76 and 77). The paralysis of the trapezius varies in degree according to the extent to which the muscle is supplied by the spinal accessory and by the cervical plexus respectively. Ordinarily the uppermost fibres of the trapezius are innervated by the spinal accessory, whilst the middle fibres of the muscle are supplied by the third and fourth cervical nerves, and the lowest fibres

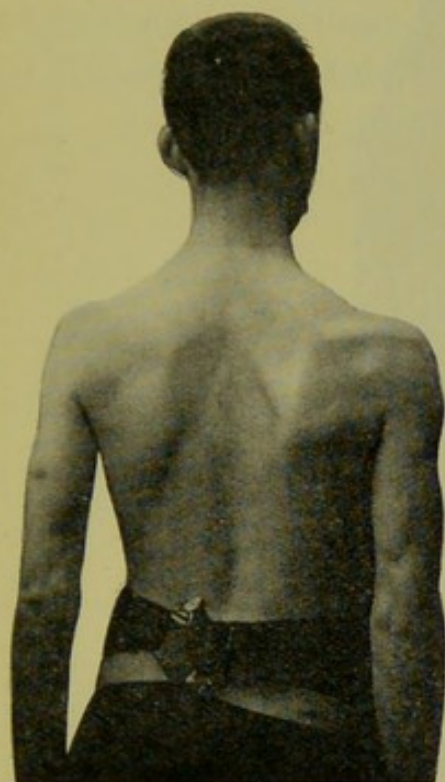


FIG. 79.

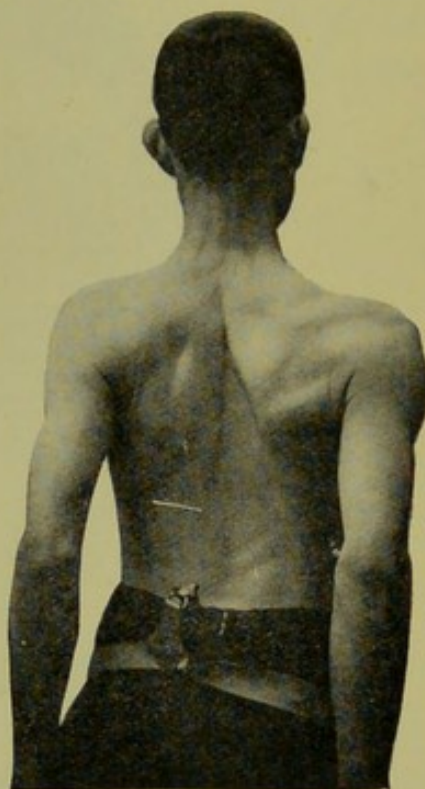


FIG. 80.

Paralysis of right spinal accessory nerve.

Fig. 79.—Showing position at rest.

Fig. 80.—Showing position on adduction of scapulae.

of all by the spinal accessory. When the trapezius is paralysed, the outline of the neck is altered, owing to the levator anguli scapulae having become subcutaneous, and there is a characteristic deformity of the angle of the shoulder resulting from the displacement of the scapula (Fig. 78). The scapula on the paralysed side is displaced downwards and outwards, and rotated outwards, so that its inner border instead of being parallel with the spine, is inclined from below upwards and outwards. When the patient braces his shoulders back, the scapula is imperfectly approximated to the middle line, and the rhomboids on the paralysed side are visible subcutaneously (Figs. 79 and 80).



The **Twelfth** or **Hypoglossal Nerve** is also entirely motor in function. Immediately after its exit from the skull it receives amongst other connections a small communicating branch from the cervical sympathetic. The hypoglossal supplies all the intrinsic muscles of the corresponding half of the tongue. Outside the skull



FIG. 81.—Paralysis of right hypoglossal nerve from a stab-wound below the jaw, showing atrophy of corresponding half of tongue and marked deviation to the right when protruded.

it is joined by branches from the first and second cervical nerves, and from these two nerves the depressors of the hyoid bone are supplied, through the *descendens hypoglossi*.

The symptoms of hypoglossal paralysis are very characteristic (Fig. 81). The corresponding half of the tongue is atrophied and wrinkled. When the tongue is protruded the healthy side causes the tip to be pushed round to the paralysed side in a sickle-shaped curve. If the nerve is divided suddenly, by accident or



operation, the patient feels for a few days as if the paralysed half of the tongue were a foreign body, interfering with articulation and mastication. But this sensation soon passes off as the patient becomes accustomed to his hypoglossal palsy.

If the lesion of the hypoglossal be extra-cranial, after it has received the small communicating branch from the cervical sympathetic, we may sometimes observe vaso-motor changes in the atrophied side of the tongue. In two of my cases where the twelfth was divided intentionally for the treatment of facial palsy by

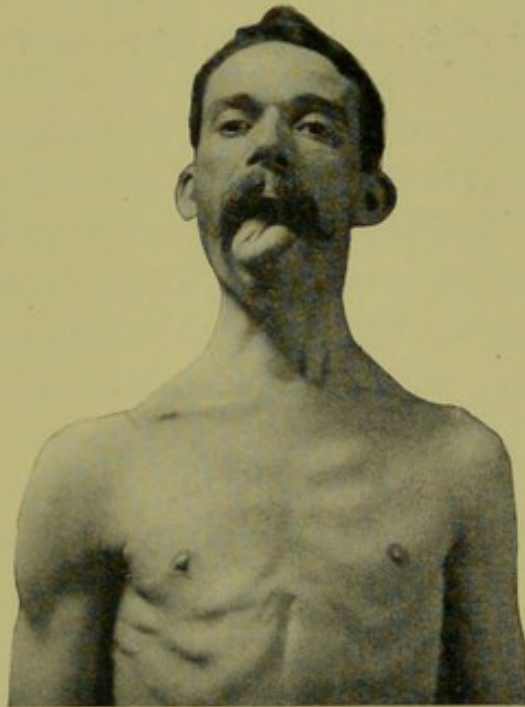


FIG. 82.—Paralysis of spinal accessory and hypoglossal on right side, showing downward and outward displacement of right shoulder, also atrophy of right half of tongue with deviation to the right on protrusion.

means of facio-hypoglossal anastomosis, the tongue was pale on the paralysed side. From unilateral paralysis of the hyoid depressors, the larynx may be pulled over towards the sound side during swallowing.

The **hypoglossal nucleus** within the medulla, as we have already mentioned, is closely connected with the lowest cells of the facial nucleus, viz., those which supply the orbicularis oris. Hence in lesions in the neighbourhood of the hypoglossal nucleus, the muscles of the lips are paralysed together with those of the



tongue. This weakness of lips and tongue in nuclear lesions is generally bilateral, owing to the close proximity of the hypoglossal nuclei to the middle line.

Intra-cranial lesions of the hypoglossal nerve, *e.g.* from a patch of syphilitic meningitis, very frequently involve other cranial nerves in the neighbourhood. One of the commonest multiple palsies is that which produces Hughlings-Jackson's syndrome, *viz.*, hemiatrophy of the tongue, paralysis of the trapezius and sternomastoid, and paralysis of the vocal cord and soft palate, all on the same side (Fig. 82). This is the result of a lesion implicating the twelfth, the eleventh, and the lowest roots of the tenth nerve.



## CHAPTER XI

### PAIN AND OTHER ABNORMAL SUBJECTIVE SENSATIONS

THERE is, perhaps, no symptom for which we are more frequently consulted than that of pain. For its satisfactory treatment the underlying cause must first be determined—sometimes no easy matter.

With the exception of cases where pain arises in a healthy individual from some unduly strong stimulus, pain is always pathological. The vast majority of pains are due to irritation of some peripheral sensory nerve or of a posterior root. Less commonly pain may be due to abnormal sensitiveness of the cortical centres, and is functional in origin. Stimulation of the surface of the brain gives rise to no pain, but the meninges are exquisitely sensitive, the cerebral membranes being innervated by the trigeminal nerve. Intra-cranial diseases therefore probably cause pain chiefly through the intermediation of the sensitive meninges. It is possible, however, that the pain in some cases of syringomyelia may not be of meningeal origin, but due to actual distension of the syringomyelic cavity by the fluid within, though against this view is the fact that pain is a late phenomenon in this disease.

Spontaneous sensations of discomfort vary in degree and in kind. Milder varieties, not amounting to actual pain, are classed as *dysæsthesiæ*. They include such symptoms as spontaneous tingling, "pins and needles," dulness, itching, flushing, &c., whilst among the more severe varieties are the intense and agonising pains of tic douloureux, angina pectoris, renal or biliary colic, or the lightning-pains of tabes.

In the diagnosis of the cause of any particular dysæsthesia or pain, there is one invariable rule which we should always follow, namely, to make a careful local examination of the part of the body to which the abnormal sensation is referred. Only in



this way can we escape gross errors, such, for example, as that of mistaking the pain of herpes zoster for that of pleurisy. In every local pain we should first search for a local cause, whether in the skin, muscles, bones, joints, glands, or other subjacent structures. Pain due to local disease is usually more or less continuous, and accompanied by objective phenomena such as redness of the skin, swelling or tenderness of the diseased tissues, rigidity of joints, and so on. The painful cramps of tetanus, rabies, and strychnia-poisoning are easily recognised and need not be further described.

Some pains are generalised all over the body, for example, the pains of acute illnesses such as influenza, smallpox, and other fevers of rapid onset. In such cases the elevation of temperature, the presence, perhaps, of a rash, and usually the occurrence of other similar cases in epidemic form, all help us in the diagnosis.

Intractable paroxysmal pains of hemiplegic distribution, in the face, trunk and limbs, so-called *hemiplegia dolorosa*, are highly suggestive of a lesion localised in the **optic thalamus**.<sup>1</sup> In such thalamic lesions there is also hemi-anæsthesia of the affected limbs and face, together with spontaneous choreiform or athetoid movements and also hemi-ataxy on voluntary movement. These cases of *hemiplegia dolorosa* must be carefully distinguished from the joint pains which are not uncommon in ordinary chronic hemiplegia, which are due to secondary arthritic changes and are usually alleviated by massage, hydro-therapeutics and anti-rheumatic remedies.

Most cases of pain or discomfort, however, are localised to some more definite area, and therefore for diagnostic purposes the most convenient plan of studying pains and other subjective sensations is by considering the different parts of the body in turn.

**Headache.**—**Cephalalgia.**—A diagnosis of "headache" alone is never sufficient. Headache is not a disease, but merely a symptom.

When a patient complains of headache, local causes should

<sup>1</sup> Dejerine and Roussy, *Revue neurologique*, 1906, No. 12.



first of all be excluded. Amongst the commonest *local extra-cranial* causes we should bear in mind rheumatic affection of the occipito-frontalis muscle, with its diffuse tenderness on brushing the hair, and with aggravation of pain on movement of the scalp. This is often relieved promptly by hot applications. Erysipelas is accompanied by local redness, heat and œdema, and by fever. Periostitis of the pericranium causes tenderness on pressure and is often syphilitic in origin, in which case the pain is commonly worse at nights.

Headaches from local causes in the *cranial bones* are most commonly due to inflammation of the mucous membrane lining the various air-cells, *e.g.* the mastoid, frontal, or ethmoidal cells, or even to an ordinary coryza. Here the previous history of the case, together with the local examination, will serve to indicate the cause. Less frequently caries of the bones or local exostoses may be present. Carious teeth often cause headache, referred especially to the temporal region.

*Gross intra-cranial disease* may produce intense headache, either from local affection of the meninges as in the various forms of meningitis (syphilitic, tuberculous, or pyogenic), or from general increase of intra-cranial pressure, as in diffuse meningitis, intra-cranial abscess, gumma, or tumours. Headaches of intra-cranial origin are often associated with the other classic signs of increased intra-cranial pressure, especially with vomiting and optic neuritis. In every case of obscure headache we should make a careful ophthalmoscopic examination. The position of the headache does not necessarily correspond with that of the tumour. Tumours of the posterior fossa produce the most severe headache.

Then there are the headaches which result from abnormalities of the intra-cranial circulation, especially from arterial hyperæmia, as in renal disease or in suppressed menstruation, or temporarily from drugs such as nitrite of amyl, erythrol tetranitrate, or alcohol. Hyperæmia produces a throbbing pain, sometimes associated with giddiness, tinnitus, affection of vision, and a tendency to attacks of epistaxis. The venous hyperæmia of severe cardiac disease or of emphysema may also produce headache, which is aggravated



by coughing. The headache of anæmia is probably mainly toxic in origin, rather than due to actual deficiency in the supply of blood to the head.

Certain cases of hemiplegia are preceded, for days or even weeks, by headache. This is especially common in *cerebral thrombosis* (*encephalomalacia*), where a premonitory headache is of considerable diagnostic value. The onset of a *cerebral hæmorrhage* is often coincident with a headache. Therefore if an elderly man complains of headaches and bleeding from the nose, we should be cautious in checking epistaxis which may act as a safety-valve, and may save him from an attack of cerebral hæmorrhage.

There is another group of headaches which are produced by peripheral irritation in various parts of the body. Thus, for example, visceral irritation may cause headache, as in ovarian or uterine diseases, or in the headaches from which so many women suffer at the menstrual periods, and frequently also throughout the menopause. In some people the swallowing of an ice causes sudden frontal headache, when the ice reaches the œsophagus or stomach. This is a typical "reflex" gastric headache. Every autumn we come across cases of "gun headache" amongst sportsmen, not simply the result of the auditory stimulus of the noise of the gun, but due partly to the shock of repeated recoils of the weapon. Ocular headaches are fairly frequent, sometimes the result of disease such as glaucoma or iritis, but much more commonly arising from errors of refraction, especially hypermetropia and astigmatism. Even apart from this, headache may result from prolonged eye-strain, *e.g.* after sight-seeing in picture-galleries, being commoner in people who have some error of refraction.

A large group of headaches are *toxic* in origin, the toxins altering the intra-cranial circulation, usually in the direction of raising the blood-pressure. The onset of certain infective fevers is associated with headache, for example in smallpox and influenza (commonly associated with pain in the back), in enteric fever associated with dyspeptic symptoms, in scarlatina, pneumonia, &c. In such cases the temperature, the characteristic rash, and the other signs and symptoms will guide us. Poisoning by toxic



substances is also the main cause of the headache of dyspepsia, whether it be the well-known "Katzen-jammer"—the bursting morning-headache and nausea following a joyous alcoholic evening (this headache, by the way, can often be relieved by a 20-grain dose of calcium lactate), or the headache of chronic dyspepsia especially when associated with a constipated intestine. Headache also results from poisoning with carbonic oxide, carbonic acid and other respiratory sewage in ill-ventilated rooms or at crowded meetings. Other poisons, again, are autogenetic in origin, as are the headaches of gout, uræmia and diabetes.

Sunstroke causes acute diffuse headache. Severe cases are often accompanied by other symptoms such as delirium, hyperpyrexia and coma. Neurasthenia and exhaustion, whether from overwork, from excessive study or from other excesses, are often associated with headache, frontal, occipital, or circular (*douleur en casque*). The post-epileptic headache following a fit is sometimes severe and may be associated with vomiting.

Bilateral headaches are most commonly toxic. The headache of dyspepsia is usually referred to the frontal region, that of constipation to the occiput, whilst vertical headaches are most commonly due to anæmia or to debility. Some cases of concussion of the brain are followed by obstinate headaches, recurring for many months. These, I believe, are sometimes partly toxic in origin, a smaller amount of toxin being efficient in producing headache after concussion than in the case of a healthy individual, whilst in other instances the headaches occur on slight mental exertion, especially where the patient has been allowed to return to work prematurely. Hence the importance of complete physical and mental rest after a severe head injury, even in the absence of signs of an organic lesion.

Most of the headaches to which we have referred are bilateral or mesial in situation. Let us now consider a different group—the unilateral or circumscribed pains.

Sometimes these are due to local disease of the scalp, pericranium or skull, in which case local examination will generally reveal the cause. Or they may result from intra-cranial disease,



for example, meningitis, abscess, gumma or tumour. If the underlying disease be near the surface of the skull, the site of the pain sometimes corresponds with that of the disease. But this is by no means always the case. I remember a striking case of right-sided cerebellar tumour where the pain was confined to the left supraorbital region. The growth was diagnosed and successfully removed.

Some headaches are associated with great pallor of the face—apparently due to vaso-motor spasm of the cerebral vessels, often relieved by inhalation of amyl nitrite. Others are associated with arterial hyperæmia, throbbing arteries, and a flushed face. These are sometimes promptly relieved by compression of the carotid artery on the corresponding side. Such angio-neurotic headaches are rarely bilateral.

A very acute circumscribed variety of headache is known as the *clavus hystericus*, an agonising pain usually referred to the vertex, as if a nail were pressing into the brain. It occurs in certain cases of hysteria and neurasthenia. It is unassociated with any other evidences of intra-cranial disease, and its very intensity leads us to be suspicious as to its true nature.

The pain of sick-headache or *migraine* (hemicrania), with its paroxysmal attacks occurring at intervals of days or weeks, the patient during the intervals being free from headache, is usually easy of recognition. Migraine is a family disease which generally appears in childhood and recurs throughout the strenuous period of life, tending to disappear in old age. The pain of migraine is often alleviated by pressure on the common carotid artery of the corresponding side, but reappears when the pressure is removed. This headache generally culminates in vomiting, and is sometimes preceded by a visual aura in the form of a scintillating scotoma, consisting of a blind area in one half of the visual field, usually, but not always, on the side opposite to that of the unilateral headache, the blind area being bounded at its periphery by a luminous zig-zag coloured spectrum. This scotoma not infrequently develops into a temporary total hemianopia. The headache of migraine is generally unilateral, and is referred to the side contra-lateral to that of the



visual phenomena. Thus if the visual sensations are in the left side of the visual fields, the headache is generally right-sided, and *vice versa*. Less commonly a migrainous attack may be preceded by a non-visual aura of some sort, *e.g.*, by a subjective sensation of tingling in one hand spreading slowly up the arm to the face and tongue, and followed by headache on the opposite side of the head. If the tingling be right-sided there may be slight transitory aphasia. This variety of migraine is distinguished from a minor epileptiform attack by the greater intensity and unilateral limitation of the migrainous headache, by the slow, deliberate march of the migrainous aura, lasting perhaps for many minutes, by the absence of unconsciousness, by the absence of clonic movements, and by the fact, pointed out by Gowers,<sup>1</sup> that the premonitory tingling of migraine may spread bilaterally to the tongue and lips, whereas in an epileptiform attack, if the aura spreads to the tongue or face, it remains unilateral. Migraine and epilepsy may alternate in the same patient. *Migraine ophthalmoplégique* is a rarer variety, in which, in addition to hemicranial pain, there is transient paralysis of the third nerve on the same side as the headache, with ptosis, external strabismus, mydriasis, &c.

We now pass to pains in the region of the trigeminal nerve. Of these *tic douloureux* is the most agonising pain from which a patient can suffer. The pain rarely attacks all three divisions of the nerve, but is usually confined to one division (especially the supraorbital), or it may attack two adjacent divisions. The disease is hardly ever bilateral except in cases of diabetes. The patient has paroxysms of intolerable agonising pain in the area of the affected division. During the attack, the face is often thrown into strong involuntary tonic spasm on the affected side, there is excessive lachrymation, and sometimes secretion of nasal mucus and saliva, all on the affected side. Not only do paroxysms occur spontaneously, but the slightest stimuli often suffice to induce an attack, and therefore the patient avoids chewing food on the affected side. I have known cases in which it was impossible for the patient to wash his face for weeks at a time, lest an attack

<sup>1</sup> *British Medical Journal*, Dec. 3, 1906.



should be thereby precipitated. Inveterate trigeminal neuralgia sometimes drives the patient to suicide.

Apart from these, there are numerous varieties of more localised paroxysmal neuralgic pains referred to individual branches of the trigeminal nerve, and associated with "tender points of Valleix" over their foramina of exit. In such local neuralgias, and in tic douloureux itself, we should always search carefully for some local exciting cause in the mouth, nose, ear, or eye. A carious or inflamed tooth may cause neuralgia in the whole of the corresponding division of the fifth nerve, and the dental surgeon by extracting it will relieve the condition. But we must beware of extracting sound teeth simply because the patient refers neuralgic pain to them. Sometimes an abnormally-placed tooth, though healthy in itself, may cause neuralgia. Thus a lady of fifty-eight had a constant burning pain along the right side of her tongue for eight years, together with a feeling of numbness in the area of the second division of the fifth nerve. This had been vainly treated by numerous drugs, whilst all the time the real exciting cause lay in an imperfectly-erupted lower wisdom-tooth on the corresponding side, the date of the pain coinciding with the first appearance of the tooth. Disease of the antrum or other accessory air-sinus, nasal polypi, and other local lesions may all cause localised neuralgias. If, in addition, the patient be anæmic or gouty, the tendency to neuralgia is increased. But anæmia or gout alone will not cause a local neuralgia. Some local determining cause must also be present, though it is sometimes difficult to discover. Syphilitic basal meningitis or gumma, implicating the fifth nerve in the floor of the skull, may cause trigeminal neuralgia. Such cases usually show other evidences of intra-cranial disease, and we should look for signs of involvement of the sensory or motor root (see page 145). If such lesions last any considerable time, they tend to produce some anæsthesia of the affected nerve-area. Localised anæsthesia will suggest an organic neuritis rather than a mere neuralgia.

Let us now consider the various pains which may be met with in the trunk. Firstly, there are the various root-pains, due



to irritation of the corresponding posterior root or roots in the affected area. Sometimes such root irritation is due to disease of the spinal meninges (tubercle, syphilis, or tumour), to osteoarthritis, caries or tumours of the spinal column, or to intra-thoracic aneurisms and new growths. Bone pains in the spine are associated with local tenderness and rigidity. If we see a patient supporting his head with both hands owing to pain in the neck, this is almost pathognomonic of disease of the cervical vertebræ. Root-pain commencing unilaterally and later becoming bilateral is practically pathognomonic of a tumour of the spinal meninges. These pains when due to organic lesions of the roots, are not infrequently associated with a degree of hyperæsthesia or anæsthesia of the painful area—*anæsthesia dolorosa*. If the spinal cord be compressed or infiltrated by the same lesion as that which implicates the posterior roots, we have evidence of sensory or motor paralysis of the parts below the lesion, with the usual changes in the reflexes, &c. The *girdle-pains of tabes* are due to affection of the corresponding posterior roots. Tabetic girdle-pains vary in degree from the sensation of a narrow constricting cord to one of a broad cuirass enveloping a large part of the trunk. Such a cuirass often feels incomplete either in front or behind (Fig. 89, p. 205). Root-pains may also occur in some cases of disseminated sclerosis (*sclerosis multiplex dolorosa*), and unless this fact be borne in mind a false diagnosis of spinal tumour may be made.<sup>1</sup> Another root-pain is that associated with herpes zoster, which is a disease of the posterior root-ganglion. *Herpetic pain* is practically always unilateral, and may either precede or succeed the eruption of the herpetic vesicles. It may last for months after the vesicles have disappeared. The pain of herpes is often so sharp that it may be mistaken for that of pleurisy, from which it is distinguished by auscultation. Herpes zoster is often accompanied by a lymphocytosis of the cerebro-spinal fluid. Pleurodynia is a pain in one or more intercostal spaces, due to a "rheumatic" myalgia of some of the intercostal muscles. It somewhat resembles the pain of pleurisy, but is easily distinguished

<sup>1</sup> Frankl-Hochwart, *Neurologisches Centralblatt*, 1906, s. 973.



by the normal temperature and by the absence of friction-sounds on auscultation. There is also a very common trunk-pain which we meet with in people who are neurasthenic or debilitated. It is a deep boring pain, usually below the inferior angle of one or other scapula. It is more diffuse and less superficial than the pain of herpes, and it has none of the physical signs of pleurisy or pleurodynia. The pain of traumatic neurasthenia, especially after a railway or other accident ("railway spine"), may simulate that of organic spinal lesions, especially when a hysterical paraplegia coexists. But the diagnosis can usually be made by noting the excessive hyperæsthesia of the spine, the absence of signs of organic disease and the presence of various hysterical "stigmata" (see later, p. 365). Mammary neuralgia or mastodynia also occurs in hysterical and neurasthenic patients, and must be distinguished from disease of the gland by means of physical examination.

We have also to bear in mind the various *reflected pains* which may occur in visceral diseases. Thus, for example, in pericarditis there may be precordial or epigastric pain. Physical examination will clear up the diagnosis in cases of aneurism and of mediastinal growths. One of the most severe of all trunk pains is the well-known *angina pectoris*. This is a paroxysmal suffocative pain, or feeling of intolerable oppression in the region of the heart, often radiating down one or both arms, but especially down the left arm. Together with this, there is a sensation of impending death. It is commonest in male patients at or after middle life, and is usually, though not invariably, associated with evidence of vascular degeneration. It has to be distinguished from toxic or neuralgic angina, so-called "pseudo-angina," a similar but much less serious affection, met with most commonly in young girls, in women who have been lactating too long, or in patients before middle life who smoke tobacco or drink tea to excess.

Irritation of the sensory nerves at the gastric end of the œsophagus, by abnormal acids or other irritants in the stomach, may cause burning pain, usually referred to the seventh left chondro-sternal junction, and sometimes also to the left inter-



scapular region. Such pains are associated with other dyspeptic symptoms to which we need not here refer further. As regards the situation of reflected pains in diseases of various parts of the gastro-intestinal tract, it is useful to bear in mind Mackenzie's rule,<sup>1</sup> that pain due to affections of the digestive tract is referred across the middle line of the abdomen, in regularly descending areas as we pass from the stomach towards the large intestine. Thus the epigastrium is the region for gastric pains (disease at the cardiac end causing pain higher up than pyloric affections), the umbilical area is the region for pains of the small intestine, the hypogastric area the site of pains due to the large intestine. A striking experimental corroboration of this can be obtained at any time by taking a sharp purgative drug. When the familiar colicky pains appear, they are felt first in the region of the umbilicus, but soon they descend lower and lower, and when they arrive close above the pubes, the call for evacuation of the bowel becomes "urgent and imperative."

To discuss fully the various causes of acute abdominal pain would require many chapters of description. We have to bear in mind not only diseases of the gastro-intestinal tract, in the form of catarrh, ulcer, muscular spasm, &c., but also perforations of various hollow viscera, the stomach, gall-bladder, intestines (including the vermiform appendix), rupture of a pyo-salpinx or of a tubal pregnancy, biliary or renal colic, acute pancreatitis, torsion of an ovarian pedicle, &c. In every instance, not only should we carefully examine the whole abdomen, but we should, if necessary, examine the pelvis, *per rectum* or *per vaginam*, and investigate the urine and dejecta.

Apart from acute renal colic, a floating kidney is a fairly common cause of diffuse abdominal pain, especially in poorly-nourished women with lax abdominal walls. Here again, local examination of the abdomen will reveal the cause.

Before leaving the subject of abdominal pains, we must not fail to recall the familiar *crises* of *tabes dorsalis*:—gastric crises associated with pain and vomiting, intestinal crises associated with colic and diarrhoea, diaphragmatic crises with hiccough,

<sup>1</sup> *Brain*, 1901, vol. xxv. p. 373.



bladder crises, &c. All these may closely simulate the pain of acute abdominal disease. But the history of the case, together with an investigation of the pupils, knee- and ankle-jerks, and the other phenomena of tabes, will usually save us from error.

Lumbago, or pain in the lumbar muscles, a variety of myalgia, is usually easily recognised. The pain is intensified by active muscular contraction and also by passive stretching, caused for instance by the stooping posture. It is also associated with tenderness on pressure. Lumbo-abdominal neuralgia, on the other hand, is a diffuse and more superficial pain, not confined to the lumbar region but spreading forwards to the front of the abdomen, and sometimes to the groin, genitals or gluteal region. It is paroxysmal, and during the paroxysm there may be cramp-like spasms of the abdominal muscles or of the cremaster. It is associated with the "tender points" of a true neuralgia, these being situated over the vertebral spines, the iliac crests, the linea alba, inguinal canal, scrotum or labium. Sacral pain is often due to uterine disease, as in the familiar uterine dysmenorrhœa or the well-known pains of labour.

Coccygodynia or neuralgic pain in the region of the coccyx, is practically confined to the female sex. The pain may be spontaneous, or it may be induced by sitting or walking or by the contraction of any of the muscles attached to the coccyx, *e.g.* during defæcation. It is often associated with local tenderness. Before making a diagnosis of mere neuralgia, local disease of the coccyx or of adjacent structures must always be excluded by local examination, both externally and *per rectum*.

**Pains in the Limbs.**—Brachial neuralgia, generally a unilateral affection, is referred, as a rule, to the whole area of distribution of the plexus, namely to the lower part of the neck, the shoulder and the whole upper limb, being most intense in the proximal part of the limb. It is rare to meet with neuralgia confined to an individual nerve-area, such as that of the median or ulnar, except in cases of local injury or disease of the nerve-trunks. The pain of brachial neuralgia is aggravated by movement of the limb, which feels heavy and numb, though there is no



paralysis. The "tender points" are over the nerve-trunks, such as the musculo-spiral, circumflex, median or ulnar nerves.

If anæsthesia or trophic changes be superadded, we probably have to do with structural changes in the nerve-trunk, that is, with a neuritis, not a mere neuralgia. In every case of brachial neuralgia we must carefully examine the nerve-trunks in their entire course, to exclude the possibility of organic lesions compressing or infiltrating the nerves. In addition to pain, brachial neuritis often produces weakness and atrophy of the corresponding muscles, and impairment or perversion of cutaneous sensation.

Analogous to brachial neuralgia and neuritis in the upper limb, we have in the lower limb *sciatica*, a term which includes sciatic neuralgia and sciatic neuritis. In every case of so-called sciatica we have to decide which of these two is present. In sciatic neuralgia there is usually a dull aching pain, more or less constant, in the back of the thigh, with occasional paroxysms of darting or boring pain, generally from above downwards, along the course of the sciatic nerve. Any movement of the limb whereby the nerve is made tense, or any local pressure as from sitting on a hard chair, brings on a paroxysm. Therefore the patient habitually keeps the hip and knee slightly flexed on the affected side, so as to relax the nerve. It is not uncommon to find a slight degree of scoliosis in the lumbar region, the concavity being towards the sound side. The "tender points" are at the fifth lumbar spine (especially on lateral pressure from the affected towards the healthy side<sup>1</sup>) over the posterior iliac spine, the sciatic notch, the popliteal space, the peroneal nerve below the head of the fibula, and behind the malleoli. Passive stretching of the nerve increases the pain, for example by flexion of the hip with the knee extended. Blunting of sensation in the peroneal or posterior tibial area is uncommon and indicates an organic neuritis or perineuritis, as also do any alterations in the electrical reactions of the muscles, or any considerable degree of muscular atrophy. In sciatic neuritis the temperature of the limb is generally lower

<sup>1</sup> Raimist, *Neurolog. Centralbl.*, 1909, p. 1087.



than on the healthy side. The ankle-jerks should always be tested on both sides. In sciatic neuritis the jerk may be diminished or lost, whereas in neuralgia it remains normal. In both affections we may observe exaggeration of the cremasteric reflex on the affected side.

*Meralgia paræsthetica* is a variety of neuralgia occurring in the area of distribution of the external cutaneous nerve of the thigh. It consists in paræsthesia or actual pain in the outer aspect of one thigh. The pain is often induced by standing or walking, possibly owing to stretching of the fascia lata. In some cases it results from the pressure on the nerve by a badly-fitting corset. It is sometimes associated with flat-foot on the same side. Here, as in brachial or sciatic pain, the presence of an area of impaired sensation would indicate a neuritis rather than a neuralgia.

In rare cases we may find neuralgia in the area of the anterior crural or of the obturator nerve, and this may be symptomatic of an intra-pelvic tumour, or of an obturator hernia.

The pains of brachial or sciatic neuralgia and neuritis, and of meralgia paræsthetica, are unilateral. Let us now consider the bilateral pains which may be met with in the limbs.

Bilateral pains should always suggest to our minds either a toxic cause attacking the peripheral nervous structures of both limbs, or some central disease of the spinal meninges affecting the posterior roots bilaterally, or again some angio-neurotic condition such as Raynaud's disease, erythromelalgia, or intermittent limp.

Pains in the muscles or joints are a common symptom in people who work under compressed air, as in divers or workers in deeply sunk caissons, whether under ground or under water. The symptoms of *caisson disease*, or "decompression paraplegia," are most likely to occur when the worker ascends too abruptly to the ordinary atmosphere. All such workers ought to pass through a "decompression-chamber," where the atmospheric pressure is gradually reduced to normal. If this be not done, bubbles of nitrogen are set free in the blood and may either form emboli in the arterioles of the central nervous system with consequent small foci of necrosis, or the nitrogen may effervesce out of the



capillaries into the nervous tissues, especially into the substance of the spinal cord. Capillary hæmorrhages may also occur. Clinically in such cases not only have we severe pains in the limbs but also aural symptoms due to labyrinthine affection:—deafness, giddiness and tinnitus, sometimes even actual rupture of the tympanic membrane. There may also be anæsthesia and paraplegia of spinal type, and such paralysis may be permanent. Slighter cases clear up quickly, if the air-extravasation has been merely from the capillaries without air-embolism of the arterioles.

The *lightning pains* of tabes may be unilateral or bilateral. They are commoner in the legs than in the arms, since tabes is a disease which generally begins in the posterior root-fibres of the lumbo-sacral region. These pains are variously described by the patient as stabbing, burning, tearing, or bursting, and are commonly associated with local hyperæsthesia of the skin. They are frequently mistaken for rheumatic pains, and all the more so inasmuch as they often coincide with changes in the weather.

Tight "tourniquet" pains around the lower limbs, in broad zones rather than narrow, are sometimes an early and persistent symptom in disease of the lumbo-sacral region of the cord. They are due to irritation of the posterior roots, and may also occur in tabes. Root-pains also occur, though less commonly, in certain cases of multiple sclerosis.

The *root-pains* of tumour or inflammation of the spinal meninges, or of spinal caries, are more or less constant, with paroxysmal exacerbations. Inflammatory affections of the meninges are usually bilateral from the outset, with corresponding bilateral pains. But in cases of meningeal tumour the pains are generally unilateral at first, and become bilateral as the disease spreads to the opposite side. The level of the pains in meningeal disease varies with the level of the affected posterior roots. Thus in cervical meningitis, tumour or caries, there is pain in the neck, spreading down one or both arms along the corresponding root-areas; in thoracic cases the pain is around the trunk, and in lumbar or sacral cases it is in various parts of the lower limbs. Meningeal pain is often associated with local hyperæsthesia corresponding to the uppermost



roots affected, and with tonic spasms of the muscles at that level. If the meningeal lesion affects the cord within, whether by compression or by infiltration, there will be in addition to root-pains the other signs of organic cord disease—so-called *paraplegia dolorosa*, with its anæsthesia, motor weakness and alterations of reflexes below the level of the lesion. Inflammatory, tuberculous and syphilitic affections of the spinal meninges are always associated with cellular changes in the cerebro-spinal fluid (see p. 411).

Affections of the peripheral nerves may also produce pain. Thus in peripheral neuritis there is not only pain, with hyperæsthesia of the skin of the feet and hands, but there is intense muscular tenderness on pressure, together with a degree of tactile anæsthesia, and in severe cases muscular paralysis and muscular atrophy, accompanied by the reactions of degeneration.

Pains localised in single nerve-areas should always lead us to examine the nerve-trunk in its entire extent. *Tubercula dolorosa* are multiple growths (usually neuro-fibromata) in the connective tissue of the nerve-trunks, many of them forming little subcutaneous nodules easily palpable and exquisitely tender, others less accessible in the deeper nerve-trunks, causing referred pains in the particular nerve areas. If these growths not merely irritate but interrupt the nerve-fibres within the nerve-trunks, there may in rare cases be areas of anæsthesia. Clinically we seldom find motor paralysis from such growths, except as a result of pressure on the spinal cord or base of the brain by a neuroma on one of the spinal or cranial nerve-roots.

It is convenient here to refer to erythromelalgia, where there are cyanosis and pain in one or both feet in the dependent posture, relieved by elevating the limb; to Raynaud's disease, which may be associated not only with local pallor, cyanosis or gangrene, but also with subjective sensations of tingling or pain; and to intermittent limp, when the patient after a few steps becomes unable to walk farther, owing to intolerable pain in the muscles of the leg. To these conditions we shall return later, when studying the nervous affections of the vascular system.

Paroxysmal spontaneous pain in the periphery of a limb,



ascending towards the trunk, sometimes occurs as a variety of sensory fit in gross disease of the cortical sensory areas in the contralateral post-central gyrus. Thus in one case of my own, where there was a focal lesion of the left post-central gyrus, the earliest symptom was paroxysmal pain in the right fingers and hand.<sup>1</sup>

Finally, we should refer to the group of pains met with in hysteria and neurasthenia. These are more often areas of hyperæsthesia than of spontaneous pain. They are specially common in the neighbourhood of joints, whose slightest movement causes intense pain. In other cases the muscles are apparently hypersensitive, so that any attempt at movement of the limb, active or passive, causes an illusion of pain—so-called *akinesia algera*, of psychical origin. But the history of the case, in which there has often been a preceding local injury, the absence of signs of structural disease, local or central, and the presence of other hysterical or neurasthenic phenomena, will aid us in our diagnosis. It may be necessary to give a general anæsthetic in order to eliminate gross local organic disease.

<sup>1</sup> *Review of Neurol. and Psychiatry*, 1908, p. 379.



## CHAPTER XII

### ABNORMALITIES OF SENSATION: HYPERÆSTHESIA, PARÆSTHESIA, ANÆSTHESIA

WE have already considered the anatomical course of the chief sensory paths from the periphery to the perceiving centres in the brain (Chapter I.). Let us now proceed to consider the methods of clinical investigation of the various forms of sensation.

All parts of the surface of the body are not equally sensitive. Thus the tip of the tongue, the lips, the finger-tips, in the order mentioned, are most sensitive to cutaneous impression, whilst other parts such as the dorsal aspect of the trunk, the upper arm, and the calf of the leg, are least sensitive. These differences depend on various factors, such as thickness of epithelium, relative abundance of sensory end-organs, &c., into which we need not enter more minutely here.

All sorts of ingenious apparatus have been devised for the accurate measurement of minute differences in sensibility to touch, pressure, pain, temperature, and so on. But for clinical diagnosis, we should avoid complicated apparatus and content ourselves with the simplest possible methods which, while accurate enough for practical purposes, do not impose too great a strain on the patient's attention nor demand too high a degree of intelligence on his part.

The most important varieties of sensory stimuli which we employ in testing a patient's sensory functions are light touches, pin-pricks, cold and hot objects, all of which refer to *cutaneous sensations*. We have also to consider other sensations, such as *joint-sensation* (or sense of position on passive movement), *active muscle-sensation* (kinæsthetic sense, or sense of active muscular contraction) and, lastly, the *vibration sensation* produced when a sounding tuning-fork is placed over the subcutaneous surface of



a bone or upon a finger-nail. There are other varieties of sensory stimuli, such as electro-cutaneous sensibility (which is generally, but not always, parallel in intensity with the pain-sense), and there is the sensation of pressure and appreciation of differences of pressure, &c. But these, though physiologically interesting, are of minor clinical value.

There is perhaps no better criterion of neurological dexterity than the accuracy with which an observer can map out areas of diminution or loss of sensation on the one hand, or of perverted or exalted sensation on the other. Both experience and patience are required, in order to obtain trustworthy results.

Inasmuch as we are largely dependent on the intelligence and goodwill of our patient for accurate answers, we must as far as possible try to eliminate all distracting outside factors. Therefore we direct the patient to close his eyes when we are testing sensation, so that his attention may not be diverted by watching what is being done. We must also be careful not to weary a patient by too prolonged examination, lest as he gets tired or impatient his answers become inaccurate. The simpler our methods of examination, the better are our results likely to be. We have also to contend with wide variations in the intelligence of different patients, in their education, and in their attentiveness; this latter may be modified by pain, by anxiety, or by psychical deficiencies. Sometimes we have to deal with deliberate attempts on the part of the patient to mislead us. Fortunately, patients who simulate disease generally make blunders so gross as to prevent an erroneous diagnosis on the part of a careful observer. Of course the physician must be careful to avoid suggesting the presence of sensory changes to the patient under examination.

**Clinical Investigation of Sensation.**—At the start, the patient's eyes should be closed, or some object should be interposed between his eyes and that part of the body which is being tested. We then proceed to test the various *cutaneous sensations*—touch, pain and temperature, separately and in turn.

*Touch* is tested by means of some soft light object, such as a



tuft of cotton-wool, a feather, or by gentle pulling or stroking of the hairs. Loss of sensation in the hairs is called "tricho-anæsthesia." *Pressure* is tested by means of a pencil or other blunt object; if such pressure be steadily increased a "deep" sensation of pain is ultimately produced. *Cutaneous pain* is tested by pricking, or better by scratching, with a sharp needle; *cold* by blowing on the skin, or by a cold object such as a metal spoon or a test-tube containing ice-cold water; *heat* by breathing on the skin or by a warm object such as a test-tube containing hot water.

Each variety of sensation should be examined separately, before passing on to the next kind of stimulus, and the results should be recorded on an outline-chart of the body. In mapping out areas of abnormal sensation, it is useful to have a skin pencil with which to mark the patient's skin, before copying the result on our chart.

An important practical point in mapping out areas of anæsthesia, is to begin within the anæsthetic area, and to work towards the normal skin, not in the reverse direction. It is easier for a patient to recognise the moment when he first feels a sensation than for him to observe when he first loses it. On the other hand, in mapping out areas of hyperæsthesia or of paræsthesia, we should work from normal skin towards the hyperæsthetic area, asking the patient to call out as soon as his sensation changes.

In setting about the examination of the sensory functions, we usually begin with that of touch. The patient's eyes being closed, we touch him lightly on both sides of the face simultaneously and observe not only whether he feels the touches, but whether they are equally distinct on the two sides. We then touch symmetrical spots on the neck, shoulders, hands, trunk, and lower limbs. We next proceed to do the same with light needle-scratches, then with cold and with warm objects. If the patient has an area of diminished or altered sensibility, we generally discover it by this method. When we find an area of abnormality, we proceed to map it out carefully, making separate observations for touch, pain, and temperature, and noting whether the areas coincide or overlap.

Besides noting whether a patient feels a stimulus, for instance a



tactile one, we should also notice whether he localises it accurately. This is accomplished by asking him to place his finger on the spot where he was touched, for instance, the dorsum of the hand. A normal individual can do this accurately to within a fraction of an inch. But in certain varieties of anæsthesia, the patient, whilst able to tell that he has been touched, makes an error of several inches in localisation. This is called "atopognosis." Horsley<sup>1</sup> maintains that errors in the localisation of cutaneous impressions are, in cases of cortical lesions, always in a proximal direction, *i.e.* the patient refers the stimulus to a point higher up the limb. Sometimes the patient, when touched on one side of the body, feels the sensation at the corresponding spot on the opposite side. This is termed "allocheiria," and occurs chiefly in certain cases of hysteria.

When testing pain, we sometimes find that though the patient correctly perceives and localises the stimulus, there is an abnormally long interval of time, perhaps amounting to several seconds, between the stimulus and the patient's perception of pain. This is called "delayed sensation," and is met with chiefly in cases of tabes.

When charting areas of very slight cutaneous anæsthesia, it is often difficult, despite the utmost care as regards our stimuli, to obtain an exact outline of the area of altered sensibility. Changes in the quality of sensations may exist which are undetectable even by cotton-wool touches. Nevertheless the patient, if he tests his own skin, may be conscious of an abnormality too delicate to be discovered by another person on objective examination. But if we have a specially intelligent patient and get him to explore his anæsthetic area by stroking with his own finger, indicating where he perceives a line of transition between normal and abnormal, it is often possible for him, by such "auto-exploration," to map out the area of altered sensibility with great accuracy.<sup>2</sup>

So much for cutaneous sensations. But there are other forms of sensation which are of clinical importance. *Joint-sense* is tested by moving a joint passively into various positions backwards and

<sup>1</sup> *Brain*, 1906, p. 137.

<sup>2</sup> Trotter and Davies, *Rev. of Neurol. and Psych.*, 1907, p. 761.



forwards, then holding it fixed in a certain position, such as that of semi-flexion, and asking the patient to imitate exactly that position with the limb of the opposite side. It not infrequently happens that when a patient is in doubt as to the position of his joint, he begins to make slight voluntary movements of the joint before answering. These must not be permitted, since he thereby gains information as to the position of the limb, not from his joint-sense but through an entirely different sense, viz., the kinæsthetic sense or sense of active muscular contraction.

To test this *kinæsthetic sense*, we notice whether the patient, when raising his limbs, can detect differences in the weights of objects of similar size, for example a shilling and a sovereign, either placed in his hand, or hung in a sling over his hand or foot. For this purpose we sometimes employ a series of leather or wooden balls of equal size, loaded with different weights. Normally, according to Weber's law, a healthy individual should detect an increase of one-third in the weights of two successive objects. Tabes is the disease in which this sense of active muscular contraction is most markedly diminished, and where the joint-sense is notably impaired also. The loss of these two senses is probably the main factor in the production of tabetic ataxy.

We purposely avoid using the term "muscular sense," for several reasons. Firstly, it is ambiguous, since it has been used to include two entirely different senses:—joint-sense and kinæsthetic sense. Moreover, it might also be confounded with a third sense, the *sensibility of muscles to pressure* with the fingers. Normally such pressure, if moderate in degree, is painless; but in certain diseases, as in peripheral neuritis, in the various forms of myositis, and in the abdominal muscles superficial to an area of peritonitis, the muscles become exquisitely tender to the lightest pressure. On the other hand, it is common to find in tabes that severe compression of the muscles and tendons, for example of the leg muscles, and especially of the tendo Achillis, is painless (Abadie's sign). This muscle and tendon analgesia is often present in early stages of the disease.

It is sometimes of value to observe the patient's power of



recognising, without seeing them, the forms of solid objects placed in his hand—so-called *stereognostic perception*. Normally a patient should be able to recognise familiar objects such as a key, a coin, or a chain. But in some cases the patient, though able to feel the presence of some object, cannot describe its form and qualities, without seeing it. Such “astereognosis” may be due to impairment of sensation either from peripheral disease, from thalamic lesions, or from disease in the cortical centres.

Lastly, there is the *vibration-sense* (pallæsthesia, or “osseous sense”) described originally by Egger. This is tested by means of a low-pitched tuning-fork, which is set into vibration and placed upon the subcutaneous surface of a bone. In normal individuals a characteristic vibratile thrill is felt. But in certain diseases involving the posterior roots, such as tabes, or in transverse lesions of the spinal cord, the vibration-sense may be lost in the bones corresponding to the affected roots (Fig. 83). Loss of this sense may be the earliest form of anæsthesia in root-lesions as in tabes, where it sometimes precedes cutaneous anæsthesia. In Brown-Séquard paralysis vibration-sense is lost on the same side as the muscular paralysis<sup>1</sup> (see Figs. 10 and 13). But the vibration-sense is not an exclusive property of bones, though bones are most strikingly sensitive; it can be perceived in other tissues, notably in the nails, which are closely connected with the periosteum, and even in the connective-tissues, though in them less intensely.

Excessive sensitiveness to normal stimuli is termed *hyperæsthesia*. Such hyperæsthesia is usually accompanied by a degree of discomfort or even pain, even though a stimulus be used which is ordinarily painless. The term *paræsthesia*, or perversion of sensation, signifies that an ordinary stimulus evokes an unusual sensation, as for example a feeling of tingling when the skin is

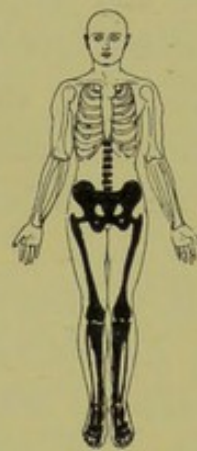

FIG. 83.—Tabes with loss of vibration-sense in bones of lower limbs, pelvis, lumbar, and lower dorsal vertebræ. The bones with loss of vibration-sense are shaded black.

<sup>1</sup> Vide Bing, *Neurolog. Centralblatt*, 1910, p. 173.



touched, or a feeling of acute pain when moderate cold is applied. Under the head of paræsthesiæ we may also include such phenomena as multiple sensations (polyæsthesia), allocheiria, &c.

Strictly speaking, diminution of sensation should be designated *hypo-æsthesia*, and the term anæsthesia should be reserved for total loss of sensation. It is usual, however, to speak of "slight," "moderate," and "total" anæsthesia. When only one form of cutaneous anæsthesia is referred to, we sometimes find it convenient to talk of *tactile anæsthesia*, of *analgesia* or loss of pain-sense, and of *thermo-anæsthesia* or loss of temperature-sense. *Dissociated anæsthesia* is where some forms of sensation, such as tactile sense, are normal, whilst in the same area others, such as pain and temperature-sense, are lost. This occurs especially in syringomyelia and in the Brown-Séquard syndrome.

We speak of *hemi-anæsthesia* where one-half of the body, right or left, is affected, and of *para-anæsthesia* where both legs or both arms are affected owing to a lesion of the spinal cord or to a symmetrical affection of the posterior roots. We also speak of radial, ulnar, peroneal anæsthesia, &c., where the sensory loss corresponds to the distribution of a single peripheral nerve.

**Hyperæsthesia.**—Universal hyperæsthesia is rare. It is chiefly met with in hysteria, but also occurs in other affections, as in strychnia-poisoning, where the slightest touch may suffice to evoke a violent spasm. Hemi-hyperæsthesia is chiefly found in neurasthenic and hysterical patients and may be associated with other hysterical "stigmata." Thus I remember the case of a soldier with traumatic hysteria who had hemi-hyperæsthesia, accompanied by abnormal widening of the visual field and by increased acuity of smell, taste, and hearing, all on the hyperæsthetic side of the body.

In the thalamic syndrome, hemi-hyperæsthesia to temperature and pain sometimes coexists with hemi-anæsthesia to tactile stimuli and with impairment of joint sense, loss of osseous sense and astereognosis in the affected limbs.

Hyperæsthesia in more or less symmetrical root-areas of the trunk or limbs, due to irritation of the posterior roots, is not



uncommon in diseases causing pressure on the spinal cord or its meninges, as in caries or tumours of the spine. Here the hyperæsthesia corresponds to the area supplied by the uppermost root involved, and is usually associated with anæsthesia and motor weakness in the parts below.

Odd irregular areas of hyperæsthesia are amongst the commonest stigmata of hysteria, and do not correspond either to root-areas or to the distribution of peripheral nerves. Tender areas are particularly common over hysterical joints and over certain vertebral spines in hysteria, and we frequently notice that the lightest touches cause severe pain, whereas, when the patient's attention is diverted, deep pressure on the same spot may be painless. Pressure on such tender spots may sometimes excite a hysterical attack—"hysterogenic" areas—and in other cases may restrain or stop an attack—"hysterofrenic" areas. To this subject we shall return when discussing the diagnosis of hysteria.

Next in frequency after hysterical hyperæsthesia are the areas of cutaneous hyperæsthesia in tabes. Tactile hyperæsthesia is specially common in cases with gastric or other visceral crises, in the root-areas corresponding to the viscus affected. It is also common in the areas where lightning-pains are felt, and like these pains it may be one of the earliest evidences of the disease. Thus a patient with incipient tabes, for years before he reached the stage of ataxia, was so hyperæsthetic around the trunk that it was agony for him to pull his shirt on, or to sponge his body when bathing. Tabetic hyperæsthesia may occur not only on the trunk but also on the limbs, and even on the face. Hyperæsthesia is specially frequent round the orbits in cases of tabetic ocular palsies.

Hyperæsthesia in the areas of peripheral nerves occurs in the true neuralgias, as in trigeminal neuralgia, where the neuralgic area is often exquisitely tender, especially over the foramina of exit of the various branches. The patient may be unable to wash his face for weeks at a time, since the lightest touches induce a paroxysm of neuralgia. Localised hyperæsthesia sometimes precedes the eruption of herpes zoster, and may persist for weeks or months after the eruption has passed away. Lastly,



we may mention the hyperæsthesia of the hands and feet in multiple neuritis, where there is often present a degree of anæsthesia. The coexistence of hyperalgesia to light pressure with anæsthesia to light touches is very characteristic of alcoholic neuritis.



FIG. 84.—Universal anæsthesia in a hysterical patient. Sterilised safety-pins have been pushed through the skin on both sides without producing bleeding. Hysterical contracture of left hand is also present.

**Paræsthesia**, or perverted sensation, has much the same diagnostic significance as hyperæsthesia. It may also be mentioned that when a peripheral cutaneous nerve is in process of recovery after an injury, there is often a stage of paræsthesia through which the skin passes before normal sensation is restored.



**Anæsthesia.**—Universal anæsthesia of the skin and accessible mucous membranes to all forms of stimuli is exceedingly rare, occurring only in hysteria. Fig. 84 shows such a case in a girl, in whom it was possible to push pins through the skin on both sides of the body without causing pain.

Hemi-anæsthesia always indicates a central affection. In every case of hemi-anæsthesia we must determine whether the disease is functional or organic, and if organic, at what level in the sensory tract the lesion is situated, whether in the cortex, internal capsule, or lower down.

*Hysterical hemi-anæsthesia* is commoner than organic. It varies in degree, from total anæsthesia down to the slightest degree of comparative blunting of sensation, only discoverable on comparison of the two sides. Not uncommonly it tends towards the "segmental" type, and it is frequently accompanied by other hysterical stigmata, especially by blunting of the special senses on the hemi-anæsthetic side, particularly by concentric contraction of the visual field, and by other features which we shall study later. We should remember that hysteria sometimes coexists with organic disease, thereby complicating the diagnosis.

*Organic hemi-anæsthesia* may also vary in its degree, from slight to severe anæsthesia; but it is never absolute in degree as in some cases of hysteria. It is generally more marked on the limbs than on the trunk or face, and more intense at the periphery of a limb than at its proximal end. It is never marked off by a sharp line running across the limb, as in the "segmental" anæsthesia of hysteria, but fades gradually in intensity as we pass from the hand to the shoulder. A degree of atropognosis is always present in organic hemi-anæsthesia. The special senses are unaffected (their paths probably do not traverse the internal capsule), with one exception, namely that of vision, in cases where the lesion implicates the optic radiations. But here again we get a homonymous hemianopia, unlike the hysterical contraction of the visual field to which we shall refer later.

If we find that a hemi-anæsthesia is organic in origin, we have then to determine whether the lesion is cortical in situation or



whether it is lower, in the internal capsule, optic thalamus, or elsewhere. In cortical hemi-anæsthesia the other signs of cortical disease will aid the diagnosis. The presence of monoplegia rather than hemiplegia, or the occurrence perhaps of Jacksonian fits, will point to a cortical localisation, remembering that the cortical motor areas are also partly sensory. Cortical anæsthesia is less profound than capsular, and is most distinct at the periphery of the affected limb. Indeed, in cortical anæsthesia it is the rule for the trunk to be little or not at all affected. Marked astereognosis and atopognosis with but slight tactile and motor loss will also point to a cortical lesion, probably in the upper parietal region.

Capsular hemi-anæsthesia (which, by the way, is generally the result of a lesion not actually in the capsule but in the postero-external part of the optic thalamus) is never monoplegic in type but always affects the entire half of the body, including the trunk. Hemi-anæsthesia from a thalamic lesion, as we have seen, is associated with paroxysmal pains of intolerable severity in the affected limbs and side of the face, and sometimes with hemi-hyperæsthesia to pain and temperature. The thalamic syndrome also includes hemi-ataxy of the limbs and spontaneous choreiform or athetoid movements. The deep reflexes are unaffected, and the plantar reflex remains of the normal flexor type, since the pyramidal motor path is intact. Such cases often have a history of transient motor hemiplegia at the onset, but this motor weakness rapidly disappears and is succeeded by paroxysmal pains in the hemi-anæsthetic limbs and face. The intensity of capsular or thalamic anæsthesia is deeper than in cortical cases, but not so markedly intensified at the periphery of the limbs. It is associated with hemianopia if the lesion extend backwards, or with motor hemiplegia, most marked in the leg (but not a monoplegia), if the lesion extend forward into the pyramidal motor path.

We may also have hemi-anæsthesia from organic lesions of the sensory path below the level of the optic thalamus; in fact, at any level above the sensory (fillet) decussation in the medulla. Such lesions, although uncommon, can be correctly localised by the coexistence of other signs. Thus a unilateral lesion



in the *dorsal aspect of the pons*, implicating the trigeminal nerve or nucleus, together with the remainder of the sensory fibres belonging to the other side of the body, will cause a *crossed hemi-anæsthesia*, *i.e.* anæsthesia of the face on the side of the lesion, and of the arm, trunk, and leg on the opposite side (Fig. 12, p. 18). A lesion of the sensory path in the medulla below the level of the trigeminal nerve, must be more widespread laterally to produce a complete hemi-anæsthesia, since the path for temperature and pain is here at some distance from the tactile path (Fig. 11, p. 17).

Anæsthesia also occurs in certain lesions of the spinal cord. We should note, however, that there are many cord diseases in which anæsthesia is absent, such as progressive muscular atrophy, amyotrophic lateral sclerosis and acute anterior poliomyelitis. Disseminated sclerosis is also a disease in which sensory changes are frequently absent. But if the spinal cord be destroyed or divided at a certain transverse level, whether by trauma or by disease such as acute softening, whereby sensory as well as motor paths are interrupted, all the sensory impressions ascending in the posterior and lateral columns (Figs. 8 and 10, pp. 10 and 14) will be lost below the level of the lesion. We then have a *para-anæsthesia*, the upper limit of which corresponds with that of the highest sensory root affected. And since in many of these cases there are irritative or inflammatory processes affecting the roots immediately above the area of destruction, it not unfrequently happens that there is a narrow zone of paræsthesia or of hyperæsthesia immediately above the anæsthetic area. In cases where the cord is gradually compressed by progressive disease in the meninges or vertebræ, there is usually a progressive paraplegia with the usual alteration of reflexes. Here anæsthesia appears late in the disease, being preceded by spontaneous subjective sensations or *dys-æsthesiæ*, after which hyperæsthesia appears, and last of all anæsthesia. The anæsthesia of a total transverse lesion implicates all forms of sensation, both superficial and deep.

When a cord lesion is incomplete in its transverse extent, certain forms of sensation may escape. Thus unilateral lesions of the cord produce *Brown-Séguard paralysis*. Most commonly this is the result



of a stab or bullet-wound, but it may also be caused by softenings or growths. Or a lesion which was originally more extensive, *e.g.* a hæmorrhage, may clear up so as to become a unilateral one. In the typical Brown-Séquard syndrome, as will be seen from Figs. 10 and 13, there are on the side of the lesion the well-known motor and vaso-motor paralyses, together with loss of sensation in the joints and muscles and loss of vibration-sense, whilst on the opposite side there are thermo-anæsthesia, analgesia and some tactile anæsthesia. In thermo-anæsthesia from cord lesions, the areas of anæsthesia to cold and to heat are sometimes co-extensive. But this is not always so; sensibility to heat may be abolished without loss of sensibility to cold, or *vice versa*, or the areas of loss to heat and to cold may differ widely in extent. If the lesion be above the lumbar enlargement, as is generally the case, the motor paralysis is of the upper neurone type, with spasticity, increased deep reflexes and an extensor type of plantar reflex. If, as sometimes happens in stab-wounds, the lesion destroys the most lateral

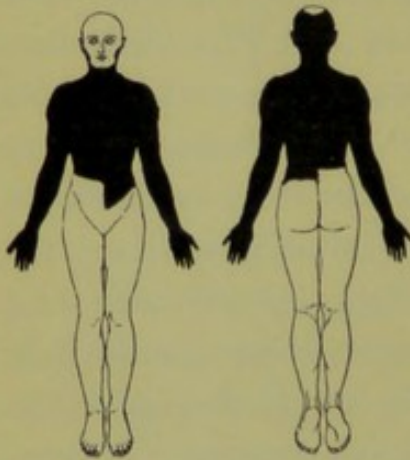


FIG. 85.—Syringomyelia, indicating area of thermo-anæsthesia and analgesia in the patient shown in Fig. 86.

region of the cord but does not quite reach the middle line, thereby sparing the postero-internal column, the deep structures on the side of the lesion preserve their sensibility. In any case, on the side of the lesion, a narrow zone of anæsthesia exists, corresponding to the posterior root-fibres cut across at the level of the lesion. And above the anæsthesia there is a zone of hyper-æsthesia from irritative root-changes.

*Dissociated anæsthesia*, often without motor paraplegia, is characteristic of disease in the region of the posterior cornua of the cord or in the substantia gelatinosa of the medulla, as in syringomyelia and syringobulbia, where there are analgesia and thermo-anæsthesia, with loss of vibration-sense, corresponding to the area of spinal cord affected, whilst tactile sensation remains unimpaired (see Fig. 85). The patient often burns his fingers accidentally



without pain, and he may develop painless whitlows in his analgesic fingers—so-called Morvan's disease. He may also have spontaneous joint disintegrations, with fractures and osteophytic or destructive changes in the articular ends of the bones. In most cases of syringomyelia there also is some atrophy of the anterior cornua; we should therefore be on the look-out for a coexisting muscular atrophy of spinal type, involving especially the small muscles of the hands. If the pyramidal tracts

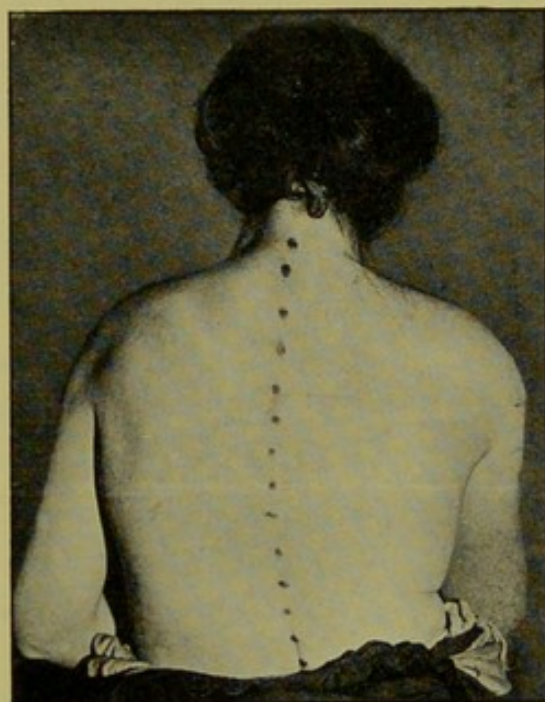


FIG. 86.—Syringomyelia with arthropathy of right shoulder-joint and scoliosis.

become involved in syringomyelia, a spastic paraplegia is super-added, and sooner or later a degree of scoliosis or even kyphoscoliosis develops (Fig. 86).

But unilateral cord lesions and syringomyelia are not the only diseases which produce dissociated anæsthesia. A small lesion such as an area of softening or of new growth, in the *ponto-cerebellar angle* of the pons at the level of the auditory nerve, will cause deafness of the same side with analgesia and thermo-anæsthesia of the opposite side, tactile sensation being unaffected. If the cerebellar peduncle be involved, there will be cerebellar phenomena also, such as we have already studied.

*Tabetic anæsthesia* is the commonest of all organic anæsthesiæ.



In this disease the sensory loss tends to follow fairly closely the distribution of the posterior roots affected by the tabetic process. Thus it is commoner in the lower limbs than in the upper. Joint-sense and vibration-sense usually become impaired earlier than cutaneous sensations, whilst analgesia precedes tactile anæsthesia. In the upper limbs the fingers on the ulnar side of the hand are usually affected earlier than the other digits, and there is often

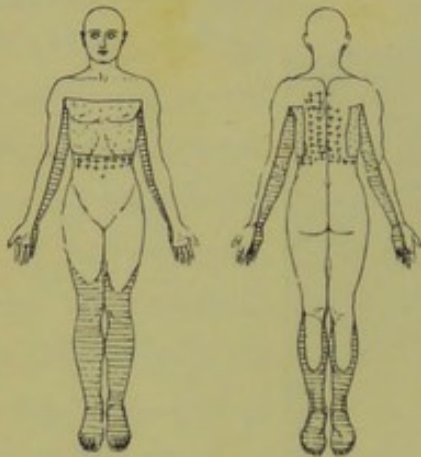


FIG. 87.—Early tabes, showing “cuirass” of subjective girdle-feeling (dotted area) with zone of cutaneous hyperæsthesia below the cuirass, passing up between its limits posteriorly (crosses). Analgesic areas (horizontal shading) in upper limbs ( $C_8$  and  $Th_1$  roots) and in lower limbs ( $L_4$ ,  $L_5$ , and  $S_1$  roots).

a strip of analgesia running longitudinally along the inner side of the whole upper limb, corresponding to the eighth cervical and first thoracic roots (Fig. 87)

In many tabetics the ulnar nerve behind the elbow loses its normal sensitiveness on pressure—Biernacki’s sign. And on the trunk it is common to find a broad zone of analgesia, and sometimes of tactile anæsthesia as well, the upper border of which is at the level of the second ribs in front. This zone is often incomplete laterally or posteriorly, just as the subjective “cuirass” sensation may be. Analgesia of the glans penis is another early sign of tabes, also loss of the normal tenderness of the testicle

on pressure. Tendinous analgesia, on pinching the tendo Achillis (Abadie’s sign), is also present in the majority of tabetic patients. But tabetic anæsthesia is not always sharply limited to root areas, and we should seek for confirmatory evidence of the disease in the pupils, deep reflexes, cerebro-spinal fluid, &c.

Anæsthesia in peripheral nerve palsies of sensory or mixed nerve-trunks, is of course confined to the distribution of the affected nerve or nerves. If a cutaneous nerve be paralysed we have loss of “epicritic” and “protopathic” cutaneous sensations, whilst the deep sensibility in muscles, bones and tendons is still preserved (see p. 14). If a mixed nerve-trunk be paralysed, muscular paralysis with atrophy is added to anæsthesia,



both cutaneous and deep, and the diagnosis, as a rule, presents no difficulties. It must be borne in mind that as a mixed nerve recovers from its paralysis, sensation usually returns before motor power and protopathic sensation before epicritic. The anæsthesia following an attack of herpes zoster sometimes lasts for a considerable time after the eruption has disappeared. In the anæsthesia of multiple neuritis, whether resulting from alcohol, diphtheria, diabetes, septic poisoning, or other causes, the disease is generally

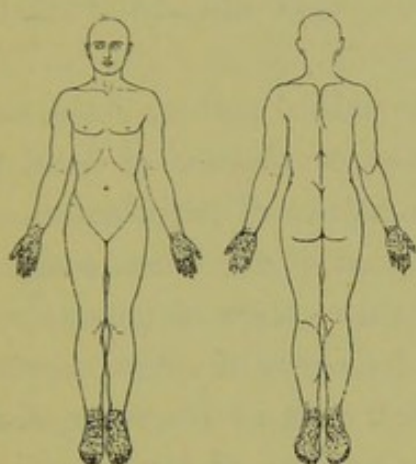


FIG. 88.—From a case of multiple neuritis, showing “glove” and “sock” areas of anæsthesia.

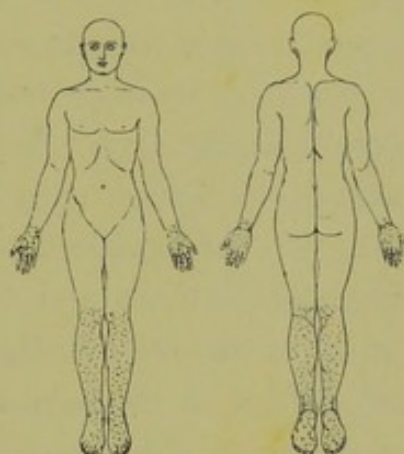


FIG. 89.—From another case of peripheral neuritis, showing “glove” and “stocking” areas of cutaneous paræsthesia.

bilateral and symmetrical, affecting hands or feet or both. Subjective tingling sensations usually precede the anæsthesia, which is of the “glove” and “sock” variety, not marked off sharply as in the “segmental” anæsthesia of hysteria, but shading off gradually at the upper margin (see Figs. 88 and 89). Most cases have also some superadded motor weakness in the form of drop-foot and drop-wrist. Lead paralysis differs from ordinary peripheral neuritis in being entirely a motor palsy, free from sensory changes, and whilst affecting the muscles innervated by the musculo-spiral nerve, it usually leaves the supinator longus unimpaired. Moreover, the extensor communis is less severely paralysed than the extensor indicis and extensor minimi digiti.



## CHAPTER XIII

### ORGANIC MOTOR PARALYSIS OF UPPER NEURONE TYPE

IN the investigation of the various motor palsies, apart from those affecting the cranial nerves which we have already studied, we should proceed in a definite order.

We commence by inspection of the palsied limb or limbs, noting the posture of the limb, the presence or absence of local muscular atrophy or hypertrophy, the existence of pathological swellings, &c. We then proceed to palpation of the bones and joints, following their outlines and testing their range of passive movement, so as to discover whether the deficiency of active movement may not be due to mechanical causes, such as fractures, dislocations, ankyloses, adhesions or inflammations of bones or joints, and so on. Thus in the case of a semi-comatose lady, whom I saw within a few hours after a carriage accident, there was apparent inability to move the left arm or leg. This might have suggested a lesion of the right cerebrum producing hemiplegia, but a preliminary investigation of the bones showed that the left femur and left clavicle were broken. It was therefore unnecessary to diagnose an intra-cranial lesion of the pyramidal tract, especially as the plantar reflexes were normal on both sides. The result proved the correctness of this view.

We should also observe whether the muscles of the affected part are rigid, stiff and spastic, or whether they are loose, relaxed and flaccid.

Lastly, we proceed to investigate the patient's powers of voluntary movement of the affected limb. In doing this, it is not enough to tell the patient in general terms, to "move the arm," and so on. We should test each joint and each movement separately, fixing the proximal part of the limb and instructing the patient to perform various movements:—flexion, extension.



rotation inwards and outwards, &c., separately and distinctly. Thus, for example, when we direct a patient to pronate his forearm, we must fix the humerus and see that he does not abduct the shoulder to make up for deficiency in pronation. To determine whether a particular muscle is taking part in a movement or not sometimes requires very close observation, not only by inspection but by palpation of the muscle or of its tendon. But, as Beevor has remarked,<sup>1</sup> the physician "must avoid the error of assuming that the tightening of a tendon from the stretching of a passive muscle is evidence of contraction of the muscle."

Suppose that a particular movement of a limb is deficient, we estimate the deficiency in different ways, according to its degree. If the weakness is slight, we detect it by interposing some resistance, so as to load the muscles. This is accomplished either by means of weights, or, in the case of the hand, by making the patient squeeze our hand or compress an oval spring-dynamometer or, in the case of the leg, by holding the limb down and making him elevate it against resistance.

If the weakness is more marked, it can be detected without loading the muscles. The weight of the distal part of the limb may already be too much for the muscles to lift, as, for example, in cases of drop-wrist and drop-foot, due to weakness of the extensors of the wrist and dorsiflexors of the foot. But even in these, a minimal degree of voluntary contraction may perhaps still be present, and can still be detected by placing the limb passively in such a posture that its own weight is no longer a factor, *e.g.* by testing the extensors of the wrist with the forearm midway between pronation and supination, or testing the movements of the elbow by passively abducting the upper arm and getting the patient to flex and extend his elbow in a horizontal plane. Or we may even observe the limb when it is supported on all sides by water, as in a warm bath. In this way we may detect minimal movements. And in such cases we watch carefully, not only for movement of the joint, but for contraction of the tendons of the

<sup>1</sup> *Croonian Lectures*, 1904, p. 4.



muscles concerned. These latter may sometimes be felt to contract, when they are too feeble to overcome the inertia of the joint.

By inspection and palpation we also note whether in the affected limb the muscles are normal in volume and firmness, whether some are enlarged and stronger than usual—*hypertrophy*—or whether some are diminished in size—*atrophy*, so that there is flattening, or even hollowing, in place of the normal muscular contour. In some cases, an apparent increase in volume is accompanied by weakness of the enlarged muscles—so-called *pseudo-hypertrophy*.

If a muscle is atrophied, its electrical reactions, both to faradic shocks and to the continuous galvanic current, should be investigated. The reactions may be normal, or they may be merely quantitatively diminished. Or they may be qualitatively altered, as in the “reactions of degeneration” (see later, p. 401). Or they may be “mixed,” where some fibres of the muscle are normal, whilst others intermingled with them are degenerated.

Reaction of a muscle to direct percussion is sometimes of value. This phenomenon consists in a contraction of the whole bundle of muscle-fibres in their entire length. Response to direct mechanical excitation often persists when the deep reflexes are lost; thus, for example, when the knee-jerk is absent in tabes or peripheral neuritis, the quadriceps still responds to direct tapping. In most cases of lower motor neurone lesion, this *mechanical irritability of the muscle-fibres* is increased but the contraction is more flickering than in a healthy muscle. In muscular dystrophy, the mechanical irritability is lost in the affected muscles. In certain patients, especially on percussing the pectorals or other flat muscles of the chest, we may observe a wave of contraction dashing outwards suddenly in both directions from the point of percussion, longitudinally along the muscular fibres, and immediately followed by a temporary small muscular swelling at the point of percussion. This phenomenon is called **myoidema**; it is common in pulmonary tuberculosis, but occurs also in many other wasting conditions not associated with muscular paralysis, and need not detain us further.



The term *paralysis*, when applied to voluntary muscles, signifies loss of the power of voluntary contraction, due to interruption, functional or organic, in any part of the motor path, from the cerebral cortex down to and including the muscle-fibre. This latter part of the definition is necessary so as to exclude such cases as ankylosed joints, where movement is impossible from mechanical reasons without true paralysis. Strictly speaking, paralysis is total loss of voluntary motor power, lesser degrees of impairment being called *paresis*. But we often employ the term paralysis to include partial as well as complete loss of power.

The distribution of motor weakness differs according to the site of the lesion of the motor path. Thus in a unilateral brain lesion, there is usually paralysis of one side of the body, including the face, trunk and limbs. This is termed *hemiplegia*. A bilateral cerebral lesion produces *diplegia* or *double hemiplegia*, the limbs on both sides of the body being affected. Paralysis of a single limb resulting from a cerebral lesion is termed cerebral *monoplegia*. Spinal or peripheral monoplegia is less common.

Paralysis of the limbs resulting from a lesion of the spinal cord is most commonly bilateral—*paraplegia*—and usually affects the legs alone; but if the lesion be in the cervical region, it affects both arms and legs. It must be distinguished from a cerebral diplegia, in which the face is sometimes also affected. In rare cases both arms may be paralysed from a spinal lesion, with little or no affection of the legs; this is *brachial paraplegia*. A unilateral spinal lesion may also cause a monoplegia, but this is uncommon. The term *crossed* or *alternate hemiplegia* means that as a result of a single lesion there is paralysis of some parts on the right side and of others on the left. For example, a lesion in the right side of the pons at the level of the facial nerve will cause paralysis of the right side of the face and of the left arm and leg. There are, of course, other varieties of crossed paralysis.

When paralysis is due to a lesion of a peripheral nerve, it may either be asymmetrical, when the motor weakness is limited



to one or more nerve-trunks, as in most traumatic nerve-palsies, or more commonly bilateral and symmetrical, as in the various forms of toxic neuritis, affecting either the upper or lower or all four limbs.

If paralysis be due to primary affection of the muscles themselves, as in the myopathies, its distribution is usually bilateral, and it affects all four limbs and sometimes even the face.

We must remember that it is not uncommon to meet with multiple lesions in a single case; yet, in diagnosis, it should always be our endeavour to try to account for all the symptoms by a single lesion.

Suppose, then, that a patient is suffering from motor paralysis (mechanical impediments having been excluded), the first question is—Is the paralysis *functional or organic*? If it is organic, we proceed to the further questions—*Where* is the lesion situated? (anatomical diagnosis), and *what* is its nature? (pathological diagnosis).

**Is the Paralysis Functional or Organic?**—Sometimes the distinction between functional and organic motor paralysis is easy; at other times it is a matter of considerable difficulty, cases of early disseminated sclerosis being particularly liable to be mistaken for hysteria; moreover, it is possible to have a combination of functional and organic disease in the same patient.

More detailed consideration of the diagnostic features of hysteria will be postponed till a later chapter (see p. 361), and we shall only here refer to some of the main features which enable us to decide that a case is organic rather than functional. Firstly, the history of the case often guides us; for instance, functional paralysis frequently follows an emotional shock or a prolonged mental strain, whereas traumatism, as in railway accidents, is equally liable to cause functional or organic disease.

There are two classes of signs and symptoms which point to functional rather than to organic disease—firstly, the absence of characteristic signs of organic disease, and secondly, the presence of certain phenomena peculiar to functional disease.



Muscular atrophy, while much less frequent in functional than in organic palsies, is not pathognomonic of organic disease. Thus Fig. 208 (p. 380) shows a case of hysterical monoplegia with extensive muscular atrophy, a rare combination. But the electrical reactions of degeneration never occur in functional paralysis. Their presence signifies undoubted organic disease, somewhere in the spino-muscular neurone. Paralysis of a single muscle is pathognomonic of organic disease; it never occurs in functional paralysis, which affects whole muscle-groups or, to

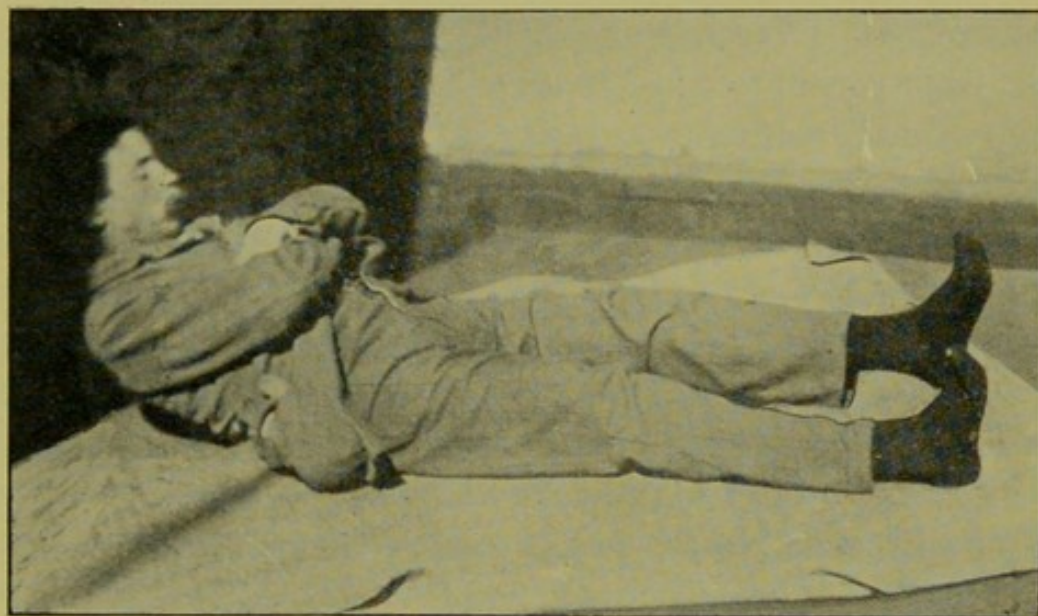


FIG. 90.—Case of left hemiplegia, showing phenomenon of *combined flexion of hip and trunk* on attempting to sit up without using arms.

speak more accurately, whole movements. To sum up, then, the diagnosis between functional and organic paralysis is easy if the organic palsy is of the lower motor neurone type. It is chiefly when the organic lesion is in the upper or cortico-spinal neurone that difficulty is liable to occur, *i.e.* in cases where there is little or no muscular atrophy, and where the electrical reactions are normal. In such cases the presence or absence of other hysterical stigmata is of great value.

A valuable sign of organic as contrasted with hysterical hemiplegia is Babinski's *combined flexion of the hip and trunk*, a phenomenon almost invariably present in organic cases. To elicit this the patient lies flat on his back on a smooth hard surface, such



as a table or the floor, with his arms crossed in front of his chest and the legs not allowed to touch each other. We then ask him to sit up without using his arms. (See Fig. 90.) As he does so, the organically paralysed lower limb becomes flexed at the hip and the heel is raised from the surface. Meanwhile the shoulder on the healthy side is carried forwards, as if to counterpoise the contralateral lower limb. In hysterical hemiplegia this sign is absent, and the hysterically paralysed limb remains unraised. Another useful test to distinguish between organic and functional paralysis is the *phenomenon of Grasset and Gaussel*,<sup>1</sup> which is also confined to organic cases. This consists in inability on the part of the organically hemiplegic patient to raise *both* lower limbs simultaneously from the surface when lying down as before, although he is still able to lift either lower limb separately. The reason for this peculiarity is that in organic hemiplegia the patient, when he tries to lift both lower limbs at once, is unable to fix the pelvis. In testing for this sign, we must be careful to see that the two legs do not touch each other, since the patient often tends involuntarily to help up the paralysed limb by means of the sound one. Of course, the sign is only present in cases of incomplete hemiplegia. Another way of showing the same phenomenon is to direct the patient to raise the lower limb of the paralysed side and hold it in the air. If we now grasp the sound leg and raise it up, the other limb at once falls down again, because the pelvis cannot be steadied by the muscles on the paralysed side. On the other hand, if the patient first raises the sound leg and we then passively lift the paralysed one, the sound limb still remains in the air, the pelvis remaining fixed by the non-paralysed muscles of the healthy side. In hysteria there is no such difference between the separate and the simultaneous raising of the legs.

In some cases of spastic paraplegia the rigidity of the lower limbs is of diagnostic value. Thus when we passively lift one lower limb off the bed and find that the other lower limb is thereby lifted up as well, we may be practically certain that the rigidity and paralysis are organic and not functional.

<sup>1</sup> *Revue neurologique*, 1905, p. 881.



A careful study of the reflexes is also of the utmost importance. The presence of an extensor plantar reflex in a patient beyond the age of infancy is pathognomonic of organic disease (see later, p. 319). The deep reflexes, whilst they may be exaggerated both in functional and in organic paralysis, are usually normal in functional cases. True ankle-clonus of organic disease is generally readily distinguished from the "pseudo-clonus" of functional disease. Absence of the deep reflexes may occur in organic, never in functional disease.

Incontinence of the bladder and rectum is not uncommon in organic diseases of the spinal cord and brain, but practically never occurs in functional paraplegia.

**Where is the Organic Lesion?**—Suppose we have come to the conclusion that the patient's motor paralysis is organic in type, we have to ask ourselves at what point in the motor path the lesion is situated. First, we must decide whether the lesion is in the upper (cortico-spinal), or in the lower (nucleo-muscular) motor neurone. The distinctive characters of these two types are as follows:—

**ORGANIC MOTOR PARALYSIS.**

Upper (cortico-spinal) Neurone. Supra-Nuclear Paralysis.	Lower (spino-muscular) Neurone. Nuclear and Infra-Nuclear Paralysis.
1. Diffuse muscle-groups affected, never individual muscles.	1. Individual muscles may be affected.
2. Spasticity and hyper-tonicity of paralysed muscles.	2. Flaccidity and atonicity of paralysed muscles.
3. May have superadded "associated movements" on attempted voluntary movement.	3. No "associated movements."
4. No muscular atrophy, except from disuse.	4. Atrophy of paralysed muscles.
5. Electrical reactions normal.	5. Reactions of degeneration.
6. Deep reflexes in paralysed limbs present, and usually increased.	6. Deep reflexes of paralysed muscles diminished, and often absent.
7. If foot affected, plantar reflex extensor in type.	7. Plantar reflex, if present, is of normal flexor type (unless flexors of toes are themselves paralysed).

Let us consider some of these points more in detail. Paralysis due to an upper neurone lesion never affects an individual muscle,



but always a diffuse muscular group. The converse, however, is not true, and we must remember that even a lower neurone lesion may produce a diffuse paralysis, where a series of adjacent nerves or nuclei are affected. But if individual muscles are picked out by paralysis, the adjoining or intermingled muscles being perfectly normal, the cause is certainly a nuclear or infra-nuclear lesion.

Paralysis from a cortico-spinal lesion is rarely permanently complete. It is more often a paresis than an absolute paralysis. In this respect it differs from the total palsy of a spino-muscular lesion.

Spasticity of the paralysed muscles in supra-nuclear lesions does not set in immediately after the onset of a sudden lesion, but usually develops gradually in the course of from one to three months. Thus in a typical supra-nuclear lesion, as, for example, in apoplexy, there is an initial period of flaccidity, gradually replaced by the so-called "late rigidity." The degree of this spasticity varies in different cases. We estimate it by moving the patient's joints passively, and comparing their resistance with that of a healthy limb.

Patients with motor paresis due to cortico-spinal lesions not uncommonly show superadded "associated movements" on attempting to execute a voluntary movement with the paresed limb. Thus, for example, if the patient tries to draw up his hemiplegic leg, he cannot do so without at the same time dorsiflexing the ankle involuntarily. This is the so-called "tibialis phenomenon" of Strümpell. Similarly in the upper limb we may note an analogous "pronation phenomenon," consisting of a forced pronation on attempting to flex the elbow.

In an upper neurone lesion, the muscles of the paralysed limb, in the vast majority of cases, undergo no appreciable atrophy, save perhaps to a very slight degree from disuse. But there are occasional exceptions to this rule, as in some cases of hemiplegia which are associated with muscular atrophy, chiefly in the region of the shoulder or in the intrinsic muscles of the hand. Such atrophies are often (but not always) secondary to arthritic



changes in the joints. But however intense the amyotrophy of hemiplegia may be, the electrical reactions of degeneration are never present. Degenerative reactions (commonly referred to as "R.D.") are pathognomonic of a nuclear or infra-nuclear lesion. Not that R.D. are necessarily present in every lower neurone lesion, for a slight lesion of a nerve-trunk may produce muscular palsy without R.D., and in many nuclear lesions, for example in progressive muscular atrophy, the reactions in the affected muscles are mixed, owing to the fact that degenerated and healthy muscle-fibres are intermingled in the same muscle, the former giving R.D., the latter being normal in reaction. Again, in the motor weakness occurring in the different varieties of myopathy, there is simple diminution both to faradism and galvanism, but no true R.D., even in the most advanced cases. The reflexes in upper and lower neurone lesions will be dealt with more fully in a later chapter (p. 316).

With reference to the differential diagnosis between an upper and a lower neurone lesion, it will be observed that no single sign of the six we have mentioned is pathognomonic, yet the sum of the various points usually enables us without difficulty to settle with which of the two neurones we have to deal. Sometimes there is a combined lesion of upper and lower neurones, as in a transverse myelitis or a myelomalacia. Here the phenomena at the level of the lesion will be of a flaccid, lower neurone type, due to destruction of the anterior cornua and anterior roots, whilst below that level there is a spastic paraplegia of cortico-spinal type, from interruption of the pyramidal tracts.

**Motor Palsies of Upper Neurone Type.**—The signs and symptoms vary according to the level at which the cortico-spinal tract is damaged. The following are the chief sites at which a lesion may occur, and the diagnostic signs of each (see Fig. 6, p. 7).

A cortical lesion in the pre-central convolution is often localised to a single limb and is more likely to produce a monoplegia than a hemiplegia, since only a very extensive cortical lesion would produce a complete hemiplegia, affecting face, arm



and leg. What we usually find is either a pure monoplegia—crural, brachial, or facial, or, if the lesion be somewhat larger, an associated monoplegia—brachio-crural, or facio-brachial. Cortical motor paralysis is commonly associated with local epileptiform attacks of the paralysed limb, because disease may irritate the cortex in addition to paralyzing it. The monoplegic limb frequently shows a cortical type of anæsthesia, which, as we have already seen, is slight in degree, more marked at the periphery of the limb, and often transient in duration.

A strictly localised subcortical lesion is often indistinguishable from a cortical one, save by the absence of irritative epileptiform phenomena; and in many cases the lesion is both cortical and subcortical.

A lesion in the motor path at the level of the internal capsule, inasmuch as all the pyramidal fibres have by this time converged to form a compact strand, produces no longer a monoplegia but a complete hemiplegia, affecting face, arm and leg. There are no Jacksonian convulsions as in a cortical lesion. If the capsular lesion extends backwards from the motor into the sensory tract, or into the optic thalamus, there may be a coexistent hemi-anæsthesia, but this is not common.

A thalamic lesion is sometimes associated with hemi-athetosis of the hemiplegic side; this athetosis does not appear immediately after an attack of apoplexy, but develops gradually in the course of many weeks. A still more extensive lesion, extending backwards along the capsule from the motor tract, through the sensory path and into the optic radiations, will cause hemiplegia, hemi-anæsthesia and hemianopia.

In rare cases we may have an *ipso-lateral hemiplegia* in which, for example, a lesion of the left cerebral hemisphere produces a left-sided hemiplegia. Some of these cases, according to Marie, are due to congenital non-decussation of the pyramids; others result from a dural hæmatoma, a meningeal hæmorrhage or a superficially situated tumour, whereby the contra-lateral pyramidal tract is compressed against the base of the skull. From the surgical point of view we must also bear in mind the



occasional occurrence of a *false ipso-lateral hemiplegia* where a blow on one side of the head, say the left, is followed by a left-sided hemiplegia. Such cases are generally due to injury of the opposite (*i.e.* the right) hemisphere by "contre-coup."

A lesion in the crus cerebri is recognised by the coexistence of third nerve palsy on one side, with hemiplegia of the opposite



FIG. 91.—Lesion of *left* crus cerebri—"Weber's syndrome." Patient is looking upwards and attempting to show the teeth on both sides. There is dilatation of the *left* pupil and paralysis of the *left* superior rectus, together with hemiplegia of the *right* face, arm and leg.

face, arm and leg, usually most marked in the face. This variety of alternate paralysis is known as *Weber's syndrome* (see Fig. 91). The third nerve palsy is often incomplete. When the lesion extends into the tegmentum and implicates the neighbourhood of the red nucleus, it may produce a unilateral tremor or a hemiataxy of the hemiplegic side, combined, as before, with a third nerve affection on the side of the brain lesion; this combination is known as *Benedikt's syndrome*. If the lesion extends outwards so as to implicate the optic tract as it winds round the outer side of the crus, there may be superadded a hemianopia.

As we come downwards along the pyramidal tract into the



pons and medulla, the type of hemiplegia changes; there is no longer third nerve palsy, but on reaching the level of the facial nerve, another variety of alternate hemiplegia appears. This consists of facial palsy, peripheral in type, on the side of the lesion, together with hemiplegia of the arm and leg on the opposite side, the so-called *Millard-Gubler syndrome*. Other cranial nerves on the side of the pontine or bulbar lesion, for example, the trigeminal, the sixth, or the hypoglossal, may be affected together with the pyramidal tract, and, as in the *Millard-Gubler syndrome*, may co-exist with hemiplegia of the opposite arm and leg, but such cases are rare. As they descend through the medulla the pyramidal tracts of opposite sides converge and eventually lie so close together that at this level a strictly unilateral lesion seldom occurs, there being usually damage to both pyramidal tracts affecting the limbs of both sides, though perhaps in unequal degree. And together with this, there are "bulbar" symptoms—disorders of articulation, phonation, or deglutition, from implication of the tenth, eleventh and twelfth cranial nerves or nuclei.

The diagnosis of motor paralysis due to lesions of the pyramidal tract within the cord depends on the level of the lesion. The two pyramidal tracts decussate at the lower end of the medulla oblongata, so that a unilateral lesion of the spinal cord produces an ipso-lateral instead of a contra-lateral motor paralysis. If the lesion be in the cervical region, the arm and leg on the corresponding side will be affected; but if it be situated below the cervical enlargement, the leg on the side of the lesion suffers alone. A primary unilateral lesion of the cord generally interrupts not only motor but sensory paths, and produces the well-known *Brown-Séguar* paralysis, to which reference has already been made.

Bilateral motor paralysis of upper neurone type is due to bilateral lesions, which may be situated either in the brain or in the spinal cord. When both pyramidal tracts are affected within the brain (and the commonest cause is a double focus of softening, in the region of the posterior part of the lenticular nucleus, though less commonly the lesions are cortical or subcortical) a double



hemiplegia is the result. In these cases of double-hemiplegia or diplegia there are, besides the signs of hemiplegia on both sides (frequently unequal in degree), what are known as "pseudo-bulbar" phenomena. In pseudo-bulbar paralysis, the symptoms of which we have already studied (p. 113), it is uncommon for the two attacks of hemiplegia to occur simultaneously on the two sides; they more usually occur successively, and it is only after the hemiplegia has become bilateral that the pseudo-bulbar symptoms appear. Such patients are generally excessively emotional, tending on slight provocation to laugh or, more frequently, to weep with a peculiar "spastic" wail, and an unnatural slowness of expressional movement.

Bilateral pyramidal lesions within the spinal cord produce paraplegia, affecting all four limbs if the lesion be above the cervical enlargement, but affecting the lower limbs alone if the lesion be below the cervical region; it is commonly of the ordinary spastic type, with increased deep reflexes. If the sensory tracts be interrupted by the same lesion as that which has affected the motor tracts, we have superadded an anæsthesia whose upper limit corresponds to that of the highest affected segment. Such cases of combined sensory and motor paralysis usually have loss of control of the sphincters. If the cord lesion be sufficiently extensive to implicate the anterior cornua, there will be muscular atrophy, localised to the segment affected, *i.e.* at the upper boundary of the spastic paraplegia. But it is important to remember that if the lesion of the cord be one which *completely* divides it (*e.g.* a stab or bullet-wound), so that there is no connection between the cord-segments above and below the lesion, the paraplegia is then flaccid in type and the deep reflexes are absent in the paralysed limbs. The plantar reflexes, however, persist and are of the extensor type, be the lesion complete or incomplete.

The differential diagnosis between tumours arising within the spinal cord and those growing from without, is sometimes difficult. In extra-medullary tumours, arising from the nerve-roots or meninges on the posterior aspect of the cord,



root-pains, unilateral or bilateral, usually precede the signs of transverse cord lesion, viz., paraplegia with affection of sensation, increased deep reflexes, &c. But if the extra-medullary growth starts in front of the cord, root-pains are absent or late. If the anterior roots be involved, muscular atrophy of root distribution is a valuable focal sign. Spontaneous reflex spasms of the lower limbs are commoner in extra-medullary than in intra-medullary growths. An extra-medullary tumour situated laterally sometimes compresses the cord so as to produce an incomplete Brown-Séquard syndrome. Thus in one case of my own, where an endothelioma was removed from the first thoracic root on the right side, the patient had asymmetrical spastic paraplegia, more marked in the right leg, together with impairment of thermal and pain sense in the left leg and left side of the trunk.

The tendency is to localise a spinal tumour below its actual level. Sometimes valuable indications are provided by studying the vibration sense of the vertebral spines, this sensibility often being lost up to the level of the growth.

Sometimes a diagnosis of extra-medullary tumour is made, and operation or autopsy shows the condition to be one, not of tumour but of *localised* subacute or chronic *lepto-meningitis*. This mistake may sometimes be avoided by studying the exact distribution of the initial root-pain. In tumour this pain is localised to a single root at the start; in meningitis the pain is more diffuse, affecting a considerable number of root-areas.

Sometimes the lesion is not horizontal, but higher on one side than the other, and then the upper limit of the anæsthesia will be correspondingly uneven on the two sides, and the distribution of muscular atrophy from anterior cornual destruction correspondingly asymmetrical.

We also meet with cases of bilateral spastic paraplegia without any affection of sensation. Such cases may be examples of slowly progressive primary lateral sclerosis, a rare disease, or what is more usual, of amyotrophic lateral sclerosis, where the signs of a progressive muscular atrophy are superadded to rigidity of the



lower limbs with increased deep reflexes. A pure motor paraplegia is more frequently due to disseminated sclerosis, to an imperfectly recovered transverse myelitis, or to some other vascular lesion, as thrombosis or hæmorrhage, in which the sensory functions have subsequently become restored, the motor tracts remaining permanently sclerosed. The history of the case is sufficient to distinguish these diseases.

Syringomyelia, when it affects the pyramidal tracts, may also produce a spastic type of paraplegia; but it is readily recognised by the accompanying characteristic dissociated anæsthesia, to which we have already referred (p. 202), and frequently by the coexistence of atrophic changes in the bones, joints and muscles, muscular atrophy occurring when the anterior cornua are implicated in the gliomatous process.



## CHAPTER XIV

### ORGANIC MOTOR PARALYSIS OF LOWER NEURONE TYPE

**Motor Palsies of Lower Neurone Type.**—Here, as in upper neurone lesions, the signs and symptoms differ according to the level at which the spino-muscular neurone is diseased. The most important diagnostic fact, for localising purposes, is the presence or absence of sensory phenomena. If, in a lower neurone motor palsy, sensory changes are present, we have to do with a lesion of a mixed nerve, that is, of a nerve containing sensory as well as motor fibres. If, on the other hand, sensory changes are absent throughout the course of the disease, the spino-muscular neurone is probably affected, either before it is joined by the sensory fibres (*i.e.* the lesion is in the anterior cornu or anterior nerve-root), or after it has parted company with them (*i.e.* the lesion is in a purely motor nerve-branch or in the muscle itself).

A lesion of the *anterior cornu* within the cord (as of its homologue in the motor nuclei of the bulb) is unassociated with any sensory paralysis, and therefore produces a pure motor palsy of the corresponding muscle fibres. A lesion of the *anterior nerve-root*, emerging from the anterior cornu, produces identical signs, and is often indistinguishable from an intra-spinal nuclear lesion. In nuclear or anterior-root lesions, therefore, we find pure motor palsy, of lower neurone type, unassociated with any sensory change. The commonest examples of such lesions are chronic anterior poliomyelitis (progressive muscular atrophy) and certain types of lead paralysis. Acute anterior poliomyelitis (infantile paralysis of spinal type) in the early days or weeks of the disease is frequently associated with pain and tenderness of the limbs. As the malady subsides into the chronic stage, the pain and tenderness pass off. Landry's paralysis is a pure motor paralysis of the whole spino-muscular neurone, to which we shall refer presently. A nuclear or



anterior root lesion is further characterised by the "root" distribution of the motor paralysis, so that in this respect it differs from the paralysis due to a lesion of a peripheral nerve (see Tables of Root Distribution, p. 34). Lesions of peripheral mixed nerves are always associated, at the onset at least, with sensory changes. In the case of lesions of peripheral purely motor nerves (*e.g.* the nerve of Bell to the serratus magnus), the distribution of the motor palsy is totally unlike that of a nuclear or anterior root lesion.

To distinguish between a nuclear and an anterior root lesion is sometimes difficult, and may in some instances be impossible. The co-existence of spastic phenomena corresponding to lower parts of the cord points to an intra-spinal lesion, and indicates a co-existing lesion of the adjacent pyramidal tract. Total escape of the pyramidal tract, on the other hand, would suggest an anterior root lesion, though not necessarily so, since acute anterior polio-myelitis does not affect the pyramidal tract. Another point which may sometimes help us is the subsequent course of the disease; if the paralysed muscles

recover, this is in favour of an extra-medullary anterior root lesion rather than an affection of the anterior cornu, inasmuch as regeneration of nerve-fibres only occurs in extra-spinal lesions, an intra-spinal lesion of the grey matter being irreparable.

A pure anterior cornual lesion, with its absence of cutaneous anæsthesia, can only be confounded with a lesion either in a purely motor nerve, or with one in the muscle-fibres themselves. The history of the onset of the disease is of great importance, so also

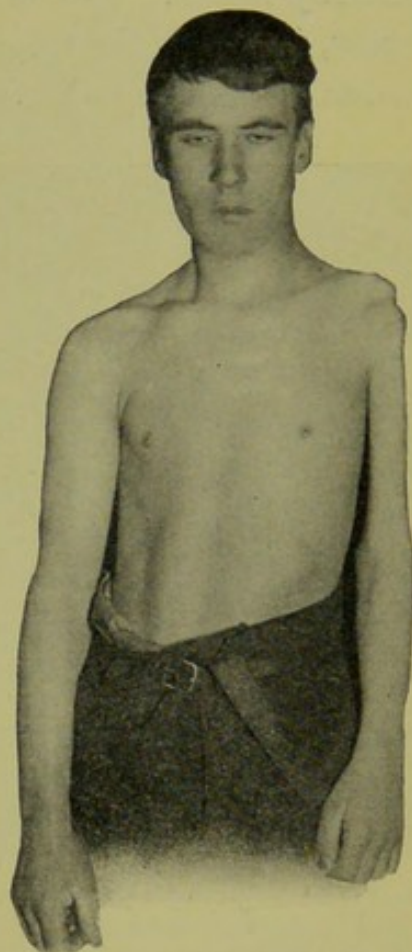


FIG. 92.—Old acute anterior polio-myelitis, with atrophy of deltoid and biceps, and deficient growth of the humerus on the left side.



is the exact distribution of the muscular paralysis. The two chief diseases specially affecting the anterior cornua are infantile paralysis and progressive muscular atrophy. *Acute anterior poliomyelitis* or infantile spinal paralysis is really a constitutional disease due to an infective virus. It has a sudden onset, generally febrile. The virus, whilst causing congestion of various organs, including the spleen and lymphatic glands, has a specially intense effect upon the central nervous system and produces a

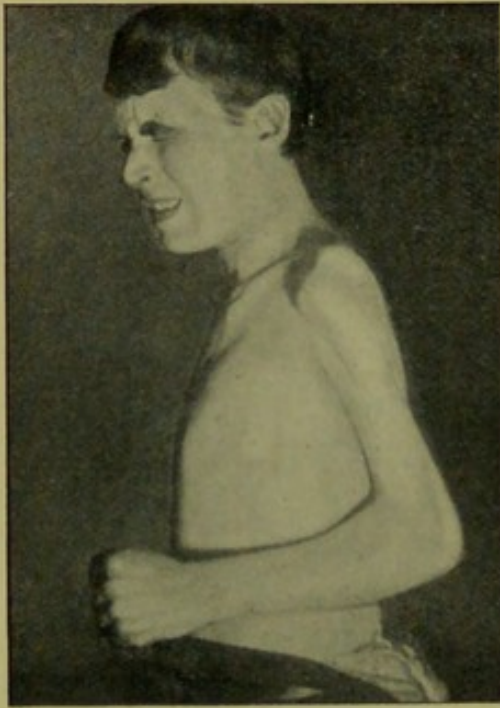

FIG. 93.—Old infantile paralysis with total loss of deltoid and biceps. Shows action of the supinator longus in flexion of elbow.

special perivascular infiltration around the anterior spinal arteries, which supply the anterior horns. The spinal meninges are also hyperæmic, hence there are pains in the limbs, aggravated by passive movement. A large number of muscles, sometimes in all four limbs, may be paralysed at the beginning. But in a week or so most of the paralysis clears up, leaving a residuum, almost always unilateral, of paralysed muscles which undergo rapid wasting. There is no exaggeration of tendon reflexes below the level of the lesion, since the pyramidal tract is unaffected. Figs.

92, 93, and 94 are examples of cases of old infantile paralysis, showing the extreme degree of atrophy which results, and if the disease occurs in childhood, as is most often the case, the subsequent want of growth in the limb. The wasted limb is often cold and blue, and the patient can frequently tolerate, without pain, faradic stimulation of a strength which is intolerable in the sound limbs.

*Chronic anterior poliomyelitis*, or progressive muscular atrophy, has a gradual, insidious onset. It occurs almost always in adults and, though beginning unilaterally, generally becomes bilateral.



It usually shows itself first in the small intrinsic muscles of the hands (Fig. 95); more rarely it begins in the shoulder muscles. In this disease we observe fibrillary worm-like tremors in the wasting muscles, whose electrical reactions are a mixture of R.D. with healthy reactions. This is because here and there in the diseased area a healthy anterior cornual cell survives, together with its corresponding healthy muscle-fibre. If the adjacent pyramidal tracts be sclerosed, we have amyotrophic lateral sclerosis, in which the deep reflexes are exaggerated and the plantar reflexes extensor in type.

There is a rare infantile variety of progressive muscular atrophy—*Werdnig-Hoffmann* type—due to degeneration of the anterior cornua. The disease begins in infancy, often during the first few months after birth. The muscles of the lower limbs are attacked first, producing weakness and wasting, though the atrophy may be masked by subcutaneous fat. The knee-jerks disappear and the atrophied muscles lose their electrical excitability. The disease gradually spreads upwards to the medulla and is fatal, with bulbar symptoms, in from one to six years.

There is another peculiar form of muscular atrophy which is hereditary and runs in families, known from its distribution as Tooth's "*peroneal*" type, or as the *progressive neuritic amyotrophy* of Charcot and Marie. It comes on in childhood, commencing in the distal muscles of the limbs, more often the lower limbs and the

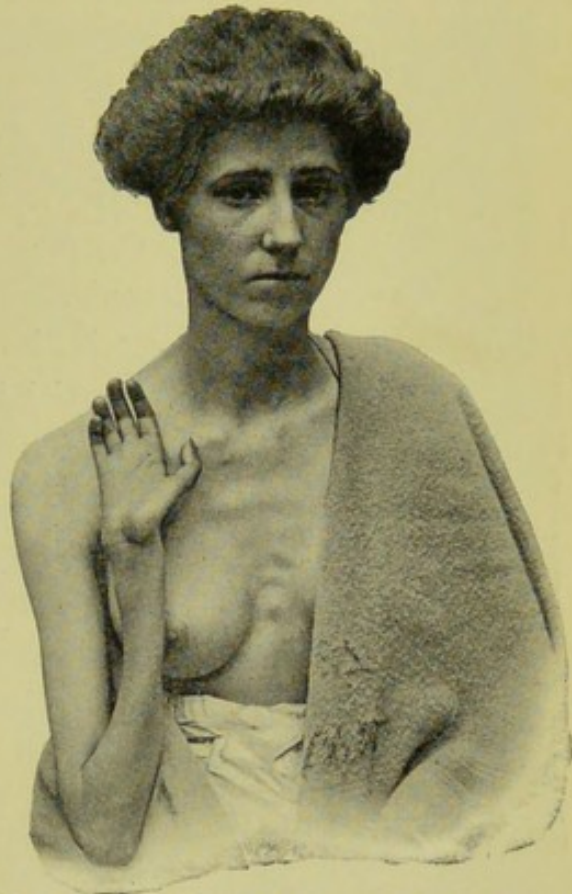

FIG. 94.—Old infantile paralysis (acute anterior polio-myelitis). Paralysis and atrophy of all the muscles below the elbow, with exception of supinator longus.



peroneal muscles, and gradually producing weakness with contractures. Talipes equino-varus appears, for which tenotomy is often done, as was the case in the patient shown in Fig. 96. But if the patient's feet be passively supported, say by metal supports at the ankles, until the paralysis of the limbs has become complete (as in the patient shown in Fig. 98), talipes does not

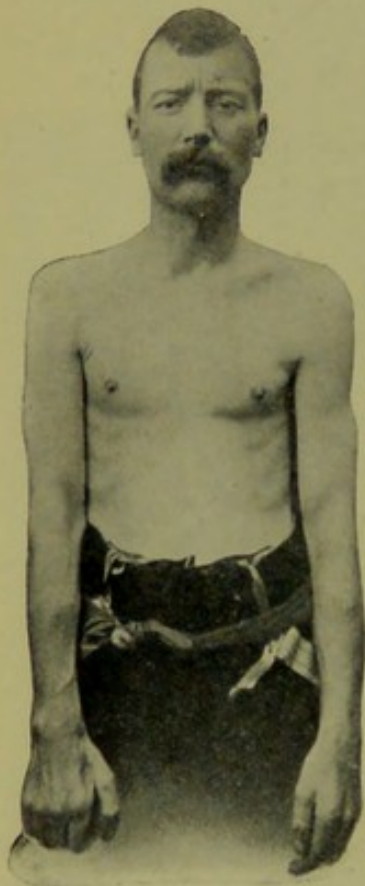


FIG. 95.—Progressive muscular atrophy in a man aged 32. The patient was also tabetic.

appear even in the totally paralysed limb. Later, the intrinsic muscles of the hands undergo wasting (Fig. 98). In fact, early claw-foot and claw-hand in young people are almost pathognomonic. The only other disease of diagnostic importance in this connection is interstitial hypertrophic neuritis. The disease hardly ever extends to the muscles of the hips or shoulders. The facial and trunk muscles also escape. It is interesting to note that when all the muscles below the knees are paralysed, the patient may still be able to walk alone, though the gait is high-stepping from drop-foot. This was so in both the patients here figured. The deep reflexes are lost in the atrophied muscles. Thus in the little boy (Fig. 96) the ankle-jerks were lost, whilst the knee-jerks remained brisk, since the thigh muscles

were unaffected; in the girl (Fig. 98) the knee-jerks and ankle-jerks were both lost. Pathologically the disease is associated with atrophy of the anterior cornual cells, whilst the anterior nerve-roots are said to be healthy.<sup>1</sup> But there is marked degeneration in the intra-muscular nerve-fibres of the affected muscles. There is also a curious degeneration in the posterior columns, closely resembling that of *tabes dorsalis*.

*Hypertrophic interstitial neuritis* is another family disease

<sup>1</sup> Dejerine and Armand-Delille, *Revue neurologique*, 1903, p. 1198.



which begins in childhood or adolescence. In this disease, besides a flaccid muscular atrophy of the limbs, commencing peripherally and less intense in the proximal muscles, there are marked sensory changes, resembling those of tabes, *i.e.* shooting pains, anæsthesia, analgesia (especially at the periphery of the

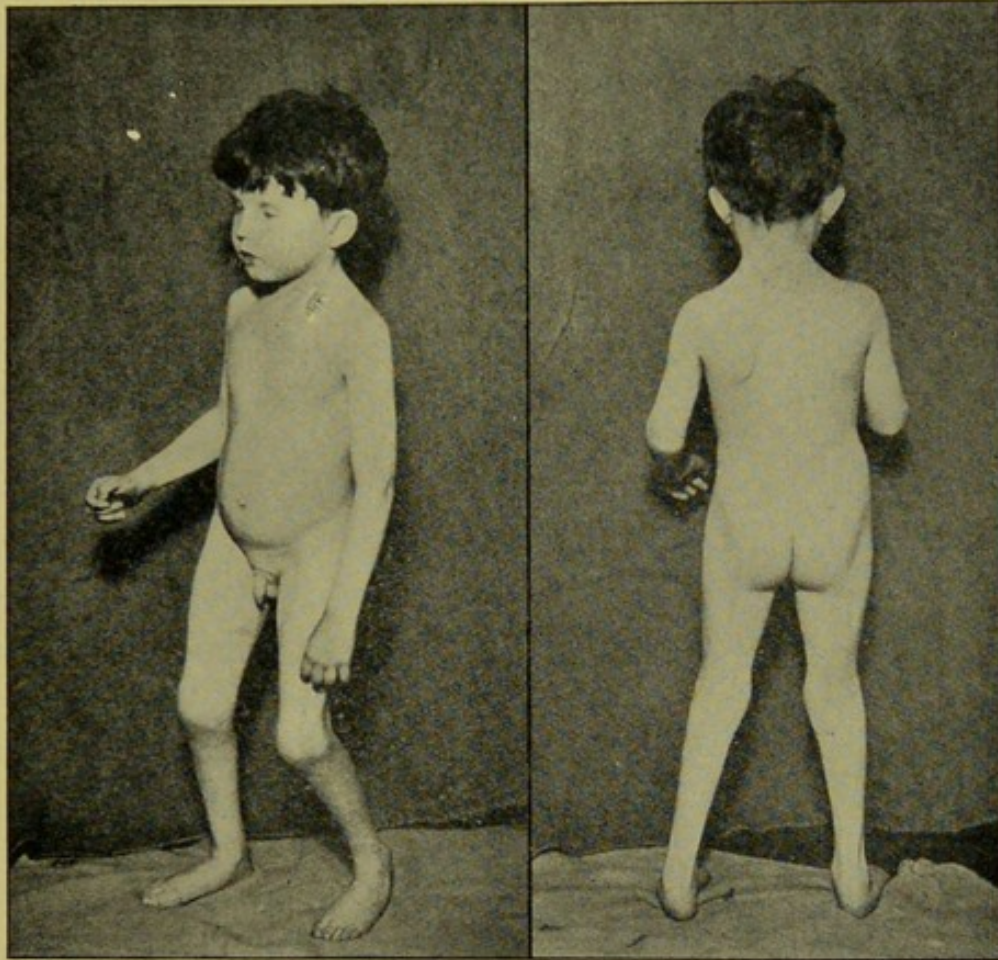


FIG. 96.

FIG. 97.

Figs. 96 and 97.—Peroneal type of muscular atrophy (Charcot-Marie-Tooth). In spite of total paralysis below the knees, the patient is still able to stand and walk.

limb), loss of joint-sense, &c. There is marked ataxia of the limbs together with loss of the deep reflexes, kypho-scoliosis, and Argyll-Robertson pupils. In some cases exophthalmos has been observed.<sup>1</sup> Pathologically we find a sclerotic thickening of the peripheral nerve-trunks, extreme in degree, often palpable during life, or even visible if the patient be thin. There is also a degeneration of the posterior columns, somewhat like that of

<sup>1</sup> Boveri, *La semaine médicale*, 30th March 1910, p. 145.



tabes dorsalis. The muscles show atrophy, proliferation of sarcolemma nuclei, and fatty infiltration.

A lesion of a *spinal nerve* after the union of its anterior with its posterior root, but above the point where it divides

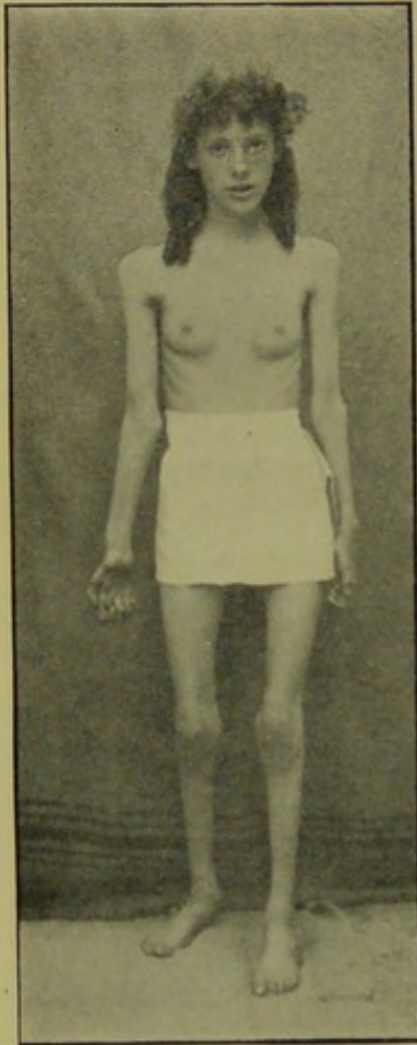


FIG. 98. — Peroneal type of muscular atrophy (Charcot-Marie - Tooth). Showing atrophy of intrinsic muscles of hands.

into branches to form plexuses or individual nerves, is characterised by a combination of motor and sensory paralysis, the distribution of which is not according to peripheral nerves, but according to root areas, motor and sensory (see Tables of Muscular Localisation, p. 34, also Fig. 20, p. 35). Thus, for example, Fig. 99 is the photograph of a sailor who received a violent blow on the right side of his neck from an iron winch. This produced paralysis of the deltoid, supra- and infra-spinatus, biceps, brachialis anticus, and supinator longus and brevis, together with an area of cutaneous anæsthesia along the outer side of the whole upper limb, from the shoulder to the hand. All this would be difficult of explanation on the theory of multiple injuries to the numerous peripheral nerves which supply these various parts. But the motor distribution is that of the fifth cervical root, whilst the anæsthesia of the hand corresponds to the

fifth and a small part of the sixth root, and as a matter of fact this lesion was subsequently verified by operation.

Lesions of *peripheral mixed nerves*, when complete, are usually easy of diagnosis, inasmuch as there are paralysis and atrophy of all the muscles supplied by the particular nerve, together with anæsthesia in the area of its cutaneous distribution. It is un-



necessary to discuss the signs of paralysis of all the various mixed nerves. The question is one of anatomy. Let us select one or two illustrative examples. Ulnar paralysis affects certain muscles of the hand and forearm, of which the most important diagnostically are the interossei and the two ulnar lumbricales. Owing to paralysis of the interossei, extension of the interphalangeal joints is impaired, especially in the two ulnar fingers whose lumbricales are also affected. Anæsthesia of one and a half fingers and of the corresponding part of the hand is also present (see Figs. 100 and 101, which are taken from a case where the nerve was cut by the bursting of a soda-water bottle). In old-standing cases, the unopposed common extensor of the fingers undergoes contracture and produces a claw-hand, this for the same reason being most evident in the two ulnar fingers. The hypothenar eminence also becomes flattened and the palm hollowed, so that the flexor tendons become visible beneath the skin.

Figs. 102 and 103 are from a case of division of the sciatic nerve from a bullet-wound in the thigh in a young soldier. It shows how all the muscles below the knee are atrophied and paralysed, the hamstring muscles having escaped, since the nerve was divided below the level of the

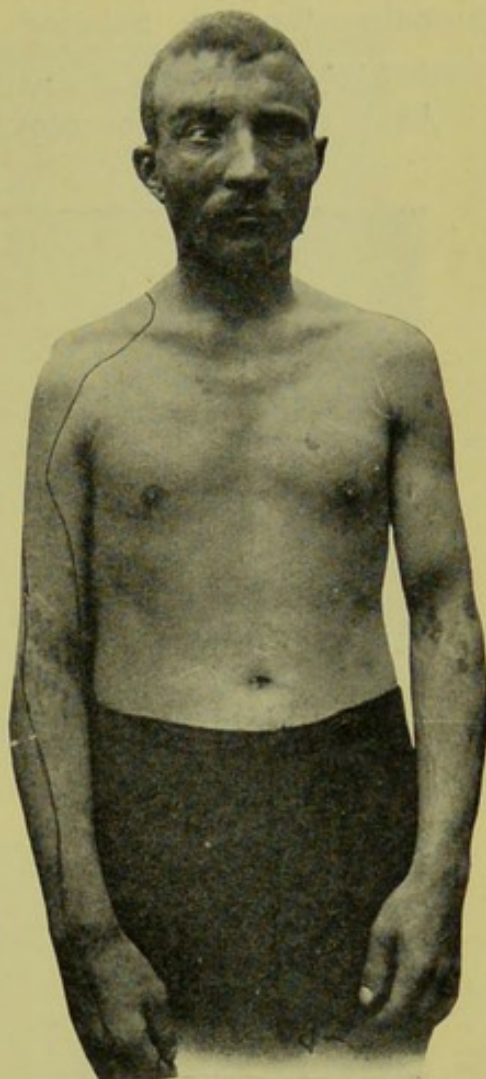


FIG. 99.—Case of rupture of  $C_5$  root in a sailor aged 29. There are atrophy and paralysis of deltoid, supra- and infra-spinatus, biceps, brachialis anticus, and supinators longus and brevis, together with anæsthesia along the outer side of the limb, from the neck to the thumb and index (in the area indicated by black line). The figure shows the atrophy of the deltoid with downward displacement of the limb at the shoulder-joint.



hamstring branches. Besides the muscular atrophy with the usual drop-foot, we have anæsthesia in the areas of the peroneal, musculo-cutaneous, anterior tibial, short saphenous and both plantar nerves.

As a mixed nerve recovers, sensation returns more rapidly

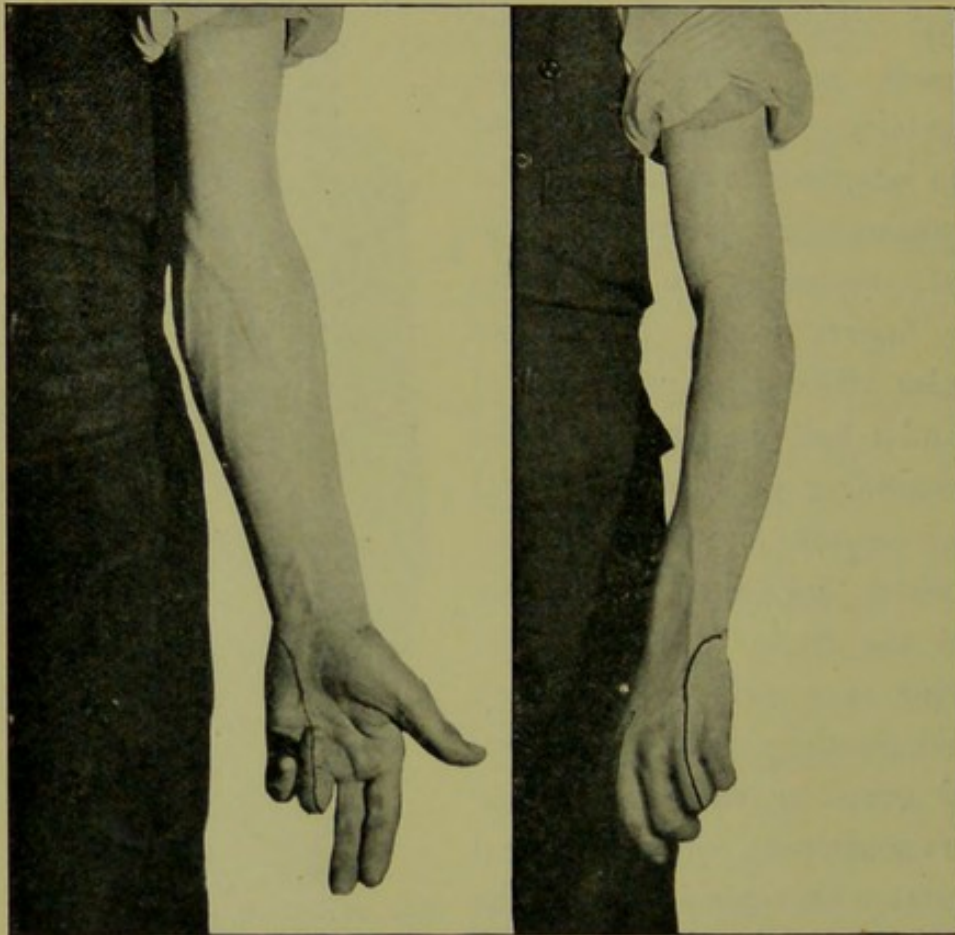


FIG. 100.

FIG. 101.

Figs. 100 and 101.—Ulnar paralysis, from a wound of the nerve behind the internal condyle of the humerus. The area within the black line is anæsthetic.

than motor power, and protopathic sensation earlier than epicritic. We must therefore be prepared to find that in a long-standing case the sensory loss is less complete than in a recent one, or it may happen that sensation is quite restored when motor power has not yet returned. This rule, however, is by no means invariable.

As an example of paralysis of a pure motor nerve, we may



select the posterior thoracic, or nerve of Bell, which supplies the serratus magnus. Fig. 104 is from such a case, and it shows the




FIG. 103.

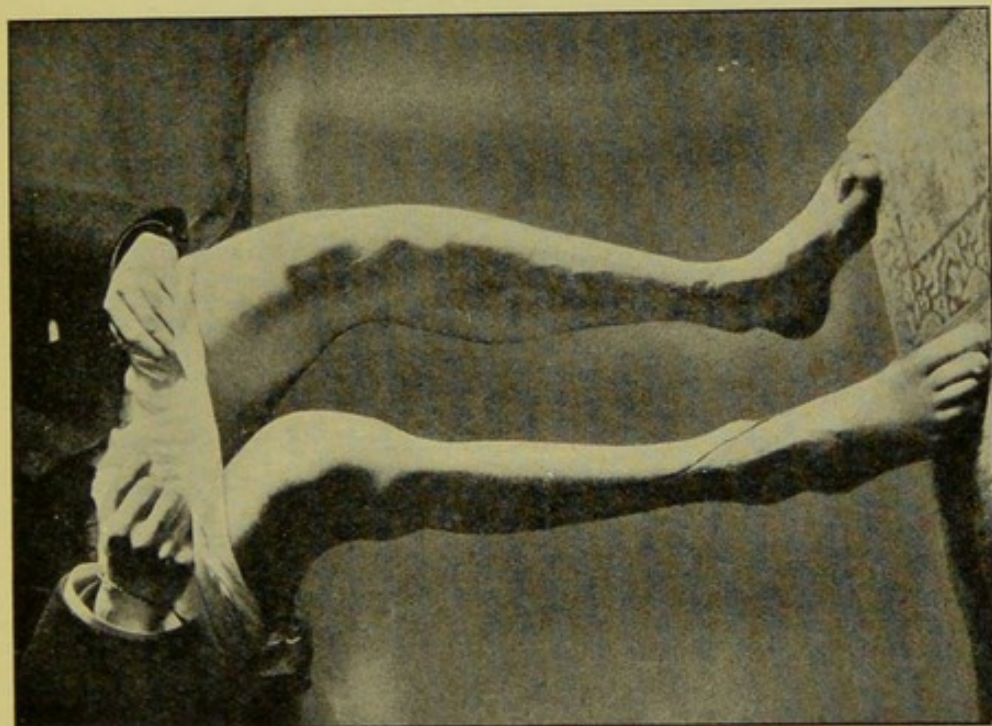


FIG. 102.

Figs. 102 and 103.—Paralysis of great sciatic nerve on right side, from bullet wound of thigh. Showing muscular atrophy below knee, with drop-foot. The black line indicates the upper limit of the anæsthesia.

characteristic “winging” of the scapula when the patient holds his arms horizontally forwards.

When a pure motor paralysis of lower motor neurone type



recovers, this indicates that it must have been of extra-medullary origin, since regeneration of nerve-fibres does not occur within the central nervous system.

Besides such lesions of individual nerve-trunks, we have also to bear in mind so-called *multiple* or *peripheral neuritis*—a very common disease, affecting the mixed nerves symmetrically on both sides, sometimes in the arms, sometimes in the legs, sometimes in all four limbs, and even also other nerves such as those of

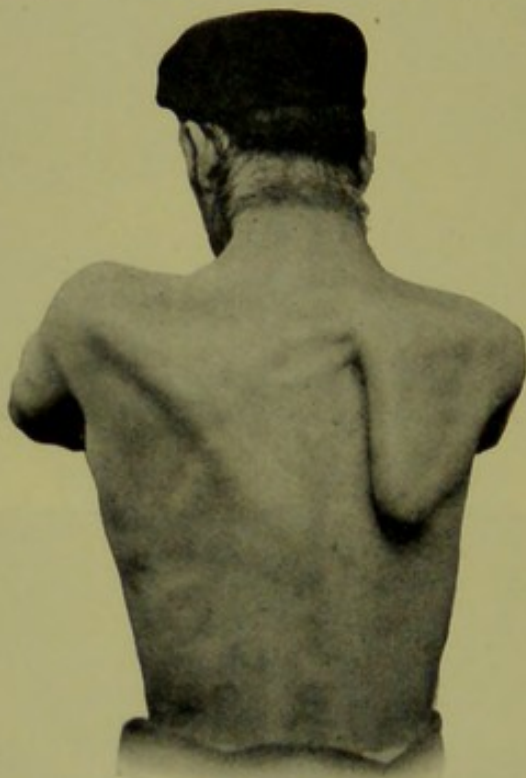

FIG. 104.—Paralysis of serratus magnus on right side. The patient is holding both arms horizontally forwards. The lower fibres of the trapezius are also paralysed.

the soft palate, diaphragm, and so on. Such neuritis, when affecting mixed nerves, is easy of diagnosis. The distribution of the sensory and motor abnormalities is characteristic. The patient has subjective tingling feelings in the hands and feet, and on examination we find diminution of sensation to light touches in the “stocking” and “glove” areas of the limbs, often with extreme hyperæsthesia of the soles to pressure. Moreover, the muscles of the limbs are exquisitely tender on being grasped. The motor paralysis, of the lower motor neurone type, specially affects the anterior tibial and peroneal groups in the legs, producing drop-foot, and the extensors



of the wrists and fingers, producing drop-wrist (Fig. 105). The commonest causes of multiple neuritis are chronic poisoning by alcohol, arsenic (specially associated with cutaneous eruptions), the diphtheritic poison, beri-beri (associated with œdema of the limbs and of certain serous cavities), diabetes, septicæmia, and other poisons. *Lead neuritis* is a peculiar form which practically never attacks the sensory fibres. The upper limbs are generally affected, the muscles attacked being the extensors of the fingers and wrists, producing wrist-drop. The long extensors of the

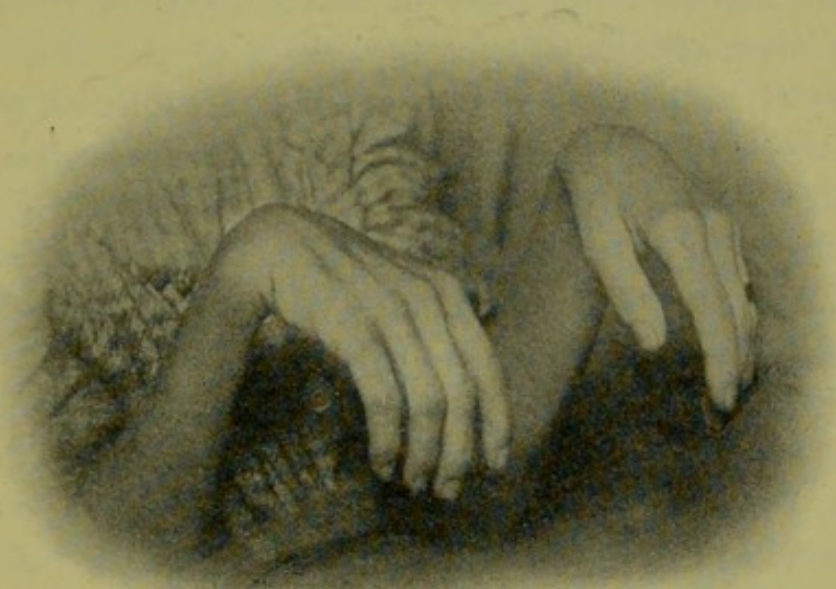

FIG. 105.—Alcoholic neuritis with drop-wrist.

thumb become paralysed later, the extensor ossis metacarpi pollicis remaining unaffected. The supinator longus usually escapes, so that the disease contrasts with musculo-spiral paralysis, with which it might be confused on superficial examination. The blue line on the gums and other signs of plumbism also aid us in the diagnosis.

Sometimes the lower motor neurones are paralysed in their entire extent, from anterior cornu to periphery, the disease commencing in the lowest spinal roots and spreading upwards towards the bulbar motor neurones. This affection, known as *acute ascending paralysis*, or *Landry's paralysis*, might be confounded with an ordinary peripheral neuritis were it not for the absence of sensory



changes. The paralysis, commencing in the legs, and spreading up the trunk to the arms, is of the usual flaccid type with loss of reflexes. There is no time for muscular atrophy or reactions of degeneration to develop, and if the respiratory muscles become paralysed the patient dies, generally within a week from the onset. The sphincters remain unaffected. Various organisms have been cultivated from the cerebro-spinal fluid and from the peri-dural tissues in such cases. The spleen is frequently enlarged, as in certain other infective disorders.

Before leaving the subject of nerve lesions of lower motor neurone type, we must refer to lesions of the *cauda equina*, the mass of nerve-roots, lumbar, sacral and coccygeal, contained within the lowest part of the spinal theca. According to the roots affected, anterior or posterior, we have motor and sensory symptoms, both distributed in "root" fashion, not according to peripheral nerves. The clinical picture varies according to the level of the lesion. When the whole cauda is involved, we find paralysis (of lower motor neurone type) of all the muscles of the lower limbs, together with anæsthesia below the folds of the groins in front, including the genitals, and below the upper part of the buttocks behind, together with loss of control of the bladder and rectum. If the first, second, and third lumbar roots escape, the anæsthesia is less extensive (Fig. 20, p. 35), sparing the upper part of the thighs. If the third lumbar roots escape, thereby sparing the quadriceps, the motor paralysis is correspondingly less, and the knee-jerks survive, though there is still paralysis of the glutei and hamstrings and of all the muscles below the knees, with loss of ankle-jerks and paralysis of bladder and rectum as before. If the lesion be lower still, the area of paralysis, motor and sensory, is correspondingly diminished. Below the second sacral roots there is no paralysis of the lower limbs, but there is a characteristic "saddle-shaped" area of anæsthesia on the buttocks, perineum, scrotum and penis, with a small strip running from the perineum down the postero-internal aspect of the thighs. Here also the bladder and rectum are uncontrolled, and the anal reflexes are lost, but there is no motor weakness of the lower



limbs, and all the reflexes of the lower limbs are normal. And so on, the area of paralysis diminishing as we descend, until when there is a lesion of the fourth and fifth sacral and the coccygeal roots, the only signs are paralysis of the levator ani, with anæsthesia of the anus and perineum, the sphincter ani remaining intact.

The chief difficulty in the diagnosis of lesions in this region is to distinguish between a lesion of the cauda and one of the *conus medullaris*—that part of the spinal cord which extends below the third sacral segment. In both cases the motor power of the legs is unaffected, and there is anæsthesia of the “saddle” area, with loss of sexual power and of control of bladder and rectum. Cauda lesions, however, are more often gradual in onset than conus affections, and are usually accompanied by intense sacral “root” pains, and the ultimate anæsthesia of a cauda affection is frequently preceded by cutaneous hyperæsthesia. A bed-sore is commoner in a medullary lesion than in a cauda lesion. Finally any “dissociation” of anæsthesia, such as analgesia or therm-anæsthesia without tactile anæsthesia, points to a medullary lesion. If both cauda and conus are included in the same disease, the cauda symptoms mask the others.

Let us now turn to motor palsies resulting from affections *within the muscles* themselves. Some of these are really the effect of diseases of the intra-muscular fibrous tissue. This is the case in acute myositis where there is an interstitial inflammation within the muscle, often with a good deal of effusion, so that any sudden movement causes acute pain; tenderness on pressure is also present. Lumbago and the familiar “stiff neck” are common varieties, and their diagnosis usually presents no difficulty. **Trichiniasis** is a disease in which the muscle-fibres are invaded by the *trichina spiralis* worm. Here there is a history of the patient having eaten some meat, usually pork, which turns out to have been trichinosed. Within a day or two he develops gastro-intestinal symptoms and becomes feverish, with widespread muscular pains, rigidity, and stiffness, especially in the muscles of the limbs. In severe cases the pharynx, tongue, diaphragm, and even the laryngeal muscles may become affected. Together



with this, there is a peculiar œdema of the face and eyelids, spreading thence to the limbs, and sometimes to the serous cavities. The blood contains a marked excess of eosinophile leucocytes, and the temperature is raised. The symptoms last usually four or five weeks.

Sometimes, when a patient has had his forearm fractured and put up in splints, the bandages may be applied too tightly and the blood-supply of the muscles is interfered with by the pressure. As a result there are swelling and pain in the hand, and unless

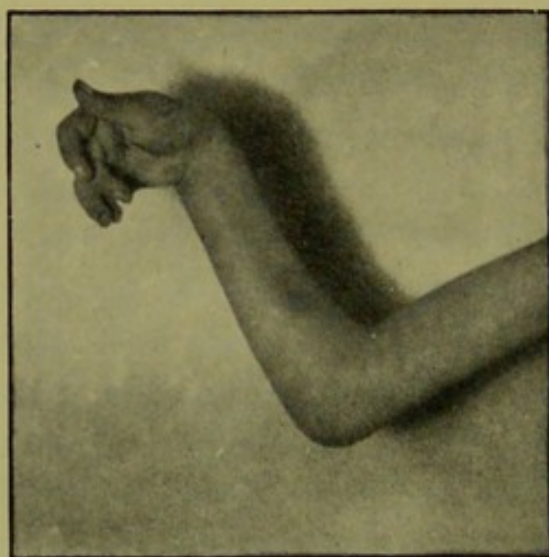


FIG. 106.—Ischæmic myositis.

the bandages be loosened, **ischæmic paralysis** (v. Volkmann) may develop. This is a variety of myositis. At first the muscles of the forearm swell from œdematous effusion; later they become shrunken, hard, and contracted by interstitial fibrous tissue, the fingers being in a flexed position (see Fig. 106). Active movements are lost, and even passive movements are painful. The hardness and stiffness of the muscles and the absence of R.D., together with the normal condition of sensation, suffice, with the history of the case, to distinguish it from a neuritis.

But we also meet with cases of muscular weakness and atrophy localised in certain muscles, where the motor nerves and nuclei are healthy, but the muscle fibres themselves are primarily diseased. This group of diseases is called **muscular dystrophy**, **idiopathic muscular atrophy**, or **myopathy**.



Clinically we recognise two main classes of myopathy :— (1) those cases in which all the affected muscles waste from the outset ; and (2) those in which certain muscles undergo a false enlargement before they ultimately become smaller—so-called pseudo-hypertrophic paralysis. But there is really no essential difference between these two varieties. Even in pseudo-hypertrophic cases, certain muscles undergo atrophy from the beginning, whilst in

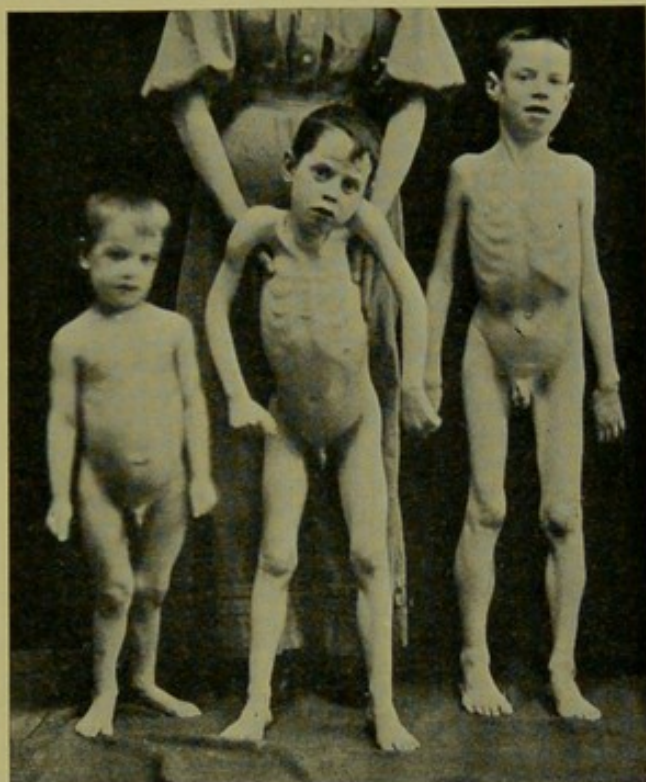

FIG. 107.—Family of pseudo-hypertrophic brothers, æt. 4, 8, and 12. The youngest and the oldest can still stand and walk ; the middle child can no longer do so. In the two older boys the lower fibres of the pectoral muscles are absent.

the others atrophy and enlargement may be combined in varying proportions.

Muscular dystrophy is a congenital disease. Not that the symptoms appear at birth, for the child is usually born apparently healthy. The age of onset of noticeable symptoms varies from two to sixty years, though most cases occur in childhood or youth.

The chief distinguishing features between myopathic atrophies and muscular atrophies of nuclear origin, spinal or bulbar, are as follows :—The age of onset is earlier, as a rule, in myopathy than



in progressive muscular atrophy or amyotrophic lateral sclerosis. Myopathy often runs in families; progressive muscular atrophy does not. The muscles affected are different in the two cases. In progressive muscular atrophy and amyotrophic lateral sclerosis, the wasting most commonly begins in the small muscles of the hands, attacking muscle-groups corresponding to segments of the cord. In myopathy the larger muscles are generally affected, whilst the small muscles of the hands escape. Amyotrophic lateral sclerosis tends to spread up to the bulbar nuclei, and to produce bulbar paralysis. Myopathy does not cause bulbar palsy. It is true that in one type of myopathy—the Landouzy-Dejerine—the face is affected, and that in pseudo-hypertrophic cases the masseters are sometimes enlarged; but myopathic palsy hardly ever affects the tongue, and never the larynx. In myopathy some of the

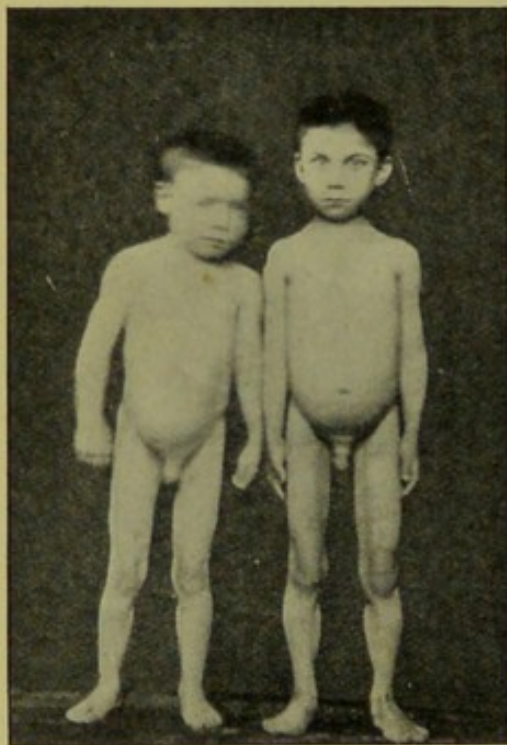

FIG. 108.—Pseudo-hypertrophic myopathy. Front view, showing enlargement of calves and thighs.

diseased muscles may be enlarged, whilst others are wasted. Enlargement of muscles never occurs in nuclear disease. When a myopathic muscle voluntarily contracts, we may sometimes notice a ball-shaped swelling in the middle of the muscle, especially in the deltoid or quadriceps, which is due to the fact that the dystrophy is most marked at the extremities of the muscles. The long bones of the limbs corresponding to the myopathic muscles undergo a degree of rarefaction and atrophy, and the normal ridges for muscular attachments become smoothed down.<sup>1</sup> Fib-

rillary tremors, which are so common in progressive muscular atrophy, are rare in myopathy. Lastly, in myopathy, unlike amyotrophic lateral sclerosis, the deep reflexes are never increased.

<sup>1</sup> Merle and Raulot-Lapointe, *Nouvelle Iconographie de la Salpêtrière*, 1909, No. 3.



In fact, in myopathy the knee-jerk may disappear from wasting of the quadriceps.

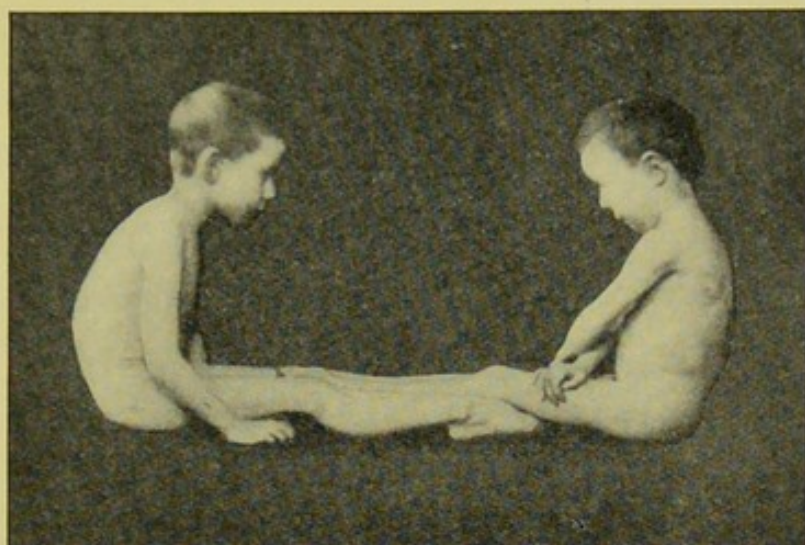


FIG. 109.—Pseudo-hypertrophic myopathy. Side view, showing absence of lordosis in sitting posture.

The pseudo-hypertrophic variety of myopathy generally begins in childhood. It is the most rapidly progressive form of myopathy,




FIG. 110.—Pseudo-hypertrophic myopathy. Showing method of attaining the erect attitude.

and in most cases the patient dies before attaining adult age. Boys are affected four or five times as often as girls. The cases tend to run in families, and to select patients of the same sex in each family. Thus we often find several brothers affected whilst the sisters escape.



But though the females generally escape themselves, they tend to transmit the disease to their male offspring, so that antecedent cases in a family are always on the mother's side. Children of the same woman by different husbands may suffer from the disease. It is therefore unwise to marry a widow, however young and charming, who has a pseudo-hypertrophic child. The symptoms of pseudo-hypertrophic paralysis are entirely motor. The first symptom which is usually noticed is that the child falls easily, gets up with difficulty, and cannot run or jump like other children, nor

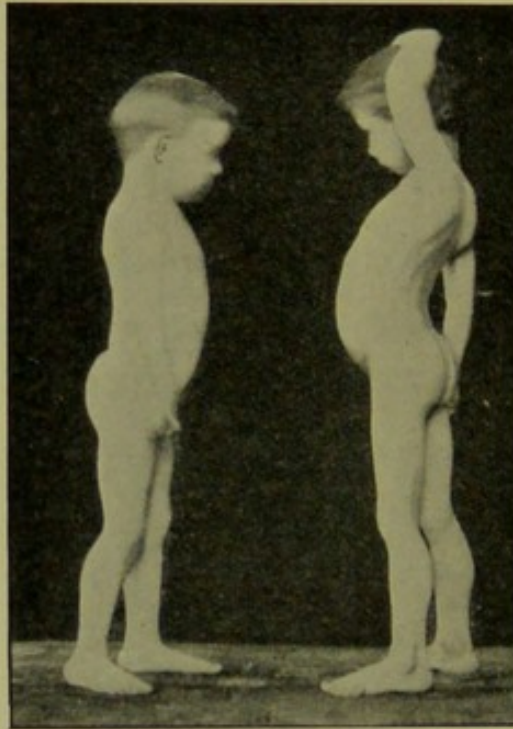


FIG. 111.—Pseudo-hypertrophic myopathy. Side view, showing lordosis when standing.

can he walk on his heels, keeping the feet raised in front. This weakness gradually increases until in a few years the patient becomes unable to stand or even to sit up in bed. The arms become weak later than the legs. Figs. 108 to 111 show two such patients. In them we notice the characteristic "pot-belly" and the lordosis when standing. The gait is wide-based and waddling, somewhat like that of the comic-opera sailor, and there is often a high-stepping action to clear the toes from the ground. But most characteristic of all is the way in which the patient rises from the floor when placed



flat on his back. He first rolls round and gets on to his hands and knees. Then, keeping his feet wide apart, he drags his hands along the floor towards his feet until the knees are straightened. Then he shifts his hands up to his knees and proceeds to extend the hip-

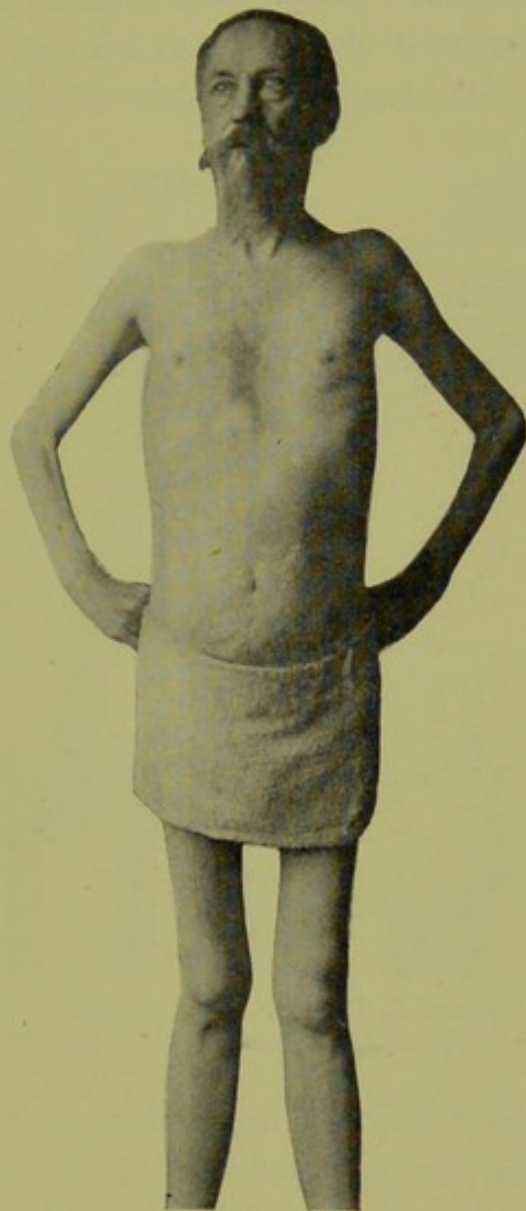


FIG. 112.—Muscular dystrophy. Erb's juvenile type.

joints by climbing up his thighs. When he has reached the upright position, he leans his trunk backwards to keep the hips extended.

In pseudo-hypertrophic myopathy certain muscles are specially enlarged and hard—*e.g.* the calf muscles and the infra-spinati. Other muscles may also become enlarged—*e.g.* the quadriceps, glutei, deltoid, biceps, and triceps. On the other hand, certain



other muscles waste from the first, without any initial stage of enlargement. Thus the latissimus dorsi, teres major, and lower fibres of the pectoralis major are often absent, so that the folds of the axillæ are poorly marked, and if we lift up the child by the axillæ he slips through our grasp. (See Fig. 107.)

The enlarged muscles ultimately shrink and become smaller. As the calf muscles shorten, they produce a talipes equinus which

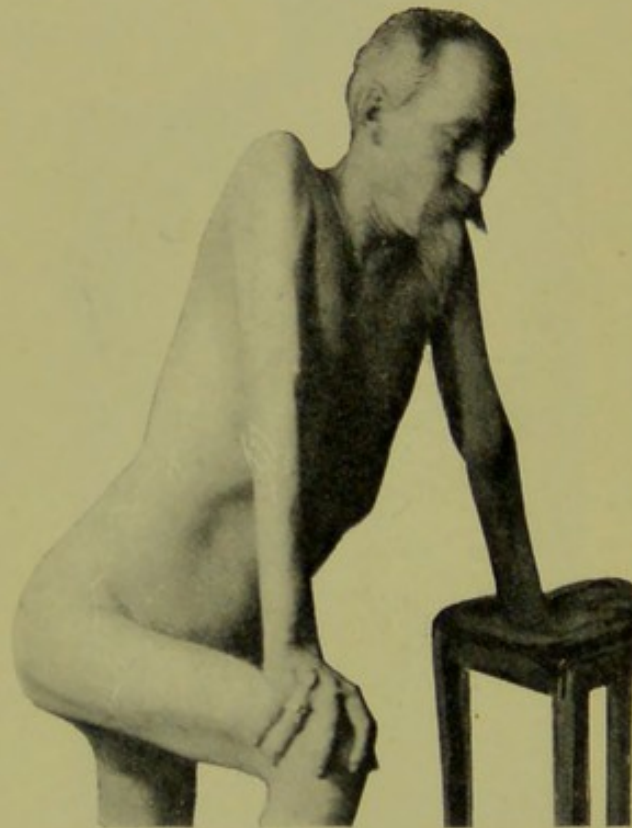

FIG. 113.—Muscular dystrophy. Erb's juvenile type. Patient endeavouring to rise to standing posture.

still further hampers the walking powers. When the patient becomes bedridden, the contractures rapidly attain an extreme degree. As the quadriceps wastes, the knee-jerk disappears.

**Primary atrophic myopathy** is a less common type, and owing to absence of muscular enlargement, it is more likely to be confused with progressive muscular atrophy of spinal origin. At least three varieties have been recognised, according to the muscles which are first attacked. Thus we have (*a*) Erb's juvenile type, affecting the muscles of the shoulder-girdles and upper arms; (*b*) Landouzy and Dejerine's facio-scapulo-humeral type, where the atrophy



begins in the face; (c) a type beginning in the lower limbs, chiefly in the anterior thigh muscles.

In these atrophic varieties there is no striking preference for boys; both sexes are equally liable. The age of onset too is a little later, commonly between 15 and 35 years, except in facial cases, where the atrophy may come on in early childhood.

In *Erb's juvenile type* the atrophy begins in the large muscles

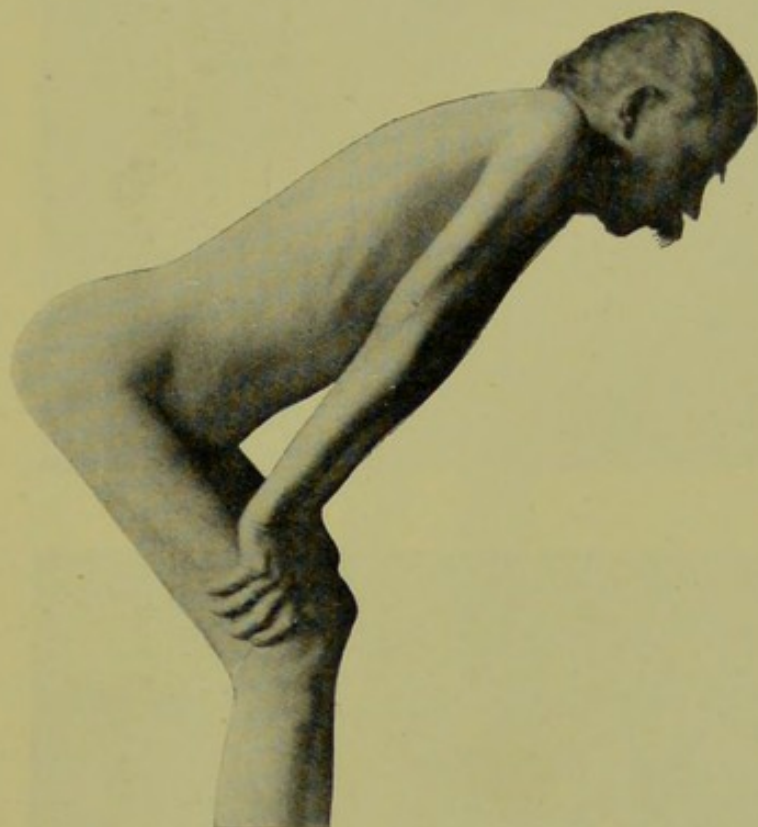


FIG. 114.—Muscular dystrophy. Erb's juvenile type. Patient rising to erect posture.

of the upper arms and shoulders, especially the biceps, triceps, and supinator longus. Figs. 112, 113, and 114 are from such a patient, aged 47, who was a professional "living skeleton" in a travelling "freak" show. In his case the wasting was first noticed at the age of 19. In some instances, as in this particular case, the arms and legs are attacked about the same time. Or the disease may begin in the arms and spread to the legs. The deltoids and spinati often escape, even when the biceps and supinator longus are wasted, the condition in this respect differing from cases of spinal origin; and the forearm muscles, except the supinator longus,



generally escape too. From weakness of the glutei and quadriceps, the patient when rising to the standing posture

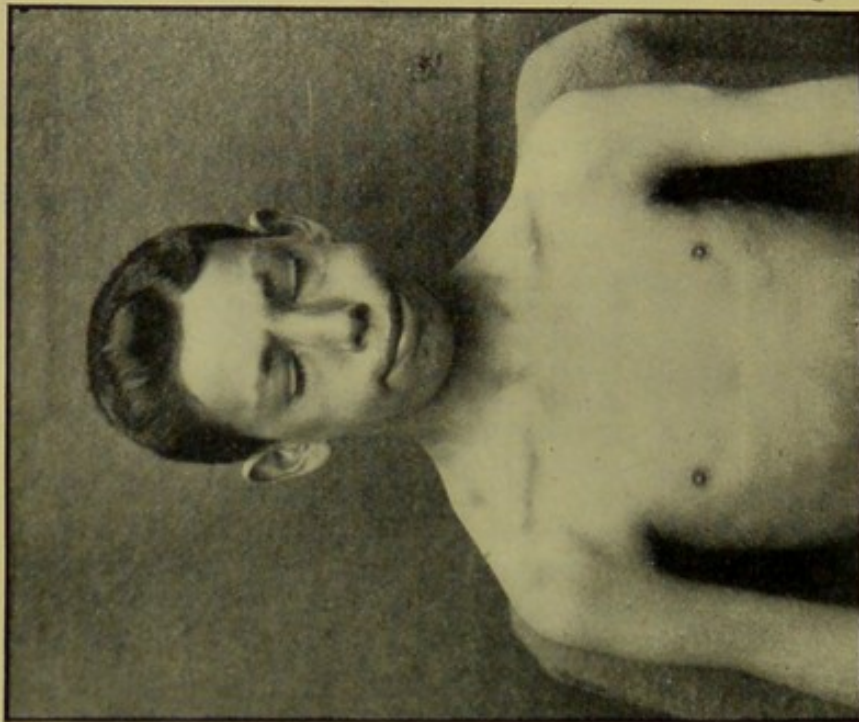


FIG. 116.

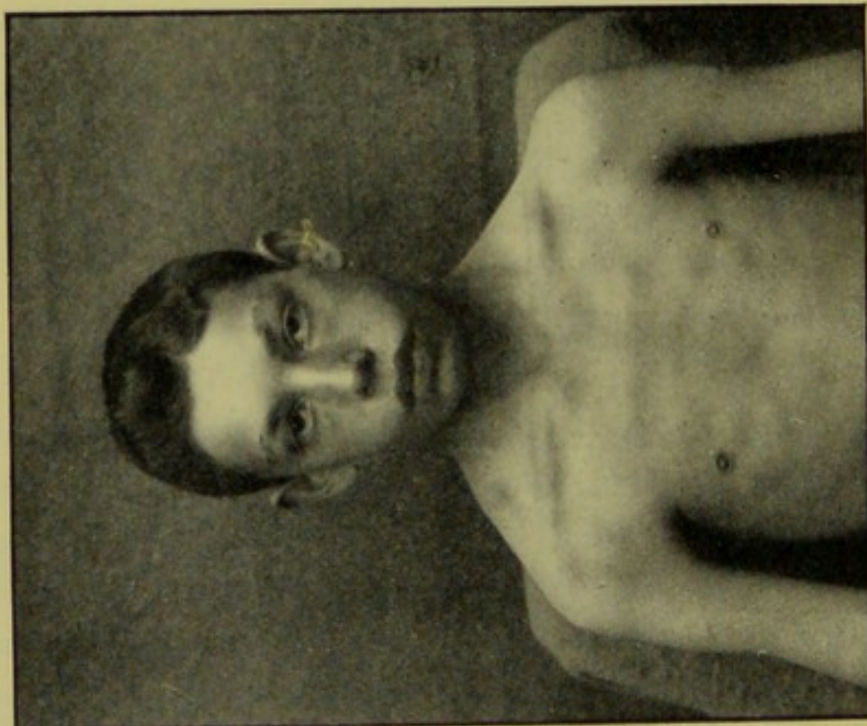


FIG. 115.

Figs. 115 and 116.—Myopathy: Landouzy-Dejerine type. Fig. 115 shows position at rest. Fig. 116 shows weakness of orbiculares oculorum and orbicularis oris on attempting to screw up the eyes and blow out the cheeks; also upward displacement of scapulæ and wasting of lower part of pectoral muscles.

may have to climb up his legs, as does a pseudo-hypertrophic case.

The *facio-scapulo-humeral* variety of *Landouzy-Dejerine* com-



mences in early life, the facial muscles being earliest affected. The orbiculares oculorum and oris are weak, so that the patient cannot close his eyes tightly nor blow out his cheeks (see Figs. 115 and

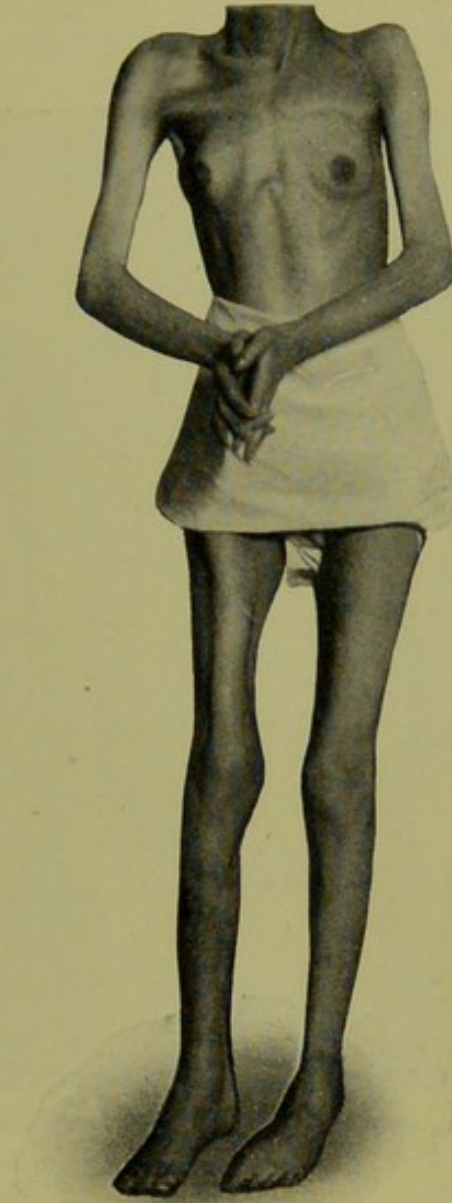


FIG. 117.—Muscular dystrophy; type beginning in lower limbs, but having advanced to upper limbs. Patient pressing hands together, to show atrophy of greater portion of pectoral muscles. Intrinsic muscles of hands unaffected.

116). His lower lip droops and projects forwards, and his mouth habitually hangs open. The smile is peculiarly transverse and has a “forced” look, the angles of the mouth being drawn outwards but not upwards. The tongue, ocular and jaw muscles are un-



affected. Later the disease spreads to the scapular and upper-arm muscles, and finally to the spinal muscles and lower limbs.

A third type of the disease, of which Figs. 117 and 118 are an example, begins in the legs, and attacks the arms later. In this patient the legs became weak at the age of 12. When she

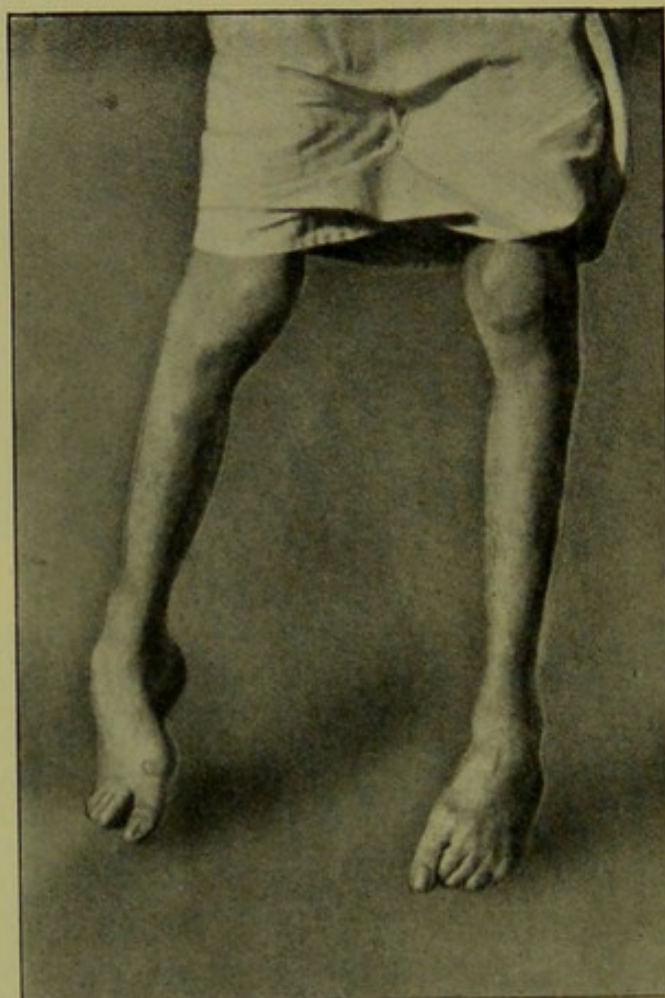


FIG. 118.—Muscular dystrophy. Same patient as in Fig. 117. Showing deformity of feet.

came under observation at the age of 28 she was still able to use her arms, which were contracted at the elbows, for knitting and to feed herself, though she was no longer capable of walking, owing to claw-foot.

**Other Varieties of Muscular Wasting.**—Wasting of muscles sometimes occurs as a secondary phenomenon in other diseases, where there is no implication of the spino-muscular motor neurone. Thus the muscles may become small from disuse, as may be seen in a limb which, owing to a fracture, has been confined for several



weeks in splints. Disease of a joint is generally accompanied by well-marked atrophy of the surrounding muscles. This arthritic muscular wasting specially affects the extensor muscles of the joint—for example, the quadriceps in disease of the knee-joint, the interossei in osteo-arthritis of the hands, the deltoid in disease of the shoulder-joint. A degree of muscular wasting also occurs in the paralysed limbs in ordinary hemiplegia. Part of this may be the result of disuse, but there are other cases where the degree of wasting is excessive, and disproportionate to the paralysis. Lastly, we may meet with marked wasting of muscles in rare cases of hysterical paralysis (see Fig. 208, p. 380). But all these muscular wastings can be distinguished from that due to disease of the lower motor neurone by the absence of electrical reactions of degeneration.



## CHAPTER XV

### RECURRENT AND TRANSIENT PALSIES

THERE are certain forms of motor paralysis which come and go. They tend to recur again and again, and in the intervals between his attacks the patient is able to execute all voluntary movements in a normal or almost normal fashion.

Of these diseases **myasthenia gravis** is the most serious. In myasthenia certain muscles become infiltrated with deposits of small round cells resembling lymphocytes, especially the striated muscles innervated by the upper cranial nerves, though sometimes the muscles of the limbs and trunk, and even the respiratory muscles, may become affected. The disease is characterised by the fact that the patient becomes, after very moderate exertion of the affected muscles, abnormally easily fatigued, and the affected muscles are, for the time, paralysed. The patient wakes up in the morning practically normal, but as the day goes on, certain muscles gradually become paralysed. Perhaps the muscles most often affected are the levators of the upper lids. Thus ptosis appears, often of unequal degree on the two sides (see Fig. 119). To this may be superadded an external ophthalmoplegia, generally incomplete. The facial muscles also become weak, and the patient has a peculiar "nasal" form of smile, in which the angles of the mouth are drawn upwards but very slightly outwards. The masseters and other masticatory muscles may also be affected, so that the patient cannot chew more than a few mouthfuls. The palate, tongue and larynx may all be implicated, producing for the time the phenomena of bulbar palsy. In fact, the disease was formerly named "asthenic bulbar paralysis." To correct his ptosis, the patient may tilt his head backwards. But sometimes the neck muscles are affected, so that the head falls loosely backwards or forwards. In the limbs it is chiefly the large proximal



muscles which are affected. But the most characteristic feature is the transitoriness of the paralysis, and its recurrence on slight exertion. Thus the patient can walk a short distance, but soon has to stop; he may speak a few sentences, and then his voice becomes weak and his articulation indistinct. In the affected muscles, the electrical reactions are altered and we have the "myasthenic reaction." Faradic shocks applied to the




FIG. 119.—Myasthenia gravis in a man of 35. Marked weakness of masseters and of lower facial muscles; also right-sided ptosis. The patient is making a maximum effort to clench the jaws and show the teeth.

muscles at first produce brisk contractions, but on repeated stimulation the faradic excitability temporarily disappears. In contrast to true bulbar palsy, there is no muscular atrophy as a rule, although in very severe cases, slight wasting may supervene.<sup>1</sup> The reflexes, deep and superficial, together with the sphincters, are unaffected. If the respiratory muscles become severely affected, the patient may die from respiratory failure. In addition to

<sup>1</sup> See E. Levi, *Rivista di patologia nervosa e mentale*, 1906, p. 450.



motor phenomena we may also have evidences of fatigue in the special senses and even in common sensibility. Thus the myasthenic patient may have temporary impairment of visual acuity with temporary contraction of the visual fields, and in rare cases temporary diminution of sensation has been observed in the limbs.<sup>1</sup>

**Thomsen's disease** or "**myotonia congenita**," is a rare congenital affection of the voluntary muscles, which appears to be due to their possessing an excessive proportion of undifferentiated sarcoplasm and muscle-nuclei, and relatively too small a proportion of the anisotropic or fibrillar element. This latter contracts briskly, whereas sarcoplasm contracts very slowly. In Thomsen's disease, whenever the patient starts to perform a voluntary movement, his muscles are thrown into a state of tonic spasm, which does not relax at once but passes off gradually, the muscles slowly becoming supple, until at length he can perform the movement, say that of walking, in a normal fashion ("ce n'est que le premier pas qui coute"). But if he stops and starts again, or if he tries to hurry his original speed, this stiffness reappears, and has again to be, as it were, worked off. The lower limbs are most commonly affected, the affected muscles often being somewhat enlarged, but other muscles may also show the phenomena. Thus the patient's eyes may remain temporarily firmly closed after a cough or sneeze, his mouth may remain open after a yawn, and so on. The sensory functions and the reflexes are unaffected. But the affected muscles have a characteristic reaction to electrical stimulation. Their excitability is increased to both faradism and galvanism. To galvanism KCC is equal to ACC (instead of being greater, as in health), and the contraction set up, whether by galvanism or by faradism, is remarkably persistent, lasting for a time after the stimulus has ceased. The disease runs in families.

**Eulenberg's disease** or "**paramyotonia congenita**," is a family affection somewhat like Thomsen's disease, in which a tonic spasm appears in certain voluntary muscles, more particularly in the face,

<sup>1</sup> Tilney and Mitchell Smith, *Neurographs*, 1911, vol. i. p. 178.



so that the patient is unable, for a quarter of an hour or longer, to open his eyes or to speak. Less often the muscles of the limbs are affected. The condition, however, differs from Thomsen's disease in its immediate exciting cause. The tonic spasm of Eulenberg's disease is excited not by exertion but by cold, and is generally relieved by warmth. The two diseases, however, are closely allied, and have been observed coincidentally in members of the same family.<sup>1</sup>

**Myotonia atrophica**<sup>2</sup> is a rare disease, intermediate in its characters between the myotonias and the myopathies. It sometimes occurs in several members of the same family. The patients are more often males than females, and the symptoms usually appear in adult life. The myotonic phenomena generally precede the muscular wasting. The first symptom is usually a difficulty in relaxing the grasp. Myotonic phenomena in other muscles are slighter in degree, and are chiefly seen in the muscles of mastication, the facial muscles and the tongue; they are rare in the lower limbs. Atrophy of myopathic type appears later, irregular in its distribution, chiefly affecting the facial muscles, the sternomastoids and the vasti muscles of the thighs. It may also be present elsewhere in lesser degree, as in the forearm muscles and the dorsiflexors of the foot.

Another interesting variety of transient paralysis is known as **intermittent limp** or "**dysbasia angio-sclerotica**" ("claudication intermittente" of Charcot, or the "intermittirendes Hinken" of German authors). An analogous condition in horses, known as "spring-halt," has been familiar to veterinary surgeons for many years. The patient is most commonly a man of middle age, sometimes of gouty constitution, who very often has been an inveterate tobacco-smoker. The symptoms are very characteristic. At rest he feels no disability. But when he begins to walk, though he starts off normally, he soon begins to feel his legs tired, heavy and painful. A cramp-like pain appears and gradually becomes intolerable, making him limp; and if he perseveres with

<sup>1</sup> Delprat, *Deutsche med. Wochenschrift*, 1892, s. 158.

<sup>2</sup> Rossolimo, *Nouvelle Iconographie de la Salpêtrière*, 1902, p. 63. Batten and Gibb, *Brain*, 1909, p. 187.



his attempt, he finally becomes, for the time, totally unable to walk a single step. He rests, the pain and weakness pass off, only to return when he starts to walk afresh. If we examine such a patient during a paroxysm of temporary incapacity, we find his feet and legs cold, and perhaps purple or mottled red. But what is most characteristic of all is that the pulse in the feet, in the posterior tibial or the dorsalis pedis artery, is absent or nearly so. There are no sensory changes, the reflexes are normal, and, except during the paroxysms, the motor power of the limbs is unimpaired. All these phenomena appear to be the result of a temporary spasm of the arteries of the limb (the arteries themselves being frequently already narrowed by arterio-sclerosis), so that during walking an increased blood-supply to the muscles is not forthcoming, hence there result temporary anæmia, pain and weakness in the affected muscles. In rare instances similar phenomena have been observed in the arms.

Rare cases have also been observed where a hemiplegia, partial or complete, sometimes accompanied by aphasia, occurs in an elderly patient, indistinguishable at first from an ordinary cerebral hæmorrhage or thrombosis. But within a few hours all the hemiplegic phenomena suddenly disappear, leaving the patient perfectly normal. The patient may have a series of such attacks of transient hemiplegia at intervals of days, weeks or months. For over three years I watched the case of an elderly cabman who had numerous attacks of left hemiplegia lasting for a day or so, leaving him absolutely well in the intervals. Another case of mine was in a vigorous business man, aged fifty-one, who had frequent attacks of temporary aphasia with right hemiplegia. Similar cases have also been recorded by Grasset<sup>1</sup> and by Langwill.<sup>2</sup> Such cases may be termed *angio-spastic hemiplegia*, and are probably due to temporary spasm of one middle cerebral artery, analogous to the spasm of peripheral vessels in intermittent limp. They must be carefully distinguished from the transient hemiplegia which is not uncommon in general paralysis of the insane.

<sup>1</sup> *Revue neurologique*, May 30, 1906.

<sup>2</sup> *Scottish Medical and Surgical Journal*, June 1906.



Amongst the transient paralyses we must also bear in mind the various craft-palsies, professional cramps, or **occupation neuroses**, in which the limb is normal for all motor actions except one particular movement—often, unfortunately, the one on which the patient's livelihood depends. The commonest variety is the so-called writer's cramp or scrivener's palsy, though we also meet with similar conditions in the cramp of pianists, violinists, telegraphists, typists, tailor's cutters, hair-cutters, hammer-men, cow-milkers, watch-makers, harpists, cigarette-makers, sempstresses, and so on. The cramp comes on, not during the period when the sufferer is learning his occupation, but after he has become an expert and requires to perform the particular skilled movement repeatedly for prolonged periods. For all other movements except that particular one, the limb is normal. Thus in writer's cramp the patient can use his hand normally for piano-playing or for grasping and using a heavy tool. This is because the weakness is not due to muscular but to cerebral fatigue. A professional cramp does not appear in its fully developed form at first, but passes through different stages of severity. In the slightest variety there is simply a degree of stiffness or spasm in performing the act, with a subjective sensation of pain and of intense mental discomfort and fatigue. In other cases a temporary paralysis appears when the patient attempts to write, so that the pen can no longer be held in the hand. In still more severe cases tremor is superadded to spasm in the affected muscles. The diagnosis is easy, inasmuch as the phenomena, whether spastic or paralytic or perhaps a combination of both, only supervene when the one skilled motor action is performed, and the same muscles can be used for all other actions without pain, spasm or weakness.

There is also a curious hereditary disease known as "**family periodic paralysis**." This malady may run through several successive generations of the same family, attacking one or more members of the same generation. Males and females are both liable. The patient, who is otherwise apparently healthy, has attacks of flaccid paralysis of all four limbs, recurring irregularly without apparent exciting cause. The duration of a paroxysm varies from two or three days down to a few hours. The attacks



generally come on during the night when the patient is in bed. He wakes up and finds himself more or less widely paralysed. First the legs are affected, later the arms, and last of all the muscles of the trunk and neck. The cranial nerves usually escape. In the limbs the paralysis starts proximally and the distal parts are affected last, so that the patient may still be able to move his toes and fingers when he has lost all power in the hips and shoulders. In severe cases the intercostal muscles may also be paralysed. Most striking of all is the fact that during these paroxysms of flaccid palsy the affected muscles, for the time, lose their excitability to faradic, galvanic, or mechanical stimulation, and all the reflexes in the affected limbs disappear. Sensation is unimpaired and the sphincters are unaffected. An additional point is that during the paroxysm, the left ventricle becomes temporarily dilated, as can be proved by percussion and occasionally by the appearance of a systolic mitral bruit. The muscular paralysis passes off in the reverse order to that in which it came on. The toes and fingers recover before the proximal muscles, and the muscles earliest attacked are the last to recover. The patient then remains apparently normal until his next attack, weeks or months later.

Sudden attacks of hemiplegia may also occur in **general paralysis of the insane**, constituting a variety of so-called "congestive attacks." But although the patient may recover rapidly from his hemiplegia, often within a few days, he is not a normal individual, for careful physical examination will always reveal evidences of the disease, mental or physical, *e.g.* facial tremors, pupillary changes, or, most constant of all, lymphocytosis of the cerebro-spinal fluid.

Amongst other transient affections we may mention those of **muscular cramp** and of **tetany**. The conditions are easily recognised, and may temporarily interfere with the movements of the affected limbs. Both are painful affections, tetany being most commonly seen in infants, whilst cramp is most often met with in healthy adolescents or adults who have been performing some unwonted prolonged muscular effort. Cramp is also a



distressing symptom in cholera, in some cases of diabetes, and occasionally in exophthalmic goitre. Tetany is generally bilateral, and has a characteristic posture of the hands and feet (see Fig. 33, p. 76).

Occasionally we see patients who complain that their legs suddenly give way in the street, causing them to fall. This may be due to various causes. For example, it is a not uncommon symptom in *tabes*. The tabetic patient often has hypotonia of the muscles about the knees and also deficient joint-sense, a combination of phenomena which may make him fall unexpectedly. In such a case the condition of the deep reflexes, the state of the pupils, and the other phenomena of *tabes* render the diagnosis easy. Other cases of sudden falling are due to *minor epilepsy*, where the patient has an attack of momentary unconsciousness during which he falls, but recovers consciousness at once and gets up again, not knowing why he has fallen. Here the diagnosis will depend on the observation of other epileptiform attacks, major or minor. We should particularly inquire for the occurrence of sudden pallor of the face or fixity of expression, indicating a passing attack of *petit mal*, too slight, perhaps, to produce a fall.

In other cases, again, we have to do with sudden *vertigo*, as in *Menière's disease*, causing the patient to fall. Such cases are recognised by the concomitant auditory phenomena (see p. 161), and by the fact that they are not associated with loss of consciousness.

Sudden weakness of a limb may occur in *hysteria*, especially after some emotional shock. Hysterical paralysis may persist for variable periods of time, varying from a few hours to many weeks or months. The paralysis not uncommonly recovers as suddenly as it came on, sometimes under emotional or religious excitement, under hypnotic suggestion, or under energetic stimulation, electric or thermal, for example, that of a *Pacquelin cautery*. Hysterical paralysis never attacks a single muscle, but always a group of muscles. It is never accompanied by reactions of degeneration, no matter how much the hysterical limb may be wasted. We diagnose hysteria by a



process of exclusion, noting not only the absence of certain signs of organic disease, but looking also for the presence of various hysterical "stigmata," to which we shall refer later.

But we must not forget that in many cases of apparently hysterical and transient paralysis in young women, the patient after one or more of such attacks may afterwards develop the signs of **disseminated sclerosis**. The onset of disseminated sclerosis may be indistinguishable from an attack of hysterical paralysis, the weakness of the limb in both diseases may be transient and may apparently clear up completely for a time. But a series of such attacks should always raise in our minds the suspicion of an underlying disseminated sclerosis and should make us give a guarded prognosis, especially if the patient has had more than one attack of weakness, not necessarily in the same limb. We should pay particular attention to the state of the optic discs. Early optic atrophy will exclude mere hysteria, so also will an extensor plantar reflex or anything approaching a true nystagmus. In fact, the disease which is most often wrongly diagnosed as hysteria is incipient disseminated sclerosis.



## CHAPTER XVI

### INCO-ORDINATION

A NEWLY-BORN child cannot co-ordinate the movements of its limbs. Certain co-ordinated vital actions, such as sucking, swallowing, respiration, &c., are performed well from birth, but in an infant's limbs the movements are mostly of an aimless restless character, with the exception, perhaps, of grasping movements of the hands. And even these latter differ from the co-ordinated grasp of later life, inasmuch as the infant's thumb is hardly used at all for opposition, and the flexion movement of the fingers occurs chiefly when some object comes in contact with the hand, the movement being reflex rather than voluntary.

The child only learns after long practice to use its muscles in such a fashion as to produce properly co-ordinated movements of the limbs. Walking, writing, swimming, the playing of any game, are all performed awkwardly at first. Skill is at last attained by frequent repetition, and once a co-ordinated action has been thoroughly learned, the effort for its performance becomes infinitesimal, so that in time it is performed more or less automatically.

Every co-ordinated action involves contraction not only of the so-called prime-movers but of their antagonists, and if these two groups are not properly balanced, the attempted movement is awkward and jerky. This condition occurs in a number of diseases and is termed *ataxia* or *inco-ordination*. This means clumsiness, unsteadiness, or awkwardness in the performance of movements in a non-paralysed patient who was previously able to execute these movements in normal fashion.

In testing for ataxia of the upper limbs, we ask the patient to perform such an action as picking up a small object, say a pin, from a smooth surface. If he is ataxic, he fumbles



during the attempt, or may perhaps pounce on the object in a sudden, jerky fashion. Another useful test is to ask the patient to lift a brimming glass of water to his lips and notice whether he spills it. Or we may ask him to touch rapidly the tip of his nose with each index finger in succession. If he is ataxic, his finger misses his nose by a greater or smaller interval, or, on reaching it, the finger shows additional oscillatory movements. Other good tests for ataxia are to make the patient button or unbutton his coat or collar, or to write with a fine-pointed pen. In every case, we should observe whether the unsteadiness is increased or unchanged when the patient shuts his eyes. Slight degrees of ataxia due to sensory impairment may be noticed only when the patient is deprived of the help of his visual impressions.

In the case of the lower limbs we detect moderately severe ataxia by observing the patient's gait, asking him to walk "heel-and-toe" along a straight line, then to turn sharply and come back. In well-marked locomotor ataxia the gait is broad-based, the feet are lifted too high and the heels are brought down with a stamp. In cerebellar disease, on the other hand, the patient reels or lurches along, being especially unsteady when turning round (see later, "Postures and Gaits"). To detect ataxia of a single lower limb, we ask the patient to place one heel on the opposite knee, or to trace with one foot a circle or some other pattern on the floor, or we ask him when lying down to touch with his toe our own finger held in the air. And here also, in ataxia of the lower limbs, we should always note whether the patient's unsteadiness is increased or unchanged by shutting the eyes. In tabetic ataxia of the lower limbs, the unsteadiness is increased when the eyes are shut. *Romberg's sign* consists in the tendency of a patient, who can stand steadily with the eyes open, to fall when he closes them. Thus an early sign of tabes is the so-called "wash-basin" sign, where the patient falls into his basin when washing his face. A minor degree of Romberg's sign can often be detected in the earlier stages of tabes, where the patient is still able to stand with the eyes shut, but the tendons



on the dorsum of the foot are seen to exhibit irregular restless contractions, the so-called "danse des tendons."

Ataxia of the bulbar muscles has already been referred to (see Dysarthria, p. 109). As to ataxia of the muscles of the trunk, its diagnostic significance is less than that of the limbs, inasmuch as by the time that the trunk muscles are recognisably ataxic, the limbs already show very marked unsteadiness. Ataxia of the head and trunk muscles is evidenced by swaying movements when the patient sits up.

Having detected ataxia in the movements of any limb, we must always determine the condition of the sensory impulses from that limb, testing not only the various forms of cutaneous sensibility but also the deep sensations, especially the kinæsthetic sense and, still more important, the joint-sense. Finally, we must determine the condition of the deep reflexes, noting their exaggeration as in disseminated sclerosis, or their abolition as in tabes or in Friedreich's ataxia. We also note the type of plantar reflexes.

The commonest variety of ataxia is that due to deficiency of peripheral impressions—not so much from the skin as from the deeper structures, the muscles and joints. Thus in lesions of *peripheral sensory nerves* an anæsthetic limb is often ataxic. Division of the *posterior roots* of the brachial plexus, the anterior roots remaining intact, causes marked ataxia of the upper limb. In fact such a patient may be totally unable to move the limb if his eyes are closed, so that he no longer has the guiding influence of vision. Degeneration of the posterior roots and posterior columns, as in *tabes*, produces marked ataxia. A tabetic patient is ataxic because of deficiency of afferent impressions, more especially from his muscles and from his joints. If the muscle-tonus is lost and the muscles are hypotonic, as in many cases of tabes, the patient has, as it were, to "pull in the slack" before the muscles come into proper play, thereby making the movement jerky, inharmonious, and flail-like. Joint-sense being impaired, he has to perform a maximal movement in order to get the sensation of having moved the joint at all. Thus in walking when he lifts his leg, owing to want of proper joint-sense, he throws the limb up with



abnormal suddenness and to an unnecessary height in order to gain the sensation of flexion of the joint. He then stamps it down with excessive emphasis to make sure that it really is extended. Such a patient with ataxia of sensory origin compensates for the deficiency of sensory impressions from his limbs by means of his vision. When watching his partially anæsthetic limbs, he can control them better. Hence if he closes his eyes, the regulating influence of vision is lost and he becomes much more ataxic. This is the probable explanation of Romberg's sign in tabes.

Ataxia similar to that of tabes also occurs in other organic cord lesions implicating the posterior columns, as, for instance, in *tumours* or *chronic sclerosis of the posterior columns*, whether combined or not with lateral sclerosis—*e.g.* some cases of disseminated sclerosis or spinal syphilis. In such diseases the other signs and symptoms guide us to a correct diagnosis.

Ataxia combined with spasticity occurs in the early stage of *subacute combined degeneration* of the spinal cord, generally a disease of middle life. This disease occurs chiefly in conditions of profound anæmia. In the first stage of the malady there are loss of joint-sense and subjective sensations of tingling, &c., in the lower limbs, not unlike tabes, but with increased knee-jerks and extensor plantar reflexes. Vibration-sense in the bones of the lower limbs is lost long before any cutaneous anæsthesia develops. After lasting for weeks or months the disease then changes its type, and in this second stage the spastic paraplegia becomes severe and marked anæsthesia develops in the lower limbs and trunk. Lastly, and usually abruptly, within a few days the type changes once more, and there is a terminal stage of flaccid paraplegia lasting a few weeks, with absolute anæsthesia of the lower limbs and trunk, loss of the knee-jerks, the plantar reflexes remaining extensor in type. The paralysed muscles rapidly waste and lose their faradic excitability. The bladder and rectum are uncontrolled and the lower limbs become œdematous. The whole disease from start to finish lasts about two or three years.



But a patient may be ataxic when all his peripheral sensations are normal. This occurs in the different varieties of cerebellar ataxia. Let us take, for example, *Friedreich's ataxia*, a developmental disease affecting mainly the afferent tracts in the cord leading upwards to the cerebellum, which is the centre for automatic co-ordination (the cerebellum itself being intact). In Friedreich's ataxia the patient becomes ataxic, as in tabes, but with the cutaneous and joint-sense intact. The ataxia is unaffected by closing the eyes. The age of the patient, who is commonly an adolescent, the presence of scoliosis, of manus cava, and of pes cavus (Figs. 120 and 121), the normal pupillary reactions, the presence of nystagmus, the absence of lightning pains or of bladder trouble, all serve to distinguish this disease from tabes, though in both diseases the deep reflexes are absent. The plantar reflexes in tabes are flexor in type, whilst in Friedreich's ataxia they are of the extensor variety.

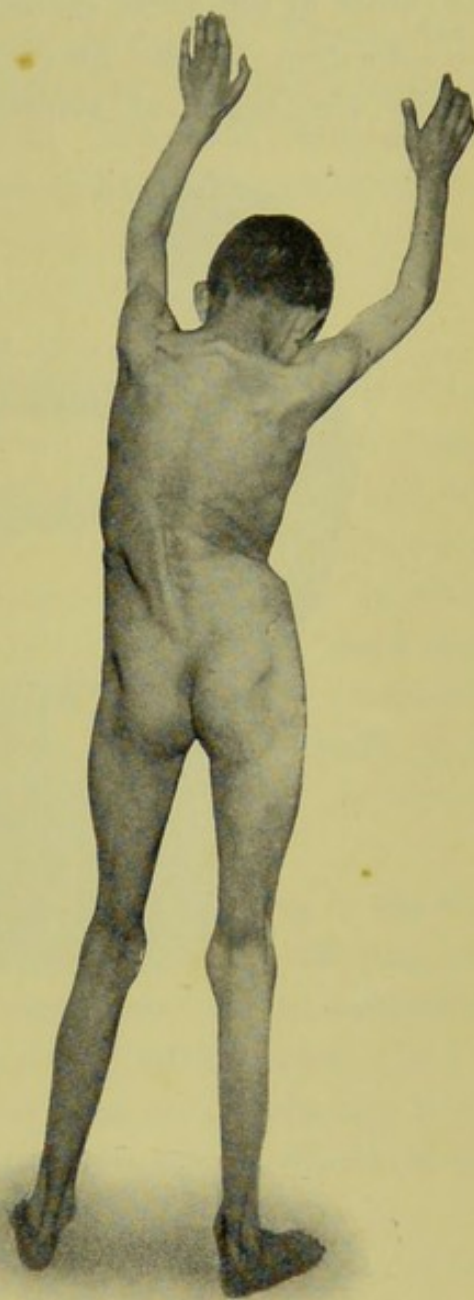


FIG. 120.—Friedreich's ataxia. Showing scoliosis.

Well-marked ataxia combined with muscular atrophy, absence of deep reflexes, and deformity of the feet and hands, also occur in family *hypertrophic interstitial neuritis*. In this disease, however, unlike Friedreich's ataxia, we never have an extensor plantar reflex, whilst there are well-marked sensory changes in the limbs.



Ataxia also occurs in certain localised lesions of the *medulla oblongata*. Thus, for example, a unilateral lesion may interrupt the fibres of the direct cerebellar tract and thereby interfere with co-ordination of the ipso-lateral limbs. Such a lesion (commonly the result of thrombosis of the posterior inferior cere-




FIG. 121.—Friedreich's ataxia. Showing pes cava and manus cava.

bellar artery), which usually interrupts at the same time the fibres of Gowers' tract, may extend inwards to implicate the inter-olivary arcuate fibres and the fillet, together with the nuclei of the lower cranial nerves. It produces a characteristic unilateral bulbar syndrome.<sup>1</sup> The symptoms are as follows:—From interruption of

<sup>1</sup> Babinski and Nageotte, *Revue neurologique*, 1902, p. 358.



the cerebellar afferent fibres there is ataxia (or asynergia) of the ipso-lateral limbs. From interference with the tract for pain and temperature we have analgesia and therm-anæsthesia of the opposite side of the body (see Fig. 11, p. 17). From interference with the oculo-pupillary centre in the bulb there is myosis and pseudo-ptosis (see later, "Cervical Sympathetic Paralysis," p. 336), and there may be difficulty of deglutition due to affection of the cranial nerve nuclei. If the lesion extends forwards to implicate the pyramid of the same side, there is hemiplegia of the contra-lateral arm and leg.

*Marie's hereditary cerebellar ataxia*, due to primary parenchymatous degeneration of the cerebellum itself, is somewhat similar to Friedreich's ataxia, but there is no loss of knee-jerks, and the age of onset is somewhat later. *Olivo-ponto-cerebellar atrophy* is a disease described originally by Dejerine and Thomas, in which there is a primary atrophy of the cerebellar cortex, the bulbar olives, the grey matter of the pons, the middle cerebellar peduncles, and sometimes the restiform bodies. Clinically there is marked ataxia or asynergia. The disease does not run in families, and its onset is in advanced life.

Cerebellar ataxia also occurs in cerebellar tumours, in vascular lesions of the cerebellum, in disseminated sclerosis affecting the cerebellum or its peduncles, in cerebellar abscess, in encephalitis of the cerebellar cortex, an acute disease of febrile onset which is sometimes met with in children, and it occurs occasionally in old age as the result of a primary senile atrophy of the cerebellar cortex, especially affecting the Purkinje cells.<sup>1</sup>

*Cerebellar ataxia*, better termed cerebellar *asynergia*, differs in several important respects from the ataxia due to deficient afferent impressions. It is chiefly evidenced in the cerebellar gait, which has a staggering, reeling character, like that of a drunken man, but without the stamping of the true tabetic. We recognise several factors in the production of cerebellar ataxia. Part of the ataxia, especially that of the trunk muscles, is due to vertigo, the patient being unsteady in his gait

<sup>1</sup> Rossi, *Nouvelle Iconographie de la Salpêtrière*, No. 1, 1907.



because he feels giddy. A cerebellar gait therefore occurs in many cases of labyrinthine disease. If a cerebellar patient lies down, his vertigo is diminished and there being no longer any effort required to maintain equilibrium, his movements are much less unsteady. Another factor in cerebellar ataxia is the existence of the muscular hypotonia which we often meet with in cerebellar disease; this hypotonia, in unilateral cerebellar lesions, is more marked in the limbs of the affected side. The third and most important factor in cerebellar ataxia is the want of the co-ordinating influence of the cerebellum on the cerebral motor cortex. This connection is a crossed one, the right cerebellum being connected with the left cerebral cortex, *via* the right superior cerebellar peduncle and the left red nucleus. Some tumours of the frontal lobe are associated with cerebellar ataxia, probably owing to indirect interference with the functions of the contra-lateral side of the cerebellum. True cerebellar ataxia, unlike the ataxia of *tabes dorsalis*, is uninfluenced by closure of the eyes.

Ataxia also occurs in some affections of the higher cerebral centres. For example, there are certain *toxic* affections in which the patient becomes ataxic. The most familiar variety is that of acute alcoholic intoxication. Part of this ataxia may possibly be due to cerebellar intoxication, but a large part of it is cerebral, as evidenced by the "mental ataxia," the disordered articulation, &c. The temporary ataxia of *fatigue*, of writer's cramp and of other occupation-neuroses is also probably of cerebral origin, so also is the transient ataxia which sometimes follows enteric fever or other exanthemata.

There are certain diseases of the cerebral cortex, in which ataxia is distinct. In *chorea* the patient not only exhibits spontaneous involuntary movements, but he also has distinct ataxia on voluntary movement. In organic *monoplegia* or *hemiplegia*, especially when slight in degree and amounting merely to paresis, distinct ataxia often exists in the paretic limbs. Hemi-ataxia is one of the characteristic phenomena in lesions of the *optic thalamus*. In such cases the limbs on the side contra-lateral to the lesion are not only ataxic but also partially anæsthetic with loss of



joint-sense, whilst spontaneous pains in the affected limbs are commonly present. Sometimes ataxia of the limbs precedes an attack of hemiplegia—*pre-hemiplegic ataxia*, especially in threatened softening from arterial thrombosis. More often the ataxia appears during convalescence from a slight hemiplegic attack—*post-hemiplegic ataxia*, where the patient has to learn the process of co-ordination again in his paretic limbs. This form of ataxia must be distinguished from athetosis, the involuntary slow writhing movements of the limbs which occurs in old and severe cases of hemiplegia, especially of infantile hemiplegia.

Ataxia is one of the most striking signs of *disseminated sclerosis*, where the unsteadiness of the limbs is often associated with a superadded coarse oscillatory tremor—the so-called intention-tremor. How much of the unsteadiness in disseminated sclerosis is due to cerebral and how much to cerebellar disease it is difficult to say in any individual case. Intention tremor is also present in some cases of family hypertrophic interstitial neuritis (see above, p. 227). The tremor of hemiplegic distribution which is observed in the limbs in cases of *lesions of the red nucleus or rubro-spinal tract* (see p. 86) is present at rest, but becomes exaggerated on voluntary movements, rendering them ataxic. In this respect it contrasts with the tremor of paralysis agitans, which can usually be controlled to permit of the performance of a voluntary movement.

Finally we may meet with ataxia of the most varied types in *hysteria*. Here the affection is probably one which implicates the highest psychological centres. The diagnosis of hysterical ataxia rests on the presence of other stigmata of hysteria, together with the absence of evidence of organic disease. Sometimes hysterical ataxia is associated with “cortical” anæsthesia of the affected limb. In such a case the patient may be able to move the limb normally with her eyes open, but when they are closed ataxia appears. This does not necessarily occur in every hysterically anæsthetic limb, for in many cases profound anæsthesia may be present without ataxia. The diagnosis of hysterical ataxia, however, seldom presents much difficulty to a



careful observer. The disease which is most often mistaken for hysteria is disseminated sclerosis in its earlier stages. In both diseases we may have a history of transient weakness of a limb, apparently clearing up completely for a time. But in disseminated sclerosis there are objective evidences of organic disease in the form of pallor of the optic discs, nystagmus, alterations of the abdominal and plantar reflexes, sphincter trouble, and so on.



## CHAPTER XVII

### POSTURES AND GAITS

**Postures.**—In health the posture of the body and of its various members is determined partly by gravity, partly by the relative strength of the muscles at the various joints. Therefore, inasmuch as the flexor muscles of our limbs are usually more powerful than the extensors, the ordinary posture of the limbs at rest is one of slight flexion. This is easily verified by observing a sleeping child. In the erect attitude the muscles of special importance in maintaining equilibrium are the extensors of the hips and knees; whilst in standing on one foot the peronei are of particular importance by inclining the whole lower limb outwards from the ankle up, and bringing the centre of gravity over the foot. The minor varieties of posture in different healthy individuals, which we learn to recognise as part of each man's personal characteristics, are largely the result of differences not only in muscularity but of habit. The pose of a powerful, muscular man is widely different from that of a thin, debilitated invalid. Moreover, if from exercise or want of exercise, certain groups of muscles are more or less developed than the normal, the posture is further modified, even in health. For example, we all know the characteristic straddling gait of the professional jockey.

Similar principles apply to those cases of organic disease where certain muscles or groups of muscles are affected by paralysis. Paralysed limbs gradually assume characteristic postures, and these **postures of organic disease** are not matters of haphazard, but are determined by anatomical rules.

If the muscular paralysis be the result of a *lower motor neurone lesion*, in the anterior cornua, anterior nerve-roots, nerve trunks or muscle-fibres, the paralysed muscles become wasted.



Their unopposed non-paralysed antagonists slowly become contracted, and fix the limb in a certain definite posture which is best demonstrated if the patient tries to throw the paralysed muscles into action, in which case the antagonists contract alone.

For example, Fig. 122 is a photograph of a woman who had



FIG. 122.—Chronic myelitis of fifth cervical segment, with atrophic paralysis of deltoid, biceps and supinators.

a localised lesion in the anterior cornua of the cord at the level of the fifth cervical segment. Amongst the chief muscles supplied by the anterior cornua at that level are the deltoid, biceps and supinators. These muscles underwent atrophy and their unopposed antagonists became contracted. As a result we see that from paralysis of the deltoid and contraction of its opponents the shoulder



is adducted, similarly from paralysis of the biceps the elbow is extended by its opponents, and from paralysis of the supinators the forearm is hyperpronated by their antagonists. This posture is characteristic of a cord lesion at the fifth cervical segment.

Fig. 123 shows the posture assumed in a case of paralysis of the external popliteal nerve. This nerve was divided by a bullet-

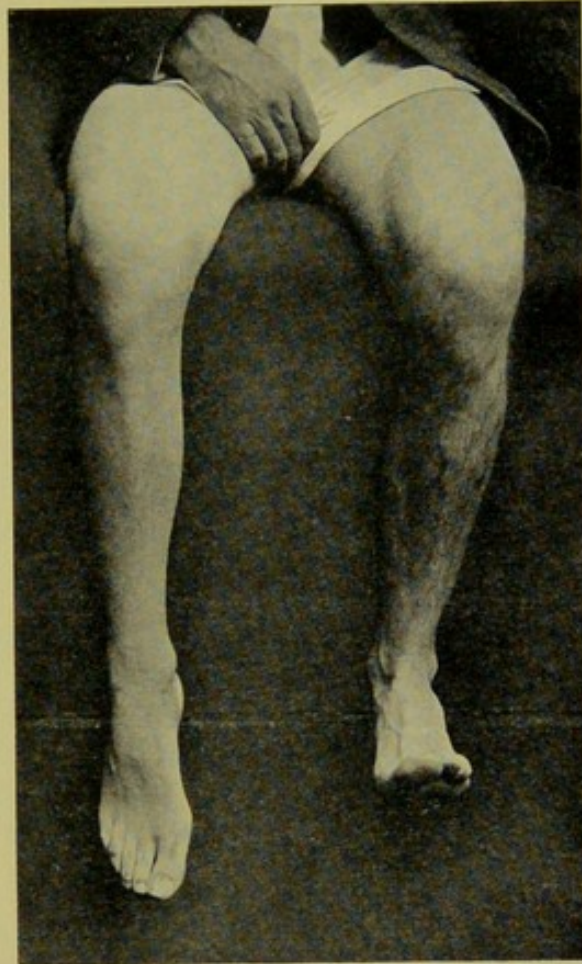


FIG. 123.—Paralysis of external popliteal nerve of right leg, the result of a bullet-wound. Showing muscular atrophy and drop-foot.

wound in an officer's right leg. In addition to anæsthesia corresponding to the cutaneous distribution of the nerve, the figure shows the presence of foot-drop due to paralysis of the anterior tibial group of muscles, with unopposed contraction of the calf muscles. Here, of course, the action of gravity is a factor as well, the weight of the foot tending to increase the foot-drop.

Fig. 124 shows the posture in a case of paralysis of the musculo-spiral nerve. The patient is trying to extend both his wrists. On the paralysed side we notice the atrophy of the



supinator longus and the paralysis of the extensors of the wrist and fingers, also the characteristic swelling on the dorsum of the hand, probably bursal in origin, which appears in long-standing cases of drop-wrist.

Lower motor neurone lesions affecting the muscles of the hand produce certain highly characteristic postures:—

- (1) The so-called monkey-hand (*main de singe*), in which

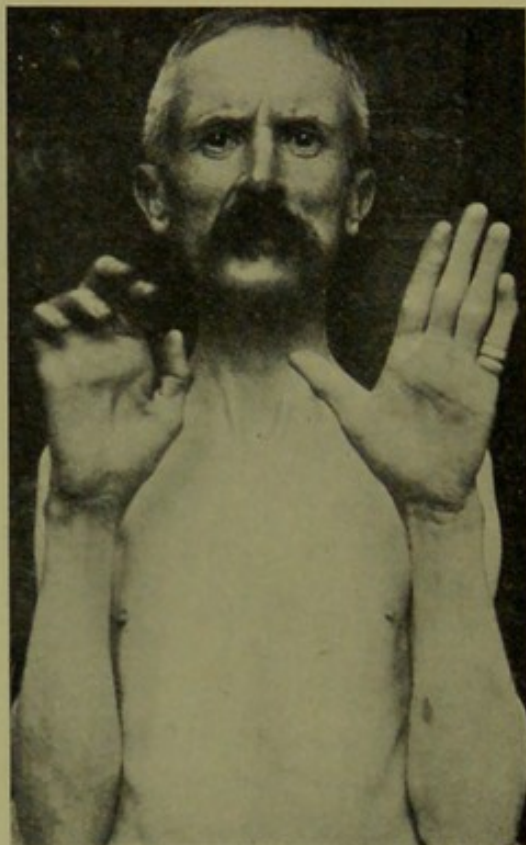


FIG. 124.—Case of claw-hand from rupture of first thoracic root, following a dislocation of the right shoulder. Note the atrophy of intrinsic muscles of the right hand; also the pseudo-ptosis on that side, due to affection of cervical sympathetic.

there is a localised wasting of the thenar muscles with loss of the power of opposing the thumb.

(2) Claw-hand, or *main en griffe*, due to paralysis of the interossei and lumbricales, in which the fingers are now controlled by the long flexors and extensors alone. In this condition the proximal phalanges become hyper-extended, whilst the two distal phalanges are flexed in a hook-like fashion. Meanwhile the power of abducting the fingers by the interossei is lost. When the ulnar nerve alone is paralysed the deformity is more marked in the two



ulnar fingers, since the lumbricales corresponding to the index and middle fingers (supplied by the median nerve) escape.

(3) The preacher's hand (*main de prédicateur*), specially common in syringomyelia. In this variety, from survival of the long extensors, the hand is extended or even hyper-extended, at the wrist. The loss of the movements of adduction and abduction in the extended fingers, due to interosseal paralysis, develops when the "main de singe" becomes the "main en griffe." As a matter of fact, these three positions of the hand occur in lesions

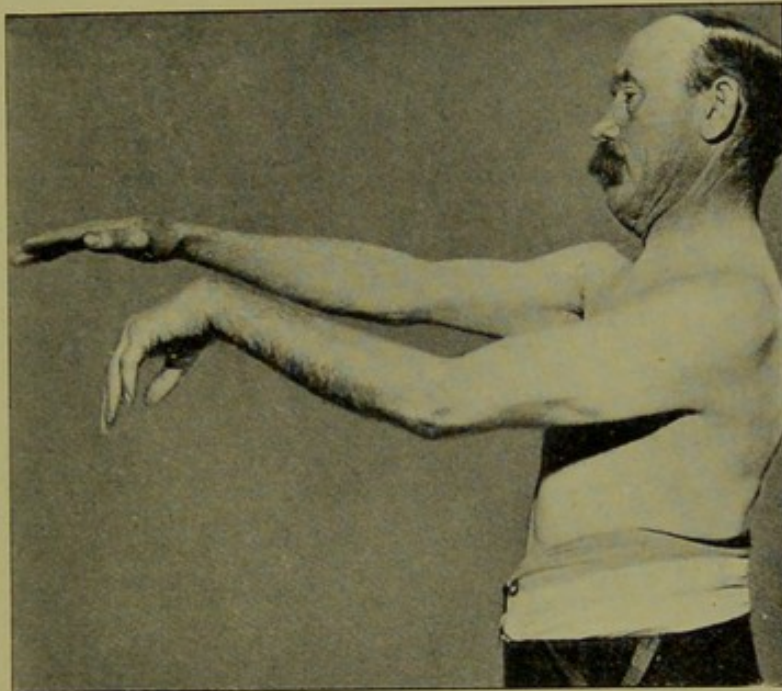


FIG. 125.—Left-sided musculo-spiral paralysis. Showing drop-wrist and atrophy of supinator longus.

not only of the anterior cornua (as in progressive muscular atrophy, syringomyelia, amyotrophic lateral sclerosis), but also in anterior radicular lesions, in lesions of the lower roots of the brachial plexus (see Fig. 124), in toxic or infective neuritis, in leprosy, in family neuritic diseases like peroneal muscular atrophy and hypertrophic interstitial neuritis.

If the paralysis be due to an *upper motor neurone lesion*, the law which determines the posture is different. We no longer have atrophic paralysis, limited to a particular muscle or muscles as in a lower motor neurone lesion. Instead, there gradually develops a spastic paralysis, in which all the muscles



of the affected limb or segment of a limb are more or less paralysed and in a state of hyper-tonus. The muscles which are normally more powerful are therefore placed at an advantage during the process of spastic contracture, and a posture results which is an exaggeration of the normal attitude at rest, so that, for example, in

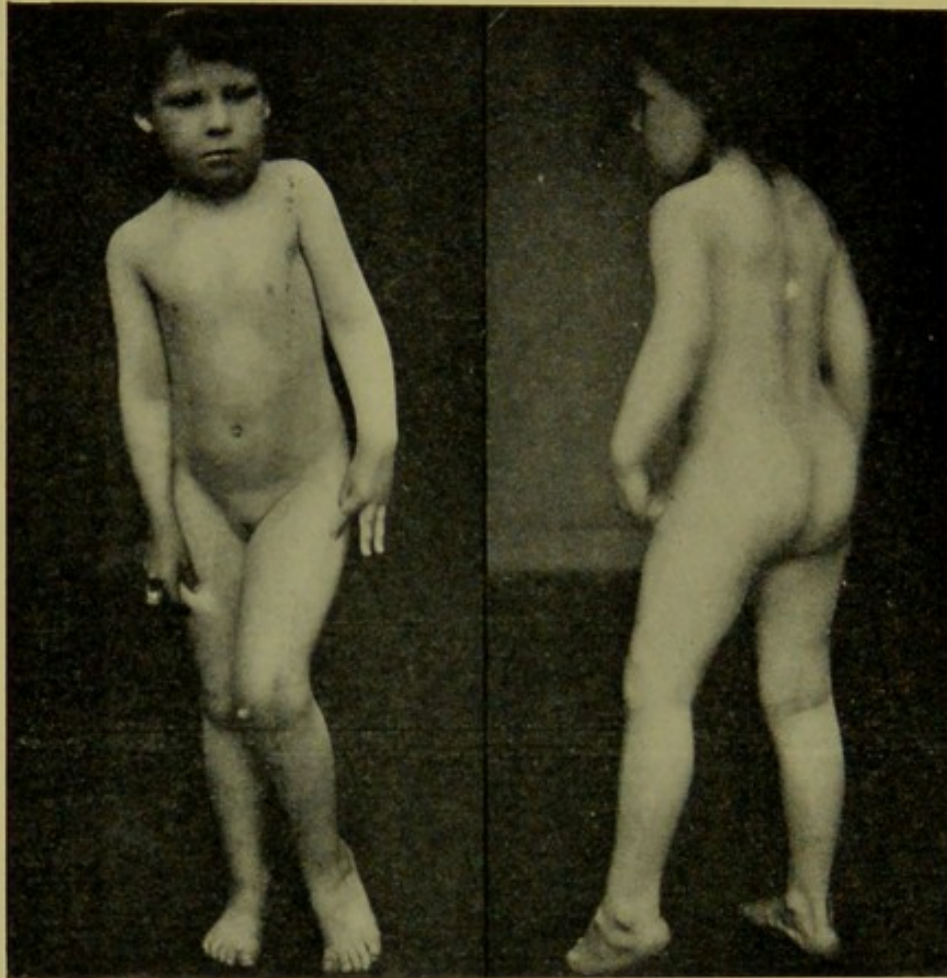


FIG. 126.

FIG. 127.

Case of left-sided infantile hemiplegia in a patient aged 7 years. Onset of hemiplegia five years previously. Showing posture of limbs. In Fig. 126 note athetosis of left fingers. In Fig. 127 note inversion of ankle and drawing up of heel.

a chronic hemiplegia the familiar posture of the upper limb is that of flexion with pronation, that of the lower limb being one of slight flexion at the hip and knee, with extension and inversion of the ankle, and a tendency to dorsiflexion of the toes (see Figs. 126 and 127).

This spastic posture in hemiplegia does not come on at once.



There is an initial flaccid stage, lasting several weeks or even months, before the spastic rigidity sets in. (In a small number of cases the hemiplegia may remain permanently flaccid.) But even during this flaccid stage the postures of the hemiplegic limbs

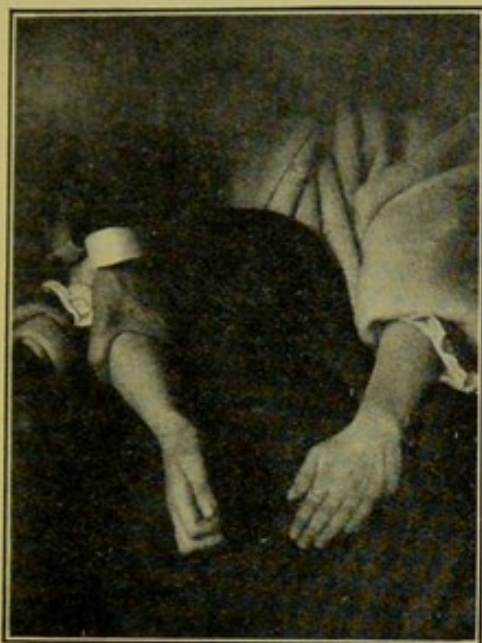

FIG. 128.

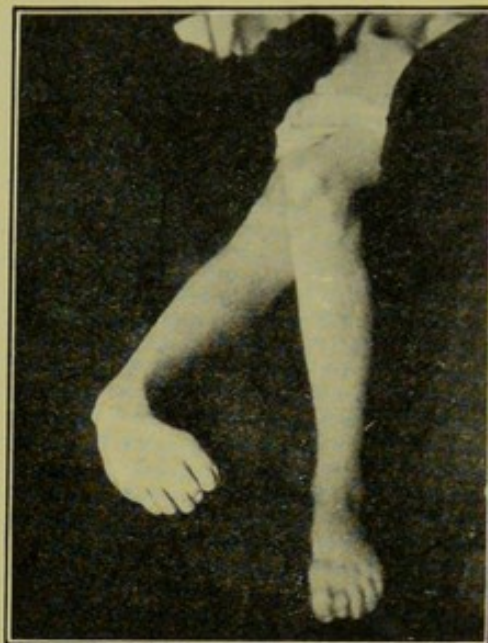


FIG. 129.

From a case of right-sided hysterical hemiplegia in a left-handed patient. Showing contractures of hand and foot. The right forearm was rigidly supinated, but is being passively semi-pronated by the physician, to show the posture of the hand.

are often different from those of the unaffected side at rest. One of the most characteristic signs is an apparent broadening of the

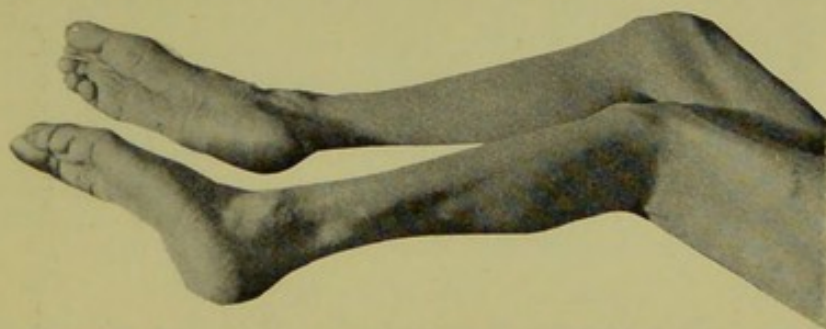


FIG. 130.—Functional paraplegia. - Showing longitudinal fold of soles.

lower limb (Heilbronner's<sup>1</sup> "breites Bein"). This consists in an outward rotation of the lower limb at the hip-joint, due to its own weight when in the recumbent posture (analogous to the

<sup>1</sup> *Deutsche Zeitschrift für Nervenheilkunde*, Bd. 28, 1904, s. 1.



displacement which occurs in fracture of the neck of the femur). The thigh, therefore, when looked at from the front, appears broader than on the healthy side. Moreover, the flaccid paralysed muscles fall back by their own weight, and on transverse section the thigh forms a flattened oval instead of an approximate circle as on the

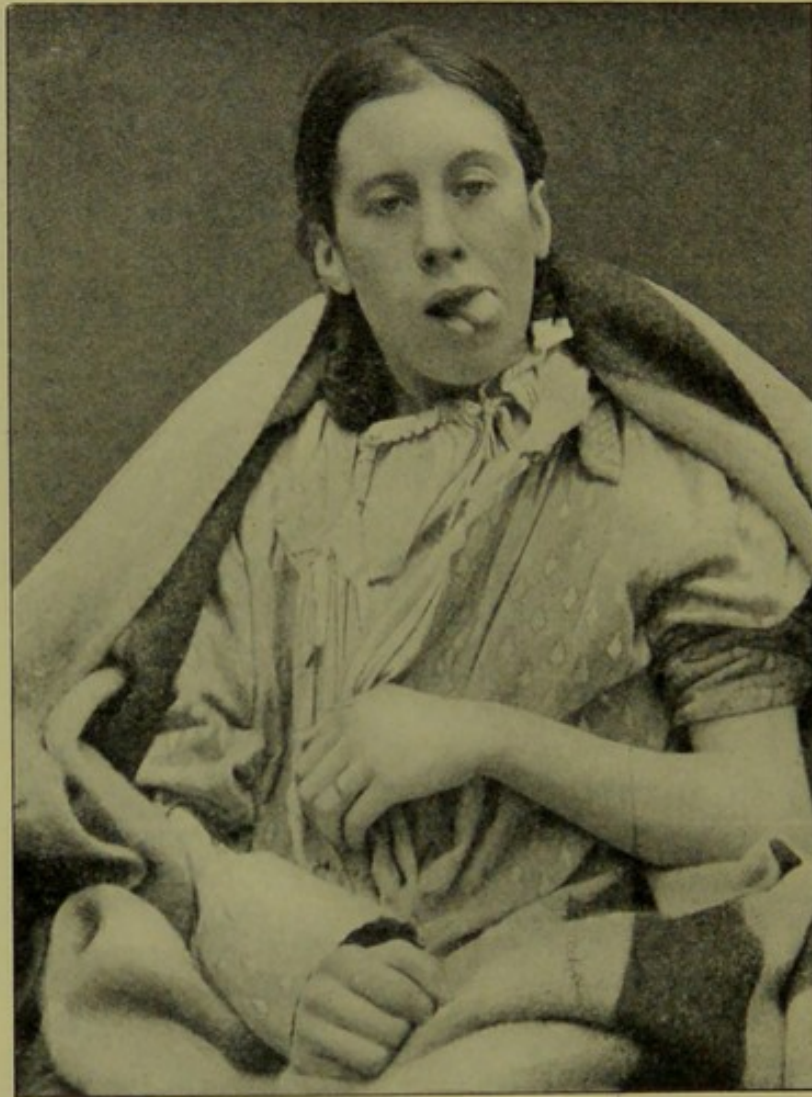

FIG. 131.—Left-sided hysterical hemiplegia with glosso-labial spasm on protrusion of tongue. The left upper limb was also rigidly contracted at the shoulder and elbow, the hand being flaccid.

healthy side. This apparent broadening of the paralysed thigh can be well seen if the patient be seated on a hard, flat seat. It does not occur in hysterical hemiplegia.

In functional paralysis the conditions are different. Hysteria, it is often said, may simulate organic disease—thus we may have functional hemiplegia, paraplegia, or monoplegia. But if we



examine carefully we usually find that this similarity is more or less rough and inaccurate. And why? Because hysterical contractures are not governed by anatomical rules ensuring the preponderance of the stronger muscles. Hysterical contractures usually present some points in which they differ from the postures of genuine organic lesions. Thus, for example, we do not have loss of deep reflexes nor muscular atrophy with R.D. as in lower motor neurone lesions; nor do we have an extensor plantar reflex nor a true clonus as in genuine pyramidal disease. Moreover, if hysterical hemiplegia affects the face we have, not a true paralysis, but a glosso-labial hemispasm. Figs. 128 and 129 are from a case of functional hemiplegia, in which the contracture alone was enough to distinguish it from an organic case. Instead of the usual flexed and pronated posture of the upper limb, we observe that the elbow and wrist are extended, the forearm is supinated, and the fingers are half-bent in a hook-like fashion, whilst in the lower limb the inversion of the ankle is overdone, out of all proportion to the ordinary equinus position. The contracture in this patient appeared suddenly, as is so often the case in hysteria, unlike the gradual development of an organic contracture. Fig. 130 shows a peculiar contracture of the soles in another case of hysterical paraplegia, in which the feet had a fold running longitudinally along the soles, totally unlike any organic contracture.

Fig. 131 shows a case of left-sided hysterical hemiplegia, in which the contracture of the upper limb differs from that of organic disease; for whilst the shoulder, elbow and wrist are rigid, the fingers are flaccid—a combination which does not occur in

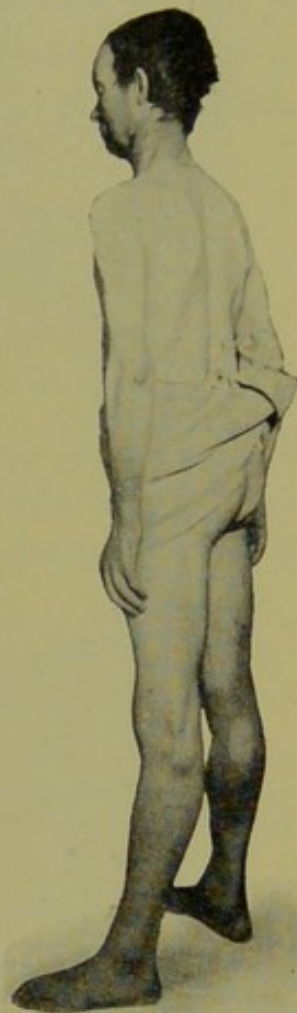


FIG. 132.—Hyper-extension of knees in a case of tabes—*"genu recurvatum."*



organic hemiplegia. We also observe that this patient has glosso-labial hemispasm. When she protrudes her tongue it deviates considerably to the paralysed side, but in such an exaggerated fashion that it is easy to recognise the deformity as spasmodic, not paralytic. We also note that, when the tongue is protruded, the face on the paralysed side goes into a state of spasm, so that the left naso-labial fold is deeper than on the healthy side, a condition which is the reverse of what we find in organic hemi-

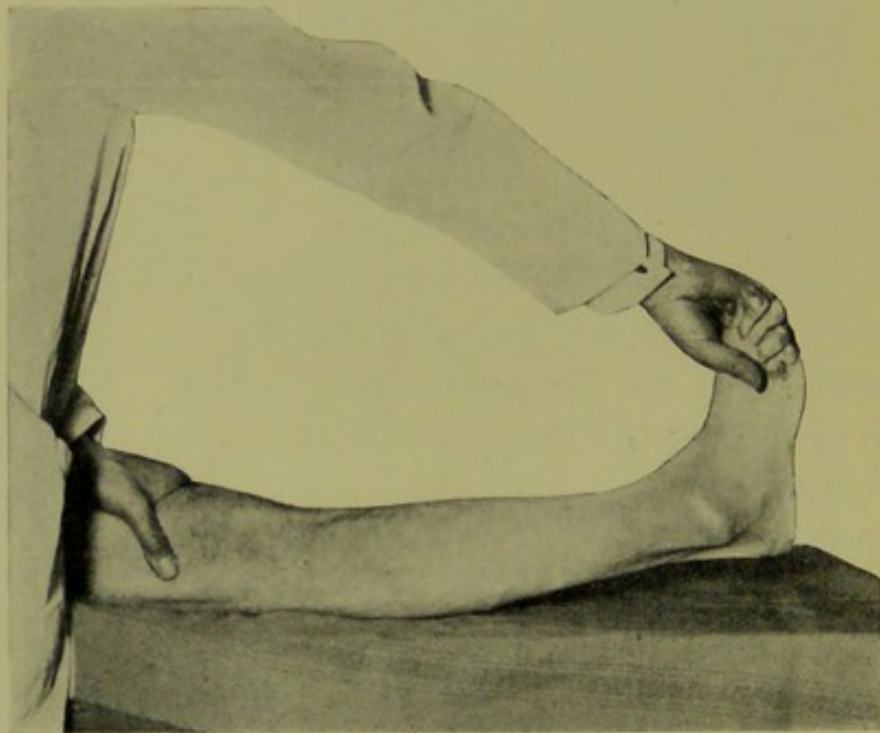


FIG. 133.—Tabetic hypotonia of popliteal muscles.

plegia. *Glosso-labial hemispasm* such as this is not a common sign, but when it occurs it is pathognomonic of hysteria.

Hysterical contractures often, but not always, disappear during sleep or during deep anæsthesia. If the contracture has persisted for months, adhesions may form in the joints, so that even under an anæsthetic the contracture may not completely relax, and we may have to break down the adhesions forcibly.

The postures of organic paralyses, then, whether supra- or infra-nuclear, are definite and comparatively simple, being governed by the anatomical rules we have mentioned. Hysterical postures, on the other hand, being under no such restrictions, may assume



the most varied and weird appearances, examples of which might be multiplied indefinitely. Whether spastic or paralytic, the

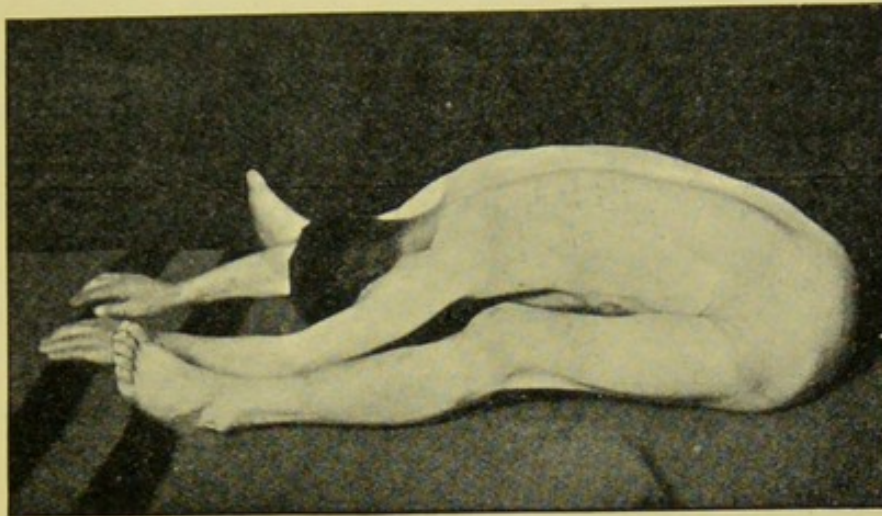


FIG. 134.—Tabetic hypotonia of gluteal and hamstring muscles.

motor phenomena of hysteria are usually "systematised." As Babinski has pointed out, they merely affect one or more "systems" of voluntary movements which the muscles of the

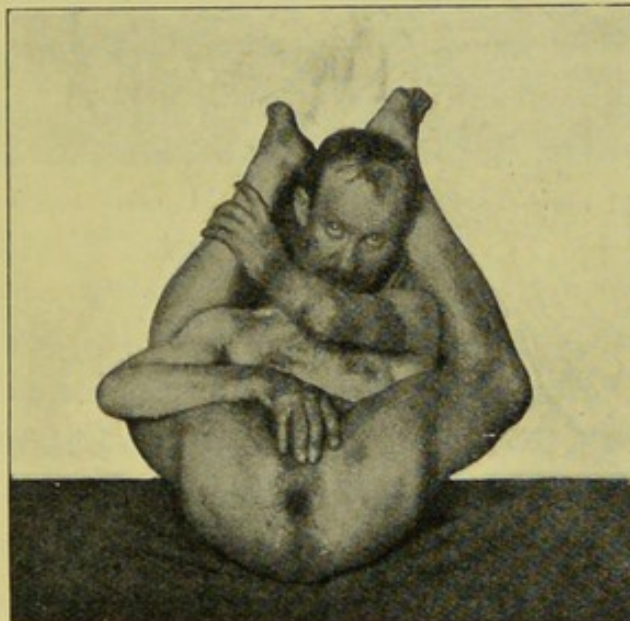


FIG. 135.—Tabetic hypotonia of muscles of lower limbs and trunk.

face or of a limb are called on to perform. Hysterical postures are caricatures or exaggerations of some spastic or paralytic posture, which, however, never corresponds in distribution to a peripheral nerve nor to a spinal segment but to some well-recognised attitude. Therefore a hysterical paralysis or a



hysterical contracture can always be imitated, whereas an organic contracture is never accurately imitated by a hysterical patient.

In many cases of tabes dorsalis there is marked deficiency of muscular tonus, a condition known as *hypotonia*. This slackness of the muscles has a remarkable influence on the patient's postures. Thus, for example, hypotonia of the peronei increases the difficulty of standing, since whenever the patient lifts one leg, the other fixed leg is no longer pulled outwards as in health to bring the



FIG. 136.—Tabetic hypotonia of adductor muscles.

centre of gravity over the fixed foot. When the hamstrings and sural muscles behind the knee are hypotonic (see Fig. 132), the joint becomes hyper extended in the erect posture—the so-called “*genu recurvatum*”—unlike the knee-joint of a healthy individual, in which, however strongly the knee be extended, there always remains a concavity behind. This hypotonia of the popliteal muscles produces another very characteristic sign of tabes, which is that when the patient lies in bed with the knee extended, the heel can be passively raised whilst the back of the knee remains in contact with the bed (see Fig. 133). Hypotonia of the muscles of the trunk and lower limbs in tabes may permit of the patient assuming the most extraordinary postures without pain—postures which are impossible to any ordinary individual



who is not a professionally trained contortionist (see Figs. 134, 135 and 136).

**Amyotonia congenita** (sometimes, though less aptly, called *myatonia congenita*) is a condition of extreme flaccidity of the muscles, which are soft and lax on palpation. When thrown into voluntary contraction they do not harden like ordinary muscles, and it may be impossible by palpation to distinguish them from the subcutaneous tissues. The joints are flail-like, and can be placed in all sorts of fantastic postures (see Fig. 137). There is no

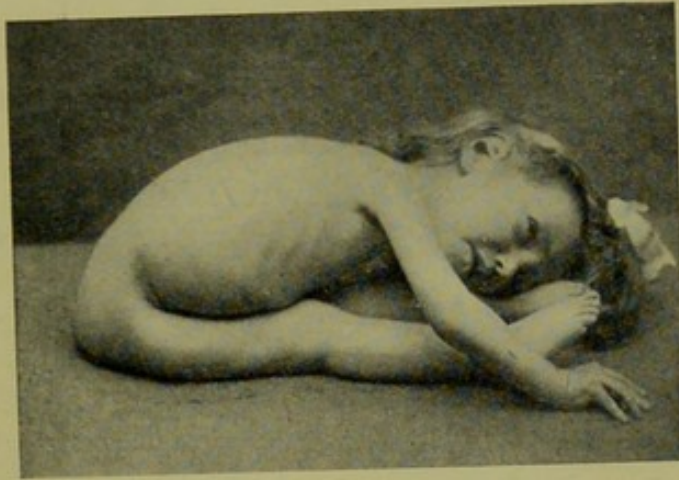


FIG. 137.—Amyotonia congenita in a child of  $2\frac{1}{2}$  years, showing inability to sit up.

true motor paralysis, although voluntary movements are devoid of vigour. The amyotonia is most marked in the lower limbs. The sphincters are unaffected. The electric excitability is diminished both to faradism and to galvanism, but without polar changes. The child can bear strong faradic stimulation with unusual stoicism. The deep reflexes are absent, whilst the cutaneous and organic reflexes are normal. The condition is a congenital one, closely allied to myopathy, with which it is sometimes combined. The phenomena are usually detected within the first twelve months after birth. Sometimes the symptoms improve, and the deep reflexes may even return, but the patient never attains normal muscular power. Pathologically the muscles show changes identical with those found in primary myopathy.



**Gaits.**—Unlike some of the lower animals—for example, the chicken or the lamb—the human infant at birth cannot stand or walk. It is not until the child reaches the age of about eighteen months that he begins to walk. First he learns to stand, and then after repeated efforts he succeeds in walking. During the process of learning, he reels and falls about just like an adult with cerebellar disease.

We do not all of us walk exactly in the same fashion. Even healthy individuals show minor differences in gait. An old man walks differently from a youth, a soldier differently from a sailor, and a woman advanced in pregnancy differently from a maiden. The wearing of ordinary boots with artificial heels also modifies the gait, so that in health the first part of the boot to show signs of wear is usually the back of the heel on the outer side. Ladies' high-heeled boots modify the gait still more, throwing the weight of the body unduly forwards towards the heads of the metatarsal bones.

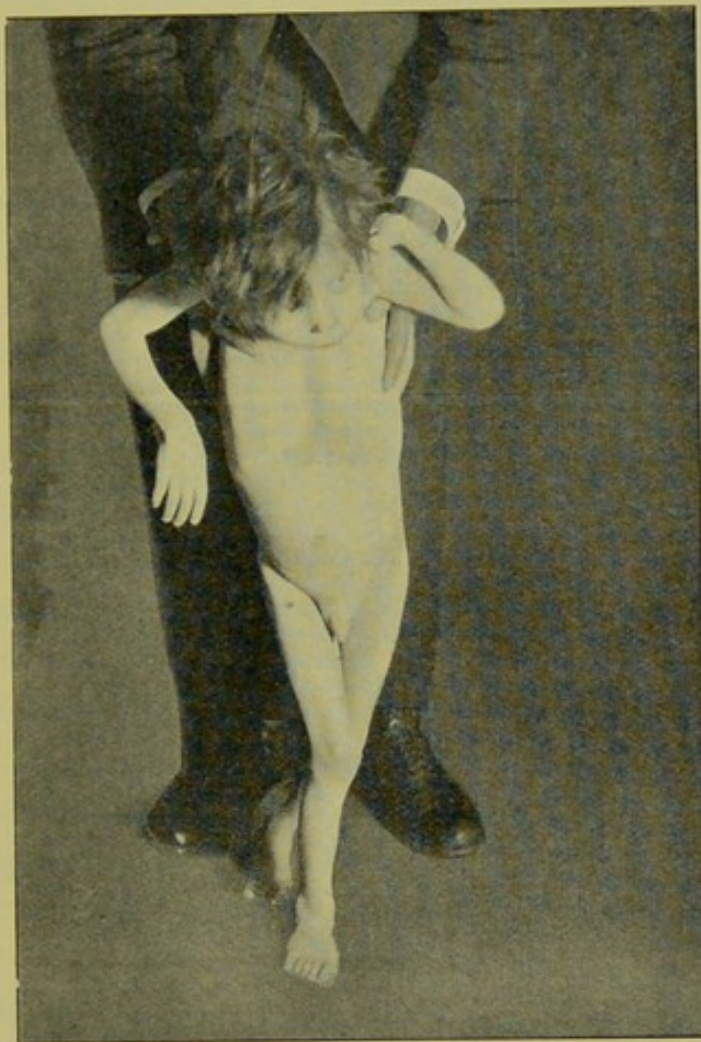When testing the gait in cases of nervous disease it is advisable to have the patient's lower limbs well exposed, and without boots. To get a good view of the limbs it is well to have a minimum of clothing on the patient. A good plan is to have him clad in some light garment like a shirt, whose tail is pulled forwards between the legs from behind and pinned in front, thereby leaving the upper limbs free. We ask the patient to walk straight away from us towards some given point, then to turn round and come back.

In a *normal gait* the limbs are moved forward easily, the feet neither scraping the ground whilst being lifted, nor being unduly stamped down as they descend. The forward-moving or "active" leg is the one which carries the weight of the body. The trunk and pelvis therefore lean a little towards the corresponding side during the "active" phase of each limb. This trunk movement is attained partly by the action of the gluteal muscles, partly by the sacro-lumbar muscles of the same side. A short, thick-set person with a broad pelvis tends to have a "waddling" gait, as the weight of his trunk is shifted across from one side to the other.



When the gluteal muscles are weak, the patient waddles excessively, in his efforts to throw his weight to each side alternately.

The gait is altered in various diseases. Thus it may become spastic, ataxic, reeling, high-stepping, and so on.



diplegia = lesion  
of motor cortex

FIG. 138.—Spastic diplegia. Showing “scissor-gait.”

A *spastic gait* occurs in lesions of the pyramidal tract—for example, in hemiplegia, in diplegia, and in spastic paraplegia. In *organic hemiplegia* the active forward-projection of the limb is especially difficult on the paralysed side, and the weight of the body has to be carried forwards by the aid of the other side *plus* gravity, unlike the normal gait where the weight is carried entirely by the “active” advancing leg. Thus when the hemiplegic leg ought to be in the “active” phase, it is not properly flexed at



the knee or ankle, nor is it actively pushed forwards but merely dangles forward like a pendulum, not directly forwards, but swinging in a circular fashion round the opposite hip as on a pivot. When the "active" phase of the non-paralysed limb occurs, the hemiplegic foot (owing to weakness of the peronei and dorsiflexors of the ankle, with over-action of the inverters and calf muscles) stays on the ground too long, thereby scraping the front part of the foot, especially the ball of the great toe; the stride of the paralysed limb is therefore shorter than on the healthy side. In a case of *spastic diplegia*, or double hemiplegia, the patient is unable to project either leg forwards in the ordinary way, but has to jerk each forwards in turn with a circular swing, so that, in a well-marked case, not only does the patient take abnormally short steps, catching the ball of each foot on the ground, but from the circular swing of the limbs, together with their adductor spasm, they cross alternately in front of each other, producing the cross-legged or "scissor" gait (see Fig. 138). Meanwhile the trunk and upper limbs make violent jerky movements, swinging the body from one side to the other. In ordinary *spastic paraplegia* from cord disease, there is not the cross-legged gait of diplegia, but the patient moves stiffly along, taking abnormally short steps, the front part of the feet clinging to the ground, thus wearing out the toes of the boots. Meanwhile the tendency to ankle-clonus causes a "trepidation" of the whole body in severe cases, from tremor of the feet. Such a patient stumbles over the slightest obstacles.

The *gaits of hysteria* are of the most varied types. For example, in hysterical hemiplegia, the patient often pushes the paralysed foot along the ground as if on a skate, or drags it helplessly along with its dorsum resting on the ground, as seen in Fig. 139. If this is bilateral, the patient is totally unable to walk or stand. Or the foot may be held in a position of *talipes calcaneus*, or the patient may walk on the outer border of the foot (see Fig. 140) when walking, even when no such posture is present at rest; or one lower limb may be acutely flexed at the hip and knee, so that the patient has to use crutches.

Or again, the patient may have a zig-zag gait, or he may



throw one leg about with a wild flourish before bringing it to the ground, or may suddenly kneel down every few steps—these are tics of gait. *Astasia-abasia* is the term applied to a condition in which a hysterical patient is unable to stand or walk, although capable in the recumbent posture of performing all movements of the lower limbs normally. The varieties of hysterical gaits are practically unlimited, but every one of them differs in some respect from the gait of organic disease.

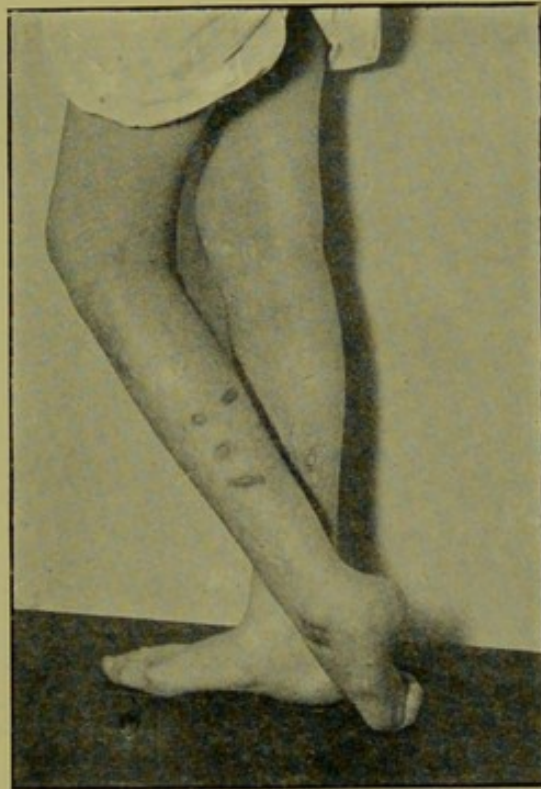


FIG. 139.—Gait in a case of left-sided hysterical hemiplegia. The marks on the left leg are scars of self-inflicted burns.

The *side-gait* (Schüller's "Flankengang") is a useful means of diagnosing between organic and hysterical hemiplegia. To test it, the patient is placed on a line and made to move along it sideways in a given definite direction—say, towards the right. A normal individual during this movement, first leans his trunk to the left, then balancing his weight on the left leg, he lifts the right from the ground, abducts it by a muscular effort, brings the trunk erect again, puts down the right foot, last of all lifting the left leg, adducting it and placing it alongside the right. How is



this performed in organic hemiplegia? We find that the hemiplegic patient moves sideways towards the paralysed side well, but badly towards the healthy side, so that in right-sided hemiplegia the patient, when going sideways towards the right moves normally, but when going towards the left he drags his right leg in the movement of adduction. This difference in the side-gait on the two sides in organic hemiplegia is often quite evident when the forward gait shows very little abnormality. To show the phenomenon properly, the patient must not be too severely

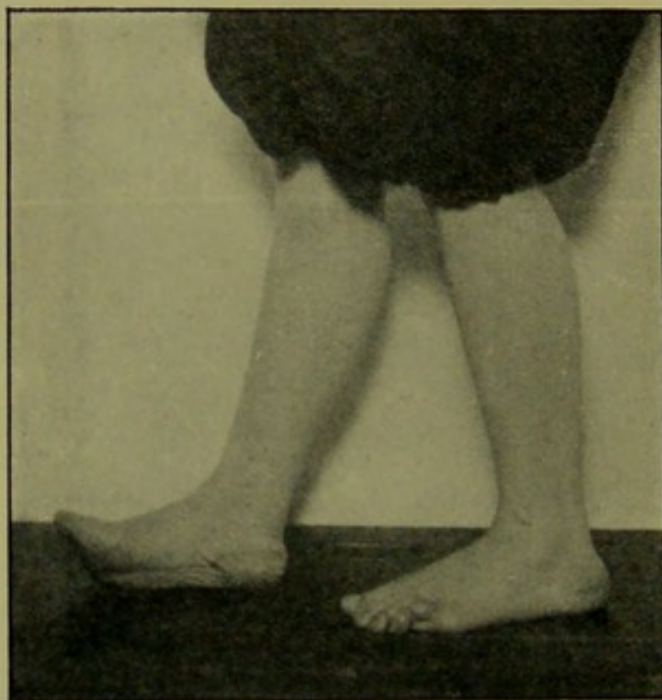

FIG. 140.—Gait in a case of hysterical monoplegia of right leg.

paralysed to stand or walk, nor must he have shortening of the limb, as in old infantile hemiplegia. These two exceptions, however, are readily recognised by other signs. In hysterical hemiplegia the side-gait is impaired on both sides, not merely on the healthy side.

An *ataxic gait* is seen most typically in tabes dorsalis; but it occurs also to a lesser degree in other diseases implicating the posterior columns of the cord—for example, in Friedreich's ataxia, in chronic meningo-myelitis, or in tumours of the posterior columns, also in ataxic paraplegia or postero-lateral sclerosis, whether due to disseminated sclerosis or to other causes. Of all these, the



tabetic gait is the most characteristic. In this there is no motor weakness of the limbs, but they are characteristically unsteady. The patient walks on too broad a base, with his legs unduly wide apart. He lifts them suddenly and violently, raising them too high, then bangs them down forcibly in flail-like fashion, stamping the heels on the ground. He tries to guide his tottering course by watching the ground. Therefore if his eyes be shut, or if he be in the dark, and especially if he narrows his base by placing the feet close together, he tends to fall. In slight cases of tabetic ataxia, when the patient is in this position, he may not actually fall, but we can see the tendons on the dorsum of the feet actively in movement, in the effort to preserve the balance. With this gait we usually have absence of the knee- and ankle-jerks, Argyll-Robertson pupils, and various other signs, such as lightning pains, anæsthesiæ, crises, and lymphocytosis of the cerebro-spinal fluid. In *Friedreich's ataxia* the patient is commonly an adolescent, and though the knee- and ankle-jerks are absent, as in tabes, the pupils react normally, there are no lightning pains nor crises, and we usually find nystagmus, scoliosis, pes cavus, and a peculiar affection of articulation. In *ataxic paraplegia* or *postero-lateral sclerosis*, where the lateral columns are implicated as well as the posterior, the patient is ataxic, but with increased knee-jerks, possibly ankle-clonus, and usually an extensor type of plantar reflex.

A *reeling* or *titubating gait* is one of the commonest signs of *cerebellar disease*, although it is also met with in severe vertigo of any variety, whether from alcoholic intoxication, from ear disease, from diplopia, or other cause. In cerebellar disease the patient staggers along, with an occasional sudden lurch to one or other side, but neither lifting his feet too high nor stamping them down, as in tabes. Not uncommonly the cerebellar patient has a tendency to stagger persistently in some particular direction, depending on the position of the cerebellar lesion—thus he may tend to fall forwards, backwards, or to one side. As a rule, he manages to pull himself up after he has deviated one or two steps from his straight course. In some cases of unilateral tumour of the cerebellum the posture of the head is altered, the ear being tilted



towards the shoulder on the side opposite to the lesion, and the face turned slightly in the reverse direction, *i.e.* towards the side of the lesion. This is well seen in Fig. 141, which represents a woman who had a tumour originating from the meninges over the right petrous bone, and invading the right lateral lobe of the cerebellum. This growth was successfully localised and removed, but the patient unfortunately died shortly after. This "cerebellar

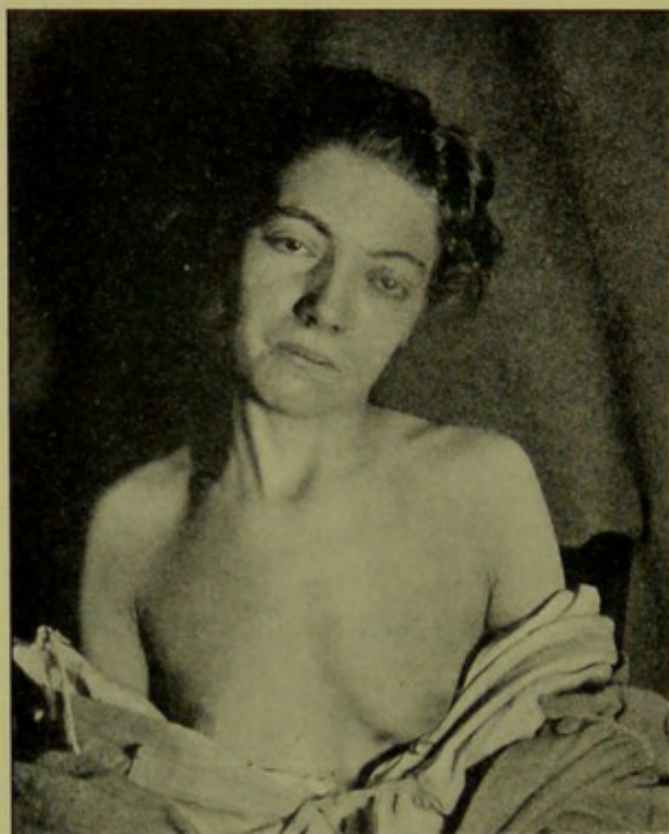

FIG. 141.—Case of right-sided cerebellar tumour arising from meningeal sheath of auditory nerve.

attitude," however, although common in lateral lobe tumours, is not constant in its direction. For example, cases have been recorded where the lateral tilting of the head was towards the side of the lesion, and the rotation of the face to the opposite side. Possibly these differences are associated with the intra- or extra-cerebellar origin of the growth.

A *high-stepping gait* occurs in patients who have foot-drop. Such a patient, to clear his foot from the ground, lifts the leg too high, flinging the ankle up as it were, instead of actively dorsiflexing it. This gait occurs typically in *peripheral neuritis*,



also in *muscular dystrophies*, and occasionally in lesions of the *cauda equina* or lower part of the *lumbo-sacral region of the spinal cord*. It also occurs unilaterally in paralysis of the *external popliteal nerve*. The gait and posture of muscular dystrophy also possess other characteristic features. Thus from weakness of the gluteal muscles the patient in the erect posture arches his back, in order to keep the hips extended (see Fig. 142); this produces lordosis and "pot-belly." Further, the weakness of the glutei, as already explained, causes a waddling gait, the legs being planted wide apart; and as we have already seen, the mode of rising from the ground in such cases is pathognomonic. Such a patient when placed on the ground and told to get up rolls round on his face, then gets on his hands and knees. Then to get on his feet, he extends the knees, and suddenly, pressing his hands on one knee after the other, proceeds to extend the hips and straighten the spine by "climbing up" his own thighs until he reaches the erect posture.

The posture and gait of *paralysis agitans* are diagnostic, so much so, that patients have a strong family resemblance (see Figs. 143 and 144). In a well-marked case the patient stands with the trunk stooping forwards, the face appearing "starched" and expressionless—the so-called "Parkinsonian mask," in which there is little or no emotional play of features. The upper limbs are slightly abducted at the shoulders, semi-flexed at the elbows, slightly extended at the wrists, flexed at the metacarpo-phalangeal joints, and extended at the inter-phalangeal joints, as if holding a pen—the "interosseal" attitude—and very often they show the

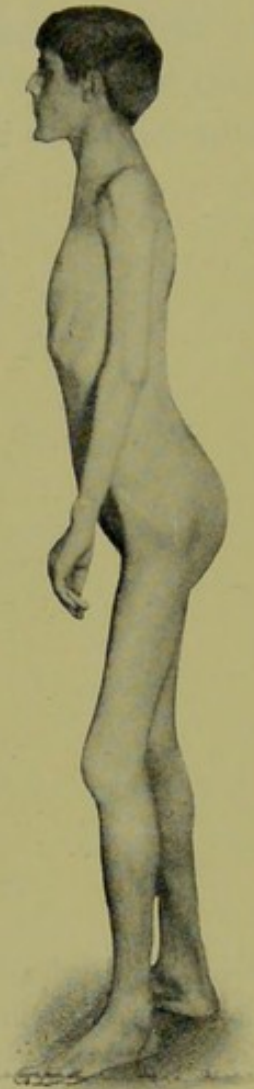

FIG. 142.—Muscular dystrophy in a lad of 17. Showing lordosis.



familiar rhythmic, "pill-rolling" tremor. The tremor may affect the proximal joints as well, and even the lower limbs, face, jaw, palate and tongue. All the voluntary movements of the trunk and limbs are slow and stiff, the upper limbs no longer "swing" as the patient walks (in unilateral cases this loss of swing is confined to the arm of the affected side), and the gait is "festinant." The patient moves forward with short, shuffling steps, and when he turns, his trunk moves slowly *en masse*, as if made of glass, whilst his steps in walking tend to get faster and faster, as if he

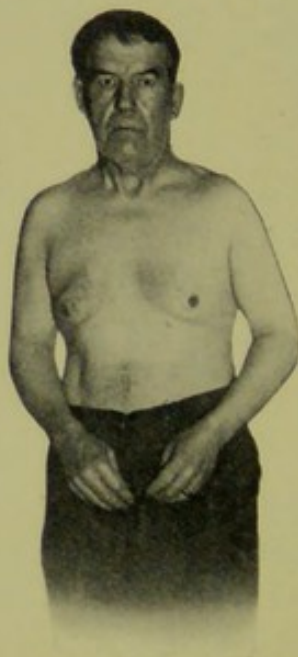

FIG. 143.—Paralysis agitans—bilateral.

were "chasing his own centre of gravity." This is called "propulsion." Still more frequently do we observe "retropulsion," in which the patient, when pulled gently from behind, tends to run backwards with short, hasty steps. This retropulsion may sometimes be induced even by the act of looking upwards. A slighter degree of this same posture and gait is not uncommon in simple old age, and may also occur in pseudo-bulbar paralysis and in the multiple lacunar softenings of the brain described by Marie and Ferrand.

The gait in *chorea* is sometimes peculiar, partly owing to a degree of ataxia, partly from the presence of additional irregular involuntary movements. Sometimes one foot seems as if it were



momentarily entangled by an invisible obstacle, which holds the child back for an instant, the patient then hastily resumes his forward progress; or his knee may give way suddenly, causing him to fall.

Many chronic *epileptics* have a peculiar slouching posture and gait, the posture of the hands, as Spratling<sup>1</sup> has pointed out, being specially characteristic. The fingers are habitually flexed,

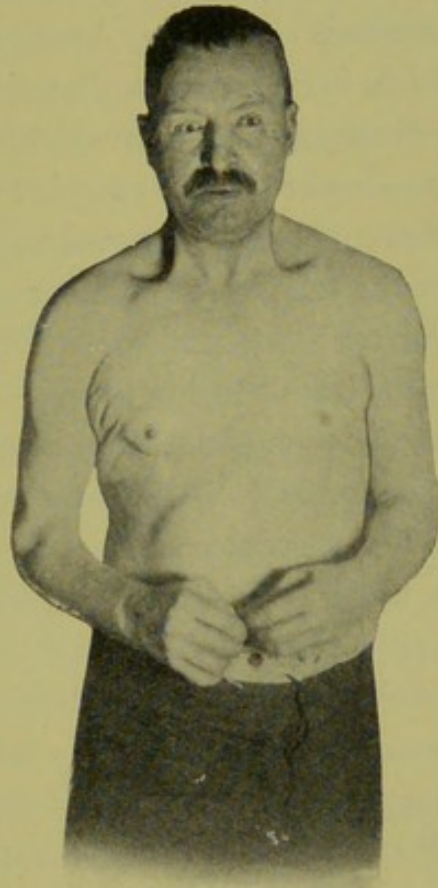


FIG. 144.—Paralysis agitans—bilateral.

and the wrists bent to a right angle, and the patient often has a marked forward stoop of the shoulders.

Various *deformities* produce abnormalities of gait and posture. If, for example, one lower limb is shortened from disease of the bones or joints, from malformations such as coxa vara, or congenital dislocation of hip, or from infantile paralysis, the gait becomes correspondingly altered.

<sup>1</sup> *New York Medical Journal*, 1905, p. 849.



## CHAPTER XVIII

### TROPHO-NEUROSES

THE central nervous system exercises a profound influence on the nutrition of all the tissues. There is, however, no evidence of the existence of special nerves whose function is trophic and trophic only. The control over nutrition which the nervous system possesses is probably exercised in a complex fashion, in which there are several factors involved. Striated muscles, for example, undergo atrophy when the cells of the corresponding motor nucleus in the cord or medulla are destroyed, or when the motor nerve-fibre leading from the nerve-cell to the muscle-fibre is interrupted. The result is muscular atrophy, the different varieties of which we have already studied (see p. 222). Afferent nerve-fibres conveying sensory impressions, whether conscious or subconscious, have also a profound influence upon tissue-nutrition, especially upon that of the skin and its appendages. Therefore in anæsthetic areas trivial injuries are liable to produce destructive tissue-changes. Lastly, the central nervous system indirectly influences the tissues through their blood-supply, by means of its connections with the sympathetic vasomotor system. The sympathetic system may also be disordered primarily, apart from the central nervous system, not only in gross lesions of the sympathetic chain, but also in the so-called angio-neuroses.

Excluding, then, the muscular atrophies and the angio-neuroses, which are studied elsewhere, let us direct our attention to certain trophic disorders which are associated more or less directly with affections of the cerebro-spinal nervous system. Trophic disorders may be distributed widely all over the body, or they may be limited to certain circumscribed areas corresponding to a peripheral nerve, to a posterior root, or to some division of the spinal cord or brain.



**Generalised Trophic Disorders.**—Of these, one of the best examples is the well-known *anorexia nervosa*. In this affection, without evidence of structural disease of any organ, the patient (generally a young woman) loses appetite and becomes progressively emaciated, often to a profound degree. The condition sometimes follows a shock, physical or mental, perhaps an *affaire du cœur*, though in other instances we can find no apparent exciting cause. In diagnosing this condition, we have first to exclude other conditions, such as diabetes, tuberculosis, and malignant disease, which commonly produce emaciation. The patient generally exhibits certain "stigmata" of functional disease. Of these stigmata the most frequent is a hemi-anæsthesia, usually slight in degree and generally left-sided (see later, p. 368).

In marked contrast to this is the rare affection known as *adiposis dolorosa*, or Dercum's disease. It occurs chiefly in middle-aged women, many of the patients being alcoholic or syphilitic. The patient is diffusely obese, and, in addition, she has localised fatty lumps in the subcutaneous tissue, forming large pendulous swellings, chiefly on the limbs and trunk. These swellings may be symmetrical or asymmetrical. They appear and steadily increase in size, consisting of fat and of an embryonic form of connective tissue. The arms are most frequently the sites of the swellings, which are usually tender on pressure and may have spontaneous pains. Certain areas, however, such as the hands, feet, and face, are always spared. The nerve-trunks are tender, and there may be areas of blunting or loss of cutaneous sensibility. Sometimes the thyroid and pituitary glands are indurated, but the patient has none of the mental or physical features of myxœdema.

A curious condition of the bones results from hypertrophy or functional over-activity of the anterior lobe of the pituitary gland.<sup>1</sup>

<sup>1</sup> Acromegaly cannot be ascribed, as was formerly thought, to deficient pituitary secretion, for as Tamburini and Modena have pointed out (*Rivista sperimentale di Freniatria*, 1903, fasc. 3 and 4), experimental destruction of the gland does not cause acromegaly, nor do malignant growths, nor tuberculous disease of the gland produce it, but only conditions such as hypertrophy or adenoma.



Hyper-secretion by this gland appears to set free in the body certain abnormal substances whose action is to cause an extraordinary growth of bony tissues. If the disease sets in before the age at which the epiphyses have become joined, the bones grow enormously in all their dimensions, and the result is gigantism. But if the

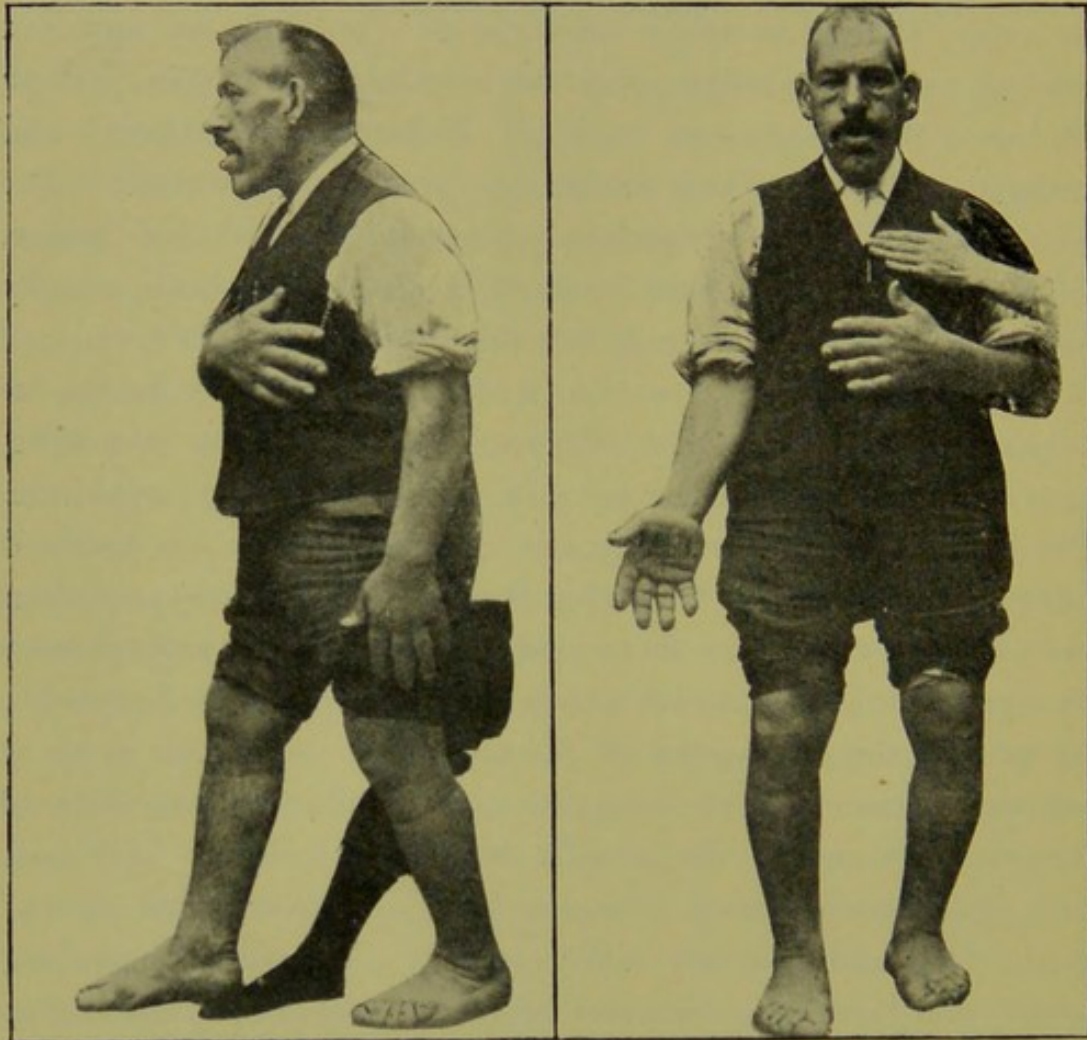


FIG. 145.

FIG. 146.

Acromegaly of eight years' duration in a man aged 42. The patient had bi-temporal hemianopia.

affection begins after the epiphyses have united, the overgrowth of the bones is confined to their ends, producing acromegaly.

The phenomena of **acromegaly** are very characteristic (see Figs. 145 and 146). There is a progressive enlargement of the bones and soft parts, most marked in the hands and feet, but also affecting other parts, notably the skull and face. The skull



becomes enlarged and thickened, all its bony ridges are exaggerated; the margins of the orbits, the cheek-bones, and most striking of all, the lower jaw, become enlarged. The mandible becomes prognathous, the lower teeth biting in front of the upper, instead of *vice versa*, and the teeth become widely separated. The soft parts also share in the hypertrophy. The lower lip, the tongue, uvula, tonsils, and the cartilages of the ears, all become enlarged, and the skin of the face becomes thick and coarse. The hands and feet increase in size (not the nails), so that the patient requires gloves and shoes several sizes larger than before. Spinal curvature is also present, usually a cervical kyphosis, and the thorax, pelvis, and even the external genitals become enlarged. Glycosuria is a fairly common complication. In female patients amenorrhœa occurs. In addition to these phenomena the patient complains of severe headaches, owing to the intra-cranial pituitary tumour. This tumour, from its position in the *sella turcica*, frequently encroaches on the adjacent optic chiasma, and then there is produced a corresponding affection of the visual fields (see p. 124) usually commencing as a bi-temporal hemianopia, which may, as the disease advances, progress to complete blindness.

Apart, however, from pituitary disease, which strictly speaking, although intra-cranial, is not primarily a nervous disorder, we sometimes have widespread overgrowth of the tissues, confined to one-half of the body and probably of cerebral origin. Fig. 147 represents such a patient with left-sided *hemi-hypertrophy*, in whom all the bones of the left side (as verified by skiagrams), including those of the face, limbs, pelvis and thorax, together with the soft tissues of the face, tonsil, tongue and testicle, were larger than on the right side. But the right side of the cranium, and probably also the right side of the brain, were larger than the left.

Passing next to trophic disorders of more limited distribution, it is convenient to discuss them in certain groups.

Bilateral thrombosis of the arteries of the corpora striata, and especially of the lenticular nuclei—a not uncommon occurrence in fatal poisoning by sewer gas—produces what Dana<sup>1</sup> has called

<sup>1</sup> *Journal of Nervous and Mental Disease*, 1908, p. 65.



the "*corpus striatum syndrome*," in which, in addition to coma (with perhaps hemiplegia or diplegia from affection of the adjacent pyramidal paths), there is a gangrenous condition of the skin and sometimes of the lungs as well.

**Trophic Changes in the Skin and its Appendages.**—*Glossy*

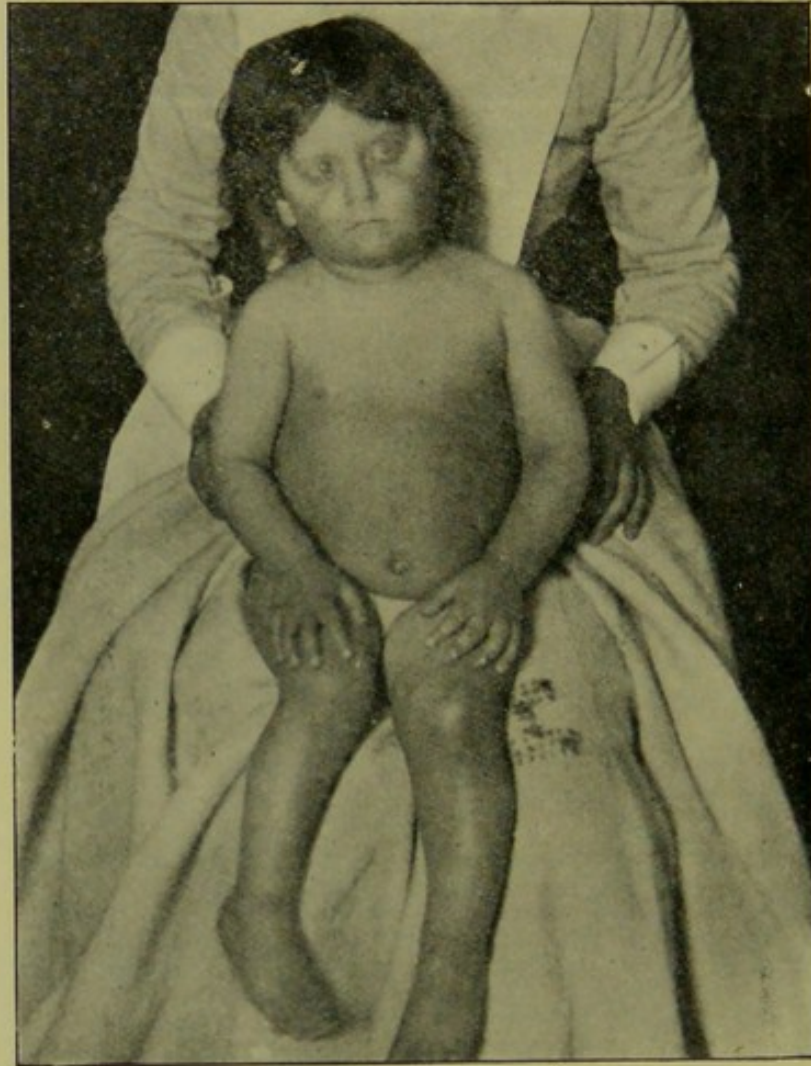


FIG. 147.—Left-sided hemi-hypertrophy.

*skin* is a condition met with chiefly in the hands, in certain cases of long-standing peripheral nerve palsies, whether traumatic or neuritic in origin. It is also a frequent accompaniment of osteoarthritis, not only in the ordinary "rheumatoid" variety, but also in the arthritis which comes on in hemiplegic limbs. The skin of the fingers becomes thinned and atrophic, with a peculiar smooth, shiny surface. The nails in many cases are altered, being longitudinally striated and excessively curved from side to side. The



finger-pads are wasted and the finger-tips taper to a point, as is seen in Fig. 148, which is taken from a case of right-sided brachial neuritis.

*Perforating ulcers* occur most typically in *tabes dorsalis*. They are generally situated on the foot, on its plantar surface, especially at the metatarso-phalangeal joint of the great or little toe. They may also occur under the heel or under the terminal phalanx of the hallux. Each ulcer begins as a thickening of the epidermis, like a corn. Suppuration occurs under this, and the pus finds

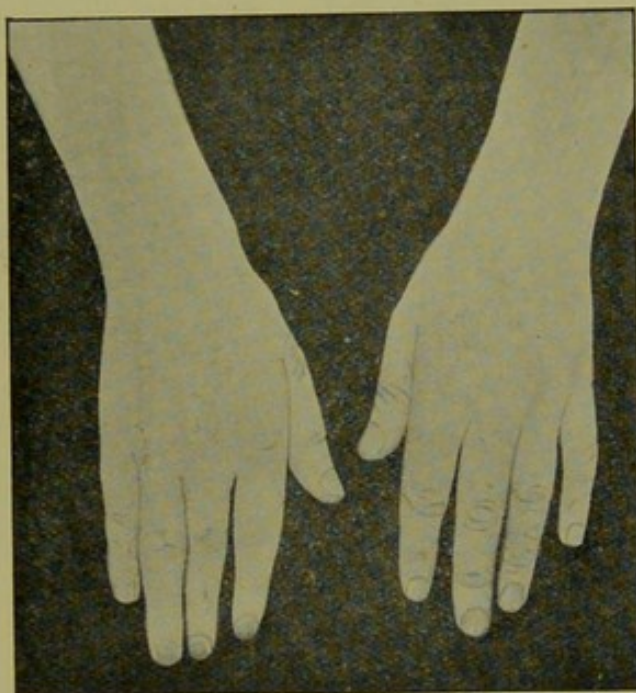


FIG. 148.—Right-sided brachial neuritis with glossy skin and tapering finger-tips.

its way out through a small opening in the centre (Fig. 149). A narrow sinus is thus formed which increases in depth until it may extend into the joint beneath, which is often disorganised, and carious bone may be felt at the bottom. Sometimes the ulcer heals up under treatment. The tabetic perforating ulcer is painless. Somewhat similar trophic ulcers are met with in certain cases of *spina bifida occulta* and also in *syringomyelia*, but in this latter disease they are commoner in the hands. *Diabetic neuritis* is also occasionally associated with perforating ulcers of the feet, a minor variety of diabetic gangrene. In *leprous neuritis* perforating ulcers are not infrequent, though it is commoner to



have a still more extensive loss of tissue, whole phalanges dropping from the fingers and toes. *Painless whitlows*—in so-called “Morvan’s disease,” a sub-variety of syringomyelia, are found at the finger-tips. These whitlows are sometimes the result of trivial injuries which in a normal individual would not produce any serious results. In other cases the explanation is found in the absence of sensibility to temperature and pain, which is

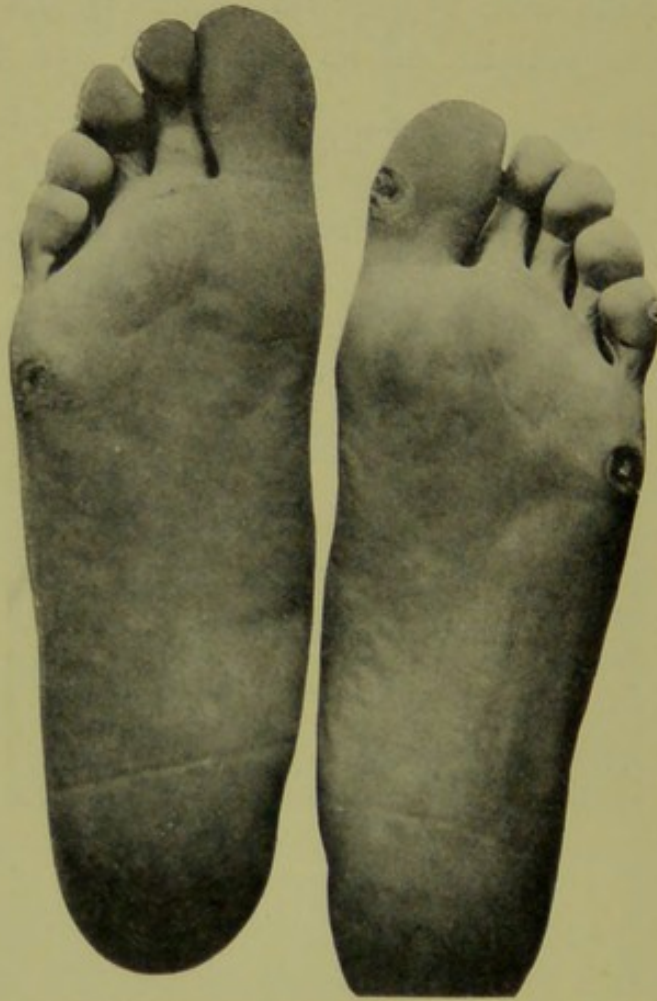

FIG. 149.—Perforating ulcers in tabes.

characteristic of the disease, so that the patient burns the fingers painlessly and produces blisters and even areas of sloughing.

In certain cases of tabes there may be a perforating ulcer in the mouth. First the teeth become loosened and fall out, then the alveolar margin of the jaw is absorbed, and if the upper jaw be affected a perforation into the nasal cavity may be established.

*Herpes zoster* is a very typical example of a trophic cutaneous disorder which has a direct nervous origin, viz., inflammation or



thrombosis of the corresponding posterior root ganglion. In this affection a crop of vesicles appear, which are distributed in a definite metameric area, corresponding to the posterior root whose ganglion is diseased. In the case of facial herpes it is the Gasserian ganglion which is inflamed, in whole or in part, whilst herpes of the external auditory canal is associated with in-

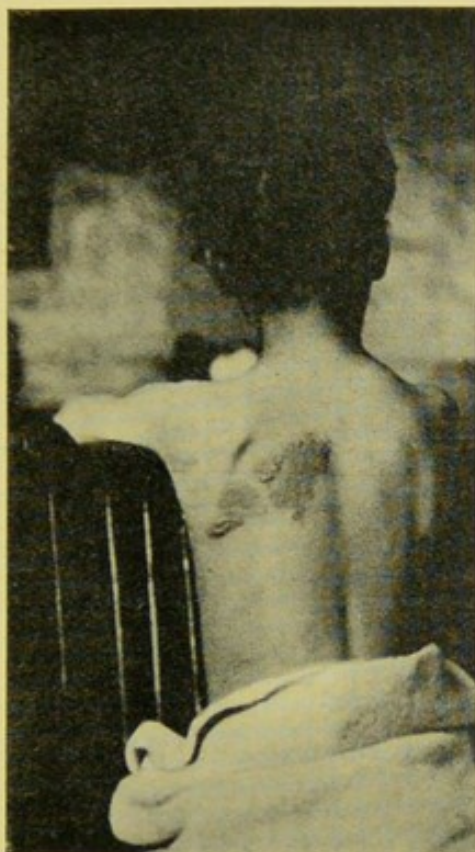

FIG. 150.

Herpes zoster in area of fifth dorsal root. Second day after appearance of eruption.

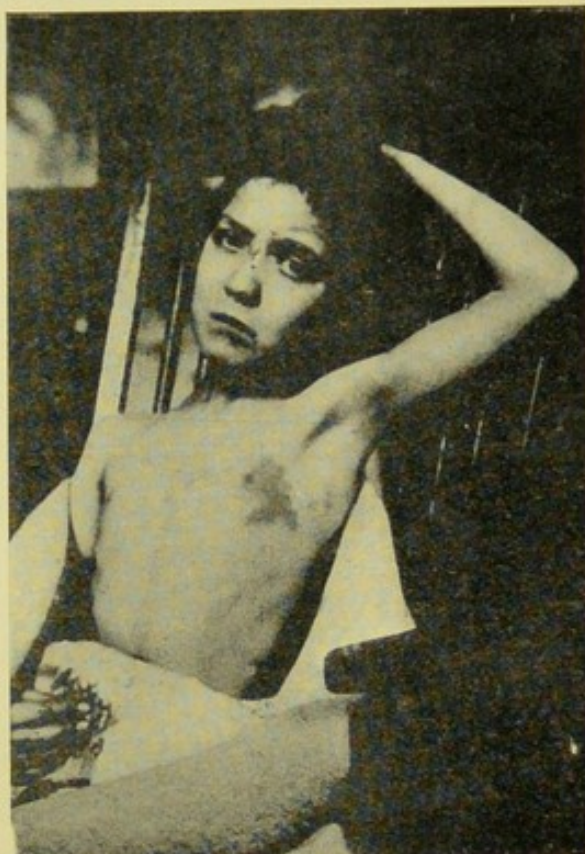


FIG. 151.

Herpes zoster—the same patient as in Fig. 150. Eruption surrounds the nipple, and thence extends inwards to mid-sternum.

flammation of the geniculate ganglion. The herpetic vesicles usually become pustular and subsequently permanent scars may remain. Herpes is sometimes preceded, for a day or two, by pre-herpetic pain in the area where the eruption is about to appear; and not infrequently the eruption is followed by prolonged and intractable post-herpetic neuralgia. Figs. 150 and 151 are from a typical case of herpes in the area of the fifth thoracic root. Sometimes herpes develops in the course of diseases of the



vertebræ or of the spinal meninges. Such an occurrence signifies that the morbid process has attacked the corresponding posterior root ganglion or ganglia. Even in simple herpes zoster we can sometimes elicit Kernig's sign<sup>1</sup> (see p. 60).

*Bed-sores* result from inflammatory and destructive changes in the skin and underlying tissues of bedridden patients, whether in cases merely enfeebled by prolonged illness (especially in enteric fever) or, more commonly, in severe organic paralysis, such as hemiplegia or paraplegia. Most bed-sores, occurring as they do at the sites of pressure, can be prevented by careful nursing, by keeping the patient's skin scrupulously clean and dry, by placing him on a water-bed, and by hardening the epidermis by local applications of methylated spirit. But sometimes in spite of the most assiduous nursing, bed-sores may develop within a few days or even within a few hours of an initial paraplegia or hemiplegia. This so-called *acute decubitus* is of grave omen.

The commonest site for a bed-sore in a hemiplegic patient is over the great trochanter on the paralysed side. In paraplegia from cord lesions, *e.g.* acute myelitis, the bed-sore commonly forms over the middle of the sacrum (Fig. 152). A bed-sore commences as an area of redness of the skin, bullæ then develop and burst, leaving an ulcerating or sloughing surface beneath. The sloughing process may extend down to the periosteum and bones, and in sacral decubitus the infection may extend into the vertebral canal, producing a fatal cerebro-spinal meningitis, septic organisms gaining access not only from the skin, but from the intestinal discharges. Bed-sores are also met with in advanced cases of bedridden dementia, even where there is no paralysis. In these patients, as in cases of prolonged fever, the sores develop on the pressure points, *viz.* the heels, hips, backs of the scapulæ and even on the inner sides of the knees. We also meet with excoriations of the skin, which may amount to bed-sores, in

<sup>1</sup> This fact, together with the frequent occurrence of lymphocytosis of the cerebro-spinal fluid, shows that in herpes zoster the pathological process is not necessarily limited to the posterior root-ganglion, but is part of a more widely diffused meningeal irritation.

Bilbeza, *Archives générales de Med.*, Feb. 27, 1906.



cases of violent chorea, where the patient knocks his limbs against surrounding objects.

Before leaving the subject of destructive trophic lesions of the skin, we must mention *symmetrical gangrene*, a localised gangrene

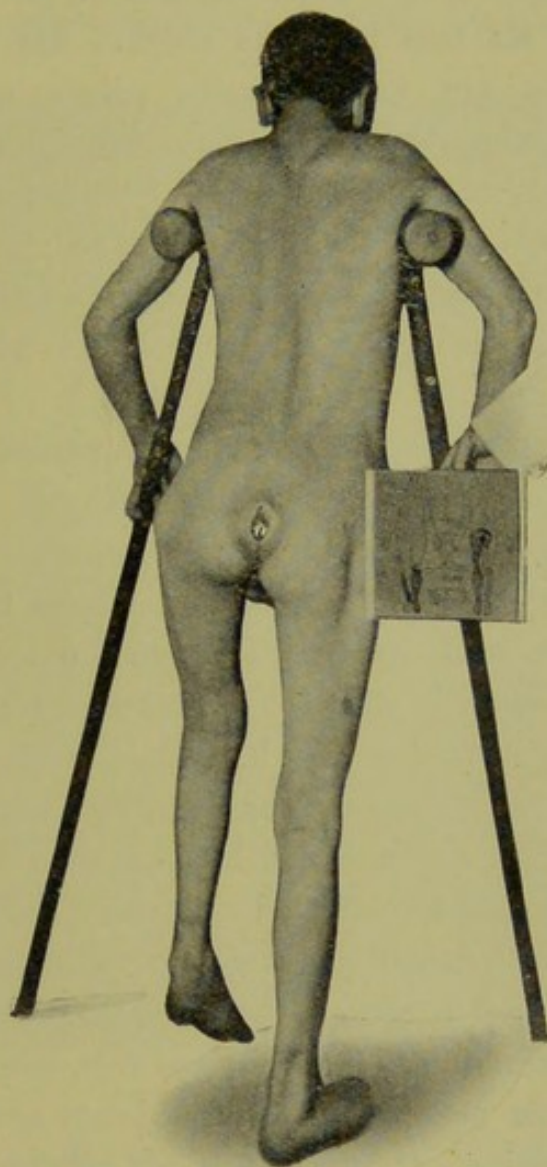


FIG. 152.—Lumbo-sacral myelitis with sacral bed-sore or decubitus. Showing atrophy and paralysis of muscles below left knee. The small chart on the right indicates the coexisting area of anæsthesia.

chiefly occurring in the tips of the fingers and toes, and preceded by pains or paræsthesiæ of the parts. But to this, the most severe phase of Raynaud's disease, we shall refer again when we consider the angio-neuroses.

The commonest points of incidence of *rodent ulcers*, especially



on the face, as Cheatle<sup>1</sup> has shown, are at the positions where the various branches of the trigeminal nerve become cutaneous, especially over the points of emergence of the infra-orbital, infra-trochlear, temporo-malar and lachrymal nerves, and also with particular frequency at the inner canthus of the eye and at the angle where the ala nasi joins the cheek. He has also shown that these spots are the favourite points of incidence of leucoderma and scleroderma. The precise significance of these facts is still obscure, but Cheatle has recorded the curious fact that rodent ulcers are frequently limited to the distribution of normal nerve-areas and that the spread of a rodent ulcer ceases abruptly when it reaches a cutaneous area which has become denervated by division of its sensory nerves.

There are other trophic lesions unaccompanied by necrosis or ulceration, and consisting in local changes affecting one or more elements of the skin or subcutaneous tissues, whether in the direction of atrophy or of hypertrophy. Perhaps the most typical examples of this variety are scleroderma, leucoderma, and cutaneous nævi. *Scleroderma* is a disease in which the skin becomes abnormally hard and fibrous. The condition may be diffuse or circumscribed. In the rarer diffuse variety, large areas of skin, usually symmetrical, and especially in the upper limbs, become hard and rigid, losing their elasticity so that the affected skin can no longer be pinched up with the fingers. Sometimes there is a preliminary œdematous stage. As the disease advances, the sclerotic process may extend to deeper structures such as tendons, and this, with the rigidity of the skin, limits the movements of the joints and may produce permanent deformities. If the fingers are affected, they become tapering at the tips and permanently flexed. If the face is affected, it becomes immobile and mask-like. Circumscribed scleroderma, or morphœa, is the commoner variety, where small patches of skin become hard, white and ivory-like, the distribution of the patches being somewhat similar to those of herpes zoster—*i.e.* metamericly, in the area of a posterior root, or of one of the divisions of the trigeminal nerve on the face.

<sup>1</sup> *Brit. Med. Journal*, April 29, 1905.



*Leucoderma*, or disappearance of pigment from circumscribed patches of skin, is also commonly distributed, more or less, in nerve-areas. The patch of absolute pallor has a pigmented edge where it joins the normal skin, and it tends to spread slowly along the particular area. This disease, of course, is most striking when it affects patients of sallow complexion or of dark-

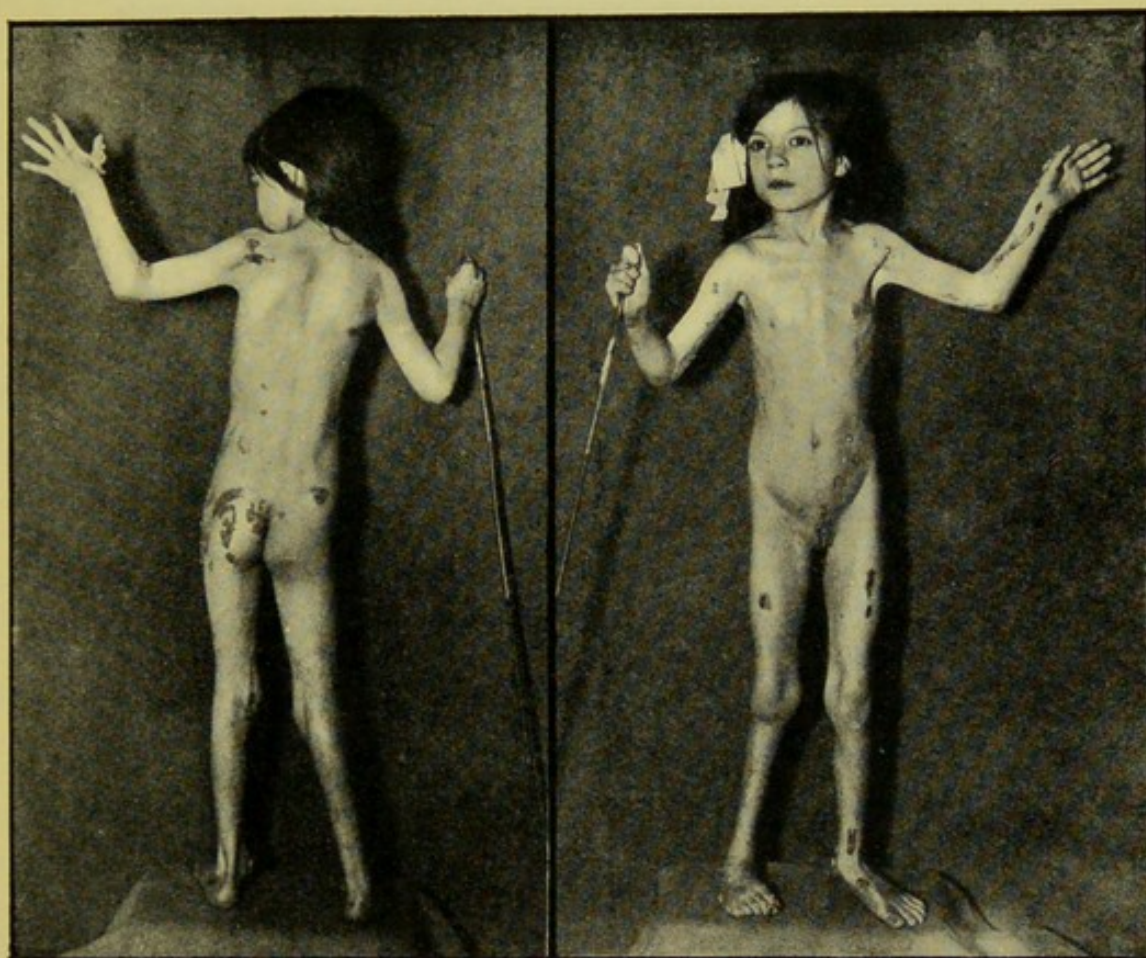


FIG. 153.

FIG. 154.

Congenital verrucosis of metameric distribution.

skinned race. *Leucoderma* also occurs in the maculo-anæsthetic type of *leprosy*, where the leucodermic patches are often red and hyperæsthetic at the edges and anæsthetic in the centre.

Figs. 153 and 154 represent a little girl aged eight, in whom patches of warty growths were distributed metamERICALLY on the limbs and trunk.

Congenital *cutaneous nævi*—"port-wine stains"—are also commonly distributed in root areas on the trunk or in the trigeminal



distribution on the face. The trigeminal area is affected with special frequency, one, two, or all three divisions of the trigeminal being mapped out, more or less accurately. It is an interesting fact that a cutaneous nævus on the face may be associated with hypertrophy of the subjacent deep tissues, with enlargement of the eyeball, and even with a nævoid condition of the

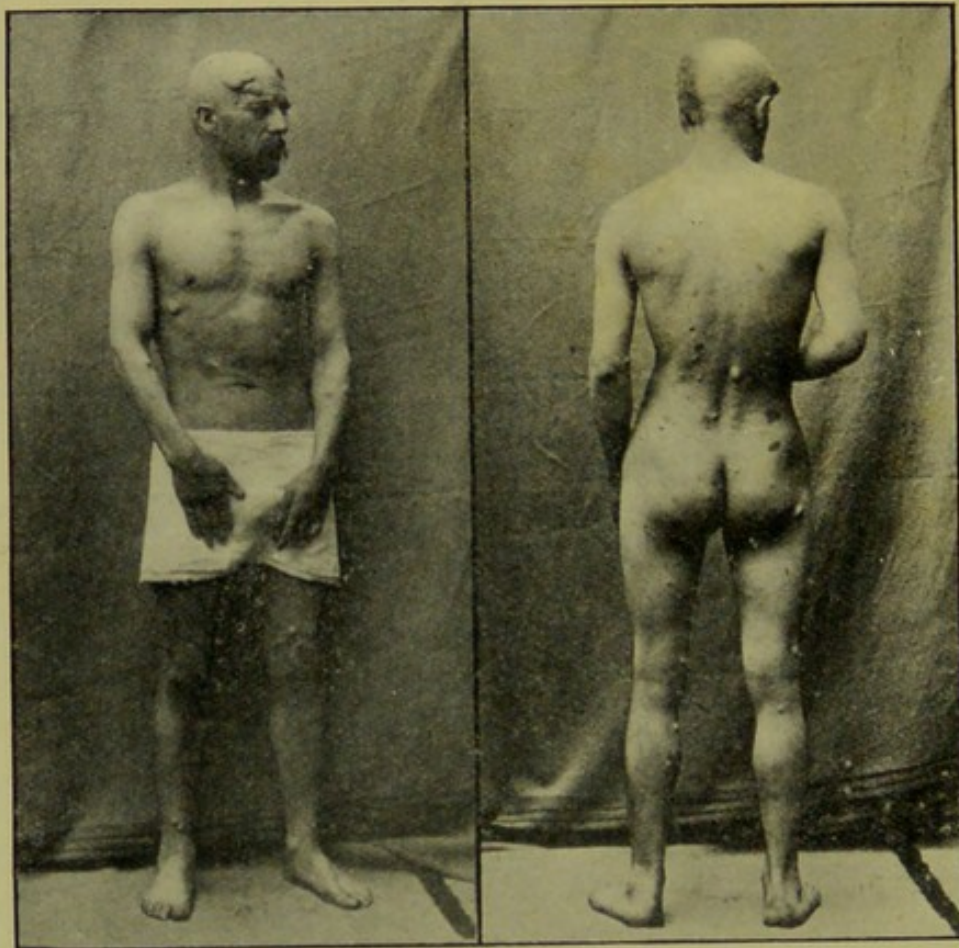


FIG. 155.

FIG. 156.

von Recklinghausen's disease in a man aged 38.

nasal mucous membrane and of the dura mater on the corresponding side, all of which structures are innervated by the trigeminal nerve. More than this, cases of nævus of the face may be associated with recurrent epistaxis from the nævoid nasal mucosa, and sometimes they develop sudden infantile hemiplegia with epileptiform convulsions, due to sub-dural hæmorrhage from the dural nævus.<sup>1</sup>

<sup>1</sup> Cushing, *Journal of American Med. Association*, 1906, p. 178.



Large neuro-fibromata—so-called *plexiform neuroma* or *elephantiasis nervorum*—are more common on the trigeminal nerve, especially in its upper divisions, than on any other nerve of the body. Such a tumour is generally part of a more widespread affection known as *von Recklinghausen's disease* (see Figs. 155, 156). In this disease we find, in a complete case, neuro-fibromata, often of fairly large size, forming painless swellings on the face or elsewhere, together with multiple soft fibromata forming sessile or pedunculated growths (known as *molluscum fibrosum*) and also patches of cutaneous pigmentation distributed more or less definitely in nerve areas. The neuro-fibromata of von Reckling-

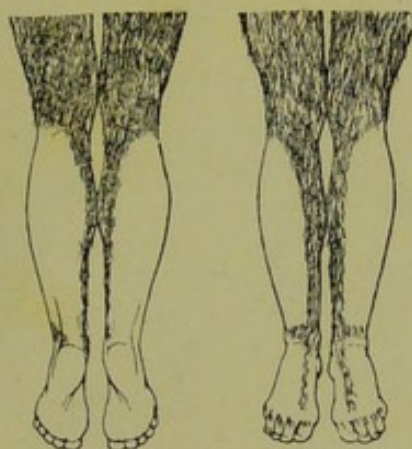

FIG. 157.—Case of tabes with loss of hair in area of L<sub>5</sub> and S<sub>1</sub> roots.

hausen's disease do not cause symptoms except by accidental mechanical compression of adjacent structures. The disease often appears in childhood and remains stationary for many years, when it may suddenly resume its spread, new tumours cropping out all over the body.

Various cutaneous lesions are present in many cases of *arsenical neuritis*. A brownish macular pigmentation of the skin is, of course, common in chronic arsenical poisoning, without neuritis. But in arsenical neuritis we frequently observe special cutaneous affections, such as glossy skin, herpes zoster, falling of the hair, and most characteristic of all, hyperkeratosis of the palms and soles, where the epidermis becomes much thickened and tends to desquamate. In addition to these skin lesions, we have the ordinary signs of a peripheral neuritis, such as drop-wrist, drop-foot, &c.



There is a rare trophic affection of the skin, described by Gowers as *local panatrophy*, in which certain circumscribed areas of the face, trunk, or limbs, varying in size from the diameter of a cherry to that of an orange, undergo local atrophy of all the subcutaneous tissues down to the bone, the skin becoming also slightly thinned. These patches look like subcutaneous excava-

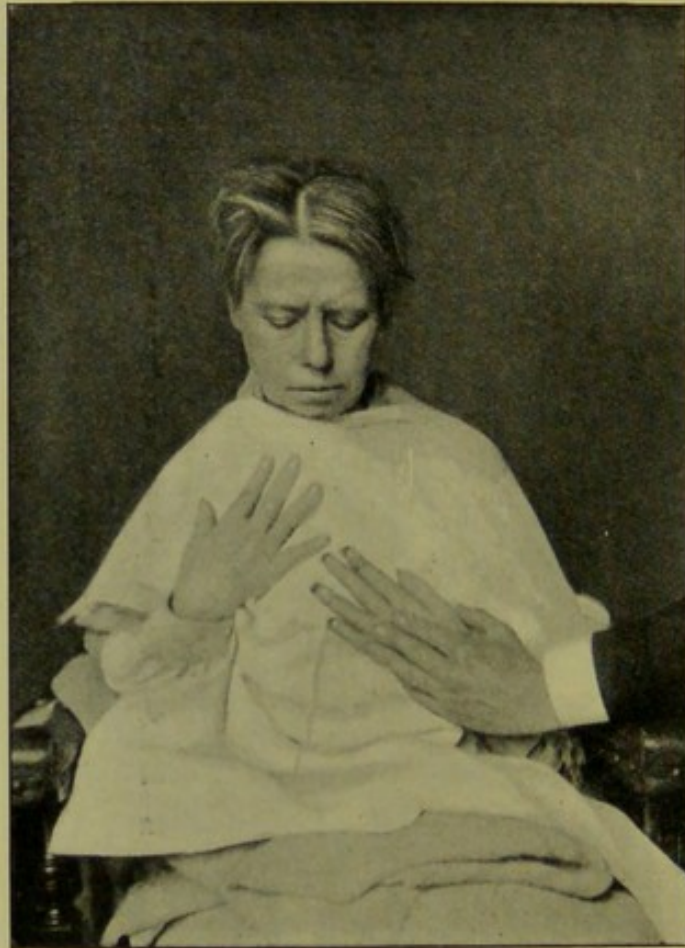

FIG. 158.—Case of left-sided hemiplegia with hæmorrhages under all the finger-nails on the left side, and under the nail of the right little finger.

tions, and although trophic in origin, they do not correspond to regular nerve-areas but are quite irregularly distributed.

Trophic changes are sometimes present in the hair. *Hypertrichosis*, or excessive growth of the hair, is met with most frequently on "hairy moles," which are, moreover, excessively pigmented in the skin as well. It is important to remember that a hairy mole in the lumbo-sacral region is often an indication of a *spina bifida occulta*. Local hypertrichosis also occurs occasionally



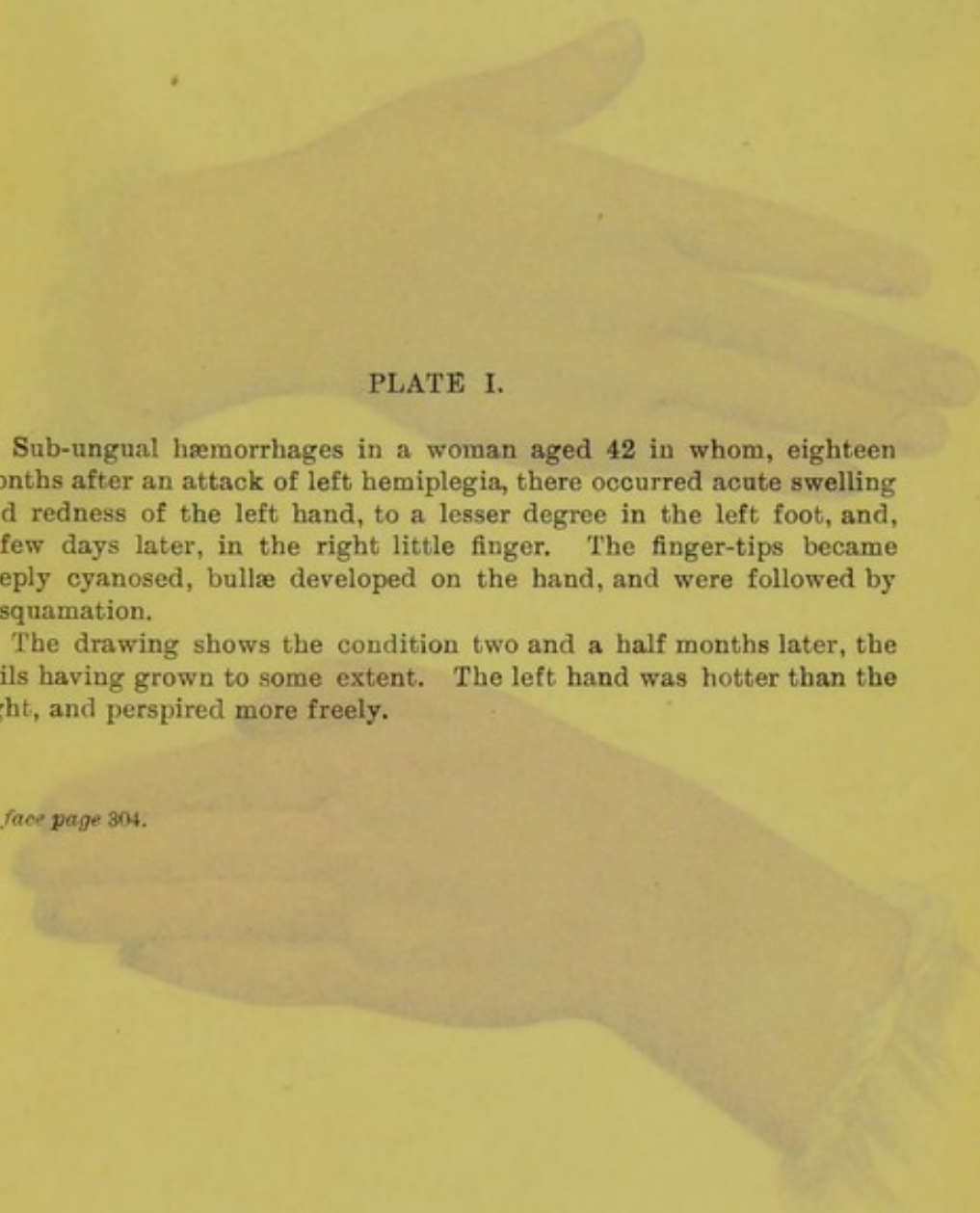


PLATE I.

Sub-ungual hæmorrhages in a woman aged 42 in whom, eighteen months after an attack of left hemiplegia, there occurred acute swelling and redness of the left hand, to a lesser degree in the left foot, and, a few days later, in the right little finger. The finger-tips became deeply cyanosed, bullæ developed on the hand, and were followed by desquamation.

The drawing shows the condition two and a half months later, the nails having grown to some extent. The left hand was hotter than the right, and perspired more freely.

*To face page 304.*



There is a rare trophic affection of the skin, described by Flowers as *local panatropy*, in which certain circumscribed areas of the face, trunk, or limbs, varying in size from the diameter of a cherry to that of an orange, undergo local atrophy of all the subcutaneous tissues down to the bone, the skin becoming also slightly thinned. These patches look like subcutaneous excava-

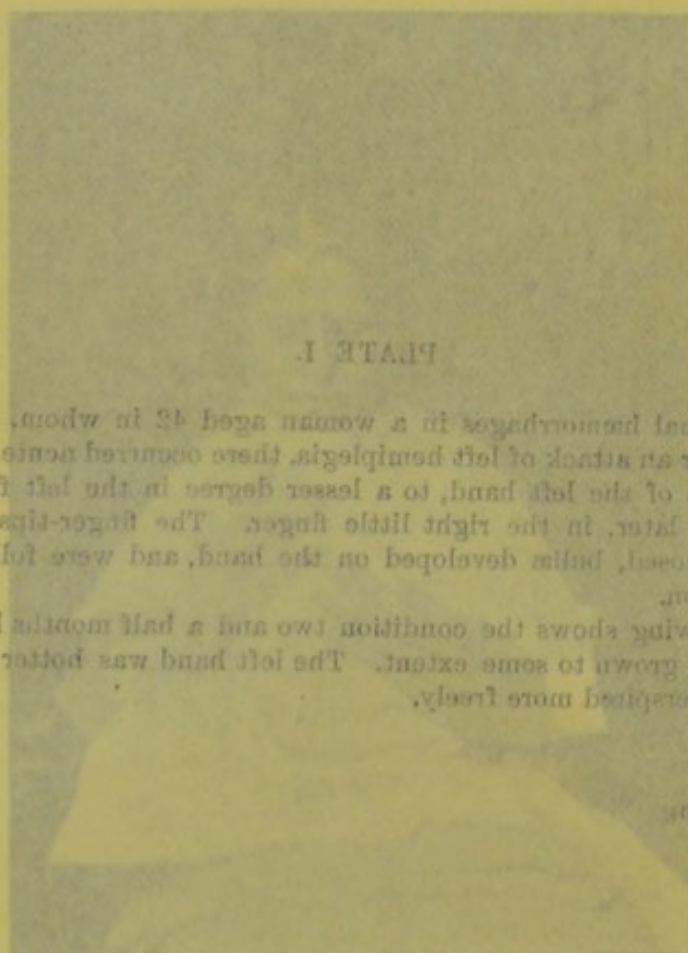
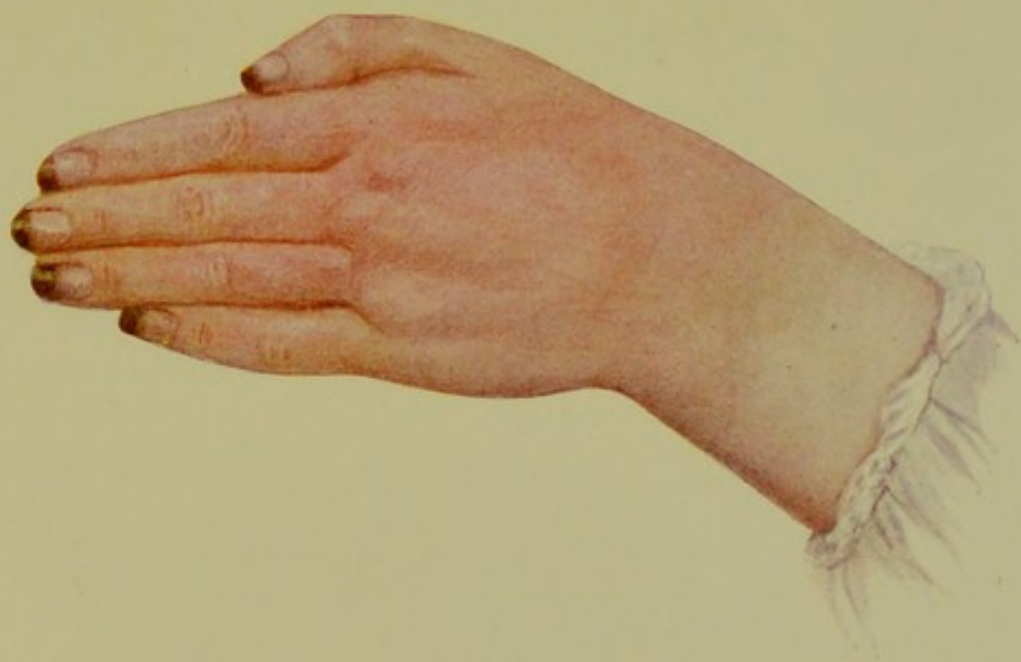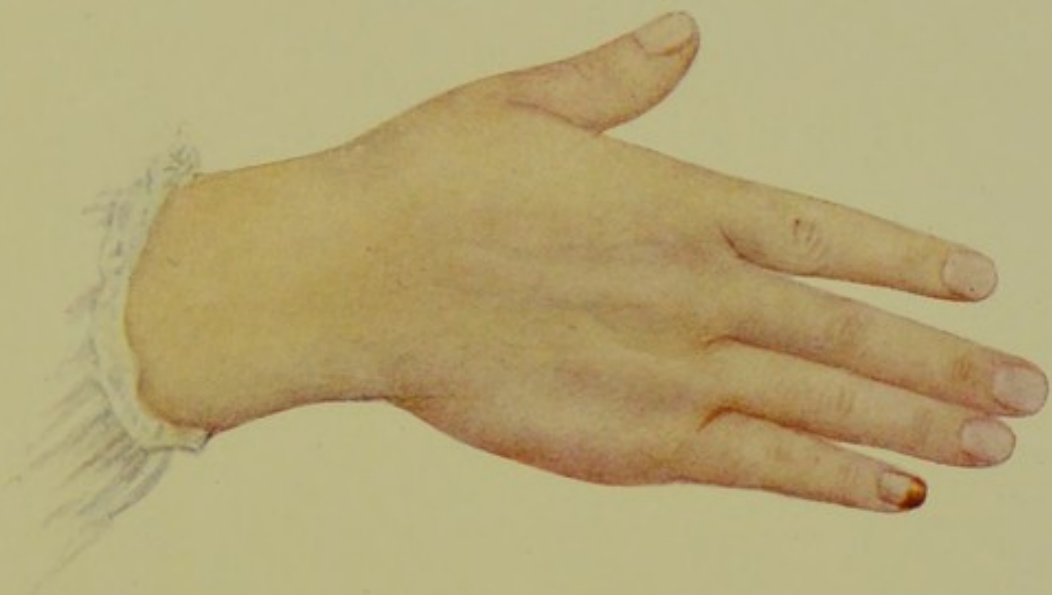


FIG. 138.—Case of left-sided paraplegia with hemorrhages under all the finger-nails on the left side, and under the nail of the right little finger.


tions, and although trophic in origin, they do not correspond to regular nerve-areas but are quite irregularly distributed.

Trophic changes are sometimes present in the hair. *Hypertrichosis*, or excessive growth of the hair, is met with most frequently on "hairy moles," which are, moreover, excessively pigmented in the skin as well. It is important to remember that a hairy mole in the lumbo-sacral region is often an indication of a *spina bifida occulta*. Local hypertrichosis also occurs occasionally











in other nerve-areas. The hair may also be affected in various ways in other nervous affections. Well-authenticated cases have been recorded of *blanching of the hair* of the scalp within a few hours, as a result of profound emotion. It is not uncommon to meet with patches of whitened hair in nerve-areas which have been the site of severe neuralgia. Even in the ordinary greyness of advancing years, and in the idiopathic premature greyness of

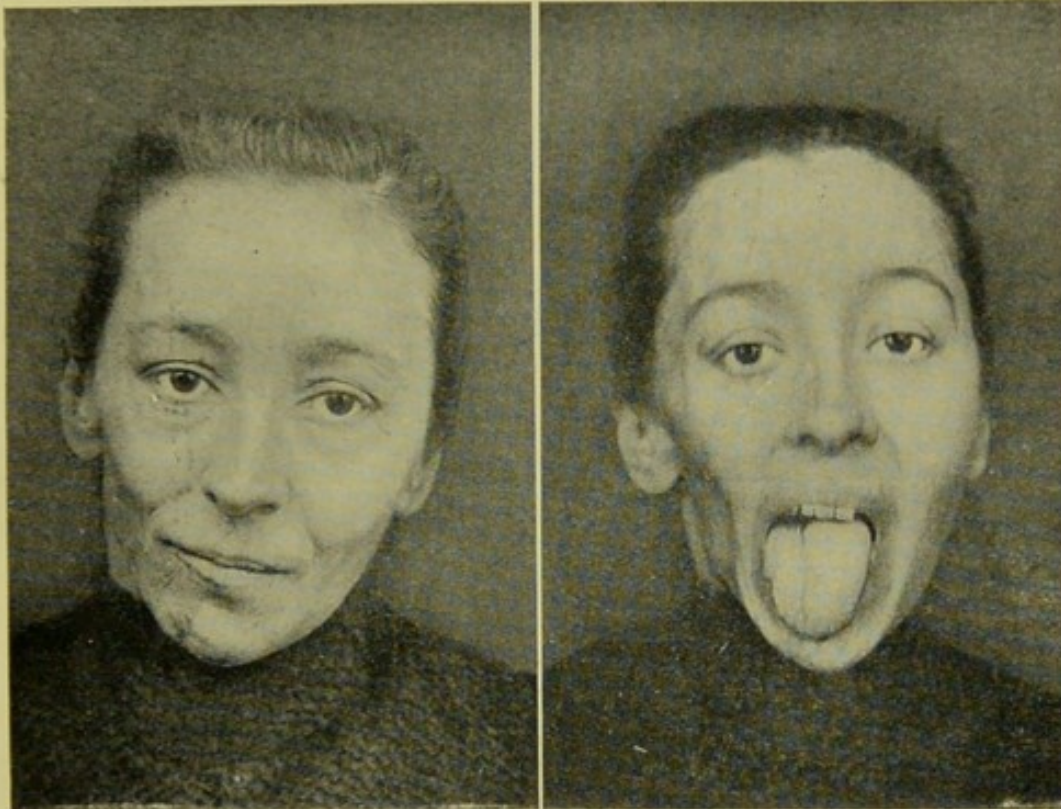


FIG. 159.

FIG. 160.

Right-sided facial hemiatrophy, also implicating the corresponding side of the tongue.

youth, as Cheatele<sup>1</sup> has pointed out, the maximum greyness often appears in nerve-areas in the scalp and beard. There is a variety of *localised alopecia* where the hair falls out suddenly in a certain nerve area. Fig. 157 is from a case of tabes where there was a curious absence of hair in certain root-areas in the legs. Many cases of exophthalmic goitre, as Walsh pointed out,<sup>2</sup> have a band of alopecia at the frontal end of the scalp. We

<sup>1</sup> *Brit. Med. Journal*, July 22, 1905.

<sup>2</sup> *Lancet*, 1907, p. 1080.



occasionally meet with cases of *universal alopecia*, where the hairs all over the body fall out, and the patient may remain permanently hairless, his skin meanwhile being considerably thinned.

Trophic changes in the *nails* occur in a number of nervous diseases. Sometimes the nails become hypertrophied, as in the toe-nails of patients with *chronic paraplegia* from any cause. In *peripheral neuritis*, especially the arsenical variety, we may



FIG. 161.—Hemi-hypertrophy of right side of face.

meet with excessive curving, brittleness, atrophy and even falling of the nails. In *tabes* the toe-nails, especially those of the big toes, are sometimes shed, whilst in some cases of *cerebral hæmorrhage* we find hæmorrhages under the nails of the hemiplegic hand (Fig. 158 and Plate I.). As the nail grows, the hæmorrhagic area is gradually cast off.

**Trophic Changes in Bones and Joints.**—An affection which possesses characters common to this group and to the group of cutaneous trophic lesions is *progressive facial hemiatrophy*. It is



probably referable, as we have already seen, to a lesion of the trigeminal nerve or nucleus. Not only is the skin on the affected side of the face atrophied and wrinkled, but the bones, and especially the lower jaw, become smaller (Figs. 159 and 160).

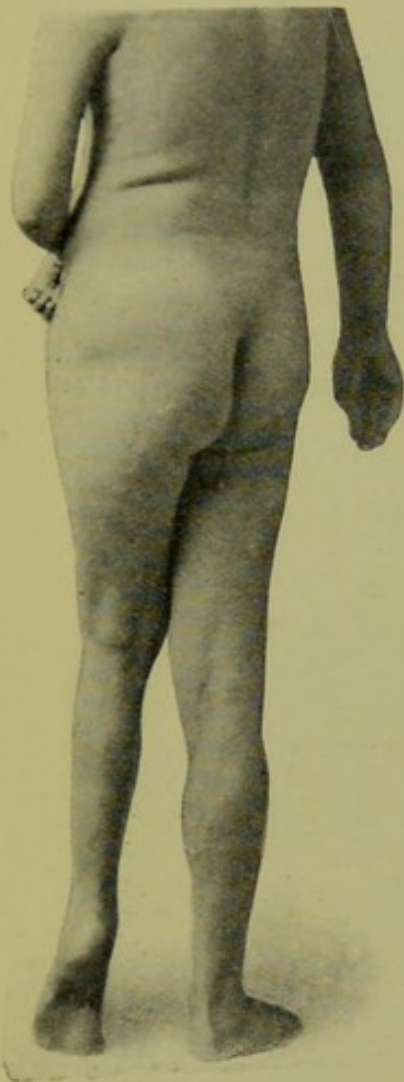


FIG. 162.—Old infantile hemiplegia, left-sided, with arrested growth of limbs.

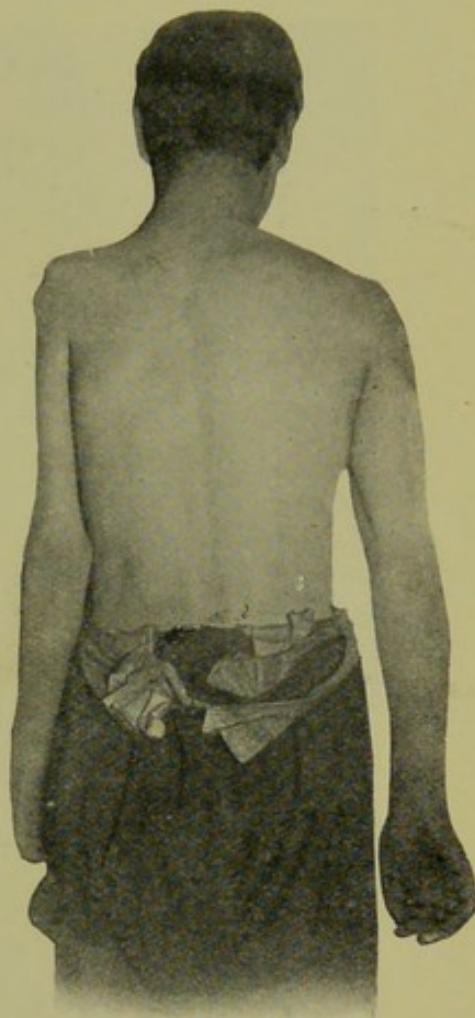


FIG. 163.—Old poliomyelitis anterior acuta. Paralysis and atrophy of biceps, triceps, and deltoid on left side, with arrested growth of humerus.

Still more rarely, we meet with cases of *facial hemi-hypertrophy*, where the bones and soft parts of one side of the face become progressively larger. In the case shown in Fig. 161, the enlargement of the face followed an injury to the forehead in childhood on the side which afterwards became enlarged.

It is not uncommon to find atrophic changes in the bones of paralysed limbs. In paralytic affections of children, whether of



the upper neurone type, as in *infantile hemiplegia* (Fig. 162), or of the lower neurone type, as in *acute anterior poliomyelitis* (Fig. 163), the bones of the paralysed limb become arrested in their growth and are smaller in all their dimensions than are the healthy limbs. Even in some cases of *hemiplegia in adults* the bones of the

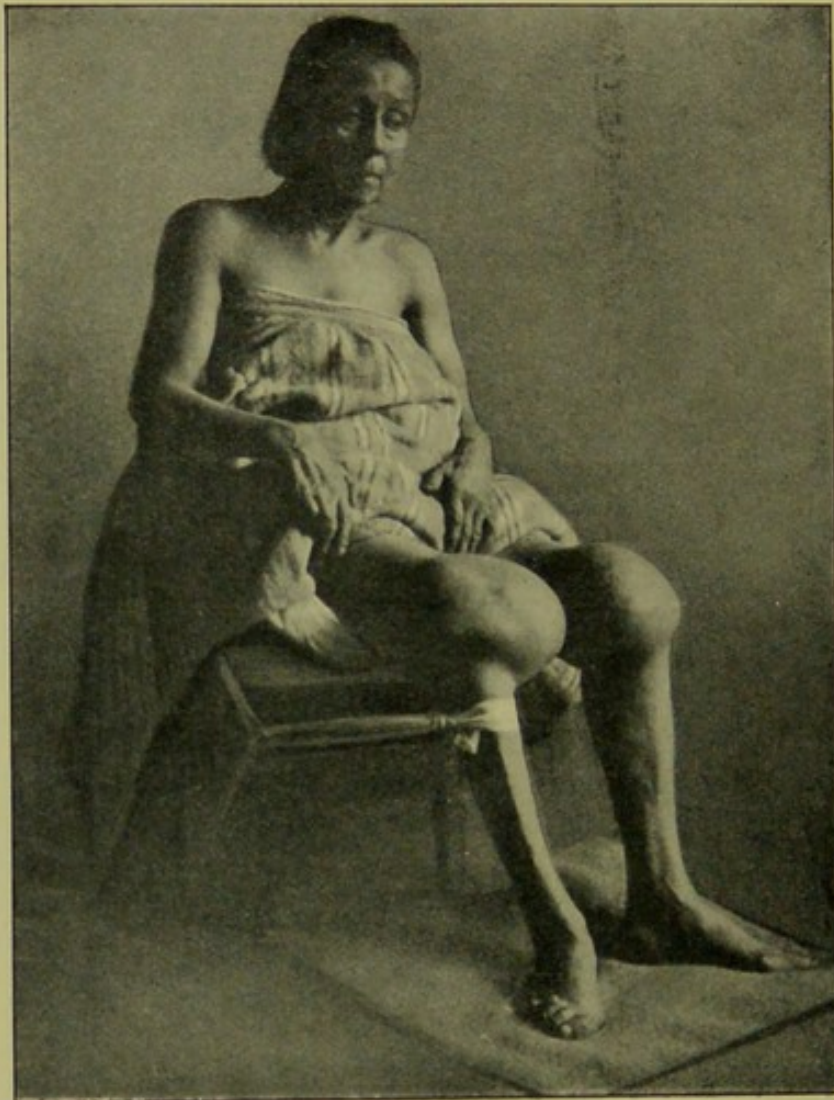


FIG. 164.—Tabetic arthropathy of both knees and of right foot. The patient's right leg is tied to the chair to prevent involuntary tabetic movements.

paralysed limbs become excessively brittle. I remember a case of hemiplegia in a middle-aged woman where moderate passive movements under an anæsthetic, during an attempt to break down adhesions in the hip-joint of the hemiplegic side, caused a fracture of the neck of the femur. The brittleness of the bones in certain *insane patients* and their liability to fractures on trivial injuries are well known. Moreover, there is a rare disease known as



idiopathic *fragilitas ossium*, where the patient, otherwise healthy, may fracture his bones from minimal accidents, as, for example, where a lad fractured his humerus by throwing a cricket-ball. Similar spontaneous fractures also occur in certain cases of *tabes* and of *syringomyelia*, but in these two diseases the fractures are

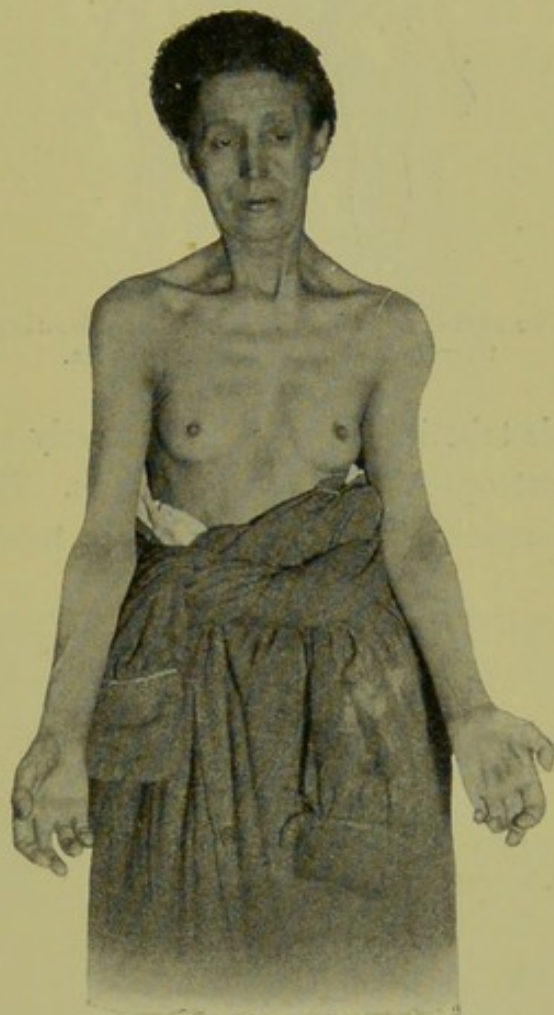


FIG. 165.—Syringomyelia with arthropathy of left shoulder-joint.  
Atrophy of intrinsic muscles of left hand.

painless, so that the patient may continue to use the fractured limb in a fashion impossible to a normal individual.

Trophic changes in joints—the so-called *arthropathies*, are met with most typically in *tabes* (constituting Charcot's joint), in *syringomyelia*, and in some cases of leprosy. The large joints are generally those affected, the knee and the tarso-metatarsal joint being the joints most commonly attacked in *tabes* (Fig. 164), the shoulder in *syringomyelia* (Figs. 165 to 168). But in *tabes* even



the smaller joints may occasionally be affected, as in the patient shown in Fig. 166, where the terminal joint of the thumb was thus

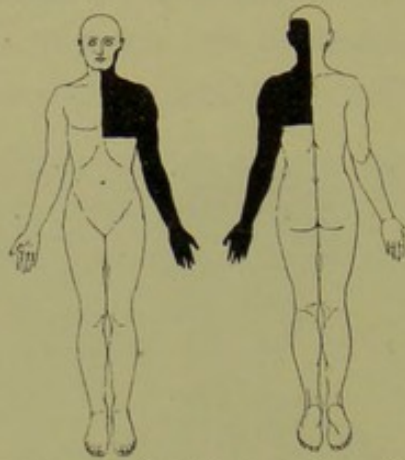


FIG. 166.—The same case of syringomyelia. Showing the area of therm-anæsthesia and analgesia.

diseased. Female tabetics seem to be relatively more liable than male patients to osteopathies and arthropathies. The exciting cause of a tabetic arthropathy is often some trivial traumatism, such as

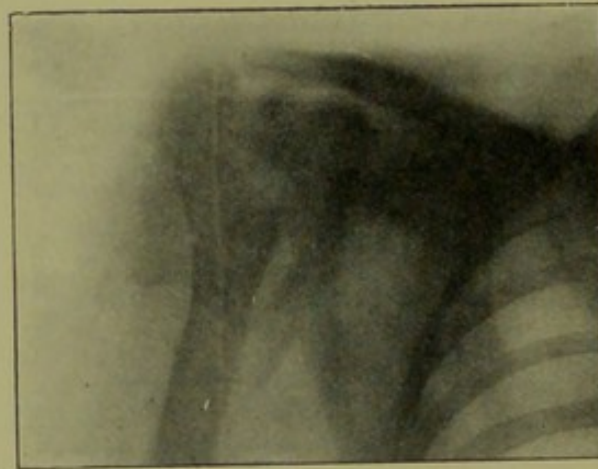


FIG. 167. — Syringomyelia (same case as Fig. 165). Radiogram of shoulder-joint. Showing fracture of upper end of humerus, also osteophytic outgrowth from axillary border of scapula.

a twist or sprain in a joint in which the sense of pain is diminished or lost, hence the greater frequency of tabetic arthropathies in the lower limbs. The joint swells painlessly, and rapid destructive changes occur in its articular surfaces, which become eroded and may disappear, together with a considerable part of the adjacent bone. Fractures of the articular ends are common,



both in tabetic and in syringomyelic joints. The ligaments become lax and the joint abnormally mobile, so that in the

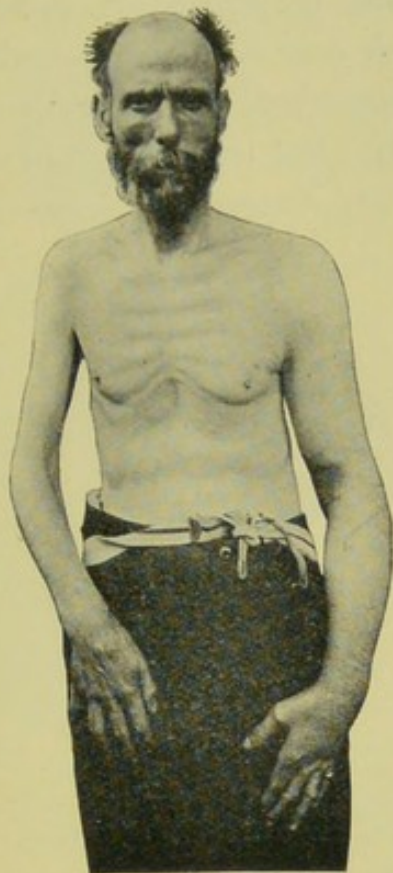


FIG. 168.—Syringomyelia with arthropathy of left shoulder-joint, the limb being swollen and displaced downwards "en masse" at the shoulder.

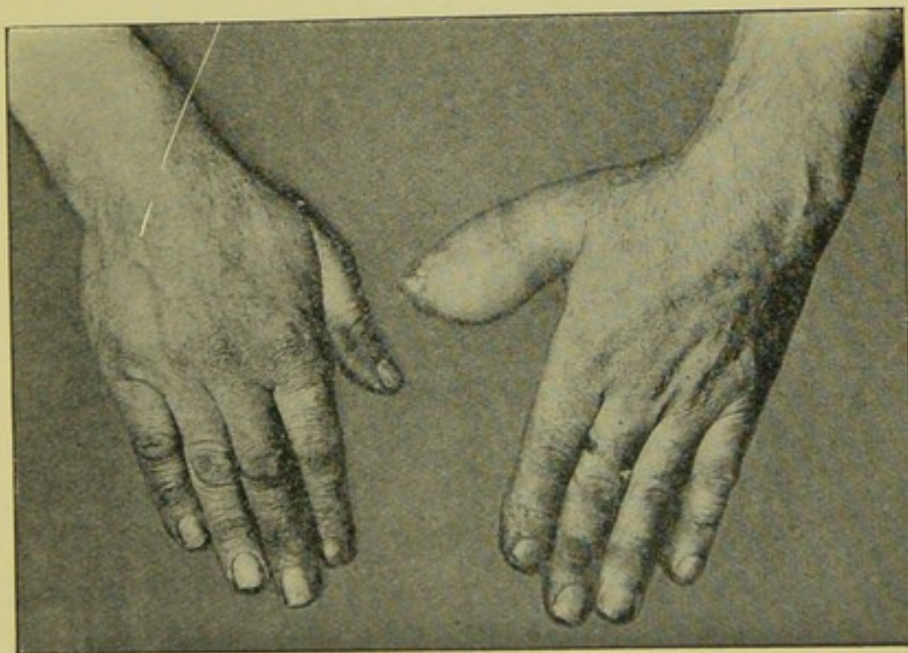

FIG. 169.—Tabetic arthropathy of left thumb.



knee we may be able to produce lateral passive movements, or even to bend the joint into all sorts of curious positions (Fig. 170). The joint is sometimes distended with a glairy gelatinous fluid, which may be blood-stained. In the later stages this fluid may be reabsorbed, throwing into relief the deformity of the bones (Fig. 171). But the changes in such arthropathies are not entirely destructive. Osteophytic outgrowths are often formed

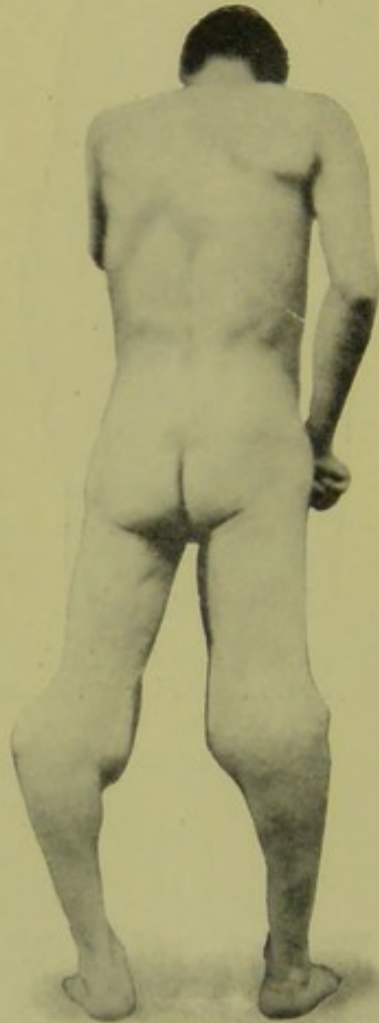


FIG. 170.—Tabetic arthropathy of knee-joints.

in the peri-articular tissues, causing irregular thickening of the bones, and producing little islands of new bone amongst the tissues around the joint. These can be readily detected on palpation and verified by skiagrams (Figs. 172 and 173).

Joint affections of a different kind are met with in some cases of chronic hemiplegia. The joints of the paralysed limbs, two or three weeks after the hemiplegic attack, become swollen and



deformed. But, unlike the tabetic and syringomyelic arthropathies, hemiplegic joint-affections are acutely painful. Moreover, the changes in hemiplegic joints are not destructive but more of

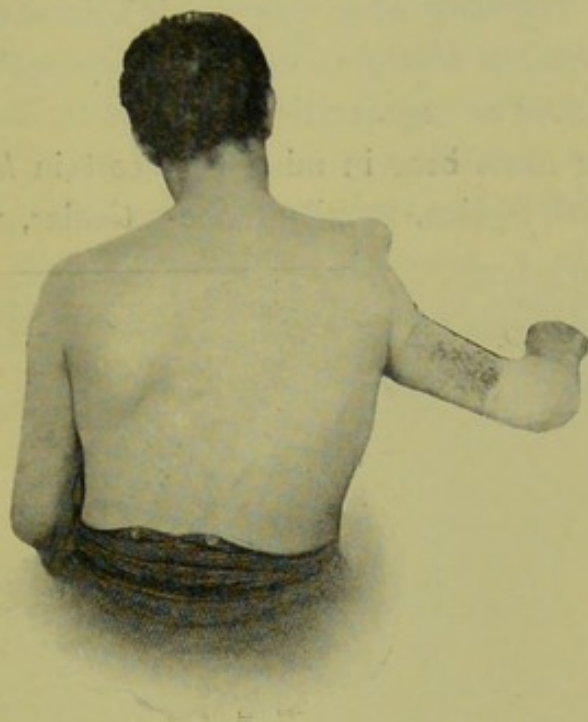


FIG. 171.—Syringomyelia with arthropathy of right shoulder-joint, and destruction of head of humerus. Well-marked scoliosis.

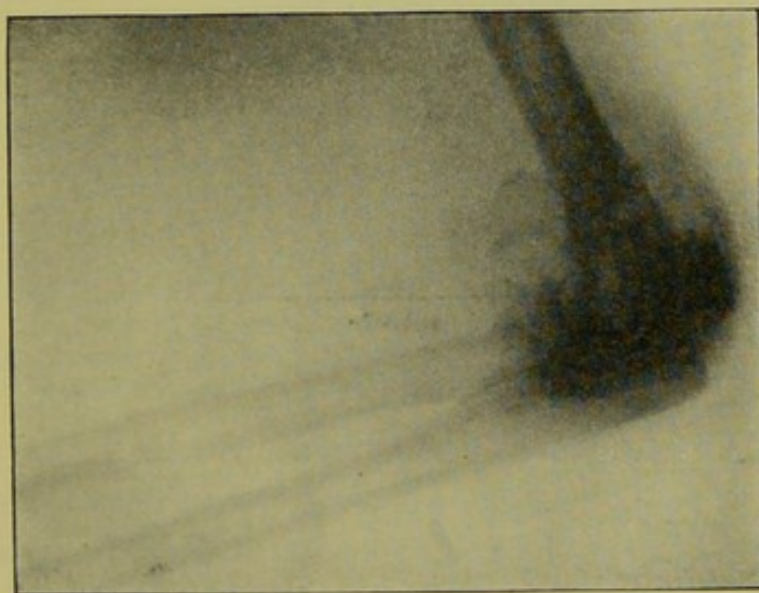


FIG. 172.—Tabetic arthropathy of elbow-joint. Radiogram showing bony deposits in the tissues around the joint.

the nature of a subacute osteo-arthritis, with pain and rigidity on passive movements and with a tendency to the formation of



fibrous adhesions within the joint and to thickening of the joint capsule. When the fingers are affected, they lose their normal outline and become clumsy-looking and "sausage" in appearance. Together with this hemiplegic arthritis it is not uncommon to have a degree of muscular wasting, but without electrical reactions of degeneration.

Finally, we must bear in mind that certain *hysterical* patients complain of joint-pains, usually mono-articular, which may more

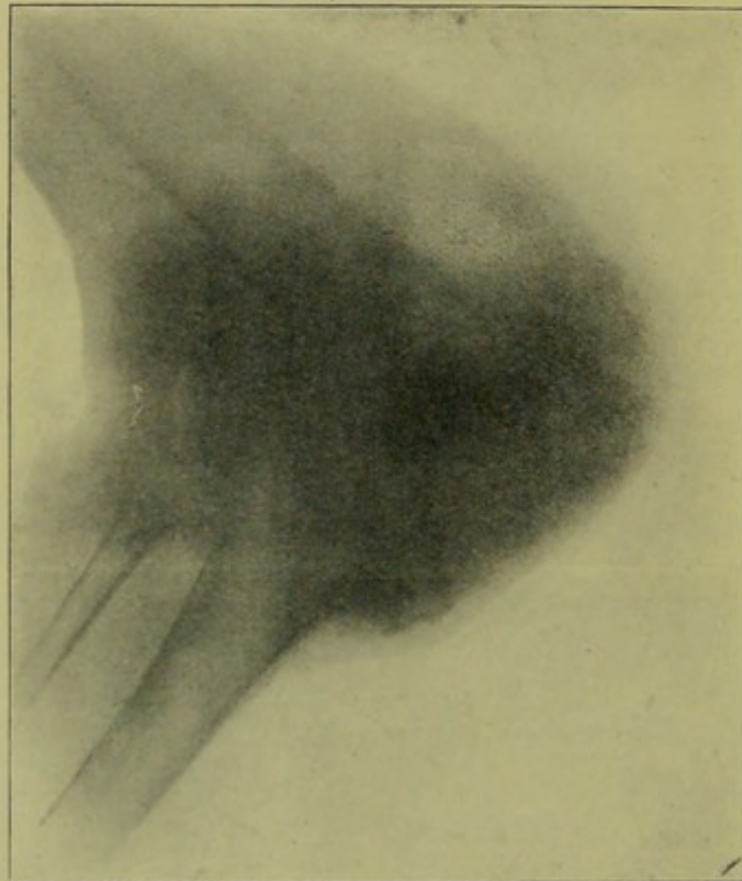


FIG. 173.—Radiogram of tabetic arthropathy of knee, from patient shown in Fig. 164. Showing disappearance of articular surfaces and presence of bony deposits in peri-articular tissues.

or less closely simulate organic joint disease. The patient is commonly a young woman who, after some local injury to the joint, or after some emotion, or perhaps from being acquainted with another patient who has joint disease, suddenly complains of intense joint-pain, together with cutaneous hyperæsthesia in that region. The joint is rigid and resistant to passive movement, and if the condition has persisted, as is sometimes the case, for weeks or months, fibrous adhesions may form. But



there is no true swelling of the joint when compared with the corresponding limb of the opposite side, though a false appearance of swelling may appear to be present owing to disuse-atrophy of the adjacent muscles. The presence of other hysterical "stigmata" often aids in the diagnosis, but an accurate opinion is sometimes a matter of considerable difficulty and is arrived at by a process of exclusion. Accomplished surgeons have been known to operate on such joints and only on opening the joint to discover the absence of organic disease. The result of such operations, fortunately, if aseptic, is that the patient usually recovers from her pains.



## CHAPTER XIX

### REFLEXES

FOR clinical purposes we have to consider three varieties of reflexes :—

- (1) Superficial or skin reflexes, *e.g.* the plantar reflex.
- (2) Deep or tendon reflexes, *e.g.* the knee-jerk.
- (3) Organic or visceral reflexes, *e.g.* vomiting, micturition, parturition.

Of these three groups, the first two have to do with striated voluntary muscles. They have their reflex centres within the cerebro-spinal axis, and many of them can be inhibited by voluntary effort. The third group, that of the visceral reflexes, is concerned not with voluntary muscles alone, but also with involuntary non-striated muscles which are controlled by the sympathetic nervous system and are incapable of direct voluntary restraint—*e.g.* the muscular walls of the stomach, bladder, rectum, or uterus. Such visceral reflexes can be performed, more or less perfectly, independently of the central nervous system. Normally, visceral functions go on, for the most part, unconsciously. But even they may occasionally evoke consciousness, as when visceral pain occurs, or when striated voluntary muscles are required to supplement an act originally initiated by non-striated muscles, or when the reflex act causes stimulation of a cerebro-spinal sensory nerve. Thus, to take an example, the act of defæcation is practically unconscious and uncontrollable, so far as the movement of the large intestine is concerned. But when the lower end of the anal canal has its mucosa stimulated, the perineal muscles come into action, and the act then becomes a conscious one and is more or less under control.

**Skin Reflexes.**—These are movements obtained by slight stimulation of certain areas of skin or mucous membrane. The result is a movement, quick or slow, of the skin near the point of stimula-



tion, but not exactly under it. In certain animals such as the horse, skin reflexes can be obtained by touching almost any part of the trunk. But in man the skin as a whole is less mobile, and it is usually only from certain special areas that skin reflexes can be elicited. If the stimulus be too strong, it may cause a reflex so violent as to involve almost all the voluntary muscles of the body. Or if the stimulus, even though slight, be a painful one, as for example a pin-prick, the result is a rapid "defensive" movement—*e.g.* sudden flexion of a limb or abrupt closure of the eye.

The following table gives a list of the chief skin reflexes which are of clinical importance, and the mode of testing each. All are more easily elicited in young people than in old; in fact, if we wish to demonstrate the skin reflexes with certainty, we select a child for our subject.

	METHOD OF ELICITING.	RESULT.	SEGMENTAL LEVEL.
Conjunctival . . .	Touching cornea.	Orbicularis oculi contracts.	
Pharyngeal . . .	Touching posterior wall of pharynx.	Pharynx contracts.	
Palatal . . . . .	Touching soft palate.	Palate is elevated.	
Scapular . . . . .	Stroking skin in inter-scapular region.	Scapular muscles contract.	C5 to Th1.
Epigastric . . . . .	Stroking downwards from nipple.	Epigastrium dimples on side of stimulus.	Th7 to Th9.
Abdominal . . . . .	Stroking downward from costal margin.	Abdominal muscles contract on side of stimulus.	Th11 to L1.
Cremasteric . . . . .	Stroking inner and upper part of thigh. Or pressure over Hunter's canal, or over adductor tubercle.	Testicle is pulled up.	L1 and L2.
Gluteal . . . . .	Stroking skin of buttock.	Gluteal muscles contract.	L4 and L5.
Plantar . . . . .	Stroking sole of foot.	Tensor fasciæ femoris contracts, hallux and other toes flex, ankle is dorsi-flexed.	L5 to S2.
Bulbo-Cavernosus	Pinching dorsum of glans penis.	Bulbous urethra contracts.	S3 and S4.
Superficial Anal .	Pricking skin of perineum.	External anal sphincter contracts.	S5 and Coccygeal.

Absence of the *abdominal reflex* is not uncommon in acute abdominal conditions, notably in appendicitis and enteric fever.<sup>1</sup> In young adults whose abdominal walls are apparently normal and in whom there is no œdema or excessive obesity, absence of this reflex is strongly suggestive of disseminated sclerosis, as has been pointed out by Strümpell, E. Müller,<sup>2</sup> and others. Exaggeration of the abdominal reflexes is fairly common in the gastric or intestinal crises of tabes, being associated with cutaneous hyperæsthesia of the abdomen.

<sup>1</sup> Rolleston, *Brain*, 1906, p. 99.

<sup>2</sup> *Neurologisches Centralblatt*, 1905, p. 593.



Of all the superficial reflexes, the *plantar reflex* is the one which has the greatest practical importance. In order to test it, the patient should be lying down, his feet being comfortably warm. The limb to be tested is now partially flexed at the hip and knee, and also rotated so as to rest on its outer side. Then with some hard object such as the end of a penholder, we gently stroke the sole of the foot from behind forwards, especially towards its inner side. Meanwhile we watch carefully for the first movement of the great toe. Normally this is a movement of plantar flexion (see Fig. 174). The movement of the other toes is of less importance. It is interesting also to note that, simultaneously with the toe movement (a "cortical" reflex) we have a brisk con-

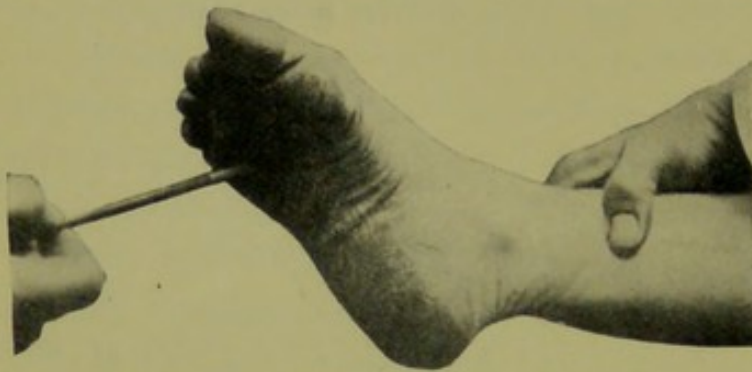


FIG. 174.—Normal plantar reflex.

traction of the tensor fasciæ femoris (Brissaud's reflex), medullary in origin, which may occur even in cases where the toes show no movement. This proves

that the plantar reflex is not a phenomenon confined to the foot but that it implicates the whole lower limb. If we employ a stimulus which is too strong, we may have, in addition, dorsiflexion of the ankle, and this may obscure the toe movement. Hence the importance of a gentle stimulus, graduated so as just to elicit the toe phenomenon and no more.

This normal plantar reflex, flexor in type, only occurs when the reflex arc is intact, and when, in addition, the lower reflex arc is in connection with the cerebral motor cortex by an uninjured pyramidal tract. In this sense it is a "cortical" reflex.

If the pyramidal tract, conveying motor impulses downwards from the cortical "leg-centre," be interrupted in any part of its course by injury or disease, or if it be non-developed, as in infants who have not learned to walk, the type of plantar reflex is different and is known as *Babinski's phenomenon*, or the *extensor plantar reflex*, whose spinal path, traversing the lumbo-sacral



region, is no longer controlled by pyramidal impulses. In this sense it is a pure "spinal" reflex. In the Babinski phenomenon, stimulation of the sole produces extension of the hallux instead of flexion (see Figs. 174 and 175). Moreover, this extensor movement of the great toe is slower than is the normal, brisk flexion. Sometimes, in addition to extension of the hallux, we observe a fan-like spreading out of the toes—"phénomène d'éventail." An extensor plantar reflex is practically always pathological, except in infants too young to walk (generally disappearing after the age of six months), and if constantly present it indicates an organic lesion, and one which implicates the pyramidal tract.<sup>1</sup>

It is therefore of the utmost value in the diagnosis between hysteria and organic disease.

Somewhat resembling the Babinski reflex, but apparently distinct from it, is Gordon's<sup>2</sup>

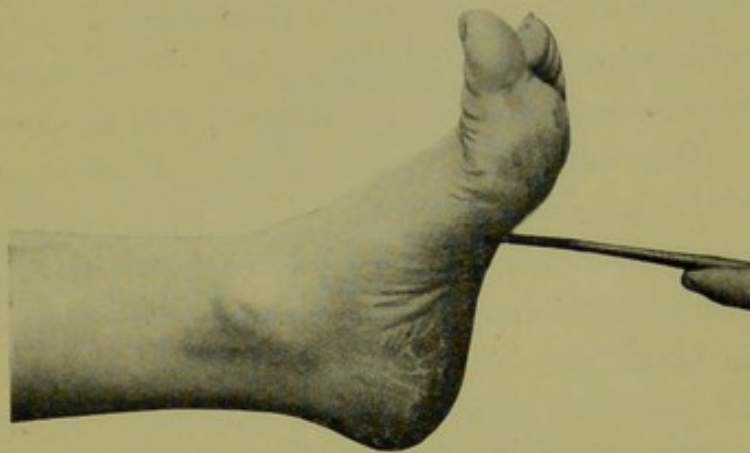


FIG. 175.—Babinski's extensor plantar reflex.

*paradoxical flexor reflex*, which consists in an extension movement of the great toe or of all the toes when we press deeply, through the calf muscles, between the heads of the gastrocnemius, on to the deep flexor muscles beneath. To elicit this reflex, the physician should place himself on the outer side of the patient's leg, the muscles of which must be completely relaxed. This is attained either by directing the patient to lie on his back or making him sit with his feet on a stool. The "paradoxical flexor reflex" is never present in health: it occurs only in organic, and especially in irritative, lesions of the pyramidal tract. It is sometimes associated with the Babinski reflex, but may occur in cases where the Babinski sign is absent.

<sup>1</sup> There is one exception to this rule. This is in the case of a lower motor neurone lesion affecting the flexor muscles of the toes and sparing the extensors. In such a case the only possible movement would be extension. But the other signs of lower neurone lesion, especially the electrical reactions, will prevent error.

<sup>2</sup> *American Medicine*, 1904, p. 971.



*Oppenheim's reflex*, a contraction of the extensor longus hallucis and tibialis anticus, is elicited in a slightly different way, viz., by firm stroking with some hard object (such as the handle of a percussion-hammer) just behind the postero-internal border of the tibia, from above downwards. Its significance is the same as that of the paradoxical flexor reflex.

The *cremasteric reflex* is very easy to elicit in young children, by stroking the inner side of the thigh. But in old men it is sluggish or apparently absent. Even in them, however, it can usually be elicited by sudden firm pressure backwards against the sartorius muscle in the region of Hunter's canal, or against the adductor tubercle of the femur; this often succeeds when stroking the skin in the usual fashion is of no avail. The cremasteric reflex is sometimes exaggerated on the affected side in cases of sciatic neuralgia.

The *bulbo-cavernosus reflex* is of great diagnostic value in determining whether the lowest segments of the spinal cord are intact in a lesion about the level of the third sacral segment—where the ordinary reflexes of the lower limbs give us no help. To obtain the bulbo-cavernosus reflex, we place one finger behind the patient's scrotum, pressing upwards against the bulbous part of the urethra. With the other hand we pinch, or prick with a pin, the dorsum of the glans penis; the bulbous urethra is at once felt to give a brisk twitch. Loss of this reflex indicates a lesion somewhere in its reflex arc, either in the anterior cornua of the third and fourth sacral segments, or in the corresponding motor or sensory roots of the cauda equina. Loss of the bulbo-cavernosus reflex is a fairly common sign in tabes, being due in that case to a lesion of the afferent fibres of the reflex arc.

The *superficial anal reflex* can be easily obtained by pricking the skin of the perineum with a long "bonnet-pin," and watching whether the external sphincter contracts. This reflex is sometimes lost in anæsthesia of the perineum, or in lesions of the fifth sacral or of the coccygeal segment, or of their corresponding motor roots.

Organic hemiplegia usually produces, at first at least, loss of the unilateral superficial reflexes all down the paralysed side, with one exception—viz. the plantar reflex, which persists, but from the first is changed into the extensor type. In hysterical hemiplegia,



on the other hand, even though cutaneous hemi-anæsthesia be present, the unilateral skin reflexes on the paralysed side are usually preserved, with the exception of the plantar reflex which is often lost. An extensor plantar reflex never occurs in pure hysteria. In hysteria there may be absence not only of any toe movement on stimulation of the sole, but there may also be loss of the reflex contraction of the tensor fasciæ femoris. This "combined" absence of reflex movement both of the toes and of the fascia lata of the thigh is always strongly suggestive of hysteria. It is probably due to a latent muscular spasm.

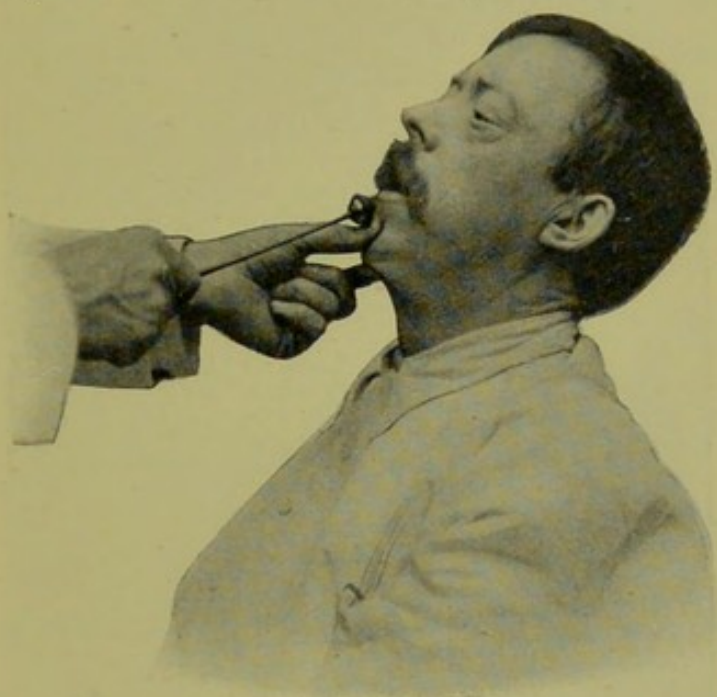

FIG. 176.—Method of eliciting jaw-jerk.

**Deep or Tendon Reflexes.**—The following table gives a list of those deep reflexes which we commonly study when investigating cases of nervous disease :—

	METHOD OF ELICITING.	RESULT.	SEGMENTAL LEVEL.
Jaw . . . . .	Tapping lower jaw, supported in half-open position.	Jaw closes.	Pons.
Biceps . . . . .	Tapping biceps tendon.	Biceps contracts.	C5 and C6.
Supinator longus	Tapping styloid process of radius.	Supinator longus contracts.	C5 and C6.
Scapulo-humeral	Tapping vertebral border of scapula, near base of spine.	Teres minor, Infraspinatus, &c., contract.	C5 and C6.
Wrist . . . . .	Tapping upper part of radius.	Wrist and fingers extend.	C6 to C8.
Triceps . . . . .	Tapping triceps tendon.	Triceps contracts.	C7 to Th1.
Carmo-metacarpal	Tapping dorsum of wrist.	Fingers flex.	C8 and Th1.
Knee . . . . .	Tapping patellar tendon.	Vastus internus, &c., contract.	L3 and L4.
Ankle . . . . .	Tapping tendo Achillis.	Calf muscles contract.	S1 and S2.



The *knee-jerk* may be taken as a type of these tendon reflexes. It has been a matter of dispute whether it is really a true reflex or not. Strictly speaking, the jerk occurs too soon after the tap for a nerve impulse to have time to travel up to the reflex centre in the cord and down again to the muscles. But so long as the reflex arc is intact, there is a constant "reflex tonus" in the vastus

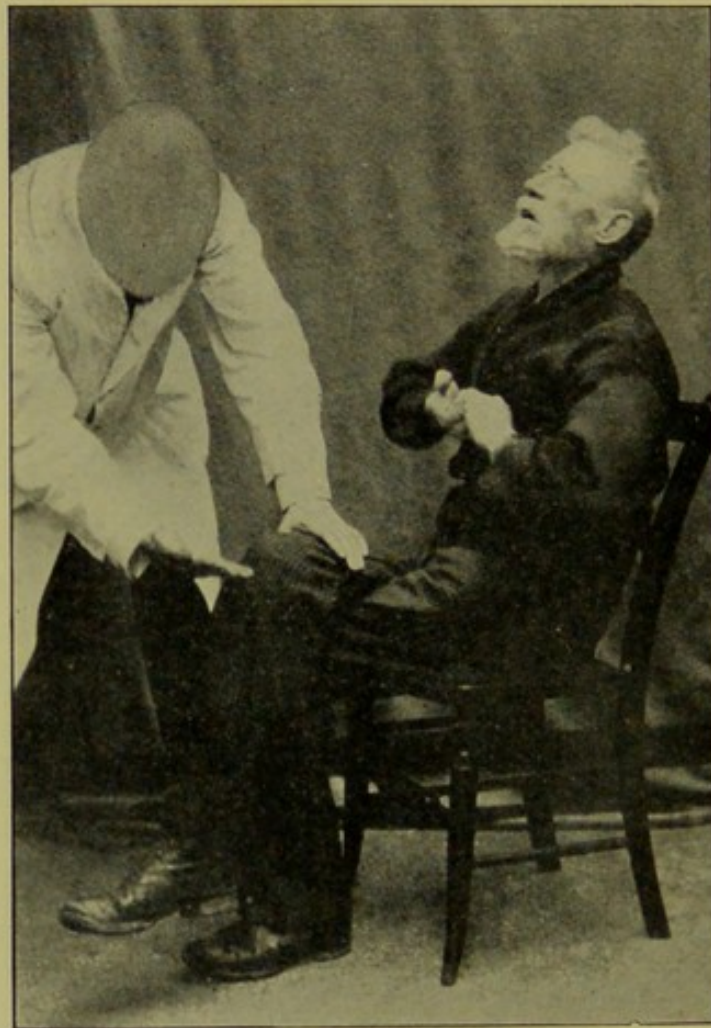

FIG. 177.—Knee-jerk. Reinforcement by Jendrassik's method.

internus muscle which, when the tendon is struck, permits the jerk to occur. If this reflex tonus be lost from interruption of the reflex arc at any point, the jerk can no longer be obtained. Therefore, for practical purposes, the knee-jerk, though not a true reflex action itself, is an index of the integrity of the reflex arc.

To obtain the knee-jerk, we feel for the patellar tendon and strike it either with the edge of the hand or with some other fairly heavy object, such as a rubber percussion-hammer or a heavy



paper-knife. The result is a brisk contraction of the quadriceps. If we grasp the vastus internus with our other hand we can feel the jerk in cases where it is too feeble to move the knee-joint. The knee must be somewhat bent to put the quadriceps slightly on the stretch, and the muscles must be absolutely relaxed. This latter point is of importance ; for sometimes it happens

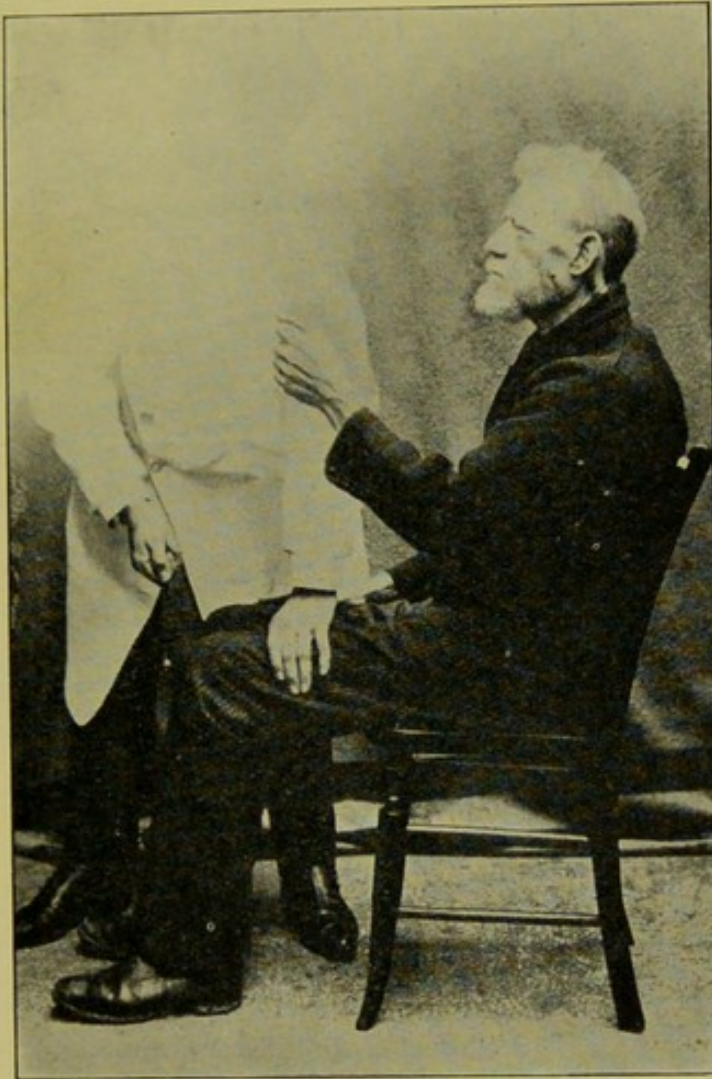

FIG. 178.—Knee-jerk. Reinforcement by Laufenauer's method.

that a patient may have his muscles in a state of excessive spasm, so that we may fail to elicit the knee-jerk, and yet, if we succeed in relaxing the muscles by passive movements, the knee-jerk is not only present but found to be increased. The knee-jerk in such a case is not absent, but only "concealed" by the spasticity of the muscles.

In testing the knee-jerk the patient may be sitting on a table



with his legs dangling in the air, or better, on a chair with the soles of the feet flat on the ground and the knees gently semi-flexed, or one knee may be crossed over the other. A feeble jerk may be "reinforced" either by Jendrassik's method (Fig. 177), in which the patient hooks both hands together, pulling them one against the other, and looks up towards the ceiling, thereby diverting

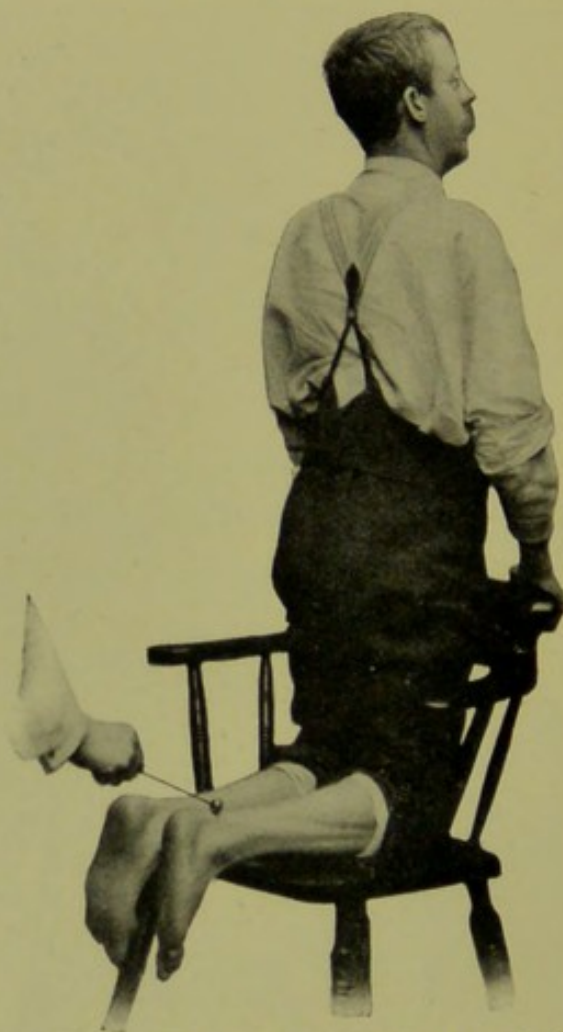

FIG. 179.—Method of eliciting ankle-jerk.

his attention and relaxing the leg muscles. An even better method of reinforcement is Laufenauer's, in which we grasp the patient's quadriceps whilst the patient sits with his soles flat on the ground. The patient then grasps our upper arm with one hand, and suddenly squeezes when told to do so; meanwhile, down comes the percussion-hammer (Fig. 178). The advantage of this method is that we can feel for ourselves whether the patient really is directing his attention to the act of reinforcement. More-



over, this method can be employed to reinforce feeble reflexes of the upper limbs, whereas Jendrassik's method is only available for reflexes of the lower limbs. Many other methods of reinforcement have also been suggested, *e.g.* by making the patient gaze at the ceiling and draw a long breath (Krönig<sup>1</sup>), or by making him read aloud from a newspaper or book as fast as possible (Rosenbach<sup>2</sup>).

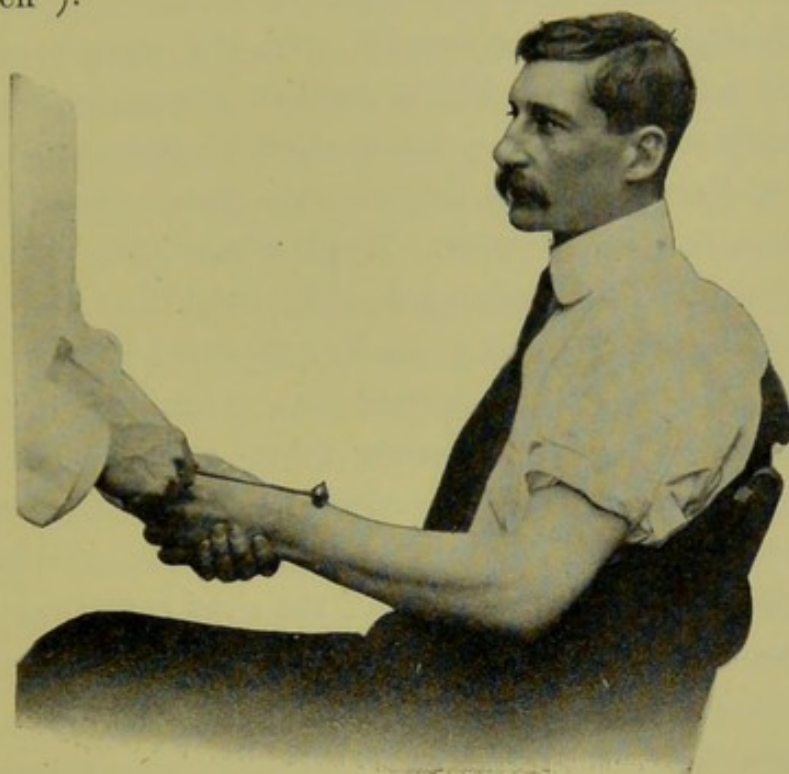


FIG. 180.—Supinator-jerk.

Reinforcement will make a feeble jerk more evident; but it has no effect if the jerk be absent.

The *ankle-jerk* has a diagnostic significance equal to that of the knee-jerk. To test it, we make the patient kneel on a chair with his feet projecting over the edge, and then tap the tendo Achillis (Fig. 179); a brisk extension movement of the ankle is the result. In tabes the ankle-jerk is often lost before the knee-jerk. In sciatica loss of the ankle-jerk indicates a neuritis as distinguished from a mere neuralgia.

In the upper extremity we have various deep reflexes at our disposal. Of these, the *supinator-jerk* is ordinarily the most acces-

<sup>1</sup> *Berlin klin. Wochenschrift*, 1906, No. 44.

<sup>2</sup> *Münchener med. Wochenschrift*, 1907, No. 2.



sible. In testing it, we support the patient's hand in a semi-supinated posture, with the elbow loosely bent to a right angle. We tap with our hammer close above the styloid process of the radius (Fig. 180). The supinator longus at once contracts and produces a flexion movement of the elbow. To elicit the *triceps-jerk*, the best way is not, as stated in some text-books, to allow the elbow to hang over the back of a chair, but rather to support the upper arm horizontally, with the elbow loosely flexed at a right angle. Then, feeling for the triceps tendon, we tap it with our hammer, and the muscle at once contracts.

**Loss of Deep Reflexes.**—Sometimes these reflexes cannot be elicited, even on reinforcement. This is almost always pathological (although in very rare cases a healthy individual is found to be devoid of deep reflexes), and generally indicates a lesion of the reflex arc. If this lesion be in the afferent limb of the arc, there may also be anæsthesia of the corresponding nerve- or root-area. If it be in the anterior cornu, or in the efferent motor path, there will be muscular paralysis, with atrophy of the particular muscle.

The following is a list of some of the chief conditions in which there is loss of the deep reflexes:—

<i>Disease.</i>	<i>Site of Lesion.</i>
Neuritis (Alcohol, Diabetes, Diphtheria, Lead, Arsenic, Tubercle, Cachexia, &c.) . . . . .	} Peripheral nerves, sensory or motor.
Peripheral Nerve Palsies . . . . .	
Tabes Dorsalis . . . . .	} Posterior columns of cord.
General Paralysis of Insane (tabetic type — Tabo-paralysis) . . . . .	
Friedreich's Ataxia . . . . .	
Subacute Combined Degeneration of Posterior and Lateral Columns—late stage of . . . . .	
Any focal lesion in Grey Matter of Cord . . . . .	Reflex centre in cord.
Infantile Paralysis (Acute Anterior Poliomyelitis) . . . . .	} Anterior cornua of cord.
Progressive Muscular Atrophy (Chronic Anterior Poliomyelitis) . . . . .	
Amyotrophic Lateral Sclerosis . . . . .	
Syringomyelia . . . . .	
Thrombosis of Anterior Spinal Artery . . . . .	} Anterior cornua and peripheral motor nerves.
Landry's Paralysis . . . . .	
Myopathies (Pseudohypertrophic and Atrophic types) . . . . .	} Muscle itself.
Amyotonia congenita . . . . .	
Increased Intra-Cranial Pressure (especially Hydrocephalus and Tumours of Posterior Fossa).	
Pneumonia.	
Family Periodic Paralysis (during attacks).	
Immediately after attack of Major Epilepsy (post-epileptic coma).	
During Spinal Anæsthesia.	
Complete transverse lesion of Cord.	

From this list we see that, in addition to permanent organic lesions within the reflex arc itself, there are other conditions where



the deep reflexes are abolished. Thus these reflexes are lost in the final stages of increased intra-cranial pressure, especially in hydrocephalus and in tumours of the posterior fossa.

This is attributed by Raymond and others to a curious degeneration of the posterior spinal roots, which sometimes occurs in such conditions, whereas van Gehuchten<sup>1</sup> ascribes it to loss of function of the rubro-spinal tracts, from pressure on the mesencephalon.

The knee-jerks are often lost during pneumonia. In the attacks of the rare disease known as family periodic paralysis (see p. 253), the deep reflexes in the affected limbs are temporarily abolished, owing to temporary paralysis of the muscle-fibres. The deep jerks are abolished for a few minutes just after an epileptic fit, during the stage of coma and flaccidity. Spinal anæsthesia temporarily abolishes all the deep and superficial reflexes in the lower limbs (see p. 419). We should also remember that in *complete* trans-section of the spinal cord, all the deep reflexes below the level of the lesion are lost. If, however, the lesion be not complete, and there still survives some nervous tissue connecting the upper and lower portions, then the deep reflexes are exaggerated. In both instances the plantar reflex, if present, is extensor in type.

**Exaggeration of Deep Reflexes.**—Sometimes the deep reflexes are exaggerated, so that the slightest tap on the tendon produces an unusually brisk contraction. This may be the result of various poisons—*e.g.* tetanus, or strychnine-poisoning—rendering the reflex centres unduly explosive; or it may occur in simple neurasthenia. But organic lesions of the pyramidal tract are by far the commonest causes of permanent exaggeration of the deep reflexes. In cases of organic disease, we look also for the presence of *clonus*. A clonus is a rhythmic series of muscular contractions, produced by sudden passive stretching of the tendon, the clonus continuing so long as the tension of the tendon is maintained.

*Ankle-clonus* is the commonest clinical variety of clonus. To elicit it, the knee is passively flexed (the angle of flexion varying in different cases), and the ankle is suddenly dorsiflexed by upward pressure on the sole of the foot (Fig. 181). Ankle-clonus is due, as Weir-Mitchell has pointed out, to contraction, not of the

<sup>1</sup> *Le Névrose*, 1907, vol. ix. p. 39.



gastrocnemius but of the soleus muscle, since the position of the knee which is best for eliciting ankle-clonus is one in which the gastrocnemius is relaxed.

A *spurious ankle-clonus* is sometimes obtained in cases of hysteria. This can usually be differentiated from genuine clonus by a char-

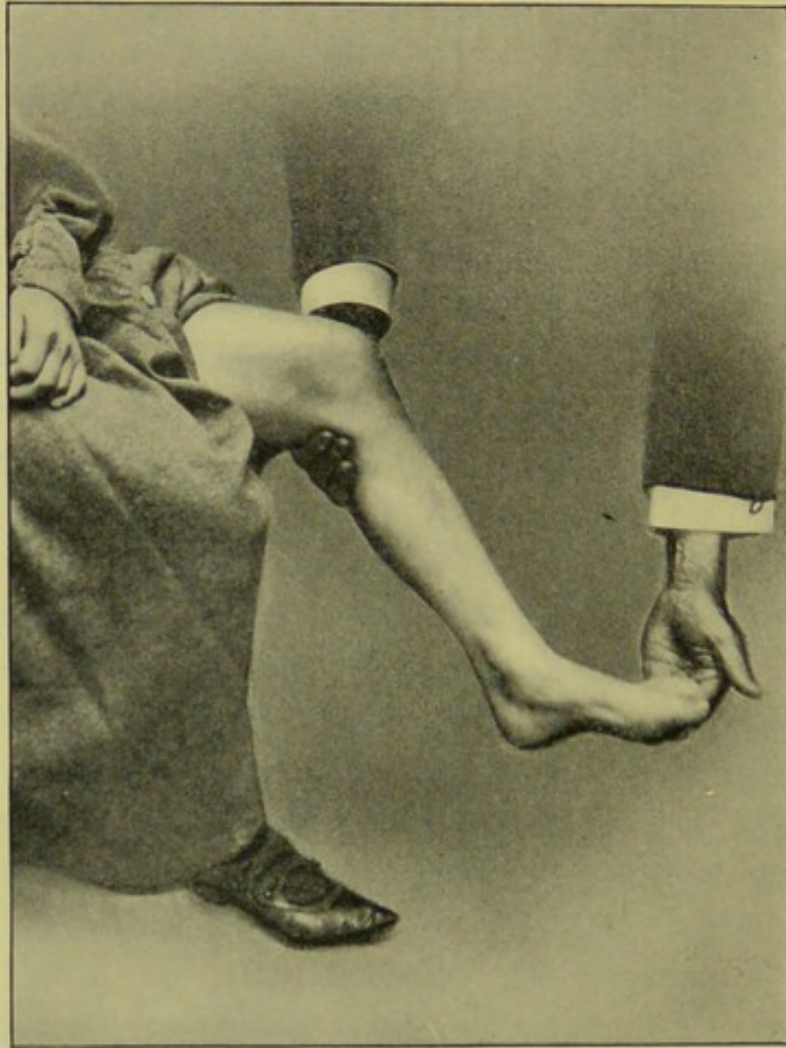


FIG. 181.—Method of eliciting ankle-clonus.

acteristic feeling of voluntary contraction in the muscles, especially at the commencement of the clonus, difficult to describe in words. Spurious clonus is generally poorly sustained and often irregular in rhythm. It is never associated with an extensor plantar reflex.

*Knee-clonus* or *rectus-clonus* is best obtained by sudden downward traction on the patella, the knee being passively extended.

In chronic organic affections of the pyramidal tract, practically every one of the deep jerks may become exaggerated into clonus.



Thus in advanced disseminated sclerosis we may find in the same patient jaw-clonus, elbow-clonus, wrist-clonus, finger-clonus, knee-clonus, ankle-clonus, toe-clonus, &c.

The presence of true clonus indicates that the reflex arc is hyper-excitable, owing to withdrawal of the regulating or restraining influence normally exerted through the pyramidal tract. Exaggeration of the deep reflexes is therefore one of the cardinal signs of a chronic lesion of the upper or cortico-spinal motor neurone.

It is unnecessary to give a list of the various organic diseases in which the deep reflexes are exaggerated. Suffice it to say that any chronic lesion of the pyramidal tract will produce exaggeration of the deep reflexes below the level of the lesion. Thus in paraplegia due to myelitis, to lateral sclerosis, or to some other affection of the lateral columns, or in hemiplegia from organic brain disease, there is exaggeration of the deep reflexes in the paralysed limbs, owing to injury or disease of the pyramidal fibres.

There is an important exception to this rule, to which we have already referred, namely in *total* trans-section of the spinal cord, as in some cases of fractured spine. Such total lesion produces a permanent flaccid paralysis of the lower limbs, with loss of the deep reflexes. But if the lesion be incomplete, we have the usual spastic type of paraplegia, with increased deep reflexes. In both instances, whether the lesion be total or partial, we have an extensor type of plantar reflex.

We should also mention that in the early stages of *peripheral neuritis* the deep reflexes may be exaggerated. But this soon passes off and is succeeded by their diminution and loss. Again, in *subacute combined degeneration* of the lateral and posterior columns of the cord, there is an early stage of spasticity with increased deep reflexes, and a terminal stage of flaccid paralysis with loss of reflexes.

Sometimes in spastic paraplegia the muscular rigidity of the paralysed limbs is so excessive that it may be almost impossible to obtain the knee-jerks and other deep reflexes, which we should ordinarily in these cases expect to find exaggerated. This is because the muscles are already in a state of tonic spasm. But



if we succeed in temporarily relaxing them, by passive changes of posture, we can sometimes obtain the increased jerks and even the clonus. In most cases, the spasticity and the presence of an extensor plantar reflex will prevent errors in diagnosis.

*Pupillary Light Reflex.*—This occupies a special category of its own. The reflex is elicited by exposing the pupil to light, after previous shading. Normally under such conditions the pupil contracts briskly, both when stimulated directly and when the pupil of the opposite eye is exposed to light (consensual reflex). In some respects the pupil reflex to light, although occurring in a non-striated muscle, is analogous to a deep reflex, and it is useful to remember that in tabes this reflex disappears, as do the ordinary tendon-reflexes. But the subject of the various pupil-reflexes and their connections with the third nerve, with the ciliary ganglion, and with the cervical sympathetic is discussed elsewhere (see "Cranial Nerves," p. 127, and "Cervical Sympathetic," p. 336).

**Organic Motor Reflexes.**—These are concerned with the sympathetic nervous system and with the contraction of non-striated, involuntary muscles. The contraction of non-striated or smooth muscles is slow, unlike the brisk twitch of a reflex in a striated muscle. The following is a list of organic reflexes which are of diagnostic interest. In some of these, such as the cilio-spinal or the scrotal, the reflex movement is executed entirely by non-striated muscle. In others, such as the vesical, uterine, or rectal, the non-striated muscle is reinforced by voluntary striated muscles.

	METHOD OF ELICITING.	RESULT.
Cilio-spinal . . .	Pinching or scratching skin of neck.	Pupil dilates.
Scrotal . . . . .	Repeated stroking of perineum or application of cold.	Dartos contracts.
Vesical . . . . .	Distension or irritation of bladder or posterior urethra.	Bladder-wall contracts.
Rectal . . . . .	Distension or irritation of upper part of rectum.	Rectum contracts.
Genital . . . . .	From cerebrum or periphery.	Erection of corpora cavernosa.
Uterine . . . . .	Distension or stimulation of uterus.	Uterus contracts.
Internal anal . . .	Distension of anus by finger.	Internal sphincter ani contracts.

In all of them, with the exception of the cilio-spinal, the reflex movement can be accomplished, more or less perfectly, independently of the central nervous system.



In some text-books the statement is made that the reflex centres for the bladder, uterus, and rectum are situated within the cord. But within recent years clinical and pathological evidence has been brought forward, notably by L. R. Müller,<sup>1</sup> showing that the lowest reflex centres for the contraction of the bladder, and of the neighbouring hollow viscera possessing non-striated muscular walls, are situated extra-spinally, in the hypogastric and hæmorrhoidal plexuses of the sympathetic.

The sympathetic vesical centre can be stimulated from the cerebro-spinal system. Micturition in the adult is a voluntary act, but only to this extent that it can be voluntarily initiated. This is accomplished by contracting the diaphragm and abdominal walls, producing a rise in the intra-vesical tension, which starts the reflex; meanwhile the striated constrictor urethræ is voluntarily relaxed. But the non-striated bladder-wall itself, the so-called detrusor urinæ, is not under control of the will. Once started, the bladder empties itself spontaneously, and we can stop the act only by forcibly innervating the constrictor urethræ, usually a matter of considerable effort. But reflex micturition is often excited by irritation of the urethra, especially of its vesical end. Thus if a few drops of urine trickle into the prostatic urethra, an imperious reflex act of micturition results, which is difficult to prevent. Similar phenomena are produced by the irritation of a posterior urethritis.

The fibres from the brain and spinal cord to the sympathetic vesical centre reach it through the lowest spinal roots, from the third to the fifth sacral, so that lesions of the spinal cord or cauda equina constantly cause bladder trouble. This generally takes the form of initial *retention* of urine, followed after several days by intermittent *reflex incontinence* ("incontinenza a getto" of Italian writers<sup>2</sup>), in which the bladder contracts intermittently and expels the urine at intervals. Such reflex incontinence is generally associated with incomplete emptying, so that a certain amount of

<sup>1</sup> *Deutsche Zeitschrift für Nervenheilkunde*, 1901, Band 21, s. 86.

<sup>2</sup> Rebizzi, *Rivista di Patologia Nervosa e Mentale*, 1905, p. 80.



“residual urine” remains in the bladder. In cases of coma or of the deep insensibility of fevers such as typhoid, we observe an initial retention of urine, followed by distension, paralysis of the bladder-wall and overflow dribbling (“incontinenza per regurgito”).

The sensory nerves from the bladder pass through the sympathetic by the rami communicantes, and along the posterior roots into the spinal cord. They serve to inform us of the distension of the bladder. There are also higher micturition centres, some in the spinal cord (in the lower sacral segments), others higher still in the brain, in the corpus striatum and optic thalamus; others, highest of all, in the motor cortex, between the arm and leg centres, controlling the sub-cortical and spinal centres. When these higher centres, spinal or cerebral, are hyper-excitabile, whether from disease or from emotion, we may have *precipitancy* of micturition, or even enuresis, a condition in which the brain and spinal cord on the slightest provocation send impulses which relax the compressor urethræ. A similar condition exists in infants who have not learned to control their subcortical micturition centres.

*True dribbling of urine* (“incontinenza vera”), as distinguished from intermittent contraction of the bladder, occurs most typically in cases of tabes and is mainly due to anæsthesia of the bladder, which being now insensitive to distension, is no longer stimulated to contract by the normal accumulation of urine. The tabetic patient with an anæsthetic distended bladder expels his urine, not by contraction of the bladder but by pressure with his abdominal walls. This can readily be verified if we have to pass a catheter for the purpose of emptying a tabetic patient's bladder. True dribbling also occurs in an over-distended bladder which, from obstruction in the prostate or urethra, has become flaccid, paralysed and atonic.

The *internal anal reflex* is tested by inserting a finger within the anus. Normally the finger is tightly grasped by the non-striated internal sphincter. This reflex is independent of the superficial anal reflex of spinal origin, to which we have already referred. When the internal anal reflex is lost, the anus no longer



grasps the finger but remains open for several seconds, " yawning," after the finger has been withdrawn. Such loss is most commonly due to anæsthesia of the anus, as in tabetic or other lesions of the cauda equina. The result is incontinence of fæces. If there be a lesion within the spinal cord, above the spinal centre in the conus medullaris, there is intermittent rectal incontinence. But if the lesion be in the afferent nerves from the rectum, the internal sphincter remains relaxed, and the fæces, if fluid, dribble away continuously when they enter the rectum, the patient being unconscious of the fact.

To test the *scrotal reflex*, which is an excellent example of a purely sympathetic motor phenomenon, the patient stands bending forwards with his legs wide spread and scrotum hanging free. The skin of the perineum is now stroked with some hard object five or six times in succession. After a few seconds an extremely slow, worm-like contraction appears in the non-striated dartos muscle, beginning near the perineal part of the scrotum and spreading forwards. This reflex can also be elicited by the application of cold to the perineum or scrotum.



## CHAPTER XX

### AFFECTIONS OF THE SYMPATHETIC. ANGIO-NEUROSES

To most of us the mention of the Cervical Sympathetic recalls memories of our early days as students of physiology, and more particularly the memory of a classic experiment of Claude Bernard upon the rabbit. But it is perhaps not sufficiently realised that the cervical sympathetic is also of considerable clinical importance.

First of all, let us recall a few anatomical points. The sympathetic nervous system forms two gangliated cords, coursing like two strings of beads, one on each side, close in front of the vertebral column, and extending from the base of the skull to the front of the coccyx. Above, these chains are connected with plexuses which enter the cranial cavity; below, they converge and end in a loop on the coccyx. Each chain is made up of multipolar nerve-cells and nerve-fibres, all of them involuntary fibres destined mostly for organs which possess smooth muscle-fibres and for blood-vessels. In addition to its own longitudinal fibres, the sympathetic chain receives connecting-fibres from the central nervous system. These are called the *rami communicantes*—some of them white, some of them grey. They unite the sympathetic to the anterior primary divisions of the spinal nerves. The white *rami*, consisting of medullated fibres, pass from the spinal cord to the sympathetic ganglia; they are all efferent in function, and leave the cord through the anterior nerve-roots. A certain number of white rami, viz. those emerging along with the seventh, ninth, and tenth cranial nerves, and those emerging with the second and third sacral nerves, pass directly to the viscera and blood-vessels, to end in small peripheral ganglia, without joining the sympathetic chain itself. To these two sets of splanchnic nerve-fibres, cranial and sacral, the name *para-sympathetic fibres* has been given, to distinguish them from the ordinary sympathetic



nerves and ganglia. The grey *rami*, consisting of non-medullated fibres, originate in the sympathetic ganglia, and, like the others, join the spinal nerves. Some of them are afferent, going into the spinal cord, reaching it through the posterior nerve-roots; others turn off with the peripheral nerves and supply to the skin involuntary efferent fibres, whose functions are vaso-motor, vaso-inhibitory, pilo-motor, secretory, &c. In addition, the sympathetic cords give branches, either directly or through the great pre-vertebral ganglia (the cardiac, solar, and hypogastric plexuses), to the various glands and viscera of the body, to the heart and blood-vessels, to the genital organs, and to the non-striated muscles of the body generally.

In addition to the ordinary ganglia of the sympathetic chain, there are also minute *micro-sympathetic ganglia* or *hypospinal ganglia* of Marinesco and Minea,<sup>1</sup> which are so small that they can only be identified by microscopic examination of the spinal nerves immediately below the junction of the anterior and posterior nerve-roots. These microscopic ganglia are closely connected with the rami communicantes. Their precise function is still obscure.

Lastly, the cervical part of the sympathetic chain has very special "oculo-pupillary" fibres, which are clinically of considerable importance. These supply the dilator pupillæ, the non-striated part of the levator palpebræ superioris and the orbital muscle of Müller—a small bundle of non-striated muscle which lies behind the globe of the eye and bridges across the sphenomaxillary fossa at the back of the orbit. The cervical sympathetic also supplies secretory fibres to the submaxillary gland, and, like the sympathetic elsewhere, it supplies fibres to the cutaneous blood-vessels, also (through the hypoglossal nerve) to the vessels of the tongue, and, lastly, fibres to the sweat-glands of the head and neck.

The pupil-dilating fibres have a peculiar course, which it is important to remember (see Fig. 182). Arising from the pupil-dilating centre in the medulla, they descend in the lateral column

<sup>1</sup> *Neurologisches Centralblatt*, 1908, s. 146.



of the spinal cord to the cilio-spinal centre in the lower cervical region. They emerge from the cord through the anterior roots of the first and second thoracic segments, and enter the inferior cervical ganglion of the cervical sympathetic by white *rami communicantes*. They then ascend in the cervical sympathetic to

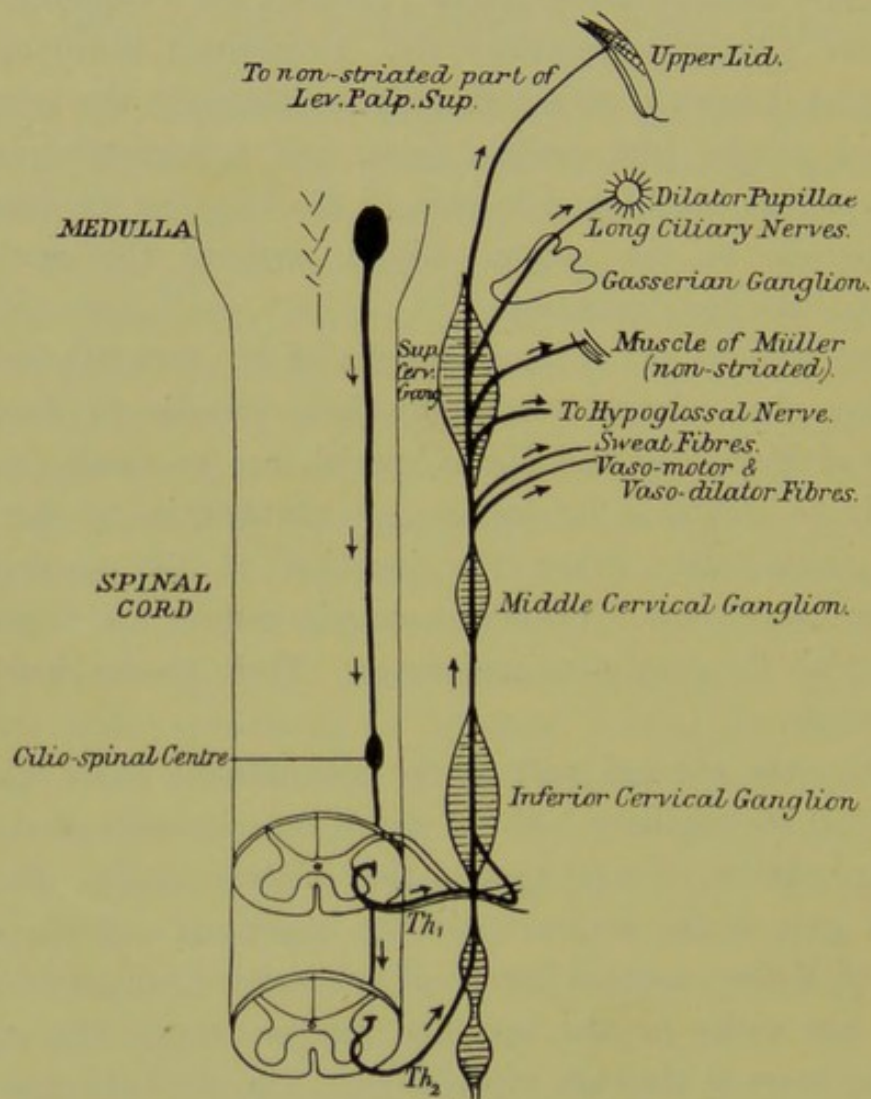


FIG. 182.—Diagram of course of oculo-pupillary fibres of cervical sympathetic.

the Gasserian ganglion and pass thence to the orbit (along the ophthalmic division of the fifth cranial nerve), and *via* the long ciliary nerves to the pupil. They do not traverse the ciliary ganglion (see Fig. 55, p. 127).

It is evident that ocular and other symptoms may be produced not only by lesions of the ascending fibres of the cervical sympathetic, but also by lesions within the cord, affecting the fibres in



paralysis of c. syph. } = contracted pupil  
drooping of upper lid  
eye sinks into orbit

their downward course from the medulla (this being remarkably frequent in syringobulbia and in unilateral lesions of the medulla), or by lesions of the first two thoracic nerves or of their anterior roots, or even by lesions of the ophthalmic division of the fifth cranial nerve, though this last is rare.

The signs of **paralysis of the cervical sympathetic** are very characteristic. Fig. 183 shows a woman who was sent to hospital with the history that six years previously she had some tuberculous glands removed from the right side of her neck. When she recovered from the anæsthetic, she learned that the jugular vein had been injured during the operation. But other structures had also been injured, and amongst them was the cervical sympathetic (which lies behind the carotid sheath), because afterwards she noticed that the right eyelid drooped a little, that the right side of the face flushed less than the left, and that when she chewed, a small patch of excessive perspiration appeared below the right eye. We observe from the photograph that the right pupil is smaller than the left, from paralysis of the dilator pupillæ. Moreover, the affected pupil does not dilate when shaded, yet it contracts briskly to light and on convergence, since the third cranial nerve, which through the ciliary ganglion innervates the sphincter pupillæ, is unaffected. Further, we notice that the upper lid droops, making the palpebral fissure narrower than on the healthy side. This is due to paralysis of the non-striated part (tarsalis superior) of the levator palpebræ, which is inserted into the upper edge of the tarsal cartilage. The voluntary, striated fibres of the levator, inserted into the skin of the upper lid and supplied by the oculo-motor nerve, are unaffected, and the patient is therefore able to elevate the lid voluntarily to its full extent. This, therefore, is not a true ptosis, but a "pseudo-ptosis."

We also notice that the right eye has sunk into the orbit, owing to paralysis of the non-striated orbitalis muscle of Müller, which normally keeps the globe pressed forwards. This "enophthalmos" narrows the palpebral fissure still more. The difference in antero-posterior projection between the two eyes is seen best if we make



the patient lie down, we then stand behind and look down at the forehead and eyeballs from above.

On palpating the two globes, we find that the intra-ocular tension is diminished on the affected side.

Such are the "oculo-pupillary" symptoms of cervical sympathetic paralysis. There are, however, one or two additional points. When the cervical sympathetic is paralysed, it no longer responds to stimulation. There are two clinical ways of stimulating it. One

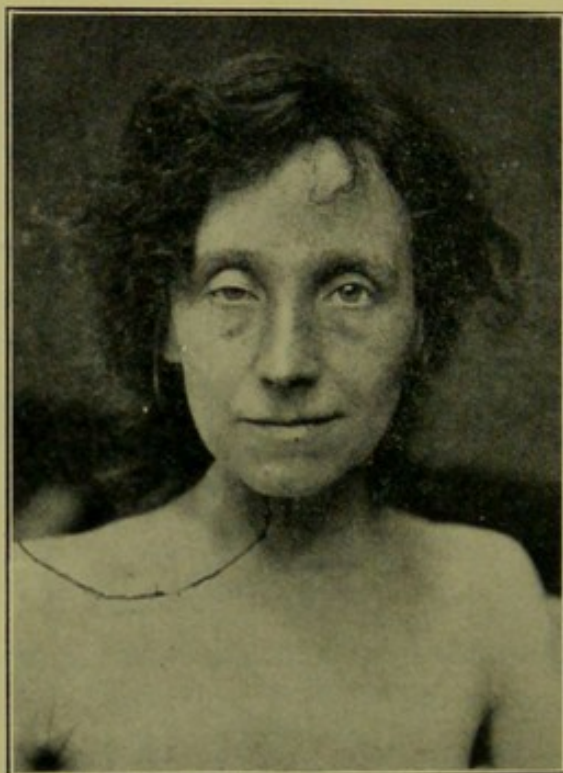

FIG. 183.—Paralysis of cervical sympathetic on the right side. The black line encloses an area of anæsthesia, due to division of cutaneous nerves.

is by pinching or pricking the side of the neck, when we produce a dilatation of the pupil on the same side; this "*cilio-spinal reflex*" is abolished in cervical sympathetic palsy. Another method of stimulating the cervical sympathetic is to drop into the conjunctiva a few minims of a solution of cocaine. The result is that the pupil dilates, the upper lid retracts, and the eyeball is pushed slightly forwards. All these phenomena were absent in the patient just referred to. She also told us that when her face flushes, it does so only on the healthy side. Moreover, her face on the



affected side no longer sweats except in one little patch below the orbit, where it sometimes sweats spontaneously when she chews. To verify this point we made her sweat profusely by means of pilocarpin, and found that the right side of the face remained dry, except in a small area below the inner canthus of the eye. This survival of a little oasis of sweating on the dry side might perhaps mean that a small twig of the sympathetic had escaped injury,

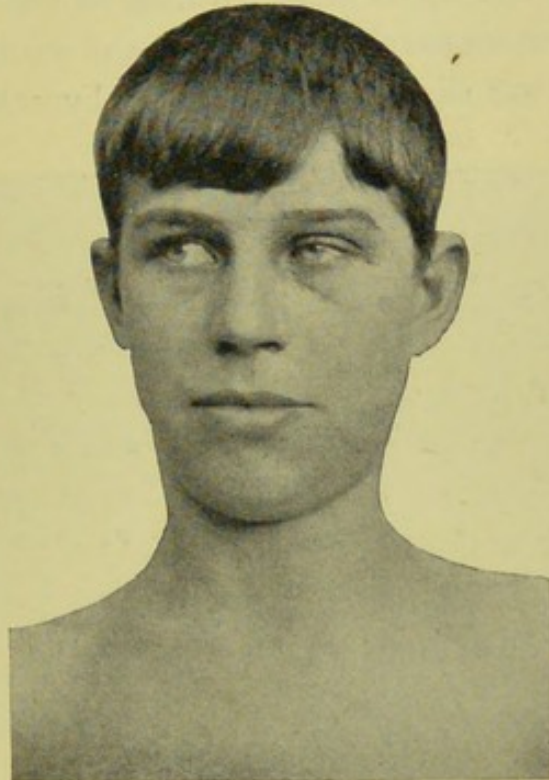


FIG. 184.—Paralysis of the left cervical sympathetic from a tumour at the root of the neck.

or more probably that sweat fibres to that part of the face are supplied through a branch of the trigeminal nerve.

So much for lesions of the sympathetic chain itself. But the oculo-pupillary and other fibres may also be damaged at some point between the spinal cord and the inferior cervical ganglion. Fig. 184 represents a boy of seventeen who had felt a tingling sensation down his left arm for several months. A few weeks before he came under observation, he noticed that a swelling had appeared in the lower part of the neck on the same side. At a glance we see that the cervical sympathetic is affected. There are pseudo-ptosis, myosis, and enophthalmos. The left cheek



is a little fuller than the right. The cilio-spinal reflex was absent on the left side. On examining the root of the neck, we found that the left clavicle was bulged forwards at its inner end, the supra-clavicular fossa being filled up. Further, there was percussion-dulness all over the apex of the left lung, with diminution of breath sounds and of vocal resonance. There was also a strip of diminished sensation to touch and pain along the inner side of the left upper limb, reaching to the wrist and corresponding to the cutaneous areas of the first and second thoracic roots. Moreover, there was slight wasting of the hypothenar muscles of

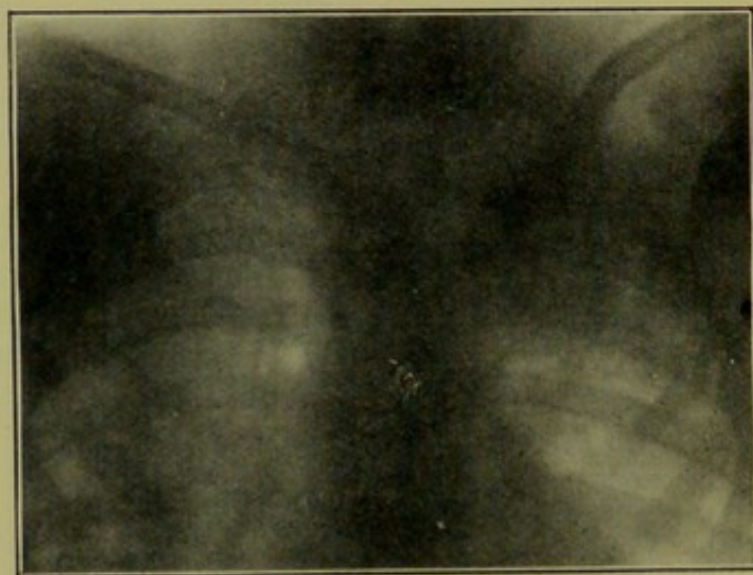


FIG. 185.—Radiogram, showing tumour at apex of left lung, in patient represented in Fig. 184.

the left hand, supplied by the first thoracic root. The skin of the left hand was dry, whilst that of the right was moist, and the patient himself noticed that in hot weather only the right side of his face sweated. On comparing corresponding arteries of both sides we found that the pulse in the left upper limb was smaller than in the right. All this pointed to the presence of a solid mass behind the left clavicle, compressing the subclavian artery, affecting the first and second thoracic nerves, including not only their sensory and motor fibres but also the cervical sympathetic fibres. This diagnosis was confirmed by radiography, which showed very clearly (Fig. 185) a tumour at the apex of the left lung. This tumour grew rapidly,



compressed the subclavian vein, producing œdema of the left upper limb, and within six months the patient died.

Fig. 186 is that of a seaman on an Atlantic liner who was thrown by a heavy sea against an iron rail, rupturing the whole of the brachial plexus on the right side. He was unconscious for a number of days, and during this period he was trephined over the left Rolandic area on the supposition that the paralysis

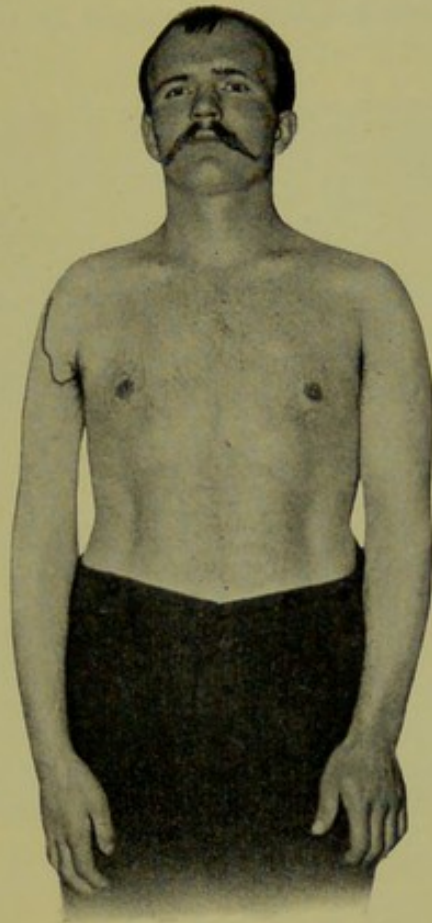


FIG. 186.—Rupture of brachial plexus on right side. Total anæsthesia of right upper limb below black line.

of the arm was of cerebral origin. In addition to complete motor and sensory paralysis of the upper limb, obviously of lower motor neurone type, resulting from the brachial plexus palsy, he showed very beautifully the oculo-pupillary signs of cervical sympathetic paralysis on the right side—enophthalmos, myosis and pseudoptosis (see Fig. 187). In this patient, however, the pupil still dilated to cocaine, probably because some pupil-dilating fibres,



entering the cervical sympathetic from the second thoracic root, had escaped injury.

Figs. 188 and 189 are those of a soldier who came under my observation during the South African war in 1901. He had been wounded in the neck by a Mauser bullet. At the time of his injury he was lying on his face, firing at the enemy. The bullet entered his neck an inch and a half below the left mastoid process, crossed the middle line in front of the vertebral column, and came out through the seventh right interspace in the posterior axillary



FIG. 187.—Paralysis of right cervical sympathetic from rupture of brachial plexus.

line, lodging in his bandolier. He immediately felt a sensation "like an electric shock" all over his body, but especially in the right upper extremity, which became at once totally paralysed. He had hæmoptysis owing to the perforation of the lung, and for a few days some difficulty of swallowing, probably due to injury of the œsophagus. In about three weeks the hæmoptysis gradually ceased, and the right upper limb recovered power, so that when I first saw him, two and a half months after the injury, he was able to move it freely at all joints. Ever after the accident he



noticed that he did not sweat on the right side of the face and neck, nor in the right upper limb.

The photographs show that the patient has an area of slight analgesia (bounded by the thick black line) along the inner border of the right upper limb, corresponding to the areas supplied by the eighth cervical, first thoracic, and second thoracic nerve-roots. He also has slight weakness of the small muscles of the thumb,

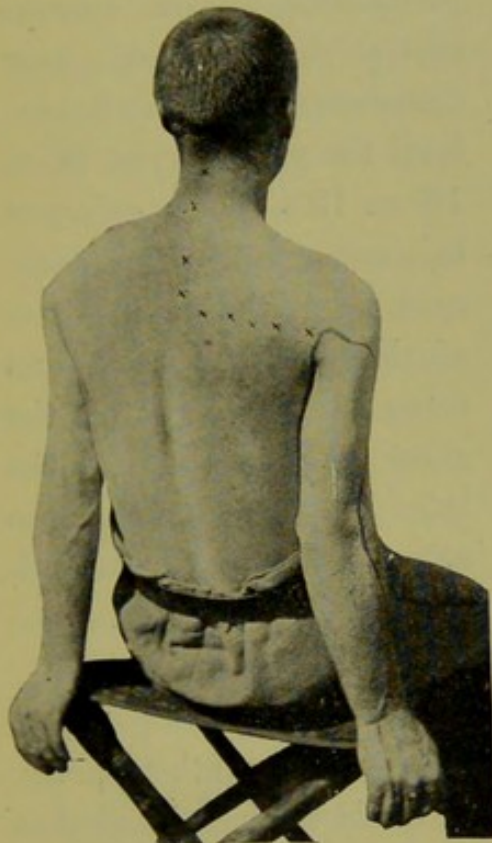


FIG. 188.

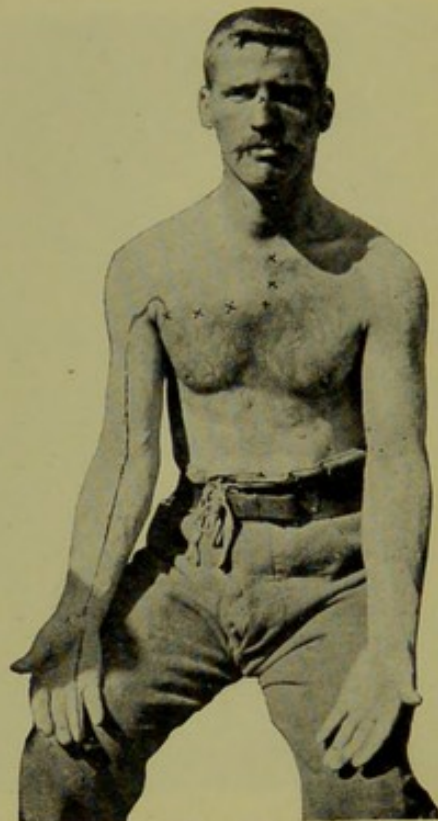


FIG. 189.

Figs. 188 and 189.—Paralysis of the right cervical sympathetic, from a bullet wound of the lower roots of the brachial plexus. The area of the right upper limb within the black line is anæsthetic. The crosses on the trunk indicate the boundary of an area of anidrosis.

innervated by the first thoracic root. We also observe that the right cervical sympathetic is paralysed, so that he has contraction of the pupil, enophthalmos, and pseudo-ptosis on that side.

But there is a point of special interest in this patient's photographs. They demonstrate a point which, so far as I know, had not previously been mapped out in the human subject, viz., the extent of skin supplied with sweat-fibres by the cervical sympathetic. In the tropical heat to which we were exposed, this



patient sweated profusely, except in an area on the right side of the head, neck, upper limb, and upper part of the trunk. That area remained dry, and the boundary between sweating and non-sweating skin was sharp and distinct. In order to photograph it, the happy thought occurred to blow powdered charcoal on the skin. This stuck on the sweating side, and blew off on the dry side. We were then able to photograph the non-sweating area, to




FIG. 190.—Paralysis of the right cervical sympathetic, showing oculo-pupillary phenomena and area of anidrosis.

which the cervical sympathetic should have been distributed. As may be seen from the photographs (Figs. 188 to 190), the boundary of this area, marked by crosses, runs down the middle line of the head and neck, and turns horizontally across the chest at the level of the third rib in front and the spine of the scapula behind, including the whole of the upper limb.

Before leaving the subject of cervical sympathetic palsy, it should be mentioned that excision of the cervical sympathetic has been employed therapeutically in certain

diseases. Thus in cases of glaucoma, ophthalmic surgeons have recommended this operation to diminish the intra-ocular tension, and a certain amount of benefit has resulted. Bilateral excision of the cervical sympathetic has also been tried for the relief of epilepsy, in the hope of paralyzing the cerebral vasomotor nerves and thereby rendering the brain hyperæmic, especially in cases where fits were ushered in by blanching of the face. But the results recorded have not been sufficiently good to warrant us in recommending this procedure.



Let us now consider briefly the reverse condition, viz., irritation or stimulation of the cervical sympathetic. The signs are exactly the opposite of those produced by paralysis. We therefore have dilatation of the pupil, exophthalmos or forward projection of the eyeball, widening of the palpebral aperture (Stellwag's sign), and delayed descent of the upper lid when the patient looks downwards (von Graefe's sign). All these phenomena can be produced, to a certain degree, by dropping into a healthy eye a solution of cocaine, which stimulates the cervical sympathetic.

Fig. 191 is that of a man who had lymphadenomatous enlargement of the lymphatic glands. During his stay in hospital, we noticed that quite rapidly, within a day or two, he developed on the right side exophthalmos, widening of the palpebral fissure, and some dilatation of the pupil. There was also in hospital at the same time a soldier who had similar signs in one eye due to an aneurism at the root of the neck, pressing on and irritating the cervical sympathetic. If such pressure continues, the signs of stimulation may pass off and be replaced by those of paralysis. Our lymphadenomatous patient, however, died nine weeks after the appearance of stimulation phenomena, without any change in the direction of paralysis.

Certain cases of apical phthisis and apical pneumonia are accompanied by inequality of the pupils, probably due to irritation of the cervical sympathetic by changes in the pleura. There is a good deal in favour of the view that




FIG. 191.—Stimulation of the right cervical sympathetic.



many of the signs of exophthalmic goitre are the result of stimulation of the sympathetic, whether by excessive or perverted thyroid secretion. Figs. 192 and 193 are from a case of exophthalmic goitre where the symptoms were preponderatingly right-sided. The tachycardia of this disease is probably due to stimulation of cardio-accelerator fibres, which we know are

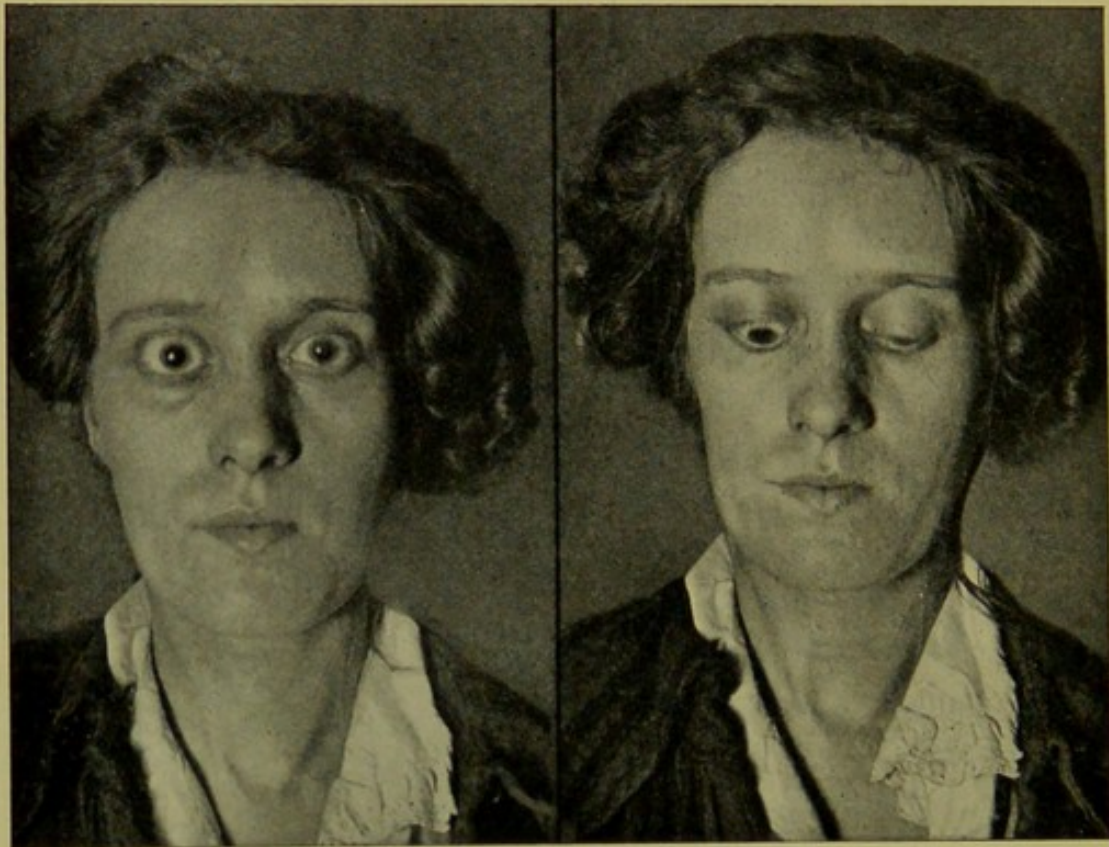

FIG. 192.

FIG. 193.

Exophthalmic goitre, the ocular symptoms being more marked on the right side. Fig. 193 shows von Graefe's sign in the right eye on looking downwards.

derived from the sympathetic. The thyroid enlargement may perhaps be explained as a result of vasomotor paralysis of the cervical vessels, including those of the thyroid gland itself. The leucopenia of polymorph cells in the blood, together with the excess of lymphocytes, is probably a secondary result of the disordered thyroid secretion.

But though affections of the cervical sympathetic are the most readily recognised, we must not forget that the thoracic and abdominal portions of the sympathetic may also be diseased,



although the symptoms thereby produced, being mainly visceral, are less easy of diagnosis. Thus some cases of angina pectoris may be the result of irritation of the cardiac plexus, while the peculiar reflex vaso-constriction of the pulmonary vessels, with its transient dilatation and irregularity of the right heart, met with in certain gastric and hepatic disorders, has been regarded as an affection of the thoracic part of the sympathetic. Affections of the abdominal sympathetic or of its great pre-vertebral ganglia produce still more striking clinical phenomena. Thus the rare condition known as acute dilatation of the stomach, and many of the symptoms of acute peritonitis, such as the intestinal paralysis, meteorism, small pulse, and general collapse, may be the result of acute paralysis of the solar plexus—the “abdominal brain”; while irritation of the solar plexus is exemplified in cases of lead colic, with its pain, constipation, and increased arterial tension. The various visceral “crises” of tabes—gastric, intestinal, renal, &c.—may also be due to irritative changes in the various parts of the abdominal sympathetic. To the same cause also may be attributed the intestinal symptoms of exophthalmic goitre, consisting not in ordinary diarrhoea with loose motions, but rather in an abnormal frequency of defæcation. Muco-membranous colitis, with its characteristic paroxysms, has been ascribed by Mathieu and others to some disorder of the solar plexus, though pathological evidence on the point is scanty. To solar or splanchnic disease may also, perhaps, be attributed such affections as orthostatic albuminuria, diabetes insipidus, and certain forms of glycosuria.

In addition to visceral disorders, disease of the abdominal sympathetic is also associated with certain pigmentary changes in the skin. Of these, the most striking examples are furnished by the cutaneous pigmentation which is occasionally present in exophthalmic goitre and, still more, by Addison's disease, with its characteristic bronzing of the skin, its asthenia and its paroxysmal diarrhoea. Addison's disease is probably the result of two factors—irritation of the abdominal sympathetic and inadequacy of suprarenal function, the proportional rôle played by each of these varying in different cases.

**Angio-Neuroses.**—These comprise a group of diseases which



appear to depend on disorders of the sympathetic fibres which regulate the blood-vessels. A considerable amount of evidence<sup>1</sup> points to the conclusion that the paroxysmal unconsciousness of epilepsy is associated with sudden cerebral anæmia and that the tonic stage of a major epileptic fit is accompanied by cortical anæmia, whilst the clonic stage is associated with return of arterial circulation. It is uncertain what proportion of these phenomena is due to sudden stoppage of the heart (we may sometimes feel the patient's pulse stop at the onset of a fit) and how much to vasomotor spasm of cortical vessels.

The paroxysmal dyspnoea of *asthma*, with its slow and laboured breathing, is doubtless to be referred to a neurosis of the thoracic sympathetic, whether, as some hold, the phenomena be the immediate result of a sudden vascular engorgement of the bronchial mucous membrane, or whether produced, according to another view, by spasm of the non-striated bronchial muscles. In any case, the paroxysmal nature of the affection, its apparent toxic origin in some cases, its connection in other cases with nasal or other reflex sources of irritation, its frequent association with the gouty diathesis—all these facts indicate a functional and not an organic lesion of the sympathetic.

Most angio-neuroses, however, affect the blood-vessels of the more superficial parts of the body, such as those of the skin or of the muscles. Amongst the cutaneous angio-neuroses, perhaps the commonest is the syndrome known as *Raynaud's disease*. The mildest degree of this is *local pallor* ("local syncope" or "dead finger"), where the affected parts, usually the fingers, less frequently the toes, the edges of the ears, or the tip of the nose, suddenly become cold to the touch and of a waxy white colour. Together with this, the patient feels a tingling or other peculiar sensation (acro-paræsthesia). Actual blunting of sensation to touch may be present. One or both hands may be affected, sometimes identical fingers in both hands; the thumb is less often affected than the other digits. The attacks last from a few minutes to several hours and are commonest in winter.

<sup>1</sup> A. E. Russell, *Lancet*, 1909, April 3, 10, and 17.



They are often brought on by washing the hands in cold water, or by fine digital movements such as sewing or piano-playing. As the attack passes off, the patient feels a sensation of tingling or even of pain. A more severe variety is that of *local asphyxia* or cyanosis, in which the affected digits suddenly become discoloured, varying in tint from a dusky blue or slate-colour to an intense purplish-black. Pressure on the discoloured area causes a white mark which persists for several seconds, before the lividity slowly reappears. The pain is usually more intense than in local syncope. As the attack passes off, the affected part often sweats freely. But the most severe variety of Raynaud's disease is *symmetrical gangrene*, which is usually preceded by local asphyxia and sometimes by local syncope. As a rule, the gangrenous process is confined to a small part of the cyanosed area. In its mildest form the necrosis is limited to the epithelium, so that only desquamation results; more often a small blister forms, with blood-stained contents. This bursts, leaving an ulcer which subsequently cicatrises. The nails may be lost and subsequently reproduced. Or the necrosis may extend deep into the tissues, forming a dark slough. Whole phalanges may undergo dry mummification and be cast off, leaving a conical stump. The bones as a rule escape necrosis. Pain is usually severe during the initial cyanosis. The symptoms of Raynaud's disease are due to local spasm of the vessels, the sudden onset and disappearance of the symptoms being incompatible with any other hypothesis. The coexistent sensory symptoms are probably due to imperfect blood-supply. A paroxysm of local syncope or cyanosis can usually be relieved, as Cushing has pointed out, by applying a tight flat rubber tourniquet around the limb above, so as to occlude all the vessels, both arteries and veins, and leaving it on for several minutes. Then, when the tourniquet is taken off, there is a temporary vasomotor paralysis, the whole limb flushes to the finger-tips, and a wave of redness wipes out the local pallor or cyanosis. Raynaud's disease is sometimes associated with paroxysmal hæmoglobinuria, probably due to vasomotor spasm of the renal vessels. In rare cases paroxysmal impairment of vision has been noted, and during



such attacks the retinal arteries on ophthalmoscopic examination have been seen to be spasmodically contracted.

In striking contrast with Raynaud's disease is the condition known as *erythromelalgia* (see Plate II.), which usually attacks one or other foot. There is pain of a burning or stabbing character, often of excruciating severity, occurring in paroxysms lasting from a few minutes to several hours. This pain is always aggravated by a dependent posture of the limb, by voluntary movement, or by warmth, whereas it is diminished by a horizontal or elevated posture, by rest, and by cold applications. The earliest attacks consist simply of pain. As the disease progresses, however, redness and swelling of the foot are superadded; more rarely, redness precedes pain. The redness is of a bright tint, often confined, for instance, to the ball of the big toe or to small areas of the sole or edge of the foot. Sometimes it is diffused over the foot. The redness increases in intensity, and if the limb be allowed to hang down, the "vascular storm" continues, with bounding arteries, local rise of temperature, and intense cutaneous hyperæsthesia. As the attack subsides the redness is replaced by cyanosis. In one case which I observed, desquamation of the affected area occurred after each paroxysm.

But there are other cases in which the vasomotor symptoms are intermediate in type between the two extremes of Raynaud's disease and erythromelalgia. These two diseases may coexist, or may succeed each other in the same patient. Erythromelalgia is sometimes one of the earliest signs of organic cord disease, such as disseminated sclerosis, and this points to its origin from an affection of the spinal vasomotor centres, perhaps in the "inter-medio-lateral" group of nerve-cells between the anterior and posterior horns, to which Bruce<sup>1</sup> directed special attention. A few rare cases have also been observed of *family gangrene*, somewhat resembling Raynaud's disease. Fig. 194 represents three brothers, aged five, four and three years respectively, in all of whom, one winter, areas of local necrosis appeared in the feet. The eldest child had necrosis of the skin of both heels, followed by similar

<sup>1</sup> *Trans. Roy. Soc. of Edin.*, 1906, vol. xlv. part i. p. 105.







PLATE II.

Case of **Erythromelalgia** in a man aged 52. The condition affected both lower limbs.

The upper drawing shows the appearance of one foot during a paroxysm when the lower limb is supported in a horizontal position. The sole of the foot is of a bright pink colour, this colour also extending on to the dorsum of the terminal phalanx of each toe.

The lower drawing shows the effect of allowing one foot to hang dependent for a few minutes. There is extreme cyanosis extending as high as the ankle. There was also severe pain, partially relieved by reassuming the horizontal posture of the limb.

*To face page 350.*





which attacks the retinal arteries on ophthalmoscopic examination have been seen to be spasmodically contracted.

In striking contrast with Raynaud's disease is the condition known as *erythromelalgia* (see Plate II.), which usually attacks one or other foot. There is pain of a burning or stabbing character, often of excruciating severity, occurring in paroxysms lasting from a few minutes to several hours. This pain is always aggravated by a dependent posture of the limb, by voluntary movement, or by warmth, whereas it is diminished by a horizontal or elevated posture, by rest, and by cold applications. The earliest attacks consist simply of pain. As the disease progresses, however, redness and swelling of the foot are superadded; more rarely, redness precedes pain. The redness is of a bright tint, often confined,

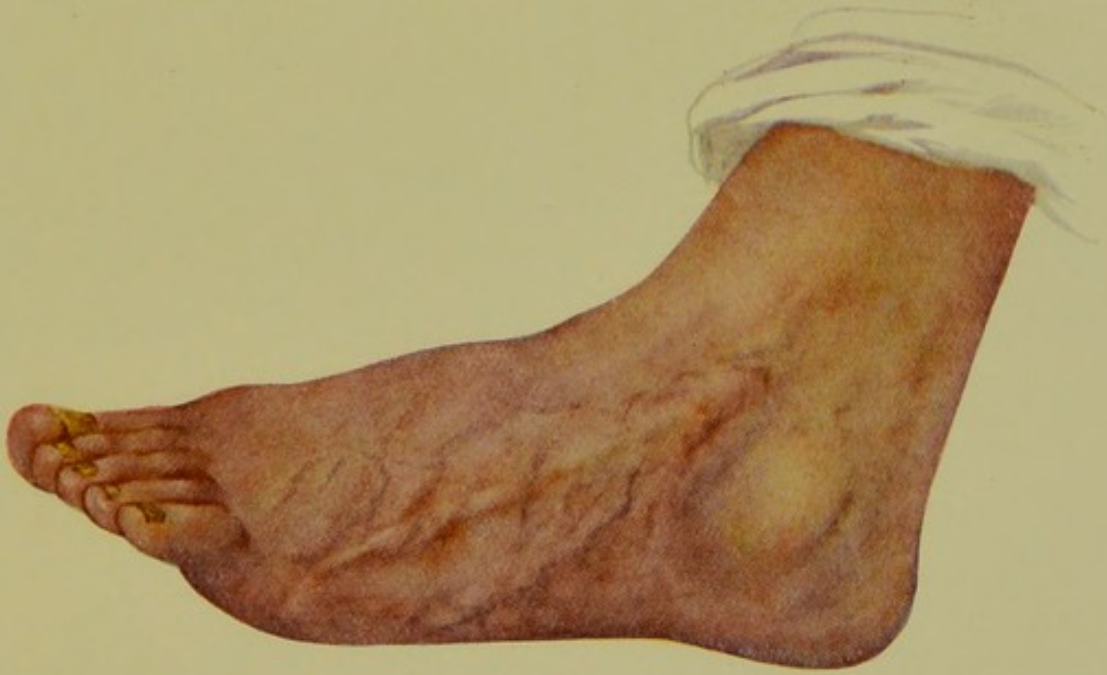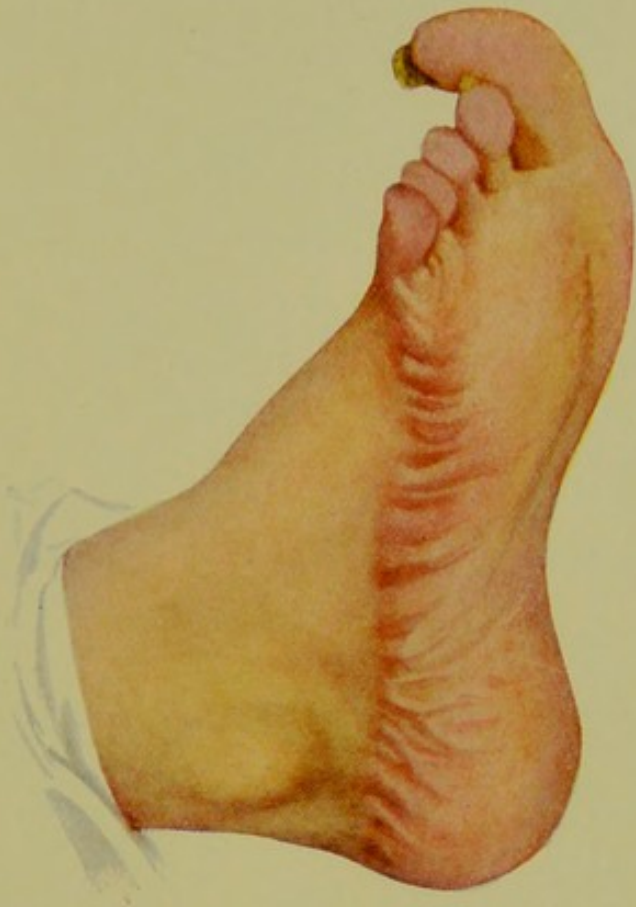PLATE II.

Case of *Erythromelalgia* in a man aged 52. The condition affected both lower limbs. The upper drawing shows the appearance of one foot during a paroxysm when the lower limb is supported in a horizontal position. The sole of the foot is of a bright pink colour, this colour also extending on to the dorsum of the terminal phalanx of each toe. The lower drawing shows the effect of allowing one foot to hang vertically for a few minutes. There is extensive cyanosis extending as high as the knee. There was also severe pain, partially relieved by resuming the horizontal posture of the limb. Inverted I which ceases after each paroxysm.


But there are other cases in which the vasomotor changes are intermediate in type between the two extremes of Raynaud's disease and erythromelalgia. These two diseases may coexist, or may succeed each other in the same patient. Erythromelalgia is sometimes one of the earliest signs of organic cord disease, such as disseminated sclerosis, and this points to its origin from an affection of the spinal vasomotor centres, perhaps in the "inter-medio-lateral" group of nerve-cells between the anterior and posterior horns, to which Bruce<sup>1</sup> directed special attention. A few rare cases have also been observed of *family gangrene*, somewhat resembling Raynaud's disease. Fig. 194 represents three brothers, aged five, four and three years respectively, in all of whom, one winter, areas of local necrosis appeared in the feet. The oldest child had necrosis of the tips of both heels, followed by similar

<sup>1</sup> Trans. Roy. Soc. Edinb., 1884, vol. xlv, part 1, p. 105.











areas on the dorsum of the right foot and on the fourth left toe. The second child had cyanosis and some necrosis of the dorsal surfaces of both feet, whilst the youngest had severe necrosis of the hallux, fourth and fifth toes on the right side, and a smaller area of necrosis on the plantar surface of the left hallux. It is possible that the paroxysms of *family periodic paralysis*

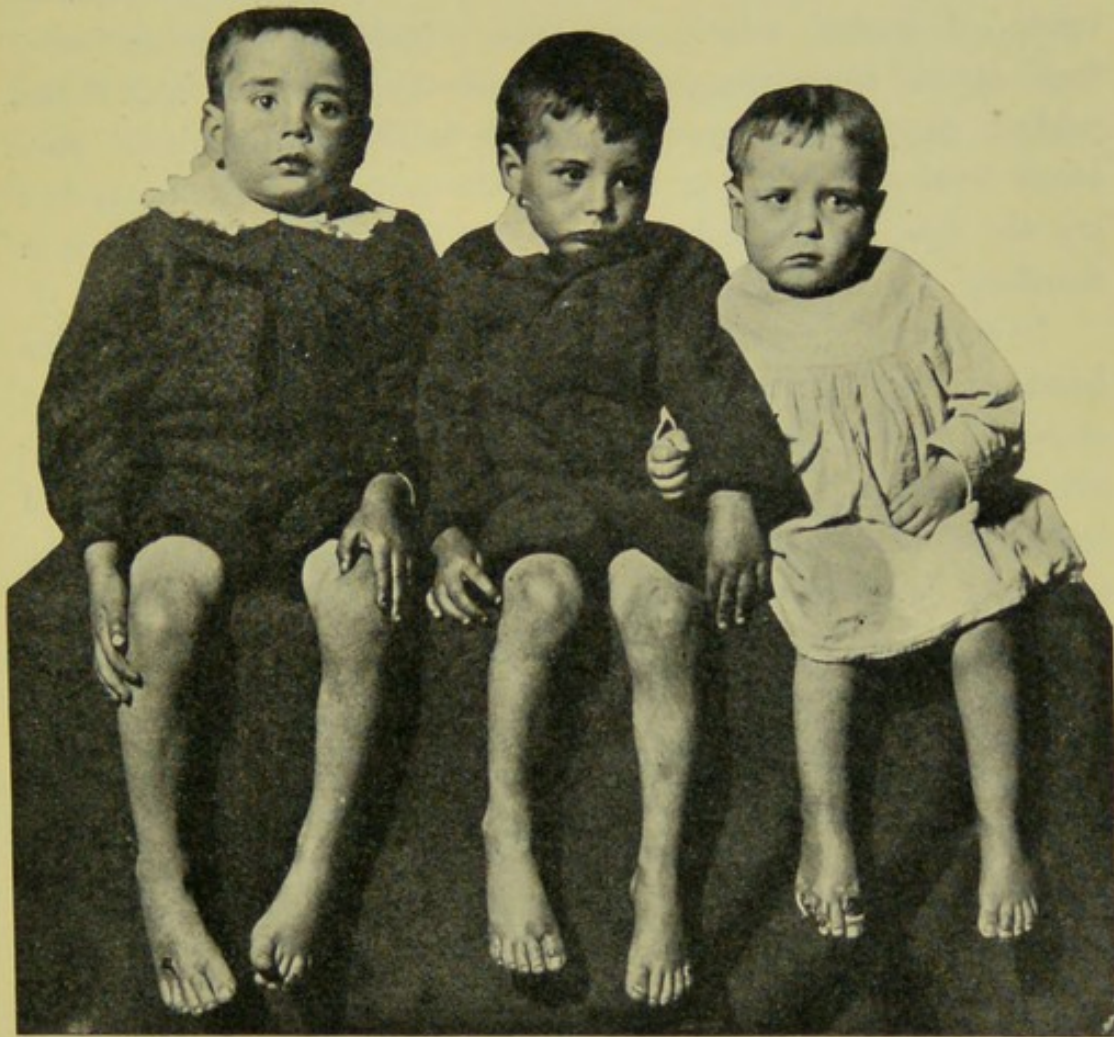

FIG. 194.—Family gangrene in three brothers, affecting the feet.

(see p. 253) may be the result of a recurring vaso-motor spasm of the anterior spinal artery, which, as we have seen, supplies the anterior cornua of the spinal cord.

Another paroxysmal disease of angio-neurotic origin is intermittent limp, whose symptoms we have already described (p. 251), where the arteries not of the skin but of the deep structures are in a state of temporary spasm.



*Acute angio-neurotic œdema*, or Quincke's disease, is undoubtedly a vaso-neurosis. It is characterised by paroxysmal attacks of sharply-localised, hard œdema in the cellular tissue of various parts of the face, trunk, or limbs. After lasting a few hours or days, the swelling, which is remarkably firm and does not pit on pressure, passes off spontaneously. It may also attack mucous membranes, for example, those of the respiratory or gastro-intestinal tract. A gastric attack may cause urgent vomiting, an intestinal attack meteorism, colic, and bloody diarrhœa, and if the patient happens to have an attack in the larynx, death may result from asphyxia. In the skin, the parts most often attacked are the lips, cheeks and eyelids. The disease sometimes runs in families.

In chronic hemiplegia it is not uncommon to find œdema of the hand or foot on the paralysed side. Permanent coldness and cyanosis are very common in the paralysed limbs in cases of old anterior poliomyelitis. Even in warm weather the flaccid limb remains cold and sometimes blue in the hand or foot, as the case may be. Such cyanosis differs from that of Raynaud's group in being permanent and not paroxysmal.

Certain varieties of *urticaria* may be referable to affection of the nervous system, as in certain cases where the characteristic itching wheals appear on sudden emotional excitement. These patients appear to have a specially low coagulability of the blood due to deficiency of calcium salts in the liquor sanguinis. But urticaria is much more often toxic in origin. *Dermographism*, on the other hand ("factitious urticaria" or "urticaria scripta"), is a reflex cutaneous phenomenon. It is elicited by stroking the skin firmly with a smooth, hard object, such as the head of a pin or the finger-nail. If, for example, we draw a diagram or write on the patient's skin in this way, a red area appears within a few seconds. The skin then becomes elevated into a hard, white ridge, which can not only be felt but seen, as if the pattern or writing had been embossed on the skin (see Fig. 211, p. 387). This lasts for many minutes and passes off gradually. Unlike true urticaria, dermographism is unaccompanied by itching.



The phenomenon is commonest in neuropathic people, but is not confined to them; it is particularly common in exophthalmic goitre,<sup>1</sup> and may sometimes be found in apparently healthy individuals.

Lastly, we have to refer to certain abnormalities of sweating which are due to nervous disorders. We have already alluded to localised anidrosis or absence of sweat in certain cases of cervical sympathetic palsy. But sometimes we meet with *paroxysmal localised hyperidrosis* or excessive sweating. Figs. 195 and 196 show the areas of excessive sweating in two patients. In one the

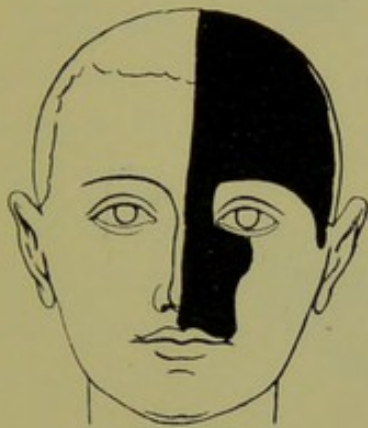

FIG. 195.—Area of localised sweating during mastication of pungent substances. From a man aged 29. The condition was congenital.

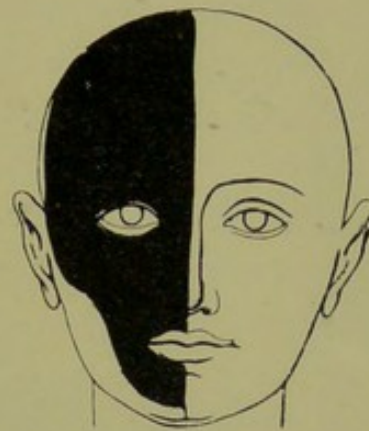

FIG. 196.—Area of localised sweating during mastication of pungent substances. From a man aged 35, in whom the condition appeared at the age of 28.

condition was congenital, and consisted in excessive sweating on the left side of the scalp and face, corresponding to the whole of the first division and part of the second division of the trigeminal. In the other, the whole area of the trigeminal on the right side was affected and the condition appeared at the age of twenty-eight. In both these patients, who were otherwise healthy, the paroxysms of sweating occurred only on chewing highly-flavoured articles, such as onions or pickles. This condition suggests some hyperexcitability of the reflex sweating centre for the face, possibly within the pons. Fig. 197 is a photograph of an area of hyperidrosis on the left hand and wrist of a young woman of nineteen.

<sup>1</sup> Dreschfeld, *Brit. Med. Journal*, November 18, 1905.



In her, the paroxysms occurred three or four times a day, spontaneously, chiefly about the time of the menstrual period or when she was excited. In this case the distribution suggested a segmental or root area, apparently about the eighth cervical and first thoracic segments, and counter-irritation over the lower part

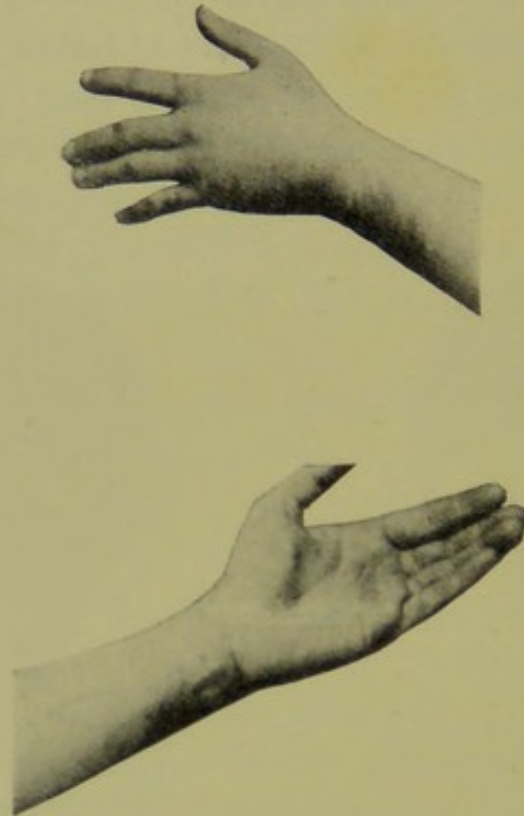

FIG. 197.—Localised hyperidrosis along ulnar border of forearm and hand.  
The dark area is due to powdered charcoal adherent to sweating skin.

of the neck, front and back, near the exit of these roots, produced rapid amelioration of the condition.

In certain chronic cases of hemiplegia, we not infrequently observe excessive sweating of the hand and foot on the paralysed side. This is doubtless due to changes in the sweating centres in the central nervous system.



## CHAPTER XXI

### THE NEUROSES

THE boundary between organic diseases and the so-called functional diseases or neuroses is entirely imaginary. The old definition of a neurosis as a nervous disease devoid of anatomical changes is inadequate. Disease is inconceivable without some underlying physical basis. The lesion need not be visible microscopically; it may be molecular or bio-chemical. In certain diseases, such as epilepsy and paralysis agitans, the essential underlying lesion is still undiscovered, yet we no longer class them as neuroses in the strict sense of the word. Therefore when we as physicians talk of neuroses, although we may have a fair general idea of what we mean, we find it difficult to express our definition in words.

In "functional" nervous diseases the underlying physical changes are slight in degree and they are often capable of cure. In this respect they differ not only from ordinary organic diseases due to gross anatomical lesions, which almost always leave behind them some permanent damage, but also from such steadily progressive and incurable affections as paralysis agitans. Nevertheless we must recognise that the neuroses are real diseases, as real as smallpox or cancer. A sharp distinction must be drawn between a hysterical or a neurasthenic patient and a person who is deliberately shamming or malingering. The imitation of other diseases—*neuromimesis*—which is often seen in hysteria is not a voluntary affair. The hysterical or neurasthenic patient usually has no knowledge of the disease which he or she may unconsciously simulate. The various paralyses and pains from which hysterics and neurasthenics suffer are as real to the patients as if they were due to gross organic disease.

The three chief neuroses proper are neurasthenia, psychasthenia,



and hysteria. Neurasthenia is an "exogenous" neurosis; psychasthenia is essentially "endogenous"; so also is hysteria, although outside factors may act as exciting or precipitating causes. Each of these neuroses has fairly distinctive characteristics of its own, but in practice they are often combined with each other and may also coexist with organic diseases. Thus a hysterical patient may suffer from neurasthenia, or a psychasthenic patient from hysteria; nor is there anything to prevent a neurasthenic patient from having, say, an attack of cerebral hæmorrhage. Moreover, any gross organic disease may induce hysterical or neurasthenic phenomena in addition to the signs of organic lesion. In fact certain cases of grave organic disease (especially disseminated sclerosis and some cerebral tumours) may at first produce symptoms which are indistinguishable from those of functional disease—which, in fact, are functional. In such cases the neurologist must be on his guard to detect the underlying organic affection, and to distinguish its symptoms from those of the superadded hysteria or neurasthenia. Functional symptoms, then, may coexist with gross organic disease.

Let us briefly recall some of the characteristic symptoms of the chief neuroses—neurasthenia, psychasthenia, and hysteria—and note in what respects they differ, if at all, from analogous symptoms produced by gross organic diseases.

**Neurasthenia** is not a primary disease. It is exogenous, the result of something else. The commonest cause is over-strain, mental or physical. It may also be produced by excess in drugs such as alcohol, tobacco, or cocaine; or, again, by the toxins of various infective diseases such as influenza, enteric fever, &c. Or neurasthenia may result from organic diseases, whether these be of the nervous system (*e.g.* tabes, disseminated sclerosis) or of other systems (as in gout, rheumatism, cancer, and so on). Lastly, a particularly frequent cause is traumatism, especially in railway accidents which produce a common type of neurasthenia including the so-called "railway spine." Patients with a low power of resistance are, of course, specially liable to become neurasthenic from any accidental cause, but we must remember that even



healthy individuals, without neuropathic taint, may be rendered neurasthenic as a result of over-strain or trauma.

The symptoms of neurasthenia are chiefly subjective. The patient complains of undue fatigue and feebleness of attention, so that sustained mental effort becomes impossible—so-called “brain fag.” There is “irritable feebleness,” with general depression of the whole nervous system. The patient’s memory, however, is unimpaired, and he relates his woes with great wealth of detail. He is full of aches and pains, but on physical examination there is little or nothing to be made out in the way of anæsthesia or motor paralysis. Amongst the motor symptoms, the chief is *asthenia* or excessive tendency to fatigue. When this affects the internal ocular muscles it constitutes asthenopia or tiredness of the eyes on attempting to accommodate as in reading. Or the neurasthenic patient may feel his limbs tremulous whenever he attempts any exertion. But there is never a true motor paralysis. Individual movements, although they may be feeble and tremulous, are never impossible. The sensory symptoms of neurasthenia include subjective sensations *ad infinitum*, all of them disagreeable. Pains and dysæsthesiæ of various sorts are specially common in the head and along the vertebral column. Vaso-motor symptoms are common, including a curious violent pulsation of the abdominal aorta which may feel almost subcutaneous. The patient often complains of sudden flushes of heat or cold traversing the trunk, limbs, or face, also of paroxysmal sweating, and so on. Sometimes we can see transient blotches of redness at the sides of the neck, spreading upwards over the angles of the mandibles on to the cheeks. Gastro-intestinal atony is common, with anorexia, dyspepsia, and constipation. An element of auto-intoxication may thus be superadded which aggravates the general malnutrition. The superficial reflexes may be exaggerated, especially the abdominal reflexes. Sometimes if we stroke the abdomen in a circular direction the umbilicus moves so smartly that it seems to be chasing our finger round. The knee-jerks in neurasthenia are sometimes abnormally brisk and accompanied by a sudden feeling of shock in the spine, making the patient start. True ankle-clonus, however,



does not occur, and the plantar reflexes, if present, are of the normal flexor type. The sphincters are unaffected. Most neurasthenics are poorly nourished, but not all of them. For purposes of treatment neurasthenic patients can be divided into two classes, viz., those in whom the arterial tension is above normal, and those in whom it is abnormally low. The cases where there is increased arterial tension, according to Fleury, are generally toxic in origin and require special attention to the organs of excretion. In cases with sub-normal arterial tension, on the other hand, we devote ourselves to augmenting the patient's nervous energy by anabolic treatment in the form of diet, massage, electrical and hydro-therapeutic measures.

**Psychasthenia** is a much more serious affection, in which the mental phenomena overshadow the physical. Unlike neurasthenia, which is usually a disease of adult life resulting from some extraneous cause, psychasthenia is an endogenous disease, the culmination of an ingrained neuropathic heredity, and its earliest indications appear in adolescence or even in childhood. In short, the psychasthenic, like the poet, is born, not made. Moreover, while neurasthenia is an eminently curable affection, the psychasthenic patient remains psychasthenic all his life, though his symptoms may be alleviated.

The outstanding symptoms of psychasthenia, as Janet has emphasised, are the psychasthenic "stigmata," the obsessions, and the imperious acts. The *stigmata* of psychasthenia may be psychical or physical. The psychical stigmata of psychasthenia are mental anergia and irresolution. The psychasthenic feels himself incapable of fixing his attention, whether for physical or mental effort; he has a feeling of general hesitation and doubt, and has to lean for moral support on others possessing a stronger character than his own. This anergia or defective will-power in psychasthenia differs from the anergia of true melancholia in that the psychasthenic is distressed by his anergia, and whilst desirous to act, finds himself unable to do so, despite extraordinary and even agonising efforts. The melancholic patient, on the other hand, is not merely anergic but also apathetic, and his failure to act causes



him little or no distress. Sometimes the psychasthenic has a feeling of double personality, in which he feels as if he had two co-existing egos. The double personality of psychasthenia differs from that of hysteria, in which the duality is an alternating one, as a rule unknown to the patient.

The physical stigmata of psychasthenia are evidenced in the patient's actions. Everything he does tends to be clumsy and *gauche*; his very gait may be ungainly; he is often a "tiqueur"; he is full of affectations and mannerisms. In addition he may have numerous neurasthenic symptoms, amongst which all sorts of cephalic sensations are specially common, *e.g.* sensations of fulness or emptiness in the head, of looseness or tightness, of creaking or sawing, and so on. Physical or mental over-exertion or excitement may even induce an epileptiform fit. Gastro-intestinal atony is common, with all its train of symptoms in the form of dyspepsia, constipation, &c.; the circulatory and vaso-motor systems may be affected, *e.g.* by paroxysms of palpitation, attacks of blushing or pallor, excessive sweating or abnormal dryness of the skin; the sexual functions are usually diminished, in male patients spermatorrhœa is particularly common, and, as in neurasthenia, the general nutrition is usually below par.

The second great characteristic of psychasthenia is the presence of *obsessions* or dominant ideas of various sorts. These are almost always of a depressing type and may be of the most varied forms. A psychasthenic obsession comes on spontaneously in paroxysms and cannot be inhibited by any effort of the patient. When the obsession arrives, it occupies the patient's entire attention, so that, for the time, he can think of nothing else. In the intervals between his paroxysms the psychasthenic is a fairly normal person, taking an interest in the ordinary incidents and pleasures of life. In this respect he differs essentially from the melancholic, whose depression is continuous, who lives in constant gloom and derives no pleasure from life. Although the obsession is often an idea which is repulsive to the patient, yet it is most insistent and tends to recur again and again. The patient recognises it as being a morbid idea, yet he cannot throw it off. The different



obsessions vary in their tendency to become translated into actions. Thus, though psychasthenics often have obsessions of suicide, they very rarely attempt suicide; on the other hand obsessions to steal (kleptomania), to drink (dipsomania), and to perform sexual acts are more difficult to resist. A certain proportion of professional "tramps" are simply psychasthenic individuals obsessed by the impulse to wander from place to place, unable to settle down, even when offered the work for which they profess themselves to be looking. We should note that though the psychasthenic patient may have obsessions, he has no delusions or hallucinations; reasoning powers are unimpaired. He must therefore be clearly distinguished from the insane patient.

The third characteristic feature of psychasthenia is the occurrence of *imperious acts* (i.e. an irresistible tendency to perform some special act), and of paroxysmal *imperious ideas*. Imperious acts include the innumerable varieties of *tics*. As to the paroxysmal imperious ideas, these include such varieties as the mania for perpetually asking questions (*folie de pourquoi*), the mania of fussy tidiness, the mania of counting things over and over (*arithmomania*), the mania of searching for objects, and so on. *Manias* of this sort, of course, interfere with normal mental processes, interrupting them to such an extent that the patient finishes by accomplishing practically nothing in the way of mental work. Imperious ideas may also be of an emotional nature; these include the innumerable forms of *phobia*, such as agoraphobia (fear of being in open spaces), claustrophobia (fear of being inside buildings, especially public buildings), aichmophoba (fear of sharp objects), rupophobia (fear of dirt), toxicophobia (fear of being poisoned), ereuthophobia (fear of blushing), fear of death, fear of illness, fear of performing organic functions such as micturition or defæcation (*coprophobia*), unreasonable fear of certain animals or insects, and so on, *ad infinitum*. In most of these psychasthenic phobias there is, coexistent with the repulsion for the particular act or object, a strong attraction to that same object or act. This mixture of apprehension and attraction, as Raymond<sup>1</sup> has pointed out, is

<sup>1</sup> *Bulléin Médicale*, 1907, No. 30.



one of the causes of the mental agitation which accompanies a psychasthenic phobia.

Lastly, we come to the subject of **Hysteria**. This is a disease which is much commoner in women than in men. It is more frequent during adolescence and adult life than in childhood or old age, although it may sometimes occur in little children of 8, 6, or even 4 years. Whilst no race and no people is exempt from hysteria, it is relatively more frequent in the Latin races and amongst the Jews. Many cases of hysteria have a nervous heredity. Hysterical, alcoholic, or tuberculous parents are prone to have hysterical children. We sometimes find physical or emotional shocks as exciting causes, or a combination of the two, as for example after an earthquake, a stroke of lightning, or a railway accident. Imitation of other hysterics may produce epidemics of hysteria, whether in adolescents as in girls' schools, or in adults as in certain religious "revival meetings." In some cases disease or irritation of the genital organs is a causal factor, but probably much less frequently than Freud and his followers would have us believe.

Hysterical states shade imperceptibly into normal mental states, there being no hard and fast line of demarcation. A certain susceptibility to suggestion and a certain emotional reaction exist, of course, in normal individuals in widely varying degrees. Such phenomena are especially marked in children. In fact, as Schnyder<sup>1</sup> has said, we may speak of the "physiological hysteria" of childhood. But if an adult reverts to the childish susceptibility to suggestion and to infantile emotional reactions, we consider him or her pathological, hysterical in fact.

For purposes of convenience we shall consider the symptoms in four groups—psychical, sensory, motor, and lastly, visceral and vascular. In each of these groups we may find excess, diminution, or perversion of the normal nervous processes.

**Psychical Symptoms.**—These are invariably present in hysteria to a greater or less degree. The most outstanding feature is *deficiency of inhibition*. The patient reacts too readily to stimuli or suggestions, whether originating in the outside world or within her

<sup>1</sup> *Journal de Neurologie*, 1907, p. 281.



own body. One of the most striking instances of this is found in the phenomena of hypnotic suggestion, whereby a peculiar form of temporary hysteria—the hypnotic trance—is artificially induced by suggestion, and can be made suddenly to disappear by the same means. This disappearance of symptoms during or after hypnosis is sometimes taken advantage of in the treatment of hysteria by hypnotic suggestion. But it is open to the objection that instead of strengthening the patient's feeble inhibition, it utilises that



FIG. 198.

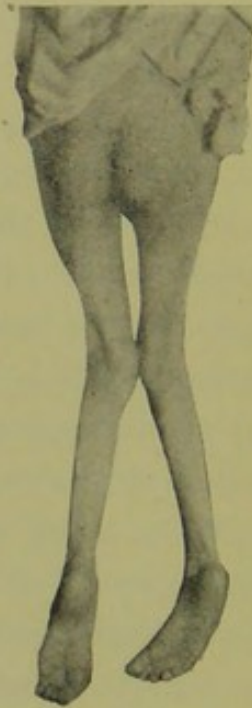

FIG. 199.

Figs. 198 and 199.—Case of hysterical paraplegia of fourteen years' duration. Showing a characteristic hysterical posture of the feet when the patient is passively supported.

fault. Yet if the result be that the patient has a hysterical suppression of her hysterical symptoms (on the mathematical principle that  $- \times - = +$ ) it is, to some extent, a benefit. But results obtained by this plan are less likely to be permanent than when we strengthen the patient's inhibition or self-control by positive measures.

Deficient inhibition being the keynote of the hysterical "*ψυχή*," we find, accordingly, that the patient is excessively emotional and changeable in disposition, often excitable and perhaps



passionate. She giggles or cries on slight provocation, and one of the most familiar forms of hysterical "fit" consists merely in alternate loud laughter and crying. Her will-power is feeble, she is swayed by passing whims; and this want of self-reliance leads to another very characteristic symptom—the craving for sympathy. If that sympathy be shown, as is so often the case, to an injudicious extent by the patient's relatives and friends, her recovery may be indefinitely delayed. Hence it is generally of supreme importance to remove the hysterical patient completely from her old surroundings, and to isolate her until the vicious circle is broken.

Figs. 198 and 199 are photographs of a woman aged 37, who for over fourteen years had lain on a bed of sickness unable to move her legs, a case of hysterical paraplegia. But she was cherished by the sympathy of a devoted mother and of various benevolent lady-visitors, anxious to soothe

her dying moments. She was admitted to hospital, and as a result of six weeks of isolation and massage, she recovered the power of walking, as will be seen from the other photograph (Fig. 200). This successful result was due quite as much to

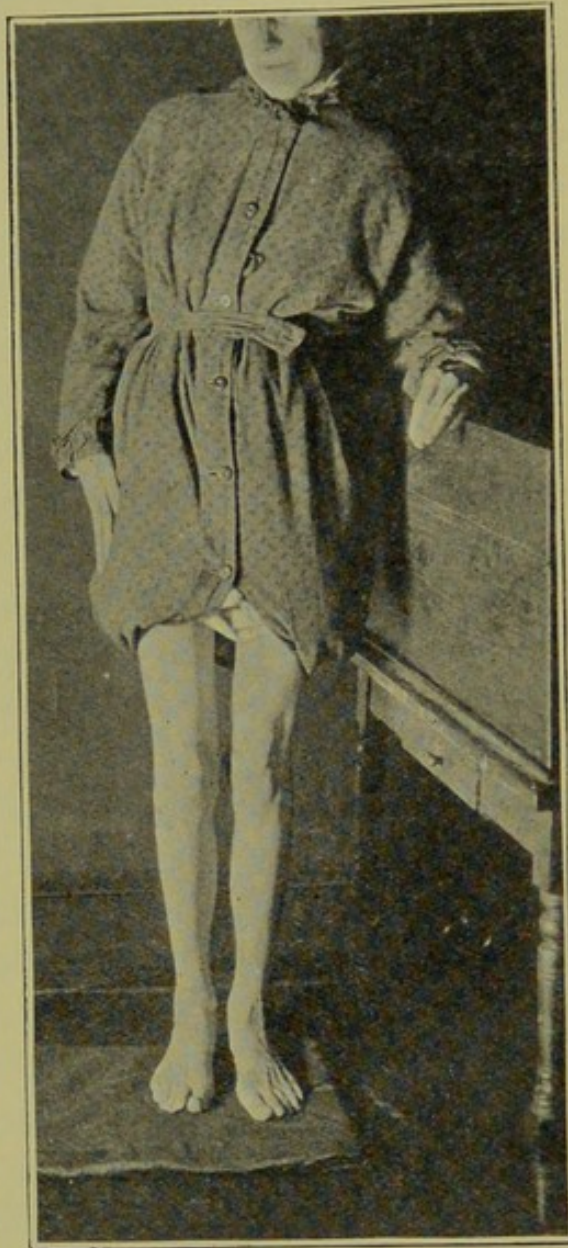

FIG. 200.—The same patient as in Figs. 198 and 199, after six weeks' treatment, showing restoration of power of walking.



the isolation as to the other measures, such as special diet, and massage.

It is convenient to mention here, in connection with the psychical symptoms, the *hysterical affections of speech*. Sometimes there is excessive volubility—a *diarrhœa verborum*. In other cases we find the reverse condition of hysterical mutism, where the patient is absolutely dumb. Hysterical aphasia usually deviates in some gross or paradoxical fashion from organic aphasia. It is often accompanied by curious tricks of pronunciation or of intonation. In less severe cases it is not uncommon to find merely loss of voice, or hysterical aphonia—where the patient can only utter her tale of woe in a whisper, breathing it softly into the ear of a sympathetic listener. Hysterical aphonia has characteristic laryngoscopic appearances, in the form of adductor paralysis of the cords, with which we are familiar.

Patients with mutism or aphonia sometimes suddenly recover their voice when the dominant obsession is loosened, *e.g.* by administration of chloroform (by the physician), or of an excess of alcohol (by the patient), or by some sudden shock, physical or mental. Intra-laryngeal faradism cures immediately many cases of hysterical aphonia.

*Articulation* in hysterical and psychasthenic patients may be affected in all sorts of curious fashions. I have seen several patients who drew a breath between each separate syllable, *e.g.* “hos—pi—tal.” Some psychasthenic “tiqueurs” interpolate curious barking, grunting, or snorting noises amongst their words. One lady was afflicted in this way to such an extent that new neighbours who settled in an adjoining house thought the noise was made by a sick dog, and made a humane suggestion that the animal should be put out of its pain. And yet this lady could recite long dramatic passages of poetry and prose, though in ordinary conversation, or even when not talking, her bark made her society a mixed pleasure.

*Stammering* in its different varieties is not uncommon in hysterical patients. Unlike ordinary stammering which comes on in childhood, hysterical stammering may develop suddenly in



adult life. Thus in a hospital nurse aged 33, who stood up sharply and knocked her head against a mantel-shelf, severe hysterical hemiplegia came on next day, and stammering some six weeks later, lasting for several months.

**Sensory Symptoms.**—These are of greater diagnostic importance than is commonly realised. Pain of some sort occurs in nearly every case of neurasthenia and in many cases of hysteria. Unlike ordinary pains, which are generally caused by some peripheral irritation, hysterical and neurasthenic pains are entirely central in origin—*psychalgia*—and should really be classed as hallucinations. But in every case we must be careful to see and to examine the painful spot, and to exclude peripheral irritation, before labelling any pain as hysterical or neurasthenic.

*Hysterical pains* may be referred to any part of the body; but they are especially common in certain situations. For example, hysterical headache is often of the "clavus" type, which is a boring pain localised to one small spot on the skull. Occipital headache is particularly common, so is hemicrania. Pains in the spine may simulate those of organic disease. Pain in the breast—*mastodynia*—or in the joints may lead to difficulties in diagnosis. It is only by careful local and general examination, revealing the presence of other hysterical stigmata and the absence of signs of structural disease, that we can avoid errors. Cases have been known in which amputations have been performed for hysterical joint-pains. Some time ago I saw a young lady who had already had one toe removed by a surgeon, but the pain recurred in another toe, and the case was undoubtedly hysterical.

Closely related to these pains are the *areas of hysterical hyperæsthesia*, and especially of hyperalgesia or excessive tenderness. Pain on pressure over certain spots, whether such pain be functional (hysterical or neurasthenic) or organic in origin, has occasionally to be differentiated from the simulated tenderness of a malingerer. In such cases *Mannkopf's sign* is valuable. This consists in a change in the pulse-rate whilst the painful spot is being pressed on—usually a temporary acceleration of from 10 to 30 beats per minute. This is common in functional cases. Sometimes, on the other hand,



the pulse is slowed, especially in cases of scars from organic injuries.<sup>1</sup> In cases of malingering, however, no alteration in the pulse-rate is produced. Universal hyperæsthesia is rare. We also meet with cases of hemi-hyperæsthesia. More usually this excessive tenderness is circumscribed in small areas—little islands of skin or subjacent tissues of the head, trunk, or limbs. Sometimes the tenderness is cutaneous and elicited by gentle stroking of the skin; sometimes it is subcutaneous, and only elicited on deeper pressure.

Such tender points are chiefly situated in the vertebral, inframammary, epigastric, and inguinal regions, and except when mesial, are more frequently left-sided (except in left-handed people, in whom they are more commonly right-sided). Tender points are less common on the head, and rarest on the limbs. Graves<sup>2</sup> has directed attention to the frequent presence, in hysterics of either sex, of hyperalgesia to pin-pricks together with tactile anæsthesia, confined to the nipples and their areolæ.

Of all the tender spots, that in the left inguinal region is perhaps the commonest. From some supposed connection with the ovary, it has been called "ovarian" tenderness, but the symptom is as frequent in male hysterics as in females, so that the term is a misnomer. Moreover, in this connection, Steinhausen<sup>3</sup> examined 500 healthy soldiers—males, not Amazons—and found that in no less than 88 per cent. brisk pressure in the inguinal region on either side produced a reaction of some sort, the phenomena being either sensory (unpleasant tickling or pain), motor (hardening of abdominal muscles, various reflex and protective movements), psychical, or vaso-motor and sympathetic (dilatation of pupils). And yet there was not a single ovary amongst them.

These tender points may be associated not merely with pain, but with so much disturbance as to be actually *hysterogenic*. This does not mean that they induce hysteria—the hysteria is already present. It means that pressure on such a spot induces a hysterical fit or paroxysm. The best-known hysterogenic area is in the left

<sup>1</sup> Hudovernig, *Neurolog. Centralbl.*, 1910, s. 408.

<sup>2</sup> *Journal of Nervous and Mental Diseases*, October 1905.

<sup>3</sup> Steinhausen, *Ueber die physiologische Grundlage der hysterischen Ovarie. Deutsche Zeitsch. f. Nervenheilk.*, xix. s. 369.



inguinal region, but such areas may be anywhere. I know of one patient who had a hysterogenic spot in one axilla and who wore a sort of truss over it, to prevent accidental pressure.

Sometimes deeper pressure on the hysterogenic spot or elsewhere may arrest a hysterical fit when in progress. Areas, pressure on which causes cessation of the paroxysms, are called *hysterofrenic*. The inguinal region is the best known of these. Strong faradism over the inguinal region will stop most hysterical fits; so also will a hypodermic injection of apomorphine with its resultant vomiting.

Hysterical hyperæsthesia may also affect the special senses, so that there may be hyper-sensitiveness of smell, vision, hearing, or taste. This is less common than loss or diminution of special senses, to which we shall refer later. I had for some time under my care a patient who could not tolerate bright light, especially if the room had a blue wall-paper. He preferred to stay in a darkened chamber; or if the blinds were up, he shaded his eyes with his hand. After some weeks of treatment, he completely lost this photophobia.

In rare cases an actual enlargement of the visual field has been observed, generally in one eye only. Thus, in a soldier with hysterical wry-neck and anæsthesia of one side of the body, the visual field on the non-anæsthetic side, when measured with the perimeter, was much larger than in a normal individual.

*Hysterical anæsthesia* is extremely common, and is of the greatest diagnostic value. A degree of anæsthesia exists, I am convinced, in the overwhelming majority of hysterical cases, except those occurring in childhood. Some time ago I looked through my notes of 63 consecutive cases and found that anæsthesia was present in 50 and absent only in 12. The remaining case of the series had unilateral hyperæsthesia.

Hysterical anæsthesia is usually unnoticed by the patient herself, and only discovered on examination by the physician.<sup>1</sup> Some-

<sup>1</sup> Babinski considers that hysterical anæsthesia is mainly the result of suggestion by the examining physician. With this view I cannot agree. Many patients who are highly susceptible to suggestion have no anæsthesia. Moreover, undoubted cases of hemi-anæsthesia have been known to develop



times, however, the patient complains of actual numbness, and this is chiefly in cases where the affected limb has motor paralysis as well, so that her attention is called to it.

Janet showed an ingenious method of demonstrating that in some cases of hysterical anæsthesia, sensory impulses really reach the brain-centres, though the patient does not consciously perceive them. Taking a case of complete hemi-anæsthesia he makes the patient shut her eyes, and tells her to say "Yes" each time she feels a touch or prick, and to say "No" when she does not feel it. In certain cases the patient not only says "Yes" every time she is touched on the normal side, but also says "No" every time she is touched upon the anæsthetic side. This is pathognomonic of hysteria.

Cutaneous anæsthesia in hysteria may be complete or partial in degree, or it may be dissociated. Diminution or loss of painful sensations is even commoner than tactile anæsthesia. Many of the mediæval witches were simply hysterics. Their hysterical analgesia (*sigillum diaboli*) was usually demonstrated by sticking pins into them, and if an analgesic area was discovered, they were promptly thrown into the nearest pond or stream. If they sank and were drowned, their innocence was established; but if they floated, it was additional evidence of guilt.

Whatever be its degree of intensity, hysterical anæsthesia never maps out an individual nerve-area such as that of the radial, median, ulnar, or external popliteal. Its commonest distribution is a *hemi-anæsthesia* (27 out of 50 cases) which is mostly left-sided, except in left-handed patients. It is a remarkable fact that a hysterical patient never suffers any physical disability owing to the existence of anæsthesia, no matter how profound. Unlike a patient with organic anæsthesia, the hysteric never cuts or burns herself unconsciously in an anæsthetic area.

Hysterical hemi-anæsthesia, including the accessible mucous membranes of the eye, nose, mouth, pharynx, vagina and rectum, is usually accurately bounded by the middle line; but not always.

before any medical examination had taken place, the anæsthesia being discovered accidentally either by the patient or by some lay observer. (See a case by S. A. K. Wilson, *Brain*, 1911, p. 320.)



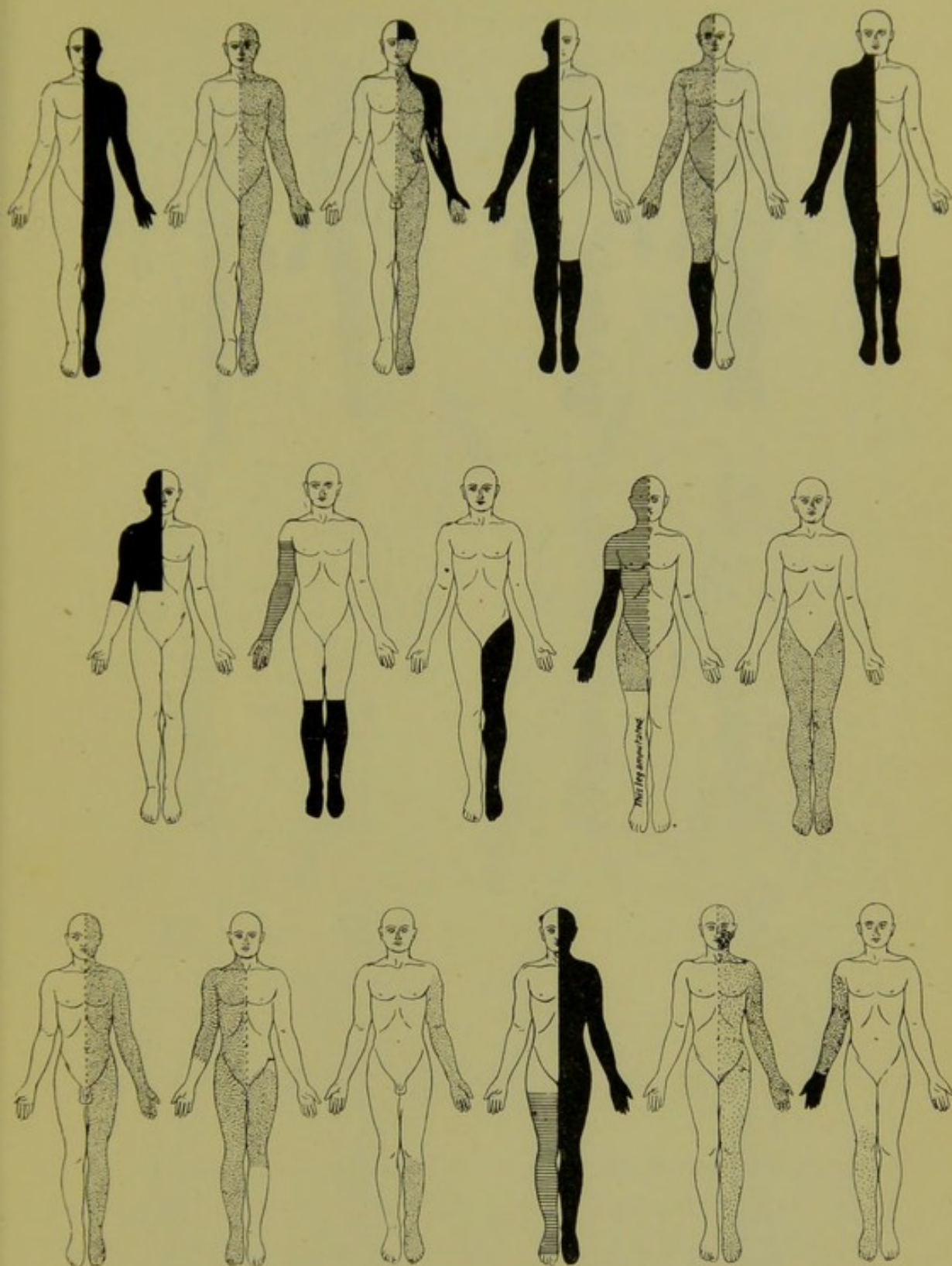


FIG. 201.—Various types of hysterical anæsthesia. Dotted areas indicate slight sensory loss, shaded areas more severe impairment, and black areas total loss of sensation.



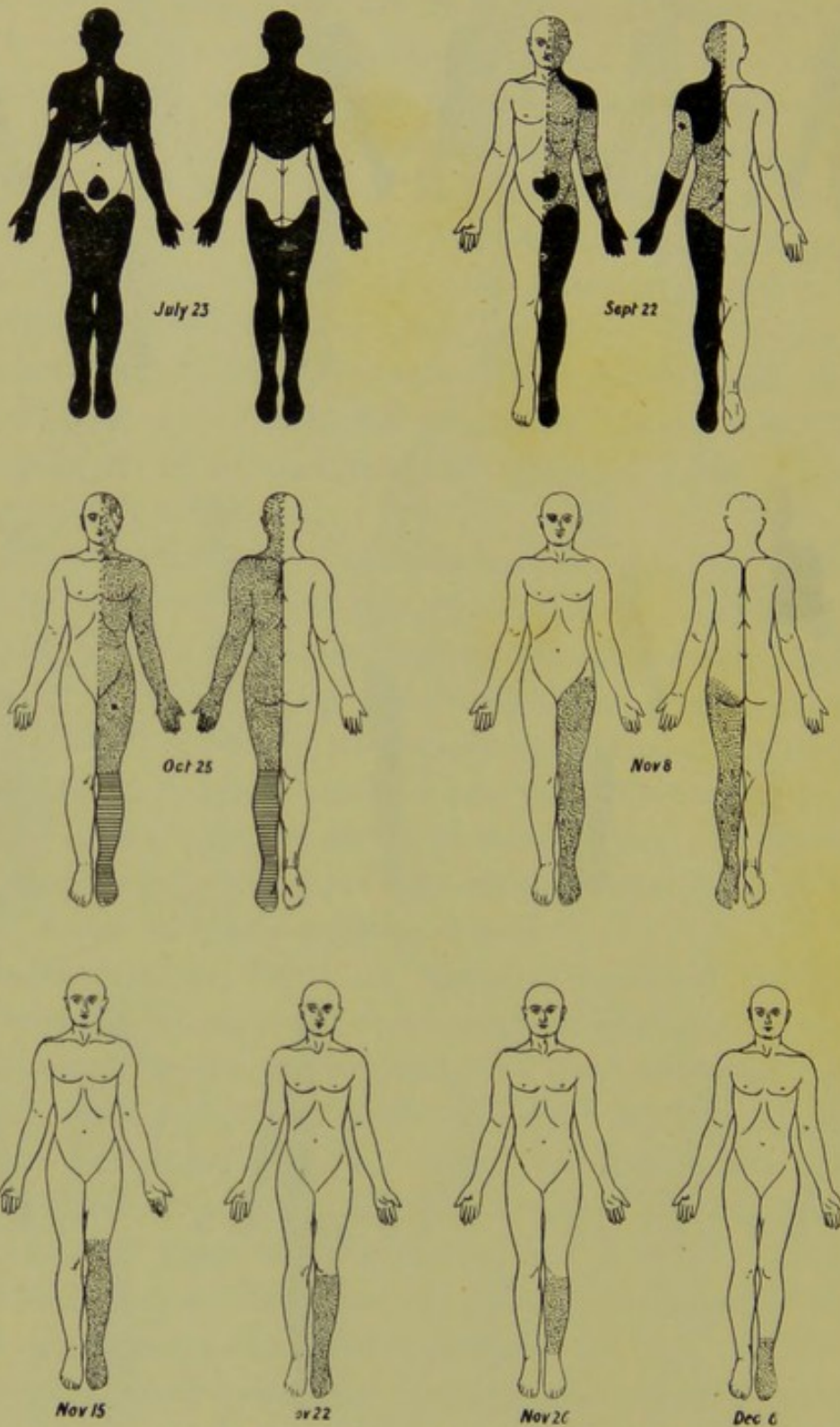


FIG. 202.—Case of hysterical paralysis in a girl aged 17, showing progressive improvement in the anaesthesia.



It may either extend farther over and encroach on the non-anæsthetic side, or it may leave certain areas with normal sensation, even on its own side, especially the head, the nipple, and the genitals, as may be seen from the charts (Figs. 201 and 202).

Bilateral universal anæsthesia is rare (see Fig. 84, p. 198). We generally find, somewhere or other, one or more islands of

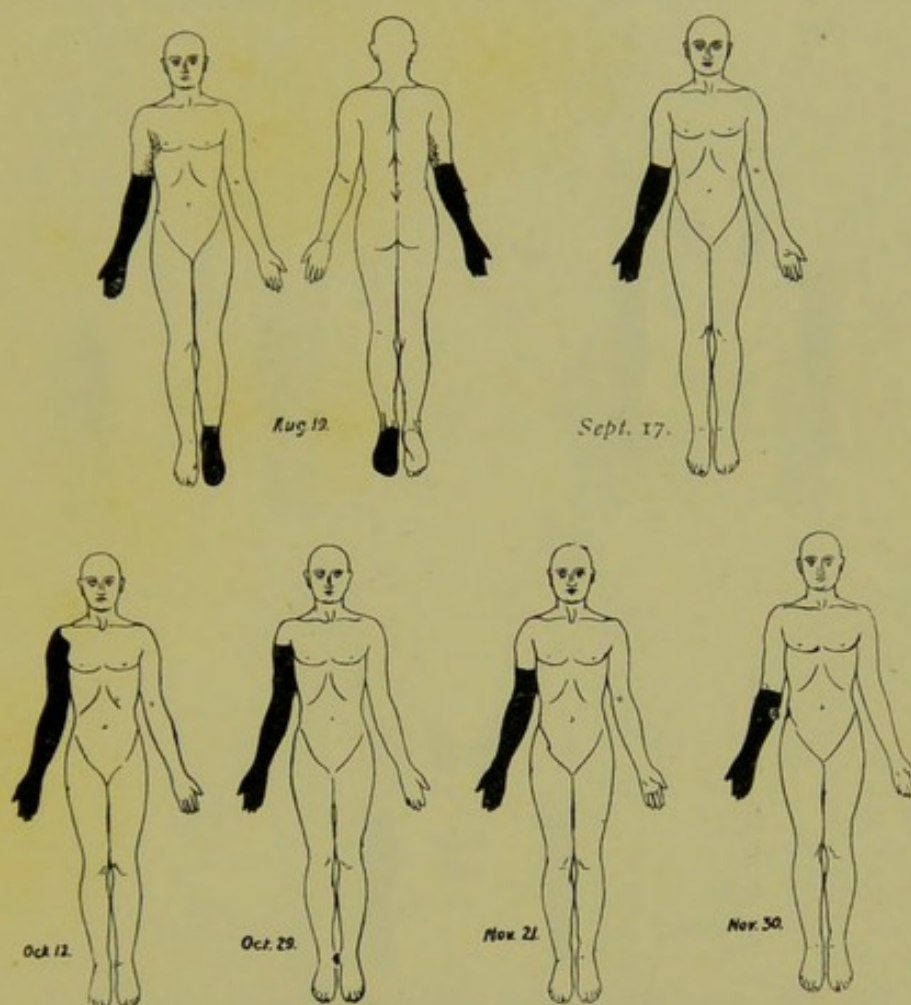


FIG. 203.—Case of hysterical paralysis in a left-handed patient, showing progressive improvement in anæsthesia.

normal sensation, or even of hyper-sensitiveness. Pharyngeal anæsthesia is one of the commonest hysterical stigmata. It is not necessarily accompanied by loss of the pharyngeal reflex.

In many cases the anæsthesia, though unilateral, is more marked on the face or limbs than on the trunk. It may affect special levels of a limb (knee, elbow, or shoulder), or it may stop abruptly at some horizontal line (shoe, sock, stocking, mitten, glove, sleeve).



This "segmental" anæsthesia sometimes occurs in association with hemi-anæsthesia (10 out of 50 cases) or by itself (12 out of 50) on one or both sides (Figs. 203 to 205).

The mode of onset and disappearance of hysterical anæsthesia is interesting. Sometimes the anæsthesia comes on gradually, and the patient is unconscious of the defect. In other cases it occurs

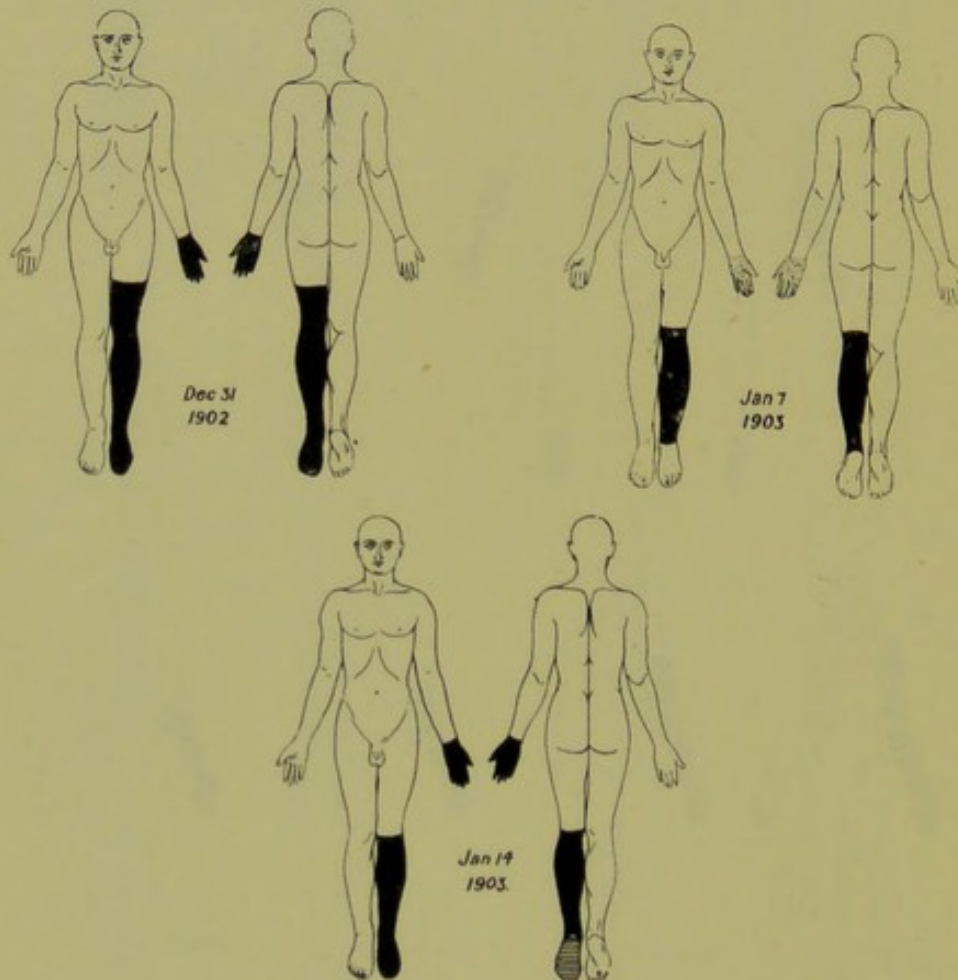


FIG. 204.—Case of hysterical hemiplegia, showing variations in anæsthesia.

suddenly, especially after a hysterical fit, and the patient is then more likely to notice her "numbness."

We seldom have the chance of watching the onset of hysterical anæsthesia, but we may often study its mode of disappearance, and Figs. 202 to 205 show charts of several cases of hysterical anæsthesia in various stages of recovery. Unlike organic anæsthesia, which, if it recovers, fades gradually all over the recovering area, hysterical hemi-anæsthesia may suddenly fade to segmental



(Fig. 202), and segmental anæsthesia recedes by jumps from a higher to a lower level, bounded usually by an "amputation line" drawn transversely across the limb. Sometimes it relapses temporarily to its old level before resuming its progress towards recovery (Figs. 203 and 204). More rarely it clears up first at the periphery.

*Anæsthesia of Special Senses.*—Most cases of hysterical anæsthesia also have diminution or loss of the special senses—smell,

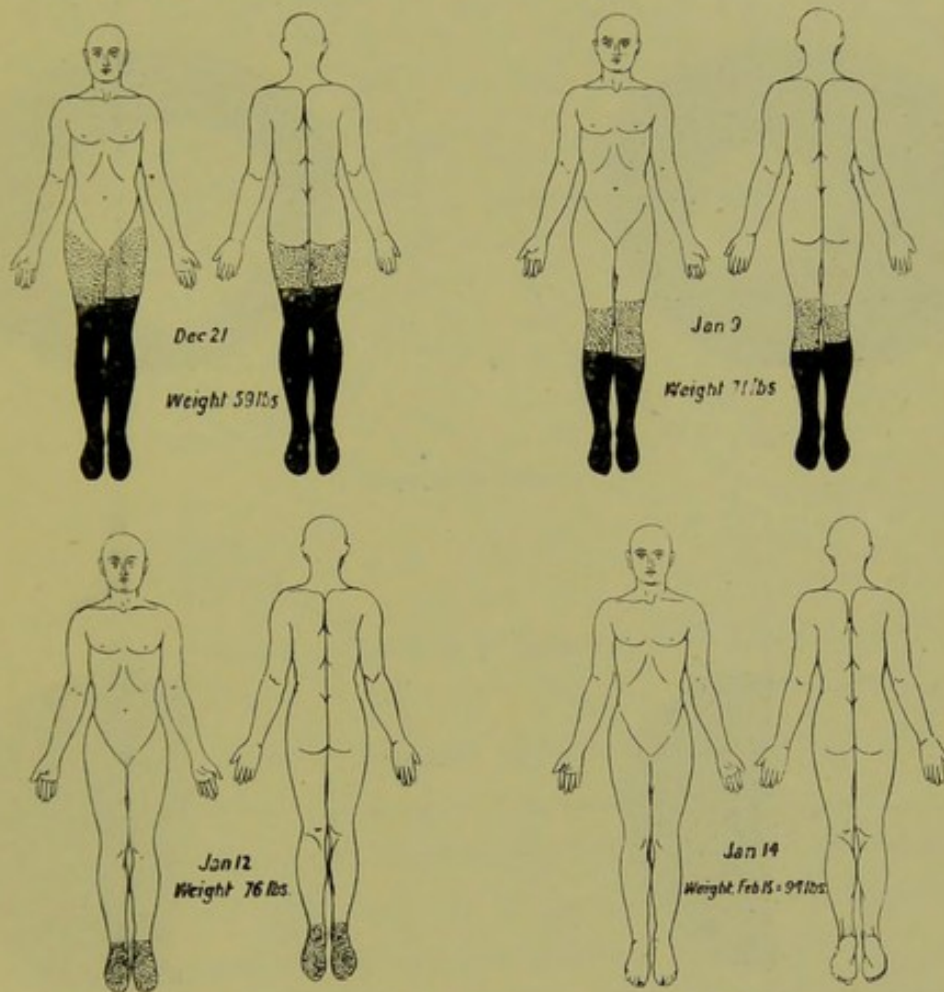


FIG. 205.—Case of hysterical paraplegia with anæsthesia in a girl aged 19, showing progressive improvement.

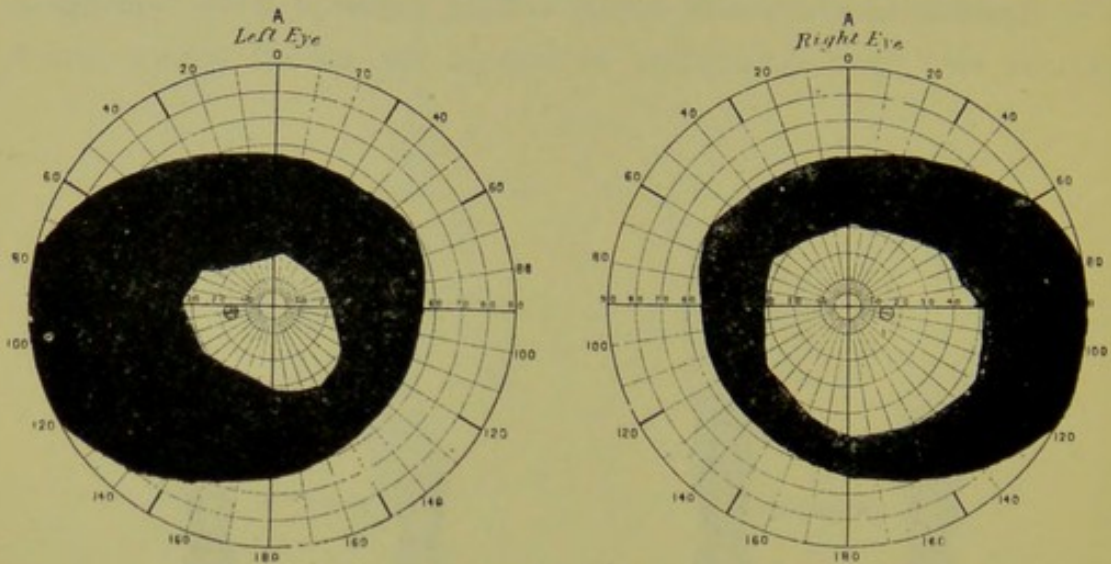
vision, taste, and hearing—generally unilateral and on the same side as the cutaneous anæsthesia, rarely on the opposite side. This combination of unilateral affection of special senses and of cutaneous sensation is pathognomonic of hysteria, and does not occur in organic disease.

The affection of vision in hysteria is not a hemianopia such as we often get in organic hemiplegia. It is a concentric contraction

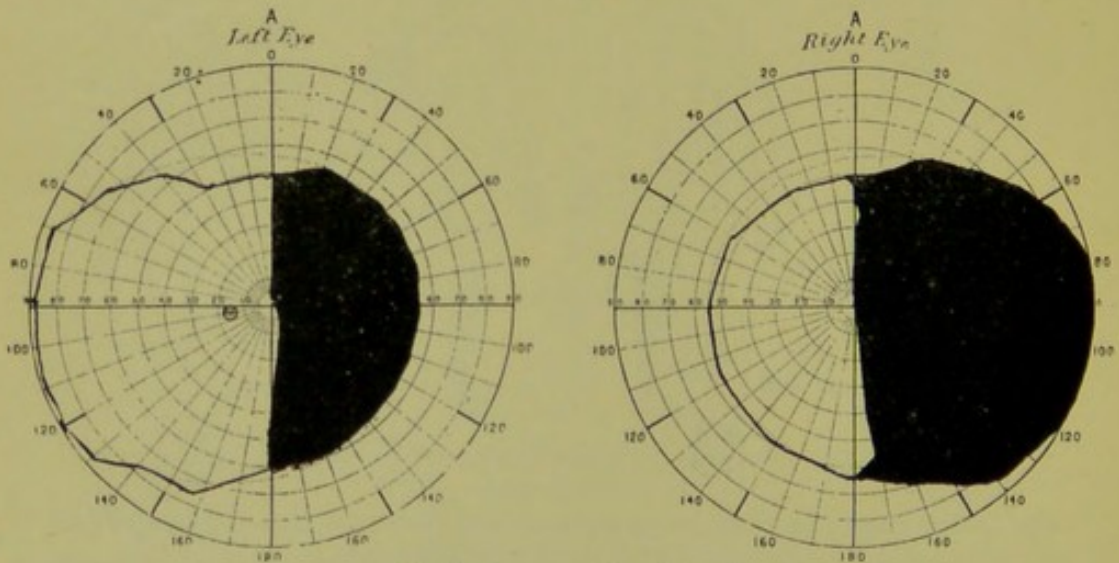


of the whole visual field, as will be seen from the accompanying perimetric charts (Fig. 206). It is more marked in one eye than in the other—"crossed amblyopia"—the smaller field being on the hemi-anæsthetic side, usually the left.

The colour-fields are also contracted, but in a different order



Crossed amblyopia.



Right homonymous hemianopia.

FIG. 206.—Visual fields from cases of hysterical and organic hemiplegia respectively, in which vision was affected.

to that which occurs in organic optic atrophy. In hysteria the blue field diminishes first and the red last of all, whereas in organic atrophy the red field is usually first affected.

Sometimes, when charting the visual field of a hysterical patient, we notice that the field becomes progressively smaller and smaller,



as we continue our examination, so that our perimetric outline has a *helicoid* or spiral shape (Fig. 207). This form of perimetric tracing does not occur in organic disease.

Sometimes we have hysterical blindness or apparent amaurosis in one eye, and yet by means of prisms we may produce a diplopia, which in organic cases would be impossible. In very

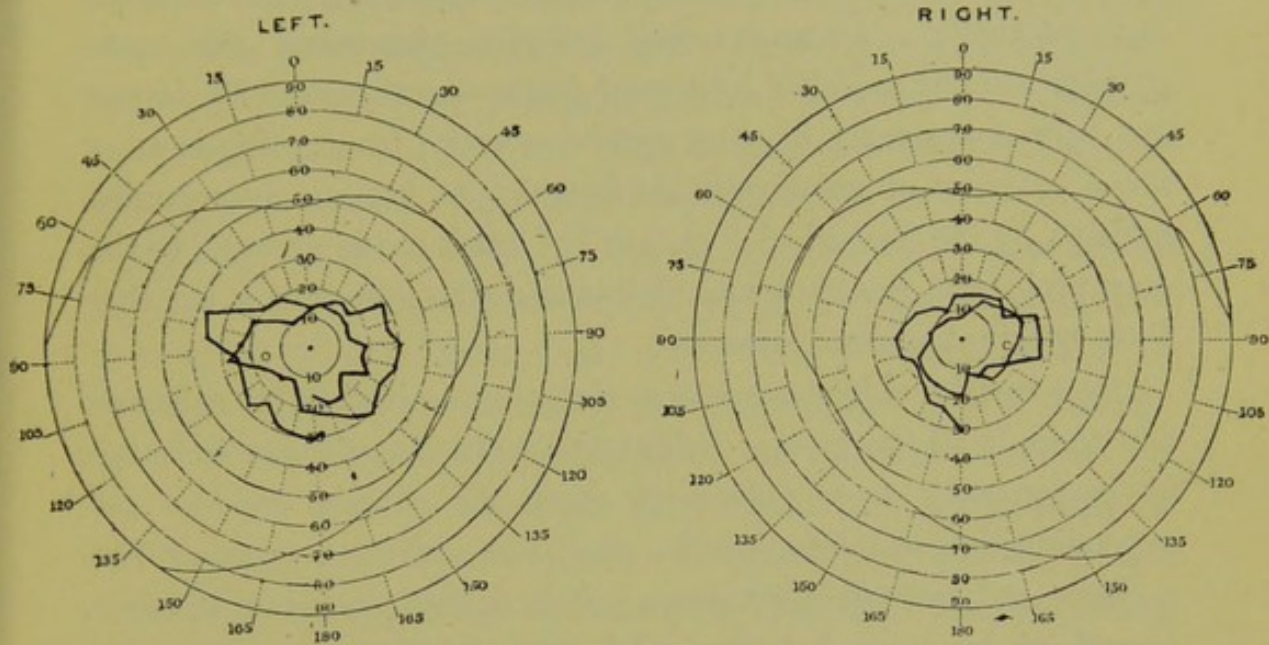


FIG. 207.—Helicoid contraction of visual fields in a case of hysteria.

rare cases complete bilateral hysterical blindness has been observed.

Space does not permit us to discuss the other peculiarities of hysterical eye-affections and of hysterical loss of smell, taste, and hearing, but we may mention, in passing, that complete bilateral loss of taste, as Hughlings Jackson pointed out, is practically always hysterical.

*Hysterical Paræsthesia*, or Perversion of Sensation.—In some cases of hysteria a touch on one limb or one side of the body is felt by the patient at the corresponding spot on the opposite side—*allocheiria* (Obersteiner). In another variety, of which I have seen an example, a touch on the radial border of the limb was felt on the ulnar, and *vice versâ*. *Haphalgnesia* (Pitres) is the term used when intense pain is caused by touching the patient with certain



substances, such as metals, which normally should only cause a tactile sensation.

Paræsthesia may also affect the special senses, as, for example, in *monocular diplopia* or *polyopia*, which is always hysterical. *Micropsia*, where everything looks very minute, and *macropsia*, where surrounding objects seem gigantic, are both frequently hysterical.

**Motor Phenomena.**—These may be subdivided into irritative and paralytic. Amongst the *irritative phenomena*, the most striking are the so-called hysterical fits or paroxysms. Hysterical fits vary enormously in type and in severity, from a simple emotional outburst of uncontrollable laughing or crying, accompanied perhaps by the hysterical “globus” or “ball in the throat,” to the most prolonged, dramatic and violent muscular movements, together with apparent unconsciousness.

One variety of hysterical fit is sometimes mistaken for epilepsy, and there is all the greater liability to make this mistake since the fit is generally over before we reach the patient, and we are dependent for our information upon the accounts, more or less accurate, of unskilled witnesses. But if the physician is lucky enough to be present during a fit, there is seldom any difficulty in diagnosis. Thus, for example, the patient never hurts herself in falling; there is no stertorous breathing; her face is not livid, nor does she bite her tongue as in epilepsy; she may, however, bite her lips or snap at the fingers of the bystanders. She never empties the bladder or rectum during the fit; her eyes are generally tightly closed, and if the physician tries to open them, the patient actively resists. A hysterical fit is not followed by coma and hardly ever by vomiting.

But we must remember that sometimes we have hysterical fits which are post-epileptic—*i.e.* which immediately succeed an attack of true epilepsy. The antecedent epileptic fit in such cases is usually of the “*petit-mal*” type, consisting perhaps in a mere transient pallor of the face, with momentary loss of consciousness, and then passing directly into a hysterical fit. Therefore, in every case it is important to inquire very carefully as to the precise mode of onset, lest we overlook a case of combined epilepsy and hysteria.



Charcot's "*grande hystérie*," with its initial period simulating epilepsy and its subsequent phases of contortions, kicking, and struggling (clownism), passionate attitudes (opisthotonos, crucifixion attitude, &c.), and delirium, often with hallucinations of animals, is less common in this country than in France, but once seen, it is a magnificent performance and can never be forgotten. It is totally unlike any kind of epileptic or organic fit, and its diagnosis is easy. It may last from a quarter of an hour to several hours at a time. This "status hystericus" is commoner than the "status epilepticus," but the patient has no subsequent stupor such as that which succeeds a severe epileptic fit.

Amongst other varieties of fits, to which we can only briefly refer, we may mention *catalepsy*, in which the patient suddenly becomes speechless, motionless, and stiff. Sometimes she is conscious all through the fit, at other times she is in a dreamy mental state. Meanwhile, if the limbs be passively moved into any posture, however fantastic, they remain fixed there like a doll's limbs. In one case of mine the patient, a woman of 28, could be lifted up during the attack by the head and heels and laid across two chairs like a log.

*Hysterical trance* may come on spontaneously, or may succeed a hysterical paroxysm. It is a condition in which the patient appears as if in a deep sleep; but the muscles are seldom completely relaxed, and we may observe slight tremors of the eyelids. In more severe cases, the heart and respiration may become so feeble and slow that the condition simulates death. Hysterical trance may last hours, days, or weeks; and several cases have been authenticated where such a patient has been buried alive, either deliberately, as in the case of some Indian fakirs, or by accident in this country. Novelists know this, and when the heroine is thus buried, she is exhumed in the last chapter by the villain for the sake of a magnificent diamond ring on her finger; whilst her finger is being cut, to get the ring off, the patient awakes.

We can only mention other varieties, such as *somnambulism* and *double consciousness*, this latter, when in extreme degree, being a condition in which the patient's character alternates



between normal and abnormal, the two individualities being mutually unconscious of each other, but each one, as its turn comes, takes up the thread where it left off last.

A minor degree of double consciousness can be demonstrated, by a simple experiment, in many cases of hysteria where there happens to be hysterical anæsthesia of the upper limb. If in such a case we screen the anæsthetic limb from the patient's view, she does not feel pin-pricks or touches on the limb, nor does she recognise familiar objects when placed in the hand. But if a pencil be placed in the "screened" hand, it is grasped in a position suitable for writing, and if we now trace a letter or a word on the back of the anæsthetic hand (the patient's attention meanwhile being diverted by another observer) this letter or word is reproduced in writing, entirely unknown to the patient's consciousness. Analogous sub-conscious phenomena can be demonstrated in many apparently normal people by means of a small wheeled platform or "planchette" carrying a pencil.

We also meet with a hysterical type of *ambulatory automatism* where the patient (more often a man than a woman) has attacks in which, without adequate motive, he has a sudden and irresistible impulse to wander from home. He makes a long journey, sometimes undergoing great hardships *en route*. Finally, days, weeks, or even months afterwards, he suddenly wakes up in some strange town or country, entirely unaware of how he got there. For example, I have known of a boy who disappeared from school in this way, of a young officer who deserted from his regiment, and of a business man who left his wife and family, all these cases without any adequate cause. These cases are closely related to the somnambulistic stage of the hypnotic trance, and if such a patient be hypnotised he becomes able to give a complete account of his wanderings from the moment of his disappearance to the time when he woke up and "found himself." The diagnosis between hysterical and post-epileptic ambulatory automatism, to which we have already referred (p. 69), is not always easy. We should carefully inquire for evidences of epilepsy, major or minor, we should look for the presence of hysterical stigmata (though



even in hysterical cases stigmata may be absent), whilst the reconstruction of the "lost" period of time when in the hypnotic trance is highly suggestive of its hysterical origin.

Various *localised motor disturbances* also occur in hysteria and psychasthenia. Such, for example, is the large group of "tics" and "habit spasms" which we have already studied (p. 90). A true tic is essentially and primarily a psycho-motor act, either an emotional expression or a movement which has become a habit. Of these tics, the commonest are grimaces, jerkings of the head, trunk, or limbs, and tremors of various parts, rapid or slow. Thus, for example, a lady's maid, aged 46, had tonic spasm of the orbicularis oculi on both sides (blepharospasm), and could open her eyes only by opening the mouth as well. Another girl, æt. 19, had a clonic or jerking paroxysmal blepharospasm, associated with "humping up" of one foot. Another girl of 19 had rapid "twiddling" movements of the left thumb and fingers, with pronation-supination movements of the forearm and a pseudo-clonus of the left ankle. Another girl, aged 20, who previously had suffered long from recurrent vulval abscesses, had attacks of rapid antero-posterior movements of the pelvis. Another patient had rapid violent flexion-extension movements of the left elbow whenever a thunderstorm occurred, the hand meanwhile dangling loosely at the wrist. Such cases of localised motor disturbances might be multiplied almost *ad infinitum*.

*Hysterical Paralysis* may be either flaccid or spastic in type, and may affect any of the voluntary muscles; but, unlike paralysis due to organic lesions, it never attacks a single muscle nor the muscles supplied by a single nerve, nor are the electrical reactions of degeneration ever present. A further point about hysterical paralysis is that though it may roughly resemble the posture of an organic paralysis, it never does so with accuracy; there is always some point of difference to be detected. The reason for this we have already discussed (p. 275).

Let us study one example each of hysterical monoplegia, of paraplegia, and of hemiplegia.

Fig. 208 is that of a nurse, aged 32, with hysterical monoplegia of the right arm of eight months' duration, in whom there was



extreme muscular wasting and claw-hand. The paralysis came on after a strain of the shoulder in lifting a heavy patient, and somewhat resembled a lesion of the brachial plexus. But we observed that the trapezius was paralysed, and that the whole scapula was displaced downwards—unlike an organic brachial-plexus case, in which the arm would be displaced downwards at the shoulder-joint. Moreover, the electrical reactions were normal



FIG. 208.—Hysterical monoplegia of right upper limb, accompanied by muscular atrophy, but without changes in electrical reactions.

in the wasted muscles, and there was a “glove” of anæsthesia, unlike the “root” anæsthesia of an organic case. The patient was treated for several weeks by battery and massage, without effect at first, but the result proved our diagnosis to be correct, for at a religious meeting she was suddenly cured.

Figs. 198 and 199 are from a case of hysterical flaccid paraplegia of fourteen years' duration in a woman of 37, which at first sight might be mistaken for a cord-lesion with muscular atrophy and anæsthesia. But the anæsthesia was of the “stocking” type,



the reflexes, deep and superficial, and the electrical reactions were normal, the sphincters were unaffected, and there were no bed-sores; and the result of six weeks' isolation and massage was to restore the power of walking (Fig. 200).

In some cases of hemiplegia the posture is sufficient to diagnose hysteria. For example, in the patient shown in Figs. 128 and 129

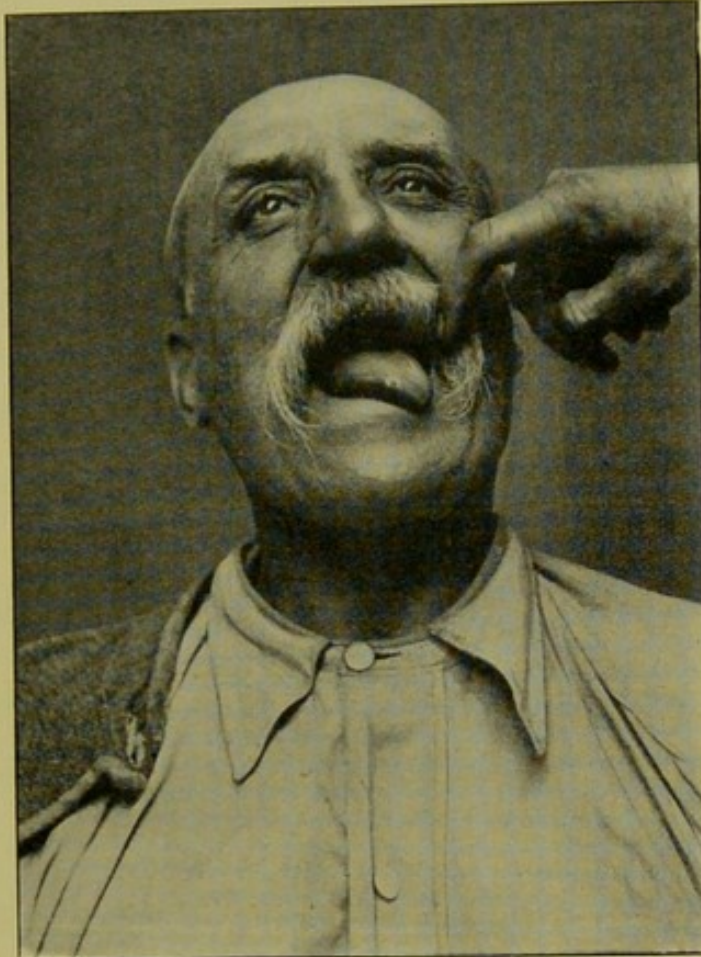


FIG. 209.—Left-sided hemi-glossic spasm in a case of hysterical hemiplegia, showing position of tongue when protruded.

(p. 273), instead of the ordinary posture of an organic case, with the upper extremity flexed and pronated, the lower extremity flexed at the hip, extended at the knee and ankle, and slightly inverted, there was a curious posture of the hand and foot unlike that of organic disease. Moreover, her face entirely escaped, in spite of the severe paralysis of the arm and leg; and she had hemi-anæsthesia and loss of special senses down one side, a combination which never occurs in organic hemiplegia.



The face and tongue are rarely affected in hysterical hemiplegia. But in certain cases we may find instead of weakness, spasm of the face and tongue on the affected side, when the patient shows the teeth or protrudes the tongue. This hysterical *glossolabial hemi-spasm* is rare, but Figs. 209 and 131 (p. 274) are good examples of the condition.

We may also refer to "Lasègue's symptom" (Nothnagel's "Seelenlähmung") in which a patient with an anæsthetic limb cannot move it when the eyes are closed, but is able to move it when she opens her eyes and looks at it. Another feature worthy of mention is hysterical pseudo-ptosis. In organic ptosis due to lesion of the third cranial nerve, there is always a compensatory over-action of the frontalis muscle. But in hysterical pseudo-ptosis this is absent, and the condition is really due, not to paralysis of the levator palpebræ, but to spasm of the orbicularis oculi (see Fig. 61, p. 136).

Before leaving the motor phenomena of hysteria, it may be well to refer to the gaits of hysterical and psychasthenic patients, which are sometimes most peculiar.

*Astasia-abasia* is a hysterical condition in which, although the patient can move his legs normally when lying or sitting, he collapses at once when he tries to stand or walk. Children are more often affected than adults. A boy, aged 12, had this symptom for a long time, but was cured by an application of the faradic wire-brush to his spine. One patient, a doctor aged 55, used to flourish his left leg in the air and bring it down with a stamp like that of a unilateral locomotor ataxia. The phenomenon, an ambulatory tic, was so dramatic that he had to carry a stick to beat off the crowds of little boys who studied his gait in the streets. Another patient was a worthy married lady who every now and then, when walking, sat down suddenly on the ground, rolled backwards and spread out her lower limbs like the letter V.

Perhaps the commonest hysterical gait is a dragging gait, in which the patient trails the limb helplessly along, often scraping the inner border, or even the dorsum of the foot, on the ground (see Fig. 139, p. 283), unlike an organic hemiplegia in which the outer side of the sole is dragged.



Some authorities state that muscular atrophy does not occur in a hysterical limb. But this is not accurate, for in certain rare cases, one of which is shown in Fig. 208, we may meet with profound atrophy. But this atrophy is due to disuse and is not associated with the electrical reactions of degeneration.

Contractures of the most pronounced type may be met with

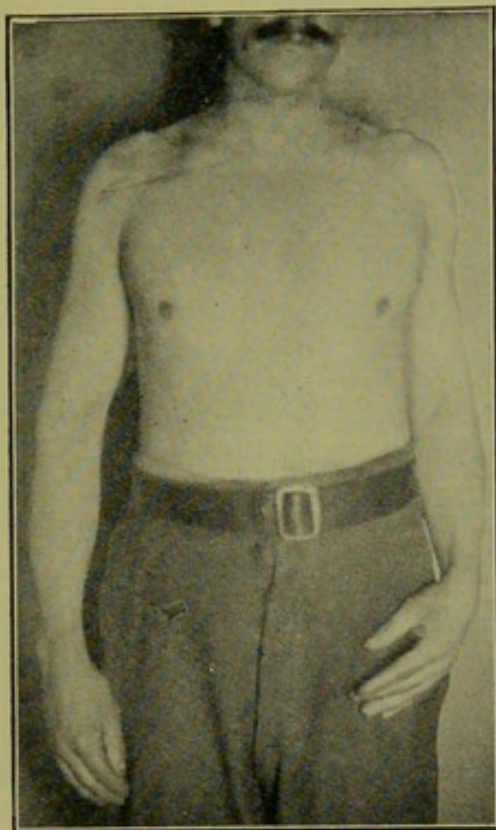


FIG. 210.—Hysterical contracture of the left hand and elbow, following an injury to the elbow.

in hysterical paralysis. But here, again, they always differ in some respect from those of organic cases. Fig. 210 is the photograph of a soldier, aged 32, whose horse rolled on him at the Tugela, and who afterwards developed a stiff left arm, flexed at the elbow and wrist, and with the thumb and index finger held stiffly parallel.

A study of the **reflexes** is of great diagnostic importance in every case of hysteria. The deep reflexes may be normal or exaggerated, but in pure hysteria they are never lost, although sometimes they may be "concealed" by the presence of muscular spasm. True ankle-clonus does not occur, but a pseudo-ankle-clonus is often met with. In a girl of 19, the subject



of thread-worms and pruritus ani, this pseudo-ankle-clonus used to come on spontaneously when sitting or standing at ease. One can often distinguish it from a true organic clonus by the peculiar upward start of the foot before it sets off on its first downward push. Further, pseudo-clonus is, as a rule, poorly sustained.

The superficial reflexes are often diminished especially on the anæsthetic side. The plantar reflex in hysteria, if present, is always of the normal flexor type, never of the extensor or Babinski type. A persistent extensor plantar reflex only occurs in cases of disease of the pyramidal tracts, and in infants who have not learned to walk and in whom the pyramidal tracts are not yet myelinated.

The pupil-reflex to light is never lost in pure hysteria, though in rare cases it may be "concealed" by the presence of pupillary spasm. I remember one case of fixed dilated pupils in a hysterical woman, but this was due to the taking of belladonna by the patient.

As to the bladder and rectum, although we may have frequency of micturition in hysteria, we never have true incontinence. Retention of urine, on the other hand, is a fairly common symptom. It once broke out as an acute epidemic in a school for young ladies and continued until the doctor judiciously handed over the duty of catheterisation to a female nurse of mature years. The symptom at once subsided in a gratifying manner.

**Visceral and Vaso-motor Phenomena.**—It is important to remember that hysteria affects the sympathetic nervous system as well as the cerebro-spinal. Let us refer very briefly to some of the visceral and vascular phenomena.

We may meet with abnormal slowness of the heart, or we may observe abnormal rapidity with palpitation, chiefly paroxysmal, constituting a variety of pseudo-angina, especially in hysterical, or neurasthenic young mothers who have been lactating too long. These cases are easily distinguished from true angina by the absence of signs of organic cardio-vascular disease.

In the digestive system we meet with curious hysterical phenomena. Aërophagy, or swallowing of air, is achieved chiefly by



gulping movements of the pharynx. I remember a little school-boy who could swallow air and distend his abdomen till his waistcoat could not be buttoned. We are all familiar with hysterical dysphagia or spasm of the œsophagus, with its sudden intermissions and the difficulty experienced equally with liquids and with solids, in which nevertheless a large stomach-tube can be easily passed. The hysterical "globus" or "ball in the throat," which the patient tries to swallow, is an emotional phenomenon often met with at the onset of a hysterical paroxysm. Hysterical vomiting has always to be excluded in gastric disorders of young women. It is often associated with *anorexia nervosa*, where the patient will take hardly any food. "Fasting girls," of whom we now and then read in the daily press, are generally examples of this kind of hysteria. They may become extraordinarily emaciated, but even they do take a little food now and then.

Rhythmic movements of the stomach or intestine accompanied by curious rumbling noises are sometimes met with. The commonest variety is the intestinal, and at dinner-parties one sometimes hears these noises in nervous young servant-maids waiting at table. Much less frequently we hear violent gastric borborygmi. One young girl whom I saw had constant, noisy to-and-fro gurgling in the upper part of the abdomen, like a steam-pump, and on palpating the abdomen the stomach could be felt rhythmically contracting and relaxing, blowing and sucking air backwards and forwards. This phenomenon was so startling to strangers that the unfortunate girl had to retire to her own room if friends came to call on the family. Somewhat similar abdominal noises in another hysterical patient, a lad of 19, were apparently produced by spasmodic contractions of the diaphragm, for they ceased when he drew a deep breath and held it.

The French patient who earned an honest living at a Parisian music hall by making musical noises with his anus was probably another example of visceral hysteria.

We must also bear in mind the pseudo-pregnancies which now and then occur, in which spurious enlargement of the abdomen sometimes goes on to a spurious labour. Then "parturiunt montes,



nascitur ridiculus mus"—all that is produced being, at the most, a small uterine cast. Phantom abdominal tumours can best be differentiated from genuine ovarian or uterine enlargements by giving an anæsthetic, when the abdomen at once collapses.

It is sometimes more difficult to diagnose pseudo-appendicitis. Thus one patient whom I saw, aged 33, had had her abdomen opened twice in different London hospitals for supposed appendicitis, the symptoms being those of recurrent pain and tenderness in the right iliac fossa, with constipation and vomiting. But she had also right-sided hemi-anæsthesia, with loss of special senses all down that side. We were thus led to suspect the hysterical nature of the abdominal symptoms, and accordingly her next attack was cured by sal volatile, without laparotomy, and she has had none since.

Hysterical diarrhœa sometimes occurs, as in the case of a public speaker who was often attacked in this awkward way just when his turn arrived to address the audience.

Spontaneous hæmorrhages are very rare in hysteria, and no hæmorrhage should ever be diagnosed as hysterical unless all other causes can be excluded. But a certain number of cases of pseudo-hæmoptysis and pseudo-hæmatemesis occur. In one girl whom I watched, the phenomenon seemed to be produced by sucking of the gums; in another it was apparently the result of pharyngeal suction. In both cases, physicians of wide experience who saw the case in consultation failed to discover any organic cause in the chest or abdomen.

Sometimes a limb affected by hysterical paralysis or anæsthesia may show abnormal vasomotor spasm, so that if pricked or cut it bleeds less freely than normal.

Secretory phenomena also occur, though rarely, as for example in blood-stained tears or blood-stained sweat, which may be unilateral. Polyuria often occurs after a hysterical fit, whereas hysterical anuria or suppression of urine is extremely uncommon.

Certain skin affections occur in hysteria. Cutaneous hæmorrhages are rare, if we exclude cases of voluntary traumatism. Bedsores do not occur. The gangrenous patches described as hysterical



gangrene are always self-inflicted, by means of caustics or other methods (see Fig. 139, p. 283). Hysterical blue œdema sometimes occurs, especially in contracted limbs; it usually affects the skin over a joint and produces a degree of cyanosis and swelling, but this swelling does not pit on pressure. Hysterical œdema may last for weeks or months. It generally disappears suddenly. Thus in

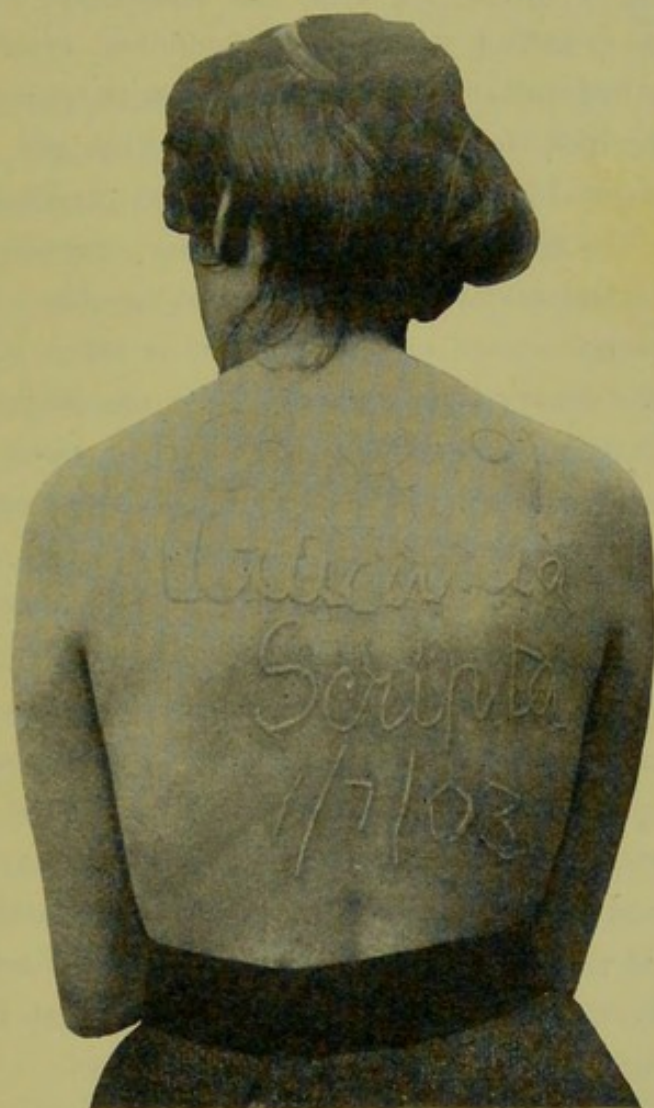

FIG. 211.—Case of dermatographism in a hysterical young woman.

a case recorded by Raymond, it suddenly cleared up when the patient had the glad stimulus of an unexpected legacy. Dermatographism is commoner in hysterics than in normal people. Fig. 211 is an excellent example in a girl with hysterical tremor of the legs, in whom, when the skin was stroked with the finger-nail, a white raised wheal appeared and remained for an hour or more.



This "factitious urticaria," or "urticaria scripta," unlike ordinary urticaria, does not itch.

Hysterical cough is very common; it is usually loud and hacking, going on all day and ceasing during sleep. It is not accompanied by expectoration, and is commonest in young hysterics. We may have other peculiar modifications of respiration. Thus in a girl of 24 who had hysterical fits, expiration was a curious grunting noise of a bigeminal type—two grunts between each inspiration. We also meet with paroxysmal rapid breathing, sneezing, hiccup, and yawning. One girl, aged 10, the subject of hysterical hemi-anæsthesia, yawned persistently for three weeks during her waking hours. She then stopped and had an attack of hysterical mutism lasting for two months.

When hysteria occurs in childhood it is often mono-symptomatic and the ordinary hysterical stigmata are frequently absent. Girls are much more frequently affected than boys, even before the age of puberty. Perhaps the commonest symptoms of hysteria in childhood are astasia-abasia and hysterical aphonia. The various forms of habit-spasm are common in young psychasthenics.

The diagnosis between hysteria and organic disease is sometimes easy; in other cases it is a matter of extreme difficulty. In doubtful cases special attention should be paid not only to the psychological symptoms but to the special senses, to the condition of the optic discs, to the type of anæsthesia which may be present, to the posture of the limbs in cases with motor paralysis, and to the condition of the reflexes, especially the plantar reflex and the bladder functions. Further, we should never forget that hysteria and organic disease may coexist in the same case.



## CHAPTER XXII

### ELECTRO-DIAGNOSIS AND ELECTRO-PROGNOSIS

It is not necessary to enter into a full discussion of the various physiological phenomena produced by electrical stimulation of different tissues, still less to discuss the nature of electricity itself or the *rationale* of its effects. It will suffice here to recall a few of the more practical points in the physiology of electrical stimulation.

Clinically, electrical stimulation is of value chiefly in the examination of muscles and of motor nerves. Electrical examination of sensory functions is of but little practical importance, except perhaps when mapping out areas of loss of taste, where a mild galvanic current is an excellent gustatory stimulus.

For diagnostic purposes the three most important forms of electricity are the *faradic*, interrupted, or induced current, the *galvanic* or continuous current, and the *vibrant* electricity, which is the result of discharging a powerful induced current through a Crookes' vacuum-tube, producing the well-known X-rays. The application of this latter—so-called skiagraphy, though of great practical importance, does not specially concern the neurologist. We have to consider more particularly the faradic and the galvanic currents.

To produce the *galvanic current*, we employ a galvanic battery (preferably a dry-cell battery, which can be carried about without spilling) and this battery must have sufficient electro-motive force or voltage to overcome the resistance of the skin, which is a bad conductor, and to stimulate the muscles and nerves underneath. In cities where there is an electric light system run by the continuous current, we can utilise this current to charge an accumulator which can be carried about, or we may use the current direct from the



main, provided we are careful to reduce the voltage sufficiently. This is accomplished by means of shunts, resistances, or rheostats.

**Faradic, or induced electricity,** is obtained by induction. In a faradic machine there are two coils of wire, concentrically placed—the primary coil within the secondary. When a galvanic current passes along the primary coil, there is produced, at the moment of closure and again at the moment of opening of the primary current, an instantaneous faradic shock in the secondary coil, no shock occurring during the period of flow of the primary current, so long as its strength remains constant. Within the primary coil there is usually a bundle of soft iron wire, which becomes converted into a magnet when the galvanic stream flows round the primary coil. Now a magnet pushed within a coil produces an instantaneous faradic or induced shock in that coil; so that as the soft iron is alternately magnetised and then de-magnetised by the primary coil, we have the effect of the magnet superadded to that of the primary coil. We can vary the strength of the faradic shocks in the secondary coil in several ways, by pulling the iron bundle in or out, or by sliding a cylindrical brass shield between the primary and secondary coils (the effect on the secondary coil being greatest when no shield is interposed), or lastly, by having the secondary coil on a sliding sledge, so that we can pull the two coils apart. This last is the best and most delicate way of varying the intensity of the faradic shocks in the secondary coil.

We apply the electrical current to muscles and nerves by means of metal electrodes of various sizes, some flat and disc-like, others with rounded bulbous ends. The metal surface of the electrode should be covered with chamois-leather. The electrode is screwed on to a holder, which must have a contact-key whereby we can interrupt the current at will. The chamois-leather should be soaked before use, and the skin should also be well moistened, in warm water to which a little salt has been added, to render it a better conductor. The salt, however, spoils the leather, which must in consequence be frequently renewed.

We should have a galvanometer in the circuit of the galvanic



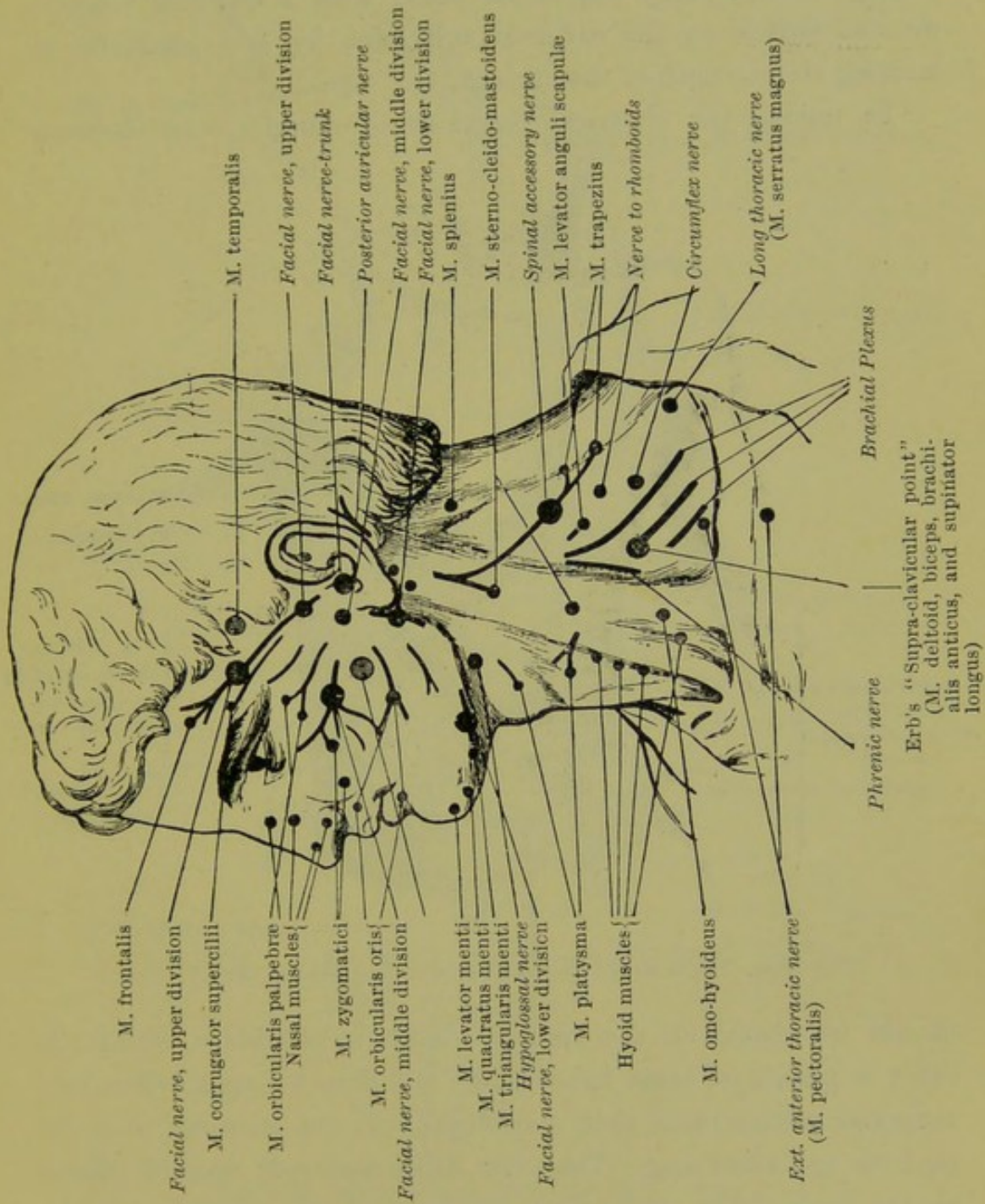


FIG. 212.—Motor Points of Face and Neck. (Erb.)



current, so as to measure the strength of current which penetrates the tissues. There should also be a commutator or sliding switch, whereby we can reverse the direction of the current. The galvanic battery should be fitted with a collector whereby we can switch on the different cells, one by one, gradually increasing the strength of the current.

In testing the electrical reactions of muscles, one electrode

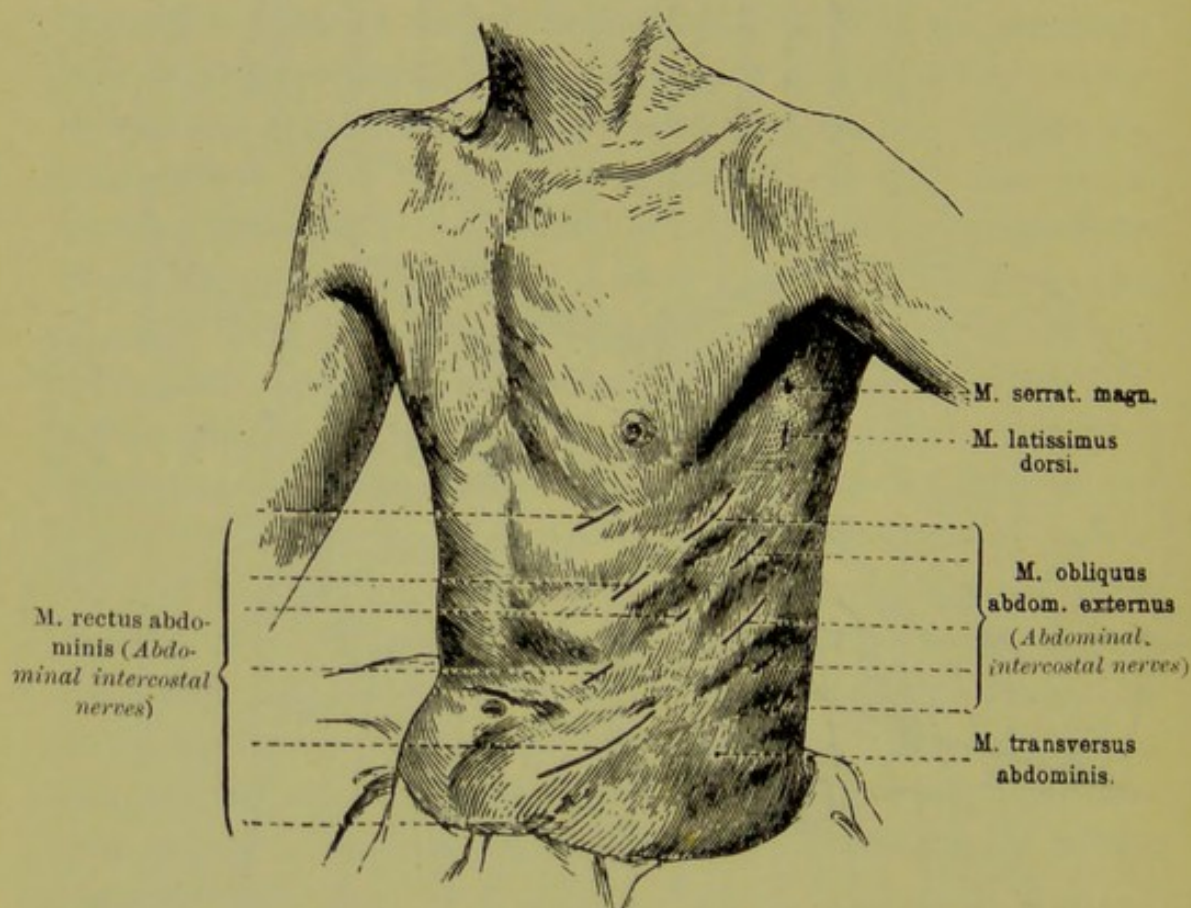


FIG. 213.—Motor Points of Abdominal Wall. (Erb.)

should be placed on the spot we desire to stimulate, whilst the other is placed on some far-distant "indifferent" spot, where any muscular contractions that may occur will not interfere with the part we are observing. Thus the indifferent pole may be placed on the back of the neck, or on the front of the abdomen, or the patient may sit upon it, or he may hold it in the opposite hand. We then fix our attention on the other pole which we are watching. To stimulate isolated nerves or muscles, either the electrode should be a small one, or we may employ the edge of a disc electrode.



The patient must be placed in a good light, so that we can see the slightest movement of the muscle we are examining. Some-

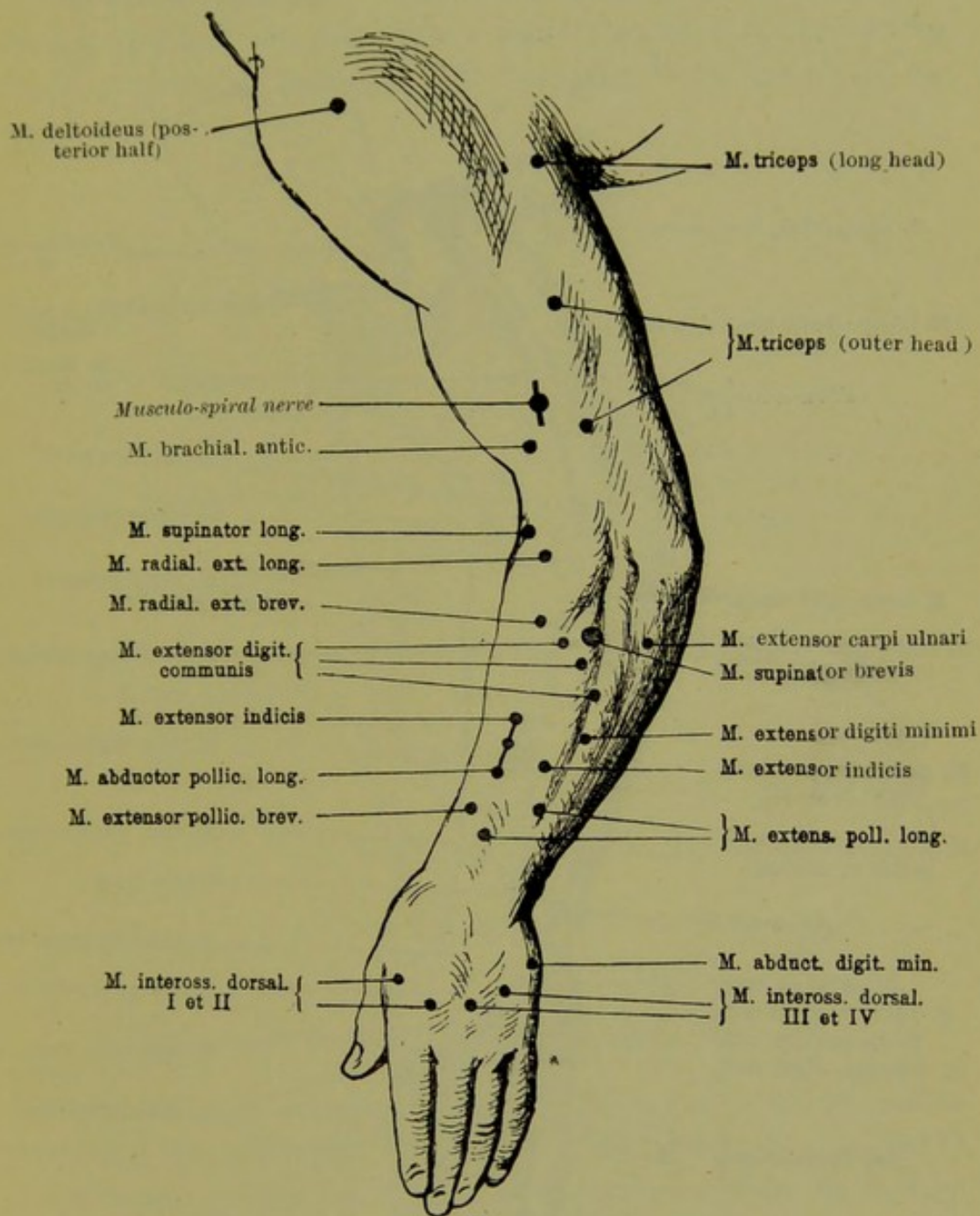


FIG. 214.—Motor Points of Upper Limb. (Erb.)

times by placing our finger on the tendon of the muscle, we can feel a contraction too faint to be visible. The patient should be made to relax all the muscles of the region which is under examination. Before applying the electrodes to the patient, we



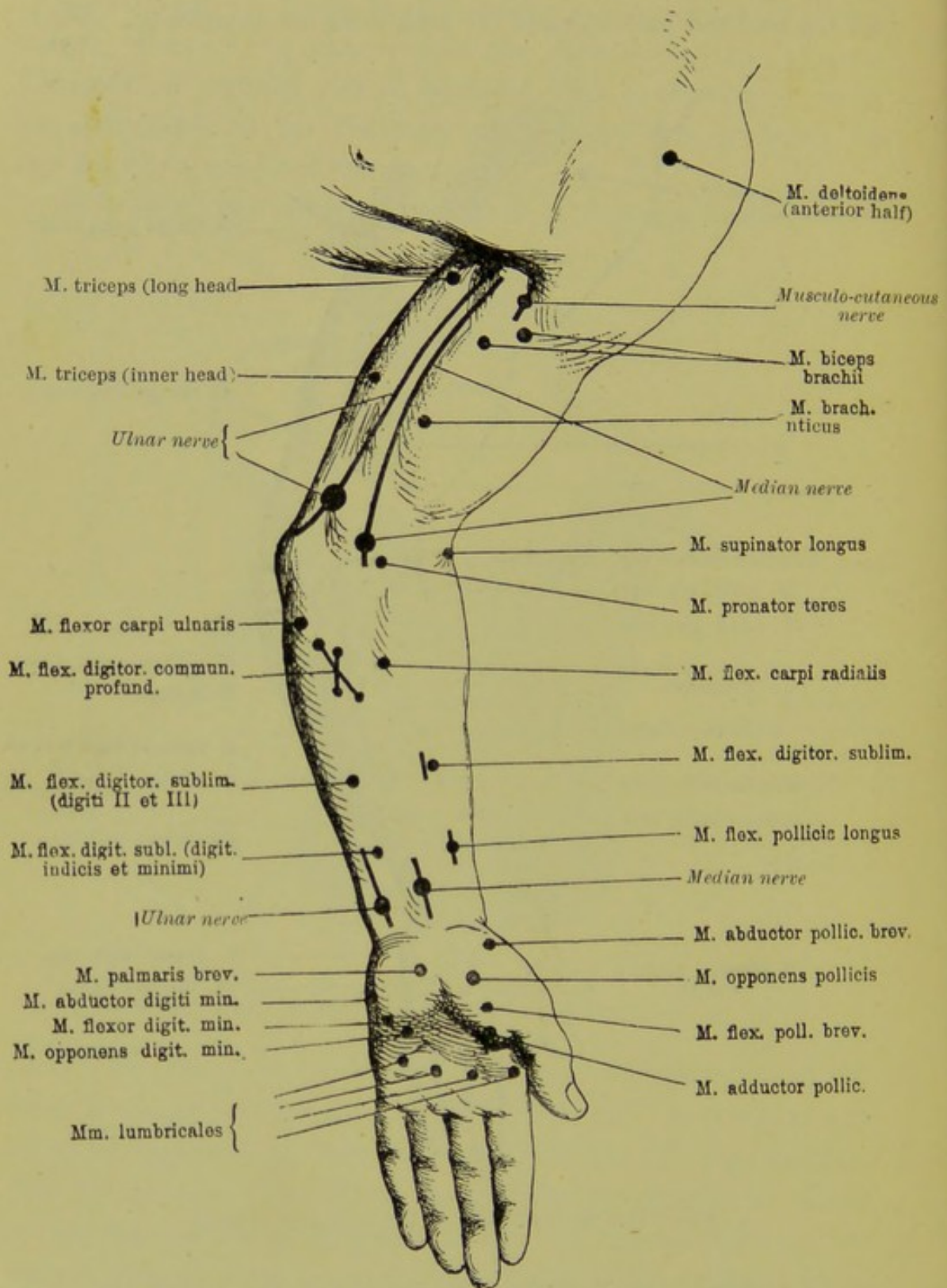


FIG. 215.—Motor Points of Upper Limb. (Erb.)



should make it an invariable rule to test the strength of the current on our own skin, to avoid startling him by too violent a shock.

**Electro-Diagnosis.**—We should commence with faradic shocks. Ordinarily these are produced in rapid succession by a vibrating Neef's hammer, "making" and "breaking" the circuit of the

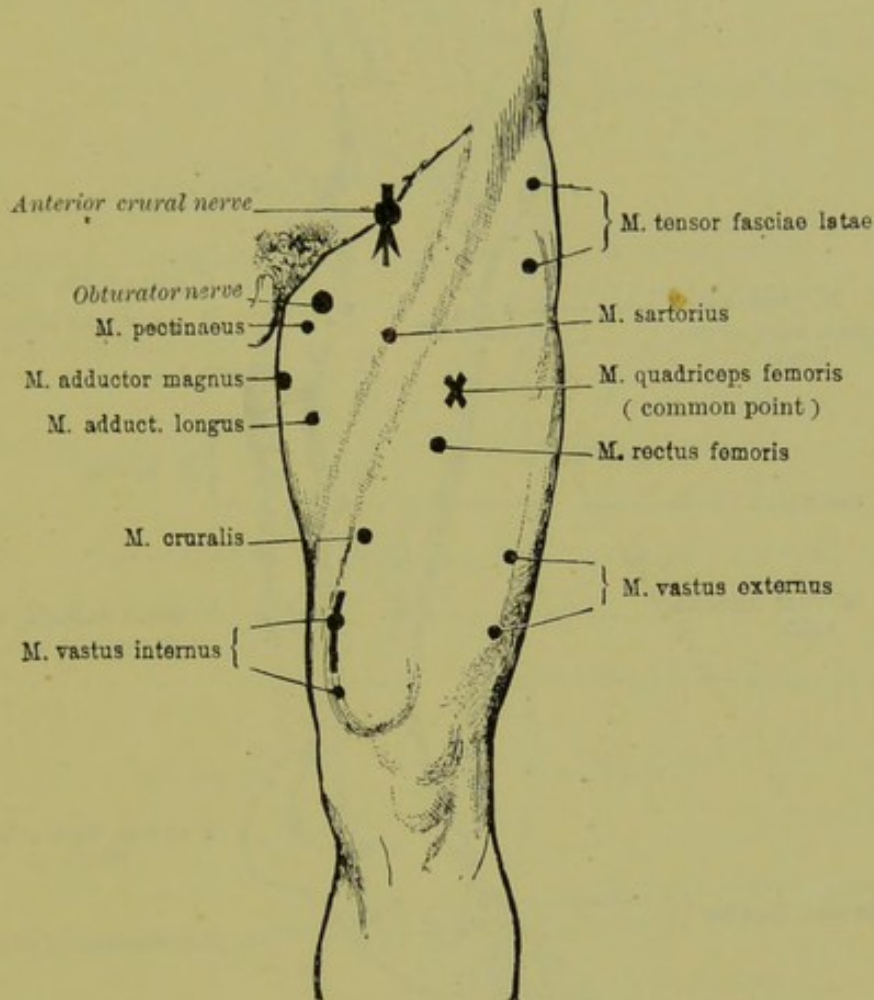


FIG. 216.—Motor Points of Anterior Thigh Muscles. (Erb.)

primary coil. If these are too painful to be borne, we may often overcome the difficulty by loosening the spring of the Neef's hammer and making and breaking the primary current by moving the spring with our finger. This produces an isolated faradic shock, each time we press the spring into contact with or remove it from the screw. Such single shocks are often tolerated by a patient who cannot bear the ordinary series of shocks in rapid succession. In children, however, it is sometimes impossible to get the patient to submit even to single shocks, and it may be necessary in them



to give a general anæsthetic, in order to make an accurate electro-diagnosis.

Whenever possible, we should compare the reaction of the suspected muscles with that of other muscles which are healthy,

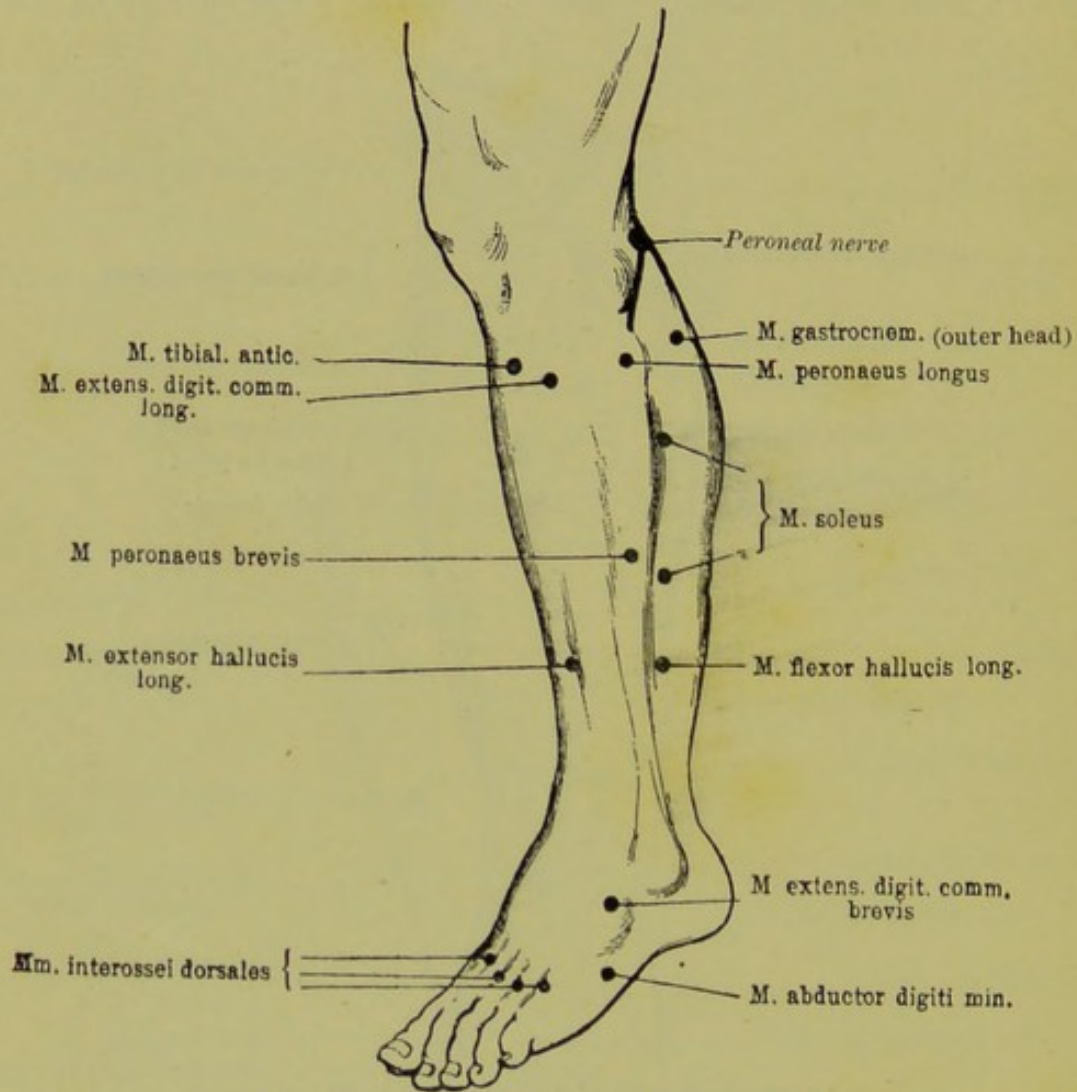


FIG. 217.—Motor Points of Leg. (Erb.)

preferably the corresponding muscles of the opposite limb. Of course, when the disease is bilaterally symmetrical, this is impossible. An electrical examination, to be complete, would have to include observations on every accessible muscle and motor nerve in the body; this, however, is practically unattainable, and we usually content ourselves with selecting a group of muscles in the affected area and testing each muscle carefully, both with faradic shocks and with the continuous current, commencing with the faradic.



**Faradic Reactions.**—Faradism stimulates a muscle most efficiently, not by direct action on the muscle-fibres but through the motor nerve. To stimulate an individual muscle by faradism we seek for the place where the nerve enters the muscle.

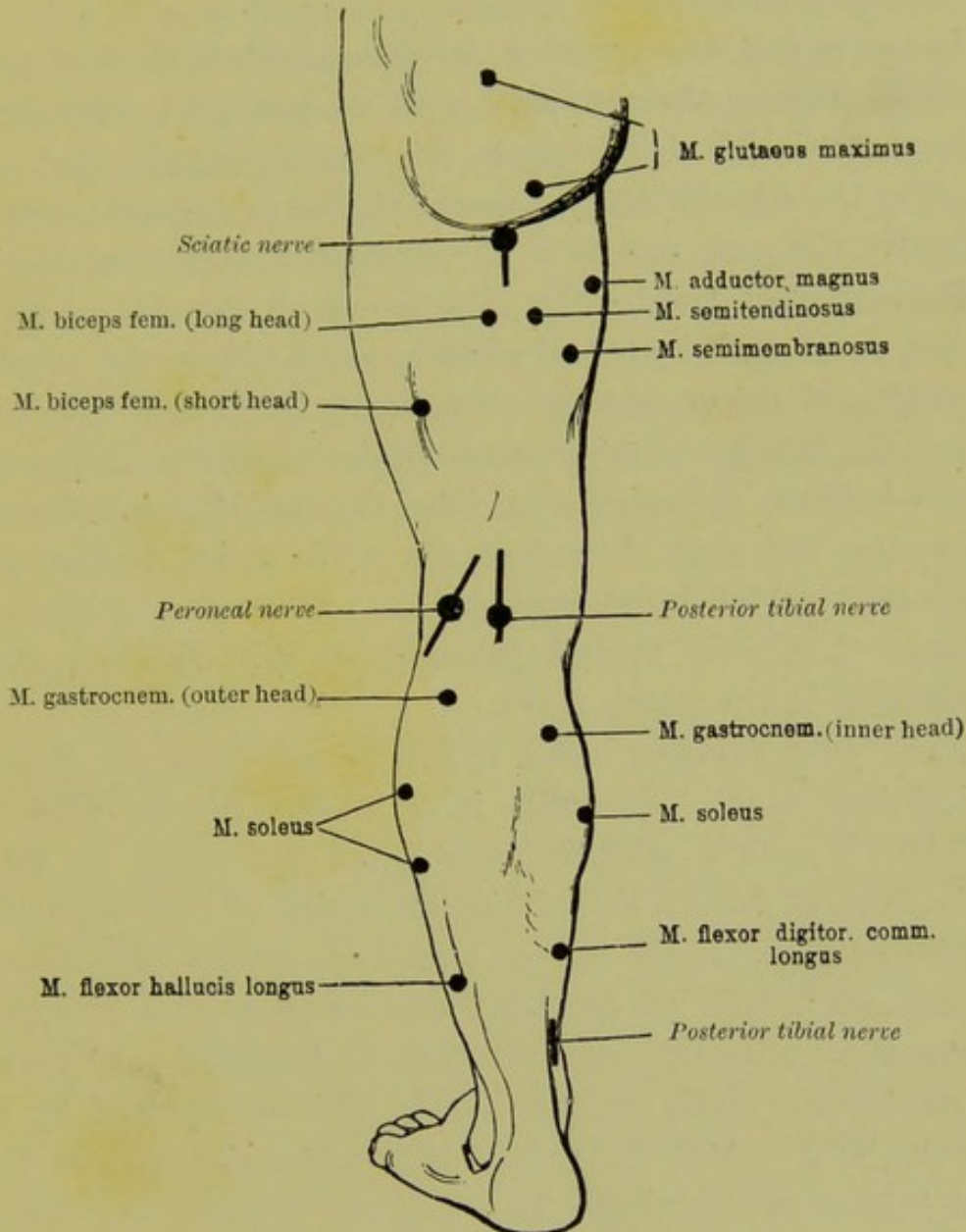


FIG. 218.—Motor Points at back of Thigh and Leg. (Erb.)

This is usually a well-defined spot known as the “*motor point*” of the particular muscle. Faradism applied at such a “*motor point*” provokes a maximal contraction in that individual muscle. The positions of the chief “*motor points*” are indicated in Erb’s well-known diagrams (Figs. 212 to 218). A faradic shock of a given strength produces a much greater effect when applied at



such a "motor point" than when applied directly over an indifferent bundle of muscle-fibres.

Besides stimulating individual muscles, we can stimulate whole groups by applying our electrode over a nerve-trunk, such as the ulnar or musculo-spiral.

In testing faradic reactions we commence with feeble shocks and gradually increase their strength until we just get a contraction of the muscle. We then compare this contraction with that produced by the same strength of shocks applied to a healthy muscle, preferably the same muscle of the opposite limb, if available.

**Galvanic Reactions.**—The galvanic current stimulates a motor nerve-fibre at the moment of closure, and again at the moment of opening of the current, but not during the period of flow, so long as the strength of the current remains constant. In the case of muscle-fibres, galvanism stimulates them at closure and again at opening, and even throughout the whole period of flow, provided the current be strong enough. Even when a nerve is degenerated, directly applied galvanism is still able to produce contractions in the muscle-fibres.

The "*polar reactions*" of a muscle to galvanism are of great clinical importance. Normally, in a healthy muscle, when we stimulate it with a galvanic current, not too strong, we get a brisk twitch at closure, then during the period of flow the muscle remains relaxed until the current is suddenly opened, when we may get another twitch at opening. The contraction at closure is greater if we stimulate with the kathode (negative pole) than if we employ the anode (positive pole). This is expressed by the formula  $KCC > ACC$  (kathodal-closure-contraction greater than anodal-closure-contraction). To verify this clinically on a healthy muscle, we gradually increase the strength of our current by means of the collector. Meanwhile, we make an occasional double movement of the commutator, whereby the testing pole is suddenly changed from kathode to anode and back again. Presently, as the current is increased in strength we find that at one position of this double movement we get a brisk twitch of the muscle, whilst in the reverse position we get none. The



first twitch in a healthy muscle always appears at the kathode. Then if the current be still further increased, a twitch appears at both phases of the commutator, but the kathodal contraction remains the greater. As a matter of convenience it is best to employ a current just strong enough to give KCC, whilst as yet there is no ACC. Meanwhile we notice on the galvanometer the number of milliamperes of current which are required to produce the earliest twitch at closure.

If the strength of the galvanic current be still further increased we obtain a twitch at opening, the anodal contraction being produced first and the kathodal opening contraction last of all. The order of appearance of these different contractions in a healthy muscle, as the current progressively increases in strength, is therefore as follows: KCC > ACC > AOC > KOC, and is indicated in the following amplification of the same facts:—

1. Weak current	.	.	.	KCC	...	...	...
2. Medium current	.	.	.	KCC	ACC	...	...
3. Moderately strong current	.	.	.	KCC	ACC	AOC	...
4. Very strong current	.	.	.	KCC	ACC	AOC	KOC

Of these phenomena, we usually concern ourselves, for practical purposes, only with the first two, that is, with the contractions on closure, observing whether the kathodal closing contraction is greater than the anodal closing contraction, as it ought to be in health.

To recapitulate, in a normal nerve-muscle organ we obtain a good contraction on faradic stimulation, while to galvanism there is a brisk twitch on closure, KCC being greater than ACC.

**Abnormalities in Electrical Reactions.**—Sometimes the excitability of the nerve-muscle organ is increased, both to faradism and to galvanism. This condition of hyper-excitability is met with most typically in *tetany*, where both nerve and muscle are too easily thrown into contraction. Somewhat similar is the so-called “*neurotonic*” reaction, described by Marina<sup>1</sup> in certain cases of hysteria, by Remak<sup>2</sup> in patients with progressive muscular atrophy, and by Handelsman<sup>3</sup> in syringomyelia. This phenomenon consists not only in excessive excitability both to faradism

<sup>1</sup> *Neurologisches Centralblatt*, 1896, No. 17.

<sup>2</sup> *Ibid.*, 1896, No. 13.

<sup>3</sup> *Ibid.*, 1911, s. 418.



and galvanism, but also in a tendency for the muscle to remain in a state of tetanus for 10 to 30 seconds after the stimulus has ceased. The phenomenon is not provoked by stimulation of the muscle itself, but only by excitation of the nerve.

We sometimes meet with simple diminution of excitability, both to faradism and to galvanism, but without alteration of polar reactions—that is to say, KCC remains greater than ACC. Such *diminution of electrical excitability* is met with in simple arthritic muscular atrophy, in the atrophy of disuse and also in the various myopathies, whether pseudo-hypertrophic or atrophic in type.

Temporary loss of faradic excitability occurs in myasthenia gravis, though not in every case. When present, the *myasthenic reaction* consists in the fact that after a certain number of faradic shocks, the muscle gradually reacts less and less, until at last it shows no contraction to the strongest faradic shocks. We wait a few minutes and then test again, when we find that the faradic excitability has reappeared, but can again be exhausted in a similar fashion. The galvanic reactions of the affected muscles remain unchanged throughout the disease. A myasthenic reaction can also be produced experimentally, *e g.* in the frog's muscles, by poisoning with yohimbine.<sup>1</sup> This suggests that the phenomenon is toxic in origin.

During the paroxysms of the rare disease known as *family periodic paralysis*, the paralysed muscles are, for the time, totally inexcitable either by faradism or by galvanism. In the intervals between the attacks of paralysis, the muscles react normally.

The *myotonic reaction* is met with chiefly in Thomsen's disease (myotonia congenita), but has also been observed in certain types of syringomyelia accompanied by myotonia. It consists in the fact that on faradic stimulation the muscular contraction persists for some time after the stimulus has ceased, as if the muscle, once contracted, cannot relax. Moreover, in this disease galvanic stimulation of the muscle produces curious wave-like contractions, and KCC is equal to instead of greater than ACC.

**Reactions of Degeneration.**—By far the most important modi-

<sup>1</sup> Gunn, *Rev. of Neurol. and Psychiat.*, 1908, p. 150.



fication of electrical reactions is the condition known as the "reactions of degeneration," or colloquially as R.D. This condition is present when the nerve-muscle organ has undergone degeneration, from disease or destruction of the spino-muscular motor neurone. As a result of such a lesion, the motor nerve-fibre disintegrates within a few days and loses its power of conducting impulses. The corresponding muscle-fibre undergoes important changes; it loses its fibrillar or anisotropic element, the element which contracts with a brisk twitch and can be stimulated with a faradic shock; whilst it retains only its sarcoplasm, a less excitable element, which contracts slowly and can still be stimulated by galvanism.

In a typical case the phenomena are as follows:—to *faradism* there is no response, since the nerve has degenerated; to *galvanism* the muscle-fibres still respond—in fact for a short time they become hyperexcitable, contracting to a weaker current than in health. But their polar reactions are altered. The anodal contraction on closure is now equal to, or greater than the kathodal ( $ACC > KCC$ ). Moreover, what is equally characteristic, the response of the muscle is no longer a brisk twitch; it is a slow, sluggish, almost vermiform movement. If a nerve be divided, the reactions of degeneration do not appear at once. It is only after some ten days or so that they develop. Once established, the reactions of degeneration persist, unless the nerve regenerates and re-establishes a connection between the muscle and the motor nucleus. In the process of recovery, voluntary motor power reappears before faradic excitability returns. In many cases recovery does not take place and the nerve-muscle organ remains permanently degenerated, as, for example, where the motor nucleus in the cord or medulla is destroyed, or where a nerve-trunk is completely divided and its ends have not been reunited.

In certain cases we meet with *partial or incomplete reactions of degeneration*. These consist in a sluggish contraction to galvanism, ACC being greater than KCC, but the reaction to faradism is not lost, but only diminished. This condition indicates a less severe injury of the nerve-fibres than if typical R.D. be present.



Sometimes we have *mixed reactions*, where some fibres of a muscle retain their normal reactions whilst adjacent fibres have reactions of degeneration. This is best exemplified by cases of progressive muscular atrophy where degenerated muscle-fibres are interspersed amongst the healthy.

To sum up, then, the presence of R.D. always indicates a lesion somewhere in the lower or spino-muscular motor neurone. We should be careful to wait ten days or a fortnight from the onset of the paralysis before giving this verdict, inasmuch as we have seen that it takes some time for degeneration to become established. R.D. occur in lesions of peripheral motor nerves, also in gross nuclear diseases such as acute anterior poliomyelitis, hæmorrhage, or thrombosis in the anterior cornua or motor nuclei. Mixed reactions, on the other hand, are found in progressive muscular atrophy and in bulbar palsy, where the nerve-cells of the motor nuclei are picked out one by one, leaving adjacent nerve-cells unaffected.

**Electro-Prognosis.**—In many paralyses due to organic lesions of peripheral motor nerves (of which the commonest instance is that of a neuritis of the facial nerve), it is of importance to be able to estimate not only the degree of degeneration which has occurred, but also the prospects of recovery. To make an accurate prognosis we must wait at least ten days, and preferably a fortnight, before making our investigation, so as to allow time for degenerative changes to have occurred. Electrical examination at any earlier date is practically valueless for purposes of prognosis. If, after a fortnight's motor palsy—say, in a case of Bell's paralysis—we get typical R.D., the degeneration of the nerve is severe and recovery will not commence for three months at least, possibly not for a year, and the patient may even remain permanently paralysed. And at the best, if recovery does occur, it will probably be imperfect and associated with some contracture. If partial R.D. be present, the prognosis is less grave and recovery may be expected within six or eight weeks. If the reactions be normal, or if there is simply a diminution to faradism and galvanism, but without polar changes, recovery may be looked for in from three to six weeks, or even sooner.



## CHAPTER XXIII

### THE CEREBRO-SPINAL FLUID

THE cerebro-spinal fluid is secreted by the ependyma covering the choroid plexuses. The amount secreted may be considerable. In cases of cranial or spinal injury where the subarachnoid space is in communication with the surface, as much as 2 to 4 litres daily have been observed to escape. In some patients, as St. Clair Thompson and others have shown, a spontaneous flow of cerebro-spinal fluid occurs through the cribriform plate and drips constantly from the nose.

The posterior lobe of the pituitary body pours its secretion through the hollow infundibulum into the cerebro-spinal fluid of the third ventricle. Experiments by Cushing and Goetsch<sup>1</sup> have demonstrated that normal cerebro-spinal fluid contains a substance which gives the same reaction as extracts of the pars nervosa itself. The fluid receives various products of metabolism from the nerve-centres. It may undergo changes in lesions of these centres or of their meninges; hence the clinical importance of its examination.

In the adult, the spinal cord terminates at the level of the lower part of the first lumbar vertebra. Below that level the arachnoidal sac extends as a hollow cavity as low down as the second sacral vertebra (see Fig. 219). There is thus a considerable extent of arachnoidal cavity devoid of spinal cord, occupied simply by the roots of the cauda equina and by the cerebro-spinal fluid which bathes them. From this region we can withdraw cerebro-spinal fluid without risk of injury to the spinal cord. In order to do so, we enter the cerebro-spinal cistern from behind, somewhere between the laminae of the second lumbar and the second sacral vertebra.

The two widest inter-laminal spaces are the one between the third and fourth, and the other between the fourth and fifth

<sup>1</sup> *Am. J. of Physiology*, 1910, vol. xxvii. p. 60.



lumbar laminae. Of these we usually select the space between the fourth and fifth laminae, because, as a rule, it is slightly the larger. These two inter-laminal spaces are very easily found as follows: we

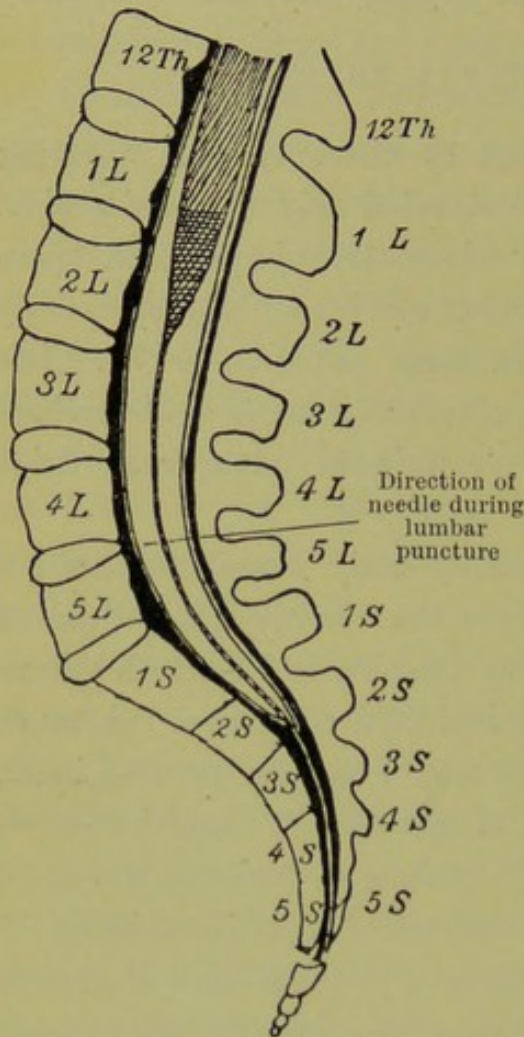


FIG. 219.—(After Raymond.) Diagram of lower end of vertebral column and its relations to the spinal cord and cauda equina. The double-shaded portion of the cord is the conus terminalis, with which the filum terminale is continuous.

draw a horizontal line across the patient's back, at the level of the highest margin of the iliac crests. This line intersects the vertebral column at the tip of the fourth lumbar spine. We make our puncture immediately below this spine (Fig. 220).

It is convenient to use an all-glass syringe which is readily sterilisable on which to mount our needle, which should be of fairly large calibre. The needle itself is made of platinum and iridium, which is less liable to snap and can also be boiled without rusting, unlike a steel needle. It must be long enough to reach into the arachnoidal sac, and yet short enough to stop short within the sac without penetrating to the dura on the far side. For this purpose the most suitable length of needle is about 8 centimetres, or just over three inches.

As to the patient's posture during the operation of "thecal puncture," he may be lying on a bed or couch, in the left lateral position, with the knees and shoulders approximated. But it is better, if possible, to have him sitting on a low seat, stooping well forwards, with his knees separated, his arms hanging loose, and his hands touching the ground. In this way the laminae are separated to their utmost extent (see Fig. 220).



We carefully sterilise the skin at the site of puncture and render it anæsthetic by means of a spray of ethyl chloride. The operator places his left index finger on the fourth lumbar spine as a guide, and with his right hand pushes in the needle, about half an inch below and half an inch to the right of this spot (so as to avoid the dense interspinous ligament), directing the point of the needle horizontally forwards and a little inwards. The ligamentum subflavum, deep in, between the laminæ, is somewhat resistant, and the needle is felt to be checked here. But we push firmly on, if no bone is struck, and suddenly the needle penetrates the ligament and dura-arachnoid and is now in the arachnoidal sac (see Fig. 221). If we strike on a lamina instead of the ligament, we withdraw slightly and try a point above or below.

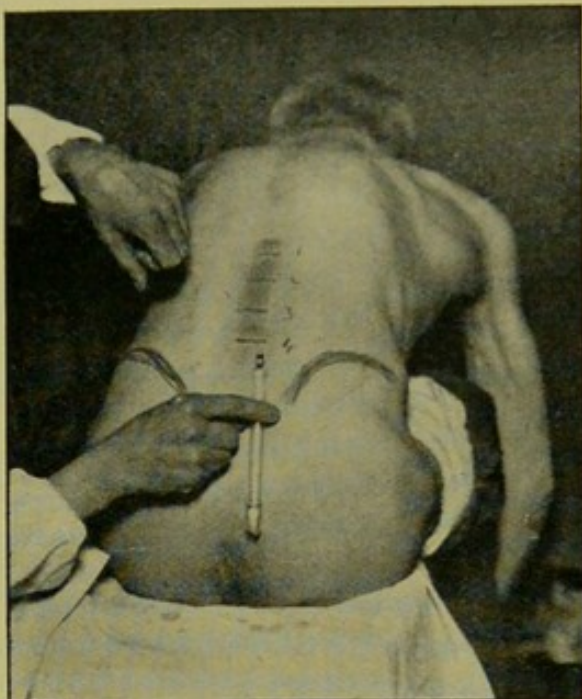


FIG. 220.—Lumbar puncture. Fluid dropping from needle into test-tube.

Sometimes during the operation the patient feels a sudden, sharp pain shooting down his right thigh and leg. This simply means that our needle has touched one of the roots of the cauda equina *en route*, and is of no other significance.

We now detach the syringe and allow the cerebro-spinal fluid to escape through the needle, collecting from 3 to 5 c.c. in a sterilised test-tube. It is better not to employ suction by the syringe, unless some difficulty be experienced in getting the fluid to run. The pressure of the fluid as it escapes may be measured, if desired, by means of a rubber tube with a manometer attached. Normally the fluid trickles out slowly, drop by drop. The first few drops should be discarded, since they may be mixed with blood from our needle-wound of the superjacent tissues



Occasionally it happens that even when we have successfully penetrated within the ligamentum subflavum, no fluid will flow. This is usually due to blocking of the needle by a small plug of blood-clot or shred of muscle or connective-tissue, during the process of puncture. Or it may be due to one of the cauda equina roots floating against the end of the needle. Such conditions are easily rectified by passing a sterilised stilette along the needle, to clear it. Sometimes it happens that the needle pierces the ligamentum subflavum but pushes the spinal theca in front of it, so that, even though the stilette shows the needle to be free from

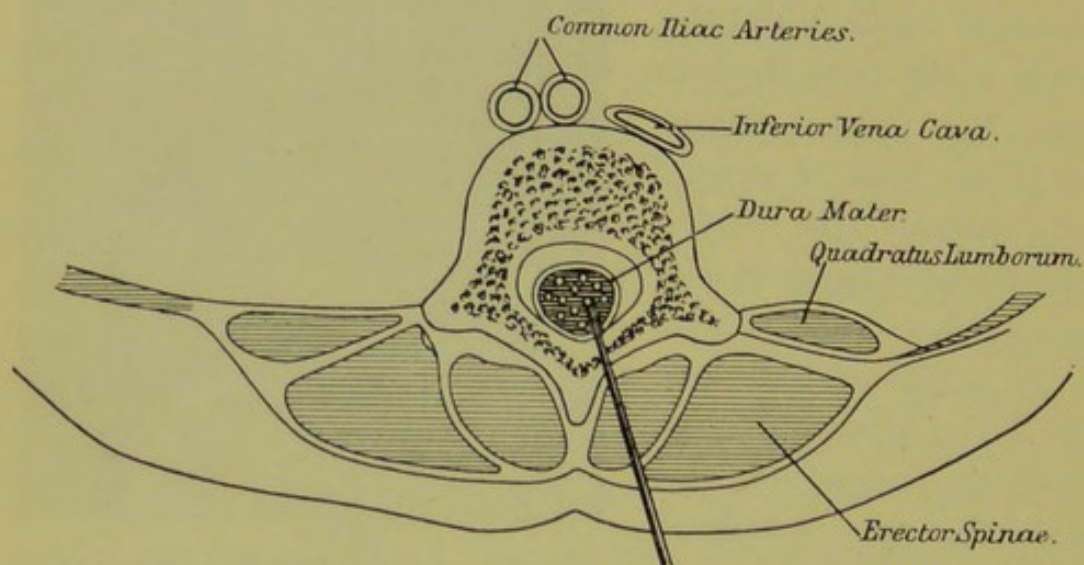


FIG. 221.—Horizontal section at the level of the fourth lumbar vertebra, showing the relations of the parts concerned in thecal puncture.

obstruction, no fluid comes. In such cases it is best to withdraw the needle and puncture at the next space above.

Sometimes the intrathecal pressure is increased, so that the fluid escapes in a jet, instead of drop by drop. This occurs chiefly in intra-cranial tumours and in the various forms of meningitis, although even in these conditions an increased pressure of fluid in the lumbar region is by no means constant, for sometimes in meningitis there is occlusion of the foramen of Magendie, or of the foramina of Key and Retzius, or the cerebellum may be partially impacted in the foramen magnum, cutting off the intra-ventricular from the spinal pond.

The fluid may be accidentally mixed with blood from the wounding of an arachnoidal vein during the puncture; this is



an accident which cannot be foreseen. In most cases such bleeding clears up after a few seconds, the fluid becoming progressively clearer and clearer. But admixture of blood also occurs in cases of pre-existent subarachnoid hæmorrhage, cerebral or spinal, as in fracture of the skull, intra-ventricular hæmorrhage, or in trauma of the spinal cord. We can sometimes distinguish between hæmorrhage due to the local puncture and hæmorrhage which results from a previous intra-theal lesion. We do this by centrifuging the fluid. In local hæmorrhage due to puncture, the blood corpuscles fall to the foot of the centrifuge-tube, leaving the superjacent fluid clear and limpid, whereas in a pre-existing cerebral or spinal hæmorrhage the fluid (which during its flow is equally tinged from start to finish, and generally less deeply tinged than in local hæmorrhage), remains of a yellow colour even after centrifuging.

The withdrawal of a small quantity of cerebro-spinal fluid in most cases causes the patient no discomfort. But in a small proportion of cases he may complain of severe headache, appearing an hour or two later, and lasting perhaps for several days. This is usually in patients who have been walking about as usual after the puncture, and headache can generally be prevented by recommending the patient to rest for a day or so, or at least to avoid physical exertion.

Normal cerebro-spinal fluid is absolutely colourless, like water. It has a specific gravity of 1006 to 1008. It is alkaline, contains a trace of serum-globulin and of albumose, and also a substance which reduces Fehling's solution and forms glucosazone crystals. Microscopically it contains a few large, flat, endothelial plates, and perhaps an occasional lymphocyte. It contains no organisms.

**The Diagnostic Significance of Cerebro-spinal Fluid.**—For diagnostic purposes, the fluid may be examined in various ways.

(1) *Physical Characters.*—Instead of being clear and limpid like water, the fluid may be opalescent, turbid, cloudy, or even purulent, as in some cases of meningitis. In severe jaundice it has been observed to be yellow and clear, whilst in cases of recent hæmorrhage either into the brain or cord, as we have mentioned, it may be blood-stained. In hæmorrhages of older date, say a week or more, the fluid may be of a clear yellow colour.



In cases of sudden hemiplegia, we are sometimes in doubt whether the lesion is hæmorrhage or thrombosis. The diagnosis between these two conditions may be very difficult. But the treatment of the two is diametrically opposite. In a case of thrombosis we stimulate, and, if necessary, push our anti-syphilitic remedies, whereas in cerebral hæmorrhage we try to lower the intra-cranial blood-pressure and diminish the force of the heart. If in a doubtful case we perform lumbar puncture and obtain blood-stained fluid, or fluid which has a yellow tinge even after centrifuging, the diagnosis may be much simplified. I have performed lumbar puncture in a comatose patient moribund from cerebral thrombosis and obtained normal clear fluid. In traumatic cases it is of great value in indicating the presence of intra-cranial hæmorrhage. Cathcart of Edinburgh<sup>1</sup> recorded a case in which, after a head injury, examination of the cerebro-spinal fluid helped to settle the diagnosis of intra-cranial hæmorrhage. He trephined, tied the ruptured artery, and saved the patient's life. But in compound fracture of the skull lumbar puncture may yield nothing, if the fluid happens to be escaping by other channels, viz. through the lacerated membranes.

The freezing-point of the cerebro-spinal fluid has been studied by various observers:—so-called *cryoscopic examination*. Widal, Sicard, Ravaut,<sup>2</sup> and others have recorded a lowering of the freezing-point in certain diseases such as meningitis, tuberculous or otherwise. But, on the whole, cryoscopy has not been of much practical value.

(2) *Chemical Characters*.—These are of some value. Thus, for example, a marked excess of albumin is found in acute meningitis, and to a lesser degree in tabes and in general paralysis of the insane, the proteid concerned in tabes and general paralysis being an euglobulin. A convenient method of examining this globulin is by Noguchi's test,<sup>3</sup> which is performed as follows:—To two parts of cerebro-spinal fluid are added five parts of a 10 per cent. solution

<sup>1</sup> *Scot. Med. and Surg. Journ.*, Edinburgh, 1902, p. 145.

<sup>2</sup> *Compt. rend. Soc. de Biol.*, Paris, August 20, 1900.

<sup>3</sup> *Journal of Experimental Medicine*, 1909, vol. xi. p. 84.



of butyric acid in normal saline solution. This mixture is heated to boiling-point, and then one part of a normal (4 per cent.) solution of sodium hydrate is added and the mixture is again boiled briefly. On standing for two to thirty minutes, if a globulin be present, there is a flocculent or granular precipitate. An even simpler method of detecting globulin (and one which is free from the olfactory drawbacks of Noguchi's method) is by means of ammonium sulphate.<sup>1</sup> On to the surface of a saturated solution of ammonium sulphate in a test-tube a small amount of cerebro-spinal fluid is allowed to flow by means of a fine pipette. If globulin be present, a fine white ring appears at the junction of the two fluids.

In acute meningitis, whether tuberculous or septic, sugar is almost always absent. In chronic meningitis, in tabes, and in general paralysis of the insane, it is often diminished.

Another chemical point, which my colleague, Dr. Hebb, investigated in a number of my cases at the Westminster Hospital, is as to the presence of cholin in the cerebro-spinal fluid. Normally cholin is not detectable in any appreciable quantity. But in organic degenerative diseases of the nervous system, cholin may be demonstrated in the blood and cerebro-spinal fluid, and can be crystallised out as a combined platinum salt, according to the method of Halliburton and Rosenheim.<sup>2</sup> Thus, for example, Hebb obtained cholin-platinum crystals from the cerebro-spinal fluid in cases of cerebral hæmorrhage, syringomyelia, disseminated sclerosis, &c. This test may occasionally be of value in the diagnosis between hysteria and gross organic disease. But it is too complicated for ordinary clinical work.

(3) *Bacteriological Characters.*—These are chiefly of value in cases of meningitis, to determine the particular organism causing the disease. Thus, for example, in epidemic cerebro-spinal meningitis the meningo-coccus (*diplococcus intra-cellularis*) is found; in tuberculous meningitis, the tubercle bacillus; and in other varieties of meningitis we may find staphylococci, streptococci,

<sup>1</sup> Jones, *Review of Neurol. and Psychiatry*, 1909, p. 379.

<sup>2</sup> *Brit. Med. Journ.*, 1907, p. 1043.



pneumococci, and so on. We should remember that failure to discover tubercle bacilli does not necessarily exclude tuberculous meningitis, though their presence would confirm such a diagnosis.

To demonstrate the bacilli in tuberculous meningitis it is convenient to allow the fluid to stand for 12 to 24 hours, by which time a fine coagulum has usually formed. This is removed by a needle, spread on a slide, fixed and stained in the usual manner.

In doubtful cases inoculation experiments on guinea-pigs are of value. In Landry's ascending paralysis various organisms (tetra-cocci and others) have occasionally been isolated from the cerebro-spinal fluid and blood.

(4) *Microscopic Characters*.—Clinically, microscopic investigation has proved by far the most valuable mode of examination of the cerebro-spinal fluid. A good method is to centrifuge a given quantity of the fluid, say 5 c.c. for five minutes, thereby collecting into a small deposit all the cellular elements which may be present. We then carefully decant off all the superjacent fluid, turn the empty tube upside down and scrape the bottom with a fine capillary pipette. In this way we collect the sediment, which is transferred to a slide, fixed by heat, stained by methyl blue or by Jenner's stain, mounted in Canada balsam and examined with the microscope.

Specimens prepared as above described afford a permanent record of the variety and intensity of the cellular contents present. To obtain absolute accuracy of counting we employ Fuchs and Rosenthal's<sup>1</sup> counting-chamber, a modification of the Zeiss blood-counting chamber. In using this, a small quantity (10 cubic mm.) of cerebro-spinal fluid is mixed by means of a special pipette with 1 cubic mm. of a staining fluid containing methyl violet and acetic acid. A drop of the mixture is placed on the counting stage, and the cells are counted. The results so obtained correspond with those found in centrifuged deposits, but are more accurate. But the preparation so obtained is not a permanent one, and I am, therefore, now in the habit of employing both the centrifuge and the counting chamber—the one to yield a permanent

<sup>1</sup> *Wiener medizinische Presse*, 1904, s. 2084.



specimen, the other to ensure accurate counting of the cellular contents in the fluid.

In rare cases we may find parasites. Thus, for example, Castellani and Bruce<sup>1</sup> found the trypanosome of sleeping-sickness not only in the blood of such patients but also in the cerebro-spinal fluid. In fact, it is easier to identify the trypanosome in the cerebro-spinal fluid than in the blood, where it is likely to be obscured by blood corpuscles. In a few cases of malignant growths of the spinal cord or of its meninges, tumour-cells have been found in the fluid. But this is inconstant, though tumour-cells, if present, would have a high positive diagnostic value.

By far the most valuable point to be determined microscopically is the presence or otherwise of leucocytes, observing not only their number but their type. This is the so-called **cyto-diagnosis**.

Normal cerebro-spinal fluid contains no polymorpho-nuclear leucocytes and only an occasional small mono-nucleated lymphocyte, with now and then a few endothelial plates. Examination of the centrifuged deposit with a magnification of 400 diameters, according to the technique described, should show an average of not more than two or three lymphocytes to the field, or from 1 to 2 per cubic mm. Sometimes we find no cells of any sort. But in certain organic diseases of the central nervous system or its membranes, there may be a large excess of leucocytes—polymorphs or monomorphs. Briefly stated, in cases of acute microbial infection of the brain and meninges, especially the suppurative varieties,<sup>2</sup> we find a polynuclear leucocytosis, where the leucocytes are mostly polymorphs, with some large monomorphs as well. When recovery begins in acute infective meningitis, the polynuclear leucocytes in the cerebro-spinal fluid diminish in numbers and become replaced by lymphocytes. These latter in turn disappear as convalescence becomes complete.

<sup>1</sup> *Brit. Med. Journ.*, November 21, 1903.

<sup>2</sup> But it is the acuteness of the inflammatory process, not its microbial origin, which appears to be the chief factor in producing polynuclear leucocytosis. Thus I have experimentally produced abundant polynuclear leucocytosis in monkeys by injecting sterile salt solution or a sterile emulsion of coloured particles into the spinal theca.



If a brain abscess be present without implication of the superjacent meninges, as sometimes occurs, the cerebro-spinal fluid shows no excess of leucocytes. Examination of the fluid is therefore a valuable means of distinguishing between meningitis and brain abscess. In both conditions a blood-count shows a great excess of polymorphs in the blood: these may number from 10,000 to 25,000 or more (instead of from 8000 to 10,000 per cubic millimetre as in health), the leucocytosis of the blood being higher, as a rule, in meningitis than in brain abscess.

But in subacute and chronic affections of the meninges, whether tuberculous, syphilitic, or otherwise, also in certain chronic degenerative diseases of the central nervous system, we usually find a lymphocytosis, *i.e.* an excess of small monomorphs, sometimes accompanied by a small proportion of large monomorphs. In cases of acutely advancing tuberculous meningitis I have also found a considerable proportion of polymorphs (30 per cent. and upwards) amongst the monomorphs. There is often a marked lymphocytosis during an attack of herpes zoster and for a number of days afterwards. In functional nervous diseases the fluid is normal.

In several cases of lymphatic leukæmia, and in a case of chloroma at the Westminster Hospital, Hebb has also observed marked lymphocytosis of the cerebro-spinal fluid.

Let us study some illustrative cases. One case was an example of epidemic cerebro-spinal meningitis in a patient who was comatose and apparently moribund. The cerebro-spinal fluid was under excessive pressure, of turbid appearance, and the centrifuged deposit showed microscopically an average of 87·3 polymorphs to the field. Within many of the leucocytes the meningo-coccus was readily distinguished. The withdrawal of about an ounce of fluid caused marked improvement in the symptoms and the patient made a good recovery. Another case was that of an officer who had chronic otitis media on the left side. He rapidly developed mental dulness and slight aphasic symptoms, with some fever. In his case the fluid was turbid, and showed no fewer than 371 polymorphs to the field. Operation was at once undertaken and an



inflamed area of brain tissue was exposed in the temporal lobe. No abscess was found. The symptoms rapidly subsided and the patient made a complete recovery.

As an instance where the cerebro-spinal fluid was normal may be mentioned the case of a child, in whom, as is so often the case, a deep-seated pneumonia was ushered in by head symptoms simulating meningitis—so-called “meningism.” There were marked headache, some head-retraction, and squint. Moreover, an older child in the same family had previously died from meningitis, and the parents were therefore in considerable anxiety as to the possibility of a second case. The cerebro-spinal fluid, however, showed no excess of cells, and Kernig’s sign was absent. Meningitis was therefore less likely than a functional meningism, and an encouraging prognosis was given, which proved correct.

With regard to the cases of lymphocytosis, the most striking results are those observed in general paralysis of the insane and in tabes dorsalis. The lymphocytosis in these two affections (which are essentially the same disease etiologically, and which clinically are not infrequently combined in the same patient) is more marked than in any other form of organic nervous disease. Thus in a recent series of twelve cases of general paralysis examined by me, the average number of lymphocytes was 131 per cubic mm., the lowest count in any one case being 40·5, and the highest 295. In a series of fifteen tabetics, the lowest count was 14, the highest 477·1, and the average number per cubic mm. for the whole series was 125·4. This closely approximates to the average for general paralysis.

A point of importance noticed in cases of tabes and general paralysis is that not only is lymphocytosis present in practically every case, but it is often extremely marked when the other symptoms of the disease are very slight. Thus, for example, one patient had lightning-pains, analgesia of the tendo Achillis, but no ataxia, no abnormality of the pupils, and brisk knee- and ankle-jerks. Yet his cerebro-spinal fluid showed 150 lymphocytes per cubic millimetre, and he was undoubtedly an early case of tabes. The same applies to general paralysis. One patient with 239·6 lympho-



cytes per cubic mm. was an early case, with practically no mental symptoms, simply a slight loss of memory and a history of two attacks of unconsciousness followed by transient aphasia and weakness of the right hand—"congestive attacks."

We therefore possess in the cytological examination of the cerebro-spinal fluid a valuable means of recognising tabes and general paralysis in their earliest stages. If no excess of lymphocytes is present, these two diseases can usually be excluded.<sup>1</sup> Another point of interest is that during the pyrexial attacks of general paralysis, there is a temporary polynuclear leucocytosis not only of the blood but of the cerebro-spinal fluid. Thus in a case of my own there were 118 polymorphs and 25 monomorphs per cubic mm. Pappenheim<sup>2</sup> has also recorded similar cases.

A further point of interest is that the lymphocytosis in tabes and general paralysis is uninfluenced by the most energetic anti-specific treatment. In several of my cases, the fluid was examined at intervals of a month, the patient meantime having had daily hypodermic administrations of mercury; yet the lymphocytosis remained unchanged in its intensity. This is in marked contrast to what occurs in active syphilitic lesions. Thus, for example, in a case of gumma of the spinal cord, the lymphocytes, which numbered 52·6 on admission, were reduced after three weeks' treatment to 16·1, and the patient, who was totally paraplegic and anæsthetic in the lower limbs on admission, was discharged in a couple of months able to walk, without anæsthesia, and with the sphincters under control.

Another point of importance is that syphilis by itself, unless there be an active syphilitic lesion of the central nervous system, produces little or no excess of lymphocytes in the cerebro-spinal fluid. Thus in my series of twelve cases, in the five secondary cases the average number of lymphocytes was 2·7, that of

<sup>1</sup> This rule, however, is not without exceptions, for I have seen a case of tabes, with ataxia, Argyll-Robertson pupils, and absent knee- and ankle-jerks, in which the cerebro-spinal fluid contained only 3·3 lymphocytes per mm<sup>3</sup>. Erb (*Deutsche Zeitsch. f. Nervenheilkunde*, 1907, s. 438) has also recorded similar cases.

<sup>2</sup> *Monatschrift für Psychiatrie und Neurologie*, 1907, s. 536.



the six tertiary cases was 0.9, the twelfth case being one of a man who had a syphilitic chancre twenty-six years before. The tertiary cases with active syphilitic lesions, such as gummatous ulcers, rupia, and so on, had more cells than the others, but even in them the number was less than the average of the secondary cases.

We thus see that the presence of a large lymphocytosis in a patient who has had syphilis, is of grave significance and indicates serious organic disease, either a syphilitic lesion of the central nervous system, or, if very marked, tabes or general paralysis. In such cases we should carefully examine for other signs of organic disease, especially for Argyll-Robertson pupils, early optic atrophy, alterations in the reflexes, and sensory changes. Even if no other sign of organic disease be present, the presence of lymphocytosis of the cerebro-spinal fluid is an indication for the most energetic anti-specific treatment, in the hope, perhaps, of preventing subsequent developments.

The presence of lymphocytosis in tuberculous meningitis is readily understood, also that which occurs in tuberculous tumours on the surface of the brain. It is more difficult at present to account for the occasional excess of lymphocytes in cerebral neoplasms. Thus one case of glioma of the centrum ovale had no fewer than 75 lymphocytes to the field, a count which led one to expect a tuberculous mass, there being no possibility of syphilis. Yet the autopsy showed a glioma which had in no way approached the meninges, and where a hæmorrhage into the substance of the tumour ultimately caused death by bursting into the lateral ventricle.

**Therapeutic Applications of Thecal Puncture.**—Lumbar puncture was originally introduced by Quincke for the purpose of relieving intra-cranial pressure in tuberculous meningitis. This it does for the time, though it is more often palliative than curative. In one case of mine the patient, a young man, comatose and apparently moribund, regained consciousness for a day, after the withdrawal of 22 c.c. of cerebro-spinal fluid. The fluid was allowed to flow until the increased intra-theal pressure fell to normal.



The importance of this procedure, not only from sentimental reasons but possibly on medico-legal grounds, is obvious. In any case we can usually diminish or abolish the convulsions which are so distressing to the onlookers. But sometimes lumbar puncture has undoubtedly proved curative, even in tuberculous meningitis. Thus in cases recorded by Freyhan,<sup>1</sup> Henkel,<sup>2</sup> Barth,<sup>3</sup> and others, tubercle bacilli were demonstrated in the cerebro-spinal fluid and yet the patients ultimately recovered, after repeated punctures.

In other forms of meningitis associated with a polynuclear leucocytosis (apart from infective cases secondary to bone disease), especially in epidemic cerebro-spinal meningitis, good results have been obtained by the injection of antiseptic substances, after withdrawal of a corresponding quantity of cerebro-spinal fluid. For this purpose, a 1 per cent. solution of lysol has been found useful, 10 cubic centimetres being introduced at each sitting. Flexner's serum, prepared from immunised horses, injected in doses of about 30 c.c. repeated on several successive days, has also had highly encouraging results.<sup>4</sup>

In intra-cranial pressure due to other causes, as, for example, in inoperable or inaccessible cerebral tumours, lumbar puncture is sometimes of distinct benefit as a palliative measure, by diminishing urgent pressure and thereby relieving headache, vertigo, and other symptoms. Hitherto to relieve intra-cranial pressure and to diminish optic neuritis it has been the custom to trephine the skull as a palliative measure. But lumbar puncture is quicker, simpler, and less dangerous than a major cranial operation. I performed it in three cases of intra-cranial tumour where the symptoms pointed to deep-seated cerebellar disease. In all of them the headache and vertigo were greatly relieved for several weeks after the puncture, and an opportunity was afforded of studying the patient's focal symptoms with a view to subsequent removal of the growth. In intra-cranial growths we must be careful not to

<sup>1</sup> *Deutsche medizinische Wochenschrift*, 1904, No. 36.

<sup>2</sup> *Münchener medizinische Wochenschrift*, 1900, s. 133.

<sup>3</sup> *Ibid.*, 1902, No. 21.

<sup>4</sup> *Ker, Edin. Med. Journal*, Oct. 1908.



withdraw too large a quantity of cerebro-spinal fluid, lest sudden diminution of pressure cause a hæmorrhage into the tumour (a result, by the way, which sometimes occurs after a palliative trephining). In a case recorded by Masing<sup>1</sup> this actually occurred; but in his case the fluid was allowed to run for a quarter of an hour and no less than 10 c.c. were withdrawn. I have had under my observation several cases of persistent tinnitus and giddiness, of many months' duration, in which a single lumbar puncture with the removal of less than 10 c.c. of fluid permanently relieved the condition. We must, of course, be careful to eliminate all the ordinary causes of tinnitus and giddiness, aural or otherwise, before resorting to this treatment. In fractures of the base of the skull, coma may be relieved in a remarkably short time by the withdrawal of cerebro-spinal fluid. I saw such a patient after a carriage accident, in whom lumbar puncture was followed by rapid improvement. The procedure may, if necessary, be repeated several times on successive days.

Uræmic coma and convulsions, and cases of puerperal eclampsia, are often relieved in a striking manner by lumbar puncture, and in several instances life has undoubtedly been saved by this means. For example, McVail<sup>2</sup> records two cases of acute nephritis in which, notwithstanding energetic treatment by purgatives, hot-air baths and pilocarpin to induce free perspiration, coma and convulsions supervened. Lumbar puncture was performed, 20 to 28 c.c. of cerebro-spinal fluid were withdrawn, and within three or four hours the coma passed off, the convulsions ceased, and both patients ultimately made a complete recovery. Cases like these raise the question as to whether the headache, coma, and convulsions in nephritis are really caused entirely by "uræmic poisoning" of the brain-centres, or whether they may not be largely due to a sudden increase of intra-cranial pressure—part of the general œdema.

Again, in cases of tetanus, we know that the tetanus poison has a selective action on the motor nerve-cells of the spinal cord and brain. Therefore, in addition to removing the tetanus

<sup>1</sup> *Neurol. Centralbl.*, 1904, p. 1116.

<sup>2</sup> *Brit. Med. Journ.*, 1903, vol. ii.



bacilli at the site of inoculation, by excision of the original wound, we endeavour to neutralise the toxin by means of antitoxin. This is sometimes administered hypodermically; but it is more efficacious, as Roux and others have shown, if injected into the cranial cavity through a small trephine opening, and some remarkable recoveries have followed this method of treatment. But the procedure is not free from danger. In one case at least,<sup>1</sup> a patient died of cerebral abscess at the site of the trephine-opening eight weeks afterwards, long after all symptoms of tetanus had disappeared. It is simpler and better to administer the antitoxin (with perhaps the addition of stovaine and morphine) by means of a lumbar puncture needle. Strychnine poisoning is also successfully treated by intra-theal administration of eucaine. It may be necessary to give a general anæsthetic to relax the opisthotonos, before performing the spinal puncture.

Injection of anæsthetic drugs by thecal puncture—so-called **spinal anæsthesia**—is useful when we desire to perform operations on the lower limbs or trunk without rendering the patient's brain unconscious. Various substances have been successfully employed as spinal anæsthetics, amongst which may be mentioned cocaine, stovaine, and a mixture of novocaine with strychnine.<sup>2</sup> It is desirable, if possible, to have a solution which is isotonic with the blood-serum, *i.e.* having the same osmotic tension.

For spinal anæsthesia in operations on the pelvis and lower

<sup>1</sup> Gibbs, *Brit. Med. Journ.*, July 1, 1899.

<sup>2</sup> The following are examples of anæsthetising solutions:—

1. Stovaine, 5 per cent.; glucose, 5 per cent. in water. Sp. gr.=1023. Dose=1 c.c. (Barker, *Brit. Med. Journ.*, 1908, p. 248.)
2. Stovaine, 4 per cent.; sod. chloride, 0.11 per cent.; suprarenin borate, 0.01 per cent. in water. Sp. gr.=1005. Dose=1 c.c. (Bier, quoted by Barker, *Brit. Med. Journ.*, 1907, p. 665.)
3. Stovaine, 1.5 per cent.; cocaine, 0.5 per cent. in water. Dose=4 c.c. (Chaput, *La Presse Médicale*, 1907, p. 753.)
4. Novocaine, 2 per cent.; suprarenin borate, 0.009 per cent.; NaCl, 0.9 per cent. Sp. gr.=1014. Dose=5 c.c. (Braun, *Deutsche med. Wochenschrift*, 1905, s. 1667.)
5. Strychnine sulphate, 5 to 10 cg.; sterilised water, 100 grams. Of this solution 1 c.c. is mixed with 3 to 10 cg. of stovaine, and the mixture is injected. (Jonnesco, *Brit. Med. Journal*, 1909, p. 1396.)



limbs we generally select the first or second lumbar interspace, whilst Jonnesco prefers "dorso-lumbar" injection between the twelfth thoracic and the first lumbar vertebra, thereby producing analgesia of the whole abdomen and lower limbs. We perform our puncture in the mesial line, so that the roots of both sides may be equally affected. Before injecting the anæsthetising solution, we withdraw a quantity of cerebro-spinal fluid, exceeding in amount the fluid to be introduced.

Spinal anæsthesia is essentially a root anæsthesia, due to paralysis of the posterior roots. On injecting a solution of stovaine in the lumbar region, the earliest objective signs are disappearance of the knee-jerks (usually within one minute), then of the ankle-jerks (within two or three minutes), the superficial reflexes remaining as yet unchanged. Concurrently with the abolition of the deep reflexes there occurs slight analgesia of the perineum and genitals, without loss of tactile sensibility. The analgesia gradually deepens and spreads over the lower limbs, and after four or five minutes the plantar and cremasteric reflexes disappear. Temperature-sense becomes lost. Tactile and pressure-sense disappear much later and may be preserved throughout. Sense of position is last and least affected. The dartos or scrotal reflex is unaffected. Motor paralysis, due to affection of the anterior roots, supervenes last of all, in five or six minutes, beginning in the feet and soon affecting the whole musculature of the lower limbs. The deep structures also become analgesic. If it is desired to reach the higher roots by a heavy anæsthetising fluid, it is advisable to elevate the pelvis higher than the thorax, to permit the fluid to gravitate towards the thoracic region. In this way the anæsthesia may extend as high as the nipples, or even to the upper limbs. If the injection be made with the patient lying on his side, the heavy anæsthetising solution gravitates to the dependent side and therefore exercises its effects chiefly, and it may be entirely, on the roots of that side. Thus, for example, by laying a patient on his left side and injecting in that posture Barker<sup>1</sup> was able to amputate the left leg painlessly, without

<sup>1</sup> *Brit. Med. Journ.*, 1908, p. 246.



producing sensory or motor impairment of the right lower limb.

After lasting for 45 to 90 minutes, the paralytic phenomena begin to pass off. First motor power returns, then the analgesia fades away, and last of all, the reflexes, superficial and deep, reappear.

Spinal anæsthesia by means of stovaine can also be employed, as Jonnesco<sup>1</sup> has shown, at higher levels of the cord if strychnine be added to the stovaine so as to protect the cord from depressing vaso-motor or respiratory effects. For operations on the head, neck, and upper limbs Jonnesco recommends an "upper dorsal" puncture, between the first and second dorsal vertebræ. Injections at any higher level are unnecessary, besides being too close to the medulla oblongata for safety. For operations on the abdomen and lower limbs, Jonnesco recommends a "dorso-lumbar" injection between the twelfth dorsal and first lumbar vertebræ (see Fig. 222). It should be borne in mind that both in "upper dorsal" and in "dorso-lumbar" punctures the spinal cord lies immediately subjacent to the site of the puncture, and it is therefore important to stop the needle immediately its point has penetrated within the spinal theca, so as to avoid injury to the spinal cord.

In performing an "upper dorsal" injection we first feel for the vertebra prominens (seventh cervical). Then taking the first dorsal spine immediately below this (the patient's head being strongly flexed, so as to separate the laminæ), we slowly push in our needle, in the mesial plane, along the upper border of the second dorsal spine. On reaching the dura mater a momentary resistance is felt, and when the needle reaches the arachnoidal space, cerebro-spinal fluid at once begins to trickle. Unless fluid is seen to escape, we cannot be sure that the point of the needle is in the arachnoidal cavity. Sometimes it is useful to make the patient cough, to start the fluid. As soon as the fluid begins to escape we attach our injection-syringe and slowly introduce the mixture of stovaine and strychnine. After an upper dorsal injection, if the operation is to be on the head or neck, the patient should

<sup>1</sup> *Brit. Med. Journ.*, 1909, p. 1398.



be on his back. If the operation is to be on the upper limbs or thorax, he should sit up for two or three minutes before lying down.

For upper dorsal injections Jonnesco recommends relatively smaller amounts of strychnine ( $\frac{1}{2}$  mg.) and of stovaine (1 to 3 cg.),

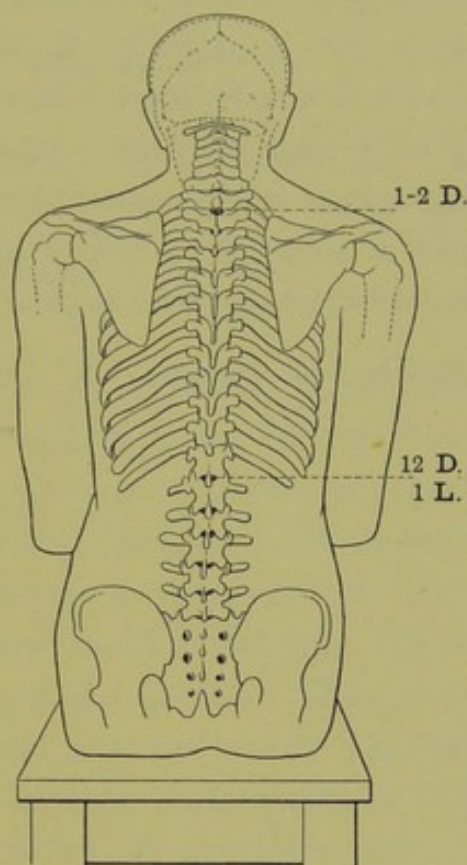


FIG. 222.—Showing sites of “upper dorsal” and of “dorso-lumbar” injections for spinal anaesthesia. (Jonnesco.)

whereas in dorso-lumbar injections the doses of strychnine (1 mg.) and of stovaine (4 to 10 cg.) are large.

Spinal anaesthesia is contra-indicated in severe scoliosis, because of the difficulty in accurately penetrating the theca. It is also better avoided in young children and in most cases of hysteria. Even apart from such cases, it should, I believe, be reserved for very special conditions, as, for example, acute abdominal cases, conditions of shock, and severe cardiac or pulmonary diseases where a general anaesthetic is particularly dangerous. From the patient's point of view, complete unconsciousness is generally preferable to the mental strain of remaining conscious whilst an operation is being performed on his analgesic legs or trunk.



Of the morbid phenomena which sometimes follow spinal anæsthesia, the most frequent is headache ; this is often of great severity and may last for days ; it is probably due to the altered intra-cranial pressure produced by the addition of the anæsthetising solution, and may generally be relieved by a simple lumbar puncture, withdrawing from 10 to 20 c.c. of fluid. In three-fourths of cases of spinal anæsthesia, according to Schwarz,<sup>1</sup> there is a slight transient albuminuria, lasting for a week or more. Another sequela, fortunately an uncommon one, is ocular palsy, chiefly of one external rectus but sometimes of some other ocular muscle ; such palsy may last for days or weeks, but ultimately clears up.

<sup>1</sup> *Zeitschrift für Chirurgie*, 1907, s. 651.



## CHAPTER XXIV

### DISORDERS OF SLEEP

“The innocent sleep,  
Sleep that knits up the ravelled sleave of care,  
The death of each day's life, sore labour's bath,  
Balm of hurt minds, great nature's second course,  
Chief nourisher in life's feast.”

—SHAKESPEARE, *Macbeth*.

MOST of us spend about one-third of our life asleep. Nevertheless the physiology of sleep is not yet completely understood. Let us recall the chief phenomena of ordinary healthy sleep. Firstly, there is diminution and then loss of conscious recognition of ordinary stimuli, such as would ordinarily attract our attention, whether these stimuli be derived from the outer world or from within the sleeper's own organism. There is also, as consciousness is becoming blunted, a characteristic and indescribable sense of well-being. Voluntary movements become languid and ultimately cease, and the muscles of the limbs relax. Meanwhile there develops double ptosis or drooping of the eyelids; the pupils contract; the respiratory movements become slower and deeper, the pulse is slowed, the cutaneous vessels dilate to a slight extent and the general temperature of the body falls, whilst many processes of metabolism, such as those of digestion and of certain secretions, are retarded.

Various explanations have been offered to account for all these phenomena. But at the outset we should recognise that the process is a complex one, implicating many other organs besides the brain. An animal from which the cerebral hemispheres have been removed still shows regular alternations of sleep and waking.

As regards the condition of the brain during natural sleep, it is generally admitted that it is anæmic. If we observe a patient or an animal that has been trephined, we see that during sleep



the volume of the brain is diminished ; it sinks in and becomes pale, *i.e.* the cortical vessels are contracted. This vaso-constriction is not confined to the superficial vessels alone ; it implicates the whole cerebral circulation, for if we succeed in examining the patient's retinal vessels with an ophthalmoscope without wakening him, we find that they present a similar vaso-constriction. Cerebral anæmia, then, is one important factor in natural sleep. After a heavy meal we are all familiar with the difficulty of doing mental work and the tendency to fall asleep. This is doubtless explained to some extent by the occurrence of temporary abdominal hyperæmia together with compensatory cerebral anæmia.

Let us next consider the condition of the nerve-cells during sleep. The activity of some of them, certainly of the cortical cells, is temporarily diminished. Some writers have suggested that this is due to a retraction of the dendrites, by a sort of amoeboid movement whereby nerve-cells previously in contact become, as it were, temporarily insulated. But the evidence in support of this theory is far from convincing. In fact, modern histological observation goes to show that nerve-cells are not merely in contact but that neuro-fibrillæ are continuous from cell to cell throughout the nervous system.

Other writers ascribe the phenomena of sleep to poisoning of the nerve-cells by accumulation of  $\text{CO}_2$ , or to intoxication by other waste-products of metabolism acting as narcotics. Be this as it may, we must bear in mind, as Claparède<sup>1</sup> has urged, that neither  $\text{CO}_2$  poisoning nor intoxication is a necessary antecedent to sleep. On the contrary, we usually sleep for the purpose of avoiding auto-intoxication and of preventing exhaustion, not because auto-intoxication or exhaustion has supervened. Healthy sleep is not necessarily a poisoning of certain nerve-centres by toxic by-products. We may feel intensely fatigued without being drowsy and, conversely, we may feel drowsy without being physically or mentally fatigued. Moreover there is a regular periodicity whereby a healthy person, whether fatigued or not, has a recurrent appetite for sleep. Sleep has a constructive,

<sup>1</sup> *Archives de Biologie*, 1905.



anabolic, invigorating effect on the whole body. Part of this effect is doubtless due to physical rest, part perhaps to interruption in the production of toxins arising from muscular contraction, and part to the absence of stimuli which during waking hours excite nervous katabolism.

Some writers have assigned special importance to a particular region of the brain in connection with the function of sleep, and especially to the floor of the third ventricle and the Sylvian aqueduct. In support of this they point out the familiar ptosis and the tendency to divergent strabismus, both of which might be explained as due to paresis of the ocular nuclei. They also recall the well-established fact that tumours in this region of the brain are specially likely to have as an early symptom persistent drowsiness. But some of these phenomena can also be explained as due to cerebral anæmia, the tumour at the base mechanically compressing and narrowing the arteries which form the circle of Willis. This has been demonstrated in several instances, notably in a case of tumour of the infundibulum and floor of the third ventricle recorded by Franceschi.<sup>1</sup> I myself had under my care a similar case in a young woman, aged twenty-six, with a large cystic growth of the pituitary body and floor of the third ventricle, in whom the chief symptoms were paroxysms of overpowering sleep. She ultimately passed into a stuporose condition and died. No paralytic phenomena occurred during life, nor was there any optic neuritis.<sup>2</sup> Another case was that of a young man of thirty-four who had intense drowsiness, paroxysmal headaches, and total loss of sexual power. He also had blindness of the right eye and temporal hemianopia of the left, with slight pallor of the right optic disc, signs pathognomonic of a lesion of the optic chiasma. All these phenomena were due to a tumour of the pituitary body. His drowsiness was so intense that he fell asleep if he sat down and only with difficulty could he be roused for examination.

Another factor in the production of natural sleep is the absence

<sup>1</sup> *Rivista di patologia nervosa e mentale*, 1904, p. 457.

<sup>2</sup> *Review of Neurology and Psychiatry*, 1909, p. 225.



of violent external stimuli such as loud sounds or dazzling light ; therefore silence and darkness, by withdrawal of stimuli, conduce to sleep. The pleasing monotony of gently reiterated stimuli often has a similar soothing effect which is quite *sui generis* and is closely analogous to the condition of hypnosis. It cannot be ascribed to cerebral anæmia, to exhaustion, nor to any toxic action.

We recognise different degrees of normal sleep, according to the strength of stimulus necessary to rouse the sleeper to a consciousness of his surroundings. The lightest is that of mere drowsiness, a stage in which the sleeper, though not directing his conscious attention to surrounding objects, can still be easily awakened by moderate stimuli such as ordinary conversation, light touches, &c. A deeper stage is sleep with dreams, where the sleeper is unconscious of his surroundings but yet his psychical centres, uncontrolled and deprived of the faculty of comparison with his environment, produce a series of fantastic mental pictures. Under the influence of dreams a sleeper may, if his cortical motor centres are still active whilst the psycho-sensory centres are uncontrolled, perform motor actions, as in the well-known stage of sleep with somnambulism. But somnambulism is rare in health, because ordinarily the cortical motor centres are dulled simultaneously with the sensory. Still more profound is the stage of deep dreamless sleep. This variety merges into what under pathological conditions we call stupor and ultimately coma. The chief distinguishing point between deep sleep and coma is that a sleeping person can be roused whereas a comatose patient cannot.

**Disorders of Sleep.**—We sometimes meet with **pathological drowsiness** or **hypersomnia**, which is most frequently associated with some variety of toxæmia. Perhaps the most common instance is that of an anæmic young woman. Here the drowsiness may be partly toxic, due to absorption of poisons, whether from a loaded intestine, from decaying teeth, or from other sources, but the main element in causation is probably vascular. In such a case the heart is devoid of



energy, and the vessels throughout the body are flabby and deficient in tone. Therefore in the erect attitude the vessels of the brain are badly filled, and if the patient sits down during the day she feels drowsy. But when she lies down at night, the brain now becomes hyperæmic from want of vascular tone, and the result is that she lies awake. This combination of diurnal drowsiness with nocturnal wakefulness is highly characteristic. In treating the condition, besides attacking the anæmia, we often administer digitalis, since, besides being a cardiac tonic, it has also a well-marked vaso-constrictor action. If digitalis be combined with iron and with bromide of potassium, the condition generally rapidly improves.

Drowsiness also occurs in other conditions. Myxœdematous patients are habitually sleepy and stupid, probably from toxæmia and thyroid insufficiency. So also are many idiots and cretins. After a severe fit of epilepsy it is common for the patient to fall into a deep post-epileptic sleep, largely due, no doubt, to toxic products produced by the nervous and muscular systems during the fit. Certain tumours of the brain, especially those in the region of the floor of the third ventricle, as we have already seen (p. 425), are associated with early and persistent drowsiness; so also are some cases of punctured wounds in the same region.<sup>1</sup> Elsewhere in the brain, tumours may also produce drowsiness at a late stage of the disease, probably from increased intra-cranial pressure, though in these cases the condition more nearly approaches coma and ultimately merges into it. The intense drowsiness produced by the combination of exhaustion with extreme cold, as in arctic travellers or alpine climbers who are in danger of being frozen to death, is probably largely due to deficient circulation, and unless vigorous measures be taken to stimulate the heart and the general circulation, sleep passes on to coma and death. The hibernation-sleep of certain animals is largely due to winter-cold, for if such animals be kept in a warm atmosphere throughout the winter, they do not sleep more than in summer time. The delightful

<sup>1</sup> Knagg, *Lancet*, 1907, p. 1477.



drowsiness produced by gazing into a red fire on a winter afternoon is something entirely different. It is probably a mild variety of hypnotic sleep, the continuous red glow acting through the optic nerves by a summation of stimuli. It is not a question of the mere heat of the fire, for unless the blaze be seen, drowsiness is less likely to supervene. A similar summation of stimuli probably explains the well-known church drowsiness. The soothing monotony of the sermon, combined with the sitting posture of the listener (who thus has the additional excuse of a degree of cerebral anæmia), and lastly the common habit of closing the eyes to avoid visual distractions, all these combine to make church-drowsiness a popular disorder. I do not refer, of course, to wild "revival" meetings, nor to militant political or sensational sermons, where the conditions both of preacher and of audience are entirely different.

But there are other pathological varieties of sleep to which we must refer. There is the drowsiness of impending *uræmic* or *diabetic coma*, both toxic in origin. There is also that remarkable tropical disease, *sleeping-sickness*, endemic in certain parts of Africa, and associated with the presence of trypanosomes in the blood, glands, and cerebro-spinal fluid. The drowsiness in this malady is doubtless due to some toxin produced by the parasites. In the later stages of the disease a peri-vascular cellular infiltration is found around the cerebral vessels, a variety of chronic meningo-encephalitis. *Narcolepsy* is another condition where the patient has sudden paroxysms of sleep, in the midst of whatever occupation he may be pursuing at the moment. These cases are hysterical. I remember one such patient who used to fall asleep when playing the piano or during a game of cards (especially if he held a losing hand). He had numerous other hysterical stigmata, and the diagnosis presented no serious difficulty. The *hypnotic trance* is another condition, analogous in some respects to ordinary sleep, but time does not allow us to discuss it here. Suffice it to say that the phenomena of hypnosis can be induced by repeated monotonous stimuli, visual, auditory or otherwise, aided by suggestion. The patient is thereby made to fall into a sleepy condition,



varying in intensity from mere drowsiness to dreams (the incidents of which are controlled by suggestion), to somnambulism, or to deep dreamless slumber lasting perhaps for many hours. There are also the well-known phenomena of *spontaneous somnambulism*, due to the remaining awake, as it were, of the cortical motor centres when the higher sensory and psychical centres have lost their power of inhibition. Such a patient gets up and acts his dream. *Nightmares* are horrifying dreams which produce so much distress that they sometimes waken the patient up in a state of dyspnœa. They are generally toxic in origin. Their commonest cause is gastro-intestinal fermentation, certain articles of diet (proverbially a lobster supper), being specially liable to produce bad dreams. In children nightmares often recur again and again with the peculiarity that the terrifying hallucination is the same on each occasion. Here again gastro-intestinal fermentation is often a factor. Still more frequently do we find that the child has adenoids, which interfere with respiration and produce a degree of CO<sub>2</sub> poisoning. Removal of adenoids and attention to the bowels cure most cases of night-terrors in children. Patients with tropical abscess of the liver, curiously enough, are particularly liable to horrible dreams, so much so that they may be afraid to fall asleep. Here again the condition is doubtless toxic. Nightmare is also a frequent symptom in patients with aortic regurgitation. In them the condition is not toxic but vascular in origin, due to irregularity in the blood-supply and to pulsation in the cortical capillaries.

Lastly let us consider the subject of **sleeplessness** or **insomnia**. Cases of insomnia may be divided into two great classes, the extrinsic and the intrinsic.

*Extrinsic insomnia* includes those cases where the sleeplessness is secondary to some outside cause, not directly arising in the cerebrum or its blood-vessels. For example, physical pain of any sort, cough, vomiting, frequent micturition, diarrhoea, pruritus, and so on, may keep a patient awake. In all such cases we must treat the primary symptom; when it is relieved, sleep will follow naturally. This group also includes emotional insomnia, which



is more often the result of grief than of joy, and more commonly associated with fear or apprehension for the future than with remorse or sorrow for the past. When pleasurable emotion does cause insomnia, it is generally due to anticipation of some happiness in the immediate future. A man does not usually lie awake because some one is going to leave him a fortune twenty years hence, but he may spend a sleepless night on the eve of his wedding. The treatment of emotional insomnia, apart from assuaging the patient's sorrow (a matter which is often beyond the physician's sphere), is best accomplished by giving some cerebral sedative, such as a mixture of chloral and potassium bromide. The insomnia of extreme joy seldom calls for treatment, but if the patient becomes too excited, here again a cerebral sedative may be given.

We are much oftener consulted with regard to the other kind of insomnia, which we may call *intrinsic insomnia*. This is commonly due to vascular, toxic, or nervous faults, or to combinations of all three.

As to *vascular* causes, the brain may be hyperæmic, rendering sleep impossible. Hyperæmic insomnia may be either of the high-tension or of the low-tension type. In high-tension insomnia the patient may be the subject of general arterio-sclerosis or of renal disease, and the hyper-tension is readily demonstrated by the Riva-Rocci sphygmo-manometer. In such cases the patient complains of a difficulty in falling off to sleep. The best remedy, as Broadbent<sup>1</sup> urged, is to give a mercurial aperient such as blue pill or calomel, say two or three times a week. This often brings down the tension in a remarkable way and induces sleep. Of course we also lay down careful regulations as to diet, &c., in these cases. Hyperæmic insomnia from low tension occurs in anæmic and neurasthenic patients, as already explained, and is characterised by the fact that when the patient sits erect in a chair he becomes drowsy, whereas when he lies down in bed the brain becomes over-filled with blood and the patient cannot get to sleep. In such cases the best remedy is a combination of a cardio-vascular tonic like digitalis with a moderate dose of

<sup>1</sup> *Practitioner*, July 1906.



bromide of potassium. Hyperæmic insomnia, whether of high-tension or of low-tension type, is often associated with cold feet. If the feet can be made warm, the cerebral hyperæmia tends to become alleviated. A cup of hot milk or hot soup, by producing abdominal hyperæmia, often relieves hyperæmic insomnia.

Insomnia is one of the most distressing symptoms of chronic heart-failure. Just when dropping off to sleep the patient suddenly starts awake with a feeling of suffocation, gasping for breath. This is probably due to deficient circulation in the medulla oblongata. We treat the condition by cardiac tonics, together with one of the non-depressant pure hypnotics, or even by morphia, cautiously administered and combined with atropine.

Next we have *toxic* insomnia, which is one of the commonest varieties met with in practice. Many cases are associated with gastric or intestinal fermentation, and especially with dilatation of the stomach. The symptoms are characteristic. The patient falls asleep, but, after an hour or two, varying according to the degree of gastric dilatation, he wakes up, perhaps after a horrible dream, with palpitation, profuse sweating or gastric uneasiness. He may have a sinking feeling with craving for food, and if he eats a biscuit or some other simple food, the stomach contents are temporarily diluted and he feels relieved for the time. This may mislead him into thinking that his sleeplessness is due to exhaustion from want of food, which is far from the fact. During his waking hours he is often very depressed, hypochondriac, and almost melancholic. When we have a clinical history of this sort, we should carefully examine the abdomen. If we find the physical signs of dilated stomach, we treat the patient accordingly, putting him on a dry dietary, free from starchy foods or green vegetables, and attending carefully to the bowels. We meanwhile administer gastro-intestinal antiseptics such as carbolic acid, creasote,  $\beta$  naphthol, or su'pho-carbolate of soda. To give hypnotics in such cases, without correcting the gastric condition, is worse than useless.

Amongst the toxic forms of insomnia we must not omit to refer to the sleeplessness produced by chronic excess in alcohol,



culminating sometimes in delirium tremens, also the insomnia of acute fevers. Both in fever and in delirium tremens, sleep can often be induced by a cold pack or cold sponging. Insomnia may result sometimes from excessive tobacco smoking, which produces its effect partly by its action on the nerve-cells, partly by its influence on the circulation. Strong tea or coffee may also act in a similar fashion, keeping a patient awake. Insomnia may occur in secondary or tertiary syphilis, even apart from the familiar nocturnal headache: this variety yields promptly to mercury.

Lastly, there is *primary* or "*nervous*" *insomnia*, due to over-fatigue, especially from mental over-work. We see many instances amongst busy professional or business men. But in most cases there are several factors involved, not only the toxins of exhaustion but those of hasty and ill-digested meals, together with a succession of powerful mental stimuli, and the persistent cerebral hyperæmia of the brain-worker.

In every case of primary insomnia, besides correcting any gastric, intestinal, or vascular fault that may be present, we should make it a golden rule to send the patient away for a complete holiday. These are also the cases for the employment of the pure hypnotics, which have a direct sedative action on the psycho-sensory cortex. The name of these drugs is legion, and I do not propose to discuss them exhaustively. Amongst the most reliable is paraldehyde. Its somewhat nauseous taste is no drawback, since it prevents the patient from acquiring a habit for the drug. Of the other hypnotics I need only mention a few, such as chloral hydrate, sulphonal, and veronal. We should never allow a patient *carte blanche* to take a hypnotic drug on his own initiative. Self-drugging with hypnotics is highly dangerous. No hypnotic should ever be taken without the express authority of the physician. Nor should any one, even though he be a medical man, prescribe hypnotics for himself; he should call in a professional colleague.

Drugs like hyoscine and morphia are our last resort in obstinate insomnia. In severe cases of excited mania or melancholia gr.  $\frac{1}{100}$  of hyoscine, hypodermically, or gr.  $\frac{1}{3}$  of morphia with gr.  $\frac{1}{100}$  of



atropine, soothe the patient in a remarkable way. Persistent insomnia in cases of insanity is of serious omen. Most alienist physicians insist on having charts kept of the amount of sleep obtained by each insane patient, since severe insomnia recurring regularly for a month in cases of insanity renders the prognosis as to recovery very unfavourable.



## CHAPTER XXV

### INTRA-CRANIAL TUMOURS

FOR clinical purposes we include under this heading not only the neoplasms proper (glioma, sarcoma, endothelioma, fibroma, carcinoma, &c.), but also gummatous and tuberculous growths, parasitic cysts, and even aneurisms and abscesses. All of these may be regarded as slowly-growing foreign bodies which, sooner or later, according to their situation within the cranial cavity, produce clinical phenomena rendering their diagnosis possible. Most tumours produce their effects by displacement, distortion, and compression of the nerve-elements. Only in a few instances (*e.g.* in carcinoma, melanotic sarcoma) are the nerve elements directly destroyed by the tumour cells. Two classes of signs and symptoms result; firstly, *general symptoms* of increased intracranial pressure, independent of the position of the tumour, and secondly, *focal symptoms*, which vary according to the particular part of the brain implicated by the growth. General symptoms enable us to say that there is a tumour somewhere within the skull; in order to locate the growth precisely, we must search for localising symptoms which are usually, though not necessarily, later in onset. If localising symptoms are absent, focal diagnosis may be impossible.

**General Symptoms.** — The cardinal phenomena of intracranial tumour are three in number, viz. headache, optic neuritis, and vomiting. To these may be added others, such as mental changes, generalised convulsions, giddiness, slowing of the pulse, &c. The triad syndrome of headache, optic neuritis, and vomiting should always suggest the possible presence of an intra-cranial growth. But before diagnosing cerebral tumour from these three signs alone, we must be careful to exclude three other conditions, any of which may produce the triad syndrome. These conditions are



kidney disease, severe anæmia, and lead-poisoning, all of them easy of recognition if we bear the point in mind.

*Headache* is the most constant symptom of intra-cranial tumour ; it generally appears at some period or other, sooner or later. Its severity is sometimes intense. Usually it is a constant dull pain with paroxysms of agonising intensity. The pain may be diffuse or localised. If localised, its position does not necessarily correspond with the situation of the tumour, except in tumours at or near the surface of the brain, where the pain may sometimes be directly over the growth and accompanied by local tenderness on percussion or pressure, or even by a local alteration of percussion-note. But too much stress should not be laid on the existence of localised pain, unless accompanied by other focal signs. Thus, for example, cerebellar tumours often produce frontal headache, and in one case of my own<sup>1</sup> a right-sided cerebellar growth was accompanied by pain limited to the left frontal region. The headache of intra-cranial tumour is intensified by excitement, by exertion, or by any temporary cerebral hyperæmia.

*Optic neuritis* or "choked disc," detected with the ophthalmoscope, should be looked for in every case of suspected intra-cranial tumour. But it should be borne in mind that while the presence of optic neuritis is one of the strongest evidences of intra-cranial mischief, no weight should be laid on its absence if other signs point to intra-cranial growth. Optic neuritis from brain tumour is relatively more frequent in hypermetropic than in myopic eyes.<sup>2</sup> Another point of importance is that intense optic neuritis may coexist with perfect vision. But in time, optic neuritis generally progresses to optic atrophy, with its accompanying blindness. Many patients with intra-cranial tumour have early transient blindness, sometimes momentary, sometimes lasting for a few hours or days at a time, in one or both eyes. Trephining the skull and opening of the dura mater relieve optic neuritis even though the growth be not removed ; they also give considerable relief to the headache. The optic neuritis of brain tumours, though

<sup>1</sup> *Edin. Hosp. Reports*, 1895. An almost identical case has been recorded by Sachs (*Medical Record*, December 22, 1906).

<sup>2</sup> Gunn, *Brit. Med. Journ.*, 1907, p. 1126.



generally affecting both eyes, may be unequal on the two sides, or it may even be monocular. On the whole, the greater intensity tends to be on the same side as the tumour, especially in frontal and cerebellar tumours, though this rule is not invariable. In cerebellar tumours optic neuritis is specially early in onset.

*Vomiting* is a less constant phenomenon than headache and optic neuritis, except in tumours of the posterior fossa, in which, from the very outset, it is rarely absent. "Cerebral" vomiting differs from the ordinary vomiting of abdominal disorders. It usually occurs independently of food, and is unassociated with other gastro-intestinal symptoms. Moreover, it is often unpreceded by nausea and thus has a curious "projectile" character. A change of posture of the head is sometimes enough to induce an attack of cerebral vomiting.

Amongst the other 'general' symptoms we must mention *progressive mental dulness*. This is apparently to a large extent the result of increased intra-cranial pressure and of persistent headache. The patient becomes apathetic, dull, and slow in answering questions; he loses interest in his ordinary affairs. Sometimes he becomes overwhelmingly drowsy and finally comatose. In the later stages the sphincters are uncontrolled. Mental changes are particularly early of onset in tumours of the pre-frontal region, altogether independently of the intensity of the headache.

*Generalised epileptiform convulsions* (as distinguished from Jacksonian attacks) may be produced by tumours in almost any part of the brain, not necessarily in the immediate neighbourhood of the motor areas. Such convulsions probably result mainly from increased intra-cranial pressure and, as a rule, occur comparatively late in the disease. But they may also, though less commonly, appear as the initial symptom of an intra-cranial growth. In such cases epilepsy is sometimes diagnosed, and until further phenomena (such as optic neuritis or focal signs) develop, the error is unavoidable. More usually general convulsions are a late phenomenon, and there are antecedent physical signs to guide us.

*Attacks of giddiness* are often complained of in brain tumour.



Sometimes these are merely indescribable feelings of confusion ; in other cases there is a true vertigo or feeling of uncertainty in equilibration. Vertigo is specially early and severe in tumours of the cerebellum, cerebellar peduncles, and corpora quadrigemina, and in them it is often associated with the motor phenomenon of a reeling or staggering gait.

Slowing of the *pulse*, permanent or transient, is a valuable corroborative sign of intra-cranial abscess. It may also occur as one of the general symptoms of tumour, especially in the neighbourhood of the medulla oblongata. In other cases, again, we may meet with tachycardia. Therefore the pulse-rate of itself is not of high diagnostic significance, compared with the other signs already mentioned. Slowness of *breathing* and a Cheyne-Stokes type of respiration may occur, but mostly in the latest stages of the disease. Paroxysms of yawning or of hiccough may also be produced by intra-cranial growths, especially those of the posterior fossa.

**Localising symptoms** are sometimes absent, and a tumour may only be revealed by post-mortem examination. This experience is commoner with temporal tumours than with those occurring elsewhere. In most cases, however, focal symptoms develop, which enable us to determine the position of the growth with greater or less precision. In a few cases radiography may reveal an abnormal shadow in the position of the tumour. In superficial tumours local percussion of the skull may occasionally yield an altered note. But in some cases we can only form an approximate idea as to the site of the disease. For example, if a patient with headache, vomiting, and optic neuritis develops a gradually increasing left hemiplegia, all that we are justified in diagnosing is a growth somewhere in the right cerebral hemisphere, probably in the neighbourhood of the motor tract. Unless additional signs appear, it may be impossible to say more, since such hemiplegia may be produced not only by tumours directly implicating the pyramidal tract, but also by frontal, temporal, or even occipital tumours compressing the motor path. Again, the occurrence of cranial nerve palsies is always suggestive of a lesion



at the base of the brain; but this rule is not invariable. For example, isolated ocular palsy of one external rectus has little or no localising value, since the sixth nerve may be paralysed (whether from traction or from increased intra-cranial pressure) by a growth anywhere within the skull. Further, we may have "false localising signs"<sup>1</sup> from compression or distortion by growths in distant parts of the brain. Thus, for example, a tumour of the frontal lobe may at a later stage produce signs of contra-lateral cerebellar

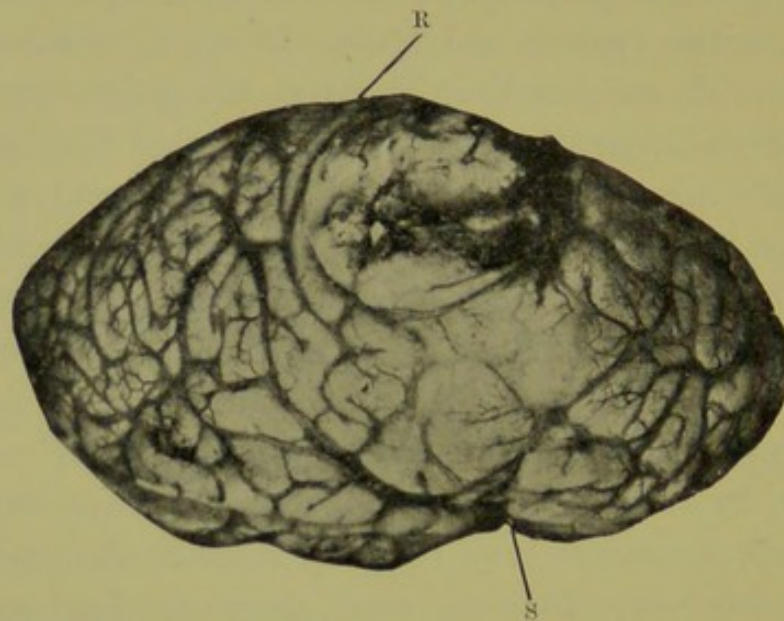


FIG. 223.—Tumour of right pre-central gyrus in its upper half. The patient had Jacksonian fits of the left upper and lower limbs without sensory impairment of the left limbs. R=Sulcus Rolandi; S=Fossa Sylvii.

disease, or a cerebellar growth may afterwards be associated with Jacksonian fits of one limb, suggestive of a lesion of the motor area, but really due to distension of the lateral ventricle of the corresponding side, and so on. Or again, localising symptoms may be masked or concealed, as in some occipital tumours in which, if the optic neuritis goes on to atrophy and blindness, the hemianopia becomes lost which might have led to a correct diagnosis. Localising signs, to be of value, should generally be early. Absence of local signs suggests that the tumour is above the tentorium, since sub-tentorial growths almost always produce localising signs early in their course.

<sup>1</sup> Collier, *Brain*, 1904, p. 490.



Bearing the above points in mind, let us now consider the chief localising symptoms of tumours in the various regions of the brain.

**Tumours of the Motor Cortex.**—The motor area, as we have already seen, comprises the pre-central convolution and the adjacent end of the second frontal gyrus, together with part of the cortex on the mesial surface of the hemisphere. Tumours of the motor region are the easiest of all to recognise clinically. In them, in addition to the general signs of intra-cranial tumour, we usually observe two classes of phenomena, irritative and paralytic.

The *irritative* group consists of Jacksonian fits, commencing in the contra-lateral face, tongue, arm, or leg, as the case may be, according to the part of the motor cortex which happens to be chiefly implicated. In a Jacksonian fit the convulsion, generally consisting of tonic spasm followed by clonic jerks, may be strictly localised to a small group of muscles, or it may spread from them to other muscle-groups, but always in a regular order (as shown in Fig. 3, p. 5). Less commonly the whole of the muscles of the contra-lateral face, arm, and leg are thrown into convulsion simultaneously. During Jacksonian convulsions, unlike ordinary epilepsy, the patient usually retains consciousness all the time, and can study his own fit. But if the convulsion spreads across the middle line and becomes bilateral, consciousness becomes lost at or before the moment of crossing.

The *paralytic phenomena* in tumours of the motor region consist in weakness of the convulsed muscles during the inter-paroxysmal periods (see Figs. 31 and 32, p. 72). Such weakness is most marked immediately after a convulsion. There is also temporary atonognosis in the affected limb and loss of the sense of position.

According as the growth is primarily cortical or sub-cortical, convulsions precede muscular weakness or *vice versá*. A cortical tumour, for example one growing from the meninges, is irritative from the first; a sub-cortical growth is usually indicated by an initial monoplegia, followed later by Jacksonian convulsions. Moreover, the precise starting-point of the convulsions in a sub-cortical growth is less constantly localised to the same muscle-group; thus, for example, a sub-cortical tumour immediately



under the arm-area may produce Jacksonian fits, commencing sometimes in the thumb, at other times in the elbow. The extent of a Jacksonian fit also varies with the extent of the tumour. A small superficial tumour will produce a highly localised fit followed by monoplegia of the affected part, whereas a tumour of the same size, situated deeper beneath the cortex, will produce an initial monoplegia, convulsions being weeks or months later in onset. The deeper the growth, the less tendency is there to localised convulsions. Tumours of the pre-central or motor area, if extending backwards across the Rolandic fissure to the post-central convolution, are usually associated with a distinct sensory aura in the affected limb at the beginning of the motor convulsion, together with a degree of anæsthesia, monoplegic or hemiplegic in distribution. The differences between cortical and sub-cortical types of anæsthesia have already been discussed (p. 200).

**Tumours of the Frontal Region.**—For clinical purposes this region of the brain-cortex, anterior to the motor area proper, may be subdivided into two parts: (1) A pre-frontal or higher psychical area, devoid of motor centres. This area, when electrically stimulated, produces no convulsion. (2) A post-frontal area, continuous posteriorly with the pre-central convolution and including the cortical centre for conjugate deviation of the head and eyes towards the opposite side. On the left side it contains, in addition, the cortical motor centres for spoken words.

**Pre-frontal tumours**, besides having the general signs of cerebral tumour, tend to exhibit mental symptoms specially early, consisting in dulness, failure of memory, tendency to childish jocularity, deficiency of attention, and neglect of the sphincters. These mental symptoms are equally likely in tumours of the right side and of the left.<sup>1</sup> Some pre-frontal tumours, however, have no mental symptoms at all. **Post-frontal tumours** have, in addition, local Jacksonian fits, especially attacks beginning with, or consisting entirely in, deviation of the head and eyes to the contra-lateral side; also, in left-sided tumours, fits commencing with sudden attacks of motor aphasia (though the absence of

<sup>1</sup> Beevor, Lettsomian Lectures, 1907.



aphasia does not necessarily exclude a diagnosis of left-sided post-frontal growth). General epileptiform convulsions, and even attacks of petit mal, are not uncommon in frontal tumours, including pre-frontal cases. Tumours beginning on the under or orbital surface of the frontal lobe may also be associated with early and persistent anosmia on the ipso-lateral side, from implication of the olfactory bulb and tract. Difficulty in moving the head and eyes to the contra-lateral side would point to a sub-cortical mid-frontal growth. Frontal tumours, whether pre- or post-frontal, are sometimes associated with a fine vibratory tremor of the ipso-lateral arm, and less markedly of the leg, on holding the limbs outstretched<sup>1</sup> (though this is far from constant), and with loss, or speedy exhaustion, of the contra-lateral superficial reflexes, especially the abdominal and epigastric. If the growth be sufficiently extensive to press backwards on the pyramidal tract, there may be an increase in the contra-lateral deep reflexes, with an extensor plantar reflex in the contra-lateral foot, and even a degree of motor hemi-paresis. Optic neuritis, generally late in onset, tends to be more intense on the side of the tumour, whilst local tenderness and alteration of percussion-note are relatively common. Some cases of frontal tumour are associated with a reeling gait, like that of cerebellar disease; whether this is due to backward displacement of the brain, producing compression of the cerebellum, or to the transmission of abnormal impulses along the crossed fronto-cerebellar path, is at present difficult of decision.

**Tumours of the Temporal Lobe** are the most difficult of all to localise, especially right-sided tumours. This is because their symptoms are produced chiefly by pressure on adjacent parts, and only to a lesser extent by true focal lesions. There are, however, two focal symptoms which are of diagnostic value. Firstly, tumours at the tip of the lobe, in the region of the uncinate gyrus, are often associated with sudden attacks commencing with an olfactory or gustatory sensation, the smell being usually an unpleasant one. This aura is followed by a curious "dreamy state,"

<sup>1</sup> Grainger Stewart, *Lancet*, November 3, 1906.



lasting several seconds, during which everything seems to the patient to be unreal or "far away." These "uncinate fits" are occasionally accompanied by smacking movements of the lips. Secondly, tumours of Heschl's convolution (on the Sylvian surface of the lobe) and of the adjacent first temporal gyrus, if on the left side, may produce word-deafness. But many temporal tumours are totally devoid of focal symptoms and only produce symptoms of pressure on neighbouring parts. Thus pressure on the internal capsule may cause a slight hemiplegia, with its accompanying disordered reflexes. Or tumours of the antero-internal aspect of the lobe may implicate the optic tract, or may extend to the crus cerebri, or to the corpora quadrigemina, producing corresponding symptoms.

**Tumours of the Post-central Convolution.**—Here the focal symptoms of a cortical growth consist of attacks commencing with a sensory aura either of tingling or of pain in the opposite face, arm, or leg, according to the position of the irritative lesion. If the growth extends across the fissure of Rolando to the pre-central or motor convolution (or even in many cases where the pre-central convolution is not actually invaded but only compressed), there is, in addition, a motor spasm of the corresponding part. Both in cortical and in sub-cortical tumours of the post-central convolution there is usually anæsthesia, monoplegic or hemiplegic, and of cortical or capsular type as the case may be (see p. 200). Astereognosis in the contra-lateral hand has also been recorded, as in a case of my own.<sup>1</sup>

**Tumours of the Supra-marginal and Angular Convolution.**—General symptoms are usually late in onset. The chief focal symptoms are due to affection of the visual paths. In left-sided cases, implicating the angular gyrus, word-blindness may occur; in irritative lesions this is transitory, in destructive or sub-cortical lesions it is permanent. A superficial tumour limited to the angular gyrus may produce "crossed amblyopia" (see p. 38). Thus a lesion of the right angular gyrus produces concentric contraction of the visual field of the left eye (see Fig. 52, p. 122). Such cases

<sup>1</sup> *Rev. of Neurol. and Psychiatry*, 1908, p. 379.



are uncommon, but have been occasionally recorded.<sup>1</sup> More usually the growth dips in so as to affect the underlying optic radiations, and then hemianopia results in the contra-lateral half of both visual fields. Hemi-anæsthesia and hemi-analgesia may be present in addition, when the posterior end of the internal capsule is affected; motor hemiplegia is uncommon.

**Tumours of the Postero-parietal Lobule** are sometimes said to be characterised by astereognosis in the contra-lateral hand.<sup>2</sup> In such cases the patient cannot recognise the form and qualities of common objects placed in his hand if his eyes are closed, whereas with the healthy ipso-lateral hand he recognises them at once. But stereognosis is a complex intellectual function, a judgment based on many sensory factors, and astereognosis has also been observed in other conditions, as in disease of the post-central gyrus, of the optic thalamus, of the posterior spinal nerves and of the peripheral sensory nerves.

**Tumours of the Occipital Region.**—This area of the brain is associated with the half-vision centre. The cortical half-vision centre is situated mainly on the mesial aspect of the occipital lobe, partly above and partly below the calcarine fissure. The lower quadrant of the half-field is represented above the fissure, *i.e.* in the cuneate lobule, the upper quadrant is below the fissure, *i.e.* in the lingual gyrus. Tumours of this region, therefore, produce as their most constant symptom half-blindness or hemianopia, which may be complete or incomplete (quadrantic), according as the whole of the cortical centre is affected or only part above or below the calcarine fissure. Wernicke's hemiopic pupillary phenomenon (see p. 130) is absent in hemianopia from occipital lesions. Tumours on the surface produce irritative phenomena, whilst those extending deeper, into the optic radiations, produce paralytic symptoms. The irritative phenomena consist of crude subjective visual hallucinations, such as luminous sparks or flashes of light, in the contra-lateral halves of the visual fields of both eyes, or in that part of the half-field corresponding to the area of cortex affected.

<sup>1</sup> Beevor, *Lancet*, 1907, p. 719.

<sup>2</sup> *Cf.* a case by Edwards and Cotterill, *Rev. of Neurol. and Psychiatry*, 1911, p. 157.



Such luminous sensations are usually followed by hemianopia in the same area of the visual field, a hemianopia at first transient, but which may become permanent. Tumours of the cuneate and lingual gyri may also press downwards on the cerebellum, in which case cerebellar phenomena are superadded.

Let us now pass to the consideration of tumours deep within the substance of the brain. These are more difficult to localise than in the case of cortical growths.

To distinguish between growths in the **Corona Radiata** and those in the **Internal Capsule** is often difficult, especially when the tumour is a large one. All that it may be possible to state is that the tumour is somewhere in one cerebral hemisphere. But with less extensive growths, producing less complete hemiplegia, the degree of paralysis of different limbs is of diagnostic value. Thus the closer a lesion is situated to the cortex, the greater is the tendency towards a monoplegia. Also if there be a hemiplegia which is complete in the lower limb but incomplete in the upper, and if we find that the hand is more affected than the shoulder, this would point to a capsular lesion rather than a sub-cortical one, since in the cortex the shoulder centre is the one nearest to that for the lower limb (see Figs. 3 and 7).

**Tumours of the Central Ganglia.**—In this region growths may develop without producing enough focal symptoms to render localisation possible. From the close proximity of the optic thalamus and corpus striatum to the motor, sensory, and visual paths in the internal capsule, a slowly progressive hemi-paresis or hemiplegia may occur, accompanied by hemianopia and a degree of hemi-anæsthesia. But if these phenomena be present, say on the right side, and nothing more, beyond the general signs of intra-cranial tumour, all that we can diagnose is a growth somewhere within the left cerebral hemisphere, and probably in its posterior two-thirds. But sometimes we can be more precise. For example, Nothnagel long ago showed that the optic thalamus is a lower reflex centre for the emotional movements of laughing and crying, and cases of thalamic lesion have been demonstrated where voluntary movements of the face were preserved whilst



emotional movements were impaired or lost on the contra-lateral side of the face. Further, a small lesion in the lower and posterior part of the thalamus may cause (probably from affection of the adjacent rubro-spinal path) spontaneous slow rhythmic movements of the contra-lateral limbs, athetoid or choreiform, increased on voluntary exertion. The plantar reflex in these cases remains flexor in type, provided the internal capsule be not involved. Again, the optic thalamus, as we have already seen, is an important station in the general sensory path, and therefore sensory symptoms are sometimes prominent, especially subjective sensations of pain, heat, and cold, in the contra-lateral side of the body, together with a degree of hemi-anæsthesia. Many cases of thalamic tumour, however, run their course without any sensory impairment whatever.

**Tumours of the Corpus Callosum** have no focal symptoms which can be regarded as pathognomonic. Tumours in the anterior part of this great commissure generally produce early mental symptoms, to which may be superadded unilateral or bilateral hemi-paresis or convulsions (cranial-nerve palsies, as a rule, being absent). But these symptoms may be the result of extension into neighbouring parts, so that to diagnose a callosal growth is always hazardous. Moreover, it is rare for a tumour to be limited to the corpus callosum without extension into one or both hemispheres. Attention has been drawn to the occurrence of apraxia (inability to perform certain movements when there is no actual paralysis of the limb) in callosal lesions.<sup>1</sup> (See p. 106).

Marchiafava<sup>2</sup> has described a peculiar degeneration of certain commissural tracts of the corpus callosum in chronic alcoholism.

**Tumours of the Corpora Quadrigemina** (and of the **Pineal Body** which lies in close apposition) are localised with comparative ease by the presence of characteristic ocular phenomena. These consist in a paralytic affection of the third nerve nuclei, more or less symmetrically on the two sides. The commonest sign is a combination of bilateral ptosis with weakness of upward and downward movements of the eyes and feebleness of convergence. The

<sup>1</sup> S. A. K. Wilson, *Brain*, 1908, p. 164; also Lippmann, *Archiv. für Psychiatrie*, 1908, xliii.

<sup>2</sup> *Rendic della R. Accad. dei Lincei*, 1910, xiv., series 5, fasc. 3.



pupillary reflex may be sluggish or absent. Certain tumours, especially teratomata of the pineal body, which occur in children, are associated with excessive growth of the body, precocious sexual development and abnormal growth of the penis and pubic hairs, also with mental precocity. (These signs are in addition to the ocular phenomena above described.) In this respect they contrast, as we shall presently see, with certain tumours of the pituitary body where the genital functions may be diminished. Less constantly, in unilateral quadrigeminal disease, a degree of deafness has been noted in the ear of the opposite side, the sub-cortical auditory centre being located in the posterior corpus quadrigeminum. If the superior cerebellar peduncle, which is in close proximity, be also implicated, we have a corresponding cerebellar asynergia or ataxia and reeling gait, while if the adjacent external geniculate body or optic radiations be involved, there is hemianopia.

**Tumours of the Tegmental Region of the Crus or Pons** produce characteristic focal symptoms from implication of the **rubro-spinal tract** (Monakow's bundle) which starts from the red nucleus, runs down in the pons, crosses the middle line and traverses the antero-lateral column on the opposite side of the spinal cord. Lesions in the crural or pontine part of this tract produce a slow rhythmic tremor of the contra-lateral hand and foot, somewhat like that of paralysis agitans, increased by voluntary exertion or excitement and ceasing during sleep. If the lesion be in the **red nucleus** itself, which is transfixed by the fibres of the third nerve, we have, in addition, third-nerve palsy of the ipso-lateral side with tremor of the contra-lateral arm and leg—a condition known as "Benedikt's syndrome." If the growth implicates the sensory tract of the **fillet**, there may be hemi-anæsthesia of the contra-lateral side of the body, but this is less common with tumours than with sudden vascular lesions such as hæmorrhage, &c.

**A Tumour of the Crusta or Ventral Region of the Crus Cerebri** is easy of recognition, from the characteristic alternate paralysis which is produced, consisting in third nerve palsy, generally incomplete, on the ipso-lateral side, with hemiplegia of the contra-lateral face, arm, and leg—"Weber's syndrome" (see Fig. 91,



p. 217). As the tumour increases in size, it tends to cross the middle line and implicate the opposite third nerve as well.

**Pituitary Tumours** produce diagnostic symptoms in two entirely different ways. Firstly, we may have signs of disordered activity of the pituitary gland itself. Excessive activity of the gland influences the growth of the bones throughout the body, producing acromegaly or gigantism (according to whether the epiphyseal cartilages have become ossified or not). But skeletal changes are not constant. They seem to occur chiefly in cases of adenomatous growth, accompanied by hyper-activity of the gland, and not in purely destructive lesions as in the sarcomata. Diminished activity, on the other hand, produces the so-called "adiposo-genital degeneration," evidenced by an excessive deposit of fat throughout the body, together with absence of sexual development if the process dates from childhood, or regression from sexual maturity if the disease appears in adult life. Thus in female patients we may observe amenorrhœa, whilst an adult male patient develops a remarkable tendency to approximate to a female type; the mammary glands enlarge, the testicles diminish in size, the abdomen becomes rounded like a woman's, and the pubic hair becomes restricted in area—"pituitary eunuchism,"<sup>1</sup> accompanied by loss of virility.

Secondly, and more constantly, there are focal symptoms produced by pressure on adjacent parts, notably on the optic chiasma. Bi-temporal hemianopia, with a hemiopic pupil-reaction, results. This may afterwards progress to total blindness of one eye with temporal hemianopia of the other (see p. 124). Curiously enough, in pituitary tumours primary optic atrophy is commoner than optic neuritis. A growth in the pituitary gland may also press backwards on the third nerves, causing ocular palsies, or it may extend upwards towards the floor of the third ventricle, in which case we sometimes note persistent somnolence. The diagnosis of pituitary tumour can occasionally be confirmed by radiography, which may show deepening of the sella turcica. Glycosuria is not uncommon.

**Tumours of the Cerebellum and Cerebellar Peduncles.**—The

<sup>1</sup> Nonne, *Neurologisches Centralblatt*, 1907, s. 735.



anatomical connections of the cerebellum are all-important, and should be carefully borne in mind (see pp. 21 to 24). Of all intracranial tumours, those of the cerebellum are the most frequent. Intra-cerebellar growths are usually tuberculous or gliomatous, whereas extra-cerebellar growths, commonly situated in the ponto-cerebellar angle of the posterior fossa, if arising from the ventral surface of the cerebellum, are generally gliomata, and if arising from the sheaths of cranial nerves (especially the auditory nerve) they are most commonly fibro-myxomata.

Vertigo, a reeling gait uninfluenced by closure of the eyes, nystagmus, and early optic neuritis are the outstanding symptoms common to growths anywhere in the cerebellum, but a closer study usually enables us to localise the lesion more exactly.

**Tumours of the lateral lobe**, whether intra- or extra-cerebellar, produce symptoms in the ipso-lateral arm and leg; these consist in paresis and diminished muscular tonus, with flaccid, flail-like muscles, together with asynergia on voluntary movement, more evident in the arm than in the leg. In the upper limb we sometimes observe slowness of *diadochokinesia*, a term applied by Babinski<sup>1</sup> to rapid alternate pronation-supination movements of the forearm. In lateral-lobe tumours, this is performed slowly and awkwardly (*dys-diadochokinesia*) on the ipso-lateral side. With this the ipso-lateral limbs are often unnaturally steady when held actively extended in the air; this is best seen in the lower limb (the patient meanwhile lying on his back). If the patient tries to stand on one leg, he does so less securely on the affected side. He lurches or reels as he walks, sometimes towards the side of the lesion, sometimes away from it. This lurching appears to be due largely to weakness of the spinal muscles. There is often weakness of conjugate movement of the eyes towards the side of the lesion, together with horizontal nystagmus, which is coarser on looking towards the ipso-lateral side. The patient has a subjective vertigo in which surrounding objects appear to rotate towards the contra-lateral side. The condition of the deep reflexes is inconstant; they may be diminished,

<sup>1</sup> *Revue Neurologique*, 1903, p. 1013.



normal, or exaggerated in the ipso-lateral limbs. In some cases there is a characteristic posture of the head (see Fig. 141, p. 286), the ear being tilted towards the contra-lateral shoulder, and the face slightly turned towards the ipso-lateral side.

According as the growth is extra- or intra-cerebellar, certain additional phenomena can be recognised. **Extra-cerebellar growths**

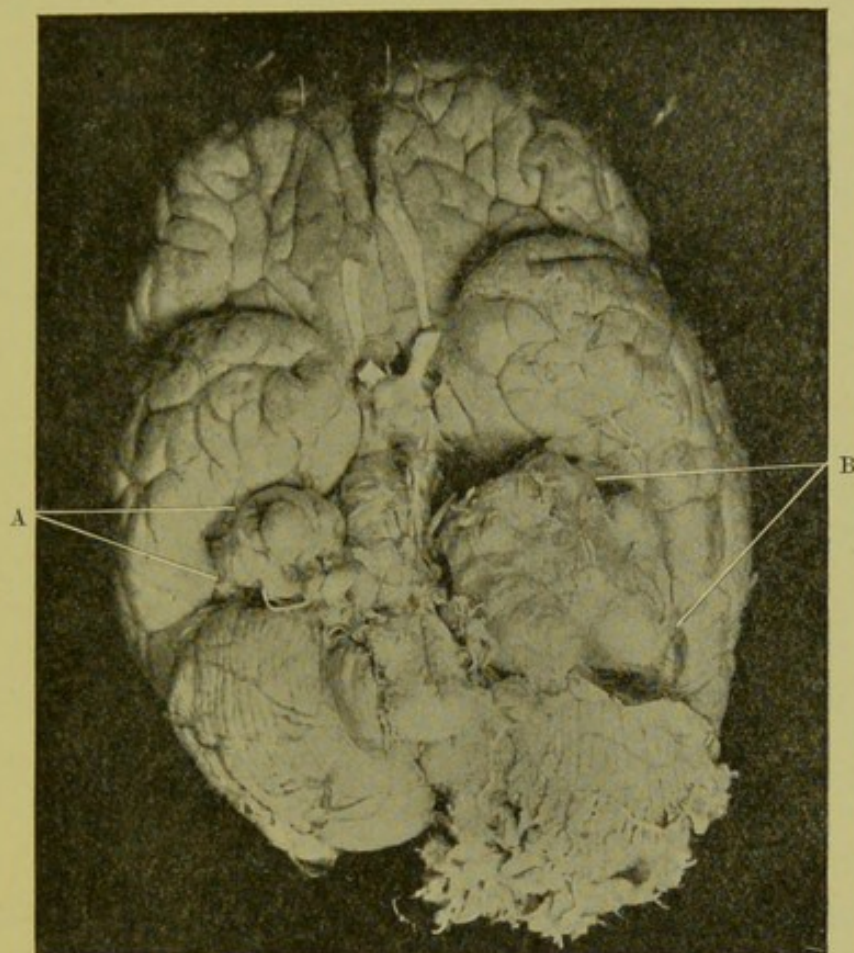


FIG. 224.—Bilateral auditory-nerve tumours (A and B) in ponto-cerebellar angles. An attempt was made to remove the larger tumour (B) by operation, hence the laceration of the corresponding lateral lobe of the cerebellum.

most frequently arise at the ponto-cerebellar angle from the sheath of the auditory nerve and are consequently associated with nerve-deafness, more or less complete, on the affected side, usually accompanied by tinnitus and with loss of thermic reflex vestibular nystagmus (see p. 134). To these is frequently added paresis of the facial nerve, a sign of great value when present. Less commonly we may have affection of other cranial nerves, such as



the sixth or fifth, with loss of corneal reflex, on the same side. In intra-cerebellar tumours, on the other hand, deafness is not an essential symptom. The plantar reflexes in pure intra-cerebellar growths are unaltered, whereas in extra-cerebellar cases, from pressure on the pyramidal tracts, there may be exaggeration of deep reflexes on one or both sides, together with an extensor type of plantar reflex, but this is far from constant. In some intra-cerebellar cases the subjective sense of rotation felt by the patient is the same in its direction as that of the apparent rotation of outside objects, viz., towards the contralateral side. In extra-cerebellar cases this is sometimes reversed, and the patient may have a subjective sensation of rotation towards the ipso-lateral side.<sup>1</sup> Some cases of tumour of the lateral lobe or of the middle cerebellar peduncle are associated with spontaneous "*forced rotatory movements*" around the long axis of the body, analogous to those produced by experimental stimulation (see p. 55). Thus in one case of my own, where there was a large sarcoma of the right lateral lobe, the patient rolled round persistently to the right side and occasionally fell over the right edge of his bed. Unfortunately the direction of rotation is not so constant as to be of absolute diagnostic value in determining the side of the lesion; but when the phenomenon occurs, it is a valuable corroborative sign, indicating an affection of one middle peduncle.

**Tumours of the Vermis or middle lobe** have the general symptoms of cerebellar growth—vertigo, reeling, nystagmus—without unilateral preponderance of ataxia on either side, until the growth extends into one or other lateral lobe. There is also a tendency to fall forwards or backwards, according as the growth is situated in the anterior or posterior part of the vermis.

In a few cases, both in middle lobe and in lateral lobe tumours, we may observe "*cerebellar fits*" of a tonic type (see p. 77).

It should be noted that asynergia is not necessarily present in

<sup>1</sup> This alleged difference between intra- and extra-cerebellar tumours as regards subjective sense of rotation is doubted by Oppenheim and by other competent observers. It is therefore too uncertain to be conclusive by itself.



all cases of cerebellar disease. Sometimes its absence is due to compensation by other parts of the brain, and some cases are instances of lesions limited to the white matter at a distance from the cortical or central nuclei and their main connecting paths. Asynergia is most constantly present in lesions implicating the posterior part of the vermis.

**Tumours of the Pons.**—In this region focal symptoms usually appear early, but general symptoms, especially optic neuritis,

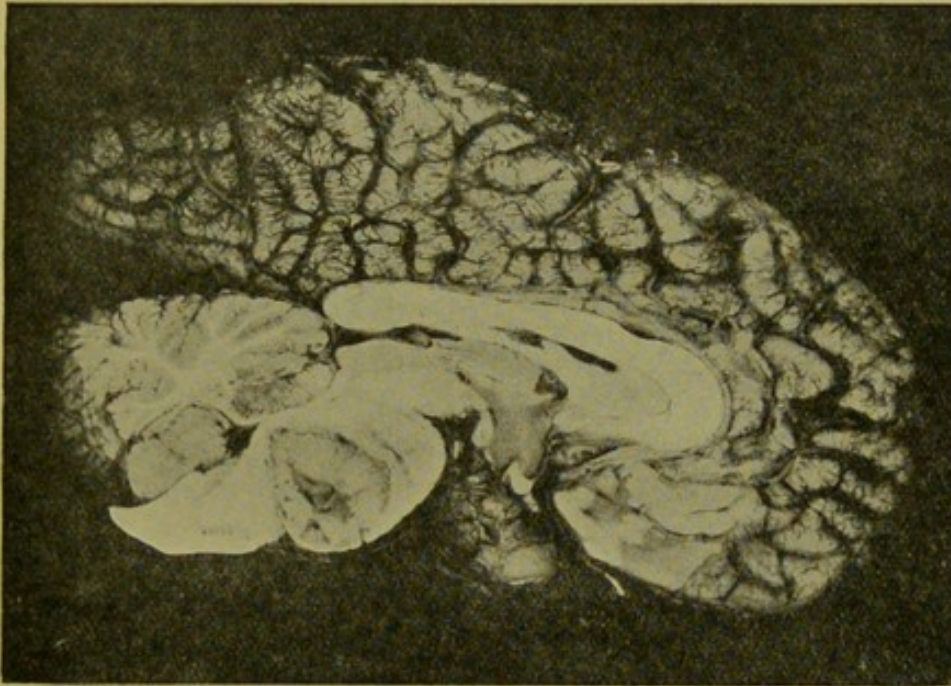


FIG. 225.—Sarcoma occupying centre of pons.

tend to be late in onset. The most characteristic sign of a unilateral pontine lesion is an "alternate" paralysis of the fifth, sixth, or seventh cranial nerve or nucleus on the ipso-lateral side, together with hemiplegia of the contra-lateral arm and leg and an extensor plantar response, or, if the growth be situated in the dorsal region of the pons, there may be hemi-anæsthesia of the contra-lateral side of the body. According as the growth is primarily intra-pontine or extra-pontine in origin, the affection of cranial nerves will be primarily nuclear or infra-nuclear in type and the grouping of the symptoms will be slightly different. We have already studied the differences between a nuclear and an infra-nuclear affection of the sixth and seventh nerves (see pp. 139



and 152). Tumours of the auditory nerve are relatively common, and often bilateral; they ultimately produce signs of extra-cerebellar growth, as we have seen (p. 449).

The clinical picture of alternate paralysis is often masked by the fact that pontine tumours rarely remain confined to one side, but tend to spread bilaterally. In such cases we depend for our diagnosis on the existence of nuclear or infra-nuclear paralysis of the fifth, sixth, and seventh nerves, together with signs of implication of the motor or sensory tracts or of the cerebellar peduncles.

**Tumours of the Medulla Oblongata.**—In this region the chief diagnostic feature is paralysis, unilateral or bilateral, of the lowest cranial nerves, from the ninth to the twelfth, producing disorders of articulation, deglutition, &c., together with signs of interruption of the afferent or efferent tracts coursing through the medulla.

**Tumours of the Fourth Ventricle** may arise either from the ependyma, or from the choroid plexus, or they may be parasitic cysts caused by cysticerci. In such ventricular growths focal symptoms may be absent. If, however, the lesion extends into the dorsal part of the pons or medulla, or into the cerebellum, corresponding symptoms develop. Glycosuria is relatively common. We have already referred to the peculiar form of vertigo which occurs in cases of free cysticercus in the ventricle (p. 160).

**Pathological Diagnosis of Intra-cranial Growths.**—In any given case it may be impossible to diagnose with certainty the nature of the growth, since the symptoms depend not on the structure but on the anatomical position of the tumour. But if there is a history of syphilis, and still more if the Wassermann reaction is positive, a gumma may be suspected, and in most cases the patient should be given the benefit of energetic anti-syphilitic treatment for a time. It must not be forgotten, however, that even gummata sometimes resist medicinal treatment, and it may be necessary to remove a cerebral syphiloma by operation. Syphilitic lesions of the central nervous system are usually associated with an excess of lymphocytes in the cerebro-spinal fluid; a normal fluid would, therefore, be against a diagnosis of syphiloma.



But an excess of lymphocytes occurs not only in tuberculous tumours, but even in true neoplasms. A sudden apoplectiform aggravation of the symptoms is suggestive either of glioma or of aneurism, gliomata from their loose texture and high vascularity being particularly liable to spontaneous hæmorrhages. Aneurisms sometimes, and arterio-venous aneurisms more often, may be accompanied by pulsating bruits; these may not only be perceptible by the patient but can sometimes be auscultated by the physician. Cerebral abscesses are mostly secondary to local infection, especially from the middle ear or other accessory air-sinuses (frontal, ethmoidal, or sphenoidal), or they may follow compound fractures of the skull; less commonly we find metastatic abscesses (*e.g.* in pyæmia and in some cases of bronchiectasis, hepatic abscess, &c.), without local infection in the head. Tuberculous growths are specially common in the pons and cerebellum, and the existence of tuberculous disease of the lungs, abdominal viscera, or elsewhere, would tend to suggest a similar cause for the intracranial mischief, particularly if the patient be a child or young adult. Calmette's ophthalmo-reaction by inoculating the conjunctiva, or Von Pirquet's cuti-reaction by inoculating the skin with a solution of tuberculin, or an estimation of the opsonic reaction of the blood to tubercle, are sometimes of value in such cases. Symptoms of cerebral tumour supervening in a patient who has already had a malignant tumour elsewhere in the body suggest that the cerebral mischief is metastatic in nature. In such cases a curative operation is out of the question, since it is probable that other tumours will be present, besides the one which has been diagnosed.

Finally, we have to bear in mind certain cases of **pseudo-tumor cerebri**, which may be divided into four groups:—(1) Cases which after showing the classical signs of brain tumour recover completely or in which an autopsy shows no lesion capable of accounting for the symptoms. (2) Cases of acute hydrocephalus, serous meningitis of the ventricles (ependymitis) without discoverable cause and relieved by thecal puncture. (3) Localised ependymitis of the Sylvian aqueduct, producing blocking of this canal with enormous



distension of the ventricles. (4) Extensive and acute softenings, with headache, choked discs, and hyper-tension of the cerebro-spinal fluid.

As a rule, however, pseudo-tumor is more rapid in its evolution, and the optic and ocular phenomena appear early and soon attain a maximum.



# INDEX

- ABADIE'S sign of tabes, 194, 204  
 Abdomen—  
     motor points of wall (Erb's diagram), 392  
 Abdominal reflex—significance of absence, 317  
 Abdominal sympathetic, diseases of—  
     pigmentary changes, cutaneous, 347  
     visceral disorders, 345, 346  
 Abductor palsy of larynx, 166, 167  
 Abscesses of brain, 453  
     aphasia from, 98  
     cerebro-spinal fluid in, 412  
     fits due to cortical, 73  
     headache due to, 175  
 Absinthe-poisoning, coma and convulsions from, 70  
 "Acetone" breath, 63  
 Achilles-jerk, 325  
 Achromatopsia, 123  
 Acromegaly, 123, 292, 447  
 Acro-paræsthesia, 348  
 Active muscle-sensation, 190  
 Addison's disease, 347  
 Adductor paralysis of larynx, 167, 168  
 Adiposis dolorosa (Dercum's disease), 291  
 Adiposo-genital degeneration, 447  
 Aërophagy, 385  
 Afferent impulses, 2, 12, 13 *et seq.* ;  
     path of, 13, 15 ; diagrams, 14, 17  
 Ageusia, 144  
 Agoraphobia, 360  
 Agraphia, 97, 103, 104  
 Aichmophobia, 360  
 Air-swallowing, 385  
 Akinesia algera, 189  
 Albinism, nystagmus in, 133  
 Albumin, excess in cerebro-spinal fluid, 408  
 Albuminuria, orthostatic, 347  
 Albuminuric retinitis, diagnostic significance, 70  
 Alcoholism—  
     amblyopia of, 123  
     articulation in, 112  
     ataxia, 264  
     coma and convulsions, 61, 70  
     facial paralysis in, 155  
     factor in nervous disease, 51, 54  
     gait in, 285  
     Alcoholism (*continued*)—  
         insomnia in, 431  
         men and women, effects in, 51, 52  
         neuritis from, 52 ; multiple neuritis from, 205, 233  
         paralysis, 155  
         Quinquaud's sign, 84  
         toxic vertigo, 161  
         tremor, 84  
 Alexia, 102 *et seq.*  
 Allocheiria, 193, 196, 374-5  
 Alopecia, 305  
 Alternate paralysis, 209, 217-18, 451  
 Amaurosis, hysterical, 373-375  
 Amaurotic family idiocy, 125  
 Amblyopia, crossed, 37, 38  
     in hysteria, 123, 372 ; in tumours, 442  
 Amblyopia, tobacco, 120, 122, 125  
 Ambulatory automatism, 70, 378  
 Ammonium sulphate test for globulin, 409  
 Amnesia retrograde, 55  
 Amyotonia congenita, 279  
 Amyotrophic lateral sclerosis, 80, 111, 220, 225, 326  
 Anæmia—  
     cerebral, causing vertigo, 159 ;  
         and sleep, 423, 425  
     headache of, 176, 177  
     mydriasis in, 128  
     optic neuritis in, 125  
     primary thrombosis of sinuses in, 59, 60  
     tinnitus in, 158  
 Anæsthesia—  
     auto-exploration of sensibility, 193  
     crossed, 16  
     cutaneous, 35, 191-8  
     dissociated, 196, 202-3  
     hemi-anæsthesia. *See that title*  
     hysterical, 197-9, 202, 367-373 ;  
         mode of disappearance, 372 ;  
         diagrams, 369-373  
     mapping of areas, 191-3  
     para-anæsthesia, 201  
     in peripheral neuritis, 188  
     spinal, after-effects, 422 ; contra-  
         indicated, 421 ; mode of in-  
         ducing, 418-422



- Anæsthesia (*continued*)—  
 of spinal lesions, 201  
   incomplete, 202  
 tabetic, 203  
 tactile, 195, 196  
 thermo-, 196, 202  
 in tubercula dolorosa, 188  
 universal, of hysteria, 198
- Anæsthetics, delayed poisoning by,  
 63  
 spinal, examples of solutions,  
 418 *note*
- Anal reflex—  
 internal, 330, 332  
 superficial, 317, 318, 320
- Analgesia, 196, 204  
 in tabes, 194, 204
- Anarthria, articulative, 97, 105
- Aneurisms, intra-cranial, 157, 453  
 pulsating sounds in, 157, 453
- Angina pectoris, 182, 347
- Angio-neuroses, 51, 347-353
- Angio-spastic hemiplegia, 252
- Anidrosis, localised, 344, 353
- Ankle-clonus, 213, 282, 327; spurious,  
 213, 328, 383
- Ankle-jerk, 321, 325
- Anorexia nervosa, 291, 385
- Anosmia, 49, 73, 118, 146; in brain  
 tumours, 441
- Anterior cornua, cells of, 2, 3, 27, 80  
 deep reflexes, loss of, 326  
 lesions, 80, 222, 224  
 motor palsy in, 222, 223  
 motor tract through, 2, 13, 27  
 posture in muscular paralysis  
 from, 267
- Anterior nerve roots. *See* Spinal  
 Nerves—Roots
- Anterior polio-myelitis (infantile  
 paralysis)—  
 acute, 222  
 chronic, 224  
 loss of deep reflexes in, 326
- Anterior transverse gyrus of Heschl,  
 39, 40, 96
- Antrum of Highmore, empyema of,  
 119
- Anuria, hysterical, 386
- Aphasia, 95, 108  
 auditory, 97, 100, 442  
 causation, 105  
 cortical centres involved in  
 (diagrams), 101, 103, 104  
 dysarthria distinct from, 109  
 functional, or temporary, 99  
 hysterical, 104  
 lachrymosis in, 51  
 Marie's views, 105  
 motor, 97, 101, 105, 440  
 sensory, 96, 97, 100-104, 105, 106  
 scheme for investigation of, 99  
 total, 105  
 visual. *See that title*
- Aphemia, 97
- Aphonia, hysterical, 116, 364,  
 388
- Apoplexy, diagnosis of, 57, 408
- Appendicitis, pseudo-, 386
- Apraxia, 106  
 in callosal tumour, 445  
 in relation to corpus callosum  
 (diagram), 107
- Arachnoidal sac, 403
- Argyll-Robertson pupil, 127, 129
- Arm, cerebral paralysis of, 9, 11  
 sensory fibres from, 19
- Arsenical poisoning—  
 cutaneous affections, 303  
 multiple neuritis due to, 233
- Arteries—  
 cerebellar, 44  
 cerebral, 41-45  
 diseases of, 58  
 of spinal cord, 45
- Arthropathies, 308-315
- Articulation, disorders of, 109-117  
 alcoholic, 112  
 ataxic, 112  
 deaf-mutes, 116  
 functional cortical disturbance,  
 115  
 general paralysis of insane, 113  
 hysterical, 116, 364  
 idioglossia, 117  
 infra-nuclear and nuclear affec-  
 tions of, 110  
 lalling and lispings, 117  
 paralytic, 110-116 *et seq.*  
 supra-nuclear affections of, 112  
 tests for, 109  
 tics of, 116
- Articulation distinguished from  
 speech, 109
- Asphyxial convulsions, 70, 74
- Associated movements, 88, 214
- Astasia-abasia, 283, 382, 388
- Astereognosis, 195; of brain tumour,  
 443
- Asthenic bulbar paralysis, 248
- Asthma, dyspnoea of, 348
- Astigmatism, headache of, 175
- Asynergia, 25, 263, 448, 450
- Ataxia. *See* Inco-ordination and  
 Tabes
- Athetosis, 49, 87, 265; double, 113;  
 figures of case, 88
- Atopognosis, 193
- Atrophy, acute yellow, coma of, 64
- Atrophy, muscular, 208, 236-238,  
 399; in hysteria, 247; Werdnig-  
 Hoffmann type, 225
- Auditives and visuals, 98
- Auditory aphasia, 97, 100, 105  
 of brain tumour, 442  
 cortical and sub-cortical, 100-101
- Auditory centre, 39, 96-100, 105
- Auditory gyrus (Flechsig), 39, 96



- Auditory nerve, affections of, and tests, 156  
 Auditory path, 39  
 Auditory word centre, 97-102  
 Aura preceding epilepsy, 66  
 Auriculo-ventricular muscle-bundle of Kent and His, 75  
 Auto-exploration of cutaneous sensation, 193  
 Automatism, 3  
     ambulatory, 70  
     hysterical, 378  
     post-epileptic, 69  
 Avellis's syndrome, 165
- BABINSKI'S** combined flexion of hip and trunk, 212; extensor plantar reflex, 318  
 Barany's thermic nystagmus, 134  
 Basilar artery, 41  
 Bed-sores, 50, 235, 298; non-occurrence in hysteria, 386  
 Bell's paralysis, 149, 231, 402  
 Benedikt's syndrome, 86, 217, 446  
 Beri-beri, 233  
 Biceps muscle, 34  
     atrophy from anterior cornual lesion, 268  
     reflex, 321  
 Biernacki's sign in tabetic anæsthesia, 204  
 Bi-temporal hemianopia, 123  
 Bladder—  
     disorders due to lesions of cord or cauda equina, 330  
     dribbling from, 332  
     in hysteria, 384  
     innervation, 331-2  
     reflex centres for contraction, 331, 332  
 "Bleeding diseases," 58  
 Blepharospasm, 93, 379  
 Blindness, in amaurotic family idiocy, 125  
     hysterical, 373  
     lesions causing, 38  
 Blood-pressure, in coma, 56  
     effect of pituitary secretion on, 26  
     intra-cranial, 408  
 Blood-vessels—  
     angio-neuroses affecting, 347-8  
     cervical-sympathetic fibres to, 334  
 Blue œdema, hysterical, 387  
 Bones—  
     atrophic changes in paralysis, 306-309  
     brittleness in disease, 308-309  
     convulsions due to injury of cranial, 73  
     sensory fibres from, 18  
     trophic changes in, 306-13  
 Borborygmi, 385
- Brachial neuralgia, 184  
 Brachial paraplegia, 209  
 Brachial plexus, paralysis of, 341  
 Brain—  
     abscess of, 73, 98, 175, 412, 453  
     anæmia of, 159, 425  
     anatomy and physiology of, 1-21  
     arterial supply, 41-45  
     base, arterial supply, 41, 43  
     circulation in, arterial, 41; venous, 45  
     concussion of, 55; headache after, 177  
     cortex, histology of, 5-6  
     hæmorrhage. *See under* Hæmorrhage, cerebral  
     hyperæmia of, 159  
     lesions, palsies due to, 9-11, 219; rhythmic tremor in, 86  
     localisation of function, 4-9  
     membranes innervation, 173  
     motor areas, localisation of, 4  
     sensory tracts in, 17  
     in sleep, 423-433  
     traumatic hæmorrhage with "compression," 59  
     tumours. *See under* Tumours, intra-cranial  
     venous supply, 45-47  
 Breathing—  
     in cerebral concussion, 55  
     in cerebral hæmorrhage, 56  
     in diabetic coma, 63  
     in hysterical trance, 64  
 "Breites Bein," Heilbronner's, 273  
 Brissaud's reflex, 318  
 Broca, cortical centre of, 43, 97, 105  
 Brown-Séquard paralysis, 11, 19, 195, 196, 202, 220  
     diagram of symptoms, 19  
 Brudzinski's signs of meningitis, 60  
 Bulbar palsy (glosso-labial-laryngeal paralysis), 111  
     articulation in, 111  
     lachrymosis in, 51  
     mixed electrical reactions in, 401  
     pseudo-, 113, 219  
     tongue tremors of, 80  
 Bulbar phenomena in Ménière's disease, 161  
 Bulbo-cavernosus reflex, 317, 320
- CAISSON** disease, 186  
 Calcarine fissure, 37; lesions of, 125, 443  
 Calmette's ophthalmo-reaction, 453  
 Capsule, internal, anatomy of, 6-8  
     motor fibres of, 6  
 Carcinoma, 434; coma of, 64  
 Caries (dental)—  
     headache due to, 175  
     neuralgia due to, 180  
 Caries, spinal, 187



- Carotids, internal, 41  
 Carpo-metacarpal reflex, 321  
 Case-taking, method, of, 48-54  
 Cataract, cortical, 120  
   and tetany of gastric origin, 77  
 Catalepsy, 68, 377  
 Catheterisation, rigor following, 79  
 Cauda equina—  
   lesions of, 234-236  
     anal anæsthesia from, 333  
     bladder trouble in, 331  
     bulbo-cavernosus reflex, loss  
       of, 320  
     gait in, 287  
     motor paralysis due to, 234  
   relations with vertebral column  
   (diagram), 404  
   roots of, 403  
 Caudate nucleus (diagrams), 7, 8  
 Cavernous Sinus, thrombosis of, 46  
 Cells, nerve, physiology of, 1  
 Central scotomata, 121  
   for colours in tobacco amblyopia,  
   119, 122  
   in retrobulbar neuritis, 126  
 Cerebellar tract, direct, 21-25  
 Cerebellum—  
   anatomy and physiology of, 21-26  
   arterial supply, 44  
   ascending tracts in connection  
   with, 29  
   ataxia, or asynergia, 263  
   connections of (diagram), 23  
   cortex, 22; low excitability of,  
   24; motor centres in, 23-25  
   equilibration, co-ordinating  
   centre for, 24, 158  
   functions, 24-26  
   indirect action on spinal cord,  
   24-25  
   intoxication of, 112, 264  
   lesions of—  
     ataxia due to, 258, 260-264  
     attitude in (fig.), 286  
     dysdiadocho-kinesia, 448  
     fits due to, 77, 448, 450  
     forced rotatory movements,  
     450  
     gait in, 285  
     motor effects, 24  
     nystagmus in, 134  
     skew deviation of eyes from,  
     138  
     vertigo in, 158  
     nuclei within, 22  
   peduncles of, 21-24, 158  
   section through (diagram), 22  
   tracts leading to and from, 23  
   tumours of, 160, 178, 285, 435-  
   438, 448  
 Cerebral ataxia, 264  
 Cerebral sinuses, thrombosis of, 46  
 Cerebral. *See also under Abscesses,*  
*Brain, Hæmorrhage, and Tumours*  
 Cerebro-spinal fluid, 51, 403-422  
   cryoscopy of, 408  
   cyto-diagnosis of, 411  
   diagnostic significance of, 48,  
   71, 407-422  
   examination of, 389-412  
   lymphocytosis of, 71, 181, 254,  
   298, 411  
   parasites in, 411  
   pathological conditions—  
     bacteriological characters,  
     409  
     cellular changes, 187-188  
     chemical characters, 408  
     microscopical characters, 410  
     physical characters, 407  
   puncturing for, 403-407  
   therapeutic applications of, 415-  
   418  
   tumour-cells in, 411  
 Cervical plexus, 29, 30, 145  
 Cervical region of cord—  
   lesions in, 128, 181, 209, 218  
   muscular localisation in, 34  
 Cervical sympathetic—  
   course and distribution, 126, 142,  
   170, 334-336  
   in diagnosis, 51  
   excision of, 344  
   lesions, 336  
   oculo-pupillary fibres, course of  
   (diagram), 336  
   paralysis of—  
     from brachial plexus rup-  
     ture, 341  
     from tumour, 339  
     symptoms of, 337-340  
   stimulation of, clinical, 338, 345  
   sweat-fibres supplied by, 343  
 Charcot's "grande hystérie," 377  
   "migraine ophtalmoplégique,"  
   140  
   tabetic joints, 309  
 Charcot and Marie's progressive  
 neuritic amyotrophy, 228  
 Chemosis, 47  
 Chloral poisoning, tremor in, 84  
 Chloroma, cerebro-spinal fluid in,  
 412  
 Cholin in cerebro-spinal fluid, 409  
 Chorda tympani, 143, 148, 152, 155  
 Chorea, 49, 86, 87  
   articulative defects in, 115  
   ataxia in, 264  
   gait in, 288  
   Huntington's, 87  
   hyoscine, 87  
   rheumatic, 87  
   sores in, 298-299  
   tic, distinct from, 91  
 Choroid artery, anterior, 42  
 Choroiditis, 49, 125  
 Chvostek's sign of tetany, 77  
 Cigarette smoking, toxic effects of, 84



- Ciliary ganglion, 126-128, 139  
     degeneration (diagram), 127  
 Ciliary muscle, innervation (diagram),  
     126-127  
 Ciliary nerves, 128  
 Cilio-spinal centre (diagram), 336  
     reflex, 51, 330, 338, 340  
 Circumflex nerve, 29-30  
 Circumvallate papillæ, 143, 145  
 "Claudication intermittente," 186,  
     188, 251, 351  
 Claustrophobia, 360  
 Clavus hystericus, 167, 365  
 Claw hand, 270  
 Clonus, 327-29  
     pseudo-clonus, 327, 384  
 Cocaine—  
     injection by lumbar puncture,  
         418  
     ocular phenomena produced by,  
         128, 341, 345  
 Coccygodynia, 184  
 Cochlear fibres, auditory nerve, 40, 156  
 Cochlear and vestibular nerves, con-  
     nections (diagram), 40  
 Colitis, muco-membranous, 347  
 Colour-blindness, 121  
 Colour vision, tests for, 121; in  
     hysteria, 373  
 Coma, 55-64  
     of acute yellow atrophy, 59  
     of alcoholic intoxication, 61  
     bladder trouble in, 332  
     carcinomatosum, 64  
     from cerebral concussion, 55  
     from cerebral hæmorrhage, 57  
     from cerebral meningitis, 60  
     diabetic, 63  
     diagnosis and causation, 56  
     hysterical trance and, 64  
     malarial, 64  
     of opium poisoning, 61  
     of pontine hæmorrhage, 59  
     post-epileptic, 62  
     and sleep, 426  
     in sunstroke, 63  
     in Stokes-Adams syndrome, 62  
     in thrombosis of cerebral sinuses,  
         59  
     toxæmic, 56  
     uræmic, 62  
 Concussion of brain, 55, 177  
 Congenital ptosis, 140  
 Conjugate deviation, 9, 138, 440  
 Conjunctiva—  
     anæsthesia, in fifth nerve par-  
         alysis, 145  
     conjunctival reflex, 150, 317  
     nerve-supply, 142-3  
 Consanguinity of parents, 49  
 Consciousness, double, 359, 377  
 Consonants, articulation of, 112, 117  
 Constipation—  
     occipital headache of, 177  
     Constipation (*continued*)—  
         toxic vertigo from, 160-1  
 Constrictor urethræ, 332  
 Contractures, hysterical, 383  
 Conus medullaris, 235  
 Convulsions—  
     generalised epileptiform, 436  
     infantile, 73  
     strychnine, 75  
     *See also Fits*  
 Coprolalia, 91  
 Coprophobia, 360  
 Corona radiata, 6  
 Corpora dentata, 21  
 Corpus callosum, relation to apraxia  
     (diagram), 107  
 Corpus quadrigeminum, 22, 37, 446  
 Corpus striatum syndrome, 294  
 Cortex—  
     arterial supply of, 41  
     cerebral, diagrams of, 5  
     lesions—  
         anæsthesia due to, 199-205  
         fits in, 65, 71-78  
         motor palsy from, 215-221  
     motor, inco-ordination in, 264  
     lesions of, 9  
     venous supply, 45  
 Cortical cells in sleep, 424  
 Cortical centres—  
     auditory, 39-40, 96-100  
     half-vision, 32, 37, 103, 124,  
         421  
     of hunger and thirst, 39  
     motor, 4-6  
     olfactory, 36, 118  
     sensory, 3  
     of speech, 96-97; diagrams, 96,  
         98; mal-development, 116-7  
     of taste, 39  
     of vision, 37, 104  
     of writing, 97  
 Cortical localisation (diagrams), 5  
 Cortico-spinal motor neurone, lesions.  
     *See Motor Paralysis*  
 Cortico-spinal tracts, 11-13  
 Cough, hysterical, 388  
 Craft palsies and cramps, 253  
 Cranial bones, headache from affec-  
     tions of, 175  
     inspection of, 52  
 Cranial nerves—  
     Abducens (Sixth), 117; lesions  
         of, 10, 126; paralysis of, 47,  
         137, 438  
     Auditory (Eighth), 156-163;  
         cochlear division, 39, 156;  
         diagrams of, 119, 120; ves-  
         tibular, 156  
     Facial (Seventh), 148-155  
         lesions at different levels,  
             148-155  
         motor root, 149-152  
         secretory and taste fibres,



- Cranial nerves—Facial (*continued*)—  
 course of (diagrams), 39,  
 142, 149, 151, 155  
 sensory root, 39, 155  
 Functions of, 49–50  
 Glosso-pharyngeal (Ninth), 39,  
 143, 163  
 course of taste-fibres (dia-  
 gram), 142–3, 155  
 Hypoglossal (Twelfth), 170–172,  
 335  
 paralysis, 170; unilateral,  
 110  
 Nervus intermedius of Wrisberg,  
 39, 155  
 Oculo-motorius (Third) 126  
 paralysis of, 131–2, 135,  
 144, 217  
 Olfactory (First), 36, 118–119  
 Optic (Second), 37, 119  
 Patheticus (Fourth), 126; par-  
 alysis, of, 46, 136  
 Recurrent laryngeal, unilateral  
 paralysis of, 111  
 Short ciliary nerves, 128  
 Spinal accessory (Eleventh), 167;  
 paralysis (diagrams), 167–169;  
 and of hypoglossal, 170–171  
 Trigeminal (Fifth), 141–147,  
 cutaneous supply to head (dia-  
 gram), 141  
 distribution, 141–143  
 incidence of rodent ulcers  
 over, 299–300  
 lingual branch of, 143–144  
 ophthalmic division, lesion  
 of, 337  
 pains in region of, 179–180  
 paralysis of, 144, 145  
 sensory root of, 16, 39  
 sweat areas corresponding  
 with area of, 353  
 taste fibres, course of (dia-  
 gram), 142  
 Vagus or Pneumogastric (Tenth),  
 164  
 paralysis, 166–168  
 Vidian nerve, 142  
 Cremasteric reflex, 317, 320  
 Crimes, in post-epileptic automatism,  
 69  
 Crossed amblyopia, 37, 38, 123  
 in hysteria, 123, 372  
 in tumours, 442  
 Crossed anæsthesia, 16  
 Crossed hemi-anæsthesia, 18, 201  
 Crossed paralysis, 9–10, 50, 209, 451  
 Crus cerebri—  
 lesions of, 10, 446  
 motor palsy due to, 217  
 tegmental region, 86  
 Cryoscopic examination, 408  
 Cuneate lobule, visual half-centres  
 in, lesions, 125  
 Cutaneous anæsthesia in hysteria, 368  
 Cutaneous sensibility, 14, 15, 191–193  
 loss of, 204  
 recovery of, 230  
 Cyanosis in chronic hemiplegia, 352  
 in erythromelalgia, 350  
 in Raynaud's disease, 348  
 Cysticercus in Fourth Ventricle, diag-  
 nosis, 160  
 Cyto-diagnosis, 411–415  
 DARTOS reflex, 333, 419  
 Deaf-mutes, 116–117  
 Deafness, 152, 156–157, 162–163, 446  
 due to drugs, 158  
 Decubitus, acute, 298  
 Defæcation, 234, 316, 333  
 Degeneration, ascending, 29  
 descending, 27  
 of spinal cord, combined, 260,  
 329  
 Wallerian, 29  
 Deiters' nucleus, 21–24  
 focal lesion of, 163  
 Delirium, 49  
 Delirium tremens, 52, 84  
 Deltoid, atrophy of (diagram), 224–6,  
 229  
 paralysis from anterior cornual  
 lesion, 268  
 paralysis of, from lesion of cir-  
 cumflex, 30  
 Dementia, bed-sores in, 298  
 Dercum's disease (*Adiposis dolorosa*),  
 291  
 Dermatomes, 33  
 Dermographism (diagram), 136, 352;  
 in hysteria, 387  
 Diabetes—  
 breath in, 63  
 coma of, 63  
 insipidus, 347  
 multiple neuritis due to, 233  
 optic neuritis in, 125  
 perforating ulcers in, 295  
 bilateral, tic douloureux, in, 179  
 Diadochokinesia, 448  
 Diaphragm, myoclonus of, 81  
 Diarrhœa, hysterical, 386  
 paroxysmal, of Addison's disease,  
 347  
 Dilator pupillæ, 127, 142, 335  
 Diphtheria, neuritis after, 130, 233  
 Diplegia, 87, 209, 219  
 causes of, 9  
 definition of, 209  
 spastic, 282  
 Diplococcus intra-cellularis, 409  
 Diplopia, 136  
 false image, position of, 131, 136  
 gait in, 285  
 monocular (hysterical), 376  
 ocular vertigo with, 161  
 tests for, 131–132



- Dipsomania, 360. *See also* Alcoholism
- Disseminated sclerosis—  
 absence of abdominal reflex in, 317  
 ataxia in, 260, 265  
 cholin in cerebro-spinal fluid in, 409  
 clonus in, 329  
 emotional state in, 51  
 erythromelalgia a symptom in, 350  
 motor paraplegia due to, 220  
 nystagmus in, 133  
 optic atrophy in, 126, 130  
 staccato speech in, 114  
 transient paralysis in, 256  
 vertigo in, 160
- Disuse, atrophy from, 246, 383
- Dorsal longitudinal bundle, 13
- Double consciousness, 359, 377
- Drop-foot and drop-wrist in peripheral neuritis, 205, 233
- Drowsiness, 49, 426-428  
 hypnotic, 428  
 pathological, 426-428  
 toxic, 431
- Dumbness—  
 of deaf-mutes, 116  
 of imbeciles, 116
- Dysæsthesiæ, 173
- Dysarthria (*see also* Articulation—defects), 109, 112-3, 257
- Dysbasia angio-sclerotica, 251
- Dysdiadochokinesia, 448
- Dysphagia, hysterical, 385
- Dystrophy, muscular. *See* Myopathy
- EAR, auditory fibres of, 39  
 disorders—gait in, 158, 161, 285; herpes of external auditory canal, 148, 155, 297; otitis media. *See that title*;  
 vertigo from, 156, 161  
 inner, afferent impulses from semi-circular canals, 158
- Echolalia, 91
- Ectopia pupillæ, 127-9
- Electricity—  
 abnormal reactions, 399-400  
 clinical application of, 391-8  
 faradic reactions, 390, 397  
 galvanic reactions, 398  
 reactions of degeneration, 400-2
- Electro-diagnosis, 377-383  
 prognosis, 384
- Elephantiasis nervorum, 303
- Embolism, 41, 44, 45-7, 98,
- Emotional states, 51
- Endolymph, 159, 162
- Enophthalmos, 51, 337, 339, 343
- Enteric fever, absence of abdominal reflex in, 317; "coma-vigil" of, 64; headache of, 176
- Enuresis, 332
- Epicritic cutaneous sensibility, 15; loss of, 204; recovery of, 14, 230
- Epigastric reflex, 317
- Epilepsy, 66-74  
 bilateral excision of cervical sympathetic for, 344  
 chronic, posture and gait in, 289  
 distinguished from hysteria, 66-9; and Ménière's disease, 163  
 infantile, 73  
 Jacksonian, 65, 71-3, 200, 438-440  
 major, or "grand mal," 68, 70  
 masked or larval, 70  
 minor or "petit mal," 65, 69, 255  
 post-epileptic automatism, 69; coma, 62  
 premonitory symptoms, 66  
 sudden falling, 255  
 "true," 70
- Epileptiform fits, 60, 71, 74, 78  
 in alcoholics, 70  
 aphasia following, 99  
 in cerebellar disease, 77  
 cerebral, classification of, 65  
 deep reflexes, abolition of, 327  
 in general paralysis of insane, 71  
 headache following, 177  
 in intra-cranial tumours, 72, 440  
 Jacksonian, 71, 200, 439  
 myoclonus allied with, 81  
 in psychasthenia, 71  
 sensory, 73  
 in Stokes-Adams syndrome, 75  
 toxic, 70  
 vertigo, the aura of, 160
- Epistaxis, 46, 176
- Equilibration—  
 afferent fibres for, 19  
 centre for, 24, 158  
 impulses, 24  
 nerve of, 156
- Erb—  
 juvenile atrophic myopathy, 243  
 motor points, 391-7  
 tetany, sign of, 77
- Ereuthophobia, 360
- Erythromelalgia, 51, 188, 350
- Eulenberg's disease (Paramyotonia congenita), 250
- Eunuchism, pituitary, 447
- Eustachian tube, obstruction causing vertigo, 158
- Exophthalmic goitre—  
 alopecia in, 305  
 cramp in, 254  
 cutaneous pigmentation in, 347  
 dermatographism in, 352  
 von Graefe's sign of, 345  
 intestinal symptoms, 347  
 Mœbius's sign, 135



- Exophthalmic goitre (*continued*)—  
 stimulation of sympathetic,  
 symptoms due to, 345  
 tremor in, 83
- Exophthalmos, 51, 227, 345
- Extensors, paralysis of, 30
- Eye, muscles of—  
 innervation of, 10, 126  
 paralysis of, 47, 131-140, 438, 447
- Eye-brow in Third nerve paralysis and  
 hysterical ptosis, 135
- Eyes, "conjugate deviation" of, 9  
*See also under* Optic, Pupils, and  
 Vision
- FACIAL ANÆSTHESIA, lesions causing, 16
- Facial hemi-atrophy, progressive, 147,  
 305-306
- Facial hemi-spasm, 93, 154
- Facial motor points (Erb's diagram),  
 391
- Facial muscles, 50; innervation, 140,  
 148-151
- Facial palsy, 149-155  
 articulative difficulty in, 110  
 auditory nerve disease accom-  
 panying, 157  
 contracture secondary to, 154  
 lesion of Sixth nucleus, associated  
 with, 130
- Facio - scapulo - humeral myopathy,  
 110, 155, 238, 242, 244
- Fæces, incontinence of, 333
- Fallopian aqueduct, 143, 148; lesions,  
 152
- Family gangrene, 350, 351  
 history, 49  
 hypertrophic interstitial neuritis,  
 226-227  
 periodic paralysis, 253, 326, 351,  
 400
- Faradic electricity, 390
- Fatigue—  
 temporary ataxia of, 264  
 tremor of muscular, 83
- Fevers, bladder trouble in, 332
- Fibrillary movements, 49, 80
- Fillet, 39; degeneration, 29; superior  
 decussation of, 19
- Fissures—  
 calcarine, 37  
 diagram, 8  
 lesions, 126, 442-3  
 parieto-occipital, 42  
 Rolandic, 4, 6, 16, 19  
 Sylvian, 4, 8, 39, 41, 96
- Fits, 49, 65-78  
 cerebellar, 77, 450  
 cerebral, 65  
 classification, 65  
 cortical lesions and, 71-73  
 epileptiform. *See that title*  
 hysterical. *See under* Hysteria  
 infantile, 73
- Fits (*continued*)—  
 Jacksonian. *See that title*  
 scheme of investigation, 66  
 strychnine causing, 75  
 in sub-cortical tumours, 71-73
- Flaccid paralysis, 28, 213, 380, 383;  
 fig., 362
- Flehsig's auditory gyrus, 39
- "Folie de pourquoi," 360
- Foramen—  
 of Key and Retzius, 406  
 of Magendie, 406
- Forced rotatory movements, 450
- Formatio reticularis, lesions of, 16
- Formication, 50
- Fractures, depressed, fits due to, 73
- Fragilitas ossium, 307-8
- Friedreich's ataxia, 89, 260-2  
 articulation in, 112  
 deep reflexes, loss in, 260, 326  
 gait in, 285  
 Marie's ataxia compared with,  
 263  
 nystagmus in, 134  
 spontaneous movements in, 89  
 tabes distinguished from, 261
- Functional and Organic disease,  
 boundary line between, 52-53,  
 355-388 *note*
- Fundus, pathological conditions of, 125
- GAIT, 267-289  
 ataxic, 284  
 cerebellar, 263, 285-6  
 in chorea, 288  
 of chronic epilepsy, 289  
 in cysticercus of Fourth Ventricle,  
 160  
 in deformities, 289  
 high-stepping, 286  
 hysterical, 282, 382  
 of paralysis agitans, 287, 288  
 side (Flankengang), 283  
 spastic, 282  
 testing, mode of, 280
- Galvanic batteries, 389, 398
- Ganglia. *See* Ciliary, Gasserian,  
 Geniculate, &c.
- Gangrene—  
 family, 351  
 hysterical, 387; fig., 283  
 symmetrical of Raynaud's dis-  
 ease, 299, 348
- Gasserian ganglion (diagram), 127,  
 128, 141, 143, 147, 335; inflamma-  
 tion (diagram), 297
- General paralysis of insane—  
 Argyll-Robertson phenomenon  
 in, 127, 129  
 articulation of, 113  
 cerebral hæmorrhage in, 58  
 cerebro-spinal fluid in, 254, 409,  
 413  
 deep reflexes, loss in, 326



- General paralysis of insane (*cont.*)—  
 epileptiform fits in, 69, 70  
 hemiplegia in, 252-4  
 pupils in, 127, 129  
 tremors, spontaneous in, 91, 113
- Geniculate ganglion, 142, 148-151, 155  
 inflammation of, 148, 155, 297
- Genital reflex, 330
- Genu recurvatum, 278: fig., 275
- Giddiness, 137, 152, 175, 417, 434, 436  
 hysterical, 162  
*See also under Vertigo.*
- Gigantism, 292, 447
- Glaucoma, 162, 344
- Gliomata, 453
- Globulin in cerebro-spinal fluid, tests for, 408-9
- Globus hystericus, 66, 76, 376, 385
- Glossio-labial hemi-spasm, 276, 382
- Glossy skin, 50, 294
- Gluteal reflex, 317
- Glycosuria, 160, 347, 447, 452
- Gordon's paradoxical flexor reflex, 319
- Gowers' tract, diagram, &c., 16-17
- Grasset and Gaussel's test, 212
- Gumma, intra-cranial, 180, 453  
 fits from, 72  
 headache due to, 175, 178  
 neuralgia due to, 180
- Gustatory path, 39, 143; diagram, 142
- Gyrus, angular—  
 arterial supply, 43  
 cortical lesion, 123, 442  
 visual word centre, 39, 97, 102  
 auditory (Flechsig's), 39
- Heschl's, 39, 96  
 tumours of, 442
- lingual, 33
- uncinate, lesions of—  
 fits due to, 72-73  
 olfactory centre, 33; disorders of, 118  
 tumours of, 442
- HABIT spasms, 90, 93, 379, 388
- Hæmoglobinuria, paroxysmal, 350
- Hæmophilia, 58
- Hæmorrhage, cerebral—  
 aphasia from, 98  
 artery of (diagram), 41  
 blood pressure in, 408  
 cerebrospinal fluid in, 407-409  
 in children, 58  
 coma in, 57  
 diagnosis of, 52, 59, 408  
 in general paralysis of insane, 58  
 Menière's disease distinguished from, 162  
 spontaneous, 57-59  
 trophic changes in nails in, 306  
 vertigo from, 158-159
- Hæmorrhage cerebral (*continued*)—  
 fits due to, 73  
 hysterical, 386  
 pontine, 59  
 retinal, 49  
 subarachnoid, 407
- Hair—  
 blanching of, 147, 305  
 falling of, 49  
 in progressive facial atrophy, 147  
 trophic changes, 304-305
- Half-vision centres, 37, 103, 125, 443
- Hallucinations—  
 auditory, 157  
 olfactory, 118  
 pain, hysterical hallucinations of, 365  
 visual, 72, 444
- Hand, muscles of, lesions of, 270-271
- Haphalgnesia, 375
- Head "conjugate deviation" of, 9
- Head injury, coma in, 55
- Headaches, 174-179  
 angio-neurotic, 178  
 gastric, 176  
 of gross intra-cranial disease, 175, 435  
 hysterical, 178, 365  
 local (extra- and intra-cranial), 175  
 in Ménière's disease, 162  
 migrainous, 178  
 neurasthenic, 177  
 post-epileptic, 177  
 reflex, 176  
 in sunstroke, 177  
 toxic, 176  
 unilateral, 177
- Head-rolling, 86
- Hearing. *See under Auditory*
- Hemeralopia, 120
- Hemi-achromatopsia, 97
- Hemi-anæsthesia, 196, 199  
 crossed, 18, 201  
 hysterical, segmental type, 199, 290, 368-373  
 organic, 199  
 capsular or thalamic, 9, 86, 173, 200  
 cortical and sub-cortical, 200, 440  
 crossed, 201  
 lesions causing (diagram), 18, 20, 200, 445
- Hemianopia—  
 bi-temporal in pituitary tumours, 447  
 definitions and cause, 123  
 diagrams, 38, 122  
 lesions producing, 9, 37, 123, 439, 443-4  
 quadrantic, 37-39  
 sub-cortical word-blindness associated with, 103



- Hemianopia (*continued*)—  
 varieties of, 123-126  
 Wernicke's pupillary reaction in,  
 130, 443
- Hemi-atrophy, facial, 147, 306
- Hemicrania, hysterical, 365
- Hemi-hyperæsthesia, hysterical, 365;  
 thalamic, 196
- Hemi-hypertrophy, facial (fig.), 289-  
 290; universal (fig.), 294
- Hemiopic pupillary reaction, Wer-  
 nicke's, 130, 443
- Hemi-paraplegia, 50
- Hemiplegia—  
 alternate, 209  
 angio-spastic, 252  
 aphasia in, 99  
 apraxia in, 106-108  
 articulation after, 113  
 ataxia associated with, 264-5  
 athetosis following, 87; fig., 88  
 bilateral, 105, 209  
 bed-sores in, 298  
 bone-changes in, 306-308  
 capsular lesion causing, 9-11  
 chronic, 308, 312  
 combined flexion of hip and trunk  
 (diagram), 211  
 crossed, 209  
 definition and forms of, 209  
 dolorosa, 174  
 gait in, 281-284  
 in general paralysis, 254  
 Grasset and Gaussel's sign of, 212  
 headache preceding, 176  
 in head injury, 57  
 hysterical (functional), 210, 212,  
 274-278, 282-284  
   abscesses of plantar reflexes,  
   321  
   anosmia in, 118  
 infantile, 308; figs., 272, 276  
 ipso-lateral, 216  
 joint affections in chronic, 312  
 lesions causing, diagnosis, 60,  
 86, 408, 437  
 loss of certain reflexes in, 320-1  
 muscular wasting in, 247  
 pandiculation in, 88-9  
 posture in, 269-271  
 transient, 253  
 tumours causing, 439-446  
 visual fields in cases of (diagram),  
 374
- Hemispasm, facial, 93
- Hereditary ataxia, Friedreich's, 261;  
 Marie's, 263
- Herpes, facial, 148, 155, 297
- Herpes zoster, 174, 181, 197, 296-298,  
 303
- Heschl's gyrus, 39, 96  
 tumours of, 442
- Hiccough in intra-cranial disease, 437
- Hippus, 129
- Holmgren's tests for colour vision, 120
- Hunger, cortical centre for, 40
- Huntington's chorea, 87
- Hydrophobia, 76; hysterical, 76
- Hyoscine chorea, 87
- Hyperacousis, 152
- Hyperæmia, cerebral, 157, 159, 175,  
 178
- Hyperæsthesia, 195-198  
 hysterical, areas of, 189, 197, 365  
 mapping out areas of, 192
- Hyperalgesia, 198, 365
- Hyperidrosis, localised, 353
- Hypermetropia, 176
- Hyper-pyrexia, 58, 59, 177
- Hyper-trichosis, 300
- Hypertrophic interstitial neuritis, 227,  
 261
- Hypertrophy of muscle, 208
- Hypnotic suggestion, 64, 361-362
- Hypnotic trance, 64, 361, 377
- Hypo-æsthesia, 196
- Hypoglossal nerve. *See* Cranial  
 Nerves
- Hypoglossal nucleus, 148, 171
- Hypo-spinal ganglia, 335
- Hypotonia of muscles, 259  
 choreic, 87  
 tabetic (diagrams of cases), 276-  
 278
- Hysteria, 355-388  
 age and sex, effect in, 66, 388  
 allocheiria in, 193  
 alternating personality, 359, 378  
 ambulatory automatism, 378  
 anæsthesia. *See under* Anæsthesia  
 ankle-clonus, spurious, 213, 311,  
 383  
 aphasia and, 104  
 articulation in, 116, 364  
 ataxia in, 265  
 bio-chemical changes underlying,  
 52 *note*  
 Charcot's "grande hystérie," 68,  
 377  
 in children, 362, 388  
 concentric contraction of visual  
 field, 123, 374  
 contractures, 273-276  
 crossed amblyopia, 38, 122  
 cough in, 388  
 dermatographism in, 387  
 double consciousness in, 359, 377  
 fits in—  
   catalepsy, 68, 377  
   classification, 65  
   distinguished from epileptic  
   fits, 66, 376  
   post-epileptic, 66, 69, 376  
 gait in, 282, 382  
 glosso-labial hemispasm, 276  
 hemiplegia, distinguished from  
 organic, 210-213, 274-277



- Hysteria (*continued*)—  
 hydrophobia simulated, 76  
 hyperæsthetic areas in, 189  
 inhibition deficient in, 361  
 joint pains in, 314  
 major, 65, 68, 377  
 minor, 65, 68  
 motor phenomena in, 376  
 muscular wasting in, 246  
 neurotonic reaction in, 399  
 organic disease, distinguished from, 52 *note*, 355, 388  
 pains of, 189  
 paralysis. *See under* Paralysis  
 plantar reflex in diagnosis of, 319, 321  
 postures in, 273-277  
 psychical symptoms, 361  
 ptosis, 136-137  
 reflexes in, 68, 319-321, 384  
 respiratory modifications, 385  
 sensory symptoms in, 365  
 skin affections in, 386  
 spasms in, 94  
 speech defects in, 364  
 trance of, 64, 377  
 transient paralyses in, 255  
 vasomotor phenomena in, 384  
 visceral phenomena in, 384
- Hystero-frenic and hystero-genic areas, 186, 365-366
- Idiocy, amaurotic family, 125
- Idioglossa, 117
- Imperious acts, 360
- Impulses, origin of, 1, 6  
 paths of, 15, 19, 24
- Inco-ordination (ataxia), 257-266  
 articulative, 107-117  
 cerebellar, 263, 450  
 due to fatigue, 264  
 in hypertrophic interstitial neuritis, 261  
 hysterical, 265  
 from lesions of rubro-spinal tract, 265  
 in new-born child, 257  
 post-febrile, 264  
 pre- and post-hemiplegic, 264  
 sensory origin of, 258  
 tests for, 257  
 toxic, 264
- Infant, new-born, movements of, 4
- Infantile convulsions, 73-75
- Infantile spinal paralysis (acute anterior poliomyelitis), 222-226, 307-309  
 lesions causing, 33, 222-225  
 loss of deep reflexes in, 326  
 trophic changes of bones in, 308
- Inguinal region, hysterical tender spots in, 365
- Injuries, effect on nerves, 14-15  
 spinal, symptoms of, 19
- Insanity, toxic varieties of, 51
- Insomnia, 429-433  
 alcoholic, 432  
 drugs, use of in, 430, 432  
 emotional, 429  
 extrinsic, 429  
 and insanity, 432  
 intrinsic, 430  
 primary or nervous, 432  
 vascular causes of, 430
- Intermittent limp, 186, 188, 251, 351
- Internal capsule—  
 anatomy, 6-8; diagram, 8  
 auditory fibres of, 42  
 lesions of, 9, 138, 199, 216  
 motor fibres, 6  
 sensory fibres, 8-9  
 tactile fibres, 16  
 visual fibres, 9, 37
- "Interosseal attitude" (diagrams), 287-9
- Intervertebral ganglion (ganglion cell of posterior root), 28, 29, 296-7
- Intra-cranial diseases and growths, 57, 71, 160, 173, 175, 434-454.  
*See also* Tumours
- Intra-cranial hæmorrhage, 57-8
- Intra-cranial pressure, 57, 71, 175, 216, 309, 408, 427  
 lumbar puncture in relief of, 415
- Involuntary movements, 79-94  
 myokymia, 80  
 reflex spasms, 92  
 rigors, 79  
 in tabes, 89  
 tremors, 83-86
- Ipsio-lateral pyramidal tract, 11
- Ischæmic paralysis, 236
- JACKSON'S syndrome, 172
- Jacksonian fits, 72-73, 200, 439-440
- Jaw reflex, 321
- "Jaw-winking," 141
- Jendrassik's reinforcement of knee-jerk, 322-5
- Jews, amaurotic family idiocy amongst, 125
- Joints—  
 hysterical pains in, 314, 365  
 trophic changes in, 308-315
- Joint-sense, 190, 259; tests for, 193
- KERATITIS, bacillus of, 146  
 neuro-paralytic, 146
- Kernig's sign of cerebro-spinal meningitis, 60, 298, 413
- Kidney disease—  
 arterio-sclerosis of chronic, vertigo in, 160  
 cerebral hæmorrhage in, 58  
 floating kidney, 183  
 nephritis, 70, 125, 417  
 uræmic convulsions of, 70, 417
- Kinæsthetic sense, 3, 190, 259; test for, 194



- Kleptomania, 360  
 Knee-clonus, 311  
 Knee-jerk, 68, 322-5  
 Korsakow's psychosis, 51
- LABIALS and labio-dentals, articulation of, 110  
 Labyrinth, disease of, 156-8, 161  
   cerebellar gait in, 263  
   vertigo of, 161-3  
 Lachrymal secretion, paralysis, 145  
 Lactation, tetany during, 77  
 Lalling, 117  
 Landouzy-D'jèrine type of myopathy, 111, 238, 242  
 Landry's paralysis, 222, 233, 326, 410  
 Laryngismus stridulus, 74, 77  
 Larynx—  
   ataxy of, 112  
   innervation of, 164-167  
   myoclonus of, 81  
   paralysis, 164-7; recurrent, 165;  
     unilateral, 164  
 Lasègue's symptom, 382  
 Lateral lobes of cerebellum, 21, 77  
 Laudanum poisoning, 61  
 Laufenauer's method of reinforcing knee-jerk, 324  
 Lead poisoning—  
   convulsions in, 70  
   optic neuritis in, 125  
   palsy in, 205, 233; absence of  
     sensory changes in, 205, 222  
   tremor of, 84  
   visceral symptoms, 347  
 Leg, paralysis of, 9, 11, 20  
   sensory fibres from, 19  
 Lenticular nucleus, tremors in lesions of, 86  
 Lenticular zone, lesions of, 105  
 Lenticulo-striate artery, 41  
 Leprosy arthropathies of, 309;  
   maculo-anæsthetic type, 301; neuritis of, 295  
 Lepto-meningitis, localised, compared with spinal tumours, 220  
 Leucocytosis of cerebro-spinal fluid, 409-415  
 Leucoderma, 301  
 Leukæmia, 58; cerebro-spinal fluid in, 412  
 Levator palpebræ superioris, innervation, 126, 336 (diagram), lesions of, 135, 140, 150, 337-8  
 Light reflex. *See under* Reflexes  
 Limp, intermittent, 186, 188, 251, 351  
 Lingual consonants, articulation of, 110  
 Lips, paralysis of, 170  
 Lispings, 117  
 Localisation, cerebral, 4-9  
 Lock-jaw, 75  
 Locomotor ataxia. *See* Tabes  
 Longitudinal sinus, superior, thrombosis of, 46  
 Lordosis (with figs.), 238-240  
 Lumbago, 184, 235  
 Lumbar puncture, 52, 403-7  
 Lumbo-abdominal neuralgia, 184  
 Lumbo-sacral cord—  
   disease symptoms in, 187  
   muscular localisation in (diagram), 34  
 Lumbo-sacral plexus and branches, 29, 31  
 Lymphocytosis of cerebro-spinal fluid, 71, 181, 254, 298 *note*, 411-5; diagnostic significance, 412-4
- MACROPSIA, 375  
*Main de prédicateur*, 271  
*Main de singe*, 270  
*Main en griffe*, 270  
 Malarial coma, 64  
 Malin\_ering, Mannkopf's sign in, 365  
 Mammary neuralgia, 182, 365  
 Mannkopf's sign of real hyperæsthesia, 365  
 Marie's hereditary cerebellar ataxia, 263  
 Masked epilepsy, 69  
 Mastodynia, 182  
 Meckel's ganglion, 142, 143  
 Medulla—  
   auditory fibres in, 39  
   cranial nerves (diagram), 119  
   lesions of, 11, 200, 217, 262-3, 336-7, 452  
   Ménière's disease, implicated in, 161  
   pupil-dilating centre in, 325  
   respiratory centre in, 4  
   sensory fibres, course of, 17;  
     diagram, 7  
   stimulation of nuclei in, 1  
 Melancholic anergia distinguished from psychasthenia, 358  
 Memory, 49; loss of, 51, 55; post-epileptic loss of, 69  
 Ménière's disease (labyrinthine vertigo), 161-3  
 Meninges—  
   cerebral, convulsions from hæmorrhage in, 75  
   pain, sensitiveness to, 173  
   spinal, diseases of, 187, 298  
     root pains of, 180, 187  
 Meningism, 413  
 Meningitis—  
   basal, 60, 155, 181  
   cerebro-spinal fluid in, 61, 407-415  
   fits due to, 75  
   fluid pressure in, 406-7  
   headache in, 175, 178



- Meningitis (*continued*)—  
 lepto-, localised spinal, 220  
 lumbar puncture for, 415-6  
 septic cerebro-spinal, 298, 409, 412  
 spinal, root pains in, 187  
 syphilitic basal, 155, 180  
 tuberculous, 52, 175, 411, 412, 415
- Menstrual periods, headaches during, 176
- Mental functions, examination of higher, 51
- Meralgia paræsthetica, 186
- Mercury poisoning, tremor of, 84
- Metameres and root distribution of sensory and motor fibres, 33
- Meteorism, 347, 352
- Meynert's fibres, 126
- Micropsia, 376
- Micro-sympathetic ganglia, 335
- Micturition, 331; centres for, 331-2; in hysteria, 384
- Middle ear—  
 disease of, 153, 156, 161  
 innervation, 142-3
- Migraine, 178; ophtalmoplégique, 140, 179
- Millard-Gubler syndrome, 11, 218
- Miners' nystagmus, 134
- Mœbius's sign in exophthalmic goitre, 135
- Moles, hairy, 304
- Molluscum fibrosum, 303
- Monakow's bundle (rubro-spinal), 13; lesions in, 139, 265, 327, 446
- "Monkey-hand," 270
- Monocular diplopia, 376
- Monoplegia, 9-11, 50, 209; causes of, 9; definition, 209; hysterical, 379-382
- Morvan's disease, 203, 296
- Motor act, reflex, 2; voluntary, 3
- Motor aphasia, 97, 103, 105, 440
- Motor areas, localisation of, 4-6
- Motor centres in cerebellar cortex, 24, 25
- Motor cortex, lesions of, 6, 9, 19
- Motor functions, investigation of, 24, 50, 206
- Motor nerves—  
 fibrillary tremors in paralysis of, 80  
 regeneration of fibres, 232
- Motor neurones, upper and lower, 27, 213
- Motor paralyses, 206-218  
 functional or organic, 210  
 lower neurone type, 28, 206-221; distinguished from upper neurone type, 213  
 distinguished from anterior cornual and nerve-root lesions, 222-5
- Motor paralyses (*continued*)—  
 distinguished from cauda equina lesions, 234-6  
 Landry's paralysis, 222, 233, 326, 349  
 level of lesion, diagnosis of, 222  
 from multiple peripheral lesions, 228, 233  
 muscles, affections within, 235  
 postures in, 267  
 plantar reflex in, 213, 319  
 sensory phenomena in, 222  
 recurrent and transient, 248-256  
 Eulenberg's disease, 250  
 family periodic paralysis, 253  
 in general paralysis of insane, 254  
 in hysteria, 255  
 intermittent limp, 251  
 in minor epilepsy, 255  
 myasthenia gravis, 248  
 myotonia atrophica, 251  
 occupation neuroses, 253  
 sign of disseminated sclerosis, 256  
 in tabes, 255  
 tetany, 254  
 Thomsen's disease, 250  
 upper neurone type, 28, 215-221; bilateral, 218, distinguished from lower neurone type, 213-5  
 exaggeration of deep reflexes in, 329  
 level of lesion, diagnosis of, 214-221  
 postures in, 270-1  
 unilateral, 215-8
- Motor points, 397-8; diagrams, 391-7
- Müller, non-striated muscle of, paralysis, 337
- Muscles, atrophy of—  
 causation, 28, 222, 224, 290  
 fibrillary tremors in, 80  
 in hemiplegic arthritis, 314  
 in hysteria, 382  
 idiopathic. *See* Myopathy  
 in neuritis, 227  
 peroneal type, Tooth's, 225  
 progressive (chronic anterior poliomyelitis), 80, 224-5, 326, 402  
 varieties of, 225, 246-7  
 dystrophy of. *See* Myopathy  
 electrical reactions, 395-396; tests for, 392  
 fatigue-paralysis, in myasthenia gravis, 111



- Muscles, (*continued*)—  
 hypotonia, 87, 259, 263, 276-8  
 motor palsies from affections within, 255  
 motor points, Erb's diagrams, 391-397  
 non-striated involuntary, reflexes of, 316, 330  
 sensation, active, 190  
 sensibility to pressure, 194  
 sensory fibres from, 18  
 testing, in motor paralysis, 206-209
- Muscle-spindle, a trophic centre, 28
- Muscular analgesia in tabes, 194
- Muscular cramp, 254
- Muscular localisation in cervical enlargement, 34  
 in lumbo-sacral cord, 34
- "Muscular sense," definition, 190, 194
- Musculo-spiral nerve, paralysis of, 28, 269
- Mutism, hysterical, 116, 364, 387
- Myalgia, 181, 182
- Myasthenia gravis, 111, 135, 248, 400
- Myasthenic reaction, 400
- Myatonia congenita, 278
- Mydriasis, 128
- Myelitis, 54, 221, 298; fig., 299
- Myoclonus, 80-83; diagram, 81, 82  
 nystagmus, 83, 134
- Myoclonus epilepticus (Unverricht's), fig., 81, 82
- Myoidema, 208
- Myokymia, 80
- Myopathy—  
 atrophic type, 237, 242-6  
 diagrams of cases, 236-246, 287  
 atrophy of nuclear origin distinguished from, 236-7  
 Erb's juvenile type, 242-3  
 facio-scapulo-humeral type, 110, 155, 238, 242, 244  
 gait and posture in, 286-7  
 pseudo-hypertrophic type, 237-9
- Myosis, 128, 339
- Myositis, 137, 194, 235
- Myotomes, 33
- Myotonia atrophica, 251
- Myotonia congenita (Thomsen's disease), 250, 400
- Myotonic reaction, 400
- Myxœdema, 427
- NEVI, cutaneous, 301
- Nails, trophic changes, 306
- Narcolepsy, 64, 428
- "Narcosis, traumatic," 55
- Nasal crises, 119
- Nausea. *See under Vomiting*
- Neck, motor points (Erb's diagram), 391
- Nephritis, lumbar puncture for, 417  
 optic neuritis in, 125  
 uræmic fits of, 62, 70
- Nerve areas, trophic changes in skin and hair over, 296-298
- Nerve-cells, anatomy of, 1  
 "Nerve deafness," 157
- Nerve fibres—  
 afferent, influence on tissue nutrition, 290  
 motor, 6-9, 28, 30  
 physiology of, 2  
 sensory, 8, 28, 31
- Nerve plexus. *See Plexuses*
- Nerve roots. *See Spinal Nerves*
- Nerves. *See under Cranial, Motor, Peripheral, Spinal, also names of particular nerves*
- Nervous system, anatomy and physiology of, 1-47  
 scheme for routine examination of, 49-51
- Neuralgia—  
 blanching of hair in, 305  
 brachial, 184  
 coccygodynia, 184  
 hyperæsthesia in, 197-198  
 mammary, 182, 365  
 meralgia paræsthetica, 186  
 post-herpetic, 297  
 sciatic, 185, 320  
 "tender points," 180, 185  
 trigeminal, 180
- Neurasthenia, 52, 54, 356-8  
 causes and diagnosis, 356-7  
 deep reflexes exaggerated in, 327  
 distinguished from hysteria, 355  
 headaches associated with, 177  
 mydriasis in, 128  
 toxic, 356-358  
 traumatic, 182
- Neuritis—  
 alcoholic, 51, 198; diagram of case, 233  
 arsenical, 302, 306  
 brachial, diagram of case, 295  
 diabetic, perforating ulcers in, 295  
 hypertrophic interstitial, 226  
 ataxia in, 261  
 lead, 233  
 leprous, 295  
 loss of deep reflexes in, 326  
 multiple or peripheral, 51, 188, 194, 197-198, 205, 286, 306, 330  
 optic. *See that title*  
 post-diphtheritic, 110, 130, 155  
 retro-bulbar, 125  
 sciatic, 186
- Neuro-fibromata, 188, 303
- Neuromimesis, 355
- Neurons—  
 cerebello-dentate, 29



- Neurones (*continued*)—  
 cortico-bulbar, 110, 112  
 dentato-thalamic, 29  
 lower motor (spino-muscular),  
 27; lesions of, 28, 211-2. *See*  
*also* Motor Paralysis, Lower  
 Neurone type  
 sensory lesions of, 28  
 spino-cerebellar, 29  
 thalamo-cortical, 29  
 upper motor (cortico-spinal), 27;  
 lesions of, 28, 215. *See also*  
 Motor Paralysis, Upper Neu-  
 rone type
- Neuroses—  
 hysteria, 361-388  
 neurasthenia, 355-358  
 psychasthenia, 358-360
- Nicotine poisoning, tremors of, 84.  
*See also* Tobacco
- Nightmares, 429
- Noguchi's test for globulin, 409
- Nuclear ophthalmoplegia, 139
- Nuclei—  
 ambiguous, 164  
 auditory, 39, 157  
 bulbar, 110, 112  
 caudate, 6, 42  
 cerebellar, 21, 24  
 cerebral motor, 23  
 cuneate, 15, 18  
 Deiters', 21-26  
 dentate, 21  
 Edinger-Westphal, 126  
 emboliformes, 21  
 globosi, 21  
 glosso-pharyngeal, 148, 155  
 gracile, 15, 18  
 hypoglossal, 148, 170  
 lenticular, 6; lesions, 113  
 medullary, 15, 110  
 ocular, 21, 25, 86, 126  
 red, diagram, 23; lesions, 86,  
 139, 217, 265, 446  
 Sixth cranial nerve, 10, 140
- Nyctalopia, 120
- Nystagmoid jerks, 134, 152
- Nystagmus, 50, 85, 133-134  
 aural or vestibular, 136  
 cerebellar, 25  
 facial, 89  
 miner's, 133  
 myoclonus, 83, 133  
 reflex (optic, vestibular), 138  
 rhythmic, 133  
 oscillating, 133
- OBSESSIONS of psychasthenia, 359
- Occupation neuroses, 92, 253, 264,
- Ocular headaches, 176
- Ocular paralysis. *See under* Paralysis
- Ocular symptoms in Raynaud's  
 disease, 350
- Ocular vertigo, 161
- Oculo-pupillary fibres of cervical  
 sympathetic, 335; paralysis of,  
 337; diagram, 336
- Oculo-motor (Third) nerve. *See*  
*under* Cranial Nerves
- Oedema, acute angio-neurotic, 352  
 blue hysterical, 387  
 in cavernous sinus thrombosis, 46
- Oesophagus, hysterical spasm of, 385  
 reflected pains of, 182
- Olfactory nerves, 118; path of, 36
- Olivary body, 16, 24
- Olivoponto-cerebellar atrophy, 263
- Ophthalmoplegia, 126-7  
 nuclear (internal, external, total),  
 139; tremor in, 139
- Ophthalmoscopic examination, 49,  
 125, 175
- Opisthotonos, 68
- Opium poisoning, coma of, 61
- Oppenheim's reflex, 320
- Optic atrophy, 123, 125, 128, 129,  
 447
- Optic chiasma—  
 course of visual fibres in, 37;  
 diagrams, 38, 124  
 lesions at or behind, 123-5, 130,  
 447
- Optic nerve, 37, 119
- Optic neuritis, 125  
 in diagnosis of coma, 61  
 headaches with, diagnosis, 175  
 of intra-cranial tumour, 435, 441  
 lumbar puncture to relieve, 416
- Optic radiation, 37, 188
- Optic thalamus—  
 lesions of, 86, 174, 200, 216,  
 443  
 micturition centres in, 332  
 reflex centre of emotion, 444  
 sensory fibres of, 16, 19, 444  
 visual fibres in, 37
- Orbicularisoculi (palpebrarum), homo-  
 logous with branchial arch of fish,  
 141; innervation, 140
- Orbital muscle of Müller, 335;  
 diagram, 336
- Orthostatic albuminuria, 347
- "Osseous sense," 195
- Otic ganglion, 148; diagram, 142
- Otitis media, 156-7  
 vertigo from, 161
- Ovarian disease, headache from, 176
- "Ovarian tenderness," 366
- PAIN—  
 course of fibres subserving, 13-21  
 diagnosis of cause, 173  
 headache, 174-180  
 hysterical, 189, 365  
 in limbs, 184; bilateral, 187  
 loss of sense of, 21, 148-150, 204  
 paroxysmal spontaneous, 188  
 reflected, 182



- Pain (*continued*)—  
 root, 187  
 tests for sense of, 191–205  
 in trigeminal area, 179–180  
 in trunk, 180–184
- Palate, soft—  
 hemi-atrophy, 147  
 innervation, 143, 152, 163  
 paralysis, bilateral, 110; uni-  
 lateral, 164, 171  
 reflex movement, 317
- Pallæsthesia, 195
- Palpebral aperture, widening of, 150,  
 345
- Palsies. *See* Paralysis
- Panatrophy, local, 304
- Pandiculation, 88
- Paracousis, 157
- Paræsthesia, 50, 198, 201  
 definition of term, 195  
 hysterical, 375  
 mapping out areas of, 192
- Paradoxical flexor reflex, 319; pupil-  
 lary reaction, 130
- Paragraphia, 103
- Paralysis—  
 alcoholic, 155, 205, 233  
 alternate or crossed, 10, 50, 209,  
 216–7, 451–2  
 atrophic changes in, 307–9  
 Brown-Séguard, 13, 19, 195,  
 201–2, 218, 220  
 bulbar. *See that title*  
 of cervical sympathetic, 337–9  
 cranial nerves, 118–172  
 crossed, 10, 50, 209, 216, 451  
 facial, 110, 140, 148–155, 217;  
 bilateral, 154 (diagram)  
 family periodic, 253, 327, 351, 400  
 Fifth nerve, 145–6  
 glosso-labio-laryngeal. *See* Bul-  
 bar Palsy  
 glosso-pharyngeal, 163  
 hypoglossal, 110, 147, 170, 171  
 hysterical, 248, 256, 273, 274,  
 380; diagrams, 283, 362, 369–  
 373, 380–1, 383  
 infantile, 224, 272, 294, 307  
 ischæmic, 236  
 Landry's, 222, 233, 326  
 laryngeal, organic and functional  
 (diagrams), 165–7  
 Motor. *See* Motor Paralysis  
 motor and sensory combined,  
 219, 228, 330  
 musculo-spiral (diagram), 269  
 myasthenia gravis. *See that title*  
 ocular, rheumatic, 137  
 infra-nuclear, 138  
 from lesions of individual  
 nerves, 130, 135–140  
 nuclear lesions, 139–140  
 supra-nuclear, 137–8  
 palatal, 95, 110–1, 152, 164–5
- Paralysis (*continued*)—  
 peripheral motor nerve lesions,  
 electro-prognosis of, 402  
 post-diphtheritic, 95, 110, 155  
 in tumours, 439–441
- Paralysis agitans—  
 articulative difficulties in, 114  
 bilateral, 115  
 diagrams of cases, 85, 288, 289  
 Parkinsonian mask, 115, 287  
 posture and gait of, 286–9  
 rigidity of, 84  
 tremor, 84
- Paramyoclonus multiplex (Fried-  
 reich's), 80–3; diagram, 82
- Paramyotonia congenita (Eulenberg's  
 disease), 250
- Paraphasia, 101
- Paraplegia—  
 bed-sores in, 298  
 brachial and crural, 209  
 chronic, trophic changes in nails,  
 306  
 definition, 209  
 gait, 281–2  
 hysterical, 274, 282, 283, 362–3  
 (figs.)  
 pure motor, 221  
 spastic, 53, 212, 219, 260, 282
- Paraplegia dolorosa, 187, 188
- Para-sympathetic fibres, 334
- Parathyroids, tetany from extirpa-  
 tion of, 77
- Parkinsonian mask, 115, 287
- Parosmia, 49, 118–9  
 paroxysmal, 119
- Patient, examination of, 48–54
- Penis, analgesia of, in tabes, 204
- Pericarditis, reflected pain in, 182
- Perimeter, use of, 121, 374
- Periostitis of skull, 175
- Peripheral irritation, reflex convul-  
 sions from, 73
- Peripheral nerves—  
 cutaneous areas, 32  
 lesions—  
 anæsthesia, 204  
 ataxia, 259  
 mixed, 222, 229–232  
 motor paralysis, 209–210,  
 222–223, 326, 402  
 sensibility and, 14–5  
 paths of sensation in, 15
- Peripheral neuritis. *See* Neuritis,  
 Multiple
- Peritonitis, 194, 346
- Peroneal muscular atrophy, 226
- Personality, alternating, 359, 378  
 "Petit-mal," 65, 69, 255
- Petrous ganglion (diagram), 142
- Pharyngeal reflex, 317
- Pharynx—  
 anæsthesia, 56  
 innervation, 163; paralysis, 163



- Phobiæ, 360  
 Pill-rolling tremor, 288  
 Pineal body—  
   tumours of, 445-6  
 Pituitary body—  
   anatomy and physiology, 25-6  
 Pituitary tumours, 123-4, 291-3, 425, 447  
   and hemianopia, 123  
 "Planchette," sub-conscious phenomena of, 378  
 Plantar reflex, 2, 28, 57, 61, 213, 219, 317  
   Babinski's phenomenon, 318-320  
   in hysteria, 320-322, 384  
 Pleurodynia, 181  
 Plexiform neuroma, 303  
 Plexuses—  
   brachial, symptoms in division of posterior roots, 259  
   cervical, 29, 141, 145  
   cervico-brachial and branches, 29, 30  
   hypogastric and hæmorrhoidal, 331  
   lumbo-sacral, 29, 31  
   solar, disorders associated with, 346-347  
 Pneumonia, loss of deep reflexes in, 327  
 "Polar reactions" of muscle, 398 *et seq.*  
 Polio-encephalitis, superior, 74  
 Polio-myelitis, acute. *See* Infantile Spinal Paralysis  
   chronic anterior, 80, 225, 326  
 Poly-æsthesia, 196  
 Polyopia, monocular, 376  
 Polyuria, hysterical, 386  
 Pons—  
   arterial supply, 41  
   cranial nerves (diagram), 119  
   facial nerve, origin in, 148  
   hæmorrhage, 57, 59, 128  
   lesions of, 10, 53, 86, 152, 201, 203, 217-8  
   nuclei, 110, 139  
   sensory fibres, course in, 17, 18  
   tumours of, 446, 451 (fig.)  
 Ponto-cerebellar angle, lesions of, 203  
   tumours in, 449 (fig.)  
 Ponto-spinal tract, 13  
 Popliteal nerve, external gait in paralysis, 287  
   posture in paralysis, 269  
 "Port-wine stains," 301  
 Post-diphtheritic paralysis, 110, 155  
 Posterior cerebral artery, 41  
 Posterior columns of cord, lesions, 15-18, 195, 259, 284, 326, 329  
 Posterior fossa, tumours of, 175, 328  
 Posterior nerve roots. *See* Spinal Nerves, Roots  
 Postures, 267-289  
   cerebellar, 285-286  
   erect and at rest, 267  
 Postures (*continued*)—  
   in functional disease, 274-277  
   in hysterical fits, 68  
   in organic disease, 270, 276  
 Pot belly, 240, 287  
 Preacher's hand, 271  
 Pregnancy—  
   pseudo-, 385  
   tetany in, 79  
 Pressure—  
   blood, in coma, 55  
   intra-cranial, 61, 71, 175, 326, 408, 427; lumbar puncture in relief of, 415  
   intra-theal, 406  
   labyrinthine, 163  
 Pressure-pain, 13  
 Pressure-sense, 192, 194  
 Progressive muscular atrophy, 80, 224-5, 326, 402  
 Progressive neuritic amyotrophy (Charcot and Marie), 226  
 "Pronation phenomenon" in hemiplegia, 214  
 Proptosis, 46, 51  
 Protopathic cutaneous sensibility, 14; loss of, 204; recovery of, 232  
 Pseudo-angina, 182, 384  
 Pseudo-appendicitis, 386  
 Pseudo-bulbar paralysis, 113, 218  
 Pseudo-hæmatemesis, 386  
 Pseudo-hæmoptysis, 386  
 Pseudo-hypertrophy, 237-9 (figs.)  
 Pseudo-memories, 51  
 Pseudo-pregnancy, 385  
 Pseudo-ptosis, 51, 337, 339, 343; hysterical, 136; diagram, 382  
 Pseudo-tumour cerebri, 453 4  
 Psychalgia, 365  
 Psychasthenia, 71, 358-360  
   imperious acts in, 360  
   obsessions in, 359-360  
   phobiæ of, 360  
   stigmata, 360-361  
 Psychic epilepsy, 69  
 Pterygoid muscle, external, action in congenital ptosis, 141  
   paralysis of, 145  
 Ptosis, 135, 382  
   bilateral, 445  
   congenital, 140  
   hysterical, 137, 382  
   pseudo-. *See above*, Pseudo-ptosis  
 Puerperal eclampsia, 70, 417  
 Pupillary reflex. *See under* Reflex, light  
 Pupillary unrest, 129  
 Pupils—  
   Argyll-Robertson phenomenon in, 127, 129  
   contraction—  
     in affections of cervical sympathetic, 337  
     in opium poisoning, 60  
     in pontine hæmorrhage, 59



- Pupils (*continued*)—  
 dilating fibres, course of (diagram), 127, 142, 335  
 dilatation of, 57, 62, 128, 135  
 examination of, 50, 128  
 irregularity in shape, 57; diagnostic significance, 128, 345  
 light reflex. *See under* Reflexes  
 motor innervation, 126  
 painful stimulation of neck, reaction to, 130  
 paradoxical reaction, 130  
 psychical dilatation, 130  
 reaction to accommodation, 130  
 size, variations in, 128
- Pyramidal cells, 6
- Pyramidal tract—  
 course, 11, 27; and diagram of, 7  
 lesions of, 9-11  
   gait in, 281  
   motor paralysis due to, 86, 217-8  
   reflexes affected by, 318-319  
   *and note*, 327; in hysteria, 384
- QUADRANTIC hemianopia, 37
- Quinquaud's sign of chronic alcoholism, 84
- RABIES, 76
- Rami communicantes, 334-336
- Raynaud's disease, 51, 53 *note*, 188, 299, 348-350
- Reactions of degeneration, 28, 208, 213, 400-2
- von Recklinghausen's disease, 302-3
- Recti muscles of eye (diagrams), 126, 131-142
- Recurrent and transient motor paralysis, 248-256
- Recurrent laryngeal palsy, 164-8
- Recurrent utterances, 106
- Red nucleus, connections (diagram), 12, 23  
 lesions, 86, 139, 265, 446
- Reeling or titubating gait, 263, 285
- Reflected pains of visceral disease, 182
- Reflex arc, 2, 28, 129, 318
- Reflex convulsions, 74
- Reflex spasms, 92
- Reflexes, 50, 316-333  
 abdominal, 317  
 anal—  
   internal, 330, 332  
   superficial, 317, 319  
 Babinski's extensor plantar reflex, 317-8  
 Brissaud's, 318  
 bulbo-cavernosus, 317, 320  
 cilio-spinal, 51, 330, 338, 340  
 conjunctival, 150, 317  
 conscious and unconscious, 2, 4
- Reflexes (*continued*)—  
 cortical and spinal, 318, 319  
 cremasteric, 317, 320  
 dartos, 333, 419  
 deep or tendon, 50, 316, 321-329  
   in ataxic conditions, 259  
   after epileptiform fits, 68, 72  
   exaggerated, 19, 111, 327  
   loss of, 320, 326  
   in upper and lower neurone motor paralyzes, 28, 213  
 effect of spinal injuries on, 20, 219  
 epigastric, 317  
 genital, 4, 330  
 gluteal, 317  
 in hysteria, 64, 68, 383  
 jaw, 321  
 light, 2, 129, 330  
   in hysteria, 64, 68, 383  
   loss of, 126, 129, 130  
   path of, 126; diagram, 127  
 of non-striated muscles, 330  
 Oppenheim's, 320  
 optic. *See above* (Light)  
 palatal, 317  
 paradoxical flexor, 319  
 pharyngeal, 317  
 plantar, 2, 28, 57, 61, 213, 219, 317, 318-322  
 pupillary. *See above* (Light)  
 rectal, 330  
 scapular, 317  
 scapulo-humeral, 321  
 scrotal, 330, 333  
 sexual, 4, 330  
 superficial (or skin), 50, 57, 316-321  
 uterine, 330  
 vomiting, 4
- Renal disease. *See under* Kidney and Nephritis
- Restiform body, 24, 39
- Retina, 37, 129
- Retinal œdema, diagnostic significance, 59
- Retinitis pigmentosa, 120
- Retro-bulbar neuritis, 125
- Retrograde amnesia, 55
- Retro-quadrigeminal hemianopia, light reflex in, 130
- Rheumatic myositis of external ocular muscles, 137
- Rickets, convulsions and tetany due to, 73, 77
- Righthandedness, 38, 40
- Rigors, 79
- Rinne's test for hearing, 156
- Rolando, fissure of, 9, 19
- Romberg's sign in tabes, 258, 260
- Root-areas, diagrams of, 35
- Root-lesions, 29, 195, 222-236
- Root-pains, 180-181, 187
- Rosenbach's sign of hemiplegia, 57



- Rotatory movements, cerebellar stimulation and, 25  
in intra-cerebellar growths, 450
- Round-worms, convulsions due to, 74
- Rubro-spinal tract, 13, 86, 139, 265  
loss of function, 327, 445-6
- Rupophobia, 360
- SACRAL pain, 184
- Sacral plexus, 29
- Sacral segments, lesions, 320
- Sacro-coccygeal root-areas (diagram), 35
- Saliva, irregularity in flow of, 150-2
- Saltatory spasms, 94
- Scapular reflex, 317
- Scapulo-humeral reflex, 321
- Sciatic nerve, paralysis of (fig.), 231
- Sciatica, 185
- Scissor gait, 281
- Scleroderma, 300
- Sclerosis—  
amyotrophic lateral, 80, 111, 221, 225, 326  
disseminated. *See* Disseminated Sclerosis  
multiplex dolorosa, 181  
postero-lateral, 285  
primary lateral, 220
- Sclerotomes, 33
- Scotomata, central, 121, 126; of migraine, 178; for red and green in tobacco amblyopia, 120
- Scrotal reflex, 330, 333
- "Seelenlähmung," Nothnagel's, 382
- Segmentation of spinal cord (diagrams), 30-3
- Semicircular canals, disease of, 158-163
- Senile tremor, 84
- Sensation—  
clinical investigation of, 190-205  
paths of, 15  
muscle-active, 190  
physiology of, 13-5  
return after mixed nerve paralysis, 232
- Senses, special, paths of, 36-40
- Sensibility, kinds of, 13
- Sensory fibres, position of, 8, 9  
fits, 73  
functions, 50  
paths, 13-21
- Serratus magnus, paralysis of, 232
- Sewer-gas poisoning, 293
- Sexual reflex, 4, 330
- Shivering, 79
- Shoemakers' tetany, 77
- Side-gait ("Flankengang"), 283
- Sight. *See* Vision
- Skew deviation of eyes, 138
- Skin—  
areas of peripheral nerves, 32
- Skin (*continued*)—  
hysterical affections, 386-7  
pigmentary changes, 301-3, 347  
sensibility of, 14, 15, 191-3  
loss of, 21, 204  
recovery of, 230  
trophic changes, 294-303
- Sleep, disorders of, 423-433  
pathological, 426  
physiology of, 423-6
- Sleeping sickness, 428  
parasites in cerebro-spinal fluid, 411
- Smell, disorders of, 49, 73, 118, 119, 145; hysterical, 367, 373; olfactory path, 36; tests for sense of, 118
- Sneezing in parosmia, 119
- Snellen's types, 119
- Somnambulism, 377, 426, 429
- Spasms, habit, 90  
hysterical, 94, 379, 387  
reflex, 92  
saltatory, 94  
*See also* Tics
- Spasmus nutans, 85
- Spasticity, 28, 213
- Special senses, paths of, 36-9
- Speech—  
articulation distinguished from, 109  
auditory origin of, 97  
cortical centres for, 96-100  
disorders, in diagnosing nervous disease, 52-4  
hysterical affections, 364  
loss of—  
aphasia. *See that title*  
articulation, defects. *See* Articulation  
causes, classification of, 95  
vocal and consonantal elements in, 109
- Sphincter ani, externus, 34, 317, 320; internus, 330, 332
- Spina bifida occulta, 295, 304
- Spinal accessory nerve, 164
- Spinal anæsthesia, 418-422  
after-effects of, 420  
contra-indications, 421
- Spinal cord—  
arterial supply, 44  
cervical region—  
lesions in, 128, 181, 209, 218  
muscular localisation in, 34  
Clarke's column, 19  
coccygeal segment, 184, 320  
combined degeneration of, 260, 329  
endogenous tracts, 19  
grey matter, focal lesion of, 326  
lateral column, 15, 16, 329  
lesions of—  
anæsthesia in, 201-3  
bladder trouble due to, 331



- Spinal cord, lesions of (*continued*)—  
 complete and incomplete, 201, 218-9  
 hemi-section of, 11, 19, 195, 200-1, 218  
 paralysis due to, 11, 19, 219  
 posterior roots and columns of, 13-21, 259-260  
 in pyramidal tract. *See* Pyramidal tract  
 rectal incontinence from, 331  
 root pains due to, 187  
 symptoms of, 19  
 trans-section, complete of, 201, 219, 326, 327, 329  
 unilateral, 218  
 lumbo-sacral region. *See* Lumbo-sacral cord  
 malignant growths in, 411  
 micturition centres in, 331-2  
 paths of sensation in, 15  
 posterior columns, 15-8, 195, 259, 284, 326, 329  
 relations with vertebral column (diagram), 404  
 root irritation from diseases of, 187  
 segments (diagram), 30-5  
 sub-acute combined degeneration, 260, 329  
 tracts of, 10-3, 17  
 tumours, intra- and extra-medullary, 181, 219; cerebro-spinal fluid in, 411  
 vaso-motor centres, diseases of, 350
- Spinal nerves—  
 anterior roots, 2, 27; lesions of, 27-35, 222-4  
 mixed motor and sensory paralysis due to, 218-9, 228, 329  
 motor paralysis due to, 27-35  
 posterior roots—  
 cutaneous areas, 32  
 distribution, 27-35  
 inflammation of ganglia, 187, 296-8  
 irritation, 180, 187, 196-8  
 lesions of, 27-35, 259, 327  
 sensory path through, 15
- Spino-muscular motor neurone lesions. *See* Motor Paralysis  
 Spino-thalamic tract, 16  
 Splanchnic disease, 346-7  
 Squint, 50, 131  
 Stammering, 115; hysterical, 364  
 Stellwag's sign of exophthalmic goitre, 346  
 Stereognostic perception, 195, 443  
 Sterno-mastoid, paralysis of (figs.), 91, 168  
 Stokes-Adams' syndrome, 62, 74
- Stomach—  
 dilatation of, 77, 164, 347  
 hysterical rumblings in, 385-6  
 reflected pains of, 182  
 Storaine as anæsthetic, 418  
 Strumpell's tibialis phenomenon, 214  
 Strychnine poisoning, 75, 327, 418  
 Stupor, 55  
 Sub-cortical cerebral tumours, 73  
 Sub-cortico spinal tracts, 11, 13  
 Sunstroke and alcoholics, 63; and coma, 63, 177  
 Supinator jerk, 321, 325  
 Supinator longus, paralysis of, 30
- Sweating—  
 abnormalities, due to nerve disorder, 51, 343-4, 353  
 centre, 353  
 cervical sympathetic connected with, 335, 338, 339, 343  
 of hysteria, 386  
 in Ménière's disease, 162
- Sylvian fissure, 9, 39, 96; arteries of, 43
- Symmetrical gangrene, 349
- Sympathetic nervous system—  
 course and distribution, 1, 334  
 lesions of, 336-344  
 thoracico-abdominal, diseases of, 347, 348  
 visceral reflexes controlled by, 316, 330-3
- Syncope distinguished from "petit-mal," 69
- Syphilis—  
 cerebro-spinal fluid in diagnosis of lesions, 414-5  
 diagnosis of, 452  
 epilepsy secondary to, 71, 72  
 irregularity of pupils in, 71, 128  
 meningitis of, 180  
 palatal perforation from, 110  
 Third nerve palsy from (fig.), 135
- Syringobulbia, 202
- Syringomyelia—  
 arthropathy (diagrams), 203, 221, 309, 313  
 cerebro-spinal fluid, 409  
 claw-hand in, 271  
 dissociated anæsthesia, 196, 202, 221  
 exaggerated deep reflexes, 327  
 fibrillary tremors, 80  
 loss of deep reflexes in, 326  
 ocular symptoms, 128  
 pain from, 173  
 perforating ulcers in, 295  
 spontaneous fractures in, 309  
 thermo-anæsthesia and analgesia, (diagrams) 202-3, 310  
 trophic changes in joints, 221, 309-13



- TABES—  
 anæsthesia of, 203-5, 332; dia-  
 gram, 204  
 ankle-jerks, 325  
 anosmia, 118  
 Argyll-Robertson phenomenon,  
 127, 129  
 arthropathy, diagnosis of cases,  
 308-14  
 ataxia, 258-66  
 bulbo-cavernosus reflex, loss in,  
 320  
 cerebro-spinal fluid in diagnosis  
 of, 414-15  
 crises in, 183, 347  
 delayed sensation in, 193  
 gait in, 284-5  
 girdle pains in, 181  
 hair, loss of, (fig.), 305-6  
 hyperæsthetic areas, 186; dia-  
 gram, 204  
 hypotonia in, 276-7  
 involuntary movements, 89, 308  
 (fig.)  
 joint and kinæsthetic senses,  
 loss of, 194  
 laryngeal, 112  
 lightning pains, 187, 197  
 light reflex, loss of, 127, 129, 313  
 muscular and tendinous anal-  
 gesia, 194, 204  
 myosis, 128  
 nasal crisis, 119  
 optic atrophy, primary, 125  
 perforating ulcers, 295  
 pupils, irregularity of, 128  
 reflexes, 128-130, 320, 326, 330  
 spontaneous fractures, 309  
 sudden falling in, 255  
 trophic changes, 295-96, 347  
 vibration sense, loss of, 195  
 Tactile sense, 13-15, 19  
 loss of, 21, 191  
 Talipes equino-varus, 226  
 Taste, cortical centre for, 39  
 course of fibres serving, 39, 143,  
 155, 163; diagrams, 142, 151  
 disorders of, 144-5, 155, 163;  
 hysterical, 367, 373, 374  
 in Fifth nerve palsy, 143  
 tests for sense of, 144  
 Tear secretion, paralysis of, 145  
 Tecto-spinal tract, 13  
 Tegmental lesions, 86, 446  
 Temperature in cerebral hæmorrhage,  
 58  
 Temperature sense, fibres serving,  
 15-20  
 tests for, 190, 192  
 Temporal lobe, disease of, 40, 72, 441  
 Tetanus, 75, 327, 417  
 Tetany, 77, 254  
 and cataract, 77  
 Chvostek's sign of, 77  
 Tetany (*continued*)—  
 endemic, of shoemakers, 77  
 from extirpation of parathyroids,  
 77  
 Erb's sign of, 77  
 Trousseau's sign of, 77  
 Thalamic syndrome, 174, 196, 200,  
 216, 444-5  
 Thalamo-cortical pathway, 8  
 Thecal puncture, 404  
 Thermic nystagmus, 133-4  
 Thigh, motor points (Erb's diagrams),  
 395, 397  
 Thirst, cortical centre for, 40  
 Thomsen's disease (Myotonia con-  
 genita), 250, 400  
 Thoracic nerves, lesions producing  
 ocular symptoms, 337  
 Thrombosis, bilateral, of corpus stri-  
 atum syndrome, 293  
 of cavernous sinus, 46  
 cerebral, 41, 45-47, 59, 98, 101,  
 159-160, 176, 408  
 spinal, 45, 53  
 "Tibialis phenomenon," 214  
 Tic douloureux, 93, 180  
 Tics, 90-92, 116  
 distinguished from chorea, 91  
 hysterical, 360  
 Tinnitus, 156, 157, 162, 175; lumbar  
 puncture to relieve, 417  
 Tobacco amblyopia, 120, 122, 125  
 Tongue—  
 ataxy of, 112  
 biting, in epilepsy, 67  
 hemi-atrophy, 146, 171  
 innervation, 143, 163, 170, 335  
 paralysis, 110, 170-1  
 taste fibres to, 143, 152, 163  
 Torcular Herophili, 46  
 Torticollis, idiopathic spasmodic, 91;  
 labyrinthine, 92; neuralgic, 92;  
 professional, 92  
 Touch. *See* Tactile sense  
 Toxicophobia, 360  
 Trance, hysterical, 64, 377  
 Traumatic cerebral compression, 59  
 Tremor, 83, 84-86  
 Quinquaud's sign in alcoholism,  
 84  
 senile, 84  
 toxic, 84: in tumours of frontal  
 lobe, 86  
 Triceps jerk, 321, 326  
 Trichiniasis, 235  
 Tricho-anæsthesia, 191  
 Trigeminal nerve. *See* Cranial Nerves.  
 Trigeminal neuralgia, 179-180  
 Trophic functions, 50  
 Tropho-neuroses, 290-315  
 bones and joints, 306  
 generalised trophic disorders, 291  
 skin and its appendages, 294  
 Trousseau's sign of tetany, 77



- Trypanosome of sleeping sickness, 411
- Tubercles of choroid, 125
- Tubercula dolorosa, 188
- Tuberculin, Calmette's and von Pirquet's reactions, 453
- Tuberculous meningitis, 52, 175, 411, 412, 415
- Tumours—
- abdominal phantom, 386
  - diagnosis, 54, 434; differential, 219, 451-4
  - intra-cranial, 72, 125, 160, 175, 177-8, 425-7, 434-454
  - Central ganglia, 444
  - Cerebellum, 157, 160, 178, 264, 285; ataxia in, 263; extra- and intra-cerebellar, 447; lateral lobe, 448; middle lobe, 450; fits due to, 65, 77, 450
  - coma in, 61
  - Corona radiata, 444
  - Corpora quadrigemina, 445
  - Corpus callosum, 445
  - Crusta of crus cerebri, 446
  - diagnosis, 452-4
  - and drowsiness, 427
  - epileptic fits from, 71, 436, 438
  - Fourth ventricle, 452
  - Frontal region, 440; anosmia in, 441; tremor of, 86
  - giddiness in, 436
  - headache of, 175, 177-8, 435
  - hemianopia from, 123
  - Internal capsule, 444
  - Jacksonian fits in, 436, 439, 440
  - Medulla oblongata, 452
  - mental dulness in, 436
  - of mid-brain, 126, 423-4
  - Motor cortex, 439
  - Occipital region, 443
  - optic neuritis, 125, 435
  - Pineal body, 445
  - Pituitary, 123, 293, 425, 447
  - Pons, 451
  - Post-central convolution, 442
  - Postero-parietal lobule, 443
  - Post-frontal, 440
  - Pre-central (fig.), 438
  - Pre-frontal, 440
  - slowness of breathing, 437; of pulse, 437
  - Supra-marginal and angular convolutions, 442
  - Temporal lobe, 441
  - Tegmental region of crus or Pons, 446
  - Vermis, 450
  - vomiting in, 436
- Tumours (*continued*)
- lumbar puncture for inoperable, 416
  - pelvic, 186
  - of spinal cord, 219; differential diagnosis, 219-220, 451; meningeal, 181, 186, 187
- Tuning-fork, tests for hearing, 156
- Typhus fever, "coma-vigil" of, 64
- ULCERS—
- perforating, 50, 296
  - rodent, 282
- Ulnar paralysis, 230
- Uncinate gyrus. *See under* Gyrus fits, 73, 441
- Unverricht's family myoclonus, diagram, 81-2
- Uræmia—
- coma of, 62, 428
  - convulsions, 70, 74
  - Jacksonian fits in, 73
- Urine—
- in alcoholic poisoning, 62
  - diabetic, 63
  - dribbling of, 332
  - hysterical incontinence and retention, 384; suppression, 386
  - reflex incontinence, 331
  - retention, 331
  - in uræmic coma, 62
- Urticaria scripta, 352, 387; diagrams, 136, 387
- Uterine disease, headache from, 176
- Uterine reflex, 330
- VASCULAR causes of insomnia, 430
- Vaso-constriction in sleep, 423-424
- Vaso-motor neuroses, 347-354, 384-388
- Veins, intracranial, 45-47
- Venereal diseases, questions as to, 49
- Ventral longitudinal bundle, 13
- Vermis, 21, 24, 25
- tumours of, 450
- Vertebral arteries, 41, 44
- Vertebral column, 50; diagram, 404
- Vertigo—
- ataxia in, 263, 285
  - causes, 158-163
  - pathological, 159-161
- Vesical reflex, 330
- Vestibular nerve—
- connections of, 40
  - lesions, 138, 156
  - tests for integrity, 133
- Vestibulo-spinal tract, 13, 21, 24, 25
- Vibrant electricity, 389
- Vibration sense, 13, 20, 190, 195
- Vidian nerve, 142
- Visceral disease, reflected pains in, 182



- Visceral phenomena of hysteria, 384-386
- Vision—  
 fibres of, path of, 36-39  
 field of, 37, 49  
   concentric contraction, 123, 442; in myasthenia, 250  
   hysterical, 373-376; diagram, 374-375  
   measurement, 121-123  
   hysterical blindness, 375  
   colour-vision, 373-375  
   hyperæsthesia, 366-367
- Visual acuity, tests for, 118
- Visual aphasia, 102-3, 105; diagrams, 96, 98  
 centres for, 37, 105  
 cortical and sub-cortical, 37-39, definition, 102  
 lesions producing (diagrams), 38, 96, 102
- Visual cortex, 36-39, 442
- Visual hallucinations, 72, 444
- Visual word-centre, 96, 100, 442
- Visuals and auditives, 98, 101
- Vocal word centre, 97, 441
- v. Volkmann's ischæmic paralysis, 236
- Vomiting, 4, 74, 152, 156, 159, 160, 161, 175, 178  
 cerebral, 436  
 hysterical, 384-386  
 reflex, 4
- WALKING. *See* Gait
- Wallerian degeneration, 27, 29
- Weber's law, 194
- Weber's syndrome, 10, 217, 446
- Weber's test for hearing, 156
- Werdnig-Hoffmann type of progressive muscular atrophy, 225
- Werner's "memoria technica," for false images (diagram), 132
- Wernicke's hemiopic pupillary reaction, 130, 443
- Wernicke's zone, disintegration of, 105
- Whitlows, painless, 203, 296
- Willis, circle of, 42
- Witches, 368
- Word-blindness. *See* Visual aphasia
- Word-centre—  
 auditory, 96; diagram, 98, 102  
 visual, 96-97  
 vocal, 96, 441
- Word-deafness. *See* Auditory aphasia
- Word-swallowing, 91
- Wrisberg, nervus intermedius of, 148, 155
- Wrist reflex, 321
- Writers' cramp, 253, 264
- Writing, motor centre for, 97
- X-RAYS in neurology, 389  
 in tumours, 437
- YAWNING, automatic extensor movements in, 88  
 in intra-cranial disease, 437
- Yohimbine poisoning, 400
- ZACHARIAS, instance of motor aphasia, 104

THE END



The first part of the book  
 is devoted to a general  
 introduction of the subject  
 and to a description of the  
 various forms of the  
 disease. The second part  
 is devoted to a description  
 of the various forms of the  
 disease. The third part  
 is devoted to a description  
 of the various forms of the  
 disease. The fourth part  
 is devoted to a description  
 of the various forms of the  
 disease. The fifth part  
 is devoted to a description  
 of the various forms of the  
 disease. The sixth part  
 is devoted to a description  
 of the various forms of the  
 disease. The seventh part  
 is devoted to a description  
 of the various forms of the  
 disease. The eighth part  
 is devoted to a description  
 of the various forms of the  
 disease. The ninth part  
 is devoted to a description  
 of the various forms of the  
 disease. The tenth part  
 is devoted to a description  
 of the various forms of the  
 disease.



PRESS OPINIONS ON THE SECOND EDITION  
OF  
THE DIAGNOSIS  
OF  
NERVOUS DISEASES

"It is a pleasure to welcome a second edition of so practical and instructive a work as Dr. Purves Stewart's. The subject is dealt with from a clinical standpoint, and careful directions are given to enable the practitioner to work out the symptoms presented by patients and to accord them their proper value in diagnosis. We can cordially commend this book to the student and practitioner who are anxious to work out their cases of nervous diseases adequately, for it is written in simple style and does not presuppose an intimate acquaintance with the more abstruse details of the anatomy and physiology of the nervous system. The plates, illustrations, and diagrammatic figures are uniformly good, and considerably enhance the value of the book."—*The Lancet*.

"It is a great pleasure to review the second edition of a good book, and there is no doubt that the quality of this volume has been fully recognised by the advanced students and general practitioners for whom it was originally written, because the second edition has appeared only two years after the first.

We found the book most readable, admirably illustrated, and representing a huge amount of thought, care, and experience. The new sections are, without exception, of great value. The fact that there are so few competitors in the field shows how difficult is the task Dr. Stewart has undertaken. We must congratulate the publishers on the printing and the illustrations."—*Edinburgh Medical Journal*.

"That Dr. Purves Stewart's "Diagnosis of Nervous Diseases" has met with the wide acceptance it deserves is proved by the fact that the second edition has now been published although less than two years have elapsed since we reviewed the first. Dr. Stewart has the happy gift of giving the gist of a matter in a few pregnant sentences, and of seeing clearly what is wanted, and consequently of being singularly lucid in expression. We can warmly commend this book to our readers."—*British Medical Journal*.

"Dr. Stewart's work was obviously one which was expected to reach speedily a second edition, and this expectation has been amply fulfilled. The clearness and terseness of diction which characterise the book would be impossible apart from clearness of judgment and vigour of decision in the mind of the writer."—*Journal of Laryngology*.

LONDON: EDWARD ARNOLD



*Pp.* xvi + 511. *With* 142 *Illustrations.* 7s. 6d. net

# THE HOUSE-SURGEON'S VADE-MECUM

BY

RUSSELL HOWARD

M.B., M.S. (LOND.), F.R.C.S. (ENG.)

SURGEON TO POPLAR HOSPITAL; ASSISTANT-SURGEON, LONDON HOSPITAL

AUTHOR OF "SURGICAL NURSING"

THIS work has been written mainly for the use of recently appointed House-Surgeons and Dressers; but the general practitioner who has not had the advantage of holding the post of House-Surgeon at a large Hospital will find it extremely useful in his daily practice.

It contains clear and concise instructions for the preparation of patients for all the important operations and their after-treatment and feeding, as well as a description of the common minor operations. Surgical emergencies and their treatment are dealt with, as well as the use of surgical apparatus, such as trusses, bandages, high boots, and colostomy and other varieties of belts.

Two chapters are devoted to the treatment of fractures and dislocations, and a concise account of the methods of inducing anæsthesia has been contributed by Dr. ASHLEY DALY. The illustrations and diagrams are numerous and comprehensive.

---

LONDON: EDWARD ARNOLD



# MR. EDWARD ARNOLD'S LIST

OF

## MEDICAL BOOKS.

### Further Advances in Physiology.

EDITED BY LEONARD HILL, M.B., F.R.S.

With Contributions from Professor BENJAMIN MOORE, University of Liverpool; MARTIN FLACK, B.A., M.B. OXON.; LEONARD HILL, M.B., Lecturer on Physiology, London Hospital; Dr. THOMAS LEWIS; Dr. ARTHUR KEITH, Curator of the Hunterian Museum, Royal College of Surgeons; Dr. M. S. PEMBREY, Lecturer on Physiology, Guy's Hospital; Dr. N. ALCOCK, Lecturer on Physiology, St. Mary's Hospital; Dr. JOSEPH SHAW BOLTON; MAJOR GREENWOOD, M.R.C.S., Director of Statistical Department, London Hospital.

448 pages. With Diagrams and Index. Demy 8vo., 15s. net.

### Recent Advances in Physiology and Bio-Chemistry.

EDITED BY LEONARD HILL, M.B., F.R.S.

CONTRIBUTORS:

Prof. BENJAMIN MOORE; LEONARD HILL, M.B., F.R.S.; J. J. R. MACLEOD, M.B., Professor of Physiology, Western Reserve University, Cleveland, U.S.A.; late Demonstrator of Physiology, the London Hospital; M. S. PEMBREY, M.A., M.D.; and A. P. BEDDARD, M.A., M.D., Assistant Physician, late Demonstrator of Physiology, Guy's Hospital.

xii+740 pages. With Diagrams. Demy 8vo., cloth, 18s. net.

### Practical Physiology.

By A. P. BEDDARD, M.A., M.D.; J. S. EDKINS, M.A., M.B., D.Sc.; LEONARD HILL, M.B., F.R.S.; J. J. R. MACLEOD, M.B.; MARTIN FLACK, M.A., M.D.; and M. S. PEMBREY, M.A., M.D.

THIRD EDITION. xx+484 pages. With Illustrations. 14s. net.

### Applied Physiology.

By ROBERT HUTCHISON, M.D. EDIN., F.R.C.P.,

Physician to the London Hospital and to the Hospital for Sick Children, Great Ormond St.

Crown 8vo., 7s. 6d. net.

### Physiology of the Special Senses.

By M. GREENWOOD, JUN., M.R.C.S., L.R.C.P., F.S.S.,

Director of the London Hospital Statistical Department; Senior Demonstrator of Physiology in the London Hospital Medical College; Examiner in Physiology to the University of St. Andrews.

viii+239 pages. 8s. 6d. net.

LONDON: EDWARD ARNOLD, 41 & 43 MADDOX ST., BOND ST., W.



**The Physiological Action of Drugs.**

An Introduction to Practical Pharmacology.

BY M. S. PEMBREY, M.A., M.D.,  
Lecturer on Physiology, Guy's Hospital;

AND C. D. F. PHILLIPS, M.D., LL.D.

With 68 Diagrams and Tracings. Demy 8vo., cloth, 4s. 6d. net.

**Human Embryology and Morphology.**BY ARTHUR KEITH, M.D. ABERD., F.R.C.S. ENG.,  
Conservator of the Royal College of Surgeons.

xii + 402 pages. Second Edition. Demy 8vo., 12s. 6d. net.

**Lectures on Diseases of Children.**BY ROBERT HUTCHISON, M.D. EDIN., F.R.C.P.,  
Physician to the London Hospital and to the Hospital for Sick Children, Great Ormond St.  
440 pages. With Illustrations. Cloth, 8s. 6d. net.**A System of Clinical Medicine.**Dealing with the Diagnosis, Prognosis, and Treatment of Disease,  
for Students and Practitioners.BY THOMAS D. SAVILL, M.D.,  
Late Physician to the West End Hospital for Diseases of the Nervous System, and to  
St. John's Hospital for Diseases of the Skin.

NEW EDITION IN ONE VOL. 8vo. 25s. net.

**A Text-Book of Medical Treatment.**

ALPHABETICALLY ARRANGED.

BY WILLIAM CALWELL, M.A., M.D.,  
Physician, Royal Victoria Hospital, Belfast; University Clinical Lecturer on Medicine,  
Queen's University, Belfast.

iv + 632 pages. Royal 8vo. 16s. net.

**A Pocket-Book of Treatment.**BY RALPH WINNINGTON LEFTWICH, M.D.,  
Late Assistant Physician to the East London Children's Hospital.  
viii + 348 pages. Flexible binding, with wallet flap. 6s. net.**The Diagnosis of Nervous Diseases.**BY PURVES STEWART, M.A., M.D., F.R.C.P.,  
Physician to Out-Patients at the Westminster Hospital; Joint-Lecturer on Medicine in the  
Medical School; Physician to the Royal National Orthopædic Hospital.

NEW AND REVISED EDITION.

viii + 450 pages. With many Original Illustrations. 15s. net.

**Fractures and Separated Epiphyses.**BY A. J. WALTON, M.S., F.R.C.S., L.R.C.P.,  
Surgical Registrar, London Hospital.

312 pages. 100 Illustrations. 10s. 6d. net.



**Glaucoma.**

**An Inquiry into the Physiology and Pathology of the  
Intra-Ocular Pressure.**

By THOMSON HENDERSON, M.D. EDIN.,

Surgeon, Nottingham and Midland Eye Infirmary.

Illustrated. 10s. 6d. net.

**A Guide to the  
Diseases of the Nose and Throat, and their  
Treatment.**

By CHARLES A. PARKER, F.R.C.S. EDIN.,

Surgeon to the Throat Hospital, Golden Square, W.

xii + 624 pages. With 254 Illustrations. Demy 8vo., cloth, 18s. net.

**Contributions to Abdominal Surgery.**

By HAROLD LESLIE BARNARD, M.S., F.R.C.S.,

Late Assistant Surgeon, London Hospital.

xix + 391 pages. Illustrated. Price 15s. net.

**Movable Kidney: its Pathology, Symptoms,  
and Treatment.**

By H. W. WILSON, M.B., B.S. LOND., F.R.C.S. ENG.,

Demonstrator of Anatomy, St. Bartholomew's Hospital;

AND C. M. HINDS HOWELL, M.A., M.B., M.R.C.P. LOND.,

Junior Demonstrator of Physiology, St. Bartholomew's Hospital.

Demy 8vo., 4s. 6d. net.

**A Handbook of Skin Diseases and their  
Treatment.**

By ARTHUR WHITFIELD, M.D. LOND., F.R.C.P.,

Professor of Dermatology at King's College; Physician to the Skin Departments,  
King's College and the Great Northern Central Hospitals.

xii + 320 pages. With Illustrations. Crown 8vo., 8s. 6d. net.

**Food and the Principles of Dietetics.**

By ROBERT HUTCHISON, M.D. EDIN., F.R.C.P.,

Physician to the London Hospital.

xx + 615 pages, with 3 Plates in Colour and 34 Illustrations in the  
text. NEW EDITION (1911), 16s. net.

**The Chemical Investigation of  
Gastric and Intestinal Diseases by the Aid  
of Test Meals.**

By VAUGHAN HARLEY, M.D. EDIN., M.R.C.P., F.C.S.,

Professor of Pathological Chemistry, University College, London;

AND FRANCIS GOODBODY, M.D. DUBL., M.R.C.P.,

Assistant Professor of Pathological Chemistry, University College, London.

Demy 8vo., 8s. 6d. net.



**A Manual of Pharmacology for Students.**

BY WALTER E. DIXON, M.A. CANTAB., M.D., B.S.,  
B.SC. LOND., D.P.H. CAMB., F.R.S.

Assistant to the Downing Professor of Medicine in the University of Cambridge;  
Examiner in Pharmacology in the Universities of Cambridge and Glasgow.

xii + 451 pages. With Illustrations. Demy 8vo., cloth, 15s. net.

**The Influence of Alcohol and other Drugs  
on Fatigue.**

BY W. H. RIVERS, M.D., F.R.C.P., F.R.S.,

Lecturer in Physiological and Experimental Psychology at Cambridge University.

Royal 8vo., 6s. net.

**The Sanitary Officer's Handbook of  
Practical Hygiene.**

BY MAJOR C. F. WANHILL, R.A.M.C.,  
Assistant Professor of Hygiene, Royal Army Medical College;

AND MAJOR W. W. O. BEVERIDGE, D.S.O., R.A.M.C.,  
Analyst to the Army Medical Advisory Board.

Interleaved with blank pages for notes. Crown 8vo., 5s. net.

**BOOKS FOR NURSES.****Surgical Nursing and the Principles of  
Surgery for Nurses.**

BY RUSSELL HOWARD, M.B., M.S., F.R.C.S.,

Lecturer on Surgical Nursing to the Probationers of the London Hospital.

NEW EDITION. With Illustrations. 6s.

**Midwifery for Nurses.**

BY HENRY RUSSELL ANDREWS, M.D., B.SC. LOND.,  
M.R.C.P. LOND.,

Examiner to the Central Midwives Board.

NEW EDITION. With Illustrations. Crown 8vo., 4s. 6d. net.


**A Text-Book of Nursing.**

BY C. S. WEEKS-SHAW.


Revised and largely Rewritten by W. RADFORD.

xiv + 344 pages. With numerous Illustrations. 3s. 6d.











15/11/18



