

Atlas of head sections.

Contributors

MacEwen, William.
University College, London. Library Services

Publication/Creation

Glasgow : Maclehose and Co, 1893.

Persistent URL

<https://wellcomecollection.org/works/qwbpysj9>

Provider

University College London

License and attribution

This material has been provided by This material has been provided by UCL Library Services. The original may be consulted at UCL (University College London) where the originals may be consulted.

This work has been identified as being free of known restrictions under copyright law, including all related and neighbouring rights and is being made available under the Creative Commons, Public Domain Mark.

You can copy, modify, distribute and perform the work, even for commercial purposes, without asking permission.



Wellcome Collection
183 Euston Road
London NW1 2BE UK
T +44 (0)20 7611 8722
E library@wellcomecollection.org
<https://wellcomecollection.org>



INSTITUTE OF NEUROLOGY
The
ROCKEFELLER
MEDICAL LIBRARY





ATLAS OF HEAD SECTIONS

PUBLISHED BY
JAMES MACLEHOSE AND SONS, GLASGOW,
Publishers to the University.

MACMILLAN AND CO., LONDON AND NEW YORK.
London, - - - Simpkin, Hamilton, and Co.
Cambridge, - - Macmillan and Boves.
Edinburgh, - - Douglas and Foulis.

MDCCCXIII.

ATLAS
OF
HEAD SECTIONS

Fifty-three Engraved Copperplates of Frozen Sections
of the Head, and Fifty-three Key Plates
with Descriptive Texts

BY
WILLIAM MACEWEN, M.D.



GLASGOW
JAMES MACLEHOSE AND SONS
Publishers to the University
1893

All rights reserved.


*ALL THE DRAWINGS AND ENGRAVINGS IN THIS VOLUME
ARE COPYRIGHT.*

ROCKY MOUNTAIN LIBRARY	
CLASS	HIST. N.
ACQ.	2529
SOURCE	MHMS.
DATE	-

PREFACE.

IN the preparation of this volume the author has received material assistance from Miss MacEachran, who has drawn the key sketches accurately from the original; from Drs. G. Ritchie Thomson and J. Hogarth Pringle, who assisted in naming the various structures; and from the two first-mentioned for much work connected with the passing of the key sketches through the press. Dr. Thomson has had the entire preparation of the Index. Messrs. Annan, of Glasgow, have faithfully produced the photogravures from the photographic plates supplied to them, which is all the more creditable as the subject was at first quite unknown to them.

GLASGOW, *October*, 1893.



INTRODUCTION.

THIS Atlas has been prepared from frozen head sections, and the keys, though made to the scale of the plates, have for the most part been drawn directly from the original. The fifty-three sections here represented have been selected from over a hundred specimens. The plates show the relation of the various parts of the brain to the exterior of the skull, thereby affording an aid to cephalic topography. The form of the brain thus seen *in situ* differs in many respects from that presented by the brain removed from the skull and placed upon a flat surface. Even the process of removal of the brain from its accurately-fitting case, in which it is surrounded by a fluid medium, destroys its symmetry; and when, after removal, the soft cerebral substance is exposed unsupported it sinks by its own weight and becomes flattened and distorted.

The main points in each plate are described in the key, and each section is complete in itself, though various structures may be traced through a series of sections. The surgeon who is about to perform an operation on the brain has in these cephalic sections a means of refreshing his memory regarding the position of the various structures which he is about to encounter. At any spot which he may select for his operation he has the relations of the various parts of the brain to the outside of the skull exposed in three different series of sections—Coronal, Sagittal, and Horizontal. In both the Coronal and Horizontal series the adult sections are supplemented by those of the child.

It is not intended in this introduction to give a separate description of the sectional anatomy of the brain, but the reader's attention is directed to several prominent features.

The difference in the size of the brain in the child and adult respectively, relatively to the rest of the head, is well marked, as may be seen on comparing Coronal Sections, series A, with series C.

The way in which the frontal lobes dip downwards near the mesial line in

front, and the thin osseous lamellæ dividing them from the ethmoidal cells and nasal cavity, are well illustrated in the Anterior Coronal Sections. The proximity of the nasal recesses to the intracranial structures suggests an easy access for erosive infective processes. For eradication of infective matter extending from the nasal fossæ through the cribriform plate of the ethmoid, or by way of the frontal sinuses, trephining in the middle line of the brow at the glabella and penetrating the frontal sinuses affords the best means of exposing the seat of disease. It gives free access to the frontal sinuses, to the cribriform plate of the ethmoid, and to both sides of the falx.

The manner in which the basal portion of the temporo-sphenoidal lobe is enclosed on all sides by resisting structures, bone, and dura mater, is well illustrated by, among others, Plates 6, 10, 42, 45, and 47. The basal portion of the temporo-sphenoidal lobe has osseous walls to the level of the superior ridge of the petrous bone, and extending beyond that point the unyielding tentorium forms a barrier stretching upward toward the mesial line where it joins the falx above. The base of the temporo-sphenoidal lobe is enclosed, as it were, in a box without a lid. Any pressure arising in the basal portion of the temporo-sphenoidal lobe will cause an expansion, chiefly in an upward direction, toward the convolutions of the operculum. The cerebral tissue near the middle line in the vicinity of the internal capsule, having no resisting structure on its inner side, has ample accommodation for displacement toward the lateral ventricle and the opposite side of the brain, and therefore pressure-effects from expansion in the base of the temporo-sphenoidal lobe will affect much less the internal capsule than the upper and outer part of the cerebrum, which is bounded outside and above by the skull, and on the inside by the falx. As a consequence, the bases of the ascending convolutions are more apt to be implicated by pressure exerted from the base of the temporo-sphenoidal lobe.

The third nerve as it passes between the posterior clinoid process and the internal aspect of the base of the temporo-sphenoidal lobe is liable to pressure exerted from within the basal portion of this lobe. Its relations to this part of the brain may be seen in Plates 41 and 45. The descending horn of the lateral ventricle dips into the temporo-sphenoidal lobe to the level of the middle of the orbit, about half an inch above the zygoma (see Plate 45).

The shape which the cerebellum presents in these sections in various planes differs from that usually delineated, and from that which it assumes when removed from the posterior fossa of the skull. Though the lateral sinus may be regarded as the external boundary delimiting the occipital lobes from the cerebellum, yet in the mesial plane the cerebellum ascends between the cerebral hemispheres to

near the level of the orbital roof (see Plate 49). Its lower portion is not altogether confined within the posterior fossa, but projects through the foramen magnum, embracing the medulla and even a small part of the cord (see Plates 18, 36, 37).

For the points in topographical anatomy, of service in illustrating the subjects of meningitis, abscess of the brain, and thrombosis of the intracranial sinuses, the reader is referred to a chapter on Surgical Anatomy in the volume on *Pyogenic Infective Diseases of the Brain and Spinal Cord*, concurrently issued.




TABLE OF PLATES.

CORONAL SECTIONS.

SERIES A. MALE, 60 YEARS.

	PLATE NUMBER.
I. Section $2\frac{1}{2}$ inches anterior to auriculo-bregmatic plane, viewed from before, - - -	1
II. Section 2 inches anterior to auriculo-bregmatic plane, viewed from behind, - - -	2
III. Section $1\frac{7}{8}$ inch anterior to auriculo-bregmatic plane, viewed from before, - - -	3
IV. Oblique section $1\frac{1}{2}$ inch anterior to auriculo-bregmatic plane, viewed from before, - - -	4
V. Section 1 inch anterior to auriculo-bregmatic plane, viewed from behind, - - -	5
VI. Section $\frac{7}{8}$ inch anterior to auriculo-bregmatic plane, viewed from before, - - -	6
VII. Section in auriculo-bregmatic plane, viewed from before, - - -	7
VIII. Section $\frac{1}{2}$ inch posterior to auriculo-bregmatic plane, viewed from behind, - - -	8
IX. Section $\frac{5}{8}$ inch posterior to auriculo-bregmatic plane, viewed from before, - - -	9
X. Section $1\frac{5}{8}$ inch posterior to auriculo-bregmatic plane, viewed from behind, - - -	10
XI. Section $1\frac{3}{4}$ inch posterior to auriculo-bregmatic plane, viewed from before, - - -	11
XII. Section $2\frac{1}{2}$ inches posterior to auriculo-bregmatic plane, viewed from before, - - -	12
XIII. Section $3\frac{1}{8}$ inches posterior to auriculo-bregmatic plane, viewed from behind, - - -	13

SERIES B. MALE, 40 YEARS.

I. Section $1\frac{3}{8}$ inch anterior to auriculo-bregmatic plane, viewed from before, - - -	14
II. Section 1 inch anterior to auriculo-bregmatic plane, viewed from behind, - - -	15
III. Section in auriculo-bregmatic plane, viewed from behind, - - -	16
IV. Section $\frac{1}{8}$ inch posterior to auriculo-bregmatic plane, viewed from before, - - -	17

	PLATE NUMBER.
V. Section $\frac{5}{8}$ inch posterior to auriculo-bregmatic plane, viewed from behind, - - -	18
VI. Section $\frac{3}{4}$ inch posterior to auriculo-bregmatic plane, viewed from before, - - -	19
VII. Section 1 inch posterior to auriculo-bregmatic plane, viewed from behind, - - -	20

SERIES C. MALE, $2\frac{1}{2}$ YEARS.

I. Section 1 inch anterior to auriculo-bregmatic plane, viewed from behind, - - -	21
II. Section $\frac{3}{8}$ inch anterior to auriculo-bregmatic plane, viewed from behind, - - -	22
III. Section $\frac{1}{4}$ inch posterior to auriculo-bregmatic plane, viewed from before, - - -	23
IV. Section $1\frac{3}{8}$ inch posterior to auriculo-bregmatic plane, viewed from before, - - -	24

SAGITTAL SECTIONS.

MALE, 30 YEARS.

I. Section of left side of head, about $2\frac{1}{2}$ inches external to median plane, viewed from within, -	25
II. Section of left side of head, about $2\frac{3}{8}$ inches external to median plane, viewed from within, -	26
III. Section of left side of head, about 2 inches external to median plane, viewed from without, -	27
IV. Section of left side of head, about $1\frac{1}{2}$ inch external to median plane, viewed from within, -	28
V. Section of left side of head, about $1\frac{3}{8}$ inch external to median plane, viewed from without, -	29
VI. Section of right side of head, about $\frac{1}{4}$ inch external to median plane, viewed from within, -	30
VII. Section of right side of head, about $\frac{5}{8}$ inch external to median plane, viewed from without, -	31
VIII. Section of right side of head, about $\frac{3}{4}$ inch external to median plane, viewed from within, -	32
IX. Section of right side of head, about $1\frac{3}{4}$ inch external to median plane, viewed from without, -	33
X. Section of right side of head, about $1\frac{7}{8}$ inch external to median plane, viewed from within, -	34
XI. Section of right side of head, about $2\frac{1}{4}$ inches external to median plane, viewed from without, -	35

HORIZONTAL SECTIONS.

SERIES A. MALE, 35 YEARS.

I. Section $1\frac{1}{2}$ inch below plane of middle of external auditory osseous meatus, viewed from below, -	36
II. Section $1\frac{1}{8}$ inch below plane of middle of external auditory osseous meatus, viewed from below, - - - - -	37


	PLATE NUMBER.
III. Section $\frac{3}{8}$ inch below plane of middle of external auditory osseous meatus, viewed from above,	38
IV. Section in plane of middle of external auditory osseous meatus, viewed from above, - -	39
V. Section $\frac{1}{8}$ inch above plane of middle of external auditory osseous meatus, viewed from below,	40
VI. Section somewhat obliquely cut $\frac{3}{8}$ inch above plane of middle of external auditory osseous meatus, viewed from below, - - - - -	41
VII. Section $\frac{1}{2}$ inch above plane of middle of external auditory osseous meatus, viewed from below,	42
VIII. Section $1\frac{1}{4}$ inch above plane of middle of external auditory osseous meatus, viewed from below, - - - - -	43

SERIES B. MALE, 50 YEARS.

I. Section cut obliquely about plane of external auditory osseous meatus, seen from below, -	44
II. Section cut obliquely $\frac{1}{4}$ inch above plane of external auditory osseous meatus, seen from above,	45


SERIES C. MALE, 5 YEARS.

I. Section in plane of middle of external auditory osseous meatus, seen from above, - -	46
II. Section cut obliquely in plane of external occipital protuberance, seen from below, - -	47
III. Section in plane of middle of orbits, seen from above, - - - - -	48
IV. Section in plane of upper third of orbits, seen from above, - - - - -	49
V. Section in plane of superior margins of orbits, seen from below, - - - - -	50
VI. Section $\frac{1}{2}$ inch above plane of superior margins of orbits, seen from above, - - -	51
VII. Section 1 inch above plane of superior margins of orbits, seen from above, - - -	52
VIII. Section $\frac{1}{4}$ inch below plane of parietal eminence, seen from below, - - - - -	53



ERRATA.

- Key Plate 7—For "saggittal" read "sagittal."
.. 21—For "Occular" read "Ocular."
.. 23—For "Odontoid process of Atlas" read "Odontoid
process of Axis."
.. 37—For "Basilar artery" read "Vertebral artery."
.. 49—For "Inferior longitudinal sinus" read "Superior
longitudinal sinus."



CORONAL SECTIONS.




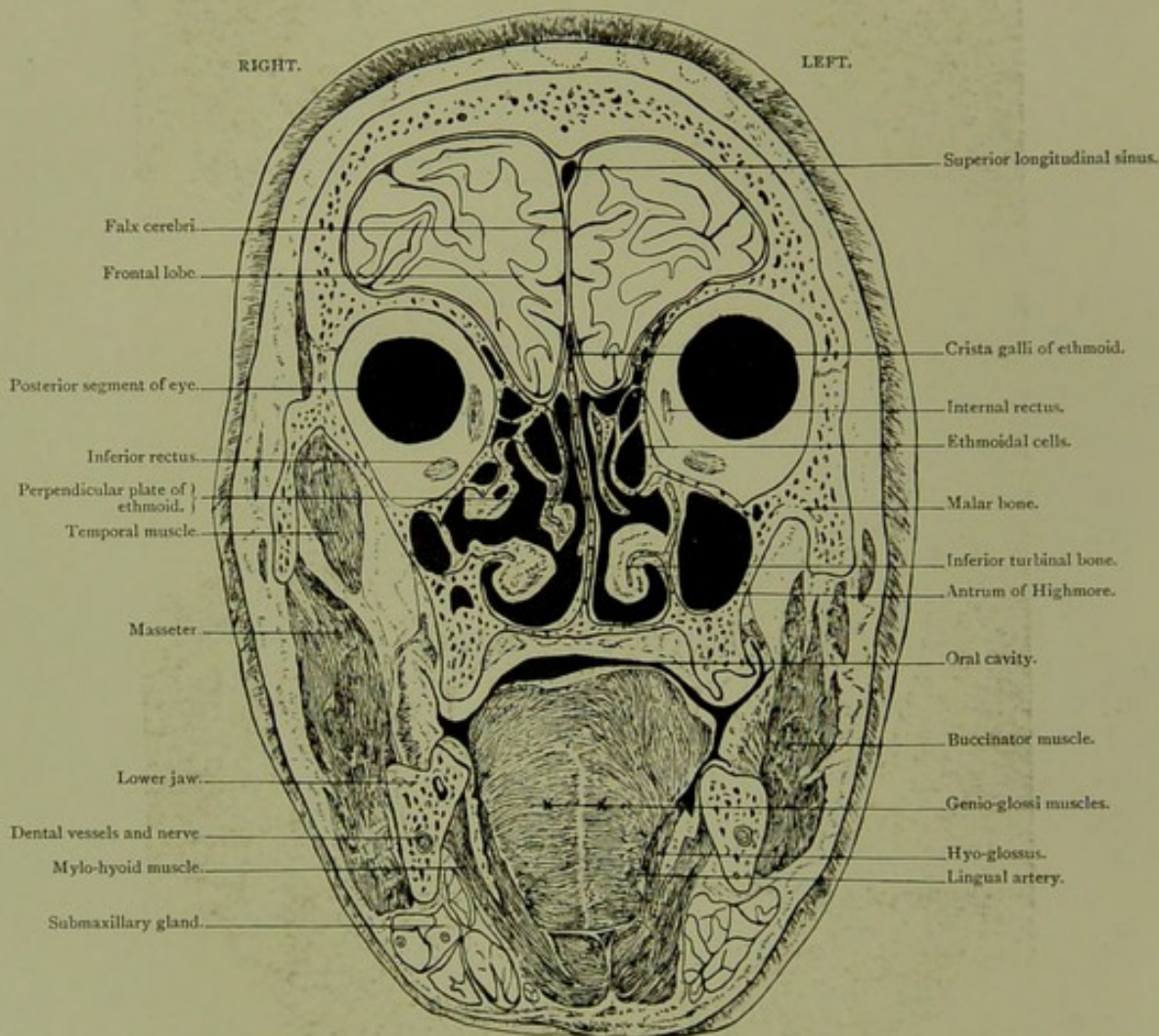
PLATE NO. I.

Coronal Section. Series A. I.

VIEWED FROM BEFORE.

CORONAL SECTION.

Series A. I.



Male, 60 years.

Scale $\frac{41}{59} = \frac{2}{3}$ Approx.

I. CORONAL SECTION, viewed from before, passing through frontal lobes, posterior aspects of eyeballs, the ethmoidal cells, antrum of Highmore, turbinated bones, buccal cavity and tongue. The proximity of the upper part of the nasal cavity and the ethmoidal cells to the brain, is clearly brought out.

PLATE N^o 1.

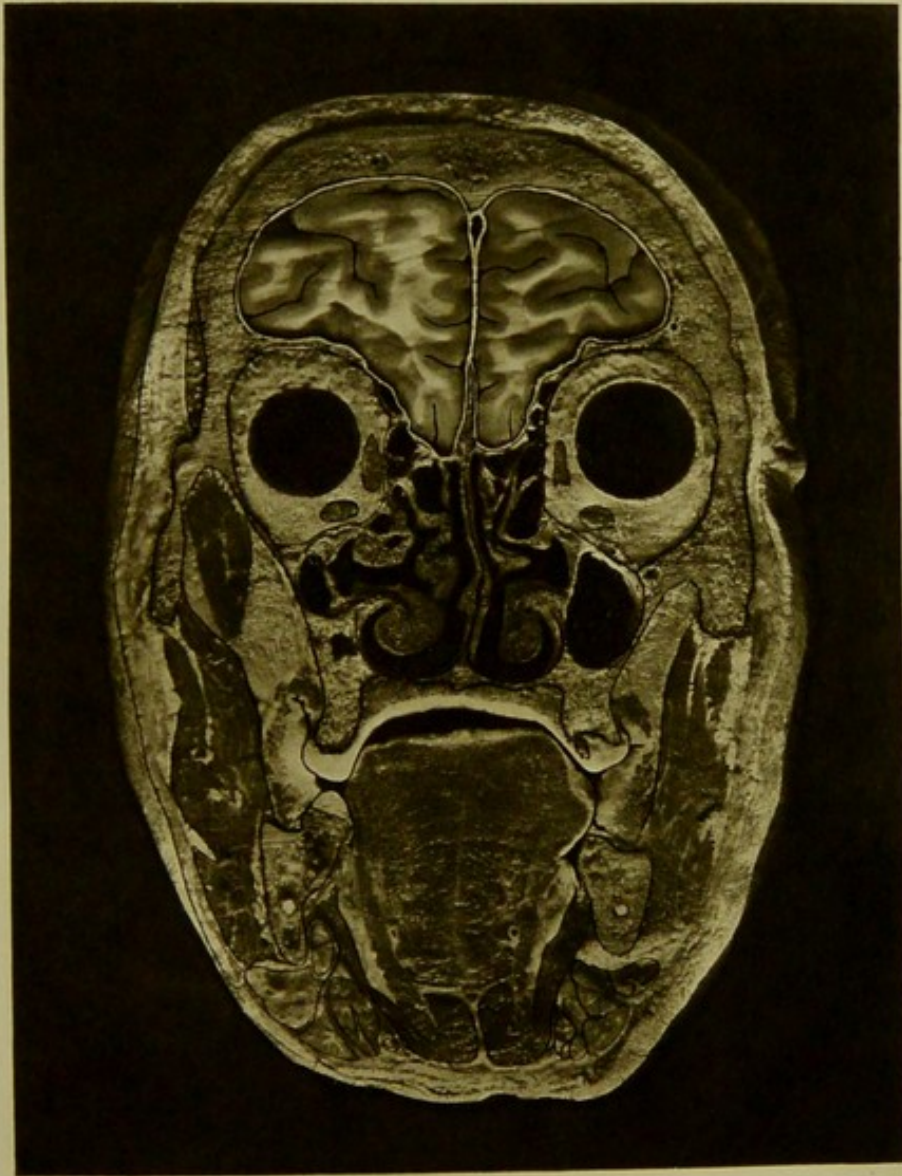




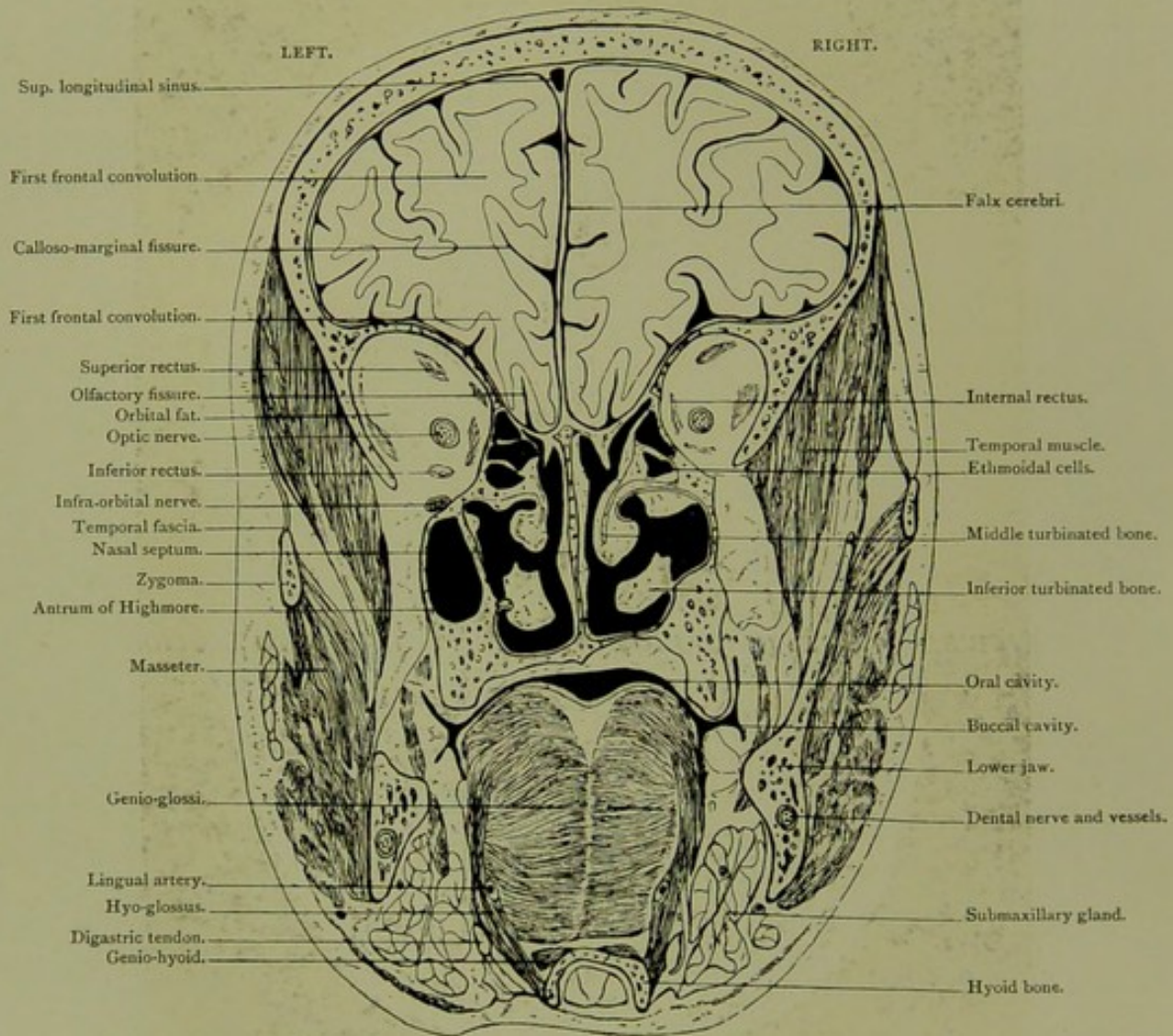
PLATE NO. 2.

Coronal Section. Series A. II.

VIEWED FROM BEHIND, HALF AN INCH POSTERIOR TO SECTION I.

CORONAL SECTION.

Series A. II.

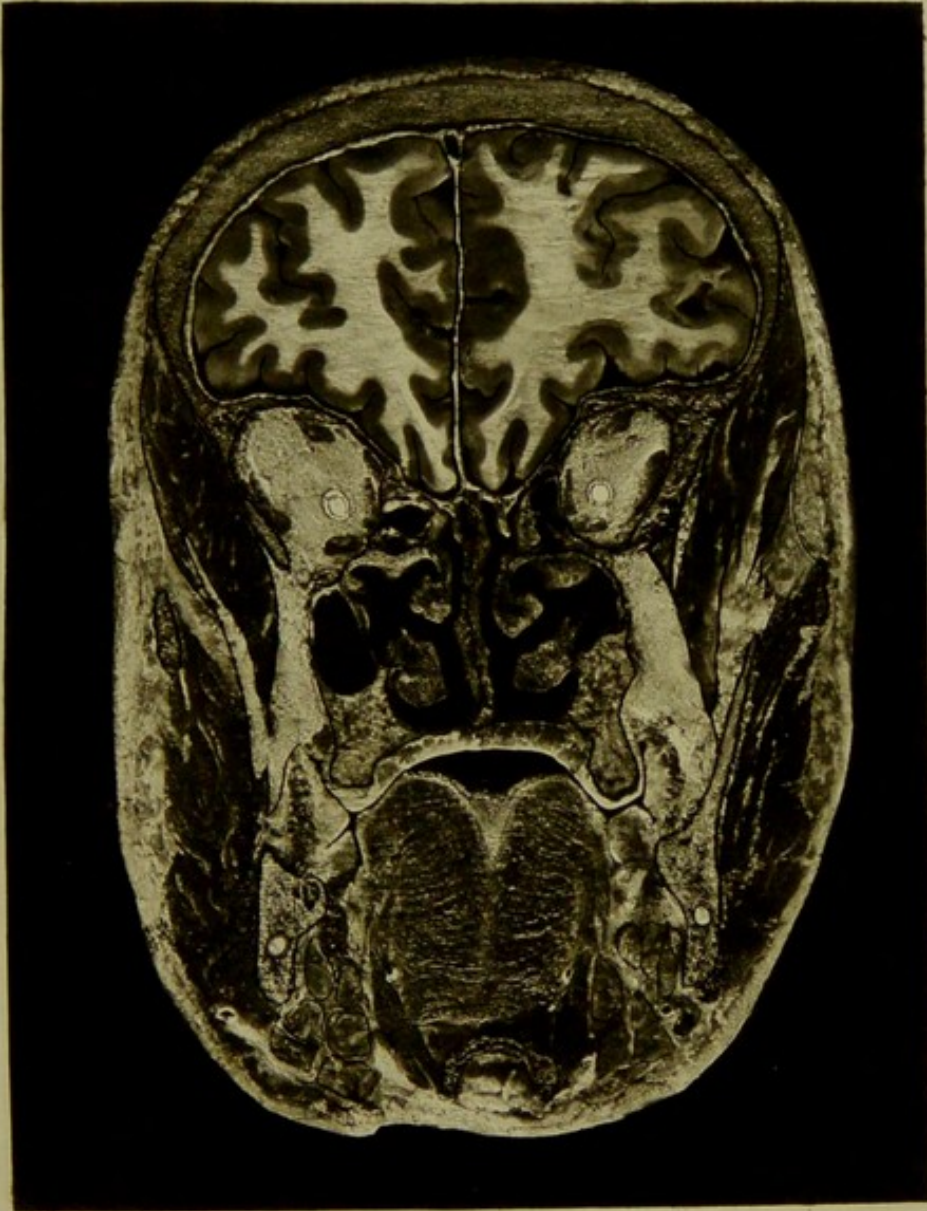



Male, 60 years.

Scale $\frac{42}{61} = \frac{2}{3}$ Approx.

II. CORONAL SECTION, viewed from behind, half an inch posterior to section I., passing through frontal lobes, orbital cavity, turbinated bones, antrum of Highmore, tongue and hyoid bone. The relation of the ethmoidal cells to the orbital and cranial cavities: the thin supra orbital, cribriform, and ethmoidal plates: the marked mesial dip of the frontal lobes: and the nasal cavity, with its spongy turbinals, are all well brought out in the section.

PLATE N^o 2.



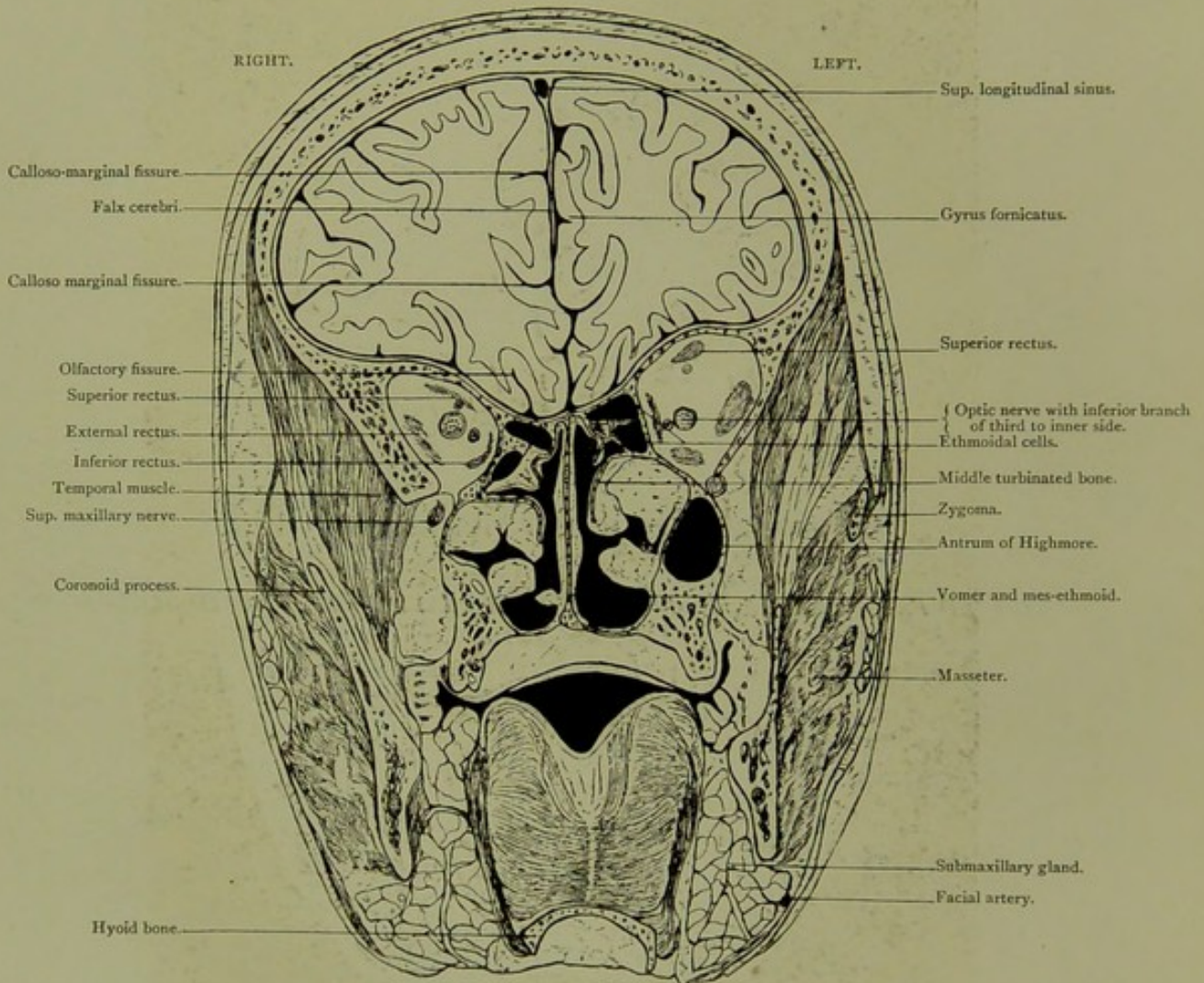


Coronal Section. Series A. III.

VIEWED FROM BEFORE, ONE-EIGHTH OF AN INCH POSTERIOR TO SECTION II.

CORONAL SECTION.

Series A. III.

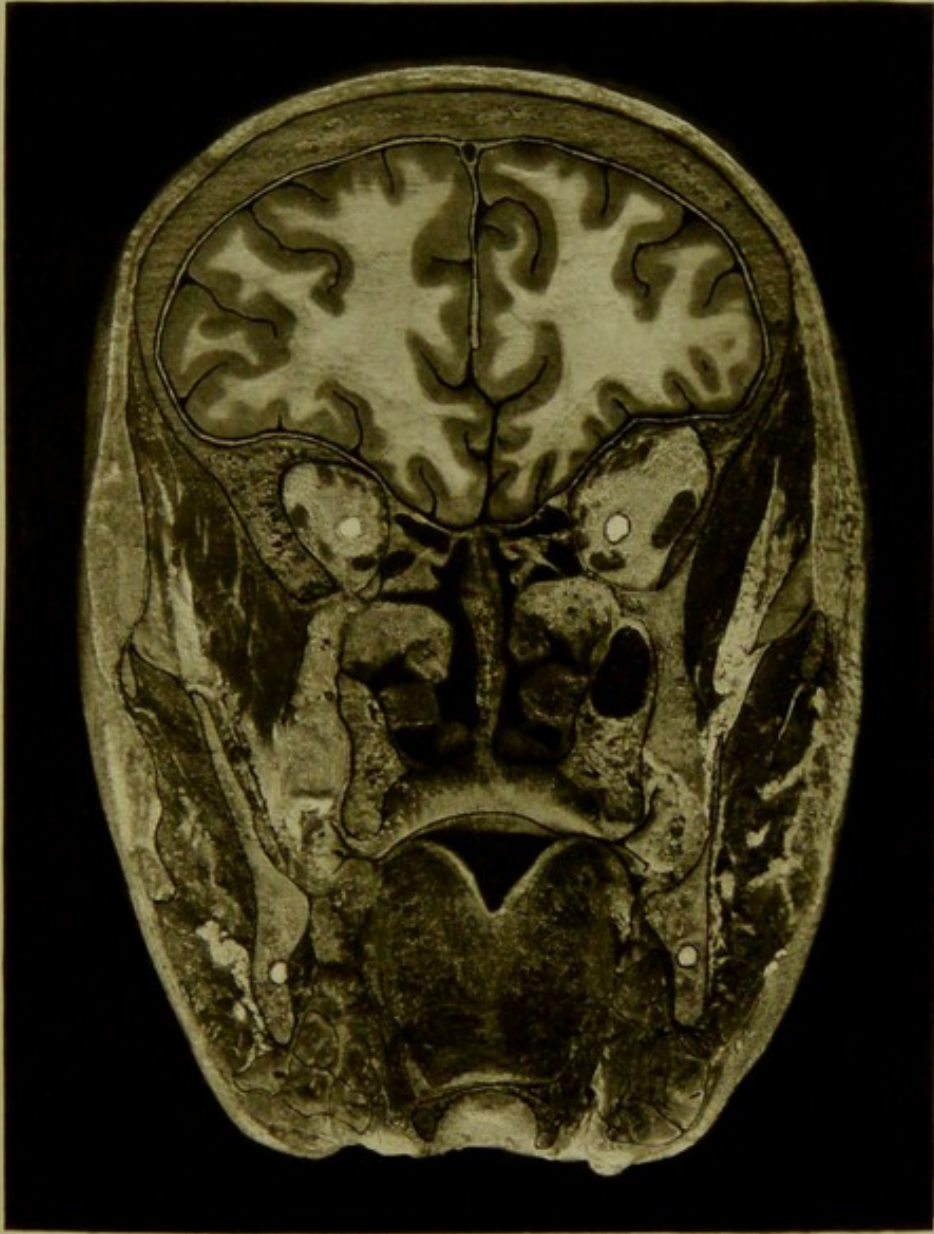


Male, 60 years.

Scale $\frac{42}{60} = \frac{2}{3}$ Approx.

III. CORONAL SECTION, viewed from before, one-eighth of an inch posterior to section II., passing through frontal lobes, orbital, nasal, and oral cavities, antrum of Highmore, tongue, and hyoid bone. The superior maxillary nerve is seen in the spheno-maxillary fossa. The inferior branch of third nerve is seen on either side, to the inner side of the optic nerve.

PLATE N^o 3.



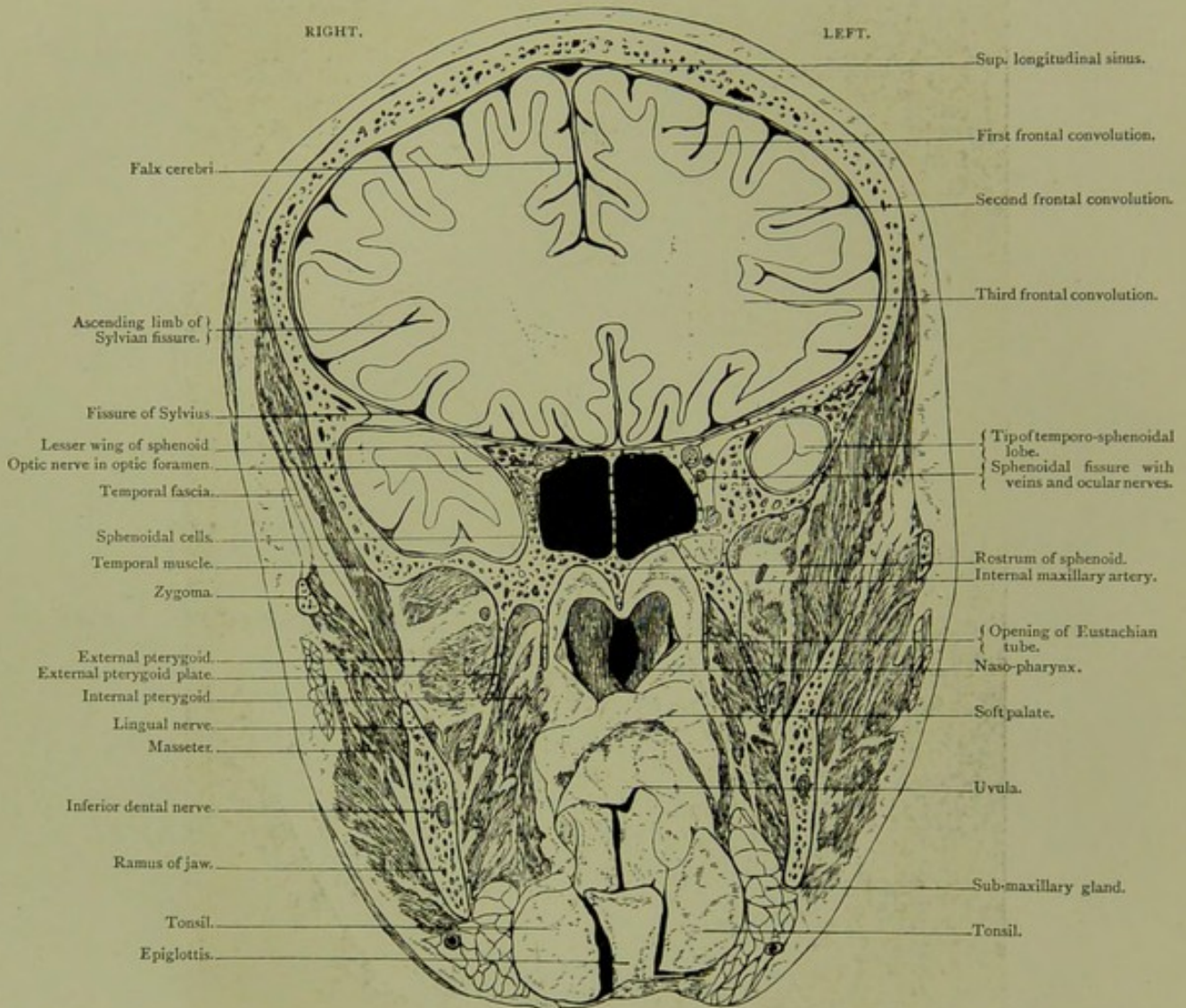


Coronal Section (Oblique). Series A. IV.

VIEWED FROM BEFORE, THREE-EIGHTHS OF AN INCH POSTERIOR TO SECTION III.

CORONAL SECTION.

Series A. IV.

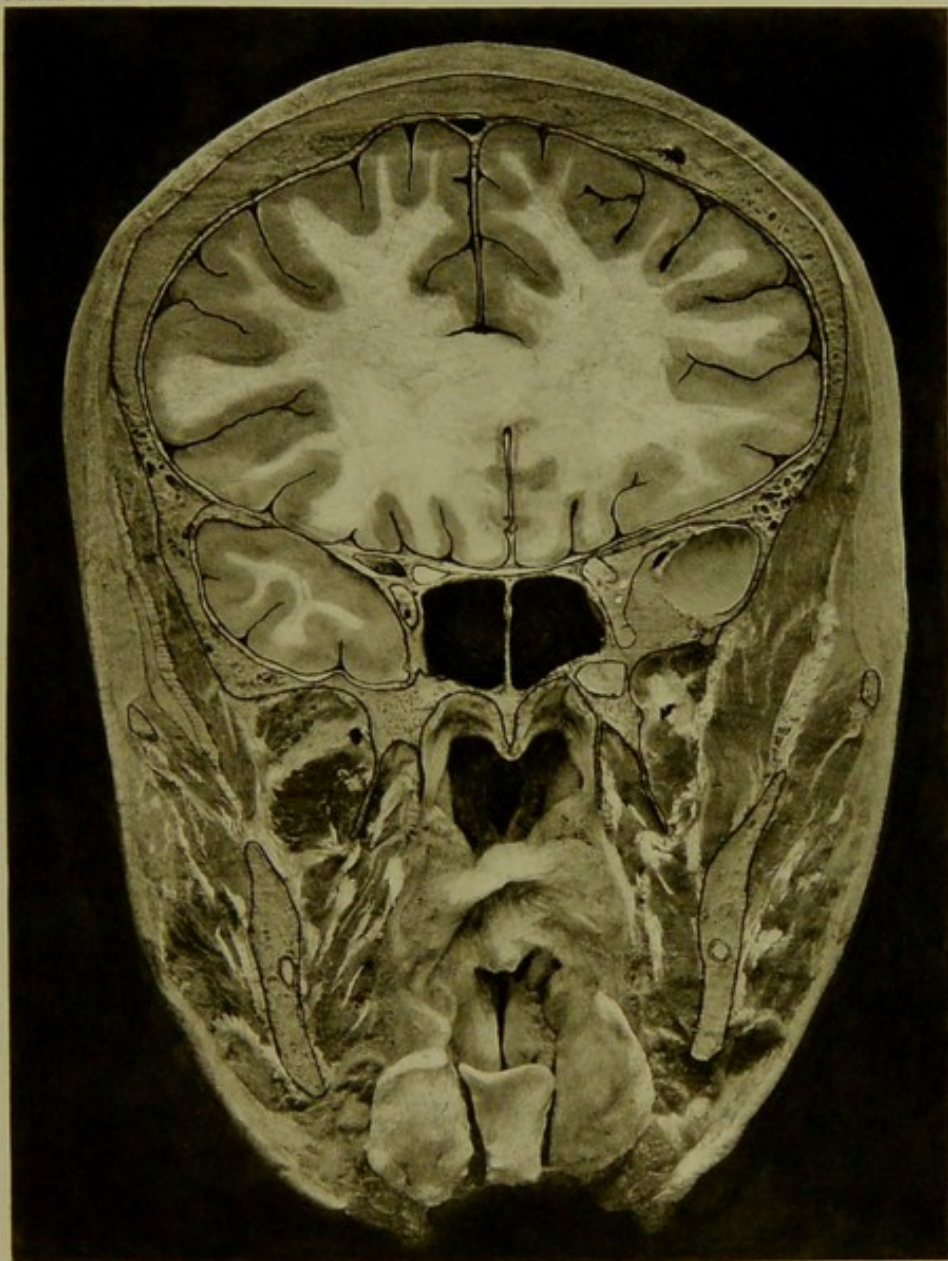



Male, 60 years.

Scale $\frac{44}{63} = \frac{2}{3}$ Approx.

IV. CORONAL (oblique) SECTION, viewed from before, three-eighths of an inch posterior to section III., passing through frontal and tips of temporo-sphenoidal lobes, sphenoidal cells, naso-pharynx, and epiglottis. On left side of section, the superior maxillary nerve is seen, just below the sphenoidal fissure on cranial side of foramen rotundum. The fronto-sphenoidal osseous ring surrounding the tip of the temporal lobe is complete on the left side, and almost so on the right. The trumpet shaped opening of the Eustachian tube is better seen in the section than in the plate. A very thin osseous plate separates the cranial cavity from the sphenoidal cells.

PLATE N° 4.



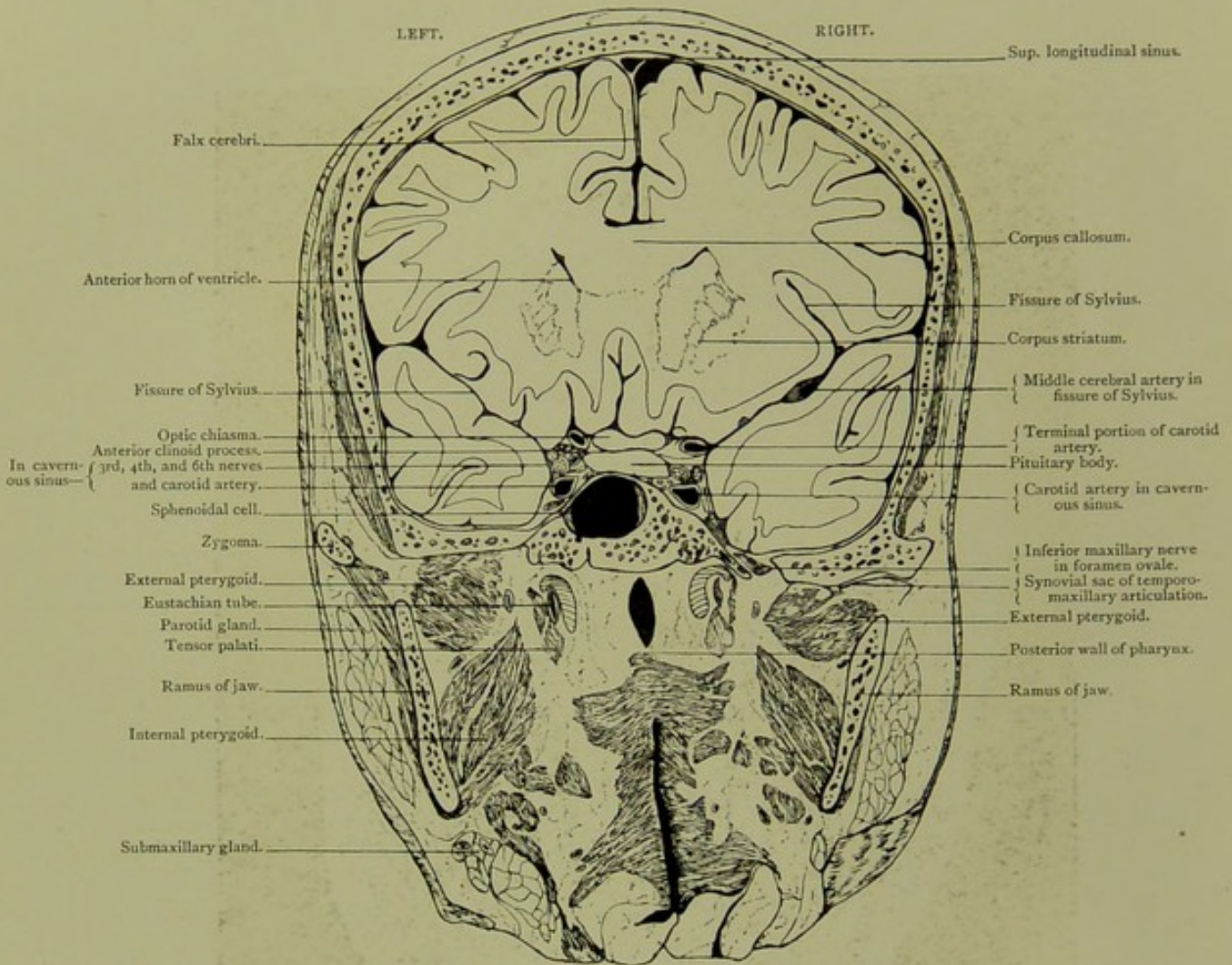


Coronal Section. Series A. V.

VIEWED FROM BEHIND, HALF AN INCH POSTERIOR TO SECTION IV.

CORONAL SECTION.

Series A. V.

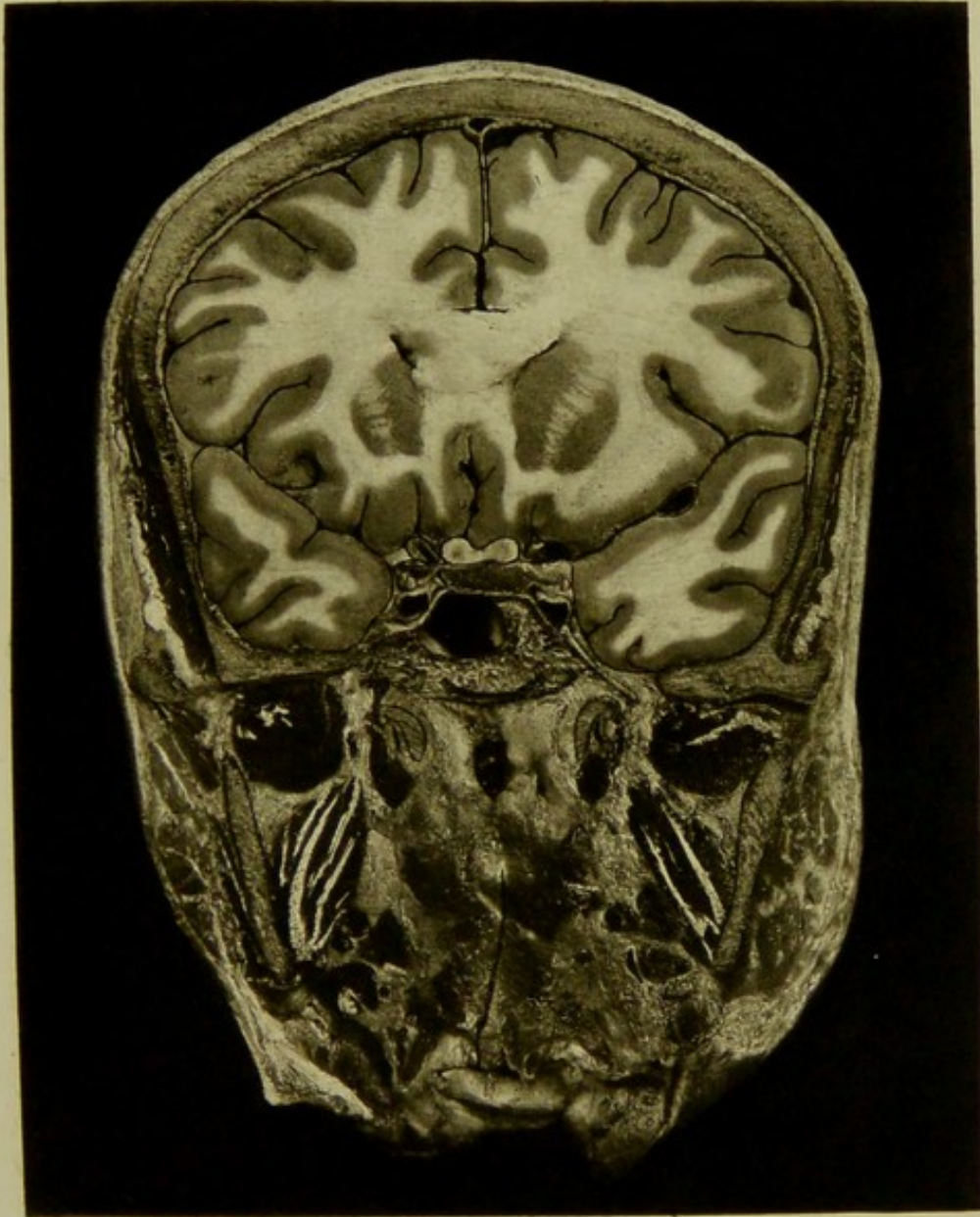


Male, 60 years.

Scale $\frac{44}{63} = \frac{2}{3}$ Approx.

V. CORONAL SECTION, viewed from behind, half an inch posterior to section IV., passing through corpus callosum, anterior part of basal ganglia, fissure of Sylvius, temporo-sphenoidal lobes, cavernous sinus with carotid artery and nerves, sphenoidal cell and posterior wall of pharynx. On the right side the middle cerebral artery is seen in oblique section in the Sylvian fissure. At the right cavernous sinus the carotid artery rests with its inner and under aspects upon the carotid groove, on the body of the sphenoid, the cavernous plexus being situated chiefly above the artery and between it and the pituitary body, while the nerves are situated at the upper and outer aspects of the sinus: the third being nearest the middle line, the fourth to the outer side of the third, and the sixth being also to the outer side, below the third and between the latter and the artery. Below the artery, and to its outer side, is the anterior extremity of the Gasserian ganglion between the two layers of the dura mater, while the inferior maxillary nerve is seen in section in the foramen ovale. The internal maxillary artery is divided twice in the section, first external, and second internal to the external pterygoid muscle.

PLATE N^o 5.






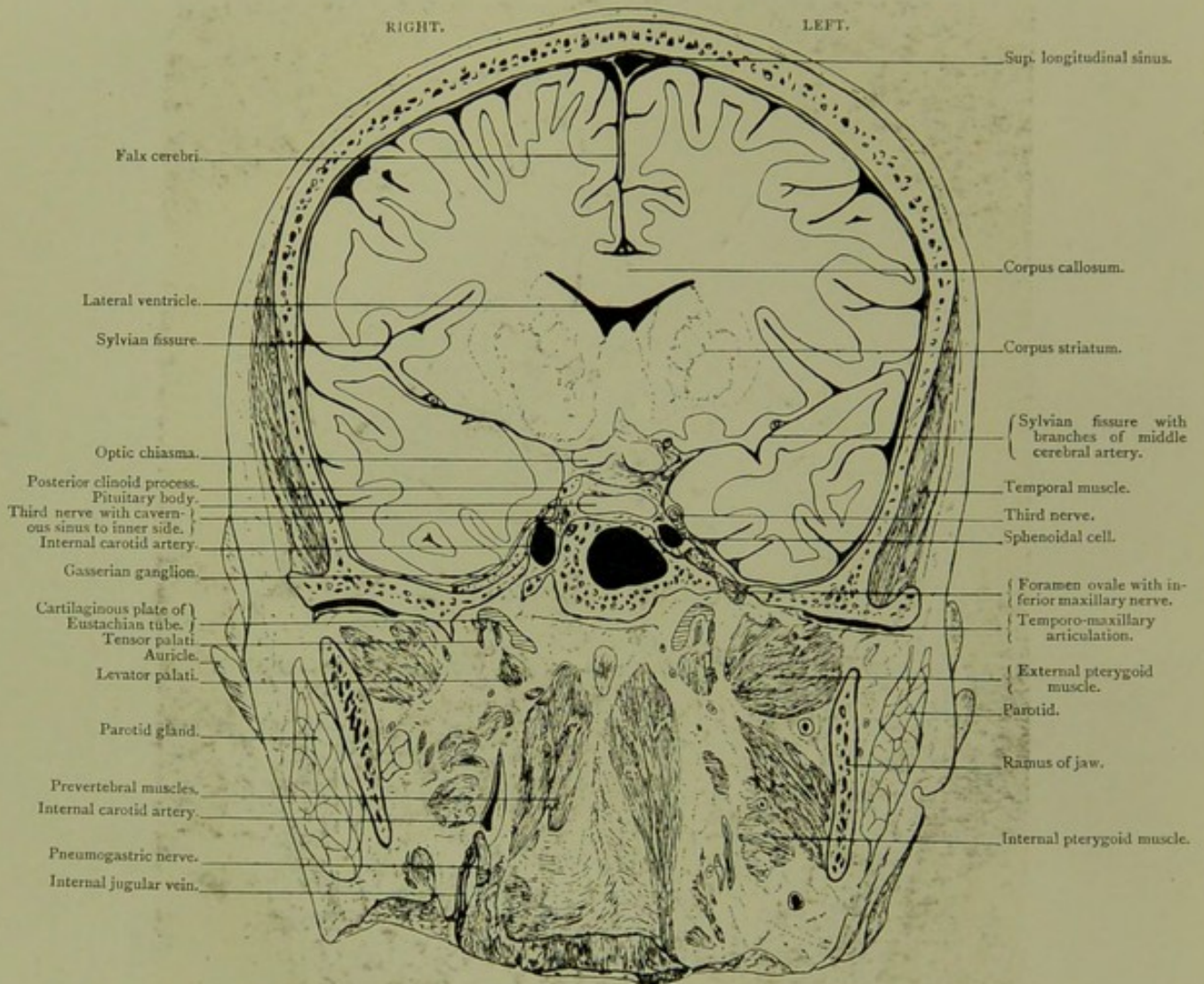
PLATE No. 6.

Coronal Section, Series A. VI.

VIEWED FROM BEFORE, ONE-EIGHTH OF AN INCH POSTERIOR TO SECTION V.

CORONAL SECTION.

Series A. VI.

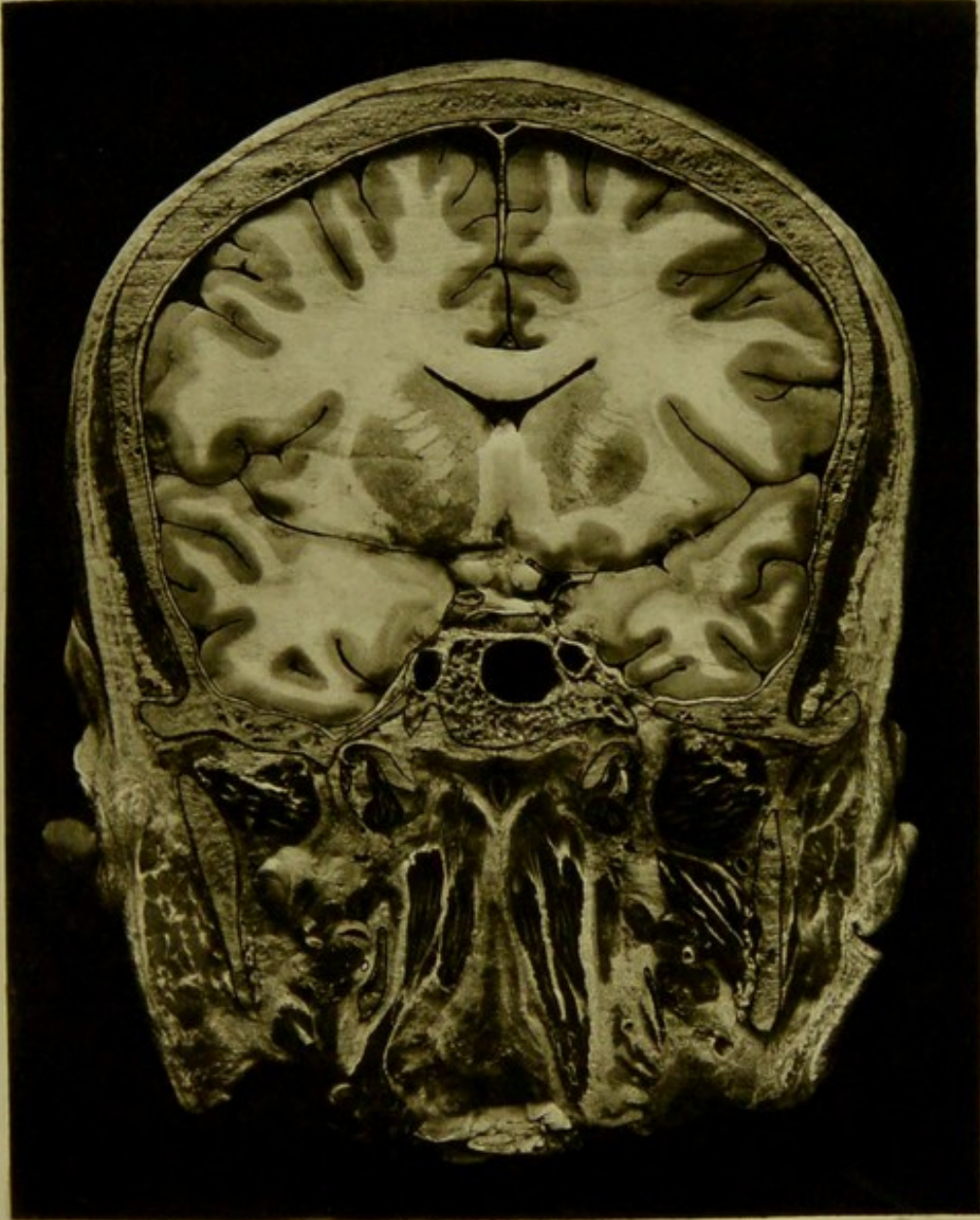


Male, 60 years.

Scale $\frac{44}{61} = \frac{3}{4}$ Approx.

VI. CORONAL SECTION, viewed from before, one-eighth of an inch posterior to section V., passing through basal ganglia, optic chiasma, cavernous sinus, sphenoidal cell, prevertebral muscles, and cartilaginous plate of Eustachian tube. The position of the third nerve relatively to temporo-sphenoidal lobe and to the ridge below the posterior clinoid process is well seen on either side. The third nerve lies here between the temporo-sphenoidal lobe, and the dura covering the posterior clinoid process and the posterior extremity of the cavernous sinus. This section is taken at the plane of the anterior aspect of the condyle of lower jaw, just in front of the auricle.

PLATE N^o 8






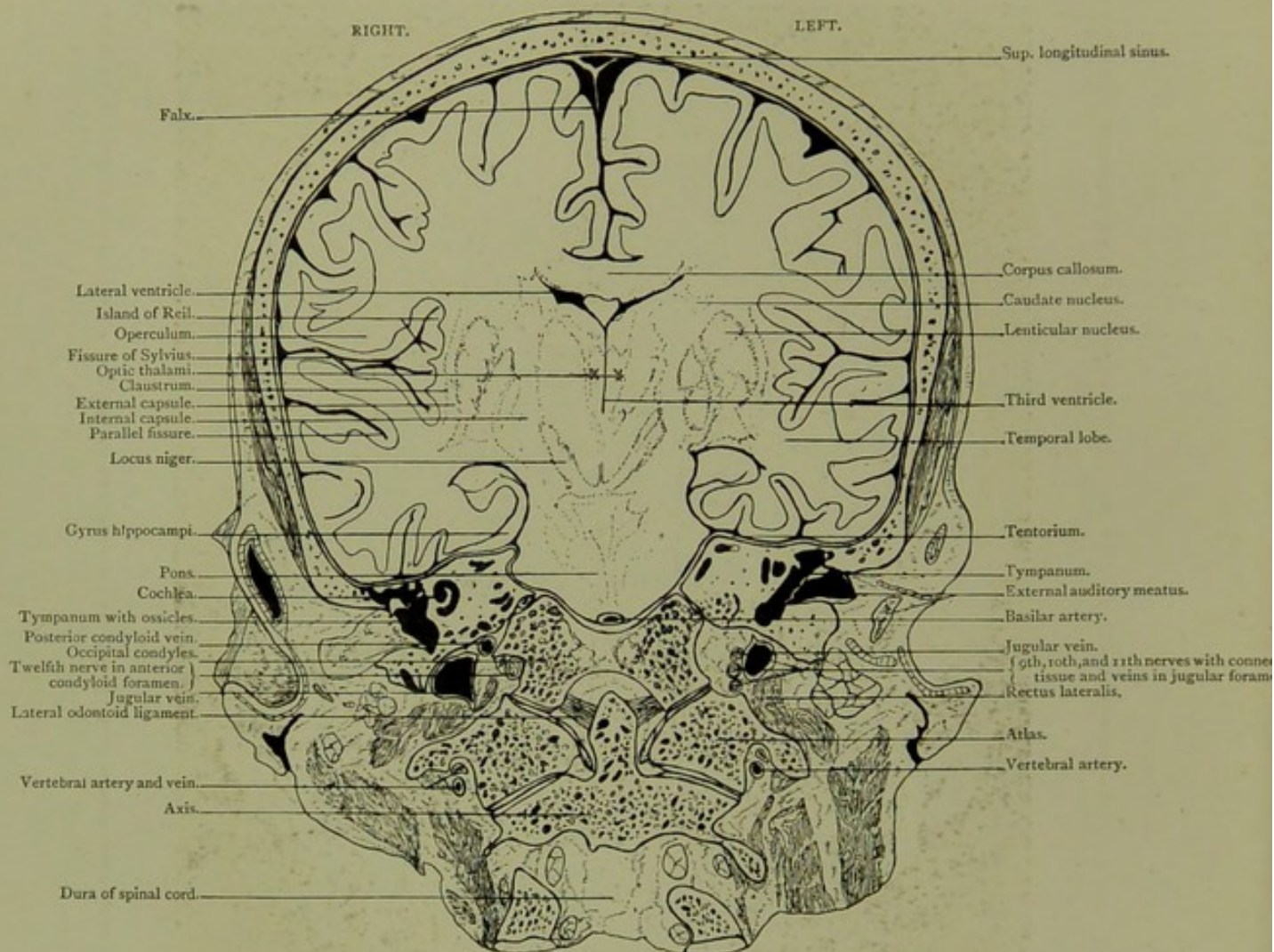
PLATE No. 7.

Coronal Section. Series A. VII.

VIEWED FROM BEFORE, SEVEN-EIGHTHS OF AN INCH POSTERIOR TO SECTION VI.

CORONAL SECTION.

Series A. VII.

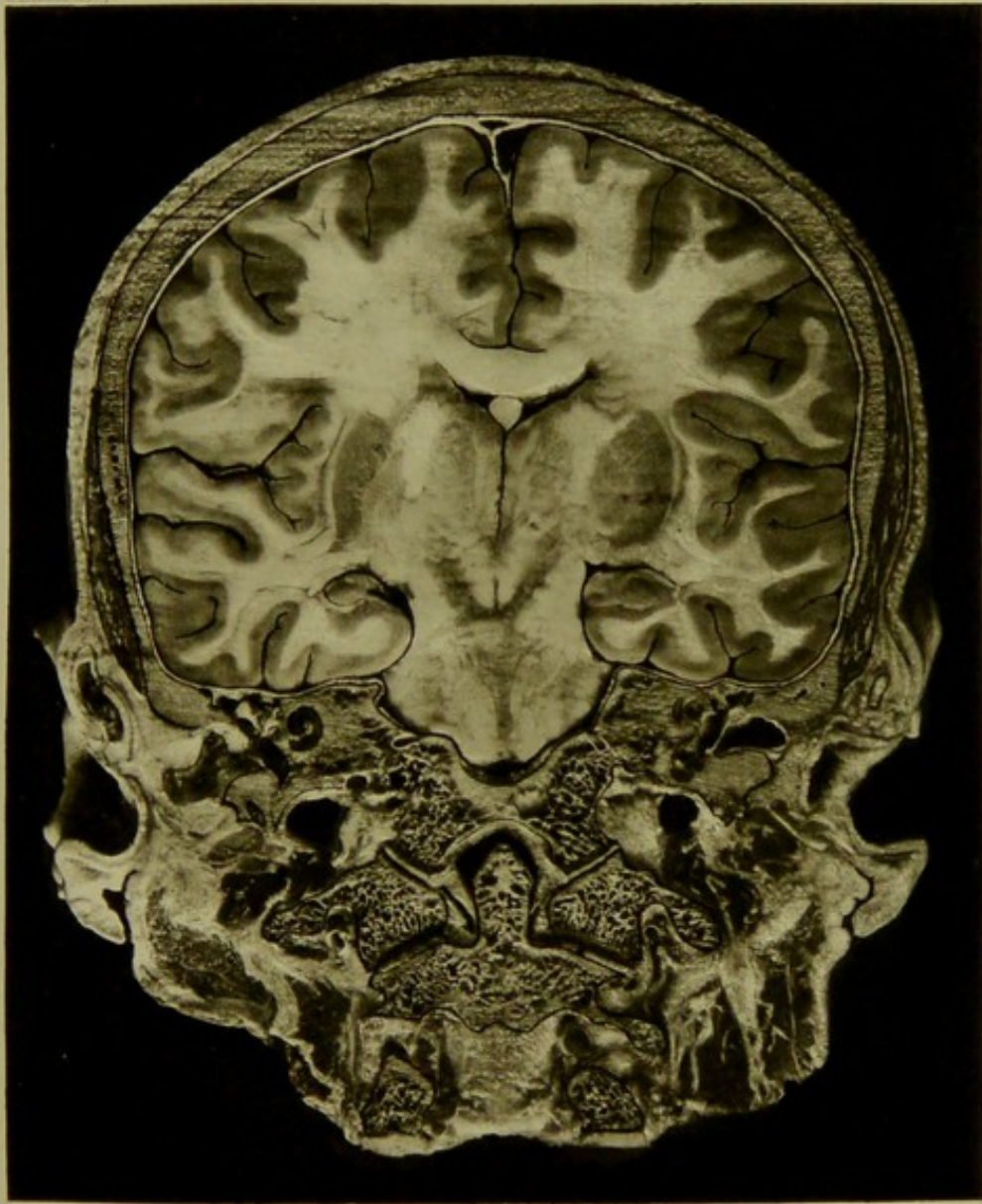



Male, 60 years.

Scale $\frac{42}{61} = \frac{2}{3}$ Approx.

VII. CORONAL SECTION, viewed from before, seven-eighths of an inch posterior to section VI., passing through frontal and temporo-sphenoidal lobes, operculum, island of Reil, basal ganglia and pons. The mass of resilient connective tissue, in which the nerves issuing from the jugular fossa are embedded, along with a venous plexus, is well seen in the specimen. Parts of the external, middle, and internal, ear are exposed. The tympanum with the attic and ossicles—incus and stapes, and the extremely thin tegmen are well seen on the right side of section. The lateral odontoid or check ligaments are visible in the section. This section is in the plane of the auriculo-bregmatic line. The saggittal suture is synostosed.

PLATE N. 7



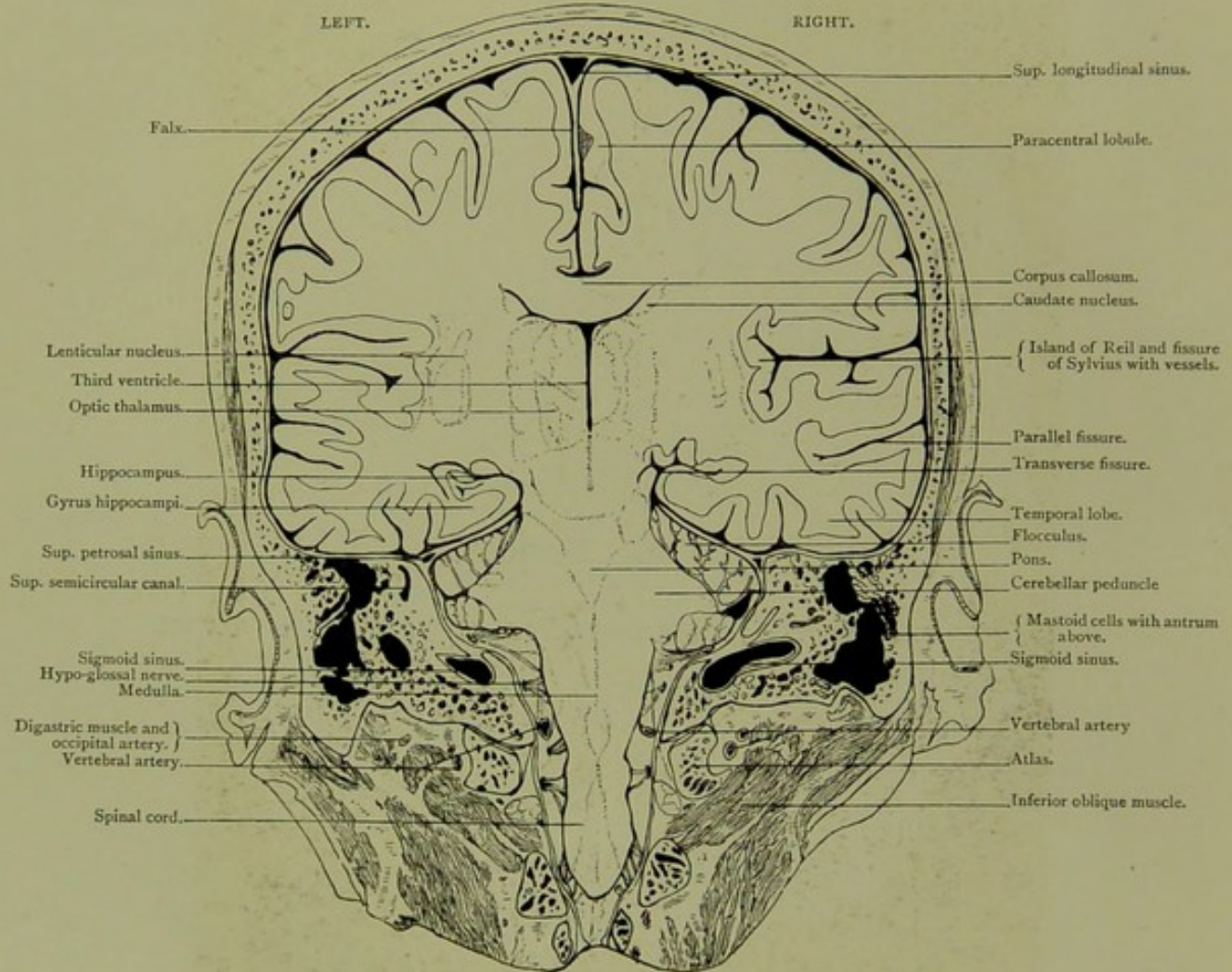


Coronal Section. Series A. VIII.

VIEWED FROM BEHIND, HALF AN INCH POSTERIOR TO SECTION VII.

CORONAL SECTION.

Series A. VIII.

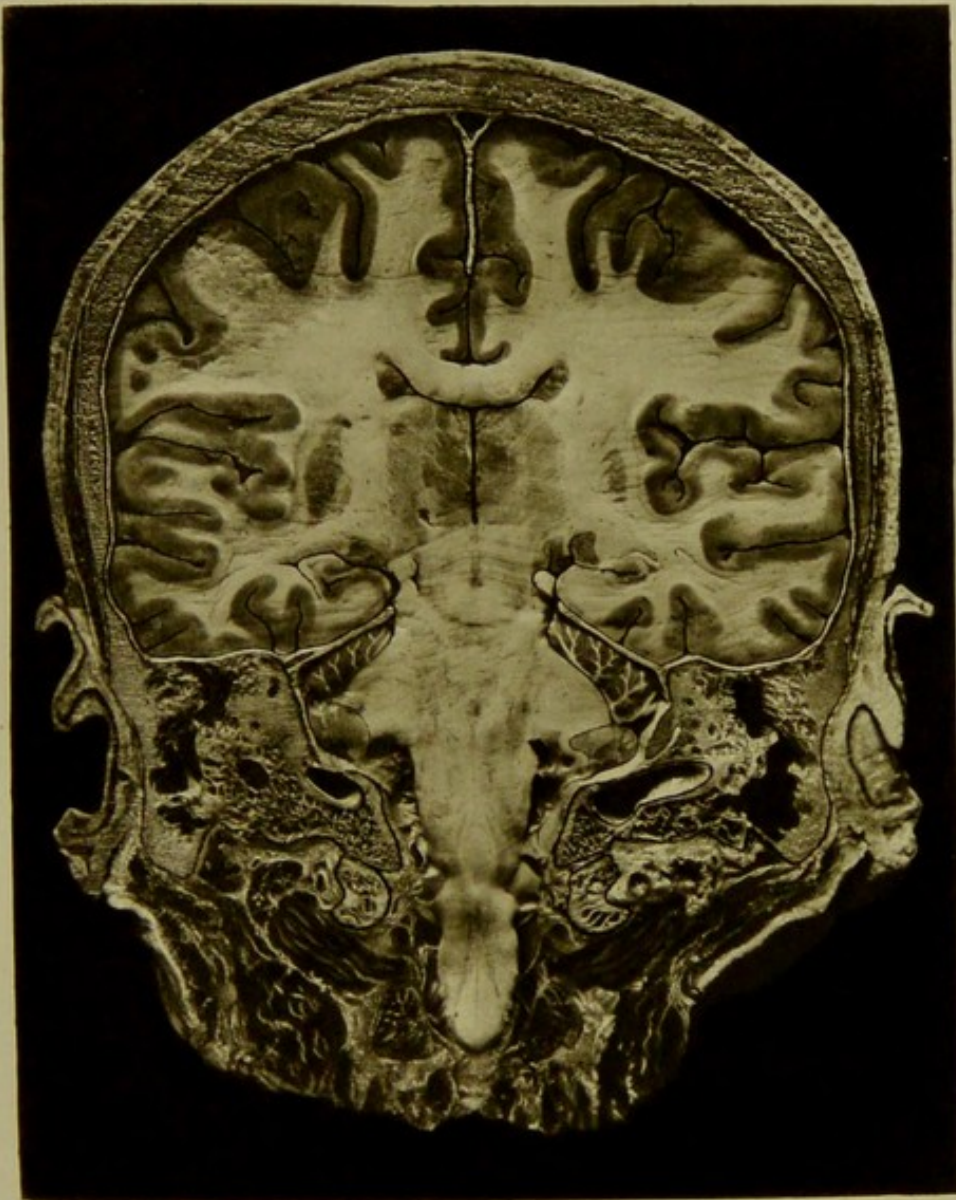


Male, 60 years.

Scale $\frac{41}{60} = \frac{2}{3}$ Approx.

VIII. CORONAL SECTION, viewed from behind, half an inch posterior to section VII., passing through paracentral lobule, island of Reil, fissure of Sylvius, temporo-sphenoidal lobe, basal ganglia, pons, medulla, and cord. The mastoid cells, temporal lobe in its relation to the tegmen antri, and the hypoglossal nerve as it passes into anterior condyloid foramen, are well seen. The section is in a plane half an inch behind the auriculo-bregmatic line, and passes through the tip of the mastoid process.

PLATE N^o 8.






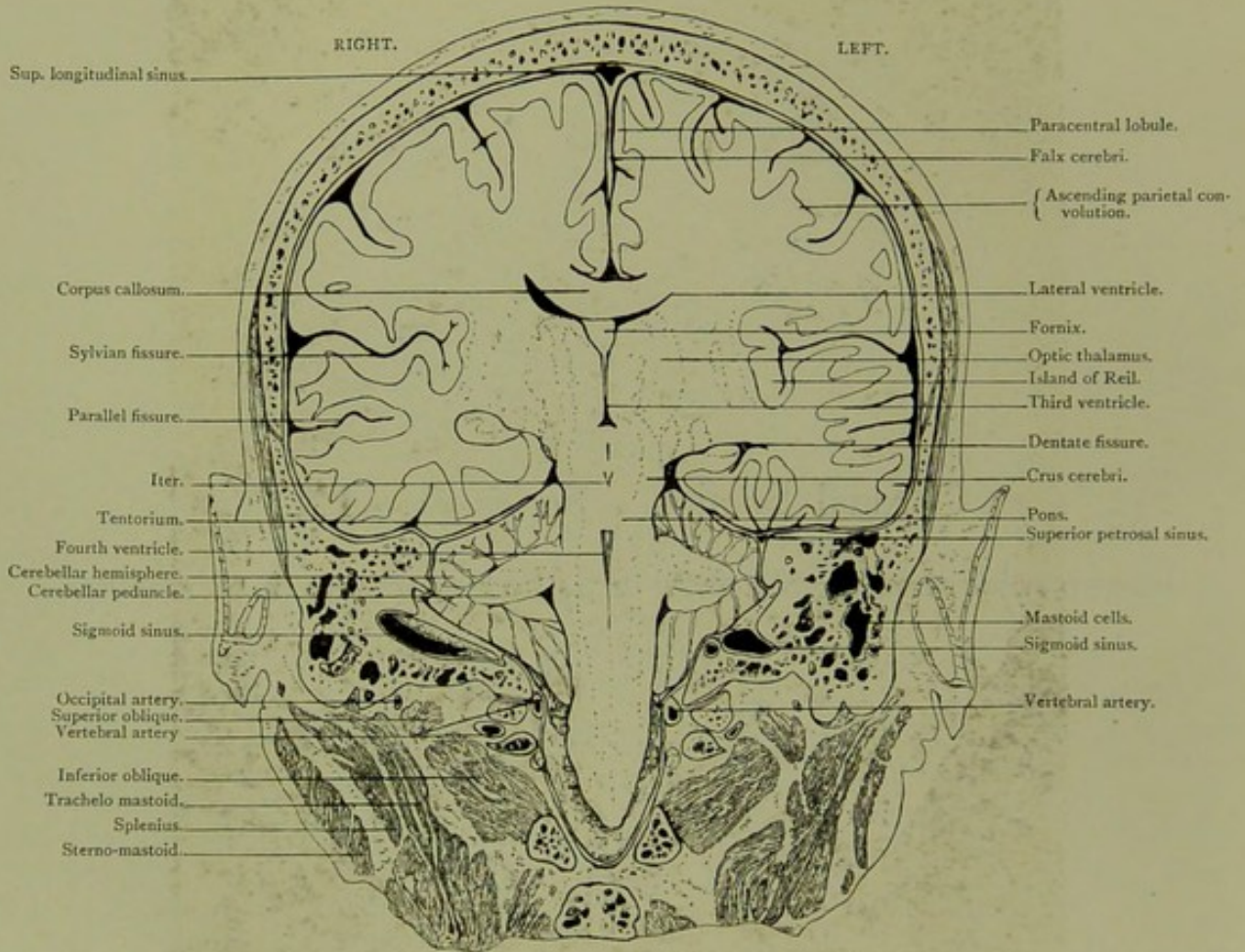
PLATE NO. 9.

Coronal Section. Series A. IX.

VIEWED FROM BEFORE, ONE-EIGHTH OF AN INCH POSTERIOR TO SECTION VIII.

CORONAL SECTION.

Series A. IX.



Male, 60 years.

Scale $\frac{38}{61} = \frac{3}{5}$ Approx.

IX. CORONAL SECTION, viewed from before one-eighth of an inch posterior to section VIII., passing through parietal and temporo-sphenoidal lobes, basal ganglia, crura cerebri, pons, cerebellum, medulla and cord. The section is in a plane five-eighths of an inch posterior to the auriculo-bregmatic line.

PLATE N° 9

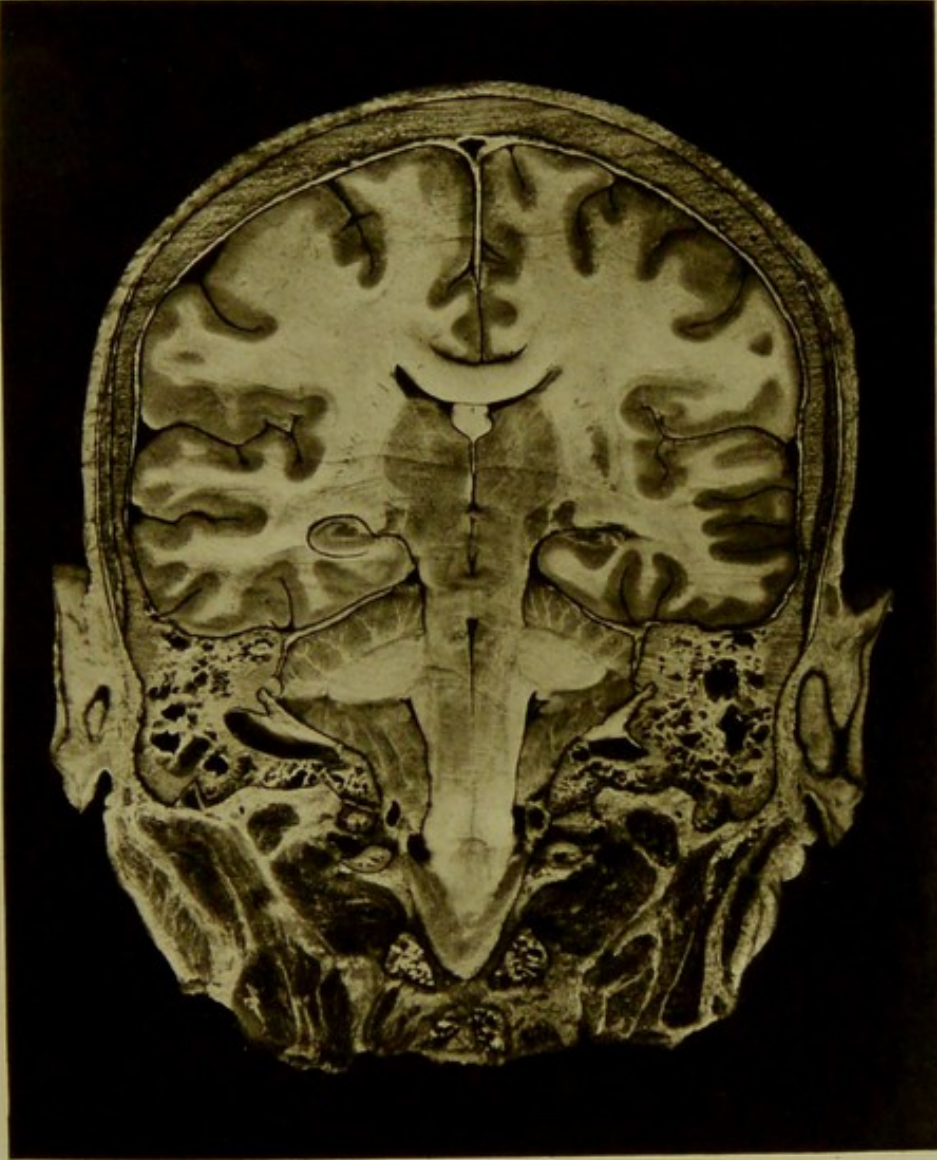




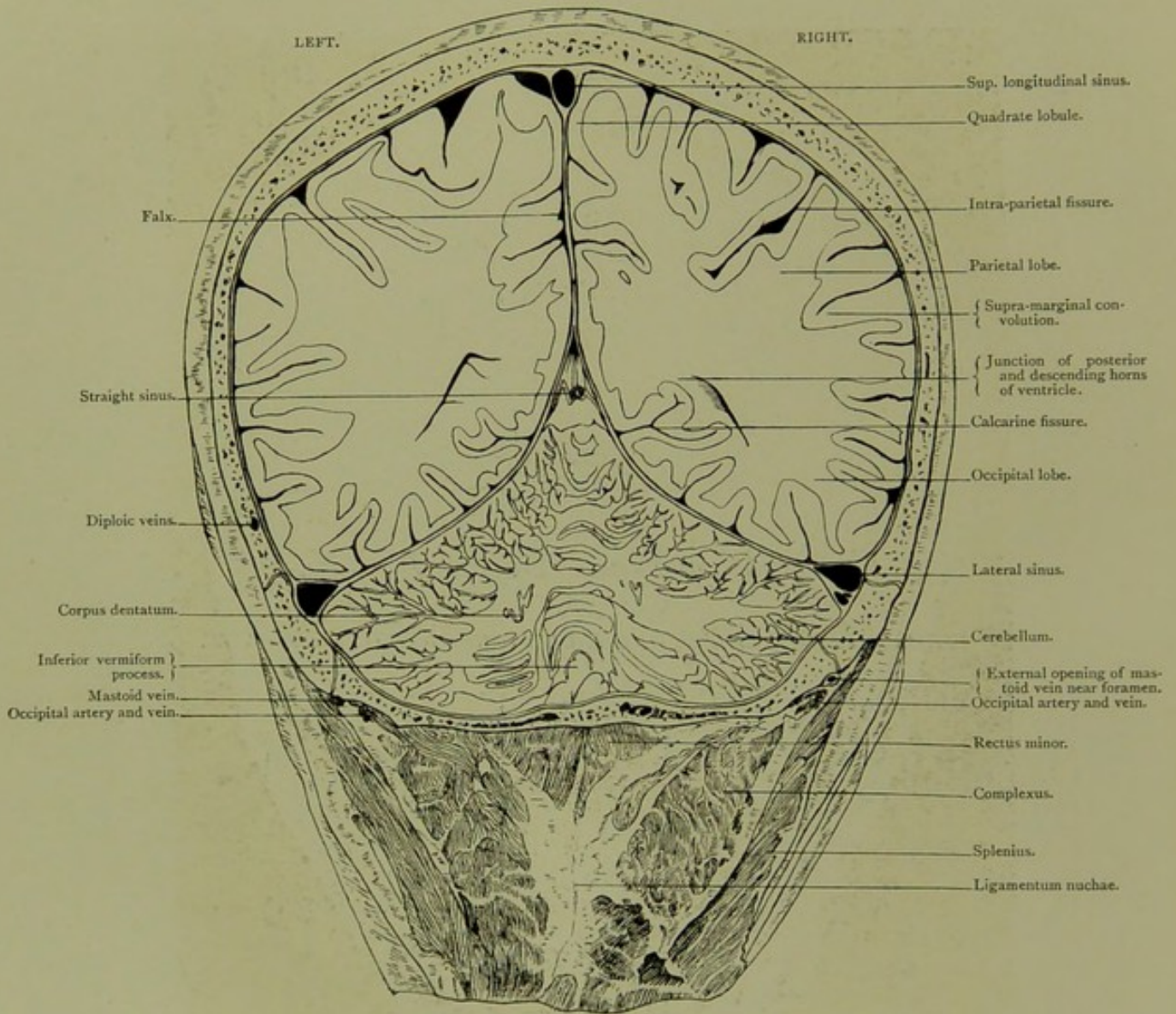
PLATE NO. 10.

Coronal Section. Series A. X.

VIEWED FROM BEHIND, ONE INCH POSTERIOR TO SECTION IX.

CORONAL SECTION.

Series A. X.

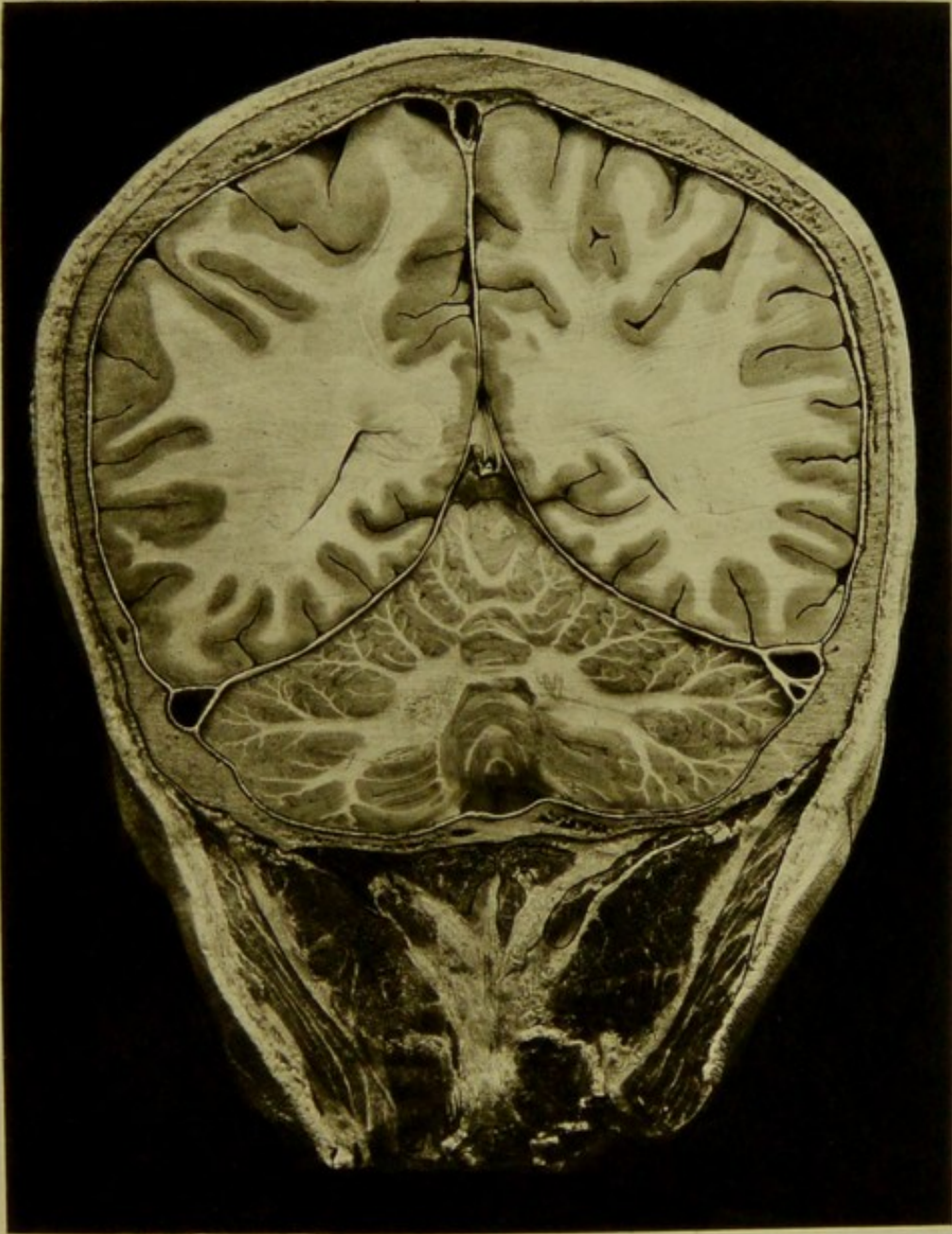


Male, 60 years.

Scale $\frac{47}{62} = \frac{3}{4}$ Approx.

X. CORONAL SECTION, viewed from behind, one inch posterior to section IX., passing through parietal and occipital cerebral lobes and the cerebellar hemispheres. The junction of the falx with the tentorium, and the orifice of the straight sinus are seen. This section is in a plane one and five-eighth inches posterior to the auriculo-bregmatic line and passes through a portion of the parietal eminence.

PLATE N° 10.






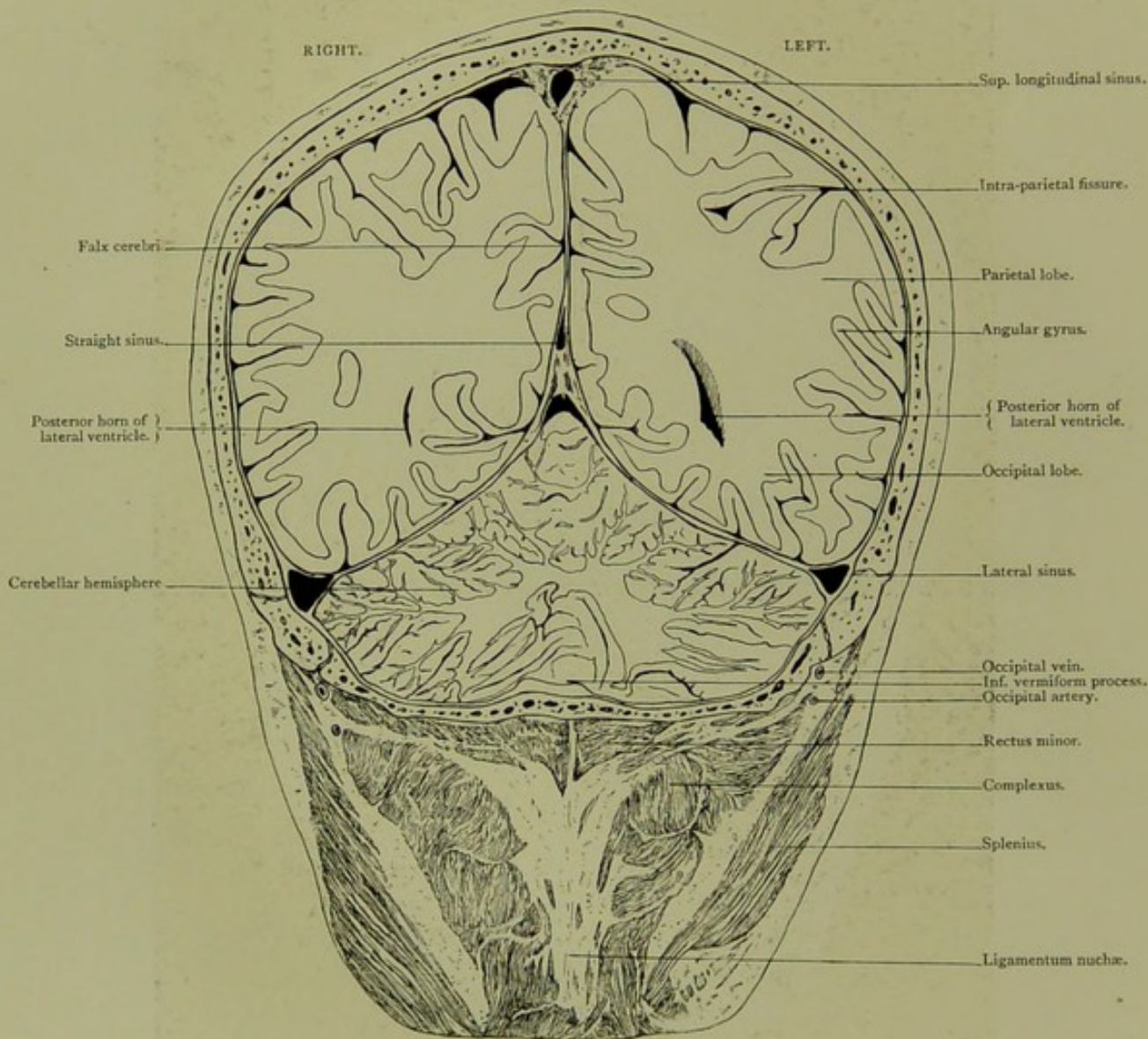
PLATE NO. 11.

Coronal Section. Series A. XI.

VIEWED FROM BEFORE, ONE-EIGHTH OF AN INCH POSTERIOR TO SECTION X.

CORONAL SECTION.

Series A. XI.

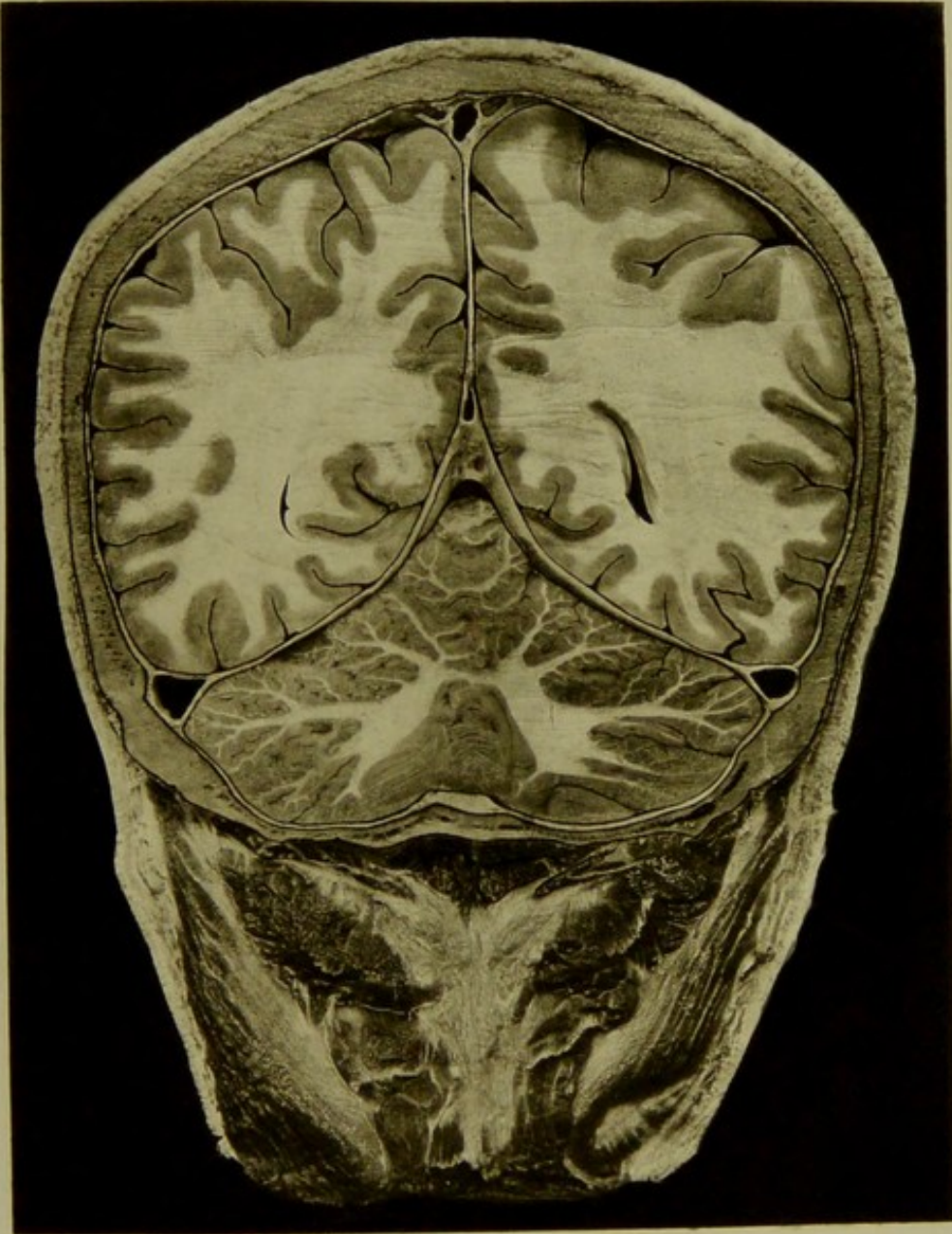


Male, 60 years.

Scale $\frac{46}{61} = \frac{3}{4}$ Approx.

XI. CORONAL SECTION, viewed from before one-eighth of an inch posterior to section X., passing through parietal and occipital lobes of cerebrum and cerebellar hemispheres. It passes through a plane one and three-quarter inches posterior to the auriculo-bregmatic line, and includes a portion of the parietal eminence.

PLATE N^o. II.



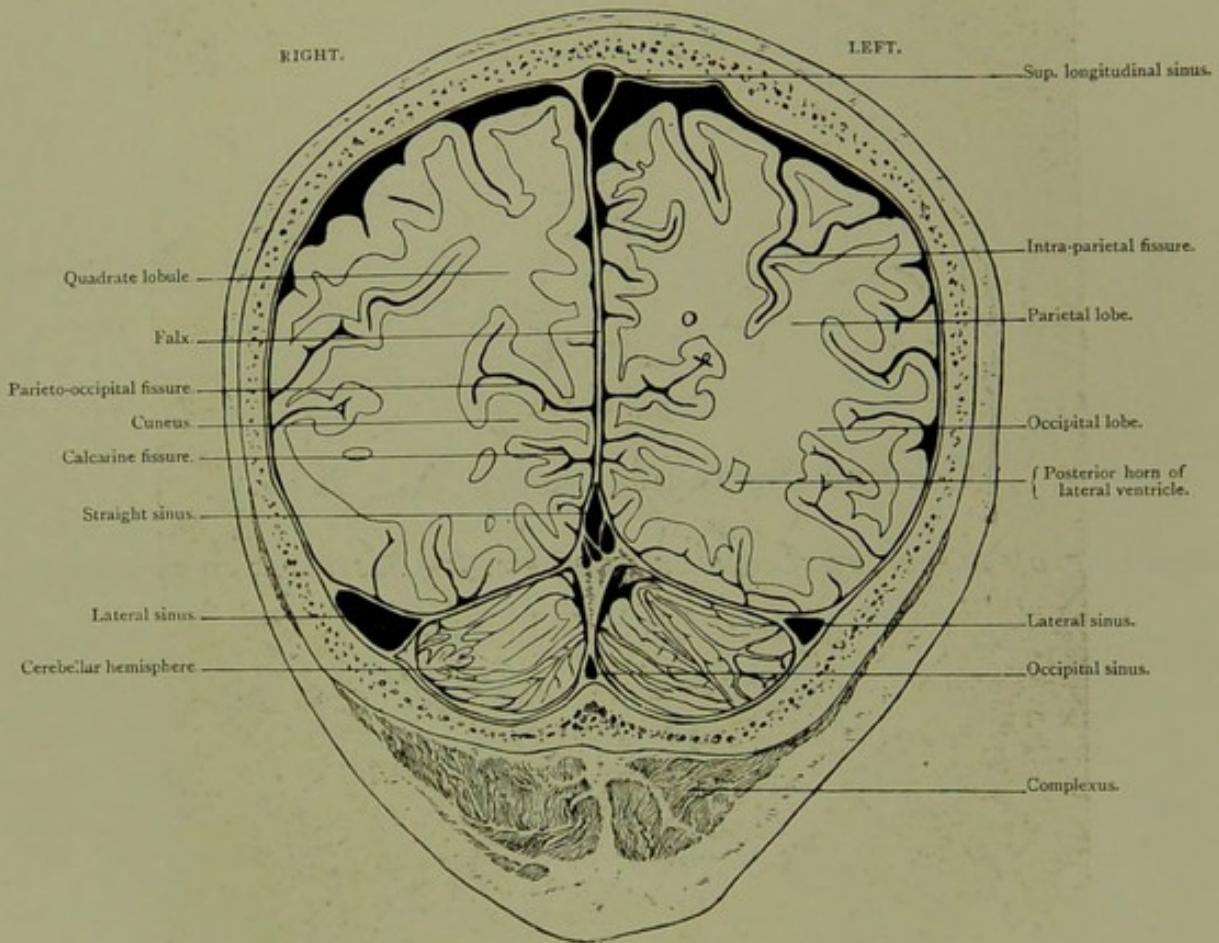


Coronal Section. Series A. XII.

VIEWED FROM BEFORE, THREE-QUARTERS OF AN INCH POSTERIOR TO SECTION XI.

CORONAL SECTION.

Series A. XII.

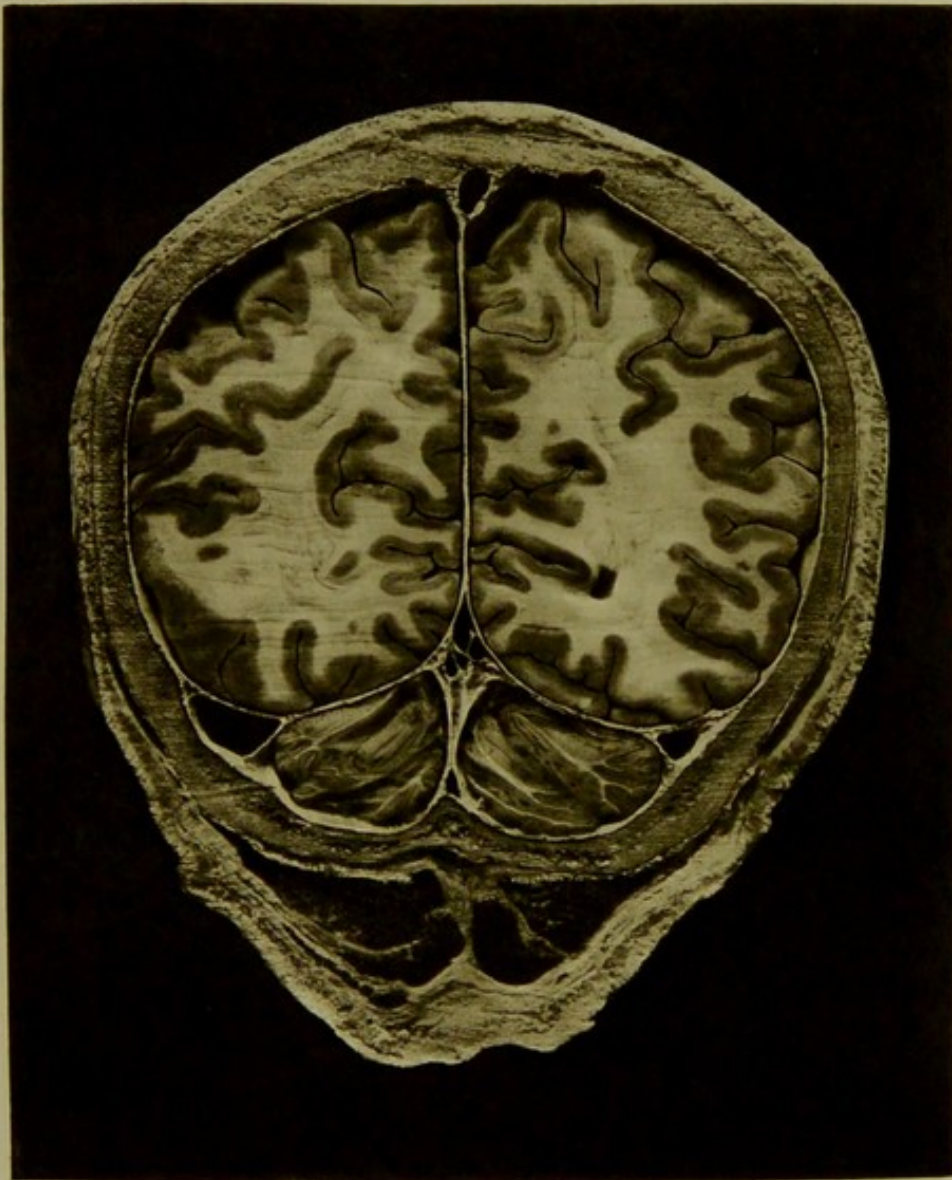


Male, 60 years.

Scale $\frac{36}{53} = \frac{2}{3}$ Approx.

XII. CORONAL SECTION, viewed from before three quarters of an inch posterior to section XI, passing through the parietal and occipital lobes of cerebrum and posterior aspect of cerebellum. The section is in a plane two and a half inches posterior to the auriculo-bregmatic line.

PLATE N° 12.

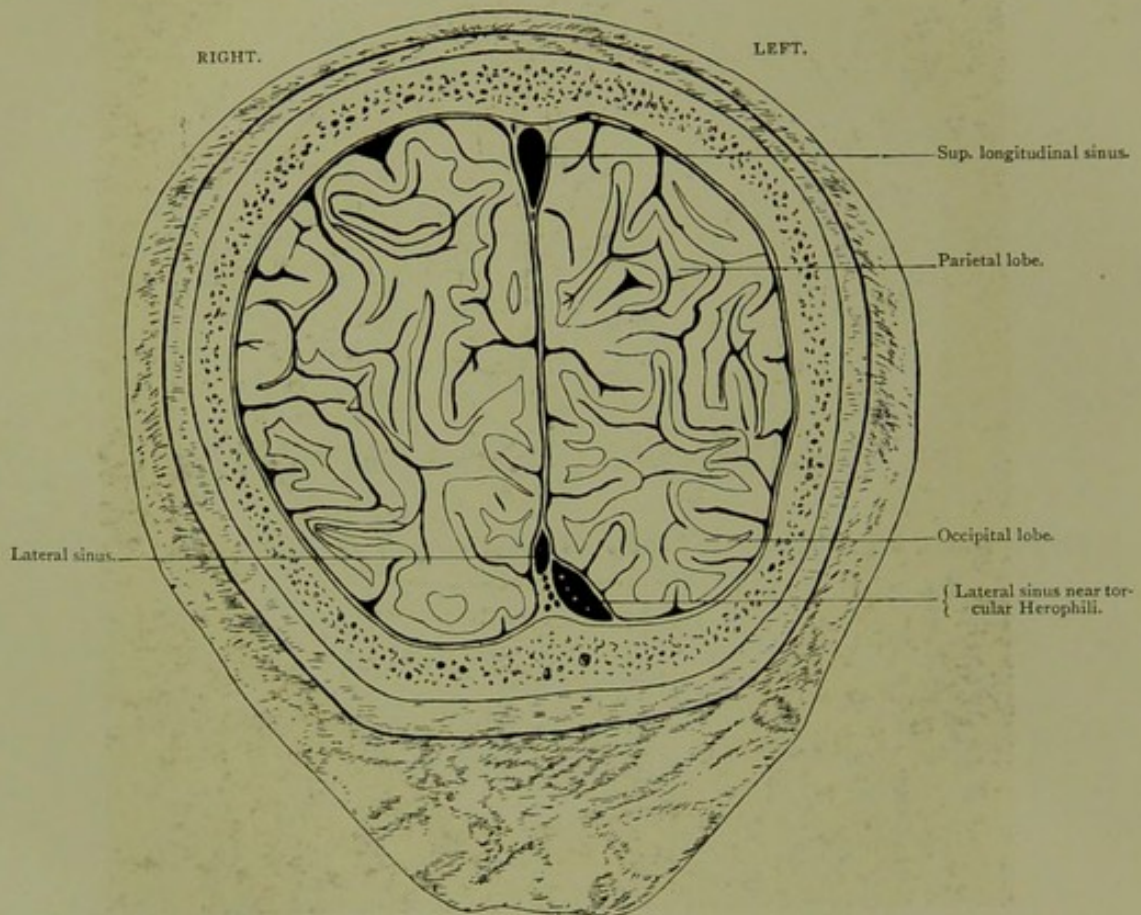


Coronal Section. Series A. XIII.

VIEWED FROM BEHIND, FIVE-EIGHTHS OF AN INCH POSTERIOR TO SECTION XII.

CORONAL SECTION.

Series A. XIII.

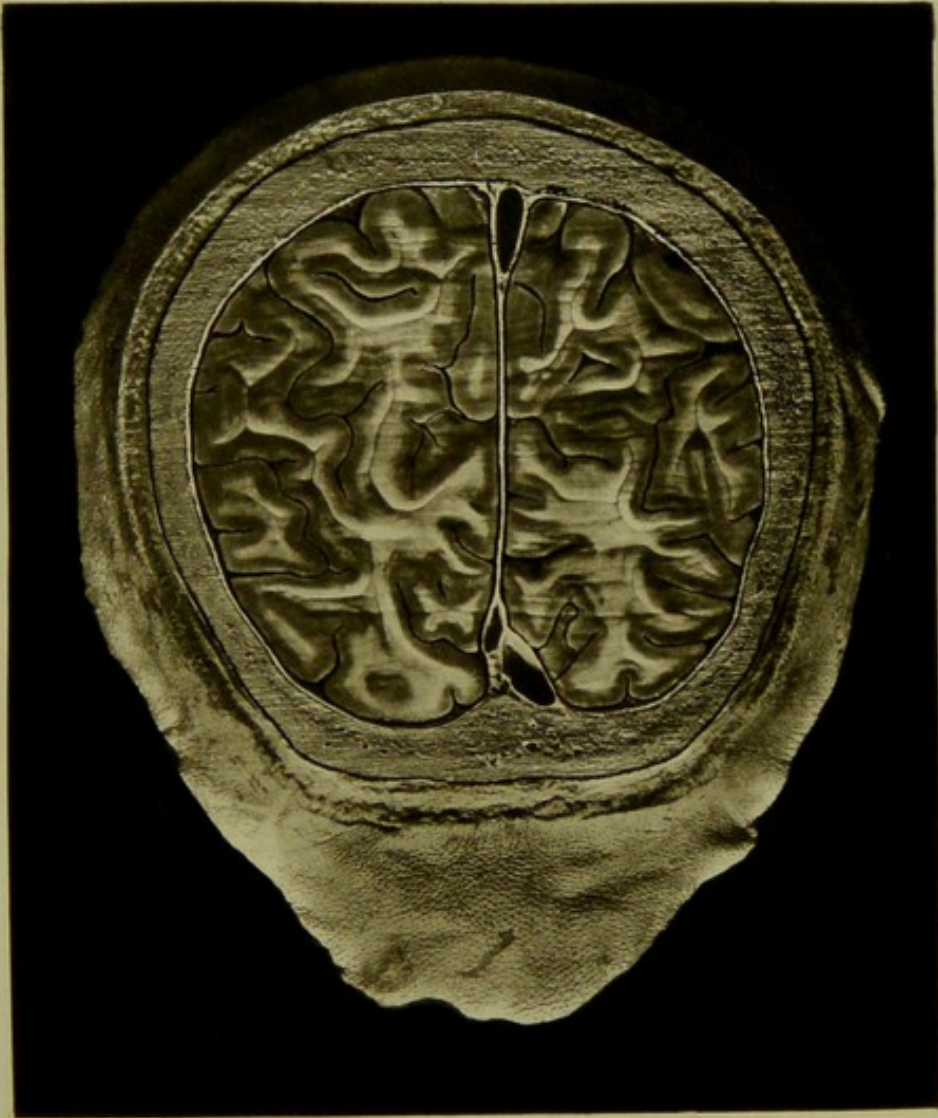


Male, 60 years.

Scale $\frac{36}{50} = \frac{3}{4}$ Approx.

XIII. CORONAL SECTION, viewed from behind five-eighths of an inch posterior to section XII, passing through posterior aspect of parietal and occipital lobes and torcular Herophili. The section is in a plane three and one-eighth inches posterior to the auriculo-bregmatic line.

PLATE N° 13.



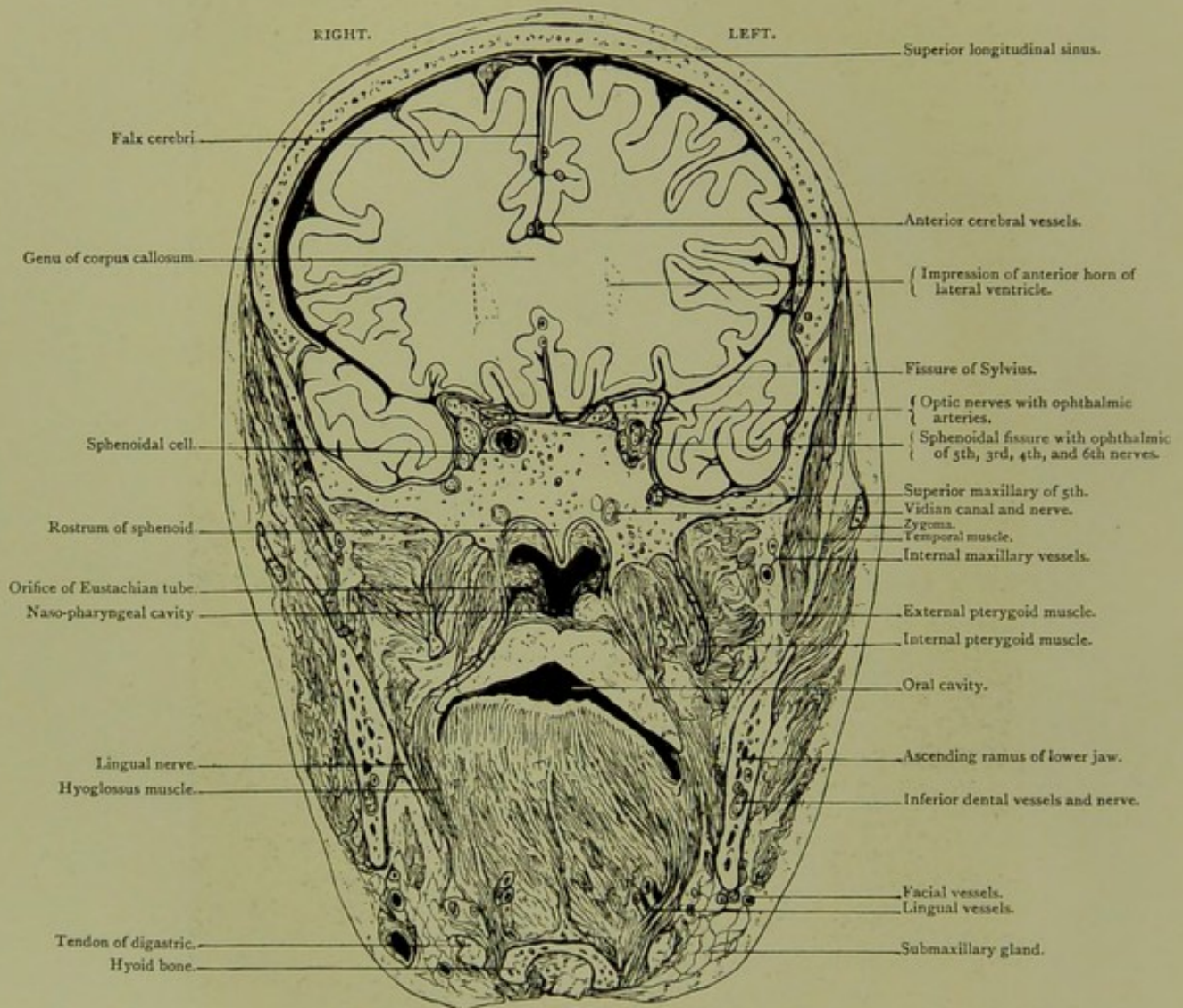


Coronal Section, Series B. I.

*AN INCH AND THREE-EIGHTHS IN FRONT OF AURICULO-BREGMATIC PLANE,
VIEWED FROM BEFORE.*

CORONAL SECTION.

Series B. I.

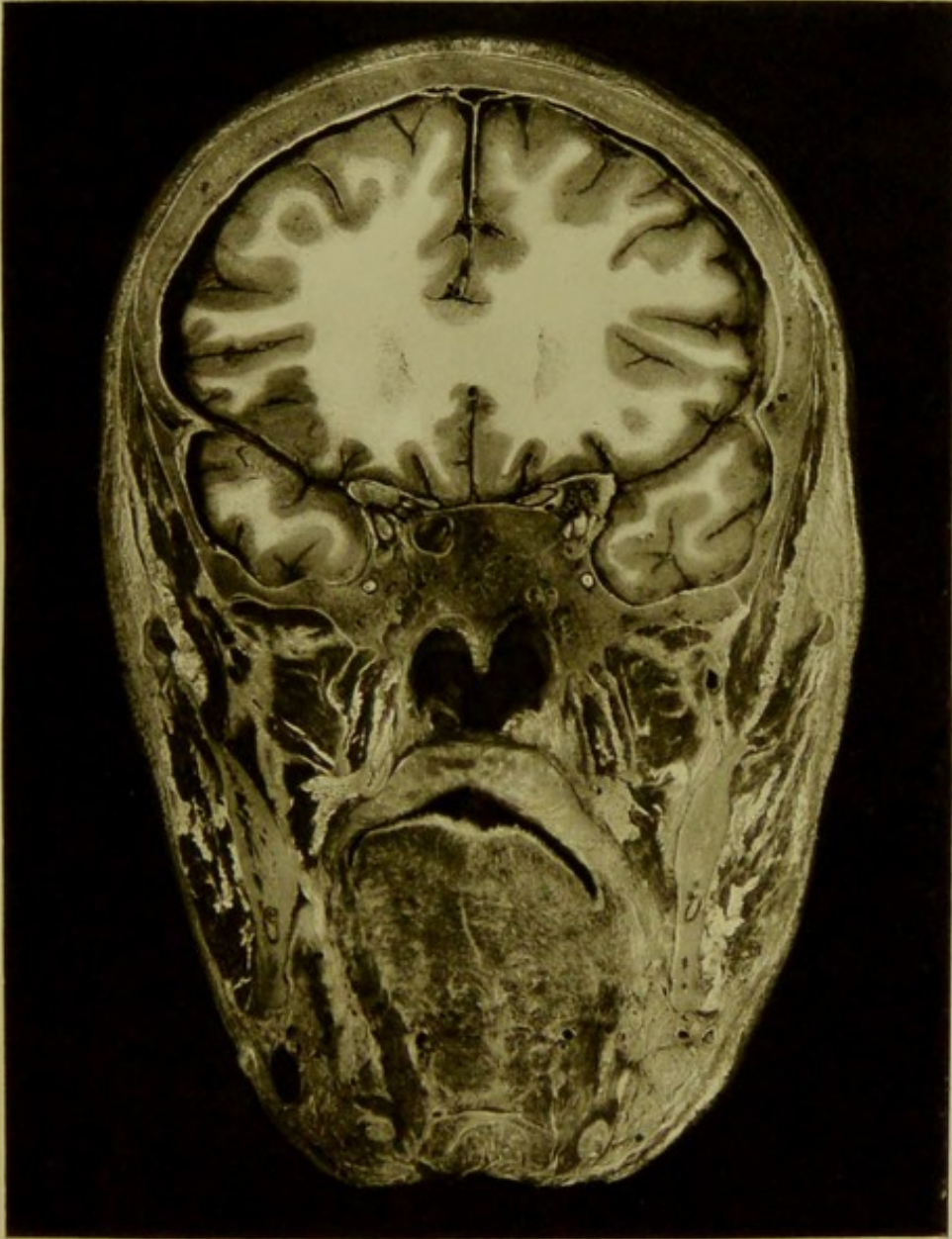


Male, 40 years.

Scale $\frac{42}{64} = \frac{2}{3}$ Approx.

I. CORONAL SECTION an inch and three-eighths in front of auriculo-bregmatic plane, viewed from before, passing through anterior clinoid processes, sphenoidal fissures, and foramina rotunda. The frontal and temporo-sphenoidal lobes, the superior maxillary nerve, internal maxillary vessels, pterygoid muscles, facial and lingual arteries, inferior dental vessels and nerve, tendon of digastric, submaxillary gland, and the pharyngeal orifice of Eustachian tube are exposed.

PLATE No 14






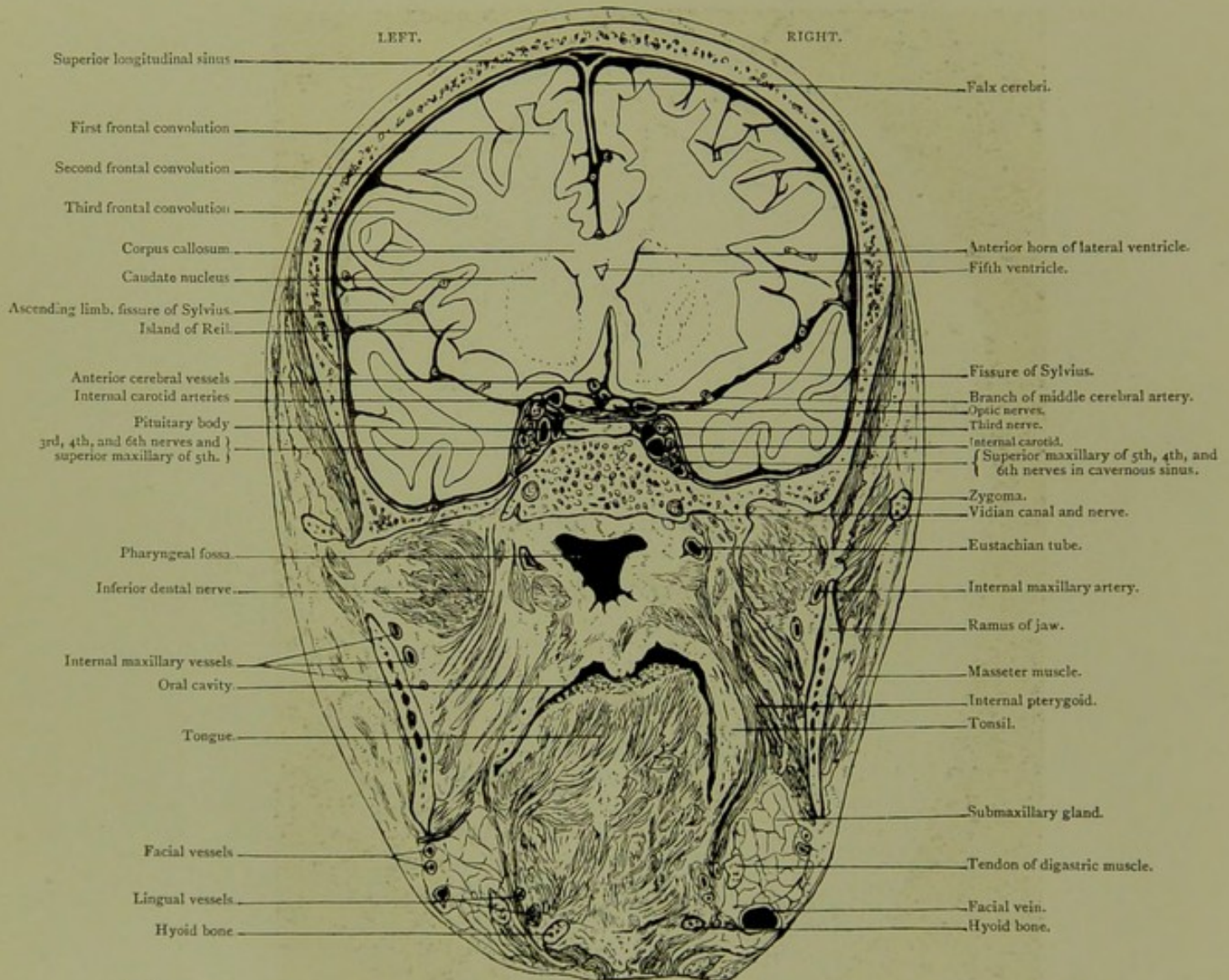
PLATE NO. 15.

Coronal Section. Series B. II.

AN INCH IN FRONT OF AURICULO-BREGMATIC PLANE, VIEWED FROM BEHIND.

CORONAL SECTION.

Series B. II.

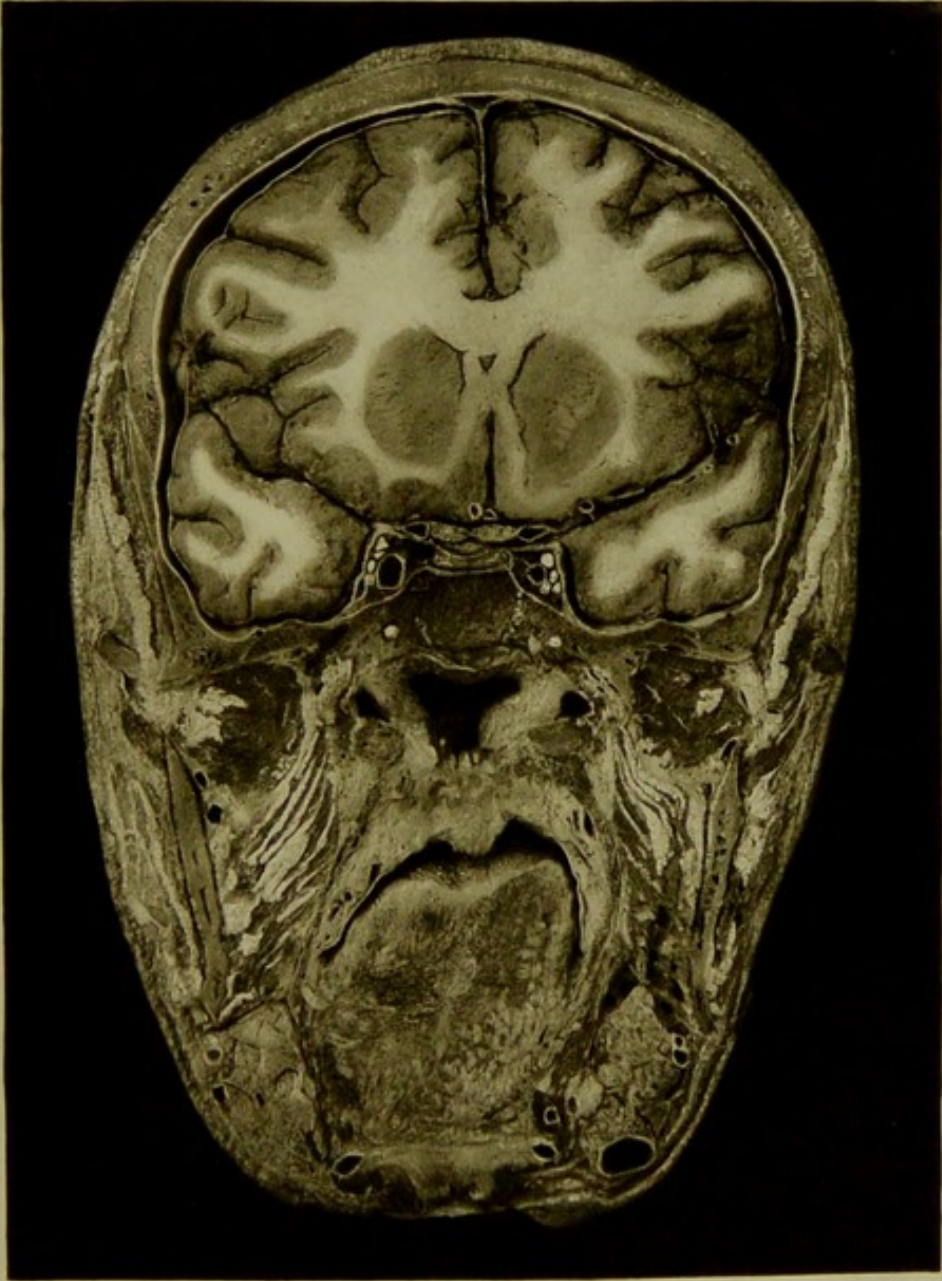

Male, 40 years.

Scale $\frac{43}{64} = \frac{2}{3}$ Approx.

II. CORONAL SECTION an inch in front of auriculo-bregmatic plane viewed from behind, passing through body of sphenoid, exposing the posterior part of frontal lobes, the anterior part of temporo-sphenoidal lobes, the fissure of Sylvius with its ascending branch, anterior horns of ventricles, fifth ventricle, optic nerve just in front of chiasma, pituitary body, cavernous sinus with its relations to the third, fourth, fifth, and sixth nerves along with carotid artery, portion of pterygoid plexus, Eustachian tube, internal maxillary, facial and lingual vessels.

PLATE N°15.



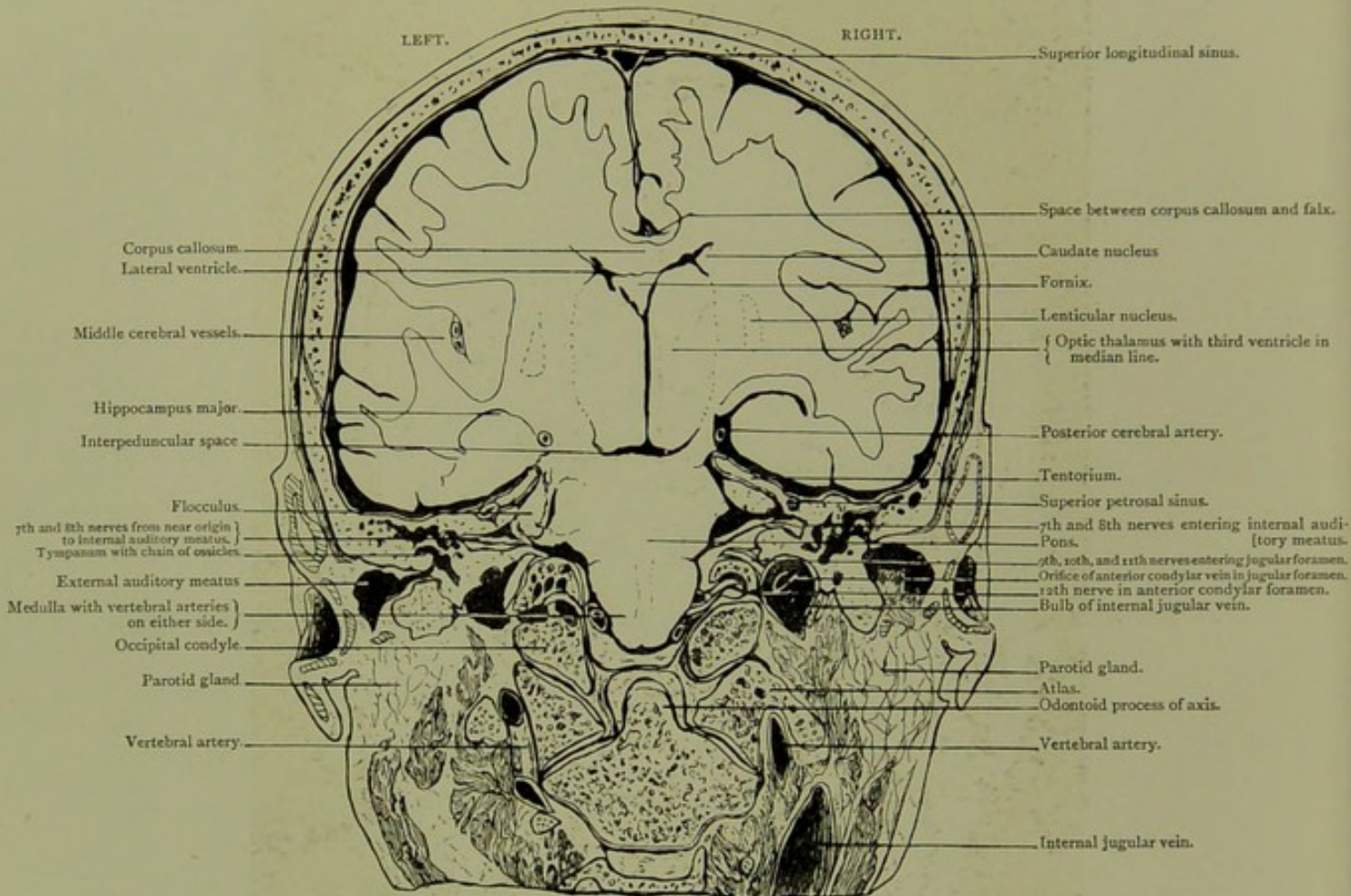


Coronal Section. Series B. III.

IN AURICULO-BREGMATIC PLANE, AN INCH BEHIND SECTION II., SEEN FROM BEHIND.

CORONAL SECTION.

Series B. III.

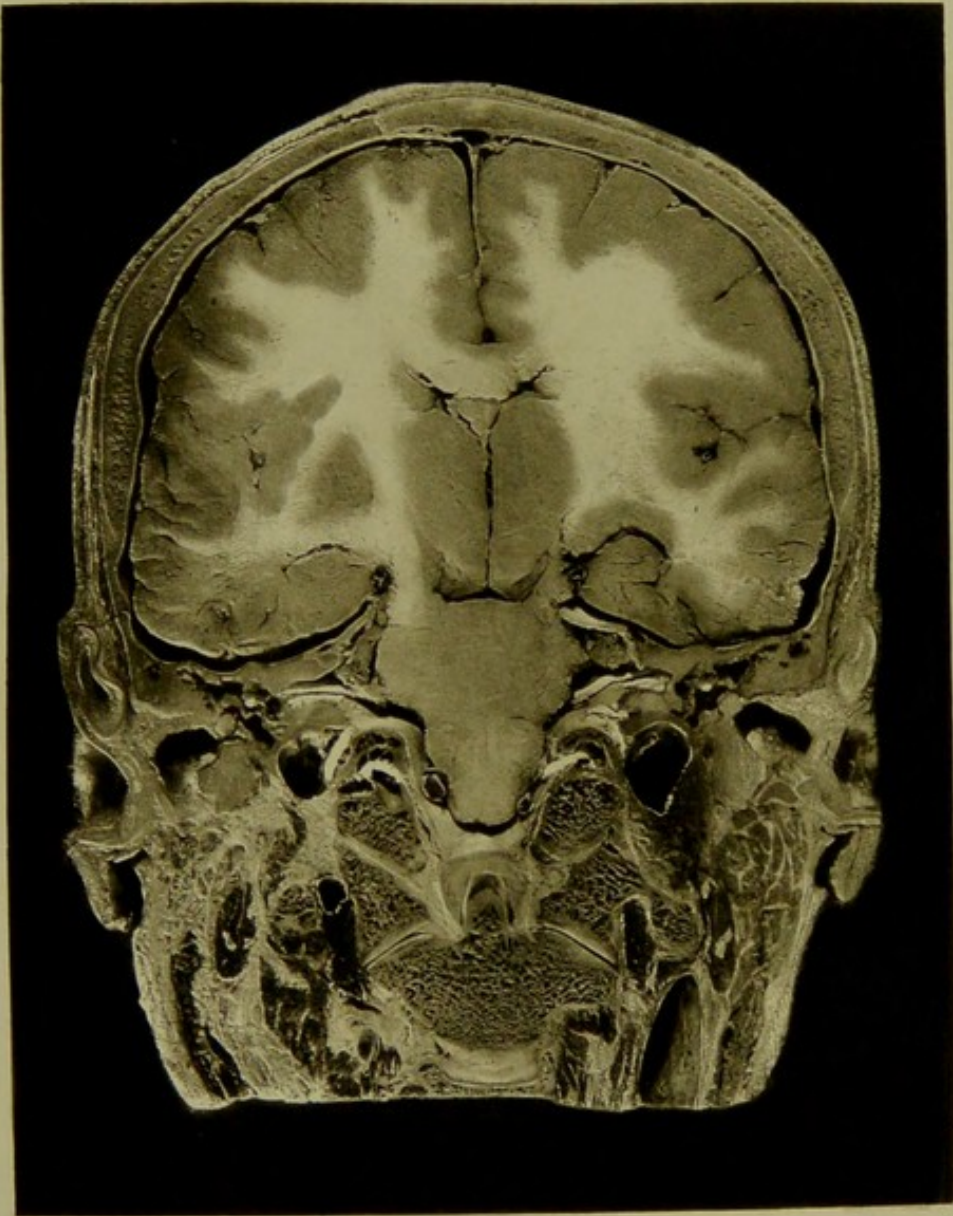

Male, 40 years.

Scale $\frac{37}{57} = \frac{16}{68}$ Approx.

III. CORONAL SECTION in auriculo-bregmatic plane, an inch behind section II., seen from behind, passing through external and internal auditory meatus, showing the middle ear with its chain of ossicles, the seventh and eighth nerves from near their point of origin to the internal meatus, the ninth, tenth, and eleventh entering jugular fossa, and the twelfth in anterior condylar foramen. The relations of the occipital condyles to the atlas and axis, the vertebral arteries, the medulla, pons, third and lateral ventricles are well seen. On the right of the photograph there is an accidental fissure, running from the hippocampus outwards. The dome-shaped part of the internal jugular vein is seen on the right side of section, with a large vein passing into the jugular fossa from the anterior condylar foramen.

PLATE No. 16.



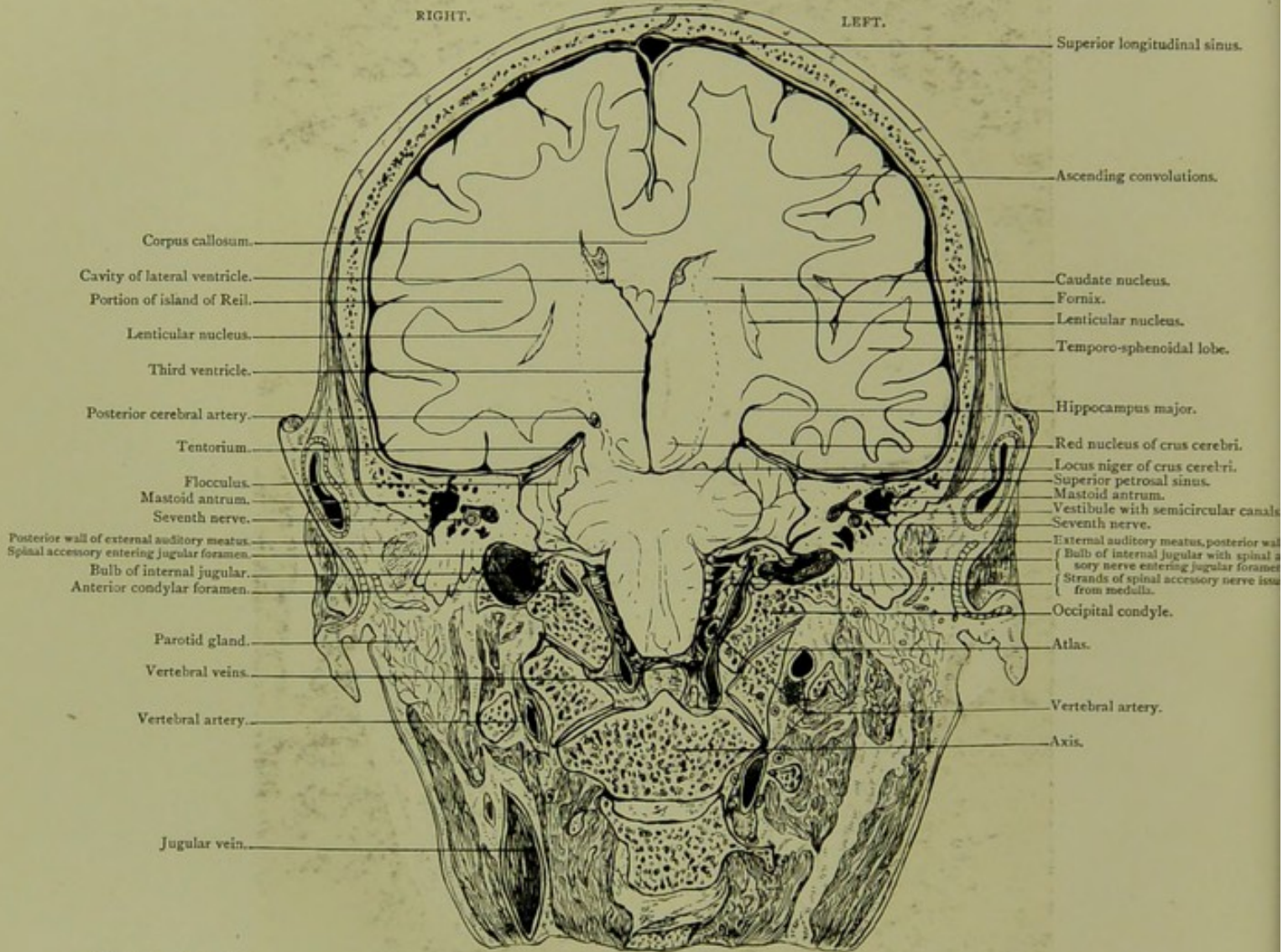


Coronal Section. Series B. IV.

*AN EIGHTH OF AN INCH POSTERIOR TO AURICULO-BREGMATIC PLANE AND TO
SECTION III.*

CORONAL SECTION.

Series B. IV.

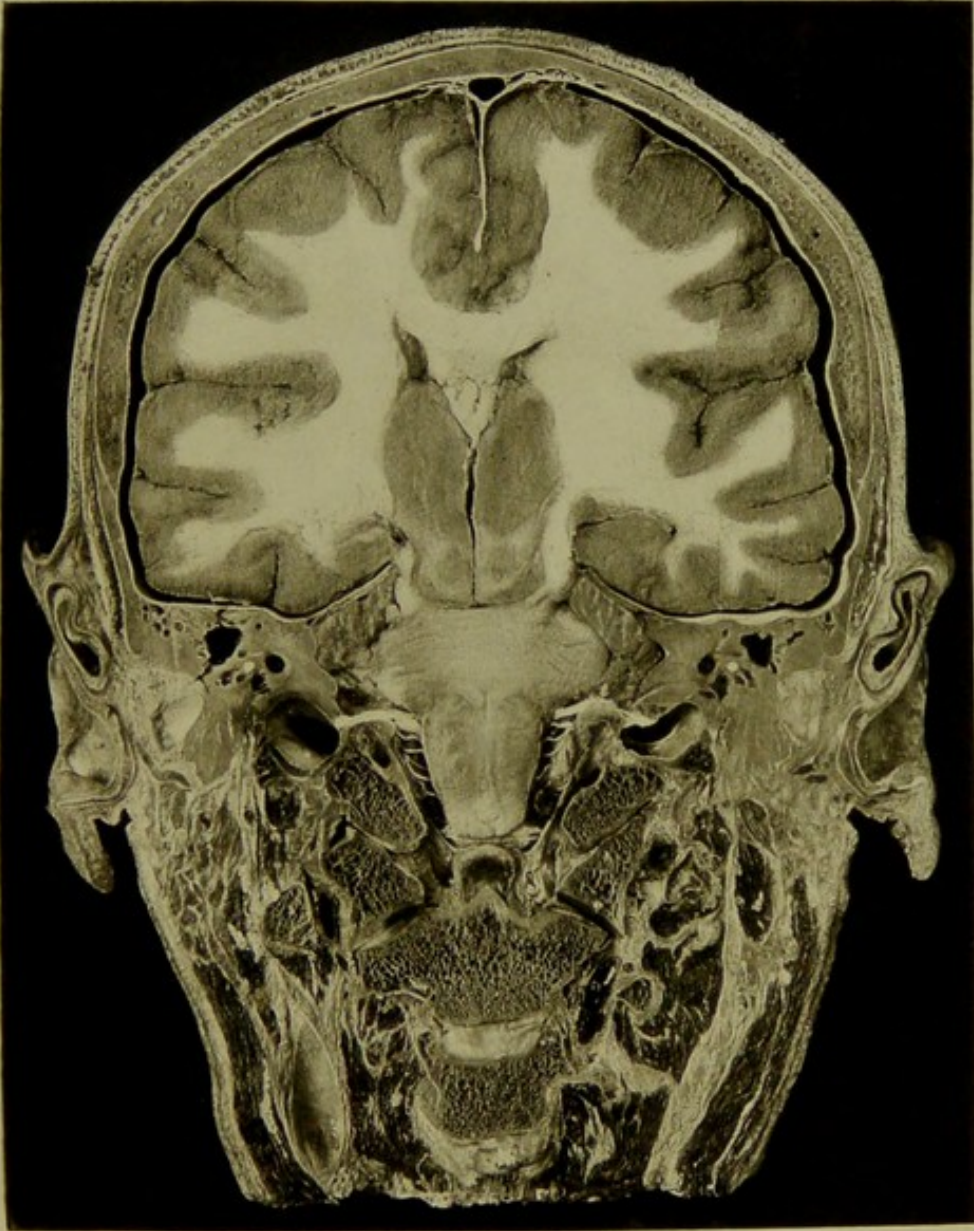


Male, 40 years.

Scale $\frac{43}{63} = \frac{2}{3}$ Approx.

IV. CORONAL SECTION, an eighth of an inch posterior to auriculo-bregmatic plane and to section III., passing through the ascending convolutions, temporo-sphenoidal lobe, basal ganglia, pons, medulla, occipital condyles, atlas, and axis. Some of the strands of the spinal accessory issuing from the medulla are traced into the eleventh nerve as it passes into jugular foramen. The junction of the sigmoid sinus with the jugular fossa is seen in specimen though not in photo.

MATE N°17



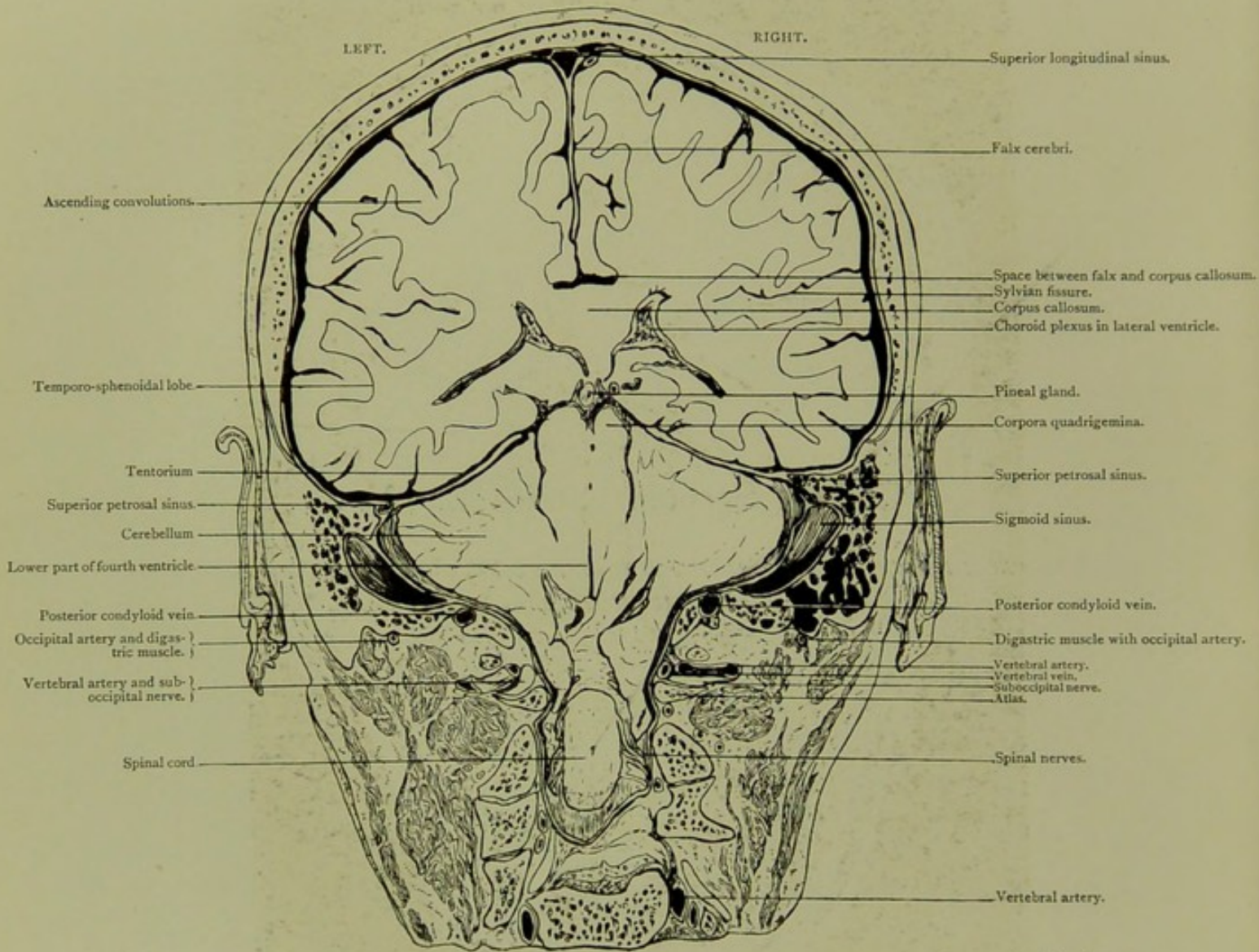


Coronal Section. Series B. V.

*VIEWED FROM BEHIND, A HALF-INCH POSTERIOR TO SECTION IV. AND FIVE-EIGHTHS
OF AN INCH BEHIND AURICULO-BREGMATIC PLANE.*

CORONAL SECTION.

Series B. V.

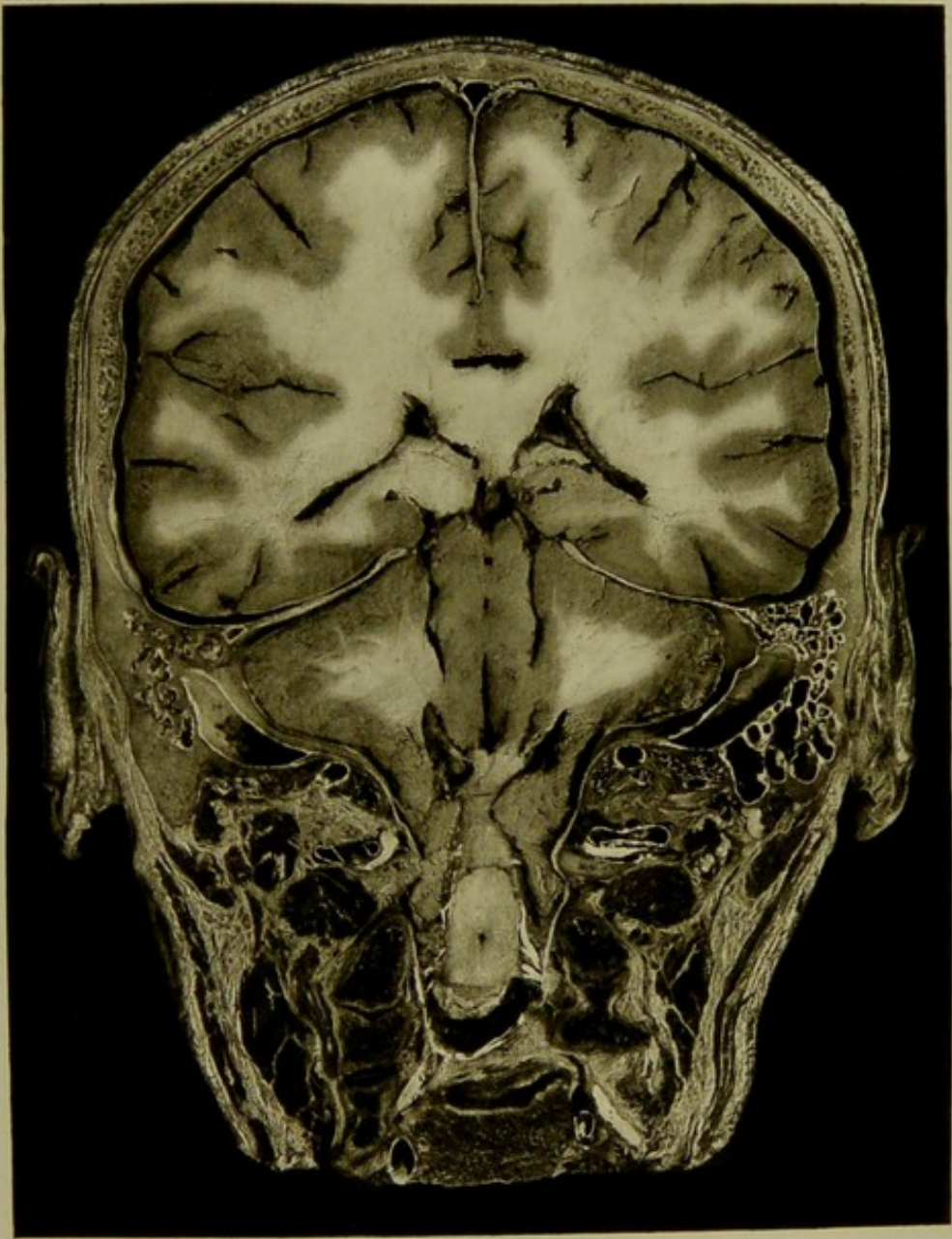



Male, 40 years.

Scale $\frac{43}{63} = \frac{2}{3}$ Approx.

V. CORONAL SECTION, viewed from behind, a half-inch posterior to section IV. and five-eighths of an inch behind auriculo-bregmatic plane. Section passes through mastoid portion of temporal, exposing the parietal and temporo-sphenoidal lobes of the cerebrum with the lateral ventricles and their choroid plexuses, the cerebellum, portions of pons and spinal cord. Attention is called to the tenuity of the osseous plate dividing lowest mastoid cells from sigmoid sinus, and to the depth to which the cerebellum penetrates into the spinal canal round the medulla and cord.

PLATE N°10.



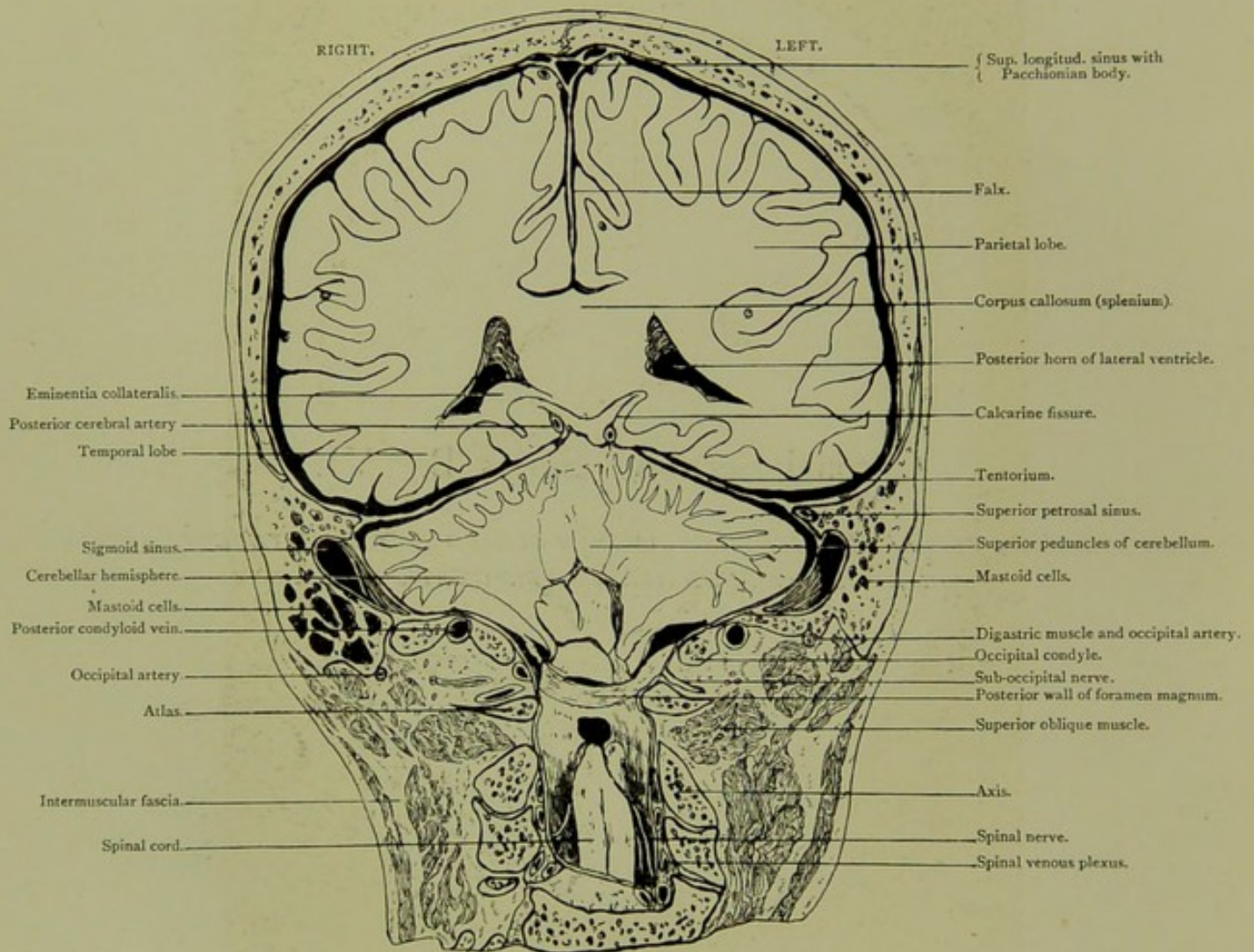


Coronal Section. Series B. VI.

*VIEWED FROM BEFORE, AN EIGHTH OF AN INCH BEHIND SECTION V, THREE-QUARTERS
OF AN INCH BEHIND AURICULO-BREGMATIC PLANE.*

CORONAL SECTION.

Series B. VI.

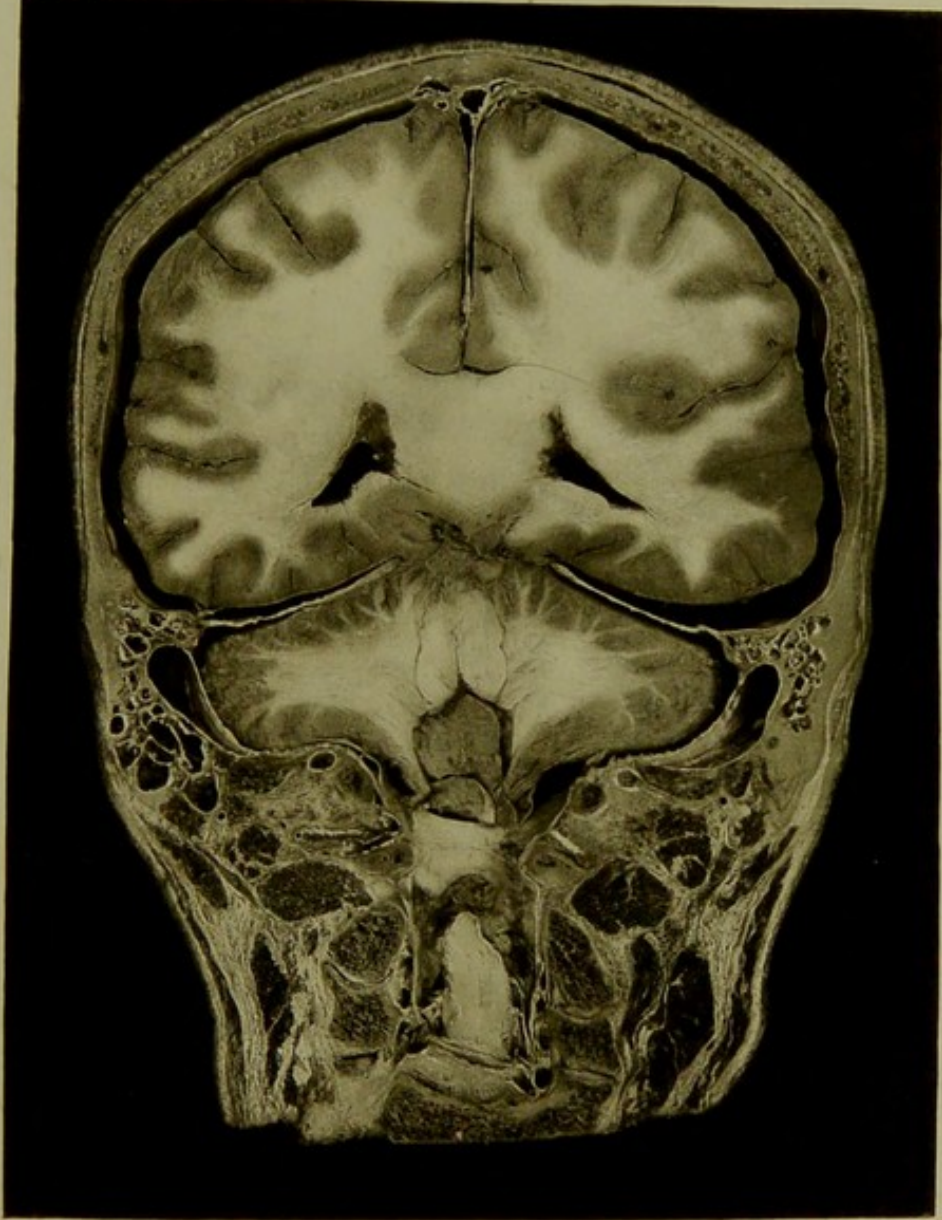



Male, 40 years.

Scale $\frac{40}{61} = \frac{2}{3}$ Approx.

VI. CORONAL SECTION, viewed from before, an eighth of an inch behind section v., three-quarters of an inch behind auriculo-bregmatic plane, passing through posterior wall of foramen magnum, and posterior mastoid cells, exposing sigmoid sinus, parietal and temporo-sphenoidal lobes, cerebellar hemispheres with their superior peduncles.

PLATE N°19.



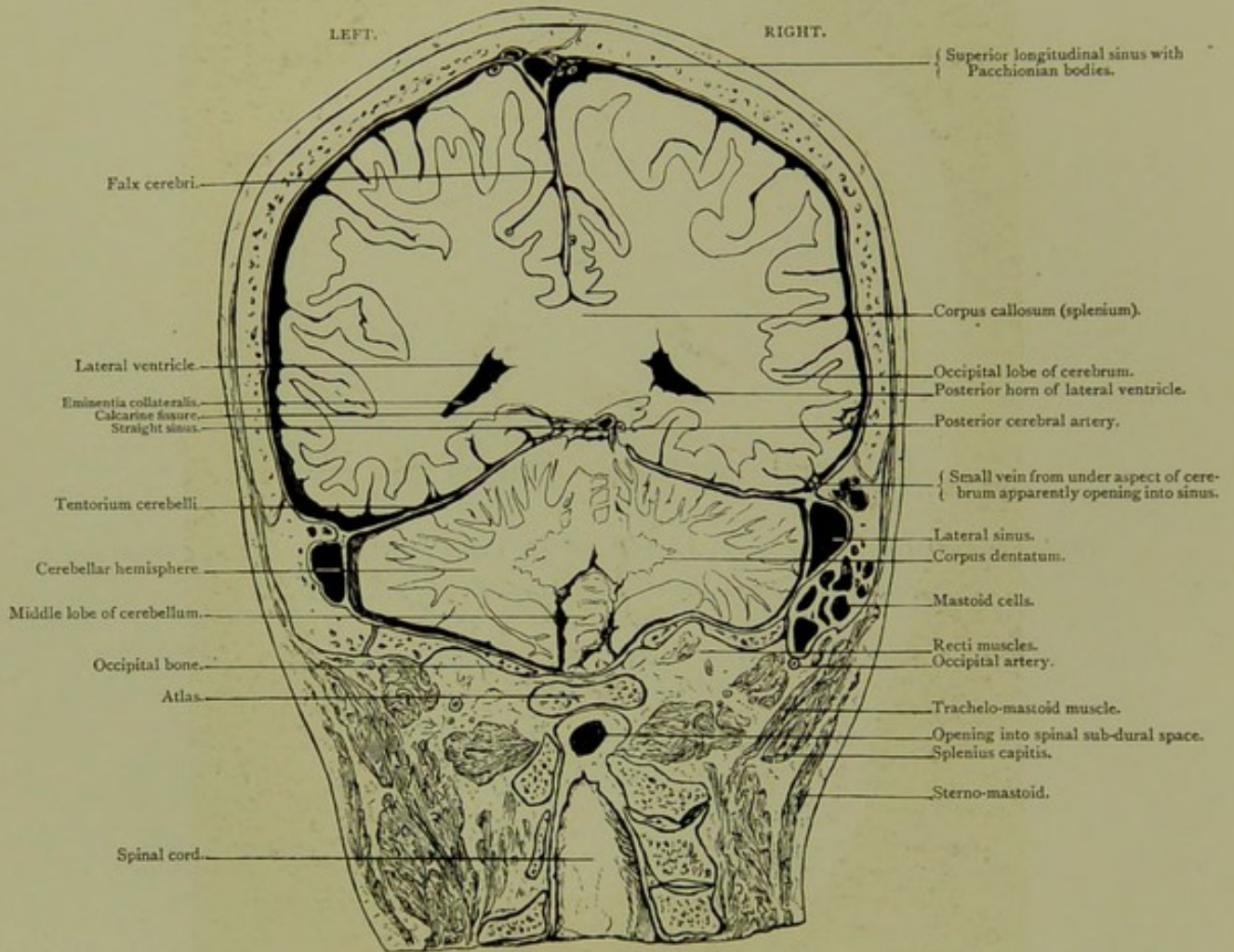


Coronal Section. Series B. VII.

*VIEWED FROM BEHIND, A QUARTER OF AN INCH POSTERIOR TO SECTION VI,
AN INCH BEHIND AURICULO-BREGMATIC PLANE.*

CORONAL SECTION.

Series B. VII.

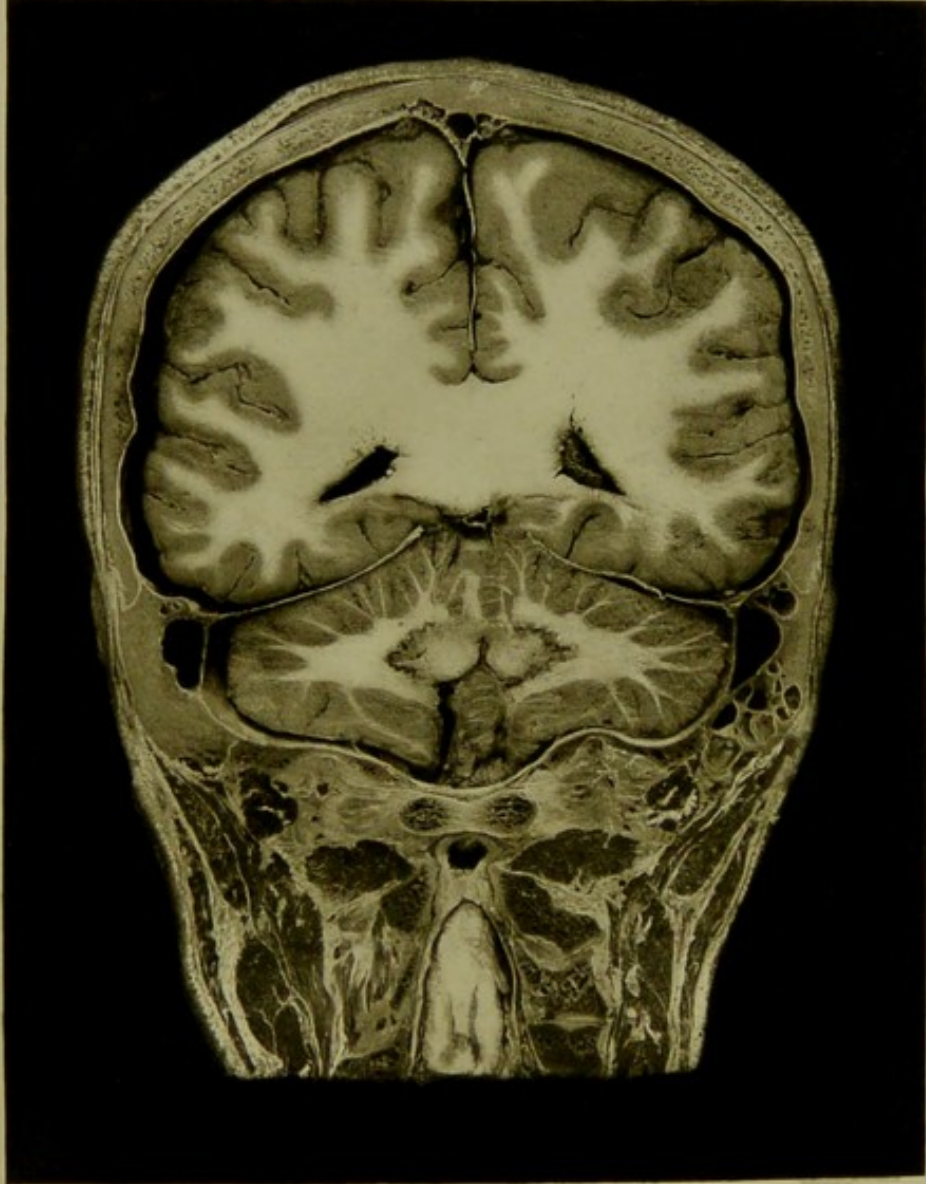


Male, 40 years.

Scale $\frac{37}{60} = \frac{3}{5}$ Approx.

VII. CORONAL SECTION, viewed from behind, a quarter of an inch posterior to section VI, an inch behind auriculo-bregmatic plane, passing through lateral sinus, parietal and occipital lobes of cerebrum, cerebellar hemispheres, atlas, and spinal canal exposed from behind. A vein is seen passing from base of occipital lobe of brain through the tentorium into lateral sinus.

PLATE N° 20.



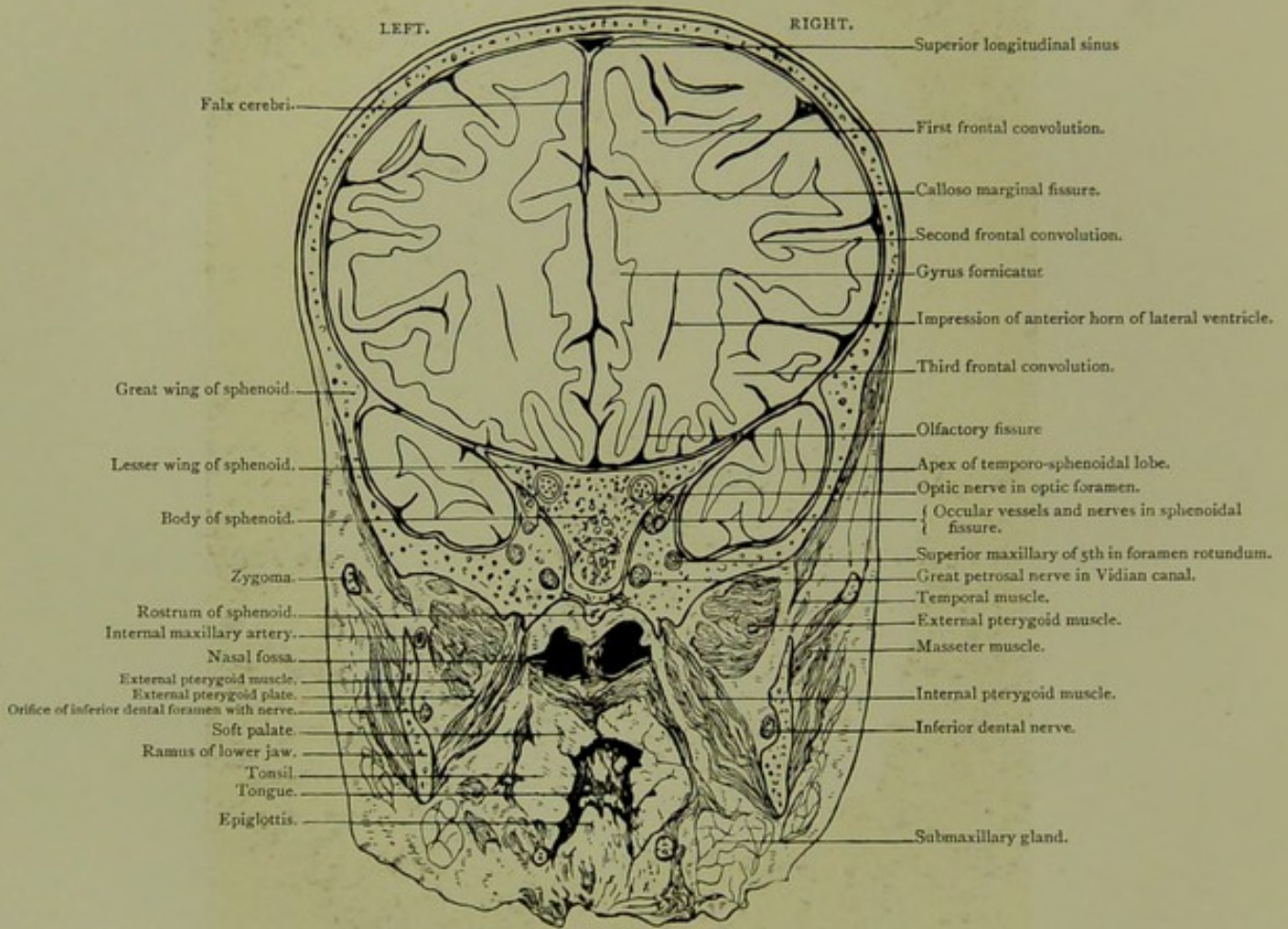


Coronal Section. Series C. I.

ONE INCH IN FRONT OF AURICULO-BREGMATIC PLANE, VIEWED FROM BEHIND.

CORONAL SECTION.

Series C. I.

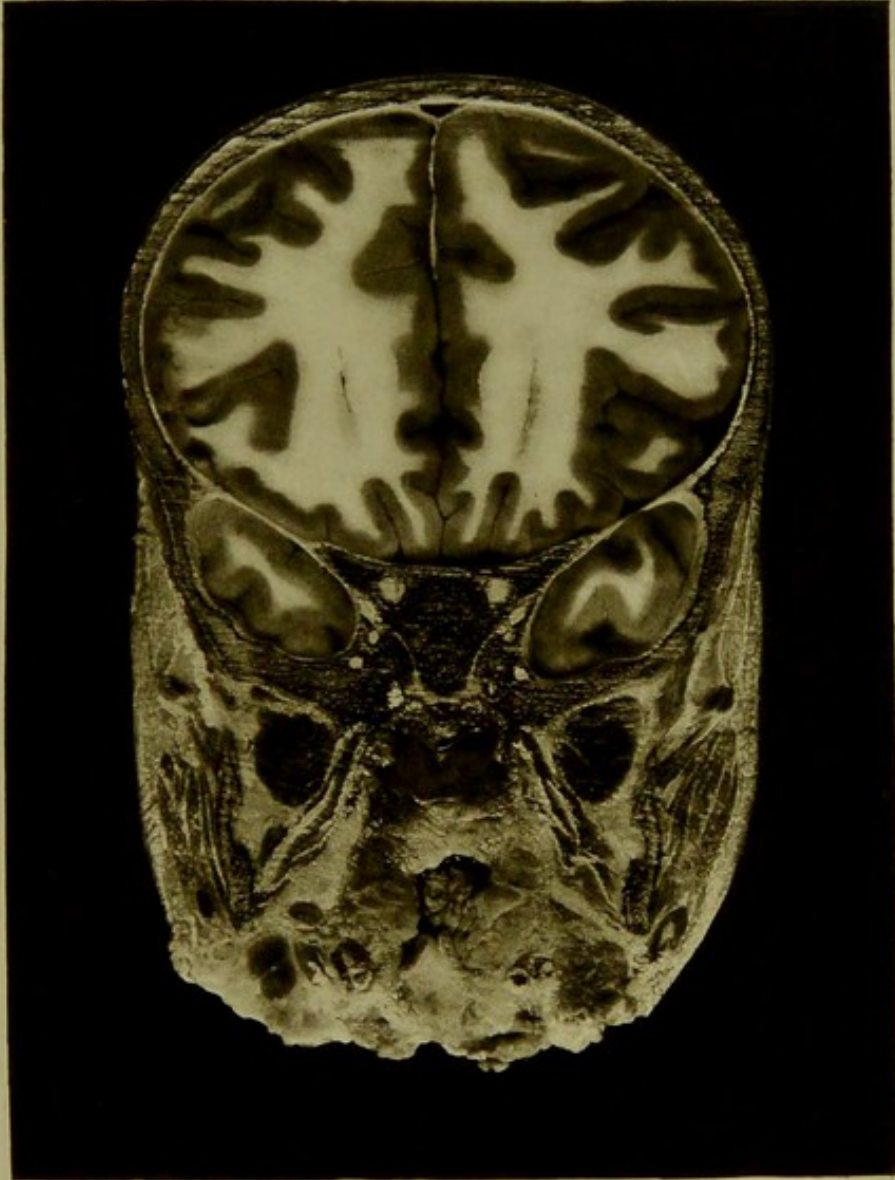



Male, 2½ years.

Scale $\frac{48}{64} = \frac{3}{4}$.

I. CORONAL SECTION, one inch in front of auriculo-bregmatic plane, viewed from behind, passing through the ramus of the lower jaw at orifice of inferior dental canal, through the body and both wings of the sphenoid, and exposing the frontal and anterior parts of the temporal lobes, the posterior nares, pharynx, and tonsils. The sphenoidal fissure, the optic, round, and Vidian foramina with their enclosed nerves are seen.

PLATE No. 21.



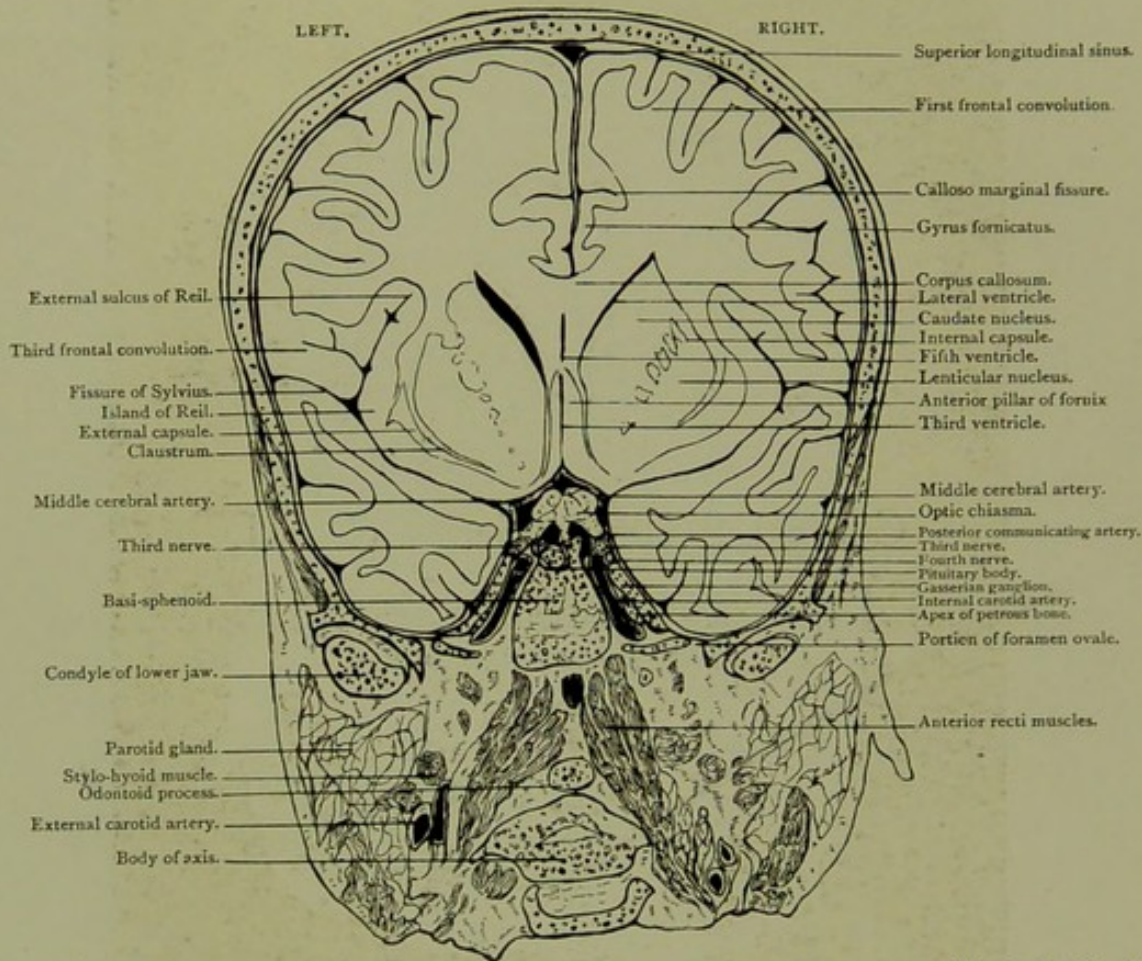


Coronal Section, Series C. II.

*THREE-EIGHTHS OF AN INCH IN FRONT OF AURICULO-BREGMATIC PLANE,
VIEWED FROM BEHIND.*

CORONAL SECTION.

Series C. II.

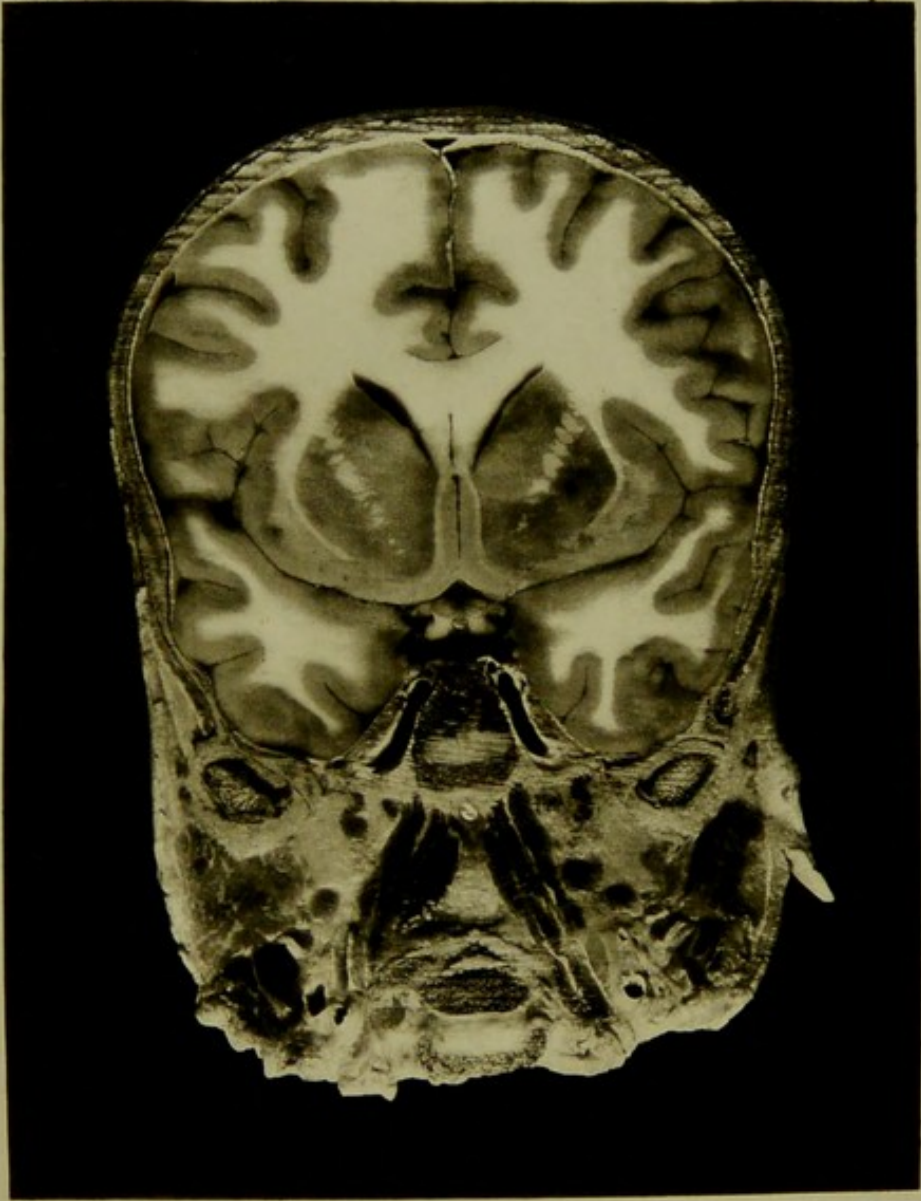



Male, 2½ years.

Scale $\frac{24}{33} = \frac{3}{4}$ Approx.

II. CORONAL SECTION, three-eighths of an inch in front of auriculo-bregmatic plane viewed from behind, passing through condyles of lower jaw, basi-sphenoid, posterior clinoid process and anterior portion of odontoid process of axis, and exposing base of third frontal convolution, island of Reil, corpus striatum, lateral, third, and fifth ventricles, anterior pillars of fornix, optic chiasma, and Gasserian ganglion. The ascending intra-cranial portions of the internal carotid arteries, the middle and anterior cerebral arteries near their origin, the third, fourth, and sixth nerves are shown, and the foramen ovale is divided just anterior to the inferior maxillary nerve.

PLATE No. 22.



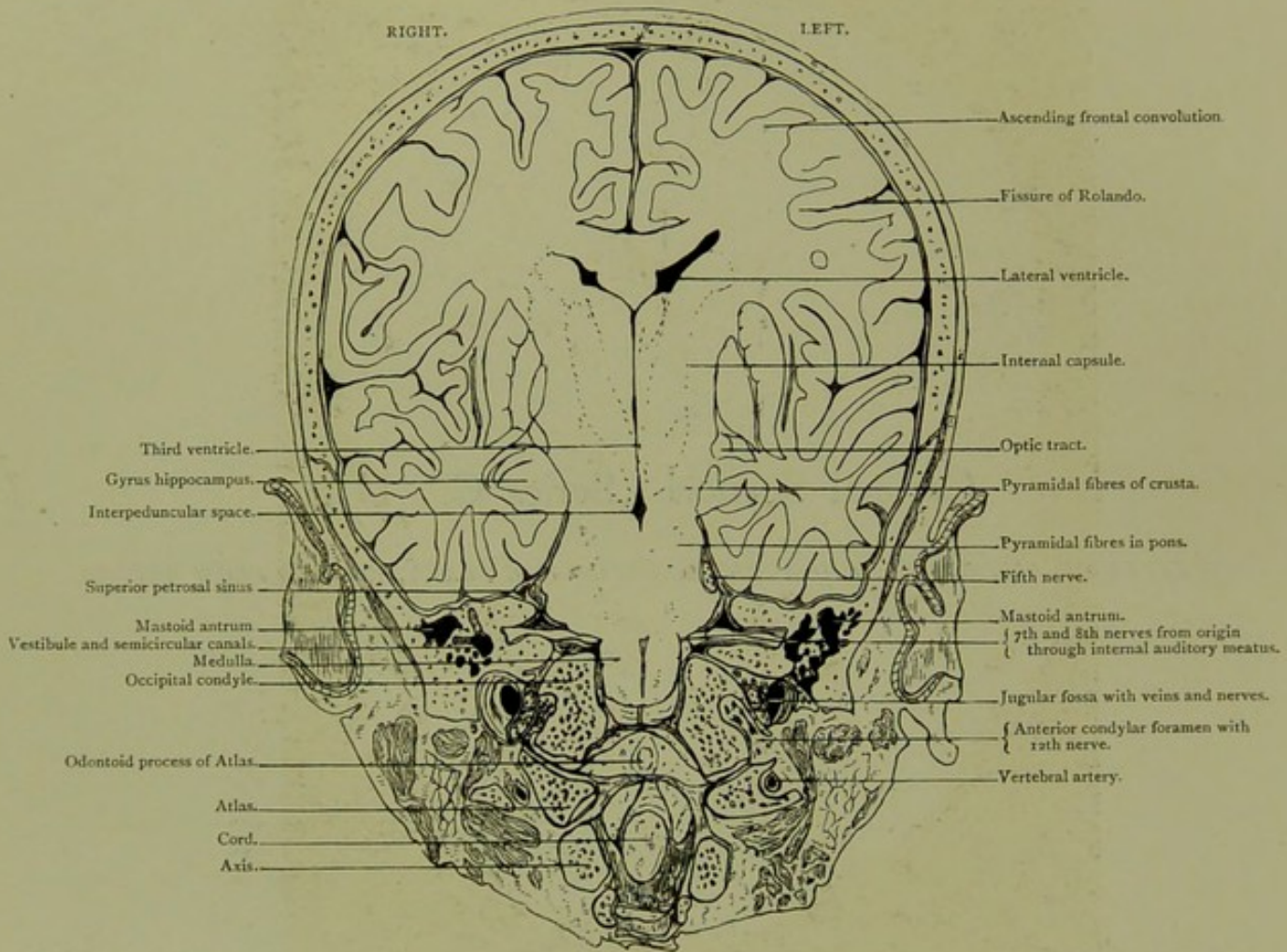


Coronal Section. Series C. III.

QUARTER OF AN INCH BEHIND AURICULO-BREGMATIC PLANE, VIEWED FROM BEFORE.

CORONAL SECTION.

Series C. III.

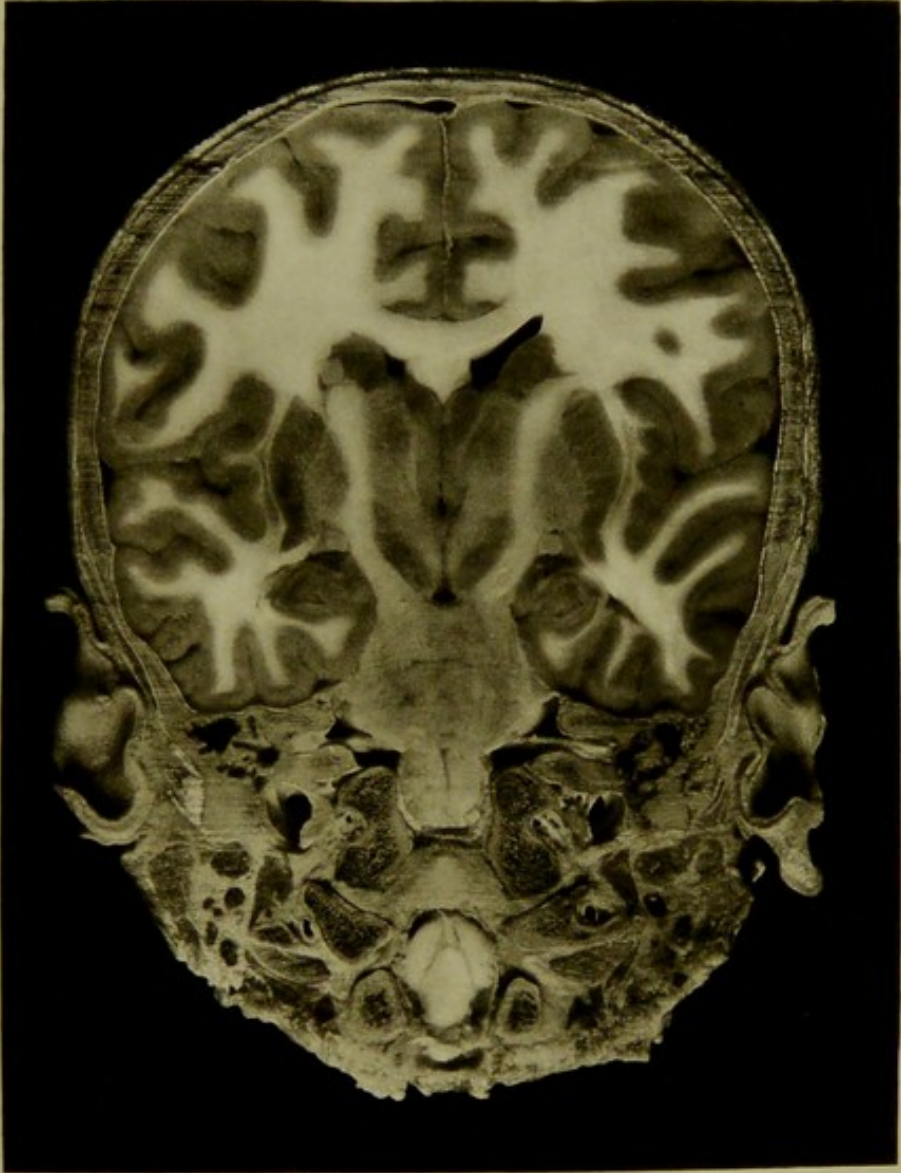



Male, 2½ years.

Scale $\frac{50}{68} = \frac{3}{4}$ Approx.

III. CORONAL SECTION, quarter of an inch behind auriculo-bregmatic plane viewed from before, passing through central convolutions, basal ganglia, lateral and third ventricles, pons, internal auditory meatus, labyrinth mastoid antrum, medulla, anterior condylar foramen and spinal cord. The course of motor strands from central convolutions can be traced down to medulla, and the origin and course of the seventh and eighth nerves are well shown.

PLATE NO 23



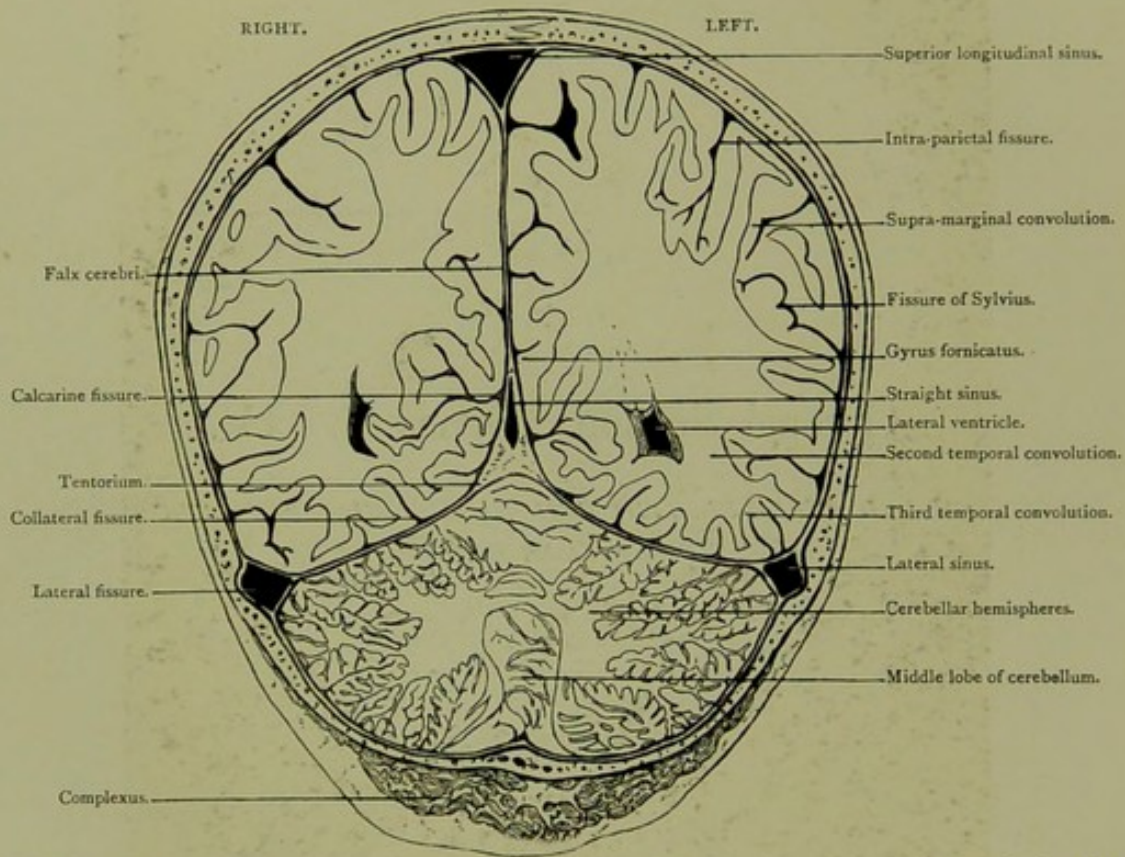


Coronal Section. Series C. IV.

*ONE INCH AND THREE-EIGHTHS BEHIND AURICULO-BREGMATIC PLANE,
VIEWED FROM BEFORE.*

CORONAL SECTION.

Series C. IV.

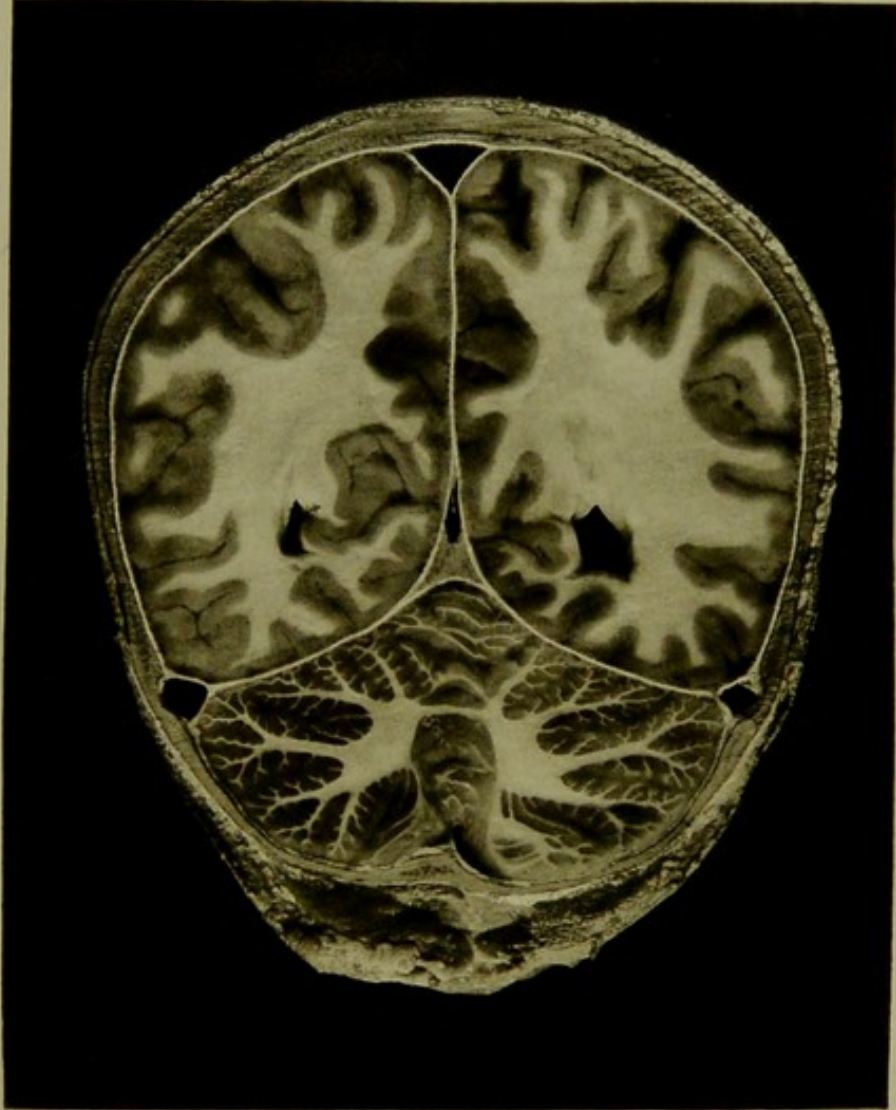



Male, 2½ years.

Scale $\frac{43}{60} = \frac{3}{4}$ Approx.


IV. CORONAL SECTION, one inch and three-eighths behind auriculo-bregmatic plane, viewed from before, passing through parietal and temporal lobes, lateral ventricles and cerebellum; showing posterior end of Sylvian fissure, calcarine fissure, and orifices of straight and lateral sinuses.

PLATE N° 24





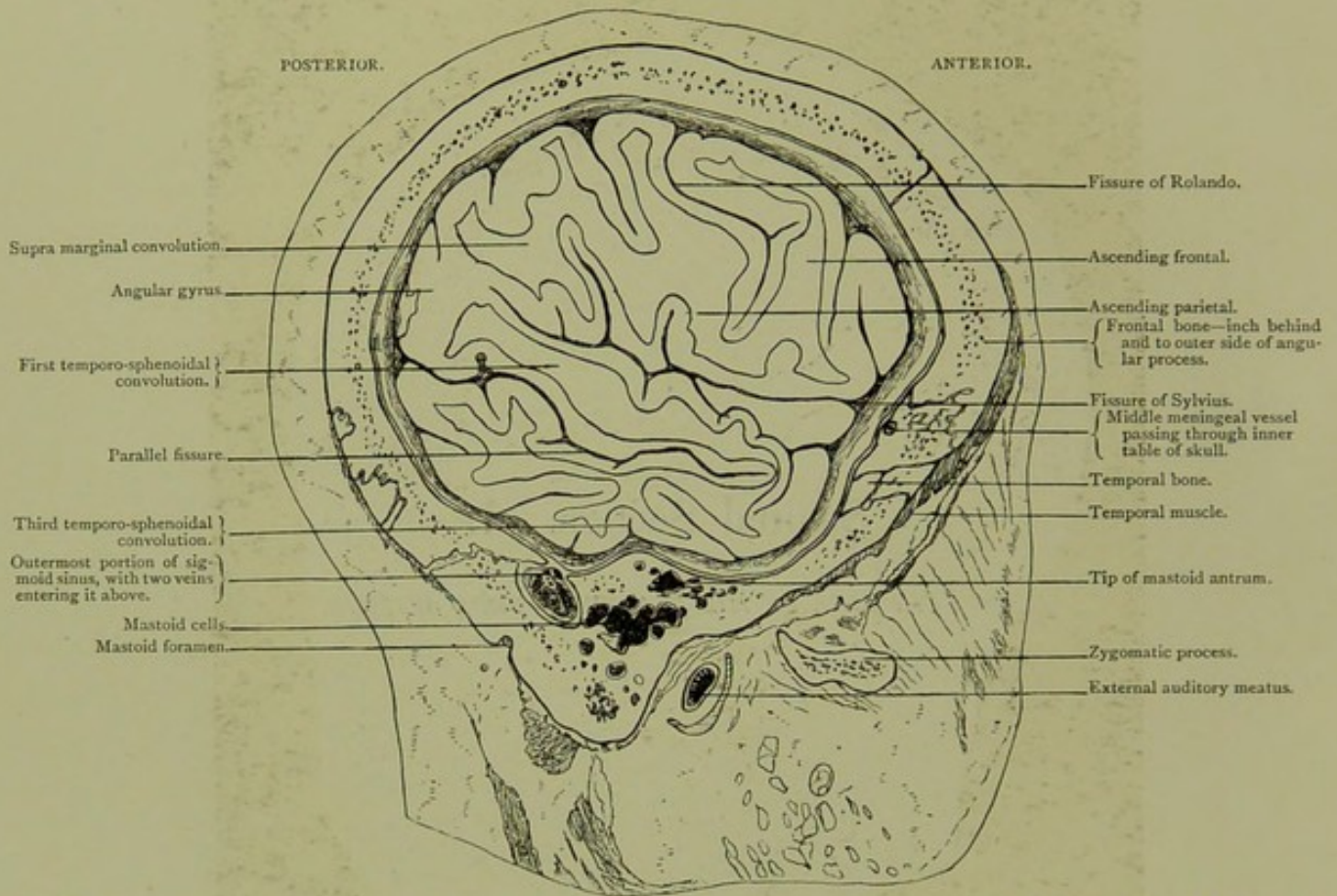
SAGITTAL SECTIONS.



Sagittal Section. I.

OF LEFT SIDE OF HEAD, VIEWED FROM WITHIN.

SAGITTAL SECTION. I.

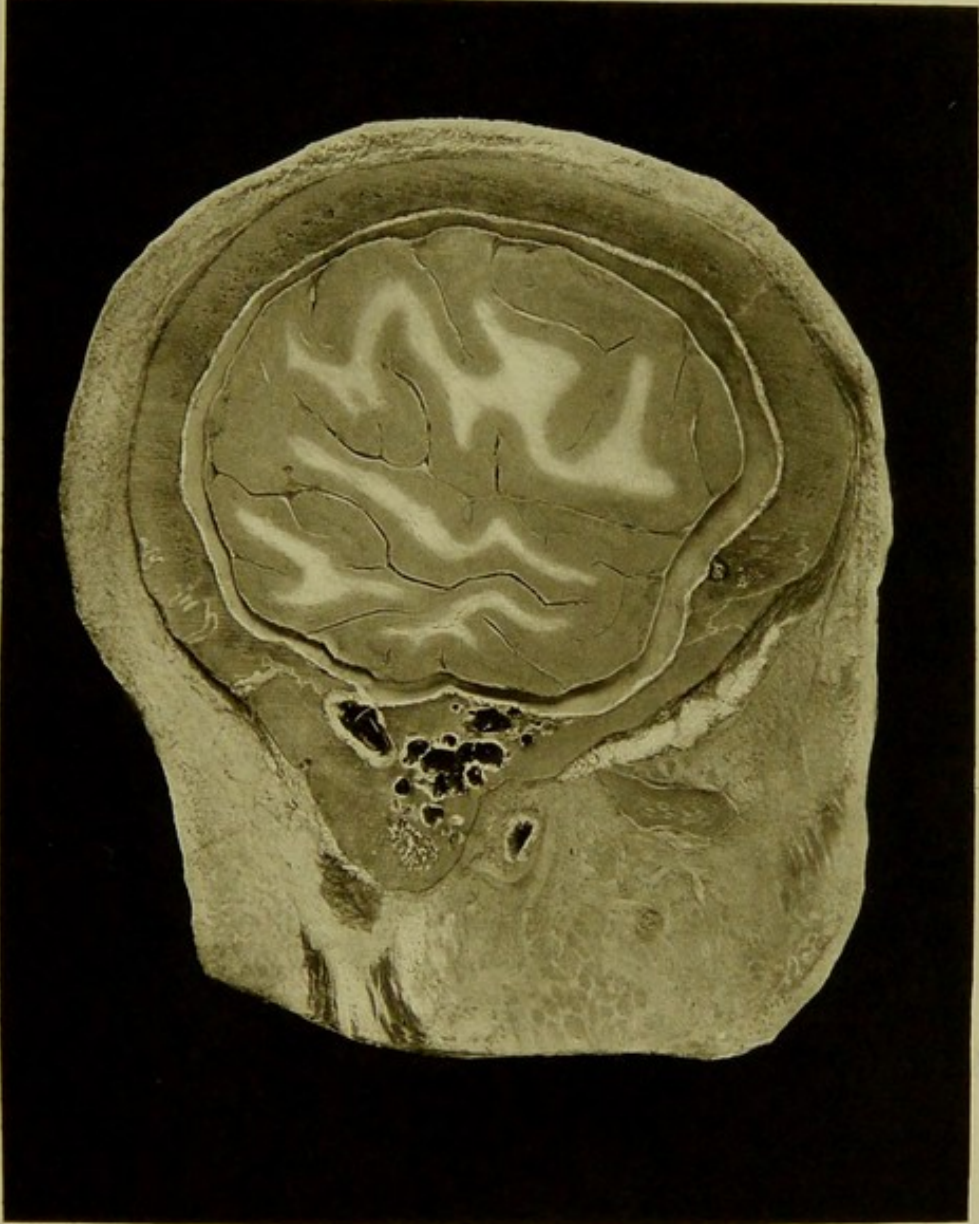



Male, 30 years.

Scale $\frac{23}{33} = \frac{1}{1.43}$ Approx.

I. SAGITTAL SECTION of left side of head, viewed from within, at level of outer aspect of mastoid cells, showing, the outermost knee of sigmoid sinus with two venous orifices at its upper part,—one passing backwards entering the mastoid foramen, the other passing forwards and upwards communicating with mastoid veins,—the mastoid antrum, a considerable portion of the temporo-sphenoidal lobe with the parallel fissure, the fissure of Sylvius and a portion of the frontal convolutions. The fissure of Rolando looks at first sight as if it were too far forward; this is due to the section excluding the greater part of the frontal convolutions.

PLATE N°25

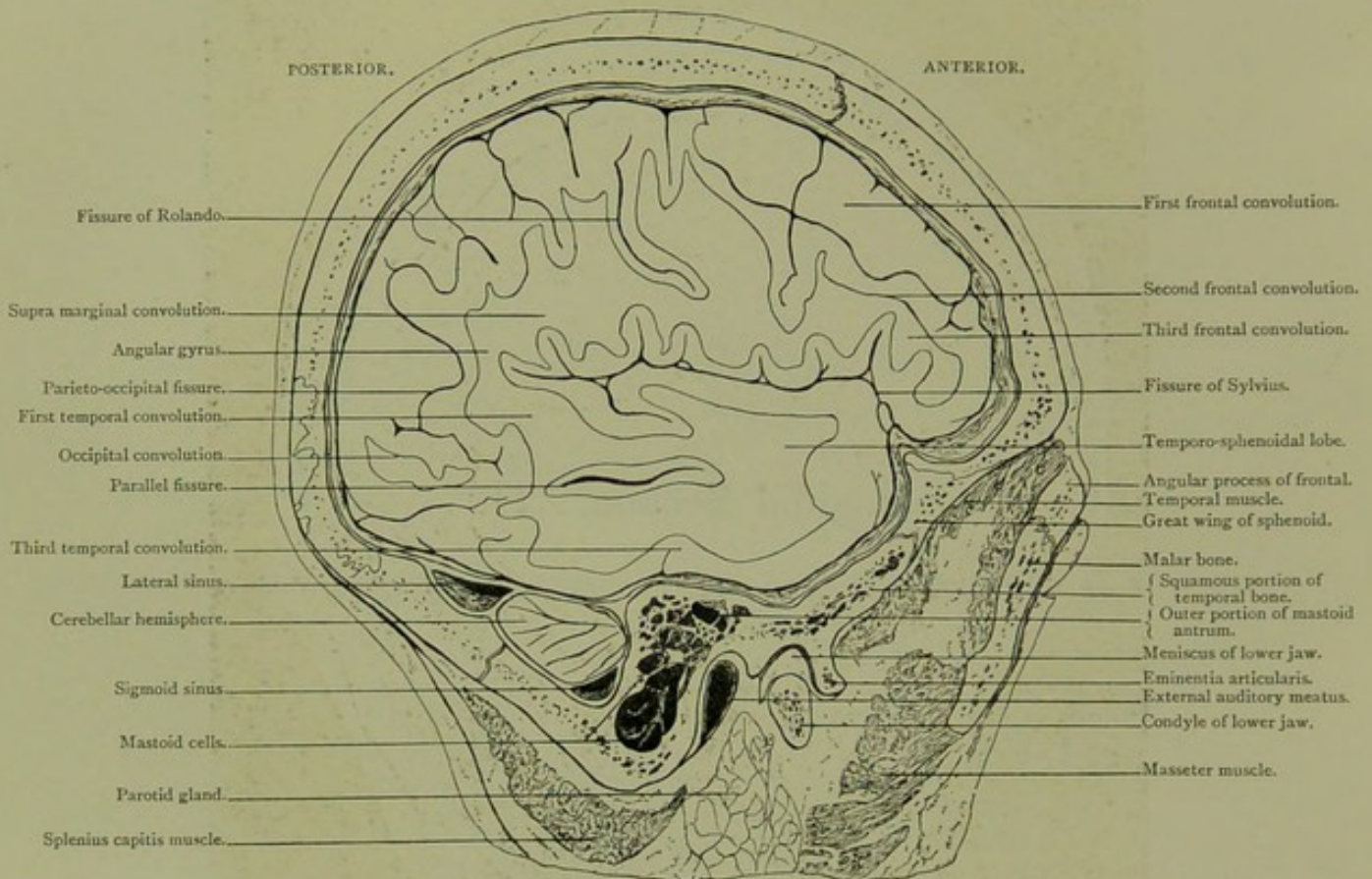




Sagittal Section. II.

*OF LEFT SIDE OF HEAD, VIEWED FROM WITHIN, THREE-EIGHTHS OF AN INCH INTERNAL
TO SECTION I.*

SAGITTAL SECTION. II.

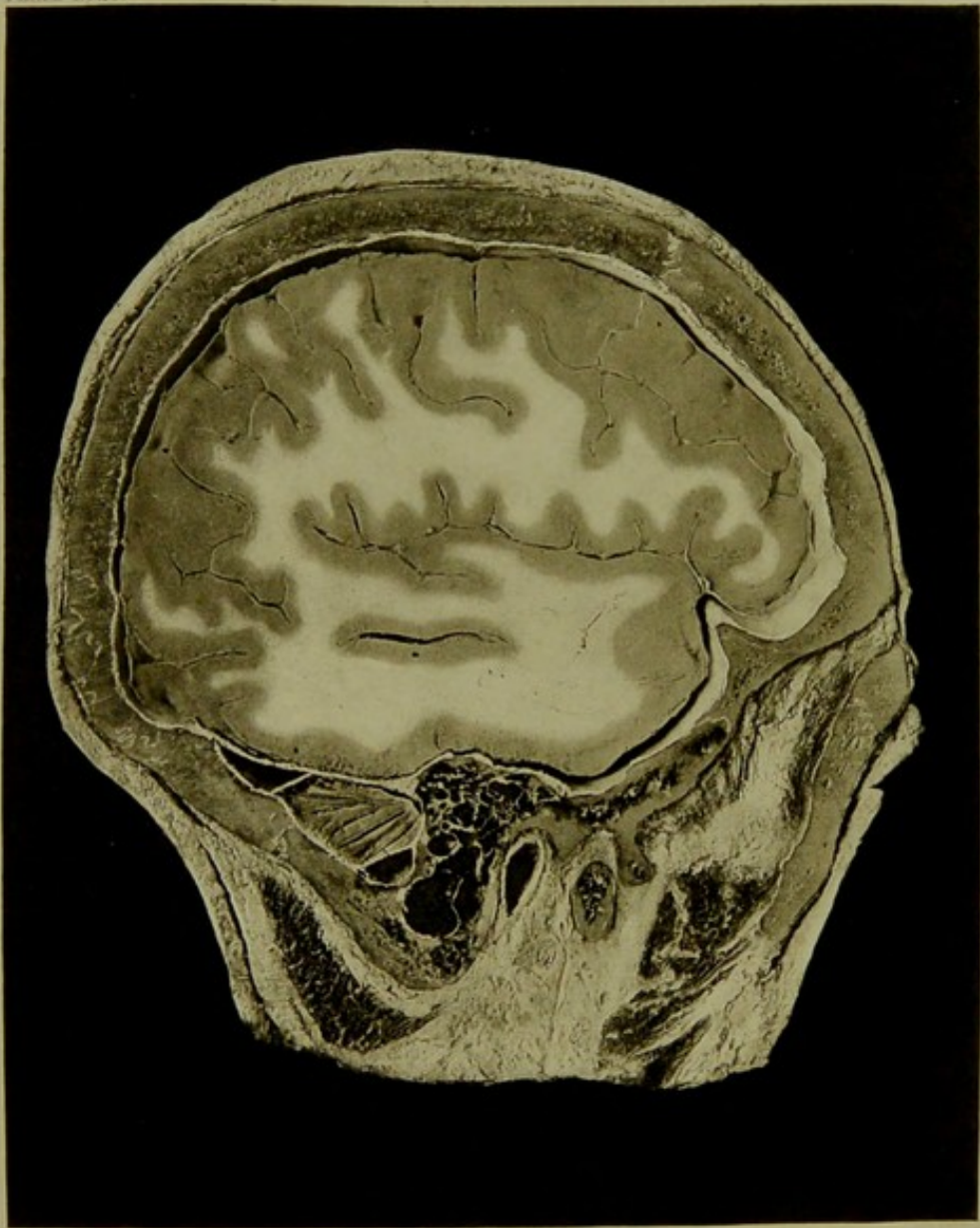


Male, 30 years.

Scale $\frac{23}{54} = \frac{2}{3}$ Approx.

II. SAGITTAL SECTION of left side of head viewed from within, three-eighths of an inch internal to section I. passing through external angular process of frontal, eminentia articularis, condyle of lower jaw, mastoid process and squamous of temporal, showing frontal, central and temporal convolutions, angular gyrus, Sylvian, parallel, Rolandic, and parieto-occipital fissures, small part of cerebellar hemisphere, mastoid antrum and cells, external auditory meatus and temporal fossa.

PLATE No 26

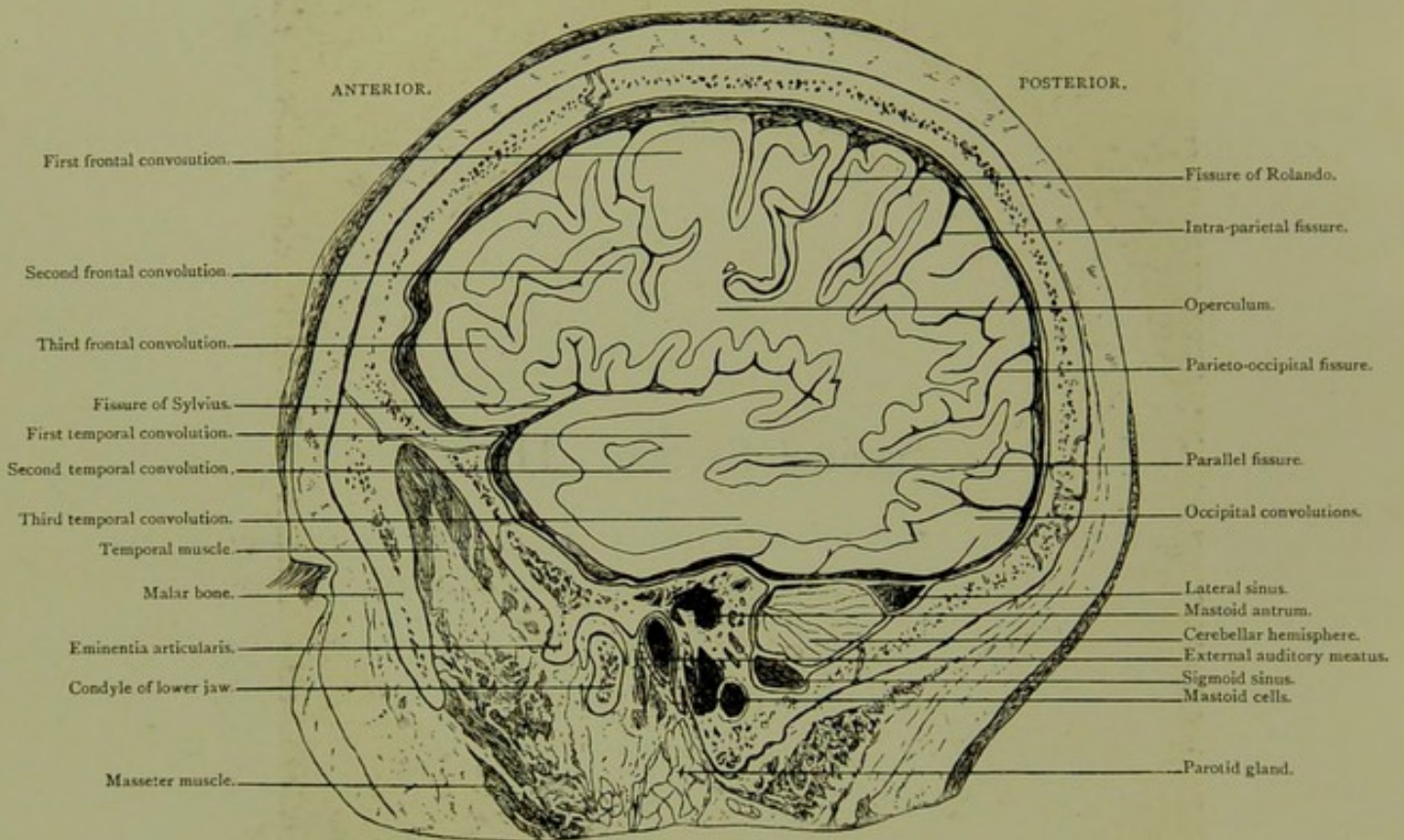




Sagittal Section. III.

*OF LEFT SIDE OF HEAD, VIEWED FROM WITHOUT, ONE-EIGHTH OF AN INCH NEARER
THE MIDDLE LINE THAN PRECEDING SECTION.*

SAGITTAL SECTION. III.

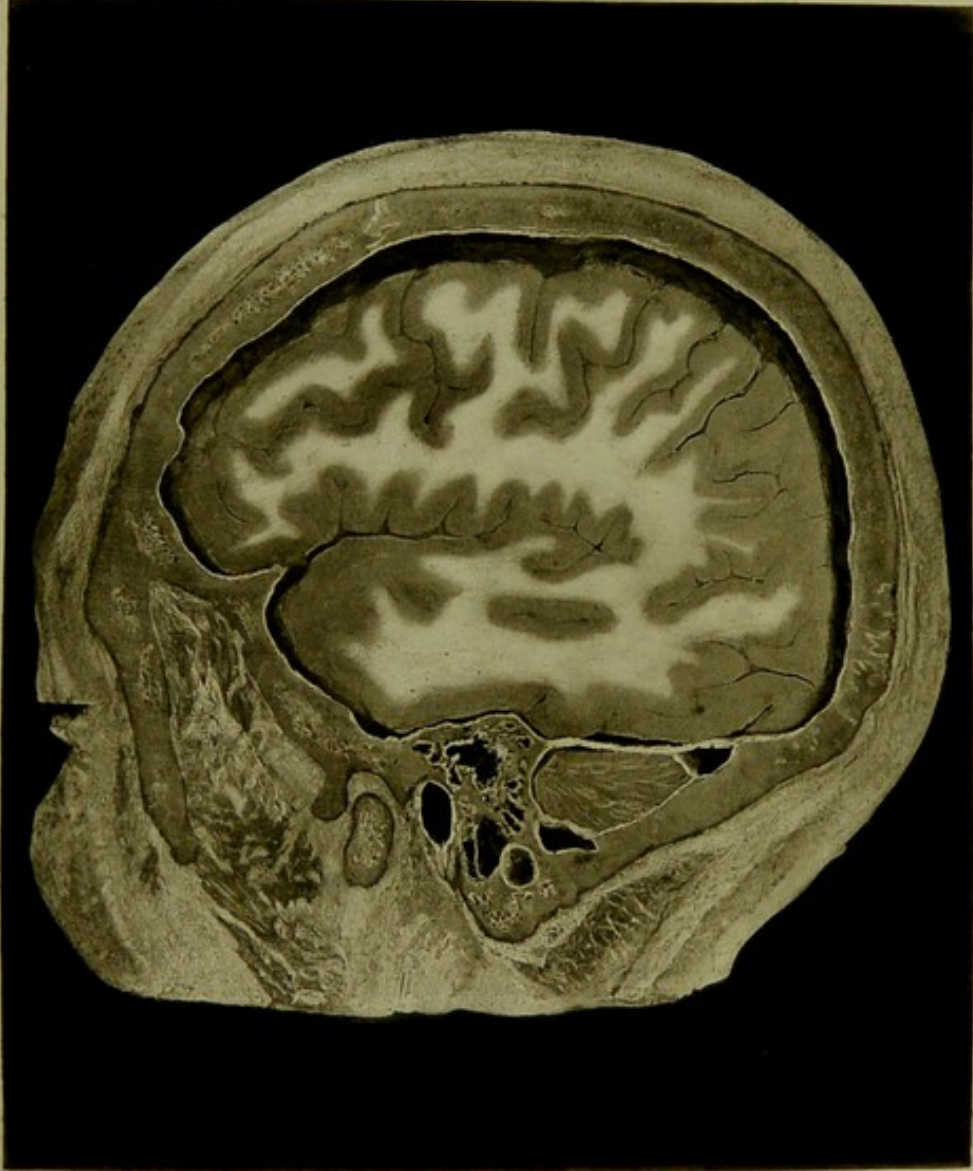



Male, 30 years.

Scale $\frac{27}{42} = \frac{2}{3}$ Approx.

III. SAGITTAL SECTION of left side of head, viewed from without one-eighth of an inch nearer the middle line than preceding section, showing the hard parts the same as in last section, mastoid antrum being more fully exposed, and seen situated on the same plane as the outer limit of the external osseous auditory meatus. The mastoid cells are somewhat reduced in bulk, and the various lobes of the brain more fully exposed.

PLATE N° 27.

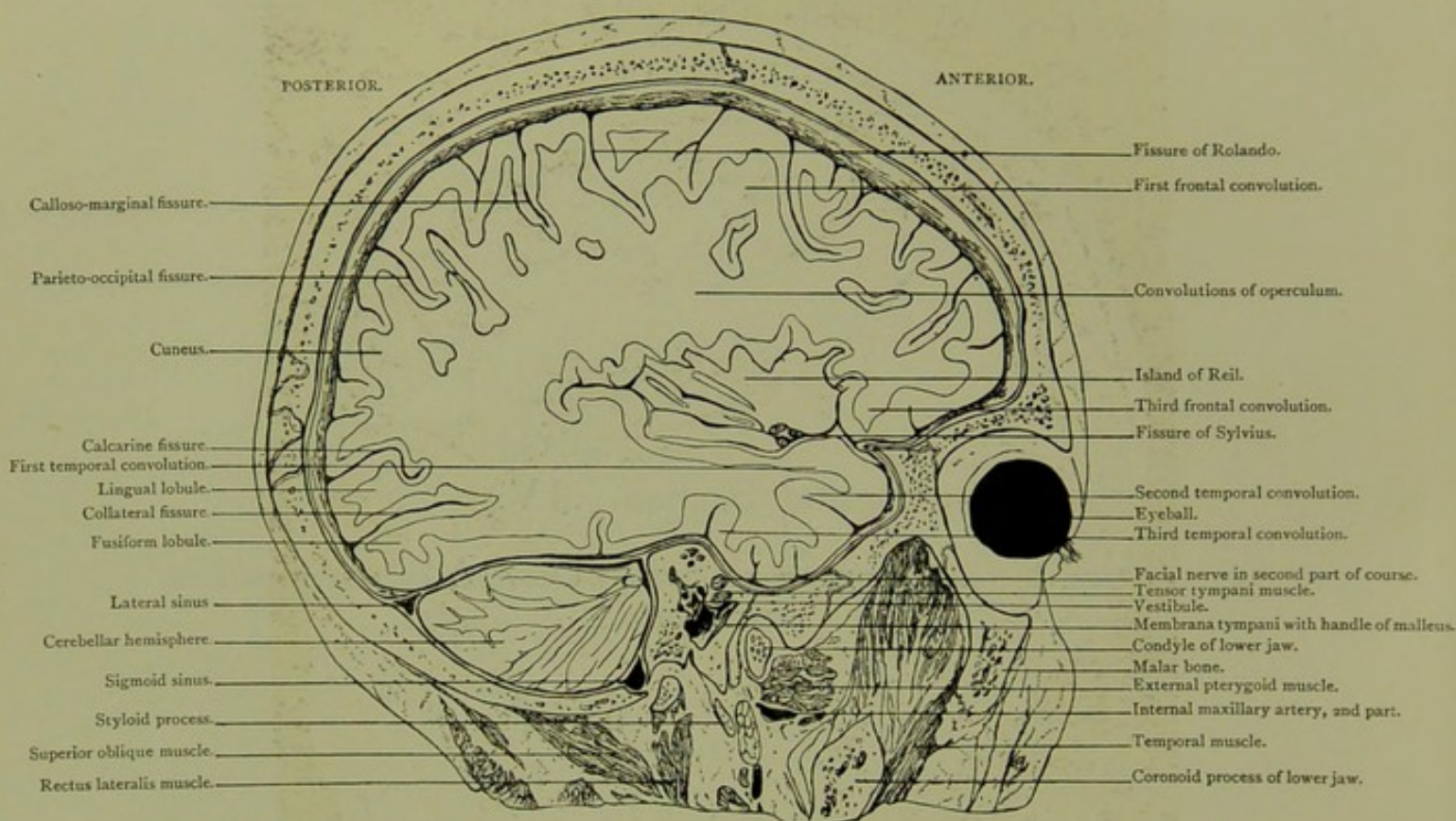




Sagittal Section. IV.

*OF LEFT SIDE OF HEAD, VIEWED FROM WITHIN, ONE-HALF INCH INTERNAL TO
SECTION III.*

SAGITTAL SECTION. IV.

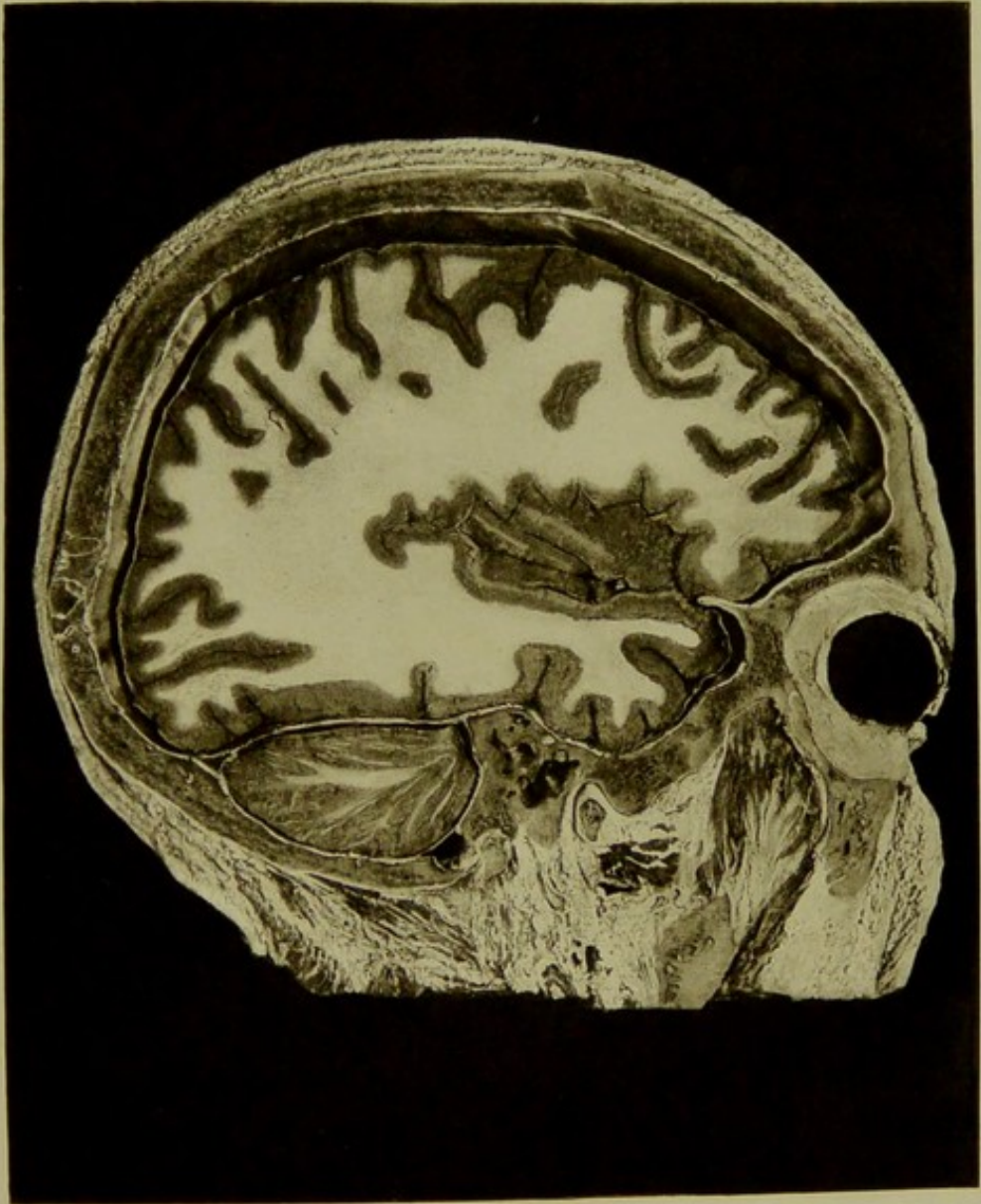


Male, 30 years.

Scale $\frac{27}{42} = \frac{13}{21}$ Approx.

IV. SAGITTAL SECTION of left side of head viewed from within one-half inch internal to section III., passing through outer third of orbit, inner end of condyle, and coronoid process of lower jaw, middle and internal ear. The frontal, central, parietal, occipital and temporal convolutions, the operculum, island of Reil and cerebellar hemisphere are shown, with outer third of eyeball, tympanum with malleus and membrane in situ, vestibule, tensor tympani muscle, and second intra-petrous part of facial nerve. In the specimen, the chorda tympani nerve traversing the tympanum, and the stapes in fenestra ovalis are seen.

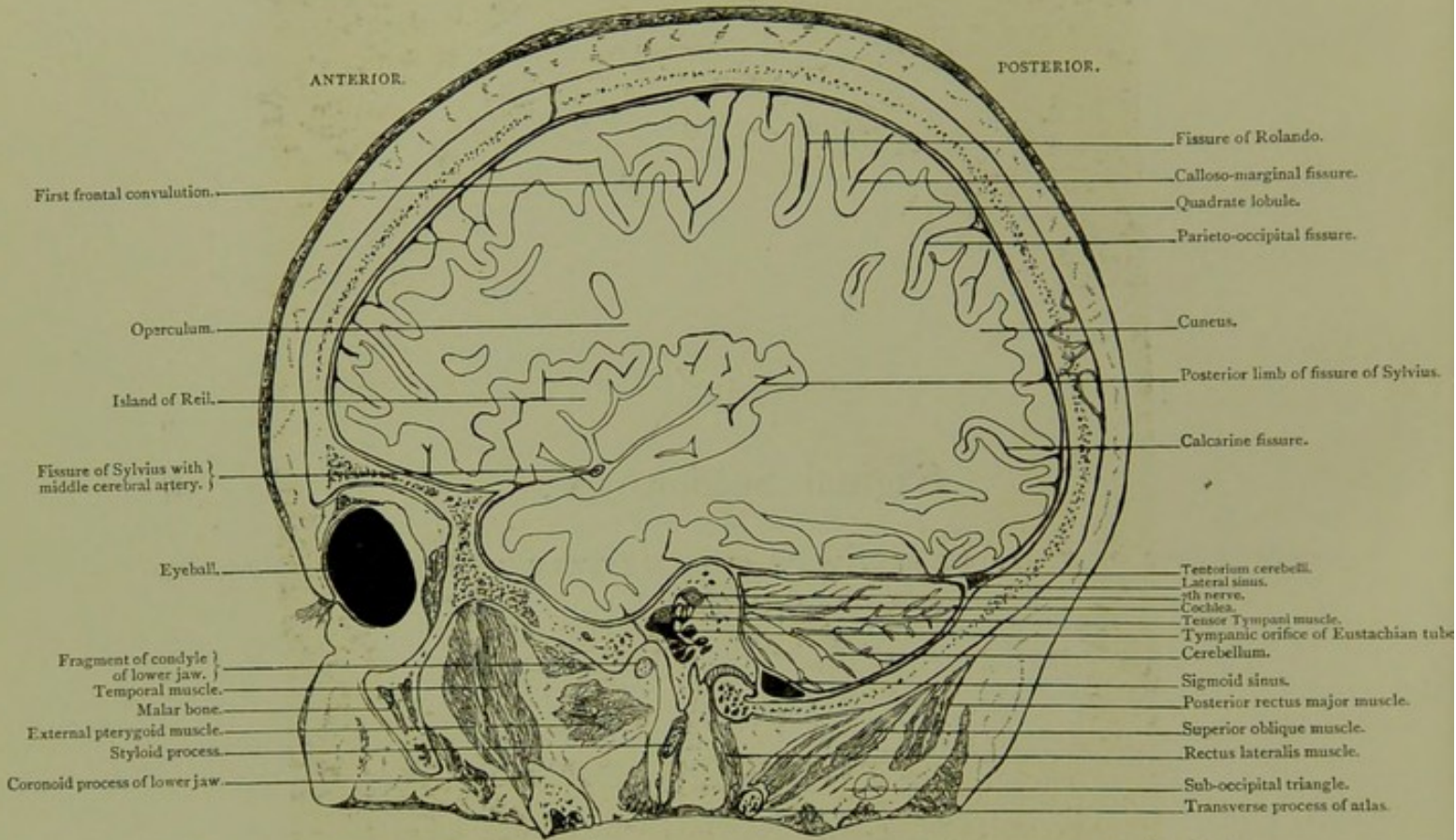
PLATE 1128



Sagittal Section. V.

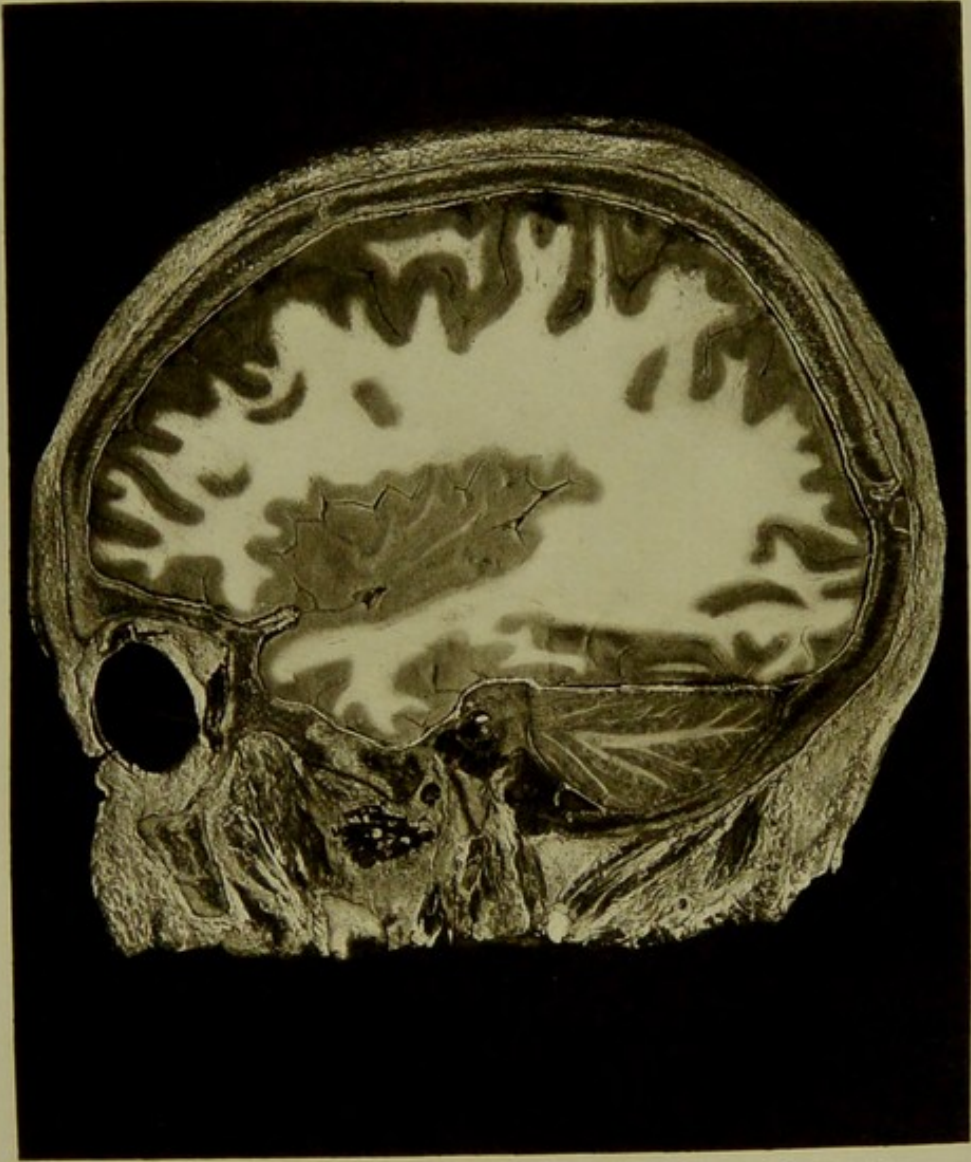
*OF LEFT SIDE OF HEAD, ONE-EIGHTH OF AN INCH INTERNAL TO SECTION IV., VIEWED
FROM WITHOUT.*

SAGITTAL SECTION. V.



Male, 30 years.

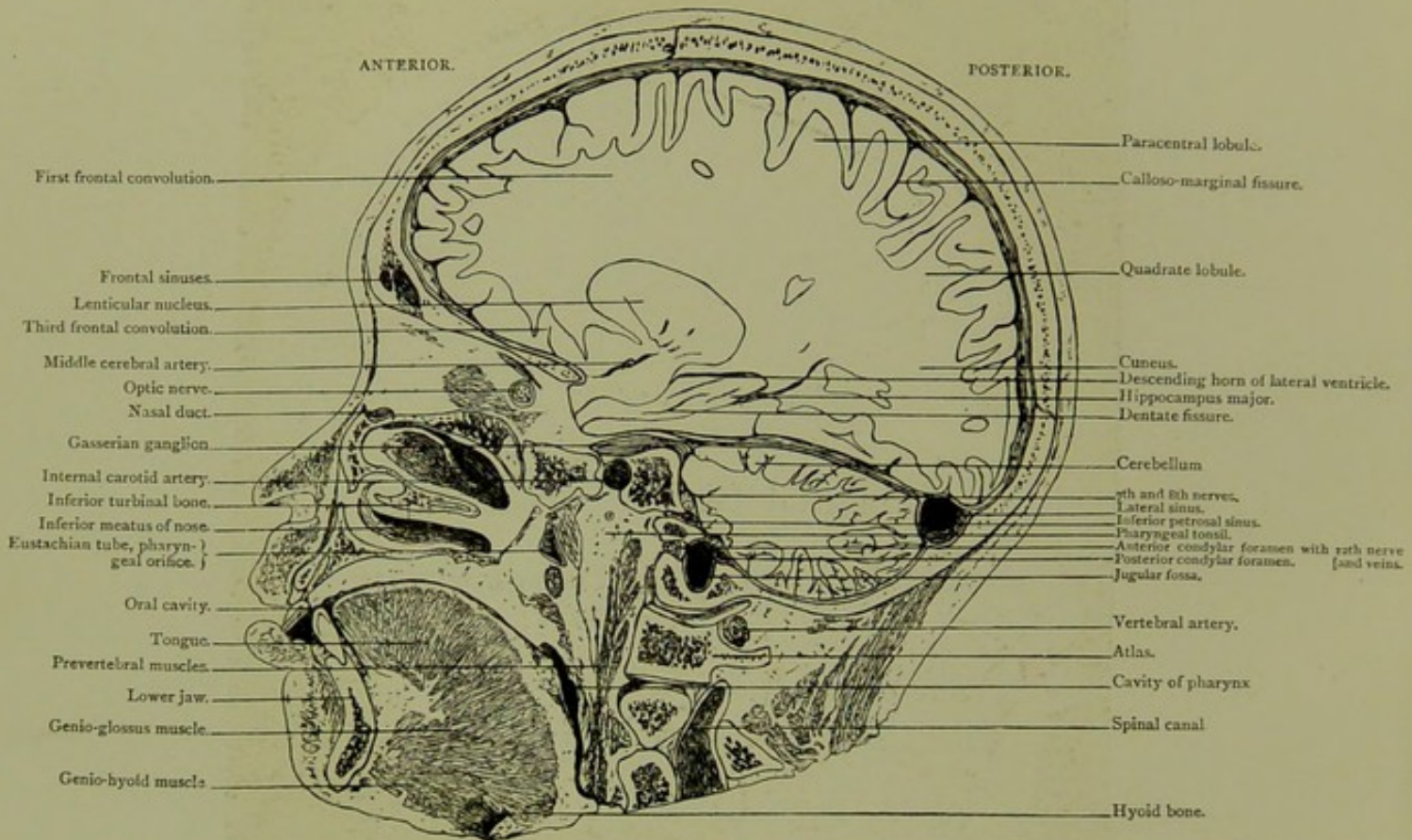
V. SAGITTAL SECTION of left side of head one-eighth of an inch internal to section IV., viewed from without, passing through outer half of orbit, malar bone, coronoid process, and inmost tip of condyle of lower jaw, styloid process and outer border of occipital condyle, showing eyeball with ocular muscles, temporal fossa, tympanic orifice of Eustachian tube, tensor tympani muscle, cochlea and facial nerve, upper portion of fissure of Rolando, operculum, island of Reil, portions of fissure of Sylvius, frontal, parietal, occipital and temporal lobes.



Sagittal Section. VI.

OF RIGHT SIDE OF HEAD, VIEWED FROM WITHIN.

SAGITTAL SECTION. VI.

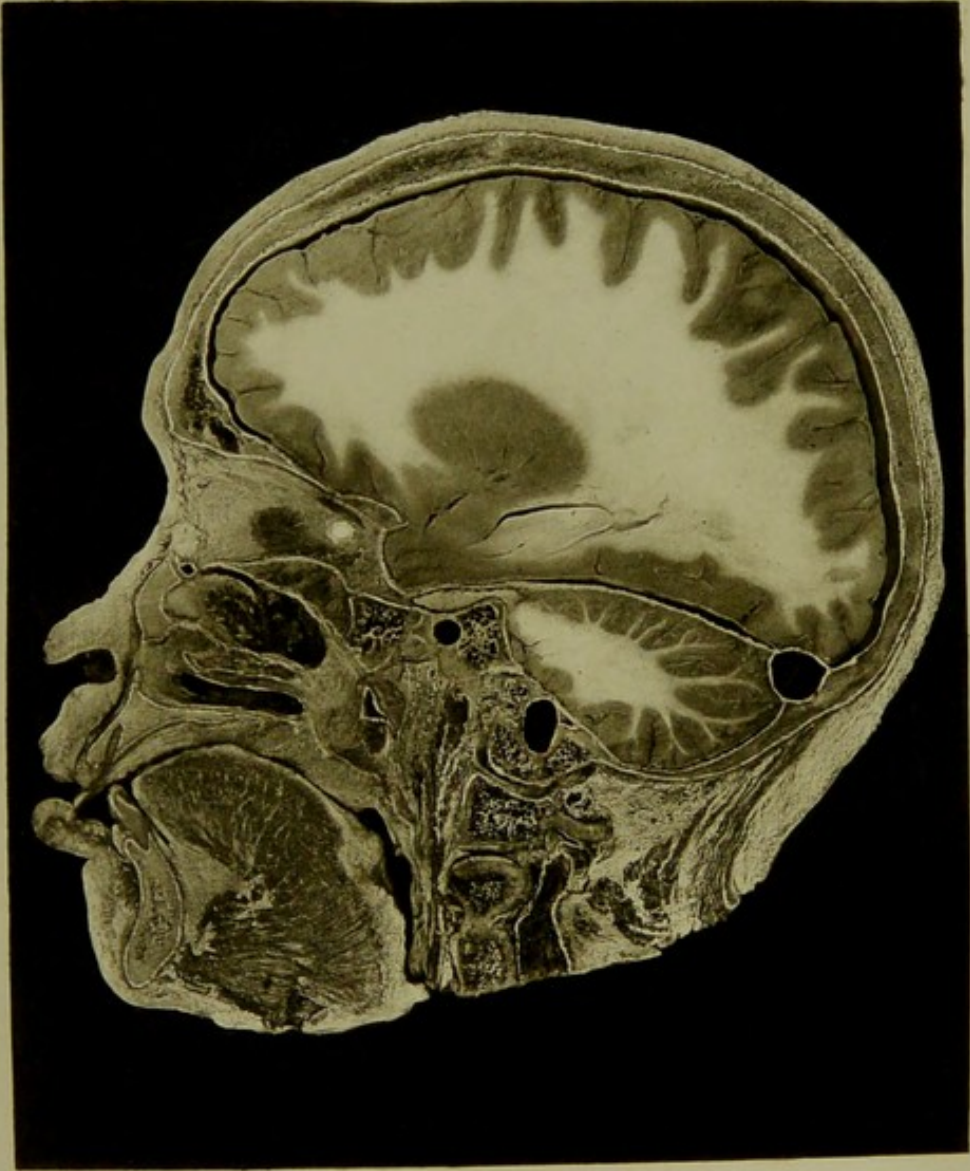

Male, 30 years.

Scale $\frac{97}{51} = \frac{1}{2}$ Approx.

VI. SAGITTAL SECTION of right side of head viewed from within, passing through, the jaws just internal to canine teeth, nasal bone and duct, inner portion of orbital cavity, occipital condyle and articular mass of atlas, showing lateral sinus, portion of jugular fossa, anterior and posterior condylar foramina, inferior petrosal sinus, vertebral artery with venous plexus, internal carotid artery, Gasserian ganglion in Meckel's space, and the relation of these to the cerebrum, cerebellum, Eustachian tube and pharyngeal tonsil. The lenticular nucleus, descending horn of lateral ventricle and spinal canal are seen.

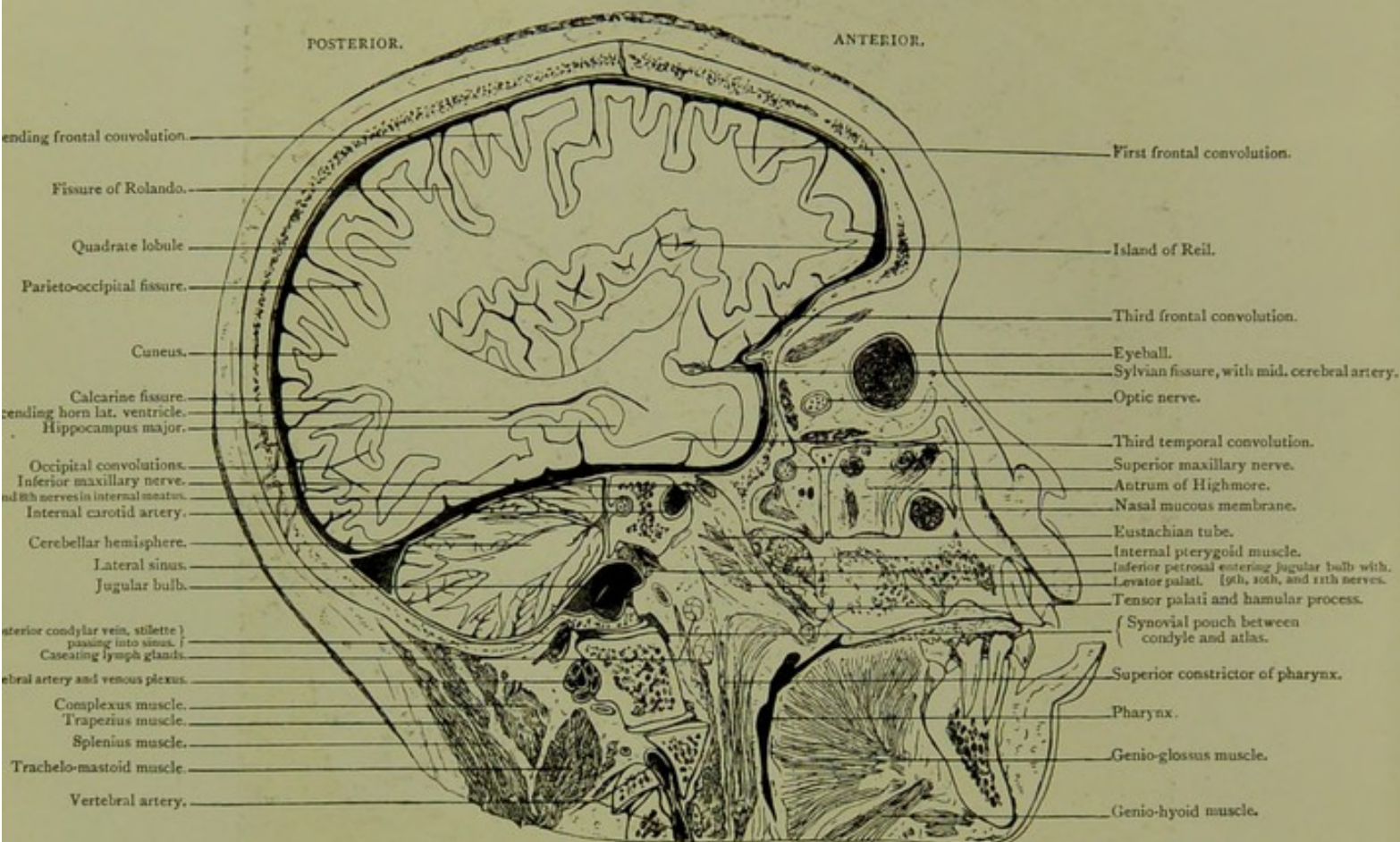
PLATE N°30.



Sagittal Section. VII.

*OF RIGHT SIDE OF HEAD, THREE-EIGHTHS OF AN INCH EXTERNAL TO SECTION VI,
VIEWED FROM WITHOUT.*

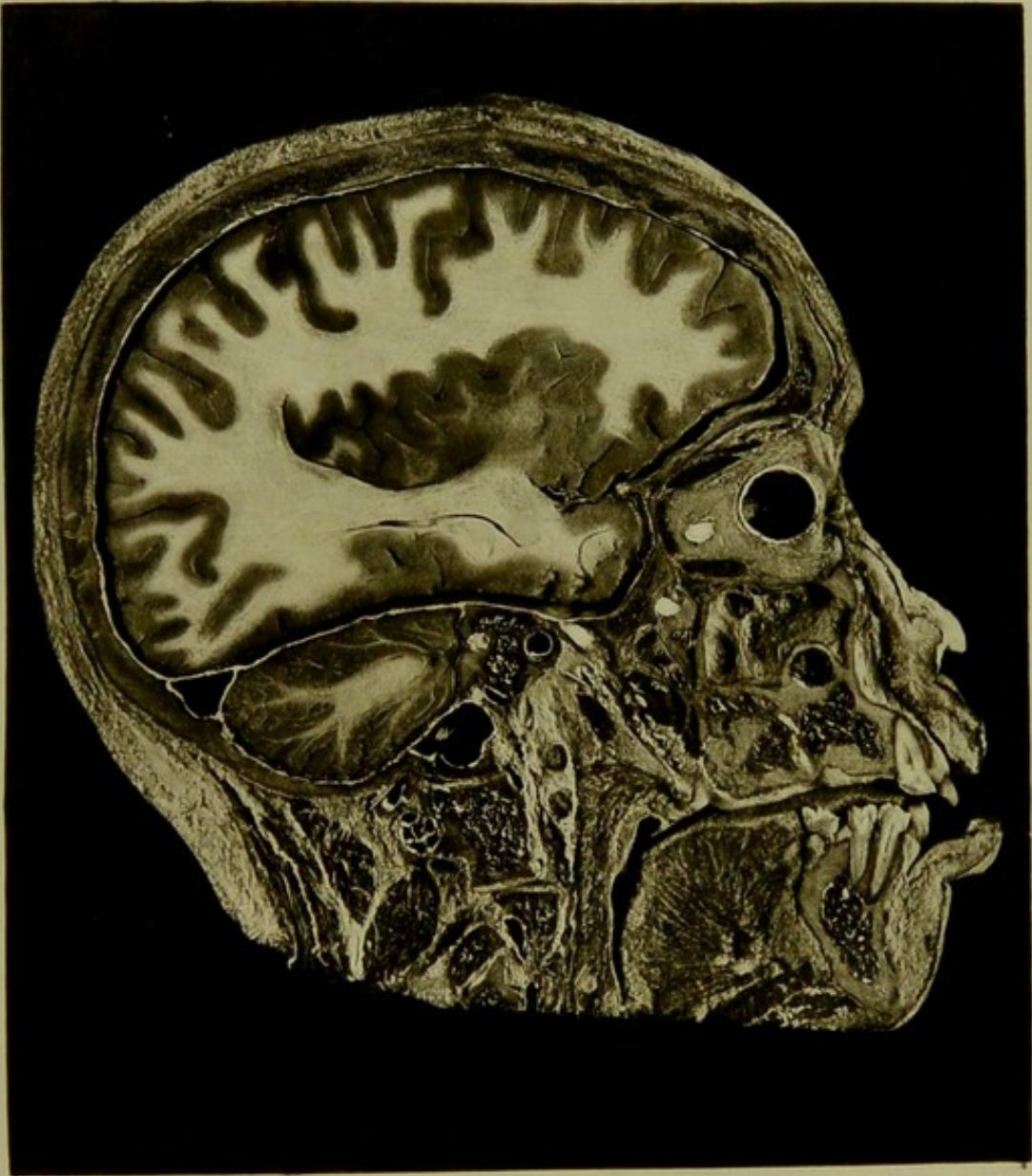
SAGITTAL SECTION. VII.



Male, 30 years.

Scale $\frac{29}{51} = \frac{1}{2}$ Approx.

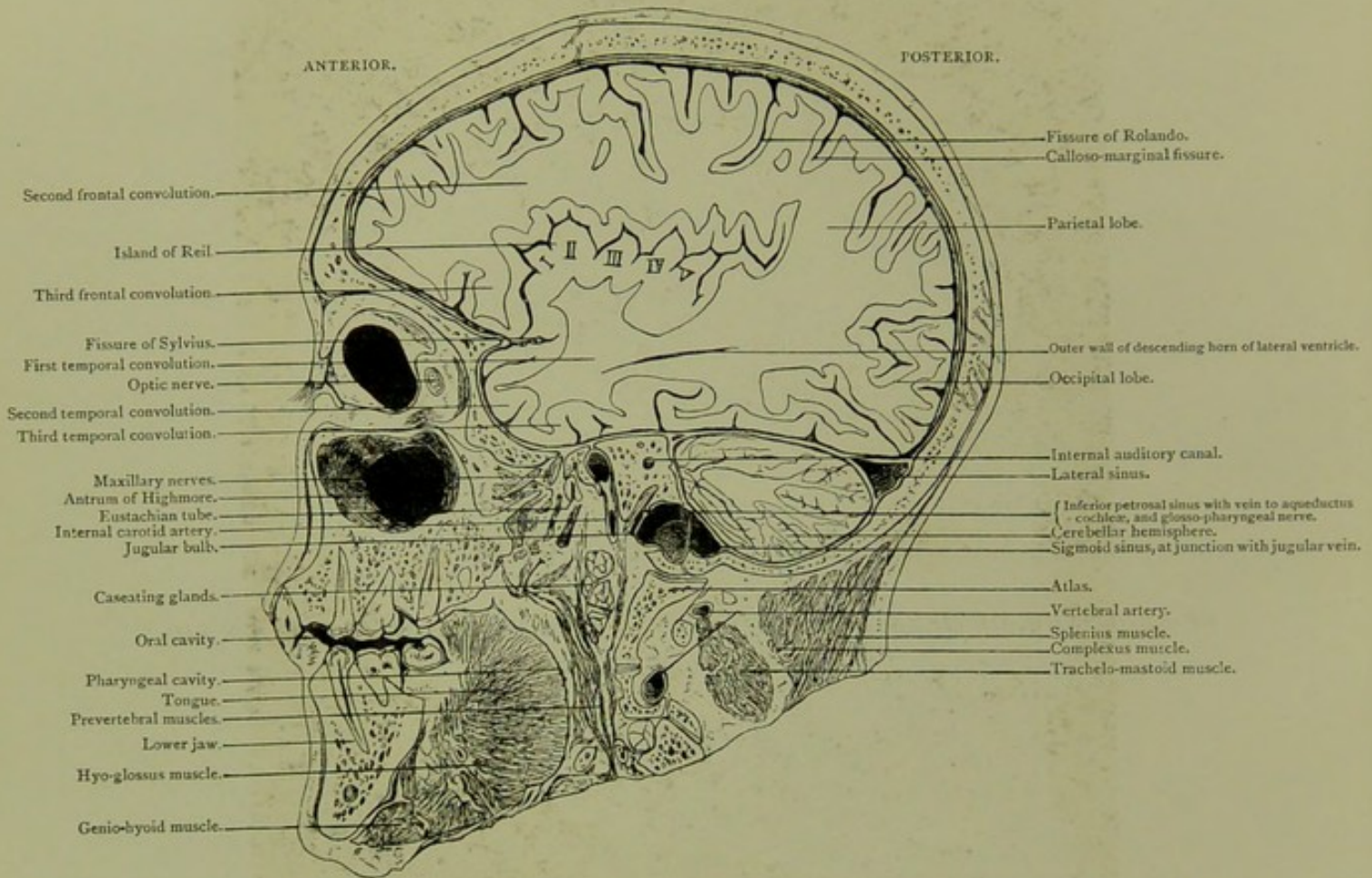
VII. SAGITTAL SECTION of right side of head three-eighths of an inch external to section VI. viewed from without, passing through the jaws in plane of first molars, inner limit of antrum of Highmore, pterygo-maxillary fossa, outer parts of occipital condyle and lateral mass of atlas, showing inner segment of eyeball, frontal, parietal, occipital and temporal lobes, island of Reil, descending horn of ventricle, cerebellar hemisphere, internal carotid artery in petrous bone, jugular fossa with entering nerves and veins, vertebral artery and posterior condylar foramen with its vein, which can be traced from without to junction of sigmoid sinus and jugular fossa.



Sagittal Section. VIII.

*OF RIGHT SIDE OF HEAD, ONE-EIGHTH OF AN INCH EXTERNAL TO SECTION VII,
VIEWED FROM WITHIN.*

SAGITTAL SECTION. VIII.

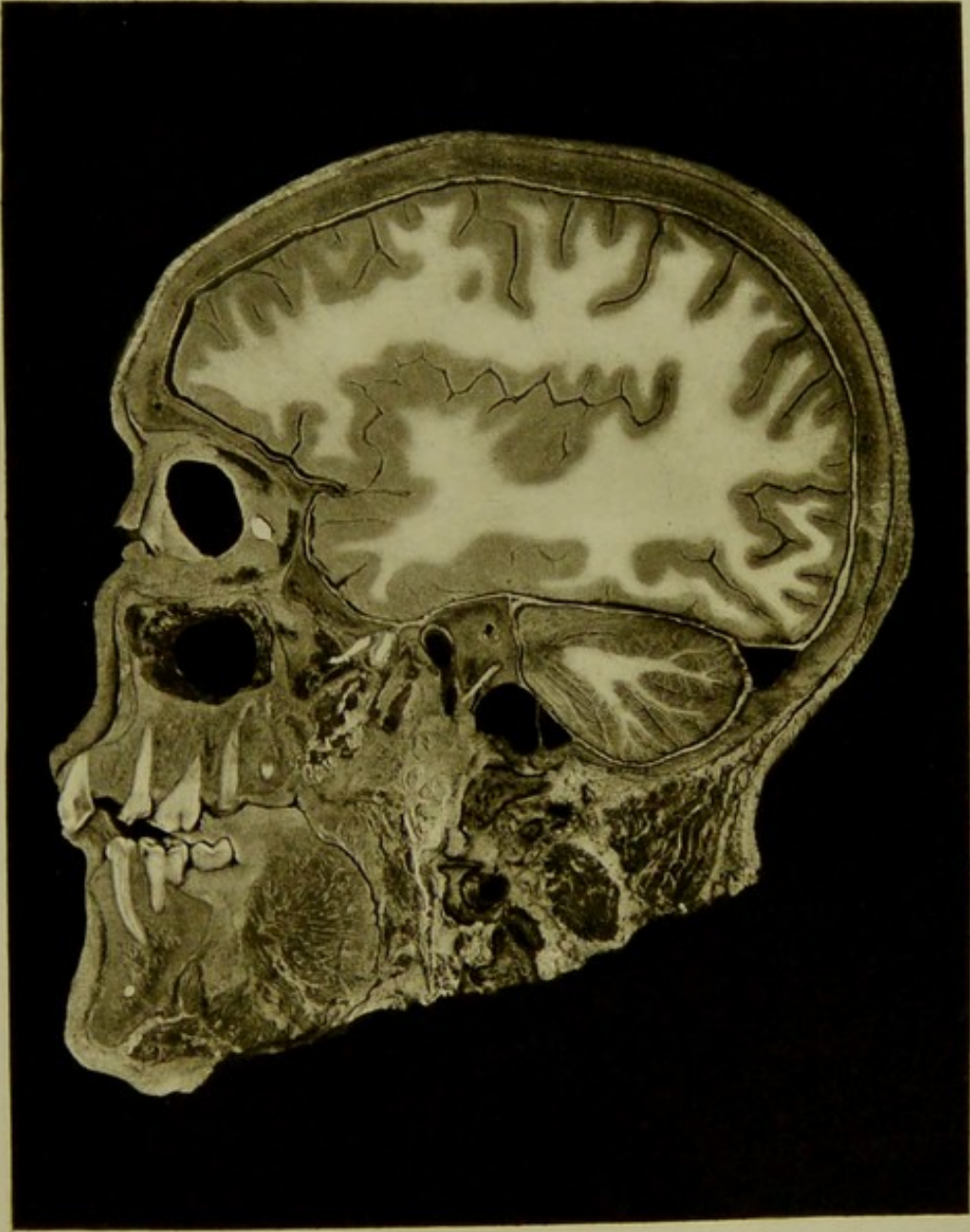



Male, 30 years.

Scale $\frac{29}{48} = \frac{5}{8}$ Approx.

VIII. SAGITTAL SECTION of right side of head one-eighth of an inch external to section VII. viewed from within—passing through, jaws inside plane of molar teeth, middle of antrum of Highmore, sphenomaxillary fissure and pterygo-maxillary fossa, occipital condyle and lateral mass of atlas,—showing portion of inner half of eyeball in orbit, frontal, parietal, occipital, and temporal lobes, island of Reil, descending horn of lateral ventricle and cerebellar hemisphere, ascending intra-petrous part of internal carotid artery, internal auditory meatus, with seventh and eighth nerves, inferior petrosal sinus with ninth nerve and vein to aqueductus cochleæ. The acute curve at the junction of the sigmoid sinus, and the jugular bulb is well seen in specimen.

PLATE N° 32.

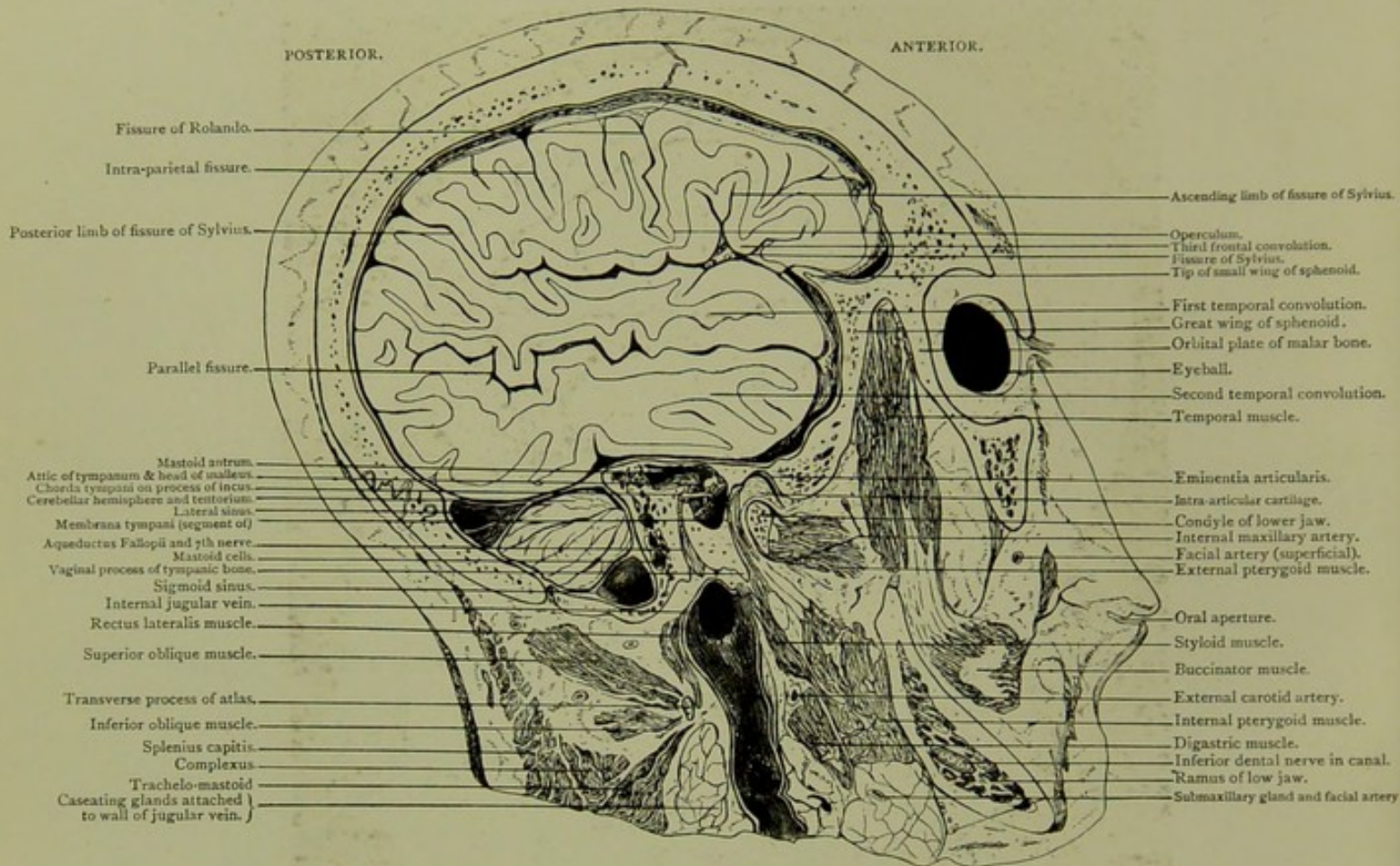




Sagittal Section. IX.

*OF RIGHT SIDE OF HEAD, ONE INCH EXTERNAL TO SECTION VIII, VIEWED FROM
WITHOUT.*

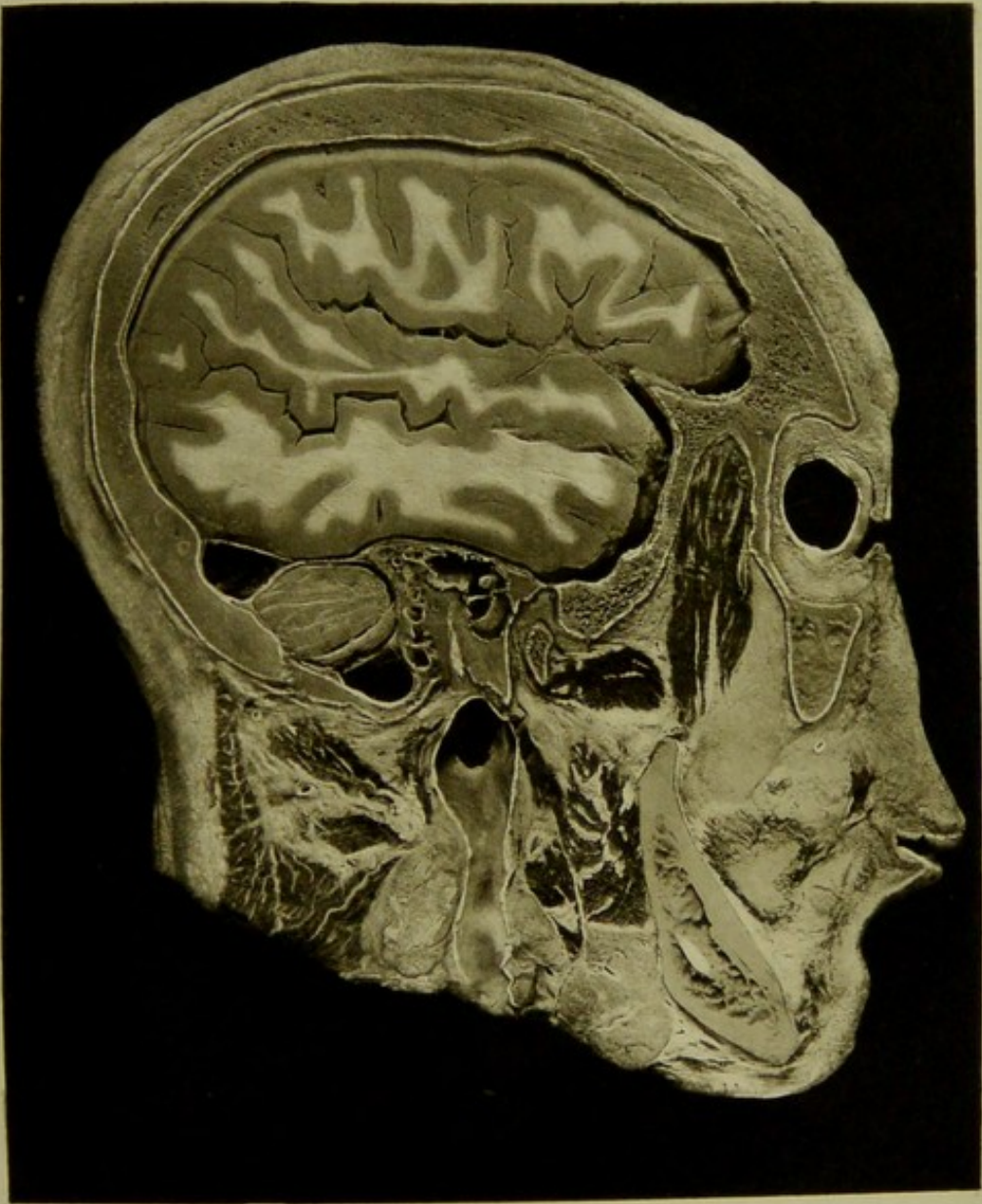
SAGITTAL SECTION. IX.



Male, 30 years.

Scale $\frac{32}{48} = \frac{2}{3}$.

IX. SAGITTAL SECTION of right side of head, one inch external to section VIII., viewed from without,—passing through, the orbit external to spheno-maxillary fissure, ramus body and condyle of lower jaw, and tip of transverse process of atlas,—showing frontal, parietal, and especially temporo-sphenoidal lobes and portion of cerebellum. The mastoid antrum, which is fully exposed, is seen separated from the temporal lobe by the thin tegmen tympani, and its relations to the tympanum and descending and oblique portions of aqueduct of Fallopius are well seen. At its junction with the tympanic attic, the aqueduct of Fallopius arches across from without inwards and forwards. The chorda tympani nerve traversing the tympanum between the process of incus and handle of malleus, which is still attached to the membrana, is exposed. The internal jugular vein, with its relations to muscles and bones, and in this instance to caseating glands, is observed in the section.

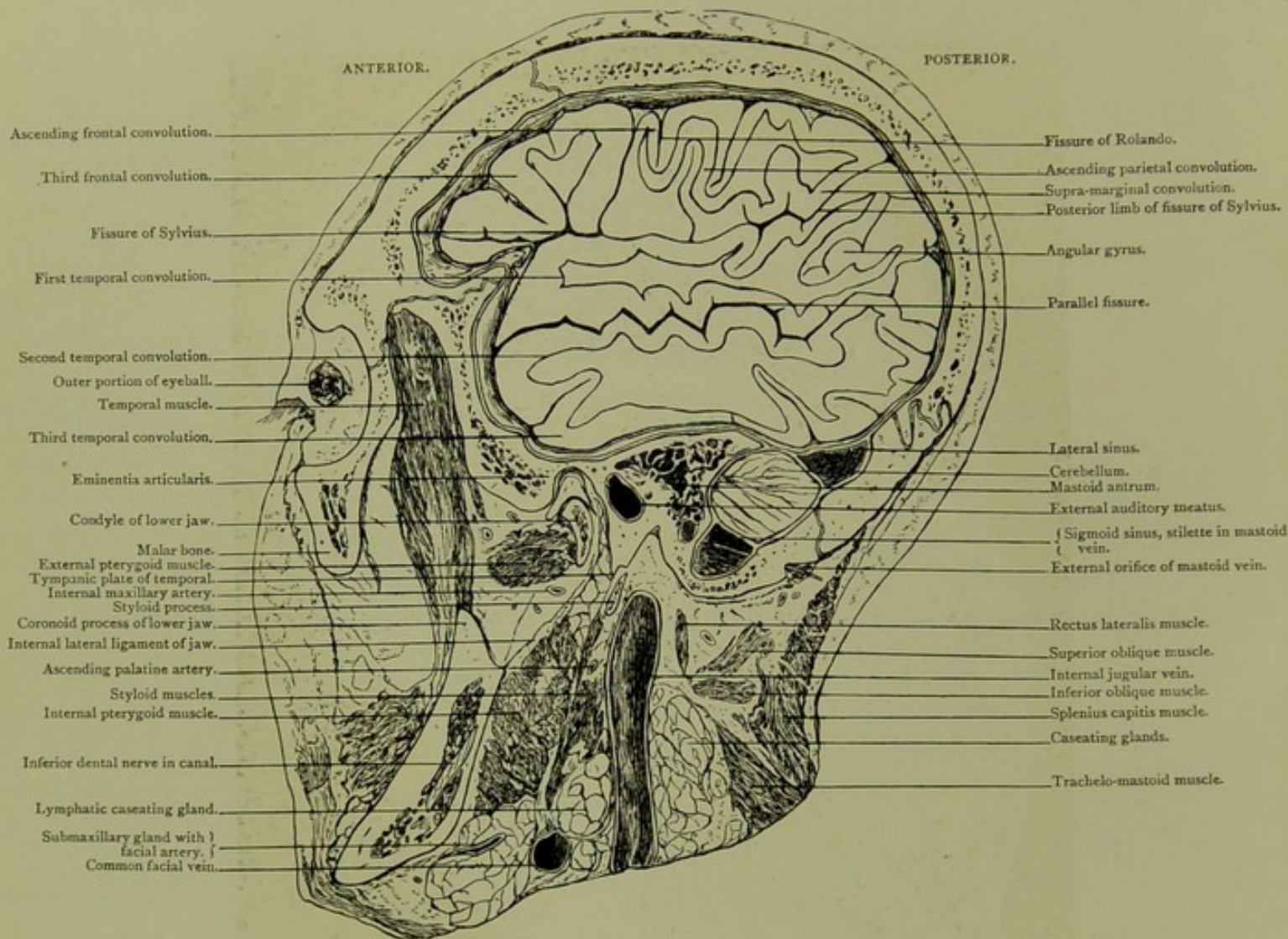




Sagittal Section. X.

*OF RIGHT SIDE OF HEAD, VIEWED FROM WITHIN, ONE-EIGHTH OF AN INCH EXTERNAL
TO SECTION IX.*

SAGITTAL SECTION. X.

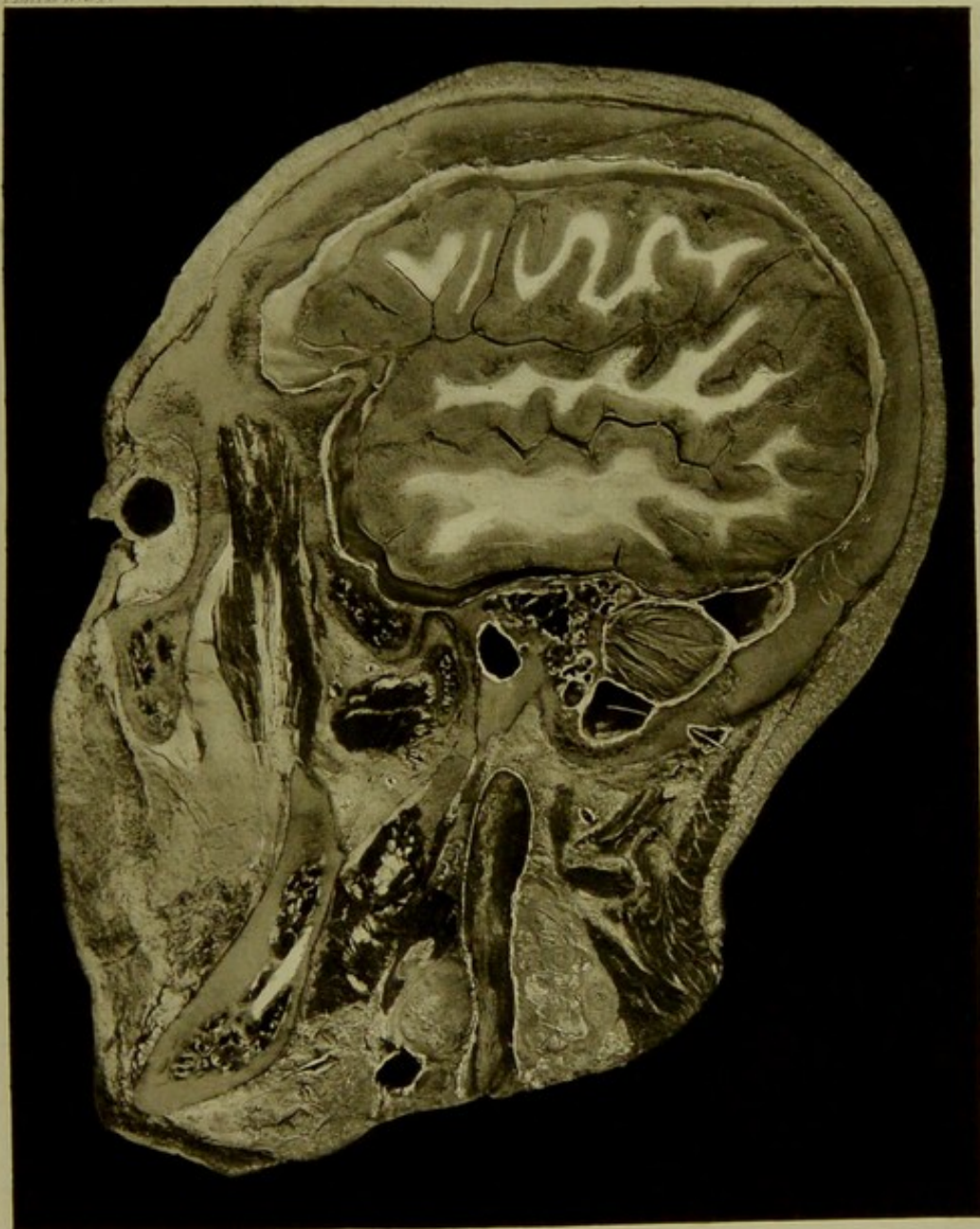


Male, 30 years.

Scale $\frac{33}{40} = \frac{5}{4}$ Approx.

X. SAGITTAL SECTION of right side of head, viewed from within, one-eighth of an inch external to section IX., and passing through the same osseous structures,—showing third frontal convolution, base of motor convolutions, supra-marginal and angular convolutions, temporal lobe and small portion of cerebellum. The outer portion of mastoid antrum with its relations to the external auditory meatus and to the middle cranial fossa is well seen, and also the relation of the mastoid cells to the sigmoid sinus and cerebellar fossa. The sigmoid sinus with mastoid emissary vein, the styloid process and its proximity to the internal jugular vein are shown.

PLATE No. 56

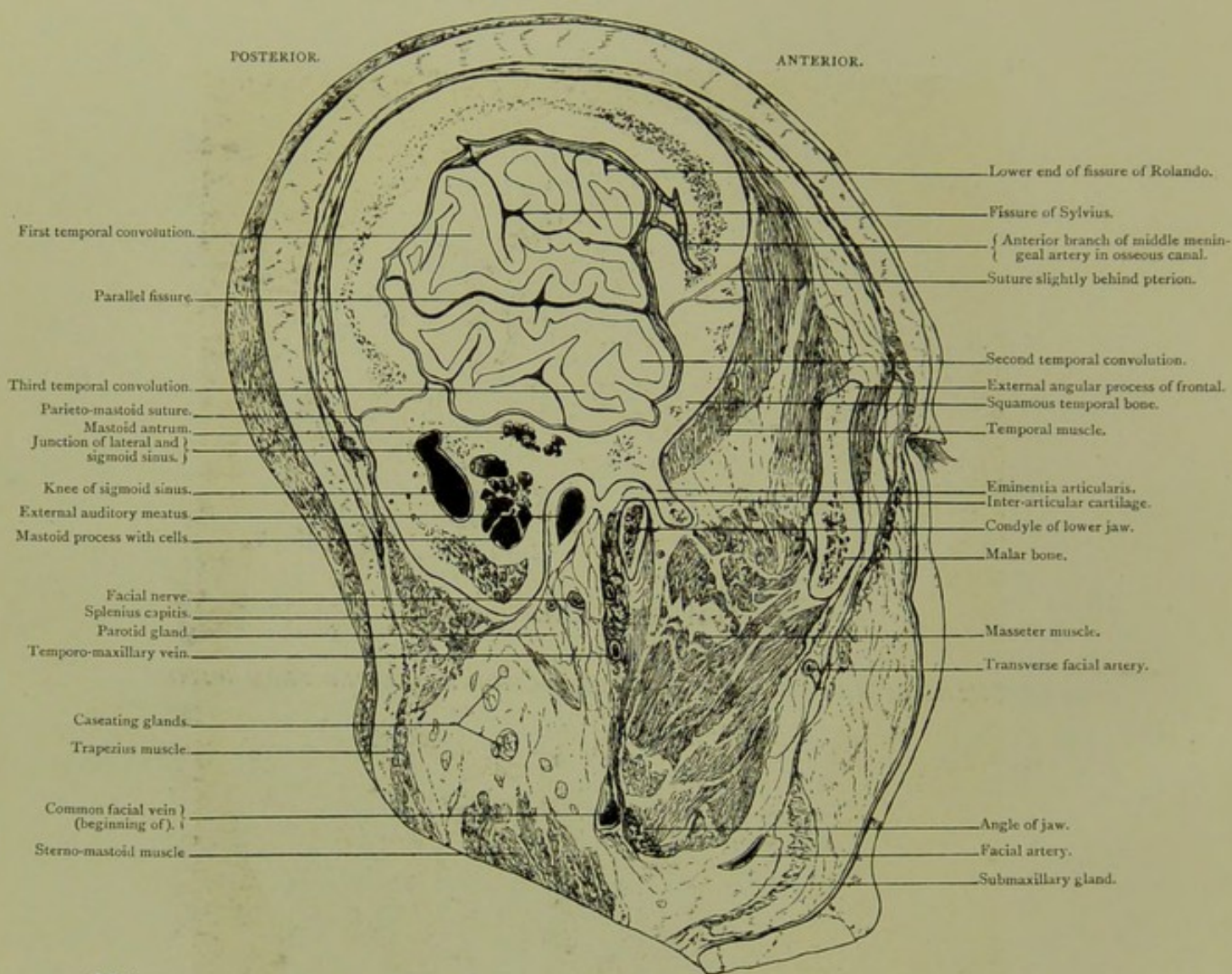




Sagittal Section. XI.

THREE-EIGHTHS OF AN INCH EXTERNAL TO SECTION X., VIEWED FROM WITHOUT.

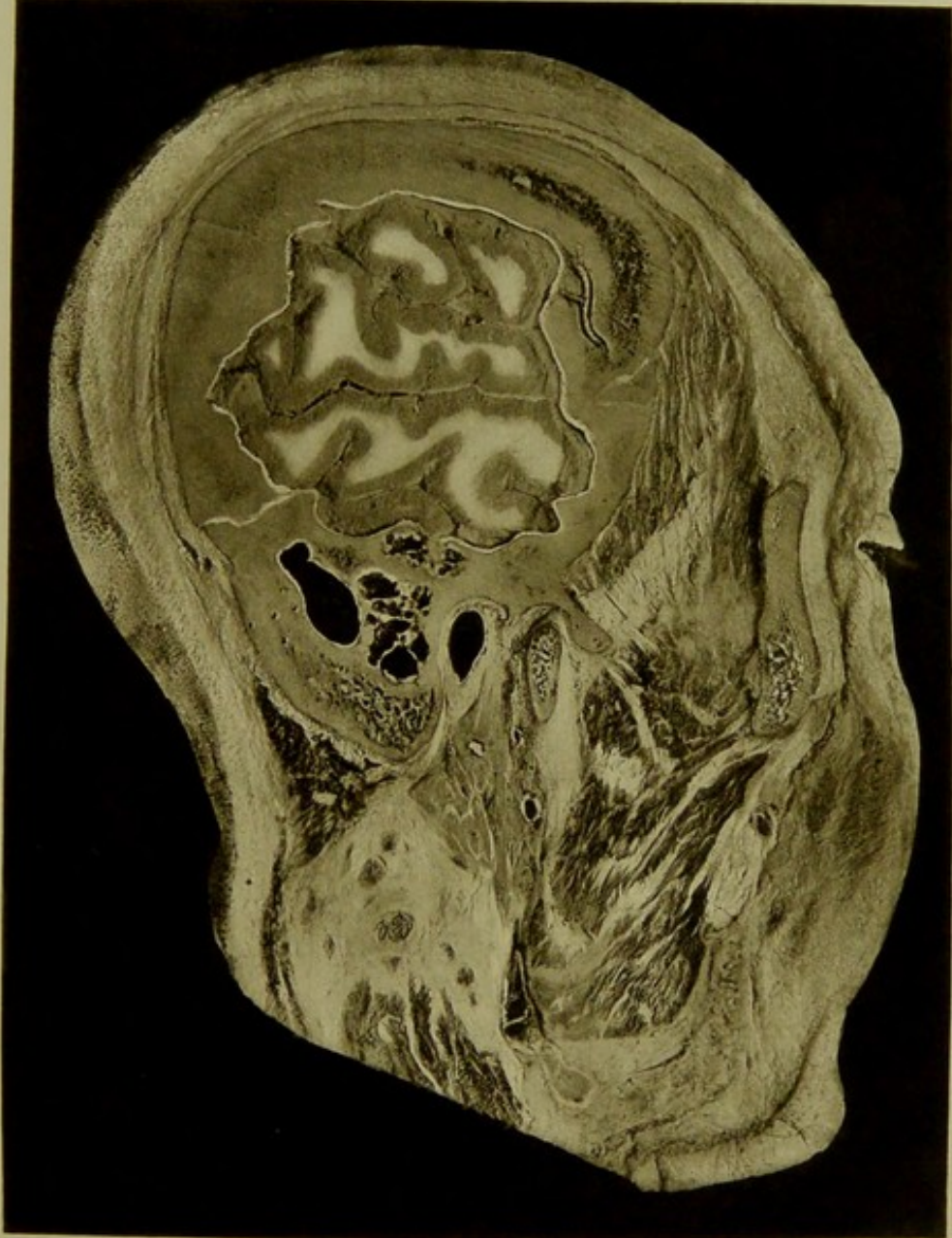SAGITTAL SECTION. XI.



Male, 30 years.


Scale $\frac{36}{52} = \frac{2}{3}$ Approx.

XI. SAGITTAL SECTION three-eighths of an inch external to section X. viewed from without, —passing through, external angular process of frontal, malar, outer limit of osseous external meatus, pterion, eminentia articularis, outer portion of lower jaw and mastoid process,—showing Sylvian and parallel fissures, middle meningeal artery in bony canal, knee of sigmoid sinus, mastoid cells and parotid gland with facial nerve and muscular arteries traversing. The superficial position of the sigmoid sinus relatively to the mastoid antrum is well shown. The aperture seen in the photograph is merely through a portion of the outer wall of the sigmoid sinus, which in the section runs considerably further forward, and is of much larger calibre than the photograph indicates. All the larger mastoid cells represented communicate with mastoid antrum.





HORIZONTAL SECTIONS.

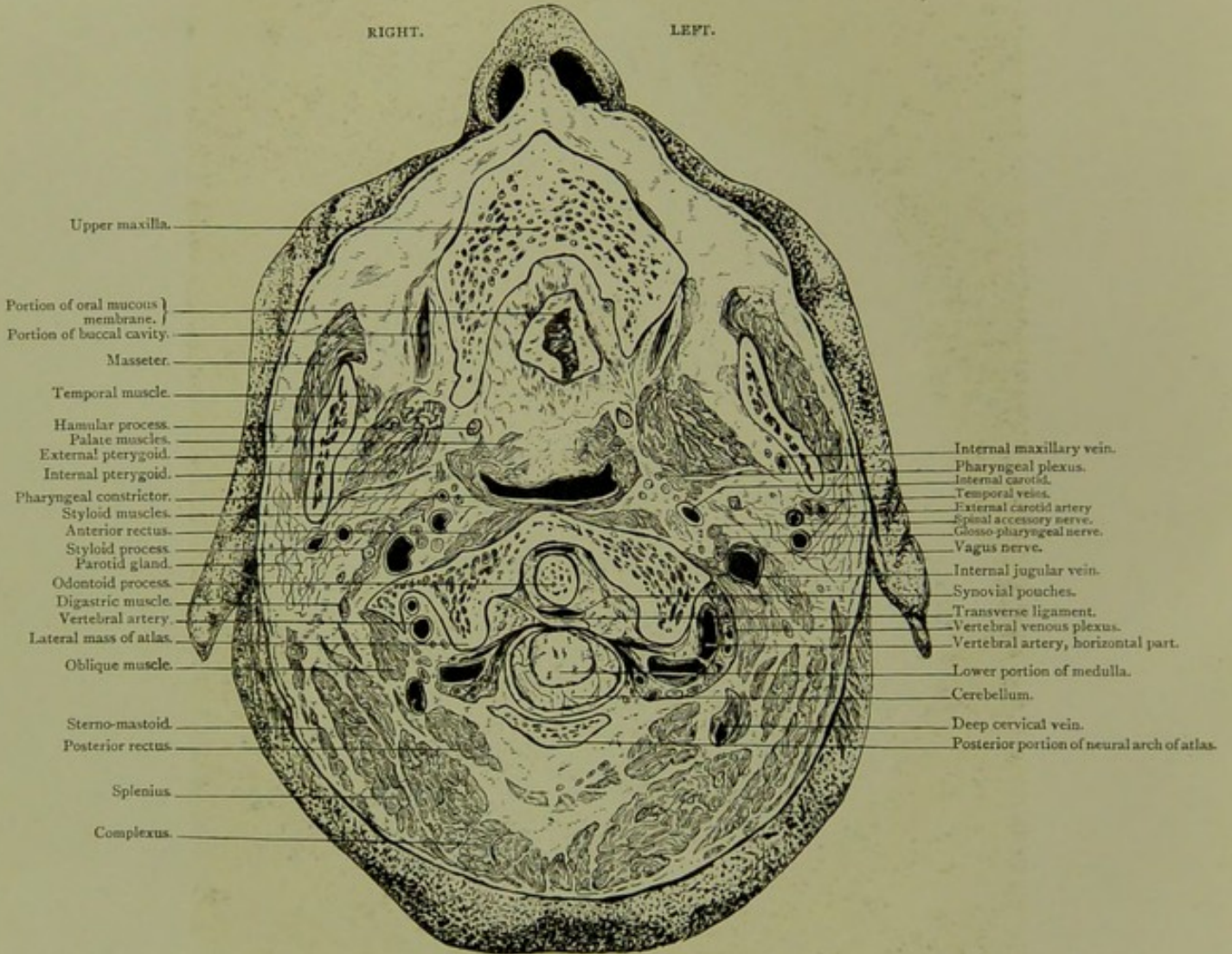


Horizontal Section. Series A. I.

VIEWED FROM BELOW.

HORIZONTAL SECTION.

Series A. I.

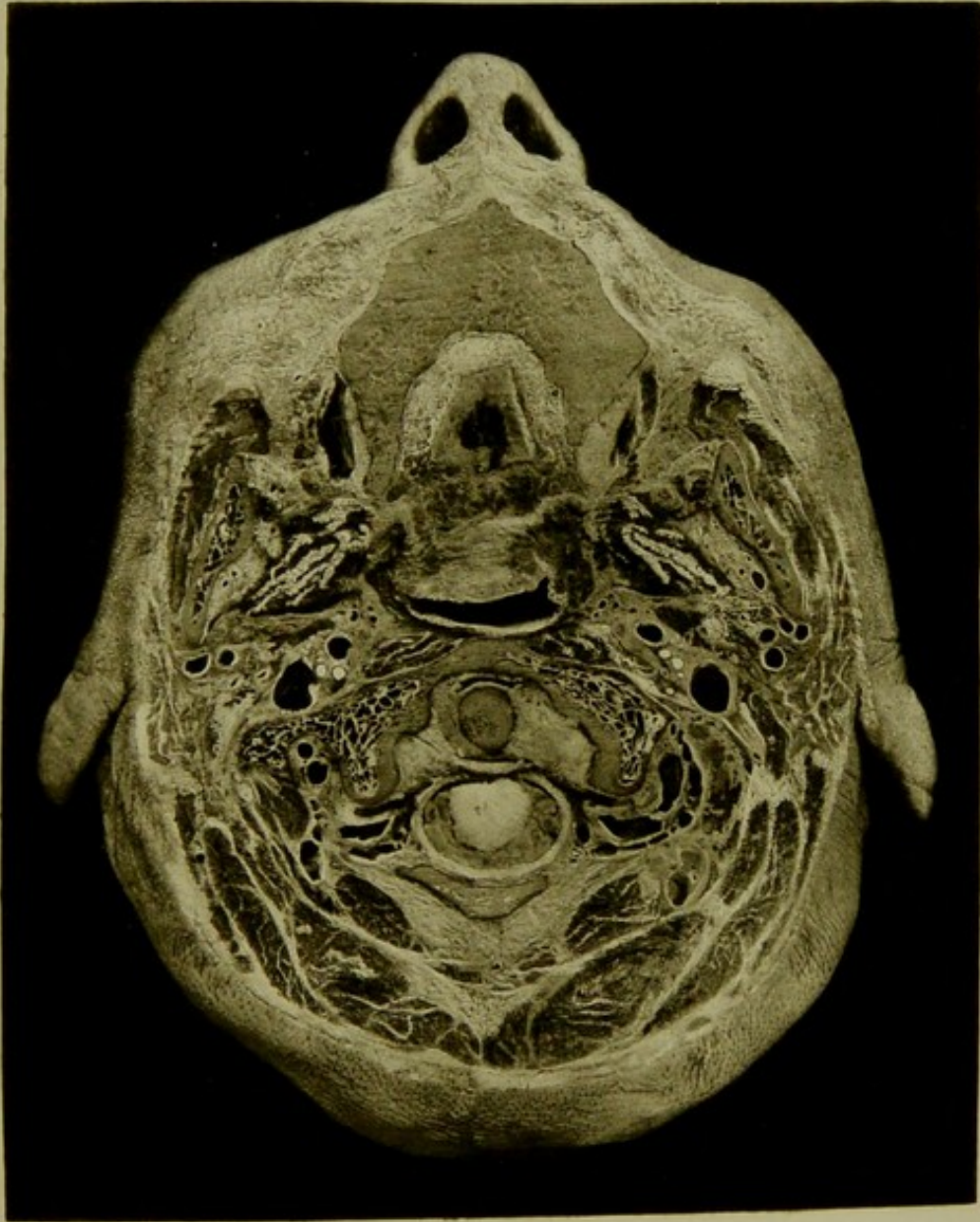



Male, 35 years.

Scale $\frac{54}{70} = \frac{3}{4}$ Approx.

I. HORIZONTAL SECTION viewed from below, passing through roof of mouth, atlas and odontoid process of axis, showing vertebral arteries and vertebral venous plexus emerging from the foramen of the atlas, and passing backwards and inwards towards the neural arch of the atlas. The cerebellum is seen surrounding the lower portion of medulla at its junction with spinal cord and at a lower level than foramen magnum.

PLATE N°36.



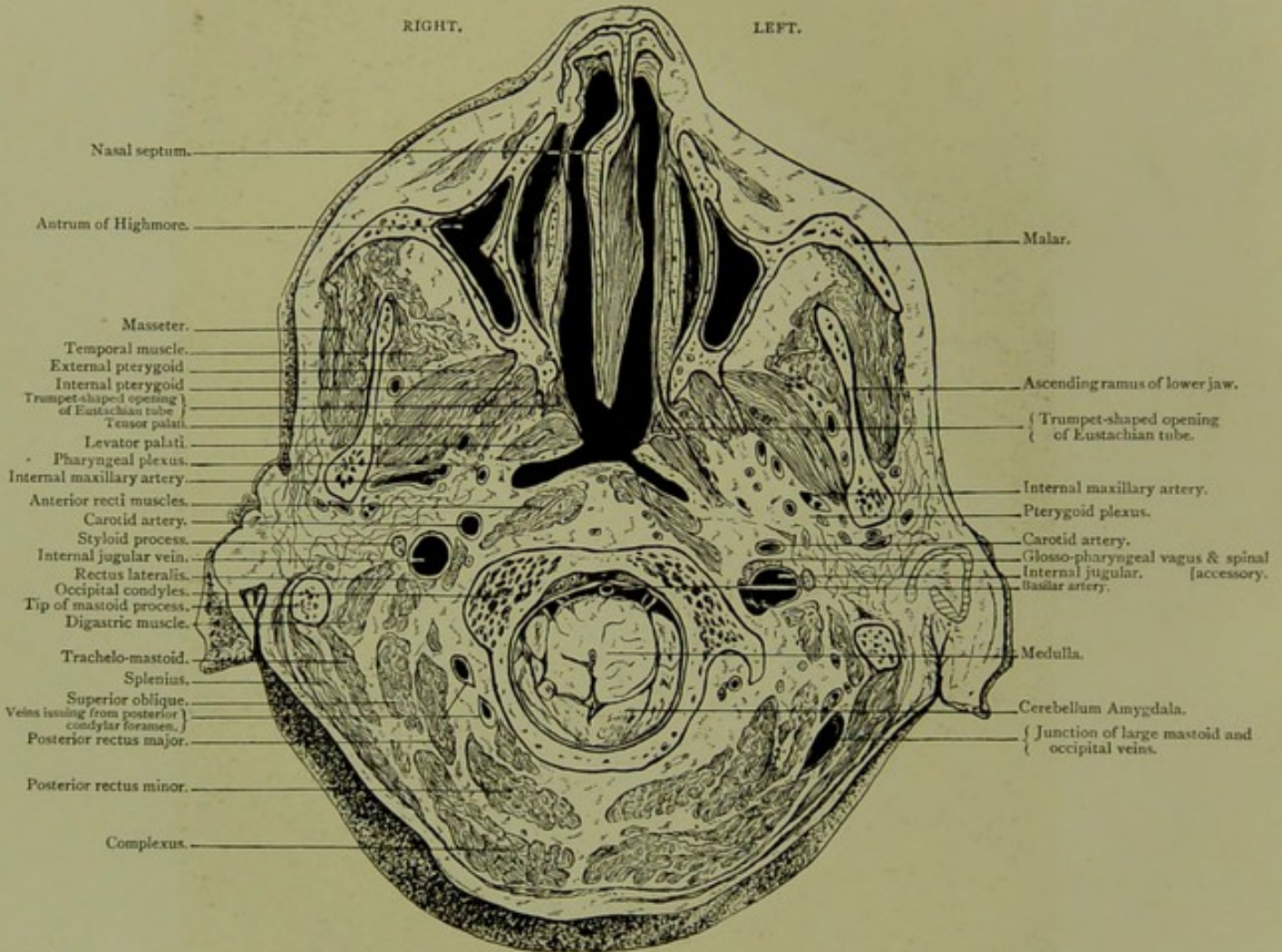


Horizontal Section. Series A. II.

VIEWED FROM BELOW, THREE-EIGHTHS OF AN INCH ABOVE SECTION I.

HORIZONTAL SECTION.

Series A. II.

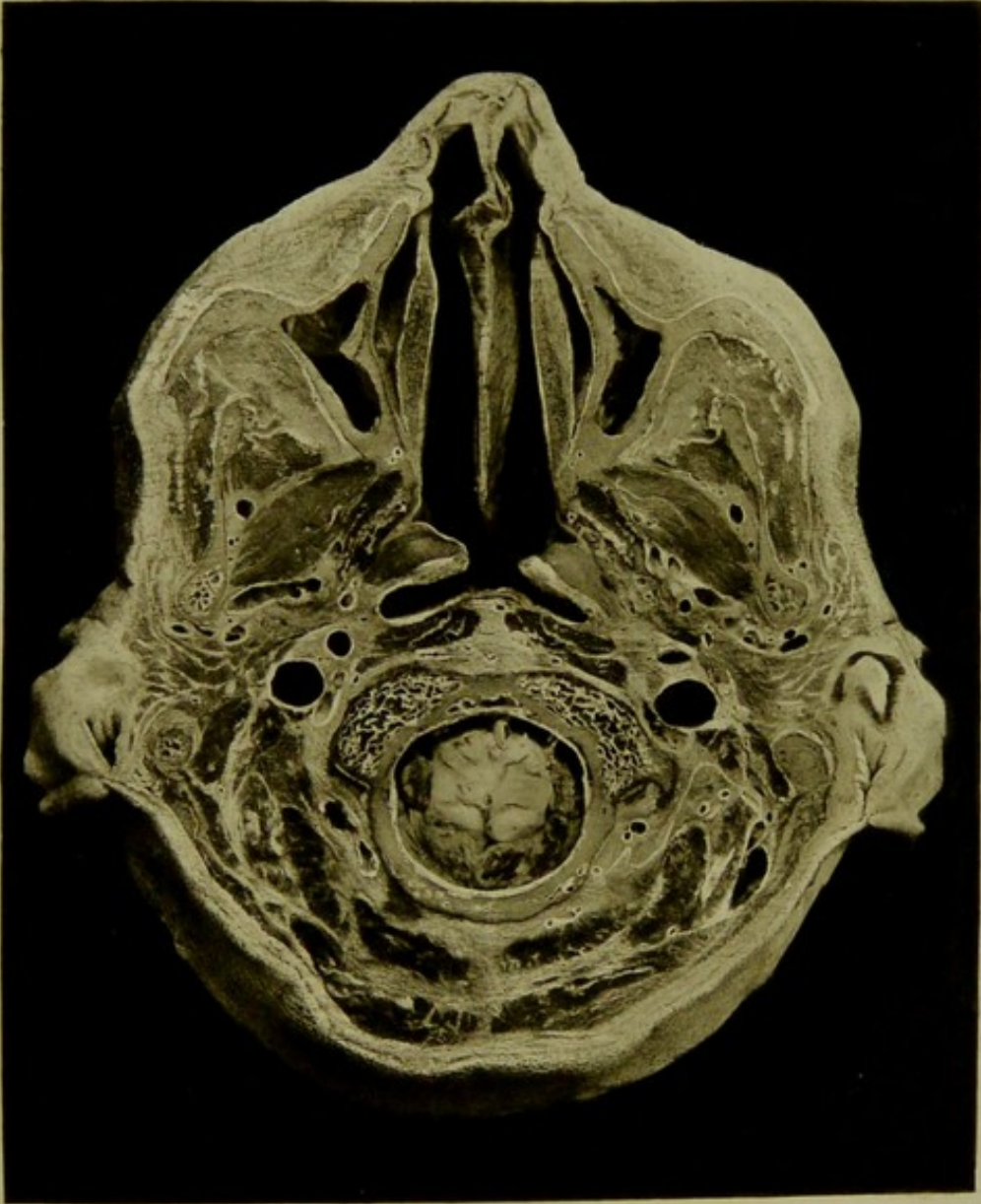



Male, 35 years.

Scale $\frac{52}{70} = \frac{5}{4}$ Approx.

II. HORIZONTAL SECTION viewed from below, three-eighths of an inch above section I., passing through the foramen magnum, the tips of mastoid processes, naso pharynx and the inferior turbinated bones, showing a portion of cerebellum and medulla, the pharyngeal plexus and lower part of the pterygoid plexus, the trumpet-shaped opening of Eustachian tube between the levator and tensor palati muscles. The cerebellum surrounds the medulla below the level of the foramen magnum.

PLATE N^o 37.



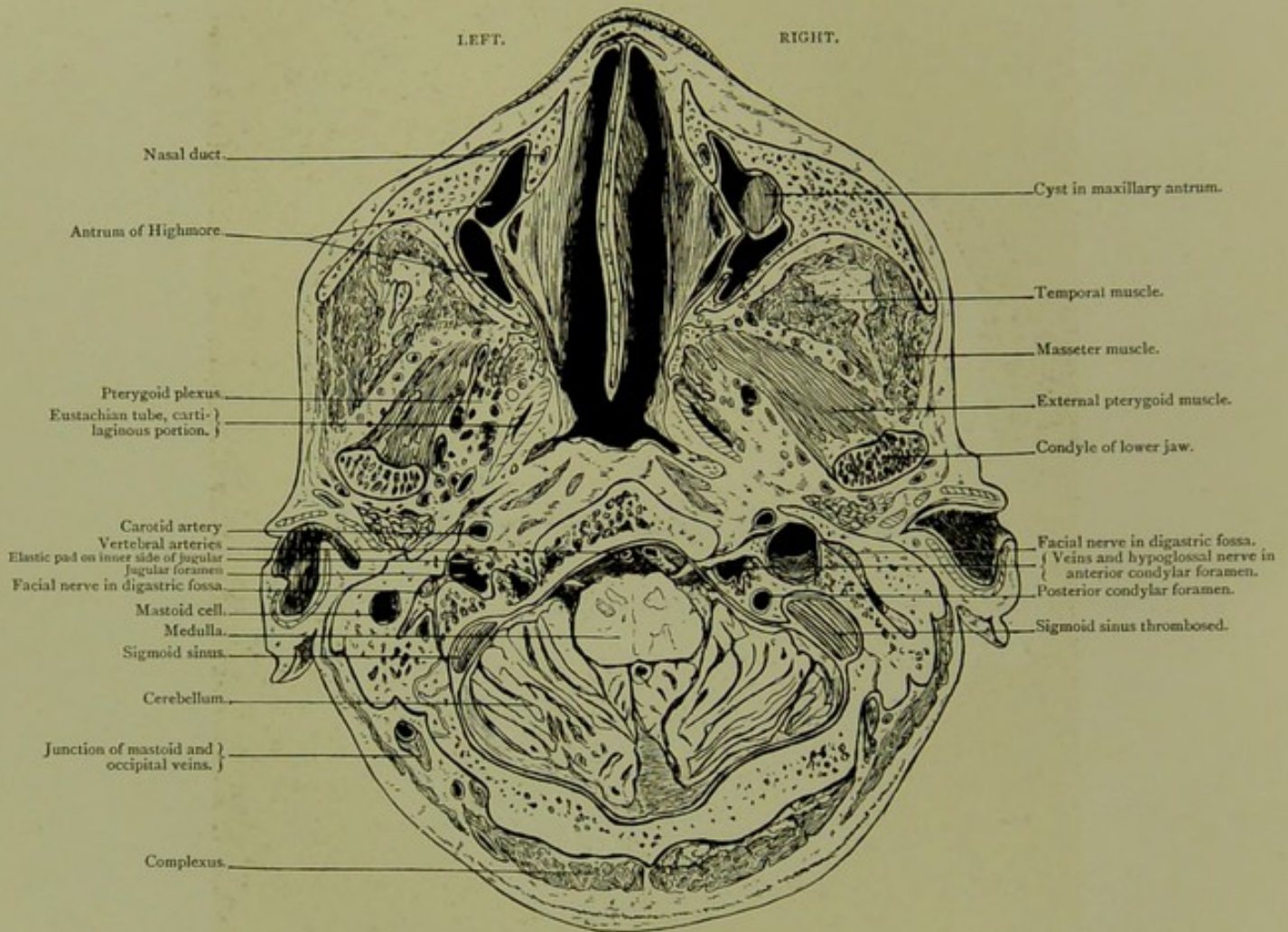


Horizontal Section. Series A. III.

VIEWED FROM ABOVE, THREE-QUARTERS OF AN INCH HIGHER THAN SECTION II.

HORIZONTAL SECTION.

Series A. III.

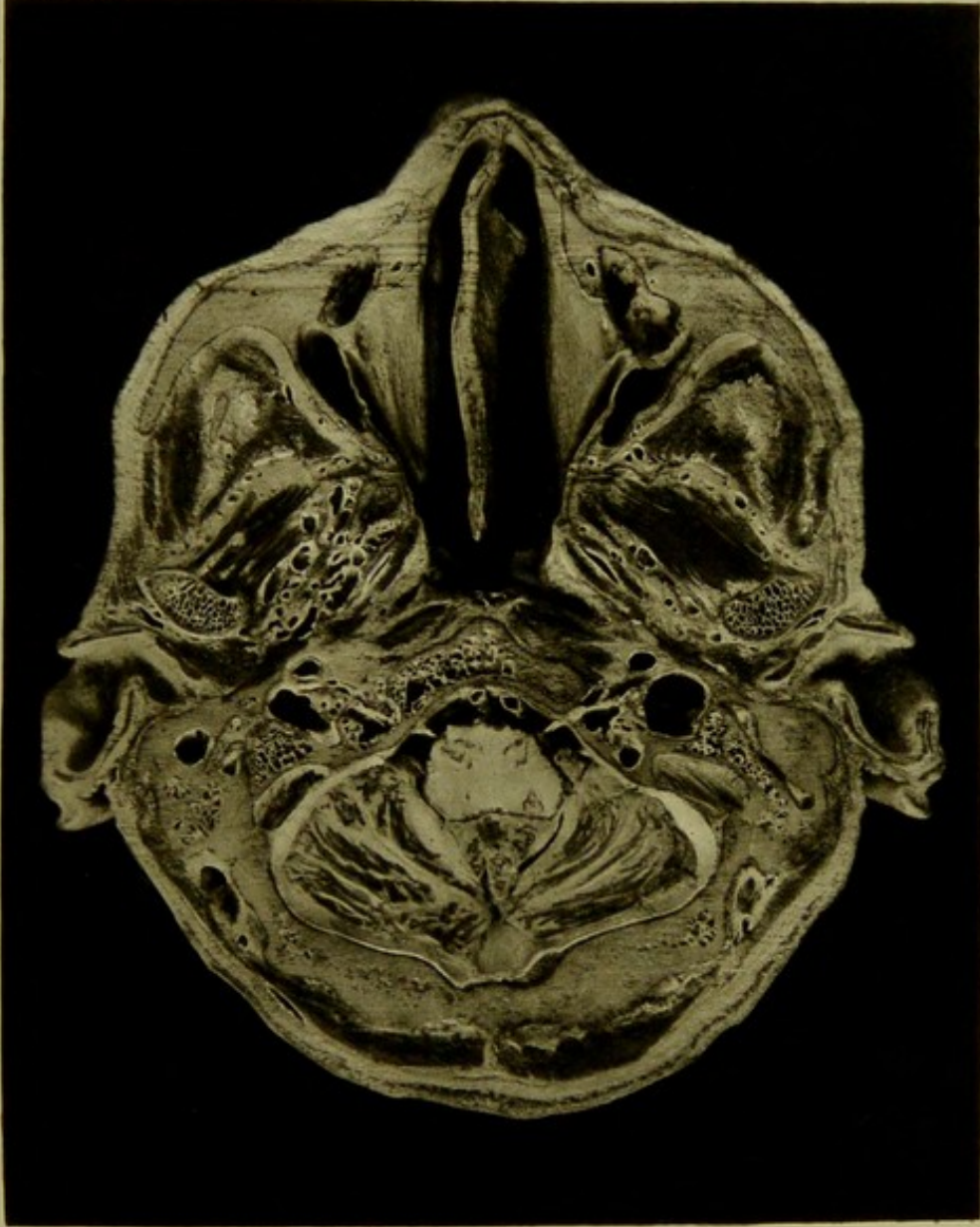



Male, 35 years.

Scale $\frac{50}{68} = \frac{3}{4}$ Approx.

III. HORIZONTAL SECTION, through head, viewed from above, three-quarters of an inch higher than section II., exposing medulla and cerebellum, pterygoid plexus, anterior and posterior condylar foramina,—the lowest portions of the sigmoid sinuses, the right being thrombosed. The pad of soft tissue with veins and nerves in jugular fossa on inner side of the internal jugular, and at level of anterior condylar foramen, is well seen on the left. A vein of large size communicates between anterior condylar foramen and internal jugular. The mastoid vein is large, and is cut at its junction with an occipital scalp vein.

PLATE NO 39.



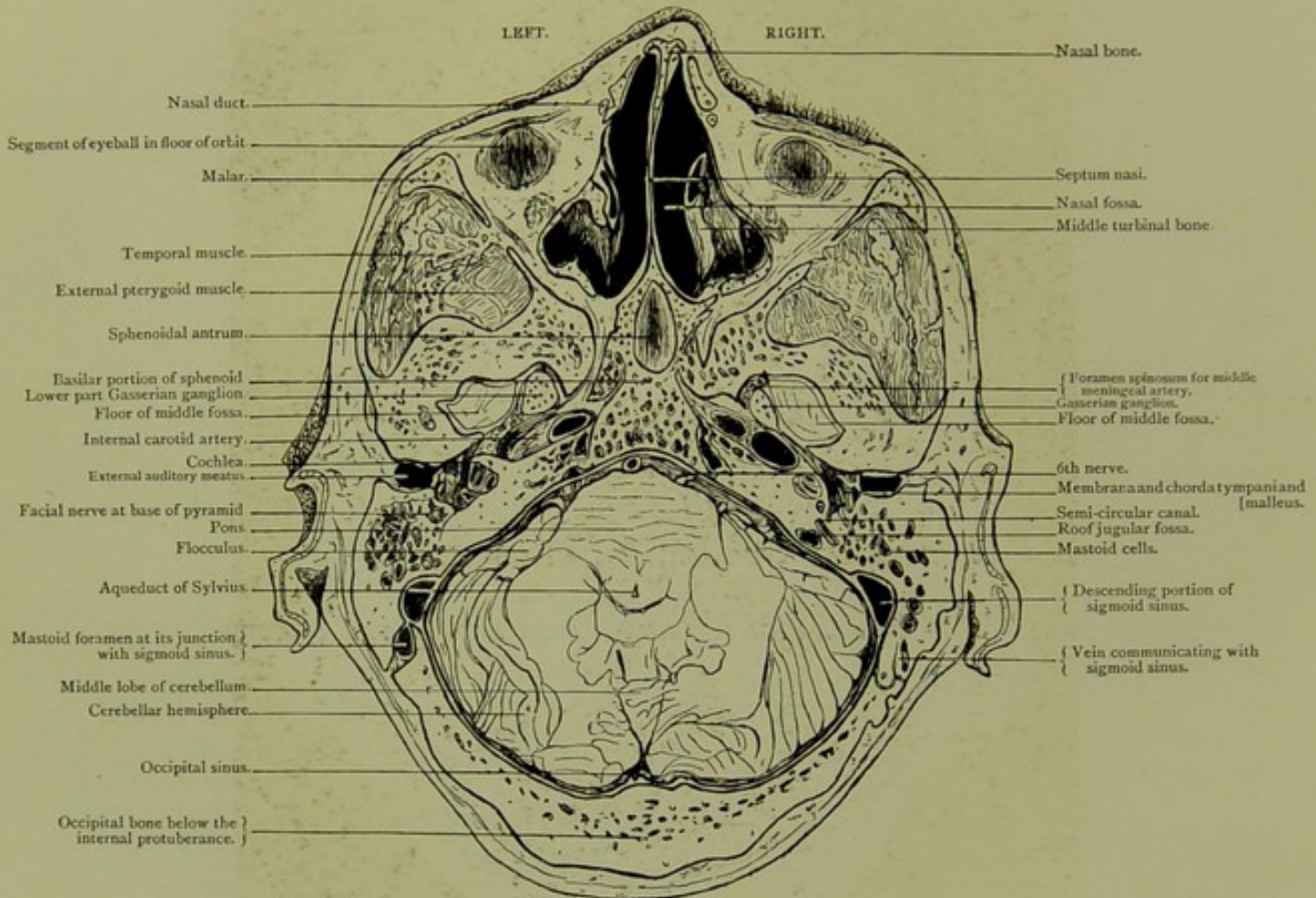


Horizontal Section. Series A. IV.

SEEN FROM ABOVE, THREE-EIGHTHS OF AN INCH HIGHER THAN SECTION III.

HORIZONTAL SECTION.

Series A. IV.

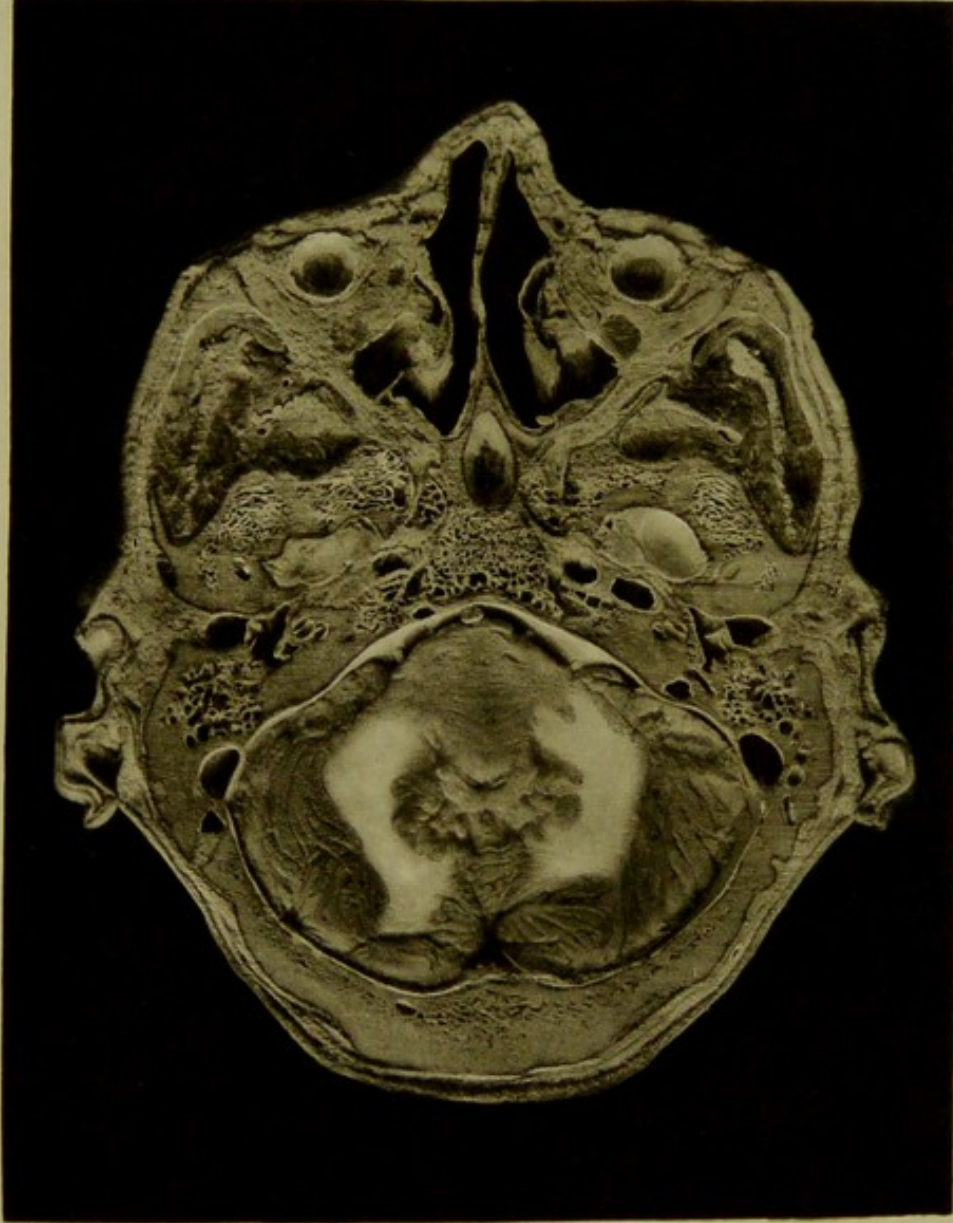



Male, 35 years.

Scale $\frac{49}{70} = \frac{7}{10}$.

IV. HORIZONTAL SECTION of head seen from above, three-eighths of an inch higher than section III., passes through orbit, sphenoidal antrum, tip of base of middle fossa with portion of Gasserian ganglion to inner side, transverse petrous portion of internal carotid artery, roof of jugular fossa, tympanum, flocculus, pons and cerebellum. On left side, the mastoid vein communicates with sigmoid sinus by an aperture, about a quarter of an inch in diameter, that of the sigmoid sinus on the same side being nearly half an inch. The mastoid vein on the right side measures a quarter of an inch in diameter in its osseous canal, while there is a second vein passing through a mastoid foramen measuring one-twelfth of an inch in diameter. On each side the membrana tympani is seen with the handle of malleus anteriorly and the chorda tympani posteriorly. On floor of middle fossa on right side a number of minute veins from pons pass through dura.

PLATE N° 29.



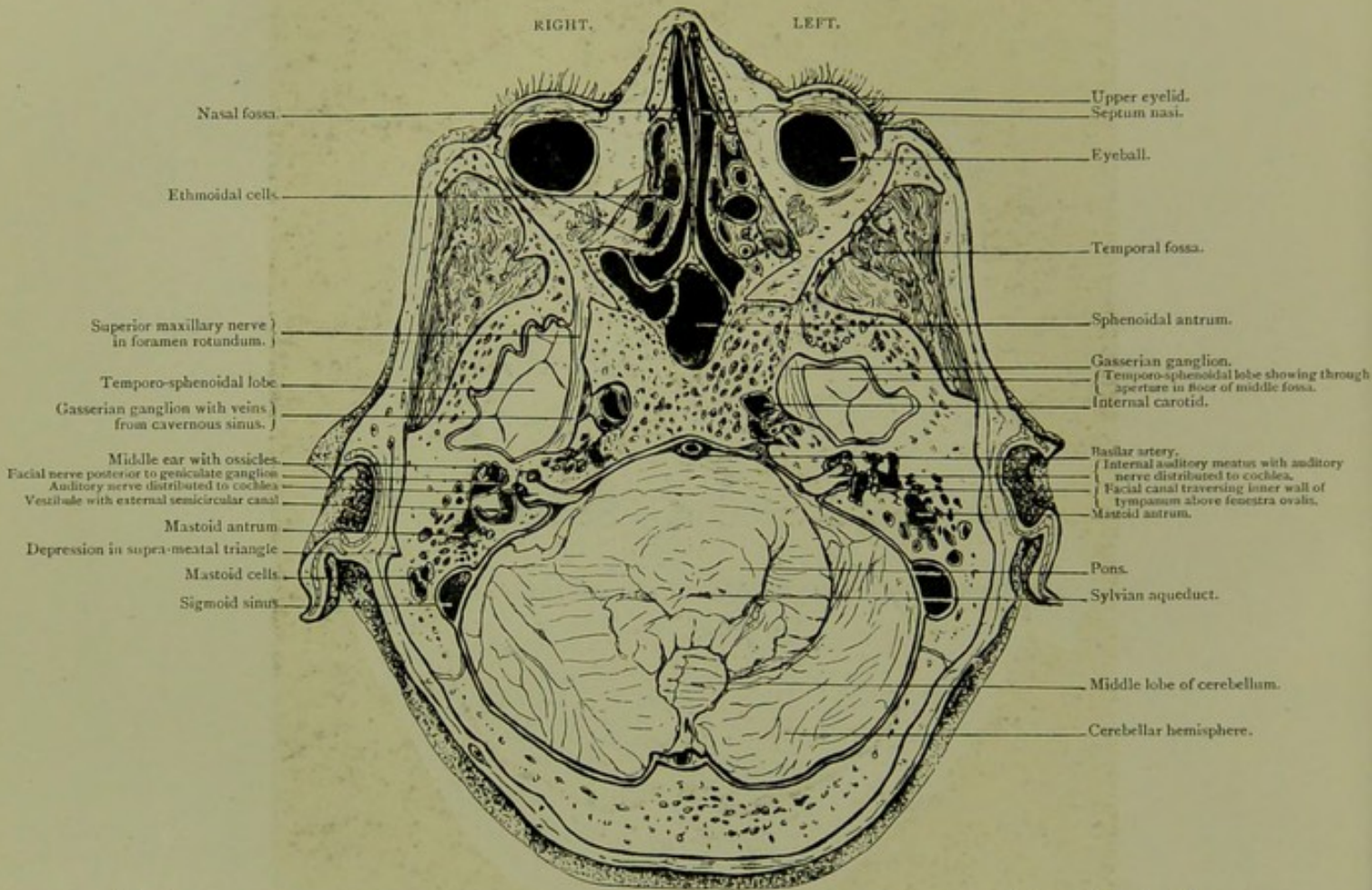


Horizontal Section. Series A. V.

VIEWED FROM BELOW, ONE-EIGHTH OF AN INCH ABOVE SECTION IV.

HORIZONTAL SECTION.

Series A. V.

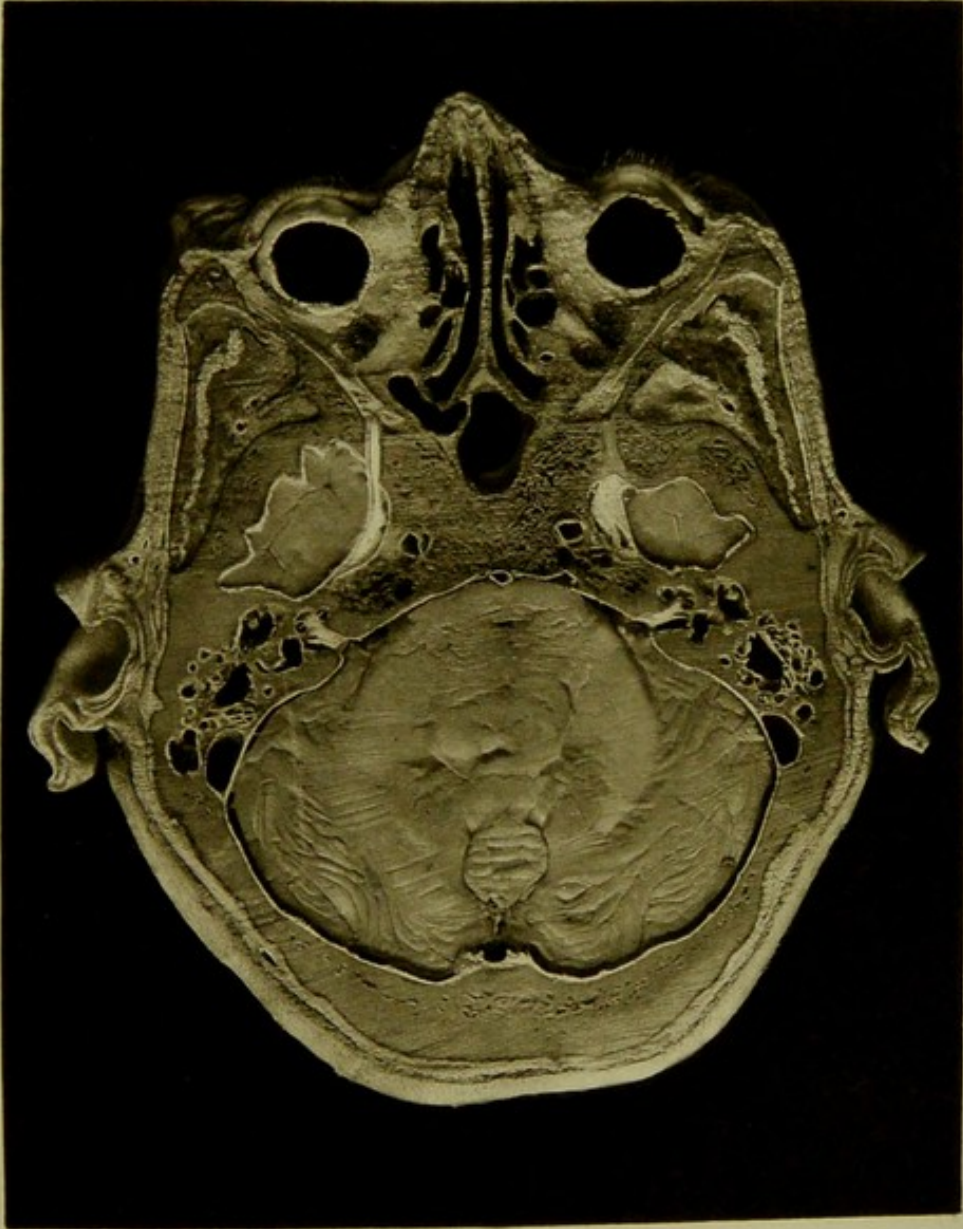



Male, 35 years.

Scale $\frac{49}{68} = \frac{3}{4}$ Approx.

V. HORIZONTAL SECTION viewed from below, one-eighth of an inch above section IV., passing through bases of temporo-sphenoidal lobes,—as they are exposed through apertures in middle fossae,—the pons and cerebellum. The mastoid antrum in its relation to the depression in the supra meatal triangle is marked on the right side. The middle and internal ear, and the internal auditory meatus, the auditory nerve and its distribution to the cochlea, are all seen on both sides, the passage between the mastoid antrum and the tympanum is exposed on the right while it has its floor complete on the left side. The facial nerve is seen on the left side above the fenestra ovalis, along inner wall of tympanum. Its canal is opened anteriorly and posteriorly.

PLATE N°40



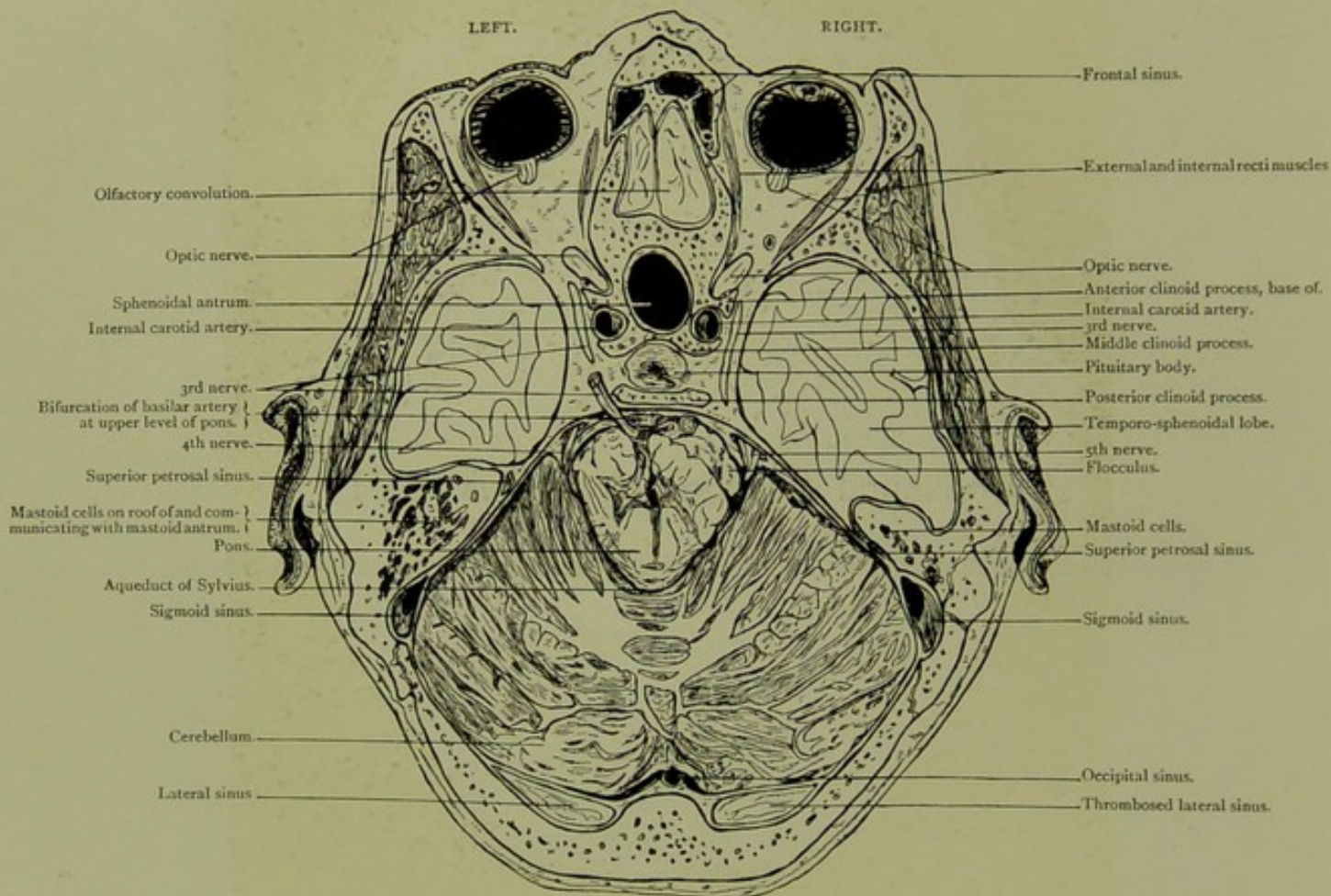


Horizontal Section. Series A. VI.

*SOMEWHAT OBLIQUELY CUT, VIEWED FROM ABOVE, A QUARTER INCH HIGHER THAN
SECTION V.*

HORIZONTAL SECTION.

Series A. VI.

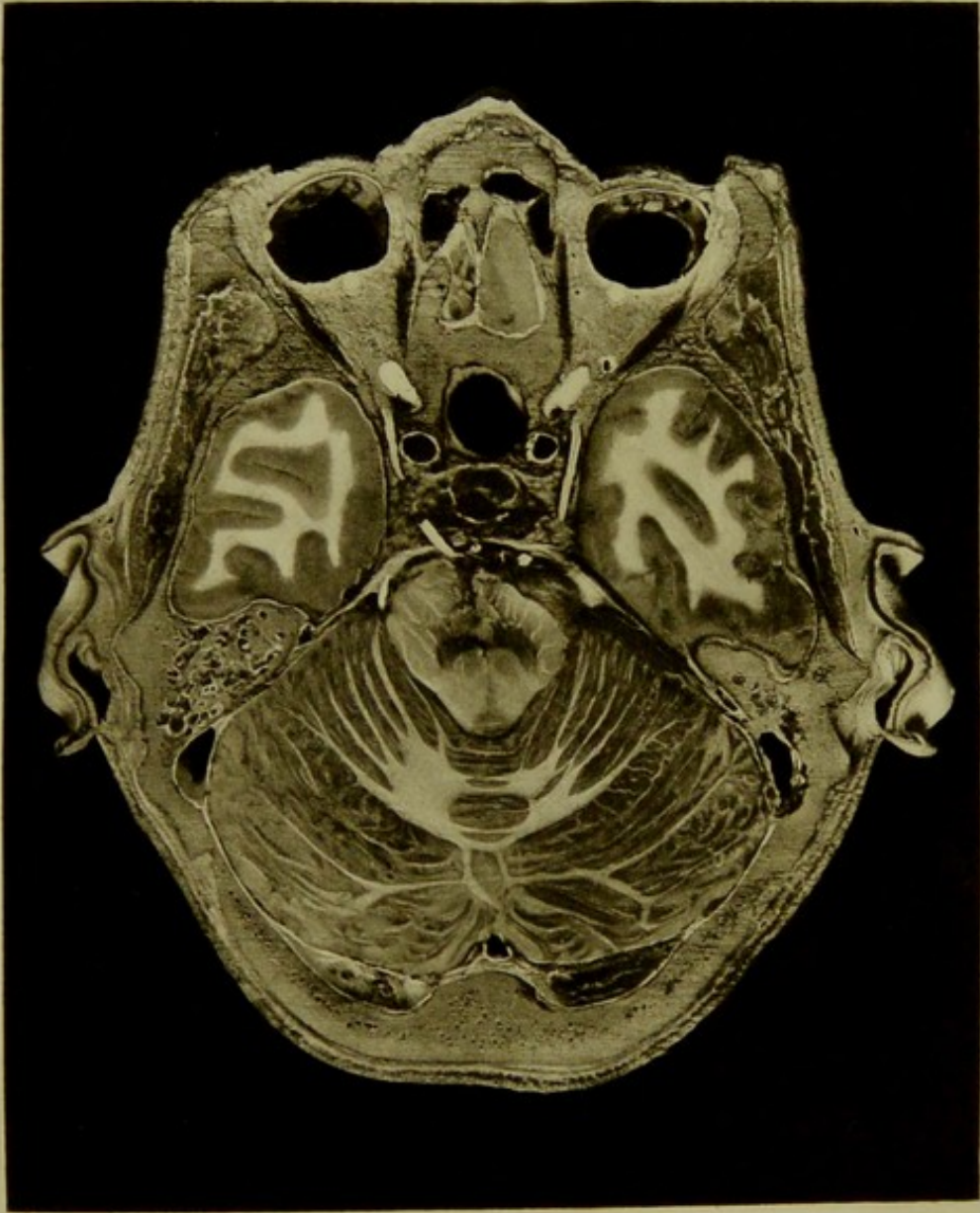


Male, 35 years.

Scale $\frac{49}{68} = \frac{3}{4}$ Approx.

VI. HORIZONTAL SECTION, somewhat obliquely cut, viewed from above, a quarter inch higher than section V. It passes through the greater part of the cerebellum, the pons, the temporo-sphenoidal lobes, and a minute portion of the olfactory frontal convolution. The cavernous sinus, the 3rd, 4th, and 5th nerves, the superior petrosal, the sigmoid and the lateral sinuses are exposed. The right lateral sinus is filled with a marasmic thrombus. The communication between the frontal sinuses and the nose is well seen in the specimen.

PLATE No. 43



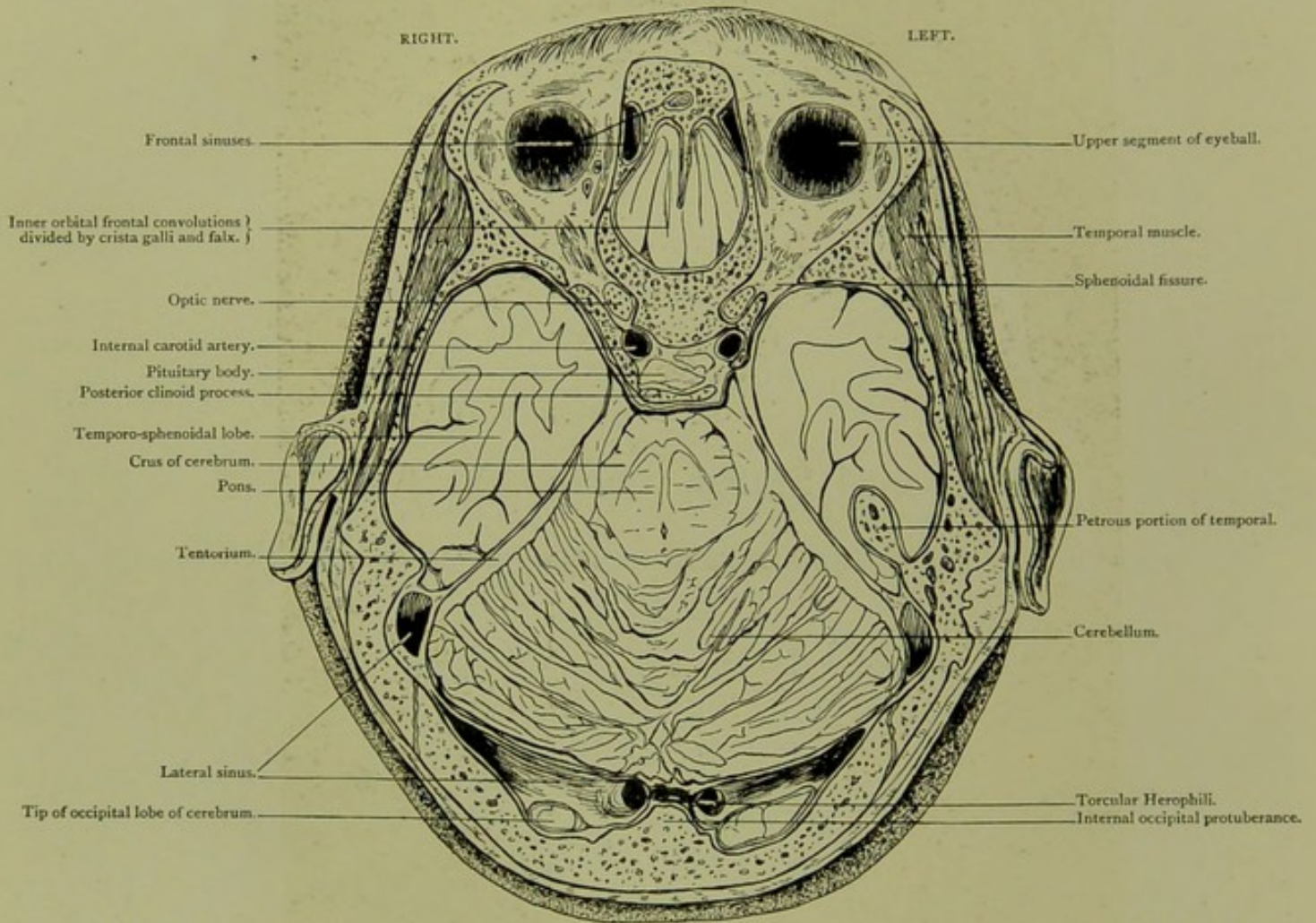


Horizontal Section. Series A. VII.

VIEWED FROM BELOW, ONE-EIGHTH OF AN INCH HIGHER THAN SECTION VI.

HORIZONTAL SECTION.

Series A. VII.

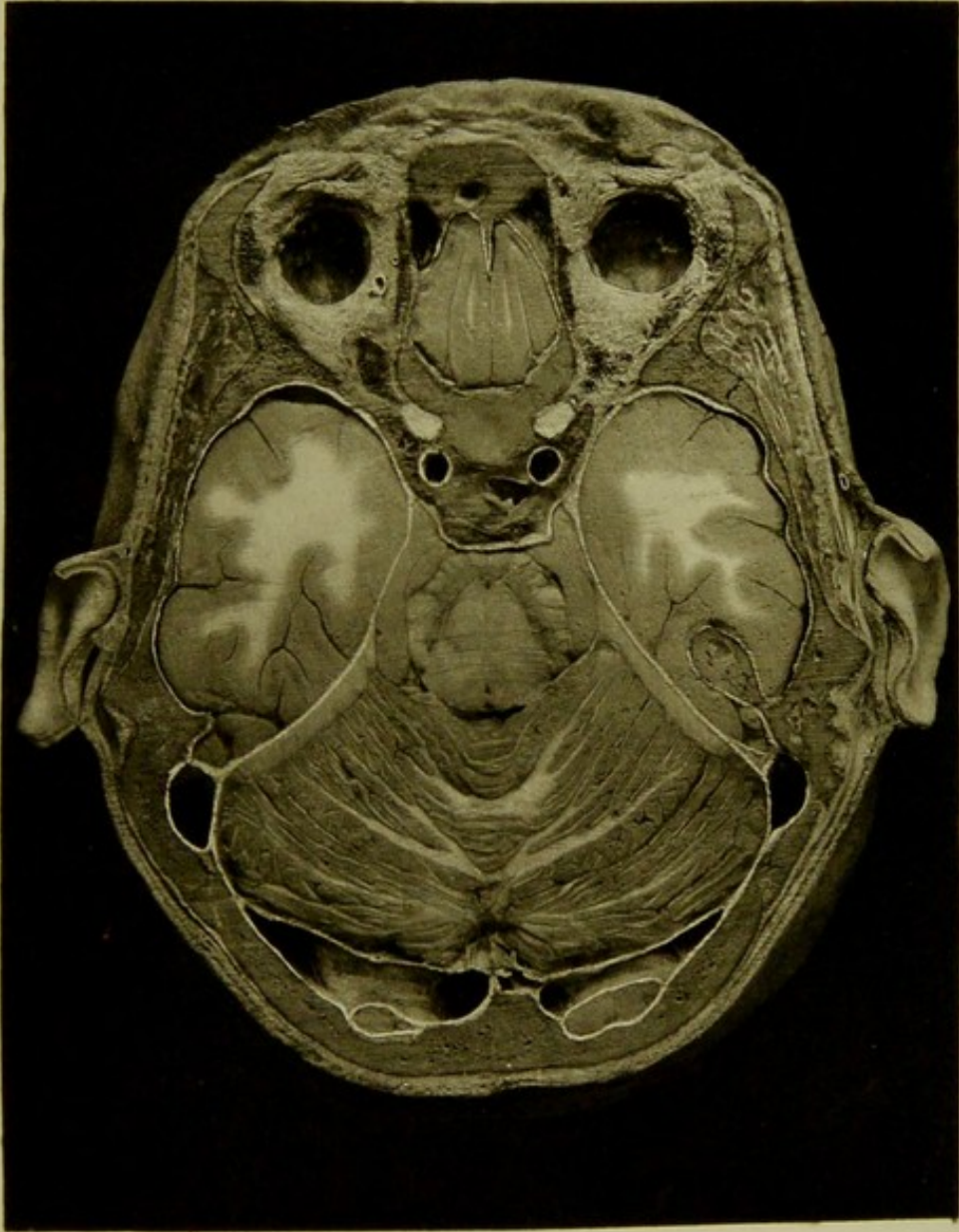



Male, 35 years.

Scale $\frac{40}{70} = \frac{7}{10}$

VII. HORIZONTAL SECTION, viewed from below, one-eighth of an inch higher than section VI, passing through external angular process of frontal bone, upper segments of eyeballs, body of sphenoid just below level of olivary and clinoid processes, internal occipital protuberance, showing inner orbital frontal convolutions, optic nerves, pituitary body, temporo-sphenoidal lobes, crura cerebri, pons, tentorium, cerebellum and torcular Herophili.

PLATE Nº 42.



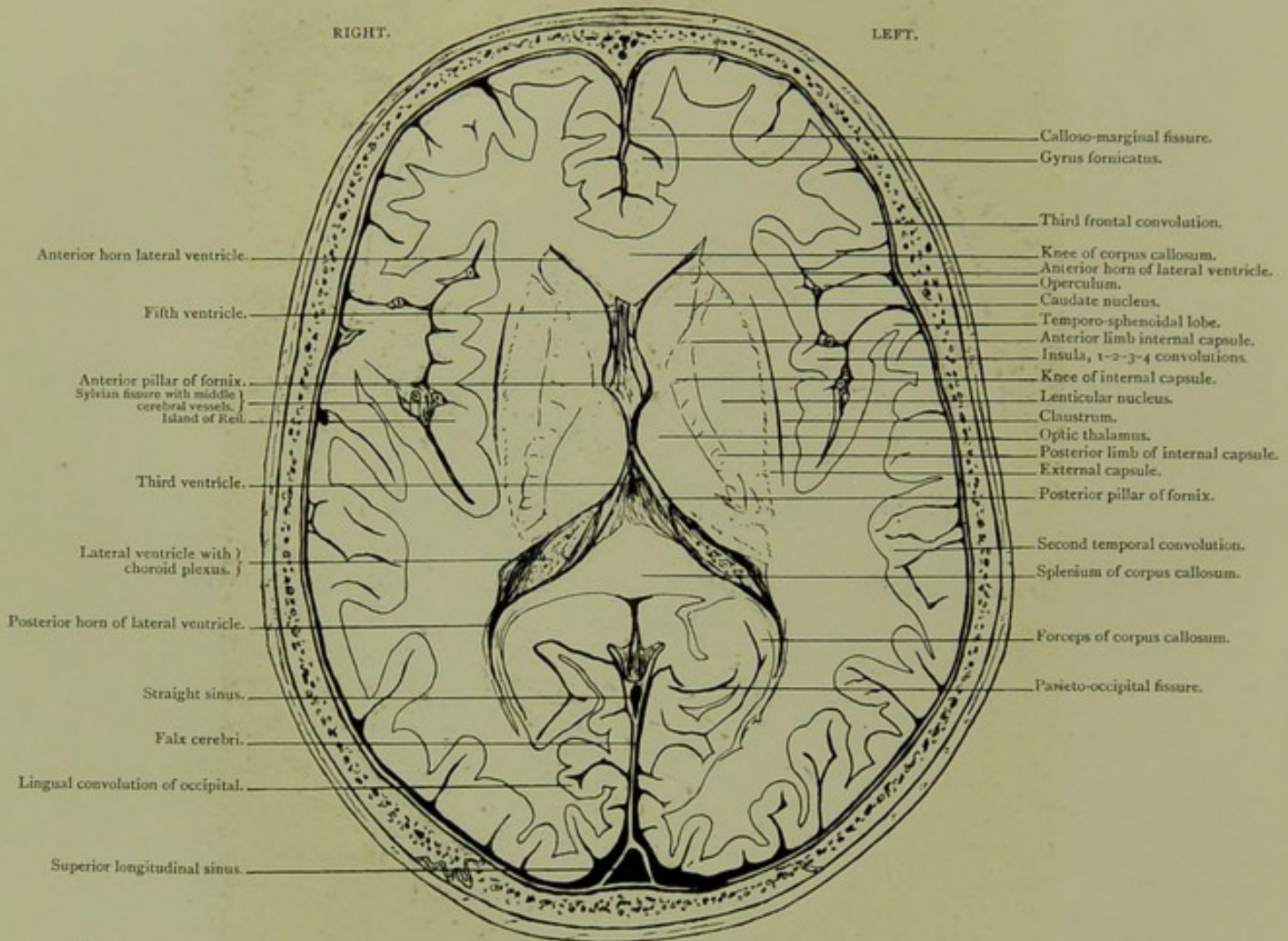


Horizontal Section. Series A. VIII.

VIEWED FROM BELOW, THREE-QUARTERS OF AN INCH ABOVE SECTION VII.

HORIZONTAL SECTION.

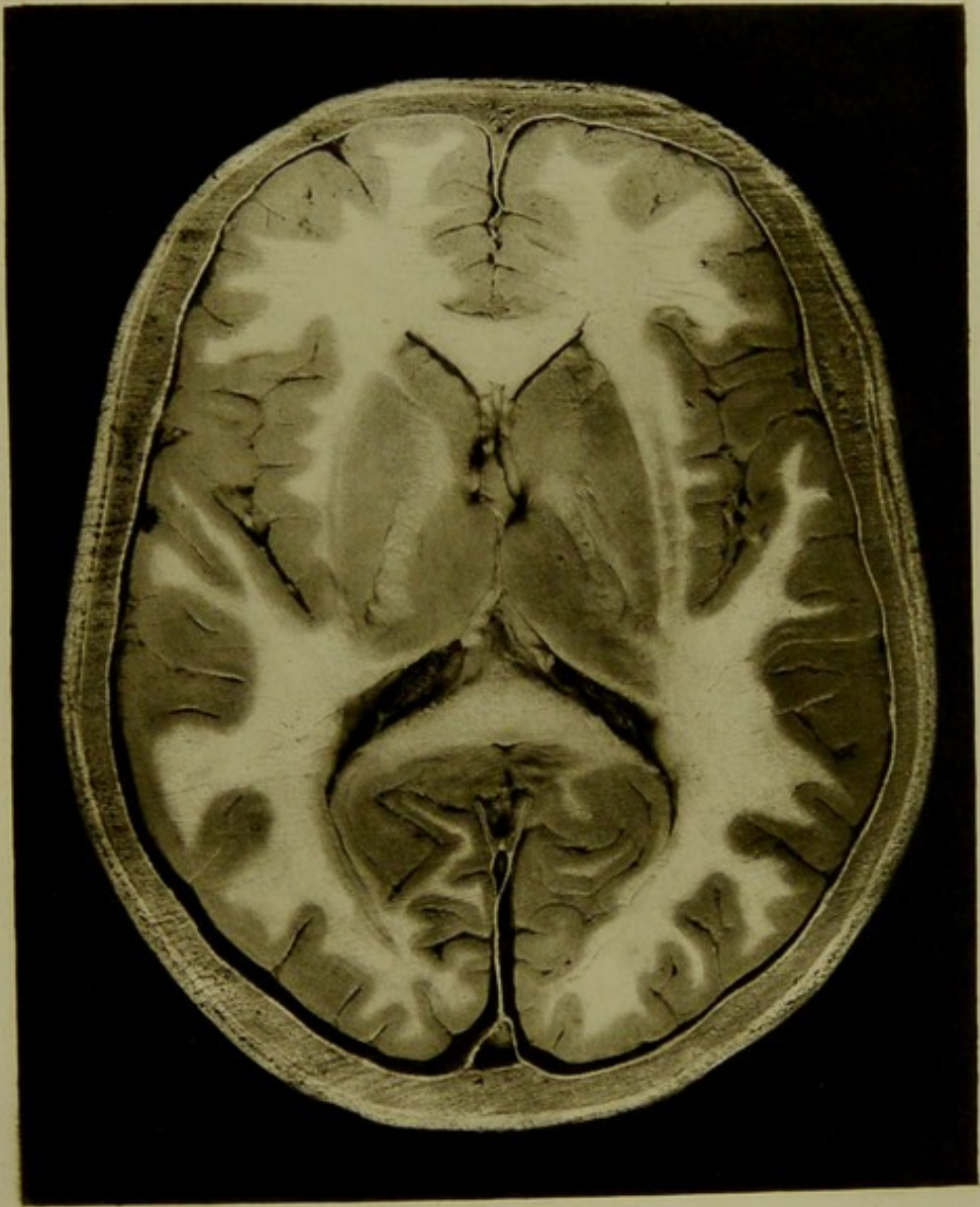
Series A. VIII.




Male, 35 years.

Scale $\frac{62}{74} = \frac{5}{4}$ Approx.

VIII. HORIZONTAL SECTION, viewed from below, three-quarters of an inch above section VII., passing through the frontal, temporo-sphenoidal and occipital lobes, the basal ganglia, operculum and island of Reil. The fissure of Sylvius, the lateral ventricles—their anterior and posterior horns—with the choroid plexuses, the anterior and posterior pillars of the fornix and the fifth and third ventricles are likewise seen.



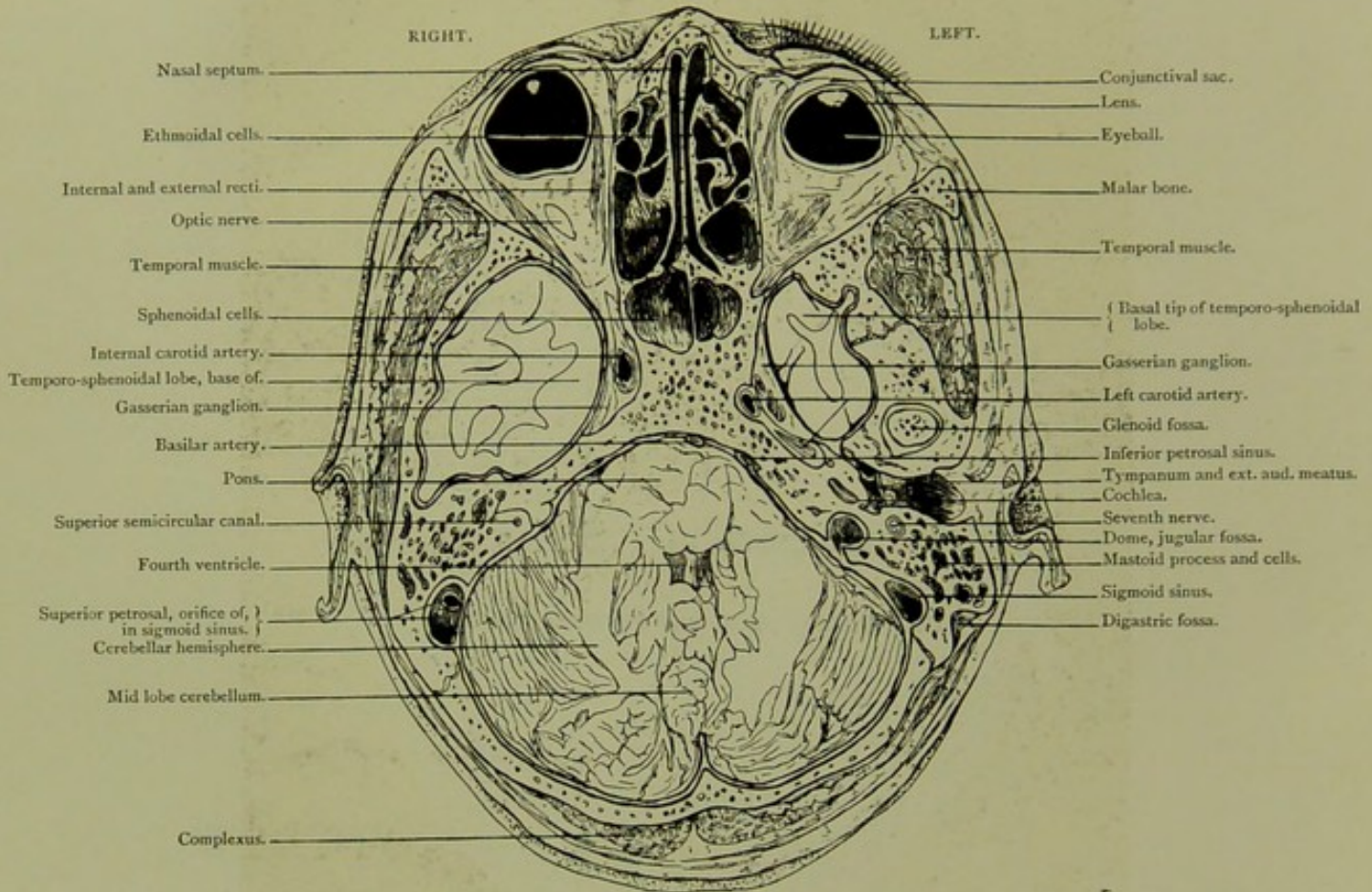


Horizontal Section. Series B. I.

CUT OBLIQUELY, SEEN FROM BELOW.

HORIZONTAL SECTION.

Series B. I.

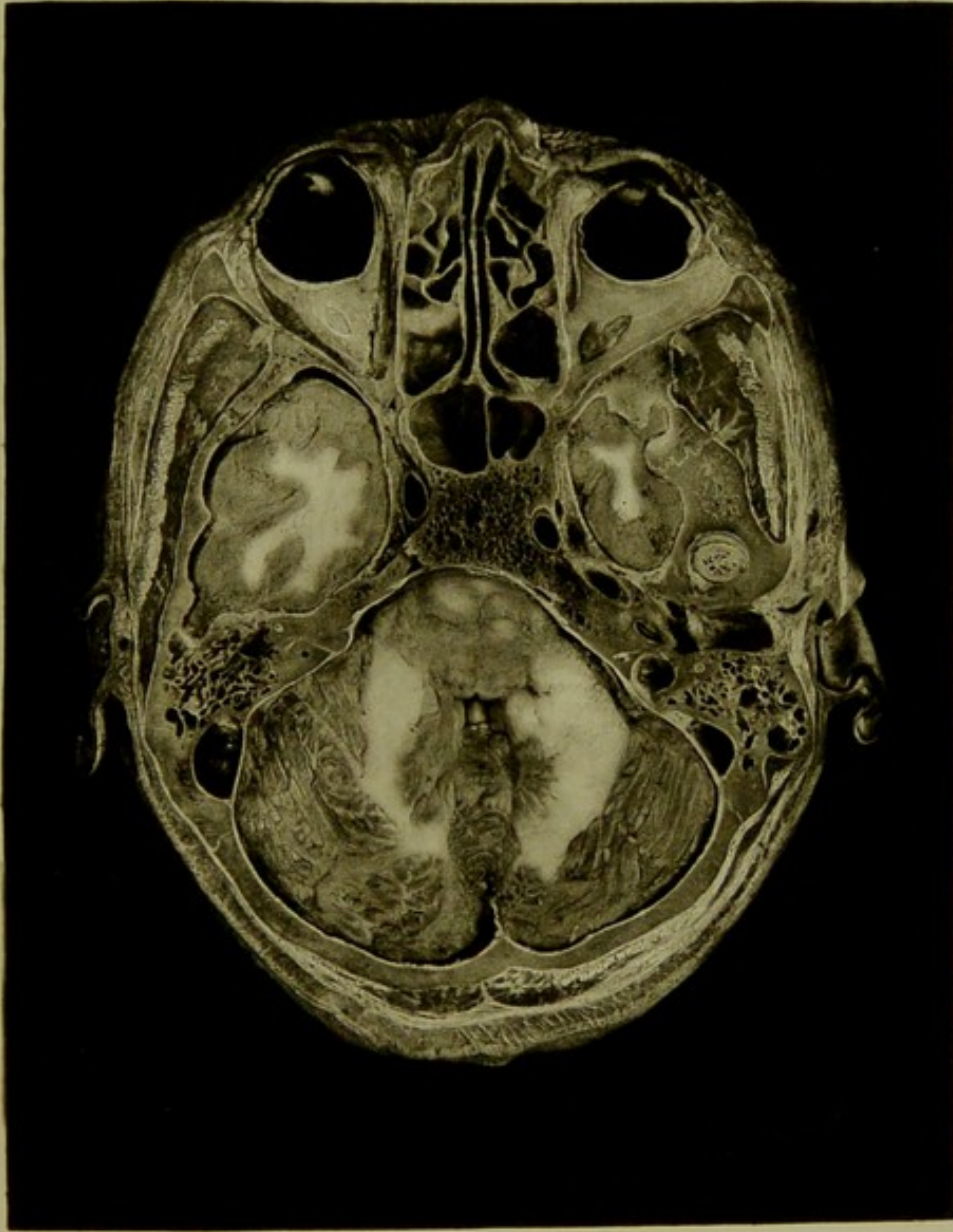


Male, 50 years.

Scale $\frac{88}{55} = \frac{2}{8}$ Approx.

I. HORIZONTAL SECTION, cut obliquely, seen from below. It passes through both eyeballs, the ethmoidal and sphenoidal cells, the floors of both middle fossæ, and the greater part of the posterior fossa of skull. On right side (left of photo.) there are seen, cancellated tissue in mastoid process, internal carotid artery, Gasserian ganglion in Meckel's space, the orifice of superior petrosal in sigmoid sinus, and the communications between sphenoidal cells and nasal fossæ. On left side, the upper and outer part of the digastric fossa, the external auditory meatus, membrana tympani, tympanic cavity with its ossicles, the cochlea, the facial nerve, the descending portion of sigmoid sinus, and the dome of the jugular fossa are all well marked. The upper limit of the dome of the jugular fossa is on the same plane as the roof of the glenoid fossa.

PLATE N° 64



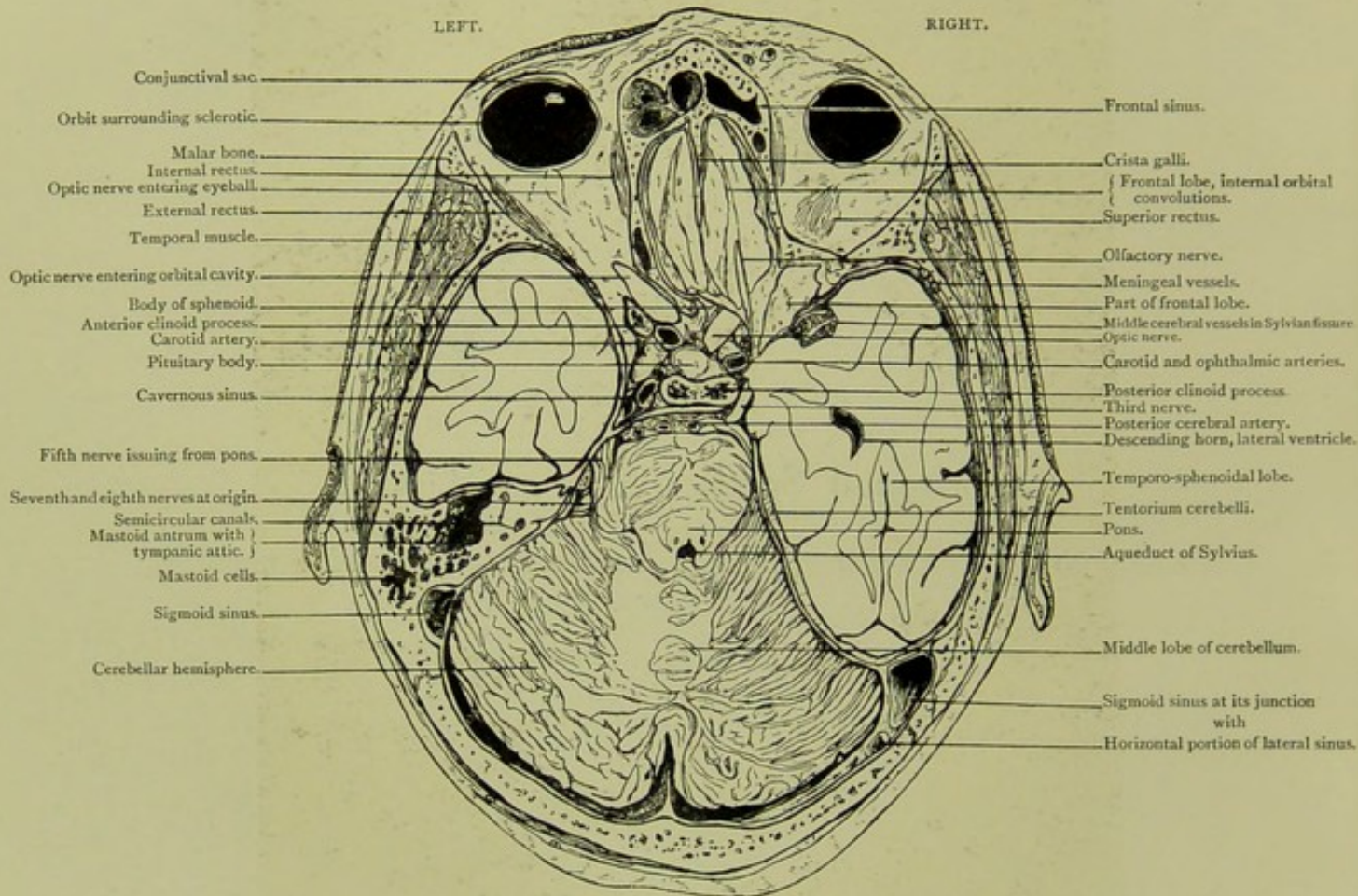


Horizontal Section. Series B. II.

*CUT OBLIQUELY, SEEN FROM ABOVE, A QUARTER OF AN INCH ABOVE LEVEL OF
SECTION I.*

HORIZONTAL SECTION.

Series B. II.

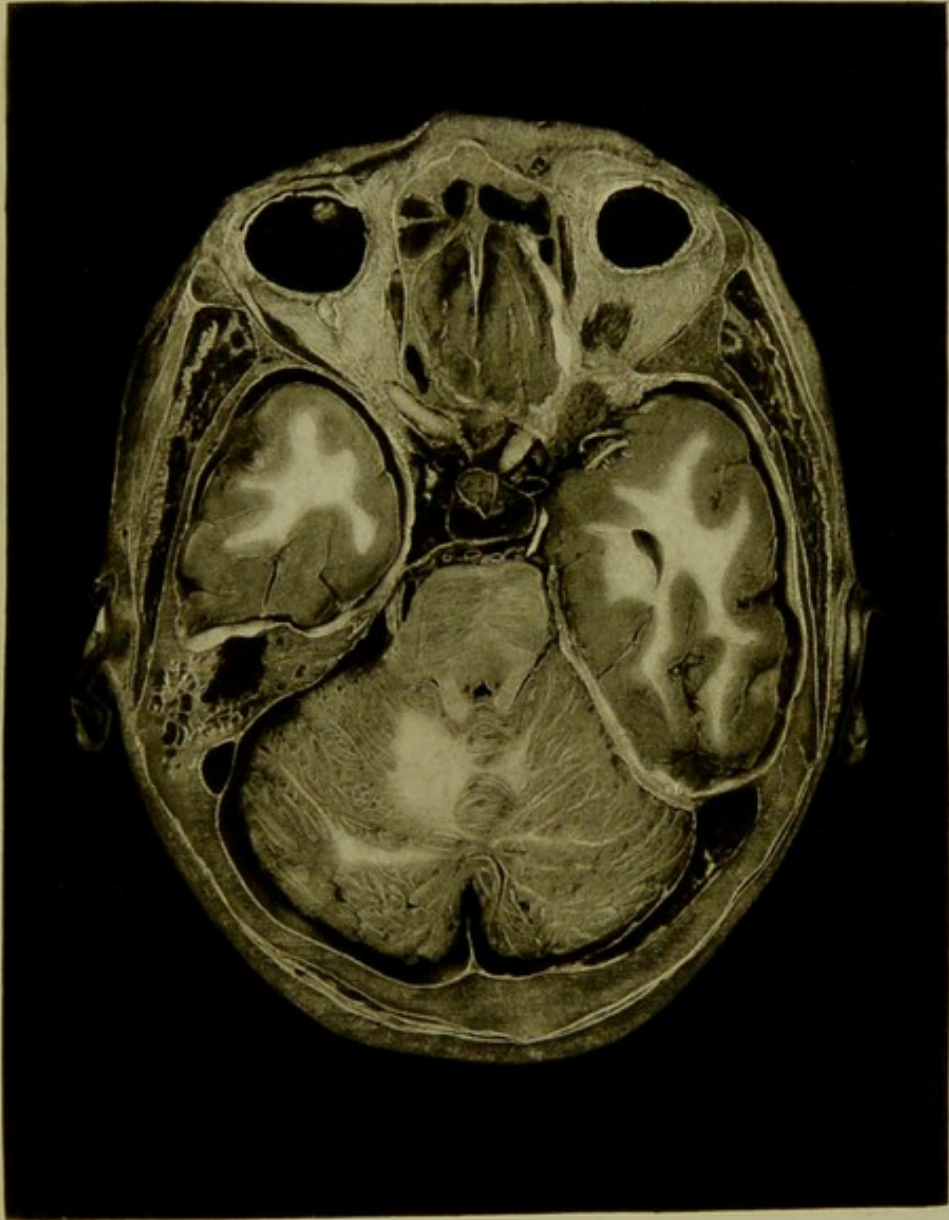


Male, 50 years.

Scale $\frac{87}{51} = \frac{2}{3}$ Approx.

II. HORIZONTAL SECTION, cut obliquely, seen from above, a quarter of an inch above level of section I. The three fossæ of the skull are exposed. The orbital convolutions alone of the frontal lobe are seen. On the *left* side the mastoid antrum in its connection with the middle ear. On the *right* side the descending horn of the lateral ventricle, and the position of the third nerve placed between the temporo-sphenoidal lobe and posterior clinoid process are well seen. The carotid artery in relation to the cavernous sinus, is better seen in the specimen than in the photograph.

PLATE NO 45.



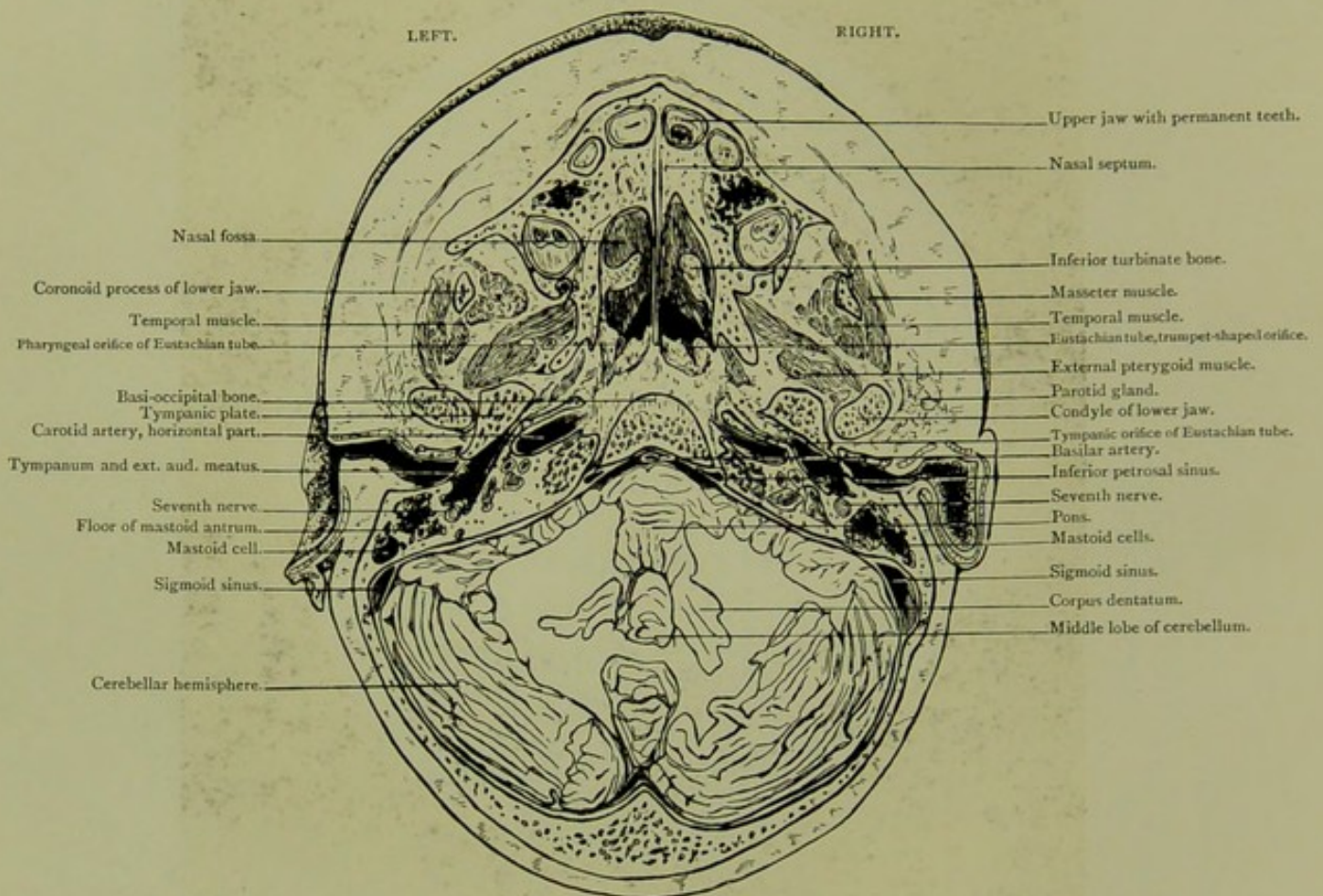


Horizontal Section, Series C. I.

SEEN FROM ABOVE.

HORIZONTAL SECTION.

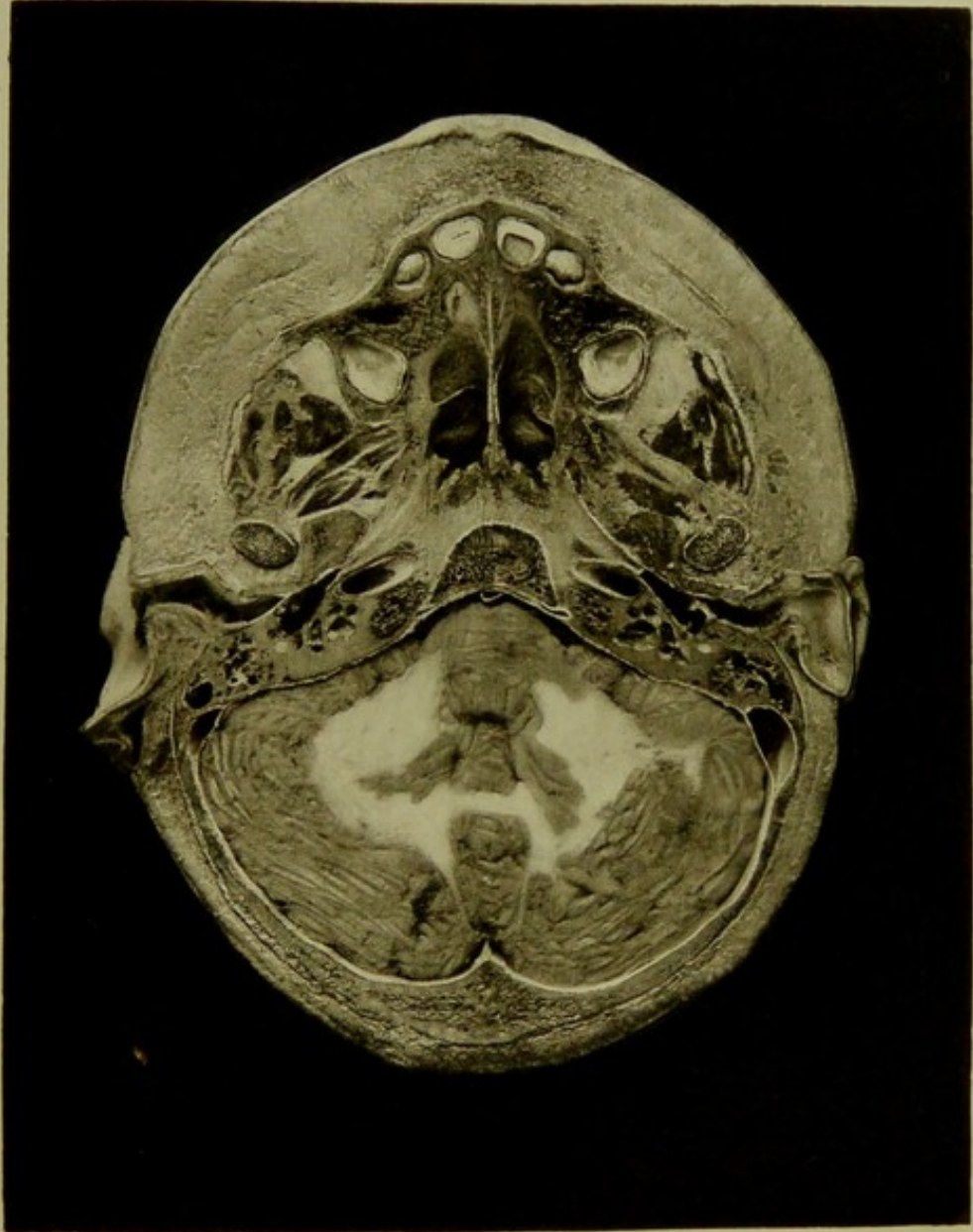
Series C. I.




Male, 5 years.

Scale $\frac{44}{68} = \frac{2}{3}$ Approx.

I. HORIZONTAL SECTION, seen from above, passing through alveolar process of upper jaw, the external and middle ears, showing relations of carotid artery to Eustachian tube, of seventh nerve to tympanum. The tympanic membrane with its ossicles, and the semi-circular canals are shown. Behind are the pons, fourth ventricle, corpora dentata, and cerebellar hemispheres. The developing teeth with their pulp cavities are seen.



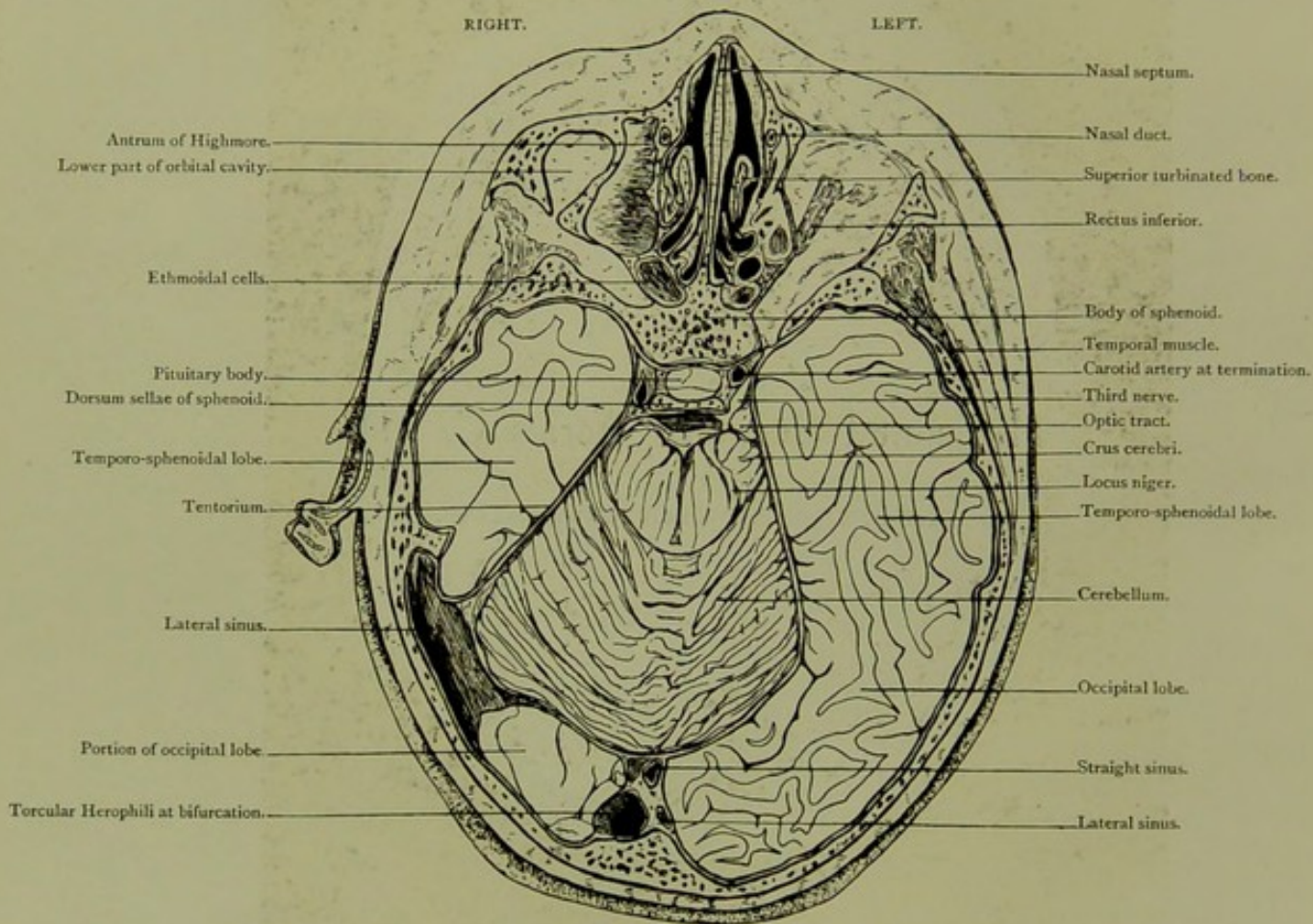


Horizontal Section. Series C. II.

CUT OBLIQUELY, SEEN FROM BELOW.

HORIZONTAL SECTION.

Series C. II.

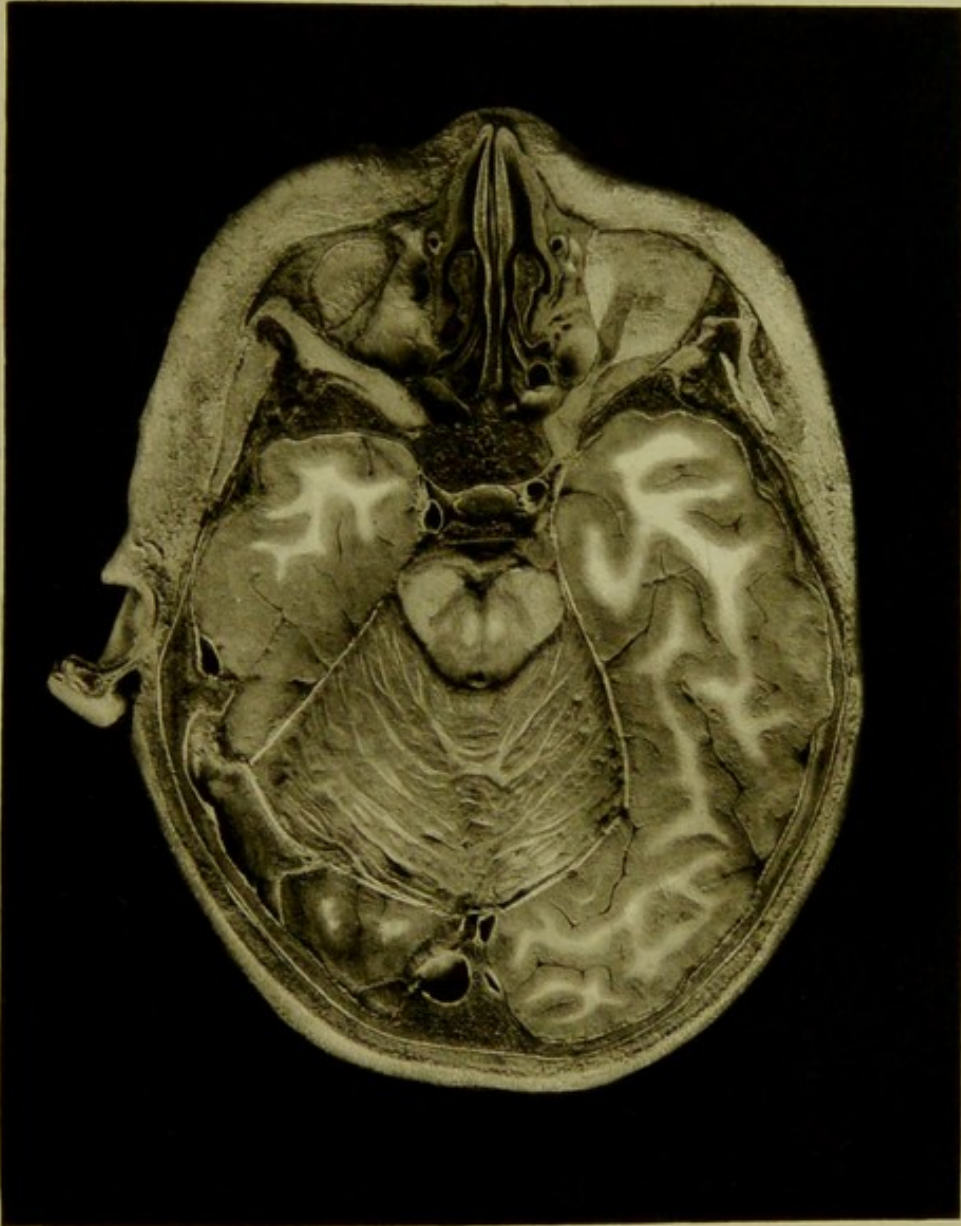


Male, 5 years.

Scale $\frac{48}{70} = \frac{2}{3}$ Approx.

II. HORIZONTAL SECTION, cut obliquely, seen from below, shows relations of temporo-sphenoidal lobe to occipital lobe, third nerve, crura cerebri, cerebellum and lateral sinus.

PLATE No 47



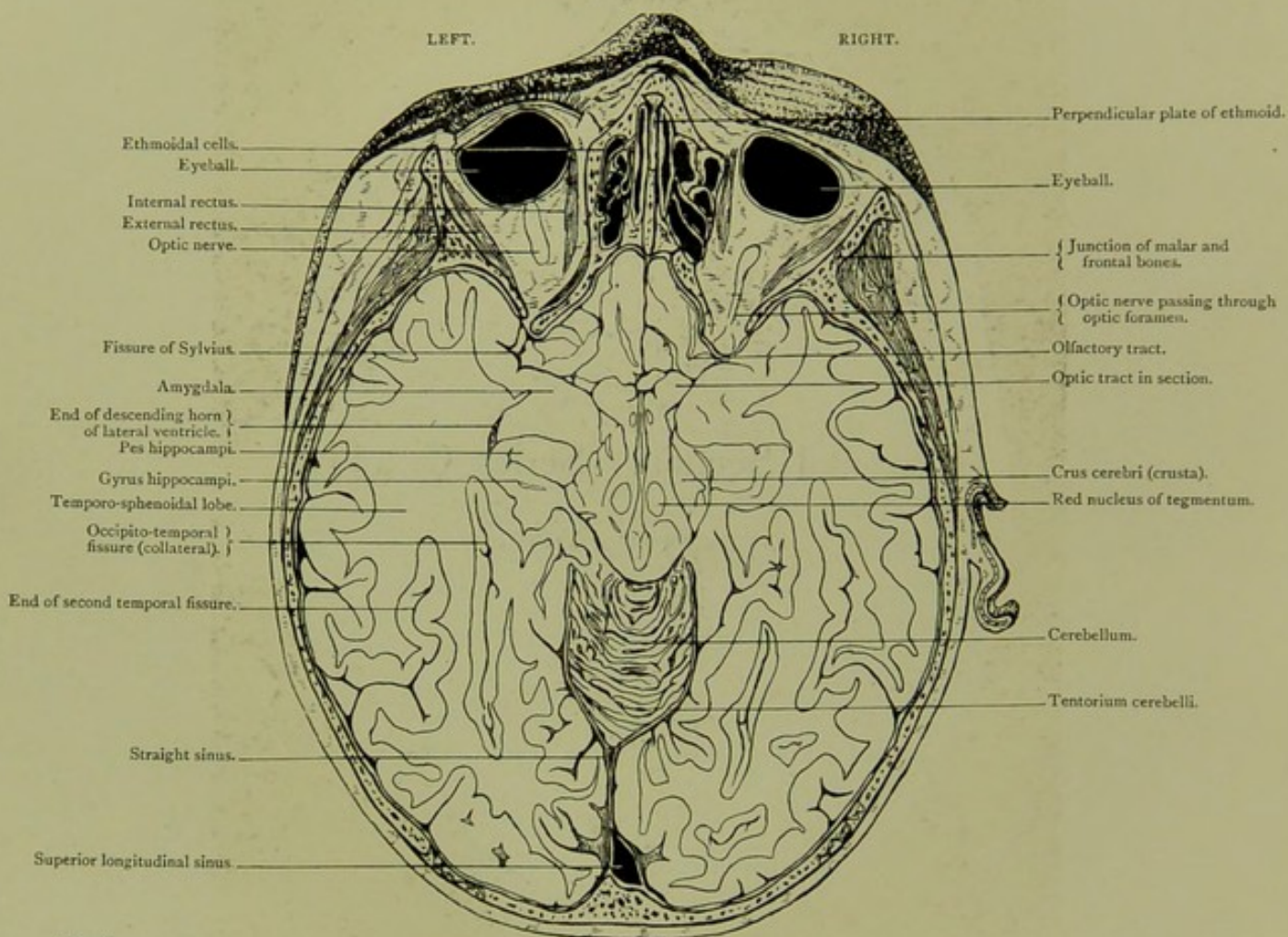


Horizontal Section. Series C. III.

SEEN FROM ABOVE.

HORIZONTAL SECTION.

Series C. III.

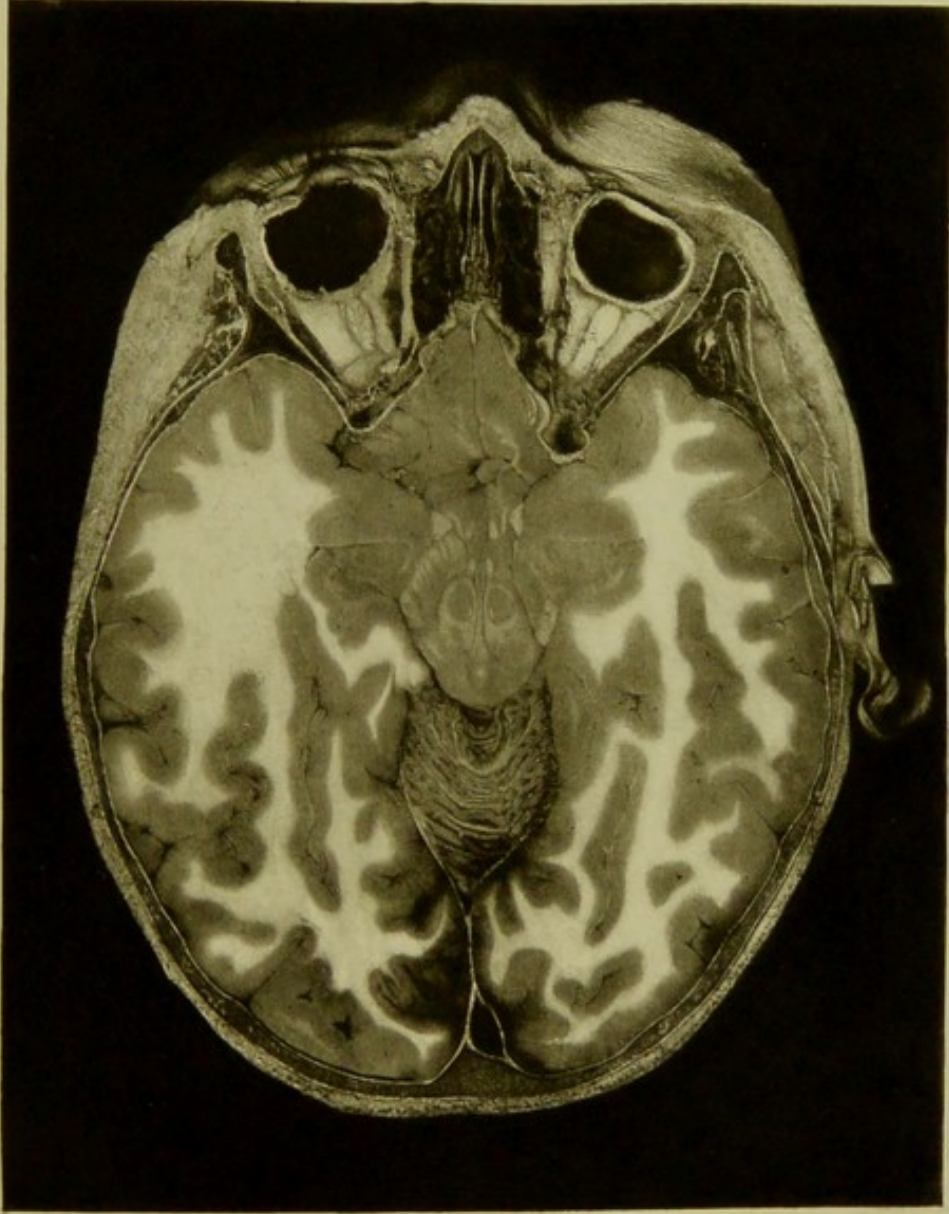



Male, 5 years.

Scale $\frac{49}{68} = \frac{3}{4}$ Approx.

III. HORIZONTAL SECTION, seen from above, at level of middle of orbits and internal occipital protuberance,—and traversing temporo-sphenoidal and occipital lobes with crura cerebri and upper portion of cerebellum. A minute portion of frontal lobe is seen anteriorly.

PLATE Nº 46.



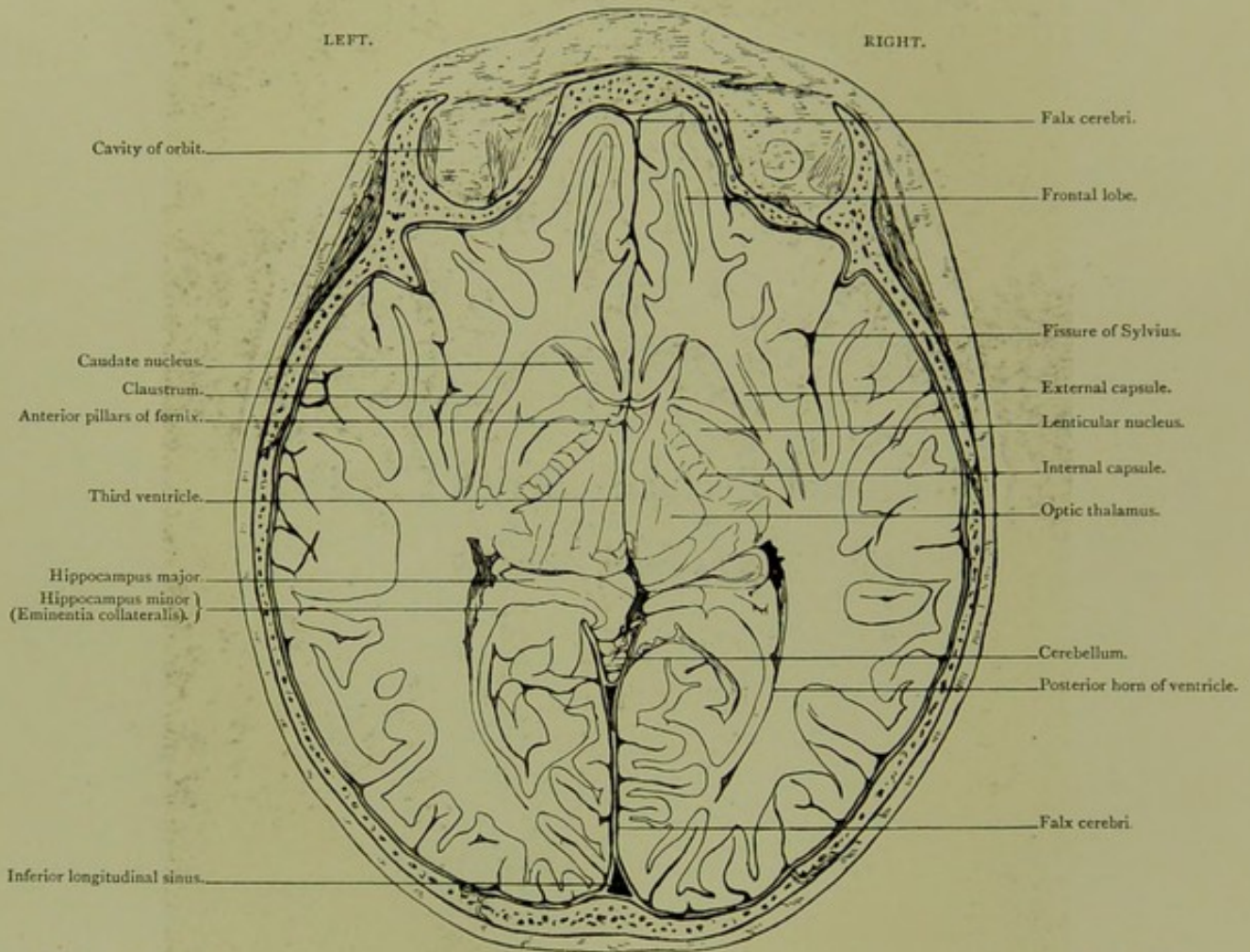


Horizontal Section. Series C. IV.

SEEN FROM ABOVE.

HORIZONTAL SECTION.

Series C. IV.

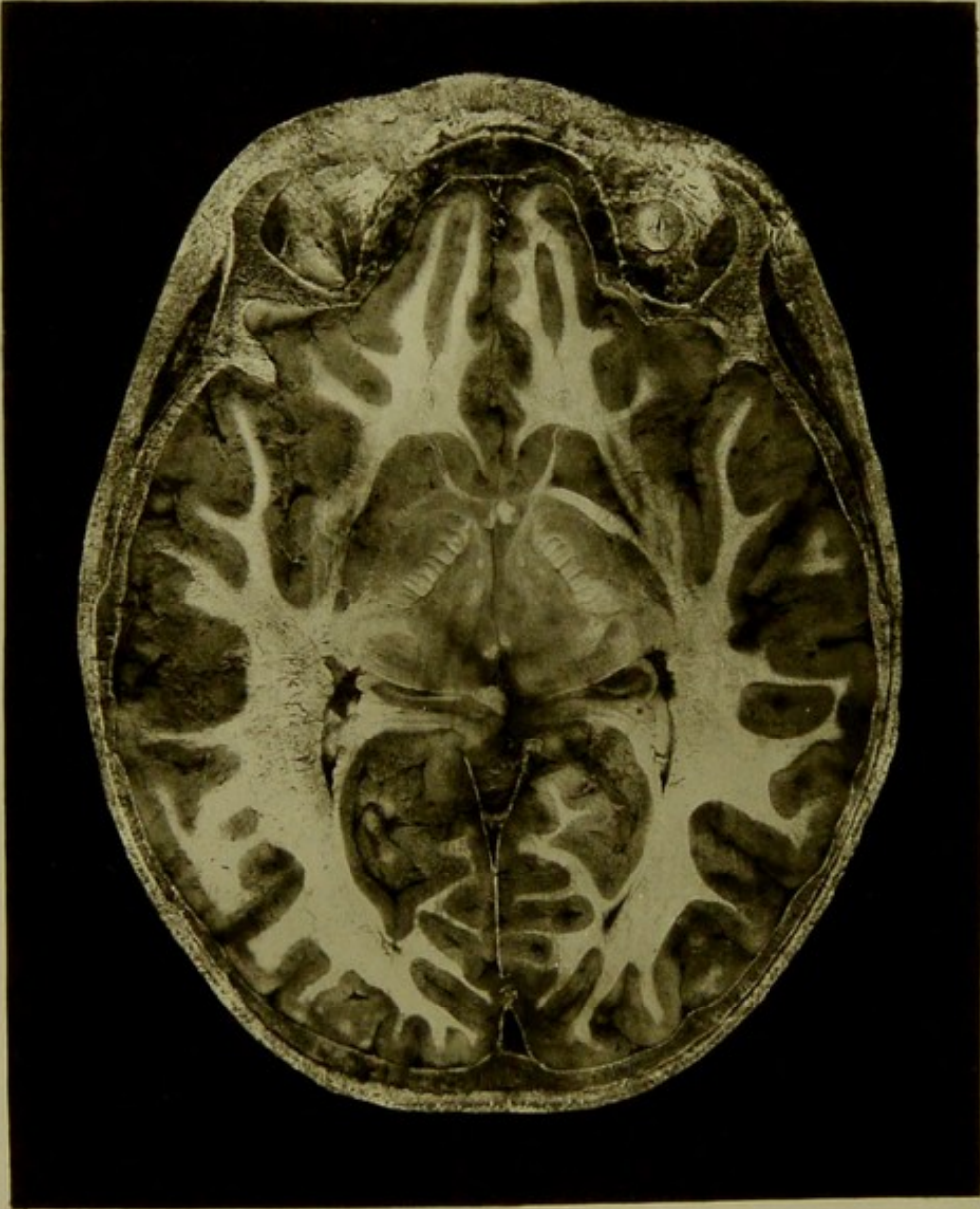



Male, 5 years.

Scale $\frac{42}{58} = \frac{3}{4}$ Approx.

IV. HORIZONTAL SECTION, seen from above, passing through skull at level of upper third of orbit and tip of auricle, exposing basal ganglia, internal and external capsules, claustrum, anterior pillars of fornix, junction of descending and posterior horns of lateral ventricles, third ventricle, and upper limit of cerebellum below origin of straight sinus.

PLATE No 49 .



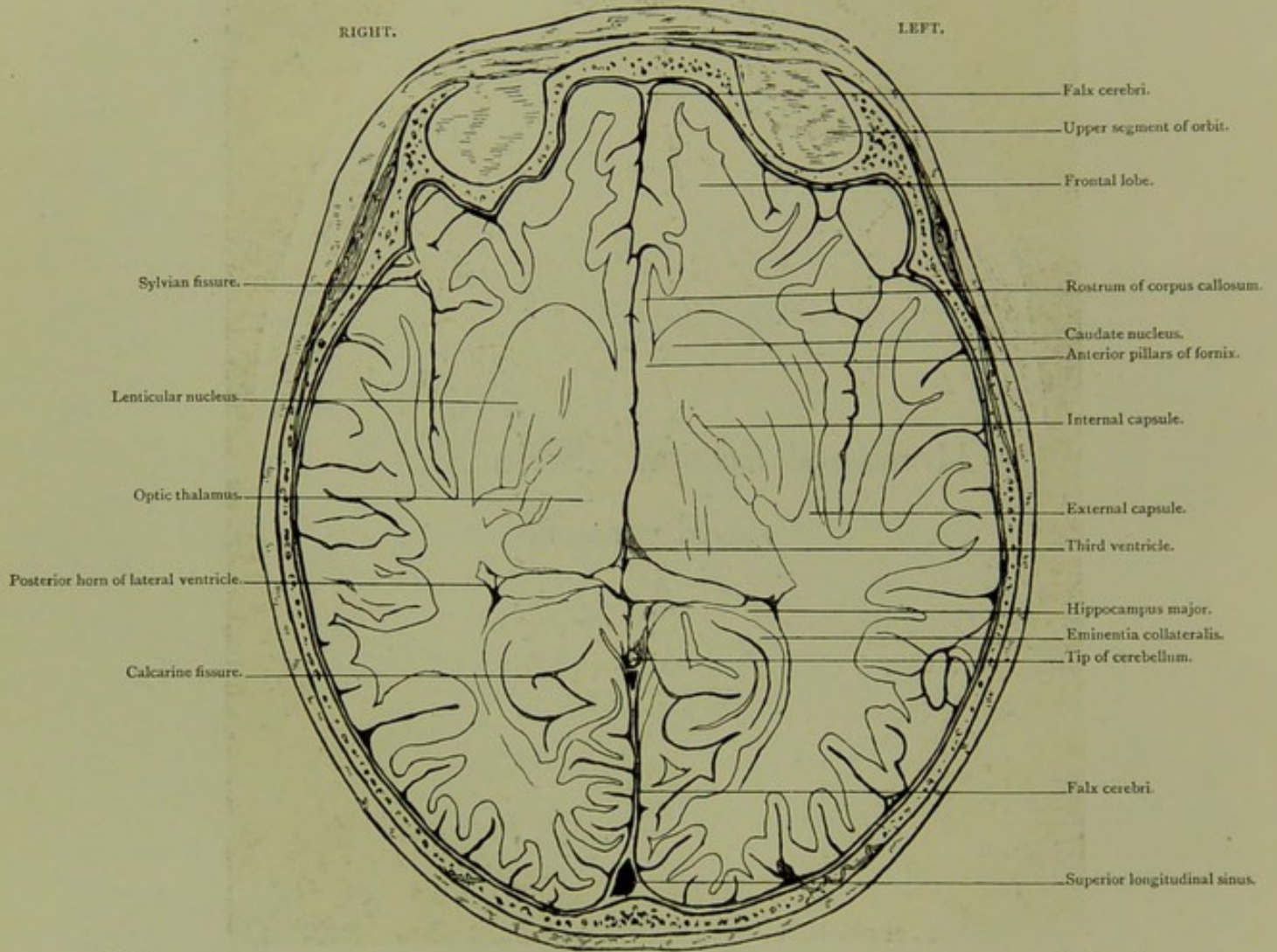


Horizontal Section. Series C. V.

SEEN FROM BELOW.

HORIZONTAL SECTION.

Series C. V.

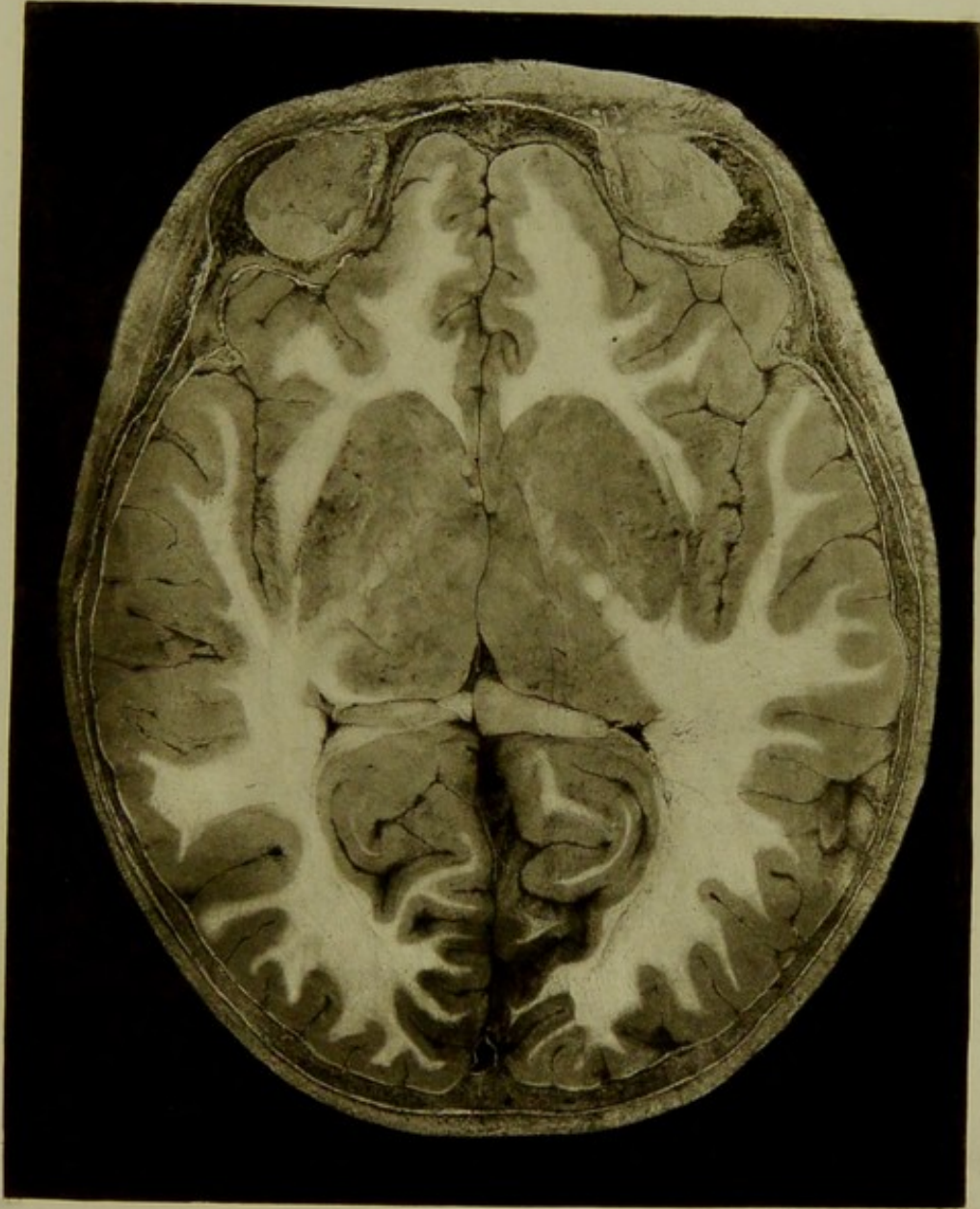


Male, 5 years.

Scale $\frac{54}{60} = \frac{3}{4}$ Approx.

V. HORIZONTAL SECTION, seen from below, passing through, lower parts of basal ganglia, third ventricle, and posterior horns of lateral ventricles.

PLATE No 50



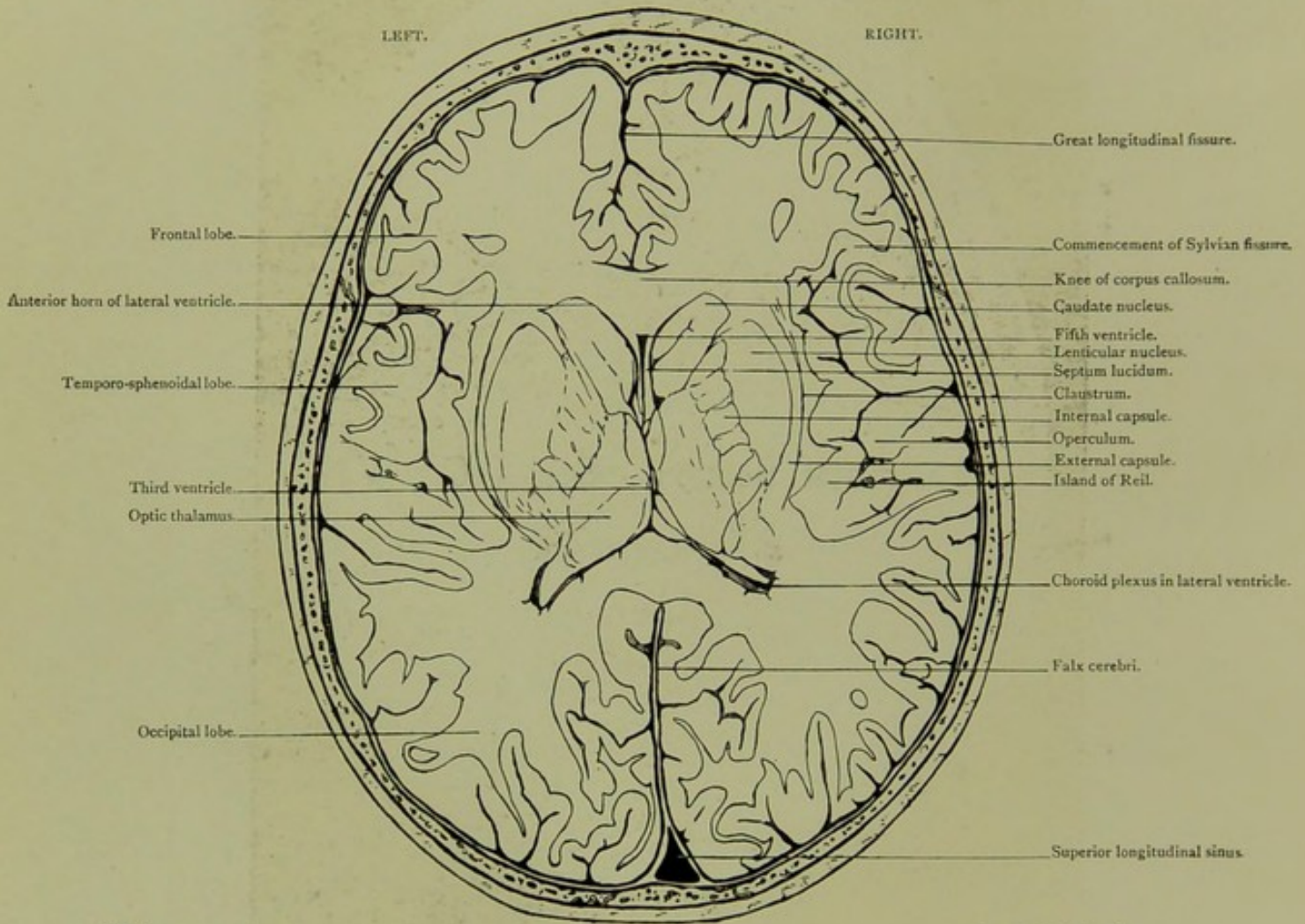


Horizontal Section. Series C VI.

SEEN FROM ABOVE.

HORIZONTAL SECTION.

Series C. VI.

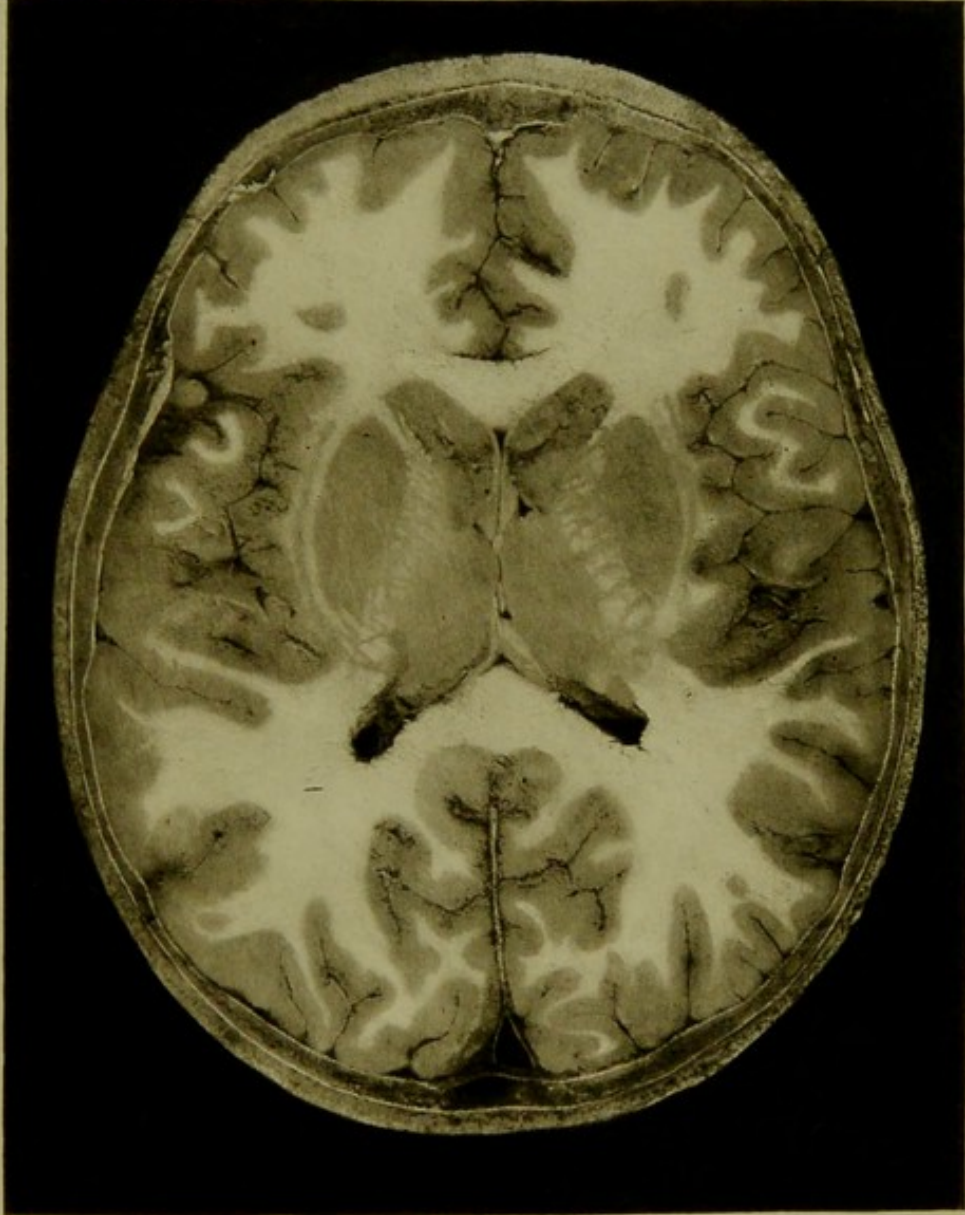



Male, 5 years.

Scale $\frac{52}{68} = \frac{3}{4}$ Approx.

VI. HORIZONTAL SECTION, seen from above, passing through basal ganglia, operculum, island of Reil, temporo-sphenoidal and occipital lobes, showing portions of third, fifth, and lateral ventricles.

PLATE No 51.



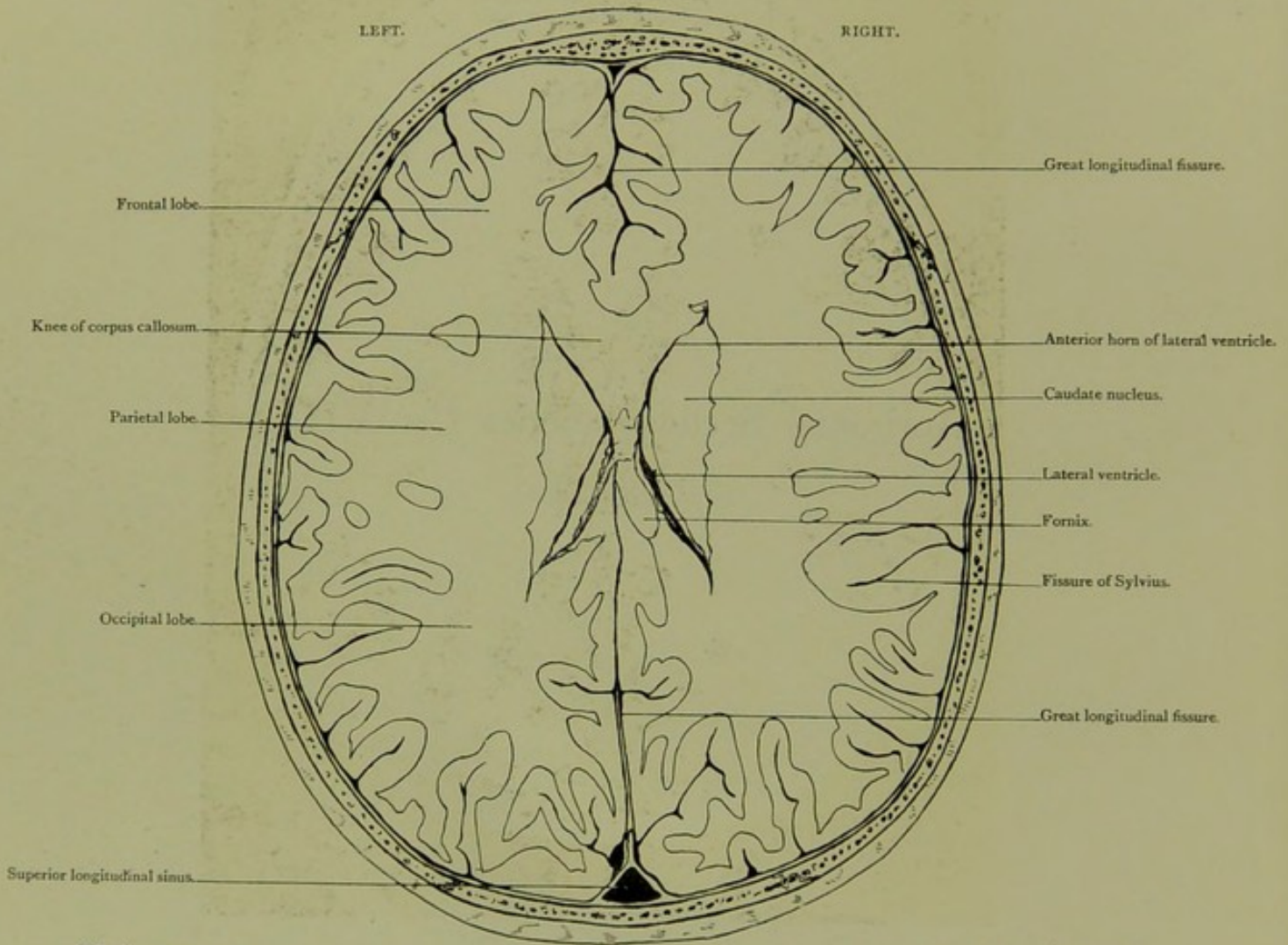


Horizontal Section. Series C. VII.

SEEN FROM ABOVE.

HORIZONTAL SECTION.

Series C. VII.

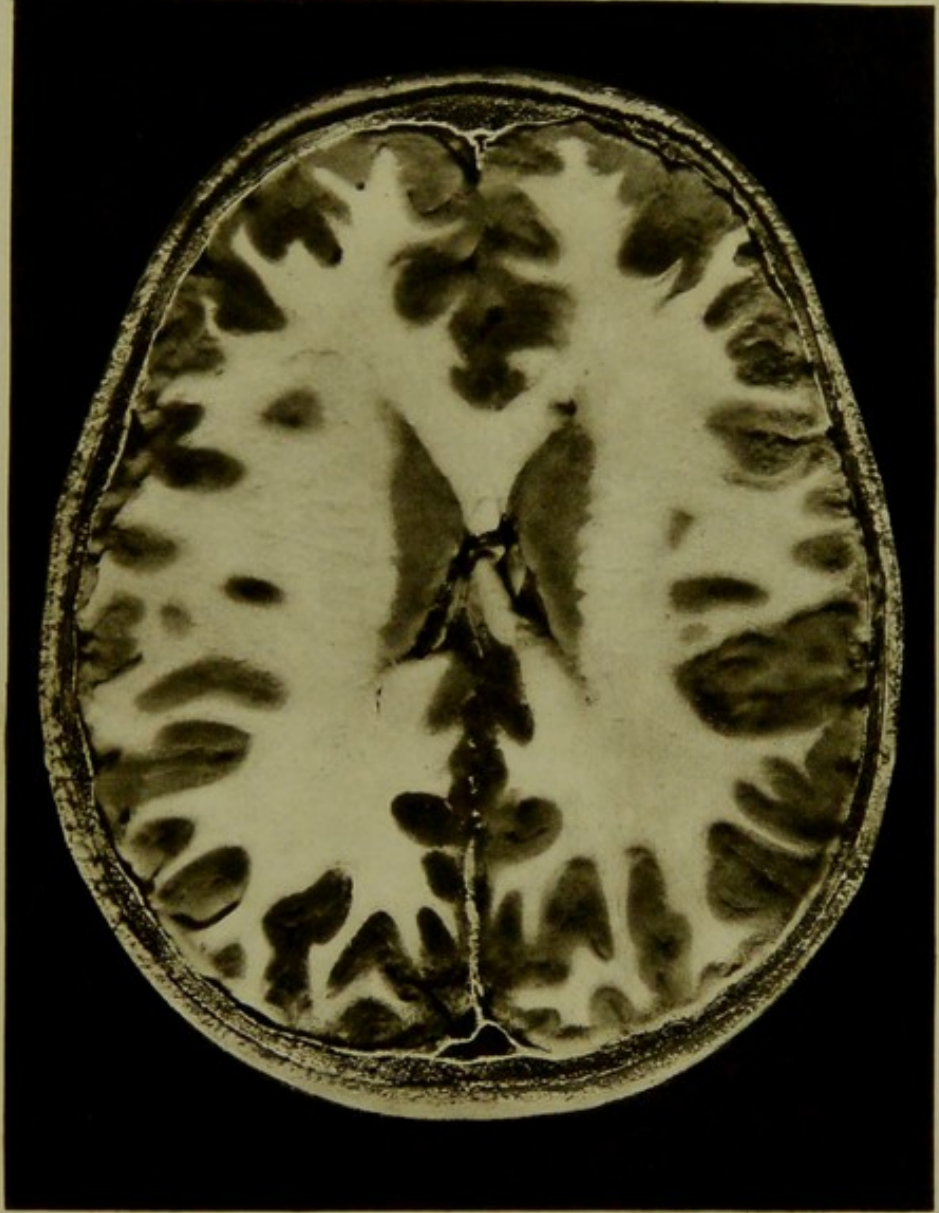



Male, 5 years.

Scale $\frac{54}{61} = \frac{3}{4}$ Approx.

VII. HORIZONTAL SECTION, seen from above, exposing upper limits of lateral ventricles.

PLATE No. 52.



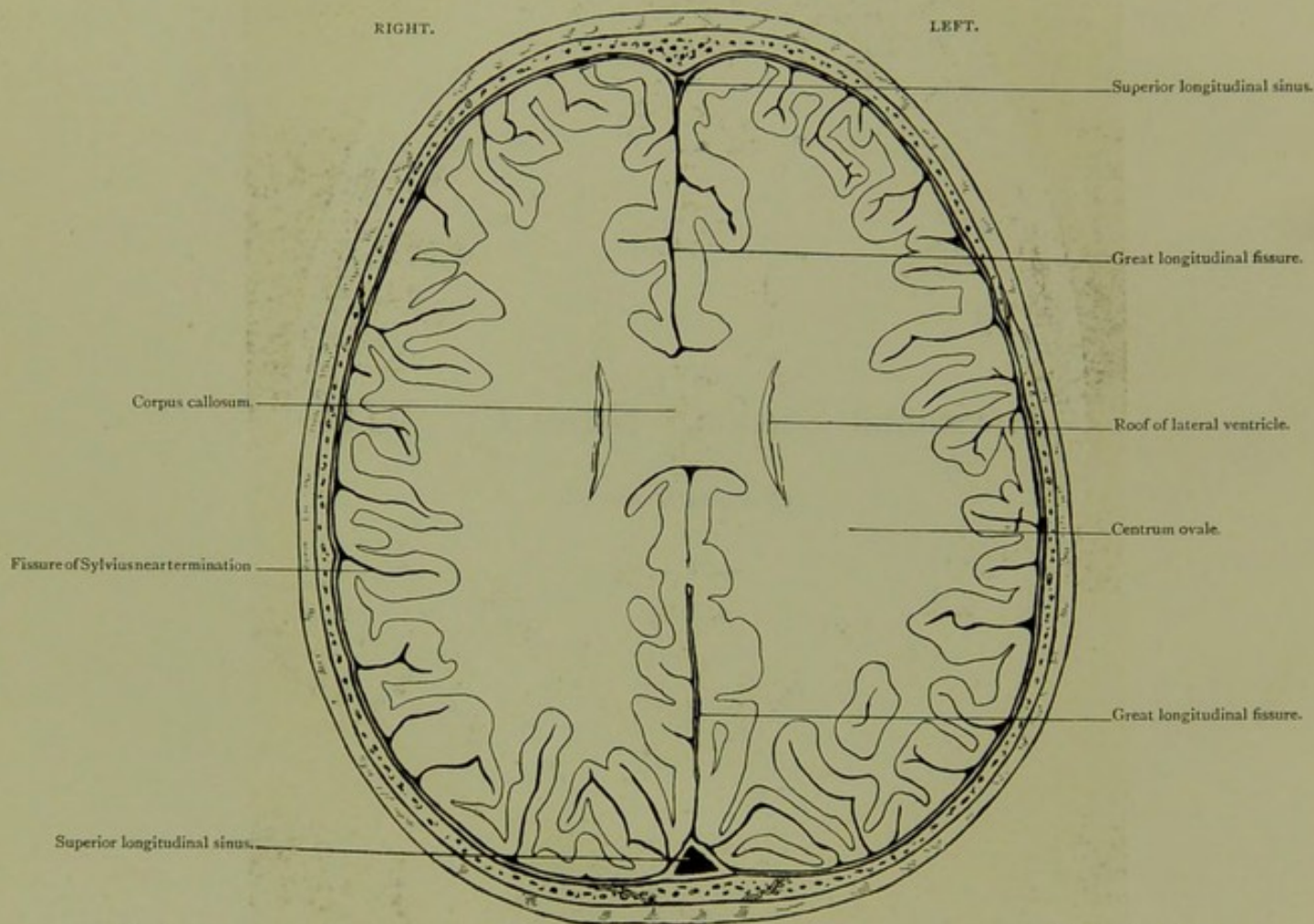


Horizontal Section. Series C. VIII.

SEEN FROM BELOW.

HORIZONTAL SECTION.

Series C. VIII.

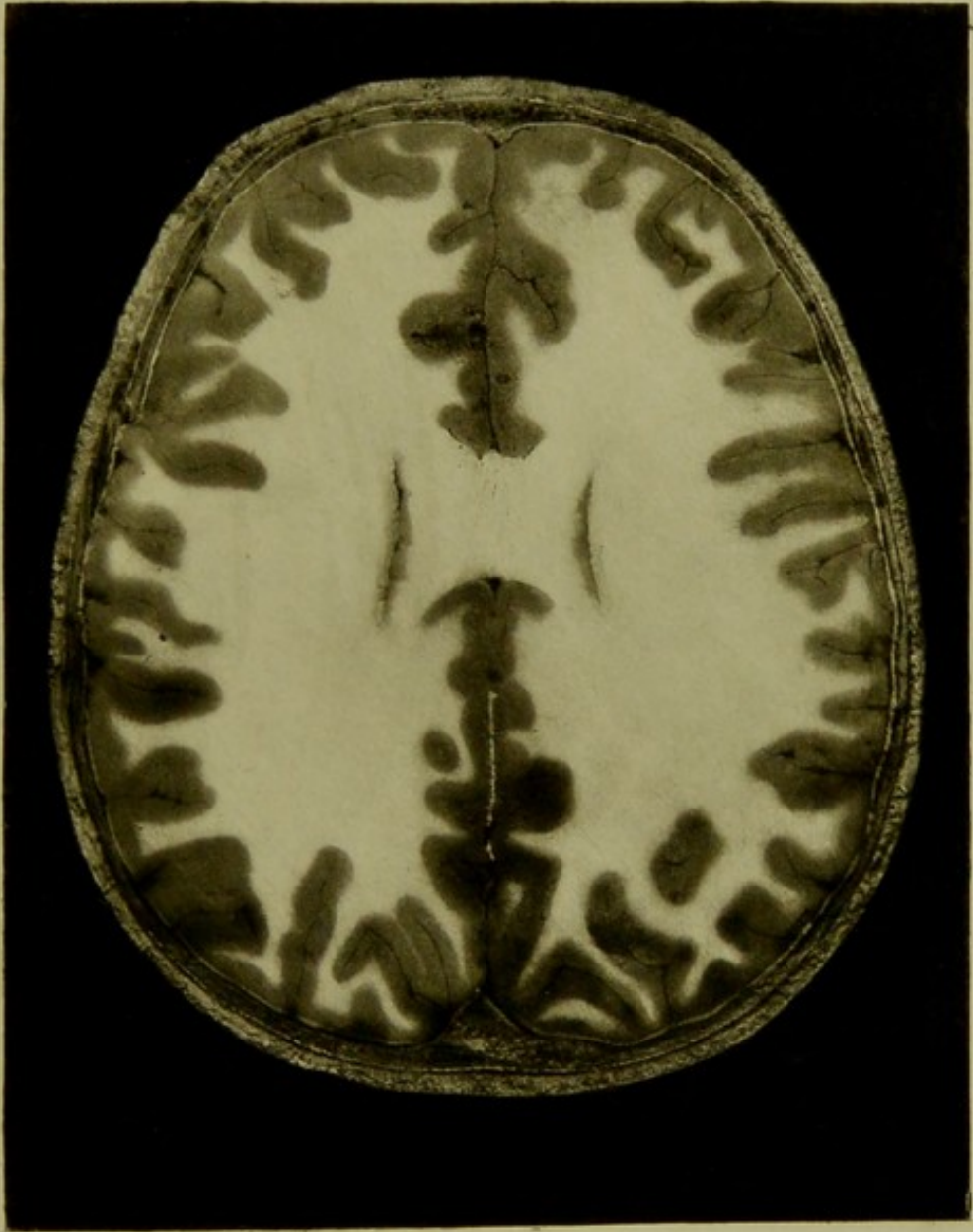



Male, 5 years.

Scale $\frac{50}{65} = \frac{8}{4}$ Approx.

VIII. HORIZONTAL SECTION, seen from below, through centrum ovale, and roof of lateral ventricles.

PLATE N° 53.





INDEX.

The figures refer to the numbers of the Plates.


- Amygdala of cerebellum, 18, 36, 37.
— of temporo-sphenoidal lobe, 48.
Antrum mastoidium, 8, 9, 17, 23, 26, 27, 33 to 35, 40, 44 to 46.
— of Highmore, 1 to 3, 31, 32, 37, 38, 47.
Aqueduct of cochlea, 32.
— of Fallopius, 17, 28, 29, 33, 39, 40, 44, 46.
— of Sylvius, 39 to 41, 45.
Artery, anterior cerebral, 14, 15.
— ascending palatine, 34.
— basilar, 7, 39, 40, 41, 44, 46.
— external carotid, 22, 33, 36.
— facial, 3, 14, 15, 33, 34, 35.
— facial superficial, 35.
— inferior dental, 1 to 4, 14, 15, 21, 33, 34.
— internal carotid in cavernous sinus, 5, 6, 15, 22, 44.
— — in neck, 6, 36 to 38.
— — in petrous bone, 30 to 32, 39, 40, 44, 46.
— — terminal portion, 5, 15, 41, 42, 45, 47.
— internal maxillary, 4, 5, 14, 15, 21, 28, 33, 34, 36, 37, 41.
— lingual, 12, 14, 15.
— middle cerebral, 5, 6, 15, 16, 22, 29, 30, 31, 43, 45.
— middle meningeal, 25, 35, 39, 45.
— occipital, 8 to 11, 18 to 20.
— ophthalmic, 14, 45.
— posterior cerebral, 16 to 20, 45.
— posterior communicating, 22.
— transverse facial, 35.
— vertebral, 7 to 9, 16 to 18, 23, 30 to 32, 36 to 38.
Articulation, atlanto-axoid, 36.
— occipito-atlantoid, 31.
— temporo-maxillary, 5, 6, 26, 33, 35.
Auricle, 6 to 9, 16 to 18, 22, 23, 36 to 42, 44 to 48.
Auriculo-bregmatic plane, sections in, 7, 16.
Bone, atlas, 7, 8, 16 to 20, 23, 29 to 33, 36.
— — neural arch, 36.
— — transverse process, 29, 33.
— axis, 7, 19, 22, 23, 30.
Bone, axis, odontoid process, 16, 17, 22, 23, 36.
— ethmoid, 1 to 3, 40, 42, 44, 45, 47, 48.
— — cells, 1 to 3, 40, 44, 47, 48.
— — cribriform plate, 1 to 3.
— — crista galli, 1, 42, 45.
— frontal, 1 to 3, 25, 26, 35, 48.
— — external angular process, 1, 26, 35.
— — orbital plates, 1 to 3.
— hyoid, 2, 3, 14, 15, 30.
— inferior maxilla, 1 to 6, 14, 15, 21, 22, 26 to 38, 46.
— — angle, 35.
— — condyle, 22, 26 to 29, 33 to 35, 38, 46.
— — coronoid process, 3, 28, 29, 34, 46.
— — ramus, 4 to 6, 14, 15, 21, 33, 36, 37.
— malar, 1, 26 to 29, 33 to 35, 37 to 39, 44, 45, 48.
— nasal, 39.
— occipital, basi-, 46.
— — condyles, 7, 8, 16, 17, 19, 23, 31, 37.
— — internal protuberance, 13, 42, 47.
— parietal, antero inferior angle, 25, 35.
— — eminence, 10, 11.
— sphenoid, 4 to 6, 14, 15, 21, 39 to 41, 44, 45, 47.
— — basi-, 22, 39.
— — cells of, 4 to 6, 14, 39 to 41, 44.
— — dorsum sellae, 47.
— — great wing, 21, 26, 33.
— — small wing, 4, 21, 33.
— — rostrum, 4, 14, 21.
— — anterior clinoid process, 5, 14, 41, 45.
— — middle clinoid process, 41.
— — posterior clinoid process, 6, 41, 42, 45.
— — external pterygoid process, 4, 14, 21, 37.
— — hamular process, 31, 36.
— — internal pterygoid process, 4, 14, 37.
— superior maxilla, 1 to 3, 30 to 32, 36, 46.
— temporal, eminentia articularis, 26, 27, 33 to 35.
— — squamous, 25, 26, 35.
— — mastoid, 8, 9, 18 to 20, 25 to 27, 33 to 35, 38 to 41, 44 to 46.


- Bone, temporal, petrous, 7 to 9, 16, 17, 22, 23, 26 to 34, 39 to 42, 44 to 46.
- — styloid, 28, 29, 34, 36, 37.
 - — tympanal, 33, 34, 46.
 - — tympanic ossicles, 7, 16, 28, 33, 39, 40, 44, 46.
 - turbinal, inferior, 1 to 3, 30, 46.
 - — middle, 1 to 3, 39.
 - — superior, 47.
 - vomer, 3.
 - zygoma, 2 to 5, 14, 15, 21, 25, 39.
- Buccal cavity, 1 to 3, 36.
- Canal, facial, *vide* aqueduct of Fallopius.
- inferior dental, 1 to 4, 14, 21, 33, 34.
 - vidian, 14, 15, 21.
- Centrum ovale, 53.
- Cerebellum, falx, 12.
- flocculus, 8, 16, 17, 39, 41.
 - hemisphere, 9 to 11, 18 to 20, 24, 26 to 34, 40 to 42, 44 to 49.
 - middle lobe, 10, 11, 20, 24, 39 to 42, 44 to 46, 50.
 - peduncles of, 8, 9, 17 to 19.
 - corpus dentatum, 10, 20, 46.
 - lower limit of, 18, 36, 37.
 - upper limit of, 49, 50.
 - ventricle, fourth, 9, 18, 44.
- Cerebral fissure, calcarine, 10 to 12, 19, 20, 24, 28, 29, 31, 50.
- calloso-marginal, 2 to 9, 14 to 19, 21 to 23, 28 to 32, 43, 50 to 53.
 - collateral, 2, 4, 28, 48.
 - dentate, 9, 30.
 - great longitudinal, 1 to 24, 43, 48 to 53.
 - intra-parietal, 10 to 12, 24, 27, 33.
 - olfactory, 2, 3, 14, 21.
 - parallel, 7 to 9, 15 to 18, 22, 23, 25 to 27, 33 to 35.
 - parieto-occipital, 12, 26 to 31, 43.
 - Rolandic, 7 to 9, 16 to 19, 23, 25 to 35, 52, 53.
 - Sylvian, 4 to 10, 14 to 19, 21 to 29, 31 to 35, 43, 45, 48 to 53.
 - — ascending limb, 4, 15, 33, 34, 51, 52.
 - — transverse, 8, 9, 16, 23.
- Cerebrum, angular gyrus, 11, 25, 26, 34.
- ascending frontal convolution, 7 to 9, 16 to 18, 23, 25 to 34, 51 to 53.
 - ascending parietal convolution, 8 to 10, 17 to 19, 20, 23, 25 to 35, 51 to 53.
 - caudate nucleus, 7, 8, 15 to 17, 22, 23, 43, 49 to 52.
 - claustrum, 7 to 9, 16, 17, 22, 23, 43, 49 to 51.
 - corpora quadrigemina, 18.
 - corpus callosum, 4 to 9, 14 to 20, 22, 23, 43, 50 to 53.
 - — forceps, 43.
 - — genu, 14, 43, 51, 52.
 - — rostrum, 50.
 - — splenium, 19, 43.
 - corpus striatum, 5, 6.
 - crus, 7, 9, 17, 19, 23, 42, 47, 48.
- Cerebrum, crus, crista, 23.
- cuneus, 12, 28 to 31.
 - external capsule, 7 to 9, 16, 17, 22, 23, 43, 49 to 51.
 - falx, 1 to 22, 42, 43, 48 to 53.
 - fornicate gyrus, 3 to 9, 14 to 24, 43, 50 to 53.
 - fornix, 9, 16, 17, 22, 43, 49, 50, 52.
 - frontal lobe, first frontal, 1 to 7, 14 to 16, 21, 22, 27, 28 to 31.
 - — second frontal, 1 to 6, 14 to 16, 21, 22, 26 to 32, 52.
 - — third frontal, 2 to 4, 14, 15, 21, 22, 26 to 34, 43, 49 to 51.
 - — orbital convolution, 1, 2, 41, 42, 44, 45, 49 to 52.
 - fusiform lobule, 28.
 - gyrus hippocampi, 7, 8, 23, 48.
 - hippocampus major, 8, 16, 17, 30, 31, 48 to 50.
 - hippocampus minor or eminentia collateralis, 19, 20, 49, 50.
 - island of Reil, 7 to 9, 15 to 17, 12, 28 to 32, 43, 51.
 - internal capsule, 7 to 9, 16, 17, 22, 23, 43, 49 to 51.
 - lenticular nucleus, 7 to 9, 16, 17, 22, 23, 30, 43, 49, 50.
 - lingual lobule, 28, 43.
 - locus niger of crus, 7, 17, 47.
 - occipital lobe, 10 to 13, 20, 26 to 32, 42, 47, 51, 52.
 - olfactory tract, 48.
 - operculum, 7, 8, 27 to 29, 33, 43, 51.
 - optic chiasma, 5, 6, 22.
 - optic thalamus, 7 to 9, 16, 17, 23, 43, 49, 51.
 - optic tract, 23, 47, 48.
 - paracentral lobule, 8, 9, 30.
 - pineal gland, 18.
 - pituitary body, 5, 6, 15, 22, 41, 42, 45, 47.
 - quadrate lobule, 10 to 12, 29 to 31.
 - red nucleus of crus, 17, 48.
 - septum lucidum, 15, 22, 43, 51.
 - supra-marginal lobule, 10, 24 to 26, 34, 53.
 - temporo-sphenoidal lobe, 4 to 9, 14 to 35, 40 to 45, 47 to 51.
 - ventricle, lateral, 6 to 9, 16 to 18, 23, 24, 43, 52, 53.
 - — — anterior horn, 5, 14, 15, 21, 22, 43, 51, 52.
 - — — descending horn, 10, 18, 30 to 32, 45, 48.
 - — — posterior horn, 11, 12, 19, 20, 43, 49, 50.
 - — — choroid plexus, 18, 43, 51.
 - — — third, 7 to 9, 16, 17, 22, 23, 43, 49 to 51.
 - — — iter, 9.
 - — — fifth, 15, 22, 43, 51.
- Cochlea, 7, 16, 29, 39, 40, 44.
- Conjunctival sac, 44, 45.
- Cyst in antrum of Highmore, 38.
- Epiglottis, 4, 21.
- Eustachian tube, pharyngeal orifice, 4, 14, 30, 37, 46.
- cartilaginous portion, 5, 6, 15, 31, 32, 38.
 - tympanic orifice, 29, 46.
- Eye-ball, 1, 28 to 34, 39 to 42, 44, 48.
- Fenestra ovalis, 40.
- Fissure, sphenoidal, 4, 14, 41, 42.

- Fossa, digastric, 9, 18, 44.
 — glenoid, 44.
 — jugular, *vide* Foramen jugular.
 — middle cranial, floor, 39, 40, 44.
 — nasal, 1 to 3, 37 to 40, 44, 47.
 Foramen, anterior condylar, 7, 8, 16, 17, 23, 30, 38.
 — jugular, 7, 16, 17, 23, 30 to 32, 39, 44.
 — magnum, 8, 9, 17 to 19, 23, 37.
 — mastoid, 25, 39.
 — optic, 4, 21, 48.
 — ovale, 5, 6, 22, 32.
 — posterior condylar, 18, 19, 30, 31, 38.
 — rotundum, 4, 14, 21, 31, 40.
 — spinosum, 39.
 Frontal sinus, 30, 41, 42, 45.
 Glands, cervical lymphatic, 31 to 35.
 Gland, parotid, 5, 6, 16, 17, 22, 26, 27, 35, 36, 46.
 — submaxillary, 1 to 5, 14, 15, 21, 33 to 35.
 Inter-articular temporo-maxillary cartilage, 26, 33, 35.
 Inter-peduncular space, 16, 23.
 Ligament, internal lateral of lower jaw, 34.
 — lateral odontoid, 7.
 — transverse of atlas, 36.
 Mastoid antrum, 8, 9, 17, 23, 26, 27, 33 to 35, 40, 44 to 46.
 — cells, 8, 9, 18 to 20, 25 to 27, 33 to 35, 38 to 41, 44 to 46.
 Meatus, auditory, external, 7, 16, 17, 25 to 27, 34, 35, 39, 44, 46.
 — auditory, internal, 16, 23, 31, 32, 40.
 — nasal inferior, 1, 30, *vide* Fossa, nasal.
 — — middle, 1, *vide* Fossa, nasal.
 Medulla oblongata, 8, 9, 16, 17, 18, 23, 36 to 38.
 Muscle, buccinator, 1, 33.
 — complexus, 10 to 12, 24, 31 to 33, 36 to 38, 44.
 — digastric, posterior belly, 8, 18, 19, 33, 36, 37.
 — — tendon, 2, 14, 15.
 — genio-glossus, 1, 2, 30, 31.
 — genio-hyoid, 2, 30 to 32.
 — hyo-glossus, 1, 2, 14, 22.
 — levator palati, 6, 31, 36, 37.
 — masseter, 1 to 5, 15, 21, 26, 27, 35 to 38, 46.
 — mylo-hyoid, 1.
 — obliquus capitis, inferior, 8, 9, 33, 34.
 — — superior, 9, 19, 28, 29, 33, 34, 36, 37.
 Muscles, ocular, 1 to 3, 29, 31, 32, 41, 44, 45, 47, 48.
 Muscle, pharyngeal constrictor, superior, 31, 36.
 Muscles, prevertebral, 6, 30, 32.
 Muscle, pterygoid, external, 4 to 6, 14, 15, 21, 28, 29, 33, 34, 36 to 39, 46.
 — — internal, 4 to 6, 14, 15, 21, 31, 33, 34, 36, 37.
 — rectus capitis, anticus, 22, 36, 37.
 — — — lateralis, 28, 29, 33, 34, 37.
 — — — posticus, major, 11, 29, 36, 37.
 — — — — minor, 10, 11, 20, 36, 37.
 — splenius, 9 to 11, 20, 26, 31 to 37.
 Muscle, sterno-mastoid, 9, 20, 35, 36.
 Muscles, styloid, 22, 33, 34, 36.
 Muscle, temporal, 1 to 6, 14, 21, 25 to 29, 33 to 42, 44 to 47.
 — tensor palati, 5, 6, 31, 36, 37.
 — tensor tympani, 28, 29.
 — trachelo-mastoid, 9, 20, 31 to 34, 37.
 — trapezius, 31, 35, 36.
 Nasal duct, 30, 38, 39, 47.
 — septum, 1, 2, 37 to 40, 44, 46, 47.
 Naso-pharynx, 4, 14, 15, 37.
 Nerve, abducens, VIth, 4, 5, 14, 15, 21, 39.
 — auditory, VIIIth, 16, 23, 30, 31, 40, 45.
 — chorda tympani, 33, 39.
 — facial, VIIth, 16, 17, 23, 28 to 31, 33, 35, 38 to 40, 44, 46.
 — glosso-pharyngeal, IXth, 7, 16, 23, 31, 32, 36, 37.
 — hypoglossal, XIIth, 7, 8, 16, 23, 30, 38.
 — inferior dental, 1 to 4, 14, 15, 21, 33, 34.
 — infra-orbital, 2.
 — lingual, 4, 14.
 — olfactory, Ist, 45.
 Nerves, ocular, in cavernous sinus, 5, 15.
 — — in sphenoidal fissure, 4, 14, 21.
 Nerve, oculo-motor, IIIrd, 3 to 6, 14, 15, 21, 22, 41.
 — — at posterior clinoid process, 6, 41, 45, 47.
 — optic, IInd, 2 to 4, 14, 15, 21, 30 to 32, 41, 42, 44, 45, 48.
 — pneumogastric, Xth, 6, 7, 16, 23, 31, 36, 37.
 — spinal-accessory, XIth, 7, 16, 17, 23, 31, 36, 37.
 Nerves, spinal, 18, 19.
 Nerve, sub-occipital, 18, 19.
 — trigeminal, Vth, 23, 41, 45.
 — — Gasserian ganglion of, 5, 6, 22, 30, 39, 40, 44.
 — — inferior maxillary division, 5, 6, 31, 32.
 — — ophthalmic division, 4, 14, 15, 21.
 — — superior maxillary division, 3, 4, 14, 21, 31, 32, 40.
 — trochlear, IVth, 4, 5, 14, 15, 21, 22, 41.
 — Vidian (great petrosal), 14, 15, 21.
 Oral aperture, 33.
 — cavity, 1 to 3, 14, 15, 30 to 32, 36.
 Orbits, 1 to 3, 28 to 34, 39 to 42, 44, 45, 48 to 50.
 Pacchionian body, 19, 20.
 Palate, soft, 4, 21.
 Pharynx, 5, 30 to 32, 37.
 Pons Varolii, 7 to 9, 16, 17, 39 to 42, 44 to 47.
 Pterion, 35.
 Pyramidal motor tract, 23.
 Semicircular canals, 8, 17, 23, 28, 39, 40, 44, 45.
 Sinuses, *vide* Venous intracranial sinus.
 Spinal cord, 7, 8, 18 to 20, 23, 30.
 Sub-occipital triangle, 29.
 Supra-meatal triangle, 40.
 Suture, parieto-mastoid, 35.
 — spheno-parietal, 35.

- Teeth, permanent, developing, 46.
 Tentorium-cerebelli, 7 to 12, 16 to 20, 24, 26 to 34, 41, 42, 45, 47 to 49.
 Tongue, 1 to 3, 15, 21, 30 to 32.
 Tonsil, 4, 15, 21.
 Torcular Herophili, 13, 42, 47.
 Tympanum, 7, 16, 28, 29, 33, 39, 40, 44 to 46.
 — attic, 7, 16, 33.
 — membrane, 7, 16, 28, 33, 39, 44, 46.
 — ossicles, *vide* Bone, temporal.
 — passage to antrum, 33.
 — pyramid, 39.
 — tegmen, 7, 16, 33.
 Uvula, 4.
 Vein, anterior condylar, 16, 30, 38.
 — deep cervical, 36.
 — diploic, 10, 39.
 — facial, 14, 15, 34, 35.
 — inferior cerebral, 19, 20.
 — internal jugular, bulb, 16, 17, 23, 30 to 32, 38, 39, 44.
 — — in neck, 6, 7, 16, 17, 33, 34, 36 to 38.
 Vein, internal maxillary, 36.
 — mastoid, 10, 34, 37 to 39.
 — occipital, 10, 11.
 Veins, pharyngeal, 36, 37.
 Vein, posterior condylar, 7, 18, 19, 30, 31, 37, 38.
 Veins, pterygoid plexus of, 15, 37, 38.
 Vein, temporal, 36.
 — temporo-maxillary, 35.
 — to aqueduct of cochlea, 32.
 Veins, vertebral plexus of, 7, 17 to 19, 31, 36.
 Venous intracranial sinus, cavernous, 5, 6, 15, 22, 45.
 — — inferior petrosal, 30 to 32, 44, 46.
 — — lateral, 10 to 13, 20, 24, 26 to 35, 41, 42, 45, 47.
 — — occipital, 12, 39, 41.
 — — sigmoid, 8, 9, 18, 19, 25 to 29, 32 to 35, 38 to 41, 44 to 46.
 — — — knee, 18, 25, 35.
 — — straight, 10 to 12, 20, 24, 43, 47, 48.
 — — superior longitudinal, 1 to 22, 43, 48 to 53.
 — — superior petrosal, 8, 9, 16 to 19, 23, 41, 44.
 Vestibule, *vide* Semicircular canals.







22, WEYMOUTH STREET,
PORTLAND PLACE, W.

Dec 20 1893

My dear Page.

Please accept the
accompanying volume
as a small acknowledgment
of your kindness in caring
for my little boy, and as
a testimony of regard from
my wife & myself.

Wishing you a pleasant Christmas

Yours Sincerely
David B. Lees.

