

The fundus oculi, with an ophthalmoscopic atlas illustrating its physiological and pathological conditions.

Contributors

Frost, W. Adams.
University College, London. Library Services

Publication/Creation

Edinburgh : Young J. Pontland, 1896.

Persistent URL

<https://wellcomecollection.org/works/g2gq9bjs>

Provider

University College London

License and attribution

This material has been provided by This material has been provided by UCL Library Services. The original may be consulted at UCL (University College London) where the originals may be consulted.

This work has been identified as being free of known restrictions under copyright law, including all related and neighbouring rights and is being made available under the Creative Commons, Public Domain Mark.

You can copy, modify, distribute and perform the work, even for commercial purposes, without asking permission.




Wellcome Collection
183 Euston Road
London NW1 2BE UK
T +44 (0)20 7611 8722
E library@wellcomecollection.org
<https://wellcomecollection.org>

THE
FUNDUS OCULI




W. ADAMS FROST


NATIONAL HOSPITAL LIBRARY
Not to be taken away

INSTITUTE OF NEUROLOGY

The
ROCKEFELLER
MEDICAL LIBRARY

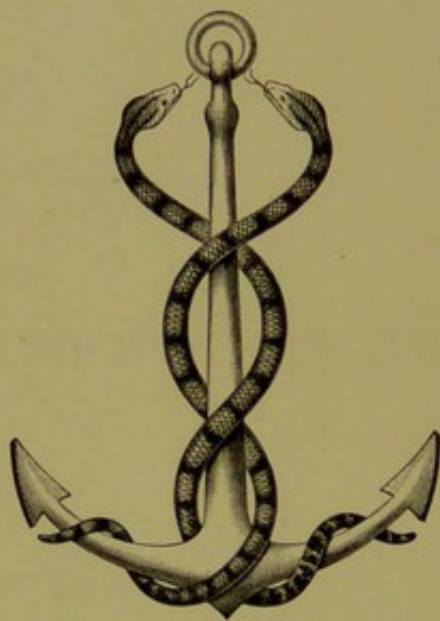







THE FUNDUS OCULI.



NUNQUAM ALIUD NATURA, ALIUD SAPIENTIA DICIT.

THE
FUNDUS OCULI

WITH AN
OPHTHALMOSCOPIC ATLAS

*ILLUSTRATING ITS PHYSIOLOGICAL & PATHOLOGICAL
CONDITIONS.*

BY
W. ADAMS FROST, F.R.C.S.,

OPHTHALMIC SURGEON, ST. GEORGE'S HOSPITAL; SURGEON TO THE ROYAL
WESTMINSTER OPHTHALMIC HOSPITAL.

EDINBURGH AND LONDON:
YOUNG J. PENTLAND.

1896.

NATIONAL HOSPITAL LIBRARY
Not to be taken away

EDINBURGH: PRINTED FOR YOUNG J. PENTLAND, 11 TEVIOT PLACE, AND 38 WEST
SMITHFIELD, LONDON, E.C., BY SCOTT AND FERGUSON AND BURNES AND COMPANY.

| | |
|-----------------------------------------------------------------------------------------------------------------|------------|
| ROCKEFELLER MEDICAL LIBRARY INSTITUTE OF BACTERIOLOGY THE NATIONAL HOSPITAL QUEEN SQUARE, LONDON, W. 1 | |
| CLASS | HIST N |
| ACCN. No. | 5239 |
| SOURCE | ecatalogue |
| DATE | |

P R E F A C E.

THE ophthalmoscope is no longer the instrument of the few. Nearly all students in our medical schools learn its use. That most of them, when in practice, neglect to employ it as a means of diagnosis is, I believe, largely due to the want of a key to interpret what it reveals. One object of this work is to supply this deficiency.

The physician, using the word in its more special sense, finds the ophthalmoscope as essential in some cases as the stethoscope in others. He may often, however, be left in doubt or led astray by want of familiarity with conditions of the fundus which have no direct bearing upon the diagnosis. It is chiefly with the view of meeting this difficulty that "physiological variations" have been so fully dealt with in the following pages.

To professed ophthalmologists I offer no apology for a work that can contain little that is new to them. For I presume that their wants are similar to my own. I have often felt the need, for teaching purposes, of a series of drawings of the fundus, more varied and more modern than those which we possess.

All honour to those who first depicted for others appearances which they had themselves been among the earliest to recognise. The Atlases which they produced are, and must ever remain, monuments of patient labour and artistic skill. But these older

works have become scarce, and our knowledge of ophthalmoscopic appearances has advanced since they were published.

It seems to me, therefore, that the time has come when we may, with advantage, take stock of our knowledge. If we agree as to facts, we shall not dispute much over theories. If we can agree as to what may be considered known, we shall advance with greater safety into the great unknown.

In the body of the work I have endeavoured to summarise our knowledge of such conditions of the fundus as are likely to be met with in the ophthalmic clinique of a large hospital.

The figures in the coloured plates have, with few exceptions, been drawn from cases occurring in my own practice, and I am greatly indebted to the artist, Mr. A. W. Head, for the care and skill with which he has executed the drawings.

In conclusion, I beg to thank numerous friends for much valuable advice, particularly Dr. Penrose, for the revision of those parts of the book which deal with general medicine, and Mr. Sydney Stephenson, for assisting me in correcting the proof sheets.

17 QUEEN ANNE STREET,
LONDON, W., *May* 1896.

CONTENTS.

| | PAGE |
|--------------------------------------------------------------------------------------------------------------------------------------------------------------------------------------------------------------------------------------------------------------------------------------------------------------------------------------------------------------------------------------------|------|
| INTRODUCTION, | 1 |
| PART I.—PHYSIOLOGICAL VARIATIONS. | |
| CHAPTER I. | |
| THE NORMAL FUNDUS, | 9 |
| Sclerotic—Choroid—Retina. | |
| CHAPTER II. | |
| THE OPTIC DISC, | 28 |
| Optic Nerve—Sheaths of Optic Nerve—Blood Vessels of Optic Nerve—Terms “Disc” and “Papilla”—Division into three Zones—Central Zone—Porus Opticus—Physiological Cup—Intermediate Zone—Variations in Colour—Vari- ations in Level—Margin—Distribution of Nerve Fibres—Reflex from Nerve Fibres—Hypermetropic Disc—Connective Tissue Ring—Scleral Ring—Pigment Ring—Oval Shape. | |
| CHAPTER III. | |
| THE RETINAL VESSELS, | 47 |
| Ophthalmoscopic Appearance of Arteries and Veins—Central Light-Streak— Distribution on the Retina—Cilio-Rétinal Vessels—Unusual Tortuosity— Bifurcating Veins—Projecting Loops—Persistent Hyaloid Artery—Pulsation in Retinal Vessels. | |
| CHAPTER IV. | |
| THE MACULA LUTEA, | 62 |
| Definition—Anatomy—Ophthalmoscopic Appearance—Radiating Striae—Reflex Ring—Foveal Reflex—Blood Vessels of Macula—Gunn's Dots. | |

| | | PAGE |
|-----------------------------------------------------------------------------------------------------------------------------------------------------------------------------------------------------------------------------------------------------------------------------------------------------------------------------------------------------------|--|------|
| CHAPTER V. | | |
| DEVELOPMENTAL IRREGULARITIES, | | 68 |
| Coloboma of Choroid—Opaque Nerve Fibres—Congenital Crescent of the Disc— Coloboma of the Disc. | | |
| PART II.—PATHOLOGICAL CONDITIONS. | | |
| CHAPTER VI. | | |
| AFFECTIONS OF THE CHOROID, | | 87 |
| Choroiditis—Classification—Disseminated Choroiditis—Stage of Exudation— Atrophic Stage—Stage of Complications—Choroiditis of Macular Region— Diffuse Choroiditis and Choroido-Retinitis—Choroido-Retinal Sclerosis—Causes of Choroiditis—Rupture of Choroid. | | |
| CHAPTER VII. | | |
| OPTIC NEURITIS OR PAPILLITIS, | | 114 |
| Anatomical Considerations—Definition of Terms—Physiological Variations of the Disc—Symptoms of Papillitis—"Choked Disc" and "Descending Neuritis"—Causes of Papillitis—Papillitis from Orbital Causes—Papillitis from Intracranial Orbital Causes—Papillitis from General Orbital Causes— Results of Papillitis. | | |
| CHAPTER VIII. | | |
| NEURO-RETINITIS AND RETINITIS, | | 133 |
| Symptoms—Subsidence—Degeneration—Stellate Figure at the Macula— Albuminuric Retinitis—Diabetic Retinitis—Leucocythæmic Retinitis—Retinitis Circinata—Plastic Retinitis and Cicatricial Changes. | | |
| CHAPTER IX. | | |
| OPTIC ATROPHY, | | 147 |
| Post-Neuritic Atrophy—Simple Atrophy—Hereditary Optic Atrophy—Secondary Atrophy—Simple Glaucoma. | | |
| CHAPTER X. | | |
| AFFECTIONS OF THE VASCULAR SYSTEM OF THE RETINA, | | 158 |
| General Considerations—Hyaline Thickening—Sclerosis of Walls—Aneurism— New Vessels in the Vitreous—Intraocular Hæmorrhage—Recurrent Hæmorrhage in Young Men—Arterial Embolism and Thrombosis—Symptoms—Re-establish- ment of the Circulation—Thrombosis of the Vena Centralis—Symmetrical Changes at the Macula in Infants—Leukæmic Retinitis. | | |

CONTENTS.

xi

CHAPTER XI.

| | PAGE |
|-----------------------------------------------------------------------------------------------------------------------------------------------------------------------------------------------------------------------------------|------|
| PUNCTATE CONDITIONS OF THE FUNDUS, | 199 |
| Gunn's Dots—Metallic Dots—Neuritic Dots—Hyaline Excrescences from Lamina Vitrea—Nettleship's Dots, associated with Night Blindness—Tay's Choroiditis—Colloid Change in Pigment Layer—Hyaline Proliferations on the Disc. | |


CHAPTER XII.

| | |
|-----------------------------------------------------|-----|
| PIGMENT CHANGES IN THE RETINA, | 204 |
| Retinitis Pigmentosa—Pigment Streaks on the Fundus. | |

CHAPTER XIII.

| | |
|-----------------------------------------------------|-----|
| DETACHMENT OF THE RETINA, | 213 |
| Causes—Ophthalmoscopic Appearance—Commotio Retinae. | |

| | |
|------------------|-----|
| INDEX, | 221 |
|------------------|-----|



LIST OF ILLUSTRATIONS.

(a.) FIGURES IN THE TEXT.

| FIG. | PAGE |
|----------------------------------------------------------------------------------------------|------|
| 1. Diagram to illustrate the enlargement of the image in direct ophthalmoscopic examination, | 4 |
| 2. Horizontal section of eyeball. (ARLT and EPINGER), | 10 |
| 3. Perpendicular section of choroid, | 12 |
| 4. Choroidal capillaries seen in horizontal plane, | 14 |
| 5. Diagram of the vessels of the choroid. (GRAEFE and SAEMISCH), | 15 |
| 6. Pigment epithelium of retina. (GRAEFE and SAEMISCH), | 16 |
| 7. Perpendicular section through human retina, | 21 |
| 8. Diagrammatic section of retina. (MERKEL), | 22 |
| 9. Section through optic nerve and papilla, | 29 |
| 10. Diagram of blood vessels of optic nerve and disc. (GRAEFE and SAEMISCH), | 31 |
| 11. Disc appearing to be oval from astigmatism, | 44 |
| 12. Oval disc, | 45 |
| 13. Cilio-retinal vessels of large size, | 50 |
| 14. Tortuosity of arteries and veins, | 51 |
| 15. Cork-screw twist of retinal vein, | 52 |
| 16. Projecting loops in retinal vessels, | 53 |
| 17. Do. do. (RANDALL), | 53 |
| 18. Bifurcating vein, | 54 |
| 19. Abnormalities in retinal veins. (WERNER), | 54 |
| 20. Do. do. (STEPHENSON), | 54 |
| 21. Communicating branch between veins, | 55 |
| 22. Bifurcating vein. (STEPHENSON), | 55 |
| 23. Bifurcating retinal veins. (STEPHENSON), | 56 |
| 24. Do. (RANDALL), | 56 |
| 25. Vessel projecting into vitreous from the disc, | 57 |
| 26. Remains of hyaloid artery, | 58 |
| 27. Section of retina in macular region. (DIMMER), | 63 |
| 28. Section through the macula. (BIRD and SCHÄFER), | 64 |
| 29. Entoptic appearance of vessels at macula. (GRAEFE and SAEMISCH), | 66 |
| 30. Diagram of lamina cribrosa, | 78 |
| 31. Diagram of hypothetical condition of lamina cribrosa in congenital crescent, | 78 |

| FIG. | | PAGE |
|------|------------------------------------------------------------------------------------------------------|------|
| 32. | Coloboma of optic disc. <i>RE.</i> (BENSON), | 80 |
| 33. | Do. do. <i>LE.</i> do. | 81 |
| 34. | Do. do. (RANDALL), | 82 |
| 35. | Partial defect in disc, | 83 |
| 36. | Hyperæmia of the choroid from a recent wound of the eye, | 90 |
| 37. | Diagram showing the semi-decussation at the chiasma, | 115 |
| 38. | Section through optic nerve and papilla, | 116 |
| 39. | Section through macula. (BIRD and SCHÄFER), | 135 |
| 40. | Glaucomatous cup, | 156 |
| 41. | Diagram to explain apparent break in a vein where crossed by an artery, | 161 |
| 42. | Symmetrical changes at the macula in infants (inverted). <i>RE.</i> Mr. Warren Tay's case, | 191 |
| 43. | Do. do. <i>LE.</i> do. | 191 |
| 44. | Leukæmic retinitis, | 196 |
| 45. | Retinal pigment streaks, Mr. Doyne's case, | 210 |
| 46. | do. Mr. Stephenson's case, | 211 |

(b.) FULL-PAGE PLATES.

PLATE

I. PHYSIOLOGICAL CUPPING OF OPTIC DISC.

Fig. 1. Physiological Cup.

,, 2. Do. Connective Tissue Ring.

,, 3. Do. Oval Disc. Striation of Upper and Lower Borders.

II. RETINAL REFLEX.

Fig. 4. Moderately Dark Fundus. Striation of Disc Margin. Dark Macula.

,, 5. Very Dark Fundus. Retinal Reflex. Oval Disc. Fovea Centralis conspicuous.

,, 6. Dark Fundus. Retinal Striation Limited to Disc-Margin. Disc of rich red colour.

III. FUNDI, SHOWING CHOROIDAL VESSELS.

Fig. 7. Light Fundus. Choroidal Vessels with Light Interspaces.

,, 8. Dark Fundus. Choroidal Vessels with Dark Interspaces. Retinal Reflex.

IV. CONGENITAL CRESCENT OF OPTIC DISC.

Figs. 9 and 10. Congenital Crescents. "Gunn's Dots."

V. VARIATIONS OF DISC MARGIN.

Fig. 11. Pigment on Disc. Connective Tissue on Disc.

,, 12. Absence of Central Zone of Disc. Peculiar Colour. Connective Tissue Ring.

,, 13. Physiological Cup. Narrow Crescent on Temporal Border.

,, 14. Grey Red Disc. Exaggerated Connective Tissue Ring.

VI. CONGENITAL CRESCENT OF OPTIC DISC.

Fig. 15. Congenital Crescent.

,, 16 and 17. Congenital Crescents. Large Physiological Cups.

PLATE

VII. CONGENITAL CRESCENT OF OPTIC DISC.

- Figs. 18 and 19. Congenital Crescents. Tortuous Veins.
 „ 20 and 21. Congenital "Mottled" Crescents.

VIII. CONGENITAL CRESCENT AND COLOBOMA OF DISC.

- Fig. 22. Congenital Crescent.
 „ 23. Do. Above.
 „ 24. Congenital Abnormality of Disc (Partial Coloboma).
 „ 25. Coloboma of Disc.

IX. COLOBOMA OF FUNDUS.

- Fig. 26. Coloboma of Fundus.
 „ 27. Do. do.

X. CONGENITAL PIGMENT DOTS ON FUNDUS.

- Fig. 28. Congenital Pigment Dots.
 „ 29. Do. do.

XI. PUNCTATE CONDITIONS OF FUNDUS.

- Fig. 30. Physiological Dots in Macular Region. ("Gunn's Dots.")
 „ 31. Diffuse Punctated Condition of Retina.

XII. CONNECTIVE TISSUE ON DISC AND OPAQUE NERVE FIBRES.

- Fig. 32. Connective Tissue on Disc.
 „ 33. Do. do.
 „ 34. Opaque Nerve Fibres.
 „ 35. Do. do.

XIII. OPAQUE NERVE FIBRES.

- Figs. 36 and 37. Opaque Nerve Fibres.

XIV. OPAQUE NERVE FIBRES.

- Fig. 38. Opaque Nerve Fibres.
 „ 39. Do. do.

XV. CHOROIDITIS.

- Fig. 40. Choroiditis. Early Stage.
 „ 41. Do. Advanced.

XVI. CHOROIDITIS.

- Fig. 42. Choroiditis. Advanced.

XVII. CHOROIDITIS. Advanced.

- Fig. 43. Choroiditis. Secondary Pigmentation of the Retina.

XVIII. DISSEMINATED CHOROIDITIS.

- Fig. 44. Disseminated Choroiditis with Conspicuous Pigmentation.

- PLATE
 XIX. PIGMENTATION OF RETINA SECONDARY TO CHOROIDITIS.
 Fig. 45. Pigmentation of Retina from Choroiditis.
- XX. DISSEMINATED CHOROIDITIS.
 Fig. 46. Disseminated Choroiditis. Stage of Exudation.
 „ 47. „ „ Stage of Atrophy.
- XXI. CHOROIDITIS. Atrophic Stage.
 Fig. 48. Areas of Choroidal Atrophy without Pigmentation.
- XXII. CHOROIDITIS AT MACULAR REGION.
 Fig. 49. Superficial Choroiditis at Macula.
 „ 50. Choroiditis at Macula.
 „ 51. Do. at Macula. Old.
 „ 52. Do. do. do.
- XXIII. HIGH MYOPIA.
 Fig. 53. Myopic Crescent (Stationary).
 „ 54. Progressive Myopia.
 „ 55. Choroiditis and High Myopia.
- XXIV. SENILE CHOROIDITIS AND POST-NEURITIC ATROPHY.
 Fig. 56. Senile Choroiditis.
 „ 57. Post-Neuritic Atrophy. Cicatricial Changes at Macula. Choroidal Atrophy.
- XXV. RETINAL OEDEMA AND MEMBRANOUS FORMATION IN RETINA.
 Fig. 58. Choroiditis. Oedema of Retina.
 „ 59. Do. Membranous Formation in Retina.
- XXVI. CHOROIDO-RETINAL SCLEROSIS.
 Fig. 60. Choroido-Retinal Sclerosis, or Diffuse Choroido-Retinitis.
- XXVII. CHOROIDO-RETINAL SCLEROSIS.
 Fig. 61. Choroido-Retinal Sclerosis, or Diffuse Choroido-Retinitis.
- XXVIII. RETINAL ATROPHY WITH SECONDARY PIGMENTATION.
 Fig. 62. Atrophy of Retina with Secondary Pigment Changes.
- XXIX. DIFFUSE CHOROIDITIS.
 Fig. 63. Diffuse Choroiditis. "Map-Like" Choroiditis.
- XXX. RUPTURE OF CHOROID.
 Fig. 64. Rupture of Choroid.
 „ 65. Do. do.
- XXXI. PAPHILLITIS.
 Fig. 66. Paphillitis (Subsiding).
 „ 67. Paphillitis.
 „ 68. „ with Hemorrhages on Disc. Retention of Physiological Cup.
 „ 69. Paphillitis (Disc much Swollen).

PLATE

- XXXII. PAPILLITIS. POST-NEURITIC AND SIMPLE ATROPHY.
 Fig. 70. Papillitis. With "Ridging" of the Retina.
 „ 71. Post-Neuritic Atrophy. Atrophy of Choroid near Disc.
 „ 72. Post-Neuritic Atrophy.
 „ 73. Primary Atrophy.
- XXXIII. LEUKÆMIC RETINITIS. PAPILLITIS.
 Fig. 74. Leukæmic Retinitis.
 „ 75. Papillitis. Much Swelling. Vision Unaffected. Subsidence.
- XXXIV. THROMBOSIS OF CENTRAL VEIN.
 Fig. 76. Thrombosis of Central Vein.
 „ 77. Do. do.
- XXXV. RETINITIS WITH HÆMORRHAGES.
 Fig. 78. Retinitis. Hæmorrhages and White Dots. Recovery.
 „ 79. Retinal Hæmorrhages. (Thrombosis?)
- XXXVI. ALBUMINURIC RETINITIS AND NEURO-RETINITIS.
 Fig. 80. Retinitis at Macula. Hyaline Thickening of Artery.
 „ 81. Neuro-Retinitis.
- XXXVII. ALBUMINURIC RETINITIS.
 Fig. 82. Albuminuric Retinitis.
 „ 83. Retinitis. Without Implication of Disc.
 „ 84. Albuminuric Retinitis. "Star Figure" at Macula.
- XXXVIII. STELLATE FIGURE AT MACULA AND POST-NEURITIC ATROPHY.
 Fig. 85. Stellate Figure at Macula of Unusual Character.
 „ 86. The Same Eye. Two Months Later.
 „ 87. Post-Neuritic Atrophy.
- XXXIX. SUBHYALOID HÆMORRHAGE.
 Fig. 88. Sub-Hyaloid Hæmorrhage at Macula.
 „ 89. The Same Eye. Fourteen Days Later.
- XL. CHANGES IN VESSEL WALLS. NEW VESSELS IN VITREOUS.
 Fig. 90. Degenerative Change in arterial walls.
 „ 91. New Vessels in the Vitreous.
- XLI. EMBOLISM OF CENTRAL ARTERY.
 Fig. 92. Embolism of Central Artery.
 „ 93. Do. do. Modified by the presence of a Cilio-Retinal Vessel.
- XLII. RETINITIS PIGMENTOSA. PIGMENTATION FROM CHOROIDO-RETINITIS.
 Fig. 94. Retinitis Pigmentosa.
 „ 95. Choroido-Retinitis. With unusual Pigmentation.

- PLATE
 XLIII. RETINITIS PIGMENTOSA.
 Fig. 96. Retinitis Pigmentosa.
- XLIV. RETINITIS PIGMENTOSA.
 Fig. 97. Retinitis Pigmentosa. With little Pigment Deposit.
- XLV. CICATRICIAL BANDS ON FUNDUS.
 Fig. 98. Choroiditis. Secondary Pigmentation of Retina. Formation of Cicatricial Bands.
 „ 99. Cicatricial Bands on the Fundus.
- XLVI. DETACHMENT OF THE RETINA.
 Fig. 100. Detachment of the Retina.
 „ 101. Do. do.
 „ 102. Do. do.
 „ 103. Do. do.
- XLVII. COLOBOMA OF DISC. GLAUCOMA SIMPLEX.
 Fig. 104. Partial Coloboma of Disc.
 „ 105. Glaucomatous Cup.
 „ 106. Do.
 „ 107. Do

THE FUNDUS OCULI.



THE FUNDUS OCULI.

INTRODUCTION.

THE OPHTHALMOSCOPE not only enables us to study the progress of diseases of the fundus, but it frequently leads to the recognition of morbid conditions of the general system, or of parts remote from the eye. Moreover, the fundus oculi, owing to its complex structure, and the conditions under which it is seen, presents an unrivalled field for the study of pathological processes in living tissues.

In the retinal vessels are exposed to view the minute ramifications of a terminal artery and vein, in close connection with the cerebral circulation; in the optic disc there is presented to us an optical section of a cranial nerve; in the retina we see a highly organised membrane, which, in part at any rate, is a direct continuation of that nerve; while in the choroid there is spread out before us a membrane so vascular that its colour is almost that of the blood. Nor is this all—these various structures are seen through the dioptric system of the eye, which, acting like the low power of a microscope, presents them to us enlarged about fifteen diameters.

The retinal vessels may present changes of the gravest import to the integrity of the eye. But besides this they may afford evidence of irregularities in the general circulation, of widespread vascular disease, or of alterations in the character of the blood.

The state of the optic disc may prove to us that the path of conduction between the retina and the nerve centre is interrupted, but it may also indicate the existence of disease, localised in the

brain or spinal cord, or disseminated throughout the nervous system.

Inflammation of the choroid is much more common than any other affection of the fundus, and frequently leads to loss of sight. Perhaps it is on this account that its general importance is apt to be overlooked, but it should not be forgotten that it often affords valuable corroborative evidence of the presence of syphilis or of tuberculosis.

The great liability of the choroid to chronic inflammation is probably due not only to the large amount of blood contained in its tissue, but also to the fact that the circulation is very sluggish.

Degenerative, no less than inflammatory, changes in the choroid or retina have more than a local importance, for they may indicate disease of important organs, degenerative processes in the vascular system, or widespread deterioration of tissue.

Familiarity with morbid conditions of the fundus is therefore hardly less essential to the general physician than to the specialist, a fact that has in recent years been more and more recognised. It is not, however, so generally remembered that an essential preliminary to the diagnosis of morbid conditions of the fundus is a thorough knowledge of its normal appearance. This can be attained only after some experience, since even normal fundi differ from each other within rather wide limits. For this reason a relatively large share of the following pages will be devoted to the consideration of what may be conveniently called "physiological variations."

If the variations of the normal fundus are numerous, those presented by pathological conditions are still more so; for these latter are generally the product of several factors, the relative prominence of which varies in different cases. Hence the physician will not learn much by examining only such cases as are most likely to be met with in medical practice, but must embrace every opportunity of becoming familiar with all the appearances that the fundus may present.

The primary object of this work is to advance the study of ophthalmoscopic diagnosis. Questions of treatment and prognosis, and the relation of fundus changes to general conditions, will, from time to time, be touched upon, but the treatment of affections of the fundus cannot, with advantage, be considered apart from ocular therapeutics in general, while a physician alone would be competent to write a complete treatise on medical ophthalmoscopy.

The method adopted will be to illustrate the text by coloured representations of the fundus, drawn from living cases. These drawings necessarily occupy a prominent place in the book, but it is hoped that the reader will look upon them as illustrating the text, and not merely use the text to explain the drawings.

The cases have, for the most part, been selected as typical examples of fairly common conditions. In illustrations of the fundus it has been too much the custom to devote great care to depicting the condition under consideration, while other parts of the fundus have been represented in a sketchy, diagrammatic, or conventional manner. Every part of every fundus may be important, and the attempt has therefore been made to depict the conditions present exactly as they appeared, without exaggerating particular parts or slurring over others.

The drawings of the fundus have been executed from nature by an artist, and all (except Plate II., Fig. 6, Plate IX., Fig. 26, and Plate XX., Fig. 46) were made under the direct supervision of the writer.

The direct method has been employed, except for the drawings on Plate XXIII. As these represent cases of high myopia, the indirect was found to be more suitable.

Most of these pictures represent more of the fundus than can actually be seen at one time by the direct method. Without altering the position of the mirror it is impossible to see more than the optic disc, and a narrow zone round it. But different parts can be viewed in quick succession, and it is usual in drawings to piece

these together so as to form a single picture. The practice is too obviously convenient to need defence.

The drawings were made by the aid of artificial light, and appear to the best advantage when viewed under the same conditions.

They are life-size, but it must be remembered that the apparent size of the ophthalmoscopic image may vary in different observers. The actual retinal image received by the observer must be of the same size as the part of the patient's eye which produces it (if both his eye and that of the patient are emmetropic and of the same dimensions). But the apparent size of the mental picture will depend upon the distance to which the observer projects his retinal image.

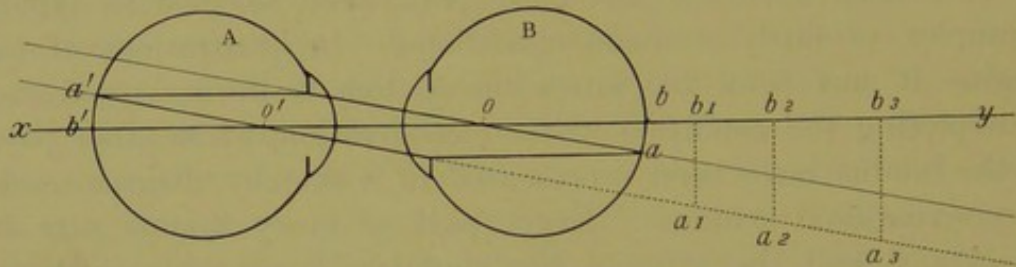


FIG. 1.—Diagram to illustrate the enlargement of the image in direct ophthalmoscopic examination.

This will be evident from Fig. 1, in which A represents the eye of the observer, and B that of the patient. Both are emmetropic and of identical dimensions, and they have a common principal axis, xy . Let ab represent a portion of the patient's eye seen by A. b lies on the principal axis of B, therefore its image, b' , is on the principal axis of A. Let a ray, ao , from a pass through the optical centre o , then all other rays from a will, after emerging from the eye, be parallel to ao . Let one of these, $a'o$, pass through o , the optical centre of A, then it will be unrefracted, and will cut the retina at a' . This point will give the position of the retinal image of a .

It will be found that the image $a'b'$ is equal to the object ab . For since ao and $a'o$ are parallel, the angles at o and o' are equal, and since the distance from o and o' to their respective retinae are equal, $ab = a'b'$.

It is evident that A may project the retinal image $a'b'$ to b_1 , b_2 , or b_3 , or to any other distance, and that the size of the virtual image will vary accordingly.

Since the apparent size of the ophthalmoscopic image may not be the same to different observers, it is necessary in describing

appearances to use a standard of measurement obtained from the eye under observation. The best unit for this purpose is the diameter of the optic disc. For example, we may describe a patch of choroiditis as being 3 dd. from the macula, and having a diameter of $\frac{dd}{4}$. For smaller measurements the diameter of the main vessels may be used.

To facilitate measurements of this kind the writer, in conjunction with Mr. Sydney Stephenson, designed a fundus-gauge, consisting of a rectangular network of fine wires, which, when attached to an ophthalmoscope, threw its shadow on the fundus, thus mapping it out into squares. The practical utility of the instrument is somewhat diminished by the impossibility of rendering these shadows visible on the disc.


Opposite each chromolithograph will be found a short account of the case, together with the chief points which are illustrated by it. If information is required in respect of any particular ophthalmoscopic appearance, a reference to the index will show the part of the text in which the condition is discussed, and the drawings in which it is depicted.

It must not be supposed that any picture, however accurate, can equal in beauty the actual ophthalmoscopic image. The brilliancy and freshness of the living fundus cannot be reproduced. Some appearances vary with the slightest alteration in the direction of the incident light, and the attempt to fix them in a drawing gives an unnatural hardness. Others depend on differences in level, or on one tissue being viewed through another, which, although presenting no perceptible opacity, may not be perfectly transparent. A faithful representation of these is difficult. Of course, such appearances as depend upon rhythmical changes in form, as for example pulsation, or upon apparent change of relative position, as in parallaxic movements, cannot be depicted at all. For these reasons the fundus can only be adequately studied by means of the ophthalmoscope.

Much, however, will be learnt from these pictures by anyone who will use them as a means to an end, and not as the end itself. To such an one they will explain many things which he will remember to have seen and not understood ; they will in the future enable him both to see and to perceive.

This work is, to some extent, an amplification of the "Lantern" Lectures which I have delivered at the Royal Westminster Ophthalmic and at St. George's Hospitals, and such of my readers who attended those lectures will recognise many of the lantern slides. Many new drawings have, however, been added, and the text is much fuller than was possible in a course of lectures.

PART I.
PHYSIOLOGICAL VARIATIONS.



CHAPTER I.

THE NORMAL FUNDUS.

My object is not so much to lay before my readers examples of rare conditions of the fundus, as to show them how the more common appearances, both normal and pathological, are produced. Physiological variations will therefore receive an unusual amount of attention, and abnormal conditions will be considered not so much from the standpoint of the completed picture, as from that of the details which go to produce it.

By dealing in this manner with the material at our disposal, it is hoped that the reader may be led to abandon the pernicious belief that diagnosis consists merely in giving a name to an ophthalmoscopic picture. Such a picture is necessarily the sum of many factors which may be combined in very different proportions. Unless this be borne in mind, there is a twofold possibility of error. On the one hand, a single name may be used to include a number of conditions which, presenting some features in common, may differ in many important respects. On the other hand, different names may be given to ophthalmoscopic appearances which are the result of identical pathological processes.

Diversity of appearance is not confined, however, to pathological conditions: the normal fundus-image is also the sum of several variable factors; hence no two fundi are exactly alike, and it is therefore impossible to take a single type as the normal standard, and to class all departures from it as abnormal.

Even if we exclude from present consideration such physiological variations as conspicuous abnormalities in the vessels, opaque nerve fibres, and striking irregularities in the shape of

the optic disc, we still have scope for wide variation in the extent to which the choroidal vessels are visible, in the colour of the fundus, in the amount of retinal-reflex, and in many other minor points. Even experienced observers often find it difficult to discriminate between a physiological variation and a slight pathological change.

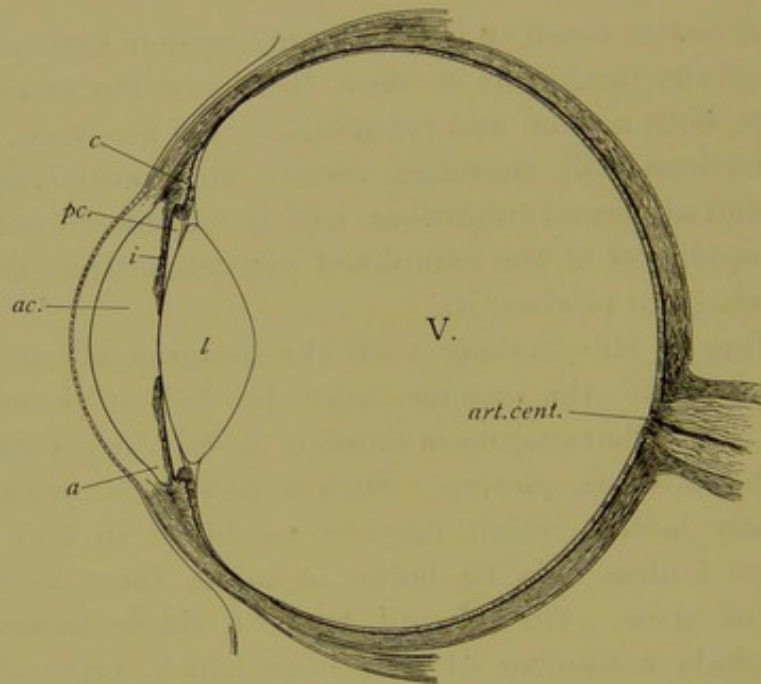


FIG. 2.—Horizontal section of eyeball. Drawn to scale from measurements of numerous specimens (reduced from ARLT and EFINGER'S "Horizontale Durchschnitt").

ac. Anterior chamber; a. angle of anterior chamber; pc. posterior aqueous chamber; i. iris; V. vitreous; l. lens; c. ciliary body; art. cent. central vessels of retina.

The "fundus" may be roughly defined as the inner surface of the posterior hemisphere of the globe. It will simplify the subject if we consider separately the factors which contribute to the ophthalmoscope image,—first of the fundus generally, and then of two special parts of the fundus, namely, the optic disc and the yellow-spot.

Each tunic of the eyeball contributes something towards the

ophthalmoscopic image of the fundus, but by far the largest share is due to the choroid.

The *sclerotic* may be said to constitute the panel on which our picture is painted. By virtue of its rigidity it helps to maintain the globular shape of the eyeball, and affords a firm leverage for the ocular muscles, which are attached to it. It is thickest posteriorly, where it is continuous with the dural sheath of the optic nerve, and becomes gradually thinner anteriorly, until, near the cornea, it is slightly thickened by reinforcements from the tendinous insertions of the muscles. The sclerotic is pierced around the optic nerve by the two long ciliary, and the numerous posterior ciliary arteries, and near the cornea by the perforating branches of the anterior ciliary arteries, while, about the equator, there traverse it obliquely from before backwards, and from within outwards, veins which correspond in function with the arteries; these, from the arrangement of their converging tributaries, have been called *venæ vorticosæ* (Fig. 5 *Vv.*).

The sclerotic itself is not usually visible, as it is covered by the nearly opaque choroid. But in all eyes except the darkest, and possibly in them also, it has some influence on the ophthalmoscopic picture, since a certain amount of light reaches it through the choroid, and, being reflected, serves to lighten the fundus. The extent to which this occurs is in inverse proportion to the amount of pigment in the choroid and retina.

In the albino there is no pigment, and the sclerotic is then visible as a white surface between the choroidal vessels. The vision of albinos is always defective, and they suffer from nystagmus; for this latter reason it has not been possible to obtain a painting of the fundus. But a similar appearance is often met with in the eyes of fair persons, although, as a rule, it is not equally marked over the whole fundus. A good example of such a fundus is to be seen in Plate III., Fig. 7.

The sclerotic is, however, best seen where the choroid is absent, either as the result of a congenital defect, as in coloboma, or

owing to its destruction by disease. The former of these conditions is seen in Plate IX., Figs. 26 and 27, and the latter in Plates XVI., XXI., XXII., and in many others. When thus exposed, it presents a brilliant white surface, unlike the dull dead-white colour of inflammatory exudation.

In deeply pigmented eyes, on the contrary, the choroidal vessels, as a rule, are not visible. Little light is reflected from the sclerotic, and the fundus consequently has a dull, sombre appearance (Plate II., Fig. 6). In the eyes of dark races, the

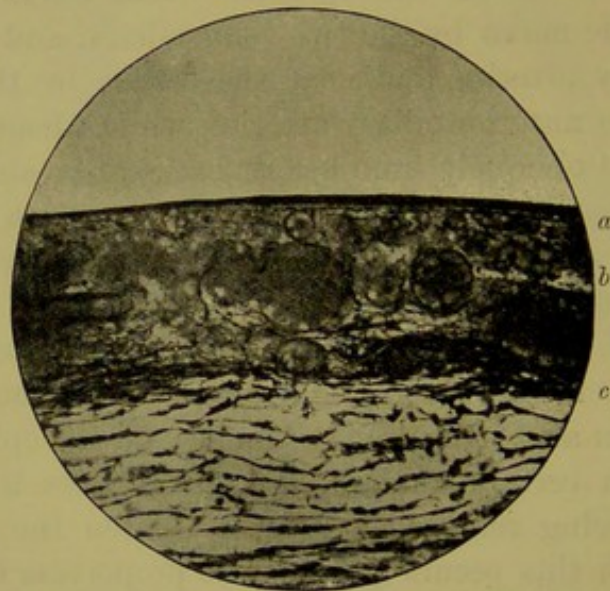


FIG. 3.—Perpendicular section of choroid. (From a specimen prepared by Mr. TREACHER COLLINS.)

a. Pigment layer of retina ; *b.* choroid ; *c.* lamina fusca.

small amount of light reflected from the fundus sometimes renders satisfactory ophthalmoscopic examination difficult. Plate XLII., Fig. 95, shows the eye of a half-caste, and although it represents a fundus which is abnormal, it will serve to show the colour which is frequently seen in dark races.

Between the sclerotic and the choroid is some loose cellular tissue—the suprachoroidea (Fig. 3, *c*). The outer layers of this, which are deeply pigmented, adhere firmly to the sclerotic, and are

sometimes called by a separate name, the "lamina fusca." The spaces in the suprachoroidea are said to be lined by an endothelium, and probably form part of the lymphatic system. The ciliary nerves which supply the uveal tract pierce the sclerotic round the optic nerve entrance, and run in the suprachoroidea.

The *choroid* takes by far the largest share in the production of the ophthalmoscopic picture. Owing partly to the amount of pigment it contains, and partly to the fact that it is composed to a large extent of blood vessels, which become collapsed after death, its minute anatomy is less easily demonstrated than that of the retina. For our knowledge of this subject we are largely indebted to the researches of Iwanoff and Sattler.

The pigment epithelium usually adheres to the retinal surface of the choroid, although a study of its development proves that it really belongs to the retina. It will be described later on. Next to the retinal pigment lies the lamina vitrea; this is usually described as structureless, but Sattler has recently shown that its deep surface is marked by a network of fine interlacing lines. Next comes the capillary layer, or "chorio-capillaris." These capillaries are the largest in the body, and the oval nuclei in their walls are very conspicuous. When more than one layer of capillaries can be distinguished, the more superficial contains the finest vessels. This is shown in Fig. 4, which is from the choroid of a rabbit.

The richness of the capillary network varies in different eyes, and in different parts of the same eye, being almost always greatest near the posterior pole, while towards the periphery the network becomes more open.

Between the chorio-capillaris and the larger vessels which feed it, we have what might be called an intervascular layer, consisting largely of elastic fibres, and containing as a rule no pigment. The more external layer is made up chiefly of arteries and veins lying in a deeply pigmented stroma. The position of the vessels in these layers is shown in Fig. 3, but they are abnormally conspicuous

owing to the choroid being congested. The specimen from which the drawing was made, was taken from a case of recent injury.

Perivascular lymph sheaths accompany the veins and become continuous with the intercapillary spaces.

Throughout the choroid are found unpigmented cells which appear to vary greatly in number. In the outer layers are also pigmented cells which vary much in form, size, and in the amount of pigment which they contain.

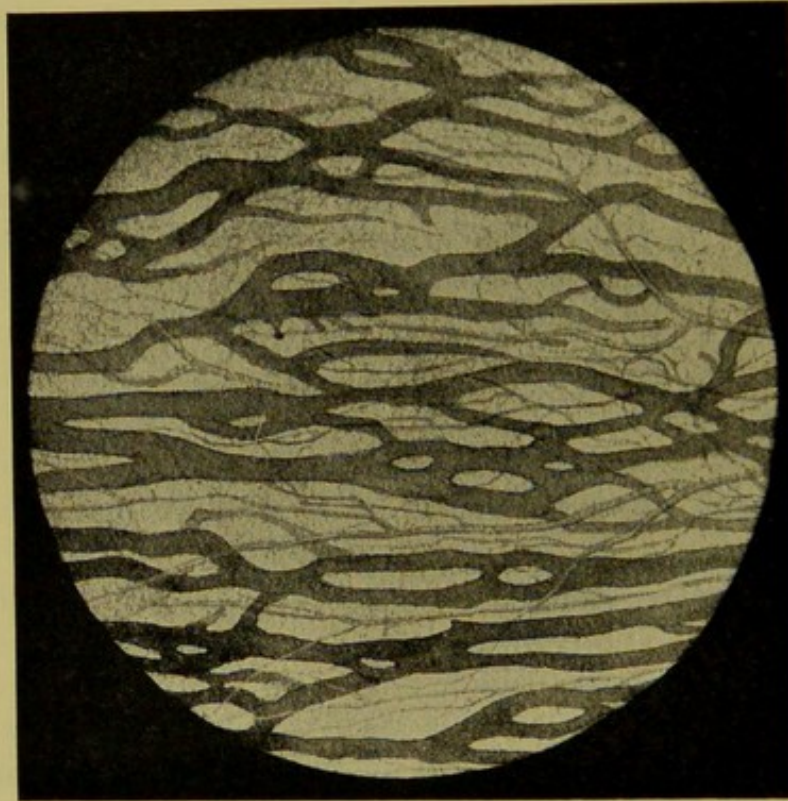


FIG. 4.—Choroidal capillaries seen in horizontal plane. (From an injected specimen by Mr. JNO. GRIFFITH.)

The uveal tract becomes modified anteriorly to form the ciliary processes and muscle, and, still more anteriorly, the iris, but with the anatomy of these parts we are not now concerned.

The greater part of the uveal tract derives its blood supply

from the posterior or short ciliary arteries (Fig. 5, *Ab*), which pierce the sclerotic round the optic nerve. The ciliary region is supplied by two long and numerous anterior ciliary arteries. The former (Fig. 5, *Aa*) pierce the sclerotic one on either side of the optic nerve, then course forward between the sclerotic and choroid. The perforating branches of the anterior ciliary arteries, on the other hand, pierce the sclerotic about 5 mm. from the corneal margin.

No distinction can be made between the smaller arteries and

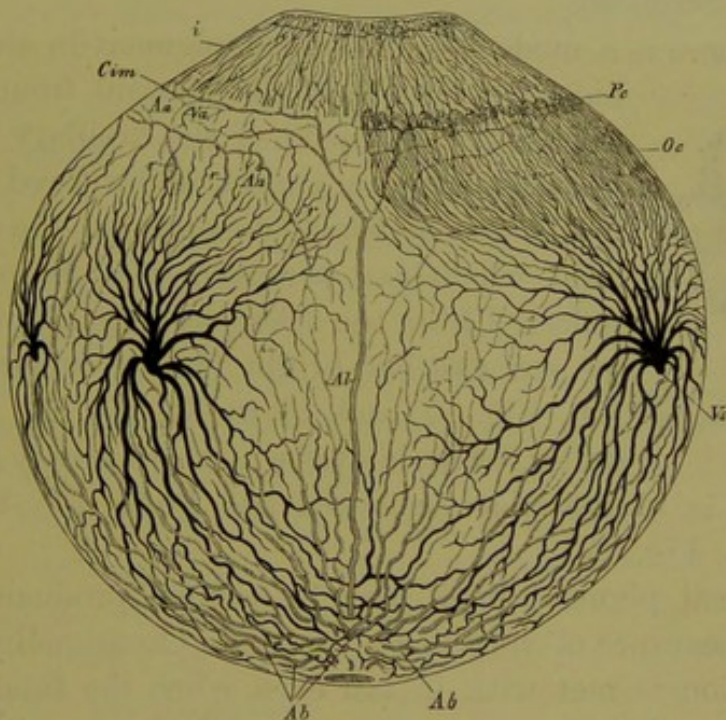


FIG. 5.—Diagram of the vessels of the choroid. (GRAEFE U. SAEMISCH.)

Aa. Anterior; *Al.* long—*Ab.* short—ciliary arteries; *Vv.* venæ vorticosæ; *Cim.* circulus iridis major; *i.* iris; *Pe.* ciliary process; *Oc.* ciliary muscle.

veins of the choroid, but as the latter unite into larger trunks they assume a peculiar appearance owing to their being arranged in regular bold curves. The separate veins are nearly parallel but gradually converge, an arrangement which has led to their being called venæ vorticosæ (Fig. 5, *Vv*); finally all the veins are collected into six or eight large trunks which pierce the sclerotic somewhat obliquely near the equator.

The ophthalmoscopic appearance presented by the choroid is largely dependent on the pigment-layer of the retina. It will therefore be necessary in this place to consider this layer. It consists of a single layer of hexagonal cells, arranged in juxtaposition as in a tessellated pavement. Each cell contains pigment granules which are more numerous at its periphery than in its centre. From each cell a fine filament passes for a short distance between the rods and cones, constituting the adjacent layer of retina (Max Schultze).

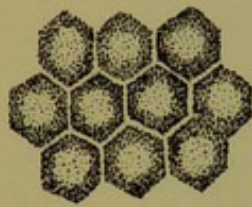


FIG. 6.—Pigment epithelium of retina. (GRAEFE U. SAEMISCH.)

When there is a moderate amount of pigment in this layer, it hides all details of the choroid from view, but the great vascularity of the capillary layer gives to the fundus an almost uniform red colour, the brightness of which depends on the amount of light which can penetrate the choroid, and be reflected from the sclerotic. In Plate I., Fig. 1, we see a rather bright fundus colour; in Plate VI., Fig. 17, and Plate X., Fig. 29, it is much duller, while in eyes which are deeply pigmented, the fundus is almost slate coloured (*see* Plate II., Fig. 5, and Plate XLII., Fig. 95).

The retinal pigment itself may be visible, producing in dark eyes the appearance of very fine stippling. Occasionally an analogous condition is met with in fair eyes, when the fundus has the appearance of being peppered over with fine grains of gunpowder.

When the retinal pigment is less abundant the observer is able to see a certain distance into the choroidal substance. The appearance will then depend upon the amount of pigment in the stroma of the choroid; this is usually proportionate to the pigmentation of the pigment layer of the retina, but exceptions are not uncommon.

When there is no pigment in the choroidal stroma, as in albinos, the choroidal vessels are visible on the white background

of the sclerotic, which receives a mere tinge of red, probably from the capillary layer of the choroid. The constant association of nystagmus with this condition has, unfortunately, hitherto prevented me from obtaining an accurate drawing. Choroids which are but slightly pigmented are, however, comparatively common, and in such cases a variable number of choroidal vessels are seen separated by interspaces which are lighter than the vessels, and sometimes almost white (Plate III., Fig. 7).

No difficulty should ever arise in distinguishing choroidal from retinal vessels. The former are more numerous, of larger size, and so close together that the interspaces are often narrower than the vessels. They run in nearly parallel lines, and frequently anastomose; they do not, like the retinal vessels, diminish in size towards the periphery. No distinction can be made between the arteries and the veins of the choroid. The absence from the choroidal vessels of the central light-streak, seen in most of the retinal vessels, gives them a flat riband-like appearance, which is in striking contrast to the cylindrical form of the retinal vessels.

The choroidal vessels are usually more easily recognised at the periphery than at the centre of the fundus, but even when they are visible over the whole of the rest of the fundus, none are to be seen within the area of the macula.

Loring¹ attributes the chief share in the production of these differences to the superficial capillary layer of the choroid. But the facts seem to be more in accord with the generally accepted view, which is that they depend upon variations in the pigment layer. The choroidal vessels are, as a rule, much more visible in fair than in dark eyes, and the pigmentation of the fundus shows some correspondence with that of the skin. It is quite true, as already pointed out, that individual exceptions to this rule are not infrequent, but that such are merely personal peculiarities is at once evident if we compare the eyes of dark and fair races.

¹ "Text-book of Ophthalmology."

There does not seem to be any evidence that the closeness of the capillary network varies to any appreciable extent in different individuals. It is true that the network is more open towards the periphery than near the centre, and some colour is thus lent to Loring's view, but it is impossible to conceive of it varying in adjacent areas to a degree which would be necessary to account for the differences in the ophthalmoscopic appearances.

Moreover, the evidence afforded by disease leading to destruction of this capillary layer seems to show that its effect is not to conceal the larger vessels, but to give the fundus a red tinge as if it were covered by a transparent red veil.

There is usually a relation between the pigmentation of the retinal pigment layer and that of the choroidal stroma. Sometimes, however, eyes with deeply pigmented choroids have the retinal pigment sufficiently thin to allow the choroidal vessels to be visible. We then have the appearance known as the "*choroïde tigrée*," in which the choroidal vessels are seen as pale bands separated by spaces of dark colour (Plate III., Fig. 8). In dark fundi this can usually be seen at the periphery, and not unfrequently in other parts.

Local excrescences of pigment in the form of isolated dots are not uncommon, and they can in no sense be considered pathological. As we shall see later on, some pigment is generally present round the circumference of the disc.

A less common form of pigmentation is shown in Plate X., Figs. 28 and 29. In this a portion of the fundus, usually sector-like in shape, has scattered over it groups of pigment dots, which may be black or dark-brown. For the most part the individual dots are angular or irregular in shape, rather than round, and their diameter is usually less than that of the main retinal vessels. The dots are collected into groups, the fundus between the groups presenting nothing abnormal. Most of them appear to lie deeper than the retinal vessels, although there are occasional exceptions to this. They differ from pathological pigment deposits by the

absence of any decoloration of the portion of the fundus on which they rest, and by the sharp limitation of the individual dots, each having a well-defined outline, and being quite separate from its neighbours. Vision is unaffected, and there seems to be no tendency for the condition to alter in any way.

The cases depicted in Plate X., Figs. 28 and 29, were under the observation of Mr. Stephenson, who kindly permitted me to have drawings made. They have been published by him with another case,¹ and I understand that he has since seen four others.

A similar case has been published by Jaeger in his Atlas. He considered it to be an early stage of retinitis pigmentosa.

Larger areas of pigmentation are occasionally met with in eyes which are presumably healthy. They are brown, rather black, and tend to have a regular oval or circular outline. They are probably analogous to moles on the skin. Dodd² has published a case of this kind, with an illustration of the ophthalmoscopic appearance.

The *retina*, which now claims our attention, is the innermost coat of the eye-ball, and may be considered as the end organ of the optic nerve. It is, therefore, functionally of great importance. It takes, however, a smaller share in the formation of the ophthalmoscopic picture than either of the other tunics, owing to its transparency.

The retina is attached to the optic disc, its superficial layer being directly continuous with the fibres of the optic nerve. Anteriorly it terminates in the ciliary region in a jagged margin, the ora serrata, which adheres firmly to the uveal coat. Between these points it is kept in contact with the choroid merely by the pressure of the vitreous, except at the yellow spot, where it adheres slightly to the choroid.

Under the microscope the retina can easily be seen to consist of several layers, which differ considerably from each other. The examination of the minute structure of these, and of their connec-

¹ *Trans. Ophth. Soc.*, vol. xi., p. 77.

² *Trans. Ophth. Soc.*, vol. xv., Plate IX.

tions with each other presents, however, great difficulties, and although much has been discovered in recent years with regard to them, there are still many points that remain obscure.

The different layers from without inwards are enumerated in the following table.

The numbers correspond with those in Fig. 7.

- | | | |
|---------------------------------|---|----------------------------------------------------------------|
| FIBRES OF MÜLLER. | { | 1. PIGMENT LAYER. |
| | | 2. BACILLARY LAYER (rods and cones). |
| | | 3. EXTERNAL LIMITING MEMBRANE. |
| | | 4. EXTERNAL NUCLEAR LAYER. |
| | | (a.) Nuclei of rods and cones. |
| | | (b.) Fibres of do. (<i>syn.</i> external fibrillar layer). |
| | | 5. EXTERNAL MOLECULAR LAYER (<i>syn.</i> internuclear layer). |
| | | 6. INTERNAL NUCLEAR LAYER. |
| | | 7. INTERNAL MOLECULAR LAYER. |
| | | 8. LAYER OF NERVE CELLS. |
| 9. LAYER OF NERVE FIBRES. | | |
| 10. INTERNAL LIMITING MEMBRANE. | | |

1. The *pigment layer* has already been dealt with. It sends down processes between the elements of the next layer to an extent which is believed to increase with the amount of light entering the eye. Notwithstanding this close connection with the bacillary layer, in microscopical preparations it often becomes separated, and when the retina during life becomes detached from the choroid the pigment layer usually remains in contact with the latter.

2. The *bacillary layer* is so called because it consists of fine parallel bodies, which were named *bacilli* before bacteriological investigations had given a different significance to the word. It is now more frequently called the layer of rods and cones.

The elements composing it are of two kinds, the more numerous are straight bodies, of uniform thickness; these are the "rods." The other elements—the cones—are seen interspersed amongst the

rods at almost regular intervals. They are shaped like champagne bottles (Fig. 8), and have their narrow ends directed towards the pigment layer.

The cones obviously consist of two portions, which correspond respectively with the body and neck of the bottle. The rods also show a division at the same level into an inner and outer segment.

In the peripheral parts of the retina the cones are separated from each other by about three times their diameter, but, as the

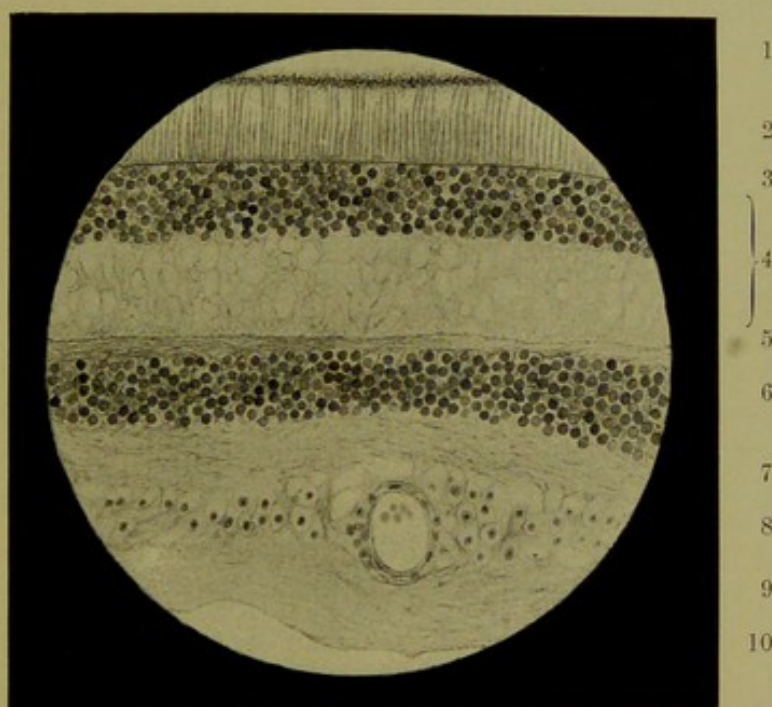


FIG. 7.—Perpendicular section through human retina. The numbers refer to the various layers as described in the text. (From a preparation by Mr. JNO. GRIFFITH.)

region of the macula is approached, they become more numerous, each cone being now surrounded by a ring of rods which separates it from its neighbours. It is usually said that within the macula itself cones alone are present. This, however, is denied by Borysiekiewicz.¹ He describes the rods as gradually assuming the characteristics of the cones as the fovea centralis is approached,

¹ "Weitere Untersuchungen über den feineren Bau der Netzhaut," 1894.

and he considers that the elements at the fovea should be looked upon as rods and not as cones.

3. The *external limiting membrane* is so named in contradistinction to the internal limiting membrane which lies on the vitreous surface of the retina. It is visible under the microscope as a sharply defined line. Its structure possesses no features of importance.

4. The *external nuclear layer* (sometimes called external granular) has the appearance of being divisible into two parts, an outer which consists chiefly of nuclei, and an inner which is made up almost entirely of parallel fibres continued from the rods and cones. It must, however, be remembered that these fibres traverse the whole of this layer, and indeed pass through all the layers to reach the nerve cells, although, in the inner layers they are less easily demonstrated.

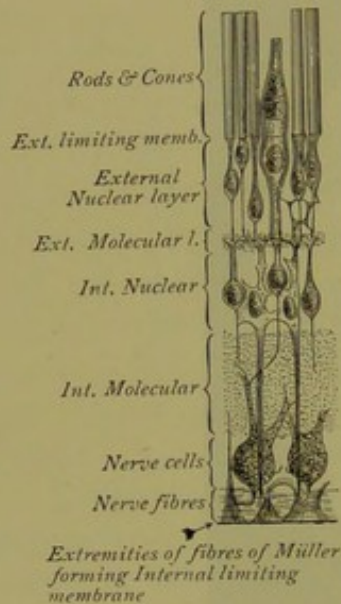


FIG. 8.—Diagrammatic section of retina. (Modified from MERKEL, *Arch. f. Ophth.*, Leipzig, bd. xxii., p. 2.)

This part of the retina in microscopical sections contains numerous vacuoles, which are more conspicuous than the fibres. The latter, like all the fibres in the retina, can only be well seen after special treatment.

The nuclei of this layer are round or oval bodies, developed on the fibres from the rods and cones. The two sets of fibres differ from each other in the thickness and in the position and size of their nuclei.

5. & 7. The *outer and inner molecular layers*.—These two layers have been described in various ways, and there seems still to be much doubt as to their structure. They contain numerous small oval and round cells and an anastomosing network of fibres, held, on the one hand, to be nervous, and, on the other, to consist of connective tissue only. The inner layer is much thicker than the outer, but otherwise they resemble each other.

6. The *inner nuclear layer* resembles the nuclear portion of the external nuclear layer (4). A connection has been demonstrated between the nuclei of this inner nuclear layer and the nerve cells in the next layer (8); concerning its connection with the more external layers there is much uncertainty.

8. The *layer of ganglionic nerve cells* consists of large multipolar cells from each of which one process passes into the layer of nerve fibres. From the other surface project a number of processes, varying from one to four, most of which appear to be lost in the adjacent inner nuclear layer; a few, however, can be traced as far as the external nuclear layer.

9. The *layer of nerve fibres* is thickest near the disc, and stops short before reaching the ora serrata. It consists of fibres which are continuous with those of the optic nerve, but which differ from them in having lost their outer coating of the white matter of Schwann, or medullary sheath. They are, in consequence, thin and transparent. The larger vessels of the retina lie in this layer.

10. The *internal limiting membrane* is a thin not conspicuous membrane, which is usually described as being formed by the expanded extremities of the fibres of Müller.

The fibres of Müller, to which reference has just been made, are not shown in the figure, they are straight filaments, which pass vertically through the intervening layers from the external to the internal limiting membrane. They have usually been considered as forming part of the connective tissue framework of the retina. Borysiekiewicz¹ has, however, shown that they are directly continuous with the bases of the cones. And if this is really the case, it is probable they constitute nerve organs of great importance.

The structure of the retina is somewhat modified at the macula. This will be considered later on.

The vessels of the retina are branches of the central artery and vein. Those that are of sufficient size to be visible with the

¹ *Loc. cit.*

ophthalmoscope lie in the fibre layer, and fine offshoots pass from them into the deeper layers. The veins, like those of the choroid, are surrounded by perivascular lymph channels.

The great vascularity of the choroid, its close proximity to the layer of rods and cones, and the fact that even superficial choroidal disease soon impairs vision, would seem to indicate that the choroid plays a very important part in the nutrition of the retina, probably through the medium of its pigment layer. That the supply of arterial blood through the central vessel is of more vital importance is proved by the fact that when the latter becomes plugged by a clot, there is instantaneous and total blindness, which is permanent, unless the circulation be quickly restored.

One result of the relative position of the vessels and the sentient layer is that the visual field has gaps in it corresponding to the larger vessels. These are not observed under ordinary conditions, because we are accustomed to their presence, and there are no large vessels near the yellow spot where vision is most acute. If, however, light is thrown into the eye obliquely through the sclerotic, so that the shadows of the vessels fall upon nerve-elements which are unaccustomed to them, they are seen and are projected as dark branching lines, like the branches of a leafless tree ("Purkinje's Figures").

Although the main retinal vessels usually avoid the yellow spot region, there is here a very fine network of smaller vessels, which can also be viewed subjectively in a manner which will be described later.

Another result of the position of the sentient layer is that vision is impaired by the slightest loss of transparency in the superficial layers.

We pass now to the effect produced on the ophthalmoscopic picture by the retina. Owing to its almost perfect transparency (excluding, of course, its pigment layer), the retina itself is usually invisible in the normal condition, its existence being only rendered

evident by the presence of the blood vessels. These, as already stated, lie in the fibre layer, sometimes even projecting a little above the general surface.

Although the retina is not usually visible, its presence is sometimes indicated near the disc, where the fibre layer is thicker than elsewhere, and also at any point where some of the fibres cross a vessel owing to the light being caught and reflected, so that we become conscious of the existence of a fine, grey, gauzy veil, or of wavy streaks, overlying the red surface. The effect produced is very variable, and difficult to describe or depict, for the appearance presented varies with the direction of the incident light, and therefore with every change in the position of the ophthalmoscope mirror. Hence any attempt to depict it in a drawing gives an unnaturally hard result.

The more pigmented the fundus, the more conspicuous is this retinal reflex, and in very dark eyes, as in Plate II., Figs. 5 and 6, it may extend over the whole fundus, and almost conceal the red choroidal reflex, replacing it by a grey surface.

Usually, however, this reflex is observed only when the light strikes the retina at a certain angle, so that it is seen to shift from one part to another as the mirror is moved; this phenomenon is spoken of as the "shot-silk" appearance, although "watered silk" would be a more descriptive term.

All these reflex appearances are most marked in young eyes, and tend to disappear with advancing age; they are also more conspicuous under a feeble illumination, and with a concave than with a plane mirror.

An extreme case of retinal reflex was brought to my notice by Mr. Stephenson in November, 1891, and has since been published by him.¹ The patient was a boy, aged 9, of rather dark complexion. The fundus presented a series of bright silvery circles concentric with the disc margin, their outline being a little irregular and broken in places. Near the disc they were well defined, but they

¹ *Trans. Ophth. Soc.*, vol. xii., p. 115.

became less so, and formed less complete rings towards the periphery of the fundus; the general arrangement was suggestive of the waves radiating from a stone thrown into smooth water. Each band was about twice the thickness of the largest retinal vessels, and the individual bands were separated by spaces slightly wider, in which the normal choroidal reflex was visible. They appeared to lie in front of the retinal vessels. There were also present very fine straight lines, radiating from the disc, as in Plate III., Fig. 8, apparently produced by the retinal nerve fibres.

The condition appears to be an extreme example of that which has been described under the term "concentric retinal striation."¹

All these reflex appearances are probably due to irregularities in the surface of the retina, and possibly are in some way connected with the folded condition of that tissue during foetal life, a connection that might also explain the more frequent existence of these appearances in hypermetropia, which may be looked upon as an arrest of the normal process of development. For a very full account of the manner in which such irregularities reflect the incident light, the reader is referred to Dimmer's work.²

A wisp of the patient's hair coming between the light and the mirror throws shadows on the retina, which might, by a careless observer, be mistaken for a retinal reflex; such hair shadows, however, ought never to cause any confusion.

Occasionally in eyes which appear to be normal we meet with minute pale dots, which may be white or yellowish. These may be single, but are more commonly arranged in clusters as in Plate IV., Figs. 9 and 10, Plate XI., Fig. 30. Since they have the appearance of being quite superficial, and are often only to be seen when the light falls on them obliquely, they probably do not lie in the pigment layer, but are produced by some irregularity of surface which reflects the light powerfully.

¹ Bristowe, *Ophth. Rev.*, London, vol. x., p. 322.

² "Die ophthalmoskopischen Lichtreflexe der Netzhaut," 1891.

I believe that Marcus Gunn¹ was the first to call attention to these dots, which he found in all the members of one family, six in number, whom he examined. His paper also contains a reference to four other individual cases. The appearance, indeed, is far from rare, but is easily overlooked, owing to the fact that the dots readily disappear when the light is thrown full on to them. From the name of Mr. Gunn's first case they are sometimes referred to as "Crick's" dots. Plate XI., Fig. 30, shows the grouping of some of these spots, but gives an exaggerated idea of their distinctness; similar dots, but fewer in number, are to be seen in Plate IV., Figs. 9 and 10, and Plate III., Fig. 8.

Isolated spots of exceeding minuteness, having an absolutely metallic lustre, and looking like minute particles of mercury, are occasionally met with; it would be impossible to depict these adequately.

All these punctate conditions will be considered in greater detail later on.

In the following chapters we shall consider two parts of the fundus which are of especial importance: the entrance of the optic nerve—the so-called optic disc; and the central region—the macula lutea, or yellow spot.

¹ *Trans. Ophth. Soc.*, vol. iii., p. 110.

CHAPTER II.

THE OPTIC DISC.

IN order to understand the appearances presented by the disc it is necessary to have an accurate conception of the anatomy of the optic nerve.

We need not consider the cerebral connections of the nerve fibres, but may start from the optic foramen where the nerve enters the orbit. In the orbit the nerve is slightly slack, thus allowing of the movements of the globe. About fifteen millimetres behind the globe it is pierced on its outer side by the central artery and vein, which travel up its axis to the interior of the globe, where we will leave them for the present.

The optic nerve will be seen in a longitudinal section (Fig. 9) to pass through a funnel-shaped opening in the sclerotic, the larger end of which is directed backwards. To accommodate itself to this opening, the nerve becomes considerably reduced in size; not only so, but at the level of the posterior surface of the sclerotic it changes its character, for while behind this point it is white and opaque like other nerves, it here becomes greyish, and gelatinous in appearance. This is due to the fact that at this point the white matter of Schwann, which so far has encased the axis cylinder of each nerve fibre, ceases, only the more transparent axis cylinder going on. If the opening in the sclerotic be examined with the microscope (Fig. 9), it will be seen to be crossed by fibres derived from the sclera. In fact it is not a single large opening but a collection of openings like those of a sieve, through which the bundles of nerve fibres separately pass. The structure has therefore been named the lamina cribrosa. It has a very

important influence on the ophthalmoscopic appearance of the disc.

We are in the habit of looking upon the optic nerve as consisting entirely of nerve fibres passing from the retina to the brain, but recent investigations¹ have shown that it contains about an equal number of coarser fibres, in which conduction takes place in the opposite direction. Although the number of fine centripetal fibres is very great, the retinal cones are about eight times as numerous.

The nerve is invested in its whole course by a loose sheath.



FIG. 9.—Section through optic nerve and papilla.

This is derived from the intracranial dura mater, which at the optic foramen is also continuous with the periosteum of the orbit. Anteriorly this dural sheath blends with the sclerotic. Closely investing the nerve is the less conspicuous pial sheath which is continuous with the pia mater. This sends down processes between the bundles of nerve fibres, which give off secondary trabeculae, so that the whole nerve is permeated by a connective tissue frame-

¹ Max Knies, "Relation of Diseases of the Eye to General Diseases," 1895.

work which is continuous with the pia mater ; a rather thick process also accompanies the central vessels, forming their connective tissue sheath. The pial sheath ceases at the lamina cribrosa. The space between the dural and pial sheaths, called the intervaginal, or inter-sheath space, is easily visible to the naked eye in the section of the optic nerve seen after enucleation. Posteriorly this space is continuous with the sub-arachnoid space within the cranium ; anteriorly it passes up to the sclerotic, extending sometimes into the posterior larger end of the scleral opening, or even into the substance of the sclerotic itself. It appears to terminate in a cul-de-sac, but injection experiments have shown that there are fine channels passing from it into the substance of the nerve anterior to the lamina cribrosa.

A small process of arachnoid is usually described as passing a short distance along the nerve adhering intimately to the dural sheath, but the existence of this is denied by some authorities.¹

It is believed that the intervaginal space constitutes a lymph-channel, the direction of the stream being towards the globe, and that a return current exists along the connective tissue sheaths of the central vessels.

The optic nerve is supplied with blood by branches from the central vessels. Around the entrance of the nerve into the sclerotic that membrane is perforated by the posterior ciliary arteries, these give off branches in the substance of the sclerotic, which, by anastomosing, form a more or less complete arterial circle—the circle of Haller. From this numerous fine twigs pass into the nerve in front of the lamina cribrosa, anastomosing with those which come from the central vessels. In this way there is formed within the head of the nerve a fine vascular network connected both with the choroidal and retinal systems, which is not without influence on the ophthalmoscopic appearance of the disc. Anterior to this plexus the retinal vessels have no communications with any other blood vessels.

¹ See Gowers, "Medical Ophthalmoscopy," 3rd edition, 1890.

The ophthalmic artery, of which the central artery of the retina is a branch, comes off from the internal carotid by the side of the anterior clinoid process, and enters the orbit through the optic foramen on the outer side of the nerve. The ophthalmic vein, into which the central vein of the retina usually opens, runs into the cavernous sinus, reaching it through the sphenoidal fissure. It has a very free anastomosis with the facial vein at the upper and inner angle of the orbit.

Immediately in front of the lamina the nerve passes through

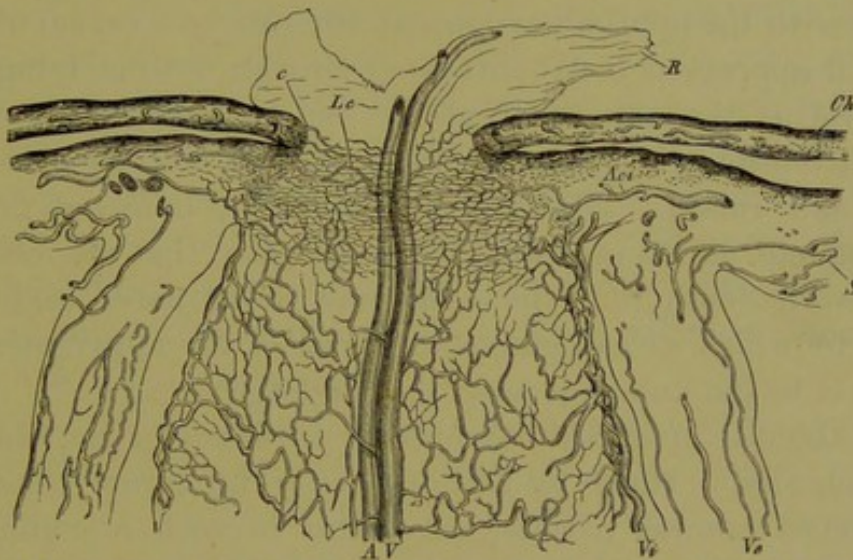


FIG. 10.—Diagram of blood vessels of optic nerve and disc. (GRAEFE U. SAEMISCH.)

R. Retina; CA. choroid sclerotics; c. edge of choroidal foramen; Aci. branch of posterior ciliary artery.

an opening in the choroid, which usually embraces it closely. This, unlike the lamina cribrosa, may be considered as a true opening, although occasionally a few pigmented fibres can be traced from the choroid into the nerve substance.

Immediately after passing through the choroid, the fibres of the nerve bend nearly at right angles over the choroidal margin, and spread out in all directions to form the fibre layer of the retina. It is to be noted, however, that they are massed most abundantly above and below, while the fibres on the outer side,

which go chiefly to the yellow-spot, form a much thinner layer than those on the inner side of the disc.

The nerve fibres being merely conductors, are of necessity more numerous near the disc than at the periphery of the fundus, and their accumulation here causes the head of the nerve to project above the level of the rest of the fundus, a circumstance that has led to its being spoken of as the optic papilla.

While the term optic papilla is fairly descriptive of the anatomical formation of the head of the nerve, that of optic disc, which is more frequently used, indicates the appearance which it presents with the ophthalmoscope, at any rate to a casual observer. To such it appears as a flat surface of circular outline, lying on the same level as the adjacent fundus. We shall presently see that a little attention will generally show that the surface is in reality convex and raised. The optical illusion is, however, generally very complete, and is probably due to the fact that we look down an unknown depth into the semi-transparent nerve, and, having nothing by which we can gauge the level of the apparent surface, we refer it to the known level of the fundus.

The absence of a definite opaque surface can be illustrated experimentally. Thus, it is quite easy to throw shadows of linear bodies on other parts of the fundus in such a manner that they are clearly visible with the ophthalmoscope. It will be found, however, that the disc is incapable of receiving such shadows.

Under no circumstances is it possible to see beyond the lamina cribrosa. When that structure is visible, the rather brilliant whiteness of its tissue is mottled by grey spots, corresponding to the openings of the nerve fibres. This can be seen in Plate I., Fig. 1, and Plate XLVII., Figs. 106 and 107, and in many of the other figures. In the normal condition, however, the greater part of the lamina is hidden from view by the nerve tissue over it. This forms a translucent substance, permeated by a rather rich capillary plexus, which gives it a

reddish colour, and impairs its transparency, so that no details of the structure of the lamina are visible, although the latter reflects a certain amount of white light.

It will be convenient to consider the disc as consisting of three separate parts or zones, although all three are not always to be recognised in a single eye.

First. The central zone, which is usually of white colour, and contains the central artery and vein, surrounded by a ring of connective tissue, and frequently by a portion of exposed lamina cribrosa, which forms the floor of a depression.

Secondly. The intermediate zone, which extends from the boundary of the central zone to the outermost zone or margin. This is of an uniform pinkish colour, of a tint which varies much in different eyes.

Thirdly. The outermost zone or margin, extending from the edge of the intermediate zone to the commencement of the general fundus-colour. This may vary from a mere line to a band of considerable width, encroaching on the fundus on the one hand, and on the disc on the other.

The central zone in some eyes may be said to be non-existent, the intermediate zone closely embracing the central vessels (*see* Plate II., Fig. 4, Plate III., Fig. 7, Plate V., Fig. 12, Plate VII., Figs. 18 and 19, Plate XIII., Figs. 36 and 37, and others). As a rule, however, the vessels are surrounded by a ring of connective tissue, which, being comparatively non-vascular, is of paler colour than the rest of the disc, Plate III., Fig. 8, and Plate X., Figs. 28 and 29.

The transition from the almost white colour of the connective tissue sheath to the rosy hue of the intermediate zone may be gradual or abrupt. Sometimes this connective tissue sheath instead of closely embracing the vessels, presents a funnel-like opening, so that the vessels can be traced a short distance into the nerve. The depression thus formed is called the porus opticus, and is different in appearance from the forms of physiological cup

to be presently described (Plate I., Fig. 3, Plate III., Fig. 8, Plate V., Fig. 13).

It is, however, more common for the lamina cribrosa to be exposed to view over a portion of the disc adjacent to the vessels; in such cases it evidently lies on a deeper level than the intermediate zone, in fact it forms the floor of a depression. This depression, which is called the physiological cup, or excavation, presents great variety of size and form, but it can always be distinguished from a fully-formed pathological excavation by the fact that, while it only involves a part of the disc, pathological cupping affects the whole.

Before considering the different varieties of physiological cupping, it will be necessary for us to digress in order to see how differences in level can be recognised with the ophthalmoscope. One of the most striking effects of such differences is the parallax movement that takes place when in the direct method of examination the observer moves his head in a plane perpendicular to the line of sight. Under these circumstances parts that are relatively depressed appear to move in the same direction as the observer's head. The phenomenon is identical with the optical illusion familiar to everyone who has watched the landscape from the window of a train in rapid motion; distant objects then appear to move in the same direction as, and near ones in the opposite direction to, the train. With the ophthalmoscope a very slight difference in level gives rise to a considerable parallax, because the effect is magnified by the dioptric system of the eye.

When the examination is made by the indirect method, on the observer moving his head the whole image appears to move in the opposite direction, and when he moves the lens it appears to move in the same direction as the lens, but in both cases the more superficial parts appear to move more than the deeper. It is often stated that the parallax is more conspicuous with the indirect than with the direct method, but my own opinion is the reverse of this.

A rough estimate of the difference in level can be formed from the extent of the parallactic movement, but for its accurate measurement lenses must be placed behind the sight-hole of the mirror in the direct method. A very minute difference in level of two points will prevent both being seen in focus with the same lens. A difference of every dioptré of refraction indicates a difference of 0.3 mm. of level, so that to find the difference in level of two points, it is only necessary to ascertain the lens which brings each respectively into focus, and to multiply the difference between these by 0.3. For example, the edge of a cup is seen without any lens while it requires a $-3 D$ to bring the floor into view, the depth of the cup is 0.9 mm. Again—the refraction of the edge is 1.0 D of hypermetropia ($+1.0$), while that of the floor is 1.0 of myopia (-1.0), that is a difference of 2 D , the depth of the cup is 0.6 mm., and so on. The same rule holds good for the measurement of projections above the plane of the fundus.

Physiological cups differ much in respect of their area, extent, depth, and position. Perhaps the most common form is that shown in Plate I., Fig. 2, in which the cup occupies the centre of the disc, and its outline is nearly circular. In this instance the edge is rather steep, so that the vessels on reaching it dip down abruptly out of sight, and reappear, but of course out of focus, on the floor of the cup. It is not uncommon for the cup to present a steep edge on the nasal side, while on the temporal, the floor slopes up gradually to the level of the fundus (Plate I., Fig. 3, Plate VI., Figs. 16 and 17, Plate XI., Fig. 30, Plate XXX., Fig. 65). In these instances the cup was of such a depth that the edge and the floor could not be seen distinctly simultaneously. Plate I., Fig. 1, is an example of a large but more shallow cup, and the mottling produced by the lamina cribrosa is plainly visible. The cup approaches the margin of the disc most nearly on the temporal side, and, judging by the course of the vessels, it seems to be less steep here.

The lamina cribrosa when thus exposed to view presents a

white surface mottled with circular grey spots which correspond to openings in its structure.

Other varieties of physiological cupping are seen in several figures, but it should be carefully noted that all possess one feature in common, namely, that they do not involve the whole disc. The uncupped portion may be only a narrow zone, or a crescentic area on one side of the disc, but it is always present. In this respect physiological cups differ essentially from those of pathological origin, since the latter, when fully developed, always involve the whole area of the disc (Plate XLVII., Figs. 105, 106, 107).

The central vessels vary in their relation to the physiological cup. Most commonly they appear on its floor, run up the sides, and curve over the margin (Plate I., Figs. 1, 2, 3, and others). But they may emerge from the uncupped portion of the disc, or may pierce the edge of the cup. Finally, they may spring from the centre of the cup floor, and come forward to the level of the fundus as if no cupping were present. Occasionally they look as if they were pushed aside by the cup, lying under, and curving over its steepest edge. In such cases (Plate XI., Fig. 30, and Plate XXX., Fig. 65), the vessels may at one moment be almost concealed from view by the overhanging edge, but come into view on the observer moving his head, owing to the parallax movement they then appear to undergo.

Some authorities¹ consider that the physiological cup is not a true excavation, but that the apparent absence of tissue in front of the lamina is due to its transparency. If this be the case it is difficult to see why the vessels should so often dip down into the apparent excavation, or why the latter should usually present a sharply defined edge. Moreover, the appearance presented by the lamina cribrosa in a physiological and in a glaucomatous cup is almost identical, although the latter is known to be a true excavation.

¹ Loring, "Text-book of Ophthalmology."

Microscopical sections, for example that in Fig. 9, show that in the area of the physiological cup the tissue of the nerve is thinned, and that the surface of the disc presents a true depression.

We now pass on to consider the intermediate zone of the disc. This extends from the central zone to the margin, and therefore occupies by far the largest part of the disc. It contains the whole mass of the nerve fibres, together with a plexus of fine blood vessels, derived from the branches of the central vessels, and from the circle of Haller (*see* p. 30). It is by the colour of this portion of the disc that we judge of the state of nutrition of the optic nerve. Atrophic changes, when they reach a certain stage, cause diminution in the capillary circulation, and increased transparency of the nerve fibres, so that the lamina cribrosa then becomes more visible, and this part of the disc paler (Plate XXXII., Figs. 71, 72, 73).

Increased vascularity, on the other hand, occurs in the early stages of optic neuritis and causes increased redness of the disc, and diminution in the transparency of its substance (Plate XXXI., Fig. 66, Plate XXXII., Fig. 70, Plate XXXVI., Fig. 81, Plate XXXVII., Fig. 84).

In order to recognise pathological changes in the colour of the intermediate zone it is of course necessary to be familiar with the variations which it may present in health, and these are very numerous.

As already explained, the colour of this portion of the disc is mainly due to its capillary circulation. The transparency of the nerve fibres not only allows the red tint or capillary blush to be visible, but it also permits a certain amount of light to be reflected from the surface of the lamina. The closeness of the capillary network circulation varies in different individuals. It is probable that the transparency of the nerve fibres also does so, and there are possibly other structural differences which affect the colour. Apart from these, the apparent tint of this portion of disc is influenced to some extent by contrast with the colour of the

adjacent fundus. Other things being equal, a disc will appear lighter when the fundus is very dark.

If, for the present, we exclude from consideration discs which may be considered exceptional, we shall still see that there is great variation. The most usual colour is a rosy tint only slightly paler than the rest of the fundus, for example, Plate I., Figs. 1 and 2.

The colour may be slightly deeper than this and duller (Plate II., Fig. 4); or it may be a deep rich red, as is well seen in Plate II., Fig. 6.

A disc that looks light by contrast is shown in Plate III., Fig. 5, and Plate IV., Fig. 8.

In exceptional cases the colour is a dull dirty red, as in Plate VII., Figs. 18 and 19. The same colour is seen in part of the disc in Plate VIII., Fig. 22, the central part of Plate V., Fig. 14, Plate VIII., Fig. 24. It will be noted, however, that discs of this colour generally present other unusual features, so that they can hardly be considered as typical.

The form and the extent of this intermediate portion of the disc necessarily depend on the size, shape, and position of the physiological cup. If there is no cup, the intermediate zone may extend up to the centre of the disc (Plate II., Fig. 4, Plate III., Fig. 7, Plate V., Fig. 12), or there may be a zone of connective tissue forming a white, or pale, band round the central vessels.

More commonly this part of the disc forms a broad belt surrounding a central cup, which may be large or small (Plate I., Figs. 1 and 2).

It is not unusual for the cup to open outwards, under these circumstances the intermediate zone is displaced to the nasal side (Plate XI., Fig. 30).

Differences in the level of the disc surface are important in connection with inflammatory swelling of the head of the nerve, but in the normal condition they hardly come under consideration, for, unless special care be taken in the examination, the inter-

mediate zone always appears to be flush with the adjacent fundus. But if a section of the eye be examined after its excision, the disc will always be found to project slightly above the fundus. And, even in the living eye, careful examination with the ophthalmoscope will often afford indications that it is really raised.

Indeed, if it be borne in mind that the nerve fibres from all parts of the retina crowd into the disc, and there become continuous with the fibres of the optic nerve, and that the apparent level of the fundus is not the surface of the retina, but its pigment layer, it will be obvious that the surface of the disc must project beyond the apparent level of the fundus.

It must be remembered that the appreciation of relief and depression is largely due to experience, training, and unconscious reasoning. So much is this the case that it is well known the same figure may appear in relief or depressed according to the incidence of light upon it, or even in accordance with the preconception of the observer. In looking at the disc we see down an unknown depth into its semi-transparent substance. The colour is a blend of the capillary network, reflection from the lamina, and the tissues of the nerve fibres. There being nothing to fix the level, it is naturally referred to that of the adjacent fundus. There are, however, often indications that the real level is above this; sometimes on the surface a fine gauzy piece of connective tissue is visible, which, from the parallax movement it undergoes, is evidently in front of the fundus level. But the most certain indication of the true level lies in the course of the vessels. These can often be seen to spring forward from the centre of the disc, and then to bend over in gentle curves to reach the level of the retina (Plate I., Figs. 2 and 3, Plate X., Fig. 28). Such vessels are always supported on the disc surface, which, being transparent, is invisible. The cases in which a vascular loop springs forward unsupported are too exceptional to be considered in this connection, and moreover present a totally different and unmistakable appearance. In commencing optic neuritis, the

tissue of the disc becomes hazy, and then its true level is easily discerned. Actual swelling of the disc occurs in this condition, but in the early stage there may be turbidity without swelling.

There remains for consideration the margin of the disc. Under this term is included any part of the disc which lies beyond the intermediate zone and a narrow belt of the fundus around the disc. Strictly speaking, this cannot, of course, be included under the term margin, but as the variations that it presents are connected with alterations in the disc itself, the arrangement is convenient.

The margin of the disc may be merely a line marking the division between the intermediate zone of the disc and the fundus. In such cases it corresponds to the edge of the choroidal opening. Over this line, however, pass the nerve fibres from the retina to the disc. These form a thick mass, so transparent that the fibres themselves are invisible, but their presence considerably softens the disc margin. This is seen from the fact that when the fibres are atrophied, and their transparency thus increased, the disc margin is seen as a hard sharp line, quite unlike its appearance in health (compare Plate XXXII., Figs. 71 and 73, with those which represent normal discs).

The nerve fibres are not evenly distributed over the margin, but are most numerous above and below, and least numerous on the temporal side. In the latter situation the fibres are short, and come from the macula, but the fibres from the parts immediately above and below the macula curve round to reach the upper and lower margins of the disc.

As already stated, the nerve fibres of the disc, as well as those of the retina, are almost transparent, and, as a rule, invisible. In young eyes, however, especially if the fundus is dark and the refraction hypermetropic, a certain amount of light is reflected from the surface of the fibres, so that they may be visible, although transparent. It would seem that with advancing years some

change occurs in the tissues which renders them less reflecting; the nature of this change is not known, but the appearance produced by light reflected from their surface is common in children, rare in middle life, and unknown in old age.

The appearance referred to produces in the least marked cases merely a light halo round the disc (Plate VI., Fig. 15, and Plate X., Fig. 29), while in the most marked, a gauzy film, which has a fibrillar appearance, covers the disc margin. This is most conspicuous above and below, because the nerve fibres are here most abundant (Plate I., Fig. 3, and Plate II., Figs. 4 and 6). It is also frequently seen near the larger vessels, probably because the surface is here a little raised. This condition must not be confounded either with that known as opaque nerve fibres (Plate XII., Fig. 34, and others), which will be described presently, or with blurring of the disc margin, due to turbidity of the nerve fibres produced by optic neuritis (Plate XXXI., Fig. 66). In the condition under consideration there is no loss of transparency. The disc margin can be seen through the gauze-like film that covers it. The appearance is not fixed and constant like that produced by real opacity, but changes with alterations in the direction of the incident light, so that it may be most marked at different parts of the margin in succession. This shiftiness and unreality in the appearance make it difficult to depict it in a satisfactory manner, for as soon as it is fixed in a drawing it has an unnatural hardness. Although the natural appearance, however, cannot be accurately reproduced, the figures referred to above, in which the attempt has been made, come near the truth. Somewhat analogous appearances are sometimes seen in other parts of the retina. They also result from reflection from the surface of a transparent tissue, which is not itself visible (Plate II., Fig. 5). The term reflex phenomena is sufficiently descriptive of this class of ophthalmoscopic appearance.

Another condition of disc and fundus occurs in association with hypermetropia, and may resemble optic neuritis so closely

that it can be distinguished from it only by the fact that it remains stationary. In these cases the disc margin is blurred, white lines frequently accompany the vessels, and the latter are unnaturally tortuous. I have myself only met with well-marked examples of this hypermetropic disc in cases in which the hypermetropia was of high degree, but Hubert Bristowe¹ has collected a considerable number of cases which seem to show that, although this appearance only occurs in hypermetropic eyes, the degree of error has no influence upon its frequency. Extreme hypermetropia may be regarded as an arrest of development, and it seems not unreasonable to look upon the tortuosity of the vessels in these cases as connected in some way with a tardy disappearance of the folded condition of the retina, which exists in early foetal life.

The disc margin, if we adopt the definition laid down at the commencement of this section, instead of being a mere line separating the intermediate zone from the fundus, may be a band of appreciable width encircling the intermediate zone like the tire of a wheel (Plate I., Fig. 2, Plate V., Fig. 12, Plate XI., Fig. 31). In the majority of such cases the band is obviously a part of the disc, since it is marked off from the fundus by a much more defined boundary than that which separates it from the remainder of the disc. Its colour is much paler than the intermediate zone, but it has not the brilliancy of exposed sclerotic.

This band is sometimes called the scleral ring—an obvious misnomer, since it lies entirely within the disc. The real scleral ring is never seen in its entirety except in pathological conditions. (For examples, see Plate XXIV., Fig. 56, Plate XLVII., Figs. 105, 106, and 107.)

The proper term for this band is the connective tissue ring, and it is formed by a band of comparatively non-vascular tissue, which is probably continuous with the pial sheath of the nerve. The

¹ *Ophth. Rev.*, London, vol. x., p. 321.

nerve fibres lie entirely within this ring, and are bound together by it.

The connective tissue ring may be complete, or it may be present at one part only, or it may be very wide at one part, usually the lower, and narrow elsewhere. In the last case it constitutes one variety of the condition to be presently described under the name of congenital crescent of the disc (Plate VI., Fig. 15).

Occasionally this connective tissue ring is developed to such a degree as almost to constitute a malformation of the disc (Plate V., Fig. 14). The space available for the nerve fibres is then encroached upon, and the fibres being consequently crowded together, with less than the usual amount of connective tissue between them, the intermediate zone has a peculiar dull greyish colour, easily mistaken for atrophy. I have seen this grey colour only in adult eyes. It seems probable such discs in early life would resemble that shown in Plate V., Fig. 12.

In very exceptional instances it would seem that the connective tissue ring not only encroaches on the intermediate zone, but also on the choroid, so that the total area of the disc is increased. Such cases may be looked upon as a variety of coloboma of the disc (Plate VIII., Fig. 24).

The scleral ring can only be visible owing to the opening in the choroid being larger than the space occupied by the optic nerve, so that the sclerotic, or the junction of the sclerotic and the upper end of the dural sheath of the nerve, is exposed. It is sometimes difficult to be certain whether a ring should be classed as scleral or as connective tissue, but a complete scleral ring, evidently lying beyond the disc, is probably never met with in health. It is not uncommon, however, for the sclera to be exposed at one part of the circumference, usually the outer. This is seen in Plate V., Fig. 13. The condition then resembles that known as the myopic crescent. Indeed, it can only be distinguished from it by the absence of myopia. Sometimes over

such an area only some of the layers of the choroid are absent, and we may then have the appearance depicted in Plate VII., Figs. 20 and 21, and Plate XV., Fig. 40.

It is possible that certain cases of congenital crescent are due to exposure of the sclerotic below the disc, although the writer has never seen a case in which this explanation of the appearance was not open to doubt.

The disc margin is usually more or less pigmented. The amount of pigment varies much. It may form a complete ring

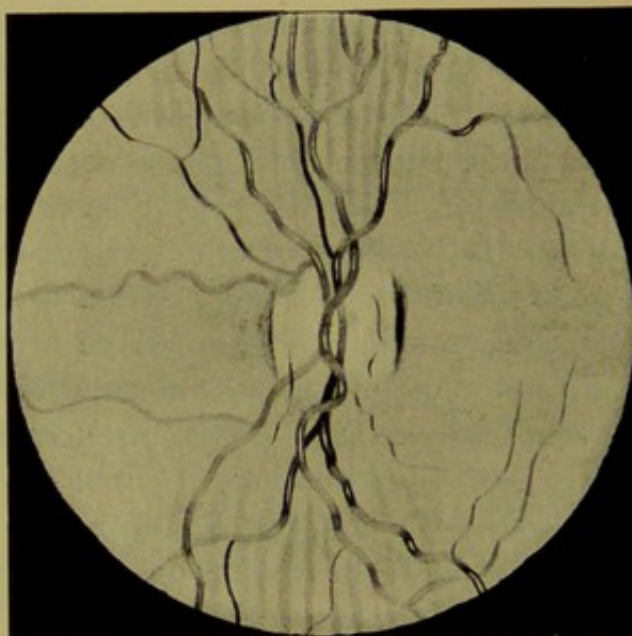


FIG. 11.—Disc appearing to be oval from astigmatism.

round the disc. Most commonly it is defective in some situations, while in others the pigment is abundant. In many cases, on the fundus are broken lines of pigment parallel to the one which coincides with the disc margin (Plate IV., Fig. 9, Plate VIII., Fig. 22). Less frequently a small amount of pigment lies within the boundary on the disc itself (Plate II., Fig. 5). Exceptionally, coarser masses of pigment are met with in this situation, which may even cover a considerable part of the disc (Plate V., Fig. 11).

If the figures be examined it will be seen that, while there is great variety in the distribution of this marginal pigment, it is exceptional for it to be absent altogether.

The outline of the disc is usually nearly circular, although minor irregularities, such as a slight flattening of some part of its circumference, are very frequent. Oval discs are, however, by no means uncommon, and then the vertical meridian is always the longer (Plate II., Fig. 5). Fig. 12 represents rather an extreme example of this, the ratio of the vertical to the horizontal meridian being as five to three.

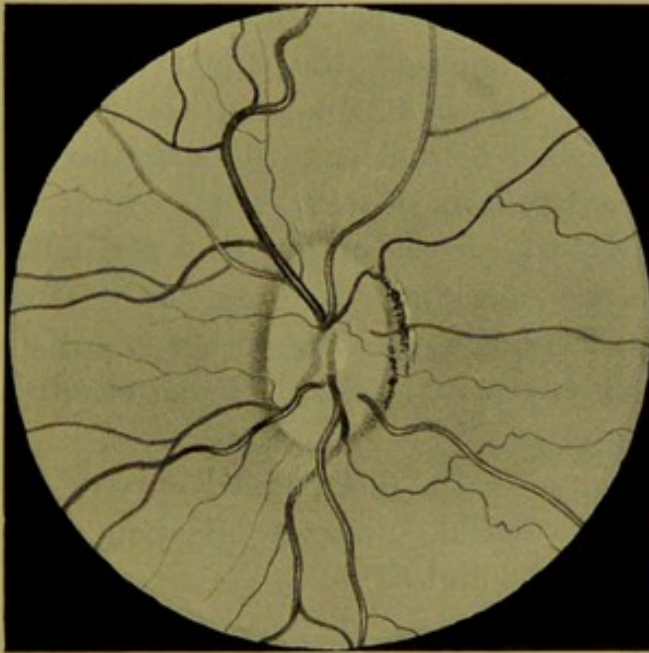


FIG. 12.—Oval disc.

The presence of astigmatism, however, may cause a disc to appear oval when it is not so in reality, owing to its being more magnified in one direction than in the other. In direct ophthalmoscopic examination the enlargement is greatest in the meridian of greatest refraction, but the actual effect produced (as is well shown in Fig. 11, p. 44) depends less upon the difference in the apparent length of the meridians of the disc than upon the contrast

between the sharp definition of all lines running parallel with one principal meridian, and the indistinctness of those at right angles to this.

Thus, Fig. 11 represents a case of astigmatism of 6 *D*. The fundus is shown as it appeared when viewed through a spherical lens, which corrected the *horizontal* meridian. All *vertical* lines are seen with unnatural sharpness, so that the lateral edges of the disc, and all vessels running in a vertical direction, stand out boldly, while the upper and lower margins of the disc and all horizontal vessels are blurred, or, at any rate, not conspicuous. A very fair idea of the appearance can also be obtained by looking at a drawing of a normal fundus through a cylindrical lens.

With the indirect method, the contrast between the vessels is less marked, but the oval shape of the disc is readily seen. When the object lens is held close to the eye, the longest diameter corresponds to the meridian of least refraction (*i.e.*, the reverse of the appearance by the direct method), as the lens is withdrawn from the eye, the meridian of greatest refraction elongates, either actually, or relatively to the other meridian, so that the disc becomes circular, and then elongated in the opposite direction.¹

In high myopia, also, the disc usually appears to be oval with the long diameter vertical, owing to its being viewed obliquely (Plate XXIII., Figs. 53 and 54).

¹ For an admirable description and explanation of the changes produced by withdrawal of the lens in the indirect method in the various conditions of refraction, the reader is referred to a paper by M. Parent, *Rec. d'ophth.*, Paris, 1881, p. 544.

CHAPTER III.

THE RETINAL VESSELS.

WE now return to the central artery and vein, which we left at their point of entry into the eye, the artery having been just reinforced from the plexus in the head of the nerve (Fig. 10, p. 31).

Owing to our habitually seeing the vessels magnified by the dioptric system of the eye, we are apt to forget how small they really are. The diameter of the largest probably does not exceed one-hundredth of an inch.

Although we commonly speak of seeing the retinal vessels, it must be borne in mind that what we see is not the vessel, but the column of blood within it—a fact that can be easily demonstrated by pressing on the globe with the finger during ophthalmoscopic examination. The effect of this is to empty the vessels near the disc, and it will then be seen that the empty portion of the vessels will disappear from view, their walls being too transparent to be visible. By careful focussing, the presence of the vessel wall can occasionally be recognised by the existence of a fine line on each side of the vessel, separated from the blood column by a very narrow interval; this is most easily seen where one vessel crosses another.

In the larger vessels the arterial blood is usually much brighter than the venous, but in the smaller branches the distinction cannot always be made, and the degree of difference varies in individual cases. The arteries also appear brighter than the veins from the presence of the streak of light which courses down the centre of the vessel, and which is less marked in the veins.

The cause of the central light-streak has been much debated, and the question cannot perhaps yet be considered finally settled.

Until recently it was generally held that it was due to reflection from the anterior convex surface of the vessel or blood column. Loring has, however, argued in favour of its being produced by a reflection from the fundus behind the vessel, modified by the vessel acting as a cylindrical lens. The objections to this view are so cogent that it is difficult to see how it has obtained any supporters. Thus, the reflex is not affected by the colour of the background; it exists on the disc as well as on other parts of the fundus; and, if Loring's explanation were true, the streak would necessarily be red and not white.

As to the distribution of the retinal vessels, we are met by the initial difficulty that there is no arrangement sufficiently common to be considered as the normal type. Perhaps the most usual arrangement is for the central artery and vein to emerge from the centre of the disc—each as a single vessel—close to each other. In such cases the artery is, in the great majority of cases, on the nasal side of the vein. Each vessel then divides into an upper and a lower trunk, unless, as is often the case, the division has already taken place in the nerve. The upper and lower division soon bifurcate into an inner and outer branch, so that we now have four named vessels, the superior temporal and nasal, and the inferior temporal and nasal. The temporal vessels are usually larger than the nasal, and they curve round above and below the region of the macula, giving off branches which pass towards the macula, but before they reach it become too small to be visible. Besides the vessels just described, separate small twigs usually emerge from different parts of the disc surface, the most constant of these pass over the temporal border of the disc and run in an almost horizontal

¹ The reader who desires fuller information on this subject is referred to the following, among other, papers:—Story, *Ophth. Rev.*, London, vol. xi., p. 100; Jäger, "Ergebnisse der Untersuch. mit dem Augenspiegel, 1876;" Schneller, *Arch. f. Ophth.*, Leipzig, bd. xxvi., ab. i.; Loring, "Text-book of Ophthalmology;" Dimmer, "Die Ophthalmoskopische Lichtreflexe der Netzhaut," 1891; and *Ber. ü. d. Versamml. Heidelberg ophth. Gesellsch.*, 1891.

direction towards the macula, but they also appear to stop short before they reach it.

The vessels are usually somewhat tortuous throughout their course, but vary greatly in this respect. The veins may, broadly speaking, be said to accompany the arteries; that is to say, their general direction is the same, and their branches usually correspond to those of the arteries. But the curves made by the two sets of vessels are often quite dissimilar, the veins being usually more tortuous than the arteries. An artery and its corresponding vein will frequently cross and recross each other, sometimes the one and sometimes the other being superficial.

In some retinae the vessels proceed a long way from the disc without bifurcating (Plate V., Fig. 11).

There is usually a relation between the number of vessels and their size, but there are exceptions to this rule also, and in some eyes the vessels are unusually numerous, while their size is little, if at all, below the average.

The vessels as they pass from their point of origin over the disc margin are usually seen to make gentle curves, having their convexities forwards. As they lie on the surface of the disc this indicates, as already pointed out, that the disc is slightly convex.

The presence of a physiological cup modifies the course of the vessels. When the cup is central, the main vessels usually emerge from its floor, but instead of passing straight forwards they follow the walls of the cup, climbing up them and curling over the edge of the cup to reach the surface of the retina (Plate I., Figs. 1 and 2). If the cup is large and displaced laterally the vessels are similarly displaced, as if they had been pushed aside by the cup.

On the fundus the larger vessels lie in the fibre layer of the retina. Only here and there do nerve fibres lie superficial to them. Their presence is then indicated by a silvery gauzy reflex.

When, as is usually the case, the arteries and veins are equally

numerous, the veins are broader than the arteries in the ratio of about four to three.

Vessels sometimes emerge from the margin of the disc, which, when traced backwards into the nerve, appear to bend away in a peripheral direction. It is probable that such come, not from the central artery, but from the arterial circle round the head of the nerve, or from one of the choroidal vessels. They, therefore, belong more properly to the choroidal than to the retinal system, although in their distribution they differ in no way from the branches derived from the central artery.

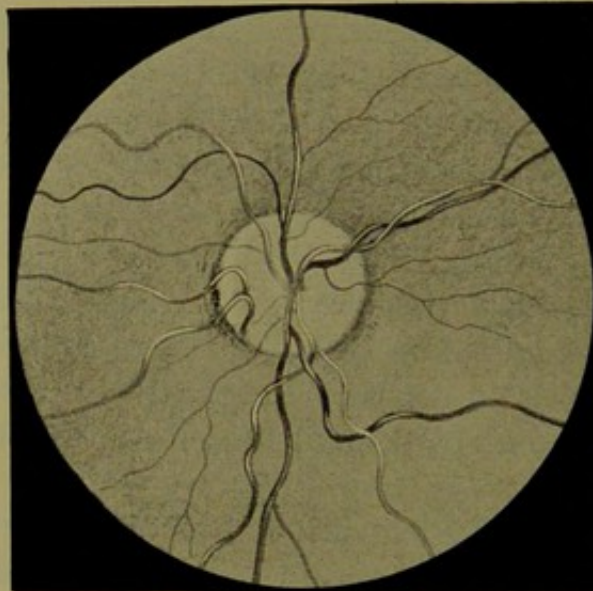


FIG. 13.—Cilio-retinal vessel of large size.

These vessels, which are named cilio-retinal, are commonly of small size and solitary, and emerge at the temporal border (Plate XIX., Fig. 45). But occasionally vessels, both arteries and veins, as large as primary branches of the central vessels are met with, and they may emerge at any part of the margin (Plate VI., Fig. 15, and Fig. 13 above).

Usually it is only a matter of inference, from the direction of the vessel, that it comes from the choroidal system, and it is

impossible to be certain that it has not sprung from the central vessel in the substance of the optic nerve. Some authorities have indeed doubted whether any of these vessels are really of ciliary origin.¹ Several cases are, however, on record, in which it has been possible to trace the connection of such vessels with the choroidal system, either with the microscope or with the ophthalmoscope.

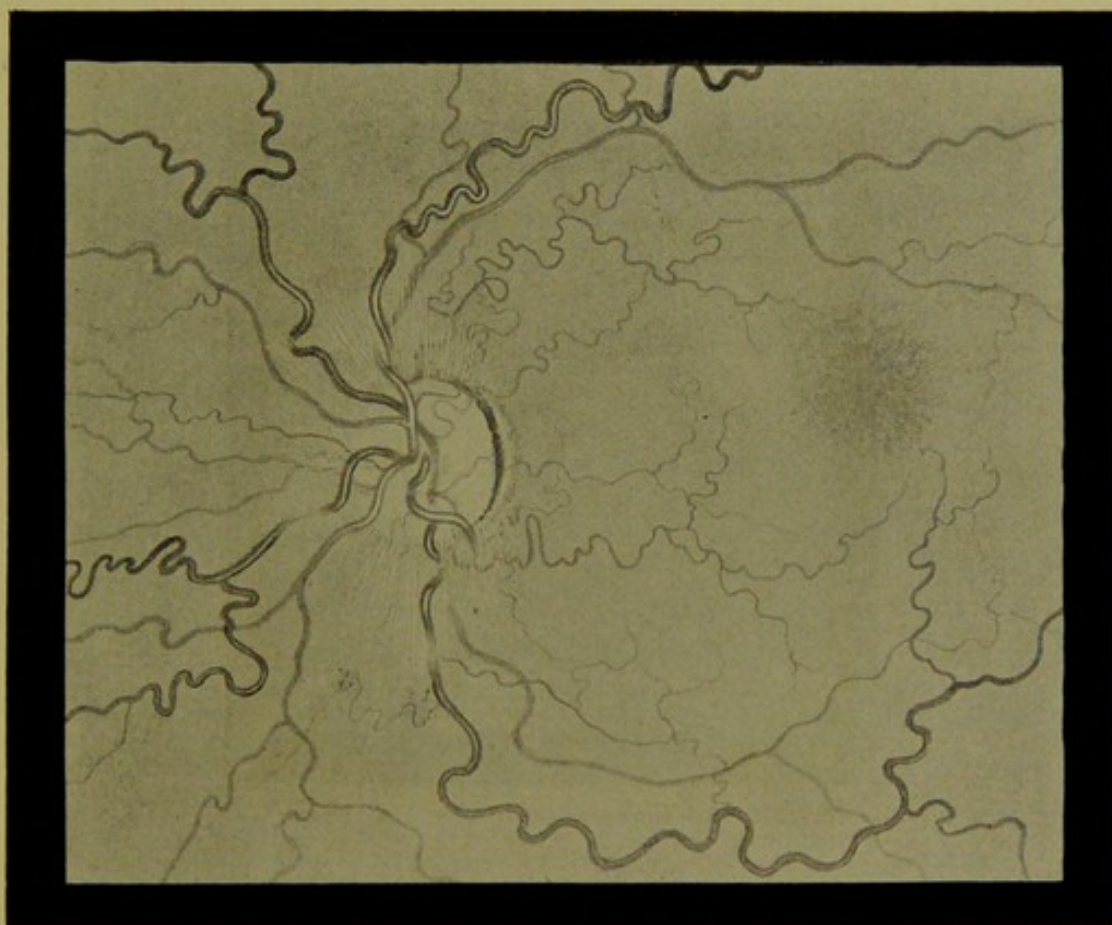

FIG. 14.—Tortuosity of arteries and veins.

Thus, Nettleship has described and figured a microscopical section of a disc in which a vessel of large size could be traced from the sclerotic near the nerve entrance into the substance of the disc.² The case was one of optic neuritis, but although this

¹ See Schnabel and Sachs, *Arch. Ophth. and Otol.* N.Y., vol. xiv., p. 268.

² *Ophth. Hosp. Rep.*, London, vol. ix., p. 162.

might account for some increase in the size of the vessel, it could hardly explain its presence as a new formation. Birnbacher¹ describes a section of a perfectly healthy eye in which a vessel, believed to be an artery, as it lay in the choroid near the opening for the optic nerve, gave off a branch, which passed towards the papilla for a short distance, and then bending over the border of the choroid, entered the superficial portion of the nerve fibre layer of the retina, and ran towards the macula.

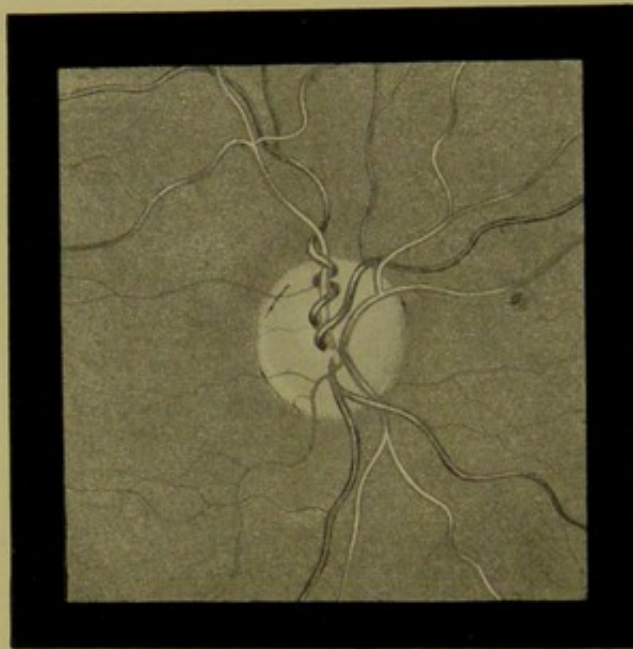


FIG. 15.—Cork-screw twist of retinal vein.

Randall² gives a diagram showing the ophthalmoscopic appearances in a case in which one of these vessels could be seen with the ophthalmoscope joining a choroidal vessel 2 dd. from the disc-margin. Similar conditions have been described by other observers.

The existence of these cilio-retinal vessels is not devoid of practical importance, since occasionally when the main trunk of the central artery has been occluded by an embolus, the presence of one of them has permitted a portion of the retina to retain its

¹ *Arch. Ophthalm. and Otol.*, N.Y., vol. xvi., p. 32.

² *Trans. Am. Ophthalm. Soc.*, p. 513.

function, and to remain unaltered in appearance. An instance of this is shown in Plate XLI., Fig. 93.¹

Smaller twigs emerging from the outer margin of the disc, and coursing towards the macula, are exceedingly common;² their size usually renders it impossible to be certain whether they are arteries or veins. The larger cilio-retinal vessels generally appear at other parts of the margin, and they not uncommonly bifurcate close to their point of exit, as in Fig. 13, p. 50, and Plate VI.,

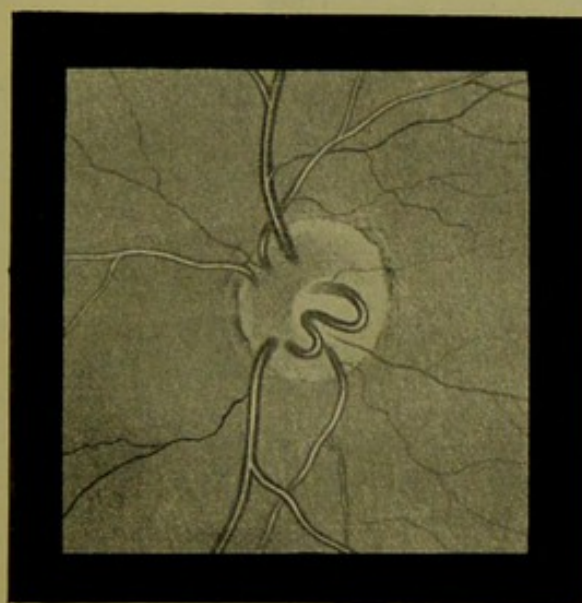

FIG. 16.—Projecting loops in retinal vessels.

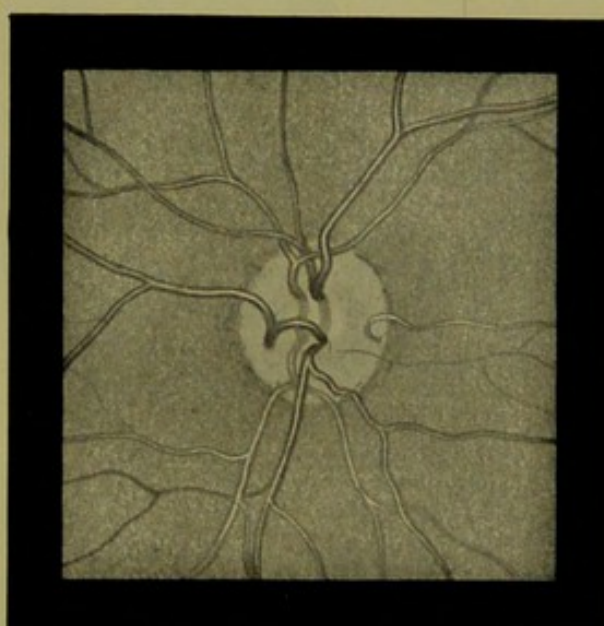

FIG. 17.—Projecting loops in retinal vessels. (After RANDALL).

Fig. 15. The majority of cilio-retinal vessels are arteries, given off from the circle of Haller; when they are veins, they must be offshoots of the choroidal vessels, since the circle of Haller consists only of arteries.

A case has been recently published by Lawford,³ in

¹ See also Benson, *Ophth. Hosp. Rep.*, London, vol. x., p. 161, and Birnbacher, *Centralbl. f. prakt. Augenh.*, Leipzig, 1883, p. 207.

² In a paper by Messrs. Lang and Barrett (*Ophth. Hosp. Rep.*, London, vol. xii., p. 59) they are said to occur in 16.7 per cent.; but the number of cases examined—48—is too small to establish the frequency of the condition. The writer's impression is that it is more common than this.

³ *Trans. Ophth. Soc.*, vol. xv., Plate VIII.

which all the retinal vessels—both arteries and veins—in one eye

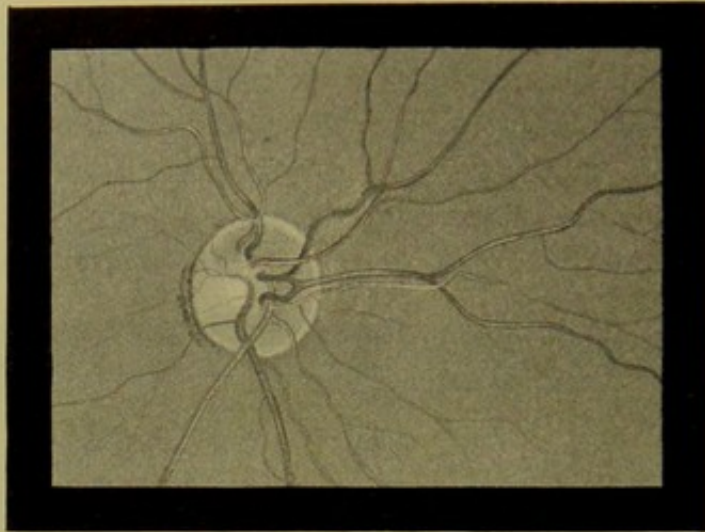


FIG. 18.—Bifurcating vein.

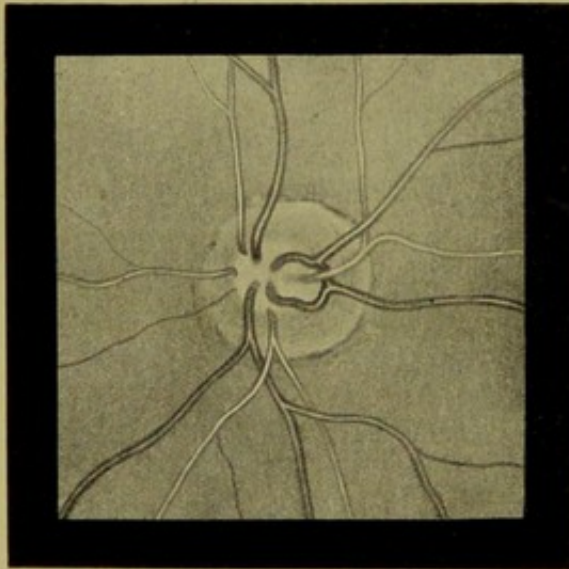


FIG. 19.—Abnormalities in retinal veins.
(After WERNER.)

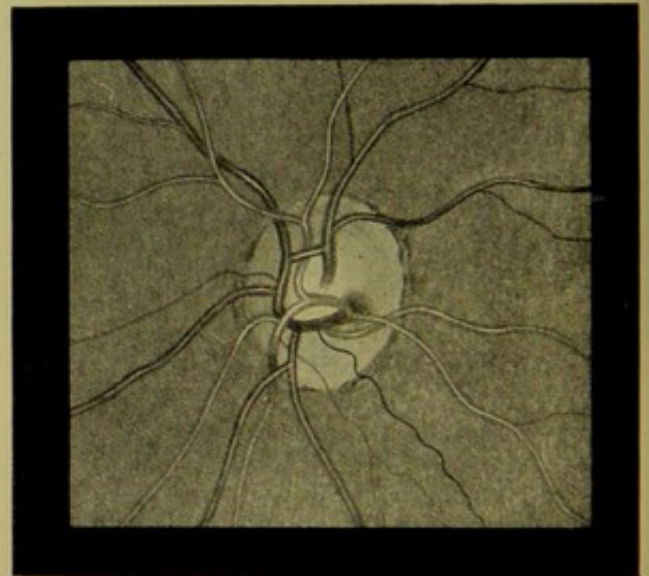

FIG. 20.—Abnormalities in retinal veins.
(After STEPHENSON.)

emerged from the margin of the disc—a condition which occurs normally in the felidæ and some other animals.

The retinal vessels never run even an approximately straight

course, but their sinuosities present great variations in number, character, and size. They are generally most numerous in the veins, and a serpentine or wavy course, such as is shown in Plate VII., Figs. 18 and 19, is not rare.

Both arteries and veins may be very tortuous, as in Fig. 14, p. 51. We shall see later on that tortuosity of the retinal veins is a symptom of optic neuritis, but in such cases they are also distended, while the arteries are unaffected. Another point of distinction is that physiological sinuosities lie (with occasional

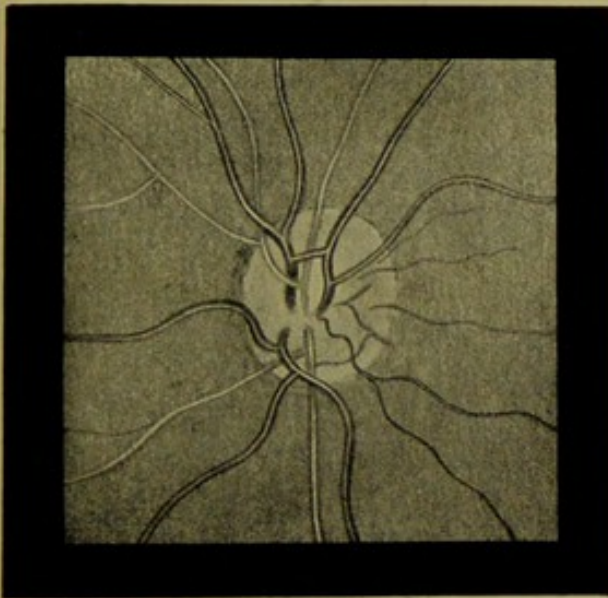


FIG. 21.—Communicating branch between veins.
(After STEPHENSON).

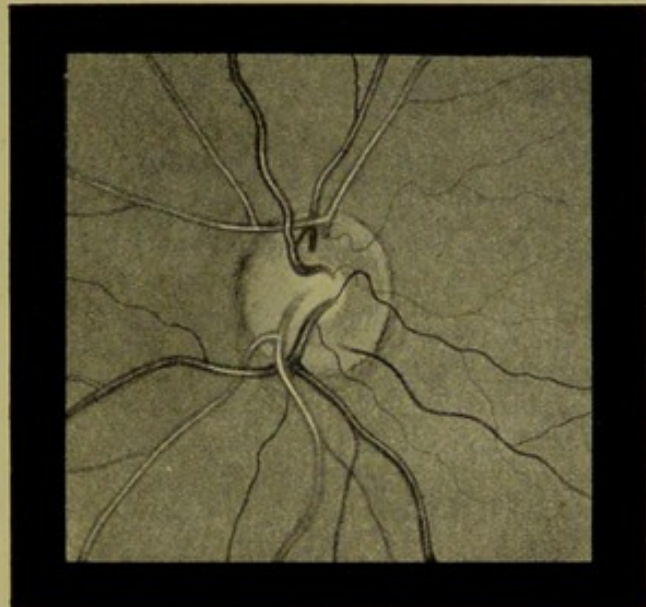


FIG. 22.—Bifurcating vein.
(After STEPHENSON).

exceptions) in the plane of the retina, whereas many of the curves produced by papillitis are perpendicular to it.

It seems that unusual tortuosity of the retinal vessels is more frequently met with in hypermetropic than in other eyes. Hypermetropia, however, is so common a condition that too much stress must not be laid upon the connection. But making due allowance for this, tortuosity of vessels and hypermetropia are so frequently seen together that the association cannot be accidental. Hypermetropia

is a condition of imperfect development; may not tortuosity of the retinal vessels be in some way connected with retarded disappearance of the folded condition of the retina, which exists at an earlier stage of development?

Apart from general tortuosity of the retinal vessels,¹ a single vessel—usually a vein—may present a series of twists. These usually lie in the plane of the retina, although isolated pro-

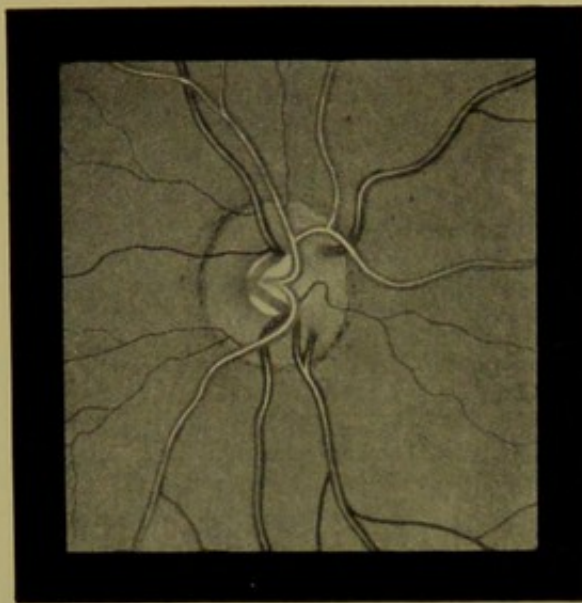


FIG. 23.—Bifurcating retinal veins.
(After STEPHENSON.)

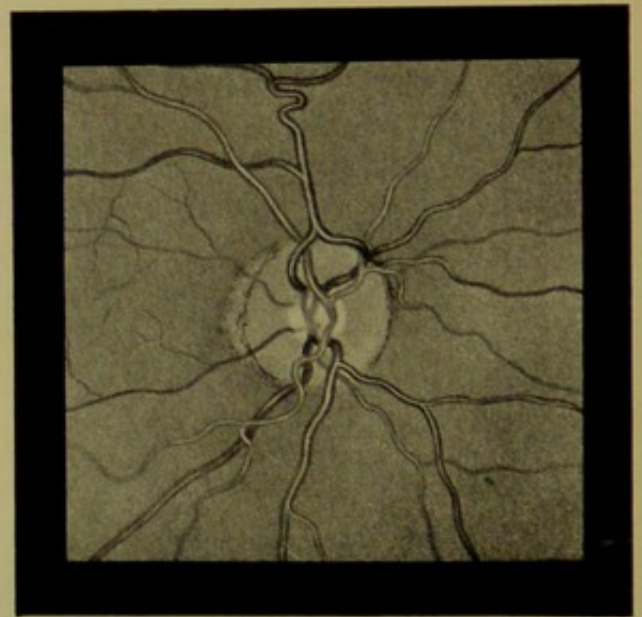


FIG. 24.—Bifurcating retinal veins.
(After RANDALL.)

jecting loops are occasionally seen on the larger vessels near the disc.

Minor irregularities are exceedingly common. Thus an artery and a vein may be twisted round each other like the strands of a rope; more often, as in Fig. 15, p. 52, it is the vein that is twisted round the artery.

Occasionally, retinal veins as they proceed towards the disc bifurcate (Figs. 18, 19, 22, 23, 24), or give off branches that

¹ For good examples of tortuous retinal vessels the reader is referred to—Benson, *Trans. Ophth. Soc.*, vol. ii. p. 55; Nettleship, *ib.*, p. 57; Mackenzie, *ib.*, iv., p. 154.

communicate with an adjoining vein (Figs. 20 and 21). Sometimes one vein on the disc will take upon itself to receive most of the others, and will go round a great part of the disc collecting them (Fig. 20). In other cases a vein will bifurcate just before it disappears into the disc, an artery passing through the fork (Fig. 24).

A rarer anomaly is shown in Figs. 16 and 17, p. 53. Here a vein forms a loop, each end of which disappears into the disc. An analogous case is published by Lawford,¹ in which one

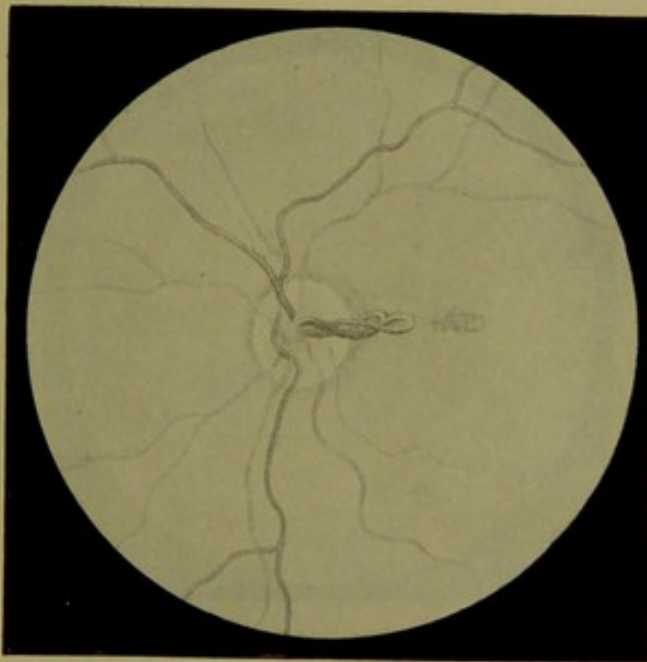

FIG. 25.—Vessel projecting into vitreous from the disc.

extremity of the loop disappears at the centre of the disc, the other at its margin.

An extreme instance of tortuosity of single veins is shown in Plate XXI., Fig. 48. Others might be given, but as they occur in almost infinite variety no useful purpose would be served by doing so. Fig. 25, however, represents a condition which must be exceedingly rare. A large vessel is seen to leave the centre of the

¹ *Trans. Ophth. Soc.*, vol. xv., p. 195.

disc, to project into the vitreous at an angle of about 45° with the apparent surface of the disc, and after proceeding about a disc diameter, to divide into two branches, which twist round the parent stem, and then return to the disc, in which they are lost. The eye had normal vision.

Some who saw the case considered that the vessel was a persistent hyaloid artery. Its size, direction, and bifurcation are, however, all against this view, and I should look upon it myself as an exaggerated example of a kink in a retinal

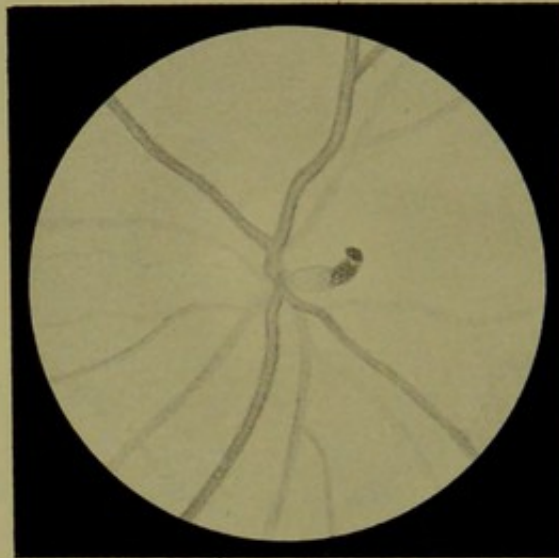


FIG. 26.—Remains of hyaloid artery.

vessel, and consider that the returning branches again emerge as other vessels.

W. S. Little¹ has published a somewhat similar case. Here, however, the vessel did not return to the disc, but could be traced on to the retina. It is difficult, therefore, to see on what ground the author considers it to be an example of persistent hyaloid artery.

The double loop in the vein shown in Fig. 16, p. 53, is probably

¹ *Trans. Am. Ophth. Soc.*, 1881.

of a similar nature. It will be seen that both extremities of the loop disappear into the disc. The patient from whom the sketch was made was suffering from slight optic neuritis associated with albuminuria.

Persistence of the hyaloid artery as a blood-carrying vessel in any great part of its course is one of the rarest congenital abnormalities, although small portions of the vessel are not infrequently seen. This vessel is a foetal structure, which passes from the centre of the disc straight through the vitreous to the posterior pole of the lens, where it breaks up into a plexus. A retrogressive process occurs in the vessel, commencing at the lens, and spreading backwards, so that at birth no vestige of it should remain. The space in the vitreous, however, in which it lies—canal of Cloquet or Stilling—persists throughout life, probably as a lymph space, although its walls are too transparent to be visible with the ophthalmoscope. Some congenital forms of posterior polar cataract are, doubtless, connected with the remains of this vessel. Instances have been recorded in which the hyaloid artery has persisted in nearly its whole course as a blood-carrying vessel, but more commonly it only forms a fine impervious thread, or an empty tube. Fig. 26 shows a portion of the vessel persisting near the disc, in the form of a truncated cul-de-sac, like the finger of a glove, projecting into the vitreous, only its anterior extremity is drawn in focus. It was of a light slate colour, and had a thin gauzy appearance; probably, therefore, it did not contain blood.

Pulsation of the retinal vessels is a condition to which I must refer, although for obvious reasons it cannot be depicted. The retinal arteries are, of course, much below the size of vessels in which pulsation occurs; it is, therefore, never seen in them, except as an abnormal condition, the essential feature of which is that the resistance offered by the intraocular pressure to the entry of blood is increased either actually, or relatively to the propelling power of the heart. This may occur

either from increased intraocular pressure, as in glaucoma, or from diminished propelling power, as in aortic regurgitation. Arterial pulsation may also be produced artificially, by making pressure on the globe during ophthalmoscopic examination, and thus raising the intraocular tension. It is usually seen, not as a rhythmical alteration in the calibre of the vessel, but as a sudden disappearance and reappearance of a portion of the vessel on the disc.

Arterial pulsation is also said to occur in exophthalmic goitre, and is attributed to vasomotor paralysis. I have looked for this symptom in all cases that have come under my notice, but hitherto without success.

While arterial pulsation always indicates the presence of abnormal conditions, it is otherwise with pulsation in the veins, which is very commonly present in perfectly normal eyes, and is due to purely physical causes within the eye itself. The veins are readily compressible, but much more so in some eyes than in others. At the height of the arterial pulse-wave there is a momentary slight increase of the intraocular pressure; this is transmitted to the veins, and the blood in the part nearest the centre of the disc is pressed out of the eye, so that a corresponding part of the vessel disappears. We thus see one or more veins on the disc alternately shortening and returning to their full length. The pulsation is less sudden than that which occurs in the arteries, and often resembles the to-and-fro action of a piston. It never affects more than a short piece of the vein, and is most commonly seen just at the point where a vessel curls over the edge of a physiological cup, although it occurs also in other conditions. For example, in Plate I., Fig. 1., the venous trunk, formed by the union of the two lower veins, is just visible after passing beneath the artery and before it dips into the cup. Such a vein would be likely to show pulsation, the short piece referred to rhythmically disappearing. Again in Plate I., Fig. 3, the lower vein would be likely to exhibit the same phenomenon.

A slight increase in the intraocular pressure, whether occurring spontaneously, or induced in the manner just described, will cause venous pulsation, while a greater rise of pressure will produce an arterial pulse. Venous pulsation can therefore hardly be said to possess any diagnostic value, for it is present so frequently in normal eyes, that in a case of suspected increase of tension it would generally be impossible to prove that pulsation had not always existed. Moreover, it is an undoubted fact that it may be present at one time and not at another in a perfectly healthy eye—a circumstance which is probably due to variations in the action of the heart.

The explanation given above of the mechanism of venous pulsation is not universally accepted, some authorities holding that it is produced by the direct pressure of the artery on the vein in the nerve or disc.

CHAPTER IV.

THE MACULA LUTEA.

WE have now to turn our attention to the central part of the fundus, which in men and apes presents a modified structure, and possesses a highly exalted function. This differentiation of the centre from the remainder of the fundus marks the highest stage reached in the evolution of the eye, and is no doubt an essential factor in binocular vision.

This central region has been called the yellow spot (*macula lutea*) or, more briefly, the macula. The name is derived from a transient discoloration which takes place in this area after death, and has no connection with its ophthalmoscopic appearance. In the centre of the macula is sometimes to be seen a minute depression, which is usually called the *fovea centralis*.

The macula presents no sharply defined boundary either with the microscope or with the ophthalmoscope. Anatomically it may be defined as the region in which the bacillary layer is represented by cones only. With the ophthalmoscope it sometimes appears to be surrounded by a silvery halo or reflex ring. Either of these limitations will include an oval area, the major axis of which is transverse and about the same length as the diameter of the disc. Its centre is situated about a disc and a half from the outer margin of the disc, and a little below the horizontal meridian.

Until recently the macula has usually been described as lying on the same level as the rest of the retina, but presenting near its centre a depression which was called the *fovea*

centralis. Recent investigations by Dimmer¹ have shown that the depression commences at the border of the macula, and shelves down gradually to the centre, where sometimes there is another, smaller, depression. This small and occasional depression corresponds with the white spot seen with the ophthalmoscope, and hitherto called the fovea centralis; Dimmer would call this the foveola, using the term fovea as synonymous with macula.

If we accept these views, the ophthalmoscopic appearances are brought into harmony with the anatomical structure. Thus, the reflex ring is at once explained by light being reflected from the slightly raised convex edge of the depression. The thinning of the retina within the area explains the colour of the macula. In pigmented eyes this is often dark from the pigment of the choroid showing through, while in lighter eyes, the capillary layer of the choroid gives it a richer red.

Of the anatomical modifications of this part, the most

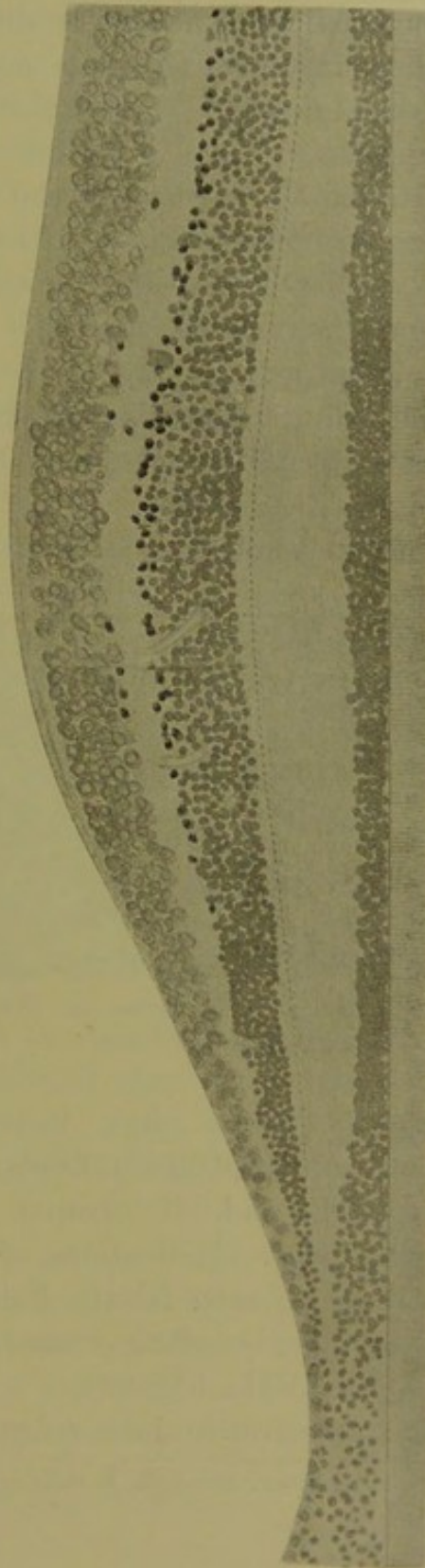

FIG. 27.—Section of retina in macular region. (After DIMMER.)

¹ "Beiträge zur Anatomie und Physiologie der Macula lutea des Menschen," 1894.

characteristic is the entire disappearance of the rods from the bacillary layer, so that the cones are numerous, and in contact with one another. As the centre is approached they increase in length.

Round the borders of the macula most of the layers become somewhat increased in thickness, and they then gradually thin down. This is especially noticeable in the layer of nerve cells. Around the macula, the cells are ten deep, while at the fovea there is but a single layer.

According to Golding Bird and Schäfer,¹ there is a depression in the external limiting membrane, corresponding in position to the fovea (Fig. 28).

An anatomical peculiarity of this region, which has a

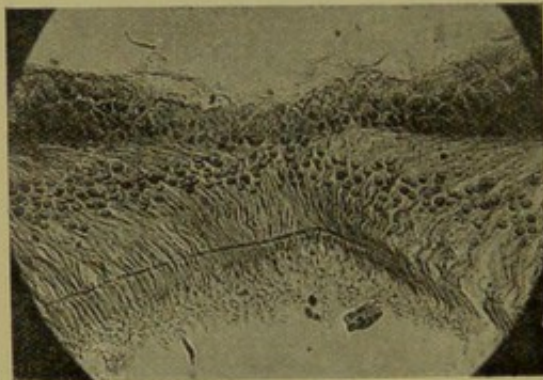


FIG. 28.—Section through the macula. (After GOLDING BIRD and SCHÄFER.

considerable influence upon the ophthalmoscopic appearance under certain conditions, is the oblique direction assumed by the fibrillar elements, namely, the cone-fibres, and the fibres of Müller. Instead of traversing the retinal layers in a perpendicular direction, as in other parts, they become more and more oblique as the centre is approached. The

result of this is that, instead of seeing merely the inner extremities of Müller's fibres, the whole length of the fibres is exposed, and, if opaque, they appear as lines radiating from the fovea. Indications of this arrangement of the fibres can sometimes be seen faintly indicated in normal eyes (Plate III., Fig. 8); it is often conspicuous in pathological conditions (Plate XXXVII., Fig. 84).

The appearance just referred to is not identical with that

¹ *Internat. Monatschr. f. Anat. u. Physiol.*, Leipzig, 1895, bd. xii., heft. 1.

described by Bristowe,¹ in which there were bright radiating lines, "suggesting a resemblance to the petals of a sunflower." This latter phenomenon is evidently a reflex appearance, analogous to the watered-silk streaking that is seen in other parts of the retina, and, as in that condition, the streaks appear to lie on a plane anterior to the retina. The striation, on the other hand, which is produced by the retinal fibres, lies in the retina.

The ophthalmoscopic appearance of the yellow spot varies much. In light fundi it is seldom conspicuous, and its position may only be recognisable by a slight deepening of the colour of the fundus (Plate III., Fig. 7), or by an absence of visible blood vessels. In these light fundi the fovea centralis is often not noticeable, while in moderately dark fundi, on the other hand, both yellow spot and fovea are usually conspicuous. The former as a dark area, sometimes showing fine pigment stippling (Plate II., Figs. 4 and 6); the fovea as a rounded white dot in its centre (Plate II., Fig. 5). In very dark eyes the macula is often of a still deeper hue than the rest of the fundus (Plate X., Fig. 29; Plate XLII., Fig. 95).

As already stated, in some eyes which are perfectly normal, faint indications can be seen of striæ radiating from the fovea (Plate III., Fig. 8). This radiating or star-like appearance is doubtless due to the alteration in the direction of the fibres at this part, already described. In normal eyes it is seldom to be seen, and is never conspicuous, but in some morbid conditions it is very marked (Plate XXXV., Fig. 78; and Plate XXXVII., Fig. 84).

A reflex appearance at the macula, which is common in young subjects, is that of a delicate white or silvery ring of oval shape, corresponding in size with the boundary of the macula, and seeming to float just in front of the retina. This reflex ring or halo is seen best with a concave mirror and by the direct

¹ *Ophth. Rev.*, London, vol. x., p. 322.

method, but it can also be seen by the indirect method. Sometimes it is visible in its entirety; more commonly one or other part of it comes into view according to the position of the mirror. It is impossible to depict it without making it appear more substantial than the reality. The macular halo is doubtless due to thickening of some of the layers of the retina at the borders of the yellow spot, a slight convexity being thus produced, which reflects the light.

The smaller central depression, when it exists, also has its reflex appearances. The most common of these is a minute

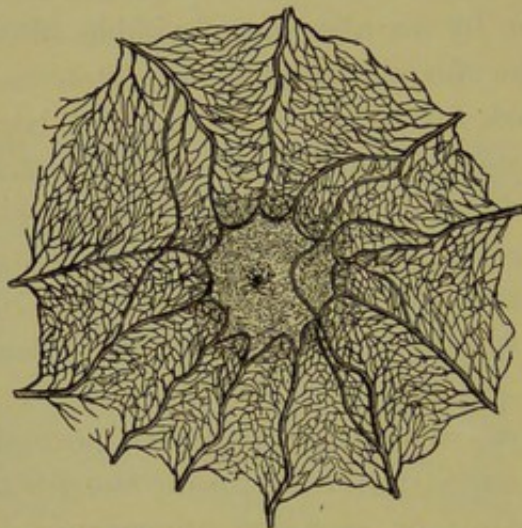


FIG. 29.—Entoptic appearance of vessels at macula. (GRAEFE u. SAEMISCH.)

crescent of light, embracing about half the circumference of the depression, and traveling round it as the mirror is moved. Another is a short beam of light appearing to project from the bottom of the depression a short distance into the vitreous. This has received the name of the policeman's lantern reflex, which, if rather fanciful, is yet sufficiently descriptive. This appearance was first described, I believe, by Marcus

Gunn,¹ who considered that it was usually associated with myopia; it is, however, certainly met with in all states of refraction.

Ophthalmoscopic examination of the macula without the previous employment of a mydriatic is often difficult, because the pupil contracts strongly when the light falls on this region, and also because the corneal reflection of the mirror lies in the line of sight. Hence many observers are less familiar with

¹ *Trans. Ophth. Soc.*, vol. viii., p. 173, and *Ophth. Hosp. Rep.*, London, vol. xi., p. 348.

the physiological variations of this part than they are with those of the optic disc. Consequently, when an unexplained amblyopia leads to a thorough examination, changes at the macula are apt to be diagnosed on rather insufficient evidence.

Reference has been made to the absence of visible vessels within the macula. Their invisibility is, however, due only to their small size. With the microscope they can be traced to the edge of the fovea.

Their presence can also be shown by what is known as the entoptic method, in which shadows of the vessels are thrown upon the retina, and are projected by the subject of the experiment as if they were the images of external objects. The experiment is performed in the following manner:—A white cloud is looked at through a pinhole in an opaque diaphragm. The latter is then rapidly moved about, care being taken to keep the aperture within the area of the pupil. The visual field at first appears of an uniform grey colour; it is soon seen, however, to be crossed by a network of darker lines, which branch and anastomose, thus forming a fine plexus (Fig. 29).

White or yellowish dots are occasionally met with at the macula in eyes which appear to be healthy. Some of these are conspicuous notwithstanding their minute size, owing to the hard, sharp appearance which they present. Others are seen with difficulty, and only when the light is feeble or strikes them obliquely. The latter are identical with those described by Mr. Gunn under the name of "Crick" dots. They will be described more fully later on (Plate III., Fig. 8; Plate IV., Figs. 9 and 10; Plate XI., Fig. 30).

CHAPTER V.

DEVELOPMENTAL IRREGULARITIES.

So far we have been dealing with conditions which in no way impair the function of the eye, and which may therefore be termed physiological. We must now turn our attention to those which are due to an arrest of, or to an irregularity in, the process of development. These may be said to lie on the borderland between physiological and pathological conditions; for, on the one hand, they are congenital and stationary; on the other, they usually interfere to some extent with function.

COLOBOMA OF THE CHOROID.

Coloboma of the choroid is one of the most conspicuous of these conditions. Its morbid anatomy can only be understood by bearing in mind the principal stages in the process of development of the eye.

The optic nerves and retinae are formed from the neural epiblast, and are at first represented merely by two hollow protrusions from the anterior cerebral vesicle. Each of these protrusions subsequently becomes differentiated into a tubular stem—the optic stalk, and a more globular extremity—the primary optic vesicle. At this stage the optic stalk contains no nerve fibres.

The vitreous body and the blood vessels of the optic nerve and retina are developed, on the other hand, from the mesoblast, a process of which enters the globe below, and in so doing pushes the wall of the primary optic vesicle in front of it.

The wall of the primary optic vesicle thus becomes invaginated, and doubled on itself, and its cavity obliterated. This pushing

in of the mesoblastic process, while obliterating the primary optic vesicle, produces a new cavity—the so-called secondary optic vesicle. This contains the process of mesoblast, which subsequently becomes the vitreous. It is bounded by the now reduplicated wall of the primary vesicle, which afterwards becomes the retina. The retina, in the early stages of its development, presents numerous folds, and the entrance of nerve stalk is much larger in proportion to the rest of the organ than is the optic disc into which it develops. The wall of the secondary optic vesicle is necessarily imperfect below, where there is a gap to permit the entry of the process of mesoblast. This gap, which may be called the foetal cleft, extends anteriorly to the lenticular depression in the cutaneous epiblast, and posteriorly to the optic nerve stalk.

The portion of mesoblast that lies outside the cleft eventually surrounds the eye and becomes differentiated into choroid and sclerotic. That inside the cleft, besides developing into vitreous, carries a number of blood vessels into the interior of the globe. The greater number of these disappear early in foetal life, but others are pushed into the optic nerve stem—along the wall of which nerve fibres are now growing—and become the central vessels of the retina. Up to a comparatively late period another vessel also persists—the hyaloid artery. This extends from the centre of the optic nerve across the cavity to the posterior surface of the lens, where it breaks up to form a plexus.

In the normal course of development the mesoblastic process should disappear, and the cleft close, so that at birth no vestige of either should be visible. According to most authorities¹ the closure of the cleft commences posteriorly and extends forwards. It should be completed by the end of the second month. The closure may be arrested or delayed at any stage, so that a gap may remain in the ocular tunics extending from the ciliary body to the disc, or stopping short at any distance from the latter.

¹ Bock, "Die angeborenen Kolobome," etc., 1893.

Associated with this is usually a defect in the corresponding part of the iris. This coloboma of the iris looks like a neatly performed iridectomy. It is not immediately due to non-closure of the foetal cleft, for the iris does not exist at the time at which this should take place, but is a later outgrowth from the choroid. In the normal course of development the iris presents no cleft at any stage.

The condition produced by non-closure of the foetal cleft is usually spoken of as coloboma of the choroid. Its ophthalmoscopic appearance is shown in Plate IX., Figs. 26 and 27. If the above account just given of the development of the eye is correct, it would be more accurate to look upon the condition as primarily a coloboma of the retina. It would seem, however, that the patency of the cleft so modifies the conditions of development that all the tunics are imperfectly formed.

As to the condition of the retina, its pigment layer is always completely absent over the area concerned, while at the margins of the gap pigment is frequently heaped up. The nervous elements appear to be absent, if we may judge from the fact that the visual field always shows a gap corresponding to the coloboma. It is true that in a few eyes which have been examined microscopically, some tissue has been discovered which was believed to be retinal,¹ but only in small amount, and very imperfectly developed. The retinal vessels may, however, be present and course over the coloboma as in the figures. This is to be explained by the fact that they are a late development from the mesoblastic process, as explained above.

The choroid may be said to be practically absent, since neither pigment nor blood vessels exist, and the normal choroid is mainly made up of these.

The sclerotic, also, is modified, so that it yields to the intraocular pressure and becomes bulged outwards. This is seen to a slight degree in Plate IX., Fig. 26, but sometimes the protrusion is so extreme that a cyst is formed which may be larger than the eye

¹ Hess, *Arch. f. Ophth.*, Leipzig, bd. xxxvi., p. 137; Bock, *loc. cit.*

itself, which in such cases is always smaller than normal. In this circumstance we have an explanation of some of those rare cases of supposed absence of the eye (anophthalmos) associated with the presence of a cyst in the lower eyelid. But, although such an extreme condition is rare, some degree of microphthalmos is common in coloboma.

When a coloboma reaches nearly to the disc (as in Plate IX., Fig. 26), the latter appears shortened in its vertical diameter; this is probably due mainly to the fact that the bulging of the sclerotic tilts the disc forwards, and its vertical diameter is thus foreshortened. If the disc is involved in the coloboma, it may be unrecognisable except as the meeting point of the vessels, or it may present a deep depression much larger than the normal disc. The subject of coloboma of the disc will, however, be considered later, as well as the possible connection between congenital crescent of the disc and delayed closure of the cleft.

Delay in the closure of the cleft is probably due to persistence of the mesoblastic process beyond the normal time. This persistence may affect one part only, when a partial coloboma will be produced. This appears to have been the case in the left eye of the patient whose right eye is depicted in Plate IX., Fig. 27, for although the fundus presented a normal appearance near the disc and towards the periphery, there was an irregular area of exposed sclerotic about 2 dd. below the disc, which roughly resembled the upper portion of the coloboma depicted in the figure.

Coloboma of the iris is not unfrequently present without any defect in the choroid. Even then, however, the gap is usually directed downwards, although exceptional cases are met with in which it occupies other situations.

Coloboma of the choroid, on the other hand, seldom exists without a corresponding defect in the iris; such cases have, however, been recorded.¹

¹ F. J. Becker, *Arch. f. Ophth.*, Leipzig, bd. xxii., p. 221; Talko, *Klin. Monatsbl. f. Augenh.*, Stuttgart, 1875, p. 215; Benson, *Dublin Journ. Med. Sc.*, 1882; Hoffmann, "Inaug. Dissert.," 1871.

It is generally held that coloboma of the choroid, from arrested development, can occur only in the downward direction. It is true that defects in other directions have been described, but as these were associated neither with coloboma of the iris, nor with microphthalmos, they have usually been attributed to destruction of the choroid by inflammation, and not to its non-development.

Recently, however, the writer saw a case¹ in which a coloboma of the choroid on the temporal side co-existed with coloboma of the iris similarly situated, and with microphthalmos. The patient was a girl aged 11. The diameter of the right cornea measured only 9 mm., and the whole eye was evidently small. There was a coloboma of the iris on the temporal side, involving about one-eighth of its circumference. The margin of the lens was visible through this, and presented no abnormality. The coloboma of the choroid extended from the temporal periphery to a point about $\frac{40}{5}$ from the temporal side of the macula, where it ended in a rounded border. There was nothing abnormal either in the appearance of the optic disc, or in the direction of the principal vessels.

Some writers have attributed coloboma to an inflammatory process occurring during intra-uterine life. It must be admitted that a case like the above gives some colour to such a view, but the almost constant position of the defect downwards is strong evidence in favour of the foetal cleft being in some way concerned in its production.

OPAQUE NERVE FIBRES.

A conspicuous congenital abnormality of the disc is that presented by the condition known as opaque nerve fibres. We have seen that at the level of the lamina cribrosa the fibres of the optic nerve change their character; for, whereas behind the lamina they consist of axis cylinders encased in medullary sheaths; in the fibre layer of the retina there are axis cylinders only. It

¹ *Trans. Ophth. Soc.*, vol. xiii., p. 144.

occasionally happens, however, that a few fibres on the retina are also encased in medullary sheaths like those in the optic nerve. We then have such an appearance as is represented in Plate XII., Figs. 34 and 35, and Plate XIV., Fig. 38. It will be noticed in all these that the disc itself presents nothing abnormal. Evidently, therefore, the affected fibres have not retained their medullary sheaths continuously from the optic nerve, but have thrown them off before traversing the lamina, and again resumed them. This was found to have actually occurred in some cases, which were examined both ophthalmoscopically during life, and microscopically after death.¹

The ophthalmoscopic appearance will vary with the number and position of the affected fibres, but there are certain features common to all cases. The patch is of a very brilliant white colour, quite unlike an inflammatory exudation, or a patch of exposed sclerotic. Its surface can usually be seen to be fibrillated. When, as sometimes occurs, it appears to be rough, or almost crystalline, its fibrillar nature is clearly indicated at the edge of the patch, where it merges into normal fundus, by the fine brush-like processes into which it splits.

The retinal blood vessels are usually wholly or partially embedded among the opaque fibres.

The white area is usually in contact with the margin of the disc, and extends on to the retina about a disc diameter. Occasionally there is a clear space between the patch and the disc as in one of the tufts in Plate XIV., Fig. 38. It is rare for the opaque nerve fibres to lie at any distance from the disc, but a case is recorded by Recklinghausen,² in which a space of 4 mm., or about two disc diameters, intervened.

In extreme cases, the disc itself is involved (as in Plate XIII., Figs. 36 and 37, and Plate XIV., Fig. 39), so that a great part,

¹ Schmidt-Rimpler, *Klin. Monatsbl. f. Augenh.*, Stuttgart, 1874, p. 186; Manz, *Arch. f. Augenh.*, Wiesb., bd. xxix., p. 220.

² *Virchow's Archiv*, bd. xxx., p. 375; and Usher, *Ophth. Rev.*, London, vol. xv., p. 1.

or even the whole, of the disc may be hidden. The part that remains visible is commonly of a dark dull colour, similar to that which is met with in extreme examples of congenital crescent (compare Plate VIII., Fig. 22, with Plate XIII., Figs. 36 and 37, and Plate XIV., Fig. 39). No doubt this colour is partly due to contrast with the adjacent white patch, but it is probably mainly produced by the crowding together of the remaining nerve fibres, and the diminution in the quantity of interstitial tissue, caused by the disproportionate amount of space occupied by the coarser opaque fibres. In these cases where the disc is involved there can be little doubt that the opaque fibres are continued through the lamina; indeed, this was proved to be the case in an instance recorded by W. Manz.¹

The conducting power of the affected fibres is not impaired, and vision therefore is not appreciably affected. At the same time the opacity of the fibres prevents images being formed on the sentient layer beneath them, and the size of the blind-spot is consequently increased to an extent corresponding to the patch of opaque nerve fibres. Usually this increase is too slight to be observed, but in the case from which Fig. 39 was taken it was quite perceptible with the perimeter.

Microscopical examination of eyes in which the presence of opaque nerve fibres has been discovered during life, has not often been possible. But particulars of a few such cases are given in the papers just quoted.² The affected fibres in all presented varicose swellings, which were connected with the axis cylinders; but the explanation of this association is not obvious.

A condition that bears some resemblance to opaque nerve fibres is the striated appearance of the disc margin (Plate I., Fig. 3, and Plate II., Fig. 4), already described as being not infrequently seen in young eyes, especially if the fundus is rather dark. In these cases, however, there is not the brilliancy of opaque nerve fibres, and the striation, instead of being definitely

¹ *Loc. cit.*

² *Loc. cit.*

localised at one part of the disc, shifts its position according to the direction of the incident light.

A case has been recorded¹ in which a patch of opaque nerve fibres disappeared when the optic disc became atrophied. This cannot be a constant result, as the writer has seen the conditions of opaque nerve fibres and optic atrophy in association.

It is not uncommon to see masses of connective tissue on the disc. In the slighter cases little white threads, so fine as to be easily overlooked, lie in front of the apparent level of the disc, and may indicate the real position of the summit of the nerve head; they may, however, project a short distance into the vitreous, and undergo tremulous motion after the eye has been quickly moved. It is difficult to depict such fine opacities in a satisfactory manner. In more marked instances a well-defined white mass is seen over the central vessels, often sending out processes which accompany the branches of the arteries a short distance; in such cases the connective tissue may either form a dense white mass, or a light feathery fluff over a part of the disc (Plate XII., Figs. 32 and 33).

A somewhat analogous appearance, which is rare, is a white, or grey ring about the diameter of the disc, and lying well in front of it; it probably has some connection with the canal of Cloquet.

Indeed, it is not improbable that many of the finer gauzy shreds which lie on a plane anterior to the disc may be remnants of the hyaloid artery.

CONGENITAL CRESCENT OF THE DISC.

I have chosen the above title for this condition in preference to that of Coloboma of the Disc, which is sometimes applied to it, both because it sufficiently describes the ophthalmoscopic appearance, without committing us to any theory as to its pathology, and also because there is another condition of the disc to which the term coloboma can be more appropriately applied.

¹ Wagenmann, *Arch. f. Ophth.*, Leipzig, bd. xl., p. 256.

These congenital crescents are exceedingly common, at any rate in a slight form. They consist of a crescentic area of paler colour than the rest of the disc, situated, with a few exceptions, directly downwards, or downwards with a slight obliquity.

The contrast between the colour of the disc and that of the crescent is generally better seen by the indirect than by the direct examination. The boundary line between the crescent and the rest of the disc usually forms a segment of a larger circle than the remainder of the disc margin, and is sometimes a straight line. The disc and crescent together usually form a figure that is nearly circular or oval; in the latter case, the direction of the axes corresponds to the astigmatism, which is very often present. This is seen in Plate VII., Figs. 18 and 19, in which there was astigmatism of 4.0 *D*. It will be noticed that while the coloured portion of the disc is round, it, and the crescent together, form an oval, the long diameter of which corresponds to the meridian of greatest refraction.

In many instances visual acuity is subnormal after the refraction has been corrected.

A slight degree of this anomaly, as shown in Plate VI., Fig. 15, may be taken as an example, while Plate VIII., Fig. 22, represents a very pronounced form of it. The other drawings show intermediate varieties (Plate VI., Figs. 16 and 17; Plate VII., Figs. 18 and 19).

It will be seen that the limbs of the crescent pass round the disc to a varying extent, and frequently become prolonged into a narrow band of the same colour which encircles the remainder of its circumference. Fuchs, in his admirable paper¹ on this subject, speaks of this as the scleral ring; it is possible that in some cases the limbs of the crescent merge into the scleral ring, but in all the cases I have myself seen it has seemed to me that they blended with the connective tissue ring, and that both the crescent and this ring formed parts of the disc, and did not lie

¹ *Arch. f. Ophth.*, Leipzig, bd. xxviii., ab. 1, p. 139.

beyond it. The same author also says that the area of the crescent is generally slightly depressed, but admits that the uniform appearance of its surface renders accurate measurement of its level difficult. I have not been able to satisfy myself as to the existence of this depression in any uncomplicated case. Nor does it seem to me that the abnormal arrangement of the vessels, of which he speaks, is at all common. This consists in the larger retinal vessels passing first to the inner side of the disc, and afterwards bending round to be distributed over the outer part of the fundus.

The physiological cup is very often absent in these cases (Plate VII., Figs. 18 and 19). When present, it appears always to open towards the crescent; that is to say, the edge furthest from the crescent is steep, while on the side towards the crescent the floor of the cup slopes up gradually; the vessels either creep round close under, or pierce the steep edge.

The colour of the disc in well-marked cases generally differs from the normal, in being darker (Figs. 18 and 19); this is not merely the effect of contrast with the white crescent, although, doubtless, that has some influence. The disc, also, often has the appearance of being composed of a more transparent although darker substance than usual, so that the vessels instead of disappearing into it suddenly, pass out of sight gradually as if they were sinking into a semi-transparent substance. This is well seen in Plate VIII., Fig. 22.

Congenital crescent has been explained as due to a kind of partial deficiency in the substance of the disc, a gap existing so that one sees down a short distance into the scleral sheath. There is seldom, however, sufficient difference in level between the disc and the crescent to allow us to accept this explanation. Another view is that there has been a non-closure of the foetal cleft at the disc, so that here we have exposed the sclerotic or the junction of the dural sheath and sclerotic; if this explanation be true, the crescent must lie beyond the disc, its limbs being

continuous with the scleral ring. Analogous crescents of very small size are met with at the outer margin of the disc, as in Plate V., Fig. 13, and no doubt they may occur below, but in all well-marked cases of crescent in this situation, they have seemed to me to form a part of the disc. When, as in Plate VII., Figs. 20 and 21, the crescent is partially covered by choroidal tissue, it must be considered to lie beyond the disc, but these seem to differ materially from the ordinary form of congenital crescent

Congenital crescents, in the opinion of the writer, are due to

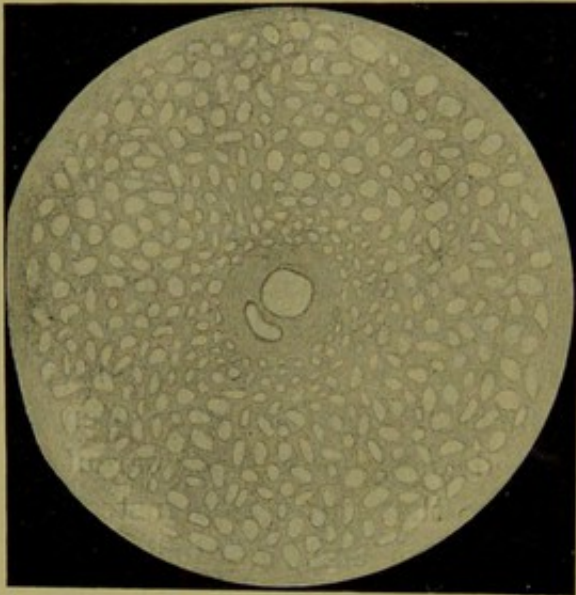


FIG. 30.—Diagram of lamina cribrosa ; connective tissue uniformly distributed.

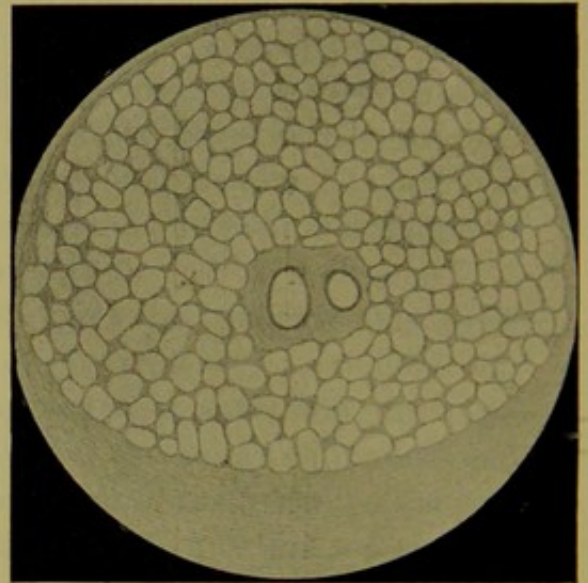


FIG. 31.—Diagram of hypothetical condition of lamina cribrosa in congenital crescent ; much connective tissue below, little elsewhere.

an uneven distribution of the tissue of the lamina cribrosa. Fig. 30 shows diagrammatically the normal arrangement of this ; if now we suppose the tissue of the lamina, while maintaining its proper proportion to the nerve tissue, to be massed at the lower part instead of being evenly distributed through the nerve (Fig. 31) we have an explanation of the ophthalmoscopic appearances.

According to this explanation, the colour of the disc is due to

crowding together of the nerve fibres, with very little tissue between them. We saw a similar effect produced in an analogous manner in cases of opaque nerve fibres.

A variety of congenital crescent not often seen is shown in Plate VIII., Fig. 23. In this the crescent, which is of large size, is situated above the disc. It is interesting to note, that notwithstanding the unusual position of the crescent, the physiological cup is still directed towards it. The writer has seen several examples of small crescents situated above. In one of these, the disc in the other eye presented a crescent above and below.

A disc such as that shown in Plate VIII., Fig. 24, presents some points of analogy with congenital crescent. But here the connective tissue forms a wide ring, and the remainder of the disc is depressed. It would, therefore, be probably more correct to look upon this as a partial coloboma of the disc.

COLOBOMA OF THE DISC.

Coloboma of the disc may occur in various degrees, and present very different ophthalmoscopic appearances.

As already stated, coloboma of the choroid may extend to, and involve the disc, which in some cases may be seen lying in the coloboma, but not much altered, except that its surface has a downward inclination, which makes it appear oval with its long diameter transverse. In other cases—and these are the more numerous—the upper margin of the disc is sharply defined, or overhanging, while the lower merges into the coloboma without any distinct line of demarcation.

Coloboma of the disc may, however, be present without any gap in the choroid. In well-marked cases, the disc area is much increased in size, and presents a large and deep depression. This may be funnel-shaped, so that no floor is visible, or there may be a glistening bluish-white floor, the colour of exposed sclerotic, or, again, the depression may be filled up by a semi-transparent

substance, which can be penetrated with the light from the ophthalmoscope to an uncertain depth.

Good examples of this condition are seen in Figs. 32 and 33, which represent respectively the right and left eye of the same patient. The disc area in the right eye is about three-and-a-half times the normal diameter. Above, the vessels dip down gradually into the deep depression, and disappear from view. Below, they

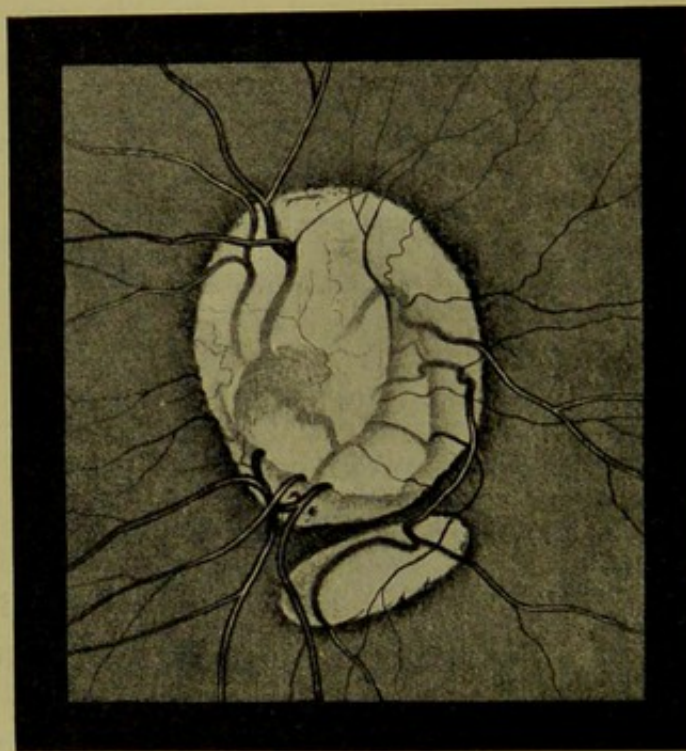


FIG. 32.—RE. Coloboma of optic disc. (After BENSON, *Dublin Journ. Med. Sc.*, 1882.)

curve abruptly over the upper edge of the crescent, which is on the same level as the fundus, to reach a lower depth; they then run over a level terrace, and disappear over its edge into the deepest depression.

The left eye (Fig. 33) shows a somewhat similar condition, but in a much less marked degree. It is to be noted that in both eyes there are indications of imperfect closure of the choroidal cleft.

Coloboma of the disc doubtless depends on a non-closure of the cleft that exists in early foetal life at the lower part of the nerve. Probably, also, the nerve sheath retains to some extent its embryonic condition of a hollow tube, with the nerve fibres spread out on its inner surface, instead of being collected into a compact cord.

A condition analogous to Plate VII., Fig. 21, is shown in

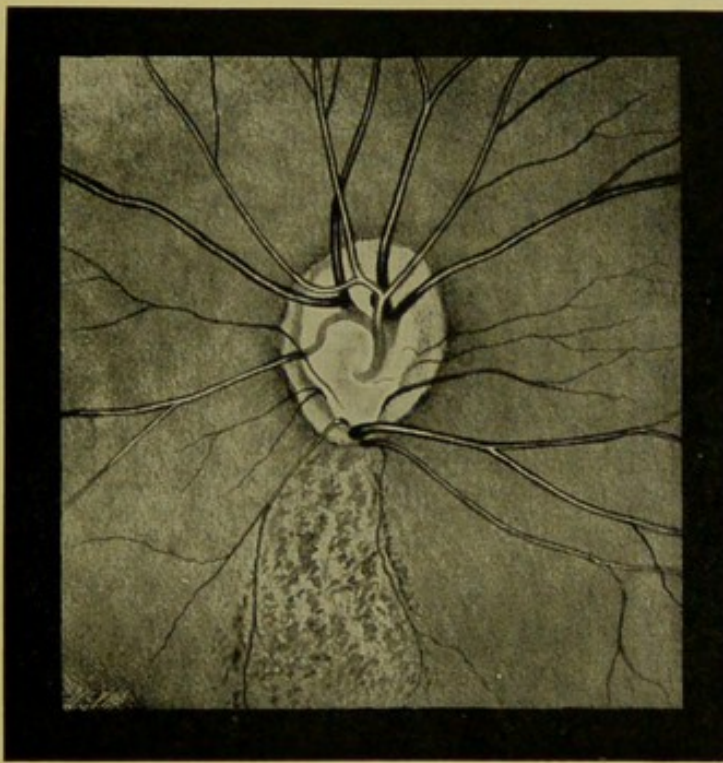


FIG 33.—*LE.* Coloboma of optic disc. (After BENSON, *loc. cit.*)

Plate VIII., Fig. 25, but the hollow involves less of the disc area, and is filled up by a semi-transparent substance. The vessels emerge near the centre, and all, except those which pass upwards, disappear gradually into the depression; below is a crescentic uncupped area like a congenital crescent, over the edge of which the lower vessels curve abruptly. Plate VIII., Fig. 24, probably represents an analogous, but less marked, condition.

In some cases of partial coloboma the depression occupies but

a small portion of the disc. It is situated near its border, as in a case published by Mr. Randall, the drawing of which is reproduced in Fig. 34. The disc had twice the normal diameter, and presented at its upper part a narrow crescentic portion of approximately normal colour on the same level as the fundus. Of the upper vessels some emerge through this, others come round its lower edge. The lower vessels come out from under the edge of this crescent, and one, larger than the others, again disappears into the depression at the lower part of the disc. The greater part of the disc was on a level 6 *D.* lower than

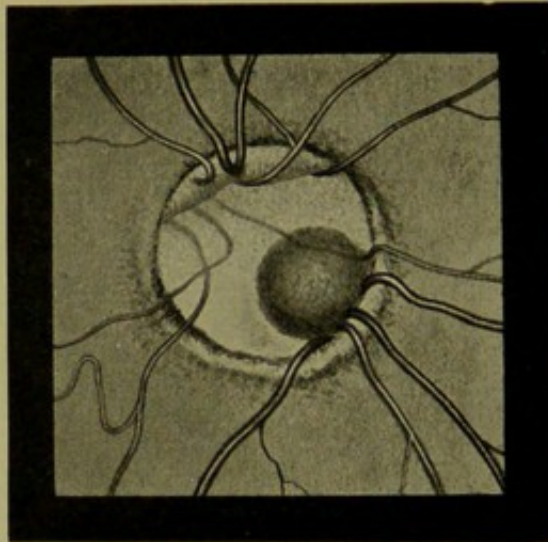


FIG. 34.—Coloboma of disc. (After RANDALL, *loc. cit.*)

the upper part, and was divided into two parts, the upper having a greenish opalescent colour, like exposing sclerotic, the lower resembling a congenital crescent. In the lower and inner part of this, close to the disc margin, was the circular pit already referred to. This appeared to be 4 *D.* deeper. Into its upper part dipped the large vessel already mentioned, while from its lower margin three vessels emerged.

Circular or oval depressions like that just described are occasionally seen in discs which present no other abnormality. They are generally of grey colour, and have an ill-defined

appearance of depths, owing to the impossibility of seeing the floor clearly. This difficulty may arise from the small amount of light that is reflected from the bottom of a deeper and narrow depression, or from a partial filling up by a substance which is imperfectly transparent.

A case of this kind with normal vision has been recorded by Marcus Gunn.¹ In this there was a small patch of choroidal atrophy close to the disc margin on the lower and inner side. In the outer part of the disc was a funnel-like excavation, which

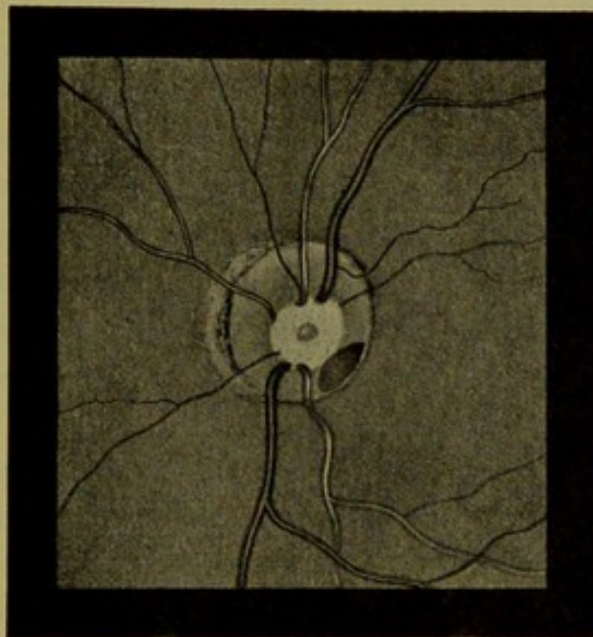

Fig. 35.—Partial defect in disc.

passed so deeply into its substance that the floor could not be seen by the direct method. The outer edge of the disc overhung the depression. When this is the case the area of the depression may vary with the position of the observer, owing to the parallax displacement of the overlapping edge.

Mr. Stephenson has been good enough to furnish me with a diagram (Fig. 34) of a similar case seen by him. The patient was a boy of ten, with normal vision. In the left eye was a large

¹ *Trans. Ophth. Soc.*, vol. vi., p. 375.

circular cup, with stippled floor. On the disc in the lower and outer quadrant a dark reddish brown patch, reaching to the disc margin. It appeared to be situated deeply in the papilla. On moving the head, parallax displacement of the disc margin and the patch was seen, so that the size of the patch appeared to vary. An exactly similar case is recorded by Peltsohn.¹

The disc depicted in Plate XLVII., Fig. 104, is apparently an example of a condition analogous to those just described. The whole disc area is larger than normal. The greater part of it is deeply cupped, and the floor of the cup presents a pale crescent on its outer side. It is to be noticed that there is an area of partial atrophy of the choroid adjacent to the disc, as in Mr. Gunn's case, and that, although the vision and the visual field were normal, the other eye was blind from old (probably congenital) choroiditis. The association suggests the possibility that the deformity may be in some way connected with an inflammatory process, occurring either before the disc is fully formed, or while it is incapable of resisting an intraocular pressure slightly above the normal.


A very similar condition of the disc, occurring in both eyes, and associated with normal vision, has been depicted by Dolganoff.²

If the reader will now compare the illustrations representing an abnormally developed connective tissue ring (Plate V., Figs. 12 and 14, and Plate VIII., Fig. 24) with those showing congenital crescent (Plate VII., Figs. 18 and 19, and Plate VIII., Fig. 22), and those of partial coloboma of the disc (Plate VIII., Fig. 25, and Plate XLVII., Fig. 104), he will see that there are some points of resemblance between these conditions. For example, in all there is an abnormal relation between the connective tissue and the nervous structure of which the disc is composed; in all, a part of the disc presents a peculiar dull-red colour; and in all, the vessels tend to emerge in an irregular manner.

¹ *Centralbl. f. prakt. Augenh.*, Leipzig, 1888, p. 339.

² *Arch. f. Augenh.*, Wiesb., bd. xxviii.

PART II.
PATHOLOGICAL CONDITIONS.



CHAPTER VI.

AFFECTIONS OF THE CHOROID.

IN the first part of this work we reviewed the different conditions of the fundus, which, as they are stationary and cause no impairment of function, may be called "Physiological Variations." We now pass on to deal with conditions which are Pathological. The line of demarcation, however, is not well defined; indeed, a definition which should separate, with scientific accuracy, pathological from physiological conditions, is impossible. For practical purposes, we may consider as pathological such as are progressive, or have been so at any time since birth, and such as impair vision. This definition, however, if rigidly applied, would include some cases of congenital malformation and exclude others, and it would exclude some cases of intra-uterine disease which have become quiescent before birth.

The sclerotic is not, as far as is known, the starting-point of any morbid process in the fundus. Pathological conditions, apart from affections of the head of the optic nerve, are therefore classed as choroidal or retinal, in accordance with what is believed to be the primary seat of the disease.

The choroid and retina differ so greatly in structure that there is seldom any difficulty in localising early changes in the one or the other. But many affections begin in the one coat and invade the other, and in an advanced stage of disease, it is sometimes impossible, from the ophthalmoscopic appearances alone, to determine which was first affected, although this can usually be inferred from the experience afforded by other cases in which the progress of the disease has been watched. Such diseases are spoken of as choroido-retinal, or as retino-choroidal,

the first word indicating in each case the tunic primarily affected.

We have to deal, therefore, with the ophthalmoscopic appearances produced by affections of the choroid, the retina, and the optic nerve.

The choroid is, as we have seen, extremely vascular. A comparison between the number of vessels in its tissue, and the number of the ciliary arteries which supply it, would also seem to show that its circulation must be sluggish. Both these reasons probably explain its great liability to degenerative processes and to chronic inflammation; while the large share taken by the choroid in the ophthalmoscopic picture of the fundus renders the results of these processes conspicuous. These results are usually classed as choroiditis.

CHOROIDITIS.

Choroiditis is, therefore, a rather wide term, since it is used so as to embrace inflammation in actual progress, and the results of inflammation which has long since subsided. It includes affections that may depend upon different causes, produce different changes in the fundus, and affect vision to any degree between an impairment that can be discovered only by careful examination and total blindness. Attempts at classification have been made on the basis of the supposed cause of the disease, on that of the ophthalmoscopic appearances produced, and some varieties have even been named after their discoverer.

No classification is entirely satisfactory, but we may conveniently adopt two primary divisions—the suppurative, and the exudative or plastic. The former might be called acute, the latter subacute or chronic. Serous choroiditis was formerly believed to exist as the cause of glaucoma and of detachment of the retina. There is, however, no evidence that this view is correct, and the choroid is not the kind of tissue that could be attacked by a serous

inflammation in the sense in which that term is ordinarily employed.

Atrophic choroiditis is a term sometimes applied to cases characterised by the destruction of large areas of the choroid, without much evidence of preceding inflammation. As, however, most forms of choroiditis lead in their later stages to atrophy, it will be more convenient to consider the condition as a result of choroiditis, rather than as a separate variety.

Suppurative choroiditis occurs not infrequently as a result of puerperal septicæmia. It is generally, if not always, due to the presence of septic emboli in the choroidal veins. It rapidly leads to inflammatory exudation into the vitreous, while at the same time the conjunctiva often becomes acutely inflamed. The exudation may break down into pus which may perforate the sclerotic, or the vitreous may become converted into a solid, opaque mass, which undergoes a certain amount of shrinking. In either case the eye is rapidly lost.

It is conceivable that there may be an early stage in which ophthalmoscopic examination would be possible. If so, the opportunity does not appear to have been seized; an omission which is no doubt owing to the rapidity with which the media become opaque, and also to the fact that the gravity of the patient's general condition masks the importance of the ocular symptoms.

Exudative or plastic choroiditis is the most common form, and is usually meant when the term choroiditis is used without any qualification. The disease, as a rule, commences in different foci, when it is called disseminated, but it may attack a large extent of fundus at the same time, and is then called diffuse. The distinction is to some extent artificial, for the disseminated variety is often accompanied by diffuse changes, and a case originally disseminated may at a later stage resemble the diffuse variety, owing to the separate areas having increased in size and become confluent. Still, the terms are useful, as they are

descriptive of the ophthalmoscopic appearances at an early stage. Moreover, the majority of cases of disseminated choroiditis remain so throughout.

The term *circumscribed choroiditis* is sometimes used when the disease is limited to an isolated portion of the fundus, other than the macular region, while affection of this latter area is termed *central choroiditis*. Other names, also, have been used to designate minor variations, but they need not be enumerated.

Hyperæmia of the choroid is sometimes described as an early stage of choroiditis. Examination of eyes after removal shows that

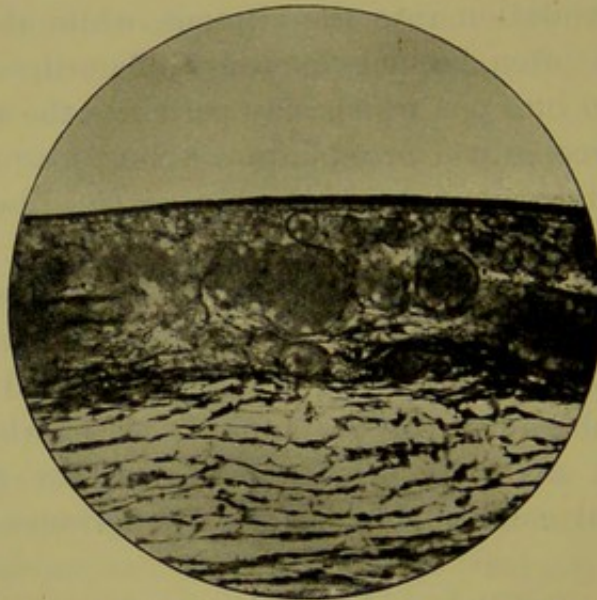


FIG. 36.—Hyperæmia of the choroid from a recent wound of the eye.
(From a preparation by Mr. TREACHER COLLINS.)

such a condition is exceedingly common, and occurs in a variety of circumstances. Thus Fig. 36 is an example in which it was caused by a recent injury; while the case from which Plate XXXIII., Fig. 73,⁴ was taken, was one of leucocythæmia, in which distension affected other vessels also.

The number of vessels in the choroid is so great that it seems probable that even in health there may be considerable variations

in the amount of blood that it contains. Such variations might be brought about through vasomotor influences, and might also be due in part to the presence of muscular tissue in the stroma of the choroid.

But, although the amount of blood in the choroid is known to vary in disease, and probably does so in health, there are no ophthalmoscopic signs by which we can directly recognise these variations. Even in such a disease as pernicious anæmia there is no appreciable pallor of the fundus. In leucocythæmia the colour of the fundus sometimes, it is true, appears orange rather than red, but this is due to the change in the colour of the blood and not to alterations in its quantity. In the case from which Plate XXXIII., Fig. 74, was taken, there was no direct ophthalmoscopic evidence of hyperæmia of the choroid.

Although hyperæmia of the choroid produces no appreciable change in the colour of the fundus, it is probably sometimes the cause of hyperæmia of the disc, for the colour of this is partly due to vessels derived from the short ciliary arteries which also supply the choroid. This no doubt explains why in some cases of sympathetic ophthalmitis hyperæmia of the disc in the sympathising eye is a prominent symptom. There is always, at the same time, slight obscuration of the disc margin; indeed, in the absence of this it would be difficult to diagnose the hyperæmia with certainty. An example of this was published some years ago by the writer.¹

Disseminated choroiditis, if it runs its complete course, passes through the following stages, viz. :—(1) that of exudation; (2) that of atrophy; (3) that marked by the existence of certain complications.

The stage of exudation commences with the appearance of small rounded areas of cell infiltration in the superficial layers of the choroid. These, when rendered visible by thinning or destruction of the retinal pigment over them, appear with the

¹ *Trans. Ophth. Soc.*, vol. iii., p. 73.

ophthalmoscope as circular pale areas, which look as if the fundus colour had been washed out (Plate XV., Fig. 40, Plate XX., Fig. 46, Plate XXII., Fig. 49).

These areas increase in size, maintaining a round or oval shape, and usually become encircled by a more or less perfect line of pigment. The increase takes place not only in superficial extent but also in depth, so that the exudation may invade and replace all the layers of the choroid.

The disease now passes into the atrophic stage. The exudation undergoes degenerative changes and is absorbed. But the structure of the choroid has been destroyed, so that on the disappearance of the exudation, the sclerotic is exposed to view. The pigment changes are, however, permanent, so that we now see with the ophthalmoscope circular or oval areas of exposed sclerotic, bordered by pigment which lies on a more superficial level (Plate XV., Fig. 41, Plate XXV., Fig. 58). The appearance will of course vary with the size of the atrophic areas. These may still be small and separate, or they may have increased in size to such an extent as to have come into contact, or coalesced with each other (Plate XVI., Fig. 42).

If the morbid process continues it passes into what may be called the stage of complications, although some of these complications may supervene earlier. The retina now undergoes extensive degeneration, and may become diffusely pigmented (Plate XVII., Fig. 43, Plate XLV., Fig. 98). In this stage connective tissue may form in the retina over the affected areas (Plate XXV., Fig. 59). Meanwhile, the disease, spreading forwards, reaches the ciliary region, and interferes with the nutrition of lens and vitreous, causing opacities to appear in both, while the iris often become adherent to the lens.

Eventually, the secretory function may be so impaired that the intraocular tension becomes subnormal. At this stage the lens usually becomes opaque, and all perception of light is lost.

The three stages of choroiditis, which have just been sketched,

may overlap, and therefore a single fundus often furnishes examples of each. The progress of the disease is generally slow, and a case may take many years to run its course. The majority of cases come to a standstill before total blindness has been caused, and such an arrest of the process may occur at any stage.

The ophthalmoscopic appearances caused by destruction of choroidal tissue and by deposition of pigment are permanent. Mere exudation, on the other hand, is likely to undergo some absorption. If, therefore, the disease aborts in the exudative stage, the changes in the pigment layer may alone persist (Plate XVIII., Fig. 44, and Plate XIX., Fig. 45). If, on the contrary, it is not arrested till the atrophic stage is reached, there will be, in addition to the pigment changes, areas of exposed sclerotic (Plate XXI., Fig. 48, &c.).

It must be remembered the arrest of the disease may be only temporary, and that the later stages may be entered upon after years of quiescence.

It is evident from what has been said that the ophthalmoscopic appearances of choroiditis may differ widely. It will therefore be necessary to consider in greater detail some of the more common variations that are met with in each stage.

STAGE OF EXUDATION.

In this stage the spots of exudation may be of small size, and distributed over the whole fundus, as in Plate XX., Fig. 46, or they may be more numerous near the equator, as seen in Plate XVIII., Fig. 44, which, however, represents a later stage of the disease. It is often stated that disseminated choroiditis usually commences at the periphery, but exceptions are certainly very numerous.

The ophthalmoscopic appearance will, of course, also depend on the size of the individual areas of exudation. In some cases they remain exceedingly minute, even not exceeding the diameter of

the primary retinal vessels. Such a condition is exceptional, and might appropriately be called guttate choroiditis, had not the term been applied to another condition.

The appearance will also depend upon the degree to which the retina is implicated. In recent or relapsing cases the retina is sometimes œdematous over the affected area (Plate XXV., Fig. 58). This condition will be considered in dealing with the stage of complications. Changes in the retinal pigment are so commonly present at all stages that they will be more conveniently dealt with here.

Probably in all except the lightest eyes, some destruction of the pigment layer is necessary before the exudation becomes visible. This de-pigmentation may be limited to the affected spots, or may occur over a considerable area of the fundus, causing the choroidal vessels to become visible. The latter is seen in Plate XX., Fig. 47; and Plate XLV., Fig. 98, which represent a later stage.

More conspicuous ophthalmoscopic changes are caused by the deposition of pigment over and around the exudation. It is only exceptionally in ordinary disseminated choroiditis, that this pigmentation does not occur as in Plate XX., Fig. 46; Plate XXI., Fig. 48; Plate XXII., Fig. 49. In the form of choroiditis that complicates progressive myopia, on the other hand, large areas of choroid undergo atrophy with little or no pigment deposit (Plate XXIII., Figs. 53, 54, 55), hence the occasional application of the term atrophic choroiditis to this condition.

The pigment deposit in some cases is excessive, and when the disease subsides, it may form the most prominent appearance, as in Plate XVIII., Fig. 44; Plate XIX., Fig. 45.

The pigment usually forms rings or discs of nearly circular shape. Exceptionally, it may be irregularly deposited, as in Plate XLII., Fig. 95. This, however, was drawn from the eye of an Eurasian, and it is probable that the dark races would present pigment changes different from those commonly met with

in Europeans. The material at my disposal, however, is too limited to justify any positive conclusions on this point.

ATROPHIC STAGE.

The appearance presented in the stage of atrophy will largely depend upon the course run by that of exudation. If arrest of the disease has occurred while the spots were still small, numerous small white areas of nearly circular shape will be seen scattered over the fundus, each surrounded by a ring of pigment. This form of the disease seems to occur most frequently in inherited syphilis, and the ophthalmoscopic appearances are often first discovered when the cornea begins to clear after an attack of interstitial keratitis,—a fact that should induce caution in giving a prognosis as to recovery of vision, even when the corneal affection is comparatively slight. In this variety the choroidal plaques seen are usually most numerous towards the periphery, although the central region enjoys no immunity.

Sometimes pigment deposit around the patches is delayed, or does not occur (Plate XXI., Fig. 48). It is, however, quite exceptional for the atrophic stage to be reached without some deposition of pigment taking place.

If the disease be not arrested early, the areas of exudation increase in size, come into contact with, and then merge into, each other, while pigment, if absent before, is generally now to be seen bounding the patches of atrophy. The transition from the exudative to the atrophic stage will be evident by comparing Plate XX., Figs. 46 and 47, which represent the same case at the two stages. The interval between the time of making the two drawings was two and a half years. When the patches have attained a considerable size, and have undergone complete atrophy, they may continue to increase without evidence of fresh exudation, probably because the destruction of a large number of the choroidal capillaries interferes with the nutrition of the adjacent tissue, so that it

readily becomes atrophied. In this way immense tracts of the sclerotic may become denuded, as in Plate XVI., Fig. 42, and Plate XVII., Fig. 43.

The atrophic stage is, however, best seen in high and progressive myopia. In the majority of cases in which the myopia, although high, is stationary, there is at the outer side of the disc a crescentic area of choroidal atrophy, which allows the sclerotic to be visible (Plate XXIII., Fig. 53). The existence of this myopic crescent, as it is called, usually indicates that protrusion of the coats of the eyeball at its posterior part, which is called posterior staphyloma. Hence the crescent itself often goes by this name. The crescent may have a cleanly-cut, regular outline (Plate XXIII., Fig. 53), in which case the myopia is probably stationary. On the other hand, it may have an ill-defined and irregular boundary passing imperceptibly into the choroid (Plate XXIII., Fig. 54). In this event the myopia is progressing, and it is probable that in time separate areas of choroidal atrophy will appear beyond the limits of the crescent. As the latter increases the atrophic areas may coalesce and a large irregular patch of sclerotic lie exposed to view.

While the convexity of the myopic crescent is thus extending in the direction of the macula, its arms spread gradually further round the disc, till meeting they may encircle it by an atrophic ring, which may subsequently increase in breadth.

The atrophic patches which result from disseminated choroiditis are often incomplete, since some large choroidal vessels are generally to be seen crossing them. In the atrophy associated with progressive myopia the destruction of the choroid is, on the contrary, usually complete. Pigment deposit, also, which is the rule in disseminated choroiditis, is the exception in myopia.

These cases of progressive myopia are obviously of a different nature from the simple non-progressive form. The latter may be looked upon as an exaggeration or perversion of the physiological

increase of refraction which occurs in early life. Progressive myopia, on the other hand, is essentially a morbid process.

A peculiar displacement of the vessels on the disc is said to be common in myopia. The condition referred to is not present in either of the myopic eyes shown in Plate XXIII., but it will be seen in Plate XI., Fig. 30, which represents a hypermetropic eye. In the opinion of the writer, this arrangement is not so frequently associated with myopia as generally stated, and is certainly often met with under other conditions.

Atrophy of a zone of choroid immediately around the disc sometimes occurs as a degenerative change in old people; an example of this is seen in Plate XXIV., Fig. 56. A much narrower zone of atrophy is commonly met with in advanced cases of chronic glaucoma (Plate XLVII., Figs. 105, 106, and 107).

Atrophy of the pigment layer of the retina round the disc is not an uncommon sequence of post-neuritic atrophy, and occasionally the disturbance extends into the substance of the choroid, as in Plate XXIV., Fig. 57, and Plate XXXII., Fig. 71.

STAGE OF COMPLICATIONS.

Implication of the pigment layer of the retina is so common in choroiditis that it can hardly be considered a complication so long as it is limited to the affected areas.

Diffuse pigment changes, however, sometimes occur, consisting both in deposition and removal of pigment. An example of the former is seen in Plate XVII., Fig. 43, and of the latter in Plate XX., Fig. 47, and Plate XXIV., Fig. 56.

The bacillary layer of the retina is affected early in most cases of choroiditis. Owing to the transparency of the retina, this cannot be diagnosed with the ophthalmoscope, but it may be inferred to have taken place from the impairment of vision.

In a late stage of the disease extensive degenerative changes

may occur in the retina, leading to destruction of its nervous elements, and increase in its connective tissue. The retinal vessels will now be much shrunken, and the disc assume a dull dirty-white colour like parchment. At this stage pigment may find its way forwards through the layers of the retina, and on reaching the surface, assume the stellate arrangement that exists in retinitis pigmentosa. The ophthalmoscopic picture may now exactly resemble that of retinitis pigmentosa, while the subjective symptoms of night blindness, and contraction of the visual field, which characterise that disease, may also be present. (Compare Plate XIX., Fig. 45, Plate XLII., Fig. 94., and Plate XLIII., Fig. 96.)

Œdema and inflammatory exudation are met with in the retina in some cases of acute choroido-retinitis occurring in the secondary stage of syphilis. When œdema occurs in a chronic case, it indicates the formation of a fresh patch of choroiditis. The soft-looking white colour, shading off into the adjacent fundus, is characteristic, and is seen in Plate XXV., Fig. 58.

The retinal vessels may pass unchanged over an œdematous area, or their calibre may appear to be irregularly diminished, owing to the vessel being partly concealed from view in places where it happens to be less superficial than usual.

A variety of choroiditis, in which retinal œdema is a prominent feature, occurs in association with isolated patches of old choroidal atrophy. The subjects of this affection are usually young adults of sedentary habits and anæmic aspect. The condition has no connection whatever with syphilis, but a family history of tubercle can often be elicited. In the course of a few weeks the œdema clears up, and there is exposed to view a patch of partial or complete atrophy of the choroid.

The occurrence of retinal œdema may also mark the commencement of a more diffuse choroiditis, as will be seen from the history of the case from which Plate XXIX., Fig. 63, is taken.

In a late stage of choroiditis, masses of connective tissue form in the retina. These probably indicate adhesion between the two membranes, and may be looked upon as cicatricial in character. The macular region is most commonly affected. The cicatricial material may consist of a large irregular patch, with processes jutting out from it, and running into the retina in different directions. Or it may present numerous round or oval openings as in Plate XXV., Fig. 59. In either case the border of the patch presents bays, with regular curves, the concavities of which are directed away from the centre of the patch. The colour of these cicatricial masses resembles that of exposed sclerotic, but is a more dead white, and lacks the bluish tinge of sclerotic. The presence within the white area of round or oval patches of comparatively normal fundus, evidently lying on a deeper level, is characteristic.

This condition must not be confounded with that which has been described by Manz as *Retinitis Proliferans*; in this latter the exudation lies in front of the retinal vessels.

The complications of choroiditis are by no means limited to the retina. Opacities in the vitreous may be present at any stage of the disease. When they occur early, as is frequently the case in choroiditis of syphilitic origin, they are usually situated in the forepart of the vitreous, and are fine—"dust-like." They are either fixed, or but slightly moveable. Such opacities blur the fundus, but are easily overlooked owing to their small size and forward position. To see them well, a convex lens is required behind the ophthalmoscope, and they are often more conspicuous with a plane than with a concave mirror. The blurring of the disc produced by such opacities is often mistaken for optic neuritis, but it should be noted that there is no distension or tortuosity of the retinal vessels, and no evidence of swelling of the disc.

In the later stages of choroiditis, the opacities met with are larger, and form dark threads or masses of irregular shape. They

can be made to float about freely in the vitreous, by directing the patient to move his eye rapidly, and then to look fixedly in one direction. Such opacities may lie at any depth. Their dark colour is, of course, due only to the interception of the light reflected from the fundus; if they are of large size, and placed far forwards, light is often reflected from their surface, and they then appear to be white or grey. The wide excursions made by these opacities indicate that the vitreous has become abnormally fluid.

At this stage opacity of the lens is not uncommon. It usually commences as a posterior polar cataract, *i.e.*, a central opacity of the posterior pole which may have striæ radiating from it. This may remain unchanged for an indefinite time, or the whole lens may become opaque, and assume the dead-white chalky appearance which is met with only in blind eyes.

By this time posterior synechiæ will have formed. At first these are fine and thread-like, but later there may be total adhesion between the iris and lens. Throughout the progress of the case the ciliary injection, which we are accustomed to see in ordinary plastic iritis, is usually absent.

At any stage fine dots, keratitis punctata, may appear on the posterior surface of the cornea. These may clear off and reappear many times. Their presence interferes mechanically with vision, but they do not appear to be accompanied by any perceptible increase of the fundus mischief. They always indicate that the disease has reached the anterior part of the uveal tract.

In the latest stage the function of the secretory apparatus becomes impaired or destroyed, and the intraocular tension sub-normal. Detachment of the retina is then likely to occur. The reason that this complication is not present more frequently in choroiditis is probably the formation of adhesions between the choroid and retina.

In a few cases the vitreous contracts and draws the lens and

iris backwards; the anterior chamber then has an enormous depth, while the iris, being seen through a great depth of aqueous, (which, with the cornea, acts like a convex lens), has a peculiar brilliant appearance.

CHOROIDITIS OF THE MACULAR REGION.

The reader will have gathered from the illustrations already referred to that in disseminated choroiditis the yellow spot region often remains unaffected. This is due to the fact that the disease usually commences in the equatorial region, and spreads slowly. The macular region may, however, be involved either by extension from the periphery, or primarily.

Förster¹ has given the name areolar to a form of choroiditis which occurs in this region, and presents the appearance of numerous round or oval areas of choroidal atrophy with intervening normal fundus. It usually affects a considerable area, and appears to differ in no essential respect from disseminated choroiditis.

There are other forms of central choroiditis which are more definitely confined to the macular region. Old persons are especially liable to choroiditis of this part of the fundus, a fact that should always be borne in mind in forming a prognosis as to the result of extraction in cases of senile cataract.

Central senile choroiditis appears in two forms. In the one there is de-pigmentation of a circular area of the fundus, having a diameter of about twice that of the optic disc. Over this area the superficial layers of the choroid undergo atrophy, so that the larger choroidal vessels become visible. I have not been able to secure a typical illustration of this condition; but a good example will be found in Wecker and Jaeger's atlas, Fig. 97, while a more advanced stage has been shown by Mr. Nettleship.² The other form resembles disseminated choroiditis, but the affected areas

¹ *Ophth. Beitr.*, Berlin, 1862, p. 97.

² *Trans. Ophth. Soc.*, vol. iv., p. 165.

are smaller and more closely aggregated. Plate XXII., Fig. 50, is an instance of this.

The progress of the disease being slow, and the patients old, an opportunity of tracing the malady through its various stages seldom arises. A large area of atrophied choroid is, however, often met with, which must be the result of choroiditis in the central region. In such cases the sclerotic often has the appearance of being pushed backwards. The whole patch is usually encircled by pigment, which also sometimes forms an irregular trellis-work over the patch and at a little distance in front of it.

Almost complete absence of the choroid at the macula is occasionally met with in young people. In some of these the defect is probably congenital. Examples of this are seen in Plate XXII., Figs. 51 and 52. Both were from young and healthy women, who had only recently discovered that the vision of one eye was defective; but from the advanced condition of the changes, it is obvious that they were not of recent date. Although the affected areas differ in size, they present many points of similarity. In both, there is an area of sclerotic completely exposed, crossed by choroidal vessels. In both, this is bounded by a pigment ring, which overhangs it, and with the ophthalmoscope was obviously anterior to it. The pigment forms a network with numerous openings, through which the sclerotic is visible. In Fig. 53 the area of pigment deposit is considerably larger than that of the atrophy.

Such cases as these are considered by many to be examples of defective development of the choroid, and hence are called coloboma of the yellow spot. It seems to me that the presence of extensive pigmentary changes renders this view highly improbable, and that the presence of choroidal vessels disproves it. It is more probable that the condition is the result of a localised choroiditis occurring in early childhood.

Isolated patches of choroiditis, or the results of former attacks,

may be met with in any part of the fundus. It is possible that some of these isolated areas are the result of hæmorrhage.

There is, however, ground for suspecting that these large isolated areas of choroidal atrophy at the macula or elsewhere, represent the site of former tubercular deposits.

Stephen Mackenzie¹ has published the case of a girl, four years of age, who had been ailing for eighteen months before coming under observation, with frequent feverish attacks, headache and vomiting, and chronic disease of knee. Shortly before admission sight became defective.

She was found to have double optic neuritis. In the macular region of *LE.* was a patch, larger than the disc, of yellowish colour, bordered by pigment, and a slightly smaller patch in a more peripheral situation; in *RE.* were several smaller patches. None of them appeared to be much raised.

The child had a continuously high temperature. Later, she became drowsy, had convulsions, and died after being in the hospital about five weeks.

At the *post-mortem*, which was confined to the head, a quantity of yellow lymph was found at the base of the brain. Some miliary tubercles at the base of the brain, and in the fissure of Sylvius. There were several masses of tubercle in the brain substance. Microscopic examination of these showed the characteristic appearance of aggregated tubercle. The pia mater was everywhere occupied by tubercular infiltration. The trunk of the optic nerve was infiltrated throughout the whole length examined with round cells. The patches in the choroid showed a number of small round cells, and in places, tubercles containing giant cells. Tubercle bacilli were not found either in the choroidal or in the cerebral nodules, but there can be no reasonable doubt as to the tubercular character of the latter, and the microscopical characters of the choroidal areas were obviously identical with them.

Occasionally, large tubercular masses have been found growing from the choroid. For example, in the discussion on the above, Dr. Barlow² mentioned a case in which an eye was excised for an intraocular growth, which, on examination, proved to be a hemispherical mass of tubercle, reaching from the disc to the ora serrata, and presenting the character of confluent tubercle. The child died a year later with cerebral symptoms, and caseous tubercular growths were then found in the brain and bronchial glands. Mr. Brailey also stated, in the same discussion, that he had found a growth, the size of a pea, having the structure of tubercle, near the optic disc in an excised eye. The patient

¹ *Trans. Ophth. Soc.*, vol. iii., p. 119.

² *Loc. cit.*

presented no other symptoms of tubercular affection, and the subsequent history is unknown.

Carpenter, in a paper on this subject,¹ has given illustrations of the ophthalmoscopic appearances of several cases in which the history pointed to the choroiditis being of tubercular origin.

How far contusions of the eye are capable, apart from hæmorrhage, of starting progressive changes in the choroid, is at present doubtful. It is seldom that conclusive evidence can be obtained that the fundus was normal before the accident, and it must also be remembered that pigmentary disturbances of a degenerative character may occur in any blind eye. For these reasons, cases of choroiditis attributed to injury must be accepted with caution. This subject will be referred to again in dealing with rupture of the choroid.

An affection of the choroid, more superficial than those yet described, produces an ophthalmoscopic appearance of rather closely aggregated pale-yellowish dots, with soft outline. These are most numerous in the macular region, to which they may be entirely confined.

Attention was first directed to this condition by Hutchinson and Waren Tay.² It is commonly called "Tay's Choroiditis." The cases first described occurred in persons who were past middle life, and the condition was thought to be of a degenerative character. Similar ophthalmoscopic appearances have, however, been met with in patients of all ages. The affection commences in the superficial layers of the choroid, probably in the lamina vitrea; it tends to spread forwards into the pigment layer of the retina, and not backwards into the true structure of the choroid. For this reason, and also because the ophthalmoscopic appearance is similar to that produced by other

¹ "Tuberculosis of the Choroid," 1890.

² *Ophth. Hosp. Rep.*, London, vol. viii., p. 231, 1875.

conditions, which are believed to be situated in the retina, further consideration of these cases will be deferred till we come to deal with retinal affections.

DIFFUSE CHOROIDITIS AND CHOROIDO-RETINITIS.

The early stage of diffuse choroiditis is characterised by large, pale coloured, areas on the fundus (Plate XXIX., Fig. 63). These are of various sizes, of irregular shape, and are separated by spaces of healthy-looking fundus. The patches are largest and most numerous towards the periphery. Some form complete islands, while others of larger size, have an irregular outline, indented with bays, and fissured by tracts of healthy fundus. A fancied resemblance of the whole distribution to a continent bounded by an irregular coast line, beyond which are numerous islands, has led to this form of choroiditis being sometimes described as "map-like." Many of the areas resemble oak leaves in shape, and the term "leaf-like" has also been employed.

The changes have a superficial appearance. There is no border of pigment to the patches, although some mottled pigment can sometimes be seen on their surface, while over others, which are of older date, the pigment layer is completely destroyed.

The progress of these cases is so slow that it is difficult to say what is their ultimate fate. Plate XXIX., Fig. 63, was taken from a young man, of rather delicate appearance, but presenting no physical signs of disease. There was no history of syphilis, congenital or acquired. During the two years he was under observation no appreciable changes occurred in the ophthalmoscopic appearance. In this case the choroiditis was preceded by retinal œdema.

Later in life we meet with diffuse choroidal changes, of which some probably represent a later stage of the condition just described, while others may be the outcome of disseminated choroiditis. The course of the disease is exceedingly chronic.

The patients affected, if not old in years, are of senile aspect, and the majority are the subjects of tertiary syphilis. The disease should therefore be looked upon as being of a degenerative, rather than an inflammatory character, and might be described as a choroido-retinal sclerosis.

The appearance presented, although of course varying to some extent in different cases, is sufficiently uniform and characteristic to render the diagnosis easy. In some points it resembles retinitis pigmentosa; the condition has therefore sometimes been called choroido-retinitis pigmentosa. If the reader will compare Plate XXVI., Fig. 60, with Figs. 61 and 62, he will readily see that all have certain features in common. Over the greater part of the fundus the choroidal vessels are visible. Nowhere is the structure of the choroid destroyed in its whole thickness, so that these vessels are exceedingly numerous. In many places, and especially near the disc, their walls have undergone a change which has rendered them opaque, so that they appear white. As in the case of similar changes in the retinal vessels, there is no reason to suppose that they are obliterated. A few of these vessels are accompanied by white lines (Plate XXVII., Fig. 61); in some cases these are much more numerous than in the illustrations. It will be noted the red fundus colour is replaced by a reddish brown. This is no doubt due to exposure of the stroma of the choroid by the destruction of the capillary layer; in a few places where the latter remains, it is seen covering the surface like a red veil.

There is a certain amount of pigmentation of the retina resembling that which is present in retinitis pigmentosa, but it is more massive and not specially abundant at the periphery as in that disease. In Plate XXVIII., Fig. 62, the pigment appears to a great extent to be deposited in the choroid itself, and the retinal vessels are more diminished than in the other cases. The circular white areas appear to consist of congeries of vessels, but it is not clear why they assume this form. In Plate XXVI.,

Fig. 60, there is some circum-papillary atrophy, and the disc is of a dirty hue, while in Plate XXVII., Fig. 61, which represents a less advanced condition, these features are absent.

The subjective symptoms vary much, and correspond but little with the ophthalmoscopic appearances. It is, indeed, not uncommon to find similar appearances in the two eyes of the same patient associated with great differences in vision. Usually, the impairment of vision is not as great as might be expected from the ophthalmoscopic changes. This is in part to be explained by the fact that the macular region is less changed than the rest of the fundus. There is generally night blindness, and the fields are often contracted. In the case from which Plate XXVII., Fig. 61, was taken these symptoms were absent, and the vision was normal. Stanford Morton has described and depicted a marked case¹ in which, while central vision was normal, night blindness and contraction of the visual fields were present.

The ophthalmoscopic appearances are due to a diffuse affection of the choroid, attacking primarily its more superficial vascular layers, and invading the retina secondarily. The alterations in the walls of the choroidal vessels, and the limitation of the changes in the early stages to the neighbourhood of the disc, point to a degenerative disease of the short ciliary arteries as the immediate cause of the fundus changes. As to the more remote causes we know little. Among them must no doubt be reckoned tertiary syphilis and senility, but it is not improbable that any widespread affection of the choroid, such, for example, as that depicted in Plate XXIX., Fig. 63, might be followed in after years by the condition under consideration.

In one patient who was under the writer's care the condition followed retinal hæmorrhages. The case is so unusual that the details may be of interest.

John H., 67. First seen July 1890 with a history of a sudden failure of vision having occurred three weeks previously in the *RE*. There were numerous hæmorrhages scattered

¹ *Trans. Ophth. Soc.*, vol. v., p. 142.

over the retina, chiefly in the fibre layer. The condition resembled that shown in Plate XXXV., Fig. 79, which was taken from another patient. The condition of the vision was not noted.

Fourteen months later *OD.* atrophic; white lines along the retinal vessels. White soft areas on retina, probably altered hæmorrhages. *V.* = hand movements.

In January 1893—2½ years after the attack—choroidal vessels visible over whole fundus. *OD.* atrophied. Superior temporal vein accompanied by white bands. Below *YS.* a patch of dirty grey colour, from which straight processes passed in several directions. Below the superior temporal vein a circular white area like those seen in Plate XXVII., Fig. 61, but smaller. *LE.* remained normal throughout. The patient was seen in June, 1895, and was in the same condition as before.

The next case shows that a similar condition may result from disseminated choroiditis.

Henry P. Had been, in 1881, under the care of Mr. Nettleship, who kindly furnished me with particulars of his condition at that time.

No history of syphilis could be obtained. He married at the age of 18, and had six children; three are living and said to be in good health. (The deaths of the others had no bearing on the case.) He has never been out of England; he lived in Bedfordshire till 1854, since then in London.

With the exception of attacks of acute rheumatism in 1865, 1869, and 1874, he has always had good health.

He was a letter carrier by occupation. He thinks that his sight has never been "strong," but he first noticed a definite failure at the age of 22. It appears to have been slight, and to have increased very slowly, if at all, until the age of 44, when it became rapidly worse. He went to St. Thomas' Hospital, where he was found to have disseminated choroiditis chiefly in the central region. The fields were approximately normal. He attended off and on for two years without any appreciable alteration taking place. In 1890 he came under the writer's notice at the Royal Westminster Ophthalmic Hospital.

He was at this time 53 years old, anæmic in appearance, fair, with sandy hair turning grey. Vision *LE.* = $\frac{6}{60}$, and it has remained nearly constant. *V.* of *RE.* has fluctuated without obvious cause. In 1890 it was $\frac{6}{36}$; in January 1891, $\frac{6}{9}$; October 1891, the same; January 1892, $\frac{6}{18}$; in 1894, 6 Sn. at 20 cm. Visual fields nearly normal in extent. No night blindness. Knee jerks absent. No other indications of ataxy.

The ophthalmoscopic appearances in January 1896 had not appreciably altered since he was seen in 1890, and were as follows:—

LE. OD. pale, retinal vessels normal, edge of *OD.* a little hazy. In central region, over an area with ill-defined boundary measuring roughly 4 dd., numerous choroidal vessels visible. The greater number are pale—nearly white; some of these have a central red streak. Towards the periphery of the affected area there are several red vessels of normal size bounded by white lines. There are a few masses of pigment on the surface of the affected area. The spaces between the vessels are very small, and of light brown colour. In periphery of fundus no choroidal vessels are visible, but there are several deposits of pigment, mostly in the form of streaks.

The condition of the *RE.* is similar but less marked, and *OD.* is not pale.

CAUSES OF CHOROIDITIS.

Syphilis, both hereditary and acquired, is certainly the most frequent cause of choroiditis.

The choroiditis which results from hereditary syphilis, is often first discovered as an attack of interstitial keratitis is clearing up, and in the majority of instances there is no reason to suppose that it existed prior to the corneal affection. It is most probable, in such cases, that it is the ciliary part of the uveal tract which is primarily affected, and that the disease spreads thence both to the cornea and to the choroid. The case may, however, be uncomplicated throughout by any corneal affection. Cases of choroiditis undoubtedly occur in young subjects in whom there is no reason to suspect a syphilitic taint as in Plate XV., Fig. 40; in such the disease would seem as a rule to be limited in extent, and to become quiescent early.

The choroiditis of acquired syphilis may occur at any time after the period of the skin affection. It usually follows it within a few months, but sometimes not till years afterwards.

A feature which is fairly constant in syphilitic choroiditis is the circular shape of the patches, and the completeness with which the affected areas of the choroid become atrophied, so that the fundus is dotted over with punched-out round holes. This feature will, of course, be absent if the patches have become confluent. It is due to the mode in which the disease begins, *viz.*, from circular nodules of exudation, analogous to gummata.

Cases of syphilitic choroiditis occurring early in the course of the disease are sometimes accompanied by œdematous or inflammatory changes in the retina, and by the presence of very fine dust-like opacities in the anterior part of the vitreous. The concurrence of these conditions may generally be taken to indicate that the disease is of syphilitic origin. But choroiditis occurs, and that not very rarely, in cases where syphilis may be

excluded, and I know of nothing in the character of choroiditis, apart from the points just mentioned, which will serve to indicate whether it be of a specific nature or not.

Tubercle, as a cause of choroiditis, appears to me not to have received the amount of attention which it deserves. Tubercular iritis is a recognised condition, particularly in young subjects, and tubercular foci of inflammation are met with in the choroid in many cases of tubercular meningitis, and disseminated tuberculosis; such differ in no essential respect from spots of early disseminated choroiditis. It is true that they are usually of small size, and rather more raised, but such differences may be explained by the fact that the disease is always recent, and probably very active. The general disease being so fatal, the opportunity of watching the progress of the choroidal affection is not likely to occur often, and I do not know of any case in which this has been done.

Bearing in mind the frequency of tubercular affections of glands and joints, it might be well to consider whether many hitherto unexplained cases of choroiditis have not had a similar origin.

In dealing with large isolated patches of choroiditis, we gave reasons for believing that some of them were the result of tubercular masses which had undergone degeneration. It is quite likely that smaller areas may be due to a similar cause, and it is certain that tubercles in the choroid are not confined, as they were at one time believed to be, to cases of miliary tuberculosis.

Rheumatism has been suggested by Leber¹ as a cause of choroiditis. Personally I am not acquainted with any evidence which supports the view that choroiditis is more common in rheumatic subjects than in others.

¹ Helmholtz, "Festschrift," Art. xii., 1892.

RUPTURE OF THE CHOROID.

Blows upon the eye sometimes cause a tear in the choroid; the rent usually lies in the neighbourhood of the disc, and runs in a direction roughly concentric with its margin. At first it may be impossible to diagnose the lesion, because blood is poured out from the torn vessels, but when this is absorbed, the rupture is seen as a narrow band of exposed sclerotic, over which the retinal vessels pass unchanged. Pigment is often accumulated at the margins of the rent. The condition is now to be distinguished from atrophy, the result of choroiditis, only by the shape of the patch and the history of injury.

Irregular areas of choroidal atrophy may be met with in patients who give a history of an injury, and such are frequently diagnosed as ruptures of the choroid. It must not be forgotten that an injury often draws attention to a defect already present; still, it seems not improbable that in some of these cases the injury has caused choroidal hæmorrhage, and that the effused blood has led to atrophy of the choroidal tissue.

Although some ruptures of the choroid remain unchanged for years, others show a tendency for the exposed sclerotic to become pigmented. For example, in the case shown in Plate XXX., Fig. 64, seven months after the injury the borders of the patch were pigmented, and a month later its whole surface was of a steel grey colour.

In a case published by Benson,¹ the rupture, when seen three weeks after the injury, was cream-coloured, and there was no trace of hæmorrhage or pigmentation. A month later the area of the rupture was darkly pigmented, and there were a few spots of choroidal atrophy scattered about.

The shape of the rupture in Plate XXX., Fig. 65, is unusual,

¹ *Trans. Ophth. Soc.*, vol. ii., p. 62.

and beyond it are three isolated pale areas, which may be presumed to be tears in the choroid. The connection of the condition with the injury admitted of no doubt, as when the eye was first seen the vitreous contained blood. Unfortunately the progress of the case could not be followed.

The shape of the rupture is probably in some way dependent upon the firm connection between the choroid and the disc, but it is not easy to see what determines its position.

In cases of old choroido-retinitis, white bands, probably cicatricial, are sometimes seen on the fundus. These bear some resemblance to rupture of the choroid (Plate XLV., Fig. 98), but they are usually straight. Two cases recorded by Kenneth Campbell as examples of equatorial rupture of the choroid should be compared with these cases.¹

The fact that the rupture becomes pigmented, and that separate areas of choroidal atrophy are often found associated with rupture, raises an interesting question as to the extent to which a contusion of the eye is capable of causing fundus change apart from typical rupture of the choroid.

Siegrist² has recently suggested that the areas of partial choroidal atrophy near the disc, occasionally seen after contusions of the eye, are secondary to rupture of the short ciliary arteries. He gives illustrations of four cases which presented the following features in common:—(1) An injury from a blunt body; (2) yellowish decoloration of an irregular map-like area adjacent to the disc; (3) an interval of a few weeks between the receipt of the injury and the full development of the atrophic area, which afterwards remains unchanged.

In the case depicted in Plate XXX., Fig. 64, it will be observed that there are several small patches about the disc, where choroid is defective. It is doubtful whether these were

¹ *Trans. Ophth. Soc.*, vol. xii., Plate VII., and vol. xv., Plate IX.

² *Mitth. a. Klin. u. med. Inst. d. Schweiz*, Basel u. Leipzig, bd. iii., p. 9, 1895.

due to the injury or had existed previously. In the former case the above explanation might account for them.

A case of pigmentation of the retina following concussion of the eye, which was recorded by J. Hutchinson, jun.,¹ was probably also of this nature.

¹ *Trans. Ophth. Soc.*, vol. ix., p. 116.

CHAPTER VII.

OPTIC NEURITIS OR PAPILLITIS.

THE intraocular termination of the optic nerve—the so-called optic disc—is the only part accessible to ophthalmoscopic examination. Changes, therefore, may be present in the optic nerve or tracts, in the nerve centres, or in any link of the chain connecting these, without giving rise to any ophthalmoscopic signs, even though they may be sufficiently pronounced to cause complete blindness. At the same time, lesions which are situated anterior to the chiasma usually initiate degenerative changes, which, creeping down the nerve, eventually become recognisable at the disc. Any injury of the optic nerve that interferes with the local circulation is rapidly followed by conspicuous changes in the disc and retina. On the other hand, lesions posterior to the chiasma do not, as a rule, cause atrophic changes in the discs. But owing to the semi-decussation of the centripetal nerve fibres in the chiasma (*see* Fig. 37, page 115), they may cause defects in the visual fields of both eyes (hemianopsia).

It should not be forgotten that the chiasma, besides affording an opportunity for the redistribution of the nerve fibres from the two retinae, also acts as one of the commissures connecting the two halves of the brain. The commissural fibres indeed form about a third of the entire mass of the chiasma.

Many intracranial conditions cause inflammatory changes in the disc, a fact that will excite no surprise when we bear in mind the short course of the optic nerves, their direct continuity with the brain substance, and the intimate connection which subsists between their sheaths and the cerebral meninges.

It must always be remembered that the visible changes in the disc may be merely part of a lesion of the nerve trunk, and as we cannot see beyond the lamina cribrosa and ascertain the state of the optic nerve by direct inspection, the prognosis is necessarily doubtful.

We have seen that choroiditis commonly leads to atrophy of the choroidal tissue, and that the resulting ophthalmoscopic appearances are conspicuous and characteristic. In the retina, on the contrary, atrophic changes neither occur so readily, nor are they so conspicuous. This latter fact is due to the transparency of the retina, which renders it practically invisible. Atrophy of its tissue can therefore only be recognised with the ophthalmoscope when it is accompanied by changes in the pigment layer, or by diminution in the size of the retinal vessels. These changes occur in many degenerative conditions, but usually only at an advanced stage.

Inflammatory conditions, on the other hand, rapidly produce visible changes in the retina, which are largely due to loss of its transparency, and to obstruction to its circulation.

Inflammation of the intraocular termination of the optic nerve is commonly spoken of as optic neuritis. The term papillitis more accurately indicates the localisation of the visible changes in the optic disc or papilla, but is not yet in such general use.

When there are inflammatory changes both in disc and retina the condition is called neuro-retinitis.

Inflammation of the trunk of the nerve behind the globe, without implication of its intraocular termination, is indicated by the term retro-bulbar neuritis.

In order that the significance of the ophthalmoscopic appearances presented in these conditions may be appreciated, a

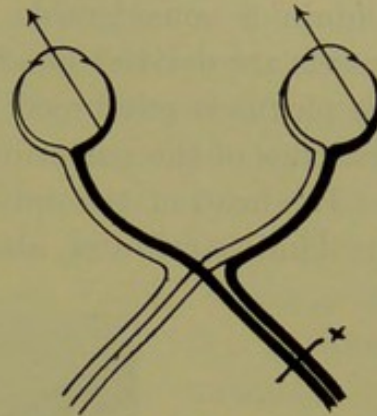


FIG. 37.—Diagram showing the semi-decussation at the chiasma.

x Lesion of right tract causing loss of left half of each visual field.

clear conception of the anatomical arrangement of the parts is necessary.

If the reader will refer to Fig. 38 he will see that the lamina cribrosa is covered by the nearly transparent nerve fibres, which contain a considerable number of minute blood vessels. These vessels are derived chiefly from branches of the central artery, but the plexus is reinforced by twigs from the arterial circle formed by branches of the posterior ciliary arteries.

The head of the optic nerve, or that part which lies anterior to the lamina cribrosa, although nearly transparent, is not perfectly




FIG. 38.—Section through optic nerve and papilla.

so, owing to the large number of blood vessels that it contains. Its transparency varies in different eyes, and while it always allows a certain amount of white light to be reflected from the lamina, it is never sufficient to permit the details of that structure to be seen through it. The floor of a physiological cup forms an apparent exception, but it must be remembered that this is covered only by a thin layer of nerve tissue.

The more transparent, therefore, the nerve tissue, the brighter

the colour of the disc. The transparency is usually greatest in light fundi, and in these we may see discs that present all gradations in colour, from a pale rose to a white but faintly tinged with red.

In dark fundi, on the other hand, the nerve tissue is usually less transparent, and we may then get grades of colour from a deep rich red (as in Plate III., Fig. 6) to a dusky, dirty-looking red, which appears to be mixed with grey. The latter colour, however, is seldom met with, except in connection with other congenital peculiarities of the disc—*e.g.*, opaque nerve fibres (Plate XIII., Figs. 36 and 37), congenital crescent (Plate VIII., Fig. 22), or exaggerated connective tissue ring (Plate V., Fig. 14). In some dark fundi, on the other hand, the disc looks pale by contrast.

Not only does the colour of the disc differ much in different eyes, but it is not uniform throughout. For a detailed description of the appearances which may be presented by different parts of the disc, the reader is referred to the anatomical description. It is sufficient here to point out—first, that the outer half of the disc is often paler than the inner, because the layer of nerve fibres is there thinner; and, secondly, that in the part occupied by the physiological cup there is an entire absence of vascularity, and the lamina cribrosa is seen as a white surface mottled with grey.

The margin of the disc, also, presents considerable variations, according to the extent to which it is softened by the passage over it of the nerve fibres. These are most abundant at the upper and lower borders of the disc, so that the edge usually appears softer in these situations than elsewhere. In addition to this, the margin is more or less softened, according to the amount of light reflected from the surface of the fibres. Consequently, while it never presents so hard a line in the normal condition as in advanced atrophy, it may yet vary from a fairly sharp line to one that is rather indistinctly seen as through a transparent film. (Compare Figures on Plates I., II., and III., with Plate XXXII., Fig. 73).

These physiological variations in the colour of the disc, and in the sharpness of its outline, have been fully dealt with in the first part of this work, because, from their existence not being sufficiently borne in mind, a pathological condition has often been erroneously supposed to be present in perfectly normal eyes.

The earliest effect of inflammatory or œdematous conditions of the head of the nerve, is to impair the transparency of its tissue. As a result of this, the margin of the disc becomes less distinct, while its surface appears duller, owing to some loss of light reflex from the lamina ; for the same reason it seems redder, even when there is no actual hyperæmia.

A similar appearance is produced by slight turbidity of the vitreous, due to the presence of fine dust-like opacities in its anterior part. To avoid overlooking these opacities, careful search must be made with a convex lens behind the ophthalmoscope, and a feeble illumination. The plane mirror will also be found of advantage in doubtful cases.

Blurring from imperfect focussing during the examination, as in uncorrected myopia, could only be mistaken for commencing neuritis by a careless observer. But the hypermetropic disc, described on p. 41, may simulate optic neuritis so closely that the distinction cannot be made with the ophthalmoscope alone. The diagnosis must then rest upon the presence of hypermetropia, the state of the vision, and the progress of the case.

The state of the vision may be of little assistance in distinguishing optic neuritis from other conditions. The turbidity of the nerve fibres does not interfere with their function of conducting impressions from the retina to the brain. Hence even marked papillitis may coexist with normal vision, a fact first pointed out by Hughlings Jackson.

Distension of the retinal veins is a sign of papillitis which commonly makes its appearance soon after the blurring of the disc margin, although it sometimes precedes it. The distension is mechanical, and due to obstruction to the return of blood through

the central vein. It is characterised not only by increased breadth of the veins, but also by their elongation, so that they become abnormally tortuous, and present an appearance that has been appropriately designated "snake-like" (*see* Plate XXXI.).

The distension becomes more marked as the vessels are traced from the periphery towards the disc. It is often greatest just before the vessel dips into the substance of the head of the nerve. At this point the distended vessel may undergo a rather sudden reduction in size, and may in consequence present an appearance not unlike an engorged leech.

In pronounced cases, the sinuosities of the vein occur not only in the plane of the retina, but also perpendicularly to it. When this is the case, some segments of the vein appear darker than others, because the column of blood in them is seen "end on," as it were, and the vessel may appear broken in places owing to its dipping into the substance of the swollen retina (Plate XXXIII., Fig. 75; Plate XXXIV., Figs. 76 and 77; and Plate XXXVI., Fig. 81).

Distended veins usually appear dark in colour; this is in part due to a greater thickness of blood being looked through, and in part to the retarded current taking up more effete products, so that the venous character of the blood is exaggerated.

Swelling of the head of the nerve is another important sign of optic neuritis. It was present in a marked degree in the cases from which Plate XXXI., Fig. 69; Plate XXXII., Fig. 70, and others, were taken, and is indicated in the pictures by the bold curves made by the veins as they pass on to the disc. No drawing, however, can adequately represent the ophthalmoscopic effects produced by differences in level. These depend on two chief causes,—the parallax displacement that occurs when the head is moved, and the impossibility of accurately focussing at the same time points which are on different levels. The parallax movement may be seen either with the direct or with the indirect method of examination. With the direct method, the parts that

are nearest the examiner move in the opposite direction to his head; with the indirect, the whole image moves with the lens, but the nearer parts move more than the distant. Differences in focus can only be recognised by the direct method. The strongest convex lens with which the summit of the prominence can be distinctly seen gives a clue to the extent to which it projects, each dioptré of refraction corresponding to 0.3 mm. of level. It is usual to take some object, such as a vessel or band of lymph in the most prominent part of the disc, and to gauge the swelling from this. It is evident, however, that other factors have to be considered in estimating the intensity of the papillitis, such as the superficial extent of the swelling, the number of new vessels, hæmorrhages, &c.

Hyperæmia and congestion of the disc are frequently present, and may cause it to appear of the same colour as the fundus. If its margin is at the same time indistinguishable, the meeting of the retinal vessels may be the only guide to the position of the disc. The existence of venous congestion is inferred from the fact that the retinal veins show signs of stasis. Active hyperæmia from dilatation of the smaller arteries and capillaries may also be present, and may bring into view arterial twigs which, in the normal condition, are too minute to be visible, and may even cause new vessels to develop (Plate XXXVI., Fig. 81). The hyperæmia is confined to the disc; the retinal arteries remain unchanged, or may even be diminished in size.

Congestion can seldom be diagnosed by the colour of the disc alone, since such great variations may exist within physiological limits. But the increased vascularity of the nerve tissue impairs its transparency, and renders the disc margin less distinct. Redness, unaccompanied by blurring of the margin, must not be considered as pathological, unless it is known to be of recent origin.

It will be evident from what has been said, that, although no difficulty can arise in recognising fully developed papillitis,

the case is different in the early stage. Indeed, when only slight blurring of the disc margin, and slight redness of its surface are present, it may be difficult, or even impossible, to be certain whether we have to deal with a physiological or a pathological condition. The latter in the early stage is frequently confined to one eye, or is more advanced in one than in the other, but exceptions are so numerous that the rule is not of much practical value. Failure of vision proportionate to the visible change is strong evidence that the condition is pathological. On the other hand, retention of normal vision by no means excludes pathological change. Much more important is the fact that physiological conditions are stationary, while those which are pathological tend either to resolve or to become aggravated, so that any remaining doubt will be dissipated by the lapse of time.

It was formerly held that there were two varieties of optic neuritis, which contrasted with each other in respect both of their mode of causation and their ophthalmoscopic appearance. The one, presenting great swelling of the disc, and all the signs of venous obstruction, was called choked disc—a term which corresponds to the "*Stauungspapille*" of the Germans. The other form, showing blurring of the disc margin but less swelling and no signs of venous obstruction, was called descending neuritis.

The so-called choked disc was believed to be produced by retardation of the current in the central vein, either by blocking of the cavernous sinus, or by pressure from fluid in the nerve sheath. In either case the swelling of the head of the nerve was thought to be aggravated by the unyielding scleral ring. We now know that complete obliteration of the cavernous sinus may take place without any ophthalmoscopic signs, owing to free anastomosis between the orbital and facial veins at the angle of the orbit. Moreover, when venous obstruction does exist, independently of inflammation of the nerve-head, the changes that occur are not identical with those

included under the term choked disc. Pathological evidence, also, is against the theory of venous obstruction behind the globe, or of compression exercised by the scleral opening. Gowers states that he has never, in pathological specimens, seen signs of compression behind the lamina cribrosa or by the scleral ring. He considers that the venous obstruction is secondary to inflammatory changes in the disc, and that the pressure is exercised by the inflammatory products within the nerve-head, a view which has been confirmed by other observers.

On the other hand, we must not lose sight of the clinical fact, whatever be its pathological explanation, that in many cases, dilatation of the retinal veins precedes the other signs of neuritis.

Ulrich¹ examined *post-mortem* three cases of cerebral tumour, in which optic neuritis had developed only a few days before death. He found œdema of the nerve trunk, apparently an extension of a similar condition from the brain substance, and compression of the central vessels within the trunk of the nerve. Such a condition, however, is certainly exceptional.

Deutschmann² holds that the so-called choked disc has no connection with obstruction from pressure, but that it results from irritating particles in the cerebro-spinal fluid carried down the nerve sheaths, and mechanically arrested at their distal extremities—a view identical with that advanced by Leber at the International Medical Congress in 1881. Deutschmann arrives at this conclusion from the fact that examination of pathological material shows that compression of the vessels, when present, is always anterior to the lamina cribrosa, and secondary to exudation into the head of the nerve, and is, therefore, a result, and not the cause of the swollen disc. Also, that when the central vein is really obstructed, as by a thrombus, the symptoms are very different from those which are presented by the so-called choked disc. The retinal veins are, indeed, distended and tortuous, but the disc does

¹ *Arch. f. Ophth.*, Leipzig, bd. xviii., p. 53.

² "Ueber Neuritis optica und Gehirn-Affectionen," 1887.

not become much swollen, and extensive hæmorrhages occur—conditions which are depicted in Plate XXXIV., Figs. 76 and 77, and which will be described in detail later on.

Experiments on rabbits gave results consistent with Deutschmann's views. It was found that the intersheath space might be injected with fluid, almost to the bursting point, without any effusion taking place into the retina, but that the retinal arteries became diminished and the veins distended, while hæmorrhages occurred into the retina. On the other hand, when fluid containing tubercle bacilli was injected, severe optic neuritis was set up.

I would point out in passing that the good results Brudenell Carter seems to have obtained by incision of the nerve sheath in cases of optic neuritis, are quite as consistent with the theory that the fluid contains deleterious particles, as with that which attributes the neuritis to its mechanical pressure. It is obvious that an operation of this kind must so modify all the conditions present that its action might be explained in several ways.

It follows from what has been said that the term choked disc can no longer be employed to express the result of a distinct pathological process, but it may be retained as descriptive of a particular grouping of the ophthalmoscopic signs of papillitis.

Optic neuritis, or neuro-retinitis, may be due to various conditions, which may be conveniently classified under the three heads—local, intracranial, and general. In the cases that depend upon a local cause, the affection is monocular, while in those which result from intracranial or general conditions, both eyes are eventually affected. Even in these latter cases, however, it is common for one eye to be attacked before the other, so that the fact of the condition being monocular at the moment of examination is not conclusive evidence in favour of a local cause.

The following table shows the different conditions which are generally recognised as capable of setting up neuritis or neuro-retinitis; isolated cases have, however, been recorded, which were thought to be due to other causes, and it is possible that

anything capable of causing peripheral neuritis may occasionally affect the optic nerves.

| | |
|----------------------|-----------------------------------------------------------------------------------------------------------------------------------------------------------------------------------------------------------------------------------------------------------------------------------------------------------------------------------------------------------------------------------------------------------------|
| LOCAL CAUSES. | <ul style="list-style-type: none"> Cellulitis of orbit. Periostitis ,, Wounds ,, Tumours ,, Thrombosis of the orbital veins and their tributaries, especially the <i>vena centralis retinae</i>. Hæmorrhage into the nerve sheath. Wounds or tumours of the optic nerve. Wounds of the globe. |
| INTRACRANIAL CAUSES. | <ul style="list-style-type: none"> Meningitis—<i>a.</i> Traumatic. <i>b.</i> Tubercular. <i>c.</i> Syphilitic. <i>d.</i> Pyæmic, especially from disease of middle ear. <i>e.</i> Epidemic cerebro-spinal. Tumour. Abscess. Aneurism (especially in the cavernous sinus). |
| GENERAL CAUSES. | <ul style="list-style-type: none"> Acute febrile diseases. Albuminuria. Influenza. Anæmia (all forms). Scurvy. Diabetes. Malarial poisoning. Syphilis. Poisoning from lead and possibly other agents. Leucocythæmia. Pyæmia. Hereditary predisposition. |

It is evident that several of the causes enumerated above might act in different ways, and might, therefore, be placed in either of the three classes, according to circumstances. For example, syphilis may act as a general cause through the condition of the blood, thus producing a primary syphilitic papillitis. This is certainly very rare, and its occurrence is denied by some authorities. Or it may act as a local cause by producing a gumma of the nerve or periostitis at the apex of the orbit; or, finally, as an intracranial cause by leading to a gumma of the brain or a gummatous meningitis.

Cases occur from time to time in which optic neuritis is the only discoverable symptom. Such cannot be classed under any of the above headings, and the term idiopathic neuritis may, therefore, be provisionally applied to them pending fuller knowledge as to their pathology. These cases are often accompanied by headache. They are more common in women than in men, and have been attributed, but often on insufficient evidence, to cold and suppression of the menses.

PAPILLITIS FROM ORBITAL CAUSES.

Orbital affections may set up papillitis either by pressure on the nerve, or by direct extension of inflammation to its structure from the orbital cellular tissue. Wounds of the nerve immediately produce ophthalmoscopic changes only when they are situated anterior to the point at which the central vessels enter the nerve, the appearances then resemble that produced by thrombosis of the central vein. When the lesion is behind this point an atrophic process creeps down the nerve, and does not appear at the disc for several weeks.

Tumours of the optic nerve may cause papillitis, but these cases are rare. Proptosis and immobility of the eye are prominent symptoms.

Optic neuritis has sometimes been found in eyes excised on

account of recent wounds of the front part of the globe, but opportunities of ophthalmoscopic examination under these circumstances can hardly arise.

Optic neuritis occurs in some of the cases which have been called acute retro-bulbar neuritis. These may conveniently be considered here, although they form a distinct clinical group. The characteristic symptom is a very rapid or sudden loss of vision in one eye, which may be complete. Sometimes this is preceded or accompanied by tenderness on pressing the eyeball back into the orbit; and headache or neuralgia may be present. The pupil is often dilated, and does not act even to concentrated light, but its associated movements remain unimpaired. In the majority of cases vision gradually returns after a few days, recovery commencing in the periphery of the field, and extending gradually towards the centre, where a permanent scotoma may remain. With the return of vision the pupil again becomes active. Some cases develop a papillitis a few days after the onset of the symptoms; others run their course without any ophthalmoscopic change, a difference which probably depends upon the situation of the lesion.

Sometimes no recovery of vision occurs, and then optic atrophy eventually supervenes, whether papillitis has been present or not.

Although both eyes are never affected simultaneously, the second eye is sometimes attacked after a long interval.

The following cases illustrate some of these points:—

Dr. V., 70, a retired medical man. *RE.* defective for several years from immature cataract. $V. c+4 D. = 14$ Jaeger.

Had been confined to bed for some weeks with bronchitis. On waking one afternoon he found that he was quite blind with the *LE.*, which had previously had no defect. He was unable to see the light of a candle held a few inches away. When seen by the writer the next morning, there was bare perception of light, and the pupil was inactive. Ophthalmoscopic examination negative. Two days later he could make out the position of objects in the room which lay in the periphery of the field. Vision gradually improved, and in a fortnight he could read 1.0 of Snellen's reading types, but was unable to see the middle letters of the longer words. Three months later $V = \frac{4}{5} c+4 D. = 0.3$ Snellen, but there was a minute central scotoma. There was no ophthalmoscopic change throughout.

In the following case both eyes seem to have been attacked, with an interval of a year and eight months:—

Miss C., aged 22. A nervous excitable woman of distinctly neurotic tendency.

The history of the *LE.*, which was first attacked, is partly compiled from notes kindly furnished me by Mr. Lawson.

2nd September 1888.—Attacked by severe neuralgia in left temple. The next day this had gone, but it returned, with less severity, on the third day. On the fourth day, on waking in the morning, she found that she could not see with the *LE.* A fortnight later (17th September) she consulted Mr. Lawson, who found *V. RE.* $\frac{6}{8}$ and 1 Jaeger. *LE.* letters of 19 J. made out, but unable to see the whole of a letter at a time. *OD.* muddy-looking, margin hazy. Two days later (19th September) she was seen by the writer. She still complained of much dimness in *LE.*, but *V.* was found to be $\frac{6}{8}$. There was very slight blurring of the disc margin. Not seen again for two years, she then stated that the *LE.* recovered completely a few days after her last visit.

7th May 1890.—Seen on account of failure of *RE.* She stated that for several days she had had pain over the right brow. Three days ago (4th May) *V.* of *RE.* failed rapidly, and continued to get worse till the day before her visit. When seen (7th May) *LE. V.* $\frac{6}{8}$ *RE.* 19 J. letters only. Visual field normal. Disc margin thought to be a trifle hazy. Decided tenderness on pressing the globe back into the orbit.

10th May.—*V.* worse. Could see the black and white of 19 J., but could make out no letters, and could not count fingers. *V.F.* normal in extent. The test-object occasionally lost, but no definite scotoma could be mapped out. *OD.* margin decidedly blurred. No swelling. No distension of veins. Small vessels on *OD.* seen quite clearly. Mercurial pill twice a day.

11th May.—Disc margin more blurred. Veins engorged.

12th May.—Disc margin indistinguishable. Veins to arteries as five to two. Very slight swelling of disc. *V.* improved. Counts fingers at 12 in.

13th May.—*V.* fingers at 18 in. Disc margin a little clearer.

14th May.—Patient says that the cloud which has covered the whole field had lifted at the edges. She could make out the position of objects in the room which lay in the periphery parts of the field, but was unable to see the light of the fire when looking straight at it. Is taking the mercury, and is kept in a dark room. Ophthalmoscopic appearances unaltered.

2nd June.—There has been steady improvement. *V.* = letters of 10 J. Lateral margins of disc quite clear. Still cloudy above and below. Colour of disc pale. To take mercury in small doses, and iron.

7th June.—*V.* $\frac{6}{8}$ and 1 J. puzzled out.

3rd July.—*V.* $\frac{3}{4}$ *c* - 0. 5 *OD.* $\frac{3}{4}$ one letter. Disc nearly normal in appearance. Not seen again.

PAPILLITIS FROM INTRACRANIAL CAUSES.

The anatomical connections of the optic nerves explain the mode of action of some of the intracranial causes of optic

neuritis. The prolongation of the cerebral meninges into the sheaths of the nerve favours direct extension of the inflammation in meningitis. The continuity of the subarachnoid and the intervaginal spaces, allows changes in the quantity and quality of the cerebro-spinal fluid to produce corresponding changes in the contents of the nerve sheaths. Formerly it was held that the mere distension of the latter produced optic neuritis mechanically by pressure on the nerve, and strangulation of its tissues. As already pointed out, it is more than doubtful whether papillitis can be produced in this way. But there can be no doubt that if the fluid contain irritating substances, these may set up inflammatory changes in the nerve-head. Optic neuritis may also be caused by inflammation spreading from the brain along the optic nerve by continuity of tissue. It was formerly thought that this descending neuritis produced ophthalmoscopic appearances which could be distinguished from the condition which was believed to be due to excess of fluid in the sheaths, and which was known as choked disc. It is now agreed on all hands that this distinction cannot be made, and the best authorities consider that most instances of papillitis, resulting from intracranial conditions, are really examples of descending neuritis.

Next to meningitis, the most frequent intracranial cause of optic neuritis is tumour. It is probable that the large majority of cases of intracranial tumour cause papillitis at some stage, but, as it may be transient, and unaccompanied by any impairment of vision, it may sometimes escape notice.

Both discs are nearly always affected, although one may be attacked in advance of the other. When papillitis is present in one eye only, in a case of intracranial tumour, the fact does not assist in determining the side of the brain on which the growth is situated, since the results of post-mortem examination have shown that the affected eye is on the same and on the opposite side in nearly equal proportions. The liability to papillitis does not appear to depend upon the nature or size of the growth, and the

character of the connection between the intracranial and ocular conditions is still doubtful. The balance of opinion seems at present to incline to the belief that the papillitis results from a direct extension of inflammation along the nerve tissue, although the special liability of cerebellar tumours to excite it, hardly supports this view.

The existence of binocular papillitis may, therefore, materially strengthen the diagnosis of cerebral tumour. But it has *per se* no localising value, for, although it is more often due to cerebellar, than to other, tumours, it may result from a neoplasm situated in any part of the brain.

Cases of optic neuritis, accompanied by persistent dropping of clear fluid from the nose, have been observed.¹ Frontal pain and cerebral symptoms of some kind appear always to be present. It is probable that the fluid comes from the subarachnoid space, although analysis has not yet proved conclusively that it is cerebro-spinal fluid.

PAPILLITIS FROM GENERAL CAUSES.

General conditions may act on the optic nerves in many different ways. In acute febrile diseases, it is probable that the papillitis is in many instances directly caused by meningitis. But it has occurred in cases in which there has been no other reason to suspect any cerebral complication. An instance of this has been recorded by Stephenson.² In this case, well marked double optic neuritis, with impairment of vision, followed a mild attack of measles. Optic neuritis may occur in the course of any of the specific fevers, but is said to do so with especial frequency in typhus. In the case from which Plate XXXVI., Fig. 81, was taken, enteric fever was probably the cause of the neuritis,

¹ Nettleship, *Ophth. Rev.*, London, vol. ii., p. 1; Priestley Smith, *ibid.*; and Leber, *Arch. Ophth. and Otol.*, N. Y., vol. xxix., p. 271.

² *Trans. Ophth. Soc.*, vol. viii., p. 250.

although the patient had also suffered from disease of the middle ear.

Many general diseases would seem to produce neuritis by causing changes in the composition of the blood. This mode of action is obvious, for example, in leucocythæmia. In this disease the immense increase in the number of white corpuscles impedes the circulation through the small vessels of the retina. In anæmia and scurvy, also, the character of the blood has no doubt a direct influence in causing neuro-retinitis, by allowing fluid to transude more readily through the walls of the capillaries. There are other general morbid conditions, attended by great alterations in the blood, in which the mode of production of the neuritis is not so obvious; as examples—diabetes, lead poisoning, and albuminuria may be cited. In these it is probable that other conditions (besides the state of the blood) contribute to the result. For instance, in albuminuria, besides the fact that the blood is highly charged with nitrogenous compounds, we have to take into consideration the changes in the walls of the blood vessels, and the hypertrophy of the left ventricle of the heart.

The ophthalmoscopic appearances of optic neuritis vary in different cases, as will be evident by comparing the several figures in the Atlas. These variations depend chiefly upon the severity and stage of the inflammation, and on the degree to which the retina is involved, but only to a comparatively slight extent on the cause of the condition. Neuritis from intracranial affections and from Bright's disease are, however, types of two very different classes. In neuritis from intracranial conditions, the changes are either confined to the disc or are most marked there; the retina is affected, if at all, secondarily, and late in the disease; and hæmorrhages are the exception rather than the rule (Plate XXXI., Figs. 67 and 69, may be instanced as examples). The disc is much swollen, its margin indistinct or invisible, the veins engorged and tortuous. In albuminuric retinitis, on the other hand, there are numerous retinal hæmorrhages, large soft woolly looking

patches of effusion, and some glistening white dots; the disc margin may be blurred or invisible, but the swelling of the disc is inconsiderable (*see* Plate XXXVI., Figs. 82 and 84). This distinction cannot, however, always be made, indeed, the conditions may be reversed; hence it is impossible to diagnose the cause of the neuritis by the ophthalmoscope alone.

Papillitis may subside completely; the inflammatory products may undergo a partial organisation into connective tissue; or the disc may pass into a state of atrophy.

The inflammatory products in the retina show no tendency to organise, or to break down into pus. On the contrary, when the neuritis subsides, they are generally absorbed, but they may produce permanent degenerative changes in the retina.

When neuritis begins to subside (as in Plate XXXI., Fig. 66), the nerve-head becomes paler and the swelling diminishes. Gradually the margin of the disc clears, generally first on the temporal side. The tortuosity of the vessels persists longer, and if it has been very great, may never subside. The vessels are often accompanied on the disc, and for a short distance beyond it, by fine white lines. These are due to effusion into, or changes in, the sheath of the vessels (Plate XXXI., Fig. 67). Sometimes these lines remain permanently, and then afford important evidence of the previous existence of neuritis. It must not be forgotten, however, that a similar appearance is produced by the bands of connective tissue that are not uncommon as a congenital condition.

If the inflammatory material effused into the head of the nerve undergoes organisation, the disc will remain of a whiter colour than normal, and its margin may be blurred and irregular. It is important to note that these conditions may exist with normal vision. As a rule, however, persistent pallor following neuritis indicates that some of the nerve fibres in the disc have become atrophied. When this is the case the vision is subnormal,

and the visual field is usually contracted. Although such a partial atrophy is necessarily permanent, it need not be progressive. It is due to the nerve fibres having been subjected to so much compression that they are unable to recover even when the pressure is removed.

CHAPTER VIII.

NEURO-RETINITIS AND RETINITIS.

So far we have chiefly dealt with the changes that occur in the disc itself, and are included under the term papillitis; we now pass on to consider those cases in which the retina also is affected—neuro-retinitis. The venous obstruction may mechanically induce changes in the retina. As the pressure in the capillaries becomes greater, hæmorrhages occur into its substance. These, as well as hæmorrhages from other causes, will be considered in detail later on. Meanwhile other retinal changes may occur. These are chiefly of two kinds—(a) soft-edged, woolly-looking patches, round, oval, or kidney-shaped, varying in size, but having an average diameter equal to half that of the disc (Plate XXXVI., Fig. 81, and Plate XXXVII., Fig. 82); (b) small, more brilliant and harder looking dots, the larger ones about the diameter of the primary retinal vessels, others much smaller. These usually appear at a later stage than the woolly patches (Plate XXXVI., Figs. 80, 81, Plate XXXVII., Fig. 82, and Plate XXXVIII., Fig. 87), except in the yellow spot region, where they are sometimes seen soon after the onset of the inflammation. In this situation they tend to arrange themselves in lines radiating from a centre, as shown in Plate XXXVII., Fig. 84, and to a less degree in other figures.

Our present knowledge points to the conclusion that identical ophthalmoscopic appearances may be due to different pathological conditions. Thus the microscope shows that the larger patches described under (a) may be due to varicose swellings of the nerve fibres, to cellular exudation (the cells being derived either from the white corpuscles of the blood, or from the nuclear layer of

the retina), or to fibrinous exudation which coagulates between the nerve fibres. Fat globules are usually found associated with all these conditions, and are derived both from the breaking down of the retinal elements, and from degeneration of the effused products of inflammation. The small chalky dots (*b*) are probably generally due to changes in the fibres of Müller.

Neuro-retinitis is not unfrequently accompanied by wavy swelling of the retina, as indicated by tortuosity of the vessels, the curves of which are perpendicular to the normal plane of the retina. More rarely the surface is thrown into regular parallel ridges, like those left on the sand by the receding tide. An example of this is shown in Plate XXXII., Fig. 70. Nettleship¹ has recorded a case, which, judging from the excellent chromo-lithograph that accompanies the description, is of the same nature. He, however, attributes the lines in his case to imperfect subsidence of choroidal œdema. But the similarity of the lines to the ridges of a detached retina, and the association with neuro-retinitis seem rather to point to a retinal origin. It is not improbable that œdema of the choroid does occur in neuro-retinitis, but the free anastomosis of the choroidal vessels is not favourable to its sharp limitation.

The changes in the retina, like those in the disc, may proceed either to resolution or to degeneration of tissue.

Even very extensive retinitis may recover. Thus, the woolly patches may be absorbed completely, and hæmorrhages may be converted into white patches, which eventually disappear (Plate XXXV., Fig. 78, and Plate XXXVII., Fig. 83). The most persistent lesions are the fine chalky dots, which are most numerous at the macula, but also occur in other parts of the retina. Even these, however, may completely disappear. For example, in the case from which Plate XXXV., Fig. 78, was drawn, only a very few small white dots remained in the neighbourhood of the macula some months later. On the other

¹ *Trans. Ophth. Soc.*, vol. iv., p. 167.

hand, extensive exudation in the macular region sometimes produces permanent scarring, such as is seen in Plate XXIV., Fig. 57. That the retina does not more often recover from the results of inflammation is due to the fact that the cause of the inflammation is generally persistent. When it is transient, as in the albuminuria of pregnancy, recovery from very extensive retinitis is not uncommon.

When degenerative changes ensue, the soft woolly patches are replaced by smaller flat-looking areas, with well-defined but irregular outlines. These have a brilliant, sometimes almost a metallic lustre, which it is difficult to depict satisfactorily. Occasionally, the surface of the patches looks irregular, as if composed of a crystalline substance. That this is really the case seems probable, from the fact that prismatic colours can now and then be seen. Such crystals probably consist of cholesterine. The scarring at the macula referred to above (Plate XXIV., Fig. 57) must also be looked upon as a degenerative change.

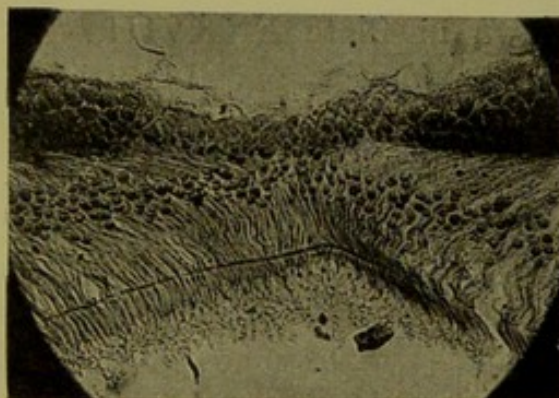


FIG. 39.—Section through the macula. (After GOLDING BIRD and SCHÄFER.)

Allusion has been made to the stellate arrangement that retinal effusions tend to assume when situated in the region of the macula. This appearance is well seen in Plate XXXVII., Fig. 84, and to a lesser degree in Plate XXXV., Fig. 78, and Plate XXXVI., Fig. 80. This characteristic grouping is due to the anatomical distribution of the fibrillar elements of the retina, and particularly of the fibres of Müller at this part, already described on page 64, and shown in Fig. 39. It will be noted that at the actual centre the fibres are vertical, and this corresponds with the fact that the radiating lines stop short before reaching the centre.

This explanation of the production of the star-figure is not universally accepted. Thus, Marcus Gunn¹ attributes it to œdematous swelling. This tends to stretch the retina in all directions, but the stretching is resisted at the macula by adhesion between the retina and the choroid. Consequently the retina is thrown into radiating folds, much in the same way as would happen if an attempt were made to draw the centre of a sheet through a ring. Degenerative changes occurring along the lines of creasing would account for the star-figure persisting after the subsidence of the swelling.

The stellate arrangement is not confined to such changes as are obviously inflammatory or degenerative in character. A case which does not seem to belong to either of these categories is shown in Plate XXXVIII., Fig. 85. The patient was young, and apparently in good health. The loss of vision was rapid, if not sudden, and preceded the appearance of the changes at the macula by eight or eleven days. Considering how conspicuous those changes were, they proved somewhat evanescent, for in thirty-two days they had in great measure disappeared (as shown in Plate XXXVIII., Fig. 86). The history of the case seems most consistent with some interference with the circulation, inducing secondary changes, possibly of the nature of œdematous effusion, in the retina at this part; but the appearances are, it must be admitted, quite unlike those met with in embolism of the central artery, for in such cases the whole retina becomes opaque, and although at a later stage the changes become limited to the macular region, they do not even then assume the star-like form.

The two following cases seem to be examples of the condition just described :—

A woman, aged 33 (Dahrenstadt, *Centralbl. f. prakt. Augenh.*, Leipzig, February, 1892), had had pain over the left eye for three months, but the sight had only failed two days before her visit. When seen V. was $\frac{1}{100}$, and a sector-like defect was present in the lower and inner quadrant of the field. There was some blurring of the disc margin, and a

¹ *Trans. 8th Internat. Ophth. Congress*, Edinburgh, 1894.

patch of retinal effusion close to it above. In this situation the veins were somewhat distended and tortuous. At the macula was a stellate figure, consisting of about fifty lines radiating from near the centre; the lines diminished in size towards their peripheral extremities, and appeared to be composed of numerous dots. The diagnosis made was thrombosis of the superior temporal artery. Treatment by iodide of potassium, mercurial inunctions, and massage, was followed on the second day by improvement. The superior temporal artery eventually became converted into a fine red streak, bounded by white lines, and the star-like figure gradually disappeared till scarcely a trace of it remained. There was no history of syphilis, and albumen was not present in the urine.

Frau L., aged 59 (Hirschberg, *Centralbl. f. prakt. Augenh.*, Leipzig, 1882, p. 330). Three days before visit sudden loss of vision in *RE*. Arteries atheromatous. Palpitation without valvular lesion, and hæmoptysis without physical signs, were present. Urine normal.

RE. V. = $\frac{1}{100}$. Visual field normal in extent, a central positive scotoma having a radius of 8°. Optic disc normal; between it and the fovea, a large number of extremely minute white dots, which had an almost crystalline brilliancy. Nine days later, the scotoma had diminished, but the patient complained of seeing a violet cloud in the centre of the field. The fovea was seen to be surrounded by a wreath of regularly arranged white dots, and similar dots were thickly crowded between the disc and the fovea.

A month later these dots had arranged themselves into fine lines, radiating from the disc; in another month, there was in this situation a star-like figure with fifteen rays, while between the *YS* and the disc were four rays, arranged like the letter X. Nine months after the first visit, the fundus was normal.

A somewhat similar case has been published by Mr. Hartridge (*Trans. Ophth. Soc.*, vol. ix., p. 144), with a chromo-lithograph, in which the changes were noticed after a blow on the eye.

The following varieties of retinitis are of sufficient importance to be dealt with separately:—

ALBUMINURIC RETINITIS.

Nephritic, or albuminuric retinitis, may occur in any form of renal disease, but is most commonly associated with the contracted granular kidney. The disease, as far as its ophthalmoscopic appearances are concerned, is met with in two forms, which may conveniently be called *acute* and *chronic*, corresponding respectively to the inflammatory and degenerative varieties of Gowers.¹ The acute form is characterised by large areas of retinal effusion, by hæmorrhages, and by much blurring of the disc margin; the

¹ "Medical Ophthalmoscopy."

chronic by smaller retinal spots of brilliant white colour. At a later stage these latter are replaced by flat-looking glistening spots of slightly larger size and of irregular shape, or by large glistening areas formed by coalescence of the smaller dots. On the surface of these, glistening crystalline-looking bodies of minute size can sometimes be seen; these are probably crystals of cholesterine. On several occasions the writer has seen prismatic colours in such bodies. There is often an irregular deposit of pigment over these old patches. Hæmorrhages are generally absent or few in number, and the disc may be unaffected. The chronic may represent the late stage of the acute variety, or may occur independently.

The soft woolly patches (such as those seen in Plate XXXVII., Fig. 82) may be due to several pathological conditions which frequently coexist; as, for example, effusion of fluid among the nerve fibres, exudation of leucocytes, and varicose swellings on the nerve fibres. The smaller, more glistening dots, seen in the same picture, are caused by fatty degeneration either of effused products or of the tissue of the retina. When situated at the macula they tend to assume the spoke-like arrangement shown in Plate XXXVII., Fig. 84.

In many cases lymph is exuded into the perivascular sheaths; the vessels are then seen to be bordered by white lines, or they may in places be entirely concealed by the effusion, and so present an appearance of broad white bands. A somewhat similar appearance may be produced by the vessel wall itself undergoing degenerative changes which convert it into a band of chalky whiteness (Plate XL., Fig. 90). According to Brailey and Edmunds,¹ changes in the retinal vessels are to be found with the microscope in most cases of chronic contracted granular kidneys, even although the ophthalmoscopic appearances may be normal. These changes consist in "a general thickening and hyper-nucleation of the coats of the arteries, without any diminution of

¹ *Trans. Ophth. Soc.*, vol i., p. 44.

their calibre, with a somewhat similar affection of the capillaries." In another condition, thought to be a later stage of this, "the arterial walls are thick and structureless, and the capillaries hyaline and rigid, standing open on section. In other instances thickening of the arterial wall both increased the diameter of the vessel and also narrowed its lumen, in some cases, to complete obliteration. The arteries in the kidneys in the same patients presented similar changes."

Hyaline thickening of the vessel wall does not impair its transparency. It may, therefore, exist without any ophthalmoscopic sign. The condition can sometimes be recognised by the brilliant, rather glassy appearance presented by the retinal arteries, (which has been aptly compared to bright copper wire), and by the light streak being abnormally conspicuous. At the point where an artery, thickened in this manner, crosses a vein the latter vessel may appear broken, and the gap to be only partly filled by the artery (Plate XXXVI., Fig. 80, and Plate XXXVII., Fig. 84). It would seem that in some cases the thickened artery, by pressing on the vein, retards the blood current, and causes dilatation of the vein on the distal side. But in the cases shown, as well as in one recorded by Marcus Gunn,¹ there was no such dilatation; therefore, it is impossible to accept the view that the apparent break in the vein corresponds with any considerable obstruction of the blood current, and some other explanation must be sought for the appearance. We shall consider this subject again when dealing with changes in the walls of the vessels (*see* page 160).

Albuminuric retinitis usually occurs only at a late stage of chronic renal disease; its presence may, therefore, be taken to warrant a serious prognosis with regard to length of life. This view has been confirmed by statistics. Stedman Bull² found that, out of a total of 104 cases of albuminuric retinitis, no fewer than 85 died within two years of the discovery of the retinal changes; while, of the remaining 19, only 4 were under observa-

¹ *Trans. Ophth. Soc.*, vol. xii., p. 124.

² *Trans. Am. Ophth. Soc.*, 1886, p. 184.

tion for more than a year. Miley¹ took infinite pains to trace the career of all the patients who were treated in the London Hospital for acute and chronic renal disease (exclusive of acute scarlatinal cases) in the years 1884-5-6. The results are in accord with Dr. Bull's, but they have the advantage of enabling a comparison to be made between the renal cases with retinal complication and those without it, and show that the prognosis in the former is much more serious than in the latter.

It is doubtful how far these statistics, compiled from hospital patients, are applicable to those in easier circumstances. Renal disease is an affection which, above all others, is aggravated by exposure and want of care. Its deleterious consequences may be long delayed, on the other hand, by care as to diet and clothing, choice of climate, vigilant regulation of the excretory functions, and that attention to the thousand-and-one details of hygiene and comfort, which is possible only in the case of the well-to-do.

Although, however, the actual duration of life may be greater in private patients, it cannot be doubted that albuminuric retinitis is even in them a grave factor in the prognosis.

The prognosis, with regard to sight, depends chiefly upon the tendency to hæmorrhage and the existence of degenerative changes at the macula. There is always considerable liability to retinal hæmorrhage in all cases, owing to the pathological state of the capillaries already described, but cases differ much in this respect. Extensive changes of a degenerative character in the region of the macula preclude the recovery of useful vision, and even inflammatory exudation there, if at all abundant, is usually followed by permanent impairment. The disease is progressive, but its course is so chronic that, unless intercurrent attacks of hæmorrhage take place, the deterioration in the vision is often not much noticed by the patient.

Uræmic amblyopia may occur independently of any retinal

¹ *Trans. Ophth. Soc.*, vol. viii., p. 132.

changes, and cause sudden and complete blindness. In such cases the pupils are usually dilated, and their reaction to light sometimes persists, even though perception of light may be entirely lost. Rapid and complete recovery follows the elimination of the poison.

Retinitis resulting from the albuminuria of pregnancy differs from that due to chronic renal disease. The retinal changes are of the typical acute form, very large white areas being common. There is, consequently, considerable impairment of sight. In spite of this, and of the extensive retinal changes, complete recovery of vision may take place if the pregnancy terminate before the retinal tissue has undergone degeneration. It must, however, be remembered that the retinitis is likely to recur with each succeeding pregnancy.

Retinitis occasionally results from acute scarlatinal nephritis. These cases are analogous to the preceding as regards the character of the retinal disease; the prognosis is probably less hopeful, but they are not sufficiently frequent to permit a positive statement on the subject.

DIABETIC RETINITIS.

Diabetes is undoubtedly a cause of inflammation of the retina. The appearances presented by diabetic retinitis have been described in great detail by many authors.¹ Unfortunately, the descriptions differ much from each other, while they all contain points of resemblance to the chronic form of albuminuric retinitis. It would seem, therefore, that there are no ophthalmoscopic signs which enable us to discriminate with certainty between albuminuric and diabetic retinitis.

The cases in which new vessels are formed in the vitreous in diabetic patients will be mentioned later on.

¹ For a summary of the views of various authors on this subject see Oscar Dodd (*Arch. Ophthalm. and Otol.*, N. Y., vol. xxiv., p. 206).

LEUCOCYTHÆMIC RETINITIS.

Leucocythæmic retinitis is so closely associated with the condition of the blood, and is accompanied by such marked changes in the appearance of the retinal vessels, that its consideration may be conveniently postponed till we come to discuss affections of the vascular system of the retina.

RETINITIS CIRCINATA.

Among the rarer forms of inflammation is that to which the name of Retinitis Circinata has been given by Professor Fuchs.¹

The characteristic feature of the condition is the presence of a belt of white dots (or a white surface formed by their coalescence) surrounding the macula, and enclosing an oval area of considerable size; the white belt usually reaches nearly to the upper and lower temporal vessels. Its width varies, but it seldom exceeds half the diameter of the disc, and it may be broken at several points. Changes at the macula itself are also present.

The band is made up of small white dots of irregular shape; these tend to run together, and thus form larger white patches lying in contact. The retinal vessels pass over their surface unchanged.

Nothing is known of the morbid anatomy of the affection, which occurs in persons who are well past middle life, and does not appear to depend upon any recognised general disease. It runs a very chronic course, the appearances changing but little in the course of years.

PLASTIC RETINITIS AND CICATRICIAL CHANGES.

There are some forms of retinitis in which the inflammatory exudation becomes organised and converted into strands of con-

¹ For further details the reader should consult Professor Fuch's original paper (*Arch. f. Ophth.*, Leipzig, vol. xxxix., p. 229), and Holmes Spicer (*Trans. Ophth. Soc.*, vol. xiv., p. 132).

nective tissue. In this manner may be explained some of the tightly stretched bands, or irregularly shaped white membranes with well-defined hard edges, which are sometimes seen on the retina. An example of the latter is shown in Plate XXV., Fig. 59, and of the former in Plate XLV., Fig. 99. These changes may conveniently be grouped under the term cicatricial, since they are probably produced by the contraction of new-formed fibrous tissue. But they may be due to a variety of causes, and it is not always possible to be certain whether the visible changes really lie in the retina or in the choroid. The changes at the macula, following inflammatory exudation (Plate XXIV., Fig. 57), are also probably cicatricial, but are not included in this section.

The condition depicted in Plate XLV., Fig. 99, is characterised by the presence of white bands radiating from the disc, which have the appearance of being tightly stretched. Some of the bands at their peripheral extremities spread out fan-wise, as if they had originally been broader, and had shrunk to their present dimensions. As, however, they lie beneath the retinal vessels, it is difficult to conceive of any great shrinking having occurred, since the vessels show no evidence of being displaced. In the case from which this drawing was made there was a history of syphilis, and it is probable that all these cases are due to this disease. The term *retinitis proliferans* would have been appropriate had it not been applied by Manz and others to a totally different condition, in which membranous exudations are formed in front of the retina.

A somewhat similar appearance, as far as the direction of the bands is concerned, is now and again seen in progressive myopia. In such cases the lines are not so conspicuous, as they have not such a brilliant whiteness, as in Plate XLV., Fig. 99, but are more like those in Plate XXXII., Fig. 70. They are usually most conspicuous between the disc and the macula, but they do not extend far towards the periphery. It is difficult to determine whether they are situated in the retina or in the choroid, but in either case they

probably result from the traction on the tunics. They have sometimes been described as cracks or tears in the choroid, but they differ so essentially from the ruptures of the choroid with which we are familiar, that it is difficult to believe that they are of this nature. Their appearance is sometimes suggestive of ridges in the retina, but the lack of any evidence that they are raised above the level of the rest of the retina makes the acceptance of this explanation equally difficult. It seems more probable that along the lines of greatest traction the fibrous elements of the retina become hypertrophied at the expense of its nervous tissue, and that the resulting bands are analogous to cicatricial tissue.

The more membranous form of cicatricial change shown in Plate XXV., Fig. 59, has already been referred to as a retinal complication of advanced choroiditis. Here an irregular glistening white patch is formed. In the case depicted it is seen to occupy a large area, and to present numerous round or oval openings, while the border of the patch presents deep concavities or bays, with hard sharp edges. This appearance of the border, and the presence of circular openings, afford a means of distinguishing such a patch from an area of exposed sclerotic, which it occasionally resembles in colour.

These membranous patches in the retina are usually the result of old choroiditis. The retina becomes adherent to the choroid over the affected area, inflammatory exudation takes place from the choroid into the retina, and the resulting opacity is partly inflammatory and partly cicatricial.

It is not often that there is any difficulty in distinguishing between an area of exposed sclerotic and connective tissue in the retina. The difference in the shape of the patch in the two conditions has already been mentioned. The area of choroidal atrophy is usually bordered by pigment, and the pearly whiteness of exposed sclerotic is sufficiently characteristic.

The condition which has been described by Manz¹ under the

¹ *Arch. f. Ophth.*, Leipzig, bd. xxii., p. 229; and bd. xxvi., p. 55.

name of retinitis proliferans differs from that which I have called plastic retinitis in that the membranous formations which constitute the typical ophthalmoscopic appearance of the affection lie entirely in front of the retina.

The membranous opacities may arch over the disc in a tent-like manner, and so conceal it wholly or in part. They have the appearance of being tightly stretched, as if they had undergone contraction, and are brilliant white in colour. Towards the periphery they either spread out fan-wise or divide into processes which are attached to the fundus. In other cases the opacity appears to have a preference for following the course of the vessels, lying, however, well in front of them.

When there are, at the same time, opacities in the vitreous, obscuring the view, the condition might be mistaken for detachment of the retina ; but the mistake could hardly occur if a good view were obtained, as the tightly stretched look of the opacity in retinitis proliferans is very different from the soft wavy appearance of a detachment.

Analogous to these cases, and possibly of the same nature, are those in which brilliant, glistening white bands stretch tightly across the vitreous from one part of the fundus to another. Many of them widen out fan-wise towards their attachment, so that they present the appearance of having become narrowed in the middle by contraction. Sometimes vessels can be traced some distance into the bands.

The pathology of retinitis proliferans is at present obscure. That it is due to direct inflammatory exudation from the retina, as implied by its name, is hardly consistent with the ophthalmoscopic appearance, for wherever there are gaps in the membrane, the fundus appears normal, or nearly so. It is true that in Manz's cases changes were found in the retina on microscopical examination, but there was no evidence of their direct connection with the membranous opacity.

Dr. S. Schultze¹ has given good reasons for believing that this condition is always the result of hæmorrhage into the vitreous. In most of the published cases there is a history of sudden loss of sight some years previously, and in Schultze's two patients this was known to have been due to this cause.

¹ *Arch. f. Augenh.*, Wiesb., bd. xxv.

CHAPTER IX.

OPTIC ATROPHY.

ATROPHY of the optic nerve may depend upon a variety of causes. It may be conveniently considered under the following heads, *viz.*:—(1) Post-Neuritic Atrophy; (2) Simple Atrophy; (3) Hereditary Optic Atrophy; and (4) Secondary Atrophy. Lastly, Simple Glaucoma will be included.

POST-NEURITIC ATROPHY.

We saw at the conclusion of Chapter VII. that papillitis may result in a partial atrophy of the disc which may remain stationary. The atrophy in other cases is progressive, and the prognosis is then exceedingly grave, as complete blindness is the usual result. Increasing pallor of the disc, if accompanied by progressive impairment of vision, is a sure indication that the nerve is degenerating. While the pallor of the disc is increasing its margin becomes clearer, generally first on the temporal side (Plate XXXII., Fig. 72). When the atrophy is complete, the disc will present a dead white colour, the physiological cup will be filled up, and the margin, though clearly visible, does not usually present the hard line characteristic of simple atrophy (Plate XXXII., Fig. 71).

The foregoing signs of post-neuritic atrophy are illustrated in Plate XXXII., Fig. 72. The atrophy in this case is not complete, being more advanced in the outer part of the disc, which is here of the typical uniform white colour. The corresponding part of the disc margin is distinct. The inner half of the disc still shows by its blurred outline the presence of

neuritis. We may contrast with this Plate XXXII., Fig. 73, which is an example of simple atrophy—that is, atrophy not preceded by neuritis. The disc margin is here abnormally hard and sharp, and presents no irregularities. The surface of the disc is not of the dead white uniform colour, but is bluish or greyish, and is somewhat mottled from the lamina cribrosa being seen through the abnormally transparent and wasted tissue. This mottling is often much more pronounced than in this instance.

This form of atrophy will be considered more fully presently.

The following table may serve to emphasise the main points of distinction between the post-neuritic and simple forms of atrophy :—

| | <i>Post-neuritic Atrophy.</i> | <i>Simple Atrophy.</i> |
|-----------------|------------------------------------------------------------------------------|----------------------------------------------------------------|
| COLOUR OF DISC, | Uniform. Dead white. | Stippled. Bluish or greyish white. |
| SURFACE „ | Flat. Physiological cup usually filled in. | May be very slightly concave. Physiological cup not filled in. |
| MARGIN „ | Not more distinct than normal. May be blurred in places. Is often irregular. | Much more distinct than normal. Not irregular. |
| LARGER VESSELS, | Diminished in size. Accompanied in places by white lines. | Normal. |

Simple atrophy never simulates the post-neuritic, but the latter in an advanced stage may exactly resemble simple atrophy. This is owing to the products of inflammation being entirely removed so that the tissue of the nerve head again becomes transparent, and allows the lamina cribrosa to show through. This explains the colour of the disc in Plate XXXII., Fig. 71, which is like that of simple atrophy; although from the history

of the case, the small size of the arteries, and the white lines accompanying them, it is certain that the condition was post-neuritic.

The atrophic changes consecutive to neuritis are not always limited to the disc. In some cases they invade the adjacent choroid, so that the disc is encircled by a ring of choroidal atrophy. In others the pigment layer of the retina becomes extensively atrophied, as seen in Plate XXIV., Fig. 57, and Plate XXXII., Fig. 71.

SIMPLE ATROPHY.

This is sometimes called primary atrophy, but the term is open to the objection that in the cases intended to be indicated by it, the atrophy is, in reality, always secondary to, and a direct extension of, atrophic changes in the trunk of the optic nerve. If employed, therefore, it must only be as a contrast to post-neuritic atrophy, and not as implying that the head of the optic nerve is the primary seat of disease.

There is a variety of optic atrophy, intermediate between these, which would, without hesitation, be classed under simple atrophy, were it not for the circumstance that in the early stage there is some evidence of neuritis, as shown by a slight and temporary blurring of the disc margin. This slight neuritis is a concomitant affection, and evidently not the cause of the atrophy, and the cases would therefore be correctly classified under simple atrophy. Some cases of hereditary optic atrophy afford examples of this condition.

I do not purpose discussing at all fully the various conditions which may lead to optic atrophy, but only to direct attention to those which are most common or best known.

The most typical examples of descending atrophy are furnished by cases in which the conductivity of the optic nerve is completely destroyed by an injury at some spot between the optic com-

missure and the point of entry into the nerve of the central vessels. Immediate and total blindness of the corresponding eye results, but no visible change occurs in the disc till about three weeks later, the exact date depending on the seat of the lesion, and possibly varying also, but to a less degree, in different individuals. Progressive pallor of the disc, without alteration in the size of the vessels then appears, and it increases till the disc assumes the appearance characteristic of complete simple atrophy. The injury in these cases may be either a penetrating wound of the orbit, or a blow on the head, usually in the frontal region.

When, on the other hand, the lesion affects a part of the nerve that contains the central vessels, conspicuous changes immediately make their appearance in the fundus. The most marked of these are diminution in the size of the arteries and extensive hæmorrhages. The fundus presenting an appearance resembling that caused by thrombosis of the central vein.

The gravity of the injury in punctured wounds of the orbit is often overlooked, owing to the external opening being small. In these cases it is not uncommon for other orbital nerves to be injured at the same time. Optic atrophy following severe blows has in former times been classed as reflex amblyopia; but there can be little doubt that the lesion which destroys vision is a fracture passing across the optic foramen. Holder¹ has shown that this foramen is implicated in 60 per cent. of fractures of the skull.

Periosteal thickening from rheumatism or syphilis may bring about the same result more gradually. In such cases the more diffuse character of the lesion, as compared with that due to injury, is likely to lead to simultaneous implication of the nerves passing through the sphenoidal fissure.

Pressure on the optic commissure may cause simple atrophy in both eyes, bi-temporal hemianopsia accompanying the

¹ Quoted by Snell, *Trans. Ophth. Soc.*, vol. xi., p. 136.

failure of vision. Distension of the third ventricle in internal hydrocephalus is said by Gowers frequently to act in this manner. The loss of sight that occurs in acromegaly is believed to be due to pressure exerted on the commissure by the enlarged pituitary body.

Sclerosis of the spinal cord or brain is not unfrequently accompanied by similar changes in the optic nerves, which cause impairment of vision, and, later on, atrophy of the discs.

The particular form of optic atrophy which most frequently comes under the notice of the ophthalmic surgeon is that resulting from posterior sclerosis (locomotor ataxy). This would seem to be due not so much to the relative frequency of dorsal, as compared with other forms of sclerosis, as to the fact that in it vision is affected early, before the general symptoms have led the patient to seek the aid of the physician.

It is obvious that the relative frequency of the various forms of disease of the nervous system as causes of optic atrophy, must be ascertained from general, and not from ophthalmic, clinics. A statistical inquiry in this direction by Uhthoff¹ showed that optic atrophy occurred in 45 per cent. of cases of disseminated sclerosis, in 18 per cent. of locomotor ataxy, and in 7 per cent. of general paralysis.

Disseminated sclerosis being such a frequent cause of optic atrophy, it becomes important to follow Uhthoff's conclusions a little further, the more so as the symptoms in many cases closely resemble those of tobacco amblyopia.

A marked feature is the want of correspondence between the ophthalmoscopic changes and the vision. Thus, out of 100 cases (excluding 7 in which there were opacities of the media), there was pronounced optic atrophy in 3; in all these vision was bad. Thirty-seven cases showed various degrees of pallor of the disc; vision was affected in 23 of these, but unaffected in the other 14.

¹ "Die bei multiplen Herdsklerose vorkommenden Augenstörungen," 1889. (A good abstract in *Ophth. Rev.*, London, vol. ix., p. 1.)

Optic neuritis was present in 5 cases; vision being affected in 4, and unaffected in 1. The ophthalmoscopic appearances were normal in 48, only 5 of these had bad vision, while in the remaining 43 it was unaffected.

As to the visual field, a central scotoma (without any general limitation) was the most common condition found. This observation is important, inasmuch as the existence of a central scotoma in a smoker might easily lead to a diagnosis of tobacco amblyopia—a mistake the more likely to occur if (as sometimes happens in disseminated sclerosis) the ocular should precede the general symptoms by a considerable interval of time. For many other interesting points, we must refer the reader to Dr. Uthoff's original paper.

The ophthalmoscopic appearance characteristic of simple atrophy is progressive pallor of the disc. This depends chiefly upon diminution of the capillary circulation, but it is possibly aided by increased transparency of the nerve tissue. When the atrophy is advanced (Plate XXXII., Fig. 73), the diagnosis is easy. The disc margin is hard and sharp, the surface is white, tinged with grey or blue, slightly mottled from the openings of the lamina cribrosa showing through, and is often slightly concave. In rare cases the disc has a greenish hue. In an early stage it is often difficult to decide whether a slight degree of pallor is really pathological, owing to wide differences in colour that normal eyes present. Since the nerve fibres form a thinner layer on the outer than on the inner side, pallor confined to the outer half of the disc must not be diagnosed too hastily as pathological. Pallor of the inner half is a safer guide, although even there we may be misled by a congenital condition. In cases of doubt the disc should always be examined by a feeble illumination. Sometimes a disc, which under a strong light appears quite white, will then be seen to have a distinct rose-tint.

The diagnosis will be materially assisted by taking into consideration other points besides the ophthalmoscopic appear-

ance, such as the visual acuity and the field of vision. Physiological pallor is usually equally marked in both eyes; it is seldom, on the other hand, that early atrophic changes are equally advanced in the two eyes. If different degrees of pallor on the two sides coincide with a difference in vision, there can be no room for doubt. If the diagnosis cannot be made at the first examination, the subsequent progress of the case will usually reveal its nature.

The larger vessels on the disc as a rule retain their normal size, even when simple atrophy is fully developed, although they are sometimes slightly diminished in cases of old standing; in post-neuritic atrophy, on the other hand, the vessels are commonly reduced in size. The smaller vessels, however, disappear in all forms of advanced atrophy.

HEREDITARY OPTIC ATROPHY.

This is an occasional cause of partial blindness in young adults. It attacks several members of a family at the age of puberty, and a history can often be obtained that others of a previous generation have been similarly affected. The disease shows a decided preference for males, although the females are sometimes affected. Like other hereditary affections, it may be transmitted through unaffected females to their offspring.

The failure of vision is more rapid in its onset than in other forms of atrophy. The patient notices a foggy appearance before his eyes, which increases in intensity, so that in the course of a few weeks vision may be reduced to counting fingers. There succeeds a more gradual deterioration, which usually progresses for some months, and then ceases before total blindness is reached. In the early stage a central scotoma is usually present, without any general limitation of the visual fields. There may be considerable failure of vision before any change is visible with the ophthalmoscope. Then progressive pallor of the disc makes its appearance. This

may be preceded by slight haziness of the disc margin, and hyperæmia, and, in exceptional cases, by typical papillitis.

Nothing is definitely known as to the cause of the affection. The fact that males alone are affected, and that the onset of the symptoms coincides with the maturing of the sexual functions, may perhaps indicate that the latter stand in some causal relation to the disease. A history of sexual excesses can indeed sometimes be obtained. It is probable, however, that while any marked disturbance in the balance of the nervous system may determine the onset of the atrophy in cases where the hereditary predisposition exists, similar causes would be inoperative in a healthy individual.

Hereditary optic atrophy was first described by Leber,¹ and, more recently, Habershon² has given an admirable *resumé* of all that is known of the disease.

The history of a family in which blindness appeared in six generations has been published by G. M. Gould.³ The main facts are as follows:—

The males alone were affected, but the unaffected females transmitted the tendency to their male offspring.

A feature in the family history was the high infant mortality. For example, in the third generation there were two families descended from female members. The one consisted of 7 males, and 1 female (who transmitted the tendency). Of the males 4 died before the age of a year, the remaining 3 developed optic atrophy at the ages of 23, 28, and 33 respectively. The other family comprised 4 males; 1 died in infancy, the others developed atrophy at the ages of 34, 28, and 23 respectively.

This infant mortality is also noticeable in the family of a case which was under the writer's care. I am indebted to Mr. Menteith Ogilvie⁴ for the details of the family history. In neither instance could the infantile deaths or the miscarriages be attributed to inherited syphilis.

¹ *Archiv. f. Opth.*, Leipzig, bd. xvii., 1871, p. 249.

² *Trans. Opth. Soc.*, vol. viii., 1888, p. 190.

³ "Ann. Opth. Otol.," 1893.

⁴ Read before the Ophthalmological Society, January 30, 1896.

The patient (Allen J.) developed optic atrophy at the age of 22. His failure of vision was accompanied by severe headache, and preceded any pallor of the discs by some months. Eventually both discs became atrophied.

The patient's mother had 16 pregnancies. Two resulted in miscarriages at 4 months. Of the 14 children born alive, 8 died before the age of 16 months. Of the remaining 6, 3 were females. The 3 males became affected with optic atrophy at the ages of 15, 22, and 25 respectively.

Another peculiarity which could have no connection with the atrophy, and was common to all the members of the family who were examined, was unusual tortuosity of the retinal vessels. These are shown in Fig. 14, p. 51.

SECONDARY ATROPHY.

Degenerative changes, secondary to a similar condition of the retina, may take place in the optic disc. Atrophy of the tissue of the retina occurs, as we have seen, in retinitis pigmentosa, and in advanced choroiditis. It also follows embolism of the central artery, but these cases are not included in this section.

The atrophy which is secondary to retinal degeneration, produces an appearance which differs both from simple and from post-neuritic atrophy. The disc is not white, but yellowish. It is generally described as waxy, but the colour is rather that of dirty parchment. Moreover, its surface has a flat uniform appearance, and not unfrequently it is surrounded by a narrow halo of choroidal atrophy. The vessels are always diminished in size.

The condition is difficult to depict, but it is shown to some extent in Plate XXVIII., Fig. 62, Plate XLII., Fig. 94, Plate XLIII., Fig. 96, Plate XLIV., Fig. 97, and Plate XLV., Fig. 98. Probably the appearance is due to the nerve tissue becoming atrophied without there being at the same time any great diminution of its capillary circulation.

Gowers¹ is of opinion that waxy atrophy occurring in a young subject, and not associated with retinitis pigmentosa, is strong evidence of congenital syphilis.

¹ "Medical Ophthalmoscopy."

SIMPLE GLAUCOMA.

Non-inflammatory, or, as it is called, simple glaucoma, produces, in addition to the characteristic cupping of the disc, a considerable degree of atrophy. The ophthalmoscopic appearance met with in that disease may, therefore, be considered in this place.

It must, however, be remembered that glaucoma is not primarily an affection of the optic disc. The essential feature of the disease is a disturbance of the balance between secretion and excretion of




FIG. 40.—Glaucomatous cup.

the intraocular fluid. The increase in the intraocular pressure thus caused, if of sudden onset, and of considerable degree, so impedes the circulation, that the media become turbid, and inflammatory or congestive conditions supervene—*acute*, *subacute*, or *inflammatory glaucoma*. The disease may then drift into the chronic stage, but until this occurs the appearances of the disc, which are typical of glaucoma, are not seen.

When, on the other hand, the increase of pressure is slight, but long continued, the media remain clear, no congestive or inflam-

matory symptoms are present, and we get the characteristic cupping of the disc—*simple*, or *chronic glaucoma*.

It would be beyond the scope of this work to discuss the causes of simple glaucoma, and we may pass at once to the consideration of its ophthalmoscopic appearances. These are depicted in Plate XLVII., Figs. 105, 106, and 107. The most conspicuous change is a pushing back, as it were, of the whole disc surface, while the atrophy of the nerve tissue causes the edge of the disc to be seen as a hard line, and the lamina cribrosa to become visible.

The cupping is shown in the illustrations by the abrupt curves made by the vessels at the margin of the disc. With the ophthalmoscope it is also shown by the parallax movement of the floor of the cup when the ophthalmoscope is moved in the vertical plane, and by the fact that a concave lens is required to focus the floor. The strength of the lens required also gives the depth of the cup, each dioptré of refraction corresponding to 0.3 of a millimetre of depth. It will be noted in all the illustrations that the cupping involves the whole disc. This is a characteristic feature of the fully-formed glaucoma cup, and affords a contrast to the physiological cup, which never involves the whole disc.

The cupping is produced by the long continued action of a pressure, which may not be very greatly above the normal. The opening for the optic nerve yields, because it is a weak spot in the outer tunic, and the lamina cribrosa is pushed back, while at the same time the nerve tissue in front of it becomes atrophied. Since the edge of the sclerotic coincides with the smallest part of the nerve, it often forms a sharp overhanging edge. (Fig. 40, page 156.)

As a rule, the retinal vessels are pushed back and follow the outline of the cup. Occasionally, however, as in Plate XLVII., Figs. 106 and 107, the veins, but not the arteries, are depressed. A frequent, but not constant, accompaniment of the glaucoma cup, is a ring, or halo, of atrophied choroid round the disc; this is present in all three figures.

CHAPTER X.

AFFECTIONS OF THE VASCULAR SYSTEM OF RETINA.

WITH the ophthalmoscope we view a terminal artery and vein under a magnifying power of about fifteen diameters, and actually see fluid circulating within them. Similar conditions exist nowhere else in the body. Observation of changes in the vascular system of the retina has therefore an important bearing on general pathology. On the one hand, abnormal conditions of the blood may cause impediment to the circulation, or changes in the tissues, which, although they may be widely distributed throughout the system, can be recognised in an early stage and with precision only in the retina. On the other hand, widespread vascular degeneration may first manifest itself by changes in the retinal blood vessels.

Although conditions of the vascular system in general may often be diagnosed with the ophthalmoscope, changes in the cerebral circulation are not registered on the fundus with that rapidity and precision which was at one time believed, and which might perhaps have been expected from the intimate anatomical connection between the vessels of the brain and the retina.

In the first place, as already pointed out, slight degrees of anæmia or congestion of the disc are not easy of recognition, owing to the great individual differences in the tint of the disc. In the second place, the intraocular tension, acting like the air chamber of a fire engine, tends to keep the circulation uniform, and to prevent slight differences in the blood pressure from effecting marked changes in the retinal circulation.

Obstruction to the return of venous blood from the retina

produces, as we shall see, marked ophthalmoscopic changes, but total occlusion of the cavernous sinus, into which in the normal condition that blood flows, may exist without any fundus changes, owing to the free anastomosis between the orbital and facial veins.

The following are among the chief ophthalmoscopic appearances which are due, more or less directly, to changes in the retinal circulation:—Alterations in the width of the blood column, in the shape of the vessel, in the breadth and brilliancy of the light-streak, or changes in the colour of the blood. The walls of the vessels, or the perivascular sheaths, may be abnormally visible, or even completely opaque. There may be hæmorrhages into the retina, from which may be inferred increased blood pressure, changes in the constitution of the blood, or disease of the vessel walls. Lastly, there may be the group of symptoms associated with the blocking of one of the main retinal vessels.

Some of the above conditions are due to local, others to general or distant causes, and their value as a means of diagnosis will be better appreciated when we have considered in more detail the circumstances under which they occur.

Under ordinary conditions the walls of the retinal vessels cannot be seen with the ophthalmoscope. The width of the visible blood column is usually assumed to indicate the diameter of the invisible vessel. In the normal condition of the vessels this is sufficiently accurate, because the walls are extremely thin. But in some morbid states the vessel walls are thickened, and so opaque that they hide the blood stream wholly or in part; under such circumstances the width of the blood column may afford no indication whatever as to the diameter of the vessel.

Changes in the wall may be present without loss of transparency. In retinitis pigmentosa, a hyaline thickening occurs which encroaches on the lumen of the vessel, so that the blood stream may appear with the ophthalmoscope as a mere thread,

although the external diameter of the vessels, when measured by the microscope may be unaltered.

In hereditary syphilis a similar condition of the retinal vessels is met with.¹ The thickening affects chiefly the inner coat; a deposit of hyaline transparent substance is formed which, gradually narrowing the lumen of the vessel, may lead to its complete obliteration. In a later stage the resemblance to retinitis pigmentosa is still greater, owing to the retina undergoing extensive fibroid degeneration, and its superficial layers becoming pigmented.

In chronic Bright's disease, an analogous vascular change is found,² but here the thickening occurs chiefly in the outer coat, so that the lumen of the vessel is not encroached upon. It is said that this condition of the vessels is commonly found with the microscope in Bright's disease, even when no ophthalmoscopic signs have been present during life. A similar condition occurs in the capillaries, so that they stand rigidly open on section. The absence of any marked ophthalmoscopic evidence of vascular change is due to the fact that the deposited material, being transparent, is invisible, and, as the lumen of the vessel is not encroached upon, the width of the blood column is unaltered.

Careful examination, however, will often reveal the presence of this hyaline thickening, at the point where one vessel crosses another (Plate XXXVI., Fig. 80, and Plate XXXVII., Fig. 84). It will be seen that the more superficial vessel appears to pass through, but not to fill, a gap in the deeper vessel. In fact, the appearance is as though the vein were entirely broken through, an illusion that is rendered the more complete by the vessel at each side appearing darker at the point where it stops short. The apparent gap is, no doubt, filled by the thickened artery, which, being transparent, is invisible. The thickening of the artery,

¹ Holmes Spicer, *Trans. Ophth. Soc.*, vol. xii., p. 116; Brailey & Edmunds, *Ophth. Hosp. Rep.*, London, vol. x.

² Brailey & Edmunds, *Trans. Ophth. Soc.*, vol. i., p. 44.

moreover, pushes the veins more deeply into the retina, and the bending thus produced causes the dark colour, owing to the vessel being seen at this point more or less "end-on" (Fig. 41).

The only difficulty in accepting this explanation is, that it would appear at first sight that the vein should be visible through the transparent wall of the artery, but the greater depth of the vein, and the highly refracting nature of the hyaline substance, probably prevent this. It has been suggested that the thickened artery actually impedes the venous current at the point of crossing; this seems highly improbable, as there is no distension of the vein on the distal side, and none of the other effects of venous obstruction, such as hæmorrhage and œdema.

Another result of this hyaline thickening is that the light streak becomes broader and extends further along the arteries.

So far we have been dealing with thickening of the vessel wall by a transparent substance, but the thickening may be accompanied by opacity. For example, in a late stage of albuminuric retinitis, degenerative changes occur in the walls of the vessels which render them completely opaque, so that the blood column is hidden from view, and the vessel is seen as a white riband (Plate XL., Fig. 90). It is often impossible to be sure whether the appearance is due to change in the wall of the vessel or in the perivascular sheath. In the latter case, however, the band is wider, while its margins are less regular.

We have seen that perivasculitis (as it is awkwardly called) is sometimes associated with neuritis. It may, however, occur

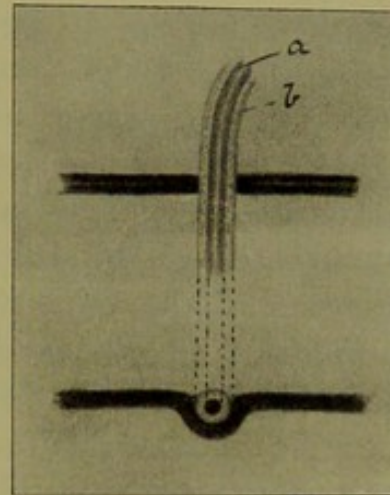


FIG. 41.—Diagram to explain apparent break in a vein where crossed by an artery.

a, Visible blood column; *b*, invisible hyaline substance. The upper figure shows the surface of the retina. The lower represents an imaginary vertical section at the point of crossing.

independently of that condition. Mules¹ has described and depicted a case of advanced renal disease, in which all the retinal arteries were converted into white bands, and he refers to other published cases of the condition. In some instances the amount of deposit so greatly increases the diameter of the vessels, that, as they approach the disc, the bands of exudation merge. The disc may then appear to be covered by an irregular membranous opacity, from which processes stretch out along the vessels. These extreme cases appear to be generally of syphilitic origin.²

Apart from changes in the vascular wall, or perivascular sheath, real alterations in the calibre of the vessels may be met with. The distension of the veins which occurs in neuritis has been already considered. Enormous distension also occurs in leucocythæmia (Plate XXXIII., Fig. 74). It must be remembered that sometimes the veins are flattened out by the intraocular pressure, and therefore appear to be dilated. In such cases, the light streak is either broad and indistinct, or it is absent.

Real diminution in the size of the arteries occurs in advanced atrophy of the retina, and when they are badly filled, as in partial occlusion by an embolus.

Aneurism of the retinal arteries is so uncommon that it may be looked upon as an ophthalmoscopic curiosity. Both the fusiform and the sacculated variety have, however, occasionally been seen. Story & Benson have recorded a case³ in which both these conditions were present in the same eye. Most of the aneurisms formed globular swellings on the vessel wall. The case was one of retinitis, with "considerable fibrous proliferation and perivasculitis," and the aneurismal dilatations were probably due to degenerative changes occurring in the vessel wall, in consequence of the retinitis.

¹ *Trans. Ophth. Soc.*, vol. ii., p. 47.

² Meyer, "Altérations des parois vasculaires," *Rev. gén. d'ophth.*, Paris, 1892.

³ *Trans. Ophth. Soc.*, vol. vi., p. 111; *ibid.*, vol. iii., p. 108; *ibid.*, vol. vi., p. 336.

NEW VESSELS IN THE VITREOUS.

In rare instances new vessels are developed from the retinal system, and project into the vitreous. These, for the most part, come from the disc and are very fine and convoluted. After coming forwards a certain distance into the vitreous, the majority form loops and return to the disc. Irregular swellings sometimes exist at the summit of the loops, many of which can be seen to consist of closely packed spiral turns of the vessel, while in others the shape of the swelling suggests that they are so formed, although the separate turns of the spiral cannot be distinguished (*see* Plate XL., Fig. 91). Sometimes a more open spiral, like the tendril of a vine, is met with in a vessel running an otherwise straight course. The new vessels may be few in number, and apparently unconnected with each other; they may be arranged in a long leash of almost parallel vessels; or they may form a flat-looking vascular web, resembling the mesentery of a frog, but devoid of any visible supporting tissue. It is probable, however, that in the latter case a transparent framework really exists,—indeed, in some instances, this has become opaque and visible at a later stage. Although the new vessels generally spring from the disc and form loops, they have been known to come from the periphery of the fundus, and to end in the vitreous in free extremities (*see* case by Coccius).

Comparatively few examples of this condition have been published, it would therefore be rash to form any conclusion as to its cause. It may, however, be noted that diabetes was discovered in many patients, while its existence was not excluded in several others. In my own case the urine contained albumen, but no sugar. Syphilis was present in a large proportion of the patients. In several instances there had been hæmorrhage into the vitreous. It is probable that some morbid condition of the vitreous necessarily precedes the formation of the new vessels.

Appended are short abstracts of the cases which have been recorded :—

COCCHIUS (quoted in Zander, "On the Ophthalmoscope").—Punctiform opacities throughout vitreous. Retinal veins remarkably tortuous. Numerous vessels coming forward into vitreous. Some arising from the retinal vessels, others from the disc. Some of the vessels ended anteriorly as white threads, others formed loops.

JAEGER ("Hand-Atlas," Fig. 72).—Male 27, two years before visit, temporary failure of V. with chromatopsia after violent headache (migraine?). Similar attack seven months later, and again eight months after this; a month before visit, a similar failure without pain in head, followed by only partial recovery.

When seen, slight turbidity of vitreous chiefly near disc. Fine vessels springing from disc, and spreading in various directions into posterior third of vitreous. Most formed loops, having closely packed spiral turns at summit. Some of the vessels changed into white cords, and eventually all disappeared, the fundus presenting a normal appearance in four months.

NORRIS (*Trans. Am. Ophth. Soc.*, 1879, p. 547).—Female. No history of syphilis. Flocculi in vitreous. New vessels coming forward into vitreous, and forming loops, the summits of which were visible with 7 D.

CHARNLEY and FOX (*Ophth. Hosp. Rep.*, London, vol. x., 1881, p. 193).—Girl, 19. No history of syphilis. Iritis both eyes, four months before visit. When seen *RE.* = $\frac{5}{00}$ keratitis punctata. Nearly complete posterior synechia. *LE.* keratitis punctata below. No synechia. New vessels in vitreous, media too turbid for accurate observation. After treatment with mercury, vitreous cleared. Springing from *OD.* a large vessel which passed straight into vitreous, and then curving upwards was lost near equator. A group of small vessels springing from centre of *OD.* passed into vitreous, most formed loops and returned to point of origin. An anterior extremity of loops, spiral coils. Five months later vessels had entirely disappeared, and V. normal.

CHARNLEY and FOX (*loc. cit.*).—Girl, aged 14. *RE.* had been operated on for internal strabismus. V. $\frac{2}{00}$, *cc.* in each eye. Ophthalmoscopic appearances not noted till three months later.

RE. margins of *OD.* hazy. Vessels enlarged and slightly tortuous. A figure shows a single fine vessel spring from *OD.* below its centre, one branch of this soon terminates in a fine loop, the other makes five spiral turns, and later on divides into three branches, each of which terminates in a loop. A similar vessel emerging from above the disc makes six spiral turns, and returns to its point of exit; a fine supporting framework of connective tissue supported this vessel. In the *YS.* region were traces of old choroiditis. After five months mercurial treatment, vitreous clearer, vessels smaller.

CHARNLEY and FOX (*loc. cit.*).—Woman, 51 (Mr. Fitzgerald's case). Seen April 1st, 1880.

RE. V. = $\frac{2}{00}$ clots in vitreous. No history of syphilis. No albumen in urine. Eight months later, vitreous slightly hazy. Below *OD.* a small greyish spot of connective tissue

on retina, from which springs a bunch of vessels upwards and forwards into vitreous. Some present free extremities, others form loops and return to point of origin. Spiral twists at summit of loops. The vessels float freely in vitreous. No detachment of retina. The vitreous subsequently became too hazy for ophthalmoscopic examination.

HIRSCHBERG (*Centralbl. f. prakt. Augenh.*, Leipzig, 1881, p. 48).—Woman, 23. There had been choroido-retinitis with blurring of *OD.*, and hæmorrhages in both eyes. On vitreous clearing, the vessels were seen.

HIRSCHBERG (*Centralbl. f. prakt. Augenh.*, Leipzig, 1883, p. 325).—Woman, 60. Failure of V. in both eyes, worse in *LE.*, in which punctate retinitis. In *RE.* vessels spring into vitreous from *OD.* in all directions, except up and in, most formed loops and returned to point of origin, swelling at summit of some of the loops. Urine examined for excess of urea without result. Albumen and sugar not mentioned.

NETTLESHIP (*Trans. Ophth. Soc.*, vol. iv., 1884, p. 150).—John K., 50. Seen August 1883. V. failing seven months; the *LE.* first. Had had choroiditis a year previously, followed by secondary symptoms.

LE. opacities in vitreous. Extensive detachment of retina.

RE. $\frac{2}{10}$ and 16 J., a posterior synechia below. Numerous webs in vitreous. A good many rounded hæmorrhages of rather small size on fundus, chiefly at upper periphery, also several dark ones, apparently in front of retina near *YS.* Two weeks later, a close meshwork of very small tortuous vessels on the outer side of disc, and another patch of vessels on inner side. No evidence of obliteration of any of the central vessels. Disc, pale and hazy. The vitreous became clearer, and on October 23rd drawing (reproduced) was made. There is a flat transparent vascular membrane attached to the outer border of *OD.*, and projecting straight forwards into the vitreous. Its vessels are looped and very numerous. One larger one forming its anterior free border. The top of the membrane visible with 4 D.

December 6th. Condition unaltered, except that the hæmorrhages have dispersed. Still some fine webs in vitreous. V. $\frac{2}{10}$, 14 J., barely, January 14th, 1884. The web was bent over to the nasal side.

February 21st. Two fresh growths of vessels have appeared in form of long narrow leashes, one passing up and out, the other inwards, from the upper part of the disc. The original membrane has bent over still more towards the nasal side of the disc. These conditions are shown in a second figure.

August 21st. V. $\frac{2}{10}$, 14 J. Fundus much as last note, but a good deal of white opacity (connective tissue?) about the bases of some of the vascular growths.

The veil-like growth at the disc has turned, so that it is now nearly horizontal, instead of vertical as before.

Communicated by Mr. ERNEST CLARKE.—A. B., 19, actress. First seen February 26th, 1887. History of syphilis. V. *RE.* = $\frac{6}{6}$.

LE. $\frac{6}{18}$. Vitreous very hazy from fine dust-like opacities. On the outer side of the *OD.* apparently spring from the central artery two vessels which came forward into the vitreous. Both were tortuous, the upper one being cork-screw shaped; they formed loops, the extremities of which moved about freely with the ocular movements. Under iodide of

potassium the vitreous cleared, and V. improved to $\frac{5}{8}$, but the vessels remained unchanged during the two months the patient was under observation.

CARMALT (*Trans. Am. Ophth. Soc.*, 1887, p. 545).—Case mentioned in which hæmorrhages into vitreous were followed by formation of vessels running from retina nearly to lens. They formed loops twined among each other.

THEOBALD (*Trans. Am. Ophth. Soc.*, 1887, p. 542).—Woman, 52. Repeated small hæmorrhages into retina near *OD.*, which was swollen; retinal veins distended. Later a globular hæmorrhage the size of the disc into vitreous. This disappeared, and V. became normal. A few weeks V. improved to normal. Then fresh hæmorrhages and brownish string-like opacities. V. again became normal. Then a reddish, nebulous floating opacity seen in front of *OD.*, which seemed a few weeks later to consist of a mass of blood vessels.

NETTLESHIP (*Trans. Ophth. Soc.*, vol. viii., 1888, p. 159).—Charles O., 48. Diabetes. Three to four years. V. began to fail about same time. No gout or syphilis. No albumen. When seen the *LE.* was blind from glaucoma, secondary to iritis. *RE.* Over whole central region retina œdematous and hazy; in some parts densely cloudy. Near *YS.* some densely opaque yellowish white masses of deposit. Retinal vessels considerably distended, and in various parts a few scattered blood spots. Close to fovea two or three vessels of medium size suddenly appear in retina, having every appearance of springing directly from choroid into retina. The largest, followed up and out, divides into a network of minute vessels, which project forward in the form of fine loops into vitreous, where the most prominent are seen with 6 *D.* On a few are small swellings, perhaps capillary aneurisms.

AUTHOR'S CASE (unpublished).—Woman, 54. First seen June, 1889. *LE.*, $\frac{2}{3}$. *RE.*, $\frac{6}{11}$. The failure of vision stated to be recent. There was hæmorrhage at the yellow spot. Urine pale, 1022. Trace of albumen. No sugar. Suffers from giddiness, headache, and œdema of feet. Patient lived at a distance, and was not seen again till November. Then vessels seen springing from disc, and extending into vitreous (Plate XL., Fig. 91). Later a gauze-like material became visible, accompanying the vessels, and soon afterwards the vitreous became opaque.

HIRSCHBERG (*Centralbl. f. prakt. Augenh.*, Leipzig, 1889, p. 8).—Man, 47. Had syphilis a year previously. Punctiform opacities in vitreous. A striated hæmorrhage in retina. Slight optic neuritis. Improved, but some months later V. became worse. A bluish mass of connective tissue seen on disc, hiding exit of vessels. Extending upwards and inwards $2\frac{1}{2}$ dd., a vascular web, resembling framework of a fly's wing, as seen under the microscope.

HARLAN (*Trans. Am. Ophth. Soc.*, 1889, p. 426).—Female, 50½. A year before visit an inflammatory attack in *LE.*, which recovered in three months.

Five months before visit, rapid or sudden failure of V. in *RE.* When seen, V. *RE.*, $\frac{3}{8}$, yellowish white spots on *YS.* region; remains of old hæmorrhages. Vitreous quite transparent. Vascular web springs from disc, and projecting into vitreous at an angle of 45°. The web appeared to consist of vessels only, no stroma being visible.

In *LE.* remains of hæmorrhage at *YS.*; vitreous hazy. Vessels springing into vitreous from *OD.*, but fewer. Urine, trace of albumen; no casts. One month and again four months

later, fresh hæmorrhages occurred. *RE.* without change in web. Eight months after visit vitreous hazy; slight keratitis punctata. Most of the vessels had disappeared; others reduced to dark lines. V. $\frac{2}{30}$.

J. HUTCHINSON, Jun. (*Ophth. Hosp. Rep.*, London, vol. xi., p. 191).—Thos. R., 28. Remains of optic neuritis in both eyes. *RE.* $\frac{2}{30}$, 19 J., *LE.* $\frac{2}{30}$, 16 J. There was a strong probability of syphilis.

RE. In front of *OD.*, covering a considerable part of its outer half, a patch of small new vessels, surrounded by lymph, and projecting 6 *D.* into vitreous.

At first it was thought that there were several small vessels. As the lymph cleared away under antisyphilitic remedies; a single small branch was seen to come off from the central artery, and to coil itself up in a corkscrew manner. In the *LE.* the conditions were similar, but less marked, and ultimately disappeared. A year later all lymph had disappeared, only a beautifully coiled single vessel remaining.

The same author publishes another case in which in each eye there was a crescentic patch of vascularised lymph placed nearly vertically over each disc. There had been optic neuritis, and the patient had had syphilis.

ELSCHNIG (*Arch. Ophth. and Otol.*, N. Y., vol. xxii., p. 75).—A case of embolism of the central artery. Partial restoration of the circulation, but the disc became atrophic. A month after the occurrence of embolism, a loose greyish tissue was seen over supero-temporal quadrant of disc, projecting into vitreous, carrying fine vessels and vascular networks. Three months later a fine network of vessels covered the entire disc.

INTRAOCULAR HÆMORRHAGE.

Among affections of the vascular system of the retina, hæmorrhage claims an important place, from the frequency with which it occurs either alone, or as a complication of other conditions. It is common in all forms of retinitis, but is especially frequent in that associated with renal disease. It is met with in a considerable number of cases of papillitis, in which there is much swelling of the disc. Lastly, it may occur in any condition which involves grave alteration of the blood, as, for example, anæmia,¹ scurvy, or leucocythæmia.

The capillaries are the source of the bleeding in nearly all cases. Even the more copious extravasations, which might be thought to be furnished by larger vessels, are commonly preceded by smaller hæmorrhages, which are certainly of capillary origin. In renal disease the walls of the capillaries are in a condition

¹ Mackenzie, *Trans. Ophth. Soc.*, vol. i., p. 48; *ibid.*, vol. ii., p. 40; *ibid.*, vol. iv., p. 132.

which predisposes to hæmorrhage. In papillitis, from any cause, the pressure on the walls is increased by the obstruction to the circulation caused by the inflammatory exudation into the nerve head. In the other cases enumerated above, the alterations in the character of blood permit its more ready exudation through the capillary walls.

The ophthalmoscopic appearance produced by a hæmorrhage will depend upon its depth in the retina. The most common situation is the fibre layer, and the blood has then a distinctly striated arrangement. This is seen in Plate XXXV., Fig. 79. Also in the hæmorrhages near the disc in Fig. 79. Solitary effusions of blood into the fibre layer form what are sometimes spoken of as flame-shaped hæmorrhages. Examples may be seen in Plate XXXVII., Fig. 84, and Plate XXXI., Fig. 68. When several such hæmorrhages lie in the same line, the appearance may resemble a vessel, the course of which is partially concealed from view. This is the case to some extent in Plate XXXV., Fig. 78. But when there is at the same time much swelling of the retina the resemblance is much closer.

When extravasation of blood takes place into the other layers of the retina, it is seen either as a granular area formed by the aggregation of small red dots, as some of the hæmorrhages in Plate XXXV., Fig. 78, or as an irregular patch, as in Plate XXXVII., Fig. 83.

Extensive retinal hæmorrhage is occasionally met with in old people (Plate XXXV., Fig. 79). The condition, which is usually attributed to degenerative changes in the walls of the vessels, has sometimes been called retinitis apoplectica, from a supposed analogy between it and cerebral apoplexy. The retinal vessels are, however, far below the size of those which are known to undergo atheromatous changes, and the retinal affection does not seem to indicate any special liability to cerebral hæmorrhage. The condition makes its appearance suddenly, and the hæmorrhages take place in all parts of the retina almost simultaneously. Although

the disc is little, if at all, swollen, the veins are often distended and tortuous. It is probable that in most of these cases the cause of the ophthalmoscopic conditions is thrombosis of the central vein. This subject will be referred to later on.

Retinal hæmorrhage occurs not unfrequently in association with glaucoma, but the nature of the connection between the two conditions is not understood. In these circumstances the extravasations are numerous and of small size. Occasionally the blood flows into the glaucomatous cup, as in a case recorded by Hartridge.¹ The papilla then presents a blood red surface; the vessels appearing to emerge from behind a disc of red.

Extravasation may take place beneath the hyaloid membrane. The blood then spreads equally in all directions, and therefore forms a thin layer of nearly uniform colour, with a circular contour. Hæmorrhages of this kind are most frequently seen in the region of the macula. When they occur in other situations, they are usually less regular in outline.

In sub-hyaloid hæmorrhage in the macular region, the blood, from the action of gravity, tends to sink to the lower part of the affected area. Hence we may get bagging of the blood below, and its complete disappearance above. The line marking the upper limit of the blood may, in this event, be perfectly straight, so that the patch has now the shape of a D with its convexity directed downwards. These points are seen in Plate XXXIX., Fig. 88. The greater amount of blood near the lower margin is shown by the darker colour; the thinness of the layer elsewhere by the fovea centralis being visible through it, and by the fact that the patient can see objects although they appear to be covered by a red veil. The outline is usually more regular than in this instance. When first seen the hæmorrhage had the form depicted, and there was nothing to indicate that it had ever extended further. In a few

¹ *Trans. Ophth. Soc.*, vol. xi., Plate IV.

days, however, a remarkable change occurred in the retina immediately above, apparently indicating the extent to which the hyaloid had been detached; this consisted in a change of colour to a slate-grey. At the same time this area, and that still occupied by blood, became sprinkled with minute dots of a crystalline appearance. Meanwhile the layer of blood had become somewhat thinner, so that retinal vessels previously hidden had again become visible.

Masselon¹ has recorded an interesting case, in which the straight boundary of a semicircular hæmorrhage varied with the position of the patient's head so that its direction was always horizontal. As the blood thus shifted its position retinal vessels previously concealed again became visible. Evidently, therefore, the straight boundary of the extravasation was due to the action of gravity upon fluid blood lying free in a cavity. Such an explanation, however, would not apply to the case published by Silcock in which the straight border was below, and oblique in direction.

The prognosis in these circular hæmorrhages, is more favourable than in the other forms, owing to the thinness of the layer of blood, and to the fact that the tissue of the retina is not implicated.

It has been suggested that these hæmorrhages are choroidal and not sub-hyaloid. The evidence, however, in favour of their being sub-hyaloid is very strong. The sharpness of their outline is not consistent with extravasation into a tissue like the choroid, and in many instances the patient has seen external objects as through a red veil, showing that the layer of blood is at any rate in front of the layer of rods and cones. The colour of the extravasation being nearly that of the vessels, it is not easy to be certain of the relation of the latter to the hæmorrhage; but in a case observed by Stanford

¹ "La clinique Ophthalmologique," p. 19, 1895.

² *Trans. Ophth. Soc.*, vol. vii., p. 176.

Morton,¹ this doubt was set at rest by the area of extravasation² becoming white after some months, and it could then be distinctly seen to lie in front of the vessels.

To return to retinal hæmorrhages in general:—sometimes patches of extravasated blood present no appreciable change even after some months, but they usually become darker. When the layer of blood is thin, as in the cases of sub-hyaloid extravasation just described, complete absorption may take place. In other instances yellowish white or white patches are left, due to fatty degeneration of the disturbed retinal tissue, such as are to be seen in Plate XXXV., Figs. 78 and 79. Sometimes minute crystalline bodies can be seen on the surface of these. Eventually these patches may entirely disappear and there may be nothing to mark the site of the hæmorrhage. It is, however, very common for pigment spots to persist; these are probably not due to blood pigment, but to disturbance of the pigmentary layer of the retina which causes it to proliferate.

Exceptionally, the layer of blood is so thick, or its colour so dark that no light is reflected through it from the choroid. It would seem that such transmitted light is necessary to give the red colour. In its absence we get a dark slate colour, even darker than that depicted in Plate XXXIX., Fig. 89. If the area occupied by this colour is large, the loss of light may render ophthalmoscopic examination difficult or impossible. In such cases a better view can often be obtained by the indirect method, because a larger portion of the fundus is then seen and sufficient light is obtained from the part not occupied by the extravasation. In some of these cases of slate coloured extravasation the blood is probably beneath the retina. Under such circumstances the retinal vessels may be visible over the grey area.

Hæmorrhage from retinal vessels is sometimes so copious that

¹ *Trans. Ophth. Soc.*, vol. ix., p. 145, with chromolithograph.

² Good examples of D-shaped extravasations are to be seen in the illustrations which accompany the following papers:—*Trans. Ophth. Soc.*, vol. iv., p. 148; *ibid.*, vol. vi., p. 335; *ibid.*, vol. viii., p. 26.

it bursts through into the vitreous, which may then be too opaque for the source of the bleeding to be discovered. It is probable that the majority of vitreous hæmorrhages are derived from the ciliary processes. When, however, a copious extravasation into the vitreous has been preceded by smaller hæmorrhages into the substance of the retina, it is a fair inference that both come from the retinal vessels.

Hæmorrhages into the vitreous may occur at all periods of life. They are especially frequent in women at the climacteric. They also occur in young men, but these latter cases present such definite characteristics that they constitute a distinct clinical group calling for separate consideration.

RECURRENENT INTRAOCULAR HÆMORRHAGE IN YOUNG MEN.

Young men, not suffering from any obvious impairment of health, and following their usual occupations, are occasionally attacked by sudden and profuse intraocular hæmorrhage, which leads to serious impairment of sight. Considering the amount of blood poured out, vision often recovers with surprising rapidity, but the liability to relapse renders the prognosis most grave.

Attention was first called to these cases by Eales¹ in 1880. Four instances have since been recorded by Hutchinson,² two by Abadie,³ and others from time to time by various authors.

The extravasation may take place into the substance of the retina, but usually it breaks through into the vitreous. It may be so copious that satisfactory ophthalmoscopic examination is rendered impossible. There may be only a faint fundus reflex, and the vitreous may be seen to contain a gauzy film of blood.

¹ *Birmingham Med. Rev.*, July 1880, and *Ophth. Rev.*, London, 1882.

² *Trans. Ophth. Soc.*, vol. i., p. 26.

³ *Ann. d'ocul.*, Bruxelles, 1886, p. 36.

Smaller extravasations in the retina sometimes precede the large hæmorrhage into the vitreous. They may be accompanied by retinitis, but in many instances an extensive bleeding into the vitreous has occurred without any premonitory symptoms.

Numerous causes have been assigned for these hæmorrhages, but it cannot be said that their pathology is thoroughly understood. Constipation has existed in many of the patients, and in some there has been a history of repeated epistaxis, but apart from this, none of the published cases appear to have shown any indication of the hæmorrhagic diathesis. A gouty history may now and then be obtained, and Mr. Hutchinson is inclined to attach considerable importance to this as an etiological factor.

The following case (which was under the care of the writer, and of Dr. Nelson of Belfast), may be cited as an example:—

Repeated hæmorrhages into vitreous, resulting in blindness.

Mr. G. P., 27. A tall muscular man, of slightly anæmic aspect, was first seen by the writer on September 12th, 1889. He was very deaf from nerve disease, for which he had been treated in October 1888 with mercury, pushed to salivation. About this time he noticed failure of vision, and saw Mr. Nelson, who kindly furnished me with the following note as to his condition:—

Some haziness of retinae near discs. In *LE.* some hæmorrhages and whitish exudation. Two days later a fine gauzy film in each vitreous. V. $\frac{2}{3}$ each eye. During the next few weeks a whitish exudation occurred along the vessels near the disc, and several hæmorrhages occurred. By February both eyes had cleared considerably.

The patient believes that after this his vision recovered completely. At any rate, until five days before his visit to the writer, he could read small print without difficulty. Then a rapid deterioration occurred, and when seen V. *RE.* $\frac{6}{7}$ some letters picked out slowly; *LE.* $\frac{6}{7}$.

In *RE.* a large floating dark mass in vitreous, and the upper part of the retina was studded with small hæmorrhages. *LE.* floating film in vitreous. No swelling of disc. Visual field normal in each eye.

There was no history of constipation or epistaxis, and no evidence of a hæmorrhagic diathesis. Mr. Hutchinson was of opinion that the patient had had syphilis. The writer and some others who examined the patient with especial reference to this point, failed to obtain any evidence of this. There was a strong history of gout on his mother's side, but the patient himself had not suffered.

The blood was examined by Dr. Cavafy, who found the corpuscles normal in number, the red a little pale, some oval or flask-shaped. A recognisable quantity of hæmatoblasts and microcytes. Heart, lungs, and urine normal.

The patient was treated with purgatives, iron, and then subcutaneous injections of pilocarpine. Vision improved to *RE.* $\frac{6}{8}$ and *LE.* $\frac{6}{12}$, but it varied much owing to the movements of the opacities.

In February, 1890, he had influenza, and on recovering suffered from large hæmorrhage into the left vitreous. This was absorbed, but a relapse occurred and reduced vision to bare *p.l.* In April there was no *p.l.* in the *LE.* and no fundus reflex. Vision *RE.* = $\frac{6}{8}$, but during the next four months three attacks of hæmorrhage occurred, the last reducing vision to bare *p.l.*

ARTERIAL EMBOLISM AND THROMBOSIS.

We have seen that the retinal circulation is terminal, or entirely dependent upon the artery and the vein which pass along the centre of the optic nerve. Hence, if either of these vessels becomes occluded, marked symptoms rapidly make their appearance.

Occlusion of the arteria centralis retinae.—The arteria centralis may become occluded either by a clot carried into it from a distance—*embolism*; or by coagulation taking place *in situ*—*thrombosis*. The ophthalmoscopic signs are identical and due to the sudden arrest of the circulation. The disc immediately becomes a dead white colour. The arteries may be only slightly smaller than normal, reduced to mere threads, or even altogether invisible. The light-streak is absent from them, and they may so closely resemble the veins in colour that a distinction cannot be made with certainty. The veins, as a rule, are either normal, or slightly reduced in size; occasionally they taper towards the disc. Pressure on the globe fails to produce pulsation in either set of vessels. Sometimes the blood stream, both in arteries and veins, but more frequently in the former, is divided into segments, like the column of mercury in a broken thermometer, portions of blood alternating with what look like spaces. Doubtless some of these gaps are portions of the vessel that are really empty and collapsed, while others in which the diameter of the vessel is maintained are probably filled with liquor sanguinis.

A similar interruption of the blood column has been seen in the retinal vessels of animals recently killed.¹ The colourless spaces contained no red corpuscles, but were filled with blood plasma and white corpuscles. The red corpuscles were heaped together in the coloured portions of the vessels.

Within an hour or so after the arrest of the circulation by a clot, marked changes occur in the retina. Its tissue becomes opaque, and of a uniform soft-looking white colour. This is most marked in the neighbourhood of the disc, but often reaches to the periphery of the fundus.

The macula itself escapes, and is seen as a cherry-red spot amid the surrounding white. This spot looks like a hæmorrhage, but most authorities are now agreed that it is really the natural colour of the fovea accentuated by contrast with the white fundus. Small hæmorrhages into the retina do, however, now and then occur in cases of embolism. This appearance of the macula is seen in Plate XLI., Figs. 92 and 93, but it is less conspicuous than is sometimes the case. The absence of visible change at the macula is not accompanied by any retention of its functional activity.

The appearance of the retina closely resembles that presented by œdema (Plate XXV., Fig. 58); it is, however, probably due rather to what might be called *post-mortem* changes in its tissue than to true œdema.

Later the collapsed arteries contract, and the small amount of blood which they contain being pressed out, they become nearly or quite invisible. The contraction is more marked near the disc, the vessels at the periphery of the fundus may even retain their normal calibre, while at the disc they taper down to mere threads. As already mentioned, the veins also are often smaller at the disc; probably the appearance in both cases is caused by the intraocular pressure forcing blood out of the eye along the vessels in which the resistance is diminished.

¹ Friedenwald, *Ophth. Rev.*, London, vol. xii., p. 161.

At a still later stage the vessels may again become visible, or even abnormally conspicuous, in consequence of degenerative changes taking place in their walls, converting them into white bands (Plate XLI., Fig. 92). Meanwhile the disc passes into a condition of complete atrophy, and the degeneration may spread up the nerve as high as the chiasma.

Even in the latest stage it is not uncommon for the arteries to carry a thin stream of blood. In such cases either the embolus has shrunk and so allowed some blood to trickle past, or a collateral circulation has been established.

A shrinking of the clot has been found in several cases where a *post-mortem* has been obtained. In some of these, although the symptoms during life had indicated that the vessel was completely occluded, the clot was found after death adhering to one side of the vessel, covered by endothelium, and only slightly encroaching on the lumen of the vessel; in two cases in which the symptoms were typical, examination made at eighteen months¹ and three years² respectively, revealed nothing abnormal in the arteries.

Collateral circulation, on the other hand, has never been proved *post-mortem*, although it has occasionally been suggested by the clinical evidence. Assuming that it can occur, the most obvious collateral channels are the vessels in the sclerotic, derived from the short ciliary arteries which form the circle of Haller. It has also been suggested that blood may possibly enter the arteries at a peripheral part of the retina, although no anatomical anastomosis exists there. The grounds for this latter assumption are that the arteries in embolism are often larger towards the periphery; that recovery of circulation has occurred where the clot lay anterior to the lamina; and that in a case of Hirschberg's (which will be referred to later) the blood was seen to move in the artery from the periphery towards the disc. Not one of these reasons is, however, of much weight.

¹ Hirschberg, *Centralbl. f. prakt. Augenh.*, Leipzig, 1884, p. 7.

² Popp, *Inaug., Diss.* 1875 (extract in *Ophth. Hosp. Rep.*, London, vol. viii., p. 616).

There are, indeed, good reasons for doubting whether a collateral circulation is ever established when the occlusion of the central artery is complete. The course followed by these cases is hardly analogous to that of restoration of the circulation after ligation of an artery. In the latter case the collateral circulation may fail to establish itself, but if it is once established the new channels enlarge, and the conditions steadily improve. In cases of retinal embolism it is otherwise; notwithstanding that the vessels carry blood, atrophic changes occur in their walls and in the nerve. The establishment of a collateral circulation must be rendered difficult by the intraocular pressure, but once formed it would tend to increase, and would prevent the onset of atrophy. Moreover, collateral circulation has never been seen to occur in cases (like that shown in Plate XLI., Fig. 93), in which a cilio-retinal vessel remained patent, while the main retinal artery has been occluded, although the conditions here are most favourable for such an event. It is therefore not unreasonable to conclude that when, after complete blocking of the central artery, the circulation is re-established, this is due to a breaking up of the clot, to a change in its position, or to a diminution of its bulk.

Even when there is no evidence of any re-establishment of the circulation, the retinal opacity disappears. At a late stage pigmentary disturbance, or a well-defined circular area of choroido-retinitis in the central region may be met with, as in a case published by the late J. E. Adams,¹ where embolism had occurred twelve years previously in the one eye, and eighteen months in the other.

At first sight, it seems strange that so many cases of embolism of the arteria centralis retinae should have been recorded, since the chances of a clot being carried into that particular vessel alone must be remote. But it must be remembered that in no other part of the body would plugging of so small a vessel give

¹ *Trans. Ophth. Soc.*, vol. iii., p 114, with chromolithograph.

rise to such disastrous consequences. Even in the brain, where embolism of a larger artery produces very serious effects, and where the circulation, as in the retina, is terminal, it is doubtful if embolism of an artery of this size would cause more than transient symptoms, of which the significance would probably be overlooked. On the other hand, the total loss of vision that immediately occurs when the retina is deprived of arterial blood, at once drives the patient to seek advice.

The commonest cause of embolism is valvular disease of the heart, especially vegetations on the mitral valve. In such cases, emboli become detached from the valve, and carried into the circulation. In many instances retinal embolism has led to the discovery of cardiac mischief previously unsuspected. In other cases, careful examination has failed to detect any evidence of heart disease. Among other causes may be mentioned, septic emboli, detached clots or other particles from aneurismal cavities, from new growths, or from atheromatous patches.

It is probable, as suggested by Priestley Smith,¹ that many of the cases diagnosed as embolism have really been instances of arterial thrombosis. A clot may form in the vessel owing to some roughness of its lining, or it may occur during great retardation of the circulation, as in syncope, or possibly as the result of spasm of the arterial walls. The last would account for the transient attacks of blindness which, in many cases, have preceded the final catastrophe, and for the fact that vision is sometimes lost simultaneously in both eyes—symptoms which are inexplicable on the theory of embolism.

Priestley Smith's own words on this subject are as follows:—
“Blocking of the retinal artery is due, in a considerable proportion of cases, to spontaneous thrombosis. The causes of this accident are heart failure, either from disease of the heart or other causes, spasm of the blood vessels, diseases in the walls of the vessels, alterations in the quality and amount of the blood.

¹ *Ophth. Rev.*, London, vol. iii., p. 47.

Thrombosis may be distinguished from embolism by a history of transient failure of sight, resembling the permanent attack in the mode of onset, and especially of simultaneous failure of the fellow eye at the moment of onset."

A most interesting case, bearing on this subject, has recently been published by Benson¹:—

A man, aged 32, apparently in perfect health, had defective sight in both eyes, *RE.* $\frac{6}{36}$, *LE.* $\frac{6}{36}$. Vision had only been failing a little over a year, and there were no ophthalmoscopic changes. He had had numerous attacks of transient, but complete blindness of the *LE.* during the past four years. Some of these attacks only implicated one section of the field. Lately, the attacks had been more frequent. During one total obscuration the eye was examined with the ophthalmoscope; the inferior temporal artery was entirely bloodless for a distance of 4 disc diameters from its point of emergence. During examination, the bloodless portion shifted towards the periphery slowly, till it reached the next large bifurcation, when it suddenly disappeared, leaving the blood vessels normal. An opportunity for examination occurred during two attacks of partial blindness, and the same phenomenon was witnessed.

The recurrent attacks of blindness in one eye pass off so quickly and completely that the patient may cease to attach much importance to them. The prognosis, however, cannot be considered otherwise than grave, when it is remembered that many cases of permanent blindness give a history of having previously had attacks of this kind.

The following instance came under the writer's own observation:—

Mrs. H., 46. For two or three years had frequent transient attacks of blindness in the *RE.*—"quite a common occurrence." The attacks usually occurred in the morning whilst dressing, but also at other times. The blindness generally lasted a few minutes, and recovery was sudden and complete.

One morning, eight months before her visit, after an attack which differed in no respect from the others, sight only returned to the upper half of the field, and that imperfectly.

When seen, fingers were counted badly, and only in the upper part of the field, which could not be mapped out. The disc was pale, and the arteries of the upper half of the retina were thought to be a little diminished. *LE.* normal in all respects.

No history of any general symptoms could be obtained. No signs of heart disease. Four months later there was no change.

These cases have nothing in common with those already

¹ *Trans. 8th Internat. Ophth. Congress, 1894.*

described under the term, acute retro-bulbar neuritis (p. 127), except the suddenness with which vision is lost.

The agreement between the subjective symptoms and the ophthalmoscopic appearances in retinal embolism, led long ago to a recognition of the pathology of these cases; while the frequency of a fatal result from cardiac disease, or cerebral embolism, has produced abundant confirmatory *post-mortem* evidence. The earliest case in which this was obtained was the now historical one, in which the diagnosis was made during life by Albrecht von Graefe, and confirmed *post-mortem* eighteen months later by Schweigger. Since then numerous cases have been recorded in which a *post-mortem* examination has been made. Among these may be mentioned the following:—

| AUTHOR. | REFERENCE. | Interval between embolism and post-mortem. | REMARKS. |
|------------------------|---------------------------------------------------------------------------------------------------------------------------|--------------------------------------------|----------------------------------------------|
| NETTLESHIP, | <i>Ophth. Hosp. Rep.</i> , London, vol. viii., p. 9. | 4 months. | |
| SICHEL (jun.), | Quoted by Nettleship, <i>loc. cit.</i> | 14 months. | Not conclusive. |
| GRAEFE and SCHWEIGGER, | <i>Arch. f. Ophth.</i> , Leipzig, bd. iv., ab. 2, p. 230; Schweigger, "Vorles. u. d. Gebrauch des Augenspiegels," p. 140. | 18 months. | |
| PRIESTLEY SMITH, | <i>Brit. Med. Journ.</i> , London, 1874, vol. i., p. 458. | 4 months. | |
| SCHMIDT, | <i>Arch. f. Ophth.</i> , Leipzig, bd. xx., ab. 2, p. 286. | 10 months. | |
| GOWERS, | "Medical Ophthalmoscopy." | 2 months. | |
| SCHNABEL and SACHS, | <i>Arch. Ophth. and Otol.</i> , N. Y., vol. xiv., p. 274. | 3 months. | See <i>infra</i> , p. 186. |
| HIRSCHBERG, | <i>Centralbl. f. prakt. Augenh.</i> , Leipzig, 1884, p. 2. | 18 months. | Nothing abnormal found in vessel. |
| ELSCHNIG, | <i>Arch. Ophth. and Otol.</i> , N. Y., vol. xxii., p. 74. | 7 weeks. | Degeneration of retina at macula. |
| POPP, | <i>Inaug. Diss.</i> , 1875. Quoted by Elschmig, <i>loc. cit.</i> | 3 years. | Nothing abnormal found in vessel. |
| WAGENMANN, | <i>Arch. f. Ophth.</i> , Leipzig, bd. xl., ab. 3, p. 221. | 1 year. | Clot adherent to and fused with vessel wall. |

Although re-establishment of the retinal circulation may occur, as already stated, it is usually either not sufficiently complete or too long delayed to restore the function of the retina. The prognosis is therefore almost hopeless.

Indeed, it would seem that when the nervous elements of the retina are deprived of arterial blood for only a few hours, they degenerate, even though the supply be then renewed. Such degeneration may ascend through the disc and optic nerve as high as the chiasma. This accounts for the clinical fact that atrophy of the disc usually occurs eventually, even when the circulation has been completely re-established. It supervened in both the cases shown in Plate XLI.

In the following case the circulation was seen to re-establish itself during ophthalmoscopic examination :—

Embolism—Re-establishment of the circulation during examination (WOOD and WHITE, *Ophth. Rev.*, London, vol. i., p. 49).—The patient, a man aged 31, was seen an hour after sudden total loss of vision in the *RE*. The ophthalmoscopic appearances were typical of embolism. There was extreme pallor of the disc, and the characteristic white appearance of the retina. The vessels, both arteries and veins, were beaded; in some complete collapse of the vessel alternating with portions of the blood column. Pressure on the globe produced no pulsation. On repeating the pressure a wave passed rapidly through the vessels. The upper ones filled first, the lower after an interval of two or three minutes, and the disc resumed its normal rosy tint. There was simultaneous restoration of vision to $\frac{2}{3}$. In two days all opacity of the retina had disappeared, and V. was $\frac{2}{3}$; there was slight contraction of the upper part of the visual field, which persisted.

Eales has also published a case in which he was able to watch the more gradual recovery from complete obstruction :—

Embolism—Partial recovery in five hours, nearly complete gradual recovery (*Ophth. Rev.*, London, vol. i., p. 139).—The patient, a female aged 20, was seen an hour after sudden and total loss of vision in the right eye. Typical retinal œdema was present. The veins contained blood, but were rather small. The arteries much contracted, and the blood column broken. Five hours later, the blood column was continuous in the arteries, and pulsation could be produced in them by pressure, *i.e.*, on slight pressure being made, the artery on the disc collapsed between each pulse. The disc was paler than in *LE*. On the following day the vessels were fuller, and objects could be perceived in the upper periphery of the visual field. On the next day (the second after the plugging) fingers could be counted in at 18 inches, in the upper and outer part of the field. On the third day objects could be seen over the whole field except a small central area. On the eighth day the œdema was less, and had disappeared from the yellow-spot region, but the centre of the field had not recovered perception of light. A month after the plugging “marked

pulsation" was produced by pressure. *OD.* a little pale, *YS.* normal. Central scotoma still present, but smaller. Three months after the plugging ophthalmoscopic appearances normal (doubtful pallor of disc). Still a small absolute central scotoma.

If the clot lie in the main trunk of the ophthalmic artery, recovery of the retinal function may result from its being carried past the origin of the arteria centralis which would thus be again open to the circulation. Recovery may also result, as already pointed out, from shrinking of the clot, allowing blood to trickle past it, or from a shifting of the position of the clot, again rendering patent part of the lumen of the vessel.

It seems probable, also, that in some cases the plug itself may not be a real clot in the sense of being formed of solid fibrin, but that it may consist of a collection of corpuscles—a kind of exaggeration of the rouleaux which the red corpuscles form outside the body. An increase in the propelling force, or some sudden pressure might start a breaking up of such a conglomeration, which would be quickly completed by the blood streams. Such would appear to be the most feasible explanation of the following exceptional case recorded by Mules:—

Plugging of a retinal artery by a white clot—sudden recovery (MULES, *Trans. Ophth. Soc.*, vol. viii., p. 151).—Kate A., 21. Noticed suddenly a blank over the upper part of the visual field of the right eye. She was seen within an hour. The field, taken roughly, was contracted above. With the ophthalmoscope, the lower main artery from its point of exit from the disc to just beyond its first bifurcation, was of full size, but dead white in colour, as if stuffed with cotton wool. Beyond this there was an abrupt transition to the normal appearance of the vessel which was continued to the periphery. Faint œdema accompanied the vessel, pervading the adjacent retina, which was ticked with glistening specks. No changes at the macula.

Massage was commenced at once, and continued for two or three minutes. Ophthalmoscopic examination then showed the vessel to have resumed its normal appearance. The patient noticed an improvement in vision, and it was found to be normal (there is no note of its acuity previously). The *VF.* some hours afterwards still showed a defect above. The next day it was normal in extent, but there was a triangular defect in the field with its apex at the fixation point, and its base reaching up 35°. Three months later this was still present, but smaller in size. Fundus and vision normal.

The colour of the plug in the above case would seem to indicate that it consisted largely of white blood corpuscles. I am not aware of any pathological evidence of the occurrence of such a

clot, but the condition of the blood, which was discovered by Schultze¹ in a case of retinitis proliferans, suggests the possibility of such an embolus. He says:—"Examination of the blood showed the red corpuscles to be normal. The white were decidedly increased in number, and in addition to the usual isolated white corpuscles, there were many sausage-like aggregations of the same. Some of the constituent corpuscles presented the form and structure of white corpuscles; others formed a homogeneous cloudy mass, permeated throughout with fat globules. These aggregations were about the diameter of a white corpuscle, but of very different lengths. In some instances their length was ten times the breadth. In every microscopical field several of these sausage-like bodies were found. An examination of the lymph glands and spleen disclosed nothing abnormal. The patient was aged 25; he had not the appearance of leukæmia, and the mucous membranes were of the normal red colour."

In the cases just quoted, re-establishment of the circulation took place suddenly within a few hours, and was followed by a restoration of the normal ophthalmoscopic appearance, and recovery of practically normal vision. We have now to consider those in which the circulation is re-established more gradually, and after a longer interval. In such, recovery is seldom complete.

The following is an abridged account of a most interesting case, which is the more valuable as it was watched throughout its course by a competent observer:—

Embolism—Gradual re-establishment of circulation, preceded by reversed current in one artery (HIRSCHBERG, *Centralbl. f. prakt. Augenh.*, Leipzig, 1884, p. 70).—Anna S., 26, was seen the day after sudden loss of vision in the *RE*. Examination of the heart disclosed a systolic murmur at the apex, mitral insufficiency, and dilatation, with hypertrophy of the left ventricle. *LE*. normal in all respects. *RE*. V. reduced to hand movements in the upper part of the field.

Ophthalmoscopic examination.—No œdema. *OD*. white and well defined. It was difficult to distinguish between the arteries and the veins (the distinction was easy at a subsequent stage, and the description now given was confirmed by the examinations then made).

¹ *Arch. f. Augenh.*, Wiesb., bd. xxv., p. 304, 1892.

Veins.—The lower small, but not thread-like. The upper thread-like. Fine lines along all, even to the smaller divisions.

Arteries.—Blood column broken. In several a non-rhythmical slow movement of the little cylinders of blood was clearly visible. The movement was in the normal direction—from the disc—except in the case of the inferior temporal artery, which formed a remarkable exception, as in it the movement was towards the disc. (This vessel was in consequence at first taken to be a vein, but subsequent examinations proved beyond doubt that it was really an artery.) On one occasion a minute blood cylinder was seen to travel up this artery to the disc, and after meeting apparently with some slight resistance at the centre, to enter the upper artery. No important change was produced by pressure.

Massage was practised. The next day (2nd from occurrence of the embolism), in the evening, fingers could be counted in the nasal part of the field. The arteries were fuller, being at times of normal width on the disc.

3rd day.—V. further improved. The inferior temporal artery uniformly filled towards the periphery, but near the disc it only contained a few blood cylinders, which still moved very slowly towards the disc. There was distinct œdema above the disc. In the evening the whole appearance had changed. The pallor of the disc had disappeared. The appearance of the vessels was normal, except that the inferior temporal artery, 2 dd. from the disc, presented a small apparently bloodless space, on the distal side of the artery, and its branches were thread-like. V. letters of Sn. 30, at 6 ins. ($\frac{3}{8}$).

4th day.—V. $\frac{1}{3}$. Concentric contraction of field to about 10°. Inferior temporal artery as before, but a second smaller clear space, close to that described, lay between it and the disc. The vessel between the two spaces was of normal width and of dark colour. The smaller clear space appeared to move synchronously with the radial pulse towards the disc, without, however, permanently changing its position to any appreciable degree. Pressure on the globe now caused arterial pulsation on the disc, as in the normal condition.

7th day (evening).—The arteries and veins presented the normal difference in colour. The inferior arteries smaller than normal. No movement of the clear space, and the dark portion had extended, and was continued as a fine red line into both branches of the vessel. Disc whitish. Slight blurring of its margin.

9th day.—At the moment of commencing the examination, the inferior nasal artery and the main trunk above it were seen to be quite empty, appearing as white branching lines. In an instant they resumed the normal appearance, the change being too sudden for movement of the blood to be followed.

11th day.—Arteries on and near *OD.* very small, and accompanied by white lines. They were wider towards the periphery. *OD.* quite white six weeks after the embolism. All the arteries small, but not thread-like. The perivasculitis had extended towards the periphery. Pressure caused pulsation in the upper and lower divisions of the arteria centralis.

This reversed current in the arteries has been observed in other instances of embolism.

Embolism—Partial re-establishment of circulation—reversed arterial currents—optic atrophy (ELSCHNIG, *Arch. Ophth. and Otol.*, N. Y., vol. xxii., 1893, p. 75.—Woman, aged 56. Seen 5 days after sudden blindness in *LE.* Disc and surrounding retina white. Retinal

vessels very small, the veins on and near the disc pulsating, V.=p.l. Next day (6th), a pulsating centripetal movement in veins.

8th day.—Blood column in inferior nasal artery interrupted by a small white cylinder. Spontaneous venous pulsation, slight arterial pulsation on pressure. Retinal opacity less marked.

12th day.—Short red blood-cylinders passing into superior nasal artery and its two terminal branches. In the course of an hour this movement ceased, the blood from one of the branches passed in the reverse direction, partly into the main trunk and partly into the other branch. Later the normal direction was resumed. This process was frequently repeated.

13th day.—Circulation sometimes suddenly stops and then begins again. Eventually the disc became atrophic. New vessels projected from it into the vitreous.

Hirschberg explains the reversed arterial current on the hypothesis of an anastomosis between the arterial systems of the retina and choroid in the ciliary region. There is, however, no anatomical evidence of this, and the phenomenon may be accounted for in other ways. For example, if there were a valve-like clot situated at a bifurcation of an artery which allowed blood to pass only into one division, the current might, by exercising a suction action, draw blood from the occluded vessel. Again, a reversed current may result as suggested by Elschmig, simply from the lowered pressure in the collapsed vessel. As soon as an artery becomes plugged, the blood pressure in it and all its branches on the distal side of the obstruction sinks to that of the intraocular pressure, the blood pressure in the veins will for a short time remain almost at its normal height; hence there will be a tendency for the blood in the capillaries to flow back into the arteries until the pressure in the arteries and veins is equalised. If only the upper or the lower artery were plugged, the other remaining patent, an anastomosis between the corresponding venous systems, might keep the blood pressure in the vein constantly higher than in the affected artery.

The following cases seem to point to a plugging either incomplete at first or becoming so later on:—

Embolism—Alternate filling and collapsing of artery on disc occurring rhythmically—autopsy (HIRSCHBERG, *Centralbl. f. prakt. Augenh.*, Leipzig, 1884, p. 2).—The patient, a man aged 45, was seen four hours after sudden loss of vision of RE. No p.l. Usual signs of embolism present. Next day the blood column in the veins was in segments which travelled slowly towards the disc.

2nd day.—This movement was less, sometimes stopping.

3rd day.—More œdema, primary branches of arteries well filled, those of second magnitude small, but not thread-like, veins dark, not small, no visible movement.

4th day.—The following curious rhythmical movement noted:—On the disc the upper and lower divisions of the central artery were in line, thus forming what was practically a single vertical vessel, but the main trunk of the central artery was not itself visible. On the previous day this vertical vessel had been well filled, now it was empty forming a narrow white band. Above and below it bifurcated, the branches being of fair size. A little below the centre of the vertical vessel, there appeared a small cylinder of blood which gradually elongated till it reached the bifurcation above and below, the whole vessel thus being filled. After a short time it would again empty, and the phenomenon would be repeated. This only occurred a few times, and the vessel then remained full. The œdema gradually subsided, but the disc remained white, and the arteries and veins became smaller towards the disc than at the periphery. The patient died six months after the occurrence of the embolism. The plugged artery was not discovered at the autopsy, but the vessel between its origin and its point of entry into the nerve seems not to have been fully examined.

The next case in which the artery was only partially blocked is important since it was completed by an autopsy.

Incomplete embolism—Autopsy three months later (SCHNABEL and SACHS, *Arch. Ophth. and Otol.*, N.Y., vol. xiv., p. 263).—Paul G., 33. Endocarditis two years previously. Seen fifteen hours after sudden failure of *LE*. Disc, blue-grey, its margin blurred. Arteries and veins on *OD*. reduced to threads, and not to be distinguished from each other. At the periphery they were fuller, and were distinguishable. Twenty-four hours after the loss of vision the arteries of normal size. Veins fuller than before, but smaller than the arteries. They narrowed towards the disc. Slow intermittent movement of blood column in the veins towards the disc. A sudden blindness of the *RE*. occurred one day, and lasted five minutes. The patient died three months after the occurrence of the embolism.

Autopsy 48 hours after death. Extensive cardiac lesions. Situated at the level of the lamina cribrosa, an embolus whose length was twice the diameter of the vessel. It was partly granular and partly hyaline. One part was attached to the vessel wall, the remainder projected into the lumen of the vessel, two-thirds of which it occluded. Endothelium had grown over the clot, shielding it from direct contact with the blood. Behind the embolus the vessel was of normal calibre. There was no dilatation of the vessels entering the nerve from the circle of Haller. Extensive atrophic changes in the nerve and retina.

The papillo-macular region sometimes retains its normal colour and its functional activity, although the central artery is completely occluded. This immunity is, doubtless, due to the presence of small vessels—the so-called cilio-retinal—which emerge from the temporal margin of the disc. In the few

instances¹ recorded in which these vessels have modified the symptoms of embolism, they appear merely to have secured the immunity of the part of the retina to which they were distributed, and to have taken no part in establishing any collateral circulation by anastomosing with branches of the occluded artery.

An example of this condition is seen in the case depicted in Plate XLI., Fig. 93, which is now published for the first time.

THROMBOSIS OF THE VENA CENTRALIS RETINÆ.

Thrombosis of the central vein has during recent years been recognised as accounting for appearances of the fundus which were previously attributed either to embolism of the central artery, or classed as hæmorrhagic or apoplectic retinitis. It is probable that many cases described as hæmorrhagic glaucoma were really examples of venous thrombosis. The recognition of the pathology of these cases is mainly due to the writings of Michel,² Angelucci,³ and W. Wolf.⁴

We shall presently see that marked retinal changes result from occlusion of the central vein. It might be thought that similar symptoms would be produced by phlebitis of the cavernous sinus, into which the ophthalmic vein opens. This, however, is not the case. Thrombosis of the cavernous sinus commonly causes ophthalmoplegia from implication of the nerves which lie in its wall, and may also give rise to some proptosis from œdema of the orbital cellular tissue. But, as a rule, no ophthalmoscopic signs are present, and in the cases in which they have been observed it is probable that the thrombus had extended down the ophthalmic

¹ The following cases may be quoted:—Birnbacher, *Centralbl. f. prakt. Augenh.*, Leipzig, 1883, p. 207; Leplat, *ibid.*, supplement to 1885, p. 489; Benson, *Ophth. Hosp. Rep.*, London, vol. x., p. 340; Knapp, "Ber. ii. d. Versamml. d. Ophth. Gesellsch.," 1885, p. 219 (two cases); Schüller, "Embolie der Art. cent. ohne Betheilung der macularen Gefässe," 1888; Wadsworth, *Trans. Am. Ophth. Soc.*, 1890, p. 672.

² *Arch. f. Ophth.*, Leipzig, vol. xxiv., ii., p. 37.

³ *Ann. di. ottal.*, bd. ii., 1880.

⁴ "Ueber Thrombose der Retinalvenen."

vein. This immunity of the retina is due to the free communication between the orbital and facial veins at the inner angle of the orbit. This anastomosis, however, has dangers of its own, for it enables facial erysipelas to cause thrombosis of the retinal veins, as occurred in a case recorded by Knapp.¹

Thrombosis may result from stagnation of the blood current, or from changes in the vessel wall. In papillitis both these conditions may be present, and it is possible that in some cases of papillitis, in which the retinal veins are much distended and the hæmorrhages numerous, there is actually coagulation in the central vein. But it is equally certain that thrombosis may occur without any antecedent papillitis. Some of these cases are possibly due to pressure on the vein from an atheromatous artery. A more common cause is extension of a phlebitis of the orbital veins.

Some of the results of venous obstruction have come under our notice in dealing with optic neuritis. In thrombosis of the vein these results are much more marked, because the obstruction is more complete, its onset is more sudden, and there is not, as in neuritis, simultaneous pressure on the artery. The retinal veins become distended and extremely tortuous; and the retina swollen and possibly œdematous. Consequently the veins are seen to make bold curves, the convexities of which stand out in relief, while the concave portions are hidden in the substance of the retina. The disc margins are indistinct or invisible, but the disc itself is not generally much swollen. A striking feature is the large quantity of blood that is extravasated, chiefly into the fibre layer. It is most extensive round the disc over an area having a radius of about 2 dd., where it may form an almost uniform surface. Towards the periphery, also, there are numerous hæmorrhages, but they tend to be more scattered. Examples are shown in Plate XXXIV., Figs. 76 and 77. In the following case the diagnosis was confirmed *post-mortem* :—

¹ *Arch. f. Augenh.*, Wiesb., bd. xiv., p. 257.

Thrombosis of vena centralis—autopsy (MICHEL, *Arch. f. Ophth.*, Leipzig, vol. xxiv., p. 2).—Peter M., 58. Loss of vision of *LE.* discovered on waking (this previously was the only useful eye). Seen within four days. Ophthalmoscopic appearances almost identical with those described above, and shown in Figs. 76 and 77. V.=counting fingers. Marked sclerosis of peripheral arteries of the body. Emphysema of lungs. No albumen in urine. There was some temporary improvement in vision, but fresh retinal hæmorrhages subsequently occurred. Died from hydrothorax. A detailed description of the microscopical appearances in the retina is given in the original paper. The following are the most important points:—

Sections of the optic nerve showed a completely organised thrombus in the central vein, about 6 mm. behind the globe. The ophthalmic artery and the cavernous sinus were normal. In the retina the lumen of the arteries and veins free; adventitia of arteries somewhat thickened. The perivascular sheaths of the veins distended, and containing lymph corpuscles, scattered in some places, and crowded in others.

In thrombosis of the central vein, loss of vision is generally sudden, and for this reason some of the cases have been diagnosed as embolism of the artery. The following table will serve to contrast the ophthalmoscopic signs of the two conditions:—

| <i>Thrombosis of Central Vein.</i> | <i>Embolism of Central Artery.</i> |
|------------------------------------------------------------------------|--------------------------------------------------------------------------------|
| 1. Arteries,—calibre normal or slightly diminished. | 1. Arteries filiform. |
| 2. The veins are tortuous. | 2. Course of veins normal. |
| 3. Veins turgid, and appear interrupted (from being buried in retina). | 3. Veins decrease towards the disc (blood column may be broken into segments). |
| 4. Venous pulsation on pressure. | No pulsation. |
| 5. Extensive retinal hæmorrhage. | No hæmorrhages, or very few. |

In cases of retinitis, a single vein sometimes becomes greatly distended and tortuous, while extravasations take place in the portion of the retina drained by it. Such a condition is depicted in Plate XXXVII., Fig. 83, and is probably due to thrombosis of the affected vein. A case has been published by Wolf¹ in which a portion of a retinal vein, limited on either side by the crossing of an artery, appeared empty, while on the peripheral side of the obstruction, the vein was distended to three or four times its normal calibre. The author attributes the obstruction in this case to the pressure of the thickened arteries.

¹ *Loc. cit.*

If the blocking of the vein is incomplete, hæmorrhages may be absent, and there may be no impairment of vision. It is possible that some cases of unioocular optic neuritis, in which the signs of venous obstruction are conspicuous, are due to thrombosis; Plate XXXIII., Fig. 75, may be an example of this. Although the fundus changes were very conspicuous, vision was normal throughout. The condition was attributed to a rather severe blow on the temple. Fifteen months later all swelling of the disc had disappeared. Its margin was clear, except above and below, and a few grey bands of tissue in front of the centre of the disc alone remained as evidence of the former papillitis.

SYMMETRICAL CHANGES AT THE MACULA IN INFANTS.

This is an affection of the cerebro-spinal system, occasionally seen in young infants, to which attention was first drawn by Waren Tay.¹ It causes changes at the macula somewhat similar to those which result from embolism of the arteria centralis retinæ, but less extensive. Indeed, it seems probable that this resemblance is more than accidental, and that the changes at the macula are due to a failure of the circulation in the extremities of the vascular loops, which converge towards the fovea centralis (*see* Fig. 29, p. 66).

Although many points require further elucidation, the clinical history of these cases is well established. It is briefly as follows:—

The disease has a tendency to attack several children in a family at about the same age. At birth they are apparently healthy. When they are a few months old, however, it is noticed that the head cannot be held up, then it is discovered that the muscles of the back and of the limbs are gradually losing power. There is an entire absence of pain, and the child is not fretful—indeed, a listless lethargic behaviour and an absence of crying appear to be conspicuous. In some of the cases there has been optic neuritis

¹ *Trans. Ophth. Soc.*, vol. i., p. 55, and vol. iv., p. 158.

going on to atrophy, but in most, when the case was first seen, the macula alone in each eye presented anything abnormal. It is almost sufficiently descriptive of the condition of the macula to say that it exactly resembles that seen in embolism. The central region of the fundus is occupied by a soft white patch, having a diameter of 1.5 to 2 dd. In the middle of this is the typical cherry-red spot. It is evident that central vision is not lost in the earlier stages, for the child fixes the light during ophthalmoscopic examination in the persistent manner that is

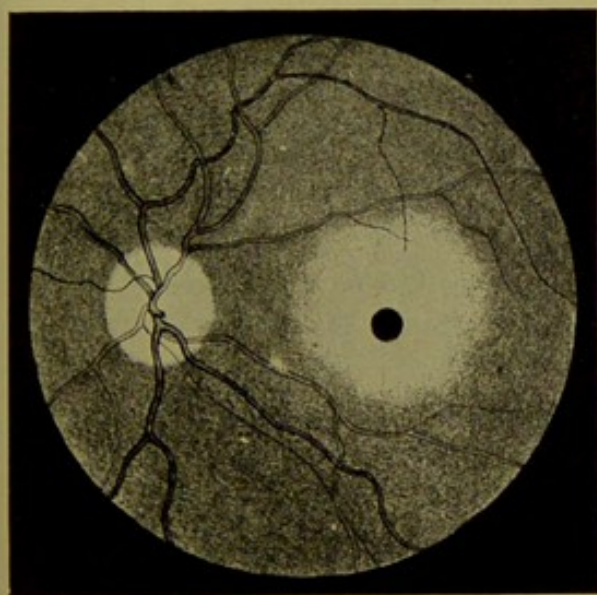


FIG. 42.

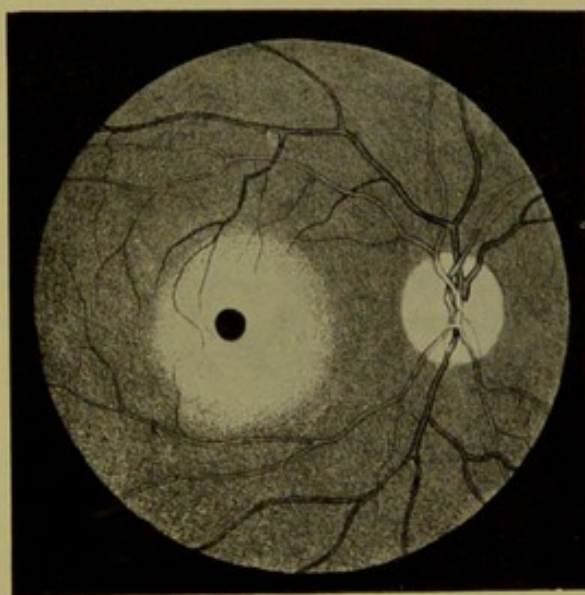


FIG. 43.

Warren Tay's case of symmetrical change at the macula in infants (inverted).

common in young infants. It is possible, however, that the fixation-point is surrounded by a wide belt of blindness, corresponding to the white retinal area. The disease appears to be invariably fatal, from progressive weakness.

There have been two autopsies recorded, and a microscopical examination of the retina in a third case. The most complete is that of Kingdon's second case¹ (No. 7 in the appended list of cases) The child died at the age of one year, after having sunk into a

¹ *Trans. Ophth. Soc.* vol. xii., p. 126.

weak, lethargic condition. "The symptoms during the last four days reminded one of the attacks which occur during the later stages of general paralysis of the insane." *Post-mortem*—The posterior fontanelle was closed, the anterior nearly so. Dura mater very firmly adherent to the skull along the line of the superior longitudinal sinus. No marked excess of cerebro-spinal fluid. Sulci over whole brain appeared wider than usual. Arachnoid and pia mater neither thickened nor adherent. No meningitis.

The brain was examined after hardening, but nothing abnormal was detected in the primary fissures or convolutions. A large number of sections from different cortical areas of the brain were examined, and similar changes were found in all, viz.—the different layers of cells were not so readily distinguished as usual. The large pyramidal cells were, almost without exception, of a rounded or oval outline. The cell substance did not stain well either with methyl aniline blue-black, hæmatoxylin and eosin, or acid fuchsin. The protoplasm had lost its even granular appearance, and was mostly collected into an irregular shrunken mass around the nucleus, leaving large spaces between the contents and the wall of the cell. The same changes were present to a less degree in the small pyramidal cells. Deiter's cells seemed to be largely increased in number, but it was doubtful whether many of these were not altered pyramidal cells. Sections of the spinal cord at the second and third cervical vertebræ showed well marked descending degeneration.

A microscopical examination of the eyes made by Mr. Treacher Collins showed the choroid to be normal. In the central area of the retina the only defect found was that the outer molecular layer seemed spaced out and enlarged, as though there had been some localised œdema. In both retina there was a prominent fold in the macular region. A similar condition, it will be seen, was present in case 8 (*see* p. 194).

The autopsy in the other case, which was under Dr. Knapp, was less complete, since neither the spinal cord nor the eyes were

examined. There was marked alteration in the large and small pyramidal cells of the cortex, and atrophy of the cerebral convolutions from arrested cerebral development.¹

The following is a summary of the cases hitherto recorded:—

Three cases in one family by Mr. Waren Tay (Trans. Ophth. Soc., vols. i. and iv.).

(1.) Eldest child (male). Seen at age of 12 months, when the typical ophthalmoscopic appearances were already present.

When two or three weeks old the child was noticed to have little power of holding up its head, or moving its limbs. The weakness increased, but at the time of the visit no paralysis could be discovered.

Four months later child lying almost helpless. Changes at macula unaltered, but discs becoming atrophic. Died at the age of a year and eight months.

(2.) Second child (male). Seen a few months after birth, with similar condition of the eyes. Nothing amiss could then be discovered with the muscular or nervous system, but at age of 6 months he began "to get weak all over," like the first child. When 18 months old admitted into London Hospital. Had convulsive seizures. One morning a definite epileptiform convulsion, the right side of the body being rigid and the eyes deviating to the right. The discs were atrophic, the yellow spots as in the first case. There were two other fits. Child sank and died after being in hospital 24 days.

(3.) Third child of same family, also a male. When seen a few weeks after birth there was optic neuritis, but no general weakness. At the age of 6 months the discs were atrophic, and the typical macular changes were present. The child now appeared to be beginning to fail like the first. The case could not be followed.

Two cases in another family by Mr. Waren Tay (Trans. Ophth. Soc., vol. xii.).

(4.) Male child, aged 11 months, lay helpless in mother's arms. No power to lift his head. Typical changes at each macula. Discs thought to be grey. V. apparently defective. Patient was sixth and youngest child.

(5.) The eldest child (male), said to have presented similar symptoms, he wasted and died at the age of 15 months. Four other children—three females and one male—not affected.

Three cases in one family, by Mr. Kingdon (Trans. Ophth. Soc., vols. xii. and xiv.).

(6.) Eldest child, a male (born 1885), well developed at birth, subsequently became weak in the back and limbs, was good tempered and apathetic, wasted and died at 2 years.

The second child, a girl (born 1886), was unaffected when seen at age of 5½ years.

(7.) Second case, third child, a male (born October 1890). Seen at age of 8 months, when typical changes were present in the eyes, as well as impaired movement of trunk and limbs, and inability to hold up head. Child apathetic, seldom crying; evidently great muscular feebleness. Changes at macula as in other cases. Child gradually became weaker and died. The autopsy is given on p. 191.

A fourth child, a male (born April 1892), was seen when 10 days old, and again when nearly 2 years old, and presented nothing abnormal.

(8.) A fifth child, female (born April 1893), (*Trans. Ophth. Soc., vol. xiv.*), was first seen

¹ B. Sachs, *Journ. Nerv. and Ment. Dis.*, N. Y., September, 1887.

when 3 months old. Muscular weakness was then commencing, but the fundi were normal. When 5 months old there was a suspicious haze at each macula. When 8 months old the typical appearances were present at the macula. The child died, and both eyes were removed and examined by Mr. Treacher Collins. His report, which has not been published, is as follows:—

The optic nerve is much atrophied. There is considerable increase in the amount of the fibrous tissue between the bundles of nerve fibres, and also a large increase in the number of round cells in the nerve. There is considerable cupping of the optic disc, due to atrophy of the nerve fibres—almost down to the lamina cribrosa—and not to depression backwards of that structure.

No inflammatory exudation is seen between the dural and pial sheaths of the nerve. The central artery is full of blood clot; the central vein is empty; no alteration is seen in the wall of either vessel.

The choroid in the region of the yellow spot has its vessels dilated, but no inflammatory or other changes are seen in it. The retina at the yellow spot has a fold or ruck in it, so that it is slightly detached in that region from the choroid. It is there much thickened, due to enlargement of the outer molecular layer, the tissue of which is much spaced out, here and there cavities being left; the condition is apparently due to œdema.

So far as can be made out, the other layers show no changes. Elsewhere than in the yellow spot the retina appears healthy.

(9.) Goldzieher (*Centralbl. f. prakt. Augenh.*, Leipzig, 1885, p. 219) mentions a case of an infant with similar ophthalmoscopic appearance. The child died.

(10.) Magnus (*Klin. Monatsbl. f. Augenh.*, Stuttgart, 1885, bd. xxiii, p. 42). Female child, aged 18 months, the eldest. Muscles weak and flabby, unable to hold up head. Ophthalmoscopic appearances at macula, as in other cases. Discs not atrophic.

(11.) Hirschberg (*Centralbl. f. prakt. Augenh.*, 1888, p. 14) saw a feeble looking child with similar condition of macula. It was said to be suffering from an incurable disease of brain and spinal cord.

Two cases in one family, by Wadsworth (Trans. Am. Ophth. Soc., 1887, p. 572).

(12 and 13.) Female, 11 months, sixth child. (The fifth, born four years before patient, presented similar symptoms, and died at age of 18 months.) Child unable to sit, stand, or hold up her head. Muscles wasted. Fundi as in the other cases. Discs not well seen, owing to persistent fixation of the light. Four and a half months later child did not fix and discs were grey.

(14.) Case by Knapp (*Ber. ü d. 17ten Versamml. d. ophth. Gesellsch.*, Heidelberg, 1885, p. 217). Seen when 4 months old. General condition improved. It then rapidly sank and died at age of 2 years.

A *post-mortem* was obtained as already mentioned, but it did not include an examination of the eyes.

(15.) Female, 19 months (C. B. Carter, *Arch. Ophth. and Otol.*, N. Y., vol. xxiii, p. 126), second child. Eldest died at 7 months, after an illness of a week, "with spasms." Parents were second cousins. Patient well till three months old. Then gradually increasing weakness, without paralysis. When seen, unable to lift the head or to sit up. Limbs moved slowly. Tonic contractions of muscles of neck and limbs every hour. Pupils active. Does not follow a light. Changes at the macula as in the other cases. Discs pale six weeks later. The discs were completely atrophic. Child died two weeks later. No autopsy.

LEUKÆMIC RETINITIS.

Marked fundus changes occur in the later stages of most cases of leucocythæmia. Nor is this to be wondered at when it is remembered how largely the appearance of the fundus depends on the blood in the choroidal and retinal vessels, and how profound is the alteration that the latter undergoes in this disease.

In normal blood the proportion of white to red corpuscles is one white to three or four hundred red. In the splenic vein the proportion of white corpuscles is much higher, namely, one to sixty or seventy red. In leucocythæmia, the number of white corpuscles progressively increases, so that, in a late stage of the disease, they may equal, or even exceed, the red. This alone is sufficient to alter appreciably the colour of the blood when seen in bulk, or in the blood vessels of a tissue as vascular as the choroid, and explains the pale yellowish or orange tint which the fundus presents in some of these cases. The white corpuscles are larger than the red, and they have a decided tendency, not shown by the latter, to dawdle along the wall of the vessel, or even to remain in contact with it. This tendency, together with their accumulation in the vessels, seriously impedes the circulation. There can be no doubt that most of the fundus changes are due to this cause.

The most constant and conspicuous of these changes is the enormous distension and tortuosity of the retinal vessels. The arteries may be affected to an extent only slightly less than the veins, and, as the change in the blood tends to diminish the difference in colour between the two sets of vessels, it is sometimes difficult to distinguish between them.

A less constant ophthalmoscopic appearance is produced by the presence of small, rounded, white spots, chiefly at the periphery; the larger of which are raised above the level of the retina. They

probably consist of leucocytes which have escaped from the overfilled capillaries (Gowers). In other cases there are white dots which are due to degeneration of the tissue of the retina.

In leucocythæmia there is a strong tendency to hæmorrhage, as shown by the frequent co-existence of epistaxis, and bleeding from the alimentary canal, and by profuse hæmorrhage following slight wounds. Notwithstanding this tendency, retinal hæmorrhage, although sometimes extensive, is by no means a constant symptom.

Lymphatic deposits occur in many organs. In a remarkable case, published by Leber,¹ such growths were present in all four eyelids, and, as he believed, from the great proptosis, also in the cellular tissue of the orbits.

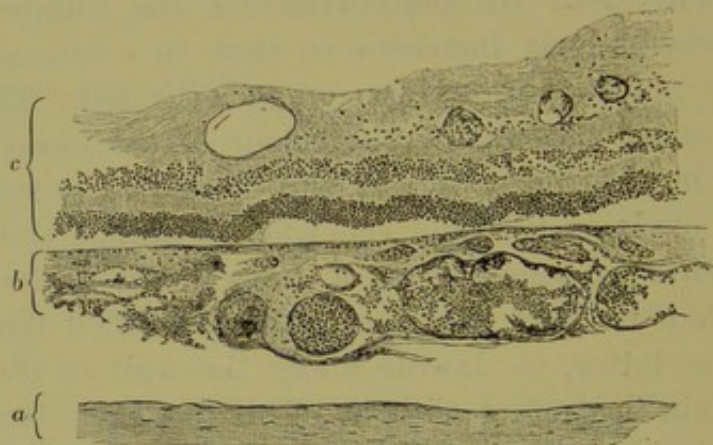


FIG. 44.—Leukæmic retinitis.
a, Sclerotic; b, choroid; c, retina.

An illustration of the ophthalmoscopic appearance that may be present in this disease will be seen in Plate XXXIII., Fig. 74. The veins and arteries, especially the former, are enormously distended, make snake-like curves, and are similar in colour. It is to be noticed that the light-streak on them is unusually conspicuous. The whole fundus has an indistinct appearance as if veiled by some cloudiness of the media, although no definite opacities were visible.

¹ *Arch. f. Ophth.*, Leipzig, bd. xxiv., ab. i., p. 295.

The patient from whom this drawing was made died six weeks later. Mr. John Griffith examined the eyes *post-mortem*, and kindly favoured me with the following report, as well as with the microscopical section from which Fig. 44, p. 196, is drawn:—

Post-mortem on January 30th, 1893. Both eyeballs, with optic nerves, were removed intact. After being hardened in Müller's fluid for about six weeks, the *LE.* was used for making a "jelly preparation," and the *RE.* was used for microscopical sections.

The papilla was slightly swollen, and the retinal vessels, especially the veins, like the vessels in all parts of the globe, were gorged with leukæmic blood.

The changes in the retinal vessels, as described and depicted by Mr. Edmunds (*Trans. Ophth. Soc.*, London, vol. x., p. 157), were not present.

The walls of the blood vessels were normal, and all the vessels contained blood (not coagulum), in which the leucocytes appeared to predominate. The choroid showed this vascular distension in a remarkable manner, being two or three times its natural thickness.

Contrary to what might be expected, there was no excess of leucocytes in the perivascular tissue; in fact, it appeared as if diapedesis had been thrown into abeyance.

The ciliary processes and iris were slightly swollen, but were otherwise normal.

The optic nerve, at its junction with the globe, was somewhat bulbous, but there was no excess of cellular elements in the inter-sheath space. The optic nerve itself showed no signs of inflammation, the swelling being due, as I believe, entirely to mechanical œdema of the papilla, which obstructed the venous return.

In a case published by Oeller,¹ the changes in the choroid and retina were more advanced. Unfortunately no ophthalmoscopic examination had been made. The following is a greatly abridged account of the conditions found *post-mortem*:—

Spleen much enlarged. A great accumulation of leucocytes not only in its vessels, but in their sheaths, and throughout its parenchyma. In the liver and lungs the vessels, even to their finest branches, choked with leucocytes. In the eye the choroid was in places double the normal thickness, and contained leucocytes so crowded together that it was impossible to ascertain whether they were in the vessels or free in the tissue. The larger vessels were enormously dilated, and most of them were filled with blood corpuscles in the proportion of from six to ten white to one red; only in a few did the red preponderate. In other situations there were no free corpuscles, but the choroidal vessels were filled with them, the white preponderating. The head of the optic nerve was moderately swollen. In the nerve itself there was an excess of nuclei, and the interstitial tissue was increased. In the retina the fibre and nerve cell layers were nearly double the normal thickness; the layer of rods and cones were much atrophied. The retinal vessels dilated, and very tortuous, and from them capillaries (new?) could be traced as far as the outer granular layer.

¹ *Arch. f. Ophth.*, Leipzig, bd. xxiv., ab. iii., p. 239.

In a case recorded by Walter Edmunds,¹ the walls of the retinal arteries were much thickened, and the endothelium proliferated, the veins were filled with clot, containing an excess of leucocytes, but their walls were not thickened.

We have seen that many pathological changes in the optic nerve and retina depend upon general conditions. Thus, they may be associated with diseases of the central nervous system, with changes in the character of the blood, or with affections of the heart or kidneys.

The importance of vision in all the occupations of life leads patients who suffer from its deterioration to seek advice earlier than they might do on account of general symptoms. Hence those who practice ophthalmic surgery have the first opportunity, in many cases, of recognising general conditions of grave import to health or even to life. Opportunities of this kind are, however, useless, without sufficient knowledge of medicine in general. To the physician, on the other hand, the ophthalmoscope frequently lends valuable aid in forming a diagnosis, or in determining a prognosis. It will, however, prove a misleading guide if he has not had sufficient experience in its use to be familiar with the more common physiological variations of the disc and fundus.

In the conditions of the retina which remain to be considered, the connection with general disease is less direct or less obvious.

¹ *Trans. Ophth. Soc.*, vol. x., p. 157, and Figs. 1 and 2, Plate VI.

CHAPTER XI.

PUNCTATE CONDITIONS OF THE FUNDUS.

SEVERAL conditions resemble each other in presenting a number of pale dots scattered over the fundus. None of these are larger than the width of the primary divisions of the retinal vessels, and some are much smaller.

Some of these dots doubtless originate in the choroid, and subsequently invade the retina, or, at any rate, its pigment layer. It is equally certain, however, that others are of retinal origin. Our knowledge is not yet sufficiently advanced to permit us to make a complete classification, but we may conveniently include these conditions under the designation of punctate conditions of the fundus, and consider them under the following heads:—

(a) The dots described by Marcus Gunn, and called by his name, have already been described (p. 26). They are of small size, occur chiefly in the yellow spot region, and are arranged in groups. The usual mode of arrangement is seen in Plate IV., Figs. 9 and 10, and Plate XI., Fig. 30, but the dots never appear so conspicuous as this; indeed, one of their chief characteristics is that they are difficult to see, being often visible only when the light is feeble, and falls on them obliquely. Their colour does not approach whiteness, they are merely a paler colour than the fundus, sometimes having a yellowish tinge. They are most frequently seen in the dark eyes of young subjects in whom the retinal reflexes are well marked.

(b) Minute silvery dots are occasionally seen. Unlike the preceding variety, they do not occur in groups, but are isolated. They are so small that they would easily be overlooked, were

it not for their great brilliancy, which gives them a metallic appearance, like particles of mercury. They may be met with at any age, and, although more frequently seen between the disc and the fovea centralis, they may occur in any part of the fundus. The writer has most frequently seen them in cases in which the ophthalmoscope has been used with especial care to ascertain the cause of an unexplained amblyopia. But they are also found in eyes with normal vision. They are too small and round for crystals of cholesterin, and are probably due to some irregularity of the retinal surface, which causes total reflection to take place, the metallic brightness being produced by the image of the ophthalmoscope mirror. Their brilliancy of reflection suggests the term metallic dots.

(c) The dots of chalky whiteness which are often seen in the yellow spot region in cases of neuro-retinitis have already been sufficiently described in dealing with that condition.

(d) Isolated dots, few in number, and of white colour, are occasionally seen in the eyes of persons past middle life. Hyaline excrescences projecting from the lamina vitrea of the choroid into the retina are known to occur in such eyes, and the appearance is attributed to them.

(e) According to Nettleship,¹ a condition of the fundus occurs in young persons, in which the spots are small, round, and dead white in colour. They usually lie between the macula and the periphery, the macula itself being free. He has met with the condition in several members of the same family, in whom it was associated with night blindness and contraction of the visual fields. At the periphery of the fundus, beyond the area occupied by the white dots, were pigment changes, consisting in a mottled appearance of the pigment layer, and, in some instances, in deposition of pigment, which, however, had not the typical arrangement characteristic of retinitis pigmentosa.

¹ *Trans. Ophth. Soc.*, vol. vii., p. 301; and vol. viii., p. 163.

The peripheral pigment changes and the subjective symptoms might be thought to point to the condition being a variety of retinitis pigmentosa. But against this is the fact that in two sisters who were seen by Nettleship¹ after an interval of five years, no appreciable change had occurred. True retinitis pigmentosa, however, occasionally appears to remain stationary for many years. The cases, therefore, would have to be watched for a long period before any positive conclusion could be arrived at. A mottled condition of the fundus at the periphery is sometimes seen as a result of inherited syphilis, but there were no definite signs of this disease in any of the cases.

These cases are considered by Nettleship to be identical with one described by Mooren² under the title retinitis punctata albescens.

(f) The next group of cases has been described under a variety of names, a glance at which will indicate that they represent different views as to the pathology of the affection under consideration. The following are some of the terms used:—"Tay's choroiditis,"³ "Infiltration vitreuse de la rétine (Masselon)"⁴ "Punctate retinitis," "Central senile guttate choroiditis."

The common characteristics of these cases are that the dots are round, pale yellowish, about the diameter of the primary retinal arteries, and occur chiefly in the central region of the fundus. They are met with, as a rule, only in persons past middle life, and, unless very numerous, do not cause serious impairment of vision.

A typical example of this condition is given by Nettleship,⁵ whose paper is illustrated by an excellent chromo-lithograph. In Masselon's monograph also there are some good photographs.

Owing to the extreme slowness with which the condition changes, and to the fact that vision is not much affected, little

¹ *Trans. Ophth. Soc.*, vol. xiii., p. 292.

⁴ Masselon, "Infiltration vitreuse de la rétine," 1884.

² "Fünf Lustren," 1882, p. 216.

⁵ *Trans. Ophth. Soc.*, vol. iv., p. 162.

³ *Ophth. Hosp. Rep.*, London, vol. viii., p. 231, 1875.

is positively known about the progress of these cases. It is probable, however, that eventually further degenerative alterations occur, leading to atrophy of the central part of the choroid.

(g) Dots resembling those of Tay's choroiditis are sometimes met with in the eyes of younger persons (Plate XI., Fig. 31), but in these cases they are much more numerous, and are not limited to the macular region. The condition remains without appreciable change for many years, and is not, as a rule, associated with any impairment of vision, although in some cases there has existed a slight degree of night blindness, and in a few slight contractions of the visual field. The condition is probably due to some change in the pigment layer, possibly a colloid degeneration such as described by Wedl and Bock.¹

Under the term colloid disease of the macular region, G. de Schweinitz² has described a grouping of these dots in the macular region. They were closely aggregated, and covered a circular area of about three disc diameters. In the illustration given by the author the dots appear very similar to those in Plate XI., Fig. 31, but they are described as having a raised appearance, and seeming in places to be piled one above the other.

It is at present doubtful whether these cases should be considered to constitute a separate group, or should be included in the class described by Nettleship, which have been considered under (e), or finally, if they represent a variety of Tay's choroiditis.

The following list shows the main characteristics of the different varieties of punctate conditions :—

SUMMARY OF PUNCTATE CONDITIONS.

(a) *Gunn's small dots*.—Pale or yellowish, in groups in Y.S. region. Difficult to see. Chiefly in young eyes.

(b) "*Metallic*" dots.—Minute, isolated. Occur in any part of fundus. Conspicuous from their brightness. Occur at all ages.

¹ *Path. Anat. des Auges.*, p. 219, and Fig. 100.

² *Trans. Am. Ophth. Soc.*, 1894, p. 212.

(c) *Neuritic dots*.—Irregular shape. Chalky whiteness. In *Y.S.* region, and between this and *OD.* Associated with signs of neuro-retinitis.

(d) *Hyaline excrescences from lamina vitrea*.—Isolated white round dots. Usually in old persons.

(e) *Nettleship's dots*.—Minute, dead white, round. Numerous, uniformly scattered between macula and periphery. Associated with pigment changes at periphery and night blindness. Occur in several members of same family. Stationary or very slowly progressive.

(f) *Tay's choroiditis*.—(Central guttate choroiditis. Infiltration vitreuse de la rétine.) Pale or yellowish, approaching whiteness. Scattered chiefly *Y.S.* region. Occur after middle life.

(g) *Colloid change in pigment layer*.—Numerous pale dots, almost in contact. Occurring over whole fundus. Most numerous in *Y.S.* region. No impairment of vision. Met with in young adults.

HYALINE PROLIFERATIONS ON THE DISC. (*Syn.* Amyloid Bodies, Drusenbildungen.)

Clusters of small, glistening, globular bodies are occasionally seen on the disc. They are highly refracting, of grey or bluish-grey colour, and are closely aggregated, like an unthinned bunch of grapes.¹ They have generally been considered as being of the same nature as the outgrowths from the lamina vitrea of the choroid, and, as they are most commonly situated on the margin of the disc, it has been thought that they are connected with that structure. Microscopical examination, however, of two papillæ, in which these bodies had been seen with the ophthalmoscope² has shown that they may also be present in the nerve behind the lamina cribrosa. They would appear, from this case, to be composed of a material almost identical with the hyaline substance sometimes met with in the outer coat of the blood vessels, and to result from a degenerative change in the interstitial tissue of the nerve and papilla. The condition does not appear to cause any impairment of vision, unless the nerve fibres are pressed upon.

¹ For two excellent illustrations of the ophthalmoscopic appearances see Nieden, *Arch. Ophth. and Otol.*, N. Y., vol. xviii., p. 198.

² Sachsaler, *Beitr. z. Augenh.*, Hamb. u. Leipzig, heft xxi., 1895.

CHAPTER XII.

PIGMENT CHANGES IN THE RETINA.

PIGMENTARY DEGENERATION OF THE RETINA—RETINITIS PIGMENTOSA—SCLEROSIS OF THE RETINA.

Under these various names has been described a disease, which has usually a definite clinical history, and which presents a characteristic ophthalmoscopic appearance, although many points in its pathology are still obscure.

The first symptoms manifest themselves, as a rule, about puberty; exceptionally, however, the disease is found to be already considerably advanced in childhood. These latter cases are usually regarded as examples of the congenital form of the disease.

The most noticeable subjective symptom is usually night-blindness; that is, a disproportionate lowering of the visual acuity under reduced illumination. This may be so pronounced that a patient who is not conscious of any defect in broad daylight may require to be led by the hand at dusk, or on going in the daytime into a badly lighted room.

Night blindness also occurs in other affections, especially in cases of advanced choroido-retinitis in which there is much atrophy of the pigment layer. Occasionally it is absent, or at least not prominent, in cases of retinitis pigmentosa, which are otherwise typical. That it depends neither upon the severity of the disease, nor upon the stage in which it is seen, appears from a case published by Hutchinson,¹ in which this symptom was absent, although the disease had existed for twenty years, and the ophthalmoscopic signs were well marked.

¹ *Ophth. Hosp. Rep.*, London, vol. vi., p. 39.

A nearly constant symptom is concentric contraction of the visual field. Of this the patient is usually unconscious, although he describes vividly enough its direct consequence, namely, that in walking towards a point on which his gaze is fixed, he knocks against intervening objects.

The fundus changes in retinitis pigmentosa are characteristic, but in the early stage they may easily be overlooked, since they are then limited to the periphery. The most noticeable is the deposition of pigment in the superficial layers of the retina. At first the pigment is seen only towards the equator, and may be limited to a few branching streaks, or dots with processes shooting out from them (as in Plate XLIV., Fig. 97). As the pigment become more abundant, it forms an irregular network, as in Plate XLII., Fig. 94. If examined closely, it is now seen to consist for the most part of irregular spots of pigment with processes jutting out and anastomosing with similar branches from other spots. The appearance presented by the pigment deposits has been compared with that presented by bone-corpuscles under the microscope. A comparison with moss, teased out and flattened, would be more accurate. The pigment often invades the sheath of a blood vessel, and may then conceal the blood column for a short distance. Under the microscope, vessels too small to be visible with the ophthalmoscope, are found thus encased in pigment, and the appearance presented to the ophthalmoscope of black branching lines (as in Plate XLV., Fig. 97) sometimes suggests that the pigment may be lying in the course of vessels which are too small to be visible. There is, however, no known anatomical arrangement of the fine vessels which enables us to accept this as the explanation of the arrangement of the pigment when it is abundant, as, for example, in Plate XLII., Fig. 94.

In choroiditis the distribution of the pigment is, as already pointed out, quite different. It encircles or covers the areas of choroidal exudation, so that when the latter has been absorbed the

pigment remain in the form of rings or discs as in Plate XV., Fig. 40; and Plate XVIII., Fig. 44. It must, however, be remembered that in a late stage of choroiditis secondary pigmentation of the retina may occur, and produce a condition identical with retinitis pigmentosa.

Both in choroiditis and in retinitis pigmentosa the source of the pigment is the pigmentary layer of the retina, which, it will be remembered, lies next the choroid. The stellate arrangement of the pigment deposit which characterises retinitis pigmentosa only occurs when pigment has reached the surface of the retina. To do this it must traverse all the retinal layers, and it is probable that degenerative changes in these are a necessary preliminary to its passage.

In the early stage of retinitis pigmentosa the symptoms are night blindness and some contraction of the visual field in each eye. The ophthalmoscopic changes may be limited to the equatorial zone, and consist of only a few streaks or dots of pigment. Sometimes normal fundus can be seen at the periphery beyond the affected zone. The portion of the visual field that is lost is always greater than would correspond with the pigmented area of the retina. Consequently, even when there exists a peripheral zone of healthy fundus, the periphery of the field is usually lost. In exceptional cases, however, of this nature, the defect in the field consists in a band corresponding in position with, but wider than, the band of pigment. Such a condition is called a ring scotoma. In the description facing Plate XLII., Fig. 94, is seen the chart of a field, in which such a ring scotoma appears to be in process of formation.

The advance of the disease is shown by increase in the amount of pigment, which slowly creeps towards the central region, and by progressive contraction of the fields. Central vision, although usually eventually impaired, may long remain unaffected in a good light. It is usual, as the area of pigment deposit increases, for the

pigment layer to undergo some atrophy, so that the choroidal vessels become visible.

In advanced cases, as Plate XLIII., Fig. 96, there are other changes which indicate degeneration of the retinal tissue. The width of the blood column in both the arteries and the veins becomes reduced, and the disc assumes a dull greyish appearance.

The change in the vessels is due to a hyaline thickening of their walls, which encroaches on the lumen. It does not interfere with the transparency of the vessel wall; the blood column, therefore, remains visible, but may be reduced to a mere thread.

The change in the disc occurs not only in retinitis pigmentosa, but in some cases of old choroiditis. Although easily recognised, it is difficult to describe or to depict. The term waxy is often applied to it, but a comparison to old parchment would perhaps be more appropriate. Its surface looks dull and flat, as if its transparency were impaired. Its colour is pale grey, with a yellowish tinge. The margin may look a little hazy, probably from impaired transparency of the nerve fibres, but there is an entire absence of any swelling. Sometimes it is surrounded by a halo of choroidal atrophy.

Posterior polar cataract occasionally develops, but less frequently than in choroiditis.

The progress of the disease is very slow, and the ophthalmoscopic appearances often present no appreciable alteration after an interval of three or four years. The night blindness, however, usually increases.

It is evident from what has been said that the deposition of pigment, although giving a name to the disease, is not the only tissue alteration in the retina. Indeed, there is good reason for believing that the pigmentation of the retina is merely secondary to other changes, and is not an essential feature of the morbid process. In the first place, the amount of pigmentation stands in no constant relation to the duration of the disease or to the

degree of visual impairment. Secondly, pigmentation, identical with that of retinitis pigmentosa, may occur as a secondary change in any condition which has caused atrophy of the retina with great diminution of its vessels. It also occurs in animals after experimental division of the optic nerve. Lastly, cases are occasionally met with which exhibit most of the symptoms of retinitis pigmentosa, but show no deposition of pigment.

The above facts point to the process being degenerative rather than inflammatory, and it is strange, therefore, that it should usually commence in early life. Indeed, the etiology of the disease is involved in obscurity. Its typical form does not seem to depend upon inherited syphilis, although Loring states that there is a form of the disease due to this cause, and that it affects one eye only. This is so opposed to what we know of syphilitic affections that the statement requires corroboration.

The writer has seen an affection of the pigment layer in syphilitic children, which produced in the periphery of the fundus a mottled appearance, with numerous small pale, but not very conspicuous dots, possibly due to a colloid degeneration of the pigment cells, but the cases were not under observation sufficiently long for the subsequent stages to be followed.

Consanguinity in the parents is believed by many authorities to be a frequent cause of retinitis pigmentosa. It is difficult to estimate the truth of this without knowing the proportion of these to other marriages. It is certain, however, that in this country only a very small proportion of the cases of retinitis pigmentosa are the offspring of marriages of consanguinity. The disease usually affects several members of the family, and is hereditary to a marked degree. The liability to it would doubtless be greatly increased by intermarriages between members of a family in which it existed.

Retinitis pigmentosa occurs in a large proportion of deaf mutes, but the cause of this association is unknown.

A degenerative process, which might be called choroido-retinal sclerosis, is sometimes met with in the adult fundus. It produces

appearances in some respects resembling retinitis pigmentosa, and is usually accompanied by similar symptoms. There is deposition of pigment in moss-like masses, but these are fewer and more isolated than in retinitis pigmentosa. There is atrophy both of the pigment layer and of the capillary layer of the choroid, so that the choroidal vessels are visible, and the spaces between them are of chocolate colour. In a late stage of the disease, the choroidal vessels, especially near the disc, become white. These changes are probably secondary to diffuse choroiditis, and have been described more fully with that condition on page 106 (for examples, see Plate XXVI., Fig. 60, and Plate XXVII., Fig. 61).

PIGMENT STREAKS ON THE FUNDUS. (*Syn.* Angioid Streaks.)

Pigment derived from the pigment layer of the retina tends to arrange itself, as we have seen, in the form of branching spots, forming an open network in retinitis pigmentosa, or in thicker lines bordering a patch of choroidal atrophy, or more rarely in large masses in choroiditis. In all these cases the pigment is black.

Cases have been described which differ from all these, in the fact that the pigment is not black, but of a dull red brown, like the pigment moles described on page 19. It is arranged in long irregular streaks, which in respect of their size, mode of branching, and course, somewhat resemble blood vessels, but their borders are irregular and jagged, their diameter variable, and the bends that the streaks make are more angular than is usual in blood vessels. Moreover, no direct connection can be traced between them and the vessels of the choroid or retina.

The writer is acquainted with six published cases, which, although they present differences of detail, are sufficiently similar to warrant the conclusion that they are identical in nature.

In all, both eyes were affected. In Mr. Doyne's patient there was a history of an injury to each eye; there was considerable

choroidal or retinal hæmorrhage in the one eye, and the history pointed to its having occurred in the other. In some of the other cases, the history of sudden failure many months before the ophthalmoscopic examination, and the presence of small extravasations, point to the probability of a hæmorrhagic origin.

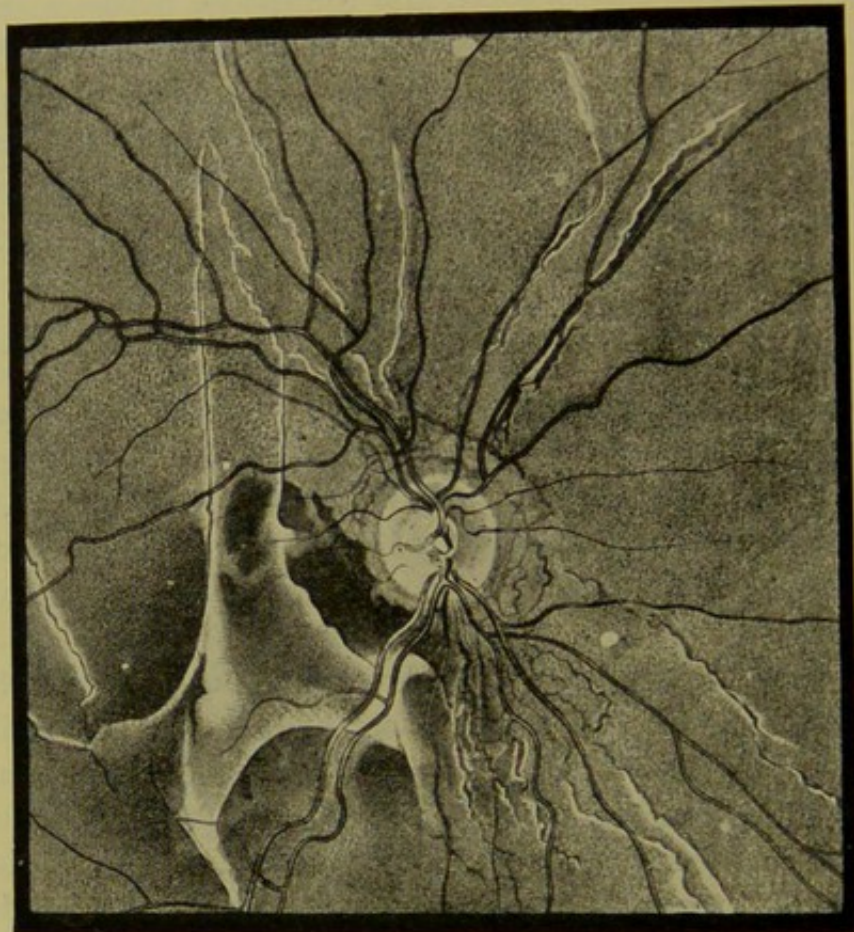


FIG. 45.—Mr. DOYNE'S case of retinal streaks.

The following is a brief summary of these cases¹:—

(1.) Otilie K., young adult (KNAPP, *Arch. Ophth. and Otol.*, N. Y., bd. xxi., p. 289, 1892).—Taken ill in 1889 with vomiting and diarrhœa, five days later sudden pain and dizziness in

¹ All the published accounts are accompanied by illustrations. The last three by chromolithographs, which give a good idea of the appearance of these streaks, and the first by a drawing in black and white, which shows their distribution.

eyes, following exposure to bright light. Then gradual deterioration of V. When seen three months after commencement of illness, both *OD's* white, fields contracted, vessels of normal calibre. Fundi dull and mottled. A month after first visit choroidal pigment showed disturbance, and there was seen a system of dark-brown or black streaks lying beneath the retinal vessels, radiating in every direction from the neighbourhood of the disc, their diameter was irregular. No hæmorrhages seen, but some of the streaks had red portions. Eighteen months later no material change but the red portions of the streaks had disappeared.

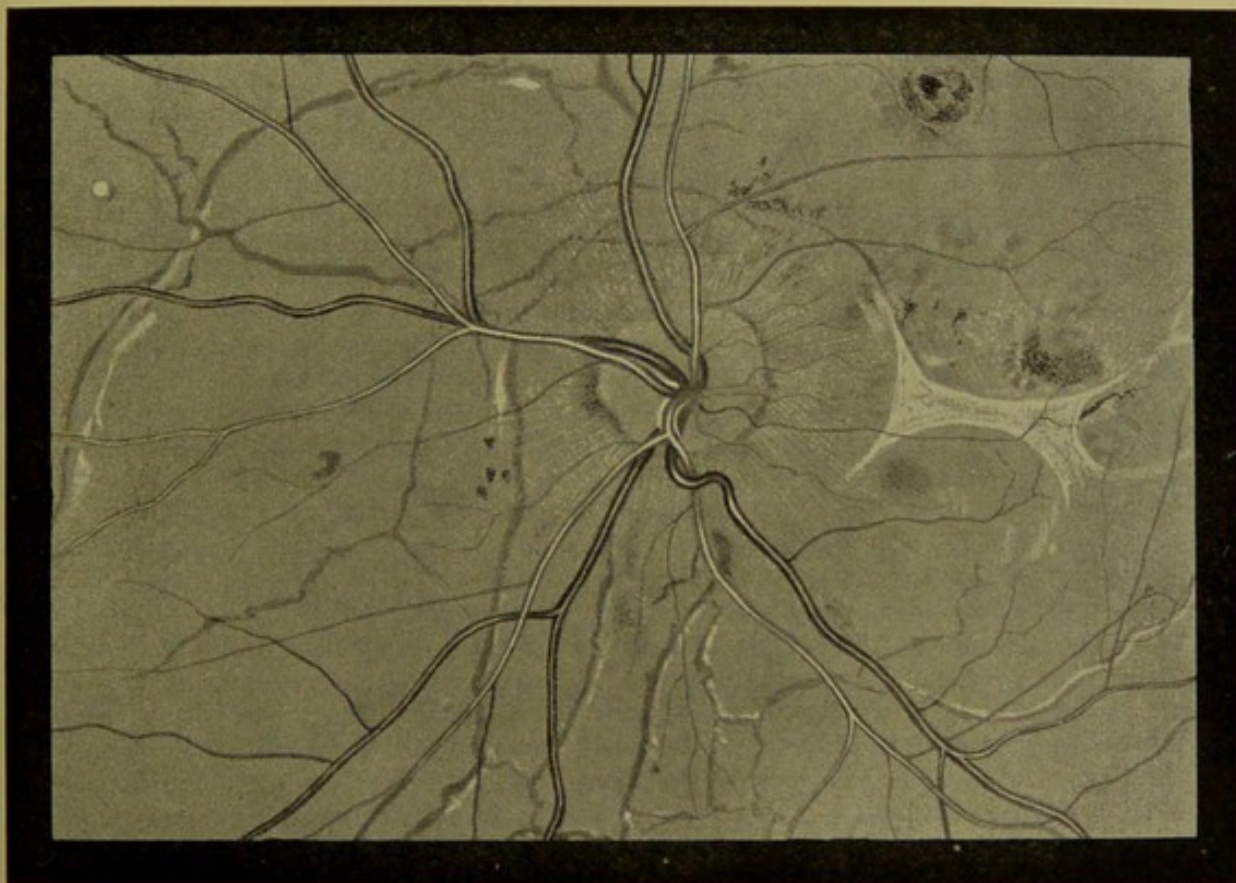


FIG. 46.—Mr. STEPHENSON'S case of retinal streaks.

(2.) Mrs. H., 83 (PLANGE, *ibid*, p. 282).—In 1879 she noticed a failure of vision. There was a transient improvement, but in the course of years V. failed again. When seen, the condition noted was as follows:—

Brown membranous filaments in each eye, about diameter of retinal vessels. They were 2-3 dd. long, and ran in the general direction of the vessels. At the peripheral end of each, a small hæmorrhage. In *RE*. three such striæ united at the nasal side of disc. Another filament ran to *YS*. from opposite side of *OD*., and ended in a white atrophic plaque which included the macula. In the *L*. a single pigment stria running up and in from nasal side of *OD*. and ending in a hæmorrhage. Patient was watched for six months, during this time

the hæmorrhages in *RE.* partially absorbed and recurred several times, the membranes developing as the hæmorrhages underwent absorption.

When seen ten years later, the following was the condition:—*RE.* dull-brown streaks radiating from the disc. Their origin near the disc is not sharply defined, but they appear to proceed from a layer of opaque greyish-white glistening tissue, they are here double the diameter of the central vessels, towards periphery they become narrower and break up into a number of plaques and points of the same colour. The striæ are included in broader bands of lighter colour, which give the appearance of retinal reflex. A patch of atrophic choroiditis at *YS.* V. finger eccentrically at 3 *M.*

LE. four main pigment striæ run from neighbourhood of *OD.* towards periphery; they are about the size of the primary retinal veins; near the disc some give off communicating branches which, uniting, form an incomplete circle round the disc. V. normal.

With a few exceptions the striæ are depicted in both eyes as lying beneath the retinal vessels.

(3.) Male, name and age not stated. (DOYNE, *Trans. Ophth. Soc.*, vol. ix., p. 128).—More than ten years ago, an injury to *LE.* followed by loss of central vision. This recovered and when seen V. $\frac{6}{8}$.

Six weeks ago, blow on *RE.* Central vision lost. An extensive choroidal hæmorrhage which is clearing up, leaving patches of atrophy. In both eyes pigmented lines radiating from the disc. In the eye depicted (Fig. 45, p. 210) they are mostly accompanied by white bands; their outline is jagged and irregular; they are coloured grey, some being reddish-brown. They all lie beneath the retinal vessels. Most of the lines run in a radial direction from *OD.*, but they are connected near *OD.* by similar small lines parallel with disc margin.

(4.) Samuel G., 42 (STEPHENSON, *Trans. Ophth. Soc.*, vol. xii., p. 140).—About fifteen months before he was seen the left eye began to fail. After deteriorating for three to four weeks the sight again improved. Three months before he was seen both eyes failed, the left being the worse. The sight continued to deteriorate up to the time of his visit. There was a systolic murmur, believed to be mitral, otherwise the patient appeared to be in good health. The ophthalmoscopic appearances were similar in the two eyes. Those in the left eye are shown in Fig. 46, p. 211. Brownish-black ragged branching lines radiate from the disc, a few are accompanied by white bands. They all lie beneath the retinal vessels. A few small hæmorrhages, and a patch of cicatricial tissue, with concave borders at *YS.* Later, fresh hæmorrhages occurred.

(5.) Josephine P., 23 (WALSER, *Arch. f. Augenh.*, Wiesb., vol. xxxi., p. 345, 1895).—In *RE.* a broken line of pigment surrounding the disc and lines radiating from it. The lines were grey, with a tinge of brown, and their outline was jagged. They lay on a deeper level than the retinal vessels. Some accompanied by white lines. V. = $\frac{6}{8}$. No history of injury. *LE.* presented a similar condition.

(6.) Johan M., 22 (*ibid.*).—The ophthalmoscopic appearances were similar to those in the preceding case, and were present in both eyes. V. = $\frac{6}{8}$. No history of injury. Drawings are given of both cases.

CHAPTER XIII.

DETACHMENT OF THE RETINA.

AN old standing detachment of the retina presents an ophthalmoscopic appearance so striking and characteristic that its recognition is easy, but in an earlier stage, while the retina is still transparent, the diagnosis is more difficult.

The term detachment is generally limited to cases in which the retina is separated from the choroid by fluid, but a somewhat similar appearance is occasionally produced by œdematous or other thickening of the retina itself. The retina may be mechanically pushed forward by a choroidal tumour; in such cases there is generally, in addition, a larger area of secondary detachment, beneath which there is fluid.

Although it is not proposed to discuss fully the pathology of retinal detachment, with regard to which many points are still undetermined, there are certain mechanical conditions which must be borne in mind in any consideration of the subject.

If a recently excised eye is bisected and examined, it will be seen that, while the choroid adheres rather firmly to the sclerotic, the retina, on the contrary, can hardly be said to be attached at all, except at certain points, for it can readily be lifted up with a pair of forceps. The adherent parts are the optic papilla, where the retinal nerve fibres and those of the optic nerve are continuous, the ora serrata, and the macula lutea. Between these points the retina is kept in contact with the choroid merely by the pressure of the vitreous. Another factor to be considered is the rigidity of the sclerotic, while the retina is so flexible that it readily falls into folds, and is, besides, very easily torn.

A consideration of these facts will show that if there occur a sudden diminution in the pressure exerted by the intraocular fluids,—as, for example, by vitreous escaping through a wound, there will be a tendency for the retina to fall away from the choroid. As long, however, as no fluid finds its way between the two membranes, they will remain in contact, but if the retina should tear, or if fluid should exude from the choroidal vessels, detachment of the retina will at once take place.

Conditions produced thus suddenly by accident may be established more gradually by disease. In the late stage of many morbid conditions the vitreous becomes unnaturally fluid and reduced in volume; detachment will then occur as soon as a rent in the retina admits fluid from the vitreous, or as soon as exudation takes place from the choroid.

This explains how it is that although the disease is chronic, detachment usually occurs suddenly. Gradual detachment might occur without any rent in the retina, if *pari passu* with the shrinking of the vitreous, subretinal exudation occurred, but the clinical history in most cases points to a sudden occurrence of detachment.

In cases of choroidal tumour the process is probably similar, though here the force acts by a push from behind instead of by a pull in front: the retina resists separation till its tissue tears, then there is extensive floating up.

It was formerly held that most cases of detachment were caused by subretinal exudation. To Nordenson¹ we owe the modern theory of vitreous traction, with which the clinical facts are entirely consistent. Detachment usually occurs, apart from traumatic cases, in eyes of low tension. It is nearly always accompanied by opacities in the vitreous, which in many instances are known to have existed prior to the occurrence of the detachment. Where a blow on the eye causes detachment, without

¹ "Die Netzhautablösung," 1887.

producing an external wound, there is probably always a tear of the retina.

Eyes which are highly myopic are especially prone to detachment. In such the vitreous is usually unduly fluid, and often contains opacities. Apart from the state of the vitreous, it is not easy to see what is the connection between myopia and detachment. At first sight it might seem that the increasing volume of the globe might lower the intraocular tension, but the continuous enlargement of the globe must be due to the resistance of the sclerotic being less than the pressure of the intraocular fluid, and if the latter became less the globe would cease to enlarge. The increased bulk of the vitreous, however, in these cases is probably made up by fluid, and as the rate of absorption and secretion may vary with conditions of the general circulation, it is quite possible that there may be greater fluctuations in the intraocular tension than in the normal condition, and that detachment takes place during a temporary lowering of the tension.

At the moment of detachment the patient is frequently conscious of a corresponding loss in the visual field, and usually throughout the case the detached portion of the retina remains blind. Exceptionally, however, the defect in the field is smaller than would correspond with the detachment; and the defect may even escape notice altogether if the examination be conducted in a good light. It is probable that in a subdued light a deficient area would always be discovered.

In some cases the vision, and probably, also, the extent of the detachment, vary from time to time, and it is quite common for patients to say that they are much better on first rising in the morning.

We now turn to the ophthalmoscopic appearance presented by detachment. In old standing cases this is so striking that the diagnosis is easy, for the detached retina becomes opaque, and is conspicuous from the white reflex which it affords (Plate XLVI.,

Figs. 102, 103). Indeed, such a detachment can only escape observation by the surgeon failing to carry his examination sufficiently towards the periphery.

The optical conditions of the detached portion are those of the fundus of an extremely hypermetropic eye. That is to say, it can be seen from a distance, and if looked at with the ophthalmoscope close to the eye, it can be focussed with a strong convex lens. Its details are then seen with great clearness. The surface is thrown into numerous irregular folds which are approximately parallel. The summits of these reflect the light from the mirror, and often look like white lines; the furrows between them, on the other hand, are in shadow and are consequently less conspicuous. The vessels follow the folds of the retina. They often appear darker than normal, the central light-streak is absent, and they always look small, like the vessels in hypermetropia. The dark colour is probably due to contrast and the absence of the light streak; the small size, of course, depends on their being less magnified by the dioptric system, owing to the retina being well in front of its focus. The absence of the light streak is less easily explained, but possibly it depends upon the plane of the retina not being perpendicular to the line of vision, as in the normal condition.

When the detached retina is transparent the diagnosis is less easy. Hence these cases frequently escape detection. If the transparency is perfect the recognition of the detachment depends solely on the appearance of the vessels. More commonly the transparency, although sufficient to allow of a good choroidal reflex being seen, is not absolute. In these circumstances the summits of the folds into which the retina is thrown reflect the light and appear white, as in Plate XLVI., Fig. 101.

A rent can be sometimes observed in the retina. Much more frequently it is either too peripheral to be seen, or is hidden by some folds of retina.

Detachment occurs first at the periphery, and tends to spread

towards the centre, especially, if it is situated above. When very extensive it obstructs the view of the remainder of the fundus. Occasionally, the detachment reaches to the macula, if the retina remains attached here, as it usually does for a time, the fovea is seen of its natural colour lying at the bottom of a depression. In a case under my care the outline of the macula was marked out by a grey line which, from the parallaxic movement, evidently lay on a level anterior to the macula. It is probable that in this instance the retina had torn away from the macula, and that the grey line represented its free edge.

Except in recent cases, there are usually several distinct folds of detached retina lying at different levels.

When the retina is pushed forwards by a solid growth, as a choroidal sarcoma, the displaced portion is sometimes smooth and dome-shaped, and it may present a dark slate colour owing to the pigmented tumour showing through it. In some cases the vessels on the surface of the latter can be made out. In these cases there is usually also an ordinary detachment at a distance from the tumour, which does not differ from one produced by other causes.

The vitreous is seldom completely clear in detachment of the retina. It usually contains some floating opacities, and not unfrequently it is sufficiently turbid to render the diagnosis difficult or impossible. In the great majority of cases the lens eventually becomes opaque, and in time assumes that uniform yellowish-white appearance which has already been described as characteristic of a blind eye. In such cases the tension is generally subnormal.

Detachment always shows a decided tendency to increase, and, although in the later stages the media are too opaque for ophthalmoscopic examination, total detachment can frequently be seen in a section of an eye after enucleation. In such specimens the retina comes forwards from the optic nerve entrance in the form of a hollow tube, which anteriorly spreads out to reach the

ora serrata, the whole structure somewhat resembling a convolvulus flower. In the centre, running from the disc to the back of the lens, there can often be seen a fibrous cord, which is the sole remnant of the degenerated vitreous. Occasionally, cysts can be seen in the substance of the retina in these old detachments.

Œdema of the retina can hardly be mistaken for detachment if the media are sufficiently clear to permit a thorough examination. The appearance is much softer and more uniform, the vessels are not wavy, and the retina is not thrown into folds (*see* Plate XXV., Fig. 58). A mistake might more easily be made in the case of fixed membranous opacities in the vitreous, which, when extensive, have been named retinitis proliferans. Here, however, the opacity is more glistening, and the membrane is tightly stretched instead of being wavy. Detachment of the retina is not unfrequently associated with this affection.

COMMOTIO RETINÆ.

Blows on the eye from a blunt body are sometimes rapidly followed by a diffuse cloudiness of the retina—a condition which has received the name commotio retinæ.

The injury is usually severe, and is followed by impairment of vision, episcleral injection, and a spasmodic contraction of the pupil, which only a very free employment of atropine will overcome. For these reasons the fundus has often not been examined sufficiently soon after the accident for the changes, which are somewhat evanescent, to be discovered.

If the fundus be examined in about an hour after the injury, certain parts of it will be seen occupied by a smooth greyish-white cloudiness, like that which is present in embolism (Plate XXV., Fig. 58, and Plate XLI., Fig. 93). At first the cloud is thin in places, thus allowing the fundus-reflex to be visible through it, but in a short time the denser portions increase, and the whole surface may

become white. The retinal changes reach their height in from twenty-four to thirty-six hours, there may then be a greyish-white area ten or twelve times the diameter of the disc, shading off gradually at its margins into healthy retina. The vessels usually pass over it unaltered, but they may appear to be slightly diminished.

The process then begins to subside. The opacity becomes less dense, so that the fundus-reflex is again visible, and it diminishes in area, so that in three days (sometimes even in two) from the commencement of the subsidence, the fundus may have regained its normal appearance.

Berlin¹ was the first to give a connected account of commotio retinæ, and no better description of the symptoms has since been published. The above remarks are largely derived from his original paper.

It will be noted that while the condition resembles detachment in following a blow, and in presenting a white surface in place of the normal red reflex, yet it differs from it in that there is neither any alteration in the level of the retina, nor any indication of its being thrown into folds.

¹ Zehender, *Klin. Monatsbl. f. Augenh.*, Stuttgart, 1873, p. 44.

INDEX.

| | PAGE | | PAGE |
|---------------------------------------------------------|----------------------------------------------------|-------------------------------------------------------------------------|--------------------------------------|
| Development of eye, | 68 | Gunn, coloboma of disc, | 83 |
| Diabetes, new vessels in, | 163 | " Crick dots, 27, 67, 199; iv. ^{99, 10} | 66 |
| Diabetic retinitis, | 141 | " macular reflex, | 136 |
| Diffuse choroiditis, 106; xxix. ⁶³ | 48 | " star-figure at macula, | 139 |
| Dimmer, light-streak on vessels, | 63 | " thickened arteries in albuminuria, | 153 |
| " macula, | 26 | Habershon, hereditary optic atrophy, | 137 |
| " retinal reflexes, | 28 | Hæmorrhage in albuminuric retinitis, | 167 |
| Disc (<i>see</i> Optic Disc), | 151 | " anæmia, | 168 |
| Disseminated sclerosis, | 19 | " glaucoma, | 167, 196 |
| Dodd, pigmented moles on retina, | 84 | " leukæmia, | 167 |
| Dolganoff, coloboma on disc, | 211 | " intraocular, | 146 |
| Doyme, pigment streaks on fundus, | 203 | " " causing retinitis pro- | 172 |
| Drusenbildungen on disc, | 181 | liferans, | 124 |
| Eales, embolism, recovery during examina- | 172 | " " in young men, | 169 |
| " recurrent hæmorrhage in young men, | 138, 160 | " into sheath of optic nerve, | 168; xxxv. ^{78, 79} |
| Edmunds, blood vessels in albuminuria, | 198 | " " glaucomatous cup, | 169; xxxix. ^{88, 89} |
| " " in leukæmia, | 180 | " retina, | 26 |
| Elschnig, embolism, pathological examination, | 174; xli. ⁹² | " subhyaloid, 169; xxxix. ^{88, 89} | 30 |
| Embolism, | 178 | Hæmorrhagic retinitis, 168; xxxv. ⁷⁹ | 156; xlvii. ^{105, 106, 107} |
| " causes, | 177 | " " physiological, 41; ii. ⁶ ; vi. ¹⁵ | 62 |
| " late changes in, | 53, 186; xli. ⁹³ | " " macula, | 66 |
| " modified by cilio-retinal vessels, | 183 | Harlan, new vessels in vitreous | 169 |
| " recovery after, | 174 | Hartridge, hæmorrhage into glaucoma cup, | 137 |
| " symptoms, | 4 | " star-figure at macula, | 114 |
| Enlargement of ophthalmoscopic image, | 66 | Hemianopsia, | 70 |
| Entoptic appearance of vessels at macula, | 24 | Hess, coloboma, microscopic examination, | 176 |
| " " " retina (Purkinje's | 188 | Hirschberg, embolism, | 180 |
| figures), | 60 | " " with microscopic ex- | 71 |
| Erysipelas, causing retinal thrombosis, | 94 | amination, | 150 |
| Exophthalmic goitre, | 187 | Hoffman, coloboma with entire iris, | 150 |
| Exudative choroiditis, | 102 | Holder, fracture of optic foramen, | 172 |
| Facial vein, anastomosis with orbital veins, | 64 | Hutchinson, recurrent hæmorrhage in young | 204 |
| Förster, areolar choroiditis, | 62 | men, | 105 |
| Fovea centralis (<i>see also</i> Macula), | 65; ii. ^{4, 5, 6} ; iv. ¹⁰ &c. | " retinitis pigmentosa, without | 113 |
| " " anatomy, | 173 | night-blindness, | 166 |
| " " ophthalmoscopic appearance, | 76 | " Tay's choroiditis, | 200 |
| Friedenwald, interrupted blood column in | 142 | " (jun.), choroiditis after concussion | 203 |
| retina, | 10 | of eye, | 207 |
| Fuchs, congenital crescent, | 1 | " " new vessels in vitreous, | 59 |
| " retinitis circinata, | 155; xlvii. ^{105, 106, 107} | Hyaline outgrowths from lamina vitrea, | 150 |
| Fundus, gauge for, | 137 | " " " optic disc, | 91 |
| " normal appearance of, | 180 | " thickening of retinal vessels, 138, 160, 207 | 41, 92, 120 |
| Glaucoma, | 30 | Hyaloid artery, | 41 |
| Gould, hereditary optic atrophy, | 155 | Hydrocephalus causing optic atrophy, | 55 |
| Gowers, albuminuric retinitis, | 155 | Hyperæmia of choroid, | 41 |
| " embolism, pathological examination, | 180 | " of disc, | 118 |
| " sheaths of optic nerve, | 30 | Hypermetropia, disc in, | 48 |
| " "waxy" atrophy of disc, | 155 | " retinal vessels in, | 71 |
| Graefe, embolism, pathological examination, | 180 | Jackson, Hughlings, normal vision in papillitis, | 48 |
| Granular layers of retina, | 20 | Jaeger, light-streak on vessels, | 71 |
| Griffith, leukæmic retinitis, pathological ex- | 197 | Jessop, subhyaloid hæmorrhage, | 71 |
| amination, | 197 | | |

| | PAGE | | PAGE |
|--------------------------------------------------------------------------------------|------------|--------------------------------------------------------------------------------------------------------|---------|
| Keratitis punctata in choroiditis, | 101 | "Metallic" dots on fundus, | 27, 199 |
| Kingdon, symmetrical changes at macula, | 191 | Meyer, retinal vessels in syphilis, | 162 |
| Knapp, pigment streaks on fundus, | 211 | Michel, thrombosis of vena centralis, | 187 |
| Lamina cribrosa, | 29 | Miley, prognosis in albuminuric retinitis, | 140 |
| " " in congenital crescent, | 78 | Moles pigmented on retina, | 201 |
| " " glaucoma, | 157 | Mooren, retinitis punctata albescens, | 201 |
| " " optic atrophy, | 154 | Morton, S., choroido-retinal sclerosis, | 108 |
| " " physiological cupping, | 34 | " subhyaloid hæmorrhage, | 171 |
| " fusca, | 13 | Mules, perivasculitis, | 162 |
| " vitrea of choroid, | 13 | " vessels in albuminuric retinitis, | 162 |
| " " outgrowths from, | 200 | " white clot in retinal vessel, | 182 |
| Lang and Barrett, cilio-retinal vessels, | 53 | Müller's fibres, | 20 |
| Lawford, retinal vessels all emerging at margin of disc, | 51 | Myopia, | 97 |
| " vascular loop on disc, | 51 | " choroiditis in, 97; xxiii. ⁵³ 54, 55 | 143 |
| Lead poisoning as cause of papillitis, | 130 | " cicatricial lines in, | 143 |
| "Leaf-like" choroiditis, | 105 | " crescent in, 97; xxiii. ⁵³ | 215 |
| Leber, hereditary optic atrophy, | 153 | " detached retina in, | 215 |
| " rheumatic choroiditis, | 111 | Nerve-sheaths, | 29, 128 |
| Leukæmic retinitis, 195; xxxiii. ⁷⁴ | 195 | " distension of, 123, 128 | 123 |
| Light fundi, 16; ii. ⁴ ; xxiii. ⁵³ | 16 | " incision of, | 123 |
| Light-streak on vessels, | 47 | Nettleship, central senile choroiditis, | 102 |
| Limiting membranes of retina, | 20 | " dropping of fluid from nose with papillitis, | 129 |
| Little, W. S., vessel projecting into vitreous, | 58 | " embolism, microscopic examination, | 180 |
| Locomotor ataxy causing optic atrophy, | 151 | " new vessels in vitreous, | 165 |
| Loops made by vessels on disc, 51, 53 | 51, 53 | " parallel ridges on fundus after papillitis, | 134 |
| Loring, chorio-capillaris, effect of, | 17 | " tortuous vessels, | 56 |
| " light-streak on vessels, | 48 | " white dots and pigment changes with night-blindness, | 200 |
| " physiological cup, | 36 | Neuritis (<i>see</i> Optic Neuritis), | 114 |
| Lymph sheaths of choroidal vessels, | 14 | Nieden, hyaline proliferations on disc, | 203 |
| " " retinal vessels, | 24 | Night-blindness in choroiditis, | 99 |
| Lymphoid deposits in leukæmia, | 196 | " choroido-retinal sclerosis, | 108 |
| Mackenzie, S., anæmia causing hæmorrhage, | 167 | " retinitis pigmentosa, | 204 |
| " tortuosity of retinal vessels, | 56 | " with white dots and pigment changes, | 200 |
| " tubercle of choroid, | 103 | Nordensen, detachment of retina, | 214 |
| Macula, anatomy of, | 64 | Norris, new vessels in vitreous, | 164 |
| " colloid change at, | 202 | Nose, escape of clear fluid from, in papillitis, | 129 |
| " ophthalmoscopic appearance of, 65; ii. ⁴ 5, 6; iii. ⁷ &c. | 62, 65, 66 | Nuclear layers of retina, | 20 |
| " reflexes at, | 62, 65, 66 | Œdema of choroid, | 134 |
| " stellate figure at, 135; xxxv. ⁷⁸ ; xxxvii. ⁸⁴ | 135 | " " optic nerve in papillitis, | 122 |
| " " of unusual character, 135; xxxviii. ^{85, 86} | 190 | " " retina, 99; xxv. ⁵⁸ | 197 |
| " symmetrical changes at, in infants, | 190 | Oeller, leukæmic retinitis, | 153 |
| " vessels of, | 67 | Ogilvie, hereditary optic atrophy, | 153 |
| Malaria causing papillitis, | 124 | Opaque nerve fibres, 72, 74; xii. ^{34, 35} ; xiii. ^{36, 37} ; xiv. ^{38, 39} | 73 |
| Manz, opaque nerve fibres, microscopical examination, | 73 | " " microscopic examination, | 73 |
| " retinitis proliferans, | 144 | Ophthalmoscopic image, enlargement of, | 4 |
| Margin of disc, | 40 | Optic atrophy, | 147 |
| Masselon, infiltration vitreuse de la rétine, | 201 | " " after embolism, | 176 |
| " subhyaloid hæmorrhage, | 170 | " " injury, | 148 |
| Measles causing papillitis, | 124, 129 | " " neuritis, 147; xxxii. ^{71, 72} ; xxxviii. ⁸⁷ | 148 |
| Medullary sheaths of nerve fibres, | 28 | | |
| Meningitis causing papillitis, | 124, 128 | | |

| | PAGE | | PAGE |
|------------------------------------------------------------------------------------------------------------------------------------|-------------------------------|-------------------------------------------------------------------------------|----------------------------------------------------------------------------------------------------|
| Optic atrophy, hereditary, | 153 | Pigment moles on retina, | 19 |
| „ „ in acromegaly, | 151 | „ ring round disc, . . . 44; i. ₁ ; ii. ₆ &c. | 16 |
| „ „ „ disseminated sclerosis, | 151 | „ stippling, | 210 |
| „ „ „ glaucoma, | 155 | „ streaks on fundus, | 204 |
| „ „ „ hydrocephalus, | 150 | Pigmentary retinitis (<i>see</i> Retinitis Pigmentosa), | 211 |
| „ „ „ locomotor ataxy, | 151 | Plange, pigment streaks on fundus, | 90 |
| „ „ „ post-neuritic, | 147 | Plastic choroiditis, | 142 |
| „ „ „ secondary to fundus affections, | 155 | „ retinitis, | 176 |
| „ chiasma, | 29, 114 | Popp, embolism, | 180 |
| „ „ pressure on, | 150 | „ „ with microscopic examination, | 33 |
| „ disc, anatomy, | 28 | Porus opticus, | 87 |
| „ „ atrophy, | 147 | Post-neuritic atrophy, 147; xxxii. _{71, 72} ; xxxviii. ₈₇ | 97; xxiii. ₅₃ |
| „ „ inflammation of, | 114 | Posterior staphyloma, | 101 |
| „ „ ophthalmoscopic appearance of, | 32 | „ synechiæ in choroiditis, | 71 |
| „ „ oval shape of, | 45 | Power, semicircular hæmorrhage of macula, | 90 |
| „ „ unusual colour of, 38, 43, 74, 77; v. _{12, 14} ; vi. ₁₅ ; viii. ₂₂ ; xiii. _{36, 37} | 150 | Puerperal septicæmia, suppurative choroiditis in, | 59 |
| „ foramen, fracture through, | 28 | Pulsation in retinal vessels, | 199; iv. _{9, 10} ; xi. _{30, 31} ; xxxiii. ₇₅ ; xxxv. ₇₈ |
| „ nerve, anatomy, | 122 | Punctate conditions of the fundus, | 24 |
| „ „ œdema of, | 114, 115, 127 | Purkinje's figures, | 90 |
| „ „ retro-bulbar affections of, | 29, 128 | Pyæmia causing choroiditis, | 124 |
| „ „ sheaths of, | 124 | „ „ papillitis, | 52 |
| „ „ tumours of, | 31 | Randall, cilio-retinal vessels, | 82 |
| „ „ vessels of, | 122 | „ coloboma of disc, | 73 |
| „ „ wounds of, | 122 | Recklinghausen, opaque nerve fibres, | 172 |
| „ neuritis, 114; xxxi. _{66, 67, 68, 69} ; xxxii. ₇₀ ; xxxiii. ₇₅ ; xxxvi. ₈₁ | 129 | Recurrent hæmorrhage in young men, | 41, 65 |
| „ „ from general causes, | 127 | Reflex appearances of fundus, | 25 |
| „ „ „ intracranial causes, | 125 | „ „ „ concentric retinal striation, | 65 |
| „ „ „ orbital causes, | 118 | „ „ „ halo round disc, 41; ii. ₆ ; vi. ₁₅ | 65 |
| „ „ normal vision in, | 131 | „ „ „ macular reflexes, | 25 |
| „ „ results of, | 115, 127 | „ „ „ retinal radial striation, | 25 |
| „ „ retro-bulbar, | 131; xxxi. ₆₆ | „ „ „ shot-silk or watered silk appearance, | 99 |
| „ „ subsidence, | 118 | Relapsing choroiditis with retinal œdema, | 19 |
| „ „ symptoms of, | 68 | Retina, anatomy, | 115; xxxviii. ₆₂ |
| „ vesicle, | 124 | „ atrophy of, | 213; xlvi. _{100, 101, 102, 103} |
| Orbit, cellulitis of, | 124 | „ detachment of, | 101 |
| „ periostitis, | 124 | „ „ in choroiditis, | 217 |
| „ tumours of, | 124 | „ „ in intraocular growth, | 215 |
| „ wounds of, | 124 | „ „ in myopia, | 134; xxxii. ₇₀ |
| Orbital veins, phlebitis of, | 188 | „ parallel ridging of, | 25; ii. _{4, 5, 6} |
| Oval disc, | 45 | „ reflex from, | 36, 48, 49 |
| Papillitis (<i>see</i> Optic Neuritis), | 114 | „ vessels of (<i>see</i> Blood Vessels), | 168 |
| Parent, astigmatic disc by indirect method, | 46 | Retinal hæmorrhage (<i>see</i> Hæmorrhage), | 133 |
| Peltesohn, coloboma of disc, | 84 | Retinitis, | 137; xxxvi. ₈₀ ; xxxvii. _{82, 84} |
| Periphery of fundus, ophthalmoscopic appearance of, | 13, 17, 18 | „ „ „ albuminuric, | 138, 160; xxxvi. ₈₀ ; xxxvii. ₈₄ |
| Perivasculitis, | 161; xl. _{90, 91} | „ „ „ broken veins in, | 141 |
| Phlebitis of cavernous sinus, | 187 | „ „ „ circinata, | 168; xxxv. ₇₉ |
| „ „ orbital veins, | 188 | „ „ „ diabetic, | 195; xxxiii. ₇₄ |
| Physiological cup, | 34; i. _{1, 2, 3} &c. | „ „ „ hæmorrhagic, | 204; xlii. ₉₄ ; xliii. ₉₆ ; xlv. ₉₇ |
| Pigment dots in choroiditis, | 95 | „ „ „ leukæmic, | 106 |
| „ „ on retina, | 18; x. _{28, 29} | „ „ „ pigmentosa, | 106 |
| „ „ epithelium, | 16 | „ „ „ senilis, | 106 |
| „ „ in rupture of choroid, | 113 | | |
| „ „ on disc, | v. _{11, 13} | | |

| | PAGE | | PAGE |
|-----------------------------------------------------|----------------------------|---------------------------------------------------------------|---------------------|
| Retinitis pigmentosa, secondary to choroiditis, | 99 ; | Symmetrical changes at macula in infants, | 190 |
| " prognosis in, | xix. 45 139 | Sympathetic ophthalmitis, hyperæmia of | |
| " proliferans, | 144 | disc in, | 92 |
| Retro-bulbar neuritis, | 115 | Tabes dorsalis as cause of atrophy, | 151 |
| Rheumatic choroiditis, | 111 | Talko, coloboma with entire iris, | 71 |
| Rupture of choroid, | 111 ; xxx. 64, 65 | Tay's choroiditis, | 105 |
| " " equatorial, | 112 | " symmetrical changes at macula, | 190 |
| Sachsaler, hyaline proliferations on disc, | 203 | Theobald, new vessels in vitreous, | 165 |
| Schäfer and Golding Bird, anatomy of fovea, | 64 | Thrombosis of cavernous sinus, | 187 |
| Schnabel and Sachs, cilio retinal vessels, | 51 | " of central artery, | 174, 179 |
| " " embolism, | 180 | " " vein, | 187 ; xxxiv. 76, 77 |
| Schneller, light-streak on vessels, | 48 | " of retinal veins, | 189 ; xxxvii. 83 |
| Schultze, state of the blood in a case of | | Tortuosity of retinal vessels, 51, 55 ; vii. 18, 19 ; xxi. 48 | |
| retinitis proliferans, | 183 | Tubercle as a cause of choroiditis, | 99, 103, 110 |
| Schwann, white matter of, | 28 | Tumour, intracranial, | 124 |
| Schweigger, embolism with microscopical ex- | | " intraocular, | 217 |
| amination, | 180 | " of optic nerve, | 124 |
| Schweinitz de, colloid change at macula, | 202 | " of orbit, | 124 |
| Scleral ring, | 43 ; v. 13 | Ulrich, intracranial growths, autopsies, | 122 |
| " in glaucoma, | 156 ; xlvii. 105, 106, 107 | " disseminated sclerosis, as cause of | |
| Sclerosis, choroido-retinal, | 106 | atrophy, | 151 |
| " disseminated, | 151 | Usher, opaque nerve fibres, microscopic | |
| " of walls of retinal vessels (<i>see</i> Blood | | examination, | 73 |
| Vessels), | 161 ; xl. 90, 91 | Vascular system of retina, | 158 |
| Sclerotic, | 11 | Veins, bifurcation of, | 54 |
| Scurvy as a cause of papillitis, | 124 | " choroidal, | 15 |
| " " retinal hæmorrhage, | 167 | " retinal, thrombosis of, | 189 ; xxxvii. 83 |
| Semicircular hæmorrhages, | 169 ; xxxix. 88 | " " tortuosity, 51, 55 ; vii. 18, 19 ; xxi. 48 | |
| Senile choroiditis, | 98, 102 ; xxiv. 56 | Venæ vorticosæ, | 15 |
| Serous choroiditis, | 89 | Vitreous, bands in, | 145 |
| Sheaths of optic nerve, | 29, 128 | " dust-like opacities in, | 118 |
| Sichel, embolism, microscopic examination, | 100 | " new vessels in, | 163 ; xl. 91 |
| Siegrist, rupture of ciliary arteries, | 113 | " opacities in choroiditis, | 100 |
| Simple atrophy, | 149 | " undue fluidity of, | 101 |
| " glaucoma, | 155 | Wadsworth, symmetrical changes at macula, | 194 |
| Smith, Priestley, embolism and thrombosis | | Wagenmann, opaque nerve fibres disappearing | |
| of retinal arteries, | 178 | in atrophy, | 75 |
| " " embolism, microscopic | | Walser, pigment streaks on fundus, | 211 |
| examination, | 180 | Wedl and Bock, colloid change in pigment | |
| Spicer, retinal vessels in inherited syphilis, | 160 | layer, | 202 |
| Stellate figure at macula (<i>see</i> Macula), | 135 | Wolf, W., embolism with microscopic | |
| Stephenson, coloboma of disc, partial, | 83 | examination, | 180 |
| " concentric retinal striation, | 25 | " thrombosis of vena centralis, | 187 |
| " measles causing papillitis, | 129 | Wood, White, embolism, recovery during | |
| " pigment dots, | 19 | examination, | 181 |
| " " streaks, | 211 | Wounds of globe causing papillitis, | 124 |
| " " retinal veins, unusual course, | 54 | " " " hyperæmia of choroid, | 91 |
| Stilling, canal of, | 59, 75 | " optic nerve, | 124, 150 |
| Story, light-streak on vessels, | 48 | " orbit, | 125 |
| Story and Benson, aneurisms on retinal arteries, | 162 | Yellow spot (<i>see</i> Macula), | 64 |
| Syphilis and choroiditis, | 109 | | |
| " choroido retinal sclerosis, | 106 | | |
| " disease of retinal vessels, | 160, 162 | | |
| " papillitis, | 125 | | |

PLATE I.

PHYSIOLOGICAL CUPPING OF OPTIC DISC.

FIG. 1.—PHYSIOLOGICAL CUP.

Alice W., 18. *LE. Drawing made in 1888.*—A healthy girl, of moderately fair complexion. V. $-1.5 = \frac{3}{8}$.

Description.—Margin of *OD.* pigmented. A large physiological cup, having a diameter slightly greater than half that of the *OD.* On its floor the mottling produced by the lamina cribrosa is well seen. The cup is deepest on its nasal side, where the difference in refraction between floor and edge was 3 *D.*

In 1894 the condition was unchanged.

FIG. 2.—PHYSIOLOGICAL CUP. CONNECTIVE TISSUE RING.

Arthur P., 12. *LE. Drawing made February 1890.*—Low hypermetropia. V. normal.

Description.—The centre of the *OD.* presents a cup of circular outline. The floor of this is shown out of focus; when in focus it could be seen to be stippled, as in Fig. 1. The circumference of the disc presents a pale soft-looking band—the connective tissue ring.

FIG. 3.—PHYSIOLOGICAL CUP. OVAL DISC. STRIATION OF UPPER AND LOWER BORDERS.

Minnie W., 12. *LE. Drawing made November 1889.*—Complexion moderately dark. Hair dark brown. Slight hypermetropia, no astigmatism.

Description.—Physiological cup steep towards centre of *OD.*, shelving gradually towards temporal border. Slight blurring of upper and lower borders of disc by a greyish film, presenting evidence of striation. Margin of *OD.* pigmented. Downwards and outwards an irregularity of margin, as if the fundus had encroached on the disc.

2
3
4
5
6
7
8
9

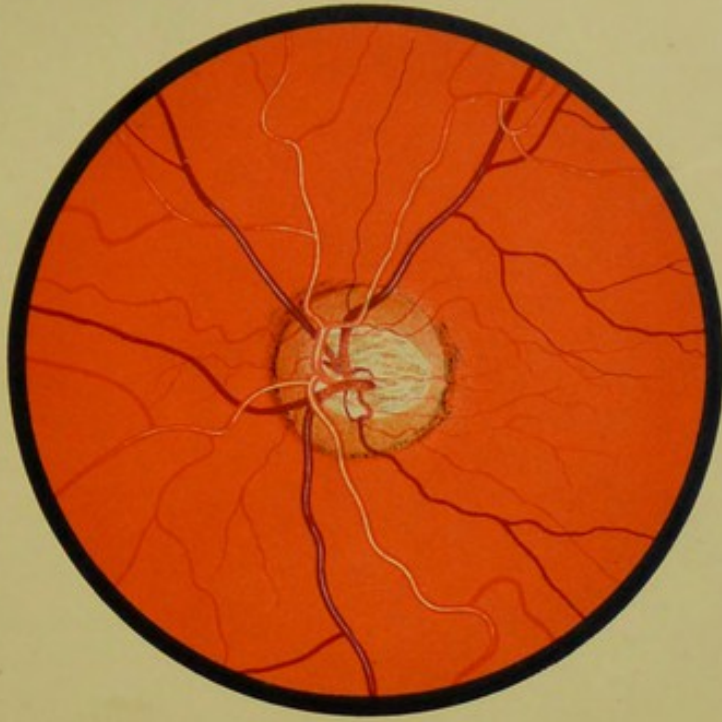


FIG. 1. LE.

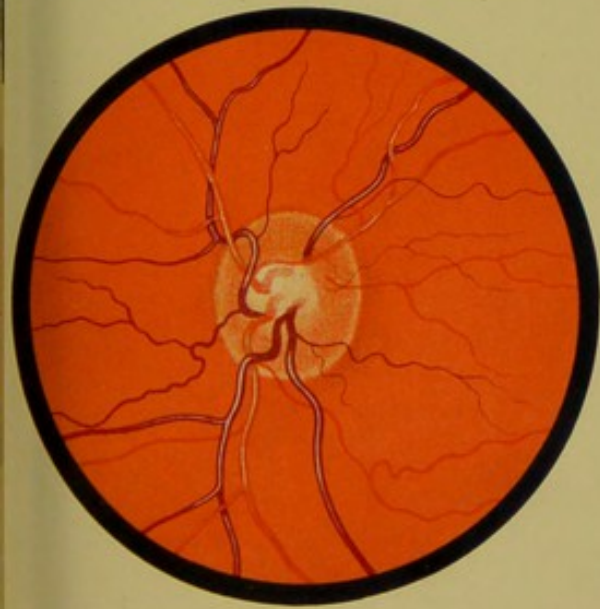


FIG. 2. LE.

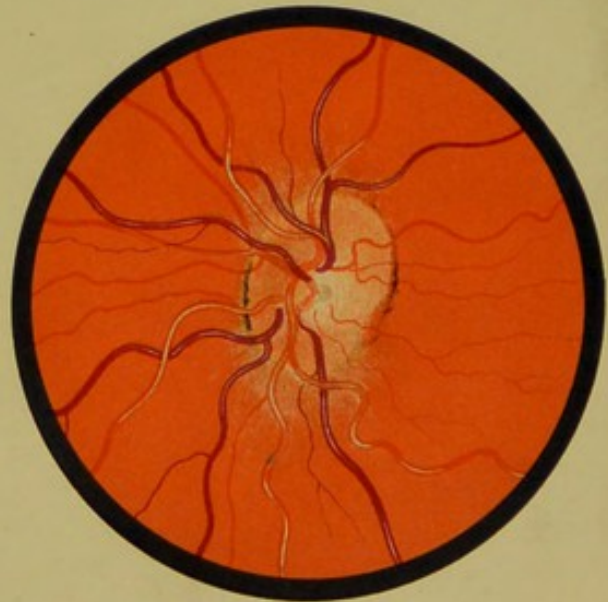

FIG. 3. LE.

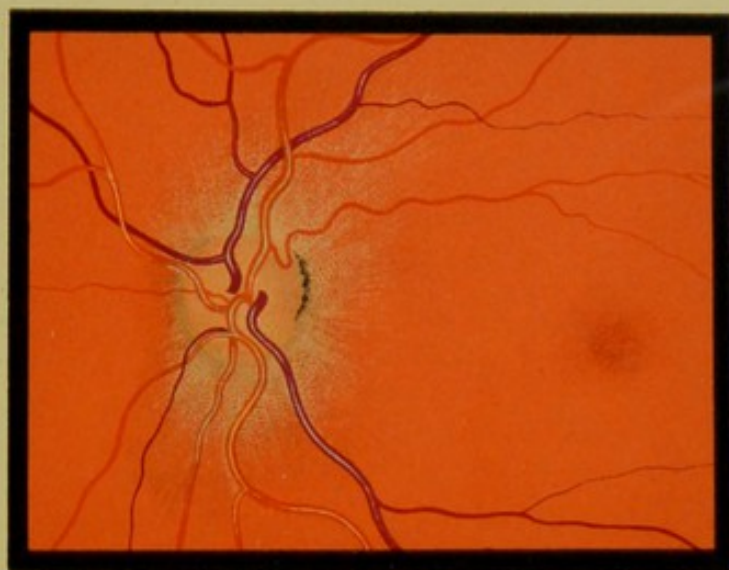

FIG. 4. L.E.

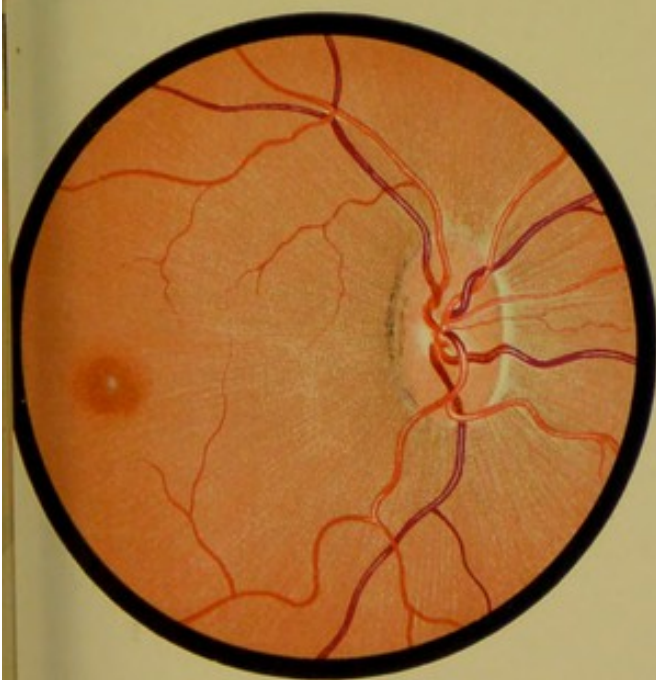

FIG. 5. R.E.

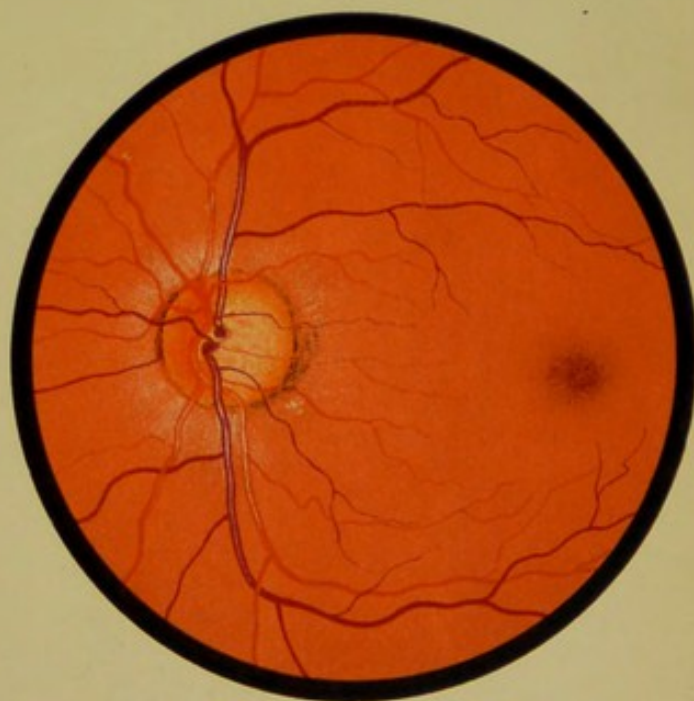


FIG. 6. L.E.

NATIONAL HOSPITAL LIBRARY
Not to be taken away

PLATE III.

FUNDI, SHOWING CHOROIDAL VESSELS.

FIG. 7.—LIGHT FUNDUS. CHOROIDAL VESSELS WITH LIGHT INTERSPACES.

Lena L., 8. *RE*. *Drawing made March 1892.*—Very fair complexion, light hair, blue irides. Slight hypermetropia. $V. = \frac{2}{3}$.

Description.—Over the greater part of the fundus a large number of choroidal vessels are visible. The spaces between them are reddish white. In the central region no choroidal vessels are visible, and the fundus is darker. The macula is seen as an area having a slightly darker colour than the surrounding fundus.

The disc margin has a soft appearance. White lines accompany the inferior temporal artery on the disc.

FIG. 8.—DARK FUNDUS. CHOROIDAL VESSELS WITH DARK INTERSPACES.
RETINAL REFLEX.

Edith S., 7. *RE*. *Drawing made in 1888.*—A brunette. Irides dark brown.

Description.—Over the part of the fundus that surrounds the disc the choroidal vessels are visible. The spaces between them have a brownish-black colour, an appearance sometimes called "Chorioide tigrée." Over the same area can be seen fine lines radiating from the disc. These, like those in Fig. 5, are due to light reflected from the retina. The macula is seen but faintly, and there are indistinct lines radiating from its centre. Near the macula are several minute white dots. With the ophthalmoscope these were seen best with a feeble illumination—"Gunn's dots."

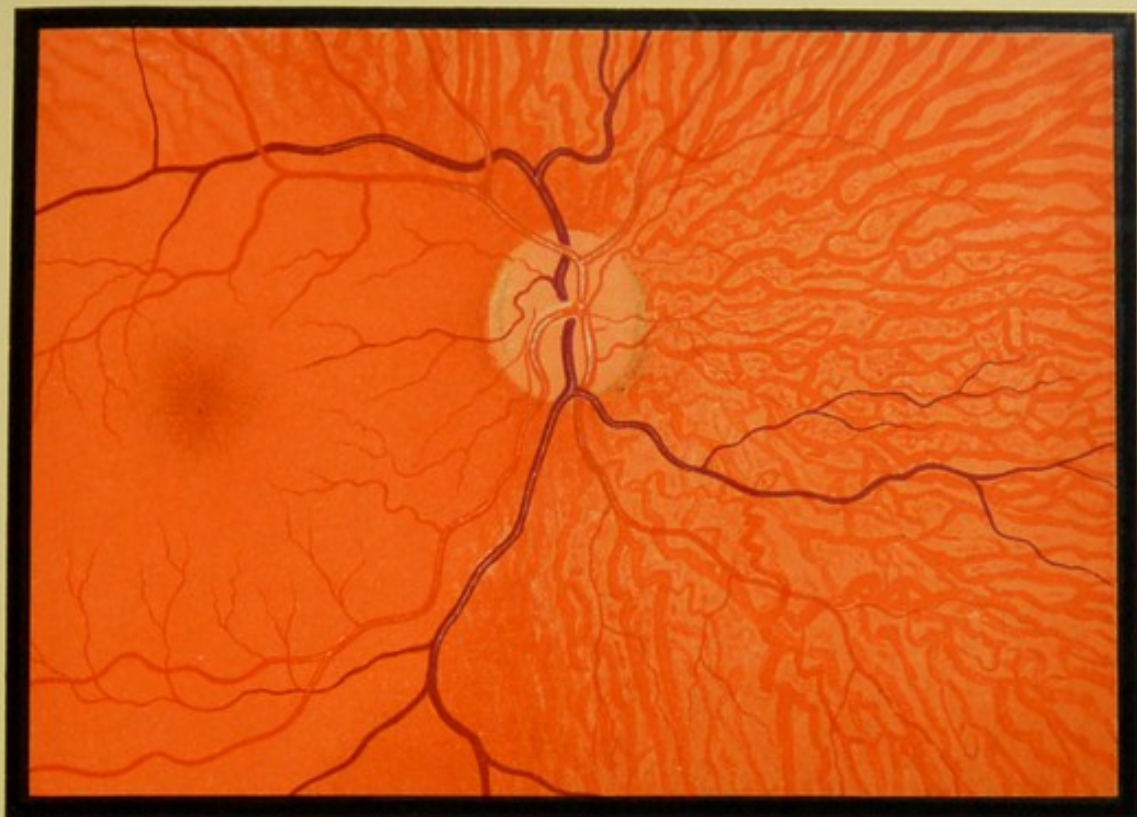


FIG. 7 R. E.

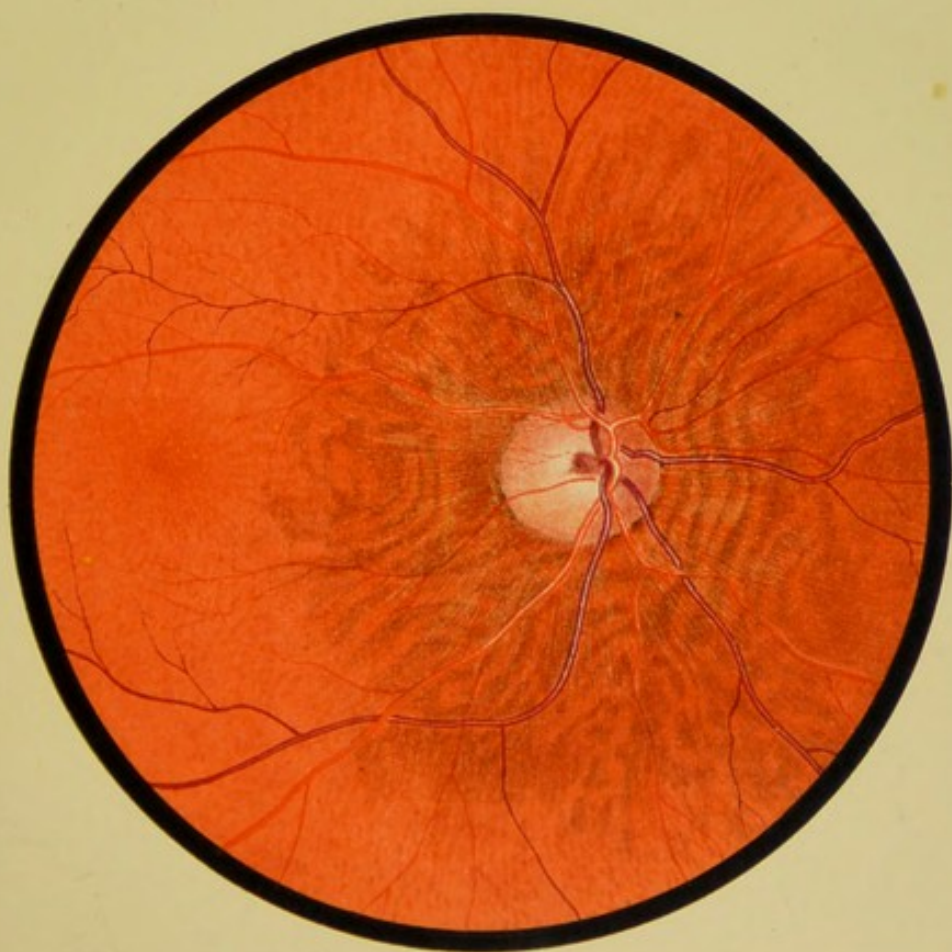


FIG. 8 R. E.

NATIONAL HOOR. ...

Not to be taken away.

PLATE IV.

CONGENITAL CRESCENT OF OPTIC DISC.

FIGS. 9 AND 10.—CONGENITAL CRESCENTS. "GUNN'S DOTS."

Fig. 9.—Alice H., 11. *RE.* Drawings made 1888.

V. (under atropine) = $\frac{6}{18}$ c. + 1.5 sp. \odot + 0.75 cyl. | = $\frac{6}{8}$.

Description.—Occupying the lower tenth of the disc a pale crescent, its surface slightly stippled. Its arms pass round the disc, becoming narrower and continuous with the connective tissue ring.

The border of the disc is pigmented, and there are lines of pigment on the fundus, concentric with the temporal border of the disc.

The macula is visible as a dark red area. On, and near, it are several small yellowish dots.

Fig. 10.—Represents the *LE.* of the same patient.

V. (under atropine) = $\frac{6}{38}$ c. + 3.0 sp. \odot + 0.50 cyl. | = $\frac{6}{8}$.

Description.—Occupying a little less than the lower fourth of the vertical diameter of the disc, a pale crescent, stippled with grey. Margin of disc less pigmented than *RE.* Surrounding the disc a light yellowish halo—retinal reflex. Lower vein on the disc crossed by a few delicate connective tissue fibres. Macula as in *RE.*, but fewer dots. The dots were only visible in certain positions of the ophthalmoscopic mirror; when seen they were always in the same position.

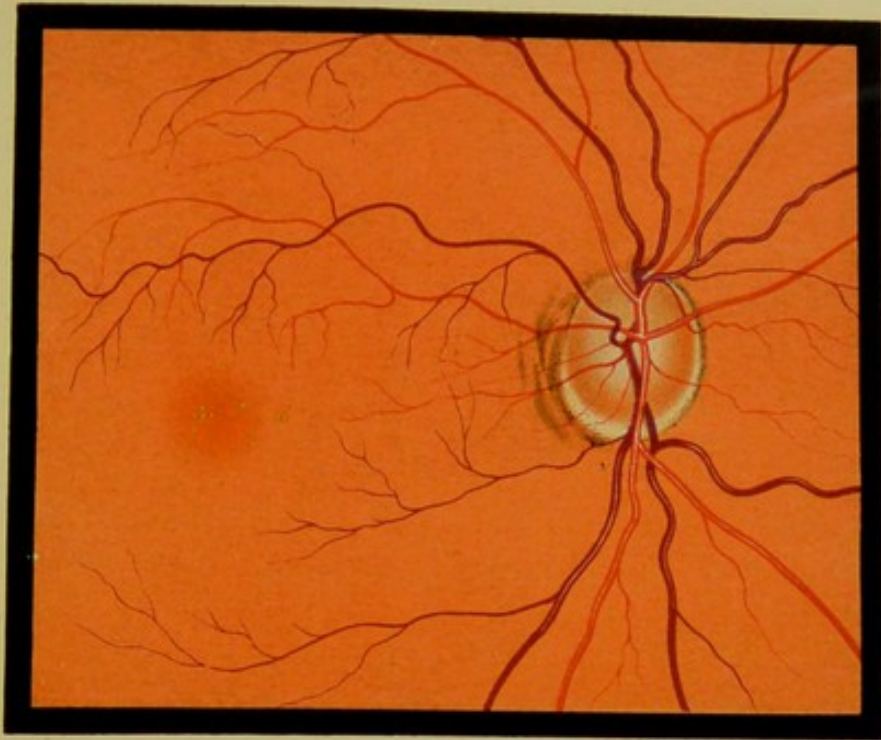


FIG. 9. R. E.

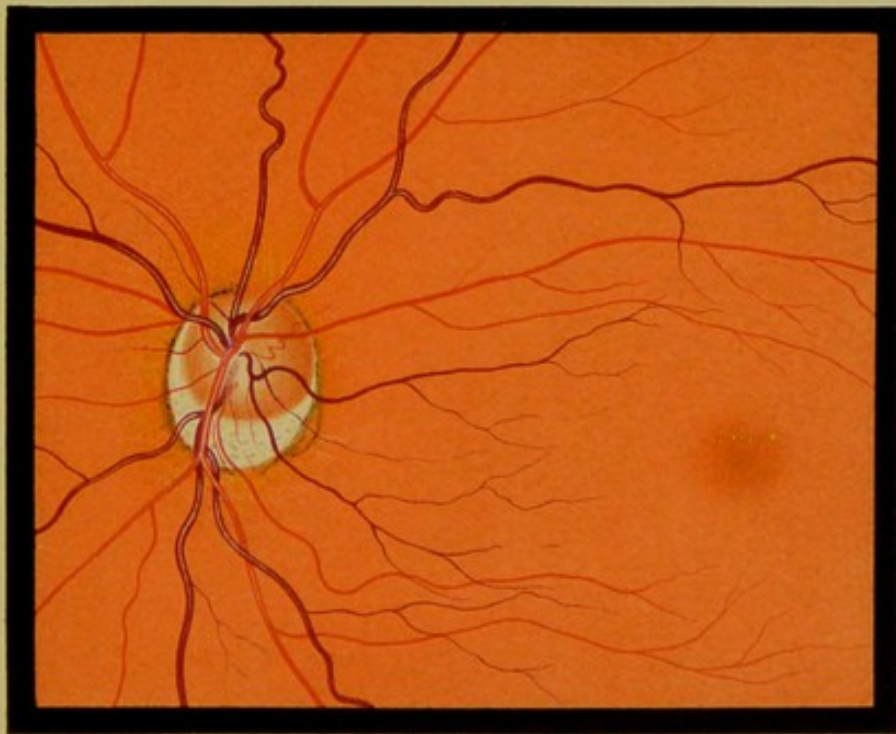


FIG. 10. L. E.

NATIONAL HOSPITAL LIBRARY
Not to be taken away

PLATE V.

VARIATIONS OF DISC MARGIN.

FIG. 11.—PIGMENT ON DISC. CONNECTIVE TISSUE ON DISC.

Ernest W., 6. *RE*. *Drawing made in 1888.*—V. (under atropine) + 1.0 \ominus + 0.50 *cyl.* | = $\frac{2}{3}$.

Description.—The temporal border of the disc presents a considerable mass of black pigment which encroaches upon the disc. The retinal vessels on the disc are crossed by numerous fine bands of connective tissue. The upper and lower veins proceed an unusual distance before giving off any branches.

FIG. 12.—ABSENCE OF CENTRAL ZONE OF DISC. PECULIAR COLOUR.
CONNECTIVE TISSUE RING.

Daisy S., 12. *LE*. *Drawing made in 1889.*—V. (under atropine) - 6.0 - 1.50 *cyl.* — = $\frac{6}{12}$.

Description.—The disc is of a uniform dull red colour, as if the red were mixed with grey. The vessels disappear into the centre of the disc gradually, as if they were dipping into a semi-transparent substance. The colour of the disc extends right up to the point of entry of the vessels. The disc is encircled by a white band of unequal width. In the greater part of its extent, it resembles the connective tissue ring as seen in Fig. 2, but on the temporal border it is broader and whiter. Numerous choroidal vessels are visible, one of unusually large size.

The patient was seen in 1894, and the conditions showed no appreciable change.

FIG. 13.—PHYSIOLOGICAL CUP. NARROW CRESCENT ON TEMPORAL BORDER.

Laura P., 14. *RE*. *Drawing made December 1892.*

Description.—A large physiological cup, deepest near the centre of the disc. It appears to reach to the temporal border, gradually becoming more shallow. On the temporal border of the disc is a narrow white crescent, more brilliantly white, and more sharply marked off from the disc than is usual with a connective tissue ring.

FIG. 14.—GREY-RED DISC. EXAGGERATED CONNECTIVE TISSUE RING.

Joseph P., 51. *RE*. *Drawing made in 1888.*—V. (under homatropine) + 1.50 = $\frac{2}{3}$ each eye.

Description.—The greater part of the disc is of a greyish colour, tinged with red. Encircling this, and not very sharply marked off from it, is a white band, broadest on the temporal border.

The other eye presented a similar condition, but the disc was redder, intermediate in colour between that of this Fig. and that of the disc in Fig. 12.

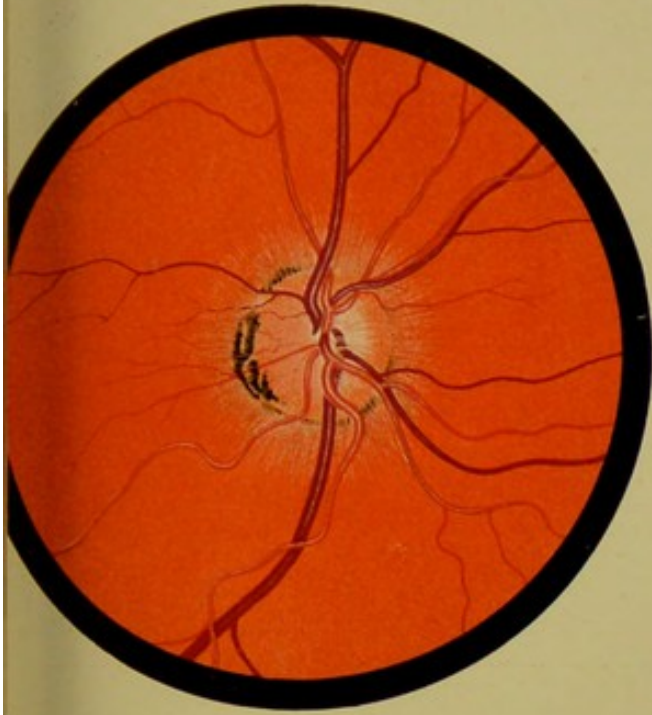


FIG. 11. R. E.

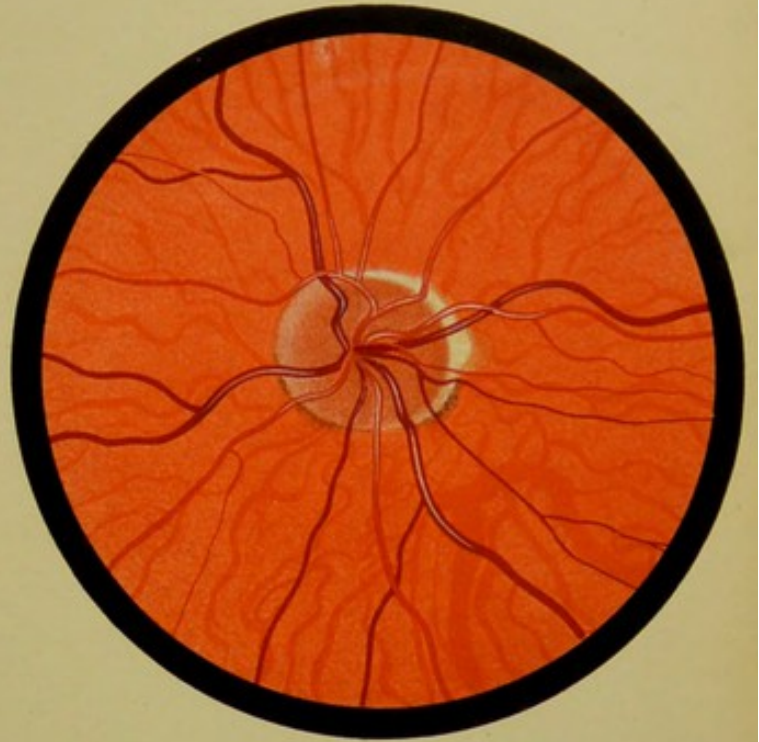


FIG. 12. R. E.

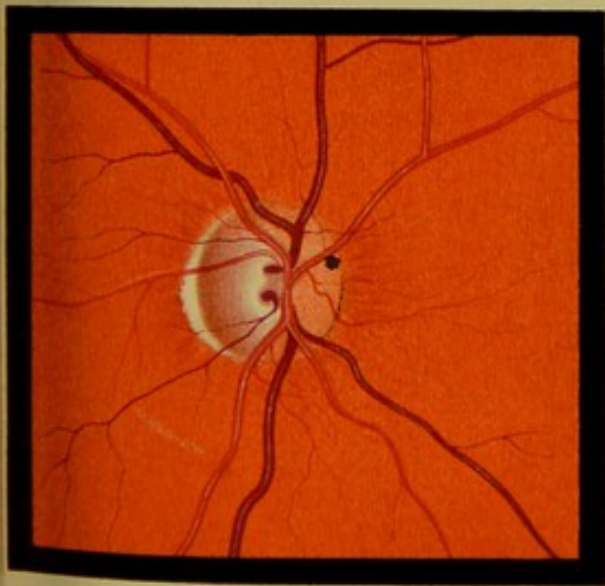


FIG. 13. R. E.

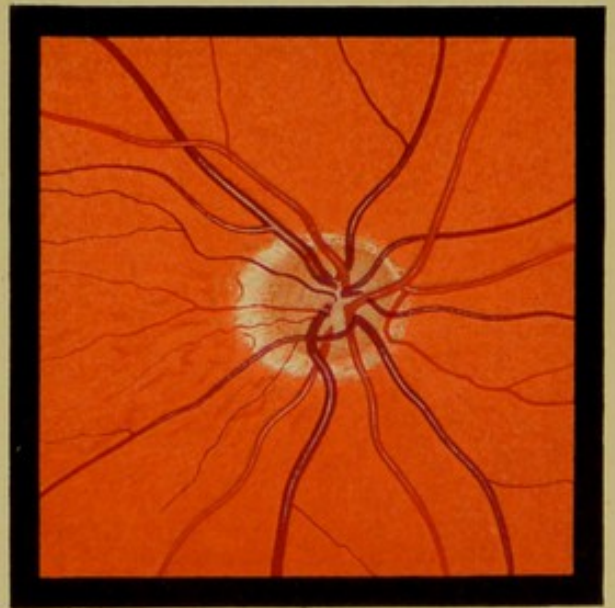


FIG. 14. R. E.

NATIONAL HOSPITAL LIBRARY

Not to be taken away

PLATE VI.

CONGENITAL CRESCENT OF OPTIC DISC.

FIG. 15.—CONGENITAL CRESCENT. CILIO-RETINAL VESSEL.

Ernest E., 7. *LE.* Drawing made in 1888.—V. (under atropine) $+4.5 = \frac{2}{3}$.

Description.—There is a large physiological cup. The uncupped part of the disc has a peculiar plum colour. Below is a pale crescent, having a maximum width equal to one-fifth of the vertical meridian of the whole disc. It extends further round the disc on the temporal than on the nasal side, and is continuous with a narrow pale band which encircles the disc. Surrounding the disc is a pale yellow halo.

At the lower and outer edge of the disc there emerges a large artery—cilio-retinal, which almost immediately bifurcates, and is distributed to the lower temporal quadrant of the retina.

FIGS. 16 AND 17.—CONGENITAL CRESCENTS, LARGE PHYSIOLOGICAL CUPS.

Fig. 16.—Eliza C., 11. *RE.* Drawings made in 1888.


V. (under atropine) $+1.0 \text{ } \text{C} + 0.50 \text{ } \text{cyl.} = \frac{2}{3}$.

Description.—A large physiological cup, opening downwards and outwards. The uncupped portion of the disc is of crescentic shape, and of a dark dull red colour. The two large temporal veins curve boldly round the edge of this.

In the lower temporal margin of the disc a crescent, measuring at its widest part, a sixth of the total diameter of the disc. Well marked pigmentation of disc margin.

Fig. 17.—Represents the *LE.* of the same patient. V. (under atropine) as *RE.*

Description.—Very similar to Fig. 16, but the crescent is narrower; the colour of the disc not as dark.



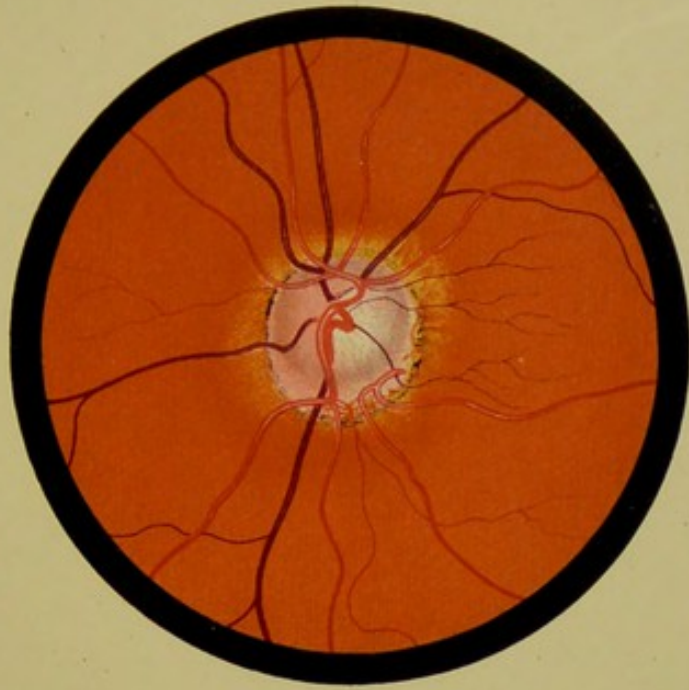


FIG. 15. LE

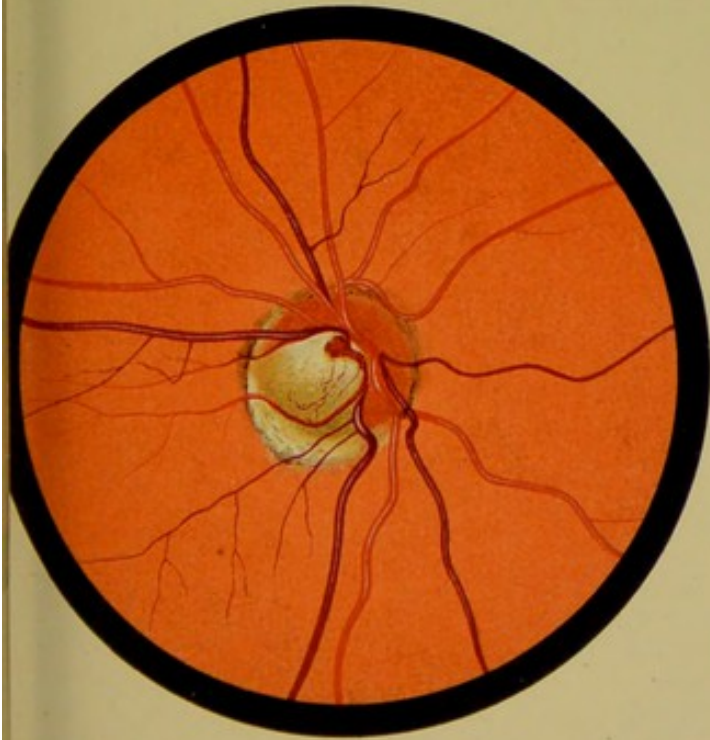


FIG. 16. RE

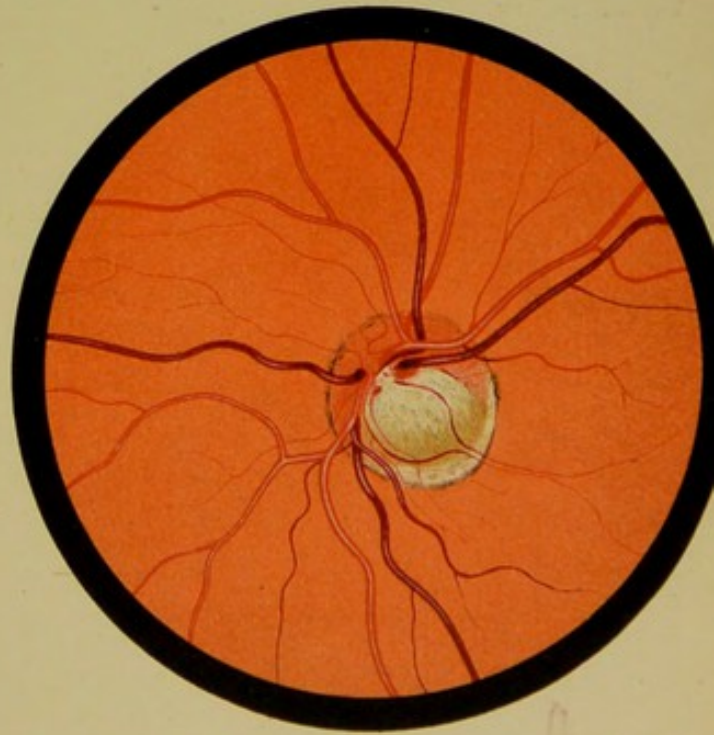


FIG. 17. LE

NATIONAL HOSPITAL LIBRARY

Not to be taken away

PLATE VII.

CONGENITAL CRESCENT OF OPTIC DISC.

FIGS. 18 AND 19.—CONGENITAL CRESCENTS. TORTUOUS VEINS.

Fig. 18.—Alice B., 7. *Drawings made in 1888.*—*RE.* correcting lenses, as found by shadow-test, $+1.50\text{C} + 4.0\text{ cyl. } |$.

Description.—At the lower part of the disc is a white crescent, measuring at its widest part about a sixth of the total vertical diameter of the disc. The remainder of the disc has a peculiar dull-red colour. There is no physiological cup.

The superior nasal vein is unusually tortuous.

Above and below the disc the choroidal vessels are visible.

Fig. 19.—*LE.* of the same patient.

Refraction as in *RE.*

Description.—At lower part of disc a white crescent, having at its widest part a diameter equal to a fourth of the total disc diameter.

Several of the retinal veins run a very tortuous course. Above and below the disc the choroidal vessels are visible.

Colour of the disc similar to *RE.*, but darker.

FIGS. 20 AND 21.—CONGENITAL "MOTTLED" CRESCENTS.

Fig. 20.—John P., 15. *RE.* *Drawings made in 1888.*—*V.* $+0.50\text{C} + 1.0\text{ cyl. } | = \frac{6}{12}$.

Description.—Physiological cup opening towards temporal border. The lower vessels curve boldly round the margin of this. On the temporal side of the disc a crescent having a mottled appearance. A cilio-retinal vessel emerges from its lower and outer border. Choroidal vessels seen faintly round disc.

Fig. 21.—*LE.* of same patient. *V.* as *RE.*

Description.—Similar to *Fig. 20*, but crescent better marked. Choroidal vessels faintly visible round the disc, with pigment between them. At the upper and outer part of the disc-margin a rounded pale area with soft outline.



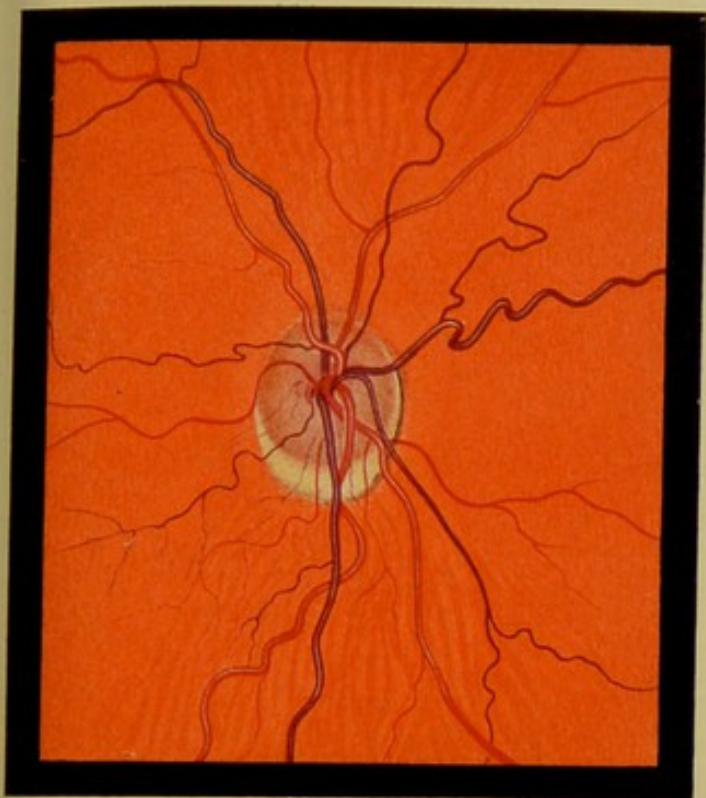


FIG. 18 R E

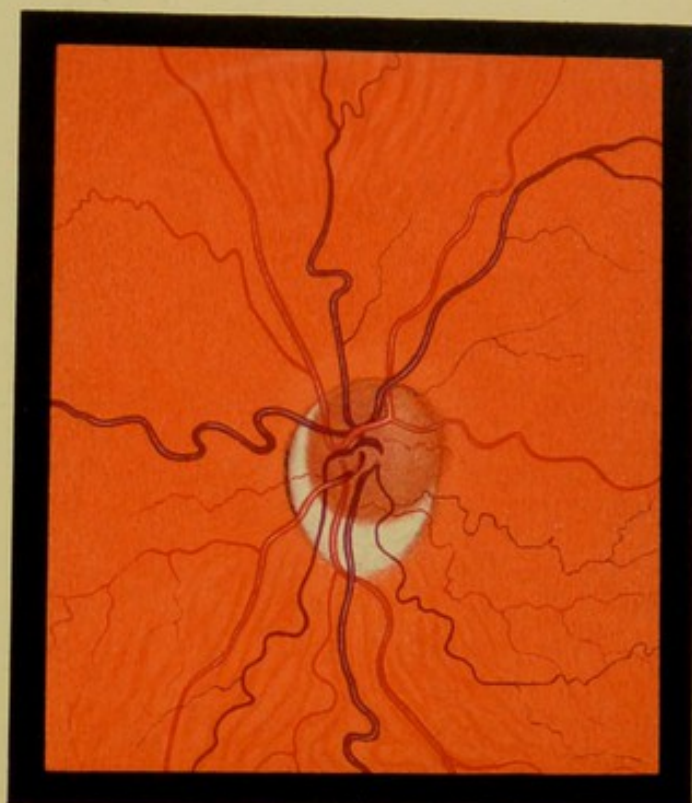


FIG. 19 L E

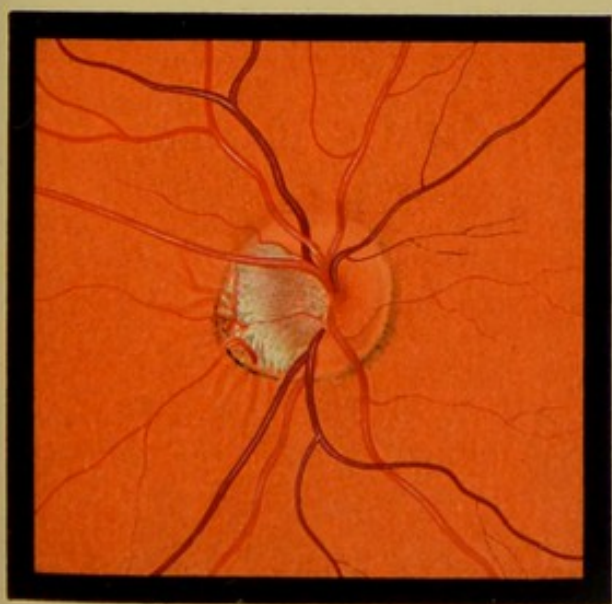


FIG. 20 R E

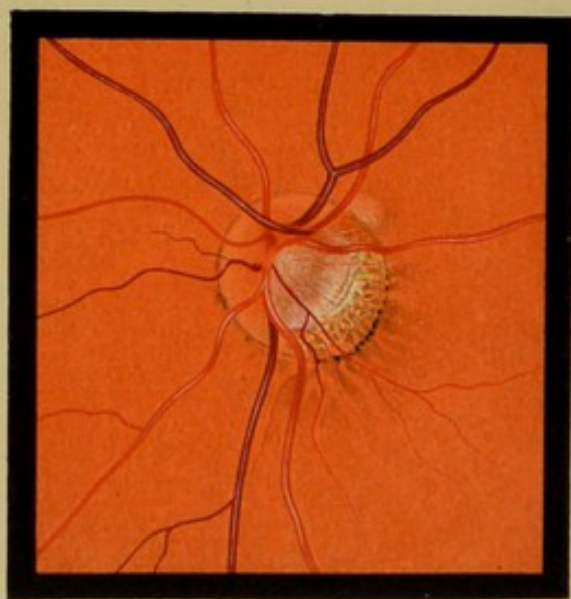


FIG. 21 L E

NATIONAL HOSPITAL LIBRARY
Not to be taken away

CONGENITAL CRESCENT. COLOBOMA OF DISC.

FIG. 22.—CONGENITAL CRESCENT.

Florence G., 18. *LE.* Drawing made in 1888.—V. -5.0 cyl. = $\frac{6}{8}$. *RE.* a small crescent below the disc similar to Fig. 18. V. $-7.5 - 1.5$ $\searrow_{30^\circ} = \frac{6}{8}$.

Description.—The disc consists of two parts. The upper, which is slightly the larger, is of a dull red colour, and the vessels disappear into it gradually, as if passing into a semi-transparent substance. The lower portion, which forms the crescent, is white, stippled with grey.

In 1894 the condition was unchanged.

FIG. 23.—CONGENITAL CRESCENT ABOVE.

Alice R., 18. *LE.* Drawing made in 1890.—V. $-3.0 - 1.50$ cyl. = $\frac{6}{8}$.

In *RE.* a similar crescent below V. downwards and inwards. V. $-0.50 - 2.50$ $\searrow_{20^\circ} = \frac{6}{8}$.

Description.—The crescent is large, and somewhat pointed above. The remainder of the disc is oval, and presents a physiological cup with a sharp lower edge, over which the vessels curve abruptly.

Two years later the myopia had increased 2 D., and the corrected V. in each eye was $\frac{6}{8}$. There was no change in the appearance of the discs.

FIG. 24.—CONGENITAL ABNORMALITY OF DISC (PARTIAL COLOBOMA?).

Joseph J., 48. *RE.* Drawing made November 1890.—V. $-1.75 - 1.75$ cyl. $\searrow_{20^\circ} = \frac{6}{8}$ partly. The *LE.* presented a somewhat similar appearance.—V. $-3.0 - 3.5$ $\searrow_{20^\circ} = \frac{6}{8}$ partly.

Description.—The whole disc area has about twice the normal diameter. Within this, nearer to its upper than its lower border, is a circular area, a little smaller than the normal disc, of dull reddish-grey colour, resembling the coloured portion of the disc in Fig. 22, but less red. The circumferential portion consists of a broad band, wider below than above; this is white stippled with grey, like the crescent in Fig. 22.

The upper veins curve over the boundary line between the white and red portions, as if they were dipping into a cup. The other vessels disappear gradually into the red portion.

Subsequent History.—Seen November 1894—no change.

FIG. 25.—COLOBOMA OF DISC.

Robert P., 15. *RE.* Drawing made June 1890. Compound myopic astigmatism. Corrected vision $\frac{6}{8}$.

LE. Emmetropia. V. = $\frac{6}{8}$. In this eye a small congenital crescent down and in.

Description of RE.—The whole disc area has a diameter about twice that of a normal disc. It is slightly irregular in shape, but is approximately circular. At the lower part is a crescent, measuring at its widest part about a fourth of the whole vertical diameter; the arms of this crescent embrace the remainder of the disc. The upper margin of the crescent is sharply defined, and the lower vein curves over it, as if dipping into a cup. The remainder of the disc consists of two parts which, however, are not sharply separated. The upper is the colour of a normal disc, the lower, smaller, is similar in colour to 22. Into it some vessels gradually sink.

Subsequent History.—Seen November 1893—no change.

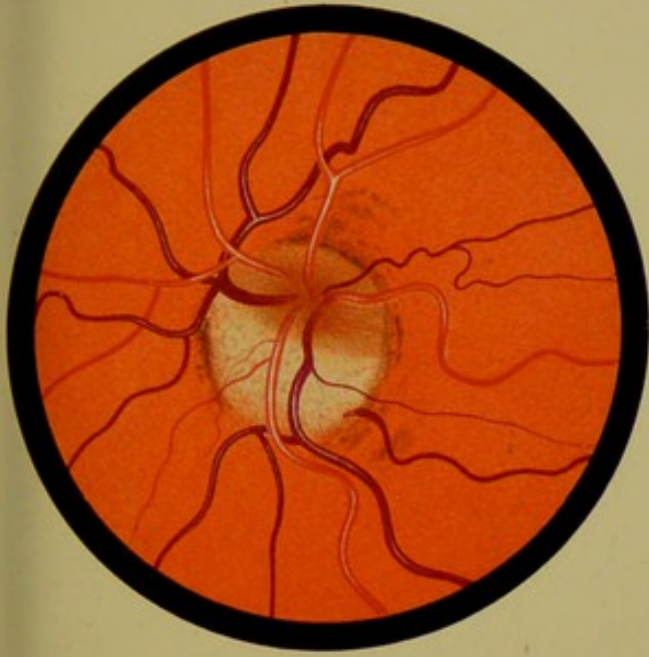


FIG. 22. L. E.

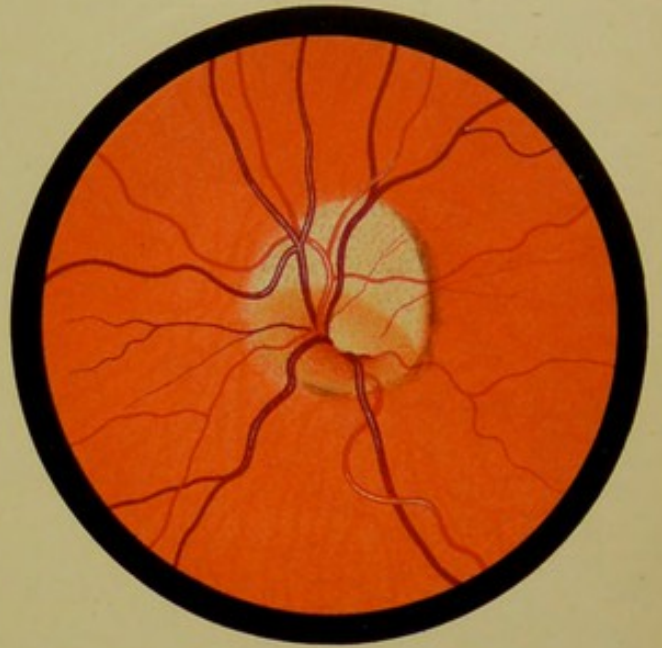


FIG. 23. L. E.

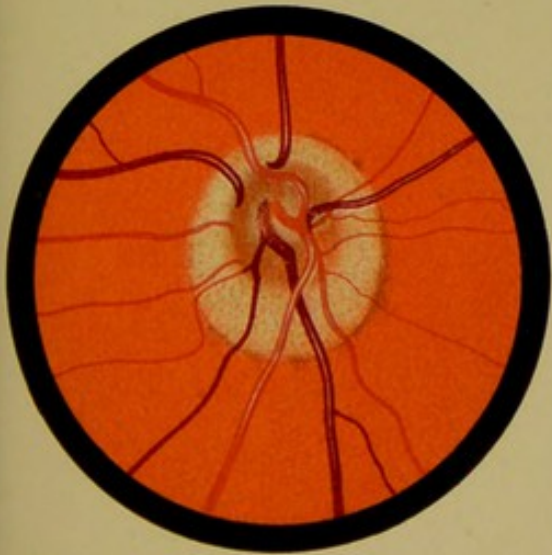


FIG. 24. R. E.

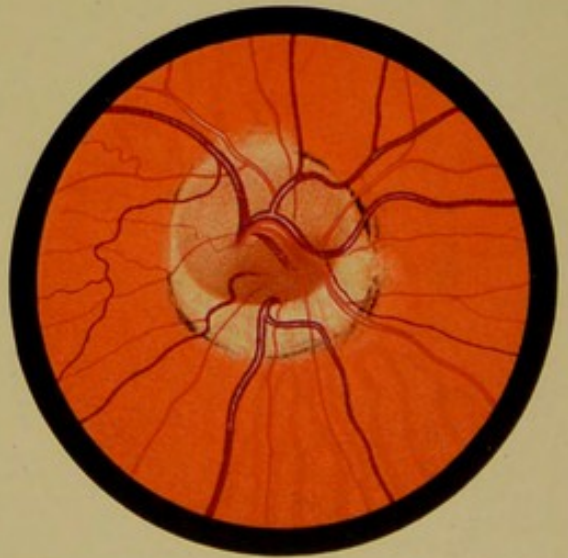


FIG. 25. R. E.

NATIONAL HISTORICAL LIBRARY
Not to be taken away

PLATE IX.

COLOBOMA OF FUNDUS.

FIG. 26.—COLOBOMA OF FUNDUS.

Woman, 45. *LE.* Drawing made October 1888. (Lent by Mr. Hartridge.)

RE. presented nothing abnormal. $V. = \frac{6}{8}$.

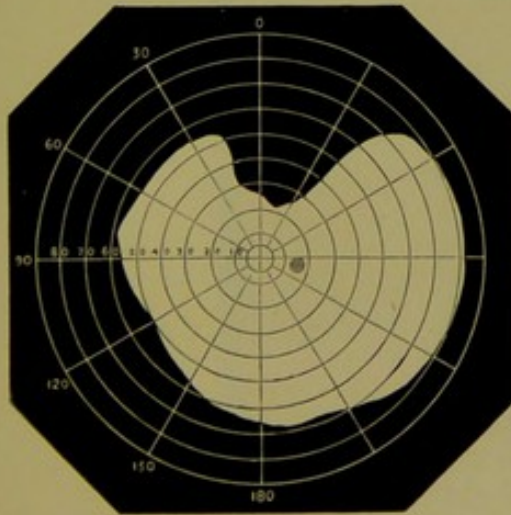LE. $V. = \frac{6}{38}$. Triangular defect in visual field above. A typical coloboma of the iris.

Description.—A large white area extending from half a disc diameter below the disc downwards to beyond the limit of ophthalmoscopic examination. The margin is sharply defined and pigmented in places. Above it looks like the sharp edge of a depression, an effect which is increased by the manner in which the retinal vessels curve over.

The disc is oval; its long diameter transverse. Above it is a crescent on which some small vessels are visible.

FIG. 27.—COLOBOMA OF FUNDUS.

Mrs. O., about 40. *RE.* Drawing made March 1889.



LE. $V. = \frac{6}{12}$, $Hm. = 1.5$ *D.* External appearance normal. Below the disc a circular patch of exposed sclerotic having a diameter about twice that of the disc.

RE. coloboma of iris, $V. = \frac{6}{38}$. A triangular defect in upper part of field. Typical coloboma of iris.

Description.—Extending downwards from about two disc diameters below the disc to beyond the limits of ophthalmoscopic examination, a white area of scleral whiteness, widening towards the periphery, its surface is stippled in places, and its border pigmented. A transverse line of pigment and a small tongue of normal

fundus divide off a smaller portion above. This portion bears in size and position a resemblance to the patch that existed in *RE.*

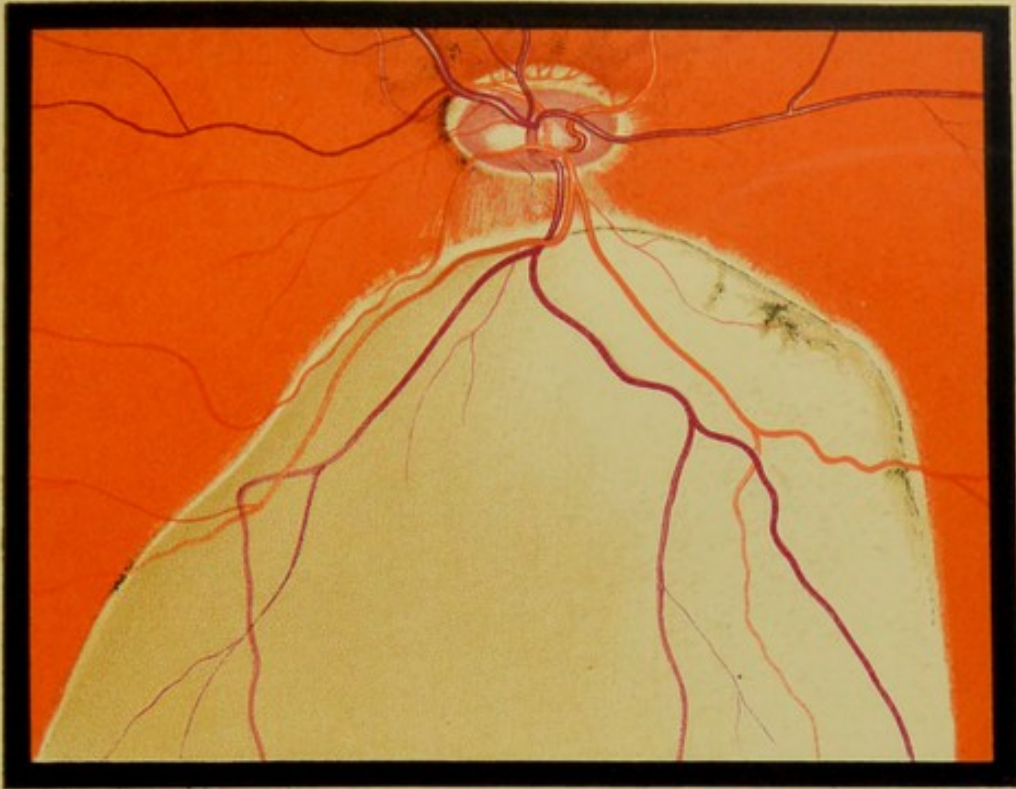

FIG. 26. L.E.

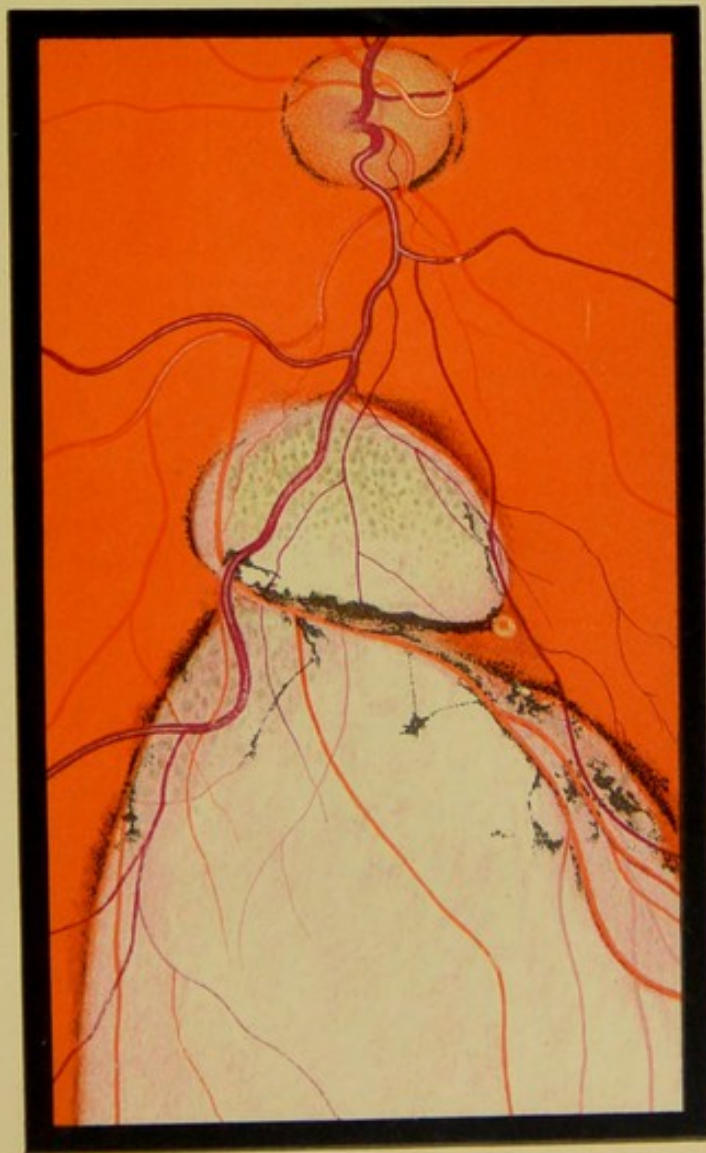

FIG. 27. R.E.

NATIONAL HISTORY LIBRARY
Not to be taken away

PLATE X.

CONGENITAL PIGMENT DOTS ON FUNDUS

FIG. 28.—CONGENITAL PIGMENT DOTS.

Jno. W., 5. *LE*. Drawing made in 1888.—The youngest of six living children. There was no consanguinity of the parents. The other children presented no similar condition, but two of them had a pigment spot on the disc, close to its temporal border.

The *RE*. presented nothing abnormal.

Description.—Groups of pigment dots scattered over the lower sector of the fundus.

FIG. 29.—CONGENITAL PIGMENT DOTS.

Sidney P., 13. *LE*. Drawing made in 1888.—The fifth of seven children. There was no consanguinity of the parents. Four of the other children and the mother were examined, and presented no similar appearance. V. (under atropine) each eye $+1.75 = \frac{7}{4}$.

Patient stated, in answer to questions, that he saw worse at night than the other boys in the school, but there was evidence of the correctness of this statement.


The *RE*. presented nothing abnormal.

Description.—In the upper part of the fundus several groups of pigment dots. The groups are fewer than in Fig. 28, but the dots composing them are more numerous and more closely aggregated.

The fundus is of the sombre-red type. Macula visible as a still darker area. Retinal striation round disc well marked.

Subsequent History.—A year later these cases were unchanged.

Note.—Drawings of both these cases formed part of a paper read by Mr. Sydney Stephenson before the Ophthalmological Society, and published in Vol. XI. of the *Transactions*. They are now published by permission of Mr. Stephenson and of the Council of the Ophthalmological Society.



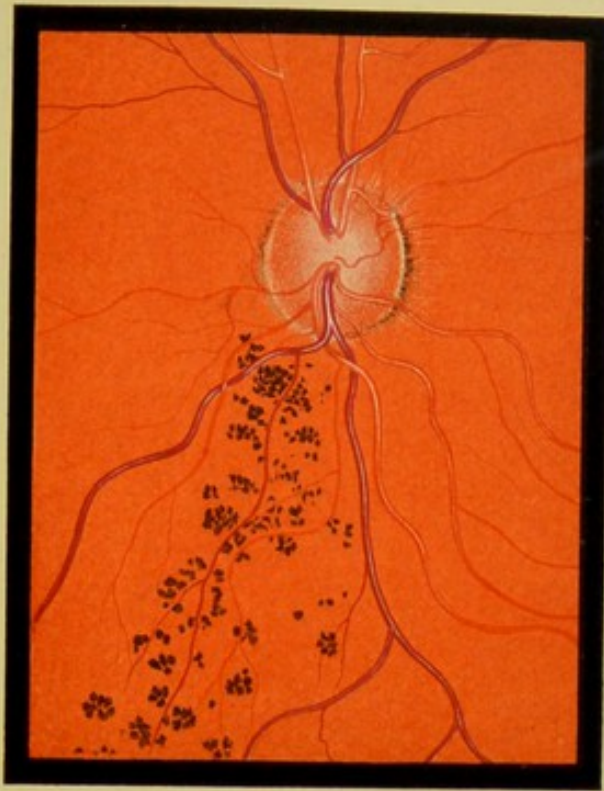


FIG. 38 L.E.

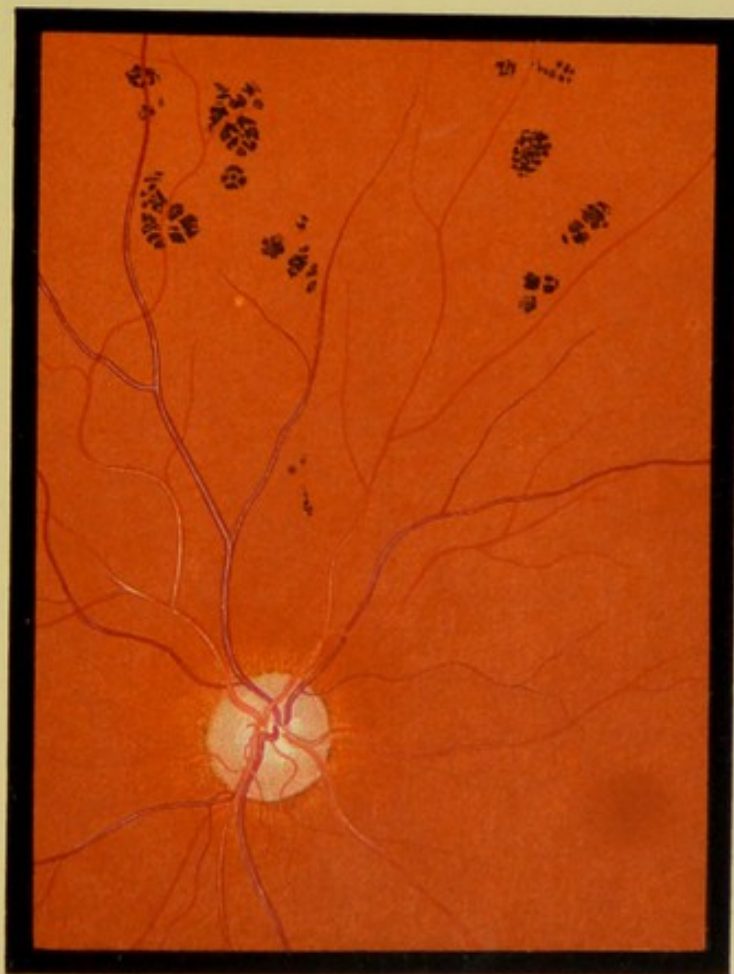


FIG. 39 R.E.

NATIONAL HISTORY LIBRARY
Not to be taken away

PUNCTATE CONDITIONS OF FUNDUS.

FIG. 30.—PHYSIOLOGICAL DOTS IN MACULAR REGION. ("GUNN'S DOTS.")

George P., 11. *RE*. Drawing made in 1888.

There were corneal nebulae in both eyes.

V. (under atropine) *RE*. + 1.25 = $\frac{5}{8}$.

LE. + 1.75 = $\frac{7}{8}$.

The macular halo, and the "watered-silk" appearance of the whole retina were conspicuous, but have been purposely omitted from the figure.

Description.—Fundus of the moderate light type. Macula seen as a dark area. On this, numerous yellowish minute dots; a little lower down, two small groups of similar dots. These dots could only be seen in certain positions of the ophthalmoscopic mirror, but when seen they were always in the same position. In the drawing they are necessarily too conspicuous. For similar dots see Figs. 9 and 10. Nearer the disc are two pairs of dots which are somewhat larger, and are possibly of a different nature.

Large physiological cup, the "intermediate zone," being reduced to a crescent. The distribution of the vessels on the retina is typically normal.

FIG. 31.—DIFFUSE PUNCTATED CONDITION OF RETINA.

Mrs. P., 43. *RE*. Drawing made in November 1888.—The patient had been seen in 1884, and the ophthalmoscopic appearance had not appreciably changed. V. *RE*. + 2.5 = $\frac{5}{2}$. *LE*. + 2.5 = $\frac{5}{2}$, slight concentric contraction of right *VF*, and considerable contraction of left. The ophthalmoscopic appearances were similar in the two eyes.

Description.—The disc is normal, and presents a complete connective tissue ring. The whole fundus is closely sprinkled with small pale dots. Towards the macula the dots are larger and fewer, they are absent from the central part of this region. Towards the periphery of the fundus, the dots are packed less closely, but are still numerous. The largest have a diameter equal to that of a primary branch of the retinal artery, the smallest are so minute as to be barely visible. The great majority are of a nearly uniform size intermediate between these extremes. The dots are of a dull yellowish-white colour, are devoid of brilliancy, and have a soft appearance. They lie entirely beneath the retinal vessels.

No pigment deposits were seen anywhere, except the ordinary pigment line near the disc.

The patient was seen again at intervals till 1896, and no appreciable change was observed in the appearances.



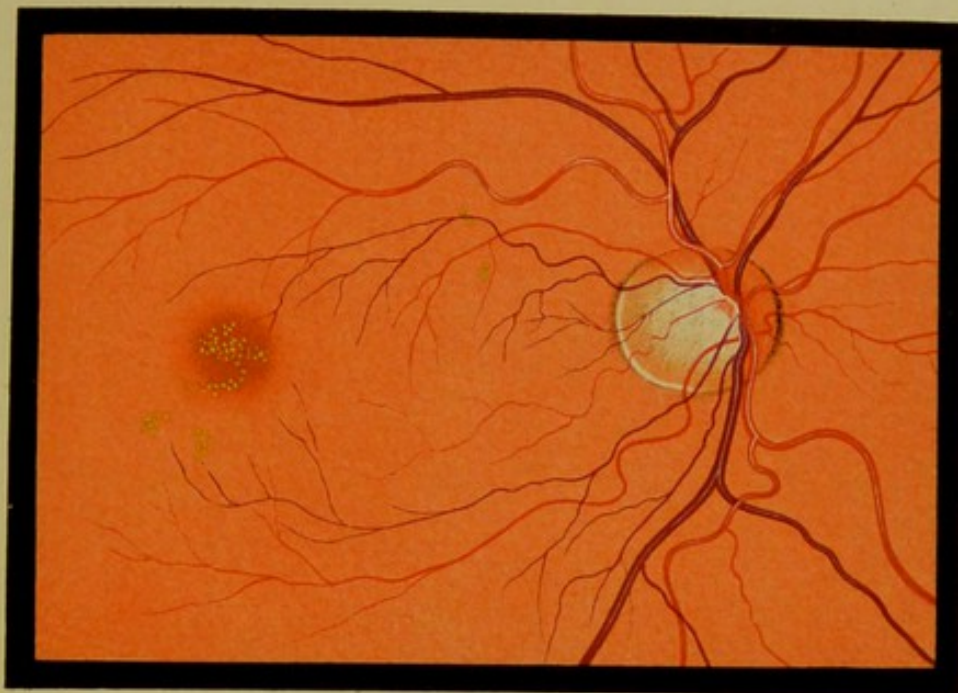


FIG. 30. R. E.

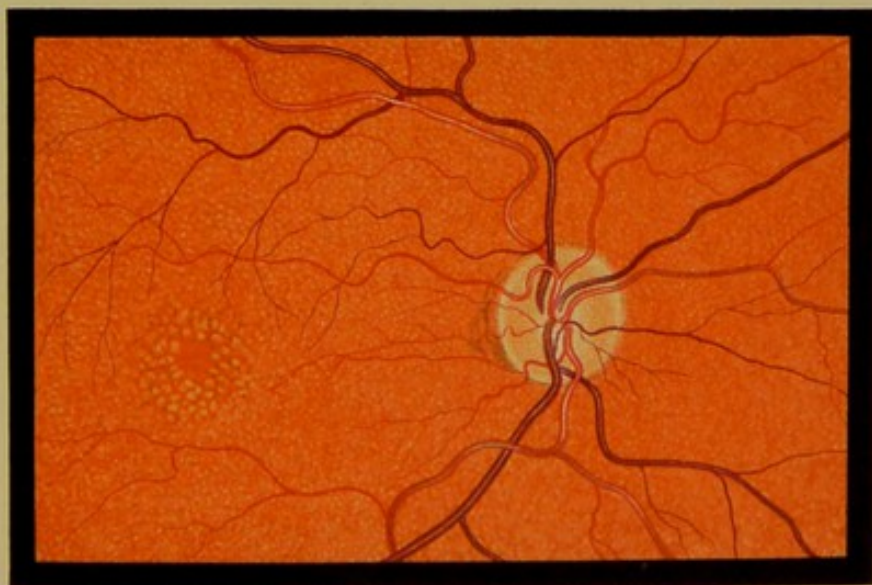

FIG. 31. R. E.

1880-1881

PLATE XII.

CONNECTIVE TISSUE ON DISC AND OPAQUE NERVE FIBRES.

FIG. 32.—CONNECTIVE TISSUE ON DISC.

Henry A., 13. *RE*. Drawing made in 1888.

V. under atropine *RE*. + 3.0 *D.* \ominus + 1.0 *cyl.* — = $\frac{2}{3}$.

LE. + 3.0 \ominus + 1.5 *cyl.* — = $\frac{2}{3}$ (3 letters).

The condition in the *LE*. was similar, but less marked.

Description.—Whole fundus faintly stippled with pigment. To the nasal side of the centre of the disc a broad vertical white band, lying in front of and concealing the vessels. From this numerous fine white threads pass over the upper part of the disc, and a few over its inner part.

FIG. 33.—CONNECTIVE TISSUE ON DISC.

Margaret B., 10. *LE*. Drawing made in 1888.

V. under atropine *RE*. + 7.0 *D.* = $\frac{2}{3}$ (2 letters).

LE. + 7.0 = $\frac{2}{3}$ (3 letters).

Description.—Fundus mottled with fine pigment. Choroidal vessels seen faintly. A nearly vertical white band in centre of disc. Offshoots from this accompany the upper and lower vessels, and two others pass outwards. Retinal striation seen on upper part of disc.

FIG. 34.—OPAQUE NERVE FIBRES.

Emily A., child. *RE*. Drawing made in 1888.


Description.—Fundus of the moderately dark type. Projecting from the upper part of the disc two broad brilliantly white, finely fibrillated processes. They conceal the upper border of the disc, and lie beneath the retinal vessels. The fibrillar nature of the patches is best seen at their peripheral extremities, where the component fibres separate from each other.

FIG. 35.—OPAQUE NERVE FIBRES.

Frederick H., 13. *LE*. Drawing made in 1888.

Vision each eye = $\frac{2}{3}$.

Description.—Two masses of brilliant white fibres proceeding from the lower margin of disc. Several of the fibres pass in front of the vessels. The fibres appear to form a thin layer, the fundus being visible between them in places.



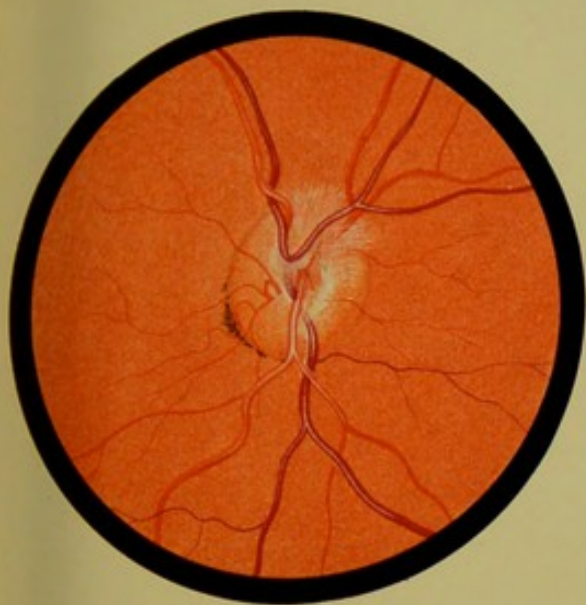


FIG. 32. R. E.

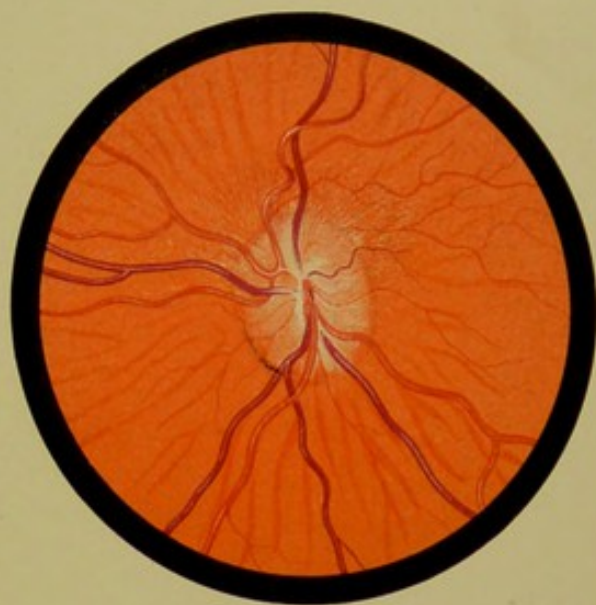


FIG. 33. L. E.

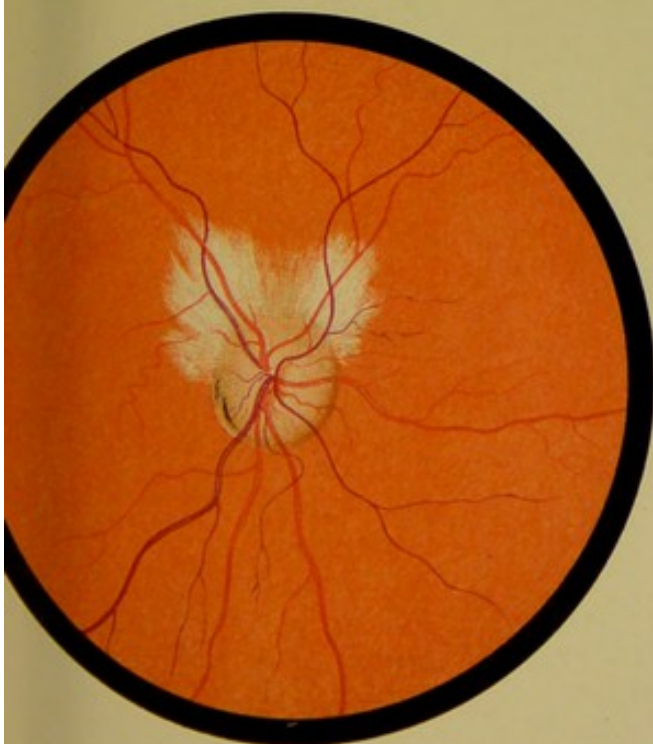


FIG. 34. R. E.

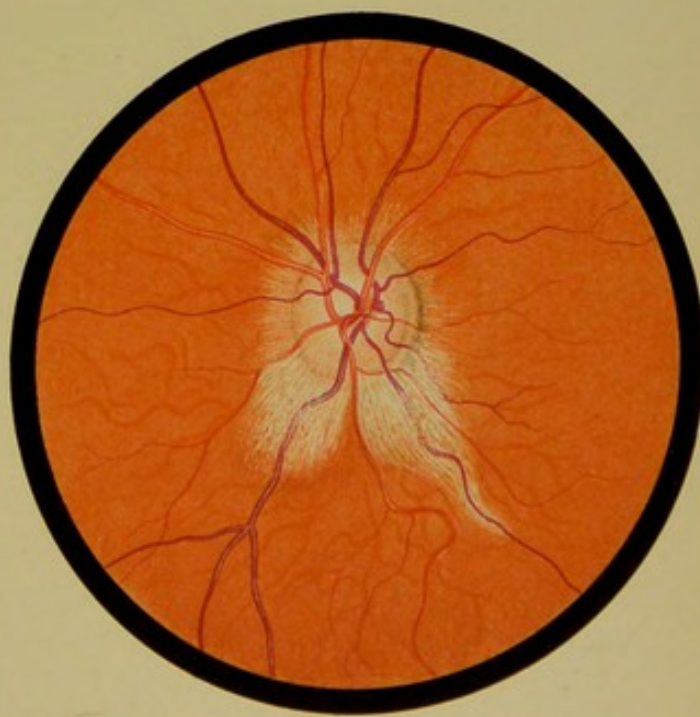


FIG. 35. L. E.

NATIONAL HOSPITAL LIBRARY

Not to be taken away

PLATE XIII.

OPAQUE NERVE FIBRES.

FIGS. 36 AND 37.—OPAQUE NERVE FIBRES.

Fig. 36.—John F., 12. *RE.* Drawings made in 1888.

V. +4 *OD.* \odot 1.0 *cyl.* | = $\frac{2}{3}$.

Description.—Fundus of the moderately dark type. A dense, hard-looking mass of white fibres surrounding the disc, and concealing its upper and inner part. The remainder of the disc has a peculiar plum colour. Some of the vessels are completely hidden in places; others are seen faintly through the fibres.

Fig. 37.—*LE.* of the same patient. V. + 5 *OD.* \odot 1.0. *cyl.* | = $\frac{6}{24}$.

Description.—The distribution of the fibres differs somewhat from that seen in Fig. 36, and less of the disc is covered; in other respects the two eyes are similar.

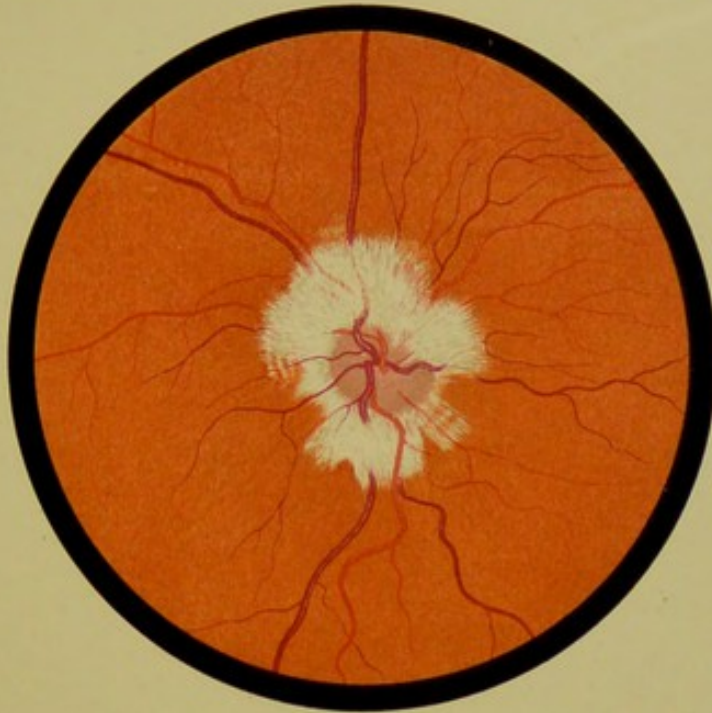

FIG. 36. R. E.

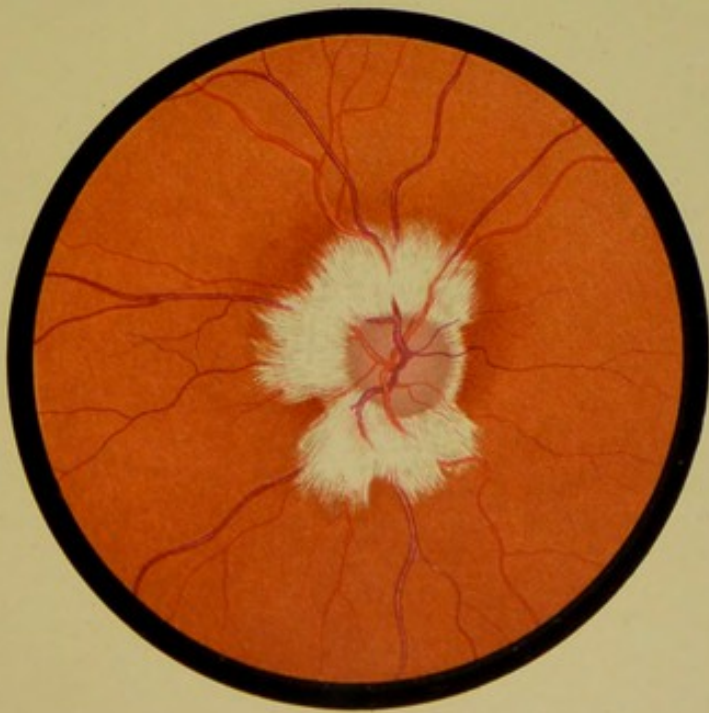


FIG. 37. L. E.

NATIONAL HOSPITAL LIBRARY
Not to be taken away

PLATE XIV.

OPAQUE NERVE FIBRES.

FIG. 38.—OPAQUE NERVE FIBRES.

Rachel V., about 12. *LE*. Drawing made in 1888.

Description.—Above the disc two masses of opaque nerve fibres. That on the temporal side is separated from the disc by a narrow strip of normal fundus.

FIG. 39.—OPAQUE NERVE FIBRES.

Eliza D., 40. *RE*. Drawing made in January 1890.

V. (under homatropine) + 1.5 + 1.50 *cyl.* — = $\frac{2}{3}$.—The visual field was taken carefully, and the area of the blind spot found to be perceptibly increased.

Description.—A large white fibrillated mass covering nearly two-thirds of the disc, and extending about three disc diameters on to the fundus. The vessels, where covered, are for the most part entirely hidden.

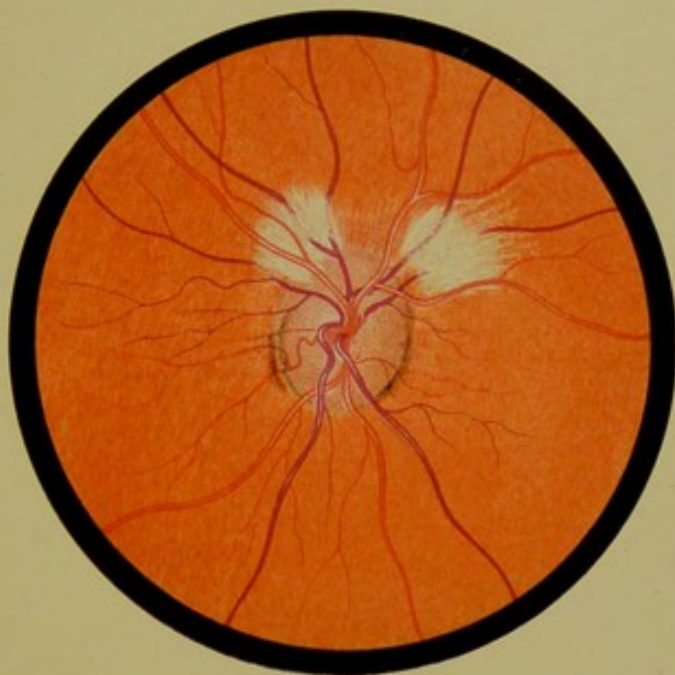


FIG. 38 L.E.

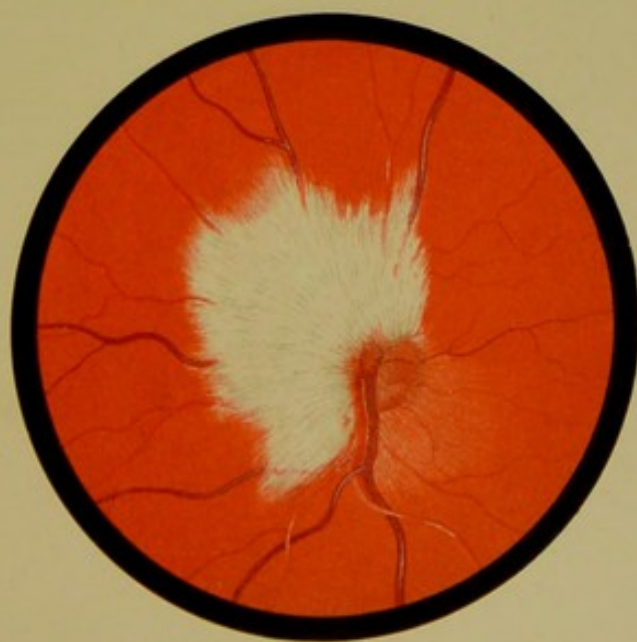


FIG. 39.

NATIONAL HOSPITAL LIBRARY
Not to be taken away

CHOROIDITIS.

FIG. 40.—CHOROIDITIS. Early Stage.

Essie W., 24. *RE.* Drawing made October 1889.—A healthy looking girl. No evidence of syphilis, inherited or acquired. Both parents living and in good health. An elder brother suffers from tubercular disease of the hip. Family and personal history, in other respects, unimportant.

The patient was seen in March 1889 for dimness of *LE.* due to "keratitis punctata." The dots were minute; there was no circumcorneal injection. Pupil active, no adhesions. A few weeks later the *RE.* became affected in a similar manner. The patient was treated with mercury. The corneæ cleared after a few weeks, and the condition of the fundus, depicted in Fig. 40, was then discovered. The *LE.* presented a similar appearance. The V. at this time was *RE.* + 0.50 = $\frac{6}{8}$. *LE.* - 0.50 = $\frac{6}{8}$.

Description.—Disc normal. On the temporal side, beyond the connective tissue ring, a mottled crescent, on which several choroidal vessels are visible. On the nasal border a brush of connective tissue or of opaque nerve fibres. Between the disc and macula, numerous irregular pale areas mottled with fine pigment. Above a disc of pigment, a pigment ring enclosing healthy fundus, and another enclosing an atrophic area. The periphery of the fundus was normal.

Subsequent History.—The case was seen at intervals till April 1894. During this period there were, at least, five attacks of "keratitis punctata" in each eye; sometimes one eye and sometimes the other being affected. It is probable that there were other slighter attacks or relapses. V. varied only with the condition of the cornea. No appreciable change took place in either fundus.

FIG. 41.—CHOROIDITIS. Advanced.

Miss L., 20. *LE.* Drawing made March 1889.—Physiognomy typical of inherited syphilis. Patient very deaf. Both corneæ presented central cloudiness, the remains of former keratitis. She is the youngest of twelve children, eight of whom died in infancy, and one later of consumption. One of the survivors, a sister, who was the eldest of the family, was seen, and presented no signs of inherited syphilis. The other survivor, a brother, was not seen, and no reliable account of his condition was obtained. Patient stated that her sight has always been defective; eight years ago both eyes became inflamed, and continued so about a year.

V. *RE.* = $\frac{5}{18}$; *LE.* counts fingers. The condition of the fundus of *RE.* was not noted.

Description.—Over nearly the whole fundus are numerous circular patches of choroidal atrophy. The larger round or oval, the smaller more irregular in shape. Most of these are partially surrounded by pigment which also tends to form a network with irregular meshes, inclining to a circular shape; some of this pigment lies in front of the retinal vessels. Towards the disc the choroidal changes cease rather abruptly; a space of about two disc diameters on the temporal side of the disc being almost normal.



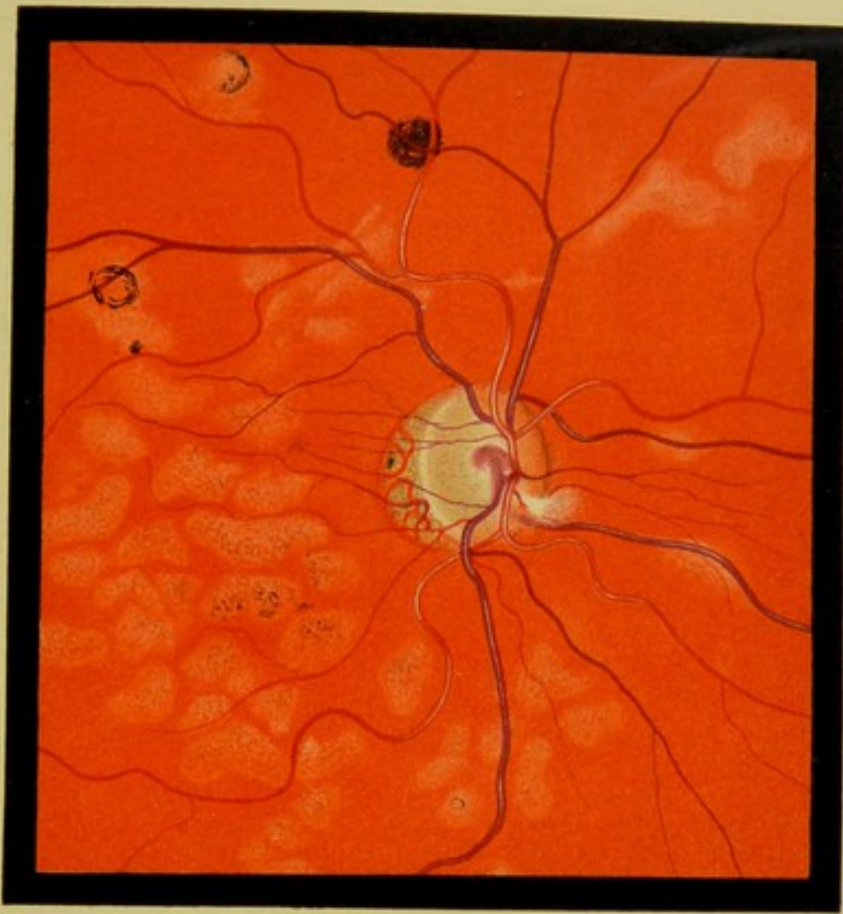


FIG. 40. R.E.

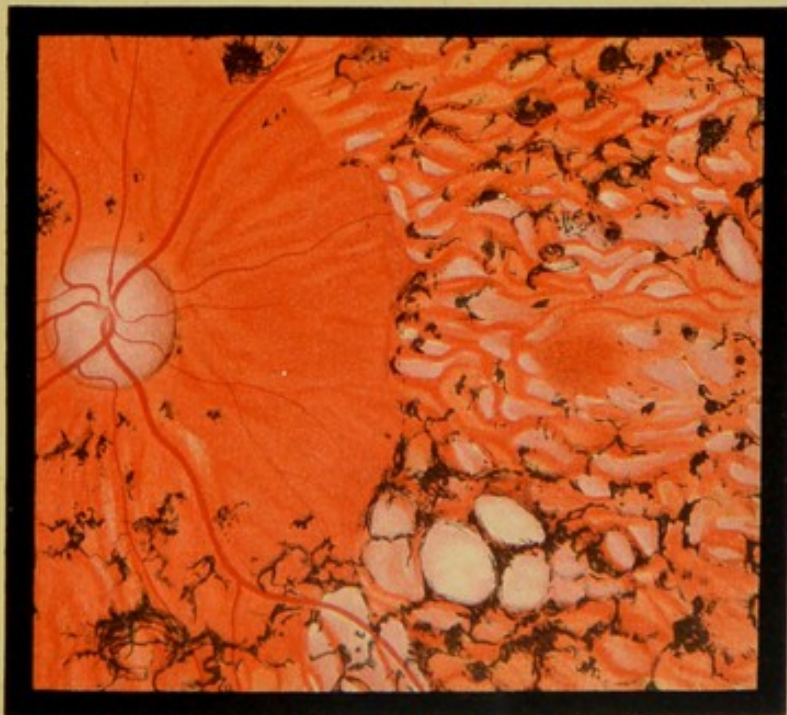


FIG. 41. L.E.

NATIONAL HOSPITAL LIBRARY
Not to be taken away

PLATE XVI.

CHOROIDITIS.

FIG. 42.—CHOROIDITIS. Advanced.

Harriet E., 24. *LE.* Drawing made February 1890.—The teeth were typical of inherited syphilis; in other respects the patient's physiognomy presented nothing characteristic. Patient is the fourth of ten children, two of whom died at birth, and two during infancy. No further details obtainable. V. *RE.* = $\frac{6}{18}$.

LE. There was a posterior polar cataract, and there were a few floating opacities in the vitreous. V. hand movements.

Description.—Numerous round and oval areas of choroidal atrophy. They vary in size, the larger having a diameter twice that of the disc. In all, the sclerotic is completely exposed, although many are crossed by a few choroidal vessels. Above the disc a large area evidently formed by the coalescence of smaller ones.

Near the macula is a group of five small circular areas of exposed sclerotic. Some of the patches are surrounded by pigment, but in most situations the pigment seems to be deposited without reference to the atrophic areas.



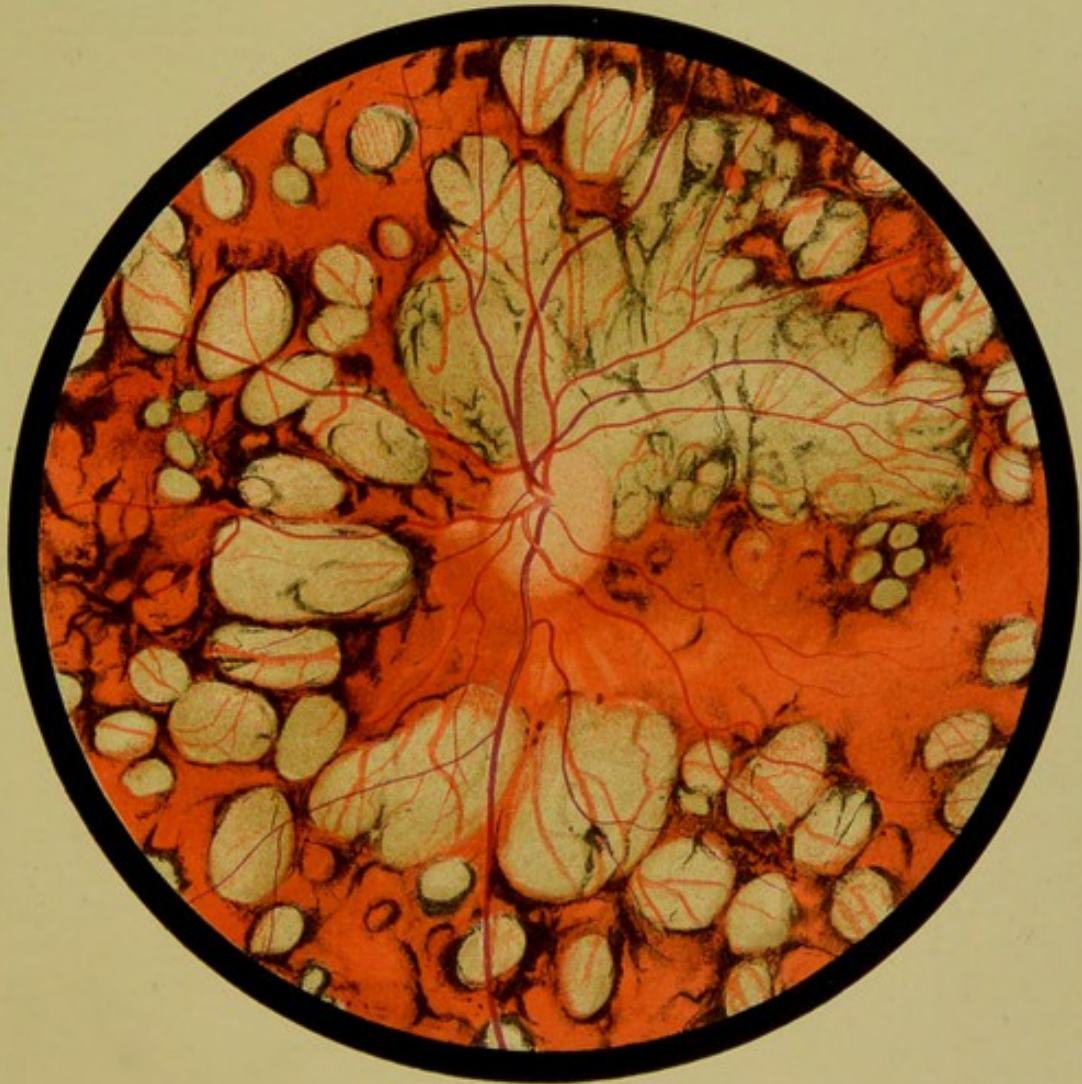


FIG. 43. L.E.



PLATE XVII.

CHOROIDITIS. ADVANCED.

FIG. 43.—CHOROIDITIS. Secondary Pigmentation of the Retina.

Mary A., 60. *RE.* Drawing made in 1890.—Said to have had good health till her marriage at the age of twenty. Fifteen months later she was delivered of her first child, craniotomy, or some analogous operation, being performed. A few months later nearly all her hair came off. She next had a miscarriage. Then, eighteen months after her first confinement, a child, which was said to have been healthy, but it died of "fever" at the age of twelve. Then followed two miscarriages, and then two children in succession, each of whom died at about thirteen months from "fits." Her sight began to fail a few months after her first confinement, and has steadily deteriorated since. V. is now *RE.* $-2 D = \frac{6}{12}$; *LE.* fingers. But at night her sight is so much worse that she has to be led.

The ophthalmoscopic appearances in the two eyes were similar.

Description.—An immense area of exposed sclerotic surrounding the disc, except on its temporal side. Beyond this large oval areas, almost in contact with each other, and a few similar isolated patches. The macula is free from these, but presents a good deal of pigment deposit. There are large masses of pigment in several situations.

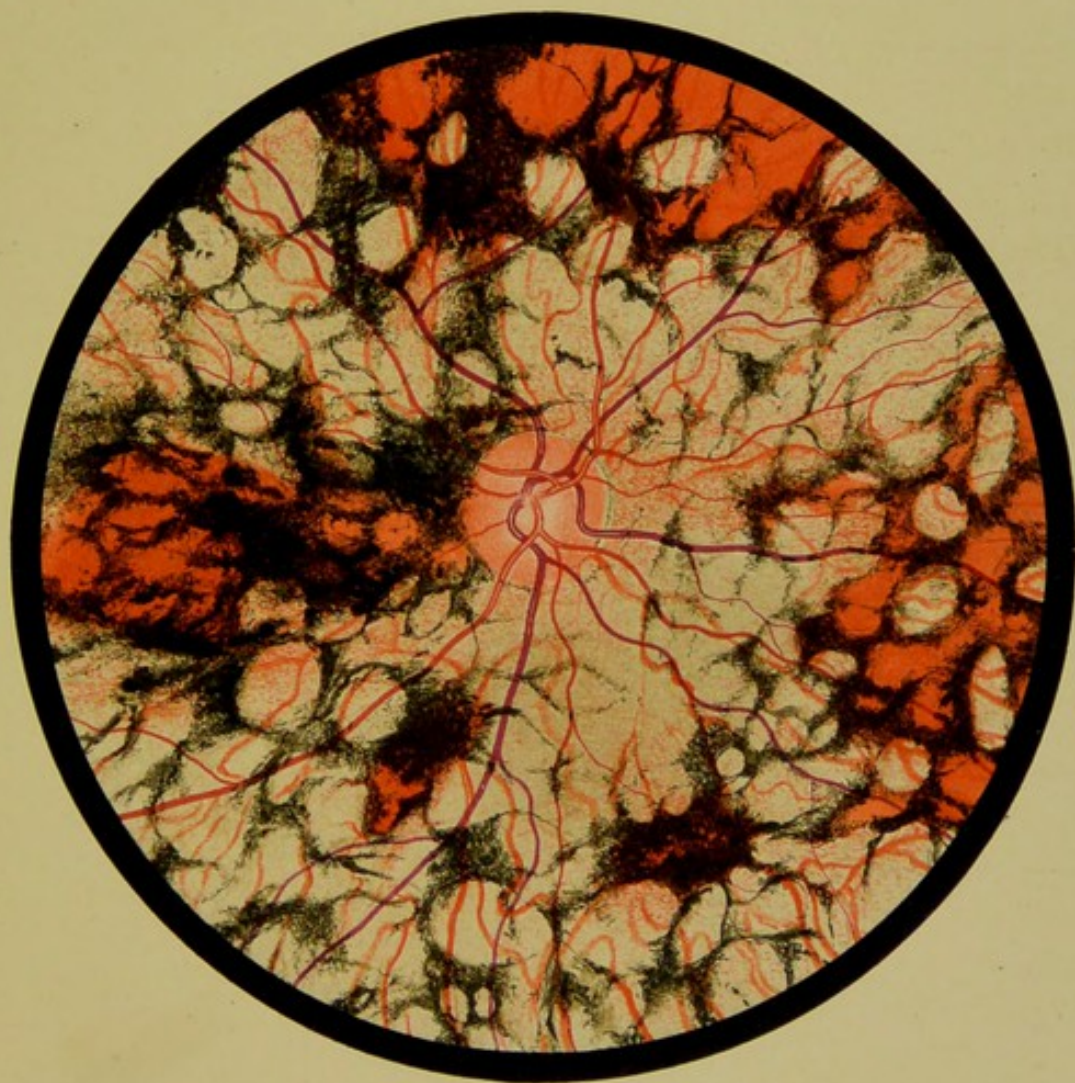


FIG. 43. R. E.

NATIONAL HOSPITAL LIBRARY
Not to be taken away

DISSEMINATED CHOROIDITIS.

FIG. 44.—DISSEMINATED CHOROIDITIS WITH CONSPICUOUS PIGMENTATION.

Amy D., 29. *RE.* Drawing made July 1890.

She enjoyed good health till her marriage in 1878. About a month later she noticed a vaginal discharge, and two weeks after this a rash appeared all over the body, which persisted for a year, and left permanent scars. In July 1879 the vision of *RE.* began to fail. She believes that the *LE.* was always defective.

She had no miscarriages. Her first child was born in April 1881. The child, when seen in 1893, had typical syphilitic teeth, and was suffering from choroiditis, with pigmentation of the retina, and recent iritis. Two other children were born in 1883 and 1885 respectively. One died of pleurisy, the other is said to be healthy, but has not been seen.

The fundus of *RE.* was first examined in 1885; at the date of the drawing it had not appreciably changed. The *LE.* presented similar changes, but in addition there was a connective tissue formation in the macular region.

Description.—On the temporal side numerous circular areas of partial atrophy of the choroid. The majority are circular or oval; some are surrounded by a border of pigment. On the nasal side there are areas of similar size, so closely aggregated as to be almost in contact. The majority of these are almost completely covered by pigment, those which are only bordered by pigment show less atrophy than those on the temporal side.

Subsequent History.—The patient was seen at intervals till 1896, and no appreciable change occurred.

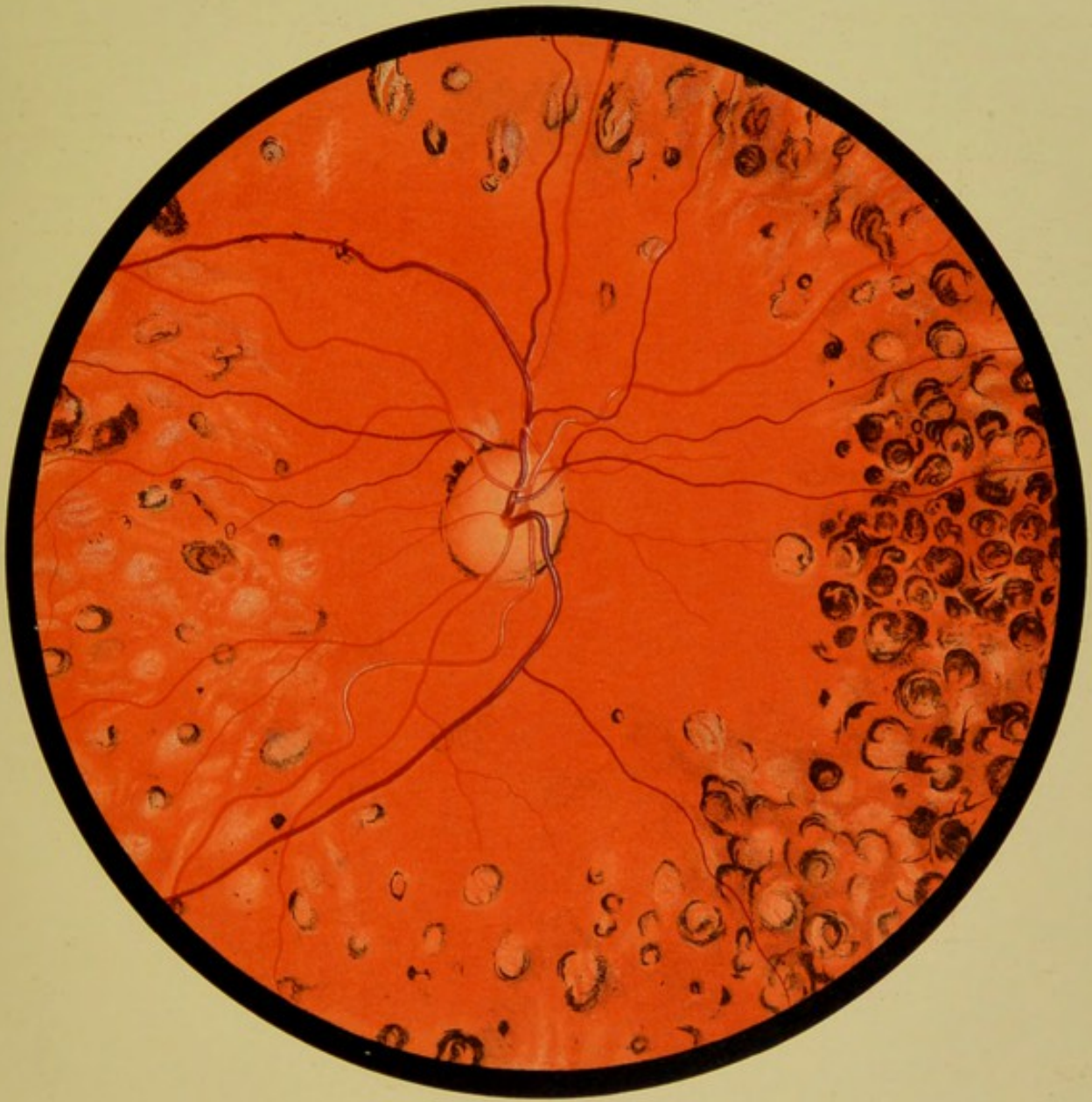


FIG. 44. R. E.

NATIONAL HOSPITAL LIBRARY
Not to be taken away

PLATE XIX.

PIGMENTATION OF RETINA SECONDARY TO CHOROIDITIS.

FIG. 45.—PIGMENTATION OF RETINA FROM CHOROIDITIS.

Henry S., 45. *RE.* Drawing made February 1889.—Twenty years ago he noticed "black spots" before the *RE.*; the vision failed gradually soon afterwards, and has been defective ever since. There was no history of acquired syphilis, nor were there any signs of an inherited taint.

RE. V. = hand movements, and that only on the outer part of the field.

LE. V. = $\frac{6}{8}$. Ophthalmoscopic appearance normal.

Description.—Disc rather pale and dull-looking. Connective tissue ring well marked. The superior temporal artery is of fair size, but its branches are small. In the lower part of the retina only one artery is visible, and this is a cilio-retinal vessel. The choroidal vessels are seen as pale streaks. Towards the periphery numerous pigment rings, enclosing fundus of normal colour. Above the disc are some circular areas of pigment like those in Fig. 44. In some situations the pigment forms a network—the meshes tending to assume a circular form.



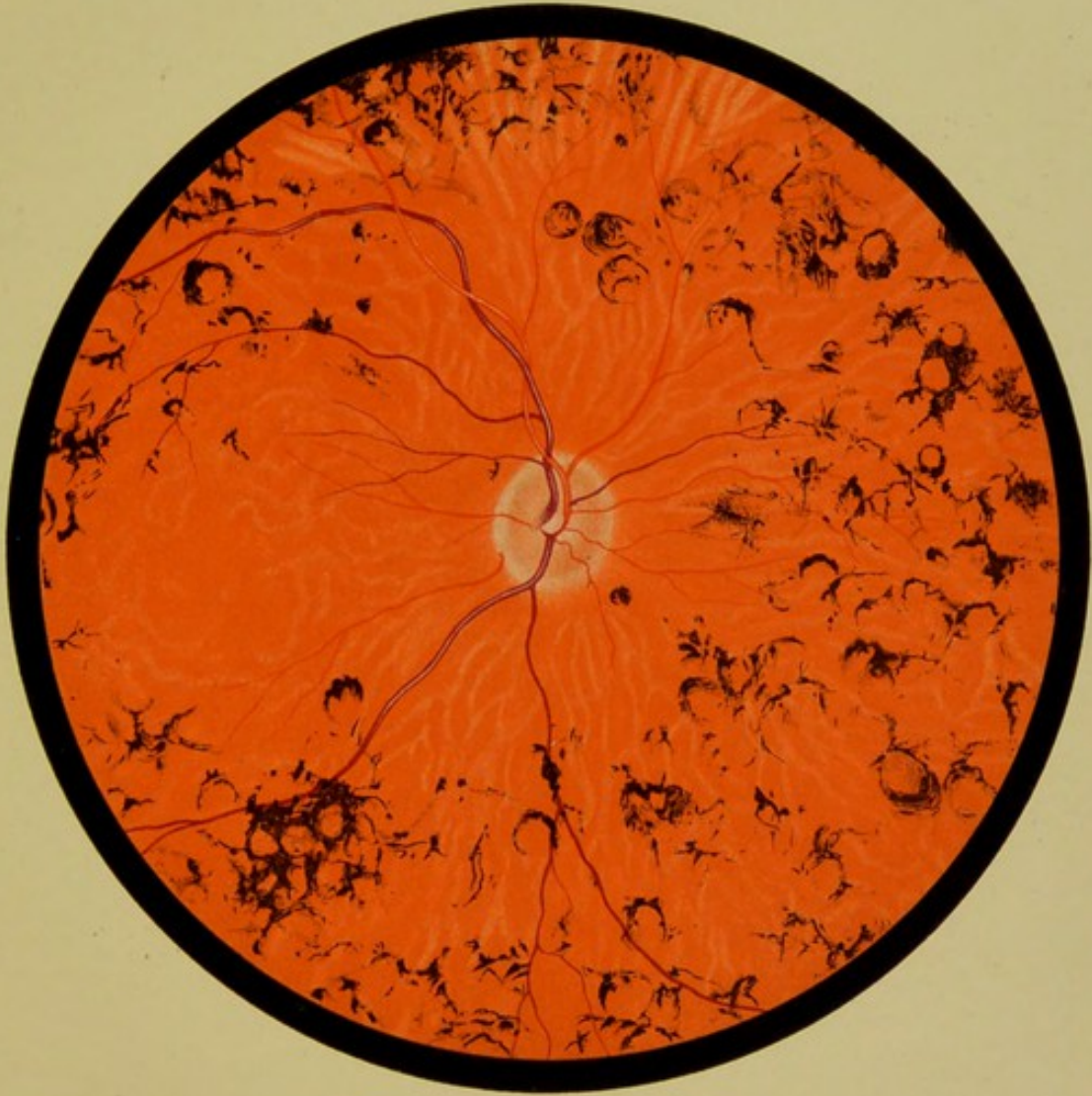

FIG. 45. R. E.

NATIONAL HOSPITAL LIBRARY
Not to be taken away

DISSEMINATED CHOROIDITIS.

FIG. 46.—DISSEMINATED CHOROIDITIS. Stage of Exudation.

William S., 39. *RE*. Drawing made October 1888.—In 1883 he had a chancre, followed by sore throat and rash; he was under treatment for six months and considered himself to be cured. In March 1887 his sight became defective, especially at dusk. In July 1887, V. *RE*. = $\frac{6}{24}$, *LE*. = $\frac{6}{12}$. Numerous very fine opacities in the vitreous. The fundus of *RE*. as depicted. The *LE*. presented a similar, but less advanced, condition. At the date of the drawing, V. *RE*. = $\frac{6}{36}$; *LE*. = $\frac{6}{12}$.

Description.—Margin of disc indistinct. Scattered over the fundus numerous soft-looking pale areas of roundish shape, the majority varying in diameter from $\frac{1}{4}$ to $\frac{1}{3}$ of the diameter of the disc. Besides these there are very numerous small pale dots crowded together over the whole fundus.

Note.—This patient was originally under the care of Mr. Hartridge, who published the case, with a chromolithograph, *Trans. Ophth. Soc., U. Kingdom*, London, Vol. IX., 125. This Figure is reproduced from the original drawing by permission of Mr. Hartridge, and of the Council of the Ophthalmological Society.

FIG. 47.—DISSEMINATED CHOROIDITIS. Stage of Atrophy.

Drawing made March 1891.—It represents a later condition of the same fundus as Fig. 46. V. *RE*. = hand movements only. *LE*. = 4.5 Snellen. The fundus of *LE*. presented a similar appearance.

Description.—The smaller pale dots have disappeared. The choroidal vessels are more visible. In place of the soft-looking pale areas there are sharply defined larger areas of exposed sclerotic, which have retained a round or oval shape. Some of these have an incomplete pigment border, and there are other incomplete pigment rings. The margin of the disc is well defined.



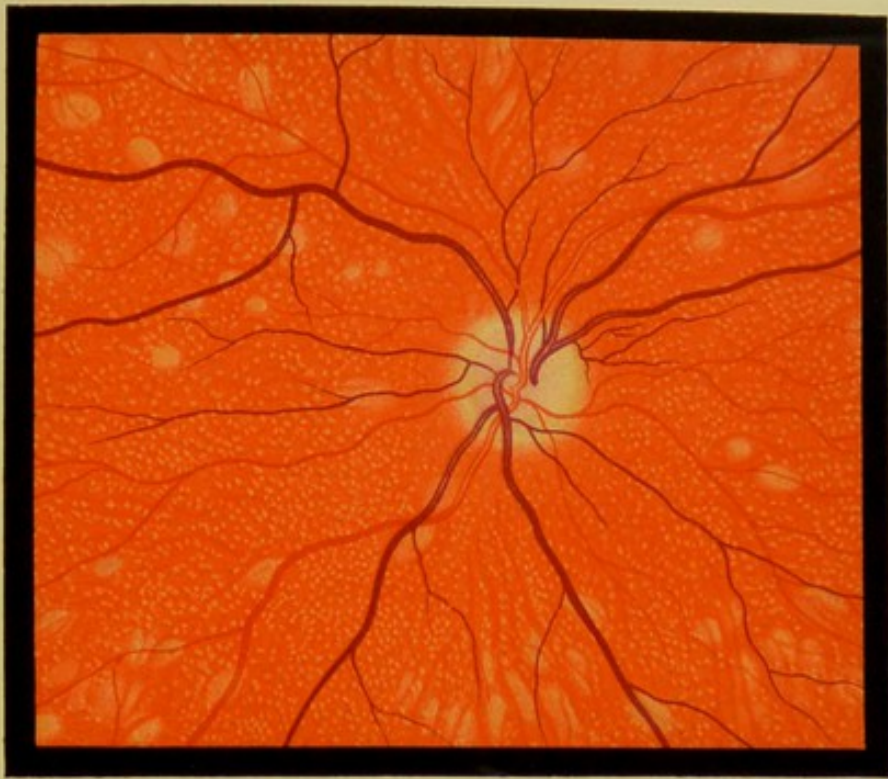


FIG. 46 R.E.

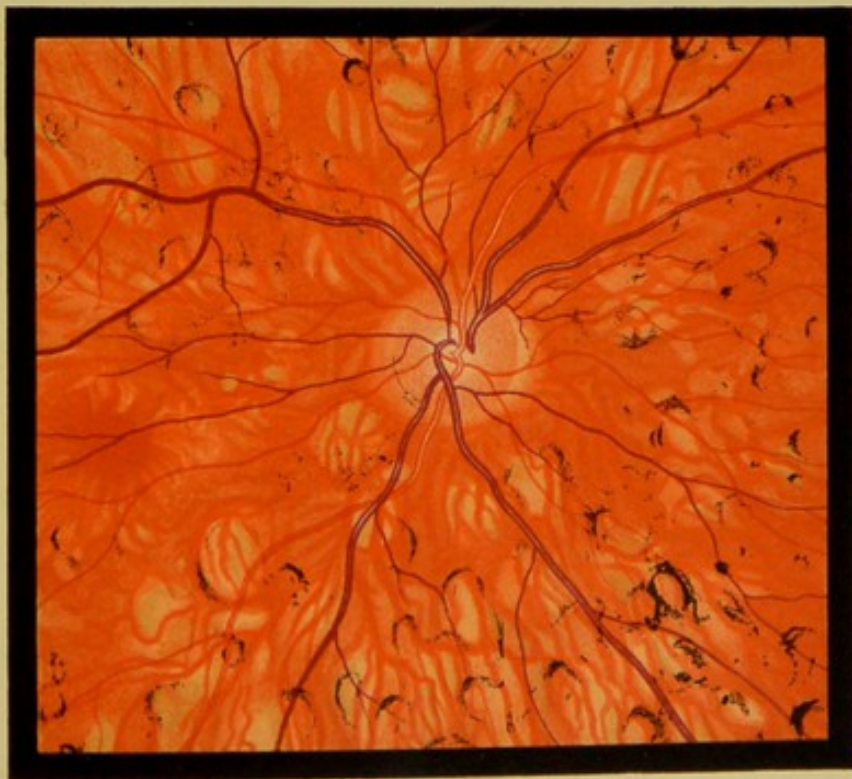

FIG. 47 R.E.

NATIONAL HOSPITAL LIBRARY

Not to be taken away

PLATE XXI.

CHOROIDITIS. ATROPHIC STAGE.

FIG. 48.—AREAS OF CHOROIDAL ATROPHY WITHOUT PIGMENTATION.

William L., 70. *RE.* *Drawing made in 1888.*—Patient has always been in good health. He is robust in appearance and looks younger than his years. No history of syphilis.

V. RE. $\frac{6}{38} + 1.5 = \frac{6}{18}$. Ophthalmoscopic appearance as depicted.

LE. $\frac{6}{38} + 1.5 = \frac{6}{6}$. A few patches of choroidal atrophy.

Description.—Fundus of the dull red type, like that shown in Fig. 15. Choroidal vessels faintly seen.

The inferior temporal vein runs a very tortuous course near the disc, and there is a twist in the superior nasal vein. Several round and oval areas of choroidal atrophy, crossed by vessels. None of the areas have a complete pigment border, and the majority show no pigment.



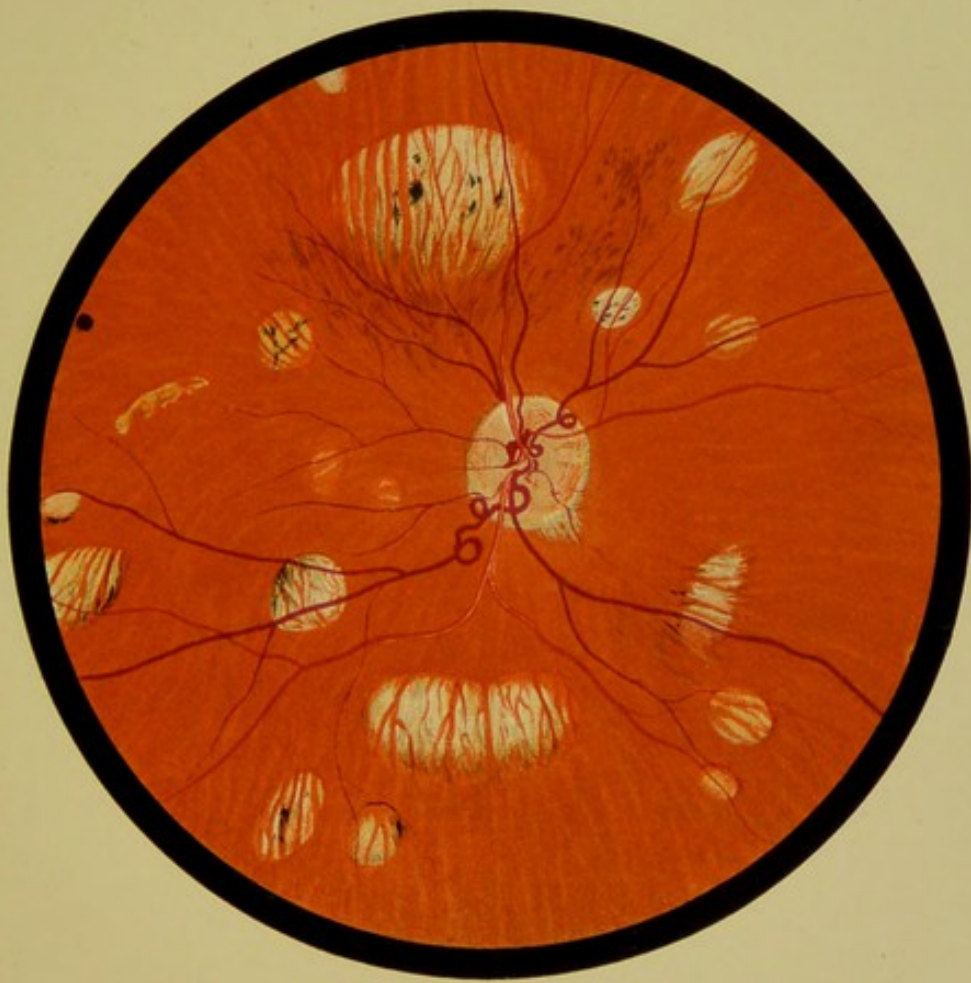


FIG. 48 R E

NATIONAL HOSPITAL LIBRARY
Not to be taken away

CHOROIDITIS AT MACULAR REGION.

FIG. 49.—SUPERFICIAL CHOROIDITIS AT MACULA.

Sarah B., 49. *RE. Drawing made October 1890.*—Attended for failure of V. due to "keratitis punctata." V. *RE.* $+1.25 = \frac{5}{8}$. *LE.* $+1.0 = \frac{4}{5}$. She was at this time under treatment for a syphilitic rash. The cornea cleared, and V. of *LE.* improved to $\frac{5}{8}$, but that of *RE.* became reduced to counting of fingers, and this only in the lower and outer part of the field. The fundus of the *LE.* was normal.

Description.—The central region for a space of about 3 *dd* occupied by round, pale, flat-looking areas, closely aggregated. The largest have a diameter equal to about $\frac{1}{2}$ that of the disc, but at the circumference of the affected area there are much smaller spots. Between the central patches, the fundus is dark. There is no deposit of pigment anywhere.

Subsequent History.—In January 1892 the pale areas on the fundus had not appreciably changed in size or number, but there were distinct indications of choroidal vessels crossing the larger ones. In front of the disc (2 *dd*) two small red spots of irregular shape, connected by a gauzy material, which was difficult to see owing to its transparency. No vessel could be seen to have any connection with these spots.

December 1893.—The two red spots described above, replaced by a distinct vascular loop, formed by a single vein projecting from the inner part of the disc. The summit of the loop visible with 4 *D.* Some of the larger pale spots at the lower part of the affected area have become confluent.

FIG. 50.—CHOROIDITIS AT MACULA.

Ann G. *LE. Drawing made October 1890.*—Complained of recent failure of vision. General health good. No history of syphilis. V. each eye $+2.25 = \frac{9}{8}$.

The ophthalmoscopic appearances in the two eyes were similar.

Description.—Disc normal; well marked connective tissue ring. The macular region, for the space of about a disc and a half diameter, occupied by small roundish spots, a few of the larger showing a scleral whiteness, and one of these is crossed by a choroidal vessel. Most of the spots are pale and soft-looking. There is some pigment round the whiter spots.

FIG. 51.—CHOROIDITIS AT MACULA. Old.


Sophia E., 24. *LE.* Defect only discovered recently. V. = fingers. *RE.* Normal.

Description.—In macular region an oval patch of choroidal atrophy, crossed by a few choroidal vessels. Surrounding it is a complete ring of pigment, and beyond it a narrow band of pale fundus. The exposed sclerotic lay on a much deeper level than the adjacent fundus.

FIG. 52.—CHOROIDITIS AT MACULA. Old.

Kathleen F., 23. *LE. Drawing made in 1889.*—Defect recently discovered. V. = $\frac{5}{8}$. *RE.* Normal.

Description.—An oval area of completely exposed sclerotic, crossed by choroidal vessels. Surrounding this a broad belt of pale fundus, partly covered by pigment. Above and below the pigment is more abundant, and through circular openings in it sclerotic is exposed.



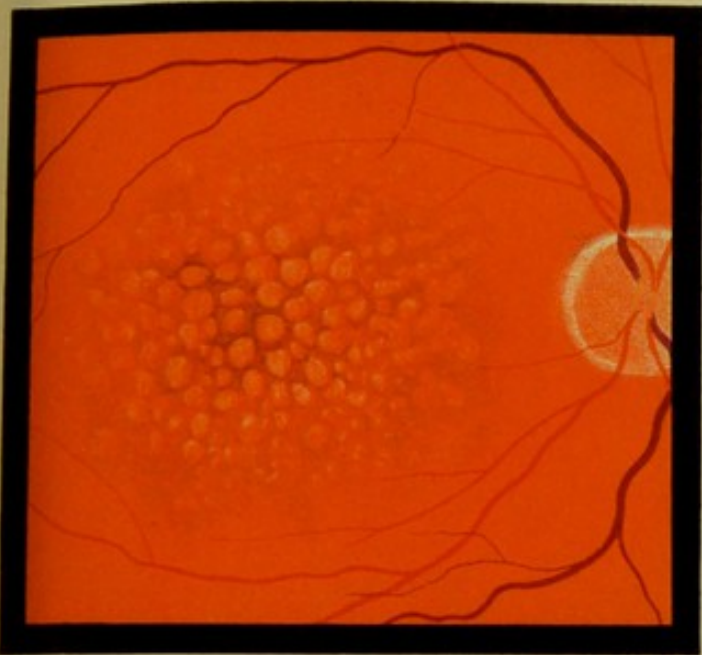


FIG. 49. R.E.

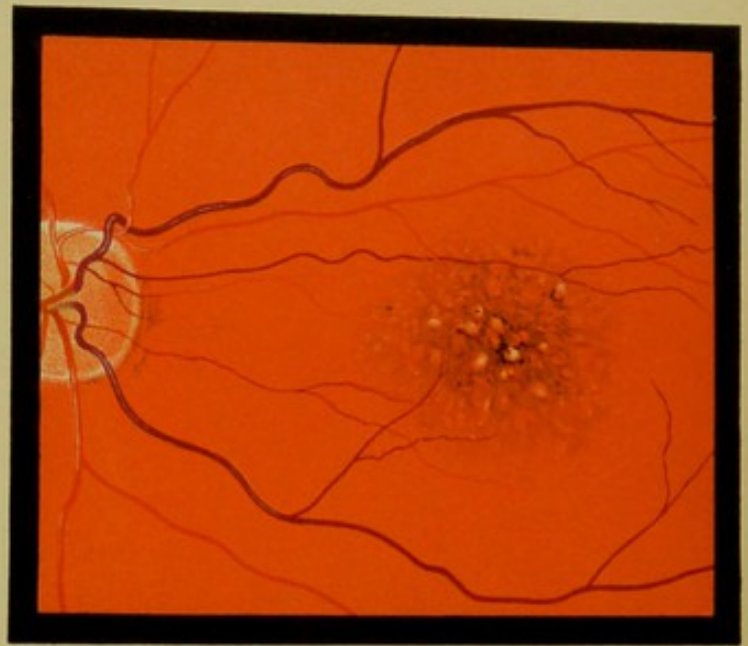


FIG. 50. L.E.

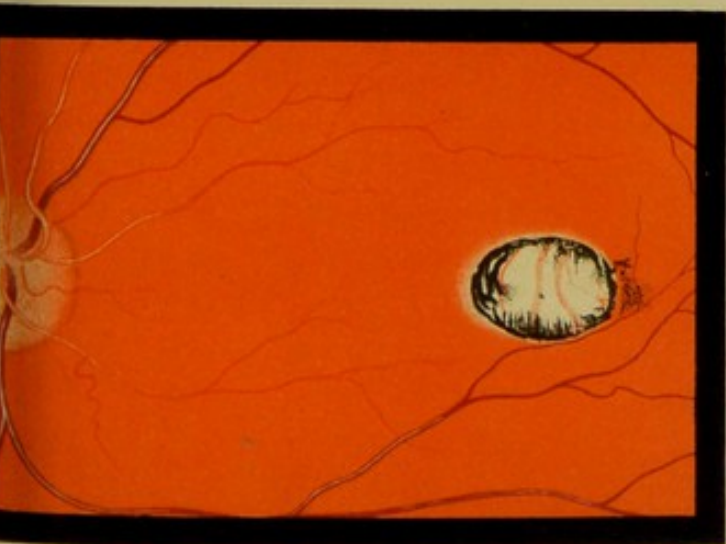

FIG. 51. L.E.

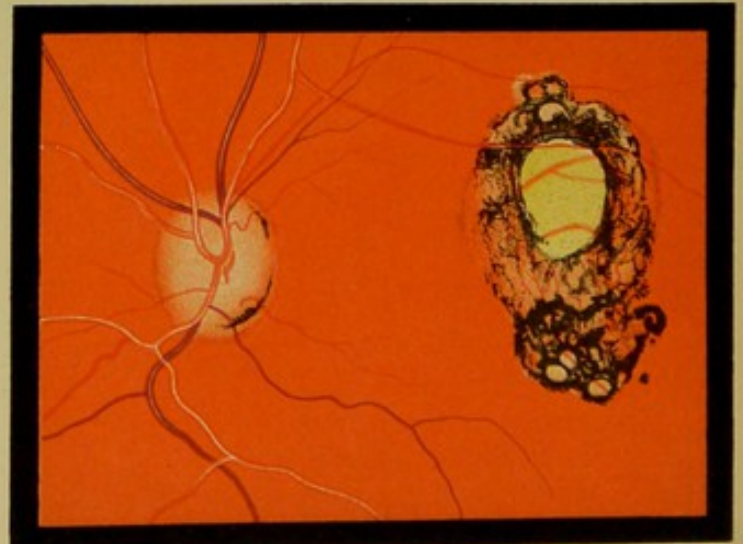


FIG. 52. L.E.

NATIONAL HOSPITAL LIBRARY
Not to be taken away

PLATE XXIII.

(Drawn by the Indirect Method.)

HIGH MYOPIA.

FIG. 53.—MYOPIC CRESCENT STATIONARY.

Alice D., 15. *RE.* inverted. *Drawing made November 1888.*—Moderately fair complexion. V. $-14 D = \frac{6}{15}$.

Description.—Disc oval, with long diameter vertical. On its temporal side a crescentic area of exposed sclerotic, having a regular, sharply-defined border. Choroidal vessels visible over whole fundus.

FIG. 54.—PROGRESSIVE MYOPIA.

Mary S., 42. *RE.* inverted. *Drawing made January 1889.*—Said to have been only moderately short-sighted till ten years ago, and to have been gradually getting worse since. In *LE.* numerous opacities in vitreous, extensive choroidal atrophy, V. = 0.3 Snellen at 2 inches. Distant V. not improved to $\frac{6}{60}$.


RE. peripheral striae in lens. V. not noted.

Description.—Disc oval, of a peculiar purplish colour. On temporal side of disc a crescent of exposed sclerotic. This is connected with a large irregular area of exposed sclerotic in the macular region. The central part of the latter shows some remains of choroidal tissue and some pigment deposit. Partial atrophy of the choroid has taken place immediately adjacent to the larger area.

FIG. 55.—CHOROIDITIS AND HIGH MYOPIA.

Charles W., 38. *RE.* inverted. *Drawing made in 1892.*—Always short-sighted. Stated that ten years ago he could read small print at about ten inches. In 1890 he attended the Royal London Ophthalmic Hospital, and his V. was noted as $\frac{6}{60}$, and 2.0 Snellen at 6 inches in each eye. At date of drawing V. was 1.0 Snellen at 4 inches, and the Myopia was about 10 D. The *LE.* was similar.

Description.—On the lower and outer side of the disc an area of choroidal atrophy approximately crescentic, but irregular, in shape. Scattered over the fundus numerous rounded and irregular atrophic areas. The surface of many of these is speckled with pigment, but none have a pigment border. Similar speckling with pigment is seen in other parts of the fundus where there is no atrophy. The choroidal vessels are everywhere visible.



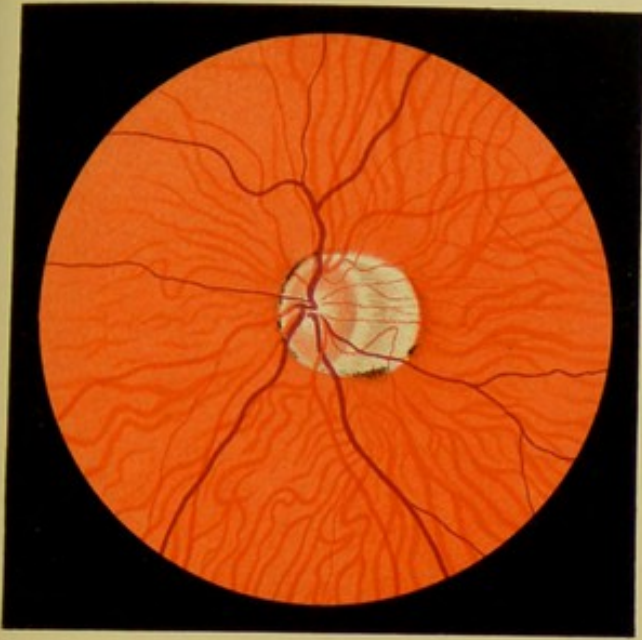


FIG. 53. R. E.
(Inverted).

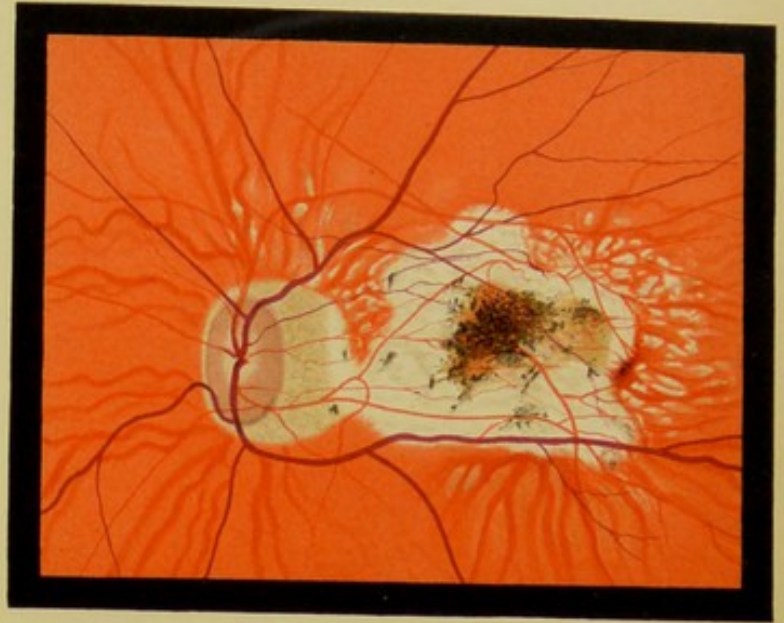

FIG. 54. R. E.
(Inverted).



FIG. 55. R. E.
(Inverted).

NATIONAL HOSPITAL LIBRARY

Not to be taken away

SENILE CHOROIDITIS AND POST-NEURITIC ATROPHY.

FIG. 56.—SENILE CHOROIDITIS.

Jabez C., 83. *LE.* *Drawing made March 1892.*—Has a typical senile aspect; has always enjoyed good health. Vision began to fail gradually two or three years ago, and became steadily worse till six months ago, since which he thinks that it has remained stationary. V. in each eye $\frac{1}{50}$. The ophthalmoscopic appearance is similar in both eyes.

Description.—Disc of rather dark colour. Surrounding it a wide belt of choroidal atrophy, which is complete, with the exception of some large vessels which remain. Beyond the atrophic belt on the temporal side is an irregular area of partial choroidal atrophy. The choroidal vessels are everywhere visible, and some of the spaces between them are pigmented.

FIG. 57.—POST-NEURITIC ATROPHY. CICATRICAL CHANGES AT MACULA.
CHOROIDAL ATROPHY.

Margaret R., 27. *RE.* *Drawing made December 1892.*—V. *RE.* no *p.l.*; *LE.* *p.l.* only.—Five years ago was seized with headache and occasional vomiting. After two months these symptoms subsided, and at the same time V. failed rapidly, reaching its present condition in three months. The headache and vomiting have not recurred.

Description.—Disc greyish white, not mottled. Physiological cup visible. Surrounding the disc a pale band of irregular width, continuous below with a broad pale area, while above two processes shoot out from it. The larger of these forms a white band, with almost parallel sides, but widens out fan-wise above. The whole fundus is sprinkled with fine pigment dots.

At the macula an irregular star-like patch of pale colour, from which processes diverge in all directions.



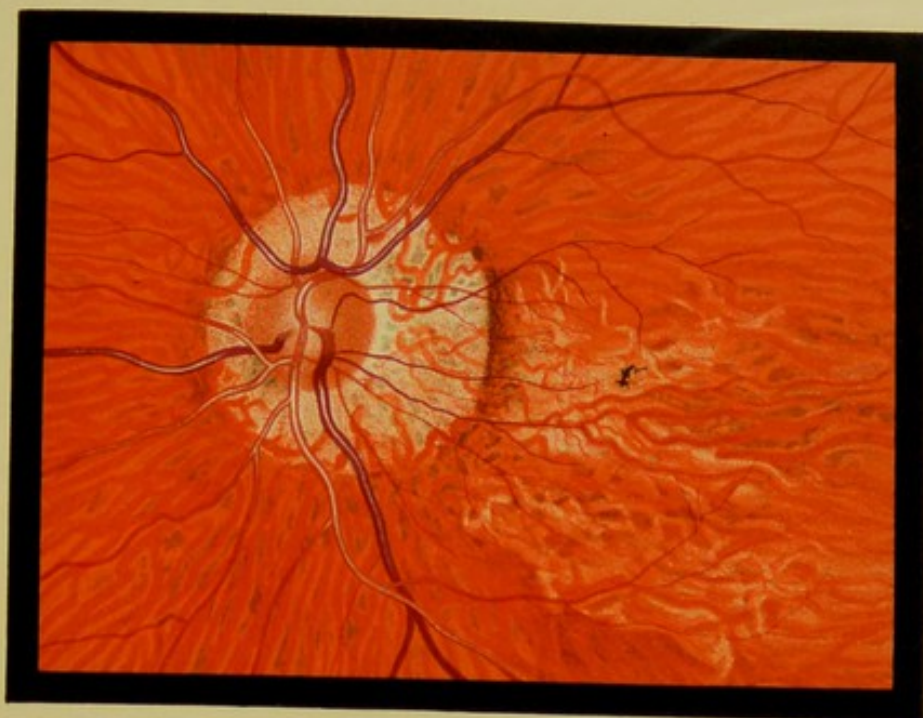


FIG. 56. L.E.

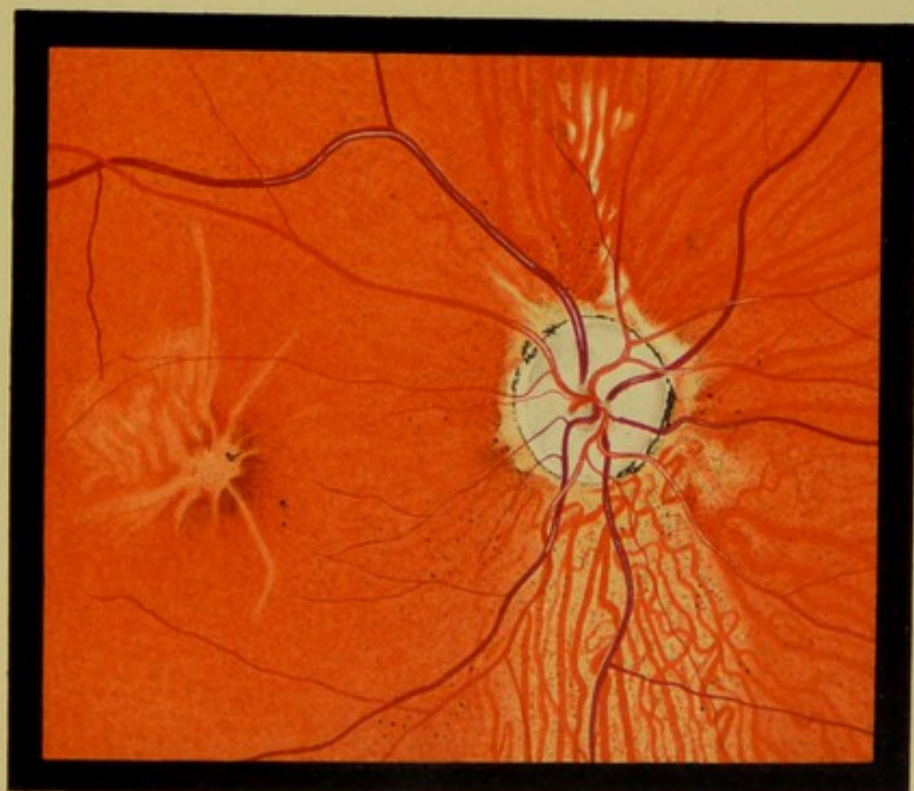

FIG. 57. R.E.

NATIONAL HOSPITAL LIBRARY

Not to be taken away

PLATE XXV.

RETINAL ŒDEMA AND MEMBRANOUS FORMATION IN RETINA.

FIG. 58.—CHOROIDITIS. ŒDEMA OF RETINA.

Thomas W., 45. *LE.* Drawing made September 1889.—*RE.* normal in all respects. *LE.* V. fingers only, date of failure of V. not stated. No history of syphilis was elicited. Has suffered from stricture of the urethra.

Description.—A few circular areas of complete choroidal atrophy and numerous imperfect pigment rings. Margin of optic disc slightly blurred especially downwards and outwards, where it merges into a grey soft looking area, which extends for a distance of three disc diameters on to the fundus. This shades off very gradually into the adjacent fundus. Near its nasal border is a linear hæmorrhage. Surrounding the macula, except on the side next to the patch of retinal œdema, a series of short white lines directed as if radiating from the centre of the macula.

FIG. 59.—CHOROIDITIS. MEMBRANOUS FORMATION IN RETINA.

Emily H., 24, married. *LE.* Drawing made October 1890.—The notes of this case are incomplete, and the patient could not be traced. V. *RE.* = $\frac{6}{24}$, *LE.* = $\frac{6}{36}$.

Description.—A few circular and oval areas of almost complete choroidal atrophy, and some pale areas of similar size and shape.

In the central region, an irregular mass of glistening white tissue, in it are numerous oval openings with sharply cut edges, and through these the fundus is seen as if on a deeper level. The white tissue lies entirely beneath the retinal vessels.



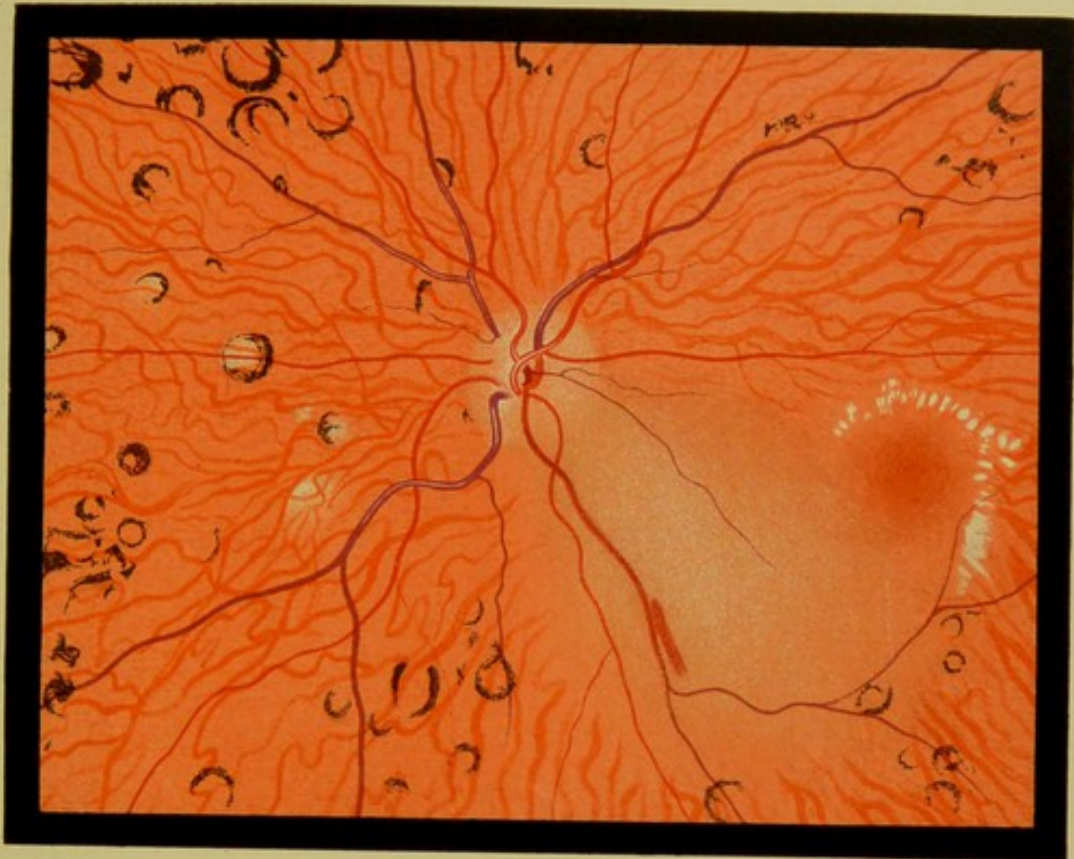


FIG. 58. L.E.

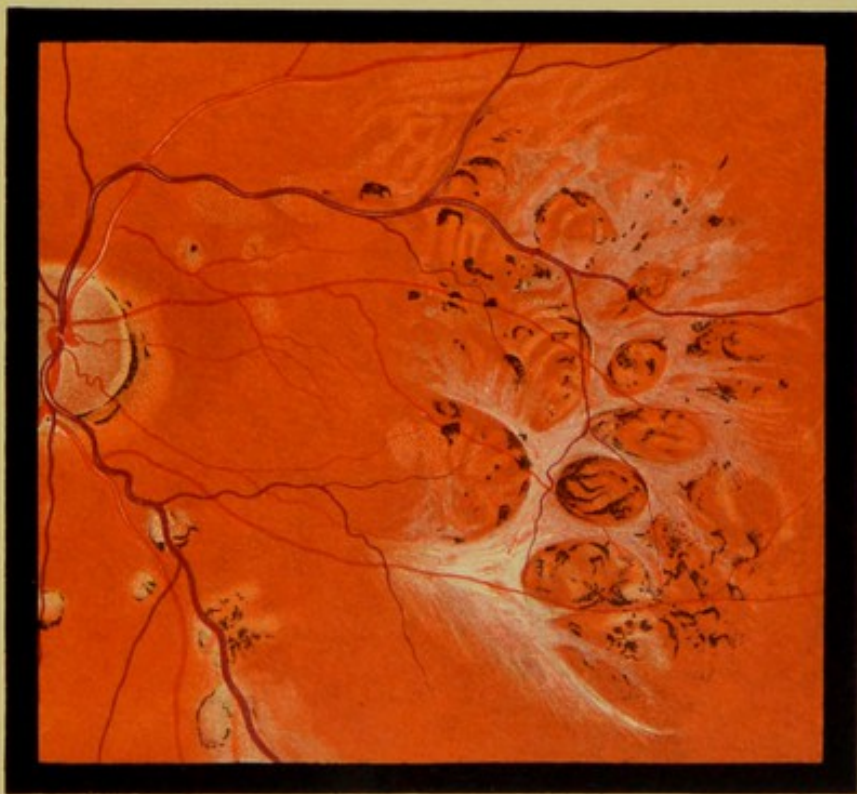


FIG. 59. L.E.

NATIONAL HOSPITAL LIBRARY
Not to be taken away

CHOROIDO-RETINAL SCLEROSIS.

FIG. 60.—CHOROIDO-RETINAL SCLEROSIS, OR DIFFUSE CHOROIDO-RETINITIS.

Edward S., 55. *RE.* Drawing made June 1889.—He enlisted at the age of 21, served ten years in India, and left the service at the age of 37. Always had good health. No history of syphilis was elicited.

Noticed no defect of vision till about a year after his discharge, when he experienced some difficulty in seeing at dusk. This gradually increased, until he had to be led about after sunset.

V. *RE.* $\frac{6}{18}$ — 0.50 = $\frac{6}{12}$ letters. *LE.* — hand reflex only. The field of *RE.* showed great concentric contraction. (*See Chart.*)

The field of the *LE.* could not be taken.

He is quite unable to walk alone after dark, either out of doors, or in a room fairly well lighted with gas.

The ophthalmoscopic appearances *d.* were similar in the two eyes.

Description.—Disc rather dark, surrounded by a pale halo. Retinal arteries very small, except the superior temporal, which is only slightly diminished. The light-reflex is absent from them.

Over the whole fundus an immense number of choroidal vessels are visible. Some have the normal red colour, others are bounded by white lines, while others, again, are completely white. This is especially the case near the disc. The spaces between the vessels are light chocolate-brown, except in a few places, where small red patches remain. At the macula no choroidal vessels are visible. There are isolated superficial deposits of pigment in several situations.

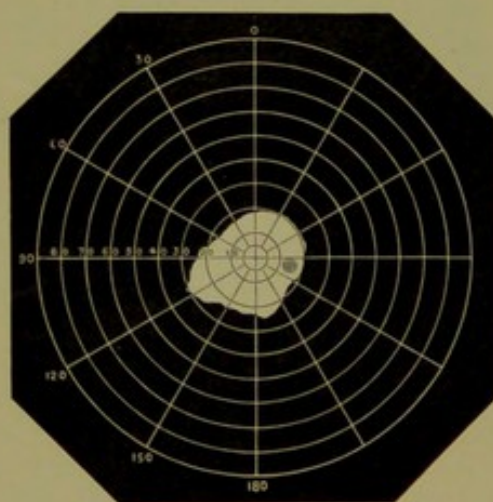



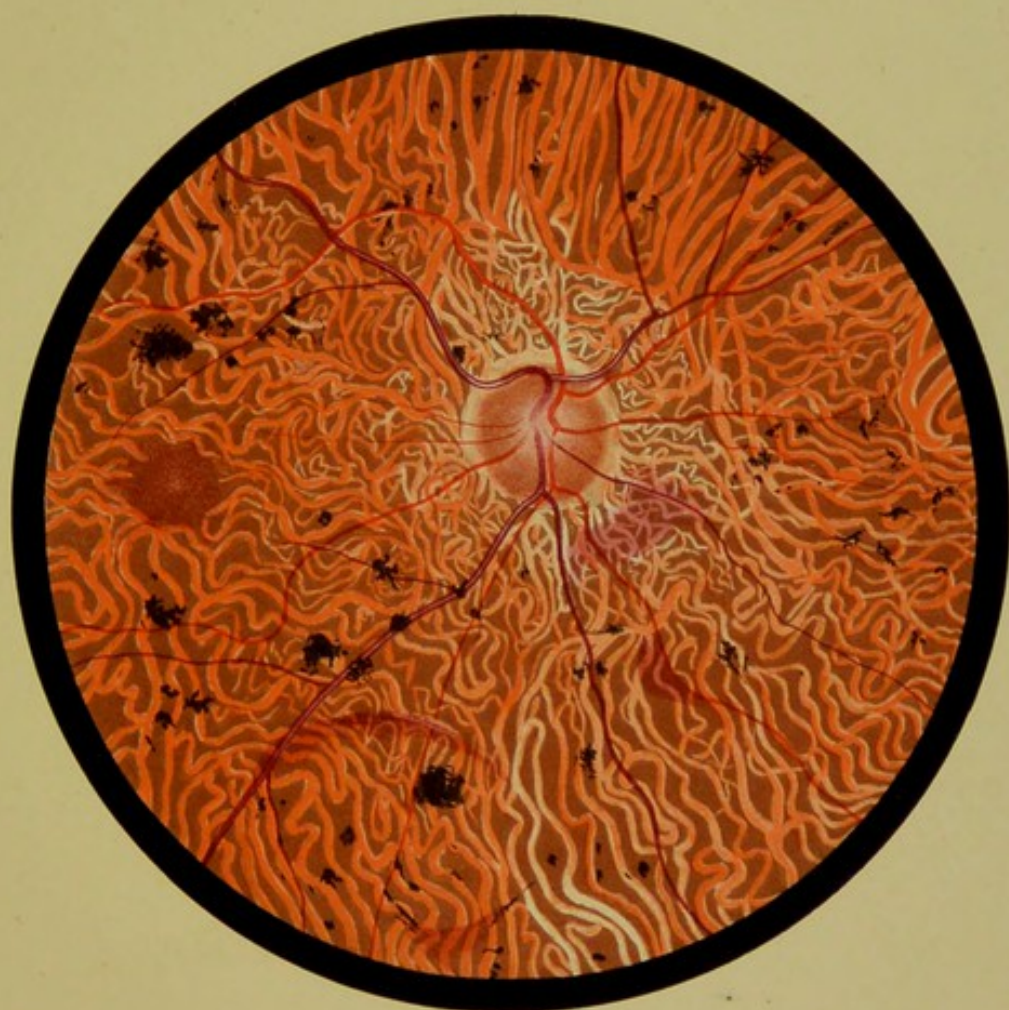


FIG. 60 R E



CHOROIDO-RETINAL SCLEROSIS.

FIG. 61.—CHOROIDO-RETINAL SCLEROSIS OR DIFFUSE CHOROIDO-RETINITIS.

Alfred R., 51. *RE.* Drawing made July 1890.—A gardener, has always lived in the country. No history of syphilis or of malaria could be obtained. Patient looks in perfect health. Has had no serious illness. Has been married twice. Two children, now grown-up, by his first, and two by his second wife—all said to be healthy. His parents were not related, and they both lived to old age.

Vision of *LE.* noticed to be defective six months ago. It could not be ascertained with certainty whether this eye ever had good vision. About the same time he experienced a difficulty in seeing in a dull light. V. *RE.* = $\frac{5}{6}$. *LE.* +2 D. = 9 Snellen at 10 inches. Visual fields normal, both in a bright and in a dull light. The *LE.* presented similar ophthalmoscopic appearances, but they were perhaps a little more advanced.

Description.—The disc presents nothing abnormal. No diminution in the retinal vessels. Choroidal vessels visible over whole fundus, but they are not nearly as numerous as in Fig. 60. Many of them are pale, and some are white. This is especially the case above the disc, and in several isolated round areas. A conspicuous round white patch above the disc; this appeared, on careful focussing, to consist of numerous white vessels. There are several isolated superficial deposits of pigment, and in the upper part a considerable speckling with fine pigment.

Subsequent History.—Seen in January 1892. No appreciable change.



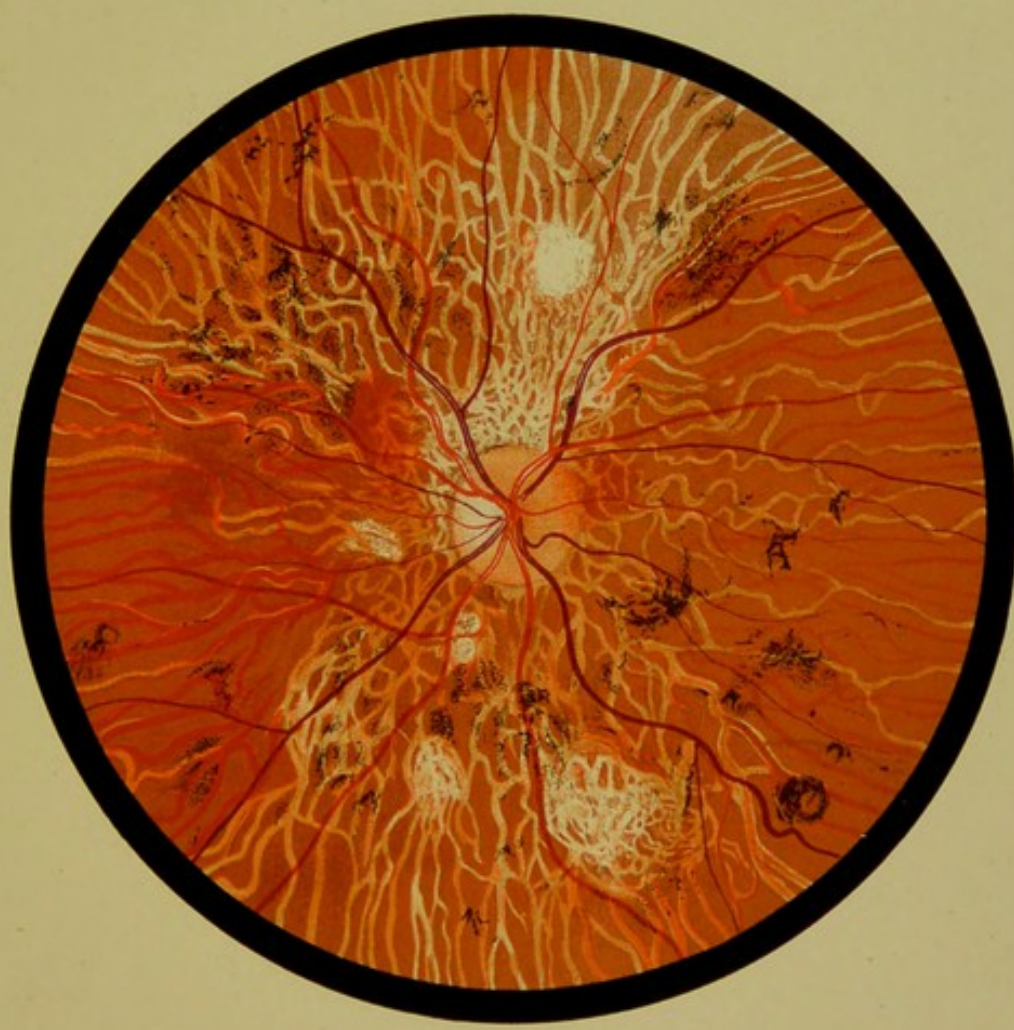


FIG. 61. R. E.

NATIONAL HOSPITAL LIBRARY
Not to be taken away

PLATE XXVIII.

RETINAL ATROPHY WITH SECONDARY PIGMENTATION.

FIG. 62.—ATROPHY OF RETINA WITH SECONDARY PIGMENT CHANGES.

Mary B., 77. *LE.* *Drawing made in 1888.*—Vision said to have been failing six months, but no reliance could be placed on the history. The patient was of senile aspect, and weak in intellect.

Description.—Fundus of the dull-red type. Disc dirty-looking colour. Arteries reduced to threads and few in number. Veins also small. Choroidal vessels everywhere visible as pale lines, except at the macula, which presents a normal appearance. Towards the upper periphery dense masses of pigment, which seem to lie in the choroidal stroma. There are also some superficial pigment deposits.



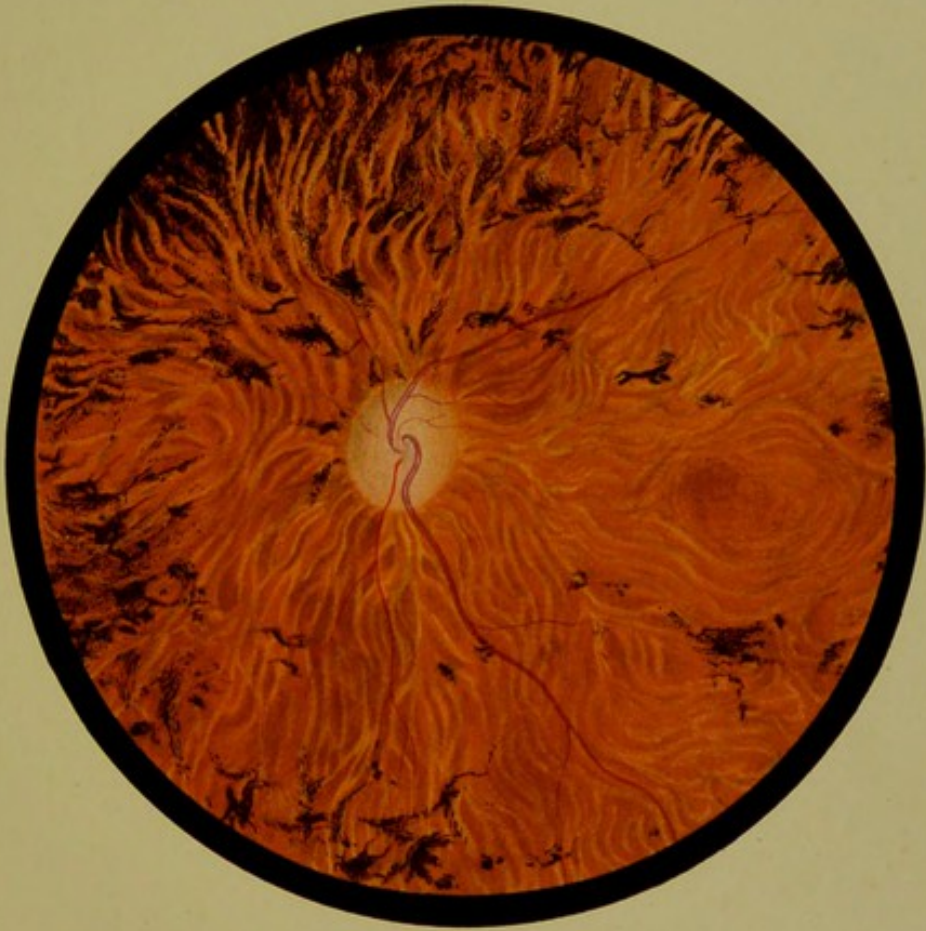


FIG. 63. L.E.

NATIONAL HOSPITAL LIBRARY
Not to be taken away

PLATE XXIX.

DIFFUSE CHOROIDITIS.

FIG. 63.—DIFFUSE CHOROIDITIS. "MAP-LIKE" CHOROIDITIS.

Thomas S., 25. *LE*. Drawing made December 1889.—A tall delicate-looking man, but without any history of bad health, or of definite illness. No history of syphilis.

First seen September 9th, V. = $\frac{6}{60}$. He stated that *LE*. had been defective six weeks, varying, but on the whole steadily getting worse.

The *RE*. appeared to be normal in all respects.

Ophthalmoscopic appearances in *LE*. on September 9th. Fundus blurred, but no definite opacities seen in the vitreous. Retinal veins much distended, but not tortuous. No swelling of the disc. Above the disc a white, woolly area, with ill-defined margins, extending three disc diameters from disc. In region of macula, indistinct white spots, and pigment disturbance. In the lower and outward periphery, a large patch of choroiditis, which was thought to be old. On December 6th (date of the drawing), V. had improved to $\frac{5}{60}$ (4 letters). The appearance of the fundus had greatly changed.

Description.—The disc margin is clear, the woolly patch above the disc and the changes at the macula have disappeared.

Projecting inwards from the periphery on all sides towards the central area, but not reaching it, are numerous pale areas, with a mottled surface. These are irregular in shape, at the upper part they mostly form elongated islands in healthy fundus. Below, the areas are larger, and are separated, either by broad belts of normal fundus, or by narrow bands which look like choroidal vessels. The latter are not visible anywhere in the healthy part of the fundus.

Subsequent History.—On February 6th, 1890, V. = $\frac{5}{60}$ (2 letters), fundus unchanged.



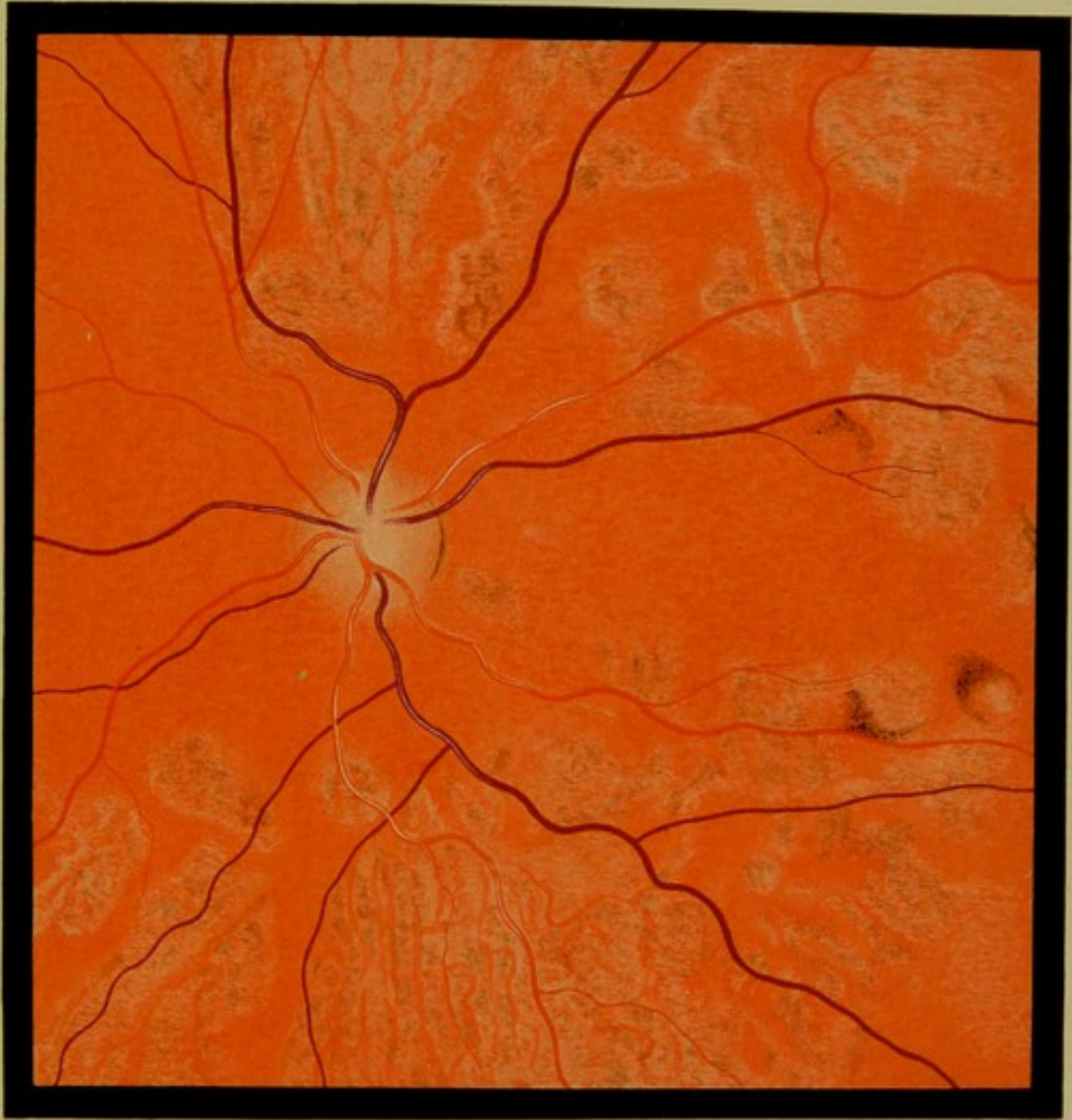


FIG. 63 LE.

NATIONAL HOSPITAL LIBRARY
Not to be taken away

RUPTURE OF CHOROID.

FIG. 64.—RUPTURE OF CHOROID.

Charles H., 15. *RE*. Drawing made *January* 1893.—Struck on the *RE* with a stone on December 31st. He was seen the same day. There was subconjunctival hæmorrhage, the pupil was dilated and inactive, $V. \frac{6}{30} - 2 D = \frac{6}{5}$. The ophthalmoscopic appearance was not noted. On January 2nd the appearance depicted was discovered. $V.$ was now $\frac{5}{6}$ without glasses. On January 28th— $V. = \frac{5}{6}$.

Description.—Midway between disc and macula an irregular white band, consisting of two parts meeting each other at an angle. The upper has a few hæmorrhages on its surface, the lower is crossed by a band of pigment. The band measures at its widest part $\frac{1}{10}$ of a disc diameter, and lies beneath the retinal vessels.

Above, and close to the disc, a few pale patches, mottled with pigment.


Subsequent History.—In June he found that $V.$ was defective. When seen on July 2nd, there was a small patch of dark colour at the macula. $V.$ reduced to counting fingers, and that only at the periphery of the field. More pigment on the edges and borders of the pale band.

August 25th.—Macula difficult to see, although no definite opacity was visible in the media. The white band is now of steel-grey colour.

FIG. 65.—RUPTURE OF CHOROID.

Alfred E., 22. *RE*. Drawing made *March 26th*, 1893, at which time $V.$ was $\frac{6}{80}$. Blow on the eye on January 31st. When seen, three days later, pupil slightly dilated and inactive. $T-$. Blood in vitreous. Fundus reflex, but no details, visible. $V. = 24$ Snellen at 20 c.m. February 11th, a white band indistinctly seen on temporal side of disc. $V. = 12$ Snellen at 20 c.m.

Description.—To temporal side of the disc, a white band, broad below and narrow above, roughly concentric with the disc margin; further out, a shorter, nearly vertical band connected with the first by a horizontal white line. Processes jut out from both vertical bands, and between these are bays with sharply-cut concave borders. The bands are speckled with fine hæmorrhages, and the lower part of the larger is crossed by choroidal vessels. To the temporal side of both bands are three isolated white areas of long oval shape, which, if joined, would form a line almost parallel to the long vertical band.



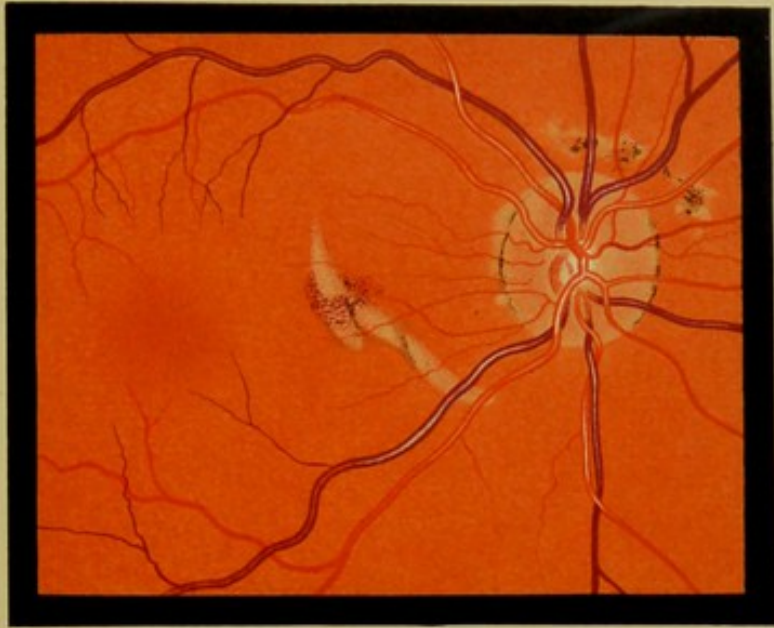


FIG. 64. R. E.

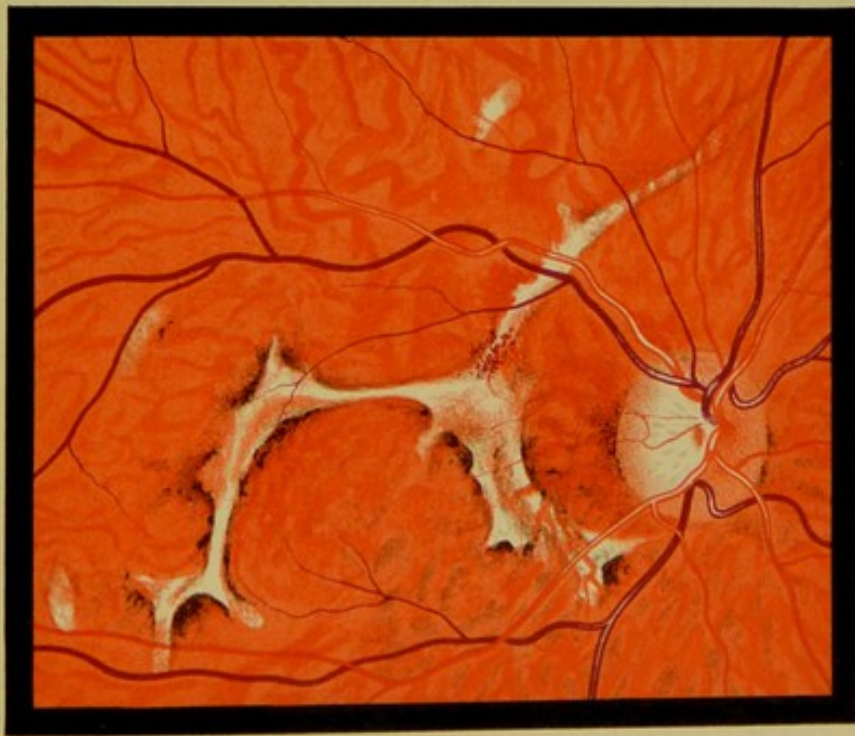


FIG. 65. R. E.

NATIONAL HOSPITAL LIBRARY
Not to be taken away

PAPILLITIS.

FIG. 66.—PAPILLITIS. Subsiding.

Annie T., 26 (married). *RE*. Drawing made July 24th, 1889.—First seen July 13th, stated that V. of *RE*. had been noticed defective ten days, and was now improving. V. *RE*. = $\frac{6}{12}$, *LE*. = $\frac{6}{8}$. Two months ago she had a sore throat, followed by an eruption, which has now disappeared. When first seen, the margin of the disc was more indistinct than in the Figure, and the colour was nearly that of the fundus. There was also a small linear hæmorrhage downwards and inwards from the disc. She was treated with mercury, V. improved, and the disc became paler. On July 24th, the date of the drawing, V. of *RE*. = $\frac{6}{8}$.

Description.—The disc shades off gradually into the fundus without any distinct boundary line. The retinal veins are somewhat tortuous. Some of the arteries are accompanied by white lines.

Subsequent History.—August 20th—The disc presented a normal appearance.

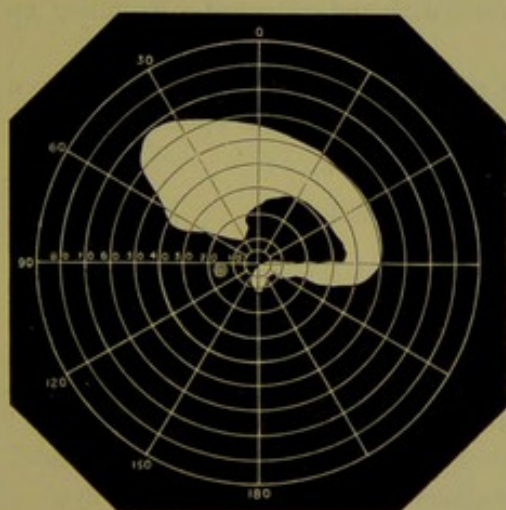

FIG. 67.—PAPILLITIS.

William R., 40. *LE*. Drawing made April 1889.—Vision of *LE*. failing six months. No history or signs of syphilis. No cerebral symptoms. Reflexes normal. V. *RE*. = $\frac{3}{8}$; *LE*. = hand reflex. Visual field on April 13th as shown in the chart; on April 27th it was normal. The drawing was made between these dates. *RE*. normal.

Description.—Disc swollen, of a greenish-grey colour, margins blurred. The upper veins are full, and make sinuous curves. Near the superior nasal vein are two hæmorrhages in the fibre layer. White lines accompany the lower vessels on the disc.

Subsequent History.—January 1892—Both discs were very white, there were white lines accompanying the upper vessels in the left eye, V. = $\frac{6}{12}$ in each eye. Stated that six months after the drawing was made he went to the Royal London Ophthalmic Hospital for failure of the *RE*. The *LE*. at this time had, he believed, completely recovered. He attended as an out-patient, but had lost his notes. The *RE*. recovered, and neither eye has given him any trouble since.

FIG. 68.—PAPILLITIS. With Hæmorrhages on Disc. Retention of Physiological Cup.

James G., 26. *LE*. Drawing made April 1892.—At Christmas he fell downstairs. He was stunned for a few minutes. He did not vomit. The next morning he went to work as usual, and had no symptoms for two or three weeks. He then complained of pain in the head, for which he was blistered and treated in various ways without benefit for two weeks. He then came under the care of Dr. Bell of Leystonstone, who has kindly furnished me with particulars of the case. At this time he was suffering great pain, paroxysmal in character, in forehead and occiput; the severe pain would last for hours, and be succeeded by slighter pain. There was insomnia, the bowels were constipated, and the tongue coated. There was a foul-smelling muco-purulent discharge, mixed with blood, which appeared to come from the naso-pharynx. Pupils equal, sluggish. Urine loaded with lithates; patient drowsy, and answering questions slowly. Treated with purgatives and bromide of potassium. He improved, but the pain and discharge continued, and he was admitted into St. George's Hospital under Mr. Pick. The eyes were examined a few days after admission, and papillitis with hæmorrhages discovered in both eyes. $V. = \frac{2}{3}$, in each eye. Visual fields normal.

Description.—Disc margin indistinguishable, except on the temporal side, where it is quite distinct. Several striated hæmorrhages. Veins dark and distended. No filling up of the physiological cup.

Subsequent History.—The symptoms gradually subsided, and he was discharged. Seen again December 1893. Has had no symptoms since his discharge. The optic discs appear quite normal.

FIG. 69.—PAPILLITIS. Disc much Swollen.

Silva T., 51. *Drawing made June 1889*.—No history of syphilis. *V. of LE*. failed about three months ago, and that of the *RE*. soon afterwards.

For six months has suffered from vertigo, and constant pain in the left temporal and occipital regions, with occasional vomiting. Has occasionally experienced numbness of left side, and in left leg, and sometimes "pins and needles" in right arm.

When seen there was left facial paralysis, and the left ear was deaf. Knee-jerks normal. $V. < \frac{6}{8}$ in each eye. The ophthalmoscopic appearances were similar in the two eyes.

Description.—Disc swollen, and "woolly." Paler than normal. Veins tortuous. Arteries somewhat diminished in size. A small hæmorrhage obliquely downwards from the disc.

Subsequent History.—A month later—Giddiness, noises in the head, and pain, chiefly on the right side of the head, have been nearly constant, but there have been no convulsions or vomiting. Four months later it was noted, "mental condition not very clear, talks incoherently." She was soon afterwards removed by her friends, and the result of the case is unknown.

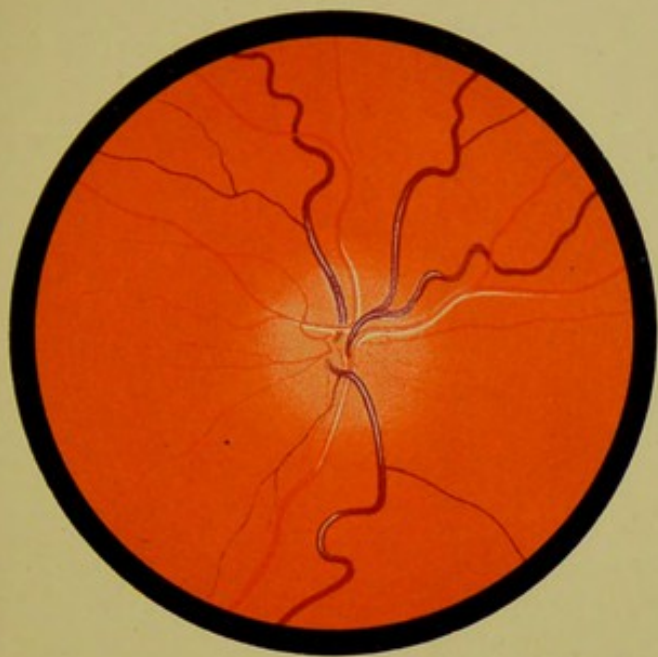


FIG. 66. R.E.

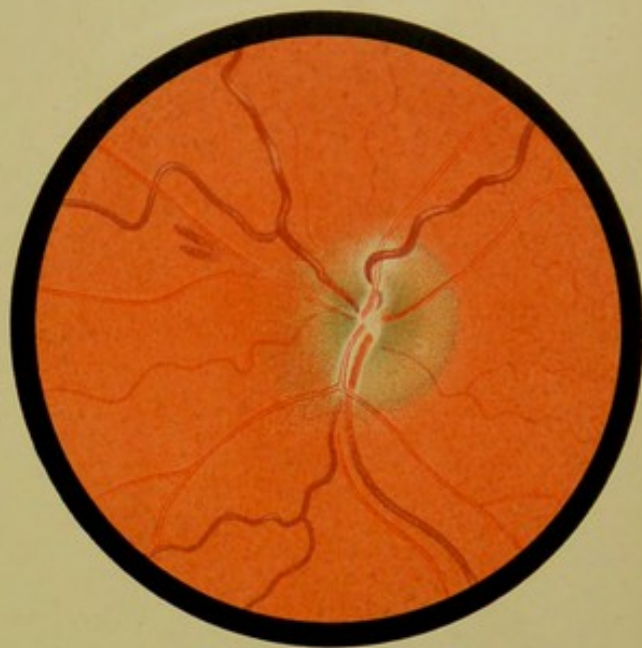


FIG. 67. L.E.

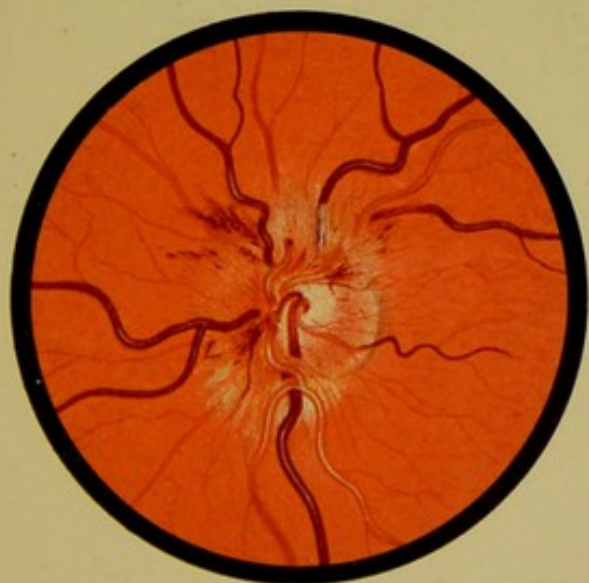

FIG. 68. L.E.

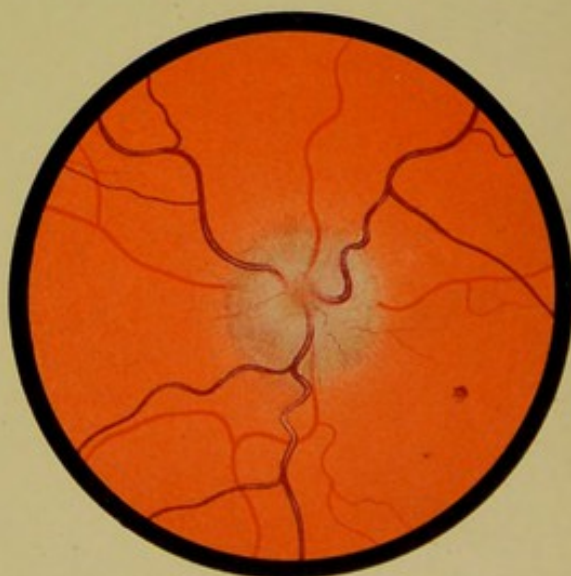


FIG. 69.

NATIONAL HOSPITAL LIBRARY
Not to be taken away

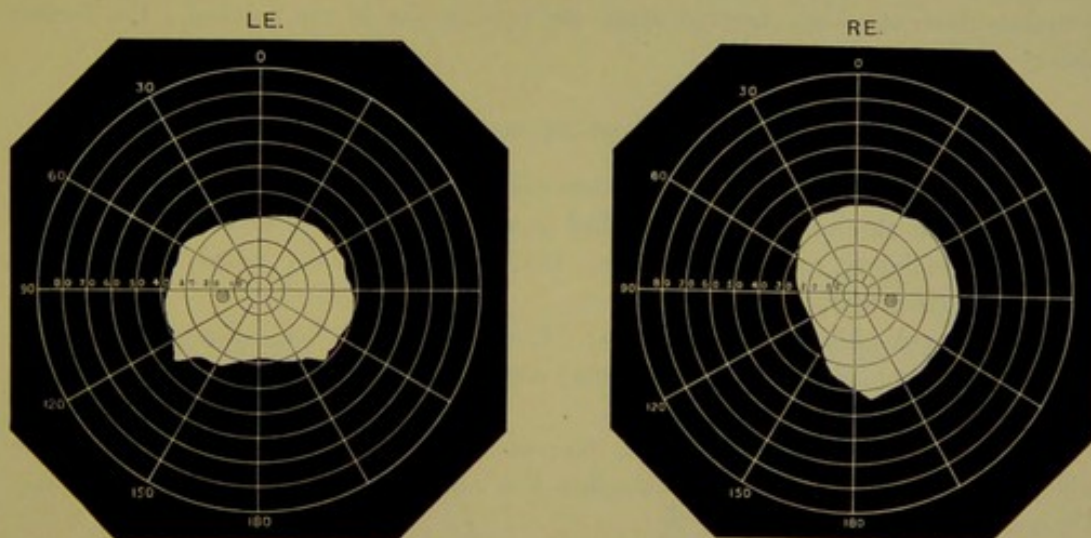
PAPILLITIS. POST-NEURITIC AND SIMPLE ATROPHY.

FIG. 70.—PAPILLITIS. With "Ridging" of the Retina.

Louisa H., 31. *LE.* Drawing made March 1890.—Admitted into St. George's Hospital, February 20th, for headache, from which she had suffered, off and on, for three years. Said before admission to have had "fits" and twitching movements of the left hand. While in the hospital there were occasional twitchings of the facial muscles; it is not stated on which side.

She was treated with mercury and iodide of potassium. During the two months she was in the hospital the headaches improved, but the vision deteriorated.

The diagnosis of cerebral syphilis was made, but the notes do not give the evidence on which it was based. Visual fields contracted. *See charts.*



V., *March 8th.*—*RE.* $+3 D. = \frac{6}{12}$; *LE.* $+1.75 D. = \frac{6}{9}$. *March 29th.*—Each eye, $\frac{6}{18}$.

The ophthalmoscopic appearance of the disc was similar in the two eyes.

Description.—Disc swollen. Margin indistinguishable. Veins tortuous. Arteries small. On the temporal side of the disc the fundus presents about eight parallel horizontal light lines, giving an appearance as if the retina were thrown into folds.

Subsequent History.—April 19th, both discs atrophic, the appearance resembling simple atrophy, the margins being quite clear. Arteries diminished. Fields slightly smaller. V., *RE.* $= \frac{6}{36}$; *LE.* $= \frac{6}{18}$.

FIG. 71.—POST-NEURITIC ATROPHY. Atrophy of Choroid near Disc.

Frances S., *LE.* 9. *Drawing made October 1889.*—An intelligent child. *V.* failing about a month. A specimen of her writing done a month ago was shown, and was unusually good. *V.* is now $\frac{6}{60}$ in each eye, and she is quite unable to read or write. No general symptoms of any kind. No signs or history of inherited syphilis. *RE.* disc atrophic.

Description.—Colour of disc greyish white. Outer margin sharply defined, the remainder of the margin is indistinct. The choroid adjacent to the disc, except on the temporal side, has undergone partial atrophy. The fundus generally has fine pigment dots sprinkled over it. The retinal arteries are much diminished. The upper one is accompanied on the disc by a white line.

Subsequent History.—The child was admitted into the Belgrave Hospital for Children on account of fretfulness, believed to be due to some intracranial condition. No definite symptoms, however, were observed while the patient was in the hospital. The further history could not be traced.

FIG. 72.—POST-NEURITIC ATROPHY.

David C., 40. *RE.* *Drawing made November 1889.*—An agricultural labourer. Has always lived in the country. Always had good health. Denies excesses of any kind. No history of injury. About December 1887 vision gradually failed without pain, headache, or other symptoms.

When seen *V.* *RE.* = $\frac{6}{60}$ and 6 Snellen; *LE.* = $\frac{6}{18}$ and 1·8 Snellen. Concentric contraction of both visual fields. Colour-vision very defective. Pupils act with convergence, but not to light. No ataxic symptoms.

Description.—Nasal border of disc blurred; temporal border clear. Whole disc white, especially its outer half. The colour is a uniform dead white without stippling. Veins distended, but not tortuous.

FIG. 73.—SIMPLE ATROPHY.

John B., 51. *LE.* *Drawing made July 17th, 1889.*

Gait ataxic. Knee-jerks absent. *V.* failing, gradually, six months; it is now *RE.* = 19 Jaeger. *LE.* = hand reflex. Pupils noted as acting to light, but only feebly with convergence.

Description.—Outline of disc hard and regular. Surface bluish-grey, slightly stippled. No small vessels are visible. The large vessels are of normal size.

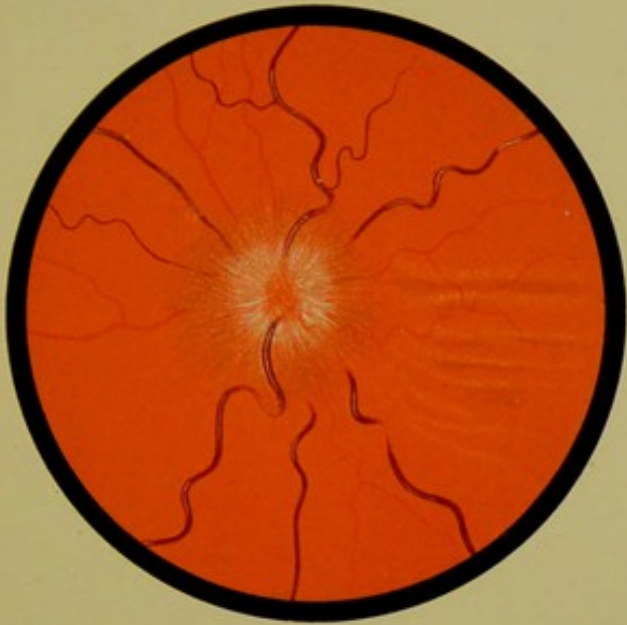


FIG. 70. L.E.

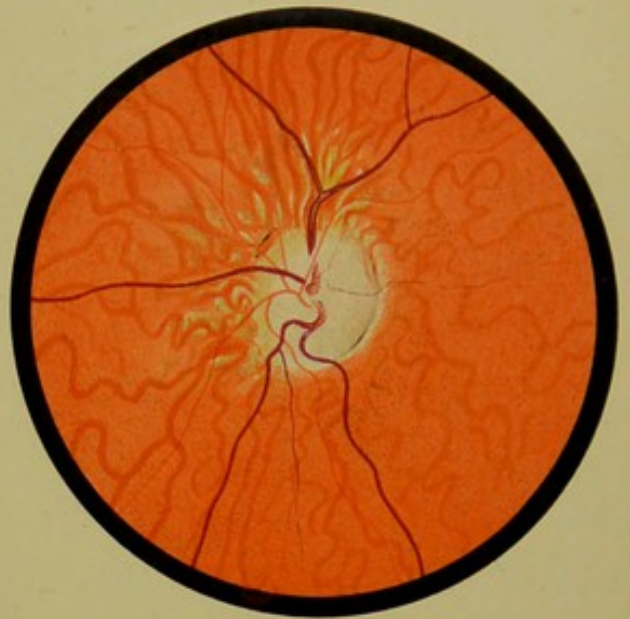


FIG. 71. L.E.

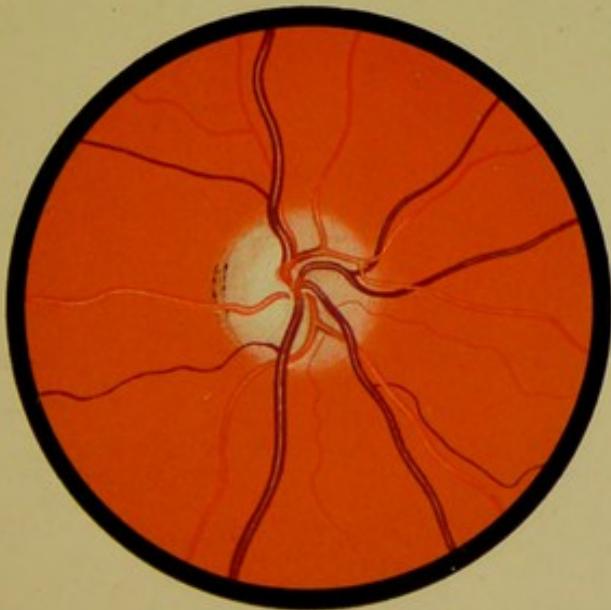


FIG. 72. R.E.

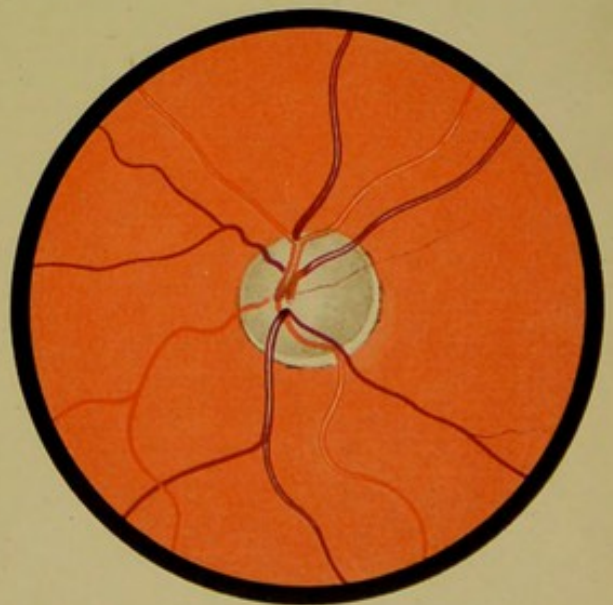


FIG. 73. L.E.

NATIONAL HOSPITAL LIBRARY
Not to be taken away

LEUKÆMIC RETINITIS. PAPILLITIS.

FIG. 74.—LEUKÆMIC RETINITIS.

Ada Smith, 26, single. *RE. Drawing made December 6th, 1892*—Always lived in London. No history of syphilis or alcoholism. Influenza in June 1891; no other definite illness. Father died of heart disease and phthisis. One brother died of rheumatic fever and heart disease; one brother, four sisters, and mother living, and reported healthy.

Patient suffered for many months from shortness of breath, pain in chest, and enlargement of abdomen.

Admitted to Westminster Hospital, December 8th, 1891, under Dr. Donkin. Rather emaciated, slight dyspnoea. Temperature, 99; pulse, 96, soft. Spleen reaching from iliac crest to cardiac dulness, and beyond the middle line. Loud systolic bruit, loudest over nipple. Urine 1025. No albumen or sugar. Catamenia scanty.

Blood corpuscles, 4,500,000 to sq. mm. Proportion of white to red, 1-4.

Improved and went out in a few weeks, but returned April 7th, 1892, having had severe epistaxis. More emaciated. Spleen larger. Liver extending 1.5 ins. below costal cartilages. In June diarrhoea several weeks. November 11th, 1892, further increase in size of liver. November 24th, V. *RE.* $\frac{6}{24} + 2.0$ *D.* $\frac{6}{18}$.

Description.—Disc margin indistinguishable, its centre indicated by an ill-defined grey area, and by the converging of the vessels. General colour of fundus a trifle pale. The veins distended to about four times the normal width; the arteries, which resemble them very closely in colour, are also somewhat dilated, being perhaps half as wide again as in the normal condition. Both arteries and veins are extremely tortuous, and make bold curves as they cross the position of the disc margin. At the summits of these curves the light streak is unusually conspicuous. Some of the other curves also show a brilliant light streak at their summit; but in the upper temporal vein the light streak is remarkably uniform and broad, but not brilliant. The whole fundus has a misty appearance, and in places the vessels appear gradually to disappear into fog. Probably this mistiness prevents any small vessels being visible.

Subsequent History.—Became gradually worse, and died on January 29th.

Autopsy.—Veins generally full, the blood in them of a brownish colour, and most of it clotted, the clot being granular, and partly of a yellowish colour. Numerous old pleuritic adhesions. Greater part of lungs consolidated, of pinkish-grey colour, friable. Mediastinal

glands very large. Liver, 162 oz., pale and soft. Spleen, 67 oz., fairly firm, "beefy," of brick-red hue, on section shows a pyramidal yellow infarct. Except in size no material difference from normal. The microscopical appearance of the fundi has been described in the body of this work under the heading of "leukæmic retinitis."

Note.—This case, with a chromo-lithograph from the same stones as Fig. 74, has been published in *Trans. Ophth. Soc., U. Kingdom, London, xiii., p. 72.*

FIG. 75.—PAPILLITIS. Much Swelling. Vision Unaffected. Subsidence.

Kate H., 20, single. *RE.* Drawing made January 1893.—On December 7th, she fell and struck the outer side of right orbit. Considerable ecchymosis followed. As soon as she could open the eye, she noticed that all objects had appeared to have a trembling movement. It was the annoyance caused by this that led her to seek advice on December 21st. V. was then $\frac{5}{6}$, and the visual field was normal. With the ophthalmoscope the condition depicted was found. The *LE.* presented nothing abnormal.

The urine contained neither albumen nor sugar.

Description.—The disc is replaced by a grey, soft-looking area, shading off gradually into the fundus, without any line of demarcation. This area is not less than three times the normal disc diameter, and its surface has a distinctly striated appearance. With the ophthalmoscope it could be seen to be considerably raised. Between the disc and the macula are numerous hard, small, white dots, which near the macula appear to have coalesced into four or five lines converging towards its centre. The veins are distended and extremely tortuous. They make bold curves as they pass over the edge of the swollen papilla. The convexities of their curves exhibit a strong light reflex; the concavities are often hidden from view in the retinal tissue, so that the continuity of the vessels appears interrupted. The arteries show no change.

Subsequent History.—The patient was seen at frequent intervals for about four months. During the first part of this time she was treated with mercury, and later with tonics. No change took place either in the ophthalmoscopic appearances, or in the vision. She was seen again in March 1894. All trace of swelling of the disc had disappeared; its margin was clear, except above and below, where it was a little fluffy. There were some fine bands of grey tissue in front of the centre of the disc. The veins presented a normal appearance. V. $\frac{6}{8}$, visual field normal.

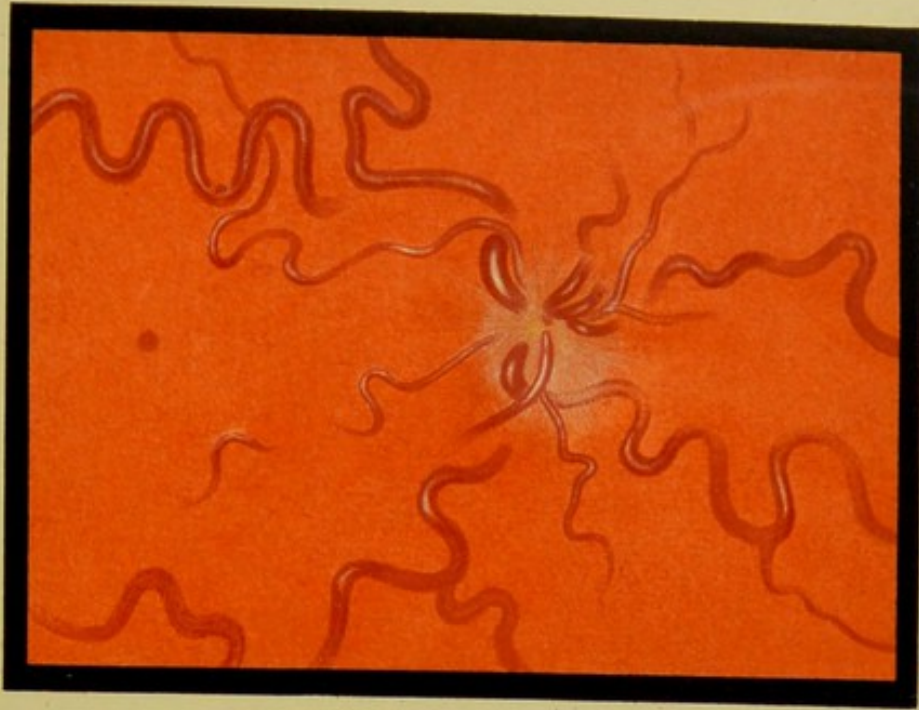

FIG. 74. R. E.

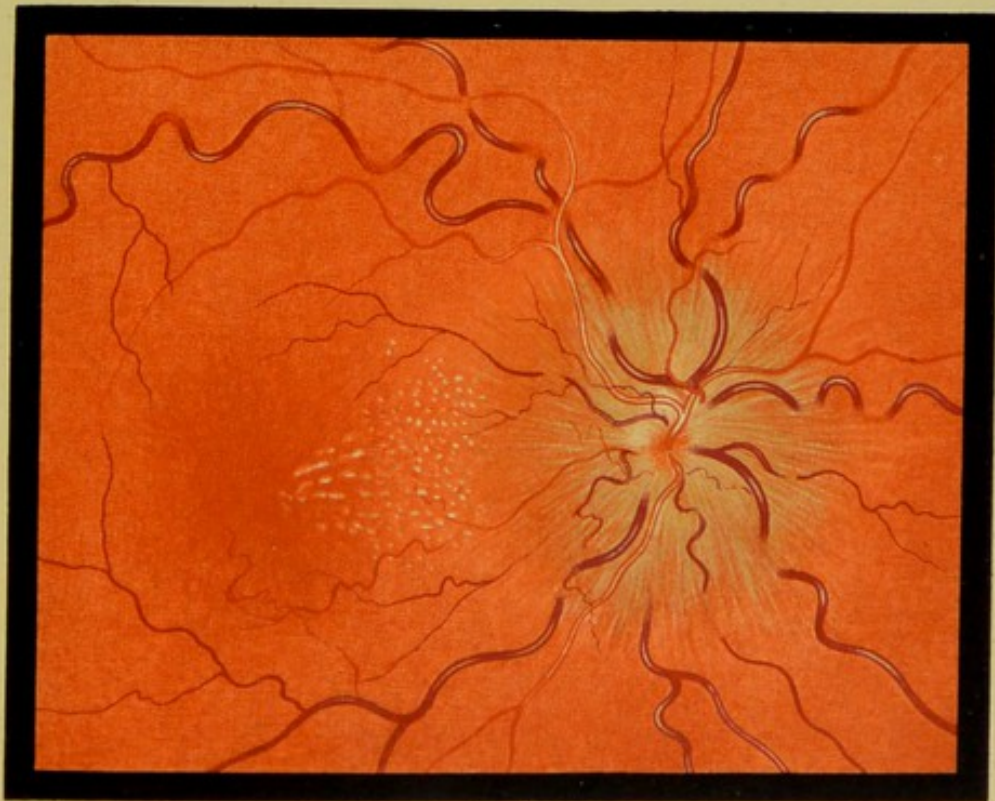

FIG. 75. R. E.

NATIONAL HOSPITAL LIBRARY

Not to be taken away

THROMBOSIS OF CENTRAL VEIN.

FIG. 76.—THROMBOSIS OF CENTRAL VEIN.

Mrs. Lyell, 35. *LE.* Drawing made March 20th, 1894.—Seen February 13th, 1894. A year ago had erysipelas of left side of face, lasting a week. The *LE.* never as good as right; a week before visit it was noticed to be worse. It then remained stationary till two days ago, since when it has been getting worse. *RE.* $\frac{6}{18} + 1.0$ *D* = $\frac{6}{8}$. *LE.* $\frac{6}{60} + 2$ *D* = $\frac{6}{24}$.

Urine acid—no albumen. Fundus of right eye normal; *LE.* as depicted.

Description.—Disc margin indistinguishable. Veins distended and tortuous. Arteries small, and few in number. Numerous hæmorrhages in fibrous layer, becoming more scattered towards the periphery. Downwards and outwards a white patch—probably an altered hæmorrhage. Owing to rapid onset of vitreous opacity, a second sitting could not be obtained, and the drawing is therefore somewhat incomplete.

Subsequent History.—The vitreous became too opaque for the fundus to be seen, and remained so for many weeks. In September it had cleared. The vessels were as in the drawing; there were fewer hæmorrhages, but numerous white areas. December 4th—*V.* = $\frac{6}{80}$. Veins still distended, but much less tortuous. Arteries small, and accompanied by white lines. A few scattered hæmorrhages having a granular appearance. A few fine vessels, probably of new formation, on the disc.

FIG. 77.—THROMBOSIS OF CENTRAL VEIN.

Sarah S., 48. *LE.* Drawing made November 1892.—Vision of *LE.* said to have been failing 18 months. *V. LE.* fingers; *RE.* $\frac{6}{8}$.

Has always had good health. Catamenia ceased two years ago. Urine showed a large cloud of albumen.

Description.—Disc margin indistinguishable, no swelling of disc. The adjacent fundus for a distance of about 3 *dd.* covered with numerous striated hæmorrhages. Beyond this distance the hæmorrhages become less abundant and are less distinctly striated, many being quite irregular in shape. The extravasations are also irregular in the yellow-spot region. The fundus between the hæmorrhages has a yellowish tinge, and the disc margin is occupied by an ill-defined broad band of lighter colour, which fades off gradually into the fundus on the one side, and into the centre of the disc, which is abnormally red, on the other.

The retinal veins are somewhat distended, and extremely tortuous. The convexity of most of the curves shows the light streak very conspicuously, while most of the deeper curves are hidden in the substance of the retina. The superior nasal vein, traced towards the disc, appears to plunge almost vertically into the retina two disc diameters from the disc, and to be invisible from this point. A much smaller vein joins the main upper vein near the disc, but it is doubtful if this is the same vessel. There is a small arch formed by a vein just below the centre of the disc. The perivascular sheath is seen along several of the veins. Only a few arteries are visible. They show no alteration in size.

Subsequent History.—Could not be traced.



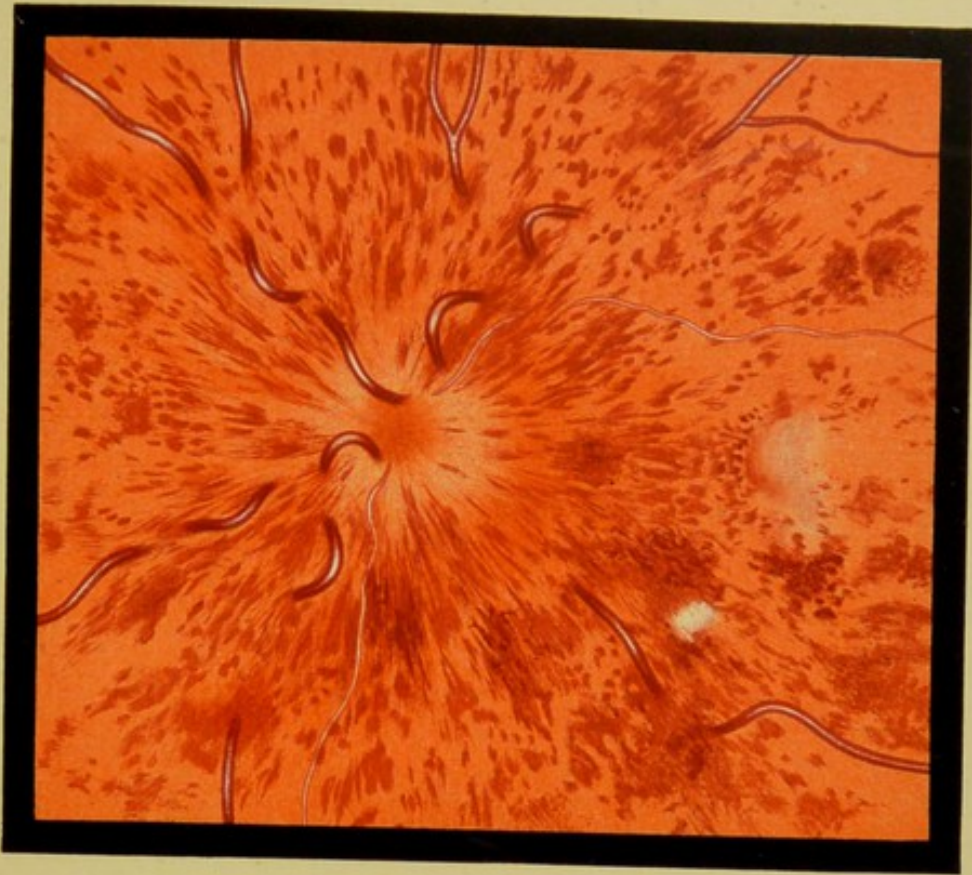


FIG. 76. LE.

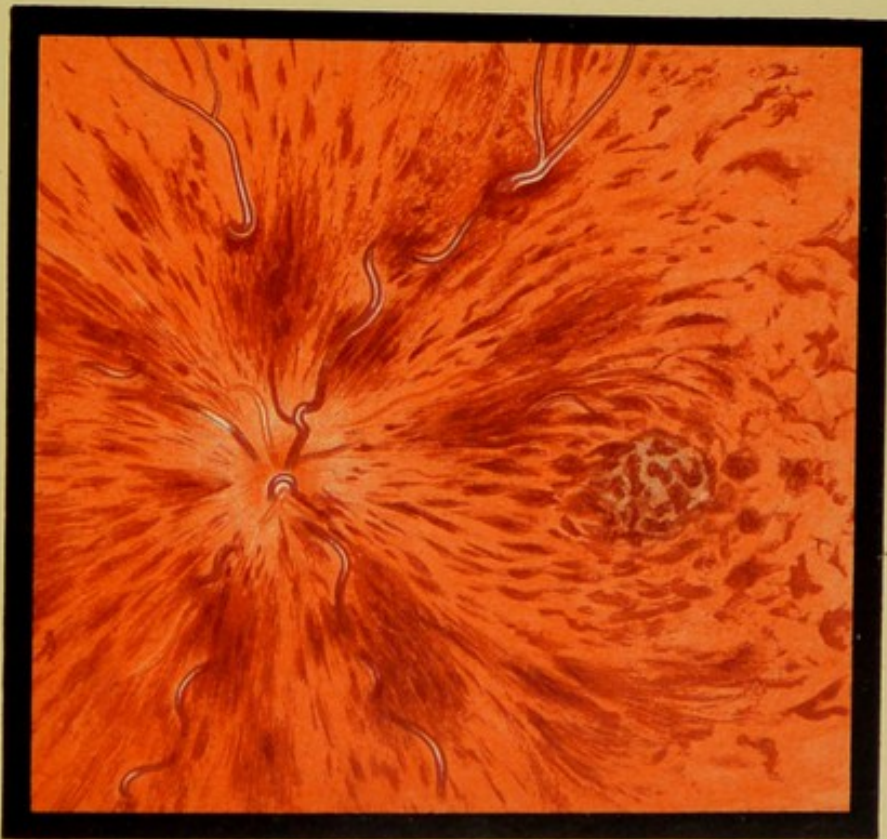


FIG. 77. LE.

NATIONAL HOSPITAL LIBRARY
Not to be taken away

RETINITIS WITH HÆMORRHAGES.

FIG. 78.—RETINITIS. Hæmorrhages and White Dots. Recovery.

Jane R., 57. *RE.* Drawing made September 1889.—V. *RE.* $< \frac{6}{80}$. No reliable account could be obtained as to the date of the failure; *LE.* normal. No albumen in the urine.

Description.—No blurring of disc margin. Hæmorrhages in the fibre layer near the disc. Midway between disc and macula a white patch, surrounded by a granular-looking hæmorrhage. To the temporal side of macula another similar hæmorrhage without any white. A few isolated dark extravasations of blood. In the macular region numerous small dots of chalky whiteness, which on the temporal side of the macula appear to have coalesced into four or five lines, which converge towards its centre.

Subsequent History.—In March 1890 the hæmorrhages had all disappeared, and left no trace. In the region of the macula a few white dots only remained. V. + 3 D = $\frac{6}{8}$.

FIG. 79.—*RE.* RETINAL HÆMORRHAGES. Thrombosis?

James T., 66. *Drawing made March 1890.*—V. of *LE.* noticed defective in December. The *RE.* failed soon afterwards. Early in January he was confined to bed with "rheumatism and cold," and afterwards with influenza. V. *RE.* = $\frac{3}{8}$. *LE.* = fingers.

Patient's aspect very senile. Pulse hard. No albumen in urine.

LE. opacity of lens, which prevented a clear view of the fundus, but white patches could be indistinctly seen.

Description.—Numerous hæmorrhages scattered over the fundus, lying chiefly in the fibre layer of the retina. The nasal border of the disc concealed by blood. No perceptible swelling of disc. Several white patches, which are probably caused by changes in effused blood. Both arteries and veins are small.

Subsequent History.—Could not be traced.

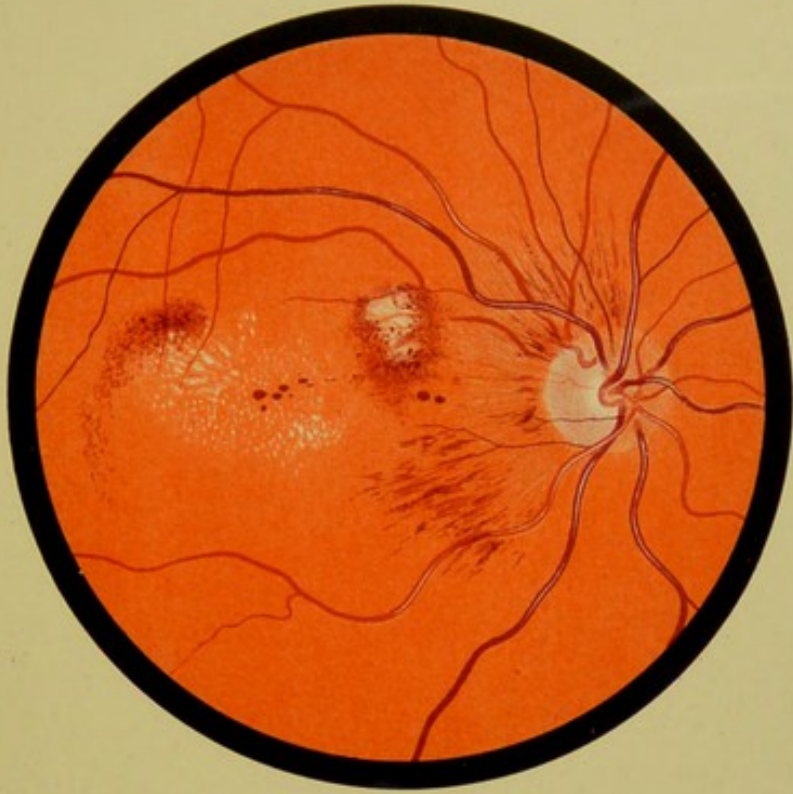

FIG. 78 R. E.

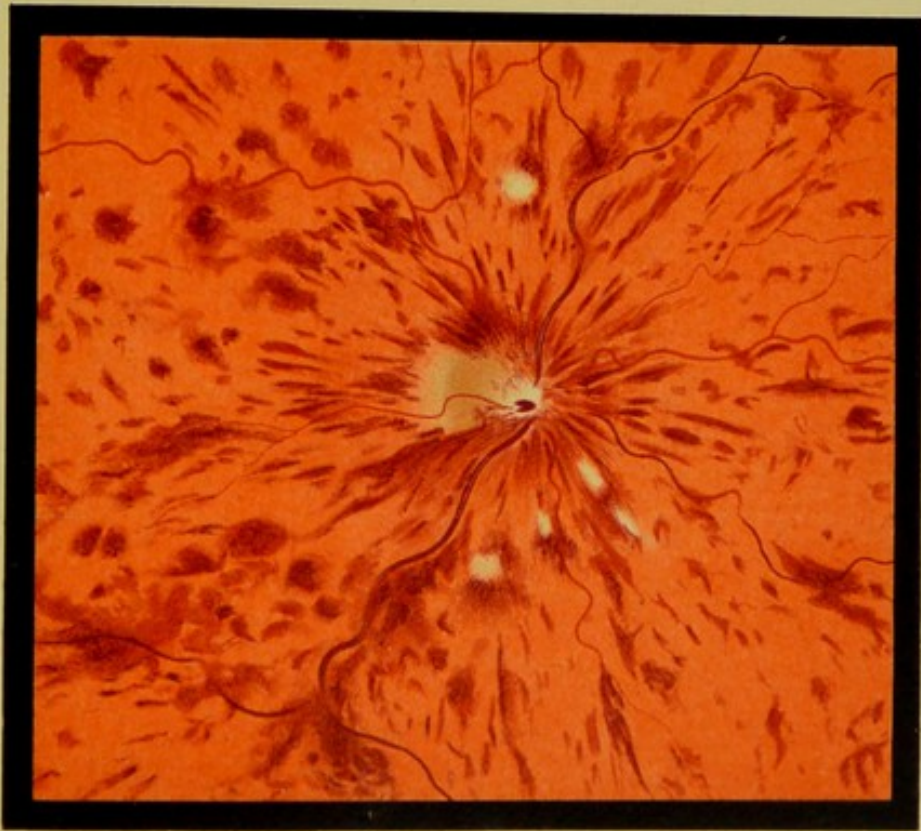

FIG. 79 R. E.

NATIONAL HOSPITAL LIBRARY
Not to be taken away

ALBUMINURIC RETINITIS AND NEURO-RETINITIS.

FIG. 80.—RETINITIS AT MACULA. HYALINE THICKENING OF ARTERY.

Eliza R., 52. *RE.* Drawing made May 1892.—A stout woman. Œdema of feet only after prolonged standing. Micturition rather frequent. Urine contains a distinct trace of albumen.

V. failing gradually two or three years, is now *RE.* = $\frac{6}{24}$, *LE.* = $\frac{6}{36}$.

In *LE.* a large hæmorrhage on disc, extending about a disc diameter into the fibre layer of retina, and a few small hæmorrhages near macula.

Description.—Disc normal; central light streak on arteries unusually well marked. The inferior temporal vein, a disc-and-a-half or 1.5 *dd.* from the disc, is crossed by a small branch of the corresponding artery. The artery has the appearance of passing through a gap in the vein, which is larger than the visible diameter of the artery. On either side of the gap the vein appears to terminate in a dark spot. The diameter of the vein is the same on each side of the apparent gap. The lower half of the macula is embraced by a group of chalky-white dots, arranged in lines converging towards the centre of the macula.

Subsequent History.—February 1893—No hæmorrhages. White dots fewer. Vessels as before. V = $\frac{6}{6}$ each eye.

FIG. 81.—NEURO-RETINITIS.


Samuel G., 17. *LE.* Drawing made September 1890.—Was admitted into St. George's Hospital from one of the Metropolitan Asylum Hospitals, where he had been a patient for enteric fever. This was complicated with a mastoid abscess and facial paralysis, which had recovered before admission. He complained of defective vision, and on examination optic neuritis in both eyes was discovered.

Perforation of membrani tympani of some years standing. No mastoid or temporal tenderness. Adenoid tissue in naso-pharynx. The condition in the ear was thought to be secondary to this.

On September 1st, V. *RE.* + 3 *D.* = $\frac{6}{12}$, *LE.* + 2 *D.* = $\frac{6}{12}$, but on September 17th corrected V. was $\frac{6}{6}$ in each eye. The visual fields were nearly normal.

The ophthalmoscopic appearances were similar in the two eyes.

Description.—Disc swollen and woolly-looking; margin indistinguishable. Retinal veins tortuous. Arteries small. Numerous soft-looking woolly patches. In the course of the inferior temporal vessels, a large area of opaque retina. Chalky-white dots between disc and macula, and around macula.



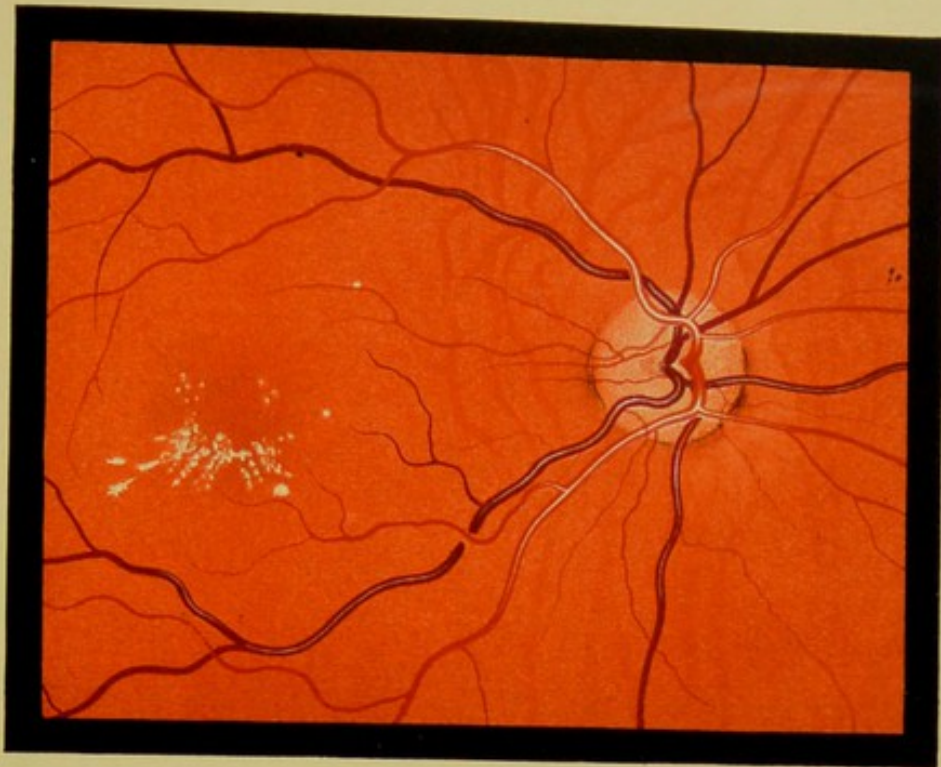


FIG. 80 R.E.

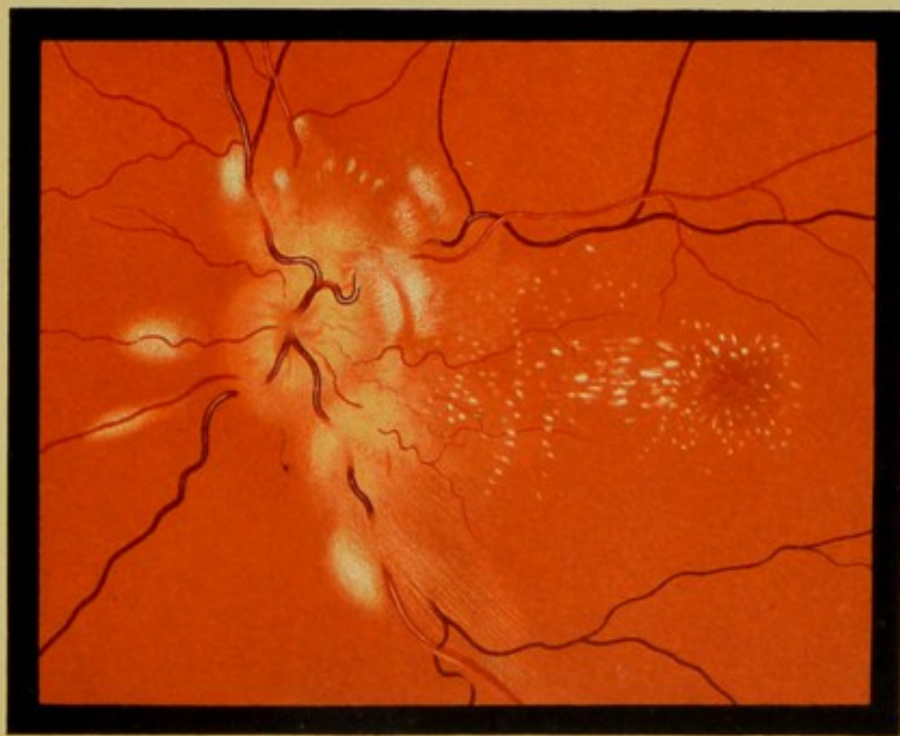


FIG. 81 L.E.

NATIONAL HOSPITAL LIBRARY
Not to be taken away

ALBUMINURIC RETINITIS.

FIG. 82.—ALBUMINURIC RETINITIS.

Samuel S., 33. *LE.* Drawing made January 1890.—He applied on account of failing vision, which was $RE. = \frac{6}{24}$, $LE. = \frac{6}{36}$. He had a typical renal aspect, and he was transferred to the physician, who reported—"Urine, *sp. gr.* 1010 acid, nearly solid from albumen. Heart apex in 7th space in nipple line. Reduplication of first sound at apex, second sound accentuated. Pulse hard. Much œdema of face and legs. Some fluid in abdominal cavity."

The condition of the two eyes was similar.

Description.—Disc margin blurred, especially on temporal side. No swelling of disc, white lines on the upper and lower veins on the disc. Between disc and macula a few hæmorrhages. Several white "woolly" patches. Small chalky dots near macula.

Subsequent History.—He was seen at intervals for a few months. His general condition improved, but no appreciable change took place in the fundus. Early in 1891, on enquiries being made, it was reported that he had died some months previously.

FIG. 83.—RETINITIS. Without Implication of Disc.

Elizabeth S., 53. *RE.* Drawing made July 1889.

V. of *RE.* noticed defective a month. $RE. < \frac{6}{60}$ and 16 J; $LE. = \frac{6}{9}$.

Description.—Appearance of disc normal. Veins distended and very tortuous. This is especially the case with the superior temporal, which in several places appears to dip into the swollen retina and become hidden from view. The inferior temporal vein is also hidden for a short distance a little way from the disc. The macula is normal. Above the space between it and the disc numerous soft-looking, woolly white areas. Numerous hæmorrhages, of somewhat granular appearance.

FIG. 84.—ALBUMINURIC RETINITIS. "Star-Figure" at Macula.

George S., 58, a sexton. *RE.* Drawing made January 1889.—Dimness of V. noticed a month. Now $RE. = \frac{6}{18}$, $LE. = \frac{6}{9}$. Legs slightly œdematous. Pulse of high tension. First heart sound reduplicated. Urine has been passed with undue frequency for some years. During an attack of pleurisy some months ago it contained blood. Now *sp. gr.* 1012 albuminous.

Description.—No perceptible swelling of disc, but its margin quite indistinguishable. A few flame-shaped hæmorrhages near the disc. A few "woolly" patches on fundus. Numerous small white dots round the macula. On the macula these appear to have coalesced to form lines converging towards its centre.

The inferior temporal vein, where it is crossed by the artery, appears to present a gap about twice as wide as is required for the passage of the artery, as in Fig. 80.

Subsequent History.—In February 1890 Mr. Fisher, of King's Langley, under whose care the patient was, wrote:—"Six months ago he developed uræmia, and remained more or less comatose for three weeks. He then gradually recovered but kept his bed, and his eyesight remained very defective. Three weeks ago a second attack came on, and he died in 48 hours."



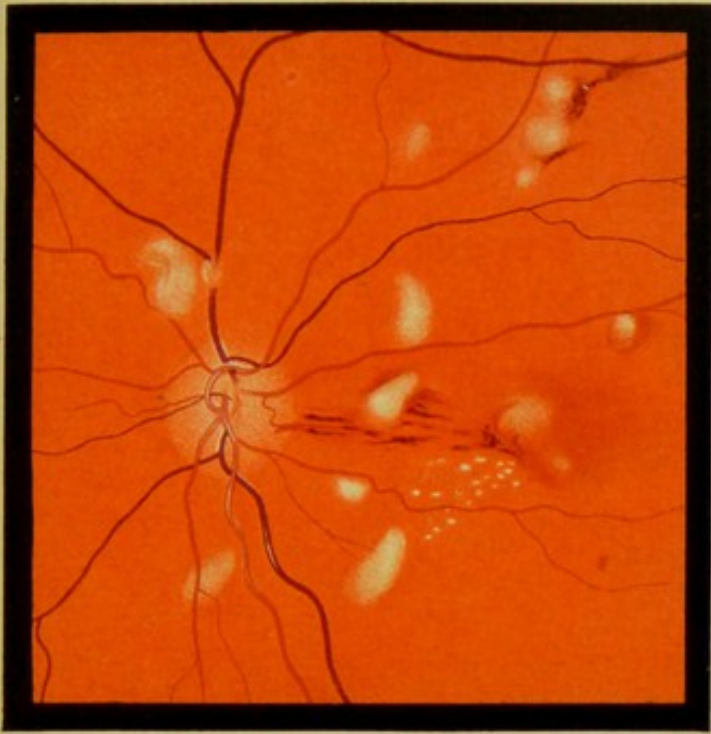


FIG. 82. L.E.

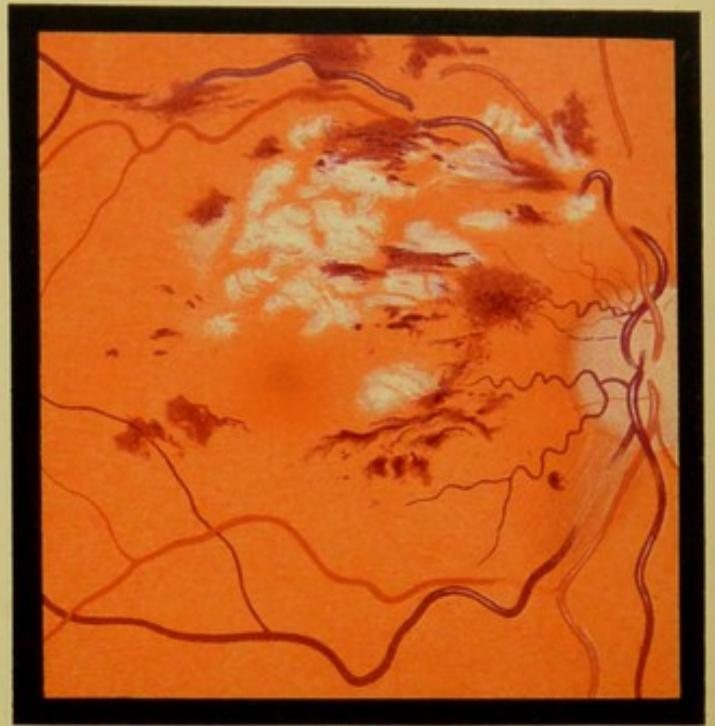

FIG. 83. R.E.

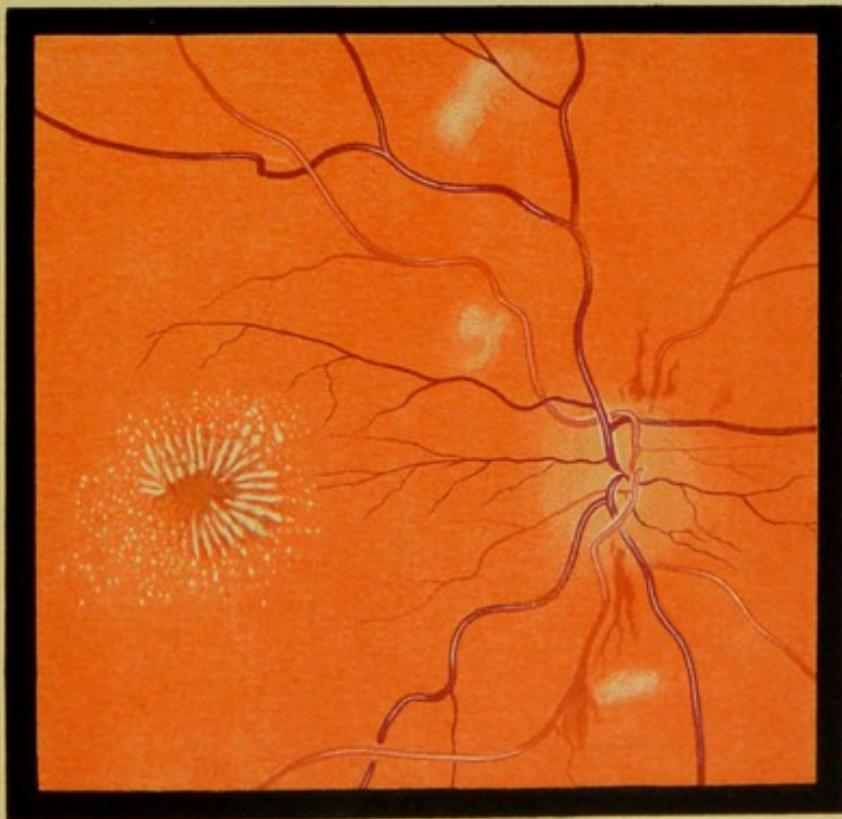


FIG. 84. R.E.

NATIONAL HOSPITAL LIBRARY
Not to be taken away

STELLATE FIGURE AT MACULA AND POST-NEURITIC ATROPHY.

FIG. 85.—STELLATE FIGURE AT MACULA OF UNUSUAL CHARACTER.

Lizzie B., 21. *Drawing made July 27th, 1888.*—First seen at St. George's Hospital, on July 11th. She stated that on July 6th she had experienced an uncomfortable sensation in the left eye, as if from a foreign body, and that at the same time she noticed a fog before the eye. Two days later the sight had improved, and it then remained the same till her visit.

Patient somewhat anæmic. Has always been considered delicate, but does not appear to have had any definite illness. She has suffered since childhood from severe headaches, affecting the whole head, and usually accompanied by vomiting. These used to come on every three weeks, and to last for two or three days. They have been less frequent during the last two or three years, and during the past year she has had very few attacks. Menstruation has always been regular. No constipation. Urine acid, no albumen.

V. $RE. = \frac{6}{6}$, $LE. = \frac{6}{24}$. Visual field (roughly tested), normal.

The disc margin presented the striated appearance frequently seen in dark eyes, but this was more marked than in the right eye. There was also some slight real blurring. On the upper and outer quadrant of the disc a minute hæmorrhage. The retinal arteries were thought to be smaller than normal. As there was a suspicion of embolism, the macular region would certainly have been carefully examined, but nothing abnormal was noted at this visit.

At the next visit, on July 11th, V. the same, and the appearance depicted was discovered. The visual field was carefully tested and found to be normal for white. There was a small scotoma for red (test object 3 mm.) below the fixation point.

Description.—Some retinal striation on upper border of disc, but elsewhere it was less marked than before. The small hæmorrhage on the disc still present. Retinal veins twice the diameter of the arteries (in the other eye the proportion was 3 to 2).

The macula of dark colour, radiating from it in all directions an immense number of fine hard lines. Each line was thicker at its centre than at either extremity, the thickened portions corresponding in position with the oval reflex-ring often seen in this region. The lines were approximately a disc diameter in length. Beyond them, especially above, numerous extremely minute white dots.

FIG. 86.—THE SAME EYE. Two Months Later.

The ophthalmoscopic appearances had much changed. V. still $\frac{6}{24}$.

Description.—The fine striæ have disappeared, in their place a few short and thick lines of chalky whiteness. The retinal dots are fewer and larger.

Subsequent History.—January 16th, 1889. Only a few dots round the macula, and a few isolated dots between disc and macula. The disproportion between arteries and veins no longer noticeable. V. = $\frac{6}{9}$.

FIG. 87.—RE. POST-NEURITIC ATROPHY.

Edwin B., about 35. *Drawing made May 1889.*—The full notes of this case have been lost. The patient, some months before, had been an in-patient at a general hospital for symptoms believed to depend upon a cerebral gumma. He became blind while under treatment there.

Description.—Veins tortuous, hidden in places on the disc. Arteries diminished. Disc white, its margin indistinct, except on temporal side. A few chalky dots between disc and macula. A hæmorrhage downwards and inwards from disc.

Subsequent History.—It was ascertained that the patient was removed to a lunatic asylum in 1892, and that he recovered sufficiently to be discharged in six months. In April 1894 he was said to be suffering from frequent fits.

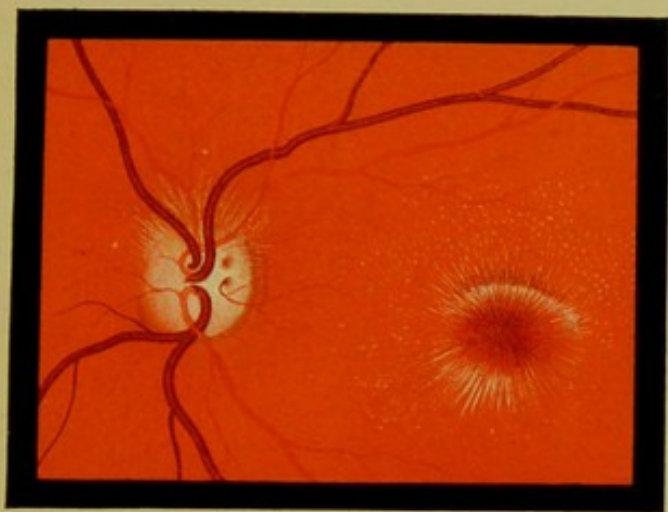

FIG. 85. L.E.

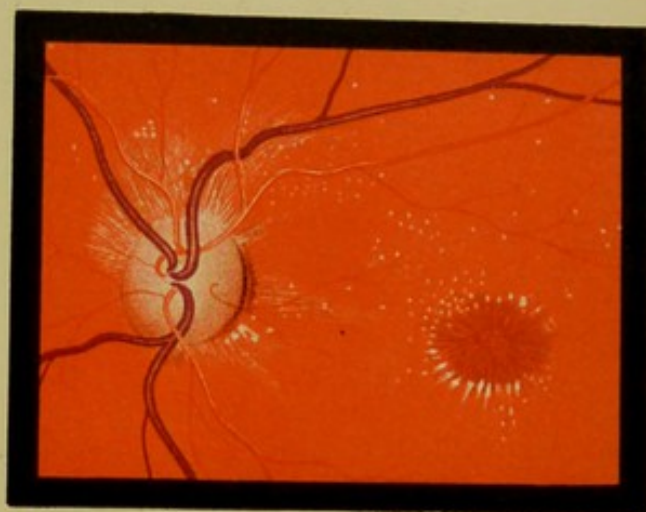

FIG. 86. L.E.

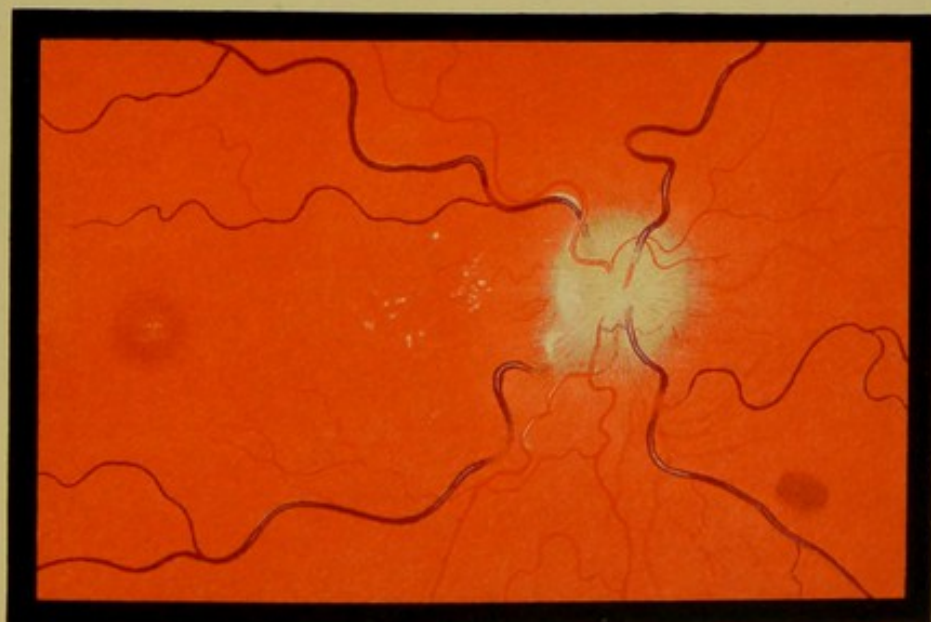

FIG. 87. R.E.

NATIONAL HOSPITAL LIBRARY
Not to be taken away

SUB-HYALOID HÆMORRHAGE.

FIG. 88.—SUB-HYALOID HÆMORRHAGE AT MACULA.

Phœbe K., 63. *RE*. Drawing made April 12th, 1889.—On March 31st, whilst lifting a patient, she noticed a sudden flash in the right eye. Since then vision has been dull, and all objects have appeared red.

When seen, V. = counting fingers. A central scotoma, having a radius of about 10° . This corresponded with the changes in Fig. 89 rather than with those in this figure. *LE*. normal.

Description.—Extending from a point half a disc diameter on the temporal side of the disc to a-disc-and-a-half beyond the fovea D-shaped hæmorrhage. The straight limb is horizontal, and forms its upper boundary. The colour of the extravasation is deepest below; through the upper part the fovea centralis can be seen as a pale spot. Beyond the temporal border of the extravasation a few hæmorrhages.

FIG. 89.—THE SAME EYE. 14 Days Later.

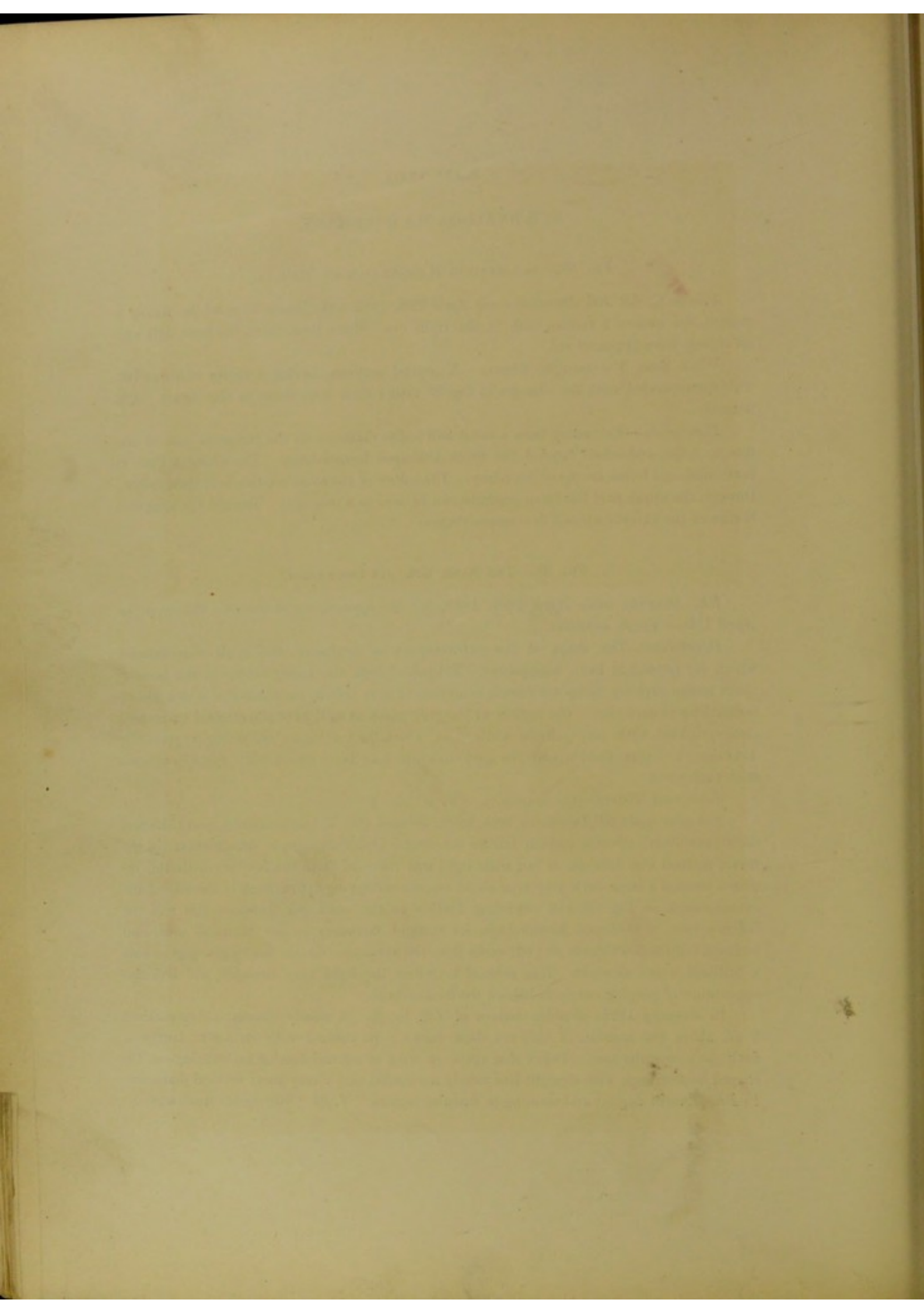
RE. Drawing made April 26th, 1889, but the appearances shown were discovered on April 17th.—Vision as before.

Description.—The shape of the extravasation is unaltered, the small hæmorrhages which lay beyond it have disappeared. Extending from the upper border of the hæmorrhage to the superior temporal vessels is an area of grey colour, the surface of which shows indications of striation. The surface of the grey patch as well as of the original extravasation sprinkled with very minute white dots, which had a highly refracting appearance. Between the extravasation and the grey area are four large round white spots in contact with each other.

Subsequent History.—On May 10th. V. $+1.25 = \frac{3}{8}$.

Not seen again till December 10th, 1892. Stated that V. had remained good till a few days previously, when a sudden failure occurred. Ophthalmoscopic examination by the direct method was difficult, as but little light was reflected from the fundus; with the indirect method a large dark-grey area could be seen occupying approximately the site of the extravasation in Fig. 88, but extending further to the nasal side, between this and the inferior vein, a D-shaped hæmorrhage, its straight boundary to the temporal side, and inclined a little downwards and outwards from the vertical. Above the upper edge of this a brilliant white crescent. This seemed to reflect the light very strongly, and had the appearance of peeping out from behind the hæmorrhage.

In *January* 1896.—Sudden failure of *LE*. to $\frac{6}{38}$. A nearly circular extravasation, 3 *dd.* above the macula, of uniform dark colour. In contact with its lower border a dark grey crescentic area. Below this again—a strip of normal fundus intervening—a D-shaped hæmorrhage, with straight line nearly horizontal, and a very short vertical diameter. In *RE*. pigment deposit and staining in macular regions. V. *p.l.* Still under treatment.



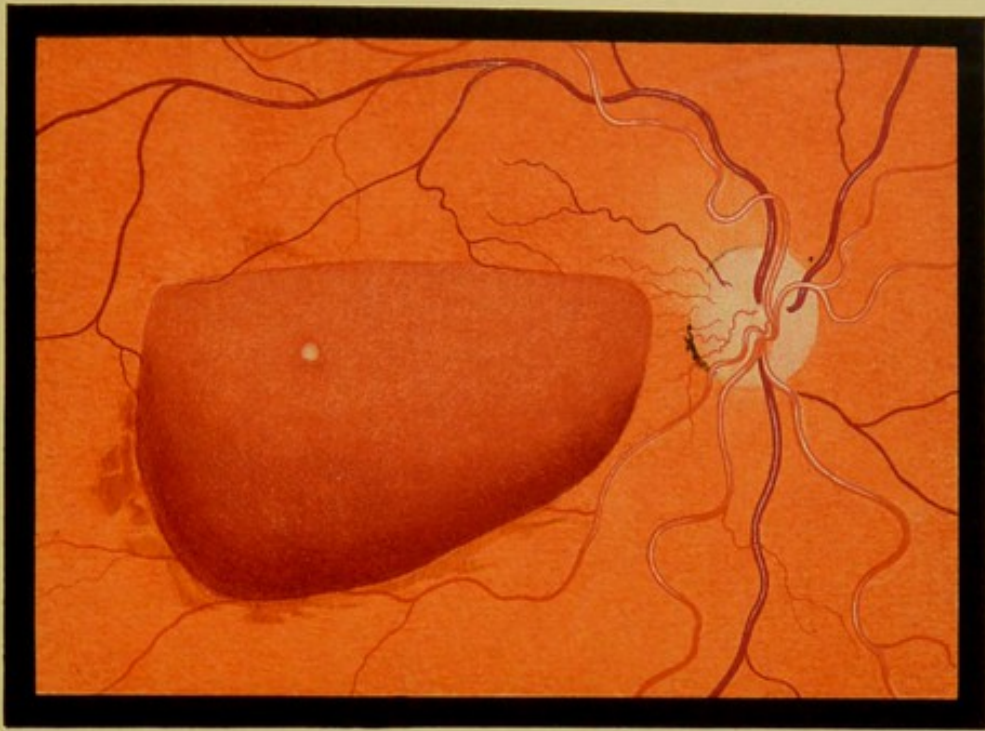


FIG. 88 R E.

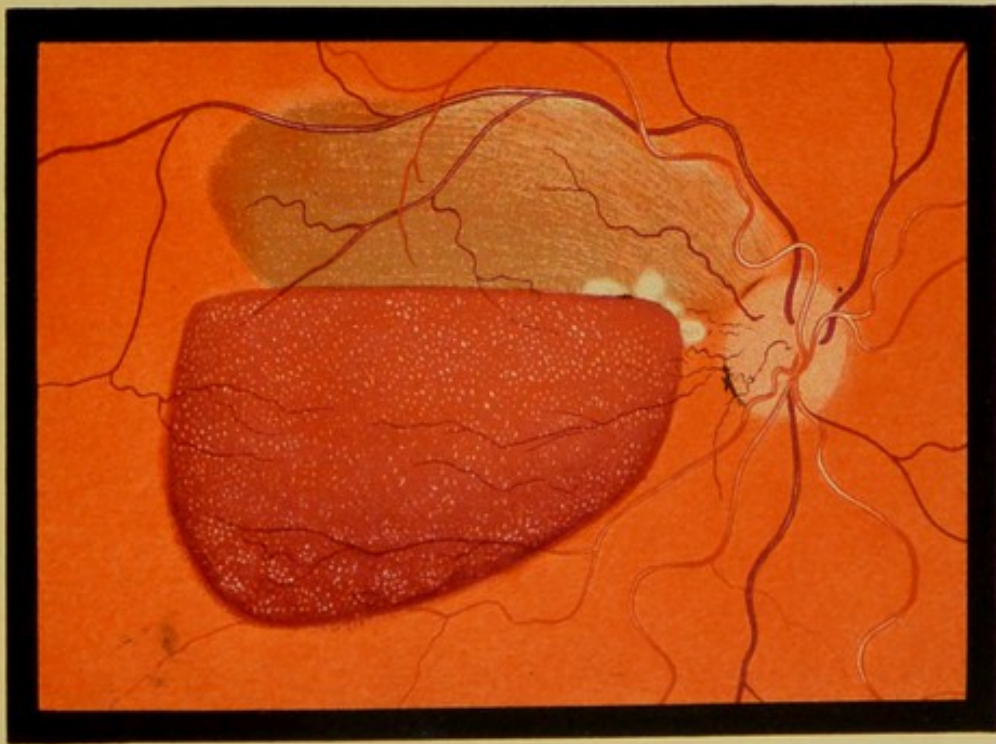


FIG. 89 L E.

NATIONAL HOSPITAL LIBRARY
Not to be taken away

CHANGES IN VESSEL-WALLS. NEW VESSELS IN VITREOUS.

FIG. 90.—DEGENERATIVE CHANGE IN ARTERIAL WALLS.

Ann H., 43. *RE*. Drawing made July 1889.

Six months previously, in the eighth month of pregnancy, there was sudden loss of vision in the *LE*., followed by gradual partial recovery. She has had three similar attacks; the last, which occurred a month ago, was not followed by any improvement. In the *LE*. no definite opacity can be seen in the media, but there is only a faint fundus-reflex obtainable. V. *LE*. no *p.l.*, *RE*. = $\frac{6}{18}$.

Urine pale, acid. A well-marked cloud of albumen.

Description.—Inferior temporal artery in part of its course converted into a white band of the width of the corresponding vein. In places, a thin blood stream is visible down the centre. A small vessel passing upwards and outwards is entirely white, and the inferior nasal artery is similarly affected on the disc. Two uniform-looking hæmorrhages. No changes at the macula.

FIG. 91.—NEW VESSELS IN THE VITREOUS.

Frances C., 54. *RE*. Drawing made November 1889.—First seen June 3rd for recent failure of right eye, V. *RE*. = $\frac{6}{34}$, *LE*. = $\frac{6}{6}$. There was a hæmorrhage in the macular region, and a corresponding defect in the visual field, which was otherwise normal. Urine pale, cloudy, *sp. gr.* 1022. Faint trace of albumen. Patient suffers from headache, giddiness, and œdema of feet.

On November 12th, V. *RE*. $\frac{6}{18}$. The ophthalmoscopic appearances depicted were discovered.

Description.—Several of the retinal vessels have white lines accompanying them on either side, and some of the smaller ones appear as white bands. There are several small hæmorrhages, one below, of a peculiar feather-like shape. A few soft white patches on the retina. Springing from the disc are numerous fine vessels. The majority of these lay in a plane anterior to the disc (2.0 D). Some appear to have at their distal extremities swellings of the same colour. Most of these latter were ill-defined, and had the appearance of hæmorrhages, but the shape of others suggested that they were composed of the closely packed convolutions of a fine vessel.

Subsequent History.—In January 1890 the vessels were accompanied by a thin gauze-like membrane which was sharply limited below, but shaded off gradually above. There was a smaller bundle of new vessels on the inner side of the disc.

The vitreous soon afterwards became opaque. But in May 1892 it had partially cleared, and the fundus could be seen indistinctly. Upwards and inwards from the disc a brilliant white membrane could be seen with some vessels on it. It appeared to be too smooth for a detachment of the retina.



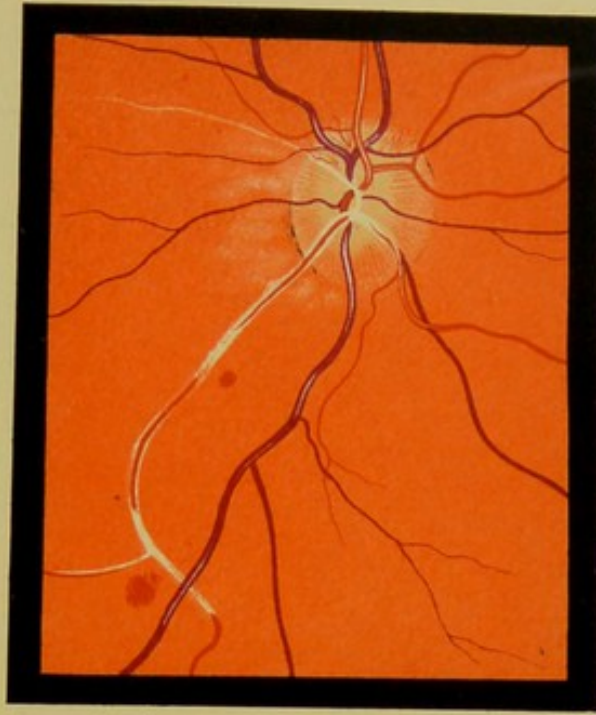


FIG. 90. R. E.

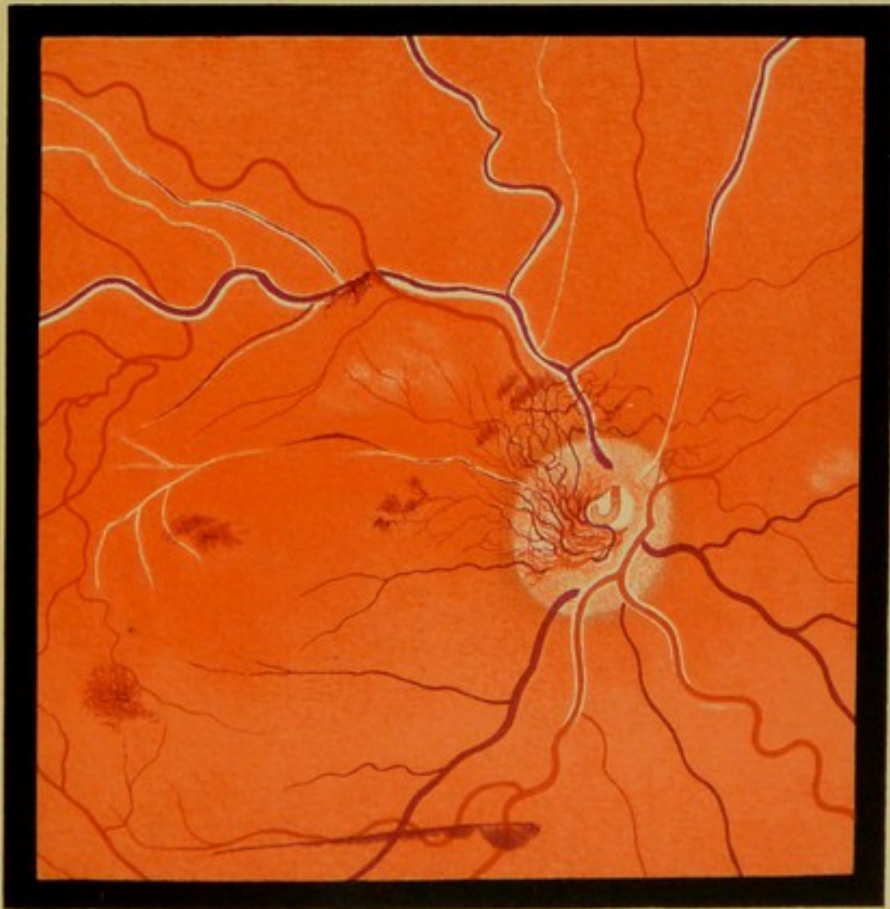

FIG. 91. R. E.

NATIONAL HOSPITAL LIBRARY

Not to be taken away

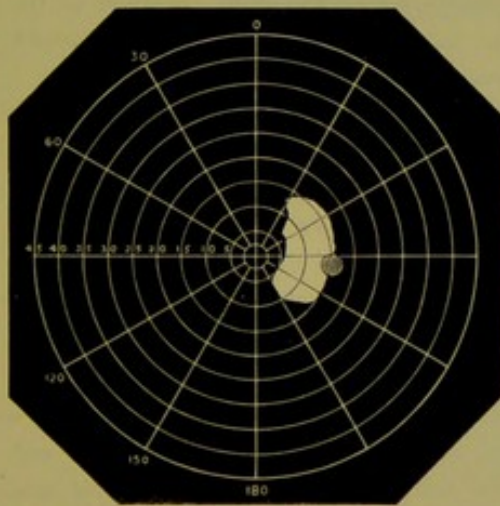PLATE XLI.

EMBOLISM OF CENTRAL ARTERY.

FIG. 92.—EMBOLISM OF CENTRAL ARTERY.

Emma T., 50. *RE.* Drawing made November 13th, 1888.—Three weeks after discovery by the patient of the loss of vision.¹

First seen on October 26th. Stated that on October 21st she had had a slight fall, to which, at the time, she attached no importance. On waking on the morning of the 23rd, she discovered that she could only with the *RE.* distinguish light from darkness, and she experienced a sensation of fulness over the right brow.



At the age of nine she had rheumatic fever; this was followed by chronic pains in the limbs for three or four years. From eleven till fifteen she lived at Charlton, near Woolwich, and had several attacks of ague, followed by chorea, affecting the right arm and leg, and the speech a little. At twenty-eight, she had rheumatic fever again, and diphtheria, and was confined to bed five weeks. At forty-two she had another attack lasting two weeks, and another lasting five weeks a year ago. She

has since had chronic pains in legs. Two months before her visit, she found one morning on waking that she had a difficulty in speaking—this lasted a month.

For a long time she has suffered from palpitation and shortness of breath on exertion.

A loud mitral systolic murmur, slight œdema of feet and ankles. *V.*, hand movement only, and this over a very limited area (*see* Chart).

Description.—Disc of normal colour; retinal veins unusually dark, their size is approximately normal, but they become smaller on the disc. No venous pulse could be produced by pressure.

¹ The patient was under the care of Mr. Hartridge, to whom I am indebted for the notes of the case, and for the loan of the original drawing.

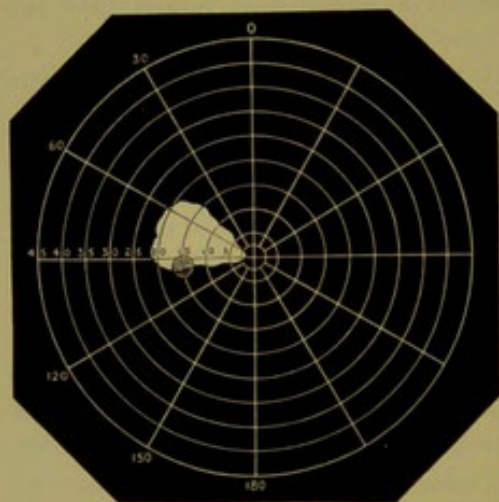The width of the blood stream in the arteries is much diminished; in several the artery is replaced by a white band, with a narrow thread of blood visible down its centre. In the macular region a whitish area, in which the macula is seen of its normal colour, with a minute fovea centralis. There are hæmorrhages on and near the disc.

Subsequent History.—In July 1890 the macular region appeared normal. The disc was atrophic. V. = no *p.l.*

FIG. 93.—EMBOLISM OF THE CENTRAL ARTERY. MODIFIED BY THE PRESENCE OF A CILIO-RETINAL VESSEL.

Henry T., 40. *LE.* Drawing commenced July 18th, 1893, 44 hours after the loss of V.; and completed the following day.

First seen July 17th; stated that twenty-four hours previously he had suddenly lost the sight completely (no *p.l.*) in both eyes. In a few minutes the sight returned to the *RE.*, but the *LE.* remained blind. The attack was accompanied by a feeling of faintness.



A rather anæmic, nervous man. He had rheumatic fever twenty years ago; does not know that his heart was affected. Heart sounds normal. V. *RE.* — 2 D = $\frac{6}{8}$; visual field normal. *LE.*, can just see hand movements over a small area of the field, extending from the fixation-point to the blind-spot. See chart.

Description.—The whole fundus, except an area on the temporal side of the disc, of a whitish colour, only faintly tinged with red. The disc margin, except on the temporal side, is indistinguishable. The size of the retinal vessels is normal, the light-reflex is absent from some of them. In the centre of the macular

region is a brilliant red spot, looking like a hæmorrhage, round this a light band, and round this latter again a broader dark band. Between the disc and macula an irregular area of normal coloured fundus, rather abruptly limited above, but shading off gradually below. This is crossed about its centre by a small (cilio-retinal) vessel, which emerges from the temporal border of the disc. Near the macula are several pale bands on this normal area, which converge towards the macula.

Subsequent History.—Some months later the disc had undergone white atrophy, and there was no *p.l.* The upper arteries were small, especially near the disc.

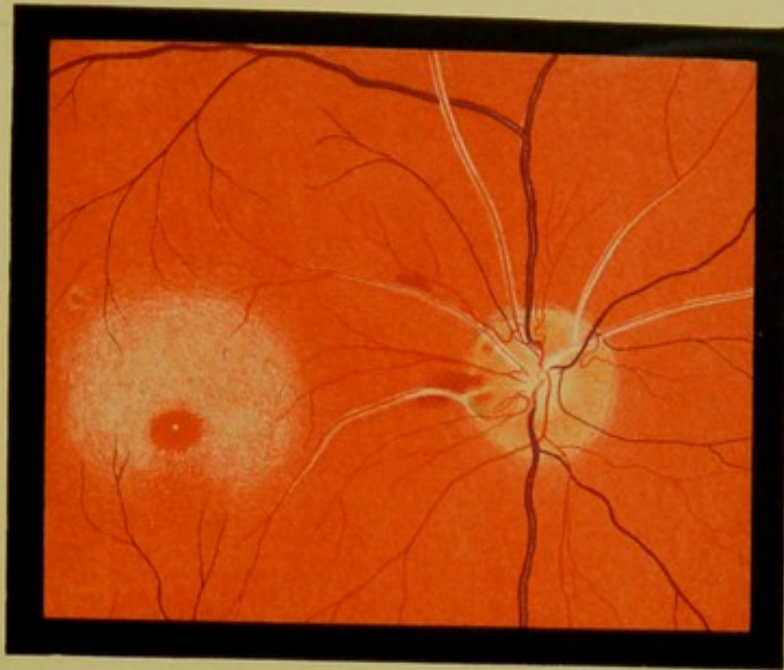


FIG. 92. R.E.

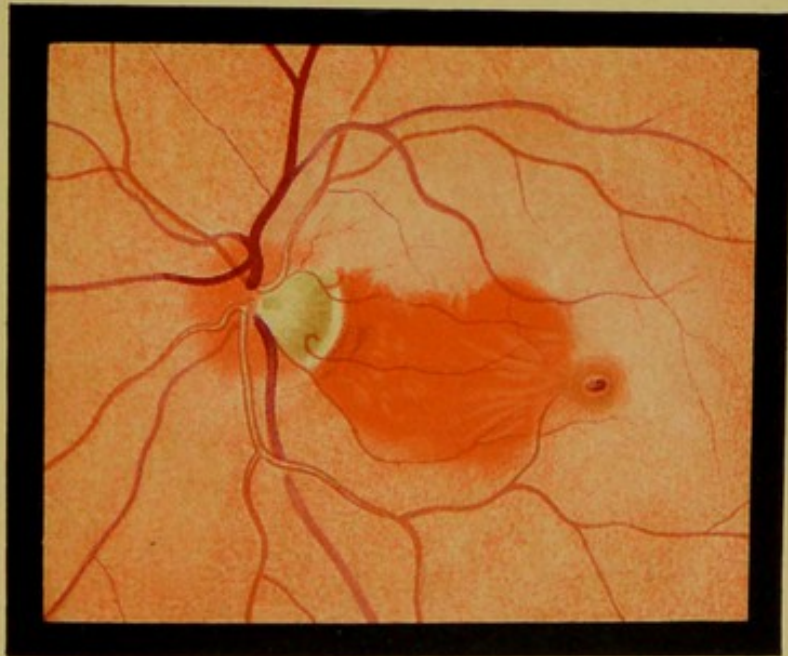


FIG. 93. L.E.

NATIONAL HOSPITAL LIBRARY

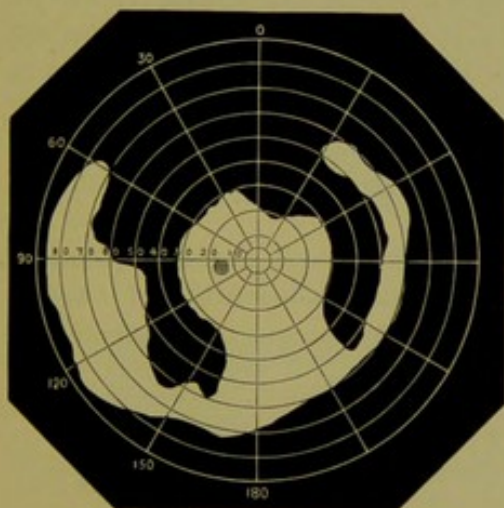Not to be taken away

RETINITIS PIGMENTOSA. PIGMENTATION FROM CHOROIDO-RETINITIS.

FIG. 94.—RETINITIS PIGMENTOSA.

Alice M., 23. *LE.* Drawing made August 1888.—Patient is the third of five children. Both parents living and reported healthy; they are not blood relations. None of the other children are known to have defective sight. The eyes of one brother and one sister were examined and found normal.

Patient presents no sign of inherited syphilis. There is no history or probability of the disease having been acquired. She has little colour, but is not markedly anæmic. She is not considered strong, but has had no definite illness.



The defect in the vision of the *LE.* was first noticed in January 1887, after an inflammatory attack (conjunctivitis?). Since then it has altered a little, if at all. She was not conscious of any defect in the *RE.*

First seen March 1888. $V. = \frac{5}{6}$ in each eye. The visual field of the *RE.* normal, that of *LE.* as shown in the chart. In answer to questions, patient said that she saw worse at night, but the difference does not seem to have been very marked, and the visual acuity was not lowered disproportionately on diminishing the light. With Förster's photometer, however, there was marked diminution of

the light-sense in both eyes, but especially in the left.

In the *RE.* were some isolated pigment streaks in the periphery of the retina, some of them accompanying the vessels. The disc of normal colour, surrounded by a pale band. The vessels of normal calibre.

Description.—Disc has a dirty-looking colour. Retinal vessels rather small. Towards the periphery the characteristic network of pigment. Beneath the pigment network the choroidal vessels are visible to an abnormal extent. At the extreme periphery the fundus seemed rather less pigmented, but the choroidal vessels were more visible. Below the macula is an area of partial choroidal atrophy, with a rather dense pigment deposit.

Subsequent History.—Patient seen at intervals till November 1894. There were fluctuations in the vision (at one time it went down to $\frac{6}{8}$), but no permanent alteration. No appreciable change occurred in the ophthalmoscopic appearances in either eye.

FIG. 95.—CHOROIDO-RETINITIS. With unusual Pigmentation.

Charles W., 37. *RE*. Drawing made May 1889.—Patient is a Eurasian, employed in Government service in India. Seven years ago he had a chancre. He was treated with mercury. No secondary symptoms followed. He married shortly afterwards, and has had three children, which are said to be healthy.

Four years ago he had an inflammatory attack in the *RE*, which he believes did not permanently affect the sight. Three years ago, on returning to India after a year's furlough, the sight of the right eye failed rapidly, falling to perception of light only in two weeks. It has remained in the same condition since. The left eye began to fail about the same time, but more gradually, and with fluctuations. At the date of the drawing *V. RE. p.l.* slight concentric contraction of the visual field. *LE. $\frac{6}{24}$* . The condition of the fundus was similar in the two eyes. In the *LE* there were fine dust-like opacities, and a few films, in the anterior part of the vitreous.

Description.—Fundus of the dark sombre type. Disc normal. Choroidal vessels visible as pale streaks. Numerous irregular spots of pigment, showing no tendency to form a network.

Subsequent History.—Treated with mercurial inunction, and iodide of potassium internally, with intervals, for six months. *V. of RE.* was then unaltered, that of *LE. = $\frac{6}{18}$* . The visual field of *LE.* was normal. No change in the appearance of the fundi. He returned to India shortly afterwards.

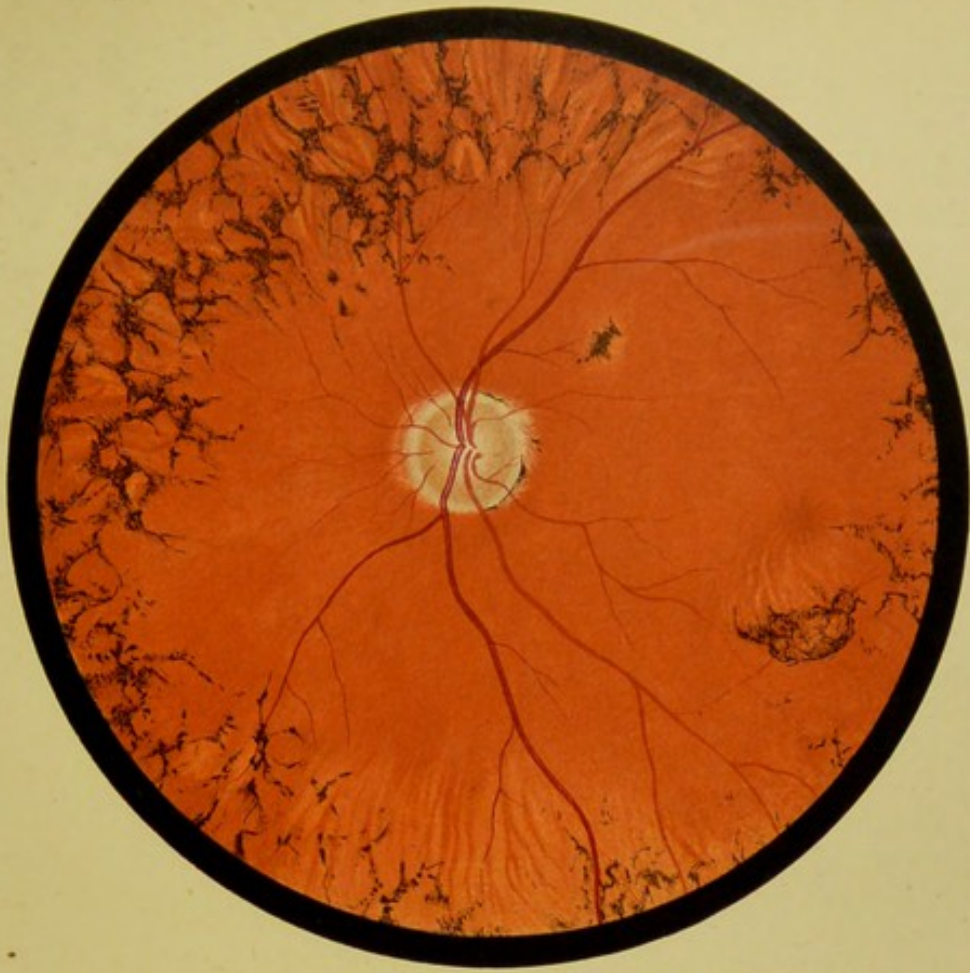


FIG. 94. L.E.

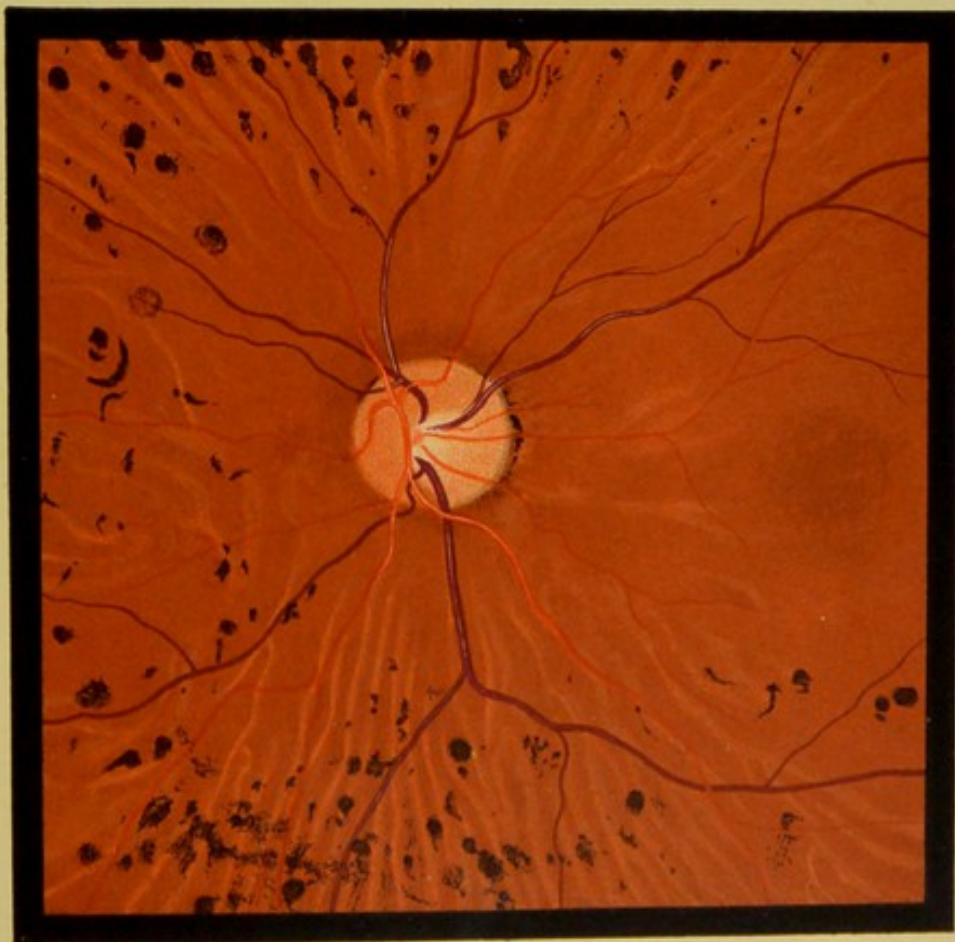

FIG. 95. L.E.

NATIONAL HOSPITAL LIBRARY
Not to be taken away

PLATE XLIII.

RETINITIS PIGMENTOSA.

FIG. 96.—RETINITIS PIGMENTOSA.

James D., 35. *LE. Drawing made 1889.*—First seen, August 1885. Patient has black hair, and moderately dark complexion. Is rather anæmic. Parents not blood relations. He stated that his sight had been failing gradually for ten years. At first the defect was only noticed at night, and it has always been worse then.

In 1879 he attended Moorfields for iritis. From his notes it does not appear that the ophthalmoscope was used, and his V. was noted as $c. - 2.0 D = \frac{6}{8}$.

When seen in 1885, V. $c. - 2.0 D = \frac{6}{8}$. On the capsule of each lens a thin layer of buff-coloured opacity of irregular shape, and presenting numerous gaps. Visual field contracted. Marked night-blindness.

At the date of the drawing V. $- 2.0 D = \frac{6}{8}$.

The fundus was similar in the two eyes.

Description.—Disc somewhat pale, having an opaque appearance, difficult to describe or to depict, the margin softer than normal. Over the whole fundus the choroidal vessels are visible, the spaces between them are dark and mottled. Towards the periphery numerous branching lines of pigment forming an irregular network. The inferior nasal vein has a pigment streak in contact with it for some distance.

The retinal vessels, both arteries and veins, are reduced in size.

Subsequent History.—Was seen at intervals till October 1895. No appreciable alteration took place.



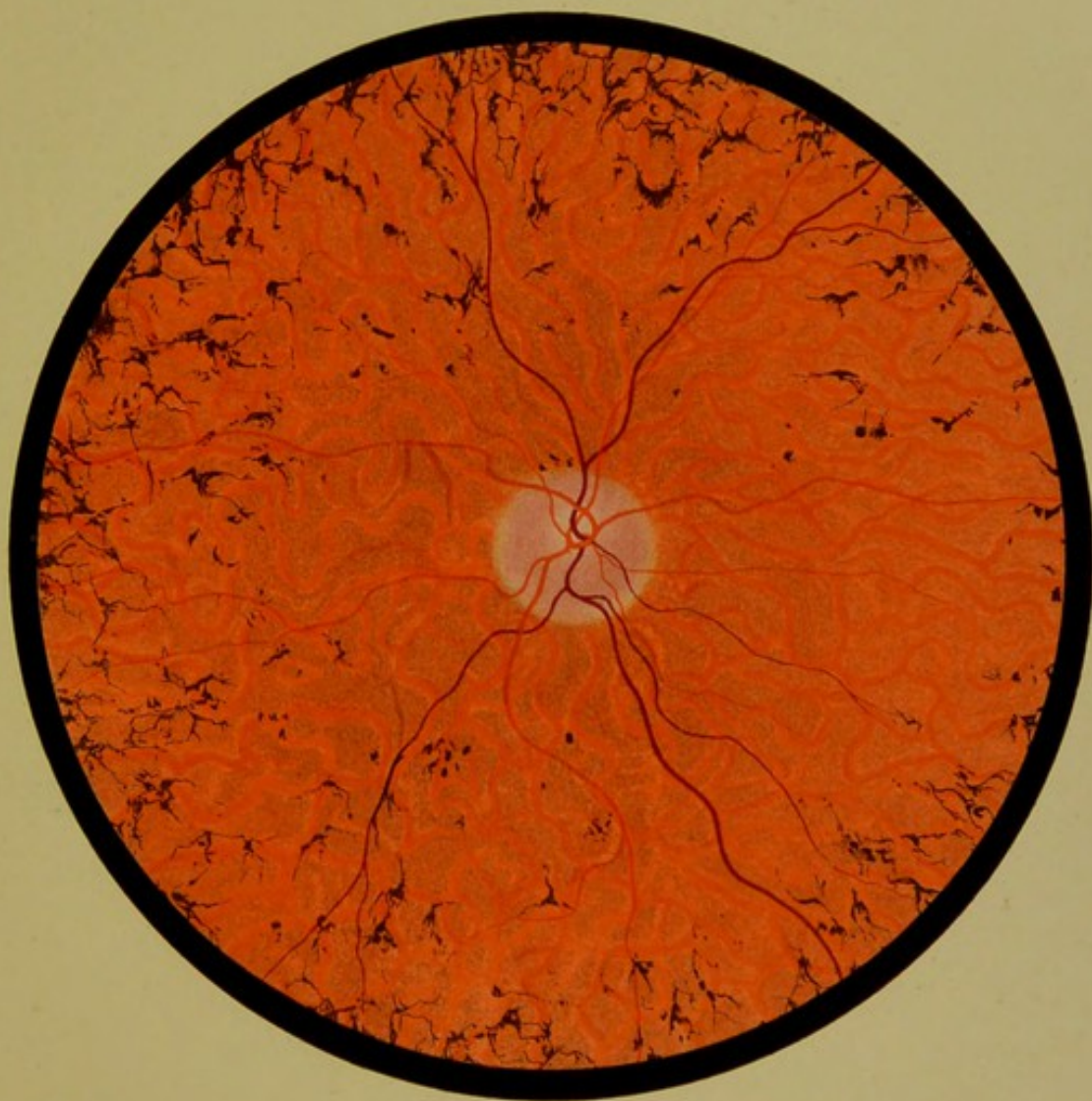


FIG. 96. L.E.

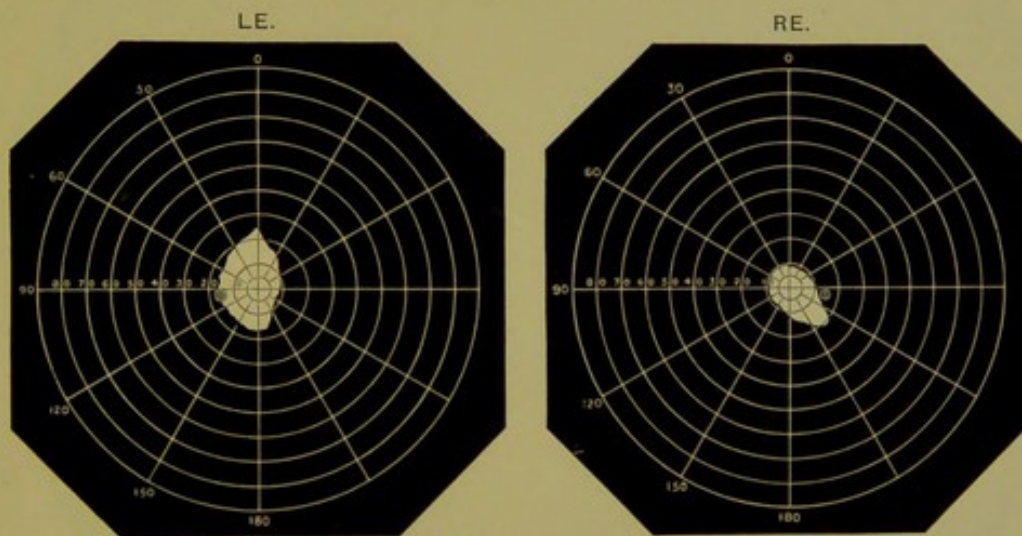
NATIONAL HOSPITAL LIBRARY
Not to be taken away

RETINITIS PIGMENTOSA.

FIG. 97.—RETINITIS PIGMENTOSA. With little Pigment Deposit.

James C., 35. *RE.* Drawing made February 1889.—Stated that he had always been slightly short-sighted. For the last two or three years he had noticed much difficulty in seeing at night.

V. *RE.* -2.25 $D = \frac{6}{18}$; *LE.* -3.0 $D = \frac{6}{24}$. Visual fields contracted.



Patient's parents were not blood relations. He has two brothers, who are stated to have no affection of the sight.

Description—Disc dull and waxy-looking, like dirty parchment. The superior and inferior nasal arteries are only slightly diminished in size. Of the superior vessels only the nasal branch is visible, and the diameter of this is about half the normal. Over the whole fundus the choroidal vessels are visible, separated by grey mottled spaces as in Fig. 96. In the lower and outer quadrant are several irregular pale areas speckled with pigment dots.

Towards the periphery are branching lines of pigment; the shape and disposition of these suggests that they follow the bifurcations of blood vessels. A vein on the temporal side is covered with pigment for a considerable distance.

NATIONAL HOSPITAL LIBRARY
Not to be taken away



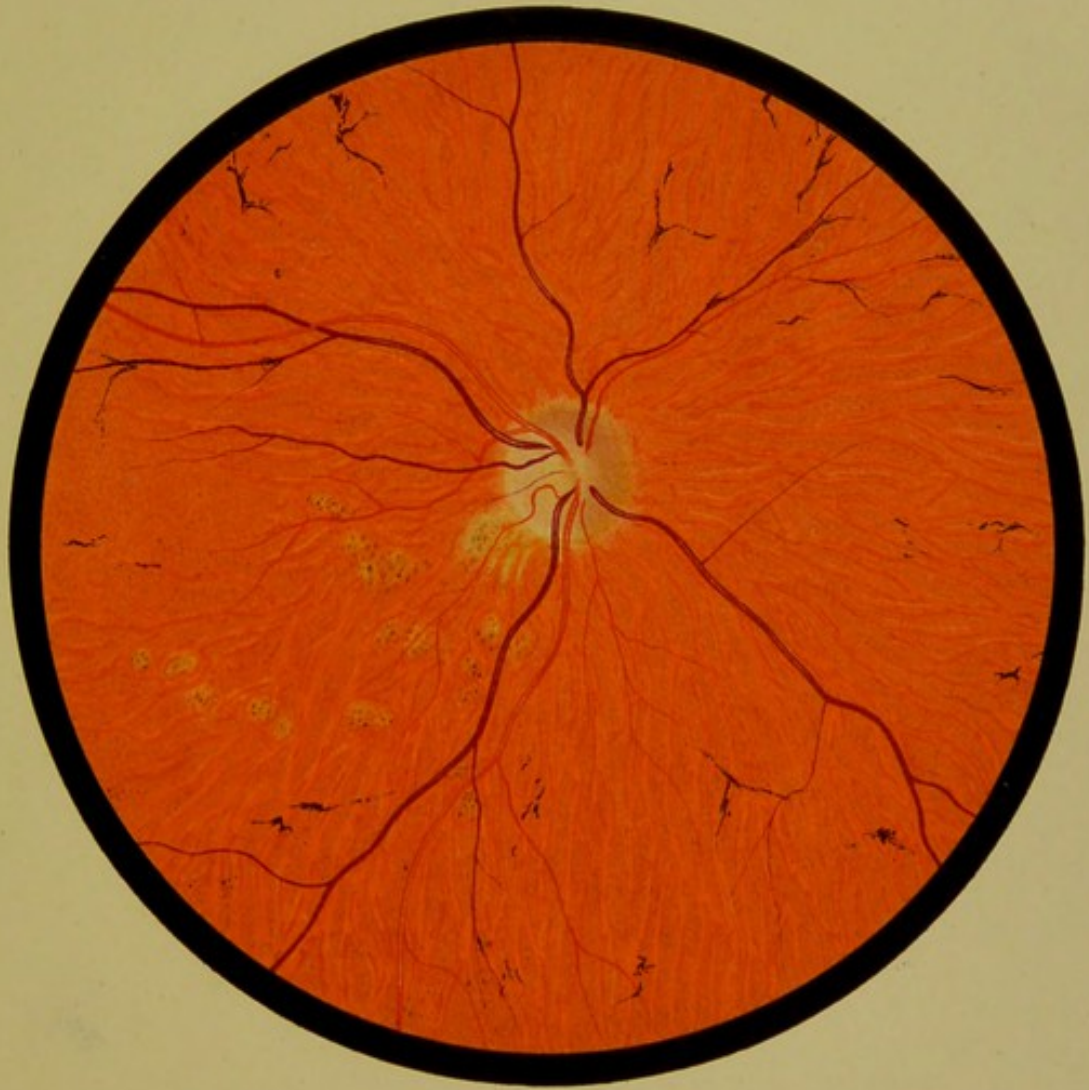

FIG. 97. R. E.

NATIONAL HISTORICAL LIBRARY
Not to be taken away

CICATRICIAL BANDS ON FUNDUS.

FIG. 98.—CHOROIDITIS. SECONDARY PIGMENTATION OF RETINA.
FORMATION OF CICATRICIAL BANDS.

Harriet D., 41. *RE*. Drawing made September 1888.—*LE*. opacities in lens, fundus not seen. Sight of *RE* said to have failed suddenly nine years ago; to have improved, and then to have slowly deteriorated. The history, however, was variously given on different occasions, and is probably unreliable. No history of syphilis. Has had ten children, said to be all healthy. $V. = \frac{6}{36}$. Visual field contracted chiefly above.

Description.—Disc waxy-looking as in Figs. 96 and 97, and encircled by a wide pale band.

Choroidal vessels visible over lower part of fundus. In the lower and outer quadrant a large deeply pigmented area. The pigment appears thickly massed without any definite arrangement. Near the disc is a sharply defined area entirely free from pigment. Passing horizontally inwards from the disc, a white band with almost parallel sides. Above this, a similar band, partly covered by pigment. On the temporal side of the disc beyond the unpigmented area, a similar band which has a choroidal vessel lying on it. A fourth band passes upwards and outwards from the disc, starting by the union of two processes, and terminating peripherally in a small circular spot.

Subsequent History.—Seen again January 1896. *LE*. lens opaque, pigmented lymph on capsule. *V. p.l.* The conditions in *RE* seem unchanged, except that there was perhaps more pigment on the white bands. $V. = \frac{6}{24}$.

FIG. 99.—CICATRICIAL BANDS ON THE FUNDUS.

Annie G., 19. *LE*. Drawing made February 1889.—First seen December 1888. Applied on account of recent failure of vision. The *LE*. had always been defective and diverged. *V.* fingers. Ptosis of this eye only.

The failure of the *RE*. seem to be due partly to paralysis of accommodation. $V. \frac{6}{36} + 2.0 D = \frac{6}{12} + 5 D = 0.3$ Snellen.

Description.—Disc normal. A pigment ring on lower and outer margin. Three white lines diverging from the disc, that on the nasal side spreads out fan-wise towards the periphery. Downwards and inwards, two smaller bands not reaching to the disc. One ends in round white area, exactly like the upper band in Fig. 98. They all lie beneath the retinal vessels.

Subsequent History.—Under antisyphilitic treatment the accommodation recovered, and on March 3rd, *V.* without glasses was $\frac{6}{6}$ and 0.3 Snellen.

On April 3rd, she returned, accommodation having again become paralysed three days previously. By June 5th it had again recovered. There was no reason to suspect the use of a mydriatic.

Two weeks later, she was admitted into the medical wards for loss of power in right arm and leg, and right facial paralysis. She left the hospital much improved, and has not been seen since.

NATIONAL HOSPITAL LIBRARY
Not to be taken away

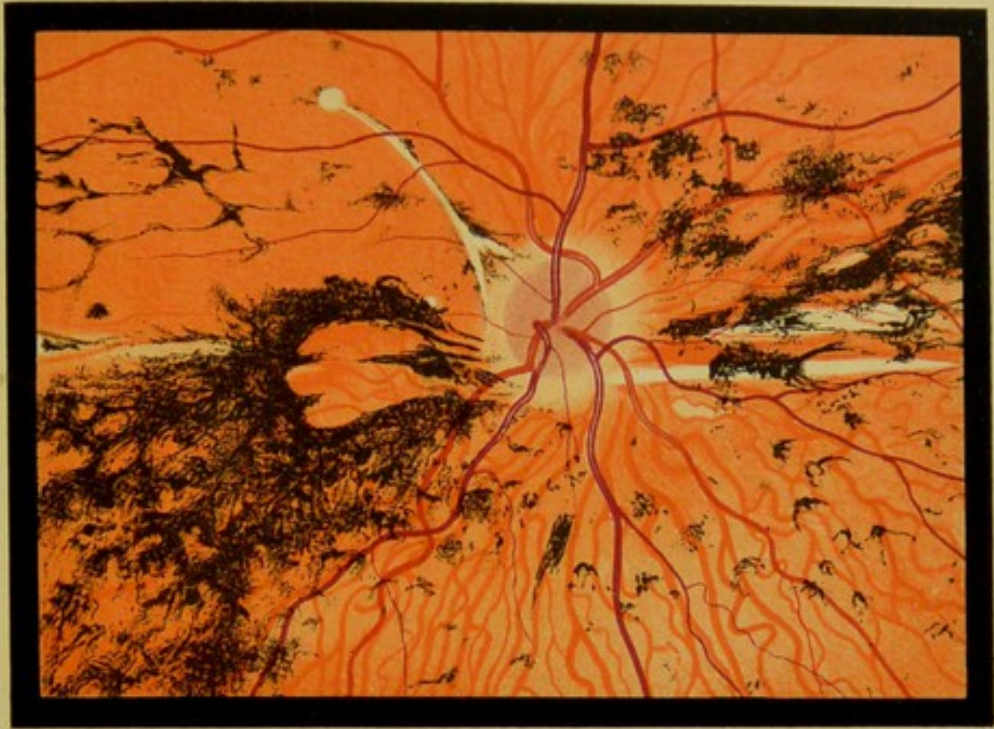

FIG. 98. R. E.

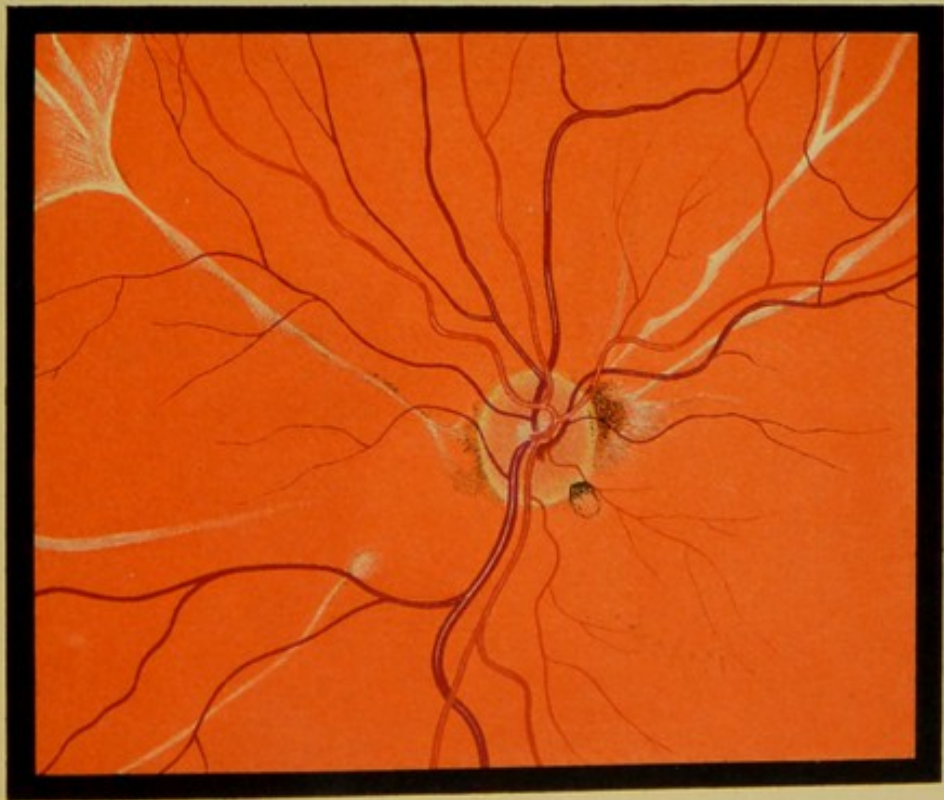

FIG. 99. L. E.

NATIONAL HOSPITAL LIBRARY
Not to be taken away

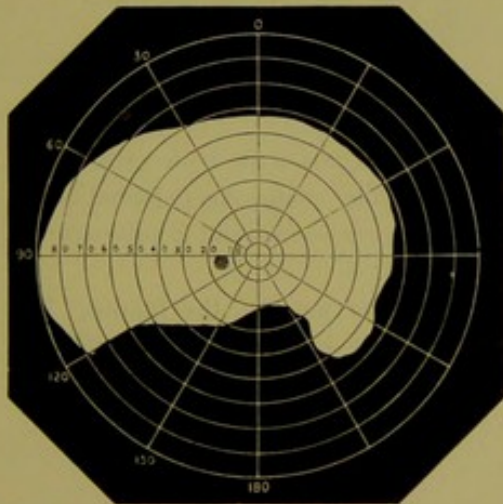DETACHMENT OF THE RETINA.

FIG. 100.—DETACHMENT OF THE RETINA.

Helena A., 20. *LE.* Drawing made November 1888.—In January 1887 she was struck violently in the *LE.* by a cork from a soda-water bottle. As soon as she could open the eye, all objects appeared red. A few weeks later she noticed that the lower part of the field was defective.

When seen two months later V. *RE.* = $\frac{6}{9}$; *LE.* = $\frac{6}{12}$. Lower part of visual field deficient. See chart.

A fine network of opacities in the anterior part of the vitreous. Upper part of retina detached. The summits of the folds visible with +4 *D.*



At the time the drawing was made the conditions had not appreciably altered.

Description.—Only the upper part of the fundus is shown. The disc would be situated about a-disc-and-a-half below the margin of the drawing. The upper two-thirds of the drawing show the retina floated forwards. It has a greyish colour, some red being faintly seen through it. The white lines are due to the light being reflected from the summits of the folds into which the retina is thrown.

Subsequent History.—The condition remained without appreciable change till February 1888, when the vitreous became more opaque.

In July 1893 the lens was opaque, and no fundus reflex could be obtained. Punctate opacities on the lower part of cornea. V *p.l.*

FIG. 101.—DETACHMENT OF THE RETINA.

Andrew H., 38. *LE.* Drawing made November 1889.—First seen September 1888. *LE.* thought to have always been inferior to *RE.* Three days ago a "dark cloud" came over the *LE.*, which cleared off after four or five hours, but left the vision more defective than before. In the upper part of the fundus there was a large white area, of triangular shape, with its apex towards the disc. It was doubtful whether this was due to œdema

or to detachment. V. $RE. = \frac{6}{8}$, $LE. = \frac{6}{24}$. Refraction not myopic. The condition remained unchanged for several months, except that a few opacities appeared in the anterior part of the vitreous. The patient was then lost sight of till November 1889, when V. was only *p.l.* and the fundus presented the condition depicted.

Description.—At the lower part are two dome-like detachments of the retina. The detached retina looks thin and gauze-like, allowing a considerable amount of red reflex to be seen through it. It is thrown into parallel folds, the summits of which, catching the light, appear like opaque white bands. At the upper part of the picture an old opaque detachment is sketched in, the bagging downwards of this is seen where the vessels curve round its lower border.

Subsequent History.—In 1895 the media were too opaque for any view of the fundus to be obtained. The other eye was still normal.

FIG. 102.—DETACHMENT OF THE RETINA.

Charles W., 16. *Drawing made November 1889.*—Good vision in both eyes till he received a blow on one eye a few months before he was seen. Some days elapsed before he could open the eye, and he then found that its vision was defective, and it subsequently became gradually worse.

Description.—A very extensive detachment at the lower part of the fundus. The detached portions are more opaque than in Figs. 100 and 101, but a faint fundus reflex is visible through the more peripheral part. The gap between the two detached portions became narrower towards the periphery.

FIG. 103.—DETACHMENT OF THE RETINA.

Ann C., 56. *LE. Drawing made March 1889.*—Stated that she had always been short-sighted. Five or six months ago she noticed a dimness in *LE.*, which gradually increased. V. $RE. \frac{6}{88} - 8.0 D. = \frac{6}{24}$; *LE. p.l.* Refraction, high myopia.

Description.—A very extensive dome-like detachment of the retina at the lower part of the fundus. A faint fundus reflex visible through it.

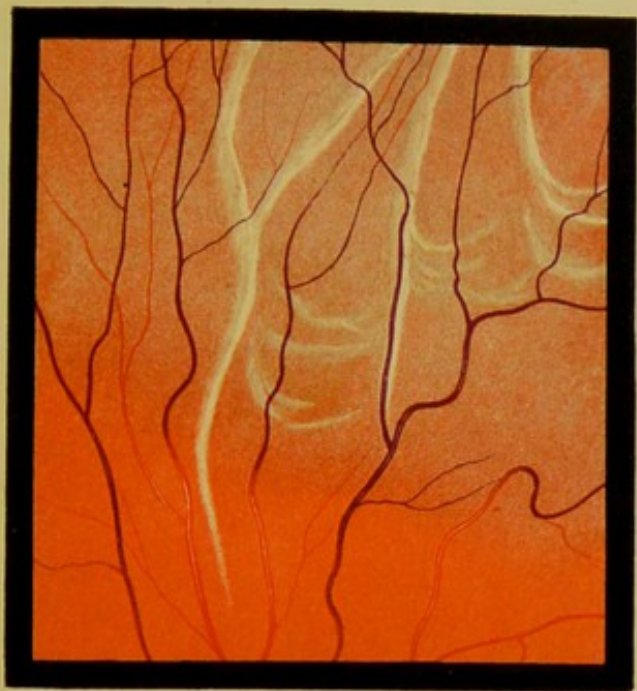

FIG. 100. L.E.

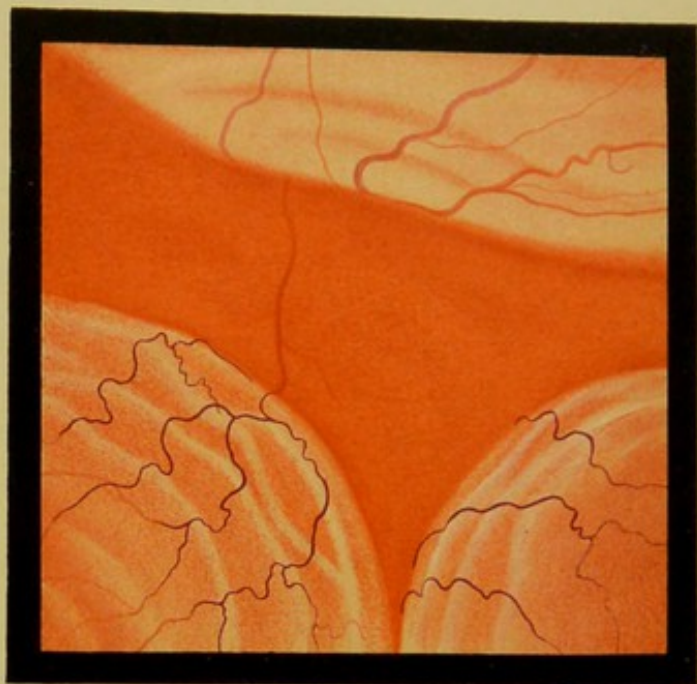

FIG. 101. L.E.

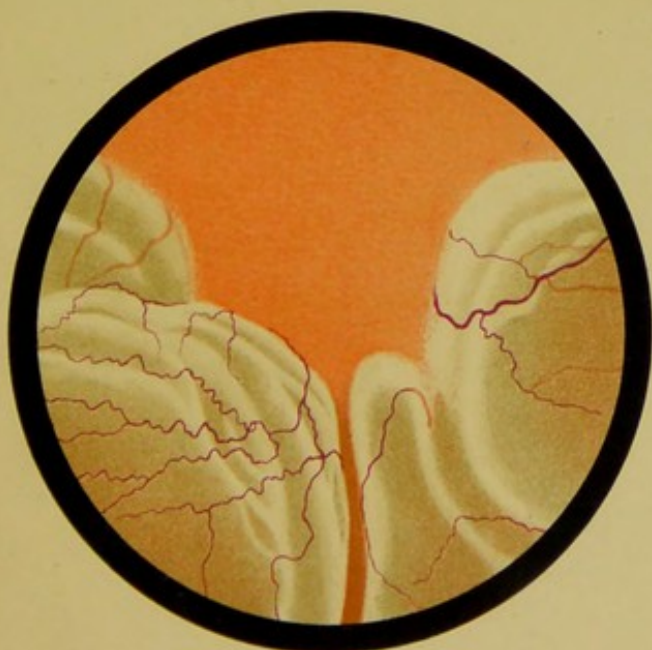

FIG. 102.

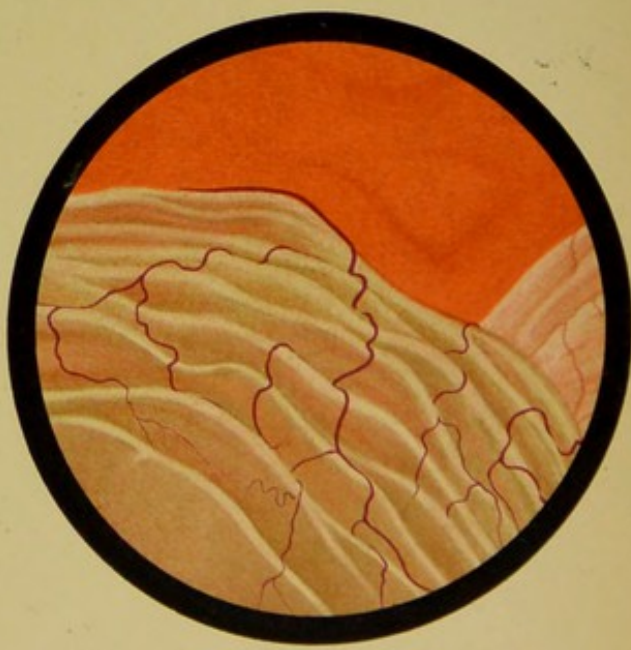

FIG. 103. L.E.

NATIONAL HOORN LIBRARY
Not to be taken away

COLOBOMA OF DISC. GLAUCOMA SIMPLEX.

FIG. 104.—PARTIAL COLOBOMA OF DISC.

Mary S., 15. *LE*. Drawing made August 1889.—A healthy looking girl. No signs of inherited syphilis, and no likelihood of the disease having been acquired.

The *RE*. had been defective as long as the patient can remember. There were large areas of choroidal atrophy. The physiological cup on the disc appeared to be filled up with a material which could not be well defined with the ophthalmoscope.

The *LE*. (that depicted) $V. = \frac{2}{3}$. Visual field normal.

Description.—The disc is of unusually large size. The greater part of it is deeply cupped. The uncupped portion forms a crescent widest above; its limbs pass round the disc forming a ring which becomes very narrow on the lower and outer border. The vessels curve abruptly over the well defined edge of the cup. The floor of the cup presents on its temporal side a white crescent. On the upper and inner side of, and in contact with, the disc, is a patch of partial atrophy of the choroid.

FIG. 105.—GLAUCOMATOUS CUP.

Alfred H., 41. *LE*. Drawing made 1888.—In the winter of 1879-80, after exposure to bad weather, he became suddenly blind whilst driving. There was no pain, and the sight returned in about three hours. In the spring of 1882, after much anxiety, the sight of the left eye gradually failed, the failure being accompanied by halos round a light. In the winter of 1883-4 there was gradual failure in both eyes with pain in the eyes and head. Mr. Streatfeild performed iridectomy on the *LE*., and a few months later on the *RE*.. The operations were followed by considerable improvement, so that he could read and write. Vision has, however, gradually failed since.

Description.—Disc oval, surrounded by a halo of choroidal atrophy. The whole disc is cupped, the larger vessels bending abruptly over its edge. The floor of the cup has a somewhat greenish tint, and is stippled.

FIG. 106.—GLAUCOMATOUS CUP.

Thomas S., 46. *RE*. Drawing made October 1888.—First seen December 1887. Vision failing gradually two or three years, more rapidly the last year. No pain in the eyes, but occasional frontal pain. Both sclerotics were of a bluish grey colour. Although the patient did not look older than his years, there was a complete arcus senilis in both eyes. This formed a sharply defined ring, about a millimetre wide, and extending right up to the sclero-corneal junction. $RE. = \frac{6}{24}$; $T + 2$. Inner half of visual field lost (see Chart). $LE. + 2.25$ $D = \frac{6}{24}$; $T.n.$ Visual field normal. The ophthalmoscopic appearance in *RE*. did

not differ appreciably from that which it presented at the date of the drawing. Fundus of *LE.* normal. Treated with eserine.

At the date of the drawing *V.* of *RE.* had fallen to hand reflex.

Description.—Whole disc deeply cupped, the veins curving abruptly over its sharp edge. It is surrounded by a narrow zone of choroidal atrophy; through this, below, there emerges a small vessel. The arteries do not dip into the cup.

Subsequent History.—Shortly after the drawing was made iridectomy was performed in both eyes. In March 1894, field of *RE.* was worse (*see* Chart), *LE.* still normal. In December 1894 the lens was becoming turbid.

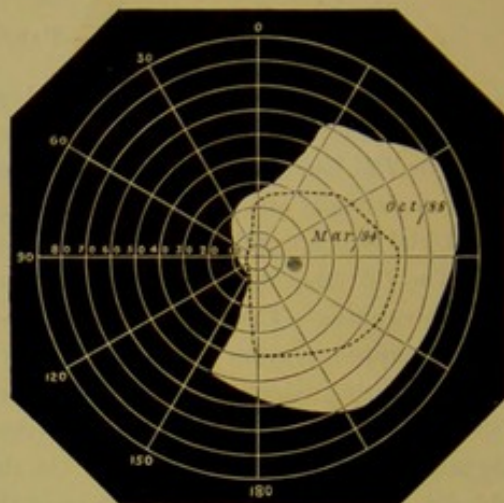
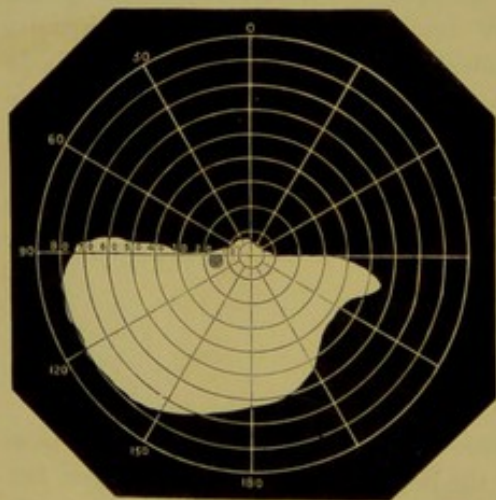


FIG. 107.—GLAUCOMATOUS CUP.

James B., 57. *Drawing made 1888.*—Vision of *RE.* began to fail very gradually six years ago. At first there was slight aching pain. He used some "eye-water" (atropine?) after which he had rapid failure of vision, with severe pain. Mr. Little of Manchester performed a large iridectomy, which completely relieved the pain, but was not followed by any improvement in the sight.



Three years ago the *LE.* began to fail, Mr. Little performed iridectomy on this eye and there was some improvement in the sight.

When seen *V.* *RE.* was only hand reflex, and the field could not be taken. With *LE.* he could read 16 J. The field in this eye was deficient above, the defect reaching nearly to the horizontal; the retained portion of the field showed no contraction (*see* Chart).

The drawing is believed to represent the right disc.

Description.—Disc deeply cupped in its whole extent, the vessels curve abruptly over its sharp edge. Surrounding the disc a band of choroidal atrophy.

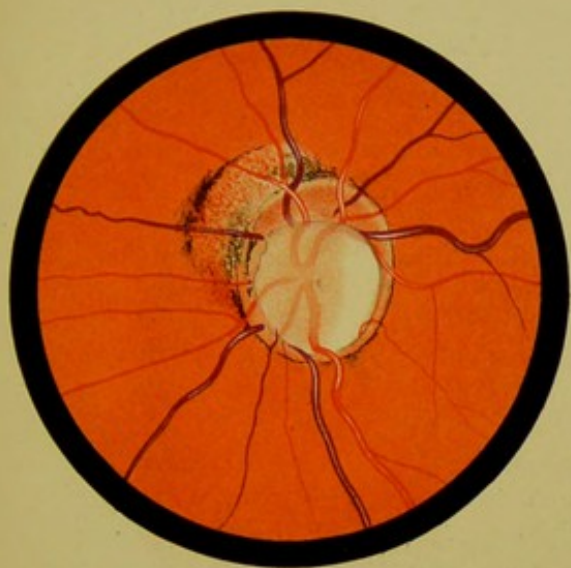


FIG. 104. L.E.

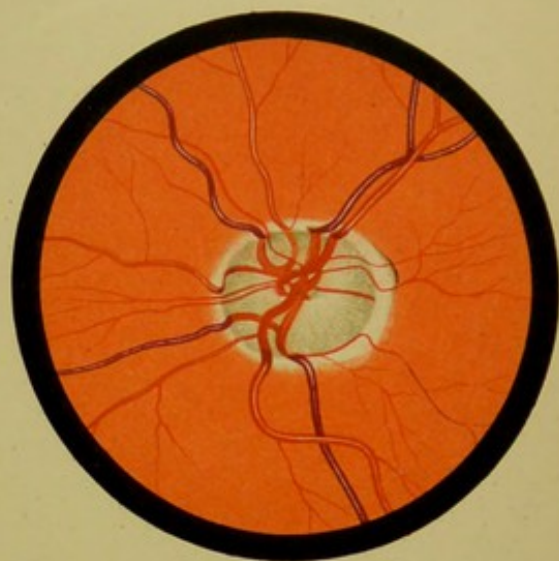


FIG. 105. L.E.

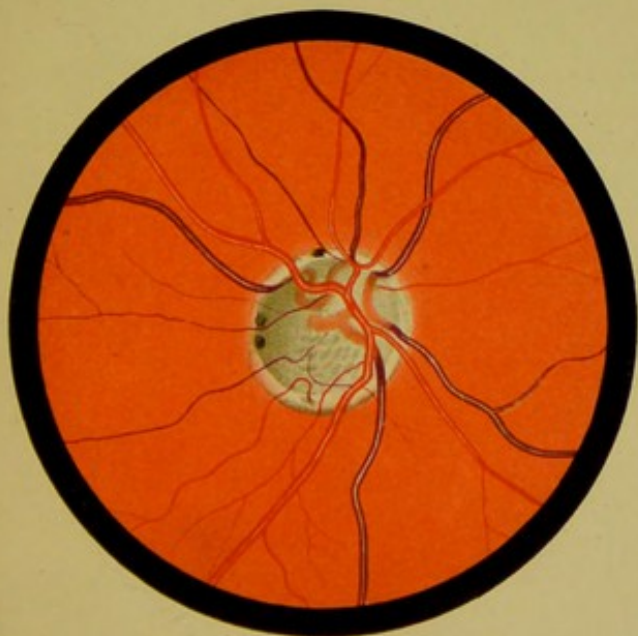


FIG. 106. R.E.

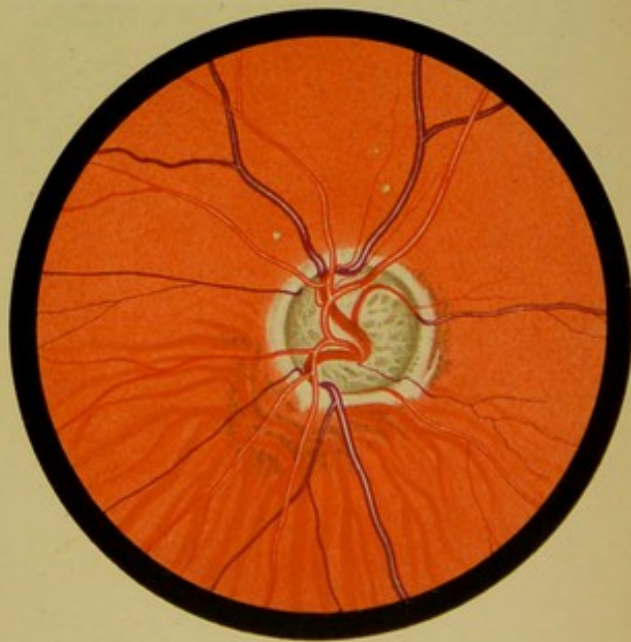


FIG. 107.

NATIONAL HOSPITAL LIBRARY
Not to be taken away

In 16 fasciculi, containing 96 plates, exhibiting 238 figures in colours from original drawings specially prepared for this work, with descriptive letterpress.
Price 21s. each.

ATLAS

OF THE

DISEASES OF THE SKIN.

By H. RADCLIFFE CROCKER, M.D., F.R.C.P.,

PHYSICIAN, SKIN DEPARTMENT, UNIVERSITY COLLEGE HOSPITAL, LONDON; FORMERLY
PHYSICIAN TO THE EAST LONDON HOSPITAL FOR CHILDREN; EXAMINER
IN MEDICINE, APOTHECARIES' HALL, LONDON.

PROSPECTUS.

PICTORIAL representation has long occupied a prominent position among the methods employed by teachers of Medicine, and in no department has it been used to greater advantage than in that of Dermatology.

All diseased conditions should be studied, first of all, on the living subject. From nature alone can we most quickly and accurately acquire information regarding normal and abnormal conditions. In Medicine the other means of gaining knowledge occupy a position of secondary importance. Yet in some departments these supplementary methods are of so great value that they may be considered as indispensable for the purposes both of teacher and student. This is particularly so in the case of Dermatology. The difficulties in the way of accurate diagnosis and successful treatment of many forms of skin disease are experienced by all workers, especially by those who have not the opportunity of seeing frequently a large variety of cases. By such the employment of *ad naturam* coloured representations of the various diseases has been found of the greatest value.

The extensive series of plates comprised in this Atlas, in the execution of which all the recently improved processes in lithography have been employed, while calculated to be of supreme interest to Dermatologists, will thus likewise prove of the highest value to all practitioners of Medicine.

Various artists have been employed to portray the conditions represented, and all have performed their work with distinguished skill. The 96 plates represent 238 life-size figures, and have been reproduced by chromo-lithography from the original water-colour drawings in the possession of the Author, who has been collecting them for many years; most of the cases from which the drawings have been made having been under his own care.

The letterpress describes not only the cases from which the drawings are taken, but also gives a general account of each disease, its differential diagnosis, and treatment.

In planning the work, the Publisher has had in view to produce a book which, as regards the mechanical production, shall be of the handsomest. It is comprised in 16 fasciculi, Royal folio size, and each fasciculus consists of 6 full-page plates, with descriptive letterpress.—Price **One Guinea** each, nett, carriage free, but orders are only received for the entire series.

The work is a most comprehensive one, and, from the great care which has been bestowed upon its production, the Publisher believes that it will be recognised as one of the most thorough and finished Atlases ever published, and as a highly representative British work.

EDINBURGH AND LONDON: YOUNG J. PENTLAND.

YOUNG J. PENTLAND'S RECENT PUBLICATIONS.

- Fourth Edition, thoroughly Revised and mostly Rewritten, 8vo, cloth, pp. xvi., 678, with Coloured Illustrations, price 21s.
- DISEASES OF THE SKIN: a Manual for Practitioners and Students.** By W. ALLAN JAMIESON, M.D., F.R.C.P.Ed., Physician to the Skin Department, Edinburgh Royal Infirmary. [*Pentland's Medical Series.*—VOL. I.
- Second Edition, thoroughly Revised and Enlarged, 8vo, cloth, pp. xvi., 728, Illustrated with Wood Engravings and Coloured Plates from Original Drawings, price 25s.
- DISEASES OF THE EYE: a Practical Treatise for Students of Ophthalmology.** By GEORGE A. BERRY, M.B., F.R.C.S.Ed., Ophthalmic Surgeon, Edinburgh Royal Infirmary; Lecturer on Ophthalmology, Royal College of Surgeons, Edinburgh. [*Pentland's Medical Series.*—VOL. II.
- Second Edition, Revised and Enlarged, 8vo, cloth, pp. xvi., 682, with Coloured Illustrations from Original Drawings, price 25s.
- DISEASES OF THE THROAT, NOSE AND EAR.** By P. M'BRIDE, M.D., F.R.C.P.Ed., Lecturer on the Diseases of the Ear and Throat, Edinburgh School of Medicine; Aural Surgeon and Laryngologist, Royal Infirmary, Edinburgh; Surgeon, Edinburgh Ear and Throat Dispensary. [*Pentland's Medical Series.*—VOL. III.
- 8vo, cloth, pp. xvi., 508, price 16s.
- TEXT-BOOK OF ABDOMINAL SURGERY: a Clinical Manual for Practitioners and Students.** By SKENE KEITH, F.R.C.S.Ed., assisted by GEORGE E. KEITH, M.B. [*Pentland's Medical Series.*—VOL. IV.
- 8vo, cloth, pp. xx., 506, Illustrated with numerous Engravings throughout the text, price 16s.
- FUNCTIONAL AND ORGANIC DISEASES OF THE STOMACH.** By SIDNEY MARTIN, M.D., F.R.S., F.R.C.P., Assistant Physician and Assistant Professor of Clinical Medicine at University College Hospital; Assistant Physician to the Hospital for Consumption and Diseases of the Chest, Brompton. [*Pentland's Medical Series.*—VOL. V.
- Third Enlarged and thoroughly Revised Edition, 8vo, cloth, pp. xx., 652, Illustrated with 195 Coloured Plates from Original Drawings, price 25s.
- PRACTICAL PATHOLOGY: a Manual for Students and Practitioners.** By GERMAN SIMS WOODHEAD, M.D., F.R.C.P.Ed., Director of the Laboratories of the Royal College of Physicians (London) and Surgeons (England).
- Second Edition, thoroughly Revised, Two Volumes, crown 8vo, cloth, Illustrated with numerous Wood Engravings. Vol. I.—Upper Limb, Lower Limb, Abdomen. Vol. II.—Thorax, Head and Neck. Price per Volume, 12s. 6d.
- MANUAL OF PRACTICAL ANATOMY.** By D. J. CUNNINGHAM, M.D., Professor of Anatomy and Surgery, Trinity College, Dublin. [*Pentland's Students' Manuals.*
- 8vo, cloth, pp. xvi., 374, with 63 Engravings in the text, price 14s. nett.
- TUBERCULOUS DISEASE OF THE BONES AND JOINTS.** By W. WATSON CHEYNE, M.B., F.R.S., Professor of Surgery, King's College, London.
- 8vo, cloth, pp. xvi., 240, with 22 pp. of Plates and Figures throughout the text, price 12s. 6d. nett.
- ECTOPIC PREGNANCY: its Etiology, Classification, Embryology, Diagnosis, and Treatment.** By J. CLARENCE WEBSTER, M.D., F.R.C.P.Ed., Assistant to the Professor of Midwifery and Diseases of Women and Children in the University of Edinburgh.
- Large 8vo, cloth, pp. xxviii., 772, Illustrated with 404 Engravings, price 31s. 6d.
- THE PARASITES OF MAN, and the Diseases which proceed from them. A Text-Book for Students and PRACTITIONERS.** By RUDOLF LEUCKART, Professor of Zoology and Comparative Anatomy in the University of Leipsic. Translated from the German, with the Co-operation of the Author, by WILLIAM E. HOYLE, M.A. (Oxen), M.R.C.S., F.R.S.E., Curator of the Museums, Owens College, Manchester. Natural History of Parasites in general—Systematic Account of the Parasites infesting Man—Protozoa—Cestoda.
- Two vols., large 8vo, cloth, pp. xvi., 1000, Illustrated with Maps and Charts, price 31s. 6d.
- GEOGRAPHICAL PATHOLOGY: an Inquiry into the Geographical Distribution of Infective and CLIMATIC DISEASES.** By ANDREW DAVIDSON, M.D., F.R.C.P.Ed., late Visiting and Superintending Surgeon, Civil Hospital; Professor of Chemistry, Royal College, Mauritius.
- Oblong 4to, Cloth, in a series of 27 Coloured Plates from Original Drawings, with Descriptive Letterpress, and 27 Engravings throughout the Text. Price 50s. nett.
- ILLUSTRATIONS OF THE NERVE TRACTS in the Mid and Hind Brain, and the Cranial Nerves ARISING THEREFROM.** By ALEXANDER BRUCE, M.D., F.R.C.P.Ed., Lecturer on Pathology in the School of Medicine, Edinburgh; Assistant Physician (formerly Pathologist), Edinburgh Royal Infirmary; Pathologist to the Royal Hospital for Sick Children.
- Volumes I-III., 8vo, cloth, gilt tops, pp. 500 or thereby each. Illustrated with Full Page Plates, many in Colours, and numerous Engravings throughout the text, price 25s. per volume.
- THE JOURNAL OF PATHOLOGY AND BACTERIOLOGY.** Edited with the Collaboration of Distinguished British and Foreign Pathologists, by GERMAN SIMS WOODHEAD, M.D., Edin., Director of the Laboratories of the Royal Colleges of Physicians (London) and Surgeons (England).
- One Volume, royal 8vo, cloth, pp. xviii., 1014, Illustrated, price 31s. 6d.
- THE HYGIENE AND DISEASES OF WARM CLIMATES: in a Series of Articles by Eminent AUTHORITIES.** Edited by ANDREW DAVIDSON, M.D., F.R.C.P.Ed., late Visiting and Superintending Surgeon, Civil Hospital; Professor of Chemistry, Royal College, Mauritius; Author of "Geographical Pathology."

YOUNG J. PENTLAND,

Edinburgh: 11 Teviot Place.

London: 38 West Smithfield, E.C.

