Edinburgh Stereoscopic Atlas of Anatomy. Sections 2,2,3,4,5 / Edited by David Waterston.

Contributors

Waterston, David editor.
University College, London. Library Services

Publication/Creation

London : Caxton Pub. Co, 1905.

Persistent URL

https://wellcomecollection.org/works/gaaru6zs

Provider

University College London

License and attribution

This material has been provided by UCL Library Services. The original may be consulted at UCL (University College London)
You have permission to make copies of this work under a Creative Commons, Attribution, Non-commercial license.

Non-commercial use includes private study, academic research, teaching, and other activities that are not primarily intended for, or directed towards, commercial advantage or private monetary compensation. See the Legal Code for further information.

Image source should be attributed as specified in the full catalogue record. If no source is given the image should be attributed to Wellcome Collection.

Wellcome Collection
183 Euston Road
London NW1 2BE UK
T +44 (0)20 7611 8722
E library@wellcomecollection.org
https://wellcomecollection.org

INSTITUTE OF NEUROLOGY

The
ROCKEFELLER
MEDICAL LIBRARY

PELVIS.

MALE PERINEUM.—No. 1.

THE SKIN AND FASCIA HAVE BEEN REMOVED FROM THE ANTERIOR HALF OF THE PERINEUM, AND THE ISCHIO-RECTAL FOSSA HAS BEEN CLEANED OUT.

The **perineal space** may be divided conveniently into two portions by a line drawn transversely across it between the anterior parts of the ischial tuberosities. The anterior portion of the space, called the urogenital triangle, is shown in this view, while the posterior part contains the ischio-rectal fossæ and the anus.

The urogenital triangle is bounded laterally by the rami of the pubis and ischium, and contains the root of the penis and the muscles, nerves and blood-vessels associated with it.

A layer of strong fibrous tissue, which is a deep portion of the superficial fascia of this region called the fascia of Colles, forms a roof for the space, under cover of the skin, and of some fatty tissue.

This layer is attached to the margin of the pubic arch on each side (12) and to the base of the triangular ligament (see No. 3) behind, while in front it is continuous with one of the layers, the tunica dartos, of the scrotum. Under cover of it lie the bulb and crura of the penis, with their muscles, resting on the triangular ligament.

The space thus covered in is bounded deeply by the triangular ligament, and into it urine may be extravasated in cases of rupture of the spongy portion of the urethra. In such cases, the spread of the fluid is limited on all sides except in front, where it may pass into the tissues of the scrotum, under the tunica dartos, to the penis and anterior abdominal wall, under the deep layer of the superficial fascia.

The muscles are (1) the ejaculator urinæ, which arises from the central point of the perineum, from the triangular ligament, and from a mesial raphé. It invests the bulb, the corpus spongiosum and part of the penis, (2) the **erector penis** on each side, arises from the inner aspect of the ischial tuberosity, invests the crus, and is inserted into its anterior part. (3) The **transversus perinei**, a small transverse muscle (see No. 2).

The **nerves** are the anterior and posterior superficial perineal nerves, branches of the perineal nerve. They appear in the posterior part of the triangle, run forwards and supply the scrotum, joining with the long pudendal branch of the small sciatic nerve. The nerves are accompanied by superficial perineal vessels, from the internal pudic.

The figures indicate—

1. Tuber ischii.
2. Sphincter ani externus.
3. Superficial perineal nerves.
4. Superficial perineal artery.
5. Inferior hæmorrhoidal vessels and nerve.
6. Ejaculator urinæ covering the bulb.
7. Crus penis, covered by erector penis.
8. Transversus perinei muscle.
9. Bulb.
10. Urethra, divided in corpus spongiosum.
11. Corpora cavernosa.
12. Fascia of Colles.

EDINBURGH: T. C. & E. C. JACK: AND 34 HENRIETTA STREET, LONDON, W.C.

MALE PERINEUM. No. 1.

Copyright: T. C. & E. C. Jack, Edinburgh, & 34 Henrietta St., London, W.C.

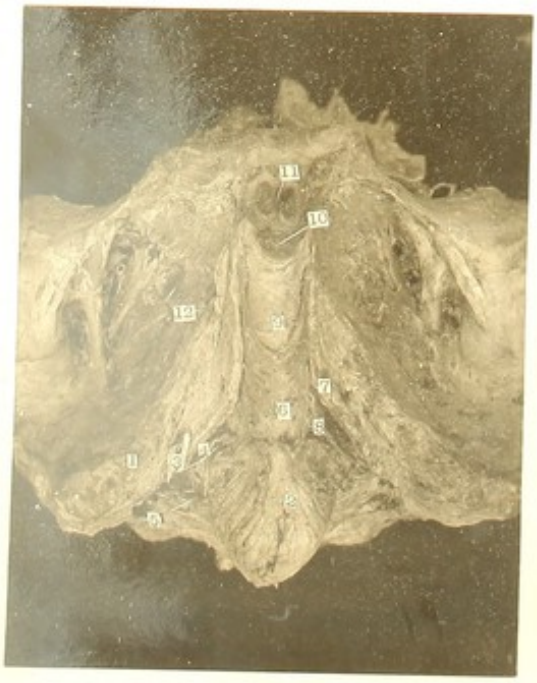

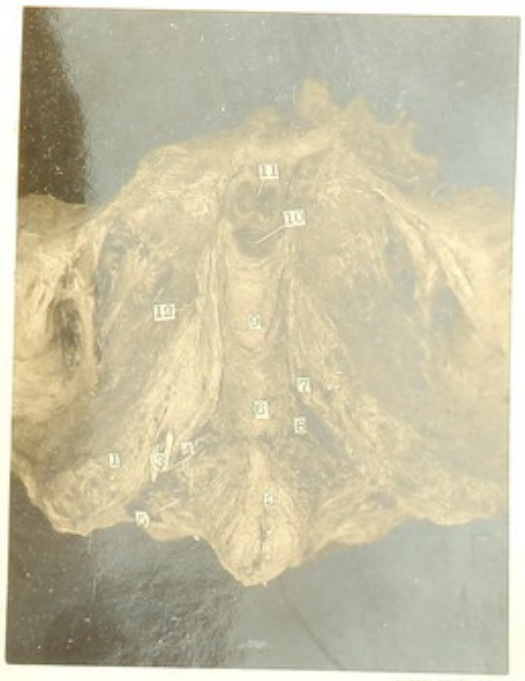

PELVIS.

MALE PERINEUM—No. 4.

STRUCTURES BETWEEN THE LAYERS OF THE TRIANGULAR LIGAMENT.

The superficial, or true, triangular ligament has been removed. Under cover of the triangular ligament is a small triangular space containing the deep transversus perinei muscle, Cowper's glands, some nerves and vessels, and the membranous portion of the urethra.

The deep transversus perinei or compressor urethræ muscle consists of a number of muscle fibres which arise from the pubic arch at the junction of the ischial and pubic portions, pass inwards towards the mesial plane, and are inserted into a mesial raphé, enclosing the urethra, and acting as a voluntary sphincter muscle.

Cowper's glands are two small glandular structures which lie embedded in the muscle, one on each side, a short distance behind the urethra. The portion of the urethra in this region is called the membranous portion, and measures about half an inch in length. Traced inwards, the urethra passes through the deep layer of the triangular ligament, which is a portion of the pelvic fascia stretching across the pubic arch, and supporting the under part of the prostate gland.

This portion of the urethra is apt to be injured in accidents causing fracture of the pelvis, and the extravasated urine is limited by the margins of the space, and often passes deeply inwards.

At the sides the dorsal nerve of the penis and the internal pudic artery pass forwards. the latter giving off the artery to the bulb.

The figures indicate—

1. Urethra.
2. Cowper's gland.
3. Compressor urethræ.
4. Levator ani.
5. External sphincter.
6. Dorsal artery of penis.
7. Transverse perineal artery.
8. Dorsal artery and nerve of penis.
9. Dorsal vein of penis.
10. Prostate plexus of veins.

EDINBURGH: T. C. & E. C. JACK; AND 34 HENRIETTA STREET, LONDON, W.C.

MALE PERINEUM. No. 4.
EDINBURGH STEREOSCOPIC ANATOMY.
Copyright: T. C. & E. C. Jack, Edinburgh, & 34 Henrietta St., London, W.C.

PELVIS.

MALE PERINEUM.—No. 2.

IN ADDITION TO THE PREVIOUS DISSECTION, THE ROOT OF THE PENIS HAS BEEN EXPOSED BY THE REMOVAL OF THE EJACULATOR URINÆ FROM THE SURFACE OF THE BULB, AND OF THE ERECTOR PENIS FROM THE CRUS PENIS.

The cut surface of the body of the penis shows that that organ is made up of two corpora cavernosa lying side by side dorsally, and of a corpus spongiosum which contains the urethra, lying ventrally. At the root of the penis these three portions separate from one another and diverge, the corpus spongiosum being continued back into the bulb, while the corpora cavernosa become continued into the crura, which lie on the sides of the pubic arch, to which they are attached. These three structures rest upon the triangular ligament.

The **bulb** is a rather cylindrical mass of spongy tissue, which enlarges as it passes back, and is sometimes notched at its extremity.

The **crura** are more irregular in shape, being flattened for attachment to the pubic arch and tapering away in front. They are also composed of cavernous tissue, and have a strong fibrous capsule.

The **transversus perinei** is a small muscle, arising from the inner aspect of the ascending ramus of the ischium, and inserted into the central point of the perineum. This muscle is often pierced by the superficial perineal nerves and vessels in their course to the surface.

The figures indicate:—

1. Ramus of Ischium.
2. Bulb.
3. Erector penis (divided).
4. Crus penis.
5. Triangular ligament.
6. Transversus perinei.
7. Superficial perineal nerves and vessels.
8. External sphincter of anus.
9. Corpora cavernosa.
10. Urethra in corpus spongiosum.

EDINBURGH: T. C. & E. C. JACK; AND 34 HENRIETTA STREET, LONDON, W.C.

MALE PERINEUM. No. 2.
EDINBURGH STEREOSCOPIC ANATOMY

PELVIS.

MALE PERINEUM—No. 3.

THE TRIANGULAR LIGAMENT AND STRUCTURES PIERCING IT.

The bulb and crura have been removed, and the urethra divided where it pierces the triangular ligament.

The **triangular ligament** consists of two layers, a superficial and a deep, of which the former, or true triangular ligament, is seen here.

It is a strong fibrous sheet which extends across the arch of the pubis from side to side, but does not reach up quite to the symphisis, and extends for some distance backwards towards the anterior portion of the ischial tuberosities.

The structures which form the root of the penis rest upon its superficial surface, and are attached to it. The crura are attached to the lateral portion, and the bulb is bound down in the centre by fascia.

The urethra passes through an aperture in the centre of the ligament, and some erectile tissue is continued from the bulb through the same opening, and at this point the artery to the bulb, which is under cover of the ligament, gains access to the bulb.

In front, the ligament is perforated by the internal pudic artery, and, in front of it, by the dorsal nerve of the penis on either side, while the dorsal vein passes through a small aperture between the triangular and the sub-pubic ligaments.

The superficial perineal nerves and vessels pierce the triangular ligament near its base, and the ducts of Cowper's glands pass through it in the wall of the urethra.

This region is the common site for rupture of the urethra, and it will be seen that extravasated urine is prevented from passing up into the pelvis by the triangular ligament.

The fluid cannot pass backwards or outwards, as the fascia of Collis is attached to the base of the ligament and to the margins of the pubic arch, and it must therefore pass forwards into the scrotum.

The figures indicate—

1. External sphincter ani.
2. Triangular ligament.
3. Attachment of bulb.
4. Urethra.
5. Dorsal vein of the penis.
6. Internal pudic artery perforating the ligament, and giving off an artery to the corpus cavernosum, and becoming dorsal artery of the penis.
7. Dorsal nerve of penis.
8. Branch of perineal nerve to muscles, running inwards behind the base of the triangular ligament.

EDINBURGH: T. C. & E. C. JACK; AND 34 HENRIETTA STREET, LONDON, W.C.

MALE PERINEUM. No. 3.

(EDINBURGH STEREOSCOPIC ANATOMY)
Copyright: T. C. & E. C. Jack, Edinburgh, & 34 Henrietta St., London, W.C.

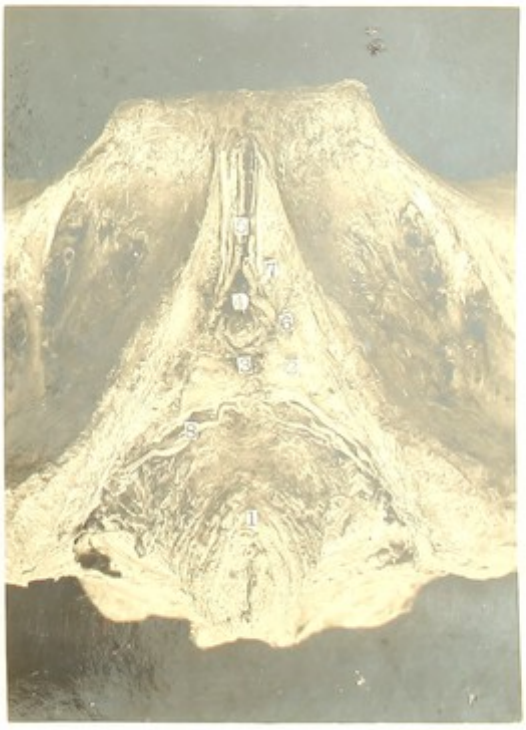

PELVIS.

MALE PERINEUM—No. 5.

THE PROSTATE GLAND, FROM THE PERINEUM.

A portion of the pubic arch has been removed, with the structures related to it. The venous plexus surrounding the prostate has been removed from the left side.

The **levatores ani** muscles are seen passing from the back of the pubis as a sort of sling on which the prostate is supported.

The layers of fascia which invest each of the muscles on its pubic and perineal aspects meet with one another at the margin of the muscle, and are continued across to join the layer of the opposite side. The layer so formed is closely associated with the under aspect of the prostate gland, and forms the under portion of its sheath. A large plexus of veins, the prostatic plexus, lies between this sheath and the capsule of the gland, and this layer forms the deep triangular ligament.

In front, the fascia forms two strong bands which pass to the back of the pubis, and are called the pubo-prostatic ligaments.

The anterior margins of the levator ani meet and decussate in the middle line between the prostate and the anal canal, and in the interval between the prostate and the rectum there is a muscle bundle, variable in size, passing from the front of the rectum to the back of the urethra, the pre-rectalis muscle. It is seen here, divided.

The obturator internus muscle has been divided vertically on each side. On its pelvic aspect this muscle is invested by a strong sheet of fascia, the parietal pelvic fascia.

This fascia blends with the fascia covering the outer surface of the levator ani muscle along a line which forms the white line of the pelvic fascia, and corresponds to the apex of the ischio-rectal fossa.

Lower down, the internal pudic vessels and nerve run in a sheath formed by this fascia in the outer wall of the ischio-rectal fossa, called Alcock's canal.

The lumen of the urethra is, of course, seen to be merely a stellate fissure on the cut surface. The walls are of considerable thickness, and the portion seen is the termination of the membranous urethra, passing into the interior of the prostate gland.

The figures indicate:—

1. Symphisis pubis.
2. Bladder.
3. Pubo-prostatic bands (divided).
4. Prostate.
5. Capsule of prostate.
6. Urethra.
7. Levator ani.
8. Fascia (anal) of levator ani.
9. Prerectalis muscle (divided).
10. External sphincter.
11. Obturator internus muscle.
12. Alcock's canal.
13. Ramus of ischium (divided).
14. Prostatic plexus of veins.

EDINBURGH: T. C. & E. C. JACK; AND 34 HENRIETTA STREET, LONDON, W.C.

MALE PERINEUM. No. 5.
EDINBURGH STEREOSCOPIC ANATOMY.
Copyright: T. C. & E. C. Jack, Edinburgh, & 34 Henrietta St., London, W.C.

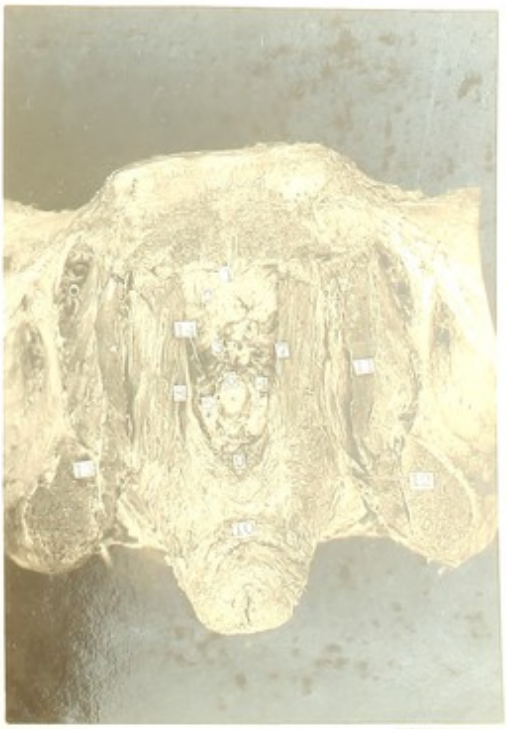

PELVIS.

FEMALE PERINEUM—No. 1.

THE SUPERFICIAL STRUCTURES HAVE BEEN REMOVED, DOWN TO THE LEVEL OF THE TRIANGULAR LIGAMENT, BUT LEAVING THE CLITORIS AND THE BULB AND CRUS CLITORIDIS ON THE RIGHT SIDE, AND THE ISCHIO-RECTAL FOSSA HAS BEEN CLEARED OUT, AND THE LEVATOR ANI EXPOSED.

The orifice of the vulva is seen to be quadrilateral or lozenge shaped, and the urethral orifice lies at the anterior angle on a slight elevation, while the aperture of the vagina is a transverse slit, somewhat concealed by two carunculæ. The anterior portion of the vulva has on each side the bulb, a large flattened mass of erectile tissue, wide behind but narrowing in front, while outside the posterior half of the vulva is seen a deep depression, in which lay a mass of large thin-walled veins.

This venous plexus lies near the anal canal, and communicates with the inferior hæmorrhoidal plexus, and is of importance in operations in this region. The crus clitoridis lies along the inner margin of the arch of the pelvis and is similar to the crus penis.

The anterior layer of the triangular ligament extends across the arch of the pelvis, as in the male, but is weakened by the large aperture in the centre for the vagina, and it did not extend back to the posterior end of the vaginal orifice.

The subject from which this preparation was made had been parous, and there may have been some tearing of the gynecological perineum, which has prolonged the vaginal aperture in a backward direction. Comparing this view with those of the male perineum, the clitoris and its crura are similar to the penis, while the bulb in the male is represented by the two bulbs of the vestibule.

There is, as it were, a division of the bulb into two halves, and the genital and urinary tracts open on the surface between them. The ejaculator urinæ muscle of the male is therefore represented by the sphincter vaginæ.

The figures indicate—

1. Central point of perineum.
2. Margin of vaginal orifice.
3. Caruncle.
4. Meatus urinarius.
5. Bulb of vestibule.
6. Crus clitoridis.
7. Triangular ligament.
8. Superficial perineal vessel divided.
9. Levator ani.
10. Clitoris.
11. Sphincter vaginæ divided.

EDINBURGH: T. C. & E. C. JACK; AND 34 HENRIETTA STREET, LONDON, W.C.

FEMALE PERINEUM. No. 1.

EDINBURGH STEREOSCOPIC ANATOMY.
Copyright T. C. & E. C. Jack, Edinburgh, & 34 Henrietta St., London, W.C.

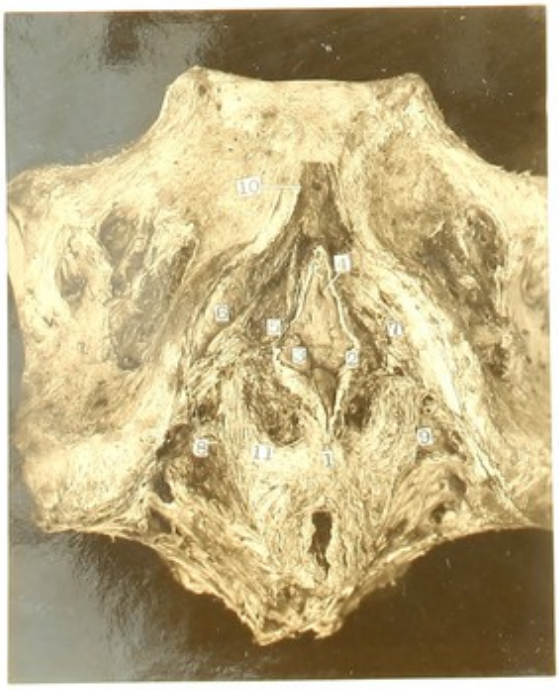

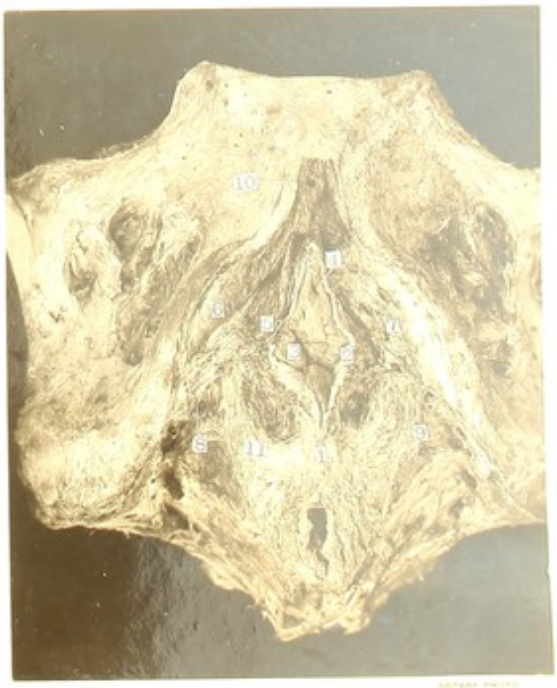

PELVIS.

FEMALE PERINEUM—No. 2.

IN ADDITION TO THE PREVIOUS DISSECTION, THE SUPERFICIAL LAYER OF THE TRIANGULAR LIGAMENT AND THE STRUCTURES SUPERFICIAL TO IT HAVE BEEN REMOVED, AND IN THE LEFT SIDE THE DEEP TRANSVERSUS PERINÆI MUSCLE HAS BEEN TAKEN AWAY, TO SHOW THE LEVATOR ANI MUSCLE.

The deep transversus perinæi arises as in the male (compressor urethræ) from the inner aspect of the pubic arch, and spreads out upon the surface of the urethra in front and the vagina behind.

The deep layer of the triangular ligament is formed in the same manner as in the male, and on its deep surface there is a large amount of very vascular tissue, which surrounds the upper part of the urethra and rests upon the anterior part of the levator ani, very much in the same position as the prostate in the male.

The dorsal nerve of the clitoris has been left on the left side, and is similar to the dorsal nerve of the penis in the male in its course and distribution. The accompanying vessels have been removed.

The figures indicate—

1. Central point of perineum.
2. Levator ani, anal fibres.
3. Levator ani, vaginal fibres.
4. Deep transversus perinæi.
5. Mass of vascular tissue.
6. Dorsal nerve of clitoris.
7. Meatus urinarius.
8. Veins of posterior vaginal plexus.
9. Dorsal artery of clitoris (divided).

EDINBURGH: T. C. & E. C. JACK; AND 34 HENRIETTA STREET, LONDON, W.C.

FEMALE PERINEUM. No. 2.
EDINBURGH STEREOSCOPIC ANATOMY.
Copyright: T. C. & E. C. Jack, Edinburgh, & 34 Henrietta St., London, W.C.

PELVIS.

FEMALE PERINEUM—No. 3.

THE PUBIC ARCH HAS BEEN REMOVED, WITH A PORTION OF THE PUBIC SYMPHISIS; PART OF THE OBTURATOR INTERNUS MUSCLE ON EACH SIDE HAS BEEN CUT AWAY, AND THE UPPER MARGIN OF THE LEVATORES ANI CUT SHORT.

The inferior surface of the bladder is seen, with the venous plexus which surrounds the neck, from which the urethra emerges.

The levator ani supports the neck of the bladder anteriorly,—some of its fibres are inserted, behind that, into the wall of the vagina, while still further back, the muscle on each side forms a thick rounded mass which passes down to the central point of the perineum, and to the anal canal.

The deep layer of the triangular ligament is formed by the fascia which invests the levator ani, passing across the middle line from the muscle of one side to that of the other.

The fascia on the outer, or parietal, aspect of the levator ani is thin and weak, but that on its inner, or pelvic, surface is of some strength.

The apex of the ischio-rectal fossa is seen, and the vessels which lie in the fascia forming the outer wall of the fossa—the internal pudic and dorsal artery of the clitoris—are seen divided.

The figures indicate—

1. Urinary bladder.
2. Levator ani.
3. Levator ani, anal fibres.
4. Levator ani, anterior fibres.
5. Obturator internus muscle.
6. Urethra.
7. Pubo-vesical ligaments.
8. Pelvic fascia.
9. Alcock's canal.
10. Vesical venous plexus.
11. Peri-urethral vascular tissue.

EDINBURGH: T. C. & E. C. JACK; AND 34 HENRIETTA STREET, LONDON, W.C.

FEMALE PERINEUM. No. 3.

EDINBURGH STEREOSCOPIC ANATOMY.
Copyright: T. C. & E. C. Jack, Edinburgh, & 34 Henrietta St., London, W.C.

PELVIS.

FEMALE PERINEUM.—No. 4.

THE SAME DISSECTION HAS BEEN CARRIED OUT AS IN NO. 3, AND A VIEW HAS BEEN TAKEN TO SHOW THE RELATION OF THE DEEPER PARTS TO THE PUBIC ARCH AND SYMPHISIS.

The bladder in the female lies at a somewhat lower level in the pelvis than in the male, and the neck is situated on a plane which passes from the lower margin of the pubic symphisis in front backwards to the lower end of the sacrum.

Looked at from the front, the neck of the bladder lies just below the lower margin of the symphisis pubis.

The large venous plexus which lies behind the lower part of the symphisis is very liable to be injured in operations for division of the symphisis pubis. Hence it is preferable to make any division of the bone some distance to the side. The pubic arch in this specimen is a particularly good specimen of the wide female pubic angle.

The figures indicate—

1. Urinary bladder.
2. Levator ani.
3. Pubo-vesical ligament and veins.
4. Urethra.
5. Levator ani, anal fibres.
6. Central point of perineum.
7. Alcock's canal.

EDINBURGH: T. C. & E. C. JACK; AND 34 HENRIETTA STREET, LONDON, W.C.

FEMALE PERINEUM. No. 4.

EDINBURGH STEREOSCOPIC ANATOMY.

Copyright: T. C. & E. C. Jack, Edinburgh, & 34 Henrietta St., London, W.C.

ABDOMEN.

MALE PELVIS.—No. 11.

IN ADDITION TO THE DISSECTION IN NO. 9, A PORTION OF THE RECTUM HAS BEEN REMOVED TO SHOW ITS ANTERIOR RELATIONS.

In front of the rectum lie the peritoneum in the upper part, and in the lower the recto-vesical fascia separating the rectum from the back of the bladder and prostate.

On this surface of the peritoneum can be seen a whitish area, gradually diminishing in size as it passes down, where the rectum was in contact with the peritoneal membrane.

The recto-vesical fascia is a part of the visceral pelvic fascia which encloses the seminal vesicles on each side, and passes across from one side to the other between the bladder and the rectum, forming a partition between them.

The sheath of the seminal vesicle of the left side has been opened, to show the way in which the fascia is arranged in relation to it.

The rectal fascia is a fairly strong layer of visceral pelvic fascia, which invests the lower portion of the rectum as it passes down between the levator ani muscles. It is continuous with the recto-vesical layer along the side wall of the pelvis.

The upper limit of the recto-vesical fascia and the termination of the contact of peritoneum and rectum are seen to be at the level of the spine of the ischium.

The figures indicate—

1. Sphincter ani.
2. Rectal fascia.
3. Rectum, lower end.
4. Recto-vesical fascia.
5. Peritoneum, area in contact with rectum.
6. Left seminal vesicle.
7. Rectum, upper end.
8. Parietal pelvic fascia, and origin of levator ani.
9. Great sacro-sciatic ligament.
10. Spine of ischium.
11. Third piece of sacrum, divided.

EDINBURGH: T. C. & E. C. JACK; AND 34 HENRIETTA STREET, LONDON, W.C.

MALE PELVIS. No. 11.

EDINBURGH STEREOSCOPIC ANATOMY

Copyright: T. C. & E. C. Jack, Edinburgh, & 34 Henrietta St., London, W.C.

ABDOMEN.

MALE PELVIS—No. 12.

IN ADDITION TO THE PREVIOUS DISSECTION, THE LOWER PART OF THE RECTUM AND THE ANAL CANAL HAVE BEEN SHELLED OUT FROM THE LEVATOR ANI MUSCLES, AND THE RECTAL FASCIA AND THE GREATER PART OF THE RECTO-VESICAL FASCIA HAVE BEEN REMOVED.

The dissection now shows, below the level of the peritoneum, the back of the bladder, the vasa deferentia and seminal vesicles, and the back of the prostate, while below the prostate is a small interval between the anterior margins of the levator ani muscles which is filled in by the deep layer of the triangular ligament. External to the levator ani muscle on each side, is the apex of the ischio-rectal fossa, and it will be noticed that the seminal vesicles lie immediately above the apex of this fossa.

The cut margin of the recto-vesical fascia has been left in position above, below, and at the sides, in order to show its extent and attachments.

The figures indicate—

1. Rectum.
2. Peritoneum.
3. Recto-vesical fascia investing the seminal vesicles, divided.
4. Seminal vesicle.
5. Vas deferens.
6. Prostate.
7. Levator ani muscle.
8. Sphincter externus.
9. Anterior margins of levator ani.
10. Bladder.

EDINBURGH: T. C. & E. C. JACK; AND 34 HENRIETTA STREET, LONDON, W.C.

MALE PELVIS. No. 12.
EDINBURGH STEREOSCOPIC ANATOMY.
Copyright: T. C. & E. C. Jack, Edinburgh, & 34 Henrietta St., London, W.C.

PELVIS.

FEMALE PELVIS.—No. 1.

The rectum has been exposed from behind, by removal of the superficial structures and of portions of the levator ani and coccygeus muscles, and a view has been taken to show the lower part of the sacrum and the coccyx in relation to it. The sacrum has been divided through the fourth piece.

This view should be compared with the corresponding view of the male pelvis (No. 10).

The principal differences between the two views arise from the much greater width between the ischial tuberosities in the female, so that there is considerably greater room for access surgically.

The peritoneum on each side, where it forms the posterior wall of the pouch of Douglas, is somewhat nodular, but its relation to the rectum is the same as in the male. In front it passes on to the posterior wall of the vagina.

In this specimen, as in the other, the rectum is empty, and the lateral flexures are not very large, but the angle between the anal canal and the lower end of the rectum is well brought out.

S and C indicate the lower part of sacrum, and the upper part of coccyx respectively.

The figures indicate—

1. Rectum.
2. Anus.
3. Levator ani.
4. Peritoneum.
5. Great sacro-sciatic ligament.
6. Superior hæmorrhoidal vessels.
7. Ureter.
8. Sacral nerve.
9. Rectal fascia.

The sacrum has been sawn across through the fourth piece.

EDINBURGH: T. C. & E. C. JACK; AND 34 HENRIETTA STREET, LONDON, W.C.

FEMALE PELVIS. No. 1

EDINBURGH STEREOSCOPIC ANATOMY

Copyright: T. C. & E. C. Jack, Edinburgh, & 34 Henrietta St., London, W.C.

PELVIS.

FEMALE PELVIS—No. 2.

IN ADDITION TO THE PREVIOUS DISSECTION, THE RECTUM HAS BEEN DIVIDED ABOUT ITS MIDDLE, AND THE LOWER PART REMOVED WITH THE ANAL CANAL, THE LATTER HAVING BEEN SHELLED OUT FROM THE LEVATORES ANI MUSCLES.

The peritoneum should be observed, and especially its reflection in the middle on to the posterior wall of the vagina.

Between the rectum and the vagina is a large venous plexus, which is most distinct at the sides, and the mesial plane is comparatively avascular.

There is no fold immediately in front of the rectum comparable to the recto-vesical septum of fascia, which is so distinct in the male.

The ureter lies at some distance, and is shown in a small part of its course on the right side.

The large vessels—internal pudic and sciatic—emerging through the great sacro-sciatic foramen are well seen on the left side.

The bone has been divided through the fourth piece of the sacrum—a level higher than can be done with safety in surgical operations, but it is not essential to go so high up in order to obtain good access to the rectum.

The figures indicate—

1. Posterior wall of vagina.
2. Vaginal venous plexus.
3. Levator ani.
4. Peritoneal reflection on to posterior vaginal wall.
5. Great sacro-sciatic ligament.
6. Superior hæmorrhoidal vessels.
7. Ureter.
8. Third sacral nerve.
9. Rectal fascia.
10. External sphincter.
11. Rectum divided.

EDINBURGH: T. C. & E. C. JACK; AND 34 HENRIETTA STREET, LONDON, W.C.

FEMALE PELVIS. No. 2.

EDINBURGH STEREOSCOPIC ANATOMY.
Copyright: T. C. & E. C. Jack, Edinburgh, & 34 Henrietta St., London, W.C.

PELVIS.

FEMALE PELVIS—No. 3.

THE ANTERIOR WALL OF THE PELVIS HAS BEEN REMOVED, AND THE PERITONEUM HAS BEEN DIVIDED AT THE ROOT OF THE BROAD LIGAMENT, AND REMOVED FROM THE BLADDER.

The urethra has been dissected out of the anterior vaginal wall.

1. **Bladder.**—The bladder in the female is of practically the same shape as in the male, and presents the same relations to the wall of the pelvis and to the peritoneum.

Posteriorly, it rests against the front of the vagina and lower part of the uterus. It is connected to them by a small amount of areolar tissue which can be easily divided when normal, allowing the uterus to be separated from the bladder.

The close apposition of this aspect of the bladder to the vagina may lead to the formation of a vesico-vaginal fistula after injury to the anterior vaginal wall.

2. **Urethra.**—In the female, the urethra measures about 1½ inches in length, and is nearly straight in its direction from the neck of the bladder to the external orifice. It lies for a great part of its course embedded in the anterior wall of the vagina, but at the upper part it is surrounded by a large amount of highly vascular connective tissue, in which some glands are situated which open into the urethra.

3. **Uterus.**—This organ in this specimen lies somewhat backwards and to the left side. A mesial position is somewhat rare in a parous female, but the deviation is more commonly to the right side.

The folds of peritoneum which invest it pass outwards on either side as the broad ligament, and the peritoneum does not completely cover the anterior surface of the uterus, as a small portion is left uncovered where the peritoneum passes off it in front on to the upper surface of the bladder.

On each side of this portion of the uterus is a very large plexus of veins, and external to this, the ureters pass forwards, and then converge inwards to the posterior angles of the bladder.

It is in this position that the ureters are liable to be damaged or included in ligatures in vaginal hysterectomy.

The figures indicate—

1. Meatus urinarius.
2. Vaginal wall.
3. Vaginal venous plexus.
4. Levator ani muscle.
5. Pelvic fascia.
6. Obturator internus.
7. Upper surface of bladder.
8. Reflection of peritoneum from uterus.
9. Broad ligament.
10. Fallopian tube, overlying ovary.
11. Body of uterus.
12. Left Fallopian tube.
13. Round ligament.
14. Ureter (left).
15. Pelvic colon.
16. Rectum (commencement of).

EDINBURGH: T. C. & E. C. JACK; AND 34 HENRIETTA STREET, LONDON, W.C.

FEMALE PELVIS. No. 3.

EDINBURGH STEREOSCOPIC ANATOMY.
Copyright: T. C. & E. C. Jack, Edinburgh, & 34 Henrietta St., London, W.C.

PELVIS.

FEMALE PELVIS.—No. 4.

IN ADDITION TO THE PREVIOUS DISSECTION, THE URETERS HAVE BEEN DIVIDED, AND THE BLADDER REMOVED. THE ANTERIOR WALL OF THE VAGINA HAS BEEN DIVIDED AT ITS ATTACHMENT TO THE UTERINE CERVIX, AND AT THE SIDE, AND REMOVED.

The vagina is about three inches long, and forms a canal which leads from the uterus to the surface. It is in the form of a transverse slit, the anterior and posterior walls being in contact, and on transverse section in some cases it appears to be H-shaped. The cervix of the uterus is, as it were, invaginated into its upper end, so that a hollow runs round the cervix, and this hollow in different regions forms the fornices. As the axis of the uterus does not correspond with that of the vagina, but is more vertical, and the anterior wall of the vagina is shorter than the posterior, the anterior fornix is very shallow, and the posterior is deep, while the lateral fornices are intermediate.

The lateral aspect of the vagina in nearly its whole length is enclosed in a large mass of very highly vascular tissue, forming a large venous plexus on either side.

The long axis of the vagina is almost parallel with that of the pelvic brim.

The figures indicate—

1. Posterior vaginal wall.
2. Cut margin of wall.
3. Vaginal venous plexus.
4. Cervix uteri.
5. Attachment of vagina to uterus.
6. Ureters.
7. Uterine venous plexus.
8. Peritoneum.

EDINBURGH: T. C. & E. C. JACK; AND 34 HENRIETTA STREET, LONDON, W.C.

FEMALE PELVIS. No. 4.
EDINBURGH STEREOSCOPIC ANATOMY.
Copyright: T. C. & E. C. Jack, Edinburgh, & 34 Henrietta St., London, W.C.

ABDOMEN.

FEMALE PELVIS—No. 5.

THE UTERINE ARTERY HAS BEEN TRACED IN ITS COURSE ALONG THE BASE OF THE BROAD LIGAMENT, AND, ON THE LEFT SIDE, SEVERAL STRUCTURES WHICH ARE FOUND IN THE BROAD LIGAMENT HAVE BEEN DISSECTED OUT.

The broad ligament is a double fold of peritoneum which passes from the uterus to the side wall of the pelvis, and which contains the Fallopian tube, the ovary, and vessels, nerves, ligaments, and some vestigial structures.

1. The Fallopian tube begins at the ovary in a wide funnel-shaped portion, with fimbriated edges, which are in close relation to the ovary. From this region the tube runs in a somewhat tortuous manner along the upper margin of the broad ligament, and enters the upper lateral angle of the uterus.

2. The ovary lies in a recess in the side wall of the pelvis, and it is somewhat oval in shape, the long axis being nearly vertical. Those organs are rarely symmetrical in position, and, in this specimen, the right ovary was displaced downwards through the displacement of the uterus to the left side. The ovary lies in the posterior fold of the broad ligament, and consequently is not seen from the front until the peritoneum forming that ligament has been removed (as on the left side).

3. The round ligament of the uterus is a rounded band of muscular and connective tissue which passes from the margin of the uterus, below the entrance of the Fallopian tube, outwards to the side wall of the pelvis, and in the latter part of its course it passes into the inguinal canal and resembles the vas deferens in its relations.

The vessels contained in the broad ligament include the uterine and ovarian arteries and veins. The veins form a large plexus round the margin of the uterus from which blood passes by the uterine vein to the internal iliac vein, and also a plexus near the ovary, from which two ovarian veins pass, with the ovarian artery, and end in the same way as the spermatic veins in the male, *i.e.* in the inferior vena cava on the right side, and in the left renal vein on the left.

The vestigial structures comprise the paroöphoron and the epoöphoron which represent the paradidymis and epididymis of the male. This view also illustrates the external characters of the uterus and its principal parts, viz., the fundus or upper rounded end, the body which diminishes in size as it passes down, and which is separated by a constriction, the isthmus, from the cervix, which is rounded and cylindrical in character, and passes into the upper part of the vagina.

The figures indicate—

1. Cervix uteri.
2. Fundus uteri.
3. Uterine artery.
4. Ureter.
5. Uterine vein.
6. Round ligament.
7. Ovarian veins.
8. Fallopian tube.
9. Ovarian venous plexus.
10. Ovary.
11. Rectum.
12. Venous plexus round cervix.
13. Vaginal branch of uterine artery.

EDINBURGH: T. C. & E. C. JACK; AND 34 HENRIETTA STREET, LONDON, W.C.

FEMALE PELVIS. No. 5.
EDINBURGH STEREOSCOPIC ANATOMY.
Copyright: T. C. & E. C. Jack, Edinburgh, & 34 Henrietta St., London, W.C.

LUMBAR REGION.—No. 1.

THE SKIN AND LAYERS OF FASCIA HAVE BEEN REMOVED, LEAVING THE CUTANEOUS NERVES, TO SHOW THE MUSCLES.

The cutaneous nerves of the lower part of the back are derived from the posterior primary divisions of spinal nerves.

From the lower six dorsal nerves branches are given to the skin through the external branches of these nerves, and branches, lower down, are given off by the upper three lumbar, and from two or three sacral nerves.

The lumbar nerves become cutaneous by piercing the lumbar aponeurosis near the outer margin of the erector spinæ, while the sacral twigs pierce the gluteus maximus.

The **latissimus dorsi** arises from the spines and supra-spinous ligaments of the lower six dorsal vertebræ, from the posterior lamella of the lumbar aponeurosis, by which it is attached to the lumbar spines, to the sacrum and iliac crest, and it also gains a separate origin from the crest of the ilium in front of the attachment of the lumbar aponeurosis. It may also gain a few fibres from the dorsal surface of the lower angle of the scapula.

The **triangle of Petit** is a small triangular intermuscular interval, above the crest of the ilium between the latissimus dorsi and external oblique muscles. It is a weak point in the abdominal wall, and may be the site of a lumbar hernia.

The **bony landmarks** which attract attention are—(1) the crest of the ilium, (2) the posterior superior iliac spines, which are on a level with the second sacral spine, (3) the sacral cornua, between which is a depression corresponding to the inferior opening of the sacral canal.

The prominence of the erector spinæ muscle is of importance, and especially the furrow at its outer margin, where the three layers of the lumbar aponeurosis unite with one another.

This furrow is a useful landmark in operations on the kidneys from the back.

The figures indicate—

1. Trapezius.
2. Latissimus dorsi.
3. Triangle of auscultation.
4. Rhomboideus major.
5. External oblique of abdomen.
6. Lumbar aponeurosis.
7. Triangle of Petit.
8. Gluteus medius.
9. Gluteus maximus.
10. Posterior superior iliac spine.
11. Sacral cornua.
12. Internal cutaneous branch.
13. External cutaneous branch.
14. Lumbar cutaneous branch.

EDINBURGH: T. C. & E. C. JACK; AND 34 HENRIETTA STREET, LONDON, W.C.

LUMBAR REGION. No. 1.
EDINBURGH STEREOSCOPIC ANATOMY.
Copyright: T. C. & E. C. Jack, Edinburgh, & 34 Henrietta St., London, W.C.

LUMBAR REGION—No. 2.

ON THE RIGHT SIDE, MUSCLES AND APONEUROSIS HAVE BEEN REMOVED TO SHOW THE ERECTOR SPINÆ, WHILE ON THE LEFT, THE GREATER PART OF THE ERECTOR SPINÆ HAS BEEN REMOVED TO SHOW THE MULTIFIDUS SPINÆ.

The erector spinæ muscle and prolongations from it fill up the hollow on either side of the vertebral column. The muscle itself consists of a flattened tendinous portion which lies superficially in the lumbar and sacral regions, and of a mass of fleshy tissue which lies on its anterior surface. From the origin of the muscle bands pass in different directions to gain insertion into ribs and vertebræ. The three principal columns into which the muscle divides are shown here. They are the ilio-costalis on the outer side, the longissimus dorsi in the centre, and the spinalis dorsi close to the vertebral spines. Cutaneous nerves emerge between the first two.

The multifidus spinæ in this region is a thick fleshy mass, covered by the erector spinæ, the bundles of which it is composed passing upwards and inwards to be inserted into the vertebral spines.

In front of these structures lies the quadratus lumborum, its outer margin projecting beyond that of the vertebral muscles.

The lumbar aponeurosis, the middle lamella of which covers the quadratus lumborum, and which gives origin to the internal oblique and transversalis abdominis muscles, has been removed, so that the descending colon is visible, with some nerves.

The figures indicate—

1. Posterior superior iliac spine.
3. Last rib.
4. Transverse process of first lumbar vertebra.
5. Spine of second lumbar vertebra.

Muscles.
6. Quadratus lumborum.
7. Ilio-costalis.
8. Musculus accessorius.
9. Longissimus dorsi.
10. Spinalis dorsi.
11. Multifidus spinæ.
12. Levator costæ.
13. External intercostal.
14. Lumbar aponeurosis, middle lamella.
15. Extraperitoneal fat, and ilio-inguineal and ilio-hypogastric nerves.

EDINBURGH: T. C. & E. C. JACK; AND 34 HENRIETTA STREET, LONDON, W.C.

LUMBAR REGION. No. 2.
EDINBURGH STEREOSCOPIC ANATOMY.
Copyright: T. C. & E. C. Jack, Edinburgh, & 34 Henrietta St., London, W.C.

LUMBAR REGION.—No. 3.

THE MUSCLES OF THE BACK HAVE BEEN REMOVED DOWN TO THE QUADRATUS LUMBORUM ON THE LEFT SIDE AND TO THE PSOAS ON THE RIGHT, TO SHOW THE KIDNEYS AND THE PLEURAL MEMBRANES.

The left kidney is normal, the right is somewhat atrophied, and displaced downwards.

The position of the kidneys from behind is as follows (see left side): In a vertical direction the kidney extends from the level of the eleventh dorsal spine to that of the lower margin of the third lumbar spine, and the outer border lies about $3\frac{3}{4}$ ins. from the mesial plane, and the inner border about 1 in.

The upper portion is concealed from view by the last rib, by the diaphragm, and by the pleura.

Lower limit of pleura. At the back the pleura is here found to pass as far down as to the transverse process of the first lumbar vertebra. Frequently it is about $\frac{1}{2}$ in. higher, *i.e.* between the neck of the last rib and this transverse process. It should be noted that the transverse process of the first lumbar vertebra is almost at the same level as the lower margin of the spine of the last dorsal vertebra.

The diaphragm has been cut away on the left side, but on the right the ligamentum arcuatum externum is seen stretching from the last rib towards the transverse process of the first lumbar vertebra.

Laterally, each kidney is in close relation to the colon, the right to the ascending, and the left to the descending.

The figures indicate—

Large numbers—corresponding dorsal and lumbar vertebrae. The small numbers—

1. Quadratus lumborum.
2. Psoas.
3. Diaphragm.
4. Ilio-lumbar ligament.
5. Right kidney.
6. Left kidney.
7. Ascending colon.
8. Descending colon.
9. Pleura approaching spine.
10. Pleura in eleventh interspace.
11. Peritoneum covering liver.
12. Nerve, artery, and vein in intercostal space.

EDINBURGH: T. C. & E. C. JACK; AND 34 HENRIETTA STREET, LONDON, W.C.

LUMBAR REGION. No. 3.
EDINBURGH STEREOSCOPIC ANATOMY.
Copyright: T. C. & E. C. Jack, Edinburgh, & 34 Henrietta St., London, W.C.

LUMBAR REGION.—No. 4.

KIDNEYS AND ADJACENT VISCERA, SEEN FROM BEHIND.

The right kidney has been displaced downwards, and is atrophied; the left kidney appears to be normal.

Left kidney. The upper portion of this kidney is seen to be in intimate relation with the spleen at its outer part, and, on its inner and anterior aspect, with the suprarenal capsule, while the splenic flexure and the descending colon lie in contact with the lower part of the outer border and the anterior surface. The renal vessels are very short, and the left renal vein receives the ovarian vein of the left side. The ureter descends in a vertical direction.

Aorta. The calibre of the aorta diminishes in a very distinct manner after the origin of the two renal arteries, and the lumbar and middle sacral arteries are seen to take origin from the posterior aspect of the vessel, and not from the side.

Inferior vena cava. This vessel lies, in the lower part of its course, close beside the aorta, but as it ascends, it passes to the right, and leaves the aorta.

Right kidney. The relation of this organ to the liver illustrates the way in which compression of the abdomen can displace the kidney downwards, since it is in contact with the sloping under surface of the liver, and therefore it is pressed downwards as well as backwards. It will be noticed also that the suprarenal capsule does not share this displacement, but remains in contact with the usual area in the posterior surface of the liver.

The right ovarian vein, with which is seen a rather tortuous ovarian artery, passes to join the inferior vena cava very obliquely.

The figures indicate—

1. Abdominal aorta.
2. Inferior vena cava.
3. Right renal artery.
4. Left renal artery.
5. Right ovarian vein.
6. Left ovarian vein.
7. Right ureter.
8. Left ureter.
9. Bifurcation of aorta and origin of middle sacral artery.
10. Inferior mesenteric artery.
11. Colon (descending).
12. Left kidney.
13. Spleen.
14. Liver.
15. Left suprarenal capsule.
16. Right suprarenal capsule.
17. Right kidney.
18. Ascending colon.
19. Second part of duodenum.
20. Right crus of diaphragm.

EDINBURGH: T. C. & E. C. JACK; AND 34 HENRIETTA STREET, LONDON, W.C.

LUMBAR REGION. No. 4.
EDINBURGH STEREOSCOPIC ANATOMY.
Copyright: T. C. & E. C. Jack, Edinburgh, & 34 Henrietta St., London, W.C.

LUMBAR REGION.—No. 5.

ANTERIOR RELATIONS OF THE KIDNEYS.

The spleen and right kidney and suprarenal capsule have been removed in order to show the structures which lie in front of them, and a portion of the inferior vena cava has been cut away.

Left kidney. The tail of the pancreas with the splenic vessels has now been exposed, crossing in front of the upper part of this kidney. The splenic vessels are extremely tortuous, and are seen to lie behind the under surface of the stomach, from which they are separated by the lesser sac of the peritoneal cavity.

The structures seen here may be said to constitute a bed for the spleen, as viewed from behind, and consist of the fundus of the stomach, the splenic flexure of the colon, and the pancreas.

Right kidney. Among the important relations of this organ, the duodenum and part of the pancreas, with the inferior vena cava and the termination of the common bile duct, must always be borne in mind, and the position and relations of these structures are well revealed in this dissection. The second and third parts of the duodenum form a loop which encloses the head of the pancreas, and the common bile duct pierces the posterior wall of the second part in its inner part. The duct of the pancreas is not fully shown, as it lies embedded in the substance of the pancreas. A network of vessels, mainly veins, lay upon this surface of the duodenum and pancreas, and must be carefully noted by the surgeon in his attempts to gain access to the termination of the common bile duct near its termination by the usual route from the abdomen, viz. by turning the second part of the duodenum inwards towards the middle line of the body, after dividing the peritoneum along the outer margin of the duodenum.

The figures indicate:—

1. Liver.
2. Left kidney.
3. Duodenum.
4. Head of pancreas.
5. Ascending colon.
6. Common bile duct.
7. Inferior vena cava.
8. Stomach.
9. Tail of pancreas.
10. Splenic artery.
11. Splenic flexure of colon.
12. Small intestine.
13. Aorta.
14. Left ovarian vein.
15. Left ureter.
16. Body of pancreas.

EDINBURGH: T. C. & E. C. JACK; AND 34 HENRIETTA STREET, LONDON, W.C.

LUMBAR REGION. No. 5.
EDINBURGH STEREOSCOPIC ANATOMY.
Copyright: T. C. & E. C. Jack, Edinburgh, & 34 Henrietta St., London, W.C.

THORAX.

BACK—No. 1.

In the dissections illustrated in this and the following four views, the subject after being hardened by formalin injections, was fixed by being embedded in plaster of Paris, so as to secure complete immobility during and after the removal of the vertebral column and the ribs. The subject was a female, who showed no marked evidence of disease of the heart or lungs. The curvature of the dorsal portion of the spine was perhaps somewhat greater than is found in a younger subject. The relations of the deeper parts to the surface are represented as they were found in this subject, but it should be borne in mind that after death, the viscera tend to be displaced downwards in relation to the spine, and this probably accounts for the somewhat lower position than usual which they occupy here.

The lower margin of each of the lungs is seen to descend as far as to the level of the eleventh dorsal spine, and is the same on both sides of the body. The lower limit of the pleura, as it approaches the spine on the right side of the body, passes below the level of the twelfth rib and descends as far as to the transverse process of the first lumbar vertebra. On the left side, it passes along under cover of the twelfth rib, and only descends below this rib for a short distance near the spine, where it is found in the usual position, *i.e.* in the interval between the twelfth rib and the transverse process of the first lumbar vertebra.

The oblique fissure of the lung begins, on the left side, on a level with the spine of the second dorsal vertebra, but as often happens, on the right side it is as low as the spine of the fourth dorsal vertebra. From its origin, the fissure passes obliquely downwards and outwards, under cover of the infraspinous region of the scapula.

Large numbers indicate corresponding lumbar dorsal spines. L indicates the quadratus lumborum muscle. The small numbers indicate—

1. Left kidney.
2. Diaphragm.
3. Left lung, inferior margin.
4. Descending colon.
5. Liver.
6. Right kidney.
7. Ascending colon.
8. Diaphragm.
9. Lung.
10. Great fissure of right lung.
11. Great fissure of left lung.

EDINBURGH: T. C. & E. C. JACK; AND 34 HENRIETTA STREET, LONDON, W.C.

THORAX—BACK. No. I.
EDINBURGH STEREOSCOPIC ANATOMY.
Copyright: T. C. & E. C. Jack, Edinburgh, & 34 Henrietta St., London, W.C.

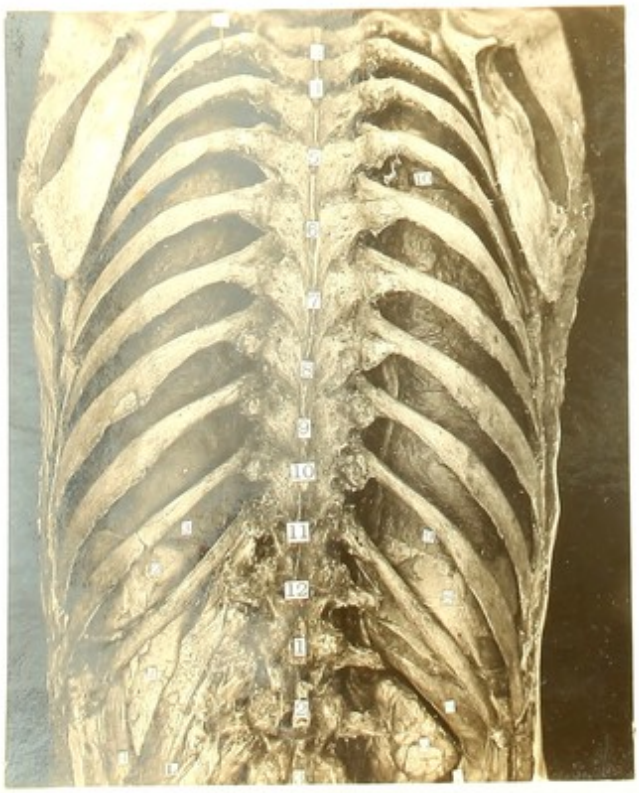

THORAX.

BACK—No. 2.

THE GREATER PART OF THE SPINE HAS BEEN REMOVED WITH PORTIONS OF THE ATTACHED RIBS, AND THE LUNGS LIFTED OUT AFTER DIVIDING THE ROOT ON EACH SIDE.

The structures shown lie mainly in the posterior mediastinum.

Aorta. The arch of the aorta, after passing backwards, reaches the vertebral column on the left side of the middle line. The aorta then passes downwards and bends slightly to the right, until it reaches the mesial plane. To its right side lies the vena azygos major, which arches forwards over the root of the right lung, and on the left side the aorta is covered by the left mediastinal pleura.

Root of the right lung. The bronchus has been divided just beyond the origin of the eparterial branch, and the eparterial and the main bronchus appear as one structure. The pulmonary veins have been divided close to their termination in the left auricle, and appear as a single vessel. The right pulmonary artery lies in front of the bronchus and between the eparterial and the main bronchus in a vertical direction.

Diaphragm. The right cupola rises rather higher than the left, and is seen to be pierced by the vena cava inferior, which then passes to the right auricle. A small part of the posterior and outer surface of this vessel lies free in the thorax, and comes into contact with the lower margin of the right lung, but the remainder of the vessel lies inside the pericardium.

Spleen. This organ is of a typical shape and size in this specimen, and its relation to the left cupola of the diaphragm should be noted.

On the right side is seen a small portion of the liver, which is not invested by peritoneum, known as the bare area of the liver. It is triangular in shape, and is bounded by the upper and lower layers of the coronary ligament.

The figures indicate—

1. Inferior vena cava.
2. Aortic arch.
3. Œsophagus.
4. Vena azygos major.
5. Root of left lung (centre of).
6. Right bronchus.
7. Right pulmonary artery.
8. Right pulmonary veins, divided at entrance to left auricle.
9. Left ventricle.
10. Liver.
11. Spleen.
12. Left kidney.
13. Aorta and margin of pleura.
14. Innominate artery.
15. Internal mammary artery.
16. Superior vena cava

EDINBURGH: T. C. & E. C. JACK; AND 34 HENRIETTA STREET, LONDON, W.C.

THORAX—BACK. No. 2.
EDINBURGH STEREOSCOPIC ANATOMY.
Copyright: T. C. & E. C. Jack, Edinburgh, & 34 Henrietta St., London, W.C.

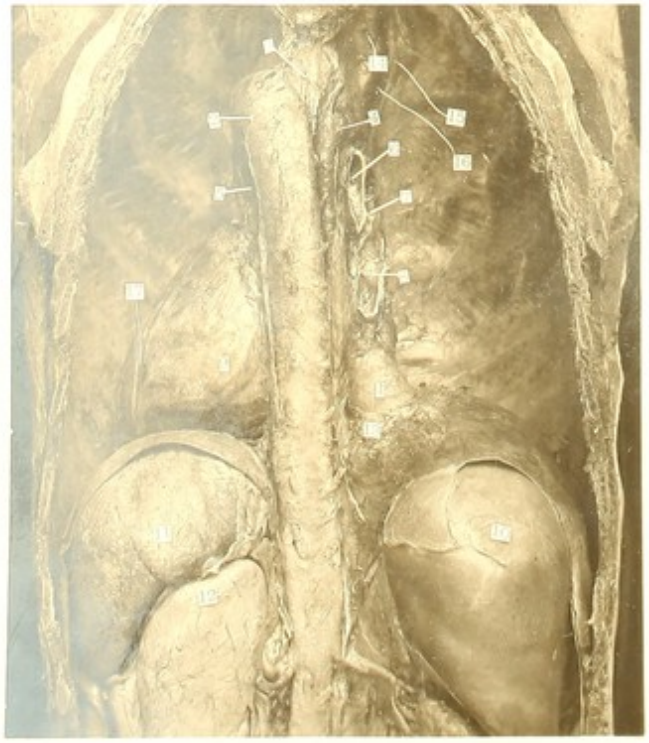

THORAX.

BACK.—No 3.

THE STRUCTURES SHOWN IN THE FORMER VIEW ARE NOW SEEN IN TOPOGRAPHICAL RELATION TO THE SPINE AND THE RIBS.

Aorta. The arch of the aorta reached the left side of the spine at a point which was vertically in front of the spine of the third dorsal vertebra. The obliquity of this portion of the view at first sight appears to make the level somewhat lower than this, but careful examination reveals that this is the proper level.

Diaphragm. The right cupola ascends as high as to lie between the eighth and ninth dorsal spines, while the left cupola is between the ninth and tenth. The scapulæ are somewhat oblique, but the lower angle of each is practically over the seventh rib.

Spleen. The relation of the spleen to the surface is very clearly brought out. The lower margin (posterior border) lies along the upper border of the twelfth rib, and extends from the side of the vertebral column as far as to the posterior axillary line. The outline of the organ may be indicated by drawing a line to represent the lower border along the rib for that distance, and joining the ends by an arch which extends as far up as to the tenth rib.

Liver. The upper border of the liver passes up into the ninth intercostal space, and the liver is covered by the lower three ribs behind, and passes down about an inch below the twelfth rib.

This view should be focussed with great care, so as to bring out clearly the structures which lie at different depths from the surface.

The large numbers rest upon the spines of corresponding dorsal and lumbar vertebrae.

The small numbers indicate—

1. Inferior vena cava.
2. Aortic arch.
3. Œsophagus.
4. Vena azygos major
5. Root of right lung (centre of).
6. Right bronchus.
7. Right pulmonary artery.
8. ,, ,, veins, joining left auricle.
9. Left ventricle.
10. Liver.
11. Spleen
12. Left kidney.
13. Aorta, and margin of pleura.
14. Innominate artery.
15. Internal mammary artery.
16. Superior vena cava.

EDINBURGH: T. C. & E. C. JACK; AND 34 HENRIETTA STREET, LONDON, W.C.

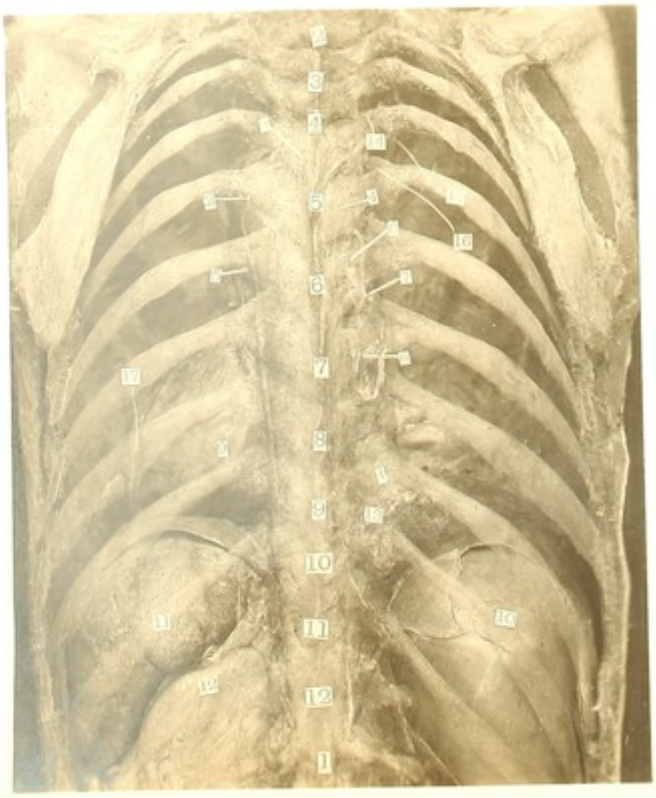

THORAX BACK. No. 3.
EDINBURGH STEREOSCOPIC ANATOMY.
Copyright: T. C. & E. C. Jack, Edinburgh, & 34 Henrietta St., London, W.C.

THORAX.

BACK—No. 4.

THE SPLEEN AND LEFT KIDNEY AND PORTIONS OF THE AORTA AND ŒSOPHAGUS HAVE BEEN REMOVED, TO SHOW THE HEART, ROOTS OF THE LUNGS, ŒSOPHAGUS, PANCREAS, AND STOMACH, FROM BEHIND.

Œsophagus. Below the bifurcation of the trachea, the œsophagus passes rather to the right, and then curves gradually forwards, and to the left side. Just above the point where it pierces the diaphragm, there is a well-marked dilatation, which is known as the **ampulla phrenica.** This ampulla is not invariably present, but on the other hand it may become very much enlarged, and contain fluids and food which do not reach the stomach. Between this ampulla and the stomach is a deep groove in which lay a strong muscular band, which formed part of the diaphragm, and which can probably act as the sphincter for the cardiac orifice of the stomach. The ampulla fills up the small angular interval between the diaphragm and the pericardium. The right vagus is seen passing on to the back of the œsophagus in its course to the posterior surface of the stomach.

Bronchi. The left bronchus is longer, narrower, and more horizontal than the right one.

Heart. The portion of the heart which is seen, includes the basal surface—the greater part of this being composed of the left auricle—and the left border, formed by the left ventricle. The great cardiac vein lies in the auriculo-ventricular groove.

Stomach. The fundus of the stomach arches up above the level of the cardiac orifice. At a lower level lie the splenic vessels and the tail of the pancreas.

The figures indicate—

1. Aortic arch.
2. Œsophagus.
3. Right bronchus.
4. Left bronchus.
5. Vena azygos major.
6. Left pulmonary artery.
7. Pericardium, cut edge.
8. Right vagus.
9. Constriction on œsophagus.
10. Stomach, fundus.
11. Tail of pancreas.
12. Splenic vessels.
13. Descending colon.
14. Diaphragm, muscular band.
15. Auriculo-ventricular sulcus.
16. Œsophagus.
17. Ampulla phrenica.
18. Inferior vena cava.
19. Bifurcation of trachea.
20. Abdominal aorta, commencement of.

EDINBURGH: T. C. & E. C. JACK; AND 34 HENRIETTA STREET, LONDON, W.C.

THORAX—BACK. No. 4.
(EDINBURGH STEREOSCOPIC ANATOMY.)
Copyright: T. C. & E. C. Jack, Edinburgh, & 34 Henrietta St., London, W.C.

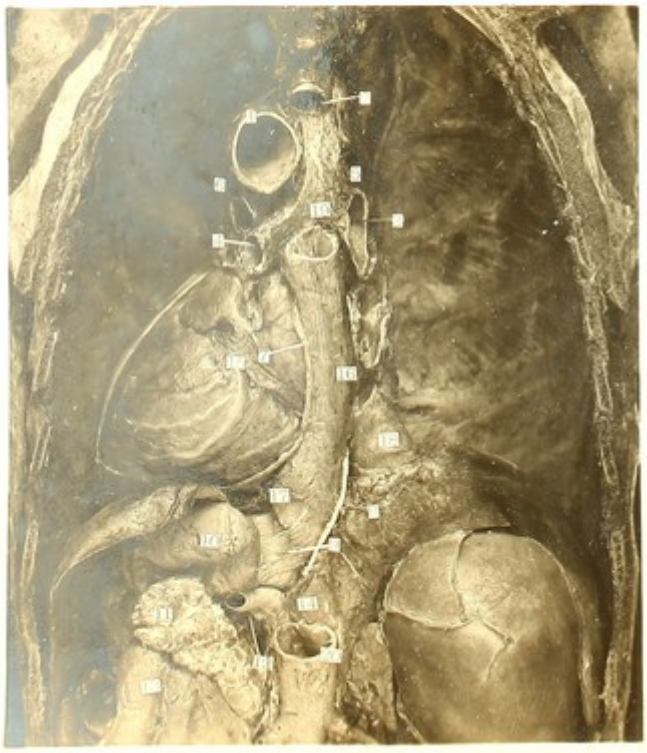

THORAX.

BACK—No. 5.

THE STRUCTURES SEEN IN THE PRECEDING VIEW ARE SHOWN IN TOPOGRAPHICAL RELATION TO THE SPINE AND THE RIBS.

The surface relationships seen here are numerous and important.

Heart. The heart extends from between the fifth and sixth dorsal spines above down to the ninth dorsal spine below, but the basal surface, *i.e.* as far down as to the auriculo-ventricular groove, extends only to the eighth dorsal spine. The apex of the heart lies in front of the ninth rib below the lower angle of the scapula, and slightly internal to it.

Trachea. The lower margin of the bifurcation of the trachea lies in front of the spine of the fifth dorsal vertebra, and the roots of the lungs, which are of considerable vertical extent, lie in front of the fifth, sixth, and seventh dorsal spines.

Stomach. The cardiac orifice of the stomach lies at the level of the tenth dorsal spine, while the fundus passes upwards almost to the spine of the ninth dorsal vertebra.

The splenic flexure of the colon and the tail of the pancreas come to lie under cover of the eleventh rib.

Very considerable differences exist between the statements made in different text books as to the level of the above structures in relation to the spines of the vertebræ.

The bifurcation of the trachea, *e.g.* is often said to be at the level of the third dorsal spine. The bifurcation is certainly at a lower level than that in this specimen. The level of the other structures may be taken as being fairly typical, but apparently considerable individual variations may be found.

The large numbers rest upon corresponding dorsal and lumbar spines.
The small numbers indicate—

1. Aortic arch.
2. Œsophagus.
3. Right bronchus.
4. Left bronchus.
5. Vena azygos major.
6. Left pulmonary artery.
7. Pericardium, divided.
8. Right vagus nerve.
9. Constriction on œsophagus.
10. Fundus of stomach.
11. Tail of pancreas.
12. Splenic vessels.
13. Descending colon.
14. Diaphragm.
15. Auriculo-ventricular sulcus.
16. Œsophagus.
17. Ampulla phrenica.
18. Inferior vena cava.
19. Bifurcation of trachea.
20. Commencement of abdominal aorta.

THORAX—BACK. No. 5.
EDINBURGH STEREOSCOPIC ANATOMY.
Copyright: T. C. & E. C. Jack, Edinburgh, & 34 Henrietta St., London, W.C.

UPPER LIMB.

BACK—No. 1.

THE SKIN AND LAYERS OF FASCIA HAVE BEEN REMOVED, TO SHOW THE CUTANEOUS NERVES AND THE FIRST LAYER OF MUSCLES.

The cutaneous nerves found in this region are the following:—

(1) The **great occipital nerve**, from the posterior primary division of the second cervical nerve, pierces the trapezius, and passes upwards and outwards to supply the posterior part of the scalp.

Below this nerve is a small branch from the third cervical nerve, which passes upwards, and then one small twig also from the fourth and fifth, but these are variable.

(2) Lower down, branches from the upper six dorsal nerves emerge near the middle line. All the above nerves come from the internal branches of the posterior primary divisions.

(3) Below these, twigs from the external branches of the posterior primary divisions become superficial, but at some distance from the middle line.

(4) The **small occipital nerve** runs upwards behind the posterior border of the sterno-mastoid muscle to the posterior part of the scalp, where it anastomoses with the great occipital. It is derived from the anterior primary divisions of the second and third cervical nerves, and is therefore a branch of the cervical plexus.

The **trapezius** muscle arises from the external occipital protuberance and from the inner half of the superior curved line of the occipital bone, from the ligamentum nuchæ and spine of the seventh cervical vertebra, and from the spines and supraspinous ligaments of all the dorsal vertebræ.

There is a quadrilateral aponeurotic area formed in the middle by a membranous portion of the muscle on each side.

Triangle of auscultation.—Between the lower border of the trapezius and the vertebral border of the scapula is an area, limited below by the upper border of the latissimus dorsi, in which the rhomboideus major is seen.

The remaining part of this area (14) is known as the triangle of auscultation, since in this region the chest wall is not covered by any thick mass of muscle, and therefore the lung sounds can be well heard here.

The figures indicate:—

Bony points. 1. External occipital protuberance.
2. Vertebra prominens.
3. Spine of scapula.
4. Lower angle of scapula.

Muscles. 5. Trapezius—Upper oblique fibres.
6. ,, Central tendon.
7. ,, Lower oblique fibres.
8. Rhomboideus major.
9. Latissimus dorsi.

Nerves. 10. Great occipital.
11. Small occipital.
12. Internal cutaneous branches from dorsal nerves.
13. External cutaneous branches from dorsal nerves.

Area. 14. Triangle of auscultation.

EDINBURGH: T. C. & E. C. JACK: AND 34 HENRIETTA STREET, LONDON, W.C.

UPPER LIMB—BACK. No. 1.

(EDINBURGH STEREOSCOPIC ANATOMY.)
Copyright: T. C. & E. C. Jack, Edinburgh, & 34 Henrietta St., London, W.C.

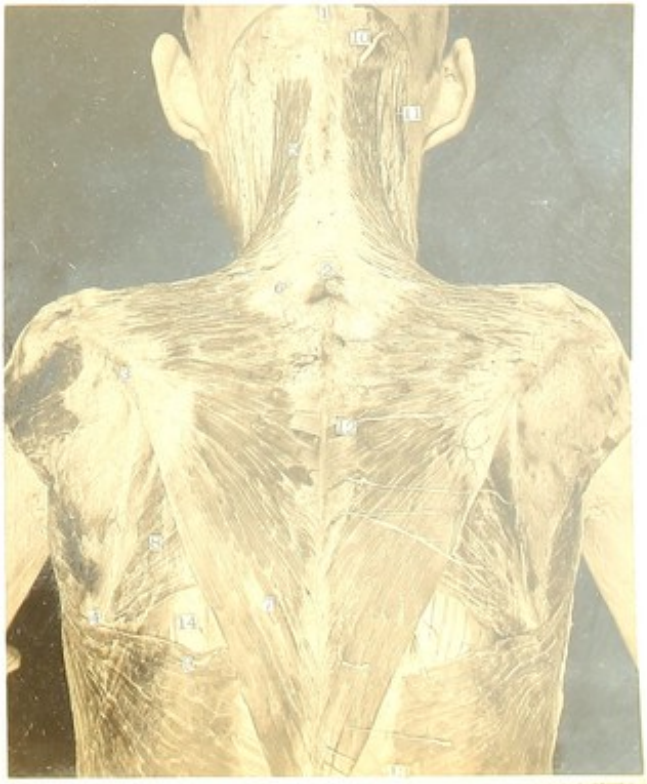

UPPER LIMB.

BACK.—No. 2.

THE TRAPEZIUS AND LATISSIMUS DORSI MUSCLES HAVE BEEN REFLECTED ON BOTH SIDES, AND THE RHOMBOID MUSCLES ON THE LEFT SIDE.

The rhomboid muscles lie side by side, and are separated from one another only by a small interval.

The **rhomboideus minor** arises from the lower part of the ligamentum nuchæ, and from the spines of the seventh cervical and first dorsal vertebræ and while the **rhomboideus major** arises from the spines of the upper four or five dorsal vertebræ below the first, and from the supra-spinous ligaments, and they are inserted into the vertebral border of the scapula, the lesser muscle opposite the root of the spine, and the greater one principally into the lower angle of the bone, but it is also attached as far up as to the spine by areolar tissue.

The rhomboids cover, among other structures, the serratus posticus superior muscle, and under the latissimus dorsi lies the serratus posticus inferior.

These two serrati muscles are extremely thin, and largely tendinous, and pass from the spines to the ribs, the upper muscle arising from the seventh cervical spine and the upper two or three dorsal, and being inserted into the second, third, fourth, and fifth ribs, external to their angles, while the lower arises from the two lower dorsal and two upper lumbar spines, and is inserted into the lower four ribs.

The levator anguli scapulæ is seen passing to its insertion into the base of the scapula from the upper angle to the spine.

The figures indicate—

Muscles. 1. Trapezius.
2. Latissimus dorsi.
3. Rhomboideus major.
4. Rhomboideus minor.
5. Levator anguli scapulæ.
6. Serratus posticus superior.

Muscles. 7. Serratus posticus inferior.
8. Ilio-costalis.
9. Longissimus dorsi.

Nerves. 10. Cutaneous external branch.
11. Spinal accessory.
12. Nerve to rhomboid muscles.

EDINBURGH: T. C. & E. C. JACK; AND 34 HENRIETTA STREET, LONDON, W.C.

UPPER LIMB BACK. No. 2.
EDINBURGH STEREOSCOPIC ANATOMY.
Copyright: T. C. & E. C. Jack, Edinburgh, & 34 Henrietta St., London, W.C.

UPPER LIMB.

AXILLA—No. 1.

THE SKIN AND FASCIÆ HAVE BEEN REMOVED, LEAVING THE CENTRAL PORTION OF THE AXILLARY, OR DEEP FASCIA, TO SHOW ITS CONNECTIONS, AND TO SHOW THE SUPERFICIAL NERVES, ETC., WHICH PASS DOWN THE ARM.

The **axillary fascia** is strong and thick, and forms the floor of the axillary space. It is continuous with the deep fascia of adjacent regions, passing, in front, on to the pectoralis major, on the inner side to the serratus magnus, behind, to the latissimus dorsi and teres major muscles, while on the outer side, it is in continuity with the general fascial investment of the upper arm. As it is connected by areolar tissue to the structures of the interior of the axillary space, it is drawn up, and forms the distinct fossa seen here.

It is pierced by some small cutaneous vessels and nerves. This fascia limits any swellings, especially fluid ones, which may occur in the axilla, and resists the spread of such to the surface.

It requires to be divided in opening axillary abscesses, and this is best done by Hilton's method, using a blunt instrument.

The structures which pass from the axilla down the upper arm are shown as seen by removal of a portion of the deep fascia. Of these, the axillary vein should always be identified first of all. It lies immediately subjacent to the deep fascia, and, when distended, overlaps and conceals the artery and some of the nerves.

Along the inner side of the vein is found the lesser internal cutaneous nerve, which unites in a variable manner with the lateral cutaneous branch of the second intercostal nerve, and with it runs down to supply the skin on the inner aspect of the arm as far as to the elbow.

Some branches of the lesser internal cutaneous nerve are seen running outwards on the coraco-brachialis and biceps.

The internal cutaneous nerve lies, in this region, to the outer side of the vein, and becomes cutaneous about the middle of the arm.

The figures indicate—

1. Anterior fold of axilla (pectoralis major).
2. Inner wall ,, ,, (serratus magnus).
3. Posterior wall ,, (latissimus dorsi).
4. Coraco-brachialis muscle.
5. Biceps muscle, short head.
6. Triceps muscle, long head.
7. Axillary vein.
8. Axillary artery.
9. Axillary fascia.

EDINBURGH: T. C. & E. C. JACK; AND 34 HENRIETTA STREET, LONDON, W.C.

UPPER LIMB AXILLA. No. I.
EDINBURGH STEREOSCOPIC ANATOMY
Copyright: T. C. & E. C. Jack, Edinburgh, & 34 Henrietta St., London, W.C.

UPPER LIMB.

AXILLA—No. 2.

THE GREATER PART OF THE PECTORALIS MAJOR MUSCLE HAS BEEN REMOVED, OPENING UP THE AXILLARY CAVITY FROM THE FRONT, AND THE CONTENTS OF THE AXILLA HAVE BEEN EXPOSED.

The structures lying within the axilla are very numerous, and most of them are highly important.

On the inner wall of the space, which is formed by the ribs and by the serratus magnus and intercostal muscles, lie the long thoracic vessels, a number of lymphatic glands, and, further back, the nerve to the serratus magnus muscle.

On the outer wall are found the structures passing to and from the arm, and the position of some of these has been already described (see No. 1).

The median nerve is now seen to lie very much in front of the axillary artery, while, higher up, the artery and the median nerve are crossed by a large and important vein, the outer of the two venæ comites of the brachial artery. The musculo-cutaneous nerve lies still further to the outer side.

The only structures visible on the posterior wall are the subscapular vessels and long subscapular nerve.

The axillary glands were somewhat enlarged in this subject, and therefore a good idea is obtained of the position and relations of some of then.

They are usually found to be disposed in the following sets :—

(1) One set lies along the axillary vessels, receiving tributaries from the arm ; (2) Another set lies along the margin of the subscapularis muscle, receiving the vessels from the back ; (3) A third set lies along the pectoralis minor and inner wall of the axilla, receiving vessels from the mammary region and front of chest. The great bulk of these glands lies in the fourth intercostal space, and it is this group which has mainly been enlarged in this specimen. The lymphatic vessels from them pass upwards towards the apex of the axilla, and converge towards a gland which is seen to be much enlarged ; (4) A central group of glands, lying in a pocket in the deep fascia, or sometimes superficial to it, may also be found.

The figures indicate—

Muscles.
1. Pectoralis major.
2. Pectoralis minor and superior thoracic vessels.
3. Serratus magnus.
4. Deltoid.
5. Short head of biceps.
6. Coraco-brachialis.
7. Latissimus dorsi.
8. Teres major.

Vessels.
9. Outer of the venæ comites of brachial artery.
10. Axillary vein.
11. Long thoracic vessels.
12. Subscapular vessels and long subscapular nerve.
13. Cephalic vein.
14. Axillary artery.

Nerves.
15. Musculo-cutaneous.
16. Intercosto-humeral.
17. Median.
18. Internal cutaneous.
19. Nerve of Bell.

Lymphatics.
20. Lymphatic gland, enlarged, from mamma.
21. Lymphatic gland and vessel from arm.
22. Upper lymphatic gland.

EDINBURGH: T. C. & E. C. JACK; AND 34 HENRIETTA STREET, LONDON, W.C.

UPPER LIMB AXILLA. No. 2.
EDINBURGH STEREOSCOPIC ANATOMY
Copyright T. C. & E. C. Jack, Edinburgh, & 34 Henrietta St., London, W.C.



UPPER LIMB.

AXILLA—No. 3.

THE PECTORALIS MAJOR HAS BEEN REFLECTED TO SHOW THE COSTO-CORACOID MEMBRANE.

Above the upper marign of the pectoralis minor, and below the subclavius muscle and clavicle, there is a small interval which is filled in by the **costo-coracoid membrane**. The formation and the relations of this membrane are as follows :—

The subclavius muscle above is enclosed in a strong fibrous sheath, which is attached to the under surface clavicle in front of the muscle and behind it.

The inner part of this membrane is extremely strong, and passes downwards to be attached to the first rib (12). The outer part is less strong, and below the subclavius muscle it is represented merely by a thin membrane which blends with the fascia of the pectoralis minor, and also passes deeply to join the axillary sheath.

The stronger portion passes from the first rib outwards to the coracoid process in a curved manner, and is called the costo-coracoid ligament.

Lying on the costo-coracoid membrane is a lymphatic gland, which is liable to infection from cancer of the breast. The membrane is pierced by the external anterior thoracic nerve as it passes to the pectoralis major, by the thoracic axis vessels, and by the cephalic vein. The thoracic axis vein is large, the artery has only a short course, and divides into branches which go to the pectoralis muscles, to the deltoid (acromial and humeral branches), and to the subclavius muscle (clavicular branch).

The lymphatic gland in this specimen is enlarged. Usually it is very small, but it can generally be detected by careful dissection.

The figures indicate—

Muscles.
1. Deltoid (divided).
2. Pectoralis major.
3. Long tendon of biceps.
4. Short head of biceps.
5. Coraco-brachialis.
6. Pectoralis minor.
7. Subclavius.

Nerves and Vessels.
8. Acromio-thoracic vein.
9. Acromio-thoracic artery.
10. External anterior thoracic nerve.
11. Gland on costo-coracoid membrane.
12. Costo-coracoid membrane, inner part.
13. Internal anterior thoracic nerve.

EDINBURGH: T. C. & E. C. JACK; AND 34 HENRIETTA STREET, LONDON, W.C.

UPPER LIMB—AXILLA. No. 3.
EDINBURGH STEREOSCOPIC ANATOMY.
Copyright: T. C. & E. C. Jack, Edinburgh, & 34 Henrietta St., London, W.C.

UPPER LIMB.

AXILLA.—No. 4.

THE ANTERIOR WALL OF THE AXILLA HAS BEEN REMOVED, TO SHOW THE ARRANGEMENT OF THE STRUCTURES WITHIN THE CAVITY.

The axillary vessels, which are directly continuous with the subclavian, commence at the outer border of the first rib, and run down to the lower border of the teres major tendon. The lower part of the vein has been removed, in the region where it overlaps the artery, but the vein has been left in the upper part, where it lies at a lower level than the artery and on an anterior plane.

The vessels rest upon the first intercostal space in the upper part, then on some areolar tissue, by which they are separated from the subscapularis muscle, and then they lie on the latissimus dorsi and teres major tendons.

They are covered in front by the pectoralis major and minor muscles and by the costo-coracoid membrane.

The great nerve cords of the brachial plexus lie at first above the artery, but they soon come to lie on different sides of that vessel, the inner cord on the inner side, the outer cord external to, and the posterior cord behind the artery. It will be seen, however, that the position of the posterior cord of the plexus is, at first, rather at a higher level than the other cords.

The external and internal anterior thoracic nerves form a plexus around the artery.

The figures indicate—

Muscles.
1. Deltoid.
2. Pectoralis major.
3. Biceps, long head.
4. Coraco-brachialis and biceps, short head.
5. Pectoralis minor.
6. External intercostal.

Other structures.
7. Axillary vein.
8. Axillary artery.
9. Outer cord.
10. Posterior cord.
11. Suprascapular nerve.
12. Superior thoracic vessels.
13. Internal anterior thoracic nerve.
14. Anterior circumflex artery.
15. Coraco-acromial ligament.

EDINBURGH: T. C. & E. C. JACK; AND 34 HENRIETTA STREET, LONDON, W.C.

Copyright: T. C. & E. C. Jack, Edinburgh, & 34 Henrietta St., London, W.C. (EDINBURGH STEREOSCOPIC ANATOMY)

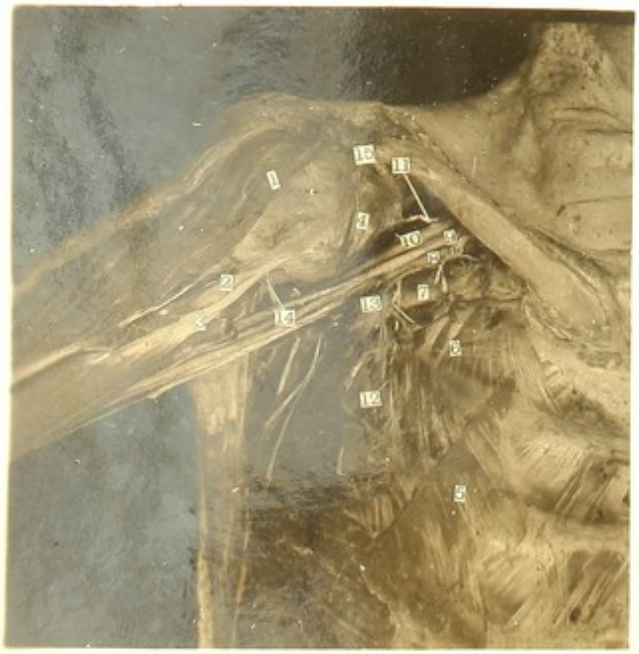

UPPER LIMB.

SCAPULAR REGION—No. 1.

THE SKIN AND LAYERS OF FASCIA HAVE BEEN REMOVED FROM THE SURFACE OF THE DELTOID, THE BACK OF THE SCAPULA, AND THE BACK OF THE ARM.

The cutaneous nerves in this region are derived from some descending branches of the cervical plexus, which have been removed, and from the circumflex nerve, of which some branches wind round the posterior border of the deltoid, and some pierce the muscle, accompanied by small branches of the posterior circumflex artery.

The prominence of the shoulder is formed by the deltoid muscle, which has a wide origin from the outer third of the clavicle, the acromion process and the spine of the scapula, from which the fibres converge to the insertion into the outer aspect of the shaft of the humerus about its middle.

The deltoid covers the shoulder joint, and the muscles arising from the dorsal aspect of the scapula.

The quadrilateral space is concealed by the deltoid, but the triangular space is seen to be a small intermuscular interval lying between the teres major and teres minor—the latter being at present indistinguishable from the infra-spinatus muscle—below the long head of the triceps.

The figures indicate—

Muscles—1. Deltoid.
2. Triceps, outer head.
3. Triceps, long head.
4. Teres major.
5. Latissimus dorsi.

Muscles—6. Infra-spinatus, and teres minor, with fascia.
7. Trapezius.

Nerves and Vessels—8 and 9. Cutaneous branches of circumflex nerve and posterior circumflex artery.

EDINBURGH: T. C. & E. C. JACK; AND 34 HENRIETTA STREET, LONDON, W.C.

UPPER LIMB-SCAPULAR REGION. No. I.
EDINBURGH STEREOSCOPIC ANATOMY.
Copyright: T. C. & E. C. Jack, Edinburgh, & 34 Henrietta St., London, W.C.

UPPER LIMB.

SCAPULAR REGION.—No. 2

THE POSTERIOR PART OF THE DELTOID HAS BEEN REMOVED, TO SHOW THE MUSCLES, ETC. WHICH IT COVERS.

On the dorsal aspect of the scapula, below the spine of that bone, lie the infraspinatus, teres minor, and teres major muscles, while the latissimus dorsi also gains a slight origin from this surface of the bone at the lower angle.

The infraspinatus muscle arises from the infraspinous fossa, excepting a small part near the neck, and from the investing fascia. The teres minor arises from an elongated flat surface on the dorsal aspect of the axillary border of the scapula, and from the adjacent intermuscular septum, while the teres major arises from an oval area on the dorsal aspect of the lower angle of the scapula.

The infraspinatus and teres minor muscles pass upwards and outwards to the greater tuberosity of the humerus, covering the back of the shoulder-joint, while the teres major passes in front of the long head of the triceps and the humerus, to reach the inner lip of the bicipital groove of that bone.

Those three muscles receive their nerve supply from different sources, the infraspinatus from the suprascapular nerve, the teres minor from the circumflex, and the teres major from the lower subscapular nerve.

Access to the shoulder-joint from behind can be gained by separating or by dividing the infraspinatus and teres minor muscles after reflecting the deltoid muscle.

The nerves and vessels of this region are more fully exposed in the next view.

The figures indicate—

Muscles.	1 Trapezius.	Muscles.	6. Latissimus dorsi.
	2. Deltoid.		7. Long head of triceps.
	3. Infraspinatus.		8. Outer head of triceps.
	4. Teres minor.	Vessels and Nerves.	9. Circumflex nerve.
	5. Teres major.		10. Posterior circumflex vessels.

EDINBURGH: T. C. & E. C. JACK; AND 34 HENRIETTA STREET, LONDON, W.C.

UPPER LIMB—SCAPULAR REGION. No. 2.
EDINBURGH STEREOSCOPIC ANATOMY.
Copyright: T. C. & E. C. Jack, Edinburgh, & 34 Henrietta St., London, W.C.

UPPER LIMB.

SCAPULAR REGION—No. 3.

THE ACROMION PROCESS HAS BEEN REMOVED, AND THE INFRASPINATUS AND TERES MINOR MUSCLES CUT AWAY, IN ADDITION TO THE FORMER DISSECTION.

The outer head of the triceps passes up along the shaft of the humerus nearly to the great tuberosity.

The long head of the triceps is attached to the vertebral border of the scapula below the glenoid fossa, and, passing down, it intersects a triangular interval between the teres major and the teres minor, dividing it into an upper and a lower part, and the upper part is known as the quadrilateral space, and the lower as the triangular. These spaces, as will be noticed, are not present in the undissected subject except as intermuscular intervals, and can only be seen as spaces by an artificial separation.

The quadrilateral space is bounded above by the teres minor, below by the teres major, internally by the long head of the triceps, and on the outer side by the humerus, and it transmits the circumflex nerve and the posterior circumflex vessels in their course from the axilla to this region.

In the lower, or triangular space, the dorsalis scapulæ artery makes its appearance, and it winds round the border of the scapula, to be distributed principally to the infraspinous fossa.

The nerves and blood-vessels of the scapular region are arranged as follows:—

A branch of the suprascapular artery passes into the infraspinous fossa below the root of the acromion, with the termination of the suprascapular nerve, and anastomoses with the dorsalis scapulæ, and both of these vessels anastomose with the posterior scapular artery, which runs along the vertebral border, under cover of the rhomboid muscles.

The figures indicate—

1. Trapezius.
2. Supraspinatus.
3. Infraspinatus and teres minor.
4. Teres major.
5. Long head of triceps.
6. Capsular ligament of shoulder.
7. Glenoid ligament.
8. Suprascapular artery and nerve.
9. Dorsalis scapulæ artery.
10. Outer head of triceps.
11. Deltoid.

EDINBURGH: T. C. & E. C. JACK; AND 34 HENRIETTA STREET, LONDON, W.C.

UPPER LIMB—SCAPULAR REGION. No. 3.

EDINBURGH STEREOSCOPIC ANATOMY.
Copyright: T. C. & E. C. Jack, Edinburgh, & 34 Henrietta St., London, W.C.

UPPER LIMB.

BACK OF ARM—No. 1.

A PORTION OF THE OUTER HEAD OF THE TRICEPS HAS BEEN REMOVED, TO SHOW THE MUSCULO-SPIRAL GROOVE AND ITS CONTENTS.

Triceps.—The outer head of this muscle arises from the posterior surface of the shaft of the humerus above the musculo-spiral groove, and from a fibrous arch which covers over the groove, while the inner head of the muscle arises from the back of the humerus below that groove, and from the intermuscular septa on either side.

Musculo-spiral groove.—This groove winds round the back of the humerus in a spiral manner from the inner to the outer side, and conveys the musculo-spiral nerve and the superior profunda vessels.

The musculo-spiral nerve, arising in the axilla from the posterior cord of the brachial plexus, lies in the musculo-spiral groove, covered by the long head of the triceps, and between the inner and outer heads of that muscle, and after piercing the external intermuscular septum, gains the interval between the brachialis anticus and brachio-radialis muscles. (See Antecubital Fossa.—No 3.)

In its course it gives off the following branches:—

(1) On the inner side of the arm, an internal cutaneous branch, a branch to the long head of the triceps, and a branch to the inner head of that muscle, the latter being called the ulnar collateral nerve.

(2) In the musculo-spiral groove, branches to all the heads of the triceps, and also a branch which is noticeable, as it runs down in the inner head muscle and ends in the anconeus muscle. While in the groove, it also gives off two external cutaneous branches, an upper and a lower, which supply regions of skin on the back and outer sides of the arm and forearm.

(3) In the last part of its course it gives muscular branches to the brachialis anticus, brachio-radialis, extensor carpi radialis longior and sometimes also to the extensor carpi radialis brevior muscles, and terminates in the radial and posterior interosseous nerves.

The superior profunda artery accompanies the nerve in the region seen here, and divides into two branches which run to the elbow behind and in front of the external intermuscular septum respectively, to take part in the anastomosis about the elbow-joint.

The figures indicate:—

1. Deltoid.
2. Outer head of triceps.
3. Long head of triceps.
4. Inner head of triceps.
5. Brachialis anticus.
6. Musculo-spiral nerve.
7. Nerve to brachialis anticus.
8. Cutaneous branch of musculo-spiral.
9. Lower external cutaneous branch.
10. Nerve to inner head of triceps.
11. Branch of superior profunda vessels.

EDINBURGH: T. C. & E. C. JACK: AND 34 HENRIETTA STREET, LONDON, W.C.

UPPER LIMB BACK OF ARM. No. 1
EDINBURGH STEREOSCOPIC ANATOMY.
Copyright: T. C. & E. C. Jack, Edinburgh, & 34 Henrietta St., London, W.C.

UPPER LIMB.

ANTECUBITAL FOSSA—No. 1.

THE SKIN AND SUPERFICIAL FASCIA HAVE BEEN REMOVED, LEAVING THE CUTANEOUS NERVES AND VESSELS IN SITU.

The antecubital fossa is a small hollow opposite the front of the elbow-joint bounded by muscles, and containing principally nerves and blood-vessels. Its roof is formed by skin and fasciæ, and contains the following structures :—

1. Nerves.—The cutaneous nerves in this region are derived from the internal and external cutaneous nerves. The former nerve pierces the deep fascia about the centre of the upper arm. Two branches, anterior and posterior, pass from it, and supply the front and inner side of the forearm. The branches pass, some over and some under the median basilic vein. The external cutaneous nerve,—the terminal branch of the musculo-cutaneous nerve,—becomes cutaneous at the outer border of the tendon of the biceps, and supplies the front and outer side of the forearm.

2. Veins.—The arrangement of the superficial veins in this region is very variable. There is, however, almost constantly, a large median basilic vein, which passes obliquely upwards and inwards from the centre of the antecubital fossa, and this is the vessel from which blood may be withdrawn in phlebotomy, or into which fluid may be transfused.

Its course and relations are therefore of interest, and it is formed in the following manner :—

The median vein passes up the centre of the forearm, and receives a tributary called the profunda vein. It then divides into two branches, the outer, usually smaller, is the median cephalic, and the inner is the median basilic vein. This latter trunk is joined by one or two ulnar branches, and the resulting vessel is the basilic, while the median cephalic is joined by a radial vein and is then called the cephalic.

3. Lymphatic glands.—Two small lymphatic glands are seen lying in the superficial fascia just above the inner condyle. These glands receive lymphatic vessels from the forearm and hand.

The figures indicate—

Veins—1. Median.
2. Median cephalic.
3. Median basilic.
4. Anterior ulnar.
5. Basilic.
Veins—6. Posterior ulnar.
Nerves—7. Internal cutaneous.
8. Musculo- or external cutaneous.
Glands—9. Epitrochlear lymphatic glands (two).

EDINBURGH: T. C. & E. C. JACK; AND 34 HENRIETTA STREET, LONDON, W.C.

UPPER LIMB—ANTECUBITAL FOSSA. No. 1.
EDINBURGH STEREOSCOPIC ATLAS OF ANATOMY.
Copyright: T. C. & E. C. Jack, Edinburgh, & 34 Henrietta St., London, W.C.

UPPER LIMB.

ANTECUBITAL FOSSA—No. 2.

THE STRUCTURES FORMING THE ROOF OF THE SPACE HAVE BEEN REMOVED, THE BICIPITAL FASCIA BEING LEFT, AND THE STRUCTURES CONTAINED WITHIN IT HAVE BEEN EXPOSED.

The bicipital or semilunar fascia is a strong band of deep fascia, which passes from the tendon of the biceps muscle to the fascia on the inner side of the forearm, and is an important insertion for that muscle.

It crosses the brachial artery.

The lateral boundaries of the antecubital fossa are the supinator longus (brachio-radialis) on the outer side, and the pronator radii teres on the inner, while the base of the space is arbitrarily taken to be a line between the condyles.

The tendon of the biceps passes into the interior of the space, to gain its insertion into the back part of the bicipital tuberosity of the radius.

On the inner side of the biceps lie the brachial artery, with its venæ comites, and the median nerve lying to the inner side of the vessel. These latter structures are seen resting on the brachialis anticus muscle.

The brachial artery has bifurcated high up and is represented in this specimen by two vessels lying, one superficially and the other deeply, and the median nerve has crossed by passing under cover of the vessels, while more frequently it crosses the artery superficially.

These variations in the artery which are of frequent occurrence, require attention in such operations as ligature of the brachial, since both trunks must be tied.

The figures indicate—

1. Bicipital fascia and biceps muscle.
2. Brachialis anticus muscle.
3. Triceps muscle.
4. Brachio-radialis muscle.
5. Pronator radii teres muscle.
6. Flexor carpi radialis muscle.
7. Brachial artery and venæ comites.
8. Median nerve.
9. Musculo-cutaneous nerve.

EDINBURGH: T. C. & E. C. JACK; AND 34 HENRIETTA STREET, LONDON, W.C.

UPPER LIMB—ANTECUBITAL FOSSA. No. 2.
EDINBURGH STEREOSCOPIC ANATOMY

UPPER LIMB.

ANTECUBITAL FOSSA—No. 3.

THE SPACE HAS BEEN OPENED UP BY DIVIDING THE BICIPITAL FASCIA AND DRAWING THE MUSCLES ASIDE, AND THE CONTENTS ARE EXPOSED.

Within the antecubital fossa, the brachial artery divides into its two terminal branches, the musculo-spiral nerve divides into the radial and posterior interosseous nerves, the median nerve gives off several muscular branches, and lying deeply on each side is found a recurrent articular artery, from the radial artery on the outer side and from the ulnar on the inner.

The musculo-spiral nerve divides opposite the bend of the elbow, where it lies between the brachialis anticus and brachio-radialis muscles, after giving off muscular branches to the brachio-radialis and extensor carpi radialis longior. The posterior interosseous branch disappears into the substance of the supinator brevis muscle, while the radial nerve runs down, and comes to lie beside the radial artery.

The median nerve passes out of the antecubital fossa by passing between the two heads of the pronator radii teres muscle.

Thus both the posterior interosseous and median nerves are liable to injurious compression by contraction of the muscles through which they pass. The median nerve contains sensory fibres, and thus pain may be produced as well as paresis of muscles, but the posterior interosseus is distributed to muscles, and therefore there are no sensory phenomena produced.

The recurrent articular arteries take part in the anastomosis about the elbow, anastomising with branches of the brachial artery seen in another view.

The high division of the brachial artery in this specimen produces some conditions which are only occasionally present, but the condition illustrated occurs with considerable frequency.

The floor of the fossa is now seen to be formed by the brachialis anticus and supinator brevis muscles.

The figures indicate—

Muscles.
1. Pronator radii teres.
2. Brachialis anticus.
3. Brachio-radialis.
4. Tendon of biceps.
5. Semilunar fascia of biceps.

Nerves.
6. Musculo-cutaneous.
7. Median.
8. Musculo-spiral.

Vessels.
9. Radial recurrent artery.

EDINBURGH: T. C. & E. C. JACK; AND 34 HENRIETTA STREET, LONDON, W.C.

UPPER LIMB—ANTICUBITAL FOSSA. No. 3.
EDINBURGH STEREOSCOPIC ANATOMY
Copyright T. C. & E. C. Jack, Edinburgh & 34 Henrietta St., London, W.C.

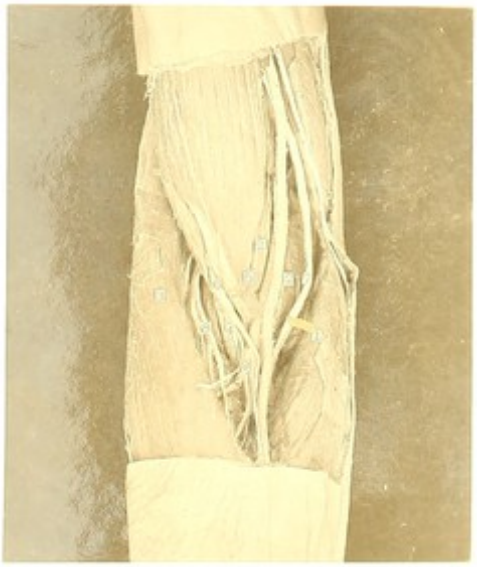

UPPER LIMB.

FRONT OF FOREARM—No. 1.

THE SUPERFICIAL STRUCTURES HAVE BEEN REMOVED TO SHOW THE MUSCLES. COMPARE WITH THIS THE VIEW OF SURFACE ANATOMY NO. 4.

The superficial muscles of the front of the forearm are arranged as follows:—The brachio-radialis muscle lies along the outer border of the forearm. To its inner side lies a group of superficial muscles belonging to the pronator and flexor group, and comprising the pronator radii teres (2), flexor carpi radialis (3), palmaris longus (4), and flexor carpi ulnaris (6); while the flexor sublimis digitorum (5) lies under cover of them.

These muscles have a common origin from the front of the internal condyle, from the investing fascia, and from the intermuscular septa, and the pronator muscle, the flexor carpi ulnaris and the flexor sublimis digitorum have each one or more accessory heads of origin, all of which lie at a deeper level.

Lower down in the forearm the fleshy bellies of these muscles are largely replaced by tendons, and the principal vessels and nerves come to lie nearer the surface between the tendons.

Thus, at the wrist, the radial artery, with its venæ comites, lies between the brachio-radialis and the flexor carpi radialis, and the ulnar vessels and nerve lie between the flexor carpi ulnaris and the flexor sublimis digitorum tendons, while the median nerve lies between the flexor carpi radialis and the palmaris longus.

The radial nerve does not accompany the corresponding artery to the wrist-joint, but in the lower third of the forearm it leaves it, and passes under the brachio-radialis to the back of the wrist.

The figures indicate—

Muscles.
1. Brachio-radialis.
2. Pronator radii teres.
3. Flexor carpi radialis.
4. Palmaris longus.
5. Flexor sublimis digitorum.
6. ,, carpi ulnaris.
7. Ext. ossis metacarpi pollicis and postannular ligament.

Other structures.
8. Median nerve.
9. Pisiform bone.
10. Anterior annular ligament, and ulnar artery passing over it.
11. Brachial artery and venæ comites.
12. Anastomotica magna artery.
13. Musculo-cutaneous nerve (a recurrent branch).
14. Radial nerve.
15. Radial vessels.

EDINBURGH: T. C. & E. C. JACK; AND 34 HENRIETTA STREET, LONDON, W.C.

UPPER LIMB—FRONT OF FOREARM. No. 1.
EDINBURGH STEREOSCOPIC ANATOMY.
Copyright: T. C. & E. C. Jack, Edinburgh, & 34 Henrietta St., London, W.C.

UPPER LIMB.

PALM OF HAND.—No. 1.

THE SKIN AND MOST OF THE SUPERFICIAL FASCIA HAVE BEEN REMOVED TO SHOW THE DEEP FASCIA AND THE CUTANEOUS NERVES AND VESSELS.

1. Superficial fascia. This fascia at the root of the fingers shows an arrangement similar to that found in the foot, in the form of a transverse band of fibres at the root of the fingers called the superficial transverse ligament.

In the fascia over the ball of the little finger a small muscle appears, the palmaris brevis, which arises from the central part of the deep fascia, and is inserted into the skin on the ulnar side of the hand.

2. The deep fascia is in three parts, a central and two lateral. The lateral portions are weak and invest the short muscles of the ball of the thumb and little finger, while the central portion is strong, and is triangular in shape. The apex is attached to the anterior annular ligament at the wrist, and gives insertion to the tendon of the palmaris longus, and the base, as in the foot, is prolonged in the form of slips which pass to the digits and become continuous with the fibrous sheaths for the flexor tendons. Between these slips digital vessels and nerves appear.

3. The cutaneous nerves are numerous and are arranged as follows from the radial to the ulnar sides :—(1) A branch of the radial nerve to the outer side and back of the thumb. (2) Branches of the median nerve, supplying both sides of the thumb. The outer one is seen. (3) The median nerve also sends branches to the index finger on its radial side (15) and to the two adjacent interdigital spaces (16 and 17), and these latter branches supply the adjacent sides of the fingers between which they lie. (4) The ulnar nerve supplies the two branches, one to the inner side of the little finger, and another to the adjacent sides of the little and ring fingers (14).

4. The ulnar nerve and artery have been exposed at the point where they pass in front of the anterior annular ligament by removing a band of fascia which covers them at that point.

The figures indicate—

1. Central portion of palmar fascia.
2. Superficial transverse ligament.
3. Fibrous flexor sheath.
4. Palmaris brevis muscle.
5. Abductor pollicis muscle.
6. Outermost lumbrical muscle.
7. Deep fascia of forearm.
8. Anterior annular ligament
9. Palmaris longus tendon.
10. Radial nerve.
11. External cutaneous nerve.
12. Pisiform bone.
13. Ulnar artery and nerve.
14. Digital branches of ulnar nerve.
15, 16, 17. Digital branches of median nerve and digital arteries.
18. Palmar branch of median nerve.

EDINBURGH: T. C. & E. C. JACK: AND 34 HENRIETTA STREET, LONDON, W.C.

UPPER LIMB—PALM OF HAND. No. 1.

EDINBURGH STEREOSCOPIC ANATOMY.
Copyright: T. C. & E. C. Jack, Edinburgh, & 34 Henrietta St., London, W.C.

UPPER LIMB.

PALM OF HAND.—No. 2.

THE DEEP FASCIA HAS BEEN REMOVED, TO SHOW THE MUSCLES, NERVES, VESSELS, AND TENDONS LYING UNDER IT.

The flexor sheaths of two digits have been opened to show the arrangement of the tendons; and the two middle lumbrical muscles have been cut away.

Muscles. The muscles of the ball of the thumb are—(1) the abductor pollicis, which is the most superficial, (2) the opponens pollicis, which lies largely under cover of it, (3) the flexor brevis pollicis, which lies to the inner side.

The **superficial palmar arch** is formed by the ulnar artery, and may be completed in several different ways, *e.g.* by anastomosing with the superficial volar; or, as here, it may not communicate with any large vessel on the radial side of the palm.

The arch rests successively on the anterior annular ligament, on the short muscles of the little finger, on the flexor tendons and lumbrical muscles, and on the digital branches of the median nerve. The ulnar artery gives off a profunda branch, and four digital vessels, whose distribution is well seen here, arise from the palmar arch.

The **ulnar nerve** lies on the inner side of the ulnar artery, just external to the pisiform bone, and soon gives off a deep branch which passes between the abductor and flexor brevis minimi digiti, while the superficial division passes on and divides into two digital branches. The inner of these is reinforced in this specimen by a twig from the dorsal branch of the ulnar nerve.

The **median nerve** enters the palm under cover of the anterior annular ligament, and therefore is not seen in that part of its course. It soon divides into (1) an outer branch, from which a stout nerve is given to the three muscles of the ball of the thumb, and digital branches to both sides of the thumb and to the radial side of the index finger, and (2) an inner division, from which two inner digital branches arise. The digital branches of this nerve give the supply to the outer two and sometimes three lumbricals.

There is here the communication in the palm between the median and ulnar nerves which is sometimes present.

The figures indicate—

Muscles. 1. Opponens pollicis.
2. Abductor ,,
3. Flexor brevis ,,
4. 1st lumbrical.
5. Abductor minimi digiti.

Vessels. 6. Tendon of flexor sublimis.
7. Tendon of flexor profundus.
8. Superficial volar.
9. Ulnar.
10. Superficial palmar arch.

Nerves, etc. 11. Princeps pollicis
12. Ulnar.
13. Outer digital branch of ulnar.
14. Muscular branch of median.
15. Radial.
16. Ligamentum longum of flexor tendon.

EDINBURGH: T. C. & E. C. JACK; AND 34 HENRIETTA STREET, LONDON, W.C.

UPPER LIMB PALM OF HAND. No. 2.
EDINBURGH STEREOSCOPIC ANATOMY
Copyright: T. C. & E. C. Jack, Edinburgh, & 34 Henrietta St., London, W.C.

UPPER LIMB.

FRONT OF FOREARM AND PALM—No. 2.

THE DISSECTION HAS BEEN CONTINUED SO AS TO EXPOSE THE DEEPER LYING STRUCTURES IN THE PALM, ESPECIALLY THE DEEP PALMAR ARCH, AND THE MUSCLES OF THE DIFFERENT LAYERS IN THE FOREARM HAVE BEEN DIVIDED AT DIFFERENT LEVELS.

The deep palmar arch is formed by the terminal part of the radial artery which enters the palm through the upper part of the first interosseous space between the heads of the first dorsal interosseous muscle, and appears between the adjacent margins of the adductor obliquus and adductor transversus pollicis. It crosses the bases of the metacarpal bones and the interossei, and anastomoses with the deep branch of the ulnar artery.

It is accompanied by the deep branch of the ulnar nerve, and it gives off some branches as follows:—(1) recurrent, which run up to the front of the carpus; (2) superior perforating, which pass backwards in the upper part of the three interosseous spaces to the dorsum of the hand; and (3) three palmar interosseous branches, of which two are seen, which pass forwards in front of the interosseous spaces and join the digital branches of the superficial palmar arch.

The deep branch of the ulnar nerve supplies all the muscles of the palm which lie to the inner side of the tendon of the flexor longus pollicis, except the two outer lumbricals, which receive their nerve supply from the median nerve.

The pronator quadratus is seen to be a flat, square-shaped muscle, which arises from the anterior surface of the ulna in its lower fourth, and is inserted into the anterior and inner surface of the lower end of the radius.

The radial artery is seen to pass from the front of the forearm by winding round the outer side of the wrist joint, under cover of the tendons of the extensor ossis metacarpi pollicis, and extensor primi internodii pollicis.

In the forearm, the median nerve is seen to lie under cover of the flexor sublimis digitorum, on the surface of the flexor longus pollicis, while the ulnar nerve and artery, at the same level, lie on the flexor profundus digitorum, under cover of the flexor carpi ulnaris, and to the inner side of the flexor sublimis digitorum.

The figures indicate—

1. Pisiform bone.
2. Scaphoid.
3. Extensor ossis metacarpi pollicis.
4. Flexor longus pollicis.
5. Pronator quadratus.
6. Transverse metacarpal ligament.
7. Tendon of a lumbrical muscle.
8. Flexor carpi radialis.
9. Flexor sublimis digitorum.
10. Palmaris longus.
11. Flexor carpi ulnaris.
12. Flexor profundus digitorum.
13. Radial artery.
14. Ulnar artery and nerve.
15. Deep palmar arch and branch of ulnar nerve.
16. Adductor transversus pollicis.
17. Adductor obliquus pollicis.
18. Opponens pollicis.
19. Opponens minimi digiti.
20. Interosseous muscles.
21. Anterior ligament of wrist.
22. Median nerve and artery.
23. Radial nerve.
24. Brachio-radialis muscle.

EDINBURGH: T. C. & E. C. JACK; AND 34 HENRIETTA STREET, LONDON, W.C.

UPPER LIMB FRONT OF FOREARM AND PALM. No. 2.

(EDINBURGH STEREOSCOPIC ANATOMY)
Copyright: T. C. & E. C. Jack, Edinburgh, & 34 Henrietta St., London, W.C.

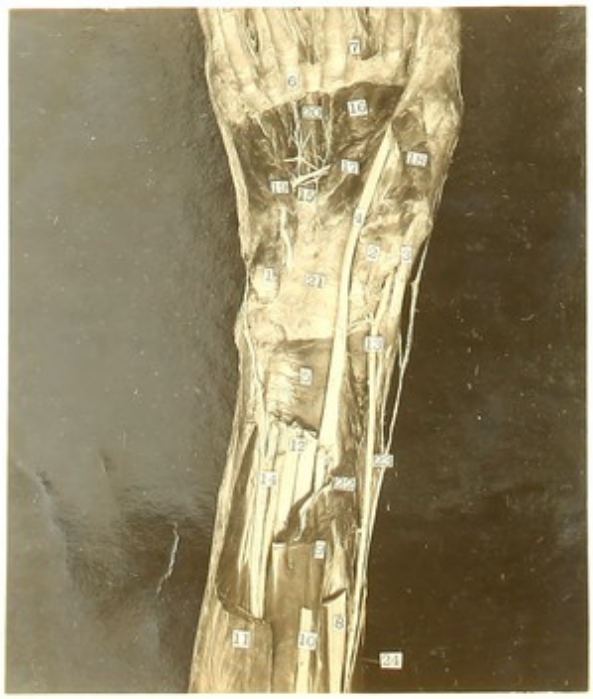

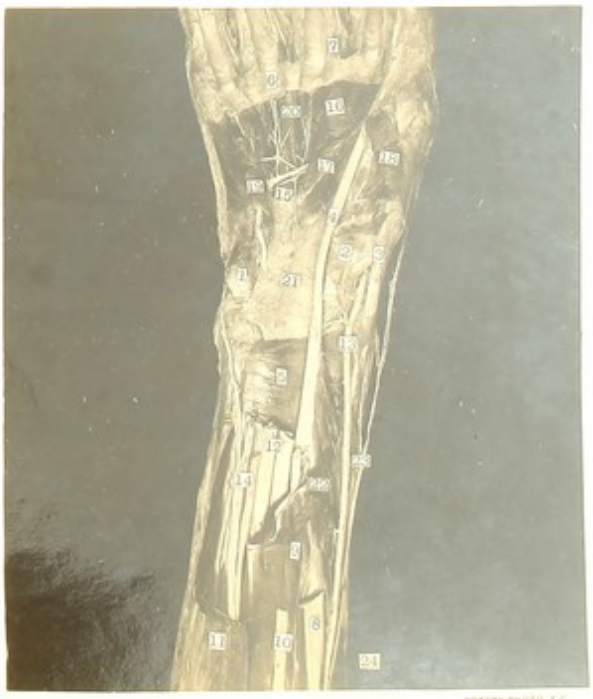

UPPER LIMB.

ARTICULATIONS—No. 1.

LIGAMENTS OF THE SHOULDER AND ELBOW-JOINTS SEEN FROM THE FRONT. THREE SPECIMENS.

A. Attached to the coracoid process are the coraco-humeral, coraco-acromial, and coraco-clavicular ligaments.

The coraco-acromial ligament (3) is triangular in shape, the base is attached to the outer margin of the coracoid process, and the apex to the tip of the acromion. The central portion is weak, and sometimes, as here, shows a triangular aperture. The outer part overlies the capsular ligament of the shoulder, from which it is separated by a bursa.

The coraco-humeral ligament (4) lies at a deeper level, and passes from the root and outer border of the coracoid process to the tuberosities of the humerus, blending with the capsular ligament.

The acromio-clavicular capsular ligament (2) consists of short strong fibres, which do not require special description. The coraco-clavicular ligament (1) is in two bands—of which the anterior, which is seen here, is called the trapezoid band. It passes from the root of the coracoid process to the under surface of the clavicle. The capsular ligament of the shoulder-joint (7) is a dense and strong but lax structure, attached to the scapula around the glenoid ligament internally, and to the anatomical neck of the humerus externally. Below the coracoid process, there is an aperture in it, through which the synovial membrane communicates with a bursa below the subscapularis muscle, and between the tuberosities of the humerus is another opening (8) which transmits the long tendon of the biceps muscle.

B. The Anterior ligament of the elbow (9) is attached, above, to the front of the humerus, above the radial and coronoid fossæ, and, below, blends with the orbicular ligament externally (11), and is attached to the tip and margins of the coronoid process of the ulna internally.

C. The orbicular ligament (12) surrounds the neck of the radius like a collar, and is attached to the anterior and posterior margins of the lesser sigmoid cavity of the ulna.

The figures indicate ligaments and tendons as follows—

In **A**. 1. Trapezoid band.
2. Superior acromio-clavicular.
3. Coraco-acromial.
4. Coraco-humeral.
5. Pectoralis minor.
6. Coraco-brachialis and biceps.
7. Capsular ligament of shoulder.
8. Long tendon of biceps and transverse ligament.

In **B**. 9. Anterior ligament of elbow.
10. Brachialis anticus.
11. Orbicular ligament.

In **C**. 12. Orbicular ligament.
13. Internal lateral ligament of elbow.

EDINBURGH: T. C. & E. C. JACK: AND 34 HENRIETTA STREET, LONDON, W.C

UPPER LIMB—ARTICULATIONS, SHOULDER AND ELBOW. No. 1.
EDINBURGH STEREOSCOPIC ANATOMY.
Copyright: T. C. & E. C. Jack, Edinburgh, & 34 Henrietta St., London, W.C.

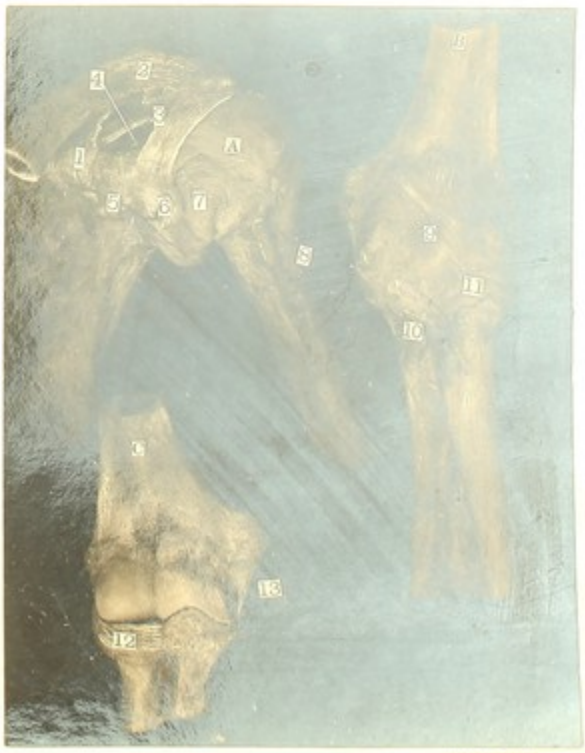

UPPER LIMB.

ARTICULATIONS—No. 2.

LIGAMENTS OF SHOULDER AND ELBOW, SEEN FROM BEHIND. THREE SPECIMENS.

A. The acromio-clavicular capsular ligament (1) requires no further description. (See No. 1).

The suprascapular, or transverse, ligament (2) bridges over the suprascapular notch, and forms a foramen which transmits the suprascapular nerve.

The posterior band of the coraco-clavicular ligament, or conoid band (3) passes from the root of the coracoid to the conoid tubercle of the clavicle.

The glenoid ligament (5) is a rim of fibro-cartilage which surrounds and deepens the glenoid fossa, and gives attachment to the capsular ligament of the shoulder (6).

B. The posterior ligament of the elbow-joint is attached above to the back of the humerus above the olecranon fossa, and to the back of the condyles on either side, and passes down to be attached to the olecranon process around the margin of the articular surface.

C. The internal lateral ligament is triangular in shape, passing from the lower part of the internal condyle above to the inner aspect of the olecranon process (9), while another band passes to the inner margin of the coronoid process (10).

A third band passes from the olecranon to the coronoid process, and joins the lower ends of the former bands to one another, bridging over a small channel which transmits some small articular vessels.

The figures indicate ligaments and tendons—

In **A.**
1. Superior acromio-clavicular.
2. Suprascapular.
3. Conoid.
4. Trapezoid.
5. Glenoid.
6. Capsular ligament of shoulder.
7. Infraspinatus.

In **B.** 8. Posterior ligament of elbow.

In **C.** 9. Posterior band of internal lateral ligament of elbow.
10. Anterior band of same.

EDINBURGH: T. C. & E. C. JACK; AND 34 HENRIETTA STREET, LONDON, W.C.

UPPER LIMB—ARTICULATIONS, SHOULDER AND ELBOW. No. 2.

EDINBURGH STEREOSCOPIC ANATOMY.
Copyright: T. C. & E. C. Jack, Edinburgh, & 34 Henrietta St., London, W.C.

UPPER LIMB.

BACK OF FOREARM AND WRIST JOINT.—No. 1. TWO SPECIMENS.

A. This dissection shows the arrangement of the superficial muscles of the back of the forearm.

The view should be compared with that of Surface Anatomy, No. 5, and the groups of muscles identified, viz., an outer set consisting of the brachio-radialis and the two radial extensors, which is separated, lower down, by the extensor ossis metacarpi and extensor primi internodii pollicis from an inner set, which consists of the extensor communis digitorum, extensor proprius minimi digiti, and extensor carpi ulnaris.

The extensor proprius indicis and extensor secundi internodii pollicis tendons are shown still lower down.

B. Wrist-Joint. A section has been made through the wrist, to show the principal synovial cavities, and the triangular fibro-cartilage of the wrist-joint.

The synovial sacs are as follows :—

1. There is a cavity for the radio-carpal and one also for the inferior radio-ulnar joints.

2. There is a cavity between the proximal and distal row of carpal bones, which is continuous with the cavity of the carpo-metacarpal articulation.

The joints in this region have the following arrangement :—

There are three lines of articulation more or less transverse in character. The first between the radius and the triangular fibro-cartilage on the one hand and the proximal row of the carpus on the other. The cavity of this joint is shut off from the others.

The second line of articulation extends in an S-shaped curve across the wrist, between the proximal and distal rows of carpal bones.

The third line of articulations between the distal row of the carpus and the bases of the metacarpals is often divided into two parts by a ligament, as here, passing from the unciform to the base of the third metacarpal. When that is so, there is a separate inner synovial cavity, and an outer one which communicates with the second line of articulations. The intermetacarpal joints are continuous with the adjacent part of this line of articulation.

3. The thumb has a separate joint for itself, at the articulation between the trapezium and first metacarpal bone.

The figures indicate :—

In A.

Muscles.
1. Brachio-radialis.
2. Extensor carpi radialis longior.
3. Extensor carpi radialis brevior.
4. Extensor ossis metacarpi pollicis.
5. Extensor primi internodii pollicis.
6. Extensor communis digitorum.
7. Extensor proprius minimi digiti.
8. Extensor carpi ulnaris.
9. Anconeus.
10. Triceps.
11. Extensor secundi internodii pollicis.

Ligament.
12. Posterior annular ligament.

In B.

Bones.
1. Radius.
2. Ulna.
3. Scaphoid.
4. Semilunar.
5. Cuneiform.
6. Trapezium.
7. Trapezoid.
8. Os magnum.
9. Unciform.
10. First metacarpal.
11. Second metacarpal.
12. Third metacarpal.
13. Fourth metacarpal.
14. Fifth metacarpal.

Ligament.
15. Triangular ligament.

EDINBURGH: T. C. & E. C. JACK; AND 34 HENRIETTA STREET, LONDON, W.C.

UPPER LIMB BACK OF FOREARM AND WRIST JOINT. No. 1.

EDINBURGH STEREOSCOPIC ANATOMY
Copyright: T. C. & E. C. Jack, Edinburgh & 34 Henrietta St., London, W.C.

UPPER LIMB.

SURFACE ANATOMY—No. 1.

AXILLA AND SHOULDER FROM THE FRONT.

The region of the shoulder and upper arm is so uniformly clothed by muscles that few bony points can be made out except by deep palpation.

Thus the **coracoid process** can be felt at the outer part of the small intermuscular depression between the pectoralis major and deltoid muscles above the figure 1, and the upper part of the shaft of the humerus can be palpated along the line of the depression, between the biceps and coraco-brachialis muscles on the outer side, and the triceps on the inner, indicated by the figure 5.

The muscular structures are important and well marked.

Notice especially the rounded outline of the deltoid as it arches over the shoulder. The anterior margin of this muscle is in apposition with the upper margin of the pectoralis major, and can hardly be distinguished from it except at the attachment of the two muscles to the clavicle, where there is a small depression, already referred to.

The hollow of the axilla is bounded in front by the margin of the pectoralis major, which presents a beautiful sinuous outline, while behind, the thick rounded margin is formed by the latissimus dorsi, teres major and subscapularis muscles.

In front of these last muscles, on the inner wall of the axilla, some of the digitations of the serratus magnus muscle are distinct at their attachments to the ribs.

The outer boundary of the axilla shows the rounded belly of the biceps, while at a higher level, the coraco-brachialis is seen in the interval between the biceps and the pectoralis major. The axillary artery lies along its lower margin and runs down to the point indicated by the figure 5.

The figures indicate—

Muscles. 1. Pectoralis major, clavicular part.
2. ,, ,, sterno-costal part.
3. Deltoid.

Muscles. 4. Belly of biceps.
5. Intermuscular interval over brcahial artery.
6. Latissimus dorsi.

EDINBURGH: T. C. & E. C. JACK: AND 34 HENRIETTA STREET, LONDON, W.C.

UPPER LIMB SURFACE ANATOMY. No. 1.
EDINBURGH STEREOSCOPIC ANATOMY.
Copyright: T. C. & E. C. Jack, Edinburgh, & 34 Henrietta St., London, W.C.



UPPER LIMB.

SURFACE ANATOMY.—No. 2.

SHOULDER AND SCAPULAR REGION FROM BEHIND.

With this view, the dissections of the scapular region should be studied.

The bony points which are of service in this region are the spine (1) and the acromion process (2) of the scapula, both of which lie at the bottom of a slight depression between the trapezius and deltoid muscles.

The muscular elevations here also are of great use. The posterior border of the deltoid is distinct, passing down to the hollow on the outer aspect of the upper arm which marks the insertion of the muscle.

In the arm itself are found the different portions of the triceps muscle, the long head passing down from the scapula, the outer head forming a prominence to its outer side, covering over the musculo-spiral groove and its contents, while the inner head shows itself on a small area rather lower down.

The deltoid here overlaps the scapular muscles and the circumflex nerve and posterior circumflex vessels, as they wind round the neck of the humerus.

The figures indicate—

1. Spine of scapula.
2. Acromion process.
3. Deltoid muscle.
4. Outer head of triceps muscle.
5. Long head of triceps muscle.
6. Inner head of triceps muscle.

EDINBURGH: T. C. & E. C. JACK; AND 34 HENRIETTA STREET, LONDON, W.C.

UPPER LIMB—SURFACE ANATOMY. No. 2.
EDINBURGH STEREOSCOPIC ANATOMY.
Copyright: T. C. & E. C. Jack, Edinburgh, & 34 Henrietta St., London, W.C.

UPPER LIMB.

SURFACE ANATOMY—No. 3.

UPPER PART OF THE BACK.

The spines of the vertebræ lie at the bottom of a furrow between the erector spinæ and other muscles on each side.

The spine of the vertebra prominens (seventh cervical) can usually be detected, but that of the first dorsal vertebra immediately below it is often equally distinct. The other dorsal spines can only be distinguished with difficulty.

The outline of the scapula is obscured by muscles covering it, but the lower angle can be made out by palpation, and the spine and acromion process can also be readily felt. About the scapula itself there are several hollows and elevations, which vary very considerably in different individuals on account of the varying sizes of different muscles.

The upper margin of the trapezius slopes outwards from the neck to the clavicle (4) and some of its fleshy fibres below this level form an elevation just above the spine of the scapula (1).

When the arms are in the attitude shown here, the scapula is rotated, so that the inner end of the spine is displaced downwards, and the lower angle of the bone rotated outwards. This accounts for the apparently low position of the spine of the scapula. Below the spine is seen a rounded elevation showing the position of the rhomboideus major muscle. The root of the spine of the scapula usually lies at the level of the second dorsal vertebra, and the lower angle of the scapula extends down to the seventh rib. The 'triangle of auscultation' lies to the inner side of this lower angle.

The figures indicate—

1. Trapezius muscle.
2. Vertebra prominens.
3. Spine of scapula.
4. Upper margin of trapezius.
5. Deltoid muscle.
6. Rhomboideus major muscle.
7. Acromion process.

EDINBURGH: T. C. & E. C. JACK; AND 34 HENRIETTA STREET, LONDON, W.C.

UPPER LIMB—SURFACE ANATOMY. No. 3.
EDINBURGH STEREOSCOPIC ANATOMY.
Copyright: T. C. & E. C. Jack, Edinburgh, & 34 Henrietta St., London, W.C.

UPPER LIMB.

SURFACE ANATOMY.—No. 4.

FRONT OF FOREARM.

The region of the elbow and front of the forearm presents one or two bony points which can be recognised from the surface, but in the upper part of the forearm the presence of the large muscular bellies conceals the shafts of the radius and ulna. The individual muscles cannot be readily distinguished from one another, but groups of them can be recognised, and the slight depression corresponding to the anticubital fossa separates an outer, or supinator, group from an inner, or pronator and flexor, group.

In the lower part of the forearm, the muscle bellies are largely replaced by tendons, and several of these can be recognised, as well as the intervening hollows in which vessels and nerves are situated.

These should be carefully studied, since wounds of this region are of common occurrence, and frequently involve division of some of these tendons, and this leads to serious impairment of usefulness, unless the tendons are recognised and the several ends united. The same holds true of the median and ulnar nerves.

Taking the upper part first:—

The internal condyle of the humerus forms a prominent landmark, from which the pronator and flexor muscles pass in different directions down the forearm, the pronator radii teres being the outermost (see Dissection of Front of Forearm, No. 1).

The supinator longus (brachio-radialis) forms the projection on the outer margin of the forearm in this region.

The tendons in the lower part are, the flexor carpi radialis and palmaris longus, lying near one another in the middle, and the flexor carpi ulnaris near the inner border. To the outer side of the first set is the hollow in which the radial artery lies, and the median nerve lies almost under cover of the palmaris longus. The ulnar artery and nerve lie under cover of the margin of the flexor carpi ulnaris, and in the hollow to the outer side of that tendon lie the inner tendons of the flexor muscles of the fingers.

The elevation at 4 is the radial head of the flexor sublimis digitorum, on which lies the radial artery.

The figures indicate—

Muscles.

1. Internal condyle.
2. Pronator radii teres.
3. Supinator longus.
4. Flexor sublimis digitorum.
5. Flexor carpi radialis tendon.
6. Palmaris longus tendon.
7. Flexor carpi ulnaris tendon.

EDINBURGH: T. C. & E. C. JACK; AND 34 HENRIETTA STREET, LONDON, W.C.

UPPER LIMB SURFACE ANATOMY. No. 4.

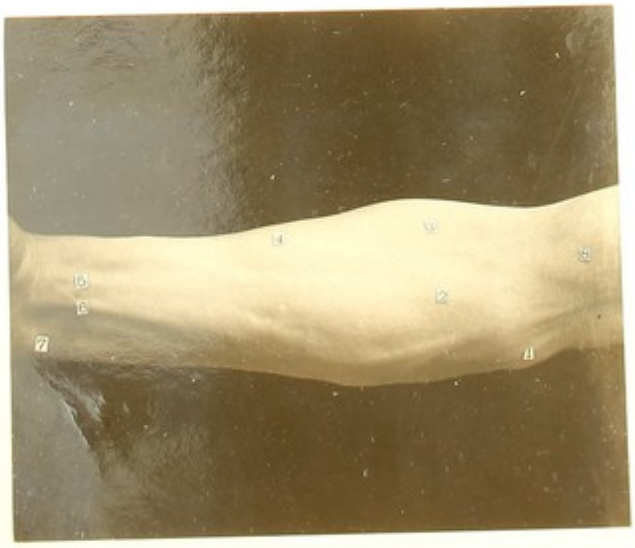

UPPER LIMB.

SURFACE ANATOMY—No. 5.

BACK OF FOREARM.

The muscular elevations and hollows here are numerous and somewhat difficult.

Taking first the bony points, we find first the tip of the olecranon (1), and the external condyle of the humerus (8), below which is a depression in which the head of the radius lies.

In complete extension, the tip of the olecranon process passes up as far as to a line joining the external and internal condyles of the humerus.

In flexion, the olecranon passes down below this line. These facts assist greatly in differentiating between a dislocation of the elbow and a fracture through the lower end of the humerus.

At the wrist are the tubercle on the back of the radius (Lister's tubercle), and the lower end of the ulna.

Passing down from the external condyle are the supinator longus and the two radial extensors, forming a single mass, and adjacent to them, but separated by a groove, is the common extensor of the fingers. Between these two groups in the lower part emerge the two deep extensors of the thumb (extensor ossis metacarpi and extensor primi internodii pollicis), which form an elevation on the radial border of the forearm.

To the ulnar side of these muscles lies the extensor carpi ulnaris and a groove separating this muscle from the flexor carpi ulnaris. The bottom of this groove corresponds to the subcutaneous surface of the shaft of the ulna.

The prominence of the anconeus muscle lies external to the outer border of the olecranon process, and passes down by the side of the shaft of the ulna.

Between 3 and 4 is a small ridge, due to the belly of the extensor proprius minimi digiti.

The figures indicate—

1. Olecranon process.
2. Supinator longus and radial extensors.
3. Extensor communis digitorum.
4. Extensor carpi ulnaris.
5. Anconeus.
6. Flexor carpi ulnaris.
7. Triceps.
8. External condyle.
9. Lower end of ulna.
10. Lister's tubercle on the radius.

EDINBURGH: T. C. & E. C. JACK; AND 34 HENRIETTA STREET, LONDON, W.C.
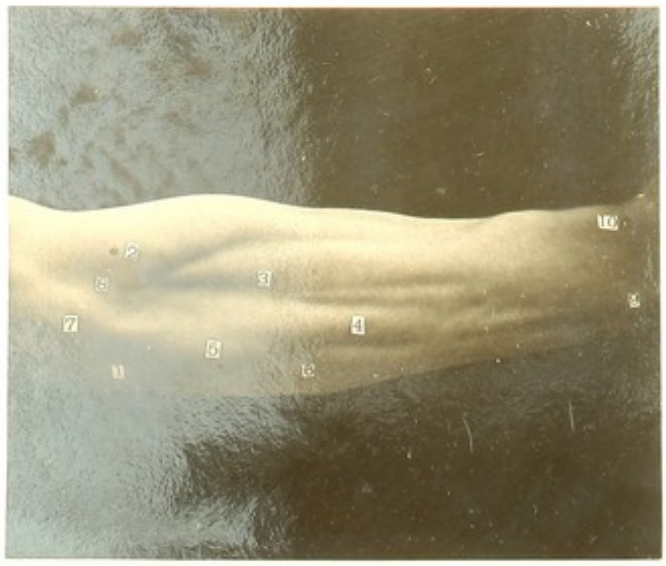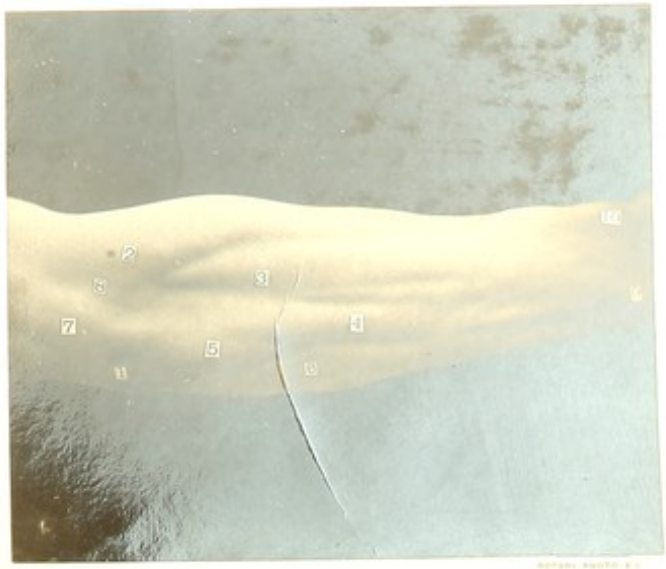
UPPER LIMB SURFACE ANATOMY. No. 5.