Club foot : its causes, pathology and treatment.

Contributors

Adams, William.
University College, London. Library Services

Publication/Creation

London, 1873.

Persistent URL

https://wellcomecollection.org/works/c7px8p24

Provider

University College London

License and attribution

This material has been provided by This material has been provided by UCL Library Services. The original may be consulted at UCL (University College London) where the originals may be consulted.
This work has been identified as being free of known restrictions under copyright law, including all related and neighbouring rights and is being made available under the Creative Commons, Public Domain Mark.

You can copy, modify, distribute and perform the work, even for commercial purposes, without asking permission.

Wellcome Collection
183 Euston Road
London NW1 2BE UK
T +44 (0)20 7611 8722
E library@wellcomecollection.org
https://wellcomecollection.org

INSTITUTE OF NEUROLOGY

The
ROCKEFELLER
MEDICAL LIBRARY

Sheet 9

NATIONAL HOSPITAL FOR THE PARALYSED & EPILEPTIC
PRESENTED TO
The Medical Library
QUEEN SQUARE, BLOOMSBURY, LONDON

CLUB-FOOT:

ITS CAUSES, PATHOLOGY, AND TREATMENT.

Digitized by the Internet Archive
in 2014

https://archive.org/details/b21270223

To the Medical Library of "the National Hospital for the Paralysed and Epileptic." from the Author Wm Adams

Feb 10th 1890.

CLUB-FOOT:

ITS CAUSES, PATHOLOGY, AND TREATMENT.

Being the Essay to which the Jacksonian Prize for 1864, given by the Royal College of Surgeons, was awarded.

BY

WILLIAM ADAMS, F.R.C.S.

SURGEON TO THE GREAT NORTHERN HOSPITAL, AND TO THE NATIONAL HOSPITAL FOR THE PARALYSED AND EPILEPTIC. CONSULTING SURGEON TO THE NATIONAL ORTHOPÆDIC HOSPITAL. LATE SURGEON TO THE ROYAL ORTHOPÆDIC HOSPITAL. FORMERLY DEMONSTRATOR OF MORBID ANATOMY AT ST. THOMAS' HOSPITAL, &c.

WITH ONE HUNDRED AND SIX WOOD ENGRAVINGS, AND SIX LITHOGRAPH PLATES.

SECOND EDITION.

LONDON:

J. & A. CHURCHILL, NEW BURLINGTON STREET.

1873.

Q.S.
1040
Author
1890

TO

THE MEMORY OF THE LATE

JOSEPH HENRY GREEN, F.R.S., D.C.L.

President of the Medical Council of Education.
President of the Royal College of Surgeons.
Consulting Surgeon to St. Thomas' Hospital, &c., &c.

This Essay is dedicated by the Author

As a tribute of respect and admiration from a pupil and friend; as a tribute, humble but earnest, to those high qualities of intellect and judgment which the medicine, science, and learning of England acknowledged; and which won for him an European reputation, and the highest honors of his profession.

Last, but not least, as a tribute in remembrance of that which is dearest to the Author, personal kindnesses never to be forgotten.

NOTE

TO

THE SECOND EDITION.

The demand for a second edition of the present work in England, and also for a special edition in America, published by Messrs. Lindsay and Blakiston of Philadelphia, shows that the study of Orthopædic surgery has of late occupied the attention of the profession in this and other countries in an increasing degree. We may therefore hope for a more general diffusion of the knowledge too long included in a so-called special branch of surgery, and to this result it will always be a source of gratification to myself to feel that I have been enabled to contribute.

Special departments in this branch of surgery, have for some years been established at St. Bartholomew's and St. George's Hospitals; but a practical knowledge of Orthopædic surgery can only be diffused through the country, by the general adoption of this method of teaching in all the Metropolitan Hospitals.

Whilst the Essay has been preserved essentially in the form and general arrangement of the subject, as originally issued, the whole has been carefully revised, and some chapters materially added to, especially that "On the Reparative process in Human Tendons" Chap. II. This subject has also been illustrated in a series of five lithograph plates added to the

present work. Some of these Plates have been transferred from the separate work on this subject, published by myself in the year 1860; and the specimens illustrating the union of the posterior tibial tendon delineated in the chromo-lithograph plate, were taken from a child who died of diptheria in July 1871, whilst under my treatment at the Royal Orthopædic Hospital.

Henrietta Street,
Cavendish Square,
December, 1872.

NATIONAL HOSPITAL FOR THE PARALYSED & EPILEPTIC
PRESENTED TO
QUEEN SQUARE, BLOOMSBURY, LONDON

PREFACE

TO

THE FIRST EDITION.

The Jacksonian prize offered by the Royal College of Surgeons in 1864 for an "Essay on Club-foot, its causes, nature and treatment," was awarded to the present Essay in April, 1865. In the hope that this work may also prove acceptable to the profession, it is now reproduced in its present form without any substantial alterations; but with such modifications as are rendered necessary by the altered circumstances under which a competitive essay is written, and afterwards published.

In writing a competitive essay, the necessity of concealing the Authorship must be a primary consideration; whilst at the same time it is impossible to avoid reference to any original observations and researches which the Author may have made. In the essay when subsequently published as a monograph, the right to claim any such observations and researches must be acknowledged; and in the exercise of this privilege, I have limited myself to making such alterations only as appeared to be necessary.

For the purpose of further illustrating the subject, I have added in an "Appendix" a series of cases affording well marked examples of the several varieties of club-foot and contractions described in the Essay.

Since my connexion with the Royal Orthopædic Hospital in the year 1851, not only has the more practical part of treating Club-Foot, and other deformities, been the subject of special attention; but I have also been enabled to investigate by many post-mortem examinations, the anatomical conditions existing in the several varieties of talipes, and thus in a measure supply a recognised deficiency in this department of surgery.

I may here mention that it was under the advice of the late Mr. J. H. Green I commenced the study of Orthopædic surgery, and upon a vacancy being declared in the surgical staff of the hospital, became a candidate for the appointment. Mr. Green's opinion was, that Orthopædy, as a new and special branch of study, in which not only the various forms of club-foot, but all the other deformities and malformations of the body were included as a group, opened up a wide field for pathological investigation and practical usefulness; and the sound judgment upon which this opinion was based, has since been proved by the extension of this branch of practice, and the establishment of other Orthopædic hospitals in this Metropolis.

The more important contributions which I have been enabled to make to this department of surgery, will be found recorded in the volumes of the Pathological Society's Transactions; in the Transactions of the Medical and Chirurgical Society; and also in a course of Lectures "on the Pathology and Treatment of Club-foot," which I delivered at the Grosvenor Place School of Medicine in the session of 1854-55, and were subsequently published in the "Medical Times and Gazette."

The history of Orthopædic Surgery, as a special branch of study is so well known, that it is needless to refer to it here, further than to allude to the discovery of subcutaneous tenotomy, the credit of which is divided between Delpech and Stromeyer, the latter having undoubtedly the merit of bringing the operation to its present state of perfection in the year 1831. From this date all the subsequent advances have been gradually introduced.

Largely as this discovery has contributed to Orthopædic

Surgery, by perfecting the cure of Club-foot, still the modern progress in this department has shown, that at least an equal degree of importance is to be assigned to the great improvement in the mechanical apparatus employed, and the combination of the operative and mechanical means, with a well regulated system of gymnastics, and special muscular exercises.

It must be admitted, however, that the advance made in this department of Surgery has been too slowly diffused through the country, and for this I believe the most certain remedy would be found, in the establishment of special wards for the treatment of this class of cases in the general hospitals of this Metropolis; and by the more general introduction of the subject in the lectures given, as well as in the surgical teaching at these hospitals.

If this object should be in any way promoted by the detailed account of the Pathology and Treatment of Club-foot given in this Essay, the author will feel that his labors have been usefully directed towards a point, the attainment of which has always been the especial object of his desire.

Henrietta Street,
Cavendish Square,
October, 1866.

CONTENTS.

CHAPTER I.

The various forms of Club-foot; and the History of Subcutaneous Tenotomy in the Treatment of this Affection. 1

CHAPTER II.

On the Reunion of Tendons after Subcutaneous Tenotomy and the rate of extension after operation, in the Treatment of Club-foot. . . 15

CHAPTER III.

On the relative Merits of Tenotomy, and Mechanical Extension in the Treatment of Club-foot. 46

CHAPTER IV.

Non-congenital Spasmodic and Paralytic Talipes—Deformities with Rigid Muscles, their Pathology, and Treatment. 61

CHAPTER V.

Non-congenital Spasmodic and Paralytic Talipes continued—Deformities with Flaccid Muscles; and Deformities with Muscles in a Healthy Condition after Recovery from Paralysis; their Pathology and Treatment. . . 75

CHAPTER VI.

Talipes Equinus—External Characters—Morbid Anatomy—Pathology—Prognosis. 92

CHAPTER VII.

Talipes Equinus continued—Treatment—Talipes Equino-varus and Equino-valgus; their Pathology and Treatment. 114

CHAPTER VIII.

Congenital Talipes Varus—External Characters in the Infant and Adult—Effects of the Deformity—Morbid Anatomy in the Infant. . . . 139

CHAPTER IX.

Congenital Talipes Varus continued—Morbid Anatomy in the Infant concluded. 162

CHAPTER X.

Congenital Talipes Varus continued—Morbid Anatomy in the Adult. . 178

CHAPTER XI.

Congenital Talipes Varus continued—Morbid Anatomy in the Adult concluded —Articulations, Ligaments, Muscles, and Tendons. . . 197

CHAPTER XII.

Congenital Talipes Varus continued—General Pathology; Etiology; Hereditary Transmission; Statistics; Complications. 213

CHAPTER XIII.

Congenital Talipes Varus continued—Operative Treatment. . . 230

CHAPTER XIV.

Congenital Talipes Varus continued—Mechanical Conditions, and Treatment in Infantile and Adult Cases. 252

CHAPTER XV.

Congenital Talipes Varus continued—Mechanical and Physiological Treatment in Infantile and Adult Cases. 273

CHAPTER XVI.

Congenital Talipes Varus concluded—Relapsed Cases. . . . 287

CHAPTER XVII.

Non-Congenital Talipes Varus. 296

CHAPTER XVIII.

Congenital Talipes Valgus, or Flat-Foot, Pathology and Treatment. . 307

CHAPTER XIX.

Non-congenital Talipes Valgus, or Flat-Foot; Talipes Equino-Valgus; Pathology and Treatment. 326

CHAPTER XX.

Congenital and Non-congenital Talipes Calcaneus, Calcaneo-varus, and Calcaneo-valgus, Pathology and Treatment. 347

APPENDIX. 371

LIST OF THE WOOD ENGRAVINGS.

Fig.		Page.
1	Spasmodic contraction of both legs and feet	64
2	Talipes equinus without paralysis of the anterior muscles of the leg and foot	93
3	Drawing from the same foot as Fig. 2 after treatment	93
4	Talipes equinus with muscles in a spasmodic condition	94
5	Talipes equinus with paralysis of anterior muscles of the leg and foot	94
6	Talipes equinus with complete paralysis of all the anterior muscles of the leg	95
7	Talipes equinus with complete paralysis of all the anterior muscles of the leg	95
8	Dissection of a case of talipes equinus, or rather equino-varus	100
9	The opposite view of the same foot as represented in Fig. 8	100
10	Case of talipes equinus in a boy	102
11	Case of congenital talipes equinus	106
12	Scarpa's shoe now used at the Orthopædic Hospital	123
13	Scarpa's shoe as modified by the Author	123
14	Scarpa's shoe modified by the Author to control inversion or eversion of the foot	124
15	Scarpa's shoe modified by the Author with Langaard's addition	124
16	Talipes equino-varus with muscles in a spasmodic condition	134
17	The same foot as shown in Fig. 16 after treatment	134
18	Talipes equino-varus with muscles in a paralytic condition	134
19	The same foot as shown in Fig. 18 after treatment	134
20	Scarpa's shoe, with transverse joint in sole-plate, corresponding to the transverse tarsal joint	136
21	Talipes equino-valgus, with the muscles in a paralytic condition	138
22	The same foot as represented in Fig. 2, after treatment	138
23	Congenital talipes varus in an infant aged five months	140

Fig.		Page
24	Congenital talipes varus in an infant in a more severe form	141
25	Severe case of congenital talipes varus in the adult	143
26	Posterior aspect of the same foot as Fig. 25	143
27	Healthy fœtal astragalus, and fœtal astragalus from a case of severe talipes varus.	152
28	Astragalus and navicular bone from a case of congenital talipes varus	154
29	Dissection of a case of congenital talipes varus from a fœtus of about the seventh month	155
30	Congenital talipes varus, with deficiency of the extensor communis, and defective development of the other extensor muscles on the anterior surface of the leg	171
31	Congenital talipes varus from a child aged six months, dissected to show the relation of the muscles and tendons of the anterior surface of the leg and foot in this deformity	172
32	Posterior aspect of same leg as Fig. 31, exhibiting relative position of muscles and tendons	173
33	Lateral aspect from fibula side of the same leg as Figs. 31 and 32	174
34	Congenital talipes varus in the adult. Lateral aspect—fibula side of leg; from same specimen as Figs. 35 and 36	183
35	Congenital talipes varus in adult. Anterior aspect from same specimen as Figs. 34 and 36	184
36	Posterior aspect of same specimen represented in Figs. 34 and 35	185
37	Astragalus from a severe adult case of congenital talipes varus	187
38	Congenital talipes varus of both feet, with deficiency of anterior muscles of the legs, below knee, and other complications	221
39	Congenital talipes varus of both feet without deficiency of muscles, but complicated with contraction and obscure malformation at knee, and other joints; club hand, &c.	223
40	Talipes varus, complicated with contraction of the knee in the flexed position	225
41	Congenital talipes varus of both feet; contraction of both knee-joints in the flexed position	227
42	Tenotomy knives	241
43	Case of infantile varus	260
44	The same foot as Fig. 43 with straight splint and bandage applied	260
45	The same foot as Fig. 43 brought into the position of talipes equinus by the straight splint and bandage	260
46	The same foot as Fig. 43 after treatment. The equinus completely removed	260
47	The Author's infantile varus splint	262
48	The same splint as in Fig. 47 applied to the leg and foot	263

Fig.		Page.
49	Congenital talipes varus of both feet in a severe form in an infant aged five months	263
50	The same case as Fig. 49 after treatment	263
51	Leather boot with steel spring attached for cases of varus	264
52	The Author's apparatus for varus in children	265
53	Mr. Tamplin's trough instrument and modified Scarpa's shoe for adult varus	266
54	Scarpa's first apparatus for varus to overcome the inversion	271
55	Diagram illustrating the construction of the apparatus for adult varus	277
56	The Author's instrument for talipes varus in the adult	279
57	Retentive apparatus to control inversion of foot and leg, arising from weakness of the knee-joint	284
58	Non-congenital talipes varus, anterior aspect	297
59	Posterior aspect of the same foot as shown in Fig. 58	297
60	Congenital talipes valgus in an infant	308
61	Dissection of a case of talipes valgus	311
62	Congenital talipes valgus, with deficient growth of leg bones below knee, &c.	318
63	Non-congenital talipes valgus, or flat-foot	327
64	Non-congenital talipes valgus, or flat-foot, severe case in an adult	328
65	Paralytic valgus; severe case in an adult	333
66	Spasmodic talipes valgus; severe case in an adult	334
67	Apparatus for talipes valgus of moderate severity	339
68	The Author's apparatus for the most severe cases of talipes valgus	340
69	Valgus splint with side spring and pad attached	341
70	Congenital talipes calcaneus	348
71	Congenital talipes calcaneus with rigid contraction of both knees, and legs rigidly flexed on body from hip-joints	350
72	Non-congenital talipes calcaneus in the adult	355
73	Non-congenital talipes calcaneus in the adult, affecting both feet	356
74	Drawing from a dissected Chinese lady's foot in Museum of College of Surgeons	359
75	Drawing from a dissected Chinese lady's foot in Museum of College of Surgeons	359
76	Drawing from a dissected Chinese lady's foot in Museum of University College	360
77	Boot used in cases of talipes calcaneus	366
78	Spasmodic talipes equinus	393
79	Rigid muscular contraction of both feet after an attack of Mauritius fever	395
80	Posterior aspect of same feet as Fig. 79	395

Fig.		Page.
81	The same feet as represented in Figs. 79 and 80 after treatment	397
82	Permanent contraction of both feet and right hand from bite of snake	400
83	The same foot as Fig. 82 after treatment	400
84	Spasmodic talipes equino-valgus	402
85	Improved condition of same case as represented in Fig. 86	404
86	Rigid muscular contraction of both feet, talipes equino-varus after an attack of paraplegia	406
87	Improved condition of same case as represented in Fig. 86	410
88	Talipes equino-varus of right foot, and talipes equino-valgus of left foot	415
89	Improved condition of same case as represented in Fig. 88	418
90	Severe talipes equinus produced by strumous abscesses in the leg, &c.	424
91	Improved condition of same case as represented in Fig. 90	424
92	Congenital varus of both feet; skin removed on convexity of feet; cicatrices shown	426
93	Improved condition of same case as represented in Fig. 92	428
94	Congenital talipes varus in an adult.	430
95	The same foot as Fig. 94 after treatment	431
96	Lateral aspect of same foot, exhibiting the complete equinus form	431
97	The same foot as represented in Fig. 94 one year from commencement of treatment	432
98	Relapsed case of congenital varus	435
99	Improved position of same feet as represented in Fig. 98	436
100	Drawing taken from casts of legs, same case as shown in Figs. 98 and 99	437
101	Severe case of relapsed congenital talipes varus	439
102	Congenital malformation, and deficiency in length of leg bones below knee	444
103	Malformation of legs, deficient length of leg bones below knee, eight toes on each foot	445
104	Congenital hypertrophy of the right leg, with malformation of the foot	447
105	Rotation of right leg at knee-joint, with the calf of leg and foot directed backwards	450
106	Congenital club-foot in a race-horse cured by tenotomy	454

LIST OF PLATES.

PLATE I.

Leg exhibiting appearances of tendo Achillis a year and a half after subcutaneous division.

PLATE II.

Microscopical appearances of tendons, sixteen, and twenty-three days after division.

PLATE III.

Microscopical appearances of new tendon, formed to reunite tendo Achillis three months, a year and a half, and three years after division.

PLATE IV.

Two feet, one in the first, and the other in the second stage of treatment, for congenital varus, after division of tendons at various dates.

PLATE V.

Two legs of a club-footed child showing good union of the posterior tibial tendons, with slender adhesions. (Chromo-litho.)

PLATE VI.

Structural changes in the muscles, in cases of non-congenital talipes.

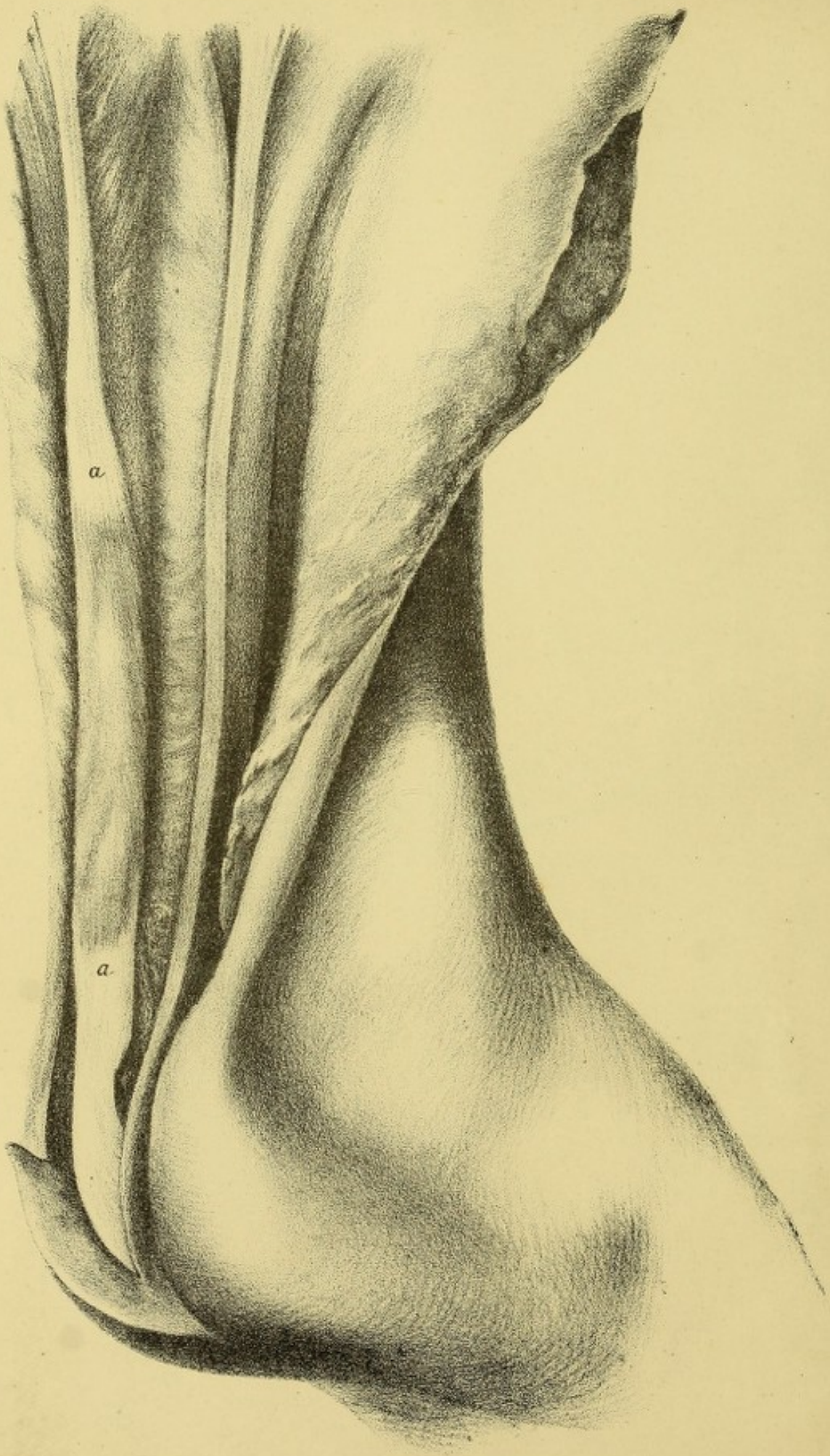

G H Fordham del.

W West imp.

DESCRIPTION OF PLATE I.

DISSECTION OF A LEG EXHIBITING THE APPEARANCES PRESENTED BY THE TENDO ACHILLIS, A YEAR AND A HALF AFTER SUBCUTANEOUS DIVISION.—FIGURE DRAWN NATURAL SIZE.

a a, Divided extremities of the Achilles tendon, two inches and a quarter apart, but connected by newly formed tendinous structure, equal in bulk and thickness to the tendon it served to reunite. The junction of the new with the old tendon by a process of fine dovetailing was very distinct, and has been well represented. In the recent state the new material, easily recognised by its translucency, was seen to be inserted between the split fibres of the old tendon, which still preserved their opaque, pearly lustre. The structure of the new tendon did not present a longitudinally striated appearance, as seen in several specimens, but was traversed by some opaque, white, glistening fibres, passing obliquely through it; this appearance, together with the loss of linear definition along its deep border, in consequence of adhesions, are also well shown.

This specimen exhibited the greatest length of new tendon I have seen in the human subject; and as the new tissue presented the microscopic characters of well-formed tendon (see Plate III, Figs. 2 and 2*a*), it may doubtless be regarded as affording a most perfect example of the regeneration of tendinous structure.

It is also important to remark in this case, that whilst the new tendon remained as a permanent tissue, elongating the tendo Achillis to the extent of two inches and a quarter, reproduction of the deformity, viz.: talipes equinus, took place to a considerable extent, some months previous to the amputation of the leg, which was performed by Mr. Curling, for recurrent fibroid tumour connected with the periosteum of the tibia, &c., and involving the muscles of the calf. The elevation of the heel is represented in the drawing, but from want of space to insert the foot, the general appearance of the deformity could not be shown.

The case from which this specimen was removed, is described in my work "On the Reparative Process in Human Tendons," Case XI. Page 36.

Fig. 1.

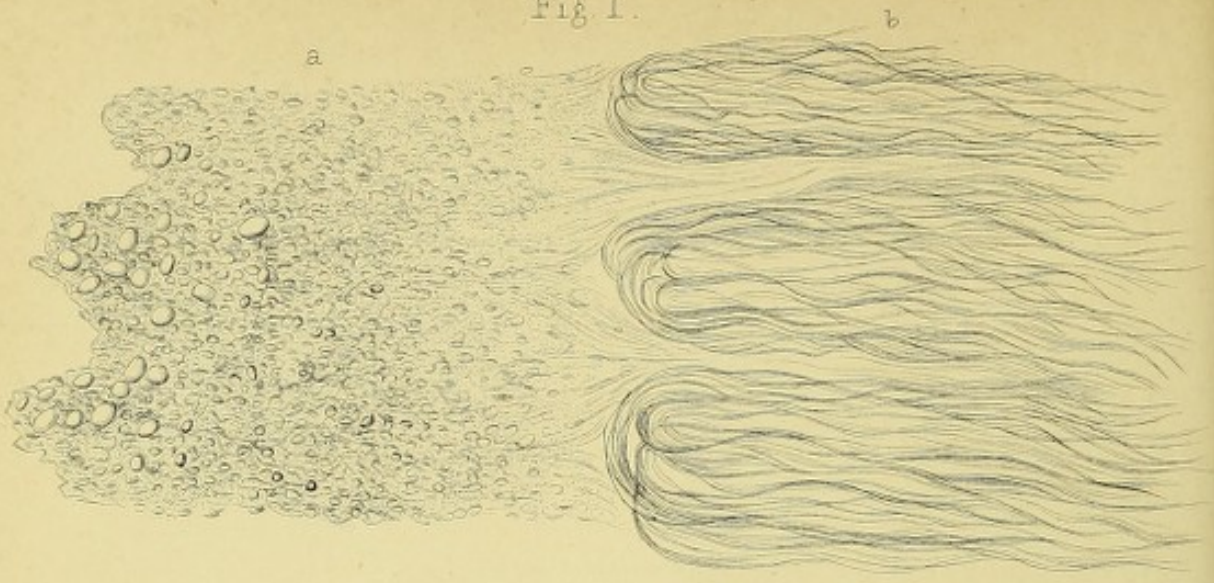

Fig. 1a.

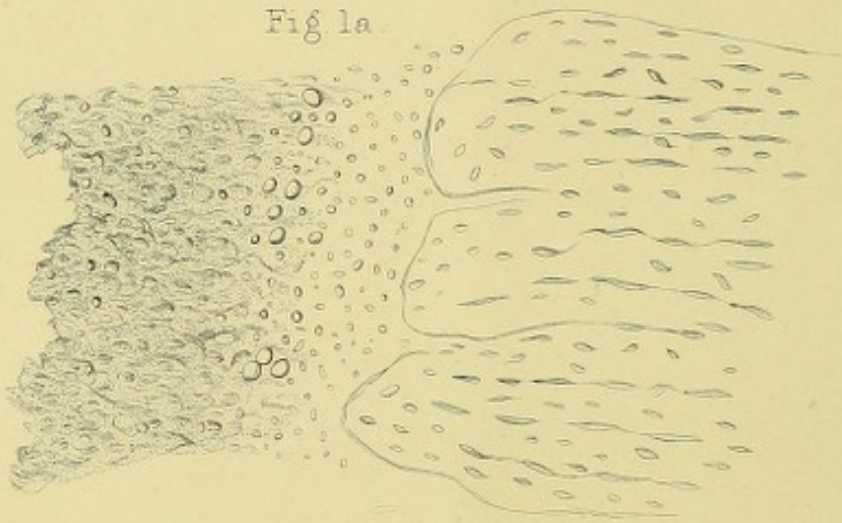

Fig. 2.

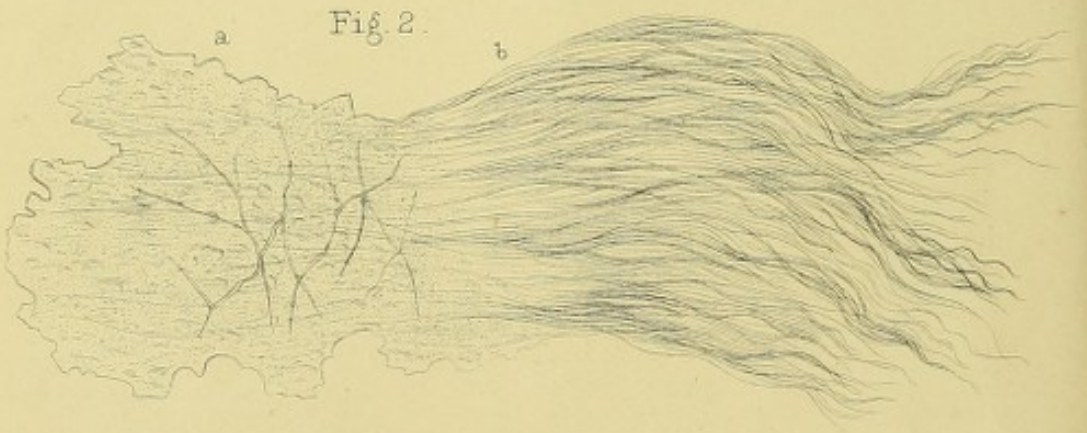

Fig. 2 a.

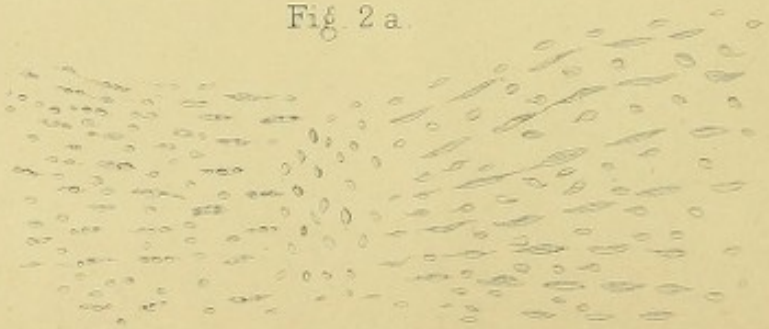

W. Adams del. G. H. Ford sc.

W. West imp.

DESCRIPTION OF PLATE II.

EXHIBITING THE MICROSCOPICAL APPEARANCES AT THE SEAT OF OPERATION IN HUMAN TENDONS, SIXTEEN, AND TWENTY-THREE DAYS AFTER SUBCUTANEOUS DIVISION. FIGS. 1 *a*, AND 2 *a* REPRESENT THE APPEARANCES OF FIGS. 1 AND 2, AFTER THE ADDITION OF ACETIC ACID.

Fig. 1. Tendo Achillis of an infant sixteeen days after division, showing the microscopical appearances of the new connective tissue *a*, and of the old tendon *b*, at the seat of division. Specimen taken from the central portion, so that the fibro-cellular tissue of the sheath, which circumferentially connected the new with the old tissue, was not included.

a. New connective tissue, presenting a nebulous, granular, and obscurely nucleated appearance, studded with molecules, and larger globules of oil. This tissue was much clearer near to the divided extremity of the old tendon, where it exhibited more of a nucleated blastematous appearance.

b. Divided extremity of the old tendon, lower end, showing a coarse separation of the structure of the old tendon into obtusely rounded bundles of fibres, between which the new material is inserted.

Fig. 1 *a. The same after the addition of acetic acid,* by which the nucleated character of the new connective tissue is brought more clearly into view. The clearness of the new tissue close to the cut extremity of the old tendon, and the abundance of small rounded, and oval nuclei, without any disposition to a linear arrangement at this part; are well shown. The acetic acid, also, has the effect in the old tendon of bringing into view the arrangement of elongated nuclei in parallel linear series, and the bundles of fibres of the old tendon now appear more angular, and of an irregular square outline at their cut extremities.

Fig. 2. Posterior tibial tendon of an infant, twenty-three days after division, from the same child as the preceding specimen, showing the microscopical appearances of the new connective tissue, *a*, and of the old tendon, *b*, at the seat of division.

a. New connective tissue, approaching in its structural characters the appearance of well-formed tendon; it exhibits a delicate but distinctly fibrillated appearance, but its margins would not split, or fray out into separable fibres; when compressed under the microscope, its edges resembled the jagged margins of a bit of torn membrane—an appearance well shown in the drawing. The new tissue was traversed by numerous blood-vessels, which ran obliquely through its substance, the smallest branches only, taking a longitudinal direction.

b. Divided extremity of the old tendon, exhibiting very distinctly, at the line of section, a process of dovetailing of the new with the old tendon, by which they are firmly united.

Fig. 2 *a. The same after the addition of acetic acid,* by which elongated nuclei, arranged in parallel linear series, both in the new connective tissue, and in the old tendon, are brought into view. The new tissue, therefore, in this specimen, approached so closely in its structural arrangement, the characters of well-formed tendon, as to justify its being described as newly-formed tendinous structure. The nuclei in the new tendon presented a dotted appearance, and at the junction of the new, with the old tendon, small, rounded, and oval nuclei were scattered without any regularity, or disposition to linear arrangement.

The case from which these specimens were removed, is described in my work, "On the Reparative Process in Human Tendons," Case III. Page 12; and the dissections of the feet, in the stages of cure, are represented in Plate IV. of the present work.

Fig. 1.

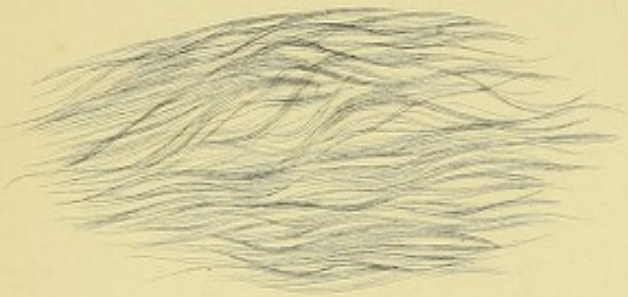

Fig. 1a.



Fig. 2.

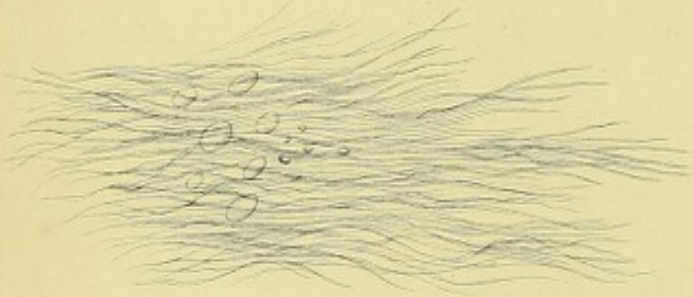

Fig. 2.a.



Fig. 3.

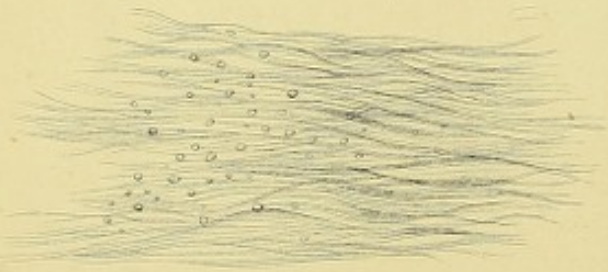

Fig. 3.a.

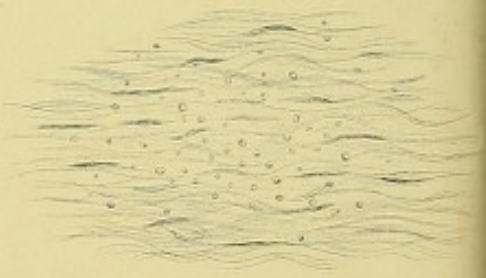

Fig. 4.

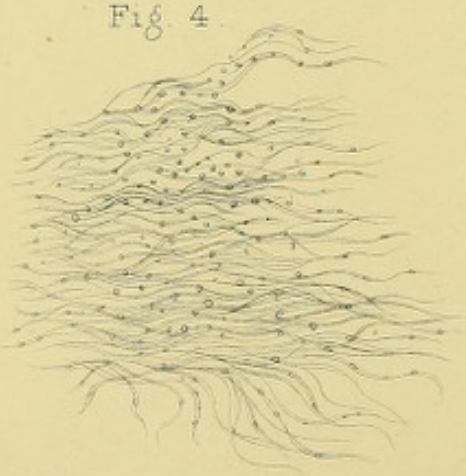

Fig. 4.a.

W. Adams del. G. H. Ford sc.

W. West imp.

DESCRIPTION OF PLATE III.

EXHIBITING THE MICROSCOPICAL APPEARANCES OF THE NEWLY FORMED CONNECTIVE TISSUE, OR NEW TENDON, AT PERIODS OF THREE MONTHS, A YEAR AND A HALF, AND THREE YEARS AFTER THE SUBCUTANEOUS DIVISION OF THE TENDO ACHILLIS. FIG. 1 *a*, 2 *a*, AND 3 *a*, REPRESENT THE APPEARANCES OF FIGS. 1, 2, AND 3, AFTER THE ADDITION OF ACETIC ACID. FIGS. 4, AND 4 *a*, REPRESENT THE APPEARANCE BEFORE, AND AFTER THE ADDITION OF ACETIC ACID, OF A TENDO ACHILLIS IN A STATE OF FATTY DEGENERATION—FROM THE PARALYTIC LEG OF A PATIENT, FORTY-TWO YEARS OF AGE.

Fig. 1. *represents the appearance of new connective tissue, or new tendon formed to reunite the tendo Achillis, three months after its division. From the specimen figured in Plate III., fig.* 1, *of my work "On Reparative Process in Human Tendons."*

The distinctly fibrous appearance of the new tissue, easily splitting into separable fibres, and its general resemblance to the structure of old tendon as represented in Plate II. of the present work, fig. 1 *b.* and fig. 2 *b*, are well shown.

Fig. 1 *a. The same after the addition of acetic acid*, by which numerous elongated nuclei, arranged end to end, in parallel linear series, are brought into view. In its microscopic characters, it will be seen that the new tissue closely resembles the structure of old tendon, as represented in Plate II., fig. 1 *a* and fig. 2 *a*.

Fig. 2.—*New tendinous structure formed to reunite the tendo Achillis, one year and a half after its division. From the specimen figured in Plate I.*

The appearance of separable fibrous tissue is very distinct, and its general resemblance to the structure of the old tendon so close, that it would be difficult to distinguish one from the other.

Fig. 2 *a, the same after the addition of acetic acid*, exhibiting the arrangement of elongated nuclei in parallel linear series, as in old tendon; but the acid did not render the new tissue in this instance so clear and translucent, as in the cases at an earlier date. The fibrous character of the new tendon remained faintly traceable, long after the addition of the acid, and the nuclei were less distinct.

Fig. 3, *New tendinous structure formed to reunite the tendo Achillis, three years after its division, exhibiting the appearance of separable fibrous tissue, similar to that represented in fig.* 2, *but dotted with minute molecules of oil.*

Fig. 3 *a. The same after the addition of acetic acid*, presenting a shaded nebulous appearance, with pale, and indistinct traces of its fibrous structure, which the strong acid did not render completely transparent, or invisible, as in the specimens of an earlier date. Dark crooked lines, in ill-defined parallel series, appeared in this structure, as if the remains of the elongated nuclei which I have described as existing in parallel linear series in the earlier specimens.

Figs. 4 *and* 4 *a, represent the appearance, before and after the addition of acetic acid, of the old tissue of a tendo Achillis in a state of fatty degeneration from the paralytic leg of a patient, aged* 42. *The same case from which the new tissue represented in figs.* 3 *and* 3 *a, was taken. The external appearances of the atrophied Achilles tendons in this case are represented in Plate III., figs.* 4 *and* 5 *in my work "On the Reparative Process in Human Tendons."*

An increased separability of the fibrous structure of the old tendon existed in this case, and is represented in fig. 4, in which the fibres are also shown to be dotted with molecular oil.

After the addition of acetic acid, this tissue presented a shaded nebulous appearance with indistinct traces of its fibrous structure, and the molecular oil was seen to be very abundant, as represented in fig. 4 *a*. The case from which these specimens, from a paralytic leg were removed, is fully described in the Appendix of the present work, Case VII., page 415.

Plate 4.

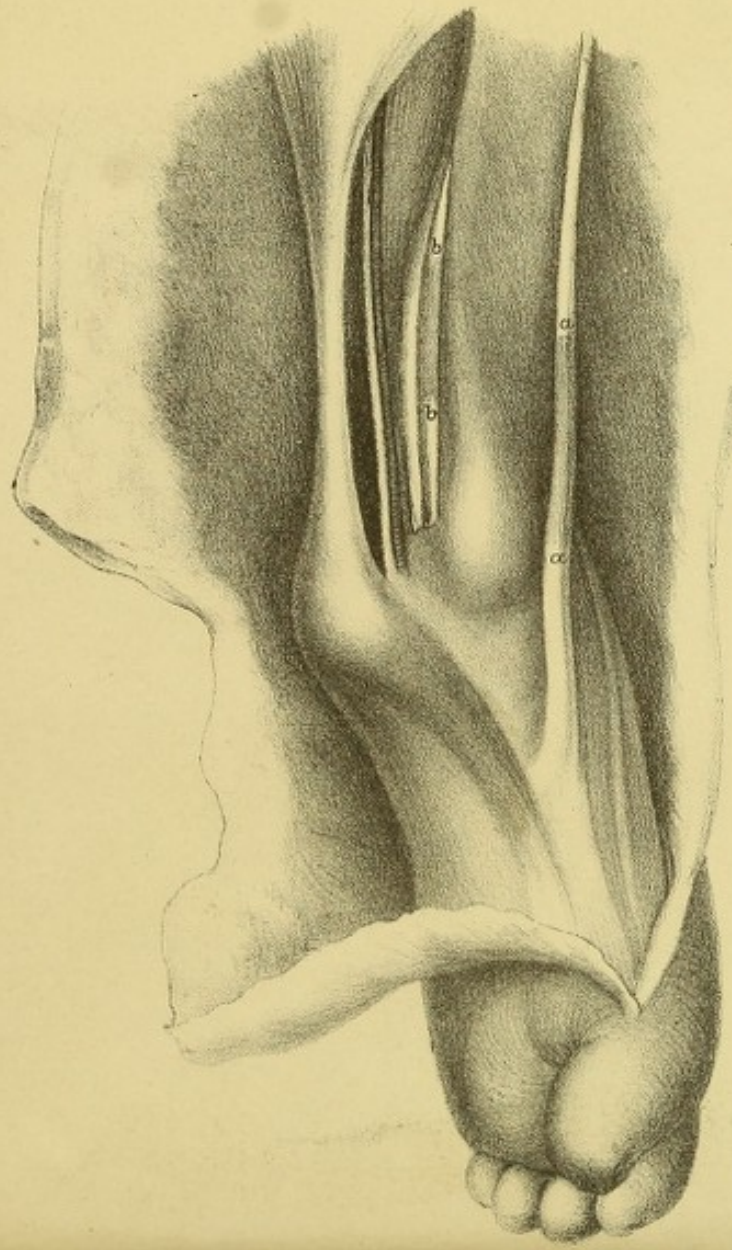

Fig. 1.

Fig. 2 a.

Fig. 2.

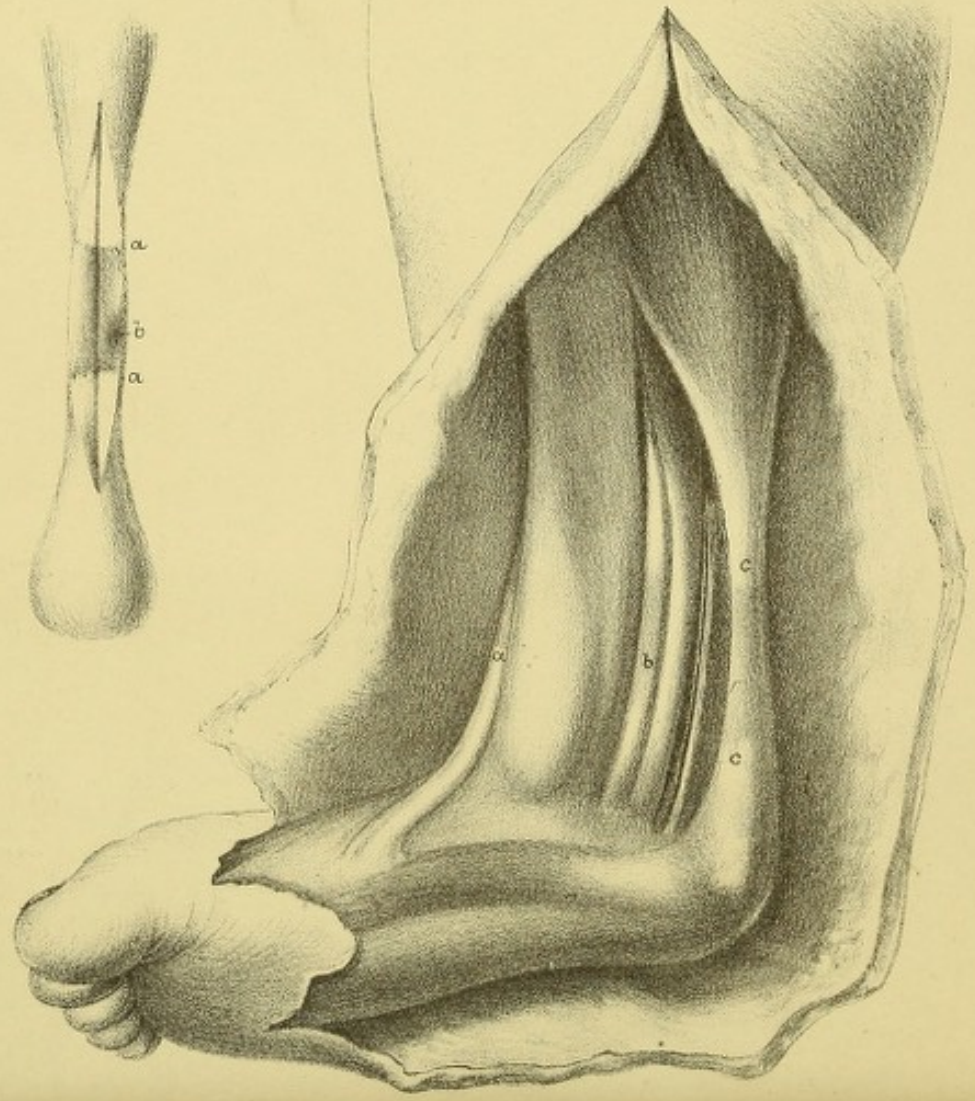

G. H. Ford ad nat.

W. West imp.

DESCRIPTION OF PLATE IV.

THIS PLATE ILLUSTRATES THE FIRST AND SECOND STAGES OF TREATMENT OF CONGENITAL VARUS, AND EXHIBITS THE REPARATIVE PROCESS IN TENDONS AT PERIODS OF SIXTEEN, TWENTY-THREE, AND THIRTY DAYS AFTER OPERATION.—BOTH FEET FROM THE SAME CASE—FIGURES DRAWN NATURAL SIZE.

Fig. 1 represents the foot at the end of the first stage of treatment, viz., when, after the division of the tibiales anticus and posticus tendons, it has been brought from the position of talipes varus into that of talipes equinus; and

Fig. 2 from the opposite leg of the same infant, represents the foot at the end of the second stage of treatment, viz., when, after the division of the tendo Achillis, it has been brought from the position of talipes equinus into a natural position with respect to the leg, or at a right angle with the leg, the deformity now being cured.—Figures drawn natural size.

SIXTEEN DAYS AFTER OPERATION.

Fig. 2. Tendo Achillis, and tibialis anticus tendon of the right foot divided.

Fig. 2 *c c. Divided extremities of the tendo Achillis* sixteen days after operation, rather more than half an inch apart; but connected by a tough cylindrical bond of union, equal in diameter and bulk to the tendon it connects.

Fig. 2 *a, represents a longitudinal section of the same tendo Achillis.* The divided extremities of the tendon *a a*, are seen rather more than half an inch apart, but connected by a solid bond of new material, or new tendon, imbedded in the lower part of which is a small clot of blood *b*. The cut extremities of the old tendon retain their abrupt and square outline, and are readily distinguishable from the new tendon, with which, however, they are firmly connected by a very fine dovetailing arrangement of old and new tissue. The microscopical appearances from this specimen are represented in Plate II, figs. 1 and 1 *a*.

TWENTY-THREE DAYS AFTER OPERATION.

Fig. 1. Tibiales anticus and posticus tendons of the left foot divided.

a a. Divided extremities of the tibialis anticus, three-quarters of an inch apart, but connected by a solid cylindrical bond of new material, equal in diameter and bulk to the extremities of the tendon it serves to connect.

b b. Divided extremities of the tibialis posticus, half an inch apart, but connected by a solid cylindrical bond of new material.

THIRTY DAYS AFTER OPERATION.

Fig. 2. The Tibialis anticus divided.

a a. Divided extremities of the tibialis anticus, nearly three-quarters of an inch apart, but connected by a cylindrical bond of new tendinous structure, very nearly equal, in diameter and bulk, to the extremities of the tendon it served to connect.

b. The posterior tibial tendon had not been divided in this foot, though the operation had been attempted; and externally the tendon presented some appearances, leading at first to the supposition that it had been divided. It therefore shows not only that division of the posterior tibial tendon is an operation liable to failure, but that in the present instance its division was not absolutely essential to the cure of the case; and no doubt the operation may be dispensed with in many cases of congenital varus.

The case from which these specimens were removed is described in my work "On the Reparative Process in Human Tendons," Case III. page 12.

Fig. 1.

Plate 5.

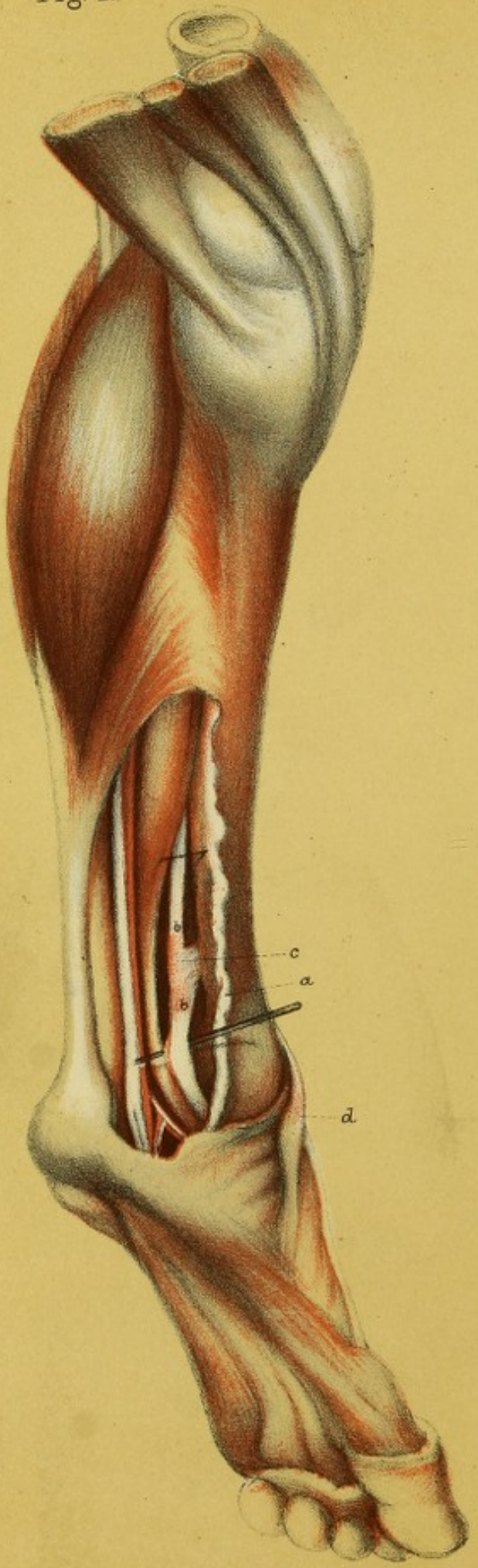

Fig. 2.

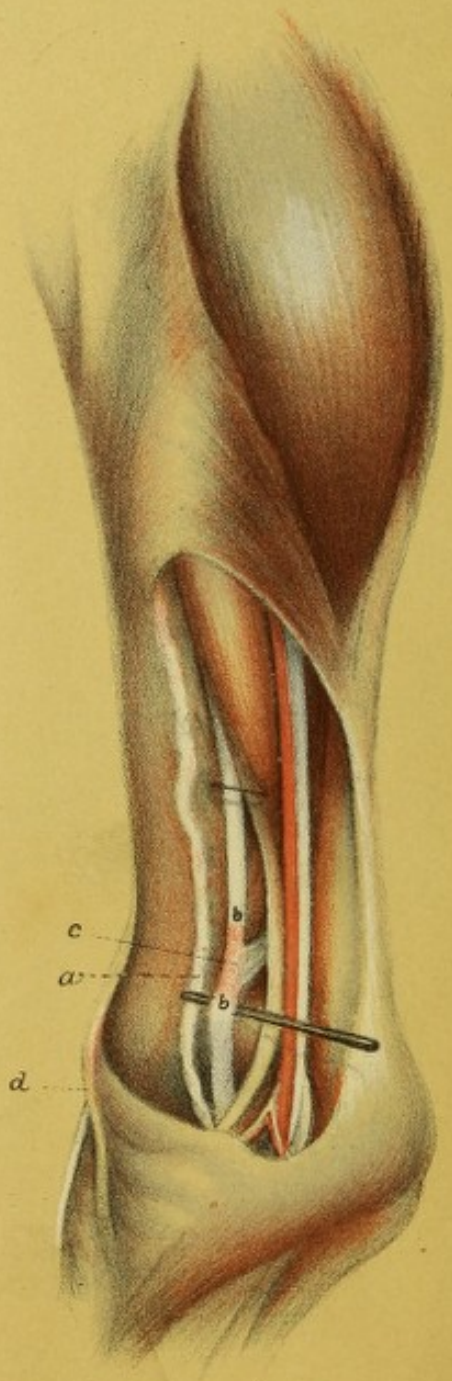

C. D'Alton del.

W. West & Co. Chromolith.

DESCRIPTION OF PLATE V.

DISSECTION OF TWO LEGS OF A CLUB-FOOTED CHILD SHOWING GOOD UNION OF THE POSTERIOR TIBIAL TENDONS, WHICH HAD BEEN DIVIDED, ONE FOUR MONTHS AND A HALF, AND THE OTHER TEN WEEKS BEFORE DEATH. SLENDER ADHESIONS TO THE SHEATH ONLY EXISTED, SUCH AS WOULD NOT INTERFERE WITH THE FREE PLAY OF THE TENDONS. DRAWN TWO-THIRDS NATURAL SIZE.

Fig. 1. Ten weeks after operation.

a. Margin of the deep fascia, and sheath of posterior tibial tendon laid open.
b b. Divided extremities of posterior tibial tendon, united by new connective tissue, or new tendon, which measured five-eighths of an inch in length.
c. Membranous bands of adhesion passing obliquely upwards to the sheath, near to the edge of the tibia.
d. Lower border of anterior tibial tendon, at its junction with the new connective tissue.

Fig. 2. Four months and a half after operation.

a. Margin of the deep fascia, and sheath of posterior tibial tendon laid open.
b b. Divided extremities of posterior tibial tendon, united by new connective tissue, or new tendon, which measured half an inch in length.
c. Membranous bands of adhesion passing obliquely upwards and outwards, to the outer portion of the sheath of the tendon.
d. Lower border of divided anterior tibial tendon, at its junction with the new connective tissue.

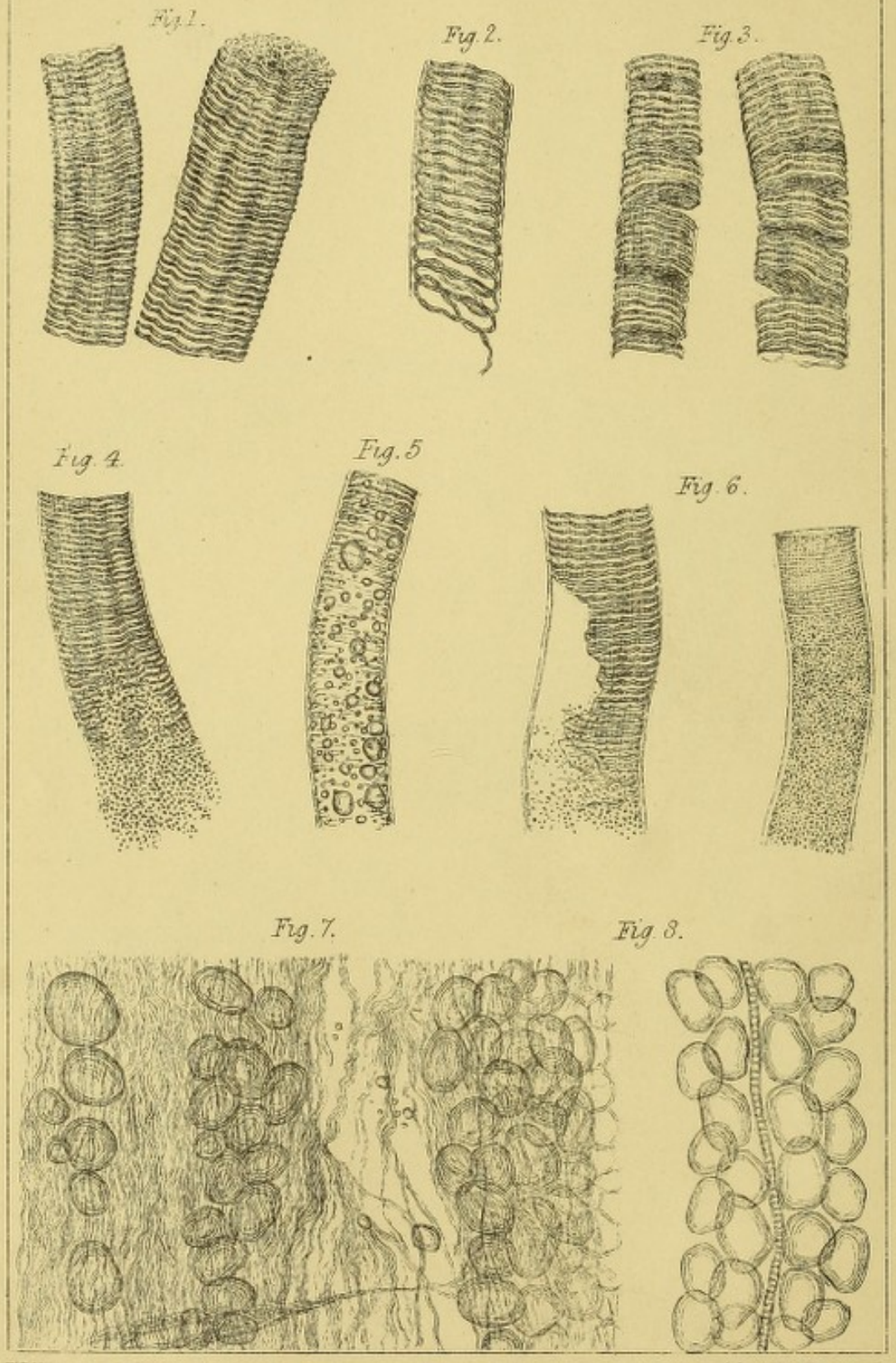

W. West & Co. lith.

After W. S. Leonard.

DESCRIPTION OF PLATE VI.

Showing the structural changes in the muscles in cases of non-congenital talipes described in Appendix, Note 4, page 382.

Fig. 1.—Muscular fibres in a healthy condition.—Taken from the extensor longus digitorum in Case 2.

Fig. 2.—Muscular fibre in which "the parts forming the transverse striæ could be entirely separated from the sarcolemma in a spiral form, and each stria, when highly magnified, exhibited a beaded structure like the ordinary fibrillæ."—Taken from the extensor longus digitorum in Case 3.

Fig 3.—Muscular fibres with transverse striæ distinct. "The fibres were all so firmly embedded in fibrous tissue that they could not be separated without being more or less torn transversely. In a second portion a little manipulated, the fibres were still seen to be broken into short lengths."—Taken from the gastrocnemius in Case 3.

Fig. 4.—Muscular fibres in the first stage of fatty degeneration.—Taken from the tibialis anticus in Case 1.

Figs. 5 *and* 6.—Muscular fibres of variable size and in all stages of fatty degeneration.—Taken from the soleus in Case 2.

Fig. 7.—Muscular structure completely degenerated, and replaced by "a large amount of fibrous tissue between rows of adipose cells. Adipose tissue abundant, and the cells arranged in parallel rows."—Taken from the gastrocnemius in Case 1.

Fig. 8.—The proper muscular structure completely degenerated, and replaced by "adipose tissue occurring as a double row of fat-cells in the neighbourhood of small muscular fibres about one eighteen hundredth of an inch in diameter, with striæ well developed." Mr. Quekett considered that these fibres, one of which is well exhibited in the drawing, "were either of new development, or else fibres that had never attained their normal size."—Taken from the extensor longus digitorum in Case 1.

CHAPTER I.

THE VARIOUS FORMS OF CLUB-FOOT; AND THE HISTORY OF SUBCUTANEOUS TENOTOMY IN THE TREATMENT OF THIS AFFECTION.

DEFORMITIES of the foot occur both as congenital and non-congenital affections; the non-congenital cases are by far the more numerous, the proportion being as about three to two, according to a statistical report of 1780 cases of deformity of the feet treated at the Royal Orthopædic Hospital,* and from which a tabulated arrangement of the non-congenital cases is given in Chapter VI. and of the congenital cases in Chapter XII.

So considerable are the deviations in form in some instances, and so altered are the relations of the foot to the leg, that a general observer would scarcely recognise it as a foot. In the severest form of congenital talipes varus in the adult, for example, the foot is not only inverted, but extremely shortened, doubled upon itself both in the direction of its length and breadth, and the toes are directed inwards, and backwards. In such cases, the leg appears to terminate in a misshapen and somewhat club-like extremity.

In other cases, there may be only a slight elevation of the heel from contraction of the tendo Achillis, when the amount of motion in the ankle-joint is limited, and lameness is produced, but with little or no obvious deformity, or alteration in the general direction of the foot. This is a common non-con-

* "Introductory Lecture," by R. W. Tamplin, *London Medical Gazette*, October, 1851.

genital affection, and between the two extremes every degree of distortion may occur.

For the sake of classification, it has been found convenient to group all the deformities of the foot in four principal divisions, as so many varieties of one genus, to which the term talipes, from *talus* and *pes*, was first applied by Dr. Little,* who suggested its application as a generic expression. In a more limited sense it had been previously used by Wanzel,† and subsequent writers.

We, therefore, recognise the following as the four principal varieties of club-foot, viz:

1st. *Talipes equinus;* elevation of the heel, with extension of the foot.

2nd. *Talipes varus;* inversion of the anterior portion of the foot, with elevation of the heel.

3rd. *Talipes valgus;* eversion of the anterior portion of the foot.

4th. *Talipes calcaneus;* depression of the heel.

There are also four compound varieties or intermediate forms, viz.:

1st. *Talipes Equino-varus;* when the foot is somewhat inverted as well as extended.

2nd. *Talipes Equino-valgus;* when the foot is everted as well as extended.

3rd. *Talipes Calcaneo-varus;* when the foot is inverted with depression of the heel, and

4th. *Talipes Calcaneo-valgus;* when the foot is everted with depression of the heel.

Each of these distortions may be either congenital or non-congenital, although the congenital nature of Talipes equinus is still doubted by some authorities. Cases of pure talipes equinus, *i. e.*, in which the heel is simply raised without any inversion of the foot, or inclination to varus, are of extremely rare occurrence; but I have met with this condition in two or

* "Treatise on the Nature of Club-Foot," by W. J. Little, M.D., London, 1839.

† Dissertatio Inauguralis medica de Talipedibus Varis auctore D. M. Wanzel, Tübing. 1798.

three instances, and am, therefore, satisfied that talipes equinus should be ranked with the congenital distortions.

It has been proved by recent investigation that many of the congenital and non-congenital distortions of the foot are essentially and intimately allied. That the deformities occurring in intra-uterine life do not depend upon arrest of development or malformation of the bones, as formerly supposed, although exceptional cases with malformation do occur; but as a general rule, like the deformities we so frequently see produced after birth, they depend essentially upon alterations in the relative position of the bones, in consequence of irregular muscular action, position, pressure, &c.

In the investigation as to primary causes it is difficult to say in any given case, seen long after the production of the deformity (for many of these congenital cases occur at an early period of uterine life), which of several possible causes contributed most to the production of the deformity; many points of interest in the pathology, therefore, remain to be determined. Still the existing conditions, when the deformity is fully developed at the period of birth in congenital cases, have been most satisfactorily proved by dissection, and by means of this knowledge we have been led to a scientific and successful treatment of such cases as were previously considered incurable.

HISTORY OF SUBCUTANEOUS TENOTOMY.

Until the year 1784, the treatment of club-foot was limited to mechanical appliances, and although there is sufficient evidence to prove from the time of Hippocrates that deformities of the foot, when slight, were frequently cured by such means, and that the mechanical contrivances were often ingenious and well adapted to the distortions, there can be as little doubt that the more severe forms of club-foot remained incurable.

In the year 1784, a physician of Frankfort, of the name of Thilenius, proposed that the tendo Achillis should be divided in the case of a young lady seventeen years of age, affected with talipes varus, which mechanical treatment had

failed to benefit. Being a physician, Dr. Little* informs us, "he (Thilenius) did not undertake the operation, but prescribed its performance," and under his direction the operation was performed on the 26th of March of the same year, by a surgeon named Lorenz, the method adopted being that of open-wound. The heel immediately descended two inches, and thereby allowed the patient to tread on the entire sole. From this fact I gather that it was not a congenital case. The "large wound" cicatrized completely on the 12th of May, and the cure is said to have been perfect.

In the year 1799 the tendo Achillis was divided subcutaneously by Petit, and Mr. Hancock in his second course of lectures "On the Anatomy and Surgery of the Human Foot" delivered at the Royal College of Surgeons of England in June 1867, when speaking of the retraction of the heel after Chopart's operation, observes, "This was first observed by Mark Anthony Petit in 1799, and to remedy this defect he divided the tendo Achillis subcutaneously; thus rendering this operation and himself famous from the former being the first example of tenotomy on record, and he the first surgeon to perform it." See *Lancet*, Sept. 7, 1867.

In the year 1803 Scarpa† published an excellent though not quite correct account of the anatomy of congenital club-foot, in which he proved by dissection the inaccuracy of the supposed cause of club-foot residing in arrest of development or malformation. Practical surgery then advanced, although slowly towards the means of cure, and the success is now one of the greatest triumphs of modern science.

In the year 1806, on the 10th of May, the operation of Thilenius and Lorenz was repeated by Sartorius, in a case of talipes equinus, resulting from abscesses on the back of the leg, of a boy thirteen years of age. Dr. Little‡ mentions these

* *Op. cit.*, page xlviii., Introduction.

† Memoria chirurgica sui piedi torti congeniti dei fanciulli, e sulla maniera di corregere questa deformita di Antonio Scarpa, 4to. Pavia, 1803.—*See* also English translation by W. J. Wishart, Edinburgh, 1818, and Longman & Co., London.

‡ *Op. cit.*, page xlix., Introduction.

cases in his work on club-foot. When a tourniquet had been applied to the femoral artery, a longitudinal incision four inches in length was made over the centre of the tendo Achillis, the integument dissected off, and the fascia divided on a director to the same extent. The tendon was then cut across, and force employed to bend the foot. As this failed, the incision was extended to the os calcis, the cicatrices were divided, and the tendon isolated. Even with this, however, the joint did not yield, and we are told by Sartorius that he employed his whole strength, when the joint, giving way, such a noise and cracking ensued as though the whole of the bones had been broken. The operator was very anxious about the possible consequences, although no fracture was discovered at the time. Symptomatic fever and suppuration followed, but the latter not to any great extent. After nine weeks the wound cicatrized, complete anchylosis of the ankle having resulted. The patient, however, was able to walk easily without a stick.

Such was the manner in which talipes equinus was treated sixty-six years ago. The result was more fortunate than might have been looked for, or would generally follow such a procedure.

In 1809 Michäelis, of Marburg, in Germany, treated several cases of talipes equinus by partially dividing the tendo Achillis; but it must be presumed he either ruptured the undivided portion, or made complete sections, from his having brought the feet at once, as he is reported to have done, into a natural position.

In the year 1816 Delpech,* of Montpellier, next suggested an important modification in this operation, viz., the avoiding of direct exposure of the tendon by open-wound. He did not expose the tendon by dissection, but transfixed the limb between the tendo Achillis and the deep muscles with a common scalpel, the wound in the integuments on either side being an inch in length; after introducing a convex-edged bistoury, he divided the tendon from before backwards, taking care to leave the bridge of the skin over the space between the divided ends

* Chirurgie clinique de Montpellier," par le Professor Delpech, Tome I., page 192, Paris et Montpellier, 1823.

of the tendon. He performed this operation in May, 1816, on a boy aged nine afflicted with talipes equinus. Here for the first time we see an approach made towards the present subcutaneous method.

Delpech also conceived the idea that the divided ends of the tendon should be retained in apposition after the operation until union had taken place, after which the uniting fibrous substance should be gradually and carefully extended, until it assumed a degree of length equal to the shortened muscle. This was a most valuable suggestion, and gradual mechanical extension after tenotomy is the method we at present adopt, but immediate extension is employed by some surgeons.*

Delpech's mode of operating, although ultimately successful, was attended with some serious consequences from the extent of the wound made. There ensued symptomatic fever, suppuration, and sphacelus of some portions of tendon and cellular tissue; extension was not commenced until four weeks after the operation, when the wounds were still uncicatrized. After three months, the intermediate substance appeared to be two inches in length, much smaller than the original tendon, but sufficiently firm to prevent flexion of the foot beyond a right angle.

The general health having suffered, indolent abscesses formed on the inside of the leg, the inside of the patella, and in the inguinal region, and neither these, nor the wounds from the operation, were healed for some months. The patient was, however, enabled to stand on the limb, take exercise, and ultimately obtained a cure. In the year 1836, he was still living, the cure having proved effectual.

Delpech† seems never to have repeated the operation, although he still believed it might occasionally be successfully resorted to.

It has been a subject of regret that Delpech's first case was so unfortunate as to prevent him repeating the operation, with

* The plan of immediate extension was recommended by the late Professor Syme of Edinburgh (see *Lancet*, March 17th, 1855), and a reply by Mr. W. Adams in *Medical Times and Gazette*, April 28th, 1855.

† "L'Orthomorphie," Tome II, D. 327, Paris, 1828.

such modifications as further reflection and experience would have suggested; but he was ignorant of the pathological basis upon which alone such operations can be conducted with safety to the patient, although it had been clearly enunciated by Hunter twenty-two years previously, and therefore it is scarcely to be regretted that further experiments were not made. When Delpech wrote his celebrated work, "L'Orthomorphie" thirteen years after this operation, he did not recommend any modification of his mode of procedure.

It is a subject for national congratulation that the great pathological law, deduced directly from accurate pathological and surgical observations, which should have determined the practice in the case operated upon by Delpech, and a knowledge of which would have enabled him to have carried off more than the full meed of praise which his warmest admirers have awarded him, had so many years previously been published in the works of the illustrious Hunter.

Hunter, in his "Treatise on the blood, inflammation, and gun shot wounds," published in the year 1794, twenty-two years before Delpech performed his operation, and thirty-seven years before the imperfectly subcutaneous operation of Stromeyer, points out as a great fundamental principle in reference to the healing of injuries, the difference between those two forms of injuries, of which one is subcutaneous, the other open to the air.

Hunter says: "The injuries done to sound parts I shall divide into two sorts according to the effects of the accident. The first kind consists of those in which the injured parts do not communicate externally, as concussions of the whole body, or of particular parts, strains, bruises, and simple fractures, either of bone or tendon, which form a large division.

"The second consists of those which have an external communication, comprehending wounds of all kinds, and compound fractures.

"Bruises which have destroyed the life of the part may be considered as a third division, partaking at the beginning of the nature of the first, but finally terminating like the second.

"The injuries of the first division, in which the parts do not communicate externally, seldom inflame, while those of the second commonly both inflame and suppurate."

We have then in this summary the law of the reparative process in these two great classes of injuries.

Sir James Paget in his "Lectures on Surgical Pathology,"* observes that "in these sentences Mr. Hunter has embodied the principle on which is founded the whole practice of subcutaneous surgery; a principle of which, indeed, it seems hardly possible to exaggerate the importance."

It may be said with truth that those who are occupied in observing the several stages of advancement which surgery has made within the last half century, will trace in the principles established by Hunter, the germs of the greatest improvements which have been subsequently introduced, and amongst these, the advance made by subcutaneous surgery must be admitted to hold a prominent position. Much additional importance is attached to the enunciation of the Hunterian law by the fact stated in the life of Hunter by Drewry Ottley, that in experiments which Hunter performed on dogs, he divided the Achilles tendons subcutaneously by introducing a couching needle under the skin at some distance from the tendon. Further allusion will be made to these and other experiments by Hunter in the next chapter, when the reunion of divided tendons will be described.

The following are the rules laid down by Delpech for the performance of the operation:

"1st. The tendon to be divided should not be exposed, its section should be made by a détour, and not by an incision of the skin parallel to it."

From these words it might be inferred that Delpech performed the subcutaneous division of the tendon; but from his own account of the operation it is clear that his idea of not exposing the tendon was comparative, in relation to the large incisions and complete dissections of his predecessors, and that he had no idea of the true subcutaneous method as at present

* London, 1853, vol. I, page 170.

employed. This great improvement was left for Stromeyer to accomplish.

The other rules laid down by Delpech relate to the after-treatment, and are practically correct, more especially as to the plan of gradual mechanical extension, and retaining the limb in its improved position for a sufficient length of time for the consolidation of the new material.

"2nd. Immediately after division of the tendon, the divided extremities should be brought into contact, and kept in this position by suitable apparatus until their reunion is effected.

"3rd. This last can only take place by an intermediate fibrous substance, *une organisation inodulaire*, so that we can and we ought to submit it, before solidification, to a gradual and careful extension, capable of giving the required length to the shortened muscles.

"4th. This extension having been effected, the parts should invariably be fixed in the position we find them at that time; and there kept, until the new substance has acquired the firmness of which it is susceptible.*

That the surgeon who could lay down these excellent rules, so well calculated to prevent disturbance of the parts after the operation, and favour the reparative process, should himself have performed the operation by means of an incision an inch in length on either side of the tendon, the exposure from which produced suppuration and sloughing, seems one of the strangest inconsistencies that ever beset a man of genius.

From the year 1816, in which Delpech's operation was performed, Dr. Little states that there are no recorded repetitions of the operation until the year 1831.

In the year 1831, Stromeyer of Hanover divided the tendo Achillis upon a greatly improved method, although less perfectly than at present performed, and in 1833 and 1834 published two Memoirs† detailing the history of six successful cases. The commencement of scientific tenotomy dates then from this

* L'Orthomorphie, Tome II, page 330.

† "Rust's Magazine," Band XXXIX, page 195, and Band XLII, page 159. "Archives Générales de Médecine," Tome IV, page 103.

period. "To Stromeyer," observes Dr. Little, "is due the honour of establishing the division of tendons on a secure and permanent basis, and of insuring its reception as a standard operation in the art of surgery."

Stromeyer not only fully appreciated the value of the rules laid down by Delpech, and the soundness of the principles on which he recommended the subsequent treatment should be conducted, but he also recognised the great source of danger in his predecessor's method of operating, viz., the large external wound and disturbance of parts.

In this respect, therefore, Stromeyer improved the operation which he performed by "puncture," as he expresses it, without external incision. He used a small bistoury, but still, like Delpech, he transfixed the limb between the tendon and the deep muscles, making two small wounds, and then divided the tendon by pressing it against the edge, rather than cutting it by any movement of the knife, which he considered would have endangered an increase in size of the cutaneous wounds.

Stromeyer describes his mode of operating in his work on "Operative Orthopædic Surgery."* and his account is transcribed by Dr. Little. "I have frequently divided," says Stromeyer, "the tendo Achillis in this manner without producing a second puncture, but this is of little moment, as two minute punctures heal as quickly as a single one." Here then is the true subcutaneous section described in the year 1838, in juxta-position with the plan of transfixing the limb. Stromeyer continues: "The performance of the operation with the point of the instrument is less to be relied on, partly from its being too weak, and also because the operator can be less certain of not causing injury to other structures in the event of the patient not remaining quiet throughout the operation."

Here we see that Stromeyer evidently prefers the plan of transfixing the limb, assigning his reason for doing so; and the number of cases so operated upon proves to us, on sufficient evidence, that it is a proceeding generally free from risk when

* "Beiträge zur Operativen Orthopädik," page 17, Hanover, 1838.

the wounds are small. I have seen it done accidentally two or three times without exciting inflammation, but at the same time think its adoption by Stromeyer goes far to show that he sought to improve the operation by diminishing what he correctly conceived to be the great defect in the operations of his predecessors, rather than to establish it on the broad basis of the pathological law pointed out by Hunter as regulating the reparative process of "injuries in which there is no external communication."

The credit, nevertheless, still belongs to Stromeyer of having reintroduced this operation, and performing it in the only way in which it can be undertaken with safety to the patient. Whether this result was arrived at as a mere practical suggestion, looking to a diminution of what appeared to be the source of failure in the method of his predecessors, or as a scientific deduction from pathological and surgical observation, Stromeyer soon had the gratification of witnessing the splendid results of this operation, which he had deprived of all its terrors. He had to contend with the strongest opposition and the severest criticism from his contemporaries, but these by his determined perseverance he overcame, and by a multitude of cases was enabled to demonstrate the safety of the operation.

Dr. Little states that it was two or three years before Stromeyer's example found imitators. Dieffenbach, of Berlin, appears to have been among the first and most energetic followers of the Stromeyerian operation. Dr. Little states that in 1839, Dieffenbach had up to that period, divided the tendo Achillis in upwards of one hundred and fifty cases of distorted feet. Bouvier, of Paris; Pauli, in Germany; Duval, who first divided the tendo Achillis in Paris in 1835; Jules Guérin, of Paris; Bonnet, of Lyons; and Scoutetten, of Strasburg, also quickly adopted it.

Such was the history of subcutaneous tenotomy on the Continent up to the year 1834, when Stromeyer had published his successful cases, and it now remains to show how the new discovery was introduced into England.

A gentleman, who is now a distinguished physician of this

metropolis, Dr. Little, was in early childhood affected with a deformity of the foot, of the variety termed equino-varus affecting the extensor muscles of the left leg, caused by infantile paralysis. The contraction was severe, and the consequent lameness and deformity such as greatly to interfere with progression.

From this circumstance, whilst a medical student he devoted much attention to these distortions, and consulted the leading surgeons of the day with regard to his own case; but from none did he receive the slightest hope of cure, the affection being invariably attributed to malformation, and anchylosis of the individual bones of the tarsus. He was, therefore, compelled to be content with the assistance afforded by wearing such mechanical supports as were in use at that time.

In the year 1832, having learnt that Delpech had divided the tendo Achillis, Dr. Little again consulted several members of the profession, himself believing in the feasibility of the operation; but was dissuaded by the fears expressed of inflammation, diffuse suppuration, exfoliation of tendons, &c. Even if the operation succeeded, it was considered doubtful whether the astragalus could be replaced beneath the axis of the tibia, and if this should be accomplished, it was thought that anchylosis of the ankle-joint would probably take place.

Dr. Little's hopes and confidence were greatly diminished by finding that Delpech narrated in his "L'Orthomorphie," published in the year 1828, the same case as previously referred to in his original work, "Chirurgie Clinique," 1823, without announcing any repetition of the operation. For a time, therefore, all idea of relief was abandoned; but his hopes were soon to be rekindled, for in the year 1834 the important modifications in the operation of Stromeyer were published, and six successful cases were detailed.

Dr. Little at once resolved to proceed to the Continent and submit to the operation, if further inquiry and investigation should appear to sanction it. In 1835, and the spring of 1836, he tells us he visited Leyden, Leipsic, Dresden, and Berlin.

Disappointment was still experienced from the adverse opinions of several distinguished professors; but Professors J. Miller and R. Froriep, of Berlin, agreed in rejecting the supposition of malformation of the bones, or of any condition existing calculated to impede replacement of the foot.

Stromeyer's operation was considered, by Froriep, to be based on sound surgical principles, and Dr. Little, therefore, determined on placing himself under the care of Stromeyer, who divided the tendo Achillis, the method of transfixing the limb being adopted without any ill effects, and by judicious treatment the deformity was completely removed.

Stromeyer was not only desirous that his patient should bring into England a cure in his own person, but with the liberality of feeling which distinguishes all great men, was anxious that he should also gain some practical experience in the mode of operating. Through his kindness, therefore, Dr. Little was permitted to perform the operation in Hanover in July, 1836. When he returned to Berlin with his cured foot, Dr. Little informs us that Dieffenbach adopted the operation with the whole ardour of his genius, and in conjunction with him Dr. Little treated upwards of thirty cases of club-foot.

On February 20, 1837, Dr. Little first divided the tendo Achillis in London. The operation had, however, been previously performed in England in May, 1836, by Mr. Whipple of Plymouth, but the plan of treatment adopted by this surgeon, was that of immediate restoration of the foot as advised by Bouvier, and not the gradual mechanical extension as recommended by Stromeyer. Mr. Whipple informs me that when he first devised this operation, he was not aware of its having been performed on the Continent, and that Sir B. Brodie, to whom he wrote on the subject, discountenanced it; but Liston sanctioned it on the ground that the chances of benefit outweighed the probability of the patient being injured by its performance.

From the year 1837, when Dr. Little by the introduction of subcutaneous tenotomy commenced his successful career in

London, the gradual development of Orthopædic* surgery may be traced in England. In the year 1838 the Royal Orthopædic Hospital was founded, and at the present time three Orthopædic hospitals exist in this Metropolis.

Our experience of the harmless character of subcutaneous tenotomy, the absence of pain and inflammation after such wounds; in fact, the practical and complete realization of the truth of the great Hunterian law, has led to the application of the same principle in the treatment of many other affections, and the subcutaneous division of tendons, as well as other subcutaneous operations, are now amongst the most common surgical procedures.† The history of all these operations forms but a portion of the general history of pathology and scientific surgery, amongst the latest and most practical improvements in which, they form a prominent and important part.

* The term Orthopædy appears to have been first used by M. Andry, Dean of the Medical Faculty of Paris, who in the year 1741 published at Paris a work in two volumes, on "Orthopædy; or, the Art of Preventing and Correcting the Deformities of the Body." He derives the term from the Greek words ὀρθὸς, straight, and παιδὸς, genitive of παῖς, a child; and, as the practice which it represents is by no means limited to the cure of deformities of the feet, I think there is sufficient reason for retaining this definition.

† See "A Sketch of the Principles and Practice of Subcutaneous Surgery," by W. Adams. London, 1857.

CHAPTER II.

ON THE REUNION OF TENDONS AFTER SUBCUTANEOUS TENOTOMY—AND THE RATE OF EXTENSION AFTER OPERATION IN THE TREATMENT OF CLUB-FOOT.

In connexion with the treatment of club-foot by tenotomy, there is no subject of greater pathological interest than the process by which divided tendons reunite, and the balance of muscular power is restored, after the foot has been brought into its natural form and direction by mechanical means. That tendons do unite after accidental rupture is frequently witnessed in the tendo Achillis, and like bones, become as strong as the original structure; and that they also unite perfectly after division by open-wound, as frequently seen in accidental injuries, have long been self-evident and self-proved facts.

The great practical fact, also, that tendons reunite firmly after subcutaneous tenotomy for the cure of club-foot has been well established since the discovery and practical application of subcutaneous tenotomy by Stromeyer in 1831, and it has also been proved by experience that in the most severe cases of talipes, unaccompanied with paralysis, as in the ordinary forms of congenital varus, the balance of muscular power is completely restored after division of the contracted tendons, no lameness or imperfection in walking remaining.

The exact nature of the process, however, by which union takes place has long remained a matter of uncertainty, and theoretical speculation; even at the present day many of the English and Continental pathologists, who have experimentally

investigated this subject, are directly at variance with respect to the nature of the reparative material, its sources, and its mode of development.

Still less are surgeons agreed upon the manner in which the new material, formed for the purpose of union when tendons are divided for the cure of deformities, is ultimately disposed of. The point at issue is mainly whether the new material formed for the purpose of reuniting the cut extremities of the tendon, remains as a permanent tissue, forming an integral part of the tendon, and thus producing the required elongation; or whether the new material is only of a temporary nature, and undergoes a process of gradual contraction and absorption, until the divided extremities of the old tendon are again brought into immediate contact, and a linear cicatrix alone remains.

The chief points of physiological importance in the process of reunion of tendons, admit of being determined by reference to the results of experiments on animals, such as:—the nature and source of the reparative material, the share taken by the inflammatory exudation, and by effused blood, the influence of the sheath, and of the cut extremities of the tendon, as well as the general appearance and structural characters of the connective tissue. There can be no doubt that the process is essentially similar in man and in animals, the differences being those of degree, rather than of structural development, the process being quicker and more active in animals than in man.

Reparative process in tendons, after division, in animals.

Numerous experiments on animals to determine the precise nature of the reparative process have been made by various surgeons and physiologists, who have minutely described the appearances presented and the general results obtained.

The earliest of these experiments were performed by Hunter, about the year 1767, and the interest attaching to them is greatly increased by the fact that in some instances the tendons were divided subcutaneously. In the life of John Hunter, by Drewry Ottley, it is stated that in the year 1767, Hunter rup-

tured his tendo Achillis whilst dancing, and this accident led him to examine into the process by which divided tendons are reunited.* "He divided the same tendon in several dogs, by introducing a couching needle under the skin at some distance from it, and killed the dogs at different periods to see the progress of the union, which was found to be similar to that of fractured bones where the skin is not wounded."

The specimens from these experiments do not appear to have been preserved in the Hunterian Collection of the Royal College of Surgeons, nor have I been able to find any description of the appearances presented on dissection; but in the Museum of the College of Surgeons there are five specimens of divided Achilles tendons from the ass and deer. The experiments were performed by Hunter, for the purpose of investigating the process of repair; and in the description of three of these specimens in the Pathological Catalogue, Vol. II., Nos 349, 351, and 352, it is stated: "The tendon was divided transversely, and it is believed by subcutaneous section." In one of the other two specimens, No. 348, the experiment was performed by open wound, and in the other, No. 354, it is stated "that the operation was probably not by subcutaneous incision."

The appearances presented by these specimens have been described by Sir James Paget in the "Descriptive Catalogue," and in reference to the specimens, Nos. 348 to 354, the divided extremities of the tendons are described as "retracted to a considerable distance from each other," and in the description of No. 352, it is stated "The uniting medium is *not distinguishable* from the tendon itself, except by being less glistening, by its fibres being less regularly parallel and longitudinal, and by its surfaces being united with the surrounding fibrous textures."

Since the time of Hunter, numerous experiments on animals have been performed by several Continental and English observers, more especially by Mayo† (1827), who operated upon several dogs, dividing the Achilles tendon by open-wound.

* The Works of Hunter, with Notes by J. F. Palmer, page 34, London, 1837.

† "Outlines of Physiology." London, 1827, and the subsequent edition.

Von Ammon* (1837), who performed numerous experiments upon horses, and three on rabbits, dividing the tendons subcutaneously.

Guérin (1838†, 1839‡, and 1841§), who alludes to the results of his observations on this subject, but without giving any details as to the animals experimented upon, or the number of the experiments.

Pirogoff (1840‖) who performed more than seventy experiments on dogs, sheep, calves, and fowls by dividing the Achilles tendons subcutaneously, and recorded the appearances observed from twenty-four hours to twelve months after the operations. He describes minutely the appearances in the different stages and the reparative process.

Koerner (1843¶) describes the anatomical appearances of the specimens of the divided and reunited tendons from the horse, preserved in the Museum of the Veterinary School at Dresden, by Dr. Prinz, who performed the experiments; and he also describes three experiments performed by himself on rabbits.

Paget (1849** and 1853††) describes the appearances presented in a series of experiments performed with the help of Mr. Savory on rabbits from three to six months old. The Achilles tendons were divided subcutaneously, and in some instances the plan of open-wound was adopted.

In the account given by Sir James Paget, the development of the new connective tissue is minutely detailed, and microscopic characters traced through all the stages of the reparative

* "De Physiologia Tenotomia experimentis illustrata," Dresden, 1837.

† "Mémoire sur l'Etiologie générale des Pieds bots congénitaux," 1838.

‡ "Mémoire sur les variétés anatomiques du Pied bot congénital," Paris, 1839.

§ "Essais sur la Méthode sous-cutanée," Paris, 1841.

‖ "Ueber die Durchschneidung der Achillossehne, als operativ Orthopædisches, Heilmittel," Von Nikoleus. "Pirogoff mit seiben Tafeln," Dorpal, 1840. For an account of these experiments, see also "Gerstaecker's Dip."

¶ "Physiologische Streitfragen über der Hulungs processnach der sub-cutaneal Tenotomie Jourl. der Chirurgie und Augenheilkunde," Von Muller und Von Ammon, Band XXXI, p. 262, 1843.

** Lect. on Surgical Path., *Medical Times and Gazette*, 1849.

†† Lect. on Surgical Path., Vol. I., London, 1853.

process, which is also considered in its physiological and surgical aspects.

Gerstaecker (1851*) performed a series of experiments (fourteen in number) on rabbits, in which he divided the Achilles tendons subcutaneously, and the animals were killed at periods from twenty-four hours to two months.

Thierfelder† (1852) performed experiments on thirteen rabbits, dividing the Achilles tendons subcutaneously, and making the examination at different periods from twenty-four hours to fifty-six days. The microscopic characters of the reparative material, and the structural changes observed are minutely detailed.

J. H. Boner‡ (1854) performed upwards of thirty experiments on rabbits, by dividing the Achilles tendons subcutaneously.

Adams§ (1855) performed experiments on sixteen rabbits, dividing the Achilles tendons subcutaneously. The animals were killed at different periods from the second to the sixty-second day; also two experiments by dividing the Achilles tendon by open wound. In this series of experiments, the reparative process in divided tendons is traced in all its stages, especially in reference to the share taken by the inflammatory exudation and effused blood, the influence of the sheath and of the cut extremities of the tendon. The general appearance and structural characters of the connective tissue in the different periods of its development are described. The microscopic characters of the connective tissue in the different stages of reparative process are also described.

* "Dissertatio de regeneratione tendinum post Tenotomiam." Adolphus Gerstaecker, Berolini, 1851.

† "Diss. Histol. de regeneratione tendinum." F. F. Thierfelder, Misenæ, 1852.

‡ "Die Regeneration der Sehnen," J. H. Boner. "Archiv. für Pathologische Anatomie und Physiologie und für Klinische Medicin," von R. Virchon, p. 162. Berlin, 1854.

§ A series of experiments illustrating the reparative process in the tendons of rabbits after division by subcutaneous and open-wound.—"Trans. Path. Soc. of London," Vol. VI, 1855. Also a Treatise "On the Reparative Process in Human Tendons." Churchill, London, 1860.

Brodhurst* (1856 and 1859) refers to experiments on rabbits in which he divided the Achilles tendons subcutaneously, but no details are given as to the number of experiments, nor are the appearances presented described in the general account given.

In addition to the numerous series of experiments made by the authors above referred to, with descriptions of the appearances presented and exact references to published accounts, from which the descriptions of other writers are generally taken, there can be no doubt that other experiments have been made, and probably both Bouvier and Duval performed independent experiments, but in the general description given by these authors of the reparative process, no exact references either to the specimens, or to any published accounts are given.

A resumé of the published descriptions of experiments on animals, as well as such post-mortem examinations in the human subject as have been recorded, will be found in a work on this subject which I have published.*

There can be no doubt that the nature of the process by which reunion of tendon takes place, after subcutaneous tenotomy, has been minutely and accurately described by the various observers to whose experiments I have just referred.

The descriptions of the phenomena observed, however, as well as the views which the observers have been led to form, more especially in reference to the influence of extravasated blood, inflammatory lymph, and the sheath of the tendon, in the reparative process, are widely different in many important respects. Compare, for example, the accounts given by Gerstaecker and Thierfelder, with the description given by Paget in the work above referred to.

Theory of the reparative process in human tendons.

The point of more direct surgical interest, viz., the *modus operandi* of tenotomy in curing deformities; or the pre-

* "On the Nature and Treatment of Club-Foot," London, 1856. Also a communication to the Royal Society, November 4th, 1859, "On the repair of tendons after their subcutaneous division." An abstract of this paper only has appeared in the "Proceedings of the Royal Society," No. 37, 1860.

† "On the Reparative process in Human Tendons." Churchill, London, 1860.

cise way in which the required elongation of contracted muscles is obtained by the subcutaneous division of their tendons, can only be determined by reference to dissections in the human subject after tenotomy has been performed for the cure of deformities; nevertheless, the opinions expressed on this subject have been matter rather of theoretical conjecture than based upon direct observation.

Delpech does not appear to have performed any experiments on animals with the view of ascertaining the nature of the reparative process, but upon observation of what takes place after accidental rupture of the tendo Achillis, he founded his theory of union by an intermediate substance, capable of extension before it becomes solidified. Delpech observes, as reunion "can only take place by means of an intermediate fibrous substance (*une organization inodulaire*), we can, and we should submit this before it becomes solidified, to a gradual and careful extension capable of giving to it the length required by the shortened muscles."*

Stromeyer's opinions on the union of tendon after division, like the opinions of Delpech, were not founded upon direct observation, since neither experiments on animals nor any post-mortem observations on the human subject are referred to. Both these early writers relied upon what they observed as to the manner in which the tendo Achillis united after accidental rupture, and their theoretical explanation of this process was, of course, in accordance with the general pathology of the time at which they wrote.

Stromeyer generally admitted the explanation of Delpech as to the reunion of tendon by the development of an intermediate connective tissue, which he believed was not formed of sufficient length to compensate for the shortening of the contracted muscles observed in many severe cases of deformity, and arguing upon this opinion, Stromeyer combined a physiological with a mechanical explanation of the way in which such cases of deformity are cured by the division of tendons. He appears

* L'Orthomorphie, Tome II, page 330.

to have believed that a dynamic influence results from the division of the tendon, *i. e.*, the irritability of the muscle being temporarily diminished by the division of its tendon, its power of contraction is weakened, and any increase of it prevented.

Stromeyer observes, "Delpech has laid it down as a rule, that we should promote the development of a connecting substance between the divided extremities of the tendon, sufficient to maintain the function of the muscle, and, therefore, we should not disturb the union of the cut ends of the tendon by too early extension. If this principle is useful for the safe performance of orthopædic operations, and is worthy to be borne in mind, it is, nevertheless, based upon the false assumption that the elongation of the shortened muscle is produced through the substance of the cicatrix. The amount of this substance of the cicatrix is too insignificant for that purpose.

"In some severe cases of talipes equinus, the gastrocnemii are several inches shorter than in their natural condition, and in wry-neck the sterno-mastoid may be shortened to the extent of several inches, yet, after the cure, the newly formed connecting substance is only a few lines in length. The elongation of the muscle, therefore, must be effected at the cost of its vital power of contractility, and this brings us to the conviction that the incision does not only produce a mechanical, but also a dynamic influence upon the muscle, and that by a temporary interruption of its irritability, its power of contraction is weakened, and any excess of it diminished. This view is confirmed by observation on healthy muscles, whose tendons have been divided by accident.*

Although in the writings of the chief Continental authorities, including Bouvier, Duval, Bonnet, Guérin, and others already referred to, we find an account given of a reparative process from experiments on animals, no post-mortem examinations in the human subject are recorded, and therefore no explanation of the phenomena observed during life in the cure of deformities by tenotomy has been given by these authors.

* "Beiträge zur operativen Orthopædik," page 14.

Reparative process in Human Tendons.

In reference to the general results of tenotomy in the human subject, and the ultimate disposal of the new connecting tissues. Mr. Tamplin remarks:

"The views of Stromeyer are, I believe, on the whole correct.

"It is true, as a general rule, that the cicatrix, after the cure is effected, measures but a few lines, often times only a line in thickness, provided proper care has been taken during the treatment. The elongation in congenital cases, and also in non-congenital cases in young subjects, is undoubtedly effected eventually at the cost of the contractility of the muscle, but not primarily, this is a secondary result, for no new uniting medium can by possibility possess the power of drawing down the muscle any more than the newly formed granulations following a burn can do. The cicatrix, as it contracts, certainly does so, but after the foot is brought into position, and hence the linear cicatrix. The force of the contraction of a cicatrix is sufficiently evident in the instances of burns alluded to, not only to draw down and overcome one muscle, but even a set of muscles as the extensors of the head and neck, or of the arm and other parts."*

Mr. Tamplin then describes two cases in the human subject in which he had examined the Achilles and other tendons, in one case a year, and the other eight months after division. In all the tendons, the reparative process is said to have been so perfect that no trace of their having been divided could be detected externally, or in a longitudinal section.

In the section, "a sort of globular appearance in one spot" is alluded to with some doubt as to its import.

In a more recent course of Lectures published by Mr. Tamplin in 1860, he observes: "I have had many opportunities of examining the muscles after death of patients whose tendons

* "On the Nature and Treatment of Deformities," by R. W. Tamplin, London, 1846, page 5.

had been divided during life, and in none could I trace the slightest difference between these and the muscles which had not been contracted.

"I would here remark that the union of the tendons which had been divided some few months was most perfect, a linear cicatrix being alone visible. This is most satisfactory, as serving to show that division of the tendon does not destroy its integrity, excepting during the time immediately following the operation, provided the necessary precautions are taken, viz., keeping the parts perfectly at rest, and as far as possible placing the divided ends of the tendon in juxta position."*

Mr. Brodhurst also agrees in the general conclusions adduced, and theory advanced by Mr. Tamplin. No post-mortem examinations in the human subject are recorded by Mr. Brodhurst, but he refers to experiments on rabbits in which he divided the Achilles tendons subcutaneously. No minute account of the reparative process as observed in these experiments is detailed, but a general description is given, and he observes: "These examinations were continued from day to day for three months, and they tend to confirm the opinion entertained by Mr. Tamplin and others of the gradual contraction of the new uniting bond, until a cicatrix alone remains which also is subsequently removed, and is not to be traced even by microscopic aid."†

With regard to the process of reunion in tendons divided in the human subject for the cure of deformities, Mr. Brodhurst observes at p. 96, in his work on club-foot:

"If the tendons of the retracted muscles of a child with congenital varus be divided and allowed to reunite, and the limb be gradually reduced to its normal direction, it is found, when extension has been made gradually and carefully, that the new bond of union slowly contracts, so as to leave no outward mark on the tendon itself of the incision which had been made. On

* "A course of Lectures "On the Nature and Treatment of Deformities," by R. W. Tamplin, "British Medical Journal," June 16th, 1860.

† "On the Nature and Treatment of Club-Foot," by B. E. Brodhurst, London, 1856, page 101-104.

dividing the tendon longitudinally, a slight depression may be observed in its centre corresponding to the section which was made, but this is also in time removed, so that, in fact, no mark is left of the section and reunion of the tendon.

"This I have verified, both in the infant and in animals. In the latter, in the course of three months, it is not possible to affirm which of two Achilles tendons had been divided.

"When, however, blood has been effused, or inflammation excited, a longer time is required entirely to obliterate the cicatrix and central depression."

The great difficulty in arriving at any satisfactory conclusions as to the ultimate disposal of the new connecting tissue, and the general results of tenotomy in the human subject, arises from the absence of facts which can only be acquired after death, and as there is nothing in the operation likely to produce death, the facts can only be obtained from such rare instances in which death should happen to occur at different periods after the operation, from circumstances not connected with it, such as convulsive affections, acute pulmonary inflammation, or any of the acute diseases to which children fall victims, while the reparative process is proceeding uninterruptedly in a healthy manner. The post-mortem examinations must therefore be extremely rare.

In the Museum of the Royal College of Surgeons are three specimens of human tendons after division for the cure of congenital varus, presented by Mr. Tamplin, of which the following description is given in the Catalogue, Vol. II. Nos. 358, 359, 360. "The tendo Achillis and the tendons of the anterior and posterior tibial muscles of a child nineteen months old. They were all divided by subcutaneous section nearly eighteen months before death. No trace of the division is discernible in any of them, their outlines and surfaces are regular, and their texture is uniform, even with the microscope no part could be found different from the rest."

In reference to these specimens I have observed in my Treatise on the Reparative process of Human Tendons, p. 66 and 152 "The preparations in the Museum of the College of Surgeons,

above adverted to, were not examined, when recent, by longitudinal section, the only method by which at a late period the difference between the old and new tendon can be recognised. Small portions have been removed from different parts of the tendons for microscopical examination, and as showing the absence of any minute structural differences in the several parts examined, the account given is valuable, but beyond this they have no bearing upon the general question as to the temporary or permanent nature of the newly formed connective tissue. The tendo Achillis and other tendons of the opposite leg should have been preserved to demonstrate any difference in the relative length of these tendons."

The result of tenotomy in the human subject after operation for the cure of club-foot, and the mode in which the permanent elongation of the contracted muscles is obtained, I have made the subject of special investigation, and have published in the work above referred to the results of fifteen post-mortem examinations of cases which had been operated upon for club-foot, and the subjects of which died at periods varying from four days, to three years after operation.

GENERAL SUMMARY OF THE REPARATIVE PROCESS.

The principal events in this process of development of new tendon after subcutaneous division, may, I believe, be described in a general summary, as follows: Let it be understood, however, that the description especially applies to the tendo Achillis. Essentially the reparative process is, no doubt, the same in all tendons; but as the anatomical conditions, under which tendons are placed in some situations vary; for instance, where tendons pass through dense tubular sheaths, as the tibialis posticus behind the inner malleolus, the flexor tendons along the fingers, &c., there is an absence of the investing cellular sheath, and of the fat and cellular tissue which surrounds the tendo Achillis, and other tendons similarly placed; and as these conditions sometimes interfere with the perfection of the reparative process, to which I will afterwards refer, it

will be better to limit the general description to the process as it appears to me to occur in the tendo Achillis, which I prefer for illustration, though it would equally apply to other tendons placed under similar anatomical conditions. The process may be best described under the four following heads, within which the principal events may be most conveniently grouped. They cannot be considered as so many different stages, because two or three of the processes described are always proceeding simultaneously.

1*st*. *Immediate results of the operation.*—After the subcutaneous division of the tendo Achillis in the human subject, for the cure of deformities of the foot, separation of the divided extremities of the tendon takes place to a very variable extent. Under ordinary circumstances, the separation of a divided tendo Achillis in an infant is about half-an-inch, and in the adult from one to two inches. This is produced in the following way: the upper portion of the divided tendon is drawn upwards by the contraction of the muscular fibres, and the lower portion is drawn downwards in proportion as the foot is restored to its natural position. The separation must, therefore, depend upon the capability of the muscular fibres to contract, and also upon the flexibility of the ankle-joint; and as in deformities the muscular structures are found in all conditions, from that of health to complete degeneration, and as the ankle-joint is also found in every degree of rigidity, from the adapted shortening of the ligamentous and other structures, &c., the separation of the divided tendon will vary in a proportionate degree. The circumstances which limit the separation of the divided extremities of the tendon are, 1st. degeneration of the muscular tissue, as in non-congenital cases of deformity of long standing, and of paralytic origin, &c.; 2nd., rigidity of the ankle-joint, produced by a variety of causes, but in congenital cases principally by the adapted shortening of the ligamentous structures; and in the non-congenital cases by old inflammatory infiltration of the structures surrounding the joint, &c.; 3rd., old adhesions in the neighbourhood of the tendon, such as result from a pre-

vious operation, or other causes. Frequently two, and sometimes all three of these conditions coexist, and in such cases scarcely any separation of the divided extremities of the tendon will take place at the time of the operation, so that the surgeon may be led to doubt whether the tendon has been completely divided.

Influence of the sheath.—The separated extremities of the divided tendon still remain indirectly connected with each other, through the medium of the cellular sheath of the tendon, by which I mean the loose-textured areolar tissue which closely invests and surrounds the tendo Achillis, and which is never divided, and often appears to be but very little injured in a subcutaneous operation; it evidently yields before the knife as the latter passes through the tense tendon. Even if this cellular sheath should be completely divided, as in an open-wound, it would not retract with the tendon, in consequence of its connexion with the subcutaneous fat and cellular tissue in the human subject; and in rabbits, in which animals no subcutaneous fat exists in the neighbourhood of the tendo Achillis, it would not retract, in consequence of its connexion with the deep fascia and sheaths of the deeper tendons.

The influence of the sheath, therefore, which I hold to be of great importance, is not destroyed, as has been supposed by Sir J. Paget, by the open-wound, though it is certainly impaired; and the reparative process in these cases is proportionally less perfect, but not to an extent permanently to interfere with the formation of a sufficient quantity of new tendon.* This cellular investment of the tendo Achillis, which is scarcely demonstrable as a sheath in an anatomical dissection, becomes very easily demonstrable as such, after the subcutaneous division of the tendon, because the loose-textured areolar tissue, of which the sheath is composed, is then put on the stretch, and being very little injured in the operation, as

* See experiments on the Reparative Process in Tendons of rabbits, after division by subcutaneous and open-wound, in the "Transactions of the Pathological Society," Vol. VI., and work "On the Reparative Process in Human Tendons," previously referred to.

I have explained, from its yielding before the knife, presents the form of a tubular sheath passing between, and connecting indirectly the separated extremities of the divided tendon. This is very readily demonstrated in the rabbit, and I have also seen the same condition in the human subject.

A very small quantity of blood is generally effused at the time of the operation within the sheath, now of tubular form, and is seen adherent to the upper and lower extremities of the tendon, but principally to the upper extremity. In many of my experiments on rabbits, there was scarcely a trace of blood; and in two examinations in the human subject, a few days after the operation, I found only a very small coagulum, certainly not sufficient to take any important part by its organization (the possibility of such a process being admitted) in the formation of the large quantity of new tendon required to connect the separated extremities of the old tendon. If the effused blood should be sufficient to fill the sheath, and infiltrate the surrounding tissues, the reparative process will be retarded and rendered proportionably less perfect. Such an event must be regarded as an unfavourable accident of the operation, instead of an essential part of the process, as it has generally been regarded, especially by the French and German authorities. In such cases, the greater part of the blood will become absorbed, and the remaining and firmer portion of the clot will be found, at a late period, enclosed in the midst of the new tendon; this I have witnessed in several instances, both in the human being and in the rabbit.

At the time of the operation, then, the separation of the divided extremities of the tendon, which remain connected by the sheath which now assumes a tubular form, and the effusion of a small quantity of blood, are the ordinary occurrences.

2nd. Commencement and nature of the reparative process.—The true reparative process commences in the human subject by increased vascularity of all the structures at the seat of the operation, viz.: the subcutaneous cellular tissue and fat, and the cellular sheath of the tendon, now of a tubular form,

passing between and connecting the separated ends of the tendon.

In the rabbit, the increased vascularity is confined to the connecting tubular sheath. For this reason, then, I regard the increased vascularity of the sheath in the human subject as essentially the first step in the reparative process, the extension of the vascularity to the cellular tissue and fat being the necessary consequence of the existence of this tissue, but unimportant as regards the reparative process. Increased vascularity of the sheath is followed by infiltration of a blastematous material into its meshes, or spaces, between its fibrous elements, so that the sheath now forming the matrix in which the reparative material is effused, presents a vascular and succulent appearance.

In the human subject, this effusion and succulency may sometimes extend to the surrounding cellular tissue, and fat, especially in clumsily performed operations, which may be followed by inflammation; but essentially I do not believe it extends beyond the sheath, because in carefully performed operations, followed by appropriate treatment, viz.: a compress and bandage applied immediately after the operation, the gap between the divided extremities of the tendon remains as a depression for several days; it does not become filled up, as it would do if the tissues were at once infiltrated; and an external examination by the finger readily detects the square and abrupt extremities of the divided tendon freely moveable in the cellular tissue, which to the touch seems flaccid, rather than distended by infiltration.

Development of the reparative material.—The blastematous material infiltrated into the meshes of the sheath increases in quantity, and, microscopically examined, exhibits the development of innumerable small oval nuclei, as shown in Plate II, Figs. 1 and 1 A. A few cells, of large size and irregular form, with granular contents, or, perhaps, with one or more nuclei, and studded with minute molecules of oil —cells such as are not met with in ordinary inflammatory effusions—may also be found according to the extent of the

inflammatory lymph, which may be accidentally intermixed with the nucleated blastema—so-called by Sir James Paget, and described by him as the proper reparative material, as distinguished from inflammatory lymph, in which development proceeds through nucleated cells, as in the ordinary exudation from a granulating surface. A blastematous material, then, in which the cell-forms do not pass in development beyond the stage of nuclei, appears to be the proper reparative material from which new tendon is developed, and any admixture of inflammatory lymph, in which the ordinary inflammatory exudation-cells are developed, must be regarded as an accidental complication of the reparative process, instead of being an essential part of it, as is generally supposed.

The changes which subsequently occur in the nucleated blastema are, 1st., the formation of capillary blood-vessels. In the specimen from a child exhibiting the reparative process on the eighteenth day after division, above described, examined microscopically by Sir James Paget and myself, newly-formed and forming capillary blood-vessels with their nucleated parietes were beautifully seen after the addition of acetic acid, and were very abundant as shown in Plate II, Fig. 2.—2nd., the nuclei assume an elongated, spindle, or oat-shaped form, and are seen after the addition of acetic acid, to be arranged in parallel linear series, as shown in Plate II, Fig. 2 A. Whether fibres are formed in this way, or in what manner the elongated nuclei are disposed of, may still be matter of opinion; but I am inclined to believe in the development of fibres from this process, after carefully examining numerous specimens, both in my experiments in rabbits, and in the specimens from the human being.

As a gradual change towards perfecting the new connective tissue in its structural characters and general resemblance to the old tendon, the divided extremities of which it serves to connect, a fibrillated appearance of the new tissue is traceable under the microscope, and in the course of time a more distinctly fibrous appearance, *i.e.*, tissue capable of splitting into distinct fibres under the microscope, becomes developed.

The fibrous tissue, however, always remains more delicate, and less distinctly separable than in old tendon.

3rd. General appearance and structure of the newly formed connective tissue, or new tendon; and its ultimate disposition. —By the development of the blastematous material above described, a solid bond of union is formed between the divided extremities of the tendon, of variable length, according to the distance between the divided extremities; and this appears to be generally from half-an-inch to an inch in children, and from one inch to an inch-and-a-half, or two inches in the adult; but it may occasionally exceed this, and yet retain its full strength and proportionate size to the extremities of the tendon it serves to connect. The greatest length I have witnessed in the human subject is two-and-a-quarter inches, and this was in the tendo Achillis of a girl aged nine years (see Plate I), a year-and-a-half after the operation.

This connecting bond of union, or new tendon, as it may with propriety be called, is of a very tough consistence, and to the naked eye appears to be homogeneous, rather than fibrous. A small portion of it cannot be split into fibres, but when teased out with needles on a piece of glass, for microscopical examination, it spreads out like a portion of serous membrane, rather than splits into fibres, though its fibrous character is readily distinguishable under the miscroscope as above described.

There is, however, one very marked peculiarity of new tendon, even at a late period, viz., that after the gradual subsidence of the vascular injection, and consequent ruddy tinge of the new tendon, it presents to the naked eye, a grayish translucent appearance, a peculiarity which it has retained up to the latest period I have had the opportunity of examining it in the human subject, viz., three years after operation; and in the rabbit, one year after operation. The grayish translucent appearance at once distinguishes the new from the old tendon in any specimen of which a section has been made in the recent state; but as the translucency is destroyed by spirit, which immediately renders the new

tendinous tissue opaque, this indication is lost after the specimen has been put into spirit. Pure glycerine, or a solution of half glycerine and half water, preserves the appearance of translucency in the new tendon for a short time—a few weeks; but gradually this solution renders the old tendon translucent, and thus the contrast between the new and the old tendon is also lost. I am not aware of any fluid in which the appearance can be retained.

I would here observe that no section, in the recent state, had been made of the human tendons presented to the Royal College of Surgeons by Mr. Tamplin, from the external appearances of which they have been adduced in support of the theory of a *linear cicatrix*, supposed to result from the contraction, and complete absorption of the new connective tissue. These tendons (the tendo Achillis, and tibial tendons of a child aged nineteen months, in whom these tendons had been divided nearly eighteen months previously)* are said not to have presented externally any appearance of having been divided, and minute portions taken by Mr. Quekett from different parts, exhibited in an equal degree the microscopic appearances of well-formed tendon. Hence, it appears to have been assumed by Mr. Tamplin that the new connective tissue had been completely absorbed, and that the divided extremities of the old tendon had again come into direct opposition, so that only a *linear cicatrix* remained. The fact that the new connective tissue, or new tendon, so closely resembles in structure the old tendon as to be scarcely distinguishable from it by microscopical examination, had not at that time been demonstrated, and it is to be regretted that in the recent section, the most important test, was not made. Sections of these tendons were made by Mr. Quekett and myself, but from the effect of spirit in destroying the translucency of the new tendon (if such existed) it was impossible to say whether any new tendinous tissue existed or not. There did appear to me to be some indications of a portion of new tendon in the tendo

* "Pathological Catalogue of the Museum of the Royal College of Surgeons," Vol. II., pp. 358, 359, and 360.

Achillis, but the traces were obscure, and as the tendon of the opposite leg was not preserved, it is impossible to say whether any increased length of the tendon had been obtained.

So far as I have been enabled to form an opinion, from the observations on the human subject, and experiments on animals now recorded, I believe that the newly-formed connective tissue, or new tendon, remains during life as a permanent tissue, and as an integral portion of the tendon, the divided extremities of which it has been formed to re-unite.

4th. Influence of the divided extremities of the old tendon; junction of the new with the old tendon; re-formation of a separable sheath on the surface of the old tendon.—The divided extremities of the old tendon take no active part in the reparative process during its earlier stages, and have but a slender connexion with the new material when first formed. A little later, certain changes are observed to occur in the divided extremities of the old tendon, and these commence earlier, and proceed more rapidly in the upper than in the lower extremity of the tendon. These changes are; 1st. The cut extremities of the tendon, with their square surfaces and sharp edges, become a little rounded, and their structure slightly softened. 2ndly. They become slightly enlarged and exhibit a disposition to split, and thin streaks of new material, of a grayish translucent appearance, are seen between the split fibres. This is the commencement of the junction between the old and the new tissues, and by the increase of new material between the split fibres of the old tendon, the extremity of the latter presents a slightly bulbous appearance. 3rdly. At a later period, this bulbous enlargement gradually diminishes, till the extremities of the old tendon again assume their natural appearance, and the new and old tendon become of uniform diameter; but the appearance of a very fine dovetailing of the new material with the split fibres of the old tendon still remains; and, in two cases above described, was distinctly traceable in the recent section at intervals of a year-and-a-half, shown in specimen figured in

Plate 1, and three years after the division of the tendon, as shown in specimen represented in Plate 3, figs. 4 and 5 in my work above referred to.

This complete and firm junction of the new with the old tendon may be regarded as essentially the final stage of the reparative process, but proceeding simultaneously with it is a further perfecting of the structure of the new tendon, as to its density, the diminution of vascularity, general resemblance to the structure of healthy tendon, except in the translucency as above described, and in the external definition of form; but in all the specimens examined at late periods, I have found *a want of definition along the deep surface of the new tendon*, arising from adhesions between this surface of the tendon and the deep fascia. In the human subject, the cellular tissue between the deep surface of the tendo Achillis, and the deep fascia presents the appearance of having been infiltrated with lymph, to a greater, or less extent, in different specimens, and its structure is proportionably increased in density, and its fibrous septa thickened. It is, no doubt, this condition of deep-seated adhesions which limits the separation of the divided extremities of the tendon, when subjected to a second operation, and hence arises the extreme importance of gaining sufficient length of new tendon after the first operation. When divided a second time, a tendon very rarely gives way with *a snap*, and the separation of its divided extremities is generally very slight. This I have found to be the case after an interval of ten years between the operations; but the adhesions would, no doubt, be much stronger when the first operation had been clumsily performed, and followed by an unnecessary amount of inflammation.

Re-formation of a separable sheath on the surface of the new tendon.—Amongst the changes which the new tendon undergoes, in its gradual improvement at a late period, I have observed the more or less perfect reproduction of a separable sheath on the surface of the tendon, such as I described as forming in the first stage the matrix in which the reparative material is effused.

This process of re-formation of the cellular sheath on the surface of the new tendon, is accomplished more perfectly, and is more easily traceable in rabbits than in the human subject. In my experiments on rabbits, I found, between the second and third month after division, a separable layer of areolar tissue formed on the surface of the new tendon through its entire length, and above and below it was continuous with the cellular sheath surrounding the extremities of the old tendon; but it was neither so delicate, nor so loose-textured as the cellular sheath of the old tendon; it adhered more closely to, and could not be so easily separated from, the surface of the new tendon. In dissecting from above, downwards, or from below upwards, in either case, from the old to the new tendon, and raising the investing cellular sheath, the line of junction of the new with the old tendon could be readily determined by this difference in the separability of the sheath, when no other indication was apparent.

In the human subject the same process takes place, but is not so easily demonstrated, owing to the existence and connexions of the sheath with the cellular tissue and fat in which the tendon is embedded, and which is entirely absent in the rabbit.

From my observations, then, it appears that in the cure of deformities, muscles are elongated by the increased length of their tendons, obtained by means of subcutaneous division and the development of new tendon formed for the purpose of re-uniting the divided extremities of the old tendon.

The circumstances which may interfere with the perfection of the reparative process, or entirely prevent it, so that non-union of the divided tendon may result, have been described by me in the work previously referred to.

Imperfect union may result, either from some constitutional defect in the reparative powers of the patient, or from injudicious after-treatment in a variety of ways, but principally from too early and too rapid mechanical extension.

On the possibility of non-union of divided tendons, and the existence of adhesions after the operation.

The non-union of a divided tendon is an event which, under certain circumstances may undoubtedly occur; but I have only seen this result once, in the course of all my post-mortem examinations, amounting at the present time to about thirty in number, and this specimen is represented in my work "On the Reparative Process in Human Tendons," Plate V., Case 12. The tendon had in this instance been divided by a hospital surgeon immediately behind the inner malleolus, a situation which Orthopædic surgeons never select, but, on the contrary, always avoid for the performance of the operation.

Next in importance to the non-union of a divided tendon, is the fact that after the operation of the division, adhesions to the adjacent structures occur, to a greater or less extent, in all tendons, and in some instances these adhesions may interfere with the free-play of the divided and re-united tendons; but I am enabled to assert, and prove from my own dissections, that such an event occurs only as a rare and exceptional condition, the rule being that only very slender and unimportant adhesions result from the subcutaneous division of tendons when carefully performed.

In the Achilles tendon, I have never found these adhesions to be close or firm enough to interfere with the free-play of the tendon after a first division; but in cases in which this tendon has been divided two or three times (and several such cases are represented in my work above referred to), I have found the adhesions along the posterior surface of the tendon close, and firm enough seriously to interfere with the free-play of the tendon, and in practice we know that a second and third division of the Achilles tendon is followed by comparatively little gain, as to the elongation of the divided tendon; hence the importance which is attached to the judicious after-treatment, subsequent to the first operation in all cases of club-foot, and the difficulties which beset the treatment of relapsed cases.

As regards the posterior tibial tendon, when its division has

been performed carefully, and with but little disturbance of surrounding tissues, I have been surprised to find, in many instances, scarcely any trace of adhesions; and in infants particularly, I have in several instances found the reparative process so perfect, that I have at first doubted whether it had ever been divided, and it was only after a very careful microscopical examination, that I was enabled to satisfy myself of the fact of a portion of new tendon, generally about half-an-inch in length, being inlaid. The line of junction between the old and new tendon, together with a little difference in colour, were the only reliable evidences of the tendon having been divided. A few slender bands of delicate areolar tissue might be observed, but these could in no way interfere with the free-play of the tendon.

In other cases, and generally at a later age, in children, say, from five to ten years of age, I have in several instances found distinct fibrous bands of adhesion between the deep surface of the posterior tibial tendon and the sheath; but not in any one instance have these bands of adhesion been close, or short enough entirely to prevent the play of the tendon, or, as it is expressed by Mr. Barwell, to annihilate the muscle to which the tendon is attached. These fibrous bands of adhesion have generally been from a quarter to half-an-inch in length, and having a direction obliquely downwards, so that the play of the tendon to very nearly, if not to its full extent, would be permitted.

During the past year, 1871, I obtained four specimens of this kind from patients who died in the Royal Orthopædic Hospital, in consequence of an outbreak of scarlet fever, and diptheria, and in every instance the appearances have been as I above described. The reunion of the posterior tibial tendon was perfect in every case, and the adhesions not sufficient in any one instance to interfere with the free-play of the tendon. These specimens have been carefully described and drawings made; two of these are delineated in Plate V., and the situation and direction of the adhesions are accurately represented.

In illustration of the fact that the posterior tibial tendon does unite after division, as perfectly as any other tendon, and

without the production of such adhesions as would seriously interfere with the free-play of the tendon, and impair the muscular power, I would not only refer to the two specimens represented in Plate V., but also to two other specimens exhibited by me to the Pathological Society, 2nd of February, 1864, and described in the "Transactions of the Society," Vol. XV., p. 235. This description is now added to the present work (see Appendix, Note 1), and it will be observed that in one of these cases the free-play of the posterior tibial tendon was limited by adhesions, whilst in the other, only very slight adhesions existed.

If these two specimens are the same as those alluded to by Mr. Barwell in the Second Edition of his work—and I presume they are, as he refers to the XVth Vol. of the "Pathological Society's Transactions"—then his description of these in the table, Nos. VIII. and IX. as "Tibialis posticus . . . . union to bone" in both instances, leaving it, of course, to be inferred that no direct union had taken place, is obviously most unfair, and quite opposed to the description in the "Society's Transactions," (see Appendix, Note 1.)

There is some discrepancy as to the period of death after the operation, as I stated it at five months, and Mr. Barwell has given it at seventeen days; but as no other case of mine is recorded in that volume, the period must have been stated in error.

Further to illustrate the perfect union of the posterior tibial tendon, I would refer to two other specimens which I exhibited to the Pathological Society on the 5th April, 1870, the description of which is recorded in the "Transactions of the Pathological Society," Vol. XXI., and this description is now also added to the present work (see Appendix, Note 2).

They were removed from the body of a boy, æt. six years and three months, upon whom I had operated for congenital Talipes varus when three months old, and in consequence of relapse of the deformity, had repeated the operations a year-and-a-half previous to death, which resulted from scarlet fever. At both the above named periods, the anterior and posterior

tibial tendons, together with the long flexor, and also the Achilles tendons, were divided.

When these specimens were exhibited to the Society, a Committee was appointed, at my suggestion, to examine and report upon the condition of the divided tendons, and in consequence of the statements which Mr. Barwell had published as to the imperfect union of the posterior tibial, and other tendons, his name was added to the Committee, who, after a careful examination reported that, "In neither case do the adhesions interfere with the movement of the tendon as performed in the dead subject."* This report will be found in full in the Appendix to the present work, see Note 2, at the end of the description of the specimens adverted to. The reparative process in the posterior tibial tendons could not possibly be more perfect than it was shown to be in these specimens.

Mr. Barwell, however, seeks to gain support for his so-called "New Method of Treatment," introduced to the profession in his work "on the Cure of Club-foot without cutting Tendons,"† heralded with such sensational headings as in Chapter III, "Impropriety of Tendon-cutting, and its evil results," "Ruthless practice in Tendon-cutting," "Table of Tendons permanently destroyed," and again in Chapter V, "My new Method of Treatment," "My method opposed to both Tenotomists and Machinists, &c., &c." I say that Mr. Barwell seeks to support this appeal to such marvellous wonders, and sensational novelties, by referring to what he calls, "certain grave evils resulting from Tenotomy," these evils being the non-union of divided tendons, and the existence of such adhesions as would utterly annihilate the action of the muscles.

Having no facts from his own experience and observation upon which any such statement could be based, he endeavours to support his assertion by *so-called* facts extracted from my work "on the Reparative Process in Human Tendons."

From the post-mortem dissections recorded in my book, after excluding the cases in which the Achilles tendon only was

* "Transactions of the Pathological Society," Vol. XXI., page 422.

† "On Club-Foot without cutting Tendons." London, Second Edition, 1865.

divided, Mr. Barwell has tabulated in the first edition of his work seven cases, in which the anterior and posterior tibial tendons were divided; and in the second edition of the same work, states that he has added two more cases, the description of which had been recorded in the "Transactions of the Pathological Society," Vol. XV., though the dates as to the period after operation do not correspond.

Now, I would first observe that in the cases tabulated by Mr. Barwell, death in most instances resulted from diarrhœa, convulsions, or fever, within a short period of the operation, and therefore during the early stages of the reparative process, which in some instances was interfered with, or partially arrested by the illness from which the death resulted; for example, in the first case recorded as "non-union of tibialis anticus," the child, æt. four weeks at the time of operation, died of cold and bronchitis on the fourth day after the operation. In the second case recorded as non-union of tibialis posticus, and non-union of flexor longus digitorum, "the child, æt. nine weeks at the time of operation, died from diarrhœa on the eleventh day after the operation. Two cases described as "Tibialis posticus . . . . union to bone," are stated to have died seventeen days after the operation, and in the other cases death occurred at various periods, up to six weeks after the operation, the longest period recorded, except in one instance in which the date was uncertain, and which had not been operated upon by me. In this case, the same as that to which I have previously referred, the posterior tibial tendon had been divided immediately behind the malleolus several years previous to death, and non-union resulted, the only case in which I have seen this event to occur.

Referring to this tabulated series of dissections, Mr. Barwell observes at page 43, in the second edition of his work, "The result, therefore, of the cases is this, that out of six divisions of the anterior tibial tendon, we have two non-unions, *i.e.*, in a third of the cases operated on, the muscle is destroyed. In every one of the nine instances in which the posterior tibial tendon, and each time the long flexor of the

toes were divided, one or both, the action of the muscles was utterly annihilated, and, of course, lameness and want of power in the foot must be the result."

I doubt whether any other surgeon than Mr. Barwell would have ventured to have recorded the cases in the above mentioned table, in which death occurred at such early periods as the 4th day, 11th day, 17th day, 18th and 23rd days, as examples of non-union of tendon, when the periods mentioned were so obviously insufficient for the completion of the reparative process. As well might a school-boy in his first attempts at gardening take up recently planted cuttings, expecting to find they had taken root.

If in the first edition of his book, Mr. Barwell had been led impulsively to make a reckless statement to support a theory of his own, we must regret the more that in the second edition, the same statements are again put forth with two additional cases, still more opposed to the published description by myself in the Pathological Society's Transactions, than any of the preceding cases.

It would scarcely be credited that any surgeon having a fair knowledge of pathology, and assuming the responsibility of authorship, which should always carry with it the highest regard for scientific truth, should put forth such a garbled statement in the shape of a tabulated series of cases; assuming as facts favourable to his own views, conditions in no way admitting of such interpretation by myself, and upon such a table base the assertions which Mr. Barwell has made, and attempt to deduce from it a rule of surgical practice in reference to tenotomy.

Conditions of tendons which have been previously divided in cases of relapsed deformity.—When recontraction of the foot takes place, and the deformity returns at a distant period after tenotomy, this does not depend upon absorption of the new material, or new tendinous tissue formed previously to unite the divided extremities of the old tendon, but upon structural alterations taking place in the muscular tissue.

In three cases of relapsed deformity of the foot which I

have examined, the new tendinous tissue formed, after the previous operations, remained, and could be easily distinguished from the old tendon; these facts must be regarded as additional evidence against the *linear-cicatrix* theory. The best illustration of this fact occurred in the case, a dissection of which is represented in Plate I. The deformity (talipes equinus) had returned a year-and-a-half after the Achilles tendon had been divided, and yet two inches-and-a-quarter of new tendinous connecting tissue could be distinctly seen in the Achilles tendon.

Another case of relapsed deformity is also represented in Plate V. of my work already referred to, and in this specimen, also, considerable length of new tendinous tissue existed.

RATE OF EXTENSION AFTER TENOTOMY.

With regard to the rate of extension after tenotomy, or the rapidity with which it is desirable to bring a foot into its natural position—say after the division of the tendo Achillis—considerable difference of opinion exists at the present time, and the treatment varies accordingly, some surgeons advocating immediate, and others gradual extension. English surgeons have generally followed the recommendation of Delpech, Stromeyer, and Little, and adopted this plan of gradual extension, but immediate extension appears to have been the system recognised by many surgeons in Scotland and America.

In Scotland, the late Professor Syme recommended the immediate restoration of the foot, and exercise of the limb in walking, three days after tenotomy. The late Professor Miller,* also, in his "System of Surgery," page 133, observes: "Instead of waiting for reunion of the tendons, and then extending their new bond of union, painfully and slowly, it is better to effect the required change of relative position soon after section, leaving the hiatus to be filled up by new matter," similar views are also entertained by Gross of Philadelphia.

* "A System of Surgery," by James Miller. Edinburgh, 1864.

Professor Gross in his "System of Surgery,"* after recommending the division of tendons in club-foot as at present performed in England, observes: "All the faulty structures having been thoroughly divided, the foot is well flexed and extended, in order to break up any morbid adhesions that may exist, and separate as widely as possible the ends of the tendons, as much force being used for this purpose as may seem to be compatible with the safety of the limb. The advantage gained in this way is generally very great, and it is remarkable how tolerant the parts are of manipulation. The little puncture made in the operation is covered with a strip of adhesive plaster, and usually closes by the next morning. The limb being bandaged from the toes up, is immediately placed in the apparatus provided before the operation. This plan has been constantly pursued by me for many years, and I have never had any cause to regret it; on the contrary, I believe it to be decidedly preferable to waiting three or four days, as usually recommended by authors; for at the end of this time the parts are often so tender as to be quite intolerant of pressure and extension. It is only in cases of an extraordinary character that this rule should be deviated from. There need be no apprehension of a want of reunion of the ends of the divided tendon when this course is adopted. I have myself never seen such a case, nor heard of one that was entitled to credence . . . . . For the first five or six days after the operation, the limb is kept at rest in an elevated position; but after that time the patient may go about on his crutch or stick, as he may find it most convenient. The apparatus must be worn day and night, from a period varying from three to twelve months according to the severity of the case."

It seems rational to conclude from the account of the reparative process above given, that the rate of extension should be regulated by the activity of the reparative process in the divided tendon, but practically it is often limited by the ligamentous rigidity of the articulations.

* "A System of Surgery," by Samuel D. Gross, M.D. Second Edition, Vol. II., p. 1020. Blanchard and Lea, Philadelphia, 1862.

In well nourished infants, the full length required in the divided tendo Achillis should, I believe, be obtained in a fortnight if practicable. In the adult, when the limb is well-nourished, it should be obtained in from three to four weeks; but in atrophied paralytic limbs it should not be obtained in less than from five to six weeks.

The object of gradual extension is not so much to elongate or stretch the new material uniting the divided extremities of the tendon, as generally supposed; but rather to regulate the length of new material, or as it may be called the new tendon, while we have the opportunity of so doing *i.e.*, during the period of its formation or regeneration; and the rate at which this is to be accomplished must have reference to the activity of the reparative process, and the length of new tendon required.

This important part of the treatment must, therefore, be left to the judgment of the surgeon, and in cases of paralytic equinus, where the ligaments do not hold the joint after division of the tendon, and the foot can be at once brought into its natural position, or even carried beyond, great caution is required to prevent talipes calcaneus, which is always liable to occur, when the extension is conducted too rapidly in cases in which there is but little resistance from the adapted shortening of ligaments; but if this ligamentous resistance exists, as in some cases of equinus of long standing in the adult, and in severe congenital varus, it will not be possible to proceed at the desired rate, and it may even become necessary to divide the tendon a second time, before the required length can be obtained.

CHAPTER III.

ON THE RELATIVE MERITS OF TENOTOMY, AND MECHANICAL EXTENSION IN THE TREATMENT OF CLUB-FOOT.

We now come to the consideration of the more practical portion of our subject.

The great objects of treatment in congenital club-foot, as well as in all other deformities of the limbs, are, 1st. The restoration of form; 2nd. The restoration of function. We may classify the means for bringing about these results under three heads.

1st. The operative; 2nd. The mechanical; and 3rd. The physiological, consisting chiefly of gymnastics, shampooing, and galvanism. The two latter come, equally with the operative, within the province of the surgeon, by whom both the mechanical and physiological treatment must be directed and regulated.

Before the discovery of subcutaneous tenotomy brought the treatment of deformities under the care of the surgeon, the method generally resorted to, consisted in a combination of the mechanical and physiological means, and such cases were entrusted to the care of mere mechanicians, or professed rubbers, who took upon themselves the treatment of these affections, although entirely ignorant of their real nature. The leading surgeons of the day having no certain means of relief to offer in the cure of such deformities, transferred such cases to this class of irregular practitioners.

Cases of club-foot when brought under the notice of Sir Astley Cooper, for instance, or any of his contemporaries, were sent to Mr. Sheldrake, of Leicester Square; Mr. Taylor, of

the Strand; Mr Laurie, of St. Bartholomew Close, or to some clever mechanician who gave special attention to the cure of deformities, and combined rubbing and "working of the joints" with mechanical support.

After a prolonged treatment, generally extending over several years, congenital varus in its slighter forms was frequently well cured, and so far as the science of the day extended, the treatment was in accordance with it, and evidently the best that could be obtained. The severe or rigid cases, however, I believe were never cured, and even those of a moderate degree of severity, but seldom.

To illustrate their failure in severe cases, I may advert to the well known case of the distinguished poet, Lord Byron, who during his childhood was placed under the late Mr. Sheldrake, as well as other mechanicians, without deriving any permanent benefit.

When the treatment was commenced sufficiently early, and continued long enough, these mechanicians often succeeded in curing the inversion of the foot, or the varus portion of the deformity, in the moderately severe, and even in some of the rigid cases; but except in very slight cases I doubt whether they ever succeeded in overcoming the equinus or elevation of the os calcis depending upon the contraction of the muscles of the calf.

Some years since I examined a gentleman who was born with a severe degree of club-foot, and, upon the recommendation of Sir A. Cooper, remained six years under mechanical treatment; the inversion was overcome, but the equinus continued and still exists to a severe degree. As a result of this, the lameness is much greater than it would have been if the varus had been allowed to remain, and the deformity of the foot, although different in kind, is still very severe. This case was no doubt curable by a judicious combination of the operative and mechanical treatment at the time it came under my observation; but it unfortunately happened that this gentleman had been operated upon many years ago by a surgeon of this metropolis for the cure of the equinus, but the after-treatment being neglected, the deformity soon returned. It can hardly be

matter of surprise that he then hesitated to submit to further treatment, and the deformity will probably be allowed to remain for life.

As a third example, I may mention the case of a woman who was born with club-foot—a severe form of varus of both feet—and came under my notice at the Orthopædic Hospital. She stated that in early childhood every attention was paid to her case by a person widely known for his cure of club-foot, and that she continued to wear irons for ten years or more, her parents being then in good circumstances, and no expense was spared. The case was, however, only half cured, and both feet are now in the condition of equino-varus. The amount of motion gained in the ankle-joint has been sufficient to prevent the arrest of muscular development; the legs are consequently strong, and not much below the natural size. She could not, however, walk more than a mile, and even this distance with difficulty, in consequence of the weight of her body being thrown on the outer margin and anterior part of the foot. The cure could doubtless have been completed by tenotomy when she came to me, owing to the favourable conditions in her case: but as the treatment would have occupied a year or more, she could not arrange to leave her family, and one child born club-footed, like the mother, demanded much of her attention.

These three cases afford very fair evidence of the results attained in severe cases, under the system of treatment resorted to, before tenotomy was introduced; and when the amount of success under the present system of treatment is compared with that of the older method, we shall be justified in characterizing the permanent cure of congenital club-foot, as one of the greatest triumphs of modern surgery, more especially when the simplicity and safety of the means adopted are considered in reference to the perfection of the results, and the advantages to the afflicted patients.

Dr. Parow,* of Bonn, has published an able description of

* "Frorieps Notizeir aus dem Gebrete der natur und Heilkunde, 1856, Band II, No. 12.

the relative merits of the three classes of remedial agents above mentioned as applied to the cure of club-foot and other deformities, and gives an historical sketch of each class.

The labours also of Bouvier, Bonnet, and Guérin, on the Continent, and of Dr. Little, in this country, have contributed a great deal to determine correctly the relative value of these methods of treatment.

The scientific treatment of talipes varus when severe, as of several other deformities of the limbs, can only be accomplished by a judicious combination of the operative, mechanical, and physiological means, whilst many of the failures still frequently witnessed in the practice of those who have not devoted much attention to the subject, are due to the want of this combination of principles, too frequently considered as antagonistic to each other, but which modern science teaches us are only valuable in so far as their mutual dependence is recognised and applied by the scientific insight of the surgeon.

I dwell upon the necessity of this combination because in English orthopædic surgery at the present day, the operative and mechanical means are too generally adopted, to the exclusion or neglect of the physiological, the value of which, increased experience daily brings before us; and it is owing to this neglect that, although the external form of the foot in severe cases may be restored, a very limited amount of motion at the ankle-joint is gained, and a great tendency to relapse continues.

If, then, without the aid of the physiological means, the operative and mechanical in combination, are allowed to be inadequate to the cure of club-foot; so, on the other hand, I cannot too forcibly insist upon the fact that the operative treatment, or tenotomy, is the most unscientific that can be adopted unless the assistance of the mechanical and physiological means be combined with it.

In cases of club-foot it is a great error to suppose that tenotomy constitutes the sole, or even the chief remedial agent. It is undoubtedly true that in the slight congenital, and in many of the non-congenital cases, the foot can be immediately res-

tored to its normal position after division of the tendons; but in the congenital cases there is some danger of non-union of the posterior tibial tendon, if the foot be too rapidly brought into its natural position; and cases of the non-congenital class, generally of paralytic origin, require the greatest care during the after treatment to prevent a feeble union of the tendo Achillis. Several cases of the latter class have come under my observation, in which the foot has been brought into its natural position immediately after the division of the tendo Achillis, and the result has been that in consequence of a very feeble union having taken place between the divided extremities of the tendon, the condition of the patient has been rendered much worse than if the deformity had never been submitted to treatment. A deformity of a much worse and quite incurable form has been produced within a few months of the operation, in consequence of the new connecting medium being too slender and elongated.

Nevertheless, so little attention has been paid to this subject; so little has the general pathology of club-foot been studied; so little has the reparative process in tendons after division been investigated; and, therefore, so little are the conditions essential to the perfection of this process understood; that we find tenotomy and immediate restoration of the foot, even with active exercise of the limb in walking within three days of the operation was recommended and publicly taught by the late Professor of Clinical Surgery, Mr. Syme, in the University of Edinburgh.

This system of treatment was strongly advocated by Mr. Syme in a clinical lecture on tenotomy, which appeared in the Lancet of March 17, 1855, and six cases were published by way of illustration;—three of equinus, two of varus, and one of valgus—treated by him in this way, and said to be successful, but no report was given beyond stating the effect of the operation within a few days. After the operation and application of a bandage in the first case, Mr. Syme observes: "The bandage will be kept on for forty-eight hours, when no further treatment will be required, as the use of the limb in walking

will be sufficient to bring the foot into its natural form." Professor Syme then proceeds to attribute to the practice of gradual mechanical extension, as adopted by the London surgeons, the promotion and extension of many of those evils which subcutaneous tenotomy was in his opinion proposed to supersede. Now we need scarcely say that the true answer to this is, that in severe cases tenotomy alone will not enable us to restore the form of the foot, in consequence of the adapted shortening of the ligaments, and in slight cases the danger of non-union, or excessive elongation of the new connecting material, should deter any surgeon from adopting Mr. Syme's recommendation.

The only scientific and successful method by which the two-fold object of the restoration of form and function can be obtained is, in slight cases of varus, the combination of the mechanical and physiological means, and in the more severe forms, a combination of the three classes of remedial agents, viz.; the operative, mechanical, and physiological, according to the conditions existing in each case.

Considering it, therefore, an established fact, that, although a large number of cases of club-foot in its milder forms are curable without tenotomy, and that these cases may be successfully treated by a combination of mechanical and physiological means; it is, nevertheless, equally certain that a considerable number of cases are met with in which tenotomy is indispensably necessary. It becomes, then, a matter of the highest practical importance, to determine the cases to which each method is especially applicable, and we will proceed first to speak of the

Cases in which it is unnecessary to resort to operative treatment.

Accoucheurs are all familiar with the fact, that children are not infrequently born with the feet a good deal inverted; sometimes the varus position of the foot is well-marked, but no obstacle exists to the perfect restoration of form by gentle manipulation. Experienced nurses are equally familiar with

the fact, and feel no alarm, because they know that manipulation alone, or what they call "working the feet," will soon remove the defect. This spurious form of varus which is unaccompanied with any structural changes, is probably the result of mechanical pressure and position *in utero* acting towards the close of gestation. The children are said to be generally of large size, and perhaps there may be in these cases some deficiency of the *liquor amnii.*

In some of the more severe cases of this class just described, I have applied an ordinary boot with a small steel spring attached to its outer side, and passing up to the calf of the leg, where it is connected with a narrow, semi-circular steel band, which by the aid of a strap encircles the leg, and a free joint is placed in the steel opposite the ankle-joint. This acts as a useful retentive apparatus, and with the exercise of the foot, which the nurse must be directed to do, nothing further will be required. Next I would direct attention to a large class of

Cases in which some doubt may reasonably exist as to the necessity for operative treatment.

Cases frequently occur of a more severe form than those just described, in which the foot can be nearly, but not quite restored to its natural form by manipulation—the foot can be everted, but the heel remains somewhat elevated, so as to limit or prevent flexion at the ankle-joint. Now, in this class of cases there is the greatest range for difference of opinion with respect to the necessity for operation.

The opponents of tenotomy, and those who believe that this operation interferes with the full development and ultimate power of the muscles operated upon, oppose tenotomy in all but the most severe forms of varus; whilst some over zealous advocates advise the operation, in all but the slightest forms of varus previously described.

Of the cases last mentioned, we may say with confidence that they are curable both with and without operation, and if the case be remediable by mechanical and physiological

means, some would object to the operation as uncalled for, holding that a necessity must clearly be shown to justify every operation in surgery, bearing in mind also the possibility of accidents and untoward circumstances.

The asserted effects of tenotomy on muscles, the tendons of which have been divided, have given rise to a second objection to operation in these cases. On this subject Dr. Little has observed: "Although the form of the member is by means of tenotomy more promptly remedied, the function of the divided muscles is often less completely restored. The author has witnessed many instances of congenital varus successfully treated without tenotomy, by others, as well as by himself, in which the muscles of the calf attained almost the normal development, whereas after tenotomy the muscles usually remain much smaller than natural, and the calf disproportionately high."*

In these remarks of Dr. Little, both the statements are equally true of different classes of cases, but, in my opinion, the results stated could not have been drawn from a comparison of cases in the same condition at the period of birth. It may be fairly assumed that in nearly all the cases cured by mechanical means, little or no structural change existed at the time of birth, and, therefore, being as we should consider them, slight cases, no reason appears why the subsequent muscular development should be interfered with; but the fact of tenotomy being required in other cases, implies that structural shortening of the muscles existed, and with this condition the bellies of the muscles are always smaller and shorter than in the healthy condition. This may be very slight at birth, but becomes more obvious every month after birth, and is conspicuous at the age children are generally operated upon for varus.

This imperfect muscular development, in severe cases, is a persistent condition; so that, as a rule, after tenotomy, as well as without tenotomy, the muscles remain smaller, and the calf higher than in healthy limbs; but the earlier tenotomy is performed, and the more quickly all the muscles of the limb

* "On Deformities," page 303.

are brought into action, the greater will be the muscular development; and this is a strong argument in favor of tenotomy as early as the first or second month after birth. By this means the muscles of the calf are brought into play at an early period, free motion at the ankle-joint being restored by division of the tendons of the contracted muscles, and thus muscular development, instead of being interfered with, is promoted, by tenotomy.

But if the results above stated by Dr. Little were based on the observation of cases, the conditions in which were all equal, the inference would be, that tenotomy exerted an unfavorable influence *per se* on the development of the muscles operated upon, and, therefore, would only be justifiable in the most severe cases, and this is the opinion apparently entertained by Dr. Little.

In congenital varus, my own experience is directly opposed to such an inference, and I can adduce sufficient evidence to prove that in these cases the general muscular development and power of the limbs in after life are in direct proportion to the early period at which the tendons have been divided, and the deformity cured. The circumference of the calf in a young gentleman at the age of eighteen, who had been operated upon in infancy for severe varus by Dr. Little, and subsequently by myself in the year 1852, in consequence of relapse, was proved by measurement to be very little below the natural standard, and two inches more than the calf of an adult, a gentleman born with varus, and who had not been submitted to any operation, until he was twenty-nine years of age, when I undertook the treatment of his case. Casts of both these cases, taken at the ages mentioned, are in my collection, and drawings from them are given in the Appendix, Cases XIII. and XIV.

In some non-congenital paralytic and spasmodic cases, when an elongated and attenuated condition of the new material has been allowed to take place, a foot really may be weakened by tenotomy, but in these cases it is not anticipated that the operation can restore the balance of muscular action, and

the conditions are very different to those present in congenital varus.

In deciding for, or against the operation in the class of cases we are now considering, some real difficulty may exist, but the rule upon which I rely in forming an opinion has reference to the degree of elevation of the os calcis. This is the test of the extent of structural shortening of the gastrocnemius and soleus muscles.

If elevation of the os calcis exists in any marked degree, I advise the operation, because the uncertain result of mechanical treatment in such cases justifies tenotomy, which may also be recommended on the ground of its diminishing the treatment from months, or perhaps years, to weeks, and thus materially expediting the cure.

In many of these cases, division of the tendo Achillis and the tibialis anticus tendon will generally be sufficient; but if when the foot is everted by the pressure of the hand, the inner malleolus does not become sufficiently prominent, we must assume that the navicular bone is drawn towards the malleolus by the contraction of the tibialis posticus muscle, and this tendon should also be divided. Now, with respect to

Cases in which operation is absolutely necessary.

In cases of a more severe grade of the deformity—ranging from those last described to the most rigid and severe forms ever met with—tenotomy is indispensably necessary.

By what indications, then, can we recognise this class of cases, so that we may at once decide upon the operation? Some authorities lay great stress upon the angle which the foot in its inverted position forms with the leg, *i. e.*, whether this angle is greater or less than a right angle; but I consider this a useless and fallacious test of the severity of the case, because it not infrequently happens that a foot drawn up to a right angle with the leg, or even beyond it, may be easily and completely everted; and sometimes, also, in these cases the os calcis may be partially, or even completely depressed, so that they must be classified with those last described.

The following are the indications upon which we must rely in determining the necessity of the operation:

1st. When the foot cannot be fully everted, or brought to a straight line with the leg by manipulation, and when in the attempt to accomplish this, the inner malleolus does not become prominent.

2nd. When the os calcis either cannot be depressed at all, or only to a slight degree, so that after the partial eversion of the foot, little or no flexion at the ankle-joint can be obtained.

When these two conditions exist, they are quite sufficient to determine the absolute necessity of the operation. The fact of the inner malleolus not becoming prominent when the foot is everted, depends upon the impossibility of drawing the navicular bone from its displaced position, and proves the existence of contraction and structural shortening of the tibialis posticus muscle to an extent which I believe cannot be overcome by mechanical means; and the rigid elevation of the os calcis also proves the existence of a similar condition in the gastrocnemius and soleus muscles.

The foot in the extremely severe form of varus occasionally met with, and of necessity included in the class of cases we are now considering, is drawn inwards and upwards, so far as to be in contact with the side of the leg, and cannot be depressed or everted beyond a right angle with the leg. In these cases, the tibialis anticus and extensor pollicis muscles are more contracted than in those previously mentioned, and a greater amount of ligamentous adaptation, and shortening of some of the ligaments exist, and most materially contributes, to the rigidity with which the foot is held in its deformed position.

Now, we have no evidence to show that any of the class of cases included within the range above mentioned, ever were cured by mechanical or other means, previous to the introduction of tenotomy. On the contrary, abundant evidence of the failure of such means exists in the numerous cases of varus now seen in middle aged and elderly people in the middle and

upper classes of society, and in which it is known that neither trouble, time, nor expense, were spared in the fruitless attempts at cure during their childhood. And as many similar cases are still, even in the present day, submitted to mechanical treatment, further evidence of the complete failure of such means may not infrequently be witnessed.

From what I have said, then, it may be gathered how complete has been the failure of the mechanical treatment, when solely relied upon; and on the other hand, how complete the success in a large proportion of cases when the operative, mechanical, and physiological means have been judiciously combined.

In the observations above made, congenital talipes varus has been selected to illustrate the relative merits of tenotomy, and mechanical treatment, because it is in this deformity that the great interest of the surgical treatment of distortions of the foot centres. The practical rules, however, in reference to the applicability of each method in some cases; and of the operative, mechanical, and physiological means, in combination, in other cases, apply equally to the treatment of the large class of non-congenital distortions, or so called varieties of club-foot.

Of the non-congenital distortions, it has already been stated that a large proportion, perhaps as many as nine-tenths of all the cases, depend upon paralytic or spasmodic muscular affections, the most frequent cause being infantile paralysis, affecting unequally some of the muscles of the leg and foot.

In this large class of cases the feet become contracted and deformed, and in the external characters may approach in resemblance the more severe congenital distortions; but as a rule, there is an absence of the ligamentous rigidity, and resistance to any force applied to remedy the distortion. The adaptation of the bones, ligaments, and other structures to the deformed position of the foot, which characterizes the congenital distortions, even at the period of birth in severe cases, and subsequently in proportion to the age of the patient, is altogether absent in the great majority of non-congenital

distortions, and exists only as a late effect in severe cases of long standing.

The result of this difference in the pathological condition of these deformities is, that, as a general rule, the non-congenital cases offer but little resistance to treatment, whether this be purely mechanical, which is alone sufficient in a large number of such cases occurring in young people during growth, or whether tenotomy be employed in addition to mechanical treatment. Tenotomy, no doubt, facilitates the treatment in severe cases, and in many of them cannot be dispensed with; in this class, however, there is the greatest range for difference of opinion.

Hence, we can hardly be surprised to see a book issuing from the press with a leading chapter "*On the impropriety of tendon cutting and its evil results*," and with another chapter on "*My new method of treatment;*" but it is with no small degree of astonishment that we find the same author, a hospital surgeon, speaking of tenotomy as "the operation of cutting tendons or muscles that had been haunting the domains of legitimate surgery for about one hundred and fifty years, and had been gradually becoming a less adventurous proceeding, when, in 1832, Stromeyer demonstrated a method of its performance without danger, or at least with very little danger, of producing suppuration and sloughing."*

In the so-called method, brought forward by Mr. Barwell, the feet are placed in an improved position, and so retained by means of tin splints placed lengthwise down the leg, and a series of elastic india-rubber cords attached to the tin splints, and passing in different directions corresponding to the paralysed weakened, or elongated muscles. The foot and leg are previously covered with adhesive plaster, which doubtless adds to the general support afforded by the apparatus, and to some extent prevents excoriations and blisters from excessive pressure, which, however, is still described as occurring in some cases. By the use of these elastic cords the author

* "On the Cure of Club-Foot without cutting Tendons," by Richard Barwell, London, 1863.

speaks of "supplying an *anterior tibial muscle*" in one case, and a "*posterior tibial muscle*" in another, or a "*tendo Achillis;*" and in the same way many other muscles are supplied, so that the foot and leg are rigged like a ship. And no doubt a very useful compensation for paralysed muscles is often thus afforded; but that this can in any way be regarded as a *curative means* for the paralytic affection, which Mr. Barwell describes as being "the head and front of the offending," has yet to be demonstrated. If it should prove to be a means of cure for paralysis, it would be a valuable addition to those at present so frequently employed, with but very limited success; but if this cannot be proved, the new method seems to be as little deserving the unbounded praise bestowed upon it by Mr. Barwell, as it can be shown to have any claim for novelty.

On the latter point, I can state that the plan was certainly brought under my notice, about sixteen years ago, by Mr. Bigg, of Leicester Square, who had a great variety of ingeniously constructed instruments upon this plan, with vulcanized india-rubber cords attached by hooks, and passing in various directions according to the deformity for which the apparatus was made;—all distortions of the feet, knee-joint instruments, spinal instruments, &c. Some of these instruments for the treatment of club-foot were adapted by Mr. Bigg to cases in St. George's Hospital, and he told me the chief difficulty was to regulate the pressure, without producing sores. The constant pressure from the elastic force could not be borne by the patient, and the plan of treatment was given up, only to reappear as "*My new method*" ten years later.

The cases adduced by Mr. Barwell, in illustration of the success of the treatment, belong generally to the class of non-congenital distortions, associated with paralysis, or arising from debility and ligamentous relaxation, such as the ordinary flat-foot, &c. In these cases, tenotomy is now seldom employed by any surgeon, the plan of mechanical extension and support being generally sufficient to remedy the deformity where no paralysis exists, or to produce such improvement

as can be obtained where the deformity is associated with paralysis.

The difficulty, I would almost say the impossibility, of applying this treatment with the necessary application of plaster, tin splints, bandage, and elastic cord to club-foot in infants will be at once apparent, and the simple varus splints which we always employ, are found to answer very well in slight cases, in which the operation can be dispensed with. Moreover, it is well known that Mr. Barwell does resort to tenotomy when consulted in cases of club-foot presenting any marked degree of severity.

The method of "*curing club-foot without cutting tendons*," then, resolves itself into this, that the author of "*My new method*,"—"*Impropriety of tendon cutting and its evil results*,"—"*Ruthless practice in tendon cutting*,"—"*My new method opposed to both tenotomists and machinists*," *&c.*, *&c.*, Mr. Barwell, does in practice actually cut tendons like tenotomists and orthopædists, as he is pleased to call them; but Mr. Barwell's explanation is, that the tendons he cuts always unite, and therefore in his hands there is no possibility of damage from dividing tendons—indeed that it is absolutely essential to the cure of the deformity that he be permitted to do so, and that the Achilles tendon must be divided; but that the tenotomists and orthopædists cut tendons which do not unite, as well as those which do, so that the difference between tenotomists, or orthopædists, and the anti-tenotomists of Mr. Barwell's school, are not found in practice to correspond to the pretentions put forward by the latter.

CHAPTER IV.

NON-CONGENITAL SPASMODIC AND PARALYTIC TALIPES,—DEFORMITIES WITH RIGID MUSCLES, THEIR PATHOLOGY AND TREATMENT.

BEFORE entering upon the description of the various distortions of the foot included under the generic term talipes, or club-foot, I propose to offer a few practical observations, on the general pathological conditions, under which the great majority of all these distortions are found to occur.

It has been stated that the non-congenital forms of talipes occur much more frequently than the congenital forms, the proportion being as three to two. The various pathological conditions under which the non-congenital distortions of the foot occur, present so many points of interest and practical importance, that I propose to devote the observations in the present and succeeding chapter to the etiology and mode of production of non-congenital distortions; reserving the observations on the etiology of the congenital forms of talipes, until I come to the description of congenital talipes varus, which is, beyond all others, the most important form of club-foot.

On the threshold of our inquiry, I desire particularly to dwell upon the importance of this branch of the subject. It includes a wide and interesting field of inquiry, and although I need hardly state that the pathology of the nervous and muscular systems has engaged the attention of many of the past and present members of our profession, it must be admitted that some of these affections still rest in the greatest obscurity. Surgical experience brings us in contact with a vast number of affections dependent upon lesions of the nervous and muscular

systems, especially paralytic and spasmodic affections of long duration, when a series of secondary phenomena have supervened, causing contractions in different joints.

Without entering fully into the pathology of these affections, I propose to describe the more prominent characters of the several classes of affections, which most frequently present themselves to our notice, and to indicate the principles by which we may be guided in their prognosis and treatment.

The great majority — perhaps as many as nine-tenths —of the non-congenital deformities of the feet, depend either upon spasm or paralysis of certain muscles, or groups of muscles. The other causes, more generally apply to the knees, hips, hands, and neck.

We have included under this class, deformities produced either by active muscular contraction, as in spasmodic equinus, and equino-varus, &c.; or by the paralysis of some muscles inducing a state of adapted atrophy in the opponent muscles, as in paralytic varus, and calcaneus. In either event, we have structural shortening of the muscles themselves, although their physiological conditions are very different, and corresponding dissimilarities are found in the structural changes which the muscular tissue undergoes.

Of the structural changes in these cases I have published some account in a paper in the Transactions of the Pathological Society, Vol. III.* In spasmodic cases, even of long standing, the ultimate muscular structure appears to undergo but little change, and I do not find the fibrous transformation described by M. Guérin; while in paralytic cases, fatty degeneration commences early, and proceeds to complete annihilation of the ultimate structure, leaving only fibro-cellular tissue, oil, and fat.

The foot may become contracted in consequence either of spasm or paralysis affecting certain muscles, or groups of muscles,

* The Plate illustrating the above paper has been copied by Mr. Aldous and is appended to the present Essay, Plate VI., and a description of the structural changes in the muscles will be found in the Appendix.

and remain permanently deformed in either of the positions described as characterizing the several varieties of club-foot.

All these deformities may be grouped and classified as spasmodic and paralytic, according to the producing cause; but a practical difficulty arises here, in consequence of the opposite views entertained by various authorities on affections of the nervous system, with regard to spasm and paralysis, so that many deformities in which the muscles are found to be in a rigid and contracted condition would by some be classed as paralytic, while others would consider them to be spasmodic.

In paralytic cases, more especially in the adult, there is no doubt that the muscles are found either in the flaccid, or rigid condition, at different periods after seizure; and in some instances, although rarely, these conditions are found coexisting in the same individual, the muscles of the leg, for instance, being rigid and contracted, while those of the upper extremity remain flaccid and lifeless—a condition of which I have seen a few examples. And if the existence or non-existence of voluntary control over the individual muscles, or the limbs affected, be assumed as the test of paralysis, then many cases of contraction and deformity with rigid muscles, which have generally been regarded as spasmodic, would be classed as paralytic affections.

In the spasmodic and paralytic deformities, taken collectively, we meet with the muscles in opposite conditions, viz., the rigid, and flaccid; and we occasionally meet with cases of undoubted paralytic history, in which the muscles, by a process of natural improvement, have gradually been restored to a healthy, or nearly healthy condition, without passing through the stage of rigidity.

The prognosis and treatment of the cases we are now considering, will be found to vary according to the rigid, flaccid, or nearly healthy condition of the muscles; and, therefore, instead of describing them as either spasmodic or paralytic, it will be found more useful, for practical purposes, to arrange all the non-congenital deformities of the feet depending upon spasm or paralysis of certain muscles in four classes, according

to the state of the muscles at the time the cases come under observation, viz.:

1st. Deformities with rigid muscles; the rigidity or tonic muscular contraction remaining as a persistent condition from the time of seizure. All non-congenital, and generally infantile affections.

2nd. Deformities with rigid muscles; the rigidity or tonic muscular contraction being consecutive to a flaccid and paralytic condition of the muscles. All non-congenital, and generally occurring in the adult.

3rd. Deformities with flaccid muscles; the contractions depending upon position and adapted atrophy of muscles, and other tissues. All non-congenital, and generally infantile affections, or occurring in early childhood.

4th. Deformities with the muscles in a healthy, or nearly healthy condition. These are cases in which the paralysis has been more or less completely recovered from; but the deformity, produced by contraction during the stage of paralysis, remains as a persistent condition. All non-congenital, and generally occurring in early childhood.

Let us first speak of the spasmodic contractions, or spastic contractures, as they are sometimes called, included in *the first class*. Convulsive affections are exceedingly common in children, sometimes occurring immediately after birth, generally when this is premature, and more especially when the labour has been difficult and protracted, and the children ill-nourished. Where death does not follow the convulsions, it frequently happens that a state of tonic spasm remains, which is marked by a rigidity of the muscles affected; and nearly all the muscles of the body are frequently involved, so that the children become frightfully deformed.

Fig. 1.

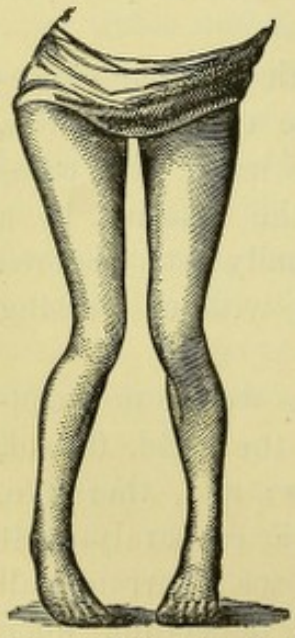

Spasmodic Contraction of both legs and feet. Rigid muscles.

In these cases the limbs are drawn in the direction of the strongest muscles, the feet

are extended, so that the toes alone touch the ground, the os calcis being elevated by the gastrocnemius, soleus, and other muscles at the back of the leg. The legs are flexed upon the thighs at an obtuse, or sometimes a right angle, by the powerful flexor muscles overcoming the action of the extensors. The thighs are more or less flexed upon the trunk, and always forcibly adducted or drawn together, through the powerful action of the large adductor muscles; so much so, that the knees touch, or overlap each other, and resist every attempt to separate them. The general direction and position assumed by the legs and feet in these cases, when the child attempts to stand, is well shown by the accompanying woodcut, Fig. 1.

In these cases the arms are approximated to the body by the action of the pectoral and other muscles connecting them with the trunk. The forearm is flexed, frequently at a right angle with the arm, by the biceps. The hands are flexed and always pronated, in consequence of the power of the flexor and pronator muscles exceeding that of their antagonists, and not because they are especially affected. Sometimes flexion predominates in the trunk, at other times extension; frequently strabismus, and occasionally wry-neck coexists with these deformities. The head frequently exhibits a close approximation in form to that commonly existing in idiots; and imperfect development of the intellectual faculties sometimes accompanies this sad condition.

These children have not infrequently a vacant or half-silly expression of countenance, and yet are more intelligent than might be supposed. Their speech is often difficult and imperfect, and in consequence of this, the intellectual faculties are often supposed to be more impaired than they really are.

When the general spasmodic contractions show themselves in this severe form, they are by no means limited to the period mentioned, viz., at, or soon after birth; but are often developed in all their severity, in respect of the number of muscles involved, between the ages of six and eighteen-months, although the intellectual faculties are seldom impaired to the same extent.

When these spasmodic contractions occur in a slighter degree, affecting only the lower extremities, they may not attract sufficient attention to be considered of much importance until the child ought to begin to walk; then its inability to stand and its deficient voluntary power over the legs become apparent, although no obvious deformity exists.

The deformities of the feet generally resulting from this affection are equinus and equino-varus. Cases of complete varus are stated sometimes to have occurred; but where the spasmodic contraction exhibits its ordinary form, we should not expect to see true varus produced, because one of the distinctive features of these spasmodic, in contradistinction to the paralytic affections, is, that all the muscles of the part affected are generally involved. The excess of power in the extensor and adductor muscles of the foot would be sufficient to produce equino-varus, just as this is the common position of the feet in *rigor mortis*, or in cases of convulsions following the administration of strychnine; but the power of the opponent muscles would be sufficient to prevent the formation of complete varus.

At a later period of life, frequently in youth, and sometimes even at an adult age, spasmodic affections also occur, giving rise to deformities of the feet. The particular characteristics of these affections at the later periods, seem to be that fewer muscles are affected, and that the mental faculties are not impaired. A remarkable case of this kind came under my observation, in which both feet were contracted in the position of extreme equinus, with flexion of all the toes to an extreme degree, which occurred as a result of the Mauritius fever, in the year 1867, in a lady, æt. 40. I have referred, in the Chapter on Talipes equinus, to this case, in which there was no interference with the mental faculties. The details of this case are given in the Appendix, Case III., and the position of the feet represented in Figs. 79 and 80.

A very severe and obstinate form is observable in girls, which is evidently connected with hysteria; and I need hardly say that in these cases the treatment must be directed against the general, rather than the local affection.

Morbid Anatomy. Of this we are unable to give any satisfactory account, as I have not found any cases in which post-mortem examinations have been recorded. From the symptoms at the time of seizure, in these cases, we may infer that congestion of the brain takes place, and that it may be followed by passive effusion or subacute inflammatory mischief, producing structural changes in the membranes or substance of the brain, such as would continue to excite irritation.

In one case of this kind in a late stage, many years after the primary affection, I had an opportunity of making a post-mortem examination. The subject was a woman, who died in St. Thomas' Hospital. Both the upper and lower extremities presented the rigid contractions with deformities usually existing in these cases, and although nothing was known of her early history, no doubt could be entertained of the nature of the affection. I found considerable opacity and thickening of the arachnoid at the base of the brain, in its central portion, and also close adhesions of the arachnoid about the medulla oblongata, and upper part of the spinal cord for about four inches. Here then, were distinct traces of inflammation, such as we should imagine generally existed in the more severe forms of this affection. The specimen is preserved in St. Thomas' Museum. The cause of the inflammation and its possible origin as a reflex action from peripheral nervous irritation are interesting inquiries, which the limits of the present essay would not permit me to follow.

That which is observable in the condition of the muscles is persistent rigidity or tonic spasm, which never relaxes, even during sleep, and by its continuance gives rise to structural shortening of the muscles affected, thus producing deformity. This condition of muscular rigidity is considered by the majority of pathologists to depend upon an excess of nervous stimulation, or, as we should call it, irritation; but without extending the inquiry, it may be observed that a precisely opposite doctrine is now taught by some good Continental pathologists and medical observers.

In a very able work on "Epilepsy," by Dr. C. B.

Radcliffe,* he endeavours to show the necessity of a complete revolution in the pathology and treatment of all diseases in which muscular contraction is in excess. He bases his pathological and therapeutical inferences upon his inquiries into the physiology of muscular contraction. The doctrine resulting from the whole inquiry is, that muscular structure does not

* The views of Dr. Radcliffe respecting nervous action and muscular contraction have an important bearing upon these cases of spasmodic contraction. Dr. Radcliffe holds that a complete revolution is necessary in the theory of muscular contraction. He refuses to call in the aid of a vital property of irritability, and in doing this he discards, as a matter of course, the notion that contraction is produced by the action of various stimuli upon this vital property. His view is this—that the muscles during life are endowed with an electricity of their own, that the state of relaxation is owing to the muscular molecules being repelled in a particular way by this electricity, and that muscular contraction is the effect of the operation of the attractive force which is inherent in this physical constitution of the muscular molecules, which operation comes into play upon the disappearance of the electricity of the muscle. In ordinary muscular contraction, the contraction is brought about by the sudden and temporary suspension of the electricity of the muscles; in *rigor mortis* the contraction is the result of the slow and permanent extinction of this electricity; in the two forms of contraction the actual cause of contraction is the same, namely, the action of the attractive force which is inherent in the physical constitution of the muscular molecules. Dr. Radcliffe also applies a similar way of reasoning to the phenomena of nervous action. He does not believe in a vital property of irritability in nerves, and therefore he does not believe in nervous action being produced by the action of a stimulus in rousing such a property of vital irritability. His view is—that the living nerves and nervous centres have an electricity of their own, that this electricity is discharged when a nerve passes from the state of rest into that of action, and that this *discharge*, which is analogous to that of the torpedo, and which takes place in the neighbourhood of the nerve, as well as in the substance of the nerve, is the agent by which a muscle is thrown into contraction by a nerve, the action of the nerve upon the muscular fibre being in fact the same (and no other) as that of the discharge of the torpedo, or of the instantaneous current of an induction coil. His view is, not that a nerve causes contraction in muscle by an excited vital principle in nerve causing excitement in a vital principle in muscle, but that the nerve in action gives out a discharge analogous to that of the torpedo, that this discharge for the moment suspends the natural electricity of the muscle acted upon, and that this suspension of the natural electricity of the muscle puts an end to muscular relaxation, and brings about muscular contraction—puts an end to muscular relaxation by removing the cause which keeps the muscular molecules in that state of mutual repulsion which is muscular relaxation, brings about muscular contraction by leaving the muscular molecule force

contract because it is stimulated, but because it is not stimulated; that it is prevented from contracting by the several vital and physical agencies which act as stimuli upon it —nervous influence, blood, electricity, light, heat, &c., and that contraction happens on the withdrawal of these stimuli, from unresisted molecular attraction of the muscle.

Prognosis. To revert to the surgical part of our subject; the prognosis must always be unfavourable in the deformities arising from these spasmodic affections, when severe, and when many muscles are involved. The rule is, that this condition of the muscular system once established, continues through life, and is susceptible only of slight improvement, either by

to obey that attractive force which is inherent in their physical constitution. These views have been advocated for several years, and the last and fullest statement of them is to be found in the lectures which Dr. Radcliffe gave at the Royal College of Physicians in London nine years ago, and which have since been published in a separate form. (Lectures on Epilepsy, Pain, Paralysis, and certain other Disorders of the Nervous System. London: Churchill and Sons, post 8vo., 1864.)

I must refer to these lectures for the evidence upon which Dr. Radcliffe founds his views, as well as for various other matters bearing upon the subject in hand; and here the only additional remark I have to make is that, according to these views, the contractions of which I have spoken are divisible into two distinct forms, one dependent upon changes in the nervous system, the other upon changes in the muscle itself. The first form is of the nature of spasm, more or less tonic; it can relax when the nerves are at rest, or when they are paralysed in various ways; it relaxes almost always, if not invariably, during sleep. The other form does not relax during sleep, or under any other circumstances; it is permanent. It is this kind of contraction which Dr. Todd called "late rigidity." Dr. Radcliffe explains this form of contraction, not, as Dr. Todd explained it, that is, supposing that the nerves of the muscles were acted upon by a permanent cause of irritation, as the dragging of a contracting cicatrix in the nervous centre, but by supposing that the muscles in which it is manifested have lost their proper electricity and vitality, and that owing to this loss, the muscular molecules are free to yield to the attractive force which is inherent in their physical constitution. He looks upon this form of contraction, in fact, as analogous in its nature, not to spasm, but rather to *rigor mortis.* In a word, he looks upon the "late rigidity" of Dr. Todd as the anticipation of *rigor mortis—rigor mortis in vitâ;* and certainly, I am disposed to think, the evidence in favour of this view appears to be more satisfactory than that which would refer it to the category of spasm. The views of muscular contraction and nervous action to which reference is now made, will doubtless become the subject of further investigation.

any efforts of nature, during the period of growth, or by any of the resources of medical science.

In the more severe cases the mental faculties also undergo but little improvement. In slighter cases, however, they are susceptible of great improvement, although the patients generally retain a vacant and half-silly appearance. The locomotive powers are either annihilated, or very materially curtailed through life.

Treatment. The treatment is for the most part unsatisfactory, in consequence of the physiological imperfection of the muscles, which are, more or less completely removed from voluntary control, and remain so, notwithstanding any operative, mechanical, or other treatment for the removal of the existing deformities, and in spite of any treatment for the general affection. In cases, however, in which the deformities are very severe; as, for instance—when the toes only can touch the ground, and the patients are unable to stand, and when, in addition to deformities of the feet, the contractions of the knees are so great as to render progression impossible, except with the aid of crutches, when the upper extremities are not involved in the affection, the patient swinging between them instead of walking—great benefit may be derived from operative and mechanical treatment, followed by a long course of shampooing and special muscular exercises.

By division of tendons, these limbs can be brought into their normal position; a firm and useful base of support is afforded by removing the deformities of the feet; and the rigidly flexed condition of the knee-joints may also be removed by dividing the ham-string tendons. After these operations the power of progression will be found to depend upon the amount of voluntary power existing in the muscles surrounding the hip-joints, whether from the partial character of the primary affection, or as an acquired improvement. Mechanical supports may be constructed so as to compensate in a great measure for the loss of voluntary power below the hip-joints, and with this assistance patients may be enabled to stand and walk, when they have never been able to do so before.

Deformities of the feet of extreme severity, are occasionally observed accompanied with severe contractions of the hamstring muscles, causing permanent flexion of the knee-joints, but with only slight contraction of the muscles surrounding the hip-joints. The distorted legs may be moveable from the hip-joints almost to their natural extent, and in such cases the removal of the deformities will be of the utmost value. The operation is rendered advisable, not only for the mechanical advantages obtained; but the patient is thus placed in a condition favourable to future improvement by shampooing, and active and passive exercise, whereas, with advancing age, the continuance of the deformity will certainly give rise to additional inconveniences.

A case in illustration of these remarks, and the advantages of treatment by tenotomy and mechanical means, is described in the Appendix, Case II.

CLASS II.—*Deformities with rigid muscles; the rigidity or tonic muscular contraction, being consecutive to a flaccid and paralytic condition of the muscles. All non-congenital, and generally occurring in the adult.*

We now pass on to the consideration of the cases included in the second class of non-congenital spasmodic, and paralytic deformities of the foot.

The deformed condition of paralytic patients, both children and adults, is matter of common observation. In old cases of hemiplegia in adults, the affected arm and leg are frequently seen in a rigid and contracted condition; the arm drawn to the side, the fore arm bent on the arm, the wrist bent on the fore arm, and the fingers closed on the palm of the hand; the leg stiff, with its muscles in a rigid condition; the knee-joint permanently flexed to a slight extent; the foot contracted, the most frequent position being that of equinus or equino-varus, so that the toes only touch the ground in the erect posture. The sole of the foot can only be brought in contact with the ground by the patient advancing the leg, in which move-

ment the toes describe a semicircular curve outwards, and the body is at the same time twisted sideways and leans forward. This gives a peculiar and characteristic gait to the individual.

When both legs are in a rigid and contracted condition in old cases of paraplegia the patient either walks by the assistance of two sticks, in which case he is liable to fall; or to avoid that danger, he avails himself of crutches, and by their assistance rather swings, than walks between them. The second class of non-congenital deformities is marked by a muscular rigidity, the pathology of which may still be regarded as obscure. It has, however, been investigated by the late Dr. Todd, one of the highest authorities on affections of the nervous system, who has given a theory of its production, supported by a series of cases.

Dr. Todd has described the morbid appearances met with in cases of hemiplegia, in which rigidity of the muscles existed; sometimes taking place simultaneously with, or soon after the paralytic seizure, and then described as cases of "*hemiplegia with early rigidity of the paralysed muscles;*"* at other times occurring slowly during the partial recovery which frequently takes place in these cases, and described as cases of "*hemiplegia with late rigidity of the paralysed muscles.*"

Dr. Todd believed the existence of rigidity in these cases, to depend essentially upon the coexistence of an irritative with a paralysing lesion of the brain. He observes "In the cases where there is no rigidity, the clot lies in the midst of softened brain, and has not in any degree encroached upon sound brain, but when rigidity exists, the clot has extended beyond the bounds of the white softening, and has torn up, to a greater or less extent, sound brain." This applies to the cases of early rigidity. The following is his explanation of the occurrence of the same phenomena in cases of late rigidity. "At the seat of the original lesion, whether it be simply a white softening, or an apoplectic clot; or a red softening,

* "Clinical Lectures on Paralysis, &c.," by R. B. Todd. London, Churchill, 1854.

with more or less destruction of the brain substance, there takes place an attempt at cicatrization, more or less perfect. Attendant on this, there is a gradual shrinking or contraction of the cerebral matter, which, acting on the neighbouring healthy tissues, keeps up a slow and lingering irritation, which is propagated to the muscles, and excites in them a corresponding gradual contraction."*

From the condition of the muscles, Dr. Todd considered that inferences as to the nature of the lesion may be drawn, which would afford important aid for diagnosis and prognosis, and he further made it the basis of an arrangement of cases of hemiplegia. There are some points of analogy between the cases described by Dr. Todd as *paralysis with early rigidity*, when "rigidity comes on simultaneously with the paralysis, or very soon after it," and the cases we have described in the 1st Class, as depending upon tonic muscular spasm, which remains persistent from the time of seizure; and the latter cases may by some be classed as examples of paralysis with early rigidity. If so, early rigidity is not an uncommon condition in infantile paralysis, and we are in error in supposing these cases to be of a spasmodic nature. It is certain, however, that these two classes of cases differ very materially in their clinical history.

Although a similar condition of the muscular system may result, the symptoms in the infantile cases differ so materially from those in the adult, that identity of structural lesion cannot well be assumed.

The pathology of the infantile cases has yet to be determined by dissection. It appears probable that in the infantile spasmodic cases, the structural changes are essentially of an inflammatory nature, while in the adult cases the immediate results are produced by degeneration of the coats of the smaller vessels leading to rupture and extravasation of blood.

Treatment. All cases of deformity, when accompanied by rigidity of the muscles, are, as a general rule, unfavourable for treatment, because after the deformity is cured, the de-

* *Op. cit.*, page 241.

fective voluntary power still remains, and also because many muscles are generally involved. In cases of hemiplegia, as generally met with in the adult, the condition of the patient is so precarious from liability to recurrence of paralysis, and consequent danger to life, that any contraction or deformity which may exist, is naturally regarded as of secondary importance. It occasionally happens, however, that the patient remains free from a second attack for many years, and then the deformity, which may have increased to an inconvenient and serious extent, becomes matter for consideration and treatment.

These cases, then, being of a compound nature, why should patients be allowed to suffer from two affections, viz.: paralysis and contraction, each giving rise to a separate series of inconveniences, when one of them is easily within reach of removal? Provided the objects to be accomplished be fairly stated and understood, there can be no objection to the surgical treatment of these cases by tenotomy. Much will depend upon the judicious selection of appropriate cases. The most favourable condition which can exist, is the comparatively healthy condition of the muscles surrounding the hip-joints. A good illustration of the advantages to be derived from tenotomy in cases in which the limbs remain in a state of rigid contraction after a paralytic seizure, in the adult, will be found in the Appendix, Case V.

CHAPTER V.

NON-CONGENITAL SPASMODIC AND PARALYTIC TALIPES CONTINUED.—DEFORMITIES WITH FLACCID MUSCLES; AND DEFORMITIES WITH MUSCLES IN A HEALTHY CONDITION AFTER RECOVERY FROM PARALYSIS; THEIR PATHOLOGY AND TREATMENT.

WE now proceed to the consideration of the pathology and treatment of the cases which I have arranged in the third class.

CLASS III.—*Deformities with flaccid muscles; the contractions depending upon position, and adapted atrophy of muscles and other tissues. All non-congenital, and generally infantile affections, or occurring in early childhood.*

In paralytic affections, whether occurring in infantile, or adult life, when the state of muscular rigidity does not take place, the muscles remain flaccid; and, if the paralysis continues, become atrophied, and gradually pass into a state of fatty degeneration, as shown in Plate VI., in which condition, they remain through life without improvement. The natural tendency, however, in infantile paralytic affections, is towards recovery, which takes place in some instances; but, in the great majority of cases, recovery is incomplete, although frequently sufficient to enable the patient to walk, either without, or with very little, mechanical assistance.

In those cases in which recovery does not take place, and

in which the muscles pass into the state of fatty degeneration, the limbs become utterly useless, and when both legs are in this condition, the patient makes no attempt to walk. I have seen several instances in which they have crawled on the floor for many years, or moved about on a sledge-like contrivance with wheels, using their arms for progression. When old enough, these patients can use the mechanical wheel-chairs, (See Appendix, Cases VI. and VII.)

When one leg, only, is affected, and the muscles have passed into the stage of fatty degeneration, the limb becomes useless, and, as the patient walks, with the assistance of a crutch, if old enough to use one, the leg dangles to and fro, and the term, "a swinging leg," frequently applied to it, well expresses its condition. Not only are such limbs useless, but, in adult life, and frequently earlier, they become the cause of much inconvenience from the intractable ulcerations which, in consequence of their low vitality, are apt to occur in them in cold weather, and, for this reason, surgeons have been occasionally called upon to amputate these limbs.

In the late Mr. Quekett's "Lectures on Histology," p. 199, published in 1852, we have an illustrated description of "fatty degeneration of voluntary muscle," taken from "the leg of a man aged 35 years, removed, at King's College Hospital, by Mr. Partridge, in which all the muscles had been replaced by adipose tissue. The limb had been rendered useless by an attack of paralysis, occurring three years after birth. Only a few fasciculi could be discovered amongst the adipose cells, and these were of very small size, and perfectly healthy." This man was a musician, and preferred taking the chance of amputation, with the prospect of obtaining an artificial leg, to retaining his useless and troublesome limb, which had long been the seat of intractable ulcerations.

When these legs are not amputated, they are disposed of in various ways. Sometimes the individuals affected walk with a crutch, the leg "swinging" as a useless member; sometimes mechanical compensation is effected by transmitting the weight of the body through a supernumerary leg attached to the pelvis,

and on which the patient sits, the paralytic limb being loosely fastened to the artificial leg-support.

In the course of time, various deformities and contractions take place in these flaccid paralytic legs, from adapted atrophy of the muscles and ligaments.

Deformities, with flaccid muscles, most frequently occur as the result of paralytic affections in children. Sometimes, though rarely, they are met with after paralysis in the adult. The muscles seldom remain in a flaccid condition after hemiplegia, or paraplegia, occurring in the adult; if the patient survives any length of time, partial recovery of the paralysis usually takes place, accompanied with late rigidity, as described by the late Dr. Todd, and which he states "results from a restorative effort of nature."* Occasionally, after adult paralysis, and, as Dr. Todd observes, "least frequently, recovery may take place without any rigidity or change in the muscles, other than a gradual restoration to their normal condition."†

In adult paralysis, the flaccid condition of the muscles appears to belong usually to the first stage, or the period of softening or disintegration of the nervous centres upon which the paralysis depends. But it is a remarkable feature in the history of that obscure form of paralysis, to which children are especially liable—and which has not been shown to depend upon destructive disease, either of the nervous centres, or nerve trunks—that the muscles either remain permanently in a flaccid condition, or pass through it towards recovery, more or less perfect, without becoming rigid.

Rigidity of the muscles, according to my experience, never follows this flaccid paralytic condition in children. In all the cases of deformity coexisting with rigidity of the muscles in children, which have fallen under my observation, there has been an absence of any pre-existing state of flaccidity of the muscles. In these cases, the account given has never been that the legs were soft and flaccid immediately after seizure, and became subsequently rigid; but, on the contrary, whether the

* "Clinical Lectures on Paralysis, &c.," by R. B. Todd. London, 1854.

† *Op. cit.*, page 206.

attack began with, or without a convulsive seizure, it has invariably been stated that the legs were from the date of the attack more or less stiff; that the joints would not freely bend in voluntary efforts, and that the muscles were firmer than those of other children. In the paralytic affections of children —infantile paralysis—if recovery does not take place, the muscles appear always to remain in a flaccid condition, and we have frequently observed this as a persistent condition, at an advanced period of life.

Paralytic deformities, with flaccid muscles, may occasionally be met with, both in adults and children, as the result of *traumatic lesion*, either of the nervous-centres, or nerve-trunks. These cases differ from those resulting from *infantile paralysis*, in the fact that sensation is involved, as well as motion, and that where the injury has been to the brain or spinal cord, the bladder and rectum are often paralysed.

In the cases which result from injury to the brain, with fractures of the skull; from injuries to the spinal cord, the result of fractures and penetrating wounds of the spine; and from wounds involving the nerve-trunks; I have seen consecutive deformities, with the muscles, either in a rigid, a flaccid, or a healthy condition, several years after the injuries.

By far the greater number of the paralytic deformities which we meet with in practice (and these are so numerous as to constitute the great majority of all the non-congenital deformities), will be found to result from *infantile paralysis*. Children thus afflicted are brought to us in every stage of this peculiar form of paralysis, and, although treatment is generally directed against the removal of certain consequences and effects, I believe that all these deformities may be prevented by judicious treatment; in fact, that there never need be another example of deformity in these cases, if the liability to their occurrence, and the mode of their production, were generally understood.

The importance of this subject, in connection with the various contractions in which it results, renders it necessary to give here a general outline of the history of infantile paralysis; but a more complete account will be found in the valuable works

of Kennedy,* West,† Reilliet, and Barthez‡ Bouchut,§ and Heine.‖

Infantile Paralysis, and its Peculiarities, as compared with Paralysis in the Adult.

Children between the ages of six months and two years are especially liable to paralytic seizures, which, like the paralytic affections of the adult, may assume the form either of hemiplegia or paraplegia; or sometimes that of general paralysis, both the upper and lower extremities, as well as speech being involved. But these are the only points of resemblance between the paralytic affections of children, and those of the adult; in all other respects, they are essentially different.

Infantile paralysis differs from the paralytic affections of the adult in the following respects:

1st. It has a marked tendency to involve only single muscles, or groups of muscles in the extremities, and in one or other of these forms, it most frequently occurs.

2nd. Motion only is affected, sensation remaining perfect, or nearly so. This constant relation does not exist in adult paralysis.

3rd. The viscera are not implicated, except in some rare cases of general paralysis, in which both arms, both legs, and nearly all the voluntary muscles of the body are affected.

4th. It is frequently neither preceded, nor accompanied by any cerebral symptoms, and, even when such symptoms show themselves, they are generally of a transient character.

* *Dublin Medical Press*, September 29, 1841: and also *Dublin Quarterly Journal of Medicine*, February, 1850.

† "On some Forms of Paralysis incident to Infancy and Childhood," *London Medical Gazette*, 1845; and "Lectures on the Diseases of Infancy and Childhood." Third Edition, London, 1854.

‡ "Traité Clinique et Pratique des Maladies des Enfants." Deuxième édition, Tome II., Paris, 1853.

§ "Practical Treatise on the Diseases of Children." Translated by P. H. Bird. London, 1854.

‖ "Beobachtungen über Lähmungszustände der untern Extremitäten und deren Behandlung." Stuttgart, 1840.

5th. In its most severe forms, it is not attended with any danger to life.

6th. Complete recovery frequently occurs; often taking place rapidly. This is extremely rare in adult paralysis.

7th. After one paralytic seizure, there is no tendency to a second attack, to which we know, in adult paralysis, patients are especially liable.

8th. Rigidity of the muscles neither occurs during, nor after recovery; they either remain flaccid, when the paralysis is persistent, or resume their healthy condition when recovery takes place. The reverse of this occurs in adult paralysis; rigidity, with partial recovery, when the patient survives, being the rule.

These peculiarities point to a special pathology of this affection, which, however, has not yet been determined. This form of paralysis generally takes place during the period of the first dentition, and would seem to be connected with the irritation attending this process, and, only in rare and exceptional cases, has it been known to occur after the age of five years. Cases at later periods are recorded, but these can with less certainty be included in the same category as those we are now describing.

It is at least doubtful whether paralysis of particular muscles or limbs, independent of traumatic lesion, is ever congenital. The cases related of limbs remaining flaccid and useless in infants born asphixiated, after difficult and instrumental labours, and of fascial paralysis, usually of one side—sometimes accompanied with loss of power in the corresponding arm—which, in some instances, have been satisfactorily traced to traumatic lesion, cannot be admitted as examples of this affection.

Accompanying Symptoms. Symptoms of transient cerebral disturbance, such as convulsions or drowsiness, often accompany the seizure in infantile paralysis. It not infrequently follows marked febrile disorders, especially measles and hooping-cough, also gastric, remittent, and typhoid fever. A slight febrile condition appears very constantly to exist, but the paralysis is said frequently to happen not only without any

convulsions or cerebral disorder, but without any symptoms at all, and when the children are in robust health.

Mode of Seizure. Occasionally it occurs in the daytime, under the direct observation of the parents, but more frequently we are told that the child was put to bed in its usual health, and, in the morning, was found to have lost the use of a leg, or an arm, or even of both. The exciting cause, therefore, is often obscure.

Liability of Sexes. Both sexes are equally liable to this form of paralysis, and I agree with Dr. West in thinking that it more frequently occurs in children of weak constitution, although the opposite opinion is held by Kennedy.

Its duration is extremely variable, Barthez and Reilliet relate a case of paralysis of the arm, in a child, lasting only twelve hours, and other cases of seven and eight days duration. Improvement frequently takes place in a few weeks, and is often complete in from three to six months. In severe cases, however, after partial improvement, the limbs remain more or less paralytic through life.

Progress. A marked characteristic of this affection is a tendency to spontaneous cure. In slight and moderately severe cases, affecting single muscles or groups of associated muscles, complete recovery is the rule, and, when this fails, great improvement occurs with very few exceptions: this I have frequently observed taking place several years after the seizure. Numerous cases of this kind are seen in every stage of spontaneous recovery, without any treatment having been adopted. In very severe cases, involving both the arms and the legs, partial recovery is the rule; the arms recover first, and more perfectly than the legs, although they have been as completely paralysed. This has constantly occurred in cases I have witnessed, and, according to Dr. Todd, the reverse takes place in adult paralysis.* It has often been supposed that unless recovery was complete in six months, paralysis remained persistent through life; but I have frequently witnessed cases of progressive improvement, without any treatment, even at ten

* *Op. cit.*, page 206.

years, or more, after the paralytic seizure. The natural progress, therefore, of this form of paralysis, is always more or less towards recovery.

Muscles affected. Some of the muscles of one leg are most commonly affected by infantile paralysis; frequently the leg and arm of the same side, and more rarely the leg and arm on opposite sides; occasionally both legs, and very rarely both legs and both arms. In the last mentioned cases, the spinal muscles, and those of the hip-joints are generally affected, and in some cases nearly all the voluntary muscles of the body, and some of the involuntary muscles are also partially paralysed.

When single muscles are affected, the most frequent to suffer are:

1st. The extensor longus digitorum of the toes.

2nd. The tibialis anticus.

3rd. The deltoid.

4th. The sterno-mastoid.

When particular groups of muscles are affected, the most frequent to suffer are:

1st. Those of the anterior part of the leg, forming the extensors of the toes and flexors of the foot.

2nd. The extensors and supinators of the hand, always together.

3rd. The extensors of the leg, and with them, generally, the muscles of the foot, as in the first class.

Other muscles than those specified are sometimes slightly weakened, and this is not uncommon at the time of seizure; but in a large majority of cases they completely recover. In the later stage, therefore, when these cases more frequently come under our notice, they present well-marked examples of paralysis of single muscles, and groups of associated muscles. The late Sir B. Brodie mentioned to me a case brought to him, in which the muscles of deglutition were paralysed in a child. The attempts to swallow were very painful to witness. He did not know the result, but death from starvation probably took place.

Morbid anatomy. With respect to the morbid anatomy of this affection, or the nature of the structural changes upon which it depends, very little is yet known. As it is seldom, if ever, a fatal disease, except, perhaps, under the circumstances mentioned in Sir B. Brodie's case, opportunities for making post-mortem examinations in recent cases must be extremely rare. Only three have been recorded. Two by Barthez and Rielliet, one of paralysis of the arm, and the other of paraplegia; an attentive examination of the brain, spinal cord and nerves in these cases, did not reveal any appreciable lesion.

The other case, recorded by Dr. Fliess, and alluded to by Barthez and Rielliet, was also one of paralysis of the arm, and a simple congestion of the membrane of the spinal cord on a level with the brachial plexus was found; the structure of the cord, the brain and the nerves were said to be perfectly healthy.

The opinion to which we are led by the clinical history of these cases is confirmed by these examinations, viz.: that this peculiar form of paralysis generally occurs without any serious or irreparable damage to the nervous-centres and nerve-trunks. Further investigations, however, are required before we can form any definite opinion as to the essential nature of this affection.

It appears probable that local congestion of the nervous-centres, or nerve-trunks, accompanied in some cases with effusion, which subsequently becomes absorbed, are the only morbid conditions in many of the slight cases in which, from the beginning, the paralysis is only partial, and from which recovery is often rapid and complete. In a case of paralysis of the leg in a child, which I had the opportunity of examining, after death, I was unable to detect any morbid condition of the spinal cord, although a very careful examination was made.

In other cases it is probable that active congestion does not take place, but that some local failure of nutrition occurs under a general febrile condition of the system; the frequent absence of cerebral symptoms, even in the most severe

cases, with extensive and persistent paralysis, is very remarkable. The rule is that in these cases the intellectual faculties are not impaired, a circumstance which distinguishes them from the severe forms of spasmodic affections with rigid muscles, previously described, in which, as a rule, the intellectual faculties are to a greater or less extent impaired persistently through life.

Under the title of "Myogenic, or Essential Paralysis," this affection is described by M. Bouchut, and, except in cases preceded by febrile convulsions, he regards it as a local affection, "accompanied by an alteration of the elementary tissue of the substance of the muscles."* M. Bouchut considers it to depend most frequently upon exposure to cold, as from children wearing low dresses, being put to bed without warm night dresses, throwing off the bed clothes, &c.; and observes that children, under these circumstances, are "most usually attacked with this paralysis, the nature of which is, according to my opinion, entirely rheumatic." The evidence of the myogenic and rheumatic nature does not appear to me sufficiently conclusive, and the children who, in restless nights, throw off the bed clothes, are, probably, frequently suffering from febrile or eccentric irritation, during which a local congestion, sufficient to produce the immediate effect, and, in some instances, followed by a failure of nutrition, rather than active inflammatory mischief, would be not unlikely to occur.

Many children, apparently in good health, become heated and feverish during the night, the skin, especially the face, being hot and burning, and the head freely perspiring. It is probable, also, that, in many of these cases, the children have slight fits, or convulsive seizures, which pass away unnoticed in the night. The morbid anatomy of this affection, and, therefore, its essential nature must be considered as not yet determined.

The diagnosis is free from difficulty, the special symptoms above enumerated enable us at once to recognise the case, as belonging to this peculiar form of paralysis.

* *Op. cit.*

The prognosis will be looked for with the greatest anxiety, as the sudden, alarming, and apparently dangerous nature of the attack, when severe, will excite the worst apprehensions. The parents, however, may be assured that there is little, or no danger to life.

When almost all the voluntary muscles of the body, and those of deglutition, are involved, as in the case mentioned by Sir B. Brodie, it is scarcely necessary to say that danger to life must be feared; but I have not known any of these cases end fatally. No permanent affection of the brain, or liability to a second attack, which so often occurs in adult paralysis, need be apprehended.

The prognosis, with respect to the recovery of voluntary power in the extremities or muscles involved, must always be very guarded. Although Kennedy supposes that the prognosis may be based upon the mode of seizure, no general rule with respect to this, or any other event, has yet been discovered. The extent and intensity of the paralysis will, however, influence the opinion in some degree.

In cases in which both arms and both legs are involved, complete recovery rarely, if ever, takes place, but great improvement generally occurs, the arms recovering more completely than the legs. In cases of less severity, complete or partial recovery is the rule; but a useful amount of improvement cannot absolutely be relied upon, as the paralysis is occasionally persistent through life, although a few muscles only are involved.

Complete recovery is, however, much more frequent than generally supposed, as shown by the large number of deformities we meet with, in which the muscles are found in a healthy condition, (so far, at least, as consistent with the amount of deformity,) although the paralysis of one or more muscles during infancy had certainly laid the foundation of the mischief.

The prognosis should be cautious and guarded with respect to the restoration of voluntary power, when the cases are seen at the time of, or soon after, the seizure, and, if seen at a later

period, when atrophy and deformity have occurred, our opinion must depend upon the exact state of the muscles, and any tendency that may be exhibited towards improvement. It is generally supposed, that unless recovery takes place within a few months, the paralysis is persistent through life, but I have seen many cases in which improvement has proceeded to a very useful extent, several years after the seizure. Bearing in mind this fact, the prognosis must vary according to the circumstances existing at the time in each case.

TREATMENT. As the nature of the structural changes producing the paralysis has not yet been determined, and the circumstances under which it occurs, differ so widely, the treatment, at the time of the paralytic seizure, must vary according to the state of the patient, and the producing cause when this can be traced.

There are, frequently, no indications of the approach of so formidable a disease, and, at the moment of seizure, the mischief is already accomplished. If irritation from teething exists, the gums should be lanced, and it is advisable to do this even where the indications are not very positive. Without advocating indiscriminate lancing of the gums, it is advisable to do so more frequently than recommended by some authorities, especially if a number of teeth should be advancing at the same time, and, even although none of them should be coming through.

Any existing febrile irritation must be allayed, and the warm bath, purgatives, and counter-irritation should be used. Alteratives may be employed, but whether mercurial treatment is useful, appears very doubtful; it has failed where I have known it to be used most freely. Dr. West recommends purgatives and tonics. Dr. Fliess advises cupping in the region of the nervous-centres, corresponding to the part affected.

Termination of infantile paralysis. If within a few months the state of paralysis does not completely disappear, the muscles remain flaccid, and a series of changes take place, which may terminate in the production of deformity. This event brings these cases within the range of surgical practice. But the

surgeon cannot hope to treat such cases successfully, unless acquainted with the general pathological history of the affection in reference to the changes which have taken place, those which are in progress, and those which may be expected to occur. An untimely interference may give rise to the most serious mischief, by creating much greater evils than those sought to be removed; but, by a judicious selection of cases, a great and lasting benefit may be conferred on the patients.

Mode of production of the deformities. The consecutive deformities of the feet, knees, hips, &c., which occur as the result of infantile paralysis, are produced by adapted atrophy of certain muscles, principally the opponents of those which have suffered paralysis. If the anterior muscles of the leg, for example, are paralysed, the anterior portion of the foot drops, and the heel is raised, not by active contraction of the posterior muscles—for division or paralysis of one set of muscles does not excite active contraction in the opponent muscles—but in consequence of the position assumed by the foot from its mechanical relations with the leg. The posterior muscles are no longer required of their normal length, nor are they ever called fully into action. They, therefore, accommodate themselves by a process of "adapted atrophy," as described by Sir James Paget, to their required length, and a permanently raised condition of the heel, producing deformity, results.

When both the anterior and posterior muscles are paralysed, the same process takes place, but at a slower rate. The same method applies to all other parts. When the paralysis is persistent, and involves all the muscles of the leg, a general atrophy, with fatty degeneration and arrest of growth takes place, as in the case examined by Mr. Quekett, and already adverted to; legs in this condition are sometimes seen two inches, or more, shorter than the opposite limbs. Of the class of *deformities with flaccid muscles*, these cases form the most numerous examples.

The *kind of deformity* produced, will vary according to the muscles involved in the paralysis. The most frequent form is

that of, Talipes equinus; and the other deformities occur in the following order:

2nd. Equino-varus.

3rd. Equino-valgus.

4th. Calcaneus, or calcaneo-valgus, and,

5th. Talipes varus.

When both feet are affected, equino-varus of one foot is generally found with equino-valgus of the other.

The *mode of progression* varies extremely, and is dependent upon the number of muscles involved, and kind of deformity produced. We frequently see children, when only one limb is affected, walking with a "throwing movement" of the leg in consequence of paralysis of the rectus femoris.

All progression is, of course, out of the question, when both legs are paralysed. The child is kept lying down, or allowed to crawl; or, with the assistance of the arms, to move about in a sitting position, attention being paid to its general health, and various remedies tried to restore power. If, in the course of time, some improvement should take place, walking, by the aid of crutches, will be attempted; but the feeble legs will, in many instances, be found unequal to the task imposed upon them, and evidently rendered less useful by the supervention of various contractions or deformities, which will certainly have been produced at this period. In such cases, all further attempts at progression are generally abandoned by the patient, and the wheel-chair, or some similar contrivance, as a substitute for legs, will be the only mechanical assistance that can be rendered. See Case VII. in the Appendix.

Principles of treatment. The possibility of benefit in such cases by any surgical procedure, seems scarcely ever to be entertained. The existence of paralysis is supposed to counter-indicate any surgical interference; but from these apparently hopeless, and essentially incurable cases, some of the most striking, and most valuable results of surgery are obtained, by a combination of surgical and mechanical treatment. Mechanical aid alone is frequently sought from the instrument maker, but his art is powerless when any considerable amount

of deformity exists; and it is only by a scientific combination of surgical and mechanical skill, that much good can be effected.

In all these cases, the treatment essentially consists in the removal of existing deformities by tenotomy and mechanical means, and a subsequent compensation for the existing paralysis, by mechanical support, varying in different cases according to the extent of the paralysis.

A fortunate circumstance in the pathological history of these cases enables us to effect these objects with remarkable success. I allude to the state of the muscles surrounding the hip-joints. In many cases in which the rectus and other muscles of the leg are paralysed, the muscles in the neighbourhood of the hip-joint are not involved. And, in the cases of infantile paraplegia, as well as those of general paralysis, described as involving both the upper and lower extremities, the rule appears to be, that the muscles surrounding the hip-joints so far recover in the course of a few months or years, as to be available for progression, even when all the muscles below the hips remain paralysed, or, at least, in a state of very partial recovery. Hitherto, I have seen very few exceptions to this rule, although, in the severe cases of general paralysis, this amount of recovery may be delayed.

Availing ourselves of this favourable condition with regard to the recovery of power in the muscles surrounding the hip-joint, it will at once be perceived how far it is practicable, by timely interference in appropriate cases, to enable such patients to walk. The deformities of the feet can easily be cured, and the feet afterwards retained in their normal position by mechanical supports, which must be extended to the thighs, and adapted so as to render the knee-joints immovable in the erect position, in fact, mechanically to anchylose the knee-joints. It can be so contrived that the knees may be bent at pleasure, in the sitting position, and again straightened on the erect position being resumed. Case VII., in Appendix, furnishes a good illustration of the extent to which these patients can be improved in adult life. This lady, at the age of 39, who had

not walked since she was five years of age, was enabled to walk with the assistance of mechanical supports, after the deformities of the limb had been removed by tenotomy and mechanical means.

CLASS IV.—*Deformities with the muscles in a healthy, or nearly healthy condition, after recovery from Paralysis.*

I have but a few remarks to offer with respect to the last of the four classes into which I have divided non-congenital spasmodic, and paralytic deformities. Cases in which the paralysis has been more or less completely recovered from, but in which the deformity produced by contraction during the stage of paralysis, remains as a persistent condition, are not infrequently met with.

It has already been stated that infantile paralysis is frequently a transient affection, that in the majority of cases, voluntary power is, more or less, completely restored; and that imperfect recovery not infrequently takes place long after the seizure, two or three years, for example. At a shorter interval, recovery is often perfect.

The production of the deformity by adapted atrophy, in these cases, is, however, a progressive change from the beginning, and the deformity, when produced, remains as a persistent condition, notwithstanding the partial, or complete recovery of the paralysed muscles.

By these facts, it is explained how we frequently meet with deformities in which the muscles are in a healthy, or nearly healthy condition, but which, from their history, have evidently been produced by an attack of infantile paralysis; spontaneous recovery from the paralysis has taken place, but the consecutive deformity remains.

The pathology of these cases has been already explained in the clinical history and general account given of the cases described in the third class of deformities.

In reference to treatment, it is only necessary to observe that these are the most favourable cases we meet with in practice, in

consequence of the absence of paralysis, or of any spasmodic condition of the muscles. After the cure of the deformity, which is most frequently that described as talipes equinus, little or no mechânical support is required, as in the cases in which compensation for existing paralysis has to be accomplished by mechanical means; and, therefore, in these cases, not only are we enabled to remove an unsightly deformity, but, also, frequently all trace of lameness.

NATIONAL HOSPITAL FOR THE PARALYSED & EPILEPTIC
PRESENTED TO
QUEEN SQUARE, BLOOMSBURY, LONDON

CHAPTER VI.

TALIPES EQUINUS—EXTERNAL CHARACTERS—MORBID ANATOMY—PATHOLOGY—PROGNOSIS.

We have hitherto spoken of the general laws and conditions which regulate deformities of the feet, and with the object of giving a comprehensive view of the whole subject, I adverted to some of the leading features in the general pathology and principles of treatment of the congenital and non-congenital distortions.

I now propose to describe in detail the anatomical characters of the various forms of club-foot, alluding to any special peculiarities in their pathology, of a practical bearing, and the means necessary to their cure or improvement. And first of

Talipes equinus, the simplest and most frequent variety of club-foot, and one to which this name has been given from the general external resemblance which the deformity, when severe, is supposed to present to the foot of the horse.

External characters.—In a well-marked case of talipes equinus, its external characters are, elevation of the heel with depression of the toes and anterior portion of the foot, without lateral inclination, either inwards or outwards. The individual walks apparently upon the toes, but really upon the extremities of the metatarsal bones, the heads of which, under the weight of the body, become more or less separated from each other, so that the anterior part of the foot acquires an increased breadth.

The longitudinal arch of the foot becomes contracted, *i.e.*, its extremities approximated, in consequence of the weight

FIG. 2.

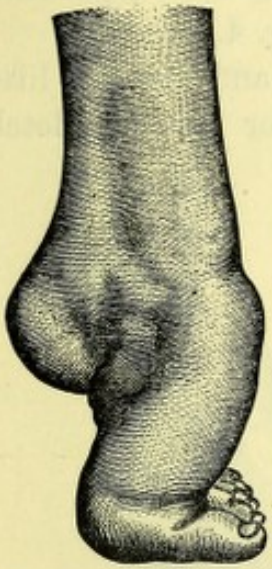

FIG. 3.

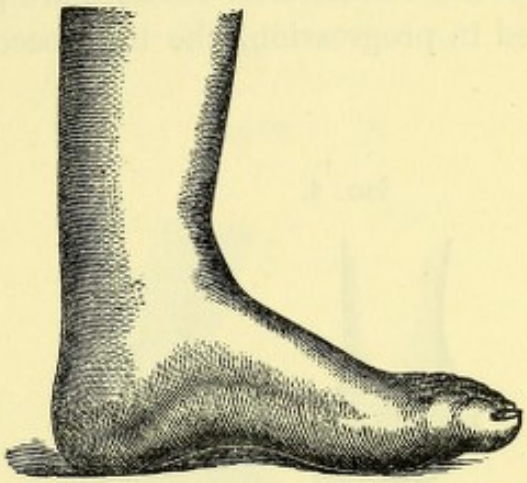

Fig. 2.—Talipes Equinus, without paralysis of the anterior muscles of the leg and foot. The toes extended and drawn upwards from their metatarsal joints.
Fig. 3.—Drawing from the same foot as Fig. 2 after treatment.

of the body being sustained by its anterior extremity. This produces a shortening of the foot, and a deep concavity in its sole, which, with the duration of the deformity, increases, and becomes a permanent condition, in consequence of the contraction of the plantar fascia, and the deep ligaments in the sole of the foot. In proportion as this contraction in the sole of the foot exists, there is a prominence of the head of the astragalus on the dorsal surface. These appearances are well represented in Fig. 2, from the foot of a lady aged 25 years.

Modifications of external characters. The condition of the muscles and duration of the deformity give rise to various modifications of the outward characters; and from the position assumed by the toes in relation to the anterior part of the foot, we may readily form a diagnosis as to the condition of the muscles; and prognosis with respect to the gain of muscular power, and usefulness of the feet after operation.

When the anterior muscles of the leg and foot retain their

power, the toes are always extended, or drawn upwards from their metatarsal joints as shown in Fig. 2; and in cases of a spasmodic character they also become flexed upon themselves at their first phalangeal articulations, thus presenting a claw-like appearance, as represented in Fig. 4.

When the anterior muscles are paralysed, and the foot little used in progression, the toes become more or less completely

FIG. 4.

FIG. 5.

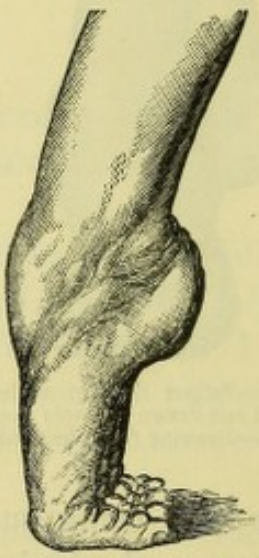

Fig. 4.—Talipes Equinus, with the muscles in a spasmodic condition. The toes extended from their metatarsal joints, and flexed upon themselves, presenting a claw-like appearance.
Fig. 5.—Talipes Equinus, with paralysis of the anterior muscles of the leg and foot. The toes flexed and bent backwards from their metatarsal articulations.

folded upon themselves backwards, both from their metatarsal and their phalangeal articulations, as represented in Fig. 5. These three conditions of the toes are, therefore, useful in aiding a rapid diagnosis to the cause of the contraction, and the general prognosis with respect to the gain of muscular power, and usefulness of the feet after operation.

A more conspicuous deviation in form occurs in some cases of talipes equinus, in which all the anterior muscles are completely paralysed; instead of the toes being extended, and the weight of the body received upon the heads of the metatarsal bones, the foot becomes retroverted, as shown in Fig. 6, and is, therefore, useless to the patient, who can only walk with the assistance of a crutch.

In this condition, the deformity may still further increase,

and the foot become completely bent upon itself in the direction of its length, the toes and metatarsal bones being, as it were, folded backwards, so that in the erect position the instep, or dorsal aspect of the foot, alone would come

FIG. 6.

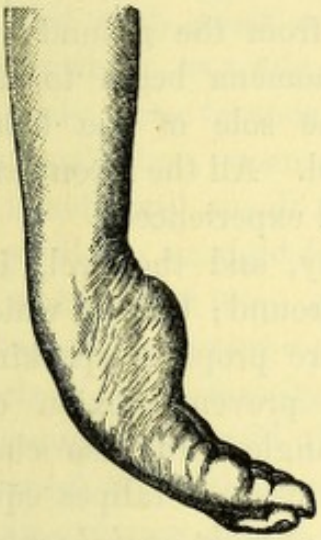

FIG. 7.

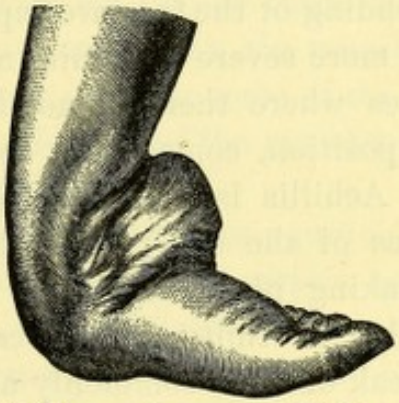

Fig. 6.—Talipes Equinus, with complete paralysis of all the anterior muscles of the leg. The foot is retroverted and has not been used in progression.

Fig. 7.—Talipes Equinus, with complete paralysis of all the anterior muscles of the leg. The foot has become retroverted and folded upon itself backwards in the direction of its length.

in contact with the ground, as represented in Fig. 7. It is only under circumstances of complete paralysis and great relaxation of the ligaments that extreme flexion of the foot upon itself, as shown in Fig. 7, takes place.

Under similar conditions, the foot may become completely inverted, so as to assume the form of talipes varus; but, deviating to a less extent, it frequently becomes somewhat twisted and contracted in a lateral direction, either inwards or outwards, these deviations being generally determined by more or less power existing in certain muscles, as well as by the superincumbent weight. However, when any lateral deviation exists, the case is no longer one of pure equinus, but is considered a compound deformity between equinus and one of the other varieties; and, according as the foot turns inwards or outwards, the deformity receives its distinctive

appellation. If the inclination be inwards, it is called equino-varus, and if outwards, equino-valgus.

The description of talipes equinus above given, is drawn from a severe case of that deformity; but we have every degree between the slightest elevation of the heel, without other deformity of the foot, and its extreme elevation, with other severe contractions above described. We frequently see the heel raised about an inch from the ground; but at a later period the consecutive phenomena begin to develop themselves, when contraction in the sole of the foot, and the bending of the toes are superadded. All the inconveniences of the more severe deformity are then experienced.

Cases where there is no deformity, and the heel, in the erect position, comes well to the ground; but in which the tendo Achillis is contracted (or more properly speaking the muscles of the calf,) sufficiently to prevent flexion of the foot taking place beyond a right angle, are also classified with this deformity, and described as cases of talipes equinus; we speak of them commonly as cases of *right-angled contraction of the tendo Achillis.*

A certain amount of lameness, accompanied with inability to walk even a moderate distance without fatigue, follows this condition of right-angled contraction of the tendo Achillis, and in consequence of the limited flexion of the ankle-joint, the stride is necessarily shortened; for the same reason, also, the feet in the act of progression are turned outwards with a twisting movement. It is difficult to recognise this condition from the absence of deformity, more particularly as feet are usually examined by surgeons, without reference to the extended position of the leg: but it may be at once detected if the following means are used. When the patient is in a sitting position, raise and extend the leg, and direct him to keep it so by a downward pressure on the knee-joint; then flex the foot, and you will at once find whether its natural angle of flexion is limited or not. In adult life the natural angle of flexion of the foot upon the leg is about 20° beyond the right angle, and this should be accomplished without the Achilles tendon

becoming very prominent and tense. At younger ages, the angle of flexion is considerably greater, and in infancy the dorsum of the foot can be made almost to touch the leg.

This condition of limited flexion at the ankle-joint is of more practical importance than it may at first appear to be, and when it has existed any length of time, and the muscles are in a healthy, or nearly healthy condition, the tendo Achillis may be divided with great advantage in some cases. In young people, however, as a rule, sufficient elongation may be obtained by a steady perseverance in mechanical treatment, by means of a Scarpa's shoe, worn continually for two or three months. Little benefit will result from tenotomy when the muscles are either paralytic, or rigid from spasm; but in some of the latter cases, where there is no general affection of the muscles of the lower extremity, tenotomy is useful.

Effects of this deformity. When severe talipes equinus exists only in one limb, and the muscles retain a certain amount of power—a favourable condition for treatment frequently met with—an extreme degree of lameness is the result, far beyond that caused by the severest form of congenital talipes varus; the length of the leg is increased as a result of the deformity, in proportion as elevation of the heel and extension of the foot coexist with immobility of the ankle-joint.

It might be supposed that this deformity would produce lateral curvature of the spine. Indeed, some have gone so far as to say, and mathematically attempt to prove, that inequality of the legs must produce lateral curvature of the spine, and in some medical works it is given as a frequent cause of this deformity; but as a rule, we do not find it so in practice, and my experience of such cases warrants the assertion that lateral curvature of the spine is a comparatively rare and exceptional result. I entirely concur in Dr. Little's opinion, that except in cases in which other conditions, favourable to the production of lateral curvature exist, it is rarely produced by this deformity of the foot. In the awkward gait of these patients, the spine appears certainly to twist

in all directions; but the muscles on both sides of the spine become equally strengthened, and thus curvature is prevented.

In addition to severe lameness, other serious inconveniences result in many cases. Painful and incurable corns form on the portions of the foot most subject to pressure; and the skin on the dorsal surface of the toes suffers from friction, becomes excoriated, and the seat of deep and painful fissures. Great inconvenience was experienced from this cause by the lady whose foot is represented in Fig. 2.

The condition of the muscles of the foot, in paralytic or spasmodic cases, and the extent to which other muscles in the lower extremity are similarly affected, have, also, much to do with the production of the lameness, and other inconveniences arising from talipes equinus. In speaking of the pathology of non-congenital deformities, I have already referred to these, and would only observe here, that in the paralytic cases, when one foot only is affected, and the extensor muscles of the leg, also, are paralysed—a very frequent condition—a single crutch is generally used, or sometimes a wooden leg from the knee is preferred. When both limbs are thus affected, the individual is totally unable to walk, even with the assistance of crutches. The successful treatment of these apparently hopeless cases, I have referred to, and a well-marked case in illustration will be found in the Appendix, Case VII.

MORBID ANATOMY OF TALIPES EQUINUS.

In this deformity, the anatomical deviations are extremely simple. The position of the foot, when not complicated by contraction of the arch from ligamentous shortening, is one which may be readily assumed in a state of health, and as the deformity is essentially a non-congenital affection, we should not expect to find the bones materially altered in form. In a case which I dissected from the body of a man aged 25 years, at St. Thomas' Hospital in the year 1852, and which is now preserved in the Museum

of the Hospital, no material changes had taken place in the form of any of the bones.* In cases which have occurred in childhood, and existed for many years, the bones become slightly altered in form; but never at any age has this been found, either practically, or by dissection, sufficient to prevent the restoration of the foot to its natural form. These feet have been restored to their natural position in patients beyond sixty years of age.

BONES.—In the production of talipes equinus, the deviations in the bones relate to position rather than form. The tuberosity of the os calcis is raised by contraction of the gastrocnemius and soleus muscles, and this bone assumes an oblique position, which varies considerably in degree in different cases. In some cases, the upper surface of the os calcis comes in contact with the posterior margin of the articular surface of the tibia, and, as a necessary result of this movement, the astragalus is thrust forwards, and obliquely downwards—partially luxated, from the ankle-joint—so that its head projects in front, on the dorsum of the foot.

With regard to the extent to which the os calcis is elevated in talipes equinus, some difference of opinion exists. According to my dissections this bone, as a rule, is much less elevated than generally supposed. It is far from my object to assert that the os calcis is not elevated in talipes equinus, the external characteristic of which is the elevation of the heel; but what I maintain, is, that in cases of long standing, such as we most frequently meet with in practice, the elevation of the heel depends more upon the depression of the anterior portion of the foot from the transverse tarsal joint, than upon elevation of the os calcis and simple extension of the foot. In no dissection of talipes equinus, or equino-varus, have I found the elevation of the os calcis so great as in cases of congenital talipes varus—compare the dissection of these deformities in Figs. 8 and 9 with Fig. 34.

In these cases, as a general rule, there is undoubtedly some

* *See* "Transactions of Pathological Society," Vol. III., p. 468, and also Appendix, *Note* 3.

degree of elevation of the os calcis, and contraction of the Achilles tendon, or muscles of the calf; but the progressive increase of the deformity appears to be due to an increase of ligamentous shortening, and adaptation of the ligamentous and muscular structures in the sole of the foot, by which the foot is bent upon itself from the transverse tarsal joint, and its anterior two thirds depressed. The effect of this is to bring the metatarsal bones into a straight line, continuous with the line of the tibia, and to throw the weight of the body directly upon the distal extremities of the metatarsal bones, as shown in Fig. 2, and also in the dissections represented in Figs. 8 and 9.

In the description of a specimen, which I dissected, and exhibited to the Pathological Society, (see Trans., Vol. VIII.

FIG. 8.

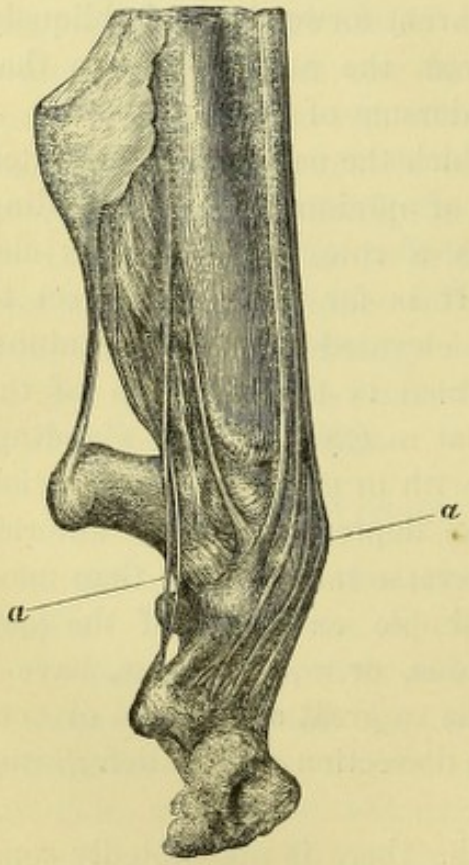

FIG. 9.

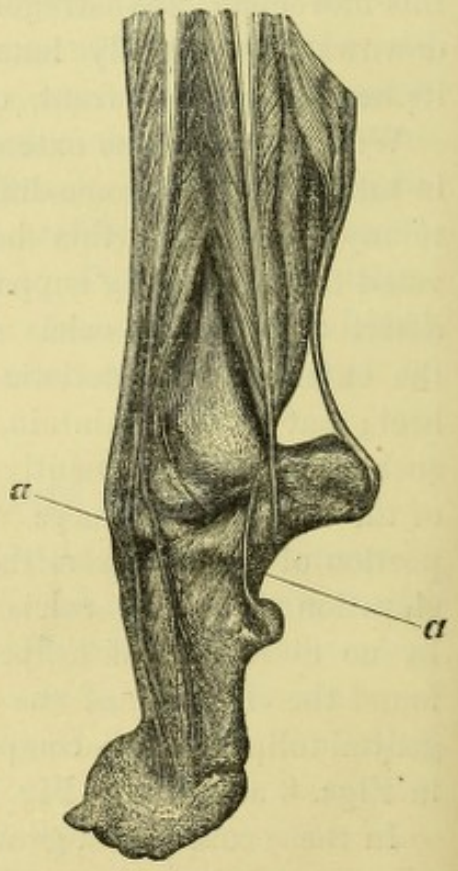

Fig. 8.—Dissection of a case of Talipes Equinus, or rather Equino-varus; showing only a slight degree of elevation of the os calcis; the deformity depending chiefly upon the foot being bent upon itself from the tranverse-tarsal joint, indicated by the line *a a*.

Fig. 9.—The opposite view of the same foot as represented in Fig. 8.

p. 393 and also Plate X. in which the specimen is represented.) I alluded to the fact of the os calcis being but little elevated.

Mr. Brodhurst questioned the accuracy of this statement, and adduced a dissected specimen to prove that the os calcis was elevated to a considerable degree; this foot exhibited and figured by Mr. Brodhurst, in the Trans. Path. Soc. Vol. X. p. 280, is now in the Museum of the College of Surgeons, No. 9, B., Pathological Series.

Upon a careful examination of this specimen, I could only come to the conclusion that it completely confirmed my original opinion that the os calcis is elevated to a much less extent than the general appearance of the deformity, and the elevation of the heel would lead us to expect; and that the transverse tarsal joint played a much more important part in the production of the deformity than the ankle-joint—in fact, that the heel was raised more in consequence of the anterior portion of the foot being depressed from the transverse tarsal joint, than by simple elevation of the os calcis, and extension of the whole foot.

I therefore requested Mr. Aldous to make drawings of this foot, taken by the camera in more direct profile than in the wood-cut in the Trans. Path. Soc. above referred to, and they are represented in wood-cuts Figs. 8 and 9, the angle of flexion from the transverse tarsal joint being indicated by the line *a a*. The specimen may be regarded as one of equino-varus rather than true talipes equinus; but as far as the displacement of the os calcis is concerned, the difference is not material.

In some cases, as in Fig. 2, the projection of the head of the astragalus on the dorsum of the foot is obvious and well defined, not only from the altered relations of the foot at the ankle-joint; but also in consequence of the navicular bone receding backwards from the head of the astragalus, in the bending of the foot upon itself. The latter movement takes place at the transverse tarsal joint, between the astragalus and navicular bones, and is followed by adapted atrophy and shortening of the structures in the sole of the foot, producing the contraction of the longitudinal arch, and a general shortening of the foot, exhibited in Fig. 2. This exists to an

extreme degree in the paralytic cases above mentioned, in which the foot is completely bent upon itself backwards as shown in Figs. 7 and 8.

I had under my care at the hospital, in the year 1866, a boy with talipes equinus, in whose foot the contraction of the arch was commencing. The case was one evidently depending upon partial paralysis of the anterior muscles; and when the foot was examined without any weight being thrown upon it, presented the ordinary appearance of a raised heel, and contracted arch, as shown in Fig. 10; but when the boy stood upon the foot, the appearance of contraction of the arch vanished, and the heel came fully to the ground. The mobility of the anterior portion of the foot from the transverse tarsal joint, was remarkably increased; and, in consequence of the loss of power in the muscles, the anterior portion of the foot fell by its own weight, but could be easily restored, nearly to its natural position, as shown by the dotted line *a a*, in Fig. 10. Slight contraction of the arch, however, had taken place, and the tendo Achillis was somewhat contracted, but not enough to require division. I treated the case mechanically, by the use of the Scarpa's shoe, and the existing amount of contraction was overcome without difficulty.

FIG. 10.

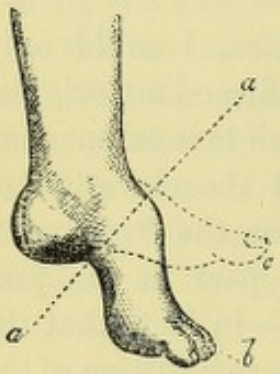

Case of Talipes Equinus in a boy. The deformity depending chiefly upon the foot being bent upon itself from the transverse-tarsal joint, indicated by the line *a a*. The flexibility at this joint was such as to allow of the foot being easily brought to a right angle with the leg, as indicated by the dotted outline *c*. Only slight contraction of the plantar fascia and the tendo Achillis had taken place.

The *metatarsal bones* in talipes equinus approach to a vertical position as represented in Fig. 8, in proportion to the duration and increase of the deformity. In the more severe forms, they are also separated from each other laterally towards their distal extremities, thus increasing the breadth of the foot at the part through which the weight of the body is directly transmitted to the ground.

In the completely paralytic cases above mentioned, the

metatarsal bones may pass beyond the vertical position in a direction backwards, and occupy a position at right angles to the axis of the leg, as shown in Fig. 7. In these cases the weight of the body is transmitted to the ground directly through the head of the astragalus and the other tarsal bones.

All the bones are found to be light, thin-walled and atrophied in cases of long standing, and especially those of paralytic origin. Their cancelli are enlarged, and filled with oily matter. These conditions are obviously the result of defective nutrition and disuse.

Cartilage. The articular cartilage on the exposed and extruded portions of the articular surfaces becomes thinned, and completely removed at the articular borders, exposing the osseous surfaces. In severe cases of talipes equinus in the adult, I have found the cartilage removed from the anterior portion of the superior and lateral articular surfaces of the astragalus, and the superior portion of the head of the astragalus; and also in some cases the inferior portions of the heads of the metatarsal bones.

Ligaments. The ligamentous structures in front of the ankle-joint, and on the dorsal aspect of the foot—especially the ligament between the astragalus and navicular bone—are found to be elongated in proportion to the degree and duration of the deformity; whilst those on the plantar aspect of the foot are contracted and shortened to a corresponding extent. The structural shortening and adaptation of the ligaments in the sole of the foot connecting the tarsal bones—especially the calcaneo-cuboid and calcaneo-scaphoid ligaments, and the plantar-fascia—always correspond to the severity and duration of the deformity, and offer the greatest resistance to its removal. The lateral ligaments of the ankle-joint are also elongated in their anterior portions, and contracted at their posterior borders. The posterior ligaments of the ankle-joint become structurally shortened, in adaptation to the altered relations of the os calcis and tibia, which, in severe cases, are in contact at the ankle-joint.

Muscles. The condition of the muscles varies essentially

as the cause producing the deformity, whether it be paralysis, spasm, or position; and is also in some degree dependent upon the duration of the deformity. The muscles will be found to present every possible deviation from the standard of health, through all the changes of fatty degeneration, and some other obscure structural changes, to the complete destruction and removal of their proper tissue, in place of which fatty matter and fibrous tissue are chiefly substituted. The changes of fatty degeneration are most marked in the cases of paralytic origin.

In spasmodic cases, even of many years duration, the changes of fatty degeneration appear to be very slowly and imperfectly developed; I have not seen any evidence of a distinct fibrous degeneration, or development of new fibrous tissue in the spasmodic cases, as described by M. Guérin. The muscular fibres in some of these cases are found to be of variable size, presenting some peculiarities, such as a brittleness, and disposition to break into short lengths.

In several examples of extreme fatty degeneration, and complete removal of the normal muscular tissue, I have seen a few minute muscular fibres about 1-1800th of an inch in diameter, with striæ well developed; adipose tissue, occurring as a double row of fat cells, existing in the neighbourhood of these small muscular fibres, which the late Mr. Quekett considered to be either of new development, or else fibres that had never attained their normal size. All these appearances are shown in Plate XII, Vol. III. of the "Transactions of the Pathological Society," published in 1852, and described in a tabular form.* The condition of every muscle of the leg is described separately in three examples of non-congenital club-foot, which were most carefully examined by Mr. Quekett and myself, with the view of determining the connexion between the different structural changes and the physiological conditions upon which they depend. I have since confirmed the general results given by several dissections and examinations, of recent specimens. Two of the specimens above

* This Plate has been added to the present Essay, see Plate VI., and a description of the muscles examined will be found in the Appendix, Note 3.

alluded to I obtained from the dissecting-room of St. Thomas' Hospital, and are now in the Museum, and one was kindly placed at my disposal by Mr. Partridge.

The contracted muscles which, in talipes equinus, become permanently shortened by adapted atrophy, are principally the gastrocnemius, soleus, and plantaris, in the calf of the leg, producing elevation of the os calcis; and the short flexor in the sole of the foot producing and keeping up the contraction in the longitudinal arch. In this condition the plantar fascia is also contracted. In severe cases of long standing, the deep muscles, both in the leg and sole of the foot become somewhat shortened; but it does not appear that they do so to an extent to prevent restoration of the foot to its natural form and position by mechanical means, after division of the tendo Achillis.

Tendons. The tendons are altered in direction rather than in their relations to each other and to the vessels and nerves, in proportion to the severity of the case. These deviations are not, however, of any surgical importance, as they occur in tendons which do not require division. The tendo Achillis, the only tendon requiring division, remains unaltered in its direction.

PATHOLOGY.—Talipes equinus is, with very rare exceptions, a non-congenital affection. It is often said to be of congenital origin by parents, but upon close inquiry we generally learn that it was not observed until the child began to put its feet to the ground.

Orthopædic authorities differ as to the congenital origin of talipes equinus. Mr. Tamplin discredits its congenital origin, and states that no example of the kind has fallen under his observation. Dr. Little, on the other hand, states that he has witnessed two cases; Mr. Brodhurst also states that he has seen one or two cases, although the case in illustration, figured in his work on club-foot certainly admits of question; and, from the direction of the toes and general aspect of the foot, appears rather to be an example of congenital deficiency of the anterior muscles of the leg, a condition of which I have seen about ten or twelve examples.

The most reliable case of congenital talipes equinus that has fallen under my observation is that represented in Fig. 11, and occurred in a child brought to me by Mr. Topham of the Caledonian Road. There was not the slightest tendency to inversion, and the case was one of true talipes equinus, with contraction only of the tendo Achillis, or rather muscles of the calf. Both the mother and nurse told me they were sure the child was born with the foot in that position, although it was less marked than when brought to me. The nurse said the foot did not bend like the other foot; that it was stiff at the ankle-joint, but had no inclination to turn laterally. They did not, however, think it of sufficient consequence to draw the attention of the surgeon to it, until the child was three or four weeks old.

FIG. 11.

Case of congenital Talipes Equinus.

It is quite true that this deformity was not observed by the surgeon at the time of birth, but still the evidence of the congenital origin in this case is, I think, sufficient to warrant it being classed as a congenital deformity.

I have seen two other instances of pure talipes equinus in infants and from the account given in these cases of the deformity being seen very soon after birth, I have classed them as cases of congenital equinus. I have also seen several cases in which the tendency to inversion has been so slight, and without sufficient contraction of the tibial tendons to require division, that the surgeon might class such cases either with equinus, or varus, according to his inclination. In these cases, the equinus portion of the deformity has been well marked, and accompanied with rigid contraction of the tendo Achillis requiring division, so that there can be no doubt of the equinus being the predominating portion of the deformity. In my opinion, therefore, talipes equinus does occur, although very rarely, as a congenital affection.

Talipes equinus is by far the most frequent non-congenital deformity, constituting nearly one half the cases of non-

congenital origin, as will be seen by reference to the following table, extracted from a statistical account of 1780 cases of deformities of the feet, congenital and non-congenital, which had been treated at the Orthopædic Hospital up to the year 1851.* Out of these 1780 cases, there were 1016 of non-congenital origin, and 999 were distributed as follows:—

Talipes equinus	401
Talipes valgus	181
Talipes equino-varus	162
Talipes calcaneus, and calcaneo-valgus	110
Talipes equino-valgus	80
Talipes varus	60
Talipes varus of one foot, and valgus of the other	5
Total .	999

NUMERICAL IMPORTANCE.—In a tabulated report of 3000 cases of various kinds of deformities treated by the late Mr. Lonsdale and myself at the Royal Orthopædic Hospital in three years, and published by Mr. Lonsdale in the "Lancet," 1st September, 1855, 495 cases of club-foot are recorded, and of these 170 were cases of talipes equinus. This deformity occurs most frequently in the right foot; next in frequency the left foot is affected; and least frequently it occurs in both feet.

ETIOLOGY.—Talipes equinus, in its ordinary non-congenital form, may be produced by any of the causes previously enumerated as producing non-congenital deformities, and which act either by *indirectly affecting the ankle-joint* through the muscular system, as spasm, paralysis, wounds of muscles, scrofulous abscesses in the course of the muscles, and in the neighbourhood of the joint, long retained position, &c.,

* "Introductory Lecture," by R. W. Tamplin. *London Medical Gazette*, October, 1851.

or by *directly affecting the joint*, as chronic inflammation, scrofulous disease, rheumatic and gouty inflammation of the joint, injuries, &c.

Spasm and Paralysis. Spasmodic and paralytic affections are by far the most frequent of the above-mentioned causes of talipes equinus; but from the variable amount of attention which has been paid to this subject by those who have reported the cases—as well as the different ways in which many of these cases have been interpreted, when seen several years after the attack, either of spasm or paralysis—there is some difficulty in ascertaining the relative frequency of these causes in the production of the deformity.

Thus, in the table above referred to, Mr. Lonsdale has reported that out of 170 cases of talipes equinus, 103 were of spasmodic, and 53 of paralytic origin. In the latter class the paralysis still existed; of the fourteen remaining cases, seven were of traumatic origin, and seven are described as cases of contraction of the plantar fascia. In a larger number of cases reported by Mr. Tamplin, it is stated, that out of 401 cases of talipes equinus, 53 only were of spasmodic character, as judged of by the existing condition of the muscles, and 104 of paralytic origin, the paralysis still existing. This leaves 244 cases without any cause assigned; but Mr. Tamplin states that in these, the muscles were either healthy, or at least did not exhibit any marked spasmodic or paralytic condition.

The relative proportion of the paralytic cases, *i.e.*, cases in which paralysis existed at the time they came under observation, it will be seen, remains but little disturbed by the increase of numbers, viz., about one-fourth of the whole. The material difference exists with respect to the spasmodic cases, and for the following reason. Those cases which did not exhibit any paralysis or other obvious cause, Mr. Lonsdale considered as cases of spasmodic origin, believing that to be the most probable explanation of the deformity; but Mr. Tamplin entered the cases strictly according to the state of the muscles at the time seen, whether spasmodic, paralytic, or healthy; and this leaves us the large number of 244 cases

out of 401, in which the muscles were in a healthy, or nearly healthy condition, *i.e.*, capable of resuming their functions after the cure of the deformity.

With regard to the latter class of cases, viz., those reported in which the muscles were in a healthy, or nearly healthy condition, my opinion is, that they are chiefly the result of slight attacks of infantile paralysis, in which only a few muscles have suffered, and in which recovery, more or less complete, has taken place; the paralysis being a transient, and the consecutive deformity a persistent condition. These cases I have arranged in Class IV, described in the previous chapter. This opinion is founded upon a careful analysis of a large number of these cases, and, therefore, in reference to the relative frequency of spasmodic and paralytic affections, as causes of deformity, experience induces me to think, that in a large proportion of all the cases we meet with in practice, paralysis lays the foundation of the mischief.

Wounds. Sabre-cuts, or punctured wounds of the gastrocnemius muscle, by inducing a state of inflammatory infiltration, and retraction of the muscle, sometimes cause deformity, such as talipes equinus. When the nerve-trunks are divided in such wounds, the case may be classed with paralytic deformities of traumatic origin; at any rate, the case becomes one of a mixed character.

Abscesses. Talipes equinus is sometimes produced by the inflammatory retraction of the muscles and other tissues consequent upon chronic abscesses, generally of a scrofulous character, occurring in the course of the muscles of the calf of the leg, and in the region of the ankle-joint. Many of these abscesses are essentially subcutaneous, and unconnected with diseased bone; but others lead down to superficial scrofulous caries, or necrosis.

In many of these cases the joint is free from disease; but the rigidity of its contraction, in consequence of the nature of the structural changes, renders it impossible to say, at a late stage, whether soft, or even bony anchylosis, has or has not occurred. Experience proves, however, that they generally

yield to division of tendons, and slow mechanical extension, of which Case XI. in Appendix forms a good illustration.

Inflammatory infiltration, and induration of all the tissues are produced by these chronic strumous affections: and abscesses which form in the neighbourhood of the joint and tendons surrounding it, often remain open for several years. The muscles are always damaged to a considerable extent by a process of atrophy, induced by the effusion of lymph, between the muscular fasciculi, and its development into fibroid tissue; a condition which has been described as "inflammatory retraction," is the result, and operates as the immediate cause of the deformity, which is increased and rendered more rigid by the adapted atrophy, and shortening of the ligaments.

Position. Another cause of deformity is to be found in long-retained position, by which a state of adapted atrophy is induced in the muscular and ligamentous tissues; so that joints which have remained in one position for a length of time, as occasionally happens under a variety of circumstances, become stiffened, and more or less deformed. Structural changes of degeneration in the muscular tissue take place slowly under these circumstances, as compared with the paralytic cases, because the nutrition of the limb is much less interfered with.

Causes directly affecting the joint. Amongst other causes which operate in the production of this deformity, are chronic inflammation of the joint, scrofulous disease, rheumatic and gouty inflammation, injuries, &c. Inflammatory infiltration is induced as a result of these conditions, and followed by adapted atrophy of the ligaments, synovial membrane, and areolar tissue, immediately surrounding the joint. In some cases destructive disease of these tissues, and of the cartilages and bones follow to a greater or less extent.

Anchylosis, or immobility of the joint affected, generally terminates these conditions. Long experience in the treatment of these cases has convinced me that bony anchylosis is a muchless frequent result of inflammatory mischief, either in the ankle, or any other joint, than is generally supposed. Soft or partial anchylosis is certainly the rule,

especially after strumous diseases, which so frequently terminate in deformity. In the cases following chronic rheumatic inflammation, and, in some cases, directly resulting from external injuries, there is a greater disposition to bony anchylosis; and if this does not occur, a much more rigid and unyielding form of contraction results, than in the other cases enumerated.

PROGNOSIS. In cases of talipes equinus, the prognosis must have reference to two distinct points, viz., the cure of the deformity; and the probability of the patient gaining complete voluntary power over the foot, and the muscles of the lower extremity, many of which are frequently involved in the paralytic or spasmodic affection, of which the deformity is the result.

The prognosis may be favourable with regard to the cure of the deformity, except when bony anchylosis has taken place—a very rare condition. The age of the patient, and length of time the deformity has existed, will, of course, influence the duration of the treatment, extending the time from six weeks, which is generally sufficient in young people, to three or four months in some rigid cases in the adult. I have succeeded in curing this deformity in patients above 60 years of age; and a gentleman upon whom I operated for equino-varus, and whose case is detailed in the Appendix, Case V., was 54 years of age.

As regards the deformity, then, age will not interfere with our giving a favourable prognosis. We may confidently undertake to remove the deformity; and with it, of course, all lameness and other inconveniences which depend upon the abnormal mechanical relations between the foot and the leg.

As to the probability of the patient gaining complete voluntary power in the foot, and usefulness of the limb, after the cure of the deformity, the prognosis must be guided by a variety of circumstances, more especially bearing in mind the cause producing the deformity, whether indirectly or directly affecting the articulation. In the former class, which are principally of spasmodic or paralytic origin, more particularly

must the diagnosis depend upon the number of muscles involved, and the precise condition of such muscles.

When talipes equinus is the result of a wound in the calf of the leg, injuring the gastrocnemius muscle, it is often observed at the time the case comes under treatment for the deformity, that the muscle retains its voluntary power, although structural shortening has taken place; and if sufficient time has elapsed for the inflammatory infiltration to clear off, the contractile power of the muscle is found to be not much impaired after the cure of the deformity; so that the control over the foot is sufficiently perfect to render mechanical support unnecessary. The prognosis in these cases will, therefore, generally be favourable, both with respect to the removal of the deformity, and the restoration of power.

When talipes equinus is produced by scrofulous abscesses occurring in the course of the muscles and neighbourhood of the joint, but not implicating the joint, the prognosis may be favourable as regards the removal of the deformity; but the opinion must be guarded and uncertain with respect to the restoration of free motion and voluntary power, in consequence of the inflammatory infiltration and degeneration of muscular tissue which accompany this condition; and also in consequence of some uncertainty as to the exact condition of the joint. The patient may, however, obtain a very useful amount of motion in the ankle-joint, as well as of voluntary power.

When talipes equinus is the result of long-retained position, there is nothing to interfere, either with the removal of the deformity, or perfect restoration of voluntary power. The deformity is never severe when free from other complications; neither does degeneration of the muscular structure occur to any considerable extent, so that the prognosis may be in all respects favourable. These cases, however, are amongst the least frequent we meet with in practice.

In cases of the second class produced by *causes directly affecting the joint*, such as scrofulous or rheumatic inflammation, injuries, &c., the prognosis must be guided by general surgical principles; but will, of course, mainly depend upon the extent

to which the joint itself, or structures immediately surrounding it, may have been destroyed, or modified by the diseased action of which the deformity is the result.

In the majority of these cases the deformity may be removed; but the restoration of free motion and voluntary power is out of the question.

Bearing in mind the relative frequency of bony and soft anchylosis, the prognosis in these cases may be more favourable than might be expected, because we find that the soft anchylosis yields to tenotomy, and well-regulated mechanical extension, without danger of creating fresh mischief in the joint, necessarily attending the method of forced rupture.

In cases following chronic rheumatic inflammation, and in some cases directly resulting from injury, the prognosis must be less favourable, as there is a greater disposition to bony anchylosis; and the condition of the parts surrounding the joint is frequently unfavourable to the recovery of free motion.

CHAPTER VII.

TALIPES EQUINUS CONTINUED; TREATMENT—TALIPES EQUINO-VARUS AND EQUINO-VALGUS; THEIR PATHOLOGY AND TREATMENT.

TREATMENT.—The treatment of talipes equinus is essentially both operative and mechanical; but in many cases—especially those of long duration, in which the adapted structural changes affecting the ligaments, and deeper textures are considerable—it is necessary to combine with these the physiological treatment, by which is meant active and passive exercises, shampooing, &c. It is useless to try mechanical treatment alone, except in cases of very slight and recent contraction, and even in these it will be found much more efficient in combination with passive exercises and shampooing.

Tendons, &c., requiring division. The only important tendon requiring division, is the tendo Achillis, with its small accompanying tendon, the plantaris. The latter is generally included in the section of the tendo Achillis, but sometimes, especially in spasmodic cases, yields before the knife without division, and may be felt as a tense little cord, which had better be divided by the reintroduction of the knife. In one instance when I left the plantaris, thinking it might be only the edge of the sheath, the patient was troubled with severe twitching and spasm, and on the third day it suddenly ruptured during an extremely violent and painful spasm.

In many cases, it is also necessary to make a free division of the plantar fascia and short flexor muscle, in the sole of the foot. In the more severe cases, in which the arch of the foot

is much increased, this had better be done as a separate stage of treatment, before dividing the tendo Achillis, which serves the purpose of fixing the os calcis. A firm resistance is thus offered to the pressure exerted against the anterior portion of the foot to expand, or, as it were, unfold the arch of the foot from the transverse tarsal joint, the mechanical centre of motion in this part of the deformity.

In the historical sketch, given in the first chapter, the account of the mode of dividing the tendo Achillis, adopted by Sartorius in 1806 was narrated. The preliminaries consisted in bandaging the leg, applying a graduated compress and tourniquet to the femoral artery, and administering fifteen minims of tincture of opium with a glass of wine to the patient. An incision, four inches in length, was made over the tendon, which was then carefully dissected, and the fascia divided on a director to the same extent. The tendon was then cut across.

The contrast between the violent, dangerous, and unscientific procedure, which we are told was also adopted by other surgeons, and the very simple operation by which we now divide tendons—characterized equally by its simplicity, freedom from danger when skilfully performed, and scientific character—is, indeed, a contrast, for which we are mainly indebted to Stromeyer.

If, at the present time, tenotomy is occasionally followed by some local inflammation, it is because the value of the true subcutaneous character of these operations is not yet fully appreciated. I have been occasionally present, when the operation has been commenced well, the puncture and size of the knife being sufficiently small; but by the time the tendon was divided, the puncture has been increased at least two or three times its original size. By such a procedure, the true subcutaneous character of the operation is immediately lost, and the chances of inflammation proportionably increased.

In order to avoid this accident, it is usually recommended that a knife should be used, which only cuts for about five eighths of an inch from the point, the rest being blunt and rounded. This precaution may be useful to those who are unaccustomed to such operations, or have but little tact in

operating; but I have seen a large tendo Achillis scratched through, rather than cut by such a cautious knife. To divide a tendon cleanly aud quickly, a cutting edge should be used, considerably longer than the breadth of the tendon. The cutting edge I use for an adult, varies from an inch to an inch and a quarter in length.

Mode of dividing the tendo Achillis. Before dividing the tendo Achillis, the patient should be placed on his stomach, with the foot hanging over the edge of the table, or bed; then let an assistant put the tendon on the stretch by endeavouring to flex the foot, whilst the leg is kept in an extended position. He must be prepared instantly to relax this tension, as the section of the tendon is completed. Then introduce the tenotomy knife with its flat surface parallel with the tendon, close to its inner or outer edge, as most convenient, when the tendon is prominent; but when the tendon is deep, and always in cases of varus in infants, the safest plan to avoid the possibility of puncturing the posterior tibial artery—an accident which I have seen occur—is to enter the knife on the fibula side of the tendon.

The knife should be passed in a direction *obliquely downwards* keeping the point close to the tendon, beneath which it may then be carried to the opposite side, and in this movement the handle should be depressed to a horizontal direction. Now turn the cutting edge towards the tendon, and divide it transversely, from the internal to its external surface. A most important lever-advantage in cutting the tendon will be gained by this method, and at the same time all risk of enlarging the cutaneous puncture will be avoided, as the pressure at this point is rather on the back than the edge of the knife.

If the knife be held *horizontally*, and entered at the lateral aspect of the tendon, considerable difficulty may be met with in dividing a tough Achilles tendon, because the tendon is thus operated upon mechanically to the greatest disadvantage; the tendon yields before the knife without division, and I have seen a surgeon in despair of cutting it, change his knife, which undeservedly he blamed, introduce a new one, and only then, after

much perseverance, succeed in dividing the tendon by scratching with the point of the knife directed upwards, whilst the handle is depressed to a corresponding extent. In such a procedure, the cutaneous puncture is generally much enlarged, and a risk of subsequent inflammation incurred.

Tendons cannot be divided with safety to the patient, unless divided neatly, quickly, and without disturbance to the surrounding tissues, and the puncture should never exceed an eighth of an inch in length. In infants, the tendons readily give way before the direct pressure of a sharp knife, in the movement just described, but in adults, a little cutting manipulation is required.

The division of the tendon is indicated by a sudden and audible snap when the muscular structure is in a healthy, or nearly healthy condition, as in the infantile cases, and those of spasmodic origin; a perceptible separation of the divided ends of the tendon also occurs, leaving a gap at the seat of operation. When atrophy and degeneration of the muscular structure has taken place, as in cases of paralytic origin, and in those of adult varus, no audible snap occurs; and in the latter class of cases, as well as in those of the most severe form at younger ages, the separation of the divided ends is extremely slight, in consequence of the condition of the muscles, and the ligamentous rigidity of the joint.

Hemorrhage does not necessarily follow the division of the tendo Achillis. I have frequently divided it, and sometimes in two or three successive cases, without even staining the knife with blood; this depends very much upon the care with which the point of the knife is kept close to the tendon. When carefully performed, it is rare to see more than two or three drops of blood follow this operation.

The moment the knife is withdrawn, the wound should be covered with the finger, and a small compress of lint applied, and held in position by a strip of adhesive plaster. This prevents effusion and infiltration at the seat of the wound. Then bandage the foot and leg up to the calf, and bind the foot to a padded splint adapted to the deformed shape of the

foot, in the same position in which it was before the operation; a splint made of tinned sheet-iron is most useful, as it can readily be bent to any shape required. In talipes equinus, a nearly straight splint should be applied along the dorsum of the foot, and in front of the ankle-joint.

The tendo Achillis is recommended by some surgeons to be divided by passing the knife flatways between the tendon and skin, and then cutting through the tendon from behind forwards. The Edinburgh School generally adopt this method, and it has been recommended by Liston, Syme, and Sir W. Fergusson; but I very much prefer the mode just described.

There is a liability to accidents in both plans. In dividing from within outwards, the skin may be cut through, and a large open-wound result, which I have seen occur two or three times. This may arise either from a too rapid and incautious operation, or from the assistant not being on the alert instantaneously on the division of the tendon, to relax the pressure he is making on the foot; this accident may also occur in the event of a spasmodic contraction of the anterior muscles taking place, when the assistant does not instantly control this by a strong counter-effort of extending the foot. While, therefore, the assistant is using force in one direction, he must be prepared suddenly either to cease, or to reverse the effort in an opposite direction. Close adhesions between the tendon and skin, either the result of a previous division, or inflammatory mischief which may have produced the deformity will especially increase the liability to this accident.

The posterior tibial artery may be punctured in dividing the tendo Achillis from without inwards, an accident which I once saw occur in a boy twelve years of age, and the jets of blood left no doubt as to the nature of the accident. The case, however, ultimately did well, pressure being employed to control the hemorrhage.

After the operation, the patient should rest for the remainder of the day, with the leg on a pillow in a flexed position, and the foot should be kept warm, especially if its temperature

is below the natural standard, as it always is in paralytic cases.

On the following day, the patient may walk about with the assistance of a pair of crutches, if able to do so, and no further confinement will be necessary. On the third or fourth day, the Scarpa's shoe, or other apparatus intended to be employed, should be applied.

Division of plantar fascia. The longitudinal arch of the foot becomes much contracted in some cases of talipes equinus and produces a shortening of the foot, with a deep concavity in its sole, as exhibited in Fig. 2. This becomes a permanent condition in consequence of contraction of the plantar fascia, and of the short flexor muscles, as well as the deep ligamentous structures in the sole of the foot. For the removal of this contraction, it is necessary to make a free division of the plantar fascia, and also of the subjacent muscles in severe cases.

The ordinary practice is to perform this operation at the same time as the division of the tendo Achillis, and subsequently to expand the arch of the foot, by direct pressure downwards, applied on the convexity of the arch, or dorsum of the foot, by means of a soft pad, held in position by the transverse strap of the Scarpa's shoe. When the cases are severe, this is sometimes assisted by resorting to a transverse joint made in the sole of the Scarpa's shoe, and a cog-wheel joint arranged externally, so that an upward pressure may also be applied. Practically this will be found the most tedious, troublesome, and painful part of the treatment, for long continued pressure is not easily borne on the dorsum of the foot.

The practice of dividing the Achilles tendon and plantar fascia at the same operation may be continued in slight cases; but many years ago it appeared to me to be advisable to make the division of the plantar fascia a separate stage in severe cases, and one which should be completed before the division of the tendo Achillis.

I proposed to apply the mechanical extending force to the anterior part of the sole of the foot, and in so doing to make use of the contracted state of the tendo Achillis as a means of

fixing the posterior extremity of the arch of the foot, so as to afford sufficient resistance to the force employed anteriorly. In this method, the fulcrum must be placed exactly over the anterior surface of the ankle-joint, by means of the oblique heel strap of the Scarpa's shoe, beneath which a soft pad should be placed. Pressure can be borne much better in this position than on the dorsum of the foot, and the arch is expanded or unfolded, much more quickly, and in a more satisfactory way. The first case in which I adopted this practice was one I operated upon the 29th May, 1854. The foot was shortened to an extreme degree, and the plantar fascia much contracted. The case was one of congenital varus, and after it had been brought into the position of talipes equinus, the severity of the plantar fascia contraction induced me to make its removal a separate stage in the treatment, on the principle above explained. The result was completely successful, as shown in Case XIII, Appendix, and since that time I have adopted the practice in all severe cases of contraction of the plantar fascia.

In some comparatively rare cases, the division of the plantar fascia is the only operation required, the deformity of the foot being unaccompanied by any contraction of the tendo Achillis. In such cases, which may be either congenital or non-congenital, the feet are short and much arched; the prominence of the instep amounts to a deformity, and a deep contraction in the sole of the foot is readily detected. Sometimes, however, it is the inner and lateral band of the fascia which is chiefly contracted, the foot having an inverted form—a pigeon-toed appearance—differing from varus, in that the sole of the foot, in the erect position, is more or less in contact with the ground; and also in the absence of the distinct muscular contractions and displacement of bones, which constitute the essence of the latter deformity.

The treatment of these cases is often tedious and troublesome, but by steady perseverance in the use of the Scarpa's shoe, after a free division of the plantar fascia, the deformity may be cured.

Severe contractions of the toes frequently coexist with talipes equinus, and sometimes give rise to the more serious incon-

veniences which accompany this latter deformity. The different directions in which the toes become contracted are represented in Figs. 2 and 4.

It might be supposed that separate operations are necessary for the removal of these contractions, but this is rarely the case. The division of the tendo Achillis, and the restoration of the foot to its rectangular position with the leg, exerts a most important influence in removing these contractions, by relieving the stretching and tension to which the anterior muscles are subjected by the elevation of the os calcis.

Exerting a slight pressure on the toes by the aid of pads and straps after division of the tendo Achillis, their contracted condition can be overcome during the time occupied in restoring the foot to its natural form. The division either of the flexor or extensor tendons of the toes, or of both in severe cases of long standing may, however, become necessary.

Cases are sometimes met with in which all the toes are contracted, with or without contraction of the plantar fascia, and with only very slight contraction of the tendo Achillis; not more than the right angled contraction previously adverted to. This condition gives rise to considerable inconveniences; the irritation produced by boots or shoes on the prominent parts of the toes, seriously interfering with walking exercise, and the treatment necessary is somewhat peculiar.

If the extensor tendons be divided in front of the ankle-joint, the deformity may be cured for a time, but will probably return. A sanction to the division of the tendo Achillis for this condition would be given by few surgeons; but for the permanent cure of the case we find it absolutely necessary when the foot cannot be flexed beyond a right angle, and therefore I advise its adoption, either with or without the division of the extensor tendons, according to circumstances. It is, however, seldom necessary to divide the tendo Achillis in children, or young people, as, during growth, sufficient elongation can generally be obtained by gradual mechanical extension made by a Scarpa's shoe.

The operative treatment of talipes equinus must, as I have

shown, vary according to the degree of deformity, and also according to the complications which may happen to exist, and must be followed by mechanical treatment.

It is assumed as an established fact, that the after-treatment should be most carefully conducted by the aid of mechanical appliances, although the contrary opinion may still be held, and was publicly taught by the late Professor Syme, of Edinburgh, who, after dividing the tendo Achillis, even in paralytic cases, allowed the patient to walk on the second or third day. How can it be imagined that the reparative process in the divided tendon is sufficiently advanced on the second or third day to admit of exercise of the joint being resumed with advantage? Yet Mr. Syme observes that after the operation the "bandage will be kept on for forty-eight hours, when no further treatment will be required, as the use of the limb in walking will be sufficient to bring the foot into its natural form," and he relates several cases in illustration of this practice.* However, the serious results which follow this procedure have been previously adverted to, such as non-union, or an extremely weak and elongated condition of the tendon, rendering the foot much less useful to the patient than before, and hopelessly incurable.

Mechanical treatment of Talipes Equinus after operation.

In the treatment of talipes equinus, mechanical extension should be commenced on the third day after the operation in infants, and also in persons of more advanced age, provided the nutrition of the leg is unimpaired; but in paralytic cases it should not be commenced until two or three days later. By that time the cutaneous puncture will be healed, although this should not regulate the practice, so much as the probable activity of the reparative process.

The apparatus by which gradual mechanical extension is made for the purpose of restoring the foot to its proper position, is that still known as the Scarpa's shoe, although it has been in course of time so materially altered and modified, that as

* See "A Clinical Lecture on Tenotomy," in the *Lancet*, March 17, 1855.

now constructed it possesses, but little resemblance to that invented by the distinguished surgeon whose name it bears.

The foot should be bandaged and placed in a Scarpa's shoe, having a joint moving in the direction of flexion and extension, corresponding to the ankle-joint, and regulated by a cog-wheel and screw. If any lateral inclination of the foot exists, a second

FIG. 12.

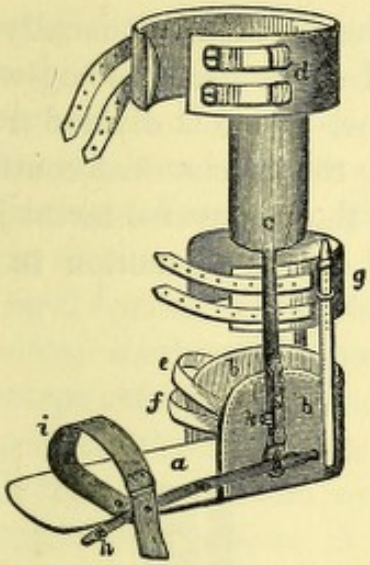

Scarpa's shoe now used at the Orthopædic Hospital.

FIG. 13.

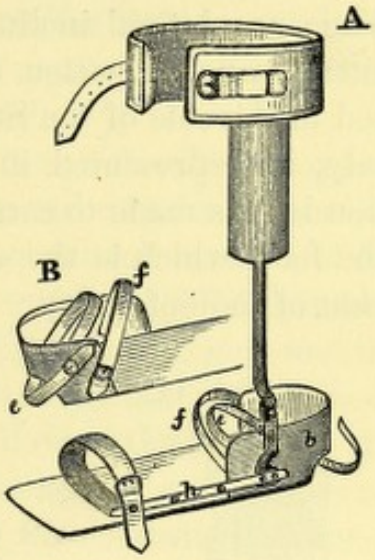

Scarpa's shoe as modified by Mr. Adams.

Fig. 12.—*a*. Sole-plate of iron, covered with leather. *b. b.* Heel-plate attached to *a*. *c*. Perpendicular bar, with a padded side-plate fixed to its upper part. *d*. Circular strap, containing a semicircular steel plate in its posterior half, which holds the perpendicular steel in its fixed relation to the leg. *e. f.* Straps by which the heel is held firmly in the shoe. *g*. Circular strap fastened above the ankle, and connected to the heel-plate by two straps, to assist in holding the heel firmly down. *h*. Horizontal steel spring fixed to the heel-plate. *i*. Strap which passes round the anterior part of the foot and draws it outwards towards the horizontal spring *h*. *k*. Cog-wheel by which the flexion and extension movements of the foot from the ankle-joint are regulated. 1. Cog-wheel, by which inversion and eversion of the foot are to some extent commanded.

Fig. 13.—A. and B. The parts modified are lettered to correspond with Fig. 12. The circular ankle strap, *g*, is dispensed with as useless. *b*. The heel plate is much diminished in size, to avoid pressure in lateral movement. *e*. This heel-strap has its power greatly increased by passing directly backwards through an aperture in the heel-plate and sole, instead of transversely across the front of the large heel-plate, as in Fig. 12. The aperture is also useful, in enabling us to ascertain whether the heel is in its place. *h*. A straight bar is substituted for a spring; it acts as well, and is less in the way.

cog-wheel joint placed opposite the ankle, and moving in the direction of inversion and eversion is generally employed, as shown in Fig. 12. This apparatus is the one in use at the present day at the Royal Orthopædic Hospital, and was first adopted by Mr. Tamplin, whose name it bears.

About sixteen years ago (see Medical Times and Gazette. March 29th, 1856), I introduced the modifications repre-

sented in Fig 13 in reference to the arrangement of the straps, and the straight side-spring. The central, or ankle joint-strap passing through a hole in the heel-plate, I have found so useful in practice, that I still continue it; but a single cog-wheel at the ankle-joint moving in the direction of flexion and extension is the only movement necessary in the Scarpa's shoe, when used for cases of equinus.

When any lateral inclination of the foot exists, usually inversion or an inclination to varus, I make use of a cog-wheel placed in the sole of the Scarpa's shoe, which is divided transversely, as represented in Fig. 14; the mechanical centre of motion is thus made to correspond to the transverse tarsal joint in the foot, which is the anatomical centre of motion in this portion of the deformity.

FIG 14.

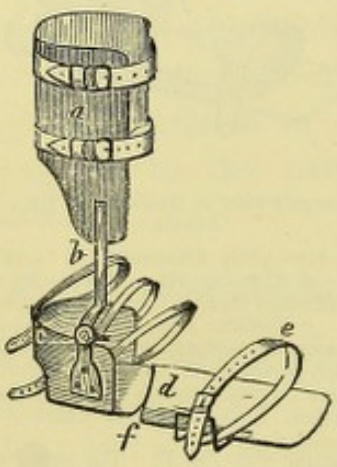

Scarpa's shoe modified by Mr. Adams with a transverse division in the sole-plate, corresponding to the transverse tarsal joint in the foot, used to control inversion or eversion of the foot.

FIG. 15.

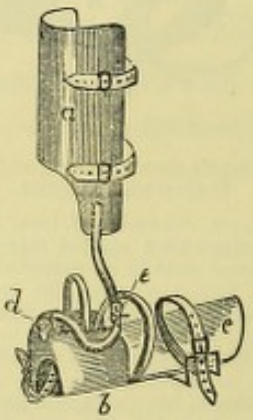

Scarpa's shoe, modified by Mr. Adams with Langaard's addition, in which inversion or eversion of the foot is controlled by a cog-wheel placed behind the heel.

Fig. 14.—*a*. Trough adapted to the calf of the leg, and affording a firmer purchase than the narrow plate generally used. *b*. Steel bar connecting the calf-trough and heel-plate, bent above the ankle, so as to adapt the trough closely to the leg. *c*. Cog-wheel at ankle-joint moving only in the direction of flexion and extension of the foot, which is received and fixed in the heel-plate by three straps, the centre one passing through an aperture at the back and lower part of heel-plate. *d*. Sole-plate moving laterally, so as to raise or depress the margins of the foot, by means of a cog-wheel placed below and in the centre of the transverse division *f*. *e*. Toe-strap passing across sole-plate and connected with a horizontal steel bar attached to outer margin of sole-plate instead of the side-spring of the ordinary Scarpa's shoe. These modifications in the Scarpa's shoe I have employed more recently than those represented in Fig. 13.

Fig. 15.—*a*. Trough adapted to calf of leg. *b*. Heel-plate. *c*. Sole-plate. *d*. Cog-wheel by which the sole-plate is moved so as to elevate or depress the margins of the foot. *e*. Cog-wheel moving in the direction of flexion and extension of the foot. In this apparatus I have added to Langaard's shoe the large trough for the calf, and the horizontal steel bar for the toe-strap, attached to the sole-plate and the arrangement of the straps I now always employ.

It is an error to attempt to overcome the inversion or eversion of the foot (or rather of its anterior portion in front of the transverse tarsal joint, which can only be involved in any such movement), by a cog-wheel acting laterally, and placed opposite the ankle-joint, as in the ordinary Scarpa's shoe, represented in Fig. 12. For the sake of adjustment in very slight cases this may be used; but if any decided degree of inversion or eversion has to be overcome, I never use the so-called *double cog-wheel action* at the ankle-joint. I prefer acting more directly upon the transverse tarsal joint, by means of the instrument represented in Fig. 14, or that shown in Fig. 15.

There are several other alterations in the shoe I employ, such as a horizontal steel bar, placed along and attached to the outer margin of the sole-plate; it acts quite as well as the old form of a steel spring, and is less in the way. I prefer this to the horizontal steel bar represented in Fig. 13, and now use it in all Scarpa's shoes. The heel-plate is much diminished in size, and perforated posteriorly, so as to allow of the principal strap which crosses the ankle, and holds the heel in position, to pass through the aperture. A trough is also substituted for the narrow circular band passing round the calf, and serves to keep the instrument more firmly in its proper relation to the leg.

There is another modification by which the disposition to inversion or eversion may be overcome by means of a cog-wheel acting laterally upon the sole-plate, but placed behind the heel, as shown in Fig. 15. In this apparatus, the cog-wheel regulating the flexion and extension of the foot is placed laterally opposite the ankle-joint, and connected with the former cog-wheel by means of a curved steel bar. The modification was suggested by Langaard, whose name the apparatus bears. I have frequently used it, but in consequence of the liability to break at the curved steel bar, prefer to employ the Scarpa's shoe, with a transverse division in the sole-plate, represented in Fig. 14,

Rate of extension. By means of the Scarpa's shoe described, the foot should be gradually brought into its natural position. The rate at which it is desirable to accomplish this should be

regulated by the activity of the reparative process in the divided tendon; but practically it is often limited by the ligamentous rigidity of the articulation.

In well-nourished infants, the full length required in the divided tendo Achillis should, according to my observation, be obtained in a fortnight, if practicable; in a well-nourished leg in an adult, it should be obtained in from three to four weeks; but in atrophied paralytic limbs it should not be obtained in less than from four to six weeks.

The object of gradual extension is not to elongate or stretch the new material uniting the divided extremities of the tendon, as generally supposed, but to regulate the length of new material, or, as it may be called, the new tendon, whilst we have the opportunity of so doing; and the rate at which this is to be accomplished must have reference to the activity of the reparative process, and to the length of new tendon required.

This important part of the treatment is, therefore, left to the judgment of the surgeon in cases which, from the absence of adapted shortening of ligaments, there is but little resistance; but if this exists, as in some cases of equinus of long standing in the adult, and in severe congenital varus, it will not be possible to proceed at the desired rate; and it may even become necessary to divide the tendon the second time, before the required length be obtained. This was necessary in the adult case of congenital varus detailed in the Appendix, Case XIII.

In the mechanical treatment of talipes equinus, care should be taken to carry the foot beyond the right angle with the leg; in fact, it should be carried to the angle natural to the period of life at which the operation is undertaken. When one foot only is affected, this may be ascertained by comparison with the healthy foot.

A disposition of the foot to turn outwards is observed in some of these cases, towards the end of treatment, so that the foot would assume the position of talipes valgus. This most frequently depends upon the flat form of the sole of the Scarpa's shoe, and the length of time the treatment has occupied. In

other words, it seems to be an effect of the long-retained position imposed by the mechanical treatment adopted. Occasionally it may result from partial paralysis of the anterior tibial muscle, not detected previous to the division of the Achilles tendon; but sometimes it depends upon a disposition to muscular contraction, and when the peronei muscles become tense, Mr. Tamplin recommends their division. I have generally found this disposition to eversion yield to passive exercises, and a slight adaptation of the Scarpa's shoe, by which the sole-plate is turned inwards from the transverse tarsal joint, and the case treated for a few weeks as a case of equino-valgus.

Physiological Treatment.

When the reparative process in the divided tendon appears to be sufficiently perfect, and the required length of new tendon has been obtained—in the tendo Achillis this can be judged of by feeling its continuity—and the foot brought into its natural position by mechanical means, passive motion should be employed, with the object of restoring the functions of the joint, and bringing the muscular and other structures into a healthy condition; and to some extent this will also assist in the restoration of the natural form of the foot.

Passive exercises should be employed during the latter part of the period occupied by the mechanical extension, when this is tedious from the amount of ligamentous resistance, the object in view being not only to prevent the stiffness of the joint, which is always produced by long-retained position, and may even result in another kind of deformity; but to preserve the muscular and other structures in a healthy condition, and to some extent assist in the restoration of the natural form of the foot.

In cases of equinus, the movements required are simply those of flexion and extension of the foot, which in children the parents or nurse can readily accomplish for a quarter of an hour, two or three times a day. The period at which this should be commenced must depend upon the condition of the

foot. When much resistance has to be overcome, I do not advocate the intermission of the mechanical extension employed. In severe contractions, the best result seems to be obtained by constantly applied and well-regulated mechanical extension. The passive exercises, therefore, should be delayed until the case is advancing towards a cure.

In cases where the deformity has been severe, motion is at first always attended with more or less pain, which in children appears to be referred to the neighbourhood of the tendons, or around the ankle-joint; but in adults to the anterior part of the ankle-joint. The pain in the adult cases probably depends upon the edges of the articular surfaces of the bones, which in these cases are more or less denuded of their articular cartilage, coming in contact with each other. In a short time, however, and by cautiously regulating the exercises, this completely disappears, and the functions of the joint are restored if the anatomical conditions admit of it.

When the foot has been thus far restored, the patient may begin to use it in walking; and then, in order to support the ankle-joint, two side steel supports should be attached to the boot, having each a joint, corresponding to the ankle-joint. These side steels are connected above by a narrow semicircular metal plate, which rests against the calf of the leg, and the extremities of the plate are connected by a strap passing across the front of the leg which it thus encircles.

It is not necessary to use this support where all the muscles retain their power, unless a relaxed condition of the ligaments of the ankle-joint and foot should exist, or there should be an inclination to any lateral deviation of the foot.

When paralysis of the anterior muscles exists, these supports are always necessary to prevent the foot falling beyond a right angle with the leg, and, for this purpose, a stop-joint at the ankle must be used. This is generally employed in all cases for the first few months, with the object of preventing recontraction; but I prefer the use of a free-joint, and rely upon exercises for this purpose. If this be attended to, there will be no fear of recontraction.

In reference to the operative and mechanical treatment of talipes equinus, two classes of cases call for special attention, one on account of the cause of the deformity, and the other on account of its degree; I allude,

1st. To the cases of paralytic origin in which the paralysis still continues, and,

2ndly. To the cases of right-angled contraction of the tendo Achillis.

It is the more necessary to make a few observations upon these two classes of cases, because, at the present time, much difference of opinion exists amongst the highest surgical authorities as to the propriety of operative treatment.

The pathology of paralytic deformities has been already described, and the general principles of treatment, applicable to these cases, both in the rigid and flaccid condition of the muscles, have been pointed out. The benefit to be derived from tenotomy and mechanical support, in the most severe form of the latter class of cases, even when both feet are affected, has also been shown, and cases adduced in illustration.

Admitting, therefore, the possibility of benefit in certain cases, the practical question is whether much good will result from tenotomy in the ordinary run of cases met with in practice, viz., those of talipes equinus in children, resulting from infantile paralysis, and in which paralysis still exists at the time when they come under treatment.

Treatment of Talipes Equinus with existing Paralysis.

When contraction of the tendo Achillis (or, rather, of the muscles of the calf), producing talipes equinus, coexists with paralysis, the contraction is easily removed by tenotomy, but surgeons frequently doubt the propriety of the practice, *i. e.*, whether the gain to the patient, under the circumstances of existing paralysis, will be sufficient to compensate for any inconvenience or sacrifice the treatment may involve; whether, in fact, the patient will be materially benefitted by the removal of the deformity. Many surgeons advise that no operation

be performed during the existence of the paralysis, but that we should wait for the return of power. They argue that, after division of the tendo Achillis, the foot swings, and is, therefore, weaker and less useful to the patient than when it is held by the contracted tendon. They consider these patients to be in a better condition with a high-heeled boot, and the persistent deformity, than with the foot, after operation, supported by the mechanical compensation of steel apparatus. Sometimes they even regard this deformity, in which the foot in the position of talipes equinus has the effect of lengthening the leg, as a natural compensation for the shortening of the limb, which always, to some extent, occurs in these paralytic cases. These opinions are erroneous, and for the following reasons.

1st. In the great majority of cases, the paralysis is limited to a few muscles, viz., those on the anterior aspect of the leg, and these are often very unequally affected. When the extensor communis is completely paralysed, the anterior tibial, and extensor pollicis, frequently retain a considerable amount of power; the anterior tibial sometimes escapes altogether, when the other muscles are paralysed; or, on the other hand, it may be the only muscle paralysed.

By allowing the deformity to continue, atrophy is induced or increased in the comparatively healthy muscles on the anterior part of the leg, as well as in the great muscles of the calf, in consequence of the motion at the ankle-joint being either limited, or entirely prevented by the contraction. Thus the muscular structures of the leg are still further damaged by the persistence of the deformity.

2ndly. If, whilst the deformity continues, there should be any return of power in the paralysed muscles, it will not be available, as flexion of the ankle-joint cannot take place. It has been previously stated that complete recovery is the rule in cases of slight infantile paralysis, and that partial recovery is almost constant, and to this circumstance we must refer the large number of cases of talipes equinus we meet with, in which the muscles are in a healthy, or nearly healthy condition, the

foundation of the mischief in these cases having been laid by the partial paralysis of a few muscles. Thus the persistence of the deformity interferes with the natural process of recovery in the paralysed muscles, and prevents the free play of such muscular power as exists. Moreover, in practice, it is found that the restoration of power is materially assisted by the removal of the contraction.

3rdly. Structural changes in the joint, such as thinning and irregular removal of articular cartilage, previously described, and adapted shortening of the ligaments of the joint, take place by the continuance of the deformity, thus rendering the cure more difficult, and less perfect in proportion to the delay.

4thly. The serious effects and inconveniences certain to arise from the continuance of the deformity, when severe, viz., extreme lameness when one foot is affected, and total inability to walk when both feet are affected; curvature of the spine, &c., render it absolutely necessary that the deformity should be removed.

For the reasons above given, it is advisable to remove the deformity when severe, in cases of talipes equinus in which paralysis still exists, whatever may be the extent of the paralysis, and the benefit to the patient will be in proportion to the severity of the case, and the length of time the paralysis has existed; but as respects the ultimate condition of the limb, as to the restoration of muscular power, the gain will be in proportion to the early period at which the operation be performed, after the contraction has become confirmed. No benefit will result from operation in cases of slight contraction with much paralysis.

A judicious selection of cases is therefore necessary in the treatment of this kind of deformity—the degree of paralysis; the degree of contraction; and, to a certain extent, even the circumstances of the patient must be considered; as amongst the poor the neglect of, or inability to carry out the mechanical and other treatment necessary in these cases, will frequently lead to a return of the deformity, so that only the more severe cases should be undertaken where such neglect is likely to arise.

In reference to this class of deformities, in which contraction is associated with paralysis, special attention must be directed to those cases of general infantile paralysis in which both arms, as well as both legs, have been paralysed. In these cases the muscles of the hip-joints as well as those of the spine—in fact, nearly all the voluntary muscles of the body—are sometimes paralysed; and during the paralytic stage, severe contractions and deformities take place, at the ankle, knee, and hip-joints. Surgeons are consulted in these cases, partly on accout of the various contractions mentioned, and partly because the patient is unable to walk.

Judgment is required in selecting the period for operating in these cases of general paralysis; as a rule, the treatment must be delayed until the spinal muscles have sufficiently recovered to enable the patient to sit upright; and the muscles of the hip-joints allow the legs being drawn up, and advanced forwards from the hips, with sufficient power to make use of this movement in progression.

This amount of improvement generally takes place at some period varying from six months to two or three years after the attack of paralysis, and then the contractions, if severe, should be removed by tenotomy, but if slight, by mechanical extension alone; and the patient will, in a few weeks, be enabled to walk with the assistance of steel supports to the legs. In consequence of the difference of opinion existing amongst surgeons as to the treatment of these cases, we frequently see instances in which the treatment has been unnecessarily delayed for many years. The advantages of treatment in a case belonging to this class which had remained in a paralytic condition up to the age of thirty-nine, and without any power to stand or walk, are well illustrated by Case VII in Appendix.

Treatment of cases of right-angled contraction of the tendo Achillis. The cases here adverted to are those included in the second class previously spoken of as requiring some special attention. It is a general opinion that when the heel touches the ground in standing or walking, division of the tendo Achillis cannot be called for; but this is certainly an error.

Slight contraction of the tendo Achillis—not enough to produce obvious deformity, but sufficient to prevent flexion of the foot beyond a right angle with the leg—necessarily produces a certain amount of lameness, for which advice may be sought. Any of the causes previously enumerated as bringing about the more confirmed deformity of talipes equinus may produce the amount of contraction described as existing in the cases we are now considering; and without entering upon the subject in detail, it may be stated that the best rule of practice will be found, not to operate upon these cases unless the muscles are in a healthy or nearly healthy condition.

The operation in paralytic cases of this class, in which the paralysis still exists is not advisable; but in some spasmodic cases where the muscles above the knee-joint are not involved, and in some cases of traumatic origin, as well as in those arising from causes directly affecting the joint, the operation may be performed with great advantage to the patient. Much will, however, depend upon a judicious selection of cases; the precise condition of the joint and the muscles must be carefully considered before the operation be decided upon.

We propose now briefly to describe the two compound varieties of club-foot, termed equino-varus and equino-valgus.

TALIPES EQUINO-VARUS.

This deformity is but a slight modification of talipes equinus; and after the detailed account given of the latter deformity in consequence of its frequency and practical importance, it will be unnecessary to say much of its compound variety.

When in addition to the ordinary characters of equinus, there is a certain amount of inversion of the anterior portion of the foot, the deformity partakes somewhat of the external characters of equinus and varus, and is therefore termed equino-varus. The elevation of the heel is the predominant condition as one of the external characters, and according to the extent of the inversion of the anterior part of the foot, the patient walks on the outer metatarsal bones, rather than on

the toes, or anterior extremities of the metatarsal bones, as in cases of talipes equinus.

The external characters are modified as in talipes equinus, according to the cause producing the deformity. It is, therefore, unnecessary to dwell upon the appearances of the spasmodic and paralytic cases, which have already been pointed out in the description of talipes equinus when dependent upon these conditions; these appearances are well represented in the annexed wood-cuts, Figs. 16 and 18.

FIG. 16.

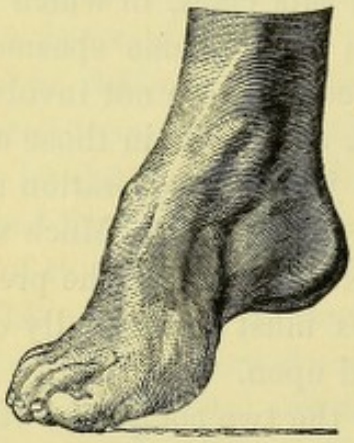

Talipes equino-varus with the muscles in a spasmodic condition.

FIG. 17.

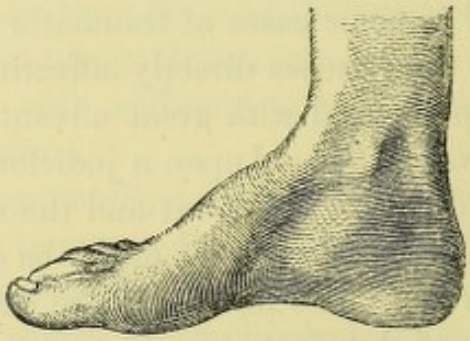

The same foot as shown in Fig. 16 after treatment.

FIG. 18.

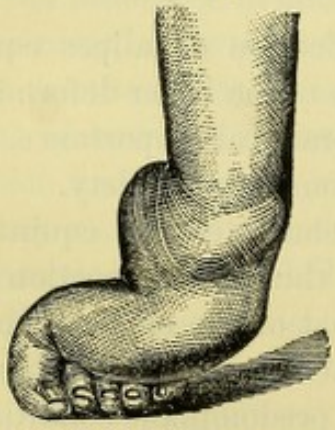

Talipes equino-varus with the muscles in a paralytic condition.

FIG. 19.

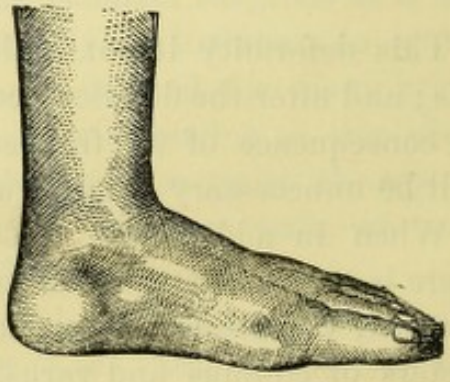

The same foot as shown in Fig. 18 after treatment.

In the spasmodic case Fig 16, the general vitality and muscular strength of the foot is indicated, and in the paralytic case

Fig 18, the general deficiency of muscular power is exhibited in the form and position of the foot.

The anatomical deviations are essentially the same as in talipes equinus; but the navicular bone is somewhat placed inwards, leaving the outer part of the head of the astragalus exposed on the dorsum of the foot, and the cuboid bone is also somewhat displaced inwards, leaving the anterior extremity of the os calcis partially exposed, as shown in Fig. 9. The movement of inversion takes place from the transverse tarsal joint, which, in this distortion, as well as in talipes varus, is a very important centre of motion.

When the deformity has existed any length of time, structural shortening of the anterior tibial muscle is generally produced, and sometimes the same condition also occurs in the posterior tibial muscle.

The pathology of this deformity is also essentially the same as that of talipes equinus. It is a non-congenital affection, and generally only one foot is affected. It occurs most frequently in the right foot; secondly, in the left foot; and thirdly, in both feet; in this respect also resembling talipes equinus. It is produced by the same causes which give rise to talipes equinus, and therefore, the great majority of cases met with in practice will be found to depend either upon spasmodic, or paralytic affections, and the muscles will be found in the same condition as described in talipes equinus.

The treatment required is essentially similar to that for talipes equinus; but in some cases the anterior tibial, or the posterior tibial tendon, or even both, may require division; and in the mechanical treatment it is the more necessary to make use of the Scarpa's shoe with the cog-wheel placed in the sole-plate, which is divided transversely at a part corresponding to the transverse tarsal joint, as represented in Fig. 20.

In these cases I now prefer having the ordinary double-cog-wheel movement attached to the side steel bar opposite the ankle-joint placed on the inner, instead of the outer side, as generally used, and the leg-trough made in the reverse way to that represented in Fig. 20, where it is arranged for the outer

side. By this new arrangement on the inner side I obtain an increased mechanical power over the inversion, and am enabled to uplift more effectually the 4th and 5th metatarsal bones, so as to overcome the lateral inclination of the foot. When the inversion is considerable, and much resistance offered to the restoration of the foot, in consequence of ligamentous shortening and adaptation, the treatment may be advantageously divided into two or three stages, as recommended in talipes varus.

The object of the first stage would then be to overcome the inversion by bandaging the foot to a straight outside splint, after dividing the anterior and posterior tibial tendons, when this should appear to be necessary, and, I have occasionally found it necessary to divide the anterior portion of the deltoid ligament.

The object of the second stage would be to overcome the contraction of the arch of the foot, which is maintained principally by the adapted shortening and contraction of the plantar fascia, the calcaneo-cuboid, and other deep ligaments connecting the tarsal bones in their plantar surface. The plantar fascia may be divided, and the adapted shortening of the deeper ligaments must be overcome by gradual mechanical extension, employed by some modified form of the Scarpa's shoe, such as that represented in Fig. 20, in which the anterior portion of the sole-plate moves in a direction upwards and downwards, by means of a cog-wheel placed beneath a transverse division in the sole-plate at the posterior part, corresponding in position with the transverse tarsal joint in the foot. During this stage of treatment, the contracted condition of the tendo Achillis is turned to good account by the surgeon, as it renders the os calcis

FIG. 20.

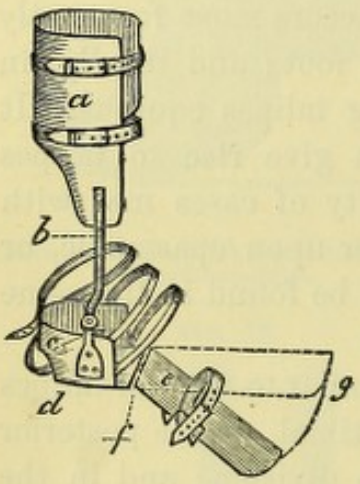

Scarpa's shoe with transverse joint in sole-plate, corresponding to the transverse tarsal joint.

a. Leg trough. *b.* Side steel bar. *c.* Cog-wheel moving in the direction of flexion and extension. *d.* Heel-plate. *e.* Anterior part of sole-plate moving from the transverse joint *f*, upwards in the direction of the dotted line *g*, by means of a cog-wheel placed beneath the transverse joint *f*. The toe-strap, and the steel bar to which it is fastened on the outer side of the sole-plate is placed rather too far backwards.

fixed, and thus affords a firm point of resistance to the uplifting force employed against the anterior portion of the foot, which has become displaced downwards and inwards from the transverse tarsal joint, a more important centre of motion than the ankle-joint in severe cases of talipes equino-varus. In severe cases this is the most tedious and troublesome stage, as the feet from their paralytic condition, which frequently exists, are unable to bear the necessary amount of pressure, and very intractable ulceration readily follows any undue pressure, so that frequent adjustment and much ingenuity and attention in padding are necessary. Moreover, it is of the utmost importance to continue this part of the treatment until its objects are fully accomplished.

The object of the third stage is to overcome the contraction of the tendo Achillis, and the elevation of the os calcis produced by it, so that the heel may be brought fairly in contact with the ground in walking, and flexion of the ankle-joint obtained to its natural extent.

As I have found by dissection that in these cases, however severe, the elevation of the os calcis is much less than would be supposed by the external appearance of the foot, and the extent to which the heel is raised from the ground; and that the deceptive appearance in this respect is due to the foot being bent upon itself from the transverse tarsal joint, as represented in Figs. 8 and 9; there is, therefore, much less to be accomplished in the third stage of treatment, than might at first be supposed. In many cases, it will be found that the contraction of the tendo Achillis has been overcome during the second stage of treatment, by the mechanical force employed against the anterior portion of the foot, so that division of the tendo Achillis is unnecessary; but generally it will be necessary to divide this tendon, in order to obtain the full amount of flexion at the ankle-joint.

TALIPES EQUINO-VALGUS.

A certain amount of eversion of the anterior portion of the foot coexisting with contraction of the tendo Achillis and ele-

vation of the heel is the characteristic of this deformity. It is, therefore, a compound variety of talipes equinus and talipes valgus; but it cannot be considered as the opposite condition to equino-varus, because whilst in the latter deformity elevation of the heel is the predominant condition; in talipes equino-valgus, the elevation of the heel is very slight, and eversion of the foot is the predominant condition, as exhibited in the accompanying wood-cut, Fig. 21.

FIG. 21.

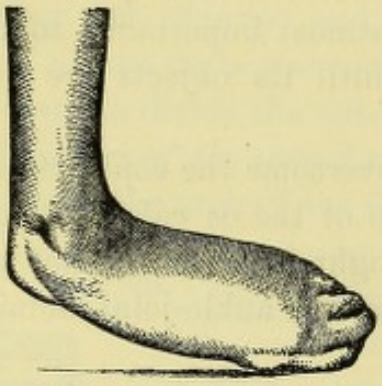

Talipes equino-valgus with the muscles in a paralytic condition.

FIG. 22.

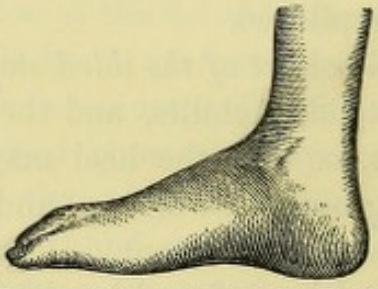

The same foot as represented in Fig. 21 after treatment.

Equino-valgus is, in fact, but a slight modification of talipes valgus, and a certain amount of contraction of the tendo Achillis is so constantly present in all the more severe forms of talipes valgus, whether of congenital or non-congenital origin, that this deformity will be again adverted to when the general and specific characters of talipes valgus are described. We shall then particularly draw attention to the influence of a contracted condition of the tendo Achillis, in modifying the external form of the foot when a disposition to eversion exists; and it will be seen that the pathology and treatment of this compound variety are essentially the same as in the so-called simple form talipes valgus.

CHAPTER VIII.

CONGENITAL TALIPES VARUS.—EXTERNAL CHARACTERS IN THE INFANT AND ADULT.—EFFECTS OF THE DEFORMITY.—MORBID ANATOMY IN THE INFANT.

THE form of congenital club-foot most frequently met with, and to which both modern and ancient writers have more especially directed their attention is *Talipes varus*, which we will now proceed to describe.

The external characters of this deformity vary considerably in the infant and the adult, according to the extent to which the foot has been used in sustaining the weight of the body in progression. The original severity of the deformity will also determine considerable differences in the external characters; but I shall not, on this account, subdivide the deformity into three or four grades or degrees, as adopted by some writers. I propose to draw the description from well marked cases in the infant, and in the adult, making allusion to the deviations in cases of extreme severity, and of the slighter forms frequently met with.

External characters of Talipes varus in the infant. The external characters in a severe case of congenital varus in an infant, such as that represented in Fig. 23, are,

1st. The anterior portion of the foot is turned inwards, and in this direction forms a right angle with the leg.

2nd. The sole of the foot looks directly backwards, and the dorsum directly forwards.

3rd. The inner border of the foot looks directly upwards, and the outer border directly downwards.

4th. The foot is shortened principally because it is bent laterally upon itself, the angle of flexion corresponding to the great transverse tarsal joint in front of the astragalus and os calcis; the shortening also in part depends upon defective growth, all the bones of the foot, in a case of congenital varus, being a little below the natural size at the period of birth.

FIG. 23.

Congenital Talipes varus in an infant aged five months.

5th. The heel appears very small and misshapen, and the skin remains thin and delicate; the tuberosity of the os calcis can be felt with difficulty, owing to the nearly vertical position assumed by this bone.

6th. The internal malleolus is less prominent than natural, and often difficult to be felt, being to some extent concealed by the navicular bone in its displaced position. The external malleolus is as prominent as in a healthy foot, and not at all displaced, although it has the appearance of being more downwards and backwards than natural, owing to the general distortion of the foot.

7th. *The surface on the dorsal aspect of the foot* is, more or less irregular, partly from the prominence of some of the tarsal bones—especially the head of the astragalus and anterior extremity of the os calcis—and partly from the constant existence of an irregularly triangular depression, corresponding to the oblique neck of the astragalus, the outer surface of which looks almost directly forwards, and can easily be felt.

In such a case as that above described, the foot cannot be restored to its natural form and position by manipulation; but its anterior portion can always be drawn a little, sometimes nearly half-way, towards the median line of the leg; the os calcis, however, is always held rigidly in its oblique position. When the anterior portion of the foot is partially drawn towards the median line of the leg, the skin on the convexity appears to be considerably in excess, and hangs loosely on the foot.

In one case which came under my care in the year 1852, and is related in the Appendix, Case XII, this redundant skin on the outer surface of the foot was dissected off by a surgeon, in the hope of producing such an amount of contraction by the cicatrix, as would overcome the tendency to inversion, and thus cure the deformity; but I need hardly say that this completely failed to effect the desired object, and that it was necessary to divide the contracted tendons before the deformity could be cured.

According to the severity of the case, so will the external characters be variously modified. In *slighter cases* than already described, all the characters above enumerated are proportionably less marked, and the foot can in some instances be twisted quite into its natural form and position, the heel also descending.

In more severe cases, the inner edge of the foot, instead of forming a right angle with the leg, may be drawn upwards, so as to form an acute angle with it, or even be in contact with the inner side of the leg, as represented in Fig. 24. The great toe is often widely separated from the second toe, in consequence of the continued action, and adapted shortening of the extensor pollicis muscle, and probably also of the abductor pollicis.

FIG. 24.

Congenital Talipes varus in an infant; in a more severe form than in Fig. 23.

In severe cases, the foot is sometimes shortened to an increased extent by a rigid contraction of the plantar fascia, which produces a deep transverse depression in the sole of the foot. There are some comparatively rare cases in which this rigid contraction of the plantar fascia is the predominant condition, the inversion of the foot being slight, and the os calcis not materially elevated.

In reference to the prognosis and result of treatment, the severity of a case is to be judged of, not so much by the external form of the foot, or whether it approaches, more or less, to a right angle with the leg, but by the amount

of resistance offered to the restoration of the foot by manipulation, to its natural form and position. This resistance, or rigidity, as it is generally termed, arises from contraction and adapted shortening of the muscles and ligaments, conditions which are found to exist in every degree of severity at the period of birth, but do not constantly bear a definite relation to the external deviations in form. Some apparently severe cases in the infant are very flexible, whilst others, presenting the same external appearance, are extremely rigid and unyielding.

This rigidity is probably in proportion to the early period of gestation at which the muscular contraction producing the deformity has taken place, and after birth this steadily increases with age, bearing a pretty constant relation to the external form of the foot.

External characters of congenital Talipes varus in the adult.

After the congenital club-foot has been used for several years in sustaining the weight of the body, and in progression, the external characters become materially modified, and the general appearance of the foot in a severe adult case is well exhibited in Figs. 25 and 26.

In the first efforts of the child to walk, the weight of the body, instead of being transmitted to the ground through the arch of the foot, so perfectly and beautifully adapted by nature to receive it, is thrown upon its outer border, or fifth metatarsal bone; this gradually yields in a direction backwards, so that after a time the child walks completely on the dorsum of the foot, and the more confirmed characters of the deformity, as seen in the adult, progressively become developed. Two important modifications in the external form of the foot result.

1st. The aspect of the sole of the foot looks upwards and backwards, as shown in Fig. 26, and the dorsum is directed downwards and forwards, as represented in Fig. 25.

2nd. A deep longitudinal furrow is gradually formed in the sole of the foot, as shown in Fig. 26. This takes place in consequence of a narrowing of the transverse arch of the foot,

produced by a folding backwards of the fourth and fifth meta-

FIG. 25.

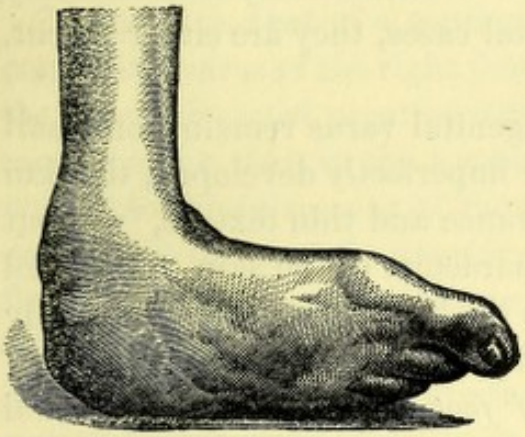

Severe case of congenital talipes varus in the adult. From a gentleman aged 26. Anterior aspect.

FIG. 26.

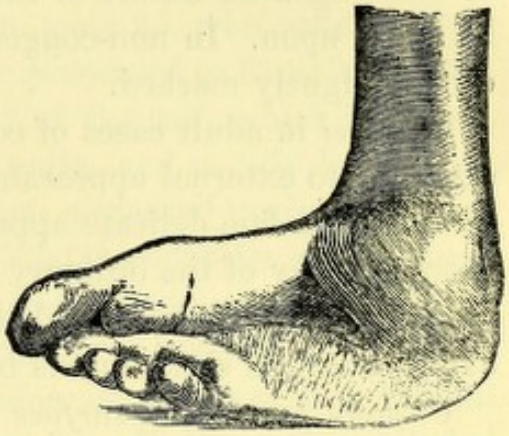

Posterior aspect of the same foot as Fig. 25.

tarsal bones, and an approximation of the latter to the metatarsal bone of the great toe, but this displacement is less than would be supposed; in the dissection of a severe adult case, represented in Figs. 35 and 36, this deviation existed only to a slight extent.

During the growth of the foot in its deformed position, a *diminution in its length* is observed to take place, and gradually increases; this depends upon two causes.

1st. The bending of the foot upon itself laterally in the direction of its length. The peculiarity of this movement, by which the sole of the foot is brought into an opposite relation with the lateral aspect of the os calcis, will be further described, and

2nd. The adapted atrophy, and shortening of all the muscles, fascia and ligaments in the sole of the foot, by which the deformed position is rendered more rigid and confirmed during growth.

The production of a *deep depression* passing *obliquely* across the sole of the foot at its posterior part, or about the junction of the middle with the posterior third of the foot, as shown in Fig. 26, results from this peculiar flexion of the anterior portion of the foot. *The longitudinal depression* terminates posteriorly in this obliquely transverse depression, the degree in which they are both developed corresponding to the severity of the case.

The two deep furrows, one taking a longitudinal, and the other an obliquely transverse direction, are at once diagnostic of the congenital nature of the affection, and may with certainty be relied upon. In non-congenital cases, they are either absent, or but slightly marked.

The heel in adult cases of congenital varus remains of small size, and to external appearance imperfectly developed, the skin retaining its fine delicate appearance and thin texture, without acquiring any of the ordinary characters of the skin of the heel when subjected to use; and the thick cushion of fat, naturally existing in this situation, is but imperfectly formed.

Cushion on dorsal surface of foot. In cases of congenital varus, it has been shown that after the foot has been used in progression, and its deformity consequently increased, the weight of the body has to be sustained by the dorsal surface of the foot, where the bones are only covered by delicate skin, and a little cellular tissue, and, therefore, but ill-adapted to resist the influence of weight and pressure. Under these circumstances, a compensative effort of nature is made, and a thickened mass of condensed cellular tissue forms in this situation; the skin also becomes considerably thickened, and covered by an abundant horny cuticle, which together form a pad or cushion on the dorsum of the foot, and protect the bones and diminish the inconveniences of weight and pressure.

Between this cushion and the surface of the tarsal bone, a large bursa is generally formed, and by the accumulation of fluid in its cavity sometimes enlarges the cushion to a very inconvenient size. This compensative provision is very inadequate to the requirements of the part, and, moreover, is attended with peculiar disadvantages, such as cutaneous and bursal inflammation, liable to be followed by a most intractable ulceration.

Atrophy of the leg. Beyond the essential and acquired external characters of the foot, it may be stated that in cases of congenital varus, although at the time of birth the leg is well developed, and the muscles in most cases healthy and nearly of their natural size; yet as age advances, the

growth of the limb below knee is defective in every respect, so that in the adult, or even in youth, the leg below knee presents the appearance of an atrophied or dwindled extremity.

In one case, that of a gentleman, aged 26, who suffered from congenital varus of the right foot, represented in Figs. 25 and 26, the leg at the most prominent part of the calf, which is always much higher than in the normal state, and in this leg corresponded to the tuberosity of the tibia, measured in circumference only eleven inches and a quarter; whilst the opposite leg measured fourteen inches in circumference at the most prominent part of the calf, which was three inches below the tuberosity of the tibia. The muscles in the adult are therefore much below their natural size in consequence of defective growth. In the patient alluded to, the thighs were very nearly of the same size, but in some cases a marked difference is observable in this part also.

The length of the club-footed leg in the adult is usually somewhat diminished, in consequence of its defective growth below knee, and shortening, to the extent of half-an-inch or an inch is frequently seen. In the case above adverted to, the leg was half-an-inch shorter than the opposite limb.

Lameness and other inconveniences from club-foot. A certain amount of lameness necessarily results in severe cases of congenital talipes varus, from the absence of any motion at the ankle-joint; and also from the altered form of the foot which affords a very insecure base of support. When one foot only is affected, the amount of shortening always present in the adult contributes to the lameness.

The peculiar mode of walking when both feet are affected, arising from the necessity of lifting one foot over the other, we are all familiar with, as sufficiently numerous examples of this frightful deformity are still frequently to be seen in the streets of this metropolis.

In severe adult cases, it is worthy of remark that the lameness is diminished by the retroverted position of the foot, and that it is somewhat increased after the cure of the deformity, unless free motion, which cannot always be accomplished, be obtained at the ankle-joint.

At younger ages, free motion at the ankle-joint is obtained to the natural extent, and the lameness completely removed.

In the earlier years of life, the inconveniences which spring from club-foot are frequently insignificant. Boys generally walk pretty well with these feet, and are often as active, and can even walk as far as other boys; but from the anticipation of inconveniences, they are, amongst the poor, usually brought up to sedentary occupations, such as tailors, shoemakers, &c.

Men with club-feet who have followed agricultural pursuits for many years, are occasionally seen continuing their labours without inconvenience, although as age advances, very serious inconveniences generally arise, more especially if the individual should become stout, or the general health fail. The feet become tender after very little walking; all sorts of boots are tried, hollowed internally so as to diffuse pressure, and relieve the tender feet, and constructed externally so as to widen the base of support, in shape often like a horse-shoe, and, indeed, in the country common horse-shoes are frequently fastened on to the leather sole of the boot.

There is a *special liability to inflammation in the bursa* and cushion of condensed cellular tissue, described as generally existing on the dorsum of the foot, and upon which the individual treads. This frequently terminates in a tedious and destructive process of ulceration from the defective nutrition in these club-footed legs, as well as from the peculiarity of the structure affected.

These ulcers are extremely difficult to heal, and they frequently continue for years, resisting every method of treatment. Crutches then become necessary, and the patient has not only a useless leg, but one that is both burdensome and troublesome.

Under the above circumstances, amputation has been occasionally performed. The specimen of congenital talipes varus dissected so as to exhibit the relative position of all the tendons, now in the Royal College of Surgeons, and from which Figs. 34, 35 and 36 are taken, was amputated more than twenty years ago by the late Mr. Ayres, of the Wandsworth-road, in conse-

quence of the intractable ulceration which existed on the dorsum of the foot, and which, for a year or two previously, had resisted all attempts to heal it. The woman, aged about thirty, was a laundress, and no doubt a wooden leg would have been much more useful to her than the foot in this condition. The amputation was performed at her request, but unfortunately she died after the operation.

"Within the last three years," (1843,) says Dr. Little,* "amputation has been performed in this metropolis for the removal of talipes varus in cases in which ulceration did not exist."

Effects of the deformity upon the mind. There can be no doubt that the existence of any physical deformity frequently exerts a most important influence upon the moral condition and character of the individual afflicted, materially modifying the natural disposition, and altering the habits of life. This is perhaps more conspicuous in the congenital deformities, and hence it is most frequently in connexion with talipes varus that such results have been observed.

It has generally been supposed that the existence of congenital talipes varus exerted an unfavourable influence upon the highly susceptible mind of Lord Byron. In more than one instance I have myself witnessed some of the worst of these moral effects, in individuals who have on account of their deformity withdrawn themselves from the society in which, by birth and education, they were intended to move, and by their accomplishments they would have adorned.

Such ill effects, however, do not always result from the influence of deformity, but, on the contrary, sometimes it appears to stimulate the cultivation of the highest qualities of the mind, of which many instances could be adduced among philosophers, statesmen and artists, who are known to have been deformed.

MORBID ANATOMY OF CONGENITAL TALIPES VARUS.

General observations. The external examination of the foot has been the chief foundation for much that has been written on the morbid anatomy of congenital talipes varus. Some

* "On Deformities," p. 268.

accounts have evidently been written from the dissection of non-congenital cases; others from old adult specimens, in which the essential and acquired changes have not been distinguished; a few accounts have been drawn from dissections of the deformity, both infantile and adult, but the examinations appear to have been very superficially conducted.

The account most generally received in this country, chiefly by the influence of the writings of Dr. Little, is that of Scarpa, which has also been generally followed by continental authorities; but in some of its essential points, this account does not agree with the result of my dissections; for instance, in numerous examinations which I have made of fœtal and infantile specimens of talipes varus, I have constantly found a decided malformation of the astragalus, the nature of which and its mode of production will be described.

The existence of any malformation of the astragalus, except that acquired by the persistence of the deformity, and the use of the foot in advancing age, is not admitted by Scarpa; but, on the contrary, he rests his theory of the curability of club-foot in the infant, very much upon the perfect formation of this bone, as well as upon the comparatively slight displacement which he considers it to suffer. In describing the position and conformation of this bone, Scarpa states,* "I have found that in children, even in the greatest degree of this deformity, the astragalus, compared with the other bones of the tarsus, is very little, or almost not at all inclined internally, or towards the internal malleolus, and that its anterior tuberosity, or the articular head of this bone, which, on the upper part of the foot, is received into the os naviculare, retains very nearly its natural direction and position with the tibia and the malleoli."

These views of Scarpa are fully adopted by Dr. Little, who in the last edition of his work on Deformities, 1853, page 276, states: "As the opinions of Scarpa generally agree with the results of the author's (Dr. Little's) experience, they are here detailed with less minuteness than their importance otherwise deserved. The conclusion to which Scarpa had arrived was, that

* "Memoir on the Congenital Club-feet of Children," by Antonio Scarpa, Pavia, 1803. Translated from the Italian by J. H. Wishart, Edinburgh, 1818, page 13.

of the entire tarsal bones, the astragalus had suffered the smallest degree of displacement; which alone proved the possibility of curing infantile talipes varus," and again, at page 277, he remarks, "the accuracy of Scarpa's opinion has been disputed by succeeding writers, but the result of my observations of more than thirty specimens of varus, from subjects of different ages, is to confirm the opinion of Scarpa, and add, that I have examined no preparation of varus in which each of the three facets of this bone, which articulate with the tibia and fibula, has not been in partial contact with the appropriate surface of these bones."

In February, 1852, I first described in a communication to the Pathological Society, (see Vol. III of the Transactions, page 455), the morbid anatomy of talipes varus as I found it in the body of a child which had lived only a few hours; and in this account the deviations in form and position of the astragalus formed a conspicuous feature. When this bone represented in Fig. 27 B, was compared with an adult astragalus taken from a case of severe talipes varus in the Museum of St. Thomas' Hospital, see Fig. 37, the close resemblance between the fœtal and adult bones "in all the more essential points" was at once obvious. And yet in adverting to these observations, Dr. Little* observes "that Mr. Adams' description confirms the author's (Dr. Little's) opinion of the immaterial changes which the bones undergo previously to the use of the part."

This is somewhat remarkable, after I had endeavoured to prove that the fœtal astragalus presented all the essential changes in form observable in the adult astragalus; and, therefore, that the deviations in form which all observers have noticed in the adult bone, were not the result of persistence of the deformity and use of the foot, as generally supposed, but a persistence of the essential conditions of the deformity at the time of birth. The accuracy of these observations I have had ample opportunities of proving, by the dissection of numerous fœtuses in different museums and collections, and by post-mortem examinations in several children who had died of in-

* *Op. cit.*, p. 277.

fantile diseases while under treatment for the deformity at the Orthopædic Hospital.

The results of my dissections are in several other points at variance with those of Scarpa and other recognised authorities, but while it is desirable to note the erroneous conclusions arrived at by Scarpa, and since perpetuated, there can be no doubt these opinions have been of essential service in supporting the asserted curability of congenital club-foot, in opposition to the theories of osseous malformation, from defective development, &c.

A good account of the various opinions held by the older anatomists and surgeons, is to be found in Dr. Little's work. Without entering more fully upon this interesting part of our subject, let us proceed to a detailed account of the anatomy of talipes varus, as I have met with it on dissection in the fœtus and infant. The description of the anatomical changes in the adult must be drawn partly from such specimens as exist in our museums (few and bad as they are for the purpose, in consequence of their having been macerated) but chiefly I shall rely upon the dissected specimen represented in Figs. 34, 35, and 36, and which has been previously adverted to as the only specimen known in this country from which the morbid anatomy in the adult can be demonstrated.*

So important does it appear that we should accurately determine the essential and acquired conditions in the morbid anatomy of this deformity, that I propose to describe.

1st. The deviations which essentially belong to the deformity at the period of birth, and the abnormal condition of the muscles occasionally met with at that period, and

2nd. The superadded or acquired conditions met with in the adult.

The description will be drawn from a well marked case of the deformity in the infant, and in the adult; in examining the slighter forms of this affection, therefore, conditions will be

* Mr. Partridge has presented to the College of Surgeons, since the present Essay was written, in 1864, two specimens of congenital talipes varus in the adult, which will be again adverted to when the adult deformity is described in Chapter X.

met with, which will approximate, rather than exactly correspond to those now described. This course is deemed preferable to the plan adopted by some authors, of describing three or four grades of the deformity, and each separately.

Morbid Anatomy of Talipes varus in the Infant.

The bones.—The following important deviations in the bones, in respect both of their position and form, present themselves at the period of birth.

Os calcis.—This bone is altered in position to an extreme degree, but its deviation in form is slight; in severe cases it occupies a very oblique, almost a vertical position, from its tuberosity being drawn upwards by the gastrocnemius and soleus muscles, as shown in Fig. 33. Its direction is also somewhat changed laterally, the anterior extremity of the bone being directed obliquely forwards and inwards, and its tuberosity inclined towards the fibula aspect of the leg, and in severe cases it is found in actual contact with the fibula. This was the case in the fœtal specimen I dissected and described in Vol. III. of the Transactions of the Pathological Society, and from which the astragalus represented in Fig. 27 B. was taken, and a similar deviation is shown in Fig. 32.

In form, the os calcis is also somewhat altered, being regularly arched in the direction of its length with the convexity directed outwards, in adaptation to the curved position of the foot, but this deviation is not very obvious, except in severe cases.

Astragalus. This bone is found, at the period of birth, to present several important deviations both in position and form. In position it is tilted obliquely forwards and downwards, and to a certain extent displaced from its socket, in consequence of the altered direction of the os calcis and elevation of its tuberosity; so that the anterior third, or more, of the superior articular facet, or trochlea, of the astragalus is thrust on to the dorsum of the foot, where it is covered only by the elongated anterior portion of the capsular ligament of the ankle-joint and the skin. Fig. 27, B, 2 and 3 represent the degree of obliquity which this

bone presents in a severe case, and sometimes it more nearly approaches the vertical position.

I have not detected any lateral inclination or rotation inwards of the body of the astragalus in any case; but, contrary to what might be expected, have observed that in every instance the body of this bone, or that portion which normally enters into the composition of the ankle-joint is, to a greater or less extent, rotated outwards, so that the external lateral articular facet is firmly in contact with the fibula, and appears to be somewhat increased in size in consequence of its anterior portion being extruded from the joint. The internal lateral articular facet of the astragalus is scarcely to be traced, and in severe cases is not at any part in contact with the articular surface of the inner malleolus. Moreover, the line of the ankle-joint, instead of being horizontal—when viewed from the front, after the joint has been laid open—presents an oblique direction upwards, and outwards towards the fibula, corresponding to the rotation outwards of the astragalus.

The astragalus presents several important deviations from its natural form, and these are observable in its head and neck,

FIG. 27.

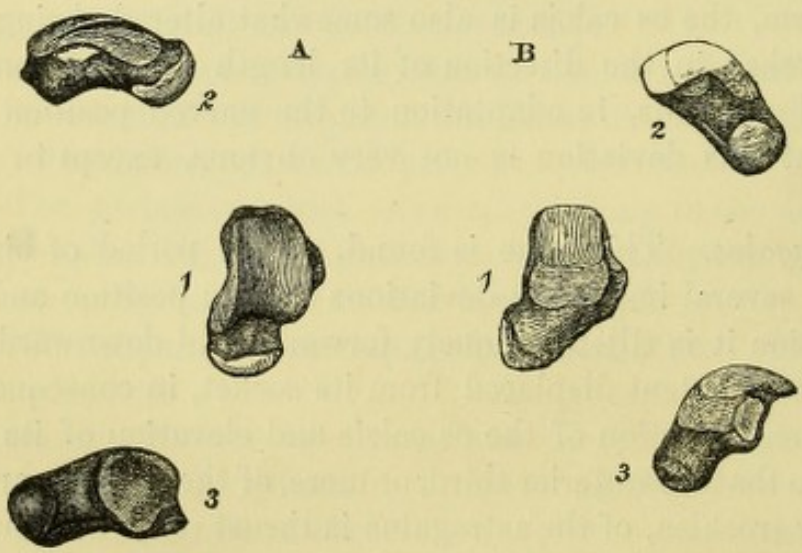

Fig. A, 1, 2, 3, represents a healthy fœtal astragalus, at the ninth month, in its superior, internal, and external aspects.

Fig. B, 1, 2, 3, represents similar views of a fœtal astragalus, at the ninth month, from a case of severe talipes varus. The child was born with spina bifida, and lived only a few hours. The obliquity of neck of astragalus, and lateral aspect of head of this bone are well-shown in Fig. B, 1.

its articular surfaces, and its posterior border, and are represented in Fig. 27, B, 1, 2 and 3, in contrast with the three corresponding views of a healthy fœtal astragalus.

The neck of the astragalus, see Fig. 27, B, 1, instead of being continued directly forwards, as in the healthy bone, Fig. 27, A, 1, inclines abruptly inwards towards the inner malleolus, forming an obtuse angle with the body of the bone. Its length also is apparently increased, but this depends upon the altered relations and imperfect development of the articular surfaces, rather than upon any real increase of this portion of the bone.

The articular head of the astragalus does not present a regularly convex surface looking directly forwards, as in the healthy bone; but has an antero-lateral aspect. In a severe case, the articular surface of the head of the astragalus is divided into two articular facets, at nearly right angles to each other, and separated by a distinctly angular ridge, as represented in Fig. 27, B, 1; one surface, the larger, looks directly inwards and articulates with the displaced navicular bone; the other looks directly forwards and downwards, and is left exposed on the dorsum of the foot by the altered position of the navicular bone, and is covered only by the elongated portion of the ligament, normally passing from the neck of the astragalus to the edge of the navicular bone.

The lateral articular facets of the astragalus present some important abnormal conditions in respect both of position and form. They are both partially extruded from the ankle-joint, and appear in front of the malleoli in consequence of the altered position of the astragalus; and the articular cartilages are somewhat extended backwards towards the posterior border of the bone.

The external articular facet is well developed, and appears to be somewhat larger than natural, from the posterior extension above adverted to. It is also to be observed that this facet is in close adaptation with the fibula, in consequence of a slight transverse rotation outwards of the body of the bone.

The internal articular facet is very imperfectly developed, and in a severe case is represented only by a small and imper-

fectly defined plate of cartilage, close to the posterior edge of the bone, as shown in Fig, 27, B, 2. In contrast to the relation between the external articular facet and the fibula, it must be especially noticed that there is only partial and very imperfect contact between the inner malleolus and the corresponding articular surface of the astragalus.

The superior articular surface of the astragalus is partially extruded from the socket of the ankle-joint, and exposed on the dorsum of the foot. This surface is also elongated by the articular cartilage, extending quite to the *posterior edge of the bone*, which is thin, attenuated, and wedge-shaped, as seen in Fig. 27, B, 3, instead of being obtusely rounded, as in Fig. 27, A, 3.

In consequence of the oblique, or nearly vertical position of the astragalus, only the posterior two-thirds, or less, of its superior articular surface enters into the composition of the ankle-joint. This portion is flattened and separated from the extruded anterior portion by a distinct transverse line or ridge, an angle as it were, formed by the junction of two surfaces, the planes of which are in different directions.

All the peculiarities above described in the fœtal astragalus especially in reference to the obliquity of the neck, and lateral aspect of the head of this bone, may be seen more distinctly marked in an astragalus with the navicular bone attached, see

FIG. 28.

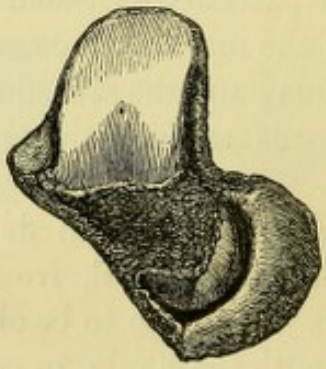

The astragalus and navicular bone, removed from a case of congenital talipes varus in a child aged 6 years. The deformity had been imperfectly cured when death occurred from scarlet fever. The obliquity of neck, and lateral aspect of head of the bone are well exhibited. The navicular bone admitted of being only partially brought into its natural position, in consequence of the existing ligamentous adaptation.

Fig. 28. I removed this bone from the body of a child aged six years, who died in the Middlesex Hospital of scarlet fever, in June, 1855, having been under treatment for the deformity at the Orthopædic hospital under Mr. Lonsdale.

So far as the external appearance of the foot was concerned, it had been brought pretty nearly, although not quite, into its natural position. Upon dissection, I was surprised to find that the position of the navicular bone had been so little altered, evidently in consequence of the adapted ligamentous shortening which held this bone pretty firmly in contact with the head of the astragalus. Considerable movement, however, was permitted between the navicular bone and the head of the astragalus; but time and growth would be required to render this increased amount of motion available, and the improved form persistent.

The altered relations of the astragalus to the navicular bone, and the deviation of the anterior two-thirds of the foot from the transverse tarsal joint—the great centre of motion in talipes varus—are well exhibited in Fig. 29, drawn from a specimen of talipes varus in a fœtus of about the seventh month.

FIG. 29.

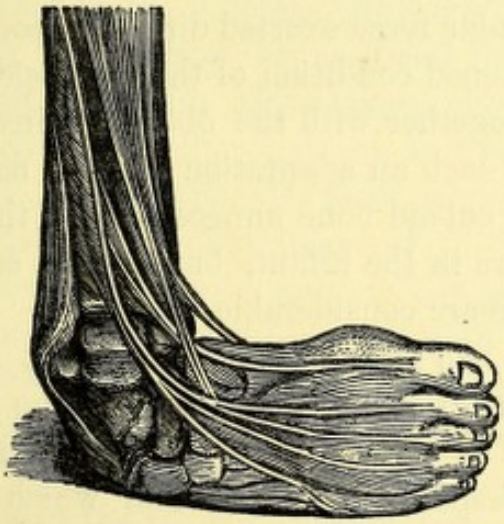

Dissection of a case of congenital talipes varus, from a fœtus, of about the seventh month, showing obliquity of neck, and lateral aspect of head of astragalus, and the lateral displacement of the navicular bone.

The navicular bone is altered in position to an extreme degree

but presents no material deviation in form. This bone is drawn inwards and upwards by the tibialis posticus muscle directly, and by the tibialis anticus and extensor-proprius-pollicis muscles indirectly, so as to bring its inner border, or tuberosity, immediately under, and in contact with the inner malleolus.

The navicular bone in its displaced position articulates with the lateral articular facet of the head of the astragalus, and therefore holds a lateral, instead of anterior position with respect to the astragalus; in fact, the long axes of these bones are parallel instead of being at right angles to each other. The long axis of the navicular bone is therefore parallel with the long axis of the leg, instead of being at right angles to it. The peculiar position of this bone does not result from a movement of transverse rotation, as described by Scarpa and other authorities, but from the vertical, or nearly vertical, position assumed by the astragalus. This will be shown when the deviations, and their mode of production, in the adult foot are described.

The cuboid bone presents no material alteration either in position or form. In all my dissections, I have observed with some surprise that this bone suffers very little, either in displacement or alteration of form, even in severe cases of varus in the fœtus or infant. In explanation, however, it may be remarked that there is no muscular force exerted directly upon this bone, and the laterally flattened condition of the inner side of the head of the astragalus, together with the obliquity inwards of the os calcis, permit of such an adaptation of parts as to render displacement of the cuboid bone unnecessary to the production of varus, as it occurs in the infant, but in the adult, the deviations of this bone are considerable.

The cuneiform and metatarsal bones are not altered in their normal relations to each other, or to the navicular and cuboid bones. The inverted position the anterior part of the foot holds with respect to the leg, and which constitutes the most conspicuous character of talipes varus, mainly depends upon the altered position of the navicular bone, os calcis, and astragalus, aided by the adapted alterations of form above described. Any material deviations in the cuneiform and

metatarsal bones in the infant, are therefore not to be expected.

Malleoli. It is of importance to determine the position and form of the malleoli in infantile varus, because, as Dr. Little* states, "the inward inclination of the fore part of the foot which constitutes the difference between talipes varus and talipes equinus, has by Stromeyer been attributed to deficiency of the inner malleolus, Delpech and Cruveilhier are likewise of opinion that this cause also greatly contributes to the maintenance of talipes varus. The author (Dr. Little) has never observed in fœtal or adult instances of dissected talipes varus, any material deficiency of this process."

It should be remarked that Stromeyer considered contraction of the muscles of the calf to be the immediate cause of both these distortions; equinus resulting, if it occurred at a late period of uterine existence, when the internal malleolus was fully formed, and varus if the contraction occurred at an earlier period.

Dr. Little also observes at page 274, that† "Paletta finding the internal malleolus deficient in size, concluded this to be the cause of the foot being drawn inward by the adductor muscles."

The inner malleolus has never, in any of my dissections of fœtal or infantile specimens, been found deficient in size, or altered either in position or form; but in the bones of a severe adult case of varus in St. Thomas' Museum, described by me in Vol. III of the "Path. Soc. Trans.," and from which the astragalus represented in Fig. 37 is taken, the inner malleolus is seen to be much shorter than natural, and presents inferiorly a flattened surface, with an articular facet, which articulated with the navicular bone. This deficiency of the inner malleolus, therefore, I regard not as an essential, but as one of a series of acquired or superadded conditions met with in the adult.

The diminished prominence of the inner malleolus in cases of infantile varus, depends upon the displaced position of the navicular bone, which is drawn inwards and upwards so far as to be in contact with the malleolus, the relative external prominence of which it therefore diminishes, and in severe cases, the

* *Op. cit.*, page 6.

† Exercitationes Pathologicæ Mediol. 1820, page 138.

outline of this process cannot be determined by external examination.

The normal size of the inner malleolus in the infant is made evident by dissection; but it is also proved by this process assuming its natural degree of external prominence during the treatment for the deformity. This it does very quickly in infantile cases, after division of the posterior tibial tendon, when the ligamentous rigidity is not considerable, but more slowly in proportion to the existence of this rigidity. The increasing prominence of the inner malleolus during treatment, depending upon the degree of replacement of the navicular bone, is always a favourable indication as to the result of the case.

The transverse relations of the malleoli, with respect to the shaft of the tibia, are unaltered in infantile cases, although when the deformity is severe, it appears from external examination, as Scarpa* observes, "as if the two bones of the leg had been turned in such a manner, that the internal malleolus is carried forwards, and the external backwards." I agree with Scarpa in considering this condition to be rather apparent than real in infantile cases; and to me it appears to depend upon the oblique direction of the os calcis, the tuberosity of which inclines towards, and, in severe cases, is in contact with the fibula; thus the inner malleolus is apparently more forward than natural. In severe adult cases, a twisting of the lower extremity of the tibia and consequent alteration in the transverse relations of the malleoli does occur to some extent.

With respect to the bones, then, it must be borne in mind

1st. That the os calcis and astragalus each occupy an oblique and, in severe cases, almost a vertical position.

2nd. That the astragalus is materially altered in form as well as in position; its neck passes obliquely inwards; and the articular surface of the head of this bone, instead of looking directly forwards, is turned towards the inner malleolus, and has therefore an antero-lateral aspect. The head of the astragalus may be said to present in severe cases two articular facets; one the larger, looking directly inwards, and articula-

* *Op. cit.*, page 6.

ting with the navicular bone; the other, the smaller, looking directly forwards, and exposed on the dorsum of the foot, in consequence of the displacement of the navicular bone. The posterior border of the astragalus is extremely attenuated and wedged in between the elevated os calcis and the posterior edge of the articular surface of the tibia.

3rd. That the navicular bone is displaced and drawn upwards and inwards, so far as to come in contact with the inner malleolus, and holds a lateral relation with respect to the head and neck of the astragalus.

4th. That the cuboid bone, although altered in its axial relations, is not materially displaced from its articular connexion with the os calcis.

5th. That the normal relations of the cuneiform and metatarsal bones are maintained with respect to each other as well as with the navicular and cuboid bones, and in consequence of the displacement of the navicular bone they are placed at right angles laterally with respect to the leg, and contribute most to the general appearance of inversion of the foot.

The point of the greatest novelty and interest in the description just given, refers to the alteration in form of the fœtal astragalus, which in every specimen examined, I have found to be more or less marked, according to the severity of the case. It may therefore be looked upon as an established fact, that in a severe case the astragalus is considerably malformed at the period of birth.

With respect to the cause of this malformation of the astragalus it appears to me, that if we look at all the abnormal conditions present in the deformity, there is little reason for supposing it to depend upon any defective power of development in the bone itself; but, on the contrary, there appears to be sufficient evidence for believing that the malformed condition of the astragalus is determined by the malposition of two of the bones with which it articulates, viz., the navicular bone and the os calcis; and that its altered form is in evident adaptation to the altered position of these bones.

This would appear to be the explanation, and it may be sup-

posed with reason, that the astragalus in its cartilaginous state, having only an osseous centre, would mould itself during the latter part of its intra-uterine growth, to the lateral position of the navicular bone, and to the elevated position of the os calcis. The altered form of the astragalus, therefore, I regard as the result, rather than the cause, of the deformity.

Cartilage has been in my dissections constantly found in those portions of the articular surfaces of the astragalus which have either been extruded from, or may never have entered into, the composition of the ankle-joint. The articular surface of the inner malleolus appears to be the only exception to this in very severe cases. Cartilage has also, in every instance, been found on the exposed outer portion of the head of the astragalus.

These facts sufficiently evince the tendency of the astragalus to develop itself in accordance with its normal typical form. The possibility of perfectly restoring the functions of the ankle-joint, and the astragalo-navicular joints, is also proved, at least so far as the bones and their articular surfaces are concerned, if their normal relative position be restored at an early period.

If this be accomplished, we may consequently infer that the astragalus, during the subsequent period of its growth and ossification, will gradually assume its natural form. On the other hand, there can be little doubt that the difficulty of restoring the functions of the joints, into the composition of which the astragalus enters, would increase in direct proportion to the extent to which ossification of this bone has been allowed to proceed in the deformed position.

By the explanation now given, if it be correct, we are enabled to determine an important practical question, as to the period at which the operation for the cure of congenital talipes varus should be performed.

In order that the astragalus may have the best chance of reverting to its natural form during the period of active growth and ossification in early infancy, the cause of its malformation, viz., the abnormal position of the navicular bone and os calcis should be removed at an early period. With this object in view, as well as for other reasons connected with the condi-

tion of the muscles and ligaments, it is advisable that the operation be performed as soon after the first month from the period of birth, as the circumstances of the case permit, having special reference to the healthy condition of the child and mother. Practically I find that the most favourable time for operation, is when the child is about two months old.

CHAPTER IX.

CONGENITAL TALIPES VARUS CONTINUED—MORBID ANATOMY IN THE INFANT CONCLUDED.

LIGAMENTS.—The majority of writers have too little regarded the condition of the ligaments in cases of club-foot, nor has any allusion been made to the subject in some of the principal works on Orthopædic Surgery. In Dr. Little's work, we have no description of any structural alteratious in the ligaments, either in infantile or adult cases of club-foot; and Mr. Tamplin* remarks. "The contraction of the ligaments does not apply to infants;" and again at page 53. "The increased severity in an infant is dependent solely on the greater amount of contraction of the muscles themselves, not so, however in the adult. In these, the severity will be greately increased by the contraction of ligaments from position."

Dissection teaches us, however, that the ligaments do contribute materially to the persistence of the deformity at all ages, and experience proves that the success of the treatment is considerably impeded by the resistance they offer to the restoration of the foot to its natural form, both in infantile and adult cases.

The ligaments gradually adapt themselves in length and form to the altered position of the bones they naturally serve to connect, in proportion to the length of time the deformity has existed previous to birth, and also in proportion to the severity of the muscular contraction which determines the external form of the foot. This ligamentous adaptation, or contraction, maintains the bones so firmly in the deformed position in severe cases at birth, that the foot cannot be restored to its natural form and position, even after division of all the contracted tendons.

* Mr. Tamplin "On Deformities," page 45.

We may conclude then that the rigidity with which the foot is held in its deformed position at birth, depends not only upon muscular contraction, but also upon the extent to which the adapted shortening of the ligaments has taken place during the latter part of the intra-uterine growth of the bones.

It is a well known fact that club-foot sometimes occurs as early as the fourth month of pregnancy, and we have the evidence of Rudolphi* that these distortions are occasionally witnessed in embryos of three or four months, whilst Dr. Little† tells us that he has anatomically examined several cases of talipes varus in fœtuses at the fourth month; and I have also made dissections of several specimens of varus in fœtuses of about the fourth or fifth month. During the remaining five months of uterine development, this process of adapted shortening, or defective growth, of some of the ligaments must be taking place. In the cases in which there is good reason to believe that the deformity occurred at this early period, as for instance when talipes varus is associated with spina bifida, the rigidity of the foot, from adapted shortening of the ligaments, is met with in an extreme degree.

In one case of this kind, I dissected in a fœtus with talipes varus and spina bifida, and from which the astragalus, Fig. 27, was taken, the foot could not be restored to its normal position, even after division of all the tendons of the contracted muscles. The most obviously shortened and resisting ligaments were the deltoid on the inner side, the anterior portion of which prevented the navicular bone being drawn sufficiently outwards from the inner malleolus; and the posterior ligamentous bands of the ankle-joint, which prevented the os calcis being depressed to its natural extent. All the ligaments in the sole of the foot, the calcaneo-cuboid, calcaneo-scaphoid, and other ligamentous bands passing between the tarsal bones were also shortened; and the plantar fascia was contracted and shortened to a very marked extent. The shortened condition of the deltoid

* "Physiologie," 6tes Buch, page 323.

† *Op. cit.*, page 270.

ligament is described by Maceever,* who states that, in the talipes varus of an infant, in whom the scaphoid and internal cuneiform bones were drawn close to the internal malleolus, he could not abduct the foot until he had divided this ligament.

As in all severe and rigid cases of infantile varus, the state of adapted shortening of the ligamentous structures above described is found to exist; so, also, are the opposing ligaments found to be elongated. The outer portion of the ligament passing between the neck of the astragalus and the navicular bone, is much elongated as it stretches over the exposed portion of the head of the astragalus. The anterior portion of the capsular ligament of the ankle-joint is also elongated, as it stretches over the extruded portion of the superior articular surface of the astragalus.

In the fœtal specimens I have examined, the ligament passing between the outer surface of the os calcis and cuboid bone, has not appeared to be materially elongated; nor have any of the other ligaments on the dorsal or convex surfaces of the foot, although they become so at a later period.

The ligamentous alterations I have described, are only to be met with in severe cases of infantile club-foot, which are comparatively rare; and I would observe that we may judge of the severity of the case, by the extent of the ligamentous rigidity, rather than by the external form,

In many cases of this deformity which would be described as severe, judging from the external form, there is but slight ligamentous rigidity, the foot being held in its deformed position by muscular contraction. In such cases, the foot can be carried half way or more towards its normal position, and the eversion of the anterior portion can always be carried comparatively further than the depression of the heel. In some cases of less severity there is no ligamentous rigidity, and the foot can be restored by manipulation quite to its normal position. In the latter cases, the deformity has probably taken place at a much later period of utero-gestation than the rigid cases previously described.

* *Edinburgh Medical Journal*, Vol. 16, page 220, 1820.

MUSCLES.—As a general rule in slight, and even in moderately severe cases of congenital talipes varus, all the muscles are in a healthy condition, and developed to very nearly their normal size at the period of birth. Some defect in size, however, exists in the contracted and permanently shortened muscles, and will be found in direct proportion to the severity of the case.

In infants affected with club-foot of a moderate degree of severity, the legs do not appear smaller than those of healthy children. Yet, if the deformity be allowed to continue, the muscles, from their state of inaction, do not grow as in healthy limbs, but remain of small size.

In several cases of severe infantile varus, in which adaptation of the ligaments has existed to some extent, whilst the astragalus exhibited in a marked degree the deviations in form above described—thus proving that the deformity had existed several months previous to birth—I have found on dissection, that the muscles did not exhibit either to the naked eye or the microscope any abnormal structural conditions.

It is therefore an established fact that appreciable changes in the musculur structures are not essential to the production of talipes varus; and that such changes do not necessarily exist at the period of birth, even in cases which would generally be considered as severe. This, is in accordance with the general opinion based on dissections, and the successful results of treatment.

Structural changes in muscles occasionally met with. Although, as a general rule, there is an absence of any abnormal condition of the muscles in cases of talipes varus, still, in my dissections, I have met with several instances of extensive and important structural changes in the muscles. The frequency of such deviations remains to be proved by future dissections. I am not aware they have been described by any other writer on the subject.

The first case of this kind that came under my observation occurred in the child from which the astragalus represented in Fig. 27 was taken, and for this specimen, which I described in "Trans. Path. Soc.," Vol. III, I am indebted to my friend Mr. Canton.

The child was affected with spina bifida in the lumbo-sacral region, and lived only a few hours. Both feet were contracted in the position of talipes varus of the most severe degree, and drawn inwards and upwards beyond a right angle with the legs. The muscles and other structures of both legs, when dissected, presented similar appearances.

The gastrocnemius was large, but not symmetrically developed, the internal head and half the muscle being very much larger than natural; the external head and half the muscle were imperfectly developed, so that, instead of there being a central raphé leading upwards from the tendo Achillis, the tendinous line passed towards the small external head. The inner half of the muscle could be easily cleaned on dissection, its surface being smooth and plump, as in well-nourished muscles of fine texture; while the outer half could not be cleaned from the quantity of fat mixed up with, and dipping between, its muscular fasciculi, its condition evidently approaching that of the extensor longus digitorum. The tendo Achillis, was of large size, and extremely tense.

The tibiales anticus and *posticus* muscles were both fully developed, if not somewhat hypertrophied, and their tendons extremely tense. The gastrocnemius and tibiales muscles were considerably shortened in their entire length, and after dissection were capable of being elongated only to a slight extent.

The extensor proprius pollicis was about, or rather below its natural size, and its tendon tense, but to a less degree than the anterior and posterior tibial tendons.

The extensor longus digitorum and *peroneus tertius*, so far as their muscular fibres were concerned, might almost be said to be absent; their tendons existed, but were of very small size, and connected above with an extremely attenuated layer of muscular fibres representing the extensor muscle. The muscular fasciculi were intermixed with fat dipping between them, so that their dissection could only be conducted to a very limited extent, and it was impossible to trace them to any connection with, or origin from the bones, or interosseous ligaments.

The space between the outer border of the tibialis anticus

and the fibula, which should be occupied by the fleshy belly of the extensor longus digitorum, was entirely filled with fat, in which no muscular fibres were traceable, even with the microscope. The existence of the rudimental portion of the extensor muscle, above described, was only demonstrated by the most careful dissection from below upwards, beginning from the delicate tendons on the dorsum of the foot.

The extensor brevis digitorum was in the same condition as the long extensor, traces of its muscular portion being found only on the most careful dissection from below upwards, beginning from the delicate tendons on the dorsum of the foot.

The peronei muscles were moderately well developed, and presented no abnormal condition.

Besides the tibialis posticus which we have already spoken of, as being fully developed, the other deep posterior muscles, the *flexor longus digitorum* and *flexor longus pollicis* were developed to about their normal size, and were healthy in structure.

The rudimental portion of the *extensor longus digitorum* muscle in this case was examined by myself and Dr. Quain, whose investigations of the fatty degeneration, and other abnormal conditions of muscular tissue have thrown so much light upon this interesting subject. We found that the muscular fasciculi were larger than the fasciculi of the healthy muscles of the corresponding thigh; the transverse markings were very indistinct, and in many parts not traceable; the sarcolemma containing a granular material studded in some parts with molecules of oil.

The second specimen of this kind which I examined, was removed from the body of a child aged ten weeks. This specimen is in Mr. Tamplin's possession, and exhibits conditions in many respects similar to those I have just described; but the arrest of muscular development was more extensive, involving all the muscles on the anterior part of the leg, and also the peronei. The only trace of muscular fibre in the situation of these muscles, was in a very thin layer of tissue connected with the tendon of the extensor longus digitorum.

A careful microscopical examination of this specimen was made by the late Mr. J. Quekett and myself in December, 1852. No trace was found of muscular structure in the situation of the tibialis anticus, extensor proprius pollicis, or peronei muscles, and only a few small fibres connected with the tendon of the extensor longus digitorum. The place of the muscular structure in the above situations was occupied by fibrous and adipose tissue. The posterior muscles were well developed. The fibres of the tibialis posticus were larger than in any other specimen examined. The muscular fibres in the external half of the soleus muscle were in a state of granular and fatty degeneration. Mr. Quekett and myself examined five specimens of club-foot.

Since the date of these examinations I have, in the course of my dissections, met with two other instances very similar to the specimen just described; and one of these having been sent to the College of Surgeons with the present Essay, is now in the Museum of the College.

From the examination of the specimens we have just described, it is certain that in some severe cases of talipes varus, there is, at the period of birth, a very defective condition of some, or it may be all, the muscles on the anterior aspect of the leg, essentially depending upon arrest of development of these muscles, and a degeneration of such portions as have been formed. The same condition may coexist in the peronei muscles; and in these cases the outer portions of the gastrocnemius and soleus muscles are found in more or less advanced stages of fatty degeneration.

It is also certain, that in these cases the muscles, or portions of muscles, which may be considered as more immediately concerned in the production of the deformity, viz.: the gastrocnemius and soleus (their internal portions more especially), the tibialis posticus, and the tibialis anticus (when the latter escapes the arrest of development met with in the other anterior muscles), are found to be well developed in their structural microscopic characters, and even hypertrophied. These are facts of which I am not prepared to offer any explanation, but to

which we may hope to discover some clue in future dissections.

In reference to my observations upon these cases, Dr. Little* has remarked, "Mr. W. Adams has witnessed absence of the extensor longus digitorum muscle. The author (Dr. Little) has never observed greater deficiency of this than other muscles. He (Dr. Little) has even found the long and short extensors well developed. The author (Dr. Little) believes that the deficiency, or atrophy and degeneration of muscles is in a precise ratio to the extent of the deformity, and the earliness of uterine existence at which the deformity is produced. The fact of hypertrophy of the part of the gastrocnemii, observed by Mr. Adams, is an important contribution to the pathology of varus, since it shows another analogy with non-congenital talipes, in which sometimes hypertrophy of the contracted muscles exist."

I cannot but doubt the correctness of the explanation here given by Dr. Little, of the condition of the extensor muscles above described. If the cause were traceable solely to the influence of long retained position, the same condition, or at least an approach to it, should be found as a constant appearance in all severe cases of fœtal and infantile varus, in which there is reason for believing, from the malformed condition of the astragalus and other indications, that the deformity had existed several months previous to birth. This is certainly not the fact, as in several severe cases which I have examined— submitting every muscle to microscopical examination—I have found the extensor, as well as all the other muscles, perfectly healthy and well developed.

There can be no doubt the altered form of the astragalus is directly dependent upon the severity and duration of the deformity; but I have observed that when the deformity has existed long enough to alter the form of this bone by adapted growth, the muscles are generally found to be perfectly healthy.

I have not yet been able to make out any essential connexion

* *Op. cit.*, page 277.

between the abnormal condition of the muscles above described, and any abnormal condition of the nervous centres, or nerve trunks, but further observations are necessary in this direction; possibly they may be found to stand in the relation of cause and effect. The arrest of muscular development may perhaps depend upon some abnormal condition of the nervous centres, and the deformity in these cases would be severe in consequence of its taking place at an early period, viz., between the third and fourth month, when the muscular tissue is in process of development. The degeneration may be traced partly to the same cause, and partly to the influence of long-continued inaction, but inaction alone would not sufficiently explain the condition described.

When giving a prognosis in any severe cases of talipes varus, the occasional existence of the arrest of development and degeneration of certain muscles, or portions of muscles, must be borne in mind. The frequency of the existence of these conditions; the possibility of their improvement by the development of muscular tissue after free motion of the ankle-joint has been obtained by tenotomy; and their influence in retarding or preventing the complete cure of the cases in which they exist, have yet to be ascertained.

The existence of these muscular imperfections, when present to the extent described in the above cases, may be diagnosed by the total absence of the power of extending the toes or the foot; and the toes are drawn downwards and flexed towards the sole of the foot, as in paralytic cases, presenting the appearance represented in Fig. 30. When the muscular imperfections are present in a less degree, there will be a deficiency in this power to a corresponding extent. Possibly these cases may have been occasionally mistaken for examples of congenital paralysis.

Although I have only had four or five opportunities of examining these muscular imperfections after death, I have in the course of my experience at the Orthopædic Hospital seen a considerable number of cases—probably twenty—in which I had no doubt the same abnormal conditions existed; and in several

of these cases the club-foot has been associated with some malformation and congenital contraction, either of the knee or hip-

FIG. 30.

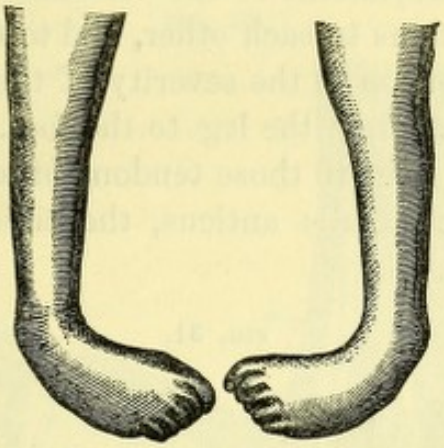

Congenital talipes varus with deficiency of the extensor communis, and defective development of the other extensor muscles on the anterior surface of the leg—Leg small, feet rigid and inflexible, toes flexed and drawn in towards the sole of the foot.

joint, or of both, as shown in Figs. 38 and 39, and in some instances with malformations in other parts of the body. I need hardly observe that these cases are extremely unfavourable for treatment, and that a permanent imperfection to a greater or less extent will be sure to remain. The feet and legs are peculiar, and their appearance diagnostic, although difficult to describe. The legs are usually thin in proportion to the thighs, as if showing a deficiency of muscular development and nutrition generally, below knee. The feet look rigid and inflexible, and really are so. When thin—and there has generally been a deficiency of subcutaneous fat in the cases which have fallen under my observation—the feet present a smooth outline, without the irregularities and prominences observable in ordinary cases of congenital varus; the four outer toes are immovably flexed and drawn inwards towards the sole of the foot; the great toe is in some cases also drawn inwards, but in other cases is extended, when the extensor pollicis muscle is less implicated than the other extensors. I had under my care at the Orthopædic Hospital, a child aged four months, in whom this condition existed in both feet, and the appearances are represented in Fig. 30.

TENDONS. I have always found by dissection of fœtal and infantile specimens of talipes varus, that the tendons are somewhat displaced in adaptation to the altered position of the bones of the foot. The deviations of the tendons relate to their direction, their relations to each other, and to the bones, and will be found, in proportion to the severity of the case, to affect all the tendons passing from the leg to the foot. It is only necessary at present to refer to those tendons of direct practical importance, viz., the tibialis anticus, the tibialus posticus, and the tendo Achillis.

FIG. 31.

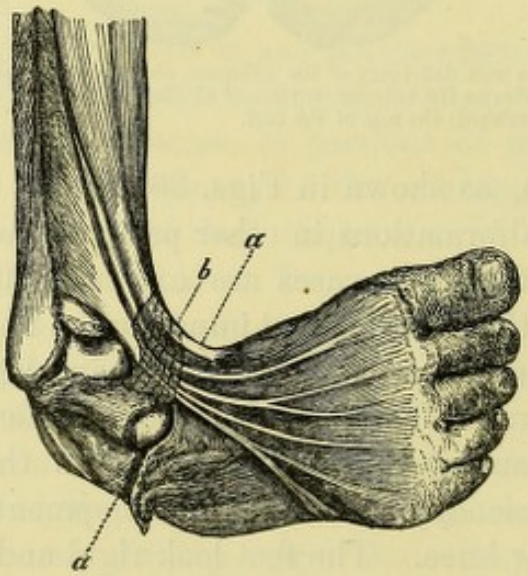

Congenital talipes varus of the right foot from a child aged six months, dissected so as to show the relation of the muscles and tendons on the anterior surface of the leg and foot in this deformity. The point we select for dividing the anterior tibial tendon is indicated by letter *b*. The ankle-joint and transverse tarsal joint have been laid open so as to exhibit the altered relations of the astragalus and navicular bone. The transverse tarsal joint is indicated by the dotted line *a a*. The obliquity of neck, and lateral aspect of head of astragalus are well exhibited.

All the tendons in front of the ankle-joint are inclined to the inner side of the leg, and *the tendon of the tibialis anticus muscle* as it crosses the ankle-joint (the point we select for its division) *b*, is placed very much to the inner side. In severe cases, such as that represented in Figs. 31, and 32, this tendon passes obliquely downwards across the inner malleolus, with an inclination backwards towards the inner cuneiform bone, which, in consequence of the altered position of the navicular bone, occupies

a lateral position with respect to the leg. In these cases, the toes have an inclination rather behind, than in front of, the transverse median plane of the leg.

FIG. 32.

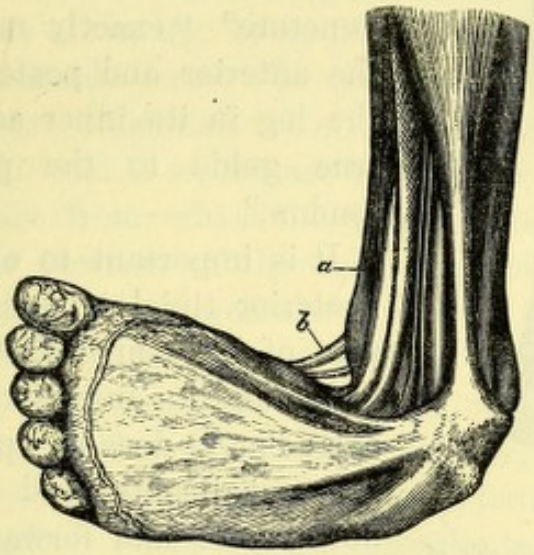

Posterior aspect of the same leg as represented in Fig. 31, exhibiting relative position of muscles and tendons. The situation we select for division of posterior tibial tendon, just above the inner malleolus, is indicated by letter *a*. The anterior tibial tendon, crossing the inner malleolus with an inclination backwards, is indicated by letter *b*. The elevation of os calcis, and position of tuberosity of this bone behind the fibula; and inclination of Achilles tendon, towards the fibula side of leg are exhibited.

The tendon of the tibialis posticus muscle does not occupy its normal position with respect either to the inner malleolus, or in its course between this process and the navicular bone. In severe varus, this tendon is less distinctly placed behind the inner malleolus than in the healthy foot, and is sometimes described as being situated on, rather than behind this process.

To some extent this is certainly correct, but the appearance is very much added to by the lateral obliquity of the os calcis, the tuberosity of which is directed towards the fibula, so that the inner malleolus itself is relatively more forward; in fact, the posterior surface of the tibia is thus more or less brought into what might be regarded as the lateral aspect of the foot. The relative position of this tendon is well exhibited in the accompanying woodcut, Fig. 32. *a*.

The general result is, that the situation of the posterior tibial tendon at the point we select for its division, viz., just

above the malleolus, is relatively more forward than in the healthy foot; hence the practical rule given by Dr. Little, that when neither the tendon or the inner edge of the tibia can be felt, as is commonly the case in fat infants, a puncture* "exactly midway between the anterior and posterior borders of the leg in its inner aspect will be a true guide to the position of the tendon."

FIG. 33.

Lateral aspect, from fibula side of the same leg as Figs. 31 and 32, exhibiting extreme elevation of the tuberosity of os calcis, and obliquity of this bone. Also the nearly vertical position of astragalus, the body and neck of which are directed downwards in a line continuous with the leg.

It is important to observe that the posterior tibial tendon in the second part of its course—between the malleolus and its insertion into the navicular bone—does not pass beneath the inner malleolus, and then obliquely downwards and forwards in front of this process, towards its insertion into the navicular bone, as in the healthy foot, because the navicular bone itself is displaced by the contraction of the tibialis posticus muscle, so as to be held in contact with the inner malleolus. This tendon, therefore, in all severe cases of varus, and even in those of a moderate degree of severity, passes directly downwards from the inner malleolus to its insertion into the navicular bone, which it immediately reaches.

In determining the position in which this tendon should be divided, it is of the utmost importance to bear in mind the altered relations above described, and which, so far as I am aware, have not been pointed out by any previous observer. At present I would only remark that the extent to which this tendon admits of being drawn by manipulation into its normal position, below and in front of the inner malleolus, must depend upon the severity of the case, and the ligamentous rigidity of the parts from adapted shortening of these tissues

* *Op. cit.*, page 299.

during the existence of the deformity. When speaking of Mr. Syme's proposed method of dividing this tendon a "little below and in front of the inner malleolus," we shall again refer to this point.

The tendo Achillis does not occupy its normal position with respect to the axis of the leg, or its relation to the malleoli, in severe cases of infantile varus. In consequence of the lateral obliquity of the os calcis, the tuberosity of this bone inclines towards the fibula, and is sometimes even in contact with it, as in the severe case from which the fœtal astragalus, Fig. 27, was taken. The position of the tuberosity of the os calcis directly behind the fibula is well shown in Fig. 32.

The tendo Achillis in passing towards its insertion into the tuberosity of the os calcis, must therefore necessarily incline towards the fibula, as shown in Fig. 32, in a degree proportionate to the severity of the case, and this I have found in every dissection I have made. There is some difficulty in judging of the exact relations of this tendon by external examination, in consequence of the diminished prominence of the internal malleolus. In a superficial examination during life, the Achilles tendon may even be supposed to deviate to the inner, rather than the outer side of the leg. I have frequently heard it described as holding this position, and it has also been remarked that this tendon is placed directly over the artery, but I have never been able to satisfy myself that it is so placed. It seems to me that the appearance is deceptive, and depends upon the diminished prominence of the inner malleolus, and also the relatively more forward position this process occupies in consequence of the lateral obliquity of the os calcis, which tends to bring the posterior surface of the tibia into what might be regarded as the lateral aspect of the foot.

If the position of the tendo Achillis be judged of by its relation to the outer malleolus, which can always be felt, the difficulty disappears. I believe it will always be found deviating towards the fibula in proportion to the severity of the case. This tendon is, therefore, further removed from the posterior tibial artery than in the healthy foot. We will now pro-

ceed to speak of the deviations in the relative position of the

VESSELS AND NERVES. As the vessels and nerves in their course from the leg to the foot, follow the direction of the deformity, they necessarily deviate to a corresponding extent, in their general direction and relations; but, practically, these deviations are of little importance, as they do not materially alter their relations with respect to the tendons.

M. Guérin has observed with respect to the vessels and nerves in deformities, that the nerves become structurally shortened, and therefore frequently tense and prominent, like the tendons; while the vessels retain their normal length and are found to be somewhat tortuous, but still holding their deep relations, and not becoming superficial or prominent. I suspect, however, that this difference between the arteries and nerves is not well founded, but that both undergo structural shortening in cases of long standing deformity, and adapt themselves to their required length.

It is undoubtedly true that, in cases of long standing contraction of the knee-joint, the peroneal nerve is tense and prominent, so that, without the greatest care, it may be wounded in dividing the biceps tendon; moreover, after the tendon has been divided, the nerve springs up, so as to occupy its place, and feels as tense as the tendon did before division. The inexperienced operator may therefore conclude that the tendon has not been completely divided, and, under these circumstances, the knife has been reintroduced and the nerve divided, much to the astonishment of the operator.

It appears to me that the prominence of the nerve in the ham, in these cases, may be explained by its superficial course, and by its not being bound down by any dense structures. On the other hand, the artery enters this space deeply by a strong tendinous canal, and is also held close to the head of the tibia by the arrangement of the structures at its bifurcation, as well as by the course taken by the anterior tibial artery, in its passage between the bones, which materially contributes to fix the artery in this situation.

In several severe infantile cases of club-foot, and, also,

non-congenital cases in the adult, which I have dissected, the posterior tibial artery and nerve have not exhibited any disproportionate length, but both the artery and nerve appeared to be equally, and proportionally shortened; in one of the most severe infantile specimens, the arteries were well injected. I have not seen the posterior tibial nerve become at all prominent, or altered in its relations to the artery, and, as in club-foot, both these structures are at a depth from the surface, and lie close to the centres of motion, the shortening cannot be considerable, or of any practical importance, even in adult cases.

I have now described the morbid anatomy of talipes varus, as found at the period of birth, and it will be observed that this deformity is not so simple and uncomplicated with organic lesions as authors on this subject would lead us to infer. It is not simply a displacement of certain bones, whether from muscular action or malposition *in utero*, which have previously been well formed, as first taught by Scarpa, and since adopted by nearly all the authorities on this subject. But, on the contrary, malformation—consecutive, or adapted malformation, it may be called—of the astragalus is always present at the period of birth, in a degree proportionate to the severity of the deformity. Various important ligamentous alterations from adapted growth are also present in severe cases. Deviations in the direction and relative position of the tendons are constantly present, and a variety of abnormal conditions in the muscular structures are sometimes met with.

CHAPTER X.

CONGENITAL TALIPES VARUS CONTINUED.—MORBID ANATOMY IN THE ADULT.

General Observations. I have hitherto described the morbid anatomy of talipes varus as it exists at the period of birth, and will now proceed to examine the anatomical conditions of this deformity, as it exists in the adult, particularly noticing the nature of the changes which take place during growth.

We are met here, however, by a difficulty which probably few would be prepared to expect, viz: the absence of specimens from which a description of the morbid anatomy of congenital talipes varus in the adult may be drawn.

It is a remarkable fact that at the time this essay was written, no Museum in London contained a single specimen of adult congenital talipes varus, dissected so as to exhibit the relations of the bones, ligaments, tendons, and muscles in this deformity; the few specimens which existed had all been macerated.*

In the Museum of St. Thomas' Hospital, there is an articulated foot from a case of talipes varus in an adult, without any history, but there is no doubt the deformity was of con-

* Since the prize was awarded to the present Essay, in March, 1865, Mr. Partridge has contributed to the Museum of the Royal College of Surgeons, two valuable specimens of congenital talipes varus in the adult. They have been carefully dissected and put up as wet preparations, so as to exhibit all the deviations of the tendons, ligaments and bones. The arteries, however, have not been preserved. These specimens present the closest resemblance with respect to the deviations of the bones, and the altered relations of the tendons, to the dried specimen from which I have taken my description, and which I sent to the College of Surgeons with the present Essay. It is now in the Museum of the College. Another specimen has since been added by Mr. Partridge, with the vessels and nerves dissected, so that a complete series now exists in the College Museum.

genital origin. I have described this specimen in the 3rd. Vol. of the Transactions of the Pathological Society, and the drawing of the astragalus, Fig. 37, was taken from it.

In the Museum of St. Bartholemew's Hospital there is the skeleton of a man, aged about fifty years, who had, according to Mr. Holmes Coote, who dissected the feet, "during life, suffered from an extreme degree of distortion of both feet (talipes varus), obliging him to walk, with the aid of crutches, on the dorsum, instead of the soles of the feet." The deformity in this case, was, doubtless, of congenital origin. The right foot has been completely macerated, and the bones articulated; but in the left, the ligaments and the insertions of the tendons remain.

This is one of the best specimens from which the morbid anatomy, as regards the deviations in the relative position of the bones and ligaments, can be studied, and it is to be regretted that the tendons and other structures were not preserved on one leg.

In the Museum of the London Hospital, there is a specimen of a foot which was dissected by Dr. Little, after it had been long preserved in a dried condition, and is figured, both in Dr. Little's "Treatise on Club-foot," 1839, p. 12, and also in his "Lectures on Deformities," 1835, p. 135. This specimen is, however, differently described in these works; in the former, it is adduced as an example of "talipes varus," being doubtless considered at that time of congenital origin, and Dr. Little observes "it may be relied on in the study of anatomical characters of this disease," but, in the latter work, the same specimen is described as one of "contracture similar in form to congenital talipes varus. No history of the case could be obtained. It is doubtless the result of non-congenital spastic deviation of the foot."

I have no doubt this specimen was taken from a non-congenital case, and I base this opinion on the fact that it differs in its anatomical characters in several important respects from those of the specimen upon which I rely for my description, and other specimens of undoubted congenital origin, which I have had the opportunity of examining; whilst on the other

hand, it closely corresponds with specimens of non-congenital deformity which I have dissected.

In Dr. Little's Lectures, p. 280, a drawing from another specimen has been given to show the relative position of the bones in severe adult congenital varus; but in this drawing the navicular bone is made to extend in an almost semicircular form, from the outer border of the head of the astragalus to the inner malleolus, and the cuboid bone is represented as of a wedge-like form, having a very extended base corresponding to the outer border of the foot, and a narrow apex directed towards the head of the astragalus and the navicular bone.

These facts are so completely opposed to the form and relative position of the same bones in all the specimens I have examined, that we can scarcely suppose the artist to have given a faithful representation of the specimen, and, therefore, reject the engraving from our reliable sources of information.

There can be no doubt that specimens of adult congenital varus have been dissected by Continental surgeons, judging from the description given by some of the earlier authorities, but, from the discrepancies which exist in these descriptions, there can be little doubt that the congenital and non-congenital forms were not always recognised.

We have in the splendid work of Cruveilhier* on Pathological Anatomy, several views of a dissected club-foot, which is said to be an example of congenital talipes varus from a woman, aged 41, and the conditions of all the soft parts in this specimen are described; but I have no hesitation in stating that Cruveilhier must have been deceived with regard to the congenital nature of this deformity.

That this specimen is an example of non-congenital talipes equino-varus of paralytic origin, there can be but little doubt; and the account given of the extreme wasting and degeneration of all the structures, strongly confirms this opinion. It is stated that the muscles were all in an advanced stage of fatty degeneration; the nerves extremely small, "we should have thought almost reduced to their neurilemma;" arteries not half

* "Anatomie Pathologique," Tome I., planche 3, 2e Livraison.

their natural size, &c. But the general form of the foot, and relative position and form of the bones, irrespective of the soft tissues, would be quite sufficient upon which to base my opinion as to its non-congenital origin. This specimen has been relied upon by Mr. Brodhurst as "a dissection of congenital varus," and at p. 38 of his work "On Club-foot," the entire description as given by Cruveilhier has been copied; but for the reasons already given, I unhesitatingly reject this specimen as one of congenital varus.

Cruveilhier has also figured the bones of several cases of talipes varus at different ages; and the relative position of the bones in one adult case, Plate IV, Fig. 1 in his work, will be found very closely to correspond with the dissected specimen from which Figs. 34, 35 and 36 in the present Essay were taken.

In the absence of all reliable specimens and drawings, I should have been at a loss to know upon what to rely for my description, if I had not had the opportunity of studying the morbid anatomy of adult congenital varus upon the dissected specimen of this deformity, which accompanied this Essay.* This specimen was formerly in the possession of Mr. Bishop, through whose kindness I was enabled to add it to my collection. It was exhibited by me to the Pathological Society on the 17th April, 1855, and in Vol. VIII. of the Society's Transactions it is fully described, and illustrated by the same woodcuts here represented, Figs. 34, 35 and 36.

This specimen, consists of the right foot and leg (below knee) of a laundress of about 30 years of age, who was born with a club-foot. She suffered from intractable ulceration from pressure on the dorsum of this foot, which was, therefore, useless to her, and became a troublesome burden. At her request the limb was amputated by the late Dr. Ayres, of the Wandsworth Road, about twenty years ago, but the woman unfortunately died after the operation. The specimen has been most carefully dissected, so as to exhibit the relative position of all the tendons, muscles, ligaments and bones, and has been preserved in a dried condition.

* This specimen is now in the Museum of the College of Surgeons.

Now, from the reliable history of this specimen, the nature of which is also confirmed by its close resemblance, as far as the bones and ligaments are concerned, to the existing specimens of adult congenital varus in our Museums, it appears to me that we may safely rely upon it for a description of the anatomical conditions of talipes varus in the adult. I therefore propose to draw the description now given, mainly from this specimen; and, although in the examination of other adult specimens, some minor points of difference may be found, still I believe it will faithfully represent the ordinary and essential condition of parts in this deformity, as it exists in the adult.

In describing this deformity in the adult, I propose to follow the same order as that adopted in describing the morbid anatomy of infantile varus.

I have shown that in a severe case of talipes varus, at the period of birth, the bones and ligaments are found already to have adapted themselves, during their intra-uterine growth, to the deformed position of the foot; that this adaptation necessarily involves considerable alterations in form of the astragalus; and that to such an extent does this take place in the rigid and severe cases occasionally met with, that the fœtal astragalus presents all the essential deviations in form met with in the adult.

During the growth and ossification of the bones, all the deviations in form described, become necessarily confirmed if the deformity be allowed to remain unrelieved; and the ligaments, also, in their adapted growth, materially tend to render the deformity permanent and incurable. The following are the anatomical deviations met with in, and essentially characteristic of congenital talipes varus when seen in the adult.

Bones. The bones do not grow at their normal rate, or attain their full proportionate development; nor do they acquire their natural degree of density; they remain thin-shelled, light, cancellous, and fatty. These changes result from a generally defective state of nutrition, constantly present in the legs of club-footed individuals, and largely contributed to by the impaired muscular action in these limbs.

In those portions of the bone, however, through which the weight of the body has been directly transmitted to the ground, viz :—the head of the astragalus, external part of the navicular bone, anterior extremity of the os calcis, and the dorsal surface of the cuboid bone, which, in its altered position, looks directly downwards—the surfaces become somewhat thickened, irregular and mammillated in appearance. The edges, grooves, and natural markings of the bones are round and ill-defined.

The os calcis is altered in position to an extreme degree, and also much in form. In consequence of the contraction of the tendo Achillis, or rather of the muscles which terminate in it, the tuberosity of the os calcis is elevated, so that this bone occupies a very oblique, or nearly vertical position, as shown in Fig. 34. It is rigidly held in this position by the retraction of the muscles of the calf and adapted shortening of the ligaments, more especially the posterior ligamentous bands of the ankle-joint. This bone is not simply elevated, but has also a marked degree of lateral obliquity, so that its tuberosity occupies a position immediately behind the fibula, see Fig. 36. I have not detected any lateral rotation inwards or outwards of the os calcis.

The tuberosity of the os calcis is seen to occupy a position immediately behind the fibula. In all the specimens

FIG. 34.

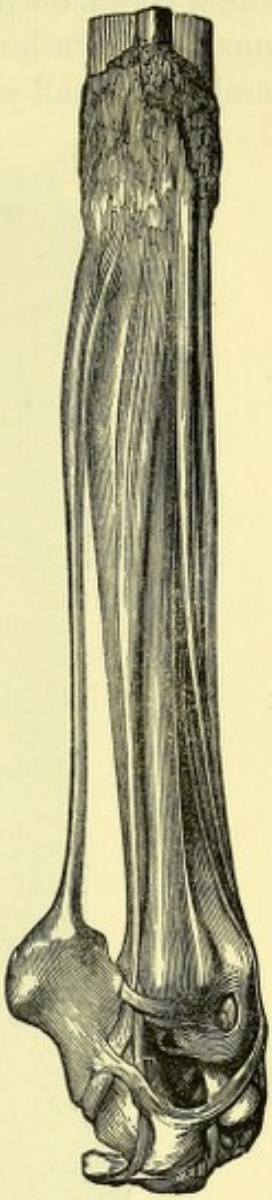

Congenital talipes varus in the adult—Lateral aspect—fibula side of leg; from same specimen as Figs. 35 and 36. The elevation of tuberosity of os calcis, and very oblique position of this bone; also the vertical direction of the body and neck of astragalus, in consequence of this bone being extruded from the ankle-joint are well exhibited. The peroneus longus tendon is seen passing directly downwards with an inclination backwards across the outer surface of the os calcis towards the sole of the foot, instead of entering the groove in the cuboid bone.

existing in our Museums, and in the articulated foot in St. Thomas' Museum, it is extremely attenuated and misshapen, and in actual contact with the fibula—see my description in Transactions of the Pathological Society Vol. III. The tuberosity is generally of small size, and somewhat misshapen.

FIG. 35.

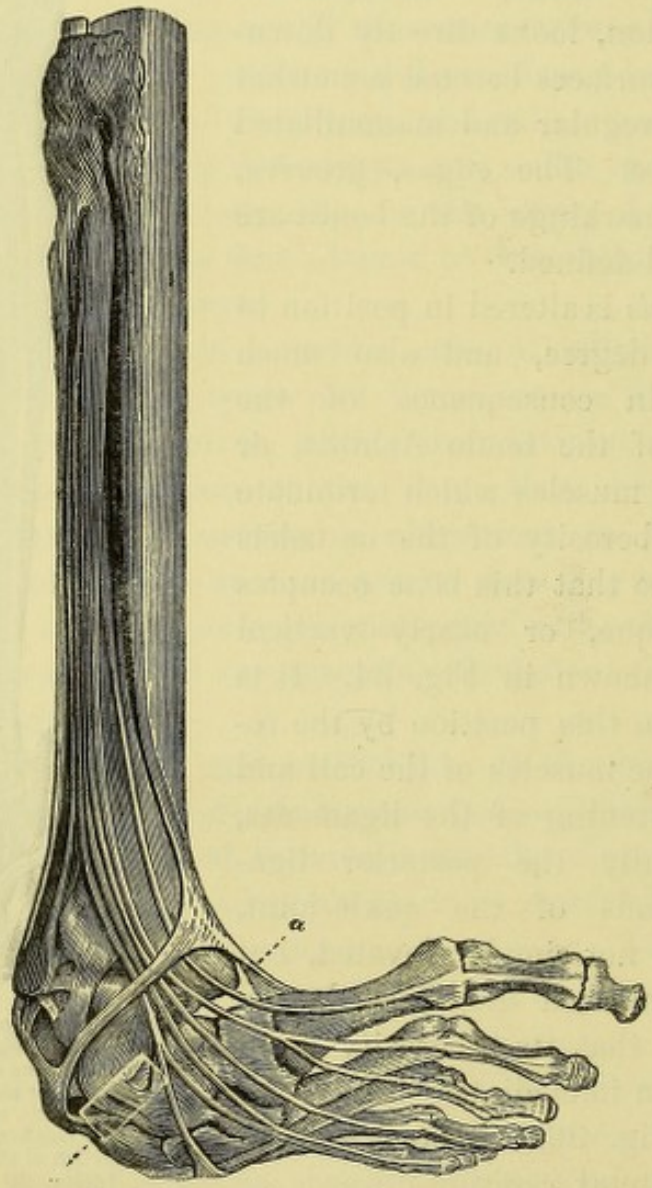

Congenital talipes varus in adult. Anterior aspect from same specimen as Figs. 34 and 36. The inverted position of the foot from the transverse tarsal joint is indicated by the dotted line *a a*, and the exposed portions of the head of the astragalus and anterior surface of the os calcis are well seen. The oblique direction of the neck of the astragalus and lateral aspect of the head, with which the navicular bone in its displaced position is articulated are well exhibited. The anterior tibial tendon is seen much displaced to the inner side.

The *superior surface* of the os calcis is in contact with the

posterior border of the articular surface of the tibia, and also with the fibula, both of which rest upon it, so that the os calcis appears to enter into the composition of the ankle-joint, as shown in Fig. 34.

FIG. 36.

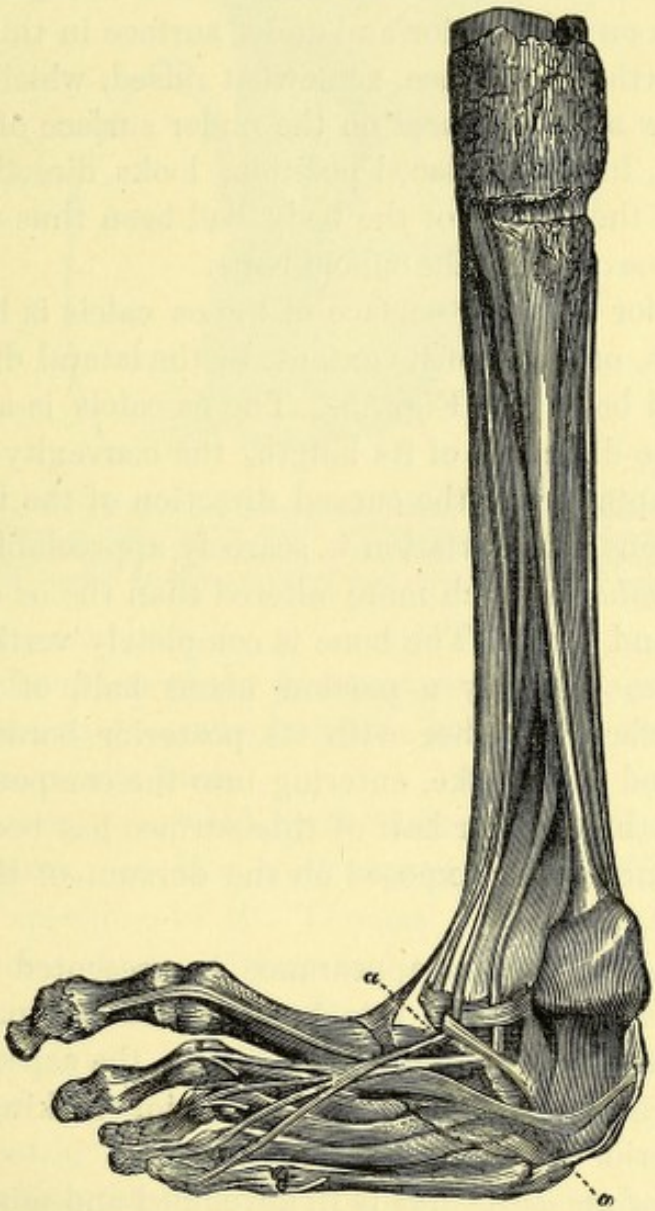

Posterior aspect of same specimen represented in Figs. 34 and 35, exhibiting the altered relations of the tendons on the leg and foot. The direction of the tendo Achillis immediately behind the fibula, and the deviation of the tuberosity of the os calcis to the fibula side of the leg are shown. The situation of the tibialis posticus tendon, rather on than behind the inner malleolus, beneath which it passes with an inclination backwards to reach the navicular bone is seen; the navicular bone and part of the cuneiform bone are both situated under the inner malleolus in this specimen. The transverse tarsal joint is indicated by the dotted line *a a*.

On its outer surface the grooves for the peronei tendons are

much less oblique than natural; the tendon of the peroneus longus muscles passes directly from the outer, round the inferior surface of the bone, to the sole of the foot. See Fig. 34.

In its inner aspect this bone is much misshapen. The projecting lip-like process—sustentaculum tali—is very irregular, and presents on its anterior and under surface in this specimen, a flattened articular surface, somewhat raised, which rests upon a similar new articular facet on the under surface of the cuboid bone, which, in its displaced position, looks directly upwards. A portion of the weight of the body had been thus transmitted through the os calcis to the cuboid bone.

The anterior articular surface of the os calcis is left exposed to two-thirds, or more, of its extent, by the lateral displacement of the cuboid bone, see Fig. 35. The os calcis is also slightly curved in the direction of its length, the convexity being outwards in adaptation to the curved direction of the foot; but in some specimens this deviation is scarcely appreciable.

The astragalus is much more altered than the os calcis, both in position and form. The bone is completely vertical in position, see Fig. 34; only a portion, about half, of its superior articular surface, together with its posterior border, which is attenuated and wedge-like, entering into the composition of the ankle-joint; the anterior half of this surface has been extruded from the joint, and is exposed on the dorsum of the foot, see Fig. 35.

An irregular flattened appearance is presented by the extruded anterior portion of this bone, which is separated from the posterior half by a transverse line; the aspects of these two surfaces, are different, the posterior looking upwards, and the anterior directly forwards.

The head of the astragalus is ill developed and misshapen, see Figs. 35 and 37. Instead of presenting a regularly convex surface directed anteriorly, it has two articular facets at right angles to each other, and divided by an abrupt line or angular ridge; one, the larger, looking directly inwards and articulating with the displaced navicular bone; the other looking directly

downwards, has been left exposed by the altered position of the navicular bone. The latter articular facet is covered only by

FIG. 37.

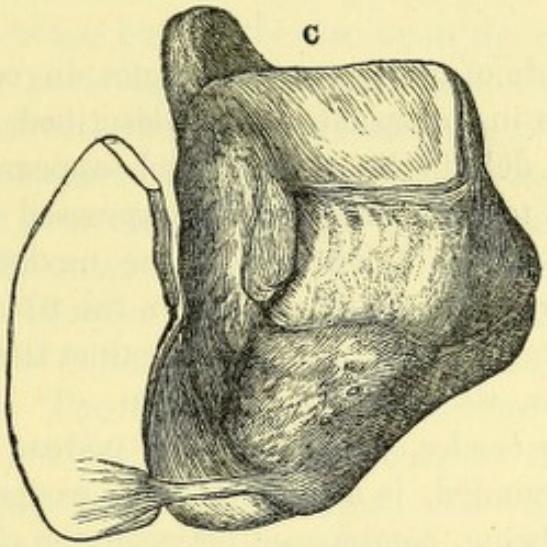

The astragalus from a severe adult case of congenital talipes varus. The navicular bone is drawn in outline for the purpose of exhibiting the lateral position which this bone occupies with respect to the long axis of the astragalus. The obliquity of the neck, and lateral aspect of the head of the astragalus, as well as the other deviations described in its superior and lateral articular surfaces are well exhibited.

the elongated portion of the ligament normally passing from the neck of the astragalus, which in this bone is ill-defined, to the edge of the navicular bone.

The deviations presented by the astragalus in a case of adult congenital varus, are also well represented in Fig 37, taken from a dried specimen in St. Thomas' Museum. The division of the superior articular surface into two portions—a transverse line separating the anterior position which has been extruded from the ankle-joint, from the posterior portion which alone has been included within the ankle-joint;—the obliquity of the neck of the astragalus; and the lateral aspect of the head of this bone, with which the navicular bone in its displaced position articulates, are exhibited; also the large articular surface for the fibula, and the small and imperfect articular surface for the inner malleolus, are well represented.

The articular surface for the external malleolus is separated from the fibula downwards and forwards, but is still distinctly

traceable, and the external lateral ligament passes across it, see Fig. 34.

The articular surface for the internal malleolus is not generally distinct, and there is often no indication of its having existed.

The inner side of the astragalus is not in contact with the inner malleolus in the specimen now described, but is separated from it by the deltoid ligament, which appears to have been folded inwards towards the joint, and pressed upwards by the navicular bone. The tuberosity of the navicular bone is directed in this specimen rather between the tibia and the inner side of the astragalus, than directly against the inferior surface of the malleolus, its more usual position.

The posterior border of the astragalus instead of being thick and obtusely rounded, is attenuated and wedge-like, in consequence of its being compressed between the elevated os calcis and the articular surface of the tibia, so that it is not visible externally in the foot we are now describing, and, of course, the groove for the flexor pollicis tendon is absent. There is no appearance of any lateral twisting or rotation of the astragalus in this specimen. Rotation inwards is generally described, but in fœtal specimens I have observed rather an inclination to rotation outwards.

The navicular bone is altered in position to an extreme degree but very little in form, see Figs. 35 and 37. The internal extremity or tuberosity of the navicular bone is drawn completely under the inner malleolus, and sometimes very much within its external boundary. The inner malleolus generally rests upon the tuberosity of the navicular bone, thus transmitting to the ground a portion of the weight of the body, and a flattened articular facet is formed on each bone.

This condition exists in the specimen in St. Thomas' Museum, see Fig. 37, and a flattened square surface on the upper part of the navicular bone is represented; but in the specimen represented in Figs. 34, 35 and 36, the navicular bone is drawn towards the ankle-joint, and more within the boundary of the malleolus than usual, so that its tuberosity is directed

rather to the space between the inner malleolus and the astragalus, than directly under the malleolus, see Fig. 35. The new articular facet is, therefore, less distinctly marked in this case than usual, and the inner malleolus has rested chiefly upon the inner cuneiform bone, but partly also upon the navicular bone. A portion of the navicular bone in its displaced position lies closely in contact with the neck and inner side of the astragalus, and is somewhat altered in form, but not to any considerable extent; in other respects, this bone remains unaltered in form.

The general direction of the long axis of the navicular bone is quite vertical, like that of the astragalus, with the body and part of the head of which, in its distorted form, it is in direct lateral relation. The long axes of these two bones are, as near as may be parallel, instead of being at right angles to each other, as in their normal relations. This relative position constantly obtains in all severe cases, whether infantile or adult, and is of the utmost importance to bear in mind in deciding upon the direction in which mechanical force is to be employed for the cure of the deformity.

The navicular bone is drawn into the position I have now described, chiefly by the active contraction of the tibialis posticus muscle. After the elevation of the heel and extension of the foot by the contraction of the great muscles of the calf, the tibialis posticus muscle acts in a direct line, so as to draw the tuberosity of the navicular bone, into which it is inserted, directly upwards and inwards, until it comes in contact with the under surface of the inner malleolus. The tibialis anticus, and in severe cases the extensor, and flexor pollicis, together with the flexor longus digitorum muscles, assist indirectly in causing this displacement of the navicular bone, which they accomplish by drawing the inner margin of the foot upwards and inwards simultaneously with, or subsequently to, the extension of the foot and elevation of the heel by the muscles of the calf.

The cuboid bone deviates considerably in position, and is also much altered in form. It is displaced inwards, in a lateral direction, from its articulation with the os calcis, so as to leave at least two-thirds of the anterior articular facet of the os calcis

uncovered, except by elongated ligamentous bands which still serve to connect these bones, see Figs. 34 and 35.

The cuboid bone retains its articular connection with the navicular bone, and follows it in its lateral displacement inwards and upwards, until checked by the *sustentaculum tali* on the inner side of the os calcis, with which it forms a new articulation. A flattened and expanded articular surface exists on the corresponding part of each bone, and by this means a portion of the weight of the body has been directly transmitted to the ground through the os calcis and cuboid bones.

As the navicular bone, by its lateral displacement, leaves the outer portion of the head of the astragalus exposed; so does the cuboid, by its lateral displacement, leave a considerable portion of the anterior articular surface of the os calcis exposed. The portions of the articular surfaces of the astragalus and os calcis thus left uncovered, look directly downwards, and in the act of progression transmit the weight of the body directly to the ground. The fact that the cuboid bone is displaced bodily inwards, from the anterior articular surface of the os calcis, should be especially noticed, because other observers describe only a separation of these bones externally, or widening of the articulation, so that "a space between them externally is left."

The cuboid bone, in addition to its displacement, undergoes a movement of rotation backwards, inwards, and upwards, the effect of which is to make its superior, or dorsal surface, look more directly downwards, so that this surface is presented towards the ground in the erect position of the body; and as the cuboid bone thus displaced is somewhat below the level of the tarsal bones, see Fig. 35, it must necessarily sustain the greater part of the superincumbent weight; while the dorsal surface of the cuboid bone, in its altered relations, looks directly downwards, the inferior or plantar surface looks obliquely backwards and upwards.

The great alteration in the position of the cuboid bone is not the result of any direct muscular action, as no tendon is inserted into, or even in contact with this bone. The tendon of the peroneus longus passes transversely inwards, across the

inferior surface of the os calcis, and thence directly across the sole of the foot to its insertion, see Fig. 36, above the level of the cuboid bone, and without any connexion with it.

In infantile varus, it has been stated that "the cuboid bone is but very slightly altered, either in position or form," and therefore it appears to me that its alteration in position essentially depends upon the influence of the superincumbent weight during progression.

Alteration in form. The cuboid bone in its displaced position becomes somewhat wedge-like from below upwards. Speaking with reference to the relations of its surfaces in the healthy foot, the long axis of its inferior or plantar surface becomes less, instead of being greater, than that of its superior surface; it is so in the specimen above figured, but not to any considerable extent, nor have I seen it assume any well marked wedge-like, or conical form, in any specimen I have examined. The dorsal surface of this bone is more convex than natural, and its edges are rounded. On its external border, and inferior surface, in the normal relations of the bone, we observe only a slight indication of the groove for the tendon of the peroneus longus, which, in this specimen, has never lodged in, or been in contact with it.

The cuneiform bones retain their normal relations to the navicular and cuboid bones, and to each other. These five tarsal bones move *en masse* in the same direction, inwards and upwards, from the great transvere tarsal joint in front of the astragalus and os calcis, after the complete extension of the foot by the elevation of the os calcis, see Figs. 35 and 36, dotted line *a a*.

In some very severe cases, as in the specimen now figured, the internal cuneiform bone is drawn under the inner malleolus and articulates with it, see Figs 35 and 36. In this specimen there is upon the superior surface of the inner cuneiform bone in its altered relations, a flattened, elevated, and smooth articular surface, upon which the inner malleolus rested, but this process also rested in part upon the tuberosity of the navicular bone. The dorsal edges of the cuneiform bones are all rounded, and thus the appearance of separation of these bones externally is much added to.

The metatarsal and phalangeal bones deviate to an extreme degree in their normal direction, with respect to the leg; but they retain their normal articular relations with the cuneiform and cuboid bones, and with each other. These bones, which collectively make up the anterior half of the foot, are, in this deformity, placed laterally at right angles with the leg on its inner side, or even beyond this, in very severe cases, and have also an inclination backwards. It is this general direction of the anterior portion of the foot which gives the external character to the deformity; but it will at once be apparent how essentially this depends upon the really more important, although less obvious, deviations in position, which I have described as taking place in the tarsal bones.

In the production of this deformity, the metatarsal bones, holding their normal relations with the cuneiform and cuboid bones, pass directly upwards and inwards, with an inclination backwards—the extension of the foot having previously taken place by elevation of the os calcis.

The displacement inwards of the metatarsal bones, which contributes so materially to the external characters of varus, depends very much upon the contraction of the tibialis anticus and extensor pollicis muscles; but it also depends upon the lateral displacement of the navicular bone, caused by the contraction of the posterior tibial muscle, and upon the lateral displacement of the cuboid bone.

The fourth and fifth metatarsal bones are so displaced in the altered relations of the anterior part of the foot to the leg, that their dorsal surfaces look directly downwards, and rest flatly upon the ground, forming together, with the dorsal surface of the cuboid bone, the most prominent part of the imperfect and irregular base of support, which the club-footed adult possesses, see Figs. 35 and 36. These bones retain their normal relations to, and are not at all separated from, their articular connexions with the cuboid bone.

The abnormal direction of these bones mainly depends upon the lateral deviation of the cuboid bone taking place, subsequently to the elevation of the os calcis; their deviation, how-

ever, is increased by a slight amount of rotation of the cuboid bone, which movement of rotation, from before backwards, is also extended to the fourth and fifth metatarsal bones, more especially to the latter, by the distribution of the weight of the body on the outer edge and dorsum of the foot, in the act of progression.

Transverse arch of the foot. The effect of the displacement of the fourth and fifth metatarsal bones, may be to narrow or compress the transverse arch of the foot by approximating the fifth to the first metatarsal bone; but as far as I can judge from the specimens of club-foot which I have examined, it appears that this result has been generally exaggerated by authors on this subject.

In the specimen above figured, which is one of extreme severity—if the leg be turned upside down, and the foot examined only with reference to the transverse arch formed by the tarsal bones, anterior to the astragalus and os calcis, and by the metatarsal bones—it would be difficult to say that any increase of the transverse arch of the foot exists. If we again restore the leg to its upright position, we see that the fourth and fifth metatarsal bones have been carried so far backwards, that the aspect of the sole of the foot is decidedly upwards and backwards. The appearance of a narrowing of the transverse arch seems to be greater in the living foot, than is shown by any of the dissected specimens, so that it would appear to depend very much upon the condition of the soft parts.

The phalanges remain unaltered in their general direction and form, with the exception of the last phalanx of the great toe. The toes generally assume, in some degree, a claw-like form, in consequence of the first phalanx of each toe being extended by the action of the extensor longus digitorum, and the second and third phalanges being flexed by the action of the flexor longus digitorum muscle. This form of the toes gives them a life-like appearance, and I have alluded to its existence in a marked degree, in cases of spasmodic equinus, and to its absence in paralytic equinus; it is also absent in non-congenital varus,

when of paralytic origin, the ordinary cause of this variety of talipes.

The last phalanx of the great toe I have observed to be very much misshapen in every specimen of congenital varus in the adult which I have examined. It holds its normal articular connexion with the first phalanx, the surface of which is unaltered; but the last phalanx itself has an oblique and twisted direction downwards, see Figs. 35 and 36; an alteration of form which probably results from the early and long continued pressure of the boot worn by the individual.

Transverse relations of the malleoli. It only remains for us now that we have described the changes in position and form observed in the bones of the foot, to advert, in completing the account of the osteological changes in this deformity, to some peculiarities in the articular extremities of the tibia and fibula. The observations made in reference to the transverse relations of the malleoli, &c., in infantile varus, are mostly applicable to the adult condition.

Inner malleolus. In cases of adult varus, a great deficiency in the natural prominence of the inner malleolus is observed in the living foot, and this process also appears to be carried forwards, very much in advance of its natural position, with respect to the foot. The want of prominence is not due to any deficiency in the size of this process, but rather to the fact of the navicular bone, and sometimes the inner cuneiform bone also, as seen in Figs. 35 and 36, being drawn inwards and upwards, so as to come into immediate contact with it, and thus destroy its relative prominence to the neighbouring parts.

It has been said in explanation of the apparently forward position of the inner malleolus that the lower extremity of the tibia becomes twisted, so as to bring it into this position, and in some very severe cases, I think this does occur to a slight extent; but generally, I believe this condition to be a deceptive appearance rather than a real change in the articular extremity of the tibia. There is certainly very little, if any, twisting of the lower extremity of the tibia in the specimen now described,

yet the advanced appearance of the inner malleolus is very obvious.

The direction of the malleoli must not be judged of by their relations to any part of the foot, on account of the lateral obliquity of the os calcis, the tuberosity of which is always directly behind the fibula, as seen in Fig 36; but it must be judged of solely in reference to the axis of the leg, and shaft of the tibia. The spine of the tibia answers very well as our guide, and it may be here observed that the posterior surface of the tibia is brought by the lateral obliquity of the os calcis, and inclination backwards of the anterior part of the foot, into what might be regarded, upon a superficial examination, as the lateral aspect of the leg, and it certainly would be so if the os calcis were held in the hand, and viewed from behind forwards, or if the leg were laid on the table in the position necessary for the division of the tendo Achillis. I believe this point to be of direct practical importance in reference to the relative situation of the tendo Achillis, the posterior tibial tendon, and the artery.

The inner malleolus may be said to be rounded in form. The posterior edge of the tibia is not well developed, and the groove for the posterior tibial tendon—shallow in this instance, but deep in others—passes obliquely forwards, cutting off, as it were, the posterior inferior angle of the malleolus, when this process is viewed from its lateral aspect.

The inner malleolus is shorter than natural, and generally presents on its inferior surface a flattened articular facet, which articulates with the navicular bone on which a similarly flattened surface exists.

In the specimen I have described, the inner malleolus has rested both upon the navicular and the inner cuneiform bones, but chiefly upon the latter. The posterior part of the inner malleolus has rested upon the inner cuneiform bone, and the anterior and inner part of the malleolus upon the navicular bone. In the latter situation a cup-like depression exists on the inner malleolus, but a portion of the deltoid ligament appears still to cover the surface of this depression, and it is

somewhat remarkable that where the inner cuneiform bone, which presents a large flattened and somewhat prominent articular facet, has been in contact with the posterior part of the inferior surface of the malleolus, the posterior tibial tendon has intervened, and is now to be seen in a flattened expanded condition, folded inwards, and covering the corresponding portion of the malleolus.

In this specimen, therefore, although the inner malleolus has articulated with, or rather rested upon, two bones; this process does not exhibit very distinct articular facets, in consequence of the intervention of the deltoid ligament in one instance, and of the posterior tibial tendon in the other.

The outer malleolus presents generally a rounding of its edges, and the groove for the peronei tendons is very shallow. The tendon of the peroneus longus in the specimen described, see Fig. 34, has been drawn rather away from, than into this groove, in consequence of an inclination backwards, which it takes to gain its groove on the outer surface of the os calcis.

The posterior surface of the outer malleolus rests upon the upper surface of the os calcis. Whether any articular connection exists cannot be seen, but a little dried ligament appears to intervene. The posterior edge of the adjacent portion of the tibia seems to have an articular connexion with the os calcis, which is drawn upwards between these bones.

CHAPTER XI.

CONGENITAL TALIPES VARUS CONTINUED.—MORBID ANATOMY IN THE ADULT CONCLUDED; ARTICULATIONS, LIGAMENTS, MUSCLES, AND TENDONS.

Conditions of the articular surfaces in the joints implicated. On the important subject of the conditions of the articular surfaces in the joints implicated, I am unable to give any positive information from my own dissection; nor, so far as I know, has the condition of the articular cartilages in any adult case, of congenital varus been described.

In the dried specimens which I have examined in our Museums, and in that from which the present description is principally drawn, see Figs, 34, 35, and 36, the articular cartilage on the exposed and extruded portions of the articular surfaces, viz., the anterior portion of the superior, and external lateral articular surfaces of the astragalus, the outer portion of the head of the astragalus, and the anterior articular surface of the os calcis, appears to be much wasted and irregularly removed, so that only a thin and imperfect layer remains.

We might expect to find these appearances not only as the result of disuse, but because the articular surfaces are superficially exposed, and subject to irritating influences; although it should be observed that they are always covered by the elongated ligaments stretched across them. These surfaces sometimes present an irregular mammillated appearance, in consequence of irregular thickening of the osseous surfaces.

In the unexposed portions of the articular surfaces, it is probable that the cartilage remains in a tolerably healthy condition, although it may be thinner than natural.

This subject is of importance, inasmuch as it relates to the restoration of the functions of the joints after the cure of the deformity, and it appears that although the exposed portions of the articular surfaces in adult varus are not in a healthy condition; still as the ligaments retain their normal relations, as far as their attachments are concerned, the articular surfaces would be found available, to a certain extent, after the removal of the deformity.

LIGAMENTS. One of the most important results of allowing congenital varus to remain unrelieved is, that during the growth of the foot in the deformed position, the ligaments become more perfectly adapted in their length and direction to the normal relations of the bones, and materially tend to render the deformity either very difficult of cure, or permanent and incurable in proportion to the time the deformity has existed.

We cannot describe the precise deviations in the ligaments from any recent dissections of adult varus, but the description I have given from dissection of severe and rigid infantile cases is, for the most part, applicable to the adult deformity.*

Some of the strongest ligaments of the foot in infants are always found to be shortened in proportion to the severity of the case, causing a rigidity of the foot in its deformed position, from which the severity of the case may be more properly judged of, than by the particular angle the foot may happen to form with the leg. This ligamentous rigidity exists to a variable extent in infantile cases, but in adult congenital cases, although some difference exists, ligamentous rigidity is constant and severe, the foot has grown in the deformed position from birth, and adapted ligamentous shortening is a certain and invariable result.

Severe ligamentous rigidity is then the rule in the adult, and the exception in the infant. As an example of this ligamentous

* Two specimens of congenital talipes varus in the adult have been presented to the Museum of the College of Surgeons since this Essay was written. They have been dissected so as to exhibit the deviations in the tendons and ligaments, and are preserved as wet preparations, so that they may be referred to in connection with this portion of our subject.

rigidity in the adult, the dissection of the club-footed man, whose skeleton is in St. Bartholomew's Museum, may be mentioned. Mr. Holmes Coote, who dissected this deformity, has furnished me with the details of the dissection, in which he makes the following observation: "On the right side I divided the tendons of the tibialis anticus, and the extensors of the toes; also the tendo Achillis. Very little mobility of the foot ensued. I then divided all the tendons, both flexors and extensors, in succession. The distortion remained, and was only partially relieved by division of the plantar fascia. By grasping the toes and then forcing them, I got the foot into its proper bearings, but I felt numerous interosseous bands give way." There can be no doubt that in this case the ligaments were very perfectly adapted, in their general direction and length, to the deformed position of the foot.

This ligamentous rigidity is generally slight in those non-congenital cases which arise from paralysis; because, although the foot has grown in the deformed position from infancy or childhood, the general nutrition of the limb is much lower than in the congenital cases, in which no paralysis exists. Practically speaking, we know that the non-congenital cases can be cured in as many weeks as the congenital cases require months.

Ligaments of the ankle-joint. In respect to congenital varus in the adult, and speaking of all the ligaments surrounding the ankle-joint collectively, it may be said that anteriorly, and on the outer side towards the front part, the ligaments are extremely elongated; and posteriorly and laterally on both sides, extremely shortened and contracted. The internal, lateral, or deltoid ligament, is also contracted in its anterior portion, and powerfully assists in retaining the navicular bone in contact with the inner malleolus.

In the specimen represented in Figs. 34, 35 and 36 we see the anterior part of the capsular ligament of the ankle-joint extremely elongated and stretched over the extruded portion of the superior articular surface of the astragalus; and the anterior portion of the external lateral ligament is seen elongated and

stretched over the extruded portion of the fibula articular surface of the astragalus.

In this specimen it is difficult to discover any ligamentous structure on the posterior aspect of the ankle-joint, and from the direct contact of the posterior margin of the tibia with the superior surface of the os calcis, it is obvious that they must be shortened to an extreme degree. The resistance offered by this ligamentous contraction to the depression of the os calcis, has been demonstrated by my late colleague, Mr. Lonsdale, in the dissection of a foot which I removed from a boy who had been under treatment at the Orthopædic Hospital, and died of scarlet fever.

In consequence of the severity of this contraction, the case had not progressed favourably. In the same specimen the contraction of the anterior part of the deltoid ligament, and consequent difficulty in the restoration of the navicular bone, after division of the posterior tibial tendon, was very obvious.

Ligaments of the tarsal joints. It may be said generally of the ligaments connecting the tarsal bones, that those on the dorsal aspect are elongated, although this is more obvious in some situations than in others; while nearly all the ligaments on the plantar aspect of the foot are shortened to an extreme degree.

In Figs. 35 and 37 may be noticed a considerable elongation of the outer portion of the ligament connecting the astragalus with the navicular bone, and this elongated ligament is stretched over the outer portion of the head of the astragalus left uncovered by the displacement of the navicular bone. A considerable elongation is also to be noted of the ligament passing between the outer surface of the os calcis and cuboid bone, and this elongated ligament is stretched across the anterior articular surfaces of the os calcis, left exposed by the displacement of the cuboid bone, see Fig. 35. The other ligamentous bands on the dorsum of the foot are but little elongated, as the tarsal joints are widened externally only to a slight extent.

In the sole of the foot, deep in the concavity of the arch, or rather in the angle formed by the lateral flexion of the anterior two-thirds of the foot, it is obvious, from the close approxima-

tion of the tarsal bones and the shortening of the foot, that the calcaneo-cuboid calcaneo-scaphoid and the other ligamentous bands connecting the tarsal bones are materially shortened, see Fig. 36. From their dried and ill-defined condition, however, they cannot be separately described.

The plantar fascia we know, from practical experience, is much shortened, and offers in its tense and contracted condition a formidable obstacle to the restoration of the foot in the adult deformity. It is also sometimes much contracted in infantile cases. In the latter class, sometimes the inner band only is contracted, but in the more severe cases the central portion is always contracted, as it is in the adult, and requires a complete division. The muscles in the sole of the foot beneath the plantar fascia, and which arise from it as well as from the os calcis, are also much shorter than is natural, so that a free division, not only of the fascia, but of the subjacent muscular fibres, is necessary to the restoration of the anterior portion of the foot to its normal position.

There would appear to be an increase in the depth at which this fascia lies from the surface, and consequently its contraction is sometimes overlooked, especially in fat children. In the specimen, Fig. 36, the plantar fascia has been dissected away, but it must have been extremely contracted.

Simultaneously with these deep structural changes affecting the bones and ligaments, other abnormal conditions are also occurring in the muscles, tendons and other structures.

MUSCLES. During the persistence of club-foot, the muscles of the leg below knee, whose office it is to regulate the movements of the foot, are almost entirely thrown out of action. It is true that the muscles of the calf still continue to assist in maintaining the erect position of the body, but in consequence of the immovable condition of the ankle-joint, these muscles are called upon to perform only a portion of their functions: so that in all the muscles of the leg very defective growth is the result. The measurement of a club-footed leg in an adult, as compared with that of the healthy leg in the same individual, in the patient, from whom Figs. 25 and 26 were taken, was found

to be two and a half inches less in circumference round the calf than in the healthy leg. The most prominent part of the calf in the club-footed leg was also three inches higher than in the healthy leg; from this we may infer that the bellies of the muscles which form the calf are deficient in length as well as in circumference. This condition obtains equally in all the muscles of the leg below knee, and accounts for the fact that the tendons are really longer in the adult club-footed leg than in the healthy leg. The high position of the calf, however, is also contributed to by the elevation of the os calcis.

As I have never dissected the leg of an adult affected with congenital club-foot, I cannot say whether the muscles at the same time undergo any process of structural degeneration in consequence of their inaction; but in the specimen recently presented to the College of Surgeons by Mr. Partridge, the muscles appear to be perfectly healthy, and well developed.

In non-congenital cases of varus and equino-varus, which are the more frequent varieties, we know that fatty degeneration of the muscles reaches an extreme degree; but in such cases paralysis most commonly lays the foundation of the mischief, and we should therefore expect such a result. I have examined several specimens of these deformities, and described and figured the appearances seen on microscopical examination in the Transactions of the Pathological Society, Vol. III. Plate 12, and this plate is now added to the present Essay.

The specimen of talipes varus showing extreme fatty degeneration of the muscles, figured by Cruveilhier, and supposed by him to have been of congenital origin, and quoted as such by Mr. Brodhurst at page 38, in his work "On Club-foot," evidently belongs to this class of non-congenital paralytic deformities.

The muscular structures in some cases are found in different abnormal conditions at the period of birth, as shown in the description of infantile varus, and therefore in such cases degeneration of the muscles would be found equally at more advanced ages; but referring to the ordinary cases in which the muscles are healthy at the period of birth, some slight struc-

tural degeneration may possibly take place during their long period of inactivity when the deformity remains unrelieved up to the adult period of life. If any such degeneration exists, however, it is proved by practical experience in the treatment of adult deformity, to be but slight and unimportant.

The leading characteristic of the muscular condition of the leg in cases of adult congenital varus appears to be simply one of defective growth; because after the cure of the deformity, even in the severest cases in adults, as that represented in Figs. 25 and 26, the small and apparently atrophied muscles of the calf acquire, after a few months' exercise, their natural degree of firmness and power proportionate to their bulk. In this case, they became, after exercise and shampooing, as hard as well nourished and well exercised muscles in a healthy individual. The expression of the patient, "that his muscles were little but good," sufficiently characterized their condition, and is opposed to the idea that structural degeneration had taken place to any considerable extent, or to a degree beyond recovery. This degree of improvement was not only manifest in the muscles of the calf, but he also acquired full power in the peronei, extensor longus digitorum, extensor pollicis, and tibialis anticus muscles, which could have been but very imperfectly called into action during the existence of the deformity.

TENDONS. The description previously given of the deviations in direction, and altered relations of the tendons in adaptation to the deformed position of the foot, in severe infantile cases of varus, is for the most part applicable to this deformity in the adult. In the adult, all these deviations become more confirmed. The osseous grooves, along which several of the tendons pass towards their insertions, become deepened in some situations, and the sheaths of the tendons become thickened.

In the specimen in St. Thomas' Museum, the groove for the posterior tibial tendon on the inner malleolus, and the grooves for the peronei tendons on the outer surface of the os calcis are seen to be much deeper than natural.

In the notes of the dissection of the case in St. Bartholomew's Museum, Mr. Coote observes, "The sheaths of the tendons were

everywhere thicker and stronger than natural." In the dried specimen represented in Figs. 34, 35 and 36, these appearances are not remarkable; but, in explanation, it must be remembered that the leg belonged to a female, and in consequence of intractable ulceration on the dorsum of the foot, which had resisted various methods of treatment for a year or two previous to its amputation, the limb had been but little used for a long time.

With respect to the tendons in the adult deformity there is another peculiarity, viz., that all the tendons below knee are really longer, and much more slender than in the healthy leg. The tendo Achillis is often not more than half its natural thickness. The increased length of the tendons depends upon the small size of the bellies of the muscles, and the thinness of the tendons is the result of defective nutrition, which affects the bones as well as the soft tissues, and gives the external appearance of a dwindled or withered limb to the club-footed leg in the adult.

Abnormal conditions and irregular distribution of tendons. In my dissections of fœtal specimens of varus, some irregularities in the distribution and abnormal conditions of the tendons, not consequent upon the deformity of the foot, were met with in several instances. These were generally supernumerary slips of tendon in the sole of the foot, and sometimes on the dorsum; or a bifurcation of the anterior tibial tendon, of which I have seen several examples; one slip pursuing its normal course, and the other passing externally to an expanded insertion into the anterior annular ligament, or the fascia on the dorsum of the foot, a little below the ligament.

In two instances, I have seen the tendon of the extensor pollicis passing between these two divisions of the anterior tibial tendon, so that as the tendons cross the ankle-joint—the point selected for division—it might be necessary to divide three tendons instead of one. In the account of the dissection of the specimen in St. Bartholomew's Museum, Mr. Holmes Coote says, "The tendon of the tibialis anticus appeared to be very long in consequence of the small size of the belly of the muscle, which arose as usual; but the tendon was inserted, 1st, into the in-

ternal cuneiform bone; 2nd, into the anterior annular ligament," and he also observes that "the tendons of the extensor communis digitorum and the peroneus tertius were united by very strong and broad fibrous bands." The frequency of the bifurcation of the tibialis anticus tendon appears to be somewhat remarkable.

Deviations in direction and relative position of tendons depending upon the deformity. These are essentially the same as in severe infantile cases, but some additional points remarkably well seen in the specimen, Figs. 34, 35 and 36, require to be noticed.

There is an inclination of all the tendons in front of the ankle-joint towards the inner side of the leg, in adaptation to the altered position of the foot.

The tendon of the tibialis anticus muscle inclines towards the inner side of the tibia above the epiphysis; it then passes obliquely downwards and backwards on the surface of the inner malleolus, and takes a curved direction inwards and backwards towards the base of the metatarsal bone of the great toe, and the adjacent border of the inner cuneiform bone, see Figs. 35 and 36. These bones not only occupy a lateral position with respect to the leg, but in adult cases are generally placed rather behind than in front of the transverse median plane of the leg.

As the anterior tibial tendon crosses the ankle-joint—the point selected for division—it is not only very much displaced to the inner side, but it also passes in an oblique direction from the inner malleolus behind, rather than in front of this process; so much so indeed, that it may possibly have been divided in mistake for the posterior tibial tendon, by those who attempt to divide the latter tendon in the position which it would occupy in the healthy condition of the foot, viz., below and in front of the inner malleolus, as recommended by the late Mr. Syme. The anterior tibial is certainly the only tendon with which the knife could come in contact, if the operation above adverted to should be attempted in a severe and rigid case, whether it be in the infant or the adult.

In describing a dissection of a case of varus in the Transactions of the Pathological Society, Sir Henry Thompson remarks, " the anterior tibial tendon is displaced backwards, so that at the lower end of the bone it passes over the back of the inner malleolus, and thence directly backwards to the first metatarsal bone." The altered relations of this tendon should be carefully borne in mind, as it is often more difficult to find than might be supposed, especially in very fat children.

The tendon of the extensor pollicis muscle is also displaced towards the inner side, and occupies in its relation to the inner malleolus pretty much the situation which the anterior tibial tendon holds in the healthy condition of the foot, see Fig. 35.

The tendons of the extensor longus digitorum muscle also incline to the inner side in their passage across the ankle-joint; but as their division is never required in this deformity, this deviation is unimportant.

The tendon of the tibialis posticus muscle has been already described in its abnormal relations in severe infantile varus; and although these deviations are essentially the same in the adult, the only difference being that the parts are more rigidly held in their abnormal relations, they may be again mentioned here in consequence of their direct practical importance.

In the first part of its course the posterior tibial tendon is not so distinctly placed behind the inner malleolus, as in the healthy foot; but is lodged in a groove, on, rather than behind, this process, see Fig. 36, and can generally be felt in this situation. The appearance of being placed on the outer surface of the malleolus, however, is very much added to, by the lateral obliquity of the os calcis, the tuberosity of which is directly behind the fibula, exposing to view the posterior surface of the tibia, in what might be regarded as the lateral aspect of the foot; and also by the inner malleolus itself being somewhat twisted forwards in the adult cases.

In the second part of its course the posterior tibial tendon does not pass beneath the inner malleolus, and then obliquely downwards and forwards in front of this process to its insertion into

the navicular bone, as in the healthy foot. The navicular bone itself is displaced by the contraction of the posterior tibial muscle, so as to be held in contact, and articulate with, the inner malleolus; and moreover it is held rigidly in this position by the adapted shortening of the ligaments, more especially, by the deltoid ligament. The posterior tibial tendon, therefore, passes directly downwards from the inner malleolus to its first insertion into the navicular bone, which it immediately reaches.

It is very desirable to study the altered relations of the tendon of the tibialis posticus muscle, both in the first and second parts of its course, because the ordinary rule of practice is to follow the method recommended by Dr. Little, and divide the posterior tibial tendon in the first part of its course, viz., just above the inner malleolus as indicated in Fig. 32*a*, in a child, and the corresponding position may be seen in the adult, Fig. 36, or in some severe cases in the adult or in youth, as it is passing across this process. The late Professor Syme, however, in a published clinical lecture,* condemned and held up to ridicule the plan of dividing this tendon in the first part of its course, on account of its proximity to the artery and the difficulty of the operation; Mr. Syme recommended its division "a little below and anterior to the tip of the internal malleolus," a situation the Professor observed, "where it is so distinctly located that it is always discovered with facility." Now, it can be easily demonstrated that in severe cases of varus, whether in the infant or in the adult, the posterior tibial tendon does not exist in the position above indicated by Mr. Syme, and, moreover, the rigidity of the ligaments is too great to allow of the tendon being drawn into this position.

In congenital cases of varus when slight, in infants, and in non-congenital cases, the possibility, and where possible, the necessity of dividing this tendon in the second part of its course will be alluded to when the operation is discussed; but there can be no doubt that the anatomical conditions of the parts determines, in all severe cases of the deformity, whether in the

* *Lancet*, March 17th, 1855. *Medical Times and Gazette*, April 28th, 1855.

infant or adult, the position in which the posterior tibial tendon must be divided.

In the adult specimen, Figs. 35 and 36, the navicular bone is situated directly under and within the inner malleolus; and the posterior tibial tendon is folded inwards between this process and the navicular bone; and the tendon is here seen in a flattened and expanded condition, its texture being probably altered by the long continued pressure to which it must have been subjected.

In a specimen of talipes varus from a man æt. 69, dissected and afterwards shown at the Pathological Society by Sir H. Thompson,* and which he kindly presented to me, he has correctly described the situation and direction of the posterior tibial tendon as follows: "The posterior tibial tendon descends in a straight line to the lower end of the tibia, and then has a slight inclination backwards, passing away from, instead of beneath the internal malleolus, to an expanded insertion into the scapoid bone." Whether this case was of congenital or non-congenital origin could not be ascertained. The late Mr. Lonsdale concurred with me in thinking it was not of congenital origin. This opinion was based upon the conformation of the bones, the condition of the ligaments, which were shortened to a less extent than in adult cases of congenital origin, and from the advanced fatty degeneration of the muscles. It exhibited the ordinary appearance of non-congenital varus of paralytic origin, the severity of the deformity depending very much upon the advanced age of the individual.

In adult cases of varus, and also at earlier ages, the posterior tibial tendon can generally be felt externally, as it passes along the inner malleolus, so that the great difficulty experienced in finding this tendon in the infant does not occur at later periods of life, when the bones are more developed and the subcutaneous fat less abundant.

The tendon of the flexor longus digitorum is separated a little further from the posterior tibial tendon, as it descends behind the malleolus, than in its normal relation, and this tendon does not pass from behind this process forwards, under the projecting

* *See* "Transactions Pathological Society," Vol. VI., page 358.

process of the os calcis, the sustentaculum tali, but a little below the level of the ankle-joint passes suddenly inwards and backwards at a right angle to the leg towards the sole of the foot. See Fig. 36. This tendon is connected with that of the flexor pollicis longus in this specimen by an extra slip in the sole of the foot.

The tendon of the flexor longus pollicis does not pass through the groove in the posterior border of the astragalus, in consequence of the absence of this groove in the flattened wedge-like form of the posterior border of the astragalus, which is compressed between the articular surface of the tibia and the upper surface of the os calcis in its elevated position. This tendon, like that of the flexor longus, passes suddenly inwards and backwards, from beneath a band of ligament, a little below the ankle-joint towards the great toe, in its abnormal position, see Fig. 36. In this specimen a tendinous slip connects the tendon with that of the flexor longus digitorum.

The tendon of the peroneus longus does not course round the external malleolus, and then forwards and downwards towards its insertion, as in the healthy foot; but it passes directly downwards with an inclination backwards, across the outer surface of the os calcis as shown in Fig. 34; and then turning round the inferior surface of this bone, instead of entering the groove in the cuboid bone, it passes transversely inwards across the concavity of the foot to its insertion. See Fig. 36.

The examination of the foot represented in these wood-cuts, shows at once that the tendon of the peroneus longus has a less distance to travel in the course above indicated, than in the healthy foot, and therefore that this is really a shortened instead of an elongated tendon, as it is generally described. In the course of the treatment of a severe adult case, shown in Figs. 25 and 26, this tendon became so decidedly tense and prominent, while the anterior part of the foot was being restored to its normal position that I divided it with great advantage. Such a procedure, however, could only be necessary in a very severe adult case, and its tension in the case alluded to, became painful under the mechanical extension employed.

The tendon of the peroneus brevis passes directly downwards from behind the outer malleolus, across the outer surface of the os calcis to its insertion into the base of the metatarsal bone,

The tendo Achillis in its course downwards, inclines towards the fibula aspect of the leg, in consequence of the tuberosity of the os calcis being placed directly behind the fibula; and at its insertion, therefore, this tendon is directly behind the fibula. See Fig. 36.

This deviation has been described in the account given of severe infantile deformity. The observations then made in reference to the deceptive appearance of the tendo Achillis being placed towards the inner rather than the outer side of the leg, and occupying a position often directly over the artery, are equally applicable to this deformity in the adult. The relation of the tendo Achillis to the outer malleolus is the only reliable evidence upon which an opinion can be arrived at as to the deviation of this tendon in the living foot. The prominence of the inner malleolus is so much diminished by the navicular bone being drawn under it, and this process itself is in some degree twisted forwards, that the relation of the tendo Achillis, with respect to it, cannot be very satisfactorily made out.

Tendons which require division. In all severe cases of congenital varus in the adult, in youth, and in the infant, the tendons which require division for the cure of the deformity are the tibialis anticus, the tibialis posticus and the tendo Achillis. In all such cases, it is also desirable to divide the tendon of the flexor longus digitorum, and sometimes the tendon of the extensor pollicis. In the slighter forms of infantile varus much less may be required, and in some cases mechanical treatment alone will be sufficient to cure the deformity.

Vessels and Nerves. The observations already made in reference to the condition of vessels and nerves in severe infantile cases of varus, for the most part equally apply to this deformity in the adult.

The vessels and nerves retain their deviations in direction, in adaptation to the deformed position of the foot, but it has

never been shown that these involve any deviations in their relative position to the tendons, so that they do not assume importance in a practical point of view. It is also probable that in consequence of the generally defective state of nutrition and imperfect growth of the muscles, described as existing in the legs of club-footed individuals, the vessels and nerves are, at the adult period of life, deficient in their normal size, in a proportionate degree; that is, the vessels and nerves are adapted to the defective growth of the organs to which they are distributed; but there is no reason to suspect that any structural changes, either in the vessels or nerves, necessarily take place.

The diminution in the calibre of the vessels, described by Cruveilhier, might be looked for here; but excepting in a paralytic limb, we should not expect to find the extreme degree of atrophy of the nerve trunks, he has described as existing in the case he dissected, and which was probably an example of non-congenital equino-varus of paralytic origin.

We know that when an organ or part of the body ceases to perform its functions, the nerves which supply it suffer atrophy and degeneration to a corresponding extent, and this cannot be better illustrated than in the wasted condition constantly observed in the optic nerve, after the loss of vision in the corresponding eye.

The conditions necessary to produce extreme atrophy and degeneration of the nerves are not present in congenital club-foot. Sensation remains perfect, and voluntary motion also exists, even in the contracted and permanently shortened muscles, although its manifestation is necessarily limited by the anatomical condition of the parts.

In the adult, the club-foot can be still further inverted at the will of the patient, while the contracted tibial muscles, and the muscles of the calf, can be felt to swell up under the influence of the will exerted to produce their contraction, although the movements of the joints, which they are intended to control, are extremely limited. The rapid improvement in muscular power after the cure of the deformity in the adult,

testifies also to the healthy condition of the nerves in cases of congenital varus, even at an advanced period of life.

It will probably be conceded that as the condition described by Cruveilhier is inconsistent with our knowledge of the clinical history of this deformity, and is quite consistent with our knowledge of the changes which take place in paralytic affections, the probability is greatly increased that the case from which he drew his description was one of non-congenital paralytic origin.

At the risk of being thought tedious, I have described the morbid anatomy of congenital talipes varus, as it exists at different periods of life; and the account I have given will be found to differ in many important respects from any description hitherto published; but I have been desirous of clearly describing the results of my own dissections and observations on such specimens as I have had at my command.

CHAPTER XII.

CONGENITAL TALIPES VARUS CONTINUED.—GENERAL PATHOLOGY; ETIOLOGY; HEREDITARY TRANSMISSION; STATISTICS; COMPLICATIONS.

ETIOLOGY OF CONGENITAL CLUB-FOOT. The cause of congenital talipes varus is, at the present day, a question of scientific interest rather than direct practical importance, since the pathological conditions at the period of birth, the principles of treatment, and the complete and permanent curability of the affection, have been satisfactorily determined beyond the possibility of doubt. The limits of an Essay scarcely allow of a full discussion of this subject, therefore only the principal arguments for and against the theories entertained at the present day, and the conclusions to which they appear to lead will be stated.

Dissection has satisfactorily disproved the theories of arrest of development and malformation. The difference of opinion therefore at present existing, is chiefly with regard to the doctrine of spasmodic muscular action from cerebro-spinal irritation, and that of malposition of the fœtus with pressure *in utero.*

Arguments in favour of the theory of spasmodic origin of congenital club-foot.

1st. The existence of club-foot, together with other articular deformities in certain monstrosities, especially anencephalic fœtuses, and also in fœtuses with spina-bifida.

In these cases spinal deformity, luxations of the chin, femur, knees, elbows, fingers, hands, and feet; club-hand and club-

foot—in one word, displacements more or less complete in all the articular surfaces frequently coexist. These have been especially described by M. Guérin,* who states that all these deformities are accompanied with considerable retraction of the muscles going to the displaced articulations, and taking place in the direction of the deformities.

2nd. The possibility of spasmodic muscular action in the fœtus being induced by maternal influence. This supposition is supported by the fact generally admitted that violent or convulsive movements of the child *in utero*, may be induced by sudden and powerful emotion excited in the mind of the mother; acting either directly by influencing the fœtal circulation, or indirectly by producing an abnormal condition of the fœtal secretions.

3rd. The circumstance that in a large number of congenital deformities, mental emotion is assigned by the mother as a cause.

4th. Defective nutrition, said to be of frequent occurrence in children thus deformed; a condition favourable to spasmodic affections, and dependent upon some failure in the health of the mother during pregnancy.

5th. The analogy urged by M. Guérin, Dr. Little, and other writers, as existing between congenital and non-congenital deformities.

6th. Hereditary tendency, sometimes traced through several generations, as in epilepsy and other nervous affections.

7th. The tendency to relapse after operation and mechanical treatment; especially adduced by Dr. Little, and supposed to depend in severe cases, upon a disposition to tonic muscular contraction still remaining.

Arguments against the theory of spasmodic origin of congenital club-foot.

1st. The absence at the period of birth, of any evidence of a spasmodic affection of the muscles.

2nd. The healthy condition of all the muscles in the great majority of cases, and their perfect obedience to the will in

* "Mémoire sur l'Etiologie Générale des Pieds-bots Congénitaux," Paris, 1838.

every movement of the leg and foot, after removal of the deformity. This is the reverse of what occurs in the non-congenital spasmodic cases, in which the muscles remain hard, tense, and prominent, for many years after the seizure—frequently for the remainder of life—and are only partially under the controlling influence of the will.

3rd. That in a large number of cases no cause, such as mental emotion from fright, shock, &c., in the mind of the mother is assigned.

4th. That instead of showing any indication of defective nutrition, the children born with club-foot are, as a rule, robust, well nourished, and otherwise well formed.

Arguments in favour of the theory of malposition and pressure in utero as the cause of congenital club-foot.

1st. The same arguments as cited against the spasmodic origin of this deformity.

2nd. The natural tendency observed in the feet to turn inwards in the fœtus *in utero*, from the way in which the limbs are packed in the normal condition.

3rd. Contractions produced by long retained position, causing non-congenital deformities; especially urged by Mr. Tamplin.

Arguments against the theory of malposition and pressure in utero as the cause of congenital club-foot.

1st. The extreme improbability, not to say impossibility, that any pressure from the uterine walls could produce these deformities in the early period of uterine life; and the fact that talipes varus has been seen as early as the third month of utero gestation, and is frequently met with in fœtuses between the fourth and fifth month.

2nd. In well observed cases of deficient *liquor amnii*, perfectly formed infants have been frequently born; and *vice versa.*

3rd. Pressure would be very unlikely to produce the extreme elevation of the os calcis which always exists, and in conse-

quence of which this bone has a nearly vertical direction, in severe cases of talipes varus. This objection has occurred to me, and so far as I am aware, has not been previously adduced.

4th. The arguments previously cited in favour of the spasmodic origin.

5th. The absence of any tendency to deformities from muscular contraction in parts which are retained, in approximation during uterine life; as in the bent knee, bent thigh, bent arm, stooping neck, flexed fingers, &c., all positions assumed by the fœtus in adaptation to the limited space it occupies.

Thus, I have arranged in numerical order, the arguments which have been adduced for, and against, the principal theories entertained by recognised authorities, with regard to the etiology of congenital club-foot. Should these congenital deformities result from spasmodic affections of the muscles, then it is quite certain that when seen a few months after the seizure, they differ most materially in the physiological conditions of the muscles, from the non-congenital cases of similar origin. A possible explanation of this may be, that in the fœtus, the affection is purely functional, or attended with such a slight organic lesion, as, under this condition of life, is easily and completely recoverable; while in the non-congenital cases, the organic lesion is usually more severe, and in many instances irrecoverable.

If the spasmodic origin of congenital club-foot be admitted, then another marked difference from the non-congenital spasmodic deformities will be found in the few muscles involved in the congenital, as compared with the non-congenital cases. In the non-congenital deformities, the implication of a large number of muscles, frequently all the muscles of the lower extremity,—often of both lower extremities, and not infrequently those of the upper extremities also,—is a well marked and prominent characteristic.

Another remarkable fact is, that while talipes varus is by far the most frequent form of congenital club-foot, its occurrence as a non-congenital affection of spasmodic origin is extremely rare, and non-congenital talipes varus is a deformity

nearly always of paralytic origin. Talipes equinus and equino-varus are the two varieties which largely predominate in the spasmodic affections.

If, in an attempt to reconcile all the facts mentioned, with the theory of spasmodic origin, difficulties should arise; it will be equally apparent that the arguments in support of malposition and pressure *in utero* are exceedingly weak. On the whole, I am disposed to agree with the dynamic or spasmodic, rather than the mechanical theory, as applied to congenital talipes varus. The weight of evidence appears to be in favour of this opinion.

But it is probable that malposition and pressure *in utero* may be the cause of some deformities, and the late Mr. Lonsdale, who was an advocate of the mechanical theory generally, assigned to this class those examples of "talipes calcaneus, and calcaneo-valgus, occasionally met with in cases of breech presentations, with the legs extended upwards, the feet being doubled upwards, and pressed against the tibia in front." An illustration of this class of cases which will be found in Chap. XX, on congenital calcaneus, see Fig. 71, but even in these cases there is a remarkable rigidity of the knee-joints, with contraction of the rectus, and other extensor muscles of the leg and foot, which renders it necessary to speak with caution.

It may also be deemed probable that if equino-varus should be produced by spasm in the fourth or fifth month of pregnancy, —as we see spasmodic affections produce this deformity in the non-congenital cases—the exciting cause may subside, and the acquired position would then be maintained by the general adaptation of all the structures involved. Thus we should have growth in the deformed position producing its effects on the bones, particularly the astragalus, without the persistence of the physiological defects in the muscular action characteristic of the non-congenital spasmodic deformities.

The malformation of the astragalus, which I have shown to exist at the period of birth, I have also satisfactorily proved to depend upon the malposition of the os calcis and navicular bones, caused by contraction of the muscles of the calf, and the

anterior and posterior tibial muscles; this malformation, therefore, is clearly an effect rather than a producing cause of deformity.

HEREDITARY TRANSMISSION.—Not only is congenital talipes varus apt to be repeated in the same family, *i.e.* for the same mother to have several club-footed children; but also a marked tendency to a reproduction of the deformity is sometimes to be noted in two or three generations.

In illustration of its hereditary tendency, the following history of a club-footed family may be adduced. T. Hall, a labouring man, aged 46, was born with talipes varus of both feet, and is said to have been pretty well cured by mechanical means. He now walks very well, and his wife (who gave me this account in July, 1855), says his feet are straight, or nearly so, but his legs are rather small. This man has a brother who was born quite free from any deformity, but has a club-footed child. He does not know of any other case of club-foot having existed in his family. Hall has had thirteen children by one wife, a strong, healthy woman; five children have been club-footed, three boys and two girls; and in four, both feet have been affected.

The club-footed children are all alive, out of six of the family living; and the mother says they were always stronger than the rest. She does not assign any cause, such as fright, &c., and says the labours have all been natural, and at full time. She is not aware of any case of club-foot having occurred in her family. Seven children have died of infantile disorders. The eldest of the five club-footed children, a girl now 19 years of age, has also lately had a club-footed child, her first child, and this is a case of talipes varus of one foot.

Although it is unusual to meet with so many instances of club-foot in the same family, the occurrence of the deformity in two generations is common enough. As a rule, we find the same kind of deformity, and the same limbs affected in the children as in the parent.

NUMERICAL IMPORTANCE. In 1851, Mr. Tamplin published in the London Medical Gazette, a statistical report of 10,217

cases of deformities of all kinds, which had been treated at the Royal Orthopædic Hospital up to that date. Of these, 1780 were cases of club-foot, inclusive of congenital and non-congenital varieties.

The relative frequency of the several varieties of congenital club-foot, was as follows :—

Congenital talipes varus . .	688
„ talipes varus of one foot and valgus of the other in the same patient .	15
„ talipes valgus . .	42
„ „ calcaneus . .	19
Total of congenital forms	764

The 688 cases of congenital talipes varus were thus distributed.

Affecting the right foot only .	182
„ left „ .	138
„ both feet .	363
Total	683

The other five were of a compound nature, viz. :—

Two cases with both knees also contracted.

One case with the wrist and fingers also contracted.

One case with talipes calcaneus of the opposite extremity.

One with malformation of the toes.

Further, it may be stated, that in two of the above cases, spina-bifida was also present.

These statistics clearly show the greater frequency of talipes varus when compared with other varieties of congenital club-foot; they show also that varus is more apt to affect both feet than one foot alone, although in this respect the difference is not very great.

Deducting the 764 congenital cases from the 1780 congenital and non-congenital cases, 1016 non-congenital cases remain;

showing the relative proportion of the latter to be greater than might be expected.

COMPLICATIONS OF CONGENITAL VARUS. Sometimes talipes varus is found to coexist with other contractions and deformities of the limbs; and also with some malformations frequently involving the brain and spinal cord. These complications also coexist with the other varieties of congenital club-foot, but in what proportion they most frequently occur with each variety cannot be stated. The following are the complications most frequently met with.

Weakness of the knee-joints. A very lax condition of all the ligaments of the knee-joints frequently accompanies congenital varus. If the thigh be grasped with the left hand, and the leg with the right, it will be found that the tibia can be rotated on the condyles of the femur much more freely than in a leg free from deformity. This ligamentous weakness of the knee-joints is met with in strong children, and appears, therefore, to be in some way connected with the deformity, although its explanation is difficult.

The effect of this complication is to increase the apparent severity of the deformity, in consequence of the leg turning inwards as well as the foot; and also to perpetuate a turning in of the foot in the act of walking, after the deformity has been cured. This condition can only be effectually controlled by steel supports carried up to the waist, and connected with a pelvic belt, which the child may be obliged to wear for three or four years.

Unless this complication be recognised and its effects mentioned when the case is undertaken, the reputation of the surgeon may suffer, because after the club-foot deformity has been cured, the child still walks with its feet turned inwards; and, moreover, in these cases, unless the necessary after-treatment be strictly followed out, the deformity is apt to return. However, under careful management, there need be no apprehension as to the result of the case, but the after-treatment will be found tedious and troublesome.

Rigidity of knee-joints in an extended position. A rigid

extension of the knee-joints is occasionally associated with club-foot. The child is born with the legs extended and the knee-joints stiff and inflexible; the thighs flexed upon the body, the feet being drawn over the shoulders. These cases are always breech presentations, and were especially adduced by Mr. Lonsdale as examples of deformity caused by position *in utero.*

This complication is, however, more frequently associated with talipes calcaneus, than with varus, and an illustration of one of these cases will be found in Chapter XX on talipes calcaneus, see Fig. 71.

Several other cases have fallen under my observation, in which congenital varus has been associated with a rigid extension of the legs, and stiff knee-joints; but in these cases there have generally been several other complications, such as stiffness of the hip-joints, club-hands, and some obscure malformations of the joints, the exact nature of which it has been difficult to determine. One case of this kind is represented in Fig. 38, taken from a child who was under my

FIG. 38.

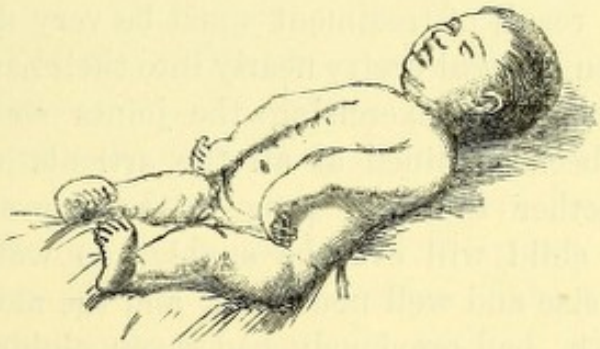

Congenital talipes varus of both feet, complicated with deficiency of anterior muscles of the legs below knee. Knee-joints stiff, with legs extended. Patellæ not traceable. Hip-joints stiff with thighs slightly flexed, and very slight motion; malformation doubtful. Both hands clubbed, and fore arms pronated. Elbow-joints stiff, with malformation. Shoulder-joints stiff, but with slight motion.

care (July, 1866) H. B., aged six months, was admitted as an out-patient at the Orthopædic Hospital, June 2nd, 1865. Both feet were deformed in the position of talipes varus, and pre-

sented the peculiarities described as existing in those cases in which the anterior muscles of the leg are deficient below knee, and represented in Fig. 30. All the toes were rigidly flexed, and the feet arched in a peculiar manner. Both knee-joints were stiff, with the legs in an extended position, but with an inclination outwards, as in knock-knee. The patella could not be distinctly felt in either knee-joint, although sometimes I thought I could detect this bone in a rudimentary condition. There appeared to be some malformation in the knee-joints, in addition to contraction. Both hip-joints were stiff, with the thighs slightly flexed, and although it was impossible to make out precisely the condition of these joints, the head of the femur on each side appeared to be displaced directly upward, and malformation of the acetabulum probably existed.

Both hands were clubbed and turned outwards, in consequence of pronation of the radius. Both elbow-joints were stiff, and some malformation appeared to exist at these articulations. Both shoulder-joints were stiff, but a slight amount of motion existed at these articulations, in which there was less evidence of malformation than in the hip and knee-joints.

It is scarcely necessary to observe that this case is one in which the result of treatment must be very doubtful. The feet have been brought pretty nearly into their natural position; and by rubbing and exercising the joints some amount of motion has been obtained at all the articulations; but it is doubtful whether this will progress to a useful extent, or whether the child will ever be enabled to walk. The child was of large size and well nourished, and the mother, a woman in good health, had previously had seven children, all perfect and now living. She went her full time with this child, the labour was not difficult or tedious, and she assigns no reason for the defective condition of this child

Another case illustrating the complications occasionally met with, affecting the knee and other joints, in cases of talipes varus, is represented in Fig. 39, of which the following is the history.

In July, 1859, I was requested by the late Sir B. Brodie to see with him a child, Master G——, aged six months, who

FIG. 39.

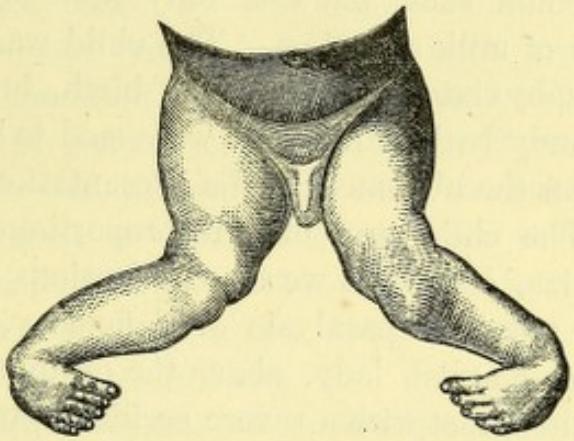

Congenital talipes varus of both feet, but no deficiency of muscles; complicated with imperfect flexibility of both knee-joints with legs extended, and distorted laterally. Probable absence of both patellæ, with malformation at knee-joints. Limited motion at hip-joints, with thighs slightly flexed; malformation doubtful. Both hands were clubbed, and elbow-joints malformed. Head contracted backwards.

had been born in Florence, and exhibited an unusual combination of deformities, viz.; talipes varus of both feet; imperfect flexibility of both knee-joints, with lateral distortion, so that the legs were in the position of a severe case of knock-knees, with the legs extended; probable absence of both patellæ, with some malformation at the knee-joints. The head of the tibia appeared to be imperfectly developed, and was thrown forwards on the condyles of the femur, which projected backwards, and could be distinctly felt in the popliteal space; very limited flexibility of both hip-joints, with tension of the adductor muscles, but so far as we could ascertain, without any dislocation or malformation at these joints, but their condition could not be accurately ascertained. Both hands contracted in the form of club-hand; imperfect power of extension of both fore-arms, probably with some malformation of the condyles of the humerus, and with dislocation backwards of the radius: no muscular tension about the elbow-joints. Contraction backwards of the head, with tension of the trapezii muscles, which, when any attempt was made to draw the head forwards,

became so prominent that a deep central depression existed between them; the face was directed upwards, and the neck projected forwards; the spinous processes of the cervical vertebræ could not be felt.

This child could suck, but was only able to draw a very small quantity of milk at a time. The child was said to have been nearly asphyxiated at the time of birth, but was resuscitated by a brandy bath. The legs were said to have been stiff, and flexed upon the abdomen. The presentation was said to be natural. The child was of full proportions, rather above the ordinary size, and there were no indications of any cerebral defect, or any muscular paralysis or deficiency. The mother of the child, an English lady, above the ordinary stature, and well-proportioned, met with a severe accident when four months advanced in pregnancy; she fell from some library steps, sideways across the back of a chair, which caught her in the loins, in consequence of which she was laid up for a month.

In this case the feet were perfectly restored by tenotomy and mechanical treatment, and there was no evidence of defective muscular development below knee; the malformation of the knee-joints, however, was sufficient to prevent the child either standing or walking without steel supports continued to the waist, and the knees being mechanically fixed. On the slightest flexion, the head of the tibia, which appeared to be small and imperfectly developed, dislocated forwards, so that no steadiness of the limbs could be obtained, and the power at the hip-joints also remained extremely feeble, so as to lead to the opinion that some defect, the nature of which could not be clearly ascertained, existed at these articulations. The child died when five years of age, but no post-mortem examination was allowed, therefore, neither the cause of death, nor the condition of the articulations could be ascertained.

Rigidity of knee-joints in a flexed position. A rigidly flexed condition of the knee-joints is occasionally, but very rarely associated with congenital varus. In a case under my care one limb only was affected, and the leg could not be extended beyond an obtuse angle with the thigh, so that division of the

ham-string tendons became necessary; they were not however, rigidly contracted, and the ligaments of the knee-joint offered the greatest resistance. The patella in this case appeared to be very small, and to lie against the lower part of the external condyle. The leg below knee was also shorter than the opposite limb.

In another case, under my care, both knees were in a rigidly flexed condition, and there appeared to be some obscure malformation in both feet, which were affected with talipes varus of a somewhat unusual form, and the bones could not be brought into their normal relations after tenotomy, so that there was little hope of this case being completely cured. It was also complicated with a flexed condition, and possibly some malformation, of the hip-joints.

Cases in which congenital contraction of one knee in the flexed position exists as a complication of congenital varus, without any malformation at the knee-joint, and also without any

FIG. 40.

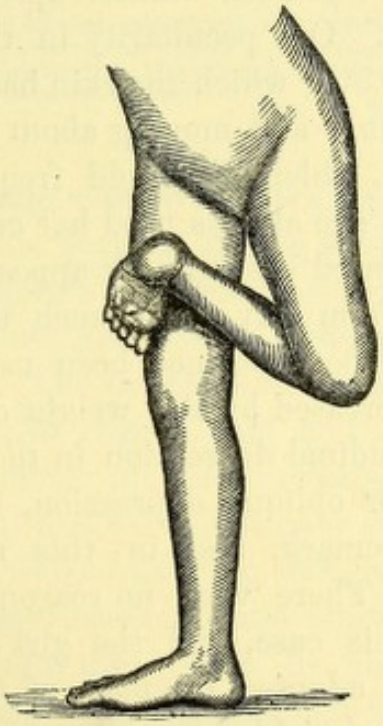

Talipes varus of left foot, complicated with contraction of the knee, in the flexed position. No evidence of malformation, or defective muscular development. Right leg perfect.

QUEEN SQUARE, BLOOMSBURY, LONDON. PRESENTED TO

defective development in the muscles are occasionally, although

very rarely, met with; but an interesting case of this kind was under my care in the wards of the Orthopædic Hospital, and Fig. 40 was taken from a photograph of this case.

The patient, a girl, S. A. Fryer, 14½ years of age, from Brighton, was admitted under my care on the 5th April, 1866. No history of the case could be obtained beyond the fact that she was born with the deformity, and had never been able to walk, except with the assistance of two crutches. No attempt had been made to cure the deformity, which was considered to be irremediable, and one surgeon had proposed amputation of the leg.

On examining the deformity, I found that the patella could be distinctly felt, and was very little below its natural size. There was no evidence of malformation of the joint, although from time alone, the surfaces of the articulation must have become somewhat altered. There was no indication of any deficiency of the muscles, either above, or below knee, and the case appeared to be one simply of congenital contraction of the knee-joint, which had been uninterruptedly allowed to increase during growth. One peculiarity in the knee-joint was its conical extremity, over which the skin had become thickened by the habit of kneeling, and moving about with the opposite leg in a bent position, which she would frequently do in-doors, although out-of-doors she always used her crutches in walking.

The club-foot presented the ordinary appearance of congenital talipes varus when, from any cause such as that existing in the present case, the foot had not been used in progression, and the distortion increased by the weight of the body. The absence of the longitudinal depression in the sole of the foot, and the transverse, or oblique depression, represented in Fig. 26, is worthy of remark, and in this respect these cases may be compared. There were no reasons against a favourable prognosis in this case, and the girl obtained a straight and useful limb. I adopted the plan of treating the knee-joint first, and this yielded rapidly to treatment. After the deformity of the knee-joint had been overcome the club-foot was cured without difficulty.

A much less favourable case, in which congenital contraction of both knee-joints existed as a complication of congenital varus of both feet, and was associated with some malformation of the knee-joints, as well as of both feet, and also of both hands, was under the care of my late colleague Mr. Lonsdale, at the Orthopædic Hospital, in the year 1857. A representation of this case is given in Fig. 41.

FIG. 41.

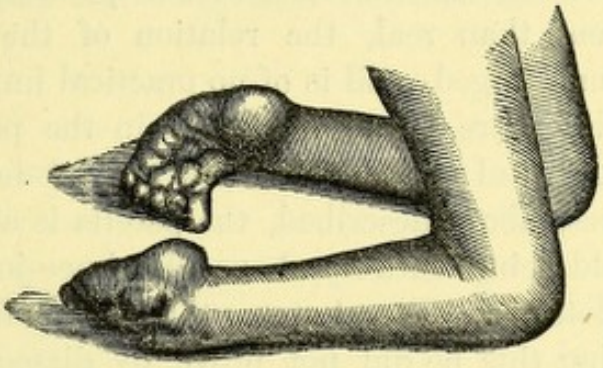

Congenital talipes varus of both feet, complicated with contraction of both knee-joints in the flexed position. Ankle-joints, and some articulations of feet remarkably rigid, and bones malformed. Patellæ very small. Both wrist-joints stiff, with hands in an extended position, several articulations of the fingers were rigid and the bones malformed.

The patient, a young man, W. Brown, aged 17, from Cornwall, was admitted into the hospital on the 25th August, 1857. In this case the ankle-joints and articulations of the feet were in a remarkably rigid condition, and at some of the articulations no movement existed. The bones were short and misshapen, and the boy was stunted in growth, and had a rachitic appearance, but without the evidence of true rachitis. The patellæ were traced with difficulty and existed as only small and rudimentary bones. Both the wrist-joints were stiff, with the hands in an extended position, and several of the articulations of the fingers were rigid and immovable. Yet by the movement of the distal extremities, this boy was enabled to play the organ, by which he earned his living. In this case, after many months of treatment, neither the knees or the feet could be completely restored, but he left the hospital able to walk with steel sup-

ports. Previous to admission he had habitually walked on his knees, and had large boots of a horse-shoe form adapted to these joints.

Altered position and imperfect development of the patella. It is only in cases of club-foot, complicated with rigid extension, or flexion of the knee-joints that the patella is observed materially to deviate from its normal position.

In some of the cases, above described, of relaxation of the ligaments of the knee-joint, the patella appears to be more external and somewhat above its normal position; but this is rather apparent than real, the relation of the tibia to the femur being unchanged, and is of no practical importance. As a general rule, there is no deviation in the position of the patella in congenital varus. In cases of club-foot, associated with stiff knees, above described, the patella is always of very small size, and being entirely above the knee-joint, can with difficulty be detected. Duval states that he has found it absent in one case, but this he did not prove by dissection. I have also seen two or three cases in which I was unable to trace the existence of the patella.

Deficiency in the length of the leg. This is a rare complication of congenital varus, but one example is mentioned in the case above adverted to at page 225. In this case the club-foot was associated with a rigidly flexed condition of the knee-joint, and the patella was imperfectly developed; the deformity was limited to one leg. I have seen several cases in which the leg below knee has been shorter than that of the opposite limb.

Excess or deficiency of toes. Occasionally we find an excess or deficiency in the number of toes, associated with congenital varus; and webbed toes, as well as other deviations are sometimes met with.

Some complications are of so serious a nature threatening the life of the child, that the deformities of the feet become altogether unimportant, except as a matter of physiological interest. It is a well known fact, that in cases of congenital malformation of the brain and spinal cord, in anencephalous fœtuses, and also in cases of spina-bifida, the coexistence of club-

foot is of frequent occurrence, as well as a variety of other deformities affecting the upper and lower extremities, and according to M. Guérin affecting also the head, neck, and spine.

M. Jules Guérin has collected and most ably discussed all the facts connected with this part of the subject, in reference to the etiology of congenital deformities. M. Guérin cites them in opposition to the theory of a mechanical cause, such as *position in utero; compression of the neighbouring parts*, &c.; and in support of the dynamic theory of the dependence of these deformities upon active muscular contraction.

CHAPTER XIII.

CONGENITAL TALIPES VARUS, CONTINUED.—OPERATIVE TREATMENT.

In a previous Chapter (Chapter III), I have dwelt upon the principles of treatment applicable to all cases of congenital varus, arranged in a three-fold division, as follows.

1st. The cases in which tenotomy is unnecessary.

2nd. Those in which the necessity of tenotomy is, by some authorities, considered to be doubtful, and,

3rd. The cases in which tenotomy is indispensable. Under this threefold division, I have discussed the relative merits of tenotomy and mechanical treatment, and having come to the conclusion that tenotomy is indispensably necessary in certain cases, a question of the utmost practical importance next presents itself, viz :—

At what age should the operation be performed? This has hitherto been decided either in accordance with some vague and erroneous notions as to the assistance derived from muscular exercise in walking; or simply by reference to the results of treatment, and as the treatment has not been based on any definite principles—neither the mode of operating, nor the after treatment being uniform—the results have been proportionately variable.

Some surgeons who by their judicious operations in infancy, and assiduous attention to the after-treatment, have succeeded in curing their cases, advocate operation at an early period; while others have so frequently seen the deformity return after their operations in infancy, that they as strongly recommend delay until the child has begun to walk, or a

little before that period, relying upon a certain amount of assistance from the use of the foot.

The general opinion given by surgeons at the present time, is, that the operation should be deferred until about the walking period, viz: the twelfth month, and sometimes later.

This opinion has doubtless been strengthened by the dictum of Dr. Little* that the most favourable period for the division of the tendons, in infantile cases of talipes, is a few months before the time when the child may be expected to make the first attempts to walk—about the age of six or eight months, until which time, in cases of talipes varus, mechanical apparatus should be used to turn the toes outwardly, reducing the deformity to the condition of talipes equinus.

The arguments adduced by Dr. Little against the early operation, *i.e.*, within the first few months are.

1st. "The objection, which on general grounds may be made to the performance of any operation however simple during the earliest months of existence.

2nd. "The curability of many cases by mechanical means alone; and the fact that many others may be half cured by mechanical means, the equinus portion of the deformity alone remaining, which may be cured at a later period.

3rd. "The necessity which exists after the early operation, for continuing a retentive apparatus till the walking period.

4th. "The liability to interruption, from illness in very young infants," which Dr. Little considers would certainly cause a reproduction of the deformity after early operations, but would be of little consequence if mechanical treatment alone were adopted.

The late Professor Lizars of Edinburgh relying upon the assistance to be derived from "the due exercise of the muscles, ligaments, and articulations of the foot," and in consequence of the liability of the apparatus to fret the skin in infancy postponed the operation to a much later period than Dr. Little.

* *Op. cit.*, page 284.

He observes,* "two or three years of age is the earliest time at which the division should be attempted, I prefer three years."

Now I propose to show that the anatomical and physiological conditions of the structures involved in the deformity must determine the age at which the operation should be performed; and that it is of the utmost importance to the perfect cure of the case, and the well being of the individual, that the solution of this important practical question should rest alone upon its scientific basis, unless influenced by any consideration of the general health of the patient.

It has been already shown in the description of the morbid anatomy of talipes varus, that, at the period of birth, very important deviations, both in form and position of the bones, and adapted shortening of certain ligaments, constantly exist, in proportion to the severity of the deformity. The deviations in form of the astragalus were particularly pointed out; and I stated that the malformed condition of the astragalus is determined by the malposition of two of the bones with which it articulates, viz: the navicular bone and the os calcis, and that its altered form is in evident adaptation to the altered position of these bones.

The effect of allowing the deformity to remain during the period of active growth and ossification of the bones, has been shown not only to induce the persistence of these abnormal conditions, but a positive increase both in the deviations of the bones, and the adapted shortening of the ligaments.

Now it must be obvious that the astragalus can only assume its natural form after the cause of its malformation, viz.: the abnormal position of the navicular bone and os calcis has been removed; and in restoring the position of these bones, the ligamentous shortening must also be overcome. To effect these objects, it is clear the operation ought to be performed at as early a period as may be consistent with the general health of the child.

I have also described arrest of development of the muscles

* "Practical Observations on the Treatment of Club-foot," 3rd Edition, page 9, Edinburgh, 1855.

of the leg, as a constant and most important effect of the persistence of the deformity, and one from which the individual never recovers. As in the deformed foot there is no power of flexion in the ankle-joint, all the great muscles of the leg remain unused, and each month, therefore, does its share of mischief in preventing muscular development, and perhaps also in causing some degeneration of the muscular tissue. The longer the deformity remains uncured, the less will be the ultimate size of the muscles of the leg, and, therefore, on this account, I strongly advise early operation.

Dr. Little's objections to early operation do not appear to me of any real value when weighed against the substantial advantages above mentioned. Infants two months old bear these operations remarkably well, often without a single night's rest being disturbed, and the mechanical treatment is borne with little or no inconvenience. The long continuance of a retentive apparatus after the operation is not always necessary to be worn during the day, but if the mechanical treatment be adopted, some apparatus must constantly be worn.

The liability to interruption of treatment from infantile complaints is much less to be feared within the first few months than at a later period; and when the foot has been completely cured, I have never seen the deformity return in consequence of a few weeks illness.

It is of the utmost advantage to complete the treatment of the club-foot before the commencement of dentition, when children are generally fretful, and become liable to so much illness, that interruptions from this cause may really be feared. Moreover, at the later period, children are so much stronger that they often resist all treatment with great violence, and in a passionate child I have known hernia produced from this cause.

Upon these grounds, therefore, I strongly advise, that if the child be in good health, the operation should be performed at about the second month. Delay beyond the second month is unnecessary, and certainly acts prejudicially upon the ultimate results of the case.

Operations required. We will now pass on to the

consideration of the necessary operations. And first as to

The tendons, fascia and ligaments requiring division. In the majority of cases, the following tendons must be divided, viz., the tibialis anticus, tibialis posticus, and flexor longus digitorum, and also the tendo Achillis. In some slight cases, we may be able to dispense with one or more of these operations, and the inversion may be overcome by mechanical means without division of the posterior tibial tendon.

The plantar fascia. In infantile cases the plantar fascia is often but little contracted, and then it will yield to mechanical treatment; but when much contracted it is necessary to divide the plantar fascia, and this is constantly required when the deformity is met with in the adult. Contraction of the plantar fascia always exists in the severest forms of infantile varus, and sometimes even in the slighter forms, when it may be regarded as a special peculiarity of the deformity.

Subcutaneous section of the ligaments has not yet received much attention, but cases of varus of extreme severity are sometimes met with in children—more commonly in boys of about twelve or fourteen years of age—which obstinately resist the ordinary method of treatment. In one case of this kind, the late Mr. Lonsdale made a free division of the ligamentous bands at the posterior part of the ankle-joint; the case was benefitted, but still remained in an imperfectly cured condition.

The deltoid ligament may be divided with advantage in some of these severe cases, and after its division the navicular bone will be more readily separated from the inner malleolus.

This result followed in a case in which I divided the anterior portion of the deltoid ligament, in September, 1859. The case was one of relapsed deformity—congenital talipes varus—of unusual severity, in a young lady, Miss A. L——, æt. 10 years, see Appendix, Case XV. In some cases of this kind, division of ligaments may undoubtedly be useful, but I have never found it necessary to employ it in infants. Probably a free division of the calcaneo-cuboid ligament, near to its connexion with the os calcis, would be useful, in addition to tenotomy and division of the plantar fascia, in some cases in

which the arch of the foot is much increased and rigidly held in this contracted condition, but I have never practised this operation. It might shorten the treatment, though I believe such contraction may always be overcome by gradual mechanical extension if continued long enough, and carefully attended to; see Appendix, Case XIII.

Mackeever* in three dissections of congenital varus in infants, found that the tuberosity of the os calcis touched the fibula, and that the os naviculare was in contact with the inner malleolus, and adherent by strong bands of fibrous tissue (the deltoid ligament?) on division of which the foot was readily restored to its natural position.

The late Professor Streckeisen† of Zurich, attached more importance to the division of ligaments, in the cure of club-foot, than to the division of tendons; and states that after division of the deltoid ligament, and some other ligamentous bands passing between the inner malleolus, astragalus, and navicular bones, he was generally able to bring the foot into its normal position, and then, as a retentive apparatus, he employed the plaster of Paris bandage.

History of the operative treatment. With regard to the division of the posterior tibial tendon, it may be observed that in the earlier days of Orthopædic Surgery, division of the larger and more easily reached tendons was thought to be sufficient. It was the usual practice either to divide the tendo Achillis alone, or in conjunction with the tendon of the tibialis anticus muscle, and sometimes with the plantar fascia.

The division of the tendon of the tibialis posticus muscle was introduced at a later period, but the fear of inflammation in dividing deep tendons, and the proximity of the posterior tibial artery, prevented the application of subcutaneous tenotomy to the posterior tibial tendon. This tendon was therefore divided by open-wound when the operation appeared to be indispensably necessary for the cure of the case; but being

* *Edinburgh Medical Journal*, Vol. XIV., 1820, page 220.

† Notizen über Bau und Behandlung des Klumpfusses aus den hinterlassenen Aufzeichnungen, von Prof. Streckeisen. Veröffentlicht bei Dr. A. Burckhardt und Dr. Fritz Miescher. Basel, 1868. (Jahrbuch f. Kinderheit, N. F. II).

found a dangerous procedure it was avoided as much as possible.

The consequence of not dividing the posterior tibial tendon in the earlier operations, *i.e.* previous to the year 1842 for varus in infantile cases, was a frequent cause of relapse of the deformity in severe cases. Its subcutaneous division was occasionally performed in adults and in youths, when the tendon could be felt externally and therefore easily reached; but the subcutaneous division of the posterior tibial tendon in infants was the last achievement of tenotomy as applied to the cure of varus, and the credit of devising a method by which this operation could be effected with safety, or with very little risk, belongs to Dr. Little,* and was accomplished in the year 1842. A fatal case after the operation, by open-wound, appears to have led immediately to this great improvement.

On the 9th August, 1834, Stromeyer† first divided the posterior tibial tendon. He passed a bistoury down to the bone, between the tendon and the artery, protecting the latter by the nail of the index finger of his left hand, and then carried the knife forwards. The external wound is stated to have been nine lines in length. In subsequent operations, Stromeyer describes the external wound as being three quarters of an inch in some, and in others an inch and a half in length; the tendon being divided in some cases by the point of the bistoury alone, and in others he opened the sheath and divided the tendon on a grooved director. The wounds generally healed from the fifth to the ninth day. The ages of the patients are not mentioned, but from the description given they could not have been infantile cases.

In 1839 Velpeau‡ states that "the subcutaneous section of the posterior tibial tendon, proposed by M. Held, Professor of the University of Strasbourg, in 1836, appears not to have been performed except on the dead subject." He then alludes to the danger of the operation above the malleolus, from the proximity of this tendon to the artery, and advises that the tendon should be divided "half an inch below and in front of the inner malleo-

* *Op. cit.*, page 297.

† Beitrage zür Operativen Orthopädik, Hanover, page 77.

‡ Eléments de Médecine Opératoire, Paris, 1839.

lus," close to the insertion of the tendon into the navicular bone.

In 1844 Weis* of Hanover also recommended this operation.

In 1855 Professor Syme of Edinburgh revived this recommendation to divide the posterior tibial tendon "a little below and anterior to the tip of the internal malleolus" and at the same time condemned the present method of dividing this tendon above the malleolus.†

In describing the altered relations of the posterior tibial tendon in congenital varus, I have already pointed out the impossibility of dividing this tendon below, and in front of, the inner malleolus in all the severe, and even in the moderately severe cases of this deformity. The reason is, that in the deformed foot, this tendon does not exist in this situation, in consequence of the navicular bone being displaced, and held firmly in contact with the inner malleolus, by the contraction of the posterior tibial muscle, the tendon of which, therefore, does not pass below and in front of the inner malleolus, as in a healthy limb. In slight congenital, and in most of the non-congenital cases, this operation may be performed in the situation recommended by Velpeau, Weis, and Syme, but in such cases its division is seldom required.

Dr. Little‡ states, "at the period of publication of his treatise on club-foot, &c., 1839, the author (Dr. L) had only operated on the posterior tibial tendon in adolescents and adults, in whom it is visible, or easily felt, by the method of Stromeyer. From this period to 1842, he was accustomed in children above the age of twelve months, from the difficulty of accurately feeling the outline of the tendon, to expose the tendon by an incision in the integuments three quarters of an inch in length, and divide it upon a director. Having about this period witnessed suppuration in a limb, ending fatally, in which a tendon had been severed after exposure, the author relinquished this departure from subcutaneous tenotomy."

Dr. Little then describes a method proposed at this time

* De Tenotomiæ Talipedibus Applic. C. Weis, page 7. Havniæ, 1844.

† See "A Clinical Lecture on Tenotomy," by Mr. Syme, *Lancet*, March 17, 1855.

‡ *Op. cit.*, page 297.

by Mr. Tamplin, "to divide the posterior tibial by effecting a puncture into the sheath of the tendon with a stillette and canula, and after withdrawal of the stillette introducing through the canula a blunt-pointed knife." The idea of thus dividing the tendon from before backwards towards the artery, (Dr. L. observes) "was novel, but both unsuccessful and unsafe." Dr. Little states, "that he tried this procedure two or three times, and then rejected the stillette and canula, substituted a small scalpel for making an aperture into the sheath, and had the knife (Fig. 122 B) made by Fergusson, as an improvement upon the tenotome of Bouvier, with which to divide the tendon, satisfied that if he should wound the posterior tibial artery, it would in all probability be by a division, and not by a puncture." This is the method now generally adopted, with the exception that the knife used has a plain rounded extremity, as in Fig. 42 E, instead of a probe-point as used by Dr. Little and represented in Fig. 122 B in his work on "Deformities" page 301.

Order in which the tendons should be divided. It is not only necessary that certain tendons above enumerated should be divided; but also that, in all cases attended with any marked degree of ligamentous rigidity, these tendons should be divided in a definite order which has been determined by practical experience, and can be proved to be strictly in accordance with the mechanical and anatomical conditions of the deformity. In slight cases, or those attended only with a moderate degree of ligamentous resistance, it is sometimes the practice to divide the tibialis anticus, tibialis posticus, and flexor longus digitorum tendons, and also the tendo Achillis at one sitting. Mr. Tamplin adopts this plan in all cases, whether severe or slight, but my own observation has led me to differ from this procedure.

In all severe cases I have found it of the greatest advantage to divide the operative treatment into two stages; the second operation being performed after an interval of a few weeks in children, and a longer time according to the age of the patient, and the severity of the case. The great practical point is to overcome the inversion of the anterior portion of the foot; or,

in other words, to convert the varus into equinus, and thus reduce a compound to a simple deformity, before dividing the tendo Achillis, as shown in Plate IV.

With this view, therefore, at the first operation I divide the tendons of the tibialis anticus, tibialis posticus, and flexor longus digitorum, and then evert the foot gradually by mechanical means. The practice at the Orthopædic Hospital is to divide the tibialis posticus and flexor longus first; but when the anterior tibial is much contracted, I prefer dividing this tendon first, because, I think more satisfactory evidence is then obtained of the division of the posterior tibial.

There is no greater error in the treatment of severe varus, or one more frequently committed by surgeons of the present day, than the division of the tendo Achillis at the first operation, either by itself, or conjointly with the division of the other tendons. By such a procedure, too many objects have to be accomplished at the same time by mechanical means and failure in some of them usually results; eversion of the foot is imperfectly obtained, depression of the os calcis is also imperfectly obtained, and the recurrence of the deformity rendered certain. It has long therefore been an established rule in my practice that the tendo Achillis should be the last tendon divided, and that its division should be delayed till the equinus alone remains to be cured, see Plate IV. Fig. 1.

The plantar fascia. If there be only a slight contraction of the plantar fascia, its division will probably be unnecessary; but when required, the general practice at the Hospital is to divide the plantar fascia and the tendo Achillis together at the second operation. However, I would recommend that when the plantar fascia is much contracted, causing an obvious shortening of the foot and increase in the convexity of the tarsus, its division be made a separate stage in the treatment, and should be performed after the division of the tibial tendons and before the section of the tendo Achillis. By so doing, it occurred to me that we might make use of the contracted condition of the tendo Achillis in fixing the os calcis, during the process of unfolding the longitudinal arch of the foot, by the application of pressure to the anterior part of the

foot, in an uplifting direction. If the tendo Achillis be divided at the same time as the plantar fascia, the foot must be elongated by direct pressure downwards on its tarsal convexity, a more painful and uncertain process than that which I have recommended. The advantages of this plan in a most severe case of adult deformity were remarkably well illustrated in the case from which Figs. 25 and 26 were taken, and in which rapid progress was made after a free division of the plantar fascia at a late stage of the treatment, but previous to the division of the tendo Achillis.

Mode of performing the operations. It is an established practice, at the Orthopædic Hospital, to divide all the tendons and the plantar fascia, from below upwards towards the skin. The knife is introduced obliquely downwards, with the flat surface parallel with the tendon to be divided. The point is then carried behind the tendon as close to it as possible, and the handle of the knife depressed. The cutting edge is now turned against the tendon, which, in infants, yields before a little direct pressure, the tendon being simultaneously made tense by an assistant who has charge of the foot. In older patients, and when the larger tendons are divided in children, a little cutting movement is required; but this is to be avoided as much as possible, and a clean transverse section made.

One great object is to avoid any disturbance of the surrounding parts, and the division should be made quickly, neatly, and with decision rather than force. The foot should be instantly restored to its deformed position by the assistant, so as to approximate the divided extremities of the tendon, and the knife withdrawn. The wound should be immediately covered with a compress of lint and a strip of adhesive plaster.

Some observations which I made, when describing the division of the tendo Achillis for the cure of talipes equinus, are also applicable to the operations on the other tendons. The foot is then to be bandaged, and a softly padded splint applied so as to retain it in the deformed position; the tinned iron splints being the best, because they can be bent into any form required. The foot must then remain undisturbed for three or four days.

The objects of immediately applying a compress, and allowing it to remain a few days, are,

1st. To exclude the atmosphere from the wound, and,

2nd. To prevent extravasation of blood, and inflammatory exudation into the subcutaneous areolar tissue. The object of retaining the foot in its deformed position is, not that direct union may take place between the divided extremities of the tendon, and a material formed which may be subsequently elongated; but to insure perfect quiescence to the part, and thus diminish the chance of inflammation.

The knives which, in my opinion, are best adapted in size and form to the various operations of tenotomy, are represented in Fig. 42. I prefer the strong spear-pointed tenotome, the point corresponding to the centre of the blade, and the cutting edge slightly convex, to the slender-pointed knife with a straight cutting edge. Slender points are apt to break in these operations, and this accident has repeatedly occurred.

FIG. 42.

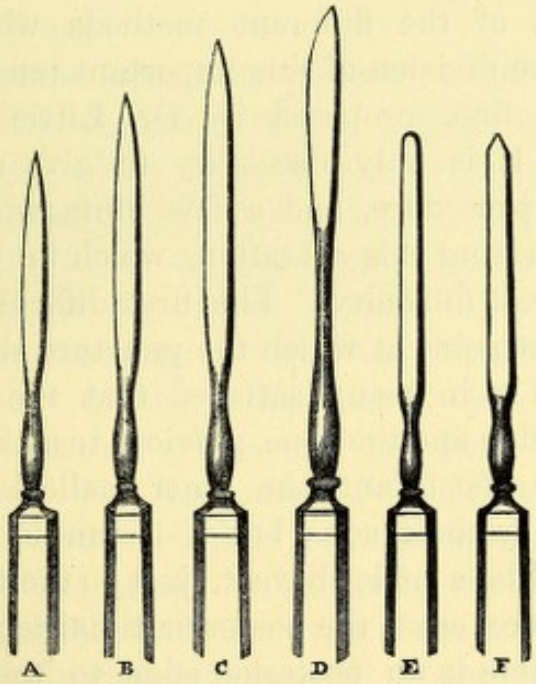

TENOTOMY KNIVES.

A, B, C. Three sharp-pointed tenotomes. A is quite large enough for division of the tendo Achillis in children, but in adults B is required. C is useful for a deep tendo Achillis in a fat leg.

D. A scalpel used for opening the sheath of the posterior tibial tendon. The point should be rather more rounded and the blade not wider than Fig. B.

E. Blunt-pointed tenotome for dividing the posterior tibial tendon.

F. Tent-pointed tenotome. The point is blunt on either side, and should be rounded, though of angular form. It will penetrate cellular tissue, which E will not, and may be used with more freedom than the sharp point, where there may be fear of wounding vessels or nerves. It may be passed beneath the biceps tendon when displaced so as to lie over the peroneal nerve. Or with a longer blade it may be passed behind the sterno-mastoid muscle. Difficulty in forcing the round point through cellular tissue under some circumstances led me to adopt this form.

The backs should be rounded and strong, and it is equally essential that the knives should carry a very sharp edge, and be well-tempered, requisites not easily obtained; but it will be found that a strong tendon easily turns the edge of an inferior knife, and I have frequently seen the operator obliged to change his knife in the course of dividing such a tendon. The knives represented, were made for me by Mr. Blaise of St. James' Street.

The anterior tibial tendon should be divided a little above its insertion, as it crosses the ankle-joint as shown in Fig. 31 B. This tendon can generally be easily felt, except in fat infants, and in these cases more difficulty may be experienced than might be expected. The altered direction of the tendon to the inner side, must be borne in mind, when it cannot be felt with certainty.

Method of dividing the tendons of the tibialis posticus and flexor longus digitorum muscles. Having already given an historical account of the different methods which have been employed for the division of this important tendon, and stated that the plan first proposed by Dr. Little is now invariably adopted; it is only necessary to give a practical description of this procedure, and a few hints which may be of service in performing this operation, which in infants is decidedly one of great difficulty. The first difficulty is in determining the exact point at which the puncture should be made; and the second is in being satisfied that the knife is really between the tendon and the bone, previous to making the section.

In the leg of a fat infant, the inner malleolus can scarcely be well defined by the touch; but if it can be made out, the puncture should be a little above it, just on the turn of the bone, where, in a severe case, the posterior tibial tendon is slightly prominent. There is no posterior edge to the tibia, as in a perfectly ossified bone; and, therefore, the exact point must be guessed. The altered direction of the tendon, which bears a constant relation to the severity of the deformity, must be accurately kept in view. The operator must take care to introduce the knife forward enough; taking the antero-posterior

diameter of the leg, the puncture may pretty safely be made exactly in the centre, as described by Dr. Little, if the case be severe. Two knives are necessary, the scalpel, Fig. D, and the blunt-pointed knife, Fig. E.

The scalpel must be thrust straight down to the tendon, and, by a movement of the point, an incision made in the sheath close to the bone. This being accomplished, the scalpel is withdrawn and a blunt-pointed knife inserted, care being taken that the point passes between the tendon and the bone. If this is done, the knife will be locked, so that it cannot be moved from side to side; but if this sensation be not distinct, the tendon has been missed. The knife should then be partially withdrawn and used gently as a probe. In this way the tendon may be discovered, and if the blunt point will not pass behind it, the knife must be withdrawn and the scalpel re-entered, to open the sheath. The blunt-pointed knife may then be again introduced, and will easily pass between the tendon and the bone.

When the knife is behind the posterior tibial tendon, it may be pushed a little deeper, with the object of including the tendon of the flexor longus digitorum; and then the cutting edge must be turned towards the tendons, an assistant at the same time putting them on the stretch by everting the foot, or turning it towards its natural position.

These tendons are often divided in this way, without any furthur movement of the knife, but a slight cutting movement may be required. The less the knife is moved, however, the better, for the sake of avoiding the posterior tibial artery, and the risk of subsequent inflammation. The posterior tibial artery is generally divided or wounded, when the point of the knife is moved about too freely, and lost, as it were, in these movements to cut the tendon.

It is always a matter of uncertainty whether the knife has passed under the tendon of the flexor longus, as well as that of the posterior tibial; but although, in a severe case, it is desirable to divide this tendon, it is of much less importance than the posterior tibial. When the posterior tibial tendon can with

certainty be felt, it may be divided with the sharp-pointed knife, which I have frequently done in the adult, and sometimes at younger ages; but as it is desirable to include the long flexor tendon, I do not advise this procedure. In infantile cases it is decidedly dangerous and unsatisfactory, as compared with the method above recommended.

Evidence of the division of these tendons. An audible snap rarely follows division of the posterior tibial tendon, either in the infant or adult; but a jerk, or sudden yielding of the foot, is generally felt by the assistant, so that if the operator be in doubt, an experienced assistant may confidently assert that the tendon has been divided. Usually, also, a distinct vibration is communicated to the hand of the operator, and if the long flexor has been divided, as well as the posterior tibial, a sort of double-click vibration is felt. This is the most satisfactory evidence to a practised hand, and may with certainty be relied upon, even when the assistant has not felt any jerk or sudden yielding of the foot, which may be prevented by the ligamentous rigidity. Either of these events, therefore, will be conclusive as to the division having been accomplished; but one of them must be distinctly present.

A depression can generally be detected between the divided extremities of the tendon in adult cases of varus, in which the tendon is, as a rule, very superficial, and can be distinctly felt previous to the operation. This also occurs, sometimes, in children and in infants when the leg is thin, but only in exceptional cases.

The difficulties connected with division of the tendons may be stated to arise from,

1st. The displacement of the tendons, depending upon the deformity,

2nd. The difficulty in defining the situation of the tendons in the fat legs of infants; this applies especially to the anterior and posterior tibial tendons.

3rd. The abnormal insertion and distribution of tendons occasionally met with, such as the bifurcation of the anterior tibial tendon, &c.

4th. The abnormal distribution of the arteries.

It once occurred to me, to find in a boy, aged four years, affected with varus in both feet, an artery of the size of the posterior tibial, pulsating exactly over the posterior tibial tendon in both legs. Mr. Lonsdale and myself discussed the propriety of attempting division of the tendon below the malleolus, but from the severity of the case, the tendon could not be felt in this situation when the foot was everted. I therefore divided the tendon with extreme caution above the malleolus, and without wounding the artery in either foot.

Accidents connected with division of the tendons occur only as rare and exceptional events, but the following have been known to occur, either at the time, or as the result of the operation.

1st. *Division of the skin so as to make an open-wound at the time of dividing the tendon.* This is most apt to occur during the division of the tendo Achillis, when adhesions to the skin exist after a previous operation. Under these circumstances, the usual indications of the division of this tendon, viz.: a sudden jerk or yielding of the foot, and an audible snap, do not occur; and the operator, thinking the tendon is not completely divided, carries his knife forwards too boldly.

We also run a risk of this accident in non-congenital spasmodic deformities, when a violent muscular contraction is suddenly induced, as I have witnessed on several occasions, during the operation; but then, an experienced assistant ought to prevent this accident, by restraining the flexion of the foot. If an open-wound be accidentally made, the foot should be instantly extended, the wound covered with dry lint, retained in position by strips of adhesive plaster, and the foot bandaged in its extended position to a splint applied in front of the ankle-joint; it should remain undisturbed for several days unless pain and inflammation supervene. Violent inflammation and suppuration in the course of the tendon may ensue, but the wound will sometimes heal by the first intention.

2*nd. Suppurative inflammation in the sheath of the divided tendon and surrounding cellular tissue.* This is most apt to follow the operation on the deeper tendons, especially the posterior

tibial, in consequence of the difficulty sometimes experienced; but I have never known it occur, except as the result of a clumsy operation. The well known freedom from inflammation which characterizes subcutaneous operations, has led some surgeons to think too lightly of these operations, and disregard the precautions above described as necessary to prevent inflammation. From such neglect, I have seen suppuration extend up to the popliteal space in one instance, and half way up the leg in another. The late Mr. Wilson of Manchester told me that he once amputated a leg at the thigh, in consequence of suppuration in the popliteal space following division of the hamstring tendons.

3rd. *Wounds of arteries.* There are two important arteries in the foot liable to be wounded in the operations for varus, viz. the posterior tibial, and the internal plantar arteries, both of which have been repeatedly wounded, and occasionally with very serious results.

a. Wound of the posterior tibial artery. If this artery should be wounded in the operation for dividing the posterior tibial tendon, the accident will, with rare exceptions, be at once indicated by the arterial jet from the wound, and by the immediate blanching of the foot. When the arterial character of the hæmorrhage is doubtful, as sometimes happens in fat children, the latter indication may be relied on. Pressure must be immediately applied by means of a graduated compress and bandage, and maintained for two or three weeks, the pressure being occasionally modified to prevent slough, which occurred in one of my cases, narrated below, through the mother neglecting to bring her child to the Hospital as directed. I have never seen pressure fail, if well applied and attended to; and so much confidence do I feel from having witnessed its success in many cases—perhaps from fifteen to twenty in all—that I would not allow the risk of this accident to deter me from attempting the division of the posterior tibial tendon in a severe case. It has been recommended to reintroduce the knife and completely divide the artery, when it is supposed only to have been punctured, but its division will generally have been complete

at the time of the accident, if the blunt-pointed knife has been used, and under any circumstances I would not recommend this procedure.

b. Wound of the internal plantar artery. This accident is apt to occur during the division of the plantar fascia, and as the sharp-pointed knife is used, the artery is more liable to be punctured than divided. It has been recommended to make complete division of the artery, but this plan has not been adopted when I have seen the accident occur, and pressure being immediately applied, these cases all terminated successfully; they occurred in children and the artery had probably been completely severed at the operation.

4th. *False aneurism.* In 1846 Mr. Tamplin* relates two cases of false aneurism as having occurred at the Orthopædic Hospital up to that date, from puncture of the artery, "in both, false aneurism was the result, and in both was it necessary to cut down upon, and tie the vessel. The first was a puncture of the posterior tibial, and the other of the internal plantar artery, in a boy eleven years of age." The operations were very formidable from the depth and small size of the arteries, but both cases terminated favourably.

Two cases have occurred in my own practice in which a diffused pulsation was observed a few days after the operation for dividing the posterior tibial tendon, and a small false aneurism had probably formed; but in both it was completely removed by well regulated pressure, and subsequently I divided the tendo Achillis in each case, and both did well.

A more defined pulsation occurred in a child operated upon by Mr. Tamplin in the year 1855. I detected the pulsation in this case, at the time when Mr. Tamplin was about to divide the tendo Achillis; no external tumour had formed. The late Mr. J. H. Green happened to be present, and agreed with me as to the probable existence of a false aneurism. Division of the tendon was delayed, and the case treated by pressure. No diminution in the pulsation occurred for a long time, and I think the pressure was continued for three or four months.

* *Op. cit.*, pages 16 and 60.

The pulsation had then entirely disappeared, and Mr. Tamplin divided the tendo Achillis, and cured the deformity. The case remained well.

A less fortunate case occurred in my own practice. On April 13, 1853, I wounded (divided?) the posterior tibial artery in a child seven weeks old. The blunt-pointed knife (Fig. 42 E) was used, and I was not aware of the accident at the time of the operation; as neither the arterial jet nor the sudden blanching of the foot indicated the mischief, the artery was probably only wounded.

After a lapse of ten days, a deep pulsating tumour was discovered, and direct pressure by a graduated compress and bandage was applied. The pulsation diminished, but a very small slough formed, in consequence of the pressure not being relieved for four days, from the neglect of the mother to attend at the hospital, and a copious arterial hæmorrhage took place. Pressure a little above the aneurism appeared to command the bleeding, and was therefore tried, but discontinued on the second day from the extension of the swelling to this part of the leg.

This pressure having been removed, a second arterial bleeding followed. On May 12, 1853, I injected from five to ten drops of the concentrated solution of perchloride of iron, as recommended by M. Pravaz, of Lyons,* into the centre of the aneurism, which was probably about an inch in diameter. At the time of the injection, loosely clotted blood plugged the small cutaneous ulcer, through which the extremity of a long and finely pointed glass-syringe containing the styptic was introduced and carried to some depth.

Both before the injection, and for five minutes afterwards, Mr. Lonsdale compressed the femoral artery, so as to insure the blood acted upon being as near as possible in a stagnant condition, a most essential point. The first effect observed, was that the loosely clotted blood filling the cutaneous ulcer

* An account of M. Pravaz's experiment and observations will be found in the *Dublin Quarterly Journal* for May, 1853, "On a New Method of producing Instantaneous Coagulation of Blood in the Arteries." By Dr. Pravaz, of Lyons.

became firmer, and that from ten to twenty minims of straw-coloured serum oozed through the ulcer, affording conclusive physiological evidence of the firm coagulation of the blood, which was also indicated by a general feeling of hardness over the sac. A piece of lint and light bandage were applied.

The cutaneous ulcer showed itself the next day to be contracted and plugged with a firm black clot. The surrounding skin, which previous to the operation, had presented a tense, shiny, swollen, and slightly reddened appearance, was now pale, and less tumefied. The aspect of the limb was remarkably changed, and a process of shrinking and contraction appeared to have commenced, so that no inflammatory results were apprehended. Progressive improvement took place; the ulcer healed in a week, and shrinking and contraction advanced. On May 25, a deep, puckered cicatrix, and a little deep-seated induration alone indicated the former seat of the aneurism. The treatment of the deformity was then proceeded with; the tendo Achillis was divided June 1, and the restoration of the foot was in a few weeks as complete as in other cases.

The operation of tying the posterior tibial artery would probably have been fatal to the child, who was much exhausted by the hæmorrhage, and the limb was in a very unfavourable condition.

The success which attended the injection of perchloride of iron has induced me to give the particulars of this case. I believe it was the first case of aneurism, and so far as I know, is the only case up to the present time, which has been treated upon this principle, and I would recommend its adoption under similar circumstances. The solution of perchloride of iron is a valuable agent if used under the conditions recommended by M. Pravaz. If brought into contact with blood only, its extraordinary coagulating power may be relied upon, and was admirably illustrated in the present case; but if applied to living tissues it is certain, from its caustic properties, to produce slough and inflammation, strong muriatic acid might almost as well be em-

ployed. This styptic appears to have been used in ignorance of the fact that it is an acid salt; it has always an acid reaction, and contains an uncertain quantity of free muriatic acid of the strongest kind. It has generally been used by drams instead of drops, and applied to vascular tissues, such as nævi, the surfaces of open-wounds, &c.; and thus, while its caustic properties have been frequently, and, it is to be regretted, fatally, demonstrated, its valuable properties as a simple coagulant of blood have been entirely overlooked. The result has been that this valuable remedy has been allowed to fall into disuse, owing to a misconception of its most useful properties, and its consequent misapplication in certain cases.

I have now fully discussed the operative treatment necessary in the ordinary cases of congenital talipes varus, but unusual circumstances occasionally arise in connexion with the treatment of the more severe forms of congenital varus when met with in the adult, rendering necessary a careful consideration of the necessity or advisability of amputation, which was performed under circumstances described in the case represented in Figs. 34, 35 and 36; or of other operative procedures which may be adopted with a view of improving the condition of the patient. Amongst the latter I must here make some mention of an operation which has been performed under the sanction of a recognized authority on the treatment of club-foot; I allude to

Excision of the Cuboid Bone. This operation was first suggested by Dr. Little,* who observes:—"He (Dr. Little) has often thought that, in inveterate varus such as Figs. 105 and 106, the treatment might well be commenced in robust subjects by ablation of the os cuboides, which in preventing the unrolling of the foot, acts as a key stone of the inverted arch. He is of opinion that, by this means, the treatment of certain cases might be reduced from twelve months to six or eight weeks."

In the next paragraph Dr. Little remarks:—"Age sets no limit to the applicability of tenotomy; the author has success-

* *Op. cit.*, page 305.

fully treated adult varus at the age of forty, and non-congenital equino-varus at fifty-four." We may, therefore, assume that, except under very extraordinary circumstances, Dr. Little would not recommend the above operation under the age of forty. A case however occurred, in which Dr. Little did recommend the operation in a gentleman aged 21, who came to this country to be cured of a severe form of congenital varus, similar to that represented in Figs. 25 and 26. The case was under the care of the late Mr. Solly, of St. Thomas' Hospital, who performed the operation on the 26th June, 1854, and by whose invitation I was present, but was not consulted regarding it. Dr. Little and several surgeons were present.

The operation was performed under chloroform, by making a free incision over the convexity and outer margin of the foot, exposing the cuboid bone, which was then removed piece-meal by the gouge. Possibly portions of other bones were also removed, the object being, in a mechanical point of view, the removal of a large wedge from the convexity of the foot, and care was taken to remove the apex of the wedge by introducing the gouge far enough towards the astragalus. The foot was then forcibly everted, and subsequently efforts were made to maintain the foot in this position by the application of the Scarpa's shoe and other instruments; but considerable difficulty was experienced in consequence of the wound interfering with the application of pressure on the convexity of the foot.

The immediate effect of the operation was to produce some improvement in the position of the foot, but the result of the case was ultimately less successful than anticipated by Mr. Solly.

Now that the anatomical conditions existing in congenital talipes varus, and the nature and extent of the structural changes and adaptations, induced by the persistence of the deformity, are better understood than formerly, and we have at our command the improved instruments to the construction of which this knowledge has led, the operation of excision of the cuboid bone is not likely to be performed again in any case of talipes varus, even in adult life.

CHAPTER XIV.

CONGENITAL TALIPES VARUS CONTINUED.—MECHANICAL CONDITIONS AND TREATMENT IN INFANTILE AND ADULT CASES.

THE general principles upon which the treatment of talipes varus should be based, and the details of the operative treatment required, having been dwelt upon, we must now devote our attention to the consideration of the mechanical and physiological treatment, intimately and necessarily connected with the operations already described.

I have shown that congenital talipes varus depends upon:

1st. The contraction and structural shortening of certain muscles.

2nd. Upon the displacement of certain bones.

3rd. Upon the adapted growth in the deformed position of some of the tarsal bones, which therefore present variable degrees of malformation, even at the period of birth.

4th. In severe cases, upon the adapted shortening of certain ligaments.

It follows therefore that after the tendons of the contracted muscles have been divided, the objects of mechanical treatment must be:

1. To insure the requisite elongation of the contracted and shortened muscles, by regulating the length of the new tendon formed during the reparative process after division.

2. To replace, or reconduct to their normal positions, the displaced bones.

3. In accomplishing the second object, to elongate the contracted and shortened ligaments.

4. To retain the bones in their normal relations, and to encourage the use of the joints in their natural directions, so that as growth proceeds, assuming the treatment to be undertaken in childhood, the bones may improve in form, and the muscles be brought into exercise with the view of promoting their structural development and physiological perfection.

The mechanical treatment, it will therefore be seen has reference

1st. To the reparative process in the divided tendons, and,

2nd. To the restoration of the form of the foot.

With regard to the first point, very erroneous ideas appear to exist. According to the usually accepted opinion, the divided tendons must be allowed to reunite, and then the new connecting material gradually stretched by mechanical means to the requisite length. The theory of stretching the new material formed in the reparation of divided tendons, I believe to be altogether erroneous. According to my* observations on this subject, the object is not to stretch tissue already formed, but to regulate the length of the new material during its formation. Where no ligamentous resistance exists, as in most of the non-congenital deformities, this can be accomplished with ease and certainty; but where much ligamentous rigidity exists, as in severe cases of congenital varus, it is sometimes impossible to gain the required length before complete reunion of the divided tendon has taken place, and then the acquirement of any additional elongation is so tedious and uncertain, that a redivision of the tendon may even become advisable.

The rate of extension must be regulated, where this is possible, by the activity of the reparative process in the divided tendons. In well-nourished infants, the required length should be obtained in a fortnight or three weeks, whilst in paralytic limbs it should not be obtained in less time than six to eight weeks.

As to the second point, viz., the restoration of the form of the foot by elongation of the contracted ligaments; it is necessary to observe that the rate of extension may proceed as fast

* "Reparative Process in Human Tendons," by W. Adams, London, 1860.

as the circumstances of the case permit, having regard to the condition of the tendon, the avoidance of pain, and the prevention of abrasion or slough from local pressure.

MECHANICAL CONDITIONS OF THE FOOT.

The conditions of the foot mechanically considered in talipes varus, which it is the object of mechanical treatment to overcome, must now be passed in review. The precise deviations in position of the different bones have been already described, and it will be seen in reference to Figs. 34, 35 and 36, that the foot, if mechanically considered, may be regarded as divided into two portions which move in different directions from two distinct centres of motion, viz.: the ankle-joint and the transverse tarsal joint. The ankle-joint as one centre of motion, regulates the movements of flexion and extension of the foot; and the transverse tarsal joint, as another centre of motion, corresponding to the articulations between the first and second rows of the tarsal bones, viz., the astragalo-scapoid, and the calcaneo-cuboid articulations—indicated by the obliquely dotted line *a a* in the Figs. 31, 35 and 36, regulates the movement of inversion of the anterior two-thirds of the foot, the chief characteristic of talipes varus.

A considerable amount of motion exists at this great transverse tarsal joint in the normal position of the foot, and in talipes varus the inversion of the foot takes place essentially from this centre of motion, and therefore involves only the anterior two-thirds of the foot. The posterior third of the foot, consisting of the os calcis and astragalus, has its centre of motion in the ankle-joint, from the construction of which it can only move in the direction of flexion and extension; at least, this is essentially the direction of its motion, although we know that when the foot is in an extended position, slight lateral movement is allowed, in consequence of the posterior part of the astragalus being narrower than the anterior and central portions.

This two-fold division of the foot, I am particularly desirous of insisting upon, more especially in reference to the position

of the mechanical centres of motion, from which the two portions move, and the different directions in which they move; because it appears to me, looking at the various instruments employed for the cure of varus, and more particularly the Scarpa's shoe, the instrument in general use, that the mechanical treatment has been conducted, as if upon the idea of the entire foot being turned inwards by some movement of rotation from a common centre corresponding to the ankle-joint, an idea which is obviously erroneous.

MOVEMENTS PRODUCING TALIPES VARUS.

The movements concurring in the production of severe talipes varus, are as follows:

1st. *Extreme extension of the whole foot*, taking place from the ankle-joint, as the centre of motion, and produced by contraction of the gastrocnemius and soleus muscles acting through the tendo Achillis, see Figs. 33 and 34. In this movement, the os calcis is drawn into a very oblique, and the astragalus into a vertical position. A condition which exists equally in severe infantile and adult cases, compare Fig. 33 with 34.

2nd. *Inversion of the anterior two-thirds of the foot* taking place from the transverse tarsal joint, see Figs. 31, 35 and 36. Supposing this movement not to take place till after the completion of the first—a supposition adopted for convenience of description and in reference to treatment, rather than from any certainty that it does so—the inversion would be produced by the anterior two-thirds of the foot being drawn directly inwards and upwards, moving in a transverse plane, and describing a quarter of a circle in a right angled varus. The centre of motion in this movement corresponds to the transverse tarsal joint, indicated by the oblique dotted line *a a* in Figs. 31 and 35.

The navicular bone is drawn directly under the inner malleolus, so that its long axis occupies a vertical, instead of a transverse direction, the bone lying side by side with the neck of the astragalus in its vertical position, see Figs. 28, 29, 31, 35 and 37. The muscles producing this movement are, the

tibiales anticus and posticus, the flexor longus digitorum, and in severe cases, the extensor and flexor pollicis.

3rd. *Shortening of the foot.* This does not depend upon a simple flexion of the foot, a bending of the foot upon itself, and an increase of its longitudinal arch as generally described, and such as occurs in talipes calcaneus of long standing; it differs in the fact that the sole of the foot is in opposite relation to the internal lateral aspect of the os calcis, instead of the inferior surface as shown in Fig. 36.

Although cases are occasionally met with, especially in infancy, in which shortening of the foot exists independently of the other movements essential to the production of true talipes varus, cases simply of contraction of the plantar fascia; still when this does exist in varus, it is generally found in the severest grade of that deformity, and depends upon an extreme contraction of the muscles concerned in the production of the second movement, and also upon contraction of the short flexor muscle of the foot, the plantar fascia, and the deep tarsal ligaments. In severe adult cases, shortening of the peroneus longus also coexists as in the case in which Figs. 25 and 26 were taken; and in the dissected foot, see Fig. 36, shortening of the peroneus longus could be easily demonstrated. It is not, therefore, essential in the production of varus that the foot should be shortened, but nevertheless this condition is constantly present in adult, and occasionally in infantile cases.

4th. *Rotation of the anterior part of the foot* taking place, not in the production of inversion, but after the inversion is complete. Scarpa first described the altered relations of the tarsal bones, producing the inversion of the foot, as resulting from a movement of rotation, and especially described the navicular, cuboid and os calcis, as being "twisted round their smaller axes," and the cuneiform, and metatarsal bones as necessarily following this rotation.

All authorities on club-foot have held to this idea of rotation, but to me it appears decidedly incorrect, and to lead to errors in the mechanical treatment. It is undoubtedly true that the navicular bone alters its axial relations, so that, instead of the

long axis being horizontal, it is vertical, and a movement of rotation might alone be supposed capable of effecting this change; this would be the case if the astragalus and the os calcis retained their normal horizontal position, but both these bones also change their axial relations from the horizontal towards the vertical direction.

Now, if the os calcis and astragalus be supposed to move first, so as to produce the extension of the foot—or even to move simultaneously with the navicular bone—it is obvious that the only movement necessary to produce the altered direction of the navicular bone is one of simple uplifting, so that the inner border, and with it the anterior part of the foot, is drawn inwards and upwards, as described in the second movement. It is therefore evident that the altered position of the navicular bone is not produced by rotation, and that rotation of this bone is not essential to the production of varus. This movement I have not been able to recognise in any infantile cases, however severe.

In adult cases, a certain amount of rotation of the cuboid, and two outer metatarsal bones does exist, and is essentially the result of the superincumbent weight telling upon the foot, in the act of progression. As a result of this pressure, it appears to me that the tarsal bones in front of the transverse tarsal joint are rotated from before backwards, the cuboid bone being changed more than any other, so that the aspect of the sole of the foot is made to look upwards and backwards, as shown in Figs. 26 and 36, instead of directly backwards. The movement of rotation, which I have described, affects the inverted anterior portion of the foot after the period of walking, and carries the outer, or in the club-foot the inferior, border of the foot further backwards than it is ever met with before this period. This is, therefore, an acquired and not an essential movement.

The two first movements, viz.: extension of the whole foot, and inversion of its anterior two-thirds, are essential to the production of varus, and therefore constantly exist in infantile cases.

The third movement, viz.: shortening of the foot, although not essential to the production of the deformity, not infrequently coexists with the first and second movements in severe infantile cases, and is constantly present in adult cases.

The fourth movement, viz.: rotation of the anterior portion of the foot, is not essential to the production of varus, and never exists in infantile cases;—or it may be perhaps more correct to say, that it only exists in a slight degree in the severest forms of infantile cases, occasionally met with; but in adult cases, it constantly exists in combination with the three other movements. It also frequently exists in youth, depending upon the cuboid bone, and the fourth and fifth metatarsal bones being carried further backwards, by the superincumbent weight transmitted to the ground through these bones, in the act of progression.

We may now proceed to consider the mechanical means best adapted to the removal of the conditions above described, and their mode of application. As the number of the above described movements usually coexisting in infantile and adult cases have been found to vary, and therefore render necessary important modifications in the instruments employed, it will be desirable to describe the mechanical treatment of the infantile and adult cases separately. And first as to

THE MECHANICAL TREATMENT OF INFANTILE VARUS.

This may be conducted on an extremely simple and efficient plan, if one great practical rule be strictly adhered to, viz.: *the division of the treatment, both operative and mechanical, into two stages;* the object of the first being to overcome the inversion of the anterior portion of the foot, and thus convert a case of talipes varus into one of equinus; and that of the second, simply to cure the equinus as shown in Plate 4, Figs. 1 and 2.

In this twofold division of the treatment, I lay no claim to novelty. Scarpa in his mechanical treatment of this defor-

mity, adopted precisely the same plan. He aimed at curing the severest forms of varus, up to the age of 10 or 12 years,* and from his description we find that in some degree he recognised the mechanical conditions as above described, in reference to the two great centres of motion, viz.: the transverse tarsal joint, and the ankle-joint; and the different planes in which the anterior and posterior portions of the foot move in the production of the deformity. Surgeons usually divide the tendo Achillis at the first operation, and this, I need hardly say, is at once fatal to the principle of treatment I am now recommending.

Tenotomy, it may be supposed, by at once overcoming great obstacles to the restoration of the foot, supersedes the necessity of this twofold division of treatment; but, except in the slighter forms of infantile varus, it does not do so, and the explanation of this fact will be found in the adapted shortening of the ligaments in severe cases.

In slight infantile cases, all the tendons recommended to be divided, viz., the tibialis anticus, tibialis posticus, flexor longus, and tendo Achillis, may be divided at the first operation; and after the foot has been retained in its deformed position for three days by a bandage and splint, the Scarpa's shoe or varus splint may be applied, and the foot, in the course of two or three weeks, gradually brought into its natural position.

In all severe infantile cases, or I would say in all those cases in which ligamentous rigidity exists, I strongly recommend an adherence to the division of the treatment *into two stages*. In these cases, the tendons of the tibialis anticus and posticus, the flexor longus digitorum, and, if necessary the extensor pollicis muscles, must be first divided; then the foot bandaged in the deformed position to a splint, and on the third or fourth day, the cutaneous puncture being healed, the first stage of the mechanical treatment, the object of which is the complete eversion of the anterior part of the foot, should be commenced.

The best and simplest method of accomplishing this, is by

* *Op. cit.*, page 41.

the application of a straight splint along the outer side of the leg as represented in Fig. 44. The splint should reach above,

FIG. 43.

Case of Infantile varus.

FIG. 44.

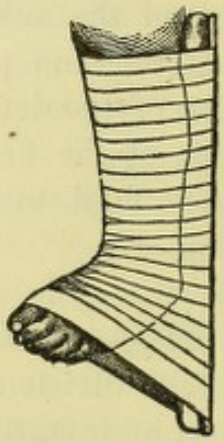

The same foot as shown in Fig. 43 with the straight splint and bandage applied to overcome the inversion.

FIG. 45.

The same foot brought into the position of talipes equinus by the straight splint and bandage.

FIG. 46.

The same foot cured. The equinus completely removed.

nearly to the knee, and extend a little below the foot. The best splints are those made of tinned sheet iron well padded. The advantage of this material is, that it can be bent

a little outwards at the lower end, as the foot is becoming fully everted. First, the foot and leg should be bandaged, and the splint being applied along the outer side of the leg, the bandage must be passed over the leg and splint from above downwards, so that a firm lever-power may be established; then the bandage should pass round the foot, and draw it towards the lower end of the splint as shown in Fig. 44.

The eversion of the foot must be accomplished gently, and very gradually, the apparatus being removed every other day that undue pressure may be avoided. By this means the eversion will be overcome, and the foot drawn into a straight line with the leg, as shown in Fig. 45, in about two or three weeks, or a little longer time may be required in severe cases. It is better this stage should be delayed too long, than that the second stage should be commenced too soon.

When the eversion of the foot is complete, as shown in Fig. 45, and there being no longer any resistance to be overcome in carrying the foot completely into the equinus position, the second stage of treatment may be commenced by dividing the tendo Achillis. The object of the *second stage of the mechanical treatment* is to flex the foot at the ankle-joint, and in so doing to gain the required amount of elongation of the tendo Achillis.

For the reasons already given, this object must be accomplished gradually, and the apparatus best adapted for the purpose, is one represented in Fig. 47, which combines all the advantages of the straight splint and the Scarpa's shoe, and which I had first made from my own design many years since by Mr. Blaise of St. James' Street.

The *varus splint*, as I call it, essentially consists of a narrow metal trough for the thigh, Fig. 47, *a*, and a long metal trough for the leg *b*, to the lower part of which is attached a flat sole-plate *c*, adapted to the foot and moving in the direction of flexion and extension from *e* to *c* by a single cog-wheel *d* placed at the junction of the sole-plate and leg-trough, or at a part corresponding to the heel, and from this point a leather strap omitted in Fig. 47, but shown in Fig. 48, softly padded, passes

obliquely across the ankle-joint, in the direction of an ordinary skate-strap. The outer side of the leg-trough is flat, and made so as to answer the purpose of a straight outside splint, against which some power to evert the foot can be exerted, if necessary; although in this stage of the treatment, the only object required should be to retain the foot in its everted position, whilst the movement of flexion at the ankle-joint is being completed. Attached to the outer margin of the sole-plate, and set off about three-quarters of an inch from it, is a rectangular steel bar, round which the toe-strap, consisting of a webbing band and buckle, is made to pass, so as to hold the foot in an everted position. The whole apparatus is fastened to the leg and thigh by webbing bands and buckles.

FIG. 47.

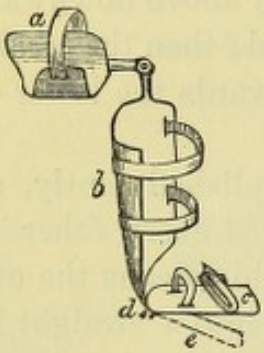

Mr. Adams' Infantile varus splint. *a*. Thigh-trough. *b*. Leg-trough. *c*. Sole-plate moving in the direction of flexion and extension from *e* to *c*, by a single cog-wheel, *d*, placed behind the heel. Ankle-strap omitted, but shown in Fig. 48. The instep-strap, passing transversely across the foot, is represented; and also the toe-strap, which acts from a rectangular steel bar attached to the outer side of the sole-plate, and set off three-quarters of an inch from it.

This varus splint is very different from the one in use at the Orthopædic Hospital, and called Mr. Tamplin's splint. It differs,

1st. In having a thigh-trough, which I have found of the utmost importance, as experience has convinced me that any apparatus employed in the treatment of varus must be carried above the knee.

2nd. In the outer portion of the leg-trough being immovable, and thereby made to act as a straight splint.

3rd. In the absence of an outside steel spring, supposed to produce eversion of the foot, but which I have always found practically useless, and inconvenient from its projection; and,

4th. In the general arrangement of the straps, and particularly in the ankle-strap or *skate-strap* shown in Fig. 48.

The flexion of the foot must be regulated by the cog-wheel placed in the varus splint above described behind the heel; and

in a fortnight or three weeks the foot may be brought into its natural position, and the required elongation of the tendo Achillis obtained. At the end of this time, or it may be longer if ligamentous rigidity exists, passive motion may be commenced, and the *varus splint* used simply as a retentive apparatus. I usually direct passive motion,—flexion and extension of the ankle-joint—to be continued for a quarter of an hour twice a day. The external appearance and form of the foot is greatly improved by its being daily exercised, as well illustrated by the accompanying Fig. 50, representing the improved condition of the feet shown in Fig. 49 after two months treatment.

FIG. 48.

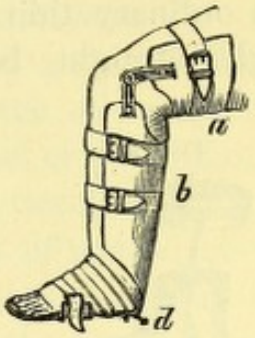

The same splint as represented in Fig. 47, applied to the leg and foot, with the straps *in situ*, and the foot brought to a right angle with the leg, by the use of the cog-wheel *d*.

FIG. 49.

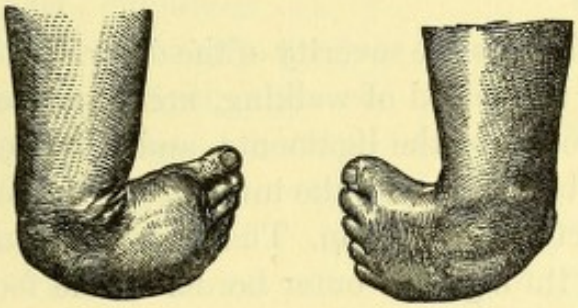

Congenital talipes varus of both feet in a severe form in an infant aged five months.

FIG. 50.

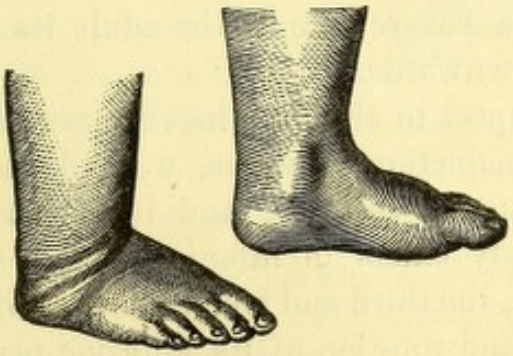

The same case as represented in Fig. 49, after treatment.

About the end of the fourth or fifth week, if the tendo Achillis should appear to be strong, the *varus splint* may be worn only at night. In the daytime the child may then wear an ordinary thin leather boot with a steel spring, or a very light straight bar attached to the outer side, having a free joint corresponding to the ankle-joint, and connected above with a circular strap round the calf of the leg as shown in Fig. 51. A stop-joint is generally recommended at the ankle; but I much prefer free motion, because the exercise is thereby facilitated, and where this is neglected I doubt whether the stop-joint will prevent recontraction of the tendo Achillis. Frequent and regular employment of passive motion I rely more upon than any mechanical aid.

FIG. 51.

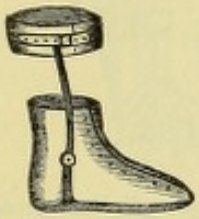

Leather boot with steel spring attached to its outer side, having a free joint corresponding to the ankle-joint, and connected above with a circular strap passing round the calf of the leg.

MECHANICAL TREATMENT OF CONGENITAL VARUS AFTER THE PERIOD OF WALKING, AND IN THE ADULT.

In congenital varus the severity of the deformity becomes much increased after the period of walking, not only in consequence of the adapted growth of the ligaments, and persistence of the deviations of the bones, but by the influence of the superincumbent weight in the act of progression. The weight is transmitted to the ground at first through the outer border of the foot, and subsequently through the exposed anterior articular surface of the os calcis, the exposed portion of the head of the astragalus, and the cuboid bone; the latter becomes gradually changed in its position, so that in a severe case in the adult its superior surface looks directly downwards.

Thus with respect to the four movements described as concurring in the production of varus, we find that only the first two, viz., extension of the foot, and inversion of the anterior portion, constantly exists in infantile cases; whilst after the period of walking, the third and fourth movements, viz., shortening of the foot, and rotation of its anterior portion, are found

to exist in an increasing degree, and are constantly present, as well marked characters of the adult deformity.

In children, from five to ten years of age, essentially the same mechanical means may be employed as in the infant, viz., a straight splint for the first stage, and *varus splint* for the second; but at this age some modification of the sole-plate is an advantage, and I prefer to place the cog-wheel or mechanical centre of motion at the side corresponding to the ankle-joint, so that the mechanical and anatomical centres of motion may correspond. The apparatus which I employ, as represented in Fig. 52, is more strictly a combination of the *varus splint* with the Scarpa's shoe. The *ankle-strap*, however, is retained at the heel, and a steel bar is fixed to the outer margin of the sole-plate, instead of the steel spring which belongs to the Scarpa's shoe. When the ligamentous rigidity is not considerable, this modified form of instrument may be employed at a much later period, especially in females; but severe and rigid cases are better treated by the apparatus which will be presently described as especially adapted for adult cases.

FIG. 52.

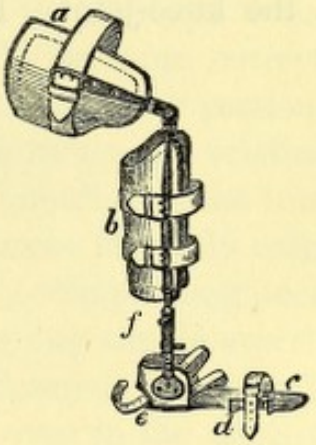

Mr. Adams' apparatus for varus in children from five to ten years of age, being a combination of the varus splint, and the Scarpa's shoe with some modifications. *a*. Thigh-trough. *b*. Leg-trough. *c*. Sole-plate. *d*. Rectangular steel bar attached to outer side of sole-plate, to which the toe-strap is fastened. *e*. Aperture in heel-plate, through which the ankle strap passes. *f*. Cog-wheel corresponding to ankle-joint, and moving in the direction of flexion and extension.

Where some tendency to inversion still exists, as frequently found in relapsed cases of varus, after the period of walking, I now have the double cog-wheel movement placed on the inner side, opposite the ankle-joint; as by this arrangement we obtain an increased power to evert the foot, by uplifting the fourth and fifth metatarsal bones, without pressure on the outer side of the foot, which is always produced when the lateral cog-wheel placed on the outer side of the ankle-joint is brought into use. This arrangement is especially useful in cases of equino-varus.

In adult cases it must be admitted the most successful results have been obtained by the use of the Scarpa's shoe, in one of the forms represented in Figs. 12, 13, 14 and 15, when judiciously applied, and constantly attended to, even in the most severe cases, up to, and in some few instances beyond, the age of thirty years. It cannot be matter of surprise that with great attention, and in competent hands, good results should follow the application of an ill adapted instrument.

For the severe adult cases, a modification of the Scarpa's shoe has been employed by Mr. Tamplin, which consists in the addition of one or two cog-wheels, placed above those corresponding to the ankle-joint, and also carrying the apparatus up to the thigh by means of a straight trough, without any motion at the knee-joint. By these means the power of adaptation,

FIG. 53.

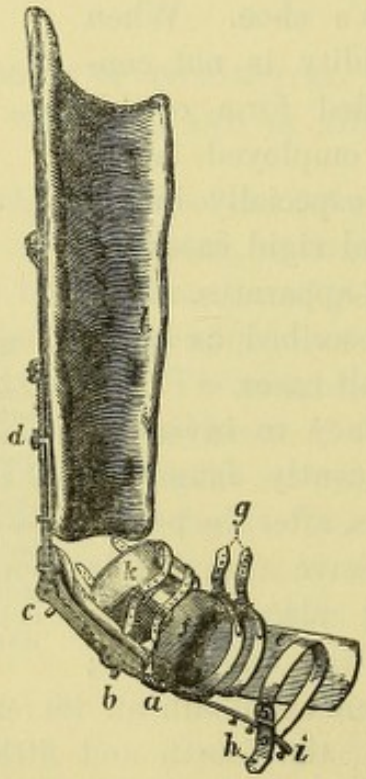

Mr. Tamplin's trough instrument and modified Scarpa's shoe for adult varus. *a*. Flexion cog-wheel, corresponding to the ankle-joint. *b* and *c*. Cog-wheels to produce eversion of the foot, placed above that corresponding to the ankle-joint. *d*. Sliding-rack, by which this portion of the instrument may be elongated or shortened. *e* and *f*. Sole-plate and heel-piece, made as in the ordinary Scarpa's shoe. *g*. Instep-straps. *h*. Toe-straps connected with the side spring. *i*. *k*. Ankle strap. All precisely the same as in the Scarpa's shoe. *l*. Leg and thigh-trough, without any hinge at the knee-joint.

and the range of motion in the Scarpa's-shoe-part of the instrument are increased, and the apparatus is rendered more fixed by the trough; but all the essential errors of the Scarpa's shoe are retained, and in consequence of the length of time the apparatus has to be constantly worn, from a year to a year and a half, or perhaps longer, a state of rigidity of the knee-joint is apt to be induced, which I have known it take three months to overcome, the gradual flexion of the knee being very painful to the patient.

That which is called "unfolding the transverse arch of the foot," is a difficult part of the treatment of talipes varus in the adult, and one for which no provision whatever exists in the construction of the Scarpa's shoe. According to the anatomical description I have given of this deformity, the so-called unfolding the transverse arch of the foot, would be more correctly described as "overcoming the rotation of the anterior portion of the foot," by restoring the cuboid bone to its normal relations.

We cannot accomplish this so-called "unfolding of the transverse arch of the foot," or as it may be more correctly called, "the restoration of the cuboid bone, and corresponding metatarsal bones, to their normal position," by any simple everting power, such as the side spring of the Scarpa's shoe, or the straight splint which is sometimes used, even in the adult deformity. It has seemed to me that the appearance of narrowing of the transverse arch of the foot is increased, after the foot has been everted by a straight splint.

Practically, we find that some special apparatus must be employed "to unfold the transverse arch of the foot." Mr. Tamplin uses a contrivance by which an uplifting force is applied to the cuboid and fifth metatarsal bones, and at the same time a depressing force to the inner side of the dorsum, the force being regulated by a screw placed on the dorsum of the foot. Mr. Lonsdale employed, with a similar object, an ingenious screw apparatus of his own invention attached to the sole of the Scarpa's shoe. The necessity for any special apparatus for the above object is, however, superseded by the apparatus I have invented for the cure of adult

varus, see Fig. 56. By this instrument, any amount of uplifting force can be directed against the cuboid, and the fifth metatarsal bone, at the same time that the foot is being everted.

My objections to the Scarpa's shoe as an instrument for talipes varus, are,

1st. That its construction is not in accordance with the mechanical conditions of the deformity it is employed to remedy.

2nd. That it is very apt to cause sloughs from undue pressure, which its faulty construction, in reference to the cure of varus, renders necessary.

3rd. That it exerts no influence over the rotation of the anterior portion of the foot—an important part of the adult deformity, and very difficult to overcome.

In support of the first objection, I need only refer to the demonstration already given, of the twofold division of the foot; the situation of the two principal centres of motion, and the planes in which the anterior and posterior portions of the foot move in the production of varus. I have shown that in the simplest form of varus in the infant, the anterior and posterior portions of the foot move in different planes, and at right angles to each other; and that by a complication of a movement of rotation, and further shortening of the foot in the adult, the sole of the foot becomes twisted, so as to look upwards and backwards, and is brought into opposite relation to the internal lateral aspect of the os calcis, see Fig. 36.

It will at once be perceived that the straight sole-plate and foot-piece of the Scarpa's shoe could only be adapted to this complicated distortion of the foot, if the different portions of the foot retained their normal relations to each other, while the whole foot suffered deviation in any given direction; then the straight sole-plate of the Scarpa's shoe, might be adapted to the foot by a series of levers and cog-wheels, and the foot restored to its normal position. But, as the relations of the component parts of the foot to each other are materially altered

in varus, and as it is an established rule of practice first to restore these altered relations, and bring the foot into the simplest form of distortion, viz.: talipes equinus; it must be obvious that the Scarpa's shoe is ill adapted to accomplish separately these different objects, and from its imperfections in this respect, arises the second objection to its use, viz.: its liability to produce sloughs.

When the Scarpa's shoe is used to produce eversion of the foot, the heel is fixed in the shoe, and the strap which surrounds the anterior part of the foot, is fastened to the spring on the outside of the shoe, so that the anterior part of the outside of the heel becomes the fulcrum. This part of the foot, I need hardly say, is ill adapted for such a purpose, as the pressure is against an edge, rather than a surface, and therefore sloughs frequently result.

Also, when any attempt is made to alter the plane of the sole of the foot;—to elevate the outer border, by means of the lateral cog-wheel—the upper edge of the outer side of the heel-plate presses against the foot, especially upon the outer malleolus, or below it, and sloughs are apt to result. Thus in the attempt to effect either of these objects, both of which must be accomplished, the risk of sloughs from pressure is incurred.

This risk of producing sloughs from pressure is completely removed in the apparatus described later, see Fig. 56, in which no pressure is made on the outer side of the foot, and the whole of the resistance to the active force employed in everting the foot, is transferred to the outer side of the leg. It is true that, by careful attention and padding, such sloughs from pressure are not often seen, but without the greatest care sloughs almost constantly follow the long continued use of the Scarpa's shoe. Mr. Tamplin says, "It will require the greatest vigilance to prevent a slough on the points of pressure."*

Dr. Little tells us that "an adolescent case of double congenital varus was admitted into the London Hospital under the care of Mr. Crichett, which had been rejected as incurable from

* *Op. cit.*, page 60.

another Hospital, on account of large ulcers with necrosis of dorsum of each foot, induced by pressure during the mechanical treatment after tenotomy. As the unhealthy character of the ulcers depended upon want of air and exercise, and the application of suitable instruments was impossible; it was determined to repeat tenotomy, and effect forcible manipulations of the members. Chloroform was upon one occasion employed. By these means the feet were gradually straightened, cicatrisation of the ulcers was thereby favoured, and within three months the lad quitted the Hospital."*

I have witnessed several cases of prolonged treatment from sloughs; return of the deformity during the necessary intermission of treatment; repeated operations; and ultimately very imperfect cures. The intractable nature of these ulcerations on the dorsum and outer side of the foot, whether produced by the Scarpa's shoe or from walking, have been previously described as depending upon the defective nutrition in these limbs, and also upon the peculiarity of the structures involved, viz., indurated skin and cellular tissue, and the bursa which constantly exists in this situation. The adult foot, Figs. 34, 35 and 36, was amputated in consequence of such ulceration, produced by walking on the deformed foot.

Such risks as those described, must be incurred when the Scarpa's shoe is employed to overcome the inversion in a severe case of varus, and the danger will only be prevented by constant care and attention; but by the use of the instrument I have constructed, such risks are completely removed, because the apparatus is not even in contact with the outer side of the foot.

The third objection to the Scarpa's shoe, viz., that it exerts no influence over the rotation of the anterior portion of the foot, is self evident, and an additional proof of the defective mechanical construction of the instrument in its application to varus.

I have shown in what respects the Scarpa's shoe appears

* "On Deformities," page 306.

to be an unscientific instrument for the treatment of varus, that is, for the removal of the inversion, or varus portion of the deformity—the first stage of the treatment—and Scarpa himself never employed it for this purpose. He knew it was not adapted to this stage of the treatment, and used it only for the removal of the equinus, or the second stage of the treatment.

Scarpa divided his treatment of talipes varus into two distinct stages, as we do at present. He describes the apparatus which we call the "Scarpa's shoe" as his "*second apparatus*" and recommends it to be used only after the complete removal of the inversion of the anterior part of the foot by another form of apparatus, which I have represented in Fig. 54, taken from Scarpa's work.

Scarpa observes, "the apparatus intended for correcting the

FIG. 54.

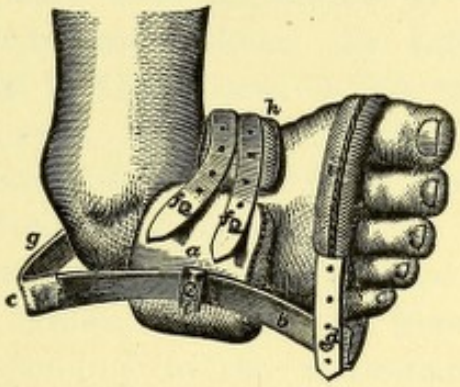

Scarpa's first apparatus used to overcome the inversion in congenital varus.

a. The semicircular spring, or fulcrum. *b*. The horizontal spring. *c*. The posterior extremity of the horizontal spring. *d*. The knob situated on the anterior extremity of the horizontal spring. *e*. The screw intended for fixing the horizontal spring upon the fulcrum. *f.f*. Two small knobs for fixing the strap *g* to the fulcrum. *g*. The strap which passes from behind the heel over the upper part of the foot, and unites the posterior extremity of the horizontal spring to the two knobs on the fulcrum. *h*. A soft cushion of old linen. *i*. The padded strap, which connects the apex of the foot to the anterior extremity of the horizontal spring.

deformity of congenital club-feet, which I am now to describe, consists of several springs, and as the cure of this disease is divided into two stages, the elastic apparatus likewise consists of two parts. The first (that represented in Fig. 54) is intended merely for turning the fore-part of the foot from within outwards, as far as its natural position and direction with the tibia. The second part of this apparatus (what we now term

the Scarpa's shoe, W. A.) is intended for retaining the forepart of the foot in its regained position with the tibia, and with the external malleolus, and for correcting the heel and retaining the tibia and fibula steadily perpendicular to the astragalus."*

This apparatus has now passed from the domain of practical, into that of historical interest; but it shows the care with which Scarpa endeavoured to avoid the liability to sloughs from undue pressure, by placing a broad and well padded fulcrum on the convexity of the foot.

* "Memoir on the Congenital Club-Feet of Children," page 24. Translated by J. H. Wishart, Edinburgh, 1818, Plate II., Figs. 2 and 3.

CHAPTER XV.

CONGENITAL TALIPES VARUS, CONTINUED.—MECHANICAL AND PHYSIOLOGICAL TREATMENT IN INFANTILE AND ADULT CASES.

I do not propose to describe in detail all the modifications of the so-called Scarpa's shoe, or what Scarpa called his second apparatus, which have been introduced by various surgeons, but will notice one or two of them. Dr. Little, Mr. Tamplin, Mr. Liston and Mr. Le Gros Clark, in this country, and on the Continent, Stromeyer, Langaard of Hamburgh, &c., have modified this apparatus in different ways, and some alterations have been also introduced in America.

Some of these modifications have reference to the method by which flexion and extension is regulated from a lateral centre of motion corresponding to the ankle-joint; but the only one worthy of mention in this respect is that invented by Dr. Little, in which the foot portion of the apparatus can be set free at the ankle-joint, so that passive motion may be conducted. In the late stage of treatment this is a most desirable object, although one much neglected. Generally, I have used the cog-wheel motion, and directed the apparatus to be taken off, and passive motion employed once or twice a day, according to the condition of the reparative process in the tendon, and the amount of ligamentous rigidity.

Many modifications, and those considered to be of the most importance, refer to the mode of everting the foot, and altering the plane of the sole, by elevating the outer and depressing the inner margin of the foot. In Mr. Clarke's apparatus

this is effected by means of a side screw and free joint, placed below the flexion cog-wheel. In Mr. Tamplin's shoe, the same movement is effected by a lateral cog-wheel, see Fig. 12.

The great practical objection to all these modifications is, that they depress the inner margin of the foot much more than they elevate the outer; in fact, that they scarcely elevate the outer side of the foot at all, which I consider to be one of the most important actions required. In Langaard's apparatus, this movement is regulated by a cog-wheel placed behind the ankle, corresponding to the centre of the heel, and connected by a horizontal bar with the lateral cog-wheel opposite the ankle-joint. The uplifting force against the outer margin of the foot is much increased by this arrangement, and I have adopted this idea in the Scarpa's shoe which I employ in some cases, see Fig. 15. In Langaard's apparatus, the flexion and extension movement is regulated by a cog-wheel placed in the usual position, viz., at the side of the ankle-joint, and the inversion of the anterior part of the foot sought to be controlled by a lateral motion in the sole of the shoe.

In 1856, or a little anterior to this date, Mr. Bigg constructed an apparatus in which the centres of motion adopted in Langaard's instrument were imitated, but free joints used, and an elastic force employed, by means of a series of india-rubber cords ingeniously arranged. The constant pressure from the elastic force is apt to produce slough; but it would doubtless, with careful management, be efficient in slight cases. Still, the cog-wheels are, in my opinion, to be preferred in severe cases, where long continued pressure must be employed to overcome the resistance offered by the contraction of ligaments.

Many years ago, an instrument was shown me called a talipede, said to have been of American invention and in which a variety of movements emanated from a ball-and-socket joint placed behind the centre of the heel. And Dr. Aveling has invented an ingenious apparatus called a talivert, in which a number of movements are combined.

These are only a few of the various contrivances which human ingenuity has, at different times invented; but if the

account I have given of the anatomy of varus be correct, it will be obvious that none of these modifications are in accordance with the anatomical or mechanical conditions of the foot in this deformity.

In nearly all the modifications which have been introduced, the foot is acted upon as a whole, the entire foot being everted from variously arranged mechanical centres of motion, and where subdivision of the foot has been attempted, as in Langaard's apparatus, it has only been by placing a joint in the flat sole of the shoe, with the object of everting the anterior portion of the foot. But the plane in which this force is exerted does not correspond with the plane in which the anterior portion of the foot moves, and the fulcrum is still placed on the convexity of the foot.

It has been my object to show that only the anterior two-thirds of the foot are concerned in the production of the somewhat complicated form of inversion characteristic of varus; and I have moreover pointed out the ill effects which frequently arise from the fulcrum being placed on the convexity of the foot, so that it will be at once perceived that all the essential errors of the Scarpa's shoe—when applied, or I would say misapplied to the cure of adult varus—are retained in all the modifications which have been employed.

It became evident to me, many years ago, from an attentive study of the dissected specimen of adult varus, Figs. 34, 35 and 36, that there was mechanically no correspondence, between the apparatus, constantly employed, viz., the Scarpa's shoe with a double cog-wheel, Fig. 12, and the mechanical conditions of the deformed foot to be acted upon.

It was my examination of this specimen that led me to suggest the apparatus, Fig. 56, which I have since employed. In constructing it I determined,

1st. To subdivide the apparatus, so that only one portion of the foot should be acted upon at a time.

2nd. To place the mechanical centres of motion as nearly as possible opposite to the anatomical centres of motion in the foot, so that the anatomy should be represented in the mechanical apparatus.

3rd. To transfer the fulcrum from the foot to the leg, thus combining all the advantages of the straight splint, with the improved apparatus for the foot, and

4th. To carry the apparatus up to the thigh and have a free joint at the knee, so as not only to steady the fulcrum effectually, and prevent the possibility of the instrument twisting round the leg, and following the foot, which the Scarpa's shoe does—but also to increase greatly the power of the instrument over the movements of the foot, without interfering with the freedom of motion at the knee-joint, which is the case in the straight splint, and in the thigh-trough above mentioned, in the apparatus used by Mr. Tamplin.

These were the great principles which it appeared to me ought to be embodied in a scientific instrument for adult varus; and in the instrument constructed, every principle which the dissected foot suggested to me was completely carried out, and I applied this instrument on the 1st of June, 1854, to a case fully calculated from its severity, and the age of the patient, viz., twenty-six years, to test the value of any apparatus, see Figs. 25 and 26.

The coincidence of this patient applying to me for relief, at the time I happened to have the valuable specimen of the dissected foot in my possession, was the immediate cause of my devoting so much attention to the construction of a new apparatus. A reference to the following diagram in which an outline of the dissected foot, represented in Figs. 34, 35 and 36, and the mechanical forces employed are indicated, will render the principles upon which my apparatus was constructed more intelligible.

It is to the following points in the construction of this instrument that I particularly wish to direct the attention of my readers.

1st. The division of that part of the instrument applied to the distortion of the foot into two portions, one adapted to the deviation of the anterior portion of the foot as above described, and the other to the deviation of the posterior portion of the foot.

2nd. The four cog-wheels A B C arranged as described in

FIG. 55.

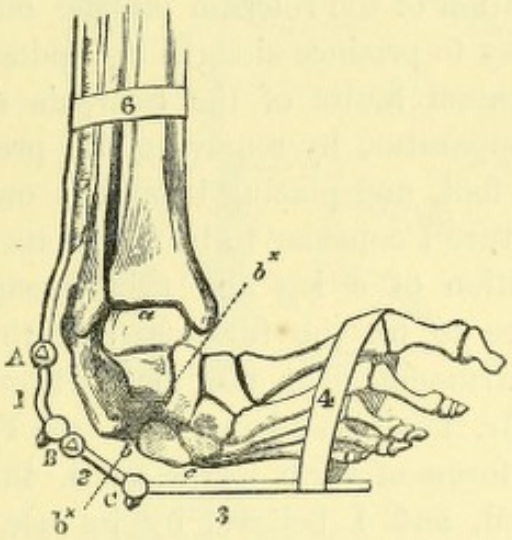

Diagram illustrating the construction of the apparatus for adult varus.

The dotted line b^* intersects the great transverse tarsal joint,—between the astragalus and os calcis and the navicular and cuboid bones,—which in the club-foot has an oblique direction, and indicates the line of separation between the anterior and posterior divisions of the foot, which move in different planes as above described. A. The first centre of motion, corresponding to the ankle-joint. *a*. Flexion and extension only allowed at this joint. B. The second centre of motion, corresponding to the transverse tarsal joint. *b*. This is a double centre of motion; the first cog-wheel moving in the direction of inversion and eversion, the second in the direction of flexion and extension, and especially useful in uplifting the outer border of the foot, and overcoming the rotation backwards of the cuboid and outer metatarsal bones. C. The third centre of motion, corresponding to the articulations between the tarsal and metatarsal bones, *c*. Inversion and eversion only allowed at this joint, which is placed in this situation for the purpose of assisting the lateral cog-wheel at B, and to allow the instrument being more accurately adapted to the curved form of the foot, rather than from the existence of any amount of motion at the tarso-metatarsal articulations. 1, 2, and 3 indicate the levers moved by the cog-wheels at the above-described centres of motion. 4 indicates the situation and direction in which the force is exerted on the foot to produce eversion. 5 indicates the fulcrum on the outer side of the leg, or point of resistance to the everting force employed against the foot from the cog-wheels at B and C. The pressure is diffused along the outer surface of the leg, between which and the side-iron of the instrument a long soft pad is placed. The action is the same as that of the straight outside splint, but may here be combined with the uplifting force. 6 represents the band and trough by which the fulcrum is retained in its position.

the diagram Fig. 55, and moving alternately in rectangular planes. As these are made to act upon short levers which can be moved in any direction, the apparatus can be accurately adapted to the curved form of the foot, and by an oblique sole-plate, it can be applied to the most severe cases of adult varus, as in Figs. 25 and 26, in which the aspect of the sole of the foot was upwards and backwards.

3rd. The uplifting movement applied to the outer border of

the anterior part of the foot in a semi-circular direction, by which the rotation of the cuboid bone, and two outer metatarsal bones, is overcome at the same time that the anterior portion of the foot is being everted.

4th. The situation of the fulcrum on the outer side of the leg. The liability to produce sloughs by undue pressure which is one of the greatest faults of the Scarpa's shoe is entirely avoided in this apparatus, by removing the pressure from the convexity of the foot, and placing it on the outer side of the leg, and this feature I consider to be one of its greatest merits.

5th. The addition of a leg and thigh-trough, with a free joint at the knee to fix the fulcrum, and thus increase the power of the instrument over the foot, without producing a stiff knee as in Mr. Tamplin's leg-trough, see Fig. 53.

To the severe forms of varus in the adult, this instrument is especially adapted, and I believe, by its use, cases may be successfully treated at a more advanced age, and in a much shorter time than the deformity could be cured by any other mechanical means.

In youth, it may with equal advantage be employed, and in all cases presenting the complications which we have described as taking place after the deformed foot has been used in sustaining the weight of the body. In a modified form, *i. e.* with only two cog-wheels, *a* and *b*, instead of four, I have advantageously employed it in the severest forms of infantile cases; but it is not often necessary to depart from the plan of procedure already described.

I should mention, with respect to the employment of this instrument in the more severe forms of adult varus, that as much of its power of adaptation depends upon the oblique sole-plate, the angle of which must be accurately adapted to the obliquity of the sole of the foot to be acted upon, it is necessary to have a second sole-plate of a simple flat description, answering to the sole-plate of the Scarpa's shoe, to be employed in the second stage of treatment, *i. e.* the cure of the equinus, after the varus has been completely overcome. In this stage, it acts in the same manner as the Scarpa's shoe, and if no tendency

FIG. 56.

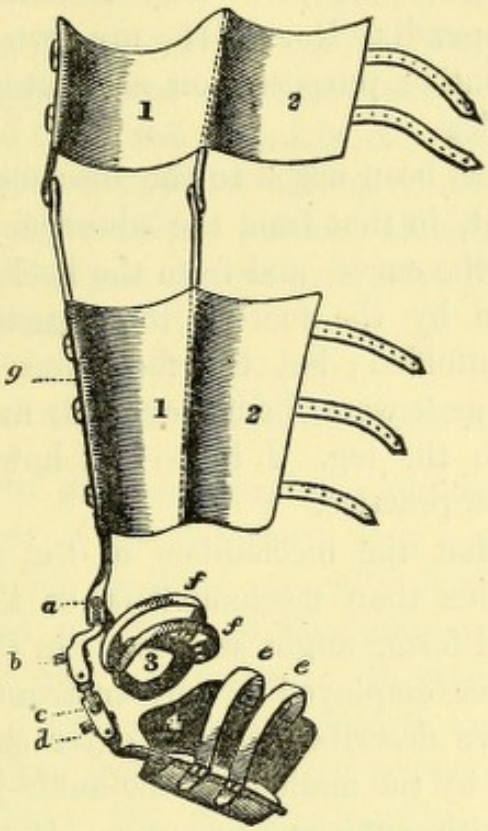

Mr. Adams' instrument for adult varus. 1, 1. Leg and thigh metal-troughs, with a free hinge-joint corresponding to the knee. 2, 2. Leather which folds over the leg and thigh, and is attached by means of straps and buckles to the outer sides of the troughs. 3. Heel-piece, composed of two pieces of steel arranged in an elliptical form, depressed on the outer side, and rising nearly to the inner malleolus on the inside. This is connected with the short, bent rectangular lever in which the cog-wheel *a* is cut, so that it may be controlled by the movements of the latter. 4. Oblique sole-plate, which in the construction of the instrument is accurately adapted to the inclination of the sole of the foot. The outer or inferior border of the foot is received into the angle between the sole-plate and the descending piece of iron, by which the latter is attached to the end lever passing along the convexity of the foot. *a*. Cog-wheel corresponding to the ankle-joint, and regulating the movements of flexion and extension. Used principally to cure the equinus by flexing the whole foot, after the inversion of the anterior part of the foot has been overcome. *b*. Cog-wheel corresponding to the transverse tarsal joint, or a little behind it, placed laterally and acting in a plane at right angles to that of *a*, used to overcome the inversion of the anterior portion of the foot from the transverse tarsal joint. *c*. Cog-wheel also corresponding to the transverse tarsal joint, or a little in front of it, and acting in the same plane as *a*. Used to uplift the outer margin of the foot. In doing this, while the foot is in its inverted position, it acts through a bent lever (regulated by *d*), and consequently by means of the sole-plate (4), raises the cuboid bone, and with it the 4th and 5th metatarsal bones in a curved direction upwards; thus overcoming the rotation backwards of these bones. This uplifting of the outer border of the foot in a circular direction can also be gained with increased mechanical advantage—in consequence of the increased length of the bent lever—by using the cog-wheel *a*, but both are useful in an adult case. *d*. Cog-wheel, corresponding to the tarso-metatarsal articulations placed laterally and acting in the same plane as *b*. Used to increase the adaptation of the instrument to the curved form of the foot, and to assist cog-wheel *b* to evert the anterior portions of the foot. These cog-wheels act upon the foot through a series of levers which pass along the convexity of the foot and to the end one of which the sole-plate is attached. These levers are best shown in the diagram, Fig. 55. *e. e.* Two straps attached to the sole-plate, 4, by which the anterior part of the foot is retained in the sole-plate, and the force applied to the inner margin of the foot. One corresponds to the ball of the great toe, and the other to the metatarsal bone of the great toe, so that the pressure can be varied alternately on these two points. *f. f.* Two straps attached to the heel-piece. One crosses the ankle-joint obliquely from before backwards, and the other crosses the tarsal bones a little in front of the ankle-joint, acting more directly downwards upon the arch of the foot. *g*. A pad placed along the outer side-iron of the leg-trough, to prevent undue pressure. It is necessary to insert extra padding along the outer side of the leg, from about three inches above the outer malleolus, during the eversion of the foot. Neither the iron nor the pad must be allowed to touch the lower extremity of the fibula.

to inversion remains, it is a matter of indifference which apparatus be used; but practically I found in the case described in Appendix, No. XIII., my own apparatus more effective for retentive purposes, on account of its firm connexion with the leg.

An objection has been urged to the mechanical construction of this instrument, in that from the absence of a fulcrum on the convexity of the curve, and from the heel not being fixed, the curve formed by the foot in the direction of its length would not be unfolded; but the foot, preserving its curved form, would be, as it were, bodily everted, and merely altered in its relation to the leg. I have not, however, found this effect the result in practice.

The fact is, that the mechanism of the deformed foot is much more complex than mechanicians, or those who merely study its external form, might suppose. In the deformed foot, the everting force employed by my instrument, acting from the fulcrum above described on the outer side of the leg, is resisted laterally by the malleoli of the ankle-joint, which hold the astragalus with sufficient firmness. If then any lateral movement inwards of the os calcis should take place, (and I have not satisfied myself that such does occur,) it would be advantageous rather than otherwise, as this bone lies obliquely in its position with respect to the bones of the leg, so that its tuberosity is directly behind the fibula, instead of occupying a central position. The result of experience, and the explanation given, are a sufficient answer to this purely mechanical objection.

We must observe, with regard to the position of the fulcrum, that to place it against the cuboid bone is decidedly wrong, because this bone is situated in front of the transverse tarsal joint—the centre of motion from which the inversion takes place—and is itself displaced inwards. Scarpa committed this error in his apparatus for varus, represented in Fig. 54; but as he does not appear to have contemplated curing this deformity, after the age of ten or twelve years, the instrument he employed was probably efficient, except in the most severe cases.

It is remarkable that the same error has been perpetuated by all those who use Scarpa's second apparatus, or the so-called Scarpa's shoe, to overcome the eversion. To place the fulcrum on the os calcis alone is not very practicable, and the difficulty and force required to fix the os calcis laterally so as to resist the everting force, would render necessary such pressure on the outer side, as would certainly produce slough, and this it has been one of my principal objects to avoid. We will now pass on to the consideration of the

DURATION OF TREATMENT IN CASES OF VARUS.

It is difficult to give any precise opinion as to the time which the removal of the deformity may occupy in cases of congenital varus; but speaking generally, it will have reference to the age of the patient, and the amount of ligamentous rigidity which the case may present. In severe infantile cases, the deformity may generally be removed in from two to three months. In children from five to ten years of age, the time will vary from three to six, or eight months, according to the ligamentous rigidity which the feet may present.

The variations as to the time required will be less in adult cases, because after the completion of growth, the adaptation of the bones and ligaments to the deformed position of the foot in cases originally slight, is such as to approximate these cases to the more severe forms at the period of birth. Very few cases will, in my opinion, be found requiring a longer period than a year, if the instrument I have recommended be employed. This apparatus is calculated to shorten the duration of treatment in adult cases, but very much will depend upon the amount of attention given to all the details of treatment by the surgeon himself.

THE MECHANICAL AND PHYSIOLOGICAL AFTER-TREATMENT.

After the complete removal of the deformity, in infantile as well as adult cases, it is essential to retain the foot in its natural position, and to improve its physiological condition

with respect to the joints, muscular action, &c., so as to prevent relapse and render the cure permanent. The after-treatment, therefore, is both mechanical and physiological; the first, consisting in the employment of some mechanical support to retain the foot in its normal position—a retentive apparatus; and the second, in the use of active and passive exercises, shampooing, and in some instances galvanism.

I have already spoken of the erroneous doctrine inculcated by Professor Syme, that cases of club-foot are curable by the division of tendons alone, without the adjunct of mechanical treatment; but this is scarcely a greater error than to suppose a case of club-foot to be cured as soon as the deformity has been removed.

Upon the importance of the after-treatment, we cannot insist too strongly. In slight infantile cases, where the muscles are strong, and the ligaments have not become adapted in their growth to the deformed position of the foot, no retentive apparatus may be required to retain the foot in its new position. In all the more severe cases, however, the deformity will certainly return, unless the foot be retained in its normal position by mechanical means, for a sufficient length of time, and appropriate measures be adopted to promote its physiological improvement.

It is generally found necessary to employ some form of retentive apparatus. The boot with steel spring on the outer side, and free joint at the ankle, see Fig. 51, is sufficient in infantile cases; but in children able to walk, I make use of a light steel support attached to the boot below, and passing upwards to the calf of the leg on each side, and connected above with a narrow semi-circular steel plate, fastened round the leg by a strap. A strap also passes from the outer side of the boot across the ankle-joint, and is fastened round the steel bar on the inner side; this supports the ankle-joint, and draws the tibia inwards, or rather keeps the inside iron parallel with the tibia, so that the former may exert a controlling power over the foot. A stop-joint, which will not allow the foot to drop beyond a right angle, is generally placed opposite the ankle-

joint, but I prefer free motion at the ankle-joint unless paralysis of the anterior muscles exists, as in many non-congenital cases.

If the deformity has been completely removed, and the ligamentous resistance overcome, it will only be necessary for the infant, or child, as it may be, to wear this apparatus in the day time for about six months, or perhaps a twelvemonth, whilst the joints are adapting themselves during growth to the normal position of the foot, and the muscles acquiring a well balanced action.

If, from the defective adaptation of the joint surfaces and ligaments, and from an unbalanced muscular action, any marked tendency to inversion of the foot remains, the Scarpa's shoe must be continued to be worn at night, or a simple rectangular tin splint is sometimes substituted, but the Scarpa's shoe is the most effective.

The physiological means consist of active and passive exercises, together with rubbing or shampooing, cold bathing, &c. In infantile cases I direct passive exercise, *i.e.*, "working the foot," in the direction of flexion and extension, to be conducted by the nurse for a quarter or half-an-hour twice a day; or it may be done for a shorter period, at more frequent intervals. In older children this is assisted by the exercise of walking, but the passive exercise must not be neglected, because if any stiffness at the ankle-joint remains, children run about without flexing the ankle-joint, and then the recurrence of the deformity is certain.

Weakness of knee-joints; additional retentive apparatus. Although the simple retentive apparatus, above described, may be sufficient in many cases, it is frequently necessary to employ a more complicated, troublesome and cumbrous apparatus, extending above the hip-joints to the waist. When the child begins to walk, it may, or may not use its feet properly, even although the deformity be perfectly cured. The feet may be perfect in form, with free motion at the ankle-joints, and without any tendency to inversion when the child is sitting, but in walking, the child still turns the feet inwards.

This state of things, I need scarcely say materially mars the

appearance of the case; some defect in the treatment, or weakness induced by the operation, or a tendency to relapse will certainly be suspected by the parents; but a careful examination will prove that the inversion of the feet depends upon the legs turning inwards from the knee-joints, in consequence of a very lax condition of the ligaments of these joints, and in some degree also upon an adapted condition of the muscles of the leg and thigh to the deformity of the foot. The latter cause is most conspicuous in children from four to five years of age, who have been accustomed to run about upon their deformed feet.

It is impossible to control this tendency to inversion of the foot and leg, except by mechanical supports acting from the hip-joint; and for this purpose, the steel support must be carried to the waist, and connected with a pelvic belt as shown in Fig. 57.

FIG. 57.

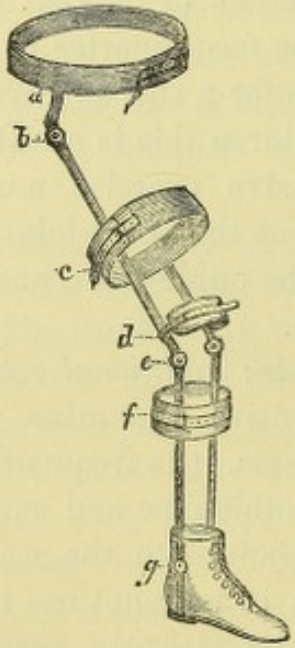

Additional retentive apparatus used to control inversion of the foot and leg, arising from weakness of the knee-joint, after the period of walking.—*a.* Pelvic belt. *b.* Free joint corresponding to hip-joint. *c.* Trough and band round thigh. *d.* Strap above knee-joint. *e.* Free joint corresponding to knee-joint. *f.* Trough and band round calf. *g.* Free joint corresponding to ankle.

A free joint should be placed opposite the knee, and the

knee-joint itself supported by a knee-cap or transverse strap above the knee and connected with the steel.

So long as there is any defect in the balance of muscular action, the use of this apparatus must be continued; and if applied when the child first begins to walk, will generally have to be worn from two to four years; because, although the defect may be slight, it would certainly lead to relapse of the deformity if the child were allowed to walk badly; and young children cannot be induced to exert any voluntary control over their movements. This tendency to inversion is quite within the control of older children, and I have never known it necessary to apply the apparatus described, to children above six or seven years of age.

The after-treatment in youth and in the adult is very simple. In some cases no retentive apparatus is necessary, but it is generally advisable to use a steel support from the boot to the calf of the leg, with the ankle-strap, and a free joint at the ankle. Although so little mechanical support is required, greater attention to the physiological treatment is always necessary, in consequence of the ligamentous adaptation which has taken place during the period of growth. On this account, stiffness of the ankle-joint is apt to remain, and in the adult, flexibility of this joint may never be obtained.

Active and passive motion must therefore be persevered in with the utmost attention and regularity. If this be neglected, and the steel support, with a stop-joint at the ankle, be worn for any lengthened period, as recommended by some authorities, an inflexible condition of the ankle-joint may, even in youth, be induced, and increased by contraction of the anterior muscles, consequent upon the foot being retained in the rectangular position by the mechanical means employed.

In December, 1855, I saw a boy aged 16, who had been cured of congenital talipes varus, seven years previously, and had ever since continued to wear the inside steel supports with stop-joints, under the direction of a surgeon who still wished him to continue their use. Both feet were tolerably perfect as to form; no disposition to inversion remained, but on the

contrary, there was rather a tendency to eversion; the heels were well down, and the feet flexed at a right angle with the legs, but they were rigidly held in this position. He had no power of extending either foot beyond a right angle, and the tendons of the anterior and outer muscles of the leg, especially of the extensor communis and peronei, were very tense and prominent, so that structural shortening of these muscles had evidently taken place as the result of long retained position. This case appeared likely to terminate in a severe and intractable form of talipes valgus, and I mention it here as an example of excess of mechanical, and neglect of physiological treatment.

NATIONAL HOSPITAL FOR THE PARALYSED & EPILEPTIC
PRESENTED TO
QUEEN SQUARE, BLOOMSBURY, LONDON

CHAPTER XVI.

CONGENITAL TALIPES VARUS, CONCLUDED.—RELAPSED CASES.

THE consideration of relapsed cases of congenital talipes varus is of the highest importance. They have been of frequent occurrence; and even now, when the pathology of club-foot is so well understood, they are frequently met with. So much indeed has this been the case, that a feeling of distrust in the complete and permanent curability of these cases, still exists in the professional, as well as in the public mind.

A provincial surgeon, in large practice, lately told me there were plenty of cases of club-foot in his neighbourhood, but that nothing could be done for them; sometimes they were benefitted by treatment, but the deformity always returned. This distrust is much strengthened in the public mind by the cases among the poor, which return to the country after having been operated upon in London, even at Orthopædic Hospitals, and in which relapse takes place, generally, in consequence of neglect of the after-treatment. Two or three such cases may happen to occur at the same time in a populous manufacturing district, and I have known them adduced by clergymen, and medical men, in argument against the vaunted curability of club-foot. We are therefore much interested in the inquiry as to the

Causes of the tendency to relapse. It appears that we must either assume the existence of an inherent tendency to relapse —an opinion entertained by Dr. Little,—or believe that the

tendency to relapse essentially depends upon some defect in the primary or after treatment.

I hold the latter doctrine as applicable to all the cases in which the primary treatment can be successfully adopted, *i.e.*, in which the deformity can be removed. I believe the only exceptions are to be found in those rare cases of arrested muscular development, affecting the anterior and outer muscles of the leg, to which I previously adverted; and even in these, although an inherent tendency to relapse undoubtedly exists, such an event may, in my opinion, be prevented, as in paralytic cases, by perseverance in the mechanical means employed.

Some surgeons have adduced as an argument against the dynamic origin of varus, the absence of any evidence of disturbed muscular action—any spasmodic affection—after the removal of the deformity. Dr. Little, however, lays great stress upon the tendency to relapse depending, in many cases, upon a continued disposition to "tonic contraction" in the muscles which produced the deformity; and therefore regards the tendency to relapse as depending upon the continuance of this disposition, and at the same time as evidence of the spasmodic origin of the deformity. He observes, "Now it is obvious that if the dynamic property of the muscles of a joint be intact, and entire flexibility be obtained, either with or without operation, no tendency to relapse should exist; for if the muscles, originally contracted be right in their functional activity, ordinary exercise would, as in the case of a sound limb, maintain the flexibility. But although volition exists in the former structurally shortened muscles of a recovered club-foot; a tendency to recontraction — tonic contraction — does in many cases (especially those most affected) exist."* Dr. Little observes that the deformity is little likely to recur in those cases in which the dynamic cause has subsided.

A sufficient explanation of the tendency to relapse in all but the exceptional cases, previously adverted to, appears to me to be found.

* "On Deformities," page 257.

1st. In the induced morbid conditions of the various tissues involved in this deformity, such as the adapted growth of the bones in the deformed position, more especially the astragalus; and also the adapted growth and relatively altered length of the ligaments; and

2nd. In the imperfect extent to which these induced conditions are frequently removed, in consequence of the great length of time necessary for the complete restoration of these deviations, when severe, leading as it frequently does, to the neglect of the after-treatment.

It appears, therefore, quite unnecessary to assume the existence of any inherent disposition to relapse, such as a continuing influence of the original producing cause of the deformity. Moreover, there is no evidence of the continuance of any spasmodic tendency, unless the fact that the deformity does sometimes return be so regarded, but to this conclusion I cannot assent.

The principal causes of relapse, then, which I recognise in the ordinary cases of varus, when submitted to treatment at a sufficiently early period, have reference to some defect, either in the primary or in the after-treatment, and may be arranged under the following heads.

1st. Defects in the operative treatment consisting of (*a*) omitting to divide one or more of the contracted tendons, or more correctly speaking the tendons of contracted muscles: (*b*) incomplete division of tendons; (*c*) division of the tendons in a wrong order, (*d*) inflammatory adhesions following clumsily performed operations, or some of the accidents, such as aneurism, &c., which may occasionally occur.

2nd. Neglect or discontinuance of the after-treatment, either mechanical or physiological.

Other causes of relapse, however, undoubtedly exist, such as

3rd. From the treatment not being commenced at a sufficiently early age.

4th. From congenital defects of muscular development, such as absence of the anterior, and outer muscles of the leg, above described.

To relate the details of relapses from all causes would be both tedious and unnecessary, therefore I will merely advert to a few of the principal facts which characterize them.

1st. I have already stated with regard to the defects in the operative treatment, (*a*) that the posterior tibial tendon was not divided subcutaneously in infants till the year 1842. Before this date, it was either performed by open-wound, when its division appeared to be absolutely necessary, or its division was altogether omitted; the general opinion being that the tendo Achillis and the anterior tibial were the principal tendons requiring division. I believe Stromeyer held this opinion, and it appears to be entertained by some surgeons, even at the present day.

The division of the posterior tibial tendon, therefore, was frequently omitted, and the more severe cases commonly returned as I believe, in consequence of this. I base this opinion mainly on the relapsed cases which have come under my observation, and upon the well known fact that since the subcutaneous division of this tendon has become the rule of practice, in cases even of a moderate degree of severity, relapse of the deformity has been of less frequent occurrence.

With regard to the incomplete division of tendons (*b*), I have examined two cases after death, (from causes not connected with the deformity) in which the posterior tibial tendon had only been cut half through in the operation performed for the cure of this deformity, and one of these cases is represented in my work "On the Reparative Process in Human Tendons" see Plate 5, *f*. I need hardly say that should it occur in a severe case, the cure of the deformity must be incomplete and relapse therefore certain.

I would here remark with regard to division of the tendons in a wrong order, (*c*) as a cause of relapse, that the error most frequently committed, is, dividing the tendo Achillis at the beginning, instead of the end of the operative treatment.

The effect of this, in severe cases is, that sufficient elongation of the tendo Achillis is not obtained, in consequence of

the difficulty of accomplishing by mechanical treatment at the same time, all the objects required in the restoration of the deformed foot. Consequently at the end of the treatment, the tendo Achillis remains as a shortened, or as it is called, a contracted tendon, and exerts a powerful influence in producing relapse of the deformity.

And next, as to the influence of inflammatory adhesions following clumsily performed operations, or some of the accidents such as aneurism, &c., *(d)* acting as a cause of relapse of the deformity; I would observe that all subcutaneous operations leave behind them slight adhesions between the tendons and their sheaths; but when the operations are carefully performed, these adhesions (the inflammatory origin of which may perhaps be doubted) are very few and extremely slender; so that they do not interfere with the free play of the tendons.

A great feature in the pathology of subcutaneous operations, is the absence of inflammation; but when from any cause the operations are followed by a perceptible degree of inflammation, adhesions of a stronger and more important character take place. I have already mentioned having witnessed suppuration along the tendons, and in case of division of the posterior tibial tendon, suppuration extending up to the popliteal space. I have also seen aneurisms produced by wounds of arteries in these operations.

Now in the above mentioned instances, and also where the same tendon has been the subject of repeated operations, close inflammatory adhesions must take place, and by their influence in limiting the free play of the tendons, become important agents in inducing a reproduction of the deformity. Of this I have witnessed several examples.

2ndly. The cases of relapse, arranged in the second class, viz., those arising from "neglect or discontinuance of the after-treatment, either mechanical or physiological," are of the most frequent occurrence.

Too much stress can scarcely be laid on the importance of careful attention to the after-treatment; especially as to the employment of mechanical supports acting as a retentive apparatus

during the time required by the bones and ligaments to adapt themselves to the normal position of the foot, and also the improvement of the muscular power by active and passive muscular exercises, shampooing, &c.

If by mechanical means, motion be allowed only in the right direction, and if by the physiological treatment, the moving agents, viz., the muscles, be proportionately improved, a sufficiently perfect state of ligamentous and osseous adaptation, and balanced muscular action will be obtained. Thus all chance of relapse of the deformity will be prevented, but neglect of any of these means, in a case even of a moderate degree of severity, will most certainly lead to a return of the deformity.

A ready excuse for the relapse is found in a temporary neglect or intermission of the after-treatment, unavoidable through illness; but it appears to me without sufficient reason, except when the child may have been the subject of some protracted malady.

In hospital practice, neglect of the after-treatment is a frequent cause of relapse, where poverty, ignorance, and neglect are necessarily common among the class of patients we have to do with; and in private practice the great length of time during which a continuance of the after-treatment is frequently necessary, perhaps three or four years in severe cases, also occasionally leads to neglect and relapse.

One of the commonest arguments, possessing at first sight a great deal of plausibility, if not of reason, is, that as muscular weakness appears to be the most prominent condition of the limb, mechanical support must retard and interfere with the increase of muscular strength. The observation is commonly made that "the child cannot gain strength so long as it wears the steel supports." Now this prejudiced and erroneous opinion, which is as frequently urged against the mechanical treatment of all other deformities, ought to be at once eradicated from the professional mind. The fact is, that this is not merely a question of muscular strength, but a question of strength and position combined.

An increase of muscular strength might, perhaps, be gained

in some cases by discontinuing the apparatus, but if irregular muscular action be allowed to remain uncontrolled, the deformity will certainly return, and in cases of congenital varus, diminished instead of increased muscular strength will ultimately result as a consequence of the wasting of the recontracted muscles. I have repeatedly known patients acting under advice, discontinue the mechanical supports, and trust to rubbing, sea-bathing, &c., instead of combining all these accessory means of treatment, and the inevitable result of this procedure has been a recurrence of the deformity.

Some years since, a boy of the age of eight years was placed under my care with club-foot, in whom the deformity had been removed by operation three times previously, at intervals of two years. The relapse appeared to have been the result partly of neglect of the mechanical treatment, but principally the omission of the physiological means which were not directed to be employed. After great perseverance, I succeeded in again restoring the form of the foot, and motion at the ankle-joint; muscular power of the limb then rapidly improved under shampooing, and passive exercises.

3rdly. In reference to the treatment not being commenced at a sufficiently early age as a cause of relapse, it must be remarked that the difficulty of curing the deformity—both with respect to the anatomical and physiological condition of the various tissues involved—is always proportionate to the lateness of the period at which the treatment is commenced. The reasons for this are, the bones during growth become ossified in the deformed position of the foot, and therefore retain their imperfectly developed forms; the ligaments become adapted to the abnormal conditions of the bones and joints, and the contracted muscles remain imperfectly developed, and also become more or less degenerated from disuse. It must therefore follow that as the cure is necessarily imperfect, a proportionate tendency to relapse exists in the cases operated upon at a late period.

4thly. With respect to congenital defect of muscular development, as the last cause of relapse mentioned, such as absence of the anterior and outer muscles of the leg; I have dissected

five or six cases in which this congenital defect existed, two of them have already been described, and in neither of them had any operation been performed. A tendency to relapse, however, would certainly have existed, although return of the deformity might probably have been prevented by some form of retentive apparatus, which the patient would have been obliged to wear during the remainder of life, as in severe paralytic cases. Fortunately such cases are extremely rare.

The causes of relapse, then, arranged in the first two classes are entirely within the control of the surgeon and parents, provided the surgeon has the opportunity of treating the case at a sufficiently early period. The cause arranged in the third class is also frequently within the control of the surgeon, as it is generally left for him to determine the period at which the operation should be performed. The cause arranged in the fourth class, being essentially a congenital defect of development, is of course beyond the reach of art, but its influence may be in a great measure controlled.

TREATMENT OF RELAPSED CASES.

We now pass on to the consideration of the treatment of relapsed cases, which will necessarily vary according to the cause producing the return of the deformity. Speaking generally, the ultimate results in such cases are much less satisfactory than those in which no operation has been previously performed. This arises partly from the time lost, and the structural changes thereby induced; and partly from the effects of previous treatment, especially in reference to the adhesions of the tendons to their sheaths and neighbouring fascia. Such cases are therefore in a less favourable condition for operation, and it is advisable to persevere with mechanical and physiological treatment as long as any advantage can be gained by it, before repeating the operations.

It will be necessary, however, in most cases to redivide one or more of the tendons; in many instances the division of the tendo Achillis is alone sufficient, but sometimes the anterior tibial requires division. It is also frequently necessary to

divide the plantar fascia, and occasionally the posterior tibial tendon.

When any marked degree of inversion remains, and is accompanied with rigidity of the foot, I have adopted the plan of treating the case throughout as if no previous operations had been performed; and divided the treatment into two separate stages.

Cases of relapse depend as much, or more, upon defective after-treatment as upon any error in the primary treatment. Where the after-treatment has not been neglected, the relapsed cases generally present the characters of equino-varus, with severe contraction of the plantar fascia, and structures in the sole of the foot. The heel is raised about an inch from the ground, and the anterior part of the foot inverted, more by contraction of the inner band of the plantar fascia, than by the tibial muscles. The toes are often remarkably inverted in cases originally severe, probably from the flexor longus muscle, the tendon of which had never been divided, remaining too short. The instep is very high and irregular, from contraction of the plantar fascia, ligaments, and muscles in the sole of the foot; the foot is consequently very short. More or less inversion is apparent in walking, and the limited flexion of the ankle-joint produces lameness, and soon causes fatigue. As the patient walks principally upon the outer border and anterior part of the foot, he is sure to suffer from troublesome corns in these situations.

All these conditions were well illustrated in a case which occurred in my own practice, see Appendix, Case XIV. Both feet were similarly affected, and in both I succeeded in accomplishing an equally satisfactory result. This patient has not only remained well, but continued to improve. In form, and function, the feet are quite perfect.

In thus concluding my description of the pathology and treatment of congenital varus, I would add that success will generally depend upon an intimate acquaintance with the anatomical changes described, and a long continuance of close personal attention during the treatment.

NATIONAL HOSPITAL FOR THE PARALYSED & EPILEPTIC
PRESENTED TO
QUEEN SQUARE, BLOOMSBURY, LONDON

CHAPTER XVII.

NON-CONGENITAL TALIPES VARUS.

Talipes varus sometimes occurs as a non-congenital deformity, generally resulting from infantile paralysis during teething, but occasionally produced by spasmodic and other affections. Although the cause upon which this deformity depends generally dates from infancy, yet, as the distortion of the foot is very slowly produced, we seldom see these cases in childhood, but generally in youth, or at a later period.

The more important affection in these cases is generally considered to be the coexisting paralytic condition of the limb, and therefore the surgeon is frequently not consulted until the adult period of life, when additional inconveniences have arisen, such as ulceration of the foot, to which these paralytic extremities are especially liable; or such an increase of distortion as to render walking very painful, or altogether impracticable, even with such mechanical assistance as the boot and instrument makers are able to give.

External Characters. The external characters of non-congenital varus approach in resemblance to those I have described as characteristic of the ordinary congenital form of varus, but they are never so distinctly marked for two reasons.

1st. Not being congenital, there is an absence of the characteristic distortion of the bones, more particularly of the astragalus, the malformed condition of which I have shown to exist at the period of birth, in the congenital form.

2nd. Being nearly always of paralytic origin, the foot is forced into its deformed position by the superincumbent weight of the body in walking, rather than drawn into it by the active tonic contraction of the muscles; and its retention in the distorted position is the result only of a slow adaptation of the ligaments and muscles.

For these reasons, therefore, the foot presents a generally rounded and smooth external surface, although it may assume the inverted position as shown in Figs. 58 and 59, sufficiently for its classification with varus as a variety of club-foot. There

FIG. 58.

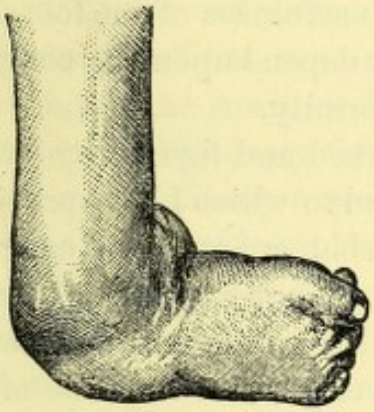

Non-congenital talipes varus, anterior aspect showing its rounded and smooth external surface as compared with the congenital form exhibited in Fig. 25.

FIG. 59.

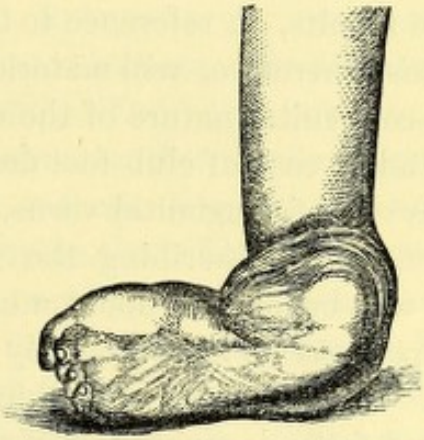

Posterior aspect of the same foot as shown in Fig. 58. The absence of the longitudinal and transverse depressions exhibited in the congenital form in Fig. 26 may be observed.

are none of the marked irregularities on the dorsal aspect, nor do we see the longitudinal and transverse depressions on the plantar aspect, described as characteristic of the congenital form in the adult. With this absence of the external markings, there is also an absence of the rigidity of the foot constantly present in the adult congenital cases.

DIAGNOSIS. There is no difficulty in diagnosing the non-congenital, from the congenital form of varus, when met with in

young people; the difference in their external characters being so strongly marked. When the non-congenital cases are seen at an advanced period of life, there may perhaps be some little difficulty, in consequence of the increased rigidity and aggravation of the deformity, acquired by age; but the paralytic and extremely wasted condition of the limb, which usually coexists with the external characters in the non-congenital form, materially assists in the diagnosis of these cases.

It is important to be aware of these facts, because in the adult, we cannot always obtain a reliable history as to the congenital or non-congenital origin of the deformity; and although the treatment will be essentially similar, important differences will be found to exist with respect to its duration, and the results, in reference to the usefulness of the foot. The *prognosis*, therefore, will materially depend upon the congenital or non-congenital nature of the deformity.

The adult case of club-foot described and figured by Cruveilhier* as one of congenital varus, and to which I have previously adverted when describing the morbid anatomy of congenital varus, was beyond all doubt a case of non-congenital varus, it might perhaps be more properly called equino-varus of paralytic origin. In this case, Cruveilhier has described a state of very advanced fatty degeneration of the muscles—a condition which certainly does not generally exist, if indeed it ever occurs in congenital varus, even in advanced age—and also extreme atrophy of the nerves, with diminution in size of the tendons, blood vessels, and other atrophic changes. All the morbid conditions described and represented in the drawing of this specimen in Cruveilhier's work, precisely agree with the conditions I have found by dissection in cases of non-congenital varus, and with those also described by other authorities, in several carefully recorded cases; while they differ very widely from the conditions in adult congenital varus, so far as they have been ascertained by dissection, and as regards the muscles, can be inferred by their physiological condition, which is always opposed to the supposition of the existence of any paralysis. Cruveilhier had,

* "Anatomie Pathologique," Tome 1, livraison 2e, planche 3.

no doubt, been told this was a case of congenital varus, and then he described the appearances presented on dissection. Mr. Brodhurst has, however, tended to perpetuate this error by relying on Cruveilhier's account, and quoting it as the ordinary condition of the muscles, tendons, nerves, vessels, ligaments, skin, &c., in congenital varus in the adult.*

MORBID ANATOMY. In cases of non-congenital varus in its ordinary form, *i.e.* of paralytic origin, the bones, ligaments, muscles, tendons, nerves, vessels, and skin, undergo all the changes of defective growth, atrophy, and degeneration, so well described by Cruveilhier in the dissection above adverted to.

Bones. The deviations in the form and direction of the bones, articular surfaces, and ligaments, in non-congenital varus, partake of the same general characters already described as existing in the congenital form. They are, however, much less in degree, obviously for the reason that the development of these structures has proceeded without interruption, not only up to the period of birth, but up to that of the commencement of the deformity. Speaking generally, the deviations in form in these structures may be said to approximate, more or less, to those existing in the congenital cases; but they never exist to the same extent, or in the same definite form. The astragalus, for instance, never presents the peculiar malformation which it constantly exhibits in congenital varus; and the adapted shortening of the ligaments, and consequently the rigidity of the foot, is always materially less. This at once explains why the deformity in adult cases of non-congenital varus can be removed in two or three months, whilst in congenital cases, more than a year is frequently required to produce the same result.

Muscles. There is an essential difference in the structural conditions of the muscles in congenital and non-congenital varus. In congenital varus, the muscles are generally healthy at the period of birth, but if the deformity be allowed to continue, their growth is impeded in a proportionate degree, the

* Brodhurst on Club-foot, page 38.

structural degeneration, however, does not take place to any considerable extent, even when the deformity has remained unrelieved up to the adult period of life.

In the ordinary form of non-congenital varus, the result of paralysis, the reverse is the case; here fatty degeneration of the muscular tissue commences as an early change, and rapidly advances to an extreme degree. This degeneration will not take place in all the muscles to the same extent, unless they are equally paralysed, which is an exceptional condition; generally the tibialis anticus, and sometimes the tibialis posticus, will be found to be in a comparatively healthy condition.

In one case of non-congenital varus which I examined in a man 37 years of age, the muscular tissue of the tibialis anticus was of a light red colour, and to the naked eye looked tolerably healthy, although microscopically examined, its structure was seen to be somewhat degenerated; every other muscle in the leg was in an extremely advanced state of fatty degeneration, the fasciculi in many parts were filled with oil and granular fat, and vesicular fatty tissue also existed abundantly, taking the place of the muscular tissue by the process of "fatty substitution" described by the late Mr. Quekett.

I am not prepared to say that fatty degeneration of some, or all of the muscles invariably exists, although it is undoubtedly the rule in non-congenital varus. This deformity may be occasionally produced by spasmodic, as well as paralytic affections, and therefore, probably, the muscular structures may sometimes be in a comparatively healthy condition, as I have found them in spasmodic equino-varus; but further observations are necessary on this point.

Tendons. In adult cases of non-congenital varus of paralytic origin, the tendons are always of much smaller size than natural. In Cruveilhier's case the tendo Achillis was less than half the size of that of the opposite leg. This is the result of imperfect growth, and also of atrophy, probably with some structural degeneration.

The deviations in situation and direction of the tendons

in non-congenital varus, approximate to the deviations in the congenital form, but they never exist to the same extent, because the displacement and altered form of the bones, and also the adapted shortening of the ligaments, are less considerable. The posterior tibial tendon, for instance, which is of the greatest surgical importance, occupies more nearly its natural position behind the malleolus; and as the navicular bone is less distinctly in contact with the inner malleolus, and not very rigidly held in its partially displaced position, the posterior tibial tendon may frequently be divided below the malleolus (the anterior part of the foot being everted by an assistant) if such an operation recommended by Mr. Syme be preferred. However, I recommend in all cases the division of this tendon about an inch above the inner malleolus.

Vessels and Nerves. The changes we should expect to find in the vessels, nerves, and other tissues, are diminution in size, and atrophy of structure. In Cruveilhier's case the arteries and veins were less than half their normal size, and the nerves extremely small, and described as almost reduced to their neurilemma.

PATHOLOGY. *a. Etiology and mode of production.*—Non-congenital varus is generally the result of infantile paralysis, occurring, during dentition, or some of the febrile disorders of childhood. In some cases, all the muscles below knee are paralysed, and then from position, and the influence of the superincumbent weight of the body in walking, acting so as to twist the foot inwards, the deformity takes place very slowly. In other cases, only some of the muscles of the leg are paralysed, generally the peronei, extensor longus, and sometimes the extensor pollicis; the deformity then takes place much more rapidly, in consequence of the unbalanced action of the tibialis anticus and posticus muscles, assisting in the inversion of the foot during progression. When the paralysis is limited to a few muscles, the real nature of the case may be overlooked by surgeons not familiar with these affections, and serious errors of diagnosis and treatment may result, see Appendix, Cases VIII, IX, and X.

Spasmodic affections are also said to give rise to non-congenital varus, but I have never seen a well marked case of permanent varus, associated with a spasmodic condition of the muscles. I have sometimes seen a foot temporarily drawn into the position of varus in spasmodic affections, and one of the best marked examples was a case of hysteria, connected with derangement of the uterine functions in a girl. It is also said to occur during the violent spasmodic condition resulting from strychnine, but generally in spasmodic affections as in the *rigor mortis* the feet assume the form of equino-varus, and as a permanent condition or deformity, this also is the variety which will be most frequently met with in spasmodic cases.

Inversion of the foot from traumatic lesions is seldom, if ever, severe enough to be classed with varus, and cases of this kind have already been mentioned in the class of equino-varus to which they more properly belong.

b. Numerical importance. In the statistical account of 1780 cases of deformities of the feet, congenital, and non-congenital which had been treated at the Orthopædic Hospital up to the year 1851, published by Mr. Tamplin, and previously alluded to; 999 cases of non-congenital deformities are recorded, and of these only 60 were classified as non-congenital talipes varus; therefore it is evident that, relatively to the other non-congenital deformities, this is one of rare occurrence.

These sixty cases of non-congenital varus were thus distributed.

Affecting the right foot only .	25
Affecting the left foot only .	20
Affecting both feet . . .	15
Total	60

By this table it is shown how much more frequently one foot is affected than both, and this corresponds with the results in the other paralytic deformities. I have previously stated that infantile paralysis, which generally lays the foundation of this, as well as most of the other non-con-

genital deformities of the foot, "most commonly affects some of the muscles of one leg."

c. Coexistence with other deformities of the opposite foot. For the reason above stated, when one foot is affected with non-congenital varus, the opposite one is generally free from deformity. Only five cases to the contrary are recorded in the above statistical table; and it is somewhat remarkable that in each instance the right foot was affected with varus, and the left with valgus. In my own experience, cross cases of this kind have generally been examples of paralytic equino-varus of the right, and equino-valgus of the left foot.

PROGNOSIS. From the pathological history of this deformity, and especially from the fact that it is generally the result of a paralytic affection, the prognosis, with respect to the power and general usefulness of the foot, after removal of the deformity, must be as unfavourable in this non-congenital form of varus, as it is favourable in the congenital form. The deformity itself can be easily cured, and, doubtless this is worth doing in most cases.

So far, then, the prognosis must be favourable; but as these cases are more frequently seen in adult life, or in adolescence, than in childhood, and as there is generally persistent paralysis of which there is no hope of cure, and often very little of improvement, they can only be undertaken with the view of improving the condition of the patient. In some cases, the inconveniences to the patient, arising from the deformity and the paralytic condition of the limb, especially when ulceration of the foot has taken place, are so great, that the ultimate advantages of curing the deformity will have to be balanced against those of amputation, and the substitution of an artificial leg. When the deformity arises from other causes, and is not associated with paralysis, the prognosis must depend upon the exact condition of the muscles, and also upon the condition of the articulations and structures involved.

TREATMENT. After considering all the circumstances in these cases of non-congenital varus, if it be determined to cure the deformity as a means of improving the condition of the patient,

they must be treated upon the same general principles and by the same means as in congenital varus. The operative, mechanical, physiological means previously recommended, are all equally applicable to this variety. Sometimes fewer tendons may require division; that of the posterior tibial tendon, for instance, may be unnecessary.

With respect to the apparatus to be employed, I would recommend the use of the straight splint in the first stage, *i.e.*, overcoming the inversion of the anterior part of the foot, and reducing the deformity to the condition of equinus: and the employment of the Scarpa's shoe in the second stage, *i.e.*, the cure of the equinus. Pressure on the convexity of the foot during the process of everting the anterior portion, and consequently the danger of producing sloughs, may be completely avoided, by the use of the straight splint. The Scarpa's shoe is frequently employed in the first stage, but I have already stated my objections to the use of this instrument in congenital varus, and they may be urged with even more force in non-congenital varus; not only is it most unscientific in its construction as not being in accordance with the anatomical conditions of the foot, but the pressure necessarily made on the convexity of the foot, in producing eversion, is most objectionable in the paralytic condition of the limb.

The instrument I described in a previous chapter, and recommended for adult congenital varus, may be used with great advantage and safety, in some of the most severe and rigid adult cases. This instrument avoids all pressure on the convexity of the foot as completely as the straight splint, and the eversion, uplifting, and unfolding of the anterior portion of the foot, may be conducted simultaneously, instead of separately, as practised at the present time at the Orthopædic Hospital, where either the straight splint, or the Scarpa's shoe is used.

One fact I would especially insist upon, viz., that the mechanical treatment be conducted with extreme caution, in order to avoid sloughs from pressure. This is very likely to take place, in consequence of the paralytic condition of the limb, and the difficulty, or sometimes even the impossibility of heal-

ing sloughs thus produced, has unfortunately been too frequently illustrated. Relapse of the deformity soon takes place, when the treatment is interrupted from this cause, and these, together with the other paralytic contractions, are among the most unsuccessful cases ever undertaken by surgeons who have little experience in the treatment of deformities.

Not more than three or four months are required for restoring the foot to its natural position, about one-third of the time occupied in curing a congenital case of varus at the same age, and this difference is sufficiently explained by the condition of the ligamentous and muscular tissues.

AFTER-TREATMENT. It will be necessary, in consequence of the paralytic condition of the limb generally existing in these cases, for the patient to wear some form of retentive apparatus, probably for the remainder of life. The precise form of the mechanical support must depend very much upon the extent of the paralysis, and especially whether extension of the leg from the knee-joint, has been lost by paralysis of the rectus muscle. If this be the case, a steel support must be carried from the foot up to the hip-joint, and connected with a steel belt round the pelvis, motion being allowed only at the hip-joint. The knee-joint must be kept stiff during the act of progression, the knee being mechanically anchylosed as it were, by what is called a gun-lock spring, or some of the other contrivances in common use, so that the patient may have the power of bending the knee while sitting. If the rectus muscle be not paralysed, the foot may be supported by a steel attached to the boot on the inner side, or by a steel attached to each side of the boot and extending up the leg to the calf, round which a connecting plate and strap must pass. At the ankle-joint, the movement may be either limited by what is called a stop-joint, or left free, according to the paralytic or healthy condition of the muscles of the leg, and amount of voluntary power over the foot at the ankle-joint.

To prevent recontraction of the ligaments and muscles, and consequent relapse of the deformity, to which there is a special

liability in many of these cases, a light and simplified form of Scarpa's shoe, without any cog-wheels, and having only a light steel leg-iron fixed at a right angle to the sole plate, should be worn at night, so long as there is still existing any distortion of the foot, depending upon ligamentous shortening and adaptation, such as would interfere with the foot being brought flatly to the ground in a natural position in progression.

CHAPTER XVIII.

CONGENITAL TALIPES VALGUS, OR FLAT-FOOT; PATHOLOGY AND TREATMENT.

We now pass on to another deformity of the foot, described as talipes valgus, and known by the common appellation of flat, or splay-foot, a deformity both of congenital and non-congenital origin. It rarely occurs as a congenital, but is very common as a non-congenital affection. Let us first speak of the congenital form.

External Characters. The name of this deformity sufficiently expresses its most obvious external characters, viz.: a diminution or obliteration of the longitudinal and transverse arches of the foot, which consequently presents a flattened external form most conspicuous in the non-congenital cases. The inner margin of the foot is depressed, and the outer margin raised; and the anterior portion of the foot is always more or less everted as exhibited in Fig. 60.

The fact that in this deformity the foot is everted, has led to talipes valgus being described as the opposite deformity to talipes varus, but the eversion very rarely exists to an extent which would bear comparison with the inverted position of the foot in varus. A recognised authority on Deformity commences his description of talipes varus by stating, "this deformity is exactly the reverse of the last considered," viz.: talipes varus.

We might therefore expect to find in the morbid anatomy of valgus, some important deviations in the relative position of the bones, analogous to the complex deviations in position, which we have described in varus; but such deviations exist

only to a very limited extent. Varus is undoubtedly the most

FIG. 60.

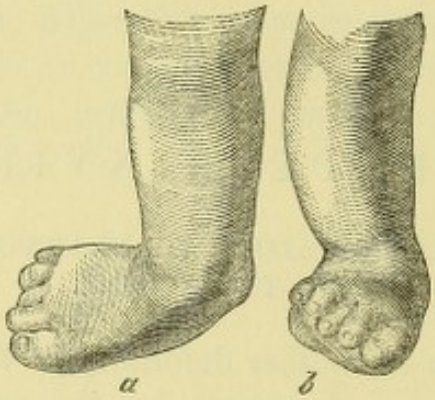

Congenital talipes valgus in an infant. *a* Profile view from inner side, showing the depression of the inner, and elevation of the outer margin of the foot. *b.* Front view, showing obliquity of foot and prominence of inner ankle.

complex deformity to which the foot is liable; but valgus, except in its severest grade, is one of the most simple; and even then, is accompanied with comparatively slight and partial deviations in the relative position of the bones.

External characters modified by the conditions of the tendo Achillis. The only essential external characters of valgus—whether congenital, or non-congenital—are, a flattened condition of the arches of the foot, and a variable degree of eversion of the anterior portion of the foot, the os calcis in many cases is neither elevated nor depressed. In cases of valgus, however, deviations in the position of the os calcis frequently occur, and the external characters of the deformity are materially modified by such deviations. The tendo Achillis may be either contracted or elongated, producing elevation or depression of the os calcis.

We speak of these conditions as belonging to the tendon, because it is a usual and convenient mode of expression, but it must be borne in mind that the essential changes take place in the structure of the muscles connected with the tendon.

From these two conditions of the tendo Achillis, Orthopædic authorities always describe two modifications, or, as they are called, compound varieties of valgus, termed equino-valgus,

when the tendo Achillis is contracted, and calcaneo-valgus, when this tendon is elongated.

This additional subdivision is undoubtedly a useless complication of the subject, because experience has shown that the tendo Achillis is, as a rule, sufficiently contracted in cases of congenital valgus, to require division; and I have repeatedly known this to be the case, even when the external appearances of the foot have led to the case being described as one of calcaneo-valgus. The error in diagnosis arises from the following circumstances.

In cases of congenital valgus, accompanied by contraction of the tendo Achillis, the arch of the foot is really reversed by the anterior portion of the foot being bent upwards from the transverse tarsal joint, at the same time that the tuberosity of the os calcis is elevated, and this bone held in an oblique position by contraction of the muscles of the calf; so that the entire foot has a somewhat flattened, and boat-shaped appearance, as seen in Fig. 60. The large mass of fat which exists in the situation of the heel in infants, so completely conceals the os calcis, as to render it difficult to ascertain its exact position, and readily to mislead, if attention be not specially directed to the exact position of this bone. It is also generally admitted, that the tendo Achillis is sufficiently contracted to require division in the severe cases of non-congenital valgus, and sometimes in the slight cases.

It would therefore be impossible to consider the external characters of talipes valgus, apart from the influence produced by the contraction of the tendo Achillis; and, instead of regarding the contraction of this tendon as forming the basis of another variety of talipes, I am induced to regard it as one of the ordinary conditions of confirmed talipes valgus, especially in its congenital form, which I propose in the present chapter to describe.

When speaking of non-congenital valgus, I shall again advert to the influence of the contraction and elongation of the tendo Achillis on the arch of the foot in this deformity, because the modifications thereby produced in the external cha-

racters are much more conspicuous in non-congenital than in the congenital cases.

It is the general opinion that an elongated condition of the tendo Achillis frequently exists in congenital valgus, but this is contrary to my experience, which leads me to the conclusion that the appearance of depression of the heel, and elongation of the Achilles tendon, is often deceptive. I have myself, in several instances, had to divide the tendo Achillis at a late stage of treatment, in cases which, when undertaken, were considered to be cases of calcaneo-valgus. When the elongated condition of the tendo Achillis does exist in congenital cases, it appears to be of little consequence, and does not at all interfere with, but rather facilitates, the favourable termination of the case; but then in the classification of such cases, they should more properly be grouped with the deformity described as talipes calcaneus or calcaneo-valgus.

Special Effects of this Deformity. After the period of walking, all the external characters of congenital valgus just described, become much more marked; and should the deformity be allowed to remain to adult life, the patient endures much more pain and inconvenience from this deformity, than from congenital varus.

With varus, persons may suffer for many years, or possibly through life; but with valgus, as a general rule, they suffer pain in walking at a much earlier period, and are sometimes quite unable to walk. Although they suffer earlier and more certainly than in varus, there is, at the same time, less fear of the very serious consequences, such as obstinate ulceration and sloughs from pressure, which I described as occurring in adult varus.

MORBID ANATOMY OF CONGENITAL VALGUS.

In describing the anatomical conditions of congenital valgus, as met with on dissection, I propose to follow the plan pursued in the account given of talipes varus, and draw the description from a confirmed and tolerably severe case, mentioning as we proceed, the deviations in excess or deficiency, which characterize the severe and slight cases; rather than follow the plan

adopted by some authorities, who describe three or four different grades of the deformity as so many subdivisions of the subject.

BONES. Much less deformity and displacement of the bones exist, even in the severe forms of congenital valgus, than we have described in congenital varus. The tuberosity of the os calcis is elevated to a variable extent; the deviation in position of this bone is generally slight, but in one severe case which I dissected, the tuberosity of the os calcis was nearly as much elevated as I have found it in a severe case of congenital varus, see Fig. 61. This will of course depend upon the degree of contraction of the muscles of the calf, and I imagine could not be produced by any pressure resulting from position *in utero*, the favourite cause of this and other congenital deformities, adopted by several Orthopædic authorities. I regard this position of the os calcis, equally in valgus and in varus, as evidence of the dynamic or spasmodic origin of the deformity.

The astragalus. In proportion as the elevation of the tuberosity of the os calcis exists, the astragalus is tilted forwards and downwards obliquely at the period of birth. There is no material alteration in the form of the head and neck of the astragalus at the period of birth as in talipes varus, but in the

FIG. 61.

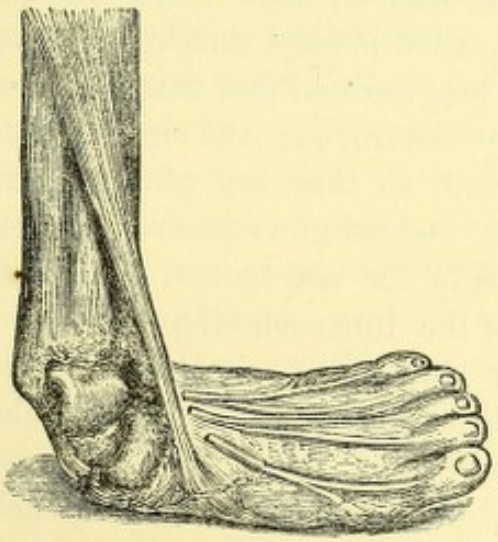

Dissection of a case of congenital talipes valgus showing the elevation of os calcis; oblique position of astragalus; and displaced position of navicular bone, by a movement of transverse rotation. The elevation of the outer, and depression of the inner margin of the foot are well exhibited; the anterior tibial tendon has been left *in situ*.

case represented in Fig. 61, the articular surface of the head of the astragalus was a little altered in shape, in adaptation to the altered position of the navicular bone.

The navicular bone undergoes a movement of transverse rotation upon its horizontal antero-posterior axis; its inner extremity is much depressed, exposing the inner and upper portions of the globular head of the astragalus; its outer extremity is raised, but not to a proportionate extent, see Fig. 61.

The effect of these deviations is, first to destroy the natural concavity of the arch of the foot, and when severe, to produce even a convexity downwards; and secondly, to produce two prominences on the inner margin of the foot, one consisting of the exposed portion of the head of the astragalus, and the other of the inner extremity of the navicular bone. Both these prominences can be seen externally in all severe cases of valgus, both congenital and non-congenital, and their nature can be recognised through the skin by manipulation.

The cuboid bone like the navicular, undergoes a movement of transverse rotation, so that its outer border is somewhat raised, but only to a slight extent, and in a severe case I have found the bone very little displaced.

There is a slight alteration of the navicular, cuneiform, and cuboid bones, together with the tarsal extremities of the metatarsal bones, in their several relations to each other, in consequence of the longitudinal and transverse arches of the foot being completely destroyed; the longitudinal arch is even sometimes reversed, so that the plantar surface of the foot presents a convex, instead of a concave appearance; the prominences of the head of the astragalus, the inner borders of the navicular, and of the inner cuneiform bones, being felt on the inner and under side of the foot, with depressions between them, caused by the separation of the articular surfaces of the corresponding joints.

In these severe cases, the os calcis is held in an oblique position, by contraction of the muscles of the calf, and the astragalus tilted forwards and downwards to a proportionate extent. The foot is, as it were, bent upwards upon itself from

the transverse tarsal joint, and assumes a boat or canoe-like form.

The toes and metatarsal bones, are drawn upwards and outwards, so that the anterior portion of the foot is flexed upon the leg with a greater or less degree of eversion, and transverse rotation outwards, the outer metatarsal bones being raised, and the inner depressed. In some slight congenital cases, there may be only a little eversion of the anterior portion of the foot, with depression of the arch, in consequence of the movement of transverse rotation at the great tarsal joint, without any drawing upwards of the toes and the metatarsal bones; but even in these cases, it is generally necessary to divide the tendons of the extensor longus muscle in front of the ankle-joint, as well as the peronei, which alone might be supposed to produce such a simple movement of eversion.

Sufficient stress is not generally laid upon the importance of the transverse tarsal joint, as a centre of motion, in a severe case of talipes valgus. The eversion of the foot, or more properly speaking of the anterior portion of the foot, appears to have been too frequently regarded as taking place from the ankle-joint, just as the inversion appears to have been similarly regarded in varus, and the apparatus employed for the treatment constructed accordingly; but it is quite clear that the ankle-joint takes very little share in the production either of the inversion or eversion, characteristic of these deformities.

LIGAMENTS. In this deformity, viz., congenital talipes valgus, I am unable to give any exact account of the deviations of the ligaments from my own dissection, nor am I able to supply this deficiency from the writings of any Orthopædic authorities. There can be no doubt that this, as well as other portions of the morbid anatomy of club-foot, in its several varieties, has been surmised from the external appearances of the foot, rather than described from dissections.

In a case of severe valgus in a fœtus which I dissected, and which is represented in Fig. 61, my desire to preserve all the structures *in situ*, prevented my making a minute dissection of the ligaments: but it was evident that the calcaneo-scaphoid

ligament and ligamentous bands connecting the astragalus and the navicular bone on the inner side were elongated, so as to allow of the rotation and uplifting of the navicular bone, and exposure of the inner portion of the articular surface of the head of the astragalus, as shown in the wood-cut.

The deep interosseous bands of ligament connecting the plantar surfaces of the tarsal bones, must also be elongated in many parts, in consequence of the flattened and altered form of the arch of the foot. As the deformity is produced either by muscular contraction, or position *in utero*—I believe the former—the ligamentous alterations must be secondary changes, taking place slowly in adaptation to the altered position of the bones. These adapted ligamentous alterations in severe cases, give a rigidity to the foot in its deformed position, and offer great resistance to its restoration, as in varus, though seldom to the same extent, and it is fortunate that the severe cases of congenital valgus are less frequently met with.

MUSCLES. In this deformity, as in cases of congenital varus, the muscles, as a rule, appear to be quite healthy in structure, and free from any physiological defect; so that after curing the deformity in an infant, the muscular power of the limb is perfect. If the deformity be allowed to continue unrelieved, defective muscular growth will be evidenced by the leg remaining of small size as in talipes varus, but this does not take place to the same extent, because the contraction of the muscles, and displacement of the bones being less in valgus than in varus, with some rare exceptions, more muscular motion is allowed in progression during the deformed position of the foot.

TENDONS. There are no very important deviations in direction, and altered relations of the tendons in valgus, such as I have described as existing in varus, in consequence of the bones being so much less displaced in congenital valgus than in varus. The deviations in direction which exist, in adaptation to the deformed position of the foot in valgus, are of no surgical importance.

Tendons requiring division. With regard to the operative treatment required in cases of congenital talipes valgus, the

division of the peronei, and extensor longus digitorum tendons, is sufficient in most cases in which tenotomy is required, but in those of greater severity the tendo Achillis also requires division. I should, however, mention that I have frequently found it necessary to divide the tendo Achillis in cases of talipes valgus, which at first appeared to be too slight to require this operation.

After curing the eversion of the anterior portion of the foot, a contraction of the tendo Achillis is sometimes found to prevent the complete flexion of the foot at the ankle-joint, which cannot be flexed beyond a right angle; and so frequently is this the case that division of the tendo Achillis may be said to be the rule of practice, and appears to be necessary in all the more severe cases.

In the most severe cases, viz., those in which the arch of the foot is reversed, the os calcis raised by contraction of the muscles of the calf, and the anterior part of the foot drawn upwards towards the leg, it is necessary to divide the tendons of all the anterior muscles, viz., the anterior tibial and extensor pollicis, as well as the long extensor.

VESSELS AND NERVES. No abnormal conditions or deviations in direction of the vessels or nerves of any surgical importance exist in this deformity.

PATHOLOGY. *a. Etiology.* In reference to the cause and mode of production of this, as well as of the other forms of congenital club-foot, the theories entertained by the leading authorities on the subject have been already discussed in Chapter XII. I would now only observe that the advocates of the mechanical theory, *i.e.* position and pressure *in utero*, urge its application very strongly in explanation of talipes valgus.

Mr. Tamplin, in speaking of congenital valgus, remarks, "in my opinion it is position *in utero*, and position alone, which occasions this kind of deformity, as well as other congenital deformities that exist without malformation."* Mr. Lonsdale particularly appealed to cases of valgus, as evidence of position and pressure *in utero*, and I am disposed to think that some of

* "On Deformities," page 207.

the slight cases of valgus, especially when associated with depression of the heel—cases which would be classed as calcaneo-valgus—may be produced by position and pressure *in utero*. The cases alluded to are such as would generally be cured by mechanical treatment without operation, and are analogous to the cases of slight inversion of the foot not infrequently seen, especially in large children, and approaching, in external appearance, cases of varus.

That the mechanical cause could operate so as to produce the elevation of the os calcis, which I have described as existing in well marked cases of talipes valgus, appears to me very unlikely; therefore, essentially I am an advocate for the dynamic theory, *i.e.* spasmodic muscular contraction, as applied equally to the production of valgus, and of all the congenital forms of club-foot.

b. Numerical importance. Talipes valgus, as a congenital affection, is of comparatively rare occurrence, and by reference to the table of 764 cases of congenital club-foot, given below, and extracted from the table of 1780 cases of deformities of the feet previously referred to, it will be seen that only 42 cases of simple talipes valgus are recorded, and 15 cases of talipes valgus of one foot associated with varus of the opposite foot. In the table above referred to, the relative frequency of the congenital deformities is seen to be as follows:—

Talipes varus	688
Talipes valgus	42
Talipes valgus of one foot, and varus of the other	15
Talipes calcaneus	19
Total congenital cases	764

The forty-two cases of congenital valgus were thus distributed:

Affecting the right foot only . .	15
„ „ the left foot only . . .	10
„ „ both feet	17

From this table, it will be seen that congenital valgus more frequently affects one, than both feet, the reverse occurs in congenital varus, and in the non-congenital forms of valgus.

Coexistence of congenital talipes valgus with other deformities of the opposite foot. The fifteen cases above referred to, in which congenital valgus of one foot coexisted with varus of the other were thus arranged :—

Talipes valgus left and talipes varus right.	5
Talipes valgus right and talipes varus left.	10

Coexistence of congenital talipes valgus with malformation of the bones of the leg. Although malformation affecting the bones of the leg cannot be said to be of common occurrence, still in the course of my experience, I have met with several examples of such malformation, and in these cases the foot is also frequently malformed. In other instances, however, the malformation is limited to the bones of the leg, the foot being generally more or less everted, but this seldom amounting to any confirmed or severe form of valgus. The more important malformations may be arranged in the following groups.

1*st. Deficient growth of the leg bones below the knee.* I have seen several examples in infants of deficiency in length of the tibia and fibula, the shortening being from half an inch, to an inch, as compared with the corresponding bones of the opposite leg. These cases were clearly of congenital origin, and not associated with paralysis, they were seen by me in infants a few months old. In these cases the foot was slightly everted, or inclined to valgus, but not rigidly held in this position.

2*nd. Malformation, or absence of the outer malleolus, probably with fusion of the fibula and the tibia.* Of this malformation several examples have come under my observation, but I have not yet had the opportunity of investigating this condition by post-mortem examination. In every instance only one leg has been affected, and the child has been brought to me in consequence of the foot being everted, and retained in the position of valgus, with sufficient rigidity to require operative and mechanical treatment. The peculiarity has been an apparent deficiency of the outer malleolus, which has been scarcely traceable, while in the opposite leg it presented its usual prominence. In these cases there has been no malformation of the foot, but a greater difficulty than usual has been expe-

rienced in retaining it in this improved position after treatment.

3rd. Deficient growth of the leg bones below knee, with a sharp curvature forwards of the tibia and fibula, and malformation of the foot. The cases included in this group are the most numerous of the series of malformations of the leg, and certainly not less than from twenty to thirty of such cases have fallen under my observation, and in the Museum of the Orthopædic Hospital are many casts of limbs thus deformed.

In these cases, the leg below the knee is very much shorter than the opposite limb, and there is always a sharp curvature forwards of the tibia and fibula in the lower third, the prominence of the convexity being from one to two inches above the ankle-joint; and in every instance there has been a deep dimpled depression of the skin reaching to the bone, with which it was adherent, over the most prominent portion of the convexity of the tibia at its curve, as represented in Fig. 62.

FIG. 62.

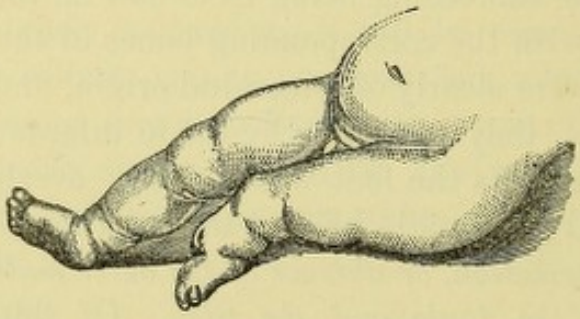

Congenital talipes valgus, associated with deficient growth of leg bones below knee, with sharp curvature forwards of tibia and fibula, and malformation of foot. A deep dimpled depression of the skin always present in these cases, a little above the ankle-joint, and corresponding to the most prominent portion of the convexity of the tibia at its curve is represented.

In these cases, the leg bones of the affected side do not grow at their normal rate, so that the patients are permanently lame, and the shortening of the limb increases proportionably with the increased growth of the opposite limb as in the case of the girl referred to below. A girl, F. A. Penrose, suffering from this malformation, was admitted under my care at the Orthopædic Hospital nineteen years ago, and then the deformed limb, the right, was about one inch shorter than the

left. This girl continues to attend at the Hospital occasionally, being obliged to wear a boot with a steel support above the ankle. With her growth, I have therefore had the opportunity of witnessing the increase in the relative disproportion in the length of the legs, and at the present time the deformed leg is five inches shorter below knee than the opposite leg. In this girl's case the foot has been brought into a useful position, but it is small and malformed, having only three toes. Although the actual measurement shows a deficiency of five inches in length below knee, I find by recent examination, that this girl requires a boot raised to the extent of six inches. This is accounted for by a slight diminution in the length of the thigh, and some tilting of the pelvis produced by her mode of walking. Another example of this malformation came under my care, in a young gentleman, 12 years of age, whose case is referred to, and an illustration given in the Appendix, Case XVI. In all the cases included in this group, which I have seen, there has been some malformation of the foot generally consisting of a deficiency of two or three toes, and the foot is always drawn into the position of talipes valgus.

In these cases, it is generally necessary to divide the peronei tendons, and the tendo Achillis, before the foot can be brought into position; and then by long continued pressure the curvature of the tibia may be diminished, and during growth the leg bones below the knee may become nearly straight.

4th. Congenital hypertrophy of the leg and thigh with malformation of the foot. I have never seen more than one instance of a malformed foot with deficiency of the toes, similar to those I have just described, associated with enlargement and increased length of the limb from congenital hypertrophy; but this case which was a very remarkable one, is related in the Appendix, Case XVIII, and an illustration given.

Other malformations are occasionally seen associated with a valgus deformity of the foot; and one of these in which deficient growth of both legs below knee, with malformation at knee and ankle-joints existed, and in which there were eight toes on

each foot, the legs and feet being remarkably distorted, is represented and described in Appendix, Case XVII.

Another remarkable example of valgus associated with some abnormal condition of the knee-joints, and in which the leg was completely rotated, so that the heel was brought directly in front whilst the foot was directed backwards, is represented in Appendix, Case XIX.

PROGNOSIS. In cases of congenital valgus, a favourable prognosis may always be given, except in the last mentioned cases, in which the deformity is associated with malformation of the bones of the leg. The result, however, will be more perfect in proportion to the early age at which the treatment of the case is undertaken, as in varus. The deformity can be cured with little difficulty, and there are no conditions calculated permanently to interfere with the anatomical and physiological perfection of the foot.

TREATMENT. Slight cases of eversion of the foot, unaccompanied by rigid muscular contraction, either pass unnoticed, or are rectified by the manipulations adopted by experienced nurses. Cases of a more severe degree of deformity, but still without rigid muscular contraction, may be cured mechanically, within a few months of birth, without tenotomy.

The cure of congenital valgus, when severe, even in the infant, can only be accomplished by a combination of the same general principles of treatment—including the operative, mechanical, and physiological means—which I have described as necessary to the successful treatment of congenital varus and other deformities. Tenotomy is required in all the more severe congenital cases, but in the latter class of cases it is advisable to divide the treatment into two stages, as in varus; the object of the first stage being to overcome the eversion, transverse rotation, and bending upwards of the anterior portion of the foot—and thus to bring the foot on a straight line with the leg—to convert the valgus into simple equinus, when contraction of the tendo Achillis exists; and the object of the second stage to obtain the natural extent of flexion at the ankle-joint, when this is limited by contraction of the tendo Achillis.

Operations required. The tendons requiring division vary very much according to the severity of the case. In the slighter cases, division of the peronei and extensor longus tendons may be sufficient; but the tendo Achillis frequently requires division, and in some severe cases it will also be necessary to divide the tendons of the tibialis anticus, and extensor pollicis muscles.

In some cases in which the tendo Achillis is only a little contracted—not more than would leave a right-angled contraction of the foot after the removal of the eversion—the practice of dividing this tendon at the same time as the extensor longus and peronei tendons, seems to answer very well. I have frequently seen it done, and have in a few cases adopted it myself with success. It may be objected that it is unscientific to divide the extensor and flexor tendons at the same time, because we cannot simultaneously elongate the tendons of the muscles so opposed in action and situation. But there can be no doubt of the fact that this plan does answer in many cases, and the explanation probably is, that the increased length of tendon required, especially in the tendo Achillis, is much less than in cases of varus.

The tendons of the extensor longus, and other extensor muscles, which it must be remembered are the direct flexors of the tarsus upon the leg, should be divided, when necessary, as they cross in front of the ankle-joint, where they are usually prominent and tense. To divide the extensor longus and peroneus tertius, the puncture should be made close to the inner border of the extensor longus tendon, and the sharp pointed tenotome passed behind the tendons, cutting from below upwards towards the skin. This is also the best position for the puncture, when all the anterior tendons require division, because after dividing the extensor longus, the knife can be re-entered from the same puncture, and passed beneath the extensor pollicis and anterior tibial tendons, without any risk of wounding the anterior tibial artery if the point of the knife be kept close to the tendons.

A pledget of lint should be applied, and held in position by a strip of adhesive plaster immediately after dividing the tendons. The foot should then be bandaged to a splint placed

in front of the leg and foot, and a little bent at the ankle-joint. It should be left quietly in this manner till the third or fourth day, when the lint and plaster may be removed, the foot bandaged, and whatever apparatus it may be thought advisable to make use of, applied.

Mechanical treatment. Three forms of apparatus will be found useful in the mechanical treatment of congenital valgus, either as adapted to cases of various degrees of severity, or to the different stages of treatment, where it is thought necessary that this should be divided into two stages, as above described.

1st. In the treatment of slight cases, in which there is no necessity to divide the tendo Achillis, I have found it best to employ a straight splint, made of thin iron and well padded, applied to the inner side of the leg, with a spring connected with its lower extremity, and passing at right angles with the splint across the inner border of the foot; a pad is connected with this spring, opposite the navicular bone, and projects inwards and upwards in the normal direction of the arch of the foot. This forms a fulcrum, over which the foot is made to bend in a curved direction inwards and downwards, so as to put the peronei and extensor muscles on the stretch, by means of a toe strap; this strap is connected at one end with a spring, and passing round the metatarsal bones, draws the anterior portion of the foot towards the spring, with which the free extremity of the strap is then also attached by a buckle.

This apparatus is essentially similar to the valgus splint represented in Fig. 69, as applied to a case of non-congenital valgus. The arch of the foot is, as it were, moulded upon the pad attached to the side spring in this apparatus, which is known by the name of *valgus splint*, and by it alone, many slight cases in infants may be cured. In cases of greater severity, in which it is thought necessary to divide the tendo Achillis as well as the extensor and peronei tendons—these operations being performed at the same time—I prefer to employ the modification of the Scarpa's shoe, in which Langaard's arrangement of the cog-

wheels is adopted, viz.: placing the cog-wheel which alters the plane of the sole of the foot behind, instead of at the side of the ankle-joint. The advantages of this arrangement which I have already adverted to, when speaking of varus, and which is represented in Fig. 15 are very great, and I now employ it in many cases where it is necessary to have a double action, in preference to the ordinary Scarpa's shoe, with two cog-wheels at the ankle joint. The latter, although frequently used, is the most unscientific instrument for the treatment of valgus; the centre of motion for lateral action being placed opposite the ankle-joint, is opposed to the anatomical conditions of this deformity, in which the transverse rotation producing the eversion takes place from the transverse tarsal joint. In valgus, Langaard's arrangement is particularly useful, as it enables us to overcome the rotation of the anterior portion of the foot from the transverse tarsal joint.

It is only necessary to remark, if the Scarpa's shoe be employed, that the horizontal side spring must be on the inner, instead of the outer side, as in varus. A Scarpa's shoe made for varus of the right foot, answers very well for the left foot in a case of valgus. A leather pad must be attached to the side-spring, so as to correspond to the normal position of the arch of the foot, which it is intended to support or rather to form, by acting as a fulcrum in this situation, whilst, by the toe-strap attached to the side spring, the metatarsal bones are being drawn downwards and inwards, as shown in Figs. 67 and 68.

2nd. In the more severe cases, in which it is thought desirable to divide the treatment into two stages, the best apparatus for the first stage, in which the object is simply to convert the valgus into equinus, is either an ordinary straight splint placed along the inner side of the leg, and towards which the foot is gradually drawn by a bandage; or else the valgus splint represented in Fig. 69, may be employed.

In the treatment of the second stage, the object of which is to cure the equinus after division of the tendo Achillis, Langaard's modification of the Scarpa's shoe will be found the

most useful. In some cases I employ a Scarpa's shoe with a single cog-wheel at the ankle-joint, and the sole-plate divided obliquely at the junction of its posterior and middle thirds—corresponding to the transverse tarsal joint in the foot—and having a rotation cog-wheel placed in the sole at the joint, by which the plane of the anterior two-thirds can be altered, so as to correspond with the rotation of the anterior portion of the foot. The valgus-pad must be attached to the movable anterior portion of the sole-plate; and the side-spring is superseded by a rectangular bar, to which the toe-strap is attached as represented in Fig. 68.

3rd. It may be necessary, in severe cases occasionally met with in youth and adults, still further to modify the apparatus employed, by carrying it up to the thigh with a free joint at the knee, in the same manner as in the instrument which I have recommended to be employed in severe cases of adult congenital varus, see Fig. 56.

Physiological Treatment. With the object of bringing the muscles into play, and of obtaining a well balanced state of muscular action, such as is essential to the preservation of the form of the foot in a healthy condition, passive exercise should be commenced as soon as the natural position of the foot is restored, as recommended in the other varieties of talipes.

After-treatment. In order to allow all the structures, bones, ligaments and muscles, to adapt themselves to the improved position of the foot after the removal of the deformity, and to guard against relapse, it will be necessary for the patient to wear some form of retentive apparatus. A boot with a steel support on the outside, carried up to the calf of the leg, and having a free joint at the ankle, should be worn in the day time, walking exercise being permitted; a leather strap attached to the inner side of the boot should pass across the ankle-joint, and be connected by a buckle with the steel support on the outer side of the leg. Inside the boot, a pad of vulcanized india-rubber should be placed, so as to support the arch of the foot. The heel of the boot should also be slightly raised and carried obliquely forwards on the inner side, so as to give

additional support to the arch of the foot. This apparatus will be required to be worn for at least a twelvemonth, or more, to hold the foot in its natural position during progression, and it will effectually support the arch of the foot.

For six months, or more, after the deformity has been cured, it is also necessary that the patient should continue to wear, during the night, some form of retentive apparatus. This may consist either of the Scarpa's shoe, or simply of a metal sole-plate, with a steel bar connected with it, and carried up to the calf of the leg, in imitation of the Scarpa's shoe, but without any cog-wheels, so that it may be light and of little inconvenience.

Relapsed Cases. From the less complicated anatomical conditions of this deformity, cases in which it has returned are much less frequent than in varus, and the tendency to relapse may be effectually controlled with the requisite attention to the after-treatment, and gradually discontinuing the mechanical support to the arch of the foot. The construction of the boots worn should also be carefully attended to, the same boot as above described, with a valgus pad and oblique heel being worn. Sometimes, also, a steel plate may be inserted in the sole of the boot, corresponding to the arch, so as to prevent the boot sinking at this part, under the weight of the body in progression.

CHAPTER XIX.

NON-CONGENITAL TALIPES VALGUS, OR FLAT-FOOT; TALIPES EQUINO-VALGUS; PATHOLOGY AND TREATMENT.

Much that has been said in the description of congenital talipes valgus may, with equal truth, be applied to the non-congenital form of this affection; but although in their external characters there may be a general resemblance, a still closer analogy exists in the deviations of the relative position of the bones. Non-congenital valgus, however, being found to exist under a variety of circumstances, occasioning much personal inconvenience, and being of frequent occurrence, it demands our attentive consideration.

External Characters. A flattened condition of the longitudinal and transverse arches of the foot, from which its vulgar appellation of flat-foot, or splay-foot, is derived, is the only essential characteristic of non-congenital valgus. When the weight of the body is borne upon the foot, its *inner margin* comes flatly in contact with the ground, and in severe cases this occurs without the addition of the weight of the body. Except in severe cases of long standing, such as represented in Fig. 64, or in spasmodic cases as shown in Fig. 66, the *outer margin* of the foot is not raised as in the congenital form, for this reason; that ordinarily, non-congenital valgus is the result of a passive yielding of the strong tarsal ligaments in the sole of the foot, and a feeble or overstretched condition of the muscles. There is no active muscular contraction; the foot is therefore mechanically moulded into the flattened and distorted condition seen in Fig. 63; but in the congenital form, the

anterior part of the foot is drawn upwards and outwards, and the tuberosity of the os calcis is also generally elevated by active muscular contraction, which occasions the uplifting of the outer margin, as shown in Figs. 60 and 61.

The natural convexity or prominence of the instep, is diminished to an extent proportionate to the flattening of the longitudinal and transverse arches. From the yielding and elongation of the deltoid ligament, the *inner malleolus* is more prominent than natural, and also nearer to the ground, owing to the flattening of the arches of the foot as shown in Fig. 63; both these facts are so apparent that it is commonly said of a child with flat-foot, "it walks on the inner ankle." *Two bony prominences*, with a depression between them, are seen a little below and in front of the inner malleolus; one formed by the inner portion of the head of the astragalus, left exposed by the altered position of the navicular bone; and the other by the tuberosity of the navicular bone. The former is most conspicuous in children, who when affected with this deformity, are often said by their parents to have two ankle-bones, or supposed to be double jointed.

FIG. 63.

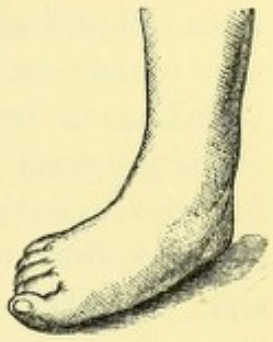

Non-congenital talipes valgus, or flat-foot, slight case in youth.

As a consequence of the sinking-in of the longitudinal arch, the foot is not only generally flattened, but somewhat elongated, and more or less everted; the eversion being most conspicuous when the foot is used in progression. The reason of the loss of elasticity in walking, particularly noticeable in the flat-footed individual, is that during progression the weight is thrown on the inner margin of the foot, which being already depressed and the foot everted, the ankle-joint is called but little into play; therefore flexion and extension of the foot from the ankle-joint are very imperfectly performed.

In a later stage, the external appearance of the deformity is much increased from the additional changes which gradually

supervene, in proportion as the ankle-joint is thrown out of use, when the structural shortening of the muscles of the calf ensues. The muscles slowly adapt themselves to their required length, and then contraction of the tendo Achillis takes place, forming an additional and most important complication, producing elevation of the os calcis, with a corresponding depression of its anterior extremity, together with the head of the astragalus, see Fig. 64.

FIG. 64.

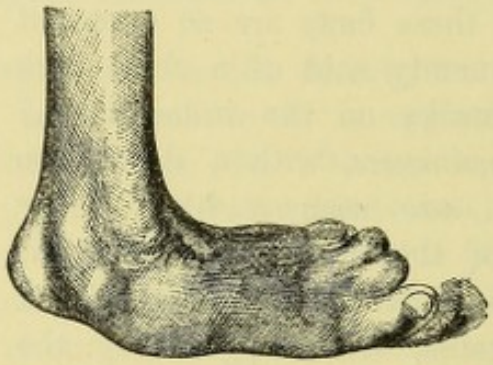

Non-congenital talipes valgus, or flat-foot. Severe case in adult; with contraction of muscles, and arch of foot reversed.

As the anterior part of the foot, in this last stage of the deformity, becomes more everted and forced upwards by long continued progression, it is rigidly held in this position by the contraction or adapted shortening of the anterior and outer muscles. The result is, that the natural arch of the foot is really reversed, the foot being bent upon itself, as it were, from the transverse-tarsal-joint, in a boat or canoe-shaped form. But we only meet with this extreme degree of distortion in very severe cases of long standing.

Special effects of this deformity. Of all the deformities of the foot, talipes valgus is undoubtedly the most painful, and seriously inconvenient. When even of moderate severity, it frequently deprives the sufferer of the power of walking more than a short distance, or of standing for any length of time, and therefore incapacitates him for many of the ordinary duties

and occupations of life. Severe symptoms, although generally, are not necessarily, associated with flat-foot in its early stage; and it is true that we sometimes see this deformity in a rather severe degree unaccompanied by any marked symptoms, and certainly without pain. Boys thus affected are sometimes enabled to take a great deal of exercise, although they walk and run awkwardly, which is alone sufficient to draw attention to the defect.

If, however, patients escape the more serious inconveniences in the early stage of flat-foot, they most certainly suffer at a later period. One such case, under my care at the hospital some time ago, was a man nearly forty years of age, who had a very severe degree of valgus in both feet; he had nevertheless earned his living as a porter for many years, carrying heavy weights, but at last the pain in his feet became so severe and so constant, that he was quite incapacitated from following his occupation, and told me he was driven to the workhouse. His case was one beyond cure, although a long continued treatment in the hospital would have improved his condition. He could not obtain admission, however, and I lost sight of the case. As a general rule, severe symptoms follow this deformity at a much earlier period, and treatment is had recourse to, while the case is capable of being cured.

Congenital valgus more frequently affects one, than both feet, as will be seen by the tables given in the last chapter; but non-congenital valgus more frequently affects both feet, and as it is commonly either produced, or undergoes serious increase, between the ages of 14 and 20, and occurs much more frequently in boys than girls, the effects are consequently more serious.

Morbid Anatomy and Etiology. The morbid anatomy of non-congenital talipes valgus, so much resembles that of the congenital form, as regards the relative position of the bones, and the mechanical condition of the foot, that it is needless to do more than refer to the description of this deformity given in the last chapter. It is, however, especially necessary to recognise the importance of the transverse-tarsal-joint as the

great centre of motion in the production of flat-foot, and to bear in mind the influence of contraction of the tendo Achillis in aggravating the deformity.

But what constitutes the essential difference between the two deformities is, that the non-congenital form, in most cases, primarily and essentially depends upon a yielding of the ligaments which connect the tarsal bones on the plantar aspect, and normally maintain the longitudinal and transverse arches of the foot; whilst in congenital valgus, the yielding of the plantar ligaments is but a secondary phenomenon, its chief characteristic being the turning upwards and outwards of the anterior part of the foot, by the active contraction of the muscles.

Muscular debility generally, but not invariably, exists in the early stage of non-congenital valgus; but the muscular contraction which comes on at a late period, and gives to the foot much of its rigidity in the deformed position—necessitating the division of tendons—is a secondary phenomenon, and depends upon adapted shortening of the muscles.

It would be impossible to give a complete description, at once applicable to all the conditions under which non-congenital valgus occurs. This deformity is seen under a variety of circumstances and depends upon very different causes, so that the anatomical conditions of the muscles, ligaments, and other soft tissues surrounding the joint vary, according to the causes producing the deformity.

I propose, therefore, not to discuss the morbid anatomy and etiology separately, as I have done in describing the other deformities; but, grouping all the cases of non-congenital valgus, according to the causes producing the deformity, to mention the anatomical peculiarities of each class.

Carrying out this arrangement, we shall find that all the cases of non-congenital valgus may be included within six classes, as follow.

1st. Valgus depending upon ligamentous and muscular debility.

2nd. Rachitic valgus.
3rd. Paralytic valgus.
4th. Spasmodic valgus.
5th. Traumatic valgus.
6th. Valgus consequent upon disease of the ankle-joint, or surrounding tissues.

Class 1. *Valgus depending upon ligamentous and muscular debility.* Non-congenital valgus occurs at different periods of life, most frequently in childhood and youth, but it is of uncommon occurrence in adults.

In children. We frequently see the feet of children turn outwards, and the arch become depressed from the superincumbent weight, and a few months later knock-knee becomes developed. This condition, when slight, is generally recoverable without artificial assistance, but in most cases mechanical support to the feet is required; if neglected, however, in the case of a child with feeble constitution, it may lay the foundation of confirmed valgus.

In boys and girls. When growth is rapid, flat-foot frequently becomes developed between the ages of fourteen and eighteen, in those of delicate constitution and lax fibre. In girls, the constitutional causes, above mentioned, more frequently predominate; but in boys, circumstances arising from their occupations, which, in the working classes, frequently compel them to stand from twelve to fourteen hours daily, and in addition oblige them to carry heavy weights, act even more powerfully than the constitutional causes.

Boys incapable of following their ordinary occupations in consequence of this deformity, apply every week at the Orthopædic Hospital for relief; the boys exhibiting, in some instances, no indications of muscular or general debility, but when questioned they are found to have been flat-footed from childhood, and remaining in this condition, have undertaken an occupation such as that of errand-boy, waiter at a coffee house, carrying out goods, &c. From the long standing required in these and other occupations, the feet had become rapidly worse and painful, so that they have been compelled to quit their situations.

This deformity is by no means confined to the working classes, but is frequently met with among school-boys, junior clerks, and cadets; in the latter class the drilling, marching, and carrying of guns, evidently tend to produce the deformity, or more frequently to increase it, when it already exists in a slight degree.

In adults. Flat-foot becomes a persistent deformity in adults, when they have suffered from it early in life, but the deformity being slight, and experiencing no inconvenience such as result from the occupations I have described, no attention has been directed to the condition of the feet. Flat-footed men, however, frequently become disabled, and many policemen are annually discharged from the force in consequence of being incapacitated for the duties by flat-foot; and soldiers are frequently obliged to leave the service from this cause, although great care is generally taken not to enlist them in this condition. Again, waiters at taverns almost proverbially become flat-footed, and dancers frequently exhibit this condition, but suffer less in consequence of their great muscular strength, in some degree compensating for the weakness of the feet.

Class 2. *Rachitic Valgus.* At the time of its production, rachitic valgus is essentially similar to the form just described as depending upon ligamentous and muscular debility, but in consequence of alterations occurring in the form of the bones, becomes of a more severe and intractable nature. It is always associated with rachitic curvature of the long bones, especially with the sharp, flattened, anterior curvature of the tibia and fibula in their lower and middle thirds. Rickets being an affection peculiar to childhood, rachitic valgus can only take place at this period of life, and like the other deformities of rickets, remains as a persistent condition, after the spontaneous cure of the disease, and solidification of the bones.

This is the only variety of non-congenital valgus, in which bones become materially altered in form; and the readiness with which the softened bones mould themselves to the distorted position of the foot, materially adds to the intractable nature of this deformity, as may be seen by examining the adult rachitic skeletons in museums.

Class 3. *Paralytic Valgus.* One of the leading characteristics of that peculiar and obscure form of paralysis, which occurs only in childhood—infantile paralysis—and furnishes so large a proportion of all the non-congenital deformities of the foot, is the frequency with which single muscles and groups of associated muscles, become suddenly paralysed. The anterior tibial is sometimes the only muscle thus paralysed, which explains the fact that in these cases the foot becomes everted, and valgus is produced.

Occasionally, although rarely, the tibialis posticus muscle is paralysed simultaneously with the anterior tibial muscle, and in such cases valgus is more quickly produced, and the deformity is exhibited in a more severe form as shown in Fig. 65.

As matter of experience, it is found that paralytic valgus frequently coexists with paralytic equino-varus of the opposite foot, and this combination existed in the case of Miss M. M. R., (see Appendix, Case VII). In these cases of paralytic valgus, the foot presents a very lifeless appearance, contrasting strongly with the cases of spasmodic valgus, represented in Fig. 66.

FIG. 65.

Paralytic valgus; severe case in adult.

Sometimes the muscles of the calf, as well as the tibialis anticus and posticus muscles are also paralysed, the extensor longus and peronei not being involved in such cases, the tuberosity of the os calcis falls down and calcaneo-valgus is produced, a most intractable deformity.

Class 4. *Spasmodic Valgus.* This form of non-congenital valgus occurs the most rarely, but is occasionally met with in the class of cases which have already been described as "deformities with rigid muscles," an important subdivision of the non-congenital spasmodic and paralytic deformities, generally consequent upon fits or convulsions during teething. I may mention that spasmodic affections generally produce

talipes equinus, or equino-varus, for the reason that all the muscles of the leg being affected, those of the greatest bulk being the strongest muscles gain the ascendancy, just as in the *rigor mortis* the foot always assumes the position of equino-varus. In some spasmodic affections, however, the feet are distorted in the position of talipes valgus as represented in Fig. 66.

FIG. 66.

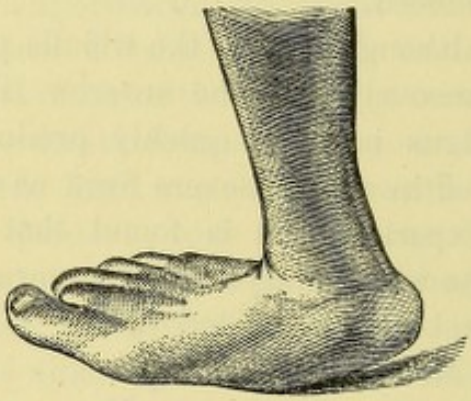

Spasmodic talipes valgus; severe case in adult.

When this deformity is seen in adults, the spasmodic affection having existed from infancy, the distortion of the foot in the position of talipes valgus assumes a degree of severity only met with in this class of cases. All the muscles are tense and rigid, and the foot inflexible; the arch of the foot is completely reversed, so that its convexity is directed downwards, and the outer margin is drawn upwards, by the contraction of the extensor and peronei muscles, the tendons of which are tense and prominent, as represented in Fig. 66. For details of this case, see Appendix, Case IV.

Class 5. *Traumatic Valgus.* Injuries involving the ankle-joint, and the lower extremities of the tibia and fibula, such as fractures of these bones, or fractures and dislocation combined, as in the so-called Pott's fracture, frequently give rise to a persistent eversion of the foot. In one instance I have seen it in its worst form, after unreduced dislocation inwards, with fracture of the fibula.

In these cases, eversion of the foot from the ankle-joint is first produced, a condition which differs from that described as

essential to valgus, in which we recognise the transverse tarsal joint as the principal centre of motion. However, in these traumatic eversions of the foot, the arch gradually gives way in consequence of the weight of the body being thrown upon the inner border of the foot, and a true valgus is produced, in consequence of which, the patient, even some years after the accident, is unable to walk more than a short distance.

Talipes valgus is frequently supposed by the patient, in consequence of the pain suffered, to be produced by a sprain or slight accident, and I have frequently known surgeons, misled by these representations, treat the case as one of injury. The pain suffered by the patients, however, generally referred by them to a particular spot corresponding to the navicular bone where I have sometimes seen blisters applied, really depends upon the stretching of the ligaments during the increase of the deformity, and will certainly be removed by properly applied mechanical support.

Class 6. *Valgus consequent upon disease of the ankle-joint, or surrounding tissues.* Chronic inflammatory affections of the ankle-joint, strumous abscesses in the neighbourhood of the joint, periostitis, caries or necrosis of the fibula, &c., frequently give rise, directly or indirectly, to persistent eversion of the foot, which subsequently becomes flattened in the form of valgus.

Valgus is occasionally seen at the commencement of chronic inflammatory mischief in the neighbourhood of the ankle-joint, and here the diagnostic powers of the surgeon will be required to distinguish between the result of weakness and the commencement of a serious affection, which may terminate in the total destruction of the ankle-joint and necessitate other more serious surgical treatment.

Numerical Importance. Next to talipes equinus, which constitutes nearly half of all the non-congenital cases of talipes, non-congenital valgus is the most frequent deformity of the foot. In the table previously given in Chapter VI, out of 999 cases of non-congenital deformities of the foot, 181 are recorded as cases of talipes valgus, in more than half of which both feet were affected.

Coexistence of Talipes Valgus with other Deformities. When talipes valgus arises from debility, in children and in youth, it frequently coexists with knock-knees, a condition which materially tends to increase the deformity of the foot.

When valgus is produced by rickets, it always coexists with some of the deformities of the long bones, pelvis, cranium, &c., which characterize this morbid condition of the osseous system.

In cases of paralytic origin, when both legs are affected with paralysis, it seldom happens that the deformity is of the same kind in both feet, and it seems pretty constantly to occur, that the left foot is affected with valgus, and the right with equino-varus. It is a singular fact, that paralytic equinus occurs much more frequently in the right than the left foot, more than in the proportion of two to one, and from the same cause, no doubt, paralytic equino-varus predominates in the right foot.

Spasmodic valgus, the rarest form, generally coexists with other spasmodic contractions of the knee and hip-joints.

Prognosis. We need hardly observe that as non-congenital valgus arises from so many causes as to admit of arrangement into six different classes, the prognosis will vary very much according to the cause producing the deformity, the severity of the case, and the age of the patient.

The prognosis will be favourable in all cases arising from *debility*, whatever may be the age of the patient. In these cases, which essentially depend upon relaxation and elongation of the ligaments, the deformity may be completely removed by perseverance in a proper course of treatment.

In *rachitic cases*, the deformity being associated with the general defect in the osseous system, and always with more or less curvature of the long bones, and frequently with knock-knees, the prognosis will be much less favourable.

In *paralytic cases*, in consequence of the paralytic condition of the muscles, the prognosis must necessarily be unfavourable; but in infantile paralysis, this condition always undergoes improvement, and sometimes spontaneous cure, so that the prognosis will vary according to the extent of

the paralysis, the length of time it has existed, and other circumstances of the case; but the prognosis must be very guarded as to the complete recovery of muscular power. The utmost that can be promised is, restoration of the form of the foot, which can easily be accomplished, and some mechanical compensation for the loss of power. This is, however, a great gain to the patient, and often enables him to walk with ease and security.

In *spasmodic cases*, relief and improvement can only be promised, in consequence of all the muscles of the leg being affected, and more or less in a rigid spasmodic condition.

In *traumatic valgus*, and in cases where this deformity is the consequence of disease of the ankle-joint, or neighbouring structures, the prognosis must necessarily be unfavourable; but considerable comfort and relief, with improvement of form in most cases, may be obtained by dividing the tendons, and the use of mechanical support.

TREATMENT. In the different forms of non-congenital valgus now described, the treatment will necessarily vary; but essentially it will consist of the mechanical, operative, and physiological means, either separately or in combination, which have already been described as necessary to the cure of the congenital form of valgus.

The principles, and in most respects the details, of the treatment are essentially similar in both the congenital and non-congenital forms of valgus. It will not be necessary for me, therefore, to do more than advert to the special points of treatment adapted to the different classes in which I have arranged the non-congenital cases of valgus. I have already adverted to the various forms of mechanical apparatus employed in the treatment of congenital valgus, as well as the tendons requiring division, the mode of performing these operations, and the after-treatment required, to promote the physiological perfection of the limb.

Class 1. *Cases depending upon muscular and ligamentous debility*, occur frequently in children, from two to five years of age, and in youth from fourteen to eighteen years of age. In

delicate children of lax fibre, the eversion of the foot may readily be controlled by a peculiar form of boot, called a valgus boot. A convex pad, made of vulcanized india-rubber, is placed inside the boot, in the normal situation of the arch of the foot, which it is intended to support, or remodel. The pad must not be too large, but should extend half way across the sole of the foot, and rise on the inner side, to support the navicular bone.

The heel of the boot should be raised on the inner side about a quarter of an inch, so as to twist the foot inwards, and throw the weight on the outer, rather than the inner side of the foot. This is best accomplished by the addition of a separate piece of leather, which can be renewed as often as it wears out, about once in three or four weeks; it is also advisable to extend the heel further forwards on the inner side, and make its anterior surface oblique instead of transverse. The valgus boot will probably be required to be worn for about two years. No steel supports are required in these cases, nor is there any muscular contraction to call for tenotomy.

In youth, the same treatment may be adopted, provided the case be seen at the commencement of the deformity, and it will generally be found sufficient not only to prevent increase of the deformity, but to restore the form of the foot. Horse exercise should be ordered, and every means taken to improve the health by appropriate tonics, country and sea air, &c., but the walking exercise must be diminished, and frequent rest en orced.

In severe cases, and especially in boys, but previous to the stage of rigid deformity with contraction of muscles, it is necessary to add a steel support attached to the outer side of the boot, and carried up to the calf of the leg, where it is connected with a semicircular steel plate, and a strap which encircles the leg. A free joint should correspond to the ankle-joint, and a leather strap attached to the inner side of the boot, should pass across the ankle-joint, and buckle outside the steel support.

These cases are generally accompanied with a sense of weakness, or aching after exercise, and frequently with pain;

but occasionally there are no symptoms, and attention is only directed to the foot by an awkwardness in the gait. Although the arch of the foot is flattened, the foot can be fully extended, and no muscular contraction exists.

In the most severe cases of this deformity, viz., those in which the arch of the foot is more completely flattened, and extension of the foot cannot be performed to the natural degree, muscular contraction will be found to have taken place. In these cases, the tendons of the extensor longus and peronei muscles, will appear more or less prominent and tense, when the extension of the foot is attempted by manipulation.

Boys engaged in occupations which oblige them to stand fourteen or fifteen hours a day, frequently present themselves at hospitals, and apply for relief when the period of suffering has commenced, and the pain obliges them to leave their occupations.

There are two ways of treating such cases, viz., either by mechanical means alone, or by tenotomy and mechanical means combined. If mechanical treatment alone be decided upon, it will certainly occupy three months or more, during which time the patient must not be allowed to walk except with the aid of crutches. Instead of the ordinary Scarpa's shoe the apparatus represented in Fig. 67 or Fig. 68, may be employed. The simplest apparatus, and that best adapted to the cases in which the rigidity of the muscular and ligamentous contraction is of moderate severity is that represented in Fig. 67. In this apparatus the eversion of the foot is controlled by the side spring (*b*) attached to the Scarpa's shoe, and adapted to the inner side of the leg; the effect of this spring, when the instrument is applied to the leg, is to

FIG. 67.

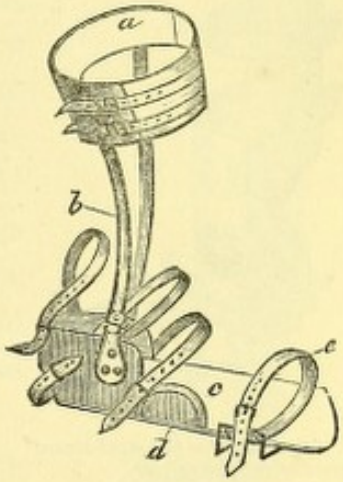

Apparatus for talipes valgus of moderate severity.

a. Circular band round leg. *b*. Steel side-spring, connected with the Scarpa's shoe applied along the inner side of the leg, and having a cog-wheel at its lower part, corresponding to the ankle-joint. *c*. Sole-plate. *d*. Valgus-pad attached to inner side of sole-plate. *e*. Toe-strap attached to rectangular steel bar on inner side of sole-plate.

give the sole-plate (*c*) an oblique direction inwards; and then the valgus pad (*d*) attached to the inner side of the sole-plate, uplifts the arch of the foot. At the same time, the toe-strap (*e*) attached to a rectangular steel bar on the inner side of the sole-plate, has the effect of drawing the foot inwards; so that the whole foot, when in the apparatus, is inverted and arched over the valgus-pad. The contraction of the tendo Achillis, if slight, may be overcome by flexing the Scarpa's shoe from the cog-wheel placed opposite the ankle-joint, and moving in the direction of flexion and extension.

If the tendo Achillis should be found to require division, this apparatus would act just as an ordinary Scarpa's shoe applied to a case of talipes equinus, the single cog-wheel movement being all that is required.

FIG. 68.

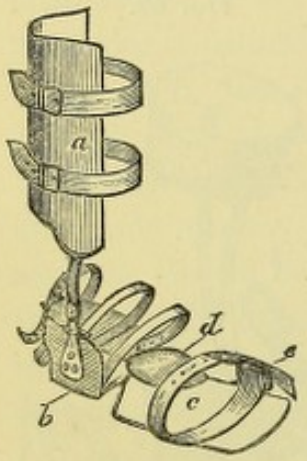

Apparatus for the most severe cases of talipes valgus.

a. Leg-trough. *b*. Heel-piece of shoe with which the leg-trough is connected by a steel bar having a cog-wheel placed opposite the ankle-joint on the outer side of leg. *c*. Movable anterior portion of sole-plate, the margins of which can be elevated or depressed by a cog-wheel placed beneath the centre of the transverse joint in sole-plate. *d*. Valgus-pad attached to inner side of anterior portion of sole-plate. *e*. Toe-strap attached to rectangular steel bar fixed to inner side of sole-plate.

In the more severe cases accompanied with an extreme degree of muscular and ligamentous rigidity, the simple side-spring apparatus last described, will not be found sufficient to control the eversion of the foot, and I therefore prefer the somewhat more complicated apparatus represented in Fig. 68.

In this apparatus, the leg is placed in a trough (*a*), which does not rise so high on the inner as the outer side of the leg, and the trough is connected with the heel piece of the shoe (*b*) by a short vertical steel bar, in which a cog-wheel is placed corresponding to the ankle-joint and on the outer side. This cog-wheel moves only in the direction of flexion and extension, and is intended to control the equinus portion of the deformity, either after division of the tendo Achillis, or when mechanical treatment alone is adopted.

The sole-plate is divided transversely at a part corresponding to the transverse

tarsal joint in the foot, which is the principal mechanical centre of motion from which the valgus portion of the deformity takes place; and the anterior two-thirds of the sole-plate (*c*) is made to move, so that its inner or outer edge, may be uplifted, or depressed, by a cog-wheel placed underneath the centre of the transverse joint in the sole-plate. The valgus-pad (*d*) is attached to the inner side of the movable anterior portion of the sole-plate, and can be uplifted by the cog-wheel at the same time that the outer margin of the foot is depressed, and the anterior portion of the foot drawn inwards by the toe-strap (*e*) attached to a rectangular steel bar on the inner side of the sole-plate.

By this apparatus, I believe we are able to exert the greatest mechanical power over the most severe cases of valgus occasionally met with, and that this power is exerted in directions corresponding with the mechanical and anatomical conditions of the deformity.

In some cases in which it is thought advisable to divide the treatment into two stages, the object of the first stage being simply to overcome the eversion of the foot; and the object of the second stage to overcome the equinus portion of the deformity, we find that the first stage can be accomplished by a very simple form of splint, with a steel spring and valgus-pad represented in Fig. 69.

FIG. 69.

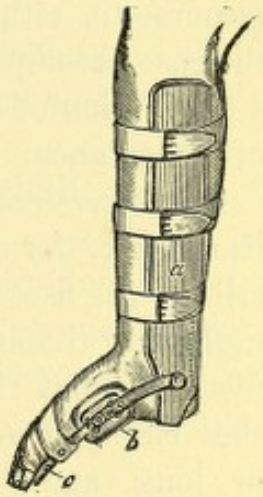

Valgus splint with side-spring and pad attached.

a. Metal spring applied to inner side of leg. *b.* Valgus-pad attached to steel spring connected with metal splint and applied to inner margin of foot, to uplift the arch. *c.* Toe-strap attached to extremity of steel spring.

A straight, metal splint (*a*) arched transversely and softly padded is applied along the inner side of the leg to which it is attached by straps; and close to its lower extremity, a little below the ankle-joint, a curved steel spring is attached to the splint, by a free joint. A valgus-pad (*b*) is connected with the steel spring, and applied to the inner margin of the foot, so as to uplift the arch. Over this pad the foot is drawn

inwards by a toe-strap (*c*) connected with the extremity of the steel spring, and sometimes a bandage may be applied round the foot and spring.

This apparatus may also be applied in some cases in which there is no contraction of the tendo Achillis, and will be found effectual in controlling the eversion of the foot.

The advantage of tenotomy in the severe cases of valgus above described is, that it materially shortens the period of treatment, and I believe without exerting any injurious influence on the muscular power or ultimate strength of the limb. If resort be had to tenotomy, it will be necessary to divide the tendons of the extensor longus and peronei muscles, as in congenital valgus; and the tendo Achillis will also generally require division. I am not, however, an advocate for operative treatment in these cases of non-congenital valgus, occurring in young people during growth, as experience has tended the more to convince me that these cases, even when severe, yield to a well conducted mechanical treatment and that there is no fear of relapse of the deformity. Tenotomy may be had recourse to, either in consequence of the unusual severity of the case accompanied with rigid muscular contraction, or when a diminution of the time occupied by the treatment be an object of importance.

The after-treatment in these cases will consist in the continued use, for about two years, of the valgus boot above described, the use of the Scarpa's shoe being also continued at night, till the arch of the foot has not only been completely restored, but has acquired a fair amount of strength; the employment of frictions, diminished walking exercise, or long standing, and measures to improve the general health.

In adults. I have already described the circumstances under which flat-foot is met with in adults. The deformity may be either slight or severe, and the foot will vary in form from the simple flattening and falling of the arch, to the boat-shaped form previously described, in which the arch of the foot is reversed, the anterior part of the foot being drawn upwards

and outwards, and the heel also raised by contraction of the tendo Achillis. When the deformity is slight, mechanical treatment, consisting of the valgus boot with steel supports, is generally sufficient. But it is at this period of life we meet with the most severe and rigid cases of deformity, old neglected cases, especially in hospital practice. The deformity has probably existed from boyhood, but without producing pain or material inconvenience, which it sometimes although rarely does. Sooner or later, however, pain and inability to follow his usual occupation induces the man to apply for relief.

In these severe forms of valgus met with in adults, tenotomy is indispensable, and several contracted tendons will require division. The treatment must be divided into two stages as above described, and the apparatus represented in Fig. 69 employed in the first stage.

In all the other classes of valgus, the principles of treatment will be essentially similar, but some variations in detail will be required according to the precise conditions of the muscles, ligaments, and other structures involved in the production of the deformity.

Class 2. *In rachitic valgus*, it is seldom necessary to divide any tendons, mechanical support alone affording all the relief of which these cases are susceptible.

Class 3. *In paralytic valgus*, the tendo Achillis frequently requires division when the deformity is of long standing, because the foot cannot be flexed beyond the right angle; but it is seldom necessary to divide the extensor or peronei tendons. Mechanical support will be necessary for some years, and will sometimes be required during the remainder of life in these cases.

Class 4. *In spasmodic valgus*, it may be necessary to divide all the anterior and outer tendons, and also the tendo Achillis, when the deformity is severe, and of long standing. I found it necessary to divide all these tendons in the case of adult talipes valgus with contraction of the knee-joints of spasmodic origin, the details of which are related in the Appendix, Case IV. In this case both feet and knees were similarly contracted, and I

divided in all twenty-two tendons. The deformity was completely removed, and this gentleman remains at the present time without any disposition to a return of the deformity, and is in a much improved condition. He will never again require to use crutches which he had used from childhood, but cannot well dispense with the assistance of two walking sticks, necessary rather for the purpose of aiding his balance in walking, than from any assistance of direct support.

Class 5. *In traumatic valgus, i.e.* after fracture of the lower end of the tibia and fibula, and injuries involving the ankle-joint or surrounding structures, and also in those cases included in the next series, viz.,

Class 6. *Cases consequent upon disease of the ankle-joint or surrounding tissues*, such as scrofulous abscesses connected or not connected with periostial or bone disease, the probability of regaining motion will depend very much upon the condition of the ankle-joint. In these cases, before determining to resort to tenotomy, we must carefully consider the extent to which the joint has been implicated, and its structures destroyed.

An unexpected amount of improvement sometimes will follow division of the tendo Achillis, either by itself or conjointly with the extensor and peronei tendons, in many cases in which the ankle-joint has not been primarily involved, even when motion at the ankle-joint could scarcely be detected, previous to the operation. When the ankle-joint has been primarily diseased, or has been materially involved in the inflammatory mischief resulting either from accident or disease, and a condition of anchylosis has become established, all operative procedures will be counter-indicated, and mechanical support must be relied upon to afford assistance in walking.

After-treatment. In all these classes of cases, the after-treatment will be essentially the same as previously described, varying, however, according to the circumstances in individual cases. Mechanical support, special exercises, manipulations and frictions, must be continued; whilst in some cases of paralysis, especially in infantile paralysis, when indications of

spontaneous improvement exist, galvanism should be applied. Careful attention to these means will effectually secure the patient against relapse of the deformity.

I have now concluded a general account of the pathology and treatment of both the congenital and non-congenital forms of valgus. It remains only to say a few words on the compound varieties of talipes, in which a disposition towards valgus constitutes a prominent feature. These compound varieties pass under the name of

TALIPES EQUINO-VALGUS; AND TALIPES CALCANEO-VALGUS.

Talipes equino-valgus is characterized by elevation, and *calcaneo-valgus* by depression of the os calcis, coexisting with eversion of the anterior portion of the foot. In *equino-valgus* eversion of the anterior part of the foot—the valgus portion of the deformity—is the predominant condition; but in *calcaneo valgus* depression of the os calcis—the calcaneus portion of the deformity—is the predominant condition. Hence, when describing in detail the external characters and morbid anatomy of the simple form of talipes, viz., valgus, and calcaneus, of which these compound varieties are but slight modifications, I have thought it desirable to make the few observations called for, in the description of these compound varieties.

In describing both the congenital and non-congenital forms of valgus, the influence of contraction of the tendo Achillis in modifying the external characters of valgus, and in materially adding to the complexity of this deformity as to its mechanical conditions, by altering the relative position of the bones, in severe cases, has been especially adverted to.

In consequence of the frequency of contraction of the tendo Achillis in both the congenital, and non-congenital forms of valgus, it would seem advisable in the nomenclature of deformities of the foot, either to do away with equino-valgus as a separate variety, or materially to add to its importance by

classifying under this term a large number of cases hitherto described as simple valgus. I am inclined to adopt the former course, and therefore generally speak of cases of talipes valgus, as existing with, or without contraction of the tendo Achillis.

CHAPTER XX.

CONGENITAL AND NON-CONGENITAL TALIPES CALCANEUS; CALCANEO-VARUS; AND CALCANEO-VALGUS. PATHOLOGY AND TREATMENT.

TALIPES CALCANEUS occurs both as a congenital and non-congenital affection, and in these two forms it differs so essentially in its pathology and treatment, that a separate description of the congenital, and non-congenital forms of talipes calcaneus, is absolutely necessary.

EXTERNAL CHARACTERS. The depression of the os calcis is the only essential character of talipes calcaneus, whether congenital as shown in Fig. 70 or non-congenital, as represented in Figs. 72 and 73, so that in the erect position, and in walking, the heel is the portion of the foot which first comes into contact with the ground. In congenital cases this is always associated with elevation of the anterior portion of the foot, which is also generally a little everted and flexed upon the leg, so that the dorsal aspect is towards the anterior surface of the leg; in severe cases, the foot is rigidly held in this position by contraction of all the anterior muscles. The position of the foot is in fact nothing more than an extreme degree of flexion from the ankle-joint, as shown in Fig. 70, a position which any healthy foot can be made to assume, more especially in infants, and therefore not involving any alteration in the relative position of the bones; but the peculiarity in congenital cases, is that the foot is fixed in this position, with more or less rigidity by muscular contraction. As far, therefore, as the external

form is concerned, the deformity is precisely the reverse of talipes equinus, which consists of an elevation of the os calcis, with depression of the anterior portion of the foot—an extreme degree of extension of the foot.

FIG. 70.

Congenital talipes calcaneus.

Depression of the heel, with elevation of the anterior portion of the foot; simple flexion at the ankle-joint. The foot is usually everted, rather than inverted, as represented in this case.

MORBID ANATOMY. In congenital talipes calcaneus the deviations are not material, either in the relative position or form of the bones of the foot. The deformity is of the simplest kind, the position of the foot being merely an exaggerated degree of one of the natural movements, viz.: that of flexion of the anterior part of the foot upon the leg, a movement necessarily accompanied with depression of the os calcis. The ankle-joint is the centre of motion, and it is scarcely necessary to observe, that it is alone from this articulation that the movements of flexion and extension of the foot can take place.

In congenital cases, the foot is not as a rule very rigidly held in this flexed or calcaneus position, and by a little manipulation it can be brought down, or extended, to a right angle with the leg. The natural degree of extension can generally be obtained in a few months, by perseverance in manipulation and passive motion. This fact is sufficient to prove that in such cases, neither the muscles nor ligaments have undergone that change of structural shortening, or adapted growth, which produces the rigidity in other congenital deformities, and which constitutes the obstacle to the restoration of the form of the foot—an obstacle which can only be overcome, either by operative, or mechanical treatment.

In some of the most severe cases of congenital calcaneus of rare occurrence, in which the foot is rigidly held in the deformed position, there can be no doubt that the ligaments at the posterior part of the ankle-joint, and the posterior portions of the lateral ligaments, are elongated, as I have found them on dissection in a case of non-congenital calcaneus of long standing;

although from the nutrition of the tissues not being interfered with in congenital cases, it is not probable that this change would take place to the same extent.

In these severe cases, also, the anterior muscles of the leg—the flexors of the foot—doubtless undergo structural shortening, and their tendons are easily to be felt tense and prominent, as they pass over the ankle-joint.

PATHOLOGY. The origin of congenital talipes calcaneus, as well as its mode of production, are not yet clearly understood. I have before adverted to the arguments for and against the different theories at present entertained, with respect to the etiology and mode of production of all the congenital deformities of the foot, and expressed my opinion generally in favour of the dynamic theory, *i. e.*, spasmodic muscular action, rather than the mechanical theory of *position in utero.*

The dynamic theory I held more especially in reference to the ordinary form of congenital club-foot, viz.: talipes varus, but some doubt was expressed with respect to its application to congenital talipes calcaneus, and calcaneo-valgus, deformities which may probably be sometimes produced by *malposition of the fœtus, and pressure in utero.*

Moreover, in addition to the arguments already stated which may favour such an opinion, we must be impressed with the fact that whilst in congenital varus, the direction in which the bones are displaced exactly corresponds with the direction in which they would be drawn by the action of the strongest muscles; the reverse is the case in congenital calcaneus, and in this deformity, if the dynamic theory be maintained, the weaker muscles on the anterior aspect of the leg, must be supposed to overcome the stronger muscles of the calf and posterior tibial region.

Position and pressure *in utero* may probably give rise to slight cases of calcaneus, with very little muscular rigidity; but the severe cases, associated with other contractions, as of the rectus muscle, when the legs are rigidly maintained in the extended position as shown in Fig. 71, are probably of dynamic origin, and depend upon some abnormal condition of the nervous system.

I have sometimes thought, that in these cases, as in varus, the nervous affection may be only of a temporary character; and that the deformity once produced, may be subsequently maintained, and aggravated, by growth of the muscles and bones in the deformed position, the fœtal movements being inadequate to the restoration of the contracted limbs to their natural position. This supposition would remove the difficulty that, whilst there are strong reasons for believing in the dynamic theory of the production of these deformities, there is certainly no evidence of the existence of any abnormal condition of the nervous system at the period of birth.

Complications of congenital talipes calcaneus. Cases of congenital talipes calcaneus sometimes occur, associated with a *rigidity of the knee-joints in the extended position;* and the legs in their extended and stiff condition are flexed upon the body from the hip-joints, so that the feet are thrown over the shoulders. These cases are always breech-presentations, and in alluding to them, Mr. Lonsdale observes, "I have seen four cases of congenital calcaneus, where it could be distinctly traced to position *in utero*, they being breech-presentations with the legs extended upwards, the feet being doubled upwards and pressed against

FIG. 71.

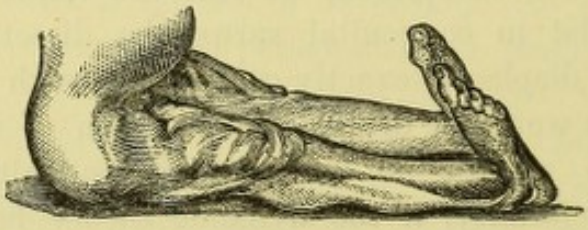

Congenital talipes calcaneus, associated with rigid contraction of both keees in the extended position, and legs rigidly flexed on body from hip-joints. Cases of breech presentation.

the tibia in front. A curious point in these cases is, that there is always a difficulty in flexing the knees, although there is a degree of motion in the joints. The patella is obscurely felt but I believe it always exists; the muscles on the anterior part of the ankle-joint are always more or less contracted, and sometimes to an extent to require division."*

* *Lancet*, September 4, 1855.

I assisted Mr. Lonsdale to make a post-mortem examination of one of these cases. The mother of the child had had three children born with the same deformity. The rectus muscle was found to be shortened, and the patella of very small size drawn up above the knee-joint, so that it could be distinguished with difficulty by external examination. The ligamentous structures of the knee-joint, anteriorly and laterally, were so much shortened, and adapted to the extended position of the joint, as to prevent flexion, even after division of the tendon of the rectus muscle. Two of these children died, but the surviving child gained a useful amount of flexion of the knee-joints by long continued passive exercise, and its own efforts in walking. This complication is a very serious one, but happily of rare occurrence. Division of the rectus tendon would doubtless facilitate the cure. It is uncertain whether contraction of the rectus muscle at an early period of uterine life produces the deformity, or whether position *in utero* is the cause; although, looking at the series of contractions in these cases, involving both feet, both knees, and both hips, the probability is in favour of the deformity being produced by spasmodic muscular action.

Numerical Importance. Talipes calcaneus is the rarest form of congenital club-foot. Of the 764 cases of congenital club-foot tabulated in Chapter XII, only nineteen were cases of talipes calcaneus, and were distributed as follows:—

Affecting the right foot only . .	3
„ the left foot only . .	4
„ both feet . . .	12

Both feet are much more frequently affected in cases of this deformity, than one foot, a condition which also obtains in congenital varus, but in a less proportion.

Prognosis. Of all the deformities of the feet, whether congenital or non-congenital, there is none in which a favourable prognosis may more confidently be given than in congenital talipes calcaneus. This form of club-foot, when congenital, is never seen except in infancy or early childhood; nor do I find

any Orthopædic authority who has witnessed it as a persistent condition, at a later period of life.

Mr. Tamplin observes, "I have never yet met with this deformity in the adult." The explanation of this fact seems to be, that the deformity, which is very rarely accompanied with rigid contraction of the muscles or ligaments, undergoes spontaneous cure, soon after the period of walking; if indeed, it be not previously removed by manipulation and simple mechanical means.

The strong muscles of the calf of the leg, together with the other powerful muscles on the posterior aspect of the leg, which act as extensors of the foot, are all in a healthy condition, and by their action tend to overcome the slight contraction of the flexors. If the balance of muscular power be not restored in this manner before the period of walking, the weight of the body still further assists the action of the extensor muscles, by pressing up the heel, and keeping the foot at a right angle with the leg.

When contrasted with talipes varus, the favourable action of the weight of the body, in restoring the natural position of the foot in congenital talipes calcaneus, is worthy of attention. In the former case, talipes varus, the weight of the body increases the deformity to an extreme degree.

Such being the ordinary and natural course of a case of congenital talipes calcaneus, although the prognosis must be proportionably favourable, yet some of the more severe forms of calcaneus would probably remain persistent unless recourse were had to tenotomy and appropriate mechanical treatment.

TREATMENT. In ordinary cases of congenital talipes calcaneus, but little treatment is required. Frequent manipulations and passive exercises, such as extending the foot, and rubbing over the anterior muscles of the leg, will be all that is necessary in ordinary cases. With this should be combined the use of a softly padded splint, applied in front of the leg and foot. A splint made of block-tin, which can be gradually straightened as the foot improves, is the best that can be employed.

In exceptional cases of greater severity, where the anterior muscles are much contracted, and the tendons tense and prominent over the ankle-joint, recourse should be had to tenotomy as a means of hastening the cure, and rendering it more certain and more perfect at an early period of life; a principle which we must recognise in the treatment of all congenital deformities, with a view to the ultimate perfection of the limb, and development of the muscular structures.

The tendons which require to be divided in the severe, and exceptional cases above mentioned, are the tibialis anticus, extensor proprius pollicis, extensor longus digitorum, and peroneus tertius. The division of all these tendons may be easily effected, by means of a simple puncture close to the inner border of the extensor longus digitorum tendons, where they pass over the ankle-joint, and will be felt tense and prominent. The smallest sharp-pointed tenotomy knife may be passed first outwards beneath the extensor and peroneus tertius tendons which should be divided towards the skin, as we divide all tendons; and then being withdrawn and reintroduced, the knife may be passed inwards beneath the extensor pollicis and anterior tibial tendons, which should be divided in the same way. If sufficient care be taken to keep the point of the knife close to the tendons to be divided, there will be no fear of wounding the anterior tibial artery. A small pledgit of lint to be immediately applied and retained in position by a strip of plaster, and the foot bandaged to a bent tin splint in front of the ankle-joint.

Mechanical Treatment. A well padded metal splint, which after the third day may be gradually straightened, till the complete extension of the foot be obtained, is the only mechanical treatment generally required. The extension should be at first very slowly conducted, and not be completed in less than three weeks, in order to insure the formation of a direct and well-formed connecting bond of new material, between the divided extremities of the tendons.

After-treatment. The continued use of manipulations and passive motion, on which much reliance is placed during

the treatment of this deformity, will be the only after-treatment required. It will rarely be necessary to employ any mechanical support or retentive apparatus; but in some cases, after operation, a light steel support may be attached to the boot used in walking.

After the treatment of congenital talipes calcaneus there is no tendency to relapse. The causes which tend to produce relapse in other distortions of the foot are all absent; such as the complicated anatomical conditions of the deformity; the difficulty of insuring the accurate adjustment and efficiency of the retentive apparatus or mechanical supports, generally required to be worn a long time after the first treatment; and lastly the defective condition of certain muscles. It has been already explained that the act of walking itself assists the cure of the case, and I have never in any instance seen even a partial return of the deformity.

NON-CONGENITAL TALIPES CALCANEUS.

We will now proceed to the pathology and treatment of the non-congenital form of talipes calcaneus, in which, for reasons previously given, we will include a description of the compound varieties generally described as calcaneo-varus, and calcaneo-valgus.

There is an essential difference between the congenital and non-congenital form of this distortion. In non-congenital calcaneus, the anatomical conditions are more complicated; in the great majority of cases, this affection is of paralytic origin, therefore the prognosis is essentially unfavourable, and the treatment only palliative, although the foot may be improved in form and usefulness. Altogether, the non-congenital cases of calcaneus are as unsatisfactory in their results, as the congenital cases are satisfactory.

External Characters. Assuming the case to be one of the ordinary kind, *i. e.* depending either upon paralysis of the muscles of the calf alone, or upon more extensive paralysis of the muscles of the leg, the external characters are

1st. Depression of the tuberosity of the os calcis, which, in a severe case, and the patient in the erect position, is the part of the foot which first comes in contact with the ground, as exhibited in Fig. 72, taken from a young woman who was under the care of my late colleague, Mr. Lonsdale; both feet were similarly affected, so that she walked entirely upon her

FIG. 72.

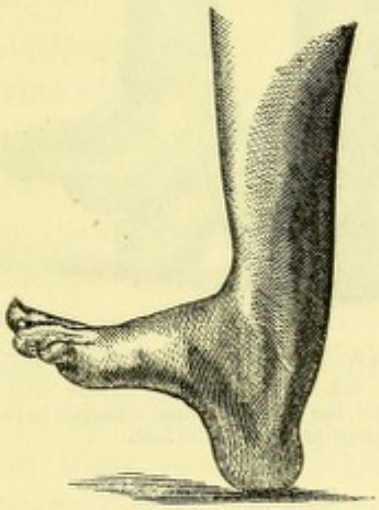

Non-congenital talipes calcaneus in the adult.

Depression of os calcis, with elevation of anterior portion of the foot which is somewhat everted, and at the same time the foot is flexed upon itself at the transverse tarsal joint.

heels; or rather the heels came first to the ground in progression as shown in Fig. 73, and then the front part of the foot was brought to the ground giving her a very peculiar appearance in walking.

2nd. The anterior portion of the foot is slightly raised, and more or less everted in an early stage; and not, as in cases of congenital calcaneus flexed and drawn upwards, so as to approach the anterior surface of the leg. At a later period, the anterior portion of the foot falls down from the transverse tarsal joint, so that the foot presents the appearance of being bent upon itself in the direction of its length, and the sole of the foot becomes deeply arched as shown in Figs. 72 and 73.

The leg is always much wasted in these cases, in consequence

of the long standing paralysis, of which the deformity is the result. The tendo Achillis instead of being tense and pro-

FIG. 73.

Non-congenital talipes calcaneus in the adult, affecting both feet.

From the same case as Fig. 72, taken from a young woman who walked pretty well without mechanical supports. In progression the heel was first brought to the ground, and the weight was then thrown partially on the anterior portion of the foot.

minent, as it generally is in other distortions of the foot, can in this deformity be scarcely felt; it may, however, be recognised as a thin flat band closely in contact with the posterior surface of the ankle-joint, and this gives a peculiarity in the outline of the leg at its posterior surface, well exhibited in Fig. 72.

MORBID ANATOMY. The bones in non-congenital calcaneus deviate considerably in position, but are altered very slightly in form. In a severe case the os calcis becomes quite vertical in its position, and the astragalus very oblique; so much so indeed, that the greater part of the trochlea of the astragalus is extruded from the ankle-joint and projects posteriorly; a condition which I have witnessed on dissection in one of these cases. As a necessary consequence of this obliquity of the astragalus, the articular surface of the tibia rests partly on the anterior portion of the trochlea, and partly upon the neck of the astragalus.

Another deviation of some importance takes place in the

relative position of the bones, consequent upon the foot becoming bent upon itself from the transverse tarsal joint, which in this deformity becomes almost as important a centre of motion as the ankle-joint. The anterior portion of the foot, including all the bones in front of the transverse-tarsal-joint, is, in a severe case, depressed or bent downwards, so as to approximate more or less towards the os calcis in its vertical position, and produce an abruptly arched, and shortened condition of the foot.

Ligaments. I have found, on dissection, the deviations in the relative position of the bones, necessarily give rise to equally important changes in the ligaments connected with the ankle and transverse-tarsal joints. The ligamentous structures at the posterior part of the ankle-joint, and the posterior portions of the lateral ligaments, become much elongated and attenuated, this condition being in some degree dependent upon the defective state of the nutrition of the limb. The ligamentous structures in front of the ankle-joint become shortened by a process of adaptation during growth, and largely contribute to the persistence of the distortion when the deformity has been of some years duration.

There is also a shortening of all the deep ligaments in the plantar aspect of the foot, and the interosseous bands of ligament, in adaptation to the abrupt flexion of the foot from the transverse tarsal joint, above described. These ligaments and ligamentous bands are thick and strong, and offer the greatest resistance to the restoration of the form of the foot.

The Plantar Fascia will be found to be shortened in this deformity, or at least contracted to an extent corresponding to the general shortening of the foot, produced by the os calcis assuming a vertical, instead of a horizontal position, and by the anterior portion of the foot becoming depressed or bent downwards from the transverse tarsal joint.

Muscles. According to the causes producing the deformity in cases of non-congenital talipes calcaneus, the condition of the muscles will be found to vary. When this distortion arises from paralysis, which it most frequently does, the muscles of the leg and foot are found to be wasted, and in a state

of atrophy. The calf of the leg becomes extremely attenuated, in consequence of the complete and persistent paralytic condition of the gastrocnemius and soleus muscles.

In cases of long standing, the muscles of the calf, and sometimes all the muscles of the leg, are found to be in the most advanced stage of fatty degeneration; the muscular structure being completely destroyed and replaced by fatty tissue, free oil globules, and fibrous tissue, in proportions varying in different muscles. This condition existed in a case in which the leg was amputated by Sir William Fergusson, and I carefully examined all the muscles microscopically. The completely paralytic and useless condition of the foot, which had also suffered much from exposure to cold, and was a constant source of trouble and inconvenience, induced this patient to request amputation.

Vessels and Nerves. In the vessels and nerves, there are no deviations in direction of any surgical importance, as in the more complicated distortion of varus; but in adult cases these structures may be diminished in size and atrophied, as Cruveilhier has described them in a case of adult non-congenital paralytic varus, although this condition did not appear to exist in the specimen I dissected.

Resemblance of non-congenital talipes calcaneus to the distortion of the foot artificially produced amongst the Chinese.

In the Museum of the Royal College of Surgeons, there is a series of eleven preparations,* made from four Chinese ladies feet, illustrating the anatomical peculiarities of this remarkable form of distortion, produced by artificial means, either tight bandaging or some compressing force being applied in early life, and continued for a considerable time during growth. I am not aware of the precise nature of the process adopted.

These preparations are preserved in spirit, and in some sections the altered relations of the bones and articulations are

* Nos. 884[a] to 984[k] Descriptive Catalogue of the Pathological Specimens, Supplement, Vol. I. in which a detailed account of the dissections is given.

displayed. Figs. 74 and 75 represent the inner and outer

FIG. 74.

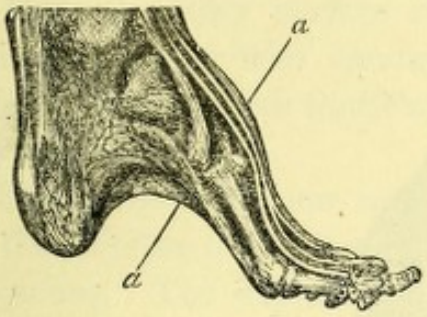

FIG. 75.

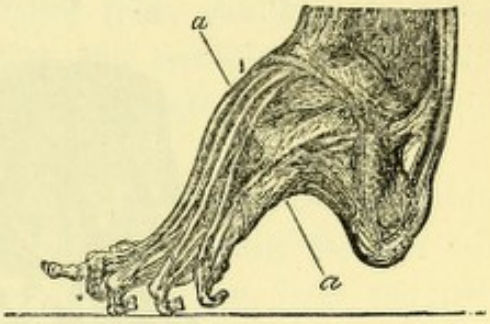

Two drawings from a dissected Chinese Lady's foot, in Museum of College of Surgeons, No. 884 c.

aspects of one of these feet, No. 884*c*, and the general characters of the distortion will be seen to approach in many respects to those described, as existing in the severe adult cases of non-congenital talipes calcaneus of paralytic origin. The tuberosity of the os calcis has been so far depressed, that it points directly downwards, and the body of this bone has a vertical direction, corresponding to the axis of the leg. In Fig. 75 the tendo Achillis is seen lying flatly against the posterior aspect of the ankle-joint, and then continued directly downwards to the tuberosity of the os calcis.

The anterior portion of the foot is bent downwards from the transverse tarsal joint, so that the foot is folded upon itself the direction of its length, the ankle-joint and the transverse-tarsal joint being the two principal centres of motion. The phalanges of the four outer toes are bent inwards in a claw-like manner, and turned laterally towards the median line of the sole of the foot; and the corresponding metatarsal bones are compressed laterally. The phalanges of the great toe alone remain extended, and give a pointed form to the compressed and distorted foot. This is well exhibited in Fig. 74, and also in Fig. 76, taken from the cast of a Chinese lady's foot in the Museum of University College, No. 4599. There is also in this Museum the left foot and part of the leg of a Chinese lady, preserved in a dried condition with the skin remaining on.

Dr. Little has also given in his work "on Deformities," page 168, a drawing of the bones of the foot of a Chinese lady. Dr.

FIG. 76.

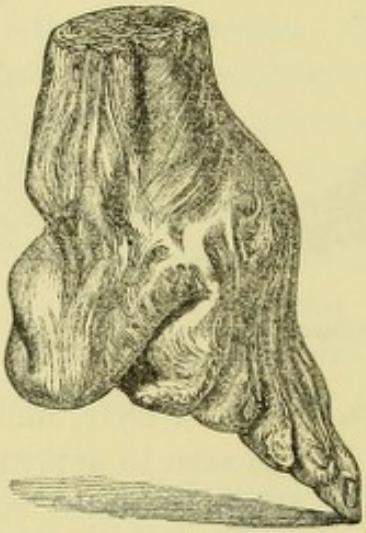

Drawing from a cast of a Chinese lady's foot in the Museum of University College, No. 4599.

Little's drawing, however, differs in one important respect from all the other specimens referred to, viz., in representing the tuberosity of the os calcis on the same level with the toes, whilst the leg is in the erect position; whereas in the drawings above given, and in all the specimens I have examined, the tuberosity of the os calcis is so much above the level of the toes, that it would be necessary for the individual to wear a boot with the heel raised from one to two inches, and I believe the boots worn by these ladies always have the heel raised to this extent.

The small model boots of Chinese manufacture, existing in several museums—one in the College of Surgeons and one in St. Thomas',—all exhibit the raised heel, and the internal surface sloping downwards from the heel to the toe. As these, however, might not be trustworthy, I endeavoured to obtain an examination of the foot of the Chinese lady, the wife of the Chinese giant Chang, exhibiting in London in the year 1866, but failed in doing so from the determination of the giant and his lady to "have nothing to do with the doctors." She, however, ex-

hibited her feet to the public, concealing the instep and ankle by a tightly fitting trouser. The boot, also exhibited, measured four inches and a half in length, and the heel was raised an inch, the inner surface sloping from the heel to the toe. The gentleman who conducted the exhibition, Mr. G. A. Cooper, informed me that the boot exhibited was similar to the one she wore.

This point is of some interest, in reference to the resemblance of the Chinese distortion, to the non-congenital form of talipes calcaneus. The explanation of the Chinese lady requiring a raised heel appears to be, that as the foot is bent upon itself, principally from the ankle, and the transverse tarsal joints, the anterior portion of the foot must necessarily be much longer than the posterior portion; and being bent downwards at a much sharper angle than ever occurs in the ordinary form of talipes calcaneus, the toes are depressed much below the level of the heel, so that although the os calcis is similarly depressed, it is still necessary in the Chinese deformity for the individual to wear a high-heeled boot. Whereas in non-congenital talipes calcaneus, the tuberosity of the os calcis is so much below the level of the toes and the anterior part of the foot, that it always comes first in contact with the ground, although in progression it is quickly followed by the anterior part of the foot, so that really the heels and the toes rest simultaneously on the level surface of the ground, the foot retaining its arched form.

Dr. Little expresses a confident opinion that the condition exhibited in the Chinese deformity might be remedied in a few weeks, even after thirty or forty years duration; but I should hesitate to concur in this opinion, believing that from the early period at which the bandaging process is commenced, several of the tarsal bones, more especially the astragalus, become much distorted and irremediably altered in form at the period when ossification is complete.

Moreover, I believe that the general adaptation of all the ligaments of the foot and of the tibio-tarsal articulation, would present an insurmountable obstacle to the restoration of the

form of the foot in this severe grade of distortion, at least at the adult period of life. If the distortion, however, could be removed, the absence of paralysis, upon which Dr. Little appears to base the opinion above expressed, would largely contribute to the cure of the case; whereas, in non-congenital calcaneus of paralytic origin, the paralysis of course remains, after the removal of the distortion, and a cure of the case cannot possibly be effected.

I have alluded to the anatomical resemblance between this artificially produced form of talipes calcaneus, and the ordinary non-congenital form of this distortion, as a matter of scientific interest, although without any practical bearing or importance.

PATHOLOGY. *Etiology and mode of production.* Infantile paralysis, occurring during the first dentition, from six to eighteen months, is generally the cause of non-congenital talipes calcaneus. The muscles of the calf are completely paralysed, and sometimes also the muscles of the leg below knee. In the latter case, however, recovery, to a certain degree, of the anterior muscles usually occurs.

Non-congenital talipes calcaneus may also result from the imperfect union of the tendo Achillis; or from union by means of an excessive length of new connecting material, imperfectly formed, either after accidental rupture of this tendon, or after its division, for the cure of the opposite deformity, viz.: talipes equinus.

The causes of this imperfect union are,

1st. Some constitutional defect in the reparative powers of the patient.

2nd. Injudicious after-treatment, *i.e.*, not sustaining the temperature of the limb, especially in paralytic cases during very cold weather; too early and too rapid mechanical extension, restoring the form of the foot before there is any evidence of the reparative material being thrown out; the mechanical treatment being altogether ignored, and the patient allowed to walk two or three days after the operation, the surgeon relying upon the unassisted powers of nature in walking, to

restore the form and functions of the foot; or, discontinuing the mechanical treatment too early, and bringing the foot too quickly into use, by which the uniting medium may be elongated and weakened.

3rd. The contraction of a burn-cicatrix on the leg, and dorsum of the foot has been known to be a cause of this deformity.

The peculiarities of talipes calcaneus, when arising from infantile paralysis—cases included in the first series—have been already described in the account given of the paralytic affections of this class of deformities, see Chapter V. In reference to those cases which spring from an imperfect union of the tendo Achillis—cases included in the second series—and which may result either from some constitutional defect or injudicious after-treatment, I have never seen a case of imperfect union of the tendo Achillis from the first cause, viz.: constitutional defect in the reparative powers of the patient. A case of this kind in which talipes calcaneus did result, is recorded by Dr. Little.* The contraction occurred in a young girl, and was the result of inflammation, not of paralysis. "Six weeks afterwards (*i.e.*, the operation), notwithstanding the heel had been carefully kept elevated, the foot was flexible and straight. . . . . She trod exclusively on the heel, and the anterior muscles of the ankle elevated the front part of the foot from the ground. . . . . The divided extremities of the tendo Achillis, still somewhat swollen, were seen, and felt nearly two inches asunder." I shall advert to the treatment successfully adopted in this case, which is worthy of imitation.

We occasionally meet with cases of talipes calcaneus which spring from an imperfect union of the tendo Achillis, produced by injudicious after-treatment, either after accidental rupture, or division of the tendo Achillis, and depending upon some of the above-mentioned causes. This result is one against which surgeons should especially guard, and

* "On Deformities," page 166.

chiefly where paralytic cases of talipes equinus are submitted to operation.

Dr. Little accurately observes "that the condition of a severed tendon approaches that of a fractured bone; too great separation of the severed ends, depression of temperature sufficient to suspend active arterial circulation, too early movement of the parts, and inherent vice of constitution, will cause tendon and bone to remain ununited, to the great detriment of the sufferer.*

In illustration of this, Dr. Little points out the slowness with which wounds cicatrise in a cold climate, and states that he has witnessed a puncture resulting from subcutaneous tenotomy bleed like a fresh puncture ten days after operation, during the rigors of a severe Berlin winter. I have not witnessed any example of non-union of the tendo Achillis from this cause; but at the Orthopædic Hospital we take especial pains to maintain the temperature of the limb after tenotomy, in paralytic cases, by rolling the limb in flannel bandages.

Numerical Importance. In the table before given of 999 cases of non-congenital deformities of the feet, 110 cases of non-congenital talipes calcaneus, and calcaneo-valgus together are recorded.

Affecting the right foot	. .	35
„ the left foot	. . .	39
„ both feet	. . .	22

And fourteen other cases coexisting with other deformities, and paralytic affections. In the above table, only one foot is affected in 74 out of 110 cases, which additionally confirms the general view that infantile paralysis, the chief cause of this deformity, generally affects only one side of the body.

Coexistence with other Deformities. Three cases of talipes calcaneus are given in the table referred to, as coexisting with equino-varus of the opposite extremity; four with equinus, and two with valgus of the opposite foot; five

* *Op. cit.*, page 168.

cases are also stated as coexisting with paralysis, I presume paralysis of the opposite leg is meant, and without deformity.

PROGNOSIS. As non-congenital talipes calcaneus is usually the result of infantile paralysis, especially affecting the muscles of the calf, and sometimes, the other muscles of the leg; and as the paralysis is generally persistent in its character, the prognosis must be unfavourable. But although there can be no hope of curing the paralysis, the foot may be improved in form, and rendered more useful.

In some cases dependent upon other causes than paralysis, as above described, the prognosis may be more favourable; but these exceptional cases will be at once recognised by the surgeon, and therefore it is unnecessary further to allude to the conditions which may be presented.

TREATMENT. It is obvious that in consequence of the existing paralysis, the most we can attempt with any prospect of success in these cases, is a palliative treatment. The foot may be improved in form by mechanical means, but tenotomy can be seldom, if ever required; and the period at which much good may be done by mechanical treatment is limited to the early stage, when the deformity may certainly be prevented, assuming the degree of severity exhibited in Figs. 72 and 73.

Strange as it may appear, this affection is nearly always overlooked in the early stage. A weakness of the limb only is recognised, but the depression of the tuberosity of the os calcis, and the incipient talipes calcaneus is seldom detected.

In the early stage, increase of the deformity may be prevented by the patient wearing a high-heeled boot in the day time, with a slight steel support on each side, furnished with what is known by the instrument maker as a "stop-joint" at the ankle, *i.e.*, a joint which will not allow of flexion of the foot; and the foot should be kept flat in a slipper with a metal sole-plate at night.

In a later stage, when deformity has taken place, but not in a severe degree, the form of the foot may be restored by a

Scarpa's shoe, represented in Fig. 20, with a transverse joint in the sole-plate regulated by a rack and pinion movement. The same kind of walking boot, but always with a stop-joint, may be used. I have more recently made use of the walking boot represented in Fig. 77; two lateral side steels are carried up the leg to a steel band round the calf, and free joints used at the ankle; but the elevation of the heel, and depression of the anterior part of the foot, is regulated by an elastic india rubber cord, placed behind the leg so as to imitate the tendo Achillis, and fastened by means of a leather strap to the heel below, and to the steel calf plate above. This contrivance will, I think, be found preferable to the ordinary stop-joint apparatus.

FIG. 77.

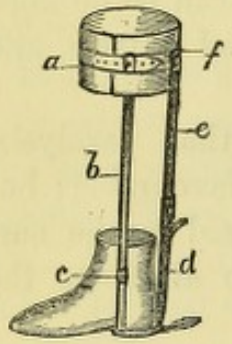

Boot used in cases of talipes calcaneus.

Boot with a steel support on either side of the leg, *b*; and free joint at ankle, *c*. An elastic india-rubber cord, *e*, passes along the posterior aspect of the leg, connected above with the calf plate, *f*, and below with the boot close to the heel, *d*, representing the tendo Achillis.

When the depression of the os calcis and contraction of the arch of the foot are well marked, the general adaptation of the ligamentous and muscular structures, to the deformed position of the foot, frequently gives to it a degree of firmness very useful to the patient, and this was the case in the young woman from whom Figs. 72 and 73 were taken. Both feet were similarly distorted, but she walked much better than might be expected. There can be no doubt that by tenotomy, and long continued mechanical treatment, the form of the feet in this case might have been improved; but from the paralysis, they would have been swinging or dangling feet, and therefore have required mechanical support which was not at the time necessary. Whether the condition of the patient, therefore, would, so far as usefulness of the feet was concerned, have been improved, is very doubtful.

In the treatment of these cases, a few experimental operations have been attempted with the view of shortening the tendo Achillis, and producing a contraction of the skin above and behind the os calcis. Dr. Little removed a portion of the tendo

Achillis, together with some of the skin above the os calcis, in two cases, but with very little benefit.

There is one class of cases, however, in which operative interference may perhaps be found useful, but further experience is required; I allude to cases of talipes calcaneus, produced by non-union of a divided tendo Achillis, or by union through an imperfectly formed and attenuated uniting medium. In a case of this kind, Dr. Little introduced a tenotomy knife, and freely incised the previously divided extremities of the tendo Achillis lacerating the imperfectly formed uniting medium. The foot was then retained in an extended position, so as to approximate the ends of the tendon, and at the end of a fortnight "abundant effusion of plastic material and adhesion of tendon had taken place."* Shortening of the tendo Achillis is said to have resulted from this operation, which I should feel disposed to repeat in a similar case. The operation is identical with that I have adopted in two cases of ununited fracture of the patella, when the uniting medium consisted only of a thin band of aponeurotic structures. In both these cases great improvement resulted. Except in this class of cases, and in some other rare form of talipes calcaneus, not depending upon paralysis, the results of treatment are extremely unsatisfactory.

TALIPES CALCANEO-VARUS AND CALCANEO-VALGUS.

Two compound varieties of talipes calcaneus have been described, characterized by inversion or eversion of the anterior part of the foot; and as the deformity has approached either to the characters of varus or valgus, so it has received its distinctive appellation. But generally it may be remarked, that these slight modifications are of but little scientific, and no practical importance; still as they have been recognised by various authors, a brief allusion will here be made to them.

Talipes calcaneo-valgus. This deformity characterized by de-

* *Op. cit.*, page 163.

pression of the heel, with eversion of the anterior portion of the foot, is but a slight and unimportant modification of talipes calcaneus.

Like equino-valgus, I scarcely think this compound variety, called calcaneo-valgus, of sufficient importance to constitute a separate class of these distortions.

More or less eversion of the anterior portion of the foot is almost constantly present in cases of talipes calcaneus, both in its congenital and non-congenital forms; it very rarely happens that simultaneously with depression of the heel, the anterior portion of the foot is drawn upwards, and retained in the flexed position, in a perfectly straight line with the axis of the leg. Some degree of eversion of the anterior portion of the foot nearly always exists, and, therefore, as in equino-valgus, the compound variety must be either magnified in importance so as to exceed that now attached to the primary form; or the modification afforded by the eversion, be disregarded in classification and assumed to be an ordinary condition of the primary form. The latter appears to me to be by far the better course. The only advantage in retaining the name is to enable the surgeon in some cases more correctly to indicate the precise deviations in form of the foot.

Talipes calcaneo-varus characterized by depression of the heel with inversion of the anterior portion of the foot, is still less worthy of separate mention than calcaneo-valgus; because the disposition to inversion very rarely coexists with depression of the heel; and when it does occur, is only slight and easily controlled by mechanical means, or even by manipulation. I have never seen the foot rigidly contracted in this position, nor have I seen the inversion greater than represented in Fig. 70, which might in strict nomenclature be described as an example of calcaneo-varus.

In both the simple and compound varieties, the pathology and treatment are essentially the same.

In concluding these chapters on the congenital, and non-congenital deformities of the feet, I would remark that if I have

dwelt at greater length than some might conceive necessary upon the pathological conditions of these very complicated affections; it is because I entertain the strongest conviction that it is only upon the sound basis of pathology we can hope to arrive at a scientific mode of treatment.

APPENDIX.

THE FOLLOWING DISSECTIONS DESCRIBED IN NOTES I. II. AND III. ILLUSTRATE THE REPARATIVE PROCESS IN HUMAN TENDONS AFTER SUBCUTANEOUS TENOTOMY.

NOTE I.*

Two legs of an infant who had been operated upon for talipes varus five months before death. Deformity cured, and good union in the tibial, and Achilles tendons.

The child æt. eleven months, had died of acute inflammation of the lungs. Both legs, as now exhibited, were free from deformity, the Achilles, the anterior, and posterior tibial tendons having been divided five months before death. In each of the Achilles tendons there was half-an-inch of new tendinous tissue inserted between the divided extremities of the old tendon, which was thus elongated. Externally, the tendon was well defined, and its surface even throughout, so that there were no traces of the operation, but the new tissue was easily distinguished on the recent section by its grey translucency, contrasting with the opaque, pearly lustre of the old tendon.

Both the posterior tibial tendons had united, but in one of them the free play of the tendon was limited by adhesions, whilst in the other, very slight adhesions existed. Mr. Adams remarked that he had already published fifteen *post mortem* examinations after tenotomy, and since the publication of his work on this subject had made at least five or six more, which

* These specimens were exhibited to the Pathological Society on the 2nd February, 1864, and the description is reprinted from the Trans. Path. Soc., Vol. XV page 235.

confirmed the opinions he had already advanced. With regard to the posterior tibial tendon, Mr. Adams observed that he employed gradual extension for a week before the operation, to limit the separation of the cut extremities, and thus favour union.

W. ADAMS.

February 2, 1864.

NOTE II.

*Three specimens, two of them illustrating the reparative process in human tendons at different periods, from a year and a half to six years; and one specimen illustrating the arrest of the reparative process by scarlet fever, of which the child died six weeks after the operation.**

The specimens consisted of three legs of club-footed children who had died of scarlet fever in the Royal Orthopædic Hospital, and had been operated upon at various periods. Some tendons had been divided six weeks before death, and others had been divided at different times, varying from a year and a half to six years previously.

Two of the legs were removed from the body of Frederick Davis, a boy who had been admitted for congenital talipes varus of both feet, into the Royal Orthopædic Hospital, when three months old, on the 7th March, 1864, and was then operated upon by Mr. Adams, the anterior and posterior tibial, and the Achilles tendons being divided in the ordinary way, and the child was discharged as cured on the 8th August, 1864.

In this case, relapse of the deformity to some extent occurred in consequence of the after-treatment not being persevered in,

* These specimens were exhibited to the Pathological Society on the 5th April, 1870, and the description is reprinted from the Trans. Path. Soc. Vol. XXI page 417.

and the child being neglected in the country. When re-admitted into the Orthopædic Hospital on the 4th August, 1868, both feet were in the position of talipes equino-varus, and in consequence of the extreme rigidity and unyielding character of the deformity, its cure was slow, and difficult to accomplish, the ligaments offering more resistance than any contracted tendons, and therefore the treatment relied upon was chiefly mechanical. The anterior and posterior tibial tendons, with the flexor longus, in both feet were, however, redivided soon after admission, and the Achilles tendons about two months afterwards.

This child died of scarlet fever on the 10th March, 1870, aged six years and three months, and at the period of death both feet had been brought into a perfectly natural position, and the boy was about to be discharged as cured, with directions to the parents to persevere in the daily employment of passive motion, in addition to walking exercise, for the purpose of increasing the range of motion, which was still very limited at the ankle-joints.

The appearances on dissection were as follows :—

Left foot. The tibialis posticus and flexor longus tendons had been divided a year and a half before death, and in both the reparative process was so perfect that, previous to a longitudinal division of these tendons being made, it was impossible to recognise the seat of division, or to distinguish the old from the new tendon. Both tendons were uniform in diameter, thickness, and rotundity throughout their length, and the only indications of an operation were to be found in thin membranous bands of adhesion between the posterior tibial tendon, and the sheath, along the edge of the tibia, not sufficient, however, to interfere materially with the free play of the tendon, which could be moved upwards and downwards sufficiently to insure the action of the posterior tibial muscle. From the thin membranous character and length of these adhesions, which varied from about a quarter to half an inch in different parts, it did not appear to me that they could interfere with the efficiency of the tendon.

A longitudinal section of the posterior tibial tendon showed that a little less than half an inch of the new tendon had been formed at the seat of division, just above the malleolus, and the new tissue was easily recognisable by its grey, translucent, and homogeneous appearance, as distinguished from the opaque, pearly lustre of the old tendon with its longitudinal striæ.

The line of junction between the old and new tendon by the process of dovetailing, the new grey tissue passing between the separated fibres of the old tendon, was very distinct. Although this tendon had been divided six years before death in about the same situation, no traces of the operation could be discerned. I expected to find some indications of it above the last operation, in consequence of the growth of the leg during the six years that intervened between the operation and death. It was evident, however, that time had obliterated all traces of the operation, performed when the child was only three months old.

A longitudinal section of the *flexor longus tendon* exhibited appearances similar to those above described in the posterior tibial tendon, but there was rather a greater length of new tissue, with some indications of a portion of old tissue intermixed at the lower part; it could hardly be stated, however, that there were distinct traces of two operations.

The anterior tibial tendon had been divided in the usual situation, as it passes over the ankle-joint, and perfect reunion had taken place, the form and outline of the tendon being restored, so that there could be no doubt as to its efficiency, though near to its insertion this tendon appeared to be rather flat and feeble.

The Achilles tendon was uniform in diameter and thickness throughout its length, and by an external examination alone, the seat of its division could not have been detected; a longitudinal section, however, showed distinct indications of its having been divided twice, and indistinct indications of a third operation were traceable at the upper part. At the lower part, an inch above the insertion of the tendon, and evidently

the seat of the last division, which had been performed sixteen months previous to death, three-quarters of an inch of new tendon had been formed, and could be easily recognised by its grey translucent appearance, and the line of junction between the old and new tendon, above and below, was very distinct. About an inch above this the tendon had evidently been divided at an earlier period, but the date of this operation was uncertain. About half-an-inch of new tendon could be traced in this situation, and a little above it there were somewhat obscure indications of a third division having been made, possibly the traces of the operation performed when the child was three months old. In this situation there was about three-eighths of an inch of what appeared to have been new tendon, as the structure at this part was less regular in appearance than the old tendon, though it had lost the gray translucency which distinguishes recently formed tendon.

Right foot. The same tendons had been divided as in the left foot, and within a few weeks of the same time, though the exact date of each operation had not been kept in the hospital case-book. Half-an-inch of new tendon had been formed in the length of *the posterior tibial tendon*, the reunion and reparative process in which was as perfect as it possibly could be; moreover, there was in connexion with this tendon an absence of the fibrous bands of adhesion which existed in the left foot, so that the perfection of the reparative process was more complete. In the sheath of the posterior tibial tendon there was only a little delicate areolar tissue, such as always exists in the sheaths of tendons, and some slender membranous adhesions, not sufficient to interfere with the free play of the tendon. A more perfect specimen of repair after division a year and a half previous to death certainly could not be produced.

The flexor longus tendon exhibited only a quarter-of-an-inch of new tendon, diminishing posteriorly, as if the separation had been hindered by the muscular fibres which descend much lower down than in the posterior tibial, or possibly the division had been less complete than in the other leg.

The anterior tibial tendon was strong and well defined in all

parts, and externally there were no traces of recent division. As a longitudinal section was not made in the recent state it was impossible to say whether this tendon had been divided at the same time as the posterior tibial, though as this is the usual practice it probably had been, and there can be no doubt it had been divided when the child was three months old.

The Achilles tendon, like that of the opposite leg, was uniform in diameter and thickness throughout its length, but on a longitudinal section two divisions were distinctly traceable; at the lower part rather more than an inch of new tendon had been formed as the result of division about sixteen months before death, and above this, half-an-inch of new tendon, as the result of a previous operation of uncertain date. The appearances were precisely similar to those described in the Achilles tendon of the right leg.

The third leg exhibited was removed from the body of Caroline Amabilino, æt. 13 years, a girl who was admitted into the Royal Orthopædic Hospital on the 3rd February, 1870, and died of scarlet fever on the 21st March, 1870. This girl was operated upon by Mr. Adams on the 3rd February, the anterior and posterior tibial tendons being divided, with the object of bringing the foot into the position of talipes equinus as the result of the first stage of treatment, the division of the Achilles tendon being deferred to the second stage, and in the present instance that tendon was not divided as the child died before the first stage was completed.

This was also a case of relapse of deformity, the girl having been the subject of congenital varus of the left leg which had been operated upon at the Orthopædic Hospital in May, 1868, when she was brought to the hospital as an out-patient. The foot was brought into a straight position, and she was enabled to walk with a boot and steel support, but in consequence of the severity of the case and the difficulty of attendance, as her parents resided in the country, partial relapse of the deformity occurred, and when she was admitted as an in-door patient on the 1st February, 1870, the foot was in the position of equino-varus of a rigid and severe form.

The posterior and the anterior tibial tendons had been divided between six and seven weeks previous to death, at the time of operation the girl was doubtless under the influence of scarlet fever poison, as the eruption appeared two or three days afterwards. In consequence of this condition of blood poisoning, the reparative process in the divided tendons had been arrested at an early stage, and very little attempt at the formation of new tendon had been made.

The divided extremities of the posterior tibial tendon were fully three-quarters of an inch apart, and imbedded in blood-stained areolar tissue, irregularly thickened by inflammatory infiltration, and adherent to the bone, or rather to the deep surface of the sheath of the tendon and the edge of its groove in the tibia; blood-stained and infiltrated areolar tissue, in which a small quantity of fat was included, also extended between, and indirectly connected the divided extremities of the tendon, but there had been no attempt at direct union by the formation of new tendinous tissue, nor was there any definition in the direction of the tendon in the tissue between its divided extremities.

The flexor longus tendon had not been recently divided. This tendon sometimes escapes the knife in operations in infancy, but at a later period it probably escapes much more frequently in consequence of the increased separation during growth, between it and the posterior tibial tendon in severe cases of varus.

The anterior tibial tendon exhibited the same indications of arrest in the reparative process as described in the posterior tibial tendon, but the divided extremities of the anterior tibial tendon which in the present case were nearly three-quarters of an inch apart, were directly connected by fibrous tissue, evidently the sheath and adjacent tissue in an infiltrated and thickened condition. This connection of the divided extremities of the anterior tibial tendon is explained by the existence of delicate fibrous and areolar tissue round this, as indeed it is found round all other tendons imbedded in fat and cellular tissue, forming a delicate fibro-cellular sheath which is more distinctly seen after division of the tendon, in consequence of the

traction exerted upon it. A certain amount of definition was therefore given to the connecting tissue between the divided extremities of the anterior tibial tendon, although the true reparative process, or regeneration of tendon seemed to have scarcely commenced. The contrast in this respect between the anterior and the posterior tibial tendons, in consequence of the absence of a loose fibro-cellular sheath in the latter, was remarkably well exhibited.

W. ADAMS.

April 5, 1870.

Report on Mr. Adams' case of division of tendons. We examined the two legs of Frederick Davis, æt. six and a half years, in which the posterior tibial tendons had been divided six years previously, and again in the left leg (both legs W. A.), a year and a half ago. In the left leg there is a fibrous band of adhesion between the tendon and the tibia measuring rather more than one-eighth of an inch, and slight membranous adhesions between the tendon and the sheath. In the right leg there are delicate membranous adhesions at the point of division between the tendon and the bone.

In neither case do the adhesions interfere with the movement of the tendon as performed in the dead subject.

In the left leg of Caroline Amabilino, aged 13, operated upon six weeks before death from scarlet fever, the ends of the divided posterior tibial tendon, are separated to three-quarters of an inch and each is adherent to the bone, and connected with its fellow by a mass of new connective tissue mixed with fat, and stained with blood. The reparative process in this latter instance has been evidently arrested or modified by the disease of which the child died, and from which she was probably suffering at the time of the operation.

RICHARD BARWELL,
CHRISTOPHER HEATH,
HENRY ARNOTT.

April 19, 1870.

Note III.

Two legs of a club-footed child, showing good union of the posterior tibial tendons, which had been divided, one about four months, and the other ten weeks before death. Slender adhesions to the sheath only existed, such as would not interfere with the free play of the tendons.

Emily Ongles, æt. 3 years, the child from whose body these legs were removed, was admitted, under the care of Mr. W. Adams into the Royal Orthopædic Hospital, 16th February, 1871, suffering from congenital talipes varus of both feet, of an extreme degree of severity.

The usual plan was adopted of dividing the treatment into two stages, the object of the first stage being to bring the foot into the position of simple talipes equinus, after division of the anterior and posterior tibial tendons, previous to the division of the tendo Achillis, and curing the equinus, which constitutes the second stage. This child, however, died of diptheria on the 11th July 1871, before the second stage of treatment had been commenced in either foot, the first stage having been unusually prolonged in the right foot, in consequence, partly of the extreme severity of the deformity, as well as from other causes. Both feet were, therefore, at the time of death, in the position of talipes equinus, the tendo Achillis not having been divided in either leg.

At the post mortem examination, it was found in the right leg that good union of the anterior and posterior tibial tendons had taken place; these had been divided on the 23rd February, 1871, rather more than four months previous to death. In the posterior tibial tendon, the line of demarcation between the old and new tendon, could still be traced (see Plate V fig. 2 *bb.*) The newly formed connecting tissue, or new tendon, measured half-an-inch in length. It was firm in structure, slightly reddened in colour, and equal in bulk and thickness to the tendon it served to unite. Thin membranous bands of adhesion a quarter-of-an-inch in length, passed from

the new tendon obliquely upwards, and outwards, to the outer portion of the sheath of the tendon, as seen in Fig. 2 *c*, and not between the tendon and anterior portion of the sheath, or edge of the tibia, as in the left foot; from the delicate membranous character of these adhesions, as well as from their direction obliquely upwards and outwards it was seen on careful examination that they did not at all interfere with the free play of the tendon.

The flexor longus tendon had not been divided.

The tibialis anticus tendon had been divided in the usual situation, as it crosses the ankle-joint, and good union had taken place by the formation of new tendinous structure, about three-quarters of an inch in length, and equal in bulk and thickness to the tendon it served to connect; the junction between the old and new tendon at its lower part is indicated at *d*.

Left leg. On dissection, the appearances presented in the left leg were essentially similar to those observed on the right. The posterior tibial tendon had been divided in the ordinary situation, viz.: a little above the inner malleolus, and good union had taken place, the new connecting tissue, or new tendon, measured five-eighths of an inch in length; it presented a ruddy tinge, and its structure was firm, and in thickness and bulk equal to the tendon it served to unite; the line of junction between the old and new tendon was very distinct, see Fig. 1 *bb*. The adhesions between the tendon and the sheath, although membranous in character, were rather shorter and firmer than in the right leg, and passed directly between the new tendon and the anterior surface of the sheath, near to the edge of the tibia, Fig. 1 *c;* in length these adhesions varied from an eighth of an inch to rather less than a quarter; in direction they passed obliquely from below upwards, and partly from this circumstance interfered less with the free play of the tendon than might be supposed; the movement of the tendon was still free.

The tibialis anticus had been divided and reunited firmly, with the insertion of nearly three-quarters of an inch of new tendon,

the lower border of which at its junction with the old tendon is indicated at Fig. 1 *d*.

The muscles generally in both these legs were in a healthy condition, but the inner head and half of the gastrocnemius muscle appeared to be disproportionately larger than the outer, and in the other specimens which I have examined there has generally been an appearance of hypertrophy of the inner head and half of the gastrocnemius muscle.

In reference to the union of the posterior tibial tendon after division, these specimens agree in the appearances represented with the others which I have examined; the adhesions being as a rule of a membranous character, and sufficiently long to allow of free play of the tendon, the use of which in the movements of the foot would tend still further to elongate the adhesions. In the large number of *post mortem* examinations which I have recorded, I have only seen one instance in which the posterior tibial tendon failed to unite after division, and this case is described and figured in my work "On the Reparative Process in Human Tendons," (Plate V.) the posterior tibial tendon had been divided by a surgeon much lower than usual, *i.e.*, immediately behind the inner malleolus in the dense tubular portion of the sheath, and no direct uniting medium ever formed, the divided extremities of the tendon above and below remaining adherent to the sheath.

Note IV.

*Three specimens illustrating the condition of the muscles, bones, &c., in different forms of non-congenital club-foot.**

The specimens consisted of two legs from the body of a man aged twenty-five, affected with talipes equino-varus of the left foot, (described in the Table as Case I), and talipes equinus of the right foot, (described in the Table as Case III). Also, the left leg of a woman aged about sixty, affected with talipes equino-varus, (described in the Table as Case II). All were of the most severe form. The last specimen, Mr. Adams was permitted to examine and exhibit to the Society, through the kindness of Mr. Partridge, who removed it from a subject in the dissecting room of King's College. The history of the case could not be ascertained. The first two specimens were removed by Mr. Adams from a subject in the dissecting room of St. Thomas' Hospital. The only particulars that could be ascertained of this case were, that the man had been in the Strand Union Workhouse three years, that the feet were contracted when admitted, and that he walked with one crutch. He died from consumption.

Thus, some of the interest attaching to these cases is lost from the absence of the early history of the deformities; but as these affections can be diagnosed with almost absolute certainty, in respect of their origin, from the general appearance alone of the feet and extremities, the absence of history may be considered of less importance than it would at first appear.

The two cases of equino-varus, Nos. I and II, in the tabular form annexed, were stated by Mr. Adams, previous to any microscopical examination of the muscles; No. I to be of paralytic, and No. II of spasmodic origin; corresponding differences in the structural alterations of the muscles were therefore anticipated, and the results, as recorded in the annexed Table, strongly favour the correctness of this diagnosis. The only diffi-

* The description of these specimens, with the table of the microscopical appearances of the muscles, is reprinted from Vol. III. Trans. Path. Soc., and the Plate in the present work, see Plate VI., has been copied by Mr. Aldous from Plate XII., in the same volume drawn by Mr. Leonard. The specimens were exhibited to the Pathological Society by me on the 18th May, 1852.

culty was with respect to No. III, and from the appearance of the limb, Mr. Lonsdale fully concurred with Mr. Adams, that this deformity was either the result of a slight spasmodic affection; or that it was a case in which recovery of muscular power had taken place after a slight paralytic attack in infancy. The latter supposition was supported by the fact of its co-existence with the paralytic deformity in the opposite foot described in the Table as Case I, and also the microscopical characters of the muscles, as described in the annexed Table.

The specimen described as Case I, presented the ordinary appearances of long standing talipes equino-varus, dependent originally upon paralysis of one or more of the extensor muscles, but especially of the extensor longus digitorum, and of the peronei. The leg was extremely attenuated; the os calcis drawn upwards to its full extent, with considerable obliquity inwards; the anterior half of the foot was inverted to full half the extent seen in a severe congenital case in the adult, and the toes were drawn downwards by the flexor muscles, compressed and misshapen.

The muscles generally were very much smaller than in a well nourished leg, probably not much more than half the size, but a remarkable disproportion in bulk existed between the extensors and flexors. The extensor longus was reduced to a very thin layer of muscular fibres, having a remarkably coarse fasciculate appearance, caused by the fibres being separated from each other by abundant and somewhat delicate fibro-cellular membrane and fat. All the muscles were of a very pale colour, and coated with a layer of deep yellow-coloured fat lying beneath the fascia, separating the muscles from each other, and dipping between their fasciculi; (for a description of the microscopical appearances of the muscles presented in this case, see the annexed Table, Case I.)

The bones presented the usual deviations in position observable in this deformity, viz., partial luxation of the astragalus forwards and downwards, produced by the oblique position of the os calcis, from contraction and permanent shortening of the gastrocnemius; and also partial luxation of the navicular bone inwards, so that its internal and upper border closely

approached the inner malleolus, the external half of the head of the astragalus being left exposed. This displacement of the navicular bone was due chiefly to the contracted and permanently shortened condition of the tibiales (anticus and posticus) muscles. The cuboid bone was also partially displaced inwards from its articulation with the os calcis, following, but not to a proportionate extent, the navicular bone. The articular cartilage on the anterior third of the superior articular surface of the astragalus, and the outer half of the head of the astragalus, which were thus exposed on the dorsum of the foot, covered only by the elongated ligaments, were irregularly absorbed, and in most parts completely removed. The denuded bone in these situations was atrophied to an extreme degree; its shell, reduced to the thinness of tissue paper, yielded to the slightest pressure, and the cells of its cancellous tissue were enlarged and filled with oil, just as in long-standing scrofulous disease of the ankle, and tarsal joints in young persons.

The specimen of talipes equino-varus described in Case II, Mr. Partridge's specimen, presented the ordinary appearances of the spasmodic form of that affection, when of long standing; originally dependent upon a spasmodic condition of the muscles of the limb generally, in which the more powerful muscles gain the ascendancy, and by their condition of tonic spasm, and permanent shortening, produce the deformity. The limb was less bulky than natural, but did not present the appearance of attenuation described in Case No. I. The os calcis was drawn upwards, and the anterior half of the foot inverted to the same extent as in Case No. I. by the rigid shortening of the gastrocnemius, and anterior and posterior tibial muscles; but the toes were drawn rigidly upwards, so that the first phalanx of each toe was at a right angle with its corresponding metatarsal bone, by the action of the long and short extensor muscles. A partial luxation upwards of the first phalanx was thus produced in each toe, the greater portion of the head of the corresponding metatarsal bone being exposed. The exposed articular cartilage of the first metatarsal bone was irregularly absorbed. The second and third phalanges of the four outer

toes were drawn downwards to a right angle with their corresponding first phalanges. The second phalanx of the great toe was not drawn downwards; but this toe was rotated inwards so that its nail looked directly outwards, and its under surface was in contact with the outer margin of the second toe.

The muscles although small as compared with those of a well developed leg, were generally of firm texture, slightly paler in colour than natural, and neither coated with layers of fat, nor exhibiting fat in their interstices as in Case No. I. There was no obvious disproportion in bulk between the flexors and extensors, (for a description of the microscopical appearances of the muscles presented in this case, see the annexed Table, Case II.) Some of the tendons were altered in their direction, more particularly that of the tibialis anticus and the tendo Achillis, the former crossing the end of the tibia above the usual point, and passing over the ankle-joint more to the inner side; the tendo Achillis deviated from its usual central position at the back of the leg, and passed downwards in a line very much nearer the inner border of the tibia, being placed over that bone rather than between the tibia and fibula, and directly covering the posterior tibial artery. The alteration in the position of the tendo Achillis appeared to depend upon the oblique direction of the os calcis and its mode of insertion into that bone; the upper part of the tuberosity of the os calcis was brought near to the fibula, while the lower half of the tuberosity into which the tendon is inserted, was turned inwards to a proportionate extent towards the inner malleolus, so that the point of its insertion being thus carried towards the inner side of the leg, the position and direction of the tendon were necessarily altered.

The specimen of talipes equinus described as Case III, was a well marked example of that deformity, but the general appearance of the limb did not clearly indicate the cause of the deformity as in the two previous cases—it was less wasted than in an old case depending upon complete paralysis of the extensor muscles, and more atrophied than in a spasmodic case, without the prominence and tension of the tendons, and rigidly

extended condition of the toes in this form, (for a description of the microscopical appearances of the muscles presented in this case, see the annexed Table, Case III.)

It is probable that the contraction of the gastrocnemius in this case was the result of slight loss of power in the extensor muscles, not amounting to paralysis, a very frequent condition, and one from which complete recovery appears to take place. Numerous patients afflicted with this deformity present themselves at the Orthopædic Hospital, generally some years after the commencement of the deformity, without any indication of existing paralysis; and after division of the contracted tendons, the extensor muscles have sufficient power to retain the foot in its normal position, although the early history of the case—the child dragging its foot after it, the coldness and wasting of the leg, the loss of power of extending the toes, and frequently the suddenness of the seizure—clearly points to a partially paralytic origin. The comparatively healthy condition of all the muscles especially contrasts with the condition of the muscles in the opposite leg, from the same individual as in Case I, and confirms the opinion with respect to the general nature of the deformity. This foot had evidently been a useful member to the individual, who used a crutch to compensate for the paralytic and deformed condition of the opposite leg.

Mr. Quekett very kindly undertook to examine the condition of all the muscles of the leg in these three cases of non-congenital club-foot, and as the specimens which I removed from the different muscles were examined, I wrote down the account given below from Mr. Quekett's dictation. The facts are not sufficiently numerous to warrant any general inferences in respect of the connexion between these different structural changes and the physiological conditions by which they are determined; but being the result of careful observation, they may be useful as furnishing a portion of the data necessary for this important inquiry. The illustrative figures (Plate XII, in Vol. III., Trans. Path. Soc.,) were drawn under Mr. Quekett's superintendence by Mr. Leonard, (this Plate, copied by Mr. Aldous, is appended to the present Essay: see Plate VI.)

TABLE SHOWING THE MICROSCOPICAL APPEARANCES OF THE MUSCLES OF THE LEG IN THE THREE CASES OF NON-CONGENITAL CLUB-FOOT ABOVE DESCRIBED.

Muscles.	CASE I. Paralytic equino-varus.	CASE II. Spasmodic equino-varus. Mr. Partridge's specimen.	CASE III. Talipes equinus without paralysis or spasmodic affection from the same patient as Case I.
Extensor longus digitorum	The mass examined consisted almost entirely of areolar tissue. Degeneration of muscular tissue complete. No muscular fibres in process of degeneration. The only trace of muscle in a large (microscopic) piece examined, were some fibres about $\frac{1}{1800}$th of an inch in diameter, with striæ well developed. Mr. Quekett considered that these fibres were either of new development, or else fibres that had never attained their normal size. Adipose tissue occurring as a double row of fat-cells in the neighbourhood of the small muscular fibres. See Plate VI., fig. 8.	Muscular fibres abundant, of the natural size, and healthy. Fibrous tissue not in excess. No adipose tissue. This muscle apparently in a healthy condition. Two healthy fibres are shown in Plate VI., fig. 1.	Muscular fibres abundant, but generally above the average size of healthy fibres. Transverse striæ distinct. The larger muscular fibres were peculiar; the parts forming the transverse striæ could be entirely separated from the sarcolemma in a spiral form, and each stria, when highly magnified, exhibited a beaded structure like the ordinary fibrillæ. Areolar tissue not in excess. Masses of adipose tissue between some of the bundles of fibres. See Plate VI., fig. 2.
Tibialis anticus.	Healthy muscular fibres abundant, and of normal size; others of equal size in the first stage of degeneration (see Mr. Quekett's lectures on Histology, p. 196). No excess of fibrous tissue, nor any adipose tissue in the part examined. See Plate VI., fig. 4.	Muscular fibres generally smaller than usual, and abundant; transverse striæ well marked. There were some muscular fibres rather above the natural size, in the first stage of degeneration. Fibrous tissue in excess. Adipose tissue occurring in masses amongst some of the fibres.	Muscular fibres abundant, but smaller than usual; otherwise healthy; transverse striæ well marked. A small amount of fibrous and adipose tissue, the latter occurring chiefly in one mass in the portion examined.

Muscles.	CASE I. Paralytic equino-varus.	CASE II. Spasmodic equino-varus. Mr. Partridge's specimen.	CASE III. Talipes equinus without paralytic or spasmodic affection from the same patient as Case I.
Extensor proprius pollicis.	Healthy muscular fibres abundant, and of variable diameter, generally below the normal size. Two minute fibres were seen similar to those in the extensor longus digitorum. Areolar tissue abundant. No adipose tissue.	Muscular fibres abundant and healthy. Only a small amount of fibrous and adipose tissue.	Muscular fibres abundant and healthy, transverse striæ exceedingly well marked. A small amount of fibrous tissue between some of the fibres, but no trace of adipose tissue.
Gastrocnemius.	No trace of muscular tissue in the parts examined. A large amount of fibrous tissue between rows of adipose cells. Adipose tissue abundant, and the cells arranged in parallel rows. Plate VI., fig. 7.	Muscular fibres abundant, but of much smaller size than usual, and the striæ indistinct in most parts; in some situations the bundles of fibres were very evident, but the striæ scarcely traceable, and the contents of the sarcolemma confused and granular. Fibrous tissue abundant. Small masses of adipose tissue existed between some of the bundles of muscular fibres.	Muscular fibres of variable size, exhibiting their striæ very well. The fibres were all so firmly embedded in fibrous tissue that they could not be separated without being more or less torn transversely. In a second portion when a little manipulated, the fibres were still seen to be broken into short lengths. Some of the largest fibres were in the first stage of fatty degeneration; in others the particles of myoline were replaced by minute globules of oil. There was a considerable amount of adipose tissue. See Plate VI., fig. 3.
Soleus.	Presented the same appearances as the gastrocnemius, with the addition, in the part examined, of one bundle of minute muscular fibres.	Muscular fibres abundant, of variable size, in all stages of degeneration as in the gastrocnemius, but more advanced. Many exhibited nothing but the sarcolemma containing the remains of the particles of myoline and minute globules of oil, the other parts of	Muscular fibres few in number; firmly imbedded in fibrous tissue, and in the first stage of degeneration. Adipose tissue distributed generally throughout the specimen. This muscle was in a more advanced state of degeneration than the gastrocnemius.

Muscles.	CASE I. Paralytic equino-varus.	CASE II. Spasmodic equino-varus Mr. Partridge's specimen.	CASE III. Talipes equinus without paralysis or spasmodic affection from the same patient as Case I.
Soleus.		the fibres being transparent and tolerably well defined. Plate VI., figs 5, 6.	
Tibialis posticus.	Muscular fibres abundant and healthy—only in one part was degeneration evident. Adipose tissue abundant, and in some parts the cells arranged in rows between the healthy muscular fibres.	The mass examined consisted almost entirely of fibrous and adipose tissues, without any traceable muscular fibres.	Muscular fibres abundant and healthy—only in one place was any degeneration evident. Adipose tissue occurring in considerable abundance between some of the bundles of fibres.
Flexor longus digitorum.	Muscular fibres healthy and abundant, but variable in size, some being less than one-fourth the natural size; these appeared to be of new formation. Fibrous tissue more abundant than natural. Adipose tissue found only in the neighbourhood of the blood vessels.	Muscular fibres abundant, of small size, but the transverse striæ well marked. Fibrous and adipose tissues abundant.	Muscular fibres abundant, of the usual size, and exhibiting their transverse striæ very well. There were some fibres of much larger size than usual in the first stage of degeneration. No excess of areolar or fibrous tissue.
Flexor longus pollicis.	No trace of muscular fibre: the mass examined consisted of alternate rows of adipose cells and fibrous tissue.	Muscular fibres abundant, but exceedingly small and degenerated like those of the gastrocnemius; very few of them exhibited transverse striæ. Fibrous and adipose tissues abundant.	Muscular fibres abundant, but rather smaller than usual; transverse striæ well seen. A small amount both of fibrous and adipose tissues.
Peroneus longus.	Muscular fibres few in number, but of the usual size, and the transverse striæ distinct. The part examined consisted principally of fibrous tissue. No adipose tissue.	Muscular fibres abundant, but smaller than usual; transverse striæ distinct. Adipose and fibrous tissues present in small quantities.	Muscular fibres abundant, but of large size, and generally in the first stage of degeneration. Considerable amount of fibrous tissue, but no adipose cells.

Muscles.	CASE I. Paralytic equino-varus.	CASE II. Spasmodic equino-varus. Mr. Partridge's specimen.	CASE III. Talipes equinus without paralytic or spasmodic affection from the same patient as Case I.
Peroneus brevis.	No trace of muscular fibres, and very little of adipose tissue, the portion examined being almost wholly composed of fibrous tissue.	Muscular fibres abundant, smaller than usual. By far the greater number of them in the first stage of degeneration. Fibrous tissue abundant, and a small amount of adipose tissue.	Muscular fibres abundant and healthy with the exception of some irregularity in size. No adipose or fibrous tissue.

CASES IN ILLUSTRATION

OF

NON-CONGENITAL, SPASMODIC, AND PARALYTIC TALIPES DESCRIBED IN CHAPTERS IV. AND V.

CLASS I.

DEFORMITIES WITH RIGID MUSCLES, THE RIGIDITY OR TONIC MUSCULAR CONTRACTION, REMAINING AS A PERSISTENT CONDITION FROM THE TIME OF SEIZURE. ALL NON-CONGENITAL, BUT GENERALLY INFANTILE AFFECTIONS.

Case I.

The following case is a good example of the affections included in the above class, when the state of muscular rigidity is confined to the lower extremities.

Miss C. S., aged two and a quarter years, was sent to me in May, 1854. When only three months old, cut the two lower incisor teeth easily; cut all the other teeth very quickly, and without much pain or apparent suffering. Had no fits or convulsions at any time. The child appeared to be well nourished, and healthy, although not robust. When six months old certainly, and the mother thinks earlier than that, she observed that the feet and legs were rather stiff, and inclined always to be drawn together, although they could be separated without difficulty. When a year old, her mother tried to put her on her feet, and found she could not stand, nor was she able to advance one leg before the other in a straight line. One leg would always cross the other, and the toes only touched the ground. She took to crawling in a peculiar

way, using only her arms, and dragging her body after her in a straight line, *i.e.*, without bending her knees. She crawled in this way for nearly six months, and then began to bend her knees, and got on much better. When first seen by me she crawled pretty well, but in all movements used her arms much more than her legs. She could not stand alone; in the attempt, the toes only touched the ground.

There was no obvious deformity of the feet or knees, although some muscular rigidity existed at these articulations; both feet were contracted at right angles, *i.e.*, flexion not being allowed beyond the right angle, in consequence of slight permanent contraction, and shortening of the gastrocnemius and soleus muscles. This appeared to be increased by temporary spasm in any attempt to stand. There was no muscular rigidity about the arms or hands, nor any indication of cerebral affection. The lower extremities were alone affected.

In this case both Achilles tendons were divided, and the child was then enabled to stand firmly on the ground, and walk without any risk of falling. The muscular rigidity at the knees and hip-joints, was not sufficient to interfere much with progression, and gradually yielded to shampooing and muscular exercises.

Case II.

Rigid muscular contraction affecting both legs, with both feet deformed in the position of talipes equinus, of an extreme degree, rendering the patient unable to stand or walk.

In September 1858, I was requested to see Master D. C. M., aged fourteen, who, in consequence of the increasing contraction and deformity of both feet, which were in the position represented in Fig. 78, had become unable to stand or walk. He had been unable to walk for six months, and could only stand with assistance. The affection had evidently commenced from infancy, as I learnt from a relative that he exhibited a peculiar stiffness

in walking when quite a child. He had been for several years subject to epileptic fits, the continuance of which had, to a

FIG. 78.

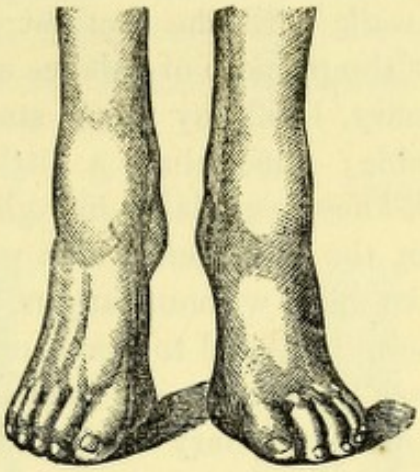

Rigid muscular contraction—Spasmodic talipes equinus, affecting both feet of a young gentleman 14 years of age.

slight extent, weakened his mental vigour, although his bodily health remained good. At the time I saw him, the fits occurred regularly once a month.

There was considerable muscular rigidity of both legs, and the knee-joints were slightly contracted. The hip-joints were the least affected, and the rigidity in the neighbourhood of these articulations was but slight; a favourable condition in reference to treatment.

He was the subject of lateral curvature of the spine, but not to a severe extent; and this might have been produced by his habit of always sitting in a stooping position, but in the family there was an hereditary disposition to lateral curvature.

In the treatment of this case, I divided both Achilles tendons on the 14th September, 1858, the day after he had had one of his usual epileptic seizures. The reparative process proceeded favourably; but I may mention that being somewhat anxious as to the possibility of the union giving way during the next fit, which occurred on the 8th October, when he had a series of epileptic fits lasting several hours, I took the precaution to raise the heels by the cog-wheels of the Scarpa's shoes, previous to the seizure, and no unfavourable result occurred.

It was remarked that during these fits, the legs which were generally much convulsed, remained comparatively quiet, the gastrocnemii remained flaccid, and the legs were not at all drawn up. The result of the case was, that at the end of two months he was enabled to walk with the feet flat to the ground, but using two sticks for the purpose of balance and support.

On the 4th February, 1859, my report states: feet very perfect, but legs feeble; knee-joints a little contracted with inclination to knock-knee, especially in right leg. He lifts up his legs feebly from the hips, but walks without sticks; and last week walked two miles without fatigue, from St. Leonards to Hastings and back. Ordered to leave off Scarpa's shoes at night, and sometimes the boots with steel supports in the day time, and to walk with ordinary boots; shampooing for the legs, and gymnastics ordered.

On the 10th August, 1859, my report states: both feet remaining well; but knees more contracted, and to supersede the necessity of dividing the ham-string tendons, and prevent any increasing contraction at these articulations, I carried the steel supports to the thighs. There was, at this time, an inclination in the family opinion opposed to mechanical treatment, and in favour of the gymnastic system of Ling, or the so-called Swedish system which I believe was adopted, and I am unable to give any further report of the case.

The effect of the operation in enabling this patient to walk under such unfavourable circumstances, was in every way satisfactory.

Case III.

Rigid muscular contraction of both feet in the position of extreme talipes equinus, with flexion of all the toes; consecutive to an attack of the Mauritius fever. The patient was totally unable to stand or walk even with crutches.

Mrs. S. æt. 40, consulted me on the 19th January, 1870. She had been brought to England from the Mauritius, and as she

was totally unable to stand or walk, even with the assistance of crutches, the journey had been accomplished with considerable difficulty.

Both feet were rigidly contracted in the position of extreme talipes equinus, with this peculiarity, that the toes were also rigidly contracted in the flexed position, as seen in Figs. 79 and 80.

FIG. 79. FIG. 80.

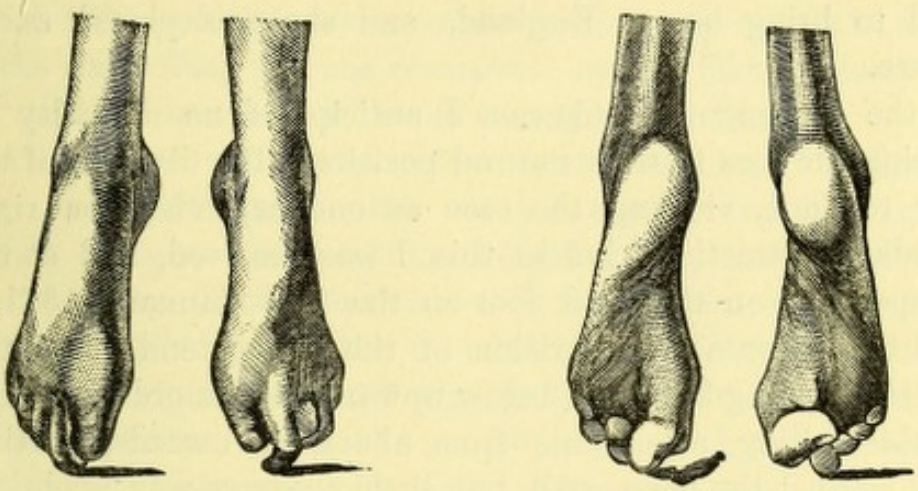

Talipes Equinus with flexion of toes after Mauritius fever.

This lady was a native of the Mauritius, and had suffered from what is well known as the Mauritius fever, during one of its most severe outbreaks in September, 1867, when in the course of three months a large proportion of the inhabitants died of the fever, which was said to be of an intermittant type. The husband of this lady informed me that the medicines chiefly relied upon by the medical men in the Mauritius were quinine and arsenic, the latter being given chiefly when they were unable to obtain the former. In the severe outbreak of fever, during which this lady suffered, the stock of quinine in the Island was quickly exhausted in consequence of the rapidity with which the fever spread, and the large doses employed by the medical men, varying from thirty up to sixty grains in each dose. The small remaining stock of quinine in the Island was by a compulsory law, put up to auction, and Mr. S. informed me that he paid as much as twenty pounds an ounce for quinine

for his wife. Some arsenic, however, had been given to this lady previous to the occurrence of muscular contraction of the feet, which took place suddenly, and was accompanied with squinting, at a time when she was so prostrate from the effects of the fever, that very little hope of her life was entertained. Mrs. S. slowly recovered from the fever, and the squinting passed away, but the feet remained permanently contracted, and rigidly fixed in the same position as seen in Figs. 79 and 80. In consequence of this condition, her husband determined to bring her to England, and she was placed under my care.

In the treatment of this case I anticipated no difficulty in restoring the toes to their natural position, after division of the flexor tendons, viewing the case as one dependent on rigid muscular contraction; but in this I was deceived, and at the first operation on the right foot on the 21st January, 1871, I found that after a free division of the flexor tendons of the great toe, cutting first from below upwards in the ordinary way, and this failing, afterwards from above downwards, cutting firmly against the bone, still but little progress was made. I then divided freely the lateral ligament on either side of the joint, making separate punctures, but with very little benefit. Operative measures thus failing, I had immediately to decide between the employment of forcible extension, or amputation of the toe. I determined on the former, and it was only after exerting all the force which I was capable of employing, whilst she was still under chloroform, that the resistance offered by fibrous or ligamentous bands, which I was unable to divide, could be overcome. As the case had not been one of inflammatory retraction, I did not anticipate that the adapted shortening of ligamentous and other fibrous structures in the neighbourhood of the joint could have offered so much resistance; as a pathological fact, however, and result of experience, it is worthy of record, more especially as the same method of treatment had to be adopted in all the toes of both feet, the smaller toes giving way under the employment of proportionally less force. Tenotomy alone, was not sufficient in any one instance,

nor did division of the lateral ligaments suffice; but the contraction of each toe had to be overcome by forcible extension, and the rupture of fibrous, or ligamentous bands. It is worthy of remark that in only one instance, viz., in the great toe of the right foot, did any suppuration follow the operation of tenotomy combined with division of ligaments, and forcible extension.

The left foot was operated upon on the 18th February, 1870, and the method of procedure by tenotomy, division of ligaments, and forcible extension was precisely the same as that adopted in the right foot, and the result was equally favourable or more so, as no suppuration followed in any one instance.

After these operations on the contracted toes, the Scarpa's shoe employed was similar to that represented in Fig. 20, having a transverse joint in the sole-plate, corresponding to the transverse tarsal joint, and with the addition of longitudinal slits corresponding to the division between the toes, so that each one might be bound separately, and retained in an extended position. With the employment of this apparatus no further difficulty was met with, and on the 22nd March, the tendo Achillis was divided in both feet. After this operation no difficulty was experienced in bringing the feet into a right angled position with the legs as represented in Fig. 81, and

FIG. 81.

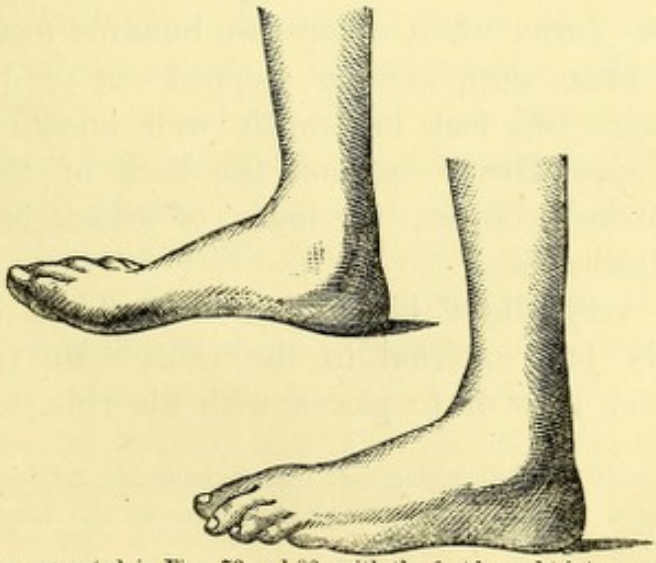

The same case as represented in Figs. 79 and 80, with the feet brought into a natural position after division of tendons and forcible extension of the toes.

good union of the Achilles tendons having taken place, this lady was enabled to walk firmly, and well. She completely regained muscular power, and before leaving England, about two months afterwards, shampooing, and passive exercises for all the joints having been regularly continued, she was enabled to walk any reasonable distance, the ankle-joints being quite free.

The only case which has fallen under my observation of talipes equinus, with contraction of the toes in a rigidly flexed position, at all analogous to that of Mrs. S., is one which occurred in a man, and was the result of a snake bite in America.

Case III*a*.

*Case of permanent contraction of both feet and right hand with rigidity of muscles from bite of snake.**

James Truss, aged 32, native of Wotton, Bucks, strong, square-built, good health—never had any previous illness—had resided about four years in America previously to the time of his being bitten by a snake there.

In August, 1856, was crossing a mountain in the neighbourhood of Oldham, a small village about thirty-five miles north of New York; when about two hundred feet above the level of the plain, supposed he stepped on, or disturbed, a snake of about two feet in length, well known there, and called a "Copper-Head," because the back of the head resembles tarnished copper; its mode of attack is similar to that of the Rattlesnake.

He felt a very slight bite about the middle of the left leg, anteriorly just external to the tibia. He turned, saw the snake, and blew it to pieces with his rifle. He walked

* For the notes of this interesting case I am indebted to my friend Dr. C. E. Harle, who devoted much time to taking cases for me at the Royal Orthopædic Hospital.

on without inconvenience, pursued his business as usual, returned to his dinner, and went out the same evening. The wound was very insignificant, quickly healed without any local symptoms, fever, or constitutional disturbance.

After three or four days, certainly less than a week, he felt a numbness in the ends of the fingers of each hand, and in the toes of both feet.

This numbness continued for two or three weeks, when it became accompanied with a stiffness and weakness which extended gradually up his legs.

This obliged him to walk with a stick, which he used for a week. After this time, the stiffness and numbness so increased, that he was obliged to substitute crutches for his stick. Still the stiffness and numbness increased; he became rigid, and lay in bed, as he states, like a log. The left leg, the leg bitten, was throughout the worst.

At this time, both legs were useless and stiff, and the arms, elbows, and shoulders had also gradually become rigid. The right hand was, as he describes it, *locked shut*, the left hand was *locked open*. The toes were *locked*, and turned under the feet. During the whole period, sensation in the several parts was unaffected.

It was not until he took to his bed that he applied for medical aid. Creosote in some form was prescribed, which he took for a week without any benefit, but rather the contrary. Strychnine was given him three times a day for two months, with no beneficial results. The strychnine affected the whole body equally. After its disuse the galvanic battery was used; this at first acted on the other parts of the body, not on the parts affected; but after its use for two hours, the right arm became sensible to its action.

The use of the battery was continued daily for five months, two or three times a day, a quarter of an hour each time. During the period of its use the legs became gradually more sensible to its action, also the shoulder-joints and elbows slowly recovered their use, and he obtained somewhat the use of his hips and knees. But the feet and hands re-

mained as rigid as ever, although he continued the use of the battery. Finding he could not obtain further relief in America, he came to England expressly for that purpose, and from the time of starting, discontinued the use of the battery.

At one of our Borough hospitals, he was told his case was hopeless; and at another London hospital, where he went into both physicians' and surgeons' rooms, walking on his knees, one of the surgeons there said, "I can do nothing for you but cut off your legs."

In November, 1861, he became an in-patient under Mr. Adams, at the Orthopædic Hospital, using crutches and walking on his toes, wearing thick-soled boots, with the soles so excavated as to admit of his turned toes, for without these

FIG. 82.

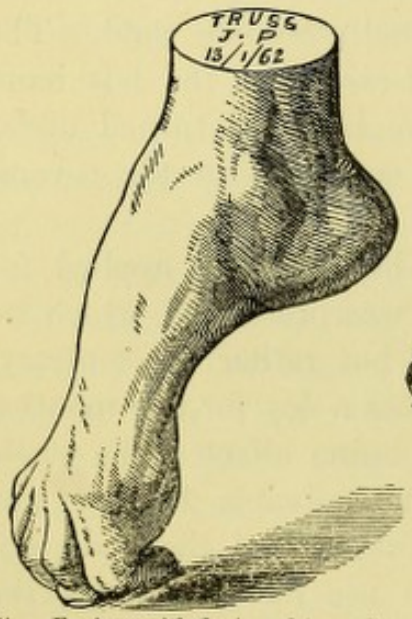

Talipes Equinus with flexion of toes after snake bite.

FIG. 83.

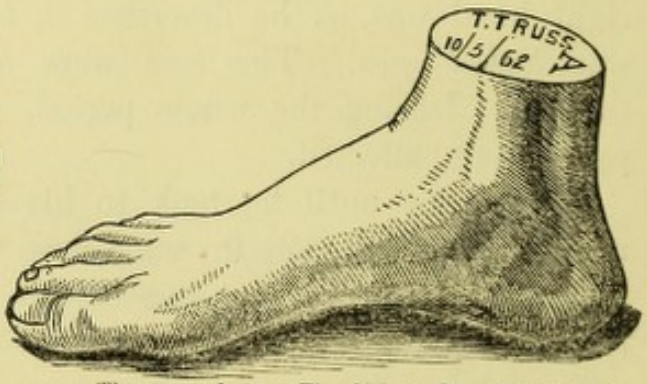

The same foot as Fig. 82 brought into a natural position after tenotomy.

boots he could not stand, though using crutches; and previously to using the boots so made, his custom was to walk on his knees with crutches. On the 29th November, 1861, Mr. Adams operated on the great toe of the left foot with success. The second operation was on the great toe of the

right foot; the third, on the left heel (tendo Achillis); fourth, on the right heel; fifth, the four toes of each foot (dividing the ligaments). Each operation proved successful. The Scarpa's shoes were used, and he afterwards wore the ordinary "boot and iron." He left the hospital, having the free use of both feet, which were quite natural (see Fig. 83).

He regained the use of the left hand without operation. The right hand remained somewhat clenched. The flexor tendons of the four fingers were rigid, but the thumb remained free. Mr. Adams wished to operate on the hand, but the man declined.

Respecting the effect of the bite of a snake on other persons, he says, he has seen persons who have been bitten by the same kind of snake, but none of the sufferers were affected as he was; nor had any of the medical men there seen any such effects from snake-bite as occurred in his case.

The ordinary effect of the bite is immediate swelling of the part bitten, attended with great local pain; but he is not aware that it is attended with much fever. The treatment invariably adopted, and generally with success, is to suck the part bitten and to "take plenty of whisky."

Case IV.

Case of rigid muscular contraction of both lower extremities, occurring in infancy and allowed to remain unrelieved until adult life; when severe deformities of both feet and knees, entirely deprived the patient of the power of walking.

Mr. W. C. U., aged twenty-seven, consulted me on the 25th of June, 1852. Both his feet were in the condition of extreme equino-valgus, seen in Fig. 84, and the knee-joints were permanently flexed to a greater extent than exhibited in the woodcut; they had also a strong tendency to overlap each other, and came always in contact when he was standing. All the muscles of the thigh and leg in each extremity were rigid, large, and prominent. He was a man of great muscular

development generally, and the legs were of proportionate size.

FIG. 84.

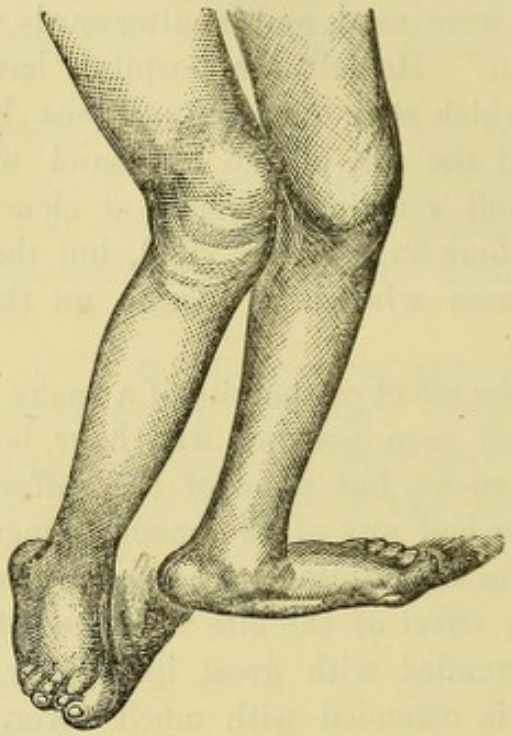

Rigid muscular contraction affecting both knees and feet—Spasmodic talipes equino-valgus in a gentleman, 27 years of age.

He was totally unable to walk, and his only mode of progression was by swinging between crutches; any attempt to walk without them was painful to witness. In advancing either of his bent and rigid legs, the pelvis was at the same time twisted sideways. The muscles of the hip-joints were but slightly affected. The adductors were slightly contracted, but the flexors and extensors acted freely. His professional avocations (he was in practice as a barrister) were necessarily much restricted, and the exclusion from many of the pleasures of society had exercised a depressing and unfavourable influence upon him. The early history of the case, as derived from one of his mother's letters, which he had preserved, rather favours the idea of a paralytic origin; if so, it more properly belongs to the second class of deformities with rigidity of muscles consecutive to their flaccid paralytic condition; but I have never met with any analogous example, and

the late Mr. Lonsdale, who assisted in the operations in this case, agreed with me in regarding it as one of spasmodic origin.

History of the Case. When between eight and nine months old, his nurse left him on the floor, and went into another room. He was then quite well. When the nurse returned, she found the child "screaming violently and looking deadly pale." Terror being the supposed cause, the medical attendant was not sent for, but he happened to call soon afterwards, and found that the baby had "lost the use of his lower limbs," which he supposed to depend upon injury to the spine in trying to turn himself. Mr. B. Travers, sen., was sent for, and he suggested that the child might have had a fit, or, possibly, a "violent strain" might have been the cause. The letter states that "his water ran from him continually, and his legs were perfectly without motion." From this description, the muscles might have been flaccid, but rigid limbs might have been spoken of in the same terms. A warm bath was ordered. A liniment was applied to the spine, and subsequently a blister. The child is said to have been ill for several days afterwards, but beyond this no further history could be obtained.

The patient himself says, that he managed to walk, although badly, with a stick till the age of fourteen years, when he was obliged to take to crutches, and had continued their use ever since.

Amongst the various methods of treatment to which this gentleman had been subjected, his legs were submitted to a system of stretching, by weights of 25 lbs., attached to each foot, whilst the body was kept in a horizontal position on a table, and held down by a sand-bag weighing 56 lbs. placed across his back. This was adopted by Mr. J. G. de Betou, who practised in London upon what is called the Swedish system of muscular movements, or the system of Ling. The torture is described as having been excessive. No advantage was gained.

I divided the ham-string tendons, the tendo Achillis, the

peronei, and extensor longus digitorum tendons in each leg, eighteen tendons in all; and by appropriate mechanical treatment, the deformity was removed, as shown in Fig 85. He

FIG. 85.

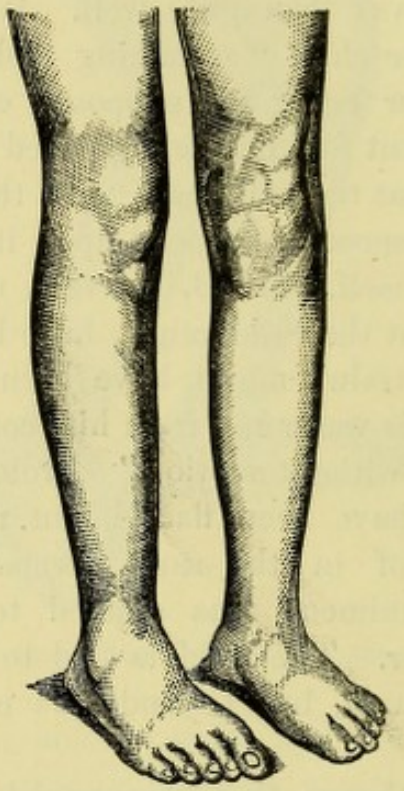

Improved condition of same case as represented in Fig. 84.

became perfectly erect, and gained more than two inches in height.

On the 22nd of September, 1852, boots with steel supports up to the thighs, were put on, and he was able to walk about pretty well with two sticks. He soon gained confidence and power. The crutches were thrown aside for ever, and at the present time, he walks very well with the assistance of sticks. Still, the directive voluntary power in the muscles of the legs below the hip-joints is imperfect, and it is doubtful whether he will ever dispense with sticks in walking. Active and passive muscular exercises, shampooing, and galvanism, were of use in the after-treatment, but in such cases we must not expect complete restoration of voluntary power;

still on the whole, the result of treatment in this case was most satisfactory, and I may mention that several surgeons who saw this gentleman with me, including Mr. South, and the late Mr. J. H. Green, considered that the severity of the case was such as to preclude all possibility of substantial relief.

NATIONAL HOSPITAL FOR THE PARALYSED & EPILEPTIC
PRESENTED TO
QUEEN SQUARE, BLOOMSBURY, LONDON

CLASS II.

DEFORMITIES WITH RIGID MUSCLES, THE RIGIDITY OR TONIC MUSCULAR CONTRACTION BEING CONSECUTIVE TO A FLACCID AND PARALYTIC CONDITION OF THE MUSCLES. ALL NON-CONGENITAL AND GENERALLY OCCURRING IN THE ADULT.

Case V.

Severe case of rigid muscular contraction of both feet, deformed in the position of equino-varus in an adult, consecutive to paraplegia, which deprived the patient of the power of walking without assistance.

Mr. I. C. M., aged 54, consulted me on the 30th September, 1852. An unusually stout man, both muscular and fat, supposed to weigh above twenty stone; had weighed twenty-two stone. The observation of weight is important in this case because it was used as an argument against dividing the Achilles

FIG. 86.

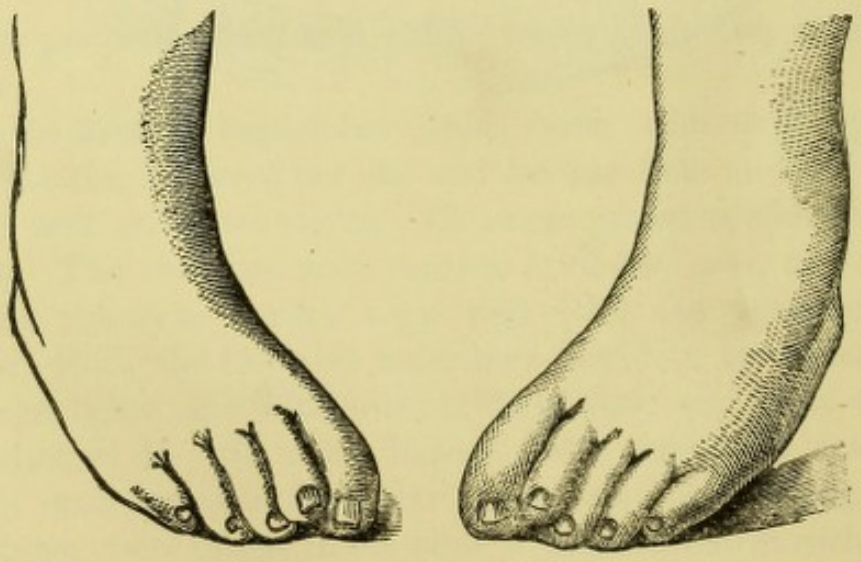

Rigid muscular contraction of both feet, talipes equino-varus, after an attack of paraplegia, in a gentleman 54 years of age.

tendons, and certainly diminished the favourable results of treatment. Both feet were contracted in the position shown in Fig. 86, equino-varus. The heels were only brought to the ground by bending the knee-joints, to relax the gastrocnemii muscles; under the enormous weight of his body, they could for a moment be brought to the ground without this, but the pain it caused in the popliteal space from muscular strain, rendered the position intolerable. In a sitting posture with the leg extended, the heel could not in either foot be forced lower than represented in the wood-cut. The feet were inverted, and in walking the weight of his body was thrown on the outer edge of the foot, towards the little toe; the skin and cellular tissue, in this situation, had become thickened and indurated. The feet also had the appearance of being very short, but this arose from their extended position and immobility of the ankle-joint in walking. The muscles of the leg on each side appeared to be of proportionate size to the rest of the body; they were firm, with a slight disposition to rigidity, rather than in the positively rigid condition frequently met with. He had some voluntary power over all the muscles of the foot; could flex and extend his knee-joint freely, and had a useful amount of power of the muscles of the hip-joint; but he could not flex the thigh, when in the erect position, to much more than half the natural extent; a certain amount of the *paralytic drag* therefore existed in progression. All the movements of the joint could be performed to an increased extent, when in a horizontal or sitting posture. He used to say that, when sitting, he could kick a man across the room as far as anybody; this seemed to be one of his best feats. He walked with extreme difficulty with the assistance of two sticks; the weight of his body was thrown forwards, and, in progression, was divided between the sticks and the legs. There was a constant liability to fall, from the toes coming in contact with any slight irregularity of the ground; this accident, rather a serious one in his case, had occurred on three occasions; this liability appeared to be increasing and was a source of great anxiety to himself and his family. Falling could only be prevented by the assistance of

two men, in consequence of his size and weight, and latterly he always walked between two men.

History of the Case. On the 29th December, 1824, he was taken ill with pain in the loins and general indisposition, said to be an epidemic fever then prevalent at Madras, where he was stationed.

On the 31st of December, paralysis of the bladder and rectum took place; retention of urine continued, and the paralysis is said to have extended gradually down the legs in the course of a fortnight, affecting the feet and toes last. Sensation and motion were said to have been completely lost from the waist downwards. The general health was not affected for more than four days. The urine was drawn off by catheter for twenty-two days; on the twenty-third day he first passed water voluntarily. The command over the rectum returned much more slowly, but was not as perfect as in healthy individuals when he came under my care.

Active antiphlogistic treatment was adopted at the time of seizure, and leeches were applied to the head and loins; subsequently counter-irritation was freely applied to the spine. In the course of from four to six months, sensation and motion began to be re-established, and the improvement was progressive.

A corresponding increase in the power of walking did not however take place, and this fact appears to have caused much perplexity to his medical attendants, who did not recognise the state of permanent contraction of the muscles of the calf. The inability to walk rather increased than diminished, and in the hope of gaining relief this gentleman came to England, and consulted Sir A. Cooper, Mr. Keate and Sir B. Brodie, who agreed in recommending mercurial treatment with counter-irritation. No benefit resulted, and he then went to Paris and consulted Magendie, Dupuytren, and Fouquier, who did not hold out any prospect of benefit. Dupuytren remarked that the case was one of irregular, or unbalanced muscular action, rather than paralysis. The patient returned to England and consulted Sir Charles Bell, who appears to have been much

interested in the case, and agreed with Dupuytren in considering an unbalanced muscular action to be a more prominent feature in the case at that time than the paralysis. He held out no prospect of benefit, and advised a return to India. This was followed, but the notorious empiric, St. John Long, was previously consulted, although fortunately the patient was induced not to follow his treatment.

This gentleman retired from India, and in 1848 tried the cold water system at Malvern. In six weeks his weight was reduced a stone and a half, with marked improvement in his powers of walking, and general health.

Subsequently his weight increased, and his locomotive powers became still further diminished. A distinguished surgeon expressed his belief that crutches would probably have to be resorted to. Among the various remedies in this case, moxas had been applied to the ankle-joints by a surgeon in India. A remarkable fact, not devoid of interest in connexion with Dr. Todd's view of regarding muscular rigidity in these cases to be dependent upon an irritative lesion of the nervous centre, is, that this gentleman had been married many years previous to the paralytic seizure without having any family, but since then he had become the father of thirteen children by the same wife, the first child was born within two years of the attack.

Now, viewing all the circumstances of this case; the contracted condition of the feet, together with the amount of voluntary power and general nutrition of the muscles of the lower extremities, I regarded it as a very favourable case for operation, and proposed division of the Achilles tendons, with the double object of giving the patient a firm base of support by bringing the feet into their normal position, and of rendering available for the purpose of progression, such amount of voluntary power as he might possess. This proposal met with considerable opposition, and at a consultation at which four surgeons besides myself were present, the opinions were equally divided. The fear of the tendons not being strong enough for the purpose of support in such a heavy man, and the essential

dependence of the affection upon a lesion of the spinal cord, were the arguments used in opposition.

Ultimately, an extremely guarded and qualified assent to the operation was given, amounting to little more than a desire not to oppose its performance if desired by the patient. Under such unfavourable auspices I might well have hesitated, but with the full confidence of the patient, a man of high scientific acquirements, and fully competent to appreciate the objects to be accomplished and mode of effecting them, I divided the Achilles tendons, that of the right foot on the 18th October, and the left on the 27th November, 1852, assisted by the late Mr. Benjamin Phillips.

The feet were gradually brought into their normal position, as shown in Fig. 87, the extension being cautiously made according to the activity of the reparative process in the formation of the new tendon.

On the 29th January, 1853, this gentleman walked round his dining room without his sticks, and taking hold only of one of my fingers, and one of his servant's fingers for the

FIG. 87.

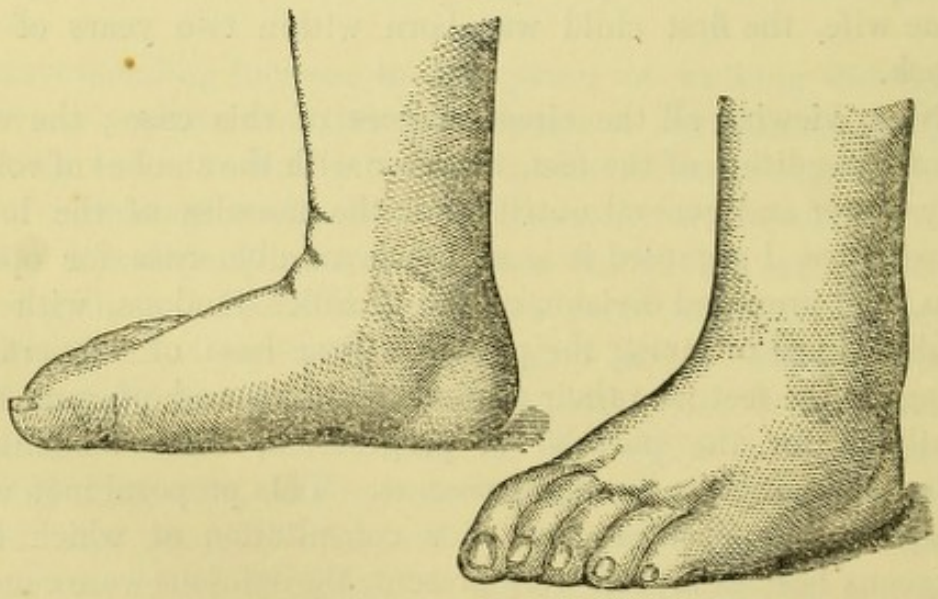

Improved condition of same case as represented in Fig. 86.

purpose of confidence and assistance in balancing his body.

Strength gradually increased with time and exercise, and he walked erect without any of the fatigue, or the distressingly laborious effort, which his unbalanced condition rendered necessary previous to the operation. A certain amount of paralytic weakness remained, so that the legs were advanced with a jerking movement. The amount of voluntary power in the different muscles, when examined separately by certain movements with the body in a horizontal position, would lead us to think that even this would disappear; but when in the erect position the enormous weight of his body told most unfavourably upon his legs, which were slightly paralytic. There can be no doubt that had this patient been a light weight, the results would have been proportionably more striking, whilst the evils to be remedied would have been scarcely less severe. Extreme weight must, therefore, be considered in our prognosis in these cases. Its effect was particularly obvious in this case in the difficulty with which the erect position was maintained for several months after he began to walk. Pain in the back, like severe lumbago, was a troublesome symptom, but Mr. Phillips agreed with me in considering it to depend upon the inability of the spinal and pelvic muscles to balance the body in the erect position. All pain gradually subsided, and the erect posture was maintained with ease and confidence, and he was enabled to walk a considerable distance without doing more than placing one hand on the shoulder of a page-boy, which he habitually did for the purpose of gaining confidence, and in some degree in aiding the general balance of his body.

The successful treatment of this case will serve to show how much it is now within our power to diminish the very serious inconveniences attending the late stage of these paralytic affections, when associated with contractions of the feet.

CLASS III.

DEFORMITIES WITH FLACCID MUSCLES, THE CONTRACTIONS DEPENDING UPON POSITION, AND ADAPTED ATROPHY OF MUSCLES, AND OTHER TISSUES. ALL NON-CONGENITAL, BUT GENERALLY INFANTILE AFFECTIONS, OR OCCURRING IN EARLY CHILDHOOD.

Case VI.

Case of infantile paralysis of both legs, two years' duration, with consecutive contraction of Achilles tendons, and the hamstring tendons of right leg. Commencing contraction at opposite knee, and the hip-joints.

On the 21st May, 1861, I was requested to see a young lady, V. C., aged seven years, in consultation with Dr. Brown Sequard and Dr. Allan.

Condition of patient. Both legs were in a paralytic condition up to the hip-joints, and had been so since severe illness in March, 1859. The nature of this illness appears to have been somewhat obscure; it was considered to have been of a rheumatic character, but the constitutional disturbance and febrile symptoms were less than in rheumatic fever. Neuralgic symptoms predominated. She suffered from acute pain in both legs, which were much swollen and discoloured. This illness lasted some weeks, and soon after its commencement, paralysis of both legs was found to have taken place. She was therefore totally unable to stand or walk, and her only mode of progression was by pushing herself along the floor with the assistance of her hands. Both hands and arms were strong and muscular, not having been affected by the paralysis,

nor had the spinal muscles or muscles of the trunk been involved, so that she was able to sit up firmly. In this position, however, she habitually crossed the legs and kept them in a bent position, which of course greatly favoured the inclination to contraction at the hips, knees, and feet; very little muscular contraction had taken place at the hip-joints, a fortunate circumstance, and she was enabled to flex and extend the thighs upon the body with considerable power. Recovery from whatever paralysis had existed in the muscles surrounding the hip-joints, had taken place to a considerable extent, and this I have stated to be the rule in such cases. The nates, however, were somewhat wasted, more especially on the left side, and this was the weaker leg throughout.

The right knee-joint had become a good deal contracted, and the ham-string tendons were tense. In the opposite knee, contraction was only commencing. She had the power of flexing both legs from the knee-joints, but no power whatever of extending them; the rectus muscle in each thigh being completely paralysed. The muscles in both legs below knee were much wasted, and she had no power of extending the toes or flexing the feet from the ankle-joint. Very little vitality existed in any of the anterior muscles of the leg. She possessed the power of flexing the toes in both feet, a pretty constant condition in these severe paralytic cases. Both the Achilles tendons were much contracted, more especially the right. The right foot was inverted in the position of equino-varus, and the left foot somewhat everted with an inclination to equino-valgus, so that neither foot could be brought into the position of a right angle with the leg, an essential condition for standing or walking.

This young lady had been allowed to remain in this condition so long without any treatment being adopted, except such rubbing as could be done by the nurse, in consequence of strongly expressed opinions adverse to any and every method of treatment having been given by the late Sir Benjamin Brodie, Professor Syme, as well as other surgeons and physicians who had seen the case.

At the consultation with Dr. Allan and Dr. Brown Sequard, I expressed a decided opinion that if the contractions of the feet and the right knee were overcome by tenotomy, and appropriate mechanical treatment, this young lady could then be made to walk with the assistance of steel supports to the legs, so constructed as to compensate for the loss of muscular power below the hip-joints.

Dr. Allan and Dr. Brown Sequard agreed with me as to the advisability of the operation for tenotomy, and therefore on the same day (the 21st May, 1861) I divided both Achilles tendons. The feet were gradually brought into their natural position by means of the Scarpa's shoe, in about six weeks. Whilst this was proceeding, I divided the biceps tendon at the right knee-joint on the 14th June. Two months after the first operation, when the Achilles tendons could be felt firmly united by new connective tissue, I allowed her to begin to walk with the assistance of steel supports attached to the boots, and carried up the legs to the waist, round which they were connected by a steel band. Free motion was allowed at the hip-joints, but the knees were kept stiff during walking to compensate for the loss of the recti muscles; in the sitting position the knees could be flexed by what is known as the flute-key joint.

With this mechanical assistance she soon gained confidence in walking, and on the 9th August, 1861, when Dr. Sequard saw her with me, my report states "much improved and walking very well about the room and garden."

Under Dr. Sequard's direction, strychnine and iron were administered in small doses, and both legs were galvanised three times a day in hot water for twenty minutes or half an hour, each time; shampooing also being regularly employed. Under this system, progressive improvement in muscular power took place, and on the 14th December, 1861, my report states, "walks very much better."

On the 14th March, 1862, my report states, "very much improved in muscular power. The rectus muscle in each thigh can now be felt; and seen to contract. With the aid of her

steel supports she could walk about without other assistance, and by taking hold of the balusters could even go upstairs."

On the 28th July, 1862, improvement is reported as still satisfactory. During the years which have since elapsed there has been a steadily increasing gain in muscular power to which a well-conducted system of special gymnastic exercises has very much contributed. The mechanical supports have been diminished, but cannot be entirely dispensed with.

Case VII.

Case of infantile paralysis, affecting both legs, with consecutive deformity of the feet, remaining unrelieved up to the age of thirty-nine; total inability to stand or walk.

On the 5th March, 1852, I was requested by my friend Dr. Goolden, of St. Thomas' Hospital, to see a lady, Miss M. M. R., aged thirty-nine, of small stature, and very thin. She was totally unable to walk, or even to stand, either with crutches or any other assistance, in consequence of the completely paralytic condition of both her legs, produced by an attack of paralysis at the age of five years, and from which only partial recovery had taken place, followed by contraction of both feet. She was always carried about by a servant, and in the drawing-room and garden, made use of a *wheel-chair*. Both her legs were atrophied to an extreme degree, with the muscles

FIG. 88.

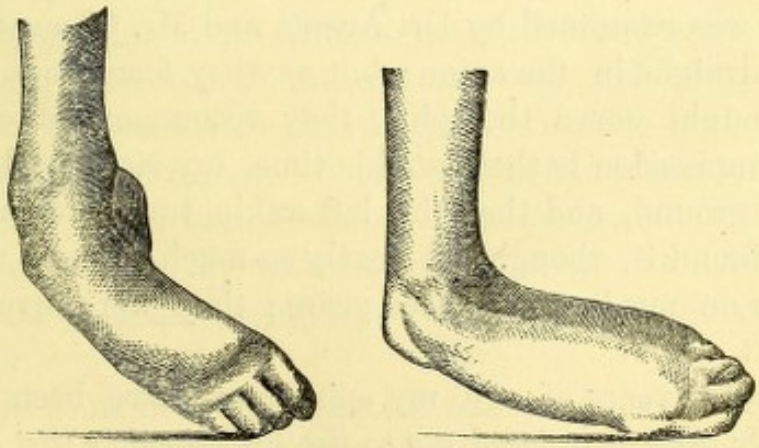

Deformity of both feet, talipes equino-varus of right, and talipes equino-valgus of left, with muscles in a flaccid condition after infantile paralysis, in a lady 39 years of age.

in a flaccid condition, and the feet contracted in the positions represented in Fig. 88, equino-varus of the right, and equino-valgus of the left foot. She had no power whatever in any of the muscles of the left foot and leg below the hip, excepting a very feeble power in the ham-string muscles. In the right leg there had been a slight general return of power in the muscles, but the rectus muscle of the thigh was now as powerless as that of the left side (probably from rupture of the ligamentum patella, the result of an accident), so that both the legs were in the so-called "swinging" condition, without the least power of extension. Yet, voluntary power existed in the muscles around the hip-joints, sufficiently to enable the patient to flex and extend these joints with tolerable force. She also suffered from a lateral curvature of the spine to the left side, of extreme severity, and accompanied with unusually severe symptoms.

History of the Case. This I give from an account written by herself:—"When five years of age, I was suddenly seized with an attack of paralysis affecting both arms and both legs, whilst sitting on a chair in the day time. It was found that I could neither get off my chair, nor even move a finger. After some days I recovered the use of my hands and arms, but to this day the left arm is weak. After some months, I so far recovered the use of my legs as to be able to walk with the assistance of an arm, and a stick in my right hand, pressing it against the right hip. From the time of my illness, I used to lie almost all day on a reclining board. When between eight and nine years of age, I was examined by Dr. Arnott and Mr. Cline, and pronounced straight in the spine; but as they feared my mode of walking might curve the spine, they recommended crutches. My own impression is that, at this time, my right heel did not touch the ground, and that the left ankle turned over in the way you found it, though not nearly so much. I now wore instruments on my legs for three years; they were invented by Dr. Arnott.

"At twelve years of age, my spine must have been curved, because Dr. Arnott ordered me to use his *tripod*, a sort of crane on a three legged stand placed behind a small chair with an

upright back; a steel arch went over the head, with a strap under the chin; a strap was also placed under each arm, both head and arms were then balanced by weights hung over pullies. In this machine I used to sit the whole day, with the exception of the time passed in exercise, or on the reclining board, until I went to France in 1829 (then sixteen years of age), I could at this time walk about a mile, and ride perfectly well. I was thrown from my horse and broke my right knee, and after this accident always *swung my legs* in walking.

"In August 1830 (then seventeen years of age), I had fainting fits, and used to remain insensible for an hour and a half, or two hours at a time. Then I was seized with those spasmodic attacks described to you by Dr. Goolden, and from this time I never walked, excepting one day after my return to England I managed to walk across the room."

This case was evidently an example of the most severe form of infantile paralysis, involving both the upper and lower extremities, and probably to a less extent, the muscles of the trunk. As far as I could learn, the paralytic seizure was neither preceded nor accompanied by any cerebral symptoms, nor marked febrile attack. Nearly perfect recovery took place in the upper extremities, as usual; but very partial improvement occurred in the lower extremities, and this was almost entirely confined to the right leg. From the fact of her having walked, there can be no doubt that the rectus muscle of the right leg had partially recovered, together with the other muscles of this leg, but the accident referred to (probably rupture of the ligamentum patellæ, which I found more attenuated and longer than that of the opposite leg, and the patella displaced to some extent upwards and outwards) reduced this leg to the same "swinging" condition as that of the left in which no recovery had taken place. Loss of health followed this unfortunate accident, which deprived her of the little muscular power she possessed in her legs available for the purpose of progression.

The fainting fits and spasmodic attacks, in which Dr. Goolden told me the diaphragm was affected, so as to cause the most

serious apprehensions, probably depended upon spinal irritation produced by a rapid increase in the spinal curvature. The effect was, that from the year 1830 to the year 1852, when I first saw her, a period of twenty-two years, she had been unable to walk, even with any amount of mechanical assistance that could be rendered her.

Relying upon the favourable condition above adverted to, viz., the existence of voluntary power in the muscles in the neighbourhood of the hip-joints; the psoas, iliacus, glutei, &c., I undertook the treatment of this case, and promised to make her walk after a manner—stiff legged I may call it—but at any rate sufficiently well for the more important purposes of exercise and health.

By division of tendons and mechanical treatment, the feet were easily brought into their normal position as exhibited in Fig. 89, in less than three months; and, with the assistance

FIG. 89.

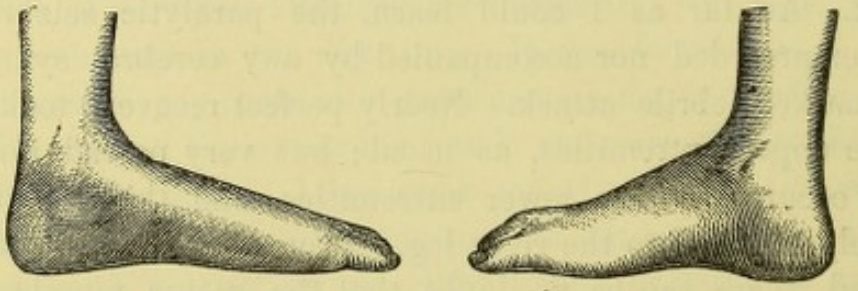

Improved condition of same case as represented in Fig. 88.

of steel supports extending above the knee-joints, she was enabled to walk, to the extreme surprise of her oldest friends who had hitherto seen her either carried in the arms of a servant, lying down, or sitting in a wheel chair. For the purposes of confidence and balance, she usually walked between her two sisters, and in a few months could take exercise for half an hour at a time. Muscular power improved, and with it came fresh accomplishments, such as walking up and down stairs without any other assistance than taking hold of the balusters, &c. She rapidly gained flesh, and her general health greatly improved. A new life seemed to open itself to her. The plea-

sures of being able to walk to church, visit her friends, see exhibitions, and in various ways to enjoy many of the pleasures of life to which she had hitherto been a stranger, may be better conceived than described.

Case VIII.

Case of infantile paralysis affecting only some of the muscles of one leg below knee, coming on suddenly and mistaken for hip-joint disease.

On the 12th September, 1856, I saw in consultation with my friend, Mr. Covey, of Wilton Street, a young gentleman, Master C., from Toronto, aged five years, who had suffered from partial paralysis of the left leg, from which recovery, to a great extent, had taken place. At the time we saw him, the peronei and extensor longus were the only muscles remaining paralysed, but in consequence of this, the foot was rapidly assuming the varus form. He walked with extreme lameness which was supposed to have been the result of hip-joint disease, for which he had been treated by leeches, counter-irritation, and a course of alterative treatment, under which the joint affection was supposed to have yielded. Not the slightest trace of hip-joint disease existed when this case came under our care, and we saw no reason to believe that any had ever existed. The first error of diagnosis in this appears to have been made, in consequence of a little peculiarity (though not one of very rare occurrence) in the mode of seizure. The boy suddenly fell whilst going up stairs, and as he afterwards limped, and complained of slight pain in his thigh, injury to the hip-joint was at once assumed by the surgeon in attendance; and a little later it was proposed to employ the actual cautery; but as this met with some objection, two other surgeons were called in consultation. Even now the error in diagnosis was not detected, but the cautery was rejected, and blisters recommended. I have no doubt that this child fell in consequence of the sudden seizure of paralysis, and if all the muscles of the leg had

suffered, the nature of the case would not have been overlooked. The deformity of the foot in this case—that of paralytic equino-varus—was easily remedied by division of the tendo Achillis, and tibialis anticus muscle. The foot was brought into a natural position, and the ankle-joint supported by a steel on either side, attached to the boot, and carried up to the calf of the leg, where they were connected by a circular steel band. A free joint was placed in the steel supports, opposite the ankle-joint, and with the assistance of this he was enabled to walk with ease and security.

Case IX.

Case of infantile paralysis affecting all the muscles of one leg, below the hip-joint, coming on suddenly, and mistaken and treated for fracture of the leg.

In the year 1857 I had under my care a boy, who suddenly fell, and all the muscles of the left leg, below the hip-joint, were completely paralysed as to motion, (sensation is generally either very little, or not at all impaired in these cases) and the mother supposed the leg to have been broken. She took the child to one of our Metropolitan Hospitals, where it was pronounced to be fractured, and set accordingly. The mother continued to attend with this child for a year, and then believing that the fracture had never been properly set, because, she said, the leg appeared to be exactly the same as when she picked him up after the accident, she brought the child to the Orthopædic Hospital. The leg was found to be completely paralytic, very much wasted or withered, and contraction of the foot, and also at the hip-joint had taken place—only to a slight extent at the hip—but there was no indication of any fracture having occurred.

By division of the tendo Achillis in this case, the contraction of the foot, which was in the position of simple equinus, was easily removed; but in consequence of the paralytic condition of the rectus muscle, as well as the other muscles of the

leg, it was necessary to carry a steel support from the foot to the hip-joint, and to connect this with a steel band round the waist, so as to compensate for the paralytic condition of the limb. With this mechanical assistance, the boy was soon enabled to walk, and some improvement in muscular power took place, but not to an extent sufficient to enable him to dispense with the steel support.

Case X.

Case of infantile paralysis of both legs; more complete in right leg, in which it was mistaken for dislocation of hip-joint.

On the 20th February, 1860, a young gentleman aged four years, Master H. E., who had never stood, or walked, was brought to me, and his condition was at that time as follows.

Both legs were paralytic up to the hip-joints, but some power existed in the muscles surrounding these articulations, sufficient to enable him to draw up his legs when lying down on the floor. I may mention that the existence of this power is of the utmost importance, as it at once decides the possibility of making a child walk who is paralysed in both legs. Without this power, no such possibility exists.

The right leg was more completely paralysed than the left, no power existed in the rectus muscle of the thigh, or in the gastrocnemius muscle of the leg, and the foot was gradually assuming the position of calcaneo-valgus. The anterior muscles of the leg, and the flexors of the toes alone exhibited any trace of power.

In the left leg the rectus muscle of the thigh was extremely feeble, but not completely paralysed. The tibialis anticus exhibited no trace of power. The gastrocnemius was also extremely feeble, and the tendo Achillis slightly contracted. The left foot was becoming deformed in the position of equino-valgus.

History of the Case. This child was said to have been a strong and healthy baby, but the mother was obliged to wean him

when four months old, and then he was fed on biscuit powder and milk. From this time his health failed, and in a week he became seriously ill; his hands remained clenched for three weeks, both feet were similarly affected, and the toes were drawn under the foot. Both legs were observed, very gradually, to become paralytic, and when six months old, his mother states that both legs were quite powerless, and he could not feel, when tickled.

When a year old, the parents thought the right leg was longer than the left, and this together with an increased prominence of the thigh bone at the right hip-joint, induced them to consult a surgeon of eminence, who considered the hip to be dislocated, an opinion in which other surgeons concurred. On two occasions chloroform was administered, and attempts to reduce the dislocation persevered in without any alteration in the form of the joint being produced. A further consultation was held at which the late Sir B. Brodie was present, and he decided that no dislocation existed, and that the prominence of the thigh bone was due to the wasting of the nates and muscles surrounding the hip-joint. I would here mention that other cases have fallen under my observation in which the same error of diagnosis has been committed.

Treatment. The contraction of the tendo Achillis in the left foot was not sufficient to require division, and therefore I ordered the mechanical supports usually given in these cases, (see Fig. 57) and with this assistance, he was at once enabled to stand, and soon began to walk, pushing a chair or a three-legged stool on wheels, before him. From that time to the present date, the improvement in muscular power and ability to walk, has steadily progressed, and the boy is now enabled to walk about the room and the garden, for a short time, without any steel supports, and to-day, October 3rd. 1866, I saw him do this. The recovery of power in the leg is very satisfactory, and both the rectus and tibialis anticus muscles are tolerably strong. In the right leg, however, the recovery in the rectus muscle, and in the gastrocnemius, has been very slight; but the general muscular development in this leg has so far improved

as to render it very useful, although he throws it outwards, with a somewhat swinging movement of the knee, in walking.

The mechanical supports are now partially discontinued, but it is still necessary for him to wear steel supports above the ankle-joints, to prevent the twisting of the feet which would become deformed without this assistance. As he walks better with the steel supports to the hips, these are also sometimes used.

In the treatment of this case, I should also mention that the legs have been regularly galvanized under hot water two or three times a day, and that in the right leg, the temperature has always been much below that of the left. Dr. Junod's exhausting apparatus has been most assiduously applied by the mother every day during the cold weather, and generally throughout the year. No inconvenience has ever attended the use of this apparatus, and its application for a quarter of an hour in the coldest weather has always been sufficient to raise the temperature of the leg, which has remained warm for the rest of the day. At the present time, the temperature of the right leg is habitually very little below that of the left, but in cold weather Dr. Junod's apparatus is still applied. In similar cases, where the temperature of the limb is very low, I always employ this apparatus, and the advantage derived from its use in raising the temperature of the limb, and in promoting the recovery of muscular power is beyond question. The point worthy of mention in this case, is the success which has attended the efforts to prevent the contractions and deformities of the feet, knees and hips, pretty constantly met with in these cases after a few years, and for the removal of which tenotomy and mechanical treatment is generally required.

THE FOLLOWING CASES ARE SELECTED FOR THE PURPOSE OF ILLUSTRATING SOME POINTS OF INTEREST IN THE PATHOLOGY AND TREATMENT OF DEFORMITIES OF THE FEET; OR SOME VARIETIES OF UNUSUAL OCCURRENCE.

CASE XI.

Case of talipes equinus, produced by strumous abscesses of the leg, and in the neighbourhood of the joint.

The young lady who was the subject of this deformity, an extreme degree of talipes equinus represented in Fig. 90, Miss M., aged 15, was brought to me on the 18th July, 1854, by Mr. Brendon of Highgate. She was of a decidedly strumous

FIG. 90.

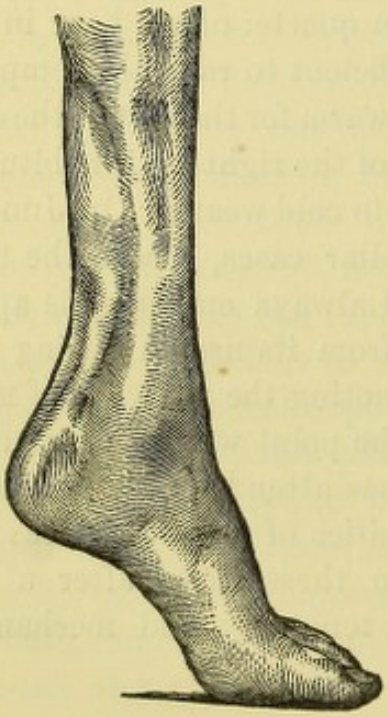

Severe talipes equinus produced by strumous abscesses in the leg, and in the neighbourhood of the joint, in a young lady 15 years of age.

FIG. 91.

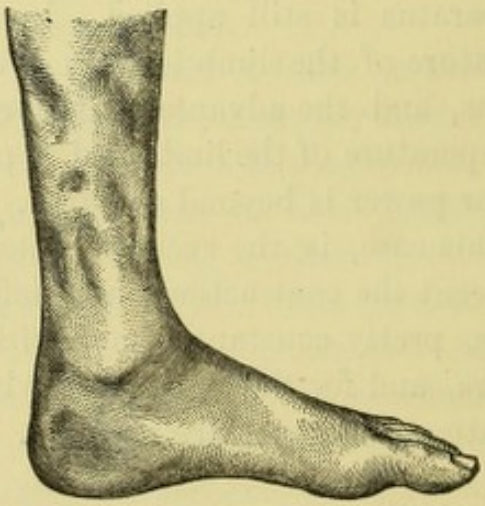

Improved condition of same case as represented in Fig. 90.

diathesis, tall, thin, and growing quickly, and had been subject to strumous abscesses in various parts of her body

since early childhood, and in the left leg, below knee, numerous abscesses had formed in the neighbourhood of the Achilles tendon, the ankle-joint, and also along the tibia and fibula; the periosteum was involved in several places, but there had been no necrosis. All the abscesses had been healed for some time before she was brought to me, but deep cicatrices remained in the neighbourhood of the Achilles tendon, and along the leg, as represented in Fig. 90.

The contraction of the foot, in the position of talipes equinus, had existed for several years, and the deformity was still increasing. As a consequence of the extreme lameness produced by this deformity, a slight lateral curvature of the spine had been produced, and the tilting of the pelvis was such as to favour the increase of this affection if allowed to continue.

From the rigidity of the contraction, it was impossible satisfactorily to detect motion in the ankle-joint, but there was no other reason to suspect the existence of joint disease. Mr. Brendon's opinion was that the joint had not been implicated and this proved to be correct. On the supposition of the existence of partial anchylosis, it had been proposed to cure the deformity by *breaking it down*, an offer which was very prudently rejected. By the simple operation of tenotomy and gradual mechanical extension, most carefully conducted by my late friend Mr. Lane, of Highgate, to whom the successful result of the case was mainly attributable, the deformity was completely removed as shown in Fig. 91, without any serious risk having been incurred. She soon obtained a slight amount of motion, which gradually increased at the ankle-joint. The muscular and other structures were of course too much damaged to allow of perfect restoration of muscular power, but still in the course of a year or two, the freedom of motion was such, that no lameness in walking was apparent.

Case XII.

Case of congenital talipes varus, in which the redundant skin on the outer surface of each foot was dissected off by a surgeon, in the hope of producing such an amount of contraction by the cicatrix, as would overcome the tendency to inversion, and thus cure the deformity.

On the 19th October, 1852, I was requested to see a child, Master A., aged one year and nine months who was the subject of congenital varus and whose feet were in the position represented in Fig. 92.

FIG. 92.

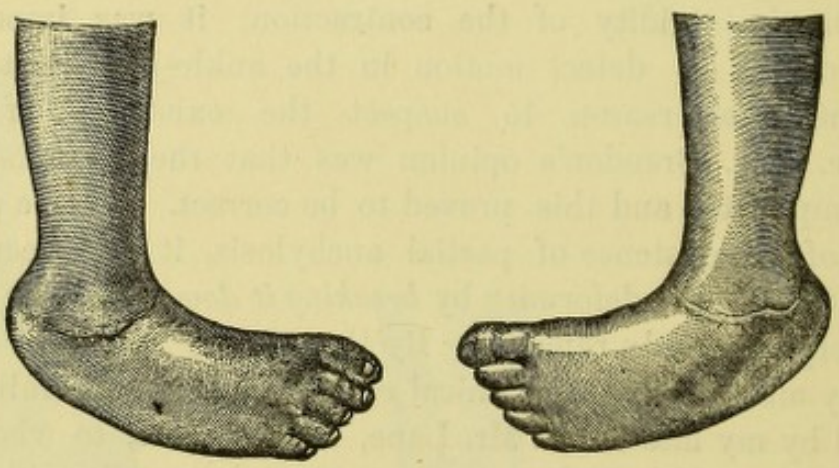

Congenital talipes varus of both feet, which had been operated upon by removal of skin on convexity of feet, cicatrices shown below ankle-joint.

I was astonished at observing two very long scars, one on each foot, reaching from the front in a curved direction, over the convexity and outer part of the foot, quite to the back, and measuring two inches and a quarter in length. There were also several scars at right angles to the larger ones, evidently from the sutures which had cut their way out. Judge my surprise when I learnt that these were the scars of operations performed only about a year previously to cure the club-foot. As far as I could learn from the family, in explanation of this extra-

ordinary and novel procedure, it appeared that the surgeon who operated commenced the mechanical treatment of the case soon after the birth of the child, using gutta percha splints, which several times caused sores, and gave rise to a great deal of pain and trouble, doubtless from the pressure of some of the hardened folds and irregularities in shape produced in adapting it when soft to the foot. At the end of about ten months, however, it seems that very little progress had been made, and then the surgeon performed the operations, the cicatrices of which are shown in Fig. 92. The idea seems to have been to endeavour to overcome the turning inwards of the foot, by the removal of as large a portion of skin as possible from the outer half and convexity of the foot.

I may remark that there often appears to be a great excess of skin on the convexity of the foot in a severe case of varus, and this is rendered very apparent by any effort to turn the foot in its proper direction. A large fold may be pinched up between the finger and thumb, and I suppose this tempted the surgeon to remove it, but upon what idea, or by what process of reasoning the suggestion of the operation was arrived at, I am unable to say. Probably he was influenced by observing the phenomena of contraction by cicatrization after burns; but he could scarcely have been aware of the true nature of the affection, and the fact that contracted and shortened muscles formed the great obstacles to be overcome. I was informed that the wound healed slowly, and that the foot required the use of poultices for two months. I sincerely hope that this was the first, and may be the last time of this operation, which might with propriety be spoken of as the *cutaneous* in contradistinction to the subcutaneous operation for club-foot, being performed.

On the 20th October, 1852, I operated upon the left foot, dividing the anterior and posterior tibial tendons, and afterwards applied the straight splint on the outer side of the leg, for the purpose of bringing the foot into the position of talipes equinus.

On the 27th October, I operated in a similar manner on the right foot, and when the eversion was complete in each foot, in

about three weeks I divided the Achilles tendons. The case progressed favourably, and in less than three months the deformity was removed and the feet brought into the position shown in Fig. 93. Shampooing and passive exercises were continued with the object of improving muscular power, and the case proceeded favourably for four years. After this I lost sight of

FIG. 93.

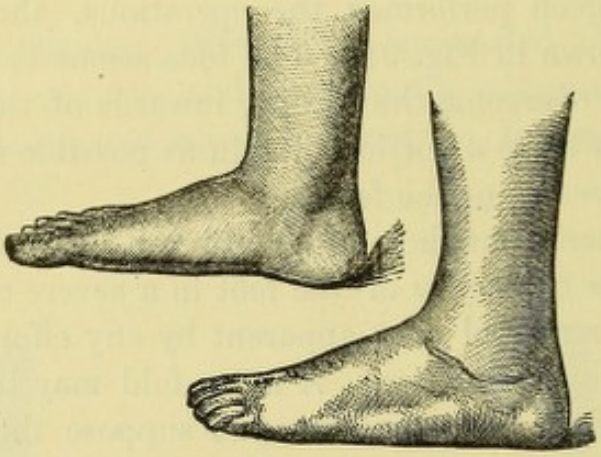

Improved condition of same case as represented in Fig. 92.

the patient who was not brought up to town again until 14th May, 1859, when I found that some relapse of the deformity had taken place in both feet, but not to a severe extent. During the three years this young gentleman had been removed from my observation, he had been wearing very badly constructed steel supports, made by an instrument-maker in the North of England. It now became necessary to redivide the Achilles tendons, and also to divide the plantar fascia. In consequence of the rigidity of the feet, the subsequent mechanical treatment was tedious, and it was six months before the feet were completely restored. By close attention to the shampooing and passive exercises, the muscular power of the legs was greatly improved and the calves became very fairly developed. I am enabled to state that this young gentleman has continued to progress favourably up to the present time, and that the feet in their general form, extent of motion at the ankle-joint, and

in muscular power, are very nearly equal to those of other boys of the same age.

One fact in connection with the cicatrices described in this case is especially worthy of remark, viz., when this child first came under treatment in October, 1852, the scar on the convixity of each foot measured two inches and a quarter in length; and when he came under treatment a second time in May, 1859, it was found that each scar had grown fully an inch in length during the six years and a half. Casts of the feet were taken on both occasions, and are now in my possession, so that the fact is satisfactorily shown. I exhibited these casts to the Pathological Society on the 21st February, 1860, (see Vol. XI), and with them adduced other facts to prove that a cicatrix, instead of wearing out as it is generally supposed to do, "appears to be persistent through life, and to grow *parî pasû* with the rest of the body, or rather with the portion of the body over which it may be placed."

Case XIII.

Case of the most severe form of congenital talipes varus in the adult; the first case in which the instrument Fig. 56, was applied.

The gentleman who was the subject of this deformity, Mr. B., 26 years of age, was a tall, moderately stout, and very muscular man. The deformity, congenital talipes varus, affecting the right foot, was of extreme severity; and the foot so rigid, that no effect could be produced upon it by manipulation.

The details of the treatment of this case are as follows.

May 29, 1854.—The first operation was performed. I divided the tendons of the tibialis anticus, extensor pollicis, tibialis posticus, and flexor longus digitorum muscles; and also the plantar fascia.

June 1.—Applied the apparatus illustrated in Fig. 56.

The eversion of the foot, and uplifting of its outer margin, proceeded very favourably until about half of this part of the deformity had been overcome.

Oct. 6.—Very little progress had been made for some weeks, and the structures in the sole of the foot (evidently the flexor tendons, as well as the plantar fascia) had become extremely

FIG. 94.

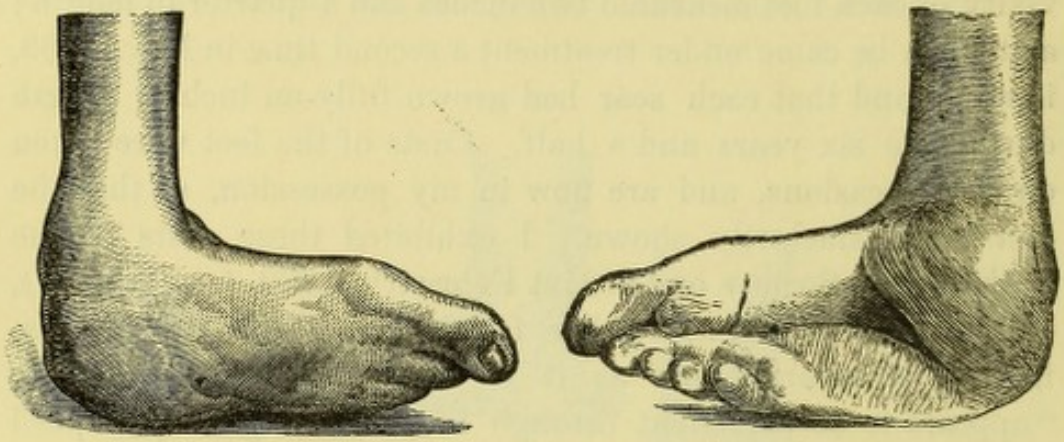

Congenital talipes varus in a gentleman aged 26; anterior aspect. Posterior aspect of the same foot

tense. The tendon of the peroneus longus was also very tense and prominent, and pain was felt along this tendon when the everting and uplifting force was increased. I therefore redivided the plantar fascia, and with it some of the flexor tendons, by a free and deep incision. I also divided the tendon of the peroneus longus, having previously determined by an examination of the dissected foot, represented in Figs. 34, 35 and 36, that this tendon, or rather the muscle to speak correctly, must be shorter than natural in a case of such severity. No inflammation or inconvenience followed the operation in the sole of the foot. The apparatus was never discontinued, and very rapid improvement followed this operation.

Nov. 14.—The inversion of the anterior part of the foot, and also the rotation of the cuboid and outer metatarsal bones—or, as it is called, the unfolding of the transverse arch of the foot—have been completely overcome. When the apparatus is removed there is no disposition to inversion. The first stage of the treatment is now finished, and complete equinus produced. The cast from which Figs. 95 and 96 have been drawn, was taken at this date.

So far as I know, this is the first case in which, "the unfolding of the transverse arch of the foot" has been overcome in the first stage of mechanical treatment, *i.e.* simultaneously with eversion of the foot.

FIG. 95.

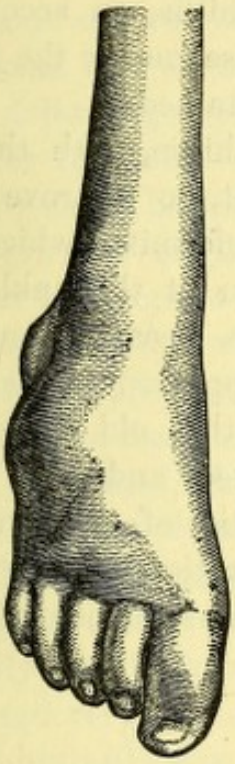

The same foot as Fig. 94, after six months' treatment, when the inversion had been overcome. Anterior aspect.

FIG. 96.

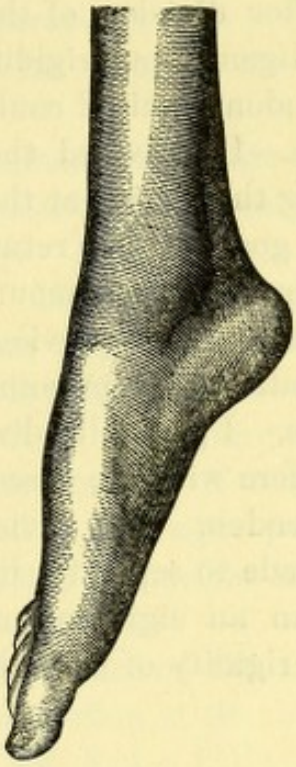

Lateral aspect of the same foot, exhibiting the complete equinus form.

Nov. 17.—I divided the tendo Achillis. Continued the same apparatus, but with a flat sole-plate, so that its action was similar to that of the Scarpa's shoe.

April 4, 1855.—The foot is now flexed at a right angle with the leg, and has been in this position two or three weeks without making further advance. The ankle-joint is very stiff. Ordered active and passive exercises to be commenced; a common boot, without any steel support, to be worn in the day time; and the instrument to be continued only at night as a retentive apparatus. After a time, the ordinary Scarpa's shoe was worn at night, as being less cumbersome.

The exercises and walking did not appear to produce much improvement, and the motion at the ankle-joint continued very limited. This evidently depended chiefly upon the ligamentous rigidity at the ankle-joint, but partly also upon the tendo Achillis not being long enough to allow of more than a right-angled flexion. The flexion of the foot had proceeded very slowly after division of the tendo Achillis, on account of the extreme ligamentous rigidity, and consequently the full length of the tendon required could not be obtained.

May 4.—I redivided the tendo Achillis, with the view of increasing the flexion at the ankle-joint, to improve the walking, and guard aginst return of the deformity, which is often induced by a limited amount of motion at the ankle-joint. I divided above the previous operation, because the tendon in this situation was prominent, and appeared to be free from adhesions. I generally divide below, that old adhesions may not interfere with the descent of the heel and rapid formation of new tendon. The divided extremities of the tendon could not be made to separate, by the application of moderate force, more than an eighth of an inch, in consequence of the ligamentous rigidity of the ankle-joint.

FIG. 97.

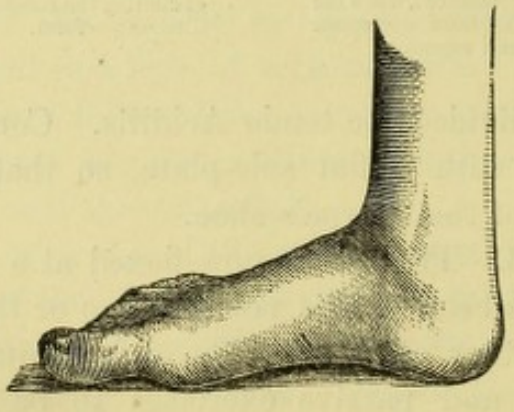

The same foot, showing the complete removal of the deformity six months after the casts, Figs. 96 and 97 were taken, and one year from the commencement of treatment.

May 24th.—Very much improved by mechanical treatment.

Foot now flexed well beyond a right angle, as shown in Fig. 97. Passive motion, and walking exercise to be resumed.

August 30.—Foot improved. Mr. B. can now walk a mile easily.

I may here observe, that during the whole of the above treatment Mr. B. was not absent from business a single day. He walked about on crutches. The operations were performed in the afternoon, and on each occasion he went to his counting-house the following day.

December 18, 1856.—I have examined Mr. B. this day, more than a year and a half since the termination of treatment, and complete removal of the deformity. There is not the least disposition to inversion of the foot He wears as neat a boot on the previously deformed foot as on the sound foot; and, as far as external appearance goes, all is perfect, and no one would imagine that he had been the subject of any deformity. Anatomically examined, the foot is very nearly if not quite as perfect in form as it was a year and a half ago; perhaps the arch is a little increased, and the instep somewhat higher, but not enough to attract the patient's attention.

The only drawback to the complete cure of the case is the stiffness and very limited amount of motion at the ankle-joint. He can voluntarily flex and extend the foot a little, and therefore motion exists at the ankle-joint. Some improvement in this respect has taken place, but not to a sufficient extent for walking purposes; practically, therefore, he has a stiff ankle-joint, which produces lameness in walking, particularly when he walks fast and takes long steps; but if he takes short steps, it is scarcely noticeable. He does not use a stick, and tells me that he can walk any reasonable distance; that long standing does not fatigue him; and that his foot is thoroughly strong and useful; but in damp and changeable weather he has something like rheumatic pain across the ankle-joint after much exercise. With regard to the stiffness of the ankle-joint, I am decidedly of opinion that much of this might have been overcome, by a long continued course of special exercises and shampooing continued for two or three years; but the business occupation of

Mr. B. was an obstacle to this being systematically followed out. The exercise of the foot, conducted by the patient himself, has already produced increased muscular development, as proved by the fact, that the circumference of the leg at the most prominent portion of the calf, which is still much smaller and higher than natural, has increased three quarters of an inch.

This patient is now free from the risk of inconvenience and dangers arising from ulcerations from pressure on the deformed foot, to which club-footed adults are especially liable, and it was in consequence of his foot becoming more tender to pressure and less useful in walking, that he was induced to apply for relief.

Case XIV.

Severe case of relapsed congenital varus of both feet, successfully treated.

A young gentleman, Master H. A., aged 10 years, from Maidstone, was brought to me on June 28, 1852. He had been afflicted with severe congenital varus of both feet, supposed by his mother to have been caused by a strong mental impression made upon her by looking at Raphael's cartoon of the Cripple at the Gate of the Temple, when she was about three months advanced in pregnancy. At the age of ten months, this child was operated upon by an eminent orthopædic authority in this metropolis. Neither expense nor trouble was spared, and the mother devoted an extraordinary amount of personal trouble and attention to the after-treatment. The rubbing and exercising were also conducted by a person especially employed. The subcutaneous division of the posterior tibial tendon had been attempted, but this must have been one of the earliest cases in which this operation was tried, and possibly the tendon was not divided. However, partial relapse took place twice in both feet, and some of the tendons were more than once divided during the first five years. At the end of this time the feet were still imperfect in form, but

the parents were assured "that what remained was in the bones, and could not be removed." Passive motion was directed and unremittingly attended to, but no improvement resulted, and the boy very slowly but progressively got worse. When brought to me the feet were distorted in the form represented in the annexed wood-cut Fig. 98.

In consequence of the repeated operations which had been performed in this case, and the very rigid condition of the feet, I was not disposed to promise success; but, in the hope of improvement, further treatment was submitted to, and commenced on the 12th of August, 1852.

FIG. 98.

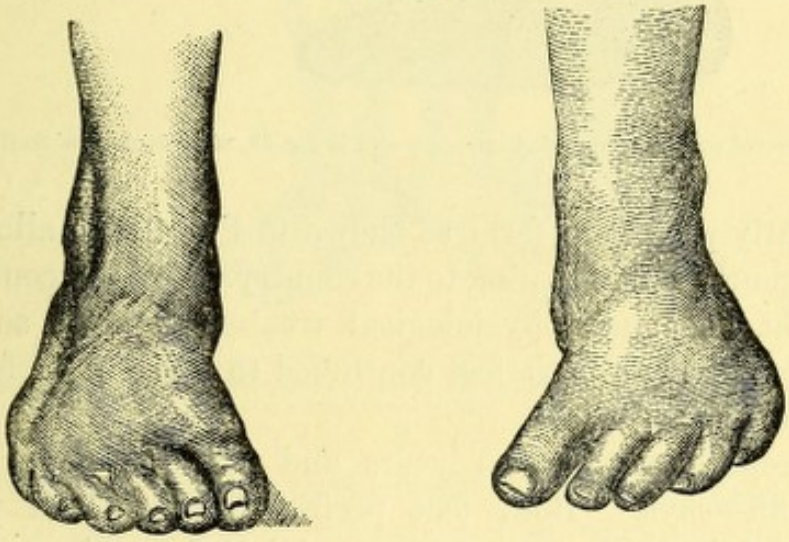

Relapsed case of congenital varus in Master H. A. aged 10 years, who had been operated upon in infancy.

In this case, I redivided the anterior and posterior tibial tendons; the tendons of the flexor longus digitorum and the extensor pollicis, the tendo Achillis, and the plantar fascia. The treatment was divided into three stages, the object of the first stage being to overcome the inversion of the anterior portion of the foot; that of the second to overcome the contraction in the arch of the foot, after division of the plantar fascia; and the object of the third, to increase the flexion of the foot at the ankle-joint after division of the tendo

Achillis. The mechanical treatment was conducted with the greatest care and attention, and in six months both feet were

FIG. 99.

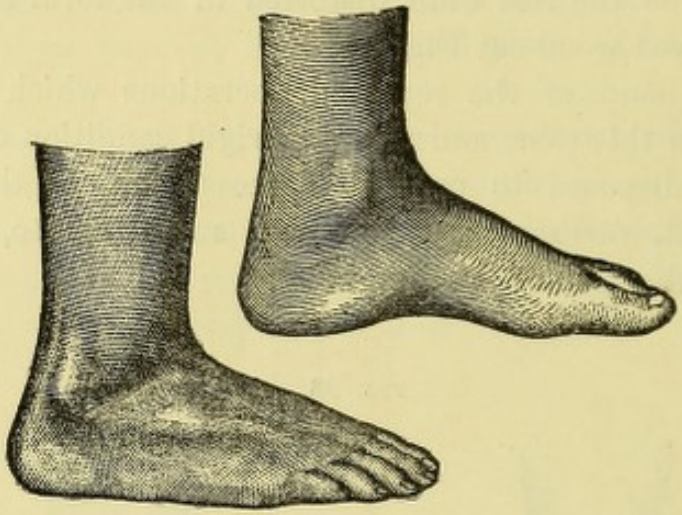

Improved position of same feet as represented in Fig. 98, after six months' treatment.

sufficiently perfect in form, as shown in Fig. 99, to allow of the young gentleman returning to the country. Under a combination of mechanical and physiological treatment, such as I have already described, both feet continued to improve in form and function.

My report, nearly two years and a half afterwards—Jan. 15, 1855—says, "Both feet perfect in form and position; also physiologically very perfect. All the muscles are strong and pretty well developed. The calves rather high, but not very small, measuring ten inches and a half in circumference. Can stand on his toes, and has a good spring from the ankle-joints. Can play at leap-frog as well as any boy in the school. Dances well;" and his drill-master states "that he had examined him attentively, and could not detect the slightest defect or weakness." Does not easily tire in walking exercise.

I have had the opportunity of seeing this young gentleman occasionally, ever since the treatment, and he not only remains well, but has continued to improve in muscular power of the

legs, and mobility of the feet, which are perfect in form as represented in Fig. 100, drawn from casts taken the 6th of June, 1860, when he was eighteen years of age.

FIG. 100.

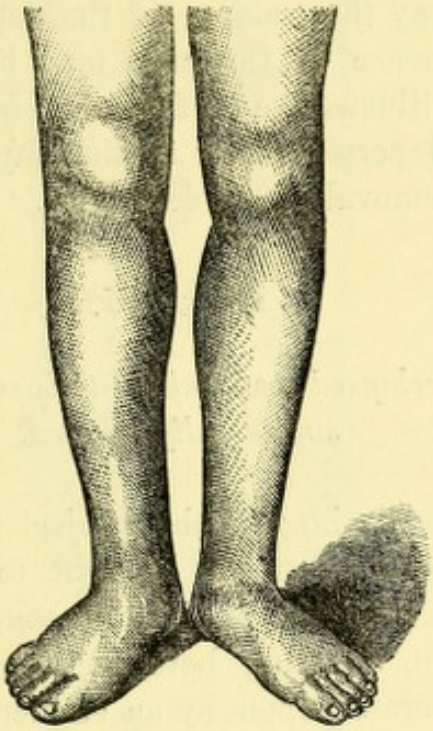

Drawing taken from casts of the legs of Master H. A. same case as shown in Figs. 98 and 99 when 18 years of age, showing the muscular development of the calves, which measured thirteen and a half inches in circumference; the feet also remaining perfect.

I have already alluded to the muscular development in this case, in which so many operations had been performed, as furnishing a complete answer to those who assert that tenotomy weakens muscles, interferes with their development, and that their functions afterwards are imperfectly restored. In this young gentleman, when eighteen years of age, the calves measured two inches more in circumference, than the calf of the gentleman, (Mr. B. Case XIII) who was born with congenital varus, and had not been operated upon until he came under my care at the age of twenty-six.

The improvement of muscular power and mobility in this case, were doubtless much contributed to by the circumstance of his entering the mercantile service as a midshipman, and the

consequent exercise of climbing, &c. After he had been two or three voyages, I had casts of the legs taken up to the thighs, see Fig. 100, for the purpose of showing the improved muscular development, and in these casts the circumference of the calf in each leg is shown to be thirteen inches and a half. It is unnecessary to say that relapse of the deformity is impossible, and the permanence of the cure may be relied upon. The case is strongly illustrative of the advantages to be gained by a long continued perseverance in the physiological treatment, after complete removal of the deformity.

Case XV.

Severe case of relapsed congenital talipes varus of both feet successfully treated.

The young lady who was the subject of the present case, Miss A. L., aged 10 years, was brought to me on 24th April, 1857. She had been the subject of congenital talipes varus of a severe form, affecting both feet, and when six months old had been operated upon by an eminent Orthopædic authority, under whose care she afterwards remained continuously for three years. At the end of this time, however, the deformity was not completely removed in either foot, and the motion at the ankle-joint was said to have been very limited. She was afterwards placed under the care of a well known gymnastic professor, and the physiological treatment, including special exercises, rubbing, and working of the feet, were steadily persevered in for a great length of time. In spite of this, however, it became evident that the deformity in both feet was steadily increasing, and at the time she came under my care, they were in the position represented in Fig. 101, drawn from models in my possession. In both feet, the elevation of the heel, the equinus portion of the deformity, existed to an extreme degree, whilst the inversion—the varus portion of the deformity—was comparatively slight, especially in the right foot, which might almost be described as a case of simple

equinus; so completely had the inversion been overcome; and the width of the foot was increased towards the toes, in conse-

FIG. 101.

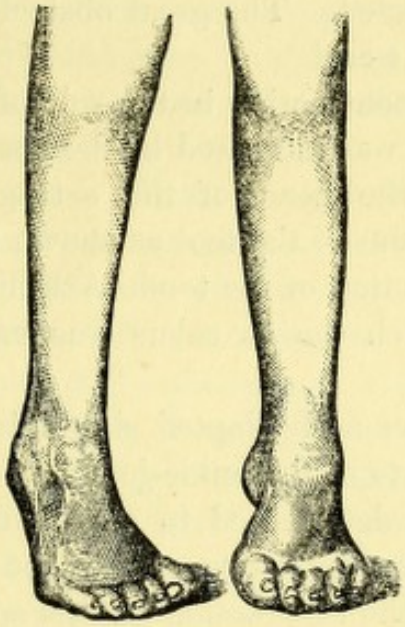

Severe case of relapsed congenital talipes varus of both feet, in a young lady, 10 years of age.

quence of the weight having been thrown upon the heads of the metatarsal bones, a condition generally met with in severe cases of talipes equinus. The feet were most rigidly held in this position, with scarcely any motion at the ankle-joint. Her gait was extremely awkward and unsteady, and powers of walking very limited.

For some time before coming under my care, special treatment for the feet had been discontinued, except by such exercises and manipulation as could be conducted at home, treatment had in fact been abandoned in despair. So completely was this the case that the parents determined that only one foot should at first be submitted to treatment, and that the other should not be operated upon until the cure of the first was accomplished.

On the 7th May, 1857, I performed the first operation on the right foot, dividing the plantar fascia and flexor tendons in the sole of the foot.

Dr. Stewart of Streatham assisted, and chloroform was administered by the late Dr. Snow. My reason for not dividing the posterior tibial tendon was that only a slight degree of inversion existed in this foot, and the posterior tibial muscle did not appear to be contracted. The great obstacles to be overcome in this case evidently were,

1st. The severe contraction in the sole of the foot, by which the arch of the foot was increased by flexion from the transverse tarsal joint, and the head of the astragalus rendered prominent on the dorsum of the foot as shown in Fig. 101.

2nd. The contraction of the tendo Achillis, or rather muscles of the calf, by which the os calcis was raised to an extreme degree.

3rd. The rigidity, and adapted shortening of the posterior and lateral ligaments of the ankle-joint.

The principle I determined to adopt in this case was to divide the treatment into two stages, the object of the first being to overcome the contraction in the sole of the foot; and the object of the second to overcome the contraction of the tendo Achillis, and ligamentous rigidity of the ankle-joint. Whilst the first stage was being accomplished, I proposed to make use of the contracted tendo Achillis as affording a firm point of resistance against the pressure applied to the anterior part of the foot, for the purpose of expanding, or unfolding the arch of the foot.

After the division of the plantar fascia and tendons in the sole of the foot, the first stage of the treatment was gradually accomplished by means of the Scarpa's shoe, having a transverse division in the sole-plate as shown in Fig. 20; and then on the 3rd July, 1857, I divided the tendo Achillis of the right foot, Dr. Snow on this occasion administering amylene; Dr. Stewart also assisted. Complete anasthesia was produced much more quickly than by chloroform, and with muscular rigidity, which would be an advantage in these operations, but in consequence of a fatal case occurring soon afterwards, Dr. Snow discontinued the employment of amylene. In consequence of old adhesions in the neighbourhood of the

tendon, the separation of the divided extremities was but slight, and the rigidity of the ligamentous structures surrounding the ankle-joint, also limited the movement of this articulation. After this operation, the foot yielded very slowly at the ankle-joint, and the treatment was tedious and troublesome. In about four months the foot was brought to a right angle, and believing that exercises might now be combined with the principle of mechanical stretching, I ordered

On the 25th November, 1857, an ordinary boot with steel supports above the ankle to be applied, and permitted a certain amount of walking exercise, in combination with special exercises for the foot. This failed, however, to increase the range of motion; and the foot still remaining at a right angle

On the 2nd March, 1858, I redivided the Achilles tendon, and also the tendon of the peroneus longus, which was tense and prominent behind the fibula. I have found by dissection that the tendon of the peroneus longus is shortened in severe cases of congenital varus; and in the case of Mr. B., No. XIII., I divided it with great advantage. After this operation the flexion of the foot proceeded more rapidly, and being now carried well beyond a right angle

On the 24th April, 1858, walking exercise was recommenced, the ordinary boot being worn, and exercises persevered in. From this date the right foot steadily improved, special exercises being used four times a day, for half an hour each time.

On the 21st June, 1858, the treatment of the left foot was commenced, and on this day I divided the plantar fascia, with some of the flexor tendons in the sole of the foot. At the same time I divided the tibialis posticus tendon, in consequence of there being more inversion in this foot than existed in the right, and the inner malleolus being less prominent; Dr. Stewart assisted, and on this occasion no chloroform was given.

The treatment was divided into two stages, as in the right foot, and the contraction of the arch of the foot being sufficiently overcome, on

The 24th August, 1858, I divided the tendo Achillis, and

also the tendon of the peroneus longus, which was tense and prominent behind the fibula; Dr. Stewart and also Mr. Street of Norwood assisted. The flexion of the foot progressed very slowly, and the anterior border of the deltoid ligament could be felt as a tense and prominent band, which appeared to prevent the inner malleolus assuming its natural prominence, by holding the navicular bone in proximity to it, and preventing this bone being carried outwards over the head of the astragalus. I therefore

On the 12th September, 1859, divided the anterior border of the deltoid ligament, a little below, and in front of, the inner malleolus.

On the 22nd September, 1859, my report states: "Both feet now very nearly alike; left foot very much improved lately. Ordered to wear an ordinary boot, with steel supports above the ankle, as on the right foot; and to commence special exercises and dancing."

December 20th, 1859. Both feet much improved.

February 7th, 1860. Improvement in both feet continues; and the special exercises are now persevered in, and continued four hours a day, for an hour each time.

September 25th, and November 24th, 1860. Improvement reported in both feet, with an increased amount of motion at the ankle-joints.

January 3rd, 1862. Improvement continues in both feet, and the gymnastic exercises are steadily persevered in.

January 12th, 1863, my report states; "Both feet now very perfect; but the continuance of gymnastics still recommended, for the purpose of increasing the range of motion at the ankle-joints, which although enough for ordinary purposes, is considerably less than the natural amount of motion in a healthy foot."

March 29th, 1864. At this time the left foot is reported to have become less flexible at the ankle-joint, in consequence of the gymnastic exercises having been partially discontinued. In all other respects the improvement had been preserved.

February 15th, 1865. Both feet reported as very perfect in external form, and the flexion of the left foot to be beyond a right angle. The motion is free, but in range or extent is not increased.

In this case both feet were so far restored in form, that only to a very critical eye would any defect be apparent; the increased width of the feet across the toes was gradually diminished, and she was enabled to wear ladies' boots of an ordinary description. Freedom of motion at the ankle-joint was so far increased, that she not only walked well, but could dance with ease and grace. No casts of these feet in their improved position were taken, but I am enabled to state that they are now as perfect in form as I have ever seen feet, which have been the subject of congenital varus, and equal to those represented in Case XIV.

Case XVI.

Congenital malformation, and deficiency in length of the leg bones below knee, in the left leg; with a sharp curvature forwards of the tibia and fibula, and malformation of the foot, which is distorted in the position of talipes valgus.

On the 20th March, 1866, a young gentleman, Master De H. aged 12 years, was brought to me for advice in consequence of malformation of the left leg and foot, the condition of which was as follows.

There was a congenital deficiency in the length of the left leg, which at the time of birth was said to have been about an inch shorter than the right; but now, in consequence of this limb not continuing to grow in the same proportion as the opposite leg, the shortening at the present time amounts to five inches and a half. There is also a slight deficiency in the length, but not amounting to more than half an inch, in the corresponding thigh bone. The tibia is curved forward in its lower third, a condition always met with in these cases, and said to have been more conspicuous in infancy, so that the bone would appear to have become straighter during growth. At the prominence of the tibial curve in front, and about three inches above the ankle-joint, is a dimpled depression in the skin, always present in these cases.

The outer malleolus was very indistinct, and evidently mal-

formed; and there appeared to be a fusion of the tibia and fibula a little above the ankle-joint.

The foot was much smaller than that of the opposite limb, and distorted in the position of talipes valgus of a severe form. The phalanges of the two inner toes were fused through their entire length, having only one nail between them, and they were partially united at the third toe. The phalanges of the two outer toes were also fused at their metatarsal extremities.

FIG. 102.

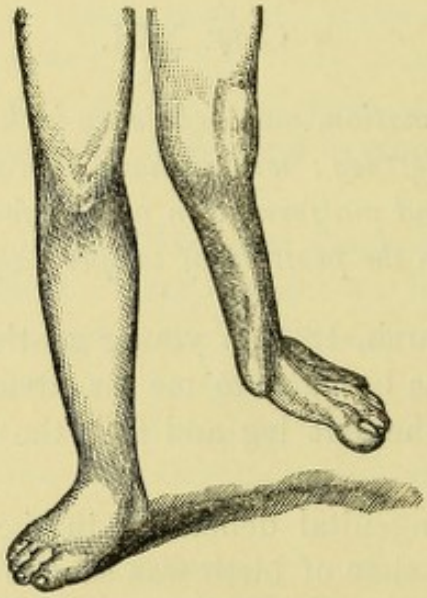

Congenital malformation, and deficiency in length of bones below knee, in the left leg; with a sharp curvature forwards of the tibia and fibula in the lower third, and a dimpled depression of the skin over the prominence of the tibial curve. Malformation of the foot, which was distorted in the position of talipes valgus, in a young gentleman 12 years of age.

The tendons of the extensor longus and peronei muscles, and also the tendo Achillis, were tense and prominent, and these muscles by their contraction evidently contributed to the increasing deformity of the foot. Some of these tendons had been divided when this patient was only a few months old, and the foot was probably at this time brought into an improved position; relapse of the deformity being produced by neglect of the after-treatment, and the boy wearing a badly constructed boot. Latterly, however, he has worn a boot raised about

six inches, having a double steel support carried up to the calf of the leg.

In consequence of the increasing deformity of the foot, he is now becoming less able to use this leg in walking. The weight of the body is thrown upon the inner side of the foot which is too tender to bear the pressure.

I have redivided all the contracted tendons, and by mechanical means am now endeavouring to bring the foot into a more useful position. To a certain extent, this will no doubt be accomplished, and at the present time it is greatly improved; so that in all probability it will be rendered useful for walking purposes. Should this fail, however, this young gentleman will ultimately require to wear a wooden leg from the knee, the foot and leg being bent upwards.

1872. This young gentleman still continues to wear the same kind of raised boot, with double steel support, but walks with considerable lameness.

Case XVII.

Case of malformation of both legs; deficient length of leg bones below knee, with deformity of feet and eight toes on each foot; left leg smaller throughout, and more deformed below knee.

Florence Filleylove, aged three months, was brought to me at the Orthopædic Hospital, on the 2nd February, 1864, in

FIG. 103.

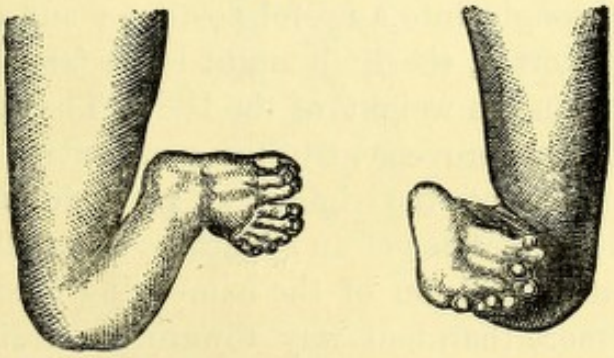

Malformation of both legs; deficient length of leg bones below knee, with deformity of feet, and eight toes on each foot; left leg smaller throughout, and more deformed below knee. In an infant three months old.

consequence of malformation of both legs, and deficient length

of leg bones below knee, with deformity of feet, as represented in Fig. 103.

The left leg was smaller in the thigh, as well as below knee and more deformed throughout. The knee-joint was malformed, and the patella not traceable. The leg bones below knee were not more than half their normal length; the leg was flexed upon the thigh at an acute angle, and bent in a twisted form with an inclination inwards.

The left foot was inverted with an inclination to talipes varus, but this deformity was slight, its chief peculiarity being that there were eight toes. The three supernumerary toes were crowded together in the normal situation of the great toe. The foot was expanded at this part, and these supernumerary toes had each an articular connection with the metatarsal bone or bones, but it was not possible to ascertain whether these were in excess, or not.

The right leg was very similar to the left, but the leg bones were of greater length, being about two-thirds their normal size. The leg was flexed upon the thigh at an acute angle, but not bent as in the left leg.

The right foot was similar to the left, having eight toes, the three inner toes being crowded together in the normal situation of the great toe. This foot was distorted in the position of talipes equino-valgus in a marked degree.

With regard to treatment, the prospects of benefit were of course very uncertain; but it seemed probable that the right leg might be brought into a useful position; and the foot being but slightly distorted, the limb might be so far improved, as to be able to sustain the weight of the body. The condition of the left leg rendered improvement to the same extent less hopeful.

In the position of the right leg, great improvement was effected by the application of an apparatus especially constructed for it; and after division of the ham-string tendons, this leg was brought more than half way towards a straight line with the thigh, when the child died of water on the brain, March 30th, 1866.

The position of the left leg was also improved, but to a less

extent than the right. No post-mortem examination was allowed, and therefore the precise nature of this complicated malformation could not be ascertained.

Case XVIII.

Case of congenital hypertrophy of the right leg, which at birth was larger than the opposite limb, and continued to grow at an increased rate; accompanied with malformation of the foot.

On the 24th December, 1863, R. I. Lloyd, aged twelve months, was brought to me at the Orthopædic Hospital, in consequence of congenital hypertrophy of the right leg, which in all its proportions in length and breadth, from the foot to the top of the thigh, was at birth larger than the opposite limb, and was said by the parents to have been at the time of birth two inches longer than the left. When he came to the hospital, this leg was still continuing to grow at a rate dis-

FIG. 104.

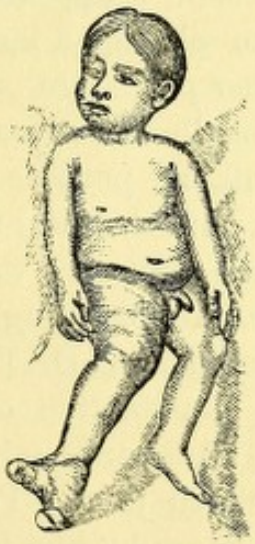

Congenital hypertrophy of right leg, which at birth was larger than the opposite limb, and continued to grow at an increased rate; accompanied with malformation of the foot. Drawn from a photograph taken when the child was nearly three years of age.

proportionate to that of the opposite limb, and when this child died at the age of three years from hooping-cough, the right

leg was four and a half inches longer than the left. Its general appearance is well represented in Fig. 104, drawn from a photograph of the child.

The foot was of large size, and malformed, with a deep cleft in its anterior portion dividing it into two unequal parts, the inner being proportionably much larger than the outer. The skin of the leg throughout was healthy, soft, and pliable, and there was no evidence of the affection being merely a cutaneous, or subcutaneous hypertrophy.

The left leg appeared to be of its normal length and relative proportions, as compared with the rest of the body. The foot was natural, and the child used this leg in progression, dragging the hypertrophied leg and foot after it in walking, but resting upon the inner side of the distorted foot; and sometimes the child would bend the enlarged leg, and resting upon the knee, would then stand with the left knee bent. The relative proportion of the legs is well exhibited in the accompanying drawing, Fig. 104, but from the position of the child, the left leg is made to appear rather smaller in proportion than it really was.

With regard to treatment, it appeared to me that no benefit would result either from placing a ligature on the main artery of the limb, or any other procedure, as from the malformation and deformity of the foot, there was no chance of its ever being made available for walking purposes. I therefore proposed amputation of the foot, and the use of a wooden leg from the knee, but before any such treatment was adopted, the child died on the 16th December, 1865, being then three years old. With the assistance of my friend, Dr. Dick, and Mr. L. S. Little, I made a post-mortem examination of the body on the 17th December. Mr. Little afterwards minutely dissected the foot, and exhibited the specimen to the Pathological Society, and the following account written by him is copied from Vol. XVI. of the Transactions of the Pathological Society.

"The right lower extremity was altogether much larger than the left. The distance between the anterior superior spinous process and the tip of the heel on the right side was twenty-

seven inches, on the left twenty-two and a half, the difference being four and a half inches, and this was chiefly below the knee. The right foot alone was removed for examination; it was covered all over by great masses of fat, in parts one and a half inches thick. Only two toes were visible, a great toe of normal appearance; and separated from it by a wide cleft, was a very broad toe with two nails. About the middle of the outside of the foot, were two little nails close together representing the fourth and fifth toes. The right foot was two and a half inches longer than the other.

"The long and short extensor of the toes, and the extensor of the big toe were present, but no tendons passed the two outer toes.

"No tibialis anticus tendon could be found.

"The tendon of the posterior tibial was very large. The long flexors of the toes and big toe were present, but no tendon passed to the outer toes. The muscles of the sole of the foot were represented by a mass of muscle and tendon matted together.

"The muscular tissue under the microscope showed no trace of fatty or other degeneration.

"On examination of the foot after removal of the soft parts, it appears that the ankle-joint is freely moveable, but the bones of the leg cannot be brought to a right angle with the foot, owing to malposition of the astragalus; the upper surface of which looks rather backwards.

"The tarsal and other joints of the foot are normal, with the exception of those at either end of the metatarsal bone of the big toe; these are fixed not by anchylosis, but the ligaments appear to be too short to allow movement to take place.

"The astragalus, the scaphoid, cuneiform, the three inner metatarsal bones, and the phalanges of the three inner toes are relatively more than twice the size of the other bones of the foot, indeed they are nearly equal to those of an adult.

"The astragalus is so large in proportion to the calcis that it projects further backwards than that bone, consequently there is no arch to the foot.

"The enlarged bones are of normal shape as are also their articulations, excepting where the large bones on the inner side of the foot articulate with the small bones on the outside.

"The other bones of the foot are of normal size. The body of the child was extremely emaciated, and formed a marked contrast to the right lower limb which was thickly covered with fat. There were also two ill-defined fatty tumours, the one on the right side of the chest, the other below the left nipple.

"The internal organs were healthy, with the exception of the lungs which were pneumonic in various stages quite sufficient to cause death."

Case XIX.

Rotation of tibia at the knee-joint, which was also contracted in the flexed position, with talipes valgus of right foot; slight talipes varus of left foot, with contraction of left knee and shortening of left thigh. Both hands slightly deformed in the position of club-hand.

Miss W., aged six weeks, was sent to me by my friend, Dr. Lavies of Warwick Square, on the 17th October, 1865. In this case, somewhat complicated deformities of both legs existed, together with contraction of the left hand.

The right leg was rotated upon the thigh at the knee-joint in a remarkable manner, so as to bring the calf of the leg and heel of the foot into a direct anterior aspect, the inclination of the foot being directly backwards as represented in Fig. 105. The patella was very small and felt with difficulty, being displaced on the outer condyle of the femur. The articular extremities of the femur and tibia appeared to be well formed, although some contraction at the knee-joint existed, and the leg was flexed as well as rotated on the thigh. The leg could be only partially restored to its natural position by manipulation, and then the foot was seen to be in the position of talipes valgus, with some disposition to calcaneus, but the drawing is taken with the foot as it appeared with the leg in its rotated position.

The left leg was contracted at the knee-joint and could not be extended beyond an obtuse angle with the thigh, it could

FIG. 105.

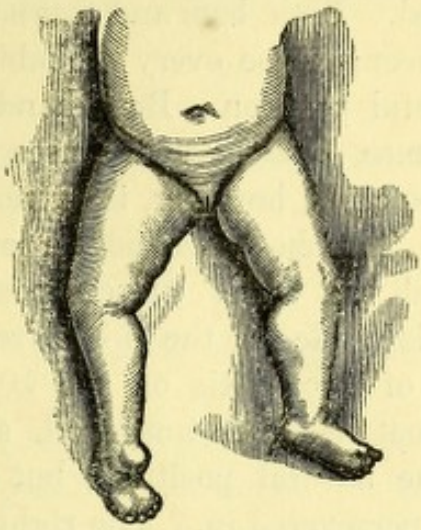

Rotation of right leg at knee-joint, with the calf of leg, and heel of foot in front, and foot directed backwards, &c.

hardly be brought so straight as represented in Fig. 105. The patella was well formed at this articulation, and no abnormal rotation of the tibia existed.

The left foot was inverted in a somewhat unusual manner, so that the aspect of the sole of the foot was directly inwards, or inclined to the position of talipes varus, but the foot did not exhibit the usual characters of this deformity in any marked degree.

The left thigh was shorter than that of the opposite limb, and the defect in length was greater than represented in the drawing.

The left hand was contracted in the flexed and pronated position at the wrist-joint, presenting the ordinary appearance described as club-hand, and a slight disposition to this deformity also existed in the right hand. The fingers in both hands were slightly webbed. No other defect existed.

It is worthy of remark in connexion with this case, that the mother had previously had two children, born with cleft palate, but without any other defect; both these children died in

infancy. The mother had had thirteen children, several healthy children being born between those deformed.

The treatment of this case up to the present time, Oct., 1866, has been essentially mechanical, and in all probability no operations will be required. Both legs and feet have been much improved, and there seems to be every probability of their being brought into a useful position. Both hands are now almost natural in appearance, and the child uses them well. The general health of the child, however, is extremely feeble, and it is much emaciated. The chest has become somewhat prominent and deformed, and the spine curved posteriorly, with an inclination to the left side in the dorsal region.

This child died of bronchitis on the 10th of Nov., 1867. The right leg and foot had been improved, and brought about half way towards the natural position; but latterly the treatment had not been persevered in. The right patella remained completely dislocated, and situated low down on the outer condyle. I tried after death, previous to dissection, to bring it into its natural position by force, but could not succeed; nor could I at all overcome the rotation outwards of the head of the tibia. Contraction of the knee-joint also remained.

In this case I was permitted to make a *post-mortem* examination, under restrictions, but the parts were not allowed to be removed for dissection. I found that the patella could not be restored to its natural position, even after the division of the rectus, it being too firmly held in its dislocated position on the outer condyle, by the adapted shortening of the capsular ligament; and this condition, together with the adapted shortening of all the ligamentous structures belonging to the knee-joint, held the tibia so firmly in its abnormal position of rotation outwards, that it could not be brought into its natural position, even after a free division of the capsular ligament.

The articular extremities of the bones were somewhat altered in shape, in adaptation to their altered relations, but this appeared to be the result of slow adaptation, rather than any primary malformation.

NATIONAL HOSPITAL FOR THE PARALYSED & EPILEPTIC
PRESENTED TO
QUEEN SQUARE, BLOOMSBURY, LONDON

ON THE

VALUE OF SUBCUTANEOUS TENOTOMY

IN

VETERINARY SURGERY.

TENOTOMY IN A RACE-HORSE.*

In compliance with your request, I have much pleasure in placing at your disposal the particulars of my case of tenotomy in a race-horse to which you have referred.

I think with you, it bears a special interest, in a surgical point of view, in corroborating so fully the fact of strength in the intermediate structure, as this animal was subjected to repetition of severe tests, as authenticated by the published records of his career and achievements as a race-horse, his case being well known.

In 1861, the Bay Colt, afterwards called "Suspicion," by Alarm out of Blue Bell, had congenital deformity of one fore foot, due to insufficient length of the flexor perforans tendon. This condition being found persistent, I was consulted on his case by Mr. Henry Allington of St. Neots, who bred him—the colt being at the time of my examination *six months* old.

I found that he could only tread on the front of the hoof, the entire sole of the foot presenting backwards and unable to touch the ground—the result at this period being that the front of the hoof was worn by contact with the ground, whilst

* The following letter from Mr. Roalfe Cox, the well-known veterinary surgeon of Mount Street, Grosvenor Square, is appended to the present work from the great interest of the case related; and it may perhaps direct more attention to subcutaneous tenotomy in veterinary surgery.

there was preternatural depth of the hoof at the back part from continuing growth and absence of attrition.

The accompanying sketch, copied from one taken at the time, represents the abnormal position.

FIG. 106.

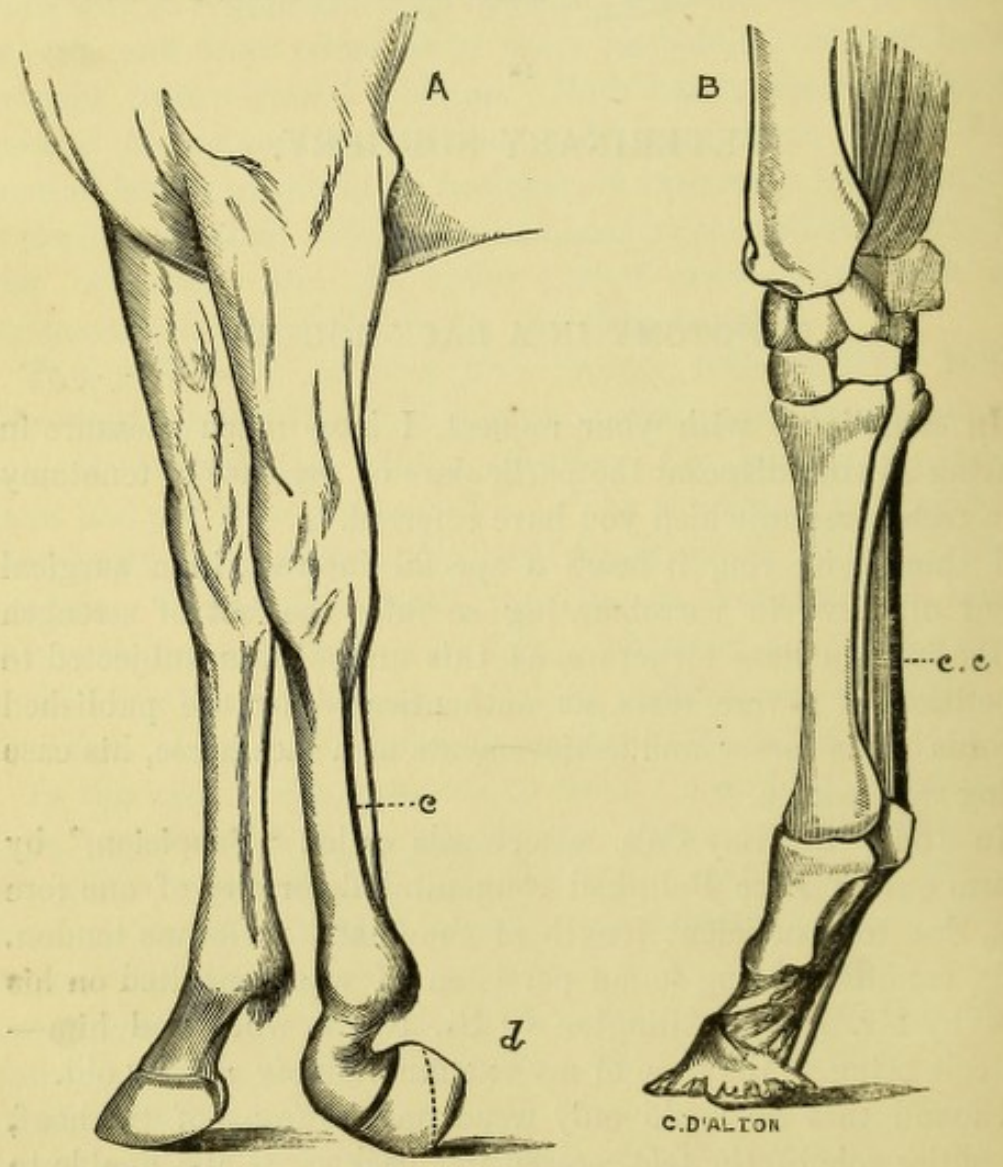

A. Sketch by Mr. J. R. Cox, of the race-horse "Suspicion," who was born with one foot contracted in the position represented. The hoof, from not having been used, grew into the form shown in the drawing, with a considerable thickness posteriorly, *d*. *c*, the point at which the flexor perforans tendon was divided.

B. Anatomical sketch, showing the relations of the superficial and deep flexor tendons. *c. c.* indicates the point at which the flexor perforans tendon was divided.

The colt being valueless for training, or indeed service of any kind, tenotomy under my advice was determined on as

the only possible resource, and accordingly, within a few days, I performed the operation under chloroform, by introducing a narrow blade between the two tendons, and dividing the inner one. The immediate result was perfectly adjusted position of the limb, and a separation to the extent of two inches between the cut ends of the tendon.

Before the colt was allowed to rise (having been placed on his side for operation), the excess of growth at the back part of the hoof was pared down to natural shape, and a bandage over a light compress placed around the leg.

On the colt resuming the standing position, the obliquity of the pastern from his own weight and pressure was rather in excess of that of the sound limb, from the divided tendon still further separating, and which I considered a desirable indication. Eventually, within a few weeks, the position became symmetrical with that of the other limb.

"Suspicion" subsequently underwent the usual course of hard work in training.

In 1863, when two years old, he ran in three races.

In 1864 he ran in six races, winning two.

And in 1865 he ran in nine races, winning two of them, the latter events being "The Goodwood Stakes," two miles and a half, beating ten horses, and "The Huntingdonshire Stakes," two miles, beating six horses. During this time, as I have since been informed by the gentleman who then owned him, this leg had never failed, nor shown indication of weakness.

J. Roalfe Cox, M.R.C.V.S.

INDEX.

Aneurism, false after tenotomy, 246.
—— treated by perchloride of iron, 248.
Apparatus employed for treatment of varus, 282.
—— most severe cases of non-congenital valgus, 339.
—— treatment of non-congenital varus, 304.
Astragalus, oblique position of, in congenital valgus, 311.
—— deviation in position and form of the, at the period of birth in congenital varus, 151.
—— deviations in form of the, in congenital varus in childhood, 152.
—— deviations in form of the, in talipes varus in the adult, 187.

Barwell's, Mr., new method of treating club-foot, 58.
—— statement as to non-union of tendon, 40.
—— tabulated series of dissections, 41.
Bones, deviations in position of, in talipes equinus, 99.
—— and form of, in infantile varus, 151.
——— in adult varus, 183.
—— deviations of, in non-congenital varus, 299.
—— in congenital valgus, 311.
——— in non-congenital talipes calcaneus, 356.
—— in the distortion artificially produced in Chinese ladies feet, 359.
Brodhurst, Mr., on the reparative process in tendons; linear cicatrix theory, 24.
—— on condition of muscles, &c., in congenital varus, 299.
—— on the degree of elevation of the os calcis in talipes equinus, 99.

Club-foot, various forms of, 1.
—— Mr. Syme's treatment of, 50.
—— lameness and other inconveniences arising from, 145.
—— effects of, upon the mind, 147.
—— etiology of congenital, 213.
Club-foot arguments in favour of spasmodic origin of congenital, 213.
—— arguments against spasmodic origin of congenital, 214.
—— arguments in favour of malposition and pressure in utero, 215.
—— arguments against malposition and pressure in utero, 215.
Complications in congenital talipes varus, 220.
Congenital talipes equinus, case of, 106.
Congenital talipes varus, hereditary transmission, 218.
—— external characters of, in the infant, 139.
——— in the adult, 142.
—— lameness, &c., arising from, 145.
—— morbid anatomy of, 147.
——— in the infant, 151.
—— deviations in form and position of the bones in the infant, 151.
—— altered position of the bones, in the infant, 162.
—— condition of the muscles, in the infant, 165.
—— structural changes in the muscles occasionally met with in, 165.
—— ligaments, adaptation of, in the infant, 162.
—— deviations of the tendons, in the infant, 172.
—— deviations of the vessels and nerves, in the infant, 176.
—— morbid anatomy in the adult, 178.
—— deviations in form and position of the bones in the adult, 183.
—— adaptation of ligaments in the adult, 198.
Congenital talipes varus, condition of muscles in the adult, 201.
—— deviations of the tendons in the adult, 203.
—— deviations of the vessels and nerves in the adult, 210.
—— etiology of, 213.
—— statistics, 218.
—— complications of, 220.
—— operative treatment in, 230.
—— excision of cuboid bone in, 250.
Congenital talipes valgus, 307.
—— external characters of, 307.

Congenital talipes valgus, external characters modified, 308.
—— special effects of, 310.
—— morbid anatomy of, 310.
—— condition of bones, 311.
——— astragalus, 311.
——— navicular bone, 312.
——— cuboid bone, 312.
——— toes and metatarsal bones, 313.
—— deviations in ligaments, 313.
—— condition of muscles, 314.
——— tendons, 314.
—— tendons requiring division, 314.
—— condition of vessels and nerves, 315.
—— pathology of, 315.
—— numerical importance, 316.
—— coexistence of, with other deformities of opposite foot, 316.
—— coexistence of, with malformation of bones of leg, 317.
—— prognosis, 320.
—— treatment of, 320.
—— operations required, 321.
—— mechanical treatment, 322.
—— physiological treatment, 324.
—— after-treatment, 324.
—— relapsed cases, 325.
Congenital calcaneus, external characters of, 347.
—— morbid anatomy of, 348.
—— pathology, 349.
—— complications of, 350.
—— numerical importance, 351.
—— treatment of, 352.
—— mechanical treatment, 353.
—— after-treatment, 353.
—— relapsed cases, 354.
Congenital hypertrophy of leg and thigh, with malformation of foot, 447.
Contraction of tendo Achillis, in talipes equinus, 105.
——— ordinary condition of congenital valgus, 309.
Cruveilhier, case of non-congenital varus, described by, as a case of congenital origin, 298.
Cruveilhier's case relied upon and quoted by Mr. Brodhurst, 299.
Cuboid bone, excision of, by Mr. Solly, 250.
—— deviations of, in congenital valgus, 312.
—— alteration in position and form of, in congenital varus in the adult, 189.

Deformities, with rigid muscles in children, 64.
Deformities with rigid muscles in children, Dr. Radcliffe's views, 68.
—— with rigid muscles in adult, 66.
——— morbid anatomy, 67.
——— prognosis, 69.
——— treatment, 70.
——— in adults, 72.
——— Dr. Todd's views, 72.
——— treatment of, 73.
—— with flaccid muscles in adults, 74.
——— in children, 77.
—— paralytic, with flaccid muscles in children, 78.
Delpech, advance made by, towards subcutaneous tenotony, 5.
—— rules laid down by, for the operation of tenotomy, 8.
—— for the after-treatment, 9.
—— views of, on the reunion of tendons, 21.

Etiology of talipes equinus, 107.
Etiology of congenital varus, 213.
—— non-congenital varus, 301.
—— congenital valgus, 315.
——— Mr. Tamplin's opinion, 315.
——— Mr. Lonsdale's opinion, 315.
—— non-congenital valgus, 329.
External characters of talipes equinus, 92.
—— of talipes equino-varus, 134
External characters of congenital valgus, 307.
—— modified by condition of tendo Achillis, 308.
—— non-congenital valgus, 326.
—— congenital calcaneus, 347.
——— calcaneus, 354.

Hereditary transmission of congenital varus, 218.
Hunter's experiments on reunion of tendons, 16.
—— discoverer of the law of subcutaneous surgery, 7.
Infantile paralysis, 79.
—— accompanying symptoms, 80.

Infantile paralysis, mode of seizure, 81.
—— liability of sexes, 81.
—— duration of, 81.
—— progress of, 81.
—— muscles affected in, 82.
—— morbid anatomy, 83.
—— prognosis, 85.
—— diagnosis, 84.
—— treatment, 86.
—— termination of, 86.

Infantile deformities, how produced, 87.
——— with muscles in a healthy condition after recovery from, 90.
Lameness, arising from club-foot 145.
Ligaments, condition of, in talipes equinus, 103.
—— condition of, in congenital varus, in the infant, 164.
—— condition of, in congenital varus in the adult, 198.
—— condition of, in congenital valgus, 313.
—— condition of, in non-congenital calcaneus, 357.
Lizars' Mr., objection to early operation in congenital varus, 231.
Lonsdale's Mr., opinion of production of congenital valgus, 315.
—— apparatus for unfolding the arch of the foot, in talipes varus, 267.
—— statistics of deformities, 107.

Mechanical treatment in talipes equinus, 122.
—— in congenital varus, 252.
—— conditions of foot, 254.
—— treatment of infantile varus, 258.
——— in adult, 264.
—— and physiological after-treatment in varus, 281.
—— treatment in congenital valgus, 322
—— of congenital calcaneus, 352.
Metatarsal bones, condition of, in congenital valgus, 313.
Morbid anatomy of talipes equinus, 98.
—— varus in the infant, 147.
——— in the adult, 178.
——— valgus in the adult, 310.
——— non-congenital valgus in the adult, 329.
—— talipes calcaneus, 351.
—— non-congenital valgus, 329.
—— congenital calcaneus, 348.
Movements producing congenital varus, 255.
Muscles, condition of, in congenital varus in the infant, 165.
—— condition of, in the adult, 201.
—— non-congenital varus, 301.
—— congenital valgus, 314.
—— non-congenital calcaneus, 357.

Navicular bone, in the infant, 155.
—— displaced position of, in congenital varus, in the adult, 188.
—— displaced position of in congenital valgus, 312.

Nerves and vessels, condition of, in congenital varus in infant, 177.
—— varus in adult, 210.
—— in non-congenital varus, 301.
—— condition of, in congenital valgus, 315.
Non-congenital talipes varus, 296.
—— external characters, 296.
—— diagnosis of, 297.
—— numerical importance, 302.
—— coexistence of, with other deformities of opposite foot, 303.
—— prognosis, 303.
—— treatment of, 303.
—— apparatus for, 304.
Non-congenital talipes valgus, external characters, 326.
——— special effects of, 328.
——— morbid anatomy and etiology of, 329.
—— included in six classes, 330.
—— 1st Class depending upon muscular and ligamentous debility, 331.
—— 2nd Class, rachitic valgus, 332.
—— 3rd Class, paralytic valgus 333.
—— 4th Class, spasmodic valgus, 333.
—— 5th Class, traumatic valgus, 334.
—— 6th Class, consequent upon disease of ankle-joint, 335.
—— numerical importance, 335.
—— coexistence of, with other deformities, 336.
—— prognosis, 336.
——— in rachitic cases, 336.
——— in paralytic cases, 336.
——— in spasmodic cases, 337.
——— in traumatic valgus, 337.
——treatment of, 337.
——— depending upon muscular and ligamentous debility, 337.
—— apparatus for most severe cases of, 340.
—— advantage of tenotomy in severe cases of, 342.
—— after-treatment of, 342.
—— treatment in rachitic valgus 343.
——— in paralytic valgus, 343.
——— in spasmodic valgus, 343.
Non-congenital talipes valgus, cases consequent upon disease of ankle-joint or surrounding tissues, 344.
——— in traumatic valgus, 344.
—— calcaneus, external characters of, 354.
—— morbid anatomy of, 356.
—— condition of ligaments in, 357.
—— shortening plantar fascia in, 357.
—— condition of muscles in, 357.

Non-congenital talipes valgus, vessels and nerves in, 358.
—— resemblance of, to distorted, Chinese feet, 358.
—— pathology of, 362.
—— numerical importance, 364.
Non-congenital talipes calcaneus, coexistence of, with other deformities, 364.
—— prognosis of, 365.
—— treatment of, 365.
—— boot used in cases of, 366.
Numerical importance of talipes equinus, 107.
—— congenital varus, 218.
—— non-congenital varus, 302.
—— congenital valgus, 316.
—— non-congenital valgus, 335.
—— congenital calcaneus, 351.
—— non-congenital calcaneus, 364.

Operations, mode of performing, 240.
—— knives best adapted for, 241.
Operative treatment in talipes equinus, 114.
—— in congenital varus, 230.
———— Dr. Little's views, 231.
———— Professor Lizars' views, 231.
—— history of, in congenital varus, 235.
—— in congenital valgus, 321.
Order in which tendons should be divided in congenital varus, 238.
Orthopædy, derivation of term, 14.

Paralysis Infantile, *see* infantile paralysis, 79.
Patella, altered position, and small size of, in some cases of congenital varus, 228.
Pathology of talipes equinus, 105.
—— equino-varus, 135.
—— congenital varus, 213.
—— of non-congenital varus, 301.
—— congenital valgus, 315.
—— non-congenital valgus, 329.
—— congenital calcaneus, 349.
—— non-congenital calcaneus, 362.
Prognosis of talipes equinus, 111.
—— non-congenital varus, 303.
—— congenital valgus, 320.
Prognosis of non-congenital valgus, 336.
Prognosis of non-congenital valgus in rachitic cases, 336.
———— in paralytic cases, 336.
———— in spasmodic cases, 337.
———— in traumatic valgus, 337.
—— congenital calcaneus, 351.
—— non-congenital calcaneus, 365.

Radcliffe's Dr., views respecting nervous action and muscular contraction, 67.
Relapse, causes of, in congenital varus, 307.
———— Dr. Little's views, 288.
Relapsed cases of congenital varus, 307.
—— valgus, 325.
Reparative process in human tendons, 23.
———— general summary of, 26.
———— influence of sheath, 28.
———— immediate results of operation, 27.
—— commencement and nature of, 29.
—— development of the reparative material, 30.
—— appearance and structure of new tendon, 32.
——junction of old with new tendon, 34
—— reformation of separable sheath on surface of new tendon, 35.
Reunion of tendons, 16.
—— Hunter's experiments on, 17.
—— Von Ammon's experiments on, 17.
—— Guérin's experiments on, 18.
—— Pirogoff's experiments on, 18.
—— Koerner's experiments on, 18.
—— Paget's experiments on, 18.
—— Gerstaecker's experiments on, 19.
—— Thierfelder's experiments on, 19.
—— Boner's experiments on, 19.
—— Author's experiments on, 19.
—— Brodhurst's experiments on, 20.

Scarpa's first apparatus for congenital varus, 271.
—— second apparatus for congenital varus, 271.
—— modifications of, 273.
Spasmodic origin of congenital club-foot, arguments in favour of, 213.
———— against, 214.
Stromeyer, improvement in subcutaneous tenotomy by, 9.
—— views of, on the reunion of tendon, 21.
Subcutaneous tenotomy, history of, 4
Syme's, Professor, treatment of club-foot, 50.

Talipes, non-congenital, spasmodic, and paralytic, 62.
———— prognosis and treatment, 63.
Talipes equinus, 92.
—— external characters of, 92.
—— spasmodic and paralytic, 94.
—— effects of, 97.

Talipes equinus, morbid anatomy of, 98.
—— deviations in bones, 99.
—— condition of cartilage in, 103.
—— condition of ligaments, 103.
——— muscles, 103.
——— tendons, 105.
—— pathology of, 105.
—— congenital, 106.
—— etiology of, 107.
—— spasm and paralysis in, 108.
—— causes directly affecting the joint in, 110,
—— prognosis of, 111.
—— operative treatment, 115.
—— division of tendo Achillis, in 116.
——— plantar fascia in, 119.
—— mechanical treatment in, 122.
—— physiological treatment in 127.
—— treatment of, with existing paralysis, 129.
—— treatment of cases of right angled contraction of tendo Achillis, 132.
Talipes equino varus, 133.
—— external characters, 134.
—— anatomical deviations, 135.
—— pathology of, 135.
—— treatment of, 135.
—— divided into three stages, 136.
—— valgus, 137.
Talipes varus, external characters in infant, 139.
—— congenital, 140.
—— external characters in adult, 142.
—— morbid anatomy of, 147.
——— in the infant, 156.
—— alterations in bones, in the infant, 151.
——— ligaments in the infant, 161.
——— bones in the adult, 182.
——— ligaments in the adult, 198.
—— condition of muscles in the adult, 201.
——— tendons in the adult, 203.
—— tendons which require division in adult, 210.
—— varus in adult, condition of vessels and nerves in, 210.
—— hereditary transmission in, 218.
—— statistics of, 218.
—— complications of, 220.
—— operative treatment in, 230.
—— Dr. Little's arguments against early operation, 231.
—— Prof. Lizars' arguments against early operation, 231.
—— Author's arguments in favour of early operation, 232.
Talipes varus, congenital, operations required in, 233.
—— history of operative treatment in, 235.
—— order in which tendons should be divided, 238.
—— mode of performing the operations, 240.
—— knives best adapted for operations, 241.
—— evidence of division of tendons, 244.
—— difficulties connected with division, 244.
—— wounds of arteries, 246.
—— wound of posterior tibial artery, 246.
——— internal plantar artery, 247.
—— false aneurism, 247.
—— excision of cuboid bone, 250.
—— mechanical treatment, objects of, 252.
—— rate of extension, 253.
—— mechanical conditions of foot, 254.
—— movements producing, 255.
—— mechanical treatment in infants, 258.
——— in older children, 264.
——— in the adult, 265.
——— Scarpa's first apparatus for, 271.
——— Scarpa's second apparatus for, 271.
—— duration of treatment in cases of, 281.
—— mechanical and physiological after-treatment, 281.
—— causes of relapse in, 287.
——— Dr. Little's opinion, 288.
——— Author's views, 289.
—— relapsed cases, treatment of, 294.
—— non-congenital varus, 296.
——— external characters, 296.
——— diagnosis of, 297.
——— morbid anatomy, 299.
——— condition of bones in, 299.
——— condition of muscles in, 299.
——— condition of tendons, 300.
——— vessels and nerves, 301.
——— pathology of, 301.
——— etiology and mode of production, 301.
—— numerical importance, 302.
—— coexistence of, with other deformities, of opposite foot, 303.
—— prognosis of, 303.
—— treatment of, 303.

Talipes varus apparatus best adapted for, 304.
—— after treatment of, 305.
Talipes valgus, congenital, 307.
—— external characters, 307.
—— external character modified by condition of tendo Achillis, 308.
—— special effects of, 310.
—— morbid anatomy, 310.
—— condition of bones in, 311.
——— astragalus in, 311.
——— navicular bone in, 312.
——— cuboid bone in, 312.
—— toes and metatarsal bones in, 313.
—— condition of ligaments in, 313
—— condition of muscles in, 314.
—— condition of tendons in, 314.
—— tendons requiring division in, 314.
—— condition of vessels and nerves in, 314.
—— pathology of, 315.
—— etiology of, 315.
—— numerical importance, 316.
—— coexistence of, with other deformities of opposite foot, 317.
——— with malformation of bones of leg, 317.
——— deficient growth of leg bones, below knee, with, 317.
——— malformation of outer malleolus, &c., 317.
——— deficient growth of leg bones below knee, &c., 318.
—— congenital hypertrophy of leg and thigh, &c., 319.
—— prognosis in, 320.
—— treatment of, 320.
—— operations required in, 321.
—— mechanical treatment of, 322.
—— physiological treatment of, 324.
—— after-treatment of, 324.
—— relapsed cases of, 325.
—— non-congenital valgus, external character of, 326.
—— special effects of, 328.
—— morbid anatomy and etiology of, 329.
—— morbid anatomy and etiology of arranged in six classes, 330.
—— 1st Class, depending upon ligamentous and muscular debility, 331.
—— 2nd Class, rachitic valgus, 332.
—— 3rd Class, paralytic valgus, 333.
—— 4th Class, spasmodic valgus, 333.
—— 5th Class, traumatic valgus, 334.
—— 6th Class, valgus consequent upon disease of ankle-joint, 335.
—— numerical importance, 335.
Talipes valgus, coexistence of, with other deformities, 336.
—— prognosis, 336.
——— in rachitic cases, 336.
——— in paralytic cases, 336.
——— in spasmodic cases, 337.
——— in traumatic valgus, 337.
—— non-congenital, treatment of, 337.
—— depending upon muscular and ligamentous debility, 337.
—— apparatus for most severe cases of, 340.
—— advantage of tenotomy in severe cases of, 342.
—— after treatment of, 342.
—— treatment of, in adults, 342.
—— treatment of, in rachitic valgus, 343.
——— in paralytic valgus, 343.
——— in spasmodic valgus, 343.
——— in traumatic valgus, 344.
——— in cases consequent upon disease of the ankle-joint or surrounding tissues, 344.
—— after treatment of, 344.
Talipes equino-valgus, 345.
Talipes calcaneo-valgus, 345.
—— calcaneus, congenital, external characters of, 347.
——— morbid anatomy of, 348.
—— pathology of, 349.
—— complications of, 350.
—— numerical importance of, 351.
—— prognosis of, 351.
—— treatment of, 352.
—— tendons requiring division in, 353.
—— mechanical treatment of, 353.
—— after treatment of, 353.
—— relapsed cases of, 354.
—— talipes calcaneus non-congenital, external characters of, 354.
—— non-congenital morbid anatomy, of, 356.
—— non-congenital condition of ligaments in, 357.
—— non-congenital plantar fascia, shortening of in, 357.
—— condition of muscles in, 357.
—— vessels and nerves in, 358.
—— resemblance of, to distorted Chinese feet, 358.
Talipes calcaneus, non-congenital pathology of, 362.
—— numerical importance of, 364.
—— coexistence of with other deformities, 364.
—— prognosis of, 364.
—— treatment of, 365.

Talipes calcaneus, boot used in cases of, 366.
Talipes calcaneo-valgus, 367.
Talipes calcaneo-varus, 367.
Tamplin's Mr., Scarpa's shoe, description of, 123.
—— trough instrument for adult varus, 266.
—— on the reparative process in tendons, linear cicatrix theory, 23.
—— opinion of production of congenital valgus, 315
Tendo Achillis, altered relations of, in congenital varus in the infant, 175.
—— relations of, in congenital varus in the adult, 210.
—— mode of dividing the, 116.
Tendons, deviations of, in the infant, 172.
—— in the adult, 203.
—— reunion of, 15.
—— non-union and adhesions after division of, 37.
—— Barwell's, Mr., statement as to non-union, 39.
—— requiring division in congenital varus in the adult, 210.
—— evidence of division of, 244.
—— difficulties connected with division of, in congenital varus, 244.
—— requiring division in congenital valgus, 314.
—— accidents connected with division of, in congenital talipes varus, 245.
—— deviations in, non-congenital varus, 300.
——— in congenital valgus, 314.
Tenotomy, history of subcutaneous, 3.
—— rate of extension after, 43.
—— rate of extension after Syme's views, 43.
——— Gross's views, 44.
—— relative merits of stretching the muscles, and, 47.
—— cases of varus in which it is unnecessary, 51.
——— doubtful whether operation be necessary, 52.
——— of varus in which operation is necessary, 55.
—— advantage of, in severe cases of non-congenital valgus, 342.
Treatment of non-congenital spasmodic and paralytic talipes, 62.
Treatment of talipes equinus, with existing paralysis, 129.
—— equino-varus, 135.
——— divided into three stages, 136.
—— operative, of congenital talipes varus, 230.
—— mechanical, of congenital talipes varus, 252.
—— congenital varus in infants, 258.
——— in the adult, 265.
—— duration of, in varus, 281.
—— mechanical and physiological, in varus, 281.
—— apparatus employed in, varus, 283.
—— after, in youth and in the adult, 285.
——— of congenital varus, 294.
—— of non-congenital varus, 303.
—— after, in non-congenital varus, 305.
—— of congenital valgus, 320.
—— mechanical, of congenital valgus, 322.
—— of congenital valgus, divided into two stages, 323.
—— after, in congenital valgus, 324
—— physiological, of congenital valgus, 324.
—— of non-congenital talipes valgus, 337.
——— rachitic valgus, 343.
——— paralytic valgus, 343.
——— spasmodic valgus, 346.
——— traumatic, 344.
—— of cases consequent upon disease of ankle-joint or surrounding tissues in non-congenital valgus, 344.
—— of congenital calcaneus, 342.
—— mechanical, of congenital calcaneus, 353
—— of non-congenital calcaneus, 365.
Various forms of club-foot, 1.
Vessels and nerves, condition of, in talipes varus in the infant, 177.
—— condition of, in congenital talipes varus in the adult, 210
—— in non-congenital varus, 301.
—— in congenital valgus, 315.
—— in non-congenital calcaneus, 358.
Wounds of arteries in tenotomy, 246
—— posterior tibial artery, 246.
—— internal plantar artery, 247.

APPENDIX.

DESCRIPTION OF SPECIMENS ILLUSTRATING THE REPARATIVE PROCESS IN HUMAN TENDONS AFTER SUBCUTANEOUS TENOTOMY.

Note 1. Description of specimens illustrating the reparative process in human tendons five months after division, 371.

Note 2. Description of two specimens illustrating the reparative process in human tendons one year and a-half to six years after division, and one specimen illustrating arrest of reparative process by scarlet fever, 372.

Note 3. Description of specimens showing good union of posterior tibial tendon; one, four and a-half months, and the other ten weeks after division, 379.

Note 4. Description of specimens illustrating condition of muscles, &c., in non-congenital club-foot, with table of microscopical appearances, 382.

SERIES OF CASES.

Case of rigid muscular contraction of both legs in a child, 391.

Case of rigid muscular contraction of both legs, with severe talipes equinus in a youth, 392.

Case of rigid muscular contraction of both feet, with severe talipes equinus in an adult, consecutive to an attack of Mauritius fever, 394.

Case of permanent contraction of both feet, and right hand, rigidity of muscles in an adult after snake bite, 398.

Case of rigid muscular contraction of both legs, with severe talipes valgus in an adult, 401.

Case of rigid muscular contraction of both feet, with equino-varus in an adult, consecutive to paraplegia, 406.

Case of infantile paralysis of both legs, three years' duration, with contraction of both feet, 312.

Case of infantile paralysis of both legs, with contraction of feet, remaining unrelieved up to the age of thirty-nine, 415.

Case of infantile paralysis of leg, mistaken for hip-joint disease, 419.

Case of infantile paralysis of leg, mistaken for fracture, 420.

Case of infantile paralysis of leg, mistaken for dislocation of hip-joint, 421.

Case of talipes equinus produced by strumous abscesses, 424.

Case of congenital talipes varus in which a portion of skin was removed to cure the deformity, 426.

Case of severe congenital talipes varus in the adult, 429.

Case of severe relapsed congenital varus of both feet, 434.

Case of severe relapsed congenital talipes varus of both feet, 438.

Case of congenital malformation, and deficiency in length of the leg, with malformation of the foot, 443.

Case of congenital malformation of both legs, with deficiency in length of leg-bones; eight toes on each foot, 445.

Case of congenital hypertrophy of right leg, with malformation of foot, 447.

Case of congenital talipes valgus of right foot, with rotation of tibia at the knee joint; contraction of both legs, 450.

THE END.

LONDON:
Printed by A. Schulze, 13, Poland Street.

BY THE SAME AUTHOR.

A NEW OPERATION

FOR BONY ANCHYLOSIS OF THE HIP JOINT WITH MALPOSITION OF THE LIMB.

BY

SUBCUTANEOUS DIVISION OF THE NECK OF THE THIGH-BONE.

Illustrated with numerous Wood-Engravings. 8vo. 2*s*. 6*d*.

Second Edition will shortly be ready.

THE SPINE:

LATERAL AND OTHER FORMS OF CURVATURE;

THEIR PATHOLOGY AND TREATMENT.

With 5 Plates and 66 Wood-Engravings. 8vo., cloth, 10*s*. 6*d*.

"The work is one which is creditable to the scientific research, and professional character of its Author . . . . . We can confidently recommend it to the profession as a reliable guide in the treatment of a very important class of cases."—*Lancet, June* 3, 1865.

ON THE REPARATIVE PROCESS

IN HUMAN TENDONS

AFTER

SUBCUTANEOUS DIVISION FOR THE CURE OF DEFORMITIES.

With 8 Plates. 8vo., cloth, 6*s*.

"The work should be on the shelves of every operative surgeon who has claims to a scientific acquaintance with his profession."—*The Dublin Quarterly Journal of Medical Science, Feb.* 1861.

SUBCUTANEOUS SURGERY:

A SKETCH OF ITS PRINCIPLES AND PRACTICE.

8vo., cloth, 2*s*. 6*d*.

"It appears to us not so much a compliment to Mr. Adams, as an act of justice to the profession, that this excellent sketch of the principles and practice of subcutaneous surgery should receive a wide circulation."—*British and Foreign Medico-Chirurgical Review, April,* 1858.

Nearly ready.

ON RHEUMATIC AND STRUMOUS DISEASES OF THE JOINTS.

Including Hip Joint Disease, and the Treatment for the Restoration of Motion in cases of Stiff-joint or partial Anchylosis. The Lettsomiam Lectures, delivered before the Medical Society of London.