

An inquiry into the difficulties encountered in the reduction of dislocations of the hip.

Contributors

Allis, Oscar H. 1836-1921.
Augustus Long Health Sciences Library

Publication/Creation

Philadelphia, 1896.

Persistent URL

<https://wellcomecollection.org/works/bpget7mn>

License and attribution

This material has been provided by This material has been provided by the Augustus C. Long Health Sciences Library at Columbia University and Columbia University Libraries/Information Services, through the Medical Heritage Library. The original may be consulted at the the Augustus C. Long Health Sciences Library at Columbia University and Columbia University. where the originals may be consulted.

This work has been identified as being free of known restrictions under copyright law, including all related and neighbouring rights and is being made available under the Creative Commons, Public Domain Mark.

You can copy, modify, distribute and perform the work, even for commercial purposes, without asking permission.




Wellcome Collection
183 Euston Road
London NW1 2BE UK
T +44 (0)20 7611 8722
E library@wellcomecollection.org
<https://wellcomecollection.org>

COLUMBIA LIBRARIES OFFSITE
HEALTH SCIENCES STANDARD



HX00035076



Digitized by the Internet Archive
in 2010 with funding from
Open Knowledge Commons

AN INQUIRY
INTO THE
DIFFICULTIES ENCOUNTERED
IN THE
REDUCTION OF DISLOCATIONS OF THE HIP.

BY

OSCAR H. ALLIS, M.D.,

FELLOW OF THE COLLEGE OF PHYSICIANS AND OF THE ACADEMY OF SURGERY, PHILADELPHIA;
FELLOW OF THE ACADEMY OF SURGERY, ALTOONA; HONORARY MEMBER OF THE
PATHOLOGICAL SOCIETY OF HARRISBURG; MEMBER OF THE AMER-
ICAN SURGICAL ASSOCIATION AND OF THE AMERICAN
MEDICAL ASSOCIATION; SURGEON TO THE
PRESBYTERIAN HOSPITAL.

THE SAMUEL D. GROSS PRIZE ESSAY.

PHILADELPHIA:

1896.

DORNAN, PRINTER,
PHILADELPHIA.

THIS LITTLE VOLUME IS DEDICATED

TO

DR. W. C. B. FIFIELD

OF DORCHESTER MASSACHUSETTS

WHOSE CORDIAL, EARNEST EXPRESSIONS OF APPRECIATION

AND APPROVAL FOR MANY YEARS HAVE BEEN A

SOURCE OF GRATEFUL ENCOURAGEMENT

TO THE

AUTHOR IN HIS WORK

1429 WALNUT STREET,
PHILADELPHIA, February 5, 1895.

OSCAR H. ALLIS, M.D.

MY DEAR DOCTOR: As Chairman of the Trustees of the S. D. Gross Fund and Library of the Philadelphia Academy of Surgery, I have the pleasure to inform you that the prize of one thousand dollars has been awarded you for the best original essay among those entered for competition January 1, 1895.

Permit me to offer my congratulations upon the success you have achieved, and believe me

Very truly yours,

J. EWING MEARS,
Chairman.

J. EWING MEARS,
W. W. KEEN,
JOHN ASHHURST, JR.,
Trustees of Gross Fund and Library.

THE conditions annexed by the testator are that the prize "shall be awarded every five years to the writer of the best original essay, not exceeding one hundred and fifty printed pages octavo in length, illustrative of some subject in surgical pathology or surgical practice, founded upon original investigations, the candidates for the prize to be American citizens."

It is expressly stipulated that the successful competitor shall publish his essay in book-form, and that he shall deposit one copy of the work in the Samuel D. Gross Library of the Philadelphia Academy of Surgery.

REMINISCENCES.

IN one of my visits to the Presbyterian Hospital in July, 1873, I found a man suffering from a recent dorsal dislocation of the femur. He had walked in his sleep from a second-story window, and in his descent had struck a clothes-line, which changed the direction and possibly modified the severity of the fall. In the erect posture the deformity was pronounced and typical; the right knee bent strongly inward toward its fellow, the foot turned inward, and the great toe could with difficulty be made to touch the floor. After full anæsthesia the patient was placed upon the floor, and various ineffectual efforts were made to reduce the dislocation. Reduction was finally accomplished by traction upward.

This was the first dislocation that I had ever seen, and, instead of being elated at my success, I was rather deeply mortified to think that success had crowned efforts put forth with no clear understanding of the nature of the accident or of the proper steps to repair it. I accordingly determined to lose no time in familiarizing myself with this subject, and, procuring Bigelow on *The Hip*, I took it with me to the dissecting-room, and there wrought out, over and over again, the problems of that justly celebrated monograph. Having satisfied myself, and thinking that I would profit by a demonstration, I invited the members of my quiz class to the dissecting-room, and readily convinced them, as I myself was fully convinced, that a knowledge of the Y-ligament was *all that was necessary to enable one to diagnosticate or restore any form of dislocation at the hip-joint*. My class was so well pleased with the

demonstration that I was induced to repeat my work with another class a year later.

Although this was more than twenty years ago, I recall the pleasure and satisfaction the work afforded me as vividly as if it were but yesterday. I speak of the pleasure, for it was an entirely new field to me; of the satisfaction, because, whatever I might lack in other departments of surgery, of this I was confident, that Bigelow knew all about the hip . . . and that I knew as much as Bigelow.

Six years passed by before I had an opportunity of putting my new attainment to a test; with what result will be seen in the history of the following case:

SIMULTANEOUS DISLOCATION OF BOTH HIPS. Peter J., colored, aged forty-two years. While removing ballast from the hold of a ship a mass of earth and stone fell upon him, partly burying him. He was removed in a condition of extreme shock, and was taken home. After a few weeks he was able to crawl out of bed, and later on was taken from one hospital to another, but, as he would not consent to what was deemed best, he was always refused admission. Finally, eighty-one days after the accident, he appeared at the Howard Hospital, at the clinic of Dr. Livingston, who detected a dislocation of the hip, and referred him to Dr. Willard, then in charge of the surgical clinic. On the following Saturday I met my colleague, Dr. Willard, who etherized the patient, and in a few seconds reduced by manipulation a typical dorsal dislocation of the left femur. The head went into the socket with the sound so characteristic of successful reductions, and with the immediate restoration of normal appearance. But when, to satisfy ourselves fully of the symmetry of the limbs, we compared them, the restored (left) limb was found markedly shorter than its fellow. This discrepancy threw grave doubt upon the success of the reduction; and the doubt was increased when a distinguished surgeon, standing by, pointed out a fulness in the thyroid region of the right limb that was absent in the one we supposed had just been successfully treated. To remove all doubt, Dr. Willard

redislocated the femur, and by manipulation, as in the first instance, restored the head with the audible thud so clear and the disappearance of deformity so sudden and complete as to dispel every misgiving as to the success of the manipulation. Then for the first time there flashed across our minds a full appreciation of the situation. Both femurs had been simultaneously dislocated. Dr. Willard had restored the left femur, the right still lay in the thyroid depression, thus enabling us to account for the fulness already alluded to, and the apparent lengthening.

This being decided upon, Dr. Willard attempted reduction of the right luxation, but failed, and sent the patient to the Presbyterian Hospital, as there were no beds at the Howard Hospital at the time. The patient then came under my care, and on the following Monday I was met by Dr. Willard, and my colleagues, Dr. Porter and Dr. Reed, and an earnest but fruitless attempt was made at reduction. A few days later Dr. Porter and Dr. Hodge assisted me in a second attempt. Manipulation, leverage, pulleys, and horizontal, oblique, and vertical traction were employed, but to no purpose. The head moved freely in all directions; it passed from the thyroid region backward to the dorsal, and from the dorsal again to the thyroid, and could be made to approach the rim of the socket, but could not be made to pass over it.

Had there been in this case only an irreducible thyroid dislocation, I would have felt no special disappointment at not being able to reduce it, since the time-honored apologies for failure would have abundantly satisfied me. The time during which the dislocation had persisted was now eleven weeks, and this, I would have argued, was ample for the filling up of the socket and for the capsule to close in around it. But no such argument could be urged in view of the fact that the socket on the left side had not filled up, and that the capsule there presented no greater obstacle to reduction than is found in recent dislocations. The left hip had entered with an audible thud, and this was good evidence that the socket was empty and covered with glis-

tening, unaltered cartilage. The left femur had been easily and instantly restored by manipulation in skilful hands, the right resisted the skill, not only of Dr. Willard, but also that of the entire surgical staff of the Presbyterian Hospital, even when that skill was supplemented by the most approved surgical appliances.

This experience led me to suspect that I had overlooked some important principle in my dissections and experimental work, though not doubting for a moment the infallibility of Bigelow's principles of reduction: I therefore again repaired to the dissecting-room, where I carefully and deliberately reviewed the teachings of this author. This work inspired in me new confidence, though it developed no new principle.

Again I became impatient to test the system, confident now that future triumphs would amply atone for my first somewhat mortifying failure. How much of a triumph my next case proved will appear in the following history:

RECENT DORSAL DISLOCATION OF THE LEFT HIP. Mr. F., a middle-aged man, had his left leg caught in the wheel of a wagon drawn by oxen. He was riding between the wheels and the oxen were walking. The accident occurred March 27, 1884. Dr. P. R. Koons saw the man about two hours after the accident. There was an apparent shortening of from two and a half to three inches. The head of the femur was in the position of high dorsal displacement; the knee was rotated strongly inward with marked adduction. Several efforts at reduction were made by Dr. Koons, with and without ether, and at each attempt the deformity disappeared to a very great degree. There remained, however, after each attempt a considerable degree of flexion of the thigh upon the pelvis. Dr. Koons accordingly brought his patient to the Jefferson Medical College Hospital on March 30th, and through the courtesy of my colleague, Dr. W. Joseph Hearn, the man was placed in my charge.

Upon examination I found no marked deformity. The thigh was slightly flexed upon the pelvis, and the knee, a little flexed, rose

above the level of the mattress. When the knee was depressed it sprung upward again.

On April 11th, two weeks after the accident, assisted by Professor Gross, Dr. Hearn, Dr. Barton, and Dr. Koons, after full anæsthesia, I began the examination of the limb. Upon flexing and rotating it, it suddenly changed its position and displayed all the signs of a dorsal dislocation. The knee was semiflexed and bent strongly in, and rested upon the right thigh above the other knee. All the signs were typical of a dorsal displacement. I accordingly flexed the leg on the thigh, the thigh on the pelvis, carried the knee inward, then upward toward the umbilicus, then with an outward sweep brought it down in extension. The result was that the head went suddenly into a position in the neighborhood of the socket with all the apparent signs of reduction, except that there were persistent flexion of the thigh on the pelvis and a tilting forward of the knee. All present exclaimed that the reduction was effected, but I pointed out the slight but ominous symptom, and insisted that there was still a radical defect, and that, while the head of the femur might lie near the socket, it was not in it. Over and over again the head was thrown into the dorsal region, and attempts were made by each surgeon present to conduct the head into the socket without any remaining deformity, but with no better success. Again, on April 22d, aided by Professor Gross, Professor Brinton, Dr. Levis, Dr. Hearn, Dr. Barton, and Dr. Koons, the whole work was carefully repeated. From a typical dorsal dislocation, with aggravated deformity, the limb was made to assume suddenly almost normal relations, and no effort to convey the head through a new route was any more satisfactory. Bigelow's plans of sudden upward jerking and of enlarging the capsular rent were adopted, but the result of one method was identical with that of all others, and the poor fellow was sent home with the same deformity that was present when he was brought to the hospital.

It was the opinion of most of the surgeons present that the head

was restored ; that it was a subluxation—a radical defect—from which the man would never recover, was my own opinion. The tilting forward of the knee and the flexion of the thigh, I knew, should not persist after a satisfactory reduction, and I therefore inferred that the head still lay below the socket.

As months rolled by the condition of the unfortunate man was kept fresh in my mind by correspondence with Dr. Koons, who reported Mr. F. as a great sufferer, and that he feared the prolonged use of morphine would lead to the formation of the morphine-habit. The persistence of the pain confirmed me in the opinion that the limb had not been properly restored, but I thought nothing but an autopsy would clear up the mystery. It was cleared up, however, much sooner than I expected, and in the following manner :

In February, 1885, nearly a year after the incident just related, and while it was still fresh in my mind, Dr. Bley and Dr. Johnson, who had returned to the Jefferson Medical College for post-graduate instruction, requested me to go with them to the Philadelphia School of Anatomy, then under the care of Dr. George McClellan, and give them practical instruction in reducing dislocations of the hip by manipulation. After strapping a cadaver to the floor, Dr. Bley effected a dorsal dislocation by flexion, adduction, and rotation inward without previous tenotomy of the capsule. I then requested him to employ Reid's method. Accordingly he knelt, and grasping with one hand the ankle and with the other the knee, he directed the knee inward toward the upper third of the opposite thigh and circumducted it, moving the knee upward and outward over the pubes and umbilicus and swinging it outward, and then brought the limb down in full extension, and the reduction was effected as if by magic, every vestige of deformity disappearing. I then requested Dr. Johnson to make a trial. He did it in almost every particular, as Dr. Bley had done, except that perhaps he pressed heavily upon the knee as he directed it ; but when he brought the limb down in extension, instead of all deformity disappearing, I was delighted to

see the same deformity present that persisted in the case of Mr. F. The thigh was so much flexed upon the pelvis that the knee was raised about a foot above the floor; the thigh was also a little abducted and rotated outward, with every manifestation of constraint. At my request the position was not disturbed, but the cause sought for by dissection. This revealed the head in the socket, *but the sciatic nerve was stretched over the neck*. Thus I had been mistaken in insisting that the reduction in F.'s case was incomplete. I was, however, right in demanding an explanation of the elastic forward spring of the knee after apparent reduction, and that condition no one present could explain.

This discovery infused new life into my study of dislocations of the hip, and I again, by means of dissections, reviewed the subject with increased interest. One point I certainly had gained, and I was satisfied that in all subsequent cases I would know when a dislocation of the hip was restored and when the great sciatic nerve was involved. The vague notion that the head had been prevented from entering the socket had been cleared up, and I felt an increasing confidence that I was now prepared for any difficulty that would present itself.

That this confidence was no better founded than my former had been will appear from the perusal of the following case:

J. H. M., aged twenty-three years, a strong, well-developed young man, fell on August 18, 1885, from a chestnut tree to the ground, a distance of about twenty-five feet. Dr. Newcomet saw the patient soon after the accident, recognized a dorsal dislocation of the right femur, and made, without ether, an unsuccessful attempt at reduction. Five hours later, using anæsthesia, and assisted by two other physicians, he again failed. The man was then taken to the Jefferson Medical College Hospital, twenty-six hours after the accident, and just before the hour for the medical clinic. Through the courtesy of Prof. Da Costa, I was permitted to take the injured man before the class immediately after his arrival. The symptoms were those

of a dorsal displacement. When fully etherized the man was placed upon a mattress upon the floor; I then flexed the leg on the thigh, the thigh on the pelvis, and seizing the ankle with my right hand, and placing the bent elbow of my left arm beneath the popliteal space, I adducted, rotated inward, lifted, rotated outward, circumducting at the same time, and brought the limb down in extension to complete the manœuvre. I failed; repeated my efforts; failed again; and then asked Professor Brinton to make a trial. He did so until, exhausted, he reluctantly desisted. Prof. Gross then undertook the manipulation, and, after witnessing two failures, tried hard not to make a third, but to no purpose. The man was then removed to an adjoining room, where Dr. Richard J. Levis, Surgeon to the Pennsylvania Hospital, Dr. Hearn and Dr. Barton, Surgeons to the Jefferson Medical College Hospital, and others tried long and earnestly, but ineffectually, to restore the dislocation.

A week later, aided by Prof. Brinton, Prof. Gross, and Prof. Pancoast, Dr. Hearn, Dr. Barton, and Dr. Reed (the latter, surgeon to the Presbyterian Hospital), a second long but fruitless effort at reduction was made.

With this failure vanished all the fancied acquisitions of my repeated studies on the cadaver, and with them all my reliance upon the dogmatic assertions of authors and teachers upon the subject. My disappointment was indeed great. What I had regarded as a science and had pursued with ardor to its supposed mastery had vanished in a moment, and left me small compensation for the labor and study I had expended upon it. I had failed after the fairest trials, and had desisted, not for want of co-operation on the part of my patients, but for want of expedients on my own part. That which impressed me more than anything else was, not that I could not reduce dislocations, but that I could conceive of no rational cause for my inability to do so.

Again I went into the dissecting-room, but found there no solution to my difficulties. Other failures, some in my own hands and

some in others, which I need not record, confirmed my now settled conviction that the rules for the reduction of dislocations of the hip-joint were few and simple, and that when these failed in the hands of a novice, he knew as much about the cause of failure as I did after years of perplexing study. -

One who has experienced only success in the reduction of dislocations may be surprised at these confessions, while he, in whose hands reductions have taken place, that have resisted previous efforts in other hands, may wish that he had had a chance at those cases. But let such a one recall the case of J. H. M. The dislocation was only a day old, and I failed before a well-filled amphitheatre. What would I not have given for success! I was followed by Prof. Brinton, whose office it was to teach, and now he had an opportunity to demonstrate, the proper means to overcome the obstacles to reduction. Witnessing my own and Prof. Brinton's failure, would not Prof. Gross have enjoyed our discomfiture, by skilfully dropping the head into its socket? And after we had failed, with four or five hundred students as spectators, all eager for the result, what would have been the exultation of Dr. Levis, Dr. Hearn, or Dr. Barton, if either could have accomplished that which we had failed to do?¹ Certainly there was every inducement for each man to do his best, and to try some new expedient after the previously tried methods had failed.

Every surgeon is aware that the reduction of a dislocation is usually a very simple and easy matter. I saw an interne in the Philadelphia Hospital, fresh from the lecture-room, take hold of a recently dislocated femur, trying to recall the method taught by the Professor of Surgery, and, before he had decided what to do, and while he was aimlessly moving it about, the head sprang into its socket with the characteristic audible thud. "I wish I had noticed how I did that,"

¹ After our failure, the young man was taken home, and, unwilling to go through life a cripple, he wrote to Prof. D. Hayes Agnew, stating what had been done for his injury, and asking his opinion about making further attempts at reduction at the Hospital of the University of Pennsylvania. The latter replied in terms so complimentary to those who had failed that the young man never sought further advice.

was his regretful, half-mortified ejaculation. Cases of restoration are reported that occurred in the hands of experienced surgeons, the return taking place during a preliminary examination, and before any intelligent effort had been put forth.

On page 66 will be found the report of a case in which the patient was deemed too ill to justify an effort at replacement, but in which the reduction was unwittingly performed by the nurse, who was changing the patient's position in bed. All such cases are confirmed by experimental study; for, after effecting dislocations of the shoulder and hip in the cadaver, I have often found the head hovering on the confines of the socket, unwilling to stay out, and often returning spontaneously or upon the slightest change of position.

The difference in different cases can also be illustrated from clinical experience. I succeeded in my first case before I had made any special study of the subject, and when I possessed only the meagre impressions that students get from lectures. In my five succeeding cases I failed, though I had made the subject one of thorough and oft-repeated experimental study. Prof. Brinton failed before his class in the case of J. H. M., whose right femur had been displaced the day before. He succeeded in the next case he took before his class, which was also a right dorsal dislocation, in a young man, injured the day before; and, to make the case still more nearly analogous, he succeeded after others had failed. Dr. Reed failed in two of my cases, but restored subspinous dislocation by the first manipulation.

The surgeons whose names I have mentioned were all practically familiar with dislocations of the femur, and brought to bear all the manœuvres that a long hospital experience and extensive reading could suggest.


Reflection upon the subject led me to believe that the true nature of the obstacles that occasionally present themselves in dislocations of the femur would always remain a matter of doubt, and that difficulties arose in the living that had no counterpart in the dead subject.

With these conclusions I had almost dismissed the subject from

my mind when, in January, 1892, a fatal result from an attempt to reduce an old thyroid dislocation induced me again to return to the dissecting-room, with the special design of studying the relation of the femoral vessels to the subject of dislocations. I soon found that my early enthusiasm in the subject had fully returned, and I now have the satisfaction of saying that I believe I have seen the exact counterpart in the cadaver of nearly every difficulty that I have ever encountered in the living subject. What I have seen I have tried to depict, tried to show its peculiar mechanism and the rationale of deliverance. Many difficulties that struck me at first as insuperable, and which, before my studies were hopelessly inexplicable, are no longer so.¹

In the Introductory Study which follows, clinical difficulties have suggested and directed experimental work. To no class of affections has clinical experience contributed so little. To anæsthesia, to the knowledge gained from dissection, to the study of fatal cases of traumatic dislocations, and to experimental work in the dissection-room do we owe all the progress we have made in this department of surgery. The clinic has really been the amphitheatre for the display of skill for the relief of the living which was gained upon the cadaver in the dissecting-room. Some have fancied that they have found in experimental work the solution of all conceivable difficulties, and have spoken with confidence upon the subject. For my part, I have been too often and too sadly disappointed in dogmatic assertions to venture upon the same course myself. I have everywhere striven to be clear and candid. My oft-repeated failures have left me no room for boasting. They have not, however, been an unmixed evil ; for, while they have been a constant menace to over-confidence, they have also been a constant spur to exertion.

¹ N. B.—None of the foregoing remarks appear in the essay as handed in. All competing writers were obliged to appear incog., and that necessitated the omission of Reminiscences.
—THE AUTHOR.



PART I.

INTRODUCTORY STUDY.

PROPOSITIONS.

THE following propositions are discussed :

I. The Capsule is the most important agent against traumatic dislocations of the femur.

II. For the laceration of the capsule and dislodgment of the head of the femur, the femur is employed as a lever.

III. Every lever has a fulcrum ; the fulera required in dislocations of the femur are bony and ligamentous.

IV. Dislocation by thrust, if possible, is infrequent.

V. Reduction by *Circumduction* is the simplest, the most brilliant, and the most hazardous of all modes of replacement.

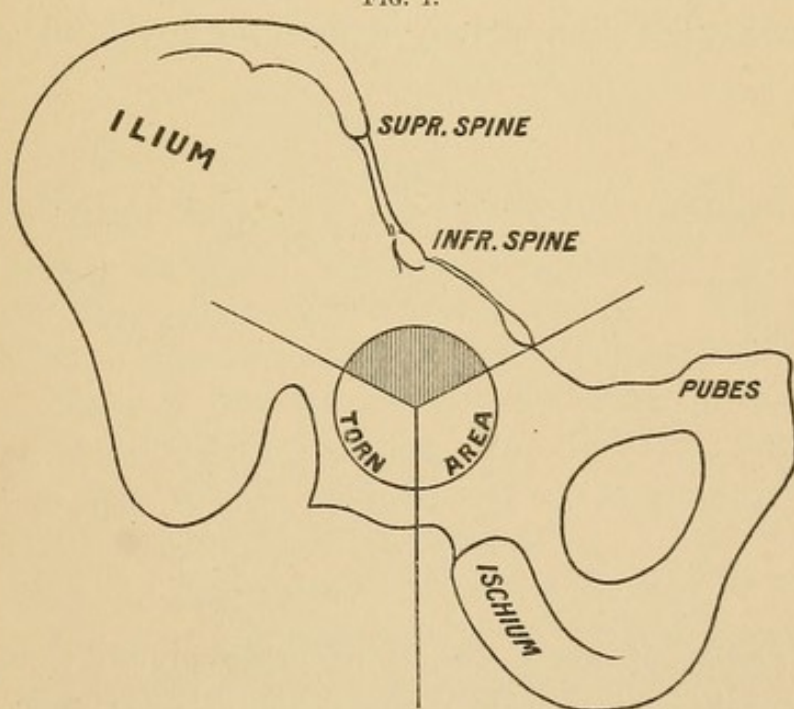
VI. Method suggested for reduction of dislocation of the head of the femur when associated with fracture of the shaft.

INTRODUCTORY STUDY.

ANATOMY.

It is a matter upon which the medical student may well congratulate himself, that the study of dislocations at the hip-joint has been reduced within a narrow compass. Thus, if I may be permitted to divide the socket into three equal parts, I may say that the havoc to capsule and muscles, attending dislocations, will almost

FIG. 1.



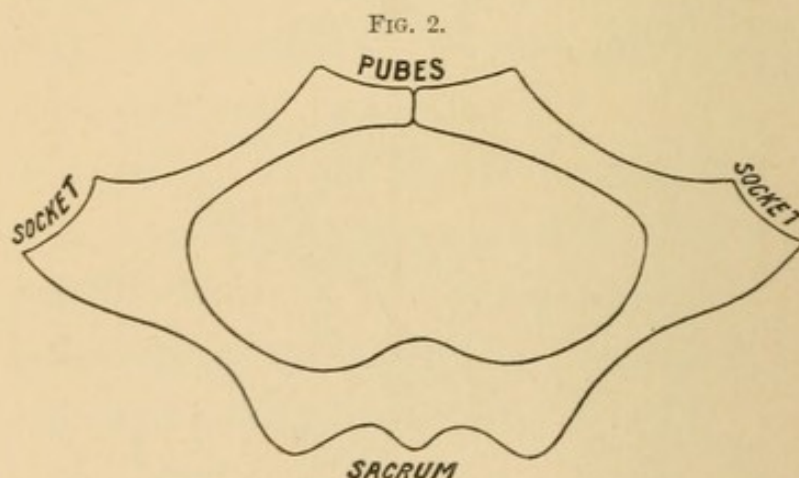
invariably be confined to the lower two-thirds, while that portion of the capsule lying within the compass of the upper third, as well as the muscles that cover it, will, with even greater certainty, escape injury. Still more important are the now well-established facts that we are indebted to the untorn remnant of capsule for the signs of dislocation and for the most effective means for its restoration.

Certainly this is one of the departments of surgery in which the labor of centuries is made readily available to the earnest student. Knowledge that was at one time vague, diffuse, and theoretical has approached the dignity of fact, and he who is willing to familiarize himself with the subject will find himself able to do more, unaided, in a few moments, than our learned Fathers in Surgery could accomplish with powerful auxiliaries in hours.

The Pelvis.

Throughout the Introductory Studies I shall speak of the pelvis as lying upon its back. In this position we usually find our patient; in this we administer an anæsthetic and make our attempts at reduction; and in this we must determine our success before the patient returns to consciousness and can assume another posture.

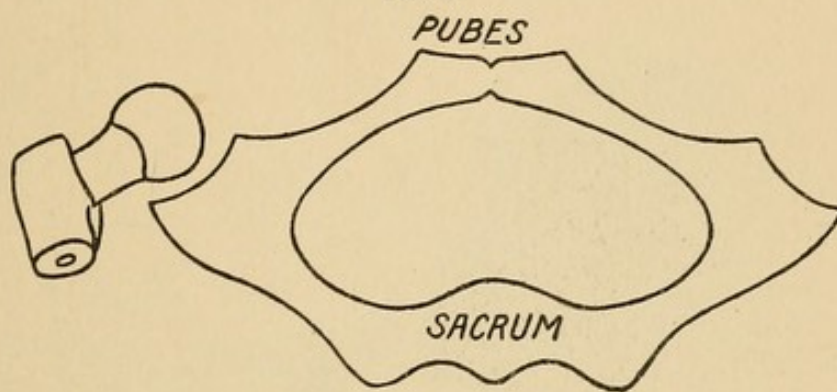
If the pelvis be placed upon its back upon the floor, the pubes becomes the highest and the sacrum the lowest part. In this position the socket lies about midway between the level of the pubes and the floor.



The situation of the socket is of great practical importance. Rudely described, a transverse section of the pelvis is lozenge-shaped, and at the extreme right and left of the lozenge lie the sockets. This position puts the femur under the advantageous control of muscles that arise from the pelvis, and gives the hips a wide separation for a firm base of support. The socket looks upward and outward: in the erect posture, downward and outward. It is situated at the junction of two irregular bony surfaces: the inner, or pubo-ischiatic; the outer, or ilio-ischiatic. These, for want of a more appropriate

name, I shall denominate the inner and outer planes. These meet at an angle of about 90° . The fact that the bony surfaces recede from the socket, permitting it to stand out in bold relief, explains why the femur can have so extensive a range of motion without danger of bony collision. The socket lies chiefly upon the pubic aspect of the pelvis; it is excluded from the dorsal region by a high acetabular ridge. The head of the femur lies in the socket; but the trochanter (Fig. 3) projects over the outer rim. The retentive apparatus exerts its influence chiefly upon the head; the motor power is attached to the trochanter and the shaft of the femur.

FIG. 3.

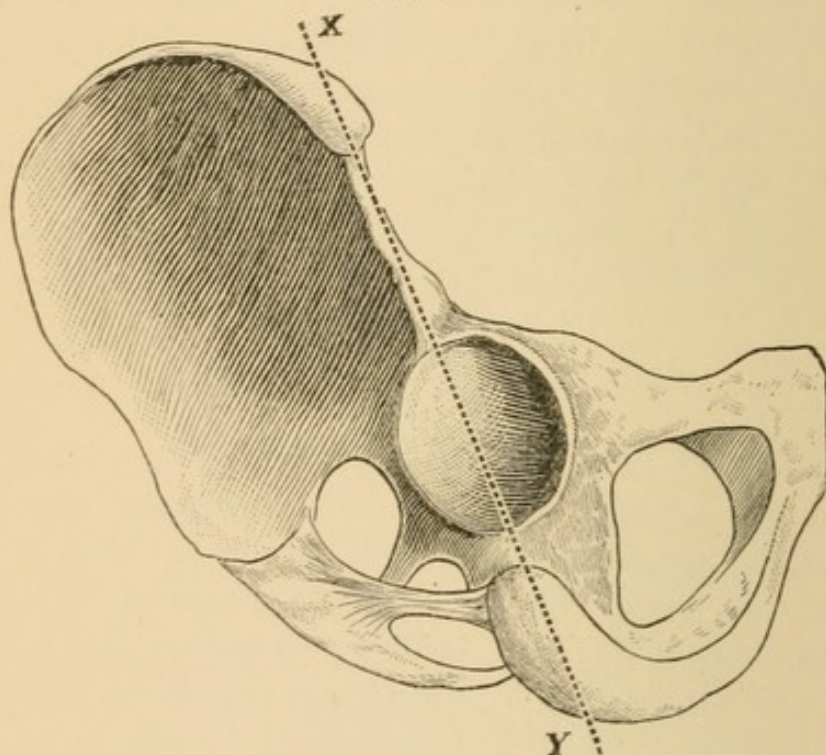


Planes of the Pelvis. I have alluded to the anatomical fact that the socket lies at the junction of two irregular bony surfaces or planes. These planes are caused by a sharp bend in the innominate bone, which, while it gives great prominence to the socket, makes the planes of the bony surfaces very distinct from each other. The ridge, or dividing-line, between these two planes, passing from the superior spine through the tuberosity of the ischium (Fig. 4, X, Y), divides the sockets into two nearly equal parts. If the head escapes upon the inner plane—no matter where—the whole lower extremity will present an entirely different series of phenomena from those of a dislocation upon the outer plane. Thus, at the outset, I am led to give great stress to the anatomical shape of the pelvis, as it gives us a rational classification of all dislocations into *Outward* and *Inward*.

After the occurrence of a dislocation outward the socket can sometimes, in thin persons, be faintly outlined. The fingers are, however, prevented from sinking into it by the remnant of untorn capsule and the tendon of the ilio-psoas muscle, which are drawn obliquely

and quite tensely across it. This muscle is relaxed by flexion under normal conditions ; but after dorsal dislocation a part of the weight of the limb would fall upon it, put it on the stretch, and prevent the examiner from closely defining the socket. If the socket can be distinctly outlined, the dislocation is outward ; it cannot be inward. The socket is deeply excavated at the expense of the ilium, ischium, and pubes. I should not say at the expense of it, for the equivalent of bony material is simply transferred from the middle to the periphery of the socket. Thus a rim is formed, raised above the level of the bone, which serves as a barrier against displacement, and may also

FIG. 4.



constitute a formidable barrier to reduction. The tendency of the head, in the normal functions of the joint, is to displacement upward and outward ; but this tendency is so fully and effectually guarded against by the depth of the socket and the unusual strength of the capsule in this particular region that dislocations in this quarter are, if possible, certainly very infrequent.

As no part of the socket is better guarded against displacement than the upper and outer, so no part is better able to resist fracture. Fracture of the rim of the acetabulum is very infrequent. It is sometimes thought to be present when the head, after reduction,

readily becomes re-dislocated; but this may be occasioned by a socket partly filled by muscle and capsule.

Security of the Socket. An interesting study in connection with the socket is the mechanism through which nature has combined great freedom of motion with the greatest possible security. Were the head held in the socket at all times by its ligaments, then its ligaments must always be tense, and the area of motion would be very limited; with a large universal range of motion the capsule can have no retentive function, except as a check to transgression.

FIG. 5.

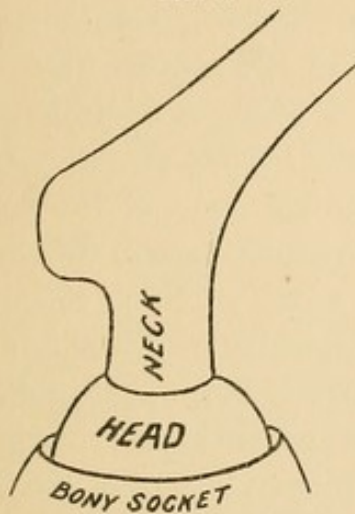
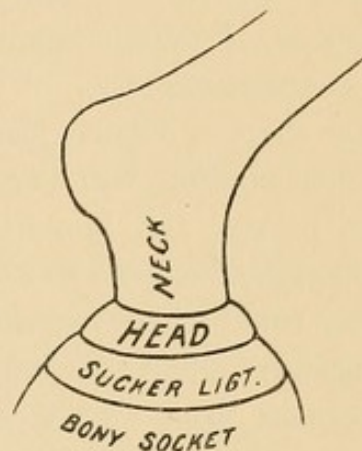


FIG. 6.



In normal limits a retentive function largely independent of capsule must be invoked, and this Weber has shown to be atmospheric pressure. To accomplish this a firm yielding cartilage, known as the cotyloid ligament, is strongly attached to the rim of the bony socket. By this method the socket is deepened and the joint is secured against the possibility of dislocation in its ordinary range of motion. Had the socket been deepened by a bony instead of a cartilaginous rim, the range of motion would have been abridged and the danger of fracture of the rim or femur would have been increased manifold. Weber showed that, after the entire capsule had been removed, it became a problem of mechanics to draw the head from the socket. From this function the cotyloid ligament is often called the sucker ligament.

Although the capsule, as a ligament, has no retentive function during the ordinary movements of locomotion, it must not be inferred that the security of the joint is wholly attributable to atmospheric pressure. On the contrary, the joint's security is largely due to muscular action. Thus the gluteus minimus and the iliacus

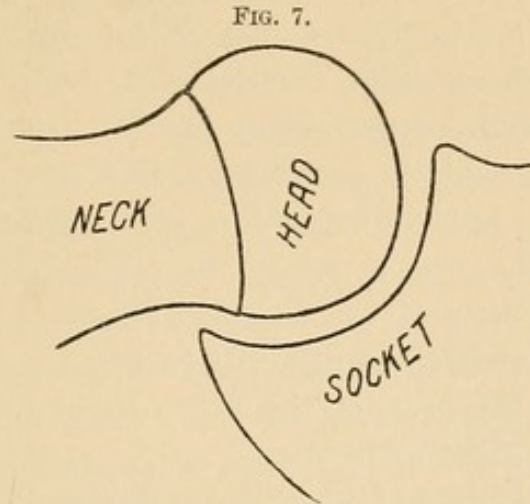
internus have insertions into the upper half of the capsule which add directly to its thickness and strength, while at the same time they act as tensors of the capsule. The *psoas magnus* is attached partly to the capsule, though in the main it passes over the part of the capsule that is especially called upon to make pressure upon the head of the femur.¹ Thus, while the capsule in itself is a fibrous structure, it becomes, under the action of these three powerful muscles, an active barrier against displacement. At every step a man makes, the head of the femur rises from the bed of the socket and tends toward displacement. Such a rising would produce a vacuum between the head and socket, the direct effect of which would be to impede capillary circulation in the bed of the socket, were there not a special provision against it. Such a mechanism designed to equalize pressure exists. Beneath the inner border of the cotyloid cartilage there is a canal leading to the central dome of the socket. This canal is filled with loose connective tissue, through which the vessels, nerves, and lymphatics find their way. Now, this loose, movable, fatty material acts as an automatic valve or piston, sinking into the canal whenever there is intra-acetabular exhaustion, and bulging forth when this condition is relieved, thus preventing any disturbances from altered atmospheric pressure, which otherwise must take place with every step. I have noticed a similar bulging and recession of the loose connective tissue beneath the web in the ischio-femoral band; but such a function is hardly necessary in the extra-cotyloid portion of the articulation. The retentive apparatus of the hip is, therefore, a complex and widely distributed mechanism. It embraces the capsule when the head tends to pass beyond its normal limits, the *psoas* and *iliacus* when the joint is in active service, the *fascia lata*, and atmospheric pressure. This provision has a wider range than might be at first supposed, for when the poor hemiplegic is bereft of all muscular support the security of the joint is still preserved by ligaments and atmospheric pressure.

The Head of the Femur.

We are very apt to associate the security of the head of the femur with the depth of the socket, but the truth is that in every useful

¹ The retentive function of the *fascia lata* will be discussed in its appropriate place.

position little more than half the head lies in contact with the socket. The diagram (Fig. 7) represents the upper half of the head entirely outside the bony socket and the lower quite within it. Indeed, the positions in which the head would seem most secure are those in



which the femur is least serviceable. The reader will note that when a part of the head is within the bony socket the neck does not come in contact with the rim; and this is true of all normal movements of the joint.

The Ligamentum Teres.

The ligamentum teres is described as a tubular structure of variable size and shape, extending from the dome and inner margin of the socket to the dimple in the head of the femur. It is covered with synovial membrane reflected from the fatty cushion in the depths of the socket. A small vessel runs throughout its length, distributing its branches on the periphery of the ligament. According to Gray (who quotes Struthers), "the teres checks rotation outward and adduction of the flexed femur; it assists in preventing dislocations of the femur forward and outward, an accident likely to occur from the necessary mechanism of the joint, if not provided against by this ligament and the thick anterior part of the capsule." This statement is very generally accepted by the profession. As a theory, it is comprehensive and almost challenges a misgiving. For my part, I join the few who believe that there are no adequate grounds for calling this a ligament. Were it as strong as steel the mechanism is such that it must rupture or tear loose from its attachments whenever called upon to prevent a dislocation. Indeed, the

ligament rarely separates from the head, but instead brings away a thin lamina of bone. Hence, were the structure ten times stronger than it is, the bones themselves must be proportionately stronger or it would avail nothing.

The *teres* is absent in the orang-outang, in the anthropomorpha, and in the South American sloth. These animals display their wonderful activities in trees, moving from branch to branch and from tree to tree with astonishing rapidity; and if any animal required a *teres* to establish a secure hip-joint, certainly it would be present in these. It is also absent in the elephant, and sometimes it is absent in man.

The alleged functions of the *teres* as a ligament are :

1. To check a tendency to dislocations ;
2. To suspend the head of the femur as in a sling, to prevent shocks in running and walking ;
3. To act as a channel of nutrition to the head of the femur.
4. It is alleged by Bland-Sutton that the structure has no special function now, and is merely a retrogression from the pectineus muscle.

Unlike the foregoing theories, and possibly no better than the poorest, is my own, viz., that the *teres* when present is an accessory lubricating agent to the joint. The chief source of synovia to the head is from the synovial membrane that covers the fatty cushion in the dome of the socket. Continuous with this is the *teres* covered by a reflection of the synovial membrane. To this membrane, and not to the head of the femur, the artery that enters the base of the *teres* is distributed. Were it not for the special provision of a fatty cushion, covered with a synovial membrane, for lubricating the head, all the synovia must be pumped up by the action of rotator and other muscles¹ that compress the capsule, and in man in the erect posture gravitation would carry the lubricant away from and not toward the articulating surface. It will be remembered that the dome of the socket is covered with a loose fatty cushion, and such a construction may be designed to enable it to follow the head through the suction which its slight tendency to displacement creates, giving it the function of a swabber to the movable head, while the liga-

¹ The *psoas*, *gluteus minimus*, and small rotators are the regulators of the capsule, and no doubt contribute to the distribution of the synovia.

mentum teres, lying flat upon it, may have the additional function of distributing synovia.

Tears from the Head. I think the ligamentum teres must vary in length. I have cut away the capsule on its inner aspect and dislodged the head by abduction upon the inner border of the socket without rupturing the teres, and at other times I have torn it completely off from the head in efforts at dislocation, and on dissection have found the head in the socket and the capsule not sufficiently torn to permit the head to escape from the socket. From experimental work I am quite disposed to think that the teres is often ruptured in severe wrenches of the hip, which may tear the capsule, but fall short of complete dislocation.

In my experiments it has been interesting to watch the teres tear from the head of the femur. It is a fact, based upon the lesions of fatal traumatic dislocations and verified by work in the dissecting-room, that this structure is usually torn from the head of the femur—rarely from the socket or in its continuity.¹ If the inner part of the capsule be removed and the thigh be abducted, the head will gradually emerge from the socket, closely surrounded by the sucker ligament (Fig. 8), which hugs the yet unbroken teres closely against

FIG. 8.

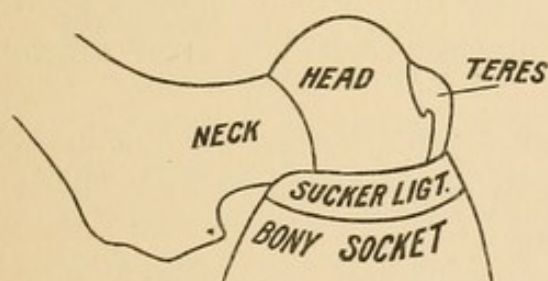
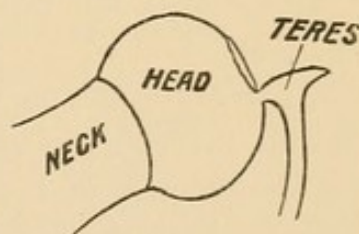


FIG. 9.



the head of the femur. As the head rises, traction is made, not on all the fibres at once, but upon the uppermost fibres only. (Fig. 9.) These fibres are the first to yield, after which the stress falls upon succeeding fibres. Hence the attachment of the teres to the head is its weakest part in accidents like dislocations; because the violence explodes upon the fibres separately and upon the most distant ones first. A very common mode of separation is for the teres to bring with it a thin lamina of bone from the head. The lamina tears from

¹ I have seen it tear through the middle and also from its acetabular attachments. In two cases in which the teres remained attached to the head it had, by its pelvic attachments, torn the transverse ligament up by the roots and dragged it out of the socket.

the bone, beginning always at the upper or most distant part, thus demonstrating that the strain is greatest at this point and that the strain does not fall equally upon the fibres under such a test. It makes no difference whether the dislocation is primarily inward or outward—the teres tears in the same manner from the head; and the ease with which it is torn off is a strong argument against its function as a ligament.

Summary of Functions. In conclusion, I think I can safely say—

1. The teres does not prevent dislocations, since it is possible to tear it from the head without completely dislocating the head.

2. The ease with which the teres can be torn after division of the capsule is also proof that its function is not that of a ligament.

3. While it is true that the teres may be torn without a dislocation taking place, it is also true that without rupturing it a complete dislocation is possible.

4. If the teres escapes rupture in the process of dislocation, it is highly probable that it will be ruptured during efforts at replacement, if circumduction be employed.

5. As there is no evidence that the teres contributes to the normal security of the joint, therefore insecurity or weakness of the articulation after the reduction of a dislocation cannot logically be attributed to its loss; nor can its absence be said to favor subsequent dislocations.

6. After reduction, no unusual position of the limb or foot (such as flexion, inversion, or abnormal eversion) can justly be attributed to the lost function of the teres.

Query. Does the teres ever reunite after dislocation?

From an anatomical standpoint, I would not deny the possibility. The probability is slight when we think that coaptation of the torn surfaces may be wholly or partially prevented by blood, muscular débris, shreds of torn tendon. Pathology alone can enlighten us on this point.

THE CAPSULE.

No single structure about the hip-joint stands second in importance to the capsule. After dislocation, the remnant of untorn capsule, as a short halter, contributes to the awkward constraint of the femur

and can be made available as an important diagnostic agent; it may also constitute a principal factor in accomplishing reductions.

The capsule cannot be studied too carefully. It is a strong membrane, and extends like a sleeve or cuff from the rim of the socket to the base of the neck of the femur. Its functions are:

1. To check the movements of the femur against a tendency to transcend the limits of safety. If one will dissect every structure from the joint but the capsule, he will be surprised at the resistance this single structure will offer to displacement.

2. To offer a large surface for the attachment of muscles that contribute toward the safety of the joint and preside over the movements of locomotion.

3. To furnish a large surface for the display of synovial membrane.

4. To form a shut sac for the retention and distribution of synovia.

The pelvic origin of the capsule is from the bony margin of the socket, except where the margin is deficient, and here the attachment is to the transverse ligament.

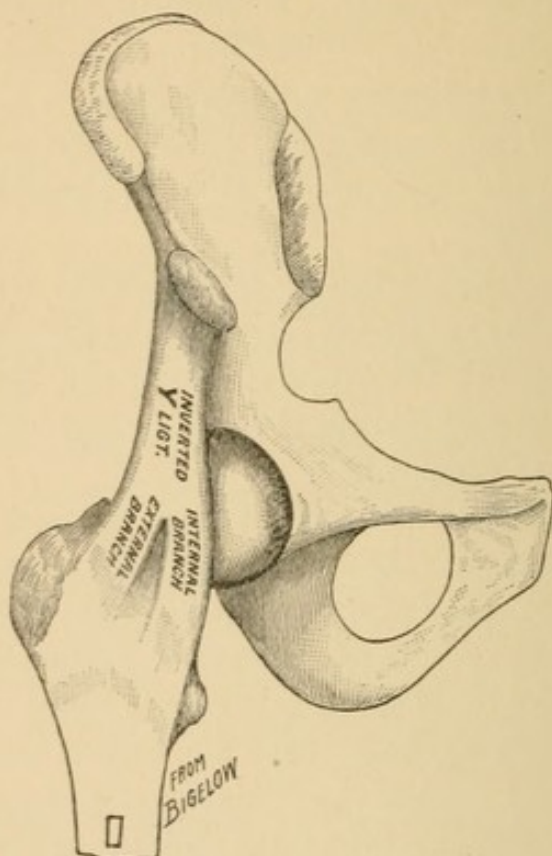
The femoral attachment is to the base of the neck—anatomists say that the attachment is to the base of the neck anteriorly and to the middle of the neck posteriorly. I will explain this attachment further when speaking of the ischio-femoral ligaments. Certain parts of the capsule are worthy of special study in connection with our subject. Prominent among these is the ilio-femoral ligament. (Fig. 10.)

The Ilio-femoral Ligament. This is not a distinct ligament, but only a remarkable thickening of the capsule anteriorly. Its pelvic origin is below the anterior inferior spine of the ilium. At this point it is thicker than the tendo-Achillis (Weber). From this point it passes down to be attached to the anterior inter-trochanteric line. In its passage to the femur it does not continue of uniform thickness, but its fibres are divided into two columns or branches, leaving a space between them where the membrane is thin and translucent.¹ As this is a very important part of the capsule, with a long and unwieldy name, Bigelow has christened it the Y-ligament; and this name has been widely accepted by teachers. I have repeatedly dissected it; and while the branches are not always equally distinct, I feel that I can unqualifiedly support the distinguished surgeon in what he claims for it. The two branches are called by him the outer

¹ See *infra*—Strength of the Capsule, p. 17.

and inner branches ; and he attributes special functions to each.¹ I shall not confine myself to this name in these pages ; for experimental work, supported by pathology, proves that much more than the Y-ligament is, as a rule, uninjured in dislocations ; and it is a fact clearly susceptible of demonstration that the less the capsule is torn

FIG. 10.



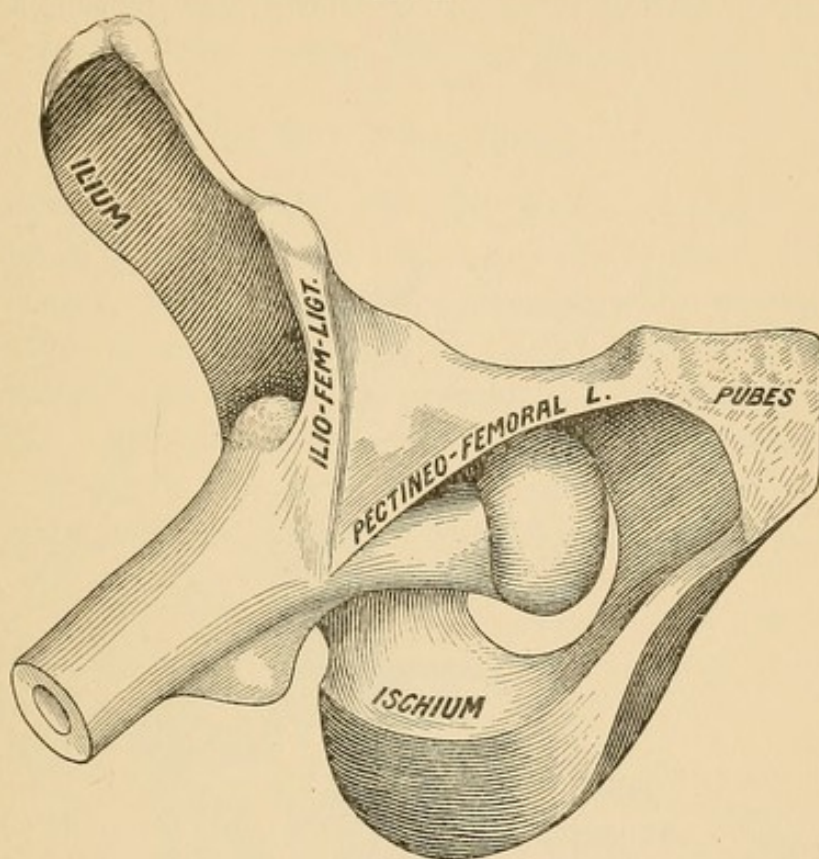
the more restraint will be exercised upon the dislocated limb, the nearer the head will lie to the socket, and usually the facility with which reduction can be accomplished will be correspondingly greater.

Pubo- or Pectineo-femoral Ligament. Continuous with the ilio-femoral ligament, but further inward, is one known as the pubo- or pectineo-femoral ligament. This structure arises from the pectineal line as far inward as the spine of the pubes ; the fibres pass outward to blend with the capsule. It presents a slightly prominent sickle-shaped border, which extends from the spine of the pubic bone to the femur just above the lesser trochanter. These fibres lie beneath

¹ The two branches of the Y are beautifully brought out by first dislocating the femur and then looking toward the light from the inner surface of the capsule. This will prove to any one that the branching is not the work of a scalpel.

the pectineus muscle and the sheath of the femoral vessels. The fibres are made tense during abduction. When I have dislocated the head inward—by hyper-abduction—this ligament has often escaped injury, the head making its escape from the socket beneath

FIG. 11.



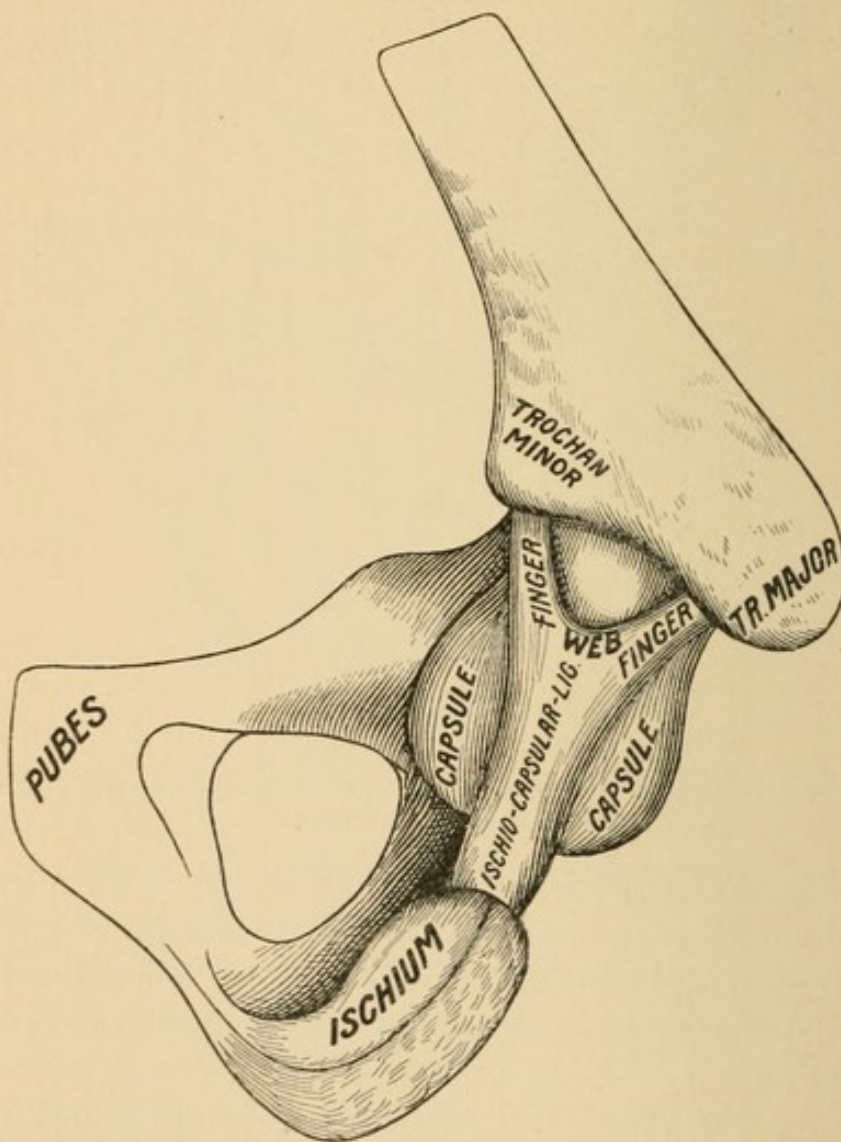
Dislocation inward—the head lying in the thyroid depression and partly covered by the pubo-femoral ligament.

it. At other times it has been torn. It is torn in all attempts to convert by rotation outward a direct inward dislocation into a sub-spinous variety. It probably always escapes when the head is dislocated downward and outward. It may constitute an obstacle to reduction.

Ischio-femoral Ligament. This accessory band is called by Gray the ischio-capsular ligament, but I think incorrectly. No two anatomists describe it alike; I will therefore describe it as I have found it. It arises from the ischial portion of the rim of the socket and sends its fibres to the capsule to be blended with them. As its fibres extend upward they separate like two fingers or terminal processes, the one extending forward to the base of the oblique line, the other running backward to the digital fossa. Between these pro-

cesses is a web, like the web between the fingers of the hand, with a distinct border and entirely free from attachment to the neck. Anatomists say that the capsule attaches to the neck posteriorly midway in its length. Now, it is true that above the web (Fig. 12) there is no capsule, and that the synovial membrane reaches only half-way the length of the neck posteriorly; but there is a function

FIG. 12.



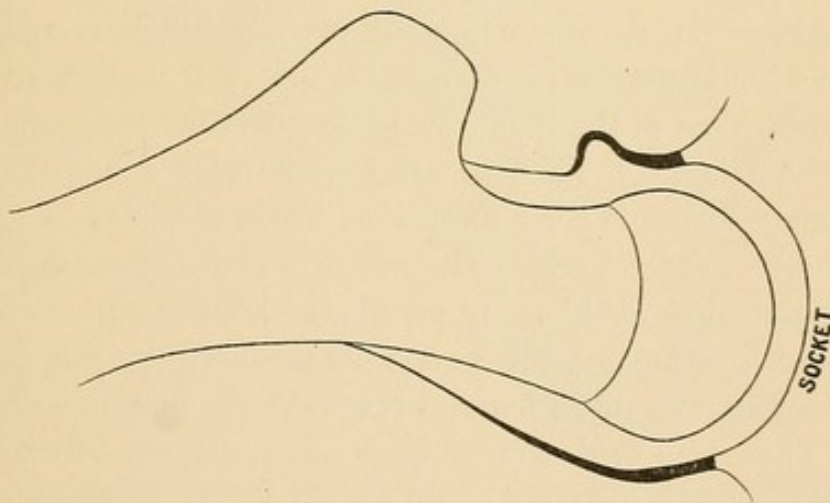
of the capsule that would be lost if the capsule attached directly to the neck midway of its length; and that function is strength. Were the fibres lost in the capsule, as described by some anatomists, they would confer no strength or barrier against dislocation. To gain strength they must pass from bone to bone, from the rim of the socket to the base of the neck. I have spoken of the web as having

a free distinct border, and have said that this web does not attach to the neck. I mean by this that it is not attached as a ligament. It is loosely attached by a reflection of synovial membrane and by connective tissue; but its only function in the attachment is to retain synovia. The absence of capsular attachment in the middle of the neck posteriorly does not weaken the joint, for any stress will take the direction of one or the other of these processes, or of both.

Strength of the Capsule.

The crowbar is so constructed that its greatest strength shall be at the point of greatest strain, *i. e.*, a point over the fulcrum, and the further we go from this point the less material do we find in the bar. Now the capsule is constructed on this plan: it is thickest where the strain is necessarily the greatest, and that is near the rim of the socket. In every strain upon the capsule the pressure must be exerted through the head of the femur and proceed from within the capsule and extend outward. The capsule may be cut with a

FIG. 13.



bistoury from without inward, but it must be burst from within outward. In every position in which the femur may be placed, if the head is thereby brought against the capsule, it will be brought against that part which is nearest to the pelvic attachment, and hence everywhere the pelvic extremity of the capsule is thicker, stronger, and more even in construction than the femoral extremity. When we examine the femoral extremity of the capsule we find that the ilio-femoral band splits and separates, making two attachments. We see the pectineo-femoral making a single femoral insertion; we

find the ischio-femoral—one at its pelvic origin—dividing into two branches at the femoral; and the question arises, What does it all mean? The answer is close at hand. The femur being a crooked bone, enjoying universal motion, with capsular fibres of unequal length, could not find a use for all the fibres were they inserted of equal thickness into the neck. Not only is this true, but, were the capsule of equal thickness at its femoral attachment, the directions of strain would be interfered with, since some parts of the capsule by its unwieldy thickness would be in the way of others. So far from the gap between the legs of the Y-ligament being a cunning device of a scalpel in the hands of Prof. Bigelow (as I have heard declared), this gap is rather the conservation of material, being thin here, with no other function than to retain synovia, while the branches themselves of the Y are rather the expressions of normal hypertrophy due to healthful physiological activities. As in the case of the mast of a ship, the strain may fall first on one rope, then on another, and lastly on both together; so the strain on the femoral attachment of the ilio-femoral ligament falls, in the ordinary functions of locomotion, first on one branch, then on the other, or upon both together. In circumduction the strain would pass around the base of the joint, starting, it may be, at the outer branch, extending then to both, then to the inner, on to the pubo-femoral, and still on to the ischio-femoral. Thus we can see that each end of the capsule has a distinct function. At the pelvic, where the head of the femur comes in direct contact with it, it is thick and strong, with no points of attenuation that would easily permit the head to slip through; at the femoral attachment, the part unapproached by the head, the material is gathered up in bundles that take the direction of greatest strain. Thus is solved the problem of maximum strength with minimum amount of material; and the crucial test, that the femoral attachment is as strong as the pelvic, is found in the frequency with which dislocations are reduced—were the capsule uniformly torn from its femoral attachment, restorations would be the exception.

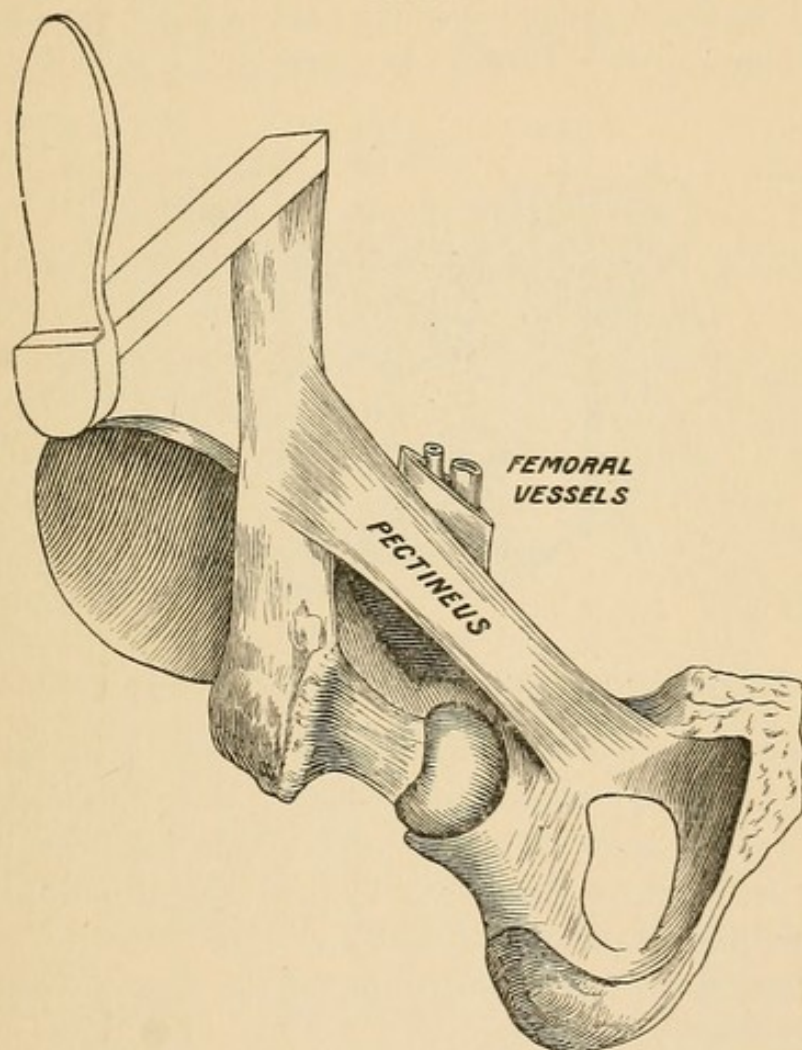
The Femoral Vessels.

The femoral vessels are very rarely injured in dislocations. Their immunity is due (1) to their anatomical relations to the joint; (2) to the muscles that lift them out of the reach of danger at the instant

dislocation takes place; and (3) to the relation of the femur to the vessels in the act of dislocation.¹

At their exit from the pelvis beneath Poupart's ligament the femoral vessels lie on a plane a little anterior to the head of the femur. They are not covered with muscles in Scarpa's triangle, but

FIG. 14.



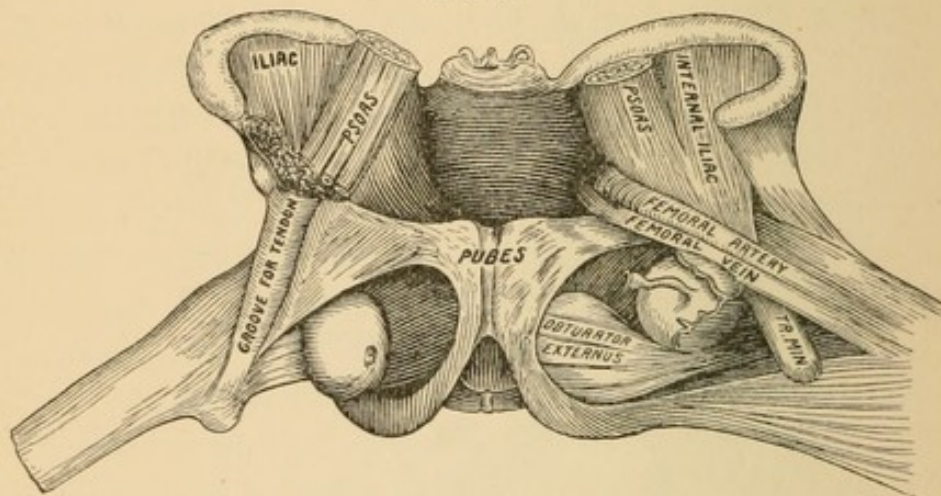
lie upon muscles which pass from the pelvis to the linea aspera. The head of the femur approaches the femoral vessels only in dislocations inward; and in dislocations inward the femur *must be flexed and abducted* the instant the rupture of the capsule takes place. Hence the muscles that constitute the floor of the femoral

¹ In the only case that I have seen reported of fatal hemorrhage the femoral vessels were ruptured by hyper-extension of the thigh upon the pelvis. In this position the vessels are drawn tensely across the head of the femur at the instant when the head bursts through the capsule. In the case reported a cavalryman was thrown from his horse and the whole thigh carried backward, so that the knee lay between the shoulders. Stimson's Treatise on Dislocations.

vessels are more or less tense, and lift them out of the way. In the accompanying figure (Fig. 14) I have represented only a single muscle—the pectineus.

If the head be dislocated inward, it will pass below the femoral vessels and leave them and their sheaths wholly undisturbed. If the limb is now permitted to descend by its own weight, the femoral vessels will be found lying across the head or neck, the head being internal to the vessels.¹ (Fig. 15.) I believe this to be the usual—

FIG. 15.



Double dislocation of the femur inward. (Dissecting-room reproduction.)

not the occasional—relation of the head to the vessels in dislocations inward. I doubt very much that the head is ever dislocated directly upward and to the outer side of the vessels. The head can, however, reach the outer side of the vessels by first being dislocated inward and then shifting its position beneath and to the outer side of them. Fig. 15 suggests the easy compression of the femoral vessels in a thyroid dislocation.

The Fascia Lata.

This structure is not concerned to any material degree in the subject of dislocations of the hip, and yet a knowledge of its normal

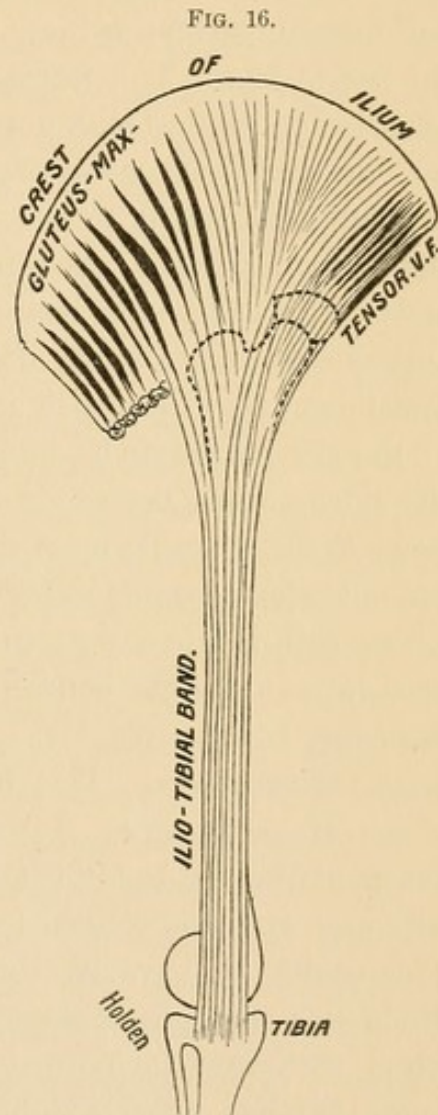
¹ Sir Astley Cooper (Fractures and Dislocations) says: "Upon examining the seat of injury it was found that the head of the femur had been thrown to the inner side of the femoral vessels;" and in a case reported by James Douglas (Monthly Journal of Medical Sciences, 1843), it is stated that the head "lay internal to the bloodvessels, having passed beneath them." Mr. Douglas cites this as an instance of the great force that was necessary to produce such an injury. This prevailing opinion that the head was dislocated directly upward and inward, external to the vessels, was due to the widespread influence of the eminent British surgeon, who never thought that an easier mechanism of dislocations was possible. Had he done so, he would probably have thought of an easier mode of reduction.

relations may be of much diagnostic value in certain pathological conditions, such as fracture of the neck of the femur and hip-joint disease—injuries that have been mistaken for dislocations. I shall not enter fully into its anatomical relations, but merely touch upon parts that illustrate important conditions.

The chief function of this fascia is in the erect posture, as in standing at rest, walking, and running; hence it enjoys to a remarkable degree the double function of muscle and tendon. That part of the fascia which especially concerns us may be said to arise from the crest of the ilium. From this crescentic bony origin the fascia, though it extends around the entire limb, for our present purpose may be said to converge to a narrow band, and finally to be inserted into the outer tuberosity of the tibia. (Fig. 16.) A threefold function of this important structure consists in its acting as a tensor to fasciæ that sheathe the muscles of the thigh, in acting as a constant check to a tendency to displacements, and in operating as an important agent in supporting the body at rest—thus relieving the over-taxed muscles.

1. *As a Tensor of the Fascia.* This is chiefly accomplished by the tensor vaginæ femoris and the posterior half of the gluteus maximus. Neither of these has a direct bony attachment, but both are inserted into this broad, dense, powerful fascia. In running and walking these muscles make tense this fascia. Their action can be studied with great ease as one ascends a flight of stairs, by holding the finger against the tendon of the fascia just above the outer condyle of the knee.

2. *As a Check to a Tendency to Displacement.* With every step



there is a tendency to displacement. Under the ordinary motions of the hip the head of the femur is not retained in the socket by arbitrary ligaments. The function of a ligament is to bind ; but the hip has the freest motion in all directions. Hence an *accommodative* pressure, supplementary to atmospheric pressure, constant but yielding, suiting itself to the varied changes that take place, is required. This is accomplished in part by muscles that are inserted directly into the capsule. But there is another entirely independent and most important agency, hitherto possibly unnoticed, reserved for the *fascia lata*. This fascia, under the control of the tensor vaginæ femoris and gluteus maximus, passes directly over the great trochanter, exerting direct active pressure upon it. The fascia lata does not have an attachment to the great trochanter. If it did, the femur could not be flexed upon the abdomen. As it is, the trochanter moves with every step beneath the fascia—to which action is probably due the large bursa always found beneath it. The first upper attachment that the fascia makes to the shaft is through the tendon of the gluteus maximus, and from this point down it is attached to the linea aspera the whole length of the bone. As proof that the fascia exerts pressure upon the head through the trochanter I adduce the following personal experience: In December, 1884, I was seized with a pain in the outer aspect of my right thigh which soon developed into an abscess beneath the fascia lata. In order to facilitate drainage, I requested Dr. D. Hayes Agnew to cut the fibres of the fascia transversely. This he did ; and, on my recovery after nine weeks of recumbency, I was not a little surprised at the insecurity of the head of the femur, which became partially dislocated with each step and returned with a decided jar and an audible sound. This could not have been due to anything but the division of the fascia lata and its consequent lengthening and changed relations, which withdrew the normal pressure from the trochanter ; thus a joint that had never exhibited the slightest disease or tendency to insecurity before the division of the fascia, became subsequently, upon my first use of it, so unstable that I feared for a time that a synovitis would ensue from the constant concussions occasioned by even the gentlest use. By degrees the tensor muscles shortened and re-established their former control ; but the security has never fully returned.

A further confirmation of the statement that the fascia, under the

control of the tensor muscles, makes pressure upon the head through the great trochanter is seen in the early symptom of *abduction* in hip-disease. Adduction—the reverse of abduction—makes *tense* the fascia and drives the head into the socket. In erect walking, the fascia makes no pressure on the trochanter in its office as a tendon, but it does make pressure through the tensor muscles. Therefore, in hip-joint disease the patient, to escape pressure from both sources, abducts the thigh and adds flexion to abduction to relax still further the psoas, the tendon of which passes directly over the head of the femur. The theory which is far too widely spread, that lengthening exists in the early stage of hip-joint disease, and is due to effusion in the joint, thus forcing the head out, cannot be sustained. There is no lengthening; the apparent lengthening is due to asymmetry. Place both limbs in equal degree of flexion and abduction (see Fig. 88), and the apparent lengthening will disappear.

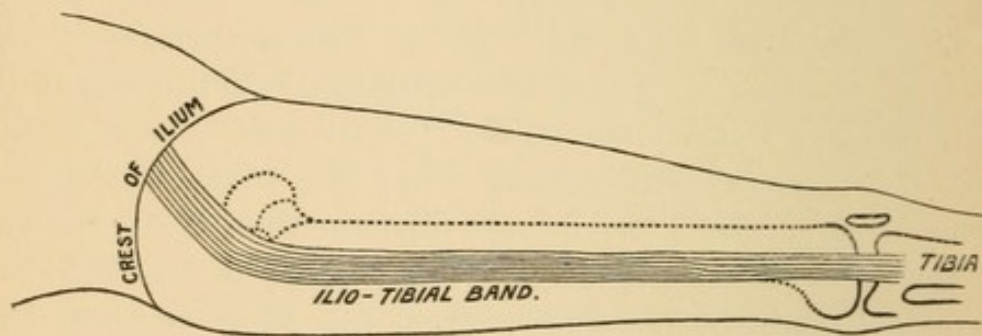
3. *As a Support for the Body at Rest.* Man in the erect posture finds himself shifting his weight from one limb to the other. This function of standing at rest has been attributed to the agency of the capsule and the ligamentum teres. This is true only to a very moderate degree, the chief agency being the strong, flexible, but inelastic band of fascia that passes from the crest of the ilium to the outer tuberosity of the tibia. (Fig. 17.) This tendon is not tense as a ligament in the erect posture, *i. e.*, when one is standing equally upon both feet. When under such circumstances it is tense, this tension is voluntary and due to the action of the tensor muscles. Were the fascia tense in the erect posture, further adduction (so important at times to preserve one's balance) would be impossible. In standing at rest, man always throws his full weight upon one limb, and the relation of this limb to the pelvis is that of adduction. Adduction makes tense the fascia, because it makes prominent the trochanter, which, as it were, presses outward against it. In standing at rest, man tilts the pelvis toward the limb on which he stands until it is finally arrested, the body balanced, and the muscles rested.¹

Hammock Function. While the more important functions of this fascia are exhibited in the erect posture, it enjoys a function in

¹ I have been told that flamingoes sleep standing on one leg, and that one can tell which of the flock is sentinel by noting which bird is standing on both legs.

the horizontal position worthy of our consideration. This I shall denominate the hammock function. In dorsal recumbency the toes turn outward. Why do they do so? It is not due to muscular action, for it persists in sleep and is present in the paralytic. It is due solely to the weight of the limb, which rotates outward on the neck of the femur. It is simply an expression of external rotation, the motor being gravity, and the radius of action being the neck of the femur. But why does the rotation stop at the *same precise limit each time*? Let a person stand erect, and, making a pivot of his heels, rotate both limbs quickly outward. They both stop suddenly and at the same precise point each time, no matter how often or powerfully the motion is repeated. Why? Because they are checked by a ligament. This check is through the fascia lata, which supports the limb as in a hammock. This support is of great value after the reduction of a dislocation. When the surgeon in such a case ties

FIG. 17.

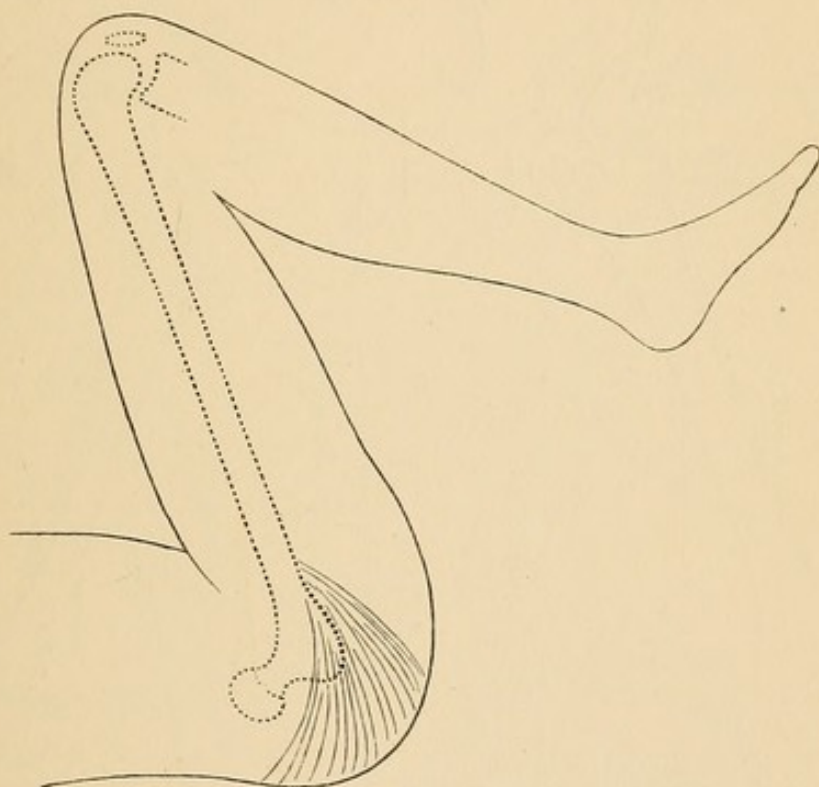


the ankles together he is practically adducting both limbs, and this compels the fascia lata to make pressure upon the trochanter. Thus a force, held in reserve and entirely unharmed by the traumatism of dislocation, is made of great service during repair. Further proof that this fascia influences rotation can be elicited in the following manner. Place a person on his back, with his heels touching each other, and note the degree of external rotation. Now, while the patient is perfectly passive, let the surgeon abduct both the patient's limbs. As the abduction increases—the knees being kept stiff—the external rotation will increase, because the limbs are passing from under the control of the fascia. Now let the surgeon approximate the patient's feet. As he does so, the normal degree of rotation will be resumed. In this manoeuvre the patient has been perfectly passive, and the change in rotation uninfluenced by muscular action.

The same effect may be produced upon the cadaver. It is this automatic mechanical control of the thigh which brings it down with such a precise degree of external rotation that makes it possible for man to run at a high rate of speed without danger of tripping or bringing the foot down insecurely.

On page 29 I have noted the reasons why it is impossible to flex the femur on the pelvis without first flexing the leg on the thigh. At this point I wish to say that, even with the leg flexed on the thigh and the ilio-tibial band thoroughly relaxed, hyper-flexion of the

FIG. 18.

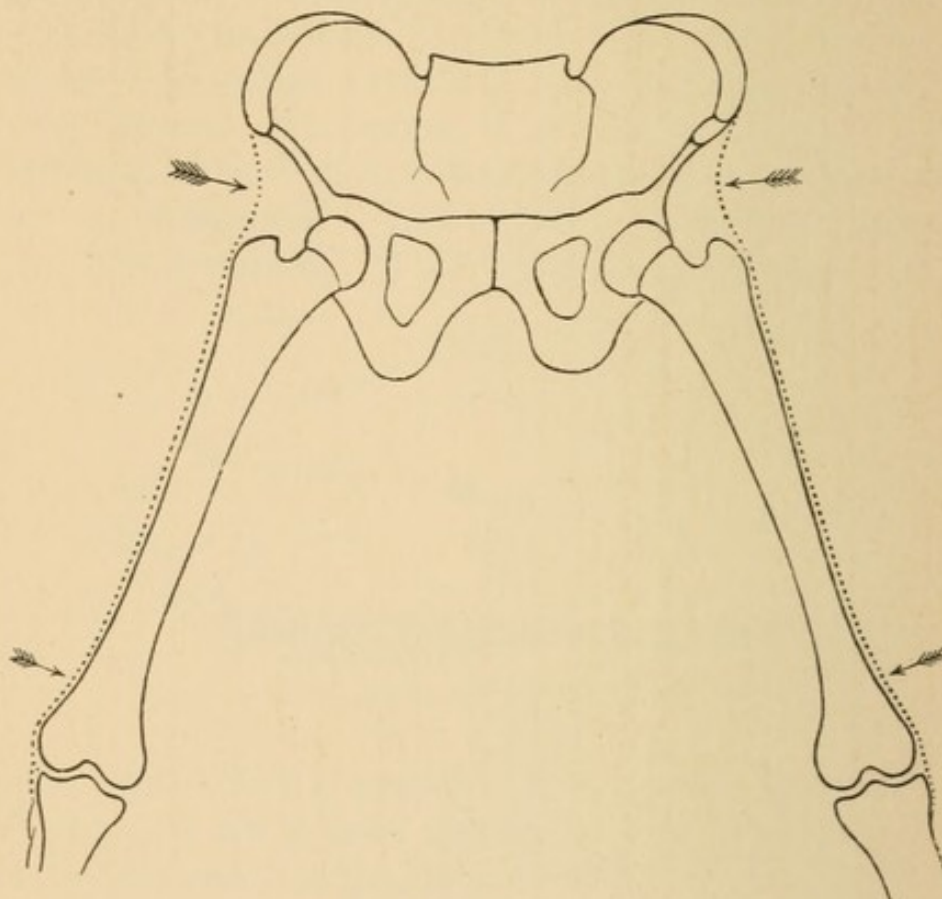


femur makes tense the upper fibres of the fascia that give support to the head in this position and tend to check a tendency to displacements. Fig. 18 indicates also how possible it is for the head to wound or even transfix the gluteus maximus (p. 65, Case IV.) when dislocation takes place during flexion, adduction, and inward rotation of the femur.

A matter of great practical value is to note the deportment of this fascia after fracture of the neck of the femur. All that I have said about the fascia lata in regard to support depends upon an unbroken femur. Let the femur be broken at any point in its continuity between the head and the condyles, and it is plain that it can

no longer make tense this fascia. Now, fracture in the shaft of the femur is easy of detection. Not so with fracture of the neck of the femur, and this is specially important, as its frequency increases with advancing years, rendering an easy means of diagnosis of inestimable importance. To avail one's self of this principle, it is necessary to note that the fascia during adduction is tense (Fig. 20) and can be felt as a firm resisting band between the trochanter and the crest of

FIG. 19.

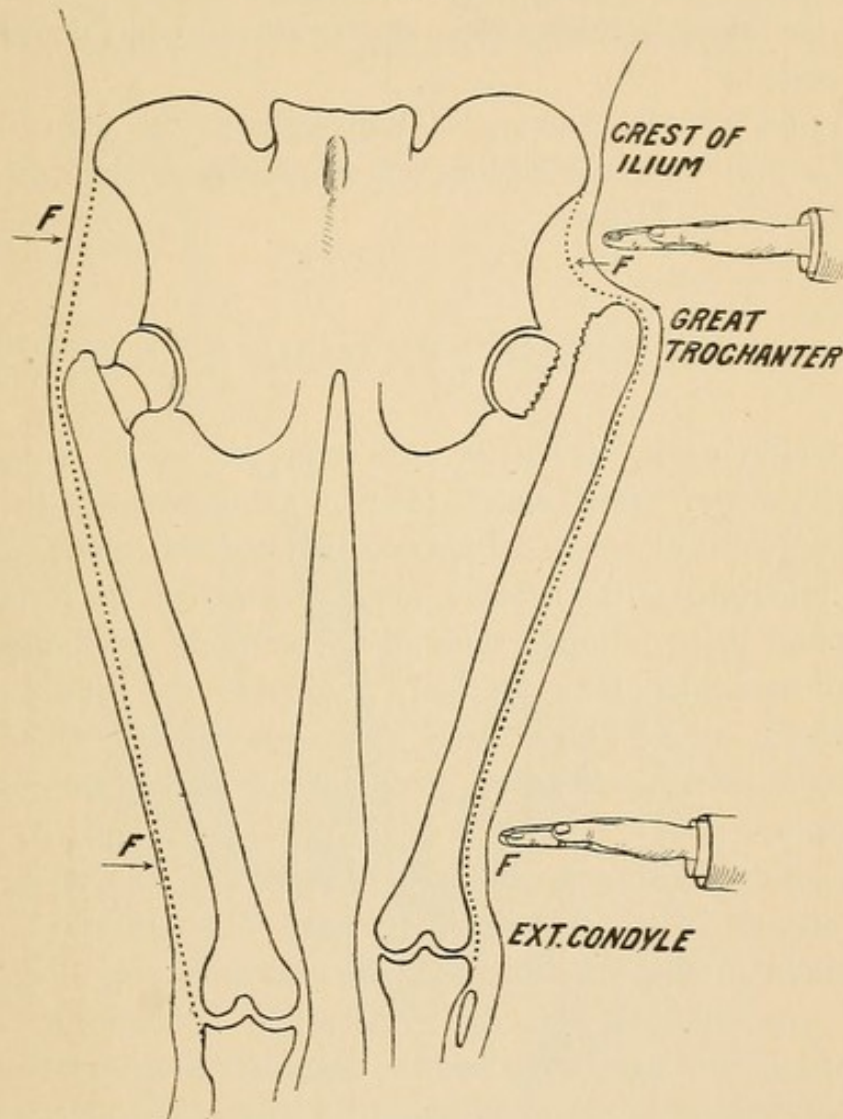


Abduction of both femurs. The arrows point to regions where the fascia lata will be notably relaxed.

the ilium, and like a firm round cord, about the size of the little finger, near the knee, above the outer condyle. The examiner can first take the sound limb, and, adducting it, bring into prominence the tendon, best felt above the outer condyle. He can then take the suspected limb, and, gently adducting it, feel the resistance. If the resisting band or cord be present in equal degree upon both sides, there is strong presumptive evidence of a sound femur. If it be absent, this, with the corroborative testimony that attends an accident, should have great consideration.

Brief Résumé of the Functions of the Fascia Lata. 1. It forms the sheath or envelope of the most important walking muscles of the thigh; during progression the tension of this fascia (through the gluteus maximus and tensor vaginæ femoris) is of the utmost advantage; through the same muscles it steadies the head of the femur in the socket.

FIG. 20.



2. It checks adduction of the extended thigh through the ilio-tibial band.

3. It checks outward rotation of the extended thigh.

4. It assists the hamstring muscles and the sciatic nerve in checking flexion of the extended limb.

5. It checks a tendency to hyper-flexion of the thigh upon the abdomen.

6. It contributes largely to man's ability to stand at rest.

7. After the reduction of a dislocation at the hip-joint the fascia lata and the untorn portion of the capsule are our main reliance in retaining the head of the femur in place. If the feet are tied together, the fascia and nothing else presses the head into the socket.

8. After fracture of the neck this ilio-tibial band is relaxed during adduction.

9. As adduction tightens the ilio-tibial band, and abduction relaxes it, the latter position is voluntarily assumed in the early stage of hip-disease.

10. As flexion of the extended limb tightens the fascia lata and drives the head into the socket, this manoeuvre elicits pain in the early stage of hip disease.

THE SCIATIC NERVE AND HAMSTRING MUSCLES.

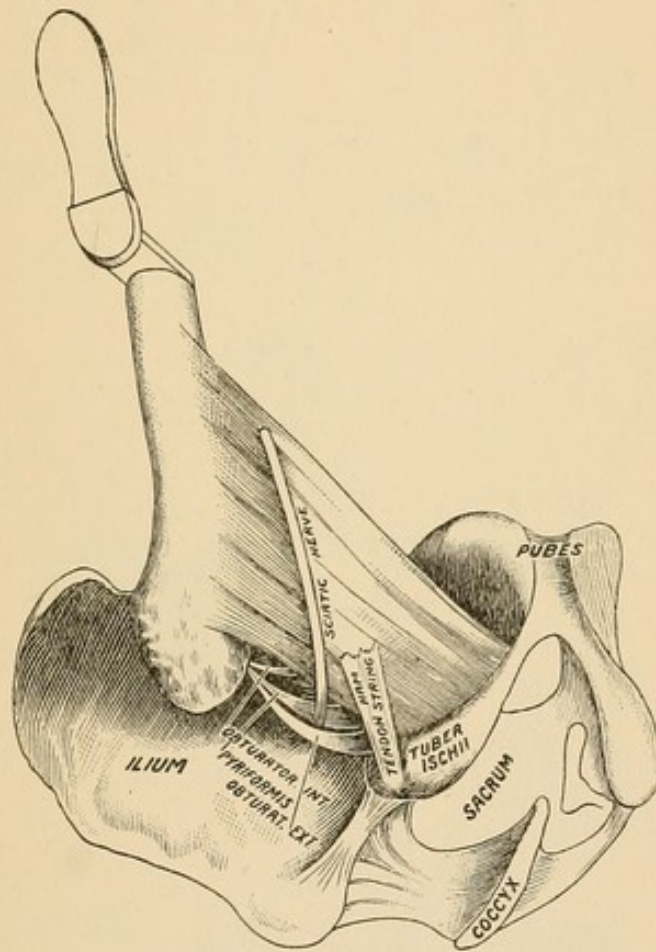
The sciatic nerve makes its exit from the pelvis at the lower border of the pyriformis muscle (Fig. 21) and proceeds in a direct line to the popliteal space. It passes between the great trochanter and the tuberosity of the ischium, but its relation to the stable pelvis is closer and more intimate than to the movable trochanter. The latter can be rotated from or toward the nerve, but cannot pinch it. It is covered by the thick, warm, fleshy gluteus maximus and the hamstring muscles, and is thus protected against sudden changes in temperature.

Since dislocations occur and are reduced with the femur in the flexed position, I shall present the nerve in its relation to the socket and muscles in this position. In the accompanying diagram the nerve is seen emerging from the great sciatic foramen, in the interspace between the pyriformis and the obturator internus, then crossing the quadratus femoris, and lying upon it and the adductor magnus until it reaches the popliteal space, where it gives off a large branch. The nerve is attached loosely to the muscles that surround it, but its special guardian is the outer hamstring muscle, the biceps. The nerve passes below the socket until it reaches the tendon of the biceps, to which it becomes quite intimately attached. In adduction, abduction, and the various movements of the thigh, the nerve follows the muscle.

As the nerve is large and practically incapable of being stretched,

it is interesting to notice how Nature, in the movements of the limb, has planned to throw the brunt of many an injury upon other and less important structures. The structures that are made tense by any attempt to flex the pelvis on the extended thigh and leg—or, what is the same thing, to flex the extended limb—are: the fascia lata, the hamstring muscles, and the sciatic nerve. I will describe only the action of the hamstring muscles, since the mechanism is practically the same in all. In Fig. 22 (p. 30) the femur and the hamstring muscles

FIG. 21.



are represented as *parallel* and of *equal* length. [Note in the diagram that the origin of the muscle (*B*) is below and to the right of the socket and that the insertion (*D*) is below and to the right of the knee-joint.] If, now, we flex the femur to a right angle, the condyles will reach as high as *E*, while the muscle, though it be equally long, will reach only to *F*. If an attempt were made to raise the tibia to the perpendicular, *F* must rise as high as *G*. It must be plain, therefore, that flexing the leg on the thigh, in walk-

ing or running, is not a voluntary or muscular action, but one of pure mechanics; for the instant the psoas and other muscles flex

FIG. 22.

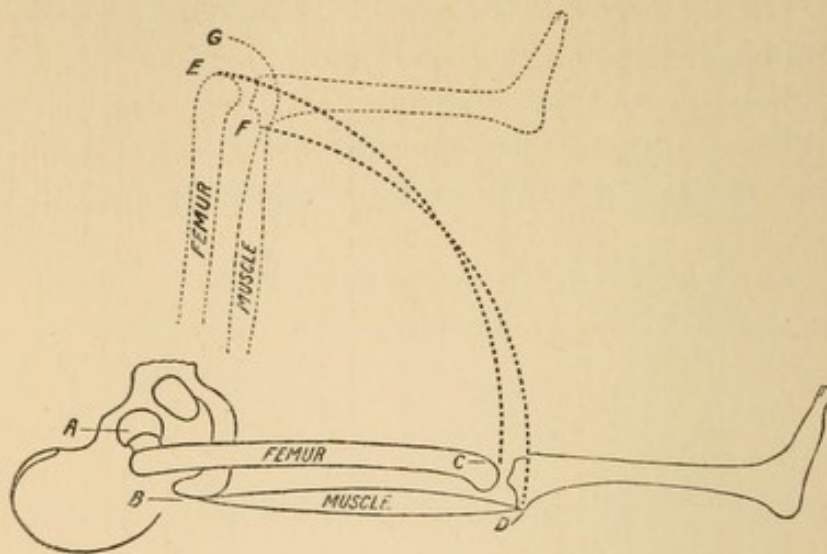
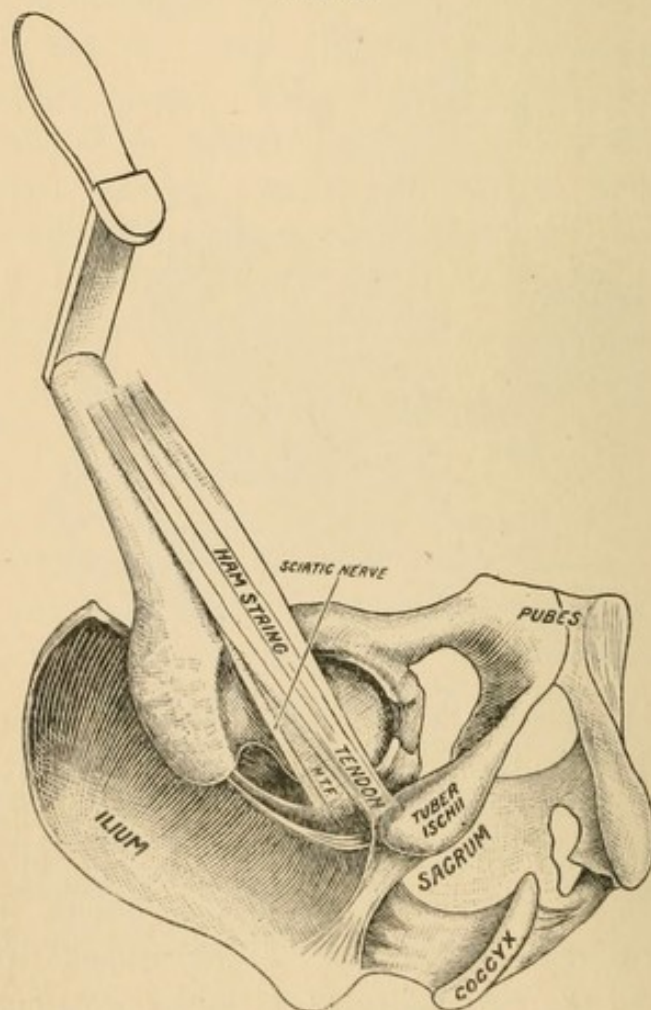


FIG. 23.

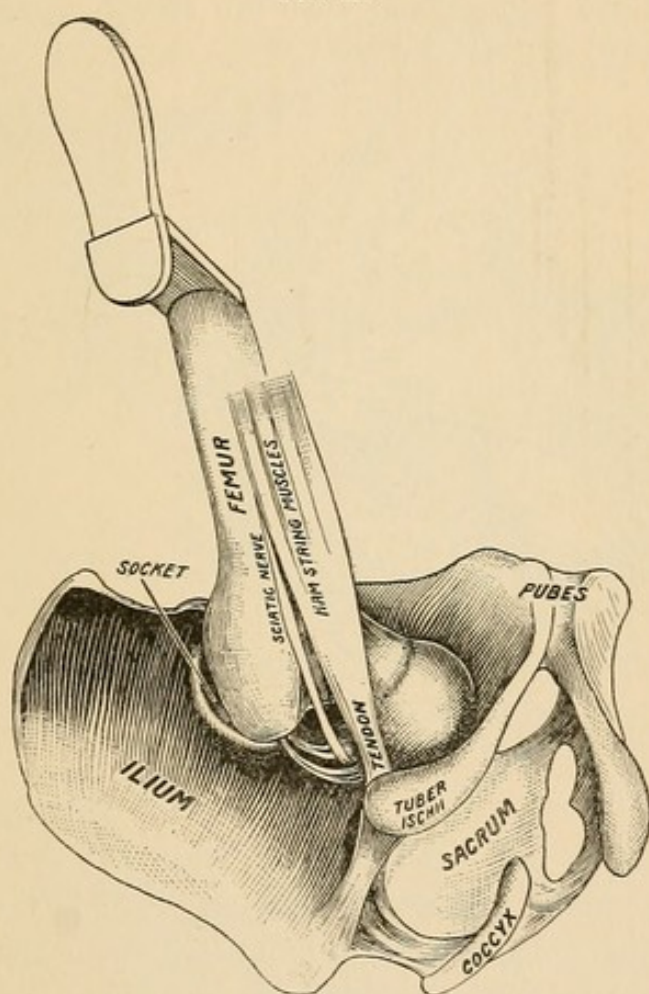


N. T. F. Neuro-tendinous fascia extending between the sciatic nerve and the tendon, binding both together and normally exercising some constraint upon the nerve.

the thigh on the pelvis that instant the leg becomes flexed on the thigh through the unstretchable fascia lata and the hamstring muscles. The important principle to which I would call attention is, *that when the femur is flexed at right angles with the pelvis the leg must be flexed to relax the nerve and the hamstring muscles.*

I have already said that the nerve follows the hamstring muscles in the various positions of the femur, as in abduction, adduction, etc.

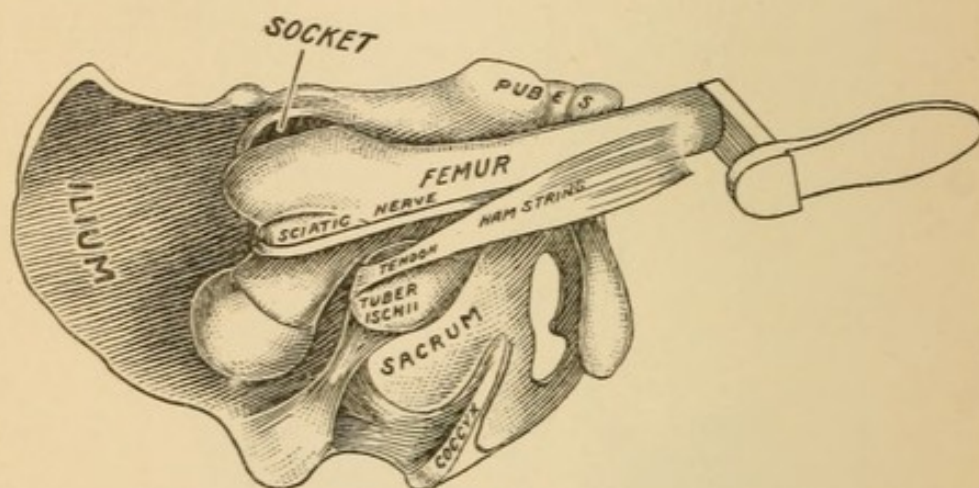
FIG. 24.



If the limb be abducted, the nerve and muscles will run parallel to the shaft of the femur. (Fig. 23.) Now, if the femur is carried still further outward, the head may burst through the capsule and be dislodged inward. (Fig. 24.) In such a case it is plain that no injury will accrue to the nerve. But suppose the head, from being in the position of thyroid luxation, should be shifted outward to that of a dorsal luxation, how is it to get there? Easily enough, but not without danger to the nerve, since there is but one possible path for a dislocation inward to take in order to become a dislocation outward, and that is, be-

tween the hamstring tendon and the socket. Now the tendon of origin of these muscles is within half an inch of the socket, and the nerve is nearer, if anything. Under no circumstances can the head be circumducted and carried outward without traumatism, more or less severe, to the nerve. *If the sweep of the knee through which this may be effected be a large one, and especially if there be sufficient extension of the leg on the thigh to shorten and make tense the nerve,* then there is great danger that the head will pass between the nerve and the tendon, and that the result represented in the diagram (Fig. 25) will take place. This condition was present in

FIG. 25.



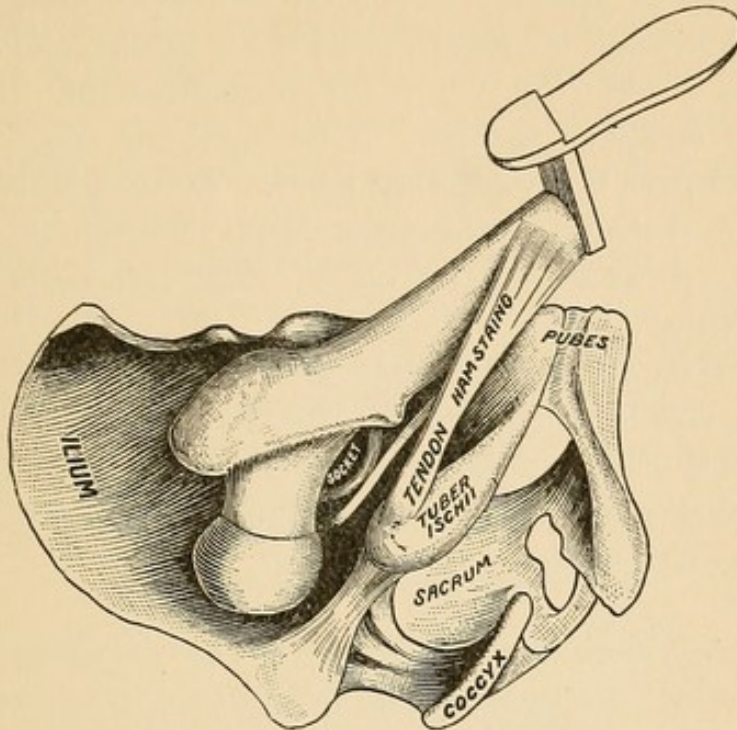
Compare Fig. 25 with Fig. 23, and note how completely the nerve may be torn from its surrounding and controlling attachments through circumductive movements after dislocation.

Quain's case (Fig. 50), and can be readily reproduced experimentally. If such a condition be suspected, the fact may be ascertained by having an assistant push upward upon the knee in the direction of the long axis of the shaft of the femur, while the surgeon, by extending and flexing the leg, will find the nerve made alternately tense and relaxed in the popliteal space, if it be *over the neck and the head out of the socket*. In such a case a successful reduction of the head will release the nerve, but the traumatism may have been so severe that a prolonged neuritis, a partial or complete paralysis, may result. Such a condition, if unrelieved by replacement, would, of course, be one of prolonged suffering.

If the head, in its transit from within outward, pass between the nerve and the socket, the former may be bruised a little, but not

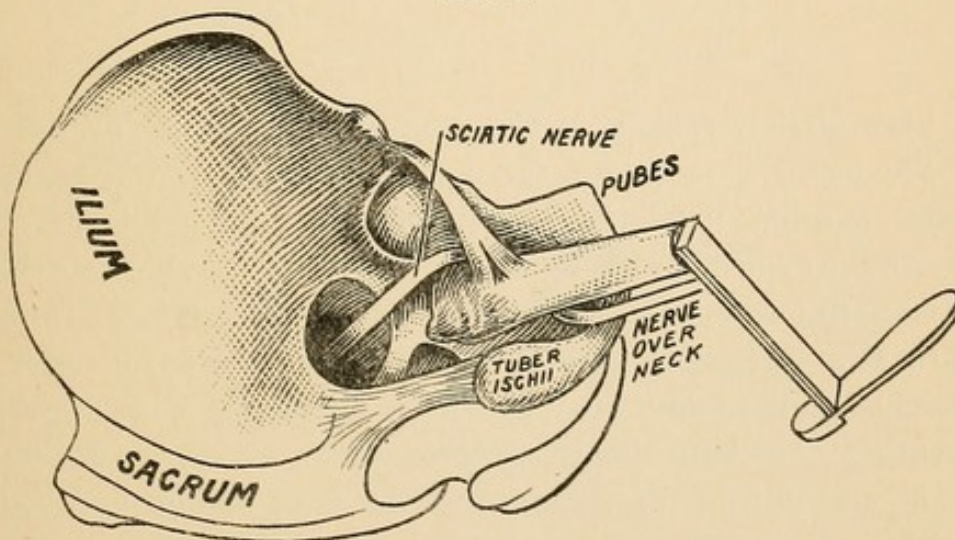
detached from the tendon, and will lie, after dislocation, between the head or neck and the tuberosity. This, taking all the varieties

FIG. 26.



of displacement into consideration, is, I think, the most frequent condition, and when it occurs the danger of hooking up the nerve through the efforts at reduction will be greatly increased if the

FIG. 27.



head in passing outward catches up the nerve and tears it from its attachments. This is no random statement. Bigelow, Morris, and

Johnson have caught it up in experimental work, and Koons did it in actual practice.¹

If the nerve be hooked up during the reduction, the following conditions will be present: The nerve will cross the front of the neck and lie beneath the untorn parts of the capsule and the tendon of the psoas muscle (Fig. 27, p. 33); it then descends through the rent in the muscular partition to the adductor magnus, beneath which it descends to the popliteal space. At least three inches of the nerve are taken up by this detour, and hence the thigh *must* be flexed on the pelvis and the leg on the thigh to accommodate them to the shortened nerve.

If the dislocation occur through flexion, adduction, and rotation inward, the capsule may yield and the head may escape outward and downward without touching the pelvis in the descent. In such cases *I have seen the head fall directly upon the nerve*, from which it can slip to either side.

FIG. 28.

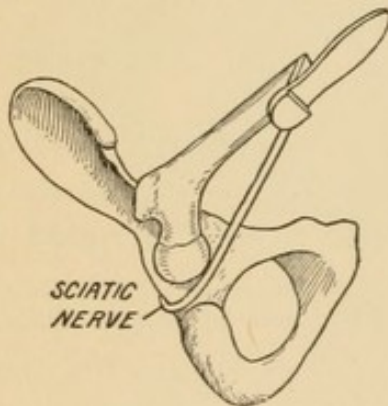
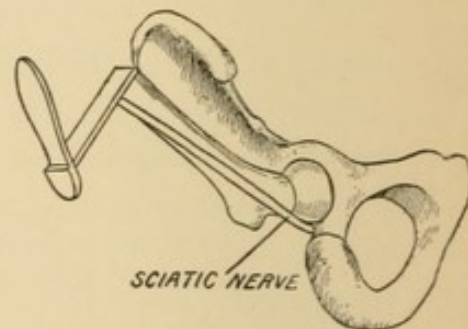


FIG. 29.



I have already spoken of the guardianship of the nerve—*i. e.*, how the nerve is protected through attachment to the hamstring muscles, and how it follows them in adduction and abduction. (Fig. 23.) As the adductor muscles are very powerful, it is highly probable that more dislocations occur through flexion, *adduction*, and rotation inward than in flexion, *abduction*, and rotation inward. Not that these muscles have any direct agency in producing a dislocation or preventing one, but, simply by their power, place the limbs in a state of adduction at the instant that the fatal flexion and rotation inward produce the displacement. In *hyper-adduction* the nerve skirts the border of the socket (Fig. 28), and the head may, in transit

¹ Reminiscences, *supra*.

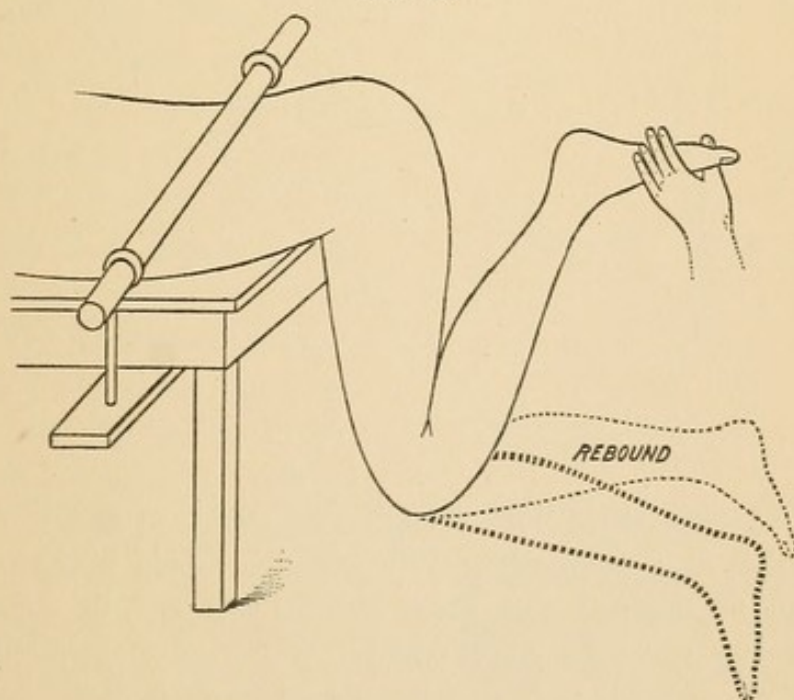
outward, scarcely touch it. In *hyper-abduction* the nerve runs parallel with the shaft (Fig. 29), and the danger to it then from dislocation outward is imminent and unavoidable. Thus we have two positions in which, if dislocations take place, we have good reasons to predict the condition of the nerve; and hence when we read in accounts of autopsies that the nerve was caught up over the neck—lacerated, slightly bruised, or uninjured—we have a warrant for placing the limb in a position between hyper-adduction and hyper-abduction that will best fulfil the conditions.

That which I have said about the nerve does not apply to the quadratus muscle. This muscle is always put on the stretch by *flexion*, and the tension is increased by rotation inward. Hence, when this muscle is torn in two with some of the fibres of the adductor magnus and the obturator externus, no other agency need be invoked than hyper-tension.

The Hamstring Muscles.

I have already stated that these muscles become, under certain circumstances, the guardians of the sciatic nerve. In their guardian

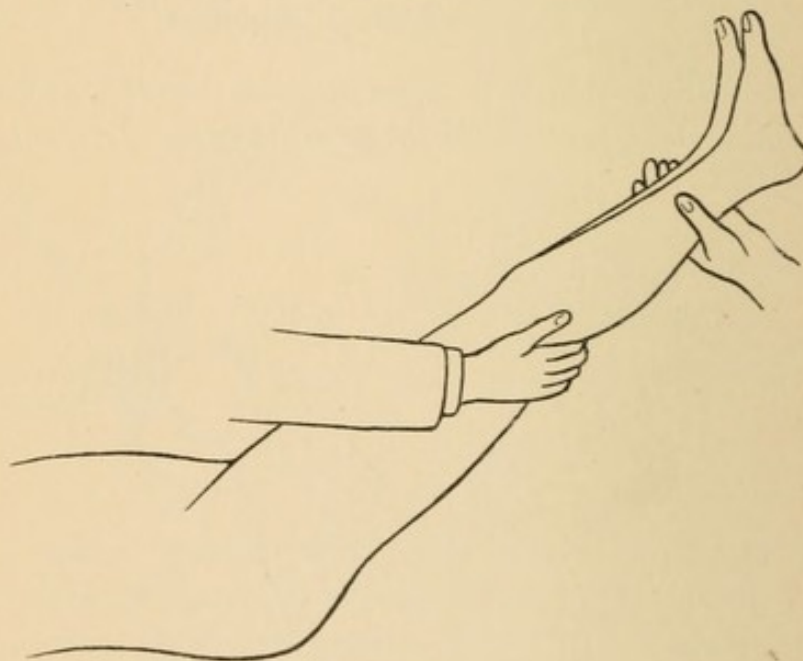
FIG. 30.



action they illustrate a principle inherent in all muscular fibre, viz., that when put upon the stretch it exhibits the property of tendon or ligament. This is strikingly brought out in the following experiment :

If a pelvis, resting prone, be securely bound to a strong table, and the thigh with flexed leg (Fig. 30) be permitted to hang freely, the thigh will hang nearly perpendicular. If now the support of the leg be gradually removed, the leg will descend until arrested by the hamstring muscles, whose tendons will stand out in bold relief in the popliteal space. If the leg be again raised and suddenly let fall, it will be so suddenly arrested as to jar the whole table, and a rebound will take place proportioned to the height and suddenness of the fall. The sudden checking of the leg with an elastic rebound demonstrates the important, long-established, but not sufficiently well-recognized, principle already mentioned, that a muscle, when it reaches the limit of extensibility, becomes a tendon or ligament, and if the force continues, the muscle must rupture in some part or tear from its bony attachments, or the bone must fracture or dislo-

FIG. 31.

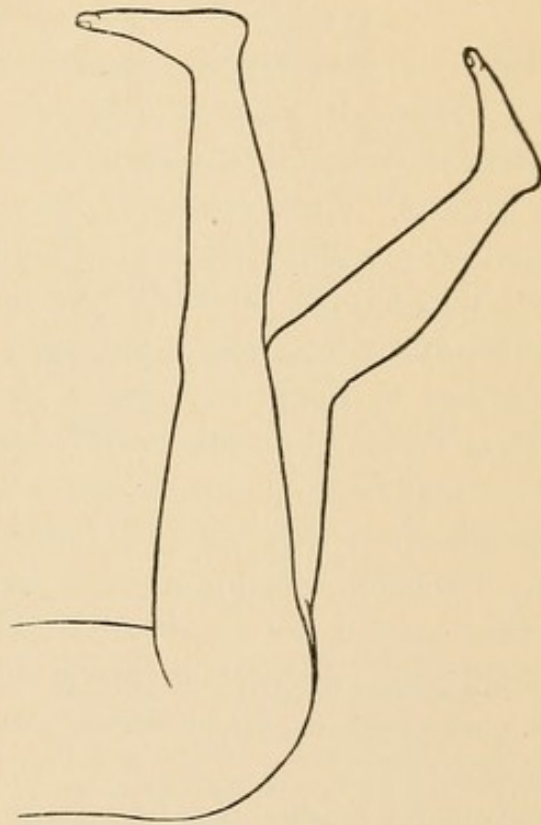


cate. Those who hold that muscles, by their contractility, aid in the reduction of dislocations, must depend wholly on theory, while the agency of muscles put upon the stretch can be demonstrated upon the cadaver. In experimental work, after removing every vestige of the capsule, I have been able, by putting the psoas muscle on the stretch, to restore the hip by the very principles of manipulation that Bigelow has so happily demonstrated as due to the Y-ligament. In manipulation with a view to restore a dislocation

one often experiences a locking and a resistance, due in part to the stretched muscles.

The sudden arrest of the falling leg in the experiment is possible only with normal soundness of the femur. If the latter be broken in any part or dislocated, the hamstring muscles will not encounter resistance to the same degree. This fact can be turned to good account, not only in investigating an injury, but also in determining that a dislocated limb has been restored. To place the tendons on the stretch, an assistant elevates both lower extremities by the heels (Fig. 31), while the surgeon marks the gradually increasing tension of the cords in the popliteal space. In the normal limb the tension of these cords will be firm and resisting, wholly uninfluenced by muscular action. It will be steady and the tendons will feel almost like so many wires. These cords will be absent in case of fracture or of *dorsal* dislocation. Again, as the elevation goes on the ascent will be arrested in the sound limb, and, if the assistant would bring the limb to the vertical, he must flex the leg at the knee. (Fig. 32.) Not so in case of dislocation outward or of fracture; the extended limb can easily be placed in a vertical position.

FIG. 32.



If the dislocation be inward instead of outward, it will be impossible to raise the extended limb to a vertical position. (This is also true of the normal condition.) The reason is that, in dislocations inward, the head rests on a bony foundation, just as when in the socket, and flexion makes tense the fascia lata and the hamstring muscles. To decide that the limb is dislocated inward one should adduct the femur — this is impossible when the head lies in the thyroid depression upon the inner plane.

In experimental work after I had restored the femur *with the body*

prone (Fig. 30) I could readily assure myself that the restoration was satisfactory by raising slightly the foot and letting it fall, while at the same time my unoccupied hand rested upon the great trochanter. If the limb were restored, the fall of the leg would simply jar the pelvis; but if it was dislocated, the trochanter would jump beneath the hand. Although this experiment has little clinical value, yet it illustrates well the principle under consideration, that a muscle when made tense deports itself like a ligament.

A STUDY OF THE MECHANISM OF DISLOCATIONS ARTIFICIALLY PRODUCED.

Many of the earlier experimenters in this field of surgery found it expedient, if not absolutely necessary, to divide the capsule subcutaneously before they could effect dislocation.

To avoid the necessity of tenotomy I resorted to fixation of the pelvis as a preliminary step in my investigations.

It may be objected that I have not imitated the mechanism through which dislocation occurs any more exactly than those whose course I wished to shun; but upon a closer study it will be seen that, in actual life, no dislocation ever occurs except on the principle of the lever and fulcrum, and, in the case of these agents, the *former is always the movable and the latter always the fixed agent*. It does not affect the principle whether, in the causation of a dislocation, it occurs when a man is slowly walking or when he is hurled from a rapidly moving car; whether it requires a minute or the hundredth part of a second. In every case the *lever must move and the fulcrum must be fixed*.

When a person steps into a deep hole, and, falling forward, dislocates his hip, the mechanism is plainly that of motion and fixation, lever and fulcrum. If a man suffers the same accident from getting his leg caught in the wheel of a rapidly moving wagon, the same mechanical principles are present, viz., motion and fixation—the lever and fulcrum. In the latter case the *inertia of the body* represents the fixation, while the rapidity of the revolving wheel twists the head out of its socket before any of the dislocating energy has been communicated to the body. This is illustrated by the trick of snapping a card poised upon the finger from beneath a penny, without dis-

turbing the penny. The penny is bound down by *inertia*, and the solution of the problem is to communicate motion to the card without communicating any to the penny. By a slow motion this trick is impossible, since both card and penny move together. So, in my early attempts at reduction without fixation, my tardy movements were readily communicated to the trunk, and I failed, because I was not imitating the traumatism of actual life. *In mechanically securing the pelvis, i. e., in preliminary fixation, I was merely immobilizing my fulcrum, and in this I was following to the letter the mechanism of all traumatic dislocations.*

FIG. 33.

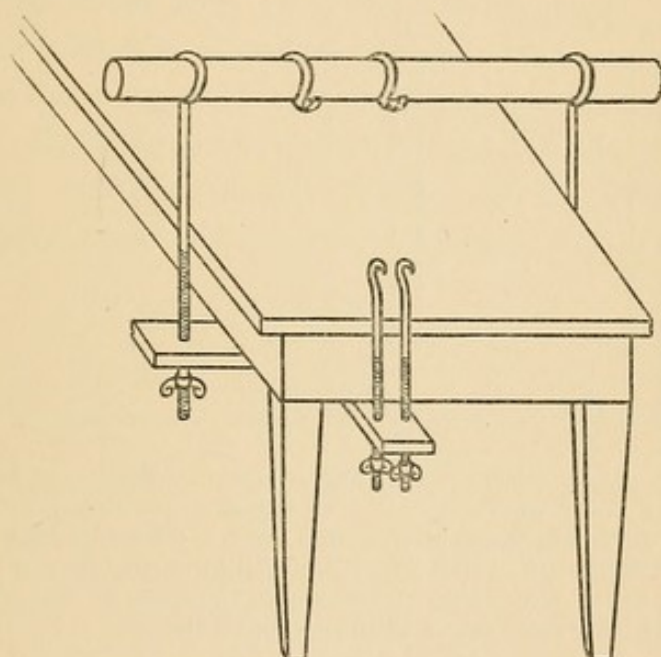


Fig. 33 represents part of a dissecting-table. Above is a cross-bar of hickory, three and a half feet long and one and a half inches in diameter. An oak strip, three inches wide and of the same length, runs parallel beneath the table. The two are connected by iron rods eighteen inches long. Two hooks slip along the hickory rod. At the end of the table is a second oak board that passes beneath the end of the table and above the cross-bar. Two iron rods, twelve inches long, with open hooks, are seen in this board. The apparatus will fit any post-mortem or dissecting-table, and the cadaver can be fastened to any part of it. If I desire to operate on the right hip, I bring the subject to the right-hand corner of the table. This permits me to make any desired manipulation. The cross-bar crosses the lumbar vertebrae above the pelvis; the lower hooks, which are between the thighs, are now connected to the hooks on the cross-bar by means of a bed-cord, which secures the pubic portion of the pelvis. Any further tightening can be done with the thumb-screws. With this the pelvis can be secured as in a vise, and the operator can watch the effect of every manipulation.

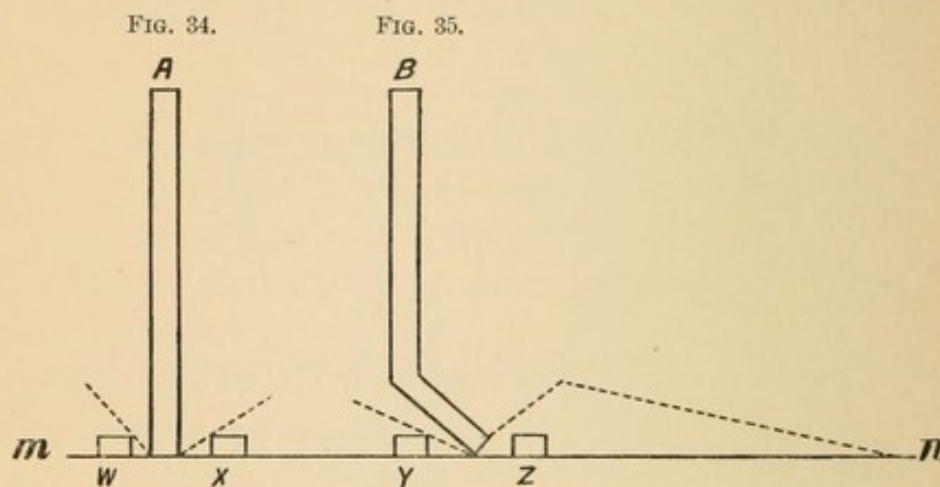
No further advantage was anticipated from fixation than that it would enable me to accomplish my purpose; but in this I was agreeably surprised. It was indeed the initiatory step to a series of most

instructive studies, each of which will be treated at length in its proper place.

The instrument that I found of great service to me is seen on p. 39.

After fixation dislocations can be performed by unaided manual effort, and the process may be carefully watched. The factors that enter into the problem are simply the mechanical powers, viz., the lever, fulcrum, power, and weight. These present interesting points for consideration, and will be taken up in order.

The Lever. If a lever is straight and round (Fig. 34), it will make no difference which surface is exposed to the fulcrum; but if



m n represents a plane surface; *w x y z*, fulcrums of equal height and distance from their respective levers; *A* and *B* are levers. If *A* be turned to the right or left, it will strike a fulcrum. If *B* be turned to the right, it cannot touch a fulcrum, owing to the bend in it; but if it be turned to the left, it will strike the fulcrum sooner than if it had no bend in it, while the bend in the lever taken together with the fulcrum will enable the lever to raise a weight to a higher point than a plain lever could do.

it is bent and has a limited range of motion, as upon an even surface, one position may make it wholly useless (Fig. 35, dotted line), while another surface may make it more advantageous than a straight lever. In the latter condition the outward prominence situated at the junction of the two arms of the lever may itself constitute an additional fulcrum and enable the operator to raise the weight much higher than could be done with a straight lever. If the lever, in addition to the bend, has a projection, then lever and fulcrum would be represented in one solid piece, and such an instrument could be made available upon a plane surface.

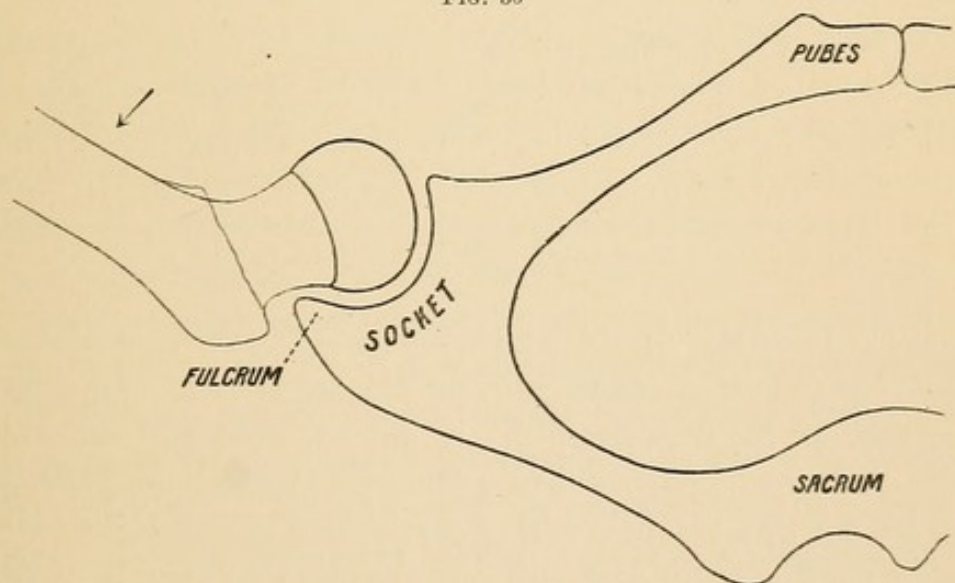
Now, the femur is a lever whose shaft is long and straight, whose neck joins the shaft at an angle of 130° , and is provided with a trochanter—all of which elements may be the occasion of disaster

to the joint and parts composing it. The shaft of the femur can hardly be used as a lever in any other positions than in abduction and extension. When dislocations take place through rotation, the bent leg, like the handle of a crank, becomes the long arm of the lever, and the neck and head the short arm.

The Fulcrum. Inseparable from the lever, without which the very name lever would have no meaning, is the fulcrum. Every quality of strength and reliability that is essential to the lever must be present in the fulcrum. In one quality only does it differ from the lever, and that is in *fixation*. The fulcrum is the pivot upon which both arms of the lever move; it is the arbitrary line or division from which both arms take their origin. Its effectiveness in levers of the first class depends upon its position—the nearer it approaches the weight the greater the power that can be exerted.

Under the normal range of motion no part of the pelvis furnishes a fulcrum, but in hyper-abduction (Fig. 36) the outer rim of the socket becomes a most advantageous fulcrum. It is advantageous,

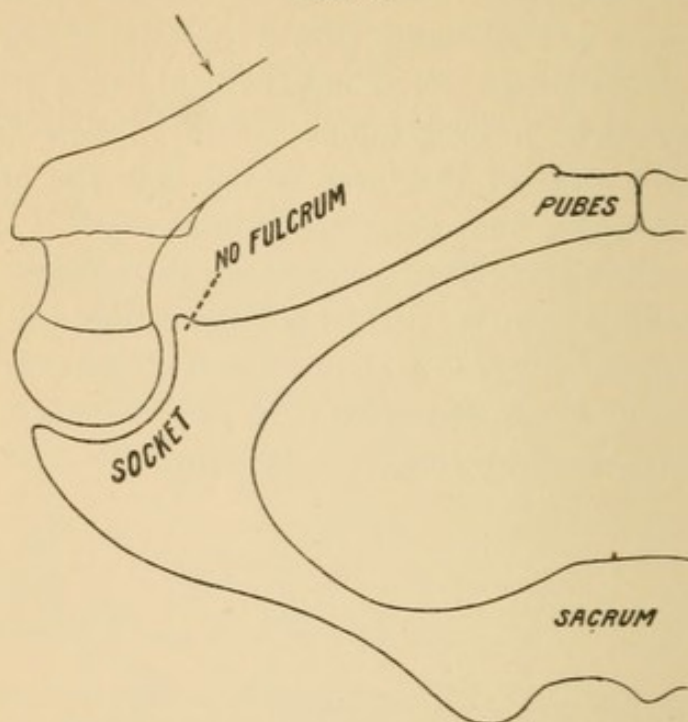
FIG. 36



because it yields a very short weight-arm with a long power-arm, and because the weight, *i. e.*, the resistance to be overcome (that of the capsule), lies almost directly over the fulcrum. In experimental work the rupture of the capsule through hyper-abduction is easier and more certain than in any other way. In simple hyper-extension the rim of the socket forms quite an advantageous fulcrum; but in this instance the *resistance* is far greater, inasmuch as the anterior part of the capsule is stronger than the internal part of it.

Other bony fulera are to be found, though not one furnishes so short a weight-arm. Thus, the great trochanter is brought against the tuberosity of the ischium in extension and rotation outward, using the bent leg as a lever. In hyper-flexion the knee strikes the abdomen before the neck strikes the rim of the socket.

FIG. 37.



In Fig. 37 is represented the principle just stated, that a bent lever may sometimes be unable to secure a fulcrum.

In marked contrast to the conditions present in hyper-abduction are those in adduction, where we find the same lever, but bent so that no part of the neck can come in contact with the rim of the socket. Hyper-adduction will bring the shaft against the pubes, and the result may be a fracture, but it cannot be a dislocation. I would therefore emphasize the statement just made, that danger of dislocation is inseparable from simple¹ hyper-abduction, because an advantageous bony fulcrum is always available, while in simple hyper-adduction it is impossible, from the absence of a fulcrum.

¹ By the word simple I mean that no other motion or force, such as rotation, shall be added to abduction or adduction.

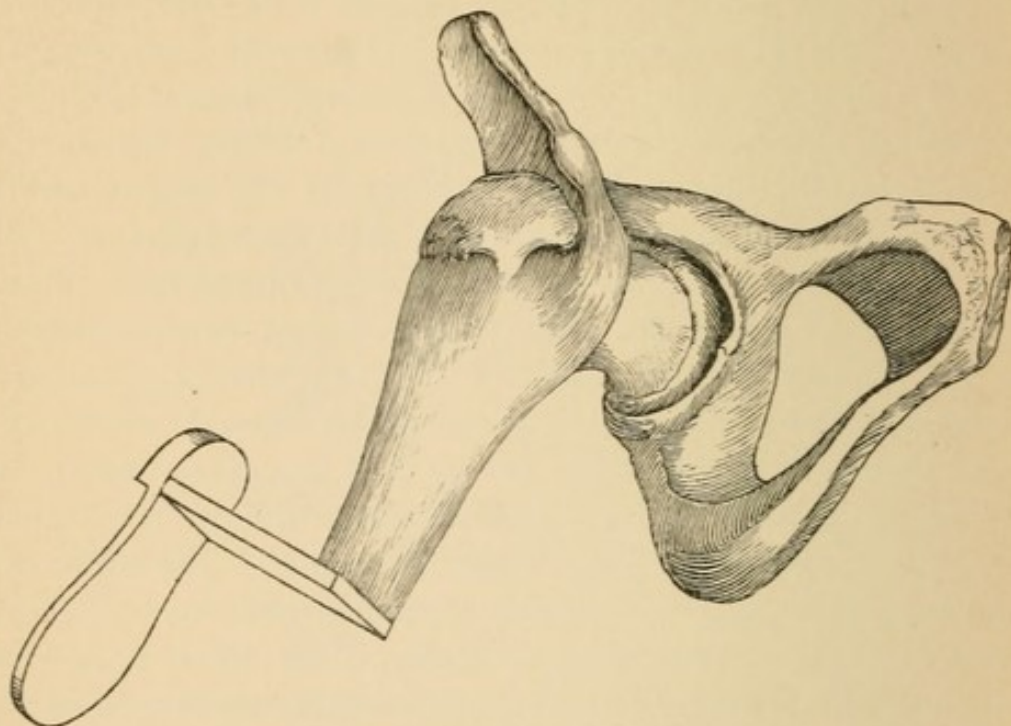
DISLOCATION THROUGH LEVERAGE, BUT WITHOUT
A BONY FULCRUM.

In all dislocations effected through leverage a fulcrum is indispensable. When the femur is flexed and adducted no bony fulcrum is available, and yet this is one of the situations most liable to dislocation. To make a dislocation possible a new force must be supplied. This will either be a *thrust*, *i. e.*, a powerful force exerted in the long axis of the shaft, *or, if through leverage, it must be through rotation*. In all efforts at rotation the bones of the leg, bent at right angles to the long axis of the femur, constitute the long or power-arm; the head and neck constitute the short or weight-arm. External rotation has never, in my hands, in experimental work effected rupture of the capsule, but, after rupture, through hyper-abduction, external rotation with extension of the limb will bring about a dislocation inward. Internal rotation, on the contrary, whether the thigh be normally extended and the leg used as a crank and turned outward, or the thigh be flexed and adducted, with similar rotation, is an effective measure to bring about dislocation. The mechanism is the same under all circumstances where internal rotation is concerned—there is no bony fulcrum. Query, What are the nature and position of the fulcrum? If we remove every structure from the joint but the capsule, it will be readily seen that by internal rotation the strong ilio-femoral ligament becomes wound across the neck of the femur. (Fig. 38.) The trochanter has been rotated up and the head is now pressing hard against the postero-inferior part of the capsule. Under these circumstances it is impossible to tell what will give way; the pressure is great and increases as rotation advances. By this manœuvre I have ruptured the ligaments of the knee-joint, made twist fractures of the shaft and of the neck of the femur, ruptured the capsule of the hip in its postero-inferior aspect, with escape of the head downward and outward, but not in a single instance has the ilio-femoral ligament been torn. This ligament therefore acts as a fulcrum in all cases of rotation inward, and, as rotation outward¹ never enters into the problem of rupture of the capsule, it can almost be put down as an axiom that, if dislocation

¹ See Remarks, p. 46.

has taken place through flexion and adduction, rotation inward accompanied it.¹ If the reader will now compare the mechanism of dislocation brought about through abduction and a *fixed bony fulcrum* with that of flexion, adduction, and a ligamentous fulcrum, he will (I am inclined to think) decide that the former is by far the easier. In six successive attempts to dislocate by the latter method,

FIG. 38.



The design of Fig. 38 is to illustrate the relation of the ilio-femoral ligament to the neck of the femur during flexion and rotation inward. The femur is represented in the position of abduction, merely to give a better view of the ligament and its relations to the neck.

i. e., by rotation, the ligaments of the knee gave way. Failing in this, dislocation was accomplished through abduction, with a bony fulcrum.

Power. This, except under pathological conditions, is always an external force, which must be exerted through the femur. The power may be exerted directly upon the femur, in abduction or in hyper-extension. It may be employed indirectly through rotation, in which case the bent leg becomes the lever upon which the force is exerted.

Weight, *i. e.*, Resistance. This lies chiefly in the capsule. Given a power capable of breaking the lever or rupturing the capsule, and the result will depend, in a great measure, upon the mode of attack:

¹ Refer to "Steps," p. 83.

1. If the capsule be attacked through abduction, there is the highest probability that it will be ruptured. (Fig. 36.)

2. If it be attacked through flexion, adduction, and rotation *inward* (Fig. 38), the ligaments of the knee may give way; the femur may yield through twist fracture, or the capsule will be torn.

3. If the attack be through flexion, adduction, and rotation outward, the capsule will resist and fracture in some part will result.

EXPERIMENTAL WORK.

The following is a record of only a few of the many experiments I have made. In many no new fact or principle was brought out; when, however, anything unusual occurred a record has been entered in its proper place.

EXPERIMENT I. Attempt made to dislocate upward and backward, attacking the upper outer third of the capsule.

Subject: Male adult, muscular, about twenty-four years of age, about forty-eight hours after death. Pelvis fastened securely, limbs projecting over the end of the table. Right leg flexed on the thigh to a right angle, thigh slightly flexed and adducted. Thigh rotated outward (*i. e.*, the ankle of the bent leg was turned inward and upward). This brought the head against the upper and strongest part of the capsule; it brought the great trochanter against the ischium. Result, fracture of the femur in the lower fourth.

EXPERIMENTS II. AND III. I repeated this experiment in two other cases. In both the ligaments of the knee gave way, depriving me of the bent leg as a lever.

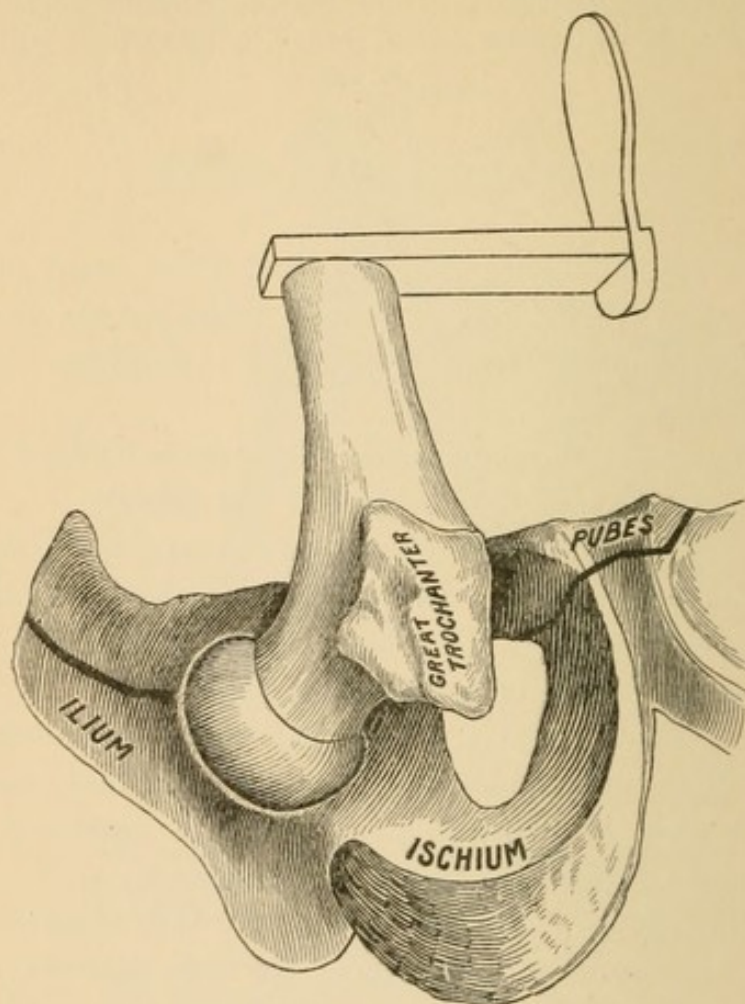
Remarks. In these experiments the tuberosity of the ischium was probably the fulcrum. By rotation outward the trochanter was brought against it, while the head within the capsule was forced against the upper front part, *i. e.*, the thickest and strongest part. In the first instance the shaft broke through twist, and in the remaining two the ligaments of the knee gave way. In none was the capsule ruptured.

EXPERIMENT IV. Attempt to dislocate outward by flexing the thigh on the abdomen. Adduction and rotation outward.

Conditions: Recent cadaver, male, about twenty-five years of age, body securely fixed. Right femur flexed, adducted, and rotated

outward, *i. e.*, the bent leg was used as a crank and turned inward. As I was not able to effect the displacement, the janitor assisted me, using nothing but manual force upon the femur and bent leg.¹ Result, fracture of the pelvis as indicated in Fig. 39.

FIG. 39.



Remarks. This was my fourth attempt to dislocate by means of flexion, adduction, and rotation *outward, i. e.*, by using the bent leg as a lever and turning it inward. In two the ligaments of the knee gave way; in one the shaft of the femur was broken in the lower third; in one the pelvis fractured. A glance at the figure will make it clear that no bony fulcrum can be made available in this mode of

¹ The reader is asked to explain how a transverse fracture of the pubes and of the ilium could result from a twist of the femur. The pelvis was fixed, and the only force exerted was manual and exerted through the bent leg. Had this result occurred from a fall or a crush the unanimous voice would be in favor of *direct* violence. In this case it was unquestionably through *twist*, precisely as in other cases I produced twist fractures of the femur.

attempting dislocation, unless the neck acts upon the upper part of the rim of the socket. The resistance to dislocation lies chiefly in the upper and outer part of the capsule; and the result in four cases (all young, in the prime of development, and in good state of preservation as far as the ligaments were concerned) clearly shows that the head cannot be made to escape through the thickest part of the capsule by flexion, adduction, and *rotation outward*.

Bigelow, who was of the opinion that the head emerged above the obturator internus and pyriformis *by a thrust in the long axis of the femur when it was extended and adducted*, was unable by any practical method to produce this variety; and, therefore, he divided with a bistoury the capsule above these muscles; and then—strange to say—dislodged the head by *flexion, adduction, and rotation outward, and not by an upward thrust*. *The fact that no experimenter has been able to dislocate directly upward without preliminary tenotomy of the capsule, taken with the disastrous results of my four cases, might suggest that, in actual traumatic dislocations, some easier way is found for the head to reach a high position than through the thickest part of the capsule.*

In the foregoing attempts to dislocate the head of the femur the resistance was solely from the capsule, with the result of fracture of the femur, rupture of the ligaments at the knee, and fracture of the pelvis. Hence, when Sir Astley Cooper¹ affirmed that ligaments present little strength to prevent dislocations, he was in error.

Dislocation Produced by Rotation Inward. (See *Mechanism*, Fig. 38.)

EXPERIMENT V. Female, about fifty years old. Pelvis secured. Right femur flexed to a perpendicular. Leg used as a crank, and turned outward (*i. e.*, inward rotation). Capsule readily ruptured, and head dislodged downward and outward.

EXPERIMENT VI. Left femur of the same subject. Hyper-flexion of femur upon abdomen. Flexed leg used as a crank and rotated downward and outward (*i. e.*, inward rotation of the femur).

Result, dislocation downward and outward, with complete rupture of the obturator externus, quadratus femoris, obturator internus, and pyriformis. In reducing this case, the great sciatic nerve was seen to stretch over the head as it was passing into the socket.

¹ Dislocations, pp. 20, 21.

EXPERIMENT VII. Male, sixty-one years old, a dissecting-room subject that had been abandoned after dissection.¹ Capsule and muscles about the joint in good, supple condition. Pelvis secured. Left femur flexed to a right angle and leg flexed on thigh. Knee adducted a little and a little extended, so that by internal rotation the head would tend to burst the capsule above the pyriformis. Result, fracture of the neck, partly intra- and partly extra-capsular. The lesser trochanter remained upon a large spicule that adhered to the head.

EXPERIMENT VIII. Right femur. Femur flexed to perpendicular, leg flexed on femur, knee gently adducted and slightly extended, as in previous case. Rotation inward, head made to press against the capsule above the pyriformis. Result, fracture of the neck of the femur, as in the previous case.

Remarks on Experiments VII. and VIII. The head was made to attack the outer upper part of the capsule, and found the capsule stronger than the agent that attacked it.

EXPERIMENT IX. Well-developed colored man, about thirty years of age. Body secured, prone. Right limb. Femur flexed at right angles to pelvis. Leg at right angles to femur, used as lever. Rotation inward (*i. e.*, ankle drawn outward). Result, ligaments of knee crackled and gave way. Dissected everything away from the hip-joint but the capsule. Limb placed in the same position. Rotation inward. Rupture of capsule posteriorly *from femoral attachment*, hence a long sleeve. (Fig. 41.)

EXPERIMENT X. Left limb. Femur extended. Leg used as a crank or lever, at right angles to femur. Rotation inward. Ligaments of knee gave way. After removing the gluteus maximus I divided the capsule close to the femoral attachment, in the interspace between the tendons of the pyriformis and obturator internus. Thus weakened, the head was with difficulty dislocated outward by internal rotation.

Observation 1. In both limbs the capsule proved to be stronger than the ligaments of the knee.

Observation 2. The fact that dislocation was possible in the right

¹ All the other experiments were upon fresh subjects in which the ligaments were in almost perfect condition. In these two, although the body had been on the dissecting-table for at least a month, the ligaments proved to be more than a match for the femurs.

limb after removing the muscles would strengthen the assumption that the muscles contribute to the safety of the articulation.

Observation 3. From experimental study, I incline to the opinion that the chief agency of the muscles is to check any range of motion that would place the joint in jeopardy ; but that, when the joint is once put to the test, the ligaments are the main safeguard.

LESIONS PRODUCED IN EXPERIMENTAL WORK. THE CAPSULE.

After dislocation some portion of the capsule still connects the femur to the rim of the socket. It was formerly believed that there was no special portion of the capsule that remained untornd after a dislocation, since the head was supposed to pass directly to its points of destination. The study of autopsies, on the contrary, presents a most constant escape of the *ilio-femoral ligament*. In experimental work it is easy to see why this portion of the capsule escapes, since, by manual effort, the head can be dislocated only in situations that do not subject the capsule to great strain.

The rupture of the capsule through rotation is due to torsion. Were the femur a straight bone, and the capsule of equal length and thickness, it would be difficult to explain why one part should yield through torsion before another, or why the whole should not rupture at the same instant. But the femur is not a straight bone. The neck joining the shaft at an angle of 130° cannot, in rotation, exert equal strain on all parts of the capsule. When the capsule is torn through torsion the lesion is invariably extensive. With the exception of the ilio-femoral ligament, all parts of the capsule have been torn in pathological studies of dislocations.

A question of vital importance to decide is the possibility of dislocating the head through a slit in the capsule. It always has been, and probably always will be, a very universal belief that the head can be buttonholed by the capsule, and that this is one of the difficulties that skill cannot overcome.

Morris,¹ after making a series of dislocations and finding the rent invariably greater than the diameter of the head, resorted to the following expedient: Prior to any attempt at dislocation he slit

¹ See a most instructive article on this subject in *Medico-Chirurg. Trans.*, vol. lx., by Henry Morris, F.R.C.S.

the capsule longitudinally, then dislocated, and found, instead of buttonholing, a rent as capacious as in any previous experiment.

Not wishing to repeat Morris's work, I exposed the capsule, and, instead of making a slit, I removed a circular disk from the capsule nearly large enough to permit the escape of the head, thinking that the borders of the opening would yield and let the head through without further laceration; but as pressure was brought against it the tense marginal fibres snapped, fibre by fibre, and the head made its escape through an opening ample for its easy return. I dare not say that a fissure in the capsule is impossible, but I insist that it is extremely improbable. I dare not say that it is impossible, but I claim that no teacher has a right to enroll it among the obstacles to the reduction of a dislocated hip until he has proved by experimental work its possibility. I therefore join Morris in an earnest protest against a most improbable theory, the legitimate fruits of which are either unwarranted rudeness, with a view to enlarge the rent, or despair and abandonment from an imaginary unsurmountable obstacle. Obstacles there really are to reductions, but the sooner we abandon the chimerical slit in the capsule the sooner the attention of the profession will be turned to the possible obstacles.

Experimental study will readily convince anyone of the correctness of the views just stated, but the plausibility of the argument is strengthened by the following considerations:

First, of the shape of the head of the femur. It must always be the head of the femur that produces the laceration in the capsule. Were the head narrow, square, triangular, or oblong the rent in the capsule would necessarily vary greatly. On the contrary, the head is spherical, and, no matter from what quarter the capsule is attacked, the round, smooth surface of the head is the effective disruptive agent.

Second. The rupture-force is always exerted on the inner surface of the capsule, *i. e.*, from within outward. While the leverage is effected through the femur or leg, the head, which is the extreme point of the short arm of the lever, is forced against the inner surface of the resisting capsule.

Third. The structure of the capsule is fibrous. It cannot stretch suddenly. The round head of the femur is forced against the short resisting cylindrical capsule, and makes every fibre pressed upon tense at the same instant. Often the first fibres to yield are those overlying the greatest convexity of the head. As these yield the

force falls upon succeeding fibres, and thus each fibre made tense snaps before the resistless advance of the head.

When a dislocation takes place by a single uncomplicated force, as by hyper-abduction, the rent is confined to the fibres pressed upon, and represents a minimum degree of laceration, equal transversely to the diameter of the head. Even this may render the restoration difficult. When dislocations are due to a twist, as by rotation, the rent is always extensive, embracing fully two-thirds of the periphery of the capsule.

After dislocation takes place the head can do no more harm to the capsule. Further efforts to enlarge the rent must be made through rotation and circumduction, which bring the *neck* of the femur against the border of the rent. To enlarge the rent in the capsule the head must be made to plow through any structure that may lie in its path, doing much destruction to muscles without any positive assurance of rendering reduction in the slightest degree easier. A point that should always be borne in mind is, that when the femur after dislocation presents marked deformity there is a minimum laceration of the capsule, and the head lies near the socket; while, when the deformity (*i. e.*, the constraint) is slight, there has been free laceration of the capsule.

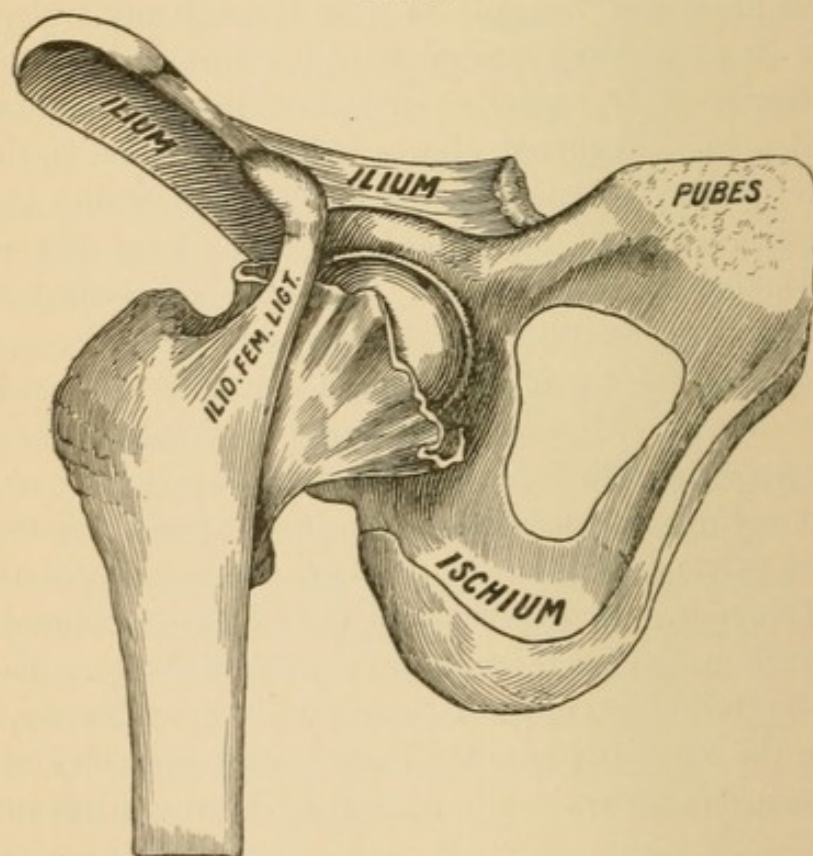
The Ilio-femoral Ligament. This I have never torn from its pelvic attachment. Bigelow, in describing a subspinous dislocation, expressed the belief that the head had reached that position through direct upward dislocation, and in its ascent had stripped up the (upper) pelvic attachment of the ligament. I record this only to dissent from it. In experimental work I have produced a subspinous luxation, but not through direct upward thrust. The lower, or femoral, attachments of the Y-ligament are not so secure. I have twice torn the outer and once the inner branch from its attachment. In most instances the entire ilio-femoral ligament remains intact.

Position of Rent in Capsule.

A matter of the greatest practical importance is the position of the rent in the capsule. All the possible lesions may be arranged under three general classifications:

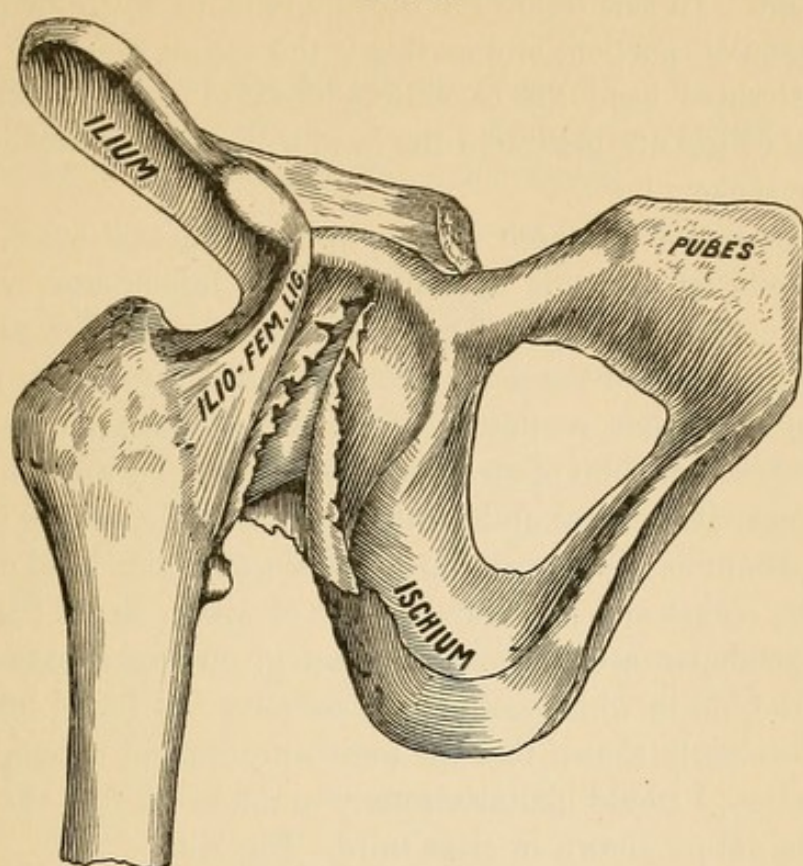
1. Those in which the capsule is torn from its acetabular or pelvic insertion. (Fig. 40.) I have torn capsule and periosteum from the rim of the socket. In this class of lesions there can be no possible obstruction from the capsule to an easy replacement, as no part of it can be driven before the head into the socket. The torn capsule, under such circumstances, must follow the femur in every displacement inward or outward, and in all efforts at reduction.

FIG. 40.



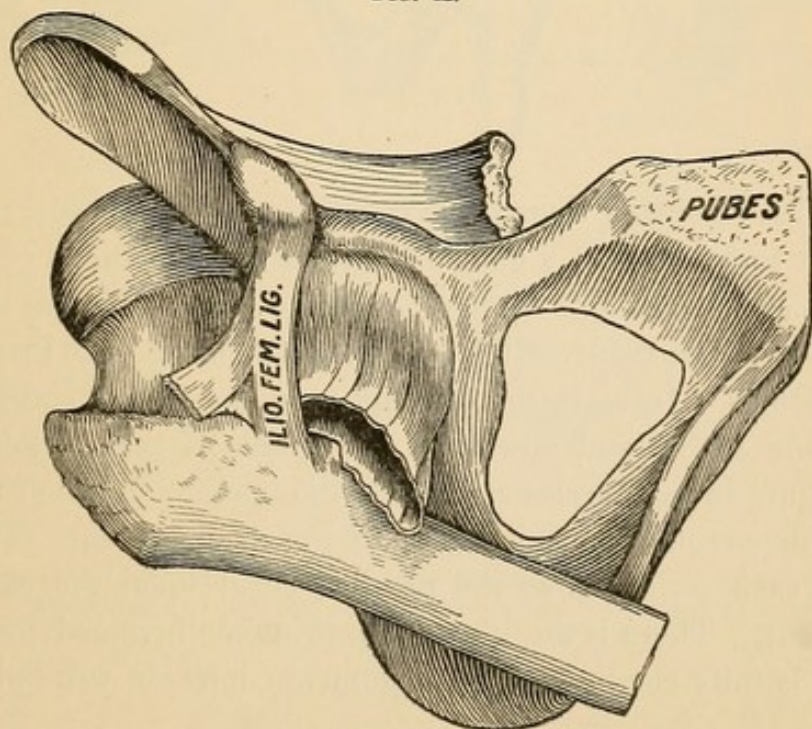
2. Those in which the rent is between the attachments, or runs obliquely from one attachment to the other. (Fig. 41.) In this lesion the part of the capsule that is attached to the acetabulum may become detached from the surrounding muscles and driven before the head into the socket during the act of replacement. In such a case only a limited amount could be driven into the socket—scarcely enough to be recognizable, yet enough to produce mischief.

FIG. 41.



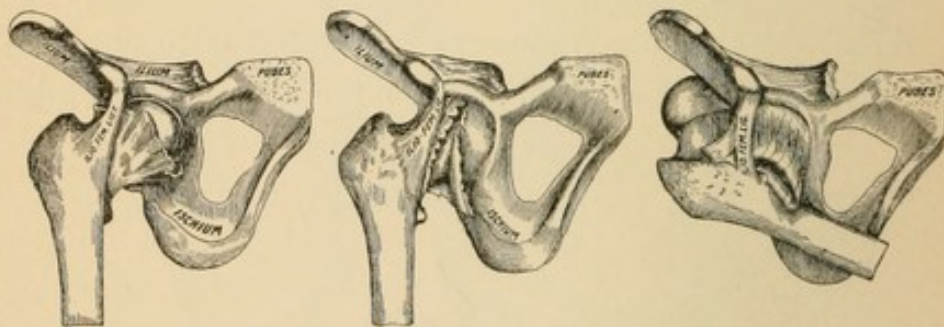
3. Those in which the capsule is torn from its femoral attachment. (Fig. 42.) This I believe to be the most frequent obstacle

FIG. 42.



to reduction. In this lesion the capsule remains entire or nearly so at its acetabular portion, and as this is the easiest point of entrance for the dislocated head the capsule is likely to resist reduction, and if vigorous efforts are instituted the head will push the capsule before it into the socket.

I have produced all these lesions in experimental work, and incline to the belief that the character of the lesion must vary with the nature of the vulnerating force. If dislocation be effected through *abduction*, the head of the femur tends to strike the capsule (Fig. 67) at a point somewhat remote from its acetabular attachment, and hence the greatest point of strain will be midway between the attachments or near its femoral and thinnest parts, while, on the contrary, when the femur is dislocated during *adduction* the head is driven toward the socket and its greatest point of strain upon the capsule is at its acetabular attachment. If in a given recent case of dislocation of the hip in which perfect replacement was found impossible, it could be clearly shown that the accident occurred through flexion and abduction, I would incline strongly to the belief that the obstacle was of the nature shown in class third—Fig. 42.



The three foregoing figures are reproduced in miniature to enable the reader to contrast at a glance the three classifications of lesions.

I have considered this topic of sufficient importance to illustrate it more fully. The reader will notice on the opposite page three series of illustrations. In each, the first figure in the series represents the head *in the socket*, and one variety of lesion of the capsule. The second figure in each series represents the manner in which the capsule will deport itself during any variety of displacement. The third figure in each series shows the possible effect upon the capsule of replacement. There is an important principle involved here; and unless it is fully comprehended, arguments later on will fail to convince.

Illustrated *résumé* of the three varieties of lesions of the capsule, showing:

X. The position of the rent in the capsule.

Y. The deportment of torn capsule during dislocation.

Z. The effect of dislocation upon the capsule.

FIG. 43.

FIRST SERIES.

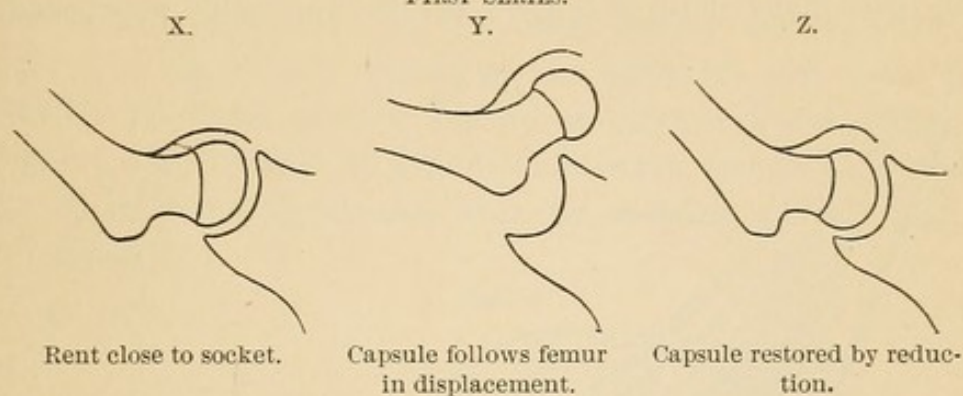


FIG. 44.

SECOND SERIES.

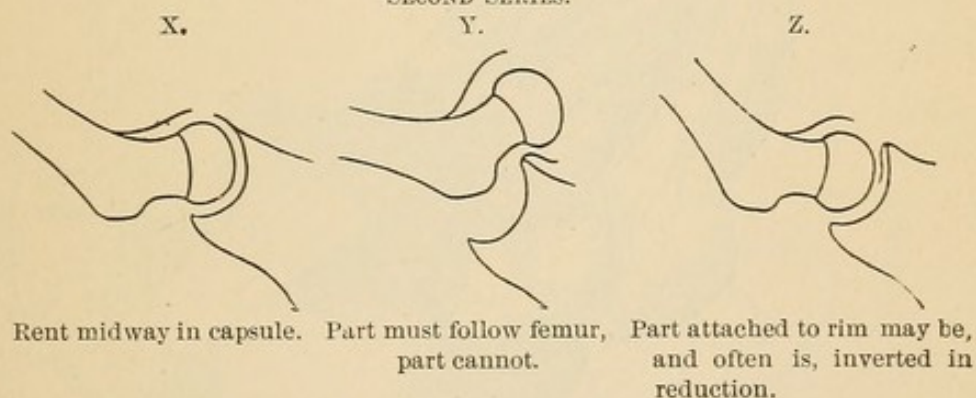
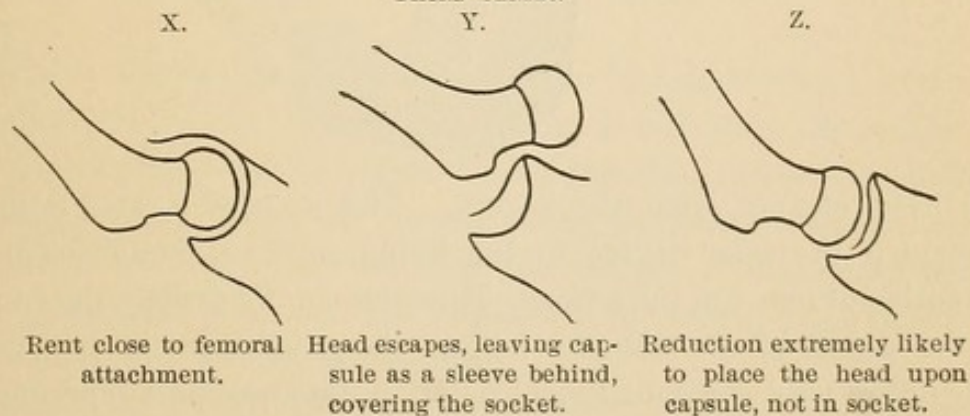


FIG. 45.

THIRD SERIES.

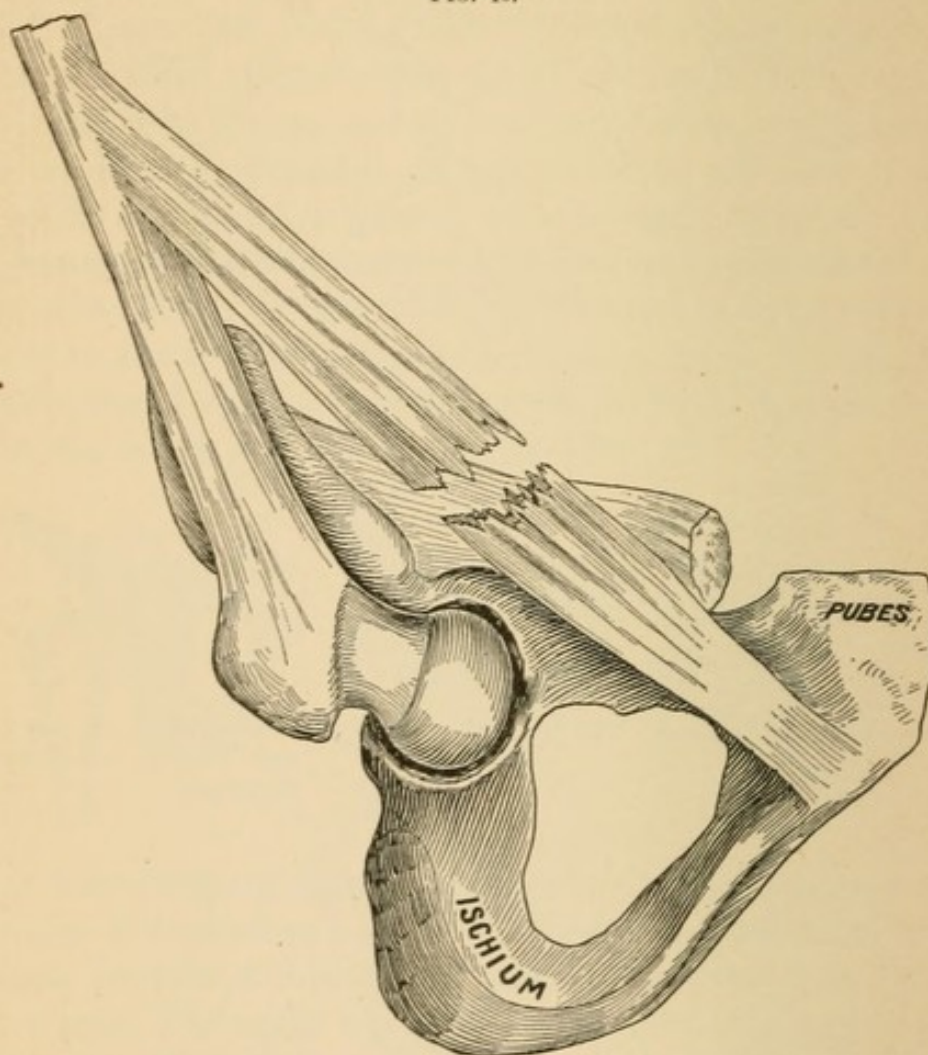


Lesions in Muscles.

The lesions in the muscles are due either to overstretching or to direct violence.

Overstretching. Muscles are easily torn in manipulations upon the cadaver. It is impossible after cadaveric rigidity to dislocate without rupturing strong muscles, such as the adductors (Fig. 46), which reach their limit of tension before the capsule is ruptured or

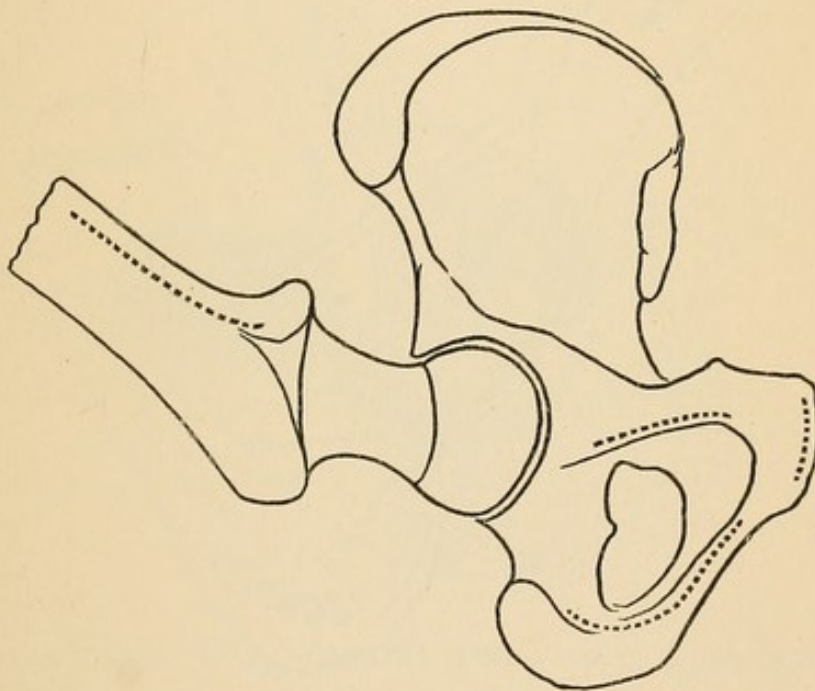
FIG. 46.



the head escapes from the socket. This condition would not be present to the same degree in the living, and yet it affords an explanation of many of the lesions. How else can we explain the rupture in the middle of the adductor longus, the gracilis, or the pectineus? One of the most constant lesions found in autopsies and experimental work is rupture of the pectineus; and this muscle is not touched by the head of the femur in dislocations either inward or outward.

Rupture of Muscles from Direct Contact. By this I mean the havoc produced by the dislocated head plowing through all muscular structure within reach. It is possible for the head to be completely dislocated without doing material mischief beyond rupture of the capsule.¹ The head may be dislocated inward, and if any mischief attend it, it may be a trifling laceration of some fibres of the obturator externus. By a glance at Fig. 47 it will be seen that all the muscles that extend from the antero-lateral aspect of the pelvis to the shaft have their origins at the boundary and would not be injured by a simple primary inward or outward displacement. Besides, too, the direction of displacement when the thigh is abducted is in the main nearly parallel with the muscles, which would favor their escape.

FIG. 47.



After a dislocation occurs the head can be made to move in a circle of which the untorn capsule and the neck constitute the radius. If the thigh be kept nearly perpendicular and the knee be circumducted through a small circle, the corresponding circle in which the head of the femur will move will be *near* the margin of the socket; while larger sweeps of the knee will necessitate correspondingly larger and more disastrous sweeps of the head.

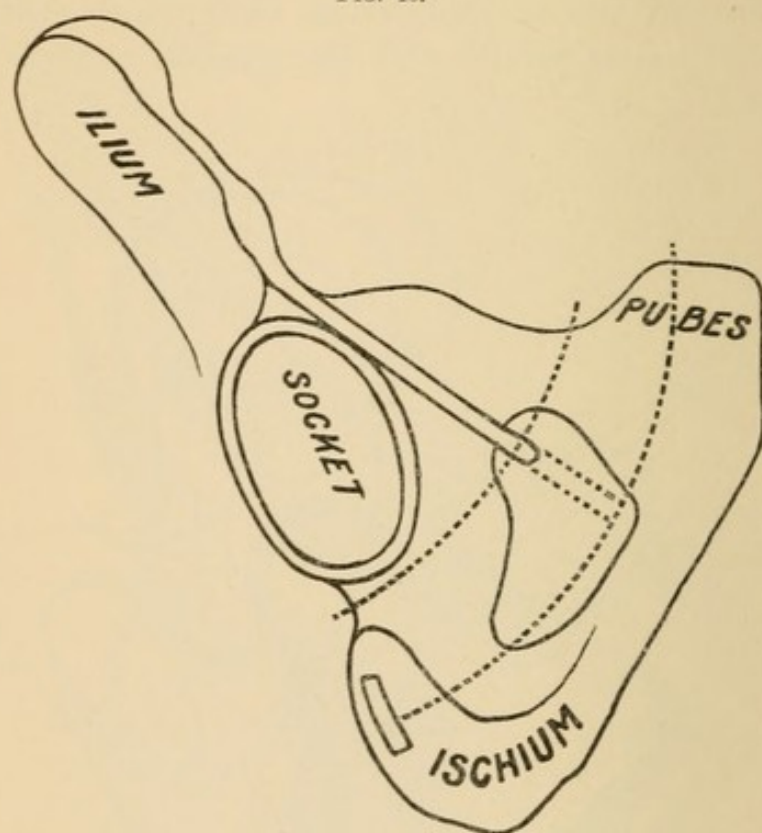
In Fig. 48 I have represented two arcs of circles. Between them,

¹ See case of Robert S—, p. 69.

upon the ischium, I represent the strong tendon of origin of the hamstring muscles—one of the important structures connected with this subject. If the head take the smaller circle, it will go above this tendon; but if it take the greater circle, and if at the same time the hamstring muscles are made tense by extension of the leg on the thigh, the head would be arrested either in the perineum or upon the ischium, as it could not pass the tendon.

If the head be dislocated primarily inward upon the pubic plane, and then by rotation be turned outward upon the dorsal plane, it

FIG. 48.

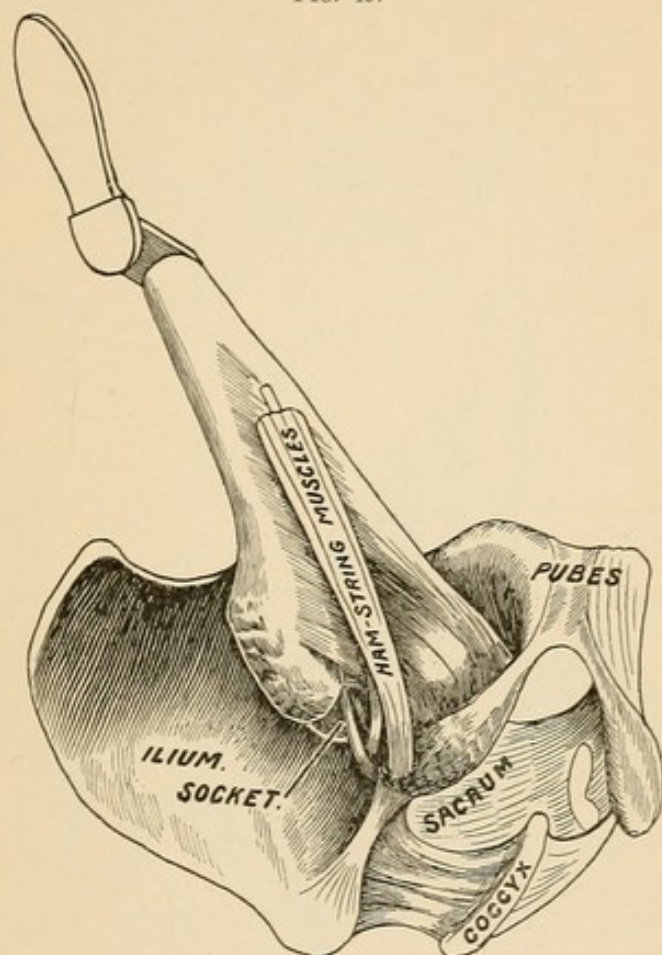


The dotted lines represent arcs of circles, of which the remnant of untorn capsule and the added length of the neck of the femur represent the radius. By varying the position of the knee an infinite number of arcs could be described. (See Fig. 102.)

must burst through the great muscular septum that separates the femoral vessels from the sciatic nerve. In Fig. 49 I have represented the head dislocated inward, and about to be shifted by inward rotation to the outer plane. Two muscles are in the way: the quadratus femoris, which cannot escape when the head is shifted from an inward (thyroid) to an outward (dorsal) position, and with it some of the fibres of the adductor magnus. The adductor brevis is often mentioned among the torn muscles; but the lesion is probably always

the result of overstretching, and not due to direct contact. As the head forces its way outward, it strikes the obturator externus and tears it in two; then, in turn, the quadratus and short upper fibres of the great adductor, all of which lesions are unavoidable when a primary inward dislocation is shifted to an outward.

FIG. 49.



In direct dorsal (*i. e.*, outward) dislocations, those that I have produced by rotation inward, the thigh being flexed or extended, the capsule is rent in the postero-inferior aspect and the head may descend between the obturator externus and internus (Fig. 51) without rupture of either.¹ If this accident occurs during hyper-flexion of the thigh, though the obturators escape, the gluteus maximus, which must be tense at the instant of escape, will be bruised, lacerated, or trans-fixed.²

Résumé of Muscular Lesions. When dislocations occur through leverage of the shaft of the femur—as, for instance, during

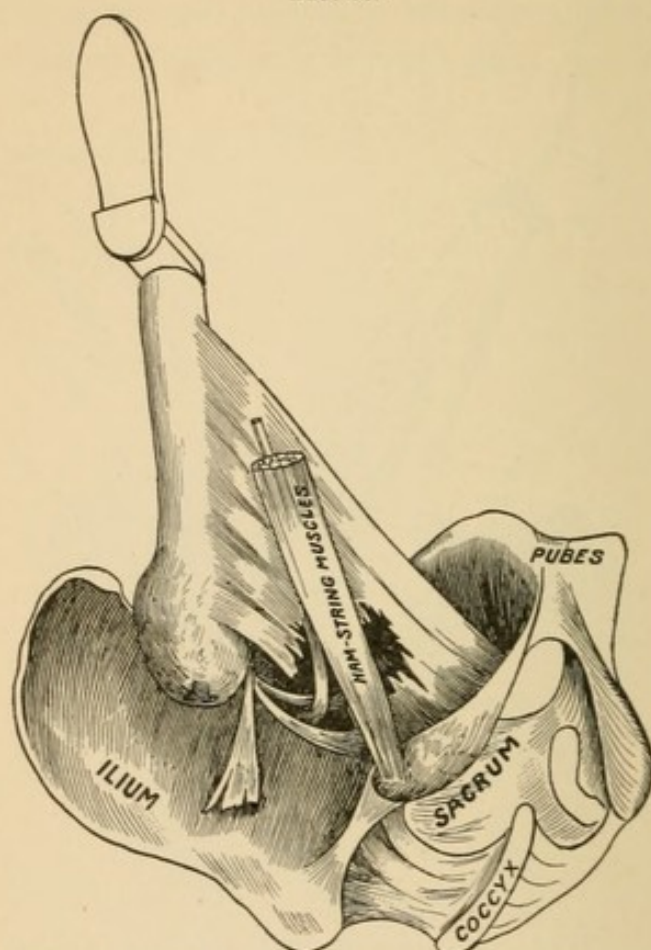
¹ G. M. Humphrey thinks this the most frequent form of dislocation (*Lancet*, Nov. 27, 1886). Although the position is frequent, the entire escape of the muscles must be very infrequent.

² See Case IV., p. 65.

abduction—the long muscles are torn prior to dislocation. It is possible for these muscles to be torn without dislocation taking place.

When dislocations occur through rotation inward, only the pyramiformis, the two obturators, and the quadratus are put upon the stretch. These may rupture through overstretching; they may be torn by the head of the femur as it bursts through the capsule.

FIG. 50.



The illustration represents the head restored to its socket after a primary inward dislocation has been shifted to an outward and then restored. Note the area of the lesion and how the nerve must be implicated in the reparative processes.

If the head escapes through rotation inward and strong flexion, the gluteus maximus can hardly escape laceration.

If the head escapes inward, every rotator muscle may escape.

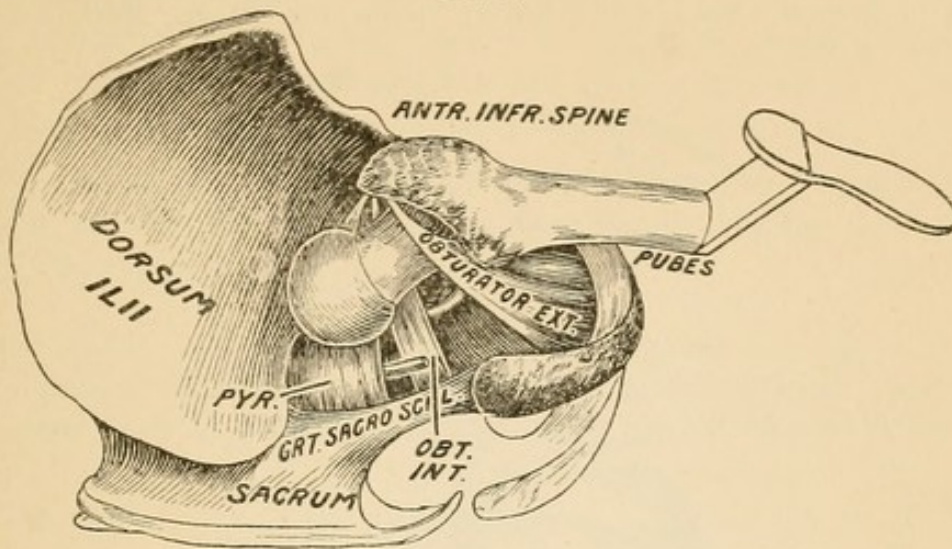
After a primary inward luxation an attempt to convert it into a dorsal will rupture the obturator externus and quadratus femoris.

The head may escape outward between the obturators without injuring either, through rotation inward. (Fig. 51.) Usually the obturator internus is torn.

Muscles are torn in the steps of dislocation prior to, coincident

with, and after the displacements. In rare instances they all escape. (See p. 69.)

FIG. 51.



The sciatic nerve has been twice reported torn completely in two. It has been lacerated, bruised, its fibres separated, and its sheath filled with blood. It has been caught up repeatedly by experimenters and carried across the neck in reductions. Partial persistent and permanent paralyses are reported as sequelæ of otherwise successful reductions. The anterior cutaneous nerve would probably be stretched across the head or neck if a thyrod were converted into a subspinous.

PATHOLOGY.

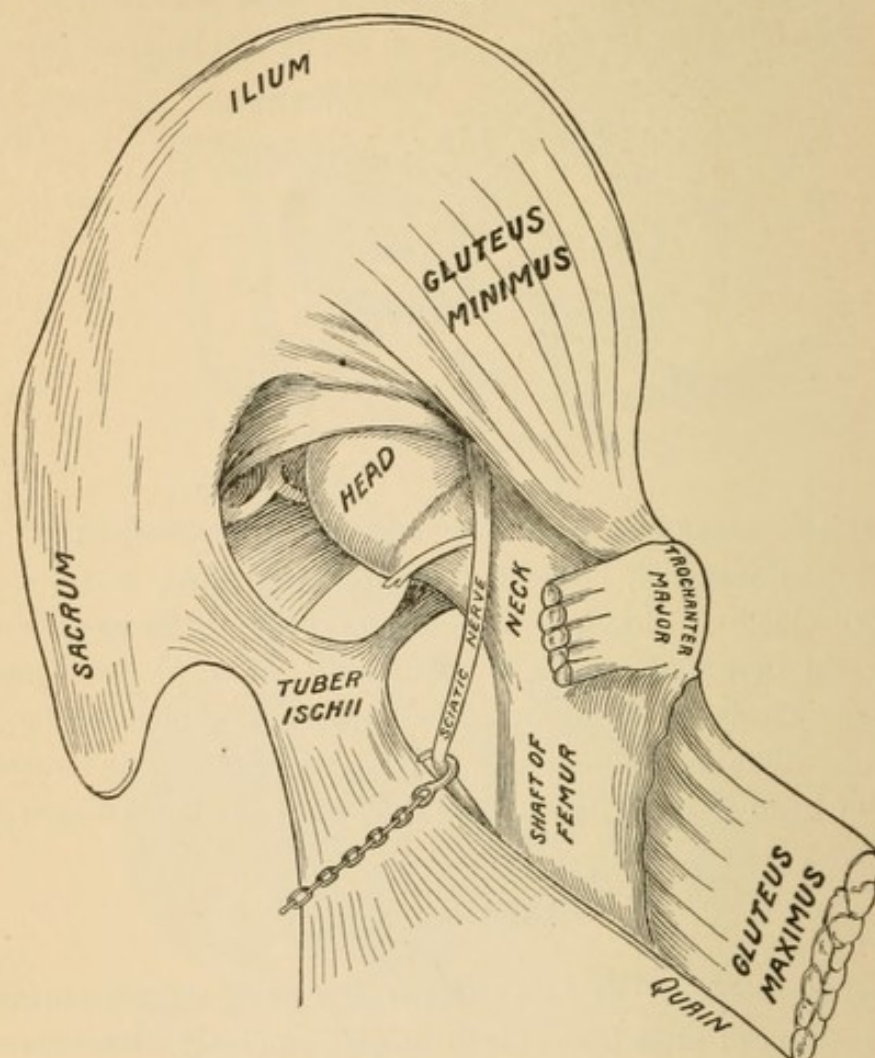
No better proof of the value of the foregoing experimental work need be adduced than that it is fully and minutely corroborated by dissections of actual traumatisms. The author has not striven to make a large collection of cases. The few that follow illustrate important points; except in a few instances, duplicate injuries have been rejected.

CASE I.—A man, sixty years old, was killed by a fall from a ladder. Symptoms: Right leg apparently, but not actually, much shortened; was *inverted* and *separated* from its fellow; the trochanter major was further removed from the spine of the ilium than normal; the head could be felt toward the back of the pelvis; the limb could be flexed, but could not be rotated outward.

Dissection. On removal of the gluteus maximus the head was found below the obturator internus (Fig. 52), which, with the great sciatic nerve, was stretched over the neck of the femur. The obturator externus and quad-

ratus femoris were torn in two. Some of the deep fibres of the gluteus medius were torn across. The capsule was rent at its inner and lower aspect, where it was torn *from the neck of the femur*. The ligamentum teres was torn from the head of the femur.—RICHARD QUAIN, *Medical Times*, vol. xviii. p. 205.

FIG. 52.



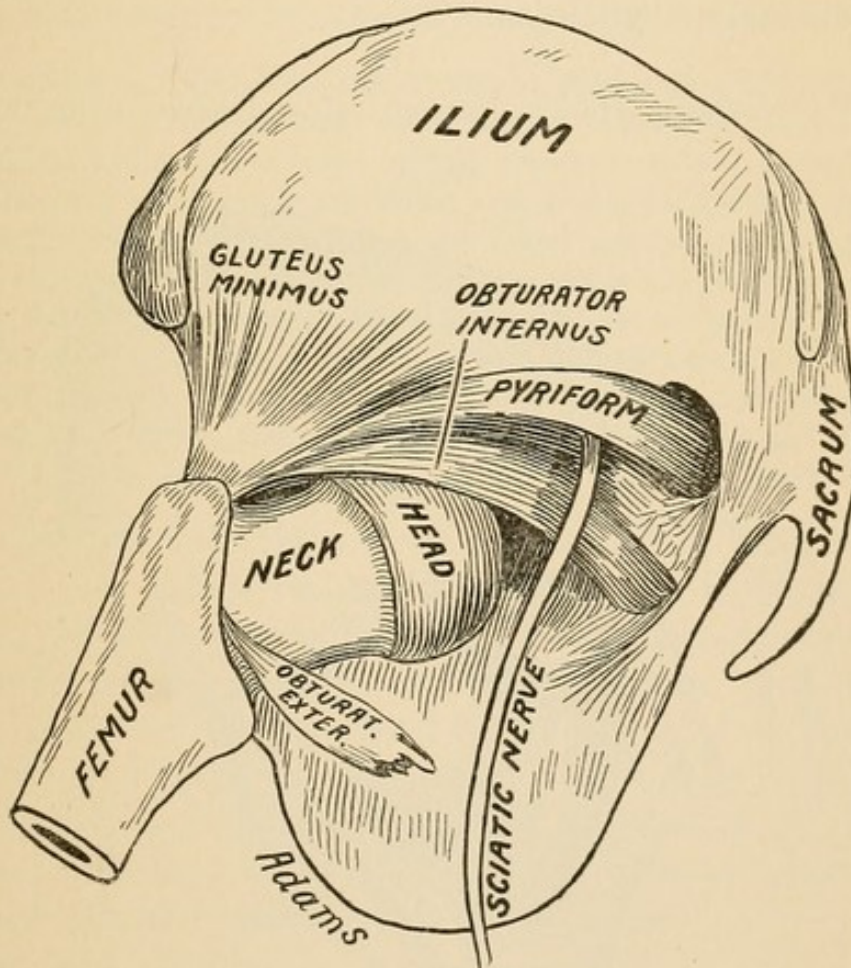
REMARKS.¹ The upward progress of the head was arrested by the nerve and the obturator internus. Morris has asserted that the nerve presents a more reasonable check than does Bigelow's position, known as "dorsal below the tendon." The mode of rupture of the obturator externus and quadratus femoris, with hooking up of the nerve, can be explained in two ways: The head might have been dislocated primarily inward, and then by unexpended force shifted outward. If such was the case, the *head* tore its way through the two muscles and hooked up the nerve. In the other—and to my

¹ The "remarks" after cases in pathology are by the author of this work, and the reader may give them whatever consideration he thinks them entitled to.

mind the more plausible—the dislocation took place during forced flexion with rotation inward. Forced flexion would make tense the obturator externus and the quadratus femoris, and, at the same time, draw the nerve down closely upon the quadratus as it crosses the neck of the femur. Now, while in this condition, if rotation inward be added—a manœuvre calculated to luxate outward—the two muscles would be torn either through *overstretching*, or through direct contact, and the nerve would be readily caught over the neck as the head fell outward.

CASE II.—I. D., twenty-nine years old, was run over by a railroad train, receiving injuries from which he died, with symptoms of septicæmia, fourteen days after the accident. Injury to the hip. Symptoms: The left

FIG. 53.



thigh, leg, and foot were inverted; the knee was directed inward, and the thigh was slightly flexed. The shortening, if any, did not exceed half an inch.

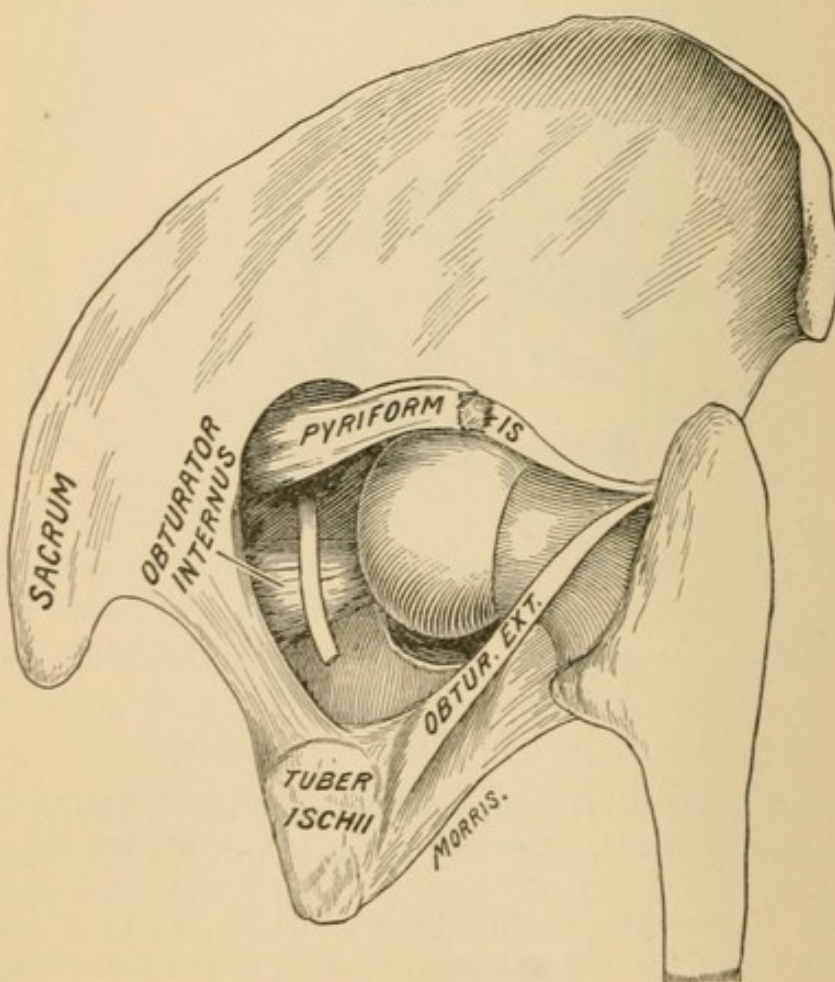
Dissection. On removing the overlying structures the head was found with the obturator internus and gemelli above it, and below it were the ruptured obturator externus and quadratus femoris. The head w

vented from ascending upon the ilium by the obturator internus. It pressed so tightly upon the head that it produced a distinct groove in the cartilage. The capsule was rent in its posterior half and torn at its femoral attachment. The mass of detached capsule, remaining attached to the (Fig. 53) margin of the acetabulum, formed, *as it became inverted by attempts to reduce the head, some obstruction to its return.*—WM. ADAMS, *Trans. Path. Soc.*, London, vol. xxi.

REMARKS. The reader will especially note the variety of rupture of the capsule: *it was from its femoral attachment*, making a cuff for the socket. (Fig. 42.) Although the difficulty was laid bare by the scalpel, and the surgeon could use his eyes in efforts at restoration, still the capsule would turn in before the head. The rupture of the obturator externus and quadratus femoris was—as in the previous case—probably due to rotation inward, which, with flexion, would cause their rupture by tension.

CASE III.—Cabman, crushed between cab and house, dying in a few minutes.

FIG. 54.



Dissection. On removing the gluteus maximus the head was found midway between the socket and the great sciatic foramen. The head lay upon the piriformis, gemellus superior, and obturator internus muscles. All these muscles retained their cellular and fibrous attachments to the torn capsule. The quadratus femoris was but slightly torn on its upper border. The gemellus inferior was completely ruptured, and so were some inferior fibres of the obturator internus. At least half of the fibres of the piriformis were torn. The obturator externus was but slightly injured; some of its muscular fibres were detached from its tendon. The tendon of the obturator internus was tightly stretched in front of, and the tendon of the obturator externus tightly stretched behind, the neck of the femur.—MORRIS, *Med.-Chirurg. Trans.*, vol. lx.

REMARKS. If the reader will turn back, he will see how the head may be dislocated between the two obturators without rupturing either. This condition will also suggest how, in the living, an attempt at reduction by flexion and circumduction might readily fail.

CASE IV.—J. A., injured by a great weight falling upon him, dying the same day. At the autopsy there were found a rupture of the bladder, a fracture of the ramus of the pubes into the foramen ovale of the right side, and a separation at the symphysis pubis and at the sacro-sciatic junction. On dissection, the gluteus maximus was found nearly torn through, with the head imbedded in its substance; the piriformis was ruptured and the superior gemellus was partly ruptured; the gluteus minimus was so completely destroyed that its remains could with difficulty be recognized; the ligamentum teres was torn from the head; the head lay upon the gemelli and the sacro-sciatic nerve; the capsule was extensively torn close to the acetabular attachment.—JAMES SYME, *Lond. and Edin. Monthly*, 1843.

REMARKS. How did this dislocation take place? Through direct thrust? Under these circumstances the dislodging head would have found the gluteus maximus in a state of complete relaxation and not in a relation to it to oppose it. But if the man were “doubled up,” as is probable, then we can account for the fracture of the pelvis and the rupture of the bladder, while a dislocation taking place when a man is doubled up would find the gluteus stretched tightly over the head, and rupture or transfixion probable. *Note in this case that the capsule is torn from the socket.*¹

CASE V.—C. D., died a few hours after admission to the London Hospital. The dislocation had been reduced by manipulation, the head passing from the dorsal position to the obturator, and thence into the socket.

On dissection, no external evidence of injury was found. On removing

¹ See p. 88.

the gluteus maximus, the bursa between it and the vastus externus was found to be ruptured and filled with blood. The sheath of the *great sciatic nerve* was distended with blood, and the nerve fibres were separated from one another. The posterior fibres of the gluteus minimus were torn across, and the cellular tissue beneath the muscle was filled with blood. The quadratus femoris was torn completely in two, and the uppermost fibres of the adductor magnus and some fibres of the gemelli and obturator internus muscles were lacerated. The capsule was perfect in front and above, but torn in its posterior part. The ligamentum teres was torn off close to the head of the femur.—J. MCCARTHY, *Lancet*, 1874, ii. 13.

REMARKS. How is it possible to have the capsule complete in *front and above*, and yet have a complete rupture of the quadratus femoris take place? *Answer.* By flexion and rotation inward; the laceration being due to overstretching. It could not have been done by direct contact with the head, for the capsule, not being torn in front, would not have permitted the head to escape in that direction. By flexion and rotation inward the nerve-injury could also be readily explained.

CASE VI.—W. A., injured by falling timbers, admitted to the London Hospital with the following symptoms: Right leg two and a half inches longer than its fellow; trochanter major less prominent; foot and knee widely separated from its fellow. No attempt at reduction was made, owing to the patient's collapsed condition. When he rallied a little the nurses, in changing his position in bed, restored the dislocation. Death on the third day.

On dissection of the hip there was found evidence of contusion on the outer aspect of the hip. Blood was found extravasated between the muscles on the outer and posterior aspects of the hip and in the cellular tissue about the great sciatic nerve. *There was no laceration of muscular tissue.* The substance of the adductor magnus and the lower border of the obturator externus were much ecchymosed. A large rent was found in the capsule on the inner aspect, extending from the ilio-pubic eminence to the upper border of the obturator externus muscle. *The capsule was torn from its pelvic attachment.* The ligamentum teres was torn from the head and lay loose in the socket. The head could easily be redislocated upon the edge of the obturator foramen; and when this was done it pushed the obturator externus before it, rendering it tense and bulging.—CURLING, *Med. Times*, vol. vii. N. S., p. 422.

REMARKS. This was a dislocation inward. Note two points: 1. There were no muscles torn. 2. The rent in the capsule was at its periphery, and from the socket. Such a rent would favor reduction, which took place while the patient was being gently handled by the nurses.

CASE VII.—Dorsal dislocation. Young man, fatally injured by a fall from a second story. Death in twenty-four hours. On dissection a large amount of coagulated blood was found beneath the gluteus maximus; the pyriformis, gemelli, obturator internus, quadratus femoris, and obturator externus were completely ruptured. The capsule was torn inferiorly and posteriorly; it was intact at the superior and internal part. The ligamentum teres was torn from the head. The head lay posteriorly upon the gluteus medius. Some fibres of the pectineus were torn.—CHARLES H. TODD, *Cooper on Fractures and Dislocations*, Case 40.

REMARKS. There is no mention of injury to the nerve; and we may infer that it escaped. As the capsule was not torn internally, the quadratus and obturator externus were not torn by direct contact with the head. The position of the limb, at the instant of rupture of the capsule, was probably that of flexion and hyper-adduction, with rotation inward. The two muscles mentioned above were torn by hyper-tension. The hemorrhage and the traumatism to the other muscles were probably due to direct contact. The pectineus was torn by overstretching.

CASE VIII.—Male, nineteen years old, strong and healthy, admitted to Edinburgh Royal Infirmary. Railroad injury. Death in a few hours. Thyroid dislocation of left femur. On dissection, fourteen hours after death, there was found an extensive extravasation of blood and many muscles torn and bruised. The obturator internus was partly torn, and some of its substance had been forced into the socket. Its tendon was not ruptured. The head had been reduced. The capsular rent was on the inner and lower aspect. The ligamentum teres, with a thin scale of bone attached, had been torn from the pit in the head.—THOMAS ANNANDALE, *British Medical Journal*, 1870, p. 101.

REMARKS. The dislocation was inward, and I infer that it was a clerical error to state that some of the fibres of the obturator *internus* were driven into the socket. It is more probable that the muscle referred to was the obturator *externus*. Two points are worthy of emphasis: 1. Some muscular material was forced into the socket. This is a fact, not a theory. 2. The teres was not torn from the head; it was peeled off from it with a scale of bone. Hence, if it had been ten times as strong, its greater strength would have availed nothing against luxation.

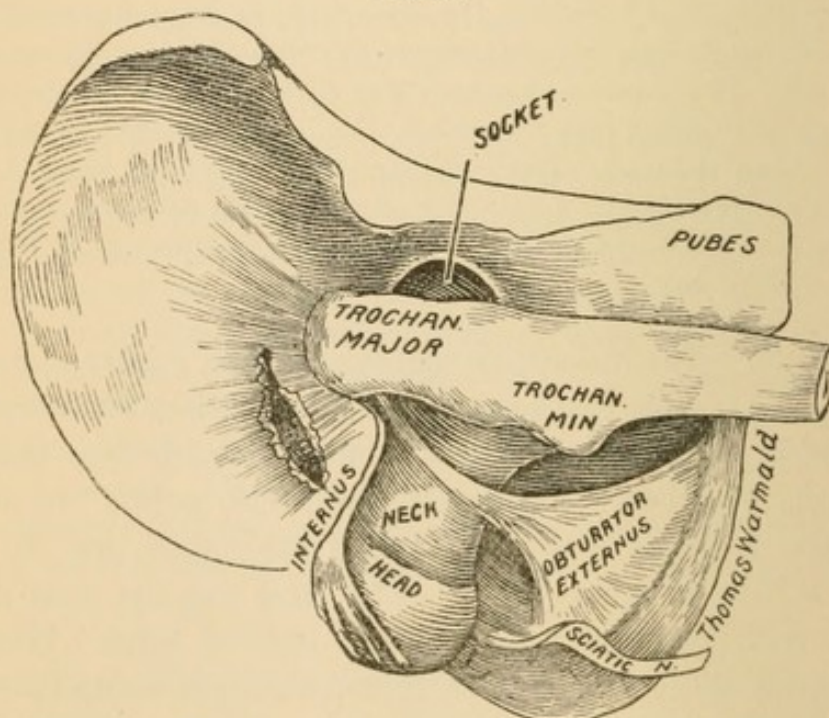
CASE IX.—Thyroid dislocation. Young man, killed by a fall from a window. Hip symptoms: Great trochanter less prominent than natural, with an unusual fulness in the groin. Adduction of the thigh resisted;

abduction easy. No marked eversion on dissection; the great sacro-sciatic nerve was found to be ecchymosed and bruised; the gracilis was torn through; the abductor longus and brevis were partly torn; the capsule was extremely torn on the inner side; the ligamentum teres was ruptured.—SHAW, *Medical Times*, vol. xvii. N. S., p. 459.

REMARKS. In this case the head was dislocated internally; but it could not have touched the gracilis nor the adductor longus. How, then, were they torn? The explanation is simple. If we accept the lesson of the dissecting-room, that internal dislocations are by abduction, we see that on abduction to a point necessary to dislocate, these muscles were put upon a severe strain, and the rupture was due, not to contact with the head, but to overstretching. On the same theory of overstretching the ecchymosis of the nerve may be explained.

CASE X.—A maniac jumped from a third-story window, receiving injuries that proved fatal in three hours. Thigh injured. Symptoms: Shortening and inversion; shaft crossed the symphysis pubis, and was immovably fixed in that position. On dissection, twelve hours after death, the gluteus medius and minimus were found ruptured at their posterior edges; the

FIG. 55.



pyriformis and the gemelli were partly torn, but the four portions of the tendon of the obturator internus which pass through the lesser sciatic notch were drawn out and separated from their connection with the muscular fibres. The head of the femur presented through a rent in the capsule

opposite the upper part of the tuber ischii above the quadratus, so that the great sciatic nerve was somewhat displaced and pressed against the tuber ischii.—THOMAS WORMALD, *London Medical Gazette*, vol. xix.

REMARKS. Bigelow lays great stress upon the anatomical structure of the obturator internus. He calls especial attention to the separate fibres that make up its tendon, and assigns to this muscle the province of arresting the head in its upward march. He has a distinct class of dislocations which he calls "dorsal below the tendon." Now, before dissection, one would have assigned this dislocation to that variety, since the head lay below the sciatic notch, and the limb crossed its fellow at a high point. But, on dissection, the obturator internus was found hanging in shreds from the trochanter, and incapable of offering the least resistance to the upward progress of the head.

This case confirms in a striking manner a result which I have stated (p. 79), that in dislocations the tendon never gives way—it tears from its insertion or from the muscle. This is easily explained in experimental work, in which the bone, capsule, tendon, and fibrous structure may undergo no change, while the muscular fibre has lost its toughness. This case, due to traumatism, proves the truth of the assertion. In experimental work I have drawn the tendons out of the muscular part precisely as described above.

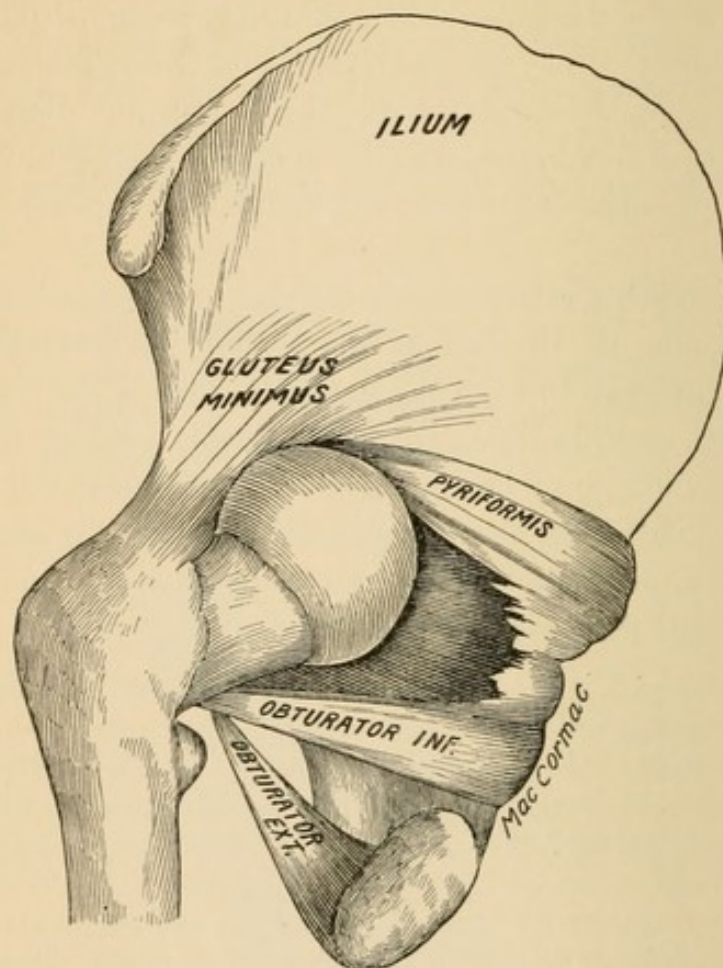
CASE XI.—Robert S., forty-five years old, was knocked down and injured while coupling railroad cars. He was unable to rise, and soon after was taken to the Leicester Infirmary and placed under the care of Mr. Marriott. Dislocation backward of right femur, with less advancement of the knee and inversion of the foot than usual. No efforts at reduction, owing to collapse. Death occurred on the following day. On dissection, the head of the femur was found immediately behind the acetabulum, having escaped below the pyriformis. No laceration of muscular fibre was anywhere detected. On manipulation, the muscles were found to be the main obstacle to reduction. The ligamentum teres was torn from the head. The capsule was freely torn all round, only a small portion remaining attached to the femur in front and behind. The cotyloid ligament and the cartilages were uninjured.—SAMUEL LEE, *St. George's Hosp. Rep.*, 1872-4, vols. v.-vii.

REMARKS. If the dislocation was below the pyriformis, the head must have been between it and the obturator internus, as it is distinctly said there was no muscular lesion. It is impossible to reproduce this injury upon the cadaver, owing to the brittle condition of the muscles. It is this condition of *head in chancery* that leads me

to classify it among the real obstacles to reduction from the usual methods.

CASE XII.—Stephen H., seventy years old, foundry laborer, crushed by a heavy weight so severely as to drive a large quantity of intestines through a rent in the scrotum. Death from peritonitis on the eighth day. Symptoms: Left hip inverted; thigh flexed and rigid; knee rested above patella of sound side; the head of the femur could with difficulty be located near

FIG. 56.



the sciatic notch; trochanter a little posterior to normal situation. On dissection, the head was found to be dislocated almost directly backward, resting behind the acetabular ridge, opposite the middle and upper half of the great sciatic foramen. The piriformis was stretched above the head. The gemellus superior was ruptured, and the obturator internus was intact. —WM. MACCORMAC, *St. Thomas's Hosp. Rep.*, 1871.

REMARKS. The fracture of the pelvis and the expulsion of the intestines through a rent in the scrotum may be reasonably explained on the theory of hyper-flexion; and this, with slight rotation inward, would effect dislocation outward.

Altered Relation of Parts After Dislocation.

Before Reduction. So long as the head remains out of the socket all the structures that attach to the great and small trochanters will be affected, some being stretched and others relaxed. If the head be dislocated inward, the great trochanter will approach the socket, and may lie in it to a variable degree. When the knee is abducted and the thigh flexed, the trochanter tends to sink down into the socket. The tendon of the gluteus minimus will follow the trochanter inward, and, with the tendons of the pyriformis and obturator internus (if untorn), will lie upon the outer edge of the acetabulum or be stretched partly over it. Usually the part of the capsule that remains untorn is that which is covered by and adherent to the tendons of the ilio-psoas and gluteus minimus, and in those cases where the capsule is actually torn beneath these tendons the torn parts of the capsule will retain their attachments to the overlying muscles. Both these muscles escape, as a rule. I have never seen in experimental or pathological investigation any injury to the psoas, but the gluteus minimus and medius are reported as utterly destroyed. (See Cases IV. and V.)

While dislocation persists the edges of the capsule are held apart, being separated to the extent of the full width of the neck of the femur. Certain writers have permitted their imaginations to guide their pens, and have stated that rapid healing of the capsule with its consequent shutting off of the socket is one of the insurmountable obstacles to reduction. I cannot indorse such a sentiment, and believe that a persistent passage to the socket is not an infrequent condition, or that, if adhesions take place, they are easily broken up.

If the dislocation be outward, the remnant of untorn capsule and the tendon of the psoas will be drawn across the socket and rest upon its outer rim. It is difficult to understand how any adhesions of the capsule to the cartilaginous rim of the socket (both lined by epithelium) could take place, or how, if they did occur, they could be formidable. Such adhesions would shorten the remnants of the capsule and must readily yield to manipulation. I am firmly of the belief that capsular adhesion (the so-called shutting off of the socket) in cases of unrestored dislocations is little worthy of serious consideration, and should be given a much less prominent position in the category of obstacles.

Conditions of the Head and Socket. The head and socket may remain unaltered for years, or they may undergo rapid inflammatory and other changes. Something can be inferred from the history of a case. If the dislocation has been effected by simple leverage (*i. e.*, if the head has been lifted out of the socket), the cartilages of the head and the socket escape without bruising. Such dislocations, taking place in adult life, will not be followed by rapid shrinking of the head or socket. Cases are reported in which the cartilages of the head and socket have been found smooth and glistening years after a dislocation has taken place. Bernard E. Brodhurst found the cotyloid cavity to retain its full depth three years after dislocation of the head of the femur. Fourier has placed a dissection upon record in which, after thirteen years of unrestored dislocation, the socket preserved its size, form, and depth (*St. George's Hosp. Rep.*, 1868, vol. iii. *Bigelow*, p. 108).

In cases like those just described (*i. e.*, in the class in which the cartilages were not bruised) a new socket is formed and a new capsule is created. The socket is formed by a thinning of the underlying bone, and probably by increased physiological activity at its margins. There is little known about such capsular attachments; but there is no reason why the new capsule should not communicate persistently with the old socket, as is the case with congenital dislocations.

Dislocations occurring before puberty must, if unrestored, lead to atrophy of all the constituents of the joints.

When dislocations are the result of direct violence (as when a person, half-stooping, receives a crushing blow from a caving embankment, or when one falls a distance, striking heavily upon the knee) the concussion to the articular cartilages is likely to be followed by inflammatory changes. If the head is not promptly restored, such inflammation would produce direct adhesion between the head and surrounding parts, and be followed—not by *a new socket*, but by *ankylosis*. If, however, the head, under these circumstances, be promptly reduced, the result will probably be *synovitis* with *ankylosis*. In one of my cases of unreduced dislocation inward into the thyroid depression, due to earth falling upon the man, the resulting inflammation and adhesions between the head and the subjacent parts were so intimate that a disturbance of the relations, in an effort to restore the part, gave rise to a distinct sense of crepitus, and at

the autopsy it was found that the head was bare of cartilage and of the outer shell of bone, which had remained adherent to the floor of the new bed.

If, in such a case, reduction is accomplished, ankylosis must ensue, and the only gain would be a better position of the limb.

Osteophytes. The growth of new bone, as a sequence of dislocations, is worthy of consideration. When the rent in the capsule is between its acetabular and femoral attachments the periosteum is not disturbed, and, unless a fracture be present, no bone repair will be needed. Two possibilities, however, present themselves. Should the capsule with periosteum be torn from the rim osteophytes might oppose an obstacle to reduction, if this be long delayed; or, if the head be promptly restored, osteophytes, springing up around the border of the socket, would greatly abridge, if not abolish, motion. Should the capsule be torn from the neck, the osteophytes would probably be less formidable, though new bone will grow, not only at the points of denuded bone, but also at the detached border of the capsule, which may be covered with periosteum.

Changes in the Socket and Head After Reduction.

These changes I shall not discuss. Those that have been noticed are: Synovitis due to traumatism, with all the symptoms of rapid inflammatory action; subacute symptoms, followed by disuse and atrophy, possibly due to turning in of the capsule or to a foreign body in the socket, such as muscle or blood. Fibrous or bony ankylosis is likely to follow under such circumstances.

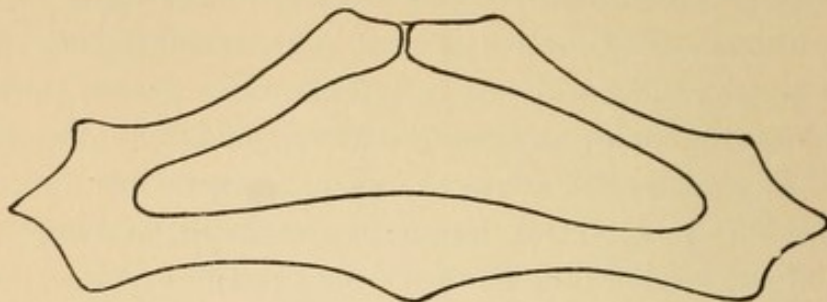
AIDS AND OBSTACLES TO REDUCTION.

Anæsthetics have swept away every device that surgical ingenuity has brought forward for the reduction of dislocations. Not a single one remains in shop or hospital, and only in works on general surgery can one still find the long catalogue of obsolete contrivances, not one of which was constructed upon the true pathology of dislocations.

The reduction of a dislocation is far from being a simple thing, and no one who truly estimates the condition of his patient will regard it as such.

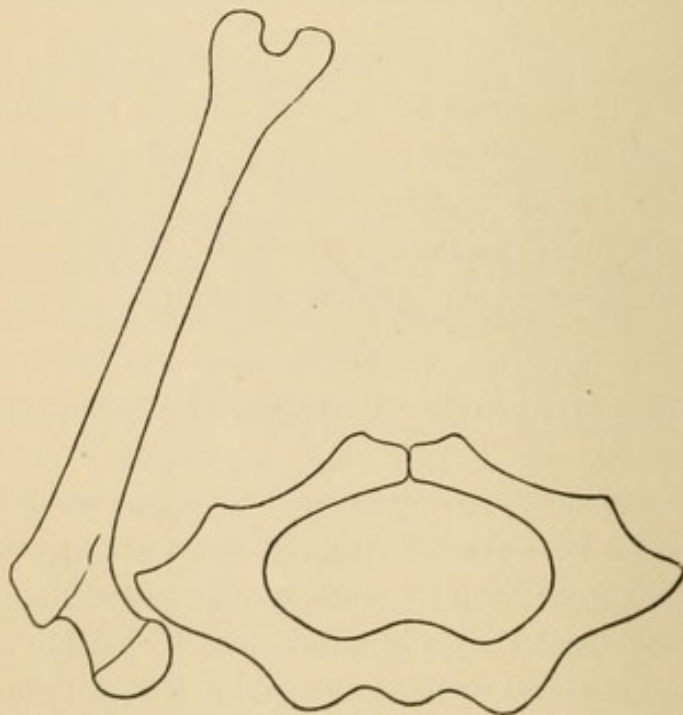
As a preliminary measure, therefore, and before the limb is touched, I earnestly recommend fixation. The fixation of the pelvis will be seen to be of the utmost importance, if we take into consid-

FIG. 57.



eration its shape. Had Nature given the pelvis a broad, flat dorsal surface, reduction would have been easier; but dislocations would be more frequent. In giving to man a narrow dorso-sacral support, Nature has thrown safeguards around the articulation, for the rocking and tilting pelvis readily accommodates itself to motion from the thighs, and thus circumvents many a vicious attack.

FIG. 58.



With the thigh bone dislocated, all efforts at its reduction are applied through the thigh itself, or through the bent leg, and always at the outer angle of the pelvis. Thus the femur, which we are

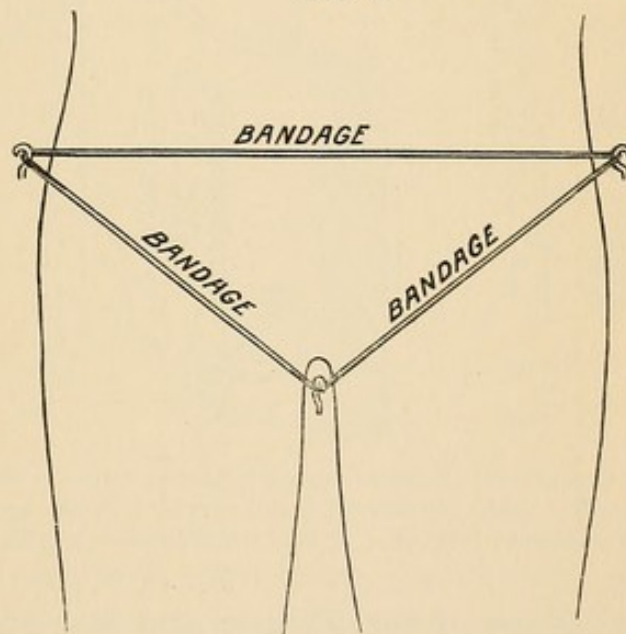
attempting to restore, becomes the direct agent or lever in moving the pelvis, and contributes to our defeat. The chief advantages of *rotation* and *circumduction* as methods of reduction are that they do not communicate to the pelvis their motion in the same degree that other methods do. But it is not difficult to show that reduction by circumduction is both unscientific and dangerous.

A method of fixation that I have often advantageously adopted, but whose only excellence is its simplicity, consists of three opened screw-eyes and a long and strong bandage. (In the shops the screw-eyes are screw-rings, but they can be readily opened.) I screw one at the junction of the thighs in the perineum, and one at the iliac flanges. (Fig. 60.) The prominences of the ilium and pubes are protected with folded towels.

FIG. 59.

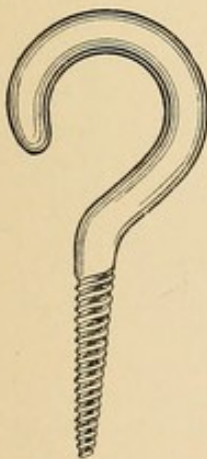

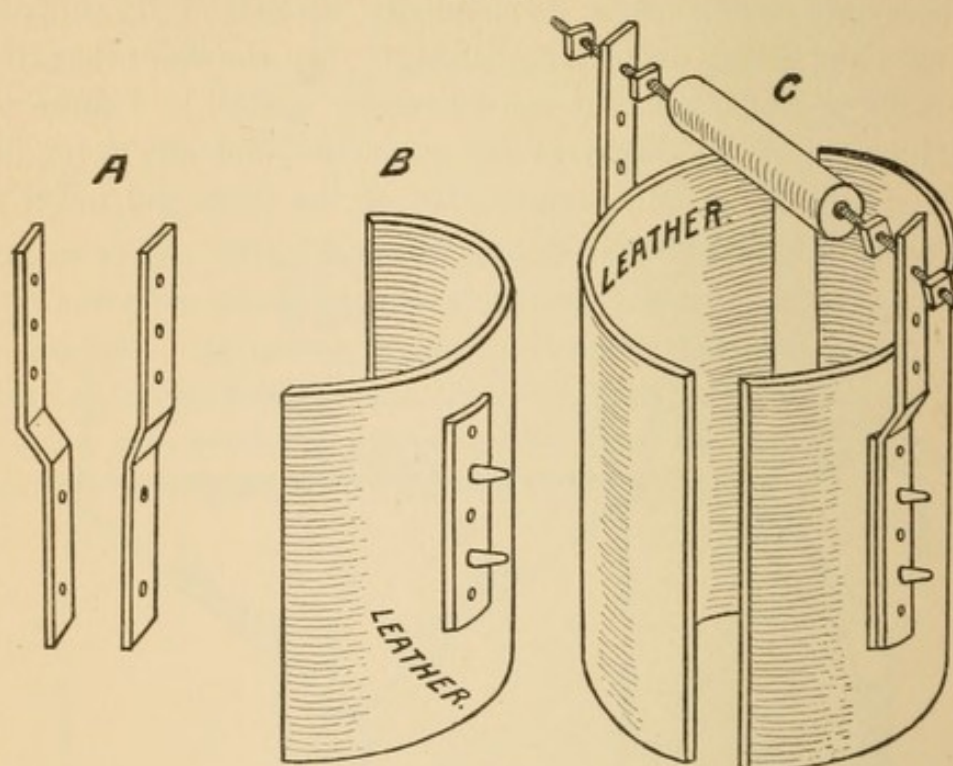
FIG. 60.



Whether the operator fixes the pelvis or not, he will find a large, heavy, muscular thigh a very inconvenient thing to handle. After he has flexed the thigh to a perpendicular he can readily grasp the ankle, but he cannot grasp the knee. Many do not attempt to grasp the knee, but, placing the hand upon it, steady it or circumduct it, while the other hand guides the ankle. Now, though this procedure is frequently successful, it is not without danger. Pressure upon the knee drives the head, in rotation and circumduction, more irresistibly against any obstacle within reach, and in my presence it once hooked up the sciatic nerve. It is much more scientific (for it is

reversing the steps of a dislocation) to lift the thigh in the direction of its long axis. This can be done by placing the bent elbow beneath the bent knee, though this is often done at great disadvantage and is tiresome. To enable me to use my strength advantageously, but not to increase it, I have often found the apparatus depicted in Fig. 61 of service.

FIG. 61.



The instrument is first thrown into a bucket of water to soften the sole-leather, and after the two halves have been secured to the part by bandage the traction bars *A* are adjusted and also secured by bandage. Finally the adjustable handle *C* is put in place.

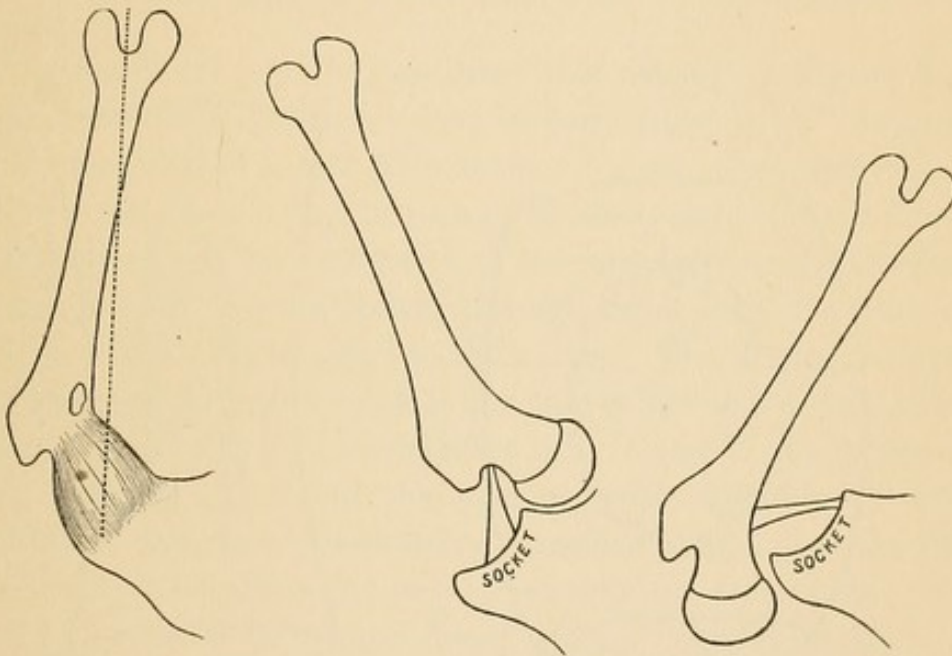
The Shape of the Femur and the Effect of Traction and Manipulation. In handling the femur we must bear in mind three things: 1, that it is not a straight bone; 2, that after dislocation it does not revolve about the head as a centre, but upon the axis of the shaft; 3, that after dislocation the head is outside the limits of the capsule, and that the remnant of untorn capsule extends between the upper part of the socket and the front part of the base of the neck of the femur. If the femur were a straight bone, traction in any direction would bring the head into line with the socket after dislocation. The different effects of traction upon the normal and dislocated head should be understood. If the head be in its socket and the femur be flexed to a right angle, traction

upward (Fig. 62) will not be resisted by the capsule, for this is now relaxed. The resistance comes from atmospheric pressure—not from a taut capsule. In such a case the line of traction does not follow the shaft, but runs from the knee through the socket (dotted line, Fig. 62). But the instant the head escapes from the socket suction has nothing more to do with it, and as the *head* is free from all attachments traction upward will be resisted by the remnant of untorn capsule and bring the *shaft* (not the head) in line with the socket. If the head be dislocated inward, upward traction will bring the great trochanter over the socket. (Fig. 63.) Under such cir-

FIG. 62.

FIG. 63.

FIG. 64.



cumstances it is folly to put forth great force in a direction perpendicular to the pelvis with a view to draw the head over the socket, for the greater the upward force the greater the difficulty in the way of the head approaching the socket.

The same principle is involved in dislocations outward. Traction upward (*i. e.*, vertically, with the body horizontal) brings the head against the outer rim of the socket. The head must now go outward (Fig. 64) before it can get into the socket. The instant it is forced outward the remnant of capsule tightens, and the head is blocked just at the moment when it should overstep the rim. Under these circumstances the thigh should be adducted, or the head rotated away from the projecting rim of the socket, when the obstacle to reduction may vanish.

The Crook in the Neck of the Femur becomes an Obstacle in Rotation. Rotation winds up and of course shortens the capsule. This obviously brings the base of the shaft (*i. e.*, the great trochanter, not the head) nearer to the socket, and when the operator hopes to turn the head into the socket the head or neck strikes the border of the now tense and shortened capsule and is thus prevented from entering the socket. Attention is directed to these obstacles to reduction, because, as such, they are created by the ill-directed efforts of the manipulator, and will all vanish under a proper change in procedure.

The Rent in the Capsule. I have elsewhere discussed the improbability of a slit in the capsule ever occurring and thus becoming

FIG. 65.

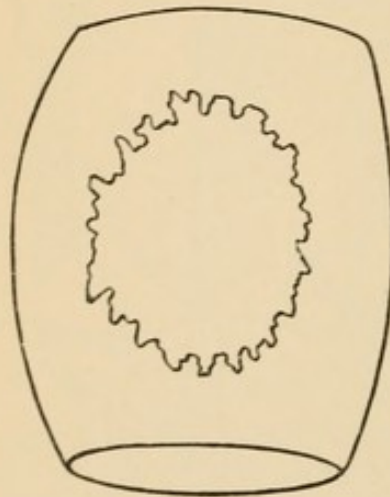
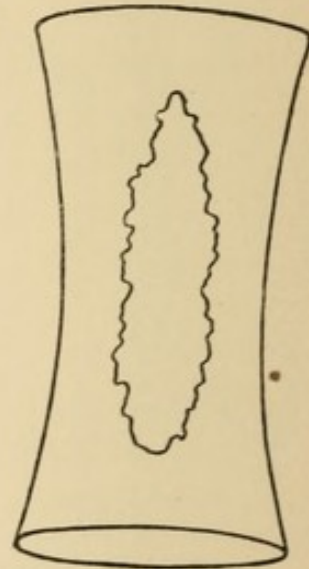


FIG. 66.



an obstacle to reduction ; but while the head cannot escape through a slit (since the smallest diameter of the orifice of exit must be, at the instant of escape, equal to the diameter of the head), yet even under these circumstances I have seen the neck of the femur so caught by the borders of the rent as that this constituted a decided obstacle to reduction. As soon as the head escapes new relations between the orifice of exit and the head are created. For an instant, while the head is escaping, the sides of the rent (Fig. 65) may bulge ; but the moment the head escapes and traction takes place between the borders of the untorn portion the orifice of exit may be narrowed, as in Fig. 66. Obviously the head cannot be returned, except that it be presented under circumstances similar to those

present at the moment of exit, as in Fig 65. I have demonstrated this repeatedly in experimental work, restoring a dislocation with ease in one position and by one method, that became impossible under changed relations.

The Rotator Muscles as Obstructors. The obstruction may arise from either of two conditions: The short muscle may not be torn, and thus obstruct the way, or it may be torn and its detached portion be pushed into the socket in advance of the head. As a rule, if we may be guided by pathology and experimental work, one or more of the short muscles will be torn. When I have attempted to dislocate upward and outward, by flexion, adduction, and rotation inward, I have torn the obturator internus before rupturing the capsule.

The point of lesion in the three short rotators is worthy of note. I have never torn the tendon from its bony attachment or ruptured it, but the tendon may be torn from its insertion into the muscle (Case X., p. 68), or the muscle may be torn in its fleshy part or from its origin. Hence there will be two parts of the muscle to consider after the lesion—viz., the part attached through tendon to the base of the neck and the part attached to the pelvis. The first part—viz., the part attached through tendon to the base of the neck—will follow the femur, that is, will be dragged after it. In one of my experiments, after a reduction, I found the tendons (with considerable attached muscle) of the three short rotator muscles caught over the neck of the femur, precisely as the nerve is caught up sometimes. In this case I had made an everted dorsal from a regular dorsal dislocation; and, in restoring the head, the three torn muscles, dangling from the neck through their attached tendons, were caught up and, after reduction, lay across the neck beneath the untorn remnant of the capsule. Their presence could not have been predicated from any deformity or restriction of motion. The second part—viz., the part attached to the pelvis—will not follow the movements of the femur, but will be passive. It may, however, if it lie in front of the head, be pushed into the socket. From experimental work I am strongly of the opinion that no part of the pyriformis or obturator internus can be pushed into the socket, for the simple reason that the fragment will be too short to reach it. Not so with the muscle that lies internal to the socket—viz., the obturator externus. I have repeatedly found the body of this muscle, lying like a dead, inert

mass, at the door of the socket, unable to pull itself out of the way or to resist the pressure from the head, and hence forced into the socket. So much for dead muscle. Whether in the living the stimulus of pain, from the pressure of the head, would excite contraction and thus clear the way is a matter of pure speculation. Under the head of "Pathology" (Case VIII., p. 67), in the history of one of the cases, it is stated that the obturator internus was pushed into the socket. I take this to have been a clerical error. The evidence of muscular structure driven before the head into the socket is incomplete extension. This matter will be taken up again in the chapter on "Cleaning Out the Socket."

The Sciatic Nerve. This, as an obstruction, has not received the attention to which it is entitled. In the reports of cases I have seen allusion to some unknown obstacle, the description of which agrees fully with what I have witnessed in experimental work. In reducing a dorsal luxation by rotation outward, I have seen the head strike squarely against the sciatic nerve and flatten it out, being thus debarred from entrance to the socket. In other cases the head would catch upon the nerve which would first resist it, then, slipping suddenly off, permit it to enter the socket, giving the impression that a tendon or portion of the capsule had given way. This has happened so frequently that I feel persuaded that many surgeons have felt the arrest from and sudden disengagement through letting go of the nerve in the circumductive sweep of Reid and Bigelow.

STEPS OF DISLOCATIONS.

In the early part of this work I have endeavored to show that the mechanism of dislocations demanded a fulcrum as well as a lever, and have pointed out the positions and movements through which a fulcrum could be obtained. I wish now to analyze the steps of a dislocation.

This is an important subject, for no one can make a dislocated head retrace its steps unless he knows and fully understands the steps of the dislocation.

Dislocation inward presents by far the simplest mechanism. Its three steps or stages are :

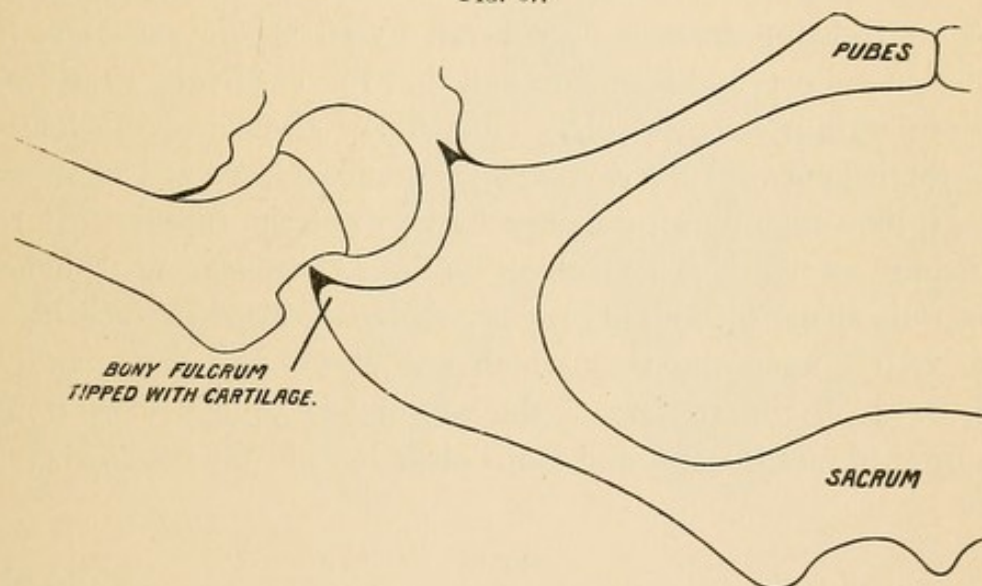
1. The rupture of the capsular ligament ;

2. The escape of the head beyond the limits of the socket ;

3. The shiftings that follow in the dislocated head.

1. *Rupture of the Capsule.* This is, of course, the initial lesion, without which a traumatic dislocation cannot occur ; but before the capsule yields in all dislocations dependent upon a bony fulcrum the head must rise out of the bed of the socket (Fig. 67) and attack the capsule, *i. e.*, the dislocating force must act from within outward ; for in no other way can the capsule be ruptured. The head rises as the distal end of the shaft descends, and rises, like the short end of any lever, upon its fulcrum. By its action the head tends to move away from the further rim of the socket, and to bring its greatest force upon the capsule at a point midway between the attachments. Thus the capsule is ruptured.

FIG. 67.



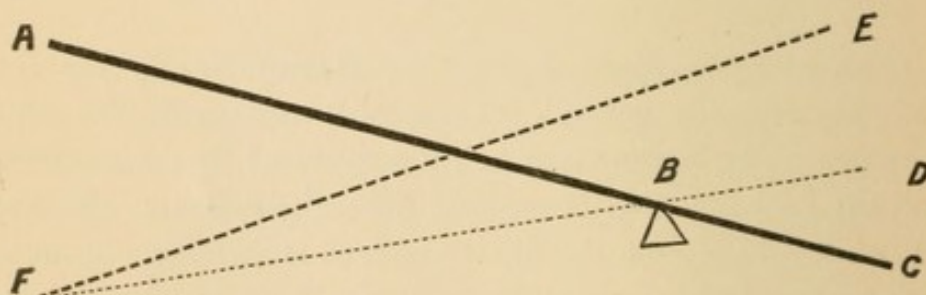
2. *Escape of the Head beyond the Boundaries of the Socket.* This would seem the natural sequence of rupture of the capsule ; but it is not. The capsule may be fully ruptured by hyper-abduction without the neck shifting its position upon the fulcrum. In experimental work I have seen the fibres yield, as it were, one by one, and after the head had emerged through the rent in the capsule, it remained directly over the socket, and all that was necessary to restore it was to raise the knee. In this class of cases, I repeat, the relations of the lever to the fulcrum are not disturbed, and often the slightest motion, such as lifting a person into a carriage or placing him in bed, is sufficient to effect a restoration (Case VI., Pathology, p. 66). In this class of cases the luxation is probably the result of

force exerted slowly. When, in experimental work, I have found such a condition present, I have been obliged to resort to a second and independent force, to get the head beyond the region of the socket, viz., to rotate outward, in order to lift the great trochanter over the brim of the socket, and then either bring the limb down in extension or push it inward, to get the head beyond the socket and into the thyroid depression.

But the fibres of the capsule do not always tear gradually, *i. e.*, one by one. They may all resist until the instant of maximum violence, and all snap at once, freeing the head suddenly; and in an instant later it is found beyond the boundaries of the socket.

Now, let us analyze the process. The long, strong lever carried outward, constitutes the primary force; the bony rim is the fulcrum, and the strong capsule offers the resistance. Note especially that the bony resisting fulcrum is covered by an elastic cartilage, viz., the peripheral cotyloid ligament, and that this cartilaginous covering of the fulcrum is compressible. (Fig. 67.) Hence, as the lever is being carried outward the cartilage is becoming more and more compressed, thus creating a secondary force, while the capsule that cannot readily stretch is fast reaching its limit of resistance. Suddenly the capsule snaps with a loud report, the compressed *peripheral* cartilage recoils upon the neck which was pressing it down, and the head, freed by the rupture of the capsule, is propelled as from a gun, upward and inward, and lands clear beyond the confines of the socket.

FIG. 68.

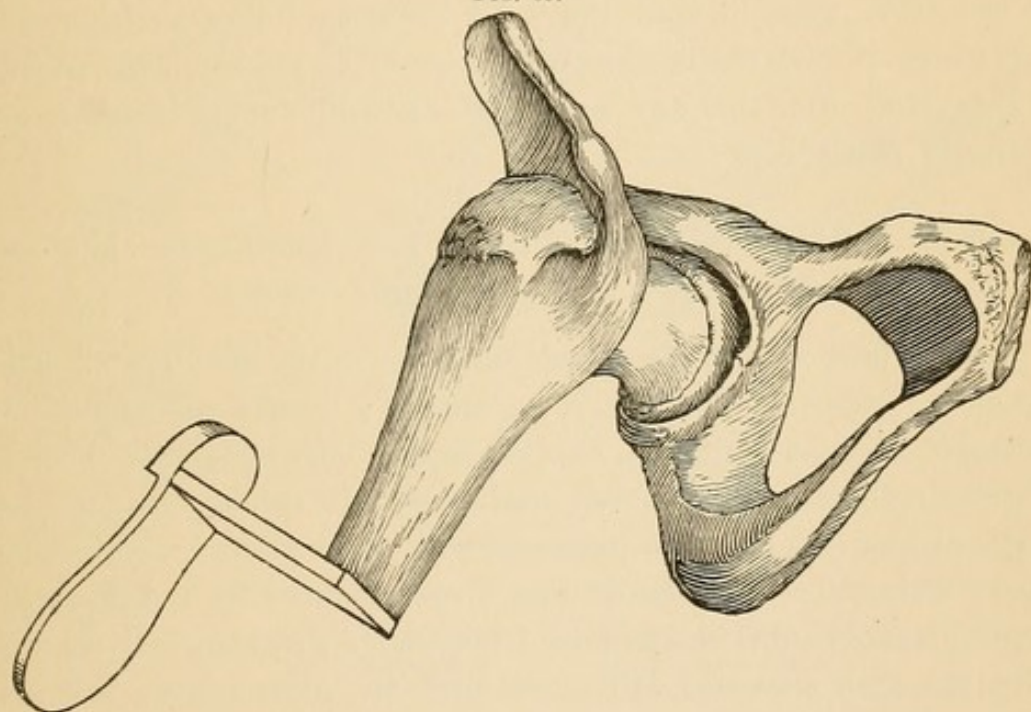


The reader can satisfy himself on this point by means of a very simple experiment. Let him take a lever (*AC*, Fig. 68), tie the point *C* down with a string and place a hard fulcrum at *B*. If power is exerted at *A*, it will break the string without disturbing the relations of the lever to the fulcrum *FBD*. But if an elastic fulcrum be

substituted, the instant the string breaks the weight-end of the lever will be thrown into the air as *FE*.

Rotation inward is an almost invariable accessory agent in producing dislocations, and the query arises : Is there a special agency in dislodging the head so constantly outward ? At first glance one can see nothing in rotation to disturb the position of the head ; for were the femur a straight bone and the capsule of equal strength and length, the whole might be twisted off, leaving the head still in the socket. Indeed, it seems a little strange, at the first glance, that the head should not be as frequently displaced inward as outward by the

FIG. 69.



act of inward rotation. The solution, however, lies in the fact that in rotation inward the ilio-femoral ligament, which is by far the strongest part of the capsule, lies upon the inner aspect of the joint. (Fig. 69.) As rotation increases the tension of the capsule increases, until finally the lower outer portion, pressed upon by the head, gives way, and the prevalent portion, feeling no longer any resistance, throws the head outward.

There is another factor concerned in the leaping of the head from beyond the boundaries of the socket, and that is found in its globular shape. As the head is spherical, the pressure from the borders of the rent increases until the maximum circumference is reached. The instant that is passed, the tissues contracting, often very powerfully,

around the diminishing globe shoot it forward with a sudden spring. Simple adduction and simple rotation may be quite enough to rupture the capsule, but when the head is shot inward into the thyroid depression or outward upon the dorsum (and that in the cadaver) an agency independent of leverage or live muscle must be invoked to explain it.

3. *Shifting of the head to a point more or less remote from the position it reached at the completion of the second stage.* Few, except in experimental work, see the head in the position to which it originally escaped in the second stage. The unexpended force, the weight of the limb, transportation, or prior unsuccessful attempts at reduction, tend to shift the head to a secondary position. In experimental work the hardest part is accomplished when the capsule is ruptured; after this any variety of dislocation may be easily and perfectly reproduced.

An Examination into the Theory that Traumatic Dislocations take Place through Thrust.

What I have said in the preceding pages about the steps of dislocations in experimental work is not theory; I have repeatedly witnessed it. In traumatic, *i. e.*, clinical, cases we are obliged to theorize. Formerly all surgeons believed, and many still believe, that in traumatic dislocations the head passes directly to its point of destination; that a dislocation upon the dorsum ilii is produced by a thrust when the thigh is extended and adducted, and that a thrust directly upward with the limb extended will accomplish an infra-spinous luxation, while a thrust inward as the thigh is abducted will produce a thyroid, perineal, or pubic luxation.

I am free to acknowledge that it is not a sufficient argument in refutation of such a theory to say that experimenters have never been able to accomplish a dislocation *by thrust*, or to say that Nature need not adopt a difficult mode when there is an easier one. I shall, however, ask the reader to examine with me the steps of a few accidental dislocations which present fairly definite data, and if he will do so without prejudice, I hope to convince him that dislocations usually believed to be due to thrust are no exception to the mechanism which I have just pointed out.

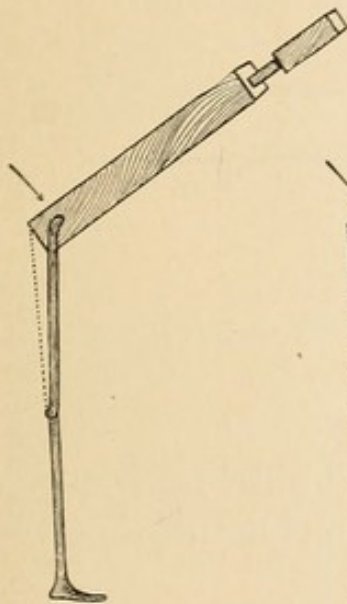
Problem 1. A man walking, steps into a long, narrow hole, falls forward, and dislocates his right femur upon the dorsum.

What is the mechanism of dislocation? Approximate data :

1. A long lever immovably fixed—*i. e.*, the extended limb in a hole.
2. Weight, the body of the man.
3. Direction of the force forward—*i. e.*, flexion of the body on the thigh.
4. Lever attached at the lower right-hand corner of the trunk.
5. Resistance to dislocation, the capsule.

The reader will please note that the body cannot fall forward indefinitely upon the fixed and extended limb. It will be checked by the hamstring muscles (Fig. 70, dotted line) before it reaches a

FIG. 70.



Flexion.

FIG. 71.

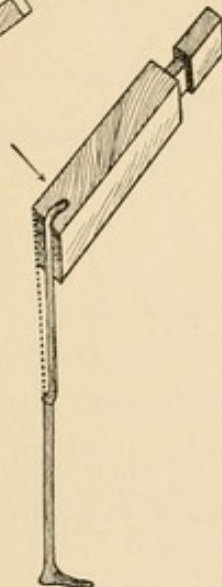
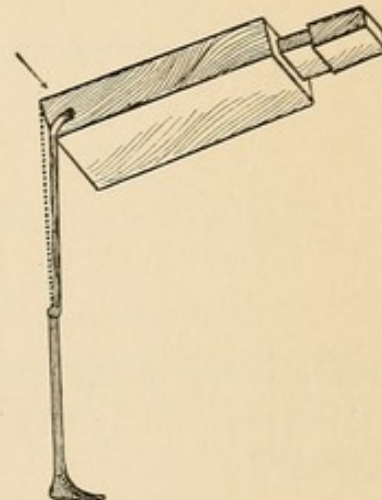
Flexion and
adduction.

FIG. 72.

Flexion, adduction, and
rotation inward.

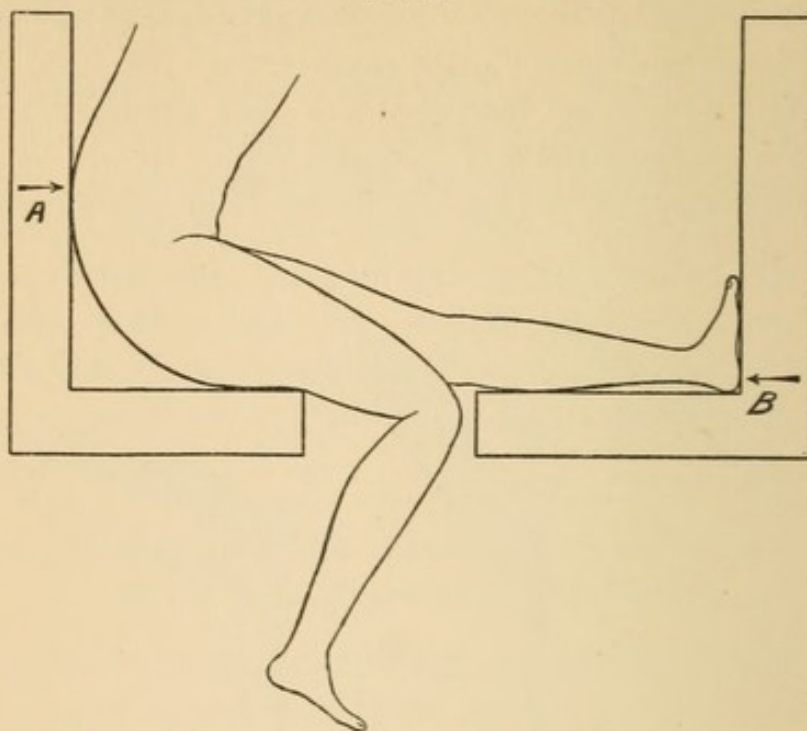
right angle. Note also that the head of the femur is attached at one corner of the body ; hence the instant the falling trunk is checked at one point (*i. e.*, in flexion) the unsupported part of the body (*i. e.*, the opposite corner) drops until checked ; and now, still under the force gravity, it has yet only one direction open to it, viz., rotation inward—three motions, all possible to a ball-and-socket joint. All these are the direct result of falling forward upon one fixed and immovable thigh. The three motions that produced the luxation are identical with forces that will accomplish the same end upon a cadaver in the dissecting-room.¹

¹ The order in which I have stated these steps is purely arbitrary. It would be equally true if I had stated them in the order of adduction, rotation, and flexion. It is not the order, but the blending of these forces that acts so effectively in dislodging the head of the femur.

Answer to Problem 1. The head was dislocated under three forces acting together, viz., flexion, adduction, and rotation inward.

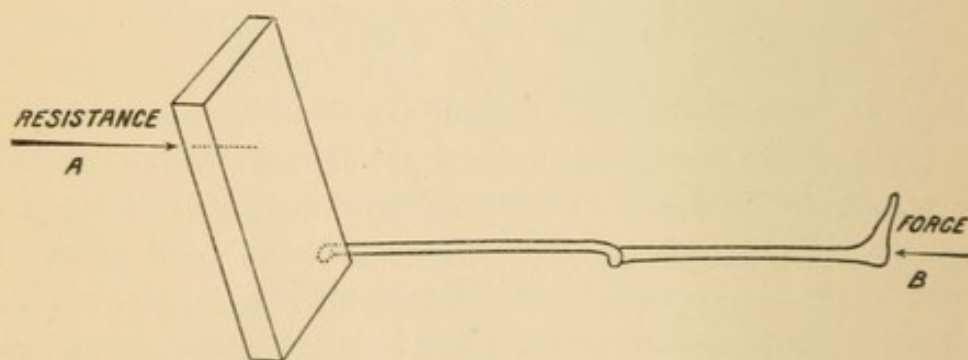
Problem 2. A tramp, sitting on the narrow foot-wide platform at the rear of a freight car, with his left leg extended and resting upon

FIG. 73.



a similar platform of the following car, has his left femur dislocated upon the dorsum ilii by a sudden slowing up of the train and coming together of the cars.

FIG. 74.



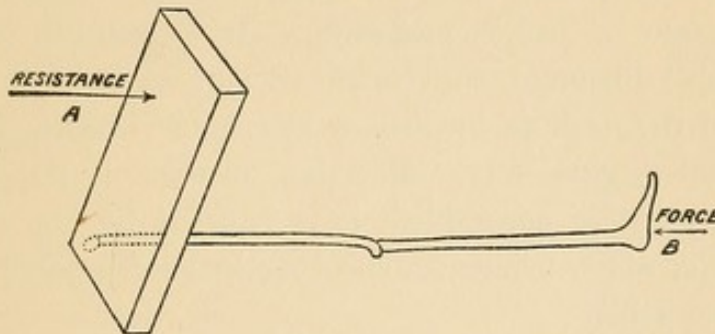
Query: What was the mechanism of dislocation? Approximate data:

1. The left limb was fully extended. (Fig. 73.) Had it been flexed, or could it have been flexed by the impact, the knee would have sprung forward and no injury would have been sustained. The force was therefore transmitted directly from the foot to the pelvis.

2. The force does not strike the pelvis squarely, but explodes upon one corner of it. (Fig. 74.)

3. The resistance comes from the perpendicular back of the car against which the man was leaning. The man was not sitting erect. Had he been he could not have fully extended his limb. The resistance therefore comes from the dorso-lumbar vertebræ. The dislocating force is directed from below and to the left; the resistance is above and to the right. (Figs. 74 and 75.) The resultant of these

FIG. 75.



three co-operating forces must be the answer to the problem, viz., flexion, adduction, and rotation inward.

Problem 3. J. P., laborer, was engaged in shovelling out ballast from the hold of a ship, standing on the bottom with his feet between the ribs. While in the act of stooping a cave-in from above struck him upon the back and pelvis. Result: Dislocation of both femurs: one, dorsal (*i. e.*, outward), the other, thyroid (inward).

Query: What was the mechanism of this double dislocation?

Probable data. As the man was standing in a semi-stooping posture, with his feet between the parallel ribs in the bottom of the hold, one effect of the cave-in was to drive him upon his knees. He would thus have feet and legs fixed in a parallel position. A second effect would be to flex still further the body on the thighs. If the body had bent squarely upon the thighs, simple flexion would not have dislocated either. As both legs were now fastened parallel, whatever motion the thighs took, they also must move parallel. If the body swayed, one thigh would be adducted, the other abducted. If the body rotated, the rotation in one hip would be internal, and that in the other of necessity external. If the legs were fastened and the femurs compelled to move parallel, then flexion, adduction, and rotation inward in one limb would require flexion, abduction,

and rotation outward in the other. Thus is brought about a double dislocation, the one dorsal and the other thyroid, and by the application of force in a way directly opposed to the theory of thrust.

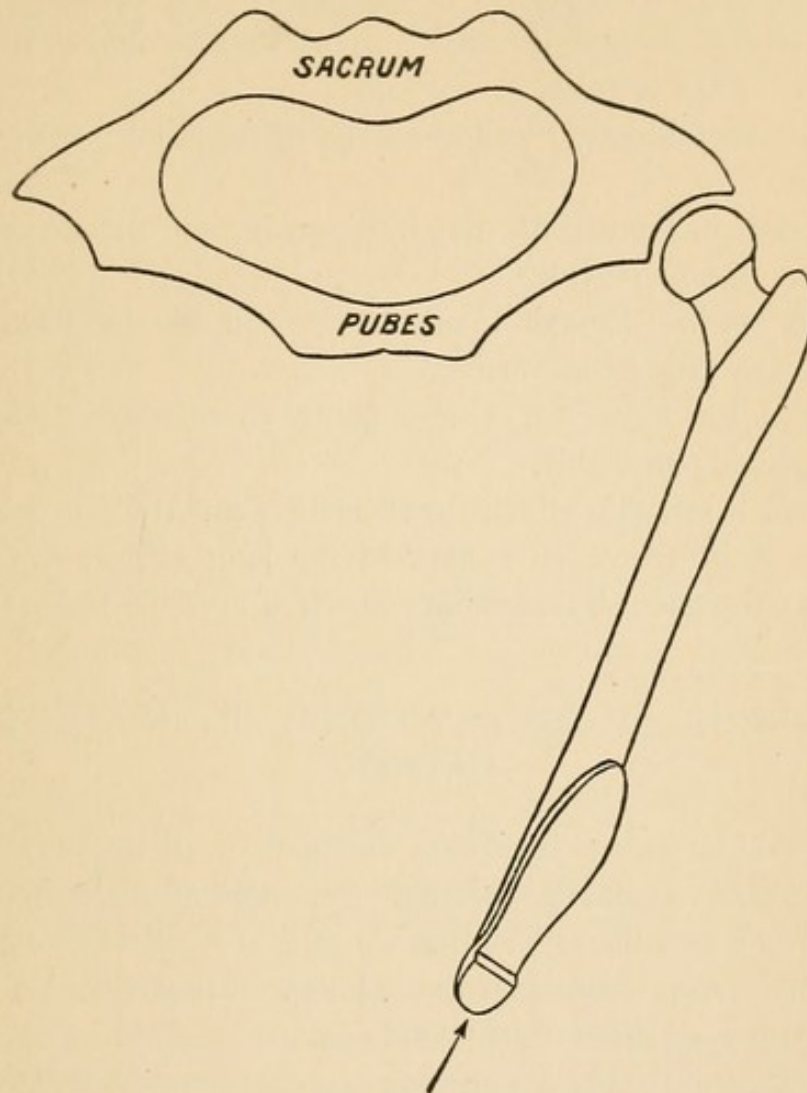
There is a further argument in support of the theory that rotation inward is a very constant, if not absolutely essential, element in the mechanism of dorsal dislocations, *viz.*, that rotation inward is an almost invariable sign and accompaniment of dorsal dislocations. If rotation inward is a factor in producing dislocations outward, the instant the head bursts through the capsule a still greater degree of rotation will take place, while the head falling outside the socket falls in a state of inward rotation. It falls until arrested by the ilio-femoral ligament, and must remain in a state of inward rotation until the neck is broken or the outer branch of the ilio-femoral ligament gives way. Rotation outward is impossible, because any attempt to accomplish it is resisted by the remnant of untorn capsule, which brings the head against some part of the outer surface of the pelvis.

Let us, however, suppose a dislocation to be possible by thrust through the extended femur. Let it be possible for the smooth head to spring from the smooth socket, through the capsule, on the outside of the socket. Why, I ask, if the thrust occurs *during normal eversion* of the foot (Fig. 76), does not the foot remain everted? and why, if the usual mode of dorsal dislocations be through thrust with the thigh adducted and everted, is not the form of dislocation known as dorsal with eversion the most common of all, instead of being very rare? How, I ask, will the holders of this opinion explain the inward rotation of 90° , when they evoke no other agency to produce a dislocation than a thrust in the long axis of the extended, adducted, and everted limb?

In defence of the theory that direct thrust in the long axis of the femur is competent to dislocate directly upon the dorsum ilii it has been urged that velocity can perform wonders; that while no one can push a tallow-candle through a pine board an inch thick, the candle can readily be *shot* through the board. Granting that circumstances alter cases, I urge against the theory of velocity that a candle with a bend in it of 130° could not be shot through a pine board, nor could a man projected with the velocity of a bullet survive the sudden arrest. So also, I would add, if a man sitting on the end of a car were to receive a thrust from another car going at

the highest rate of speed, the strongest probabilities lie in the direction of fracture, not dislocation.

FIG. 76.



Résumé of Mechanism and Effect of Traumatic Dislocations of the Femur.

1. All traumatic dislocations, unaccompanied with fracture, are the result of leverage.
2. When the femur is the lever, the outer (or the lower) part of the rim of the socket acts as a fulcrum.
3. Dislocations through leverage of the shaft of the femur occur only in hyper-abduction and hyper-extension.
4. In dislocations through rotation the bent leg becomes the long arm of the lever and the ilio-femoral ligament the fulcrum.

5. In the mechanism of dorsal (*i.e.*, outward) dislocations rotation inward is a necessary factor.

6. Dislocations inward may result from simple adduction. Adduction, rotation outward, with extension, will also produce it.

7. Dislocation through leverage pure and simple makes the smallest opening in the capsule.

8. Dislocation through rotation usually tears all but the ilio-femoral ligament.

9. The rent in the capsule may be extensive and the peri-capsular muscles may escape entirely.¹

10. Dislocations through thrust exerted in the long axis of the shaft are exceedingly improbable.

11. When the history of a case points to thrust the element of fracture is highly probable.

12. In all injuries in which thrust is an element (as in earth falling on the bent trunk, or a blow in the long axis of the shaft) a liability to subsequent inflammatory mischief must be borne in mind.

PHENOMENA OF DISLOCATIONS—SIGNS AND THEIR CAUSES.

If we exclude pain (a symptom common to all aggravated traumas), there remains not a single symptom of dislocation. The distinctive and peculiar deformities significant of dislocations can all be accurately reproduced upon the cadaver. They should, therefore, be called signs—certainly not symptoms.

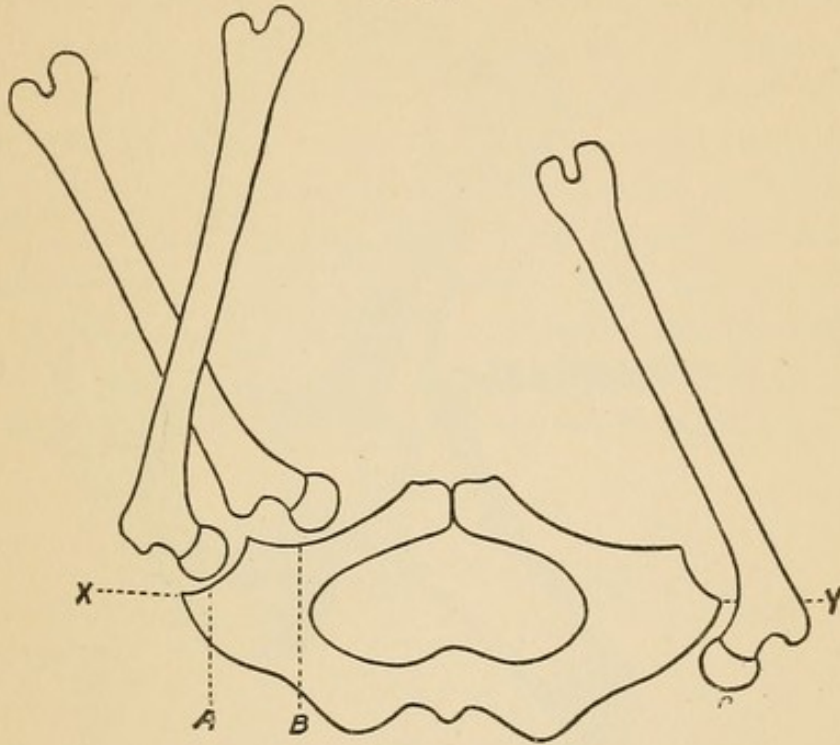
In the following study I shall take up the simplest and most frequent dislocations; explain the rationale of signs peculiar to them; show how by slight modifications other varieties may be made, and how great a change at the periphery can be made by a slight central change. I wish to repeat what I have already frequently brought forward, *viz.*, that, as we deal with lever and fulcrum in the production of dislocations, so, by the changed positions in these levers and fulcrums, we may interpret the positions of the two arms of the lever as well as the nature of the fulcrum. I shall arrange the signs of all dislocations under two general heads, *viz.*, those that occur upon the inner plane and those that take place upon the outer plane of the pelvis.

¹ See case of Robert S—, p. 69.

Signs Attending Dislocations Inward.

In dislocations inward no part of the upper end of the femur can lie upon as low a plane as is possible in dislocations outward. This is best illustrated when the femurs are compared in the flexed position.¹

FIG. 77.



XY indicates the level of the sockets (the limbs are placed vertical; A, normal; B, thyroid; C, dorsal). No dislocation inward can be below it; no dislocation outward above it.

The student while investigating the persistency and cause of signs must bear in mind the agencies under which dislocations take place; and in dislocations inward he must remember the following facts:

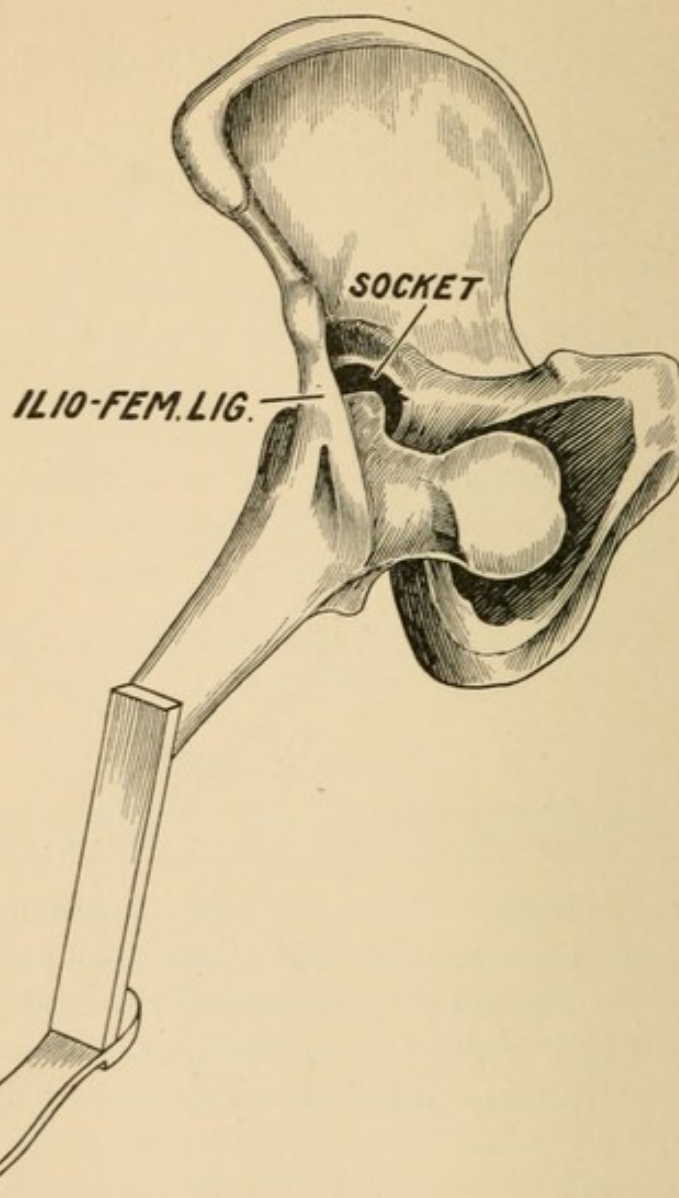
1. All dislocations *inward* occur during abduction. Hence it is not strange that, in the great majority of cases, abduction is a prominent feature.

2. The shortest, closest, and by far the most controlling attachment of the upper end of the shaft of the femur is the remnant of untorn capsule, which binds the *oblique* line of the femur to the lower spine of the ilium. This sole remnant of capsule has a one-sided action. It is made tense by rotation inward, and resists it. It holds the limb in a state of persistent outward rotation. This causes the

¹ The author first called the attention of the profession to this mode of measurement in establishing a diagnosis in an article published in the Medical Times, March 28, 1874. Dislocation of the Hip—Sciatic Variety.

tendency of the capsule to hold the femur in a perpetual state of abduction and rotation outward. These signs will not be invariably present. They may be greatly modified, but in most cases they will be typical of the injury.

FIG. 78.

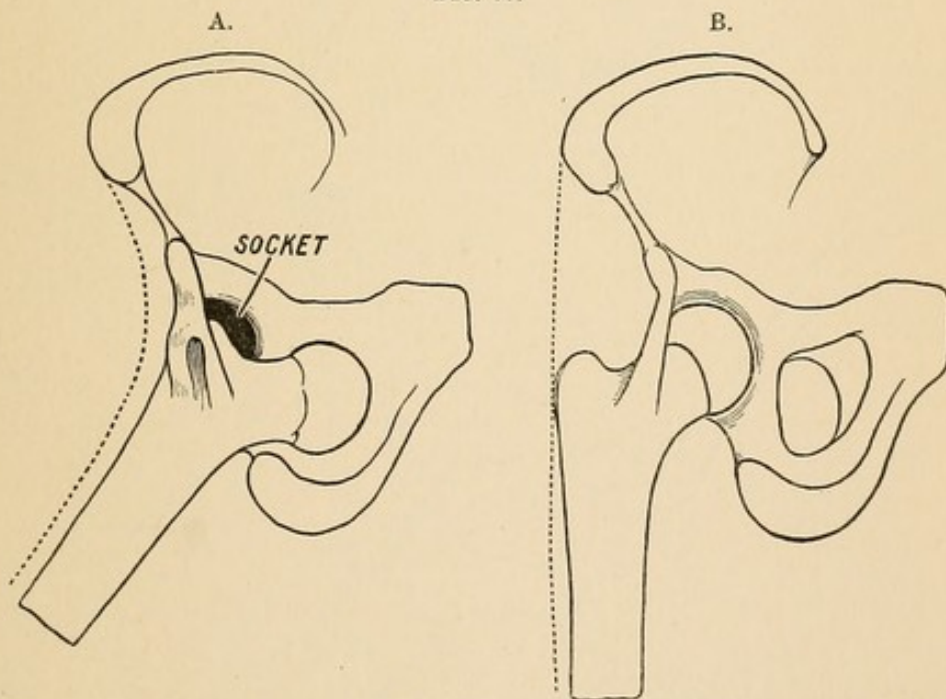


Dislocation is inward into the thigh depression, below and internal to the blood vessels. The vessels in this position would cross the neck. The constraint is due to the trochanter resting on the lower rim of the acetabulum, held in position by the remnant of untorn capsule. (See Fig. 15.)

In dislocations inward the trochanter, the head of the femur, and the remnant of capsule enter largely into the characteristic deformity. In a typical thyroid luxation (well represented in Fig. 78) the *marked constraint* under the twofold heads of flexion and abduction

are due, not to the head pressing into the thyroid depression, but to the great trochanter resting (*i. e.*, impinging) upon the lower rim of the socket. With the trochanter caught upon the lower rim of the socket, the remaining part of the capsule is not long enough to permit of full extension; hence the weight of the thigh and leg is suspended upon the remnant of capsule. (Fig. 78.) It must be observed that the fulcrum, *i. e.*, the ilio-femoral ligament, lies between the head and the knee, *i. e.*, that the femur lies obliquely beneath it. Under these circumstances, the weight of the knee would naturally swing it inward; but to do so the head must swing outward. The latter is impossible. Hence, in dislocations into the thyroid depression there is a resistance to adduction of the knee. It is to be noted further, that the position of the foot is midway between rotation outward and inward, *i. e.*, the outer and inner condyles are on the same level. In such a case the great trochanter will be found on a level with the head.

FIG. 79.



Dislocation into thyroid depression. Fascia lata relaxed. Great trochanter concealed.

Normal conditions. Trochanter major prominent.

We may note again the *concealment* of the great trochanter, and contrast it with the bold prominence in a normal condition. (Figs. 78 and 79.) We may note also the angle of depression between the crest of the ilium and the femur, due to displacement inward of the upper end of the femur, and to the relaxation of the fascia and muscles on the outer aspect of the hip.

Let us now attempt to flex the femur to a vertical position. The head lies on the thyroid depression. There will be no obstacle to flexion. But when the attempt is made to place the femur in a vertical position the pelvis will be found to move with it. (Fig. 81.) If we contrast Fig. 80 with Fig. 81, we shall see that the abduction has not been relieved; that it is the same in each position; that the pelvis has been canted, and nothing more. Note in Fig. 80, in which the abduction is apparent, that the sockets are on the same level. Note in Fig. 81, in which the abduction is apparently overcome, that the sockets are not on the same level. Two things should be borne in mind: First, adduction in dislocations inward is resisted. Second, if the two femurs are to be compared, see that the sockets are on the same level, otherwise the dislocated limb will appear much longer than its fellow.

FIG. 80.

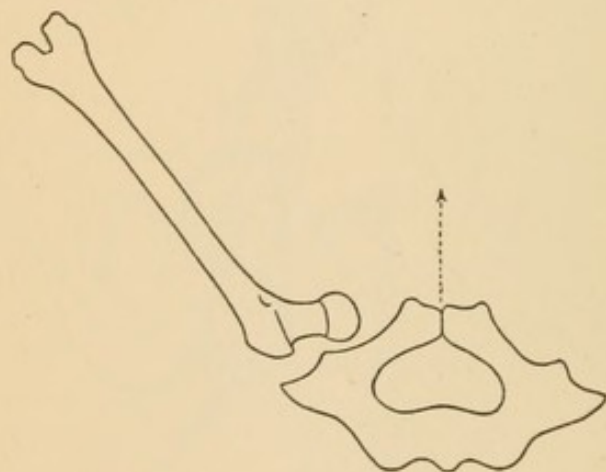
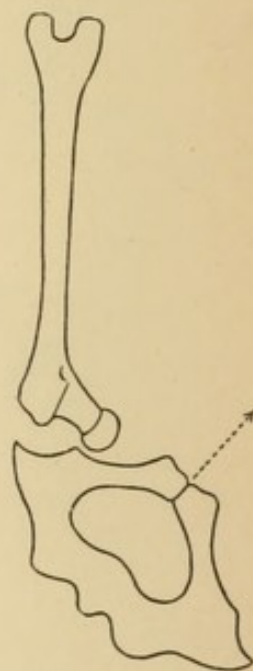


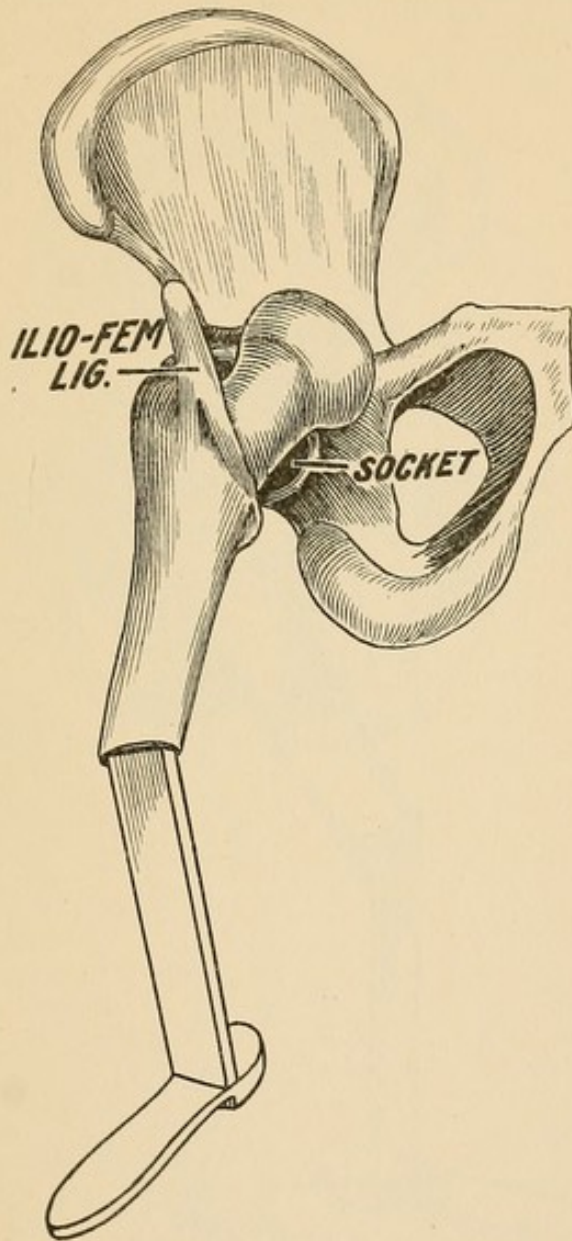
FIG. 81.



Should the trochanter slip off the lower rim and into the socket (Fig. 82) there will be quite a marked change in the position of thigh and leg. First, as to constraint. This will be decidedly less. The trochanter lies nearer the socket, and the remnant of capsule which supports the weight of the thigh and leg is not put upon the stretch until the thigh is more extended. The trochanter may lie well in the socket, or but partially, according as it is empty or occupied by capsule or muscle. The neck crosses, and may rest upon the inner rim of the

socket. The head may rise and be a little more prominent; or, if the abduction is considerable, it may still remain in the thyroid depression. In both of the conditions described the trochanter and

FIG. 82.

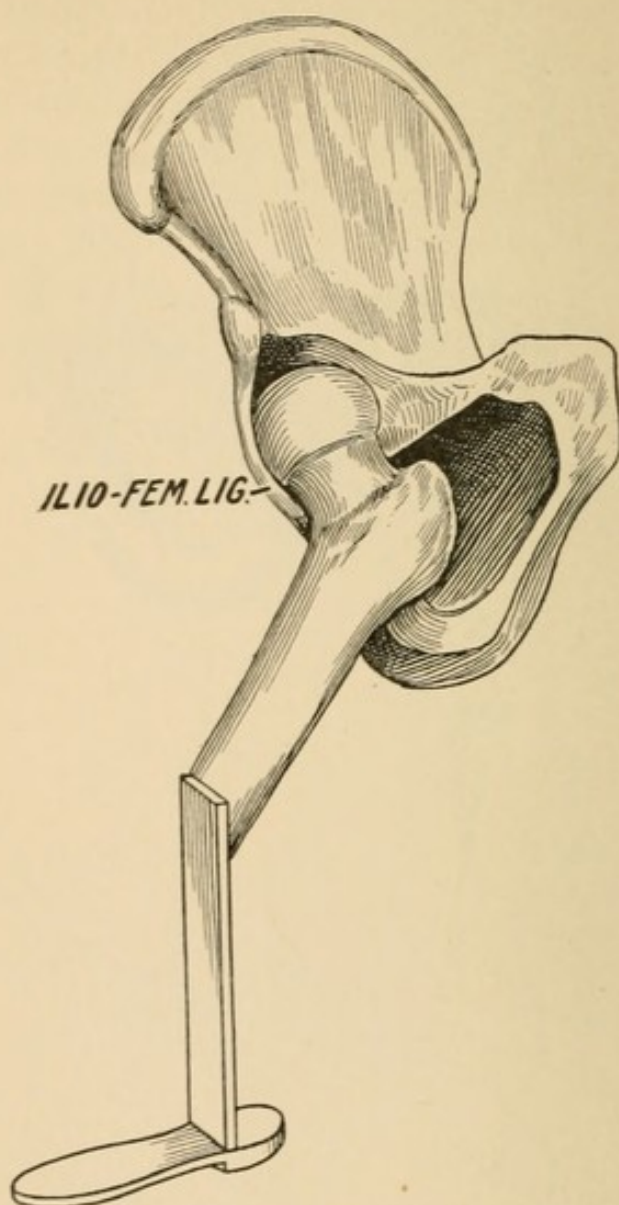


Contrast this with Fig. 78. The head by rotation outward has been shifted upward: it has escaped from beneath the femoral vessels which now lie inward or they still cross the head. (*Cf.* Fig. 15.) The trochanter now lies in the socket, and very much of the constraint has disappeared.

the capsule give character to the deformity. In this, as in the former case, the ilio-femoral ligament (fulcrum) lies across the two arms of the lever. If the long arm (knee) is carried inward, it will be resisted, because the short arm cannot move outward. With the exception of

restraint, most that has been said of the *first* condition is present in the second. The trochanter major is *lost* in both. Rotation may make the head prominent, but *not the trochanter*. If the limbs are compared vertically, all that has been said about adduction and the

FIG. 83.



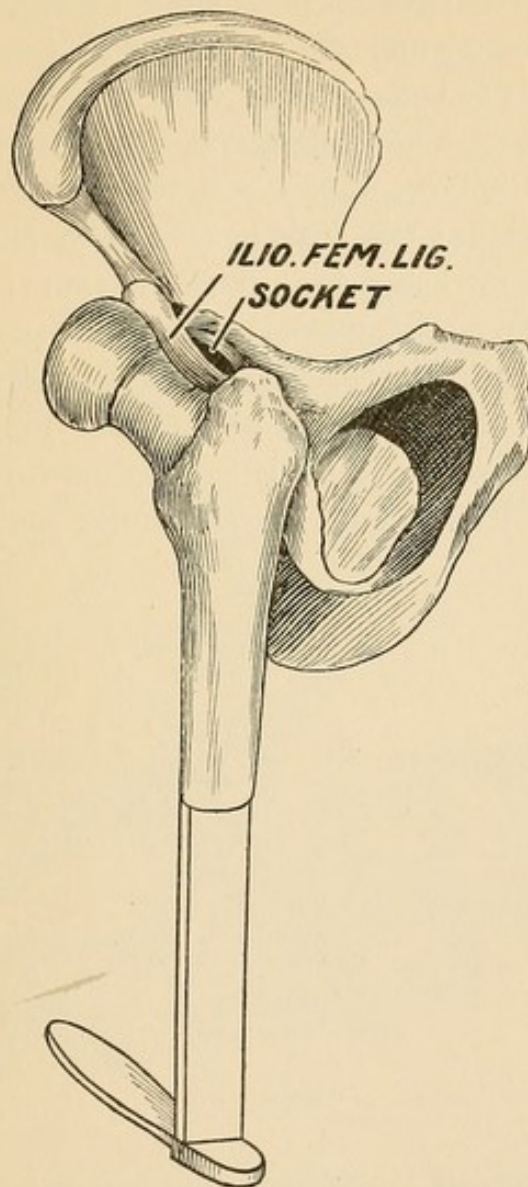
The head is now entirely outside of the femoral vessels; it has been rotated further upward and outward. Trochanter is now in the thyroid space and caught beneath the overhanging ledge of the ramus.

tilting of the pelvis must be borne in mind. In neither case is rotation exaggerated. In both rotation inward will be resisted, but rotation outward will be possible; and in this way *only* can the head be forced into prominence.

If, under the conditions just described, the ankle of the bent leg be

raised and the femur be rotated upon its axis *outward*, the effect will be to lift the *trochanter* out of the socket and to plant it in the thyroid depression. (Fig. 83.) Once in the thyroid depression, it may abut against the under surface of the horizontal ramus that forms the upper boundary of the depression. Under these circumstances there is a little

FIG. 84.

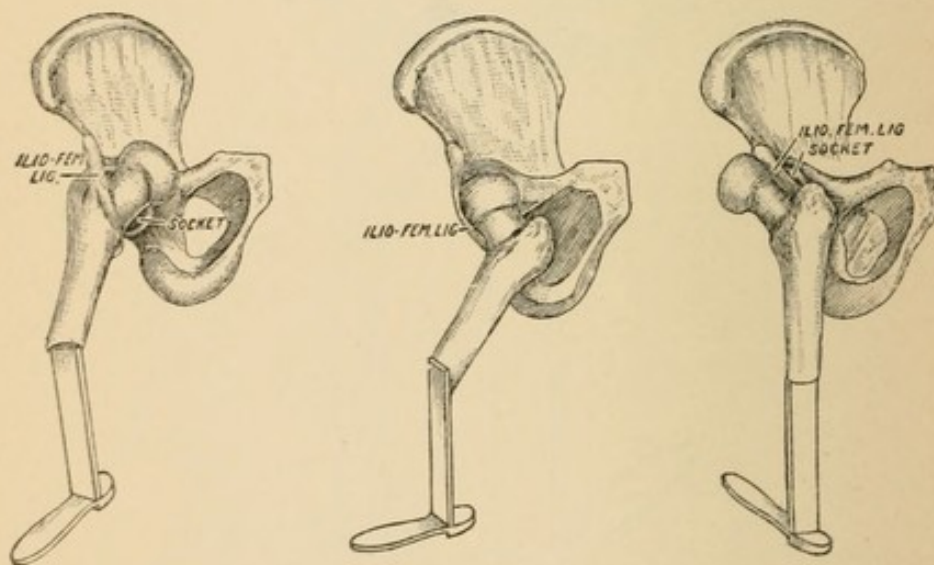


Originally a thyrod—now may be appropriately styled a reversed thyrod. All restraint has now disappeared. Note the extreme pointing backward of the foot.

fixation. The weight of the limb is supported by the remnant of capsule, but the fixed position in abduction and semiflexion is due to the trochanter being caught beneath the pubic ramus. Note that the inner malleolus and the inner condyle are looking upward. The head must therefore look upward. Note that the foot looks outward and

the heel inward. Look inward, then, for the great trochanter. The ilio-femoral ligament crossed the lever in front in Figs. 78 and 82; in Fig. 83 it lies to the outside. Let the reader bear in mind that the remnant of untorn capsule (the ilio-femoral ligament) is holding the base of the neck of the femur to the lower spine of the ilium; that it may rotate about it, but cannot get away from it. Note that the head is getting into greater prominence through rotation outward, but that the trochanter major is still obscured.

The position of the trochanter beneath the ledge of the horizontal ramus is precarious. The slightest rotation outward will lift the trochanter out of the hollow, when it will rise and rest upon the prominence on the inner side of the socket. (Fig. 84.) Now all constraint is at an end; the femur hangs from the lower spine; there is no flexion or abduction. The most important clue to the position of the head is rotation outward. *Query.* Where is the head? the trochanter? the Y-ligament? *Answer.* Look at the foot: the toes are looking backward, the internal malleolus is looking outward; then the head must be looking outward, and the trochanter must lie inward and



rest upon the inner plane. It would not rest upon the inner plane if it had been primarily a dorsal dislocation. It is therefore a dislocation with extreme rotation outward, from an original thyroid, as can be seen by a glance at the reduced figures of 82, 83, 84.

Study of the Signs Attending Dislocations Outward.

I began the explanation of the phenomena of dislocations *inward* by stating that in this variety of displacement the *trochanter major*

is brought into close contact with the pelvis; that it, and *not* the head, rests upon the bony platform; and that *the peculiar deformity is mainly due to the trochanteric end of the shaft and the untorn part of the capsule.*

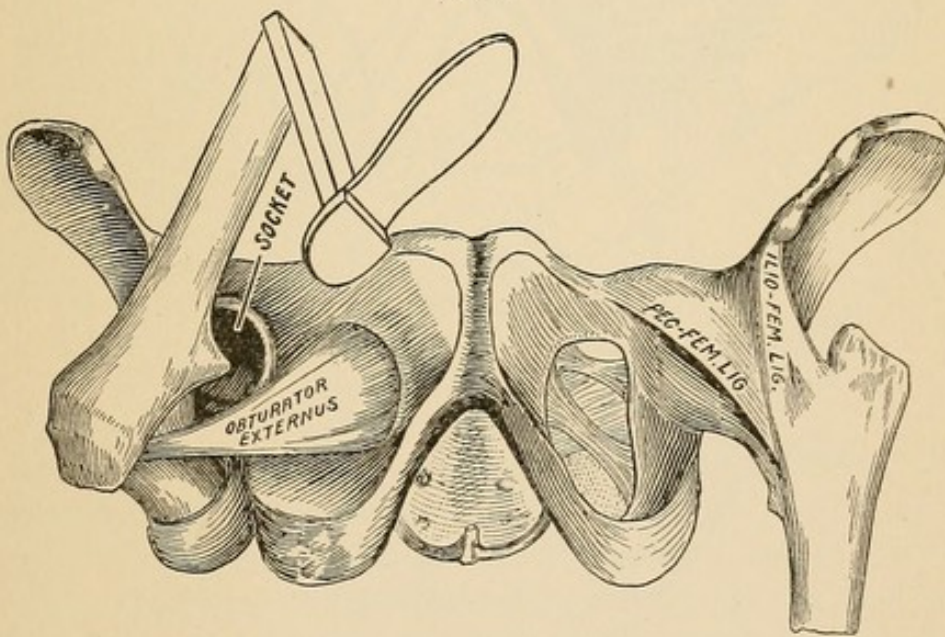
Not so in dislocations outward. In scarcely any position can the trochanter be made to touch or rest upon the pelvis. In this variety the head and neck abut against the outer side of the pelvis, and the constraint brought about by the tense remnant of the capsule (fulcrum) and the short end of the lever (head and neck) is of a very different character from that which takes place in dislocations inward.

Two facts should be recalled at the outset :

1. That rotation inward is a prime factor in producing all dislocations outward.

2. That the shortest, closest *bond* between the socket and the femur is the remnant of untorn capsule—the ilio-femoral ligament.

FIG. 85.



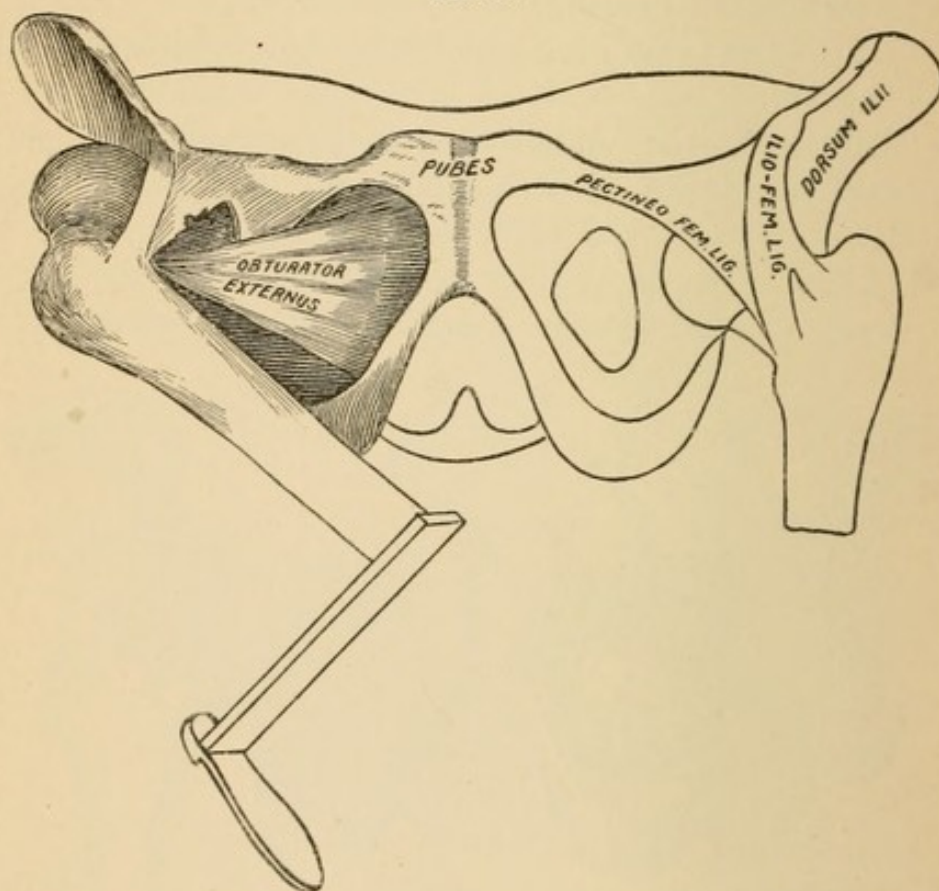
If a dislocation outward and downward between the obturator tendons could be arrested at the instant the head drops and the whole weight of the limb is arrested by the ilio-femoral ligament, the appearance would not be unlike that shown in Fig. 85. But the limb cannot remain in this position; it is not balanced; the weight of the leg drags the thigh downward.

As the knee descends it inclines inward toward the sound limb, because the head and neck, which constitute the short arm of the

lever, lie outward, and the short fulcrum (the tense and strong ilio-femoral ligament) compels the long arm of the lever to move inward as it descends.

The full understanding of this inward tendency of the long arm of the lever is of the utmost importance, and it is very easy of comprehension. All depends on the situation of the *fulcrum*. This lies between the two arms of the lever. If the long arm (knee) would move outward, the short arm (neck and head) must move inward. This is impossible. Under no circumstances can the

FIG. 86.



short arm move inward; the outer wall of the pelvis prevents this. So long as the fulcrum (the halter—the remnant of untorn capsule) is short the knee cannot be moved out. If the neck of the femur (*i. e.*, the short arm of the lever) be broken or the fulcrum (halter) be lengthened (*i. e.*, if the ilio-femoral ligament be torn), then the knee may be moved outward; but under no circumstances can the short arm of the lever move inward.

This accounts for the turning in of the knee. But how shall we account for the *rotation inward* of the axis of the femur?

The immediate or temporary rotation may be explained from the circumstance that, in all outward dislocations, rotation inward is an efficient factor at the instant the capsule ruptures, and that a sudden increase of rotation inward takes place, when the resistance from the capsule ceases and the head drops outward.

The persistent inward rotation, however, rests on a very different basis. This is not due to any original force in dislocation, or to any muscular action after it. It can be readily demonstrated upon the cadaver, and it persists during anæsthesia. The mechanism of this is simple. In the accompanying diagrams I represent (Fig. 87) the

FIG. 87.

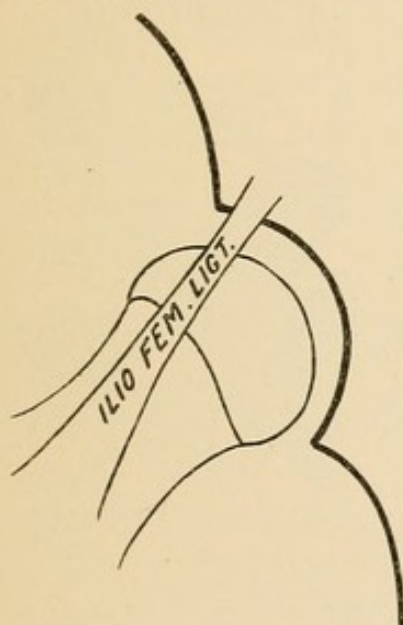
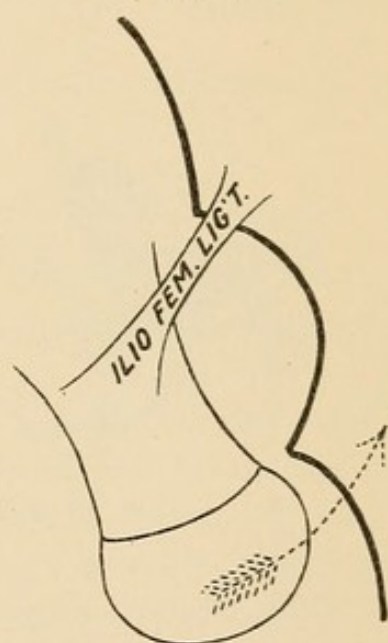


FIG. 88.



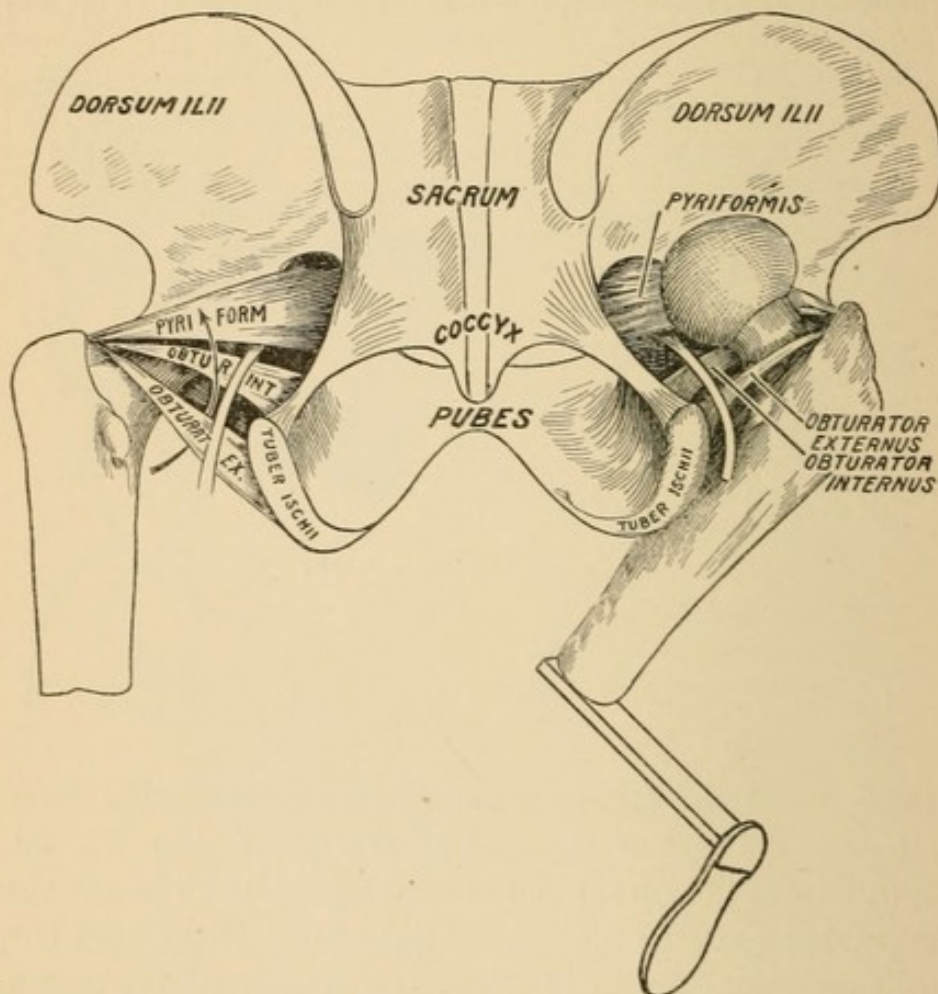
head in its socket and the ilio-femoral ligament extending from the lower spine to the base of the neck of the femur. In Fig. 88 the head is dislocated downward and the trochanteric end of the shaft is now suspended upon the ilio-femoral ligament. If the head is to be rotated, it must rotate upon the shaft as a centre, and the shaft must rotate upon the attached capsule. Any such rotation brings the head (see arrow) against the side of the outer wall of the pelvis, which arrests it. The persistency of this sign, viz., rotation inward, for years, or possibly for life, depends upon the persistency of the elements that originally produced it. Time may modify it. Thus the dislocated head may be flattened or the halter (untorn remnant of capsule) lengthened by long-continued use.

A lad dislocated his hip with all the signs of dislocation outward.

He grew up to be a man, and led an active life. The inversion gradually changed, until late in life he had eversion instead of inversion.

In Fig. 89 the upward progress of the hip is seen to be arrested by the obturator internus. This is what Bigelow terms "dorsal below the tendon." He lays great stress upon it, and makes a distinct variety of it. With Morris, I am of the opinion that the eminent author laid too much stress upon this point.

FIG. 89.



Right hip dislocated outward. Neck embraced between the two obturators. Compare Fig. 89 with Fig. 145. In the left hip, which is in place, the arrow indicates the path of the head taken by the dislocated right hip.

If the head be arrested by the tendon of this muscle, it will lie nearly opposite the lower half of the great sciatic foramen, and will manifest considerable constraint. In the majority of cases this muscle is torn in the act of dislocation, and yet the signs persist as if the tendon enjoyed its fullest integrity. By a return to Case X. (p. 68)

it will be seen that the limb was inverted and adducted, that it crossed the symphysis pubis, and was immovably fixed in this position; and yet, on dissection, the tendon of the obturator internus lay across the head, torn from the muscle of which it is a part.

I have described the two characteristic signs of outward dislocation, viz., *rotation inward* and *adduction*, and have shown that they are both dependent upon the length and position of the fulcrum (*i. e.*, the remnant of untorn capsule). It will not, therefore, surprise the student to learn that with a greater degree or total laceration of this bond of union (in other words, with the removal of the fulcrum) both these signs of dorsal dislocation would disappear.

We may thus have *dorsal* dislocation *without adduction*, and *dorsal dislocation* with eversion.

(“Everted dorsal” will be discussed under Dislocations Practically Considered.)

Aids to Diagnosis—General Consideration.

It is obviously impossible for any one to diagnosticate a dislocation of the femur who is not an expert in hip-joint disease and in fracture of the neck.

I have little to say further than to put the inexperienced upon their guard, lest they be too easily satisfied with first impressions.

If an experienced surgeon pronounces a fracture of the neck a sprain, fails to recognize a dislocation, or gives an anæsthetic “to set” a case of hip-joint disease, a young and inexperienced one has reason to fear that he may fall into like errors.

I would guard the reader against some too-prevalent errors:

First. A snap diagnosis. This the most experienced have too often occasion to regret. Give patient scrutiny to every detail of the history of the accident. Remember that occasionally persons rise up and walk after a dislocation, or after a fracture of the neck of the femur. Patients sometimes purposely mislead by exaggerating former injuries, or a drunken patient may not be believed, and an old disorder may be mistaken for a recent injury. Such a mishap is reported and had a fatal issue.

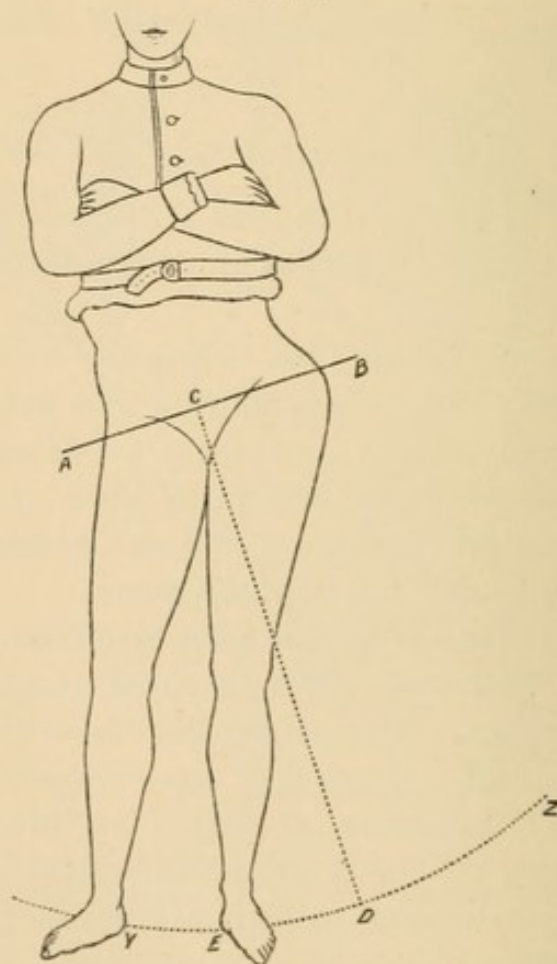
In the preliminary examination made with the patient conscious, it would be a wholesome safeguard against error to have him *out of bed, standing, and naked*.

Second. The use of an anæsthetic as an aid in diagnosis. Valuable

as this may be, do not resort to it until a careful study of the case has been made; and during the examination do not forget that serious, if not irremediable, harm may be done to a coxalgic joint or to an impacted fracture of the neck.

Third. Do not place too high a value upon the data or information that may be obtained from measurements. If you are dealing with a thyroid dislocation, remember that in one instance lengthening, in a second shortening, and in a third no difference, has been recorded. In one instance of dorsal dislocation, with apparently great discrepancy in the lengths of the two limbs, the apparently shorter and dislocated limb was, on measurement, found to be longer than its apparently longer fellow.

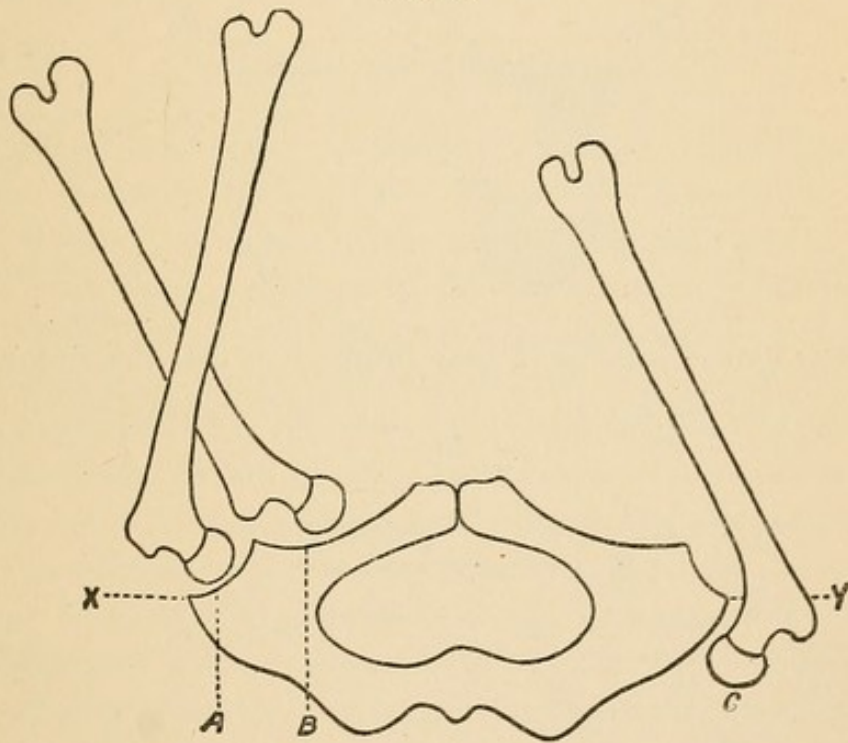
FIG. 90.



Measurements may be deceptive on account of asymmetry of the pelvis. If the head of the femur is ankylosed in an abducted position, and the two ankles are compared in the horizontal position, there will be marked shortening of the *sound* limb, or, what amounts to the same thing, marked lengthening of the affected one. It is

therefore of vital importance that the pelvis and trunk be placed in a normal position, and both limbs examined in corresponding relations to it. The accompanying outline-drawing is from a photograph of a young man supposed to have dislocation of the right femur. A consultation was called to reduce it. The diagnosis was made at a renowned medical school, at which the patient sought relief. Fortunately better counsel prevailed before an anæsthetic was administered. In the figure the patient is standing on his abducted ankylosed limb, assisted by his adducted limb. When the adducted limb was abducted to correspond with its fellow (*i. e.*, carried out to *Z*) the asymmetry disappeared.

FIG. 91.

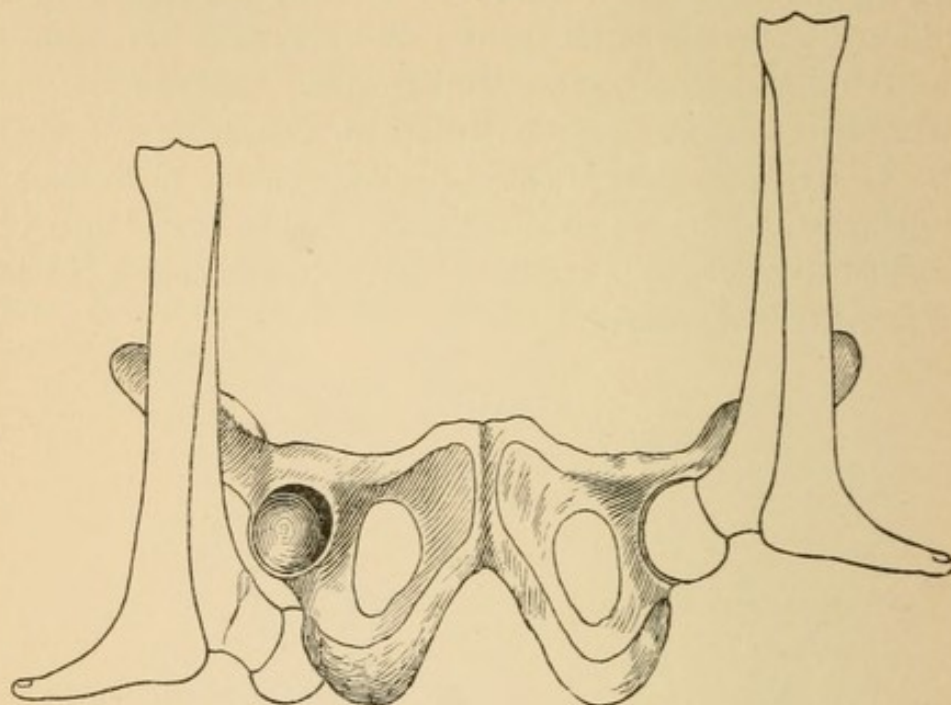


XY indicates the level of the sockets when the limbs are placed vertical. No dislocation inward can be below it; no dislocation outward above it.

I have already stated that if the pelvis is placed on its back the sockets are midway between the level of the pubes and the sacrum. I have also stated that the bony pelvis slopes upward toward the pubes and downward toward the sacrum. This condition can be turned to a valuable diagnostic service, if we examine the limbs flexed upon the pelvis as indicated in the diagram (Fig. 91). By reference to this it will be seen that if the head lies in the socket (*A*), or on the bony platform internal to it (*B*), that it (the head) will

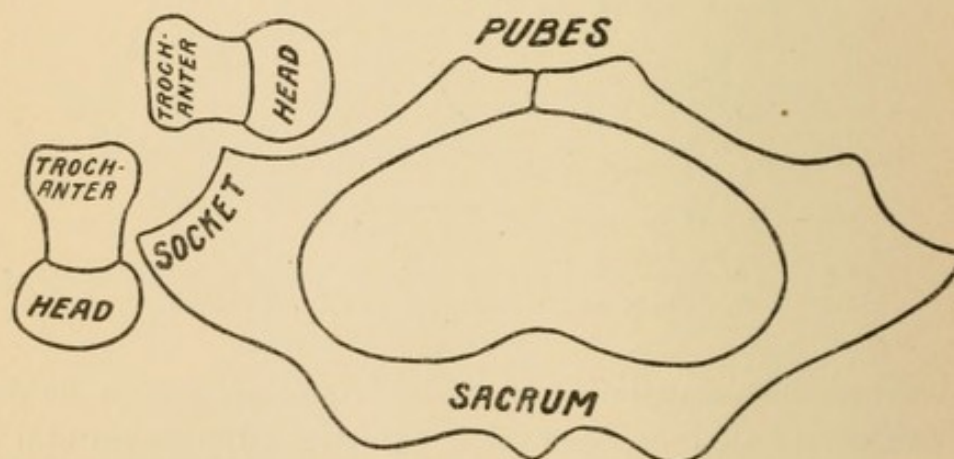
have a support, while if it is dislodged outward (C), it will have no bony support, and will hang from the socket by a remnant of capsule.

FIG. 92.



Another valuable point to bear in mind is, that the femur (thigh) is about equal in length to the tibia and tarsus (leg and heel).

FIG. 93.



Hence if the head is in the socket and the knee is vertical, the sole of the foot will swing clear of the floor—*i. e.*, it will be on a level with the socket. The same will also be true if the head be dislocated inward (Fig. 92); not so if the head is dislocated outward. Under such circumstances, with the knee vertical, the sole of the

foot will touch upon the floor, while the corresponding shortness will show itself by a comparison of the vertical knees.

A point which writers lay stress upon is that the great trochanter is much depressed in dislocations inward (*i. e.*, lies abnormally inward toward the socket). While this is true, it is also true that in most forms of dislocation the trochanter lies nearer the socket than the head does. It should be constantly borne in mind that the head is *free* after dislocation, but that the trochanter is bound by the remnant of untorn capsule to the anterior inferior spine of the ilium. Hence the mere fact of the trochanter lying near the socket is not in itself diagnostic. The position of the trochanter should, however, with the internal condyle, enable the examiner to locate the head.

Cleaning Out the Socket.

In experimental work muscular fibre becomes pulpified by manipulation and is readily pushed before the head into the socket. Muscular débris and muscular structure may be conveyed from the pubo-ischiatic plane, and parts of the capsule from either plane. I have not infrequently conveyed so much detached muscular material into the socket as to give the restored limb a constrained position, and, were it not that I could see and fully comprehend the difficulty, I might have been led to accept the theory of partial reduction due to some other cause. That which I have observed in my work has been found to be present in deaths from accidents, in which the dislocated head had been reduced, but in which the socket was found to be partly filled with pulp or fragments of muscle. (See p. 67.)

When I first noticed this effect of manipulation I was inclined to believe there was no remedy, and that, though the head was nominally restored, dislocation would readily recur in some cases, while in all the amount of foreign matter might ultimately lead to mischief. Further consideration suggested that as the difficulty was one of my own creation a partial or complete remedy might be devised. The reader will please note the following points :

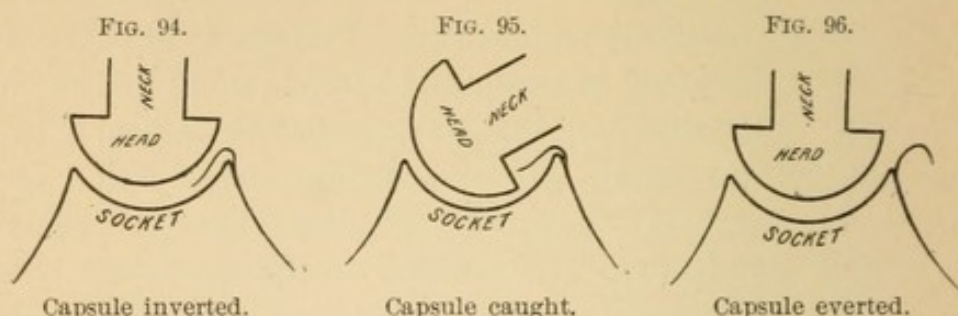
First. The shape of the head and neck.

Second. The law of attachment of the foreign substance.

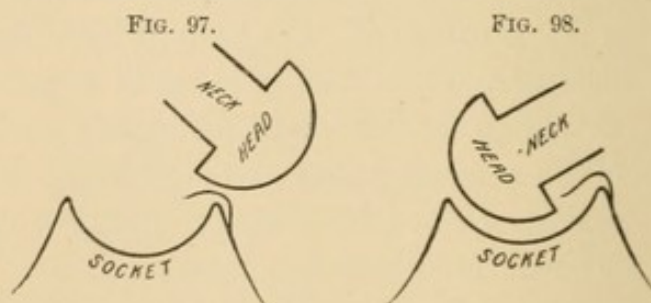
Third. The door of entrance of the foreign substance.

In the accompanying diagrams I represent the head joining the neck by an abrupt offset in order better to illustrate my meaning.

By such a shape the edge or corner can be insinuated behind anything that has been pushed before the head and which lies within and upon the floor of the socket. Now anything that has been pushed before the head (muscular fibre, parts of muscles, or capsule)



is attached, if at all, to the pelvis. Nothing attached to the femur is likely to be pushed before it; such material rather follows, or is dragged after it, in the efforts of manipulation. Hence, if it be any portion of the capsule that is turned in, it is the pelvic; it cannot be the femoral portion. As it is the pelvic, it can enter only a given distance; it cannot extend indefinitely. Finally, all the foreign substance that enters the socket must enter at its lowest segment. At this part the head escaped, and here usually free access to the socket was established. As the head drove the foreign substance into the socket at its lower section during manipulation, so during manipulation the foreign substance must be evicted by the head and expelled at the door of entrance. It is important to note that the side of the head that drives the capsule before it into the socket cannot be made available to remove it. This must be done by the opposite side, as shown in the diagram. Hence, if the capsule



has been pushed into the socket from the *dorsal* aspect, the first step is to flex and *abduct*; while, if the entrance has been made from the *thyroid* aspect, the femur must be flexed and adducted to accomplish the same end. After engaging the inverted capsule the

femur should be rotated inward to tighten the Y-ligament and drive the head down into the socket, while at the same time the knee is raised and the foreign matter is removed from the socket.

The success of the manoeuvre will be apparent by the free and unembarrassed motion of the femur. I have in experimental work repeatedly pushed so much muscular fibre or capsule¹ before the head as to prevent extension within twenty-five degrees of the normal, and to check adduction and extension. In some cases the infringement was less marked, but in every case the socket was cleaned out, and the full extent of motion was re-established by the method just described. From an experimental standpoint only I would urge upon every one the importance of testing the degree of extension and adduction after every reduction.

Bigelow, after a reduction, found that the femur did not resume normal extension, but remained semiflexed and abducted. He accordingly cut subcutaneously some tense fibres of the tensor vaginae femoris, which only partially relieved the deformity. The subsequent history of the case was to the effect that the patient never recovered the use of the joint. In this case the symptoms point to a foreign substance within the socket.

ROTATION AND CIRCUMDUCTION: THEIR DEPORTMENT BEFORE AND AFTER DISLOCATION.

In *rotation* the entire shaft of the femur turns on its long axis similarly to the motion of a gimlet.

In *circumduction* the knee moves in a circle, of which the head of the femur is the centre.

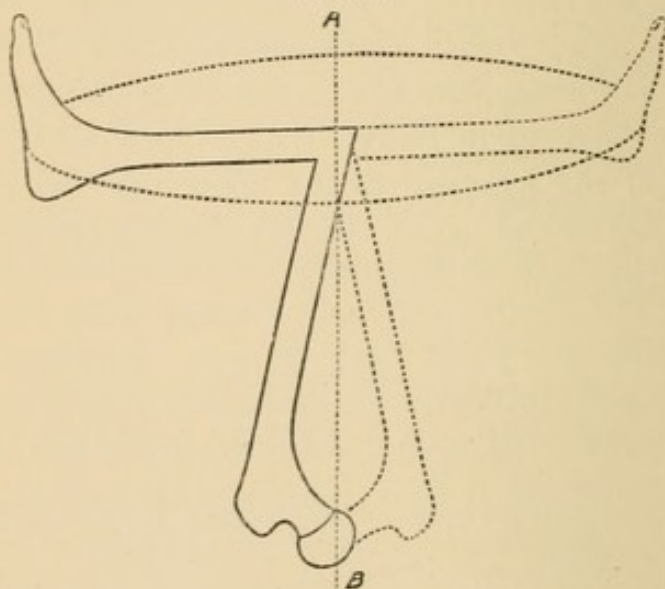
Observation. It is possible to rotate without circumduction; to circumduct without rotation; also to combine both movements in a single manipulation.

Rotation: The term is derived from *rota*, a wheel. The spokes of a wheel rotate about the axle, which is at right angles to them. In a like sense Bigelow speaks of the bent leg as the spoke of a wheel whose axle is the femur. Strictly speaking, the axis of motion

¹ When I have reduced the head into a hooded socket (Figs. 42 and 45, Z) I have—during efforts to get the rim of the head beyond the borders of the hood—experienced a sudden release which told me that the head was now at the bottom of the socket and beyond the hood. I could then turn out the capsule and exult in an empty socket and freest motion, and this, of course, entirely through manipulation.

does not lie in the shaft, because the femur is not a straight bone. The true axis of motion (Fig. 99, *A B*) is an imaginary line passing through the knee and the head of the femur. This is not a foolish refinement; it is a fact of practical value. By a glance at the figure it will be seen that the head being in the true axis, *A B*, does not perceptibly move, but that the great trochanter, lying outside the true axis, moves upon the arc of a circle whose radius equals in length the length of the neck of the femur. This suggests a useful study. Every student should familiarize himself with the amount of normal movement of the trochanter in rotation, so that he may be able to detect any defect in the shortened or impacted neck of the broken femur or the restricted motion of an inflamed joint.

FIG. 99.



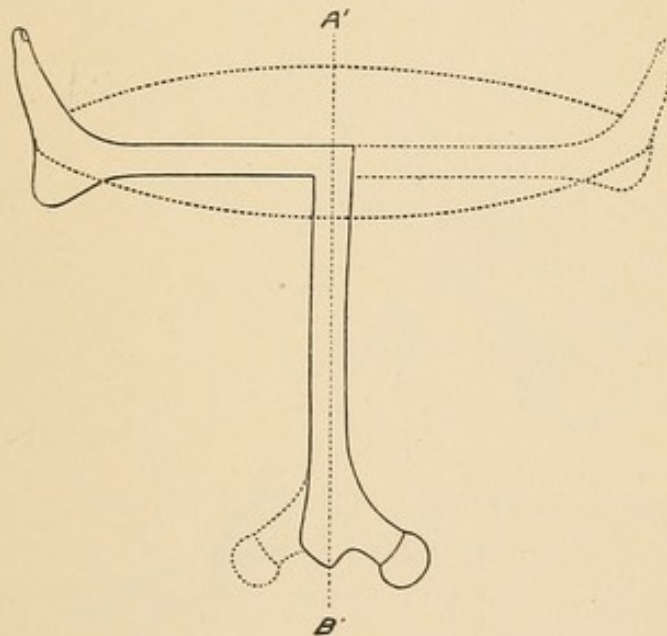
Rotation is of two kinds: internal and external. If the student stands erect, he can rotate the femur inward by turning the toes inward, and rotate outward by a contrary movement. Keeping these two motions distinctly in mind, let him flex the leg on the thigh to a right angle, and now, if he wishes to rotate *inward*, he must turn the foot and ankle as a crank *outward*; if he wishes to rotate outward he must carry the foot and ankle inward.

In the reduction of dislocations by manipulation the patient lies on his back, the thigh is placed perpendicular, and the leg at right angles to it. Now, remember that the terms "rotation inward" and "rotation outward" have no reference to the position of the head, but simply to the movement just described, and that, no matter

where the head is, rotation *inward* requires the ankle of the bent leg as a crank to be drawn *outward*, while *rotation outward* requires the ankle of the bent leg to be carried *inward*.

After dislocation the head is no longer the pivotal centre. Now the head, freed from all attachments, moves in the circumference of a circle, of which the neck is the radius. The constraint (or fulcrum) on which rotation depends is furnished by the untorn portion of the capsule. The trochanter, bound to the inferior spine over the socket by the ilio-femoral ligament, ceases to have its normal range of motion, and may, without much inaccuracy, be regarded as the pivot of motion. Now, though not strictly true, it may be said that the true axis of motion runs through the shaft of the femur.

FIG. 100.

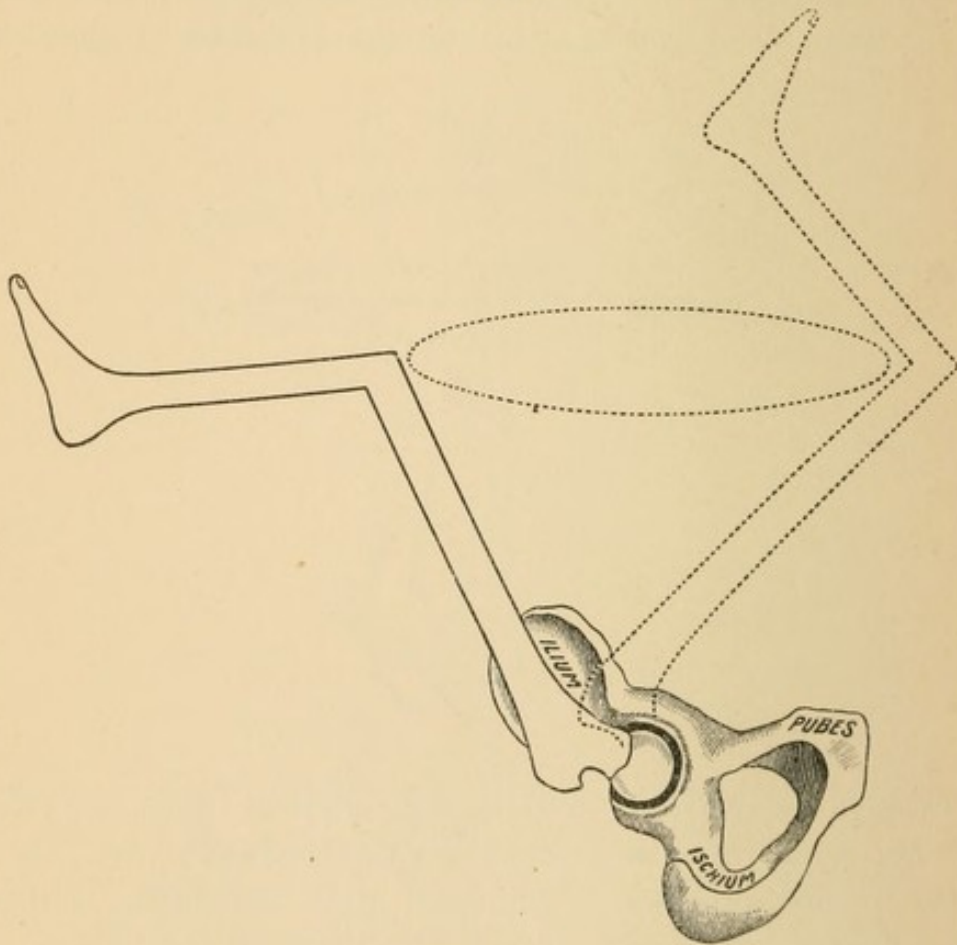


Thus things are reversed. *Before dislocation the trochanter rotated about the head; after dislocation the head rotates around the trochanter.* One point, which will bear many repetitions, is that, if after dislocation the head revolves about the trochanter, the very motion of rotation will bring the head or neck against any obstacle that is close to the socket.

Circumduction means to lead around. Circumduction can be practised on the flexed or extended limb. As employed in attempts at reduction, the patient lying on his back, the thigh is flexed to a perpendicular, while the leg is used at a right angle to it. (Fig. 101.) In the normal joint only the head lies in the axis of motion, while the knee can be made to sweep around in circles of gradually increasing diameter.

Circumduction may be either inward or outward, and, simple as it may seem, it is often difficult to comprehend what an author means when he says "circumduct inward" "or circumduct outward." If the knee is abducted at right angles to the pelvis, circumduction inward may mean upward and inward or downward and inward. If the knee lies over the pubes, circumduction outward may be upward and outward or downward and outward. As it is impossible to give concise directions that cannot be misunderstood, surgeons should always describe fully the manœuvre, preferring the charge of prolixity to that of ambiguity.

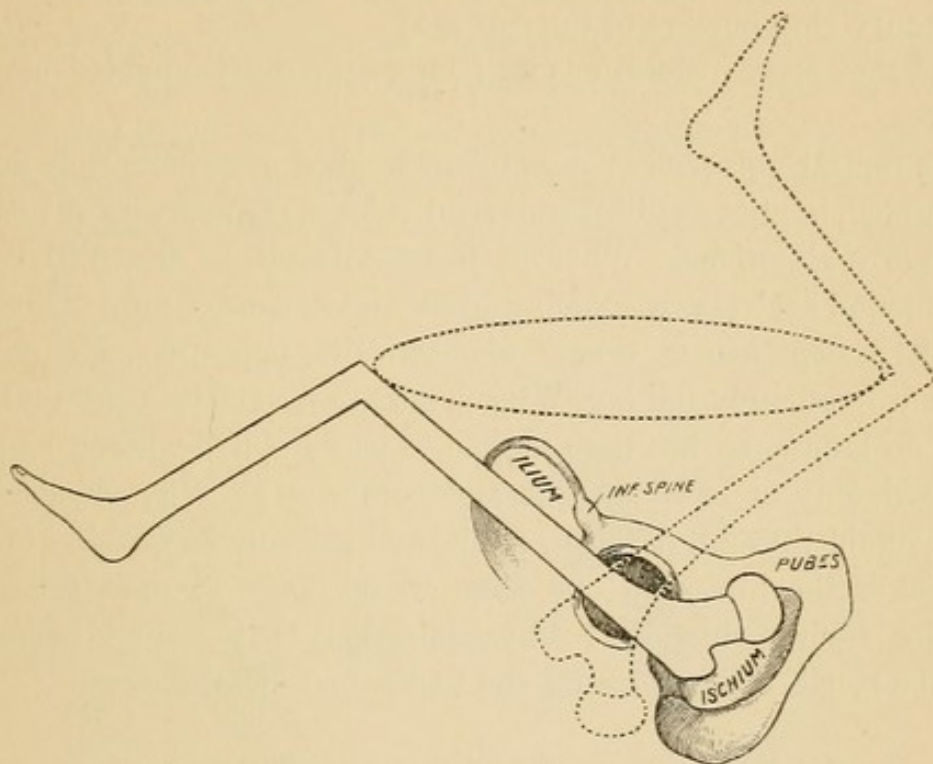
FIG. 101.



After dislocation a constraining force is present when rotation and circumduction are employed, and this force is the untorn remnant of capsule; but the effect is widely diverse in the one from the other. In rotation the ligament is wound up, and necessarily draws the head nearer the socket. Very unlike this in principle is circumduction. In the latter, if the knee is moved in a small circle, the head will move in a small circle; but if the knee

be made to take a large sweep, then the head will take a correspondingly large sweep, since it (the head) has a radius of the entire length of the ilio-femoral ligament *plus* the length of the neck of the femur. Such a sweep is most unnecessary and hazardous.

FIG. 102.



Unnecessary, because it drives the head away from, rather than approximates it to, the socket. Hazardous, for it endangers the sciatic nerve and the femoral vessels.

THE NOMENCLATURE OF DISLOCATIONS OF THE HIP.

There can be but one reason for assigning a name to a dislocation, and that is, that it furnishes the key to its restoration.

Surgeons formerly believed that all parts of the capsule were equally vulnerable, and that the head passed direct to its destination: hence as many varieties of dislocations as there are points to the compass.

Formerly it was universally believed that in the muscles lay the principal obstacle to replacement: hence depressants, depletives, and powerful mechanical appliances.

To-day the surgeon believes

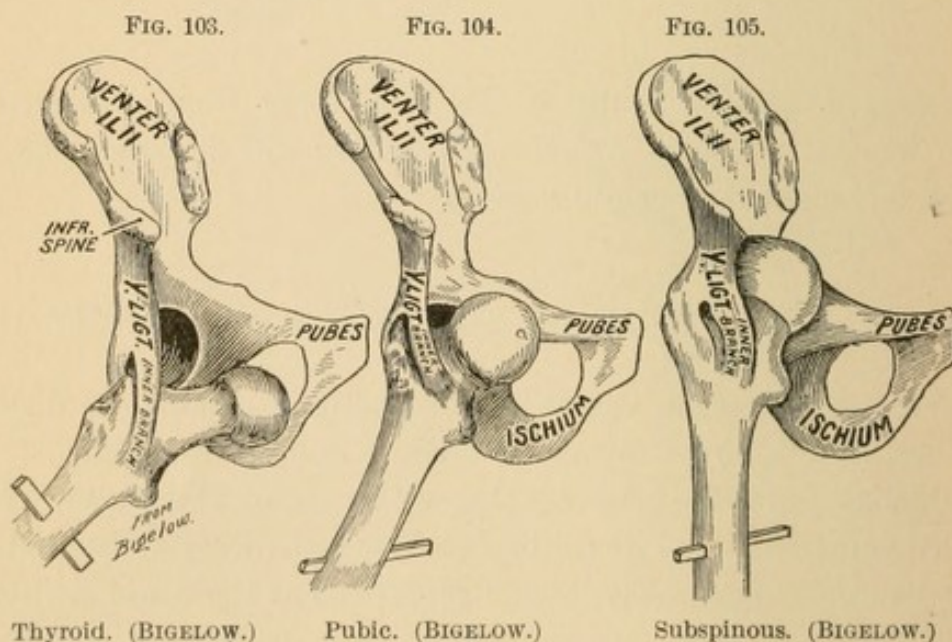
That the muscles are passive and play no active *rôle* as obstacles to reduction ;

That after dislocation a portion of the capsule still connects the femur with the socket ;

That all dislocations must be reduced with a distinct recognition of the surviving portion of the capsule ;

And that most dislocations can be restored by unaided manual effort.

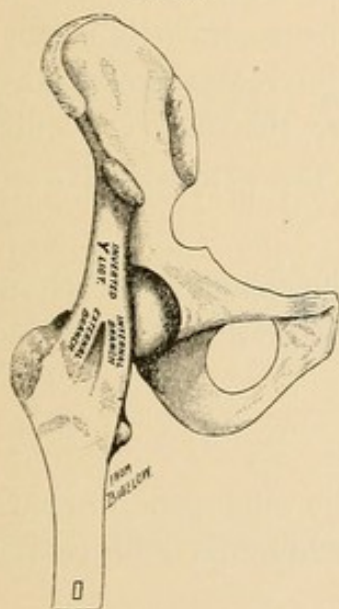
The radical universal change in the method of reduction, logically interpreted, implies a radical universal change of theory in the *mechanism of dislocations*. Whoever flexes a femur as the initial step in reduction declares by so doing his abandonment of former theories and his acceptance of others diametrically opposite. Hence the question irresistibly follows, Why persist in a nomenclature that was based on ignorance, has been proven to be false, and whose retention can lead only to bewilderment and confusion? Why should surgeons retain thyroid, perineal, pubic, and subspinous varieties of dislocation of the hip when one name would do for all, and the same rule for their reduction? Physicians may with equal propriety describe facial, colic, thoracic, and abdominal measles.



When Bigelow illustrated his memorable monograph upon *The Hip* he dissected a part, and, placing it in one position, his artist photographed a thyroid; then shifting it a little, the artist photo-

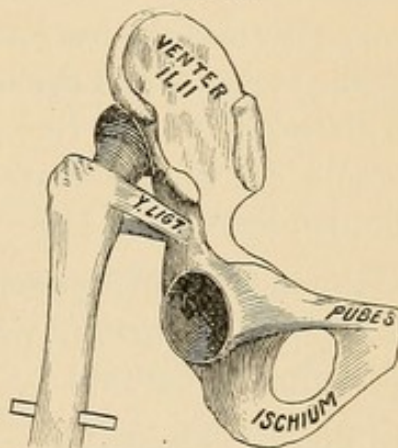
graphed a pubic; and then, by a further slight change, the preparation was posed for a subspinous. Why, while the author was arguing for the supremacy of his Y-ligament; why, when he was so eloquently demonstrating that the various signs of dislocation were all dependent upon the remnant of capsule that still bound the neck of the femur to the pelvis; why, I ask, did he not with one stroke of his trenchant pen blot out the whole list of subtle and meaningless refinements, and unburden the memory of the student as he had unburdened the closets of the surgeon and banished the cogwheels, screws, ropes, and pulleys from the domain of surgery? Why? There is but one answer, and that is, that it never occurred to him

FIG. 106.



Head in socket. (BIGELOW.)

FIG. 107.



Dorsum ilii. Mortise rotated inward 90°. (BIGELOW.)

that variety in dislocations was brought about in the precise manner in which he was illustrating it; that every variety of dislocation inward must have been primarily into the thyroid depression. In the formation of a pubic, how could the head reach this spot without first being for an instant at least a thyroid; and how, in the mechanism of reduction, can a pubic be restored save through the gateway of the thyroid depression? Again, I ask in all candor, after the specimen (Fig. 106) was placed in position to show normal relations, was it converted into the high dorsal, as represented in Fig. 107, by an upward thrust, even though every part of the capsule had been removed except the Y-ligament? or was the femur flexed and

the head dislodged at a low point, and a *low dorsal* converted into a *high one*? The latter unquestionably.

If it be urged that what I am arguing for is a dissecting-room theory, my answer is that it is the very dissecting-room theory that has revolutionized the whole subject of reduction of dislocations; but when I turn upon my objector and ask him what his theory of direct displacement is founded upon, he can only reply, theory; and when I ask what the logical result of such a theory has been, he can only reply by pointing to a most humiliating chapter in the history of modern surgery.

Were I to suggest a nomenclature for dislocations of the hip I would base my action upon the firm conviction that all conceivable dislocations are primarily either inward or outward, and that from these primary positions the head may be secondarily shifted to any point about the socket within reach of the remnant of untorn capsule that binds the shaft to the rim above the socket. The primary inward I would denominate thyroid; the primary outward, dorsal. My classification then would be:

Low thyroid,	} All present the same general characteristics, viz., abduction and rotation outward.
Mid. thyroid,	
High thyroid.	

Reversed thyroid (Fig. 84).

Low dorsal,	} All present the same general characteristics, viz., adduction and rotation inward.
Mid. dorsal,	
High dorsal.	

Reversed dorsal (Fig. 128).

I would reject the names "sciatic," "spinous," "interspinous," and "subspinous," as I do not think they stand for distinct varieties of dislocations. As the head can closely approximate positions described by authors as "subspinous," "interspinous," or "spinous" from either plane, if the names are to be retained, I would suggest the prefix thyro or dorso. We would then have thyro-spinous, etc., if the head reached the position from the inner plane, and dorso-spinous, etc., if from the outer plane. By such terms the mechanism of dislocation, diagnosis, and method of restoration would become inseparably associated with the injuries. Preferably I would say reversed thyroid and reversed dorsal, as given in the classification.


PART II.

REDUCTION OF DISLOCATIONS

BY

MANIPULATION.

METHODS AND OBSTACLES CRITICALLY EXAMINED.



REDUCTION OF DISLOCATIONS

BY

MANIPULATION.

THAT which follows upon the reduction of dislocations is based wholly upon the assumption that *all dislocations* may be classified under *two general heads*, viz., Internal and External. If the reader is not willing to accept this statement as a matter of *fact*, I ask him to do so on the ground of the *strongest probability*.

In the mechanism of *all* dislocations three distinct steps must be recognized :¹

1. The laceration of the capsule ;
2. The escape of the head from the confines of the socket ;
3. The shifting of the head from the position it occupied at the instant of escape to its final destination.

It is important that these steps be accepted as final ; that they be regarded as axioms, for upon them I base the time-honored proposition that *every dislocation must be restored through steps in the reverse order of its displacement*. If there is a first, second, and third step in the order of *displacement*, then, in the order of restoration, the first step retraced should be the last step of displacement, the second step retraced should be the second step of displacement, and the third and last step to be retraced should be the first or initiatory step of displacement. I shall begin with

DISLOCATION INWARD.

Reduction by traction—direct method—Method I.

First step. *Retrace the last step in the order of displacement ; locate the head and bring it back to the position it occupied at the instant of its escape from the socket.*

¹ For the demonstration of these steps, see p. 80.

This will usually be easily accomplished. The flexion, abduction, and rotation outward may all be characteristically present, indicating that the head lies in the thyroid depression, with the great trochanter in the region of the socket. (Fig. 78, p. 92.) Should the head lie upon or above the ramus of the pubes, upon the pubes, or in the perineum, it must be apparent that *traction* in the long axis of the femur and directed toward the socket is indicated as the proper means for the retracement of the last step of displacement.

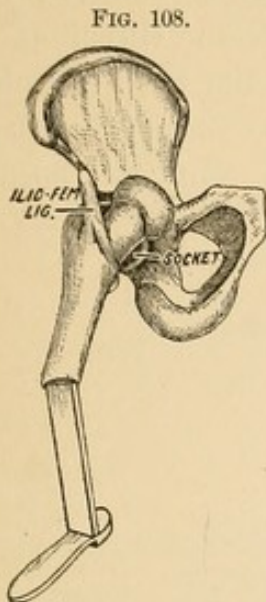
But if the last step of displacement was accomplished by external rotation, with extension of the femur, the unspent force continuing after displacement will be controlled and guided by the remnant of capsule that has escaped laceration. It is thus possible to have several distinct degrees of rotation that might give rise to as many named varieties, but all be the same in principle. From a dislocation inward with scarcely any noticeable increase of rotation outward, the rotation outward may be so great that the toes point backward¹ and the inside of the foot look outward. From the usual position in which the ilio-femoral ligament lies upon the anterior surface of the neck (Fig. 108) it may be so rotated as to lie behind it (Fig. 110). It must be plain, therefore, that in order to retrace the last step of displacement the operator should first distinctly locate the head, notice the degree of constraint, the direction of the long axis of the

¹ I. K., a flabby-looking man, rather fat, was admitted into Guy's Hospital, December 10, 1835. About one hour before his admission he was helping to carry a heavy crate down stairs, when his foot slipped and he fell backward, receiving the weight on the groin. The following are the appearances which the limb presented as he lay extended on his back: The left leg was shortened at least two inches and the foot excessively everted so as almost to give the toes a direction backward. [Had the patient been erect the turning backward would not have been interfered with.—AUTHOR.] The injured limb had a tendency to cross the sound one, so as to throw the heel of the former over the instep of the latter; nevertheless when the limbs were placed side by side they remained in that position. The leg was susceptible of all the natural motions to some extent with the exception of rotation, but the man complained of great pain while under examination. The projection of the trochanter major was entirely lost, whilst the luxated head of the bone could be felt under Poupart's ligament, just below and to the inner side of the anterior superior spinous process of the ilium, and apparently lying between the anterior inferior spinous process of the ilium and the junction of that bone with the pubes. It thus rested on the brim of the pelvis and projected upward to the abdomen. The femoral artery was not displaced, but could be traced on the inner side of the dislocated bone. Reduction: Extension was made downward by means of a jack-towel about the knee by three students, while Mr. Morgan, sitting in the bed, made counter-extension with his foot in the perineum. After three minutes the man was told to raise his shoulders from the bed, at which time forcible rotation inward accomplished the reduction with a snap.—Cooper on Dislocations, p. 124.

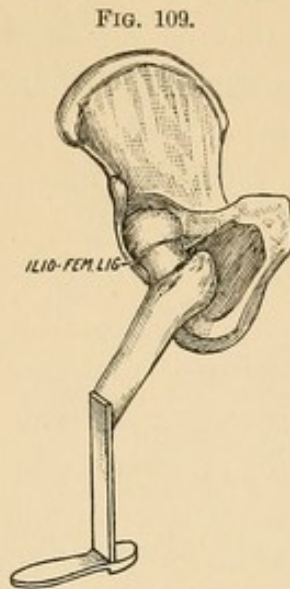
Bigelow quotes this case under everted dorsal,¹ but, I think, incorrectly. The signs are those of a reversed thyroid, while the reduction by extension and rotation inward could not reduce an everted dorsal, but would have been the correct manipulation for a shifted thyroid.

¹ The Hip, by Henry J. Bigelow, p. 101.

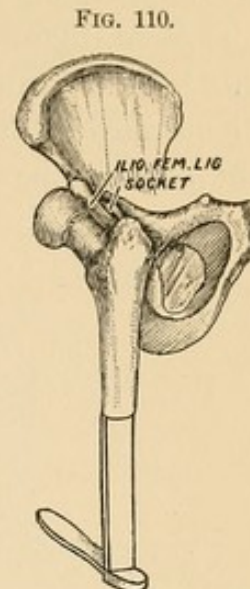
shaft, the degree of rotation as indicated in the foot. In one instance simple flexion will retrace the last step, in another traction in the long axis of the shaft, while if the displacement in the last step has



Y-ligament in front of the neck.

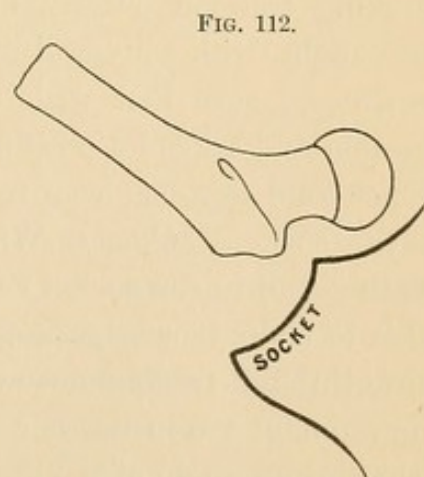
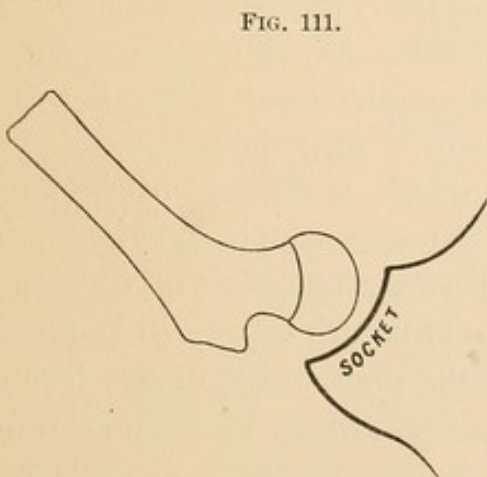


Y-ligament to the outer side of the neck.



Y-ligament behind the neck.

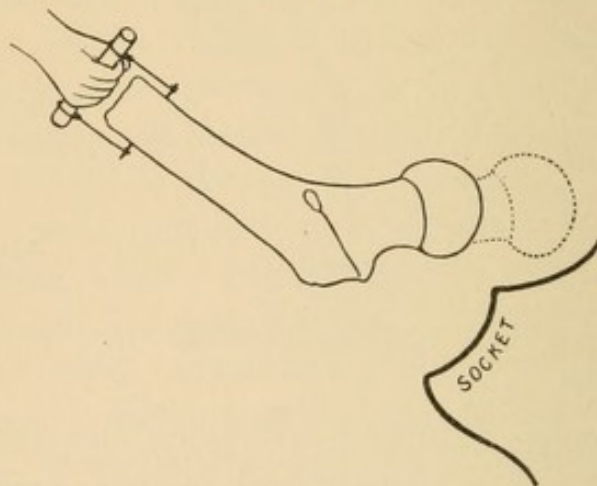
taken place through adduction, extension, and external rotation, then flexion, abduction, and internal rotation would conduct the head to the position it occupied at the completion of the second step of displacement.



Having retraced the last step of dislocation, viz., the shifting of the head to a remote position, the next question to ask is, *In what position was the shaft the instant the head left the socket?* Answer. The shaft was in a state of abduction at right angles to the trunk; and this is true, whether an instant later it was succeeded by ex-

ternal rotation or not. To produce a dislocation inward the capsule must be put upon the stretch by means of abduction, and when, an instant later, the head has sprung from the socket and lies in the thyroid depression, the shaft is still in a state of abduction. It must be plain, therefore, that as the head took the direction from without inward while the femur was abducted, the thigh should be drawn outward in the long axis of the shaft to retrace the second step of dislocation. In retracing this step it must be borne in

FIG. 113.



mind that the trochanter or head may be caught upon some of the bony irregularities of the socket or otherwise entangled. Hence, in making traction outward accompany it, if the head or shaft seems caught, with collateral movements, as slight rotation or rocking—*i. e.*, be sure that with traction the head leaves the thyroid depression and takes its position over or near the socket.

The second step has been retraced—*i. e.*, the head has been placed over the socket. *Query.* Why will not simple traction outward place the head in the socket? *Answer.* The effect of traction outward is to make tense the remnant of untorn capsule; but when this is tense through traction outward, the shaft and the two attachments of the remnant are in the same line, and as the head stands off from the shaft at an angle of 130° , it is plain that traction outward can only bring the head to a position over the socket, but cannot possibly replace it in the socket. To do this a new element must be invoked, *viz.*, direct pressure. But direct pressure alone is not the reverse of the initial step of displacement, in that the shaft was descending as the head burst through the capsule; hence, to accom-

plish the last step, elevate the knee, while an assistant makes direct pressure upon the head. (Fig. 115.) *Query.* Why will not simply

FIG. 114.

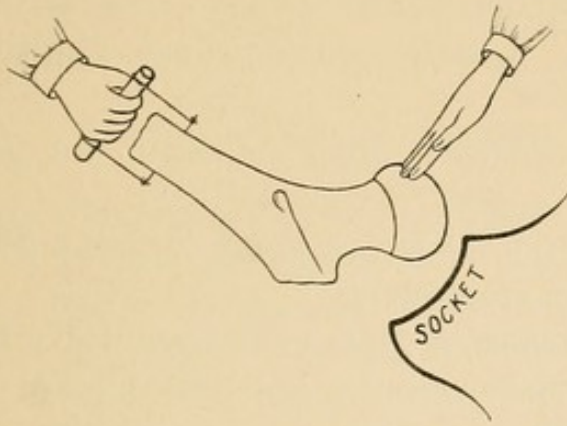
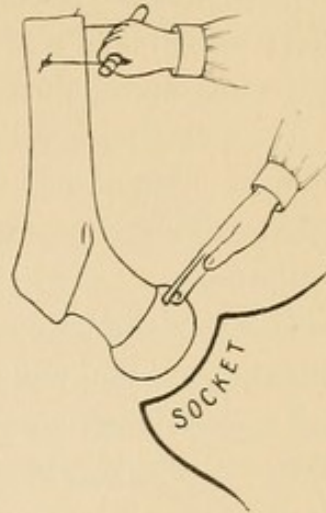
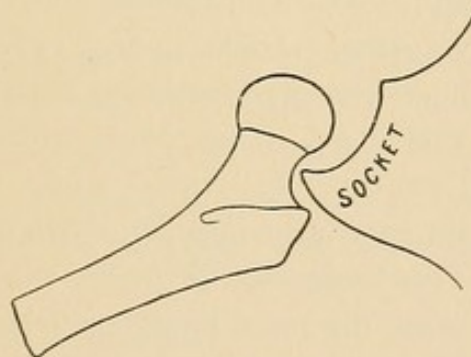


FIG. 115.



elevating the knee replace the head? *Answer.* Because it is totally unlike the first steps of displacement. In this, as the shaft descended, the neck of the femur pressing on the rim of the socket (Fig. 116)

FIG. 116.



had a bony fulcrum, which forced the head out of the socket. In the act of replacement the simple act of elevating the knee encounters no corresponding fulcrum to force the head downward as the knee rises. The necessary traction to bring the head over the socket has also compelled the head to rise above the level of the socket, and as traction, to hold the head over the socket, must be accompanied with the elevation of the knee, we are compelled to invoke a new element, viz., direct pressure to replace the head.

For the replacement of the head by direct steps I offer the following directions:

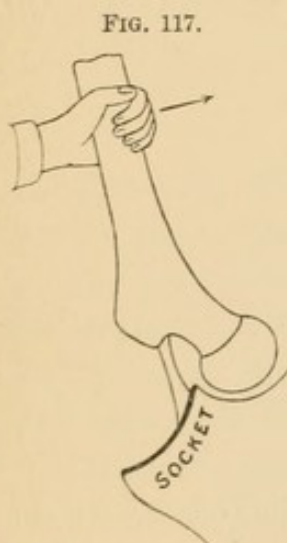
1. Flex and abduct the femur.

2. Make traction outward.
3. Fix the head by digital pressure and adduct.

The medical profession has long practised with variable success methods somewhat resembling that which has just been described. Authors recommend :

1. To flex and adduct the thigh.
2. To make perpendicular traction upon the knee, and follow traction by adduction.
3. To make traction with adduction, using the foot in the groin as a fulcrum.
4. To place the patient astride a bed-post, using it as a fulcrum while extension and adduction are made.
5. To make traction and adduction while an assistant with a fillet passed between the thighs makes traction obliquely upward and outward.

All of these have been recommended, but success in their employment does not depend upon the scientific application of the principle.



In all *adduction* is made a prominent feature ; but adduction, if attempted too early, defeats its own end. This can best be illustrated by means of a diagram. In this, Fig. 117, adduction inward makes tense the remnant of untorn capsule, which acts as a fulcrum, about which both arms of the lever revolve. As the long arm is carried inward the short arm, head, and neck must move outward. This is impossible under the circumstances, because the tense ligament drives the head against the rim or into the thyroid depression. From this it will be seen that the obstacle in this case is created by the operator, who *adducts*

before he has made traction outward. It illustrates strikingly the folly of violence or brute force.

I have entered into minute details in describing the direct method of reduction, because it is the only method in which every step is retraced. I may be going too far when I say that it is the safest, surest, and only rational method. By means of it in one of my experimental studies I reduced the head readily many times in succession from a dislocation inward, but when I resorted to rotation I encountered obstacles that could only be overcome by further

laceration of the rent in the capsule—a *most unnecessary expedient when replacement was possible without it, and a most dangerous expedient when by enlargement of the rent* through circumduction and rotation the capsule is dissected from the rent in the muscles and placed in such a condition that it is possible to drive some portion of it before the head into the socket, and render a clean and absolutely perfect reduction impossible.

Indirect Method—Reduction by Rotation.

The method just described I designate the direct method. There is another in which *rotation* forms a prominent feature, and which may properly be denominated the *indirect method*. Rotation may or may not be associated with abduction during the first and second steps of dislocation inward. The rotation recommended to effect restoration is not employed to make the head retrace its steps on the principle that it is the reverse of the agency that caused the displacement. Its efficacy is entirely foreign to the laws of dislocation, and rests for its means of success upon the utilization of the Y-ligament, *i. e.*, the remnant of untorn capsule. By the proper employment of the femur as a lever this ligament becomes a fulcrum and can be often used to great advantage.

We employ two varieties of rotation, viz., external and internal.

Reduction by means of external rotation—Method II.

First step. Flex the thigh, but not to a perpendicular.

Second step. Adduct, carrying the knee obliquely inward and downward.

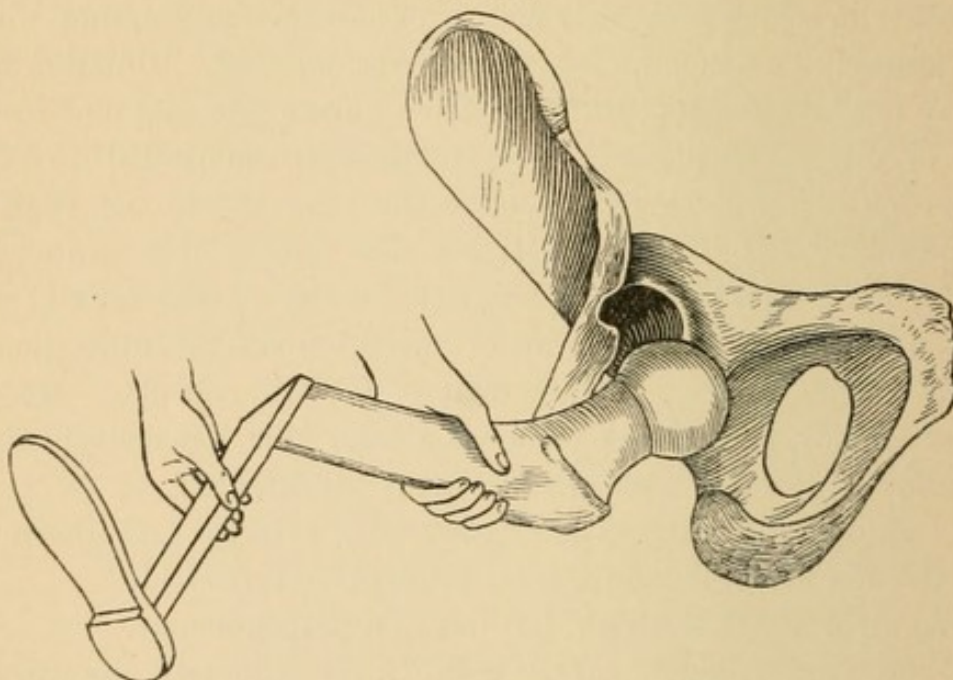
Third step. Rotate outward.

The object of the first step is to bring the head into the position it occupied the instant it passed the confines of the socket. If the head lies upon the pubes, in the perineum or above the socket, as pointed out in the first method, then simple flexion will not effect retracement, but other means must be employed to do so. Suffice it to say that no second step is to be considered until the first step is taken. In flexing the femur the operator is cautioned not to flex to a perpendicular. The reason for the caution is that such a degree of flexion tends to carry the head away from the socket and cause it to sink deeper into the thyroid depression.

We are now ready for the second step, viz., “adduct and carry the knee obliquely inward and downward.” Observe the position

of the head : it lies below and internal to the socket. The remnant of untorn capsule, which is to conduct the head back home, is attached above the socket. When the knee is vertical or slightly abducted this remnant is relaxed, but the instant the knee is adducted and directed obliquely inward and downward the remnant of capsule becomes tense and inclines to draw the head upward and outward. To facilitate this, the third manœuvre in the method is resorted to—viz., rotation outward, *i. e.*, turning the ankle of the bent leg inward and upward. (Fig. 118.)

FIG. 118.



The head of the femur has been brought to the border of the socket ; the femur is abducted, but not so much as is represented in the figure. The femur must be rotated *outward* by means of the bent leg, which is turned inward as a crank ; this makes taut the outer border of the remnant of capsule, *i. e.*, the outer band of the Y-ligament.

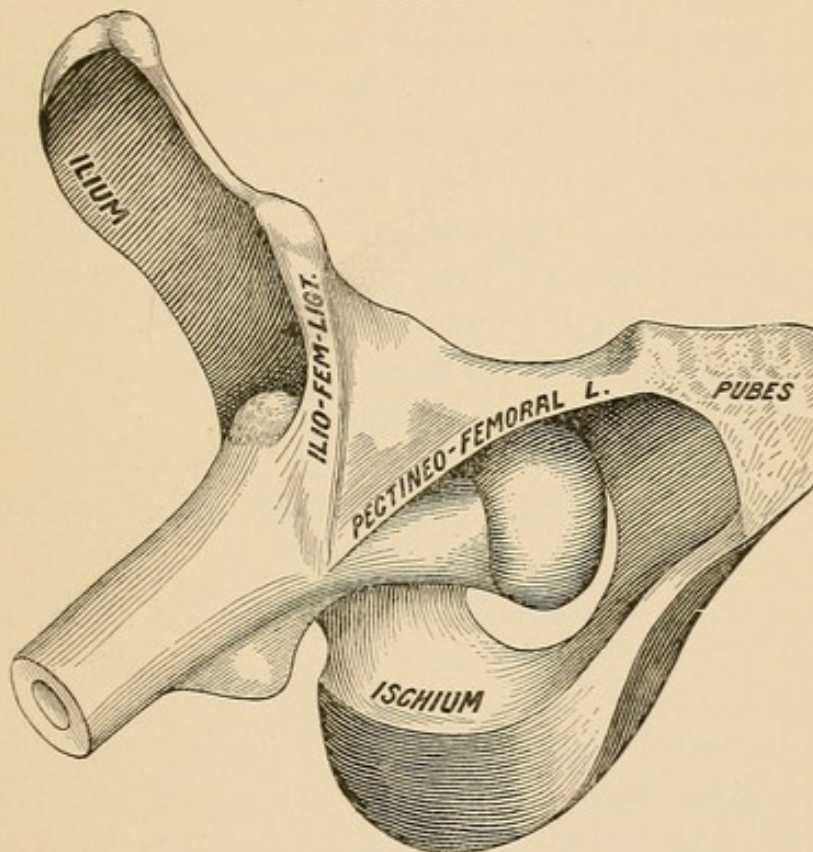
The operator must not regard adduction, extension, and rotation outward as distinct and separable movements ; on the contrary, it is the happy blending of the three that invites success. With the patient lying flat on the floor and the femur flexed, the operator places his bent elbow beneath the flexed knee and grasps the ankle with the unoccupied hand ; he then extends,¹ adducts, and rotates outward (*i. e.*, carries the bent leg inward), the combined movements sometimes advantageously accompanied with a gentle spring. I have em-

¹ Extension is the reverse of flexion, and can be accomplished with the bent elbow beneath the knee. By this means traction in the long axis of the shaft can be combined with extension, and is never to be omitted.

ployed this method with gratifying success, both in experimental and clinical work. In the case of a young adult who, from faulty diagnosis, had an unreduced thyroid dislocation, associated with fracture in the upper third of the femur, the head was easily restored eight weeks after the original accident by the method described.

Obstacles. In dislocations inward the pubo-femoral ligament (Fig. 119) often escapes uninjured. Now if the head is to be returned, it

FIG. 119.



Dislocation into the thyroid depression. The great trochanter rests against—i. e., is caught upon—the rim of the socket. The head is partly covered by the pubo-femoral ligament.

must pass beneath this band. If adduction be made too obliquely downward and inward, or if external rotation be too early attempted, the head will strike against this band and be prevented from entering the socket, or the head may pass above the band and ascend toward the horizontal ramus of the pubes. To avoid such a contingency the knee should be elevated approaching the perpendicular, and by combining adduction with rotation the reduction may often be readily accomplished. The degree of adduction will vary with the length and amount of the remnant of capsule. Whatever be the nature of the obstacle it should not be essayed by violence. Vio-

lence masks the nature and position of the obstacle which gentler measures may detect and skill overcome.

Reduction by Means of Rotation Inward—Method III. Bigelow puts this manœuvre at the head of his ten rules. His directions are: "Flex the limb toward the perpendicular and abduct a little to disengage it from the bone, then rotate the thigh strongly inward, adducting it and carrying the knee to the floor. The trochanter is then fixed by the Y-ligament and the obturator muscle, which serve as a fulcrum. While these are wound up and shortened by rotation the descending knee pries the head upward and outward to the socket."¹ Bigelow makes no reference to clinical support of this method, and I am inclined to believe that his confidence in it rests entirely upon experimental work. I have been delighted with it in certain experimental cases and disappointed with it in others. I have failed with it in clinical trials. For the purpose of a critical study I shall divide the method into three steps:

Rule.—First step. Flex the thigh, but not to a perpendicular.

Second step. Rotate strongly *inward*.

Third step. Adduct and carry knee to the floor.

The first step is identical with the preceding and needs no added comment.

Second step—*i. e.*, "rotate strongly inward." By this manœuvre the head is carried to the deepest part of the thyroid depression. Now just at the instant when the head is fixed (*i. e.*, wound up by the tense ligament) Bigelow directs that the knee be suddenly and strongly adducted with a view to prying the head over the acetabular rim into the socket. In executing it the operator must not separate "rotation inward" from "adduction and prying downward and inward." The three distinct manœuvres must be combined in a single effort: with one hand² grasping and controlling the knee, the

¹ Henry J. Bigelow: *The Hip*, p. 77.

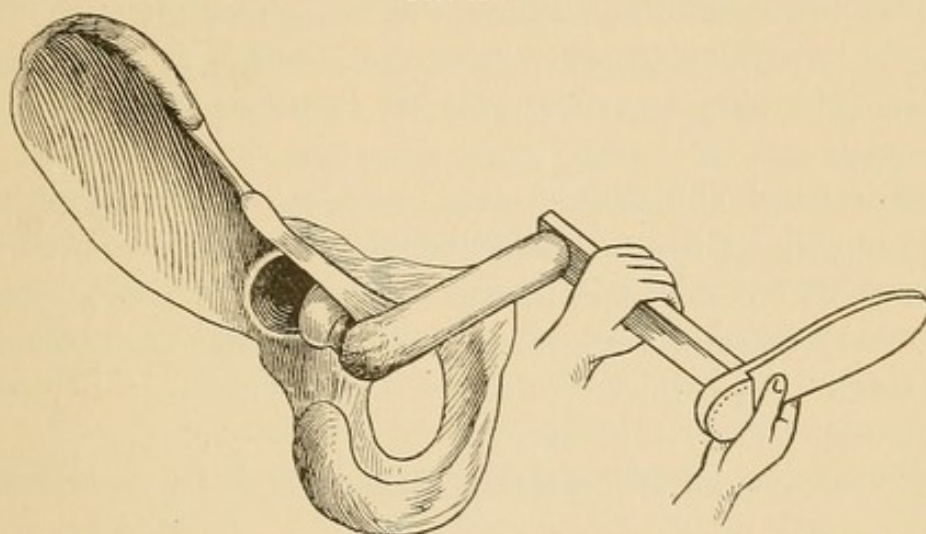
Sir Astley Cooper, in dislocations inward, combined rotation inward with the pulleys. Bramsby Cooper, his nephew, fully believing that the only resistance to reduction lay in the muscles, thus explains the advantage of rotation inward: "Rotation inward elevates the trochanter major and thereby places it in the most favorable position for the gluteus medius and minimus to draw the head of the bone toward the acetabulum." This statement appears in *Guy's Hosp. Rep.*, 1836, vol. i., just twelve years before Morton, by the introduction of anaesthesia, struck the death-blow to the theory of muscular assistance or resistance.

² I feel that I cannot too often allude to the danger of grasping and controlling the knee with the hand. An insensible or voluntary pressure upon the knee accompanies this control, which drives the head downward upon anything with which it comes in contact. The safest control is through traction with the bent elbow beneath the bent knee.

other grasping the ankle, the knee is directed inward and downward, while the ankle is turned outward and upward, the combined action resembling in some measure the movement of boring with an auger, in which both hands seem to move in opposite directions.

There are objections to this method which the operator should understand, for if properly appreciated it will not be persevered in beyond a fair trial. *The rotation is inward.* The object of this is to bring the head directly beneath the fulcrum, viz., the Y-ligament,¹

FIG. 120.



Femur adducted; rotation of the femur inward, accomplished by turning the bent leg, as a crank, outward. Notice that the socket, head, capsule, and shaft lie in the same direction.

so that when the knee is adducted and pried inward and downward the head will be pried upward and outward. Note, however, that while rotation inward brings the head beneath the fulcrum, it also brings the head into the deepest part of the thyroid depression, a condition at times very obstructive and unfavorable to reduction.

In some experimental work I have met with obstacles which could be overcome, in others I have failed, and I am inclined to the belief that the acetabular rim is more prominent and insurmountable in some cases than in others. When in some cases I have used force, as Bigelow directs, I have brought the head so strongly against the rim of the acetabulum as to denude it (the rim) of periosteum and tear the cotyloid cartilage from its attachment; and when I have persevered I have felt the head grate upon the denuded rim, and upon examination have found the cartilaginous covering of the head

¹ See p. 130, foot-note.

deeply scored when it had been forced against the naked rim of the socket.

A second defect in this method is that rotation inward often conveys the head outward, thus suddenly and unintentionally converting a thyrod into a dorsal dislocation. It is to avoid this that Bigelow recommends "strong rotation inward," holding the knee and ankle well under command, lest it dodge at the critical moment. That it is likely to do so may be learned from the fact that the head is round and covered with a smooth and slippery cartilage, while the periphery of the socket is crowning and not calculated to give a very stable support to anything pressed against it. Indeed, the probability of the head going into the socket is far less than that it slip to the right or left of it.

I have failed clinically in two instances by this method, and though in each I failed with other methods, the fact of failure is an argument that it does not possess special superiority. Since the memorable treatise of Bigelow, in 1869, this method has had a fair and impartial trial, and the verdict of the profession is in favor of rotation outward, *i. e.*, the first method of rotation.

In the opening of this chapter I designated the first method by

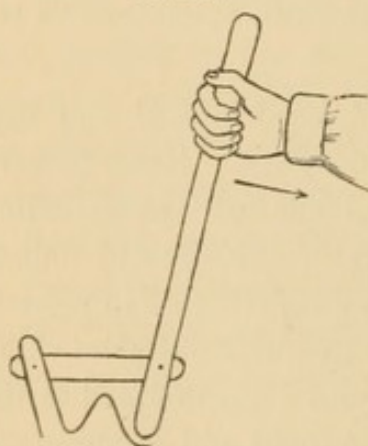
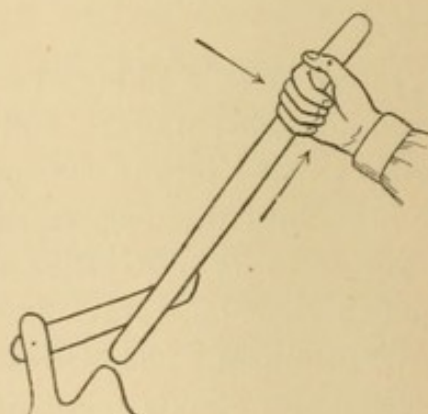
FIG. 121.¹

FIG. 122.



Figs. 121 and 122, purely diagrammatic, introduced to illustrate the lever and fulcrum (sling), and how in one case (Fig. 122) an obstacle may be overstepped by lifting the lever.

¹ While the capsule acts as a fulcrum, it is not in this case a pure one; its function is rather that of a sling. If the sling is short, depression of the lever will drive it strongly against the obstruction. (Fig. 121.) I would therefore suggest that the operator, when he gets the femur in the position he wishes by first flexing, then rotating inward to bring the head obliquely below the socket, and, lastly, adducting a little to feel the tension of the sling; that instead of sudden and powerful depression of the lever he substitute a sudden jerk upward (Fig. 122) and inward to lift the head in a measure over the rim, and combine the jerking with sudden depression.

traction as the *direct*, and the following by *rotation* as the indirect, method. Of the first I said that the steps in reduction were the literal retracement of the steps of dislocation. But I cannot say the same thing of the methods by *rotation*. In these the Y-ligament acts as a fulcrum, but the fulcrum, instead of lying beneath the lever, is attached above it, and may be said to suspend the lever; hence when the end of the long arm descends the end of the short arm is, as Bigelow styles it, pried out of the thyroid depression, over the rim, and into the socket.

If it be considered a cardinal principle in all efforts at reduction to place the shaft of the femur in the respective stages of displacement, then the first method (*viz.*, by traction) meets every requirement, while that by rotation violates them. In the method by *rotation* the Y-ligament as an agency that had no part in the act of dislocation inward is invoked to participate in the reduction, and that through adduction inward and downward, a force in no way associated in the mechanism of this variety of dislocation.

DISLOCATION OUTWARD.

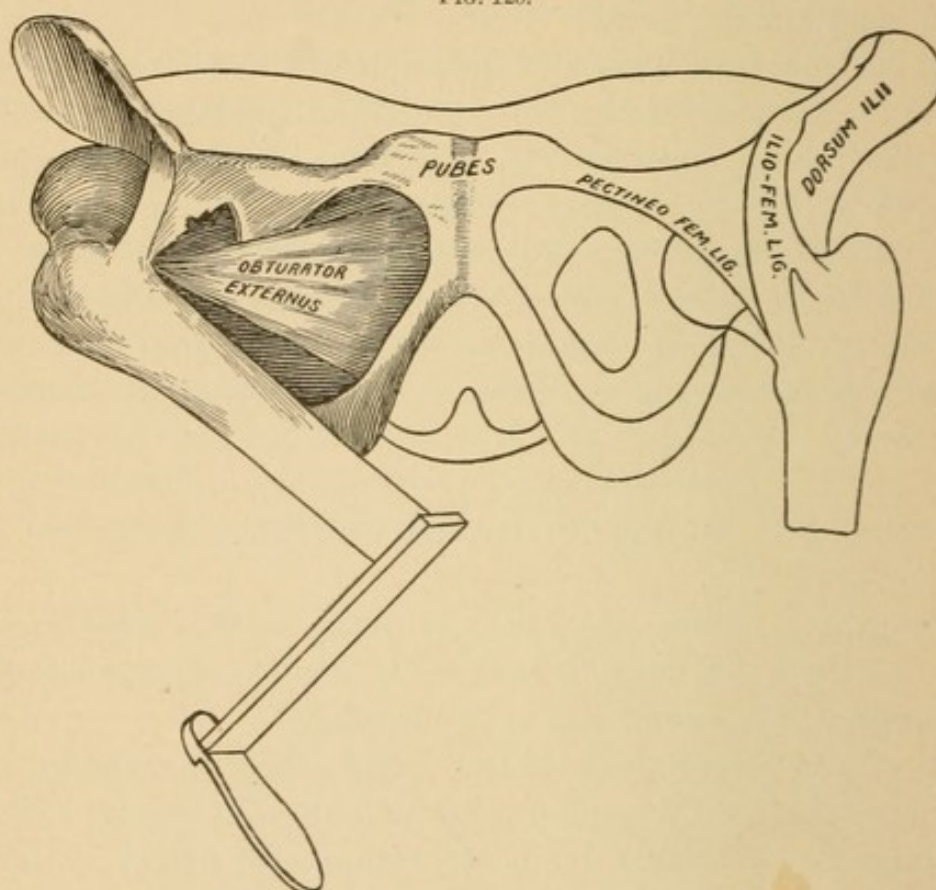
First step. *Retrace the last step in the order of displacement. Locate the head and bring it back to the position it occupied at the termination of the second step in displacement.*

This may be a very simple thing. The dislocating energy may have been spent in the second stage and the displacement in the third stage may be simply due to the unsupported weight of the leg, which drags the femur, and it inclines downward and inward. (Fig. 123.) In such a case the operator has simply to elevate the knee to a perpendicular, when it will reassume the position (see Fig. 85) it occupied at the completion of the second step of dislocation. In most instances, either because the dislocating energy is unexpended after rupture of the capsule, or to extraneous causes, such as transportation or manipulation, the head is displaced to a position remote from its place of exit. It is important then to locate it, *i. e.*, study how it reached its destination and make it retrace its own path.

I have repeatedly stated that great constraint always betokens a minimum degree of laceration of capsule, and the reverse of this is equally true, that a slight degree of constraint may be regarded as

the exponent of extensive laceration of capsule. Note especially that the untorn portion of capsule that acts as the halter of the dislocated head and neck lies on the inner side. This remnant of capsule—the ilio-femoral ligament, the Y-ligament of Bigelow—is attached to the lower spine above the socket by a single insertion; but below its fibres separate into two bundles, which Bigelow designates the outer and inner bands or branches. It stands to reason,

FIG. 123.



therefore, that the upper spinous attachments must be as strong as the two combined lower attachments, and that it would require double the force to rupture the upper that would be required to rupture either of the lower attachments, providing the latter are of equal size and length. They are not however of equal length, and after dislocation a secondary force may act alone upon the shorter outer portion, lacerating some of its fibres or completely tearing it from its attachment. The same is true of muscles. If the head has escaped with a minimum degree of laceration, the constraint will be marked, but when the obturator internus and pyriformis are fully torn the restraint will be greatly diminished.

The head may then lie upon the dorsum ilii, the whole limb may be extended, suffer itself to be rotated outward, and still exhibit nothing more than the freedom permitted by an extensive laceration of the capsule and of the short rotator muscles. In all such cases traction downward will bring the head into the region of the socket, when flexion will place the femur in the position it occupied at the close of the second step of dislocation.

But a change is possible that should be understood. The original force, which was that of *rotation inward*, may be reversed after dislocation takes place, and the third step of dislocation may yield us the position of

Dorsal with Eversion.

There is nothing in this condition to mystify the reader; it depends upon physical laws and is easily explained. By a glance at Fig.

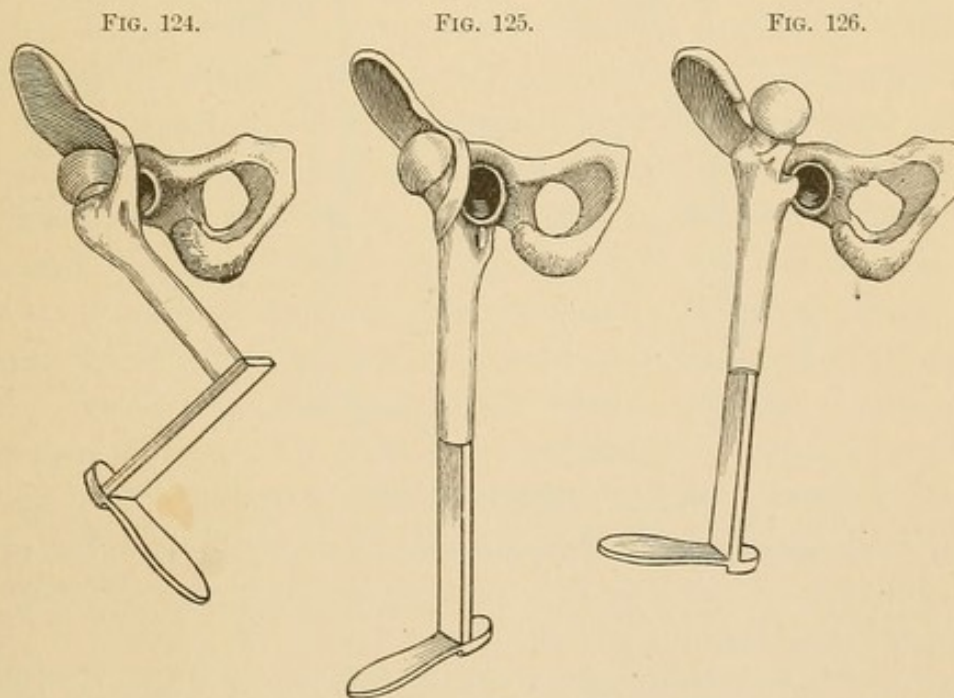


Fig. 124.—Inverted dorsal; so-called because the knee is turned inward and the foot rotated inward. In this the head turns inward and rests against the side of the pelvis.

Fig. 125.—Everted dorsal; so-called in contradistinction from the *primary* or first condition of every outward dislocation, which is dorsal with inversion. In dorsal with *eversion* the foot turns out, the trochanter (not the head) rests against the side of the pelvis, and the head looks outward. To reduce an everted dorsal (Fig. 125), it must be first converted into an *inverted* dorsal (Fig. 124).

Fig. 126 is only a shifted position from Fig. 125.

124 it will be evident that rotation outward would be possible by still further adducting the knee; or if the femur was extended

and outward rotation instituted, the laceration of the outer branch of the Y-ligament would readily liberate the head and permit of eversion. The eversion will vary in degree and the position of the head will vary. The foot may exhibit normal eversion (Fig. 125), or it may even look slightly outward and backward (Fig. 126). The head may lie against the dorsum (Fig. 125), or it may rise to a level with the anterior border of the ilium, or it may extend over the border, its neck resting on the interspinous notch (Fig. 126). The critical reader has not failed to notice a striking resemblance between two very diverse conditions, viz., a dislocation primarily inward into

FIG. 127.

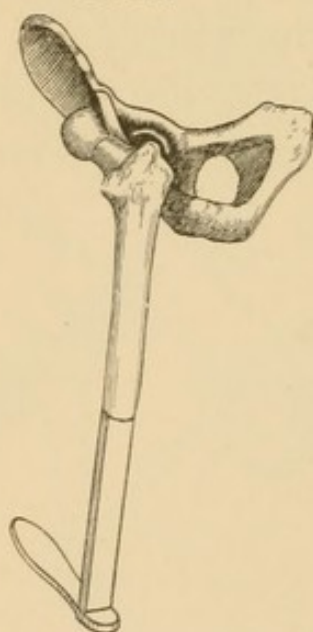

FIG. 128.

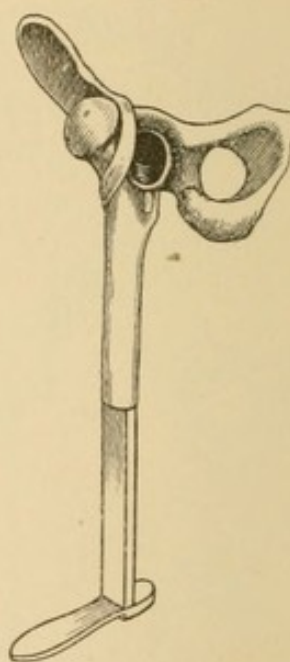


Fig. 127.—Thyroid reversed. I designate this a thyroid, because it was originally a thyroid dislocation (Fig. 78), with the head pointing inward and the foot pointing forward. It is reversed, for now the head points outward and the foot backward. I call it a thyroid reversed, and by the name indicate that it can only be reduced by converting it into a primitive thyroid, *i. e.*, into a dislocation inward, into the thyroid depression. For the successive steps of causation, see Figs. 78, 82, 83, 84.

Fig. 128.—Dorsal reversed; so-called in contradistinction from the primary dorsal dislocation, which is always accompanied with inversion of the foot and rotation inward of the axis of the shaft of the femur. The reversed dorsal is not a primary or original dislocation; it is a consecutive or secondary change from an original inverted dorsal. For its reduction the first step must be to convert an *everted* into an *inverted* dorsal.

the thyroid depression, but which has by secondary influence been rotated outward, so that the foot points outward and backward (Fig. 127), and another, dislocated primarily outward, but which by reversed action also yields a foot turned outward, or even slightly backward (Fig. 128).

As these two conditions are the result of forces directly opposed to each other, and that for their reduction they will require equally diverse methods, must be apparent.

The diagnosis between these two conditions is a very difficult one, a statement which is happily illustrated in the contradictory views of Sir Astley Cooper and Henry J. Bigelow, the former of whom regarded the case recorded on p. 120 as "upward and forward," and the latter as "dorsal with eversion." I shall not attempt to lay down any rules by which these two conditions can be distinguished; I shall rather, first, show their general resemblances, and, second, offer some general points of divergence.

(a) *In neither form of dislocation will there be evidence of decided fixation.* In the thyroid reversed, shifted upward, the Y-ligament will be seen (Fig. 127) to lie under (behind) the neck. Hence, it cannot offer any constraint except against traction. In the reversed dorsal (Fig. 128) the Y-ligament lies on the inner side and may bind the head and neck with considerable force, but even this constraint will vary with the integrity of the outer branch of the Y-ligament, which is generally torn in the reversed dorsal.

(b) *In neither form of dislocation will the limb refuse to lie parallel with its sound fellow.* There may be a little tendency to adduction, but in neither case will the limb show constraint when placed in normal extension and abduction. There are three conditions that might simulate the external rotation and parallelism, viz.: Fracture of the neck of the femur; reversed dorsal; and a reversed thyroid. Of these three conditions the former may be excluded if the patient is able to sit upon a chair. In such a posture the fractured thigh would show shortening by comparison of the knees, but the knees would look forward; in the remaining two, viz., in the dorsal reversed and in the thyroid reversed, the affected knees would look outward in the sitting posture, and the bent leg, resting on the toes, would lie behind its fellow. (Fig. 129.)

Although I cannot offer positive points of diagnosis, I will call attention to the following:


(a) Extreme outward rotation in which the inside of the foot tends to look outward—the heel forward and inward—is hardly possible in any condition save that of a primary dislocation inward, with external rotation, the head being controlled by the Y-ligament, which is untorn. The outward rotation of everted dorsal is rarely beyond

rectangular eversion. To determine whether the case in question be an everted dorsal, let the operator make a gentle attempt to rotate still further outward. This will be checked because the Y-ligament

FIG. 129.

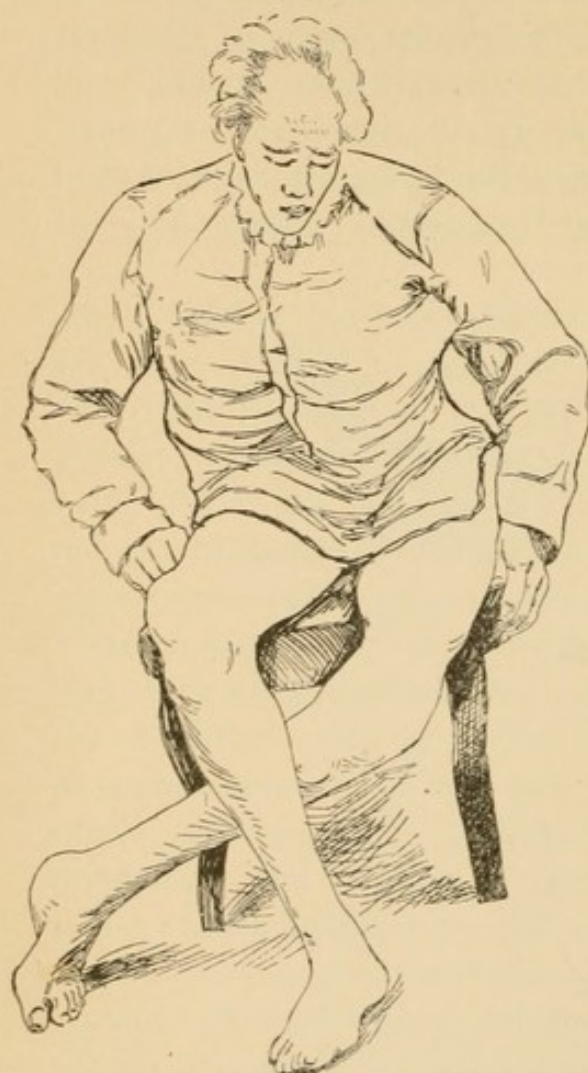

FIG. 130.

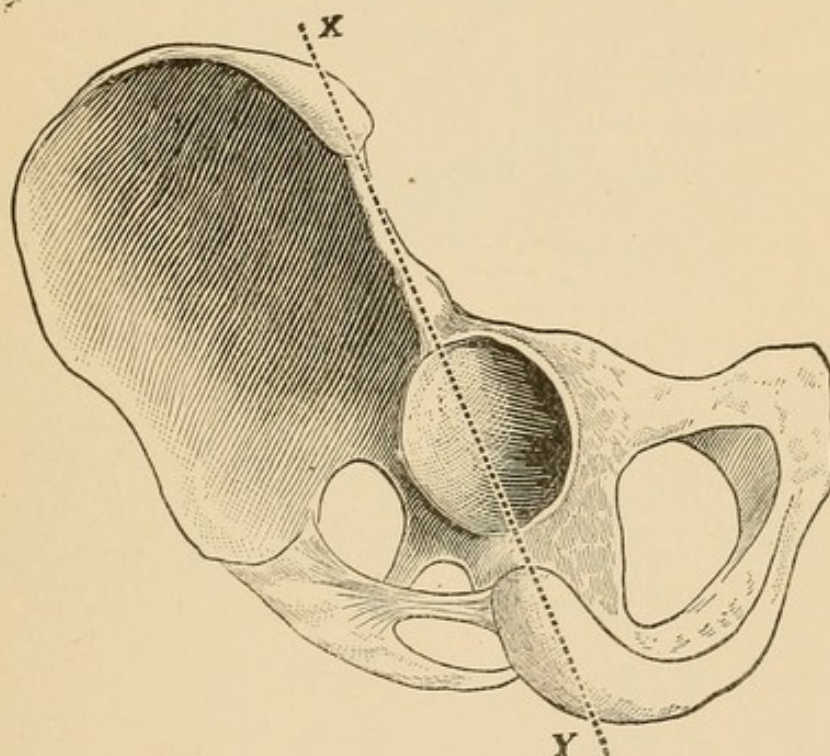


Figs. 129, 130. Everted dorsal dislocation of left femur. Originally this injury was an inverted dorsal. The accident occurred in childhood, and was caused by a fall from a ladder. The limb never gave any discomfort, but by constant use, either through flattening of the head of the femur, the deepening of the artificial socket, or the lengthening of the remnant of untorn capsule, the inverted dorsal gradually became a well-marked everted dorsal. The left, or injured, limb was the one on which he bore his weight when standing. This was owing to the great shortening and the disparity between his limbs. It will be observed that in sitting the left limb lies back of the right and rests upon the toes. If the reader turn to Figs. 125 and 126, he will see that in these the knees look outward, and in them in the sitting posture the inner side of the knee would look forward.

lies in front (Fig. 128), and external rotation will make it tense. Not so with the "thyroid reversed." In this case the Y-ligament lies behind (Fig. 127), and rotation, after the foot looks backward, can still be increased.

(b) If the foot looks backward or outward, find the head; to do this locate the inner condyle; it points in nearly the same direction as the neck. After this locate the great trochanter, it will lie internal to the dividing line between the two divisions of the bone (Fig. 131, *X*, *Y*), when the head has been dislocated primarily inward; but if the head were dislocated primarily outward, the trochanter major cannot lie internal to this line.

FIG. 131.



Lastly, make direct pressure upon the head; if it be a reversed dorsal, the head will sink; if a shifted thyroid, the upper end of the femur will have a bony support; if it be a dorsal with eversion only, the head can be felt by direct pressure; if it be a shifted thyroid, the trochanter can be felt as well as the head.

It must be evident, therefore, that retracing the last step of dislocation is not a simple or unimportant matter; that a confident rational procedure will only be based upon a knowledge of the path taken by the head. As we are now dealing with dislocations outward, the first thing to do if we are dealing with an everted dorsal, is to convert it into an "inverted dorsal." To do this, flex (this will relax the *Y*-ligament), abduct, and rotate inward. The operator should observe carefully that the head follows the manipulation;

if it does, he has retraced the last step of dislocation, and is ready to undertake the second step.

FIG. 132.

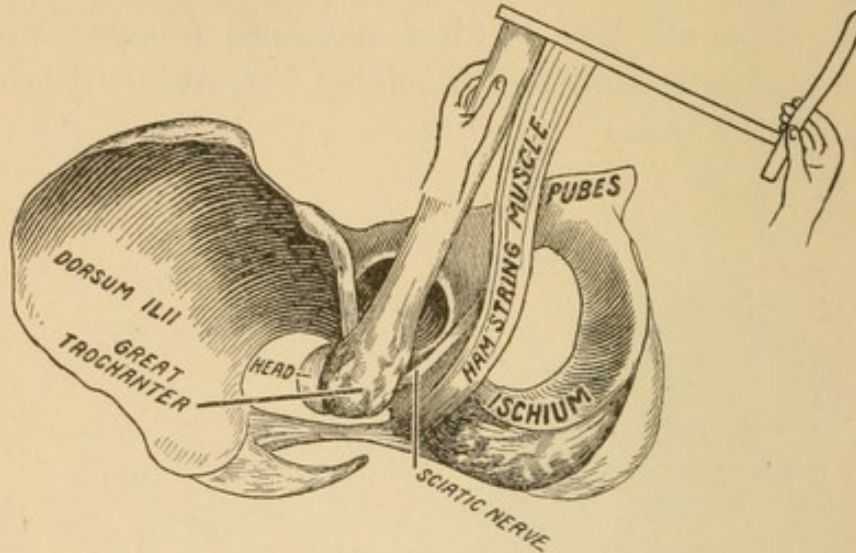
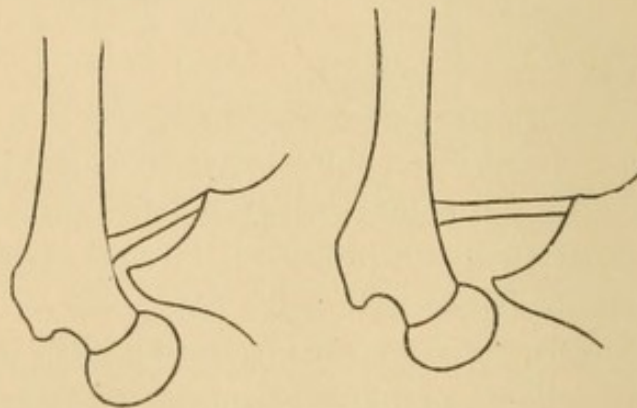


Fig. 132 represents the head of the femur beneath the overhanging capsule. The same in cross-section in Figs. 133 and 134.

Retracing the Second Step. In the second stage of dislocation the head *left* the region of the socket and *fell* outward and downward until arrested by the yet untorn part of the capsule; hence to retrace the second step—*lift*.

FIG. 133.

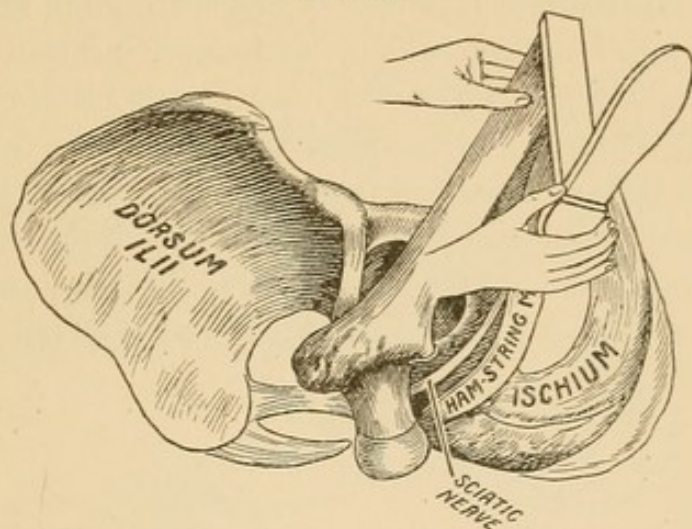
FIG 134.



If the surgeon lifts vertically upward, he will find that as the head rises it is compelled to move outward to get from under the projecting rim of the socket, and this makes tense the remnant of untorn capsule which checks the upward progress of the head at the instant when it would pass over the rim and into the socket. To obviate

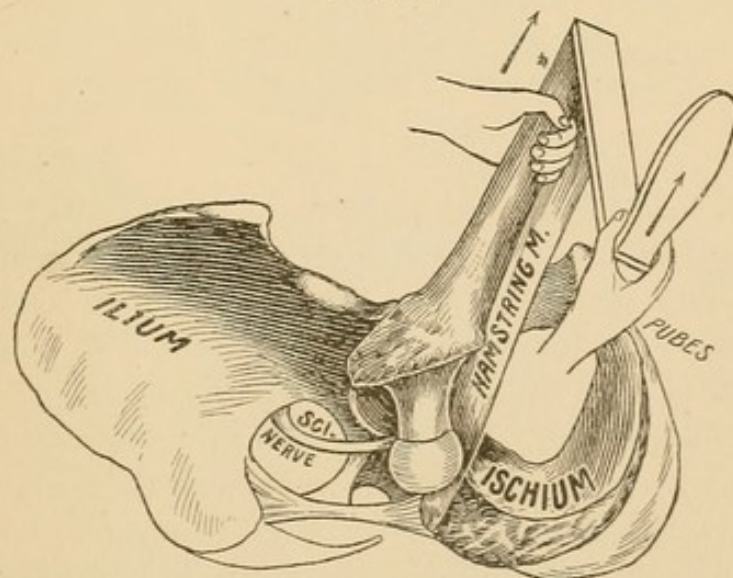
this turn the bent leg like a crank outward. This will compel the head and neck to look footward (Fig. 135). Now the limb can be lifted to a level with the socket, but on its arising it encounters an

FIG. 135.



obstacle worthy of our most serious attention. To complete the second stage, the head must be turned inward to the region of the socket, and now note that the tendon of the hamstring muscle and its attendant, the great sacro-sciatic nerve, are directly in the way. Fig. 136.

FIG. 136.

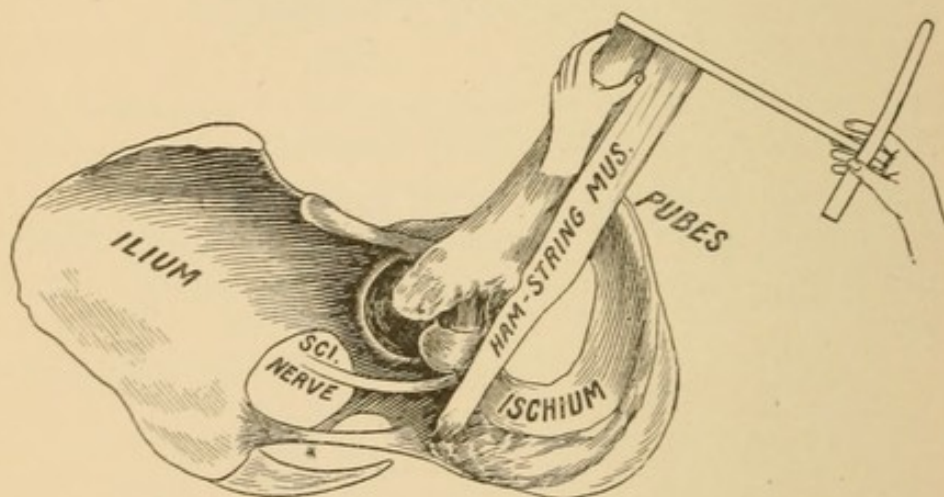


Notice that the head is at a higher point than in Fig. 135, and rests against the tendon of the hamstring muscles.

This, I say, is a most critical moment, for the head must be turned into the region of the socket, and has no other path than between

the tendon and the socket. To do this while the limb is lifted vertically with the leg flexed at right angles to the femur, which relaxes the tendon and nerve, turn the leg as a crank downward and inward until the heel looks footward. Do not use violence. If obstruction be experienced, it cannot at this stage lie in the capsule, it cannot lie in *anything* over which violence will prevail. It will lie in one of three things: Either the head strikes bone, in which case it must be lifted higher; or it strikes the tendon; or the nerve. In case it strikes the tendon it can be readily shifted, and the escape of the tendon may be followed by a similar escape of the nerve. I have frequently caught them in succession, and have so caught up the nerve as to flatten it over the head, and being spread out twice its

FIG. 137.

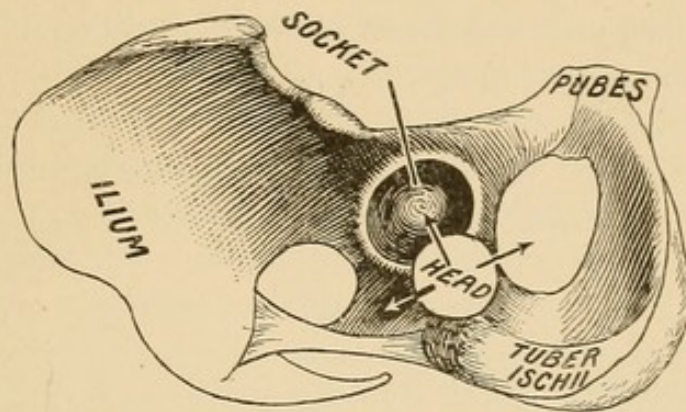


original size, it has barred my progress to the socket. Therefore, I urge caution at this stage, for if the nerve be caught and force applied, it (the nerve) has one of three destinies before it: it must effectually bar all entrance to the socket, or slip off the head and escape, or slip off the head upon the neck of the femur, from which it can with difficulty be disengaged. I speak of this as a moment of peril, for no one, when he undertakes to restore a dislocation, can tell what degree of havoc attended the original traumatism, and whether or not the nerve has been freely stripped from its attachment to the hamstring (biceps), and lies dangling like a large cord in front of the socket.

If the head has met with no obstacle in rotation, it is now ready for the last step. Please note the position of the head of the femur: it rests upon a ridge between the outer and inner planes. It has

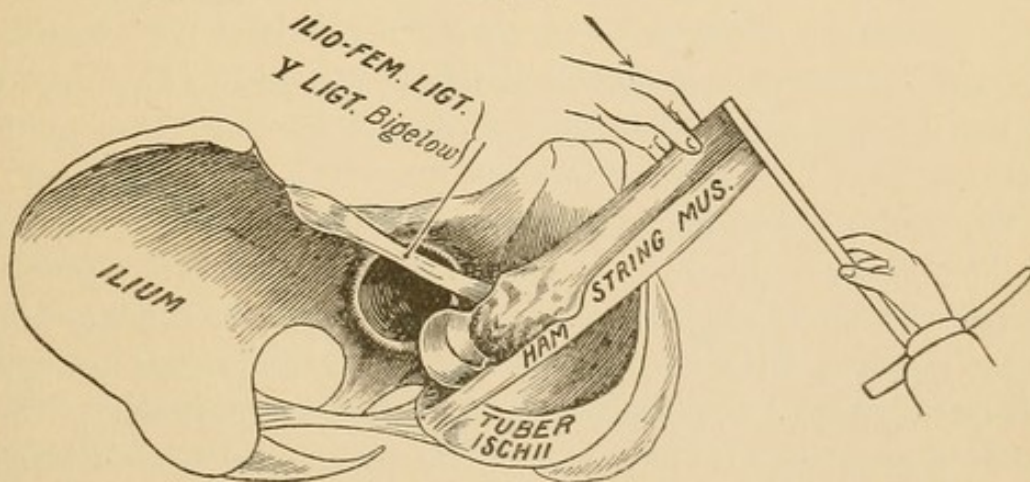
reached its present position by being lifted to a level with the socket and rotated obliquely beneath it (Figs. 137, 138). There are three courses open to it now: it can fall outward, pass inward into the thyroid depression, or ascend obliquely upward into the socket. There are two ways for accomplishing a happy replacement:

FIG. 138.



The first is by traction. By this means the knee is lifted skyward, which relaxes the remnant of capsule, while an assistant with his thumbs makes direct pressure upon the head in the direction of the socket. This may reduce it; if not, the operator may

FIG. 139.

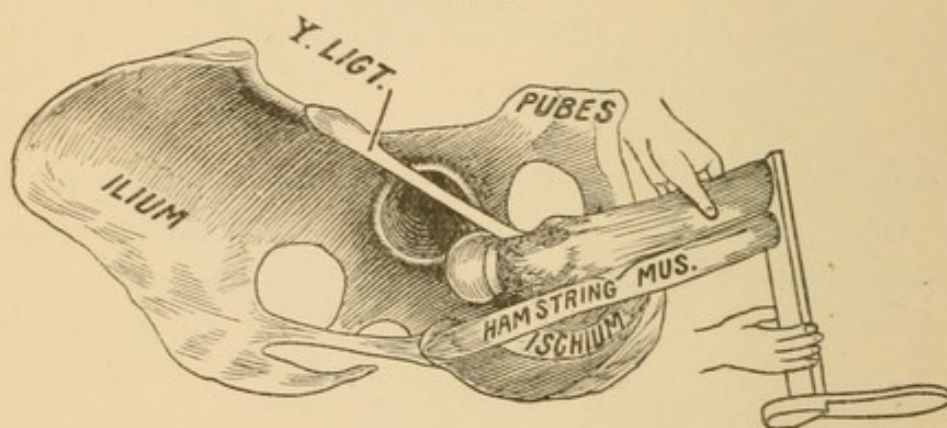


bring the knee down in extension, the assistant still keeping up the pressure upon the head. The manœuvre should not be attended with violence or dispatch. The surgeon, if he encounters resistance, should be warned by it, and retrace and modify his course. Usually the head will pass noiselessly into the socket.

The second, or indirect, method is to employ the Y-ligament of Bigelow as a fulcrum to drag the head into the socket. The reader will bear in mind the position of the head: it lies (Figs. 137, 138) below the socket, and must be directed obliquely upward and outward.

If, now, the knee, with the leg flexed, be carried directly downward in extension, the remnant of untorn capsule (Y-ligament) will be made tense, and the head be lifted into the socket. Should the head slip outward upon the dorsal aspect, it must be replaced by lifting, and, instead of extending the knee directly downward, it should be a little abducted and then extended. If, on the contrary, the head slipped inward into the thyroid depression, then the knee should be adducted and the Y-ligament tightened a little by inward

FIG. 140.



rotation. (Note the position of the foot, Fig. 140.) If, now, extension be made, the head will be directed in the course of the socket.

The reader will notice that this employment of the Y-ligament is on the same principle that was given in the directions for reducing dislocations into the thyroid depression, and the same cautions need not be repeated. Having described at length the process by which a femur dislocated outward may be made to retrace its steps, I will briefly summarize it: The patient lying supine, the surgeon kneels by his side, and if the right femur is dislocated, he seizes the ankle with his right hand and places the bent elbow of his left arm beneath the popliteal space: (1) he now turns the bent leg outward by means of the ankle and lifts upward (skyward); (2) then turns the bent leg inward and brings the femur down in extension.

Often the reduction is extremely simple and can be accomplished

in a few seconds by this method without violence ; should it fail, the method by traction should be adopted.¹

It may be asked at this point, why Reid's method, which often succeeds by magic, should not be recommended ? Reid's method is through circumduction. He labored under the misapprehension that muscular resistance was the chief obstacle to reduction, and that this was overcome by relaxing the muscles in succession, and his unfortunate success in three instances confirmed him in his belief and checked his further researches. Bigelow doubting the theory, but not knowing the true one, found it in the thick band of the capsule, the ilio-femoral ligament, after he had dissected all the muscles away.

I will here analyze Reid's method, which was also adopted by Bigelow, and has been accepted and taught almost universally. In his first step he flexes the leg on the thigh, and carries the flexed knee strongly over toward the pubes. The effect of this is to make a fulcrum of the pelvis, which raises the head of the femur to a level with the socket ; now, while the head is on a level with the socket, the knee is carried upward toward the umbilicus, and outward toward the side. As the knee goes upward and outward the head passes downward and inward, and rises upon the pelvis below the socket. Finally the knee is brought downward in extension, the head passes into the socket, and all is accomplished in the twinkling of an eye.

Now the entire success depends on the remnant of untorn capsule, as Bigelow has pointed out, but not simply upon the remnant of ligament, *but, as Agnew has pointed out, upon the shortness of it.* For if the untorn remnant of capsule compels the head to hug the rim of the socket, then Reid's circumductive sweep will be effectual the instant the head rises upon the pelvis below the socket and the knee is brought down in extension.

But if the rent in the capsule is extensive, then this extensive sweep will place the head so far below the socket that any attempt to bring the head upon the inner plane of the pelvis will be rendered impossible by its striking against the tuberosity of the ischium and the tendon of the hamstring muscles.² While, then, I caution against circumduction as a method of reduction, as its success is based on error, and its employment both unscientific and attended with great hazard, I do so with the most profound respect for one who, if not

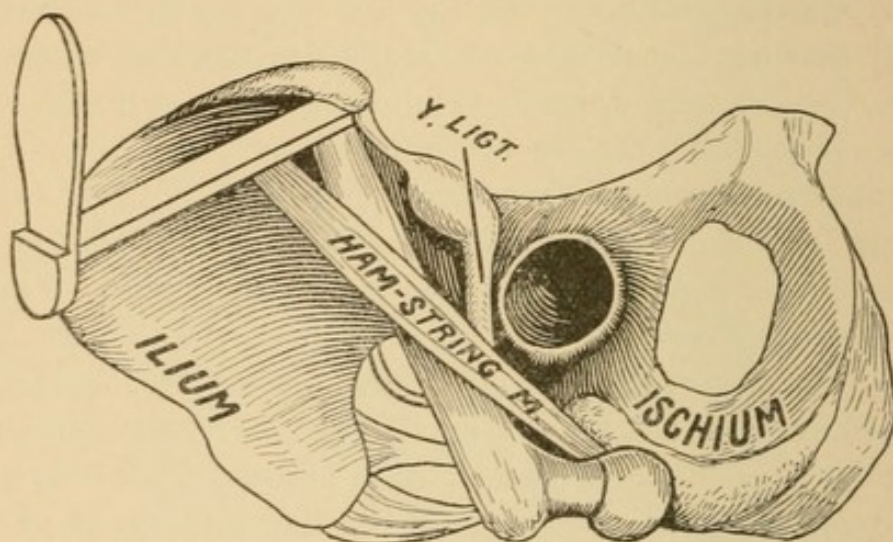
¹ For the advantages of the prone position as a means of reduction, see p. 147.

² See Figs. 48 and 102, and the accompanying text.

the pioneer in the method of reduction by manipulation, was certainly the one to stamp it with confidence, and arrest the attention of the world upon its possibilities.

I have said that the *circumductive* method is attended with danger. The chief reason for saying this is that in the employment of this plan, one hand seizes the ankle and the other is placed *upon* and directs the course of the knee. It is leverage through the femur, the power being exerted at the knee that elevates, *i. e.*, pries the head of the bone to a level with the socket, and to this manœuvre may be added

FIG. 141.



the effect of the remnant of untorn capsule. There is no direct lifting by the operator in this method; its employment does not follow the reverse steps of displacement, and its success is always at the hazard of catching up the nerve.

Obstacles. If the methods described do not succeed, failure in recent cases may be ascribed to:

- I. Lack of skill or facilities in the operator.
- II. Obstacles that prevent the head from entering the socket.
- III. Obstacles pushed into the socket by the head.
- IV. The sciatic nerve hooked over the neck of the femur.

I. Lack of skill or facilities.

Upon this point I need have little to say. I would, however, caution the operator not to get desperate and resort to rash measures in the hope that by a lucky turn he may succeed. By skill and well-directed measures the obstacles may be located and interpreted, while if overcome by ignorance or force it may not be to the advan-

tage of the patient. There are conditions even worse than an unreduced dislocation. When I sent a man home with the sciatic stretched across the neck of the femur permanent dislocation would have been preferable.¹ When Bigelow restored a hip to a partly filled socket, were the dry arthritis and subsequent ankylosis an improvement upon permanent dislocation? When—as has twice happened in Philadelphia—the femur was broken in an attempt at reduction, was fracture added to dislocation a condition preferable to uncomplicated dislocation? or did the result reflect creditably upon the skill of modern surgery? Hence do not, whatever you do, become desperate: remember that obstacles about the socket are like buoys in the channel—they not only point to danger and are to be avoided, but, properly interpreted, they are guides to port.

Failure may be the result of lack of facilities. Anæsthesia, intelligent assistants, and fixation are invaluable aids required by the most expert; therefore, do not prejudice your case by a premature attack.

II. Obstacles that prevent the head from entering the socket; closing the door of entrance or embracing the neck and holding the head in chancery.

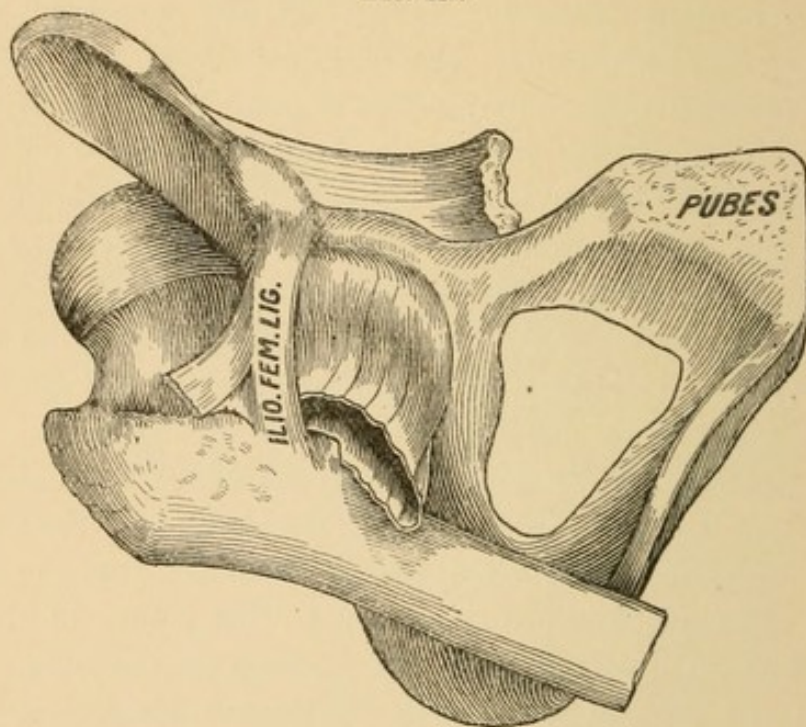
a. The capsule. While I persistently reject the very widespread theory of “slit in the capsule” and “buttonholing by the capsule,” and hold firmly to the statement previously made, that the opening of exit in the capsule is always ample for the return of the head, I quite as firmly believe that the borders of the torn capsule are capable of effectually resisting efforts at reduction whenever those efforts are not made in harmony with the process of eviction. I have repeatedly demonstrated that the rent in the capsule may be ample and afford unobstructed passage for one method of reduction, which by another mode of reduction would be impossible. I have also demonstrated that a change in the relation of the femoral head to the socket after dislocation is capable of creating a formidable artificial buttonholing, but in no instance has resistance withstood gentle, well-directed efforts at reduction.

There is, however, a rent in the capsule that may defy all possible skill. It is that in which the capsule has been chiefly torn from the femoral insertion, leaving the Y-ligament as the only remaining ligamentous band of connection between the socket and the base of the neck of the femur. (See p. 52.) Of this special obstacle Bigelow

¹ See Reminiscences, p. ix.

says that "any difficulty can be easily obviated by carrying the head of the bone toward the opposite side of the socket and thus enlarging the slit."¹ By such a statement Bigelow not only shows that he has never had practical experimental dealing with such a lesion, but his advice is that best suited for making such a difficulty still more insurmountable. Bigelow errs in imagining that he is dealing with a slit. The rent is not a slit in the long axis of the capsule, but is peripheral, the capsule being chiefly torn from its femoral

FIG. 142.



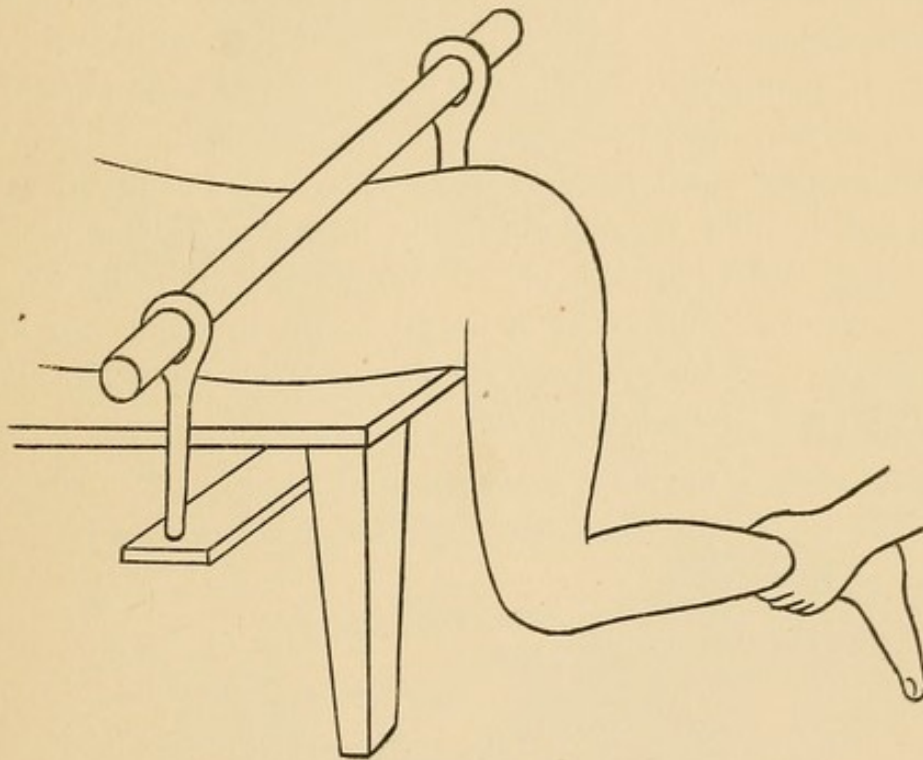
attachment. It is the *situation* of the rent that makes it formidable—not the *size* of it. The long detached capsule now covers the socket like a hood, and no possible manœuvre can "enlarge it." But the manœuvre suggested by Bigelow will have this serious disadvantage. When the rent is peripheral at the base of the neck—if the cuff of the capsule is still attached to surrounding muscles, which renders reduction, when properly attempted, still possible—I have repeatedly in rapid succession restored such a dislocation by direct replacement with as much ease as could be desired; but when I have detached the muscles from the capsule by shifting the head to the opposite side of the socket, as Bigelow directs, I have found, upon returning to the method previously employed with success, that

¹ The Hip, by Henry Bigelow, pp. 33-34. Philadelphia: H. C. Lea, 1867.

reduction was no longer possible except by pushing the capsule, now loose and disengaged from its muscular attachments, before the head into the socket. I therefore fully agree with Gellé, Malgaigne, Gunn, and others that this is a complication that may be insurmountable.

The position I found most favorable for reduction under the circumstances just mentioned is the one depicted below. It is mentioned by authors, but its merit has not been sufficiently dwelt upon. The subject was placed prone with the thigh hanging over

FIG. 143.



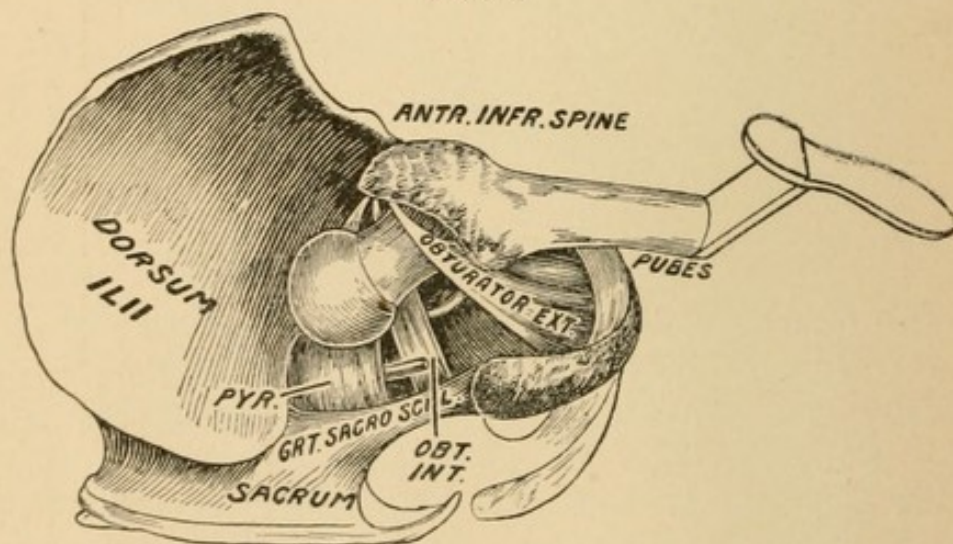
the corner of the table. In order to support the pelvis and sound limb a second table was employed. In this position the pelvis can be readily secured¹—a condition that I am certain contributed greatly to my success. The prone position has this advantage over the supine, in that it is assisted by gravity. The head, when the thigh is flexed to a right angle, lies directly above the socket, and the weight of the leg and thigh has a natural tendency in the right direction. To favor the descent of the head the ankle may be drawn outward and rocked a little, or pressure be made directly over the head or in the popliteal space. The advantages of this posi-

¹ The mode of fixation I employed is, of course, not possible in actual practice, but my success experimentally was largely attributable to it.

tion are that limited circumduction can be practised, while the weight of the limb, increased, if necessary, will always be an aid in directing the head toward the socket.

b. Muscles. Dislocations that are readily reduced, *i. e.*, that offer no resistance, are probably accompanied with free laceration of capsule and muscles. As already mentioned, the outward dislocations are usually damaging to the obturator internus, while if the dislocation were first thyroid and secondarily dorsal, then the obturator externus and quadratus femoris are necessarily torn in two. It is possible for dislocations to occur without destroying muscular fibre, *i. e.*, for a dislocation to occur between two muscles without injuring either. In such a case it is hardly fair to say that the muscles escaped by a lucky dodge—it may be nearer the truth to say they escaped by their own power of resistance. The endurance of a strong, live, healthy muscle cannot be measured by contrasting it with a dead, cold, rigid piece of lean meat. It is therefore impossible to arrive at the difficulties of actual life by investigations in the dissecting-room. Probabilities are our nearest approach, and to some of these I now ask attention.

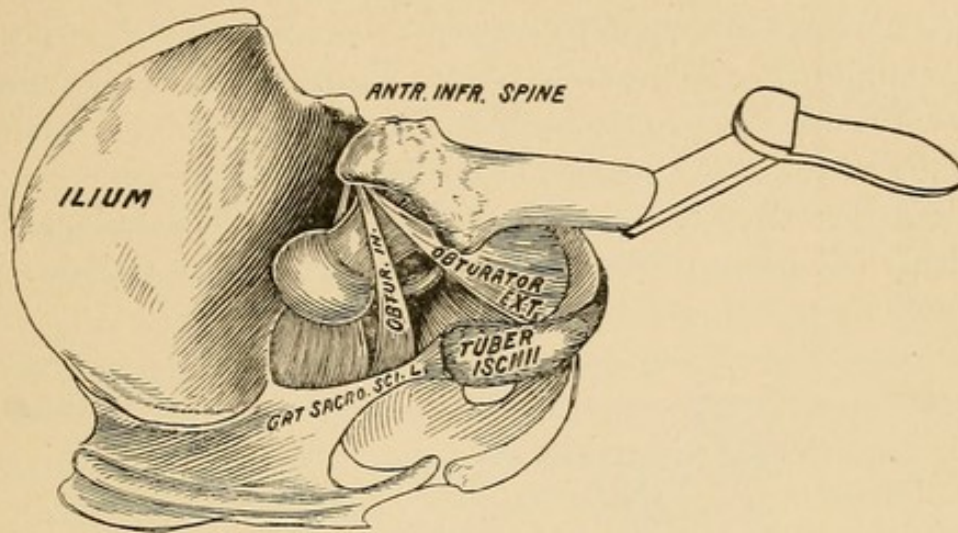
FIG. 144.



In the pathology of recent dislocations the head has been found between the obturator internus and externus. (Fig. 144.) Now there can be no possible buttonholing between these muscles, yet I am persuaded that by Reid's method—*viz.*, by flexing the knee, carrying it first toward the pubes, then up toward the umbilicus, then upward, outward, and downward in extension—embarrassing difficulties may

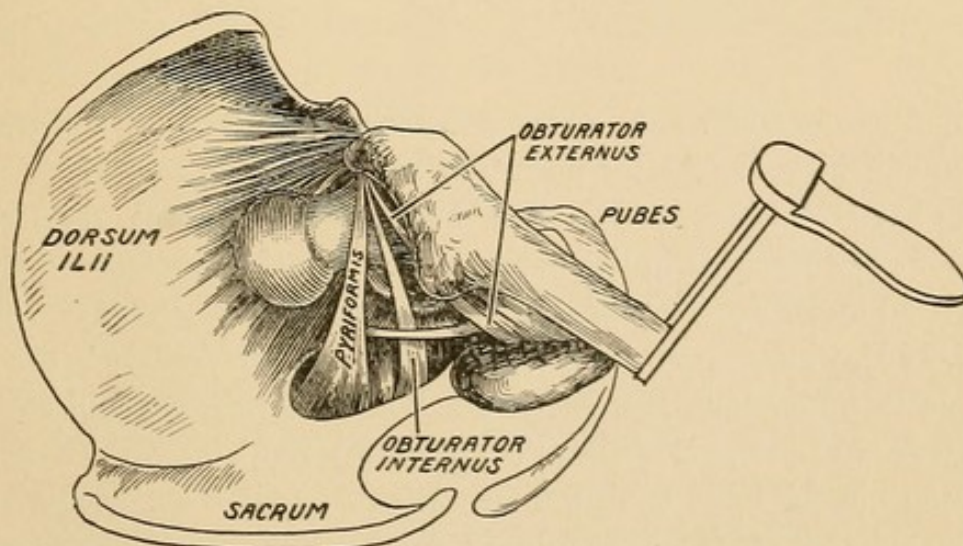
be created. As the knee takes its upward and outward path, the head passes downward and inward and will tend to rise upon the ischium. Whether through circumduction the head will be arrested

FIG. 145.



by the tendon of the obturator externus, or whether the quadratus femoris will become interposed, are speculative, but not improbable obstacles. They would not, however, be possible if the method of direct replacement were employed, as mentioned on p. 138 *et seq.*

FIG. 146.

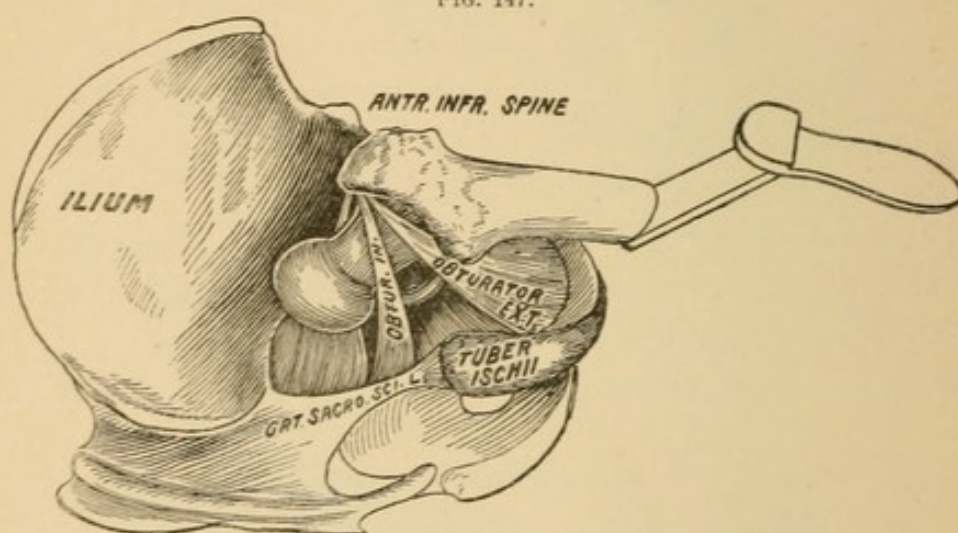


Again, the head of the femur has been found in autopsies between the obturator internus and the pyriformis (Fig. 145). And also above the pyriformis (Fig. 146). The question I wish to propose is,

Could either of these dislocations be restored by the usual modern methods of manipulation? Flexion, circumduction, and rotation might disengage the head and then reduce it—but what if they could not disengage the head? Would the conversion of a dorsal into a thyroid rupture the tendon of the obturator internus or that of the piriformis? Is it not a fair inference that muscles which could sustain, uninjured, the strain put upon them of the head bursting between them, could also sustain the strain of a much feebler force, viz., the efforts of the surgeon at manipulation?

Sir Astley Cooper, in attempting to reduce a dislocation, had it suddenly slip into a position which he believed to be the sciatic notch,

FIG. 147.



from which he could not extricate it. Surgeons have tried in vain to explain what Sir Astley meant by his advice to avoid this notch. Some have even imagined that the head passed through the foramen or got entangled in the bony notch. Bigelow interprets it that the head *ascended behind the tendon of the obturator internus* (Fig. 144), which prevented the reduction by pulleys. It is difficult for me to understand how the great London surgeon could so long persevere in the use of pulleys if this most frequent variety of dislocation should have baffled him. Be this as it may, Bigelow has truly said that no such imaginary danger can exist if one adopts flexion as a first step in reduction. But I have been baffled by the very methods that the great advocate of flexion believed were invincible.

I ask the reader now to turn back to the case of J. H. M.,

Reminiscences, p. xi., and read it carefully. Here was a recent case, in which in attempts at reduction the head passed repeatedly and unobstructedly from the outer to the inner planes of the pelvis and back again, but when the head approached the socket something barred it. In this case there was no engagement in the sciatic notch, no filling of the socket, and no obstruction from the capsule. I have often sought an explanation of the difficulty, and the only one that is in the least degree satisfactory is that, in the dislocation outward, the head passed directly between the obturator internus and the pyriformis (Fig. 147) without rupturing either. That this is possible can be shown by reference to pathology, p. 69, Case XI., but it cannot be demonstrated upon the cadaver with stiff, brittle, or disintegrating muscular fibre. While, therefore, I cannot substantiate the theory I have adopted, my reasons for accepting it are these: If those muscles had the strength to withstand, without rupture, the head bursting between them, it seems not incredulous that they could withstand a much weaker force, that of man's strength in his efforts at reduction. The nature of the entanglement, which I denominate in chancery, seems to me to account for our defeat. If the head were clasped between the tendons of these muscles, none of the ordinary efforts at reduction would avail. Sir Astley's extension with pulleys would do no good. With circumduction the tendon of the obturator internus might have been ruptured; but if it were not, it seems to be just in the position to bar effectually all entrance just at the door of the socket. In our efforts at reduction we circumducted after Reid, used Despres' method, jerked upward (Bigelow), and everything that a full force of surgeons could, on two separate occasions, suggest, but to no purpose. Acting on the supposition, then, that the head lay in chancery, *i. e.*, buttonholed between the obturator internus and the pyriformis, I would suggest the following method for dislodgement and restoration:

By a glance at Fig. 147, it will be evident that neither extension with pulleys, circumduction, nor rotation could be instituted in answer to the question, "how to make the head retrace its steps." To do this the most feasible procedure would be to draw the head toward the socket, but as the head rises the neck will be grasped all the more strongly by the tendons of the muscles. Now, while the knee is drawn inward toward the pubes, and the head made to approximate the socket, let an attendant hold the head in this position,

while the surgeon, using the upward pressure of the assistant as a fulcrum, carries the knee outward. This will compel the head to seek the interspace between the muscles, and, once that it has passed through, the reduction is virtually accomplished.

I desire to state again that this is purely theory, but a theory only put forward after other theories of this special obstacle to reduction have been explained away.

III. Obstacles pushed before the head into the socket—subluxation.

I have never been able to comprehend what authors mean by subluxations. There are but three possible positions for the head of the femur, viz., entirely outside of the socket, on the rim of the socket, and within the socket. If the head lie outside, the deformity will be great; if it lie upon the rim, the deformity will be greater; while the only position in which deformity disappears, or nearly disappears, is when the head lies in the socket. In all the alleged cases of subluxation the deformity has been trifling, and corresponds to what I have experienced when in experimental work I have pushed the capsule or portions of the obturator externus before the head into the socket.¹

In experimental work I have known four conditions to interfere with complete reduction. By incomplete reduction I mean any condition that interferes with normal movements, as adduction and extension. These four conditions are (1) muscular débris, (2) portions of muscles, (3) inversion of capsule, (4) hooking up the of sciatic nerve. All of these have been discussed in the Introductory Study.

In the first three the head is prevented from sinking to its normal depth into the socket. A few points are worthy of mention.

(1) Reduction of the head into a socket cushioned with muscular or capsular material will not be accompanied with the *report* and sudden succussion that take place when naked cartilage strikes upon naked cartilage.

(2) If the socket is partially filled, the normal movements of adduction and extension will be interfered with. Such embarrassment should be regarded as a valuable exponent of the condition present, which, if properly considered, will not be met by forced extension of the knee, a resort that temporarily helps the signs by mashing or

¹ For the removal of portions of capsule or muscular fibre from the socket, see p. 107.

compressing the foreign substance, but will not aid the patient or facilitate the removal of the foreign body.

(3) If the socket is partially filled, redislocation is extremely probable. Redislocation may take place as the result of fracture of the rim or imperfect reduction, due to a partially filled socket.

Points in regard to fracture of the rim :

(a) The fracture occurred prior to the dislocation. It could not have taken place after it ; in other words, the dislocation was the result of the fracture.

(b) No rent in the capsule took place in its continuity, but the rent was through the fractured rim, *i. e.*, the capsule retained its attachment to the fragment ; the main rent was peripheral, not longitudinal.

(c) Reduction would probably be easily accomplished, attended with bony crepitus ; attended also with complete extension and adduction.

(d) No constraint would attend reduction.

(e) Redislocation would probably attend the withdrawal of manual support, and be accompanied with crepitus.

Points in regard to restoration into a partly filled socket :

(a) Reduction will be unattended with succussion or jar. This is especially true when the material drawn before the head is considerable.

(b) *Constraint.* The incomplete reduction will make tense the ilio-femoral ligament and arrest the femur at a point before normal extension or normal adduction is reached.

(c) Crepitus will be absent.

Observation. The importance of a proper diagnosis in such a case is apparent, since in case of fracture of the rim rest and retention will facilitate perfect recovery, while rest and retention with foreign material in the socket will be attended by inflammatory processes or redislocation on the first change of position.

See cleaning out the socket, p. 107.

IV. *The sciatic nerve.*

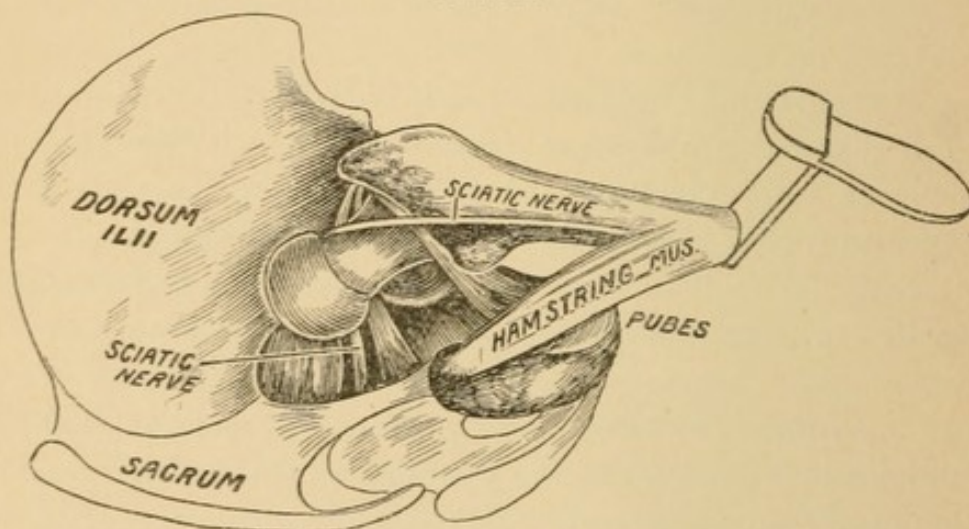
The implication of the sciatic nerve, with dislocations of the femur, has never seriously engaged the attention of the medical profession. In introductory studies I have quite fully explained the anatomical relations of the nerve to the normal and dislocated hip. (P. 28.) I shall here refer to the signs and diagnosis, and suggest a course of procedure in case the nerve is caught over the neck of the femur.

The possible dangers to the nerve are from dislocations outward, and these may be divided into two classes, viz. :

- (a) Danger to the nerve from the mere act of dislocation.
- (b) Dangers that arise from the efforts at reduction.

Danger from dislocation. The nerve may be caught up by the neck in the mechanism of dislocation. On p. 62 a pathological representation is given. The nerve has been caught up with such force as to cause its complete rupture. Every degree of impaired function is recorded, from pain and feeble action to total paralysis. I believe the mishap is likely to occur either when the dislocation is primarily inward and consecutively by a continuation of the vulnerating force converted into a dorsal, or when a direct dorsal is produced

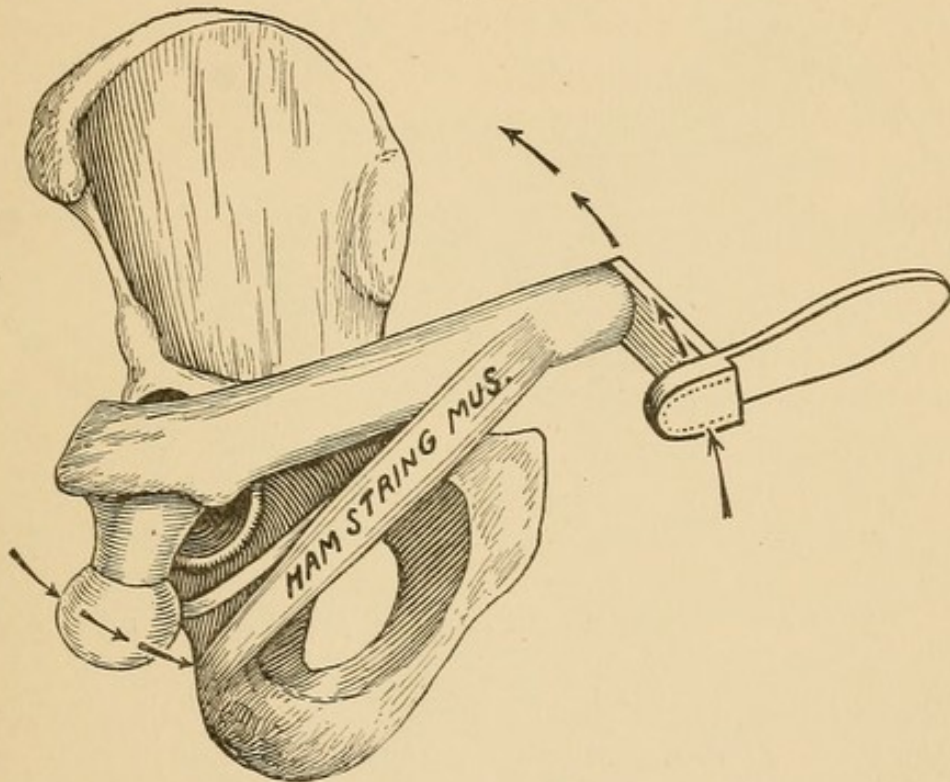
FIG. 148.



by flexion, abduction, and rotation inward. Under the former conditions, if the thigh is made to take a large circumductive sweep, the head will pass outward, rubbing strongly against the common tendon of the hamstring muscles, and detaching, if not hooking up the nerve. Such a mishap will not complicate in the least the ease of reduction, but, if the nerve has been seriously injured, an acute neuritis or paralysis may ensue, and it would be greatly to the advantage and credit of the surgeon if he could anticipate so grave a sequel. The possibility of ascertaining that the nerve is hooked over the neck rests chiefly on what can be felt in the popliteal space. When the hip is in its socket the hamstring tendons can be made tense and prominent. After dislocation they are relaxed. To push upon the knee in the direction of the long axis of the femur would still further relax these

tendons, but would tend to tighten the nerve if it had been caught up over the neck. (Fig. 148.) Extension of, not traction upon, the entire limb would not make the hamstring tendon taut if the head were dislocated, but such extension would make the nerve more tense were it caught over the neck. It is, therefore, possible to ascertain, before any attempts have been made at reduction, that the nerve has or has not been caught up.

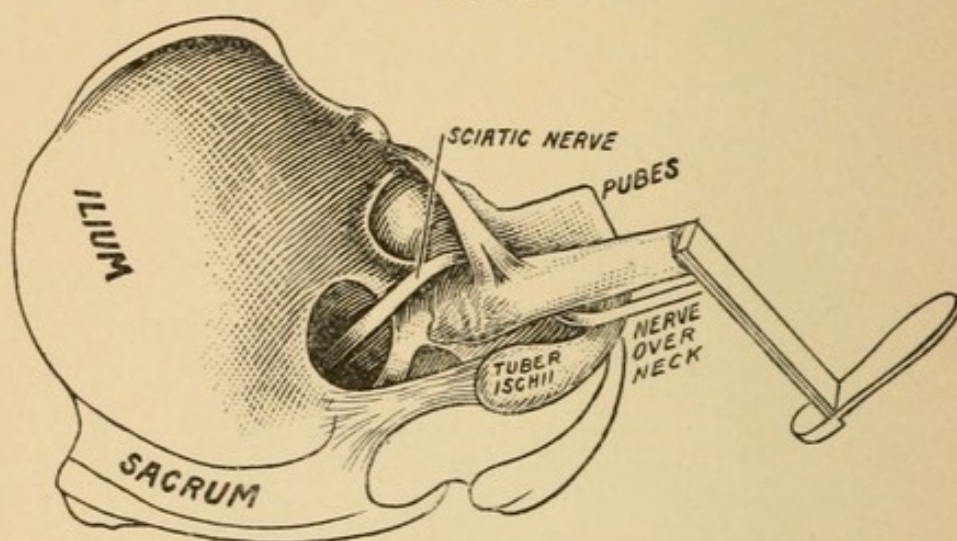
FIG. 149.



If the nerve has not been caught up, then the head lies outside of it, and must cross or approach it in its passage to the socket (Fig. 149). This is a matter of far more practical importance than it has ever received, and here I wish, again, to call attention to Reid's method of reduction. The underlying principle of this method is to relax the muscles, and to accomplish this he directs the knee to be carried over toward the pubes, thence toward the umbilicus, thence upward and outward, and completing it by bringing the limb down in extension. Gross and Agnew taught that the knee should be made to approach well the body as it made its large circumductive sweep. The danger in this consists in the fact that the greater the circle taken by the knee the larger will be the circle taken by the head. Such a sweep will force the head well down upon the tuberosity of the

ischium, and as the knee is carried outward and the head moves inward, the tendon of the hamstring muscles will be struck and hugged as the head passes toward the socket. (See arrows, Fig. 149.) I have demonstrated (Fig. 36) that one of the easiest, if not the easiest, methods of producing a dislocation is by abduction, and if the dislocation is primarily inward, and consecutively outward, the quadratus femoris¹ has been torn in two and its connection to the nerve destroyed.

FIG. 150.



Often when the head does not catch up the nerve in its outward progress, it tears it from its muscular attachments, and leaves it a loose, lifeless, dangling rope, barring the entrance to the socket, and compelling the head to strike it squarely, or slip to one side in its progress to the socket. Under such circumstances, if the large circumductive sweep were designated for the especial purpose of catching up the nerve, it would be most admirably adapted to the purpose.

At times the nerve thus disengaged becomes a veritable obstacle. Over and over I have brought the head against the nerve, which, flattened by pressure, refused to slip from the head, and thus offered a formidable barrier to the socket. The normal nerve is often the size of the little finger and may be flattened to an inch over the head, as it presses against it.

When the nerve is hooked over the neck it offers no marked resistance to reduction, and the head returns to the socket with suddenness

¹ If the dislocations were directly outward, and due to flexion, abduction, and rotation inward, the quadratus would probably be torn from overstretching. For the relations of the quadratus and nerve to the socket, see Figs. 21 and 50.

and succussion, common to all successful reductions. It is, therefore, extremely important in every case that the safety of the nerve should be ascertained before the case is dismissed.

Signs. If the nerve has been caught up, the immediate effect will be flexion of the thigh upon the pelvis, and of the leg upon the thigh, owing to the sudden *shortening* of the nerve. The change in the course of the nerve will take up three or four inches of it, and render normal extension impossible. There will be imparted to the limb a springing motion, which it can get in no other way.

Diagnosis. There are two conditions that will produce a flexion of the thigh upon the pelvis as the result of imperfect reduction, viz.: the nerve over the neck of the femur, and foreign material as capsule or muscular fibre within the socket, and both will be influenced in the same way by lapse of time. In both the flexion will be greatest immediately after reduction. In case of the nerve it will stretch and let the knee down; in case of foreign matter in the socket pressure from the weight of the limb will cause the limb to descend. The only diagnostic point is that furnished by the tense cord-like nerve in the popliteal space, which can be made to rise and disappear by extension and flexion of the leg on the thigh.

Treatment. I know of no more unpromising task than that which proposes to disengage the nerve from its new position, and in this the reader will agree with me when he considers:

1. The nerve has been detached from all its normal surroundings. It is normally connected, after its exit from beneath the pyriformis, to the gluteus maximus, hamstring tendon, the obturator internus, quadratus femoris, and adductor magnus. From these it has been torn, so that they can exercise no longer any control over it.

2. The nerve has been stretched and flattened over the neck, its sheath torn, its fibres separated.

3. It lies in a region into which blood has been poured; muscles torn and minced by efforts at reduction. If there has been a delay in discovering the position of the nerve, inflammatory products will tend to glue all the torn area together.

4. The only means available to disengage the nerve from the neck is to put the neck of the femur in such a position that the nerve will drop off; and here we must remember that the adhesion through fibrin and lymph to torn muscles will be far greater than the weight

of the loose, flabby nerve, upon which one can only bring gravity to aid in detaching and displacing it.

Hopeless as the situation is, the operator has but one course to pursue—namely :

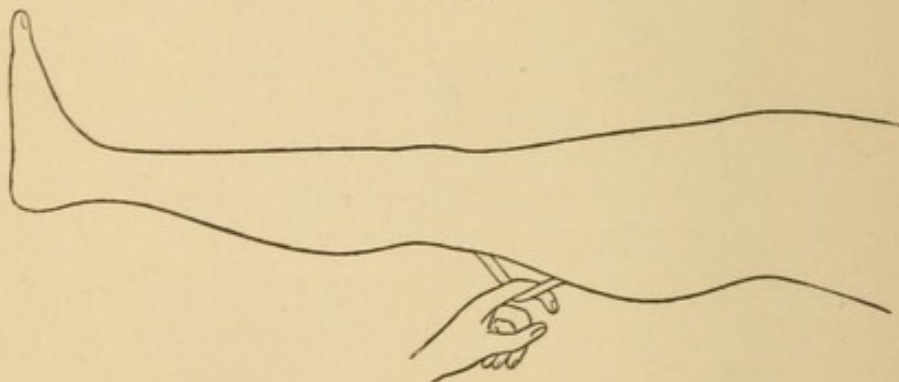
1. Redislocate the femur ; patient supine.
2. Extend the thigh.
3. Flex the leg on the thigh to relax the nerve.
4. Turn the ankle of the flexed leg out until the leg is horizontal. The head will now look perpendicularly downward.

5. Shake, rock, jar, adduct, and abduct, with a view to disengage the nerve from the neck, and make it drop down below the level of the head.

6. Rotate the head into the socket without making the nerve tense—*i. e.*, by not flexing the femur.

Assuming that no human skill can avail under the circumstances, I would suggest the following course: Cut down upon the nerve in the middle third of the thigh above the upper part of the popliteal space, seize it and draw upon it. This will take up its slack and make the nerve take a direct course from its exit from the pelvis to the point of traction. This course will be below the level of the head. The head can now be detached and rotated into its socket, the nerve itself communicating to the finger its release or any further entanglement.

FIG. 151.



The advantage of reaching the nerve at so great a distance from the seat of injury is that it furnishes a clean wound and easy access to the nerve without admitting air to the vast pulpified, disintegrated area of traumatism about the articulation. After reduction the nerve can be made to re-enter the wound by flexing the extended limb.

Dislocation of the Head of the Femur Complicated with Fracture of the Shaft.

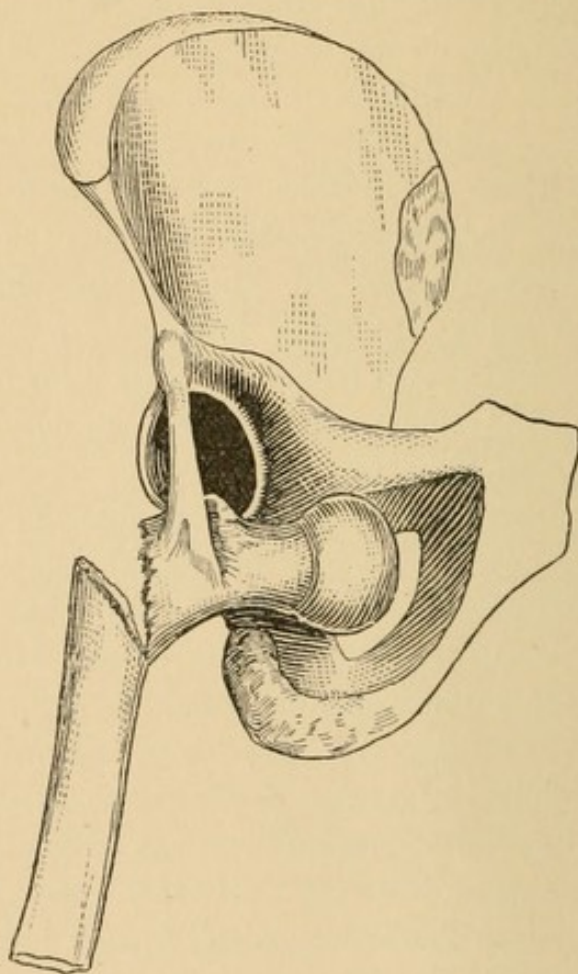
The diagnosis of such an injury will be difficult in proportion to the high position of the fracture and the degree of swelling, fat, and muscle surrounding it. Our chief reliance in detecting fracture must be in locating the upper fragment and satisfying ourselves that it is or is not affected by rotation of the shaft. If the fracture lies at the junction of the upper and middle thirds, or just below the great trochanter, the diagnosis of fracture will be facilitated by the projection of the lower end of the upper fragment. How, in addition to fracture, to make a diagnosis of dislocation in a recent case I am at a loss to state. I know of three instances—two in which the dislocation was inward and one in which it was outward—in the practice of surgeons of large hospital experience in which the element of dislocation was entirely overlooked. Such an oversight cannot with fairness be classed among “surgical blunders,” nor justified by the rarity of the injury, but must be classed with injuries whose precise nature, owing to their concealment, cannot be positively diagnosticated by other than open methods.

In every case of which I have a knowledge the upper fragment was conspicuous for its prominence and its intractability. In some instances of *uncomplicated* fracture of the upper third of the femur the upper fragment will transfix the vasti muscles which surround it, and, thus transfixed, will successfully resist the usual efforts at apposition. In one such case, after anæsthesia, I flexed the femur well on the abdomen, and with my foot in the fold between the thigh and the abdomen made counter-pressure while I exerted traction at the knee in the long axis of the shaft. By this means I released the fragment from the transfixed muscle, and when I brought it down in extension the projection of the upper fragment had disappeared. This, however, would not be the case if dislocation of the head of the femur were present. Deformity would be persistent. I therefore repeat, that while I know of no means other than palpation for recognition of the dislocation, I would state that persistent deformity under ether should lead to the suspicion of dislocation.¹

¹ To facilitate diagnosis Agnew once suggested, in a public discussion of this difficulty, the employment of a long needle to explore the acetabulum. Taking advantage of this suggestion, I would not hesitate to make an incision over the region of the socket sufficiently large to permit of digital examination. The incision need not go beneath the fascia lata, would be perfectly harmless, and would enable the surgeon to establish beyond peradventure the presence of the head in or its absence from the socket.

The difficulties of reduction of the dislocation will vary with the position of the fracture. The reader must fully appreciate the principle upon which success is based—viz., that the upper fragment, the part extending from the head to the point of fracture, is our entire lever now, and that the part of the femur from the fracture to the knee is only the agent through which we apply our force. If, as in Fig. 152, the head and neck, *i. e.*, the weight-arm, were

FIG. 152.



three inches long to the position of the fulcrum (the insertion of the Y-ligament), and the power-arm only two inches from the fulcrum to the point of fracture, the short power-arm would act at a great disadvantage, whereas, if the power-arm were equal to or longer than the weight-arm, the power would act to better advantage. Again, the only mode of acting upon the power-arm is through its connection with the long fragment of bone. The connection, between the fragments, partly periosteal, partly tendinous, and partly mus-

cular, enables us to make traction upon the power-arm in any direction, but precludes all efforts at rotation, circumduction, and leverage through the agency of the lower fragment. In every dislocation of the head of the femur complicated with fracture of the shaft the mechanical powers upon which we are to rely for reduction are :

a, the power-arm of the lever extending from the fracture to the fulcrum ; *b*, the fulcrum, viz., the ilio-femoral ligament, extending from the lower iliac spine to the oblique line of the femur ; *c*, the weight-arm of the lever, viz., the part extending from the fulcrum to the extremity of the head ; and, *d*, the power exerted upon the extremity of the power-arm. So far as the power is concerned, it could be as advantageously exerted through a strong cord attached to the free end of the short fragment as through the part of the limb below the injury. If, therefore, the operator would not attempt to make a lever out of a dangling rope, nor with it attempt to rotate or circumduct, but confine himself simply to pulling with it, he will understand what I am insisting upon, viz., that the only agency at our command is *traction*. And yet with it this difficulty can be overcome.

Reduction of Dislocation of the Head of the Femur Inward Complicated with Fracture of the Shaft in the Upper Third.

In such a case the head must be drawn outward until it lies as near as possible to the socket. (Fig. 153.) Traction outward may, with direct pressure, reduce the head. If not, the head must be held in the position beneath the socket by an assistant (Fig. 154, *A*) to prevent its slipping back into the thyroid depression, while the surgeon reverses the direction of traction and makes it inward or obliquely inward and downward. (Fig. 154, *B*.) The effect of this will be to place the lever in an erect or semi-erect position, and while traction compels the power-arm to follow it in the direction of the force, the other extremity of the lever, viz., the weight-arm, will travel in the opposite direction, viz., obliquely upward and outward into the socket.

FIG. 153.

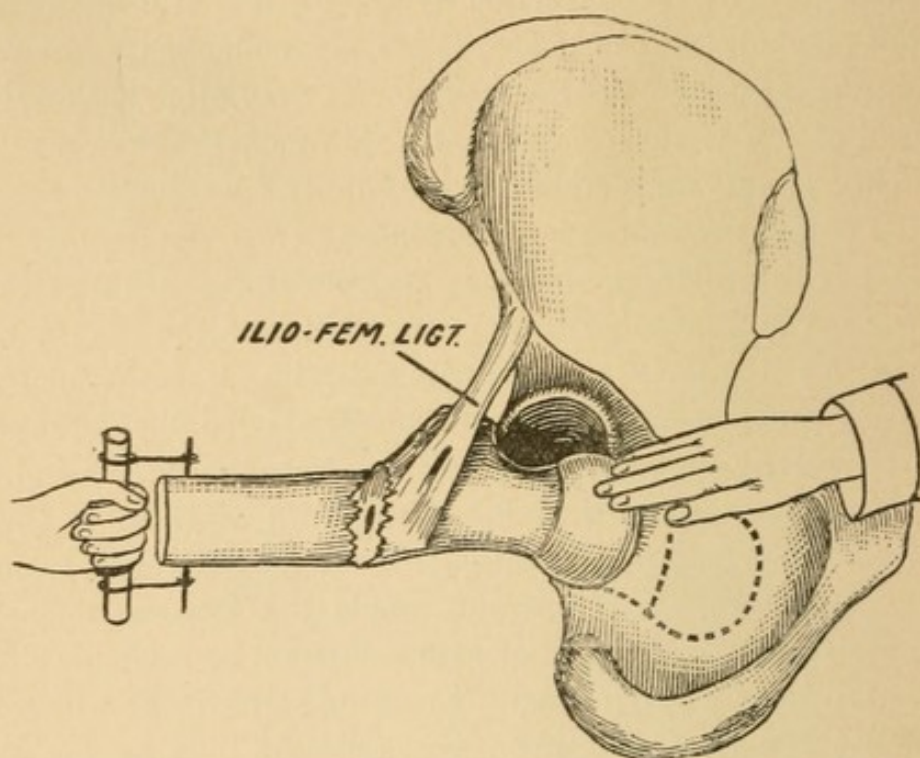
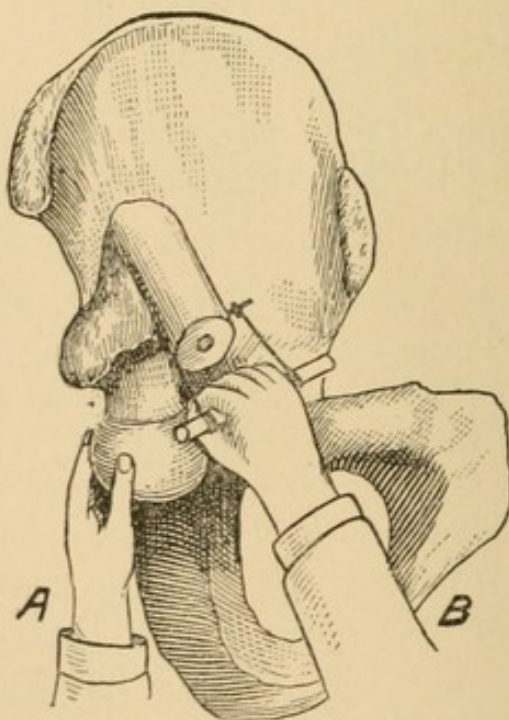


FIG. 154.



Fracture of the Shaft with Dislocation of the Head of the Femur Outward.

The principle is precisely the same as in the preceding. The first question to be considered is, In what position was the shaft at

FIG. 155.

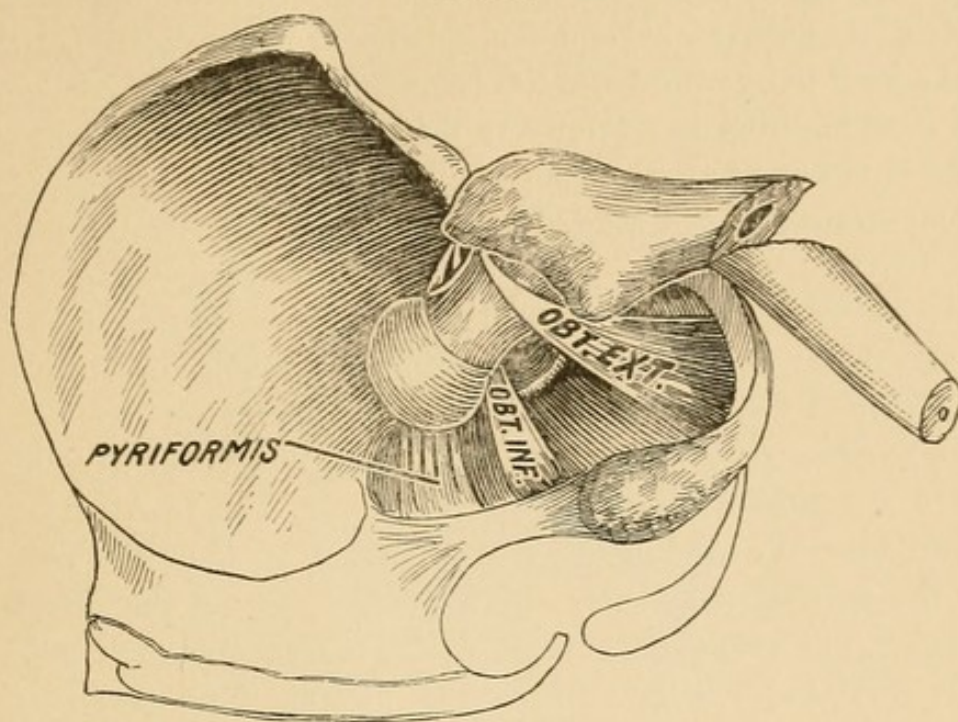
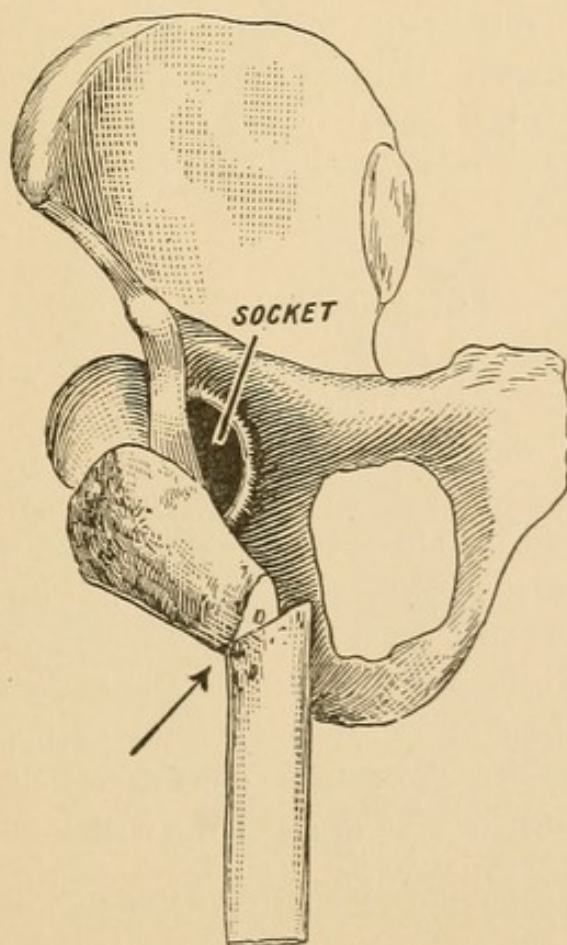


FIG. 156.



the instant the head left the socket and fell outward? This cannot be positively asserted beyond the belief that it was nearly vertical. As the head fell outward and lies below the level of the socket, the head must be lifted to a level with the socket as a preliminary step. There is but one way of raising the head to a level with the socket in complications of this kind, *i. e.*, through traction directly upward. (Fig. 157.)

*There is no possible hope of retracing the last step if this is imperfectly done; hence, in lifting upward the operator must be certain that the head follows.*¹ *Having lifted the head to a level with the socket, it must be placed over it.* To do this, traction obliquely upward and inward must be instituted. (Fig. 158.) All this time pressure upon the head or trochanter must be made by the assistant as in the previous case—not with a view of pushing the head into the socket, but with a view of preventing it from slipping back.

The head has now been brought to the rim of the socket, as in the preceding case, and now as a last step the traction made upon the end of the short fragment compels the tightening Y-ligament to drag the head into the socket. (Fig. 159, p. 166.)

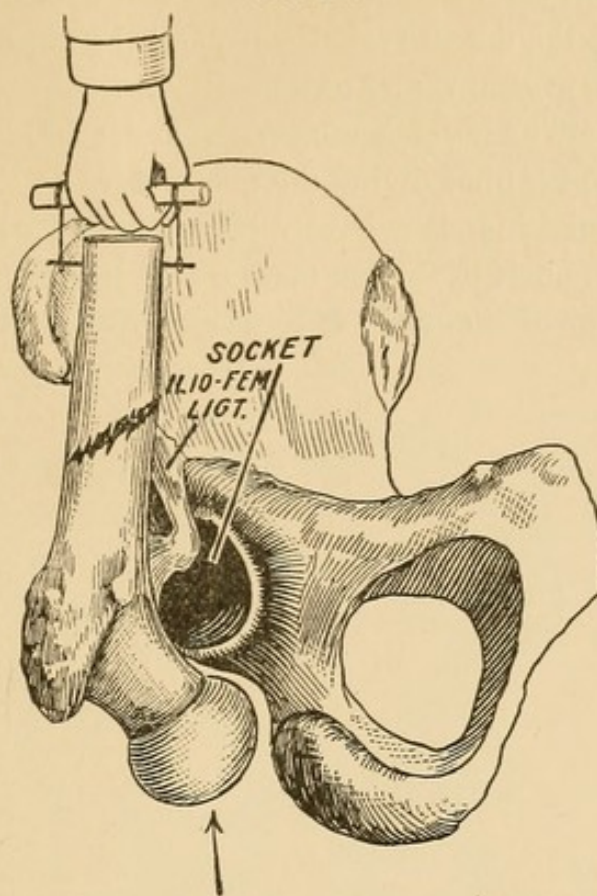
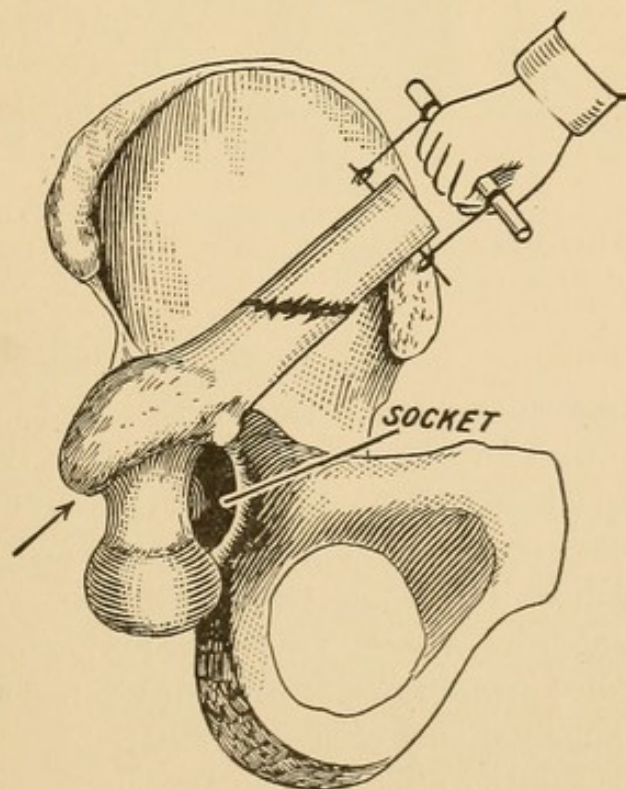
Although what I have said upon the reduction of dislocation accompanied with fracture is based entirely upon experimental work, yet the principle is the same as that in which no fracture is present, a principle that has established its correctness through universal clinical experience.

If the head of the femur in any dislocation cannot be restored, what course shall be pursued?

- I. Shall the case be abandoned?
- II. Shall the surgeon resort to tenotomy?
- III. Shall he be bolder and resort to open measures?

I. Shall the case be abandoned? If so, what will be the ultimate result? *Ans.* A moderately useful limb with fixation, probably ankylosis. The efforts at reduction have pulpified the muscles, have worn a bare-bone pathway from thyroid to dorsal; have scored and denuded the head of its covering; hence ankylosis is probable. In abandoning the limb the surgeon may deposit it in the thyroid region, if he desires to give his patient a useful walking limb, with

¹ The advantage of immobilization of the pelvis as a preliminary step cannot possibly be over-estimated. See p. 75.

FIG. 157.¹FIG. 158.¹

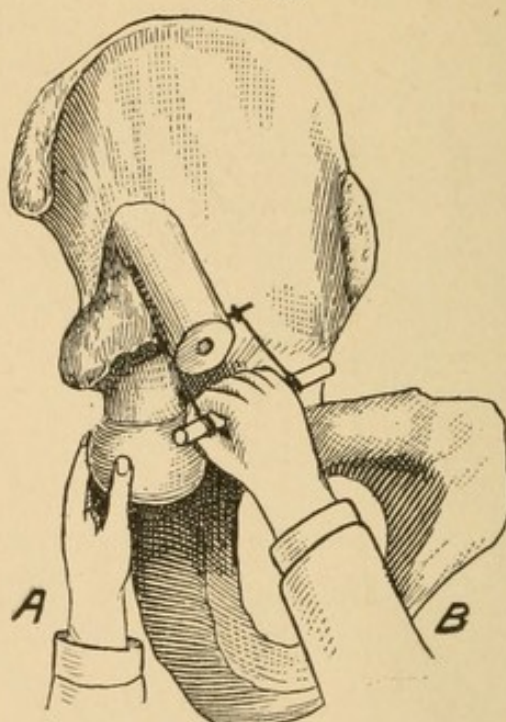
¹ The arrows in Figs. 157 and 158 represent the assistant, who makes direct pressure upon the head and follows it upward.

trifling limp; but, from a comparatively small experience, I incline to the belief that the dorsal region will yield the most active limb.

II. Shall the surgeon resort to tenotomy?

I answer, no. The obstacles to reduction are so many and varied that if the surgeon cannot divine the true nature or character of the one that is opposing him, it is hardly likely that he will be fortunate enough to overcome it by such a measure as tenotomy. The chief argument in favor of tenotomy is that suppuration may be avoided.

FIG. 159.



A represents fixation of the extremity of the weight-arm, *i. e.*, the head of the femur after it has reached a favorable position *below* the socket (Fig. 158). B represents traction upon the extremity of the power-arm.


This might be true were one dealing with a healthy area, but under the present circumstances there is danger from such a procedure. In the only case in which I attempted tenotomy—a dorsal of eight weeks' standing, that had been subjected to repeated trials at intervals by different surgeons—I succeeded in placing the limb in a position simulating reduction, if I was not entirely successful; but within a few days, an extensive abscess formed, requiring open measures. Were I to be called upon to decide between abandonment and tenotomy I would unhesitatingly choose the former.

III. Shall the surgeon resort to open measures?

If he has the courage to do his work well and thoroughly, I be-

lieve that open work will not endanger the life of the patient, and is the only rational procedure.

Operation—Suggestion. Place the patient prone and locate the head. If the dislocation be dorsal, draw a line from the head upward, parallel with the long axis of the body. Draw a second line at right angles to this, beginning at the selected point. Bisect this angle, and it will show very closely the direction of the fibres of the gluteus maximus, which should be the direction of the incision. These fibres may be easily separated. The wound must be ample to admit the hand. The obstacle must not only be overcome, but the socket must be cleansed, and the pulpified muscular structure and entire cavity cleansed out. Drainage with gauze for a day, then removed and the wound permitted to heal.



INDEX.

ANATOMY, 3

Atmospheric pressure, 7

how prevented in the socket, 8

CAPSULE functions, 13

strength of, 17

resists external rotation, 45

size of rent dependent upon manner of attack, 51

rent in classified, 52

cuff of, 64

torn without injury to muscles, 66

Circumduction, danger of, 58

discussed, 109

DISLOCATIONS, general division of, 5

of both hips, vi

recent, J. H. M., xi

altered relations after, 71

after restoration, 73

steps, illustrated, 80

mechanism and effect, résumé, 89

phenomena of, 90

signs and symptoms of, 91

diagnosis of, 103

measurement of, 105

nomenclature of, 113

dorsal, with eversion, 133

outward, manipulation of, 159

inward, manipulation of, 119

direct method of, 119

indirect method of, 125

FASCIA lata, diagnosis in fracture of neck of femur, contributes to the security of the hip-joint, 22

voluntarily relaxed in hip-joint disease, 23

Femoral vessels, immunity from danger, 18

Femur, head in socket, 9

Fixation, 75

apparatus used in experiments, 39

Fulcrum, femur as a, 41

wanting, 42

ilio-femoral ligament as, 43

HAMMOCK function of fascia lata, 23

Hamstring muscles, guardians of sciatic nerve, 35

Head of femur, relation to socket, 9

ILIO-FEMORAL ligament, 13

never torn from its subspinous attachment, 51

Ischio-femoral ligament, 15

LESIONS in capsule, 49

Lever, when femur can be used as, 40

Ligamentum teres brings thin scale of bone away, 67

MUSCLES, how torn in dislocations, 56

obturator and quadratus, torn, 59

lesions, résumé, 59

obturator internus, tendon torn from, 68

untorn in dorsal dislocation, 69

PATHOLOGY, 61

Pectineo-femoral ligament, 13

Pelvis, fixation of, for experimental work defended, 38

shape of, 4

fracture of, due to efforts at dislocation, 46

Planes of pelvis, 5

Propositions, 2

Pubo-femoral ligaments, 14

REDUCTION, aids and obstacles in, 73

Reminiscences, v

Rotation discussed, 10

SCIATIC nerve hooked up through reduction, Dr. Koons' case, viii

Dr. Johnson's case, x

relations to dislocations of, 28

protected against overstretching, 28

hooked over neck, mechanism of, 33

how influenced by abduction and adduction, 34


caught, pathology, 62


manipulation to remove, 156


Socket divided into equal parts, 3


situation of,

- Socket felt after dislocation, 5
 security of, against displacements, 7
 retentive function due to atmospheric pressure, 7
 retentive function distributed between suction-ligaments and muscles, 7
 security of, 7
 vacuum prevented, 8
 cleaning out, 107
- Sucker ligament, 7
- Suction. (*See* Atmospheric Pressure.)
- TERES, ligamentum, anatomy of, 9
 functions of, 10
 how torn from the head, 11
 summary of functions of, 12
- Thrust, theory opposed, 84
- VACUUM in socket prevented, 7
- Y-LIGAMENT, 13
 Prof. Bigelow's description of, 18









COLUMBIA UNIVERSITY LIBRARIES (hsl.stx)

RD 101 A15 C.1

An inquiry into the difficulties encountered



2002103958

RD101

A15

Allis

Dislocations of the Hip.

M. Kavanagh.

MAR 29 1948

