Surgery; its principles and practice, for students and practitioners.

Contributors

Ashhurst, Astley Paston Cooper, 1876-1932.
Augustus Long Health Sciences Library

Publication/Creation

Philadelphia : Lea & Febiger, 1914.

Persistent URL

https://wellcomecollection.org/works/qn328zju

License and attribution

This material has been provided by This material has been provided by the Augustus C. Long Health Sciences Library at Columbia University and Columbia University Libraries/Information Services, through the Medical Heritage Library. The original may be consulted at the the Augustus C. Long Health Sciences Library at Columbia University and Columbia University. where the originals may be consulted.
This work has been identified as being free of known restrictions under copyright law, including all related and neighbouring rights and is being made available under the Creative Commons, Public Domain Mark.

You can copy, modify, distribute and perform the work, even for commercial purposes, without asking permission.

wellcome collection

Wellcome Collection
183 Euston Road
London NW1 2BE UK
T +44 (0)20 7611 8722
E library@wellcomecollection.org
https://wellcomecollection.org

COLUMBIA LIBRARIES OFFSITE
HEALTH SCIENCES STANDARD
HX00014699

RD 31 A53
Columbia University
in the City of New York
COLLEGE OF PHYSICIANS
AND SURGEONS

Reference Library
Given by



Digitized by the Internet Archive
in 2010 with funding from
Open Knowledge Commons (for the Medical Heritage Library project)

http://www.archive.org/details/surgeryitsprinci00ashh

SURGERY

ITS PRINCIPLES AND PRACTICE

FOR STUDENTS AND PRACTITIONERS

BY

ASTLEY PASTON COOPER ASHHURST, A.B., M.D., F.A.C.S.

INSTRUCTOR IN SURGERY IN THE UNIVERSITY OF PENNSYLVANIA, ASSOCIATE SURGEON TO THE EPISCOPAL HOSPITAL AND ASSISTANT SURGEON TO THE PHILADELPHIA ORTHOPÆDIC HOSPITAL AND INFIRMARY FOR NERVOUS DISEASES

WITH 7 COLORED PLATES AND 1032 ILLUSTRATIONS IN THE TEXT
MOSTLY ORIGINAL

LEA & FEBIGER
PHILADELPHIA AND NEW YORK

Entered according to the Act of Congress, in the year 1914, by
LEA & FEBIGER,
in the Office of the Librarian of Congress. All rights reserved.

TO

RICHARD H. HARTE

A SURGEON OF WIDE CLINICAL EXPERIENCE

AN ABLE TEACHER

A WISE CONSULTANT

A SAFE AND SKILFUL OPERATOR

THIS VOLUME

IS GRATEFULLY DEDICATED

BY HIS PUPIL, ASSISTANT AND FRIEND

THE AUTHOR

PREFACE.

It is the function of a work such as this to furnish the foundation on which a knowledge of Surgery is to be built. Didactic and clinical lectures, papers in current journals, classical monographs, and particularly the student's clinical work and the surgeon's daily practice are valuable adjuncts, but unless the foundations have been laid broad and deep, no useful superstructure can be erected.

A text-book should afford a true perspective, placing the various branches of study in their proper relative position, maintaining their just proportions, and providing a source of information which shall indicate where further knowledge is to be gained. A student seeks clear and accurate statements, and desires to have facts set definitely before him. If the present volume supplies these wants, if it helps the student to learn surgery and proves a useful reference work for the practitioner, it will have fulfilled its purpose.

Every text-book, however, has its limitations. At best it can but teach the student to *know;* it cannot teach him to *do*. And though knowledge is power, much practical experience in laboratory, dispensary and hospital wards must supplement didactic instruction. In the present work emphasis is placed on the underlying principles, and pathogenesis, diagnosis, and indications for treatment have received particular attention. Descriptions of operations, however, have not been slighted. The more important operations have been described in detail, and in every case an attempt has been made to present clearly, if briefly, at least one method of operative procedure. The specialties of the Eye, the Ear, the Nose, and the Throat naturally are not included; and Genito-urinary Surgery, Gynecology, and Orthopedics have been discussed only so far as they come within the province of the general surgeon.

Neither publishers nor author have spared any pains in the endeavor to furnish a text-book on Surgery which shall be acceptable to the profession. The illustrations, with very few exceptions, are entirely original, and are reproductions of photographs or sketches made by the writer in his various services, especially at the Episcopal Hospital of Philadelphia. To his long association with this Hospital he owes unsurpassed opportunities for clinical work; as well as to his association with the Orthopædic Hospital, and to his former services at the Pennsylvania, the Children's, and the German Hospitals. Most of the skiagraphs are derived from the Episcopal Hospital, and were made by Dr. Thomas S. Stewart or his Assistant, Dr. A. R. Wilkinson.

Those from the Orthopædic Hospital were made by Dr. Wm. Van Korb. The illustrations of operative technique are based largely on work done in the writer's Laboratory of Operative Surgery in the University of Pennsylvania. The credit for converting the author's diagrams and photographs into admirable illustrations is due to Mr. Charles F. Bauer.

Much help has been derived from other text-books and systems of surgery. First and foremost among these must be mentioned the *Principles and Practice of Surgery* of John Ashhurst, Jr. The indebtedness of the writer of the present work to that volume can be appreciated best by those who, like himself, acquired the basis of their surgical education from its pages. Every other source of information has been studiously sought; and, thanks to the facilities afforded by the Library of the College of Physicians of Philadelphia, this laborious task has been rendered comparatively easy. It was thought inadvisable to cumber the text with bibliographical references, but the dates of publication of authoritative contributions, whether recent or of historical interest, have been indicated, and it is believed that by this means the original references may be more easily found in the *Index Medicus* or in the *Index Catalogue of the Surgeon-General's Library, U. S. Army*. The author is particularly indebted to the writings of Deaver on abdominal and prostatic surgery; and free citations have been made from the volumes published by this brilliant surgeon in collaboration with the writer.

The text of the present volume has received the criticisms of several of the author's friends. Dr. Henry Winsor and Dr. Penn-Gaskell Skillern, Jr., have devoted themselves to this work most unselfishly, and have offered many valuable corrections and suggestions. Dr. G. G. Davis and Dr. Frank D. Dickson have kindly reviewed the chapters on Orthopedic Surgery and on Diseases of the Joints. Dr. A. D. Whiting has assisted in reading the proof-sheets, and has made the index.

A. P. C. A.

811 Spruce Street, Philadelphia, 1914.

CONTENTS.

GENERAL SURGERY.

CHAPTER I.

Inflammation 17

CHAPTER II.

Diseases Resulting from Inflammation 47

CHAPTER III.

Modified Forms of Inflammation (Surgical Infections) 76

CHAPTER IV.

Tumors 101

CHAPTER V.

Surgical Technique 133

CHAPTER VI.

Injuries and their Effects 159

CHAPTER VII.

Gunshot Wounds 180

CHAPTER VIII.

Amputations 192

CHAPTER IX.

Effects of Heat and Cold; Injuries by Electric Currents, Lightning and the Röntgen Rays; Skin-grafting and Plastic Surgery . . 217

SYSTEMIC SURGERY.

CHAPTER X.

Surgery of the Blood-vascular System 227

CHAPTER XI.

Surgery of the Skin, Bursæ, Lymphatics, Muscles, Tendons, and Nerves 259

CHAPTER XII.

Fractures 294

CHAPTER XIII.

Injuries of Joints 385

CHAPTER XIV.

Diseases of Bone 416

CHAPTER XV.

Diseases of Joints 451

CHAPTER XVI.

Orthopedic Surgery 504

REGIONAL SURGERY.

CHAPTER XVII.

Surgery of the Head 551

CHAPTER XVIII.

Surgery of the Spine 592

CHAPTER XIX.

Surgery of the Face, Mouth, and Neck 619

CHAPTER XX.

Surgery of the Breast, Chest Wall, Lungs, and Diaphragm 699

CHAPTER XXI.

HERNIA 753

CHAPTER XXII.

ABDOMINAL SURGERY IN GENERAL, AND INJURIES OF THE ABDOMINAL VISCERA 802

CHAPTER XXIII.

SURGERY OF THE GASTRO-INTESTINAL TRACT 848

CHAPTER XXIV.

SURGERY OF THE GALL-BLADDER, LIVER, PANCREAS, AND SPLEEN 919

CHAPTER XXV.

SURGERY OF THE BLADDER AND KIDNEYS 958

CHAPTER XXVI.

VENEREAL DISEASES 989

CHAPTER XXVII.

SURGERY OF THE URETHRA AND PROSTATE 1015

CHAPTER XXVIII.

SURGERY OF THE MALE GENITAL ORGANS 1043

CHAPTER XXIX.

SURGERY OF THE FEMALE GENITALS 1064

SURGERY: ITS PRINCIPLES AND PRACTICE.

The word Surgery (old English Chirurgery) is derived from two Greek words, χείρ and ἔργον, signifying respectively hand and work; as distinguished from the work of the physician, surgery was therefore formerly confined to such mechanical procedures as were carried out by the surgeon under the direction of the physician. Such was the position of the surgeon in the middle ages; but, since the time of Ambroise Paré (1509–1590), who is thus justly styled the Father of Modern Surgery, the Science and Art of Surgery have advanced step by step toward such a point of perfection as long since to have entitled them to equal rank with Medicine. And though the highest functions of surgery still remain mechanical in nature, it is no longer the physician who plans and directs the mechanical treatment, but the surgeon himself who selects the patient, devises the operation, and determines at what stage of the malady surgical measures shall be employed.

Underlying all disease, and therefore necessary to an understanding of disease processes, surgeons encounter a pathological state which constitutes the process by which the bodily tissues react to injury. If the injury be very severe, immediate death of the part may ensue; and there will then be, in that part, no reaction to the injury. At the very outset of the study of surgery, it is proper to discuss at some length the reaction which takes place when the tissues are injured, because only when the underlying principles of disease and injury have been thoroughly mastered, can it be hoped to study with profit the special affections which subsequently will be discussed.

CHAPTER I.

INFLAMMATION.

The process by which the tissues react to an irritant is known as **Inflammation.** The student must therefore learn what are the usual irritants which produce these changes; he must study the changes themselves, and their results; he must familiarize himself with the subjective and objective symptoms due to these tissue changes; and he must finally learn how to relieve the patient of his suffering. It

therefore becomes necessary to discuss the *causes*, the *pathology*, the *symptoms*, and the *treatment* of inflammation.

Causes.—The *predisposing causes* of inflammation are those which render the patient especially liable to the action of irritants, which are the exciting causes. Any constitutional state, therefore, which lowers the resistance to disease or injury will act as a predisposing cause. *Age*, especially the extremes of life, influences the development of inflammation in this way. *Occupation* and *habits* also have an undoubted influence, by undermining or by strengthening the constitution. Past or present *diseases* may very seriously modify the patient's resistance to the exciting causes of inflammation.

In general it may be admitted that the *exciting* or *determining causes* of inflammation are either *mechanical* or *chemical*, using these terms in their broadest sense, and including in the latter all causes (thermal, electrical, radio-active, infective) which are not distinctly mechanical in their action. But while it is expedient to acknowledge that the process of repair which occurs after such mechanical injuries as contusions, fractures, aseptic wounds, and the like is in very fact an inflammatory process, it is nevertheless proper to recognize the fact that the vast majority of inflammatory affections are directly due to chemical irritants produced in the tissues by microorganisms, especially bacteria. Indeed, it is seldom susceptible of satisfactory proof that bacteria are entirely absent in the class of injuries first mentioned; for it is probable that all patients, and even persons in good health (Adami), have somewhere in their system certain bacteria which, being carried by the blood or lymph currents, eventually will reach the region of damaged tissue, and will there be enabled to prosecute their nefarious work to better advantage than where there exists no *locus minoris resistentiæ*.

Foreign bodies were cited formerly as examples of purely mechanical causes of inflammation; but unless it can be proved that the foreign body is aseptic, and that the part of the body where it lodges (eye, skin) is also free from bacteria, it is proper to assume even in such cases that the resulting inflammatory reaction, if noticeable, is due as much to bacteria as to the presence of a foreign body. Indeed, we know that many sterile foreign bodies (ligatures, sutures) constantly remain in the tissues after aseptic operations, and are productive of no manifest inflammatory reaction. Likewise calculi, formed in the internal organs, if sterile themselves, may be productive of only trivial discomfort until bacterial infection occurs in their containing viscus.

The bacteria which surgeons most frequently encounter as causes of inflammation are the Micrococcus pyogenes (Staphylococcus); Streptococcus pyogenes; Bacillus coli communis; Gonococcus; Bacillus pyocyaneus; Pneumococcus; Bacillus typhosus; Bacillus tuberculosis; Bacillus tetani; Bacillus mallei; Bacillus anthracis; Bacillus œdematis maligni; Bacillus aërogenes capsulatus, etc. These microörganisms are known as *Pathogenic Bacteria*, because

they are themselves the causes of disease; they take up their abode and thrive in living tissues, which they use as pabulum. They are to be distinguished from *Saprophytic Bacteria*, which exist only in dead tissues; these can be regarded as causes of disease only in a more or less indirect manner, because it is necessary that other agents, chiefly the pathogenic bacteria, shall have previously brought about the death of the tissues.

In addition to bacteria, certain other forms of microörganismal life must be recognized as occasional causes of the inflammatory process in man. Among these are certain animal parasites, certain Yeasts, or Blastomycetes, and certain Moulds, or Hyphomycetes. Among the more important of the latter may be mentioned Oïdium Albicans, which causes Thrush; the various forms of fungi, which cause the skin lesions of favus, tinea, etc.; and the Ray Fungus, which causes Actinomycosis.

The chemical substances produced by pathogenic bacteria, as a result of their action upon the tissues, are described by the general name *toxins* (Roux and Yersin, 1888); *endo-toxins* are those substances formed in the bodies of dead or dying bacteria. Both toxins and endo-toxins act as chemical irritants, and it is these products of bacteria, and not the bacteria themselves, which are regarded as causes of inflammation. The products of pathogenic bacteria are *albuminoid* in nature; those elaborated by saprophytic bacteria are *alkaloidal*, and go by the general name *ptomains*. The action of thermal, electrical, and radio-active agents as causes of inflammation will be discussed under separate sections in other portions of this volume.

Pathology.—The pathology of the inflammatory process is the same in kind, though varying somewhat in its characteristics, according to the irritant cause, and to the particular tissue affected. Certain bacteria produce a reaction so peculiarly characteristic that surgeons have dignified the resulting processes by erecting them into diseases to which special names are applied. Such are Tuberculosis, Syphilis, Anthrax, Glanders, and other affections which are grouped together as the Infectious Granulomas. These diseases therefore are described in a separate chapter (Chapter III); in the present chapter will be described only those changes which are usually understood when the term inflammation is used. Even among the bacteria which cause the changes universally recognized as inflammation, the form of reaction varies considerably, so that it is sometimes possible to assert without microscopical or bacteriological examination that the inflammation is due to one variety of bacteria, not to another. It is also sometimes possible for the experienced observer to assert that the same variety of microörganism is the cause of quite divergent types of inflammation in different organs or tissues of the body.

If one were to watch under the microscope the changes which occur in a part on which an irritant is acting, he would obtain a very accurate idea of the process of inflammation. This may be done in the pathological laboratory; but great experience is required properly to inter-

pret what is seen; and for practical purposes it is better to study, at leisure, a series of illustrations of an inflamed area, made at various stages of the process.

Studying first the *vascular tissues,* it is noted that the capillaries dilate, those which before were too small to allow the entrance of the cellular elements of the blood now increase in diameter, and it is even possible that new vascular channels may be formed. More blood comes to the part, more blood passes through it, and more blood leaves it, than in the normal state. This change is spoken of as *active hyperemia* (*determination, fluxion* of blood), to distinguish it from *passive hyperemia* or *congestion;* in this latter state, although there is more blood actually in the part than in the normal state, yet the blood

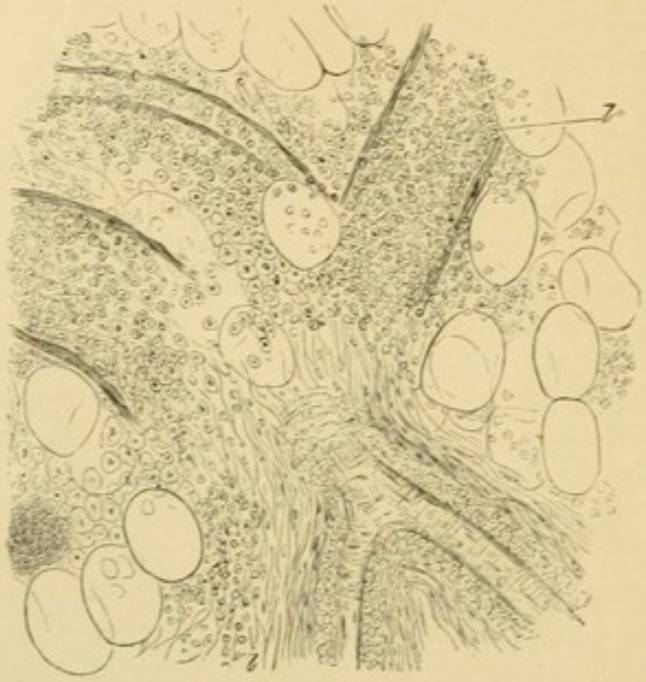

FIG. 1.—Subcutaneous tissue some distance above dead part in a case of spreading gangrene. Note *stasis, margination,* and *migration.* Three veins packed with leukocytes (*l*), which are escaping freely. Around the artery (below) there are none. Outside the vessels many larger cells are seen. × 200. (Green.)

is more or less stagnated in the part, and does not leave it, owing to venous obstruction, which is the prime cause of the congestion. In inflammation, although no cause of venous obstruction exists, the active hyperemia above described soon undergoes a change, so that the picture more nearly resembles that seen in congestion. The blood moves more slowly through the vessels, the blood cells, especially the leukocytes, tend to cling to the vessel walls (*margination*), and eventually some of the leukocytes escape through spaces between the endothelial cells lining the capillaries by a process known as *migration* (J. F. Cohnheim, 1867). In some cases of severe inflammation the erythrocytes may be forced out of the vessels as well (*diapedesis*). In the case of the leukocytes, however, the process is active (*migration*), and is not a mere matter of filtration by the *vis a tergo.* According

to recent observations it seems probable that the erythrocytes escape from the vesssels in the wake of the leukocytes, being sucked out by the currents produced in the blood-plasma by the migration of the white blood cells. In the process of migration of the leukocytes, first a portion of the cytoplasm, projected as a pseudopod, emerges through the vascular wall; then more of the cell body follows; and finally the portion still remaining within the bloodvessel flows out into that portion which has already migrated. It has been noted by Councilman that the portion of the cell to migrate first always contains the nucleus; and it has been suggested by Adami and others that there exists some relationship between "the labile, broken-up character" of the nucleus of polymorphonuclear leukocytes (perhaps karyokinetic figures) and their function of migration through the vessel walls.

It is further evident that some of the plasma of the blood has escaped from the vascular channels and is infiltrating the perivascular connective tissue; for the connective tissue cells may be seen to swell up and become engorged with foreign fluid. This fluid exudate, however, is not unaltered blood-plasma; it contains a higher percentage of proteids, and its specific gravity is higher; it also coagulates more quickly. Moreover, as will be pointed out presently, it is extremely rich in bactericidal and antitoxic substances. The increase of serum in an inflamed part is frequently very apparent macroscopically when incisions are made to relieve tension, especially in the loose subcutaneous tissues; and when inflammation occurs on free surfaces, as the peritoneum or the mucous membranes, or just beneath the cuticle, as in blisters, the outpouring of this fluid exudate is very evident. Its quantity and quality are also influenced by the variety of bacteria present.

Looking a little later at the inflamed area, the first thing to be noted is that there has accumulated in the perivascular tissues an immense aggregation of small round cells. These cells accumulate in response to an influence of chemical nature exerted upon them by the bacteria or other irritant; this influence is known as chemotactic action (Pfeffer, 1888[1]), and because the cells are drawn toward the acting body, we speak of it as *positive chemotaxis*, in contradistinction to negative chemotaxis, which term is used to describe the repelling action of certain cells or microörganisms. It is now regarded as certain that the endothelial cells lining the bloodvessel walls take an active part in the production of this round-cell infiltration, under the influence of the positive chemotactic action of the irritant. These endothelial cells may be seen to swell up and bulge into the lumen of the vessels. In this manner they seem to become possessed of agglutinative characteristics, which aid in slowing the blood stream and in producing the margination of the leukocytes already described. It is not impossible that, by their change of form, these endothelial

[1] According to the late Prof. Ashhurst, the germ of the idea of chemotaxis is to be found in the writings of Haller.

cells may render the vessel walls more readily permeable to the leukocytes.

The origin of this vast aggregation of round cells next engages our attention. By reference to our previous study of the changes in the vascular tissues, it is quite evident that large numbers of the round cells found in the inflamed tissues have been derived from the leukocytes of the blood by migration. But even in tissues without bloodvessels, such as the cornea, a similar aggregation of cells occurs in inflammation; so that it is manifest that much of the round-cell infiltration is derived from other sources than the bloodvessels. These other sources are the lymph cells, which exist in the perivascular tissues within the lymph spaces and lymph capillaries; and the fixed connective tissue cells, which as the result of a retrograde metamorphosis come again to resemble the less highly developed lymphocytes (Stricker, 1881). Stricker also believed that the intercellular connective tissues could, under the influence of the inflammatory process, revert again to the embryonal cells from which they were first derived. Whether Stricker's views should be accepted or not, is still perhaps open to discussion; but pathologists think it much more certain at present that a large proportion of the round-cell aggregation is derived from the endothelial cells lining the lymph spaces of the perivascular tissues. Indeed, according to some modern histologists (Adami) there are no such structures as those formerly described as the fixed connective tissue cells; for they hold that the only cells found in the tissues, besides the lymphocytes and the wandering leukocytes, are these very endothelial cells, and that the spaces (hypothetical or real) between them are to be regarded as lymph channels.

In regard to the origin of the lymphocytes, Warthin (1906) follows Ribbert in teaching that they are in great part derived from rudimentary lymph nodes scattered through the tissues.

The great number of cells which infiltrate the tissues at this stage of the inflammatory process, must not be regarded as a mere aggregation of previously existing cells. It is probable that all the cells multiply by continual division and subdivision under the stimulus of inflammation, and that the number of cells in the part is thus actually as well as relatively increased. This fact is evident from the mitoses which may be seen in an inflamed area under the microscope.

Thus it is that we find three main types of cells composing this cellular infiltrate: (1) *the emigrated leukocytes*, which are chiefly polymorphonuclear neutrophiles; in the early stages of inflammation there may be a relative increase of eosinophile cells; (2) *the lymphocytes*, which seldom accumulate in great numbers until the inflammation has existed for some days; and (3) cells derived from the *fixed connective tissue cells* or from the *endothelial cells*, or from both. These last named cells are conveniently classified by Adami as fibroblasts and polyblasts, the latter term, first employed by Maximow, being intended to signify that they are immature types of various different

kinds of fully formed cells; while the name fibroblast is still used to describe that form of immature connective tissue cell on which the subsequent process of repair chiefly depends.

When we come next to inquire into the object of this round-cell infiltration, we learn by observation that a veritable warfare is going on between the bacteria and these cells. We observe, for instance, that many of the cells (leukocytes and endothelial cells in particular) have, as it were, swallowed some of the bacteria; for we see such cells with one, two, three, or more bacteria in their interior. We may infer that some of the bacteria are being killed, both from the gradual diminution in their total number, as well as because the individual bacteria no longer stain so well as at first; and we also perceive that many of the body cells succumb, because their nuclei swell up, their protoplasm becomes cloudy, they fail to stain, and finally disintegrate and disappear, while the triumphant bacteria attack other cells. This process, by which the cells devour the bacteria, is known as *phagocytosis* (Metchnikoff, 1893), and the cells which thus act are called *phagocytes*.

Moreover, in addition to the defence thus provided by the cellular elements called into action by the irritants causing inflammation, there exist in the body fluids certain substances (anti-bodies) which act as very important aids in the defence. In the normal blood-plasma exist certain chemical substances termed *opsonins* (Wright and Douglas, 1903), because they act as *caterers* for the phagocytes, by preparing the bacteria for destruction. Thus it has been found that though white blood cells are active phagocytes while still surrounded by blood plasma, they are absolutely indifferent to bacteria if deprived of plasma. In the fluid exudate which is produced during the inflammatory process there are also chemical substances, known as *bacteriolysins* (Nuttall, 1888), which are extremely destructive to these causes of inflammation; these bacteriolysins are classified as *alexins* (Buchner, 1890), which destroy the bacteria, and *antitoxins* (Behring, 1890), which neutralize the bacterial toxins. It is probable that they are both produced by disintegration of leukocytes. These inflammatory exudates have a specific gravity of 1018 or higher, and contain at least 4 per cent. of albumin; they may be distinguished thus from exudates due to venous stasis, and to those caused by hydremic conditions, the fluid in the latter instances having a much lower specific gravity, and containing less albumin.

The process of inflammation, as thus far described, comprises clinically what has been termed the *first stage of inflammation*, or the *stage of temporary hypertrophy*. If at this stage of the process the invading microbes are vanquished, the parts return to their normal condition (*resolution*) without passing through the subsequent stages of inflammation. If, on the other hand, the strife is prolonged, the fluid exudate and the cellular infiltrate increase in quantity, and the product of the second stage of inflammation, known as inflammatory lymph, is formed (*lymphization, lymphogenesis.*)

Inflammatory lymph (Hunter, 1794) is a semi-solid, gelatinous substance, grayish white or slightly yellowish in tint. Though found at least for a short time in every case of inflammation which extends beyond the first stage, it is best observed in peritoneal infections, and in iritis, in both of which instances the inflammatory exudate occurs on a free surface. The false membrane of diphtheritic inflammation is another instance of lymph formation. Lymph owes its semi-solid, plastic character to the fibrin it contains. The cellular elements are not usually very numerous in the early stages of its formation, when the exudate is still "serous," but as the quantity of cells increases, fibrin ferment is formed by the destruction of some of their number, and this fibrin ferment acting upon the fibrinogen and certain calcium salts already present in the exudate, eventually forms *fibrin*. Certain infectious agents call forth an abundant exudation of inflammatory lymph; while others are characterized rather by the excessive round-cell infiltration produced. For example, peritonitis due to the typhoid bacillus is characterized by profuse serous exudate; when caused by the streptococcus, or the colon bacullus, the exudate contains a much larger proportion of cellular elements, and therefore more closely resembles typical inflammatory lymph. Moreover, fluid exudation is more abundant on surfaces, and in the loosely built cellular tissues, than in denser structures such as bone.

Lymph serves a useful purpose in more ways than one, for not only does it enmesh the microörganisms and thus prevent their diffusion in the tissues, but it also actively destroys them and their products by means of the bacteriolysins already described. It also prevents absorption of the microörganisms by protecting denuded endothelial surfaces. It is, therefore, to be regarded as a valuable defence of the body against infection, and not as a noxious product to be removed by the surgeon.

Lymph may be *absorbed*, may become *organized*, may become converted into *pus*, or may undergo other forms of *degeneration* (caseous, calcareous, etc.). If the lymph is absorbed, its cellular elements pass away again into the neighboring blood and lymph streams, or remain as fibroblasts to produce new connective tissue in the area of inflammation. Where the process of inflammation is attended by coincident productive and absorptive changes, in approximately equal degree, the condition is described as *interstitial absorption*. This condition is seen particularly in some forms of osteitis. In the process of organization, which will be described more particularly in the section on Repair (p. 29), these fibroblasts pass through various stages until adult connective tissue is formed. It is very unusual, however, for complete regeneration (*restitutio ad integrum*) to take place; almost always some of the cells remain in an immature state, while others are converted into *scar tissue*. In certain specialized forms of inflammation, lymph undergoes various forms of *degeneration*, as the caseous or calcareous, in tuberculosis; but in all cases in which

the inflammatory process continues, lymph is eventually converted into pus (*suppuration, pyogenesis*).

Pus may be defined as the product of the third stage of inflammation. By giving a broad definition such as this, we are permitted,

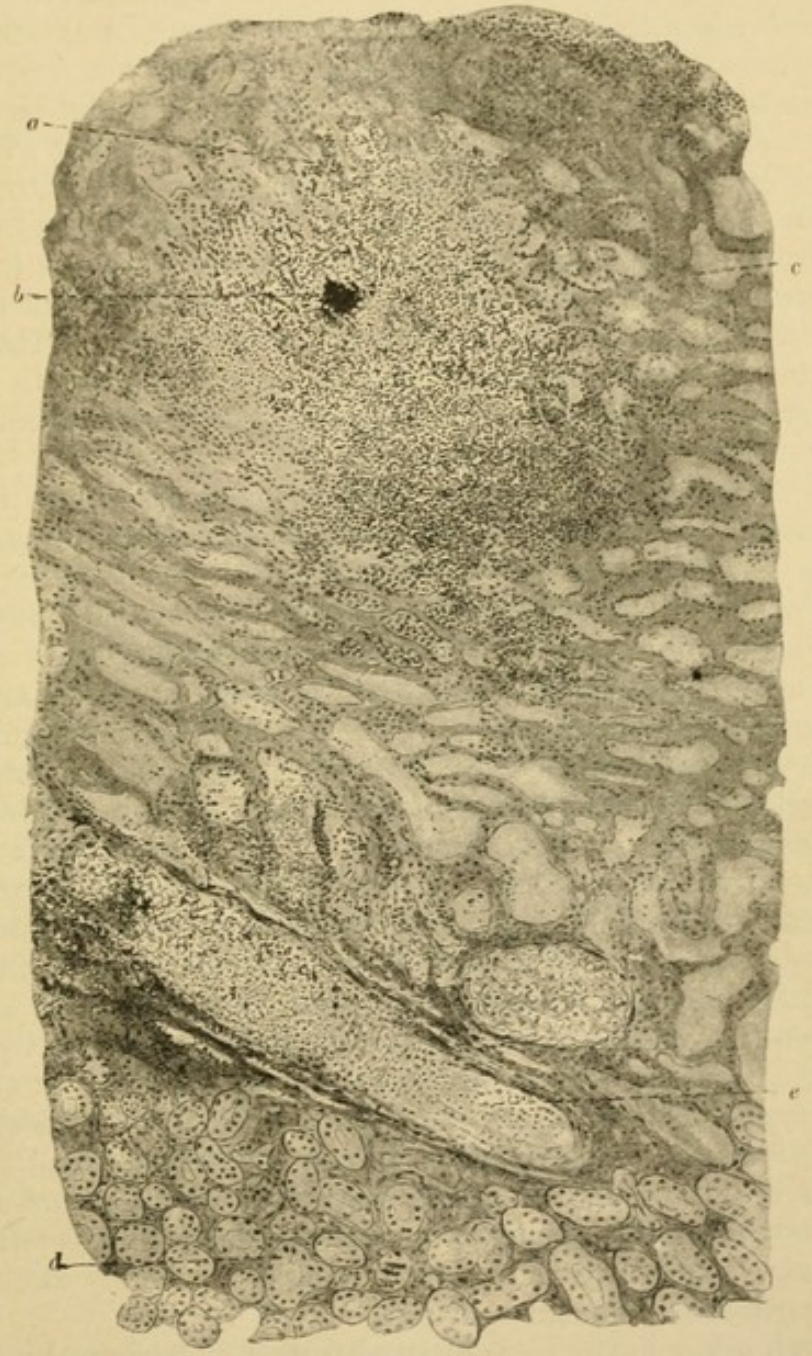

FIG. 2.—Miliary abscess in a case of septic embolism of the kidney: *a*, leukocytes advancing toward and surrounding *b*, a mass of cocci, in whose neighborhood all trace of a structure has disappeared; *c*, renal epithelium too damaged by bacterial products to take the stain; *d*, kidney tissue staining normally; *e*, vein from which leukocytes are making their way to the commencing abscess. × 100. (Green.)

as is pathologically proper, to include under the term pus, not only the healthy, laudable pus which the older surgeons were so delighted to behold, as an expression of adequate reaction on the part of the patient's tissues; but we may also embrace, under the term pus, the

products of tuberculous, syphilitic, and similar processes which, as Adami points out, "are identical with the tissue dissolution that occurs in acute abscess."

Pus, when examined under the microscope, is seen to be composed of cells and of granular detritus, more or less homogeneous in character, floating in a fluid known as the *Liquor Puris*. Bacteria usually are present also. The cells are the leukocytes, lymphocytes, and connective tissue cells, which formerly constituted the round-cell infiltration of the earlier stages of the inflammatory process; but which have been killed by the bacterial toxins, etc. The granular detritus consists of the remains of the cellular elements and intercellular substance of lymph, which have been disintegrated by the ferments (peptones, etc.) generated during the warfare between the bacteria and their toxins with the body cells and their bacteriolysins. The Liquor Puris is the slightly altered fluid exudate already described. In other words, pus has been produced from lymph by a species of liquefaction necrosis.

If pus is completely circumscribed by the body tissues it constitutes an *abscess*. If it is formed on the surface of a part it is said to be constantly "discharged." If neither formed on a surface nor well circumscribed, but rather diffusely infiltrated among the body tissues, the pus is said to form a *phlegmon;* and the inflammation is said to be *phlegmonous* in type. In any case, there is a certain surrounding area where the strife between the body tissues and the invading microorganisms still continues. This area, when surrounding an abscess, was formerly spoken of as a *pyogenic membrane*, because it was believed that pus was secreted in the same way as the secretion of a gland is produced. If the body tissues succeed in holding their own, and the invasion comes to a halt, then there is formed in the area surrounding the abscess what is known as *granulation tissue;* if, on the other hand, the body tissues continue to be destroyed by the bacteria and their toxins, then the process is described as *ulceration*, provided the change occurs on a free surface (as on the skin after burns, or in the intestines in typhoid fever, etc.). For although, from a pathological point of view, the process which occurs at the so-called pyogenic membrane of an abscess is identical with that which occurs on a free surface on which pus is being produced by ulceration, yet the latter term is never applied to the former process; we merely say that the abscess continues to increase in size.

Pus which exists in the form of an abscess may perhaps be *absorbed*, under exceptional circumstances, if the amount of pus be very small. When this occurs, the granulation tissue extends into the puriform mass, the débris is taken up by phagocytes, and is gradually carried away in the blood and lymph channels. In other cases, where the amount of pus is small, and where the abscess is deeply situated, the pus may become *encapsulated*, by the deposition in the surrounding granulation tissue of lime salts, or even by the development of extremely dense fibrous tissue. In such cases the contained pus

gradually becomes sterile. In all cases, however, in which there is any appreciable amount of pus present, the pus tends to seek an exit for itself in the direction of least resistance. When the pus has once discharged itself, the former abscess cavity will gradually assume the character of an *ulcerating*, or rather of a *granulating* surface, and the process of repair will be the same in both instances—that of an evacuated abscess and that of an ulcer.

Role of the Nervous System in Inflammation.—In the account of inflammation so far given, no mention has been made of any part played by the nervous system. This is so, because it plays only a very insignificant part in this process. Experiments have proved that even when the entire nervous supply of a part has been cut off, the phenomena of reaction to injury, as described above, occur without appreciable difference; from which fact it may be assumed either that the local vascular system is endowed with a nervous mechanism of its own (which does not appear to have been proved), or that the vascular changes seen in inflamed areas take place without the interposition of nervous action. According to Warthin (1906), however, it has been demonstrated experimentally that removal of the vaso-constrictor influence accelerates, while removal of the vaso-dilator influence retards inflammatory reaction. Too little is known of the pseudo-inflammatory changes which occur in the various neuropathies for pathologists to speak with authority about them. It is certain, nevertheless, that under certain circumstances lesions of the nervous system may very greatly influence the course of inflammation, as seen in the case of bed-sores in spinal diseases, and in certain so-called trophic lesions.

Extension of Inflammation.—This occurs (1) by *continuity*, as when bronchitis extends into the pulmonary tissue, causing pneumonia; or when urethritis extends into the bladder, producing cystitis; (2) by *contiguity*, as when pneumonic inflammation extends to the pleura, causing pleurisy; or when peritonitis developes from appendicitis; (3) by the *lymphatics*, as when a felon in the finger is followed by lymphangeitis and epitrochlear or axillary lymphadenitis; or (4) by the *blood stream*, as in certain of the exanthemata, and in metastatic inflammations.

Terminations of Inflammation.—Inflammation may terminate in two ways: (1) by *resolution*, a gradual return of the part to health; (2) by *death of the patient*. It is sometimes said that inflammation may terminate in the *local death* of the part affected; but as the surrounding parts will still be the seat of the inflammatory process, or of repair, until either death or recovery terminates the disease, it is more logical to recognize this fact in our definition. The manifestations of the local death of a part (*sloughing, mortification, gangrene*) will be considered in Chapter II.

Suppuration without Bacteria.—In what has been said above, it is assumed that the suppuration described has been caused by bacteria; and in the immense majority of instances this is the case. But it should

not be forgotton that other chemical forms of irritation, as well perhaps as certain mechanical irritants, may produce pus, if their action is sufficiently virulent or prolonged. Hypodermic injections of turpentine, mercury, croton oil, or other sterile substances, may cause all the usual phenomena of inflammation, and this may proceed so far that a fluid will be formed, which will be found to consist of the disintegrated products of tissue metabolism, and which will be indistinguishable from pus as described above, except for the facts that no bacteria will be present, and no phagocytosis will be evident. It is quite apparent, nevertheless, that, even in such cases, the round-cell infiltration, which succeeds to the early hyperemia and congestion, has been produced by chemotactic action on the part of the irritant, and that the accumulated cells and tissue fluids in the process of their reaction are converted into substances which if not technically bacteriolysins, are some other form of antibodies none the less useful for the defence of the organism.

Nor should it be assumed, on the other hand, in every case in which inflammation is produced by bacteria, that the process necessarily will extend to the stage of suppuration. In very many cases in which bacteria are present, the reaction on the part of the body tissues is sufficient to repel or to conquer the foe before pus is formed; but it is much more usual for this happy termination of the process to occur when the causes of the inflammatory reaction are sterile. This is well seen in the usual course pursued by clean wounds.

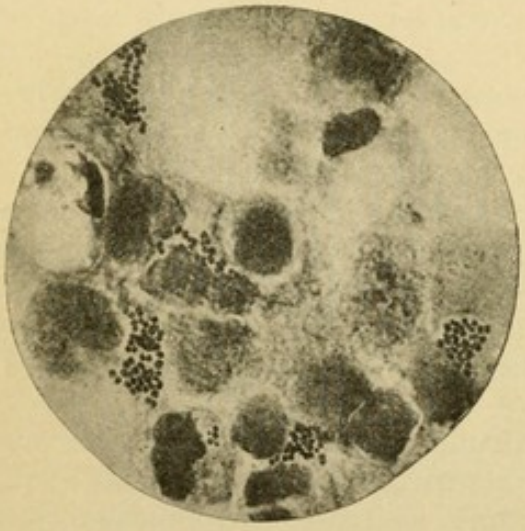

FIG. 3.—Staphylococci in pus. × 1000. (Fränkel and Pfeiffer.)

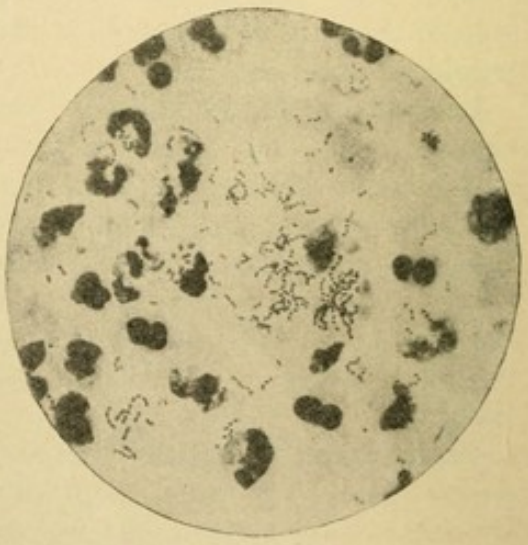

FIG. 4.—Streptococci in pus. × 1000. (Fränkel and Pfeiffer.)

Pyogenic Bacteria.—Certain microörganisms are habitually pyogenic; certain others produce pus only under special circumstances; while a few varieties have never been known to cause suppuration. It is, therefore, possible to classify pathogenic bacteria in the following manner: (1) *Microörganisms characteristically leading to pus and abscess formation*—Staphylococcus, Streptococcus pyogenes, Bacillus

anthracis. Of these, the varieties of the staphylococcus denoted by the suffixes *aureus*, *albus*, and *citreus*, and generically included under the term Micrococcus pyogenes, are those which are especially associated with acute, well-localized abscesses; they are found in felons, furuncles, carbuncles, acne, some cases of empyema, and certain forms of periosteitis, osteomyelitis, etc. The streptococcus, on the other hand, is associated with spreading infections, such as diffuse cellulitis, erysipelas, lymphangeitis; certain forms of osteomyelitis, peritonitis, etc. The Bacillus anthracis is the cause of a specific disease, which will be described in Chapter III. (2) *Those causing suppuration only under exceptional circumstances*—Pneumococcus, Bacillus typhosus, Bacillus coli communis, Bacillus pyocyaneus, Gonococcus, Bacillus tuberculosis, etc. (3) *Those which are never known to cause the formation of pus*—as Bacillus tetani.

Pathological Summary.—The first action of an irritant when introduced into the tissues is *chemotactic* in nature; this influence extends, without the aid of the nervous system, to the endothelial and other connective tissue cells lying in the perivascular tissues; it also extends to the cells of the vascular endothelium, and even to the white cells of the circulating blood. The effect of this positive chemotaxis is to slow the blood current and to cause the endothelial cells of the blood-vessels to acquire agglutinative properties. As a result, *hyperemia*, and later *congestion* is produced; *margination*, followed by *migration* of leukocytes, occurs; exceptionally *diapedesis* of the red blood cells also is present. *Round-cell infiltration* is produced in this way, as well as by the multiplication of those cells already present in the inflamed part. This constitutes the *first stage of inflammation*, that of *Temporary Hypertrophy*. The warring hosts have been assembled and the battle between the invading microörganisms and the phagocytes is next begun; the fluid exudate aids the cells in the fight by means of its bacteriolysins. *Lymph* is thus produced, constituting the *second stage of inflammation*. Owing to the progressive destruction of leukocytes and other cells, ferments are produced, which liquefy the lymph, converting it into *pus;* thus by *pyogenesis*, the *third and last stage of inflammation* is reached. In the surrounding tissues progressive destruction (*ulceration*) continues, or gradual repair (*granulation*) terminates the process.

Repair.—It has been pointed out (p. 28) that the inflammatory process may be terminated at any stage of its course as a result of the defensive powers of the organism overcoming the invasion of the irritant which was the primary cause of the inflammation. Speaking generally, we may recognize three more or less distinct ways in which repair occurs, corresponding to the three stages of inflammation described.

1. If the process of inflammation is arrested during the stage of temporary hypertrophy, before any exudate has been formed, the migrated leukocytes and other phagocytes, having destroyed the bacteria, and being no longer attracted by the chemotactic influence of

the invaders, resume their normal functions and return to their usual spheres; the white blood cells re-enter the capillaries, the lymph cells swim away in the lymph stream, and the site of former inflammation can no longer be distinguished from the surrounding tissues; it is said to have undergone *regeneration, complete repair, restitutio ad integrum.*

2. If the process of inflammation is arrested during the stage of lymph formation, complete regeneration cannot take place, because the tissues are not capable of removing completely the results of the warfare between the irritant and themselves. Some of the cellular elements may pass away again in the blood and lymph streams, but almost without exception a goodly number will remain in the previously inflamed part, will become converted into fibroblasts, and eventually will form scar-tissue. It does not seem to be certainly known whether leukocytes can become converted into fibroblasts; but there is no doubt that most of the fibroblasts are produced from endothelial or fixed connective tissue cells. Fibroblasts are elongated, caudate, or spindle-shaped cells, occasionally stellate in form.

The area of inflammatory exudation becomes vascularized by the out-growth of capillaries from the surrounding bloodvessels. These new capillaries grow as solid sprouts; and these solid processes, growing out into the exudate of inflammatory lymph, either meet other similar out-growths, or become attached to a neighboring capillary, thus forming more or less distinct loops; these loops subsequently become hollowed out, and the channels so formed are filled by blood from the surrounding capillaries. As the process of repair goes on, the fibroblasts become more and more fibrous in character "until the cell is represented by a meagre, attenuated nucleus, with but a trace of cytoplasm, lying surrounded by fibrils—*white connective tissue.*" (Adami.) The conversion of the fibroblasts into white connective tissue and the invasion of the inflammatory exudate by the capillary loops go on hand in hand; the tissue thus formed is known as *granulation tissue;* and when the process occurs on a free surface the capillary loops form the so-called *granulations.* The granulation tissue is at first highly vascular and red; as the more fully developed scar-tissue is formed, granulation is succeeded by *cicatrization,* and the capillaries are squeezed out of existence as the process of contraction in the scar-tissue continues. Thus a scar which at first is red and angry in appearance, eventually may become white, glistening, and depressed below the surrounding tissues. The area of previous inflammation, which during the height of the inflammatory process was swollen and tense, thus finally comes to occupy less space than in health.

3. If the process of inflammation has progressed to the stage of suppuration, then in almost all cases it is necessary for the pus to be discharged by the rupture of the abscess before rapair can occur. It is extremely unusual for pus to be absorbed or for scar-tissue to be formed unless the abscess has first been converted into an ulcer. Repair in this instance, therefore, is best studied as it occurs on a

free surface, and is the same as that which occurs in the healing of an ulcer (p. 53).

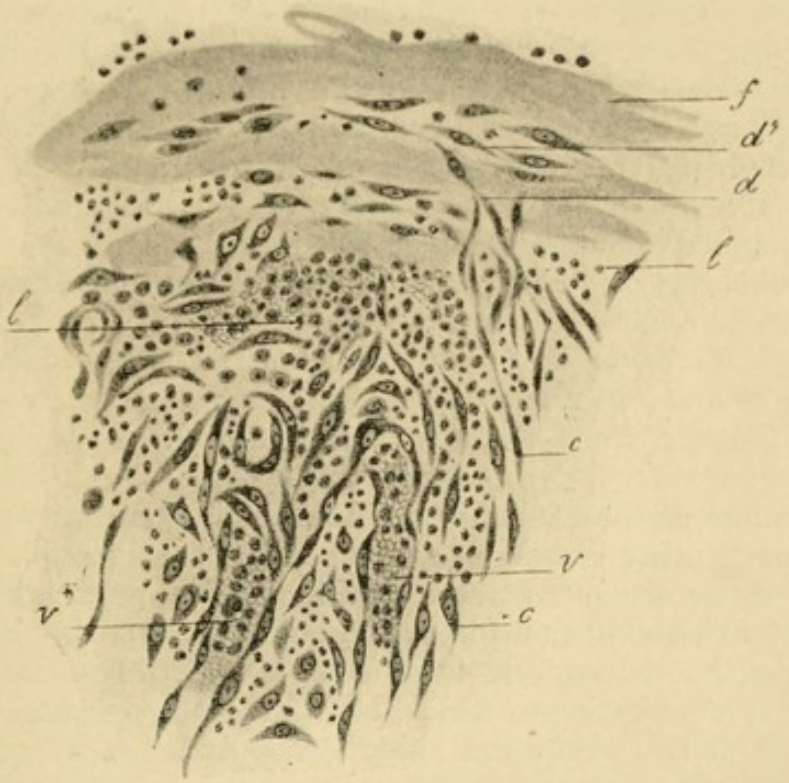

FIG. 5.—Fibroblasts and granulation tissue. Section of a cutaneous granulation: *v v'*, new-formed capillaries sprouting from depth of granulation and accompanied by connective tissue cells (*c*) and leukocytes (*l*). A layer of fibrin (*f*) covers the surface of the granulation. Between the superficial layers of the fibrin are seen large connective tissue cells (*d'*) springing from the granulation (*d*). × 300. (Cornil and Ranvier.)

Symptoms.—The *symptoms of inflammation* are *local* and *general* (or *constitutional*). Among the latter are the usual signs of *fever*, attended frequently by quickening of the pulse and respiration rate; headache, flushing of the face, brightening or injection of the eyes, and perhaps delirium at night; anorexia, with furred tongue, and sometimes nausea; dry, hot skin; thirst; usually the bowels are constipated, and the urine high colored and lessened in quantity. Under constitutional symptoms it may also be proper to include *leukocytosis*, an increase in the number of leukocytes present in the circulating blood. This leukocytosis is present in almost all acute inflammations; it is called forth by the chemotactic powers of the irritant, whose diffusible toxins, when they obtain admission to the circulating blood, are carried to the bone marrow and other portions of the body whence leukocytes are derived, and thus stimulate the production of leukocytes. In a few diseases, not usually classified as inflammations, the influence of negative chemotaxis is manifested in the diminution of the number of circulating leukocytes (*hypoleukocytosis*, *leukopenia*). Among such diseases typhoid fever and tuberculosis are the most important. What were formerly called *critical discharges* may occur either at the approach of convalescence,

or upon an unfavorable change in the patient's general condition. These discharges are described as diarrhea, diuresis, profuse sweating, and sometimes hemorrhages from the mucous membranes. Their significance, as well as the probable causes and the pathology of inflammatory fever, will be considered in Chapter II. When the inflammation is slight, constitutional symptoms may be trivial or entirely absent; when occurring in robust, healthy individuals, the *sthenic* type of fever is seen; when in the weak and debilitated, or, when the inflammation is overwhelming, even in the strong, a *typhoid* (*asthenic*, *adynamic*) type of fever will result.

The *local symptoms* of inflammation have been described from the time of Celsus under the terms (1) *Rubor*, or redness; (2) *Tumor*, or swelling; (3) *Calor*, or heat; and (4) *Dolor*, or pain; while to these classical symptoms has been added that of (5) *Functio Læsa* (modification of function); and again a sixth symptom (6) *Modification of nutrition*.

One or more of these local symptoms may be present without the disease constituting inflammation; it may be impossible to elicit evidences of one or more of these symptoms, even when inflammation is present. Friction of the skin may produce a temporary hyperemia, accompanied by redness and heat, without true inflammation being present; the erectile tissues furnish another example where the presence of one or two symptoms alone is not sufficient to qualify the affection as inflammation. On the other hand, it will be impossible in many deep-seated inflammations (meningitis, pleurisy, etc.) to detect redness, and sometimes impossible to demonstrate swelling, even though no doubt can exist that inflammation is actually present. Some of these local symptoms are more manifest in certain tissues, organs or localities, than in others. Thus conjunctivitis, periosteitis, orchitis, are especially painful; cellulitis is preëminently characterized by swelling; alteration of function is more evident the more highly specialized the tissue or organ affected (compare iritis with tonsillitis; neuritis with dermatitis, etc.); while in the cornea and in cartilage alterations of nutrition may be the only demonstrable change.

Redness is nearly universally present in superficial inflammations. It is primarily due to the hyperemia and congestion of the inflamed part. Early in the course of the disease the redness is bright, flaming, intense, as in erysipelas; later it may become bluish or almost purple, as suppuration or gangrene impends. It is not sharply outlined in ordinary forms of inflammation, but blends away in the surrounding tissues so that it is often impossible to define its exact limits. The redness due to inflammation disappears when the finger is pressed upon the inflamed spot. The rapidity with which the redness returns after the removal of pressure gives a fair idea of the activity of the circulation; if suppuration or gangrene is threatening the circulation is sluggish. It should not be forgotten that a sluggish circulation may be due to organic disease of the heart, and that this will modify the local manifestations of inflammation even in an early stage.

Swelling is due to the hyperemia, to the round-cell infiltrate, and to the fluid exudate characteristic of inflammation. Thus tissues where exudation is profuse (eyelid, scrotum, and subcutaneous tissues generally) show more alteration of form than do such structures as bone or cartilage. Blebs frequently form in the skin as the result of effusion of serum beneath the epidermis; this is seen especially in burns and severe contusions, such as those accompanying fractures or dislocations. Swelling is beneficial in so far as it tends to deplete the overloaded capillaries; it may be harmful by its tendency eventually to block the circulation and thus favor sloughing or gangrene. It may endanger life by occluding mucous channels—such as the glottis, the bile ducts, the appendix; or by compressing the urethra when the swelling occurs in the perineum. The swelling of the early stages of inflammation is tense, and rather elastic to the touch; later it becomes dense and brawny if due to exudate which is coagulable, or edematous and soft if due to non-coagulable effusion. When an inflamed area begins to "pit on pressure," it is often indicative of the presence of pus.

Heat in an inflamed part usually is appreciable to the hand, when compared with a neighboring or similar part of the patient's body which is not inflamed. In arthritis the affected joint feels hot, while the corresponding joint does not. Local heat is doubtless produced in large part by the numerous chemical reactions constantly occurring in the inflamed area. The toxins, bacteriolysins, ferments, etc., are all of them produced by forms of biochemical activity which thus far are little understood. The mere hyperemia of the part is not sufficient to account for the heat present. Yet the local temperature is rarely if ever higher than that of the circulating blood; but it is relatively higher than is that of surrounding parts, because there is more blood in the inflamed part, and especially near the surface of the inflamed part, than in surrounding non-inflamed parts; moreover the temperature of the circulating blood may be higher than normal (inflammatory fever), but its abnormal heat is derived from the local changes, not the local heat from a primary increase in the temperature of the blood. The local heat is greatest at the height of the inflammation; as the disease progresses the local temperature falls, and when suppuration occurs it is no longer above that of surrounding parts. In the case of gangrene, the temperature of the mortified part naturally becomes subnormal.

Pain due to the inflammatory process is caused by tension, from cellular infiltration and fluid exudation, producing pressure on the terminal nerve fibres of the part. The pain is much less in tissues which admit of much swelling than in fibrous tissues (felon) or bone (periosteitis); and it may be relieved by allowing the escape of the effusion through incisions. Inflammation in a part devoid of sensory nerves is not attended by pain. *Referred pain* is to be explained on anatomical grounds, and is due either to pressure on a nerve trunk, causing pain in its terminal fibres (as in the case of pain in the knee due to pressure

on the obturator nerve at the hip); or to overstimulation of a nerve causing an overflow of painful sensations into neighboring nerves derived from the same spinal segment: thus gall-bladder disease may cause pain in the shoulder through the spinal nerves derived from the same segment as that from which the pneumogastric takes its origin; pain in the testicle follows disease of the kidney or ureter; inflammation of the neck of the bladder is accompanied by pain in the head of the penis; pleurisy may cause cutaneous hyperalgesia of the abdomen. The pain felt in an inflamed part varies with the tissue affected: in the skin (insect bites, etc.) or mucous membranes (conjunctivitis, hemorrhoids, etc.) it is manifested as an itching or scalding sensation; in serous and synovial cavities it is felt as a lancinating or stabbing pain (peritonitis, pleurisy, synovitis); in fibrous tissues it is dull, aching, or boring (periosteitis, etc.). Pain usually is greatest during the height of inflammation; if the nervous structures are poisoned by toxins, the pain may be slight; sudden cessation of pain frequently is indicative of gangrene (appendicitis, strangulated hernia). At the approach of suppuration, the pain assumes a throbbing character; mortification is frequently announced by a burning pain.

Tenderness on pressure is an important modification of the sensation of pain, and may persist when pain has been lost through gangrene of the inflamed part. Thus even when the spontaneous pain of appendicitis has ceased on the occurrence of gangrene, tenderness may still persist in the surrounding area of the peritoneum. If pain is present in a part without local tenderness, the pain is referred pain, and the seat of inflammation is elsewhere. I have never seen both pain and tenderness present locally in an uninflamed part, unless the tenderness was a mere cutaneous hyperalgesia. Mistaking the latter once for a sign of local disease, I removed a normal appendix vermiformis from a youth who twenty-four hours later developed symptoms of pleuropneumonia.

Muscular rigidity is due to voluntary or involuntary contraction of the muscles governing the movements of, or protecting an inflamed part. Involuntary contraction is due to the impulse being referred to motor instead of sensory nerves, as is the case in referred pain.

Impaired function is more noticeable the more highly developed the inflamed structures. It is an old maxim that in inflammation the first functional change is always in the direction of excess. Parts which possess normally very little sensation may become acutely painful; glandular structures produce an abundant, though disordered secretion; muscular structures contract irregularly and spasmodically, as in fractured limbs, and in inflammation of the hollow viscera (appendix, stomach, gall-bladder, urinary bladder, etc.). The special senses are even more affected: scintillations of light and photophobia attend inflammatory affections of the eye; tinnitus aurium is annoying in certain diseases of the ear; perversions of taste, of smell, etc., are common in affections of the tongue and nose. At a later stage of inflammation the function of a part, instead of being

stimulated, is depressed or altogether abolished: during the height of nephritis, the urine is suppressed, and when the secretion is restored its nature may be markedly and permanently altered.

Modification of Nutrition.—The temporary *hypertrophy* seen in the earlier stages may never be recovered from; scars may become keloids; callus may never be absorbed entirely; bones, the seat of osteomyelitis, may remain permanently thickened; lymph-edema may succeed to cellulitis. *Atrophy*, on the contrary, may take the place of a return to the normal; in coxalgia the head of the femur may disappear by interstitial absorption.

Chronic Inflammation.—It is an arbitrary thing to classify inflammation as *acute*, *subacute*, and *chronic*. The former has been described; the latter is an inflammatory affection of long duration, and characterized by slight or moderate reaction. Subacute is a mean between the two. The error should not be made of classing with chronic inflammation certain results of previous inflammations, which consist essentially in the formation of scar tissue or diffuse fibrosis. It is better to speak of such changes as *old inflammations;* and to limit the term chronic inflammation to a process of reaction which is still going on, even if very sluggishly. For strictly speaking a chronic inflammation is merely one in which the irritant is weak, but continues long in action; in which only a slight reaction is produced, and in which some factor prevents healing. This reaction is not wont to go beyond the stage of formation of granulation tissue. The attacking force and the repelling garrison are so equally matched that neither can well overcome the other; cell accumulation is marked, but phagocytic power is slight; exudation is slight; tendency to suppuration is slight. Such inflammations are seen in the case of the *infectious granulomas*. When healing occurs, the scar-tissue formed is proportionate to the previous hyperplastic condition.

The *symptoms* are similar, but less in degree, than those seen in acute inflammation. As might be expected from what is known of the pathology of chronic inflammations, *swelling* is the most characteristic symptom. *Pain* usually is moderate, but may be intense, especially in bones and joints. *Redness* is slight. *Heat* often cannot be detected.

Treatment of Inflammation.—**Prophylaxis.**—The consideration of the treatment of inflammation involves first of all a study of the means of prevention. Inflammation, even when it has once commenced, frequently may be aborted by the prompt removal of the cause. If the insult to the tissues be due to a foreign body, the removal of the foreign body will prevent the reaction which its prolonged presence undoubtedly would provoke. The removal of a cinder from the eye may prevent the development of conjunctivitis; that of a splinter from the finger may prevent the formation of a felon. In some diseases and in certain parts of the body, prompt excision or amputation of the diseased member will prevent the development of an inflammation which might prove fatal. Prompt amputation of a hopelessly

mangled limb will prevent gangrene and subsequent infection; immediate removal of an inflamed appendix will abort the disease by removing its cause, before the inflammatory reaction has spread to the peritoneum.

As bacteria are the most frequent causes of inflammation, this may be most surely guarded against by preventing the entrance of bacteria into wounds, or by removing them or killing them after their entrance has been effected. The condition of the tissues when infected by bacteria is known as *Sepsis; Asepsis* is the condition when no bacteria are present; *Antisepsis* is a method by which bacteria are combated by certain chemicals termed *Antiseptics*. The constant use of antiseptics on living tissues is open to the objection that the tissues are injured as well as the bacteria; though it is true that usually the injury to the tissues is insignificant. When once bacteria have gained entrance to the tissues there are only two ways by which their destruction can be effected; the first is by the natural reaction of the tissues which we call inflammation, and which may be assisted artificially by the use of sera or vaccines (p. 44), the other method is by the direct introduction of antiseptics into the open wound.

It has been learned by long and costly experience that pathogenic bacteria are everywhere present in civilization, and that mere ordinary cleanliness will not suffice to exclude them. They are not present in the air, however, unless this be dust laden, in number sufficient to be harmful; they are carried from place to place only by actual contact of instruments, dressings, etc., on which they may have lodged. They may be killed by boiling, or by dry heat at a sufficiently high temperature; and the instruments, dressings, etc., thus sterilized will, therefore, be *aseptic*. But unless the surgeon's or the nurse's hands be also aseptic, the mere momentary contact of such hands, or of any other unsterilized thing, with the aseptic instruments or dressings, will at once be liable to contaminate them, and they will again become septic—to what degree no one can tell. Neither the hands of the surgeon nor the skin of the patient can be sterilized by boiling or by dry heat; but by thorough washing in soap and water, and by the use of certain chemicals, practically all the bacteria present on the surfaces so treated may be removed; and those still remaining may be rendered so inert that they will be incapable of exciting inflammation. As an additional precaution, boiled gloves of thin rubber may be worn.

The introduction of the practice of *asepsis* and *antisepsis* in surgery dates from 1867, when Lister published his first observations on the antiseptic method of wound treatment; his practice was founded on and confirmed by the researches of Pasteur, concerning fermentation and putrefaction; and although the science of bacteriology may be said to date from the discovery of the Bacillus tuberculosis by Koch, in 1882, the great advances made in modern surgery undoubtedly owe their existence to Lister's initiative. When no antiseptics were used, the healing of wounds was tedious in the extreme, and the inflammatory

reaction practically always extended to the stage of pus formation. Since the introduction of the practice of asepsis and antisepsis, surgeons have become accustomed to having their wounds heal with little or with no apparent inflammatory reaction. Ollier reported a mortality of 80 per cent. from excisions of the knee before adopting the antiseptic method; after adopting this method, his mortality fell to 14 per cent.[1]

Asepsis is generally acknowledged to be better than antisepsis, whenever it is practicable. In operative wounds asepsis is usually possible; but when the wound is infected before it comes under the surgeon's care, it is usually safer to adopt antiseptic principles. Wounds and wound treatment are discussed in Chapter VI.

Cure of Inflammation.—The remedial treatment of inflammation may be divided into the Local and the Constitutional. Under the former head are included such methods as *Rest* of the inflamed part; its *Position;* the use of *Heat* and *Cold; Narcotics* and *Counter-irritants; Bleeding, Leeching,* etc.; *Incisions* and *Operations; Compression; Active* and *Passive Congestion; Massage,* etc. Under the latter will be considered *Constitutional Rest; Diet; Drugs;* and the curative use of *vaccines, sera,* and *opsonins.*

Local Remedial Treatment.—*Rest* of the inflamed part is desirable to decrease the hyperemia and congestion, when these are excessive; to lessen the cellular infiltrate and the exudation; and to enable all the forces of nature to be exerted in overcoming the causes of disease, instead of expending their strength in unnecessary physiological processes which functional use of the part would entail. *Rest in bed* is indispensable in a great many inflammations of the head, trunk, and lower extremities. Rest may be procured by the use of *splints,* when these are sufficient, as in many fractures, wounds of the extremities, felons, etc.; by *gypsum cases* when rest for a longer period is desirable, as in inflammations of certain joints; by *bandages,* or *strapping with adhesive plaster,* as in fractures of the ribs, slight sprains, etc. Finally rest may be procured by *position.*

Position is of importance, because neglect to elevate an inflamed part, and thus to prevent or lessen congestion, may markedly increase the pain; may favor the occurrence of suppuration or sloughing; or invite gangrene by interference with the natural circulation of the part. Carrying the hand in a sling; keeping the foot elevated on a stool; or even going to bed for a time, will each of them prove of benefit in special cases.

Cold is an invaluable agent in the treatment of inflammation in its early stages. It is anesthetic, benumbing the part and lessening pain; it constricts the bloodvessels, decreasing the hyperemia, and some-

[1] It is true that the late Prof. Ashhurst (1895), in a series of 84 excisions of the knee-joint, had a mortality of only 8.3 per cent., the series extending through both pre-antiseptic and antiseptic periods; yet it is to be noted that he uniformly used scrupulous cleanliness, and virtual antiseptics (turpentine, alcohol, potassium permanganate) even before adopting Lister's principles of wound treatment.

times preventing excessive effusion; and it is not impossible that it lessens the physiological activities of a part, thus promoting rest. It probably lessens peristalsis in cases of peritonitis. Its chief use, however, is in inflammations of traumatic origin—wounds of the soft parts, sprains, etc.

It may be applied either *dry* or *moist*. The use of moist cold is apt to macerate the skin; but for short periods of time moist cold is very useful, as well in open wounds as in the case of subcutaneous injuries. In crushes of the extremities it is often possible to prevent widespread sloughing by the use of irrigation. If more elaborate appliances are not at hand, a pitcher may be hung over the affected part and a strip of gauze arranged to act by syphonage (Fig. 120). Dry cold is most conveniently applied by means of the ice bag; in using this, care should be taken to see that a fold of dry lint or a dry towel is kept between the skin and the ice bag, as the condensation on the surface of the latter will soon render the skin wet, and may cause superficial sloughing. Or Petitgand's method of mediate irrigation may be employed: a coil of thin-walled rubber tubing, of convenient length, is wrapped around the limb, or applied to the head, the breast, etc., and is held in place by a few turns of a roller bandage; a stream of cold water is then allowed to trickle constantly through the tube, being collected beside the bed in a suitable receptacle. The temperature to which the surface of the inflamed part has been reduced may be ascertained by testing the fluid as it runs off. Leiter's coils, which may be purchased ready made, are of flexible metal.

Heat, like cold, constringes the vessels of an inflamed part, and though not actually anesthesic, may prove more grateful to the patient. In the form of a hot water bag, dry heat is a household remedy. Baking is a valuable remedy in chronic inflammation. Moist heat is more often employed in acute inflammation than is dry. It is useful in sprains, etc., as an early application (hot water bath), having a tendency to limit or to prevent the development of subcutaneous edema. It is much more stimulating than cold, and when the circulation is sluggish, and sloughing is threatened, the surgeon may sometimes avert the danger by the use of very hot compresses frequently renewed. The use of moist heat in the form of a poultice is very agreeable to the patient, and is one of the most efficient ways of promoting suppuration when this is inevitable, as well as in hastening the separation of sloughs when these have once formed. The poultice may be made aseptic by sterilizing its ingredients, or antiseptic by incorporating antiseptic substances in it when it is being made. A poultice to be useful should be well made; and unless the surgeon knows himself how to make it well, he cannot expect nurses or other attendants to be particularly careful in its preparation. Linseed and slippery elm bark are the usual substances employed. For the separation of sloughs the yeast, or fermenting poultice is useful. The addition of powdered charcoal will make the poultice efficacious in absorbing malodorous gases. The method of preparing poultices is described

in Chapter V. All poultices should be covered with waxed paper or other impermeable material, so as to retain their heat and moisture. In the treatment of badly infected wounds, cellulitis, etc., I have derived great benefit from using an antiseptic poultice composed of gauze soaked in equal parts of 60 per cent. alcohol and corrosive sublimate solution (1 to 2000), applied dripping wet, and thoroughly covered by waxed paper and absorbent cotton; the whole dressing is then held in place by a roller bandage. It is sometimes said that there is no need to use antiseptics in wounds which already are infected, and that further infection will do good by establishing a free discharge of pus. This is an error; if there is no discharge of laudable pus in infected wounds, it only shows that the inflammation is extending, and that the body tissues have not been able to produce a sufficient number of phagocytes to combat and to vanquish the invaders. Adding to the infection, or producing a mixed infection, will not mend matters; it should rather be the surgeon's care to support his patient's strength, and to aid his tissues in the unequal struggle by destroying as many as possible of the microörganisms already present.

The *alternation of heat and cold*, in the form of douches, is useful in the later stages of the inflammatory process, aiding in the absorption of exudates and the restoration of the part to the normal condition.

Narcotics sometimes are applied locally with benefit. The tincture of arnica, lead water with laudanum or alcohol, and lately magnesium sulphate, have been popular at various times. The last named substance has the effect of a local anesthetic, and very remarkable effects are claimed from its use in erysipelas (Tucker, 1908), arthritis, orchitis, and other affections. Belladonna plaster is a favorite domestic remedy. Ichthyol, in the form of an ointment of 10 to 25 per cent. strength, is useful in soothing the pain of adenitis, in furuncles, etc., and by its sorbefacient effect seems to exert a directly beneficial influence on the course of inflammation. Ointments of belladonna and mercury are used in the same way. The internal use of mercury and the iodides may be combined advantageously with these local applications.

Counter-irritants, when applied around but not directly over the inflamed part, are often productive of considerable benefit, especially in subacute and chronic inflammations, though their exact mode of action is still a matter of dispute. Under this heading come *blisters*, *iodin*, *turpentine stupes*, *capsicum* and *mustard plasters;* also *silver nitrate*, which is astringent, and *copper sulphate*. The *actual cautery* is occasionally of value as a counter-irritant.

Local bleeding, by the use of incisions, or by means of leeches, may be of value in combating excessive inflammatory reaction. It will relieve the congestion, may perhaps prevent the formation of a harmful exudate, and almost without exception diminishes the pain. Leeches are seldom employed at the present day except in affections of the eye and ear. *Venesection*, or general bleeding, is now rarely employed. In cerebral compression its use is illogical, since the increased arterial tension is the effect, not the cause, of the lesion

within the cranium. But in the robust, plethoric, or cyanosed, with symptoms of present or threatening toxemia, in the presence of inflammation of the sthenic type, venesection is sometimes of value.

The use of *incisions* has already been referred to under the head of bleeding; by relieving tension they serve to lessen the pain, and may prevent sloughing by promoting discharge from the over-filled vessels of the inflamed area, thus aiding in the restoration of the circulation. The pain of orchitis is readily relieved by puncture of the tunica albuginea; after plastic operations (for hypospadias, etc.) multiple small incisions may prevent sloughing by reducing the edema; in extensive cellulitis the use of free incisions may prevent the development of widespread sloughing or gangrene (as in extravasation of urine). Finally the evacuation of pus is one of the main indications for incision.

Operations are frequently required in the treatment of inflammation. Drainage must be established in suppurative affections in all parts of the body (brain abscess; empyema; peritonitis); an involucrum must be cut away; sequestra must be removed; amputation and excisions must be performed, before the ultimate cure of the disease can be effected.

Compression, applied before the inflammatory process has reached its height, may prevent excessive reaction; in the later stages it will assist in promoting absorption. Swelling of a sprained ankle may be prevented by strapping; a carbuncle will rapidly decrease in size when thoroughly suported at its periphery by adhesive plaster straps; strapping a leg ulcer is almost indispensable at times.

Active and passive congestion, as introduced by Bier (1905), act in a truly remarkable manner in some inflammatory affections. Congestion lessens the pain by benumbing the part, probably by direct pressure on the nerve endings through the subcutaneous edema produced, acting thus much like the usual forms of infiltration anesthesia. It produces its curative effect probably by increasing the number of phagocytes in the part; possibly also by increasing the quantity of the exudate and thus enhancing its bactericidal properties. It has seemed to me that the value of compression in carbuncles and chronic ulcers may be due at least in some measure to the chronic passive hyperemia produced. Passive congestion is most used in the treatment of chronic arthritis; it is also of value in such localized infections as furuncles, felons, etc.; it is usually useless or actually harmful in spreading inflammations. Passive congestion is to be secured by bandaging the limb some distance above the lesion with an elastic bandage which is drawn tight enough to obstruct the venous current without intercepting the arterial. The limb below the seat of the constriction should develop a comforting glow, the superficial venules being distended, and the skin becoming a dusky blue. Under no circumstances should the constriction be tight enough to cause a fall of temperature in the limb. At first the treatment is continued for only one hour daily, but later may be used almost continuously. Active

hyperemia is secured by hot air applications (baking or the hot air douche), or by the use of cupping glasses, which are made in forms suitable to the various parts affected. Baking is particularly applicable to chronic forms of arthritis without effusion; while the cupping glass apparatus is said to be of value in the treatment of chronic sinuses, etc.; it has also been used in uterine affections. It is probable that the novelty of this treatment is causing it to be indiscriminately employed in many affections where it can only do harm.

Massage is of value in the later stages of inflammation, by promoting absorption of the exudate, rupturing slight inflammatory adhesions; and thus aiding the restoration of normal physiological action. In enforced confinement to bed, massage may be advisable to sustain the tone of the muscles of those parts not directly concerned in the disease.

Constitutional Treatment.—*Constitutional rest*, as well as local rest of the inflamed part, is often requisite. Rest in bed, in a quiet, cool, darkened room, may enable the patient to be restored to his activities in a few days, whereas a much longer period frequently would be required were he to persist in going about the house. Especially should such rest be insisted upon in the case of acute inflammations of the chief organs of the body—pyelitis, cystitis, prostatitis, affections of the gall-bladder and other abdominal organs.

Hygiene is of the utmost importance. The room of the patient, or the hospital ward, should be well ventilated, and easily warmed in winter, and cool in summer. Bathing must not be neglected, for the skin is an important excretory organ. The excretions must be watched daily, and in most cases a careful examination of the urine should be made, both as to quality and quantity. Cathartics should be given as needed; a brisk purge early in the attack is usually beneficial. A temperature chart should be kept, and the temperature, pulse, and respiration be recorded twice daily. As the patient will often be unable to entertain himself while laid up, the surgeon should see that such light entertainment as is deemed suitable is provided. The best surgeons are physicians also, and must not let their professional duty cease with the dressing of the wound or the application of a splint. On the other hand, I have sometimes seen patients who were exhausted by over-entertainment, all the members of the family congregating in the sick man's room to spend the evening, vitiating the atmosphere, and wearying the patient's mind by constant chattering among themselves. It is usually well to limit the visitors to two at a time; and to caution them to cease their visit and their conversation when the sick man no longer appears interested.

The *diet* in cases of inflammation should be simple; so long as fever continues, liquid diet is preferable. Milk, which is the most universally applicable article of food, usually can be taken by any patient, in spite of his prejudices, if he makes the attempt, and if the milk is fresh and cold. A few patients prefer it warmed. Its taste may be disguised by the use of vanilla, chocolate, coffee, etc. All kinds of

broths are suitable; fresh beef juice often is relished, or the various prepared forms of meat juice may be employed. Liquid peptonoids is an excellent article of diet. When the fever has gone, more liberal diet may be allowed: eggs, oysters, sweetbreads, chicken, chops, green vegetables, ice-cream, etc. As a rule, the patient's own desires and tastes furnish a fairly reliable guide to his diet; and if no injurious effects are manifest, he may be permitted to eat pretty much what he pleases.

Drugs are of undoubted value in the treatment of inflammation. Those most employed may be classed as (1) *Sedatives;* (2) *Cathartics;* (3) *Diuretics* and *Diaphoretics;* (4) *Stimulants;* (5) *Alteratives;* (6) *Tonics.*

Sedatives.—Opium is one of the most valuable single remedies in the pharmacopœia; but its tendency to produce constipation must be guarded against; and it is too valuable a remedy to be used indiscriminately. I never prescribe it unless there appears to be a definite therapeutic indication for its use; I consider its routine use in operations or other surgical affections as extremely injudicious. If the patient is in pain, it is the surgeon's duty to relieve the pain so far as is compatible with the cure of the disease; but usually pain may be relieved without resort to opium, by change of position, by prompt incision of an abscess, or by rest enforced by splint or bandages. If the pain really demands morphin for its relief, I think it is usually better to administer one-sixth of a grain hypodermically, and to repeat this in an hour if the patient is not relieved. In extensive burns, I order a quarter of a grain for an adult immediately, and have this dose repeated at short intervals until relief is obtained. There is no torture so great as that of a burn so extensive as to ensure death within a few hours; and it is inhuman to withhold the means of euthanasia from such patients. Closely allied to its power of producing sleep, is the action of opium for injuries of the head, in traumatic delirium, delirium tremens, etc. Besides relieving pain and securing sleep, opium serves to relax spasm; it thus proves of benefit in fractures; in retention of urine from congestion of the posterior urethra, in fissure of the anus, in pylorospasm, and similar affections.

If opium is contraindicated, other sedatives may take its place; among the most valuable of these are chloral, the bromides, hyoscin, cannabis indica, and paraldehyde. Trional is a useful hypnotic, but has no influence on pain. Aconite may be given in small doses during the height of the inflammatory fever, when of the sthenic type. Veratrum viride and antimony are now seldom used. The latter was formerly employed in the endeavor to abort inflammation by means of its so-called "anticipatory antiplastic effect." Calomel, for the same purpose, was strongly commended by the late Prof. Ashhurst, in the treatment of head injuries, and I constantly employ it with utmost satisfaction.

Catharatics usually may be administered with benefit in the early stages of inflammation. In this way toxins are withdrawn from the circulating blood, and prevented from reaching the kidneys in excess,

where they are prone to cause cloudy swelling or desquamative nephritis. In peritonitis I believe the use of cathartics to be positively harmful. In meningitis it is desirable to keep the bowels freely open. A single dose of castor oil, or blue pill, or divided doses of calomel (gr. $\frac{1}{6}$ hourly till gr. j has been taken) will be of more benefit in most cases than the popular use of salts. After having the bowels thoroughly opened once, it is usually inadvisable to continue purging the patient. If constipation persists, enemas may be used. Asafœtida suppositories, or milk of asafœtida by enema, are supposed to overcome flatulence. I have considerable doubt whether they have any very definite action.

Diuretics and *diaphoretics* were much employed formerly, and they undoubtedly are of benefit in some cases. Plenty of water by mouth is the best diuretic; when this is contraindicated, or if it cannot be taken, resort may be had to rectal, subcutaneous, or intravenous injections of saline solution. The kidneys are the chief organs of elimination for the toxins produced at the seat of inflammation, and by the imbibition of plenty of fluid the function of the kidneys is promoted, and the toxins are excreted in a more or less diluted form.

Dover's powder combines the merits of an hypnotic with those of a diaphoretic. The vegetable salts of potassium and ammonium (citrate and acetate) are especially valuable as diuretics because they are not themselves irritating; moreover, they lessen the viscosity of the blood. Digitalis and strophanthus are more stimulating; these, or the citrate of caffein, may be used when the heart shows signs of failure.

Stimulants seldom can be dispensed with in severe cases after the height of the fever has passed. Alcohol, when taken in small quantities, aids the absorption of food; it seems to act almost as a food itself when little else can be retained. It should be given in doses large enough to produce the desired effect; the amount naturally will vary with the age and habits of the patient, with his general condition, and with the condition of his heart and kidneys. The initial dose should be small (one-half ounce three or four times daily), and it should be increased rapidly so long as it appears to do good. In meningitis it is contraindicated, as tending to increase delirium; but in delirious states due purely to adynamia, as in extensive burns, or other exhausting diseases, the use of tonic doses of alcohol frequently will cause the mental state to clear up promptly. Its use in delirium tremens is to be condemned. If the delirium, from any cause, is increased by the alcohol, it is doing the patient no good, and should be reduced in quantity or discontinued entirely. Whisky and brandy are the best forms in which to administer alcohol during the inflammation; during convalescence, ale, beer, porter, or the lighter wines may be used. Champagne is the only form in which it is usually advisable to administer alcohol during the continuance of high fever.

Coffee is a valuable stimulant. It may be administered by mouth or by enema. The same is true of salt solution, as already noted when

speaking of diuretics. Atropin, digitalis, and camphor are good cardiac and vascular stimulants. I do not think much of strychnin except as a tonic.

Alteratives are used frequently in inflammation. The employment of mercury to cause the absorption of inflammatory exudates (iritis, meningitis, etc.) is world-wide. Calomel is usually the best form for administration. The iodides of potassium, sodium, etc., are widely used to aid in the elimination of inflammatory products, especially in affections of the bones and joints.

Tonics.—During convalescence it is almost always proper for the patient to take a tonic. Iron and quinin are the most valuable. Some patients will prefer Blaud's pills to the tincture of the chloride of iron, but the latter frequently is more effective. The tincture of nux vomica, or strychnin sulphate, with one of the bitters, aids materially in the restoration of appetite. In the case of children, cod liver oil, the phosphates, or arsenic may be given.

Stimulation of Phagocytosis.—This method has been attempted in both the prevention and treatment of inflammation. Mikulicz used local hypodermic injections of dilute nucleinic acid, in the effort to increase by positive chemotaxis the number of phagocytes and their bactericidal power for the prevention of peritonitis. Local inunctions of mercury are said to act in a similar way. The use of Bier's passive hyperemia has already been referred to.

Vaccines and Serum Therapy in General; the Opsonic Theory.—The phenomena of the inflammatory process are merely exaggerations of phenomena which are constantly occurring in the body in a state of health. As already mentioned, it is extremely probable that bacteria of some kind are constantly present in the body, and that phenomena of disease are prevented only by the natural resistance of the body tissues. Opsonins, as pointed out at p. 23, are normally present in the fluids of the circulating blood. When local inflammation or general disease arises, these resistive powers of the organism are increased; various other antibodies are produced, and on recovery from a certain disease a condition of immunity to that special infection may be established, and may continue for a longer or a shorter time. This immunity may be conceived of as being due to the cells of the body having acquired by training the habit of resisting a certain specific infection; so that should this same infection again occur, the body cells would be fully prepared, as the result of their previous experience, to act rapidly and effectively in repelling the foe. Their habit of forming antibodies will result in attempts at re-infection proving ineffectual.

The earliest instance in which practical application was made of the above theory, though of course the principle itself was not then understood, was the use of vaccination by Jenner (1798); in the original method the virus of the cowpox was inoculated into man, thus producing in him the disease known as *vaccinia*, which was considered to be a mild form of smallpox, the virulence of the smallpox virus

having been attenuated by passing through the cow. By thus training the body cells to reaction against the virus of cowpox, an immunity to smallpox is established.

The term **vaccines** is applied to those substances, used for prophylactic or curative injection, which contain the attenuated virus itself, not merely some of the anti-bodies produced in the course of the disease. Most vaccines contain no bacteria which have not been killed. Those substances which contain anti-bodies and perhaps dead bacteria, but certainly no living virus, are classed as **sera**; they are subdivided into *antitoxic* and *antibacterial sera*. By the use of the **opsonic index**, the use of vaccines and sera may be judiciously controlled. By collecting in a capillary pipette equal amounts of (1) the patient's blood serum, (2) blood corpuscles washed in a solution of one-half per cent. sodium citrate in normal salt solution, and (3) an emulsion of the specific bacteria of the disease from which the patient suffers; and by then examining properly prepared slides spread with the above fluid, the average number of bacteria ingested by each polynuclear leukocyte is determined. By comparing this average number with the average number of similar bacteria ingested by the leukocytes in a fluid similarly prepared from the serum of a normal individual, we obtain a ratio which may be expressed as an index by reducing the formula to unity. Thus if the average number of bacteria ingested in the first examination(the patient) was 2, and that in the second examination (normal individual) was 4, we obtain a ratio of 2 to 4, or of 0.5 to 1.0. We then speak of 1.0 as the normal opsonic index, and record the opsonic index of the patient as 0.5 (Primrose, 1907). By means of this opsonic index it is possible, in a way which so far is still rather empirical, to administer vaccines and sera so as to increase the patient's opsonic index, and thus promote the cure of the disease. This method has been employed chiefly in the treatment of tuberculosis.

Prophylaxis and treatment by vaccines and sera are most successful in the case of diseases caused by specific microörganisms. Ordinary inflammations, in which the cause is not a specific microorganism, have not so far been treated with very encouraging results. Among diseases treated by vaccines may be mentioned, besides the prevention of smallpox already referred to, the prophylaxis and cure of anthrax (Pasteur), rabies (Pasteur), typhoid fever (Fränkel, Richardson), and tuberculosis (Koch, Wright). Among those treated by sera are included: (1) By antitoxic sera, diphtheria (Behring), tetanus (Behring); (2) By antibacterial sera, typhoid, cholera, plague, dysentery, etc. Finally by the administration of both vaccines (active immunization) and sera (passive immunization), encouraging results have been obtained in anthrax by Sclavo (1903).

Antistreptococcic serum has been extensively used on general principles in ordinary types of spreading inflammation, in erysipelas, and in septicemia. (See Chapter II.) It is an antibacterial serum. The results are sometives marvellous, while more often its use appears

to be devoid of effect of any kind. Anticolon bacillus serum has also been used by some observers, but without very constant results. As a general statement, it may be said that in acute diseases, where it is necessary to supply the patient with anti-bodies already formed, sera are used; while in chronic infections, it is hoped by the administration of killed bacteria to rouse the patient's tissues to a more effectual production of anti-bodies.

CHAPTER II.

DISEASES RESULTING FROM INFLAMMATION.

The surgical diseases resulting from inflammation may be classified as (1) **Local Affections**, including *Abscess*, *Ulcer*, *Gangrene*, *Cellulitis*, *Erysipelas*, etc.; and (2) **General Affections**, including under the general name of *Sepsis*, the varieties of systemic infection known as *Sapremia*, *Toxemia*, *Bacteriemia* (*Septicemia*), and *Pyemia*.

LOCAL AFFECTIONS.

Abscess.—The pathogenesis of an abscess has been described already (p. 25), and it may be defined as a collection of pus circumscribed by granulation tissue. If the pus is not circumscribed by granulation tissue, it is not spoken of as an abscess. Thus pus in the pleural cavity is an empyema, if widely diffused; it does not become an abscess until it is walled off from the general cavity by the effusion of lymph and the production of adhesions. Pus widely infiltrating the cellular or muscular tissues does not form an abscess, but a *phlegmon*. Pus free in the peritoneal cavity is described not as an abscess of the peritoneum, but as diffuse suppurative peritonitis.

Two main *varieties* of abscess are recognized; these are distinguished clinically by their symptoms, but the pathogenesis of both is the same; they are the *acute* or *phlegmonous* abscess, and the *chronic*, *cold*, or *scrofulous* abscess. The former alone is to be considered here; cold abscess is described in connection with surgical tuberculosis, in Chapter III.

Clinical Pathology.—An abscess may arise in any place where inflammation exists. It may be caused by direct injury of the part, as by a fall, a kick, an infected wound, etc.; or it may arise secondarily, as the result of extension of inflammation from the primary focus. This extension may occur along the subcutaneous (subperitoneal, etc.) areolar tissue (causing cellulitis), along the lymphatic channels (causing lymphangeitis), or along the blood stream (causing phlebitis, and very rarely arteritis). When an abscess is suspected in a region which has not been directly injured, careful search should therefore be made for the original focus of infection; and it should not be forgotten that the intervening tissues may show no evidence of disease. Thus a sore on the foot may cause inflammation and eventual suppuration in the femoral or inguinal lymph nodes, without any evidences of lymphangeitis of the leg or thigh. Abscess of the liver may follow appendicitis, the virus of the disease having traversed

the radicles of the portal vein without leaving evidences of its passage. Infection from a wound of the mouth may spread to the areolar tissue of the neck, and there cause cellulitis and suppuration without giving signs of inflammation in the tissues of the floor of the mouth through which it passed. But in each and every case, before suppuration can occur, the earlier stages of inflammation must have existed in the part in which the abscess is ultimately formed.

As the pus within the abscess accumulates, by progressive liquefaction necrosis of the surrounding layer of lymph, the size of the abscess increases; it spreads most rapidly in the direction of least resistance (usually toward the skin surface), and *pointing* of the abscess is said to occur when the pus is contained by the epidermis alone. Occasionally an abscess will point and rupture into a neighboring cavity, as a joint, or one of the great serous cavities (pleura, pericardium, etc.); but in the case of suppuration in internal organs, sufficient plastic lymph at times is produced to confine the abscess on its inner surface, and to prevent rupture except externally. When an abscess is evacuated, the tract through which it discharges is called a *sinus* (p. 52). A *fistula* is a sinus which has two or more openings; these may be on the skin, or one may be on the skin, another in an internal cavity (intestine, joint, urethra, etc.), or both may be internal openings (as in gastro-colic, recto-vesical, and other similar fistulæ).

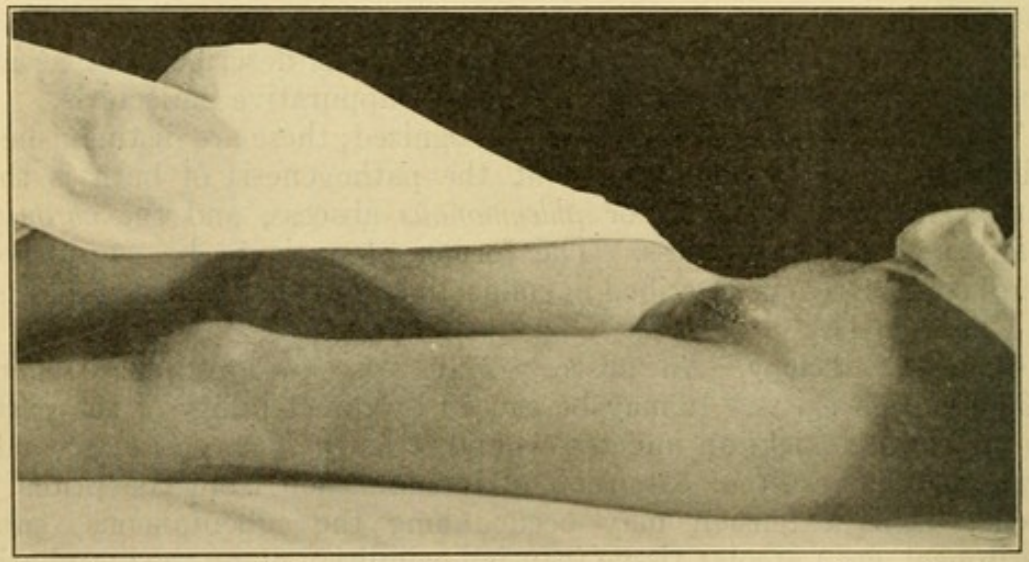

FIG. 6.—Abscess of the groin, following direct injury, one month previously. Girl, aged eleven years. Episcopal Hospital.

Symptoms.—At the onset of suppuration, the part already inflamed becomes more painful, the pain assuming a throbbing or pulsatile character; the tenderness is accentuated; the intense redness of the inflammation fades into a dusky or a bluish hue; the swelling becomes better localized; and frequently the abscess is seen to stand out above the surface of the surrounding skin (Fig. 6). As the amount of fluid within the abscess cavity increases, fluctuation,

at first indistinct, becomes unmistakable; the skin over the abscess may desquamate; it becomes thinner and thinner, and finally is entirely deprived of its nutrition at the point of greatest tension. A minute circular slough is then formed at this point, and, when this is cast off, the pus from within is discharged, the abscess cavity is more or less obliterated by the pressure of surrounding parts, and the abscess is finally converted into a granulating surface. When suppuration is deeply seated, an abscess may attain a considerable size before producing such characteristic symptoms. In such cases the overlying skin may become edematous, pitting slightly on pressure, owing to the effusion of lymph and serum in the overlying parts; rigidity and immobility of the protecting muscles are important signs; and the experienced touch of the surgeon may enable him to proclaim with certainty the presence of pus, when to one not possessed of the *tactus eruditus* a positive diagnosis would be impossible.

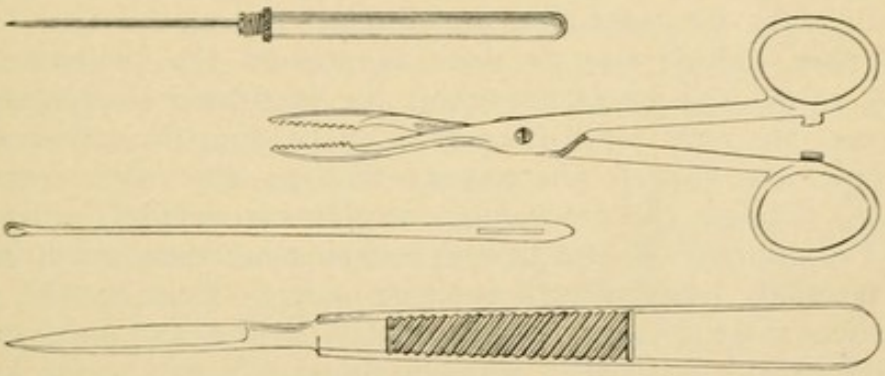

FIG. 7.—Instruments used in treatment of abscess: bistoury, eyed probe, dressing forceps, exploring needle.

Diagnosis.—It is not likely that an acute, superficial abscess, already pointing, will be mistaken for anything else. But there are many other affections with which an abscess at times may be confused. Careful and systematic examination of the patient should therefore never be neglected. The brilliant Irish surgeon, Dease, recklessly plunged his bistoury into a swelling in the femoral region, which he mistook at first glance for an abscess, and his patient died before his eyes from overwhelming and uncontrollable hemorrhage from the femoral artery, an aneurysm of which vessel had been opened. The diagnosis of an acute abscess may be determined by the *history*, by the *local signs* (fluctuation, pointing, etc.), and as a last resort by the *exploring needle* (Fig. 7). Fluctuation may be present more or less distinctly in many other swellings than those containing pus; besides aneurysms, effusions of blood, of serum, of urine, etc., may produce such fluctuating swellings; and cystic and even fatty and some other solid tumors may give a similar sensation. The surgeon's fingers, moreover, in palpating a suspicious swelling, should be placed longitudinally on the part, since the belly of a large muscle, and

even very fatty subcutaneous tissues may present indistinct fluctuation if this point be neglected. The exploring needle, or what is better if at hand, an ordinary hypodermic syringe, may be used to ascertain the presence and nature of the fluid in a doubtful case.

Prognosis.—This is good in most cases, provided treatment is prompt and efficient. But an abscess may be dangerous from its situation, from its size, or the prognosis may be peculiarly grave from the constitutional condition of the patient, or his age. A retropharyngeal abscess may cause suffocation; one in close proximity to a large bloodvessel may rupture into it, and cause death from hemorrhage or from pyemia; an abscess near a joint may penetrate its capsule and cause lasting disability or even death from pyarthrosis; an abdominal abscess may rupture into the peritoneum and cause fatal peritonitis. The drain on the patient's vitality from a large abscess, or from many smaller abscesses, may lead to death from exhaustion, or from amyloid degeneration of the viscera. In practically every case there will be loss of tissue, and a more or less evident cicatrix for years after the abscess has healed.

Treatment.—Much may be done to prevent the formation of an abscess, as pointed out in discussing the treatment of inflammation. When pus has once formed, much may be done to ameliorate the symptoms, and to cure the patient with as little disfigurement as possible. Though the process of pointing can seldom be hastened, yet by appropriate treatment the sufferings of the patient may be very materially relieved until pointing occurs. Heat or cold, whichever proves most grateful, may be applied locally, and anodynes may be administered internally, when required. Warm moist heat, in the form of a poultice, usually is most grateful to the inflamed part. But though these adjuvants may be employed with advantage in certain cases, prompt evacuation of the pus by incision is much more efficient in checking pain, by relieving tension and hastening the conversion of the abscess into a superficial ulcer. Moreover, the cicatrix resulting from a well-placed incision is much less disfiguring than one which occurs when an abscess is allowed to burst of itself. In most abscesses affecting the subcutaneous tissues it is better to postpone incision until fluctuation is evident, and until pointing has nearly occurred; but in other cases incision should be adopted much earlier, general or local anesthesia being employed as may seem indicated. When only the skin intervenes between the abscess and the surface of the body, no anesthetic is required, for freezing the skin or the use of hypodermic injections of cocain is quite as painful as the momentary stab of a bistoury; moreover, the skin overlying such an abscess has nearly all its nerves devitalized by the anemic necrosis induced by pressure of the pus. In the case of deeper abscesses, I much prefer the hypodermic use of cocain to freezing by the ethyl chloride spray; and when the cocain is properly used the entire procedure is painless except for the initial prick of the needle. When the abscess is still more inaccessible, general

anesthesia is to be preferred, since in some instances it may be necessary to undertake a formal operation, or even to open the abscess across a serous cavity (pulmonary, appendicular, cerebral abscess). In opening a superficial abscess without any local anesthesia, the surgeon should accomplish his purpose by a sudden thrust of the bistoury, which is held as a pen, and with its cutting edge toward the surgeon; thus, as the patient draws away in momentary surprise or pain, the incision will be enlarged as the bistoury is withdrawn. The depth to which it is to be introduced must be determined beforehand, and regard must be had to the anatomy of the part, lest some important nerve or vessel be wounded. In opening an abscess in a dangerous neighborhood it is much safer to adopt **Hilton's method**: to incise merely through the skin and superficial fascia, and then to introduce a grooved director, and burrow down to the abscess with this, or with a dressing forceps; when the pus is reached, the blades of the forceps are widely separated and the forceps is withdrawn, thus dilating the tract previously made.

When an abscess has been opened, it should be allowed to discharge itself slowly; the surgeon may gently support its sides, to encourage the discharge of pus, but he should by no means attempt to express it by massage, and most emphatically should he not introduce a curette into the abscess cavity to scrape away its lining membrane. Such a course destroys the granulation tissue surrounding the abscess cavity, may open neighboring venules or lymphatic radicles, and is extremely apt to cause a spread of the inflammation. When the tension on the abscess cavity is relieved by the evacuation of the pus, its walls will collapse, and in the case of small abscesses union between these apposed walls will take place in a couple of days by the process of secondary adhesion (p. 162), and a superficial ulcer alone will remain. In such cases no drain need be introduced into the abscess cavity; but in the vast majority of instances it is important to introduce between the lips of the incision some substance which will keep them from uniting until healing of the underlying abscess cavity is complete. A tube of soft rubber, commonly known as a drainage tube (Fig. 8), is much more satisfactory for this purpose than is any substance, such as gauze, which may become clogged with the discharging pus, and thus hinder, instead of promote the escape of pus from the depths of the cavity as healing progresses. It is only in very small abscesses, where the discharge is slight, that a gauze drain is useful; and if employed in other cases, where it may be of value by acting as a tampon to check oozing of blood from the walls of the abscess cavity, it is better to use a tube as well; or a

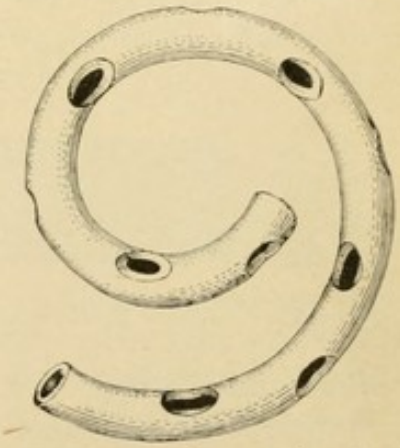

FIG. 8.—Drainage tube of soft rubber, with numerous eyelets.

cigarette drain (Fig. 10) may be employed. In small abscesses sufficient drainage may often be procured by a few strands of silkworm gut or a piece of rubber tissue.

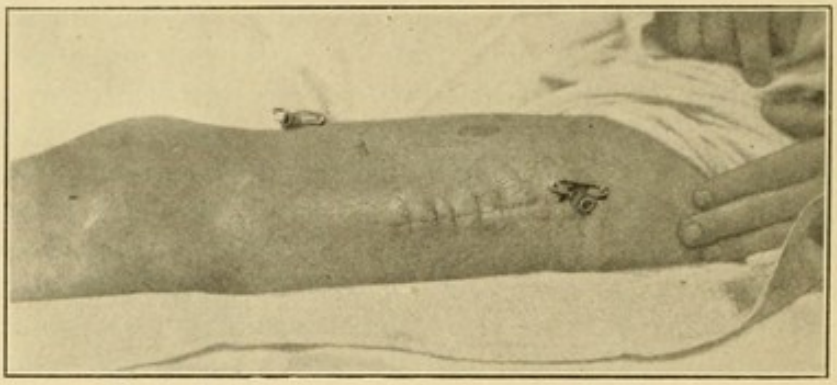

FIG. 9.—Deep abscess of thigh; through-and-through drainage by rubber tube, safety-pins to prevent displacement of tube. Episcopal Hospital.

The dressings of an abscess (gauze) will absorb the discharges better if they are moist. A solution of sodium chloride, of corrosive sublimate, of alcohol, of potassium permanganate, or other suitable antiseptic may be used for this purpose. The gauze immediately next the discharging sinus should be well crumpled up before being applied; laying many layers of flat gauze over the part will dam up the pus in the abscess cavity.



FIG. 10.—Cigarette drain, made by covering a wick of gauze with rubber tissue.

Sinus and Fistula.—These are suppurating tracts, usually due to the incomplete healing of abscesses. A sinus, as pointed out at p. 48, has only one orifice, since its other extremity ends blindly in the former abscess cavity.[1] A fistula, on the other hand, is a suppurating tract with at least two, and sometimes several, orifices, which may be either external, internal, or both. Sinuses and fistulæ may be kept from healing by the action of neighboring muscles (as in *fistula in ano*); by the presence of some foreign body (spicule of bone, ligature) which the tissues of the organism cannot destroy; or by the constant passage of the secretions of the part through the abnormal opening (salivary, fecal, or urinary fistula), instead of through the natural channel.

Treatment.—They should be treated by removal of the foreign body; by removing the obstruction to the discharge of the secretions; or by supporting the sides of the sinus with adhesive plaster or bandages to overcome the action of neighboring muscles. If the walls of the suppurating tract are thickened and indurated, they should be

[1] Such a sinus often is called a "blind fistula."

stimulated by the use of caustic injections (silver nitrate, zinc sulphate, etc.), or stimulating ointments (dilute mercuric nitrate, ichthyol, iodin) on a rope of gauze; by curetting the sinus with Volkmann's sharp spoon; or finally by slitting the tract open on a grooved director, cauterizing it with caustic potash or the actual cautery, thus producing a superficial slough and converting the sinus into an ulcer, and promoting healing from the bottom. In excessively obstinate cases a cure may be obtained by dissecting out the entire suppurating tract, and uniting the parts from the bottom with buried absorbable sutures. Many chronic sinuses, especially of tuberculous origin, may be cured by the injection of a bismuth-vaselin paste, as recommended by Beck (1908) (see Chapter XV).

Ulcer.—*Ulceration* is defined as the molecular death of a part. Some writers distinguish between an ulcer and a granulating wound, limiting the former term to the result of the process of destruction known as ulceration, and therefore denying that an ulcer, as such, can ever heal; maintaining that as soon as healing commences the term granulating wound should be adopted. Certain ulcers, however, may be granulating at one portion of their surface, while still actively ulcerating at another point (*serpiginous ulceration*); so it seems better while acknowledging the distinction between ulceration (molecular death) and granulation (process of repair), to include as is usually done, both granulating and ulcerating surfaces under the general heading of ulcer. Park tersely defines an ulcer as "a surface which is or ought to be granulating."

The *repair* of an ulcer occurs by *granulation* and *cicatrization*. The formerly ulcerating surface gradually loses its inflamed appearance; the discharge of pus lessens; the edges of the ulcer become firmer and more clearly defined; and granulations are seen springing up all over its surface. Soon these granulations become higher than the surrounding skin; often they become exuberant, forming what is known as "proud flesh." Aroung the edges of the ulcer the neighboring epithelium proliferates, gradually covering in the granulations, and being easily distinguished as a faint blue line interposed between the healthy skin and the face of the ulcer. Occasionally little patches of new skin, with this same faint bluish tinge, may be seen in the midst of the granulations, evidently arising from epithelial cells which have survived the original destructive lesion. As these changes progress on the surface of the ulcer, beneath its surface proceed the changes which have already been described under the heading Repair (p. 29); that is to say, the fibroblasts become converted into white fibrous connective tissue (*cicatrization*), and as a consequence the face of the ulcer contracts, thus decreasing the superficial area which must be covered over by the surrounding epithelium. This *contraction*, which is the prime characteristic of all newly formed cicatricial tissue, is most noticeable on the surface of the body in the healing of ulcers resulting from burns; and in mucous channels (urethra, esophagus), where strictures are the result.

Certain varieties of ulcer are described by systematic writers. The most important are:

Simple or Healthy Ulcer.—This is characterized by its innate tendency to heal. To secure prompt healing every other variety of ulcer must be converted into this form. Ordinary incised wounds healing by "second intention," and superficial burns, afford good examples of a healthy ulcer. This ulcer, if not too large, will heal of its own accord if it be protected from injury. If exposed to the air after the granulations are well formed, a scab will form over it, and healing under the scab will take place as described at p. 162. Ordinarily it is better to cover the ulcer with some mild ointment, spread not too thickly on lint. There is no object in having the ointment spread over the neighboring healthy skin also; indeed to do so frequently causes maceration and delays healing.

Inflamed Ulcer.—This is one in which infection is still progressing, the reaction of the tissues being insufficient to quell the invasion (Plate I, Fig. 3). A very severe form of inflamed ulcer is the **sloughing ulcer.** The worst form of all is **phagedenic ulcer,** usually seen only in chancroidal sores; here the destruction of tissue is frightfully rapid, and nothing short of thorough cauterization of the entire ulcerated surfaces will suffice to check the phagedena. In ordinary cases of inflamed ulcer, confinement to bed, with elevation of the part, the local use of antiseptics, and tonics and stimulants internally, may be necessary to arrest ulceration.

Weak or Edematous Ulcer.—This is characterized by the granulations being large and flabby, apparently distended with serum, of very low vitality, and easily detached in masses from the surface of the ulcer. Usually it is an evidence that proper care of the wound has been neglected, or that poultices and mild ointments (zinc oxide and boric acid) have been continued too long. As granulations contain no nervous tissue, no hesitation need be felt in snipping off with scissors the exuberant masses of proud flesh; the patient will not feel a particle of pain. Any bleeding is readily checked by pressure or by cauterization with the stick of silver nitrate. Then more stimulating ointments should be applied, particularly valuable being resin cerate, scarlet red, balsam of Peru, nitrate of mercury, ichthyol, etc.

Neuralgic or Irritable Ulcer.—This is usually of small size, placed at the ankle, below or near to one of the malleoli, and is characterized by the intense pain experienced by the patient. The skin margins are usually thickened, the ulcer has little or no discharge, its surface being glazed and exquisitely sensitive. Frequently it is evident that the ulcer involves the terminal filaments of some sensory nerve, especially the musculocutaneous or the internal saphenous nerves at the ankle (Fig. 11). If rest in bed, with elevation of the part, and cauterization of the base of the ulcer fails to relieve pain, the affected nerve some three to six inches above the ulcer may be stretched or excised (Hilton, 1877).

Indolent or Callous Ulcer.—This is the most frequent form of "leg ulcer," usually occurring in adults, on the lower half of the leg, and on the anterior or fibular aspect. The surface of the ulcer is dry, and sometimes glazed; the granulations are low and ill-formed; the edges are hypertrophied and dense, and give to the surface of the ulcer a depressed or concave appearance (Fig. 12). As cure depends upon contraction of the base of the ulcer, and on concentric cicatrization proceeding from its edges, it is evident that destruction of the callous margins is the first step in this direction. These margins surround the ulcer like a cartilaginous ring, and by their lack of elasticity and by their very bulk prevent contraction of the ulcer's base; moreover, the surrounding epithelium appears indolent and unable to proliferate so as to cover in the granulations. The ulcer

FIG. 11.—Neuralgic or irritable ulcer in a woman, aged forty-five years. Duration four weeks. Episcopal Hospital.

FIG. 12.—Indolent or callous ulcers of the leg. Episcopal Hospital.

usually is due to some trivial injury, repair of which becomes impossible from the necessity of the patients continuing their occupations as means of livelihood, and because of some constitutional condition (obesity, arteriosclerosis) which interferes with the normal circulation of the blood and lymph in the part. If the patient be put to bed and the callous margins of the ulcer be softened by poultices or simple wet dressings, the ulcer usually will soon be converted into one of the healthy type, and cure will soon be brought about. As soon, however, as the patient resumes his occupation, the old ulcer is apt to reappear whenever the skin is bruised. It is important, on this account, to take great pains to avoid injury and to maintain the skin in good condition, when once the ulcer has healed. Scrupulous cleanlinesss should be enjoined; and

where a tendency to edema of the leg exists, much benefit may be gained from the use of an elastic bandage, which usually is preferable to an elastic stocking. But it may be impossible for the patient to be laid up in bed for some weeks, which is the shortest time in which a cure may be anticipated; yet even without the advantages of rest in the recumbent position, it is by no means impossible to bring about a cure of the ulcer. Poultices and wet dressings may be applied while the patient continues at his work, and when the margins of the ulcer have become reasonably soft, it may be strapped with adhesive plaster, thus supporting the edges, preventing a re-accumulation of blood and lymph in the parts, and mechanically promoting healing of the base. The straps should be an inch or an inch and a half wide, long enough to encircle about three-fourths of the limb when obliquely applied; and are to be put on from below upward in an imbricated manner, two at a time, thus drawing the edges of the ulcer together as the two straps are crossed (Fig. 13). The strapping, which should start an inch or so below the ulcer, and continue for an equal distance above its upper margin, should be covered in by a firm muslin bandage, extending from the patient's toes to his knee. This dressing may remain in place for from five days to a week; when it is to be removed, the skin should be washed with turpentine, the edges of the ulcer (just within the blue line of new skin) touched with the solid stick of silver nitrate, and the straps again applied and covered in with a firm bandage as before. When the ulcer assumes the character of a simple or healthy ulcer, strapping may be discontinued, and ointments may by applied; but frequently the ulcer will heal under the use of straps alone. The results of this treatment, when it is carefully carried out, are remarkable: ulcers which have been open for a year or more, and on which all manner of salves have been tried, may be completely healed within comparatively few weeks. It is usually best for the patient to continue to keep the leg bandaged for a long time after apparent cure has been obtained, since relapses are frequent. In the rare cases where rest in bed, poultices, and strapping, fail to cure an indolent ulcer, its conversion into a healthy ulcer sometimes may be accelerated by dividing its callous margin by several radiating

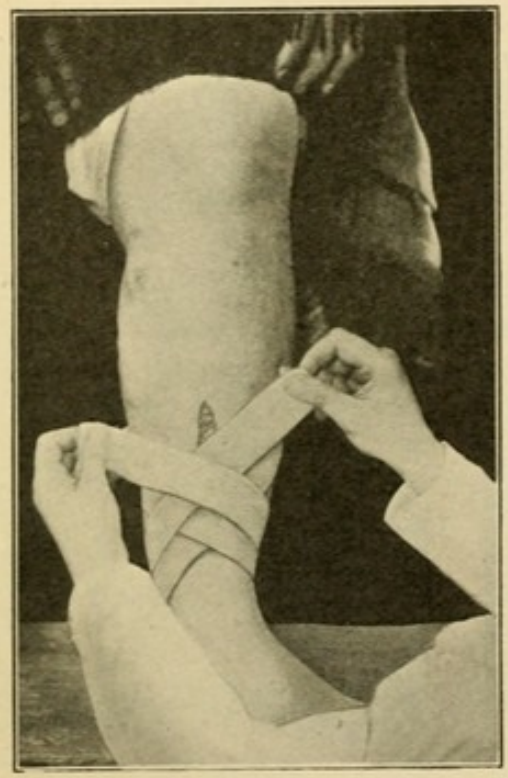

FIG. 13.—Strapping a leg ulcer. Episcopal Hospital.

incisions, or even by making criss-cross incisions extending through the base of the ulcer and its callous margin on both sides. Or the ulcer may be under-cut from the sides, separating its base completely from the deep fascia. *Skin grafting* (p. 223) has been employed to hasten the cicatrization of these ulcers, but without much success. Formal *plastic operations* (p. 225) occasionally have been adopted, but with no very permanent results. A great many of these callous leg ulcers are due to the unsuspected presence of syphilis. The typical *syphilitic leg ulcer* (Fig. 14) is situated above the middle of the leg, is characteristically round, is seldom very painful, and yields with

FIG. 14.—Syphilitic ulcer of leg, male, aged twenty-four years. Following "rupia" of six weeks' duration. Completely healed under anti-syphilitic treatment in three weeks. Episcopal Hospital.

FIG. 15.—Varicose leg ulcer. Episcopal Hospital.

remarkable facility to the administration of mercury and the iodides. But in many of the callous ulcers in which no definite history of syphilis can be obtained, much improvement often follows the administration of potassium iodide alone or with mercury. In almost all cases of leg ulcer of long duration the tibia immediately beneath the seat of disease becomes thickened; but in the case of syphilitic ulcers there is sclerosis of the bones, and as pointed out by Coues the diagnosis of syphilitic leg ulcer usually may be confirmed by a skiagraph. In very exceptional cases the callous ulcer is absolutely incurable. But life with an incurable leg ulcer is by no means impos-

sible; indeed, many persons live for fifteen to twenty years, or longer, with unhealed leg ulcers, and are able to lead very active lives. It is only in the rarest instances, therefore, that amputation is justifiable; for the risk to life usually is much less from an unhealed leg ulcer than from amputation.

Varicose Ulcer.—This is one associated with varicose veins (Fig. 15). It is difficult to heal, sometimes is attended by alarming hemorrhages, and frequently incapacitates the patient. The use of elastic bandages, hot baths, gentle massage, etc., by reducing the swelling, and improving the circulation of the limb, sometimes will bring about a cure, or at least will keep the patient in comfort. If palliative measures fail, excision of the affected veins may be done; but the operation is one of more risk than when no ulcer exists, and should not be undertaken lightly. It should never be done in the presence of active phlebitis; and if the veins are thrombosed as the result of a former phlebitis, they should be divided through healthy portions above the limit of the clot.

Warty Ulcer.—Under this name Marjolin (1846) described a form of ulcer which of late years usually has been regarded as due to malignant changes. It is not correct, however, to give the name of Marjolin to every ulcer which undergoes malignant transformation, as his original description applied merely to the clinical appearance of the ulcer, as if covered with warts. Fig. 16 represents a typical warty ulcer, which healed rapidly under appropriate treatment. When of long standing a malignant ulcer whose surface is warty frequently is found to involve the bone, which is the seat of caries, perhaps due to a primary sarcoma of bone, or possibly involved secondarily by a surface epithelioma. If the warty ulcer is malignant, it is much safer to amputate the limb than to attempt excision; but if the malignant ulcer is of the heel (I have seen two cases following burns in this situation), resection may properly be done, with restoration of the foot by the method of Mikulicz, if the patient refuses amputation.

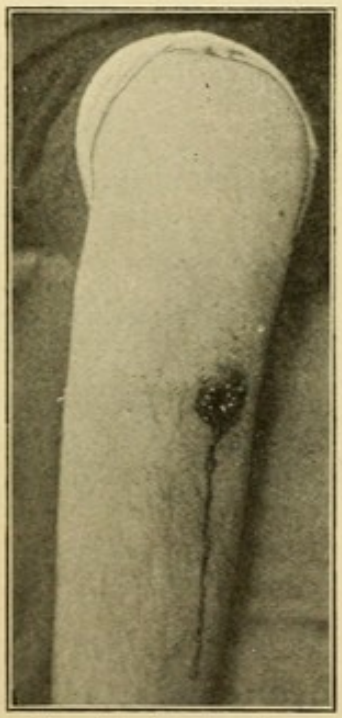

FIG. 16.—Warty ulcer of Marjolin connected with periosteitis eight months after typhoid fever. From direct injury. Aged fourteen years. Episcopal Hospital.

Gangrene (**sphacelus, mortification, sloughing**) is a term used to describe the process of death of the soft parts, or of an entire extremity with its contained bone, when this death occurs in mass; **necrosis**, though usually confined in its application to death of bone, is occasionally employed to describe the death of soft parts at a depth from the surface, where no marked inflammatory phenomena are present, the resulting *necrotic masses* corresponding very closely to

the sequestra met with in necrosis of bone. In ulceration, the dead parts are cast off in the form of pus (liquefaction necrosis), and *molecular death* of the tissues is said to occur; whereas in gangrene (*molar death*) the parts cast off (sloughs) are of such size as to be clearly visible to the naked eye.

The **causes** of gangrene are either *direct* (as in pulpefaction of a limb by crushing force, destruction by caustics, by heat or cold, by bacterial toxins, etc.), or *indirect*, from interference with the vascular supply. One of the most extensive cases of sloughing I ever saw was in a lad of 16 years, whose whole lower extremity had passed through cog-wheels; though there was no injury to the vascular supply of the limb, the pressure of each cog produced immediate death of the area it crushed, and it was over ten weeks before the sloughs had all separated and the resulting ulcers healed. The appearance of the cicatrices six years after the accident is shown in Fig. 17. Injuries which in a normal state of health would cause only trivial lesions, when complicated by vascular obstruction or constitutional disease may result in very extensive sloughing or gangrene. The same degree of inflammatory infiltration, which in the subcutaneous tissues would be harmless, when occurring beneath the palmar fascia or other dense fibrous membrane may produce such a choking off of the blood-supply as to cause extensive necrosis of the structures involved. In the old, or in younger persons with marked arteriosclerosis, so-called *senile gangrene* may follow trifling injuries, or may be caused by gradual occlusion of the arteries without external injury. In *diabetics* there is a special tendency to necrotic processes, among the mildest of which are furuncles with their central slough or core. In patients suffering from *ergotism*, gangrene of the fingers or toes, perhaps symmetrical, is a not infrequent phenomenon. It is usually preceded by premonitory symptoms, such as formication, cramps,

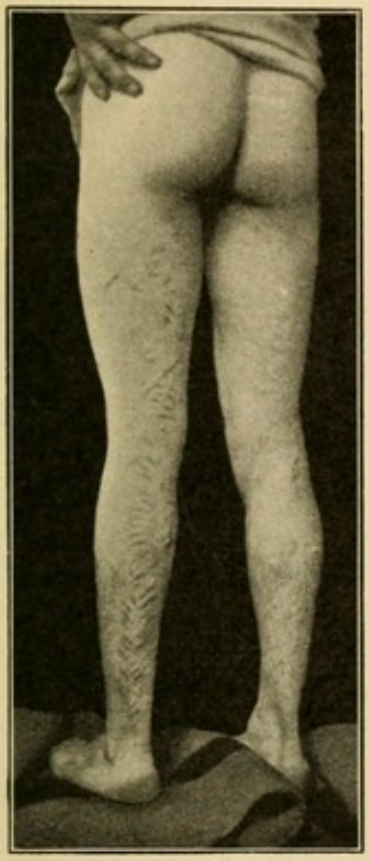

FIG. 17.—Cicatrices from sloughing, six years after injury (cog-wheels). Episcopal Hospital.

FIG. 18.—Gangrene following application for twenty-four hours by patient's mother of carbolic acid dressing. Episcopal Hospital.

local asphyxia, etc. Certain lesions of the *nervous system*, probably through vaso-motor changes, may induce bed-sores, sloughing, etc., in an alarmingly short space of time. The so-called *perforating ulcer* of the foot (p. 261), probably is due to a similar change, though arteriosclerosis is usually a factor also. **Carbolic acid gangrene** (Fig. 18) results from the direct caustic action of the solution employed, and often follows the use of a weak solution which becomes concentrated by evaporation.

Bacteria are not a necessary accompaniment of gangrene; their presence usually is incidental. In a few rare instances, bacterial toxins are believed to be the immediate cause of gangrene by causing endarteritis, phlebitis, and thrombosis. This is probably the case in noma (p. 63). Emphysematous gangrene (p. 65) is due to infection with gas-producing bacteria, the production of gas preceding the development of gangrene. Saprophytic bacteria usually invade tissues which have already become gangrenous, and produce the malodorous gases characteristic of putrefaction.

There are two main **varieties** of gangrene, the *moist* and the *dry*, dependent in large measure upon the amount of moisture in the part when the vascular current is occluded, and on the amount of evaporation which takes place. Moist gangrene usually is due to venous obstruction (thrombosis, pressure of tumors, splints, bandages, etc.); it is occasionally seen, however, after sudden occlusion of the main artery of a limb (embolism, wounds, ligation, etc.), if the venous blood already present remains in the part. Dry gangrene, of which the senile form is typical, usually is due to slowly progressing arterial occlusion, the parts deprived of vascular supply becoming mummified. Diabetic gangrene is usually rather dry.

Symptoms.—When a part which has been inflamed becomes gangrenous, the color fades into bluish green or purple, and finally into black; the pain, at first burning and intolerable, suddenly ceases; the affected area becomes numb and senseless; the cuticle is raised in bullæ filled with bloody or purulent fluid; the part instead of being tense feels doughy; and the local temperature falls. There is gradually formed, at the point where the resistive powers of the individual are sufficient to overcome the destructive lesions producing the gangrene, a *line of demarcation*, indicated by a red line encircling the gangrenous structures. In this region the usual phenomena of inflammation occur, and as this process continues, a line of granulations is formed, known as the *line of separation*. By the gradual increase of these granulations the dead tissues are pushed away, as it were; and unless assisted by the surgeon this tedious process will continue until the entire gangrenous area is extruded in the form of a slough. An entire limb may be amputated spontaneously in this way.

During the formation of the line of demarcation, there is often considerable constitutional disturbance, due to the sapremia caused by absorption from the imperfectly isolated gangrenous area; and

even during the process of granulation, before the slough is cast off, the patient is constantly exposed to infection from the decayed structures. These constitutional symptoms usually are much less or altogether absent in dry gangrene, where the process, as already mentioned, resembles mummification.

Treatment.—The separation of sloughs sometimes seems to be hastened by poulticing the part. The charcoal poultice is particularly useful in these cases, as it lessens the odor by absorbing the gases. The yeast poultice also acts well. Various chemical digestants have been used, in the effort to aid nature in dissolving the sloughs; but little more is thus accomplished than by simply keeping the parts clean and protecting them from outside infection. In the case of extensive gangrene, the most important thing is to prevent infection; amputation will surely be required later, but if infection is absent the surgeon can safely postpone it until some indication is present of the level at which it must be done. Early amputation is often needlessly high. In moist gangrene constant irrigation with dilute antiseptics is one of the surest methods of preventing infection; in dry gangrene it usually is sufficient to keep the parts well covered with sterile cotton. Periodical baking of the limb, as in chronic joint affections, is also of great service. In **senile gangrene**, where only one or two toes are affected, formal amputation may never be required, as nature will be able to remove the slough at one of the phalangeal joints with less constitutional disturbance than would be caused by an operation; if the gangrene extends beyond the toes, however, amputation should be done above the ankle; and if it extends above the ankle, amputation through the lower third of the thigh should be done: it is not advisable to wait for the line of demarcation, and to amputate at lower points than those named almost certainly would expose the patient to recurrence of gangrene in the stump. To determine the level at which amputation should be done Lejars employs (1909) the "comparative hyperemia" test: the limb is elevated, an elastic bandage is applied, exsanguinating it, and exsanguination is maintained by an Esmarch band for five or ten minutes after the elastic bandage is removed; the hyperemic blush which follows the removal of the Esmarch band will extend only so far as healthy circulation is present, and amputation may be done safely at this point. In the healthy limb the hyperemic blush extends to the toes. Arterio-venous anastomosis ("reversal of the circulation") as a method of treatment for gangrene, is discussed at p. 241. In many cases of senile gangrene it is evident that any operation would only hasten the fatal termination; under such circumstances of course only palliative treatment is admissable. In **diabetic gangrene** (Fig. 19) amputation is not to be recommended until sepsis threatens. De Witt Stetten (1912) has shown the remarkable success which attends judicious conservative treatment, especially sterilization of the limb by repeated baking. Amputation for gangrene following **frost-bite** and **burns**, should not be done until the line of demarcation has

formed, as it is impossible to know beforehand at what level the limb must be removed. In the case of gangrene resulting from **local injury** due to crushes, compound fractures, etc., amputation should be done as soon as gangrene is manifest; it is impossible to prevent infection in such cases, and delay in resorting to amputation usually will cost the patient his life. When gangrene is due to **arterial occlusion** (embolism, ligation for wound), amputation should be done at the site of the occlusion, as soon as gangrene is evident (Guthrie, 1815); but in the case of injury to the superficial femoral artery, amputation below the knee usually is sufficient, and occasionally in the upper extremity a collateral circulation may be established.

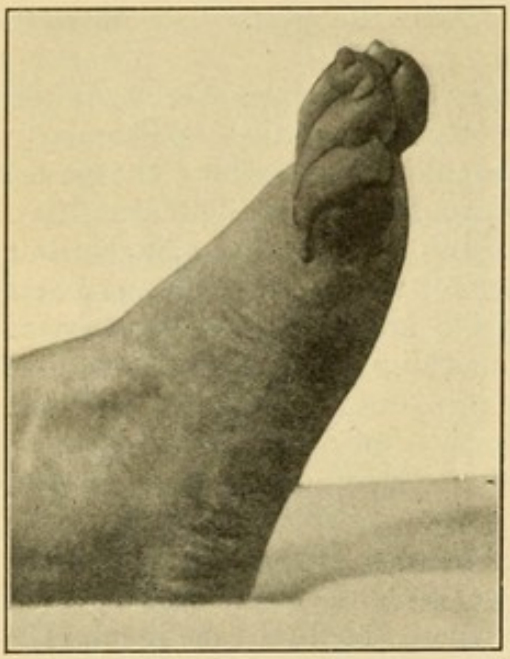

FIG. 19.—Diabetic gangrene. Aged seventy-four years. Duration two months. Healed under conservative treatment. Episcopal Hospital.

Special Forms of Gangrene.—**Decubitus or bed-sore** (Fig. 21) is due to necrosis of the skin and subcutaneous tissues from long continued pressure on bony prominences in those confined to bed, especially in those with debilitating diseases or in a helpless condition. Favorite sites are over the sacrum and sacro-iliac joints (Fig. 22); but any point receiving constant pressure (occiput, scapulæ, elbows, heels, malleoli) may develop bed-sores. They usually may be prevented by proper care of the skin, allowing no folds or creases in the bed-clothes (the patient may lie on a blanket instead of a sheet), with frequent changes of position, and use of air-pillows, rings, water-beds, etc. Scrupulous cleanliness is most important, keeping the skin dry (in cases of involuntary dejections) and protecting it after use of stimulating lotions by dusting powders or soap plaster. The same measures are important in the treatment of a bed-sore when once it has formed.

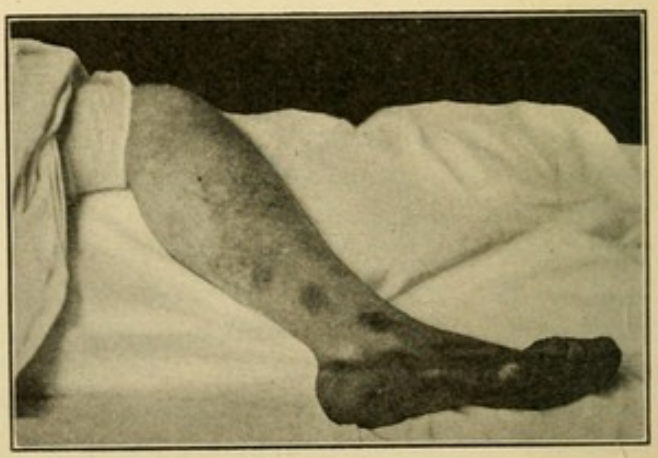

FIG. 20.—Dry gangrene from embolism; male, aged forty years. In December embolus lodged in brain, causing right-sided hemiplegia; in March (three weeks before photograph) embolus lodged in right popliteal artery. Death a few weeks later. No operation. Episcopal Hospital.

The slough should not be cut away until it is quite loose, and the underlying ulcer should be dressed with rather stimulating ointments. Constitutional treatment never should be neglected. Get the patient out of bed as soon as possible. Long continuance of a large bed-sore is a tremendous drain on the vitality and not infrequently is an indirect cause of death (exhaustion, sepsis, hemorrhage).

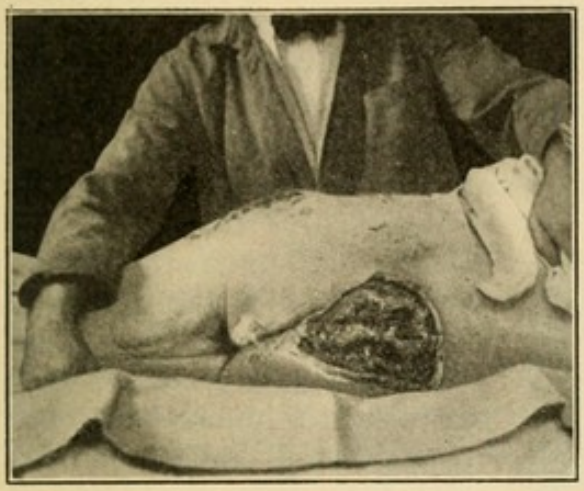

FIG. 21.—Decubitus or bed-sore, in a patient, aged seventy-eight years; duration two months. The sloughs have been cut away. Episcopal Hospital.

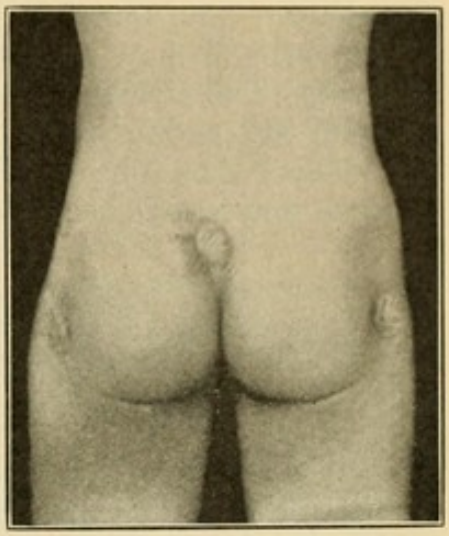

FIG. 22.—Cicatrices from bed-sores, in patient, aged twenty years, developing during typhoid fever five years ago. Episcopal Hospital.

Hospital Gangrene (*Sloughing Phagedena, Pourriture d' Hôpital*).—This scourge of military hospitals in former years probably is due to a specific microbe. Its clinical causes are crowding, bad ventilation, and generally unhygienic conditions. It is now almost unknown. It arose only in wounds, though the wounds sometimes were mere abrasions. The surface of the wound became dry, was covered with "a pulpy, ashen slough," and the circular shape and cup-like depression of the wound were considered characteristic. By attention to hygiene its development usually may be prevented. It is most successfully treated by strong antiseptics (bromin, iodin) and scrupulous cleanliness. Patients affected should be isolated. Amputation is scarcely ever necessary.

Noma.—Noma is a gangrenous affection, almost exclusively confined to childhood, usually following the exanthemata (especially measles) or typhoid fever. Various bacteria have been found by different observers, certain forms of leptothrix being those most frequently present. As mixed infection, including saprophytes, almost always exists, the etiological relation of any one form is difficult to determine. The disease affects the mouth (*Gangrenous Stomatitis, Cancrum Oris*) and the external genitals (*Noma Pudendi*), especially the genitals of female children. The ear and the rectum have also been affected. Whether in the mouth or the genitals, the disease usually starts on the mucous membrane, and in an incredibly

short space of time, perhaps three or four hours, a gangrenous ulcer an inch or more in diameter, may be present. The first thing to attract attention is often a shiny red spot on the exterior of the cheek, the gangrenous ulcer having nearly perforated before being discovered. But if this complication be kept in mind the disease may be detected at an earlier stage from fetor of the breath, disinclination for food, etc., which will lead the nurse or attending physician to examine the mouth. The constitutional symptoms are slight, and the child, though listless, may continue to play with its toys until the hour of death. The alveolus may be involved, the cheek perforated, and frightful destruction produced in a very short space of time.

Treatment should be prompt and vigorous; the child being anesthetized, a mouth gag should be introduced, the cheek everted, scraped with Volkmann's spoon, and the base of the ulcer thoroughly cauterized with fuming nitric acid applied by a stout stick; or acid nitrate of mercury may be used. If the cheek has been perforated, it is best to excise the whole ulcer; and it may be necessary to excise a couple of inches of the alveolus (Fig. 23). Free stimulation must be employed afterwards and the mouth kept constantly clean by the use of suitable washes. Death from exhaustion, bronchopneumonia, or pyemia, is the rule. The mortality varies from 70 to 95 per cent. If the child recovers, a plastic operation may be necessary to restore the cheek. Similar treatment should be adopted in the case of Noma Pudendi, which is a much rarer affection.

Fig. 23.—Noma following measles, in a child, aged three years; duration one week. The gangrenous parts have been excised. Death. Children's Hospital.

Ainhum.—This is a rare tropical disease, generally ending in gangrene, which usually is dry, affects the toes, and is almost exclusively confined to the negro race. Unna, according to Freeman (1906), regards it as a circular scleroderma which strangulates the toe. The affected parts appear as if tightly constricted by a string, and spontaneous amputation occurs after the lapse of an indefinite time. The disease may extend over ten years.

Symmetrical Gangrene.—Symmetrical gangrene is due to an obscure affection of the nervous system (*Raynaud's disease*), causing local asphyxia of symmetrical portions of the body, especially fingers and toes, probably from vascular spasm. As a rule only small superficial sloughs are formed. The symptoms are tingling, numbness, etc. Intermittent claudication may be an early sign. Little can be done in the way of treatment, except tonics and hygienic measures.

Massage and hot baths, locally, may be of benefit. The patients usually recover, though successive attacks are usual. Noesske (1909) incises the finger tip down to the bone and applies a cupping glass; his theory is that the gangrene is due to stagnation of blood from venous obstruction; and that if a constant fresh supply of arterial blood is obtained by cupping, gangrene may be prevented until the spasm ceases.

Emphysematous Gangrene (*Traumatic or Spreading Gangrene, Gangrène Foudroyante*).—Under this title three distinct affections are sometimes grouped: (1) True emphysematous gangrene, a form of gangrene due to infection with various gas-producing bacteria; (2) Malignant Edema, caused by a specific bacillus; and (3) Ordinary forms of gangrene, in which putrefactive changes are accompanied by gas production. The third form clearly does not belong here; but as the *B. œdematis maligni* is a gas-forming microbe, and as it is usually impossible to distinguish clinically infection due to it from that due to numerous other gas-forming microörganisms, there is no good reason why it should not be included in this section. When not due to the bacillus of malignant edema, emphysematous gangrene may be caused by infection with the Bacillus aërogenes capsulatus, B. proteus vulgaris, or B. coli communis, especially that first named. The condition is almost invariably observed only as a complication of severe compound fractures or lacerated wounds, but occasionally has followed punctured wounds or even mere abrasions. On the third or fourth day after the injury the wounds do not discharge as freely as might be expected, and careful palpation will detect emphysematous crackling, which extends with alarming rapidity along the subcutaneous tissues (especially along the course of the large vessels), and may involve even the muscles. The skin becomes dusky, purplish, and mottled in appearance, and at a later stage the vesications and bullæ, so characteristic of fermentative changes in already mortified parts, may develop. Incisions into the swollen and boggy tissues give exit to frothy fluid and malodorous gases. The patient sinks into a typhoid state; there is little fever; the pulse may be slow; and death ensues a short time after the infection reaches the trunk. The entire course of the disease may extend over only six or eight hours. The safest *treatment* is *immediate amputation*, high above the limit of the affected tissues. When this is impossible, free incisions should be made, the limb should be placed under constant antiseptic irrigation, hydrogen peroxide being preferred as the gas-forming bacteria are anaërobic; free stimulation should be administered, and everything possible should be done to obviate the tendency to a fatal termination. If amputation be done, the incisions should pass through absolutely healthy tissues, and the stump should be freely drained, and frequently dressed to detect the first evidence of recurrence in the flaps. I have seen only two cases of emphysematous gangrene: in the first case, under Dr. Neilson's care at the Episcopal Hospital, it followed compound fracture of the elbow in

an old man; the gangrenous emphysema invaded the chest in three hours from its first appearance, before amputation could be done, and death followed a few hours later. In the second patient (Fig. 24), in Dr. Frazier's service at the Episcopal Hospital, a lad of sixteen, whose arm had been caught in revolving rollers and the skin squeezed off from above the elbow to the wrist, I successfully removed the arm at the shoulder-joint (Fig. 163) a few hours after the emphysema spread beyond the circular slough in the lower third of the arm.

Fig. 24.—Emphysematous gangrene. Recovery after amputation at the shoulder-joint. Episcopal Hospital.

Cellulitis. — Cellulitis is the term used to describe inflammation of the subcutaneous areolar tissue. This tissue, it is known, consists essentially of lymph spaces lined by endothelial or connective tissue cells; and it is now generally believed that these spaces have no direct communication with the lymph vascular system. Certainly cellulitis, as such, is clearly distinguished from lymphangeitis on the one hand, and from infectious dermatitis on the other. The causes are almost without exception bacterial infection, streptococcic rather than staphylococcic, usually from some abrasion or lacerated wound; but occasionally cellulitis, extending to the stage of suppuration, follows a confusion, a sprain, or a simple fracture, the infection in

such cases being conveyed to the place of lessened resistance through the blood-stream. Cellulitis may also follow extravasation of urine, of blood, etc.

Symptoms.—The symptoms are those of inflammation, widely diffused beneath the skin, not in it, and characterized especially by swelling, pitting on pressure, and the absence of marked redness (Fig. 25).

Treatment. — In the early stages rest procured by splints, by the use of a sling, by elevation of the part, together with local anodyne (lead water and laudanum)

FIG. 25.—Suppurative cellulitis of right forearm, eleven days' duration. From infected wound of wrist. Incised and drained through interosseous membrane. Children's Hospital.

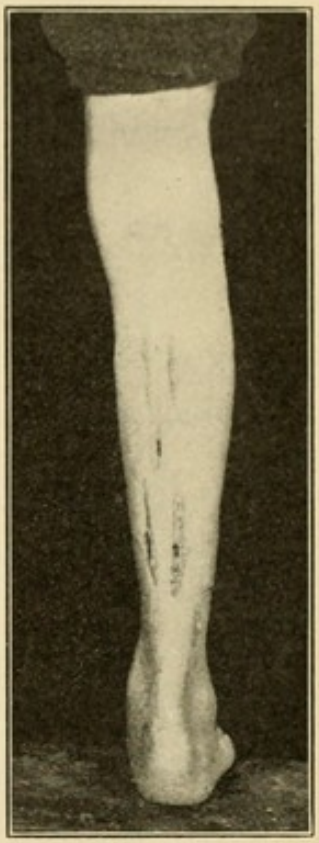

FIG. 26.—Scars from multiple incisions for cellulitis of calf. Episcopal Hospital.

and antiseptic (corrosive sublimate and alcohol) applications, may suffice to effect a cure. As soon as evidences of suppuration occur, the overlying skin should be incised, in as many places as may be necessary, to give exit to pus, sloughs, etc. If the part affected is very tense, as is frequently the case in the forearm and hand, it is advisable to make free longitudinal incisions even before pus is formed, as the relief of pressure will enable the body tissues to combat the infection much more readily, and may prevent extensive sloughing. Fig. 26 shows the scars of multiple incisions for cellulitis of the leg.

Erysipelas.—Erysipelas (a word usually supposed to be derived from two Greek words signifying red skin), known formerly as *St. Anthony's Fire*, is a specific inflammation affecting the skin, the subcutaneous tissues, or both. Occasionally the mucous or serous membranes are involved. It is a specific disease clinically; and according to some authorities its cause, the Streptococcus erysipelatis

(Fehleisen, 1884), is specific, in the sense that it causes no other disease; but equally good authorities maintain that it is not a specific microbe, but merely a variety of the common streptococcus, which for some unknown reason at certain times does not produce the usual symptoms. The seat of the inflammation is the lymphatic spaces of the skin itself (dermatitis) and of the subcutaneous tissues (cellulitis.)

Erysipelas probably always is due to the presence of a solution of continuity of the skin or mucous membrane, through which the bacteria enter the tissues; but while it is not extremely rare in patients with lacerated wounds and compound fractures, it arises much more often as the so-called idiopathic variety, in which the wound probably is some insignificant abrasion. Especially is this the case with facial erysipelas, one of the most prevalent forms, the wound of entrance being probably some excoriation of the nasal mucous membrane. The eruption is characterized by its *intense redness*, which returns immediately on the removal of pressure; by its *glazed* or *shiny surface;* frequently by *vesiculation;* by the *raised*, *irregular*, and *well-defined borders* of the inflamed area; and by the erratic manner in which it spreads (Plate I, Fig. 2). The inflammation is always most intense at the periphery of the patch, while the centre may begin to fade away very quickly. In *simple erythema* the patches have no tendency to spread, their edges are not raised, and vesiculation is unknown. In *scarlatina* the rash is not localized, it is neither well defined nor are its margins elevated above the surrounding skin; vesiculation is absent; it is a rare disease in adults; and a history of contagion may be obtainable. The dermatitis resulting from *Rhus Toxicodendron* is very difficult to distinguish from erysipelas, except by the history; the same is true of saprophytic dermatitis (*erysipeloid of Rosenbach*), due to local infection from decaying fish, etc. In ordinary *cellulitis* the redness is less, and the raised margins and vesicles of erysipelas are absent; and as the skin itself is not involved in cellulitis the disease does not affect the ears nor usually the skin over the tip of the nose, in which situations subcutaneous tissue is practically absent. In erysipelas, on the other hand, the pinna of the ear is prone to invasion.

Symptoms.—The **subjective symptoms** are marked: these are pain, tingling, and a feeling of tension in the affected parts, which are exquisitely tender; there is high fever, rapid pulse, furred tongue, often delirium, and occasionally nausea, vomiting, and chills. As a rule there are no prodromal symptoms of importance. The eruption seldom lasts more than *four days* in one spot; from the original focus it may wander irregularly over the body, or may break out in an entirely different region. As the inflammation subsides, the skin becomes brownish in hue, the vesicles dry in the form of scabs, and the part appears more or less wrinkled. In *facial erysipelas* edema is marked, the eyes being closed and the nose and ears swollen

PLATE I

FIG. 1

Lymphangeitis, the result of an infected abrasion of thumb 10 days ago which had received no treatment. Temperature 103° F.; has had one chill. (See page 268.) Episcopal Hospital.

FIG. 2

Erysipelas of face in a woman, aged 56 years. (See page 68.) Episcopal Hospital.

FIG. 3

Inflamed leg ulcer 3 weeks after a scald. (See page 54.) Episcopal Hospital.

beyond all recognition. There is a tendency for the disease to spread to the scalp; here the redness is less, and the general characteristics of cellulitis are more evident.

Complications.—In facial erysipelas there is always a danger of *meningitis*, from involvement of the angular vein or one of the emissary veins of the skull. *Nephritis* may result from the strain put upon the kidneys in the elimination of toxins. *Endocarditis*, *pleurisy*, *pneumonia*, *peritonitis*, *arthritis*, and general *septicemia* occasionally are observed. *Phlegmonous erysipelas*, so-called, is streptococcic inflammation of the cellular tissues accompanying erysipelas of the skin. If the erysipelatous inflammation invades the fauces (angina), or the larynx, producing edema of the glottis, laryngotomy may be necessary.

Prognosis. — Erysipelas is a serious disease, though seldom the direct cause of death. S. Erdman (1913) gives the hospital mortality as 11 per cent. One attack seems to predispose the patient to recurrence.

Treatment.—When occurring in a hospital ward, cases of erysipelas should be isolated; for although contagion through the air has not been known to occur, the infection of other patients by contact cannot always be prevented. The surgeon who dresses the wounds of an erysipelatous patient should not practice obstetrics while so engaged. O. W. Holmes (1843) long ago called attention to the relation between erysipelas and puerperal fever. Constitutional treatment is to be given only as indicated; stimulants and tonics, especially the tincture of the chloride of iron or quinin, are usually of benefit; a purge at the onset of the attack may do much to hasten its disappearance. In the way of local treatment very little can be done that is really productive of any marked benefit. Ichthyol ointment has been much used, and is agreeable to the patient. A saturated solution of magnesium sulphate is claimed by some (Tucker, 1908) to have almost magical power in dispelling the eruption; the parts affected should be covered with gauze wrung out of and kept constantly wet with the solution. Apart from its well-known local anesthetic action, I have not myself observed any marked advantages in the use of magnesium sulphate. Painting the skin with collodion, iodin, or strong solutions of silver nitrate (33 per cent.), about an inch beyond the margin of the erysipelatous patch, has in some cases appeared to be of value in limiting the march of the infection; but when it is remembered that the dermatitis usually subsides of itself in about four days, it is seen that no remedy can be said to be specific. When the subcutaneous tissue is affected, the treatment is the same as for cellulitis, but incisions are to be employed even earlier, owing to the greater intensity of the inflammation. Anti-streptococcus serum is harmless, and if possible should be administered in all severe cases. Erdman gave vaccines an extended trial and concluded that they were useless.

GENERAL AFFECTIONS RESULTING FROM INFLAMMATION.

In addition to the local reaction to injury, which has been studied in Chapter I under the heading of Inflammation, there is also a reaction by the organism as a whole. In even the simplest cases the local reaction is accompanied by more or less constitutional disturbance, evidenced chiefly by *fever*, by which term I think, with Adami, it is convenient to designate this condition, whether or not it is attended by elevation of temperature (*pyrexia*). Not only will many aseptic operations be followed by this so-called *aseptic fever* (Genzmer and Volkmann, 1877), but some patients on whom no operation has been done (simple fractures, etc.), also will have a slight rise of temperature and other signs of fever on the first day or two following the injury (Fig. 27). In most cases the temperature does not exceed 100° F., and if it goes beyond 101° F. after an operation it is very probable that infection is present. Yet in one case of arthrodesis, under my care at the Orthopedic Hospital, the temperature rose to over 102° F. on the second day, but the wounds pursued a perfectly aseptic course. The cause of the aseptic fever was formerly ascribed to the liberation of fibrin ferment in the circulation, due to thrombotic changes and phagocytic action at the seat of injury; but more modern investigations tend to show that it is due to the liberation of nucleins and albumoses. It is not impossible that the cocci normally found in the deeper layers of the skin may be at fault, and that the fever is really not aseptic in the strict sense of the word. No special treatment is required; the symptoms subside spontaneously in a day or so. A laxative usually is beneficial.

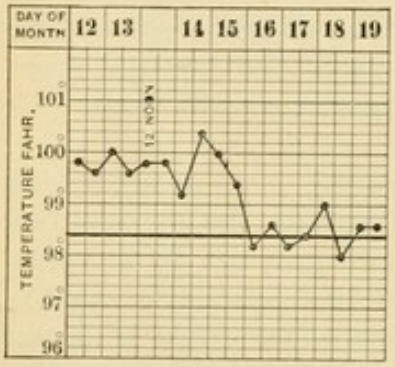

FIG. 27.—Temperature chart of aseptic fever; contusion of hip; aged sixty-four years. Episcopal Hospital.

Sepsis.[1]—When bacteria or their products enter the circulation, there is developed the condition known as **sepsis.** If the products of pathogenic bacteria enter the circulation, but the bacteria themselves remain in the tissues at the seat of primary infection, the condition is named **toxemia**; this is to be distinguished from **intoxication,** the condition due to poisoning by non-bacterial products (drugs, products of perverted metabolism, etc.). Diphtheria and tetanus are typical examples of toxemia. If the bacteria themselves are present in the circulating blood, the condition is termed **bacteriemia**; typhoid fever is a typical bacteriemia, the bacilli circulating

[1] The terminology employed by writers in describing the conditions named below is by no means uniform. I have adopted the designations which have seemed to me, after considerable study, to be most characteristic of the maladies named, and least confusing to the student.

freely in the blood, and producing the well-known roseolar eruption by lodging in the skin. If the bacteria which circulate in the blood are highly pathogenic, as the streptococcus or staphylococcus, the condition is properly denominated **septicemia**; but this term is frequently used negligently to describe any form of sepsis whatever. If the bacteria circulating in the blood lodge in various parts of the body, forming multiple abscesses, the disease is named **pyemia.** Under the name sarco-sepsis, Lockwood (1896) described a septic condition due to the presence of bacteria in the tissues, but not in the circulating blood; but as it is impossible to distinguish this condition from toxemia or septicemia during life, and as it is doubtful whether septic symptoms are produced by bacteria in the extravascular tissues, except through the entrance into the blood of bacterial toxins (toxemia) or the bacteria themselves (bacteriemia, septicemia), it seems undesirable to complicate the study of sepsis by discussing this condition further. Finally, if the constitutional symptoms are due to absorption of products of saprophytic (nonpathogenic) bacteria, the patient is said to be suffering from **sapremia.**

Toxemia.—This is the condition formerly described as *inflammatory, traumatic, surgical, sympathetic,* or *symptomatic fever.* As modern methods of clinical study have developed, it has been found that this condition may be distinguished from aseptic fever; and at the present day it is usually the latter that is meant, when reference is made to inflammatory or surgical fever. For the development of toxemia it is necessary for bacteria to be present, and they are rarely present without open wound; but in cases of intestinal obstruction, and in infective diseases of internal organs (appendicitis, cholecystitis, pyelitis) it is the rule for toxemia to exist. If no focus of infection can be discovered, the sepsis is said to be *cryptogenetic.* The presence in the blood of bacterial toxins causes the usual constitutional symptoms of inflammation, which have already been detailed (p. 31). *Traumatic delirium* (p. 175) is probably due to toxemia. If the aseptic fever customarily seen after an operation does not subside in two or three days, it is probable that some septic focus exists; and if this is not promptly relieved by drainage, the aseptic fever will become septic in nature, and the patient will suffer from toxemia, the commonest form of sepsis.

Treatment.—The treatment consists in removing the cause of infection when this is possible, and in thoroughly draining the infected area when entire removal is impossible or inexpedient. Plenty of water should be introduced into the system, either by mouth, or by the use of saline solution intravenously or by hypodermoclysis or proctoclysis. If the toxemia is known to be due to a specific cause (tetanus bacillus, colon bacillus), antitoxic serum should be administered; and even in the case of the common infections (streptococcus, staphylococcus), antitoxic serum occasionally is of benefit.

Septicemia.—Septicemia, which is the commonest form of bacteriemia seen by surgeons, is distinguished at its onset from

toxemia by no very well recognized symptoms. The febrile symptoms (pyrexia, anorexia, delirium, etc.) are all more pronounced; septic diarrhea may take the place of constipation, and intestinal or other internal hemorrhages may occur (Cf. "critical discharges," p. 31). Chilly sensations or an actual chill may occur early in the disease, perhaps due, as suggested by Adami and others, to relatively high temperature of the central nervous system. The temperature usually is not very high (100° to 102° F.). The pulse is rapid and feeble, and no drugs have power to reduce its rate; it becomes more and more rapid, and progressively weaker until death, which is the usual termination of surgical septicemia (Fig. 28). In some patients who have seemed to do well after evacuation of septic foci, rapid death occurs from so-called *terminal infection* (Fig. 29). Clinically speaking, it is usually impossible to distinguish between toxemia and

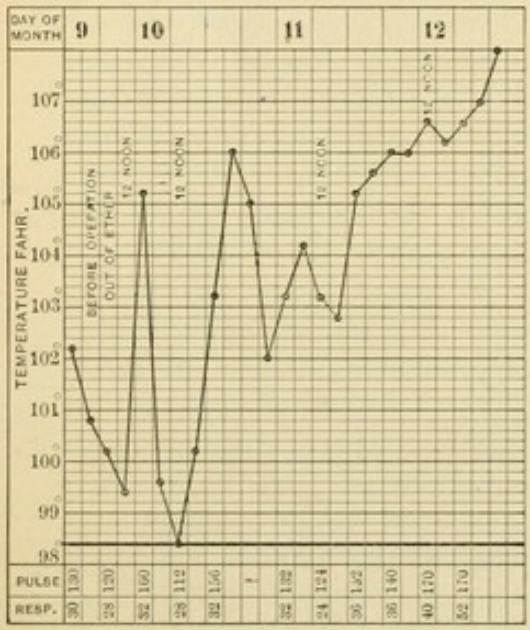

Fig. 28.—Puerperal septicemia; death. Episcopal Hospital.

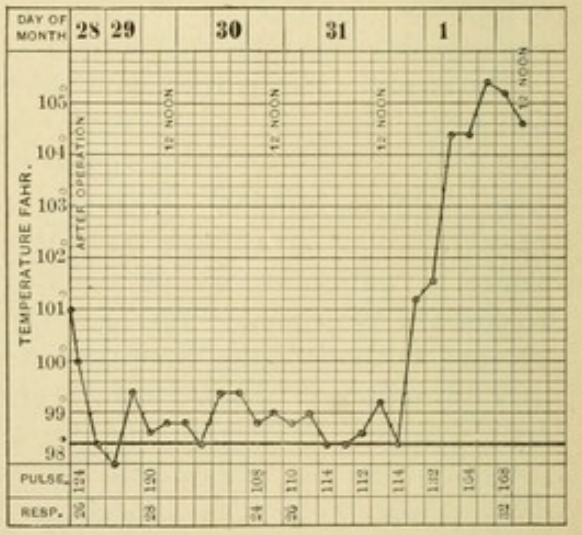

Fig. 29.—Diffuse purulent peritonitis from appendicitis. Death from terminal infection (residual abscess). Episcopal Hospital.

septicemia, except that the latter is little influenced by treatment. Sometimes by blood cultures it is possible to ascertain the presence of bacteria in the circulating blood during life; but as the number present in the blood may be few, a sterile culture is usually no proof that bacteriemia does not exist. The presence of staphylococcus albus in the culture usually is due to contamination from the skin.

Treatment.—Treatment of septicemia, as already indicated, usually is impotent to stay the course of the disease. As pointed out by Lockwood (1896), at autopsy the bacteria are found even in the coronary arteries of the heart, and the persistent rapidity of the pulse may thus be accounted for. Nevertheless, as the diagnosis is sometimes impossible, except at autopsy, all the measures suggested for the treatment of toxemia should be employed in these cases, and it is possible that, in some patients, life may be saved.

Park speaks favorably of the use of *Unguentum Credé*, which is absorbed through the skin; and he thinks benefit is derived from "the dissemination throughout the system of the antiseptic virtues of the silver itself." He also commends the intravenous use of a solution of Credé's soluble silver (1 gram of silver in 1000 c.c. of water). Barrows has used formalin solution (1 to 5000) intravenously with alleged benefit.

Pyemia.—Nearly invariably this is associated with thrombosis and embolism (p. 237). A portion (*embolus*) of the septic clot or a clump of bacteria from the original focus of infection becomes detached, and is transported in the blood stream to the nearest set of capillaries, where it lodges (embolism). Once lodged, the bacteria present in the embolus produce suppuration in the new location, and a *secondary* or *metastatic abscess* is formed. The primary thrombus

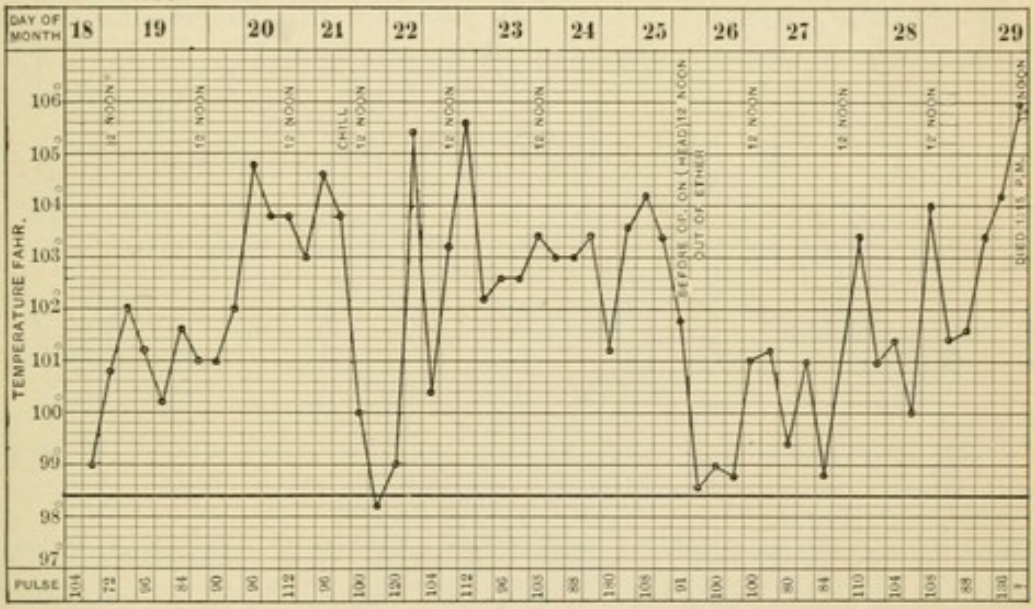

FIG. 30.—Temperature chart in pyemia; acute osteomyelitis of calcaneum; abscess of brain; death. Episcopal Hospital.

usually is venous in location, and the detached clot naturally might be expected to be arrested in the pulmonary circulation; but for some reason this is not always the case, the embolus passing safely through the lungs and being arrested first by some portion of the systemic capillary network. Occasionally, when the embolus first is carried into the venous current it travels against the usual course of the blood, and lodges in some portion of the venous channels distal to the primary lesion. This process is known as *retrograde embolism;* it may occur in suppurations in the neighborhood of the vena cava, or in the face, the blood current in the angular artery flowing sometimes toward the brain and sometimes outward. If the primary lesion is in the distribution of the portal vein (*e. g.*, the appendix), the first set of capillaries encountered by the embolus will be the hepatic, and multiple liver abscesses will result. When

in the systemic circulation, many different regions and organs may become affected; metastatic abscesses in the subcutaneous tissues or joints are most easily detected; but those in the kidneys, spleen, liver, lungs, or brain sometimes may be diagnosed during life. The original focus may be any suppurating or septic lesion. Burned surfaces and suppurative lesions of bone are among the commonest causative conditions.

Symptoms.—The symptoms are those of septicemia, with certain important modifications. The temperature is typically irregular; its variations are extreme, and the absence of periodicity is characteristic (Fig. 30). The highest temperature (104° to 106° F. or higher) on one day may be at a certain hour in the afternoon, whereas the next day the temperature may reach its highest point in the morning or not until late at night; or hyperpyrexia may be absent for an entire day or so. Chills are frequent, immediately preceding the fall of temperature, and are often indicative of the lodgement of an embolus, which may be attended by sudden pain.

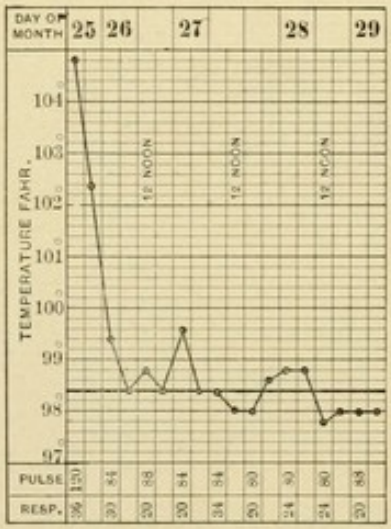

Fig. 31.—Sapremia; rapid fall of temperature after evacuation of retained secundines. Episcopal Hospital.

Prognosis.—The prognosis is extremely bad; a few patients, in whom the infection seems to be attenuated and the course of the disease chronic, occasionally recover. The staphylococcus is more frequently the causative organism than the streptococcus.

Treatment.—Treatment is the same as for septicemia. Constant vigilance is needed to detect and locate metastatic abscesses, and they should be drained immediately, when accessible; and unless the patient is so ill that a formal operation will hasten his death, the surgeon should not hesitate to evacuate abscesses of the internal organs or even the brain. By ligating or excising the main venous trunks leading from the original lesion, the infection sometimes may be successfully localized (internal jugular in mastoiditis, ovarian in parametritis, angular in facial phlegmon, etc.).

Sapremia.—When dead or dying tissue is in contact with living cells, the ptomains and other poisons elaborated by the saprophytic bacteria which infest the former may be absorbed into the patient's body, and thus produce the usual symptoms of toxemia. When healing in the wounded area has progressed to the stage of granulation, little if any absorption occurs; but injudicious probing of a granulating wound may destroy this barrier, and evidences of sepsis will follow. It is sometimes impossible to distinguish mild grades of sapremia from aseptic fever, or from a slight toxemia due to absorption of the products of pathogenic bacteria; but usually it is easy to differentiate clinically between sapremia and toxemia, because

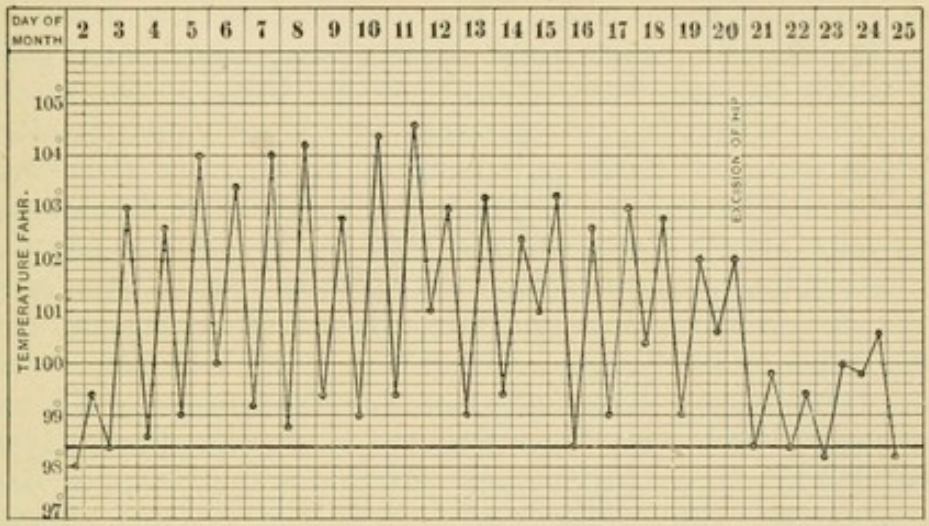

Fig. 32.—Tuberculosis of hip; hectic temperature arrested by excision of hip. Orthopædic Hospital.

in the former case there always is some dead and decaying tissue present, where the putrefactive bacteria multiply. If this material is removed, the bacteria are removed with it, absorption ceases, and health is restored. Sapremia is seen in its typical form in puerperal cases, absorption occurring from the retained secundines (Fig. 31). **Hectic fever,** which is classed by Park as chronic sapremia, is most typical in patients with tuberculous bone disease, where sinuses exist, and as a consequence the decaying bone has become infested with saprophytic bacteria. Fig. 32, from a patient with coxalgia under my care at the Orthopedic Hospital, in the service of Dr. Harte, shows hectic fever promptly arrested by excision of the hip.

CHAPTER III.

MODIFIED FORMS OF INFLAMMATION (SURGICAL INFECTIONS).

SITUATED pathologically half way between pure inflammation and neoplasms, exists a group of surgical diseases usually described as the *infectious granulomas*. This term implies that although the lesions are definitely known to be caused by specific microörganisms (which is not the case with tumors), yet the tissue reaction to these specific irritants is characterized rather by cell accumulation than by actual destruction of tissue by suppuration. It is as if the irritant were too timid to provoke vigorous resistance, yet too enduring to be overcome at the first onslaught; the tissues of the body seem either indifferent to the invasion, or unable to continue the struggle with the success which usually attends their warfare in acute inflammation. While the more important of these modified forms of inflammation (Tuberculosis, Syphilis, Actinomycosis) partake of the nature of subacute or chronic reactions, there are others (Anthrax, Glanders, Tetanus, Hydrophobia) in which the reaction is acute, and the lesions less circumscribed, but which it is nevertheless convenient to discuss in the same chapter.

CHRONIC INFECTIOUS SURGICAL DISEASES.

Tuberculosis.—Surgical tuberculosis includes all manifestations of this infection, wherever situated, which are amenable to surgical treatment. The specific cause of the disease, the *B. tuberculosis* (Koch, 1882), gains entrance to the body usually through the digestive or the respiratory tract. It has been held by good authorities that the bacilli may pass through the respiratory or intestinal mucosa and produce no lesions in it. The bacilli lodge most frequently in the lung; next most frequently in the lymphatic nodes—cervical, bronchial, or mesenteric. Occasionally infection occurs through an open wound; inoculation with tuberculous material while dissecting produces the so-called *anatomical tubercle.*

The bacillus is omnipresent in civilized life, and it is by no means improbable that it lives as a parasite in the bodies of most apparently healthy persons. It is always at hand to attack any place of lessened resistance, and to explain its prompt appearance in such locations it is usually necessary to assume that it was present previously, though latent, somewhere in the patient's body. *Scrofula*, formerly considered a distinct disease, is now generally recognized as identical

with tuberculosis; it is, however, as DaCosta says, a useful term to describe the habit of body of such as are easily infected with tuberculosis; in other words, scrofula may be considered tuberculosis in its primary, latent state.

Tuberculosis is most often primary in the lungs, digestive tract, lymph nodes, urinary and sexual organs, and the bones. Surgical tuberculosis, which is said usually to be secondary to an inconspicuous lesion of the lungs, is seen especially in the lymph nodes, the bones and joints, the sexual organs, peritoneum, etc.[1]

Pathology.—The local lesion produced by the B. tuberculosis is called a *tubercle;* its proper adjective is *tuberculous;* and it should be distinguished from a tubercule, a term which describes the anatomical form of the lesion of a skin eruption which is called tubercular, but which is in no way connected with tuberculosis. When the B. tuberculosis begins to proliferate in the tissues, its first effect is to exert chemotactic action upon the connective tissue and endothelial cells in its immediate vicinity. It does not exert positive chemotaxis upon the leukocytes circulating in the blood, and *leukopenia* not *leukocytosis* is the rule; but the number of circulating lymphocytes may be relatively increased. Locally, as the tissue cells accumulate, their appearance changes, the cells swell up, become pale, and resemble epithelial cells so closely that they are widely known as epithelioid cells. This accumulation of epithelioid cells around the tubercle bacilli causes an anemia of the central area, and the epithelioid cells themselves gradually suffer from lack of nourishment, and, instead of actively dividing and multiplying their number as at first, they seem to be unable to carry the process of reproduction further than the stage of division of the nuclei; so that among the epithelioid cells there soon appear two, three, or more large cells with multiple nuclei, arranged around the periphery or at the two poles of the cell—the so-called *giant cells.* In the area immediately surrounding the giant cells and epithelioid cells, the lymphocytes accumulate; while the centre of the tubercle is composed of tissue and cellular débris undergoing caseous degeneration, which is the form of anemic necrosis particularly characteristic of tuberculosis. Some phagocytosis exists, but it sometimes seems as if the tubercle bacilli continued their existence as parasites even within the cell bodies of their victim: they are most apt to be seen within the giant cells; they are frequently present in the epithelioid cells; but are said never to be found within the lymphocytes. The histological tubercle, thus, may be represented diagrammatically (Fig. 33) as composed of three portions: (1) a central caseous or necrotic area, in which may be a giant cell, its own centre showing commencing caseation; (2) the epithelioid cells surrounding the caseous centre, and (3) the peripheral aggregation of lymphocytes.

[1] Some modern investigators believe that the bovine form of Tubercle bacillus is responsible for "surgical tuberculosis," while the human form is that usually found in the lungs.

The products of the tubercle bacillus, spoken of generically as *tuberculin*, are not very well understood; it seems probable, nevertheless, that caseation is induced by the toxins set free from the bodies of the bacilli when they die, but that the irritant action of the living bacilli is only sufficient to provoke cell accumulation and multiplication. These various products of tubercle bacilli usually exist in greater or less amount in the body fluids and excretions of animals suffering with tuberculosis; and, when injected into other animals afflicted with tuberculosis, the tuberculin contained in them produces a characteristic reaction which may be used for the purpose of diagnosis (p. 81).

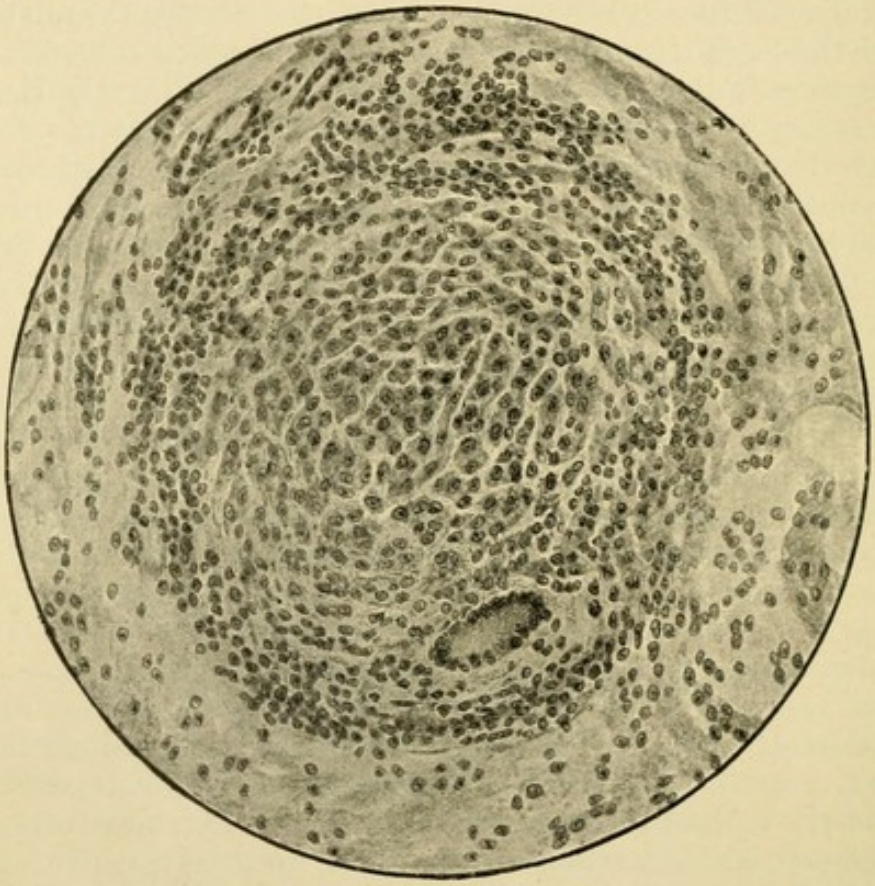

FIG. 33.—Section through a tubercle. Upon the margin of the tubercle lymphoid cells may be seen; in the centre epithelioid cells and a giant cell. (Lexer–Bevan.)

The primary tubercle may be replaced by granulation tissue formed from the surrounding connective tissue cells, and healing may occur in a manner similar to that of simple inflammation. Or the "pyogenic membrane" may isolate and encapsulate the tubercle, and thus the disease may be arrested; calcification is a frequent sequel. On the other hand, some of the bacilli may escape through the cordon of epithelioid cells on guard, and, settling in a neighboring portion of the tissues, they may there proceed to form a new tubercle; and as many more tubercles are formed, the area may become visible to the naked eye, and the centre of the entire mass may be seen as a caseous nodule surrounded by comparatively healthy tissue (Fig. 34). Two

processes may thus be initiated—either productive or degenerative; the former gives rise to *tuberculous (fungous) granulation tissue*, frequently described as the tuberculous gumma (Figs. 35 and 37), because

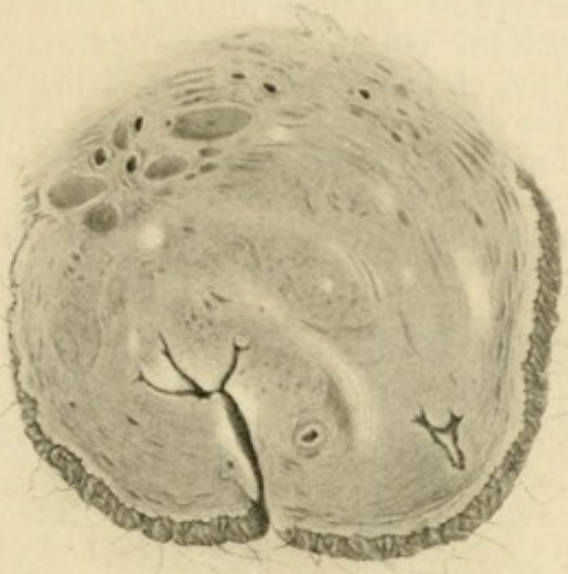

FIG. 34.—Cross-section of tuberculous testicle, showing areas of caseation. Skin adherent. One sinus has been divided in the section. From a patient in the Episcopal Hospital.

it is very difficult to distinguish it histologically from the gummas of syphilis, actinomycosis, etc.; whereas the degenerative changes result in the formation of a *cold abscess*, so named to distinguish it from the

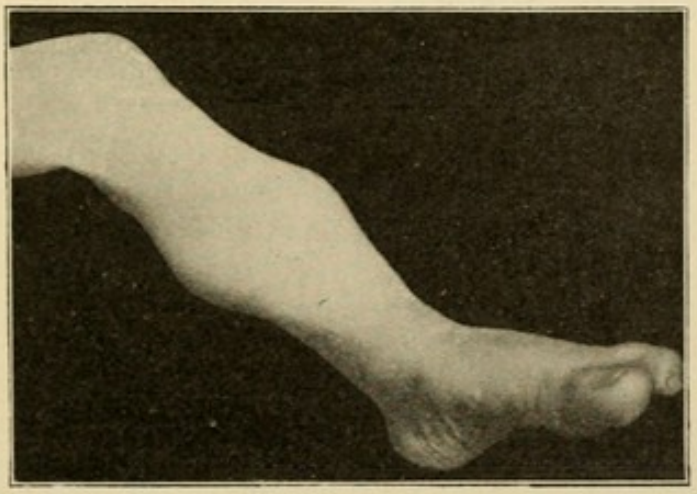

FIG. 35.—Tuberculous gummas of leg, in a baby, aged eight months. Children's Hospital.

ordinary abscess of inflammation, which is characterized by its heat. Tuberculous granulation tissue has a great tendency to displace all normal tissues with which it comes in contact: in bones it causes the

disappearance of the normal osseous structure; in joints it grows upon the synovial membranes, producing fibrous ankylosis; in tendon sheaths it spreads along their course, gradually invading the tendons and in time causing their entire disappearance. The degenerative changes, which by the process of coagulation and liquefaction necrosis change tuberculous granulation tissue into cold abscesses, are probably due, as already pointed out, to excessive destruction of tubercle bacilli with liberation of their endotoxins, and to the action of ferments set free by the death of cellular protoplasm. When the cheesy pus finds an exit for itself, the tuberculous abscess is converted into a tuberculous sinus, or if the walls of the abscess cavity are unable to collapse, as in bone, and often in the lungs, a tuberculous cavity remains. As the tuberculous sinus heals, it becomes converted into a

FIG. 36.—Scrofulous ulcers, one month duration. Two months after incomplete operation for recurrent tuberculous cervical adenitis. Episcopal Hospital.

FIG. 37.—Tuberculous dactylitis (tuberculous gummas of fingers). Children's Hospital.

tuberculous ulcer (Fig. 36). It was once hoped that by the administration of tuberculin to tuberculous patients their tuberculous lesions could be disintegrated and caused to discharge; but, unfortunately, it has been found that sudden disintegration of tuberculous foci is more apt to be followed by acute generalized miliary tuberculosis, which may be succinctly described as tuberculous pyemia. Any secondary infection, moreover, of a tuberculous focus, is prone to aggravate the condition by weakening the protective layer of epithelioid and lymphoid cells which surround the tuberculous area. The great danger when any cold abscess discharges is that of secondary (pyogenic) infection. As Calot says, the opening of a cold abscess is the opening of a door by which death soon enters.

Diagnosis.—The detection of the tubercle bacillus in the lesions renders the diagnosis certain; but in the vast majority of cases this

is not requisite, as the clinical appearances are quite sufficient to justify the diagnosis of tuberculosis. The indolence of the reaction, the slow course of the disease; the characteristic cheesy material discharged from the sinuses; the absence of leukocytosis in uncomplicated cases; and the general appearance of the patient; these all, when combined in one individual, make the actual detection of the tubercle bacillus an unnecessary task in most cases of external tuberculosis (bones, joints, lymph nodes, skin, etc.). In tuberculosis of certain internal organs, especially the kidney, it is highly desirable to detect the bacilli in the excretions. Another aid to diagnosis is the *tuberculin test* (p. 78): old tuberculin[1] is that generally used, the initial dose in adults being one-tenth of a milligramme (0.0001 gramme) hypodermically; this may be increased at subsequent injections to 1 and even to 5 milligrammes. The hypodermic use of tuberculin gives reasonably accurate results, and I prefer this method to the conjunctival test of Calmette, or to the inunction of Moro's tuberculin ointment. The cutaneous reaction of v. Pirquet is usually to be preferred in children (under twelve years of age), but as it appears to indicate the existence of latent or healed tuberculosis (very rare in children) quite as readily as an active focus, it is not regarded as so accurate as the hypodermic test for adults. The hypodermic test, unless repeated, causes reaction only when there is an active focus in the body; but it does not necessarily indicate that the lesion suspected is tuberculous. If, however, its use causes an exacerbation of symptoms in the suspected lesion (*focal reaction*) there can be very little doubt of its tuberculous character. After the hypodermic injection has been given, the patient's temperature should be recorded every two hours for a period of 24 hours: a positive reaction, indicating the presence of tuberculosis, consists in an abrupt rise of temperature to 101° or 102° F., occurring usually about the twenty-second hour.[2] Sometimes a chilly sensation is experienced as the temperature begins to rise. If the first injection is negative, a second and even a third may be given, gradually increasing the dose. I have never seen any untoward result. The reaction is positive in most cases of tuberculosis not in advanced stages; it is usually negative when secondary infection is present, with amyloid changes in the viscera and a hectic temperature; but in such cases the diagnosis is easy enough without this test. Indeed it is quite useless to employ a tuberculin test if the diagnosis can be made clinically. In v. Pirquet's method three small areas on the arm are abraded, and into

[1] Old tuberculin is a filtrate of a concentrated glycerin extract of tubercle bacilli; it is possible that some of the bacilli may not be excluded by the filter; to obviate this danger Koch has prepared two new tuberculins: of these Tuberculin Oberst (T. O.) is the supernatant liquid obtained by centrifugalization of a concentrated glycerin extract of tubercle bacilli; the sediment which forms, containing the bacilli themselves, is ground up and again centrifugalized, and forms Tuberculin Rest (T. R.). T. O. resembles old tuberculin, and may be used instead of it in diagnosis; T. R. is used in treatment.

[2] An earlier rise, especially within a few hours of the injection, probably is due to some contamination.

one or two of these the tuberculin is rubbed; the other abrasions being used as controls. On the second or third day, in tuberculous cases, the infected area shows a characteristic, erythematous, papular, and even vesicular eruption.

Treatment.—Constitutional and hygienic treatment are quite as important in surgical as in medical tuberculosis. The majority of patients with surgical tuberculosis are children of a school-going age. It is better for them to give up school for one or two years, until their constitution is strong enough for them to conquer the disease, than to attempt to keep up in their classes and grow physically worse and worse. It may not be possible for them to sleep in the open air, but they can at least sleep with all the windows in their room open, and be out of doors as much as possible during the day. In hospitals provided with suitable roof-gardens, where the patients may be kept in the open air practically twenty-four hours out of the twenty-four, it has been found that operative treatment is scarcely ever-required. In institutions where it is impossible for one reason or another to keep the bed-ridden patients out of doors constantly, it usually is quite possible for their beds to be wheeled out of doors and left out from 7 A.M to 7 P.M. It is by no means necessary to have a hospital in the country for these patients: porches and balconies, even if roof-gardens cannot be obtained, will accomplish the same results in the most thickly settled parts of the city. Hand in hand with the open air treatment must go full, wholesome diet, especially milk and eggs; and the only medicine usually required is cod liver oil, which seems to act better than any other remedy in increasing the appetite and causing the patients to put on flesh. In the rare cases where it does not do good, the syrup of the iodide of iron, the compound syrup of the hypophosphites, or other remedies, may be tried.

Locally, I am convinced that tuberculosis of the soft parts demands a different treatment from that of bone. In the latter case such remarkable results are obtained in children by local rest, without operative interference, that I am extremely conservative in urging any other surgical treatment: the use of plaster casts, braces, weight extension in bed, together with proper hygienic treatment, will cure nearly all patients in whom these methods are adopted early. As regards tuberculosis of the soft parts (lymph nodes, generative and urinary organs, peritoneum), however, local rest is usually impossible to secure, and I feel sure that better results are obtained by radical operation, removing the entire disease; and when this is impossible, as in the abdomen, at least removing the primary focus. The local treatment adapted to each form of tuberculosis will be pointed out when the surgery of those portions of the body is discussed.

Syphilis.—This is an infectious granuloma due to inoculation with the *Treponema pallidum* (*Spirochæta pallida*), a parasite described by Schaudinn and Hoffman (1905), and obtained in pure culture in 1911 by Noguchi and by Hoffmann.

Pathology.—This organism usually gains access to the tissues through some abrasion or excoriation of the skin or mucous membranes, being inoculated directly from a sore in another person suffering from syphilis (*immediate contagion*). Occasionally *mediate contagion* occurs, the virus being transmitted by means of soiled towels, eating and drinking utensils, etc. When inoculated, there follows a *period of incubation*, averaging from three to five weeks, during which the microbes multiply at the site of primary invasion, and are carried by the lymph channels to the nearest lymph nodes; so that by the time the local reaction appears at the site of original inoculation, the disease is already diffused in the patient's body. Neisser found the blood contained the virus as early as the fifth day after inoculation. The local reaction (**chancre**) resembles the tubercle in some ways: a collection of round cells occurs, and there may be a few giant cells present; but the chancre is particularly characterized by the great proliferation of the endothelial cells lining the capillaries. By proper staining methods the presence of the Treponema pallidum may be demonstrated; otherwise the histological picture is not regarded as conclusive, though endothelial proliferation is always suggestive of a syphilitic lesion.

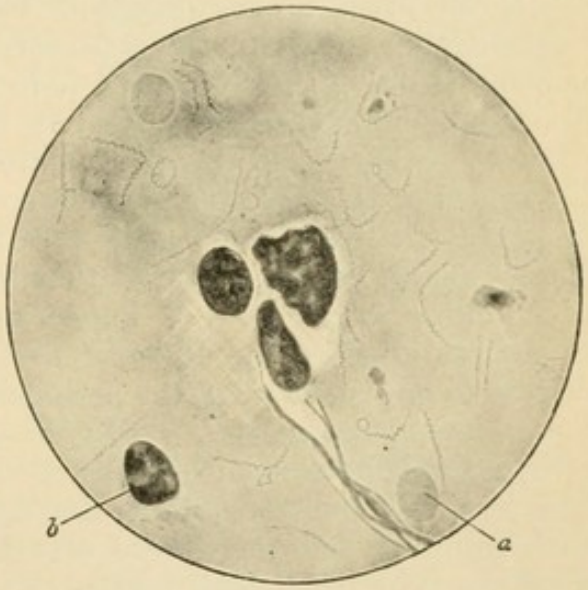

FIG. 38.—Treponema pallidum (Spirochæta pallida): *a*, red; *b*, white-blood corpuscles.

The chancre is situated in the true skin (derma); usually when first seen, exfoliation of the overlying epidermis has occurred, converting the primary lesion into a *superficial erosion;* in some cases the local reaction is much more marked, and the *deep* or *Hunterian chancre* develops. Usually very soon after the appearance of the chancre, enlargement of the regional lymph nodes may be detected; and not infrequently the lymphatics leading to these nodes are palpably enlarged. There follows the *second period of incubation*, lasting on an average about six weeks; during this period the virus of the disease is spreading past the first group of lymph nodes, and is carried by the blood-stream all over the patient's body. Various prodromal symptoms, such as fever, malaise, headache, vague "rheumatic" pains, etc., may be experienced during this time. As in typhoid fever, the infecting organisms lodge first in the cutaneous capillaries, and the well known rashes of syphilis (*secondary lesions, syphilodermas*) are produced; at the same time the lymph nodes all over the body become enlarged, especially the posterior cervical and epitrochlear

groups. The lesions of this secondary period are not confined entirely to the skin; the mucous membranes usually are also affected, the eruption appearing in modified form in the mouth, the fauces, and the vagina. The histological picture of these secondary lesions presents nothing pathognomonic of syphilis; but the proliferation of the endothelial cells lining the bloodvessels is usually sufficient at least to suggest the syphilitic nature of the disease, and the specific organism usually may be detected by smears made from the ulcerated sores. Still later, more or less typical lesions appear in the deeper structures and in the internal organs. These, which are known as *gummas*, are characteristic of the third stage of syphilis; they consist essentially of an aggregation of round lymphoid cells, with an occasional giant cell at the periphery of the lesion; bloodvessels are less conspicuous in the tertiary than in the secondary lesions of syphilis. The Treponema pallidum rarely can be found in these tertiary lesions; it is practically never to be detected in those with pyogenic infections. As in the case of tuberculosis, so here, there is a marked tendency for the centre of these lesions to undergo various forms of degeneration, of which the hyaline and fatty are the most usual. Instead of the cheesy pus so characteristic of tuberculous suppuration, the product of syphilitic suppuration is known as gummatous pus. In tertiary as well as in secondary lesions, there is a marked tendency for the disease to be *productive* at the periphery of the lesions, while *degeneration* occurs in the centre. This is thought to account for the characteristic serpiginous form of some of the later skin lesions (Fig. 930). The tertiary lesions of syphilis heal by granulation and cicatrization, with resulting deformity from contraction of the scar-tissue. The scars are typical, both on surfaces and in the interior of organs—in the former situations the regular outline, circular form, and depressed, shiny base of the cicatrix are nearly pathognomonic of a former syphilitic lesion; while the radiating, star-like cicatrices in the internal organs usually may be recognized at a glance. Secondary infection with pyogenic bacteria is a frequent occurrence in gummas; this hastens the destructive process and increases the subsequent deformity.

No tissues are exempt from the ravages of syphilis. The favorite seats for the secondary lesions are the skin, mucous membranes, and iris. In tertiary syphilis the periosteum, bones, and joints; deep subcutaneous tissues; palate and nasal structures, iris, retina, and choroid; the internal and generative organs; and the nervous system; are those most usually affected.

This brief sketch of the pathology of syphilis will suffice for the present chapter. The clinical aspects of the disease, as well as the treatment, will be discussed in Chapter XXVI, while important syphilitic lesions of the various parts and systems of the body will be described in chapters devoted to regional and systemic surgery.

Actinomycosis.—The cause of this disease commonly is known as the Ray Fungus, from its appearance under low powers of the microscope (Fig. 39); but scientists differ as to whether it shall be classed

with the moulds (hyphomycetes) or with bacteria (schizomycetes). This organism is found growing on hay and straw, and also in the ground, whence it may be incorporated in growing vegetable matter. It was first observed by von Langenbeck in 1845, in the pus from a patient with caries of the vertebræ. Formerly, instances of the disease were considered sarcomatous or carcinomatous in nature. In cattle the ray fungus is a frequent source of disease (lumpy jaw, swelled head); but few cases have been observed in which actual transmission from animal to man has occurred. The usual source of infection in man is believed to be chewing of diseased grain; but J. H. Wright (1905) claims that the ray fungus is quite commonly found in healthy mouths, both of man and beast, and asserts that the action of the cereal is merely to prepare a *locus minoris resistentiæ* where the fungus can develop.

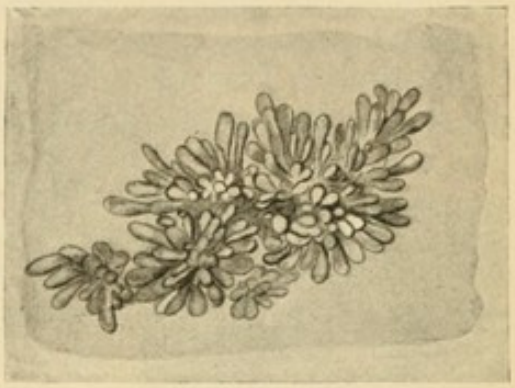

Fig. 39.—Grains of actinomyces from human pus. × 450. (Marwedel.)

Pathology.—Like the other infectious granulomas, actinomycosis is characterized by a local productive reaction. There is very little tendency to necrosis; but in mankind secondary infections are the rule, and hence suppuration is much more frequent than in the lower animals. The cellular infiltrate surrounding the focus of disease consists of small round cells, giant and epithelioid cells; conversion into granulation tissue occurs, and this tends to cicatrize. The disease is prone to extend along sinuous and branching tracts, suppuration occurring in the centre, while the sinuses are lined with the granulomatous tissue. In the pus discharged from these tracts, the colonies of the fungus are visible to the naked eye, as minute yellow granules; these impart to the fingers a gritty sensation due to the presence of calcareous salts. The disease is chronic, and unless vital parts are attacked, life may be prolonged for years. Occasionally metastatic foci are developed through the blood-stream; but the disease never extends by the lymphatics, and enlargement of the regional lymph nodes usually is an indication of secondary infection (Frazier).

Symptoms.—Four distinct varieties of human actinomycosis are recognized: the oral, the pulmonary, the abdominal, and the cutaneous. The origin of the first has already been described; from the *tissues of the mouth proper*, the jaws, the cheeks, the neck, and even the skull and brain may be invaded. The *pulmonary form*, due to inhalation, usually assumes the character of a low grade basal pneumonia; pleural effusion and invasion of the thoracic parietes are frequent. The spine may be involved, and the cold abscesses formed may closely simulate those of tuberculosis. *Abdominal actinomycosis*, especially

frequent in the neighborhood of the cecum, is of the hyperplastic type, abscess formation and intestinal perforation being rare; the disease tends rather to produce adhesions to the parietal peritoneum, and to invade the abdominal wall, producing there the characteristic lesions seen whenever the skin is invaded. *Cutaneous actinomycosis* frequently may be diagnosed without microscopical examination of the pus; the sinuses, with the involuted, hypertrophied skin; the chronic and nearly painless course of the disease; the typical "board-like" induration, sharply outlined; and perhaps the presence of hard cords under the skin running from the main lesions out in various directions; all make a picture which is not readily mistaken for anything else.

Diagnosis.—This must be made from *malignant tumors*, which may be closely simulated by the hyperplastic form; from *osteomyelitis* and *tuberculous lesions* of bones and joints; from *inflamed sebaceous cysts* of the face (Fig. 40), which, as pointed out by Lexer, sometimes bear a striking resemblance to actinomycosis; and from *gummatous* and other *syphilitic lesions*.

FIG. 40.—Multiple sebaceous cysts of the face simulating actinomycosis. Episcopal Hospital.

Treatment.—If complete extirpation is possible, this should be done; but in most cases the surgeon must content himself with freely opening all the sinuses, removing the granulation tissue with Volkmann's sharp spoon (Fig. 451), cauterizing the remaining tracts with the actual cautery or some chemical caustic (chloride of zinc 10 per cent.), and packing the wounds with iodoform gauze. Iodide of potassium is said to have a remarkable effect, administered in large doses for two or three weeks at a time and then discontinued for one week. Bevan (1908) has used cupric sulphate pills, one quarter of a grain, thrice daily, with marked benefit; he also irrigates the wound with 1 per cent. cupric sulphate solution. This method is based on the agricultural treatment of the diseased grain. Out of door life, and hygienic measures, as for tuberculosis, are of almost equal importance with topical remedies.

Madura Foot.—Madura foot, first observed in Madura, India, in 1712, is occasionally seen in America. It is due to a fungus closely resembling the actinomyces; one foot only is involved as a rule; very occasionally the hand is affected. A painless swelling forms on the sole; softening and suppuration follow. The course is chronic. Fistulæ form, heal, and again break open. Finally all the structures of the foot are invaded. Amputation is the best treatment.

Blastomycosis.—This is a surgical infection whose chief lesions are manifested on the skin, caused by organisms of undetermined

biological position, known as blastomycetes. A few cases of systemic infection have also been reported. According to Bevan (1908) "the cutaneous lesions have been mistaken most often for verrucous tuberculosis, less often for syphilis, and occasionally for epithelioma. . . . Tuberculosis is the disease which is most apt to be confused with systemic blastomycosis." The diagnosis is best made by microscopical examination of the pus from the cutaneous lesions, or by excluding the existence of tuberculosis by the usual tests. Bevan thinks potassium iodide is the most valuable remedial measure; he gives as much as 600 grains a day, well diluted. Cupric sulphate has also been used. Hygienic measures are important. In advanced cases the lesions must be treated surgically, by excision, curettement, cauterization, etc.

Rhinoscleroma.—Rhinoscleroma, a chronic infiltrating, productive infection of the nasal mucous membrane (rarely of the pharynx, larynx, and hard palate), is almost unknown in this country, though common in Austria and southwestern Russia. It is possibly due to a diplobacillus (v. Frisch, 1882). It is highly destructive, invading all surrounding tissues, and clinically resembling other infectious granulomas. Excision is the best treatment; when this is impossible enough of the growth should be removed to facilitate breathing.

ACUTE INFECTIOUS SURGICAL DISEASES.

Anthrax.—This disease, due to infection by the B. anthracis (Davaine, 1873; Koch, 1877), is common in sheep, horses, etc., and may be transmitted to man directly, or through contagion from wool, hides, etc. Invasion occurs through abrasions of the skin or mucous membrane; or through the respiratory or the intestinal tract. The period of incubation is one or two days. The local reaction consists in a cellular and serous exudate, producing marked edema, with a tendency to central necrosis. Eighty-five per cent. of cases affect the head, face, and neck. In severe cases anthrax bacilli enter the blood current, and bacteriemia results; as the bacilli are too large to pass through capillaries of ordinary size, they are arrested at various places and produce carbunculoid lesions in these new situations.

The *cutaneous form* (*Charbon; malignant pustule*) is characterized by the formation of a papule, changing into a vesicle, surrounded by an edematous area (Figs. 42 and 43); no pus is discharged. The vesicle dries up, a scab forms, central necrosis occurs, the black central core completing the typical picture. The pain ceases, and in mild cases the slough may be cast off, and spontaneous healing occur. In severer cases, lymphadenitis and angeioleucitis develop, toxemia becomes profound, and death may ensue in a few days. The *pulmonary form* (*woolsorter's disease*) is of slight surgical importance; 80 per cent. of patients are said to die by the fifth day. The *intestinal form* is characterized first by symptoms of ptomain poisoning; then by hemorrhages; and finally the lodgement of the bacilli in the cutaneous

capillaries produces a widespread carbunculoid eruption soon followed by death.

Diagnosis.—Anthrax is to be distinguished from other surgical infections by the history of exposure to the infection; by the local edematous reaction, with central black core; by the absence of pain

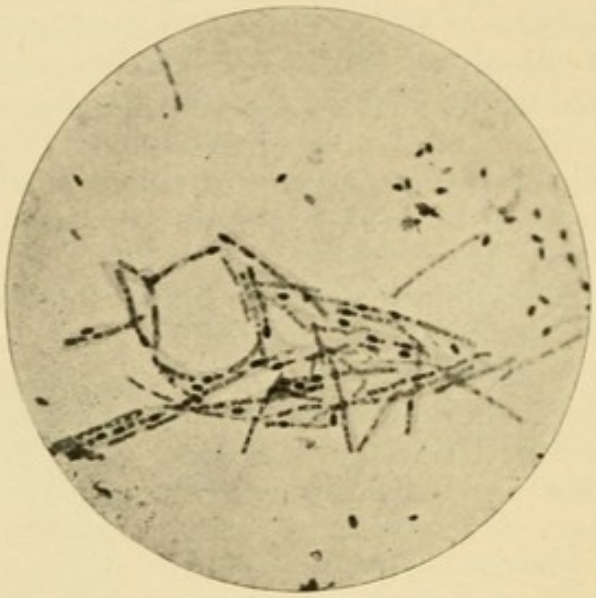

FIG. 41.—Anthrax bacilli. Spore formation. From an agar culture twenty-four hours old. About the margin of the photograph are a number of free spores. × 600. (Karg and Schmorl.)



FIG. 42.—Anthrax of face. Episcopal Hospital.

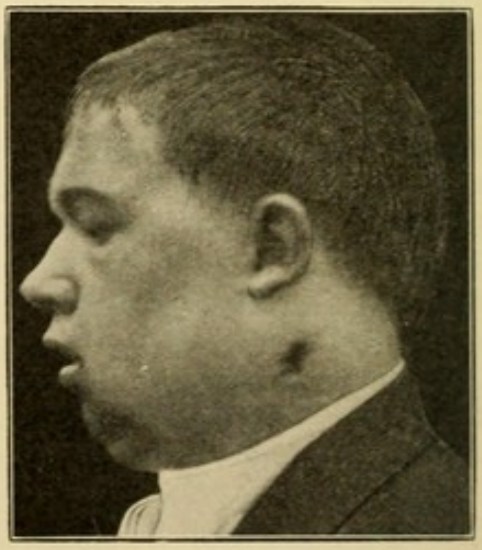

FIG. 43.—Anthrax of face. Black slough in centre of edematous area.

and suppuration; and finally by detecting the bacilli in smears made from the lesion.

Prognosis.—The mortality has varied from 25 to 33 per cent. in collected cases (Frazier, 1906); but by appropriate treatment it may be reduced to 6 per cent.

Treatment.—Excision should be done when possible, as is usually the case when an extremity is affected. Injections of pure carbolic acid around the lesion (five drops in each puncture) have seemed to be beneficial in some cases. Pressure on the pustule is to be avoided. Locally, antiseptic applications are indicated. In severe cases Barlach (1908) surrounds the lesion by a circle of punctures made by the actual cautery; he has treated 23 cases with no deaths. Most important of all, however, appears to be the use of Sclavo's serum (1897); in many cases of the disease (pulmonary and intestinal) it is the only remedy available; 30 to 40 c.c., in divided doses, are injected at different points in the abdominal wall. This dose may be repeated, if necessary, the following day. In severe cases intravenous injection should be tried (Läwen, 1908). By these means the mortality has been reduced to 6 and even to 3 per cent. in large series of cases.

Glanders (**Farcy**), due to the B. mallei (Löffler and Schütz, 1882), is common in horses, asses, and mules (equinia); sheep and goats are also affected. From these lower animals the disease is sometimes conveyed to man by the spray emitted by the horse, mule, etc., in sneezing, or by means of the purulent discharge from other sources. Occupation in stables is therefore a predisposing cause. Invasion occurs by inoculation of an abrasion of the skin (*farcy*); or of the nasal or buccal mucous membrane (*glanders*); or through the respiratory or digestive tract. The resulting infection runs an acute (very rarely a chronic) course. The local lesion somewhat resembles a tubercle; the regional lymphatics are affected early, and dissemination through the blood-stream is rapid. The lesions, wherever situated, are specially characterized by their tendency to *rapid suppuration*. Along the lymphatics, small hard nodules (farcy buds) appear, and soon suppurate. In the lungs multiple foci, which soon suppurate, are produced. A diffuse pustular eruption, sometimes mistaken for smallpox, frequently occurs in the skin (Fig. 45). In the subcutaneous tissues and muscles, hard, movable nodules appear, especially in the biceps, flexors of forearm, rectus abdominis, and pectoral muscles; the nodules soon suppurate. Bones may be invaded, and by implication of joints pyarthrosis may occur.

FIG. 44.—Bacillus of glanders (Bacillus mallei). (Abbot.)

Symptoms.—The period of incubation varies from three to seven days; malaise and indefinite typhoidal symptoms are the first to appear. In *glanders*, naso-pharyngeal granulomas are the earliest lesions, with ulcerations, causing sero-sanguineous catarrh; then pneumonic signs; and finally the cutaneous rashes, and subcutaneous and muscular nodes. Leukocytosis usually is not marked. In *farcy*, the skin affected becomes intensely inflamed; farcy buds appear along the lymphatics and soon suppurate; while the later symptoms resemble the last stages of glanders.

Diagnosis.—In the acute cases this is rarely made before death. The patient's occupation, microscopical examination of the discharges, and a negative Widal reaction, are factors which may indicate the nature of the malady. By the time the characteristic nodes appear, the patient is beyond the reach of treatment. In animals the disease may be detected by the "mallein test" (similar to the tuberculin test, p. 81). The chronic form of the disease resembles the late stages of syphilis.

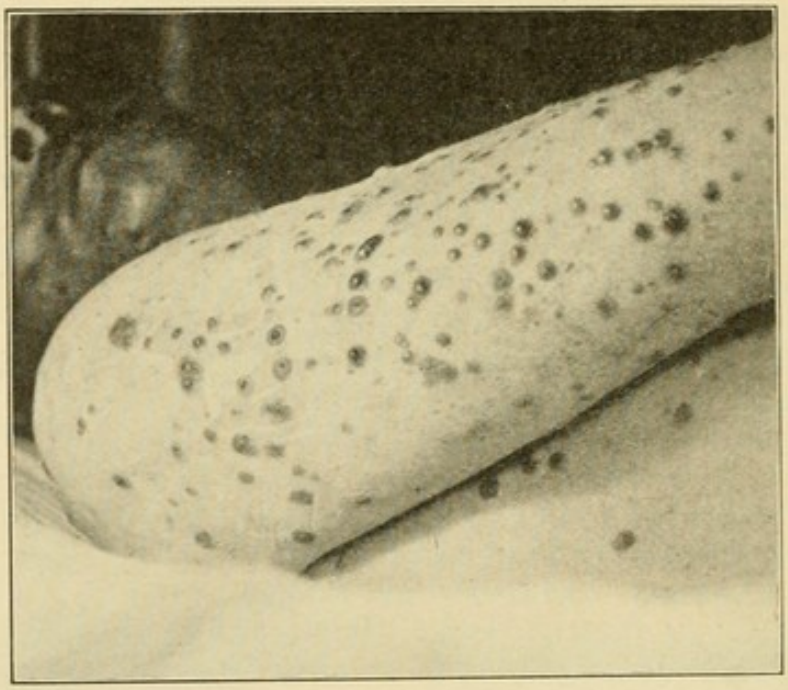

Fig. 45.—Pustular eruption in human glanders. (Dr. Zeit's case.)

Prognosis.—The disease is extremely fatal (85 to 90 per cent. of cases). Death occurs in from one to three weeks.

Treatment.—Isolation should be immediate, as the disease is easily conveyed by both immediate and mediate contagion. If an extremity be affected, amputation is indicated. Localized lesions elsewhere should be excised when possible; at least they should be opened and treated with rigorous antiseptic methods. Curettement and scrubbing are liable to disseminate the bacilli. Hygienic treatment often is all that is available.

Tetanus (Lockjaw).—This disease, characterized by tonic and clonic convulsions, and especially by locking of the jaws, is caused by the B. tetani (Fig. 46), discovered by Nicolaier in 1884, and obtained in pure culture by Kitasato in 1889. The bacillus is anaërobic and is found especially in garden soil, barnyards, stables, etc. It probably normally infests the intestinal tract of cattle, and is re-deposited with their dung. So long as the mucosa of their gastro-intestinal tract is intact, they are not liable to infection by this channel. Horses are particularly susceptible. Tetanus appears to be endemic in certain localities.

Inoculation occurs only through a wound. Cryptogenetic (formerly called idiopathic) tetanus is that form in which the wound of entrance cannot be discovered, having been insignificant in extent, or being on a mucous surface. Inoculation is favored by anaërobic conditions of the wound. Thus punctured wounds, contused and lacerated wounds, and wounds in which foreign bodies (earth, machine oil, splinters, wadding, etc.) are present, offer favorable conditions for the development of tetanus. A mixed infection, especially with saprophytic bacteria, is favorable because these organisms, being aërobic, absorb all available oxygen, and provide anaërobic conditions for the tetanus bacilli. Tetanus is seen after compound fractures and gunshot wounds; during the puerperal state, when inoculation occurs by the genital tract; in the newborn (*tetanus nascentium*) from infection of the umbilical cord; and not infrequently in cases of extensive burns. Contagion may spread from one patient to another by the medium of instruments, dressings, etc. Postoperative tetanus has been studied by Matas (1909), who suggests that it is due to germs of tetanus, latent in the patient's intestinal tract, ingested with uncooked food, and infecting the operative wound by fecal contact. There is no good evidence that it is due to the use of infected catgut.

FIG. 46.—Tetanus bacilli, showing spore formation. (Kitasato.)

Pathology.—After inoculation there is an incubation period averaging probably about nine days, but which may vary from one day to eight weeks or more; yet when so long a period has elapsed it is not always possible to exclude a more recent inoculation. The duration of incubation is due largely to the distance of the wound from the spinal cord, and to the conditions present at the site of inoculation. Experimentally the bacilli are easily destroyed by the normal tissues of the body; but if these structures (phagocytes and bactericidal fluids) are engaged in combating foreign bodies or other bacteria as well, then the tetanus bacilli begin to exert their influence more promptly. The tetanus bacilli remain in the primary wound; the disease is a pure toxemia; extremely rare are the cases where the bacilli are found in the blood, lymph, or other body tissues. The local reaction caused by the bacilli is in no way characteristic, and is insignificant in extent. The toxins they produce are alone responsible for the symptoms of the disease: so long as no toxins are produced, no evil effects are observed from the presence of the bacilli in wounds; and if toxins alone are introduced they produce symptoms identical

with those seen when the bacilli are present and multiplying in the wound. The toxins produce no symptoms until they are transported to the spinal cord; and they reach the spinal cord only by travelling along the motor nerves. Toxins are absorbed directly by the nerves of the wounded part and are transported through them to the spinal cord; if the nerve is divided the toxins will ascend as far as the section but not beyond. Toxins also enter the circulation, but cannot reach the central nervous system except when carried to the peripheral ends of motor nerves and absorbed by them. Toxin absorbed from the circulation through short nerves reaches the cord sooner than that absorbed through long nerves. This explains the early appearance of muscle cramp in the face muscles and those of the spine, which may occur before cramps in the wounded extremity.

In the anterior horns of the cord, congestion, exudation, and ecchymosis are frequently observed; but the changes are not pathognomonic for tetanus. When once the cord is invaded, the infection spreads from segment to segment, and the sensory portions are affected directly. The toxin appears to enter into chemical combination with the nerve tissue. Tonic contraction of the muscles is caused by irritation of the motor tracts; while the implication of the sensory portions of the cord renders it so exceedingly susceptible to stimulus, that clonic convulsions are often superadded to the tonic spasms. Our knowledge of the pathology of tetanus is due chiefly to the work of Marie and Morax (1902), and of Meyer and Ransom (1903).

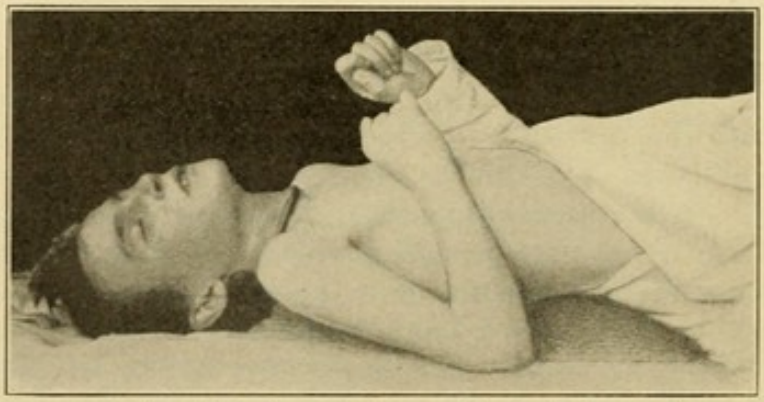

FIG. 47.—Opisthotonos in third day of tetanus; death six hours later in convulsions. Note also sardonic grin. Episcopal Hospital.

Symptoms.—Vague prodromal symptoms occasionally are noted. When the incubation period lasts less than ten days, the disease is said to be acute. Sometimes the wound seems painful, or a chill may occur. Usually the first thing noted by the patient is a stiffness of the jaws (*trismus*) or a painful contraction of the extensors of the neck; occasionally spasm occurs first in the muscles of the wounded part. These primary symptoms are quickly followed, usually in a few hours, by more or less generalized cramps, the extensors almost always overcoming the flexors. Thus the feet are fully extended, the head retracted, and the back arched, so that the entire body may be

supported on the occiput and the feet (*opisthotonos*) (Fig. 47); *emprosthotonos* is the term used for the opposite condition, when the action of the flexors predominates, and the body is bowed forward; *pleurothotonos*, in which lateral deviation of the spine is the chief feature, is extremely rare. These tonic spasms are more or less continuous, full relaxation rarely being attained at any time during the course of the disease. The clonic convulsions are superadded to the tonic spasms, and bring on again exaggerated degrees of opisthotonos, etc. Then the opisthotonos relaxes, and until again excited general rigidity is all that remains; but the jaws usually are persistently shut, the head retracted, and the back arched. The spasms are exceedingly painful, and terribly exhausting. They recur without regularity. They are easily aroused by a draught of air, a slamming door, jarring of the bedstead, etc., as the spinal cord is in a state of extreme hyperexcitability. Difficulty in swallowing is not marked, when once food has entered the mouth. Bronchorrhea is frequently troublesome, and hypostatic or inhalation pneumonia may develop. The muscles of the tongue are not affected and speech would be distinct if the jaws could be opened. Tonic contraction of the facial muscles produces the so-called *sardonic grin*. This may persist during convalescence (Fig. 48). Respiration is difficult and labored. Asphyxia is frequently threatened in the tonic convulsions. Spasm of the diaphragm causes the fearful "girdle-pain." The abdominal muscles are "as hard as a board." Retention of urine frequently occurs, and constipation is extreme. The recurring convulsions deprive the patient of sleep; nourishment can be administered only with the greatest difficulty; the mind remains clear to the end, and death is often welcomed by the patient as the only relief. High fever is an unfavorable symptom; at death, and afterwards, the temperature rises rapidly.

FIG. 48.—Risus sardonicus, persisting during convalescence from tetanus. Aged seven years; incubation ten days. From a patient in the University Hospital under the care of the late Prof. Ashhurst.

Chronic Tetanus.—This term is used in two senses: (1) For cases with an incubation period of more than ten days. (2) For those in which the patient survives more than fifteen days. In either instance the symptoms are less severe. Occasionally permanent contractures, especially of the jaws, persist after recovery.

Diagnosis.—This must be based on the suspected wound infection; on the early occurrence of retraction of the head or of trismus; on the generalized tonic and clonic convulsions; on the entire absence of delirium; and on exclusion of all other diseases. It seldom is possible

to recover the bacilli from the point of inoculation, but injection of the patient's blood serum or cerebrospinal fluid into one of the lower animals may cause tetanic convulsions.

Prognosis.—This is bad. The general mortality is about 60 per cent. Anders' figures (1905) showed a mortality of 74 per cent. for cases developing in less than ten days; and of 8.5 per cent. for those which lasted more than fifteen days. Jacobson's statistics (1906), from *all* the cases treated in various hospitals during given periods, showed a mortality of 83.1 per cent. for acute and of 43.6 per cent. in subacute cases. The longer the period of incubation, and the longer life is preserved after the symptoms develop, the greater is the chance or ultimate recovery. With early diagnosis and prompt and efficient treatment, the mortality of acute cases should be reduced to 20 per cent. or lower (Ashhurst and John, 1913).

Treatment.—Prevention is better than cure. Extreme care must be exercised in dressing wounds which seem predisposed to the development of tetanus. Septic punctured wounds should be opened and treated with the most scrupulous antisepsis. Remove all foreign bodies and sloughs. Swab the wound with 3 per cent. alcoholic solution of iodin, rinse with hot peroxide of hydrogen, and pack lightly with gauze soaked in the iodin solution. Lacerated and contused wounds must be even more freely drained than where no probability of tetanic infection exists. Inject 1500 units of tetanus antitoxin into the tissues around the wound, or into any nerves exposed in the wound; and repeat this injection at the end of eight or nine days, since by this time the antitoxin first injected will have disappeared, but toxins may not yet have been produced.

When the disease has once developed, active treatment is imperative. A few hours' delay in recognizing the malady and in instituting proper relief, may render cure impossible. Stiffness of the jaws is enough in a suspicious case to justify the use of heroic measures. The inexperienced surgeon frequently is thrown off his guard because the patient's mind remains so calm and clear. The patient should be isolated at once in a quiet, cool, darkened room, and a special nurse should be placed in charge. The principles of treatment are: (1) To remove the source which supplies the toxins (*i. e.*, the bacilli still in the wound); (2) to neutralize toxins already formed; (3) to depress the functions of the spinal cord; and (4) to sustain the patient by nourishment, nursing, etc.

1. The first indication involves *care of the wound*, which is the same as recommended for the prevention of tetanus.

2. *To neutralize the toxins*, antitoxin should be used. This is supplied in tubes containing 1500 units (5 c.c.) and 3000 units (10 c.c.) each. It is evident from the pathology of the disease that it is quite extravagant to inject it hypodermically or even intravenously. The only way in which it can act upon the toxins ascending from the wound is when it is injected directly into the motor nerves of the part affected, as first employed in 1902 by Küster in a case of laboratory infection.

When given hypodermically it is absorbed by the lymph spaces, reaches the veins, passes through the heart and lungs, and is then distributed by the arteries to the entire body, only a homœopathic dose reaching the special nerve or nerves along which the toxins are travelling to the spinal cord. If used subcutaneously at least 100,000 units should be administered in the first twenty-four hours. It has been pointed out by Ashhurst and John (1913) that antitoxin injected into the subarachnoid space of the cord probably acts directly on the nerve roots, and such immediate and favorable effects from the repeated intraspinal administration of antitoxin have been reported, that I think it should be employed in every case. Anesthesia is not necessary, though often desirable. Chloroform is better than ether. The hollow needle is inserted between the second and third lumbar spines (p. 157), and a few cubic centimeters of the subarachnoid fluid are drawn off; the antitoxin syringe is then attached to the needle, and from 3000 to 10,000 units are slowly injected. If the site of inoculation is on the upper extremity or head, the foot of the table may be raised, to allow the antitoxin to gravitate toward the medulla. This injection may be repeated every day or two, as required; it is easier than intraneural infiltration, which requires anatomical as well as surgical knowledge. If no marked improvement follows the subarachnoid injection, within six or eight hours, the main nerve or nerves leading from the site of infection should be isolated under chloroform anesthesia, and as much antitoxin as possible should be injected into each nerve, by various punctures into its substance. The nerve swells up so quickly that no large amount can be introduced; on several occasions I have injected 1500 units (5 c.c.) into the sciatic nerve all at one dose. It is not true that the pressure, rather than the antitoxic action, blocks further absorption of the toxins, since intraneural injections of saline solution are without effect. Antitoxin seems perfectly harmless, and no fear need be entertained of using too much. The incision should not be closed, but a stout silk or linen ligature, looped loosely around the nerve, should be left hanging from the wound, which should be lightly but copiously dressed. If the symptoms persist, the patient must be chloroformed again the next day, and the intraneural injections repeated. Possible injury to the nerves, which does not appear to have been reported, is of insignificant consideration, compared to the preservation of life. The nerves to be so treated in the lower extremity should be exposed in the upper thigh; for wounds of the sole of the foot, the sciatic nerve, and for injuries of other parts of the lower extremity, the anterior crural and obturator as well as the sciatic must be injected. In the upper extremity the nerves may all be exposed by a single incision in the axilla; or the brachial plexus above the clavicle may be injected. For wounds of the trunk, intraspinal injection is the best available remedy; this is also the case in wounds of the face and head. Intracerebral injections, after trephining the skull, have been used, but as the cerebrum is not materially affected by the toxins this operation

probably is useless. Rogers (1905) has used intramedullary injections with success, in desperate cases: he introduced the needle in the cervical, upper dorsal, or lumbar region, and poked around until jerking of the limbs indicated that he was scratching the cord itself.

3. *To depress the functions of the spinal cord* drugs may be given by mouth if the patient can swallow, or by the rectum; hypodermic administration is best when possible. These drugs should be administered in doses sufficient to produce some effect; 10 to 20 grains of chloral hydrate, and twice as much bromide of potassium, may be given as often as every three hours; more should be given if the patient requires it, and less if it proves to be sufficient to relieve the pain and diminish the rigidity. Morphin is of very little value. Chloretone has given gratifying results (Hutchings, 1909). It is administered by mouth or rectum in doses of from 30 to 60 grains, dissolved in whisky or hot olive oil.

Treatment by intraspinal injections of *magnesium sulphate*, introduced by Blake of New York in 1906, is based on the anesthetic effect of this drug, when injected into the subarachnoid space (Meltzer, 1905). It acts as a spinal depressant, and should not be used as a substitute for antitoxin. Solutions of 12.5 to 25 per cent. strength are employed, and 1 or 2 drachms (5 to 10 c.c.) are used at each injection (1 c.c. for every 25 pounds of body weight). It is a dangerous remedy, and several deaths have been reported following its employment.

Carbolic acid injections, introduced by Bacelli (1888), are supposed by some to have a specific action in tetanus. Subcutaneous injections of $\frac{1}{2}$ per cent. watery solution are administered, every one or two hours, preferably along the spine, until 80 or 100 cg. are given in twenty-four hours, watching for constitutional symptoms of carbolic acid poisoning. Experimental evidence (Camus, 1912) shows this treatment to be useless, but clinically some good results are reported.

4. The *nursing of the patient* is very important. Clear the bowels by a brisk purge early in the disease; watch for retention of urine; guard against bed-sores. Enforce feeding, by the stomach tube passed under a general anesthetic if necessary.

Hydrophobia (Rabies, Lyssa).—This disease, whose exact cause is unknown, is characterized by clonic spasms, especially of the faucial and respiratory muscles; it results from inoculation with the virus contained in the saliva of rabid animals, notably dogs, wolves, cats (also in foxes, sheep, goats, pigs, skunks, deer, etc.). Any mammalian may be affected. It is disputed that it is ever conveyed from man to man. Though infection occurs in the vast majority of cases by bites, it may also occur through scratches by claws infected with saliva, or by an animal licking an existing wound. Wolf bites are most dangerous, because it is said the hands and face, unprotected by clothing, are usually bitten; and because the sharper teeth more readily pene-

trate protected parts. It is possible that the virus may be partly wiped off the teeth of animals by passing through clothing.

The disease is found in dogs in two forms, the *furious* and the *paralytic*. In the former, the dog is at first sullen, retiring to his kennel, and looking askance at every one; after several hours he becomes exceedingly fidgety, continually shifting his posture; suddenly he becomes irritable, with a snapping bark, an unsteady and staggering gait; the tongue lolls from his mouth, swollen and red; the saliva is profuse and viscid; there is loss of appetite and presence of thirst. Later, paralysis of the extremities occurs, breathing and deglutition become spasmodic, and convulsions bring on death. In the paralytic form, the disease passes at once from the sullen to the paralytic stage; the dog is shy and melancholic; there is no disposition to bite; he is haggard and suspicious; has no fear of water, but does not drink; the tongue lolls, the saliva dribbles, breathing is difficult and laborious; and tremors, vomiting, and convulsions precede death (Youatt; quoted by Forbes, 1888).

Pathology.—The virus, entering the wound with the saliva, and probably derived from the salivary glands, is absorbed by the nerves of the bitten part (Di Vestea and Zagari, 1887), and travels by them to the spinal cord; whether some toxin alone, or the infective agent itself is thus transmitted, is still unknown. Some of the virus may travel through the neural lymphatics. The virus, after reaching the cord, travels up it to the medulla, cerebellum, and cerebrum; it also travels out along the spinal and cranial nerves, and in this way reaches the salivary glands of the patient, especially the submaxillary and sublingual; the saliva becomes highly infectious. After death there are found in the cerebrum, cerebellum, medulla, and cord, and also in the salivary glands, various degenerative changes, especially marked in that part of the cord which receives the nerves of the bitten part. The most important microscopic changes are in certain of the peripheral ganglia and in the hippocampal convolution. Van Gehuchten and Nelis in 1900 found changes, seen best in the ganglia of the vagus and sympathetic nerves, consisting in proliferation of the endothelial cells lining the capsule of the ganglion, and filling up the spaces between the capsule and the proper cells of the ganglion. Negri (1903) found in the pyramidal cells of the *cornu Ammonis*, and in Purkinje's cells in the cerebellum, certain cell inclusions which he regarded as parasites and the cause of the disease. Nearly all observers admit that these ganglionar changes and the presence of Negri bodies are pathognomonic of rabies; they are found in other diseases only with the greatest rarity; but many dispute Negri's claim that the bodies described by him are parasites, and deny that they are the cause of the disease. Rambaud (1907) points out that their distribution is not what would be expected of the specific cause of rabies; that the virus passes through filters which arrest the Negri bodies (Park thinks this not a valid objection); and that protozoa survive temperatures (45° C.) which readily render the rabic virus inert.

Symptoms.—After inoculation, there is a period of incubation, varying from four or five days up to several months or a year. The average period in man is forty days (Ravenel, 1901). Incubation is shortest following bites of the face and other exposed parts, also following wolf bites. The original wound usually has firmly healed long before any symptoms arise. The course of the disease was described by Virchow as embracing three stages: (1) The first stage, which may be absent, but which usually lasts from a few to twenty-four hours. There is malaise, lassitude, headache, twitching of the throat, stiffness of the neck, a feeling of suffocation, and rarely slight delirium. There is seldom any abnormal sensation in the wound. During this stage the virus probably is ascending the cord. (2) The second stage is evidenced by increasing stiffness and pain in the tongue, throat, and jaw muscles; there is dysphagia, dryness, and great thirst; profuse salivation, the saliva being exceedingly tenacious and viscid; this necessitates repeated *hawking* which has been fancifully likened to the bark of a dog. Violent spitting is exceedingly characteristic. The patient is fearful of infecting those about him. Speech is difficult, being often choked off by gasps and sobs due to pharyngeal and laryngeal spasm. Swallowing becomes impossible, the sight of food or liquids, and sometimes the very sound of running water, bringing on renewed paroxysms. The special senses become preternaturally acute; according to Rambaud, the slightest draught of air, as breathing gently on the patient, always produces faucial spasm. General convulsions ensue; there is high temperature, rapid pulse, and polynuclear leukocytosis. The urine is deficient; it may contain albumin or sugar. The mind seems in terrific dread, in unutterable despair, or furious anger. Insane impulses and delusions are not uncommon; the staring eye, tensely drawn mouth, with bloody foam on the lips, and haggard countenance precede mania, which closes the second stage. The entire duration of this frightful scene may be twenty-four to forty-eight hours; and death from asphyxia in a convulsion is frequent. (3) The third, or paralytic stage is evidenced by exhaustion succeeding to mania and convulsions: saliva dribbles from the hanging mouth, the tongue lolls, and a horrible gurgling in the throat portends dissolution (Forbes, 1881). The entire course of the disease may be run in sixteen hours, or it may last four or five days; seldom longer. In rare cases the furious stage is entirely absent, the disease resembling the paralytic type seen in dogs.

Diagnosis.—This affection, which is exceedingly rare, is distinguished from pseudo-rabies (hysteria), by the history of a bite from a truly rabid animal;[1] by the period of incubation, which is never less

[1] To determine whether or not the animal is rabid, it should not be killed immediately, but should be kept under observation for several days, or at least until the clinical signs are noted by a competent veterinarian. If such is not available, the dog's head should be cut off with an aseptic knife, and sent to a competent veterinarian or pathologist, who will determine from the microscopical appearances of the plexiform ganglion and cerebrum, whether or not the animal was afflicted with rabies. This fact may also be determined by inoculations into other animals, but this method may take several weeks.

than four days; and by the almost invariably fatal termination within ten days. In hysteria the symptoms are often immediate, the barking and hydrophobia are absurdly exaggerated, the dog is not mad, and death does not occur. Tetanus is due to a wound, not a bite; there is no excitement, fury or mania; the convulsions are tonic more than clonic; the jaws are firmly shut and cannot be opened; there is no spasm of the tongue and fauces. Tetanus is a quiet disease; apart from gritting of the teeth during convulsions, the patient makes no noise. Rabies is a furious and noisy disease.

Prognosis.—It is now said that from 10 to 15 per cent. of those bitten by rabid animals are liable to develop the disease; it was formerly claimed by Pasteur and his followers that the incidence was much higher, even as much as 75 per cent. Not only is it an unusual disease in man, but it is by no means common in dogs and other animals. It is most frequent in France, Germany, and Russia; it is very infrequent in Great Britain where there are extremely stringent quarantine laws against the importation of dogs; and almost unknown in Norway and Australia. Most surgeons never see a single case. I never saw one. Our entire knowledge of the disease is due largely to veterinarians and to directors of Pasteur Institutes. The disease when it really does occur is frightfully fatal. There are a very few well authenticated cases of recovery, accepted as such by competent critics.

Treatment.—This must be both preventive and curative. The former includes police regulation of dogs and other domestic animals, as well as ordinary surgical treatment for a poisoned wound, and, if the patient wishes, the so-called Pasteur treatment by preventive inoculation. As soon as the wound is received, constriction should be applied on its proximal side, to prevent possible absorption; and a cupping glass should be applied to suck out as much of the virus as possible. In emergency, the patient should suck the wound with his own mouth, spitting out the blood thus extracted. The best antiseptic, according to Rambaud, is corrosive sublimate (1 to 1000); the compound tincture of iodin is also good; lemon juice, which is an excellent antidote experimentally, may be used in emergency. Caustics are worthless, unless heat is used; and when available antiseptics are better than heat.

The *Pasteur treatment* is based on the theory that, even during the period of incubation, inoculation with extremely attenuated virus, whose strength is gradually increased, will be sufficient to immunize the patient against the disease. The attenuated virus is obtained from the spinal cords of rabbits dead of hydrophobia; the quantity (not the quality) of the virus in the cords gradually diminishes in dry air. The first inoculation is made with an emulsion of a cord from a rabbit dead twelve to fourteen days, and the course of treatment extends over about two weeks. There is no doubt that in the vast majority of cases inoculation of healthy animals according to this system will immunize them against rabies; but to conclude from this, that inoculation of patients already infected will also be efficient,

is not logical. From practical experience, however, it may be said that there is no good reason to doubt that inoculation according to Pasteur's method, under the latter circumstances, has rendered most of the patients so treated immune. But it must not be forgotten that the vast majority of patients treated in Pasteur Institutes never would have developed rabies under any circumstances; many of them are bitten by animals that are not rabid; and therefore their inoculation in most instances is perfectly useless. Moreover, there is not a shadow of doubt that in a few well authenticated cases no immunity has been procured by the inoculations, the patients subsequently developing and dying from the disease; and it has even been open to suspicion that these very patients might have been among that large number who, even without the inoculations, never would have developed the disease—in other words, that the danger of contracting rabies as the result of the inoculations, though very remote, is not altogether imaginary. The actual mortality attending the Pasteur treatment is given as less than 1 per cent.; but as from these statistics it is customary to exclude all those patients who develop rabies within fifteen days after the last inoculation (Rambaud), the number of those in whom immunity is actually produced is considerably less than would appear if this fact were not taken into consideration. Before a surgeon recommends the preventive treatment by inoculation he should, I think, place all these facts plainly before the patient; and if the patient wishes to take this very remote risk, and the surgeon is convinced that he was infected by a rabid animal, no time should be lost in having this treatment instituted.

The *curative treatment* is nearly hopeless. Hyoscin and curare, hypodermically, are the best drugs; chloral and morphin have little effect. Proctoclysis of saline solution, with large doses of bromides by the rectum, may be tried. Amyl nitrite or chloroform may be used for the convulsions. The saliva should be sterilized.

CHAPTER IV.

TUMORS.

In studying the inflammatory process it was seen that the local reaction induced was usually sufficient to overcome and destroy the origin of the trouble; in the case of the infectious granulomas, instead of an efficient reaction, the indications of inflammation were found to be very slight, and cellular proliferation was the main characteristic of the process. Yet in both these instances the cell proliferation was incontestably in the nature of a reaction to external stimulus. In tumors we find a pathological process characterized by purposeless, more or less unlimited, cellular proliferation of unknown cause, producing practically no reaction in surrounding tissues. The cells of tumors seem to be a law unto themselves: they do not follow the ordinary processes which subserve the purposes of the organism as a whole; their only function appears to be proliferation, and this they evince without discoverable purpose or known cause.

For an understanding of tumor processes a knowledge of embryology is necessary, because the most logical classification of tumors which has yet been proposed (Adami, 1902)[1] is that based on their histogenetic characteristics, and because the ultimate cause of tumor formation seems to lie in inherent characteristics of the cells themselves, not in stimulus from without nor in relief from constraint by surrounding structures.

Definition.—This is difficult, because the cause of tumors is not known; a definition therefore has to be formed solely from the objective characteristics of fully formed tumors. Adami accepts as satisfactory the statement of C. P. White that "*a tumor is a mass of cells, tissues, or organs resembling those normally present, but arranged atypically. It grows at the expense of the organism without at the same time subserving any useful function.*"

GENERAL CHARACTERISTICS OF TUMORS.

The word **tumor** means a swelling, and all tumors are characterized by a more or less localized swelling, which usually is both visible and palpable. Tumors may be multiple or single, may occur at any age, and in any situation.

Form.—A tumor growing on the surface of the body assumes a typically rounded form (Fig. 49); one in the internal organs, or beneath

[1] In the following paragraphs the teaching of Adami, and sometimes his words, have been closely followed.

a resistant fascia, or compressed by other parts of the body will spread in the direction of least resistance; tumors may thus become irregular in form (nodular, papillary, etc.). **Consistency** varies greatly, being dependent upon the type of tumor: fatty tumors are soft, bony and cartilaginous, are hard fibromas and are more or less firm. **Rate of Growth**: This is usually slow, the increase in size being measured by months or years rather than by weeks or days; in general, the more rapid the growth, the worse the prognosis. Slowly growing tumors seem to provoke a feeble reaction in the surrounding tissues, so that they become surrounded by a more or less well defined **capsule**; those of rapid growth extend into normal tissues in various directions before a capsule can be formed. **Manner of Growth**: Growth occurs simultaneously in all parts of a tumor, not only at the periphery or in the centre, though in certain tumors growth at one place is much more marked than at others. The more rapid the growth, the more apt are the central cells to be squeezed out of existence, and therefore in such tumors central degeneration is common, leading at times to cyst formation. **Size** varies so greatly that no clear statement can be made (Figs. 50 and 51).

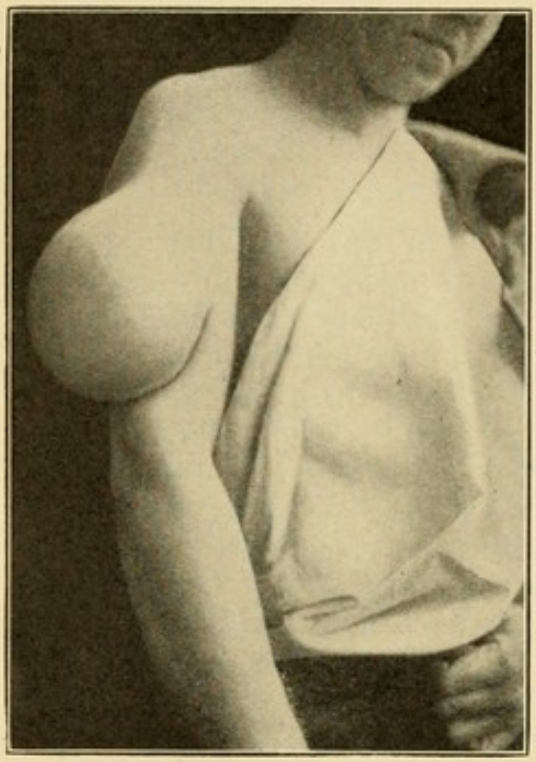

Fig. 49.—Lipoma of right arm.



Fig. 50.—Papilloma of face.

Malignancy. — From the above it is evident that certain tumors are less benign than others. Even tumors recognized as clearly benign may be dangerous from their size or position. The size of a tumor may impair the patient's health by requiring an extraordinary amount of nourishment; its position, even if small, may threaten life, as in growths of the larynx threatening suffocation, in the alimentary canal causing obstruction, or in the brain causing pressure

on vital centres. But tumors comparatively small in size and innocuous in position may by their inherent characteristics be exceedingly dangerous to life. These characteristics are (Adami): *Embryonic character* of the tumor cells, leading to rapid growth; this in turn gives the surrounding tissues no opportunity to encapsulate the growth, with the result that *infiltration* of the surrounding tissues occurs, this infiltration extending far beyond the limits visible to the naked eye or discoverable by palpation. *Metastasis:* Some of the tumor cells by their rapid growth may break into bloodvessels and be carried by the blood to the nearest set of capillaries, and may even pass through these (pulmonic, hepatic) and enter the next set, in either situation lodging and, *unless killed by the tissues of the part* in which they are arrested, giving rise there to new growths (*metastases*) similar to the original tumor. (It is held by Orth and certain other pathologists that normal cells surrounding evidently malignant cells may become infected by the latter, and themselves aid in the formation of the tumors. I think it is more reasonable to consider, with Ribbert, Adami, and others, that metastases are due to the proliferation solely of cells which have been transported from the primary tumor.) The tendency to central degeneration and cyst formation has already been alluded to; in addition, superficial parts, those furthest removed from the blood-supply, whether on mucous or cutaneous surfaces, tend to sloughing and ulceration. These malignant tumors, moreover, tend to return after removal (*recurrence*), either because this was incomplete in the first place, or because other previously normal cells become anarchistic in their turn. Further, malignant tumors produce *cachexia;* this is not in any sense a specific cachexia, but is caused by the drain on the natural resources of the body by the tumor, by anemia due to hemorrhages from its ulcerated surface, by toxemia through absorption, or by intoxication from perverted metabolism.

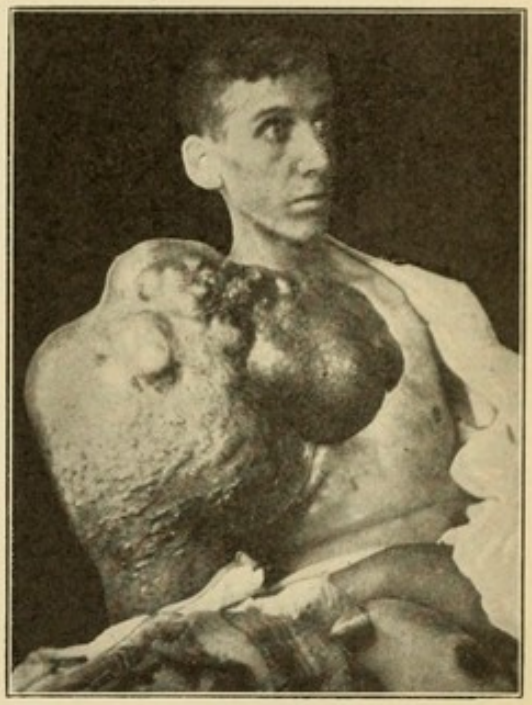

FIG. 51.—Excision of right clavicle for alveolar sarcoma, March 3, 1894, at age of nineteen years. Recurrent growth removed April 20, 1895. Present recurrence noticed September 1896. Grew very rapidly after April, 1897. From a patient in the University Hospital under the care of the late Prof. John Ashhurst.

THEORIES OF TUMOR FORMATION.

Most of the theories in favor at the present day account only for one or two types of tumor. *Cohnheim's theory* is to the effect that

during fetal life certain groups of cells become displaced from their normal site, remain undeveloped and latent (cell "rests") until some future period of adult life, and then from some unknown cause begin to proliferate and form a tumor; this theory accounts very well for tumors of distinctly fetal origin (teratomas), but there are many other tumors which under no circumstances can be considered due to cell rests. *Ribbert's theory,* a modification of Cohnheim's, supposes that, besides fetal displacement, also post-natal displacement of nests of cells may occur; but that proliferation of such displaced cells is not due to stimulation from without nor to any inherent qualities of the cells themselves, but to lack of restraint by the surrounding tissues. Yet, in the process of regeneration (p. 30) cells exhibit such qualities in marked degree, yet no tumor results except in most exceptional instances. *Parasitic Theory:* This is based chiefly on observations which tend to show the *infectiousness* of certain malignant tumors; such tumors (carcinoma and sarcoma) may be transplanted from animal to animal, their virulence, if it may be so called, being markedly increased by passing them through series of susceptible animals; and in many such tumors parasites of various kinds have been found. But the parasites are of various kinds, their etiological value has not been proved, and even if it were, this theory would explain the growth of only one class of tumors—the malignant. This reduces us, therefore, to the theory that the origin of tumors lies in perverted habits of the cells themselves, however it may be aided by the abnormal position of the cells (Cohnheim), by their release from restraint (Ribbert), or by their stimulation by parasitic forms of life. The utmost that we definitely know of tumor cells is, as Adami puts it, that *they have gained the habit of growth, and have lost that of function.*

CLASSIFICATION OF TUMORS.

Functional development of cells necessitates their specialization. The most undeveloped cells are said to be *toti-potential* (capable of everything); more developed cells are *pluri-potential* (capable of more than one thing); while cells which are most developed are *uni-potential* (capable of only one thing) (Barfurth). Basing his ideas of the nature of tumors on the inherent properties of the cells themselves, Adami recognizes three main groups of tumors, according to whether the tumor arises (1) from absolutely undifferentiated (toti-potential) embryonal cells, (2) from partially differentiated (pluri-potential) embryonal cells, or (3) from uni-potential cells, that is, cells which can form only one type of tissue. The first class (**Teratoma**) is derived from cells which might possibly, at a later period, be developed into any form of tissue or any organ, or even into a complete individual. The third class (**Blastoma**) is derived from cells which (before the tumor originates) have so far developed that they can give rise to only one form of tissue, *e. g.*, connective tissue cells can produce only connective tissue tumors, epithelial cells can produce only epithelial

tumors, etc. The second or intermediary type of tumor (**Teratoblastoma**) is derived from cells only so far differentiated that they can produce more than one form of tissue, but not all forms (Fig. 52). Tumors composed only of one tissue are rare.

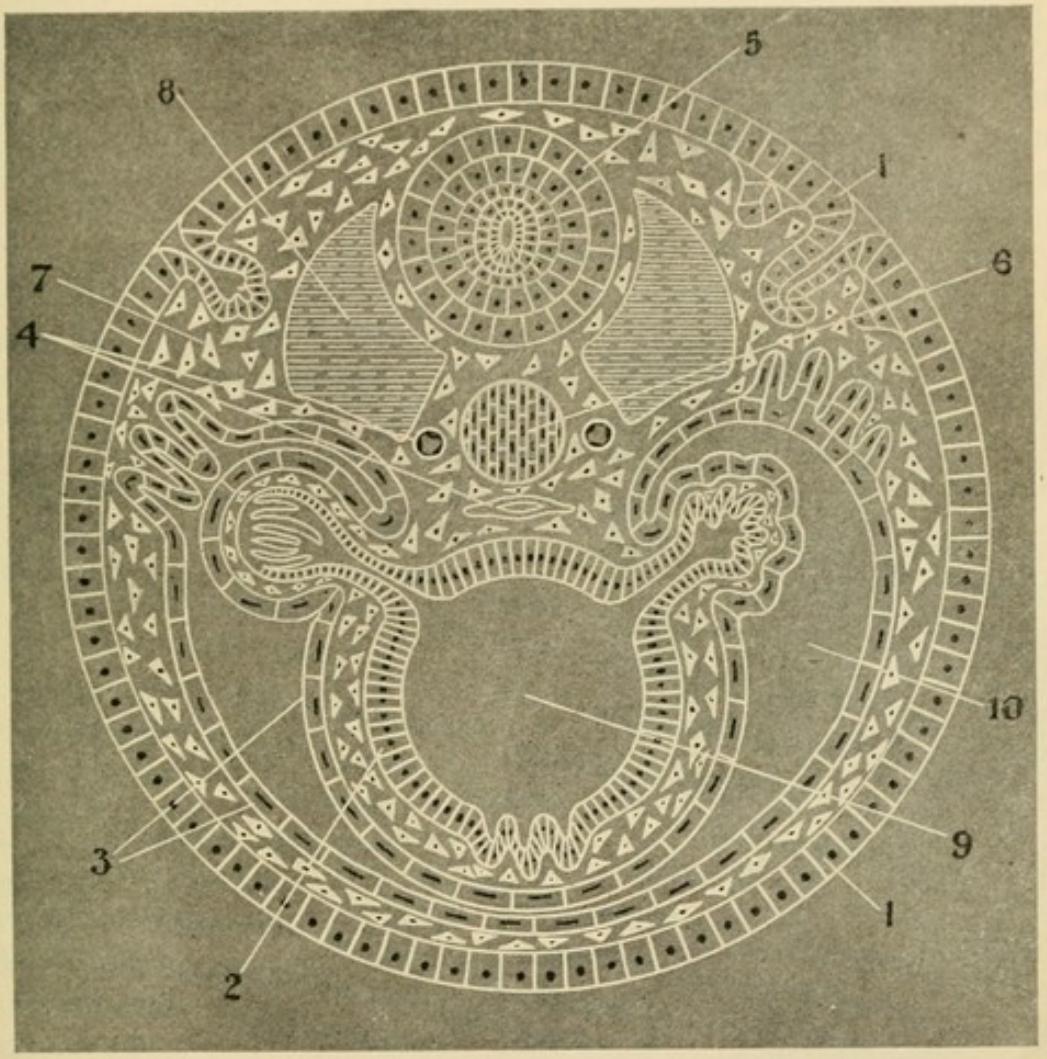

FIG. 52.—Diagrammatic representation of section through vertebrate body to show ontogenetic relationship of the various orders of tissues. *A*. Of lepidic type: 1, epiderm and its glands (epiblastic); 2, mucous membrane of digestive canal and its glands, liver, etc. (hypoblastic); 3, endothelium lining serous cavities (mesoblastic) and glands, like renal cortex, of mesothelial origin; 4, vascular endothelium of late mesoblastic origin. *B*. Of hylic type: 5, spinal cord, brain, and nerves (epiblastic); 6, notochord (hypoblastic); 7, connective tissues of the body (mesenchymatous); 8, myotomes, striated muscle of body (mesothelial). *C*. Cavities: 9, lumen of digestive tube; 10, body cavity. (Adami and McCrae.)

Teratomas.—These are divided by Adami into two main classes, according to whether the teratoma is derived from the same individual as the person possessing the tumor, or whether it is derived from a twin which, becoming atrophic in embryonal or early fetal life, remains only as a *fetal inclusion*. This latter class produces the various forms of *monsters*, chiefly of interest to obstetricians. The former class comprises those tumors usually known by the name **teratoma**. These tumors may spring from *germinal cells*, or from *non-*

germinal cells; in the former instance the tumor is found in the ovary (ovarian "dermoid"), where a large cyst is usually formed, or in the testicle, where the growth (rare) is chiefly solid, with only a small cyst; while in the latter instance the most frequent site is at one end of the cerebrospinal axis (epignathus, sacral teratoma). As such tumors spring from toti-potential cells, they may include all varieties of tissues. If the tumor contains elements formed from all three of the germinal layers it is known as an *embryoma*. Epithelial structures are most frequently found, especially hair and teeth (epiblast), or glandular tissue (epi- or hypoblast); occasionally cartilage or bone (mesoblast).

These tumors usually are present at birth (Fig. 53), but frequently are not noticed until puberty. Their size, shape, and consistency vary according to their location and the structures composing them. They usually grow rapidly when growth once begins, and may become malignant, giving rise to metastases. They are best treated by excision; but in the newborn operation should be postponed until it is apparent that the child's constitution is otherwise sufficient to support life.

FIG. 53. — Sacro-coccygeal teratoma. Italian girl, aged six months. Pennsylvania Hospital.

Terato-blastomas.—These tumors, derived from pluri-potential cells, comprise most of the so-called "mixed tumors"—tumors in which tissues are found which do not normally exist in the organ or tissue affected. In the *parotid*, and sometimes in the *submaxillary gland*, cartilaginous tumors are not unusual; in the kidney such tumors rarely have more than one variety of aberrant tissue, and have received various names according to the predominant tissue—*rhabdomyoma*, *adenosarcoma*, etc. The tumor known as *chorio-epithelioma (deciduoma) malignum* belongs to this group; it is formed by neoplastic development of cells of the chorionic villi. The *placental mole* is believed to be the early stage of such development; when the cells invade the uterine sinuses malignancy is evident and the deciduoma is present.

The terato-blastomas, as well as the pure embryomas, often exhibit malignant characteristics, and are best treated by excision.

Blastomas.—These tumors, forming by far the largest group of neoplasms, result from the independent growth of uni-potential cells. They are divided by Adami into two main groups, according as they are composed chiefly of cells arranged like epithelial, or rind, tissues (*Lepidic tumors, Lepidomas*), or of cells arranged like the stroma or pulp of tissues and organs (*Hylic Tumors, Hylomas*). The characteristic of all epithelial structures (skin, mucous membrane, endo-

thelium) is that the cells are placed closely together, there being an absence of definite stroma between the individual cells, and no blood-vessels penetrating between the various groups of cells. The characteristic of all pulp tissues (nervous tissue, muscle, bone, etc.) is that the specific cells lie in and are separated by a definite stroma, in which blood and lymph vessels may or may not be present. Lepidic and hylic tumors may be either *typical* or *atypical*. The typical blastomas are slow growing, and their structure approaches that of normal adult tissue; the atypical blastomas are composed of rather immature cells, do not closely resemble adult tissue, and grow rapidly. Typical blastomas are more or less encapsulated; the atypical are infiltrating. Typical blastomas are benign, atypical blastomas are malignant.

Examples of typical (benign) lepidic tumors are *papilloma, adenoma;* of hylic tumors, are *fibroma, osteoma*. Examples of atypical (malignant) lepidic tumors are *epithelioma, carcinoma;* of atypical hylic tumors are the numerous varieties of *sarcoma*.

In addition to distinct tumors, certain *blastomatoid growths* (Adami) must also be recognized; they approach more closely the reactive changes of inflammation, and correspond to the "continuous hypertrophies" or "outgrowths" of Paget (1853) as distinguished from the true tumor or "discontinuous hypertrophy" of that author.

Typical (Benign) Hylic Tumors.—The most important of these are tumors resembling the following normal tissues: Fat (Lipoma); Fibrous Tissue (Fibroma); Cartilage (Chondroma); and Bone (Osteoma). Although many varieties of tissue may exist in the same tumor, yet one usually is so predominant as to give its name to the growth. If another tissue is present in fairly large amount, a compound term is used, thus fibrolipoma, the tissue present in greatest abundance always being named last.

Lipoma.—This may consist rather in an hypertrophy of fat normally present (lipomatosis, a "continuous hypertrophy or outgrowth") than in an actual tumor. Multiple lipomas are not rare (Fig. 54). A lipoma rarely is well encapsulated. It grows slowly, produces no discomfort except from its size or position, and is absolutely benign. The skin over it is not discolored nor adherent, though a slight dimpling may be present occasionally, from fibrous bands supporting the tumor between the skin and deep fascia. It is soft, easily movable on the underlying tissues, and semi-fluctuating. A lipoma sometimes

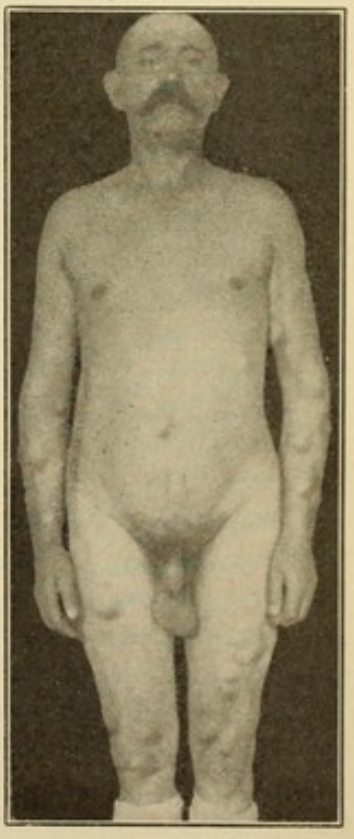

FIG. 54. — Lipomatosis affecting only the extremities, aged fifty-one years. Began at fourteen years. Father had the same condition. Episcopal Hospital.

will gradually shift its position under the force of gravity. It may occur on any part of the body, and occasionally in the sub-peritoneal fat or omentum. Its seats of predilection are the limbs, trunk, and neck (Fig. 55). It frequently is fibrous in character, then being firmer than a pure lipoma (Fig. 56). It may be attached by a pedicle deep down in a muscular interspace, occasionally to periosteum. Mucoid degeneration may occur (*myxo-lipoma*), especially in internal lipomas.

Diagnosis may be aided by freezing the growth, whereupon it will become hard.

Treatment.—If any treatment is required, excision should be done.

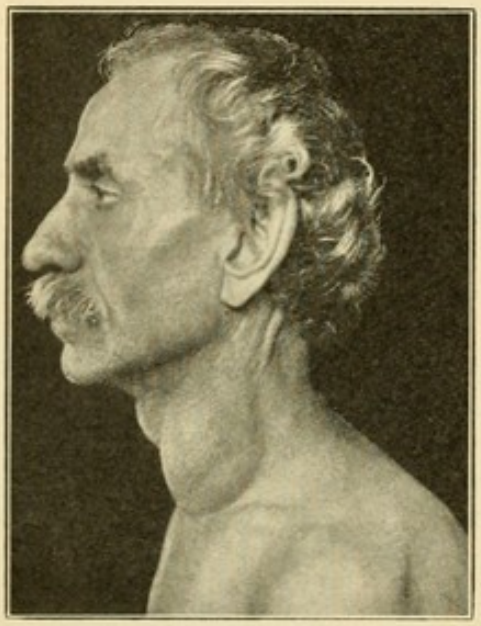

FIG. 55.—Lipoma of neck, duration nineteen years. Very soft, almost fluctuating. (Not goitre; not attached to larynx; does not rise in swallowing.) Episcopal Hospital.



FIG. 56.—Fibro-lipoma of right cheek in a girl, aged fifteen years; growing slowly for last nine years. Sight of left eye lost from smallpox in infancy. Episcopal Hospital.

Xanthoma.—Xanthoma is a small flattened benign fatty and fibrous tumor in the skin, whose nature is not well understood. It is named from its yellow color, occurs most frequently around the eyes, and is sometimes seen in persons with gall-bladder disease. Usually no treatment is required.

Fibroma.—Tumors consisting solely of fibrous tissue are rare; they usually are small (Fig. 57), frequently multiple, grow slowly, and are well encapsulated. Depending upon the amount of fibrous tissue present, fibromas are named *hard* or *soft*. The latter is the more frequent variety, and is well represented by the mucous polypi growing in the naso-pharynx. The tumor is firm to the touch, pale and glistening on section, with a capsule usually demonstrable. The favorite sites of development are the subcutaneous tissues, along nerve trunks, in periosteum, fascia, the uterus and mammary gland. Some of these must be regarded as fibroid over-growths rather than as distinct tumors, *e. g.*, *fibroma molluscum*. Fibromas frequently undergo degeneration,

particularly the mucoid, forming a tumor known as **myxoma**; this is especially frequent in mucous polyps; a tumor in or between the gluteal muscles usually is a **fibro-myxoma**. Malignant changes are by no means rare, the cells remaining immature, and proliferating with undue activity, forming the *fibro-sarcoma; myxo-sarcoma* also occurs, as well as internal hemorrhage with cyst formation.

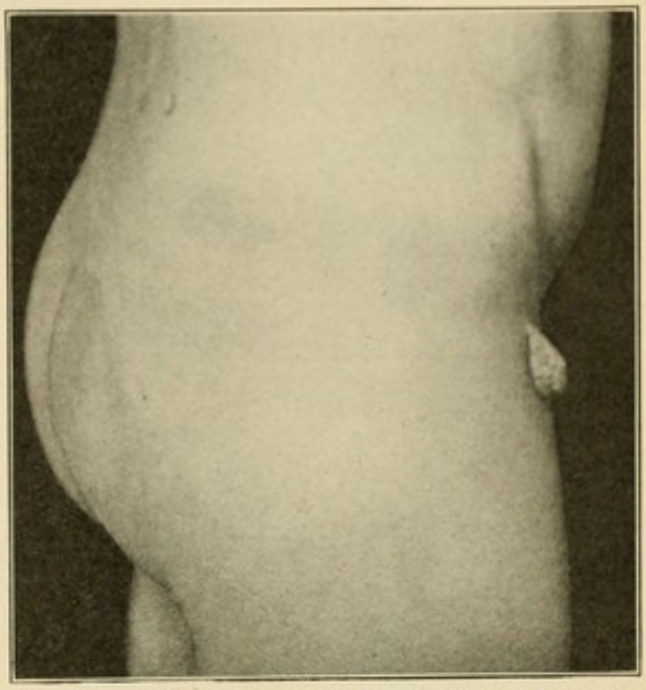

FIG. 57.—Fibroma pendulum. Episcopal Hospital.

Diagnosis.—Diagnosis is made by noting the long duration; indolent growth; firm consistence; rounded, apparently encapsulated character; and normal overlying skin.

Treatment.—Frequently none is required; but any suspicion of malignancy (Fig. 58), aroused by rapid growth, apparent myxomatous or cystic changes, etc., justifies prompt extirpation. Recurrence is not very rare, even after removal of an apparently benign tumor, and, as a rule, the recurrent is more malignant than the primary growth.

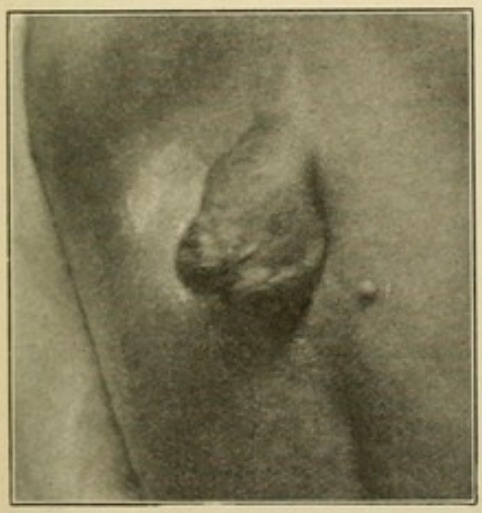

FIG. 58.—Fibroma of back, malignant degeneration. Patient aged seventy-three years; duration fifteen years. Episcopal Hospital.

Keloid or Cheloid.—The hypertrophied condition of scars, known as the *keloid of Alibert*,[1] is really a form of fibroma affecting the subepithelial tissues. It almost invariably follows some irritation, though individual predisposition has much to do with its development. Thus it is often seen in the negro race (Fig. 59); it may develop in the scars of burns, or of comparatively simple operations (Fig. 60). There is some evidence that it is of tuberculous origin. It is a crab-like (keloid) or scar-like (cheloid) out-growth, covered by red, tense, shiny epithelium; it may extend into sound tissues in various directions. It usually is tender, and irritation increases its size. Occasionally the out-growths disappear spontaneously; they usually recur after excision.

[1] To distinguish it from the Keloid of Addison (Morphœa), an affection belonging rather to dermatology than surgery.

Treatment.—Treatment consists in protecting them from irritation by the clothes or opposing parts of the body. Ointments of tar and zinc, with animal rather than mineral bases, are valuable. Thiosinamin (5 to 10 per cent. solution) hypodermically, is recommended by Park (1907).

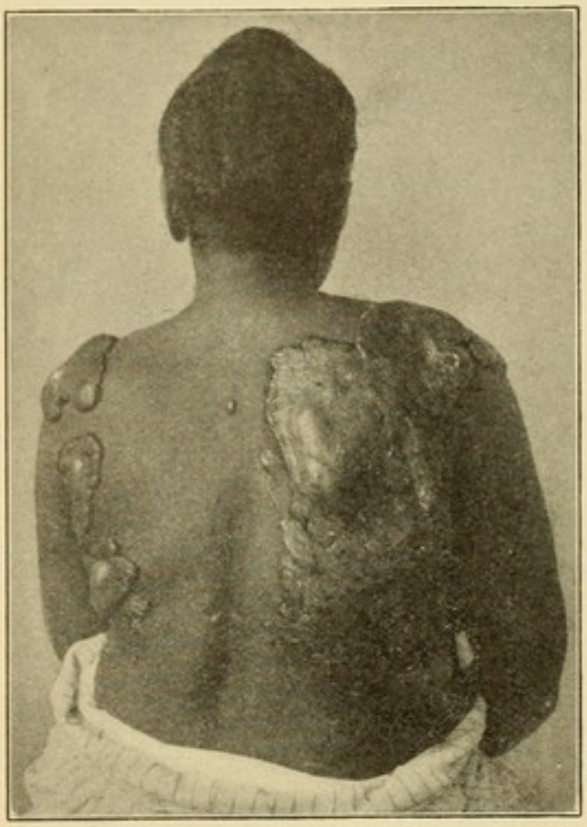

Fig. 59.—Keloid (of Alibert) in scars following a whipping from patient's mother. Patient of the late Dr. Isaac Massey, of West Chester, Pa.

Chondroma.—A tumor composed chiefly of cartilage. If it springs from preëxisting cartilage cells it is termed *ecchondroma* (cartilaginous out-growth); if from other forms of connective tissue, especially fibrous, it is called *enchondroma* (cartilaginous tumor). Its occurrence as a terato-blastoma was referred to at p. 106. Chondromas are of stony hardness, unless degenerated; usually more or less lobulated, grow slowly, but usually faster than lipomas or fibromas, the growth occurring chiefly at the periphery; are painless, immovable, frequently multiple; seldom affect the overlying skin; and are generally quite benign, but liable to form metastases. They are especially prone to mucoid degeneration, and when such occurs malignancy should be suspected. Sarcomatous changes are not unusual. True bony changes(osteo-chondroma) sometimes occur. If the skin sloughs, the cystic contents of the degenerated chondroma may discharge, leaving a most intractable sinus.

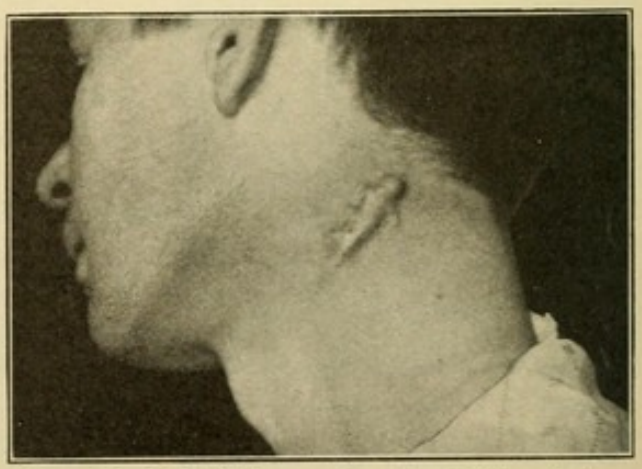

Fig. 60.—Keloid in scar of neck. Had brush burn in 1907, and keloid was excised one month later. Keloid recurred, and present photograph made one year after recurrence. Episcopal Hospital.

Ecchondromas arise from epiphyseal lines before adult life, and later also from articular, costal, and intervertebral cartilages, larynx, trachea, etc. Enchondromas spring from periosteum or bone marrow, but not from articular cartilages. Chondromas develop in early life, especially in the rachitic; affect especially the phalanges, the flat bones

(pelvis, scapula, skull), the femur, and the maxilla. When growing on the surface of a bone, beneath the periosteum, they may wear away its surface, leaving a distinct depression when they are removed.

Diagnosis.—They are to be distinguished from bony tumors by their occurrence in younger patients, by their situation, and by their multiplicity; but a differentiation is not always possible without the *x*-rays. Cartilage casts no shadow, or at most a very light one.

Treatment.—Chondromas should be completely extirpated whenever possible. Incomplete removal favors recurrence, and the recurrences are more inclined to malignancy than the primary growths. Amputation, except of the phalanges, is rarely required.

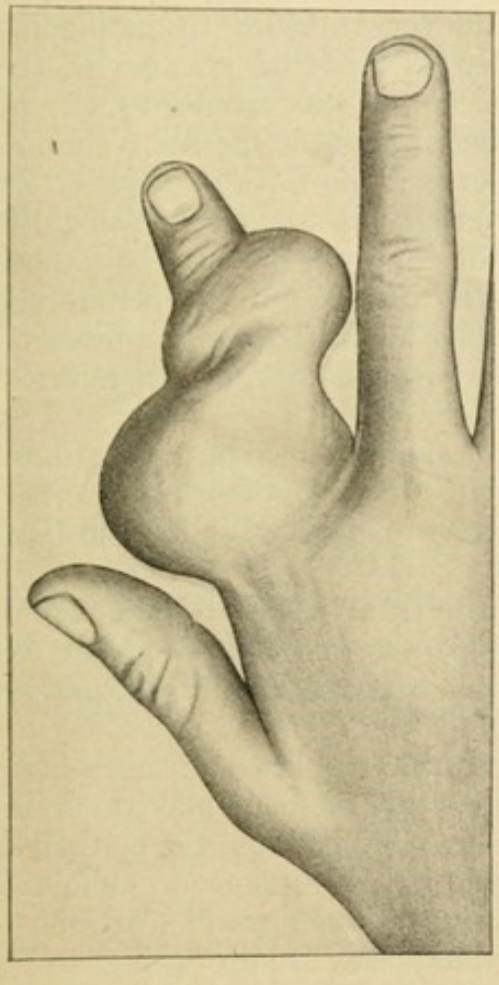

FIG. 61.—Multiple ecchondromas of finger. (Shepherd.)

Osteoma.—A true tumor composed solely of bone is decidedly rare; most so-called bony tumors are really only osseous hypertrophies. True osteoma may arise on the surface of, or within the substance of bone. In the former

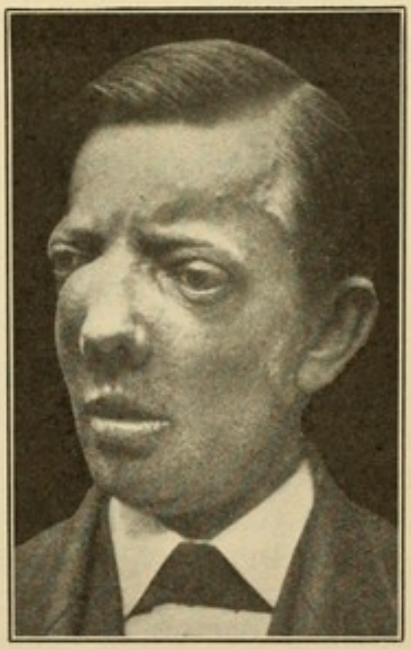

FIG. 62.—Osteoma of upper jaw. Four years' standing. From a patient in the University Hospital under the care of the late Prof. John Ashhurst, Jr.

instance it grows beneath the periosteum; in the latter it grows from the medulla, being then known as *endosteoma*. Either form may be composed of spongy or of compact bone. The tumor grows by cellular proliferation of its own elements, not from participation of elements in the surrounding bone; these latter are compressed, pushed aside, and eventually disappear before the ongrowing tumor. Thus a periosteal osteoma will excavate the underlying bone, while an endosteoma will penetrate it, break through the cortical bone, and grow more freely when thus relieved from pressure. Occasionally an

osteoma occurs in tissue which normally contains no bone. Such a tumor is a heteroplastic osteoma; it is possible that it develops from a fetal *anlage*, but usually it arises in a piece of cartilage or periosteum which has been displaced by trauma in post-natal existence. That true bone can form in chondromas has already been noted.

Ostoses.—A diffuse bony out-growth is called a *hyperostosis;* a circumscribed, more or less sessile out-growth is an *exostosis;* a projecting growth with narrow base is an *osteophyte;* while an osseous out-growth occurring in the centre of a bone (*e.g.*, arising from the diploë) is termed an *endostosis* or *enostosis*. Occasionally an ostosis of one form or another appears to become neoplastic in nature, exhibiting autonomous proliferation. Exostoses, which are the most frequent of the bony hyperplasias, usually are multiple, and very difficult to distinguish from multiple ecchondromas, especially as ossifying changes in the latter are by no means rare. They occur in the same situations (except that exostoses are very rare on the hands), present the same characteristics, and run the same clinical course. The *ivory exostosis of the skull* is an exception, which it is usually possible to distinguish clinically. It is extremely hard, and if growing from the diploë (enostosis) may be as prominent on the dural as on the pericranial surface. Ostoses are sometimes developed in the accessory sinuses of the face. Bony changes occurring in tendons, muscles, etc., are referred to at p. 274.

Diagnosis.—Diagnosis, especially of endosteomas and enostoses, may be impossible without the use of the *x*-rays, by which the denser shadow of osseous growths may sometimes be distinguished from that cast by cartilaginous tumors.

Treatment.—Rarely is any required, unless removal of one or more circumscribed out-growths is necessary to relieve pressure on nerves, bloodvessels, the brain, etc. Recurrence after thorough extirpation is exceptional.

Odontoma.—The teeth are developed from epiblast and mesoblast, and while a tumor having its origin in either element may occur in man, the vast majority of odontomas are derived from the epithelial portion, and are seen as "cysts lined with columnar or cuboidal epithelium or containing gland-like areas in their wall" (Simmons, 1907). This form, known also as *adamantinoma*, usually springs from the lower jaw, the tumor growing in and slowly distending the body of the bone; it is composed of multilocular cysts, with a bony framework (multilocular dentigerous cyst). It occurs especially in young females, is of slow growth, and usually symptomless except when causing pressure on neighboring parts. Crackling may be detected on palpation if the growth has thinned the overlying bone. Usually there is an unerupted tooth present.

Diagnosis.—Diagnosis sometimes is difficult, especially from sarcoma. Carcinoma is more frequent on the upper jaw in older patients, and ulceration is common. Exostoses and chondromas are denser and the *x*-rays may reveal the cystic nature of the adamantinoma. Sarcoma

in this situation usually is periosteal in origin, grows rapidly, quickly invades the soft parts, is not cystic, and presents no "egg-shell" crackling.

Treatment.—Opening the growth, and destroying its interior thoroughly with the sharp spoon and actual cautery, usually effects a cure. It is essentially benign. The operation may be done from within the mouth.

Myeloma.—The bone marrow contains two chief varieties of cells—those having to do directly with bone, and those supplying the blood. Adami classes under this section tumors derived from true bone marrow (osteogenetic) cells, and certain blastomatoid conditions due to disturbances of the blood cell elements in the marrow.

Giant-celled Myeloma.—This, frequently spoken of as giant-celled sarcoma, is too little malignant to be classed with atypical hylic tumors. It is composed of large numbers of *myeloplaxes* (giant cells of bone marrow) lying in a matrix formed by spindle or polygonal cells of fibroblastic type. The tumor may develop beneath periosteum, sometimes occurs in the lower jaw or clavicle, but usually arises in the interior of the shafts of long bones, near the epiphyses; it is almost the only tumor found in the radius; it occurs in the young, grows slowly, and expands the overlying bone, which may become so thin as to crackle on pressure (*spina ventosa*). The tumor itself is rather soft, quite vascular, and when sectioned resembles splenic tissue or even currant jelly; if it breaks through its bony capsule pulsation and occasionally bruit are present (*false osteoid aneurysm*). (See p. 446.) Spontaneous fracture is rare. The lymphatic system is not affected in pure myeloma; no metastases occur; and if the tumor is thoroughly removed recurrence is unlikely. Occasionally, however, the tumor undergoes sarcomatous change, the stroma cells being small, growth rapid, and recurrence usual.

Diagnosis.—A slowly growing tumor, in the interior of a bone, and near the epiphysis if in a long bone, occurring before twenty-five years of age, and not producing cachexia or metastasis, is usually a giant-celled myeloma. The diagnosis from bone cysts is discussed at p. 446.

Treatment.—Usually it is sufficient to cut away the overlying bone, clean out the tumor tissue, scrape and thoroughly cauterize the walls of the cavity; but it is safer in case of recurrence to excise the whole end of the bone affected. Amputation should be done for invasion of the soft parts.

Myelomatosis.—This blastomatoid condition effects the red bone marrow chiefly of the vertebræ, ribs, and cranium; it is a *primary multiple process* (Borst). The growths are yellowish red, pulpy, and firm, and though it is due (Adami) to proliferation of the blood-forming elements of the marrow, there is in orthodox cases no involvement of the lymphatic system or spleen (such a condition being called *myelogenous leukemia*). Albumosuria (Bence-Jones) is frequent in myelomatosis, and relations of this disease to *osteomalacia* are not

clear. *Treatment* is sometimes required because out-growths in the vertebræ press on the cord; excision should be done.

Chloroma.—Chloroma, according to Adami, is an aberrant type of myelomatosis; it is a rather malignant, multiple growth of greenish-yellow tint, affecting especially the face bones; and is frequently associated with myeloblastic leukemia (Dock).

Lymphomatosis.—As myelomatosis is due to proliferation of blood-forming marrow cells (myeloblasts, which produce leukocytes), so lymphomatosis is a corresponding state due to hyperplasia of lymphoblasts. There are many affections characterized by widespread enlargement of lymphatic tissue, notably *tuberculosis;* there are others, probably, but not certainly tuberculous; and there is *Hodgkin's disease,* of unknown cause (p. 271); *leukemia* is still another, but has no surgical interest. Adami, in addition to the above blastomatoid conditions, admits the existence of typical **lymphoma;** but far more frequent is *atypical lymphoma,* comprising the various forms of *lymphosarcoma* (p. 272).

Myoma.—The *leiomyoma* is a tumor composed of smooth muscle fibres, arranged in various directions, and inclosed in a fibrous stroma (fibromyoma). The older the tumor the more does fibrous tissue preponderate, so that finally muscular fibres may be inconspicuous (fibroids); this change may be a mere over-growth of fibrous tissue, or an actual metaplasia of muscle fibres (Adami). It occurs with overwhelming frequency in the uterus (p. 1102), but occasionally is found in other portions of the genito-urinary system or in the digestive tract, where the stomach is most often affected (49 cases collected by Deaver and Ashhurst in 1909). The tumors are usually multiple, may attain immense size, and frequently require excision.

Rhabdomyoma.—The occurrence of this tumor, except in connection with terato-blastomas (p. 106), is almost unknown. It appears usually to be malignant.

Neuroma.—A true ganglionar-celled neuroma is so rare as to be of no interest surgically. *False neuromas* are fibrous "out-growths" occurring upon nerves (*fibromatosis nervorum*). *Amputation neuromas* are somewhat similar (p. 200).

Glioma.—This is a tumor developed from the stroma of nerve tissue (neuroglia) (Fig. 63); it is found, with few exceptions (retina, cerebral nerves), in the brain; and may be either hard (when projecting into the ventricles); or soft, when it infiltrates the cerebral hemisphere without any attempt at encapsulation (p. 582).

Chordoma.—Chordoma is a rare tumor growing from bone in the region of the pituitary body, and developed from remains of the *notochord.*

Atypical (Malignant) Hylic Tumors.—Sarcoma.—The characteristics of malignancy in general (p. 103) and of atypical blastomas in particular (p. 107) have already been considered. Sarcomas are atypical hylomas of mesenchymal origin, all possessing this peculiarity, that they are composed of embryonic connective tissue cells. Sarcoma

may, therefore, occur wherever connective tissue exists; indeed, as pointed out by Bland-Sutton (1906), it may be regarded as a malignant tumor disease of connective tissue. Sarcoma occurs by preference, however, in bone, periosteum, fascia, ligaments, tendons, brain, ovaries, testicles, and skin; less often in the lungs, muscles, uterus, liver, and intestines. It grows rapidly, by cellular proliferation in all parts of the tumor, frequently assumes a lobular appearance, infiltrates in all directions, particularly along and inside of bloodvessels, and early gives rise to metastasis through the blood-stream. Though most sarcomas infiltrate equally in all directions, certain tumors extend in finger-like processes here and there, giving an *organoid* appearance to the section. Such growths have been termed *alveolar* and *tubular sarcomas*. A special characteristic of all sarcomas is the extreme

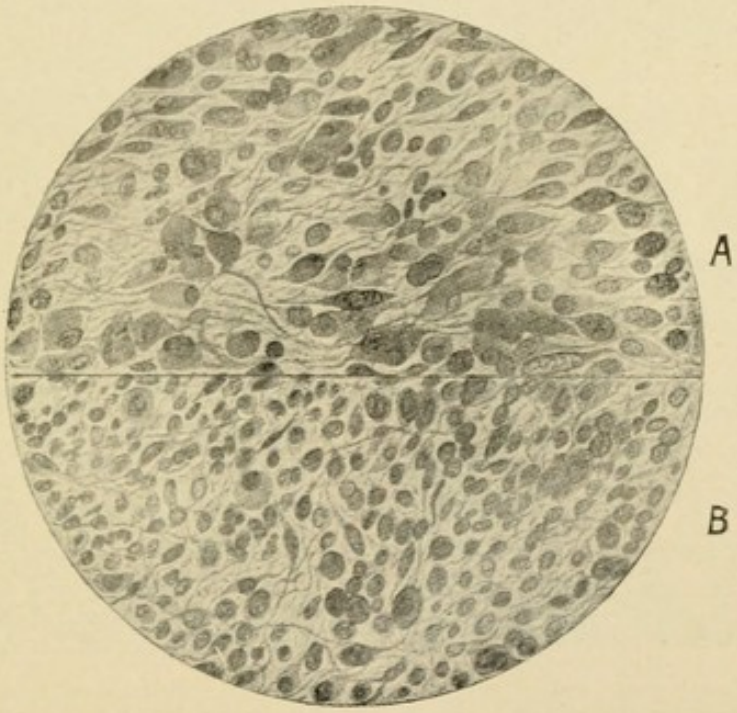

FIG. 63.—*A*, from the more typical portion of a glioma. *B*. Another region from same growth of more malignant type, a true gliosarcoma. (Thomas and Hamilton.)

meagreness of the stroma present; only with difficulty may stroma be detected, so closely are the sarcoma cells packed together. Sarcomas are highly vascular, and the walls of the bloodvessels are composed solely of endothelial cells; the sarcoma cells lie in immediate contact with the outer surface of the endothelium, and frequently grow inside the vessels. A characteristic of rapid growth and of the vascularity of these tumors is their liability to myxomatous and other degenerations, to internal hemorrhages, and to cyst formation (p. 103).

Sarcomas are classified according to the form and size of their component cells into *small round-celled, large round-celled,* and *spindle-celled sarcomas* (Fig. 64 and 65); or, where several kinds coexist, *mixed-celled sarcomas*. The smaller the cell and the less the amount

of stroma, the more malignant is the sarcoma; therefore, the large spindle-celled sarcoma (formerly called "recurrent fibroid") is the least malignant, probably because in the others the cells are less developed, the most so in this. The form of the sarcoma cell depends on the structure from which it is derived; thus, as pointed out by Adami, only cells which, in the course of their normal development, pass through a spindle-celled stage can give rise to spindle-celled sarcoma (connective tissue cells, plain muscle fibres, etc.); whereas round-celled sarcomas are developed from cells such as lymphocytes, which even when normally matured are still round. Finally, calling the above *pure sarcomas*, a group of *intermediate sarcomas* may be recognized, in which some of the cells develop beyond the embryonal stage sufficiently to give a tissue characteristic to the tumor, but do not reach full adult maturity: *fibrosarcoma, lymphosarcoma, osteosarcoma, chondrosarcoma, gliosarcoma,* etc.

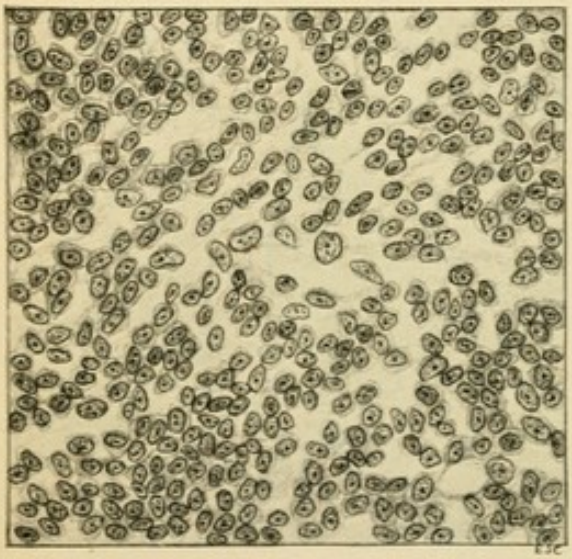

FIG. 64.—Small round-celled sarcoma from skin. (High magnification.) (From Professor Klotz.)

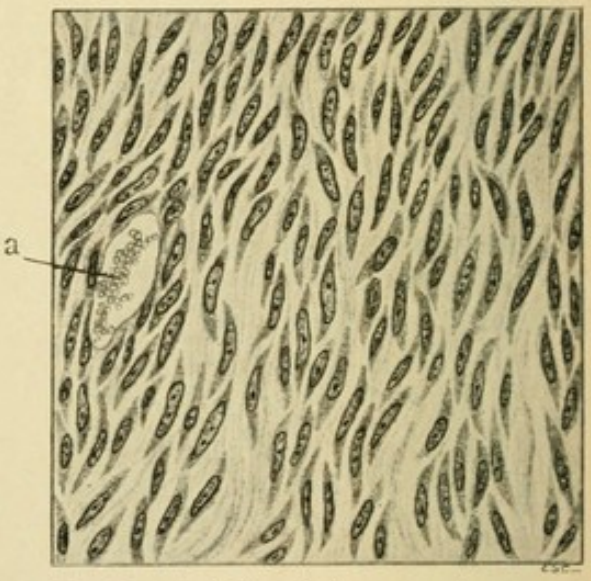

FIG. 65.—Spindle-celled sarcoma (recurrent, from forearm): *a*, delicate-walled bloodvessel in tumor. (From Professor Klotz.)

It is an interesting question, as yet undecided by pathologists, whether the term sarcoma shall be applied to a tumor composed of any cells other than connective tissue cells. Thus, if, for example, a sarcomatous tumor is found in (smooth) muscle tissue, it may have originated (1) by sarcomatous proliferation of the connective tissue cells (not muscle cells) in the tissue of a normal muscle or of a typical leiomyoma (p. 114); (2) by malignant proliferation *ab initio* of the muscle cells themselves; or (3) by a secondary sarcomatous change (anaplasia) affecting the muscle cells in a previously formed myoma. To the first tumor the name *myo-sarcoma* is properly applied; the second, which many hold is not truly a sarcoma, is best described as a *malignant myoma;* while the third is distinguishable from the others by the term *myoma sarcomatodes*. According to Adami, this last is

probably the most frequent form; but most pathologists, I believe, still regard the first as the most usual. The same question arises in connection with glioma, lyphoma, endothelioma, etc., and also with osteosarcoma, fibrosarcoma, etc., though not so pointedly in these latter, because they are formed of connective tissue alone.

Diagnosis.—Sarcoma occurs usually in the young (over forty years it is quite rare), not infrequently follows trauma, grows rapidly (weeks and months), causes early metastasis, especially in the lungs and skin; is frequently hot, and painful; and eventually produces cachexia. It is firm but not bony to the touch if growing from bone or cartilage; rather soft if in fibrous tissue or the viscera.

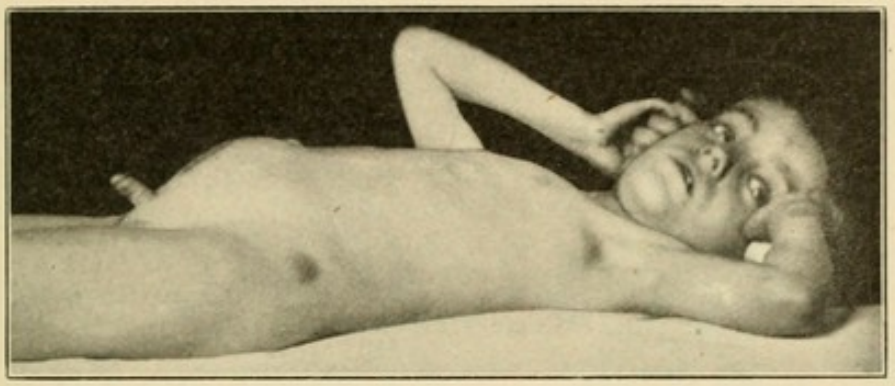

FIG. 66.—Inoperable sarcoma of pelvis; rapid growth after exploratory laparotomy six months ago. Note ecchymosis of hip from recent bruise. Children's Hospital.

Prognosis.—This is gloomy. Recurrences are almost inevitable; and even if no recurrence occurs locally, visceral metastases, undetected at time of operation, almost surely kill within two or three years.

Treatment.—Prompt extirpation, which often but not always implies amputation of the limbs, and wide cutting excision of other parts, offers the only chance of cure. Reoperation for local recurrences sometimes prolongs life, though rarely effecting a cure. If the tumor is inoperable when first seen, treatment with Coley's fluid should be tried; and in all cases it is well to use this after operation. The mixed toxins of the B. prodigiosus and streptococcus, introduced by Coley of New York in 1892, are administered hypodermically, either into the growth itself or its immediate neighborhood (initial dose $\frac{1}{4}$ to $\frac{1}{2}$ a minim), or in other parts of the body (initial dose 1 minim), the dose gradually being increased so that it is no more than sufficient to cause febrile reaction analogous to that seen with tuberculin (p. 81). It has been a clinical observation for nearly fifty years that attacks of erysipelas occasionally had a healing influence on malignant growths; and it is not an illogical theory that bacterial toxins might influence tumor cells favorably, reducing the process more nearly to that of an inflammatory reaction. As a matter of fact, the use of Coley's fluid, especially in his own hands, has secured some surprisingly favorable results: in a few instances permanent

cure has followed; in many the tumors have been reduced to operable states, or have been kept in abeyance, as it were, for sometimes they grow again when treatment is discontinued; in some, recurrence seems to have been prevented. My own experience with Coley's fluid has been very limited, but on the whole favorable; the tumor has at least grown smaller, and the pain and discomfort of the patient been noticeably relieved.

Typical (Benign) Lepidic Tumors.—Papilloma.—This is an epithelial tumor growing from skin or mucous membrane (Fig. 50). It projects above the surface, sometimes as a single nodular mass, sometimes as a definitely papillomatous out-growth. Its nourishment is derived from vessels which are carried to it in a core of the underlying connective

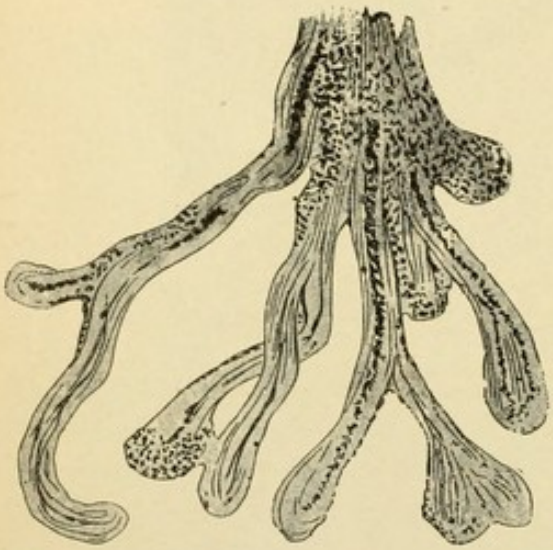

FIG. 67.—Papilloma of bladder to show the long, finger-like papillomatous outgrowths. (Ribbert.)

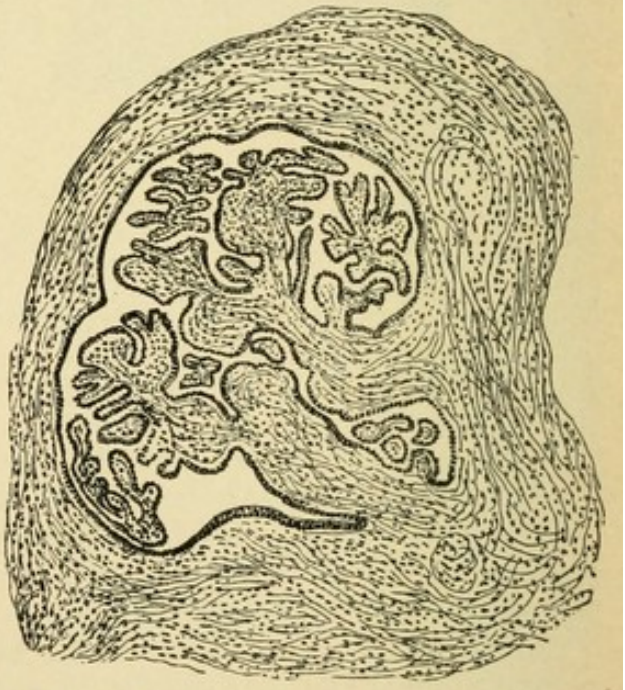

FIG. 68.—Intracystic papilloma of breast. (Orth.)

tissue; but the connective tissue itself typically undergoes no blastomatous change, merely growing as required by the independent growth of overlying epithelium. Most so-called papillomas (warts, etc., p. 259) are clearly not neoplasms, but hyperplasias due to chronic irritation. Some of the mucous polypi described as soft fibromas (p. 108) may be considered as forms of papilloma, if it is the epithelium and not the connective tissue core which becomes blastomatous; the question is very hard to decide. True papillomas occur chiefly on mucous surfaces, especially the urinary bladder, where the tumor is composed of numerous fine finger-like projections (Fig. 67); stomach (polyposis); rectum; uterus, etc. Similar tumors often grow from the mucous lining of cysts, especially in cystic adenomas (*intracystic papillomas*) (Fig. 68).

Treatment.—As malignant changes (carcinoma) are not very uncommon, papillomas are best treated by excision; and, unless this is thorough, recurrence is frequent, especially in the bladder.

Adenoma.—Instead of the lining membrane presenting out-growths, as in the case of papilloma, *in-growths* may occur; as this change is almost limited to preformed glands, the resulting neoplasm is called an *adenoma*. It is not a very common tumor, being encountered most often in the mamma, thyroid, liver, prostate, and around the margins of gastric ulcers. In the two latter situations it is probable that the change is one of *adenomatosis*, a hyperplastic reaction to chronic irritation. The more important adenomas are discussed in connection with transitional lepidomas (p. 127). The true adenoma probably always originates in cell rests; it is well encapsulated, and has no communication through ducts with the excretory channels of the gland in which it lies. The cells forming an adenoma usually retain some of their glandular characteristics, and may secrete a modified form of the natural product; this secretion then distends the acini, and a *cystadenoma* is produced. Into these cysts papillomatous growths frequently occur (Fig. 68), producing *intracystic papilloma;* or *cystadenoma papilliferum*. Here again it is exceedingly difficult to tell whether the projections are truly papillomatous or whether they are only apparently papillomatous, being caused by the adjacent in-growth of adenomatous cells. In many adenomas the fibrous stroma is markedly increased (*fibroadenoma*), and it is held by some that neoplastic proliferation of this stroma is the cause of the papillomatous intracystic projections, and that the epithelium overlying the projections is entirely passive. The cells of an adenoma always lie upon a well developed basement membrane, which invariably separates them from the underlying stroma; when the tumor grows rapidly this basement membrane may be poorly developed; and when it is absent, and the epithelial cells have broken through, lying in immediate contact with the stroma, the tumor can no longer be considered an adenoma: it has undergone malignant (carcinomatous) change. Bland-Sutton (1906) denies that such a change ever occurs. An adenoma may be very small, or extremely large and ponderous; the smaller, harder, tumors of the breast are usually painful.

Treatment.—Adenomas should be removed whenever possible; especially does rapid growth render this imperative. Recurrence is not to be feared; and metastasis is unknown.

Atypical (Malignant) Lepidic Tumors.—Carcinoma.—This includes all malignant tumors of epiblastic or hypoblastic origin. Under *carcinoma of epiblastic origin* are included all skin cancers, as well as cancers derived from the mammary and other epidermal glands, epithelium of mouth, salivary glands, naso-pharynx, etc.; while those of *hypoblastic origin* include carcinoma of the digestive tract, pancreas, liver, bladder, and respiratory tract, thyroid, thymus, tonsils, etc. Although the cause of carcinoma is totally unknown, most cases occur in persons over forty years of age, and it is most frequent in sites

which have long been subjected to irritation, or in which unhealed and chronically irritated ulcers exist—*e. g.*, lacerations of the cervix uteri, gastric ulcer, smokers' cancer of the lower lip, syphilitic ulcers of the tongue, chimney-sweep's (soot) cancer of the scrotum, cancer of the skin in workers in paraffin, pitch, chrome, etc.

Carcinoma is due to the independent (autonomous) growth of epithelial cells; and this growth is atypical. That is to say, it differs not only from the growth of epithelial cells seen in regeneration (healing of ulcers), but it also differs from the growth of epithelial cells seen in an adenoma. In an adenoma, for instance, the epithelial cells retain to a certain degree their normal character; they line the gland tubules or acini, leaving usually a distinct lumen, and rarely forming more than one layer around this central lumen; and they are always placed on a distinct basement membrane. In carcinoma, on the other hand, the in-growths of epithelial cells are usually solid, finger-like masses; there is no lumen, except in certain cancers derived from preformed glands, and even then the cells tend to pile upon each other around the periphery and to encroach on the lumen; the basement membrane is absent, and the masses of epithelial cells are in direct contact with the surrounding tissues. When seen in cross-section it appears as if there were cell nests entirely detached, lying in the connective tissues; but rarely, if ever, is this the case. It has been shown by serial sections (Petersen) that these are directly continuous with the surface epithelium, being one of the claws of the crab-like growth which gives cancer its name.

Not only does carcinoma extend in all directions into all surrounding tissues, but it has a very extraordinary tendency to extend along lymphatic channels. It was formerly thought that this extension was largely in the way of *metastasis*, *i. e.*, that groups of carcinoma cells were detached from the main tumor and carried in the lymph current away from their site of origin, until, lodged in the nearest lymph nodes, they there set up a metastatic growth entirely separate from the main tumor, leaving uninvolved tissue between. That this sometimes occurs may not be denied, but it is certain, owing chiefly to the researches of Handley (1905) in relation to mammary carcinoma, that in the vast majority of cases such extension occurs by direct continuity (*permeation*) along the lymphatic spaces of the deep fascia, and along lymph vessels, and that *the affected lymph nodes are connected with the primary tumor by innumerable fine cords of carcinoma cells.* When the lymph nodes are invaded, dissemination beyond them may occur, the carcinoma cells eventually entering the blood-stream and being widely disseminated in the lungs, spine, etc. Occasionally, dissemination by the blood occurs early, before the adjacent lymph nodes are palpably affected. These secondary growths, wherever found, reproduce the character of the primary tumor; we may find in the humerus a secondary nodule with the characteristics of the glands of the rectum, nodules in the ovary with the features of the mammary gland, etc. Secondary deposits are rarest in muscle, most frequent in the skin,

lungs, and bone, especially the vertebræ, as well as in organs anatomically related to the primary growth.

Two main varieties of carcinoma may be recognized: *Epithelioma* and *Glandular Carcinoma*.

Epithelioma.—Though this term is applied by the French to all malignant tumors of epithelial origin, it is customary among English speaking surgeons to limit it to *squamous-celled carcinoma*, and it is so used in this volume. It affects the skin, especially muco-cutaneous junctures (lips, anus, glans penis, vulva), mouth, tongue, pharynx, esophagus, etc. Very exceptionally epithelioma has been found where no squamous epithelium normally exists (gall-bladder, stomach, uterus, etc.). *Pre-cancerous changes* are well recognized clinically. Among those of most importance are the senile or seborrheic patch (*keratosis*, p. 622); *leukoplakia* (p. 647); and *Paget's disease* (p. 719). As already noted, any chronic irritation seems to predispose to the development of carcinoma.

Two forms of epithelioma are distinguishable, the superficial, and the deep-seated, of which the last will be described first.

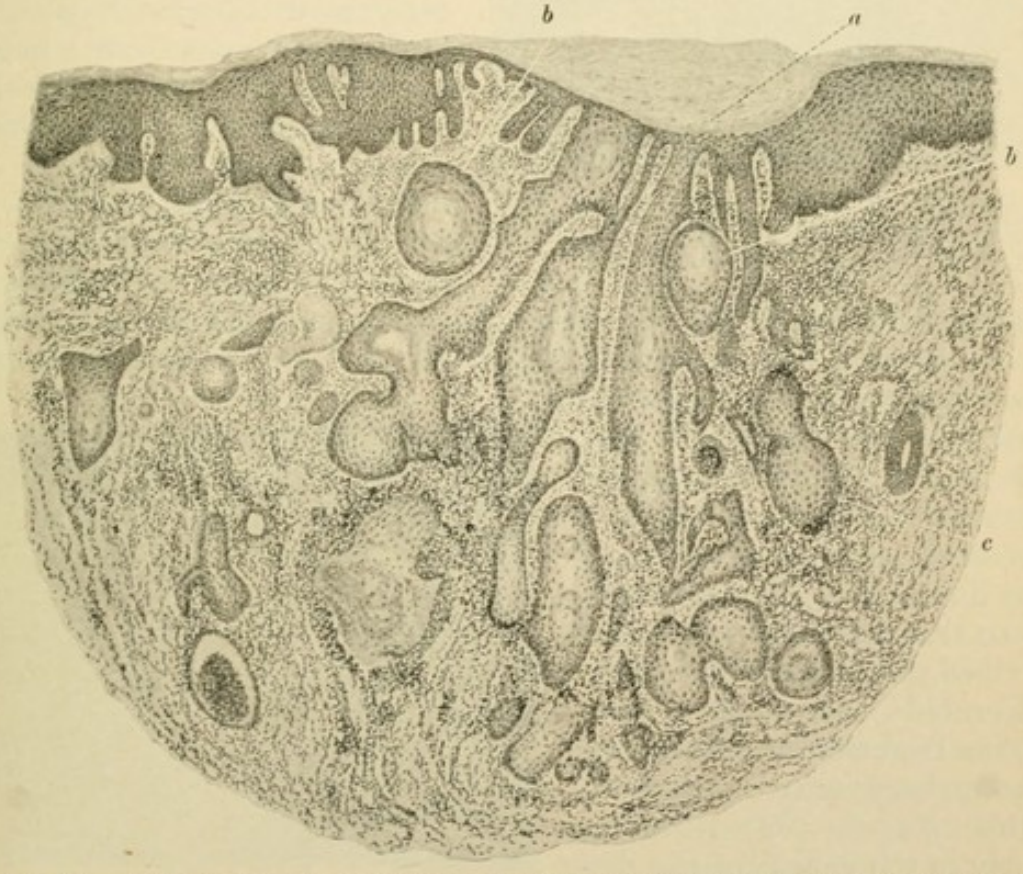

FIG. 69.—Early epithelioma of tongue, to show (*a*) region of origin by down-growth from preëxisting epithelium; *b b*, epithelial pearls; *c*, small-celled infiltration in surrounding tissue. (Petersen.)

1. DEEP-SEATED EPITHELIOMA.—This, the more frequent variety, commences as a downward proliferation of epithelial cells which preserve fairly well the typical appearance of cells of the rete

Malpighii, a few "prickle" cells frequently being discernible. These cells are very slightly anaplastic: they preserve their functions so far that they still tend to undergo horny changes, this keratosis resulting in the formation of "pearly bodies," which are really cross-sections of plugs in which the central cells have become horny, and being compressed by those outside, produce a typical laminated appearance (Fig. 69). A little round-celled infiltration may be seen around these ingrowths, evidences of reaction on the part of the stroma.



Fig. 70.—Epithelioma of nose; aged sixty-three years; duration one year. (Developing in a papilloma.) Episcopal Hospital

This form of epithelioma when growing on the skin usually is first noticed by the patient as an induration (hyper-keratosis), commencing frequently in a senile seborrheic patch (p. 622). Or it may develop from a papilloma (Fig. 70). Soon the centre becomes abraded, crusts, ulcerates, and gives the growth an umbilicated appearance (Fig. 71). This ulcer spreads; its edges may retain the features of the original nodule, but usually are less firm, ragged, and only moderately raised above the base of the ulcer. It occurs especially on the face and hands, the lower lip being a favorite site. The neighboring lymph nodes are invaded early (three to five months), and the progress of the disease is much more rapid than that form about to be described. The stench from these ulcerated surfaces is sometimes frightful, and alarming hemorrhages may occur in the later stages. Occasionally, early in the course of the disease, the ulcer is covered with warty excrescences (*Papillary Epithelioma*) (Fig. 72), forming one variety of Marjolin's ulcer (p. 58); but these warty granulations often disappear as ulceration progresses.

Fig. 71.—Epithelioma of hand; aged seventy-eight years; duration one year. Note umbilicated appearance. Episcopal Hospital.

Diagnosis.—This will be considered more in detail in the chapters devoted to regional surgery. Any chronic ulcer of the skin or adjacent

mucous membranes should be regarded with suspicion. Epithelioma in leg ulcers, though very unusual, is sometimes seen; it is less infrequent in the heel.

Prognosis is good if excision is done early, before lymph nodes are palpably enlarged; later, recurrence is frequent.

Treatment.—Early excision, in one mass with the adjacent lymph nodes and all intervening subcutaneous tissue, is the only form of treatment which offers hope of permanent cure. If an operation is contraindicated for any good reason, the *x*-rays may be applied, and in the very earliest stages the ulcer sometimes heals under their influence; but recurrence is usual, and by dilly-dallying with *x*-rays the favorable time for excision may be lost. In some inoperable cases of external carcinoma relief may be secured by desiccation with the high frequency current, or by fulguration. The former is suitable only for surface growths, while fulguration is more useful for deeply seated tumors after curettement or partial extirpation.

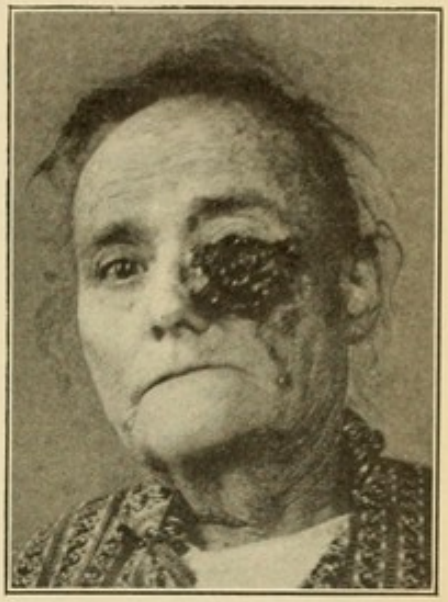

FIG. 72.—Papillary epithelioma (superficial epithelioma lately showing more malignant characteristics); aged seventy years; duration five years. Episcopal Hospital.

2. SUPERFICIAL EPITHELIOMA (RODENT ULCER, JACOB'S ULCER).—This was first described as a clinical entity by Jacob of Dublin in 1827. It was first recognized as a variety of carcinoma by Warren in 1872.[1]

The epithelial cells which grow down from the skin are extremely atypical, rounded, polygonal, or even spindle-shaped. Because they do not form "epithelial pearls," Krompecher (1903) has named this type of epithelioma "basal-celled carcinoma," on the theory that it is the only type formed from basal cells; but Adami contends that all epitheliomas are so formed, and that whereas in all others the cells develop to the horny stage, in the rodent ulcer the cells are unable to do so because they present a higher degree of anaplasia.

The favorite site of rodent ulcer is on the upper half of the face, especially near the ala nasi, on the lower eyelid, or the forehead; it is almost unknown on other parts of the body. It is often preceded by changes in the skin (keratosis, etc., see p. 622) of an irritative character, and rarely is recognized until a small ulcer has formed, scabbed over, and again become ulcerated several times. The ulcer spreads very slowly, gives little discharge, is painless; has raised, firm, glistening edges; and occasionally heals in one part while extending

[1] Borst and other pathologists class it as an endothelioma or alveolar sarcoma.

in another (serpiginous ulceration). It does not attack the neighboring lymph nodes, and, contrary to what would be expected from its high grade of anaplasia, is in general much less malignant than the deep-seated epithelioma just described; but it destroys, surely if slowly, everything in its course—eating away cartilage, bone, contents of the orbit, opening the nasal cavities and sometimes exposing the brain, before death comes. Sometimes, after progressing slowly for many years, the rodent ulcer will suddenly take on rapid growth, and assume the character of a deep-seated epithelioma (Fig. 72).

FIG. 73.—Rodent ulcer invading orbit, in a woman, aged thirty-five years; duration eighteen months. (Dr. W. Walker's case.) Episcopal Hospital.

FIG. 74.—Rodent ulcer; duration over five years. Eye destroyed. Had so far only *x*-ray treatment. Now inoperable. Episcopal Hospital.

Diagnosis.—It must be distinguished chiefly from the deep-seated epithelioma. In rodent ulcer the edges are harder, more raised, glistening, and sometimes covered with fine capillaries; the base of the ulcer is flatter and not so deeply placed; secretion is less; growth is much slower; the lymph nodes are not invaded; and microscopical examination of an excised portion will show no pearly bodies, and extremely atypical cells.

Prognosis is good with proper treatment sufficiently early.

Treatment.—Excision should be done, but it is not necessary to remove the adjacent lymph nodes. Even in advanced cases complete excision is seldom followed by recurrence, so that operation should not be refused in any case where recovery from the operation itself seems certain. Very early treatment, by an expert, with radium emanations, frequently causes the ulcer to heal without visible scar; but recurrence is not unknown. The remarks as to *x*-ray treatment, made at p. 123, apply here. The patient shown in Fig. 74 had been treated for five years with the *x*-rays before she came to me for

surgical advice; she then was a confirmed alcoholic and morphinomaniac, and the tumor was absolutely inoprable.

Glandular Carcinoma.—This is so-called because it grows in glands. Two forms may be recognized, according to the extent that the tumor departs from the typical glandular form:

1. Adenocarcinoma.—The less atypical forms, known as *adenocarcinoma*, are composed of alveolar spaces, lined with cells arranged around their periphery, and rarely piling up on each other so as to encroach on the lumen. This form is therefore known also as *columnar* or *cylindrical-celled* carcinoma (Fig. 75). By obstruction of the ducts and continued secretory action of, or from death and liquefaction of the cells, these alveoli may be converted into cysts (*cystadeno-carcinoma*). It affects especially the rectum, pylorus and lesser curvature of the stomach, cecum, etc., frequently developing from preëxisting ulcers or adenomas; or from polypi, when it is wont to assume a cauliflower-like or fungating appearance. It occurs also, but more rarely, in the cervix uteri, naso-pharynx, larynx, and gall-bladder; also from cell-rests in the neck (branchiogenic carcinoma, p. 683).

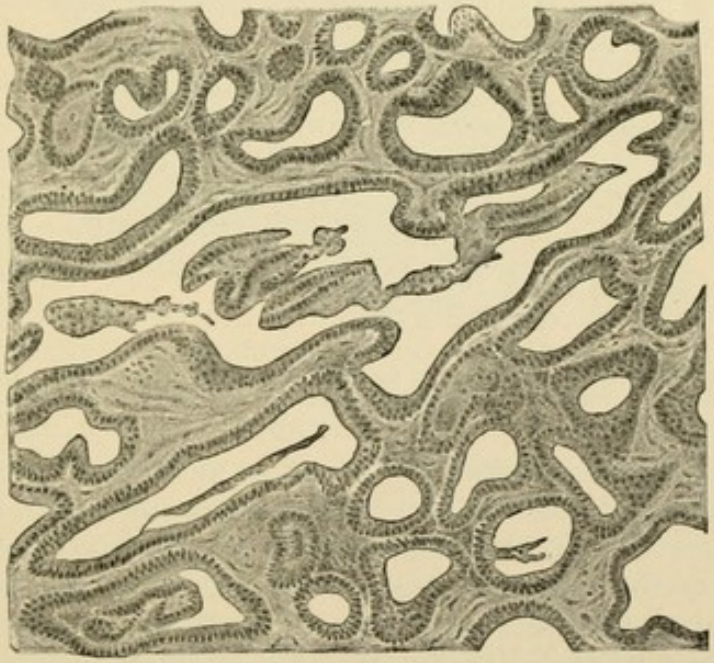

Fig. 75.—Microscopic appearance of adenocarcinoma (cylindrical-celled carcinoma) of the rectum. (Lexer-Bevan.)

2. Solid-celled Carcinoma.—The most atypical form of gland carcinoma consists of *solid* plugs of epithelial cells, there rarely being any lumen whatever (Fig. 76). All grades may exist between this form and that previously described. Two main varieties of the solid-celled carcinoma are recognized, depending upon the amount of stroma present: when this is excessive, the tumor is said to be a "scirrhus" (*scirrhous carcinoma*); when the stroma is deficient, and the cellular elements conspicuous, it is called a *medullary carcinoma*,

or, from its gross resemblance to the brain on cross-section, "encephaloid." When stroma and parenchyma are present in equal amount it is described as *carcinoma simplex*, or "acute scirrhus." Solid-celled carcinoma affects especially the mammary gland and the cervix uteri, though in both situations various combinations of carcinomatous growth may be encountered.

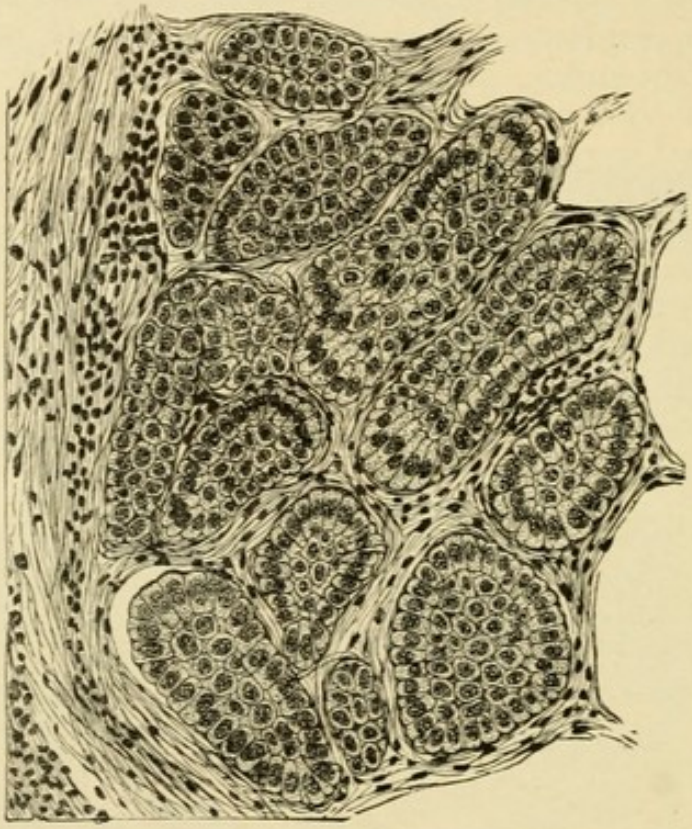

FIG. 76.—Microscopic appearance of solid-celled carcinoma, arising in the neck of the uterus. (From "Diseases of Women," Bland-Sutton and Giles.)

Gland carcinoma is especially prone to ulceration, the ulcer being deeper than in epithelioma, and there being a much greater tendency to fungosity. Colloid degeneration is not unusual, particularly in carcinomas of the intestinal tract; it is due, according to Adami, to the accumulation within the cells of modified mucin which they cannot excrete, the result being that entire alveoli may be distended with this glistening, translucent material.

Symptoms.—The symptoms of gland carcinoma depend so much upon the seat of the tumor, that their description is best postponed to the chapters on regional surgery.

Prognosis.—Untreated, or treated only palliatively, the *expectation of life* in carcinoma has been estimated at eighteen months for the medullary, and two and one-half years for the scirrhous variety; for, although, in the latter, many patients survive three, five, or even ten years, yet an equal number die in less than the average period mentioned. The prognosis after operation will be discussed with regional surgery.

Treatment.—All operable carcinomas should be excised, at the earliest possible moment, in one mass with the neighboring lymph nodes; when inoperable, palliative treatment consists in dressing the ulcer (of external cancers) with permanganate of potash or other deodorant, and in giving such stimulants, tonics, and anodynes as shall make life endurable. Certain palliative operations are applicable to inoperable internal carcinomas.

Transitional Lepidic Tumors.—Mesothelioma and Endothelioma.—In addition to the classes of lepidomas already described (derived from epiblast and hypoblast), Adami places in a separate division those tumors derived from mesothelium and endothelium. As these were themselves derived from the mesoblast, and as this in turn was formed partly by epiblast and largely by hypoblast, it is but natural to find that mesothelial and endothelial tumors present at times the characters of lepidomas (epi- or hypoblast), at others those of hylomas (mesoblast). Therefore they are well named *transitional lepidomas*, because while they usually resemble ordinary lepidomas, they at times in whole or in certain parts grade so imperceptibly into hylomas that it is impossible to say to which class they really belong. In this group, embryogenetically at least, belong the lepidic tumors of the uterus; as these closely resemble similar tumors of epiblastic (mammary) and hypoblastic (intestinal) origin, Adami supposes that the epiblast has overgrown the primary mesoblast of the genital tract. These tumors, however, frequently appear either sarcomatous (*i. e.*, mesotheliomatous) or endotheliomatous in parts, so it is evident that they possess primary mesoblastic characteristics. While there are typical transitional lepidomas (adenoma), the tumors in this group most important for the surgeon are atypical (carcinomatous) in nature. Adenoma and carcinoma of the prostate are included in this class, as well as rarer tumors of the ureters, seminal vesicles, and vas deferens; similar growths of adrenal, kidney, ovary, and uterus; also mesothelioma of the pleura, etc. For reasons already given, the tumors of the uterus resemble usually ordinary gland carcinoma. The most important surgically of all the mesotheliomas is the malignant growth of the adrenal gland known as hypernephroma.

Hypernephroma.—The medulla of the adrenal develops from the nervous system, and its cortex from the mesothelium, closely related to that which forms the cortex of the kidney. The adrenal medulla seldom gives origin to a tumor; when it does it forms a ganglioneuroma. The hypernephroma (alveolar sarcoma, angeiosarcoma, perithelioma, carcinoma, etc.) springs from the adrenal cortex, and is, therefore, classed as a mesothelioma. In it may be clearly seen the transitional type from carcinomatous (lepidic) to sarcomatous (hylic) arrangement of the alveoli (Fig. 77). Owing to fetal inclusions in ovary or testis, mesotheliomas may occur also in those organs, and more rarely in the kidney itself (Chapter XXV). The ordinary hypernephroma behaves as a malignant tumor, growing sometimes to immense size, invading the kidney, and possessing firm retroperitoneal connections.

The only treatment is prompt excision, which implies nephrectomy; the operation is difficult and bloody, and recurrence is usual. Bony metastases occur, occasionally only a single metastasis (Scudder, 1910).

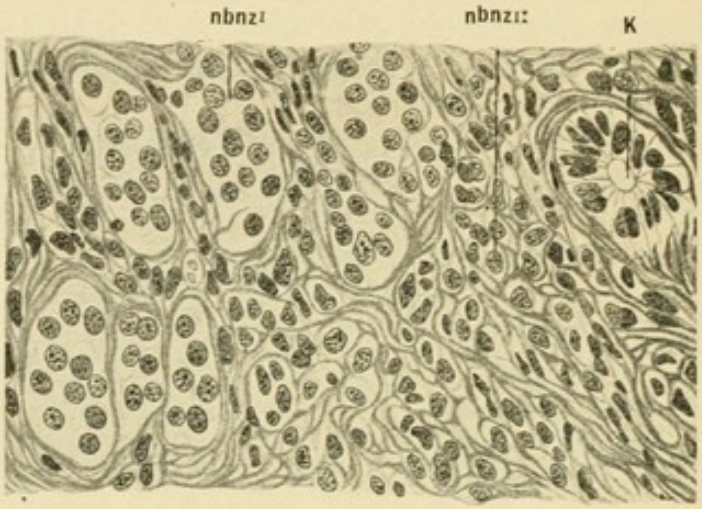

FIG. 77.—Hypernephroma of kidney. Transition from adenomatous to sarcomatous type of growth: *nbnz'*, adenomatous overgrowth of solid columns or masses of cells of adrenal type; *nbnz''*, transition to sarcomatous arrangement; *K*, a kidney tubule involved in the growth. (Debernardi.)

Mesothelioma.—Mesothelioma may arise in pleura, peritoneum, or rarely in pericardium or synovial membrane. It appears as a pseudo-inflammatory thickening of the serous membrane, producing a flattened, nodular or fungous tumor, composed of "elongated acini, lined with irregular, swollen cells, . . . resembling the curiously epithelioid type of cells we encounter in some endotheliomas," these acini lying in an abundant fibrous stroma (Adami). I have seen one mesothelioma of the pleura, in a child of three years, not recognized as such by the surgeon, who operated for empyema.

Endothelioma.—From this class should be excluded blood and lymph vascular changes not truly blastomatous. All such conditions as *nevi*, *telangiectases*, etc., will be discussed under surgery of the vascular system (p. 244). Here we have to do only with typical and atypical neoplasms of endothelial tissues. They are classed as hemangeio-endothelioma and lymphangeio-endothelioma; surgically they are not of much interest. Briefly, they are formed by concentric, and at times eccentric proliferation of endothelium of blood or lymph capillaries. An atypical hemangeio-endothelioma of the inner surface of the cranial dura mater, in which calcareous deposits have occurred, is called a *psammoma*. *Perithelioma* is a tumor in which the lymph cells lining the perivascular lymph spaces proliferate; when hyaline degeneration occurs in these cells, the tumor is called a *cylindroma*. The growth occurs in the kidney, bones, and skin. Endothelioma occurs oftenest in the skin, in the region of the parotid, in the genital glands, bones, lymph nodes, and dura (Park, 1907).

Tumors of the Carotid Body (p. 680) tend to the peritheliomatous type.

Melanoma.—There is great uncertainty whether this tumor belongs among sarcomas or not. Adami is inclined to place it among transitional lepidomas. It arises by atypical proliferation of the pigment-containing cells (*chromatophores*) of the rete Malpighii in the skin, or of similar cells in the uveal tract of the eye. Ordinary pigmented nevi, which are either congenital deformities, or *typical* as distinguished from *atypical* melanomas, sometimes become transformed in adult life into this most malignant type of tumor. Beginning in a cutaneous nevus or in the eye, a melanoma gives rapid and wonderfully widespread metastasis, by both blood and lymph channels, to skin, internal organs (especially liver), bones, lungs, brain, etc. The only *treatment* is wide excision or amputation before metastasis occurs.

Cholesteatoma.—Cholesteatoma is a tumor regarded by Borst and others as of endothelial origin; others (Ziegler) think it ectodermic, resembling ordinary dermoid cysts (p. 130). The contents consist of "white, pearl-like, glistening masses, which are concentrically arranged," apparently the remains of compressed and cornified epithelial cells. They occur in the middle ear, pia mater, and urethra. They vary in size from a cherry seed to a hen's egg. They may cause pressure symptoms in the cranium, or otitis media when in the middle ear (Lexer). Excision is the best treatment.

CYSTS.

A cyst is an abnormal but encapsulated collection of fluid, in a cavity which is not provided with any outlet. The fluidity of the contents varies from liquid to semi-solid. One cavity (unilocular) or many (multilocular) may exist. A cyst is to be distinguished from an *abscess*, which is not strictly encapsulated; from *dilatations (ectasia)* of normal channels (varix, aneurysm) which still have an outlet; from *effusions* or *transudations* into preformed and normal cavities, which are classed apart (hydrops articuli, hydrocele, hygroma, hydrothorax, hydrocephalus, etc.)—though such collections may be *encysted;* and from *cystomas*, which is a term sometimes used to describe neoplasms in which cysts form incidentally (p. 119); but a distinction cannot always be made clinically between cysts and cystomas.

Cysts may be classed as *Extravasation*, *Retention*, and *Parasitic Cysts*. All cysts tend to become spherical or oval unless compressed by neighboring parts.

Extravasation Cysts.—These are encapsulated collections of fluid not in a preëxisting cavity. An example is the hematoma, due to extravasation of blood, which as the result of reaction and condensation in the surrounding structures, becomes in time encapsulated. Certain bursal tumors (p. 281) may belong in this class. Extravasation of lymph, forming a chylous cyst, is very rare (p. 268). Extravasation of urine rarely forms a distinct cyst.

Retention Cysts.—Retention cysts arise in preëxisting cavities. They form the largest and most important class, and may arise either

because there is no opening to the cavity, or because the normal opening is obstructed. In either case it is evident that secretion or transudation into the cyst must be more rapid than absorption. Generally speaking, these cysts may be classed as post-natal or antenatal in origin.

I. **Of Post-natal Origin.**—Examples of cysts due to obstruction of ducts are *Ranula, Cysts of Bartholin's Gland, Galactocele, Sebaceous Cysts, Hydronephrosis, Hydrops Vesicæ Felleæ*, etc. Examples of cysts formed in cavities normally having no outlet are *corpora lutea* and *follicular cysts of the ovary, cystic goitre*, etc.

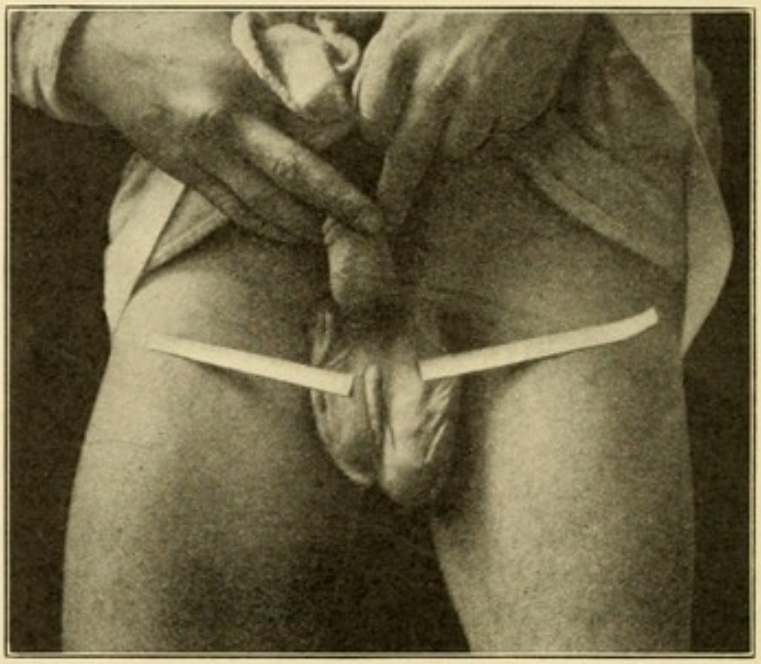

FIG. 78.—Sequestration cyst, or dermoid (congenital abnormality) of scrotal raphé. Episcopal Hospital.

Sequestration Cysts deserve separate mention. They are due to the sequestration and detachment of portions of the true skin either (1) during ante-natal development, when they are congenital, and occur along the fissural lines of the body; or (2) are caused in post-natal life by *implantation* of portions of the true skin by trauma. Most dermoids belong to the former class (Fig. 78), though some, especially pilo-nidal cysts, are occasionally of post-natal development. Implantation dermoids are seen in the fingers of sewing women, or in the faces of shavers. I have several times excised from the face cysts supposed to be wens, which on opening were found to contain two or three long hairs growing from the interior of the cyst wall, which in such cases is lined with squamous epithelium, not with secreting cells.

II. **Of Ante-natal Origin.**—These may be considered in three divisions:

1. *Cysts Due to Persistence of Parts of Embryonic Ducts.*—Thyro-glossal, Branchial, Vitello-intestinal, and Urachal Cysts: the "Tubular Cysts" of Bland-Sutton.

2. *Cysts of Genito-urinary Passages:*

(*a*) *In the Male.*—Encysted hydrocele of testis, probably due to persistence of the embryonic vasa efferentia.

(*b*) *In the Female.*—From various tubules composing the parovarium, and perhaps from the paroöphoron.

3. *Congenital Cysts of Glandular Organs.*—The liver and kidney are especially affected. The pathology is obscure.

Parasitic Cysts.—In man, two main varieties of parasitic cysts are found, those due to Trichina Spiralis and Tenia Echinococcus. The trichina, much rarer, forms very small cysts, oftenest in muscles (p. 276). The echinococcus, commonly known as *hydatid cysts*, may attain an immense size. This parasite is an inhabitant of the intestinal tract of dogs, and the ova may gain entrance to the digestive tracts of those who have to do with dogs and whose habits are not very cleanly. It is a rather rare disease in this country. The shell of the ovum is dissolved by the patient's intestinal juice, and the larva, thus liberated, works its way through the intestinal mucosa usually into a branch of the portal vein, and thus reaches the liver; here it proliferates, and one large, or innumerable small, conglomerate cyst will be found depending upon the stage of development. They are easily recognized by the "hooklets" they contain. The lungs, brain, and other parts of the body may also be affected. *Treatment* is discussed in Chapter XXIV.

FIG. 79. Elliptical incision for the removal of a tumor.

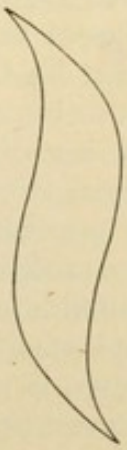

FIG. 80.—Double *SS* incision for the removal of a tumor.

GENERAL REMARKS ON EXCISION OF TUMORS.

The incision should correspond with the natural folds of the part; no skin need be removed in excising benign growths unless very large, when the redundancy may be removed with the tumor by an elliptical incision or one in the form of double *SS* (Figs. 79 and 80). If a tumor is very large, it is not wise to make the entire incision at once, as bleeding is more easily controlled by working down to the main blood-supply through a small incision, and completing this when the main vessels

have been ligated. Most external (*i. e.*, not visceral) tumors are exposed on dividing the skin and superficial fascia; if beneath the deep fascia they should be approached through the proper muscular interspace. A tumor which is encapsulated usually may be enucleated, keeping the scalpel close to the capsule. Malignant tumors necessitate the removal of healthy tissues on all sides, and usually of the overlying skin; as they frequently extend along and surround large bloodvessels, careful dissection is required. Cancers should not be removed by blunt dissection: the bruising of the tissues this entails causes egress of malignant cells into the surrounding tissues. A malignant tumor never should be cut into in the process of removal; to do this may infect the entire wound with cancer cells, and may cause alarming hemorrhage from the tumor itself which it will be very difficult to control. If a tumor when exposed is found to be so placed that it cannot be removed with safety, the operation must be abandoned; in some cases the pedicle of the tumor may be secured, and the main bulk cut away; or the main vessels may be ligated, to starve the growth (p. 655). In gastric and intestinal tumors a palliative operation is frequently possible.

If a tumor, before operation, is clearly inoperable, of course no attempt should be made to remove it. Inoperability may depend on general conditions (the cachectic state of the patient, and probability or certainty of metastases which will kill the patient within the appointed time even if the primary growth were removed), or on the local condition; fixity of the growth, especially in the neighborhood of great vessels is always a sign to be seriously considered. It is important for the surgeon to have a clear understanding with his patient as to the extent of the operation possible and permissible. While often invading and obliterating veins, carcinoma generally respects arteries, even when entirely surrounding them (Crile); so that it is usually possible to dissect the artery free. Everything but life may be disregarded in operating for malignant growths: thus it is entirely justifiable to amputate the thigh, if a tumor is so placed as to necessitate excision of the popliteal artery, which would surely cause gangrene; it is proper to excise muscles, tendons, bones, veins, arteries and even nerves, when, as in the neck, to do so will bring the operation to a successful conclusion without jeopardizing life. A patient will not miss one pneumogastric nerve or one carotid artery, and as a rule he will prefer to live without a clavicle and with a powerless arm than to keep his tumor and die. In some tumors resection of the thoracic or abdominal wall is necessary; the greater part of the stomach may have to be removed in one piece with the transverse colon, or the descending duodenum *en masse* with the head of the pancreas.

CHAPTER V

SURGICAL TECHNIQUE.

THERE are readily available so many excellent works on Bandaging, Antiseptic and Aseptic Technique, Minor Surgery, Anesthetics, etc., that in the present chapter little will be attempted beyond discussing briefly the principles underlying these procedures.

BANDAGING.

Bandages are employed to hold dressings in contact with a wound, to maintain splints in position, or simply to support the part. Those most generally useful are made of unbleached muslin, which may be torn into any width. For the fingers a bandage should be one inch in width; for the head and neck, two inches; for the forearm, two inches and a half; for the arm and leg, three inches; for the thigh and shoulder, three inches and a half; and for the trunk, four inches wide. The length varies with the part to be bandaged and with the purpose for which the bandage is employed: the finger bandages are usually one or two, and the larger from seven to nine yards in length. When prepared for use a bandage is rolled tightly into the form of a cylinder (*roller bandage*), the free end being known as the *initial extremity*. To roll a bandage by hand, fold one end on itself for about six inches; again fold it in half, thus making four thicknesses of three inches each; again fold it in half, making eight thicknesses an inch and a half long; and keep folding the bandage on itself until a solid core is formed. This core is then held in the left hand, between the thumb and first two fingers, and the free end is firmly but tightly grasped in the web of the right thumb (Fig. 81); then by alternately supinating and pronating the left hand, rotating the roller in supination but relaxing the grip on it during pronation, the free end of the bandage is guided on to the roller, which increases in size at each turn of the hand. The right hand should keep the bandage taut, so as to make the roller as firm as possible. A mechanical bandage winder is useful in hospitals or wherever many bandages are to be rolled.

In applying a bandage, the initial extremity is placed on the part, and the roller carried around the limb transversely from left to right, once or twice, to fix the bandage. As the bandage gradually covers the part, each turn should be so applied as to overlie that just below by one-third or more of its width; when it is found impossible to make the bandage lie flat on the limb, owing to the conical shape of the latter, the roller is to be carried off obliquely, the bandage fixed on the limb

by the thumb or finger of the left hand, and the bandage *reversed* (Fig. 82). If the limb is conical it may be necessary to apply the initial extremity of the bandage obliquely in order to fix it without making a reverse. When the part has been completely covered in, the end of the bandage may be fastened with a pin applied transversely to the end of the roller; or strips of adhesive plaster may be used instead. The point of the pin should always point downward toward the distal extremity of the limb.

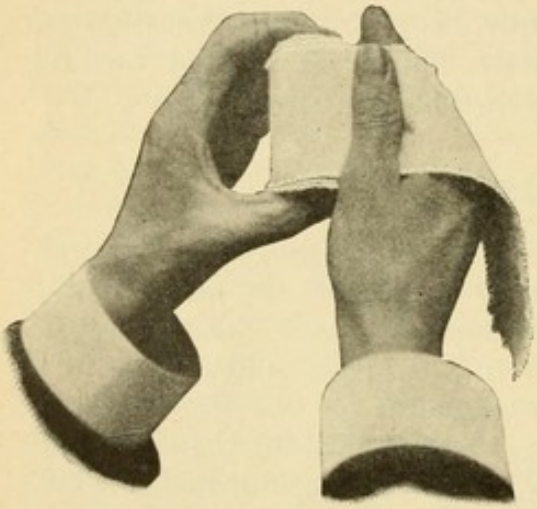

FIG. 81.—Rolling a bandage by hand. (Wharton.)

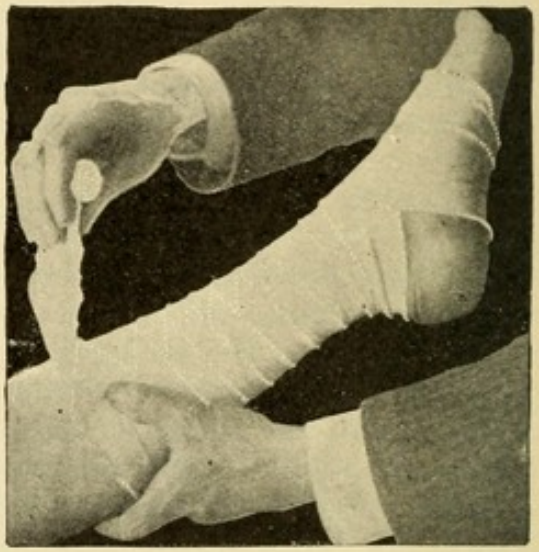

FIG. 82.—Method of making reverses. (Wharton.)

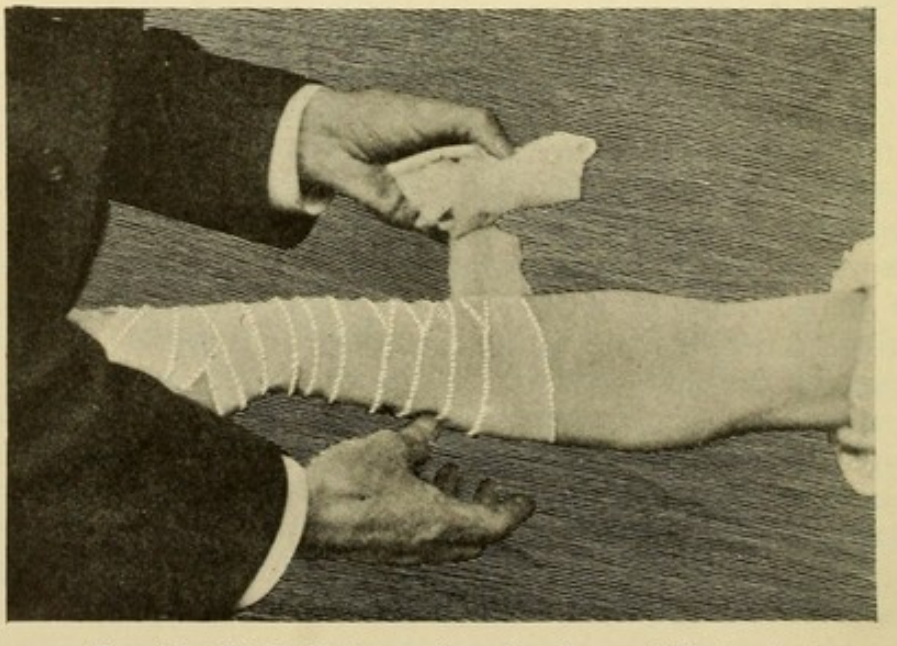

FIG. 83.—Method of removing a bandage. (Wharton.)

In removing a bandage, nothing is so clumsy and time consuming as to drag the end around and around the limb as a long streamer. The entire bandage should be bunched up and passed from hand to

hand as it is unwound (Fig. 83). If soiled, it may be removed by bandage scissors (Fig. 84), the blunt end easily slipping between the folds of bandage. Care should be taken not to cut over a subcutaneous bone (*e. g.*, the shin), and always to keep the blades at right angles to the surface of the limb, for fear of pinching up the skin between them. As a general rule, bandaging should always begin below and proceed toward the trunk, and a bandage should not be applied to a limb without covering in the entire limb from fingers or toes up to and beyond the diseased part. In limbs slightly diseased, swelling of the distal part may not always follow the careful application of a bandage to the affected part alone, but usually the whole limb is more or less inflamed, and constricting it at the seat of greatest swelling may produce marked edema of the distal part if unsupported by the bandage, and cause great discomfort to the patient. Under no circumstances should a bandage be applied so tightly as to interfere with the circulation. Hippocrates taught, and it is still absolutely true, that where it is desired to give pressure to a part by means of bandages, it is much safer to secure this by employing several superimposed bandages than to draw the primary bandage unduly tight.

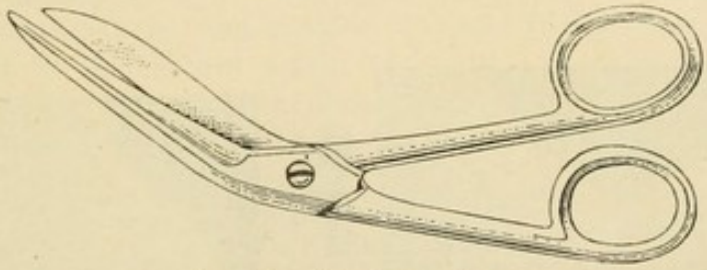

FIG. 84.—Bandage scissors.

Gauze bandages are much employed at present; but they are inferior to muslin bandages except for holding dressings lightly in place; they are of most use for the head and neck, because they are so elastic that it is rarely necessary to make reverses. But if drawn at all firmly they pull into strings and are more liable than muslin to cause injurious constriction.

Flannel bandages are of much value for support in cases of edema, varicose veins, etc. They are elastic, especially when cut on the bias, and are less apt to irritate the skin than muslin or gauze. Bandages of *elastic webbing* are used for the same purposes.

Varieties of Bandages.—The bandages most frequently employed are the *spiral* or *spiral reversed* (Fig. 82), which is universally used in the extremities; the *recurrent* (Fig. 85), used for stumps, the head, etc.; the *spica* (Fig. 86), which is employed to cover the shoulder, groin, buttock, etc.; *figure-of-eight bandages* (Figs. 87, 88 and 89), used to cover joints, to draw the shoulders backward or forward, etc.; T-bandages (Fig. 90), for holding dressings to the perineum; the *many-tailed bandage*, or *bandage of Scultetus* (1655) (Figs. 91 and 92), especially useful for abdominal wounds or other cases where the

patient cannot be supported while a roller bandage is applied. The application of these various bandages is sufficiently indicated in the accompanying figures:

FIG. 85.—Recurrent bandage. (Wharton.)

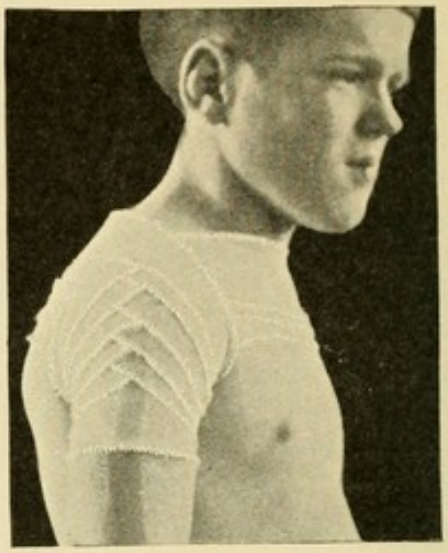

FIG. 86.—Ascending spica bandage. (Wharton.)

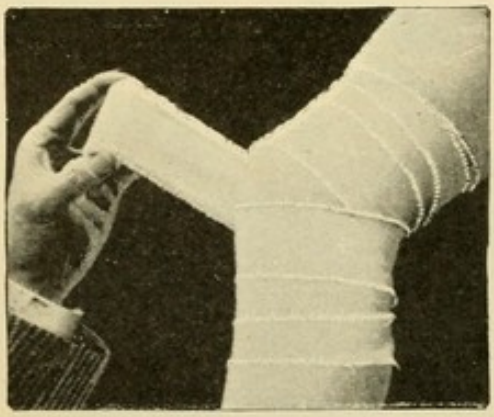

FIG. 87.—Figure-of-eight bandage of the knee. (Wharton.)

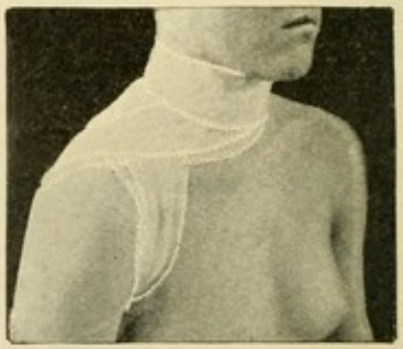

FIG. 88.—Figure-of-eight bandage of the neck and axilla. (Wharton.)

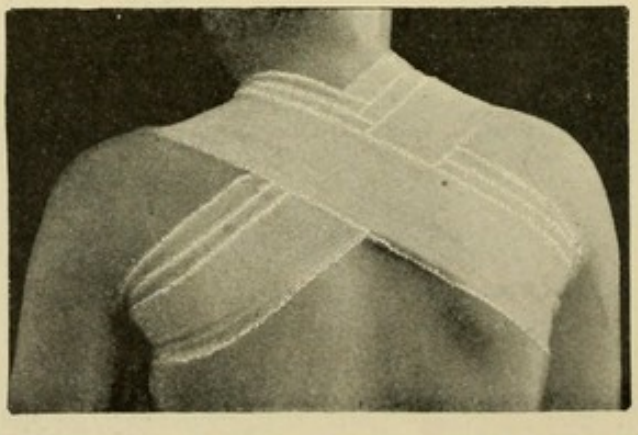

FIG. 89.—Posterior figure-of-eight bandage of the chest. (Wharton.)

Fixed Dressings.—This is a term used for bandages into the meshes of which some substance has been incorporated which on drying becomes stiff. The materials usually employed are starch, silicate of sodium, or plaster of Paris, especially the last. The bandage itself is made of crinoline or coarse meshed gauze.

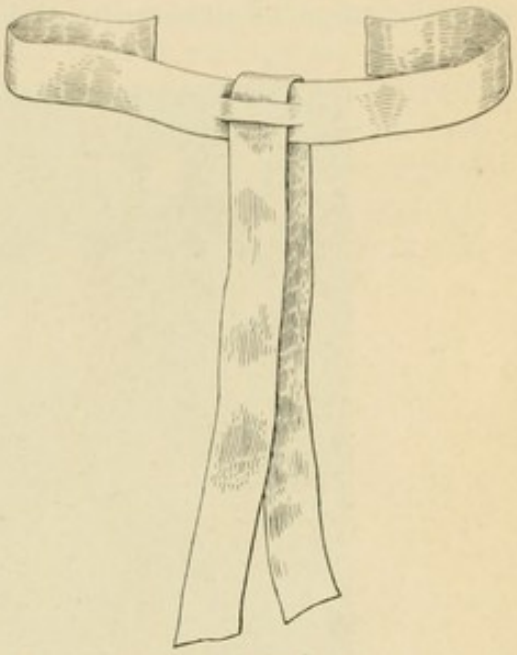

Fig. 90.—Double tailed, or T-bandage.

Plaster of Paris.—This powder is hygroscopic; when moistened and allowed to dry it is converted into *gypsum*, the process being known as *setting*. It is worked into the meshes of the bandage by a spatula; the bandage is then loosely rolled, tied in waxed paper, and put away in an air-tight box until wanted. These bandages may be kept thus for several weeks, but are always better when freshly made. When it is desired to use them, one bandage is placed *on end* in hot water which completely covers it, and is allowed to remain in the water until bubbles cease to rise. The bandage is then removed from the

Fig. 91.—Bandage of Scultetus (many tailed).

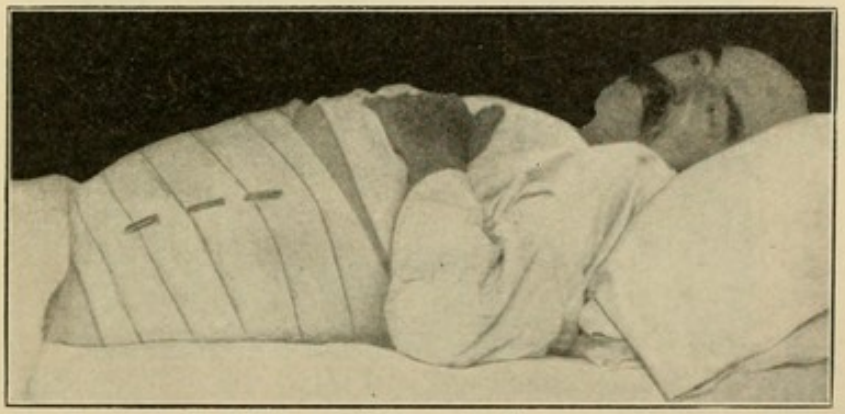

Fig. 92.—Scultetus bandage applied; overlapping turns fastened with safety-pins. Episcopal Hospital.

water, is grasped by its two ends in the hands, and is squeezed as dry as possible. It is then applied as an ordinary roller bandage to the

part (Fig. 93), which must have been previously protected by one or two layers of flannel bandage or of cotton batting; bony prominences should be additionally protected by raw cotton or felt pads. A sufficient number of plaster bandages should be applied to render the

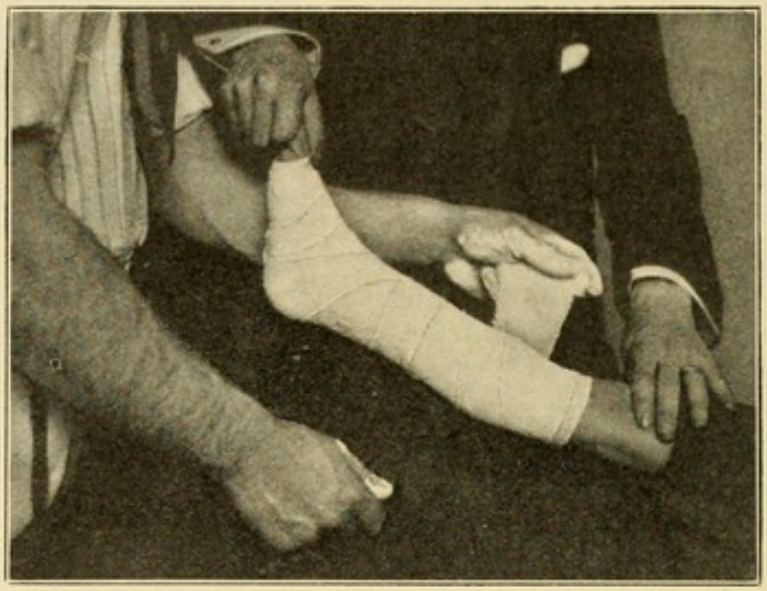

FIG. 93.—Plaster-of-Paris bandage being applied to leg. The foot should be kept at a right angle with the leg. Orthopædic Hospital.

bandage firm when it has set. Usually four to six are required for the foot and leg, eight to ten for the knee, and twelve or more for the pelvis or trunk. The bandages should be placed in the water only as needed; they set quickly, and prompt action and skilful work are required to make a satisfactory gypsum case, or "cast" as it is popularly called.

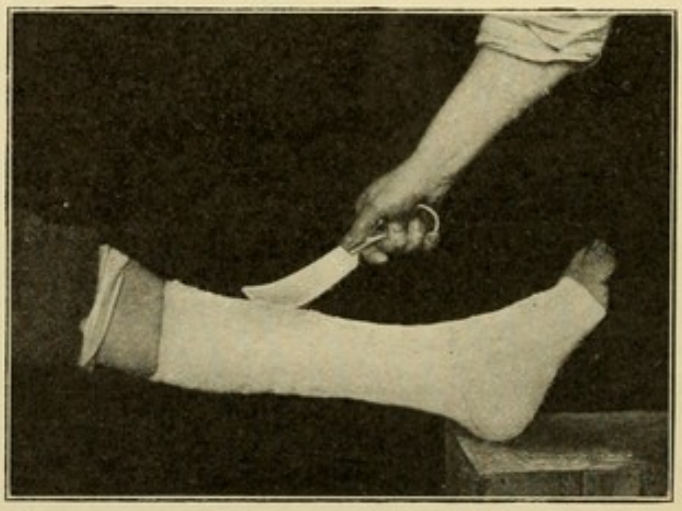

FIG. 94.—Removing gypsum case by means of Hunter's saw. Orthopædic Hospital.

Before the last bandage is applied, the projecting margins of the underlying flannel bandage may be turned down over the ends of the cast, and be held in place by a few turns of the last bandage: this covers in the rough edges of the cast, which unless covered cause great

annoyance to the patient. Finally some "plaster cream" may be rubbed all over the surface of the last bandage: this is made by adding just enough water to a couple of handfuls of plaster to make a thick paste. This refinement not only improves the appearance of the cast, but by giving it a glazed surface (enhanced by wiping with gauze moistened in alcohol) keeps the cast clean much longer. The gypsum usually is quite firm enough in half an hour for the patient to be moved easily.

Starch.—Starch is applied in the form of a paste, by rubbing it into the bandages as they are applied. It is much more brittle and liable to break than gypsum, but may be used as a top dressing to a soiled cast which it is undesirable to remove.

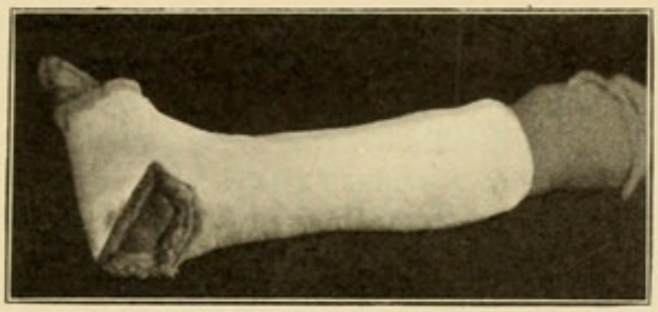

FIG. 95.—Gypsum dressing trapped. Orthopædic Hospital.

Silicate of Sodium.—Silicate of sodium is a pale yellow liquid of the consistency of mucilage. It is best applied to the bandages by rolling them on a winch in a trough full of the liquid, as in the apparatus of G. G. Davis. Silicate makes a light, ornamental cast, possessing all the good qualities of the gypsum, except that at least thirty-six hours are required for it to harden completely. It is much cleaner than plaster of Paris and is readily soluble in water.

These fixed dressings are best removed, I think, by the use of Hunter's saw (Fig. 94); when the gypsum is cut to the underlying bandage, a fact easily detected by the sensation imparted to the hand by the saw, the remaining bandages, and any part of the cast too soft to be cut by the saw, may be cut by a stout pair of bandage scissors. When desirable, a cast so removed may be sprung off and reapplied, being held together by adhesive straps or bandages. The gypsum may be cut away at any time (most easily while still setting) to make a "window" or "trap" through which a wound may be dressed (Fig. 95).

ANTISEPSIS AND ASEPSIS.

In order to prevent entrance of microörganisms into wounds at operation or other times, it is absolutely necessary to take such precautions as will kill all bacteria which might be introduced through the medium of instruments, dressings, or the hands of surgeons, assistants, or nurses; or from the skin of the patient himself, or from septic structures within his body invaded during the course of

operation. A thing is *sterile* when there are no bacteria on it, or when all the bacteria on it are dead. *Everything that has not been sterilized is considered in surgery to be septic.* It is next to impossible to remove bacteria, and entirely impossible to know clinically whether all the bacteria have been removed or not. The only recourse, therefore, is to kill them all. This is most readily accomplished by the use of moist heat (boiling), as no bacteria can survive a temperature of over 100° C. for more than ten to fifteen minutes. Everything that can be boiled may therefore be sterilized in this way, and must not again be touched by anything septic; if it is, it must be re-sterilized before it can be used safely. Instruments, basins, buckets, etc., are readily sterilized by boiling. Enough sodium carbonate (washing soda) should be placed in the water to prevent oxidation (rusting) of the instruments (tablespoonful to a quart). Dressings may be treated in the same way, but as they take much longer than instruments to cool off, and are nearly useless when wet, it is much more satisfactory to sterilize such things in a steam autoclave. For this purpose they are loosely wrapped in an outer covering, which is undone after they have been sterilized, and the contents of the package are removed only by sterile hands or instruments at the time of operation. If carefully wrapped and kept so, such dressings may be preserved in a sterile state for several days at a time; though it is always safer to re-sterilize them on the day of the operation. As the temper of knives is readily spoiled by boiling, and as their surfaces are smooth and therefore readily cleansed mechanically, I think it is best to use chemicals to sterilize them; placing them for twenty minutes in hot[1] carbolic acid solution (5 per cent.) and then in alcohol (70 per cent.) until used.

The hands of the surgeon and his assistants, and the skin of the patient, however, cannot be sterilized by heat; they must be prepared by mechanical and chemical processes. (When a surgeon speaks of his hands, he should use the term in the sense of the Greek word χέιρ, which meant the hands and forearms up to and including the elbows.) The hands are best prepared by washing in hot soapsuds, with careful use of a nail-brush, for ten minutes; then the soap is rinsed off, and further removed by soaking the hands and forearms in alcohol; finally they are soaked in a hot solution of bichloride of mercury (1 to 2000) or of carbolic acid (2.5 per cent.). The patient's skin is prepared in the same way, and is covered with sterile gauze until the time of operation. The mechanical cleansing with the nail-brush, aided by the macerating effect of heat, and soapsuds, removes all loose epithelium and probably removes almost all the germs present. The alcohol by its dehydrating effects opens up the orifices of the cutaneous glands and allows the antiseptic subsequently used to penetrate the skin more effectively, thus weakening, if not killing, the germs always present in the deeper layers. Most surgeons in this country prefer to

[1] It is worth noting in this place that *all antiseptic solutions are much more efficient when hot than if cold or merely luke-warm.*

wear over their hands thin rubber gloves which have been properly sterilized. There is no doubt to my mind that they are a most valuable addition to the surgical armamentarium, chiefly as a protection to the surgeon from contamination in septic cases. The use of gloves in no way absolves the surgeon from careful preparation of his hands, but it enables him in emergency to pass from a septic to an aseptic operation with an impunity which can never be enjoyed when he operates with bare hands. All persons concerned in the operation wear sterile gowns, and caps, and the operators wear face masks of gauze to prevent contamination of the wound or the instruments or dressings in any conceivable manner.

Iodin Disinfection.—Grossich in 1908 found if the patient's skin (without previous preparation except dry shaving) were painted with a 10 to 12 per cent. alcoholic solution of iodin shortly before operation, at the time of operation, and at the close of the operation, the wounds healed better than after the habitual methods of skin preparation. This method is popular for its simplicity and efficiency, and is now in general use. Most surgeons find an alcoholic solution of from 3 to 5 per cent. strong enough, but many do not sufficiently appreciate the fact that the skin must be dry, if the iodin is to be of any use. It must not have been wet for three or four hours at least.

Antiseptic methods of operating were introduced before aseptic methods (Lister, 1865; Lucas-Championnière, 1869, 1876), and are still most widely applicable. Here, after preparing the dressings, instruments, and skin as above, the surgeon keeps his instruments in antiseptic solutions (2.5 per cent. carbolic acid); uses sponges soaked in antiseptics for mopping out the wound; and at the conclusion of the operation applies a stronger antiseptic solution (5 per cent. carbolic acid, 5 or 10 per cent. zinc chloride, 1 to 1000 corrosive sublimate, etc.) to the entire surface of the wound. In this way he makes sure that any microörganisms introduced into the wound, accidentally, will have an unfavorable soil for growth, and that in all probability they will be so weakened by the antiseptics employed as easily to be killed by the tissues of the body. This method of operating is applicable to all primarily septic conditions (compound fractures, necrosis, abscesses, malignant tumors, most amputations, etc.), and is valuable in a somewhat modified form in all operations where the tissues are much bruised or long exposed to the atmosphere during the course of the operation (some excisions, ununited fractures, tedious dissections, etc.). When, however, the operation is of short duration (under half an hour), or when the tissues, even during a longer operation, are not bruised or otherwise unduly injured, and especially in visceral surgery, the aseptic method is superior.

Aseptic methods of operation have been in general use only for the last ten or fifteen years, and were systematized largely by Terrier and his pupils. The instruments, dressings, etc., are sterilized, and the instruments are placed in sterile water or laid on a table covered with sterile sheets. The hands and the patient's skin are prepared in the

usual way, but no antiseptics whatever are used during the course of the operation; everything coming into contact with the wound is sterile; and it depends on the unceasing and seemingly pedantic precautions of the surgeon to *keep* the wound aseptic. If one mis-step is made, the aseptic has to be abandoned for the antiseptic method; and while I think the surgeon should always employ the aseptic method when he safely can, because antiseptics are at times harmful to the patient, and occasionally delay the process of repair, yet it cannot be denied that adherence to a strictly aseptic technique is much more difficult; and it must be acknowledged that many surgeons seem incapable of practising it thoroughly. When either method is properly employed, the wound heals without noticeable inflammatory reaction, no stitch abscesses form, no discharging sinuses remain, no ligatures are slowly eliminated from its depths, no granulations persist at one end of the incision, the comfort of the patient is enhanced, and the after-treatment much simplified.

MINOR SURGERY.

Counter-irritation.—Counter-irritation is conveniently secured by the use of very hot compresses, by turpentine stupes, or by means of plasters of mustard, capsicum, etc. While these remedies are merely *rubefacient* in their effect, cantharides plaster will produce a blister (*vesication*); the surface of the plaster should be wiped with olive oil or petrolatum, so as to prevent it sticking to the cuticle. It should be removed in six or eight hours, and the blister will commonly draw for several hours more; meanwhile it should be dressed lightly with an ointment, and when fully drawn the tense cuticle should be punctured with an aseptic bistoury, and allowed to collapse on to the face of the blister as the serum exudes. When the blister shows a tendency to dry up, this may be encouraged by applying talc or other dusting powder. *Cauterization* is readily secured by means of the Paquelin cautery, in which the platinum cautery point is first brought to a red heat in an alcohol flame, and is then kept incandescent by exposing it to the vapor of benzole or rhigolene, which is pumped along the hollow handle of the cautery iron, from the receptacle where it is contained, by means of a hand bulb. To produce vesication or still slighter degrees of counter-irritation, it is sufficient merely to touch the skin with the cautery iron when at a cherry red heat, or even to hold it close to the skin without bringing the iron into actual contact with it. In certain operations the actual cautery is of the utmost value in checking the oozing of blood or destroying the fungous granulations of inoperable tumors. The wound left is rendered aseptic by the heat, and will usually heal without suppuration. Whenever using the actual cautery, the highly inflammable quality of ether must be remembered.

Acupuncture.—Acupuncture is a little operation sometimes used in cases of lumbago, etc. After preparing the patient's skin as for an

operation, six to ten sterile needles (ordinary hat pins will do) are thrust into the loins with a quick boring motion, and are allowed to remain in place a few minutes. Care, of course, must be exercised not to injure any superficial vein, nerve, etc., and not to enter the spinal canal. No anesthetic is required.

Vaccination.—Vaccination, though usually done by the family physician, is a surgical procedure. The method I prefer is the following: the skin of the arm is rubbed briskly with an alcohol sponge, and vigorously dried with sterile gauze; this arouses the circulation of the part, and makes the virus more apt to "take." Then with the belly of an aseptic and rather dull scalpel the cuticle is scraped off over an area about $\frac{3}{8}$ inch (1 cm.) square until the surface is moist. No blood should be drawn. The vaccine is then quickly applied, and rubbed into the abraded area by means of the ivory point or glass tube in which it is supplied. The vaccinated area is allowed to dry, *completely*, in the air, and no shield or bandage is employed. In a continuous series of several hundred vaccinations by this method, when house surgeon at the Episcopal Hospital, I failed to secure a "take" at the first attempt, in only two or three previously unvaccinated patients. The wound should be painted daily with a 3 per cent. solution of iodin.

Hypodermic Injections.—Convenient tablets containing the requisite amount of the drug are easily obtained from manufacturers. The tablet is dissolved in a half dram of sterile water or saline solution, or the water with the tablet in it may be sterilized in a spoon over a flame. The fluid is then drawn up into the barrel of the hypodermic syringe previously sterilized by boiling or by soaking in an antiseptic solution (which should of course have been removed by rinsing the interior of the syringe in sterile water). The sterilized hollow needle is then screwed on to the nozzle of the syringe, and any bubbles of air are expelled by driving the piston home, while the needle is held upward, until the fluid spurts. Then a fold of the patient's skin, prepared by vigorous rubbing with an alcohol sponge, is picked up between the thumb and finger of the left hand, and the needle quickly thrust obliquely into this fold, so that the point enters the subcutaneous tissues. Care must be taken to avoid entering a subcutaneous vein, wounding a nerve, etc. The best situations for hypodermic injections are over the deltoid muscle, on the outer surface of the thigh or calf, in the buttocks, the loins, or the lateral abdominal wall. No dressing is required for the needle puncture.

Use of Saline Solution.—The object of this solution is to supply a fluid as nearly like the blood as possible. The following formula is recommended by Park:

℞—Calcium chloride,	2 parts
Potassium chloride,	3 parts
Sodium chloride,	9 parts
Sterile water,	1000 parts

This should be prepared aseptically and should again be sterilized before use. In emergencies it is sufficient to add a teaspoonful of

sodium chloride (table salt) to each pint of water, boiling the solution before using. This fluid is used hypodermically (*hypodermoclysis*), by the bowel (*proctoclysis*), and by *intravenous infusion*. It is also widely employed, especially in abdominal surgery, as a substitute for sterile water. It should be injected at a temperature of from 110° to 115° F. For hypodermoclysis, proctoclysis, or intravenous use, it is convenient to let it flow out of a glass jar graduated from above downward, so that a glance will show how much has been given. In emergencies, a sterile fountain syringe or funnel will answer the purpose. The main purposes for which it is used are to combat hemorrhage and shock by restoring blood pressure (p. 175), and to dilute toxins circulating in the blood.

Hypodermoclysis.—This is the subcutaneous instillation of saline solution. A long hollow needle, with large calibre, is used; it is attached to a rubber tube connecting with the receptacle, which may be several feet higher than the patient. The clip on the tube is released, and, while the fluid is running from the needle, this is thrust into the subcutaneous tissues as in administering a hypodermic injection. The best sites for hypodermoclysis are under the mammary glands, over the lower border of the pectoralis major; in the flanks, the lateral abdominal walls, or between the scapulæ. From eight to ten ounces may be introduced through one puncture, the accumulating fluid being gently rubbed out into the tissues. Rarely more than one quart is required by hypodermoclysis. The fluid is not absorbed very rapidly, and where immediate effect is desired it should be given intravenously. The needle punctures should be painted with collodion and sealed with a scab of absorbent cotton. Under the term *axillary infusion* has been described a method of hypodermoclysis by which absorption is very rapid: a puncture is made, with a bistoury, through the skin over the pectoralis major muscle about midway between the clavicle and anterior axillary fold; then, with the fingers of the left hand in the armpit as a guide, the hypodermoclysis needle (not dangerous because blunt) is thrust through this puncture into the cellular tissues of the axilla, traversing the pectoral muscle; the solution is then allowed to flow.

Proctoclysis.—Proctoclysis, the rectal instillation of saline solution,[1] is widely employed in the treatment of peritonitis (Murphy, 1905). A soft rubber catheter is attached to the rubber tube leading from the reservoir, which should not be more than a few inches higher than the patient's buttocks; the eye of the catheter is placed just within the anus. The solution should flow into the rectum very slowly, about a pint and a half every forty to sixty minutes for an adult. If a pint and a half of the solution are placed in the reservoir every two hours, eighteen pints will be absorbed in a day, and the rectum will have periods of rest of an hour or more after each amount has been absorbed. The catheter is to remain in place continuously. This treatment may

[1] Sterile water, without the addition of salines, is just as efficient; it is not irritating to the bowel and is absorbed as readily (Trout, 1912).

be continued for four or five days if necessary. If too much fluid is administered, slight edema of the ankles, hands, and even face may appear (Murphy). The solution is placed in the container hot (105° to 110° F.), and may be kept hot by hot water bags (Fig. 805); but it is probable that owing to its slow flow, it is about the temperature of the blood or lower after traversing the tube to the patient.

Intravenous Infusion.—The patient often is so shocked that no anesthetic is required. A blunt pointed cannula is used, the eye being bevelled to facilitate its introduction into the vein. Select a superficial vein (usually the median cephalic at the elbow), and tie a tight bandage around the extremity on the cardiac side of the vein selected, in order to render it visible and fully distended. Prepare the skin and your hands in the usual way. Then make an incision somewhat obliquely to the course of the vein, about an inch long, and cut down with light strokes directly on to the vein, which may be embedded in fat. Do not tease and maul the fat; this favors infection of any wound. When the vein is thoroughly exposed in this way, thrust a grooved director across beneath the vein, and along the groove slip two ligatures. Draw one of the ligatures to the distal side of the grooved director and ligate the vein; draw the other ligature upward, on the cardiac side of the director, and loop it but do not tie it tight. Then pass a sharp scissors along the grooved director, and, controlling the blood by a finger of the other hand on the cardiac side of the director, cut the vein half way across (Fig. 96). Lay aside the scissors, and take the infusion cannula in the right hand, have the clip removed from the tube, and, while the saline solution is running from the cannula, gently insert this into the gaping wound in the vein, pointing it toward the heart, and tie the ligature already placed so as to secure the cannula in the vein. Then withdraw the grooved director and have the bandage around the limb cut, so as to allow the venous current to flow. The reservoir should not be held more than a foot or two above the patient's body, and the saline solution should not flow more rapidly than a pint in ten minutes. The amount introduced must depend on the state of the patient's pulse. Usually a quart is more than enough; occasionally several quarts will be required.

Direct Transfusion.—This operation, introduced by Crile (1906), implies the transference of blood directly from an artery of a healthy person (known as the *donor*) to a vein of the patient (the *recipient*). It has entirely superseded indirect transfusion, a method in which blood was first drawn into a receptacle, then defibrinated, and finally injected into the patient's veins. For the operation of direct transfusion local anesthesia (cocain) should be used. Crile's technique requires few special instruments beyond the silver cannula (Fig. 97); hypodermic syringes and 0.1 per cent. cocain solution (Formula A, p. 156); scalpel, scissors, two rubber-covered artery clamps (Nunneley's clips do very well), six fine bladed ("mosquito") hemostats, linen or silk ligatures; as well as needles and suture material for closing the skin wound.

Give both donor and patient a hypodermic injection of morphin half an hour before the operation. Place the donor horizontally on an operating table so arranged that its head may be lowered if the

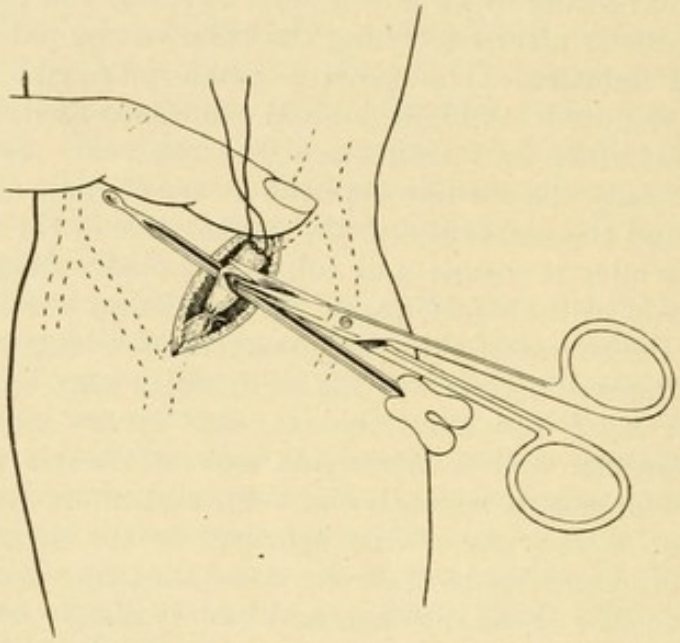

FIG. 96.—Intravenous infusion of saline solution.

donor faints. Place the recipient on another table with his head toward the donor's feet. Use cocain locally (0.1 per cent. solution). Expose first 3 cm. of the radial artery of donor, ligate distal and clamp proximal end. Divide close to the ligature. By squeezing with

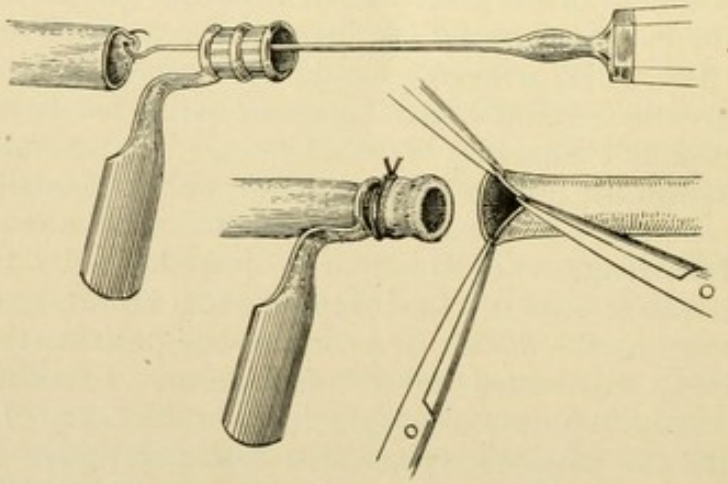

FIG. 97.—Direct transfusion of blood by means of Crile's cannula. In the upper illustration the vein is being drawn through the cannula by a sharp hook. In the lower, the end of the vein has been everted and tied to the cannula, and the artery is about to be drawn over the vein.

fingers on the free (proximal) end of the artery, the adventitia is made to project beyond the inner coats, and is cut off with scissors. As the adventitia retracts, the muscular and endothelial coats are left

projecting. Cover the artery with gauze wet in hot saline solution. Expose 3 to 4 cm. of a large superficial vein of the recipient, ligate the distal and clamp the proximal end; divide close to the ligature, and remove the adventitia as above described. Pass the vein through the cannula, which is held by a hemostat; I have found it easier to draw it through with a fine hook (Fig. 97). Evert the walls of the vein by aid of mosquito hemostats, and ligate with linen or silk the everted vein in the groove next the handle of the cannula. Then with the aid of three mosquito hemostats, draw the artery over the end of the vein, and ligate it around the other groove in the cannula. Unclamp the vein; then unclamp the artery, and let the blood flow slowly. The amount to be transfused depends on the reaction of both donor and recipient. It is best to stop the flow so soon as the donor begins to sigh, indicating respiratory embarrassment from the loss of blood. Of course, if the recipient is brought to a satisfactory state by a less amount of blood, less will suffice. It is truly astonishing to see the color return to blanched lips, the lustre to the eyes, and to behold the general *bienséance* which is produced by direct transfusion.[1]

Phlebotomy.—Phlebotomy which is usually preferred to arteriotomy for "letting blood," is generally done in the median cephalic or median basilic vein. The vein is made tense by applying a tight bandage above it, the skin is properly prepared, and a small incision (1 cm.) is made directly over and into the vein. No anesthetic is required. The spurting blood is caught in a suitable basin; it may be made to run more freely by having the arm dependent or by directing the patient to work his fingers around a bar, alternately tightening and loosening his grip. The patient should be in a sitting posture, so that any faintness may be quickly perceived. It is seldom desirable to draw more than a pint. The wound is dressed with a pledget of sterile gauze, no suture being required; and the same wound may easily be reopened for further bleeding during the next few days.

Leeching.—The Swedish leech, which is preferred, draws from three to four drams of blood. The skin is carefully washed, and the leech applied over the part to be leeched, but not directly over a superficial vein. If the leech does not bite, a little milk or blood should be placed on the skin. When he has drunk his fill he will fall off; or this may be hastened by applying salt over the leech and neighboring skin. The blood usually continues to flow for some time, so that a much larger quantity may be drawn from one leech bite than the capacity of the leech. When enough has been drawn, the bite should be dressed antiseptically, and moderate pressure applied.

Aspiration.—By means of a vacuum bottle it is easy to withdraw fluid collections through a hollow needle. The bottle is first emptied of air as far as possible by the suction pump; the valves are then turned,

[1] Several types of tubes (glass or metal, to be lined with paraffin before using) are now on the market, by which it is thought the operation of direct transfusion is rendered easier than by Crile's original technique; but I have had no personal experience with them. Those of Brewer and of Bernheim are most popular.

and, the skin having been properly prepared, the sterile trocar and cannula are thrust through the overlying tissues into the collection of fluid (hydrothorax, empyema, cold abscess, etc.). The trocar is then withdrawn, the valve turned to close its passage, and the valve leading from the cannula to the bottle is opened, allowing the fluid to flow (Fig. 98). If the lumen of the cannula is blocked by flakes of lymph, a stylet may be passed through it from time to time. The puncture should be dressed antiseptically.

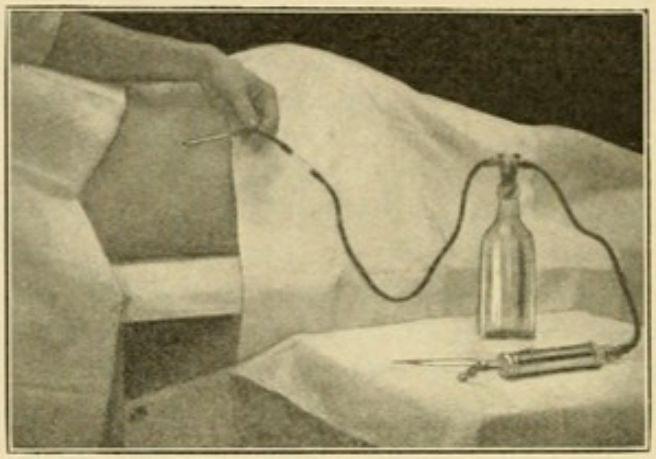

Fig. 98.—Aspiration of a lumbar abscess. Episcopal Hospital.

ANESTHESIA AND ANESTHETICS.

Certain gases, which are respirable, induce unconsciousness when absorbed through the lungs and carried to the nerve centres. The state so produced is called *general anesthesia*. In addition to unconsciousness, which implies analgesia and anesthesia, muscular relaxation is also produced.[1] It is possible to secure the same effects from some such drugs when administered otherwise than by inhalation, as by rectal administration; but, as a rule, general anesthesia is secured by inhalation of the vapor of ether, chloroform, ethyl chloride, etc. *Local anesthesia* is produced by the local use of some drug, usually introduced by hypodermic injection, which acts on the peripheral nerves; cocain and eucain are most used for this purpose.

General Anesthesia.—The patient should have his bowels well opened the day previously, and should have eaten no food for at least eight hours befor the anesthetic is administered, as all general anesthetics, especially ether, produce some degree of nausea. In operations not involving the stomach or intestines, there is no objection to the patient drinking a glass of hot water half an hour before the operation. This prevents gastric irritation from any of the anesthetic unavoidably swallowed. Before taking an anesthetic, a thorough

[1] Crile has pointed out that general anesthesia secured in the usual way does not prevent nocuous impulses from the seat of operation reaching the brain along afferent nerves. If, however, the usual methods adopted to secure local anesthesia are added to the general anesthetic these nocuous associations are avoided. To this principle of operative surgery he has given the name *Anoci-association*.

physical examination of the heart and lungs should be made, and the patient should remove false teeth, chewing gum, tobacco, etc., from the mouth as well as hairpins, earrings, etc. Some surgeons have the habit of giving a hypodermic injection of morphin half an hour before commencing the anesthetic; in a few cases it is valuable, but frequently, apart from being a pure waste of a valuable drug, it is actually harmful. The clothes should be loosened around the throat and so disposed as to make artificial respiration easy in case of emergency. During anesthetization and while recovering from the effects of anesthetics, the chests and shoulders of patients should be carefully covered, as they are very prone to catch cold. No anesthetic should be administered in the dark; change of color frequently is one of the most easily recognized signs of danger, and unless the patient is being anesthetized in a good light this cannot be appreciated. The frequency of ether deaths in negroes is probably due to inability to recognize cyanosis readily in them. The patient should be supine, with the head comfortably supported, especially in the old and round-shouldered, in asthmatics, etc. Throughout the course of anesthetization the anesthetizer must pay strict attention to his own duties, and neither attempt to follow the minute details of the operation nor to converse on irrelevant topics with bystanders. He is responsible for the life of the patient quite as much as the surgeon; and it is a sad fact that the disproportionate number of deaths from anesthesia which occur during trivial operations is usually due to carelessness of the anesthetist. With an ear for respirations, a finger on the temporal pulse, and an eye on the patient's pupils, the anesthetist need not fear to have his attention wander or to meet with unforeseen accidents.

Ether is the safest general anesthetic for major surgery, and probably is the most widely employed. Hewitt places its death rate at 1 in 16,000, five times safer than chloroform, though slightly less safe than nitrous oxide. Ether (ethyl oxide) is a heavy, highly inflammable liquid of strong pungent odor. Its vapor is heavier than air, and sinks to the floor; hence all lights should be kept high above the operating table, as occasionally patients have been seriously burned by ignition of ether fumes. I prefer to administer it by the so-called "open, drop-method," as follows:

The patient's cheeks, nose, and lips may be greased with vaselin to prevent the rubefacient effect of the ether. Place eight to twelve layers of dry wide-meshed gauze across the patient's mouth and nose, and ask him if he can breathe through the gauze. He always answers "yes." Then directing him to shut his eyes and mouth, and to breathe through his nose, hold the gauze lightly in place, but do not exclude all the air from under its edges; drop the ether gently over the gauze, one drop every second or so, moistening an area an inch and a half in diameter just below the tip of the nose (Fig. 99). When given thus slowly very little if any respiratory irritation is produced, the patient continues to breathe in his natural way, and by the time two ounces

have been administered he is usually unconscious, not having exhibited any "stage of excitement." The lower jaw should be constantly held forward by the fingers placed back of the angle, on the ramus, as anesthesia paralyzes the muscles, and unless supported the jaw may fall backward and allow the base of the tongue to force the epiglottis over the larynx. When the respirations become mechanical, like those of sleep, the pupils are found contracted but still reacting to light and the conjunctival reflexes are abolished; then, after a little more ether is administered muscular relaxation becomes complete. The time consumed is usually from ten to fifteen minutes. The operation may then be commenced.[1] The time may be shortened by excluding air more completely: this is easily accomplished by keeping the margins of the gauze in contact with the patient's face, and by adding more dry gauze on top and using it as a roof under which to drop the ether. This concentrates the ether vapor, and requires less ether; but unless cautiously and gradually done is apt to cause choking. The anesthetist should never give enough ether to cause the pupils to dilate; if they

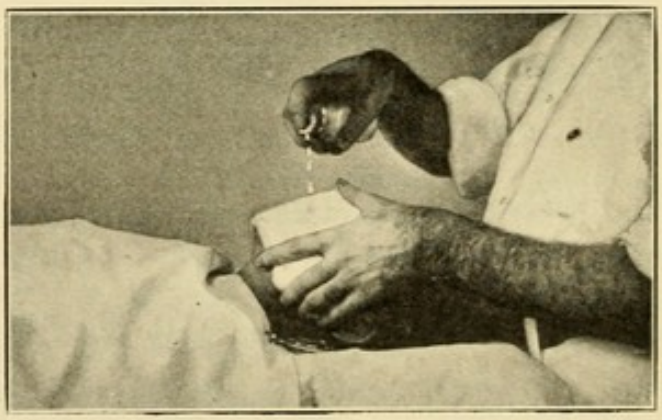

FIG. 99.—Etherization by the open, drop-method. Episcopal Hospital.

are kept contracted, but reacting to light, the patient is in the proper state for operation. Frequently during the course of an operation it may be possible to let the patient come so far from under the influence of ether as to allow his pupils to return to their normal dilated state, which should not be mistaken for the dilated state, without reaction to light, present in advanced ether poisoning. Some operators prefer and others will not allow the anesthetist to let the patient "come to" from time to time. Such idiosyncrasies must be learned by experience.

In giving ether to children, who are not reasonable enough to lie still and breathe quietly, it is better to pour a dram of ether at once on the gauze, and hold this firmly in contact with the face. After a short

[1] Many very short operations (half a minute) may be done during the stage known as "*primary anesthesia*," described many years ago by Packard. The patient is directed to hold one arm aloft, when inhalations are begun, and to hold it up as long as possible. The moment the arm drops is the opportune time for surgical intervention. In Germany this state of first insensibility from the anesthetic is known as the "Ether Rausch."

struggle, and holding the breath until thoroughly "out of breath," the child will take a few deep inspirations, and by so doing will pass completely under the influence of the ether in a very much shorter time and with very much less discomfort and danger to himself than if the struggle had been prolonged by attempting to administer the ether by the drop-method.

Certain *accidents* may occur during etherization: (1) When ether is first administered, the patient may stop breathing. This usually is due to neglect of the precaution to start the patient breathing through the gauze before any ether is dropped on it, or to pouring on a quantity of ether instead of giving it drop by drop. It is treated by removing the gauze, allowing the patient to breathe air, and then beginning over again. (2) The patient, if an alcoholic, or if he has taken ether frequently before, may be unduly exhilarated by the stimulating effect of the ether. Hence it may be necessary to use forcible restraint, and preparation should accordingly be made. So long as respiration is good, the administration of more ether is indicated, as there are very few patients, indeed, who do not succumb to its influence in a short time. (3) The patient's throat may fill up with mucus, making respiration difficult, and producing cyanosis. This generally is due to too rapid administration of ether, to neglect to hold the jaw forward, or to a preëxisting bronchitis, etc. It is best treated by pulling the jaw forward, as already described, thus opening the larynx; by turning the head to one side, or letting it hang over the edge of the table, thus allowing the secretions to accumulate in the cheek or to run out of the mouth; and finally by the use of a mouth-gag with direct removal of the mucus by sponging. The mouth-gag is rarely required by a good etherizer; but it should always be at hand for emergencies. Marine sponges are best for this purpose; each should be about an inch and a half in diameter, freshly wrung dry out of luke-warm water, and fixed firmly in a long handle. When the jaws have been opened by the gag, the tongue is grasped with gauze or a suitable forceps (Fig. 100), and pulled forward and upward. This alone may make respiration easier. If necessary, the sponges are to be passed back into the pharynx, and by a combined sweeping and rotary motion are made to collect as much mucus as possible. (4) The patient may stop breathing from no foreseen cause. This frequently is due to the administration of too much ether, occasionally to reflex inhibition from injudicious traction on the tongue or sponging, and rarely to the direct shock of the operation. It is treated by artificial respiration, by hypodermic stimulation, and by inhalations of ammonia and oxygen when once respiration is restored. (5) Vomiting occurs from neglect to abstain from food before operation, but will not occur after anesthesia is once

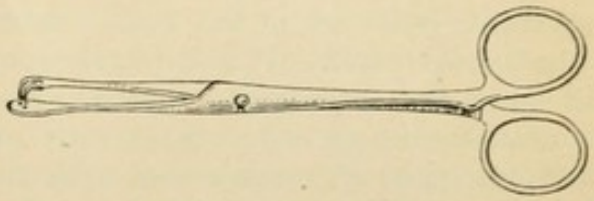

FIG. 100.—Tongue forceps.

complete, unless the patient is allowed to come out of the anesthetic too far.

Chloroform.—One death among every 3749 chloroform anesthesias is attributed to the action of the drug. Its action is more rapid than that of ether, and the zone of safety is much narrower. It has been said that the danger signals appear and the collision occurs at the same instant; there is not sufficient warning, as there is in etherization, for disaster to be avoided. The most important thing in chloroform anesthesia is to allow the mixture of plenty of air with the inhaled vapor. On this account I think the simplest way to administer chloroform is by dropping it slowly on one or two thicknesses of gauze stretched over a wire frame, made to fit over the mouth and nose in such a way that the part of the gauze moistened by the chloroform is always half an inch or more distant from the patient's lips (Fig. 101). Even stricter attention to the pulse and respiration is required than in giving ether; but a stage of excitement scarcely ever occurs, little or no bronchial irritation is produced, and vomiting during recovery from anesthesia is very unusual.



FIG. 101.—Chloroform inhaler.

Ethyl chloride is a seductive but dangerous anesthetic. It acts as quickly as, and even more pleasantly than chloroform.

Nitrous oxide, a gas which is universally employed for minor dental operations, may be equally well employed in surgery for short operations where complete muscular relaxation is not required. It exerts its influence in less than a minute and is the least unpleasant anesthetic to take. It acts largely by causing an accumulation in the blood of carbon dioxide. Special apparatus is used, including a tank containing the gas, a face mask with suitable valves to admit or exclude air or oxygen in conjunction with the nitrous oxide, and a rubber bag, inserted between the tank and the mask, in which the gas collects, but from which the expired air is excluded by an automatic valve. When a suitable admixture of oxygen is permitted, skilful anesthetists may prolong the duration of anesthesia for an hour or more. Nitrous oxide frequently is used to induce anesthesia, ether or chloroform being substituted later. As I have seen it used in this way I have not been able to see any advantages over the skilful administration of ether from the start; but when nitrous oxide and oxygen are used alone, without any recourse to ether, recovery from the anesthetic occurs much more promptly, and there are no unpleasant after-effects.

Choice of a General Anesthetic.—Unless contraindicated, ether is to be preferred, because it is the safest. Its greatest danger is post-operative bronchitis or pneumonia; but with proper precautions against

exposure of the patient, and by giving it drop by drop, such complications are not to be feared. Moreover, it is better for a patient to be nauseated and to have bronchial irritation after recovery from ether than for him to be killed by chloroform or ethyl chloride. In cases where bronchitis, phthisis, etc., exist, or where the kidneys are seriously diseased, and where some general anesthetic has to be employed, nitrous oxide and oxygen should be preferred. Chloroform is particularly to be avoided in cases of heart lesion not properly compensated, and in cases of shock. Nitrous oxide causes cyanosis, stertor, and muscular regidity, with such increase of blood pressure that it is especially contraindicated in patients with arteriosclerosis; its successful administration requires much more skill and experience than does that of ether, but when skilful assistance is available, and the operation will not consume more than thirty or forty minutes, it is when combined with oxygen a safer and more desirable anesthetic than is ether for patients with visceral lesions other than those of the vascular system.

Administration of General Anesthetic for Special Operations.—HEAD AND NECK.—It is found often in operations on the head and neck that the anesthetist is very much in the way, and that the progress of the operation interferes with the proper administration of the anesthetic. One of the simplest methods of overcoming this is to have the ether vapor conducted to the patient's mouth through a tube, so that the anesthetist may stand at some distance. This is accomplished by standing the ether bottle in a pan of warm water, to increase the rapidity of vaporization. Through the cork of the ether bottle pass two tubes—an afferent tube which is connected with a hand bulb, and an efferent tube which is three or four feet long and leads to the patient's mouth. If a hooked metal tube is attached at the mouth end, it will hang in the angle of the mouth and keep its place without difficulty. The ether vapor has never caused, in my experience, any evidence of stomatitis. If its irritating effects are feared, the vapor may be conducted by tube over or through a bottle of water before entering the mouth. The patient is first anesthetized in the usual way, and when thoroughly relaxed, the gauze is removed from the face, the mouth tube introduced, and the ether vapor forced into the mouth by use of the hand bulb.

Crile's plan is another convenient method. After the patient is anesthetized, the surgeon passes a well greased tube through each nostril to the naso-pharynx, and packs the mouth loosely with gauze. The outer ends of the nasal tube are connected by a Y-shaped glass tube to a long rubber tube, at the far end of which is a funnel lightly filled with gauze. The ether is then administered by being dropped on the gauze in the funnel. It is well to have a U-tube inserted somewhere in the tube which conducts the ether vapor to the patient, so that in it may collect any condensation from the ether vapor.

INTRATHORACIC OPERATIONS.—When the pleura is opened, the lung partially collapses, and in consequence there may be considerable

respiratory disturbance and interference with the administration of an anesthetic. To overcome this Sauerbruch, of Breslau, devised (1904) a plan for operating under *negative atmospheric pressure*, thus allowing the lung to remain expanded. In this method the patient is placed in a chamber in which negative pressure can be induced; his head projects through an opening in this chamber, and a rubber collar fitting closely around his neck makes the aperture air-tight. The anesthetist sits outside the chamber, while the surgeon and his assistants must remain inside. This plan of operating under negative pressure entails expensive apparatus, and a specially constructed operating-room, which cannot be moved from place to place. Dr. Willy Meyer, of New York, is the chief supporter of the method in America, and has had a very complete operating suite constructed in the German Hospital in that city.

Positive Pressure Method.—This was introduced by Brauer, of Heidelberg, very soon after Sauerbruch's method. Here the patient's head and the anesthetist are in a specially constructed chamber, in which the atmospheric pressure may be increased, by suitable apparatus, so that when the pleural cavity is opened the lung stays expanded. This appears to be a simpler method than that of negative pressure, and seems quite as efficient; but has not been used much in this country.

Intratracheal Insufflation.—Meltzer and Auer, of the Rockefeller Institute, New York, found in experiments on dogs, in 1909, that if a tube was passed down to the trachea almost to its bifurcation, and if air mixed with ether was constantly blown in through this tube by suitable bellows, the dog's lungs remained expanded even when both pleuræ were widely opened, that anesthesia could be maintained for hours, and that it was impossible to kill the dogs by an overdose of the anesthetic. This method was adapted for human beings by Elsberg, of New York, and is now the most approved plan for administering an anesthetic for operations on the lung, the thoracic esophagus, the cardiac orifice of the stomach and the diaphragm. It is a great convenience also in operations on the mouth and pharynx, as it prevents aspiration of mucus or blood. Briefly described, the apparatus is as follows: An electric motor is used to pump the air through a bottle of warm water, by which it is filtered, warmed, and moistened. The air is then conducted by tube to the ether bottle, where the tubing is so arranged with stopcocks that (1) all the air may pass directly on to the patient without coming into contact with the ether; (2) all the air may pass through the ether bottle, over the surface of the ether, and thus become saturated with the anesthetic before reaching the patient; or (3) some of the air may pass directly on to the patient while some passes through the ether bottle before reaching the patient. Thus the amount of ether to be administered may be accurately regulated. An oxygen tank may be connected with the tube leading to the patient, so that pure oxygen or oxygen mixed with air in any proportion may be inhaled.

The tube leading from the ether bottle to the patient is connected with a manometer, and has a Y-ending, one branch for connection with the intratracheal tube, and the other to be used as a cut out, to allow collapse of the lungs at any instant desired. The apparatus may be obtained now in very compact form.

The intratracheal tube should be fairly rigid, of the length of a stomach tube, and about half the diameter of the trachea. The patient is anesthetized in the usual manner, and the larynx and pharynx are thoroughly anesthetized with cocain solution (10 per cent.). The tube, previously sterilized, is then passed through the larynx into the trachea. This is facilitated by the use of a bronchoscopic tube or speculum. When the intratracheal tube is momentarily arrested at the bifurcation of the trachea, it is withdrawn about an inch. If the tube is in correct position air will enter both lungs; if it has been pushed in so far as to be arrested at the division of the right bronchus no air will enter or leave the left lung. When in proper position, the tube is clamped just outside the dental margin by a frame supported on the ears, resembling a spectacle frame. "The tube is now connected with the air pressure apparatus, and air is blown through at a pressure of 10 mm. of mercury. After several minutes, the pressure is raised to 20 mm. and the operation can be begun. When the pressure of the inflowing air and ether equals 20 mm. of mercury, inspiration and expiration will continue, air being inhaled and exhaled by the side of the tube. If there existed a profuse secretion of mucus in the pharynx and trachea, this will be found to have ceased soon after the insufflation was begun. Every two to three minutes, an assistant opens a vent so that the current of air which enters the tube is interrupted for a moment." (Elsberg.)

No ill effects have been noted from anesthesia maintained by this method. Far from favoring pulmonary complications, it seems to prevent them.

Local Anesthesia may be secured by *freezing* the skin with a mixture of ice and salt, or by a spray of ethyl chloride or rhigolene. The skin becomes white, covered with minute crystals of ice, and is rendered very tough. The anesthesia lasts only a few seconds, but sufficiently long for opening superficial abscesses, etc. If the patient only knew that freezing hurts as much or more than a sudden stab with a sharp bistoury, he probably would prefer to have this form of local anesthesia abandoned.

Cocain and *eucain* are the chief agents used for local anesthesia. Solutions of cocain are unstable chemically, and are destroyed by repeated boiling; in emergency, boiling for a few minutes does not impair their value. Eucain (*eucain B*) is not so toxic as cocain, is not destroyed by boiling, and is quite as efficient; but the duration of anesthesia is shorter than that produced by cocain. In general, eucain is to be preferred. The addition of saline solution, to make the solution isotonic with the blood, and of adrenalin to constringe the capillaries, thus preventing diffusion of the anesthetic and local

edema, renders the use of local anesthesia much more satisfactory. The application of an Esmarch band above the seat of operation also prevents diffusion of the anesthetic. Cocain tablets which can be sterilized by dry heat, are now on the market. Mitchell (1908) recommends that each tablet be sterilized in a glass flask as needed, being added to the sterile saline solution just before it is to be used. Finally, the adrenalin solution is to be added drop by drop to the required amount. He gives the following formulæ from Braun:

A.

Cocain hydrochlorate,	0.1 grm. (1.5 grain)
Physiological salt solution, ($\frac{9}{10}$ per cent.)	100 c.c.
Adrenalin (1 to 1000)	5 drops.

B.

Cocain hydrochlorate,	0.05 grm. (0.75 grain)
Physiological salt solution ($\frac{9}{10}$ per cent.)	5 c.c.
Adrenalin (1 to 1000)	10 drops.

Formula A represents a 1 to 1000 cocain solution, and may be further diluted with saline solution if large amounts are to be used, as in long operations by Schleich's infiltration anesthesia; while Formula B (a 1 per cent. solution of cocain) is used for operations requiring only one or two hypodermic injections, when the whole amount of the formula may be employed safely. For applications to mucous membranes (eye, throat, urethra, bladder), a 2 per cent. solution may be used, and sometimes a 4 per cent. solution. It is dropped on the surface of the eye, and is applied to the nose and throat by a pledget of absorbent cotton; while it is injected into the urethra and bladder by means of the urethral syringe, catheter, or instillator.

Hypodermic Use.—The skin is pinched up as in giving a hypodermic injection, but the needle, which enters at one end of the proposed incision, with its point directed toward the other end, is not passed into the subcutaneous tissues, but its point is arrested in the true skin, the first injection being *endodermic*, not hypodermic. As the piston of the syringe is pushed down, a distinct wheal is raised in the skin; the needle is then pushed on within the true skin until its point reaches the limit of the wheal, when another wheal is produced, and so on until the entire length of the needle has entered. It is then withdrawn and reintroduced at the furthest point reached, and the process is repeated until the line of the entire incision has been anesthetized. An incision may then be made through the skin, and, with a few added drops here and there as required, this degree of anesthesia will suffice for circumcision, removal of sebaceous cysts and small tumors, opening cold abscesses, etc. For such cases Formula B may be used. When a more extensive operation is undertaken, as one for hernia, goitre, etc., it is best to use the weaker solution (dilutions of Formula A), and special attention must be paid to nerves, bloodvessels, and connective tissue bundles (*infiltration anesthesia*). Almost any quantity of the weaker solutions may be used, especially

when local anesthesia is aided by constriction of the limb above the seat of operation.

Nerve blocking may be accomplished by perineural or endoneural injections, the latter being preferable as more accurate and permitting a wider range of operative procedure. Certain nerves (ulnar, peroneal) may be reached directly, but usually it is necessary to bare the nerve by the hypodermic use of cocain as already described. In the endoneural method (Crile, Cushing, Matas), the cocain is injected directly among the nerve fibres of the main trunks conveying sensation from the region to be operated on. Complete anesthesia follows, and as no sensory impulses can reach the nerve centres surgical shock is much diminished or totally prevented, a fact which is of value in many amputations. I generally employ 2 per cent. solutions for this purpose.

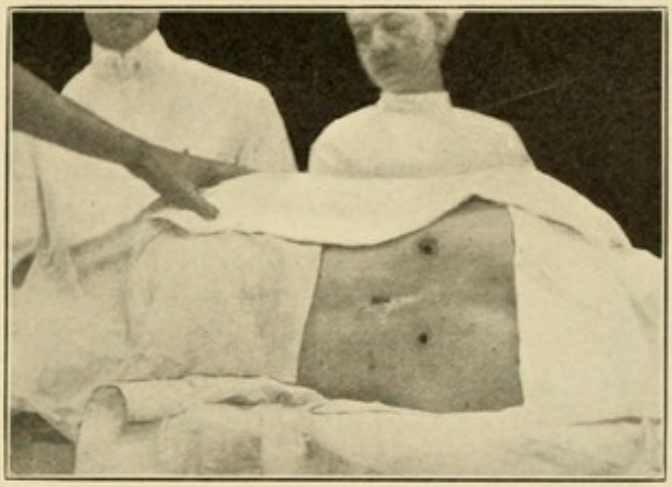

FIG. 102.—Spinal analgesia. Needle between spines of second and third lumbar vertebræ. Posterior superior iliac spines marked with iodin. Episcopal Hospital.

Spinal anesthesia is closely allied to nerve blocking. It was suggested in 1885 by Leonard Corning, of New York; was employed in 1889 by Tuffier; and has been more widely used abroad than in this country. The anesthetic acts on the roots of the spinal nerves, not on the cord itself. The injection is made usually in the second or third lumbar interspace (Fig. 102); as a rule, anesthesia (which affects both motor and sensory impulses, especially the latter) extends only to the region of the waist, and therefore operations best suited for spinal anesthesia are those on the lower extremities or pelvis. Stovain (4 per cent. solution) usually is preferred to other anesthetics, and is that which I am myself accustomed to use. About 1.5 to 2 c.c. are employed. The anesthesia begins in a few minutes and lasts nearly an hour. As positive contraindications to spinal anesthesia may be mentioned: advanced cachexia, bilateral nephritis with scanty excretion, myocarditis, pericarditis with effusion, non-compensated cardiac disease. Many operations in which spinal anesthesia may seem desirable can be done equally well under local anesthesia; but for rectal operations and prostatectomy spinal anesthesia is to be preferred, if a general anesthetic cannot be employed.

Vein anesthesia is a term used to describe a method employed by Bier (1908). He has used it in 134 operations. It is applicable to any operation on the extremities. He first renders the part bloodless by Esmarch's method (p. 433), and cuts off the general circulation by broad elastic bands above and below the seat of operation; exposing then a superficial vein, he injects into the vein 40 to 80 c.c. of a 0.5 per cent. solution of novocain in saline solution; the solution diffuses through the capillaries of the area sequestrated from the general circulation, rendering every subsequent manipulation painless. At the conclusion of the operation the anesthetic solution may be removed by washing out the veins with saline solution, but this is not always necessary, as most of the novocain escapes into the wound through the capillaries divided during the operation.

CHAPTER VI.

INJURIES AND THEIR EFFECTS.

LOCAL EFFECTS OF INJURIES.

The local effects of injury depend on the part injured, as well as on the force exerted by, and the manner of action of the vulnerating body. A smart blow with a rope will produce a wheal; if the rope slips rapidly through the hands with violent friction, a brush-burn will result; but if the rope is twisted tightly around the part, strangulation will occur. Striking the foot against a large stone will cause a contusion, but if the same stone falls on the leg it may fracture the bones. Injury of parts with abundant and lax subcutaneous tissues will be attended by much greater swelling than where these tissues are firm and resistant; injuries of certain parts are much more dangerous than similar or severer injury expended upon other parts not so highly specialized or so vascular.

The local effects of heat, cold, etc., are considered in Chapter IX.

Abrasions.—An abrasion is an injury in which merely the epiderm has been removed by slight friction; brush-burns, produced by violent friction, resemble contused wounds (p. 167). An *excoriation* is an injury produced by scratching or scraping which involves the corium. The resulting ulcers heal readily when properly protected.

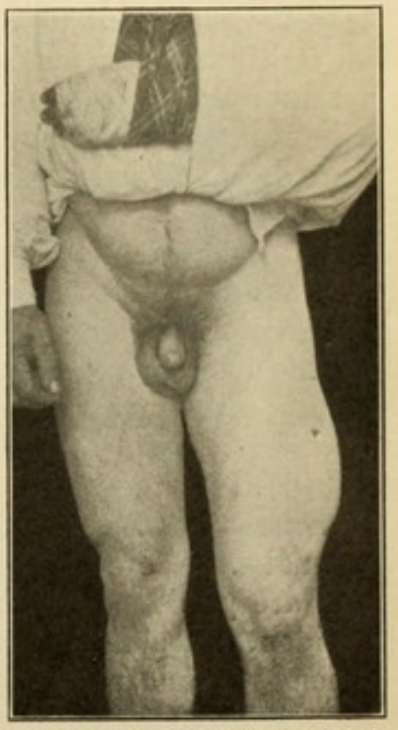

Fig. 103.—Hematoma of left thigh ten days after a fall; also fracture of shaft of left humerus. Age forty-eight years. Episcopal Hospital.

Contusions.—A contusion is a subcutaneous injury of the soft parts produced by blunt force (kicks, falls, etc.). There is always a certain amount of blood *extravasated* among the lacerated tissues; when this blood is visible in moderate amount beneath the skin, it is termed an *ecchymosis;* and as it undergoes absorption it passes through various shades of purple, green, black, and blue. A very minute ecchymosis is called a *petechia*. Blood extravasated beneath the conjunctiva remains bright red a long time, owing to oxidation through the thin overlying tissues. When enough blood is extravasated to cause an appreciable collection of fluid, it is called a

hematoma; or if clotted a *thrombus.* The skin itself, though more resistant than the subcutaneous tissues, does not always escape injury in a contusion; such injury is manifested in the course of twelve to twenty-four hours by vesicles, blisters, and bullæ. These usually appear before the ecchymoses, which rarely become apparent until the second or third day. The *diagnosis* of a contusion is easy, being based on the history of injury by blunt force; on the indentation of the soft parts (especially on the scalp), often persisting when the patient is seen soon after the accident; on the local tenderness which is rapidly followed by swelling, extravasation, and ecchymosis. The *prognosis* is good, unless there is some undetected injury to nerves, bloodvessels, bones, joints, or internal organs. The hematoma which forms seldom causes anxiety; usually the bleeding ceases spontaneously, or under the application of cold, elevation of the part, moderate pressure, etc. The *treatment* consists in securing local rest, in applying anodyne or slightly stimulating fomentations (arnica, dilute alcohol, ichthyol ointment), and in promoting absorption of the hematoma at a later date by gentle massage, firm bandaging, etc. Constitutional treatment is rarely required.

Strangulation.—Strangulation of a part results from the interruption of the circulation by the application of circular constriction so tight and sufficiently long as to cause passive changes somewhat resembling those seen in contusion. If the strangulation is not relieved (by elevation, by division of constricting bands, etc.), the part dies, and is removed as a slough by granulations at the point of constriction. All the dangers from infection, present in gangrene from other causes, arise, and life is occasionally lost.

Wounds.—A wound is a solution of continuity of the soft tissues the result of violence. A wound is *open* if the skin is as widely divided as the underlying structures; or *subcutaneous* if the division of the skin is insignificant. Wounds are also described as *incised, lacerated, contused, punctured,* or *poisoned. Gunshot wounds,* which resemble contused wounds, are considered in Chapter VII.

Incised Wounds.—Incised wounds, which may be regarded as the normal type, are those made by clean cuts with sharp instruments, and are produced by the surgeon in every cutting operation. Most accidental wounds partake more of the nature of lacerated than incised wounds, as the instruments by which they are inflicted (pocket knives, broken glass, axes, etc.), are not as sharp as surgical instruments, and even if sharp (as razors) are not wielded with the delicacy and precision necessary in surgery. *Pain, hemorrhage,* and *gaping* are the main symptoms of incised wounds. The pain varies with the size of the wound, with the sensibility of the part wounded, and with the manner in which the wound is produced. A large wound hurts more than a small one; wounds of the face and hands hurt more than those of the back and buttocks where the cutaneous nerves are less developed; and a quickly made incision causes less pain than one which is bungled. The hemorrhage depends largely on the

location of the wound, and on the implication of large vessels. Wounds of the face and scalp bleed profusely, because of the vascularity of these parts, and because in the scalp the vessels cannot contract and retract. The gaping of a wound depends on the natural elasticity of the tissues divided. A wound which runs in the direction of the natural folds of the skin will gape less than one which crosses these folds; one which divides muscles transversely will gape widely; the divided ends of tendons, arteries, and nerves may retract for several inches from the point of division.

Process of Healing in Incised Wounds.—As the result of the irritation produced by the vulnerating body, tissue changes occur which are pathologically identical with those seen in the process of inflammation; so that the healing of an incised wound is the same as Repair after Inflammation (p. 29). It is convenient to recognize different ways in which union occurs after a wound has been inflicted, although the difference is purely quantitative, depending on the extent of reaction necessitated, and though the processes, so far as they extend, are identical in all cases. Historically, three ways of union are recognized: (1) By *immediate union* (to which the term "*first intention*" as used by Hunter (1784)[1] is correctly applied); (2) by *adhesion*, as understood by Paget (1853); and (3) by *granulation*, or by *second intention*.

1. *Immediate Union.*—If the edges of an aseptic incised wound are accurately apposed so that each tissue meets its corresponding structure in the other lip of the wound; and if no foreign particles, even if aseptic, or no blood-clots, remain between the lips of the wound, then the reactive process may extend only to the stage described as that of "temporary hypertrophy." No inflammatory lymph is exuded, no granulation tissue forms, and the wound heals by *immediate union*, or by the *first intention* in the Hunterian sense. Very few incisions and yet fewer wounds heal by immediate union; very small wounds of extremely vascular parts (fingers, face), may occasionally heal without the process of reaction having extended beyond the stage of temporary hypertrophy. Such wounds when healed leave no visible scar—the tissues have undergone complete regeneration, *restitutio ad integrum*.

2. *Union by Adhesion.*—When the insult to the tissues has been greater, or when the tissues themselves have been less able to repair the damage, the process of reaction extends to the stage of lymph formation. The lips of the wound must be in accurate apposition, leaving no dead spaces, so that the effused inflammatory lymph serves as a framework in which fibroblasts and granulation tissue develop, as described at p. 30. It is this form of union which occurs in the vast majority of aseptic operative incisions, and which is commonly spoken of as "union by the first intention," though strictly speaking this term should be reserved for immediate union; but as

[1] It is the "first intention" of nature to heal wounds in this way.

for at least seventy years it has been erroneously applied by the majority of surgeons, it is perhaps useless to register a protest now. In the process of union by adhesion a scar is always produced extending to the depths of the incision, but is least conspicuous in wounds made with the greatest precision and attended by the least trauma; so that the kind of scars left by a surgeon in operating often give an idea as to the delicacy and neatness of his operative methods.

3. *Union by Granulation.*—This form of union, also known as union by the *second intention*, is that which occurs when the reactionary process extends to the stage of pyogenesis. As already pointed out (p. 27), it is theoretically possible for pus to be formed without the intervention of microörganisms; and it is likewise theoretically possible for wounds to unite by granulation without the formation of any visible pus: but for either of these events to occur in practice is excessively rare. If the lips of the wound are not brought into accurate apposition, the gaping surfaces become covered with visible granulations, and always, I believe, some pus will be seen on the surface of the healing wound (which really is an ulcer), or will be absorbed by the dressings. The process of cicatrization and contraction is pathologically identical with that seen in the healing of ulcers (p. 53). Union by *secondary adhesion* (the *third intention*) is that which occurs when two lips of a granulating wound are apposed by sutures, or in other ways, so that the fibroblasts and granulations on one lip grow across the obliterated gap into the granulation tissue on the opposite lip, thus hastening the process of repair. If there is much discharge from the wound such secondary adhesion will not occur. Healing by *scabbing*, by *incrustation*, or by *subcrustaceous cicatrization*, is that form of union (by adhesion or by granulation) which occurs under a scab formed of effused blood and lymph mixed with the dust, etc., which collects on the surface.

Treatment of Incised Wounds.—The first effort must be to check hemorrhage and to prevent infection. In operating, aseptic or antiseptic principles will be strictly adhered to, and in wounds accidentally received the surgeon, after adopting the necessary measures for arresting hemorrhage (Chapter X) will employ such methods of cleansing the wound and the surrounding parts as have already been advised in Chapter V (p. 140). Very small wounds will gape so little that the proper use of plasters, compresses, bandages, etc., will keep the edges in contact. In most wounds, however, the edges must be united by sutures.

Sutures are made of absorbable or of non-absorbable material. Absorbable sutures are usually made of catgut, which may be prepared in such a way that it will last a more or less definite time in the tissues before being absorbed (10-, 20-, and 40-day chromicized catgut). Non-absorbable sutures are made of linen, silk, silkworm gut, silver wire, etc. *Interrupted sutures* are shown in Fig. 104, each separate stitch being independent of every other stitch. Varieties of the interrupted suture are the *twisted*, or *hare-lip suture* (p. 636),

and the *quilled suture* (Fig. 105). *Continuous sutures* are those in which several or all of the individual stitches are made by one thread which is knotted only at the beginning and end of the line of suture. Various forms of continuous suture are used in surgery; the *overhand suture* (Fig. 106) is most frequently used, and is well adapted for uniting edges of fascia, skin, etc., on which there is not much tension;

FIG. 104.—Interrupted sutures; each stitch is knotted separately.

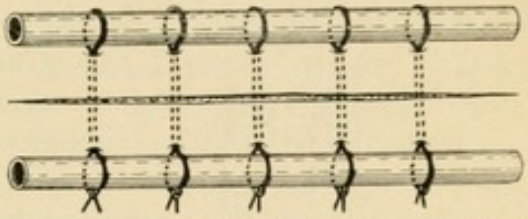

FIG. 105.—Quilled sutures; each stitch is double and tied over a quill, or preferably a rubber tube, which prevents the stitches from cutting. Useful when there is much tension on the sutures.

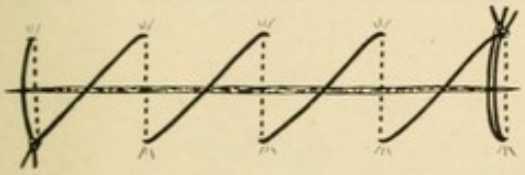

FIG. 106.—Continuous (overhand) suture.

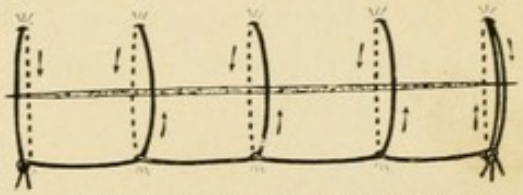

FIG. 107.—Chain or lock-stitch.

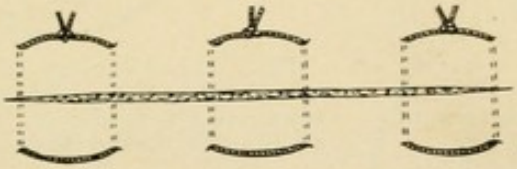

FIG. 108.—Quilt or mattress suture.

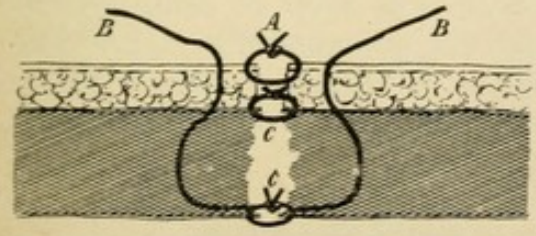

FIG. 109.—Sutures used to repair a deep wound: *A*, *superficial suture* (through the skin only); *B*, *deep suture* (passing deeply into the wound, but *not* a buried suture); *c*, *c*, *buried sutures* (to unite peritoneum, deep fascia, etc.).

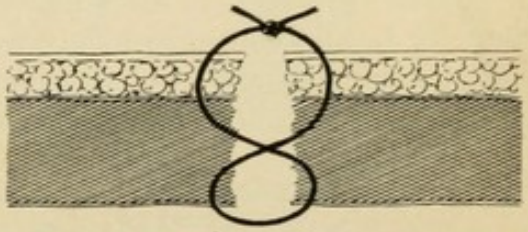

FIG. 110.—Figure-of-eight suture, employed to unite parietal peritoneum, deep fascia and skin.

the *chain* or *lock-stitch* (Fig. 107) is useful where tension is greater; while the *quilt* or *mattress suture* (Fig. 108), by passing deeply into the tissues, is useful where there is tension on the deeper parts, as it tends to evert the lips of the wound. Other forms of continuous suture are used in intestinal surgery (Chapter XXII). A suture may be *superficial*, *deep*, or *buried*, as shown in Fig. 109. As a rule only absorbable material should be used for buried sutures. Deep sutures,

also called mass sutures or splint sutures, are used to relieve tension (*relaxation sutures*), and to obliterate dead spaces in the depths of a wound in which it is not desirable to leave buried sutures; they must be strong and therefore are usually of non-absorbable material. The figure-of-eight suture (Fig. 110) is employed by some surgeons as a deep suture.

Needles.—Straight needles are most generally useful, except for inserting buried sutures, for which *curved needles* are to be preferred. Curved needles usually are held in a *needle-holder* (Fig. 111), but straight needles are easily managed in the fingers. Ordinary surgical needles are made with a *triangular* or a *lance-shaped*

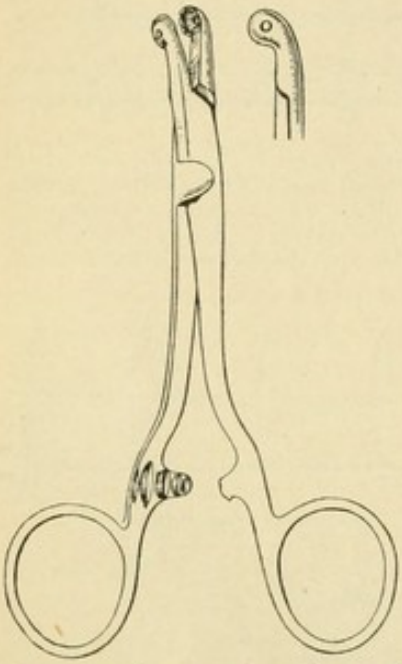

Fig. 111.—A convenient form of needle-holder.

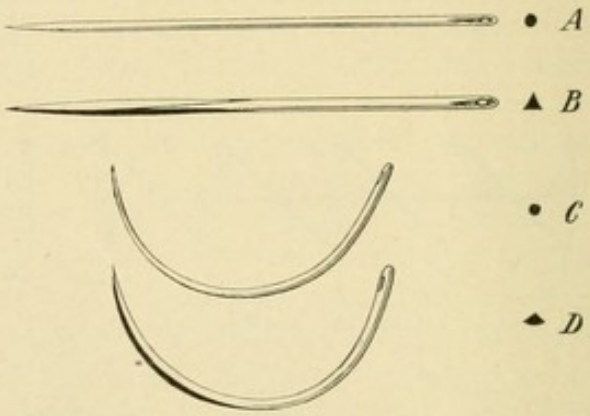

Fig. 112.—Various forms of needles. *A*, straight round-pointed needle. *B*, straight lance-pointed needle. *C*, curved round-pointed needle. *D*, curved lance-pointed needle.

point, to facilitate their introduction; but *round needles* (either straight or curved) are used in intestinal work, as less liable to cause hemorrhage or to allow fecal leakage through the puncture (Fig. 112). The eye of a needle should be large enough to be threaded easily with the suture desired; and the widest part of the needle (belly) should be

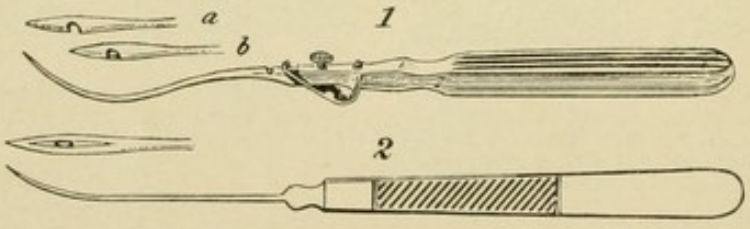

Fig. 113.—1. Reverdin's needle, showing at *a* eye opened, at *b* eye closed.
2. Ordinary mounted needle.

situated where the cutting edges ceases, not on the shaft or at the eye itself. Special forms of needles are set in handles, and have the eye near the point: the *aneurysm needle* (p. 232) has a blunt point, and is used to pass ligatures around large vessels; the ordinary *mounted needle* has been modified by Reverdin by inserting a slide by which the

eye may be opened to facilitate threading (Fig. 113), and is useful in passing deep sutures.

Suture of Wounds.—Superficial wounds may be united with superficial sutures only; if the deep fascia is divided, it should be united with either deep or buried sutures, as the subsequent strength of the part depends largely upon the accuracy with which this structure is sutured, and even in parts where strength is not requisite (as in the neck) neglect to suture the deeper layers carefully results in a spreading instead of a linear cicatrix. Divided tendons, nerves, etc., should be sutured separately by buried sutures. In extensive wounds, especially where the tissues have been much bruised, either by the injury or during the operation, it usually is desirable to provide for *drainage*, to allow the escape of effused blood, lymph, etc., which would retard healing if allowed to remain between the lips of the wound, and perhaps cause sloughing from pressure if not evacuated. Hence the importance of accurate hemostasis in all wounds, especially where drainage is undesirable (as in operations for radical cure of hernia). No dead spaces should be left in repairing wounds: they will be filled by blood-clot, and this will be a suitable culture medium for germs.

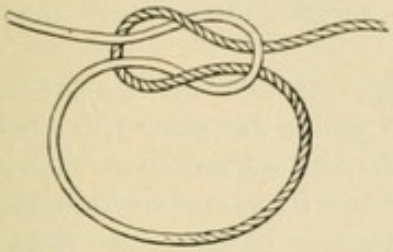

FIG. 114.—The square or reef knot, universally employed. Note that corresponding ends of the ligature pass under (or over) the loop of the knot.

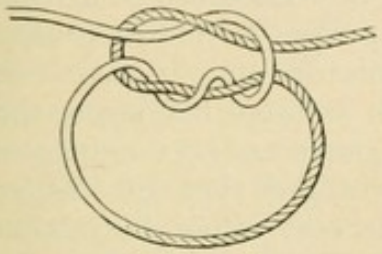

FIG. 115.—The surgeon's knot; employed rarely, but useful if the first hitch of the knot tends to slip before the second can be pulled tight. The same as the square knot except that the first hitch is double.

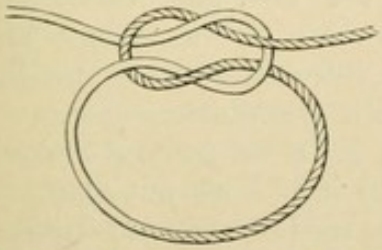

FIG. 116.—The granny knot. Note that of corresponding ends of the ligature one passes over and the other under the loop of the knot.

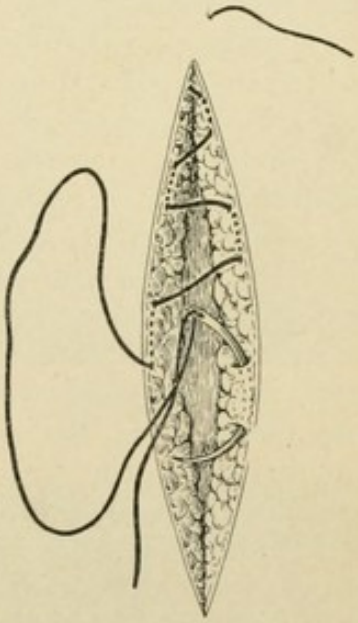

FIG. 117.—The subcuticular suture; it may be used if no dead spaces are left in the deeper parts of the wound. The needle enters the true skin at each bite, not merely the subcutaneous tissues.

Sutures must be drawn just tight enough to appose the edges of the wound without constricting the tissues. Drawing a suture too tight may break it, or may cause sloughing with a resulting stitch sinus. Sutures are secured in position by *knots*, or occasionally by clamping them with perforated shot. The knot employed should be one that will not slip, especially the *square* or *reef knot* (Fig. 114), or the *surgeon's knot* (Fig. 115), never the *granny knot* (Fig. 116). Some surgeons employ little metal clamps (Michel) to appose the skin margins, instead of sutures; or a *subcuticular suture* may be used (Fig. 117).

Dressing of Incised Wounds.—On the surface of nearly every wound there will be a slight exudation of serum between the sutures; to prevent the dressings from sticking to the wound it is therefore well to cover it with silver-foil, or to dust it with some sterile powder. Aseptic wounds may be dressed with aseptic gauze, that next the incision being crumpled up so as more readily to absorb any discharges, while the outer layers of gauze are applied smoothly and in sufficient thickness and width to protect the part mechanically and effectually to prevent the access of any microbes from the surrounding skin or from the fingers of the patient accidentally inserted beneath the edges of the dressing. This dressing is then held in place by strips of adhesive plaster, with suitable bandages, splints, etc., as required. If a tube or a wick of gauze has been employed for drainage, the dressings are to be so arranged that the discharges will be conducted into the dressings without soiling the surface of the wound; this is accomplished by carrying the drain through slits in the dressing, and surrounding its outer end with sufficient crumpled gauze to absorb the anticipated discharge; and carefully protecting this *superficial dressing* from infection by sterile absorbent cotton or more gauze, the entire dressing being suitably bandaged in place. In aseptic incised wounds the drain, along with the superficial dressing, may be removed at the end of twenty-four or forty-eight hours, without disturbing the *deep dressing*. In infected wounds the drains must remain until their tract is lined with granulations (four to six days) converting it into a sinus, which is to be treated according to the principles already discussed (p. 52) if it does not close spontaneously. Non-absorbable sutures are to be removed from the sixth to the tenth day, and in the case of aseptic incised wounds the dressing need not be changed until this time has elapsed. In small wounds of the face superficial sutures occasionally may be removed as early as the fourth day, but in the case of a larger wound, and especially in the case of deep or relaxation sutures, it is unsafe to remove them in less than a week or ten days. If a suture is found at the first dressing to be cutting out, it should be removed, trusting to the neighboring stitches to maintain the lips of the wound in apposition; and frequently it is safer to remove only alternate stitches at the first dressing, and leave the others a day or so longer, or to support the wound with strips of sterile adhesive plaster applied at right angles to its surface.

Lacerated and Contused Wounds.—Lacerated and contused wounds may be considered together, as they are produced by the same accidents, and usually coexist. In lacerated wounds the edges are torn, jagged, and irregular, not sharply cut as in the case of incised wounds; in contused wounds the lips of the wound and the surrounding parts are bruised and more or less devitalized by the original injury. Blows by blunt weapons (clubs, stones, etc.), and machinery and railroad accidents are the principal causes of contused and lacerated wounds; owing to the manner of their production they are almost invariably infected, from bacteria on the patient's skin, his clothing, or on the vulnerating weapon. Earth, machine oil, cinders, and other foreign matter frequently are carried into the depths of the wound. Gunshot wounds, forming a special variety of contused wounds are considered in Chapter VII.

Symptoms.—The *pain* of contused and lacerated wounds is less sharp and more aching than in the case of incised wounds; *hemorrhage* is less, because the vessels are twisted and torn off rather than cleanly severed; and *gaping* is often much less than the extent of the injury would lead one to expect. *Shock* is often severe, and in case of crush or avulsion of a limb may cause death immediately or so soon that no time is afforded for local reaction. This reaction in the wounded parts frequently extends to the stage of suppuration, and the tissues are so much devitalized that more or less sloughing is the rule.

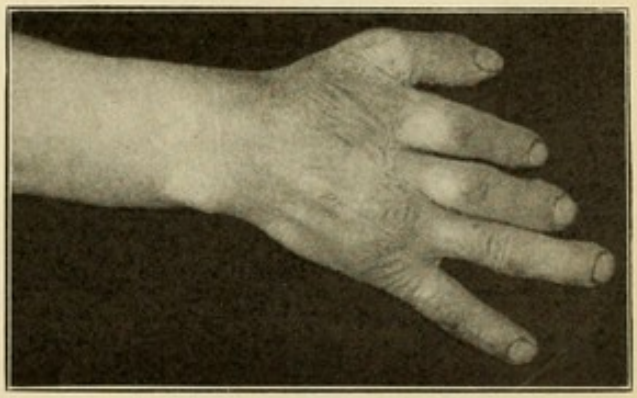

FIG. 118.—Compound fracture of metacarpals, by circular saw injury. Excision of heads of metacarpals, and suture of tendons. Episcopal Hospital.

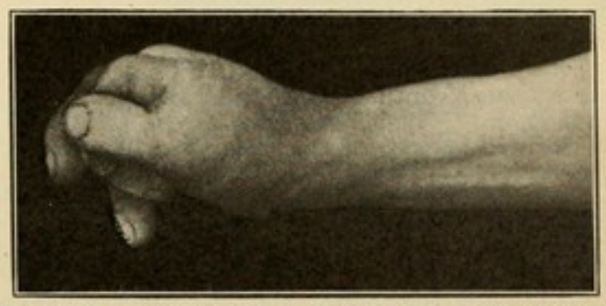

FIG. 119.—Same patient as Fig. 118. Earns $3.50 a day, working as carpenter.

Treatment.—In addition to combating shock and checking hemorrhage, the surgeon must pay particular attention to cleansing the wound. Some of these injuries are so severe that nothing less than amputation will save life (p. 192). But in lacerated wounds or crushes of the hands, much may be done without amputation, by excision of pulpefied tissue and splinters of bone, and by accurate suture of divided tendons, etc. (Figs. 118, 119). Occasionally a completely severed finger tip will grow in place if carefully sutured. General anesthesia often is indicated to allow the necessary treatment to be carried out. The object should be to make the wound approach

in character as nearly as possible to an aseptic incised wound. The wound, itself, is first packed with sterile gauze. Then the surrounding skin should be painted with 3 per cent. iodin solution, and if it is hairy it may be soaped and shaved after the iodin has become thoroughly dry. If it is not hairy it is sufficient to apply a second coat of the iodin solution after the first has dried. Then foreign bodies are to be removed from the face of the wound, slitting up pockets and crannies among the muscles and layers of fascia if necessary to extract bits of clothing, coal dust, and other foreign bodies. In some cases the filthy structures have to be cut bodily away. After the wound has been thus mechanically cleansed, it should be treated antiseptically, being swabbed out with gauze soaked in iodin solution. I have entirely abandoned the use of corrosive sublimate and carbolic acid in such cases, as I find strict adherence to the iodin technique secures better healing. Hydrogen peroxide is another efficient antiseptic; it may be applied after the iodin, but more than one thorough application tends to delay healing. In all cases the cleansing should be done with gentleness, it being an excellent maxim of Sir James Paget's that "wounds should not be scrubbed, even with sponges." In spite of the utmost care it is not always possible to ensure freedom from infection in these wounds, so it is always best to drain them, using only sufficient sutures to hold the tissues in apposition at the extremities of the wound. *Interrupted sutures always are to be preferred to continuous, in infected wounds*, since one or more can be removed at any time to relieve tension, without destroying the entire suture line. Instead of aseptic gauze it is better to use an antiseptic dressing, especially of gauze soaked in equal parts of alcohol and corrosive sublimate. In extensive wounds, where sloughing is feared, it is well to pour alcohol over the dressings every few hours, so as to keep them moist. Constant irrigation with antiseptic solutions is often of great value (Fig. 120). If no undue rise of temperature or local pain indicates excessive reaction the wound need not be inspected until the third or fourth day; and if then the surgeon finds evidence of damming up of secretions, abscess formation, or beginning cellulitis, he should not hesitate to remove as many sutures as

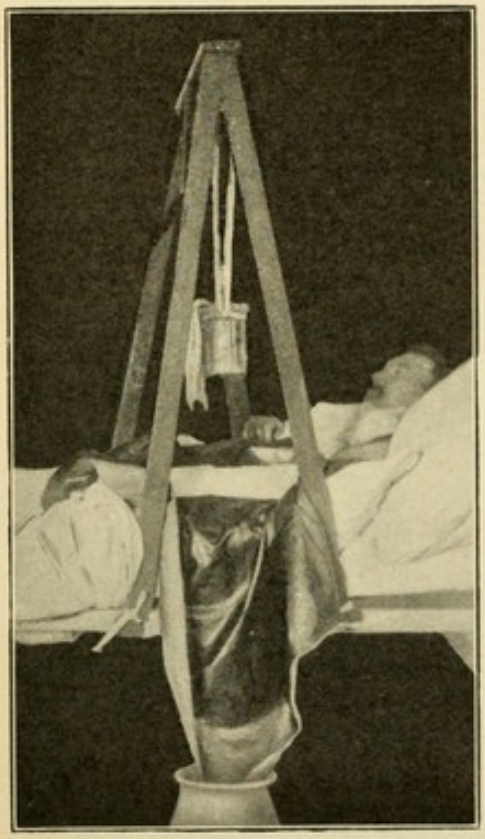

FIG. 120. — Constant irrigation for, crushes, contused and lacerated wounds, etc. The solution drips over the injured part by gauze syphonage. Episcopal Hospital.

requisite (all, if necessary), and pack the wound lightly with antiseptic gauze, using drainage tubes as indicated. In such cases the wound gradually becomes converted into an ulcer, and should be treated accordingly.

Punctured Wounds.—Punctured wounds, as the term indicates, are those produced by pointed instruments, and their importance arises from the fact that infection (not rarely tetanus) is frequent, as no free drainage exists; and because injury to deep structures (viscera, joints, nerves, etc.), may pass unperceived at first. In ordinary practice punctured wounds are produced most often by needles, nails, hat pins, splinters, umbrella tips, etc. If a needle remains in place, with part of the shaft projecting from the wound, it should be extracted, and unless known to be seriously infected,

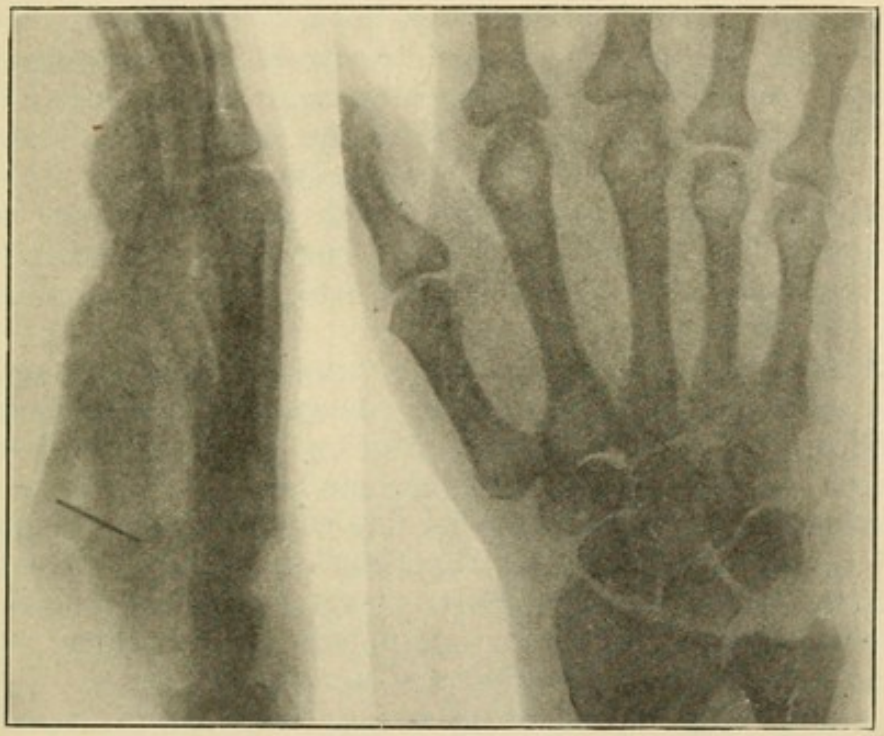

FIGS. 121 and 122.—Skiagraphs to localize needle in palm of hand.

it is sufficient to cleanse the surrounding skin and apply an aseptic dressing. In a patient at the Episcopal Hospital a hat pin which punctured the chest produced no symptoms of any kind, though from the depth and direction of the wound it is certain that the liver, diaphragm, and lung were all traversed. If the point has broken off and is completely buried in the tissues, an immediate attempt to extract it should be made if its position can be detected by palpation; if no clue as to its location exists attempt at extraction should not be made until it has been accurately located by the use of the *x*-rays, two exposures in planes at right angles to each other being made (Figs. 121 and 122). The incision, for which local anesthesia sometimes is sufficient, should be made obliquely to the course of the needle, being thus more apt to strike it than if made parallel. A

needle buried in the palm is best exposed by turning up a flap of skin. If a large joint has been punctured, the part should be immobilized, the patient being kept in bed if necessary. In wounds from splinters and rusty nails the danger of tetanus developing is greater; accordingly the puncture should be slit up, to ensure the removal of all parts of the splinter, and to allow the application of antiseptics to all parts of the wound.

Stab wounds occasionally are seen in civil practice; they partake of the nature of both incised and punctured wounds, and like the latter are of interest chiefly from the implication of joints, internal organs, bloodvessels, nerves, etc. Their treatment is considered in the chapter dealing with the surgery of these structures. *Bayonet wounds* are seldom seen nowadays, even in military surgery. In battles with Indians and other uncivilized tribes *arrow wounds* are sometimes encountered. The arrow-head is very easily detached from the shaft, and reckless attempts to extract the weapon frequently result in the head breaking off and remaining in the tissues as a foreign body. Sometimes it is better to push the arrow on and extract it through the counterpuncture. Indian arrows were frequently poisoned with rattlesnake venom or with earth containing tetanus germs, and Schell found it a universal custom to dip the points in blood which was allowed to dry on them; but such practices are rare at the present day.

Tooth wounds, especially those due to human bites, are apt to be severely infected. Dog bites are less dangerous than those of cats, rats, and other domestic animals. Monkey and parrot bites are not very rare. I have treated a case of mole bite.

Poisoned Wounds.—Under this heading it is convenient to consider snake bites and insect-stings. The latter are seldom serious in this part of the country, but in the tropics are sometimes fatal. The lesion consists in a localized, occasionally a spreading cellulitis, which is treated by evaporating and antiseptic lotions. The pain of stings is quickly allayed by plastering the bite with liquid mud, which should be washed off so soon as antiseptics are available; aqua ammoniæ also relieves the pain and neutralizes the acid poison.

Snake Bites.—Snakes (*ophidia*) are divided into two main classes, the *Colubrines*, mostly harmless, and the *Viperines*, usually poisonous (*thanatophidia—death-snakes*). To know whether the injury is from a harmless or a poisonous snake, the bite should be examined: "If the snake is harmless, two uniform rows of tooth marks will be found; if there are two or more distinct fang-marks, with or without tooth-marks, the snake is poisonous" (Fig. 123) (Mason, 1907). The venom is contained in a sac at the base of the hollow fang, which is on the upper jaw; this sac is compressed by the muscles which close the jaws, and the virus is squirted through the hollow fang much as through a hypodermic needle. Repeated biting soon empties the poison sac, and the snake is then comparatively harmless until more virus has been secreted.

The most important constituents of snake venom are a globulin and a peptone. The former destroys the coagulability of the blood, and produces molecular changes in the vessel walls; this accounts for the extravasation and hemorrhages (subcutaneous, gastro-intestinal, renal), which are characteristic of snake poisoning. The peptone produces locally "rapid edema, putrefaction, and sloughing without extravasation; constitutionally, it increases blood-pressure, accelerates the respiration, and often causes convulsions." (Mason, 1907.) In rattlesnake bites, almost the only kind seen in this country, death occurs in from 12 to 25 per cent. of cases, usually within twenty-four to thirty-six hours. Death from cobra bites, which are frequent in India, and not very rare in the Philippines, occurs usually in a few hours. Bites of copper-heads and moccasins are not so fatal, though amputation may be required for sloughing, or septicemia may kill at a later date.

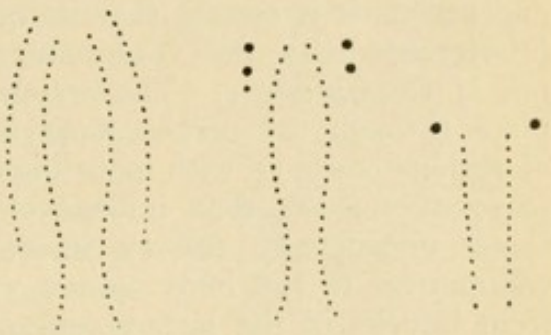

FIG. 123.—Tooth marks made by snake bites: on the left a harmless snake; fang-marks in the centre and on the right indicate a poisonous snake.

Treatment consists, locally, in the immediate application of a ligature or tourniquet around the limb above the wound, and in suction of the punctures by the mouth, or by cupping glasses when available. The venom is not poisonous when taken by mouth, if the stomach is full; but it should of course be spat out. Free incisions will make suction more effective. Amputation or excision of an unimportant part may be done. The ligature should be used intermittently, admitting only small doses of the venom into the circulation at one time; and when the wound is far enough from the trunk to make it possible, it is well to apply a high and a low ligature alternately. Mason also recommends that the limb be bandaged from its two extremities toward the wound, so as to squeeze out all the venon possible. The best local applications after free incision are oxidizing agents, such as peroxide of hydrogen, or 1 per cent. solutions of potassium permanganate or chromic acid. The actual cautery (hot coals, burning gun-powder) should be employed if these remedies are not at hand. Local treatment should be prompt, as it is probably useless after the lapse of half an hour. Constitutionally alcoholic stimulants are indicated, being pushed to the point just short of intoxication. Strychnin is considered valuable. Calmette's serum (antivenene) should always be employed when available; hypodermic injections of 10 to 20 c.c. of the stronger serum are given as soon as possible. Gastric lavage and catharsis are indicated to remove the venom excreted into the gastro-intestinal tract. Hope should not be abandoned too soon, some remarkable recoveries being recorded after the prolonged use of artificial respiration.

GENERAL EFFECTS OF INJURIES.

Shock.—The immediate constitutional effect of injury is named *shock*. A severe grade of shock is called *collapse*. Although no very accurate knowledge of the pathogenesis of shock has yet been obtained, in spite of the elaborate experimental investigations of Crile (1899), and others, it is certain that its most important features are due to interference with the vaso-motor mechanism, resulting in marked *fall of blood-pressure*. The action on the vaso-motor centre takes place through the nerves supplying the injured part, and injuries of regions endowed with more highly specialized nerves are more apt to produce shock than injuries of other parts. Severe, even fatal, shock occasionally follows injuries accompanied by insignificant traumatism to the body tissues. Shock is especially apt to occur from injuries of the larynx, and of the viscera, particularly those of the upper abdomen, involving the splanchnic, and those of the thorax involving the cardiac plexuses. Injuries of the genitalia are frequently accompanied by marked shock, when the nerves of the spermatic cord are bruised or injured. Extensive burns and scalds, affecting immense numbers of peripheral nerve endings, are followed by marked shock. Lacerated and contused wounds, gunshot wounds, mangling injuries, and crushes are often accompanied by an extraordinary degree of shock. Henderson (1908) has proposed the theory that shock is due chiefly to loss of the carbon dioxide constituent of the blood, a state to which he applies the term *acapnia;* and as carbon dioxide is a well known stimulant of the pressor mechanism of the vaso-motor system, causing rise of blood-pressure, it is not improbable that the shock which follows eventration of the intestines in certain operations may be partly accounted for in this way.

Predisposing Causes.—General debility, extreme youth and age, and organic disease of the heart, kidneys, or other viscera, are among the predisposing causes. Exposure and chilling of the body surface, if prolonged, will increase shock. Hemorrhage, by directly affecting the patient's vitality, and lowering blood-pressure, is probably the most important cause of all. Prolonged anesthetization acts in a similar manner, chloroform causing lowering of blood-pressure from the very first, ether only after long administration.

Symptoms.—The patient, if not stunned by the injury or suffering from cerebral concussion, is conscious, his mind sometimes being clear and alert, but more often semi-stuporous, as if the effort even to think were exhausting. The face is pale, the lips ashen or slightly blue; the entire body surface is pale, cold, and often clammy; the temperature is subnormal (Fig. 124); the eyes are staring or half-closed; there may be dimness of vision or actual blindness (from retinal anemia); the pupils are dilated, and react sluggishly to light; the respirations are shallow and rapid; the pulse is quick, fluttering, weak and frequently uncountable. Incontinence of feces is frequent, that of urine rare and usually portends a fatal issue. The patient

lies motionless wherever placed. This *torpid stage* may last a few minutes or several days. Death may occur without reaction, in spite of energetic treatment. If reaction occurs, the patient usually sighs deeply, moves his eyes and limbs voluntarily, and turns on his side; vomiting is not an unusual sequel. Recovery may be apparently complete in a few minutes, or may occur gradually, especially when there is some severe injury present. When reaction occurs, it may be excessive, the patient becoming mildly delirious, and exhibiting the condition described by Travers (1827) as *prostration with excitement* (*erethistic shock*). This condition, which occasionally develops immediately after the injury, the torpid stage being extremely short or altogether absent, may pass into true *traumatic delirium*, an affection probably due to some form of toxemia. The patient is restless, talkative, with bright, roving eyes and incessant action; he is really weak, though seemingly strong, and is liable to collapse at any time. He is pursued by frightful hallucinations, often acting over and over again in his delirium the drama of his injury. Traumatic delirium should always be regarded as a dangerous complication, being unusually serious when developing immediately after the accident.

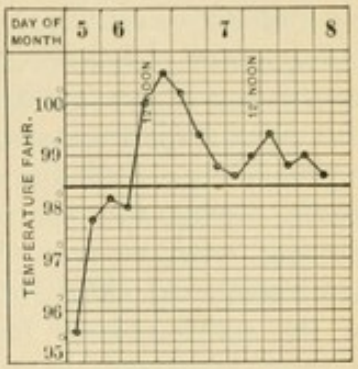

FIG. 124.—Shock and reaction. Case of multiple fractures; man, aged thirty years. Episcopal Hospital.

After death from shock there may be found no lesions sufficient to have caused death. In such cases death probably has occurred from inhibition of the heart's action (collapse.) Usually, however, the venous system is found to be filled with blood, the capillaries and arteries being comparatively empty, and the great bulk of the blood being contained in the portal system of veins and the vena cava: it is as if the patient had bled to death intravenously. Evidently the heart has ceased to act because no blood was supplied for it to contract upon, the coronary as well as the systemic arteries being thus deprived of blood.

Under the name of *secondary* or *insidious shock* has long been described a change, almost invariably fatal, usually occurring a day or so after apparent recovery from the primary shock of an injury or operation. At autopsy the right heart is found distended with clots, which may invade the pulmonary arteries, constituting *pulmonary embolism* (p. 178). It is probable that most such cases are caused by a low grade of sepsis.

Diagnosis.—To differentiate shock from internal hemorrhage is frequently impossible until the physical signs of the effused blood appear; moreover, in any case of extensive hemorrhage, shock will be present also. **Syncope** occurs without history of injury, the patient becoming unconscious, and possibly being subject to fainting fits. **Psychical shock** (fright) should not be mistaken for surgical shock;

it may result in death in the absence of all injury, especially in cardiac patients, but usually the mental trepidation soon passes off, having caused no more serious disturbance than a sinking feeling in the precordium, slight qualmishness, and a temporarily accelerated pulse. Erethistic shock and traumatic delirium are to be distinguished from *delirium tremens* and *mania a potu*. In these a history of chronic alcoholism usually can be obtained, and the delirium is somewhat different in character: in **delirium tremens** which may be regarded as the first stage of the affection, the patient is fearful and shrinking, the delirium is muttering, the hallucinations usually relate to insects, reptiles, etc., and the trembling of the hands is characteristic; in **mania a potu**, the second stage, he is violent, shouting, cursing and singing, with no fear of man or devil, breaking loose from the bed, attempting to climb out of the window, and having no sensations of the pains caused himself, grinding his broken bones together as if they were cobble-stones (Hunt, 1881), and sometimes wilfully mutilating his person. Yet as alcoholics are prone to severe injury, and therefore to shock, it is frequently impossible to say whether the ensuing delirium is alcoholic or purely traumatic. The *delirium of uremic conditions* (Chapter XXV) adds another confusing factor which is often present in injured alcoholics and others with diseased kidneys.

Prevention of Shock.—General anesthesia does not prevent shock. Ether is a cardiac stimulant, and when first administered by inhalation or hypodermically, will increase the force of the heart beat, and in this way may make the shock less than it would have been otherwise; but if long continued, the blood-pressure falls; and shock is increased. Unconsciousness, however, almost invariably diminishes the shock of an operation. The peripheral nerve trunks may be blocked by injecting them with cocain, thus cutting off impulses of all kinds which might reach the vaso-motor centre (anoci-association, p. 148); in this way operative shock may be so prevented, that, as Crile says, after cocainizing the nerve trunks and ligating the main vessels, an amputation may be done with no more effect on the patient than would be produced by cutting the sleeve off his coat. The hypodermic use of atropin is valuable in two ways: it causes a rise of blood-pressure by central action, and by paralyzing the inhibitory fibres of the vagus prevents injurious impulses from reaching the heart and producing collapse. Cocain hypodermically acts much in the same way. Morphin is less efficient, and strychnin is practically worthless except as a tonic administered for some days in advance of operation.

During an operation the most important means of preventing shock are control of bleeding, gentle manipulation, and maintenance of bodily heat. Direct trauma to the tissues, especially nerves, should be studiously avoided; direct division by the scalpel should replace blunt dissection and tearing, dragging manipulations whenever possible. Mechanical means for maintaining blood-pressure are discussed under Treatment.

Treatment.—The indications are to restore blood-pressure, prevent the loss of body heat, and keep the patient alive (by artificial respiration if necessary) until the remedies used have time to act. Bleeding must be checked by pressure, elevation, tourniquet, ligatures, etc.; the patient's head should be lowered to allow the blood to flow into the empty heart. Cover the patient warmly, and surround him with hot water bottles, hot bricks, etc.; give him atropin, digitalis, or adrenalin, hypodermically; encase his extremities in raw cotton, and bandage them from the periphery toward the trunk (*autotransfusion*), thus forcing blood to the heart; perform artificial respiration and apply massage to the heart by direct pressure over the precordium, or transdiaphragmatically through an epigastric incision. Give saline solution intravenously, and in severe cases, and where facilities exist, do direct transfusion. Adrenalin may be added to the saline solution (1 to 20,000).

Great care should be taken to be sure that serious symptoms occurring during an operation are really due to shock, and not to acute dilatation of the heart. In the latter condition, the measures above detailed for driving more blood into the right heart will only make matters worse: the head should be kept high, and, if this does not relieve, the patient should be bled, and in extreme cases the right ventricle may be punctured. In any case, artificial respiration and massage of the heart should be persisted in for fifteen or twenty minutes.

In shock from inhibition, as in operations on the larynx and thoracic organs, the most important measures are: the head-low posture with artificial respiration and cardiac massage, both secured by "rapid rhythmic pressure upon the thorax over the heart" (Crile), with the tongue drawn well forward and upward, to open the larynx. In shock due primarily to hemorrhage, the head-down posture, the use of saline solution, and bandaging the extremities are of most value. In the severest cases of shock, with cessation of respiration and circulation (*suspended animation*), adrenalin should be added to the saline solution, injecting 10 to 30 minims of a 1 to 1000 solution of adrenalin chloride, drop by drop, from a hypodermic syringe, into the rubber tube through which the saline solution runs, the entire amount being administered in about one minute (Crile). Cardiac massage will force enough of the adrenalin saline solution into the arterial system to raise the blood-pressure enough to sustain the circulation. In conjunction with the other methods detailed above, this may bring back the dead to life. If relapse follows temporary improvement, more adrenalin should be used, as its effect is evanescent.

Treatment of Traumatic Delirium and Delirium Tremens.—If the patient is not too violent, attempts should be made to dilute the toxins in the blood by the use of saline solution, by rectum, hypodermically, or even intravenously. Lumbar puncture sometimes aborts the disease. In any case the patient should be isolated, to avoid the

mutually exciting effect of other patients. Catharsis will aid elimination of toxins. Sedatives and hypnotics should be freely employed, especially veronal, and paraldehyde. Sleep should be obtained at all hazards, but morphin, hyoscin, chloral, and the bromides increase the mortality, and are much less effective than veronal and paraldehyde (Ranson and Scott, 1911). Measures must be taken to prevent the patient from injuring himself, strapping him to the bed if necessary, and never leaving him unguarded by a nurse or orderly strong enough to control his actions. Liquid diet should be taken in moderation, but the more water that can be absorbed the better. Ranson and Scott urge the use of ergot (1 dram of fluidextract every four hours) as preventative of cerebral edema and as a general circulatory stimulant. No alcohol should be given to patients with alcoholic delirium; though Ranson and Scott urge its administration at least in the first stage of the affection, all surgeons of large experience in accident wards find that *immediate and absolute withdrawal of alcohol* from patients with delirium tremens both shortens the disease and decreases the mortality. In traumatic delirium from burns, etc., in which there is clear evidence that no element of delirium tremens is present, but in which delirium is due chiefly to asthenia, the moderate use of alcohol frequently hastens convalescence.

Causes of Death after Operation.—As operations always involve the infliction of wounds, this seems a suitable place to consider the causes of death after operation. Certain of these causes are more or less avoidable; such are shock, hemorrhage, pneumonia, and sepsis. Others usually seem unavoidable, especially myocarditis, embolism, status lymphaticus, heat prostration, and conditions previously present which the operation could not remove or which it has inevitably made worse. Among the latter may be mentioned various forms of sepsis (peritonitis, pyemia, etc.), curable only by removal of the original focus and the institution of drainage, but which these measures, though judiciously and skilfully executed, nevertheless fail to relieve; asthenia from preëxisting shock or hemorrhage, death being certain without operation, but a fighting chance of recovery existing after prompt operation; and preëxisting disease of the kidneys or other organs when operation is undertaken as the only means of cure. The conscientious surgeon will never, therefore, blithely assure his patient that any operation is entirely devoid of risk, as these calamitous deaths frequently occur when least expected.

Shock.—See p. 172.

Hemorrhage.—The importance of preventing loss of blood during operations cannot be overestimated; and, fortunately, gross and sudden hemorrhages usually can be prevented, for it is these which are much more lethal than the slight ooze throughout the operation which sometimes is unavoidable. But even though quite large amounts of blood may be lost gradually without producing immediate and noticeable effects, it is much better for the surgeon to go about his work deliberately, clamping or tying bleeding vessels as he goes,

than to try to hurry along and by his very haste making less speed from having continually to return and pick up vessels which might have been caught with more effect when first divided, and thus subject his patient not only to the unnecessary if gradual loss of blood, but also to a needlessly prolonged operation, and to unnecessary tissue traumatism from repeated sponging and search for the bleeding points.

In addition to this *primary hemorrhage* which occurs at the time of operation, surgeons recognize an intermediary, consecutive, or *reactionary hemorrhage*, which occurs after recovery from the anesthetic or the shock of operation, due to the reëstablishment of the normal circulation and blood-pressure, causing bleeding from vessels which escaped notice at the time of operation owing to their collapsed condition; and a *secondary hemorrhage*, which occurs any time between the occurrence of reaction and the ultimate healing of the wound. Secondary hemorrhage is due usually to separation of ligatures (1) from their having been insecurely applied at first; (2) to their premature absorption; or (3) to ulceration of the vessel walls at the site of ligation; occasionally it is due (4) to sloughing of a vessel at another point in the wound.

The *treatment* of hemorrhage is discussed at p. 228.

Pneumonia.—Careful examination of the lungs should always be made before undertaking any operation, especially under a general anesthetic. If bronchitis or pneumonia already exists and the operation cannot possibly be postponed, as in the case of strangulated hernia, local or spinal anesthesia should be employed. To prevent the development of pulmonary complications, a general anesthetic must be given with care, guarding against choking, secretion of mucus, and inspiration of vomited particles; and pains must be taken not to expose the patient to chilling, draughts, etc., either during operation or while recovering from the anesthetic. After an operation, patients, especially if aged, should not be kept flat on the back long, being turned from side to side at suitable intervals to guard against the development of hypostatic congestion; deep breathing should be enjoined periodically; and they should be allowed to sit up or to leave the bed so soon as the condition of the wound permits.

Sepsis.—In operations on previously aseptic structures, sepsis can and should be prevented. Whenever it occurs under such circumstances, the surgeon should seriously endeavor to detect the fault in his technique, in order that a similar calamity may not occur again. In operations on already infected parts, it will not always be possible to prevent infection from spreading further, or from becoming more virulent even if still localized; but by strict adherence to antiseptic methods, unfavorable results might be made much less frequent than they are.

Myocarditis.—"Heart failure" usually is an unavoidable cause of death; detection of the lesion before operation is frequently difficult, and even skilled physicians occasionally err in estimating the ability

of an evidently diseased heart to withstand the strain of operation. The choice of anesthetic, the position of the patient during operation, avoidance of causes of cardiac collapse and of shock, the rapidity and extent of the operation itself, all deserve to be considered more attentively than usual in such patients.

Embolism.—Under the term "secondary or insidious shock" (p. 173) was formerly described a condition which is now popularly known as "pulmonary embolism." From some chemical change (bacterial or aseptic) in the blood, it becomes more prone to clot, and at various periods after operation, but usually not until convalescence seems assured, a portion of a thrombus, formed at or near the seat of operation, is detached, is carried to the right heart, and thence to the pulmonary arteries, where it may lodge; or, passing through, may cause pulmonary infarction. The *symptoms* are sudden dyspnea, cyanosis, precordial pain, collapse, and rapid, perhaps immediate, death. Busch (1909) has recently studied twenty-two deaths after operation, presenting symptoms usually ascribed to pulmonary embolism: twelve of these patients died with great suddenness, no preliminary symptoms of any kind existing; while in ten death occurred at periods varying from ten minutes to three and one-half hours after onset of the symptoms. These ten patients all came to autopsy, and in only five was a pulmonary embolus or infarction found, the five others having died from myocarditis. The *diagnosis*, therefore, is not always easy.

Treatment.—The treatment is purely symptomatic, including inhalations of ammonia, and the hypodermic use of atropin, oil of camphor, etc. Trendelenburg (1908) has proposed arteriotomy of the pulmonary artery, by opening the pericardium, with removal of the clot; he adopted the operation in one case, his patient living until the next day, while Siever's patient (1908) lived fifteen hours. As death frequently occurs with great suddenness, giving no opportunity for treatment of any kind; and as in other cases recovery under expectant treatment, though rare, is not unknown; and as the diagnosis between myocarditis and embolism is often impossible, I think Trendelenburg's operation should be regarded at present more in the light of interesting surgical gymnastics than as a practice for habitual employment.

Fat-embolism.—Fat-embolism occasionally occurs after injuries of or operations on bones. The symptoms and treatment resemble those of ordinary pulmonary embolism; lipuria is not pathognomonic, though suggestive, and it may exist in cases of simple fracture without evidence of embolism.

Status Lymphaticus.—This term is used to describe a condition in which there exists widespread enlargement of lymphoid tissue in all portions of the body—naso-pharyngeal "adenoids," cervical "adenitis," hypertrophy or hyperplasia of the bronchial and mesenteric lymph nodes, and of the thymus gland. It is most frequent in rachitic children, and subjects of it are liable to sudden death at

any time, even during natural sleep (Blumer, 1903). The true cause of these deaths is not known, but is probably to be classed as an "auto-intoxication;" death almost certainly is not due to acute enlargement of the thymus gland causing asphyxia from pressure on the trachea. Unfortunately the existence of the condition is rarely if ever recognized until death occurs. Undoubtedly some deaths charged to the anesthetic really are due to the status lymphaticus. Death may occur while the patient is under the anesthetic, or, as is more often the case, a few hours later, with symptoms of dyspnea, rapid, feeble pulse, high temperature, and restlessness, but

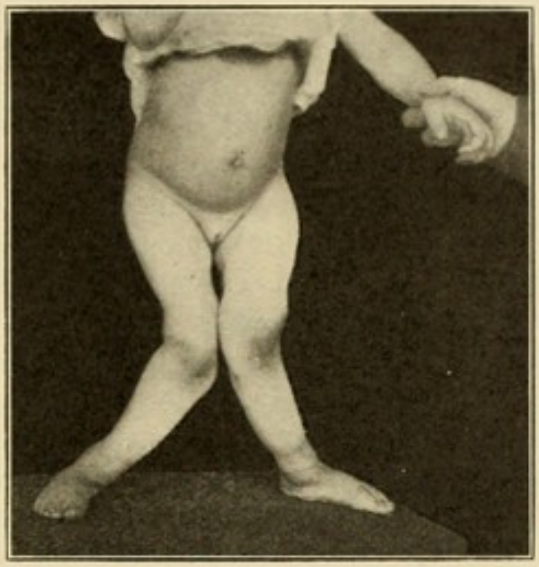

FIG. 125.—Case of severe knock-knee due to rachitis; death from "status lymphaticus" five hours after double osteotomy. Orthopædic Hospital.

with no evidence of traumatic delirium. In the case of the patient shown in Fig. 125, death occurred five hours after the completion of a double osteotomy; and at autopsy no lesions could be found other than diffuse enlargement of the bronchial and mesenteric lymph nodes. There was no evidence of pulmonary embolism, fatty or other, and death was attributed to the status lymphaticus.

Heat Prostration.—Heat prostration occasionally causes a post-operative death. The symptoms and treatment are the same as for heat prostration in other patients. It is well to postpone all operations but those of immediate necessity during the prevalence of extremely hot weather.

CHAPTER VII.

GUNSHOT WOUNDS.

Gunshot wounds are those produced by missiles projected by the explosive action of gunpowder. The missiles include the various projectiles from artillery (*shell, solid-shot, cannister*, and *shrapnel*); *bullets* from small-arms (muskets, rifles, revolvers); as well as *small shot* from shotguns. *Solid-shot* and *shells* are directed rather against defences than the soldiers on guard, and these rarely are injured except by fragments of such large missiles. *Shrapnel* and *cannister* are much alike, being composed of a collection of small missiles within an iron casing; but cannister explodes as it is discharged from the gun, while shrapnel contains an explosive in its centre, with a time fuse, and is exploded only when the time-fuse is consumed. Both shrapnel and cannister are used only at close range. The injuries produced by all forms of artillery missiles are exceedingly destructive, partaking of the nature of contused and lacerated wounds. In naval warfare such wounds are much more frequent than those from small-arms. Amputation frequently is required.

Bullet wounds comprise nearly 90 per cent. of those seen in war, and form almost the only variety of gunshot wounds encountered in civil life, with the exception of occasional wounds from small-shot or from wadding out of blank cartridges. Musket balls (round) are no longer used in civilized warfare, their place having been taken by conoidal bullets projected from rifled barrels (Fig. 126). The rifling imparts to the missiles a rotatory motion, or spin, which in the case of the modern Mauser bullet approximates 2500 revolutions per second on its discharge, at which instant its velocity is nearly 2700 feet per second (*initial velocity*). The Mauser bullet now in use in the U. S. Army is 0.30-calibre (*i. e.*, 0.30 inch in diameter), and 1.08 inches long; it consists of a core of lead and tin composition inclosed in a jacket of copper and nickel (Borden, 1913). The high velocity imparted to the modern bullet tends to make its *trajectory* (line of flight) more nearly horizontal, thus increasing the *danger zone*.[1] The rotary motion and high velocity, combined, tend to lessen the bullet's *dip*, thus enabling it to strike more nearly end-on; while both factors markedly increase its penetrating power. The *range* of

[1] When fired horizontally ("point blank") the danger zone embraces the entire trajectory of the bullet, which under such circumstances is about 700 yards in length; when aimed at a greater distance the shot is fired into the air, the trajectory is a parabolic curve, and the danger zone is removed to the area within which the bullet is liable to strike earth.

the modern military bullet is fairly accurate up to one mile. Bullets may strike elsewhere first, wounding the patient only by *ricochet*, after being deformed by the first impact; such wounds are more apt to be lacerated and contused.



1 2 3 4

FIG. 126.—Evolution of the bullet. 1, old rounded musket ball; 2, Minié bullet; 3, 0.45-calibre Springfield; 4, 0.30-calibre jacketed Springfield, model 1905. All of natural size. (Bryant and Buck.)

At close range, the modern military bullet has what is known as an *explosive effect;* that is to say, any marked resistance causes its energy to be transmitted into the surrounding tissues. The more resistant the tissues, the more marked is the explosive effect. This is particularly noticeable in bone: if the spongy, expanded epiphyses are struck, there is little resistance offered and a grooved or tunnelled wound will be produced (Fig. 127); whereas if the hard brittle diaphysis is struck the bone will be shattered (Fig. 128). Fluid-saturated or fluid-containing organs offer extreme resistance to bullets, because of their lack of compressibility; the brain, the liver, and the hollow viscera (if distended with liquid or semi-solid food) afford notable examples of this explosive action at close range. This destructive action is due to the missile's high initial velocity. Larger missiles (as the old round shot) with much lower velocity, even when almost spent, may have an equally destructive action. These facts are concisely expressed in the physical formula $M = mv$; that is, the *momentum* equals the product of the *mass* by the *velocity*, and if either the mass (as in the larger missiles) or the velocity (as in the modern military bullet) be sufficiently great, the momentum of the projectile, and hence its destructive action, will be correspondingly great.

The bullet wounds encountered in civil life (suicide, homicide, etc.) as a rule are not produced by modern military bullets, but by softer, unjacketed bullets (Minié or Springfield) of low velocity (about 700 feet per second); the calibre varies from 0.22 to 0.40 or 0.45, but is usually large; and the wounds much more resemble those seen during the War of the Rebellion. As in civil life the bullet is softer, larger, and slower, it is more easily deflected and deformed, and almost invariably lodges in the patient's body; the wound is less clean cut, more lacerated and contused, than that produced by the

military bullet; the bullet remains as a foreign body; and infection is much more frequent. In war it is very exceptional for the bullet to lodge in the patient's body; and owing to the greater velocity, the direct impact, and the rectilinear course of the bullet through the body, and its subsequent absence from the wound, infection is less usual. Unless a large bloodvessel or important organ is wounded, death in war is seldom immediate; but it appears to occur in a larger proportion of cases since the introduction of the modern bullet, largely because of its penetrating power, which causes it to cut cleanly through or to groove large bloodvessels, instead of rupturing or contusing them. The latter result, commoner with the soft bullet, favored clotting and prevented death from hemorrhage on the field.

General Character of Gunshot Wounds.—As already noted, the wounds produced by *artillery missiles* are very severe, a limb being completely carried away, the head being blown off, or a large portion

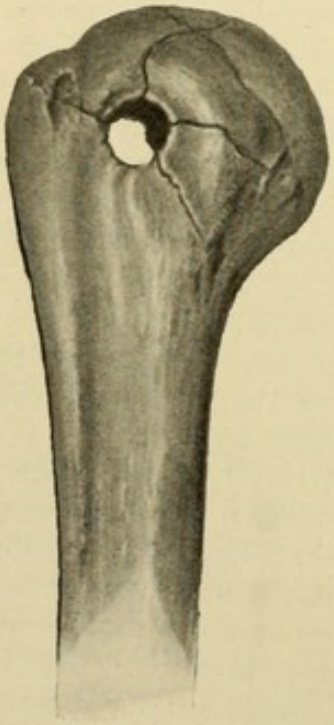

FIG. 127.—Cancellous bone perforated by bullet. (After Helferich.)

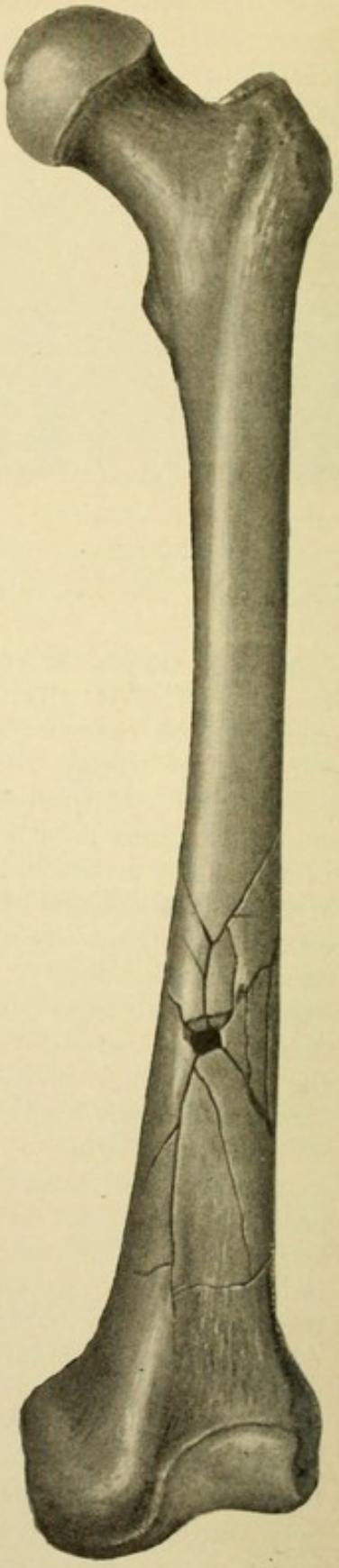

FIG. 128.—Compact bone shattered by bullet. (After Helferich.)

of the trunk being actually destroyed. In civil life such injuries are occasionally encounterred in blasting accidents, explosions, etc.; the wounds are severely lacerated and contused, and require the usual treatment for such lesions. As the skin is elastic, a slowly moving cannon-ball frequently has produced subcutaneous injuries (fractures, rupture of vessels, etc.), without lacerating the integument; such injuries were formerly attributed to the "wind" of the ball.

Bullet wounds are in the nature of punctured wounds, and either *penetrate* or *perforate* the body. If they merely penetrate, there is only a *wound of entrance;*[1] if they perforate there is a wound of entrance and also one of *exit* (Fig. 129), except in very rare cases where the bullet makes a circuit within the body and emerges again by the wound of entrance. If fired at close range (usually not over 3 feet) there will be powder-marks around the wound of entrance. The wound of exit is usually, especially in civil life, larger than the wound of entrance, and its margins may be somewhat everted. This is due to the bullet being deformed after striking, to the reduction in its velocity, to its carrying particles of flesh or bone before it into and out of the wound, or to it emerging sideways (no longer "end-on"). The wound of entrance sometimes seems smaller than the missile by which it was produced, from the elasticity of the skin. If two bullets enter by the same wound, one may pass through and the other lodge; or they may emerge by the same or by different wounds; and two bullets may enter by different wounds and emerge by the same wound of exit. One bullet may traverse successively various parts of the body, making wounds of entrance and exit in both lower or upper limbs, or in a limb and the trunk, or if the limb is acutely flexed, traversing the same limb twice. The track of the bullet forms a sinus which heals by the ordinary processes of repair. The smaller the calibre of the bullet, the less likely is sloughing to occur; wounds by bullets of 0.22 calibre frequently heal without infection, even in civil life; those by bullets of 0.35 calibre or over almost invariably suppurate throughout their extent.

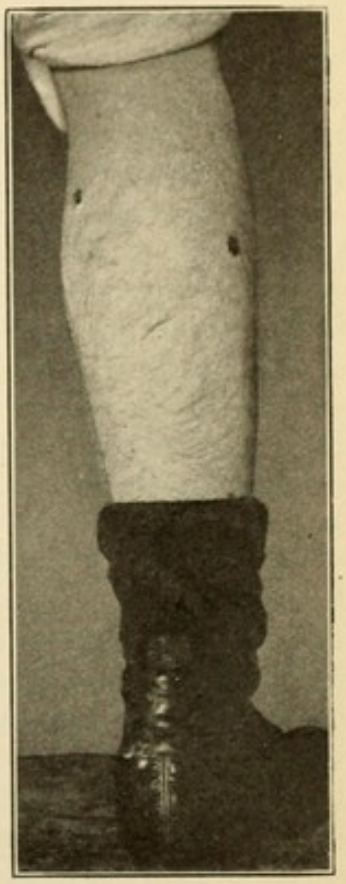

FIG. 129.—0.38-calibre bullet wound in right calf. Wound of entrance on outer side; wound of exit on median side. Five days after injury. Episcopal Hospital.

Symptoms.—These are *general* and *local*. *Shock* is seldom marked in modern warfare, unless a vital organ is wounded, or unless the bullet has been fired at close range, with explosive effect; in the heat

[1] This may be within the mouth, or even within the anus or the external auditory meatus, when it is readily overlooked.

of battle, a soldier may be scarcely aware that he is wounded until he feels the trickling blood. *Traumatic delirium* occasionally is marked, sometimes occurring at once, without any apparent shock. *Pain* rarely is great, usually being merely a stinging sensation, as if from a smart blow with a whip or stick. *Hemorrhage* seldom is profuse, unless from the wound of a large bloodvessel; under such circumstances it is likely that a large hematoma will form. Secondary hemorrhage (p. 177) is liable to occur at any time until all sloughs separate.

Prognosis.—In warfare there is one soldier killed for every four, five, or six wounded; and this proportion has been very little altered by the changes in military equipment. A large proportion of gunshot wounds, therefore, seems to be necessarily fatal; but in the remaining cases the prognosis depends almost entirely upon the treatment. By modern methods the death rate has been reduced to 5 or 10 per cent. The bullet wounds of war are not seriously infected of themselves, and if kept clean the resistance of the patients usually is sufficient to ensure a good result, at least as regards life. Injuries of the trunk are more serious than those of the extremities, because of damage to viscera; but they are also less frequent. Injuries to the extremities involving bones, joints, or bloodvessles are more serious than mere flesh wounds. The positions of the wounds of entrance and exit frequently will enable the surgeon to exclude injury of important structures.

Treatment.—In modern warfare the bullet seldom lodges, and even if it does, it rarely causes immediate trouble; hence it is not necessary to remove it. Every soldier is supplied with a "first-aid packet," and is instructed to apply the sterile gauze dressing so as to occlude the wounds of entrance and exit, fixing it in place with the bandage which is attached. Only in case of active hemorrhage is any operative treatment required on the battlefield; and if the hemorrhage, profuse at first, has ceased spontaneously, it usually is safer to apply a provisional tourniquet (Fig. 141) and transport the patient, who will be much shocked, to the field-hospital (at least three miles from the front), than to undertake what may be a serious operation in unfavorable surroundings. Here, or preferably at the military hospital at the nearest base, the injuries to nerves, tendons, bones, etc., should receive suitable treatment.

In civil life the bullet generally lodges, or is arrested by the skin on the opposite side of the body; and from its large calibre and the nature of the wound it makes, frequently requires removal; and this is best accomplished within twenty-four hours or not until the inflammation has subsided. A bullet is best detected by the *x*-rays; it may be accurately located by two exposures made at right angles to each other, with some suitable landmark as a guide (Figs. 130 and 131). If the *x*-rays are not available, the track of the bullet may be probed (except in wounds of the abdomen), after thorough antiseptic preparation. A porcelain-tipped probe (Fig. 132), first employed by Nélaton

in the case of the celebrated General Garibaldi (1862), will retain the marks of a soft lead bullet, even after the blood has been rinsed off in water; but it is of little use in detecting the modern hard jacketed bullets. The stem of a clay pipe was used by Heighway during the Mexican War (1848). Tactile sensation, transmitted through an ordinary probe, may enable the surgeon to detect the bullet's presence. The

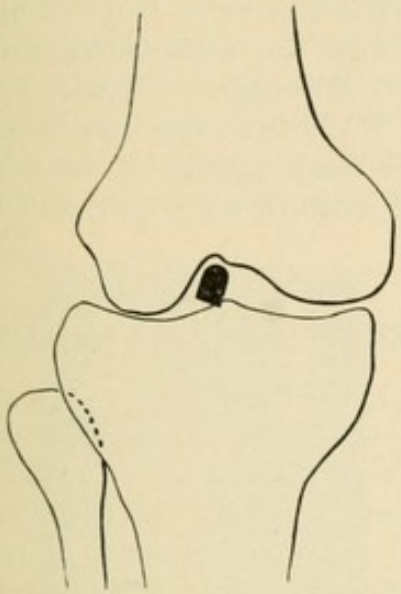

FIG. 130.—Bullet lodged in knee-joint, localized by skiagraphy; compare Figs. 131, 134, 135. Episcopal Hospital.

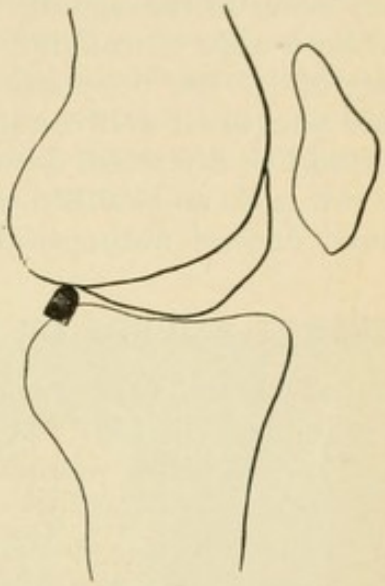

FIG. 131.—Lateral view (skiagraph) of bullet lodged in knee-joint. Episcopal Hospital.

bullet may be removed by bullet-forceps (Fig. 132) introduced through the nearest aperture, or by a counter-incision. If the bullet is situated at all deeply, in the fleshy part of a limb, it usually is necessary to dissect down upon it; under such circumstances the finger is the best probe. The incision should be closed with buried and superficial sutures, and drainage should be provided for at least twenty-four hours.



FIG. 132.—1, Nélaton's porcelain tipped probe; 2, bullet-forceps.

Small-shot Wounds.—If fired at close range, small-shot produces great damage, the wounds resembling those caused by artillery projectiles. I have seen all the soft tissues on the front of the lower forearm carried away in bulk, necessitating amputation, even though the bones were not fractured. Fingers, toes, and parts of the hand or foot are frequently blown off. If at longer range, the shot scatters, there is no powder-burn, and comparatively little damage may be

done, particularly in the case of birdshot. Of course if the eye be struck, or an important nerve or bloodvessel injured, the consequences may be very serious even from the impact of one or two shot. It is a tedious job to extract all these small shot, and it is seldom necessary to do so. If the part be treated as for a contused wound it usually does well.

Wounds from blank cartridges scarcely require separate mention. They occur in this country chiefly about the Fourth of July. I have not been able to convince myself that they are more liable to be followed by the development of tetanus, if properly treated, than other punctured and contused wounds. If the wadding has lodged, it should be extracted, entirely devitalized tissue should be cut away, the raw surfaces swabbed with solution of iodin (3 per cent.), and the wound dressed antiseptically.

GUNSHOT WOUNDS OF SPECIAL STRUCTURES AND REGIONS.

Bloodvessels.—For primary hemorrhage, the same rules apply here as elsewhere (p. 230). Usually the bloodvessels are more or less contused by bullet wounds in civil life, and thrombosis is sufficient to prevent free bleeding; if a bloodvessel is struck by a military bullet, however, it is cut across or grooved, and hemorrhage is profuse. Secondary hemorrhage is not unusual, especially if the wound becomes infected; its treatment is described at p. 232. False aneurysm (p. 233), or arterio-venous aneurysms (p. 235) are sometimes remote consequences of gunshot wounds of arteries and veins.

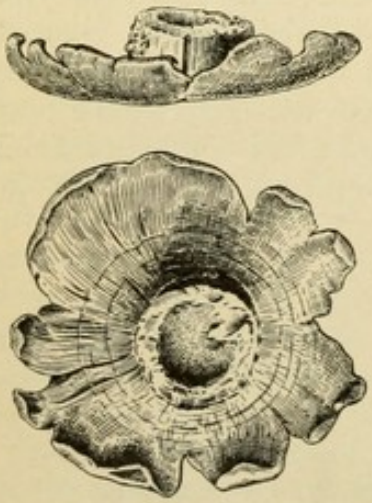

Fig. 133.—Soft bullet deformed (mushroomed) by striking bone end-on. From a patient in the Episcopal Hospital.

Nerves, Tendons.—In warfare these are not deflected by the bullet, but are cut through. Nerves may be seriously injured also by being grazed by a bullet, causing what the Germans call an "Ersschhütterung" of the nerve which England's great lexicographer might have translated by the term "tremefaction." Severed nerves and tendons should be sutured as soon as proper operative technique can be secured.

Bones.—Gunshot fractures require the same treatment as other compound fractures (p. 312). The shafts are usually much splintered (Fig. 128), unless injured by a nearly spent bullet, which is then deformed on striking (Fig. 133); fractures of the epiphyses are less serious, unless the joint is wounded.

Joints.—Gunshot wounds of joints were formerly exceedingly fatal; in the Rebellion the mortality varied from 9 per cent., for the elbow, to 84 per cent. for the hip. In the Turko-Russian War (1877) von Bergmann found that death occurred in 95 per cent. of gunshot

wounds of the knee-joint treated by accepted methods; he therefore "selected fifteen of the most serious cases of gunshot wound of the knee, . . . and treated them by immobilization and occlusive dressings. In these cases, recovery with movable joints resulted with but a single exception, where amputation had to be done and death followed" (Borden, 1907). Since that time modern military surgeons have followed von Bergmann's example, treating all joint injuries, except those requiring immediate amputation, by aseptic occlusion and immobilization. In the Spanish-American War, there were forty-three cases of injury to the larger joints, and in only two was operation required—amputation in both cases, with one death, a total mortality of 2.3 per cent.; in the Chinese-Japanese War there were forty-seven injuries, with five deaths, a mortality of 10.6 per cent.

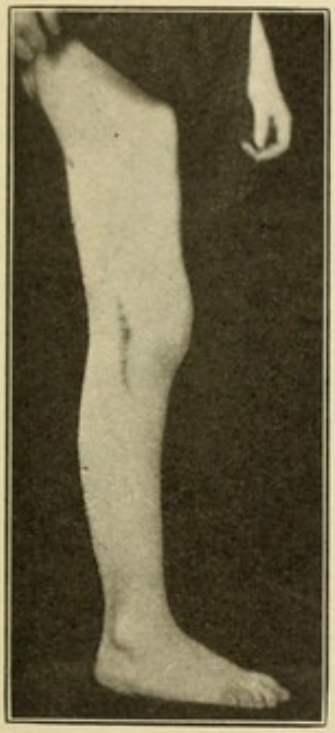

FIG. 134.—Result of arthrotomy and extraction of bullet from knee-joint; recent accident. Episcopal Hospital.

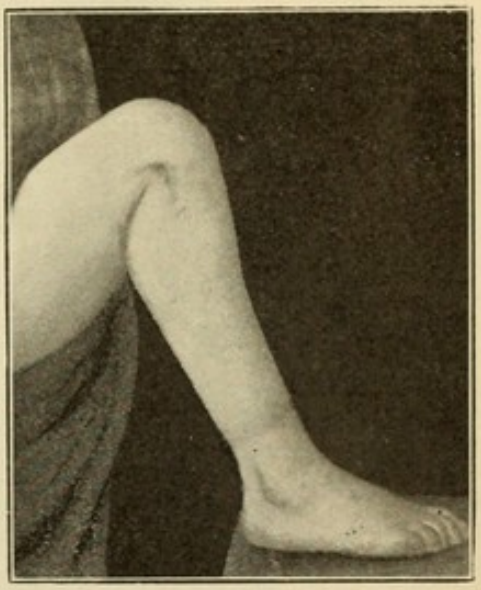

FIG. 135.—Result of arthrotomy and extraction of bullet from knee-joint. Same patient as Figs. 130, 131, and 134. Episcopal Hospital.

In warfare the bullet seldom lodges, and even in civil life it is not so apt to lodge in the joint as in the neighboring bones or soft parts; hence there is no indication to open the joint for its removal. Its location can be determined by skiagraphy, and it may be extracted at a later date if productive of symptoms. Sometimes a bullet has ulcerated into the joint after lying *perdu* for many years in the end of one of the articulating bones; under such circumstances it produces the symptoms of a foreign body or loose cartilage in the joint. Quénu (1910) has collected twelve instances in which a bullet was removed from the knee-joint (three immediate, and nine tardy operations); and I have had under my own care the patient represented in

Figs. 130, 131, 134, 135. In E. H. Ochsner's patient (1910) a bullet was successfully removed from the hip-joint ten years after the injury.

Head.—Gunshot injuries of the head are most serious when fracturing the skull or injuring the brain. The general mortality from gunshot fractures of the skull has not been materially reduced in modern wars, still being nearer 60 than 50 per cent. At close range the explosive effect is present, and death is instant (Fig. 136). Even at long range the penetrating power of the modern bullet renders injury of the brain much more frequent than formerly; and the bullet seldom lodges. In civil life these injuries frequently are the result of suicidal attempts, the wound of entrance being within the mouth, in the right temple, or in the forehead. Even if the brain is injured there may

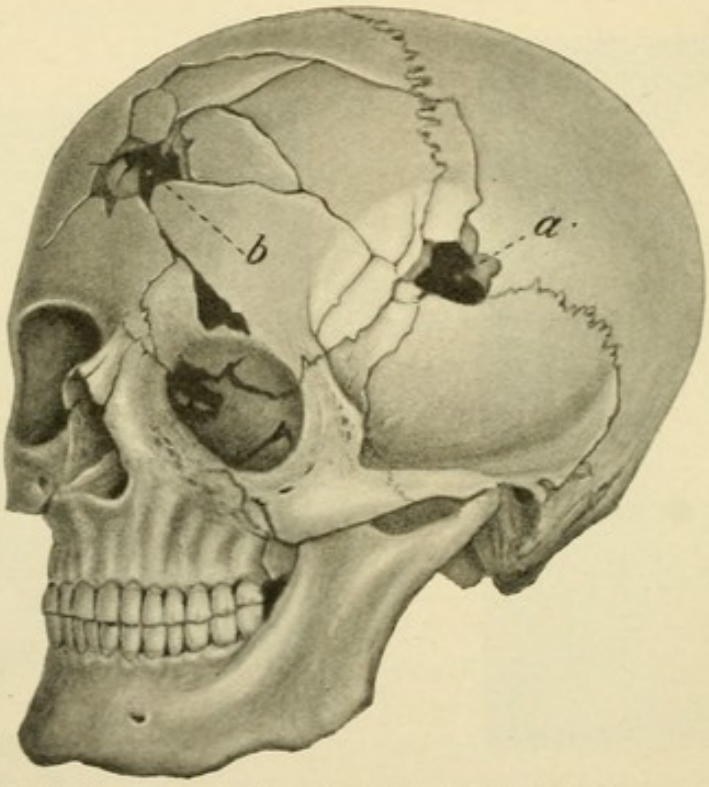

FIG. 136.—Skull, showing explosive effect of bullet fired at close range; *a* and *b*, wounds of entrance and exit. (Von Bergmann.)

be no localizing symptoms (p. 583). The only indications for operative treatment, which in no case should be attempted until complete asepsis is assured, are (1) to disinfect the wound of entrance; (2) to arrest hemorrhage; (3) to repair damage to the cranium; and (4) to remove a lodged missile if it is producing symptoms. If the wound of entrance is small, not liable to cause further trouble from infection; if the fracture of the skull is a mere puncture, without comminution or fissuring; if there are no symptoms of internal hemorrhage or compression of the brain; and if the patient does not grow progressively worse, no operation should be done. If the wound of entrance is lacerated, contused, filthy, and splintering of the skull is evident, operation should be undertaken as in any case of fracture of the skull

whether there are cerebral symptoms or not. Under such circumstances I operated (February, 1909) successfully on a patient in the Episcopal Hospital, with a suicidal wound in the middle of his forehead, removing fragments of the bullet and of bone from the superior longitudinal sinus. If under such circumstances the dura is found to be wounded it should be incised, and drainage provided for; but no attempt should be made to remove the bullet from the substance of the brain unless it is causing symptoms. In cases where it is believed the bullet is producing symptoms (for these may be due to hemorrhage and extravasation, not to the bullet), its location should be determined by skiagraphy, and its removal attempted by the nearest approach: sometimes the original track may be followed, at other times the opposite side of the skull must be opened. In following the orginal track, a heavy probe with a large bulbous end should be selected, and the patient should be so placed that the probe will sink by its own weight vertically into the bullet's track. Then by passing a bullet-forceps along the probe as a guide, it may be possible to extract the bullet.

Spine.—Gunshot wounds of the spine have increased in severity in recent wars; the mortality in the Spanish-American and Philippine campaigns was 66 per cent. (Borden, 1907). Nearly every case of injury to the spine is now a compound fracture: wounds of the arches are comminuted, but a bullet may perforate the body of a vertebra without much damage to the bone. The cord is frequently cut in two; even contusion of the cord, or "Erschütterung," may result in complete transverse lesion. In civil life, the slowly moving bullet usually is arrested by the spine, and fracture without injury of the cord is the rule. In military practice, immediate operation is not indicated. The symptoms, treatment, etc., of injuries of the spine in civil life are considered at p. 599.

Thorax.—Gunshot wounds of the thorax rarely are serious unless they penetrate and wound the viscera. Instant or rapid death frequently follows injury of the heart or great vessels; but injury to the lung at some peripheral point may be productive of no immediately serious symptoms. Especially is this so in the case of bullets of small calibre striking at more than 600 yards. In warfare the bullet seldom lodges; in civil life it nearly invariably is arrested, frequently being found beneath the skin on the opposite side of the body. It is important to look for it carefully beneath the skin, if there is no wound of exit, so as to determine if possible its course through the thorax. A bullet may seem to traverse the thorax, and yet wound no viscus; while a wound which does not penetrate far may cause alarming symptoms from hemorrhage from the internal mammary or an intercostal artery.

Symptoms.—If the bullet has traversed the thorax *above the level of the fifth rib*, and there are no signs of serious internal hemorrhage (p. 277), it is probable that the upper part of the lung has been wounded at its periphery. If the bullet is of small calibre, the

pulmonary tissue expands and occludes the wounds of entrance and exit in the lung, and little hemorrhage occurs into the pleural cavity. A larger bullet produces more of a lacerated wound, and the signs of hemothorax (sometimes pneumo-hemothorax) quickly develop. Subcutaneous emphysema (p. 728) is not infrequent. In nearly every case the physical signs of a more or less diffuse bronchitis appear; bloody mucus is expectorated; moderate fever occurs; and the patient passes through an atypical attack of pneumonia. Dyspnea rarely is severe, unless from internal hemorrhage, or from pneumothorax. If the track of the bullet passes *below the level of the fifth rib*, it may wound the diaphragm, or pierce this and entering the abdomen wound the subdiaphragmatic viscera. In a patient under my care at the Episcopal Hospital (March, 1909), the wound of entrance was in the sixth left interspace close to the sternum, and the bullet lodged beneath the skin in the eleventh left interspace about three inches from the spine. It perforated the pericardium in two places, without wounding the heart; then entered the diaphragm, grooving the esophagus; perforated the left lobe of the liver; reëntered the diaphragm, three inches back of its first passage; passed through the lower border of the lung, cut the intercostal artery near its origin, and lodged outside the pleura, as before stated. In spite of prompt operation, the patient died on the third day, of pneumonia.

Treatment.—No operation should be done except with the most complete facilities for aseptic technique. Wounds above the level of the fifth rib, not wounding the heart or the root of the lung, seldom require operation. The superficial wounds should be cleansed and occluded with sterile dressings, and the affected side of the chest strapped, as for fractured ribs (p. 323). Dyspnea is to be controlled by opiates; stimulation by atropin and strychnin may be necessary; for persistent hemoptysis, calcium chloride or horse serum may be employed. In any case where the abdominal contents may have been wounded, exploratory laparotomy is indicated. When dyspnea is extreme, and the pleura is filled with fluid, it is better to open the pleural cavity by an intercostal incision (in the seventh or eighth interspace), and evacuate the blood. Mere exposure of the lung to the air usually is sufficient to control hemorrhage from the bullet track; if hemorrhage persists, the orifices in the lung should be sutured, and wounds in the thoracic parietes tamponed, if ligation is impossible. To accomplish these manœuvres it may be necessary to excise portions of one or both ribs bordering the intercostal incision. When bleeding is arrested, the wound should be closed, with drainage. Empyema is a not infrequent sequel, in cases treated with or without operation.

Prognosis.—The mortality from penetrating gunshot wounds of the chest has fallen from 60 to 80 per cent., in the wars of the Rebellion and the Crimea, to about 20 per cent. in the Spanish-American and South African wars (O'Reilly, 1908). Rochard (1909) has reported a series of seventy-one cases of gunshot wounds of the lungs, in civil

life; in only one was operation necessary; and Thiery (1909) stated that among fourteen cases of penetrating bullet wounds, and one of stab wound of the lung, eleven patients recovered without operation; while of the four whose condition was so grave as to demand operation, two succumbed.

Abdomen.—Gunshot wounds of the abdomen may involve only the parietes, and in a patient with a very fat or pendulous abdomen the bullet may enter in front and lodge in the groin or flank without penetrating the peritoneum. In military surgery no operation should be undertaken on the field of battle, except for alarming hemorrhage. Doche (1909) has shown that when penetrating abdominal wounds are treated by laparotomy on the field, more than 95 per cent. terminate fatally; but if no operation is done, the mortality is only 50 to 55 per cent. If the patient be carefully transported to the nearest military hospital properly equipped for such work, he may arrive there still alive, and subsequently develop a localized abscess, fecal fistula, or even intestinal obstruction, which may be treated successfully by a late operation. Meantime the non-operative treatment for peritonitis advised in Chapter XXII should be adopted.

In civil life, where adequate facilities exist, immediate exploratory laparotomy should be undertaken, and wounds of the viscera repaired. No symptoms of intraperitoneal infection should be waited for. If operation is done within the first twelve hours, nearly half the patients should recover; after that time only one out of four recovers (Coley). Though the mortality in civil practice, even after prompt operation, is thus seen to be nearly as high as that which follows non-operative treatment in military surgery, it must be remembered that the character of the injuries in the former instances is more serious, and that practically all such cases terminate fatally if not operated upon; while in the case of wounds received in battle, the gastro-intestinal tract usually is empty, the wounds are smaller, clean-cut, and less contused; and many patients who die on the battlefield are not included in the military statistics.

The *diagnosis* and *operative treatment* of penetrating wounds of the abdomen are discussed in Chapter XXII.

CHAPTER VIII.

AMPUTATIONS.

AMPUTATION, derived from the Latin word meaning to lop off, to prune, etc., is by surgeons usually confined in its application to the removal of a limb, or part of a limb. If the member is removed at a joint, the operation may be termed an *exarticulation*, or a *disarticulation;* if through the bones, the operation is an *amputation in continuity*.

Conditions Requiring Amputation. — Among the most frequent and important are: (1) *Avulsion*, or *traumatic amputation*, of a limb; here there is no alternative but to trim up the stump that is left so as to hasten healing and secure good functional result. (2) *Compound fractures* and *luxations*, which sometimes leave the limb attached only by a few shreds of muscle or a strip of skin. (3) *Lacerated and contused wounds*, even without fracture, sometimes exhibit such extensive destruction of the soft parts as to demand the removal of the limb. In general, if the limb is sure to be useless if retained, or if it is sure to become gangrenous, it should be removed. (4) *Gangrene*, when constituting more than a superficial slough, usually is a cause for amputation. The special varieties of gangrene, and the proper time for amputation, as well as the level where this should be done, have been considered in Chapter II. (5) *Diseases of Bones and Joints*. These are much less often a cause for amputation now than formerly. (6) *Injury of the main artery of a limb*, when it occurs at a site which habitually results in gangrene, usually is a cause for amputation (p. 62). (7) *Malignant tumors* frequently necessitate amputation. (8) *Deformity*, including also certain non-malignant tumors, may very occasionally be a cause for amputation.

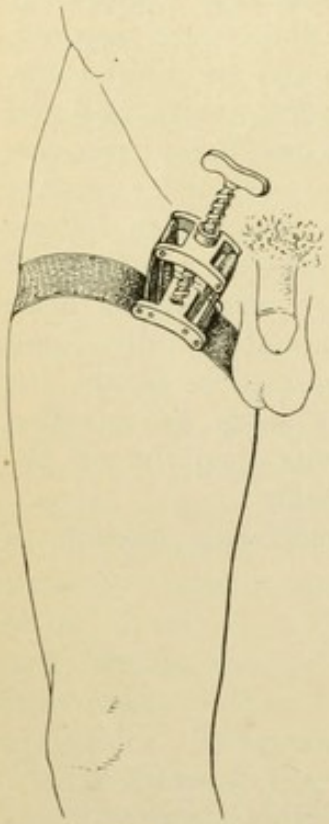

FIG. 137.—Screw tourniquet applied to thigh.

Instruments.—These include a *tourniquet* (Fig. 137), or an *Esmarch's band* (Fig. 138) for controlling the circulation; amputating knives for dividing the soft parts; *periosteotome*, or *raspatory; retractors* to guard the soft parts from the *saw*; *bone forceps*, to steady the bone as it is

sawed, in cases of avulsion or traumatic amputation, and *bone nippers* to trim rough edges off the bone after it has been sawed; *hemostatic*

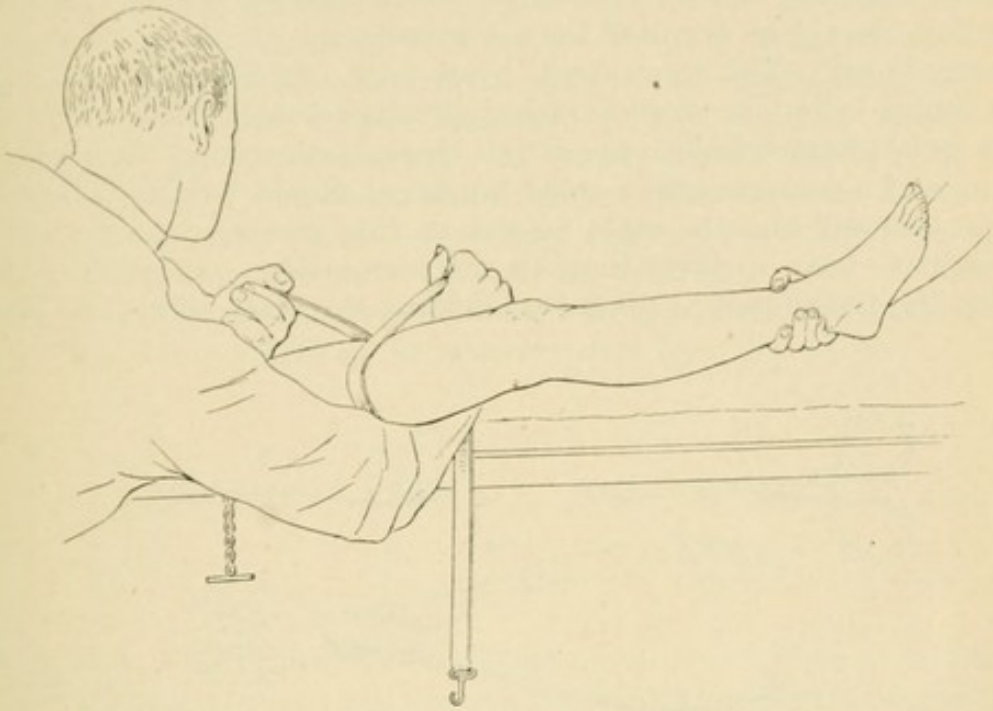

FIG. 138.—Esmarch band, showing proper method of its application.

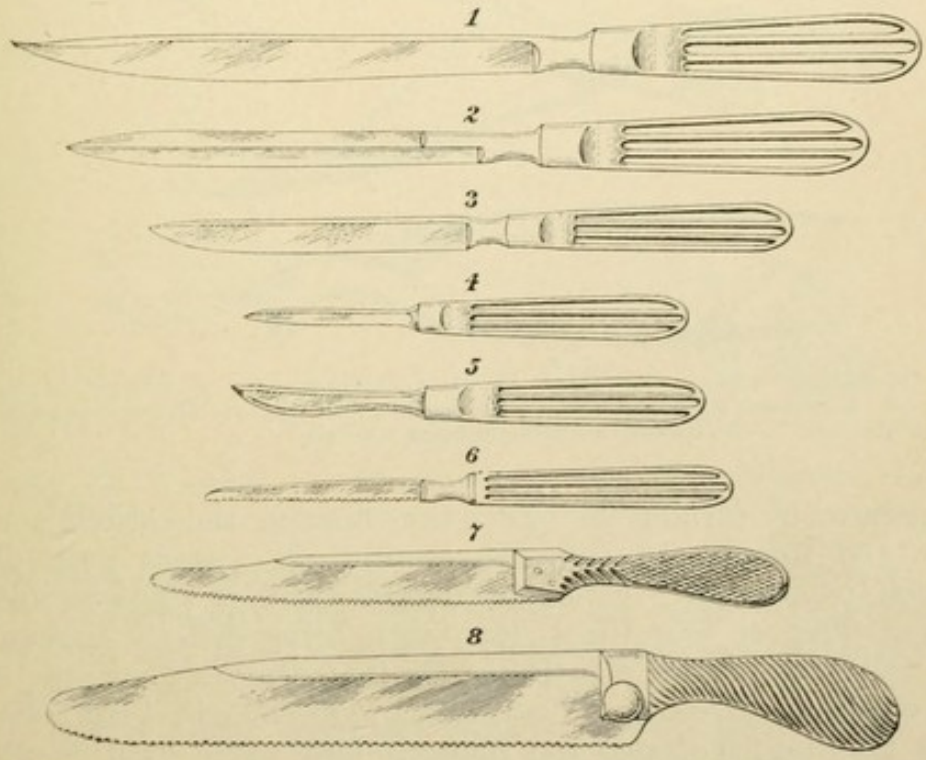

FIG. 139.—Amputating instruments. 1. Large amputating knife. 2. Catlin (double-edged knife). 3. Small amputating knife. 4. Metacarpal knife. 5. Periosteotome or raspatory. 6. Phalangeal saw. 7. Metacarpal saw. 8. Large amputating saw.

forceps, as well as *ligatures*, *sutures*, *needles*, and *scissors*. These instruments are illustrated in Figs. 139 and 140.

Tourniquet.—The screw tourniquet (Petit, 1690) is seldom employed now, Esmarch's elastic band (1873) having largely superseded it. Before applying either, especially in shocked or anemic patients, the limb should be elevated for a few moments, so as to empty it of venous blood. The tourniquet, when used, should be placed upon the limb so that the screw is either directly over the main vessels, or at a point diametrically opposite to them, compressing them against bone; and a compress (as a roller bandage) should be placed between the tourniquet and the main vessels, so that greater pressure will be brought to bear on them than on the surrounding soft parts. After fixing the tourniquet in place by buckling the strap tight, the plates

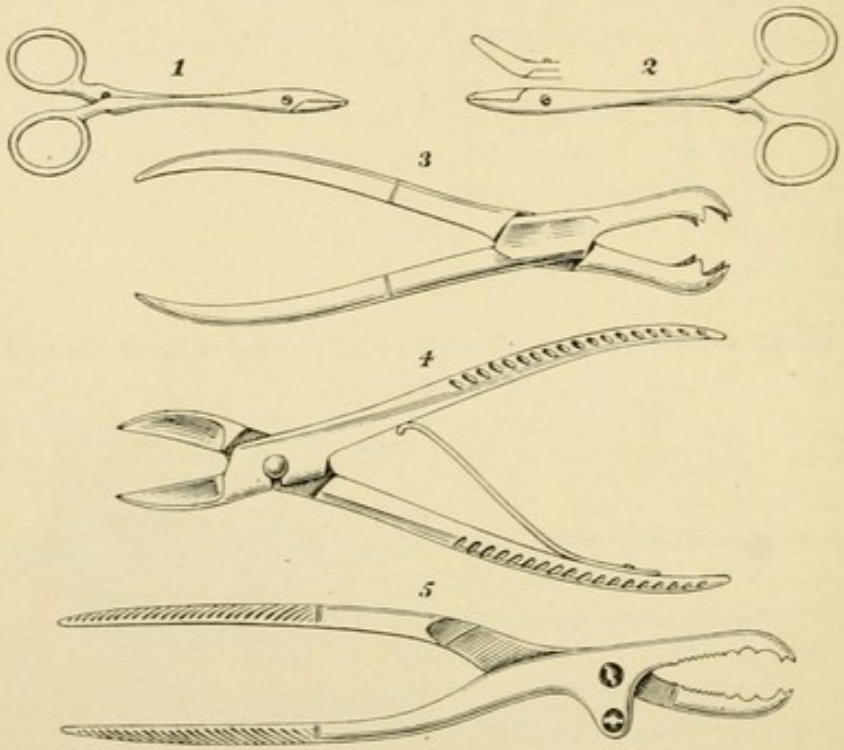

Fig. 140.—Amputating instruments. 1. Hemostatic foceps. 2. Curved hemostatic forceps. 3. Fergusson's "lion-jawed" bone-holding forceps. 4. Liston's bone-cutting forceps ("nippers"). 5. Farabeuf's bone-holding forceps.

are separated by turning the screw, thus drawing the encircling strap tighter and forcing the compress against the vessels until distal pulsation is arrested. Esmarch's elastic band is wrapped around the limb three or four times, each turn being directly superposed upon, and being drawn a little tighter than the previous one, until the circulation is arrested. If not drawn tight enough, it will increase venous bleeding; if drawn too tight, it may cause local sloughing and subsequent gangrene of the entire limb; or paralysis from pressure on the nerves, especially above the elbow, when the ulnar or musculospiral nerve may be injured. In emergencies the "Spanish windlass" (Morel, 1674) may be used (Fig. 141), or even Momburg's method of hemostasis (p. 216).

Amputating Knives.—The length should be about one and a half times the diameter of the limb to be removed, and the blade should be from $\frac{3}{8}$ to $\frac{3}{4}$ of an inch wide; one of eight or ten inches is suitable for the thigh or hip; one of six for the forearm, arm, or leg; while for the hand or foot a metacarpal amputating knife (Fig. 139, 4), with a blade three inches long and $\frac{1}{8}$ inch wide, is preferable. *Double edged catlins* occasionally are used for the forearm or leg, to aid in clearing the interosseous space. The *raspatory* is used to scrape up the periosteum before applying the saw, thus leaving a cuff of periosteum to cover the end of the bone. The *retractor* is made of muslin, being two-tailed for the humerus and femur (Fig. 142), and three-tailed for the forearm and leg (Fig. 143).

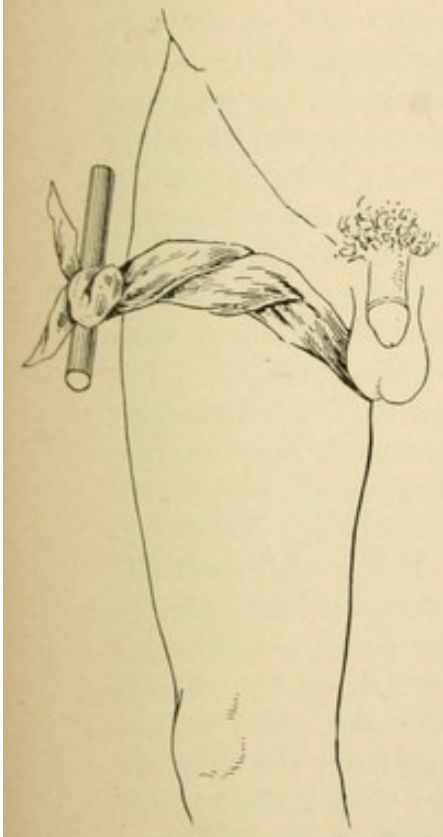

FIG. 141.—The "Spanish windlass."



FIG. 142.—Two-tailed muslin retractor, for amputations of the arm and thigh.

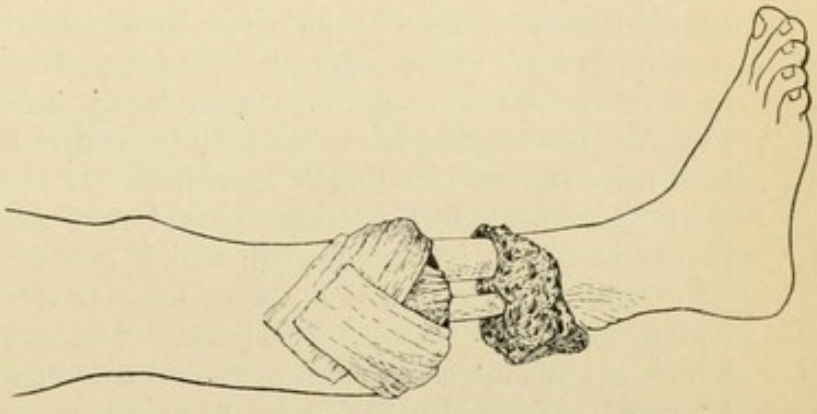

FIG. 143.—Three-tailed retractor applied for an amputation of the leg.

The *amputating saw* is about ten inches long by two and a half wide; strong-backed, and with widely set teeth. A smaller saw is used for the hand and foot. *Bone-nippers* are sometimes used for amputating phalanges, though they are apt to splinter the bone; and if larger bones are properly sawed, there should be no rough edges to trim off. *Ligatures* are of absorbable material, as are the *buried sutures; skin sutures* usually are of silkworm gut.

Operative Procedures.—A patient who is to have a limb removed usually is in a weakened and precarious state, either from shock and hemorrhage following an accident, or from the cachexia of chronic disease. Hence it is the surgeon's duty to take special pains to

prevent loss of bodily heat, and needless waste of time. In cases of accident it frequently is necessary to prepare the limb for amputation after the patient is on the table, while the anesthetic is being administered. The surgeon and his first assistant should be ready to commence the operation the instant that the patient is under the anesthetic, and the preparation of the limb should be complete at the same time. While one assistant raises the limb, the surgeon applies the tourniquet, or if he entrusts this important duty to an assistant, he should make sure before commencing his operation that the circulation is properly arrested and that there is no danger of the tourniquet slipping. One assistant should give his entire attention to the tourniquet throughout the operation. Another assistant holds the limb in a convenient position, clear of the table, and the surgeon, standing with his left hand to the patient's trunk,[1] divides the soft parts, as will be presently directed; then raises the periosteum for about an inch; and, while the soft parts are drawn out of the way and protected by the retractor, saws the bone, his assistant guarding against binding of the saw by the manner in which he holds the limb. As soon as the limb has been removed, the surgeon applies to the face of the stump a folded towel, lightly wrung out of very hot corrosive sublimate solution; this checks the slight venous ooze, and as it is gradually withdrawn, the surgeon catches with hemostats all the vessels large enough to have names, and ties them all. The main artery and vein of the arm or thigh should be tied separately; smaller arteries may be included in one ligature with their accompanying veins. Then another hot antiseptic towel is applied to the face of the stump, and, the limb being held as nearly vertical as possible, the tourniquet is completely removed. If it is only partially loosened, venous bleeding is increased. If the surgeon has done the operation with due care there should now remain only a few oozing points in the muscular masses, which can be controlled by sutures. Any redundant tendons or nerves are next retrenched, and the periosteum drawn down over the bone. Hemorrhage from the medulla, which is unusual, should be controlled by plugging with muscle tissue, by packing with Horsley's wax, or in emergency with gauze. Finally, the stump is closed, with a few buried mattress sutures of chromic catgut approximating the ends of opposing sets of muscles. A rubber drainage tube is placed across the face of the stump, just beneath the skin, and the skin is closed with interrupted sutures of silkworm gut.

Dressing the Stump.—Moderate pressure, rest, and mechanical protection are necessary. Abundant sterile gauze dressings are applied, and in a certain definite manner. Ruffled gauze is placed around each end of the tube, one end of which may be left long and brought out of the deep into the superficial dressings, as described at p. 166. The special amputation dressing is cut as shown in Fig. 144; the horizontal portion is placed *beneath* the limb, and folded

[1] In amputating the left lower extremity he stands between the patient's legs.

around it, the vertical portion being then folded up over the end of the stump. A second similar dressing is applied over the first, in reverse order, the horizontal portion being placed *above* the limb, and the vertical flap being drawn down over the end of the stump before the side pieces are folded around it. Over the gauze dressings an abundant amount of sterile absorbent cotton is arranged, burying the end of the tube, and the whole is bandaged snugly on to the stump. It is surprising how much diminution in size an apparently bulky dressing undergoes when it is properly bandged. Next the limb is bandaged firmly to a splint, which projects some inches beyond the end of the stump. It is never safe to assume that cases of amputation, especially recent accidents, will be free from traumatic delirium, and the proper time to protect the limb from injury is before the delirium develops. The stump should be kept as nearly vertical as possible for twelve hours. Usually the drainage tube may be removed at the end of twenty-four to thirty-six hours; and the stump need not be dressed, if all goes well, until time to remove the skin sutures.

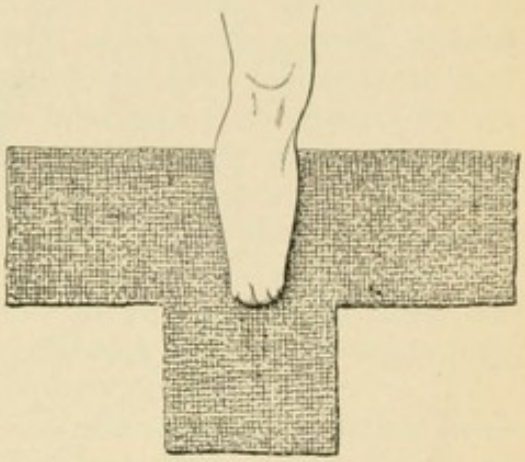

FIG. 144.—Method of cutting and applying gauze for dressing an amputation stump.

Methods of Operating.—Every method of amputating may be considered a variety of either the *circular* or the *flap* method. The circular method is to be preferred whenever a choice is possible; it is suited for all limbs where the bones are approximately in the centre of the soft parts (lower forearm, arm, thigh), provided the limb is not conical in shape. It is not desirable in amputations at joints, nor in the leg, where a weight-bearing stump is sought, since the cicatrix always falls across the face of the stump.

Circular Amputation.—In this method all the tissues of the limb are severed by circular incisions, the skin at the lowest, the muscles at an intermediate, and the bone at the highest point ("triple incision" method). The surgeon passes the knife under, around, and over the limb, so that its point is down, and its back toward his own face (Fig. 145); then, pressing the heel of the knife well into the flesh, with one long steady sweep he divides the skin and subcutaneous tissues down to the deep fascia, the blade ending with its point exactly in the place where its heel began the incision. If the skin does not now retract sufficiently, the surgeon dissects it up, with the same knife, for a distance equal to half the diameter of the limb, taking care always to direct his blade toward the deeper structures so as to leave uninjured the cutaneous vessels, and thus ensure the vitality of the skin. Then the muscles are similarly divided down to the

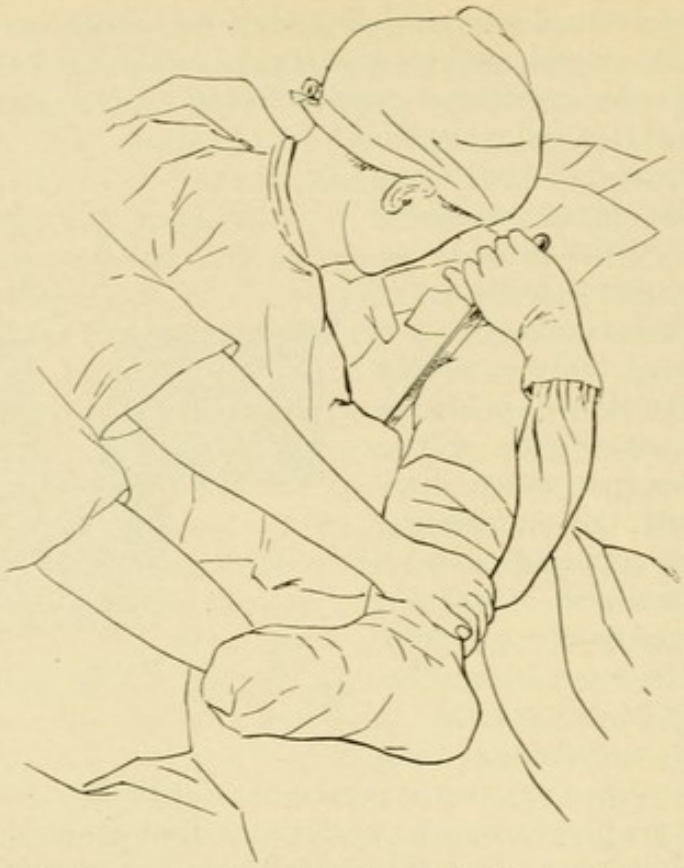

FIG. 145.—Circular amputation of the thigh, showing method of holding the knife as the first incision is started.

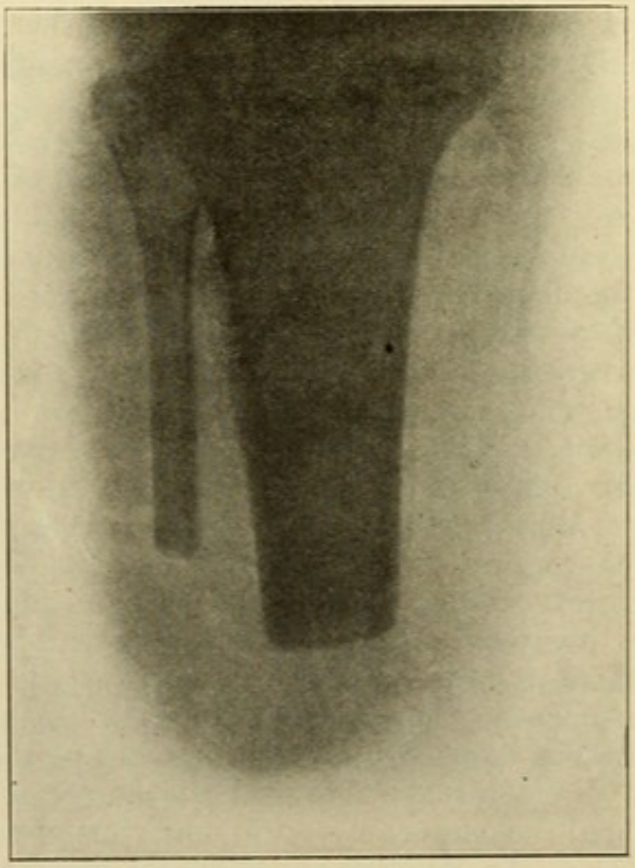

FIG. 146.—Skiagraph of stump resulting from amputation of leg by modified Sédillot method.

bone, with the same knife, by a circular cut at the point of reflection of the skin. The muscles are not separated from the periosteum further than is necessary, but this is cut through by the periosteotome, and scraped upward for an inch or more. In the forearm and leg the interosseous space must be cleared also; in doing this the surgeon should studiously avoid turning the edge of his knife upward, toward the patient's trunk, for fear of nicking bloodvessels higher than they can be conveniently tied. When the bone has been cleared for an inch or over, the muslin retractor is applied, each end overlapping the other, and all being drawn upward by an assistant. The bone is then sawed, at right angles to its long axis. In the forearm both bones are sawed at the same level, and simultaneously; in the leg, the fibula is sawed first and at least half an inch higher than the tibia (Fig. 146). After suturing the muscles, the skin incision may be closed transversely or antero-posteriorly, as seems best.

Sometimes in a conical limb there is difficulty in dissecting back the circular cuff of skin, as above described; then it may be slit at one or two points. If slit at only one point, and the angles rounded off, this constitutes the *Oval* or *Elliptical Method*, which is habitually used in many amputations, without the formality of commencing it as a circular amputation, by making the first skin incision in the form of an ellipse. If the cuff of skin is slit at two points, and the angles rounded off, the amputation becomes one by skin flaps, commonly called the *Modified Circular Method*.

Flap Amputation.—The flaps may include skin only, as in the modified circular method; the skin and superficial muscles; or the entire muscular mass with the skin. The flaps may be rectangular or curved in outline, and may be cut from without inward or by transfixion. They always should be of equal breadth at their base, whether they are of equal or unequal length. Their combined length should equal one and a half times the diameter of the limb. Care should be exercised to have the main bloodvessels in one flap or the other (usually in the shorter), and not at a point where they may be slit up as the flaps are being formed. In amputating by transfixion the surgeon raises the tissues to be cut with his left hand, and, entering the point of the knife at the side of the limb nearest himself, pushes it across and around the bone, and brings its point out diametrically opposite its place of entrance. The flap is then formed by cutting first downward and then rapidly outward, with a vigorous sawing motion. The knife is then reëntered as before, passing on the opposite side of the bone, and the second flap is cut. The remaining fibres are then divided by a circular sweep, and the operation terminated as already described. The flap which contains the principal bloodvessles should be cut last. Frequently it is more convenient to form the first flap by cutting from without inward, and the second flap only by transfixion. Though an amputation may be performed more rapidly by transfixion, this method has lost in favor since the introduction of anesthesia; since by cutting from without inward the flaps may be more accurately shaped, and the main

bloodvessels may be severed transversely, instead of obliquely as frequently happened in cutting flaps by transfixion.

Multiple Amputations.—It is occasionally necessary to remove two or more limbs at the same time. Under such circumstances it is best to do the amputation of greatest magnitude and severity first; and for the same surgeon to proceed immediately afterward to remove the second and third limb, if the patient's condition warrants the continuance of the operation. If it does not, hemorrhage from the remaining limb or limbs must be temporarily controlled, and further operation postponed. For two or more surgeons to operate on different limbs simultaneously usually increases the shock to the patient. Multiple amputations for gangrene following frostbite are much less serious than those for traumatic cases. Fig. 147 shows the result of synchronous amputation of both arms in a patient under the care of Dr. H. C. Deaver, in the Episcopal Hospital.

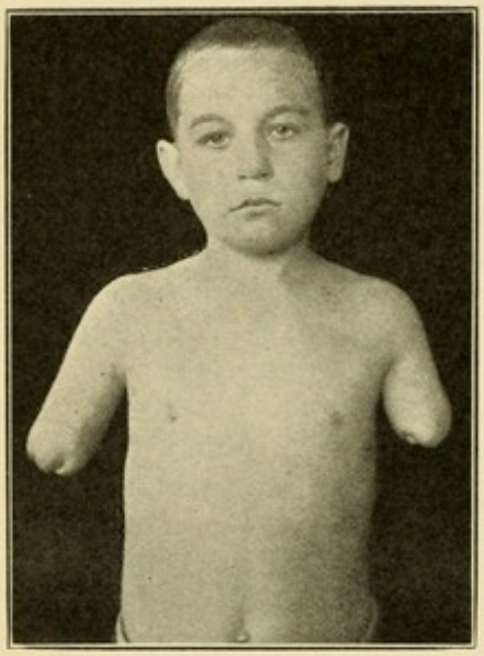

FIG. 147. — Double amputation (crush) eight weeks after operation. (Dr. H. C. Deaver's case.) Episcopal Hospital.

Structure and Diseases of Stumps.—A stump not only goes through the processes of inflammatory reaction, cicatrization, and contraction; but there also occurs actual atrophy of the muscular tissues from disuse; the bone becomes rounded off and atrophies; the nerves degenerate, and sometimes become bulbous and painful from the development of fibromas upon their ends.[1] The muscles occasionally become unduly atrophied and retracted, leaving the ends of the bone covered only by skin, or even causing the incision to break open, and producing a painful ulcer. Sometimes, from continued growth of bone, a conical stump is formed (Fig. 148). This usually is due to the natural development of the bone, being seen oftenest in amputations of the upper arm in children, as the growth of the humerus takes place chiefly at the upper epiphysis. Sometimes a conical stump forms in the leg in childhood, the growth occurring from the upper epiphysis of the tibia; whereas in the forearm and thigh, the greater part of the growth comes from the lower epiphyses. For conical stumps, and for intractable ulcers, adherent to the bone, which cannot be cured by palliative means, there is no remedy short of re-amputation, which, fortunately, is a much less serious operation than amputation. It sometimes is possible to resect the end of the bone subperiosteally, without doing a formal amputation again.

[1] Mumford (1910) sutures the ends of the nerves to each other, to prevent the development of false neuromas.

A *good stump* is one which is painless and which, in the lower extremity, can be used to support the weight of the body through

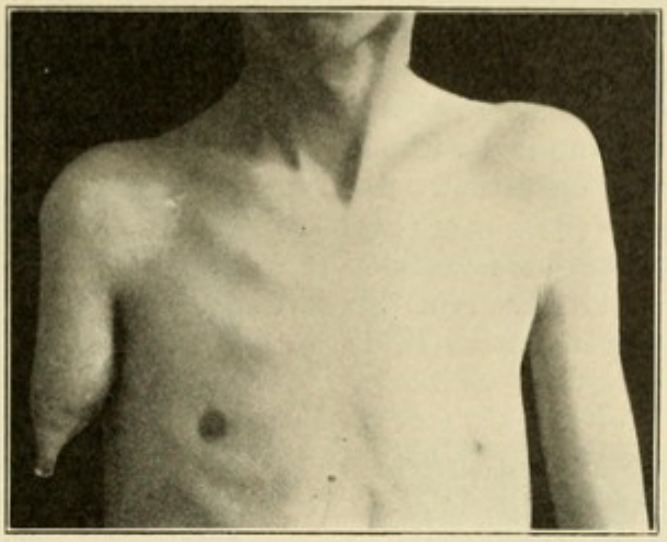

FIG. 148.—Conical or sugar-loaf stump from continued growth of bone after amputation in early youth. From a patient in the Pennsylvania Hospital under the care of the late Prof. Ashhurst.

an artificial limb. The bones should be well covered with soft parts, and these soft parts should not be adherent to the ends of the bone; if there are no such adhesions it makes no particular difference whether the cutaneous cicatrix lies across the end of the stump or at one side; but there are much less apt to be adhesions to the bone if the cicatrix of skin as well as of muscle lies to one side of rather than directly over the end of the bone. Few stumps will bear, by direct pressure on their ends, the entire weight of the body, and most artificial limbs are made to obtain their chief support from

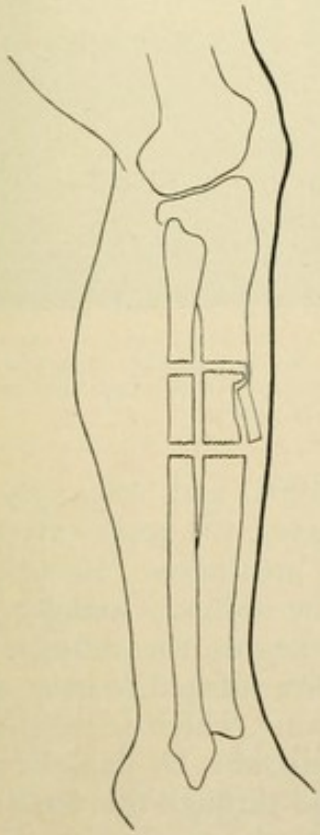

FIG. 149. — Bier's osteoplastic method of amputation. The bones are sawed at two levels, and a flap of the tibia turned across the ends at the last section.

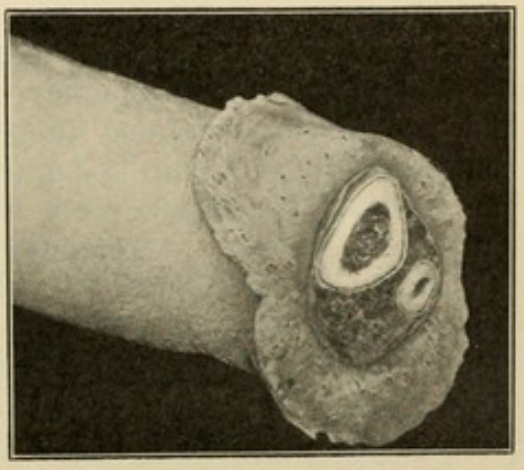

FIG. 150.—Amputation of leg by aperiosteal method of Bunge.

surrounding bony points (head of the tibia, tuberosity of the ischium). But Bier (1895) has advocated an osteoplastic method of amputating, after the Pirogoff principle, by means of which end-bearing stumps may be obtained (Fig. 149). Bunge (1905) has found that by sawing the bone 2 mm. below the level at which the periosteum is divided, and scraping out the marrow cavity for the same distance, end-bearing stumps may be obtained without any osteoplastic operation. He makes his flaps of skin only (Fig. 150). The oval method is suitable for such cases. I have used this method with perfect success (1911) (Fig. 151).

FIG. 151.—End-bearing stump (aperiosteal method of Bunge). Patient bearing all his weight on the stump twenty-five days after amputation. Episcopal Hospital.

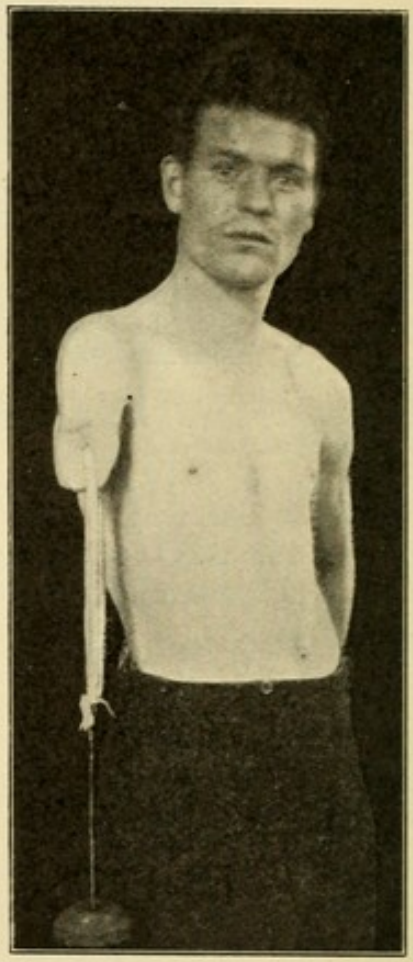

FIG. 152.—Amputation for cinematic prosthesis; freely movable stump secured by a loop composed of biceps and triceps. Episcopal Hospital.

Cinematoplastic Amputations.—Vanghetti (1906) and other surgeons have devised and practised methods of amputating the upper extremity which provide for voluntary motion in the prosthesis. In cases of recent accidents, the limb is amputated in the ordinary manner, and when the patient has recovered his normal health, the stump is reopened, and the flexor and extensor muscles are sutured to each other in the form of a loop, over the end of the bone, which is resected if too long; the loop so formed is covered on all sides by flaps of skin. When healing is complete a stout cord is passed through this tendinous loop, and each end of the cord is attached to the mechanism of the prosthesis. The patient can then, by drawing on the flexor or extensor side of his tendinous loop, flex or extend the artificial hand. I have adopted this method in some cases, but so far have not found any

manufacturer in this country who will furnish the desired cinematic prosthesis (Fig. 152). Another method, practised by Francesco (1908), is to detach the end of bone from its diaphysis, still leaving it buried in the muscular mass at the end of the stump. When healing is complete, a ring of iron is applied around the stump between the knob of bone and the diaphysis from which it has been detached. As the detached knob of bone is voluntarily movable, the ring above it can be inclined in any direction, and through attached cords transmits the movements to the prosthesis.

Mortality after Amputation.—Although this depends much more on the condition of the patient than on any other single factor, it is nevertheless proper for the surgeon to be familiar with the relative mortality of amputations for injury and for disease; and, in cases of injury, with that which accompanies primary, intermediate, and secondary operation; as well as the average mortality which attends amputation in different regions of the body. *Primary amputations* are those done before the inflammatory process has had time to develop—generally speaking, those done within twelve hours of injury; *intermediate amputations* are those done during the height of the inflammatory process; and *secondary amputations* are those performed after its subsidence, when the operation resembles that done for disease. As a rule, the lowest mortality attends primary amputations; and though since the introduction of antiseptic methods there is less inflammatory reaction than formerly, nevertheless intermediary amputations still give the highest mortality. In the case of secondary amputation the results are not so good as they seem, many patients being too shocked for primary amputation, and dying before secondary amputation can be attempted. The following table shows the death rate attending amputations in various portions of the body, for injury and for disease, as observed at the Episcopal Hospital, Philadelphia, 1900 to 1913 inclusive:

AMPUTATIONS AT THE EPISCOPAL HOSPITAL, PHILADELPHIA, 1900–1913 INCLUSIVE.

Region.	For injury.				For disease.			
	No.	Recovered.	Died.	Mortality, per cent.	No.	Recovered.	Died.	Mortality, per cent.
Hand	17	17	0	...	1	1	0	...
Wrist-joint	1	1	0	...	..	..	..	...
Forearm	10	10	0	...	3	3	0	...
Arm	30	29	1	3.3	3	2	1	33.3
Shoulder	8	8	0	...	4	3	1	25.0
Interscapulo-thoracic	1	0	1	100.0	..	..	..	...
Foot	18	17	1	5.0	3	2	1	33.3
Leg	54	49	5	9.2	16	8	8	50.0
Knee or knee-joint	6	6	0	...	3	1	2	66.0
Thigh	27	25	2	7.4	18	10	8	44.4
Hip	3	1	2	66.6	1	1	0	...
Total	175	163	12	6.9	52	31	21	40.3

It has usually been taught, and it is still stated by many surgeons, that amputations for disease are attended by a much lower death rate than those for injury. While this was perfectly true before the general adoption of antiseptic methods and modern methods of treating shock and hemorrhage, I think the relation is now reversed, though the extremely high mortality shown for amputations for disease in the above table is to be explained by the fact that a large majority of the patients were suffering not from tuberculous arthritis or malignant tumors, but from diabetic or senile gangrene. Yet the mortality in amputations for disease in this series is scarcely higher than that which attended amputations for injury before the antiseptic period.

Treatment of Crushed Limbs.—The first thing to do is to control hemorrhage and combat shock. The limb should be held vertically, and an Esmarch band applied *as near to the crushed area as practicable;* the foot of the bed should be raised, and in cases of grave anemia the other extremities should be bandaged from the periphery toward the trunk (*auto-transfusion*). The application of external heat, and other methods detailed at p. 175, should be employed for shock. If any vessels can be recognized in the wound they should be ligated; and any projecting nerves should be injected with a sterilized eucain solution (2 per cent.), since by nerve blocking it is possible to check the peripheral impulses which cause shock. Amputation should be done *as soon as the patient reacts*, or at once if the shock is not marked. *If reaction once occurs no delay in amputating should be allowed*, as the improvement frequently is only fleeting, unless the mangled limb is removed. The Esmarch band should not be left in one place more than four or five hours; sometimes, on removing it, no further bleeding will occur; but usually a little ooze persists, and the band should be re-applied higher on the limb. In a few hours its position should again be shifted (applying a second before removing the first, if necessary), since in this way it is possible to keep the bleeding checked without endangering the vitality of the parts above the wound.

If the patient does not react, or if, in spite of the skilful application of the Esmarch band, oozing of blood persists, and seems to prolong shock, the surgeon must consider whether the mere presence of the mangled extremity is not detrimental, and whether by resorting to amputation at once he will not obviate the tendency to death better than by delay. In such cases delay is fatal with extremely few exceptions; but by prompt operation, even under desperate circumstances, a life is occasionally saved. In such a patient under my care at the Episcopal Hospital (March 12, 1909), I amputated the thigh, and though the pulse could not be felt for nearly two days subsequently, recovery ensued. In such cases speed in operating is important; the time consumed need not exceed ten or fifteen minutes.

SPECIAL AMPUTATIONS.

Amputations of the Hand.—Though removal of portion of the hand is required frequently, the surgeon should exercise the utmost conservatism; no artificial contrivance can be as useful as the human hand, and though amputation of a portion of it is often a less tedious and more brillant operation than partial exicision and careful suture, yet judicious attempts at the latter are not seldom attended by gratifying results (Figs. 118 and 119).

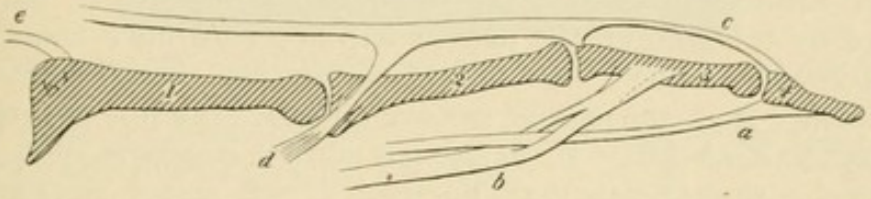

FIG. 153.—Tendinous insertions in the middle finger: *a*, deep flexor; *b*, superficial flexor; *c*, extensor; *d*, lumbrical; *e*, extensor carpi radialis brevior. Note the uselessness of the proximal phalanx (2), unless the insertion of the superficial flexor tendon is retained in the middle phalanx (3), or unless *b* is sutured to *c* over the end of 2. (After Waring.)

Amputation of the Fingers.—No tourniquet is required, and local anesthesia usually is sufficient. This is secured by injecting a few drops of 2 per cent. eucain solution at four points around the base of the finger, blocking the digital nerves. It is best to remove the fingers at a joint, but amputation is frequently done through the proximal or middle phalanx of the index and fifth fingers; this is then divided with a small saw or

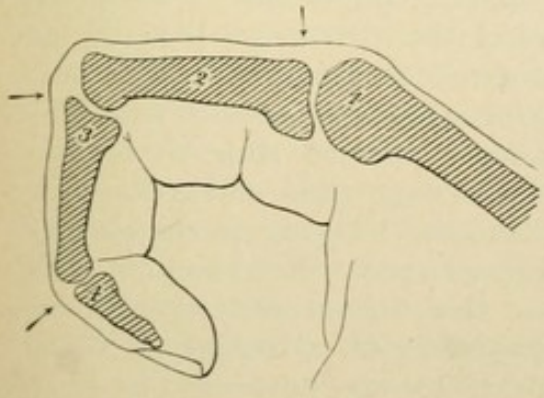

FIG. 154.—The finger-joints.

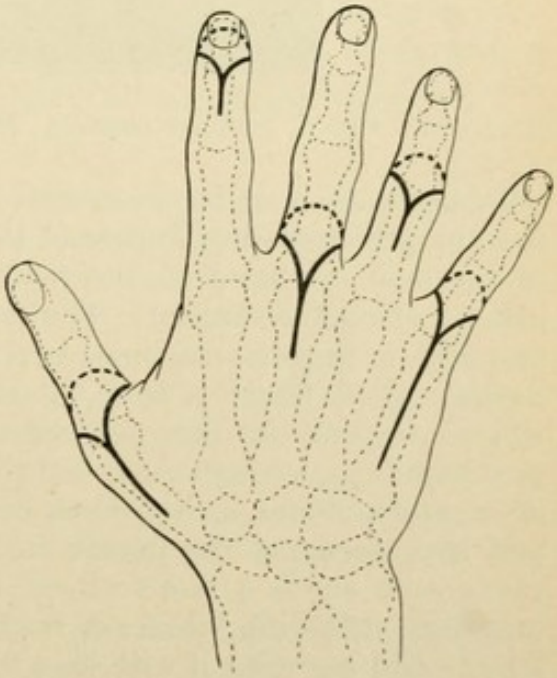

FIG. 155.—Amputation of the fingers by the racket-shaped incision.

cutting forceps. The middle and ring fingers are of comparatively little use, unless part of the middle phalanx is retained (Fig. 153); hence it is better to amputate at the metacarpal joint than to save only part of the proximal phalanx, unless the tendons can be sutured

to each other over the end of the stump. The position of the joints must be borne in mind (Fig. 154), the usual error being to expect to find them too high. In amputation by the racket-shaped incision (Fig. 155), the first incision, on the dorsum, opens the joint, and as the finger is sharply flexed the lateral ligaments are divided, and the palmar flap is formed by passing the narrow-bladed knife between the ends of the bones and cutting from within outward. It is easier to preserve the tendons if a short extensor and long flexor flap are employed. The digital arteries are ligated, the flexor and extensor tendons sutured to each other by buried sutures; and the stump is closed by bringing up the palmar flap and suturing it transversely. This is known as the "poor man's amputation" because the scar is carried away from the palmar surface and the stump is covered with the tough palmar skin. If the palmar surface is destroyed by disease or injury, a dorsal flap may be used ("rich man's amputation"). Two lateral flaps are sometimes employed.

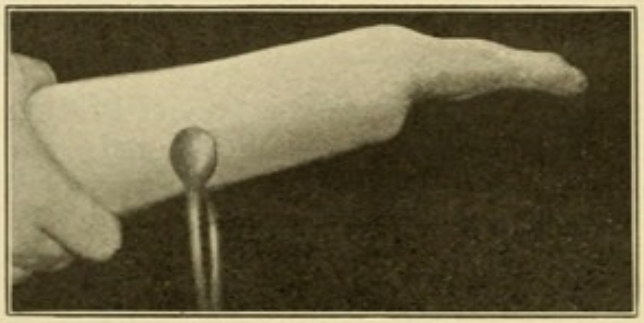

FIG. 156.—Partial amputation of right hand for crush. Everything but the thumb removed. Episcopal Hospital.

In *amputation at the metacarpo-phalangeal joints* the oval method is to be preferred; in the case of the index and fifth fingers, the apex of the oval is placed on the radial and ulnar borders of the joint, instead of on the dorsum. The head of the metacarpal bone of the two middle fingers sometimes is removed for cosmetic reasons. *Amputation of the thumb* is done by making a palmar flap whenever possible. *Amputations through the metacarpal bones* are done by antero-posterior flaps, saving as much of the palm as possible, and making the necessary incisions on the back of the hand. Owing to the variety and irregularity of the injuries to the soft parts and bones in such cases, each one is a rule to itself, and the surgeon must exercise his ingenuity in saving whatever may prove useful, attaching it to the stump, and covering it with skin flaps in any way possible (Fig. 156).

Amputations through the wrist-joint are seldom employed; a long palmar flap should be cut, and the triangular cartilage should be retained, so as to aid in the preservation of rotation.

Amputations of the Forearm.—In the lower half of the forearm I think the circular method is the best form of amputation, while below the elbow the modified circular, with antero-posterior skin flaps is quite satisfactory (Fig. 157). Some surgeons employ Teale's

method above the wrist: in this two rectangular flaps are formed, the width of each being half the circumference of the limb; the longer flap

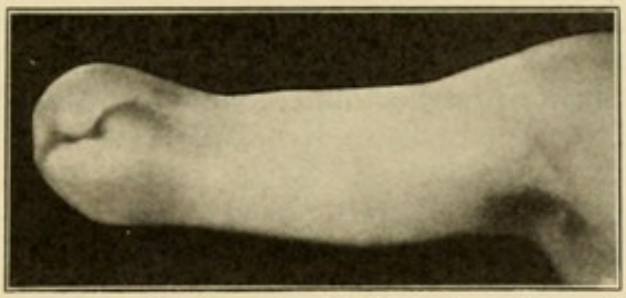

Fig. 157.—Anterior-posterior skin flaps, two inches below elbow. Episcopal Hospital.

(formed from the flexor surface) is exactly square, while the shorter flap is only one-fourth as long (Fig. 158).

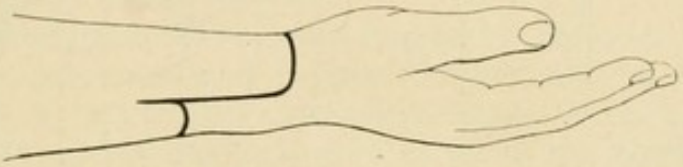

Fig. 158.—Teale's method of amputation.

Amputation at the Elbow.—This may be done by the oval method, taking a long skin flap from the thick skin covering the upper part of the ulna; or by antero-posterior flaps, the anterior being longer and including the muscular masses arising from the condyles as well as the brachialis anticus. The joint is entered just above the head of the radius.

Amputation through the Arm.—The circular method is suitable for any level up to the insertion of the deltoid; above this point lateral flaps are to be preferred. Injury by the saw to the musculo-spiral nerve is to be avoided in amputations of the middle third; and the incisions in the upper third should respect the circumflex nerve as it enters the posterior surface of the deltoid. In cases of high amputation of the arm the tourniquet is applied with the screw over the acromion and a large pad in the axilla over the vessels which are thus compressed against the head of the humerus as the arm is well abducted; or the bloodless method of Wyeth for amputation at the shoulder-joint may be adopted.

Amputation at the Shoulder-joint.—(Morand, before 1715.) *Hemostasis* is best secured by Wyeth's method (1889): two long steel pins are used, one entering in front of the acromion and traversing the anterior axillary fold, to emerge close to the chest; while the other passes from behind the acromion to the border of the posterior axillary fold, also close to the chest. The points of these pins should be guarded by sterile corks. An Esmarch band is then wrapped tightly three or four times around the shoulder, passing from above the acromion around the armpit between

the pins and the chest (Fig. 159). This band is effectually prevented from slipping down by the steel pins, and the surgeon can form his flaps in any fashion below them. If these pins are not available, the surgeon may have the subclavian artery compressed; or may cut down in the axilla and do a preliminary ligation of the axillary artery in its first portion. I adopted the latter method in

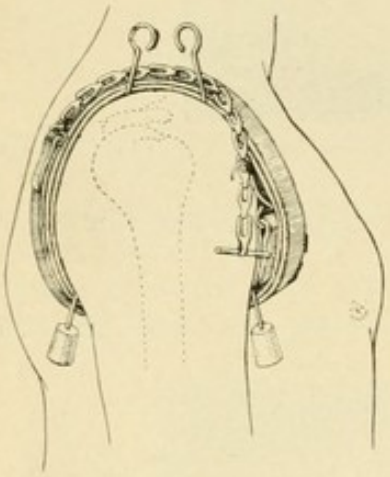

FIG. 159.—Wyeth's pins applied for amputation at the shoulder.

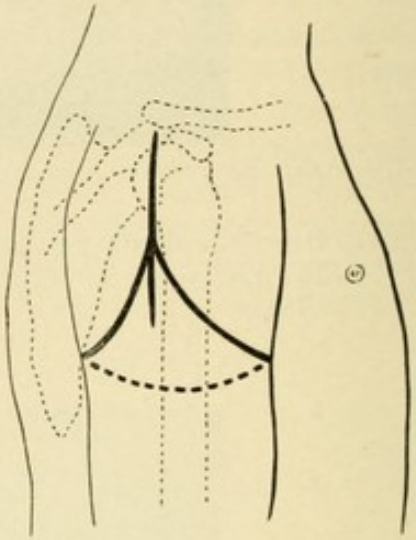

FIG. 160.—Incisions for amputation at the shoulder by Larrey's method (external racket).

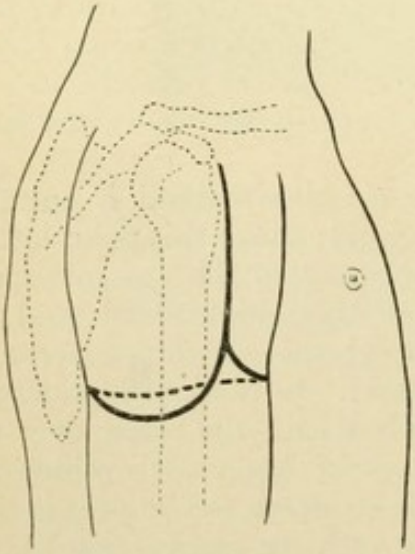

FIG. 161.—Incisions for amputation at the shoulder by Spence's method (anterior racket).

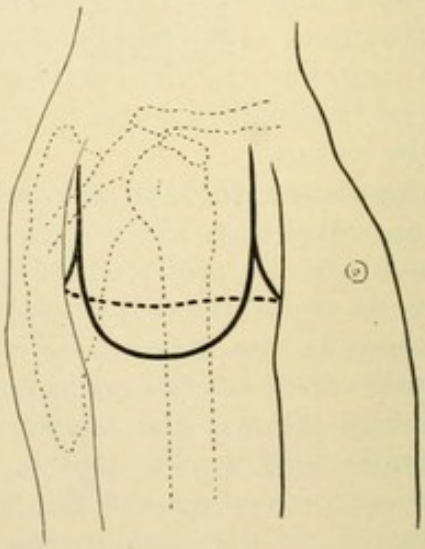

FIG. 162.—Incisions for amputation at the shoulder by Dupuytren's method (external flap).

one case, in order to inject the brachial plexus with eucain, for the purpose of preventing shock from the amputation; but I found, what is frequently the case, that the axillary artery still bled, when severed below the ligature, from the collateral circulation through the subscapular branch; a second ligature was therefore required.

The only form of amputation habitually practised at the shoulder-joint is the racket method, though it has many modifications, known

by various names. The operation of Larrey (1817), (external racket method), is now very seldom employed (Fig. 160). In Spence's amputation (1867), (anterior racket method) the incision begins midway between the acromion and the coracoid, where the point of an oval is formed, then passes down nearly to the insertion of the deltoid, and there encircles the arm transversely (Fig. 161). Dupuytren's amputation (1812), by a large deltoid flap, originally was performed by transfixion: the knife entered at the front, just within the acromion, and its point emerged behind at the level of the spine of the scapula; the flap extended down almost to the insertion of the deltoid. After disarticulation a short internal flap was cut from within outward (Fig. 162). A form of amputation midway between these two extremes (Spence and Dupuytren) may be termed the lateral flap method, the internal flap being very short, and the external being formed by an incision beginning as in Dupuytren's and Spence's methods, but not extending so high posteriorly as the former.

Lateral Flap Method.—The knife is entered between the coracoid and acromion processes, and cutting through all the tissues down to the muscle is carried downward in a broad sweep, nearly to the insertion of the deltoid, and up again as far as the posterior axillary fold. The flap thus marked out is deepened to the bone, and raised so as to expose the tuberosities of the humerus. With the arm of the patient held close against his chest, and rotated out as far as it will go, the point of the amputating knife opens the capsule by a transverse cut between the acromion and the tuberosities, and then detaches the subscapularis, attached to the lesser tuberosity, and severs the long head of the biceps. The arm is then forcibly rotated inward, and the muscles attached to the greater tuberosity are severed. The head of the bone then drops from the glenoid cavity, and may be further freed by cutting the muscles attached to the bicipital groove. The amputating knife is then passed across the joint between the upper end of the humerus and the axilla, and the axillary tissues are cut from within outward. After ligating the vessels and retrenching the nerves, the Esmarch band and the pins are removed, the muscles of the two flaps are sutured to each other, and the skin closed, with provision for drainage from the two ends of the incision.

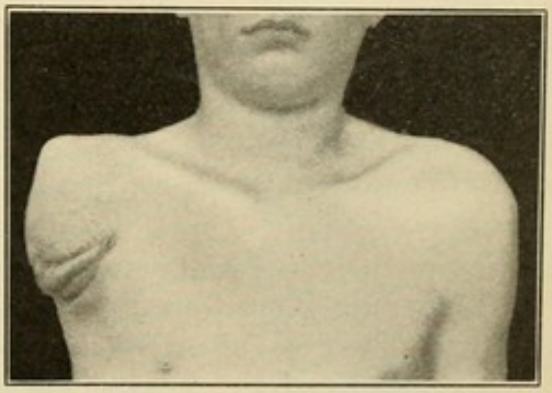

FIG. 163.—Stump resulting from lateral flap method of shoulder amputation (modified Dupuytren's). Episcopal Hospital.

This form of amputation may be very quickly performed, and it leaves a very excellent stump (Fig. 163). Its advantages are (1) the first incision is the same as that used for excision of the shoulder-joint, and permits inspection of the parts before the amputation is

performed; (2) the posterior circumflex artery and circumflex nerve are not divided, if the knife is kept close to the bone in detaching the deltoid flap; (3) either the external or internal flap may be retrenched at the expense of the other, in case of injury or disease invading one; (4) in emergencies the entire operation, up to the division of the inner flap, may be completed almost bloodlessly without the use of a tourniquet; and the main vessels can readily be controlled by the fingers of an assistant before the inner flap is severed; or the third portion of the axillary artery may be ligated through the first incision, before raising the external flap or disarticulating; finally (5) it is more nearly universally applicable than any other method of shoulder-joint amputation.

Amputation above the Shoulder.—The *interscapulo-thoracic amputation* (Berger's operation, 1887) comprising removal of the entire upper extremity, is employed usually for disease, especially sarcomas of the shoulder or scapula, though it is occasionally required for injury. The operation is best performed by opening the sterno-clavicular joint, raising the clavicle (Le Conte, 1899), and detaching the pectoralis minor from the coracoid; then the subclavian artery and vein are doubly ligated outside of the scalenus anticus, and divided; the brachial plexus is next cut, after injecting it proximally with eucain; the transversus colli and suprascapular arteries are ligated and divided, and finally the scapula is dissected away from the chest. The incisions used are shown in Fig. 164. Berger (1905) collected ninety-four cases of this operation, with eight deaths, a mortality of 8.5 per cent.; in the twenty-five cases in which the tumor originated in the scapula there were five deaths, and only three deaths among the sixty-nine cases of sarcoma of the humerus.

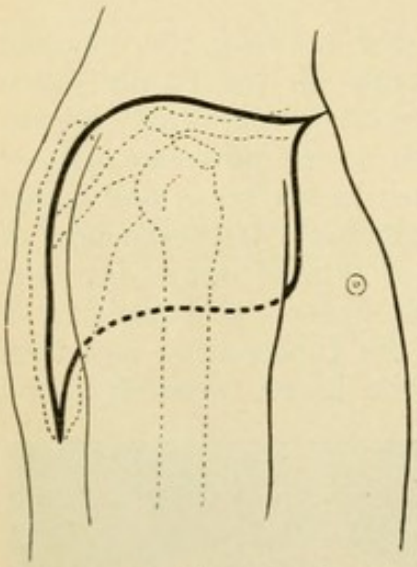

Fig. 164.—Incisions for interscapulo-thoracic amputation.

Amputations of the Foot.—The *phalanges* may be amputated by an oval incision, with a plantar flap; or, preferably, by antero-posterior flaps. The heads of the metatarsal bones should be retained whenever possible, as they afford great support in walking. A single *metatarsal bone*, with its annexed digit, may be removed by a dorsal incision. Amputations *through the metatarsal bones* are sometimes performed for gangrene following frost-bite; a long plantar and short dorsal flap are used. Amputation at the *tarso-metatarsal joint* (Lisfranc, 1815) is difficult to perform, and is seldom employed (Fig. 165). To avoid the difficulties of disarticulation Hey (1799) sawed off the projecting internal cuneiform, while Skey (1850) removed the base of the second metatarsal by

cutting forceps. It is better to saw through the foot at any level required by the length of available skin flaps (Hancock). Amputation at the *medio-tarsal joint* (Chopart, 1792) is performed thus: a transverse incision, convex forward, is made across the dorsum

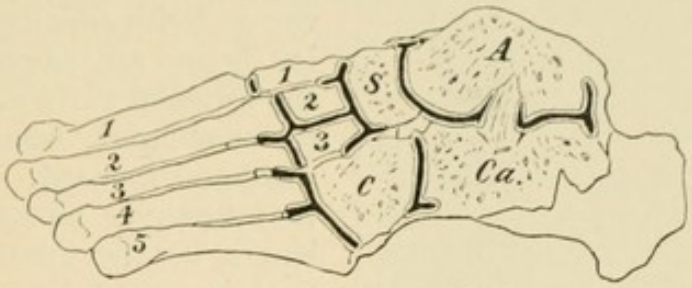

FIG. 165.—The tarsal joints: *A*, astragalus; *Ca*, calcaneum; *S*, scaphoid; *C*, cuboid; 1, 2, 3, cuneiform bones. Note the irregularity of Lisfranc's joint (between the tarsus and metatarsus). Chopart's joint is between the astragalus and calcaneum posteriorly, and the scaphoid and cuboid anteriorly. The subastragalar joint includes the astragalo-scaphoid joint as well as the astragalo-calcanean.

of the foot, from a point midway between the external malleolus and the tuberosity of the fifth metatarsal, to a point half an inch behind the tubercle of the scaphoid; the plantar flap extends from the same points *as far forward as the line of the metatarso-phalangeal joints.* The usual error is to make this flap too short. By forcing the foot downward, after making the dorsal flap, the joint between the calcaneum and cuboid is easily opened on the outer side; and the disarticulation is completed by passing between the astragalus and scaphoid. Though the scaphoid has repeatedly been left, unintentionally, it has not interfered with the result. Careful dressing and after-treatment are required to keep the calf muscles from drawing the cicatrix on to the sole of the foot. The patient walks with the ankle-joint in slight plantar flexion (Fig. 166).

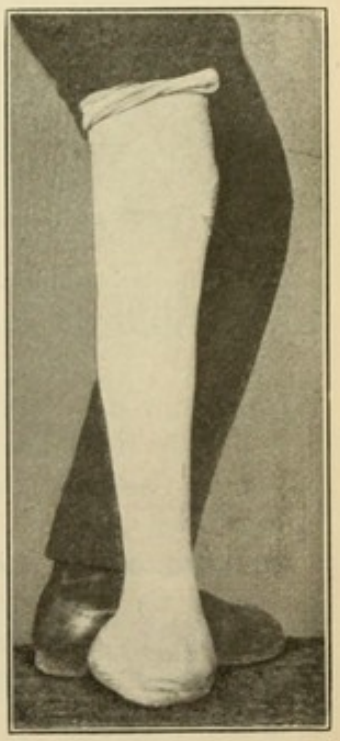

FIG. 166.—Stump thirty-two years after Chopart amputation (in 1877) by the late Prof. Ashhurst. Episcopal Hospital.

Amputation at the Ankle-joint (Syme, 1843), including removal of the malleoli, is performed by making a heel flap by cutting across the sole from one malleolus to the other. *Subastragalar amputation* (Textor, 1841) retains the motions of the ankle-joint, and greater length of limb.

Pirogoff's Amputation (1854).—In this operation all the foot is removed, except the posterior part of the calcaneum, which, still attached to the tendo Achillis and covered by the tissues of the heel, is brought up and applied to the sawn surfaces of the tibia and fibula (Fig. 167). The plantar flap is formed by cutting across the sole from

just in front of the external malleolus to just below the internal malleolus; the dorsal flap is slightly convex forward across the front of the ankle-joint (Fig. 168). The malleoli are cleared, carefully preserving the calcaneal branches of the posterior tibial artery, and the leg bones are sawed just above the articular surface. The calcis is sawed obliquely from above downward and forward. This amputation preserves almost the normal length of the extremity (lost in Syme's amputation), but is difficult to perform, and makes a less useful stump than Chopart's.

Many patients, especially laboring men, prefer to have amputation done at "the point of election" in the leg (a hand-breadth below the tubercle of the tibia), instead of through the ankle or lower leg, because the short stump is better adapted for use with the cheap "peg leg."

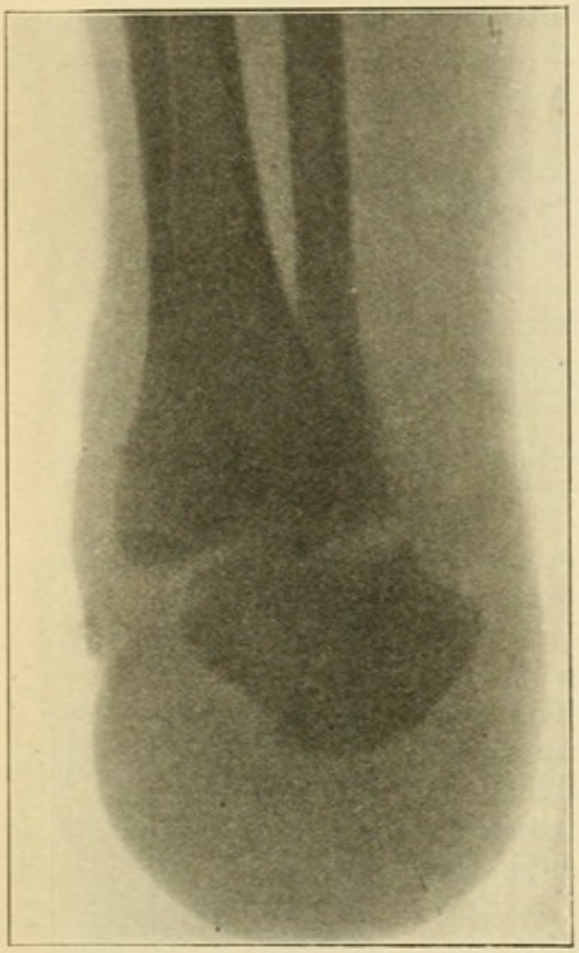

Fig. 167.—Skiagraph of stump of Pirogoff operation. (Case of Dr. H. C. Deaver.) Episcopal Hospital.

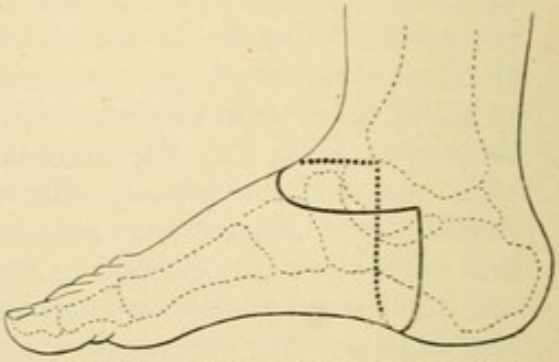

Fig. 168.—Skin incision for Pirogoff's amputation.

Amputation of the Leg.—In the lower third of the leg, anteroposterior flaps are to be preferred. Teale's method (1858) produces an excellent stump (Fig. 158). In the middle and upper leg the lateral flap method of Sédillot (1840) as modified by J. Ashhurst, Jr. (1889), is better: The knife is entered on the *inner* side of the spine of the tibia, and passes downward for about three inches, then curves backward, outlining a long flap and terminates diametrically opposite the point of beginning; a short internal flap is then formed (Fig. 169). The cicatrix is carried to the inner side of the stump, and the outer flap covers the spine of the tibia (Fig. 170). If the skin on the front of the leg is deficient, a long posterior flap may be used (Henry Lee, 1865), preferably including only the gastrocnemius muscle (J. Ashhurst, Jr., 1881).

Amputation at the Knee.—A distinction is made between amputations at the knee-joint, which are pure disarticulations, and amputations at the knee, in which a section is removed from the femoral condyles. Two methods are in use, a long anterior flap method, and a lateral flap method; the latter is more applicable to disarticulations, when the cicatrix falls between the condyles. But the anterior flap method is better even in such cases. In disarticulations the patella

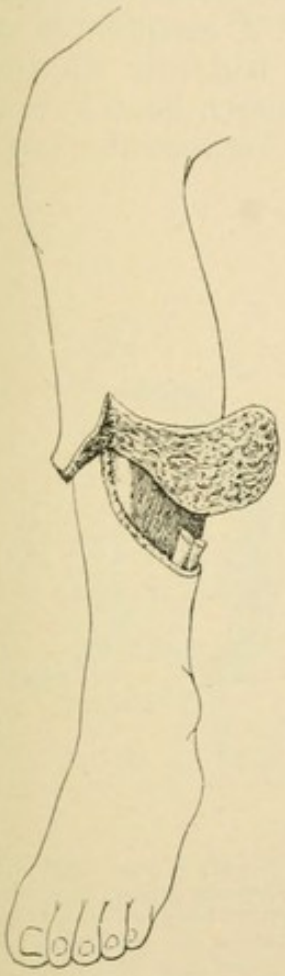

FIG. 169.—Amputation of leg by long external and short internal flaps. (Ashhurst's method.)

FIG. 170.—Stump of leg eight weeks after amputation by Ashhurst's modification of Sédillot's method. Episcopal Hospital.

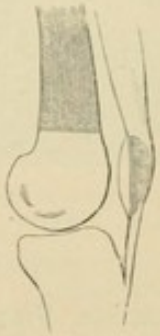

FIG. 171.—Stokes' osteoplastic supracondylar knee amputation, patella utilized: shaded parts are those brought in apposition. (Farabeuf.)

should be retained if possible; or its articular surface may be removed by a saw, and applied to the sawn surface of the femoral condyles (*transcondylar amputation* of Gritti, 1857); or to that of the femoral shaft (*supracondylar amputation* of Stokes, 1870) (Fig. 171).

Amputation of the Thigh.—The circular, modified circular, and flap methods all produce an excellent stump in the thigh. The circular is best whenever there is a choice. If flaps are used, the posterior should be cut sufficiently long. The greater retraction of muscles

in the posterior flap carries the cicatrix away from the face of the stump (Fig. 172).

Amputation at the Hip-joint (H. Thomson before 1777).—Hemostasis is secured by Wyeth's method (1890): Two steel pins are used, each $\frac{3}{16}$ of an inch in diameter, and ten inches long; one pin is introduced close to the spine of the pubis, and after traversing the adductor tendons emerges just below the tuberosity of the ischium; the other pin enters below and within the anterior superior spine of the ilium, traverses the gluteal muscles for about three inches, and emerges well above the level of the great trochanter; the points of the pins are immediately shielded by corks. A compress of gauze, two inches thick and four inches square, is laid over the femoral vessels at the brim of the pelvis, and an Esmarch band is wrapped very tightly five or six times around the hip between the steel pins and the pelvis (Fig. 173).

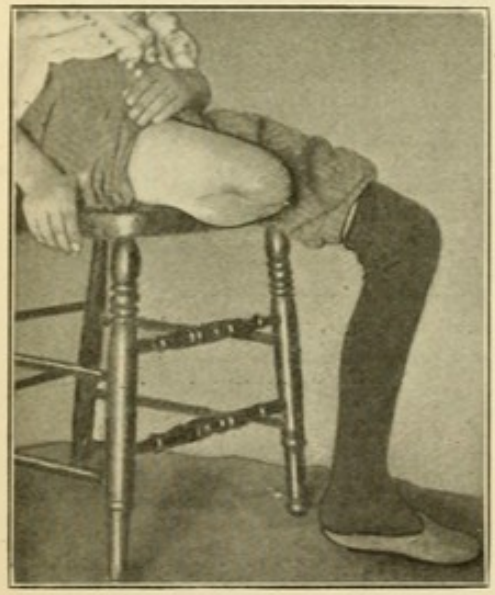

Fig. 172.—Amputation of right thigh (anterior-posterior flaps). Episcopal Hospital.

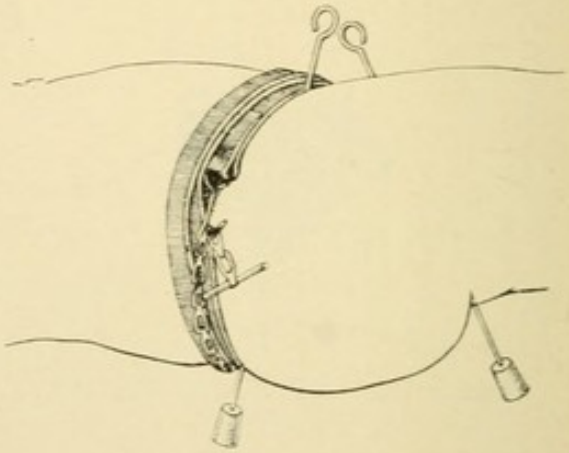

Fig. 173.—Wyeth's pins, and Esmarch band, for hemostasis during amputation at the hip-joint.

Antero-posterior Flap Method (Guthrie, 1815).—The flaps are cut from without inward,[1] with a moderately short knife; the posterior is formed first, the incision commencing above the trochanter, and crossing the back of the thigh in a curved line convex downward, to a point in front of the tuber ischii; the anterior flap is then outlined, extending at least five inches below the joint (Fig. 174). These flaps being dissected up and the joint exposed, it is opened in front, the femur being forcibly abducted and hyper-extended, bringing the ligamentum teres into view; when this has been cut and the remainder of the capsule divided, any fibres on the back of the joint are severed, and the limb removed.

In cases where Wyeth's method of hemostasis is not available,

[1] Guthrie cut them by transfixion.

and where Momburg's method (see below) is not employed, the surgeon may adopt either preliminary ligation of the femoral vessels, by an anterior racket incision (Larrey, 1817), opening the joint from the front and dividing the remaining tissues posteriorly from within outward;[1] or he may adopt Dieffenbach's method (1827), consisting of circular amputation of the thigh followed by excision of the head of the femur through an outer longitudinal incision;[2] or following Brashear's (1806) and Fourneaux-Jordan's (1879) method as modified by Senn (1893) may first disarticulate through an external incision and then, puncturing the tissues on the inner side of the thigh, introduce a double elastic tube, and compress in this way the

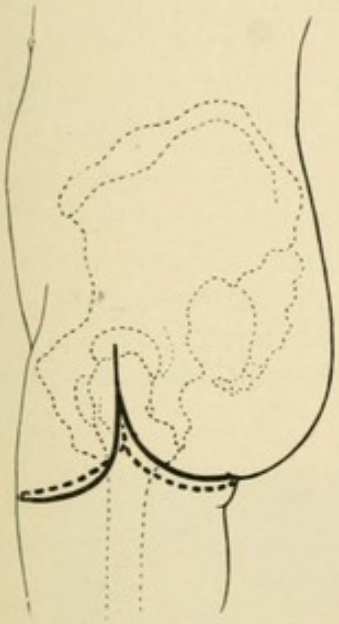

FIG. 174.—Incisions for amputation at the hip-joint by antero-poterior flaps. (Guthrie's method.)

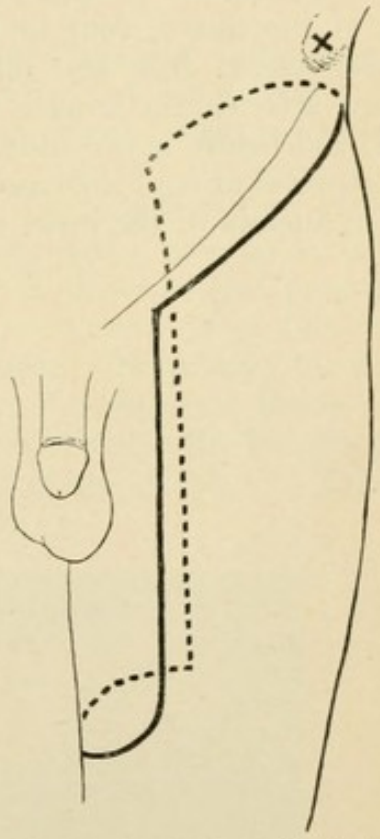

FIG. 175.—Incision for interilio-abdominal amputation

tissues of both anterior and posterior flaps before removing the limb. Compression by a forceps tourniquet, somewhat like the forceps used for intestinal anastomosis, may also be employed (Lynn Thomas, 1898). The mortality of hip-joint amputation is now about 8 per cent. in disease, and 16 per cent. in traumatic cases (Wyeth, 1910), this vast improvement in the results being due chiefly to improvements in methods of hemostasis.

[1] This is the "extirpation method" of Kocher, permitting careful dissection of malignant disease. and clamping and ligating every vessel as it is cut. It also permits nerve-blocking.

[2] If there is nothing to contraindicate subperiosteal excision, a more movable stump will be obtained.

Interilioabdominal Amputation (Billroth, 1885).—The incisions used are shown in Fig. 175. The horizontal and descending rami of the pubes are divided, and the ilium is sawed through just in front of the sacro-iliac joint, the entire intervening portion of the pelvis being removed. Ransohoff (1909) has collected thirty-four cases of this operation, which is done almost solely for malignant disease; only twelve patients survived more than a few hours. The best method of hemostasis is Momburg's (1908), which has been used by both Pagenstecher (1909) and Bier with success, in interilioabdominal amputations. This method of hemostasis had been employed up to 1909 with success in over thirty operations of various kinds. It consists in applying an Esmarch band or thick rubber tube (size of the finger) four or five times so tightly around the waist, between costal arch and iliac crests, as to stop pulsation in both femoral arteries; the band is applied only after the patient is anesthetized, and before it is removed the patient is inverted and an elastic band applied around the base of each lower extremity, so as to prevent sudden anemia of the heart when the waist band is removed.

CHAPTER IX.

EFFECTS OF HEAT AND COLD; INJURIES BY ELECTRIC CURRENTS, LIGHTNING, AND THE RÖNTGEN RAYS; SKIN-GRAFTING AND PLASTIC SURGERY.

Burns and Scalds.—The effect is essentially the same whether the injury is produced by flame (*burn*) or by hot liquid (*scald*). In scalds, however, the hair usually remains intact, while in burns it is singed.

Symptoms.—Local symptoms vary with the degree of heat and the length of contact: mere singeing of the hair and a passing erythema may be caused by momentary contact of flame, while prolonged contact with some body at much lower temperature (*e. g.*, hot water bottle) may produce a very destructive lesion. Burns may be *classified* in three degrees: (1) Erythema. (2) Vesicles and Bullæ. (3) Sloughing. The reactionary changes which occur in the burned part are identical with those already discussed in the chapter on Inflammation.

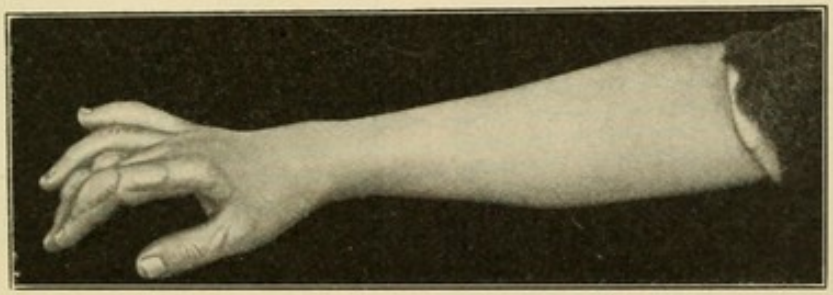

FIG. 176.—Scald of hand, second degree; twelve hours' duration; showing bullæ. Episcopal Hospital.

Constitutional effects of burns depend much more on the area involved than on the depth of the burn. A superficial burn may be attended by the gravest consequences, even death, if extensive; whereas a very deep burn, if it involves only a small area, may be almost unattended by constitutional symptoms. As in other injuries, the constitutional effects of burns may be divided into those of *shock* and *reaction;* and there usually follows, in severe cases, a stage of *exhaustion.* The pain is intense, and in extensive burns may induce hyperpnea, which, according to the theory of Henderson (p. 172), produces acapnia, and so induces shock; patients may die in the first stage, without reaction. The unburned skin is pale, the patients

feel chilly, and require to be covered up; the usual signs of shock are present. Often, however, reaction begins soon, sometimes before the patient is seen by the surgeon; and at this time *prostration with excitement* or *traumatic delirium* (p. 173) may dominate the scene. This stage lasts for a week or more, being accompanied by high fever, often with intense congestion of organs underlying the lesion (pneumonia, in thoracic burns; peritonitis, in those of the abdomen; meningitis in those of the head). There is a tendency to fatty degeneration of all organs; the liver, spleen, and lymph nodes may be enlarged; the urine is scanty, of high specific gravity, or entirely suppressed. The bile is believed to be abnormally toxic. The blood is prone to

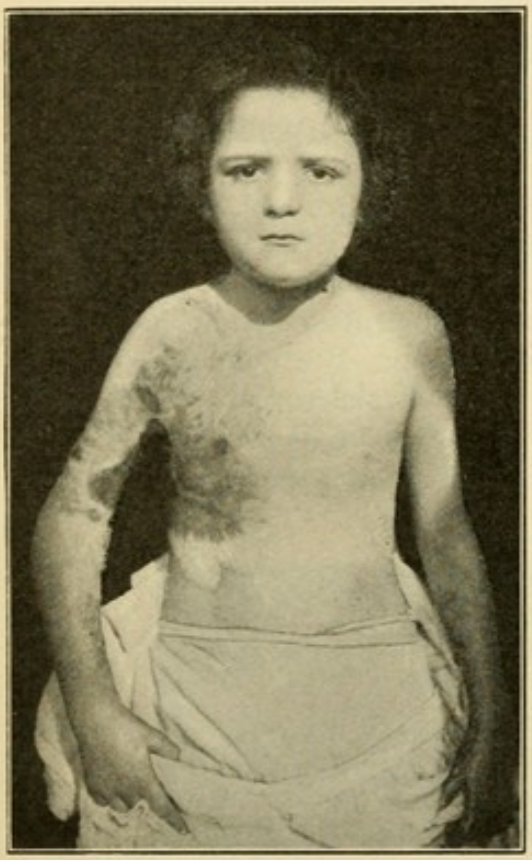

FIG. 177.—Ulcers resulting from extensive burns received three months previously. Episcopal Hospital.

FIG. 178.—Same patient, two months later, after complete cicatrization. Episcopal Hospital.

thrombosis, and capillary embolism is not infrequent; there is hyperleukocytosis and polycythemia; hemoglobinuria and albuminuria may exist. In rare cases *duodenal ulceration* (Curling, 1842), with hemorrhage or perforation, develops, possibly from excretion of toxic substances through Brunner's glands, or as the result of embolism.[1] The patient is excessively thirsty, but constantly vomits what is taken into the stomach; there may be septic diarrhea; he feels hot, is restless, and tosses off the bed-clothes. If he survives this

[1] Alexander (1912) observed this complication in four out of twenty-seven patients with extensive burns.

stage, there follows that of exhaustion, with hectic fever, profuse suppuration of the wounded surfaces, and perhaps metastatic (especially subcutaneous) abscesses.

Death from Burns may be due to *shock*, to *visceral complications*, to *exhaustion*, or to *hemolysis* and *auto-intoxication*. Among the visceral complications may be included edema of the glottis, from inhalation of steam or hot smoke. In fatal cases, death usually occurs within forty-eight hours.

Prognosis.—In local burns prognosis as to life is good, even if the part be much deformed by subsequent cicatricial contraction. Burns of the trunk are more serious than those of the extremities. If a burn involves more than one-third of the body surface it usually is fatal. General burns are always fatal. Burns are particularly serious in infants, the aged, those of intemperate habits, those with diseased kidneys, etc.

Treatment.—The indications in all cases are to *control the pain*, to *combat the shock*, and to *prevent infection*. In severe cases, where death is anticipated, the most that can be done is to promote euthanasia. This is best accomplished by the use of morphin hypodermically, and the immersion of the patient's body in a bath of saline solution at about blood-heat. Shock is combated as described at p. 175; especially important is the dilution of the blood by saline solution, which relieves toxemia and restores the fluid contents depleted by discharges from the burned surfaces. Prevention of infection involves *local treatment* of the lesions; anything which protects them from the air lessens pain, and in extensive burns nothing is so satisfactory as the continuous bath, which should be kept warm and clean by frequent change. In burns of less extent it makes little difference what dressing is applied, so long as it is aseptic, and absorbs or does not dam up the discharges. Spray the burned surface lightly with peroxide of hydrogen, and surgically cleanse the surrounding parts. Do not scrub the burns. Open bullæ with a sterile knife, and let the epidermis fall back in place as the serum escapes. Alexander had occasion to treat twenty-seven burned patients simultaneously. He concluded that for burns of the first degree the picric acid dressing was best; for those of the second degree he preferred the boric acid solution bath, which was used for three hours at a time, with intermission of six hours; and for burns of the third degree he recommends the following ointment: ichthyol, gr. xlviii; ol. olivæ, f℥ij; lanolin, q. s. ad ℥iij. *Picric acid dressing:* gauze soaked in 1 per cent. aqueous solution is laid on the burn and covered with absorbent cotton, not with waxed paper, as evaporation should be favored; the dressing is left in place four or five days. It should be used only over small areas, as constitutional poisoning has occurred (Rose, 1903). *Senn's powder* (boric acid, three parts; salicylic acid, one part) or *Billroth's powder* (equal parts of starch and zinc oxide) may be applied to small burns, and forms a scab which need not be removed for several days. *Carron oil*, made by stirring linseed oil

and lime water into a thick paste, is very grateful to the patient. So soon as granulations have formed, the burn is treated as an ordinary ulcer (p. 54).

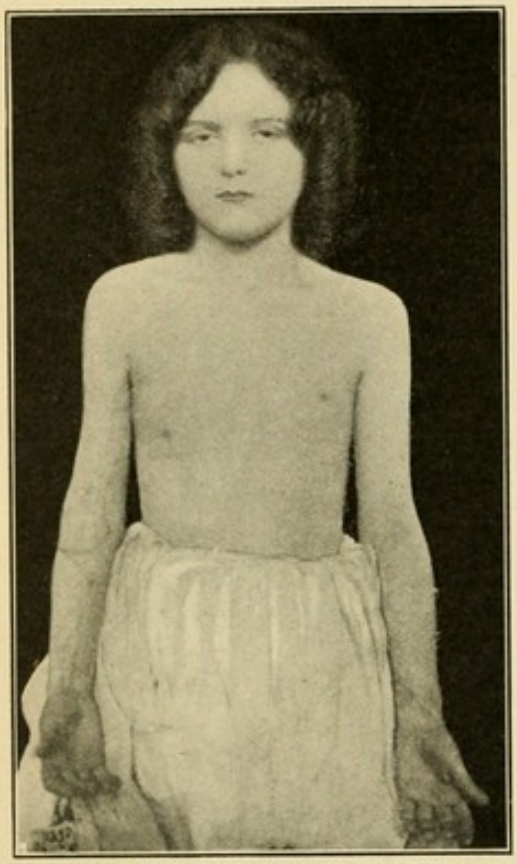

FIG. 179.—Same patient as Fig. 177, one year later, after extensive plastic operations. Episcopal Hospital.

FIG. 180.—Same patient one year after complete cicatrization, showing result of extensive plastic operations. Episcopal Hospital.

When much skin has been destroyed, healing will be slow, and skin-grafting should be employed. Amniotic membrane has given some good results when grafted on burns. A very large granulating surface should not be dressed all at one time, for fear of exhausting the patient; it is better to dress half the burned area on alternate days. If the patient is kept in a hot room the burned areas may be exposed to the air, no dressing being employed. Great care must be exercised by proper use of splints, etc., especially in burns about flexures of joints, to prevent undue cicatricial contraction; but in some cases healing can be secured only as the result of such a process (Figs. 177 and

FIG. 181.—Deformity from burns of feet. (Dr. Wharton's case.) Children's Hospital.

178), and the deformity must be overcome by subsequent plastic operations (Figs. 179 and 180). In severe grades of deformity, with painful scars which prevent conservative operations, amputation may be necessary (Fig. 181).

Effects of Cold.—In many ways these are analogous to those produced by heat, and depend more on the length of the exposure than on the intensity of the cold; moist cold, especially in a high wind, is much more apt to produce serious effects than a still, dry cold.

Constitutional Effects.—Among predisposing causes are hunger, fatigue, alcoholism, etc. There occur painful sensations in the extremities, perhaps chills, followed by uncontrollable lassitude, somnolence, coma, and death if the patient is not roused. The *causes of death* are cerebral anemia (sudden and progressive chilling); cerebral congestion (slow and continuous chilling); or embolism, in cases of sudden reheating (Lebastard). *Persons apparently dead* should be kept in a cool room, and treated by artificial respiration and gentle frictions with evaporating or stimulating liniments; when reaction commences (perhaps not for several hours), the temperature of the room may be raised gradually, stimulants administered, and the patient wrapped in blankets. Recovery has followed after being buried in the snow for eight days (Tédenat), and when the rectal temperature had fallen as low as 74.6° F. (Nicolaysen).

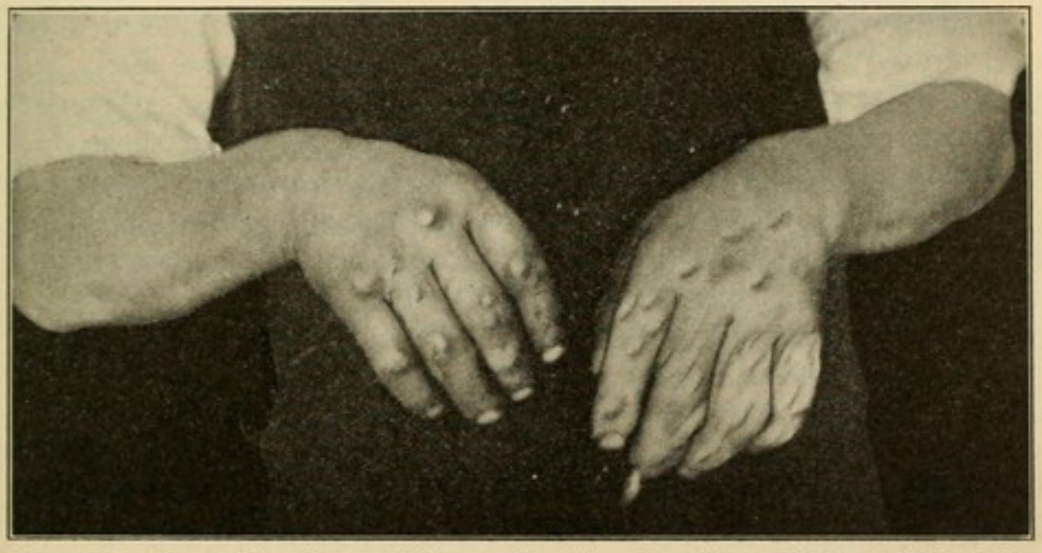

Fig. 182.—Frost-bite of second degree; duration, four days. Episcopal Hospital.

Frost-bite.—The local effect of cold is analogous to that of heat, and may be classified in three similar degrees: Erythema, Bullæ, and Eschar. The exposed part, especially the fingers and toes, nose, cheeks, ears, or the penis, becomes first the seat of congestion, attended by some tingling and pain; soon, however, the part becomes blanched, numb, and stiff, and to all appearances dead. This stage is well exemplified when local anesthesia is produced by the ethyl chloride spray. With proper treatment, the local destruction may go no

further; if this is neglected, vesicles and bullæ form (Fig. 182), and if the cuticle is destroyed and infection follows, painful ulcers develop which are long in healing. Finally, the freezing may be so intense that a local slough, or gangrene of an entire limb may occur, the larger arteries and veins being thrombosed.

Treatment of milder degrees of frost-bite consists in gentle frictions with snow or iced water until sensation is restored; the part, which now begins to tingle and burn, may next be painted with silver nitrate solution (4 to 10 grains to the ounce), which allays these symptoms; the part is then protected from injury and maintained at an even temperature by absorbent cotton. *When gangrene threatens*, vertical suspension of the limb should be adopted (v. Bergmann, 1873) with immobilization by splints; as the swelling subsides the circulation improves. The resulting sloughs are treated as advised in Chapter II. Amputation should not be done until the line of demarcation has been established.

Pernio or **Chilblain** is a vaso-motor disturbance of the skin following previous frost-bite of mild degree. It develops as the result of sudden variations in the temperature to which the part is exposed. Chilblains occur in parts most exposed to frost-bite, and are especially common in the anemic and run-down. A patient once affected is prone to have recurrence of chilblains on slight provocation. The symptoms and treatment are much the same as for mild degrees of frost-bite. Constitutional treatment should not be neglected.

Electric Currents.—These produce *local effects* (electric burns) and *general effects* (electric shocks). The former are more severe the less the area of contact, while severe shocks and milder burns follow broader contacts. The burns do not differ from those due to other causes, except in their extreme slowness in healing; Da Costa (1910) warns against use of corrosive sublimate solutions as very irritating. Skin-grafting usually is unsatisfactory, but a plastic operation may succeed. The constitutional effects of electric currents are practically identical with those due to lightning strokes.

Lightning Strokes.—Death may be instantaneous. Stunning almost always is produced, and burns frequently exist at the points of entrance and exit of the current; they resemble burns due to electric currents; arborescent marks, typical of lightning strokes, are attributed to disorganization of blood in the vessels. Persons apparently dead may recover after many hours; the usual condition of a patient just after being struck by lightning resembles that seen in concussion of the brain. Treatment consists in artificial respiration, external heat, and other methods advised for shock (p. 175).

X-ray Dermatitis.—This affection, carefully studied by Codman in 1902, is seldom seen except as the result of repeated and prolonged exposure to the Röntgen rays; before their danger was understood, skiagraphers took no precautions to protect themselves from exposure, and a dermatitis affecting the fingers was not unusual. The danger to patients is extremely slight, especially since modern methods

permit very short exposures. The dermatitis does not develop for several days after exposure, and then is characterized by slight erythema, with pigmentation and exfoliation of epiderm; a severer degree is evidenced by the formation of vesicles and bullæ, while the third degree involves a slough of the entire skin. Eventually, dystrophies of the nails, keratoses, and epitheliomas may occur.

Treatment. — No further exposure should be allowed, even if the patient thinks himself well protected by leaden shields, etc. For the intense pain which exists during the extremely slow casting of the slough, alkaline astringents give the best results. Ointments are said to favor carcinomatous changes (Leonard). When these occur, amputation is necessary.

Therapeutic Uses of the X-ray. — These should be applied by an expert Röntgenologist in consultation with a dermatologist. Some cases of lupus, a few of keloid, and occasionally a case of superficial epithelioma may be cured, at least temporarily, by periodic exposure to the *x*-rays. Their action appears to consist in stimulating an over-production of fibrous tissue, by which the growth of the cellular elements is arrested or abolished. After operation for carcinoma, and in inoperable cases, systematic treatment with the *x*-rays may delay recurrence, diminish pain, and greatly promote the patient's comfort.

SKIN-GRAFTING.

In cases of extensive ulcers resulting from burns or other causes, the practice of skin-grafting often not only accelerates healing, but may be absolutely necessary to bring it about. For the grafts to "take" well, it is essential that the granulating surface approach in type to that of the "healthy ulcer" (p. 54). There are three principal methods of skin-grafting, known by the names of Reverdin (1869), Thiersch (1874), and Wolfe (1875), or Krause (1893). In all of these methods the granulating surfaces must first be *prepared* for the reception of the grafts. Roberts (1909) recommends dressing the part for several days previous to the grafting operation with gauze soaked in formaldehyde solution (1 to 200); this renders it sterile, and the tops of the hardened granulations are then gently scraped off with a sharp razor, just before applying the grafts. The ulcer is then washed with sterile saline solution to remove the antiseptics. The slight bleeding is checked with pressure by sterile gauze. The best sites from which to obtain grafts are the adductor surfaces of the thigh, the inner surfaces of the upper arms, and the lateral abdominal and thoracic walls; hairy skin is not suitable for grafting, as, apart from the deformity which might result from reproduction of the hair, it is difficult to sterilize and less apt to grow successfully than more delicately formed skin. The region from which the grafts are taken also must be prepared as for an aseptic operation. Antiseptic methods are not successful.

Reverdin's Method.—Minute particles of the cuticle are raised on the point of a needle, cut off with a sharp scalpel, and at once transferred to the granulating surface, previously prepared. As many such grafts as may be required (a score or more) are applied over the ulcer, with the epidermic side upward, at close intervals; gently pressed down on the granulations, and held in place by strips of rubber tissue; space should be left between the rubber strips, to permit escape of discharges, and these are absorbed in sterile gauze dressings held in place by a light bandage. The part is suitably splinted, and need not be dressed for four or five days, when it will be found that many of the grafts have taken, and may be recognized as minute islets of bluish-white epiderm growing in the centre of the granulating area (Fig. 183). In time these islets coalesce, and a number of small ulcers surrounded by epiderm replace the one large surface.

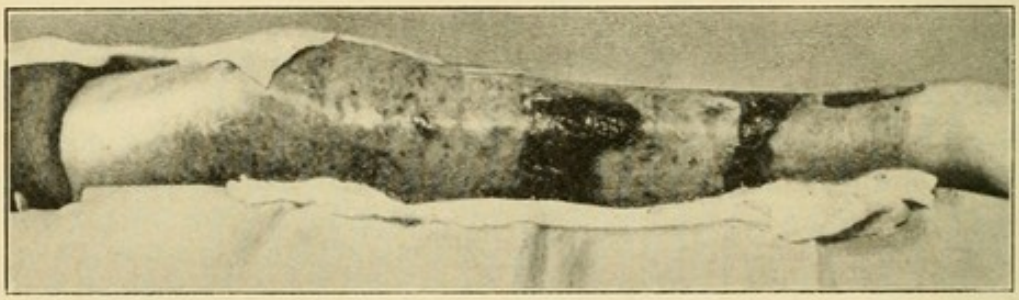

FIG. 183.—Skin-grafting by Reverdin's method, in a case of burns of leg. The white spots on the surfaces of the ulcers are islets of new-formed skin. Episcopal Hospital.

Thiersch's Method.—Long strips of epiderm, with only the most superficial layer of the cutis, are cut by means of a very sharp razor, with a rapid sawing motion, while the skin is held taut. The skin and the razor should be moistened with saline solution, to facilitate the process. The long grafts are then at once transferred to the granulating surface, previously prepared, and spread in place, covering nearly its entire surface. Dressing is similar to that for the Reverdin method. Thiersch grafts are more difficult to cut, require a general anesthetic, and are less apt to grow than the smaller grafts of Reverdin; but if they do grow, the healing of the ulcer is very much more rapid, and the resulting scar less conspicuous.

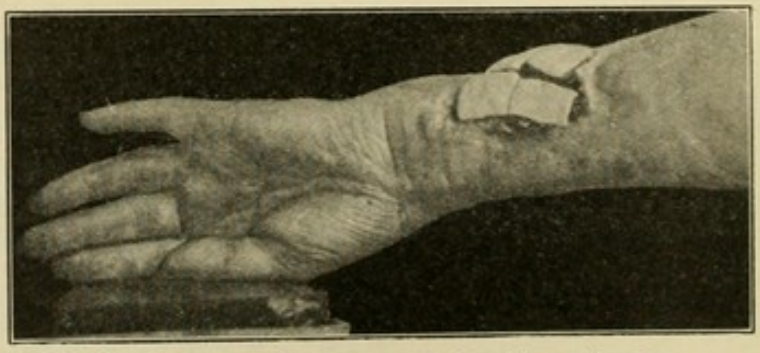

FIG. 184.—Ulcer from compound fracture. Wolfe skin-grafts from amputated leg. Episcopal Hospital.

Wolfe-Krause Method.—The entire thickness of the skin is transplanted, but without any subcutaneous tissue. The grafts may be obtained from the patient's own body, or from the healthy tissues of a recently amputated limb. As a rule, pieces an inch in diameter are large enough, leaving space for discharges from the ulcer (Fig. 184). The entire operation should be dry, and absolutely aseptic. Wolfe grafts may also be applied to the wound at the time of operation, and are preferable for such use to Thiersch grafts, which latter are better suited for application to granulating surfaces.

PLASTIC SURGERY.

The object of plastic surgery (*anaplasty*) is to restore or to improve the function or appearance of a part, deficient congenitally, or through disease or injury. Until within a few years its field was limited to the skin and subcutaneous tissues (including mucous membranes), but recently the formation of new joints (p. 471), transplantation of bone (p. 504), etc., have been done. Cinematoplastic amputations (p. 202) and prosthesis by subcutaneous use of paraffin (p. 620) are parts of plastic surgery, as are certain operations on the female perineum and vagina (Chapter XXIX). Its more limited field alone will be discussed here.

The operation consists essentially in shifting flaps of skin and subcutaneous tissue, attached by one or more pedicles, so as to cover in defects left by excision of morbid structures. Such operations will not succeed unless asepsis is maintained, and unless no active disease exists in the parts on which the operation is done. Lupus and syphilitic ulcerations must be healed, and the disintegrating process at a standstill before any plastic surgery is attempted. Another maxim of extreme importance in plastic surgery is to do too little rather than too much at each step of the operation, which is thus often better divided into several sittings.

Plastic operations may be classified as follows:

1. Anaplasty by *simple approximation*, as after excison of any tumor in which the wound edges can be brought together; in the operation for hare-lip, etc.

2. Anaplasty by *transfer of flaps from the immediate neighborhood*, by *gliding*, *stretching*, etc., as in operations for deforming cicatrices from burns, and in the Indian method of rhinoplasty (p. 621).

3. Anaplasty by *transfer of flaps from a distance:*

(*a*) By *one migration*, as in the Italian method of rhinoplasty (p. 621).

(*b*) By *successive migrations* (method of Roux), as from the abdomen to the arm, and then from the arm to the face.

4. Anaplasty by *readjustment of totally severed parts*, including skin-grafting, transplantation of bones, joints, etc.

The simpler the operation the more successful it is likely to be; hence the simpler methods always should be tried first, unless mani-

festly inadequate. Cicatricial tissue usually should be excised and not employed in plastic surgery, as it is very apt to slough. Occasionally, however, where a fold of cicatricial tissue exists (as in the knee or elbow) it will be possible to split it, forming two flaps; and if the splitting be done by a Z-shaped incision, on straightening the limb two lax flaps will be available to cover in the flexure of the joint. In all plastic operations great gentleness should be used in manipulation; strict hemostasis by the finest ligatures must be secured; and accurate, but not too tight coaptation must be procured. The flaps should contain a moderate amount of subcutaneous tissue and their bases should be broad and should contain the main vascular supply; and the flaps should be made of sufficient size, especially when cut from tissues naturally lax (neck, scrotum), as in them retraction is greatest. When flaps are transferred from a distance, or when the base of the flap is much twisted in adjustment, the base must be divided (to restore contour) in from one to three weeks after the first stage of the operation.

Diagrams illustrating the commoner varieties of plastic operations are given in Chapter XIX.

CHAPTER X.

SURGERY OF THE BLOOD VASCULAR SYSTEM.

Hemorrhage.—This is the natural consequence of injuries which sever the walls of bloodvessels. Hemorrhage may be *apparent*, when it occurs in an open wound; or *concealed* (*internal*), when it takes place into one of the natural cavities of the body. *Subcutaneous* hemorrhage, attended by extravasation or formation of a hematoma, has been mentioned at p. 160.

The signs of hemorrhage are both *local* and *constitutional*. The local signs of venous and arterial hemorrhage are different, but the constitutional signs are identical. *Venous hemorrhage* is characterized by the darker, bluish color of the blood; by its flowing in a steady stream, not in spurts; and in most cases of wounds of the extremities by the ease with which it is arrested simply by elevation of the part. *Arterial hemorrhage* occurs in rhythmic jets, and the blood usually is of a distinctly redder tinge.

Constitutional Signs of Hemorrhage.—As the volume of blood within the vascular channels is rapidly lessened by hemorrhage, the heart begins automatically to pulsate more quickly. A steady rise in the pulse rate is one of the surest signs of hemorrhage. As the quantity of blood in the system decreases, faintness comes on: there is thirst, rapid and sighing respiration (*air-hunger*); the skin becomes blanched and clammy; the lips and conjunctivæ are pale; the ears ring; vision fails; specks and blackness float before the eyes; restlessness and delirium come on; involuntary dejections may occur; and with one or two gasps the patient may seem dead. At this stage bleeding may cease spontaneously, owing to the diminished force of the circulation which permits thrombosis; but it may begin again when reaction sets in. After very severe or repeated hemorrhages, faintness is prone to recur; and the patient may be feverish and delirious for several days. Slow hemorrhage is much less serious than profuse, sudden bleeding. Patients in early adult life bear hemorrhage better than infants or the very old; and, as a rule, women bear it better than men.

Hemophilia is the name given to an obscure condition affecting males almost exclusively, and seemingly transmitted from one generation to another only through the female sex. It is characterized by an abnormal and inveterate tendency to hemorrhage even from the most trifling injuries. Mere scratches, the extraction of a tooth, etc., frequently have caused such persons to bleed to death. The vice appears to reside in a loss of coagulability of the blood, though

it was long held that the bloodvessel walls were at fault. Blood oozes in profusion from the capillaries, and no local remedies are of much avail. The internal administration of calcium chloride may be tried; and the hypodermic injection of horse or rabbit serum, and even of diphtheria antitoxin has been used in some cases with benefit. Nolf and Herry (1910) secured arrest of the bleeding in nine cases by a single hypodermic injection of 10 c.c. of a 5 per cent. solution of peptone in 0.5 per cent. sodium chloride solution. This can be sterilized by boiling. Hypodermoclysis, intravenous injections of saline solution, and even direct transfusion of blood may be tried. Plate II, Fig. 2, shows the subcutaneous hemorrhages which followed the insertion of needles for hypodermoclysis in a patient with hemophilia following circumcision; in this case recovery occurred after the direct transfusion of blood and use of diphtheria antitoxin. Yet a year later the patient was again in the ward with hemarthrosis (p. 387) following a trifling contusion of the knee.

Spontaneous Arrest of Hemorrhage.—As mentioned above, bleeding sometimes ceases spontaneously. Most very small vessels cease to bleed in a few minutes. In the case of capillaries, swelling of the endothelium occludes the lumen; in larger vessels there occur in addition *contraction* and *retraction* of the vessel walls. *Contraction* of a divided vessel is said to be an effort to restore the blood pressure to normal. *Retraction* results from the natural elasticity of the vessel, its ends being drawn back among the tissues, and its walls curling upon themselves so as to diminish the lumen, thus favoring coagulation.

Treatment of Hemorrhage.—Temporary control of hemorrhage usually can be secured by direct pressure against the bleeding point, or on the main vessel of the part close above the wound, with elevation of the wounded part. When possible a tourniquet or Esmarch band (p. 193) can be applied. For permanent control of hemorrhage the surgeon has many means at his command.

1. Position.—Elevation of the part has been mentioned already, and should never be neglected. It is a remedy so simple that it often is overlooked. Hold the wounded extremity up in the air until help arrives, if you can't do anything else.

2. Pressure.—Direct pressure on the wounded vessel always can be relied on to check hemorrhage. Use your finger if you have nothing else. A graduated compress may be held against the wounded vessel: this is made of pieces of gauze so cut as to form a pyramid when placed one on the other; the apex of the pyramid is placed against the wounded vessel, and the compress is held in place by a tight bandage. Hyperflexion of the elbow or knee over a compress will control bleeding below. Hemostatic forceps (Fig. 140) or other form of clamp may be applied directly to the wounded vessel, and in emergency the forceps may be left in place thirty-six to forty-eight hours. If the wound in the vessel cannot be found, compress the main artery, when possible, at a higher point. This, and

Fig. 1.—Multiple nevi, affecting scalp, forehead, left foot, etc., in a baby aged 2½ months. Episcopal Hospital.

Fig. 2.—Hemophilia, two days after circumcision, in a boy aged 8 years; showing subcutaneous hemorrhages; that in right thigh followed an attempt to give hypodermoclysis. Episcopal Hospital.

elevation of the part, will arrest, temporarily, any hemorrhage. Or the wound may be packed with gauze or lint. *Acupressure* (Sir J. Y. Simpson, 1859) is seldom employed at present. A long and strong steel pin is passed under the vessel, occluding it against the overlying tissues, as the stem of a flower is pinned against the coat lapel; or a ligature in figure-of-eight fashion may be wound around the two ends of the pin, compressing the vessel between the pin and the intervening tissues. *Forcipressure* or *angeiotripsy* consists in occluding the bleeding vessels by powerful clamps which are removed at once; they cause a reactive inflammation which will occlude the lumen. Skene (1897) and A. J. Downes (1902) used an electro-thermic angeiotribe.

3. Heat and Cold are efficient in hemorrhage of mild degree. Cloths wrung out of very hot water (120° F.) applied to the face of an oozing wound (p. 196) usually check all capillary bleeding. Cold, in the form of ice caps, frequently is employed in gastric and intestinal hemorrhage; and often is of value in checking extravasation in the subcutaneous tissues. The *actual cautery*, heated to a black heat only, is very efficient when other methods are not available.

4. Styptics are seldom used except for oozing. Alcohol is not very active. Alum, tannic acid, the perchloride and persulphate of iron, etc., are more valuable, especially when applied on a graduated compress. Cocain and epinephrin are employed on mucous membranes.

5. Torsion.—A bleeding vessel may be caught in forceps and twisted on itself until the forceps is twisted off ("free torsion"); or, being caught higher up by one forceps, may be twisted by another ("limited torsion"). In either case the manœuvre succeeds in approximating the walls of the vessel and in arousing sufficient reaction on the part of the intima to favor permanent occlusion. Vessels of moderate size only should be treated by torsion; usually from five to six turns are sufficient.

6. Ligation.—Ligatures, like sutures, are of absorbable or non-absorbable material. Usually catgut ligatures are preferred, and for large vessels chromicized catgut is used, though some surgeons prefer silk or linen. When a ligature is applied to a vessel it constricts it concentrically, crumpling its coats more or less, and bringing intima into contact with intima; owing to the properties of this serous surface, like that of the peritoneum, pleura, etc., prolonged contact after very moderate injury is sufficient to secure firm adhesion. It is not usually necessary to draw the ligature so tight as to rupture the inner and middle coats; it is sufficient to occlude the vessel. The method of union after firm apposition of the intima is pathologically identical with that already described in connection with the repair of wounds as union by adhesion. The walls of the vessel, with their endothelial cells, play a more important part in the process than the contained blood; indeed, it is denied by some pathologists that the blood takes any part in the process. The formation of a clot is not a necessary phenomenon, and if infection be absent firm

occlusion of vessels will occur without any thrombosis; this renders it safe (Guyon, 1868; Wyeth, 1876), though not always expedient, to ligate large trunks close to the origin of branches, or *vice versa*. Usually, however, a clot forms proximal to the ligature, and, if the vessel has been tied in its continuity (*i. e.*, in cases where the vessel has not been divided), a smaller clot usually forms on its distal side. These clots lie rather loosely in the channel, and are gradually converted into fibrous connective tissue by organization (p. 30). Should such a clot extend from the point of ligation past the origin of a large branch, there might be danger of emboli being carried away from it; hence it usually is considered proper not to apply a ligature within an inch or so of a large branch.

Rules for Ligation of Wounded Arteries.—These rules are now classic in surgery, and even today admit of very few exceptions:

1. *In cases of primary hemorrhage do not ligate the vessel unless it is actually bleeding at the time.* This rule applies to primary, not to secondary hemorrhage, and should be observed *because:* (*a*) bleeding may never recur; (*b*) it is difficult to know which artery to tie unless the surgeon sees it bleed; and (*c*) search for the artery may cause unnecessary damage and lead to infection. *Exceptions:* (*a*) if the artery is seen pulsating in the wound it should be tied whether it bleeds or not: the operation is easy, harmless, and the remedy sure; (*b*) if the patient has to be transported a long distance or will be out of reach of a skilful surgeon, it will be proper to make a search for the vessel even if it is not bleeding nor easily found.

2. *The vessel should be ligated where it bleeds and not elsewhere, no matter what the condition of the wound. Because:* (*a*) unless the wounded vessel itself is seen, the surgeon may ligate the wrong vessel and fail to check the bleeding; (*b*) ligation even of the proper vessel at a higher point will not prevent recurrence of bleeding from the distal end, nor from the proximal end if a large branch intervenes, so soon as the collateral circulation is established. There are no exceptions to this rule (Guthrie, 1815; Matas, 1909). But in certain regions (floor of the mouth, pelvis) it may be necessary to expose the bleeding point by a counter-incision, instead of through the original wound.

3. *Both ends of the wounded vessel should be ligated; and if it is only partly severed a ligature should be applied each side of the wound and the artery then divided between them. Because:* when collateral circulation develops bleeding from the distal end will occur even if this is not bleeding when the proximal is ligated. *Exceptions:* (*a*) when the distal end cannot be found, the wound should be packed after ligation of the proximal end; and (*b*) where both ends are easily found, where the injury was a clean incised wound, and where occlusion of the the vessel might cause gangrene, an attempt at circular arteriorrhaphy (p. 234) should be made.

4. *Wound of a large vessel near its origin requires ligation of the wounded vessel below the wound, and of the parent trunk above and*

below the origin of the wounded branch (Fig. 185); and *wound of a main trunk near the origin of a large branch requires ligation of the wounded vessel above and below the wound and ligation of the large branch* (Fig. 186). *Because:* in the former case the end of the bleeding vessel next the main trunk is too short to hold a ligature; and in the second case the establishment of collateral circulation will cause the branch to bleed through the wound of the main trunk unless the branch is ligated. *Exception:* in case of the main vessels (carotid, iliac, femoral, popliteal), occlusion of which may cause gangrene, the wound in the main trunk should be sutured, and only the collateral should be ligated.

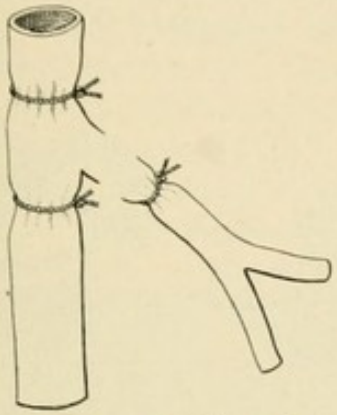

FIG. 185.—Wound of a large branch near its parent trunk requires ligation of the trunk above and below the branch as well as of the branch.

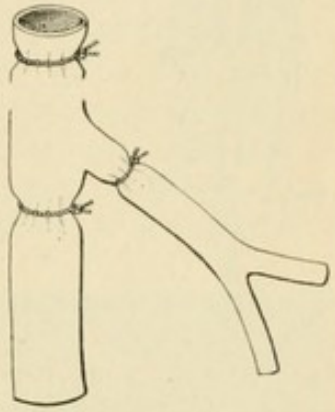

FIG. 186.—Wound of a main trunk near the origin of a large branch requires ligation of the branch as well as of the trunk.

Method of Ligating Arteries.—Arteries (and veins) may be ligated in continuity or at the seat of the lesion. In the latter case, the cut end is grasped with a hemostat, drawn slightly out of its sheath and the ligature applied well above the forceps. When ligation is done in continuity, an incision is made slightly oblique to the known course of the vessel, the proper muscular interspace is found, and when the sheath of the artery is exposed, it is picked up by forceps and cautiously divided by the edge of the knife cutting toward the forceps (Fig. 187). The threaded aneurysm needle is then gently insinuated between the artery and its sheath (entering on the side where lies the most dangerous structure, usually a vein),[1] and is gradually teased around the artery, great care being exercised not to separate the sheath more extensively from the vessel than is absolutely necessary and not to include a neighboring nerve in the ligature. When the point of the aneurysm needle emerges on the opposite side of the artery, the loop of the ligature lying in the concavity of the needle is caught in forceps and pulled through (Fig. 187). Then the aneurysm needle is withdrawn. An assistant then feels for the pulsation of the artery or its main branches below, and the surgeon temporarily constricts the artery between the ligature and

[1] Venæ comites may be tied in with their artery.

his finger, determining whether he is about to tie the proper vessel by its effect on the pulse below. In the case of anomalous high division of the brachial artery, for instance, he might be tying only one branch instead of the main trunk, as desired; and unless obliteration of the radial and ulnar pulse was sought for, his error might pass undiscovered at the time. Arteries of ordinary size are to be tied with the square knot (Fig. 114); very large arteries (innominate, iliac, femoral) or those which are atheromatous, are more safely secured by the stay knot of Ballance and Edmunds (Fig. 188).

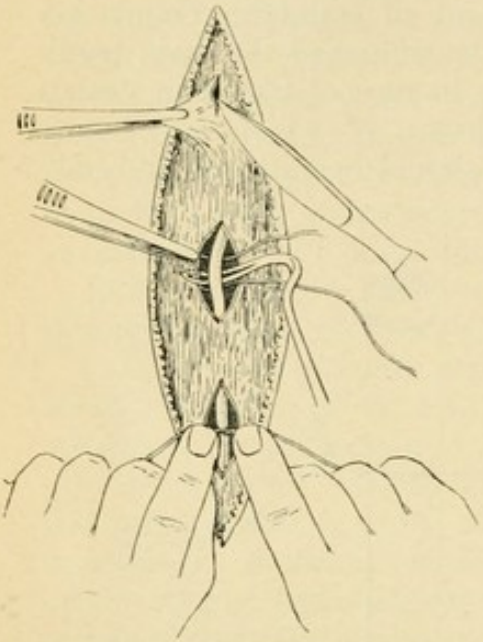

FIG. 187.—Ligation of an artery; above, the sheath is being opened; in the centre, the ligature is being passed; below, it is being tied.

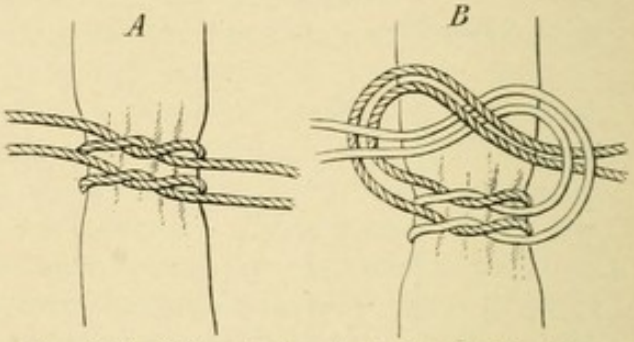

FIG. 188.—The stay-knot. *A*, double ligature passed and each end tied separately; *B*, all four ends tied as if they formed one ligature.

Secondary Hemorrhage.—This was defined and its causes stated at p. 177. It is apt to come from the distal stump of a vessel ligated in continuity, and is frequently ushered in by slight blood-stained discharges, premonitory of the violent gush when the vessel finally gives way.

Treatment.—The treatment differs in some respects from that proper for primary hemorrhage. The first rule given above does not apply, because hemorrhage having once recurred is extremely liable to do so again unless active measures are instituted. The surgeon *may* after the first, and *must* after the second bleeding adopt determined measures to prevent a return of the hemorrhage (Erichsen, 1861), and *should ligate both ends of the wounded artery in the wound, no matter what the condition of that wound, whether or not active bleeding is present when the operation is undertaken.* Should re-ligation be impossible (as in vessels at the root of the neck, or in the pelvis), a graduated compress may be applied; or neighboring collaterals may be ligated, to check the return circulation (*e. g.*, the vertebral in secondary hemorrhage after ligation of innominate.)[1] If secondary hemorrhage recurs after re-ligation in continuity, amputation should be done at the site of ligature in the lower extremity; while in the upper extremity this final step sometimes may be obviated by ligating

[1] Secondary hemorrhage recurring from an amputation stump requires re-amputation if ligation of the main trunk of the limb has failed.

the main vessel (brachial, axillary, or subclavian) at a higher point. In the lower extremity such a course would surely cause gangrene, so amputation is better.

Constitutional Treatment of Hemorrhage.—This is very much the same as that for shock (p. 175), especially valuable being elevation of the pelvis and lower extremities, autotransfusion, intravenous saline infusion, direct transfusion of blood, and the administration of cardiac stimulants.

Subcutaneous Injuries of Bloodvessels.—Injuries of either arteries or veins are attended by reactive phenomena which correspond pathologically to the inflammatory process. In cases of *contusion* this reaction may cause thrombosis of the blood within the vessels; but far more frequently the vessel is ruptured subcutaneously, causing the formation of a hematoma (p. 159). This may be absorbed if small, but sometimes remains fluid, may become infected (through the blood-stream, from a neighboring viscus, or from the deeper skin cocci), and require opening and drainage. If a hematoma progressively increases in size after its formation, it is probable that a

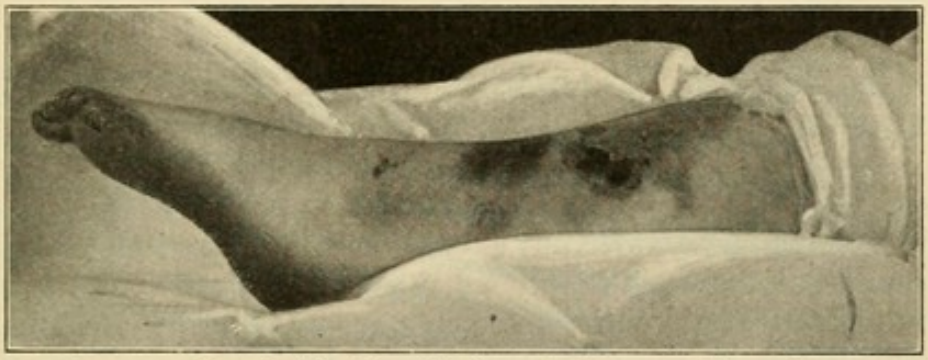

FIG. 189.—Gangrene following ligation of both ends of ruptured femoral artery and vein, in Hunter's canal. Amputation. Recovery. Episcopal Hospital.

large vessel is ruptured; it will then be proper to open the hematoma and check the hemorrhage. A hematoma due to rupture of a large vessel may cease to grow and finally become encysted, still being in communication with the source of hemorrhage: if this was a vein, a so-called *venous aneurysm* is formed; if an artery, a *circumscribed traumatic aneurysm*. A *diffused traumatic aneurysm* is more frequent in the axilla or groin, where the tissues are more readily separated by the extravasated blood; the blood in such cases is more apt to become clotted, and may very seriously compromise the circulation of the limb. The semi-clotted mass should be evacuated, and the ruptured vessels ligated. Fig. 189 shows gangrene following ligation of both ends of a ruptured femoral artery and vein, due to contusion by a heavy steel plate, and accompanied by the formation of an immense diffuse traumatic aneurysm.

Open Wounds of Bloodvessels.—These may be *incised*, *punctured*, etc., or due to *gunshot* injury. If smaller vessels have not been divided completely by the original injury, the surgeon should cut

them entirely across, and ligate both ends. For *punctured wounds* of the larger veins a lateral ligature should be applied (Fig. 190); by bringing intima into contact with intima, firm union without thrombosis may be expected. If a large vessel, artery or vein, presents an *incised wound*, and obliteration of the circulation by ligature is likely to result in gangrene (as is especially the case in the popliteal, femoral, and axillary arteries), attempt should be made to suture the wound in such a way as to *evert* its edges, thus apposing serous

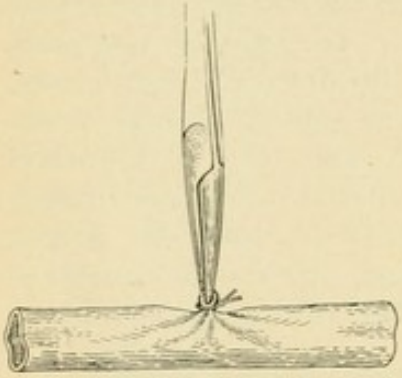

FIG. 190.—Application of a lateral ligature for punctured wound of vein.

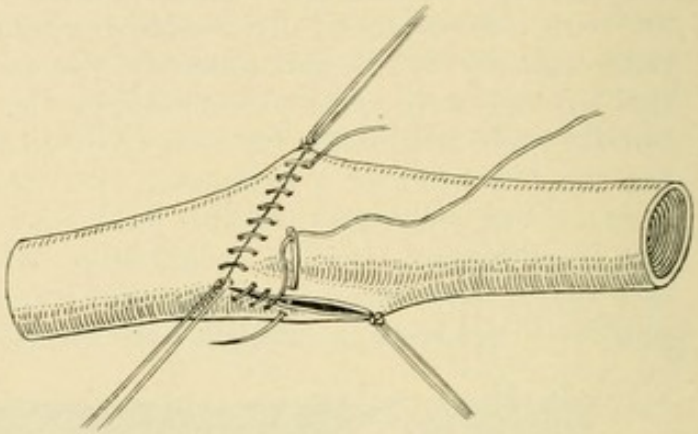

FIG. 191.—Circular arteriorrhaphy by Carrel's method: when the three stay sutures are pulled taut, the introduction of the sutures is much facilitated.

surfaces. Should such a vessel, especially an artery, be completely divided, circular arteriorrhaphy should be done (Fig. 191), using a very fine round-pointed needle and No. 500 silk, soaked in sterile vaselin (Carrel, 1902). The circulation is controlled by Crile's clamps (Fig. 192), applied directly to the wounded vessel. Even if thrombosis follows the attempt, occlusion of the artery will be so gradual that gangrene will be much less apt to ensue than after ligation. Should ligation

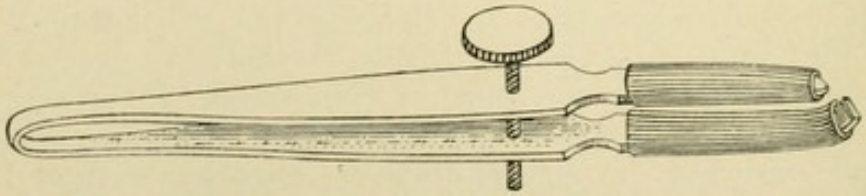

FIG. 192.—Crile's clamp for temporary occlusion of bloodvessels, blades covered with rubber.

of the main vein of a limb be necessary, the main artery should *not* be ligated also; to do so increases the risk of gangrene. According to Wolff's statistics (1908), gangrene occurred in 34 per cent. of cases where both femoral artery and vein were ligated, and in only 8 per cent. where the femoral vein alone was ligated. *Gunshot* and other *contused wounds* rarely admit of suture.

Entrance of air into veins is no longer regarded as a frightful calamity, presaging immediate death. In operating at the root of

the neck, where negative pressure in the veins during inspiration is most marked, air may be sucked into the circulation, and when in large quantity has, in a few instances, been productive of serious consequences. A sucking, lapping, or gurgling sound is heard, closely following a gush of blood from the wounded vein, and sometimes followed by the appearance of frothy blood in the wound.[1] Paleness and lividity, failure of the circulation and collapse may ensue. In a patient under my own care (1908), in Dr. Frazier's service at the Episcopal Hospital, no symptoms whatever were produced, though the sucking sound of air entering the vein (branch close to subclavian) was very pronounced. In operations in the "danger zone" the surgeon if possible should apply a compress to the region where the internal jugular and subclavian veins unite, thus causing back pressure on the main trunks above; this facilitates dissection. When the accident occurs, plug the opening with the finger until other means of arresting the hemorrhage can be applied.

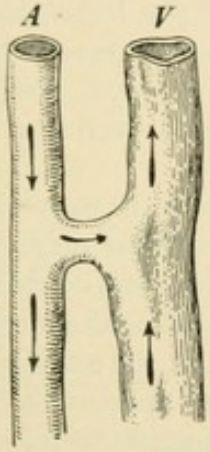

FIG. 193.—Aneurysmal varix (or direct arterio-venous fistula).

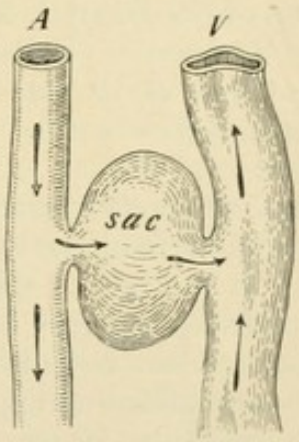

FIG. 194.—Varicose aneurysm (or indirect arterio-venous fistula).

Arterio-venous wounds occasionally occur from puncture, stab, or gunshot injury involving both artery and vein. The superficial parts may heal, leaving a form of traumatic arterio-venous aneurysm: if the artery and vein are in direct communication, the condition is known as *aneurysmal varix* (Fig. 193); if a sac intervenes, it is a *varicose aneurysm* (Fig. 194).[2] The diagnosis in either case depends on the history of injury, and the rather tardy development of signs of a traumatic aneurysm, accompanied by a susurrus, or purring thrill, and in the case of a varicose aneurysm by a distinct impulse and aneurysmal whirr. The buzzing is continuous, not disappearing entirely during diastole (except sometimes when the limb is elevated — Nélaton), but being accentuated during systole; the murmur is transmitted centrifugally, sometimes centripetally, and

[1] A somewhat similar sound, but no bleeding, follows injury of the pleura.

[2] The terminology of John B. Roberts (*arterio-venous fistula, direct or indirect*) is preferable.

the superficial veins may pulsate (Matas). An aneurysmal varix rarely gives much distress, except for the buzzing sensation on palpation; this may be audible to the patient; but the tumor seldom enlarges, and, as a rule, only palliative treatment is required. If necessary, however, the surgeon may attempt separation of the vessels and suture or ligation of the defects. A varicose aneurysm, on the other hand, is prone to grow larger progressively, and, though rarely reaching very large size, in many respects resembles an ordinary aneurysm. Operation generally is indicated; this may consist merely in ligation of the more accessible vessel (preferably the artery) above and below the sac, or in extirpation of the sac and suture of the venous and arterial orifices; better still (Bickham, 1904), would be obliteration of the sac by endoaneurysmorrhaphy (p. 257). For the success of most of these methods, preliminary control of the circulation is necessary; where this is impossible the surgeon must open the sac, plug the arterial orifice with his finger, and apply a suture to occlude the orifice as quickly as possible; the venous opening is next closed.

Injuries of the Heart.—Rupture.—Rupture of the heart may be due to injury or disease. Blood is pumped into the pericardium, causing embarrassment of cardiac action, with dyspnea, cyanosis, collapse, and death, before suture of the rent, which is indicated, can be attempted.

Wounds.—Wounds of the heart are usually *stab* or *gunshot* wounds. In cases coming to operation, the left ventricle is most often wounded, generally on the left of the sternum. The symptoms are much the same as those of rupture of the heart, though somewhat less severe; if the patient does not die within a few minutes, he usually survives several hours, affording opportunity for rational treatment. Wounds of the pleura (40 to 70 per cent.) and of the lung (30 to 50 per cent.), may coexist, and pericardial hemorrhage may come from this source, and not from a wound of the heart itself. In all cases in which cardiac injury is suspected, however, exploratory pericardiotomy should be done. Where no precordial wound exists, Matas advises an oblique incision, from the midsternum opposite the fourth interspace, downward and toward the left, dividing the fifth or sixth costal cartilage, which is excised. When an external wound makes the diagnosis more certain, Spangaro's incision (1906) in the fourth intercostal space is preferable; this extends from the left margin of the sternum out as far as necessary, the pleura being opened if already wounded. If sufficient exposure is not obtained by forcible retraction of the ribs, the costal cartilages above and below may be divided close to the sternum. The pericardium being opened and clots evacuated, the slippery heart is grasped in the left hand, and the wound sutured with a continuous chromic gut suture, hemorrhage being intermittently controlled by pressure on the venæ cavæ at their entrance into the right auricle (Rehn, 1907). Usually the pericardium should be drained for twenty-four hours, and the pleura also, if invaded, but through a separate incision. Simon has collected

(up to 1912) 241 operations for gunshot wounds, with 124 deaths (51 per cent. mortality); and 200 operations for stab wounds, with 99 deaths (49 per cent.).

Foreign Bodies.—Foreign bodies in the heart have been recorded in 118 cases (Zesas, 1910). Most have been portions of needles or encysted bullets. The diagnosis and localization are aided by radiography; and extraction by cardiotomy is indicated if any symptoms are present.

Cardiolysis is an operation proposed by Brauer (1902), and employed by Petersen, Simon, Morison, and others, consisting in excision of portions of the fifth and sixth left ribs to allow more room for expansion of a heart hypertrophied from aortic disease; much improvement in symptoms is said to have resulted. Haberer (1910) employed a similar operation for chronic adhesive pericarditis; while others have gone further, opening the pericardium and freeing its adhesions. Leriche and Cotte (1909) refer to 18 operations of the latter type, with marked improvement in all cases.

Pericardiotomy may be required for serous or purulent effusion in the pericardium. A trocar may be introduced close to the sternum in the fourth, fifth, or sixth left interspace, according to the physical signs, or, which is preferred by Matas, at the left side of the base of the ensiform. In most cases it is better to make a formal *incision*, dividing the sixth and seventh left costal cartilages close to the sternum. The latest series of 22 cases of pericardiotomy gives a mortality of 32 per cent. (Elliott, 1909).

Massage of the heart, mentioned at p. 175 as useful in shock, has been employed, according to Jurasz (1911); in 64 cases, with 13 permanent and 15 temporary recoveries. Two patients under my own care rallied only for a few hours.

DISEASES OF THE BLOOD VASCULAR SYSTEM.

Thrombosis and Embolism.—When blood coagulates within the vessels during life, the process is called *thrombosis*, and the resulting clot a *thrombus*. It is recognized clinically that there may be an aseptic as well as a septic thrombosis, though the former becomes rarer the more we learn of the subject. Infection may reach the region of thrombosis through the blood-stream, or by contiguity from neighboring parts; in the latter case it is customary to incriminate the perivascular lymphatics and the vasa vasorum as the avenue of approach. Accepting, then, *infection* as the *exciting cause* of thrombosis, we admit as *predisposing causes* anything which *slows the blood-stream*, which produces *changes in the vessel walls*, or in the *composition of the circulating blood*. The most important of these three doubtless is changes in the vessel walls; and these changes in most instances are due to bacteria or their toxins. Aseptic injury seldom is a cause of thrombosis (p. 229). Moreover, changes in the vessel walls, as in atheroma, phlebectasis, etc., also act by obstructing

the blood-current; and when the composition of the blood is altered by *disease* (*e. g.*, infections such as typhoid fever, appendicitis, suppurative inflammations; metabolic poisons, as in eclampsia, after burns, etc.), or by *injury* (as after profuse hemorrhages), very slight retardation may be sufficient to cause thrombosis. The thrombus formed of circulating blood, within the vessels, is either of the *white* or *mixed* variety: that is, it contains relatively few erythrocytes, as these flow in the axial blood-stream furthest from the vessel walls where thrombosis is inaugurated by depositon of blood-platelets, destruction of leukocytes, and formation of fibrin ferment. The thrombus thus formed may be a *parietal* thrombus only, not occluding the entire vascular lumen, or it may be a *complete* or *obstructing* thrombus. In either case portions may be broken off by external injury or simply by force of the circulation; and such an *embolus*, being carried away in the blood-stream, may, when it is arrested (*embolism*), produce a *secondary thrombus*, so named in contradistinction to the original *primary thrombus*. The thrombus, whether primary or secondary, undergoes in time certain changes analogous to organization, cicatrization, and contraction, as studied in Chapter I; by these processes the vessel affected becomes converted into a solid fibrous cord of connective tissue. Occasionally small parietal thrombi are *absorbed;* rarely obstructing thrombi become *canalized* by the gradual development in them of capillaries which subsequently dilate and re-establish permeability for the blood-stream; not seldom infective thrombi *disintegrate* by suppuration, and then the emboli derived from such a thrombus may cause metastatic abscesses (p. 73). Finally, thrombi may become *calcified*, especially in veins, where they are converted into *phleboliths*.

Phlebitis.—Phlebitis, or inflammation of a vein, is due in general to the same factors mentioned above as causing thrombosis; and, as may readily be understood from what was there said, thrombosis is a much more frequent occurrence in veins than in arteries. Venous blood normally clots more quickly than arterial; the normal venous current is slow, is opposed by the force of gravity and by the valves in the veins; the veins are superficial, not supported by the muscles, and thus liable to trauma and to extension of infection from the skin and its lesions; and their walls are thin, and liable to be varicose, thus forming pouches where the blood eddies and stagnates. In spite of all these factors which predispose to primary thrombosis, it is not impossible for phlebitis to exist, at least for a time, without thrombus formation. Thus in many cases of varicose veins (p. 242) there is chronic phlebitis (*phlebosclerosis*), with marked thickening of the venous walls, yet without thrombosis. Such cases probably are due to the action of metabolic poisons, not to septic infection, unless this is extremely attenuated. Surgeons thus distinguish clinically between *plastic* and *infective* or *septic* phlebitis, the latter being accompanied in practically all cases by thrombosis, and running a much more acute course.

The thrombus which forms in a vein as a rule extends rather rapidly in the direction of the blood-current, invading not infrequently the nearest branches in the thrombotic process; the clot extends also but to a less degree on the distal side of the obstruction. Thus thrombosis beginning in the long saphenous vein behind the internal malleolus, or in the lower leg, may extend to the femoral; and from this the iliac veins and even the vena cava may become thrombosed. Thrombosis commencing in the appendicular veins may extend to the portal vein and into the liver. Thrombosis commencing in the facial or angular vein may extend to the cerebral sinuses; and thrombosis commencing in the lateral sinus frequently extends into the internal jugular vein.

Symptoms.—These are the usual symptoms of inflammation, more or less localized to the known course of a vein. *Pain* frequently is the first symptom to attract attention; examination soon after discloses *heat*, a *dusky redness* in the line of the veins; and often the thickened, tender, cord-like vein can be palpated through the overlying tissues. Great gentleness must be used in examination, for fear of detaching an embolus. Sometimes the position of the valves can be recognized by the presence of knobby protuberances. Very rarely suppuration occurs, multiple abscesses forming along the course of the vein. There is moderate *swelling* from the first, and if thrombosis is complete, and especially if a main trunk is involved, there is a certain amount of edema in the parts beyond. In advanced cases there is total disability of the affected extremity. The disease lasts from one to three or four weeks. Permanent occlusion of the affected veins results in compensatory dilatation of collaterals, which may themselves be the cause of annoyance or disability (Fig. 195).

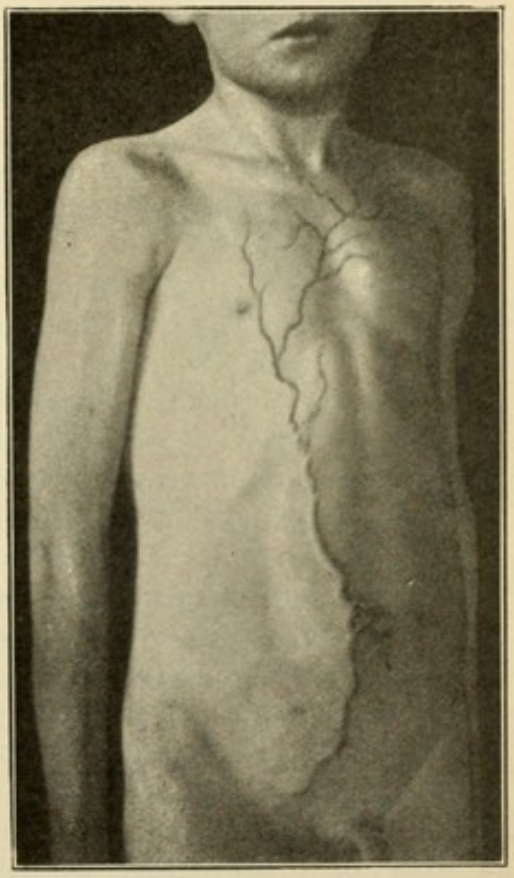

Fig. 195.—Epigastric varicosities following typhoid thrombosis of iliac veins. Episcopal Hospital.

Diagnosis.—Predisposing causes must be considered (infections, injury), and the physical signs must be accurately noted. By the latter means phlebitis may be distinguished from (1) *Lymphangeitis* (p. 268), where the redness is more flame colored, where the inflammation seems more superficial, where it does not follow the known course of a vein, where a thickened knobby cord cannot be palpated,

and where lymphadenitis is a frequent accompaniment; from (2) *Periosteitis* and *Osteomyelitis*, where the superficial veins are not affected, where tenderness and pain are limited to the bone affected, not extending past the nearest joint; where history of direct trauma is frequent; and where tapping the suspected bone almost at any part of its shaft is productive of pain at the seat of greatest disease; and from (3) *Neuralgia* and *Neuritis*, where the symptoms are localized to the known course of a nerve, and where no physical signs of inflammation are present.

Post-operative Phlebitis has laparotomy as its most frequent cause, and usually affects the veins of the left lower extremity. It not infrequently occurs after apparently aseptic operations, and it runs a comparatively mild course. Clark (1902) attributed it to injury of the deep epigastric vein by the retractors used in abdominal section.

Phlegmasia Alba Dolens is a term used to describe inflammation of the veins and lymphatics, usually of the left lower extremity, and generally due to puerperal sepsis ("milk leg"). The usual signs of phlebitis are present, but the disease is characterized especially by the marked edema, rendering the skin tense and shiny, probably due to coincident diffuse angeioleucitis; and by the pallor of the affected extremity.

Treatment.—Phlebitis is a serious disease, and requires efficient treatment. Local rest, which usually implies confinement to bed, and elevation of the limb, should be insisted on. Gentle support, as by flannel bandages, aids elevation in preventing excessive edema. Local applications have little appreciable effect, but the use of ice bags in the early stages, and of heat later, usually is grateful to the patient. Ichthyol or mercury and belladonna ointment may be applied to the seat of greatest inflammation. The skin should be kept clean, and well dried, by washing gently with alcohol once every other day or so; but under no circumstances should massage be attempted, and none but the very gentlest passive movement of the extremity should be allowed. Absolute rest of the affected part should be maintained *for at least one week after all symptoms have subsided*. If the leg is affected there will be persistent edema for many weeks or months after the patient gets about, and an elastic stocking or firm bandaging will be necessary to promote ease in locomotion. General treatment is the same as in any acute infection.

The treatment above described is sufficient in the immense majority of cases of *plastic phlebitis;* but in some cases of *septic phlebitis* it is proper to attempt to prevent the further spread of the thrombotic process by excising a portion of the main venous trunk some distance on the cardiac side of the furthest limits of inflammation. Thus for thrombosis extending up the long saphenous vein, this trunk may be doubly ligated and a section excised (Fig. 196), or the vein simply divided, at the saphenous opening. In thrombosis of the lateral sinus, following otitis media, it is the rule to divide the internal

jugular, where healthy, between two ligatures; and some surgeons advise ligating all branches and excising as much as possible of the thrombosed venous channels. In septic thrombosis of the ovarian veins, following puerperal metritis, many surgeons have attempted to prevent propagation of the thrombus by ligation above the limit of disease (Chapter XXIX). The operation of phlebotomy, with extraction of the clot and suture of the vein is not so promising as arteriotomy for arterial embolism (p. 242), as the intima of the thrombosed vein is so diseased as almost necessarily to ensure recurrence of thrombosis; nor is the operation so desirable, since gangrene is less to be feared than from arterial occlusion. Wolff (1908) showed that in the lower extremity operative occlusion of the main arteries (137 cases) caused gangrene in 20 per cent. of cases; while occlusion of the femoral vein alone (36 cases) resulted in gangrene in less than 6 per cent. In the upper extremity arterial occlusion (153 cases) caused gangrene in about 8 per cent.; only one case of ligation of the (axillary) vein was recorded, which did not result in gangrene.

FIG. 196.—Portion of thrombosed internal saphenous vein, excised at its juncture with the femoral. Episcopal Hospital.

Pulmonary Embolism. — Pulmonary embolism, sometimes an alarming consequence of venous thrombosis, and often occurring at the onset of post-operative convalescence, has been considered at p. 178. Other forms of venous embolism, affecting the viscera (especially the liver), are of comparatively little surgical interest, except when occurring in pyemia.

Arteritis.—Arteritis requiring surgical treatment is a much rarer condition than phlebitis. In chronic *arteriosclerosis*, with threatening or even developed gangrene (so-called senile or presenile gangrene), reversal of the circulation, as suggested by Carrel and Guthrie, has been attempted, by anastomosing the femoral artery and vein; the theory being that the veins, their valves being incompetent, offer less peripheral resistance to the outflowing blood-current than the sclerotic arteries. Though the operation appears to have been undertaken in about 63 cases (Zesas, 1912), there was cure or improvement in only 8 instances; whether such results justify the hazard of the primary operation must be determined for each case individually. (See Senile Gangrene, p. 61.)

Arterial Thrombosis.—Arterial thrombosis occurs as a complication of wounds, compound fractures, cellulitis, etc.; but unless affecting the main artery of a limb, which is rare, its symptoms usually are

overshadowed by those of the causative condition. When the main artery of a limb is affected, the symptoms differ only in the less sudden onset from those of arterial embolism, presently to be described. F. T. Stewart (1908) refers to 35 cases of traumatic arterial thrombosis, 31 of which terminated in gangrene. The treatment is the same as for embolism.

Arterial Embolism.—Arterial embolism, when affecting the main artery of a limb, is a condition of great gravity. The clot usually is derived from one of the cardiac valves; it is detached from no apparent exciting cause, is carried away in the blood-stream, and if lodging so as to plug an artery of considerable size, presents characteristic and well marked symptoms. The patient suffers a sudden, acute, stinging pain below the site of embolism, in the distribution of the affected artery; the limb below becomes tingling, numb, or for a time the seat of burning pain; pulsation is absent below the site of embolism; and the limb gradually grows cold, bluish, livid, and the signs of oncoming gangrene appear (p. 60). Fig. 20 (p. 62) shows gangrene due to lodgement three weeks previously of an embolus in the popliteal artery, in a patient who three months before had embolism of a cerebral artery.

Treatment.—When the embolus lodges in an accessible situation, and in one where sudden complete arterial occlusion habitually results in gangrene (especially the brachial at the elbow, the femoral and popliteal arteries), the surgeon should lose no time in resorting to arteriotomy and extraction of the clot (F. T. Stewart, 1908). This is a more promising procedure for embolism with secondary thrombosis, than for primary thrombosis, since the healthier condition of the arterial coats in the former condition makes recurrence of thrombosis less likely. According to Le Conte and Stewart (1910) arteriotomy for thrombosis or embolism has been done in 7 cases; at least 3 of the patients died, and in none was gangrene prevented. Since the publication of these statistics one successful case of arteriotomy for femoral embolism (aseptic) has been reported by Mosny and Dumont (1911).

Varix, Phlebectasis, or Varicose Veins, describes a condition in which the veins become *elongated*, *dilated*, *tortuous*, and *pouched*. Any veins may be affected, even those of bone; but superficial veins, especially the veins of the spermatic cord and the saphenous veins of the lower extremities, are most noticeably diseased (Fig. 197). The chief *cause* is gravitation, aided by obstruction to the normal venous current. *Occupation* (barbers, waiters, motormen, or others who stand for hours at a time), *tumors*, *pregnancy*, *thrombosis* (Fig. 195), or other factors producing obstruction, are all predisposing causes. Usually no one well defined cause can be found. The valves become incompetent, the blood stagnates, hypertrophy and sclerosis of the vessel walls occur, phleboliths may develop, and thrombosis may finally cause obliteration of the diseased veins. The *symptoms* of pain, fulness, weight, etc., are frequently disabling; in the lower

extremities the perivascular tissues become thickened, hard edema develops, the nutrition of the skin suffers; trifling trauma produces an abrasion which fails to heal, and varicose ulcer results (p. 57). Profuse hemorrhage may occur from spontaneous rupture of a varix. Rupture of a deep varicose vein is attended by sudden stinging pain ("coup de fouet") and subsequent appearance of ecchymosis. - *Treatment* may be palliative or radical. The former includes application of elastic bandages or stockings, after emptying the veins and reducing edema by elevation of the limb; the use of stimulating liniments, etc.; and attention to hygiene. Such treatment always should be tried first, and usually is efficient when the cause of the obstruction is temporary (pregnancy), or removable (tumor, etc.). In other cases, or when palliative measures fail to relieve symptoms, operation is indicated. If the superficial veins are varicose as a result of thrombotic obstruction of the deep veins, no operation should be attempted unless elastic support with temporary obliteration of the varicosities produces relief and demonstrates the efficiency of the collateral circulation. Very occasionally varicosities due to this cause disappear spontaneously after a few years, owing to the development of collateral circulation (Skillern, 1913).

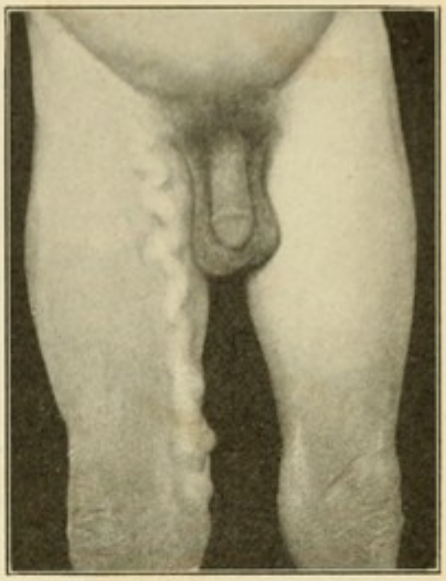

FIG. 197.—Varicose internal saphenous vein, aged sixty-three years; duration over forty years.

Operative Treatment.—Operative treatment consists in obliteration of the varicose channels at one or several points. *Schede's operation* (1877) is done by making a circular incision below the knee down to the deep fascia, thus dividing all the superficial veins; both ends of each divided vessel are then ligated, and the skin sutured. This operation also divides the superficial lymphatics and sensory nerves; sometimes is followed by edema, paresthesias, neuralgias, or trophic disturbances in the skin below; and, according to Matas, is followed by permanent cure in only one-third of the cases. Spiral division of the skin enables the surgeon to obliterate all the venous channels without severing all the lymphatics, thus rendering edema less likely; but section of the nerves can scarcely be avoided. *Trendelenburg's operation* (1890) consists in division of the main varicose trunk (usually the long saphenous above the knee) between two ligatures, the object being to break the column of blood, thus relieving pressure symptoms. It is suitable for those cases where only the main trunk, not its collaterals, is varicose; and is not suitable even for those cases if the saphenous vein is the seat of chronic phlebitis. According to Matas, 79 per cent. of patients treated by Trendelen-

burg's operation have been cured or greatly improved. *Multiple Phlebectomy*, associated with the names of Madelung (1884) and Schwartz (1888), is, I believe, the best operation in the vast majority of cases. Sections of the diseased veins, three or four inches long, are removed at the saphenous opening and in other parts of the thigh and leg, wherever the main trunks or their branches are most dilated; the intervening portions become thrombosed, contract, and produce no further symptoms; and the greater portion of the diseased tissue is completely removed from the body, which is not accomplished by either Schede's or Trendelenburg's operation. If the surgeon wishes, he can remove the entire saphenous vein through one long incision; or by passing a curette over the ligated end of the main trunk, as practised by C. H. Mayo (1906), and ripping off its branches by subcutaneous tunnelling with this instrument, the entire vein may be removed through three or four small incisions. These methods, though more spectacular than multiple phlebectomy, which is a tedious procedure, are less sure, since the diseased collaterals are left behind. In many cases, moreover, the veins are calcareous, and so densely adherent to the perivascular tissues and even to the skin, that only a formal dissection can free them. I have always employed multiple phlebectomy, except in cases due to thrombosis of the deep veins; in these I have adopted a spiral incision for Schede's operation, thus avoiding excision of the only veins the patient possessed. Operations for varicose veins are not entirely devoid of danger: in large series of operations death from pulmonary embolism has occurred in 1 or 2 per cent. of cases; the skin frequently is difficult to sterilize, and in spite of care infection of the incisions may occur; occasionally phlebitis is a sequel.

Hemangeiomas; Telangiectases.—Under these terms are included various affections of the vascular system, whose proper classification has not been determined by pathologists. In the vast majority of cases they are *congenital*, or at least are noticed first in early infancy; the lesions usually enlarge more rapidly than the part in which they are situated, and from being insignificant specks at birth may become growths of alarming size in childhood or early adult life. Sometimes they assume the character of tumors, as described in Chapter IV, very occasionally seeming to possess malignant characteristics (infiltration, recurrence).

Nevus Vasculosus.—This may affect either capillaries or venules, its color (bluish, purplish, or red) depending upon the proportion of venous blood present.

Capillary Nevi (Plate II, Fig. 1).—Capillary nevi occur in the skin, rarely in mucous membranes; they do not involve the subcutaneous tissues; they are red, or reddish blue ("mother's mark," "birth-mark," "port-wine stain"); they may be elevated above the surface of the surrounding skin, or may lie perfectly flat beneath a seemingly normal epiderm. They vary greatly in size. Elevation of the affected part does not cause them to shrink or become pale; nor does pressure

blanch them, unless very small, and then only momentarily. Usually they are multiple, are most frequent on the face and neck (perhaps branchiogenic); tend to grow larger; and may ulcerate and cause alarming hemorrhage. Sometimes they blend into *cavernous angeiomas*, described below. The *pigmented mole* may be considered a variety of capillary nevus: frequently it is hairy (*nevus pilosus*, Fig. 198); usually remains of insignificant size; but occasionally about puberty, or in adult life, from trifling of no apparent cause, begins to enlarge, assumes tumor-like characteristics, and may develop into or be inexplicably associated with *melanotic sarcoma* (p. 129).

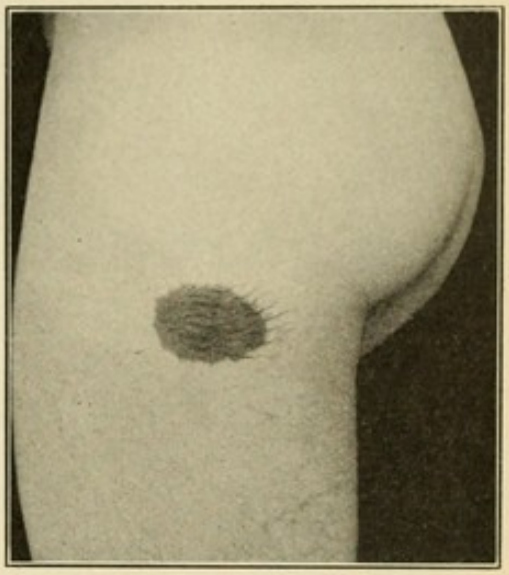

FIG. 198.—Nevus pilosus (hairy mole). Age nineteen years, growing slowly since birth. Episcopal Hospital.

Treatment.—The treatment of capillary nevi should be undertaken within the first few months of life. The application of carbon dioxide snow (Pusey, 1907), for a half minute or so, every three or four days, probably is the most satisfactory treatment for the port-wine stains or other nevi not raised above the surface of the surrounding skin. This "cold caustic," as it has been called, produces sloughing of the diseased skin, resulting in an ulcer which heals with the minimal amount of scarring. The earlier the nevus is cured, the more inconspicuous will the scar be. Fuming nitric acid is more effectual for raised capillary nevi than for port-wine stains. Electrolysis may also be employed. Moles are best treated by excision.

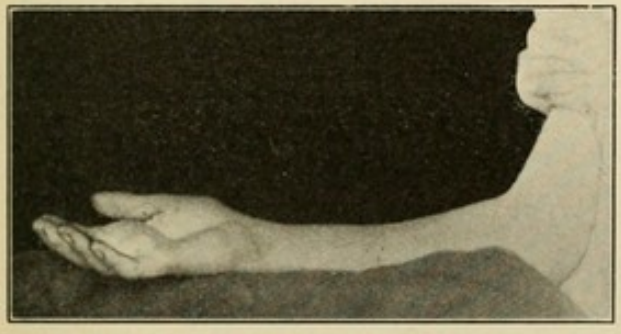

FIG. 199.—Cavernous angeioma of palm, hand dependent. From a patient under Dr. Frazier's care in the Episcopal Hospital.

Venous Nevi. — Venous nevi may occur in the skin or subcutaneously, in the latter case usually being described as *cavernous angeiomas*, their structure resembling the cavernous tissues of the penis. They form prominent lobulated tumors, easily compressible, sometimes becoming tense when the child cries or strains, emptying more or less completely when the affected part is elevated and pressure is applied, and rapidly refilling when the part is dependent (Figs. 199, 200). In the *subcutaneous* variety discoloration of the skin may not be present. The growths may be circumscribed or diffuse; the former some-

times is mistaken for a cold abscess; while the diffuse subcutaneous cavernous angeioma may involve an entire extremity and neighboring portions of the trunk, the entire limb being deformed, flabby, pudgy, and sponge-like to the touch (pseudo-elephantiasis); the muscles may be wasted, and the bones atrophic (Plate III). Muscle tissue itself may be invaded by the angeiomatous growth. Similar angeiomas occasionally are found in the viscera, notably the liver. Subcutaneous cavernous angeiomas usually are associated with lipomatous growths (*nevoid lipoma*). They seldom cause hemorrhage but may undergo thrombosis; and formation of phleboliths is not uncommon.

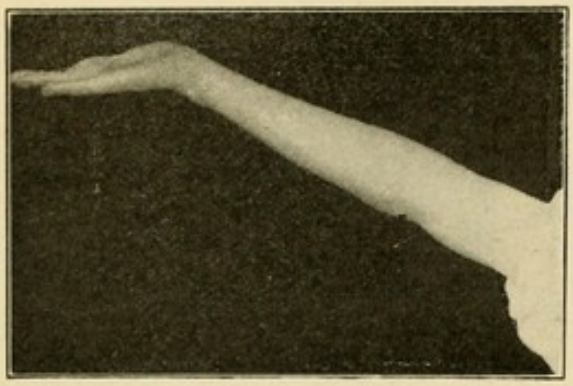

FIG. 200.—Cavernous angeioma of palm, hand elevated. Episcopal Hospital.

Treatment.—Treatment consists in excision whenever this is practicable; and in circumscribed angeiomas it usually is not very difficult. If excision be refused by the parents, the surgeon may strangulate the tumor by ligating it in sections, leaving the protruding masses to be separated as sloughs. A round nevus may be strangulated by a double or quadruple ligature (Fig. 201), while an elongated growth

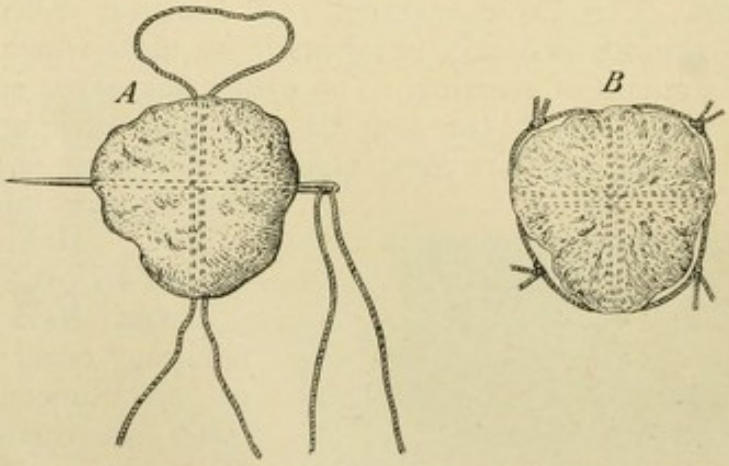

FIG. 201.—Strangulation of nevus by the quadruple ligature: *A*, the ligature being introduced; *B*, the loops have been cut and the ends of the ligatures tied.

may be attacked by Erichsen's method (Fig. 202). In cases where an elastic tourniquet or other means of controlling the circulation can be applied above the seat of operation, Wyeth's method (1903) may be adopted: this consists in the repeated injection of boiling water (1 to 2 c.c.), at intervals of several days; if the water is actually boiling, thrombosis of the blood in the angeioma will be immediate and the clot so firm that theoretically no fear of embolism need occur; but though no such result has been reported, so far as I am

PLATE III

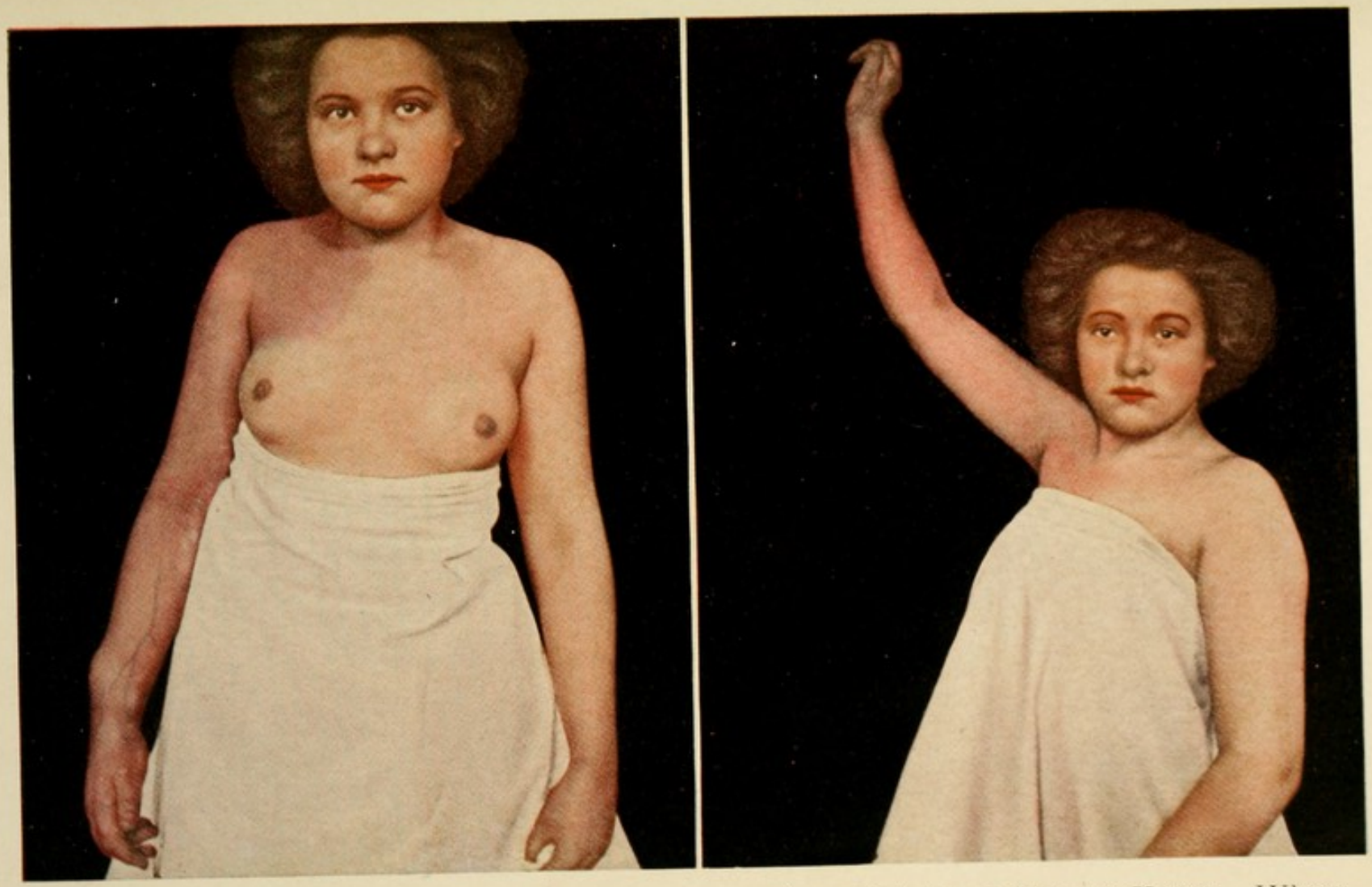

Diffuse Subcutaneous Cavernous Hemangeioma, in a Girl, Aged Sixteen Years. When the Arm is Elevated much of the Swelling Disappears. Episcopal Hospital.

aware, the surgeon should be extremely cautious in employing this method about the face, where cerebral embolism might occur, or at the root of the neck or in the axilla, where pulmonary embolism might be caused. Diffuse subcutaneous cavernous angeiomas usually can be treated only by palliation.

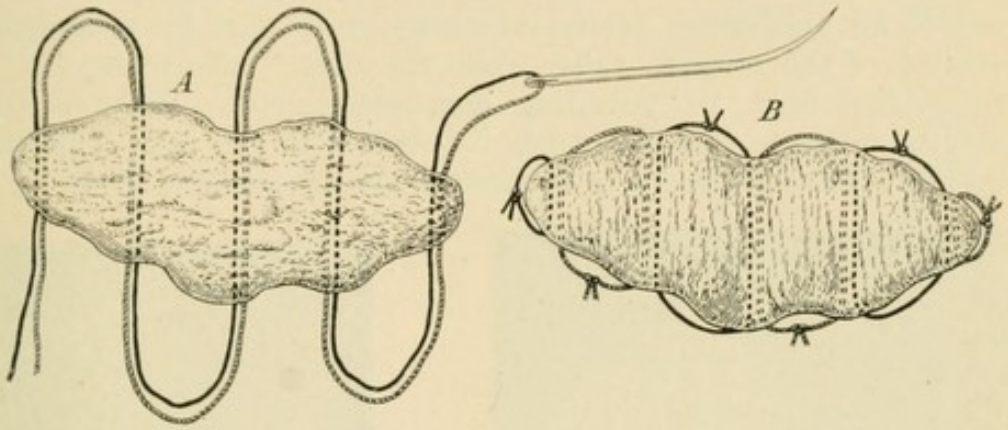

FIG. 202.—Ligation of a nevus by Erichsen's method: one-half the thread is dyed black; after the ligature has been inserted in serpentine manner (*A*), the black loops are cut on one side and the white loops on the other side of the nevus, and the black ends are tied to the black, the white to the white.

Arterial Varix.—Arterial varix, known also by the name of *Cirsoid Aneurysm* (Fig. 203), and, when capillaries are involved, by the terms *Racemose Aneurysm* and *Aneurysm by Anastomosis*, is an affection of the arterial system somewhat analogous to varicose veins, but presenting in many cases neoplastic characteristics by which it is allied to angeiomas. The arterial distribution affected (most frequently on the scalp) becomes *dilated*, *elongated*, *tortuous*, and *pouched*, forming a varicose pulsating tumor often of considerable size. It occurs usually in early adult life, from no well defined cause, though history of trauma may be obtainable, and cases have developed from congenital nevi. The tumor presents a characteristic varicose appearance, is compressible, and may be reduced in size by pressure on the main afferent arterial trunks; when this pressure is removed, the tumor again increases in size, by expansile pulsation, perhaps several cardiac impulses being required before it regains full size. Palpation and auscultation detect a systolic thrill.

Treatment.—Treatment is sought by the patient for relief from the constant murmur or whirr within the tumor, as well as on account of the deformity. Excision should be done when practicable; sometimes it becomes possible only after preliminary circumferential ligation of the main arterial channels entering the tumor (Fig. 203). In rare cases such ligation alone is sufficient to cause disappearance of the tumor.

Aneurysm.—An *aneurysm* is a hollow sac, filled with normal or altered blood, in communication with the lumen of an artery, and developed wholly or in part by progressive dilatation of the arterial walls. A *traumatic aneurysm* (p. 233) properly is not an aneurysm

at all, but a pulsating hematoma, since the sac is formed not of arterial wall, but by condensation of surrounding tissues. Arterial aneurysms are classified as *true* and *false;* formerly the term "true" was applied only to those aneurysms composed of all the arterial coats; but as this condition was found to exist only in an extremely limited number of cases of very minute (miliary) aneurysms, it has now been transferred to all aneurysms developed wholly or in part by progressive dilatation of the arterial walls; while the term "false aneurysm" is now applied only to pulsating hematomas, etc. When a true aneurysm ruptures subcutaneously it is better to call it a "ruptured aneurysm," than a diffused or consecutive aneurysm (Fig. 204).

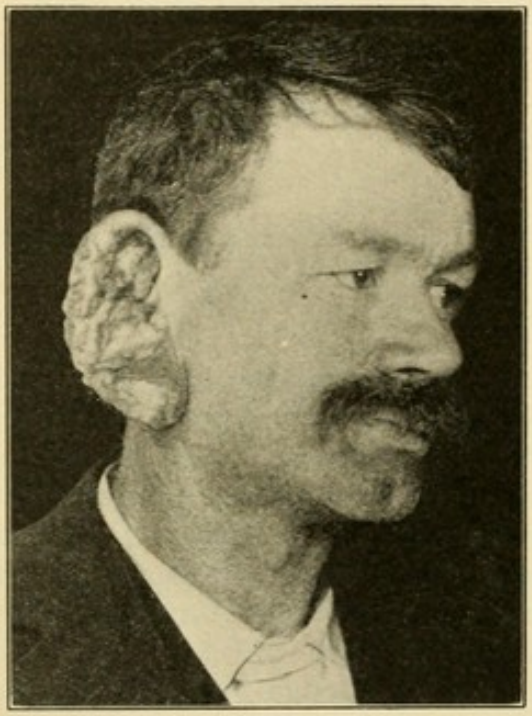

FIG. 203.—Cirsoid aneurysm, arterial varix, or aneurysm by anastomosis of right ear, treated by a series of operations by the late Prof. Ashhurst: 1. Ligation of temporal and common carotid arteries. 2. Ligation of growth by Erichsen's method (Fig. 202). 3. Amputation of ear, excision of tumor, and ligation of cut vessels separately. University Hospital.

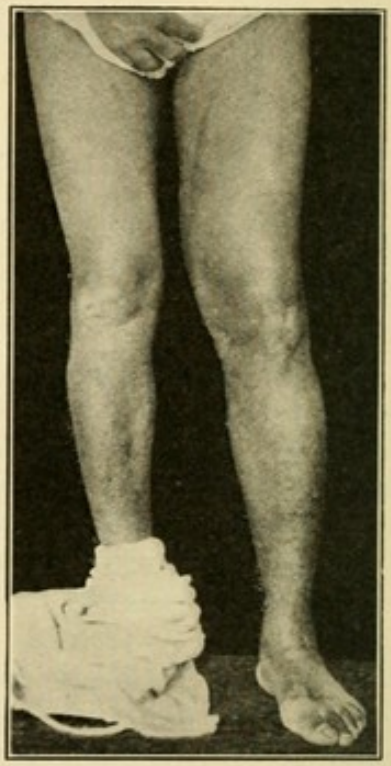

FIG. 204.—Ruptured aneurysm of left femoral artery; ligation in Scarpa's triangle thirteen years ago for popliteal aneurysm. Rupture two weeks ago. Episcopal Hospital.

Aneurysm develops by the gradual dilatation of a portion of the arterial wall previously diseased. At this earliest stage the term *arteriectasis* is applicable. As the dilatation proceeds, the middle tunic gives way, and the aneurysmal wall is formed only of the adventitia with such clots as may be deposited from the swirling blood within the sac upon the surface of the intima. The walls of an aneurysmal sac in contact with circulating blood *always are lined by endothelial cells,* which are proliferated with great readiness either by extension from the intima of the parent artery, or possibly through the medium of angeioblasts of the vasa vasorum (Matas, 1910). This endothelial lining may itself become atheromatous and calcareous.

Aneurysms are further classified as to their *form*, into (1) *Tubular* or *Fusiform* (Fig. 205); (2) *Saccular* (Fig. 206); and (3) *Dissecting Aneurysms*. Tubular or fusiform aneurysms are those which involve the entire circumference of an artery, and are rare even in the larger



FIG. 205.—Fusiform aneurysm.

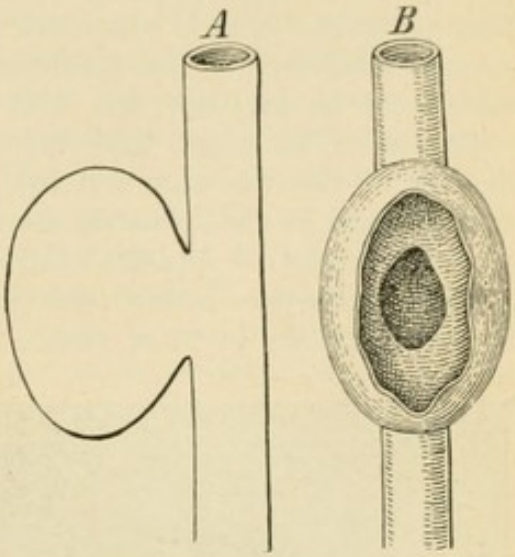

FIG. 206.—Saccular aneurysm, with small mouth.

internal vessels. Dissecting aneurysms are those in which the blood makes a channel for itself between the coats of the arterial wall for a variable distance, and again enters the arterial lumen; they are seen almost exclusively in the thoracic or abdominal aorta. The saccular aneurysm, in which the dilatation involves a portion only of the arterial circumference, communicates with the vessel by a comparatively small orifice called the *mouth* of the sac; by progressive growth of a saccular aneurysm its mouth may become so lengthened as to cause the aneurysm to resemble at first glance one of tubular or fusiform variety, especially on laying open the sac, when it will appear that there are two mouths present (Fig. 207, *B*). Though aneurysms usually are single, they may be multiple; and after cure by obliteration of one sac others may develop (Fig. 204).

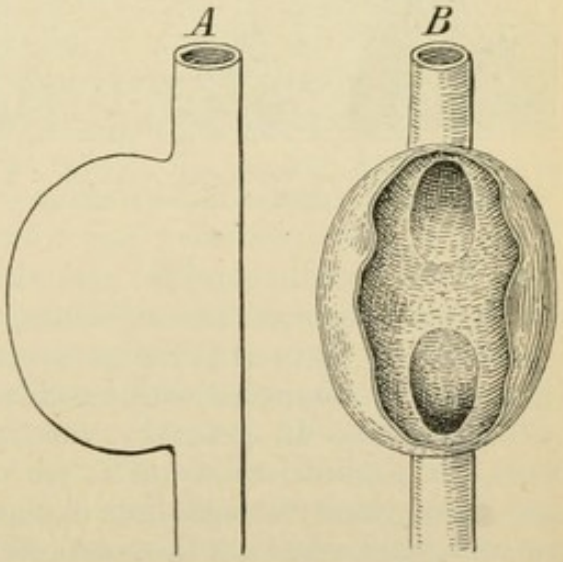

FIG. 207.—Saccular aneurysm with large mouth; when opened it appears as if there were two orifices.

The sac of an aneurysm when first formed contains fluid blood; the eddying and partial stagnation to which this is constantly sub-

jected leads in time to the deposition of fibrinous clots on the interior of the sac wall. These are deposited in successive layers, constituting the *laminated clot*. This rarely becomes firmly adherent in all spots to the sac wall, but is dissected loose by the eddying currents, thus preventing its organization. Should such firm adhesion and organization occur, and should concentric laminations be formed continuously, spontaneous cure of the aneurysm eventually might ensue by obliteration of its sac; but this is extremely rare.

Causes.—The chief underlying cause of aneurysm is precedent disease of the vascular system; aneurysm is but a symptom of this disease; and in the immense majority of cases the vascular degeneration is a sequel of syphilis,[1] though chronic alcoholism, even without syphilitic affection, is said sometimes to be a cause. The immediately apparent cause, in most cases, is some sudden strain, exertion, or accident, which causes rupture of the diseased media at its most susceptible point; the *vis a tergo* of the blood-stream then causes progressive dilatation of the artery until a well defined aneurysm exists. Constantly recurring slight trauma is recognized as a predisposing cause in that it causes localization of arterial lesions where aneurysms later develop. Thus is explained the preponderance of aneurysm in the aortic arch and at the root of the neck, where not only is the cardiac impulse strongest, but where the arteries lie against bone (vertebræ, first rib, clavicle) and where each pulsation tends to bruise the arteries against this unyielding structure; the latter explanation is adduced by Barwell (1882) to account for the frequency of popliteal (Fig. 208) as compared with brachial aneurysm.

FIG. 208.—Popliteal aneurysm, right leg. Dr. Harte's case. Pennsylvania Hospital.

Localization.—In general terms, the aorta is affected in 42 per cent., the popliteal artery in 24 per cent., the femoral in 12 per cent., and the carotid, subclavian, axillary, and innominate in about 3 per cent. each—leaving the smaller arteries of the extremities to form about 10 per cent. of cases (Crisp, 1847). Popliteal aneurysm forms from 55 to 60 per cent. of those occurring in the limbs (Matas, 1910).

Age.—Aneurysm occurs mostly in patients in active adult life; about two-thirds of cases are seen between the ages of thirty and fifty years, after arterial lesions have had a chance to develop,

[1] This was strenuously denied by Barwell (1882).

and while sudden strains are still frequent. *Sex:* It is seen in men about six or seven times as frequently as in women, owing to the greater liability of the male sex to atheroma, and to their more laborious life. *Occupations* attended by violent exertion (porters, teamsters, soldiers, sailors) are regarded as predisposing to the development of aneurysm, as are *diseases of the heart and kidneys, chronic gout, rheumatism*, etc., causing arterial hypertension and calcification.

Symptoms.—These usually are of slow development, though occasionally the patient is aware that "something has given way," experiences a sudden stinging pain, as the "coup de fouet" in rupture of deep varicose veins (p. 243), and on examination at once finds a pulsating tumor has formed. The symptoms of aneurysm may be considered as those *peculiar to the aneurysm itself*, and those *due to its pressure on surrounding parts*. There is present a rounded or oval tumor, either apparent to the eye or appreciable to the touch; it is situated along the course of an artery; it is movable laterally but not longitudinally on the artery; and it is somewhat compressible and elastic (depending on the amount of laminated clot). An aneurysm becomes more or less flaccid by pressure on the artery above, and harder and more tense by pressure on the artery below the tumor. It is covered by healthy, non-adherent skin, unless in the last stages when rupture is about to occur. The affected part is more or less disabled, with muscular weakness, paresthesia, numbness, or edema (pressure effects): pressure on *nerves* causes neuralgic pain or paralysis (of pupil, of vocal cord, etc.); on *neighboring veins* causes varicosities and edema; on *arteries* (perhaps the parent trunk) causes gangrene; on *bones* causes erosion, with intense boring pain; on *neighboring viscera* (trachea, esophagus, bile ducts, etc.), may cause serious disturbance in their functions. Aneurysms *pulsate*, synchronously with the heart: they are not merely lifted by the pulsation of the underlying artery, but as the blood enters the sac and swirls around in its interior the sac walls dilate, causing an extremely characteristic pulsation which is both *eccentric* and *expansile*. The degree of aneurysmal pulsation depends on the size of the sac and of its mouth, and on the thickness of its walls; a small aneurysm with much thickened walls and a small mouth connecting with the artery will pulsate much less than one which is large, thin walled, and possessed of a large mouth. Pulsation becomes more pronounced when the part is dependent and when pressure is made on the artery below the sac, and may almost disappear when the limb is elevated and the artery occluded above the sac. When pulsation has been made to cease by the latter method, application of the hands over the sac will enable the surgeon to detect the entering blood when pressure is removed, and will make him appreciate the facts that the sac does not always become fully distended with the first impulse from the heart, and that the pulsation is eccentric and expansile, driving the hands not only further away from the underlying artery, but also further apart from each other. *Pulsation in the artery below the aneurysm* may be

much *diminished,* as compared with corresponding pulsation on the other side of the body; this phenomenon is due to pressure on the artery by the overlying aneurysm; while the fact that the pulse below the aneurysm may be *delayed* is explicable on mechanical grounds, the aneurysm acting as the air-chamber of an hydraulic ram. Moreover, the *arterial pressure* distal to the aneurysm is less than in the corresponding healthy artery. *Bruit,* which is the peculiar whirring or rasping noise made by blood entering the sac, is present with very few exceptions (old thick-walled aneurysms almost full of clot); it occurs during cardiac systole, is therefore intermittent, and is loudest in aneurysms with large sac mouths; it may be made to cease by obliteration of the artery above the aneurysm, unless large collaterals empty into the sac; and in aneurysms of the extremities sometimes becomes louder when the limb is elevated. It may be transmitted centrifugally along the diseased artery. *Thrill* is to the hand what bruit is to the ear; but is much less marked than in arterio-venous aneurysms.

Course and Termination.—Aneurysm is an incurable disease, and if left to itself first disables and then kills the patient within comparatively few years. Apparent cure is only temporary, as other aneurysms may develop or the first recur. By proper treatment, however, symptoms may be relieved, individual aneurysms may be temporarily cured, and the life of the patient may be prolonged indefinitely (perhaps fifteen to twenty years) in comfort and reasonable usefulness (Fig. 204). Death finally comes *slowly* (from exhaustion, inanition, gangrene, etc.), *rapidly* (from pressure on trachea or larynx, on phrenic or pneumogastric nerve, from rupture and hemorrhage, etc.), or *suddenly* from syncope even without rupture.

Diagnosis.—This is made by attention to the history and physical signs. *Arterio-venous aneurysms* usually follow penetrating wounds; other signs of vascular disease may be wanting; bruit is continuous (not intermittent except sometimes when the limb is elevated—Nélaton), is transmitted both centrifugally and centripetally; thrill is marked; and compression on the afferent and efferent arterial trunk does not cause such characteristic changes in the sac. *Other vascular pulsating tumors* are less well defined in outline, do not present eccentric pulsation, have little or no bruit, and are not necessarily placed in the course of a large artery. *Other tumors may pulsate* because they overlie an artery, but the pulsation is neither expansile nor eccentric, there is neither bruit nor thrill, and obliteration of the afferent or efferent arterial trunk, while it may cause cessation of pulsation, yet produces no other change in the tumor. *Non-pulsating tumors* may be mistaken for an aneurysm with contents clotted; such growths may be movable longitudinally as well as laterally, and present a different clinical history. An aneurysm which has become diffused or inflamed may be mistaken for an *abscess* (p. 49), but attention to the history, and a careful physical examination will almost surely prevent any confusion.

Treatment.—This may be operative or non-operative. Under the latter heading are included hygienic and dietic measures, such as alone are applicable to certain forms of internal aneurysm. All other aneurysms should be operated upon, and nothing is gained by delay. The end sought by operation is to prevent blood from entering the sac, thus allowing its obliteration. This may be attempted in various ways. The methods still in most general use endeavor to secure coagulation of the blood within the sac; these may be regarded as palliative operations. Most of them act by retarding the current of blood passing through the parent artery; others act directly on the contents of the sac itself. They include *pressure* on the afferent artery; *compression* of the sac itself (as by flexing the knee for popliteal, or the hip for inguinal aneurysm), *ligation* of the afferent artery, or of the efferent artery or one of its branches; *injection* of coagulating fluids; *insertion of needles* with irritation of the intima to favor thrombosis; and introduction of metallic wire with *electrolysis*. *Manipulation* of the sac (Fergusson, 1857), in an effort to detach a clot which shall plug the efferent artery, should be mentioned only to be condemned. *Radical operations* comprise *extirpation of the sac*, with suture or ligation of the orifice or orifices into the parent artery; and *Endo-aneurysmorrhaphy*, which is the best method whenever applicable.

Pressure.—The patient should be confined to bed, and kept on a low diet with very little fluid; this slows the circulation and favors thrombosis (Tufnell, 1864). The pressure may be either instrumental (by various forms of tourniquets), or digital (Knight, 1844), which is preferable. The afferent artery is compressed until the sac ceases to pulsate. Relays of assistants are required, each one keeping up pressure for from three to five minutes, being then relieved by another who compresses the artery above or below the first point of compression before this is released by the fingers of the former assistant. In this way the circulation of blood in the sac is much diminished, favoring the formation of a laminated coagulum. Treatment is to be kept up for from two to four days, in sittings of about four hours once daily. After thirty-six hours hope of cure is much less, and continuation of pressure dangerous (sloughing, etc.). The method is most easily applicable to the femoral artery, for aneurysm of the popliteal. It should be employed only when endo-aneurysmorrhaphy or ligation are contraindicated, as in the very old and feeble, in those with serious visceral disease, etc., in whom the dangers of a cutting operation are excessive. The method is successful in perhaps half the cases treated. G. Fischer (1869), found that among 188 cases of aneurysm treated by digital compression, cure resulted in 121 (over 64 per cent.), and 38 of these patients were cured in less than three days; of 90 cases of popliteal aneurysm, 72, or 79 per cent., were cured by digital compression.

Ligation.—This may be done on the proximal side of the aneurysm, or the distal, or on both sides.

Proximal Ligation. — The *method of Hunter* (1785) consists in applying a ligature some distance above the aneurysm, allowing small branches to convey blood from above the ligature through collateral circulation, into the sac of the aneurysm (Fig. 209). The advantages claimed for the Hunterian method are: (1) accessibility of the artery; (2) healthier condition of the arterial walls; (3) gradual obliteration of the sac by formation of laminated clot. But modern aseptic operating renders the artery easily accessible at any site, and even if the arterial wall be diseased close to the sac (which is not certain), application of a ligature will strengthen it, and healing will occur normally. Objections to Hunter's operations are: (1) the existence of collateral circulation through the sac really is unfavorable to its

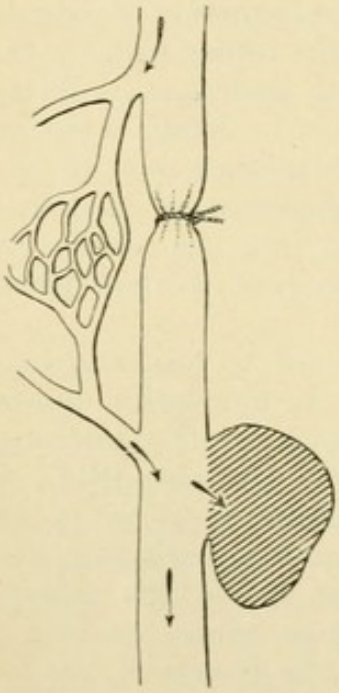

FIG. 209.—Hunter's method of ligation for aneurysm: collateral circulation from above the ligature into the sac.

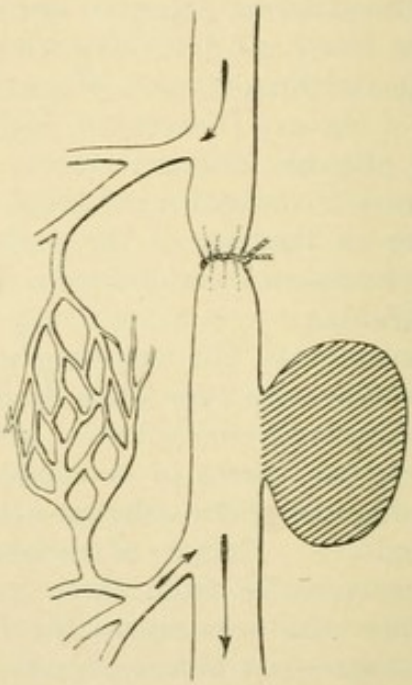

FIG. 210.—Anel's method of ligation for aneurysm: circulation through the sac completely arrested.

complete obliteration; (2) interposition of two obstacles to the circulation (ligature and aneurysm) renders gangrene more likely, as does the exclusion from the circulation of collaterals arising between the ligature and the sac; (3) if the collateral circulation is successfully established through the main trunk, recurrence of the aneurysm is likely. The *method of Anel* (1710), revived in 1856 by Broca, consists in the application of a ligature close to the sac (Fig. 210); until recent years it was considered inferior to Hunter's operation, but aseptic technique has shown it to be quite as safe and but slightly more difficult; and its manifest advantages are that the circulation through the sac is completely suppressed and yet no additional obstacle is erected to the circulation, only one set of anastomosing vessels being required, instead of two, as in Hunter's operation.

Matas, Delbet, Weber, Köhler, Le Conte and Stewart all prefer Anel's method to that of Hunter.

Distal ligation also depends for its curative effect on retardation of the circulation within the artery, with consequent thrombosis in the aneurysmal sac. *Brasdor's method* (1798) consists in ligation of the main trunk immediately distal to the aneurysm, *no branch intervening* (Hodgson, 1815) (Fig. 211); while the "*new operation*" *of Wardrop* (1828) involves ligation of one of the main branches below the sac, or of the parent trunk below the origin of a branch (Fig. 212). These methods are inferior to proximal ligation, because less certain; but are still employed in places where the proximal side of the artery is

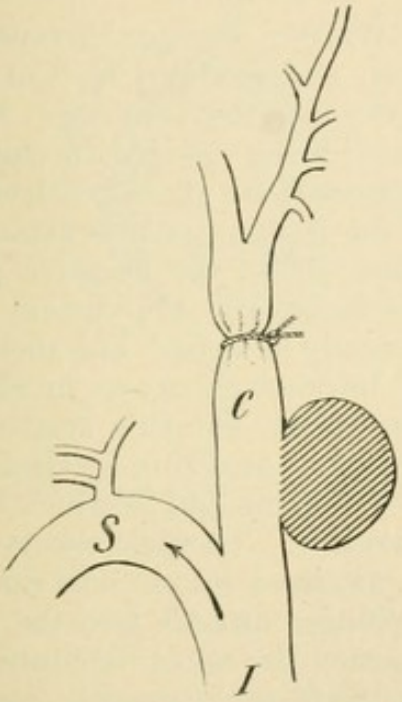

FIG. 211.—Brasdor's method of ligation for aneurysm, applied for aneurysm of the common carotid artery (*C*). *I*, innominate; *S*, subclavian artery.

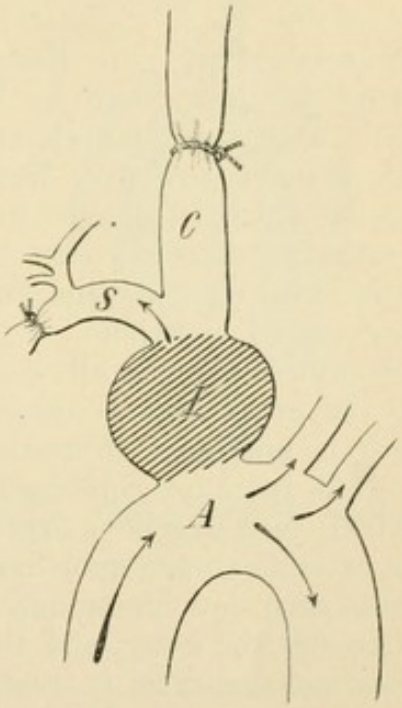

FIG. 212.—Wardrop's method of ligation for aneurysm, applied for aneurysm of the innominate (*I*). The common cartoid (*C*), and the subclavian (*S*) in its third portion have been ligated, permitting slight circulation through the thyroid axis.

inaccessible, as in Innominate Aneurysm, or large aneurysms of the first part of the Subclavian. For innominate aneurysm simultaneous double ligation of the common carotid and subclavian arteries is preferred, constituting Wardrop's method, since the subclavian is tied in its third portion below the origin of the thyroid axis and vertebral.

Double Ligation, Above and Below the Sac.—When this is immediately followed by incision of the aneurysm, evacuation of the clots, and packing of the sac, to control hemorrhage from collaterals entering the sac, it constitutes the *operation of Antyllus* (third century, A.D.); if the sac is opened first, the clots evacuated, the mouth of the sac

sought with the finger, and a probe passed up and down the parent trunk as a guide to the application of ligatures above and below the tumor, it constitutes the "*old operation*," which was temporarily revived by Syme (1857).

At the present time the *mortality* from ligation is about 8 per cent.; there is, however, also the risk of *gangrene*, requiring amputation, which occurs in an additional 8 per cent. of cases (Delbet). Gangrene is due not only to sudden arrest of the circulation, but also to pressure on surrounding tissues by the thrombosed sac, and sometimes to embolism of the artery below the sac. Even if a patient recovers and escapes gangrene, the symptoms from pressure (neuritis, edema, etc.), may be not only unrelieved but even aggravated by solidification of the sac.

Filipuncture and Electrolysis; Wiring of Aneurysms.—Wiring was introduced by Moore (1864), and modified by Corradi (1879) who passed an electric current through the wire coil. Fine gold or silver wire (No. 28 gauge) is used, being inserted through a cannula which is plunged into the aneurysmal sac; from ten feet to as many yards of wire are introduced; the positive pole is attached to the wire entering the aneurysm (Hare, 1908), the negative pole being placed elsewhere on the patient's body, and the current (70 to 80 milliampères) is allowed to run for nearly an hour. This method may be attempted in certain cases of internal aneurysm in which death is imminent from rupture, or in which Tufnell's treatment (p. 253) (perhaps combined with repeated venesection—Valsalva's method) fails to relieve urgent pressure symptoms, but in which ligation or endo-aneurysmorrhaphy are impossible. Thoracic aneurysms (aortic arch, low innominate) are to be localized by physical examination and the *x*-ray, and the cannula plunged directly into the sac; abdominal aneurysm is treated after exposing the sac by laparotomy. For thoracic aneurysm no other surgical treatment is possible, except in the case of innominate aneurysm, when simultaneous double distal ligation is preferable. In some cases of abdominal aneurysm endo-aneurysmorrhaphy can be performed, and is preferable if temporary control of the circulation can be secured. Matas (1900) found that wiring and electrolysis resulted in apparent recovery in less than 20 per cent. of cases; in 1910 he condemns the method as a "pure experiment, which is justified solely by the imminent and unavoidable danger of death from the progress of the disease itself." Eshner (1910) has analyzed 36 cases of aneurysm, mostly aortic, treated by wiring; 9 patients died within ten days, 22 lived less than one year, and 5 survived for periods ranging from fourteen months to over eleven years.

Extirpation of the Sac, known by the names of Philagrius (third century A. D.), and Purmann (1685), now finds an ardent supporter in Delbet. It removes the danger of gangrene due to pressure on surrounding parts by the clot-filled sac, as also the danger of embolism. For its successful performance it is necessary to secure

preliminary control of the circulation, when possible by application of an elastic band at the root of the limb, or even by direct clamping of the afferent and efferent artery. This latter method, however, may not prevent profuse recurrent hemorrhage from collaterals emptying into the sac. The vein should be preserved, and if important structures are adherent to the sac that portion of the sac should be left behind. According to Delbet (1907), among 86 patients treated by extirpation of the sac there were no deaths, and gangrene followed in less than 3 per cent.

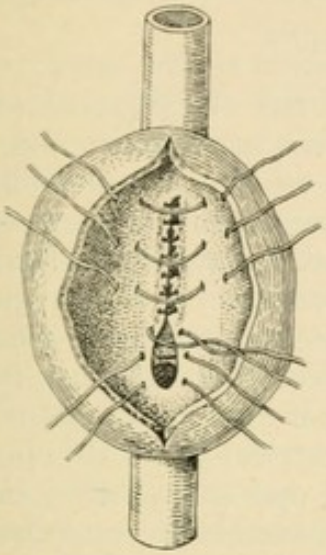

Fig. 213.—Obliterative endo-aneurysmorrhaphy.

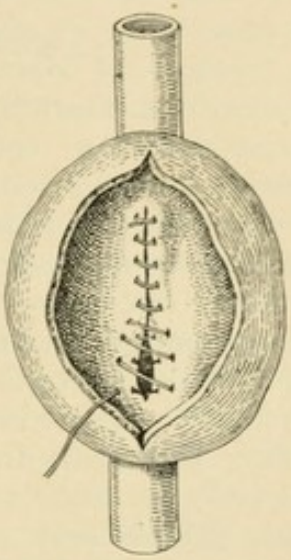

Fig. 214.—Restorative endo-aneurysmorrhaphy.

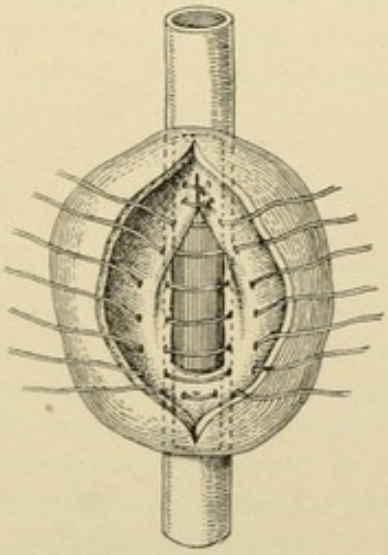

Fig. 215.—Reconstructive endo-aneurysmorrhaphy.

Endo-aneurysmorrhaphy, introduced by Matas in 1888. After controlling the circulation, the sac is opened: (1) If a fusiform aneurysm, or a saccular aneurysm with very large mouth (Fig. 207), is found, the sac is obliterated by a series of fine chromic catgut or silk sutures, approximating its walls, and occluding the lumen of the

artery adjacent to the mouth of the sac (*Obliterative Endo-aneurysmorraphy* (Fig. 213). (2) If a saccular aneurysm with small mouth is found, it may be possible to suture the margins of the sac mouth without occluding the lumen of the parent artery (Fig. 214). Orifices of collaterals are then sutured, and the sac walls approximated as before (*Restorative Endo-aneurysmorrhaphy*). (3) In rare cases the form of the aneurysm may be such that it will be possible to reconstruct by suture a channel to represent the lumen of the parent artery, though little or no evidence of such a channel exists when the sac is opened; a soft catheter may be used as a guide (Fig. 215) (*Reconstructive Endo-aneurysmorrhaphy* or *Aneurysmoplasty.*)

The methods of Matas possess over ligation all the advantages of extirpation (less mortality and diminished risk of gangrene) while at the same time they entail less trauma than extirpation, and in the restorative and reconstructive methods afford the possibility of preserving the circulation through the parent artery; and even if this circulation is preserved only temporarily, gangrene is less likely than if the circulation is occluded immediately as in extirpation. If endo-aneurysmorrhaphy is applied to cases of traumatic aneurysm, this should not be until a firm-walled adventitious sac has formed. Matas in 1910 collected reports of 110 cases of endo-aneurysmorrhaphy (including 67 aneurysms of the lower extremity), with only two deaths (1.8 per cent.) attributable to the operation, and 4 cases of gangrene (3.6 per cent.), 3 of which were chargeable to complications, not to the operation itself.

CHAPTER XI.

SURGERY OF THE SKIN, BURSÆ, LYMPHATICS, MUSCLES, TENDONS, AND NERVES.

SURGERY OF THE SKIN.

Verruca or Wart.—This is a localized hyperplasia of the epidermis, and theoretically may be distinguished from a *papilloma*, which, as noted at p. 118 is a neoplasm. The favorite sites for warts are, the hands, face, scalp, and neck. They usually appear to grow spontaneously, but in a few cases a suspicion of contagion exists; trauma followed by moisture seems a predisposing cause. They show little tendency to enlarge, scarcely ever become malignant, and occasionally disappear from no apparent cause. *Treatment* is sought for disfigurement, sometimes for pain. Removal is accomplished easily by snipping off the warts with scissors, after spraying with ethyl chloride; the base is then cauterized with silver nitrate. Or by applying a drop or so of fuming nitric acid every few days, the warts will in time shrivel up and fall off painlessly. Recurrence is rare after thorough removal.

Venereal warts are those growing upon the genitals or around the anus; they are due to irritation from uncleanliness, and have no necessary connection with any venereal disease.

Callositas or Tyloma is a diffuse hypertrophic condition of the skin, normally present to a slight degree in the palms and soles, and due to intermittent pressure. It becomes of surgical interest when the hypertrophy is so great as to cause the lesion to approach to that of *Clavus* or *Corn:* in this lesion (which frequently develops in the centre of a callosity, or may arise independently, especially on the toes) the intermittent pressure causes a pyramidal shaped up-growth of epithelial cells, which presses upon and finally separates the papillæ of the skin, and causes exquisite pain from pressure on the highly sensitive nerve-endings found in this layer. A *soft corn* is distinguished from a *hard corn* by the fact that the former is placed where its surface is kept warm and moist, as between the toes; while the hard corn develops on an exposed surface. When of long duration a bursa may be formed beneath the corn, constituting a *bunion;* this is most often the case over the metatarso-phalangeal articulation of the great toe, often being combined with *hallux valgus* (p. 549).

Treatment.—Treatment of corns consists in removal of the cause; in frequent bathing; application of such plasters as will relieve the corn from pressure; use of salicylic acid ointment (5 to 10 per cent.);

paring the surface of the corn (a frequent cause of cellulitis, angeioleucitis, and sepsis, if carelessly done); and sometimes in formal excision.

Cornu Cutaneum or Horn, is a rare affection of the skin, most frequent in old age, and about the face; it may follow the spontaneous evacuation of a wen. Closely analogous to it is the condition of *hypertrophy of toe-nails* or *onychauxis* (Fig. 216). Excision is the best treatment.

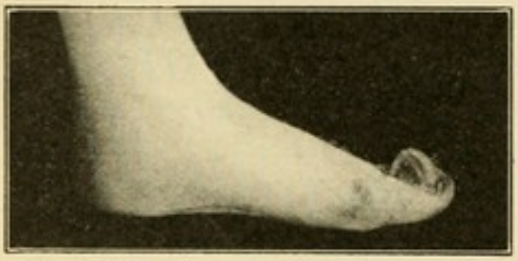

FIG. 216.—Hypertrophy of toe-nail, or onychauxis, one year's growth since the nail was last cut off. Episcopal Hospital.

Keratosis Senilis.—See p. 622.

Onychia.—Onychia or inflammation of the matrix of a nail is classed as *simple* and *malignant*. The former, or "run-around," is most frequent in children, starting from a hang-nail, and appearing as a red, swollen, tender semicircle around the base of the nail. Treatment consists in application of antiseptics, with incision as soon as suppuration is suspected. *Malignant onychia* is a severer form of the disease, occurring in persons much debilitated, and often coming under observation only in the stage of ulceration ("toe-nail ulcer"); any portion of the nail remaining should be removed, the granulations curetted or cauterized, and the part dressed with stimulating ointments. Hygiene should be attended to, and tonics prescribed. Amputation of the phalanx may be necessary if necrosis occurs.

Ingrowing Toe-nail.—Ingrowing toe-nail, seen almost exclusively in the great toe, usually is due to ill-fitting shoes, which produce a degree of *hallux valgus* (p. 549): in the early stages the form of the nail is unaltered, but the soft parts of the pulp are crowded over on its edge, and injudicious trimming of the nail down this chink predisposes to ulceration. Later, the edge of the nail becomes folded under, and by pressure on the pulp, aggravates the condition. If palliative treatment be persisted in long enough, a cure usually may be produced by keeping the parts free from pressure, and separating the overhanging skin from the nail either by antiseptic cotton stuffed into the chink, or by drawing the skin aside by adhesive plaster, while the ulcer is treated by desiccating powders after cauterizing its base. The nail should be cut square across the top, and never trimmed down at the sides. If a rapid cure is demanded, it is best to avulse the side of the nail affected (both sides if necessary) by splitting the nail down the centre with strong scissors, and grasping the portion to be removed in forceps. Local anesthesia is sufficient. Tytler (1909) applies a tight ligature around the base of the toe until it is congested, then lightly crushes with forceps the affected half of the nail; in a day or so it becomes soft and bluish, and may be cut away with scissors. As the new nail grows, properly fitting shoes must be worn to prevent recurrence.

Perforating Ulcer.—Perforating ulcer, usually seen in the sole of the foot or under the great toe, occurs in those past middle life, and is connected with arterio-sclerosis or trophic disturbances. It occurs in diabetes, and in locomotor ataxia, and probably is not a specific disease, but merely an evidence of tissue destruction due to malnutrition. It is not attended by much pain, may follow slight injury, frost-bite, etc., and frequently originates in a small slough in the centre of a callosity or corn. If untreated, the ulceration steadily progresses, eating through the foot, involving muscles, tendon, and bone; is attended by a stench, and in advanced stages perforates the dorsum of the foot. Under hygienic measures, internal administration of potassium iodide, rest in bed, and active local treatment (cleansing, curetting, etc.), temporary cure sometimes is obtained.

Furuncle or Boil.—Furuncle or boil is an infection of a hair follicle or sebaceous gland, confined to the deeper layers of the true skin, usually terminating in suppuration, with the extrusion of a central slough called the core. The usual cause is Staphylococcus aureus, which gains entrance through a minute abrasion, as from a rough edged collar or cuff. Persons with disordered metabolism (diabetes, gout, nephritis, scrofula, eczema, etc.), are especially predisposed to furunculosis. The classical *symptoms* of inflammation are present—a red, extremely tender and painful swelling, attended by local heat, in the true skin and subcutaneous tissues. Boils vary much in size, but seldom appear over two inches in diameter; they usually are multiple, sometimes appearing in successive crops. Boils usually have a marked tendency to point; those that do not, are called "blind boils."

Treatment.—Treatment includes such general hygienic and tonic measures as will prevent a continuance or recurrence of the boils; frequent bathing, with the use of alkalies (sodium carbonate) in the bath and by mouth, is important. By local treatment in the very early stages it sometimes is possible to abort a boil by pouring pure ichthyol over its surface, and making a scab with a film of absorbent cotton. In most cases, however, early incision, besides relieving pain, will accelerate extrusion of the slough, and prevent formation of neighboring boils, which are encouraged by poulticing. After extracting the core, pure ichthyol may be poured into the crater of the furuncle, or a drop of carbolic acid may be introduced on a match-stick. The surrounding skin must be kept clean and stimulated with astringent washes. In cases of persistent furunculosis, much benefit has been derived from the administration of autogenous vaccines.

Carbuncle.—Carbuncle may be regarded as an aggravated form of boil (Fig. 217). The infection spreads more widely in the subcutaneous tissues, there is phlegmonous inflammation, and the pus tends to evacuate itself through manifold orifices, by following the course of the *columnæ adiposæ* (Warren, 1881). Carbuncles are most common on the nucha, and may extend almost from the vertex to the shoulder.

In the old, the diabetic, the subjects of advanced Bright's disease, etc., it forms a very serious malady, often endangering life. There is no clear limit to the inflammation, which usually is more widespread than is apparent on the surface.

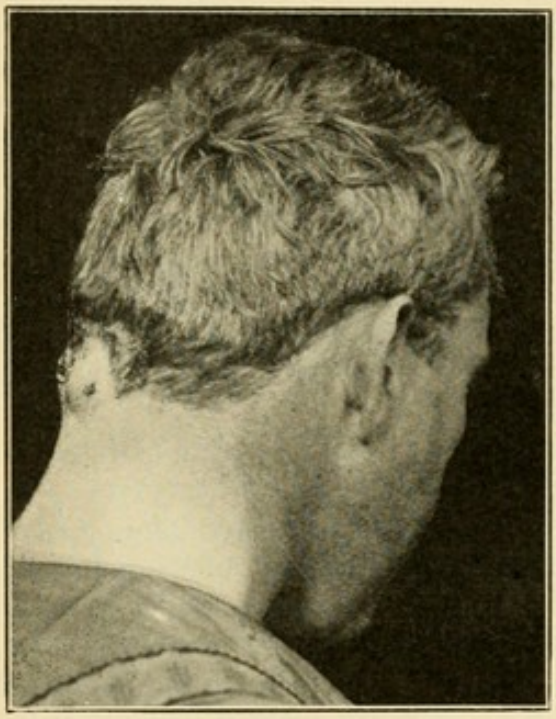

Fig. 217.—Carbuncle of neck; duration, two weeks; incised a few days ago; no improvement. Episcopal Hospital.

Treatment. — Hygienic and constitutional treatment is even of more value than in furunculosis. (1) *Small carbuncles* should be treated as boils, by early incision which may be crucial if necessary, to facilitate extrusion of the sloughs. (2) *Medium-sized carbuncles* should be incised as above, and then strapped with adhesive plaster applied concentrically, until only a small orifice is left for the discharge of pus (Fig. 218); this strapping, suggested by O'Ferral (1858) and emphasized as particularly valuable by J. Ashhurst, Jr. (1869), acts mechanically by limiting the spread of the phlegmon by erecting an impassable barrier around the base, and forcing the discharge of sloughs through the central

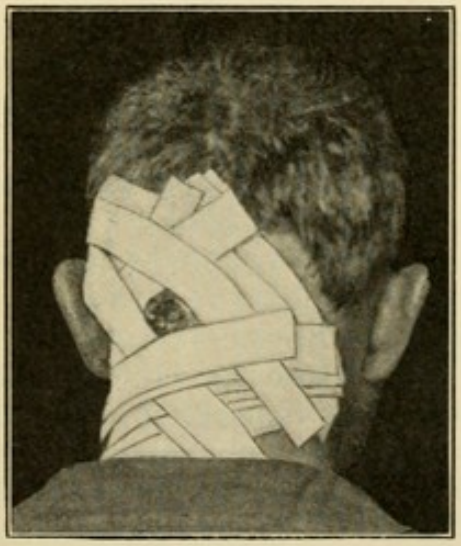

Fig. 218.—Carbuncle of neck strapped with adhesive plaster. Episcopal Hospital.

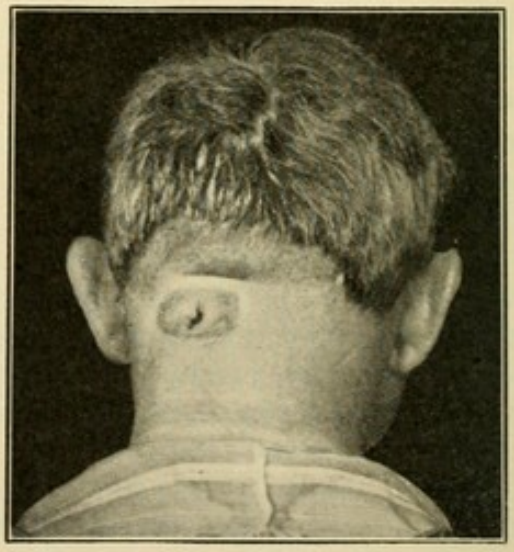

Fig. 219.—Carbuncle of neck after strapping for one week. Only a superficial ulcer remains. Episcopal Hospital.

opening; it secures local rest; and also, I believe, creates a certain degree of passive hyperemia in the diseased area, thus increasing the

phagocytic and opsonic powers of the patient. The strapping checks almost at once the excessive pain caused by the carbuncle, and as it may be left in place for several days at a time, considerably simplifies the treatment. The gauze which receives the discharge through the central opening should be changed daily. The diminution in size of the carbuncle (Fig. 219) evident when the strapping is removed is as remarkable as it is gratifying. Seldom more than two or at most three strappings are required to convert an angry volcano into a superficial ulcer, which readily heals under bland ointments. (3) *Very large carbuncles* sometimes may be excised, with benefit: the patient being anesthetized, a circular incision is made at the apparent outer border of the carbuncle; this incision is carried down to the deep fascia and muscles, which rarely are involved, and the entire sloughing mass is cut away; bleeding, which may be profuse, is checked by ligature, pressure, or cautery; and the large raw surface is packed with absorbent gauze, which should not be removed for four or five days. Free stimulation is required after the operation, and skin-grafting may be necessary to secure final cicatrization.

Tuberculosis Cutis.—The tuberculous lesions of the skin of most interest to surgeons are *Lupus Vulgaris*, *Scrofuloderma*, and *Erythema Induratum*.

Lupus Vulgaris.—The tuberculous lesions are seated in the corium, and usually are secondary to an insignificant focus elsewhere. The disease occurs in young persons of scrofulous tendencies, is most frequent in the face, and appears as one or several minute red papules, tender but not appreciable to touch, which on examination are found to be covered by a thin pellicle of altered skin, giving them, when the blood is pressed out by application of a glass slide, a close resemblance to drops of apple-jelly. The overlying pellicle is soft and easily punctured, the probe or scalpel sinking for some millimeters into the diseased area. These nodules may coalesce, the patch spreading eccentrically and healing in the middle, and thus bearing some resemblance to certain of the syphilodermas; but the apple-jelly nodules can be seen in the advancing border of the lupus patch. When lupus ulcerates (*lupus exedens*, as distinguished from simple lupus, or *lupus non-exedens*), the surrounding tissues may be widely destroyed, but the ulcer always remains superficial; its outline is rounded, its edges are not indurated, and its course is very slow (Figs. 220 and 221).

Diagnosis.—This must be made by careful examination to detect the apple-jelly nodules, by attention to the clinical history of the patient, and by exclusion of syphilis, epithelioma, or other rarer ulcerations of the skin, all of which usually occur in older patients. Lupus erythematosis, thought by many to be due to toxins of tubercle bacilli lodged elsewhere in the body, is sufficiently characterized by its usual butterfly outline, its persistent redness, the absence of the apple-jelly nodules, and its unulcerated condition.

Treatment.—The treatment includes constitutional anti-tuberculous measures (p. 82), and local remedies. The latter, whenever possible, should consist of excision, replacing the loss of tissue by skin-grafting or a plastic operation (p. 623). If excision cannot be done, the diseased spots should be gouged out with a sharp spoon, and the cavities left treated with strong antiseptics or caustics. Radiography is of value in some mild cases, as is the use of radium, Finsen light, etc.

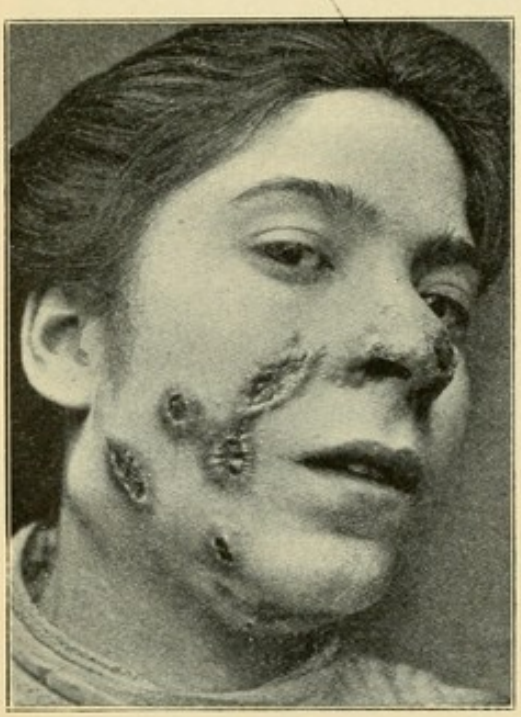

FIG. 220.—Lupus vulgaris in a girl, aged sixteen years. Four years ago the first lymph node swelling appeared under the chin. There followed tuberculous lymphangeitis, which involved the skin. Two years ago invasion of nasal mucosa occurred, and this led to involvement of the skin over the nose. (Philippson.)

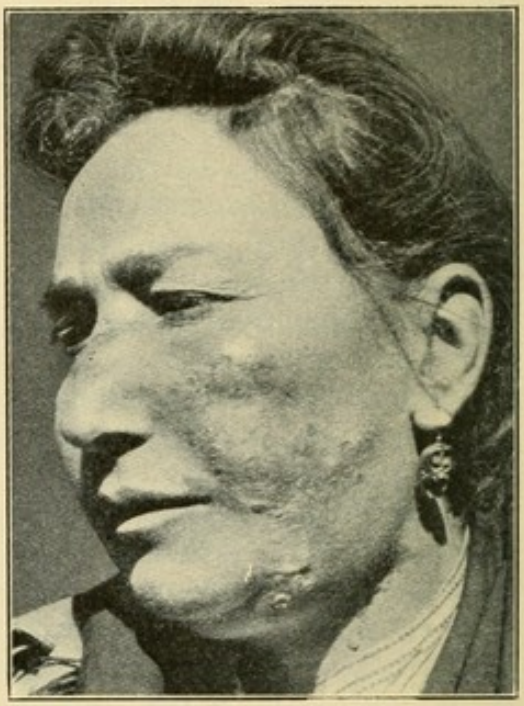

FIG. 221.—Lupus vulgaris of face, in a woman, aged thirty-eight years; the disease began twenty-three years ago in the left cervical lymph nodes. (Philippson.)

Scrofuloderma.—Scrofuloderma is the name given to the tuberculous lesion of the skin which results when this is invaded by a tuberculous process in an underlying structure, as a caseous lymph node. The condition was referred to at p. 80, Fig. 36.

Erythema Induratum or Bazin's Disease (1855) is a paratuberculous affection usually of the calves of the legs of growing girls with a scrofulous taint; it appears as multiple bluish-red indurations, resembling somewhat both furuncles and syphilitic gummas, which tend to soften and discharge, leaving indolent and very painful ulcers. These can be made to heal only by improving the general health.

Erythema Nodosum.—Erythema nodosum is mentioned merely to warn the student not to mistake its lesions for contusions or abscesses. The affection usually is bilateral, occurs in children, and

in most cases the shins are affected (Fig. 222), though sometimes the lesions appear over the subcutaneous surfaces of the ulnæ. There is no history of trauma; there is more constitutional disturbance than from bruises; and often the disease is one manifestation of an infection (perhaps some attenuated form of tuberculosis) which causes endocarditis, pleurisy, etc.

Acne Rosacea.—See p. 620.

Epithelioma.—See p. 624.

Sebaceous Cyst (Steatoma, Wen).—This is a retention cyst, due to occlusion of the orifice of a sebaceous duct. The cysts, which may be multiple, occur mostly in the scalp and face (Figs. 223 and 224); on the extremities, and especially below the level of the umbilicus they are extremely rare. The skin is adherent to the cyst at one point, the orifice of the duct, sometimes visible as a black dot; the cheesy, malodorous sebum usually can be squeezed out, after inserting a probe into

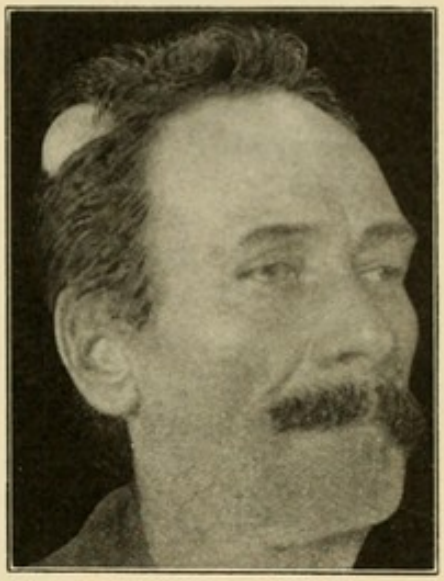

FIG. 223.—Sebaceous cyst of scalp; duration, thirty years. Episcopal Hospital.

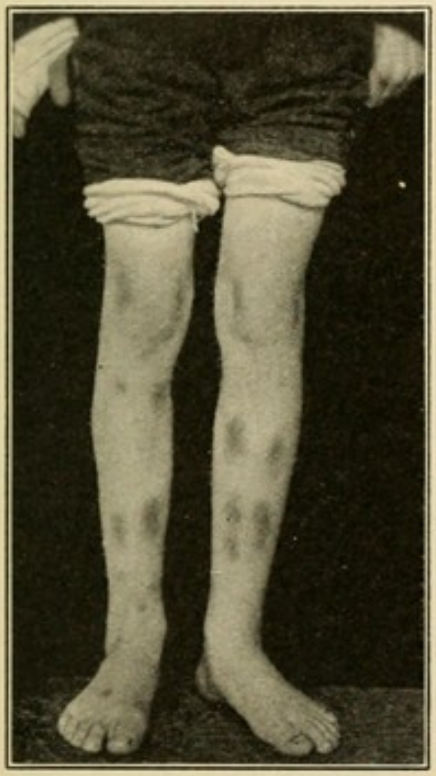

FIG. 222.—Erythema nodosum. One week's duration, following staphylococcic infection of finger and complicated by endocarditis. Temperature, 100.4° F. Episcopal Hospital.

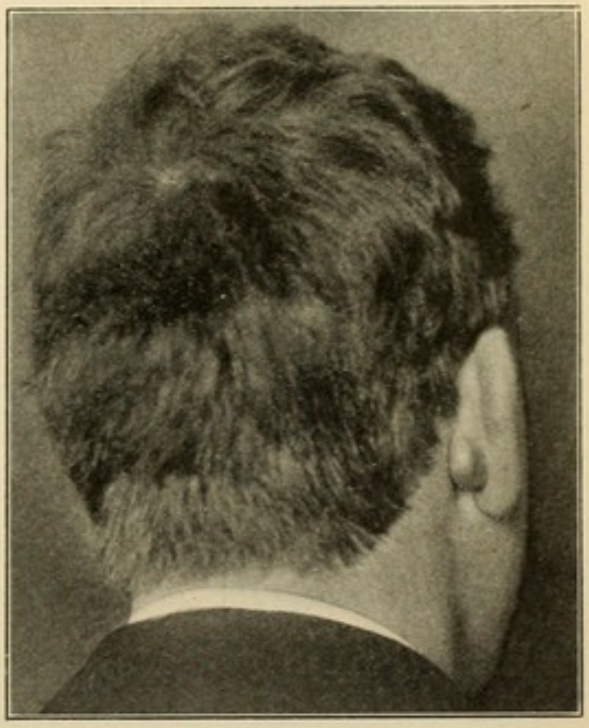

FIG. 224.—Sebaceous cyst of ear. Episcopal Hospital.

the duct. These cysts frequently become inflamed and suppurate; when they discharge spontaneously, a bleeding fungous mass protrudes which may be mistaken for a malignant papilloma; and carcinomatous changes are not unknown (p. 553). If the discharge of sebum crusts on the surface, a cutaneous horn (p. 260) may develop. Some sequestration cysts (p. 130) are clinically indistinguishable from sebaceous cysts (Fig. 226).

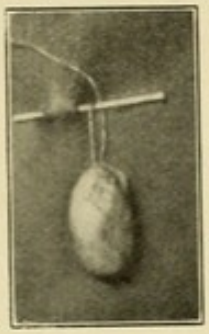

FIG. 225.—Sebaceous cyst of ear excised. (See Fig. 224.)

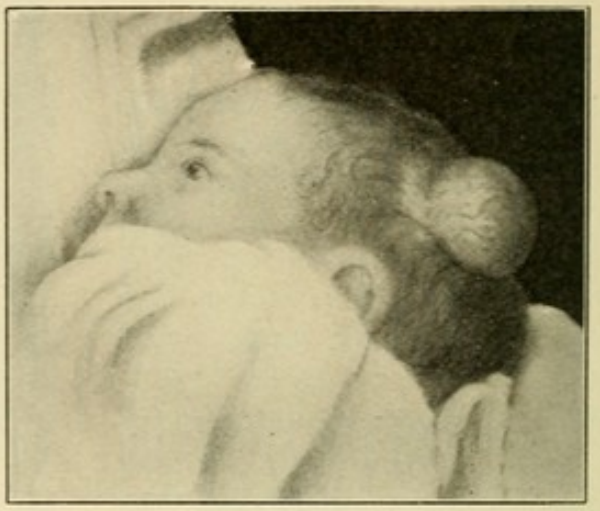

FIG. 226.—Dermoid cyst of scalp. Children's Hospital.

Treatment.—Wens are removed easily, under local anesthesia, by dividing the overlying skin and dissecting the unruptured sac from the subcutaneous tissues, to which its adhesions are light. Recurrence is frequent unless all the cyst wall is removed. If of large size some of the overlying skin may be excised.

Pilo-nidal Cysts and Fistulæ.—These are a form of sequestration cysts, mentioned at p. 130. They occur most often in the region of the anus, and may be congenital or acquired. According to Hodges (1880) only the sinus is congenital, and the hairs work their way in during post-natal life, finally occluding the orifice of the sinus and forming a cyst. Suppuration is frequent. Excision is the proper treatment (Klemm, 1909).

INJURIES AND DISEASES OF BURSÆ.

Wounds of Bursæ.—If the bursa opened communicates with a joint, serious consequences may follow; and as, in the case of a bursa which sometimes communicates with a joint, the fact of its non-communication can never be known *a priori*, all such cases should be treated as if a joint was involved (p. 386). If the wound is punctured, it should be enlarged, after suitably cleansing the part; and foreign matter should be extracted, the bursa drained, and local and constitutional rest provided. If no infection follows, the bursa will heal with partial or complete obliteration of its cavity. If suppuration occurs, daily irrigation of the bursa should be done as

soon as it is evident that no progress toward healing is being made merely by drainage. Finally, the bursa may be excised if continuance in conservative treatment is ineffectual.

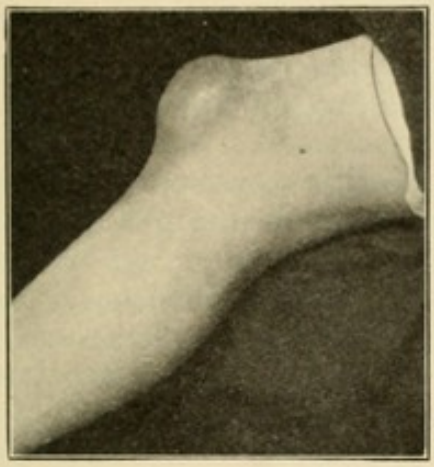

FIG. 227.—Prepatellar bursitis; two months' duration; subacute onset. Episcopal Hospital.

FIG. 228. — Olecranon bursitis, two months' duration; no acute trauma. Episcopal Hospital.

Bursitis.—Bursitis, or inflammation of a bursa, usually follows contusions, and may be acute or chronic. *Acute bursitis* follows slight continuous, or frequently intermitted trauma, as in the retrocalcaneal bursa (*Achillodynia* or *Albert's disease*, 1893), or in the olecranon bursa in those confined to bed, with gouty tendency. Relief of pressure, evaporating lotions, and rest, usually cause subsidence of the inflammation in a few hours. If suppuration occurs, early free incision should be made. *Chronic Bursitis*, which follows slight but continually repeated trauma, may be a sequel of acute bursitis or may be chronic from the start. The bursæ most often affected are: (1) Prepatellar ("Housemaid's Knee," Fig. 227); (2) Olecranon ("Miner's Elbow," Fig. 228); or (3) the bursa over the Tuber Ischii ("Weaver's Bottom").

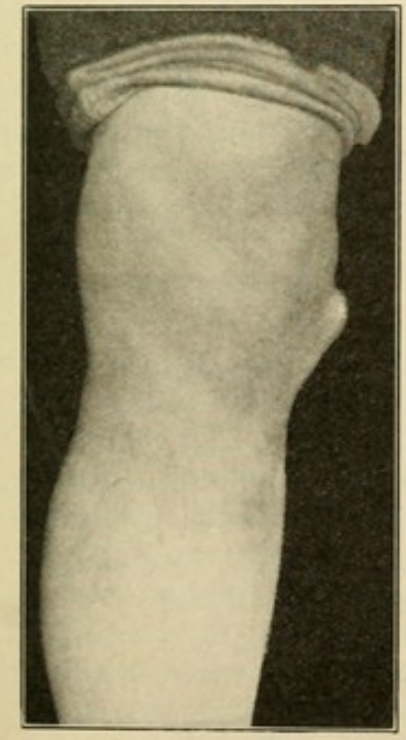

FIG. 229. — Inflammation of bursa beneath tendo patellæ, bulging on inner side of tendon. Acute onset three days ago, from acute flexion of knee. "Dispersed" by a blow. Episcopal Hospital.

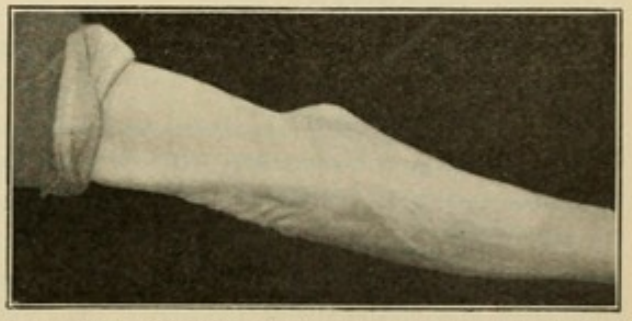

FIG. 230.—Ganglion in bursa of biceps brachii at insertion. Episcopal Hospital.

Other bursæ sometimes affected are: (4) Subacromial Bursa (see Periarthritis, p. 466); (5) that beneath the Tendo Patellæ (Fig. 229); (6) those over the Femoral Condyles (see Ganglion of Popliteal Space, p. 281); (7) Subgluteal Bursa; (8) that over the head of the first metatarsal bone (see Bunion, p. 259, and Hallux Valgus, p. 549); (9) between the tendon of the Biceps and tuberosity of the Radius (Fig. 230). By coagulation of the effused fluid, solid enlargement of a bursa may occur.

Treatment.—Treatment of chronic bursitis consists in removal of the cause, application of sorbefacient ointments, painting with tincture of iodin, etc.; and, these failing, in tapping and injection of 2 per cent. formalin-glycerin solution or dilute alcohol (never when joint-communication may exist), in incision and drainage (when healing will occur by obliteration of the sac), or in excision which is best in most cases, especially those of long duration with thick sac walls.

INJURIES AND DISEASES OF THE LYMPHATICS.

Wounds.—Wounds of the lymphatics are of little moment except when the *thoracic duct* is injured, as it may be in operations on the neck. If this accident is discovered when the wound is inflicted (by a discharge of milky fluid in the wound—*lymphorrhea*), an attempt should be made to apply a lateral suture. If this is impossible, both ends of the duct should be ligated; and this failing, the wound should be tamponed. If the injury is not discovered at the time of operation, it soon makes itself manifest by a discharge of chyle from the wound, and by rapid and progressive emaciation. There should be no delay in reopening the wound and suturing or ligating the duct. Fredet (1910) collected 58 cases of injury to the thoracic duct, with five deaths.

Lymphorrhea.—Lymphorrhea may also occur from wounds of lymphangiectases (p. 269).

Chylothorax and **Chylous Ascites** occasionally follow rupture from contusion of the thoracic or abdominal portions of the thoracic duct. Repeated tapping of the thoracic or abdominal fluid has resulted in cure in a few cases. Certain chylous cysts of the mesentery (Chapter XXIII) have a similar origin. Chyluria may result from communication with the urinary tract.

Lymphangeitis or **Angeioleucitis,** inflammation of lymphatic vessels, usually is due to spread of infection from a wound. It is seen most often on the extremities, but I have seen it on the abdomen as a result of omphalitis. There are one or several flame red, irregular streaks running from the site of infection (felon, lacerated wound, etc.) up to the axillary or inguinal lymph nodes; these streaks coalesce here and there to form broader red bands, and may again separate before reaching their terminus (Plate I, Fig. 1). They are not particularly painful or tender, seldom are palpable, and are redder and less regular

in their course than veins in cases of phlebitis (p. 239). There is considerable fever, chills may occur, and lymphadenitis usually co-exists. Treatment consists in cure of the focus of infection; in local rest by splints, confinement to bed, etc., and in applications of silver nitrate, dilute iodin, ichthyol, etc., along the course of the inflamed lymphatics. Suppuration frequently occurs in the lymph nodes, but seldom along the lymph vessels.

Lymphadenitis.—Lymphadenitis, or simply "adenitis," occurs as an incident in cases of lymphangeitis, but may also occur when no evidences of superficial lymphangeitis exist. Thus femoral or inguinal adenitis (*bubo*) frequently follows a blister of the foot, or venereal or other infection of the genitals, when no sign of lymphangeitis can be detected (Fig. 231). Epitrochlear or axillary adenitis may arise from a slight abrasion or punctured wound of the hand which healed before the secondary lesion was noticed. The *symptoms* are those usual in inflammation, and the tender, enlarged lymph nodes are distinctly palpable. Suppuration is not unusual. Secondary invasion by specific microbes (chancroidal, tuberculous) may occur, and somewhat changes the character of the lesion. Any lymphadenitis which assumes a subacute or chronic course is liable to infecton with tubercle bacilli through the blood-stream. This is especially true of cervical adenitis (p. 676). Chancroidal bubo is discussed in Chapter XXVI.

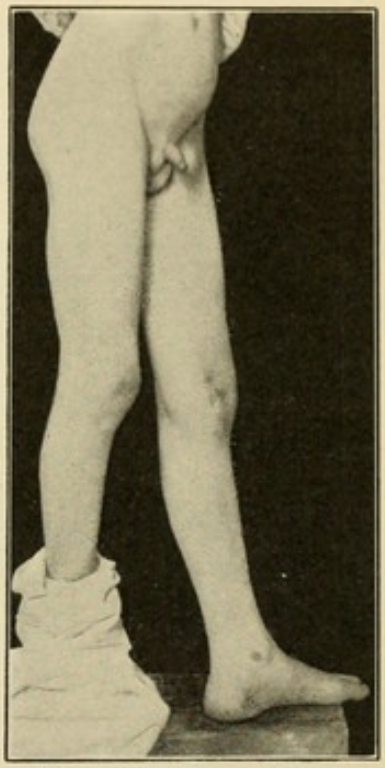

FIG. 231.—Femoral lymphadenitis; duration, two days; from infected wound of left foot two weeks ago. Episcopal Hospital.

Treatment.—Treatment of adenitis implies cure of the source of infection; antiphlogistic applications to the seat of adenitis; early incision in case of suppuration; and finally formal excision of the diseased mass of lymph nodes if the resulting sinus fails to close under conservative treatment or if the lymph nodes remain enlarged and tender without the occurrence of suppuration.

Lymphangiectasis.—Lymphangiectasis, or dilatation of lymph channels, results from obstruction to the flow of lymph. This may be due to external pressure (as from tumors or cicatrices); to operative removal of the nodes draining the part; or it may be caused by chronic lymphangeitis, causing obliteration of the main lymph vessels, often following repeated attacks of erysipelas, etc. It is much rarer as a consequence of external pressure than is phlebectasis (p. 242), because the lymphatic collateral circulation is much freer. Sometimes it affects the spermatic cord, constituting a *lymphatic varicocele*. When a distinctly localized swelling is formed,

it is known as *lymphangeioma;* this occurs oftenest as a congenital condition in the face or neck, but may develop in adult life (Fig. 232). It forms a soft fluctuating swelling, covered by healthy skin. Excision is the proper treatment, but if complete extirpation is impossible, a partial operation entails great risk of lymphorrhagia, with malnutrition; in such cases galvano-puncture may be tried. *Macromelia*, or giant growth of a part, usually is a lymphangeiomatous condition; one finger, the lips, the tongue, etc., may be affected.

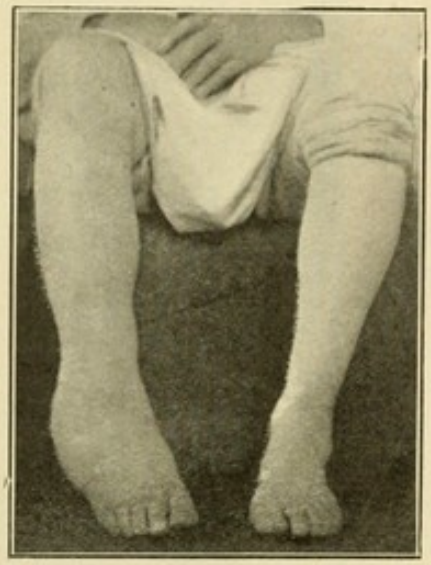

FIG. 232.—Lymphangeioma of right foot, aged seventy-five years; duration, seven years. Orthopædic Hospital.

FIG. 233.—Lymphedema; duration, one year. Episcopal Hospital.

Lymphedema, resulting from lymphangiectasis, and consisting of thickening of the subcutaneous tissues from the effused fluid with cellular reaction, occurs principally in the lower extremity (Fig. 233), often associated with chronic ulcer; or in the upper extremity following ablation of mammary carcinoma and axillary lymphatics (Fig. 744). *Hereditary persistent edema of the legs*, which has been studied by Jopson (1898), is believed by Hope and French (1908) to be a vascular neurosis, causing hard edema, which terminates abruptly at the knee or groin, there being no evidence of venous or lymphatic obstruction; but the result is very like lymphedema. If palliative treatment (bandaging, massage, etc.) fails, various operative measures may be undertaken. Excision of wedge-shaped longitudinal strips of the thickened skin and cellular tissues may reduce the bulk of the limb so as to promote ease in locomotion. *Lymphangeioplasty* (Handley, 1908) consists in inserting long strands of silk in the subcutaneous tissues from the hand or foot to the axilla or groin; these act as capillary drains and rapidly reduce the edema. Lanz (1911) drilled holes into the medulla of the femur and inserted into them strips of fascia lata still attached by one end, thus creating new

channels of drainage through the marrow cavity. Amputation is the last resort.

Elephantiasis Arabum is a form of lymphedema due to obstruction of lymph channels by *filaria sanguinis hominis*, the disease being called *filariasis*. The parasite is transferred from patient to patient through a mosquito as intermediary host. In the patient the half grown parasites lodge in the peripheral lymphatics, there become mature and produce offspring. The embryos enter the blood-stream, but appear in the peripheral circulation only at night; when the

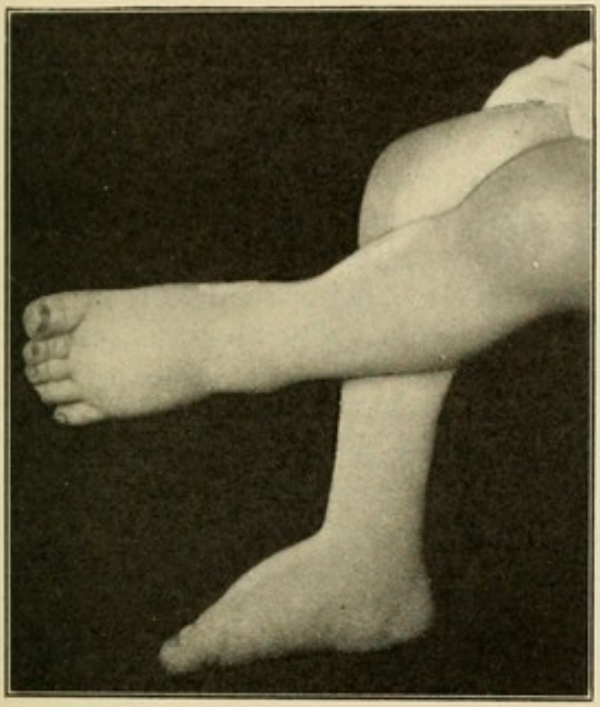

FIG. 234.—Persistent hereditary edema affecting two brothers. (See Fig. 235.) (Dr. Jopson's cases). Children's Hospital.

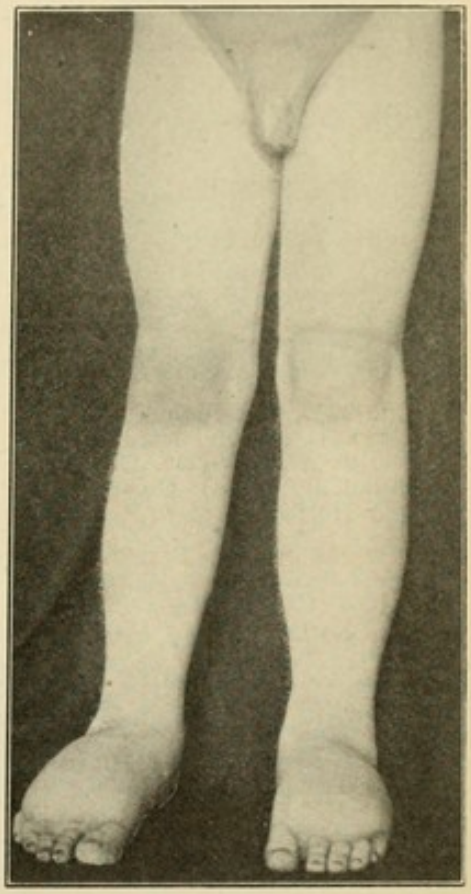

FIG. 235.—Persistent hereditary edema, in two brothers. (See Fig. 234.) (Dr. Jopson's cases). Children's Hospital.)

patient is at rest they are readily abstracted thence by the mosquito. Elephantiasis affects the lower extremities and the scrotum more often than other parts of the body. It is rare in this country, except in persons recently returned from the tropics. *Treatment:* Palliation is secured by support, bandaging, etc., but excision usually is indicated. Amputation may be necessary.

Hodgkin's Disease (1832) (**Malignant Lymphoma, Lymphomatosis, etc.**). This, according to Adami, is a condition of the lymph nodes comparable to keloid in the skin—"an excessive overgrowth of the lymphoid stroma secondary to a minimal or unrecognized irritation." The disease was referred to in the chapter on Tumors (p. 114); it

appears to occupy a place midway between the infectious granulomas and pure tumors. Sometimes it resembles tuberculosis of lymph nodes (tuberculous infection may be secondary), at others it approaches lymphosarcoma in type. A number of observers have found in the affected lymph nodes a Gram-staining, non-acid-fast, polymorphous diphtheroid bacillus.

Symptoms.—It affects young adults, especially males, becoming conspicuous first in the neck, as a diffuse, bilateral, hyperplastic lymphatic enlargement (Fig. 236). The axillary, inguinal, abdominal, and thoracic nodes are subsequently affected; even the spleen becomes enlarged. The masses are not inflammatory in character; do not adhere to the skin; the individual nodes remain discrete a long time; suppuration is unknown; enlargement is progressive, though temporary remissions may occur. Severe anemia accompanies the disease; the patient is feverish, listless, becomes dyspneic, weak, emaciated, and dropsical. There is no hyperleukocytosis, the only marked blood change being reduction in the amount of hemoglobin. The most distressing symptoms are those due to pressure of the immense masses in the neck and mediastinum, and it is for such effects only that surgical *treatment*, consisting in excision, is demanded. The disease tends under all circumstances to a fatal termination, the duration in most cases being measured by months rather than years. Excision of portions of the mass for diagnosis and prognosis often is done, as the lesions present a typical histological picture—endothelial proliferation, giant and eosinophile cells. Treatment by vaccines made from the bacillus mentioned above has been attempted by Billings and Rosenow (1913) with rather encouraging results.

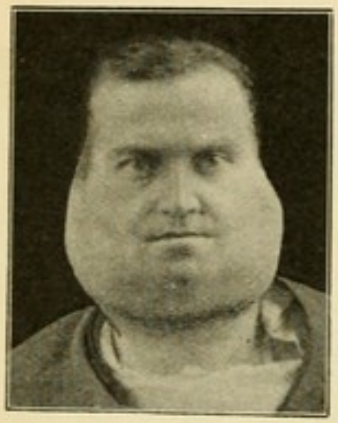

FIG. 236. — Hodgkin's disease affecting the neck and both axillæ. (Dr. J. Ashhurst, Jr.'s case.) University Hospital.

Lymphosarcoma.—Lymphosarcoma was referred to at p. 114. Theoretically we may distinguish (1) True Lymphosarcoma, from sarcomatous proliferation of the connective tissue cells of a lymph node; (2) Malignant Lymphoma, from malignant proliferation of lymphocytes in the lymph node; and (3) Lymphoma Sarcomatodes, indicating secondary (anaplastic) sarcomatous change in the lymphocytes of a benign lymphoma (p. 114). The distinction is difficult histologically and impossible clinically.

The disease may occur in the mediastinum or neck; tends to spread locally, to ulcerate, and to produce death by pressure, hemorrhage[1] or cachexia; internal metastases (liver, lung) may occur early, due to the invasion of veins by the original tumor; involvement of other groups of superficial lymph nodes is very unusual.

[1] The hemorrhagic sloughing ulceration constitutes one form of the Fungus Hematodes of the older writers.

Diagnosis.—Diagnosis is difficult: it may be distinguished from Hodgkin's disease by the rapid growth (weeks rather than months), the unilateral rather than bilateral involvement, the tendency to ulceration, and the persistently local character until the last stages; from *tuberculosis of lymph nodes* by the greater firmness, and absence of caseation and suppuration even when ulceration has occurred. *Treatment* is of little avail; excision should be attempted, especially to relieve pressure effects; but complete removal is difficult and recurrence usually is prompt.

Carcinoma of Lymph Nodes is secondary to a primary focus elsewhere. So-called primary carcinoma of lymph nodes really is an endothelioma.

INJURIES AND DISEASES OF MUSCLES.

Wounds of Muscles —Little more need be said of these than what is contained in the discussion of wounds in general (p. 165). Sutures do not hold very firmly in muscular tissue alone; therefore mattress sutures are used, and in the case of transverse division of the muscular fibres the overlying fascia (muscular sheath) is included in the sutures when possible. The cicatrix formed in a muscle may somewhat impair its contractility, but the disability is slight unless the scar is adherent to the skin or bone.

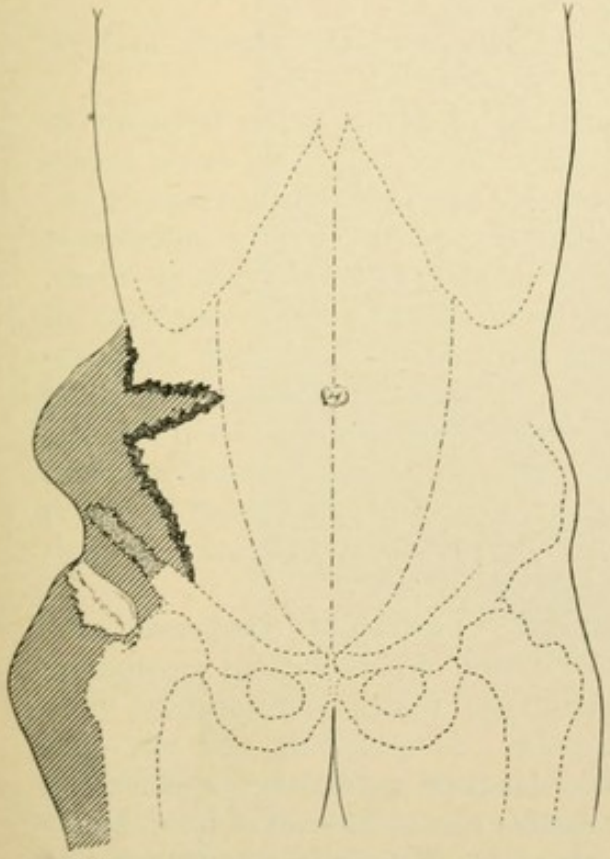

FIG. 237.—Diagram representing a case of extensive rupture of the abdominal wall complicated by fracture of the iliac crest. The shaded area indicates the extent of the resulting hematoma. (See Fig. 238.) Episcopal Hospital.

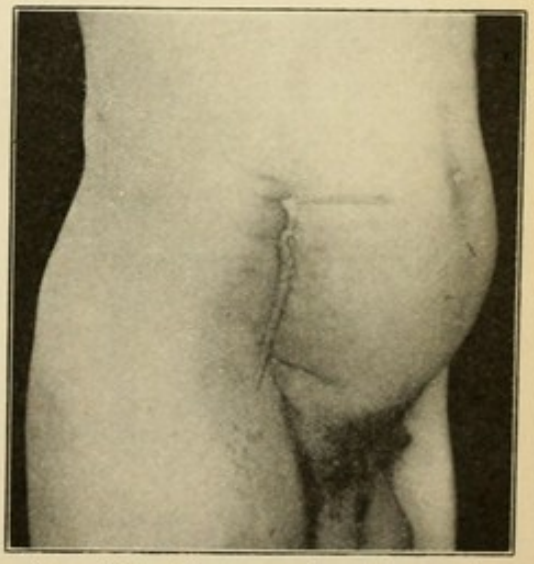

FIG. 238.—Rupture of abdominal wall and fracture of pelvis, after operation. (See Fig. 237.) Episcopal Hospital.

The *sheath of a muscle* may be ruptured by external injury (contusion) or by violent muscular contraction; the belly of the muscle, when contracted, will then protrude through the rupture, constituting a *muscular hernia*. Some forms of ventral hernia (Fig. 772) are of this nature. The *diagnosis* is based on the history of trauma and the appearance of an abnormal protrusion only when the muscle contracts; sometimes when the muscle is relaxed the aperture in its sheath is palpable. The condition may be simulated by an intermuscular lipoma. *Treatment* consists in suture of the rent.

Rupture of a Muscle, much rarer than rupture of its tendon (p. 278), usually results from violent muscular contraction, without external injury. The abdominal muscles, however, may be ruptured subcutaneously by a crushing accident (Fig. 237). The lesion is subcutaneous, and when due to muscular action alone occurs oftenest in patients with rheumatic or fibrotic tendencies. When a long muscle, such as the biceps brachii or quadriceps femoris, is affected, there is a distinct hollow perceptible between the retracted ends, and this becomes more evident during voluntary contraction. Functional impairment may be marked.

Treatment.—Treatment consists in suture of the muscle and its sheath.

Myositis.—Myositis, or inflammation of a muscle, is frequent in rheumatism and as the result of contusions. Septic myositis occurs by invasion from a neighboring focus (bone, joint, lymph node), or as a metastatic infection; it also follows typhoid fever. In such cases the ordinary symptoms of inflammation are present, and suppuration, with extrusion of sloughs (*necrotic masses*, p. 58), is the rule. In traumatic myositis the muscle becomes swollen, painful, tender, and of almost wooden hardness (Fig. 239). Suppuration is very unusual.

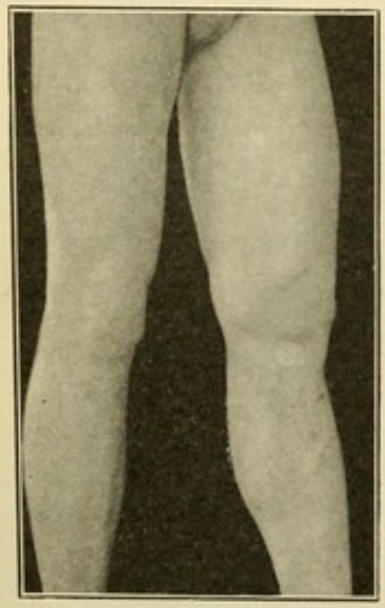

FIG. 239.—Myositis of left quadriceps femoris; unknown cause; duration, five weeks. Aged fifty-three years. Episcopal Hospital.

Treatment.—Treatment comprises rest, with application of sorbefacient ointments; anti-rheumatic remedies internally may relieve pain. Acupuncture and wet cupping may be tried. Massage is beneficial when acute symptoms subside. Metastatic abscesses in muscle require prompt evacuation.

Myositis Ossificans occurs in two forms, the stationary and the progressive.

1. **Myositis Ossificans Traumatica,** the stationary form, is due to injury, usually following sprains, luxations, repeated slight contusions, etc. If small fragments of periosteum have been detached, it is possible that these may cause bony growth in the muscles or tendons

surrounding a joint; but it is held by some that the muscle cells themselves or those of the perimysium may produce bone. The disease occurs in the adductor muscle of the thigh ("rider's bone"), in the deltoid from shouldering a musket, in the brachialis anticus (Fig. 240) following dislocation of the elbow, in the tendo Achillis following sprains, etc. The *diagnosis* rests on a history of injury, and on the existence of a localized, tender, hard, more or less movable mass in the body of a muscle or tendon. The *x*-ray usually is necessary to confirm the diagnosis. Proper treatment is excision of the bony mass, unless this shows a tendency to retrogress spontaneously when the part is put at rest.

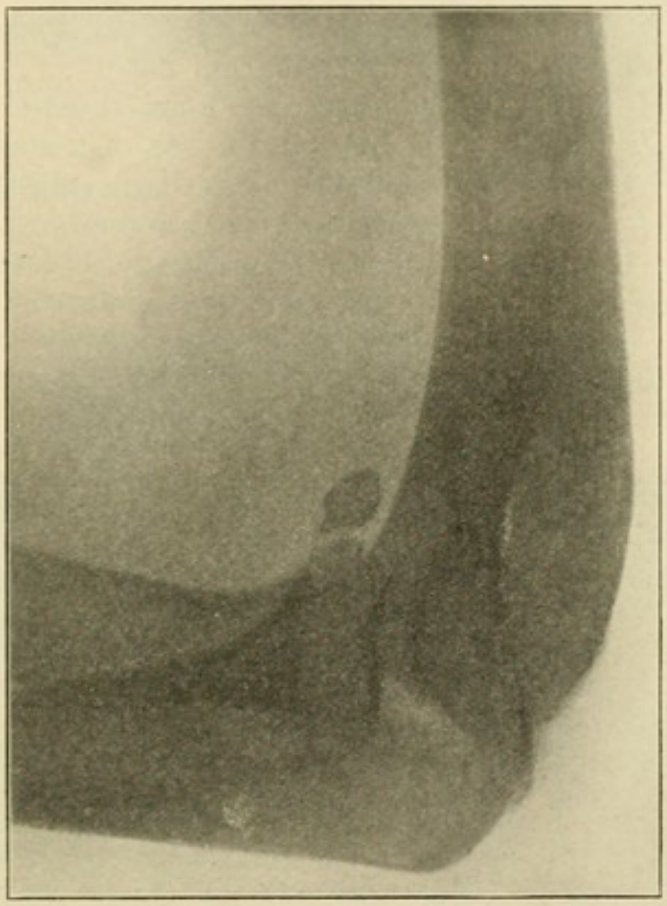

FIG. 240.—Skiagraph of myositis ossificans traumatica. New-formed bone in brachialis anticus muscle. Aged twenty-one years. Episcopal Hospital.

2. **Myositis Ossificans Progressiva** is an obscure affection, perhaps due to auto-intoxication, beginning in the first ten years of life and progressing slowly "with intervals of quiet, death occurring in ten or twelve years—either from some intercurrent disease, especially bronchopneumonia, or from inanition due to involvement of the masseter muscles." (W. Walker, 1908.) The thumbs and great toes usually have a congenital deformity (*microdactylia*) consisting in shortening of the metacarpal or metatarsal bones, sometimes with ankylosis of the phalanges (Fig. 241). The muscles oftenest affected are in the trunk, the upper extremity, and the neck, especially the tra-

pezius, latissimus dorsi, sterno-mastoid, and shoulder muscles (Fig. 242). The disease begins with soreness and stiffness in the affected muscles, attended by local cyanosis and doughiness. After weeks or months another exacerbation occurs, and finally bony masses become palpable and demonstrable by the *x*-ray. No treatment has been of any avail.

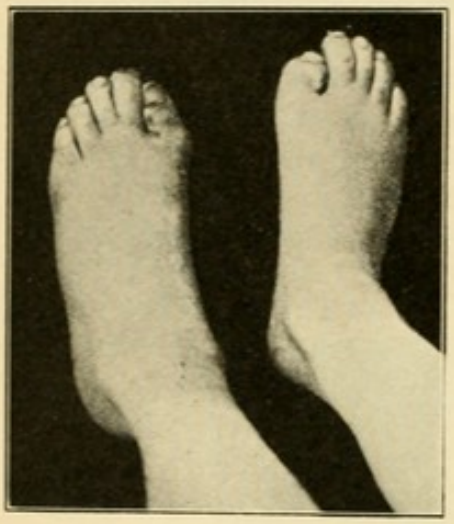

FIG. 241. — Microdactylia in a case of myositis ossificans progressiva. (Dr. Warren Walker's case.) Children's Hospital.

Contractures of Muscles resulting in limitation of articular motion (false ankylosis), follow rheumatic, gouty, or other inflammations, but are of special interest to surgeons in cases of infantile palsy or patients with bone and joint disease. Weight extension, the use of a Stromeyer splint, elastic traction, massage, passive motion, etc., sometimes are efficient in overcoming the deformtiy, but not infrequently mobilization under anesthesia, or myotomy and tenotomy are required. If the joint capsule is the seat of contracture it may have to be incised also. (See Figs. 243 and 244.)

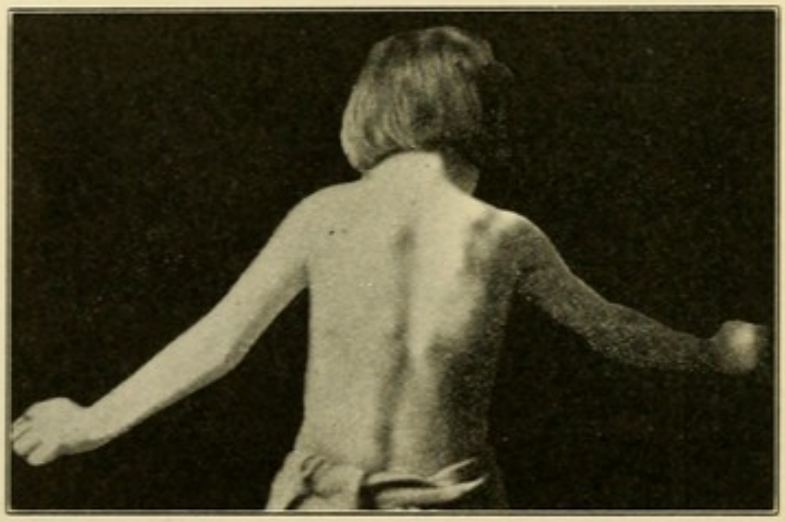

FIG. 242.—Myositis ossificans progressiva showing deposits in muscles of back. (Dr. Warren Walker's case.) Children's Hospital.

Ischemic Contracture (see p. 540).

Trichiniasis.—Ingestion of the embryos of *trichina spiralis*, a parasite infesting uncooked pork, is followed by their migration to and development in the muscular tissues. Within a week or ten days after eating the contaminated food, the patient is attacked with muscular soreness, widely distributed, which frequently is regarded as rheumatic. Diarrhea often is present, and fever is usual. Examination of the blood shows eosinophilia (even as high as 50

per cent.). Microscopical examination of excised muscular tissue confirms the diagnosis. Beyond purgation, treatment is of little value; and the duration of the disease appears to be self limited to a few weeks.

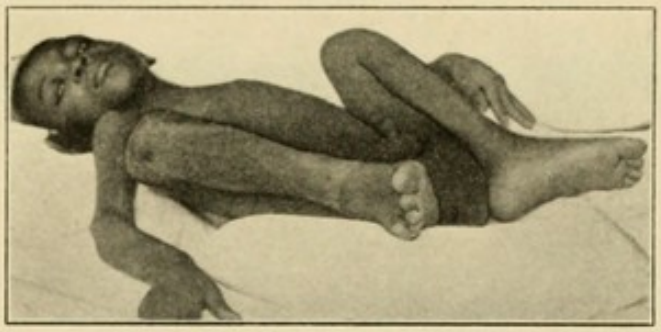

FIG. 243.—Contractures of ilio-psoas muscles following neglected case of Pott's disease of spine. Children's Hospital.

Tumors of Muscles.—*Rhabdomyoma* and *leiomyoma* have been discussed at p. 114. *Desmoids* are tumors growing from muscle or fascia, usually of the abdominal wall, analogous to keloids in the

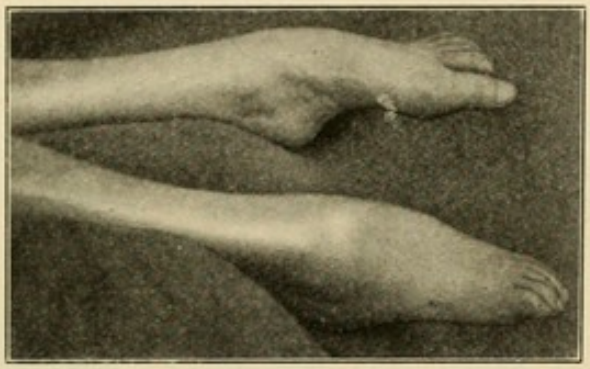

FIG. 244.—Contractures of feet, following paralysis of extensor muscles from fracture of tenth and eleventh thoracic vertebræ, five years previously. Episcopal Hospital.

skin. They usually are single, oftenest arise after pregnancy or in an operative cicatrix, and sometimes recur after extirpation, assuming sarcomatous characteristics.

INJURIES AND DISEASES OF TENDONS.

Wounds of Tendons.—Wounds of tendons are of frequent occurrence, and often are followed by marked disability, owing to adhesion of the tendons to their sheaths, to each other, to the skin, to bone, etc., even if careful primary suture has been done. Tendons retract when divided, and the surgeon must not hesitate to enlarge the original wound to find the divided ends. Usually it is better to administer a general anesthetic, especially in wounds of the flexor tendons above the wrist. Mattress sutures are preferable, and if the ends cannot be made to meet, tendon lengthening may be employed (Fig. 264).

Subcutaneous Rupture of Tendons is more frequent than that of their muscular bellies. Usually it occurs only in already slightly diseased tissues, especially in cases of periarthritis (p. 466), dystrophic arthritis, etc. Following a sudden strain, the patient is conscious of something giving way, perhaps with an audible snap; severe

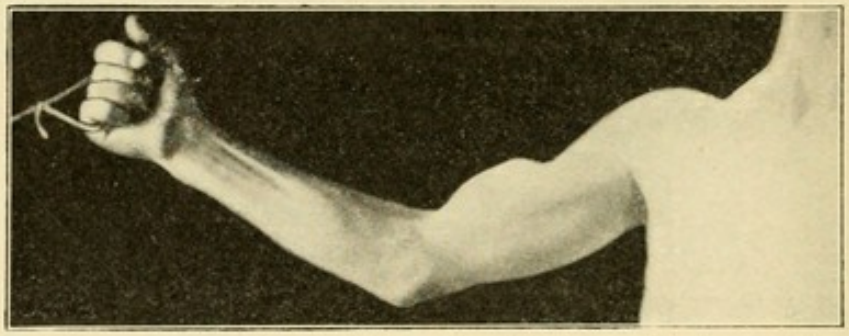

FIG. 245.—Rupture of long head of biceps brachii, forty-eight hours after accident, from violent contraction while leading unruly horse by halter. Dr. G. G. Davis's case. Orthopædic Hospital.

stinging pain occurs, and the part is disabled. Ecchymosis appears subsequently, and when the affected muscle is voluntarily contracted, a characteristic deformity is seen, owing to the loss of attachment of the tendon. The biceps brachii, especially its long scapular head, (Fig. 245), and the quadriceps femoris are often affected; rupture of one of the tendons of the extensor longus digitorum near its insertion in the finger is not unusual (Fig. 246). So-called rupture of the plantaris probably is not as frequent as supposed (p. 243). In the phalanges, firm bandaging on a splint for several weeks may prevent permanent deformity or disability; in other cases the affected tendon should be sutured.

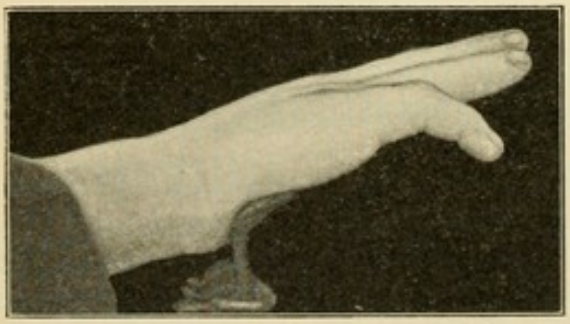

FIG. 246.—Rupture of tendon of extensor longus digitorum to fifth finger; from fall on hand two months ago. Episcopal Hospital.

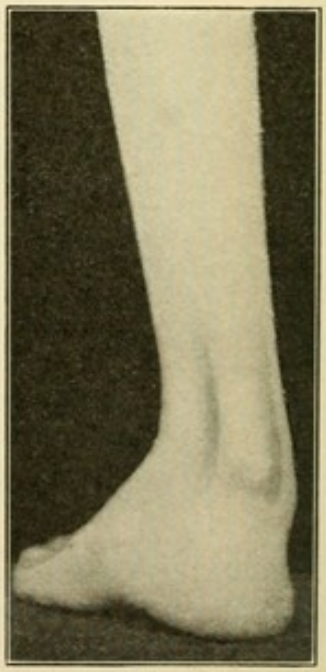

FIG. 247.—Luxation of peroneal tendons in front of external malleolus of left foot, following paralytic calcaneus. Orthopædic Hospital.

Dislocation of Tendons may be pathological or traumatic. The former is more frequent, and is secondary to changes in the contour of the neighboring joints, or to peri-arthritic lesions causing obliter-

ation of the natural groove in which the tendon lies. In cases of infantile paralysis with marked calcaneus deformity the *peroneal tendons* may be luxated anterior to the external malleolus (Fig. 247); in cases of knock-knee or simple relaxation of tissues around the knee-joint, *outward luxation of the patella* may occur; in peri-arthritis of the shoulder, *inward dislocation of the long head of the biceps* sometimes is seen, allowing a subluxation forward of the head of the humerus. These deformities may be remedied by operation if disability is marked. Correction of any predisposing deformity is the first step. In the case of the patella a suitable knee-cap may give relief, or the inner portion of the capsule may be pleated on itself, or the point of insertion of the tendo patellæ may be shifted inward. The capsule of the shoulder may be pleated, and the biceps tendon shortened.

Strains of Tendons are of frequent occurrence. Minute extravasations occur among the ruptured fibres, and the tendon is swollen, painful, and tender. Schanz (1905) has called particular attention to traumatic inflammation of the tendo Achillis, which often is mistaken for achillodynia (p. 267). Some cases of "trigger finger" (p. 543) may have a similar origin. The *treatment* is rest during the acute stage, followed by massage.

Tenosynovitis or Thecitis is the name given to a form of inflammation of tendon sheaths usually caused by repeated trauma (strains), in those predisposed to rheumatic conditions. It occurs oftenest in the extensor tendons at the wrist, but is also seen at the ankle, and elsewhere. There is a fine crackling and creaking, appreciable on palpation and sometimes audible, whenever the affected tendons are moved; this is caused by effusion of plastic lymph between the tendon and its sheath. The disease never progresses to the stage of suppuration.

Treatment.—Treatment consists in splinting the part and applying ointments of ichthyol or of belladonna and mercury, iodin, etc. Local rest should be insisted on until physical signs have been absent for a week at least; otherwise recurrence is usual. With prompt treatment work generally may be resumed in a few weeks.

Tuberculosis of Tendon Sheaths usually is secondary to tuberculous synovitis or arthritis (p. 477). See also Tuberculous Ganglion, p. 281.

Paronychia or Panaris.—This is a rather vague term, denoting a septic inflammation about the flexor surface of the finger tips (very rarely of the toes). (1) *Digital Abscess:* The mildest form is an abscess in the pulp of the finger, not involving tendon or bone. Incision in the long axis of the finger evacuates the pus and leads to rapid healing. (2) If the tendon sheath is involved the affection is known as *whitlow*. In the thumb and fifth finger such inflammation (arising from a pin prick, abrasion, hangnail, run-around (p. 260), etc.), may spread readily to the palmar bursa, with which the sheaths of these tendons usually are continuous, forming *palmar abscess* (Fig. 248). The finger tip becomes extremely painful, tender, throb-

bing, and swollen. The patient spends a sleepless night; poultices bring little relief; inflammation spreads up the tendon sheath, and the whole finger is swollen to two or three times its natural size. Occasionally a whitlow will evacuate itself if poulticed long enough (Fig. 249), but proper treatment consists in very early free incision,

FIG. 248.—Palmar abscess; duration, one week; showing ineffectual incisions made three days ago. Episcopal Hospital.

FIG. 249.—Whitlow; spontaneous rupture; duration, eleven days; untreated. Children's Hospital.

into the tendon sheath, and the application of hot moist antiseptic dressings, with suitable splint and sling. At later stages local or general anesthesia may be necessary, with numerous counter-openings and tube drainage, or antiseptic irrigation. After proper incisions, the continuous bath is especially useful. Only when incision is done at the earliest stage can sloughing of the tendon be prevented: the tendon receives its vascular supply through delicate reflections of the synovia, and very slight swelling within the tendon sheath is sufficient to obliterate this circulation. If the tendon sloughs the incision will be

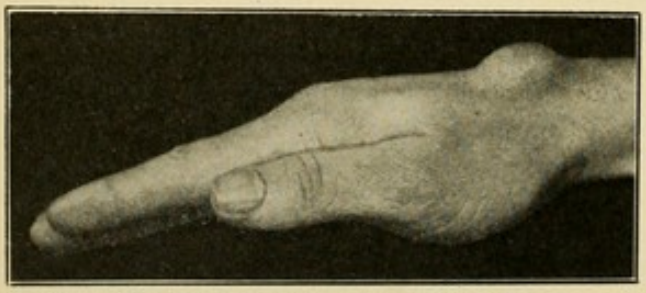

FIG. 250.—Ganglion on extensor surface of wrist (see Fig. 251). Episcopal Hospital.

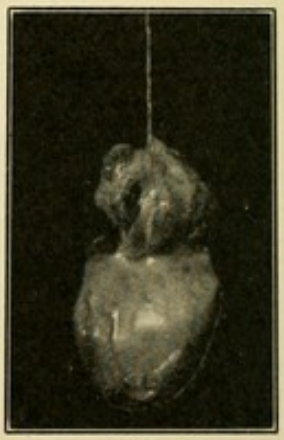

FIG. 251.—Bilocular ganglion excised from wrist (see Fig. 250). Episcopal Hospital.

slow in healing, and a stiff finger will result. Healing of a chronic sinus sometimes may be hastened by dressing it with mercurial ointment. (3) If the periosteum or phalanx is involved, the disease is known as a *bone felon*, but as the distinction from whitlow rarely can be made before incision, and as treatment is the same, there

is little use in making a separate subdivision for felons. Excision or amputation may be necessary if the phalanx becomes necrotic.

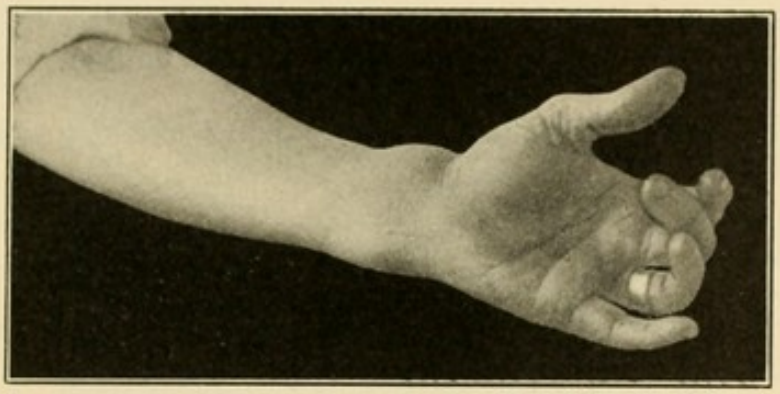

Fig. 252.—Tuberculous ganglion of right wrist and palm (hour-glass swelling). Aged forty-two years; duration, five years. Orthopædic Hospital.

Ganglion.—A ganglion is a cyst developed in connection with a tendon sheath, or from the subsynovial tissues of a joint capsule. Its pathogenesis is not well understood, but probably is a degenerative change (Clarke, 1908). Frequently slight trauma has occurred, but often no such history can be obtained. Ganglia occur oftenest in women, being especially frequent on the extensor surface of the wrist (Fig. 250); they are seen less often at the ankle or in the palm of the hand (Fig. 252) and certain bursal enlargements seem clinically identical with ganglia (Figs. 230 and 253). Occasionally a ganglion contains rice-like bodies, similar to "joint-mice" (p. 478); and sometimes a ganglion is frankly tuberculous; this is especially apt to be the case in "compound ganglia," where the cystic mass is more or less lobulated, possibly as the result of the coalescence of several distinct ganglia.

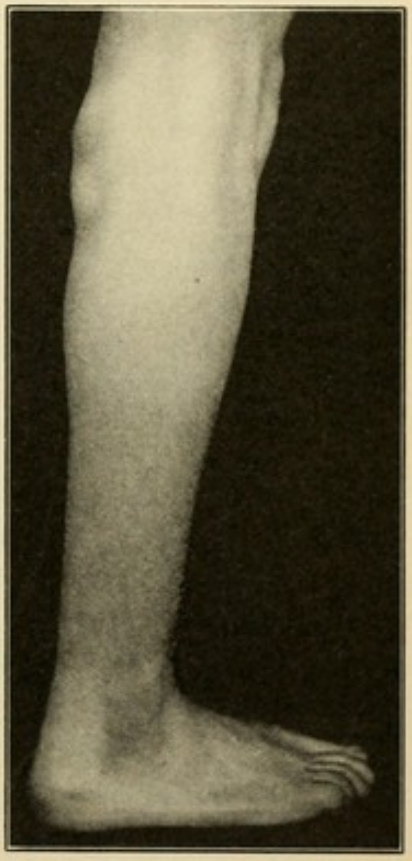

Fig. 253.—Ganglia in popliteal space; aged eighteen years; duration, over one year. Episcopal Hospital.

Treatment.—If operative treatment is refused, a small ganglion may be dispersed by a smart blow with a heavy book, the part being splinted subsequently for a week or so; recurrences may be expected in over half the cases so treated. Safer and better treatment is aspiration and injection of 2 per cent. formalin glycerin solution or of dilute iodin or alcohol; or formal excision of the ganglion. Tuberculous ganglia never should be treated by attempts at rupture.

INJURIES AND DISEASES OF NERVES.

Contusion.—Contusion of a nerve produces tingling and perhaps numbness or paralysis in its distribution. A frequent lesion is paralysis of the musculo-spiral nerve (less often of the circumflex) from pressure

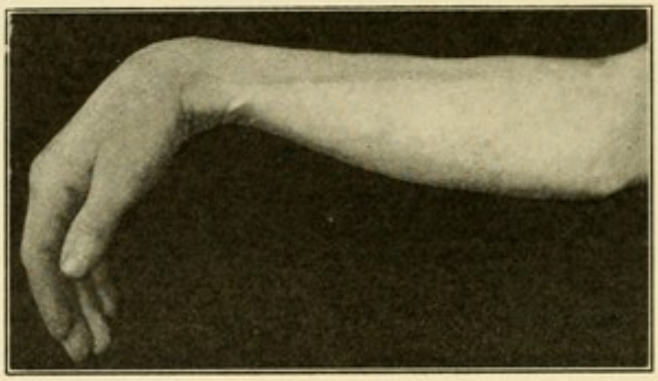

Fig. 254.—Paralysis of musculo-spiral nerve from overlying.

during sleep (*overlying*)—most seen after a debauch, the patient having lain stuporous for many hours (Fig. 254). In other cases the lesion results from a sudden blow or fall, perhaps from sudden abduction of the humerus (Fig. 255). *Crutch-palsy*, affecting the axillary nerves, especially the musculo-spiral, is caused by the patient bearing most of his weight on the axilla instead of on his hands, usually because the hand-bars of the crutches are placed too low. *Post-anesthetic palsy* is due to direct pressure, the arm having been allowed to hang over the edge of the table (musculo-spiral, ulnar); or from pressure on the peroneal nerve below the head of the fibula. This latter form of paralysis may result from improper application of a gypsum case. As a rule, the only treatment required is rest, followed by massage, electricity, etc. Subcutaneous *rupture* is extremely rare, but in compound fractures or similar accidents a nerve may be *crushed*, complete destruction of the nerve fibres occurring, and only the sheath remaining to connect the bruised ends of the nerve. The signs of loss of function due to such nerve injuries usually are subordinate

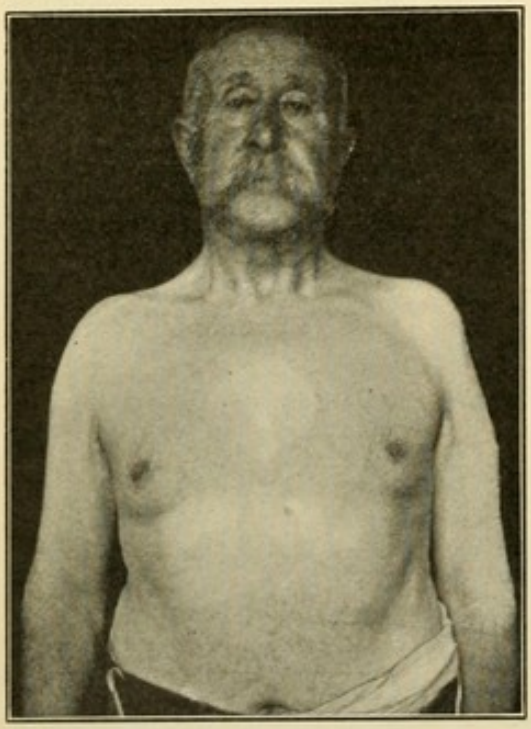

Fig. 255.—Paralysis of left circumflex nerve with atrophy of deltoid muscle, from sprain of shoulder five months ago. Patient, aged sixty years, fell twenty-seven feet. Episcopal Hospital.

to those due to the lesions of the muscles, tendons, and bones; but in all such accidents the surgeon should make tests for sensation and motion in the part supplied by any nerves which possibly might have been injured. Resection of the damaged portion, with end-to-end union of the nerve stumps should be done, as described under *Wounds of Nerves* (p. 284).

Dislocation.—Dislocation of a nerve is rare. Occasionally the ulnar nerve slips in front of the internal condyle, and causes moderate disability. Operation generally is necessary to replace such nerves and consists in restoring normal relations and suturing a layer of fascia over the nerve to hold it in place.

Stretching or Laceration.—Stretching or laceration of nerves is not infrequent as a subcutaneous injury In dislocations or sprains of the shoulder the circumflex, and more rarely the musculo-spiral nerve, may thus be damaged; or rarely the cords of the brachial plexus may be injured. (See also Neuritis, p. 287, and Periarthritis, p. 466.) According to Vandenbossche (1910) it is probable that in most of these latter cases the lesion is in the nerve roots rather than in the brachial plexus. Duval and Guillain (1898) maintained that there were no such clinical entities as paralyses due to lesions of the plexus, only two types existing, *radicular* and *terminal*, affecting either the spinal motor roots or the nerve trunks below the plexus. The usual cause of obstetrical palsy (brachial birth palsy) is either direct pressure on the plexus by forceps in delivery (rare), or stretching and laceration from attempts to deliver a shoulder by injudicious traction on the head, or in delivery of the after-coming head. The usual deformity is characteristic (Fig. 256), due to paralysis of the external rotator muscles; the hand is little affected, but supination and flexion of the forearm are imperfect or entirely absent. This corresponds to the "upper arm" type (Duchenne-Erb) of brachial paralysis, the lesion being in the outer cord (*i. e.*, fifth and sixth cervical nerves) of the brachial plexus, involving especially the suprascapular and musculo-cutaneous nerves (Fig. 636). The "lower arm" type and paralysis of the entire extremity are rare. T. T. Thomas (1914) contends that in most of these cases the nerve injury is secondary to joint damage, and that treatment of the latter is the main indication (see also Congenital Dislocation of the Shoulder, p. 513). In brachial palsy the *prognosis* is not very good, some disability usually persisting throughout

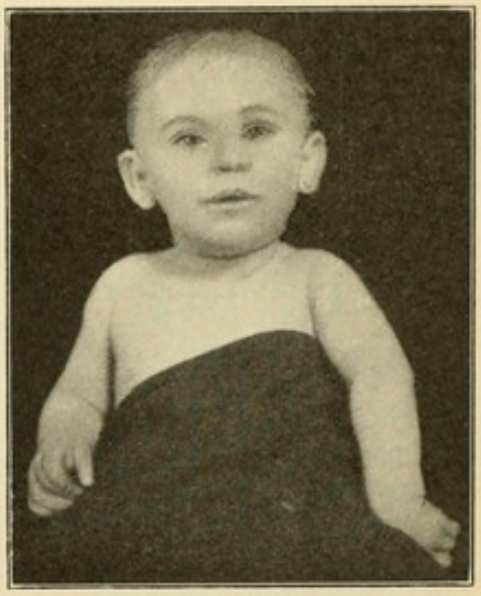

FIG. 256.—Brachial birth palsy of the left arm, in a boy aged seventeen months. Typical posture. Orthopædic Hospital.

life, no matter what the treatment. Rupture of the nerve sheaths occurs first, and there is more or less laceration of the nerve fibres themselves; intra- and peri-neural hemorrhage occurs, with marked cicatricial changes in the plexus and overlying cervical fascia. *Treatment.* After a period of rest, until acute symptoms subside, strychnin should be administered, and efforts made to improve the nutrition of the muscles by massage, electricity, baths, etc. Should no further improvement occur in six months or a year, operation must be considered. A. S. Taylor (1913) urges exploratory operation as soon after birth as the general condition of the infant warrants; but his results do not encourage imitation when it is remembered what great improvement usually follows conservative treatment. After exposing the plexus, it is dissected free from the cicatricial adhesions, irretrievably damaged segments of nerve tissue are excised, and the stumps reunited or implanted into another nerve as described below (p. 286). Alexinsky (1899) proposed transplanting the peripheral ends of the damaged nerve roots to the opposite side of the neck, and uniting them to the central ends on the other side; a similar operation has been done by Babcock (1907), in a case of anterior poliomyelitis. Muscle and tendon transplantation often will give better results than any operations on the nerves.

Wounds of Nerves.—These may be an incident in extensive lacerated wounds involving muscles, tendons and bloodvessels; or isolated injuries due to stab wounds (Fig. 257). The *symptoms* are complete loss of function in the distribution of the injured nerve; usually this implies loss of both motion and sensation. If only a peripheral sensory nerve is divided, sensation may return in time, even if the ends of the nerve are not sutured; this is due in part to regeneration, and in part to collateral circulation, as it were, in surrounding nerve filaments. But unless the ends of a motor nerve are brought into accurate apposition by suture, paralysis of motion will be permanent. After suture, the *prognosis* is uncertain, though if suture is done soon after the accident (*primary suture*) more or less complete recovery is the rule (Figs. 258 and 259); after *secondary suture* the results are very uncertain (Figs. 260 and 261).

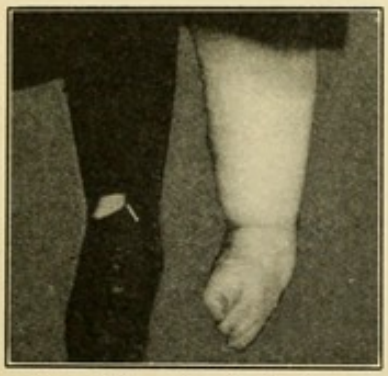

Fig. 257.—Paralysis of peroneal nerve following injury of cauda equina in spinal anesthesia; seventeen months' duration. Orthopædic Hospital.

Howell (1892) collected 84 cases of primary nerve suture, with 42 per cent. successful results, and 40 per cent. improved; and 80 cases of secondary suture, with 38 per cent. successful, and 50 per cent. improved.

Treatment.—The nerve should be exposed, and all damaged tissue excised with a sharp knife. The cicatricial tissue must be excised until the projecting ends of the nerve fibres can be seen in the cross-section.

Scissors bruise nerves, and never should be used. The ends are then united (neurorrhaphy) with very fine silk or chromic catgut threaded

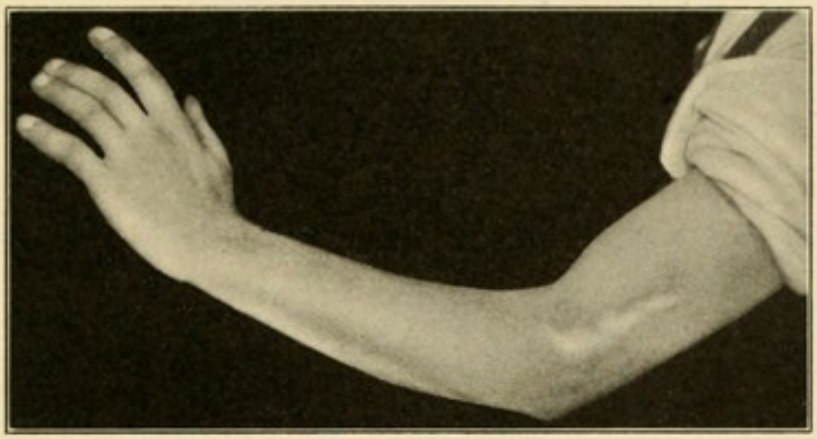

Fig. 258.—Recovery after primary suture of musculospiral nerve, for stab wound. Episcopal Hospital.

in ophthalmic needles. The sutures, some of which should be of the mattress type, pass directly through the nerve, and are tied just

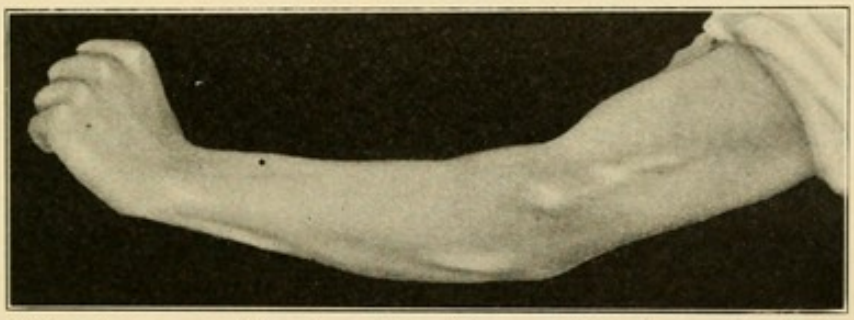

Fig. 259.—Recovery of function after primary suture of musculospiral nerve for stab wound. Episcopal Hospital.

tight enough to approximate without constricting the ends; a few guy sutures should then be applied merely through the nerve sheath,

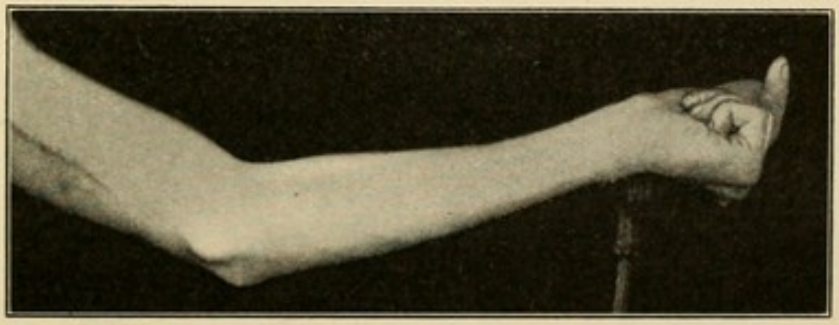

Fig. 260.—Stab wound of median nerve just after operation of secondary suture (three months after injury); showing inability to flex wrist, index finger, and thumb (see Fig. 261). (Dr. Harte's case.) Orthopædic Hospital.

to relieve strain, and prevent adhesions of the nerve fibres to surrounding structures (Fig. 262). If for any reason, the ends of the nerves cannot be made to meet (even by nerve-stretching and flexing neighbor-

ing joints), both ends may be implanted into a neighboring nerve trunk (*nerve anastomosis*) (Fig. 263), or *neuroplasty* may be done (Fig. 264). A layer of muscle should then be sutured over the nerve, to prevent adhesion to the skin; the wound should be closed; and the limb kept at rest for two or three weeks, when light massage, electro-therapy, etc.,

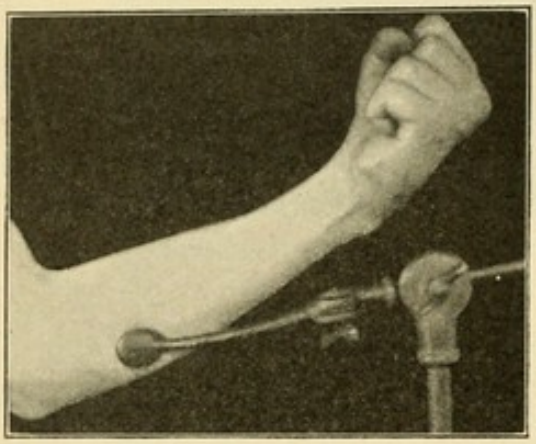

Fig. 261. — Recovery of function eight months after secondary suture of median nerve (see Fig. 260). Note power of flexing wrist, index finger, and thumb. (Dr. Harte's case.) Orthopædic Hospital.

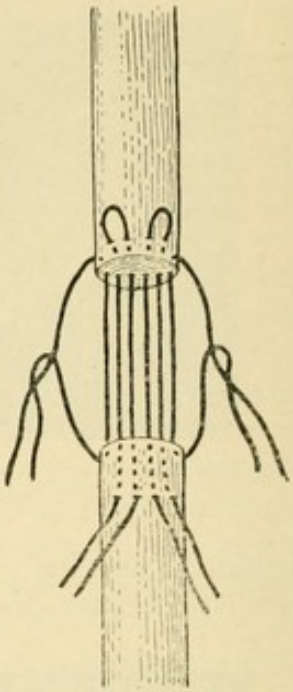

Fig. 262. — Nerve suture. Two mattress sutures have been inserted, passing into the nerve substance, and two sutures including only the sheath.

may be commenced. Sensation returns long before motion, sometimes within a few days; but hope of motion should not be abandoned

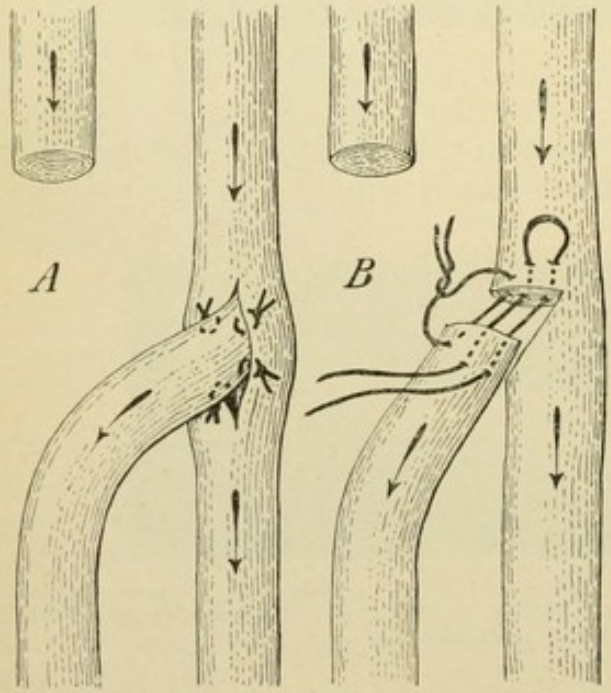

Fig. 263.—Nerve anastomosis. *A*, the distal segment of the wounded nerve is sutured into a slit in a neighboring nerve; *B*, it is implanted in a wedge-shaped incision.

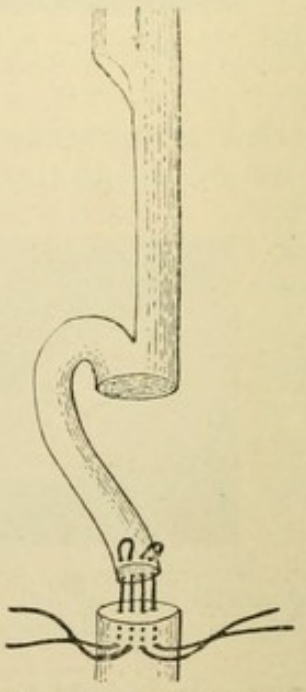

Fig. 264. — Neuroplasty. The proximal segment is split and a flap is turned down and sutured to the distal segment.

for about a year after suture, unless, of course, it can be shown that the sutures have given way. Under such circumstances the operation may be done over again. In all cases development of deformity must be prevented by splints, braces, passive motion, etc. *Regeneration* of sutured nerves depends on the formation of new axones, which some hold develop from proliferation of neurilemma cells in the peripheral segment, while others maintain that in all cases the axones grow out from the central segment, and have to penetrate the distal segment to its various terminations before function is restored. At present the weight of evidence appears to be in favor of those upholding the former view (Ballance and Stewart, 1901), and it is this teaching which justifies us in urging late secondary suture; the axone is there, merely waiting to be joined to the central segment. So long as the muscles have not become hopelessly degenerated, nerve suture may be successful (after fourteen years, Jacobson). Nerves which have no neurilemma do not regenerate; the nerves of special sense have no neurilemma; nor have the spinal nerves except peripheral to the spinal ganglia.

Neuritis.—Neuritis, as the term usually is understood, implies not a reaction to septic infection, but a form of subacute or chronic inflammation due to contusion, to pressure (from cicatrices, callus, exostoses, tumors, etc.), to recurrent trauma (*occupation neuritis*), to toxic infections (influenza, typhoid fever, etc.), intoxicants (alcohol, lead, etc.), and other less well defined causes. The pathological change is proliferation of the nerve sheath (epineurium, perineurium, and endoneurium), which compresses the nerve fibres (axones), leading to pain, impairment of function, and various trophic disturbances in the distribution of the affected nerve. The nerve trunk is hyperemic, perhaps edematous, swollen, and bulbous. Perineural adhesions are frequently present.

Symptoms.—The onset may be sudden, after exposure to cold, after violent exertions, or any factor which reduces the patient's vitality. Pain is present in the portion of the nerve diseased, and also shoots along the course of this nerve, usually in a peripheral but sometimes in a central direction. There is tenderness along the course of the nerve, and cutaneous hyperesthesia may be very marked; numbness and a sense of swelling (vaso-motor or trophic disturbances) may be present in the area of distribution. The skin becomes glossy, appears tense and hyperemic; sweating usually is diminished; incurvation or shedding of the nails may occur (Fig. 265); the muscles become atrophic and contractures and reactions of degeneration may develop.

The nerve trunks most often affected are those of the *brachial plexus*, the *musculo-spiral*, *ulnar*, and *median*, and the *sciatic*. It must be remembered that the neuritis may be only a symptom of another affection (periarthritis of the shoulder, p. 466; ischemic contracture, p. 540; sacro-iliac or hip-joint disease, p. 536; etc.).

Treatment.—Treatment comprises, first and foremost, removal of the cause, whenever this can be discovered (callus, tumor, cicatrix, etc.). In all cases *rest* is of utmost importance, and should always be the first step when no obvious cause exists. Counter-irritation sometimes is of value. The patient's general health should be improved. Antiseptics may be administered internally, especially the salicylates. Electro-therapeusis, massage, and baking, are suitable only for the chronic stages, after rest has allayed the acuter symptoms. In many cases operation is of benefit (Fig. 266), especially *neurolysis* (dissection of the nerve trunk and even dissociation of its fibres); *neurectasy* (nerve-stretching) is a less certain operation, though aiming to accomplish the same results; *neurotomy* and *neurectomy* (except when purely sensory branches are involved) seldom are justifiable until other operations have failed.

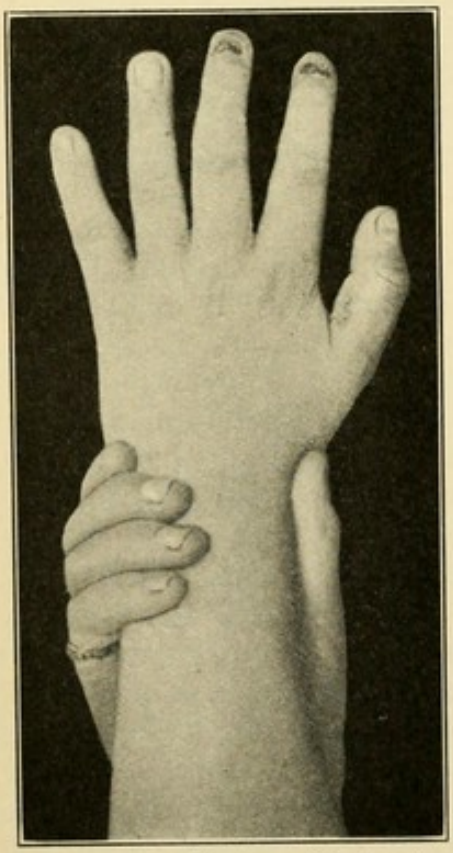

Fig. 265.—Photograph showing trophic changes in finger nails as a result of neuritis of median nerve. January 31, 1907. Episcopal Hospital.

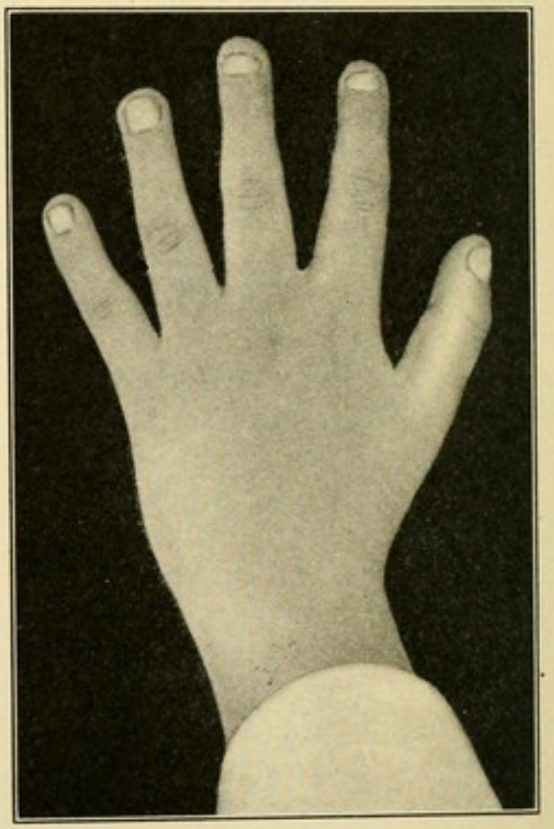

Fig. 266.—Photograph made eight weeks after operation, to show improvements in finger nails. (See Fig. 265.) Episcopal Hospital.

Neuralgia.—Neuralgia, signifying pain in a nerve for which no pathological lesion can be held accountable, remains an inscrutable problem; and to state, as is often done, that such changes as may be found on microscopical examination of the affected nerve are the result, not the cause of the disease, in no way renders the subject easier to understand. In a word, neuralgia is held to be a functional

neurosis. Many cases of supposed neuralgia, however, will be found on careful investigation to be due to *referred pain* from definite lesions elsewhere. Many are really cases of neuritis.

Symptoms.—Its symptoms differ somewhat from those of neuritis; the pain is equally great, but may come and go without apparent cause; it is more burning and aching than sharp and shooting in character; is more influenced by damp weather and exposure to cold; and may be unattended with actual changes in the overlying tissues, which are common in neuritis. The *tenderness* does not extend over the entire course of the affected nerve, but is most intense at certain points ("points douloureux,") especially where the nerve passes through a foramen (intervertebral, supra-orbital, mental, etc.), or through the deep fascia; and pressure on the nerve with the palm of the hand relieves rather than aggravates the pain, though pressure by the finger tip or pointed instrument may bring on an exacerbation of pain.

Treatment.—Treatment is much the same as for neuritis, which often can be excluded from the diagnosis only after prolonged rest has failed to give relief. Injections of cocain, alcohol, osmic acid (1 per cent.), and other substances into or around the nerve have been adopted in many cases with varying results (p. 290). Neurectasis, neurolysis, and even neurotomy and neurectomy may be done.

The forms of neuralgia most important to the surgeon are: Neuralgia of the fifth cranial nerve; Brachial Neuralgia (which has been sufficiently discussed under the heading Neuritis); and Sciatic Neuralgia.

Neuralgia of the Fifth Cranial Nerve; Tri-Facial Neuralgia or Tic Douloureux.—The pathology of this affection is very little understood. Two types are recognized: the *minor neuralgia*, and the *major* or *epileptiform neuralgia*. In the former, which probably is a true neuralgia, there is more or less continuous pain, but it is not excessively severe; usually some local or constitutional cause can be found, and on remedying this the neuralgia may stop for a time or permanently. Among such causes are caries of the teeth, sinus diseases, malaria, lead poisoning, chronic nephritis, gout, etc. The major neuralgias, on the contrary, appear to be due to some central lesion which involves the Gasserian ganglion either primarily or by extension from disease of its branches, or possibly by pressure from some intracranial growth. This form of the disease is characterized by progressively severer attacks of neuralgic pain, extending over months or years and affecting one or more branches of the fifth cranial nerve, with no discoverable cause. The mandibular and maxillary divisions are affected in most cases; the supra-orbital branch rarely is affected alone. The attacks may be brought on by a draft of air, by touching the side of the face affected, by putting food into the mouth, etc. The skin may become so hyperesthetic that for weeks or months the patient may be unable to wash his face; he may be unable to eat because of

pain aroused in the lingual and inferior dental nerves; and a state bordering on insanity may ensue finally unless relief is obtained.

Treatment.—It should be ascertained whether any local or constitutional cause for the neuralgia exists; and such conditions should receive appropriate treatment. If the disease belongs to the major neuralgia type no treatment will be of long avail unless it acts directly on the nerves or ganglion itself. The administration of salicylates, quinin, opium, or other drugs may be useful to allay the pain temporarily and thus improve the general health before surgical treatment is undertaken. This treatment implies destruction of the nerves or the ganglion, or both. The operations are divided into *extracranial* or *peripheral operations* and *intracranial operations.*

Peripheral Operations.—*Injection of the nerve trunks with alcohol* (Schlösser, 1907) has entirely superseded injections with osmic acid, as originally advocated by Bennet in 1897. These substances, especially alcohol, destroy the nerve at the point of injection, and though regeneration may take place relief is secured for from six to eighteen months, rarely for longer periods. The longest period of relief secured in my own cases was just short of one year. Patrick, of Chicago, has had large experience with alcohol injections, which he makes into the second and third branches where they emerge from the base of the skull, and into the first branch at the supra-orbital foramen. He does not attempt to make deep injections into the first branch because of danger to other structures in the orbit. He uses this solution:

	Gm. or c.c.
℞—Cocain muriate	1
Alcohol	13 5
Aquæ destillatæ q. s ad	15 5

The internal maxillary artery with its branches, including the middle meningeal, is directly in the field of operation and renders deep injections hazardous. But Patrick has had no bad results on this score in 150 cases. The needle is 12 cm. long, 1.75 mm. thick, is not acutely sharp, and is provided with a stylet. To inject the second branch, the needle is inserted at the lower border of the zygoma just in front of the coronoid process of the mandible (0.5 cm. behind a perpendicular let fall from the posterior edge of the orbital process of the malar bone); while the third division is reached from a point at the lower border of the zygoma 2.5 cm. in front of its anterior root. A tingling sensation in the distribution of the nerve indicates that it has been reached. Usually the nerves must be sought for cautiously by inserting the point of the needle in different directions. The foramen rotundum lies about 5 cm., and the foramen ovale about 4 cm. from the surface. About 2 c.c. of the solution are injected into each nerve. "If the operator feels satisfied that the needle is in the nerve (he never knows it)," writes Patrick, "less is enough." No anesthetic is necessary. The injection may be repeated in a few days if the first attempt proves unsuccessful. If bleeding

occurs through the needle the stylet should be replaced and the needle left *in situ* until clotting occurs; I punctured a large branch in one case, but no bad effect was noted.

Avulsion of the Peripheral Nerves (Thiersch, 1889) is a more formidable procedure, and usually secures no longer freedom from pain. The nerves are very slowly avulsed by wrapping them around a forceps, after adequate exposure. Not more than one complete revolution of the forceps in every half minute should be made. The supra-orbital nerve is exposed at the upper margin of the orbit; the superior maxillary at the infra-orbital foramen, whence it may be followed into the antrum of Highmore and along the floor of the orbit; and the inferior dental branch is reached by trephining the angle of the mandible. The lingual nerve may be reached at the same time as the inferior dental by removing some of the ascending ramus of the mandible (G. G. Davis, 1908). These nerves may be avulsed both peripherally and centrally, from this location, but it is well to avulse also the anterior portion of the inferior dental through the mental foramen.

The second and third branches of the fifth nerve may also be approached extracranially, at the base of the skull, by various routes, involving more or less tedious and delicate operations. These methods were employed chiefly before the general adoption of Thiersch's method, when it was thought necessary to do a formal excision of as much of the nerves as possible; they are now, I believe, very properly abandoned.

Intracranial Operations.—*Extirpation of the Gasserian ganglion* was proposed by Mears, of Philadelphia, in 1884, and first performed by E. Rose in 1890. Rose employed the *pterygoid route*, trephining the base of the skull. Hartley, of New York, and Krause, of Altoona, independently in 1892 proposed the *temporal route*, and most surgeons now employ some modification of the Hartley-Krause method. Owing to the difficulty of removing the entire ganglion, from the presence of adhesions and its intimate relation with the cavernous sinus, sixth nerve, etc., many of the earlier operations were only partial excisions, and well merited the description "bloody, difficult, and dangerous," which is still applied to them by Da Costa. To simplify the operation, Abbe (1903), merely divided the second and third branches before they left the skull, and interposed a strip of rubber tissue to prevent their reunion. Spiller (1901) by a happy inspiration suggested to Frazier that *section of the sensory root* of the ganglion would amount to a physiological extirpation of it, since this root, which is devoid of neurilemma, could not on that account regenerate. This operation, as pointed out by Frazier, is easier, is attended by less hemorrhage, does not expose the cavernous sinus or sixth nerve to injury, leaves the motor root (and consequently the muscles of mastication) intact, and, finally, involves a diminished risk of keratitis, which was so prone to follow removal of the entire ganglion.

Frazier-Spiller Operation.—A flap of soft parts is turned down, care being exercised not to injure the upper branches of the facial nerve. A sufficient amount of bone is then removed from the temporal fossa, with trephine and rongeur, and the dura is raised from the base of the skull. Frazier always ligates and divides the middle meningeal artery, as it leaves the foramen spinosum. The bura covering the mandibular division of the nerve is then incised, and the ganglion exposed. If the motor root is seen, it should be separated from the sensory; this latter is then divided or avulsed. The brain is then allowed to fall back on the base of the skull, and the soft parts are closed with drainage. The mortality following the operation in the hands of skilled operators is less than 4 per cent. The chief dangers are shock, hemorrhage, and infection.

After-care.—For weeks or months after operation the eye of the same side should be most carefully protected by a shield (an automobile goggle is suggested by Frazier), as destruction of its protecting nerve supply renders the cornea exceedingly prone to trauma and infection, and many patients have lost their sight from this cause.

Sciatic Neuralgia or Sciatica.—This is not regarded as so frequent a lesion now as formerly, since it has been shown that in most cases the disease really is a neuritis, or is merely referred pain due to pelvic (Fig. 582) or hip disorders. If no cause of referred pain can be discovered, and if rest, antirheumatic drugs, counter-irritation (blistering, cauterization), and other palliative methods are ineffectual, the surgeon may be tempted to adopt operative measures, on the theory that the affection really is a neuritis, from infection or trauma, with perineural adhesions.

Neurectasis may be secured without incision by forcibly flexing the thigh on the abdomen with the knee fully extended (the patient being anesthetized); or by exposing the sciatic nerve below the gluteus maximus, either on the inner or outer side of the biceps muscle, and stretching it over the finger both centrally and peripherally; the patient lying on his face it is safe usually to employ traction sufficient just to raise the limb from the table. *Neurolysis* is a safer and more certain operation; the sheath is opened and the nerve fibres separated from it and from each other for a distance of several inches; Pers (1908) has adopted this method 47 times, and among 42 uncomplicated cases there were only three recurrences. In many cases the adhesions extend up into the sciatic notch, and the completion of the operation may be difficult. Best exposure is secured by splitting the fibres of the gluteus maximus at the level of the great sacrosciatic foramen.

Tic Convulsif or **Spasmodic Tic** is a form of neuralgia, usually not painful, characterized by constant and often severe twitching in the muscles supplied by the affected nerves. In the neck, which is its most frequent seat, it produces *spasmodic torticollis;* it also occurs in the face, the shoulder, and very rarely in other parts of the body. Myotomy, neurectasis, neurotomy, and neurectomy have been

employed, but the disease always recurs in other muscles, no matter how wide the primary nerve excision may have been. Some neurologists go so far as to maintain that even were the cortical centres governing the region to be excised, neighboring centres would take on diseased action. At present cure of the disease seems hopeless by operation, though the temporary improvement usually secured is not to be despised.

Tumors of Nerves.—Fibrous out-growths sometimes occur on the ends of nerves in an amputation stump ("amputation neuromas"), apparently due to attempts at regeneration: the nerve fibres turn back upon themselves, being unable to make headway forward, and form painful bulbous masses, which usually have a strong tendency to recur if excised, or even after formal re-amputation. Such growths are rare except where the amputation was a bungling operation. Multiple tumors occasionally are formed along nerve trunks or at the terminations of nerve fibrils in the skin. This disease is variously known as *multiple neuro-fibromatosis* (when confined to nerve trunks); *von Recklinghausen's disease* (1881) or *molluscum fibrosum* (when occurring in the skin); and *Rankenneurom* or *plexiform neuroma,* which occurs in the form of a circumscribed thickening of the skin, due to out-growth of nerve fibrils—a condition most often found in the neck or scalp, sometimes pigmented, and usually congenital. Da Costa (1910) compares the condition of nerves in a plexiform neuroma to that of the arteries in a cirsoid aneurysm. This disease, in its various forms, usually has been considered a form of diffuse fibromatosis, blastomatoid in character; but in the second edition of his *Pathology* (1910) Adami returns to v. Recklinghausen's original theory, and to that of Klebs (1889), which lately has received support from other observers, that these growths originate in the nerve fibrils themselves, and should be classed as *Neurinomas.* Excision of one or several of the multiple growths may be required for pain or deformity: those on the nerves sometimes may be shelled out without destroying the continuity of the nerve trunk. The "plexiform neuroma" sometimes recurs after removal; sarcomatous changes may occur, though they are not very frequent.

CHAPTER XII.

FRACTURES.

The study of fractures is one of the most important subjects which can engage a surgeon's attention; they are injuries which occur constantly, in all classes of life, and under all circumstances. Even a general practitioner cannot avoid having a number of cases under his care every year; and no cases contribute as much to the fame or discredit of the man who treats them. And while it is well recognized that the most skilful and assiduous treatment cannot in all cases succeed in giving the patient a useful and comely limb, yet it is sadly true that many of the bad results constantly seen are due to sheer ignorance and neglect on the part of the practitioner.

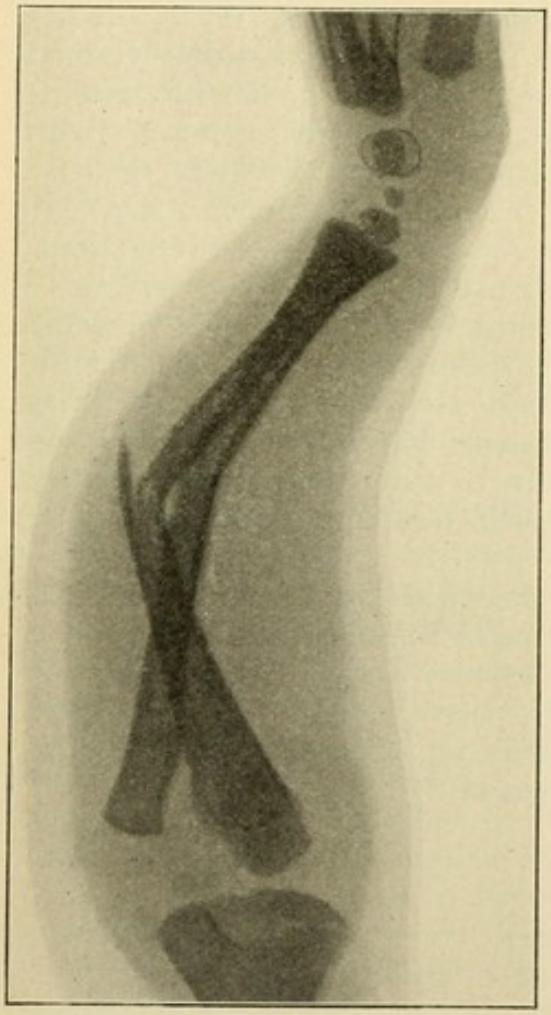

Fig. 267.—Green-stick fracture of radius and ulna with extreme deformity. Pennsylvania Hospital.

Classification.—*Fracture* of a bone may be *complete* or *incomplete*. The latter form (*green-stick fracture*) occurs almost exclusively in young children, the bone fibres in the line of extension (convexity) being completely ruptured, while those in the line of flexion (concavity) maintain their continuity (Fig. 267).

Fractures may be *subcutaneous* (*simple*) or *open* (*compound*), the latter term implying that the seat of fracture communicates with the external air through a wound of the soft parts.

Comminuted fractures are those with more than two fragments, the *lines of fracture intercommunicating* (Fig. 268). They are to be distinguished from *double* (*triple, quadruple*, etc.) *fractures* in which two (or more) separate and distinct breaks are present in the same bone.

Multiple fracture (Fig. 269) is a term which should be reserved for cases with breaks in more than one bone, the bones affected not being parallel (like the ribs, those of the forearm, the leg, hand, etc.).

Complicated fractures are those attended by some other serious injury of *the same part*, as rupture of the main bloodvessels, crushing of nerves, dislocation of neighboring joint, etc. A fracture of the lower end of the femur may be complicated by a fracture of the skull, or by a stab wound of the lung, but such a fracture is not a "complicated fracture of the femur" unless the popliteal artery is ruptured, the knee-joint dislocated, or some other serious injury exists in the immediate neighborhood of the fracture.

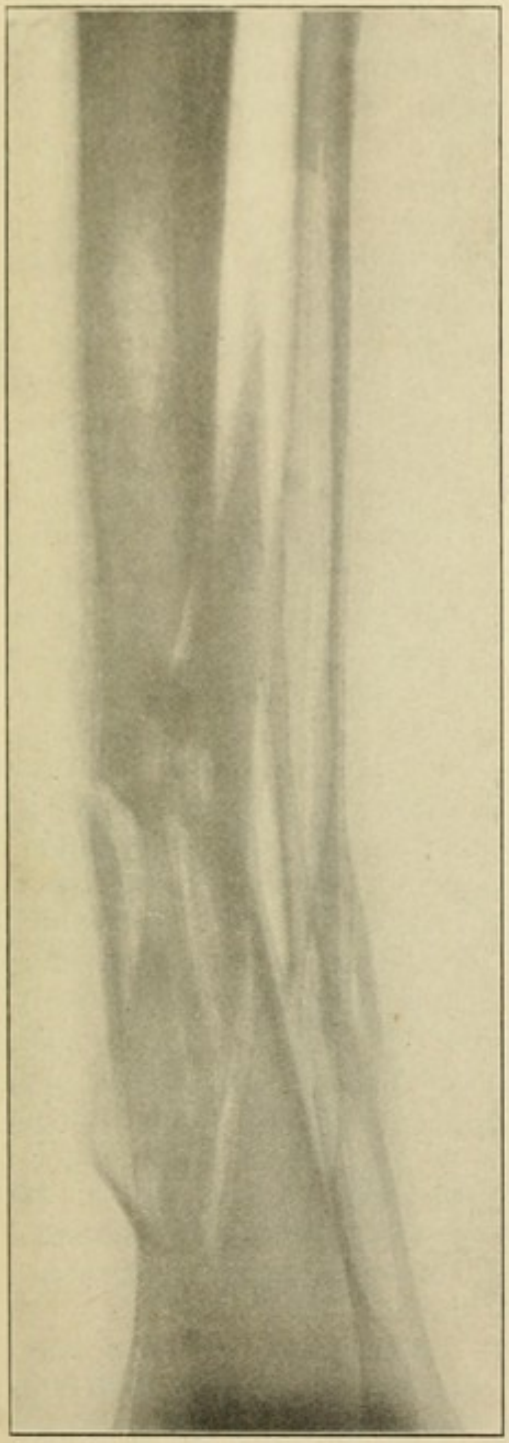

FIG. 268.—Comminuted fracture of tibia and fibula, a few hours after injury. Episcopal Hospital.

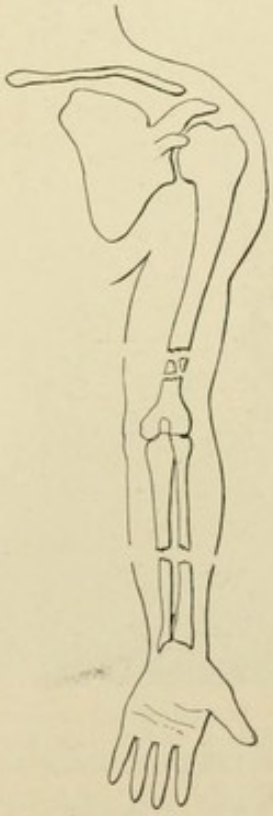

FIG. 269.—Multiple fracture of upper extremity. Episcopal Hospital.

Direction.—Fractures are further classified as *longitudinal*, *transverse*, *oblique*, *spiral*, etc. These terms are self-explanatory and are illustrated in the accompanying skiagraphs (Figs. 270, 271, 272). Transverse fractures are more frequent in cancellous bone, and when

occurring in the shafts of long bones usually are due to direct violence; whereas oblique and spiral fractures, seen almost exclusively in the shafts of the long bones, generally are due to a twisting force transmitted from a distance; and longitudinal fractures, frequently extending into a joint, usually are caused by a splitting action. A *depressed* fracture is one seen almost exclusively in the skull, in which the fragments are displaced by the vulnerating force below the level of the surrounding bone. An *impacted* fracture is one in which one fragment is driven into the other, and remains fixed (Fig. 306). Subperiosteal fracture is one in which the periosteum wholly or in great part remains unruptured.

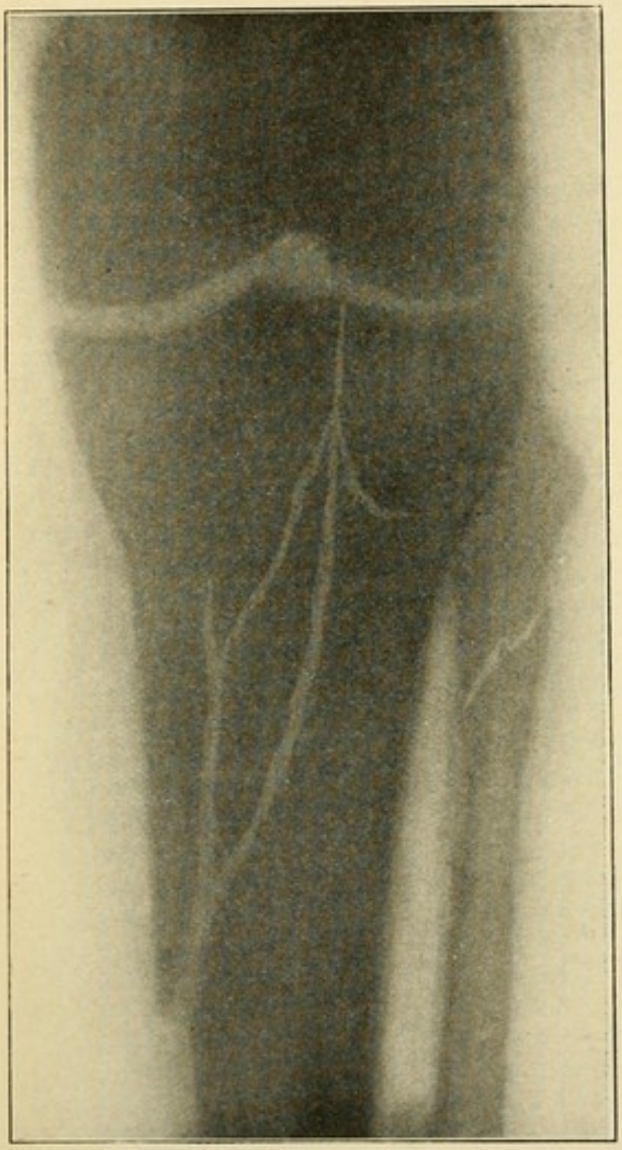

FIG. 270.—Longitudinal (splitting) fracture of tibia and fibula (involving knee-joint). Age, forty years. Episcopal Hospital.

Epiphyseal Separations. — The *epiphyses*, or articular extremities of the long bones, may be detached from the shafts (*diaphyses*) by separation along the epiphyseal line until the age when ossification is complete in the cartilage which unites epiphysis with diaphysis. The injury is most common at the lower ends of the humerus, radius, and femur; it is seen also, but more rarely, at the upper ends of the humerus, femur, and tibia, and at the lower end of the tibia. The injury, in all its aspects, so closely resembles a fracture, as to be considered by common consent along with such injuries.

Mechanism. — Bones may be broken in four different ways: (1) by torsion; (2) by flexion; (3) by distraction, and (4) by compression. For a bone to be broken by torsion, it is necessary for one of its ends to be free, while the other is fixed; the injury always is indirect, and the line of fracture usually oblique. When a bone is broken by flexion, the force may be either direct or indirect. All fractures by distraction are due to indirect violence, and practically all produced by compression result from direct violence.

Causes of Fracture.—Predisposing Causes.—These arise either from the condition of the patient or that of the bone affected. Bones of the *aged* are more liable to fracture, because more brittle, than those of young persons; but as the latter lead more active lives, and are more exposed to exciting causes, the number of fractures actually occurring in the aged is less than in the young. Likewise the male *sex*, from its greater exposure, is more liable to fracture than the female. Certain *diseases of bones* render them more liable to be

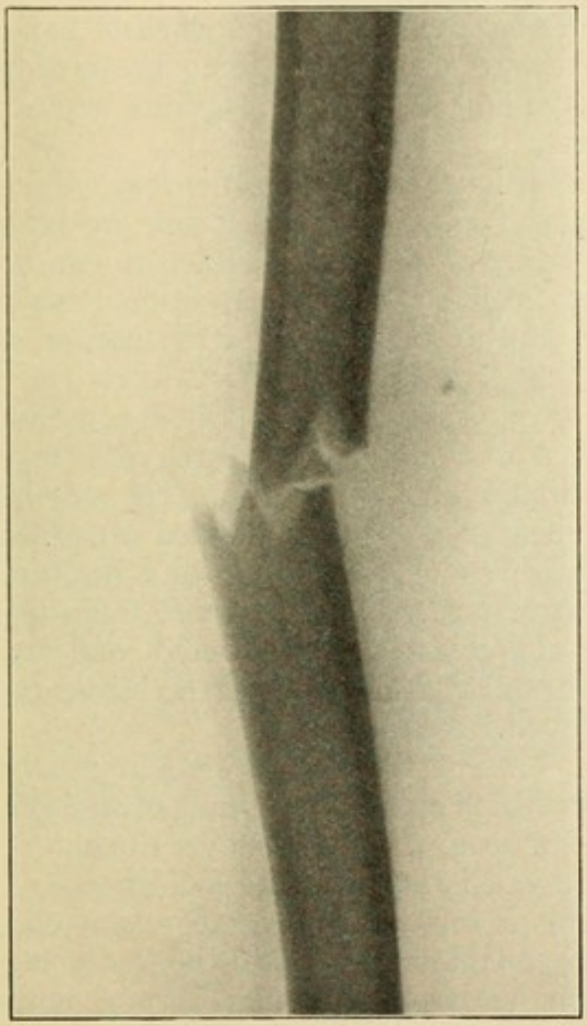

FIG. 271.—Transverse serrated fracture of humerus. Episcopal Hospital.

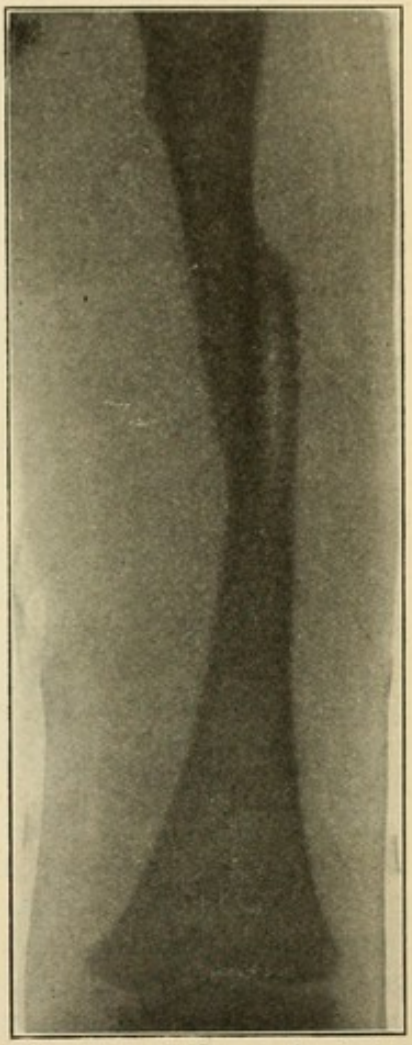

FIG. 272.—Oblique and spiral fracture of femur. Age three years. Episcopal Hospital.

broken, especially osteopsathyrosis and malignant growths. The *situation* of a bone may predispose it to fracture, the clavicle being more often broken than the scapula, the lower than the upper jaw, etc.; and the *function* of a bone has a predisposing influence, the bones of the extremities being broken more often than those of the trunk.

Exciting Causes.—Fractures may occur at the point of impact, from *direct violence* (gunshot, cart wheel, falling brick, etc.); or may be due to transmitted force (*indirect violence*), as fracture of the elbow from falls on the hand.

Fracture by muscular action usually is a variety of fracture from indirect violence, one end of a long bone being twisted violently by the muscles attached to it, and being wrenched loose, as it were, from the other end, which opposes its inertia to the sudden muscular impulse; this is the explanation of fractures of the humeral shaft from throwing a ball (Ashhurst, 1905). Muscular action may tear off an apophysis (coracoid process, greater tuberosity of humerus, anterior superior iliac spine, etc.), or may break the patella or olecranon by sudden flexion over their neighboring condyles, as an over-bent lever.

Sprain fracture (Callender, 1870) is due to separation of a ligament from its point of insertion, with detachment of a small shell of bone.

Spontaneous or **Pathological Fractures** are those due to preëxisting bone disease, where trauma is minimal, as in fragilitas ossium, secondary carcinoma of bone, etc.

Symptoms of Fractures.—In addition to a *history of injury*, which exists in all cases except some pathological fractures, there are both *symptoms* and *physical signs* by which a diagnosis of fracture can be made clinically, with very few exceptions; in such exceptional cases the use of the *x*-ray nearly invariably will reveal the true nature of the lesion.

Pain and Tenderness.—These are present in practically every case and are by no means proportionate to the apparent degree of injury, some very severe compound comminuted fractures causing the patient less discomfort than a single subcutaneous break. When no other physical signs are present, the surgeon should always suspect a fracture when there exists *persistent localized tenderness* of a bone, following injury; such a fracture may be subperiosteal or impacted, and the surgeon should treat such a case as one of fracture until the incorrectness of his diagnosis has been proved.

Swelling, Ecchymosis, etc., are present to some degree in nearly all cases of fracture (Fig. 273), owing to coincident injury of the soft parts; but they have no special significance. *Abrasion* over the seat of fracture usually shows that the break is due to direct violence.

Deformity or Displacement.—This is one of the most constant and valuable signs of fracture. It may be due either (1) to the fracturing force, or may occur subsequently (2) from muscular action; both these factors may be operative; or finally it may be caused simply (3) by the weight of the limb.

1. *Deformity from the fracturing force* is seen best in impacted and in depressed fractures. In fractures with great displacement other factors as well usually are at work.

2. *Deformity from muscular action* is seen especially in the long bones of the extremities, and occurs most markedly when the fracture is close above or below the attachment of powerful muscles—as above or below the insertion of the deltoid, below the insertion of the iliopsoas tendon, above the origin of the gastrocnemius, etc. In fractures of the patella and olecranon it is almost the only cause of deformity. It is responsible both for the shortening, and for the angular deformity, as well as for many cases of rotatory displacement.

Deformity from muscular action is dependent in part on the *natural tension of the muscles*, in part on *involuntary contraction* (spasmodic) from reflex nervous action, and in part on *voluntary action* by the patient.

3. *Deformity from the force of gravity* is seen in the outward rotation of the leg which occurs in fractures of the femur; in the deformity known as "loss of the carrying angle" in supracondylar fractures of the humerus; in the dropping of the shoulder in fractures of the clavicle, etc.

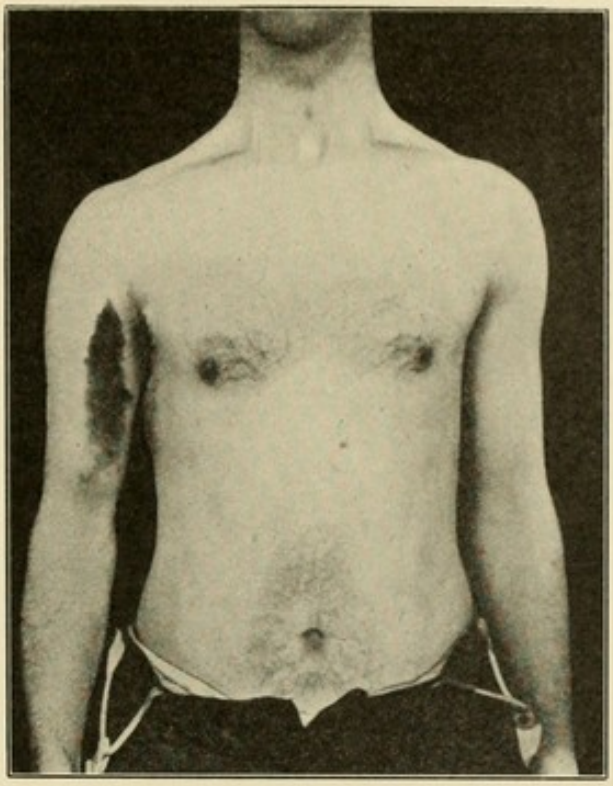

FIG. 273.—Ecchymosis twenty-four hours after fracture of surgical neck of humerus, extravasation occurring in course of long tendon of biceps. Episcopal Hospital.

Direction of Displacement.—This may be *longitudinal*, *lateral*, *angular*, or *rotatory*.

1. *Longitudinal displacement* almost always consists in *shortening; lengthening* is seen only in fractures of the olecranon and patella, and in some of the calcaneum; in fracture of the lower end of the fibula, lengthening of this bone may occur from inward rotation of the foot (Malgaigne, 1841). If the fracture is transverse, there can be no marked shortening unless there has first been lateral displacement, as the amount of shortening which occurs in an impacted fracture rarely exceeds one or two centimeters; oblique fractures, however, permit of great shortening without much lateral displacement. If the ends of the fragments are displaced so far as to pass by one another, *overlapping* is said to exist, the more prominent fragment *overriding* the less prominent. In fractures of the femur the shortening from overlapping may be from five to ten centimeters (Fig. 274). In many fractures it is requisite, and in most it is highly desirable, to take the actual measurements of the sound and injured limb between known

fixed points to determine whether or not there is shortening, and not to rely on the evidence of the eyes alone to determine this point.

2. *Lateral or transverse displacement* has been mentioned already; it occurs mostly in transverse fractures, and when marked allows overlapping.

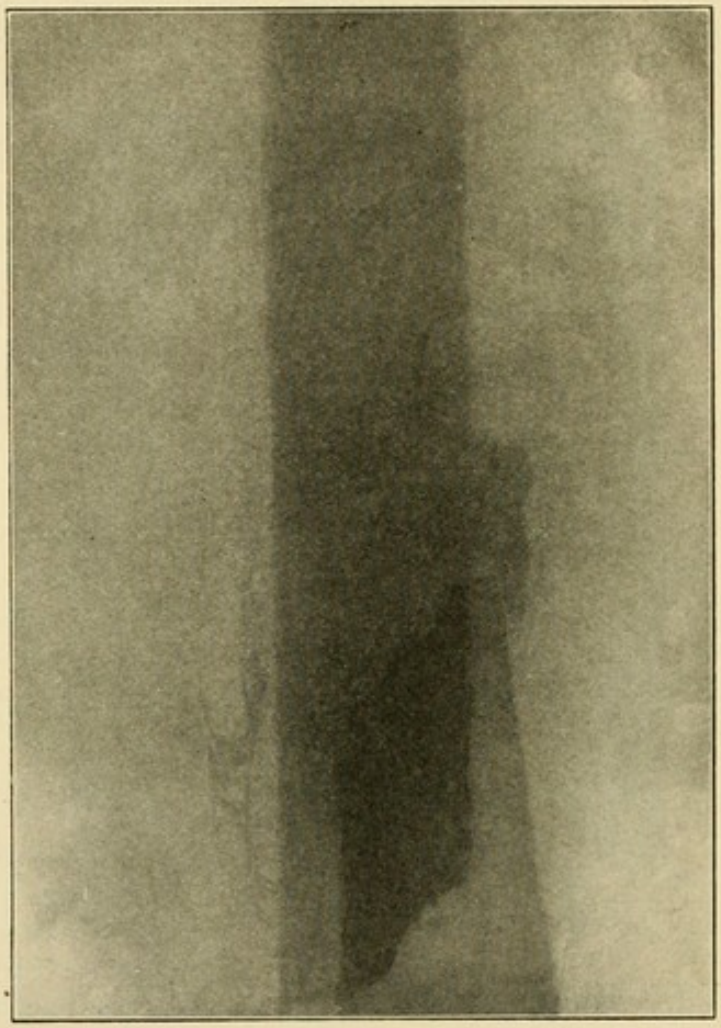

FIG. 274.—Fracture of femur, fragments overlapping two inches. Plated. Episcopal Hospital.

3. *Angular deformity* usually results from the fracturing force. This is well seen in cases of green-stick fracture (Fig. 267); but it may be originally caused by muscular action, and usually is maintained by this or by the force of gravity.

4. *Rotatory displacement* consists in the fragments being twisted on their own axis in opposite directions, either from muscular action or the force of gravity. In fractures of the radius above the insertion of the pronator radii teres the upper fragment is supinated by the biceps, while the lower is pronated by the pronator teres; in fractures of the neck of the femur the lower fragment is rotated outward by the force of gravity and the external rotator muscles, which are more powerful than the internal rotators.

Displacement may not be due to fracture, but to some other lesion. Dislocations, old joint-diseases, exostoses, as well as other affections, may cause deformity with shortening, angularity, or rotation; so the surgeon must not place reliance upon deformity alone in the diagnosis of fracture.

Mobility.—Preternatural mobility in a bone, following recent injury, implying as it does motion at some point other than the joints, is almost pathognomonic of fracture; but the normal *flexibility* of some bones (ribs, fibula, rachitic bones) should not be mistaken for abnormal mobility. In some cases mobility is so great that it is evident at a glance, the limb swinging flail-like at the site of fracture; in others, especially where only one of two or more parallel bones is broken (ribs, metacarpals, etc.), mobility may be difficult to detect. In subperiosteal and impacted fractures it is entirely absent; and in other forms of fracture it may be impossible to detect it owing to the depth at which the bone lies, existence of swelling, etc. In fractures close to a joint, and in those in which the line of fracture is wholly or in part intra-articular, no mobility may be demonstrable. While in a fracture a false point of motion exists, in a dislocation the mobility of the affected joint is diminished.

Crepitus.—Crepitus is a term used to describe the grating sensation appreciable by palpation and frequently also by auscultation (a stethoscope may be used), when the ends of the fragments are moved against each other. When present in connection with mobility, the diagnosis may be considered established. Crepitus should not be mistaken for the creaking of tenosynovitis, nor for the similar sound produced by motion of some diseased joints; nor yet for the crackling of subcutaneous emphysema. Crepitus may be absent, owing to the ends of the fragments not being in contact (overlapping, separation), or to muscular or fibrous tissues intervening; in green-stick, impacted, and subperiosteal fractures, there is no crepitus.

Loss of Function is another valuable sign of fracture, though it is by no means universally present. Patients with fracture of the fibula may continue at work, and apply for treatment only because of deformity or persistent disability; the same is true of fractures of the ribs; and of some fractures in which pain is absent owing to nerve lesions, or in which it is not appreciated owing to the development of *mania a potu*, etc.

Circumstantial Evidence of fracture, in addition to the above mentioned direct signs, is afforded by various occurrences: subcutaneous emphysema corroborates a diagnosis of fracture of the nasal bones, discharge of cerebrospinal fluid from the ear indicates a fracture of the middle fossa of the skull, etc.

Diagnosis of Fracture.—If a surgeon conscientiously and systematically examines the patient there should be very few cases in which the existence or non-existence of fracture remains doubtful. Inquiry should be made as to the *history of the accident*, including the mode of injury, the position of the patient, whether the lesion is due to a

fall of the patient, or to his being struck by another body. If he fell, it should be ascertained, if possible, how he landed—whether on the outstretched hand, whether his foot turned in or out, whether his knee suddenly flexed or became hyperextended, whether his arm was abducted or lay across the thorax, etc. Occasionally when a bone breaks a crack is heard.

Inspection.—Inspection may show the patient supporting or protecting the injured part, may reveal evident deformity, shortening, abrasion, swelling, etc.

Palpation.—Running the fingers lightly along the surface of the suspected bone, the point of greatest tenderness, nearly always corresponding to the site of fracture, can soon be determined. Supporting one end of the injured bone gently but firmly in each hand, test is then made for abnormal mobility, by attempting to increase or decrease angular deviation of the fragment, or to rotate one fragment on the other. In fractures near joints, lateral mobility, where none is normally present (elbow, knee) may thus be detected (in dislocations there is immobility rather than abnormal mobility). In most cases crepitus will be elicited during the manœuvres advised for detection of mobility, but where overlapping exists it may be necessary first to bring the fractured ends into apposition; when crepitus once has been detected it is reprehensible to make attempts at reproducing it merely for the edification of bystanders.

Mensuration.—Mensuration has been mentioned already as a valuable means of detecting shortening. In the upper extremity the fixed points employed are the tip of the acromion or the metacromial tubercle, the condyles of the humerus, and the styloid processes of the radius and ulna; in the lower extremity measurements are made from the anterior superior iliac spine or symphysis pubis to either of the malleoli; or to the lower border of the patella, head of the fibula, etc. By placing the corresponding limbs in similar attitudes and taking repeated and accurate measurements, the presence of shortening usually can be ascertained. It should not be forgotten, however, that in many persons the two lower extremities normally are not of equal length.

It is important to make a correct diagnosis and to institute proper treatment *as soon as possible* after the injury is received; deformity at first easily appreciable may soon be obscured by swelling, and not only will the diagnosis then be more difficult than if made at first, but reduction of the deformity and other proper treatment will be less effectual or even impossible if the case is not seen early. In all cases, moreover, in which fracture is suspected, the case should be treated as if fracture were present until the contrary is proved.

Skiagraphy.—Skiagraphy is a great aid in confirming a diagnosis of fracture tentatively made, or in disproving its existence when one is suspected. Whenever possible a skiagraph should be made before the patient is examined, as a matter of record; and often it is desirable for the surgeon to examine the plate before treatment is

instituted. Certainly after reduction has been attempted it is well for him to have ocular evidence of what he has accomplished; and if reduction is not satisfactory he can try again. In making radiographs the film side of the plate is placed next the patient's limb, and the picture etched on the plate is the shadow of those parts impervious to the *x*-rays. In looking at the developed plate, if it is held with the film side toward the observer, he is in the position occupied by the Crookes tube when the exposure was made, and, therefore, is looking at the shadows of the bones from the side of exposure. In taking lateral views of the limbs, that bone or portion of bone nearest the plate when the exposure was made, will be most clearly defined.

Skiagraphs often are very deceptive. For instance, if the bones overlap, and lie in the same axis, a skiagraph which superposes one shadow on the other may show no fracture; one which is taken in the same plane as that in which angular displacement occurs, may show no deformity. Hence it is a good rule always to have two plates made, exposure being in planes at right angles to each other. If the Crookes tube is too close to the limb its rays will be quite divergent when impinging on the skiagraphic plate, and all the shadows will be exaggerated; and the further a bone lies from the plate the more rays it will intercept and the larger its shadow will appear. If the Crookes tube is not accurately centred over the fracture, the shadows cast by the fractured ends will be much distorted, perhaps markedly exaggerating the deformity, amount of callus, etc. In passing judgment upon a skiagraph, therefore, it is important to take these points into consideration, and not to regard as evidence of malpractice phenomena which may be quite easily explained in other ways.

Prognosis of Fracture.—Prognosis as to life is good. In large series of statistics the general mortality from fractures is about 2.5 per cent. Compound and complicated fractures have a higher mortality. Multiple fractures, as I pointed out in 1907, in studying 240 cases, give a mortality of about 25 per cent., even when deaths occurring soon after the injury from hemorrhage, shock, visceral injuries, etc., are excluded. In general it may be said that the chief causes of death in fractures of any variety are visceral diseases (pneumonia, uremia), delirium tremens, and, in the aged, exhaustion.

The prognosis as to the function of the fractured part depends more upon treatment than any other single factor. As a rule, function is more quickly and completely restored in children and young adults than in the aged; and in those of sound constitution than those with rheumatic or gouty tendencies.

Process of Union in Fractured Bones.—It has been entirely too much the custom to regard bones as so many sticks or pieces of stone embedded in the soft tissues. The student should disabuse himself of this idea, and should aim constantly to remember that bone is a living tissue, composed of cells and intercellular substance, and differing chiefly in the composition of the latter from other tissues such as

muscle or epithelium. Bone reacts to injury or disease in very much the same way as other tissues; the phenomena of inflammation and repair may appear less active and slower than in the soft tissues, but they are none the less present. A glacier is a fluid body, though it looks solid; it flows slowly and invisibly, but none the less surely; so with bone: processes measured by minutes or hours in soft structures may take days or weeks in bone, but they are the same in kind.

When a bone is broken, the surrounding soft parts are more or less damaged, and themselves react to the injury by the process of inflammation as described in Chapter I. A certain amount of blood is extravasated between the ends of the broken bone, and the various cellular elements of the tissues in the injured area (bone cells from the marrow and periosteum, muscle cells, connective tissue cells, leukocytes, etc.), proliferate, and aid in removing débris and causing organization in the mass of inflammatory lymph which is formed. The intercellular substance of the bone is temporarily absorbed or removed from the fractured ends by osteoclasts, and the exudate forming between the fragments, which is known as *callus*, is strictly analogous to the inflammatory lymph which surrounds it and with which it is continuous. The ends of the fragments thus become soft and sticky, and may be compared to the ends of a broken stick of sealing wax which one seeks to weld together again after heating in a flame. This callus is derived largely from the medulla of bone, by proliferation of osteoblasts. This portion of it is known as *interior* or *pin-callus*, while that portion formed from the periosteum is known as *ensheathing* or *ring-callus;* the material lying between the ends of the compact substance of the bone is known as the *permanent* or *definitive callus* as distinguished from the pin and ring callus, which is called *provisional* or *temporary callus*.

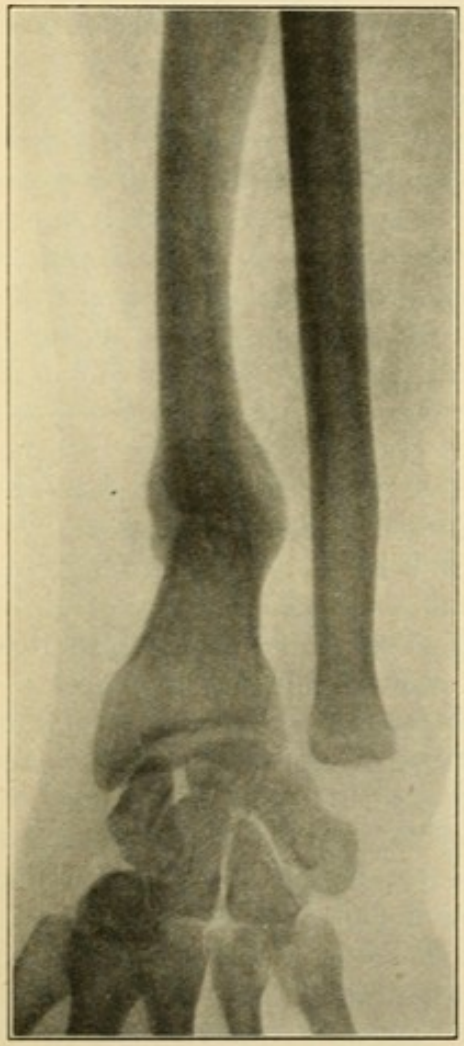

Fig. 275. — Skiagraph showing callus several weeks after fracture of radius. Episcopal Hospital.

In the course of ten days or two weeks the callus becomes impregnated with lime salts, that derived from periosteum often passing through a cartilaginous stage; and the bone can no longer be freely bent at the seat of union (Fig. 275). The callus gradually becomes

condensed as organization proceeds and remains only as a slight thickening at the site of previous fracture; but the pin callus usually is not entirely absorbed, and complete restoration of the medullary canal is rare If there has been exuberant outpouring of callus (Fig. 276), it may cause union between adjoining bones, may interfere with full flexion or extension of a joint, may limit rotation in the forearm, may grow around nerves or tendons, or cause injurious pressure on them or on vascular channels, resulting in trophic changes, edema, etc.

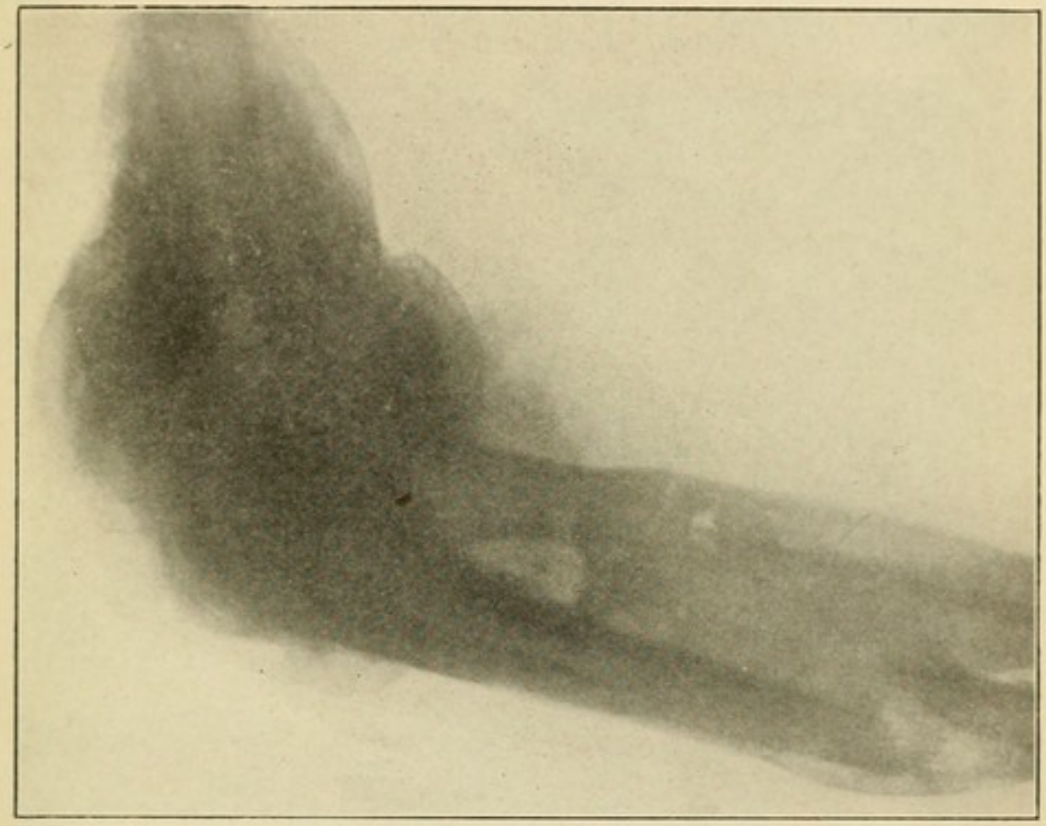

FIG. 276.—Skiagraph of exuberant callus from fractures of elbow and forearm.

If the fracture is subperiosteal the amount of ring-callus formed will be inappreciable; and the less the primary displacement and the more accurate the reduction of the fractured ends, the less will be the amount of the ring-callus. In fractures of the skull or ribs, and in impacted fractures, where displacement is slight, no appreciable callus is formed. If the periosteum is stripped up from the shaft of a bone blood-clot will form beneath it, as well as between the broken ends, and becoming organized will cause thickening of the shaft, as the periosteum will be unable to fall back into its normal position (Fig. 277). The periosteum is rarely completely detached from the broken ends, usually remaining at least on one side as a periosteal bridge (Ollier, 1867), which may secure firm bony union even in cases where marked displacement persists.

The process described above usually does not make its beginning manifest for several days after the occurrence of fracture, and is longer delayed in comminuted and in compound than in simple

fractures. In multiple fractures it is a very usual thing for one or two fractures to unite in the ordinary time, and for the other fractures to remain ununited until those first uniting are quite firm, when union may commence in the remaining fractures. In simple fractures fairly firm union is present at the end of two weeks, though at this time, and in larger bones for some weeks afterward, bending at the seat of fracture still may occur. An adult's femur requires usually eight or ten weeks for absolutely firm union to occur. It is said that in no fracture is the structure of the bone entirely restored until a year after the accident.

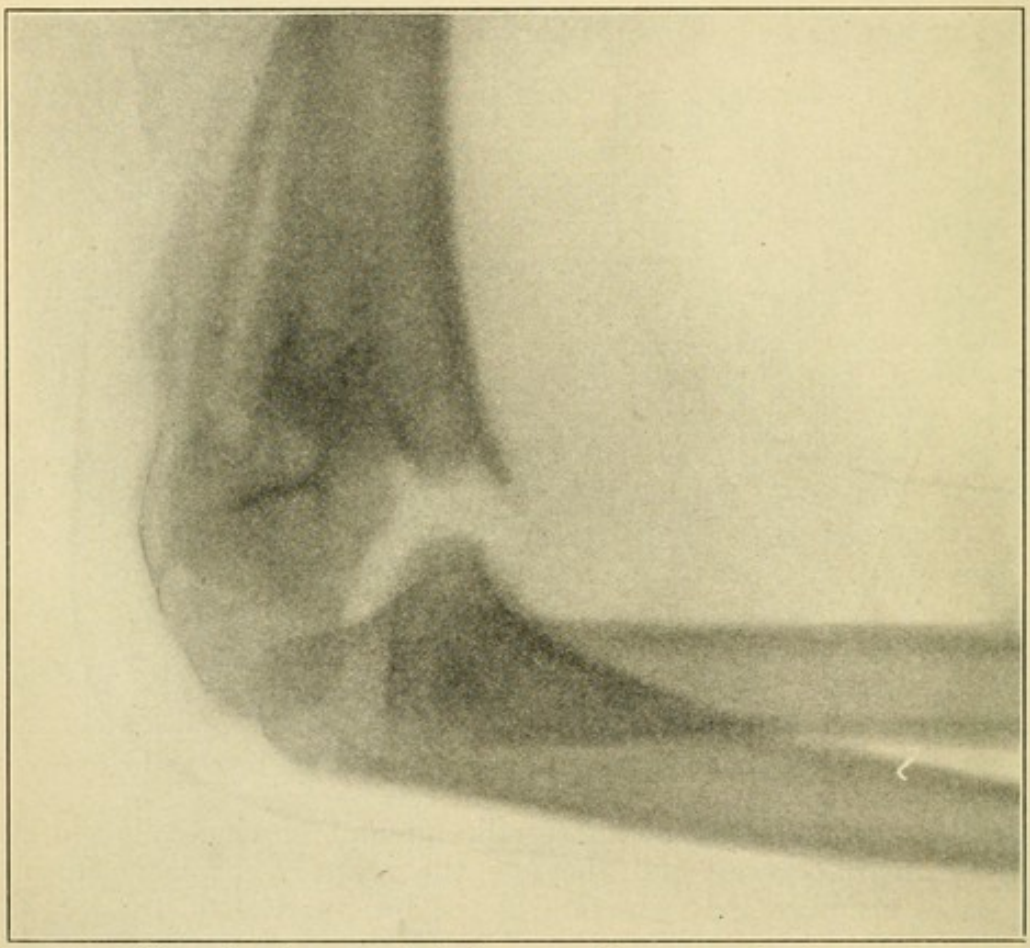

FIG. 277.—Skiagraph of supracondylar fracture of humerus, showing new-formed bone beneath bridge of periosteum, three weeks after injury. Episcopal Hospital.

Delayed union is a relative term, since no fixed limits can be set within which union should be firm. If union has not occurred at the end of ten or twelve weeks, it is usual to regard the case as one of *Non-union* or *Ununited Fracture*. In these cases the tissue between the fragments remains in a fibrous condition, no bone salts being deposited.

Treatment of Fractures.—The general principles already inculcated as proper in the treatment of inflammation guide the surgeon in the treatment of fractures. The indications are to *replace the broken bones in proper position*, with due regard for the condition of the soft

parts, to *maintain the fragments in proper position*, and to *dress the injured part at suitable intervals* until cure is complete.

Treatment of Simple Fractures.—Fractures often are received at a distance from the patient's home or a surgeon, and it becomes necessary to transport the patient to a place where the injury can be treated. The fractured limb should be rendered as immobile as possible; this may be accomplished by the temporary application of any available support (shingles, canes, umbrella ribs, bark of trees, twigs, etc.), applied over the clothing or suitable padding, or even by wrapping the limb firmly in clothing, without constriction; if the patient is unable to walk, he is carried on a shutter or on a stretcher improvised from poles and clothing, to his home or the nearest hospital.



FIG. 278.—Showing fragments of broken bone in contact "end-on," and with not too much lateral displacement for firm union.

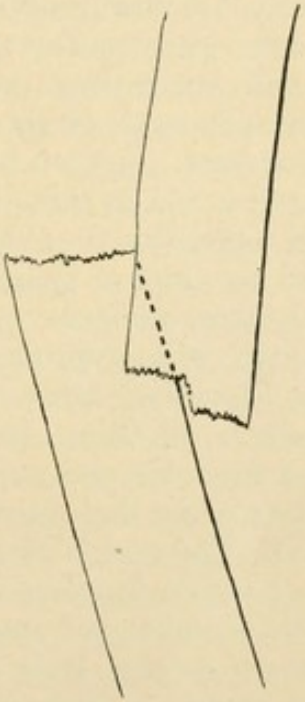

FIG. 279.—Fragments displaced laterally and with angular deformity; contact not sufficient for firm union.

1. *Reducing the Fracture.* This, which often is expressed by the term "setting the bone," is a relative term, since comparatively few broken bones can be accurately restored to their original form; and in the case of shafts of long bones it is not always necessary that reduction should be accurate. Nevertheless, the aim must be *to secure as accurate reduction as possible*, and in the case of fractures near joints (especially the elbow and ankle) it is extremely important to do so; but in the middle of the shaft of a long bone it is sufficient to secure *firm bony union*, with *no appreciable shortening*, with *preservation of the normal axis* of the limb, and *without rotation of one fragment on the other*. For the first and second results to be obtained it is necessary for the fragments to be in contact "end-on," not only

by lateral contact; and for the lateral displacement not to exceed two-thirds of the diameter of the bone (Figs. 278 and 279). The axis of the limb sometimes may be preserved without end-to-end contact of the fragments, but it is very rare for firm union to be secured (except in children), and shortening never will be absent unless end-to-end contact is obtained.

The methods of securing reduction are many, and will be described when the injuries of the individual bones are discussed. It is sufficient to point out here that other than manual force seldom is necessary, if the surgeon takes advantage of the relaxation of the muscles which may be secured by position of the limb; rarely will anesthesia be necessary, and still less often operative intervention (p. 130). Securing muscular relaxation by position, the surgeon with his hands makes extension and counter-extension on the broken bone, and, by gently but firmly applied direct pressure, pushes the ends of the fragments into contact: if reduction has been properly secured, there will be distinct crepitus as the broken ends come together, the normal length of the limb will be restored, and bony deformity will disappear. It then becomes necessary merely to maintain reduction until union is sufficiently firm.

2. *Maintaining the Fragments in Apposition.* For this purpose it is usual to employ splints or other external support, held in place by bandages, plasters, etc. Splints are made of various materials (wood, tin, wire, gypsum, etc.), and of various special forms. These will be described when discussing fractures of the several bones. It is above all things important to recognize the fact that splints are not used for the purpose of overcoming deformity, but merely to maintain the limb in correct position after the deformity has been reduced. The action of splints in this regard may be much assisted by the *position in which the limb is dressed*, and by the use of *weight extension* to overcome spasmodic muscular contraction. If a fracture is close to a joint it is necessary to immobilize the joint also; in general terms, it is desirable to immobilize so much of the limb as will prevent any lever action being transmitted to the site of fracture by movement of the portions of the limb left free.

Before a splint is applied it should be covered *smoothly* with raw cotton, oakum, or some similar material *in sufficient amount* to prevent painful pressure on the limb, special care being taken to protect bony prominences, superficial nerves, bloodvessels, etc. It often is well to apply between the splint and its padding, and over the ends of the fragments, pads suitable to prevent recurrence of deformity, provided no pressure is exercised which might injure the soft parts. An excellent rule is *never to apply a bandage beneath the splints* around the fractured region: in all fractures there is more or less injury of the soft parts, and the reactive swelling which occurs in these has demonstrated on numerous occasions the danger to which the patient is subjected by neglect to observe this rule; a bandage which seems loose enough when first applied may in a very few hours become so

tight as to cause serious constriction, perhaps resulting in gangrene of the extremity. Under all circumstances it is well to leave exposed the tips of the fingers or toes, and to direct the nurse or the members of the patient's family to examine their condition at frequent intervals; should any interference with the circulation become evident the dressings must be removed at once and be re-applied more circumspectly.

At the first visit, the surgeon should proceed to examine the injured member as described at p. 301; but he should not attempt to reduce the fracture until he has all his dressings prepared for application.

3. *The after-care of a fractured bone* involves removal of the dressing frequently enough to make sure that the soft parts are in good condition, and that reduction is maintained by the dressing employed. The surgeon never should neglect to see the patient on the day after the dressing is first applied, and to ascertain for himself that the limb is in good condition, and that the dressing is comfortable; *an uncomfortable dressing always is inefficient even if not positively harmful;* but if the dressing is comfortable it is not desirable to re-dress the limb more than two or three times weekly at first, and less often as union progresses. As the splints and bandages are being removed for re-dressing, the surgeon should support the fractured part in such a way as to substitute his support for the splints, preventing dislocation of the fragments, and rendering dressing of the fracture entirely painless. While this support is maintained, the patient's skin should be sponged off gently with dilute alcohol, employing such gentle friction as will stimulate the circulation. I do not approve of massage or mobilization in the treatment of fractures, except in so far as they are unavoidable in procuring proper care of the soft parts; and while I acknowledge the truth of the dictum (Lucas-Championnière, 1910) that "a certain amount of motion between the fragments encourages the formation of callus," I am firmly of the opinion that even the most careful immobilization by splints allows, and proper care of the soft parts, as above indicated, provides that "certain amount" of motion which is desirable, and that any surgeon who attempts more, in the vain idea that he is following modern teaching, will succeed either in stirring up such an amount of callus (especially in children) as to cause deformity and injurious pressure on the soft parts, or will (in most adults) leave his patient with an ununited fracture. When the ends of the bones become "sticky," and no tendency to displacement exists, the surgeon may then begin at each dressing to make very limited degrees of passive motion in the neighboring joints, meanwhile maintaining support at the seat of fracture. Under no circumstances should the passive motion cause pain. When union is firm enough for all external support to be discontinued, function usually will be more comfortably and quickly recovered by active movements by the patient himself, than by further attempts at passive motion; and if a fracture has been treated properly in the first place, massage rarely will be necessary to accelerate the cure.

Operative Treatment of Simple Fractures.—There are only two indications for the "open method" of treating simple fractures, so strenuously advocated by Lane (1905) and other surgeons: (1) If the fracture cannot be reduced properly without operation. (2) If proper reduction cannot be maintained without direct fixation of the fragments.

1. *When Proper Reduction is Impossible.*—Impossibility is here a relative term, since what is impossible for one surgeon may not be so for another; and I use the qualification "proper" reduction, because I do not wish to imply that operation is indicated whenever accurate, exact, perfect anatomical replacement is impossible, but only when such degree of reduction as is described at p. 307, as requisite for proper function, cannot be secured without open operation. The chief causes of irreducibility are *muscular spasm* (usually this can be overcome by general anesthesia, weight extension, or sometimes by tenotomy), *interposition of muscle, fascia*, etc., between the fragments (sometimes this can be overcome by manipulation under an anesthetic), *buttonholing of one fragment in the deep fascia, joint-capsule*, etc. (this usually requires incision), *complete rotation of a detached fragment* (apophysis, condyle, etc.), and *impaction of the fragments* (if desirable, which is not always the case, this usually may be overcome by manipulation with or without an anesthetic.)

2. *When Subsequent Displacement Cannot be Prevented.*—This also is a relative condition, depending upon the skill of the surgeon in devising and applying efficient retentive apparatus, and upon the extent to which displacement occurs. In the aged or feeble it may be wiser to permit recovery with considerable deformity than to undertake an inexpedient operation. Uncontrollable displacement generally is due to the *nature of the fracture itself* (marked obliquity, much comminution, etc.), to *muscular action*, or to the *refractory conduct of the patient.*

Apart from fractures of the patella, which are conceded to require operation (because of irreducibility) unless positive contraindications exist, the two forms of injury in which operation is most often urged, are fractures of both bones of the forearm, and those of the femur; so far as I am aware, however, it has yet to be shown that operative methods in these instances can be safely applied by the average surgeon, or that he can secure by uniform resort to operation as satisfactory results in as large series of consecutive cases as have been obtained by conservative treatment.

If operation is decided upon, it is best done either on the day of injury or not until about the end of the first week, or early in the second week after the injury, since at this time the primary swelling, etc., will have subsided, and any callus that may have formed still will be soft and easily removed; moreover, infection is less likely to follow than if early operation is attempted. The operation, *which should be strictly aseptic*, consists in exposing the fracture through the

proper muscular interspace, excising exuberant callus, removing interposed soft tissues, and in securing reduction (which is not always easy) if possible without resection of bone. Then if very slight tendency to dislocation of the fragments exists it is not necessary to use mechanical means to hold the ends in apposition, provided the surgeon feels capable of maintaining reduction by his external dressings. If there is still a tendency to displacement, the fragments (in the case of small bones) should be sutured with heavy chromic catgut, which will not be absorbed until union is so firm as to prevent subsequent displacement; in the case of the femur and in oblique fracture of the tibia it is safer to use a metal plate, since maintenance

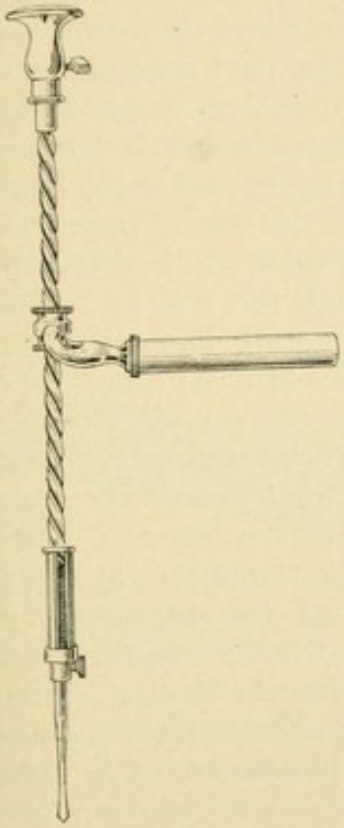

FIG. 280.—Hamilton's drill.

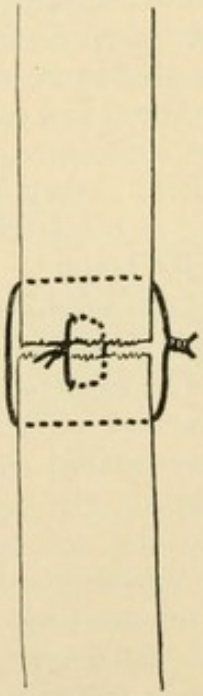

FIG. 281.—Fragments united by two wire sutures, inserted in different planes.

of reduction by external dressings alone usually is difficult. The form of plates used by Lane (1905) probably is best: these are of steel, of various sizes, and are applied to the bone without displacing the periosteum. About three screws are inserted in each fragment; the holes are bored by a suitable drill (Fig. 280) or dental engine, should extend into the medulla and should be slightly less in diameter than the screws; the screws should have round heads, should have the thread carried up to their heads and should be just long enough to enter the medullary cavity. The use of plates has almost superseded wire sutures in large bones (femur, tibia, humerus, lower half of radius), but in smaller bones (clavicle, ulna, fibula) wire sutures are efficient and may be more easily applied; it is best to use two

sutures, at right angles to each other (Fig. 281). Silver wire is much used, but it is decidedly inferior to aluminum or phosphor bronze wire, which is much more pliable and stronger. If all oozing has been controlled by ligature or suture, the wound may be closed without drainage, but in case of doubt it is better to leave a rubber tube in the wound, for twenty-four to forty-eight hours.

After such an operation the process of union is apt to be delayed, and in a fair proportion of cases operated on by the average surgeon a mild degree of infection occurs, and only fibrous union results. If the operative treatment of simple fractures were confined, as it should be, to skilful surgeons with all the facilities afforded by the best modern hospitals, no doubt better results would be obtained.

Treatment of Complicated Fractures.—*Rupture of the main artery or vein* of a limb complicating a fracture of the part requires the same treatment as when no fracture is present (p. 233); if gangrene follows amputation should be done *at the site of rupture;* but if the axillary artery is ruptured in a case of fracture of the upper part of the humerus, it usually is sufficient to amputate through the seat of fracture; and if the popliteal artery is ruptured, to amputate at the knee-joint if the fracture is below the knee, and through the seat of fracture if this is in the femur. *Injuries of nerves* require immediate suture, if it is evident that function is completely destroyed; otherwise operation should be delayed until after consolidation of the fracture, since recovery from contusion may be nearly complete. *A severe wound of the soft parts* usually takes precedence over the fracture, and must be treated suitably irrespective of the latter; if sufficient to render certain the occurrence of gangrene, amputate at the point of injury to the soft parts. *Dislocation of the neighboring joint,* most often encountered at the shoulder, usually requires incision and direct replacement of the luxated fragment; though sometimes it is possible to secure reduction by manipulation after putting up the fracture in splints; operation is best postponed until seven or eight days after the injury.

Treatment of Compound Fractures.—If the limb is so severely injured that gangrene is sure to occur, or if it would prove useless even if it could be saved, it is best to amputate at once; the site of section of the bones in such cases is determined by the condition of the soft parts available for making flaps.

A fracture which is made compound merely by the protrusion of the bones through the soft parts is much less dangerous than one in which the soft parts have been crushed or pulpefied by the same force which produced the fracture; because in the latter case there is much greater devitalization of tissue, infection is carried deeply into the soft parts, and comminution of the bones is the rule.

A compound fracture in itself requiring amputation, and complicated by a simple fracture higher in the same limb, usually will require amputation at the highest point of injury.

A compound fracture involving a joint sometimes requires ampu-

tation (almost always at the knee), but conservative treatment with strict antiseptic methods often will secure a useful limb even if motion is limited.

If it appears in any way likely that a useful limb can be saved, especially in the upper extremity, the surgeon must undertake repair of the soft parts and reduction of the fragments with antiseptic methods as detailed at p. 167. In almost every case the patient should be anesthetized, *and the primary dressing made to assume the character of a formal operation.* If the ends of the bones project through the soft parts, they should not be reduced until after the entire wounded area has been surgically cleansed. The wound in the soft parts frequently has to be enlarged, to permit of reduction and repair of the deeper tissues (Fig. 282). It seldom is necessary to resect the ends of the bones, reduction usually being possible by relaxing the muscles by the position of the limb, and bending the bones at an angle until their ends meet, then using the apposed fragments as a fulcrum on which to straighten the limb out again.

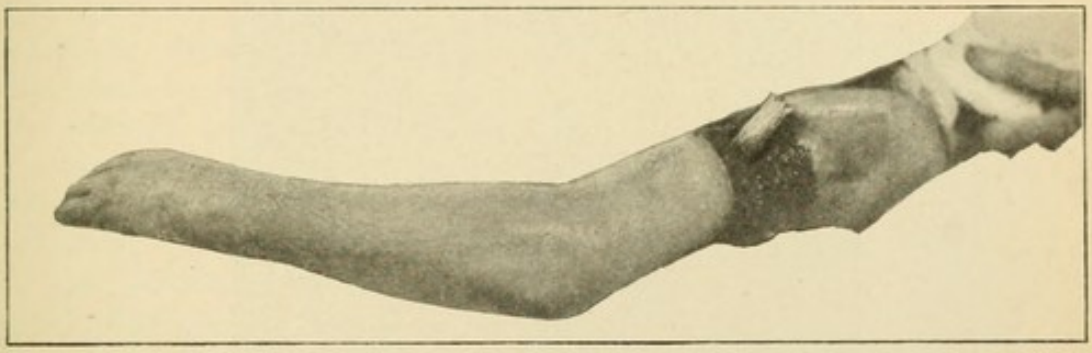

FIG. 282.—Compound fracture of humerus, bone protruding. Photographed just before operation. (See Fig. 283.) Episcopal Hospital.

Where the bones are much comminuted, such fragments as are entirely detached should be removed, while those that are partly adherent should be replaced, in the hope that they will aid in procuring union. Often the soft parts are stripped so widely from the bones that it is impossible to prevent recurrence of displacement even when reduction is easy. Under these circumstances the bones may be fixed by some form of internal splint as described in connection with ununited fracture (Fig. 283); usually it is better not to plate a recent compound fracture (since bony union seldom follows such a course), but to postpone the plating until the soft parts have healed and asepsis can be assured. Particular attention should be paid to suture of nerves, muscles, and tendons. The wound, unless very slight, should be drained for about forty-eight hours; by arranging the dressings as described at p. 166, the drainage tube may be removed without disturbing the fracture. In the lower extremity, a gypsum splint, trapped over the seat of injury, makes a very good appliance for the treatment of compound fractures; but in the upper extremity ordinary splints used in cases of simple fracture are quite satisfactory.

Frequently irrigation (p. 168) must be employed for several days to ensure vitality of the limb; and the frequency of dressings must be determined by the condition of the soft parts. Union is much

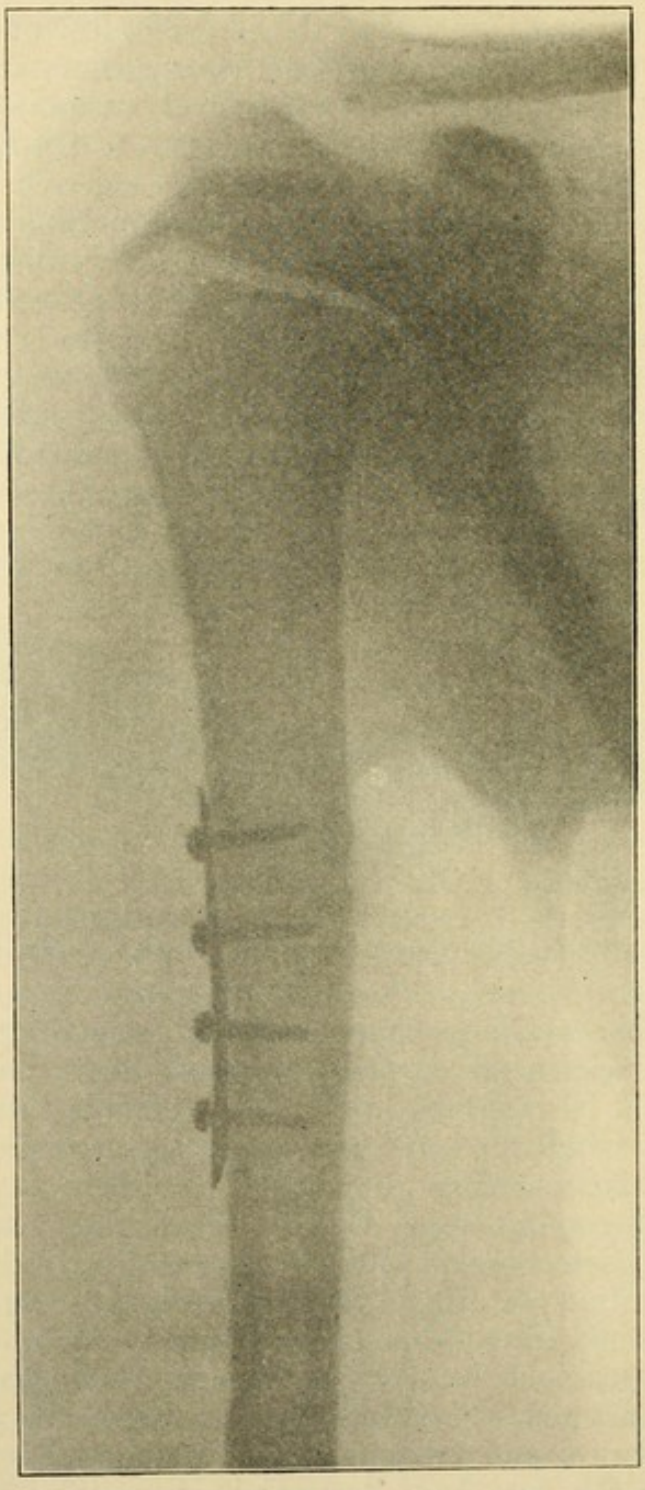

Fig 283.—Silver plate on compound fracture of humerus. (See Figs. 282 and 284.) Episcopal Hospital.

more delayed than in simple fractures; and though fibrous union often is the best that can be secured, it may furnish the patient with a useful limb (Fig. 284).

Treatment of Badly United Fractures.—If the case is seen before firm union has occurred, the position usually may be improved by

FIG. 284.—Fibrous union following plated compound fracture of left humerus. (See Figs. 282 and 283.) Episcopal Hospital.

judicious application of pads under the splints, or even by refracturing the bones manually and dressing them in the improved position. The question whether impacted fractures should be reduced is discussed under the lesions of the various bones. If the case is seen first after bony union has occurred, it is not always advisable to attempt reduction of the deformity if function is good, since non-union may result, or, even if firm union is secured, loss of function may accompany it. *Shortening*, as such, unless due to angular deformity, scarcely ever can be remedied; indeed, to secure end-to-end apposition of the fragments it often is necessary to resect their ends, thus increasing shortening; and attempts to lengthen a bone by oblique division usually are nullified by contractions in the surrounding soft parts. On these accounts, operative measures are directed toward overcoming *lateral displacement*, *rotatory* and *angular deformity*, or to the removal of *exuberant callus*.

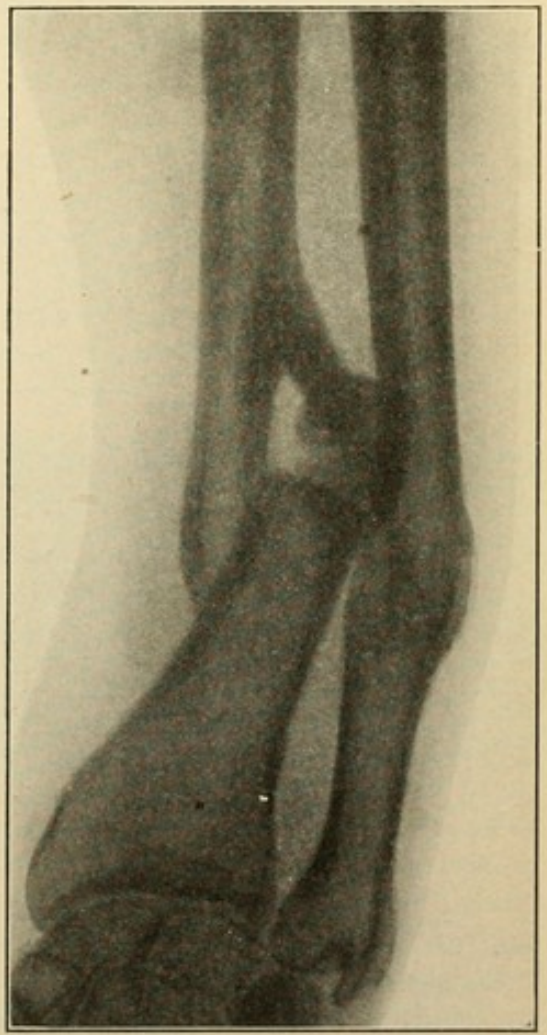

FIG. 285.—Vicious union following fracture of forearm; angular deformity and loss of rotation. Suitable for operation. Episcopal Hospital.

Careful skiagraphic studies should be made of the fractured region, so that the surgeon may

plan his method of operation in advance. In some cases simple *refracture*, by the hands or osteoclast (p. 420), will be sufficient; in others (Fig. 285) it is necessary to cut down on the fragments and *resect*, treating the case then as one of ununited fracture (p. 318); while in still others, linear or cuneiform *osteotomy* will give the best results.

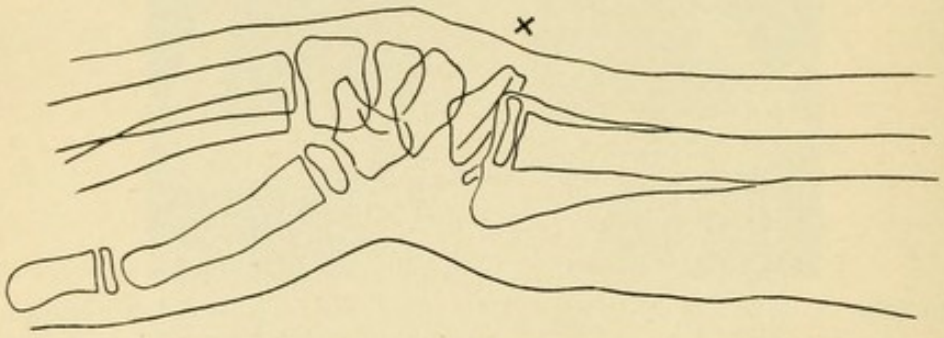

FIG. 286.—Deformity from irreducible separation of lower radial epiphysis. (See Fig. 287.) Episcopal Hospital.

In deformity from a separated epiphysis it is better usually to divide the diaphysis close to the epiphyseal line, and not to inflict further damage on the immediate site of injury, for fear of interfering with subsequent growth (Figs. 286 and 287).

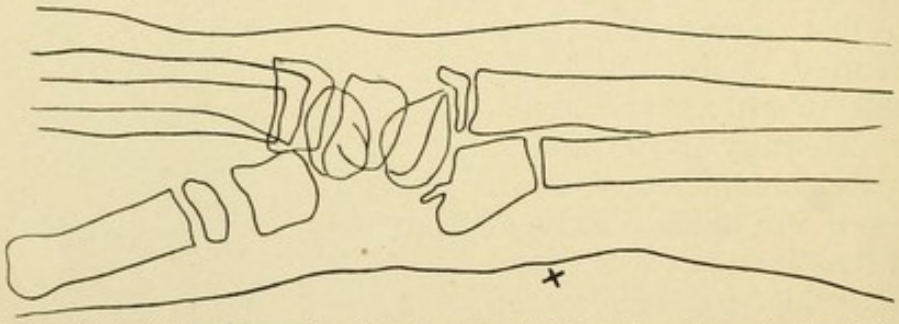

FIG. 287.—Osteotomy of radius to correct deformity shown in Fig. 286. Episcopal Hospital.

Ununited Fractures.—The distinction between *delayed union* and *ununited fracture*, as was pointed out at p. 306, is difficult to draw; save that in the former condition union frequently occurs under conservative treatment, while in ununited fracture it rarely does. The most marked degree of non-union, constituting *pseudarthrosis*, is that in which a bursa forms between the ends of the fragments, there being almost a flail-like joint present (Fig. 288). In ordinary cases there is rather dense fibrous tissue between the ends of the bones, which are pointed and atrophic; and while this may prevent lateral displacement of the fragments, it allows angulation at the seat of fracture.

Causes.—The chief causes of non-union in fractures are: (1) Failure to secure end-to-end apposition of fragments. (2) Comminution of the fragments, especially in compound fractures. (3) Imperfect immobilization soon after the accident. (4) Interposition of soft tissues. (5) Constitutional condition of the patient, rendering his

processes of repair ineffectual. These factors, several of which may co-exist, are mentioned in what I believe is their order of frequency, with the possible exception of the patient's constitutional condition, which in many cases undoubtedly is the chief cause of non-union. But it should be noted that interposition of soft tissues, though comparatively infrequent, always results in non-union when present.

Diagnosis.—The diagnosis rarely presents difficulties, if the seat of injury is carefully and repeatedly examined; it is a truism to state that the firmer the union the more difficult it is to detect motion. A skiagraph may aid, since it will show absence of bony structure between the fragments.

Treatment.—The treatment depends upon whether the patient is seen during the stage of delayed union, or whether he first comes under the surgeon's observation when non-union has existed for months or years. The surgeon should endeavor to ascertain the cause of the condition, and should attend to the patient's general health, administering cod liver oil, phosphates, thyroid extract, etc. If separation of fragments can be excluded, conservative measures should be tried first In the case of delayed union, the first thing to do is to try what strict immobilization for a period of four to six weeks will accomplish: this frequently secures firm union; but if it fails, trial should be made of functional use of the part, with the fracture supported in splints, braces,

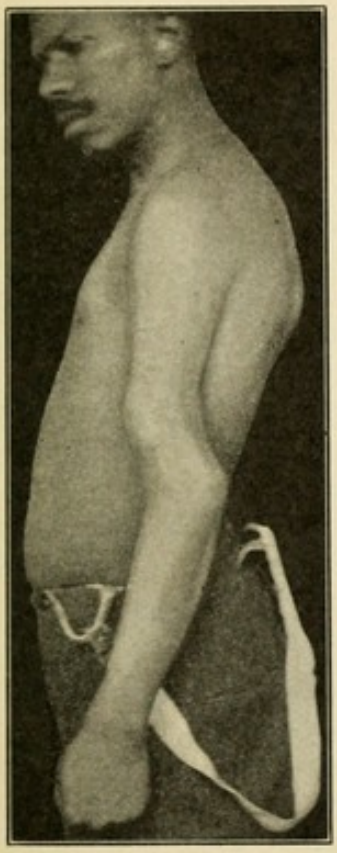

FIG. 288. — Pseudarthrosis of humerus with ankylosis of elbow, following compound comminuted fracture. Not suitable for operation. Episcopal Hospital.

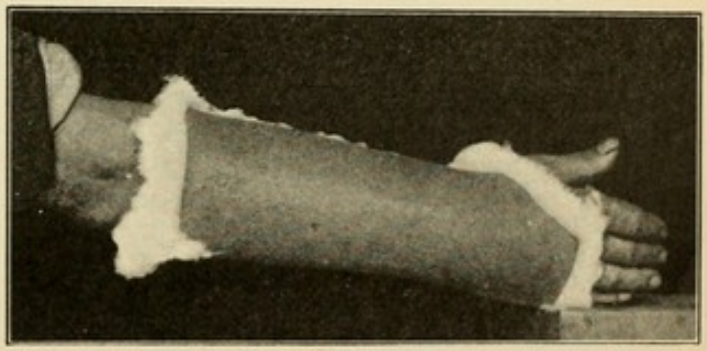

FIG. 289.—Moulded binder's-board splint, for delayed union after fracture of both bones of forearm. Episcopal Hospital.

etc.; and of rather vigorous massage of the affected limb. A fracture of the leg bones with delayed union frequently will grow firm when the patient begins to walk around in his gypsum case; for delayed union of the femur a well fitting walking brace is more efficient; while for the humerus or forearm a light splint of binder's-board to support the seat of fracture will allow free use of the hand and

elbow. The patient (Fig. 289), a skiagraph of whose forearm is shown in Fig. 347, cured his own delayed union by returning to his blacksmithing work, securing perfect functional use in spite of the bony deformity, which, however, was not appreciable through the thick mass of muscles.

Should this degree of stimulation fail to develop osseous union, the patient may be anesthetized, and the ends of the bones vigorously rubbed together, and then immobilized for a few weeks; this procedure often arouses osteogenetic processes and secures firm union when milder methods are ineffectual. Bier (1905) advocates stimulation of osteogenesis by injecting around the ends of the fragments 30 to 40 c.c. of venous blood freshly drawn from the patient.

If conservative measures fail, the question of operation rises; but in every case the surgeon should stop to consider whether any operation is apt to improve matters, or whether the patient has not a sufficiently useful limb as it is. The mere doing of an operation does not ensure the occurrence of bony union; it may leave the patient with non-union, and with increased shortening, since resection of the fragments usually is necessary. But where deformity can be decreased, and disability lessened, operation is indicated.

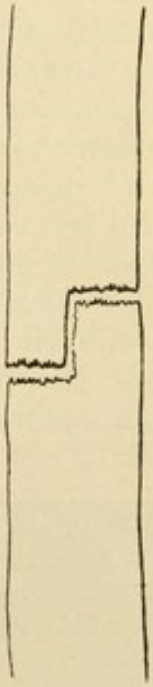

Fig. 290.—A form of mortise and tenon joint useful in operations for ununited fracture.

Operation.—The fracture is exposed through the proper muscular interspace, exuberant callus is removed with gouge, chisel, and Volkmann's sharp spoon, and the ends of the fragments are freshened with the saw, the least possible amount of bone being removed which exposes healthy osseous structure and allows proper apposition. In some cases simple end-to-end approximation is sufficient; in others a form of mortise and tenon joint is preferable (Fig. 290). In either case it is desirable to fix the fragments, and undoubtedly the best way to secure this and to encourage osteogenesis is by use of a bone transplant, taken from the crest of the patient's tibia (p. 504). The transplant may be set in the medullary cavity (intramedullary splint), or, which is easier, a slot may be cut in each fragment, and the transplant implanted laterally as a bridge. In the hip (ununited fracture of the cervix) I have secured a well-nigh perfect result by driving a bone peg through the fragments (Fig. 291). The use of such transplants is fast superseding the employment of steel plates and wire in operations for ununited fracture. The strictest aseptic technique is requisite to secure satisfactory results.

The wound should not be drained, if strict hemostasis has been secured before closing it, but in doubtful cases it is safer to leave a tube in place for thirty-six to forty-eight hours. If a sinus persists after recovery, as sometimes is the case when the plate or wire suture has been used, the foreign body should be removed, otherwise it may be allowed to remain indefinitely. Dr. Edward Martin has recently removed a silver plate inserted by my father, which only at the expiration of seventeen years began to work loose and produced a sinus.

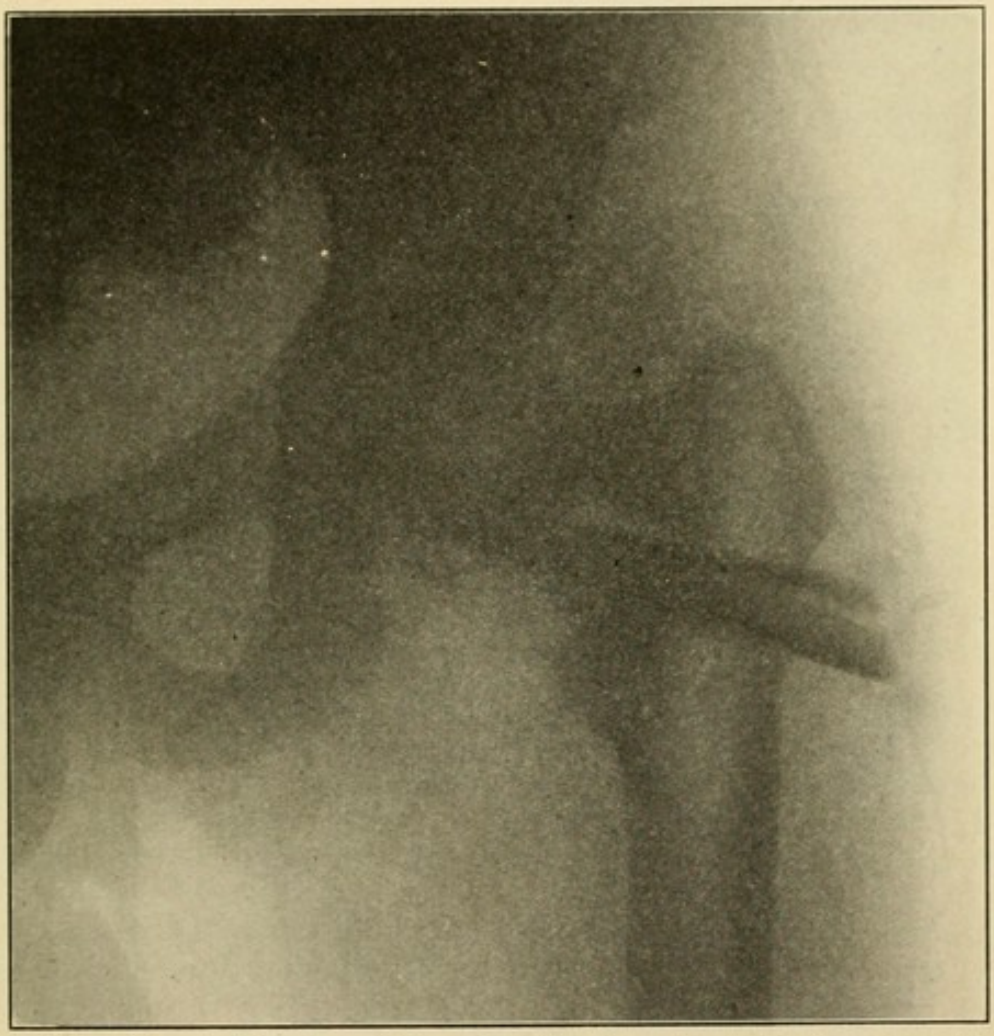

FIG. 291.—Ununited fracture of the neck of the femur treated by bone transplantation. Bony union; no shortening; free motion. Episcopal Hospital.

SPECIAL FRACTURES.

The general subject of fractures and their treatment has been so fully discussed in the preceding pages, and so many excellent monographs on the subject are readily obtainable, that in speaking of the injuries of the several bones I shall be as brief as possible. As fractures of the skull and of the spine are of interest chiefly in connection with injuries to their contained structures, their consideration is postponed to Chapter XVI and XVII respectively.

FRACTURES OF THE FACE BONES.

Injuries of the face bones are due almost without exception to direct violence; edema and ecchymosis often are marked, owing to the abundance of loose cellular tissue overlying the bones, and hemorrhage into the nasal or oral cavities is quite frequent, the fractures being compound on the mucous surface. Antiseptic sprays, mouth washes, etc., are indicated under such circumstances. Union occurs rapidly.

FIG. 292.—Fracture of nose, eighteen hours after injury. Episcopal Hospital.

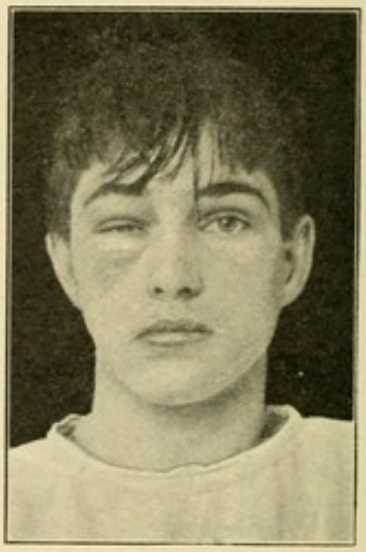

FIG. 293.—Fracture of right malar bone, from pressure by elbow in playing basket ball. Episcopal Hospital.

Nasal Bones.—These may be crushed directly inward, or as is more often the case, may suffer lateral deviation. The epistaxis following the injury usually subsides in a few minutes. The deformity is characteristic, and the diagnosis usually is made by inspection (Fig. 292), and is confirmed by crepitus as the displacement is corrected. This often may be accomplished by external pressure, but in some cases is more effectually secured by leverage from within by a bone elevator. There is no marked tendency for recurrence of deformity, and retentive appliances generally are useless save to protect the part from injury. A strip of adhesive plaster may be carried across both cheeks and the bridge of the nose, as a precaution. As swelling subsides, deformity may appear more evident, and often it is desirable to mould the nose into shape by pressure every day or so during the first week. Rarely can complete symmetry be restored. Union is firm in ten days or two weeks.

Malar Bone.—This is rarely fractured. Usually there is depression, (Fig. 293) which is best overcome by early incision under an anesthetic and direct elevation of the fragment. Fractures of the *zygoma* often are comminuted, and require the same treatment.

Maxilla.—Fractures of this bone are not frequent, but sometimes occur with multiple fractures of the face. They are often compound into the nose or mouth. Asymmetry of the alveolar process is the main diagnostic point. Impaction is usual, and must be reduced to restore symmetry. If maintenance of reduction proves difficult, it is well to have a special splint constructed by a competent dentist (Aller, 1914).

Mandible.—Fracture of the lower jaw is the most important, and, with exception of the nasal bones, probably the most frequent of those of the face. It is due frequently to a blow from the fist, sometimes to the kick of a horse, to sudden jerking upward of a mule's head, or to a fall. Fracture involves either the *body* of the bone, the *condyle*, or the *coronoid process*.

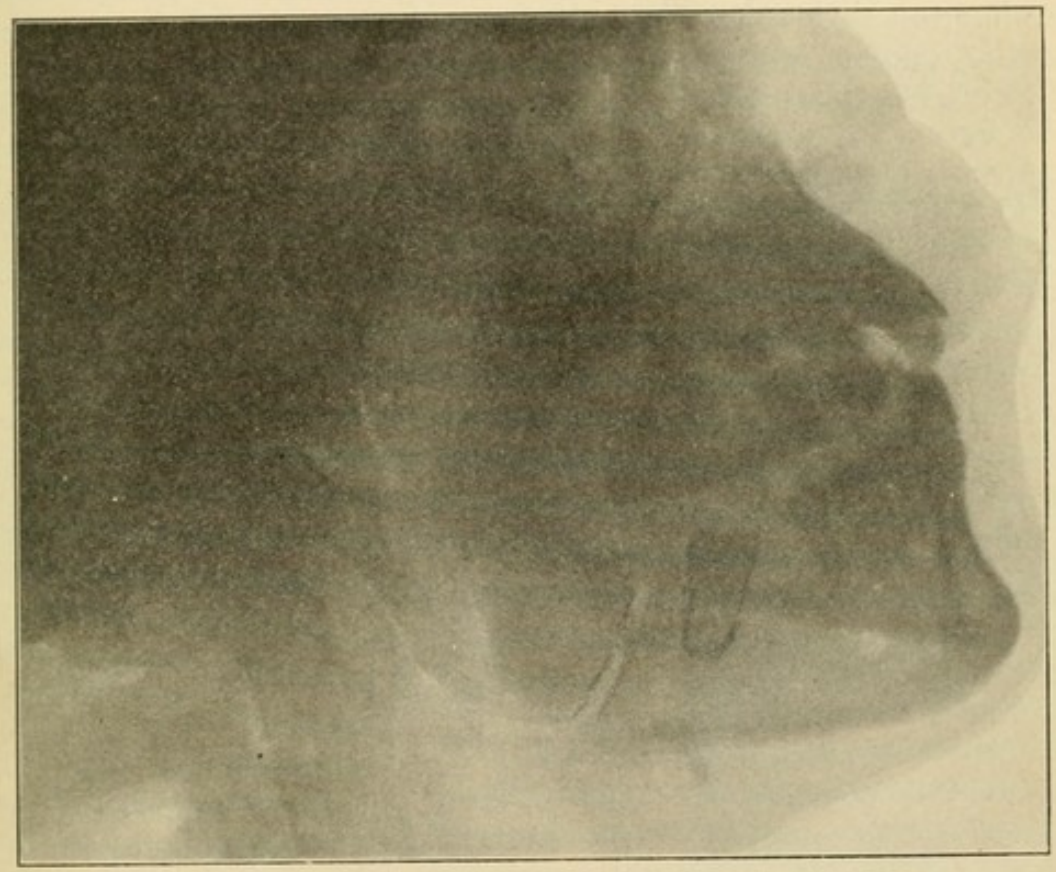

FIG. 294.—Skiagraph of fracture of mandible in front of angle. Age twenty-seven years. Episcopal Hospital.

Fracture of the body of the mandible occurs either near the symphysis, or, most often, anterior to the insertion of the masseter muscle. A rare fracture is detachment of the mental eminence, carrying the genial tubercles, and (by relaxation of the geniohyoid and geniohyoglossus muscles) permitting the tongue to fall backward, perhaps suffocating the patient; this fracture requires immediate operation with suture of the fragment (G. G. Davis, 1894). A similar condition may exist in a double fracture of the jaw, on each side of the symphysis. Fracture in front of the masseter muscle, or posterior to the mental

foramen, is the most frequent injury: the line of fracture usually is bevelled, permitting separation of the fragments as the posterior is drawn toward the middle line by the mylo-hyoid and internal pterygoid muscles; the corresponding muscles of the uninjured side increase the deformity by acting similarly on the unbroken side of the jaw (Fig. 294). In most cases good results follow immobilization for three or four weeks by a modified Barton bandage using the upper jaw as a splint; tendency to displacement becomes less a few days after the injury. Fixation by a special interdental splint of gutta-percha, such as is made by dentists, though it may be unnecessary, undoubtedly promotes the patient's comfort, and recovery ensues with little or no deformity. Double or compound fractures frequently require operation, with wiring of the fragments.

Fracture through the neck of the condyle is a serious injury, often leading to ankylosis (p. 659): the external ptyergoid muscle, attached to the condyle, rotates its broken surface forward, and as it is very difficult to replace this by manipulation, operation is indicated. If the fracture is overlooked in children, disuse of the jaw following ankylosis may result in marked retrognathism.

Fracture of the coronoid process, a very rare accident, is difficult to detect, as separation of the fragment is prevented by attachment of the temporal muscle far down the inner side of the ramus. Treatment consists in procuring rest by bandages until acute symptoms subside.

FRACTURES OF THE BONES OF THE TRUNK.

Sternum.—This is an unusual fracture, generally due to direct violence, the patient being crushed beneath a fall of earth, etc.; some cases are due to muscular action, such as violent lifting effort, parturition, etc. Visceral injury is to be feared, especially in cases caused by direct violence; it is manifested by hemoptysis, dyspnea, cyanosis, subcutaneous emphysema, etc. The line of fracture usually is transverse, and sometimes consists in a diastasis between the manubrium and gladiolus; more often a true fracture exists above or below this joint, the lower fragment projecting in front of the upper. Attempts, not always successful, are made to reduce the deformity by hyperextension of the spine over a small pillow, and drawing the arms backward. Crepitus may be detected during this manœuvre. The sternal region is then immobilized by broad strips of adhesive plaster, passed from axilla to axilla, while the chest is collapsed in expiration. In uncomplicated cases recovery is rapid, union being firm in three or four weeks. Suppuration may follow in case of extravasation into the anterior mediastinum, and is to be treated by intercostal incision or trephining the sternum.

Fracture of the ensiform process may unite with deformity, the xiphoid being turned backward and causing gastric distress (*xiphodynia*). This is best relieved by excision of the xiphoid.

Ribs.—Fractures of the ribs dispute with those of the clavicle the first place in frequency among all fractures. The injury, commonest in male adults, may be caused by direct or indirect violence; in the latter case the force usually is applied antero-posteriorly, and the ribs break at their weakest point when the limit of elasticity has been reached. The ribs most often broken (usually two or more at once) are those from the fifth to the ninth, usually in the axillary or posterior axillary line. There is great pain on forced inspiration, and on sudden motion; localized tenderness, sometimes distinct mobility and crepitus. By using a stethoscope crepitus can be detected in almost all cases, and may be traced up to its origin even from a distance. Visceral complications are unusual but serious; they should be looked for: subcutaneous emphysema indicates partial rupture of the lung; hemothorax is a grave complication, and traumatic pneumonia very fatal.

Treatment.—Treatment comprises immobilization, but rarely confinement to bed. Broad strips of adhesive plaster are applied, at the end of each forced expiration and with the arm on the affected side dependent; they run from below upward, beginning at the spine, and extending just to beyond the midline in front (Fig. 295). Immobilization of both sides of the chest is undesirable. This strapping should be renewed as often as it comes loose, every five or six days; and should be continued for four or five weeks. For the persistent pain and neuralgia which sometimes follow these injuries, massage and antirheumatic remedies may be tried; the disability seldom persists long. The treatment of injuries of the thoracic viscera is considered in Chapter XX (p. 733).

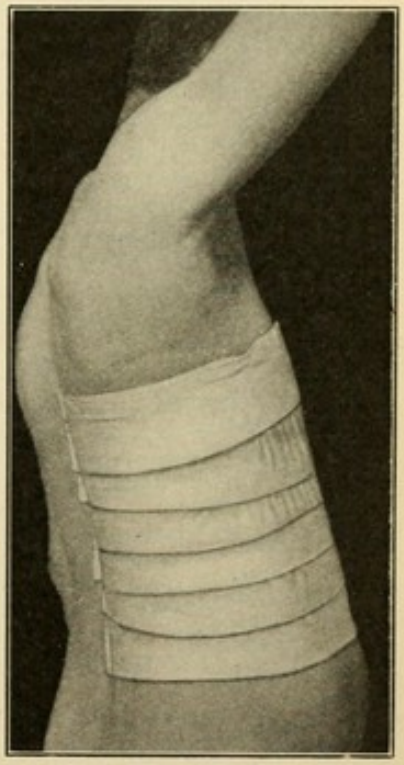

Fig. 295.—Adhesive plaster-strapping for fracture of ribs, applied with arm dependent; arm raised before photograph was taken. Episcopal Hospital.

Costal Cartilages.—These sometimes become detached at their junction with the ribs. Treatment is similar to that for fracture of the ribs.

Pelvic Bones.—These fractures usually are caused by direct violence, and are of interest chiefly from their visceral complications, which are met with in about one-sixth of the cases (Ashhurst, 1909), the general mortality being over 30 per cent. The most important are those fractures which *break the ring of the pelvis:* when the force is received antero-posteriorly, as when a heavy weight knocks a man down and lands on his symphysis pubis, the anterior part of the pelvis is crushed inward, fracturing the rami of the pubes and ischium on one or both sides or bursting the symphysis pubis, and

spreading the halves of the pelvis apart, perhaps causing diastasis of the sacro-iliac joints, or fracture of the ilium through the sacro-sciatic notch (Fig. 296). When the force is received laterally, the most frequent fracture which involves the ring of the pelvis is a vertical fracture in the neighborhood of the symphysis pubis, and one of the ilium behind the acetabulum; but force transmitted through the femur may cause comminuted fracture of the acetabular region, *not involving the pelvic ring*. Of fractures which do not involve the pelvic ring those

FIG. 296.—Fracture of pelvis, from antero-posterior force. Note diastasis of symphysis; fracture through innominate bone from iliac crest to sacrosciatic notch; separation of sacro-iliac joint. Recovery. Episcopal Hospital.

detaching one of the iliac crests are most frequent, usually being due to lateral force (Fig. 237), though the anterior superior spine alone has been detached by muscular action. The various fractures are not difficult to diagnose, as displacement usually is quite appreciable to palpation, which should always include rectal or vaginal examination. If displacement is slight, persistent localized tenderness, especially of one of the pubic rami, is a valuable sign; and a skiagraph may aid. Crepitus often is evident on attempts at motion; pain is experienced

when the trochanteric regions are crowded together, or when attempts are made to move one innominate bone on the other. While *operation* may be required for visceral complications (rupture of urethra, bladder, abdominal wall, internal hemorrhage, etc.), the fractures themselves generally unite with little difficulty. The pelvis should be immobilized by a broad canvas belt or strips of adhesive plaster; and it often is well to secure relaxation of the adductors, sartorius and rectus muscles by keeping the thighs moderately flexed. Some disability may persist from shortening of one lower extremity, due to imperfect replacement of the fragments, or from mobility due to diastasis of one of the pelvic joints.

Fracture of the Acetabular Rim is a rare injury due to force transmitted through the femur, which may become subluxated upward and backward. The diagnosis is difficult without a skiagraph. Treatment consists in applying weight extension to the femur in the abducted position, after replacing the head in its socket, and maintaining this position for three or four weeks. Use of the limb should not be allowed for ten or twelve weeks after injury.

Under the name **Central Dislocation of the Hip** is described a stellate fracture of the acetabulum caused by the head of the femur being driven through it into the pelvis by direct violence acting in the axis of the femoral neck; pregnancy seems to be a predisposing cause. Henschen (1909) has collected 139 cases. Skillern (1911) classifies the lesions as "fractura perforans" and "perforatum," according to the degree of intrapelvic displacement. The diagnosis is made from flattening of the trochanter and relaxation of the supratrochanteric structures; by palpating the luxated head in the pelvis by a finger in the vagina or rectum; and by recurrence of deformity, with crepitus, after reduction. The intrapelvic spicules of bone should not be replaced until the head of the femur has been withdrawn. The thigh should be dressed in plaster of Paris in a flexed and adducted position, and the patient should bear no weight on the limb for two or three months.

Fractures of the Sacrum and Ischium are rare. The tuber ischii has been detached by muscular violence.

Fractures of the Coccyx follow falls or kicks or parturition, and may readily be diagnosed by inserting the index finger into the rectum and grasping the coccyx between this and the thumb, when abnormal mobility and perhaps crepitus will be detected. If forward displacement is persistent, it is best to excise the occcyx at once, since if the bone unites in bad position, or if non-union results, there often ensues in women a train of neurasthenic symptoms constituting the affection known as *coccygodynia*. This is characterized by local pain, interference with defecation, vesical irritability, and sometimes a life of invalidism; all of which may be cured by removal of the entire coccyx at the sacrococcygeal articulation.

FRACTURES OF THE UPPER EXTREMITY.

Clavicle.—The entire upper extremity depends on the clavicle for its bony connection with the trunk, and this bone, therefore, is exposed to all manner of strains transmitted from the periphery. The patient falls on the hand, or on the point of the shoulder, or rarely receives a blow directly on the clavicle, which gives way usually at its weakest part, between the attachments of the sterno-mastoid and trapezius on its upper surface, and those of the pectoralis major and deltoid on its lower surface, approximately at its middle, where the two curves of the bone meet. The line of fracture nearly invariably is oblique from before backward and from without inward; and as the main function of the bone is to prop the shoulder away from the trunk, giving the humerus a greater range of motion, the main deformity consists in the shoulder falling inward and forward,

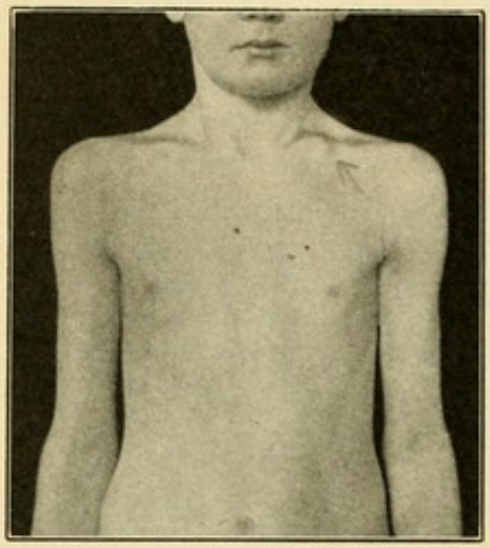

FIG. 297.—Deformity from fracture of left clavicle, much more noticeable than the average case. Episcopal Hospital.

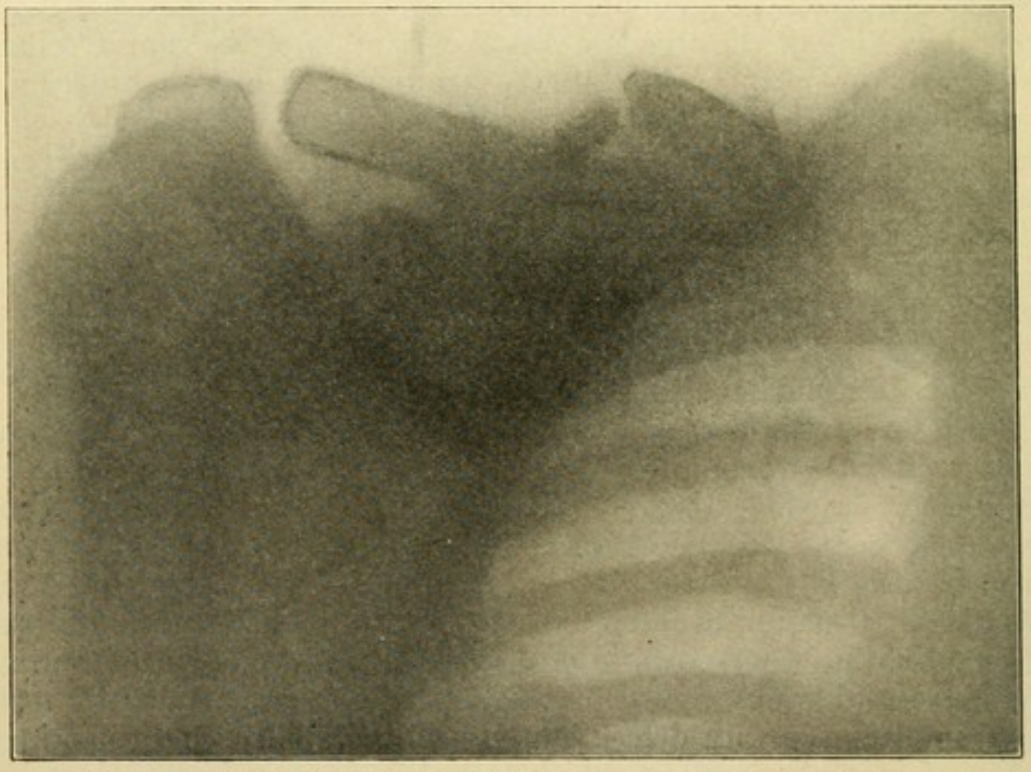

FIG. 298.—Skiagraph of fracture of clavicle, with slight comminution, from direct violence. Age twenty-three years. Episcopal Hospital.

toward the trunk, by contraction of the muscles of the axillary folds, while the weight of the upper extremity causes slight dropping of

the shoulder. The inner end of the clavicle remains in its normal position, or possibly is raised a little by the sterno-mastoid; and at the outer end of this fragment a depression can be felt, owing to the displacement inward and backward of the outer fragment (Figs. 297 and 298). In rare cases this presses on the subclavian vessels or the brachial plexus, but in the vast majority of cases the fracture is entirely uncomplicated. Owing to the inward rotation of the shoulder, the vertebral border of the scapula may become prominent. The *diagnosis* sometimes is difficult in cases of green-stick fracture, and in fat, chubby children, in whom the outlines of the bones may be hard to detect; but even in cases where deformity is absent, there will be persistent localized tenderness at the seat of fracture. In cases with deformity, the diagnosis is easy, even the attitude of the patient being more or less characteristic; he carries his head bent toward the affected side, supports the injured limb with his other hand, and is unwilling or unable to raise the arm from the side.

Fracture of the Outer End of the Clavicle, a much rarer injury, generally is due to direct violence; if the fracture occurs through the coraco-clavicular ligaments there is little displacement, but if external to them, the outer fragment is carried downward and inward, a displacement which, owing to the posterior convexity of the curve at this point, causes the inner fragment to protrude posteriorly, and produces a characteristic deformity.

Treatment of Fractured Clavicle.—Reduction of the deformity is difficult, and accurate retention of the fragments nearly impossible; nevertheless, such good functional results follow conservative treatment that operation is very rarely performed, especially as a scar would be more conspicuous than the moderate amount of deformity which usually follows conservative treatment. By placing the patient flat on the back, on a hard bed, and with a folded sheet or firm, flat pillow across the bodies of the scapulæ, this will act as a fulcrum and the force of gravity will carry the shoulder backward, rotating the outer fragment out into its normal relation with the inner. If now a small bag of shot were placed over the inner fragment, to press it down against the outer, and the head raised on a pillow to relax the sterno-mastoid, and the upper extremity immobilized by proper bandages; and if the patient could be induced to remain in this position for two or three weeks until union was fairly firm, then recovery without deformity probably would be assured. Couteaud (1909) induced 24 patients to submit to bed treatment, and secured excellent results by letting the arm hang down over the side of the bed for the first two days, thus approximating the fragments by keeping the pectoralis major tense. But even a young girl anxious to preserve her neck from trifling deformity rarely will endure such confinement, and it becomes necessary to devise some means of ambulatory treatment; and though by such treatment entire absence of deformity rarely can be secured, yet recovery of function usually is perfect. The indications are to keep the scapula flat

against the chest, thus rotating the shoulder and outer fragment away from the chest; to steady the inner fragment by a compress;

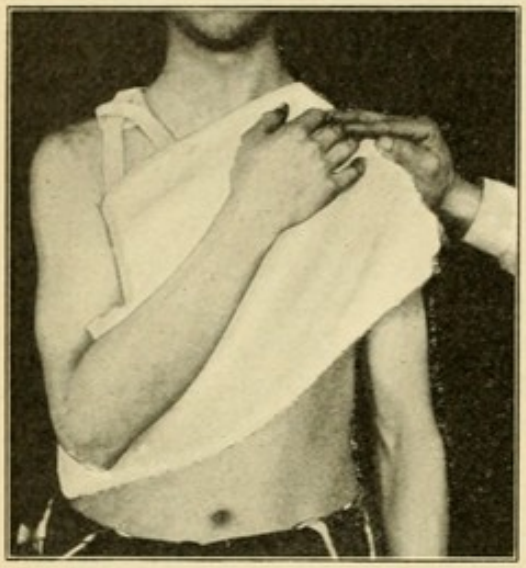

FIG. 299.—Dressing for fracture of clavicle: compress over inner fragment; arm in Velpeau position; fold of elbow and chest protected by lint. Episcopal Hospital.

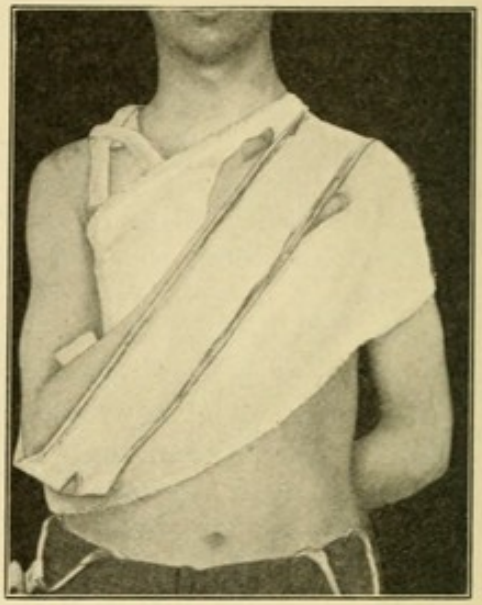

FIG. 300.—Dressing for fracture of clavicle: arm fixed by adhesive plaster. Episcopal Hospital.

and to support the weight of the upper extremity. The fact that myriad dressings have been devised to meet these points sufficiently indicates that none of them is entirely efficient. In children a posterior figure-of-eight bandage (Fig. 89), drawing the shoulders back-

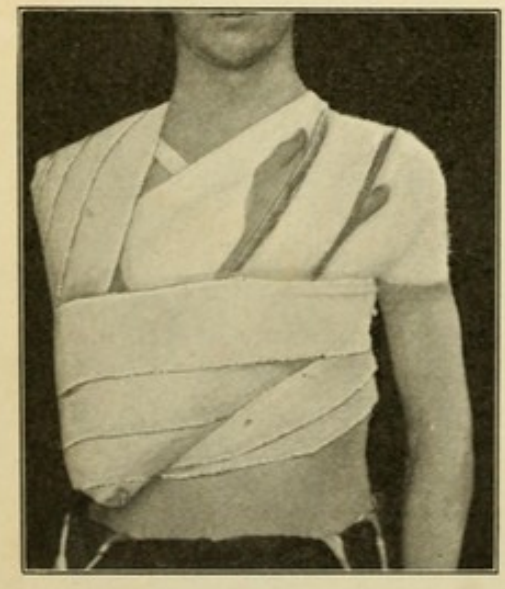

FIG. 301.—Dressing for fracture of clavicle: application of Velpeau bandage. Episcopal Hospital.

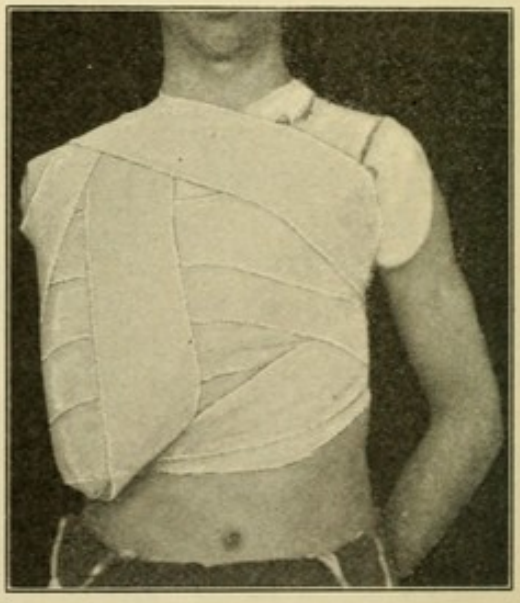

FIG. 302.—Dressing for fracture of clavicle: Velpeau bandage reinforced by figure-of-eight turns around elbow, shoulder and axilla. Episcopal Hospital.

ward, with a compress over the inner fragment, and with the arm supported in a sling, usually gives very satisfactory results. In adults,

in whom the parts are more difficult to fix, I prefer to use the dressing indicated in the accompanying illustrations. After strapping a compress over the inner fragment, and fixing the scapula by a broad strap of adhesive plaster passing across the back to the axilla of the sound side, a piece of lint is placed in the elbow, the axilla is dusted with

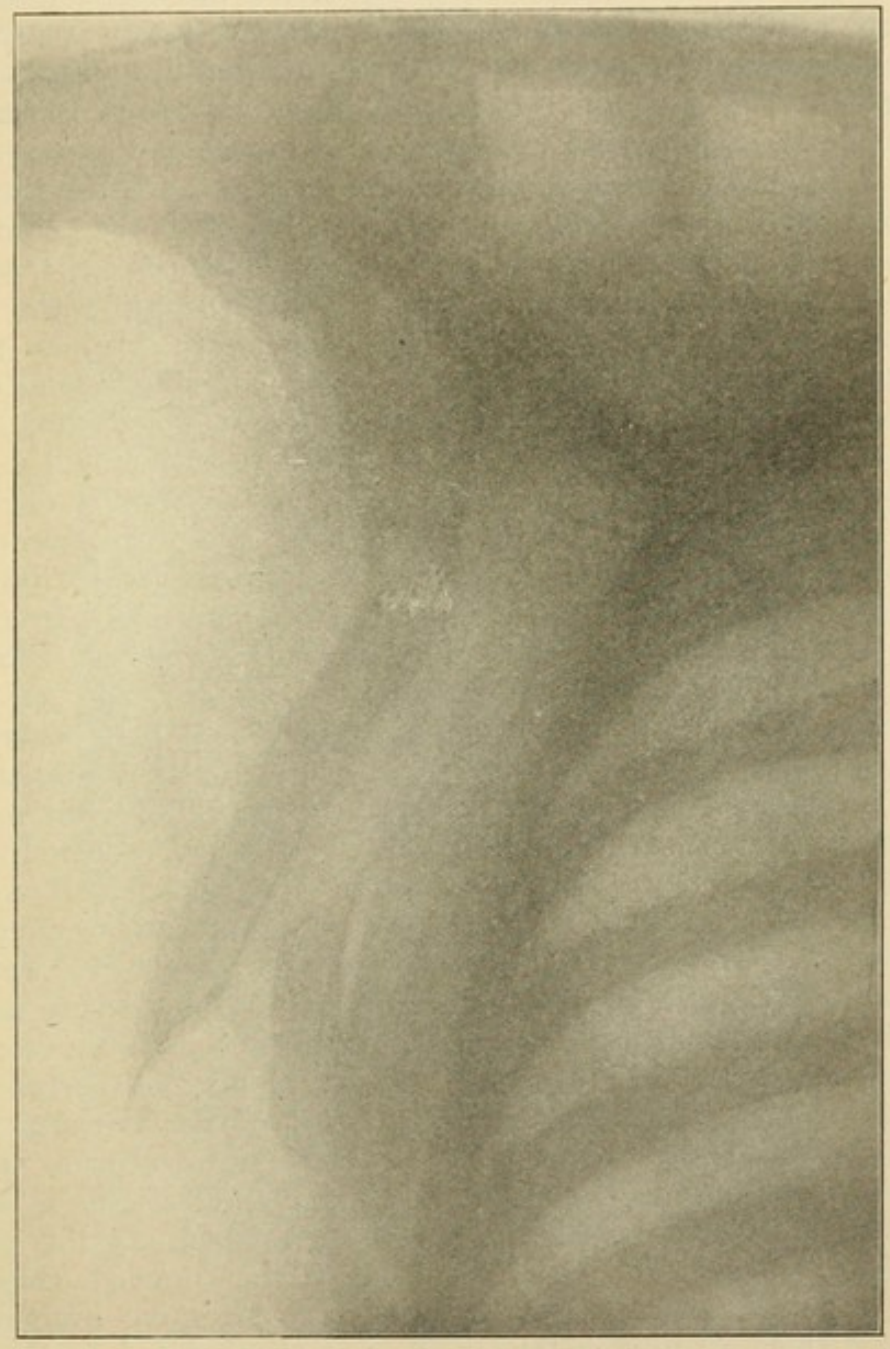

FIG. 303.—Fracture of scapula through body and near angle. Age twenty-four years. Episcopal Hospital.

boric acid powder, and a large fold of lint is fastened across the chest (Fig. 299); the arm is then slung to the chest by a board band of adhesive plaster (Fig. 300); a Velpeau bandage is then applied, fixing the arm to the chest (Fig. 301); this is reinforced by turns of the bandage beneath the elbow, crossing each other over the injured

shoulder, and passing beneath the axilla of the opposite side (Fig. 302). The last turns support the upper extremity and pull the inner fragment down, forming a valuable addition to the Velpeau bandage. This dressing need not be renewed until it comes loose—usually not for six or seven days; and at the end of four weeks may be discontinued, and the arm merely carried in a sling, its active use being prohibited until six weeks from the time of the accident. Rarely is any after-treatment required, normal use restoring function in a short time.

Scapula.—This generally is broken by direct violence. *Fractures* of *the body* of the scapula (Fig. 303) usually are more or less transverse, and the fragments are not much separated: but by fixing the angle with one hand, and manipulating the shoulder with the other, both crepitus and mobility may be detected in most cases. Disability rarely is marked. Treatment consists in immobilizing the upper extremity for four or five weeks. *Fractures of the acromion process* are more frequent than those of the body of the bone, and are to be diagnosed by persistent localized tenderness following direct injury, sometimes by crepitus, but rarely by distinct mobility unless the line of fracture is distinctly posterior to the acromio-clavicular joint. Skiagraphic confirmation is desirable, and will serve to distinguish this injury from *separation of the epiphysis*, which probably is a more frequent injury, but clinically indistinguishable from fracture. Immobilization for about four weeks is sufficient. *Fracture of the coracoid process* may occur from muscular action, or rarely from direct violence. It is a rare injury, but usually may be detected by painstaking examination, unless the patient is very muscular or fat. The process is pulled downward into the axilla by the muscles attached to it, and often may be felt here, while it is absent from its normal site just below the outer third of the clavicle. If crepitus cannot be obtained in confirmation of apparent displacement and mobility, a skiagraph must be relied on for diagnosis. *Fracture through the surgical neck of the scapula*, the line of fracture passing through the suprascapular notch and detaching both the coracoid and glenoid processes, is a rare injury which may be mistaken for dislocation of the shoulder; in dislocation, however, the arm hangs away from the side, mobility is decreased or even absent, and no crepitus can be obtained; in fracture, though the humerus is carried downward and inward with the detached fragment by the pull of the axillary muscles and those attached to the coracoid, thus producing a hollow beneath the acromion, yet attentive examination will show that there is in the axilla not the isolated head of the humerus, but a bony mass composed of coracoid, glenoid, and humerus, and that the coracoid moves with the humerus and is detached from the scapula. Moreover, there is crepitus and abnormal mobility; and when the deformity is reduced, it recurs at once; none of which phenomena are present in dislocation. Finally, skiagraphic evidence may be called in aid, and usually will determine the matter without doubt. Treatment consists in reducing the deformity as

far as possible, and immobilizing the upper extremity as in fractures of the clavicle; a folded towel or other flat support should be placed in the axilla to aid in retaining the fragment in place. Reduction usually is imperfect, callus may be exuberant, and the restoration of function may be much delayed, perhaps from involvement of the suprascapular nerve.

Humerus.—It is customary to divide these injuries into fractures of the upper end, those of the shaft, and those of the lower end of the bone.

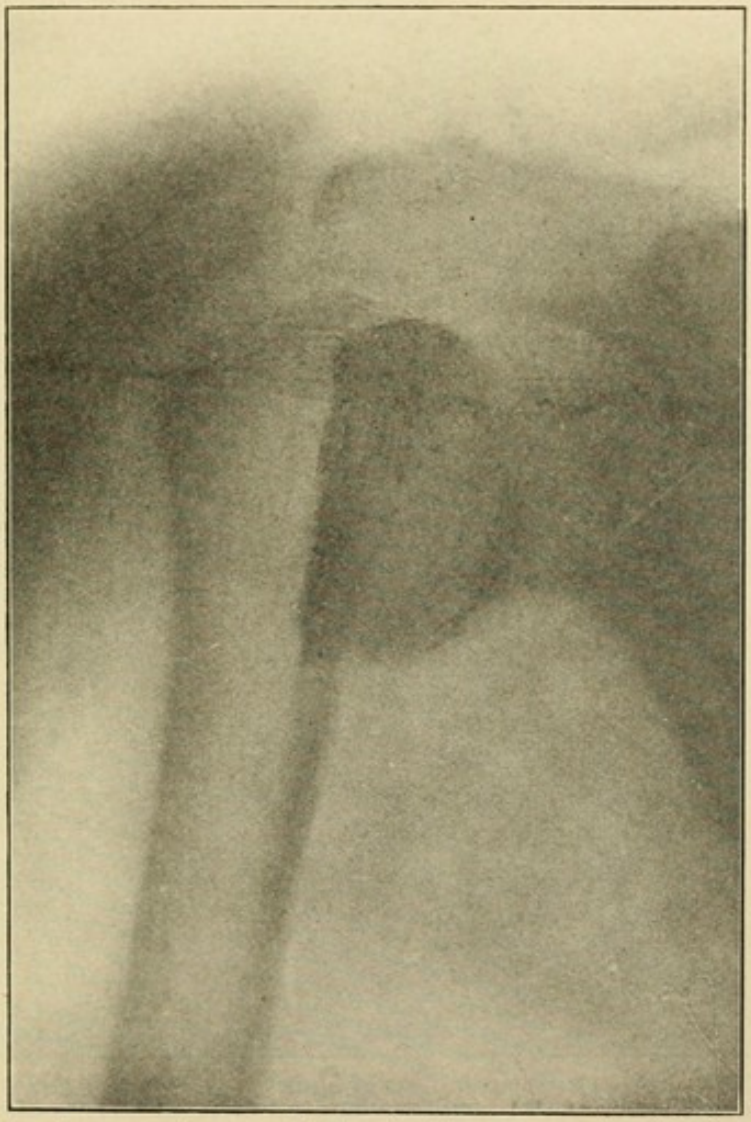

FIG. 304.—Fracture of anatomical neck of humerus. Age fifty-four years. Episcopal Hospital.

Fractures of the Upper End of the Humerus.—*Fracture of the anatomical neck* is a rare injury; the detached hemispherical fragment is wholly or largely intra-articular, and is displaced toward the axilla, turning at right angles to the shaft (Fig. 304). Sometimes the fragment is forced through the capsule of the shoulder-joint, and lies almost subcutaneously in the axilla. Palpation then detects the head in its abnormal position, while the tuberosities retain their

normal relations to the shaft of the humerus and to the acromion. Crepitus may be elicited by pressing the detached head outward against the shaft; but unless the head is clearly palpable a positive diagnosis is very difficult without a skiagraph. Most cases so diagnosed turn out to be high fractures of the surgical neck. If the head is displaced so far as to be almost subcutaneous, it is best to remove it by incision; function will be much better than if the fragment

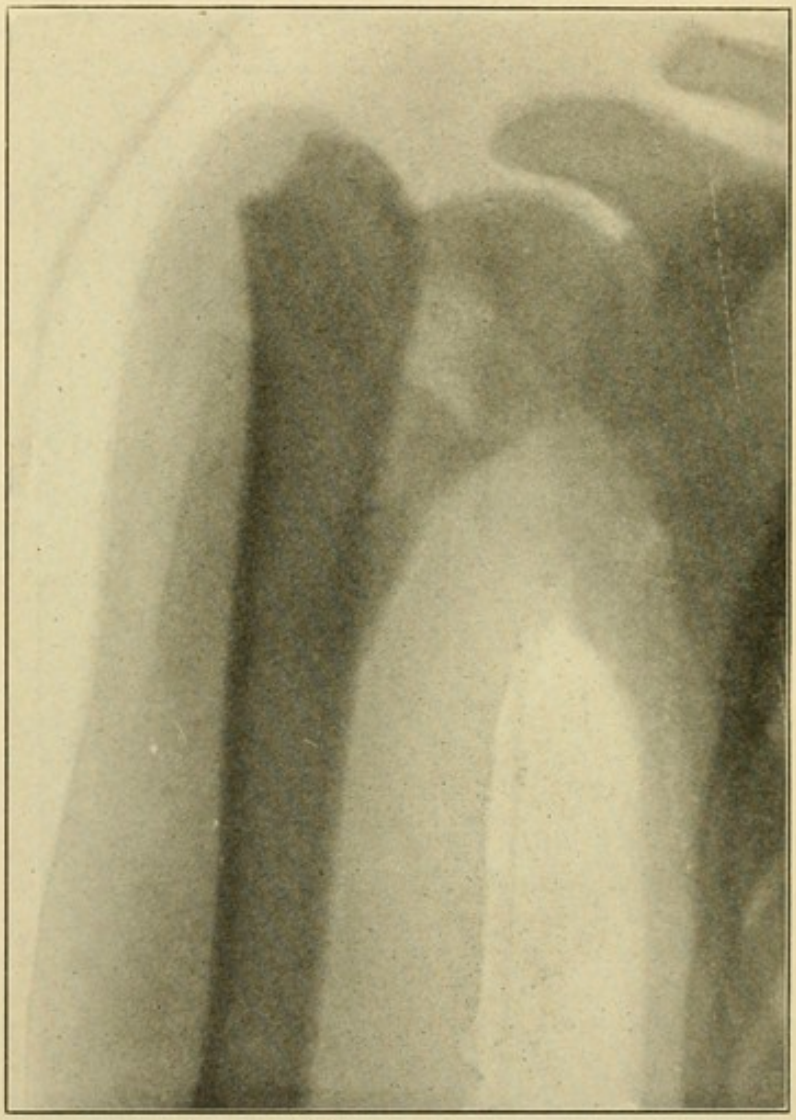

FIG. 305.—Separation of upper epiphysis of humerus. Typical displacement. Note pyramidal shape of upper end of diaphysis, and new formed bone beneath periosteal bridge on inner side of fracture, which has not been reduced. Age nine years.

remains as a foreign body to excite periarthritis. In cases where displacement is slight, the treatment described below for fracture of the surgical neck is efficient. *Fracture of the greater tuberosity* occasionally occurs from muscular action, and more rarely still from direct violence; a sprain fracture is a not unusual lesion accompanying dislocation of the shoulder. The fragment is drawn outward, upward, and backward by the external rotator muscles. Reduction may be easy, but usually is very difficult to maintain even if the humerus is

dressed in abduction. Hence operative fixation by periosteal suture of chromic catgut may be advisable. In other cases, firm bandaging over a shoulder-cap may keep the fragment in place. *Separation of the upper epiphysis of the humerus:* This epiphysis may be separated at any age until it unites with the diaphysis, not later than twenty-five years. The injury is commonest, however, at or about fifteen years of age, though sometimes it occurs as an obstetrical injury. The upper end of the diaphysis is pyramidal in shape (Fig. 305), and the epiphysis fits over it like a cap. The epiphyseal line passes on the surface of the bone just beneath the greater tuberosity, irregularly inward, being intra-articular on the inner side of the humerus, so that the detached fragment (the epiphysis) is somewhat larger than that in fracture of the anatomical neck, but smaller than that in fracture of the surgical neck. The displacement of the epiphysis depends largely on muscular action: the subscapularis in front and the infraspinatus and teres minor behind draw the epiphysis directly inward, while the supraspinatus, being unopposed, tilts its outer margin (the greater tuberosity) upward; the diaphysis usually, but not always, is drawn inward and forward, by the muscles of the axillary folds, and in typical cases is prominent beneath the anterior fibres of the deltoid. *Fracture of the surgical neck of the humerus* is the most frequent injury of the humerus in adults, and is produced usually by a fall or blow on the outer surface of the shoulder. The region included in the surgical neck is that from the epiphyseal line above, to the upper border of the insertions of the pectoralis and teres major muscles below. "High fractures of the surgical neck," sometimes called "fractures through the tuberosities," are in all respects similar to epiphyseal separations, but occur after ossification in the epiphyseal line. The typical displacement in ordinary fracture of the surgical neck consists in the lower fragment being drawn inward by the axillary muscles, and somewhat upward by the deltoid, triceps, and muscles running from the humerus to the coracoid process. Unless impaction is present the diagnosis is not difficult; the tuberosities do

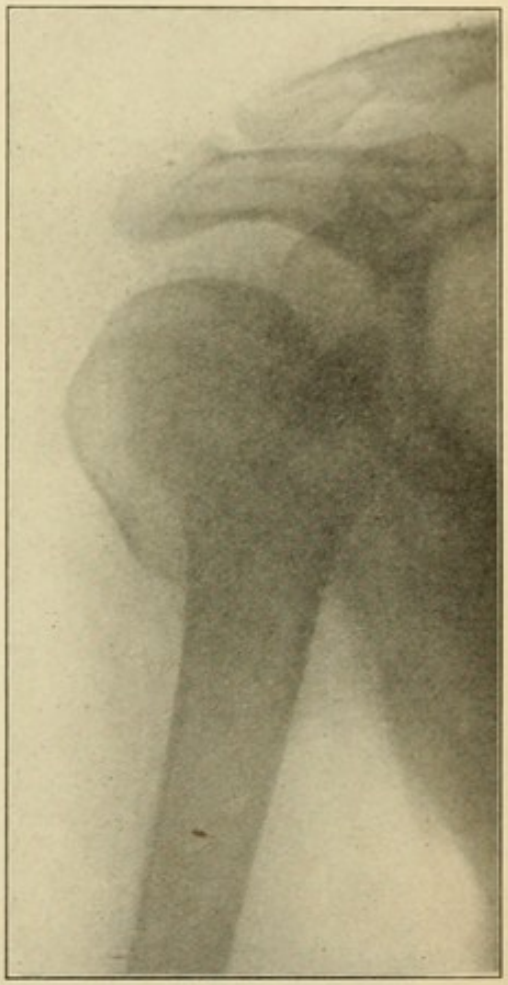

FIG. 306.—Skiagraph of impacted fracture of surgical neck of humerus. (See Fig. 307.) Episcopal Hospital.

not rotate with the shaft, and deformity, mobility, and crepitus are easily detected.

Treatment of Fractures of the Upper End of the Humerus.—After washing the parts in alcohol, a modified Fergusson's dressing (1842) is applied as follows: a primary roller is applied from the metacarpus up to the site of fracture, with the elbow flexed; this prevents swelling of the hand and forearm and adds much to the patient's comfort. The fracture is then reduced, by traction downward in the axis of the body, manipulating the upper end of the shaft so as to push

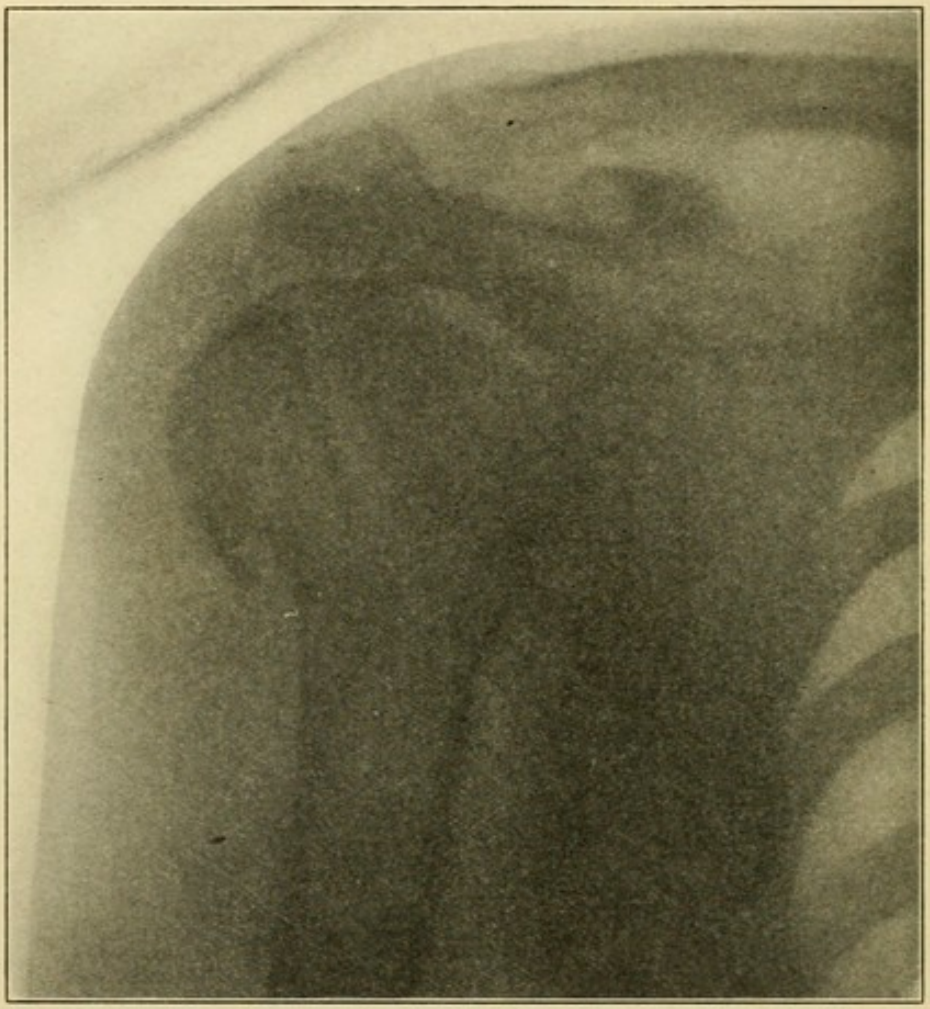

FIG. 307.—Impacted fracture of surgical neck of humerus after reduction under an anesthetic. Compare Fig. 306. Episcopal Hospital.

it out and bring it into contact with the upper fragment. Then a moulded shoulder-cap of binder's-board, well padded, is placed over the shoulder, reaching almost to the elbow, and is held in place by a spica bandage of the shoulder (see Fig. 311). A sufficient amount of raw cotton is then placed between the arm and chest to fill up the natural hollow, and to keep the shaft of the humerus from being displaced inward. The arm is then bandaged to the thorax, and a sling is applied to support the wrist. By leaving the elbow unsupported, thus gaining the advantage of extension by the weight of the limb,

there is less danger of displacement of the fragments. This dressing should be renewed about twice weekly for five weeks. I have never

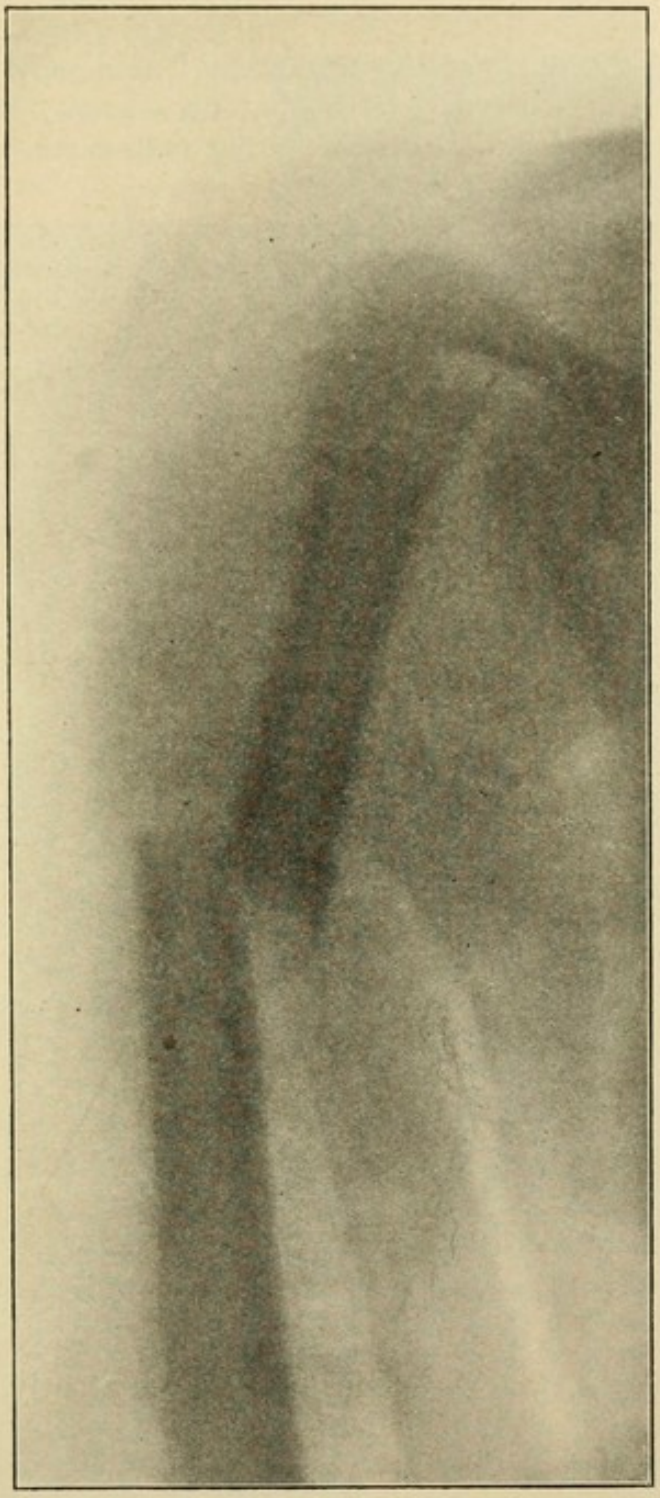

FIG. 308.—Fracture of humerus above insertion of deltoid, lower fragment displaced outward and upward by that muscle. Episcopal Hospital.

found it necessary to dress the arm in abduction in order to secure better apposition of the fragments.

In cases of fracture of the surgical neck *impacted with deformity* I believe it usually is better, except in the very old or feeble, to anesthetize the patient, free the impaction (usually easy) by forced rotation, and reduce the deformity as far as possible (Figs. 306 and 307).

Fractures of the Shaft of the Humerus.—These may occur at any level, usually from direct violence, but occasionally from muscular action. In 1906 I found references to 96 such cases, mostly due to

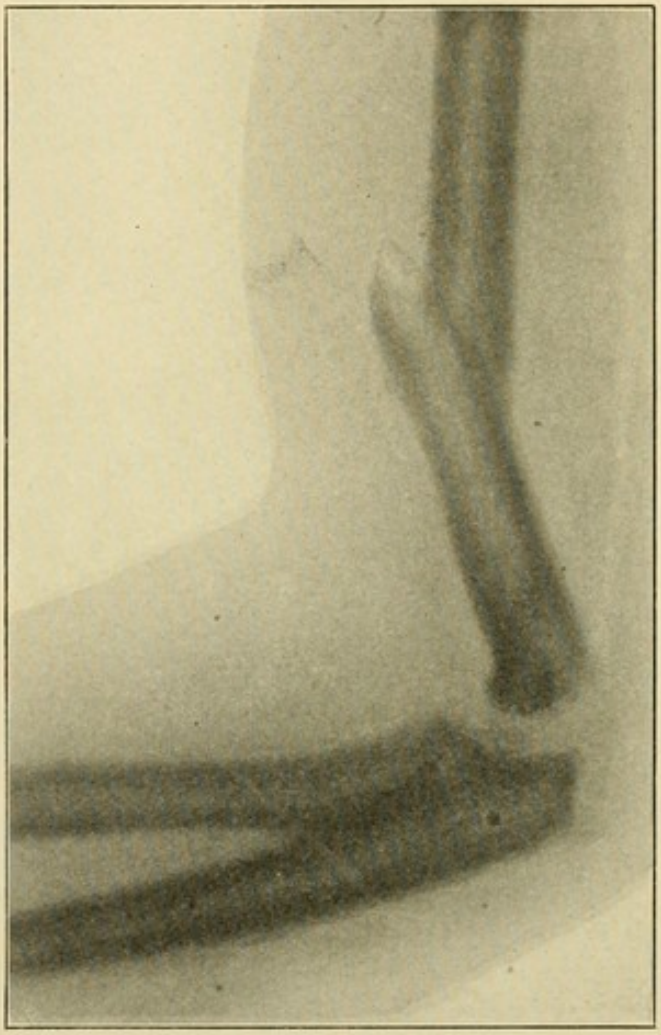

Fig. 309.—Fracture of lower third of shaft of humerus. Episcopal Hospital.

throwing a ball, the two ends of the humerus apparently being twisted apart by violent rotation of the upper end, opposed by the inertia of the rest of the limb. Fractures from direct violence are more apt to be transverse and comminuted, than those caused by indirect violence, which are more or less oblique or spiral. If the fracture is *above the insertion of the deltoid*, there is a tendency for the lower fragment to be carried up and out by this muscle; while the upper fragment is pulled inward by the axillary muscles (Fig. 308); but if the fracture is *below the insertion of the deltoid*, the reverse is

the case, the upper fragment being displaced outward by the deltoid, while the lower is drawn up toward the axilla by the biceps, triceps, and coraco-brachialis. In fractures of the *lower third of the shaft*, which are rarer, there is angular deformity forwards, owing to the action of the muscles arising from the condyles of the humerus which keep the elbow flexed, and thus bring the upper end of the lower fragment forward, as the arm falls by the side (Fig 309). In all fractures of the shaft the diagnosis is easily made, and reduction is not difficult to secure nor to maintain if an efficient dressing is applied. That which I have used with perfect satisfaction is shown in the accompanying illustrations. A primary roller is applied up to the elbow; the arm is surrounded by raw cotton; three coaptation splints of binder's-board are adjusted around the arm, one anteriorly, one posteriorly, and one externally (Fig. 310), and are secured by continuing the bandage up to the axilla; over this a shoulder-cap is next adjusted (Fig. 311), and fixed by a spica of the shoulder (Fig. 312); the arm is finally bandaged to the chest and a wrist sling applied leaving the elbow unsupported to give extension to the seat of fracture (Fig. 313). In rare cases with overlapping of very oblique fractures, weight extension can be applied as an ambulatory dressing (Fig. 314). If the fracture is in the lower third of the humerus an anterior angular splint (Fig. 315) may be used, either alone, or in addition to the use of a shoulder-cap; but in fractures above this region any attempt to immobilize the elbow will result in transferring every motion of the forearm to the seat of fracture in the humerus, and delayed union frequently will result.

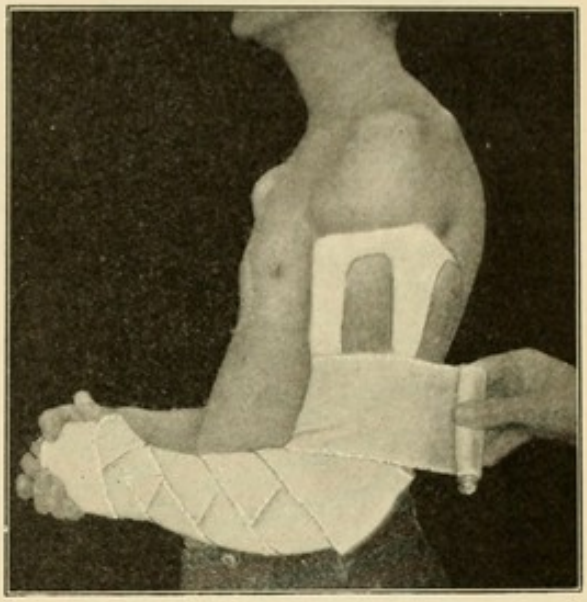

FIG. 310.—Dressing for fracture of shaft of humerus: coaptation splints around seat of fracture. Episcopal Hospital.

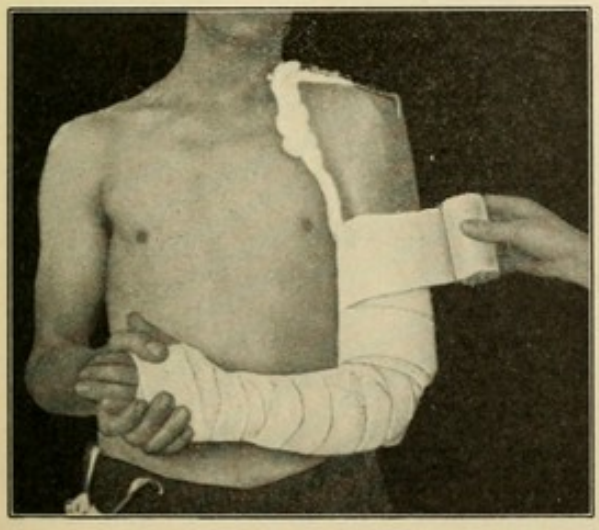

FIG. 311.—Dressing for fracture of shaft of humerus: shoulder-cap applied. Episcopal Hospital.

Fractures of the Lower End of the Humerus.—These are much more frequent in children than in adults. The usual cause in children

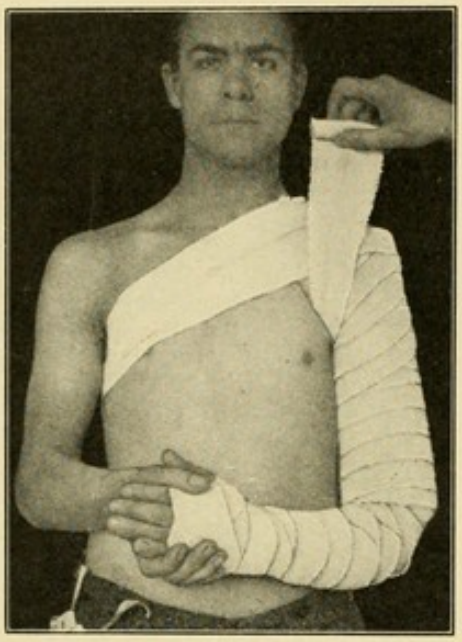

FIG. 312.—Dressing for fracture of shaft of humerus, shoulder-cap secured by spica bandage of shoulder. Episcopal Hospital.

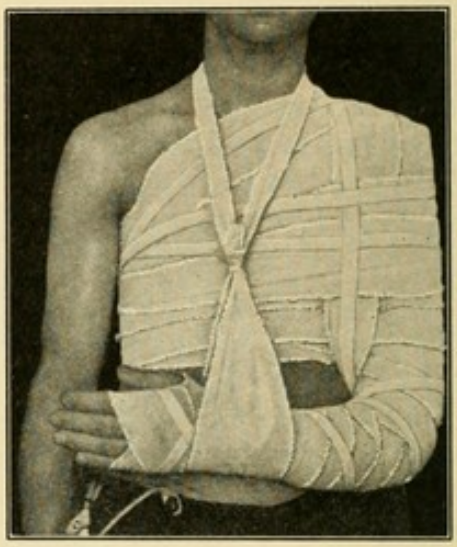

FIG. 313.—Dressing for fracture of shaft of humerus completed and wrist sling applied. Episcopal Hospital.

is a fall on the outstretched hand; in adults such an accident is more apt to cause dislocation if the lesion occurs at the elbow. Direct

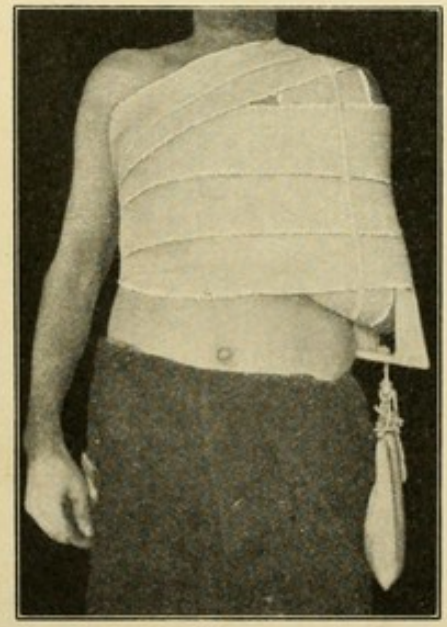

FIG. 314.—Weight extension for fracture of shaft of humerus. Episcopal Hospital.

FIG. 315.—Anterior angular splint applied to elbow. Episcopal Hospital.

injury, often resulting in compound or comminuted fractures, is a more frequent cause of elbow fractures in adults. There are several

distinct types of fracture here, which may be conveniently classified thus (Fig. 316):

1. Supracondylar Fractures
2. Diacondylar Fractures } These are the most frequent varieties.
3. External Condyle
4. Epiphyseal Separation.
5. Internal Condyle.
6. Intercondylar, T or Y.
7. Epitrochlea.

The lower epiphysis of the humerus is developed from a number of centres, and is best studied in a series of skiagraphs of normal elbows: the centre for the capitellum of the humerus appears during the first year of life, that for the head of the radius becoming visible in the sixth year, closely followed by that for the epitrochlea of the humerus. These centres are well shown in Fig. 317. The centre for the trochlea appears at eleven years, and that for the olecranon a little later. Fig. 318 is a lateral view of the normal elbow at eleven years.

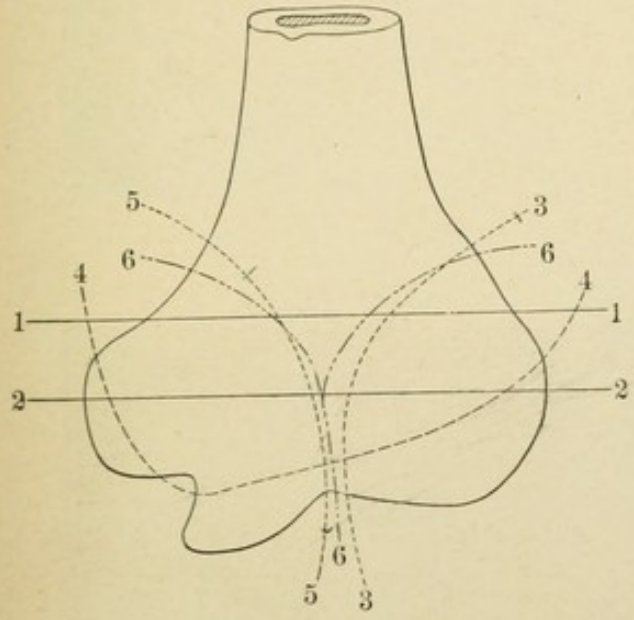

FIG. 316.—Diagram to show classification of fractures of the lower end of humerus.

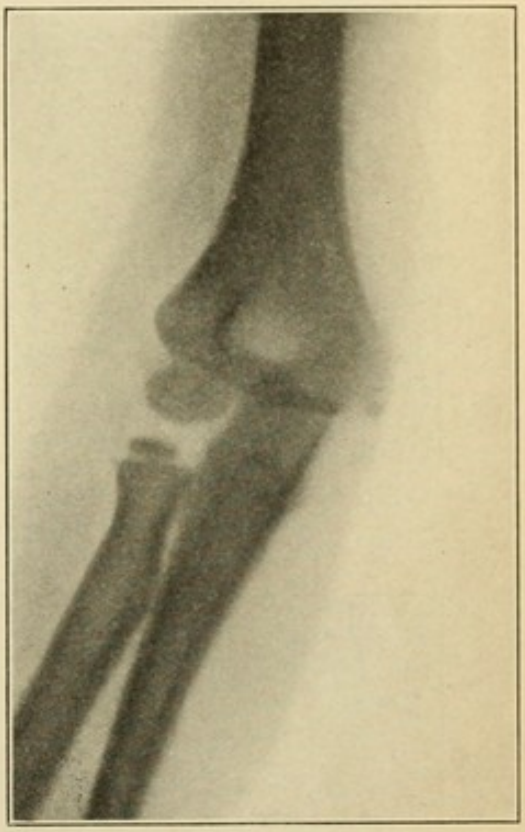

FIG. 317.—Skiagraph showing lower epiphysis of humerus at five years and eleven months (antero-posterior). Episcopal Hospital.

1. *Supracondylar Fractures* usually are due to a fall on the outstretched hand, the elbow being suddenly hyperextended, and the lower end of the humerus torn off partly by ligamentous distraction, partly by the force of the blow, which generally displaces the fragment posteriorly. The line of fracture is oblique from above downward and forward (Fig. 319). Impaction is unusual. When the elbow is extended it is found that lateral motion is possible between the forearm and

arm, the "carrying angle" is lost, antero-posterior movements give crepitus, and often the lower end of the upper fragment can be felt

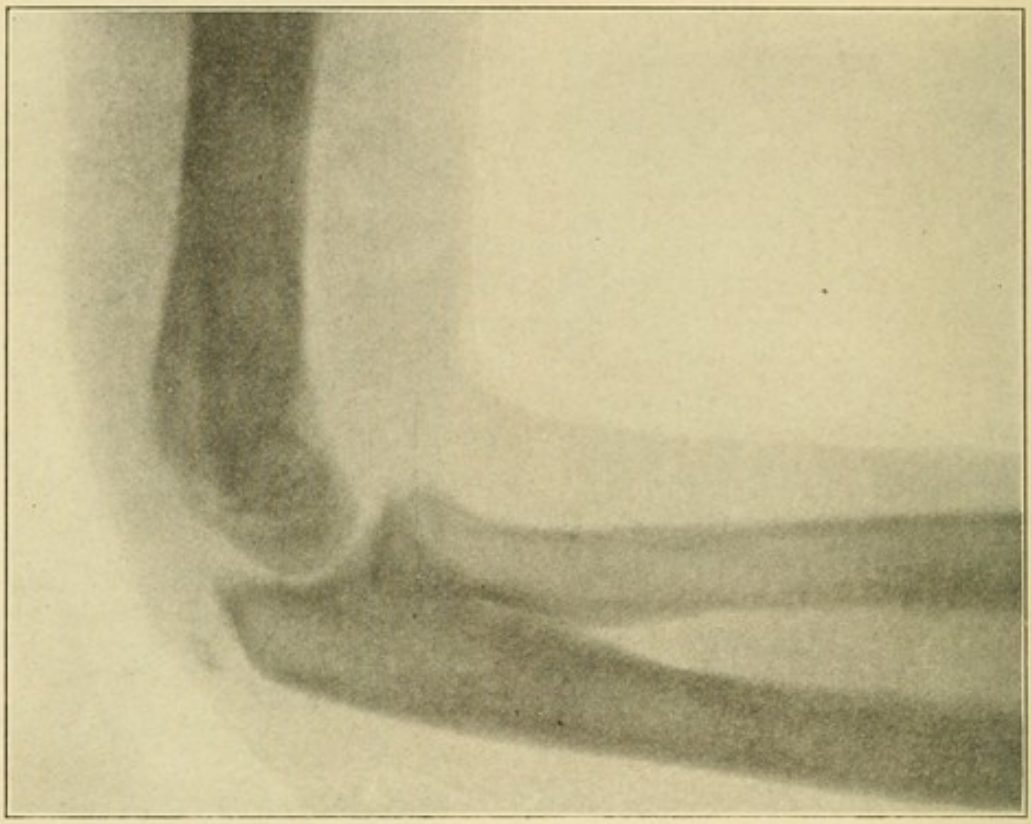

FIG. 318.—Skiagraph of lower epiphysis of humerus at eleven years (lateral). Episcopal Hospital.

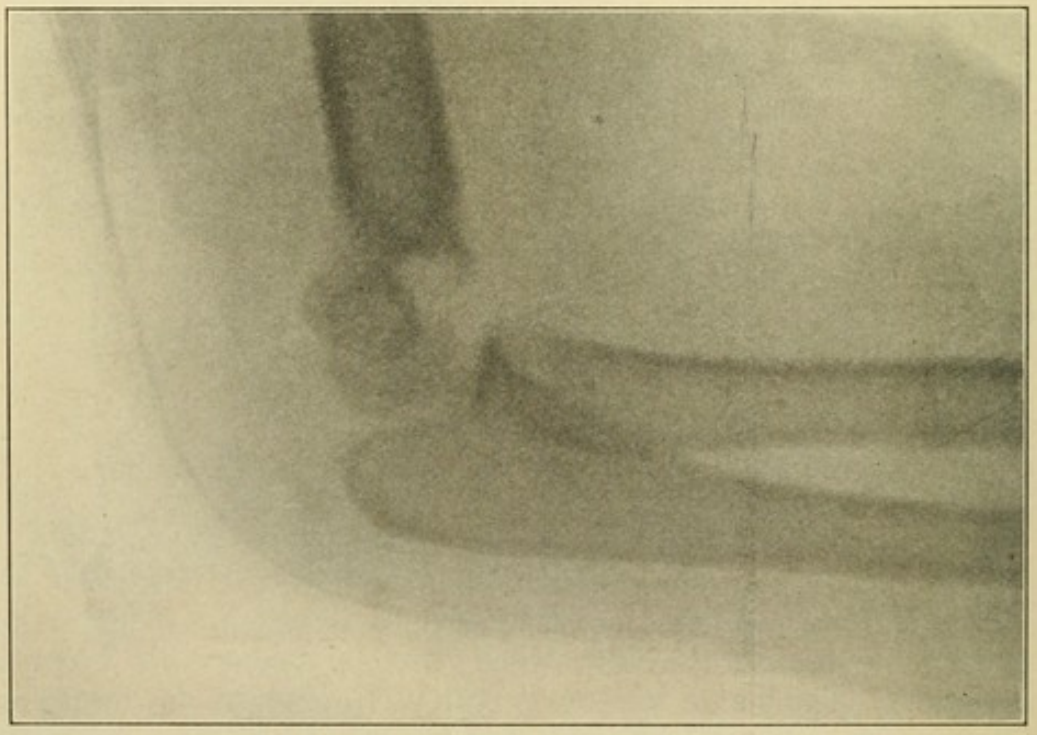

FIG. 319.—Skiagraph of supracondylar fracture of humerus; before reduction, elbow dressed on anterior right-angled splint. Episcopal Hospital.

in the bend of the elbow. The condyles retain their normal relation with the olecranon, which is not the case in posterior dislocation at the elbow, for which the deformity of fracture sometimes is mistaken.

2. *Diacondylar Fractures* are transverse fractures between the level of supracondylar fractures and that of the epiphyseal line. They usually follow a fall on the extensor surface of the forearm, the elbow being flexed, and often are impacted. The line of fracture traverses the thin layer of bone separating the olecranon and coronoid fossæ. Diagnosis is based on the history, the signs of elbow

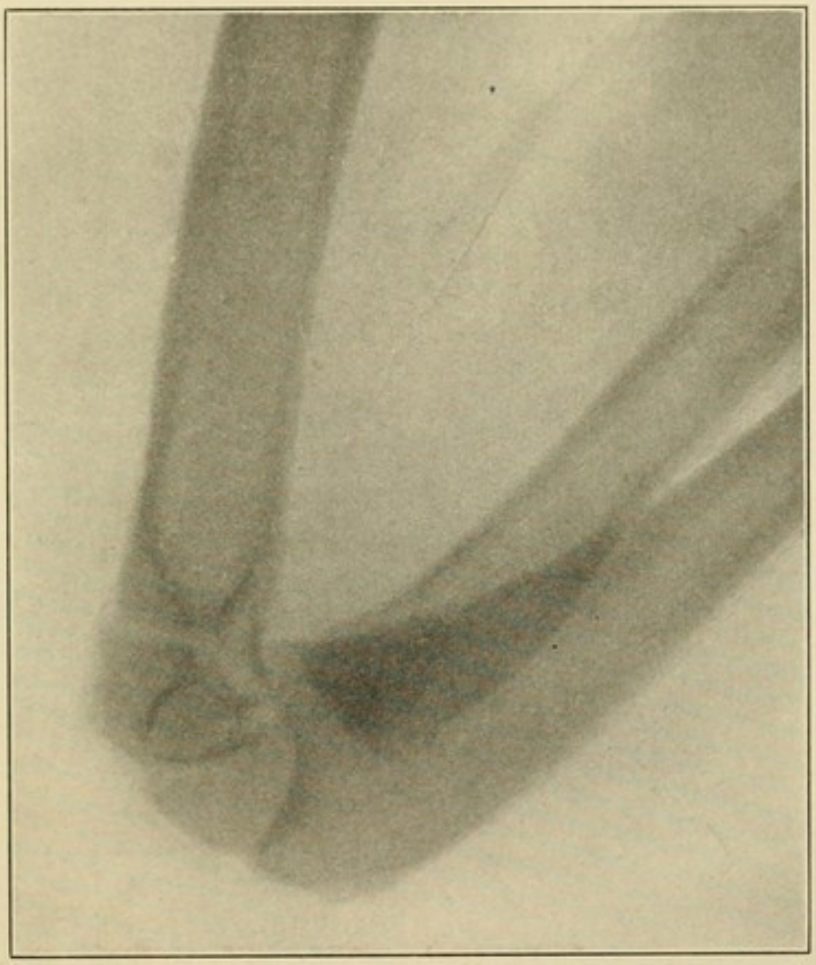

FIG. 320.—Supracondylar fracture of humerus shown in Fig. 319, after reduction dressed in position of hyperflexion. Episcopal Hospital.

injury, and skiagraphic examination. A rare form described by Posadas (1901) consists in forward displacement of the lower fragment and posterior dislocation of the bones of the forearm.

3. *Fractures of the External Condyle* usually follow falls on the outstretched hand; as the ulna does not articulate with the hand, the force is transmitted through the radius directly to the external condyle, thus explaining the greater rarity of fractures of the internal condyle. The line of fracture extends into the joint, somewhere between the capitellar and trochlear surfaces (Fig. 321); lateral

mobility usually is present, and crepitus can be detected either in this way or by moving the external condyle with thumb and finger directly

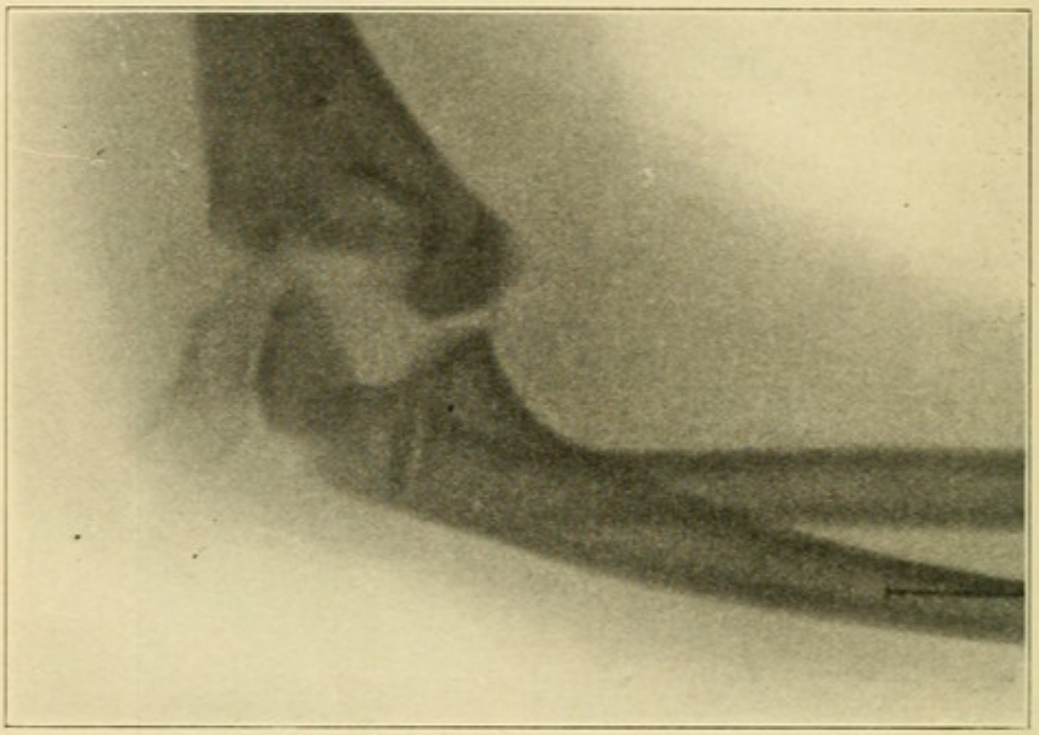

FIG. 321.—Skiagraph of fracture of external condyle of humerus.

upon the shaft. Under the name *epicondylitis*, Momburg (1910) has described what corresponds to a sprain-fracture of the external epicondyle. I have seen several cases appparently of this nature.

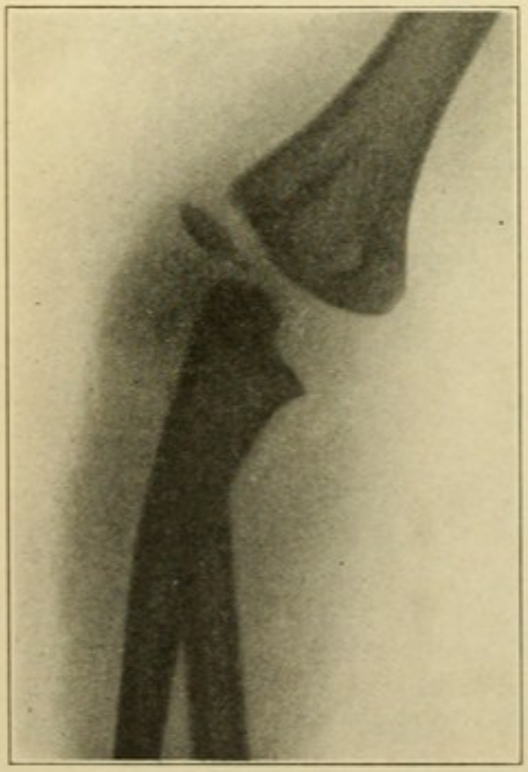

FIG. 322.—Skiagraph of epiphyseal separation of left humerus.

4. *Separation of the Entire Lower Epiphysis* may occur until its union with the diaphysis, from fifteen to seventeen years, but usually occurs before thirteen years of age. The epiphyseal line is largely *intra-articular*, passing *below the coronoid fossa*. A small shell of bone often is detached from the diaphysis also (Fig. 322); if this is not the case, and the line of fracture passes directly along the epiphyseal line (cartilage), it will not be visible in a skiagraph. Many epiphyseal separations are wrongly classed as mere sprains, because the skiagraph shows nothing abnormal. The trauma producing the injury often is slight, and deformity rarely is present; but failure to

recognize the lesion may be disastrous. The diagnosis is based on a history of injury, on indistinct, muffled crepitus, extreme pain on forced extension and persistent localized tenderness in the flexure of the elbow.

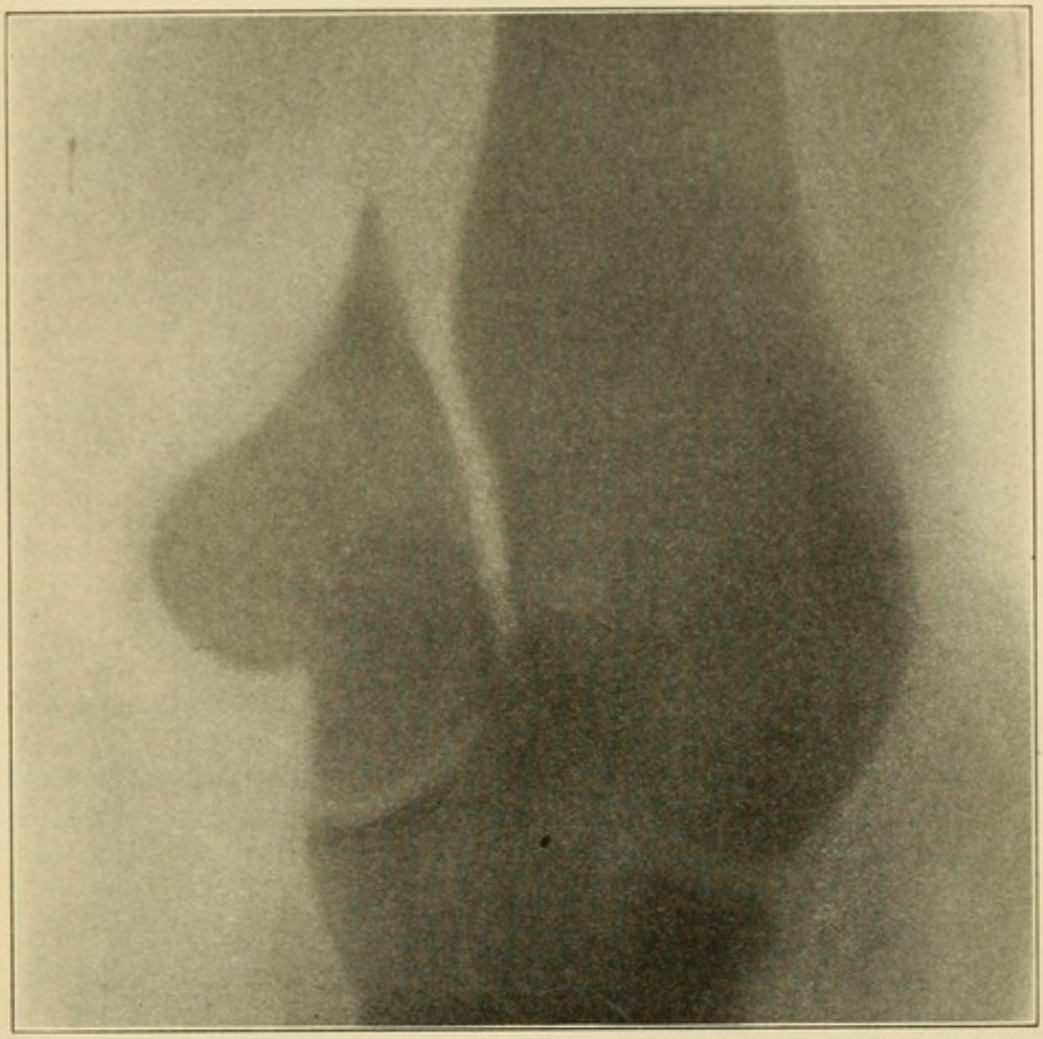

FIG. 323.—Skiagraph of fracture of internal condyle of humerus. Episcopal Hospital.

5. *Fractures of the Internal Condyle.*—These are rare in children, but being caused usually by direct violence (falls on the acutely flexed elbow) are relatively more frequent in adults. The usual line of fracture is shown in Fig. 323. The disability is extreme, the support of the ulna being destroyed: the forearm falls against the side, causing loss of the carrying angle, and the internal condyle may be moved antero-posteriorly on the shaft.

6. *Intercondylar Fractures* are very rare, especially in children. They are caused by great violence, almost always direct, the ulna being driven up between the condyles and separating them from each other and from the shaft (Madelung), resulting in a Y-fracture; or the diaphysis splitting into halves the fragment due to a supracondylar fracture (Gurlt, 1862), resulting in a T-fracture. The diagnosis rests on the independent mobility of the condyles on each other and on the shaft.

7. *Fractures of the Epitrochlea* (Fig. 324) often are epiphyseal separations of this centre, as it does not unite with the diaphysis until the

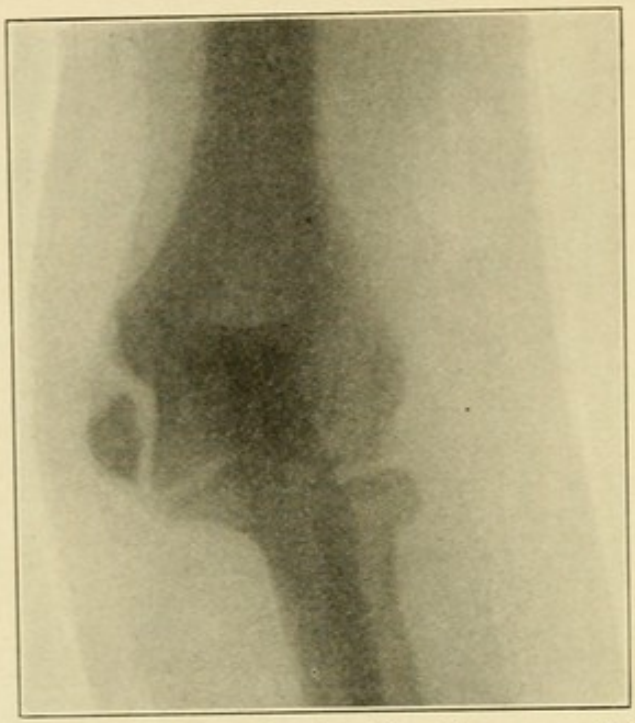

Fig. 324.—Skiagraph of fracture of epitrochlea of humerus. Episcopal Hospital.

eighteenth year. The injury usually is due to muscular or ligamentous action, and is a not unusual accompaniment of posterior dislocation of the elbow.

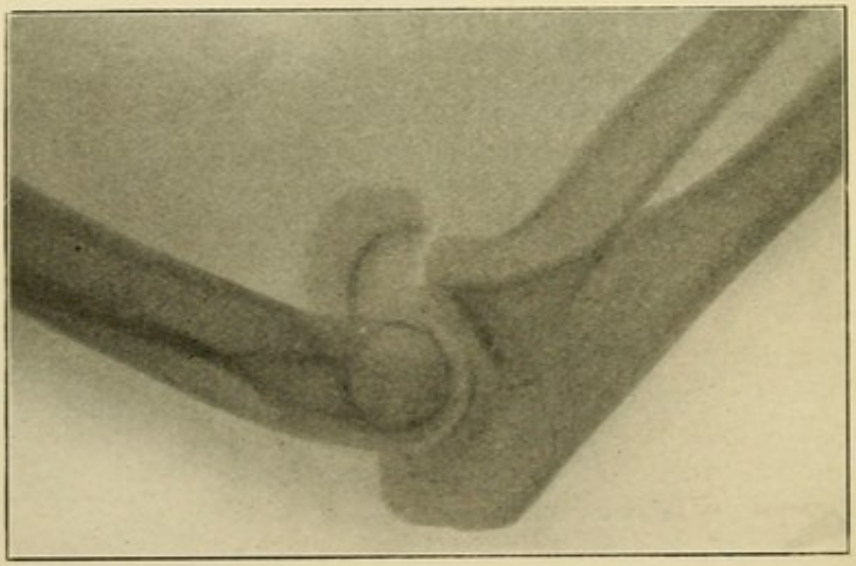

Fig. 325.—Fracture of capitellum of humerus, from fall on elbow. Age thirty-eight years. Patient under care of Dr. Jopson in University Hospital. Fragment replaced by arthrotomy. Excellent result.

Of other *rarer fractures* of the lower end of the humerus, those of the capitellum (Fig. 325) are of most importance; the fragment usually

is displaced into the bend of the elbow, and seldom can be replaced without incision.

Treatment of Fractures of the Lower End of the Humerus.—As these fractures are all close to the joint, and many of them wholly or in part intra-articular, it is extremely important to secure early and accurate reduction of the fragments, in order to lessen the amount of callus formed, and thus permit restoration of perfect function. Intelligent manœuvres of reduction can be undertaken only after a correct diagnosis has been made, and I have dwelt upon the individual lesions so fully not because their treatment is materially different, but because accurate reduction must be secured at the earliest possible moment; only in this way can surgeons hope to remove the opprobrium which has long attached to these injuries and which I believe is quite unnecessary.

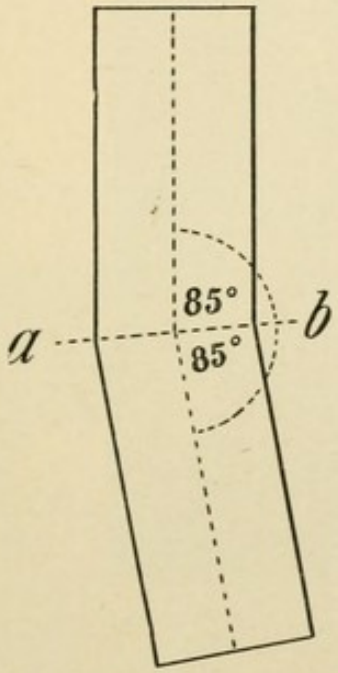

Fig. 326.—Diagram of carrying angle. (After Potter.)

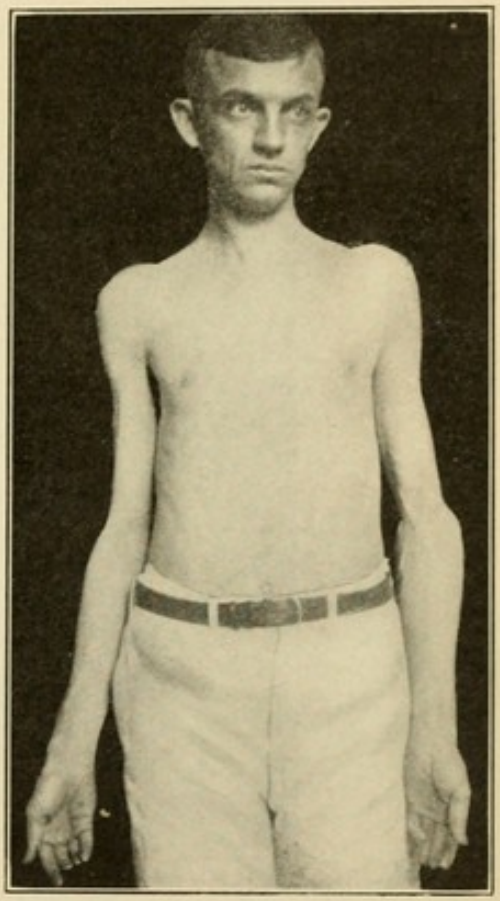

Fig. 327.—Patient showing normal carrying-angle on right and gunstock deformity on left. Children's Hospital.

Supracondylar fractures form the large proportion of these injuries, and I shall discuss the treatment of this variety at greatest length. The muscles arising from the condyles of the humerus are the only muscles attached to the fragment, and they tend to keep it flexed on the forearm. Motion transmitted from the forearm takes place between the fragment and the shaft of the humerus, not in the elbow-joint. The fragment usually is displaced posteriorly. All these considerations, as well as clinical experience, teach that it is better to dress these injuries with the elbow flexed. The fracture is reduced, by hyperextension of the elbow to relax the triceps, then by extension

and counter-extension to bring the fragment forward into its normal relation with the shaft. It is kept reduced by hyperflexion of the elbow (flexion as acute as possible), thus bringing the insertion of the triceps anterior to the humerus, and making this muscle act as a sling in holding the fragment in place. In order to preserve the "carrying angle," which is formed by an equal obliquity of the articular surfaces of the humerus and the bones of the forearm (Fig. 326), it is extremely important to flex the forearm upon the arm directly in the sagittal plane, and to keep it in that position, thus avoiding internal rotation of the lower fragment. When there is

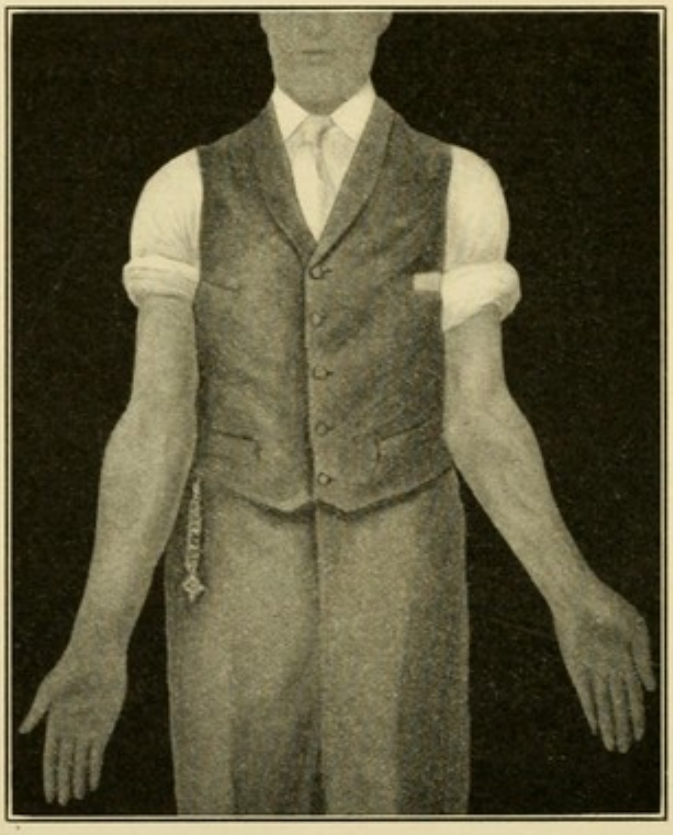

FIG. 328.—Patient showing cubitus valgus after recovery from fracture of internal condyle. Episcopal Hospital.

loss of the "carrying-angle" (cubitus varus, Fig. 327) the forearm falls to the outer side of the arm when the elbow is hyperflexed. Increase of the "carrying angle" (cubitus valgus) is a less conspicuous and much less disabling deformity (Fig. 328).

Other fractures of the lower end of the humerus must all be reduced accurately by suitable manipulations, which cannot be described at length here. All may be kept reduced by dressing the elbow in hyperflexion. The method in which this is to be done is sufficiently indicated in the accompanying illustrations: the arm and forearm act as splints to each other, and when they are bound to each other they may be rotated inward as one bone, and the hand slung around the neck (Figs. 329, 330, 331). The elbow is dressed

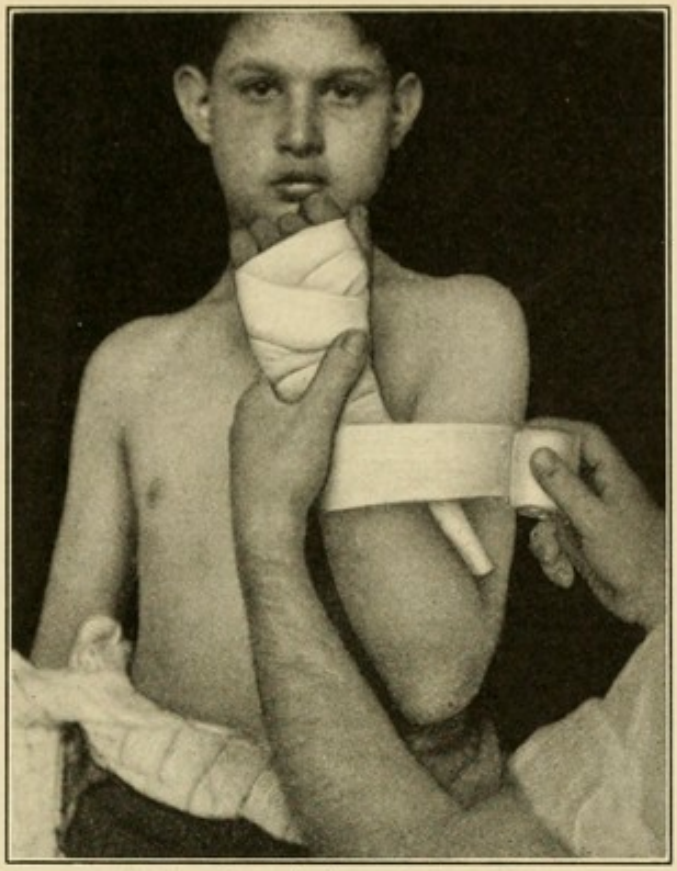

FIG. 329.—Dressing to maintain elbow in hyperflexion, first stage. Episcopal Hospital.

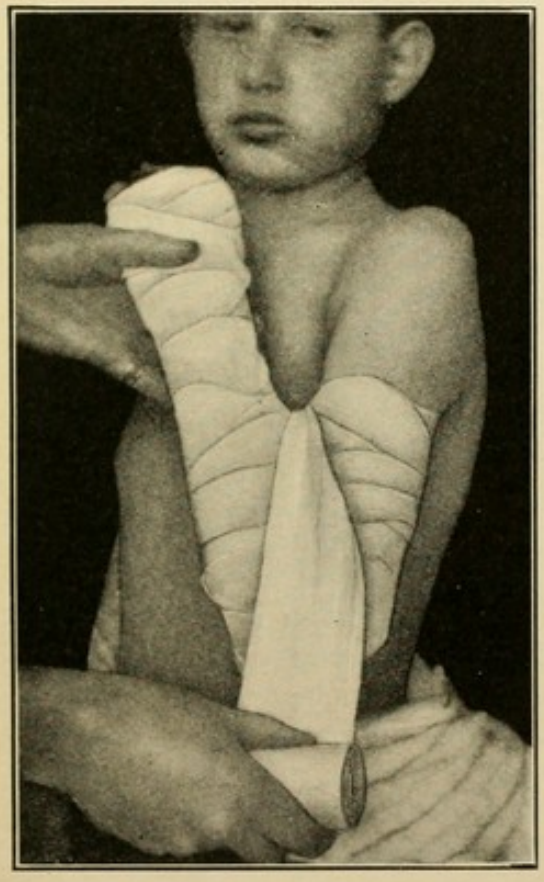

FIG. 330.—Dressing to maintain elbow in hyperflexion, second stage. Episcopal. Hospital.

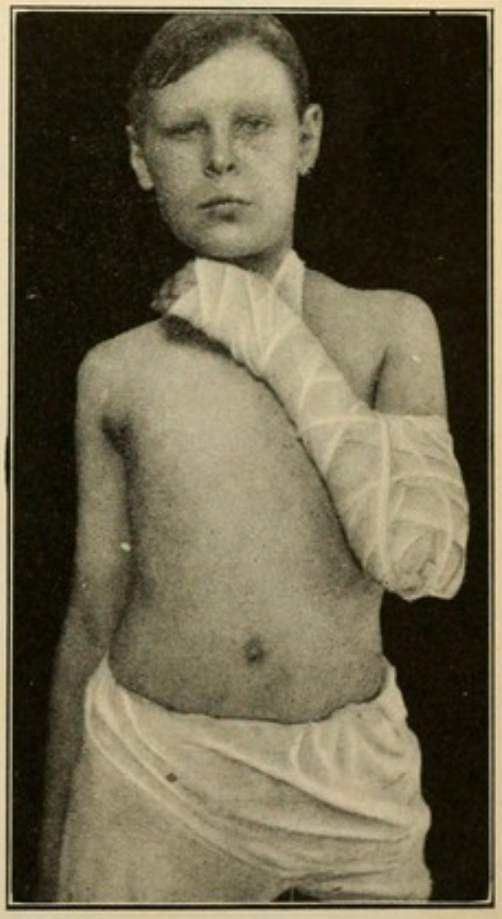

FIG. 331.—Dressing to maintain elbow in hyperflexion, completed. Episcopal Hospital.

about twice weekly, the hyperflexion being reduced at each dressing only enough to permit washing the flexure of the elbow, and re-insertion of a fold of lint. At the end of the second week the elbow may be dressed in less acute flexion, and at the end of four weeks may be carried in a sling for a week or ten days. No massage or passive motion is necessary to restore function if accurate reduction has been secured; but full extension may not be secured for several months.

Ulna.—Fractures of this bone are caused mostly by direct violence. *Fractures of the olecranon*, however, may occur from muscular action in sudden flexion, or as a "compression" fracture in hyperextension of the elbow; unless the aponeurotic insertion of the triceps is torn widely there is not much separation, but mobility and crepitus usually are distinct. In simple fractures operation rarely is indicated, as by strapping the fragment on to an obtuse angled splint (Fig. 332) reduction usually is easy; even if accurate reduction is not secured

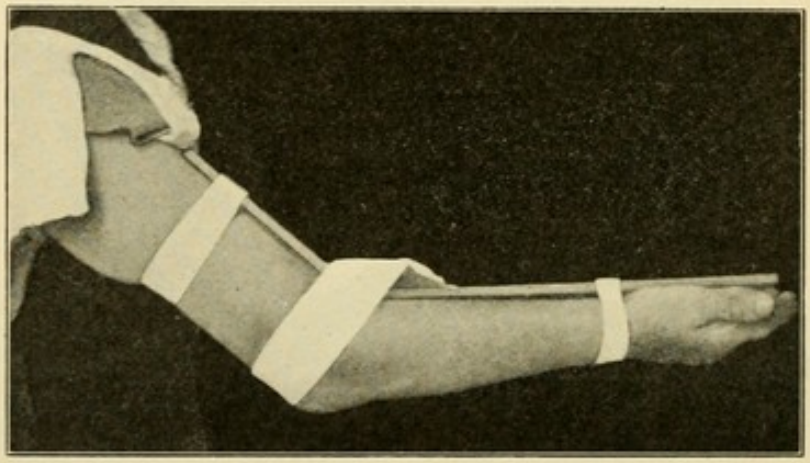

FIG. 332.—Dressing fracture of olecranon on anterior obtuse angled splint. Padding omitted to show splint better. Episcopal Hospital.

at the first attempt, it is remarkable how much improvement in position is obtained in a few days. This is one of the few fractures which prove an exception to the general rule that prompt reduction is necessary for recovery of good function. In compound fractures, operation is preferable (Figs. 333 and 334). *Separation of the olecranon epiphysis*, which appears first in a skiagraph from ten to eleven years, is a rare injury, requiring the same treatment as fracture. *Fracture of the coronoid process* is a rare accompaniment of posterior dislocation of the elbow, and is to be suspected when it is difficult to maintain reduction of this lesion. The fragment, which is partly intra-articular, and which has the brachialis anticus attached only to its base, seldom is much displaced. Treatment consists in dressing the elbow in hyperflexion for a couple of weeks, and then allowing gradual extension. *Fractures of the shaft of the ulna* are very disabling, as the ulna forms the main part of the elbow-joint, and through the interosseous ligament supports the radius and hand. Patients

with fracture of the ulna rarely can hold the forearm out for an examination without support from the other hand. In the upper part of the shaft the displacement often is backward, owing to the



FIG. 333.—Skiagraph of compound fracture of olecranon. Treated by operation. (See Fig. 334.) Episcopal Hospital.

pull of the triceps (Fig. 336); but when the trauma has been great, the ulna may be displaced anteriorly, the continuation of the force causing forward dislocation of the head of the radius (Fig. 406). In the lower part of the shaft, the pronator quadratus draws the lower

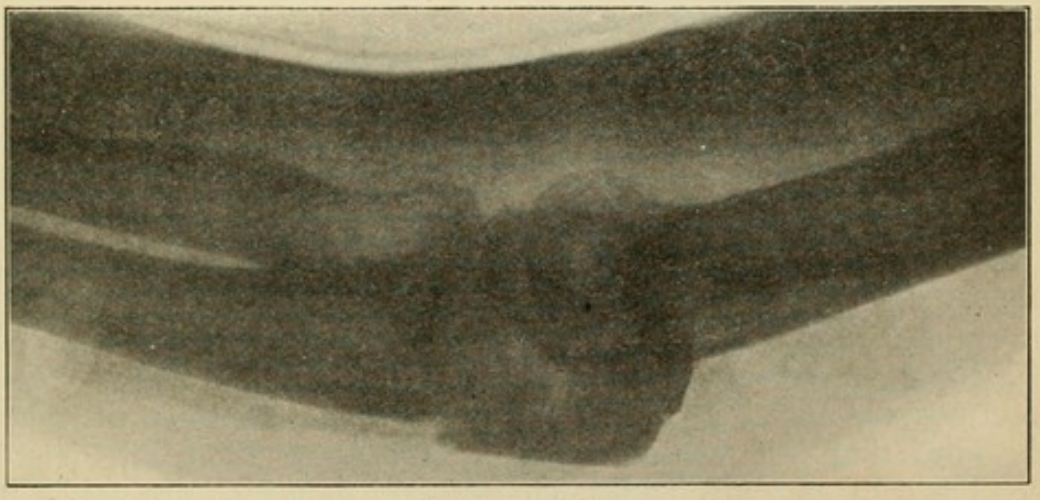

FIG. 334.—Skiagraph of compound fracture of olecranon, after suture of aponeurosis of triceps with chromic catgut. Age twenty-five years. Episcopal Hospital.

fragment against the radius, producing a deformity very difficult to overcome, though sometimes extreme abduction of the hand, by the use of a reverse Bond splint (one made for the other hand), may

succeed (Skillern, 1910). *Green-stick fractures of the ulna* are frequent, but these, as well as complete breaks of the middle and lower thirds, are frequently accompanied by fracture of the radius. *Fracture of the styloid process of the ulna* often accompanies fractures of the lower end of the radius.

Owing to the subcutaneous position of the ulna the diagnosis of these various fractures presents few difficulties; and all may be treated by immobilizing the forearm on a straight splint, with pads so adjusted as to overcome the tendency to displacement.

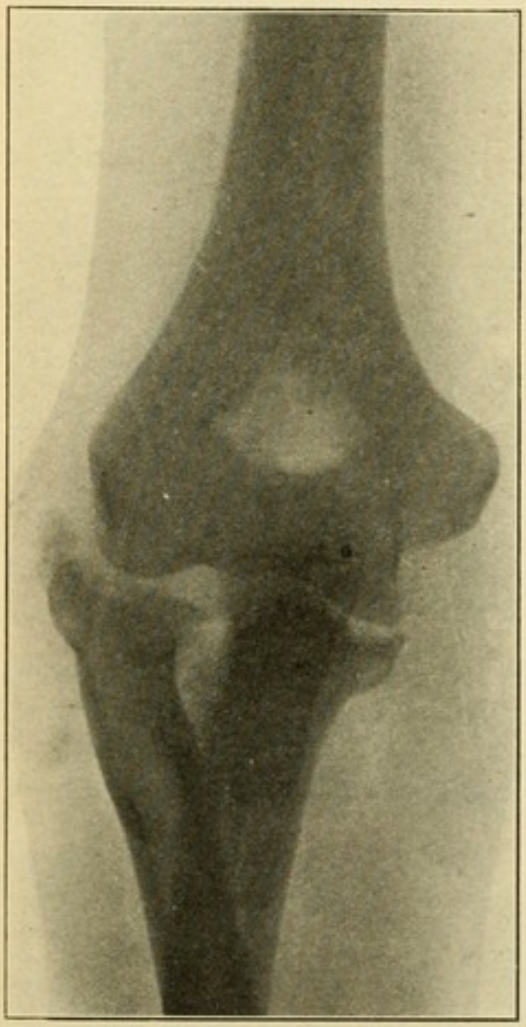

FIG. 335.—Fracture of head of radius. Age twenty-six years. Episcopal Hospital.

Radius.—*Fractures of the head of the radius* usually are caused by a fall on the over-extended palm, the force transmitted through the radius making it impinge with great force on the external condyle, and splitting the head of the radius into two or more parts (Fig. 335). The symptoms are persistent localized pain and tenderness, indistinct crepitus on rotation, but rarely appreciable mobility or displacement. A skiagraph usually is necessary for confirmation, but unless several are taken in different planes, the line of fracture may not be visible. If there is a loose fragment it is better to excise it, as non-union is frequent. In most cases, however, it is sufficient to immobilize the forearm for about four weeks *in full supination* on an anterior angular splint (Fig. 315). *Fractures of the neck of the radius* result from much the same causes as those of its head, but may accompany fractures of the olecranon from a fall on the flexed forearm; or may be accompanied by a fracture of the shaft of the ulna (Fig. 336). These fractures are apt to be impacted, and it is not desirable to disturb the impaction lest non-union result, the upper fragment being so small as to be uncontrollable. The forearm should be dressed in full supination. *Fractures of the shaft of the radius* are unusual except when accompanied by fracture of the ulna. If the fracture is above the insertion of the pronator radii teres, this muscle will pronate the lower fragment while the upper will be supinated and flexed by the biceps; to reduce the deformity the forearm should be dressed in full

supination (Lonsdale, 1838), on an anterior splint, with the elbow flexed. If the fracture occurs below the insertion of the pronator radii teres this muscle will keep the upper fragment semi-pronated, and the lower fragment should be brought into that position before the splint is applied, and so dressed.

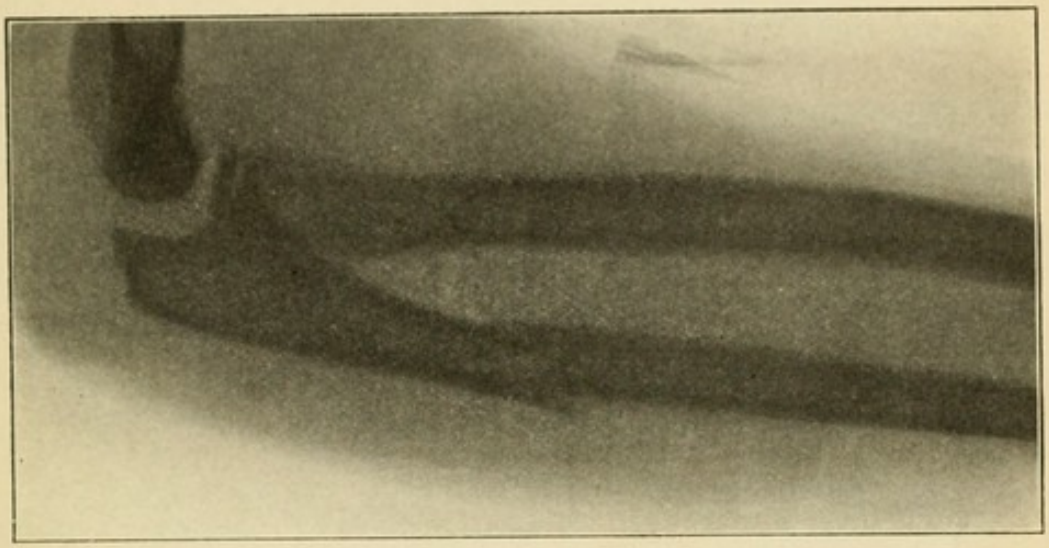

FIG. 336.—Fracture of neck of radius complicating fracture of upper half of ulna. Episcopal Hospital.

Fractures of the Lower End of the Radius.—The typical fracture in this region, one of the most frequent in the entire body, is known by the name of Colles (1814). *Colles's Fracture* results almost invariably from a fall on the over-extended palm, and the break occurs about 1 or 2 cm. above the wrist-joint; the lower fragment is displaced toward the extensor surface, often being impacted into the posterior surface of the shaft, the lower end of which protrudes

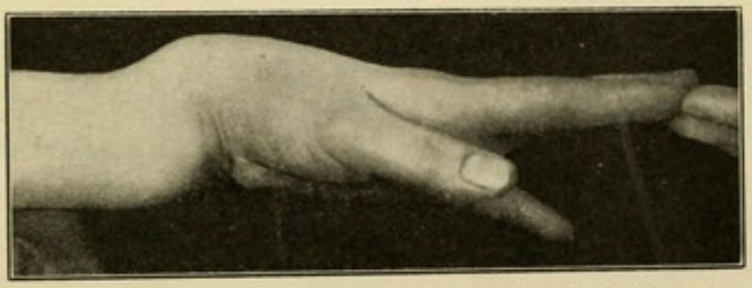

FIG. 337.—Colles's fracture of radius, showing silver-fork deformity; recent accident in patient of sixteen years. Episcopal Hospital.

beneath the flexor tendons. This typical displacement is known as the "silver-fork deformity," and Fig. 337 shows that it is well merited; often, however, deformity is much less evident. In addition to the antero-posterior displacement (Fig. 338), there usually is moderate radial deviation of the hand, rendering the head of the ulna prominent (Fig. 339). A fracture of the ulnar styloid is a frequent accompaniment. Crepitus and mobility seldom are present, and the

diagnosis usually is made from the deformity and localized pain and tenderness; but even in cases without visible deformity the lesion should be suspected from the nature of the injury. If unrecognized as a recent injury the deformity may become much more evident in the next twenty-four hours, and the patient and the surgeon whom he consults then, are apt to blame one who failed to recognize a fracture the day before. *Treatment* consists in reduction as soon

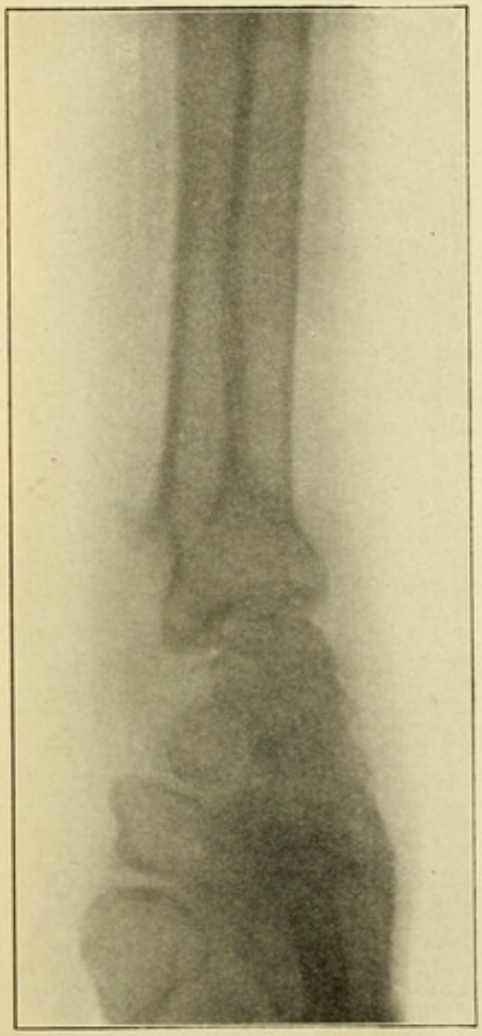

FIG. 338. — Skiagraph (lateral view) of unreduced Colles's fracture of radius, slight silver-fork deformity; duration three weeks. (See Fig. 339.) Episcopal Hospital

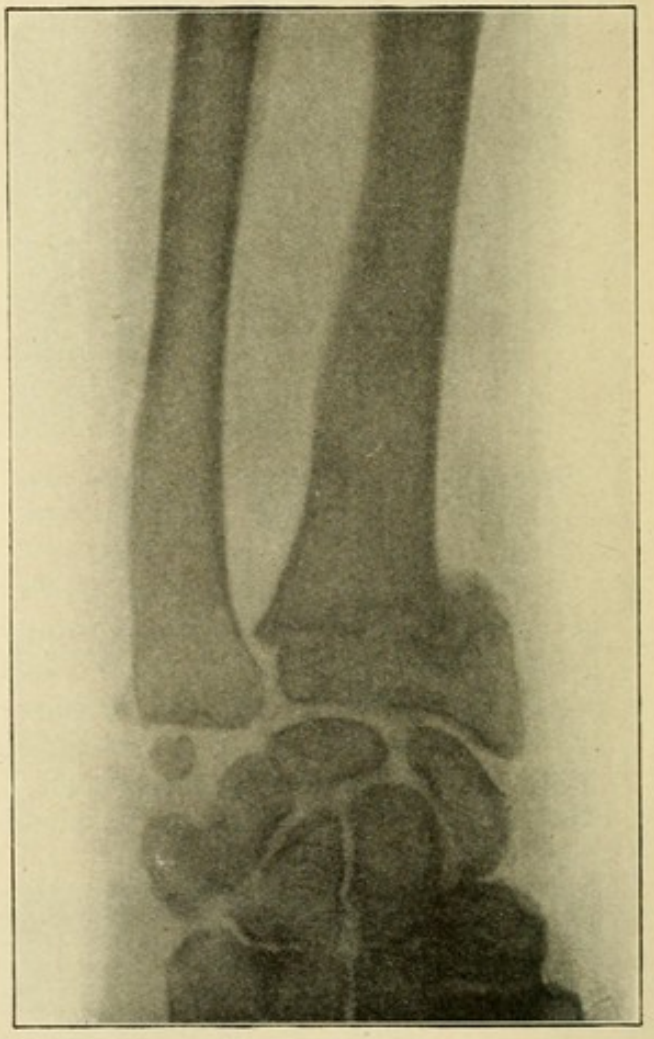

FIG. 339.—Skiagraph (antero-posterior view) of unreduced Colles's radial fracture of radius, with displacement of lower fragment, and fracture of the styloid process of the ulna. (See Fig. 338.) Episcopal Hospital.

as possible after the injury (Fig. 340): this is accomplished by hyperextension and forced adduction of the lower fragment (Fig. 341), followed by direct pressure forward on it, with counter-pressure backward on the lower end of the upper fragment. If impaction is very firm, an anesthetic may be required. Usually more force is necessary even in cases of slight impaction than the inexperienced surgeon expects; and though failure to secure accurate reduction may not materially interfere with use of the hand, some deformity will remain, and

in many cases the hand is permanently weakened. Any dressing which will hold the fragments in place may then be applied, the

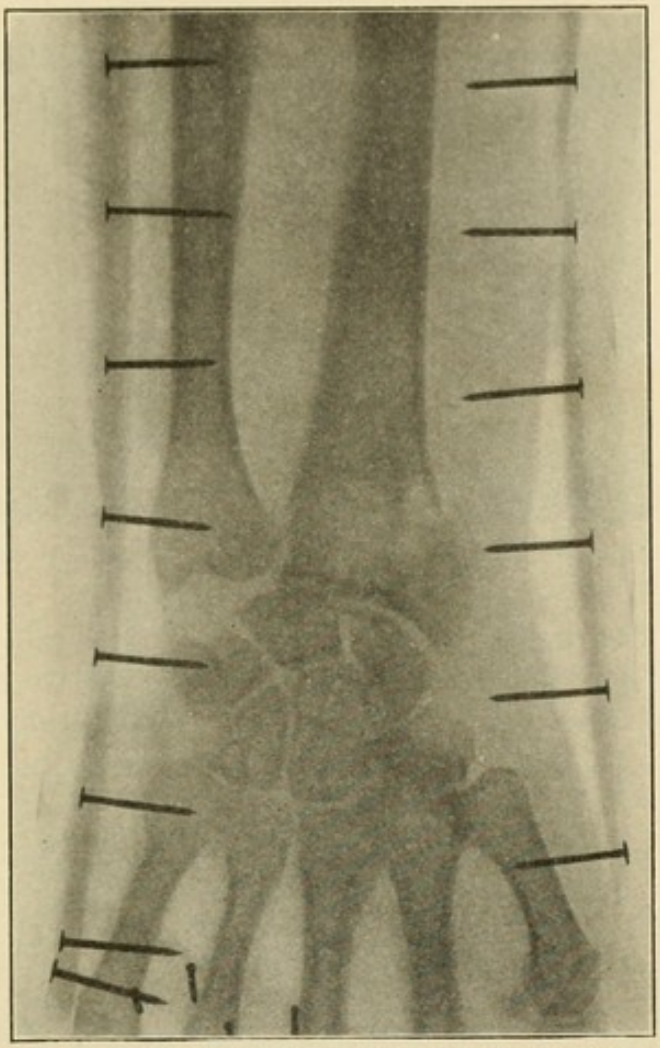

FIG. 340.—Skiagraph of recent Colles's fracture of radius and fracture of styloid process of ulna, after reduction. Episcopal Hospital.

forearm being in semi-pronation or full supination, never in complete pronation. Supination is the movement which is most difficult

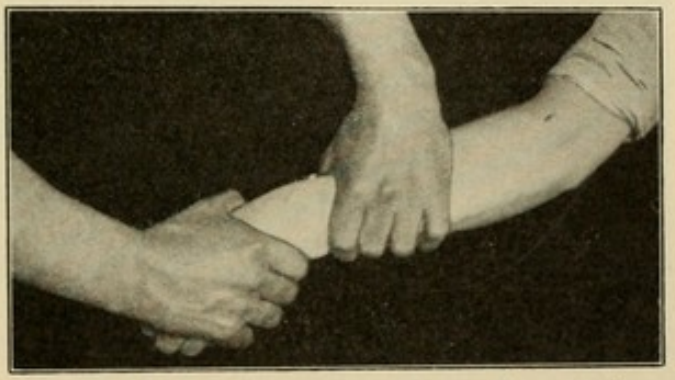

FIG. 341.—Reduction of Colles's fracture, of left radius. Episcopal Hospital.

to regain, and if the hand is dressed in pronation, it may never be regained; whereas if the fracture is put up in full supination, all

subsequent activities of the hand will be such as to encourage return of pronation. In cases where no tendency exists for recurrence of displacement, a straight posterior splint (Fig. 342) makes a comfortable

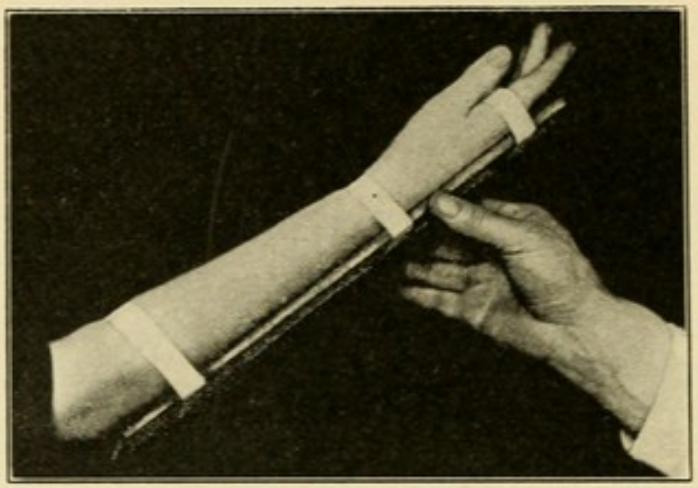

FIG. 342.—Posterior splint for Colles's fracture. Padding omitted for photograph. Episcopal Hospital.

dressing; for the first week this should extend to the proximal interphalangeal joints, but may then be shortened to the metacarpophalangeal articulations. In cases where reduction is difficult to



FIG. 343.—Bond's splint.

maintain, I prefer to use a Bond splint (Fig. 343), on the flexor surface, with two compresses, one on the dorsal surface over the lower fragment, and the other on the flexor, to fill up the natural concavity

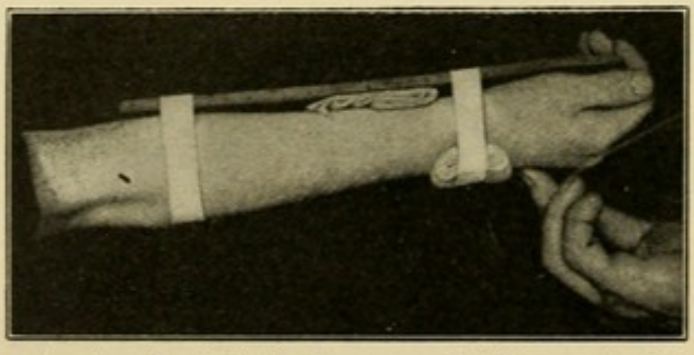

FIG. 344.—Bond splint for Colles's fracture. Padding omitted from splint, and leather guard removed to show compresses; note their form and position. Episcopal Hospital.

of the forearm above the wrist, and to retain the upper fragment in proper position (Fig. 344). Splint support should be continued for four weeks.

Other Fractures of the Lower End of the Radius.—Barton's Fracture (1838) is the name given to detachment of the dorsal portion of the articular surface of the radius; diagnosis without a skiagraph is difficult. *Reversed Colles's Fracture,* in which the lower fragment is displaced toward the flexor surface, was described in 1865 by Callender; the displacement was named "gardener's spade deformity" by Roberts (1897). *Chauffeur's Fracture,* so named because often received while "cranking" an automobile, may be of various types, the most frequent of which is one splitting off the outer surface of the articular surface of the radius through the base of the styloid process (Fig. 345). *Separation of the lower radial epiphysis* (Fig. 286) can be certainly distinguished from Colles's fracture only by radiography. All these lesions should be treated by reduction of deformity, when present, and immobilization for about four weeks.

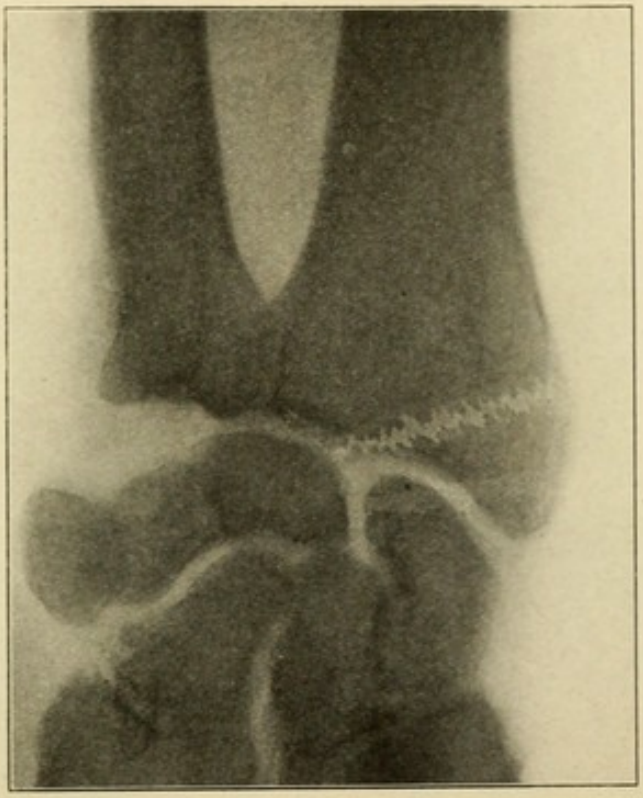

FIG. 345.—"Chauffeur's fracture" of lower end of radius, caused by kick of handle while cranking. Line of fracture emphasized in retouching skiagraph. Orthopædic Hospital.

Both Bones of the Forearm.—These fractures are frequent, either from a fall on the hand, or from direct violence. The forearm is the most frequent site of *green-stick fractures;* the deformity usually is very apparent (Fig. 346), and the treatment consists in reducing this, which usually involves making the fracture complete; but as this frequently is accomplished without much rupture of the periosteum, there is little or no tendency for the fragments to be displaced subsequently. The forearm is dressed as in complete fractures. In these the radius usually is broken a little higher than the ulna, and one

or both bones may be comminuted (Figs. 347 and 348). The diagnosis is easy, owing to the extreme mobility. Reduction should be attempted

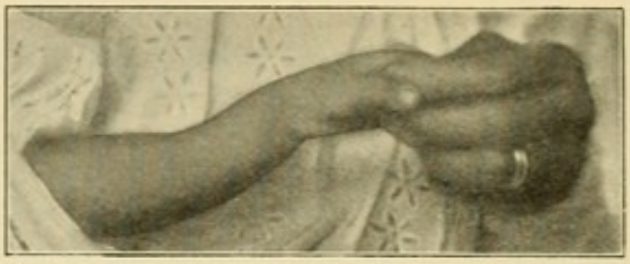

FIG. 346.—Green-stick fracture of both bones of forearm one month after injury which was untreated. Reduced under anesthetic. Children's Hospital.

by fully supinating the forearm, and making extension and counter-extension so as to overcome any overlapping. Correct replacement

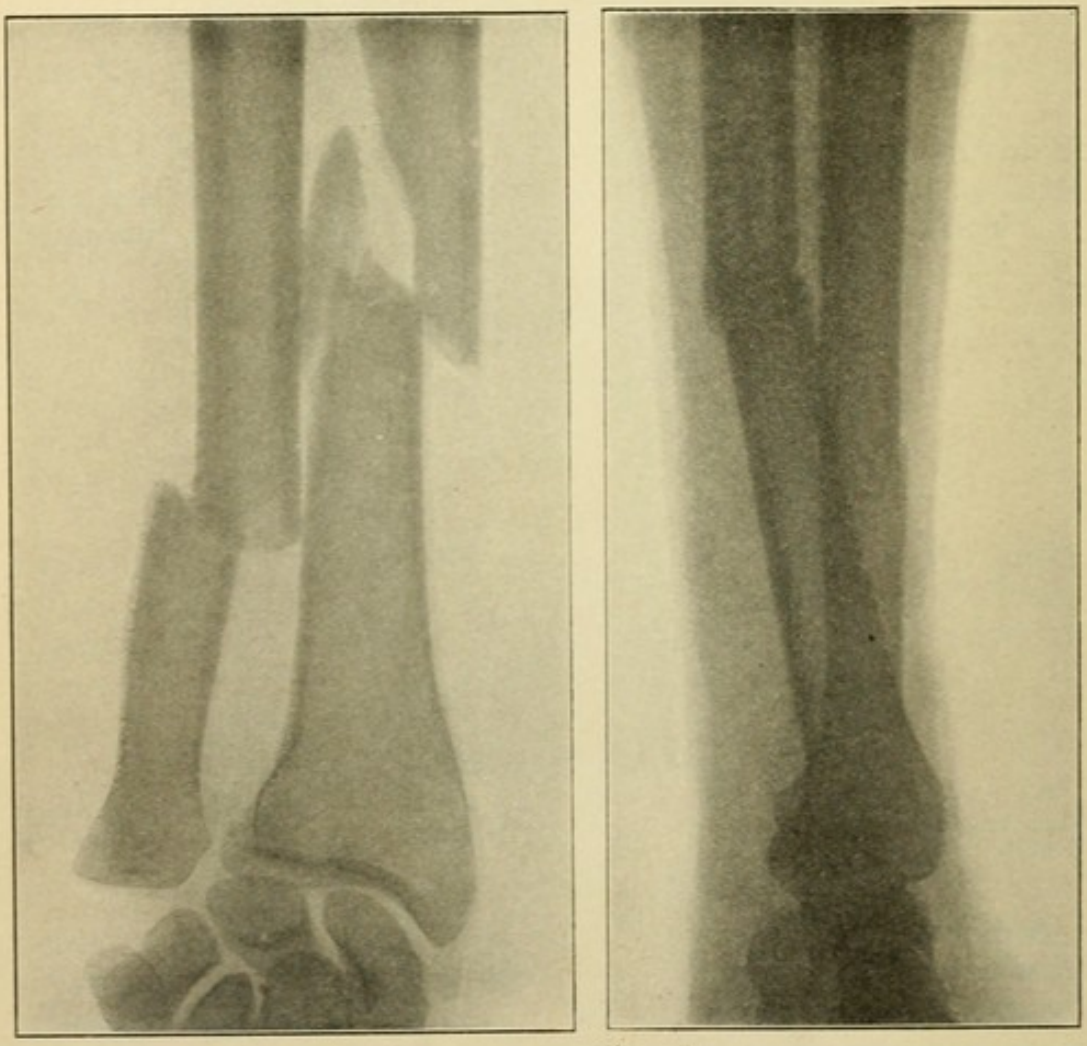

FIGS. 347 and 348.—Skiagraphs of comminuted fracture of both bones of forearm; delayed union at end of ten weeks. Patient, aged fifty-three years, then returned to work as blacksmith, and two months later union was firm. Episcopal Hospital.

of the ulnar fracture usually can be determined clinically, as this bone is subcutaneous; but the radius is buried among so many muscles

that a skiagraph frequently is necessary to ascertain the position of the fragments if the fracture is above the middle of the bone.

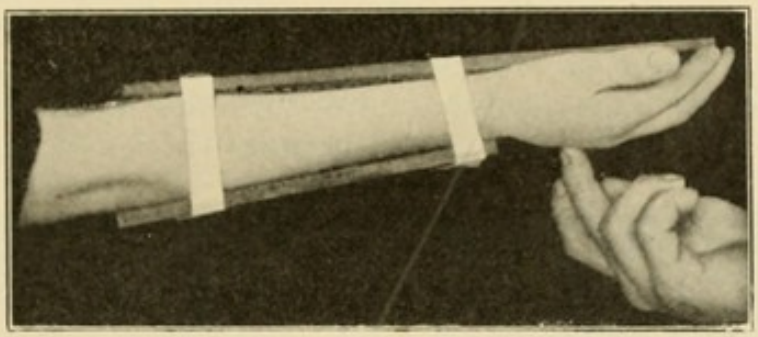

FIG. 349.—Dressing for fracture of both bones of forearm. Padding omitted. Note length of splints. Forearm in full supination. Episcopal Hospital.

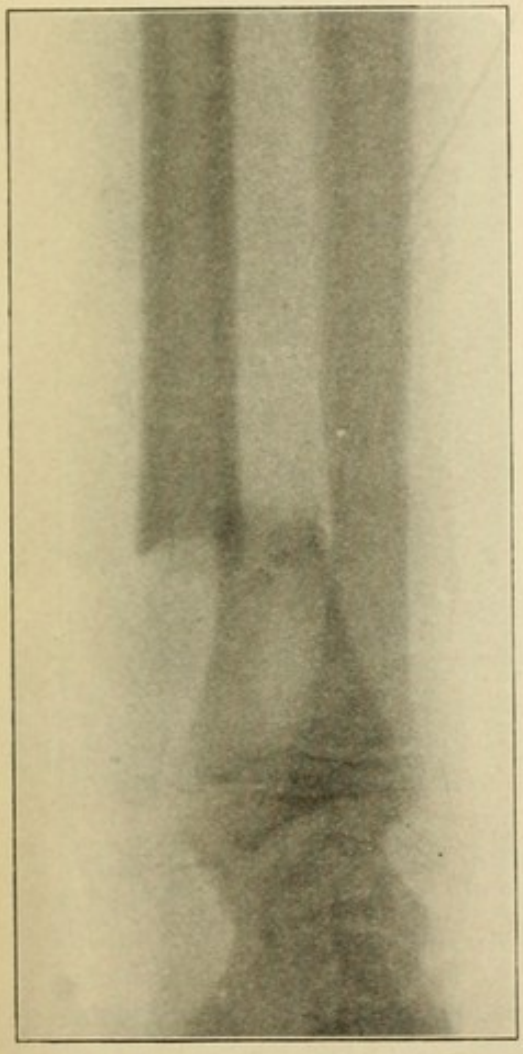

FIG. 350.—Skiagraph of fracture of both bones of forearm, before reduction; lateral view, in mid-pronation. Age nine years. (See Figs. 351, 352, 353.) Episcopal Hospital.

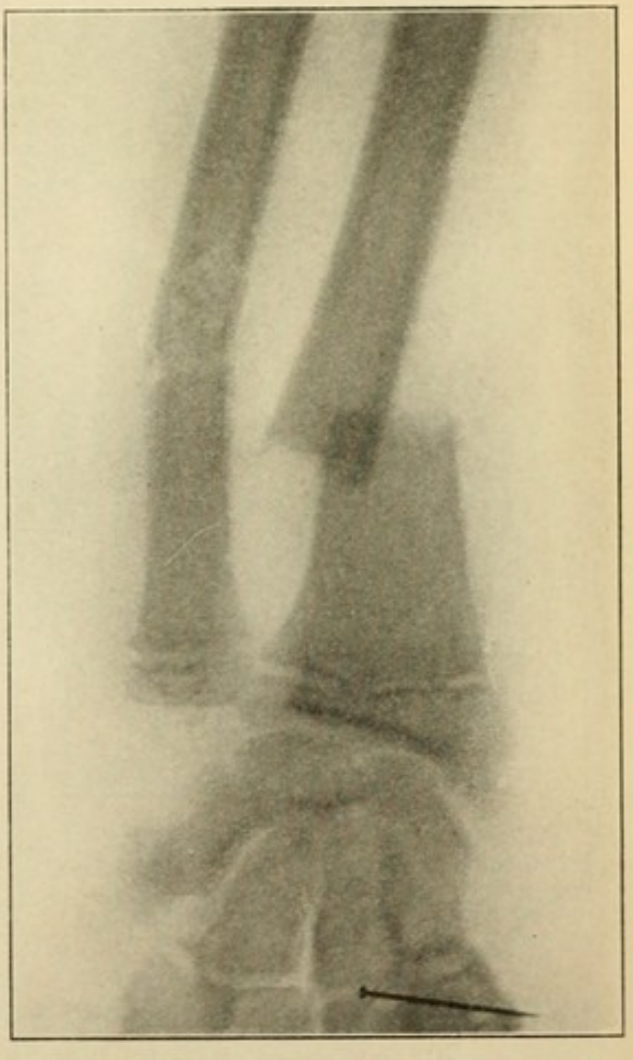

FIG. 351.—Skiagraph of fracture of both bones of forearm, before reduction; antero-posterior view. (See Fig. 350.) Episcopal Hospital.

The forearm is then dressed in *full supination* between two straight splints, that on the flexor surface extending from the bend of the

elbow to the tips of the fingers, while the dorsal splint extends from the olecranon to the wrist (Fig. 349). These splints should be a little wider than the forearm, so as to prevent crowding the bones together laterally, and they should be smoothly but thickly padded. Apply the splints with the elbow flexed to a right angle, and make sure that the palmar splint does not compress the veins in the bend of the elbow. A longitudinal pad placed between the bones, in the effort

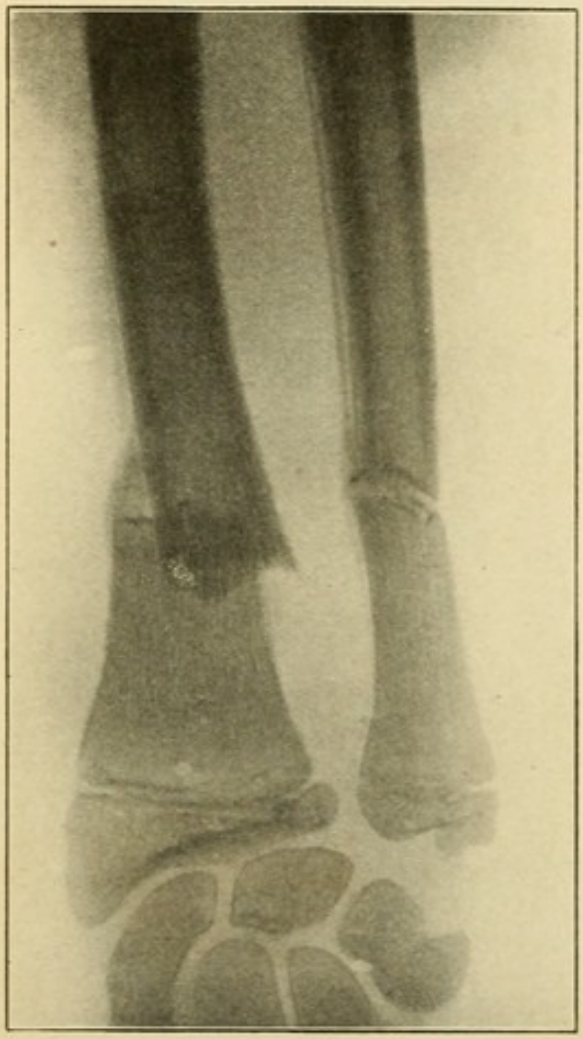

FIG. 352.—Skiagraph of fracture of both bones of forearm after reduction. Antero-posterior view, in full supination. Same case as Figs. 350 and 351. Episcopal Hospital.

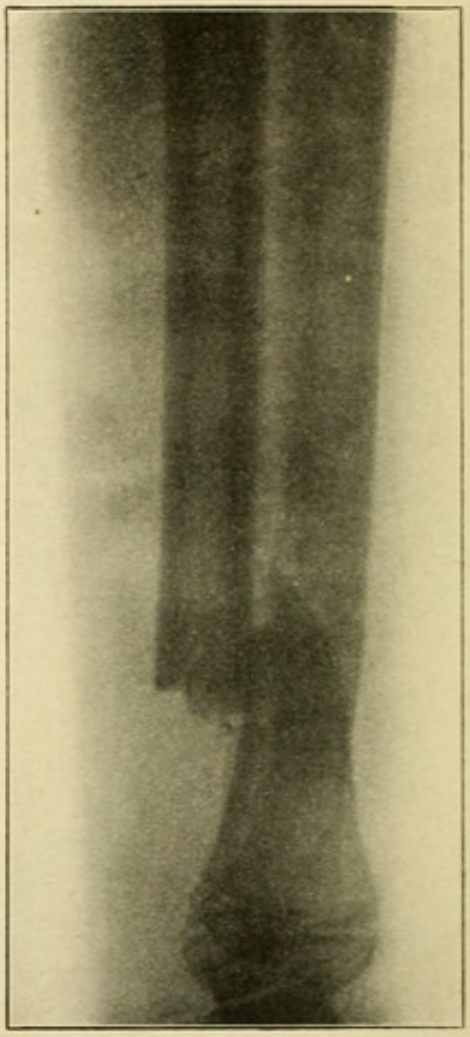

FIG. 353.—Skiagraph of fracture of both bones of forearm after "reduction." Recovery with perfect functions and no palpable deformity. Episcopal Hospital.

to wedge them apart is not only useless but harmful. Extra compresses, however, may well be placed over any of the fragments that tend to project. The splints are then strapped snugly around the forearm and held securely in place by a roller bandage. A large "handkerchief" or "triangular" sling is applied, and the forearm carried against the chest, but always in full supination. I urge the employment of this position not only because supination is the most difficult part of rotation to regain, and because the upper fragment

of the radius usually is kept in supination by the biceps, but because I have found, if the forearm is dressed in mid-pronation, as is commonly advised now, that the fragments sag by the force of gravity, and the patient recovers not only with lost supination, but with angular deformity of both bones toward the ulnar side. If attempt is made to correct this deformity by adjusting a coaptation splint over the angular projection of the ulna, this may be overcome, but the surgeon will succeed merely in forcing the ulna nearer the radius, which cannot be influenced by such an appliance, and the disability as regards rotation will be increased. It often is exceedingly difficult to keep these fractures even approximately reduced during the first week; but usually a little better position can be secured at each

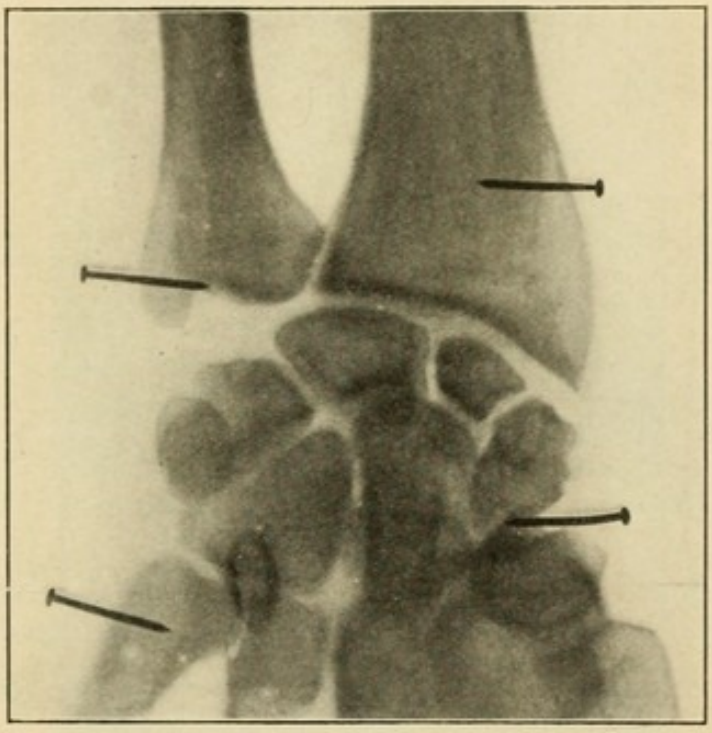

FIG. 354.—Skiagraph of fracture of carpal scaphoid. Compare with normal wrist in Fig. 355. Episcopal Hospital.

dressing, and when the ends of the bones begin to become sticky, during the second week, it will be found that deformity daily becomes less, and what looked at first like a hopeless case, will result in a very useful arm, and one with slight or no visible deformity. Skiagraphs are valuable and interesting, but I advise the inexperienced not to be terrified by the appearance of the bones in a skiagraph into thinking that only operative treatment can give his patient a good result. If he uses the eyes in the ends of his fingers, he will secure by conservative means quite as good, and in many cases a much better result than by operation, and in a shorter time (Figs. 350, 351, 352, and 353).

Carpus.—Of these fractures, that of the scaphoid is least unusual, resulting usually from a fall on the thenar eminence; the diagnosis

is made from tenderness in the "anatomical snuffbox," sometimes by dorsal displacement of one of the fragments, and effusion in the

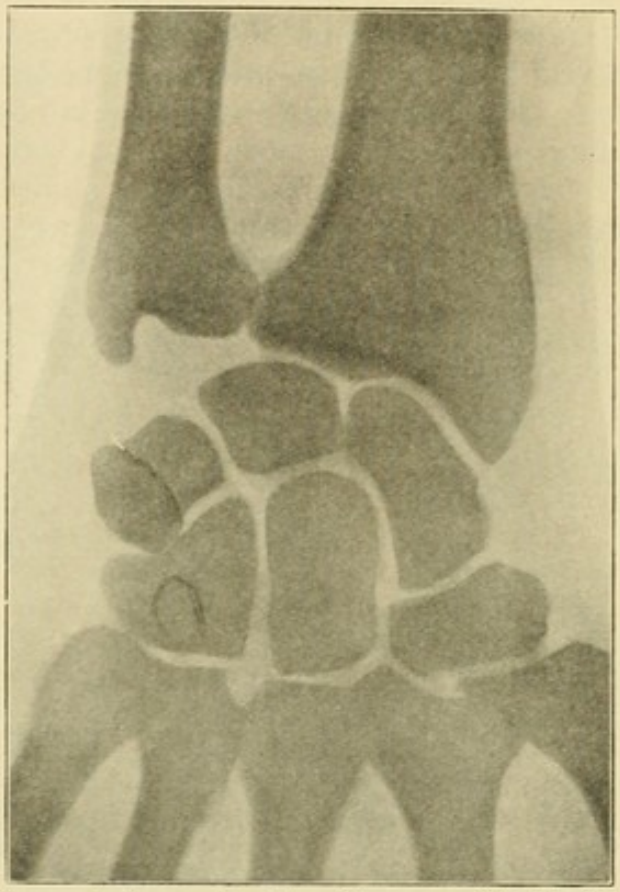

FIG. 355.—Skiagraph of normal wrist. Compare with Fig. 354. Episcopal Hospital.

radio-carpal joint. Confirmation by a skiagraph is advisable (Figs. 354 and 355). Treatment consists in excision of an irreducible frag-



FIG. 356.—Dressing for fracture of metacarpals. Hand bandaged over a roller. Episcopal Hospital.

ment, and in immobilization on a palmar splint for three or four weeks for those cases without deformity.

Metacarpus.—Fractures of the metacarpals result usually from direct violence (prize-fighting, etc.); the displacement is angular, toward the extensor surface, and may be difficult to keep reduced.

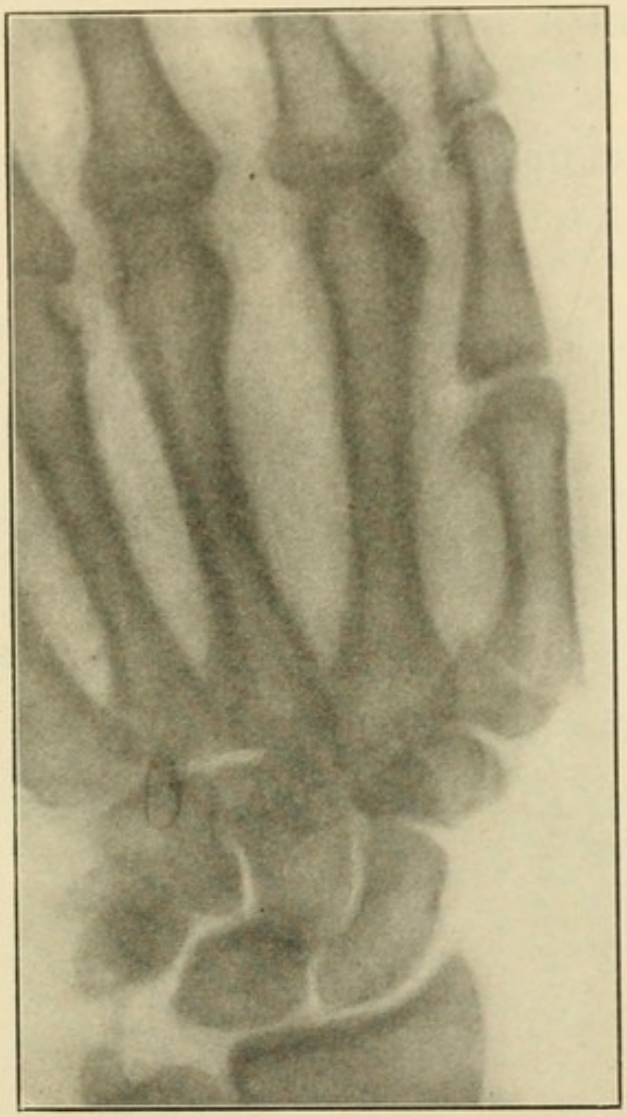

FIG. 357.—Fracture of base of thumb metacarpal. Episcopal Hospital.

The hand may be dressed on a palmar splint, the palm being well padded; or may be bandaged over a firm roller, the tension on the

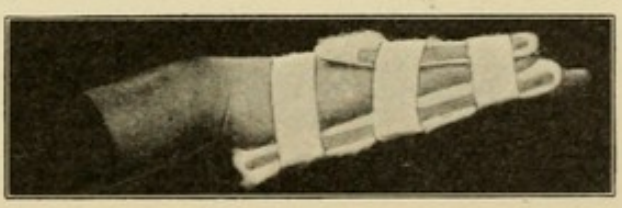

FIG. 358.—Dressing for fracture of the phalanges. Episcopal Hospital.

extensor tendons preventing deformity (Figs. 356). *Fracture of the base of the thumb metacarpal* (Bennett, 1886), may resemble a subluxation of that bone (Fig. 357).

Phalanges.—Fractures of these usually are caused by direct violence, often being compound and requiring amputation. Simple fractures are dressed on antero-posterior splints (Fig. 358) for about three weeks. If angular deformity toward the flexor surface persists, due to the pull of the interossei, Stimson (1907) advises dressing the fingers in flexion over a roller bandage.

FRACTURES OF THE LOWER EXTREMITY.

Femur.—This is the most serious fracture of the extremities that a patient can suffer, but fortunately it is less serious in children, in whom it is more frequent, than in adults. In adults fractures of the leg are much more frequent than in children. The fractures of the femur may be grouped into those of the upper end, those of the shaft, and those of the lower end.

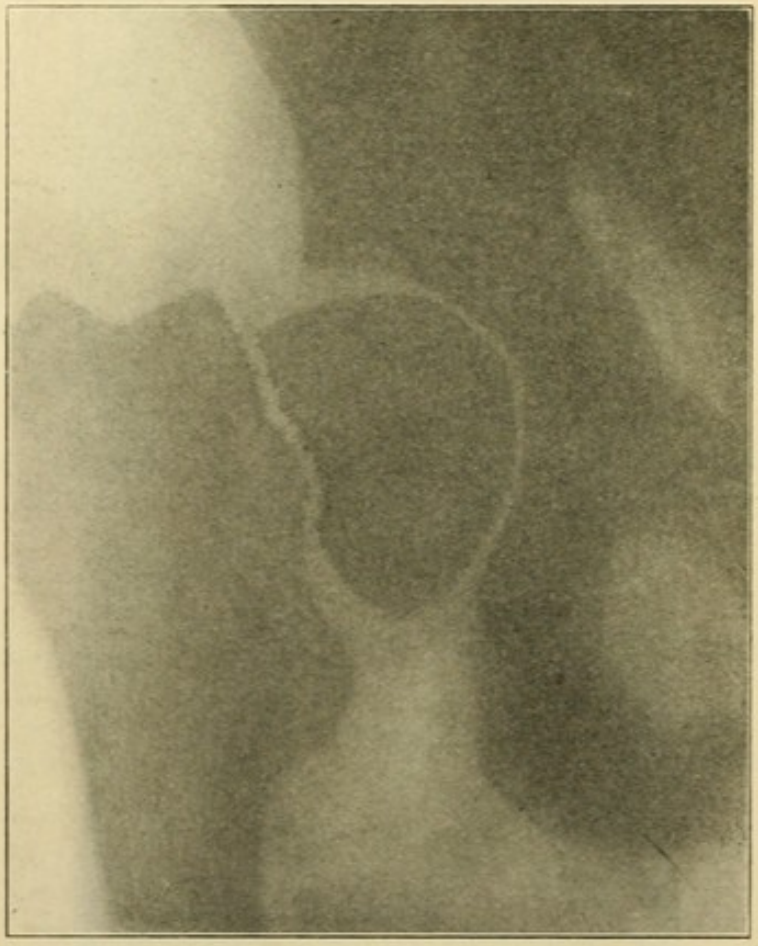

FIG. 359.—Fracture of neck of femur close to its head. Episcopal Hospital.

Fractures of the Upper End of the Femur.—Fractures of the *neck of the femur* ("fracture of the hip") are more common in adults, especially those past sixty-five years of age, than in children. The trauma in the aged often is trivial as their bones are more brittle; some cases are caused by a mere twist of the leg, catching it in a

fold of the carpet, on an uneven paving stone, etc., or by sitting down suddenly. Such injuries usually produce a fracture of the neck close to the head (intracapsular), and seldom are impacted (Fig. 359). Falls on the great trochanter, especially in patients under seventy years of age, are more apt to result in an impacted fracture close to the trochanter (Fig. 360), which is at least partly extracapsular. In children, also, fractures of the neck of the femur usually are impacted, or partial; or an epiphyseal separation of the head may occur. In impacted fractures, the impaction occurs chiefly at the expense of the posterior part of the neck, the shaft of the femur being rotated outward as the posterior margins of the fragments are driven together.

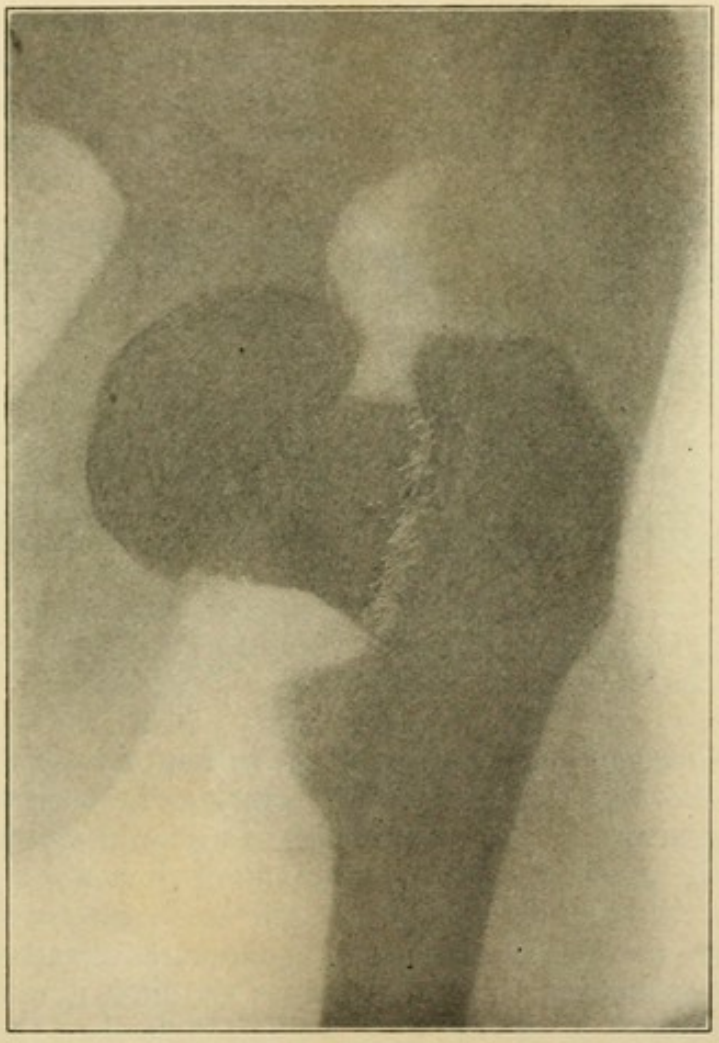

FIG. 360.—Impacted fracture at base of neck of femur. Age sixty-five years. Note also coxa vara. Episcopal Hospital.

Symptoms.—Muscular spasm is prominent, and this, with localized pain and tenderness, sometimes are alone sufficient to warrant the diagnosis in the aged. In unimpacted fractures the patient usually is unable to raise the limb from the bed; deformity is characteristic, consisting in eversion of the lower extremity, the fibular side of the foot lying on the bed; and there is moderate shortening (2 to 4 cm.), which frequently increases during the second day. In

impacted fractures the shortening may not exceed 1 cm. Normally when the thigh is flexed the great trochanter lies on a line drawn from the anterior superior spine of the ilium to the tuber ischii (*Nélaton's line*, 1847); but when there is fracture of the neck of the femur the muscles (ilio-psoas, adductors, hamstrings, glutei) passing from the pelvis to the shaft pull the lower fragment up, so that the trochanter lies above this line, and approaches or even ascends above a plumb line dropped from the anterior superior spine when the patient is lying supine (*Bryant's line*, 1879); the relation of the trochanter to Nélaton's and Bryant's lines on the two sides should be compared (Figs. 361 and 362). The trochanter is less prominent on the injured side owing to the loss of support from the neck of the bone, and by placing the tips of the fingers between the trochanter and iliac crest it will be found that the fascia lata on the injured side is relaxed (*Allis's sign*, 1877). Sometimes from the shortening a fold or wrinkle is formed over the tendo patellæ, and can be smoothed out by making

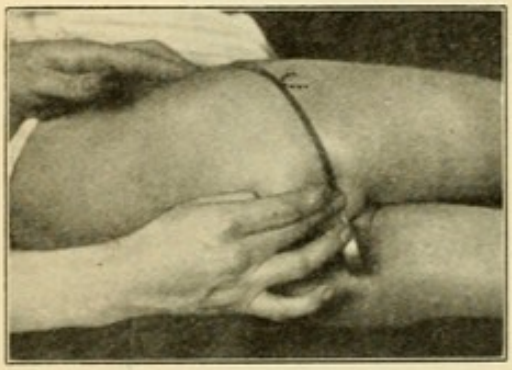

FIG. 361.—Nélaton's line: passes from anterior superior spine of ilium to tuber ischii and crosses tip of great trochanter of femur, when thigh is partly flexed.

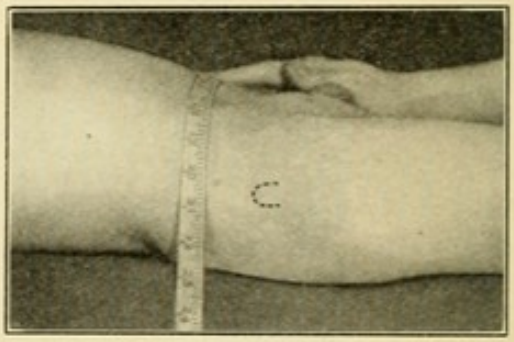

FIG. 362.—Bryant's line, a plumb line from anterior superior spine of ilium, patient supine. Orthopædic Hospital.

extension (Cleemann, 1876). In cases without impaction, mobility is present: this may be detected by rotating the entire limb, when it will be found to have a greater range of motion than the uninjured limb; and by pushing upward and pulling downward in the axis of the limb, the greater trochanter will be found to slide up and down on the pelvis. During these manœuvres crepitus usually is elicited. By palpating the trochanter as the limb is rotated, it will be found to rotate in the arc of a smaller circle than the trochanter on the uninjured side; this is because the centre of motion is transferred from the acetabulum to the seat of fracture. Usually there is an abnormal fulness over the head of the femur (just below Poupart's ligament, beneath or immediately external to the femoral artery) owing to effusion in the joint and the external rotation of the outer fragment.

Diagnosis rarely is difficult in the adult, attention being paid to the history of injury, even if slight, and to the cardinal physical signs, shortening, eversion, and crepitus. In cases with impaction,

where mobility and crepitus are absent. and where eversion and shortening are slight, the diagnosis is less certain; but the cautious surgeon will treat all suspected injuries of the hip in the aged as if they were fractures until the contrary is proved. The impaction may be slight, and is apt to be released spontaneously. A skiagraph is very useful in such cases, and as well in children, in whom green-stick fracture, epiphyseal separation, or fracture with impaction, are the usual lesions. Frequently the true nature of the case is not recognized in children, and the surgeon sees the patient first when traumatic *coxa vara* (p. 543) has developed.

Prognosis.—In the aged, death occurs from shock, pneumonia, bed-sores, exhaustion, etc., in about one out of four cases during the first year after injury; in those who recover, a useful limb results in about 60 per cent. of cases; nearly all of these will have a limp and slight eversion (Ashhurst and Newell, 1908). In children there is little disability though marked degrees of *coxa vara* may require subsequent treatment.

Treatment.—In the aged, constitutional treatment often is more important than the local; these patients should not be kept in bed after the first shock of the accident and the acutest symptoms have subsided, unless they continue to improve. Get them up in a chair a few hours each day so soon as they seem to be losing ground. Watch for and guard against hypostatic congestion of the lungs and bed-sores. Keep the bowels open and the kidneys active. Stimulate the appetite.

The usual teaching is not to disturb an impaction if one is present; and a very good rule it is in almost all cases; but in children this does not hold good if there is deformity, and in such cases even in young adults (even up to forty-eight years), it is a question whether a more useful limb might not be secured by breaking up the impaction and dressing the limb in extreme abduction as described below. Impaction is rare except in fractures near the trochanters, and non-union would not be apt to occur if the impaction were reduced in vigorous adults. But in aged persons, or speaking generally, in those past sixty years, it is far better to let the fracture stay impacted, even if there is deformity, since it is better to have them walking about with a limp and shortening and eversion, than to have them dependent on crutches or even a cane, as is almost always the case if non-union is present. Cotton suggested in (1910) producing artificial impaction in recent fractures by hammering on the trochanter with a mallet, and has practised this method with success in a number of cases.

Unimpacted fractures may be reduced by flexing the thigh on the pelvis to a right angle (to relax the iliopsoas which may press the capsule between the fragments), then making vertical traction upward on the thigh, and finally bringing the thigh down to the plane of the bed in moderate internal rotation and abduction as great as possible. This last manœuvre makes the anterior portion of the

capsule tense, and wedges the outer fragment against the detached head lying loose in the acetabulum by causing the great trochanter to impinge on the posterior lip of the acetabulum, and by keeping the iliopsoas tense across the anterior part of the joint. Whitman, who since 1904 has advocated the *abduction treatment* of fractures of the femoral neck, encases the entire lower extremity and pelvis in plaster of Paris (Fig. 363); but this is not always well borne by old people, in whom it often is better to use the ordinary Buck's extension apparatus (Fig. 364), using enough weight (8 to 12 pounds) to prevent muscular spasm. The position of abduction may be encouraged by fastening the pelvis to the opposite side of the bed. However, it is very difficult to maintain sufficient abduction without a gypsum splint, and in all adult patients I prefer the method of *lateral and longitudinal traction*, which invariably has given me better results. This was described accurately in 1869 by Phillips, was taught for many years by Maxwell, and has been revived, systematized, and

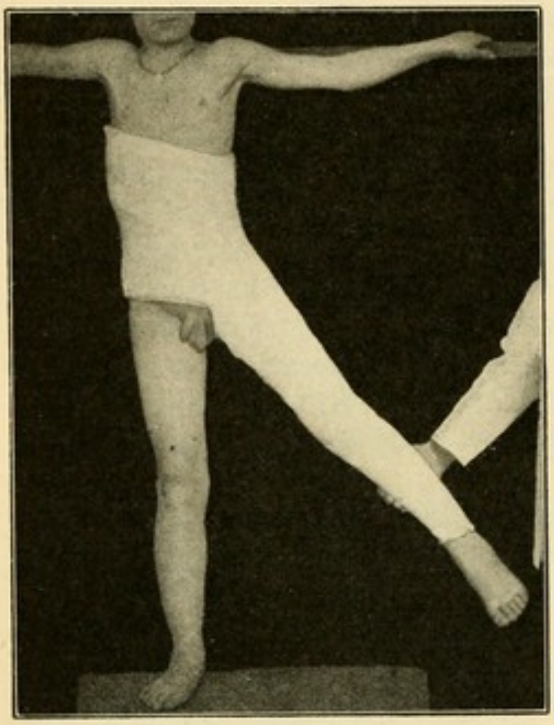

FIG. 363.—Abduction cast for separation of epiphysis of head of femur; age fourteen years. Cast has been cut off foot recently to facilitate walking. Episcopal Hospital.

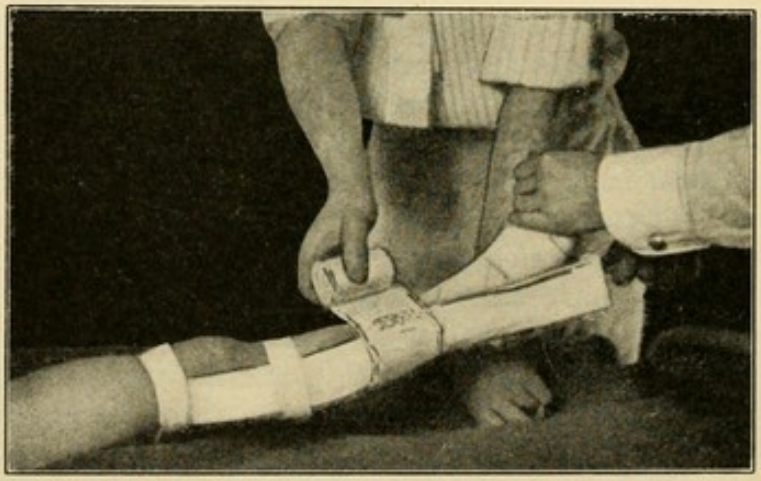

FIG. 364.—Applying Buck's adhesive plaster extension apparatus for fracture of femur. Orthopædic Hospital.

popularized, by Ruth (1899). The fracture is reduced as described above, and in addition to the longitudinal extension lateral traction also is made on the upper part of the thigh. The longitudinal

traction should be strong enough to overcome shortening, and about two-thirds as much weight should be used in lateral traction (Fig. 365). The lateral traction, which should draw the femur slightly away

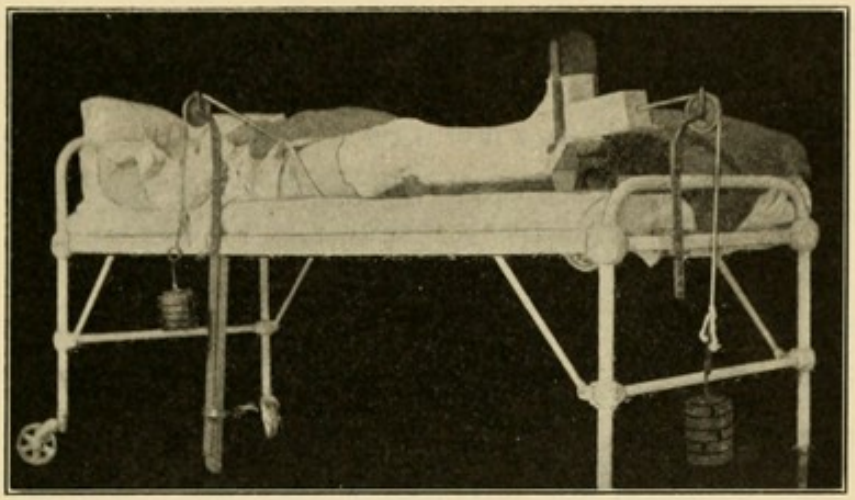

FIG. 365.—Longitudinal and lateral traction for fracture of neck of femur. Note also use of Volkmann's sliding foot splint to prevent rotation of limb. Episcopal Hospital.

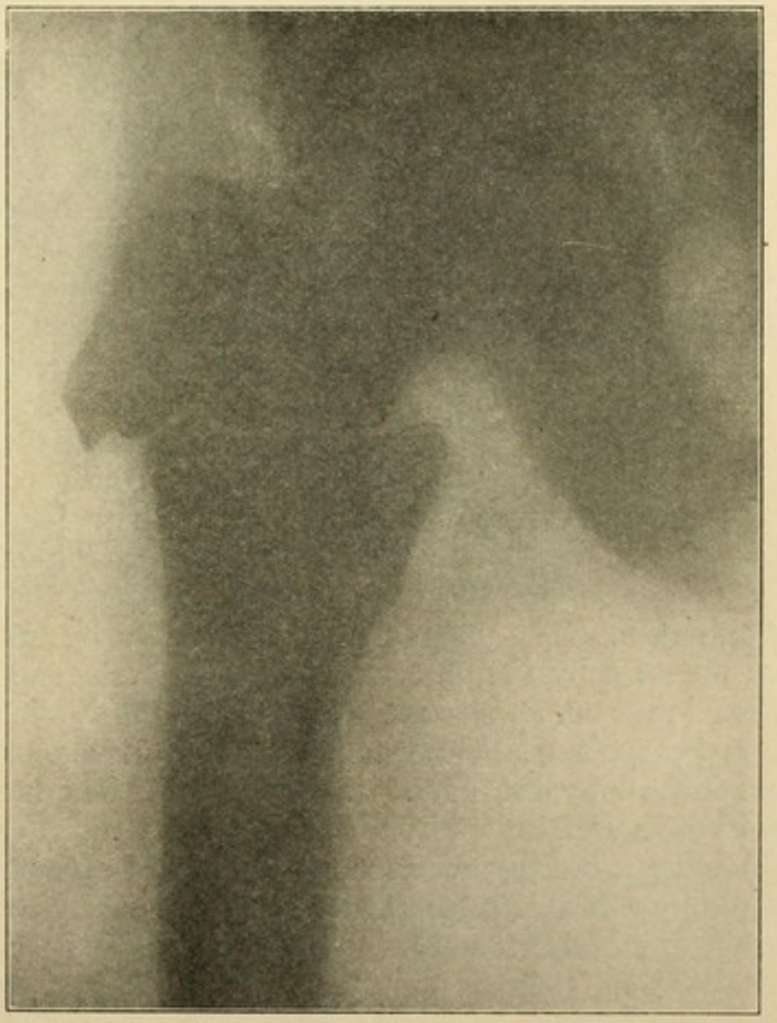

FIG. 366.—Fracture through trochanters of femur; rare and atypical line of fracture. Episcopal Hospital.

from the plane of the bed as well as laterally, overcomes eversion and keeps the capsule of the hip-joint tense, preventing it from falling in between the fragments. Every two or three days the longitudinal traction should be substituted by traction with the hands upon the thigh, and the knee should be flexed gently through about 30 degrees to prevent stiffness. Union is good at the end of four weeks. Ruth found in 1907 that among a total of 72 cases treated by this method there had been no failure of union in patients under eighty years, no failure to secure a useful limb under seventy years of age, and in those past eighty years of age success was obtained in over 60 per cent. of cases. Impacted fractures are treated in the same way, but less weight is required.

Fractures through the trochanters of the femur are not very rare, usually are due to great direct violence, and often are impacted. Three grades of this injury may be recognized (Ashhurst, 1913): the first is little more than an impacted fracture at the base of the neck; in the next, the neck penetrates the trochanteric region further, and a splitting fracture occurs; and in the severest grade the trochanteric region is entirely shattered. A linear fracture between the level of the trochanters is quite rare (Fig. 366). In most cases the lesser trochanter is fractured (Fig. 367). Binet and Hamant (1911) have collected eight cases of *isolated fracture of the lesser trochanter. Isolated fracture of the great trochanter* occurs, and may require periosteal suture to maintain reduction.

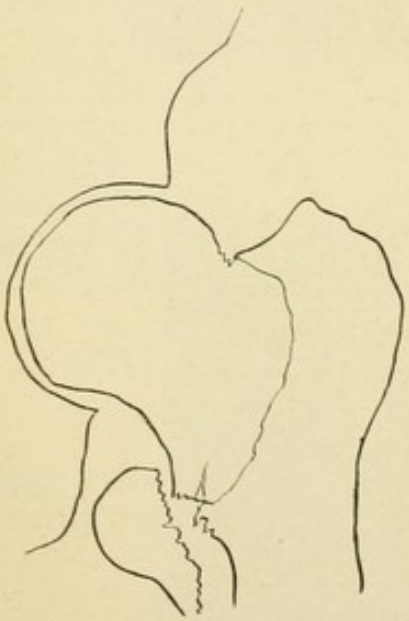

FIG. 367.—A common type of fracture through the trochanters: fracture at base of neck of femur (impacted); with separation of lesser trochanter. Age forty-five years. Episcopal Hospital.

Fractures of the Shaft of the Femur.—These are much more common in children and young adults than in old people, and usually are due to direct violence. There are three main types: (1) *Fracture below the trochanters.* The upper fragment is flexed by the iliopsoas; and rotated outward by the gluteus maximus and the short external rotators. The lower end of the upper fragment often is felt as a sharp projection in Scarpa's triangle; while the lower fragment is drawn upward and inward by the adductors (Fig. 368). The leg rolls outward from its own weight, and shortening is marked. Crepitus and abnormal mobility are easily detected. (2) *Fracture of the middle of the shaft,* often oblique (Fig. 272), is attended by more shortening than any fracture in the body, sometimes as much as 12 cm. (five inches); the leg rolls outward, there is flail-like motion and marked crepitus at the seat of fracture; the lower fragment is drawn up and in by the adductors and hamstrings, and the upper fragment projects anteriorly

(Fig. 369). (3) *Supracondylar fractures* are characterized by posterior displacement of the lower fragment which is kept flexed at the knee by the gastrocnemius (Fig. 371); and by anterior projection of the upper fragment, which may be embedded in the rectus muscle. The diagnosis of these various types of fracture of the shaft is not difficult, since the displacement is fairly constant, and if deformity is great the ends of the fragments usually can be palpated even in very muscular limbs.

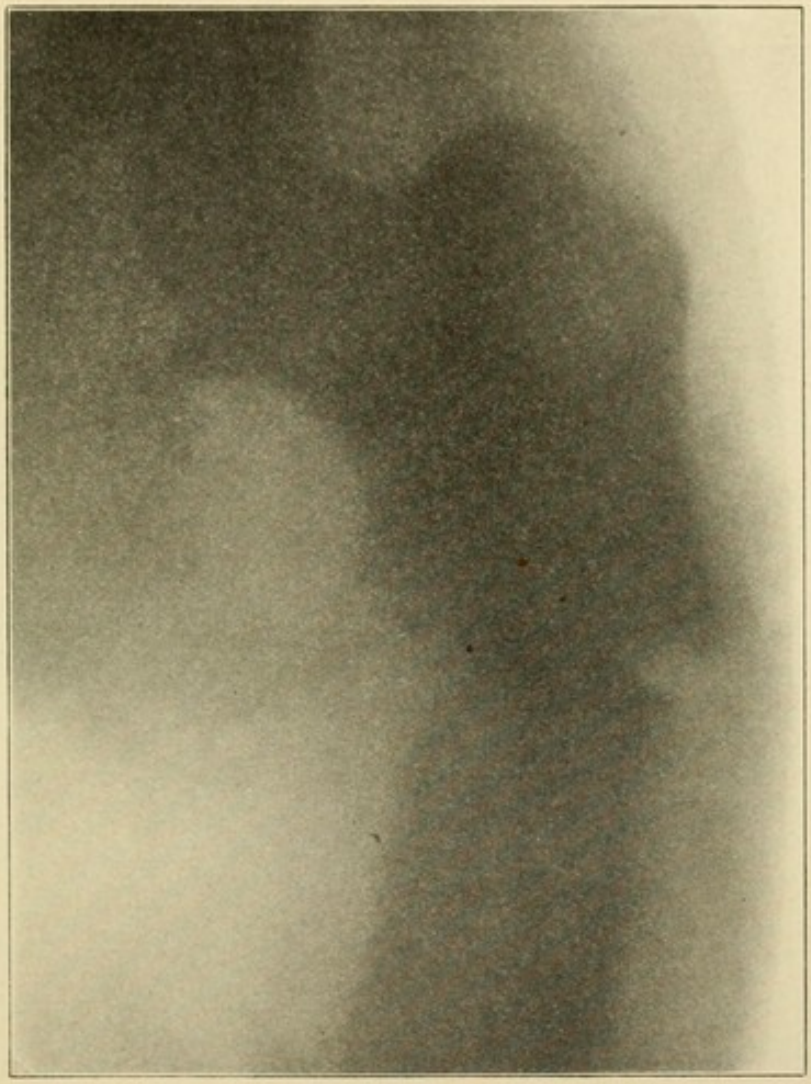

FIG. 368.—Fracture of femur below trochanters. Episcopal Hospital.

Prognosis.—The general mortality is about 15 per cent.; 90 per cent. of those who recover under conservative treatment secure entirely useful limbs, but about one out of three of these will have a limp, and only about one patient out of four will have no shortening (Ashhurst and Newell, 1908). Though many surgeons urge the operative treatment of recent fractures of the femur as a routine, I am not aware that they have published figures demonstrating even as good results as the above.

Treatment.—Reduction of the fracture is difficult, but probably could be more often obtained if the patient was anesthetized. Weight

extension should be applied in sufficient amount to overcome shortening. Ochsner has found that if the adhesive plaster is carried up to the groin, irrespective of the height of the fracture, weight extension is much more efficacious. The full amount of weight necessary should be applied during the first day or two after the accident, since shortening becomes more difficult to overcome the longer it lasts. By raising the foot of the bed from four to six inches, counter-extension is provided by the weight of the patient's body. If necessary

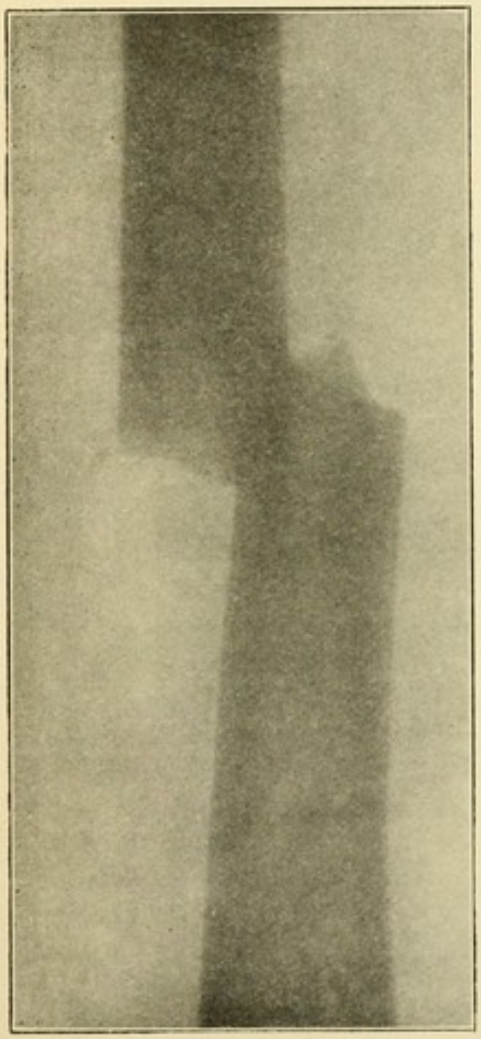

FIG. 369.—Skiagraph of transverse fracture of shaft of femur. Best position obtainable after etherization and attempts at reduction with extension by compound pulley. Femur plated. (See Fig. 370.) Age twenty-three years. Episcopal Hospital.

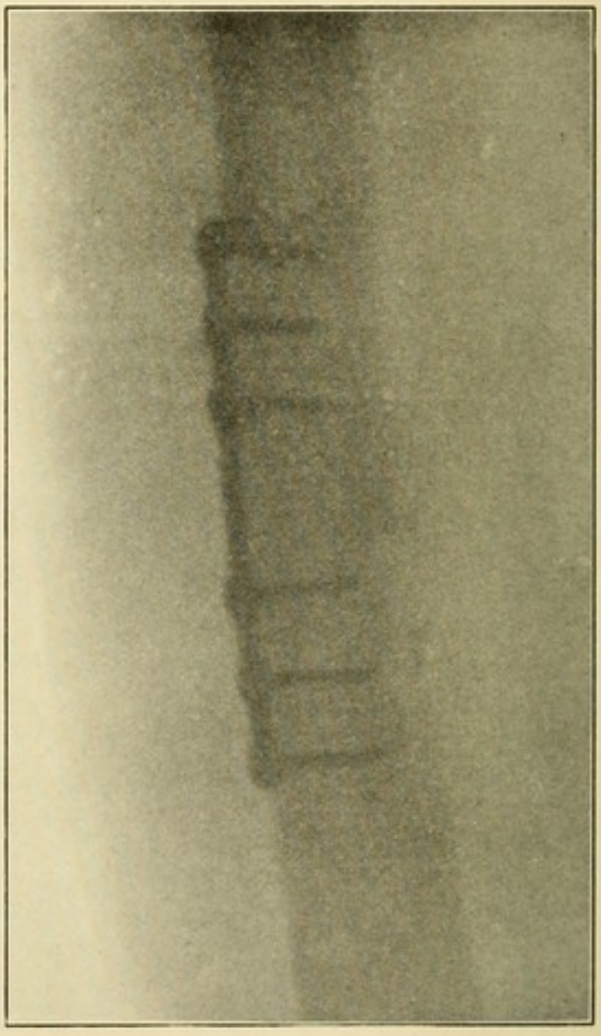

FIG. 370.—Skiagraph of patient shown in Fig. 369, three months after fracture of femur was plated. Excellent result, with scarcely appreciable limitation of motion. Episcopal Hospital.

the patient is anesthetized (usually on the second day) and, shortening being overcome by the weights, the fragments are manipulated into as accurate apposition as possible. Extension by means of the compound pulley may be necessary in very muscular adults, the extension being made by means of a clove hitch applied above the knee (Fig. 372). Sometimes angulation of the fragments over the

forearm will enable the surgeon to secure end-to-end apposition. Absolute reposition rarely can be obtained, and is not necessary to secure a useful limb. In subtrochanteric fractures it may be necessary to raise the lower fragment on a double-inclined plane, in order to approximate it to the upper (Fig. 373); and in supracondylar fractures it always is advisable to flex the knee (rarely to divide the tendo Achillis) so as to relax the gastrocnemius muscle. In fracture of the middle of the shaft the thigh is dressed in the extended position, and the seat of fracture always should be supported by coaptation splints. Rotation outward of the lower fragment is prevented by the use of Volkmann's sliding splint (1882) or similar device (Fig. 365). A long external splint (Liston, 1837), well padded, extending from the axilla to below the foot, and bandaged firmly to the entire lower extremity and pelvis, will prevent outward angulation of the fracture; and the use of a shot bag will overcome anterior displacement. In children, Hamilton's splint (1860)

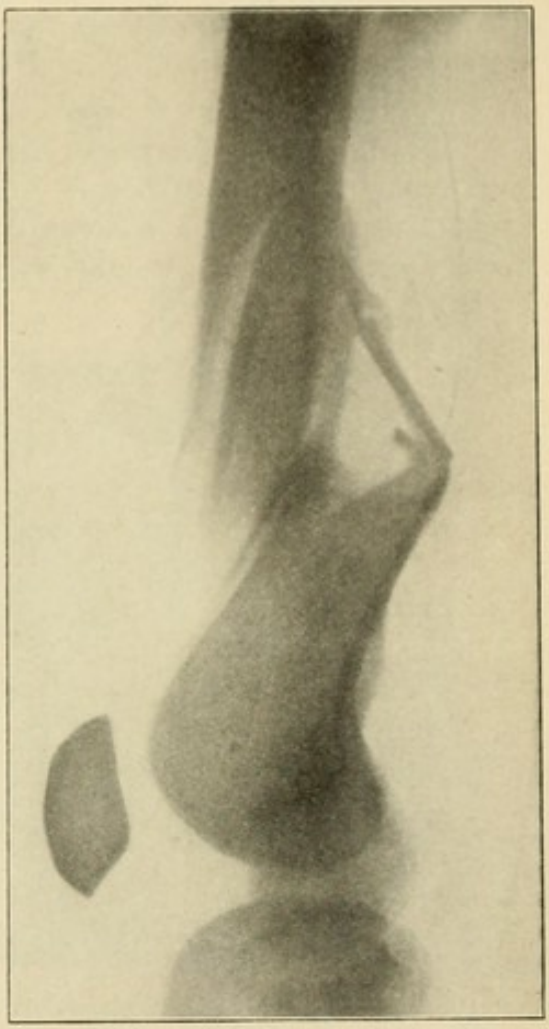

FIG. 371.—Skiagraph of fracture above condyles of femur. Lower fragment drawn backward by action of gastrocnemius. Episcopal Hospital.

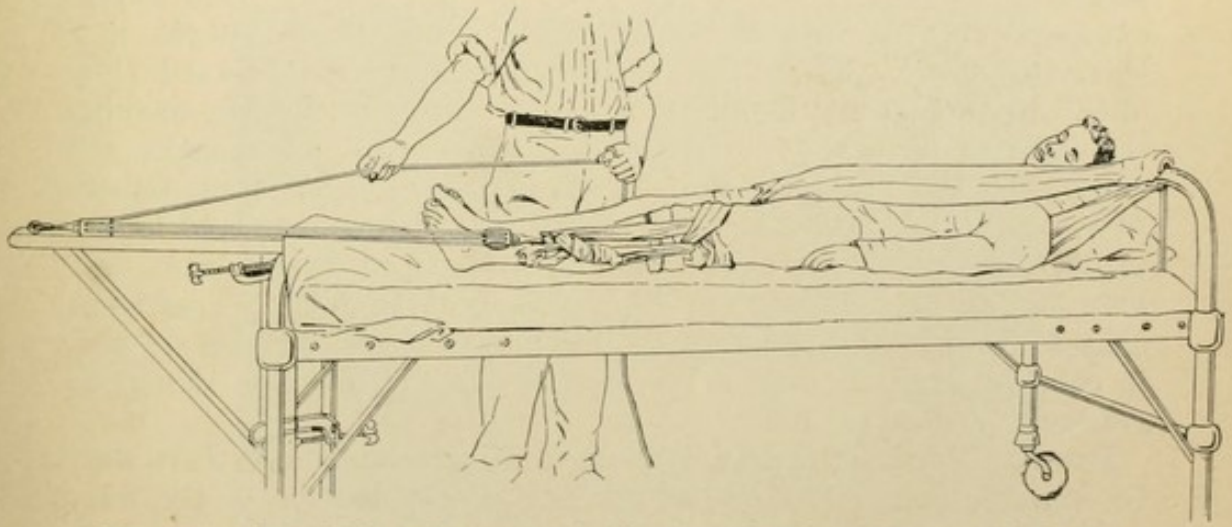

FIG. 372.—Clove hitch and compound pulley for reduction of fractures of the femur under anesthesia. Counter-extension by a sheet tied to the head of the bed. Episcopal Hospital.

facilitates moving the patient, as it fixes both lower extremities by long external splints fastened together by a cross-bar below the feet, through which passes the cord carrying the weight extension. Immobilization in adults should be continued for six to eight weeks, but after the first four weeks very light massage is permissible, above and below the fracture. Weight-bearing should not be attempted for eight or ten weeks after the injury—in general, not until four weeks after union seems solid, as subsequent shortening with angular deformity is a sad consequence of too early efforts to walk. In very young children weight-bearing may be resumed in six or seven weeks.

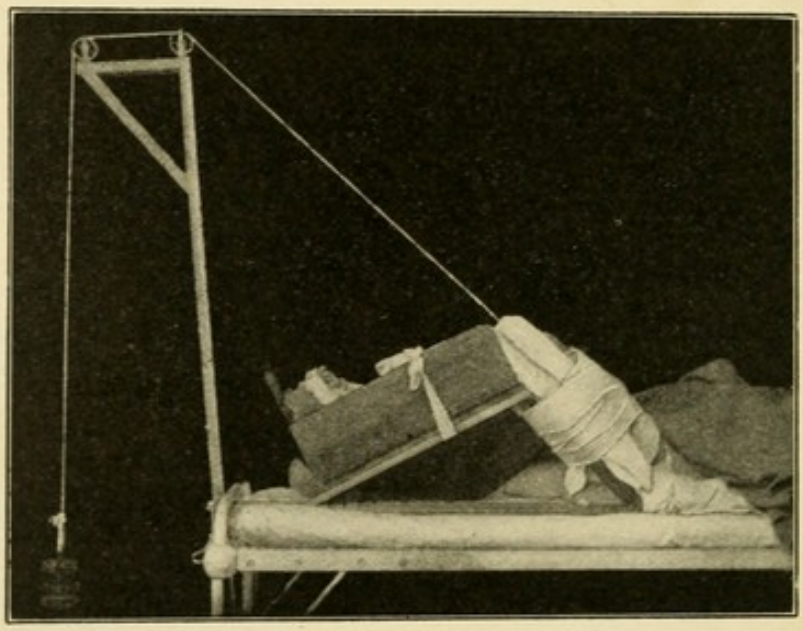

FIG. 373.—Double inclined plane, with weight extension for fracture of femur below the lesser trochanter. Episcopal Hospital.

Fractures of the Lower End of the Femur.—*Epiphyseal separation* occurs oftenest from six to ten years of age, usually from hyperextension or a twisting injury, as from having the leg caught in a revolving wheel. The epiphysis usually is displaced forward (Fig. 374). Reduction may be difficult, and is best maintained by dressing the knee in flexion. *Fracture of one or other condyle,* usually the external, is more frequent in children than adults, and occurs mostly from direct violence. There is mobility of the fragment, and lateral mobility in the knee, in addition to crepitus, localized pain, etc. Effusion, perhaps bloody, often occurs into the joint. Treatment consists in immobilization with weight-extension or plaster cast, in good position, for four or five weeks. Use of the limb should be gradually resumed.

Patella.—If these fractures occur from direct violence there may be comminution, but there seldom is much separation of the fragments unless the lateral expansions of the quadriceps tendon are ruptured; in fracture from muscular action, however, which is the

usual form, this fibrous expansion is widely torn, as the fracture takes place by sudden flexion of the knee, and the tense quadriceps breaks the patella over the condyles as an over-bent lever. The bone usually gives way more or less transversely, the lower fragment being smaller.

Diagnosis. — Diagnosis is easy, owing to separation between the fragments, free mobility, and crepitus. If the quadriceps expansion is not torn, the patient may still be able to walk; usually he is entirely disabled. I have seen, however, two cases of subperiosteal fracture, demonstrated by skiagraphs, in which there was no disability.

Treatment. — Treatment in most cases is operative, as it is difficult to secure good apposition without suture of the fragments. But in the aged, or those with visceral disease, operation is much more of a risk, and conservative treatment may secure a very useful leg. The limb is dressed on an inclined plane (Fig. 375), thus relaxing the quadriceps muscle, and the fragments are approximated by straps of adhesive plaster, much as in the case of fractured olecranon; the plaster should be readjusted every couple days to

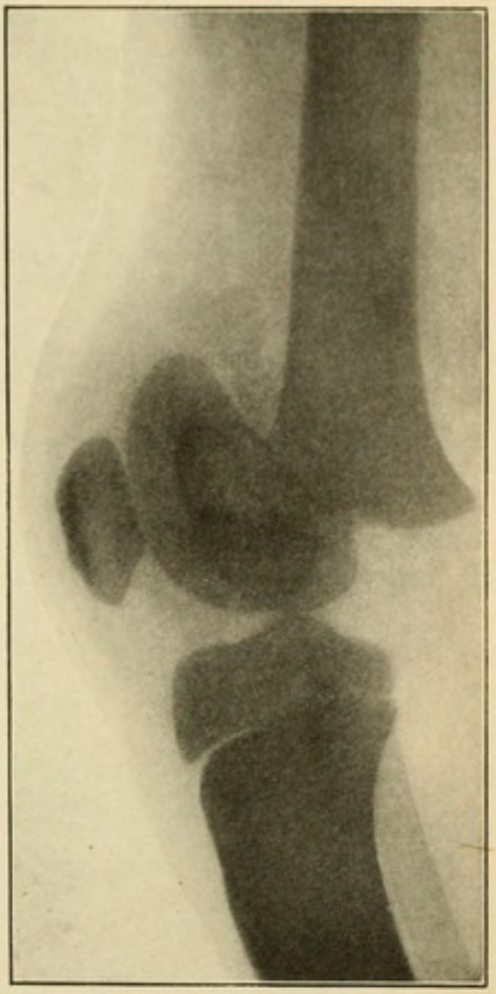

FIG. 374.—Separation of lower epiphysis of femur. Reduced under ether and knee dressed in flexion on double inclined plane. Dr. H. C. Deaver's case. Episcopal Hospital.

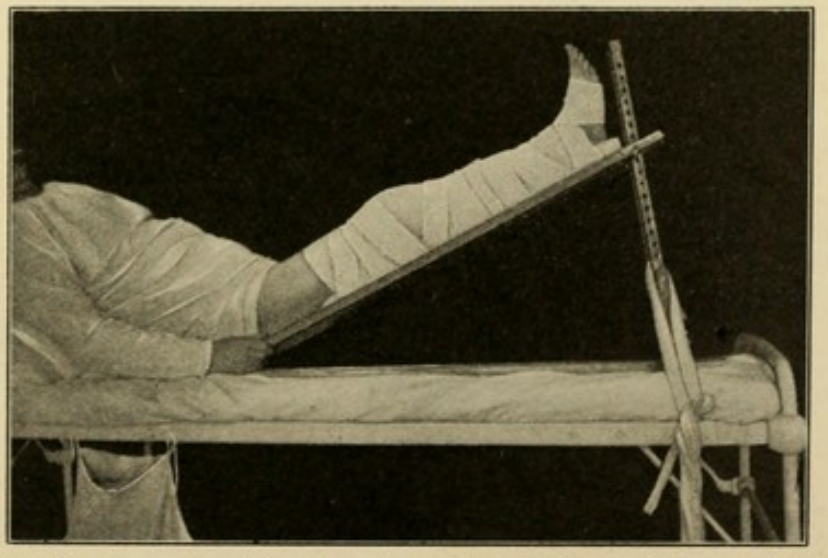

FIG. 375.—Fracture of patella, dressed on inclined plane. Episcopal Hospital

keep the fragments as close together as possible, and to avoid everting them. This dressing is continued for six weeks. Even if only fibrous

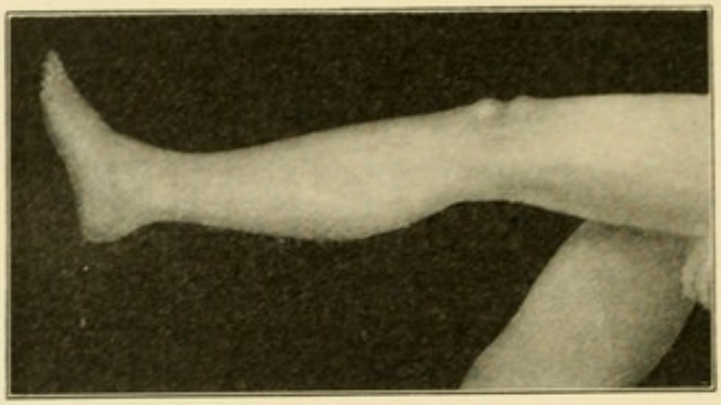

FIG. 376.—Fracture of patella with wide separation of fragments, showing power of full extension six years after injury. No operation was done. Episcopal Hospital.

union results, and if after getting about the bond of union stretches, as it frequently does, the power of extension of the knee may be retained

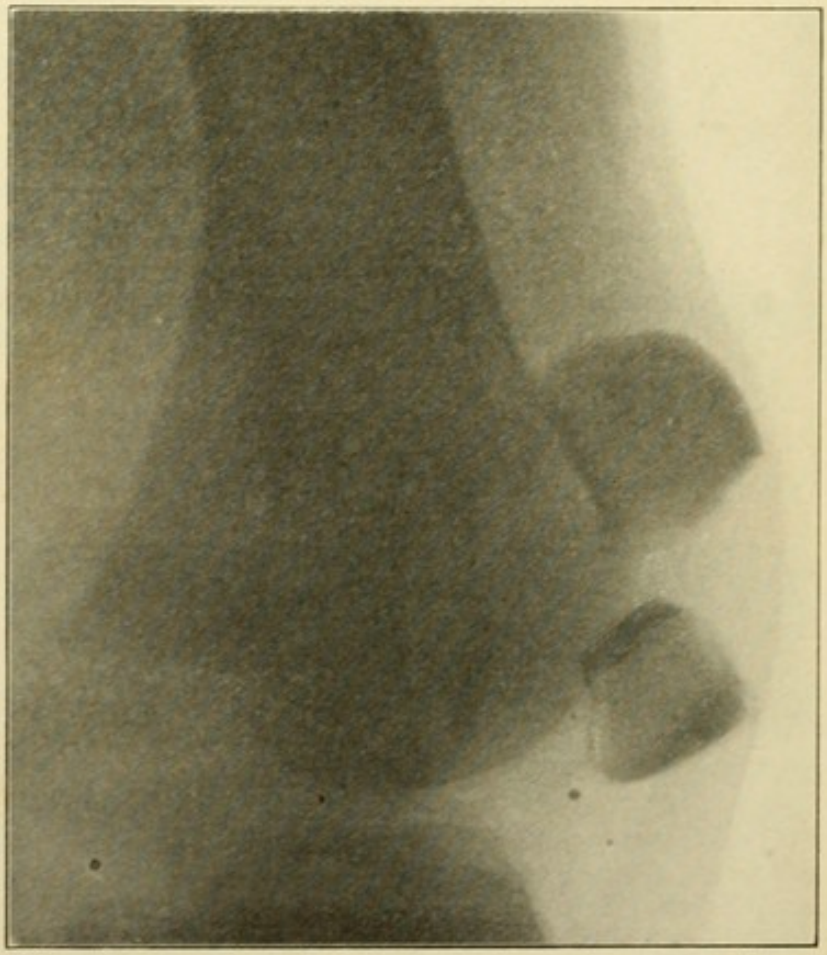

FIG. 377.—Fracture of patella before operation. Age twenty-eight years. Episcopal Hospital.

(Fig. 376); but in almost all cases there will be slight limp, and some disability in going up stairs. *Operation* is best done between the fifth

and tenth days after injury; earlier intervention sometimes is followed by infection, and infection in a knee-joint of this kind usually requires amputation, and may result in the patient's death. The mortality of operation even under the best conditions may reach 4 per cent. (E. G. Alexander, 1911). The strictest aseptic technique is imperative. A semilunar flap is turned down or up, exposing the seat of fracture. The knee-joint is widely opened, and clots are removed by forceps or sponging with moist gauze. Any fringes of the quadriceps aponeurosis turned down between the fragments are everted,

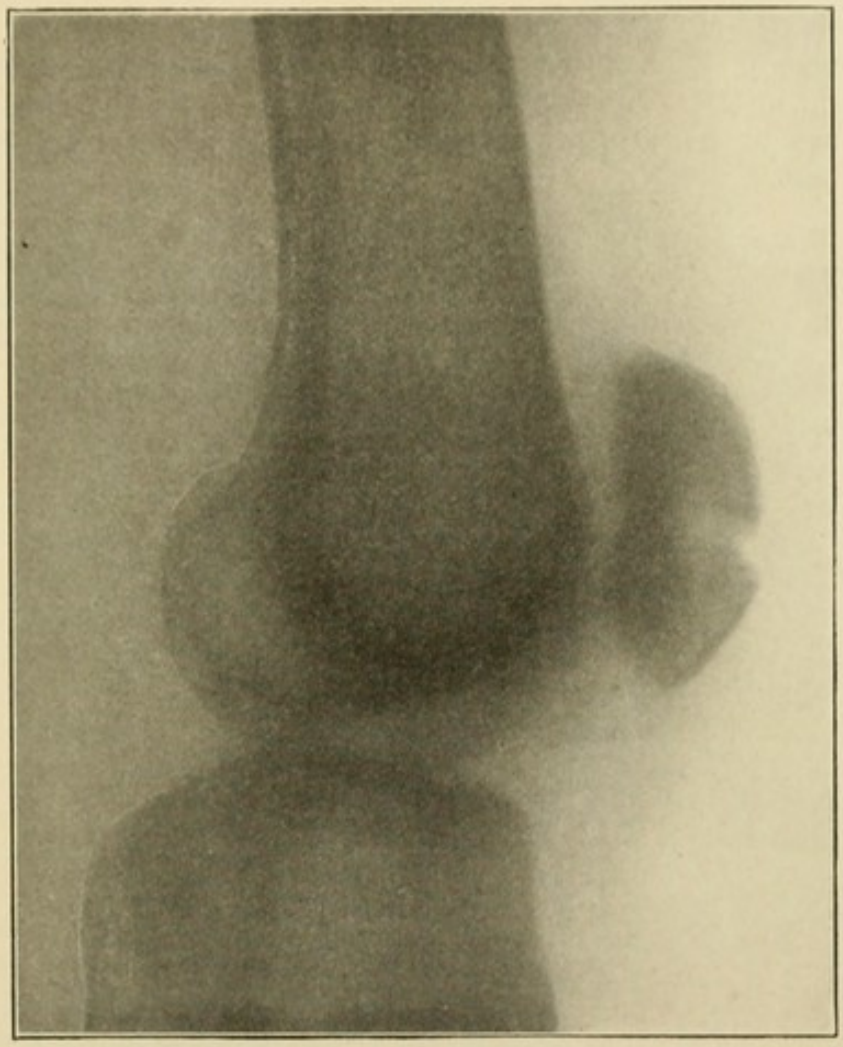

FIG. 378.—Fracture of patella after suture with chromic catgut. Episcopal Hospital.

and two holes are drilled in each fragment, from the superficial to the fractured surface, not invading the articular surface of the patella. The fragments are then sutured with a mattress suture of heavy chromic catgut or wire; the quadriceps expansion and capsule are sutured with chromic gut; and the skin with interrupted silkworm gut (Figs. 377 and 378). In some cases it is sufficient to suture the fibrous tissues alone, without direct suture of the bone (Blake, Gibbon, 1904). If all oozing has been checked, and the skin is not sutured too tightly, it is not necessary to drain the wound; otherwise a small drain

should be left for forty-eight hours. The limb is dressed on a posterior splint, which may be removed in a few days and the limb laid on a pillow, with the knee slightly flexed. Most surgeons now recommend beginning very gentle passive motion four or five days after operation, by raising the knee a few inches from the pillow once daily. No active motion should be allowed for at least two weeks, and not then unless the bone has been sutured with wire. If wire has been used, the fragments depend on it for their apposition and not on the newly formed callus. True bony union seldom results, and if absorbable bone sutures have been used, the knee should be supported by a posterior gypsum splint, or light brace, to prevent excessive flexion, for eight weeks or more after operation. With non-absorbable suture the patient may begin to walk without support in three or four weeks. If wire has been used it may require to be removed. Refracture is not very rare.

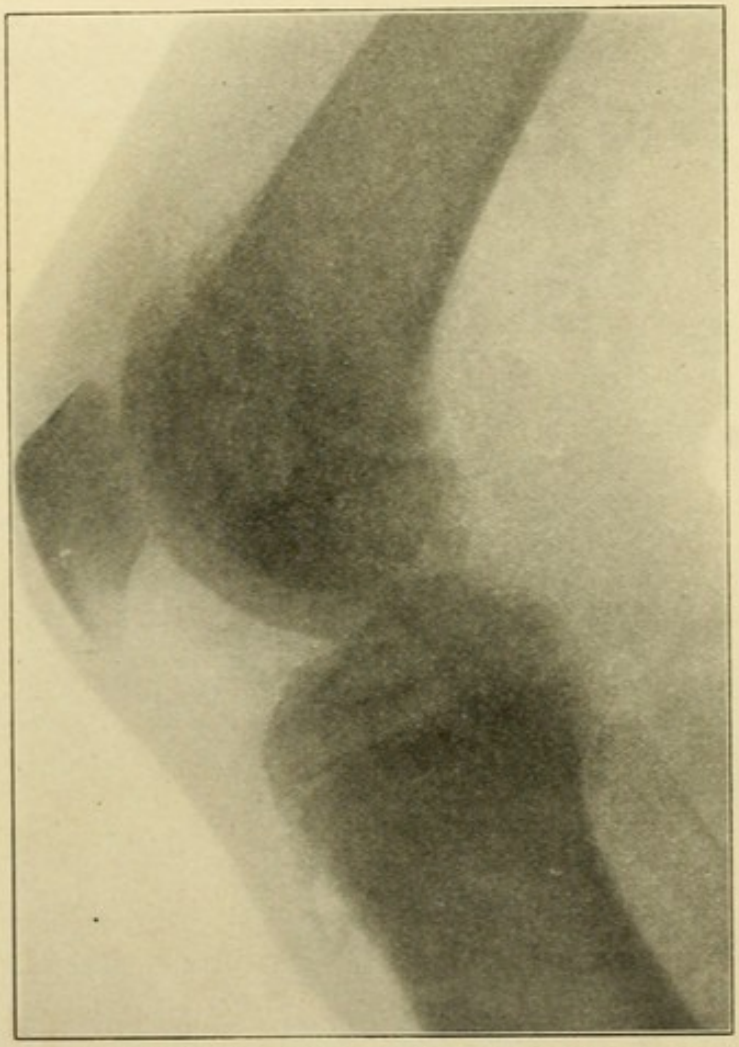

FIG. 379.—Skiagraph of partial separation of upper epiphysis of tibia. (Schlatter's disease.) Episcopal Hospital.

Tibia.—These fractures frequently are caused by direct violence, except those of spiral type following twists of the foot, and those of the internal malleolus accompanying fracture of the lower end of

the fibula. The subcutaneous position of the tibia, and the fact that it supports the main weight of the body, render it much more liable to injury than the fibula, fractures of the shaft of which rarely occur except as secondary lesions in fractures of the tibia. The fractures from direct violence often are compound or comminuted.

Fractures of the upper end of the tibia frequently run into the knee-joint (Fig. 270), and synovitis may result; as the fracture may be subperiosteal or impacted, involvement of the knee-joint with pain and tenderness over the head of the tibia, should make one suspect such a fracture. Complete *separation of the upper epiphysis of the tibia* is rare, but "starting of the epiphysis," sometimes known as Schlatter's disease (1903), is a not infrequent accompaniment of sprains of the knee in adolescents; the tibial tubercle, which forms part of the epiphysis, is partially lessened by the pull of the tendo patellæ, and periosteal thickening results (Fig. 379). Most cases resemble "sprain-fractures" (p. 298), but in some the tibial tubercle is broken loose and is palpable as a distinct fragment. Treatment consists in rest until acute symptoms subside; immobilization of the knee should be continued for several weeks.

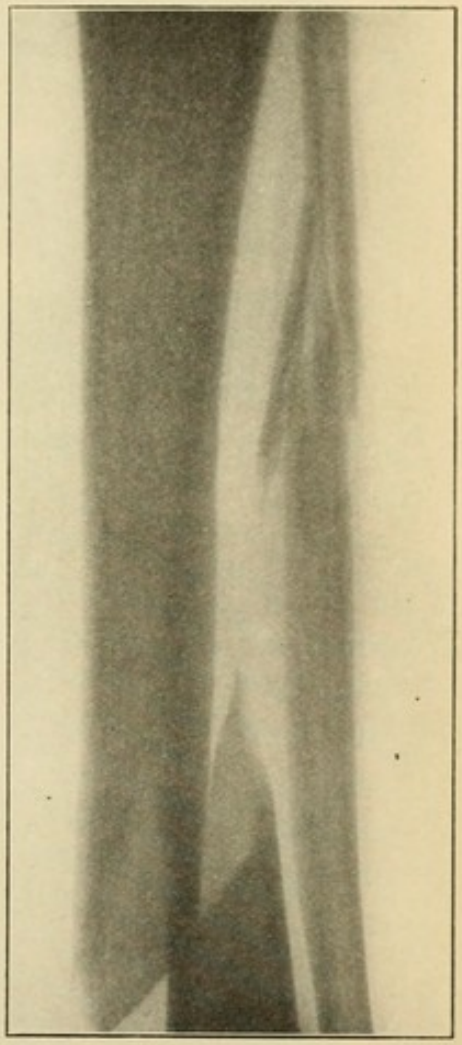

FIG. 380.—Skiagraph of fracture of both bones of leg; foot displaced backward by contraction of calf muscles; lower pointed end of upper tibial fragment protruding subcutaneously on front of leg. Fracture of fibula comminuted and typically higher than that of tibia. Episcopal Hospital.

Fractures of the shaft of the tibia generally are oblique, and deformity may be great, owing to the pull of the calf muscles on the foot which causes shortening, and angular projection forward of the upper fragment. If this is pointed, as it usually is, there is danger of its causing a slough in the skin (Fig. 380). There also is a tendency to external rotation of the upper fragment from the weight of the thigh. Owing to the deformity, mobility, and crepitus, *diagnosis* is easy. The fibula very frequently is broken also. *Treatment* consists in reduction of the deformity by extension, counter-extension, and manipulation; it may be assisted by placing the leg in Pott's position (1771)—lying on its fibular side with the knee flexed nearly to a right angle. Where posterior displacement of the lower fragment is very persistent, it may be advisable to divide the tendo Achillis. The leg may be put

up in plaster of Paris at once, in cases where the condition of the soft parts will admit of this procedure, and in which reduction can be surely maintained while the plaster is setting; in this case the dressing must extend from the toes to above the knee, and it is very important to keep the foot at a right angle with the leg. The gypsum

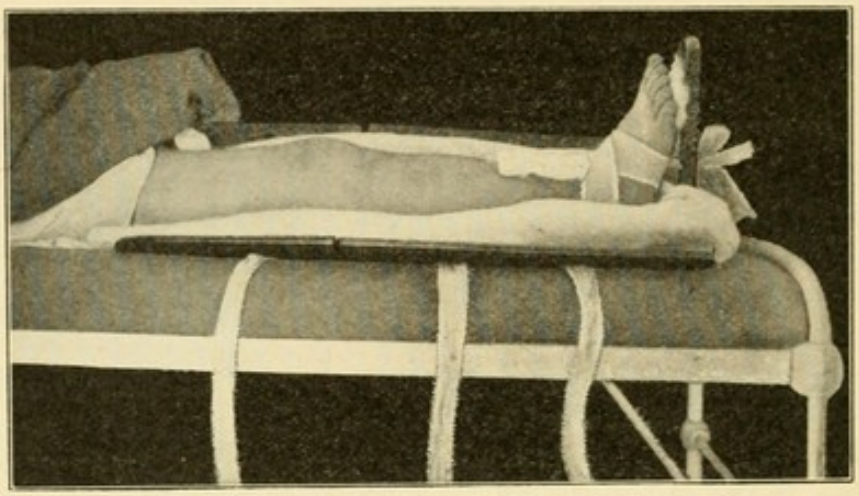

FIG. 381.—Long fracture box, for fracture of bones of leg. Note dry dressing over wound of compound fracture of tibia and foot bandaged to foot piece. Episcopal Hospital.

case must be renewed at the end of a week or ten days, as subsidence of the primary swelling will have rendered it loose and hence useless in keeping the fragments in good position. In cases where the primary swelling is great, with bullæ, ecchymoses, etc., it is better to postpone the application of a plaster of Paris dressing for a week or ten days,



FIG. 382.—Long fracture box for fracture of bones of leg, sides raised and fastened around leg. Episcopal Hospital.

keeping the leg meantime in a fracture box (Figs. 381 and 382), securely packed into a pillow which fills up all irregularities and keeps the leg straight; a small shot-bag may be laid over the projecting fragment. While in the fracture box great care must be exercised to protect the heel and malleoli from pressure by "floating" the former

on a compress placed under the tendo Achillis, and by suitably padding the malleoli; and the heel should be kept down against the foot-piece of the fracture box, to prevent equinus deformity. Rotatory displacement of either the upper or lower fragment must be guarded against. Another very good dressing is the posterior wire frame of Cabot, placed under the lower extremity from the gluteal crease to the ends of the toes, the wire being suitably padded, and the splint covered with cotton cloth. The limb is then laid on this over folded sheets or towels so applied as to equalize pressure and leave the heel free; one or two lateral splints are then applied, and fastened to the frame and each other by adhesive plaster or webbing straps with buckles.

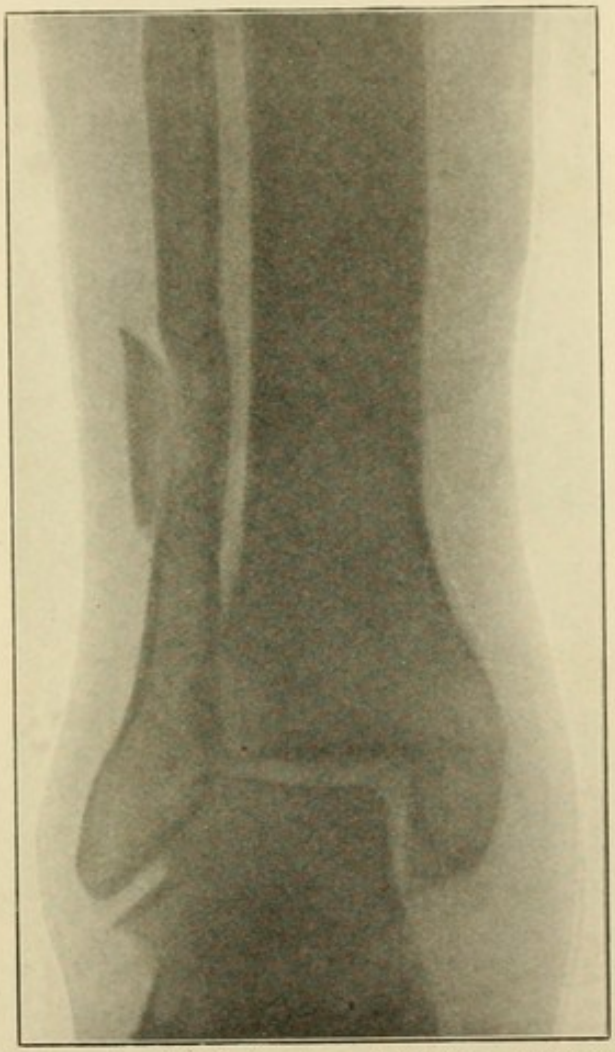

FIG. 383.—Skiagraph of Pott's fracture of left leg. Age forty-two years. Episcopal Hospital.

Fractures of the Fibula.—*Fracture of the shaft* of this bone is rare, except when accompanied by fracture of the tibia, to which it usually is secondary. In such cases the treatment described above for fracture of the tibia is to be employed. Isolated fracture of the upper part of the shaft of the fibula often results in delayed union or non-union, as it is very difficult to secure apposition of the ends of fragments buried in such a mass of muscular tissue. *Fracture of the lower fifth*

of the fibula is a very frequent injury, resulting from indirect violence, the foot, as a rule, being turned violently outward (*eversion fracture*); as the astragalus forces the external malleolus outward, the tibio-fibular ligaments act as a fulcrum, so that the fibula is bent in against the tibia above the attachment of these ligaments, and finally breaks at this point, two or three inches above the ankle-joint; the internal malleolus often is avulsed from the tibia, at the same time (Fig. 383); and to this combined lesion the name of *Pott's Fracture* is given, it having been studied carefully and graphically described by Pott in 1771. A somewhat similar lesion may result from *inversion* of

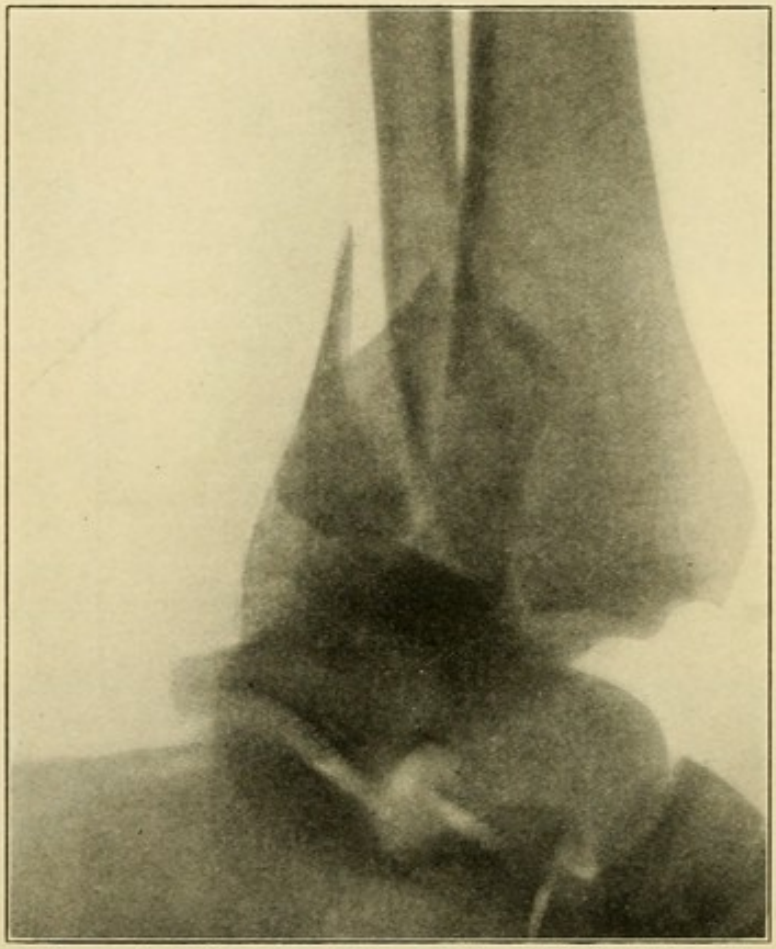

FIG. 384.—Skiagraph of fracture of lower fifth of fibula, internal malleolus and posterior articular surface of tibia, with posterior dislocation of the foot. Episcopal Hospital.

the foot, but then usually the fracture of the fibula detaches merely the external malleolus, and the tibial fracture enters the ankle-joint. No accurate description can be given of the lines of fracture in these various injuries, as they vary greatly in different cases. Other lesions, which may or may not be present, are rupture of the tibio-fibular ligament, rupture of the internal lateral ligament of the ankle without fracture of the internal malleolus, fracture of the external border of the articulating surface of the tibia, separation of the lower tibial epiphysis, or posterior dislocation of the ankle-joint (Fig. 384).

Symptoms.—Symptoms of Pott's fracture are a well-marked and characteristic deformity, consisting in eversion of the foot, and marked

prominence of the internal malleolus or of the lower end of the tibia when the malleolus is avulsed; almost always there is a tendency for the foot to slide backward, causing elongation of the heel and prominence of the tibia anteriorly. As a rule, lateral mobility is marked, and crepitus easily detected. But since fracture in this region occasionally exists without displacement, being subperiosteal or impacted, the surgeon always should treat a suspected case as one of fracture until this can be disproved by skiagraphy or otherwise.

Treatment.—Accurate reduction is imperative if a good result is to be obtained: imperfect reduction in an antero-posterior direction will limit dorsal flexion of the ankle, and imperfect correction of the eversion will render the patient liable to develop static flat-foot, and will cause lasting disability in locomotion (Fig. 385). Sometimes general anesthesia is necessary to secure reduction. Grasping the heel in one hand, and the leg in the other, the surgeon brings the foot forward until the astragalus bears its normal relation to the tibia, and then supinates the foot, so as to replace the internal malleolus and overcome the internal bowing of the fibula. If there is little reaction in the soft parts a plaster of Paris dressing, from toes to knee, may be applied at once, to be renewed in a week or ten days. In most cases, however, it is safer to dress the leg temporarily in a fracture box, with a pad below the external malleolus and one above the internal malleolus to overcome eversion, and with careful support to the heel, keeping this well down against the footboard so as to

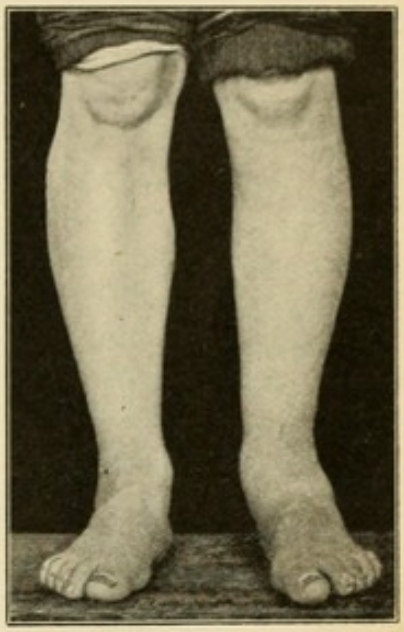

Fig. 385.—Deformity following unreduced Pott's fracture of left foot, two months after injury. Episcopal Hospital.



Fig. 386.—Dupuytren's splint for Pott's fracture. Note pads along tibial surface of leg, allowing inversion of foot. Episcopal Hospital.

prevent the development of a pointed-toe deformity; or the leg may be dressed in Pott's position on a Dupuytren splint (1819) (Fig. 386). Weight should not be borne on the foot for at least eight weeks. In many cases, where reduction has been imperfect, stiffness and edema may persist for some months, and may require massage, passive motion, baking, etc., for their relief.

FRACTURES OF THE FOOT.

Fractures of the Tarsus usually result from direct violence or falls on the feet, and often are impacted. Localized tenderness

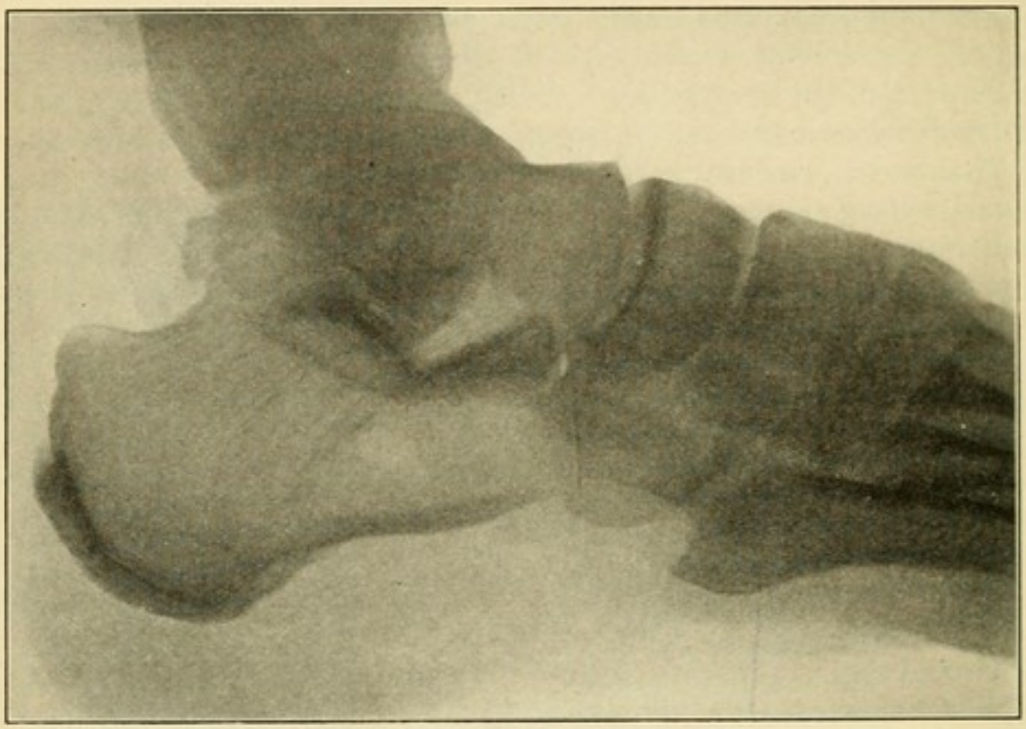

FIG. 387.—Impacted fracture of neck of right astragalus. Episcopal Hospital.

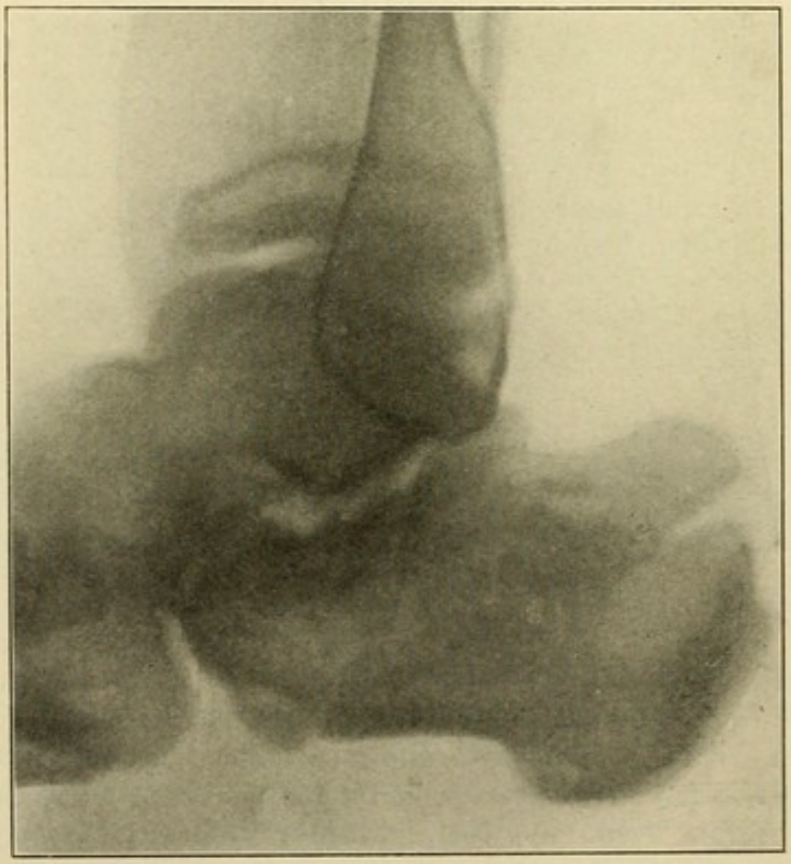

FIG. 388.—Skiagraph of fracture of calcaneum, comminuted and impacted. Episcopal Hospital.

following severe injury is the most valuable symptom, since swelling of the soft parts may obscure deformity, and since mobility and crepitus frequently are absent. Corresponding injuries often exist in both feet, and two or more bones often are fractured in the same foot. The *astragalus* most frequently is broken through its neck (Fig. 387; see also p. 414). Fractures of the *calcaneum* are more frequent, and often may be diagnosed clinically from the

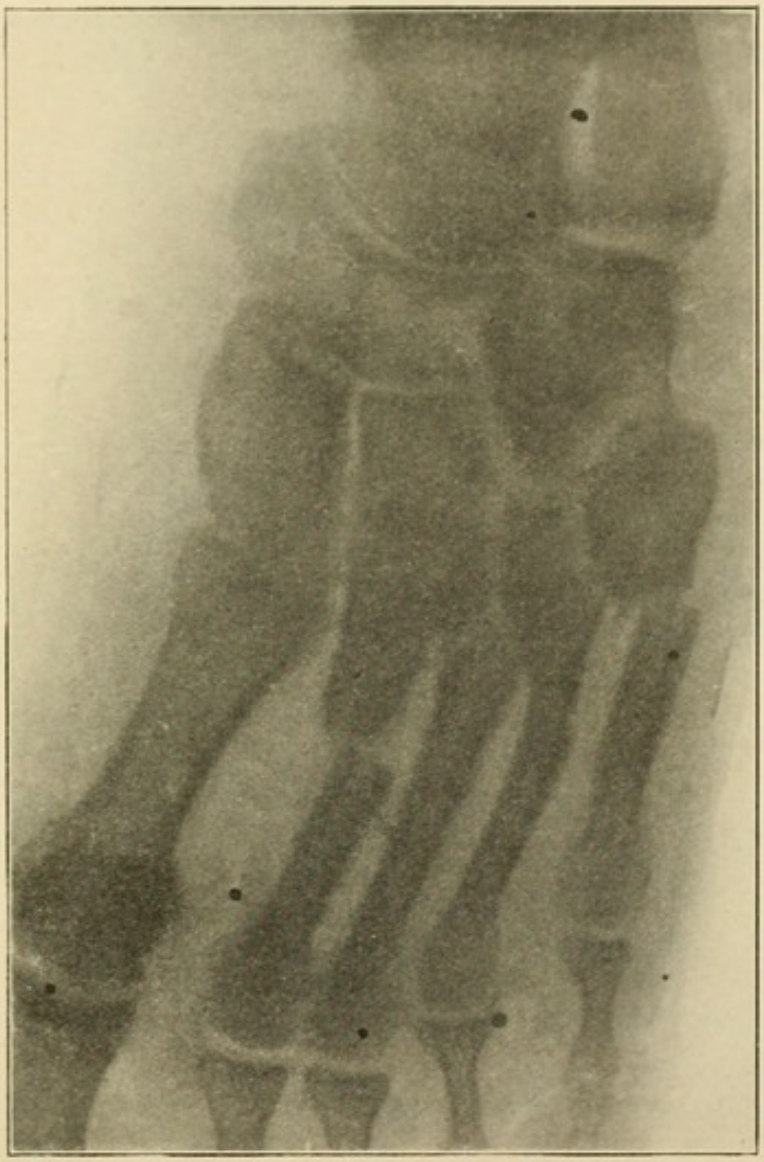

FIG. 389.—Fracture of second, third, fourth, and fifth metatarsal bones. Heavy stone fell on foot. Age twenty-three years. Episcopal Hospital.

flattening of the heel and prominence of the calcaneum below the external malleolus; if the fracture detaches the posterior half this may be considerably displaced upward by the tendo Achillis; more often there is a general crush of the bone (Fig. 388). These fractures are best treated by immobilization in good position in plaster of Paris for three or four weeks; but weight-bearing should not be allowed for several months. Traumatic flat-foot should be corrected by moulding the foot over the surgeon's knee or a sand pillow, as the plaster sets;

division of the tendo Achillis may be necessary; the eversion of the heel should be corrected also. If impaction of the calcaneum with deformity cannot be overcome without incision, it will be proper to do osteotomy of the heel portion so as to restore the normal weight-bearing surfaces. This has been done by Chutro (1909) as a secondary operation.

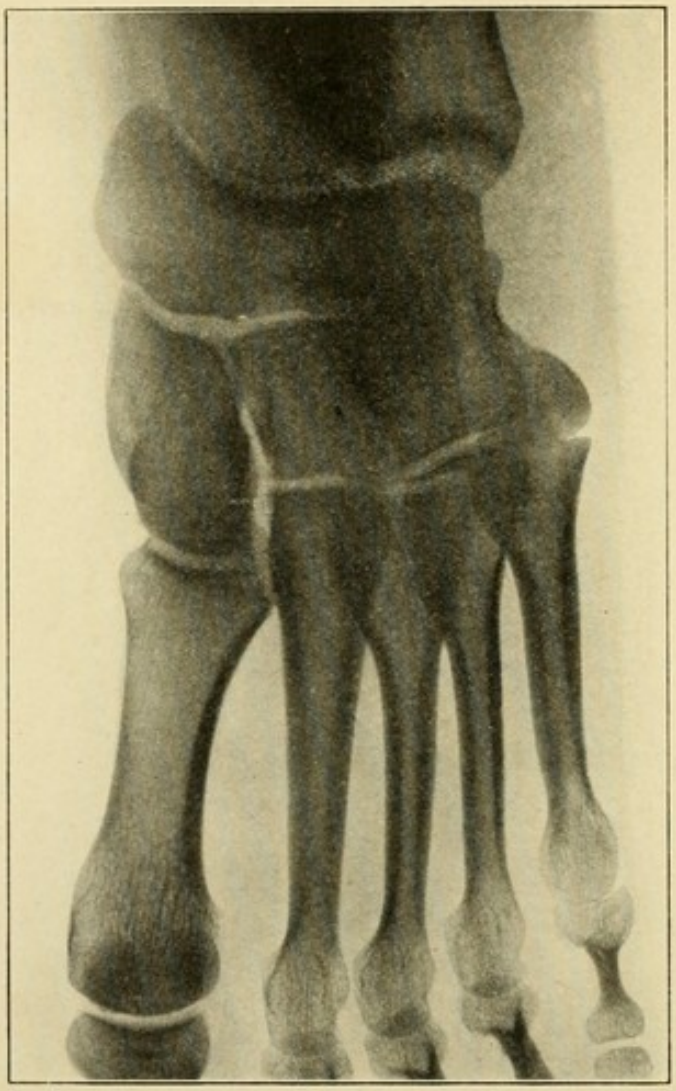

Fig. 390.—Fracture of tuberosity of fifth metatarsal bone; patient had been treated for "sprain of foot." Age twenty-three years. Episcopal Hospital.

Fractures of the Metatarsus.—The metatarsal bones usually are fractured by direct violence, usually two or three at once (Figs. 389). Deformity is slight, but disability may be great. Diagnosis is based on persistent localized tenderness usually with mobility, and sometimes crepitus. Fracture of the base of the fifth metatarsal bone (Fig. 390), or epiphyseal separation at this point, which is a less frequent injury, sometimes occurs from direct injury in stepping on the outer side of the foot.

Fractures of the Phalanges are rare, even from direct violence, and then usually are compound and require amputation.

CHAPTER XIII.

INJURIES OF JOINTS.

Sprains and Contusions.—A *sprain* is an injury to the ligamentous structures surrounding a joint, caused by a wrench or a twist; there may be a subluxation or actual dislocation of the bones composing the joint, spontaneously reduced. Ross and Stewart (1911), maintain that every sprain is a sprain-fracture, the ligament giving way at its bony attachment.[1] *Contusions* are rarer than sprains, and are due to direct injury, the blow being received over the joint or being transferred to it through the bones; by the latter mechanism may be explained fracture or displacement of intra-articular cartilages (p. 412). The joints most often sprained are those of the foot, wrist, shoulder, and elbow.

Symptoms.—The symptoms of the two conditions are those of inflammation in general, with perhaps the added special symptoms of synovitis (p. 463), thecitis (p. 279), or sprain-fracture (p. 298). The joint assumes that position in which tension is least, the ankle being in slight plantar flexion and adduction, the wrist in flexion, etc. The swelling, heat, redness, etc., may appear in a few moments, but if the joint is well supported (*e. g.*, by a shoe), and its use is persisted in, they may not manifest themselves until after support is removed. In the foot the *subastragalar joint* is that most frequently sprained, the lesion being referred to popularly as "*sprained ankle*"; the normal range of its lateral motion is suddenly exceeded either in abduction or adduction, with laceration or complete rupture of the internal or external lateral ligaments at the ankle; and in some cases there is a diastasis of the tibio-fibular joint. There commonly is effusion around both malleoli (Fig. 391). Distinction from fracture usually is possible after careful examination, by excluding abnormal mobility or localized tenderness of the bones around the affected joint, the symptoms in sprains pointing to the soft structures as the seat of lesion.

Prognosis.—The prognosis is good, though in some rheumatic patients slight disability may persist for months; and in a few cases, especially sprains of the shoulder, periarthritis may ensue (p. 466).

Treatment.—When seen early, it is best to strap the ankle with adhesive plaster (Fig. 392), applying a firm bandage over this. In mild sprains, limited use of the joint may be allowed when thus supported, but in severe cases the foot should be elevated, and kept at rest for several days. This strapping should be renewed every third

[1] By a "strain" usually is understood a sprain of slight degree, in which the tendinous rather than the ligamentous structures are injured.

or fourth day, and may well be continued until function of the joint can be resumed. In cases not seen until marked swelling has developed, it is safer to treat the joint with anodyne or evaporating lotions until tenderness and swelling begin to abate. Sprains of the joints of the upper extremity may be dressed with ichthyol or belladonna and mercury ointment, and the limb carried in a sling. Absolute immobilization (plaster of Paris, etc.) rarely is advisable, as tending to promote stiffness by interference with the circulation of blood and lymph. In later stages much benefit is derived from alternate hot and cold douches, massage, and gentle passive motion.

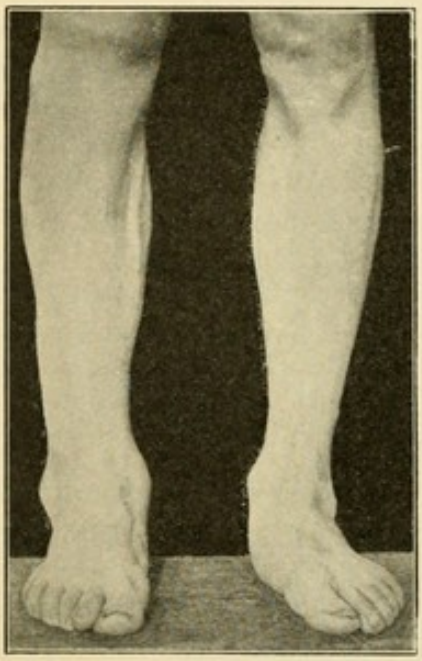

FIG. 391.—Sprained right ankle (recent accident). Episcopal Hospital.

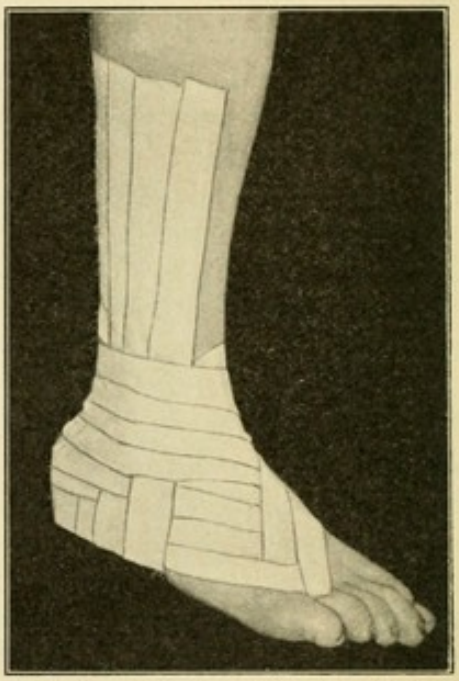

FIG. 392.—Adhesive plaster strapping for ankle. Episcopal Hospital.

Wounds of Joints.—Open wounds of joints usually are very serious lesions, since joints are very susceptible to infection. They may be incised, lacerated, punctured, etc. Gunshot wounds of joints have been considered in Chapter VII.

Diagnosis.—The diagnosis usually can be made by noting the situation and depth of the wound, or by observing the escape of synovial fluid, and the increase in its flow on manipulation or pressure of the joint; under no circumstances should a joint wound be probed with finger or instrument until all proper aseptic preparations have been made.

Prognosis.—The prognosis depends on the joint injured, on the nature of the injury, on the constitutional state of the patient, and on the treatment employed. Except the vertebral joints, the knee is the most dangerous joint in the body, but no joint wound can be regarded as trivial: even those of the phalanges may require amputation, or at least result in ankylosis. Infection is the great danger, and even supposedly aseptic operations occasionally terminate

fatally when the knee is involved (p. 375). If proper treatment is not undertaken promptly, pyarthrosis may result, followed by septicemia and death, in spite of all the resources of surgery.

Treatment.—If seen before these complications have arisen, the wound should be packed with sterile gauze, and the limb surrounding it prepared as for an aseptic operation; then any foreign bodies remaining in the wound (cinders, clothing, glass, needle, etc.), should be extracted, enlarging the wound if necessary, and evacuating blood and clots from the interior of the joint; this should then be gently irrigated (not sponged) with warm saline solution, and sutured with provision for drainage. The joint is then immobilized by splint or plaster of Paris, elevated, and surrounded by ice bags. In the case of large joints weight-extension should be applied. Constitutional treatment (purge, diuretic, sedative) should not be neglected. If the joint does well, as shown by the absence of pain and fever, the drain may be removed on the second day, and immobilization continued for one or two weeks, when function should be very gradually resumed. If the signs of infection arise (pain, fever, leukocytosis), indicating the development of septic arthritis, the dressing must be removed promptly, and better drainage instituted; this may be accomplished by a counter-opening, or by numerous openings, with saline irrigation once or twice daily, or in desperate cases by wide incision of the joint (in the knee by dividing the tendo patellæ and acutely flexing the knee—Dudley Allen, 1906), and stuffing the synovial cavity with gauze. One thorough application to the opened joint of a strong, hot antiseptic often will check the infection, usually with ankylosis as a result; but the use of weaker solutions by irrigation is of doubtful value. But if septicemic symptoms continue in spite of this heroic treatment, the surgeon has only two resources left: these are excision and amputation. In the upper extremity the former usually is successful, as it sometimes is in the ankle-joint; but for the knee-joint amputation usually is required, and, of course, should be resorted to in the case of other joints, where excision has failed. Nor should these radical operations be postponed too long, as when adopted late in the disease even they may fail to save the patient's life.

Hemarthrosis.—Hemarthrosis may follow subcutaneous wounds of joints, especially gunshot; in such cases it presents no special interest, the symptoms being those of acute synovitis (p. 463). But it may follow slight contusion in cases of *hemophilia,* and in such patients may be a very serious malady. Under no circumstances should such a joint be opened for exploration or drainage. It should be put at rest, ice should be applied, and the hemophilia treated as already advised (p. 227).

DISLOCATIONS.

Dislocation or *luxation* of a joint is a condition in which the articular surfaces of the bones forming the joint are no longer in contact.

Dislocations, however, may be *complete* or *incomplete* (*subluxation*), the articular surfaces in the latter form retaining a partial contact with each other. It is usual to classify dislocations as traumatic, congenital, and spontaneous or pathological: *traumatic dislocations* are those resulting from the application of force; *congenital dislocations* are those present at birth; and *spontaneous or pathological dislocations* are those due to malformation of the joint surfaces from disease, or to laxness of the periarticular structures. Dislocations may be *simple*, *compound*, or *complicated*, these terms having the same significance as when applied to fractures; they may be *recent* or *old*, terms of relative meaning, and which sufficiently explain themselves; and they may be *primitive*, when the displaced bone remains where originally placed by the injury, or *consecutive*, when it assumes another position owing to manipulations by bystanders, the surgeon, etc. The *direction* of the dislocation is described as it regards the distal bone or bones forming the joint: thus posterior dislocation of the elbow means that the forearm (not the humerus) is displaced backward; but there are a few exceptions to this rule, which will be noted later.

In the present chapter only traumatic dislocations are considered, pathological dislocations being discussed with diseases of the joints, in Chapter XV, and congenital dislocations in connection with orthopedic surgery, in Chapter XVI.

Causes.—As in the case of fractures, the *male sex* and *active adult life* act as predisposing causes of luxation. Certain joints are dislocated much more commonly than others: the shoulder contributes about 50 per cent. of all dislocations, while the elbow, the clavicle, and the phalanges contribute only about 5 to 10 per cent. each; the hip, ankle, and lower jaw contribute from 3 to 5 per cent. each; while the wrist, knee, etc., are very rarely dislocated.

Dislocations are caused much more often by *indirect* than *direct* violence. Usually the motion of the joint is forced beyond its normal limit, the distal bone impinging against a fulcrum formed by a neighboring bone; the capsular ligament is thus ruptured at its weakest point, and the head of the dislocated bone is forced through this opening either by continuation of the original force, or rarely by secondary muscular contraction. It thus happens that in each joint there is a more or less *typical primitive dislocation*, because the head of the bone habitually emerges at the weakest part of the capsule If direct violence is the cause, the capsule and accessory band-like ligaments are widely ruptured, and the head of the bone may pass almost in any direction. In luxations caused by leverage (the usual mechanism), the tear in the capsule always is sufficient to allow passage of the head; but it is the capsule which offers the main obstacle to reduction since by secondary displacement of the luxated bone, and by its rotation on its long axis, the tear in the capsule becomes converted into a slit with tense margins. But though this slit-like opening in the capsule is the main obstacle to reduction further

difficulty is afforded by muscular contraction and resiliency, which keep the bone in its abnormal position.

Symptoms.—There are three cardinal symptoms of dislocation. (1) Alteration in contour of the affected joint, the head of the luxated bone being absent from its socket and palpable elsewhere. (2) Change in length of the affected extremity—either shortening or lengthening. (3) Immobility or loss of normal mobility. In many dislocations there also is evident (4) Change in the axis of the dislocated bone. The only pathognomonic sign, however, is the first, absence of the head of the dislocated bone from its socket and its presence elsewhere; and even here confusion may arise, if, as in cases of fracture of the surgical neck of the scapula (p. 330), the socket as well as the head of the bone is displaced. In general, however, a dislocation may be distinguished from a fracture near a joint, by the facts that in a fracture there is abnormal mobility and bony crepitus; and that when deformity is reduced it frequently recurs; whereas in dislocation the normal mobility is decreased or entirely lost, there is no true crepitus, and deformity does not recur when the dislocation is reduced. But in dislocation caused by direct violence the periarticular structures are so widely disrupted that abnormal mobility may exist, and deformity may persistently recur; and in some cases there may be an indistinct moist crepitus due to contrition of the luxated bone with the side of the socket; moreover, dislocation and fracture may be present in the same joint, symptoms of both conditions being evident. The skiagraph offers a controlling test by which almost always it is possible to ascertain the true lesion.

Damage to periarticular structures—nerves, bloodvessels, tendons—may occur in dislocation, as in fracture, and always should be looked for before attempts at reduction are made. Other evidences of local injury, such as pain, swelling, ecchymosis, etc., do not require special description.

Changes in the Joint Surfaces occur within a comparatively short time, if the dislocation is not reduced. There always is a certain amount of blood extravasated, filling the capsule; and as this organizes the socket becomes shallower, the capsular tear cicatrizes and contracts, the surrounding ligaments, tendons, bloodvessels, and nerves become adherent in the newly formed scar-tissue; and the longer the dislocation remains unreduced, the more difficult is it to secure reposition. In the course of time the luxated bone forms for itself a new socket, which will furnish a certain degree of solidity and permits a moderate amount of motion.

Prognosis.—Prognosis is good in the majority of cases as to both life and function. Dislocations very rarely are fatal injuries unless compound or complicated. Beyond a weakness or stiffness lasting some weeks or possibly months, most patients whose dislocations have been promptly and skilfully reduced suffer no further inconvenience; but where reduction is delayed, or where unusual force has been employed in securing reduction, a certain amount of disability may persist for years or throughout life.

Treatment.—In recent dislocations efforts at reduction should be made at once, unless the patient is profoundly shocked. In many cases general anesthesia is desirable to relieve the pain and abolish muscular contraction, which is aroused anew at every attempt to manipulate the limb. Dislocations are reduced by two methods, which may be termed the *direct* and the *indirect* (G. G. Davis, 1910): in the former the limb is first placed in the attitude in which it was when the dislocated bone burst through its capsule, and the head of the bone is then pushed or pulled directly back through the rent in the capsule into its socket; in the indirect method the limb is manipulated in such a way as to bring into use the capsule itself and surrounding ligaments as a series of sliding fulcra, by means of which the dislocated bone is levered into its socket. If an anesthetic is administered, completely abolishing muscular contraction, no obstacle to reduction remains except the joint capsule, and it depends on the skill, patience, and dexterity of the surgeon to insinuate the head of the dislocated bone through the capsular opening into the socket; for this to be accomplished, *no force is required beyond what may be exerted by the surgeon's hands.* The capsule is an inelastic structure, and the tear through which the dislocated bone emerges always is as large as and sometimes larger than the head of the bone itself. If no anesthetic is given, it may be necessary to supplement the surgeon's own power by weight-extension, gravity, etc., especially if the patient has a highly developed muscular system; in other cases it will be easy to reduce the luxation by taking the muscles by surprise, as it were, and replacing the bone while the patient thinks a mere preliminary examination is being conducted.

All efforts at reduction by conservative means having failed, the surgeon may resort to arthrotomy, by which he will be enabled to enlarge the rent in the capsule, and to displace tendons, ligaments, etc., caught around the head of the bone, this latter condition being almost the sole factor which renders a recent dislocation really irreducible. Usually operation is not undertaken until several days after the injury, various surgeons having meantime maltreated the limb by applying excessive force in attempts at reduction; this renders the operation more difficult and less likely to be successful than if done before such unskilful attempts have been made.

Reduction having been secured, the joint should be kept at rest, in such a position as to prevent re-dislocation, for a period of ten days or two weeks; and for several weeks longer all violent motions, or even gentle motions of wide range, should be prohibited. Massage often is beneficial.

Compound Dislocations are to be treated according to the principles inculcated when speaking of wounds of joints. Owing to the great force necessary for their production, and the wide laceration of the soft parts, reduction usually is easy. They are most frequent at the elbow and ankle.

Complicated Dislocations.—*Fractures* complicating dislocations are discussed at p. 312. *Rupture of the main vessels* at a dislocated joint is to be treated as a wound of the vessels under other circumstances. *Lesions of nerves* accompanying dislocation should be treated conservatively until no further improvement can be expected; unless, of course, it is evident that complete rupture of a nerve trunk has occurred, when primary suture should be done.

Old Dislocations.—Some dislocations become "old" much sooner than others, and it is not always advisable to attempt reduction. Sir Astley Cooper (1822) set three months as the limit for the shoulder, and eight weeks for the hip, not because reduction could not sometimes be obtained after the lapse of a longer time, but because it was secured at the expense of such damage to the soft parts that the remedy was worse than the disease. The first question, therefore, which arises in a case of old dislocation, is whether or not reduction shall be attempted. And it may be answered affirmatively in almost every case, since even though the attempt prove a failure a skilful surgeon by judicious and gentle manipulation of a dislocated joint almost invariably will be able to improve the function of the part. But as to whether attempts at reduction will be successful, it is much more difficult to formulate an answer, much depending on the duration of the condition, the age of the patient, and the joint involved. At the present day mere duration of the condition is very little considered, since should reduction fail by manipulation, it may succeed by arthrotomy; and as a last resort the surgeon may have recourse to excision of the joint or of the head of the dislocated bone, an operation which generally will improve function, though not restoring it to normal. But the age of the patient is an important consideration; in the very old, while manipulation might succeed in securing reduction more easily than in those of active middle life, yet the risk of producing fracture would be so great, and the advantages to be gained so temporary, that as a rule it is better to leave the joint alone unless the condition is very disabling. The hip-joint is that in which dislocation becomes irreducible most rapidly; the knee probably is second, the elbow third, and the shoulder fourth. But in the hip and the shoulder, especially the latter, if massage and passive motion are persisted in long enough, a fair range of motion may be secured without reduction. In the elbow arthrotomy usually will be successful in securing reduction and a useful limb; while in the knee excision may be required.

Recurrent Dislocations are commonest at the shoulder, and may require pleating of the capsule by suture as practised by T. T. Thomas (1909).

SPECIAL DISLOCATIONS.

Mandible.—Usually this is produced through muscular action in yawning, though it may follow a downward blow on the chin. The luxation may be unilateral or bilateral, and the displacement nearly

invariably occurs *forward:* the condyle ruptures the weak anterior portion of the capsular ligament, rides forward on the eminentia articularis beyond its normal limit, and is held there by spasmodic contraction of the external pterygoid muscle, assisted by the temporal and masseter. The mouth remains open, and if only one side of the jaw is dislocated, the chin is displaced to the other side.

Treatment.—Reduction is secured by forcibly opening the mouth further, at the same time depressing the body of the bone by placing the thumbs (carefully guarded by adhesive plaster, gauze, etc.) over the back molar teeth, and finally raising the chin by the disengaged fingers. Recurrence, not very rare, should be prevented by application of a bandage, such as Barton's, for about ten days.

Subluxation of the jaw is a term employed by Sir Astley Cooper (1822) to describe a frequently repeated, usually self-reduced, unilateral displacement of the mandibular condyle, due to looseness of the intra-articular cartilage. In mild cases it constitutes the condition known as "clacking jaw"; aside from the noise of the cartilage slipping around, which is audible to the patient and occasionally to those close to him, little inconvenience is experienced. Treatment, when any is required, consists in administration of tonics, use of counter-irritants, injection of formalin or alcohol, and, as a last resort, excision of the cartilage.

Central dislocation of the jaw is a very rare lesion, usually fatal, in which the condyle is driven through the base of the skull.

Vertebræ.—See Chapter XVII.

Clavicle.—This bone may be dislocated at either end, dislocation at the acromio-clavicular joint forming an exception to the rule for nomenclature of luxations formulated at p. 388.

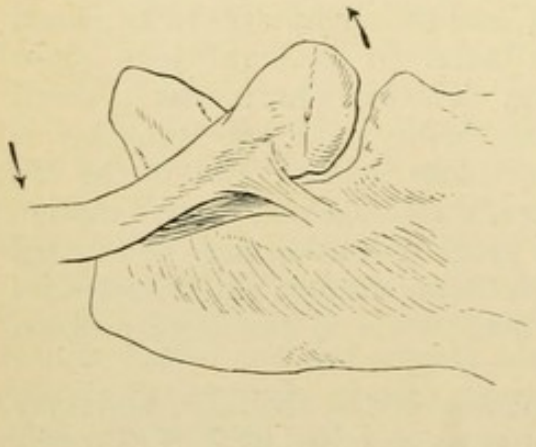

FIG. 393.—Mechanism of dislocation of right sterno-clavicular joint. See text.

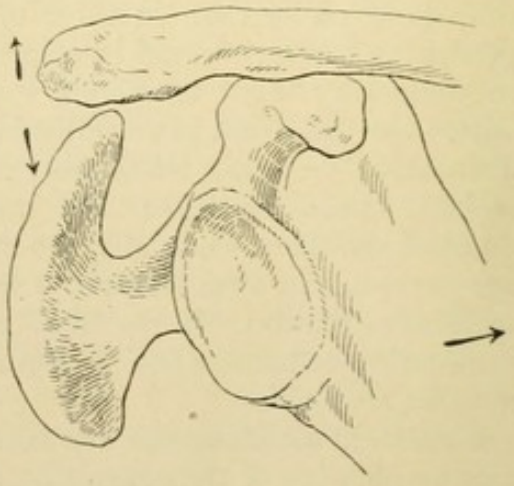

FIG. 394.—Mechanism of dislocation of right acromio-clavicular joint. See text.

Dislocation of the Sterno-clavicular Joint.—The clavicle usually is displaced *upward* and *forward*. The injury is produced by falls or blows causing sudden depression of the shoulder, the clavicle coming into contact with the first rib close to the sternum; as the

costo-clavicular ligament prevents the clavicle from giving at the point of attachment, the inner extremity is pried out of its socket over the first rib as a fulcrum (Fig. 393). The intra-articular cartilage usually is displaced with the clavicle. *Symptoms* are self-evident (Fig. 395), and reduction is easy to secure by raising the outer end of the clavicle and drawing the shoulder backward; but it is difficult to prevent recurrence. The arm may be carried in a sling, and a firm spica of the shoulder applied (Fig. 86) with a pad over the inner end of the clavicle. Some deformity almost always persists, but function is good. In some cases the joint may be opened and the bones sutured in place. *Backward dislocation* at the sternal end is rare, and may be accompanied by dyspnea, dysphagia, etc. In the only patient I have seen, under the care of Dr. F. T. Stewart in the Pennsylvania Hospital, the only pressure effects were due to compression of the subclavian vein, and were promptly relieved by drawing the shoulder backward. A posterior figure-of-eight bandage

FIG. 395.—Recurrent dislocation of sternal end of right clavicle. Orthopædic Hospital.

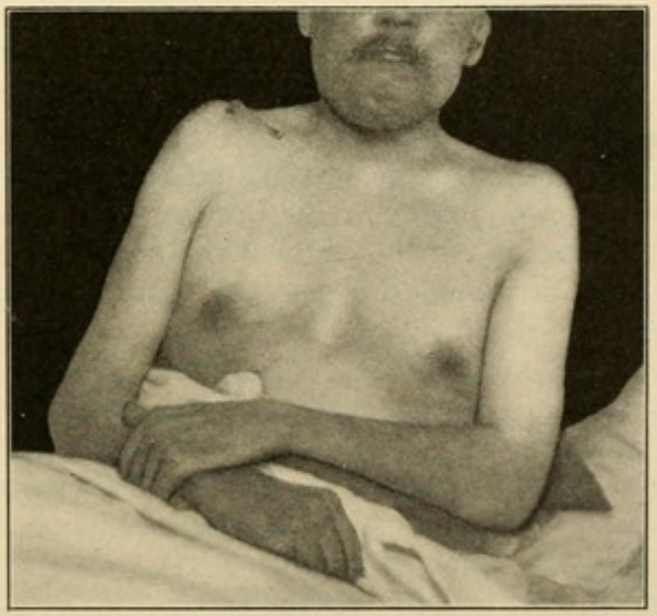

FIG. 396.—Dislocated acromial end of right clavicle. Injury eighteen months ago. Episcopal Hospital.

(Fig. 89) makes a good dressing. *Downward dislocation* at this joint may occur when fracture of the first rib coexists; it is a serious injury, the result of great direct violence.

Dislocation of the Acromio-clavicular Joint usually results from depression and inward rotation of the scapula, from falls or blows on the point of the shoulder. This carries the base of the coracoid up against the clavicle, and as the clavicle is fastened to this by the strong coraco-clavicular ligaments the only motion possible is an upward displacement of the acromial end of the clavicle, the coracoid acting as a fulcrum (Fig. 394). The deformity is self-evident (Fig. 396), and like that at the inner end is easy to overcome but difficult to keep reduced. However, by fixing the upper extremity in the Velpeau position, with the dressing advised for fracture of the clavicle, the turns of the bandage over the shoulder and under the flexed elbow (Fig. 302) will keep the bones in place as long as the bandages remain firm. This dressing should be continued two weeks or more. As in luxation of the sternal end, suture may be adopted for persistent deformity if it entails disability, which is rare. *Downward* and *backward* dislocations occur, but are very unusual.

Scapula.—The only dislocation of this bone recognized by systematic writers consists in displacement of its lower vertebral border from beneath the fibres of the latissimus dorsi, usually from indirect violence or muscular strain. If firm bandaging is not sufficient, the muscle may be re-attached by suture. The deformity seen in some cases of phthisis (winged scapula), and after paralysis of the serratus magnus muscle, closely simulates this "dislocation" of the scapula.

Shoulder.—Dislocations of the head of the humerus may occur *anterior* or *posterior* to the glenoid cavity, the posterior variety being exceedingly rare. There are many reasons for this: the shoulder usually is dislocated by injuries which produce extreme abduction of the arm, and as the force generally acts from the front, the arm is carried backward as it is abducted. As the glenoid process looks more forward than outward, such a motion throws most strain on the anterior part of the capsule of the shoulder-joint; and if while the arm is abducted slightly posteriorly an inward thrust or a pull by the axillary muscles is added, this portion of the capsule will be ruptured; or if abduction continues until the humerus strikes against the acromion, after all possible leeway has been gained by rotation of the scapula, then the head of the humerus will be pried out of the capsule over the acromion as a fulcrum. The capsule is torn loose from the glenoid, from the base of the coracoid above to the attachment of the triceps below; and through this rent, which may be increased by rotation of the humerus, the humeral head emerges in the axilla, in front of the triceps. If the arm remains in the position of extreme abduction, which is extremely rare, the condition is described as *luxatio erecta;* usually, by the force of gravity or the assistance of bystanders, the patient's arm is brought down to his side, and the head of the bone passes beneath the coracoid (*sub-coracoid dislocation*) where it usually remains, or may be displaced further inward, into a *subclavicular* position. All these (axillary, subcoracoid, subclavicular) are varieties of anterior dislocations. Posterior dis-

locations, unless congenital, usually result only from extreme direct violence, tearing loose ligaments and tendons on all sides; or sometimes by inward rotation and adduction, with a backward thrust, the lesser tuberosity impinging on the coracoid process. Sometimes they are secondary displacements, the primitive dislocation having been anterior. The head of the bone may be displaced only slightly backward (*subacromial*), or so far as to merit the term *subspinous*.

In anterior dislocations the subscapularis muscle, stretched over the capsule at the point of rupture, may itself be perforated by the head of the humerus, though usually this emerges below the subscapularis. The circumflex or musculo-spiral nerve may be stretched or lacerated, though recent observations seem to show that the lesions if permanent more often are in the spinal roots forming the outer cord of the brachial plexus (p. 283). In most cases there is tingling and numbness in the fingers, and some distention of the veins, from pressure on the axillary vessels.

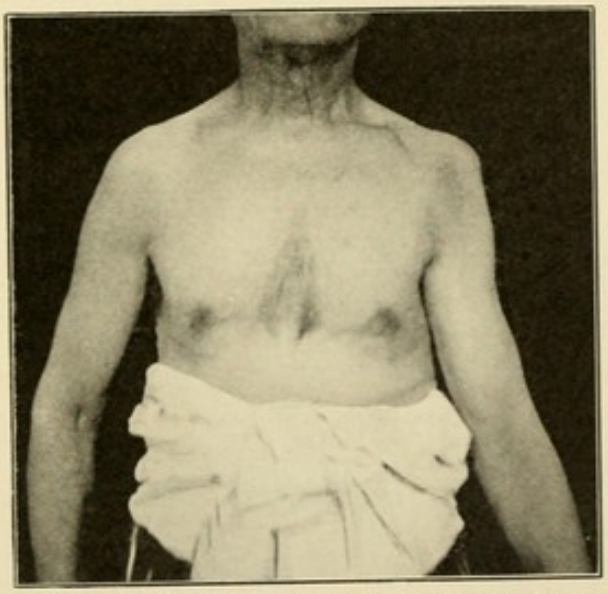

FIG. 397.—Recent subcoracoid luxation of left humerus, patient aged seventy years. Reduced without anesthetic by Kocher's method. Episcopal Hospital.

Symptoms.—The appearance of patients with dislocation of the shoulder is characteristic (Fig. 397): the arm hangs a little away from the side, there is a hollow under the acromion, and the head of the bone may be seen beneath the coracoid. As the head of the humerus has been displaced from its pedestal, and has been drawn against the side of the thorax, and as the thoracic cage is convex, it is impossible to bring the elbow against the side of the chest at the same time that the hand is placed on the uninjured shoulder (Dugas's sign, 1856). In recent cases, and in not very obese patients, the diagnosis is easy; but when swelling has occurred, and after much manipulation by others, it may be quite difficult; and it is in such circumstances that Dugas's sign and the *x*-ray (Fig. 398) become valuable aids.

In posterior dislocation the head of the bone is palpable beneath

the infraspinous muscles, the glenoid cavity is empty, the coracoid process is unusually prominent, and the other usual symptoms of dislocation are present.

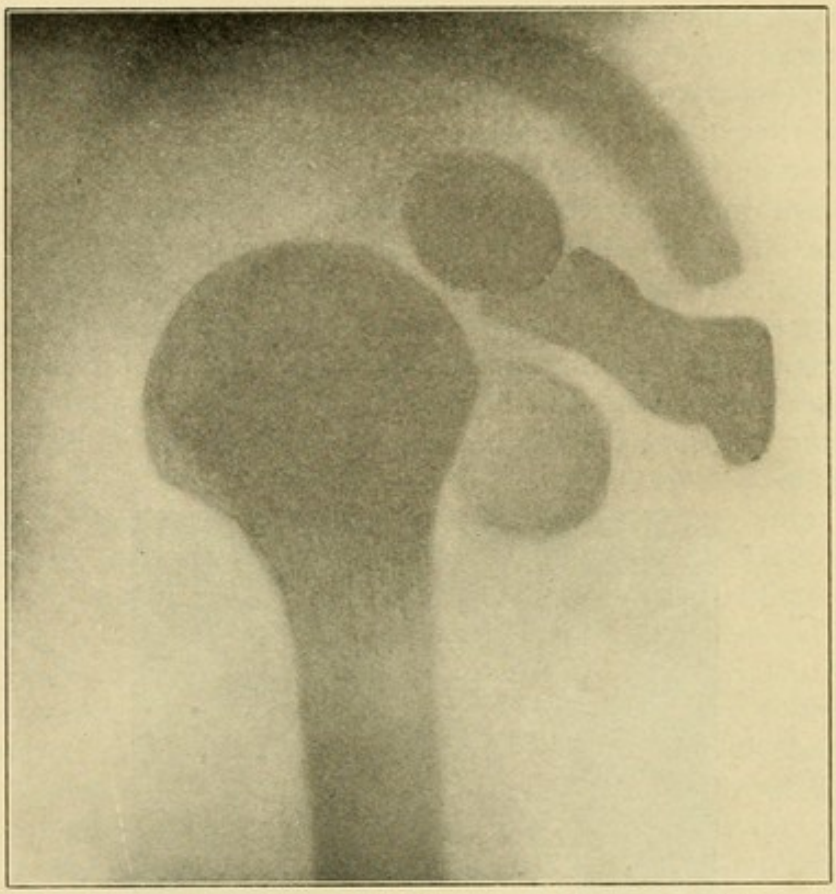

FIG. 398.—Skiagraph of sub-coracoid dislocation of humerus. (Coracoid and glenoid processes emphasized.) Episcopal Hospital.

Treatment.—The *indirect method of reduction*, or that by *manipulation*, is preferable. This was proposed in 1858 by H. H. Smith, Professor of Surgery in the University of Pennsylvania, and later (1863) systematized by him; he thought muscular contraction, especially that of the supraspinatus, as taught by Sir Astley Cooper, was the main obstacle to reduction. Kocher, later Professor of Surgery in Bern, in 1870 adopted a similar method, founded on that of Schinzinger (1862); he recognized the capsule as the chief obstacle to and best aid in securing reduction.

H. H. Smith's Method of Reduction.—The patient being on his back, (1) elevate the arm in the sagittal plane until it is nearly vertical (step two, of Kocher's method); this relaxes the supraspinatus muscle, as well as the coraco-brachialis and short head of the biceps, permitting step two to be more effectually executed. (2) Keeping the arm vertical, and using the bent forearm as a lever, rotate the humerus outward; by doing this the untorn posterior portion of the capsule is wound around the head and upper part of the neck of the humerus (Farabeuf, 1885), and acting as a sliding fulcrum draws the head

of the bone away from the chest, until the subscapularis becomes tense and resists further rotation. (3) Then slowly adduct the arm across the chest, still maintaining outward rotation of the humerus; when the elbow touches the chest, the hand is brought down to the opposite shoulder, and the bone usually will be replaced.

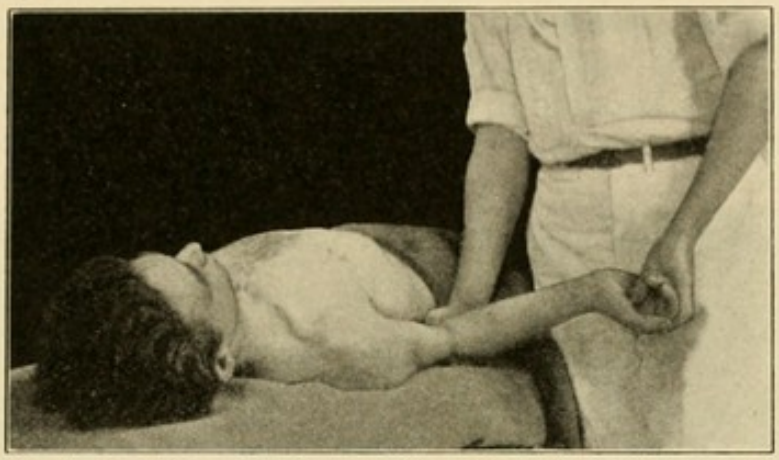

FIG. 399.—Kocher's method of reducing dislocation of shoulder, first step: outward rotation. Episcopal Hospital.

T. Kocher's Method of Reduction.—(1) Bring the elbow against the chest, and rotate the humerus outward as far as it will go, using the bent forearm as a lever (Fig. 399); do not push this outward rotation too far, and do it with a very gradual and gentle but persistent motion; force is very liable to fracture the humerus; Kocher himself broke it three times in reducing twenty-eight luxations. During this outward rotation of the humerus the same phenomena occur as during

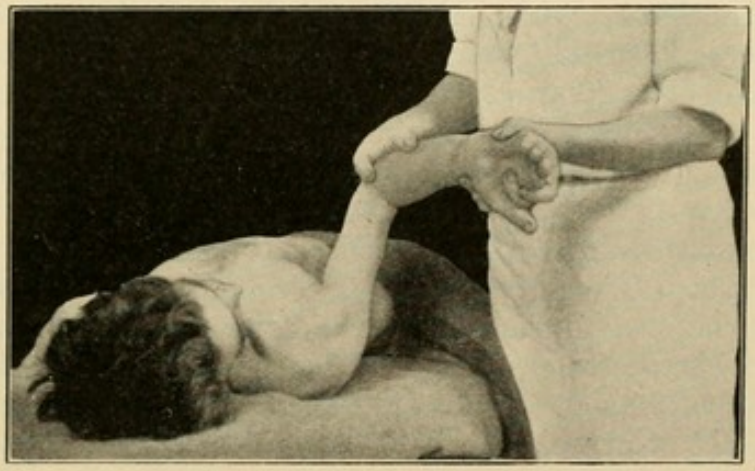

FIG. 400.—Reduction of dislocation of shoulder by Kocher's method; second step: elevation of arm in sagittal plane. Episcopal Hospital.

step two of Smith's method, but the lesser tuberosity may catch under the tense coraco-brachialis, and this is one cause of the frequency of fracture of the humerus (G. G. Davis, 1910). (2) Raise the elbow in the sagittal plane, or in slight adduction, until the arm is as nearly vertical as possible (Fig. 400); this relaxes the anterior border of the

rent in the capsule (coraco-humeral ligament), and the coraco-brachialis and short head of the biceps, which hinder the ascent of the head on to the glenoid process. (3) Rotate the arm inward, using the bent forearm as a lever, until the hand touches the sound shoulder, then quickly bring the elbow to the side of the chest (Fig. 401). This last step slides the head of the bone back through the rent in the capsule, whose posterior untorn part is now on the inner instead of the outer side of the humerus, and again acts as a fulcrum to lever the head upward; but reduction often is accomplished at the conclusion of the second step.

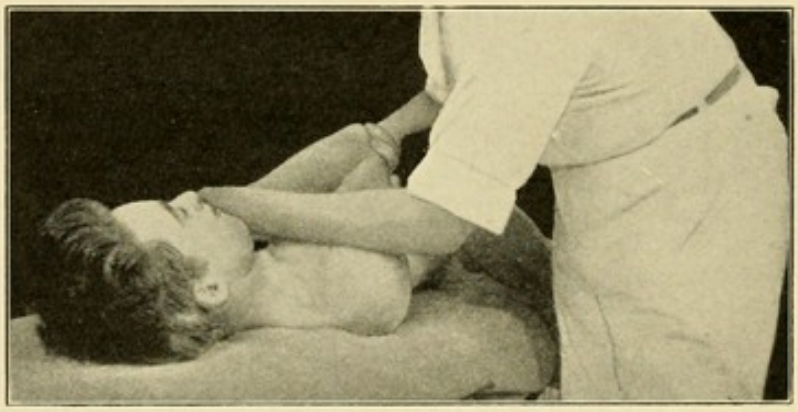

FIG. 401.—Reduction of dislocation of shoulder by Kocher's method; third step: hand brought to shoulder and elbow to chest. Episcopal Hospital.

Of these two methods, Smith's undoubtedly is the better, though neither of them rests on the anatomo-pathological basis which was erected for them by their authors; Smith thought the muscles the all important factor, while Kocher thought success depended on the gleno-humeral ligament, which was shown by Farabeuf to be of no consequence. The great advantage of these methods of manipulation is that an anesthetic usually is not required in recent cases, and that they can be applied by the surgeon without other assistance than the inertia of the patient's body. They depend for their efficiency, however, on the untorn state of the posterior part of the capsule; if this portion also is torn, the head of the humerus will not be pulled away from the chest during outward rotation, but will rotate *in situ*. Under such circumstances the rent in the capsule will be so large that no difficulty should be experienced in replacing the head of the bone by direct pressure, after it has been drawn away from the chest by extension and counter-extension.

The *methods of direct reposition* are many; all of them depend first on bringing the head of the bone opposite the tear in the capsule, and consequently *away from the chest wall and out to the neighborhood of the glenoid process;* and then on pushing or pulling it into its socket. The head can be brought away from the side of the thorax only by eliminating or overcoming the muscular contraction which holds it there, either by continuous traction or a general anesthetic.

1. *Sir Astley Cooper's Method* (1822): With the patient supine, place the heel of the unbooted foot in the patient's axilla, against the chest, and make traction downward and slightly outward on the upper extremity; the traction pulls the head free from the coracoid, and by slight leverage over the foot, the head is pushed directly into its socket. A little rotation in and out may assist. This is a very efficient method, really combining all others (extension and counter-extension, leverage, and manipulation), but it is very painful and usually requires anesthesia; and the inexpert or brutal may cause serious injury to the axillary tissues.

2. *Stimson's Method* (1900: The patient is laid on a canvas sling, with the dislocated extremity passed through a hole in the canvas and hanging free of the floor; a weight of about ten pounds is attached to the wrist or elbow. The limb is kept thus in abduction, and in a few minutes (never more than six, Stimson) reduction of the dislocation takes place quietly and without pain. No anesthetic is required, as the weight tires out the muscles which hold the head of the humerus against the chest; and as soon as it is drawn out to the region of the glenoid process, it slips into its socket spontaneously.

3. *Malgaigne's Method* (1855) is the reverse of Stimson's: The patient lies on the sound side on the floor, and a robust assistant pulls vertically upward on the dislocated extremity, till the shoulders just clear the floor, and maintains this traction till the patient's axillary muscles are exhausted; the surgeon then pushes the head of the bone into place.

Many other modifications of this principle have been devised, and constantly are being reinvented by ingenious surgeons.

In *posterior dislocations* upon the cadaver I have succeeded in securing reduction by reversing the manipulations of Kocher's and Smith's methods; but usually in life the capsule is so widely torn that the luxation is easily reduced by direct pressure forward or very slight manipulation.

After reduction, the arm is dressed in the Velpeau position and guarded use may be permitted after two weeks. It is possible that if reduction were accomplished more often by manipulation and less often by brute force less disability as the result of periarthritis would follow this injury. Yvert (1911) has studied the statistics of various surgeons and finds that 65 per cent. of the patients had persistent disability, 22 per cent. had fairly satisfactory function, and only 13 per cent. had excellent results.

Elbow.—The typical dislocation at the elbow consists in *backward* displacement of both bones of the forearm; *anterior* dislocation of both bones is rare; and *lateral* dislocations usually are incomplete and often accompanied by fracture of one or other of the humeral condyles.

Posterior Dislocation.—Posterior dislocation is most frequent from fifteen to thirty years of age, and results almost invariably from a fall on the out-stretched hand causing hyperextension of the elbow, the olecranon acting as a fulcrum and prying the bones apart; the

anterior capsule is ruptured, and the internal lateral ligament more or less lacerated, and detachment of the epitrochlea of the humerus often occurs. Fracture of the olecranon by compression sometimes is seen, and occasionally the coronoid process is broken off.

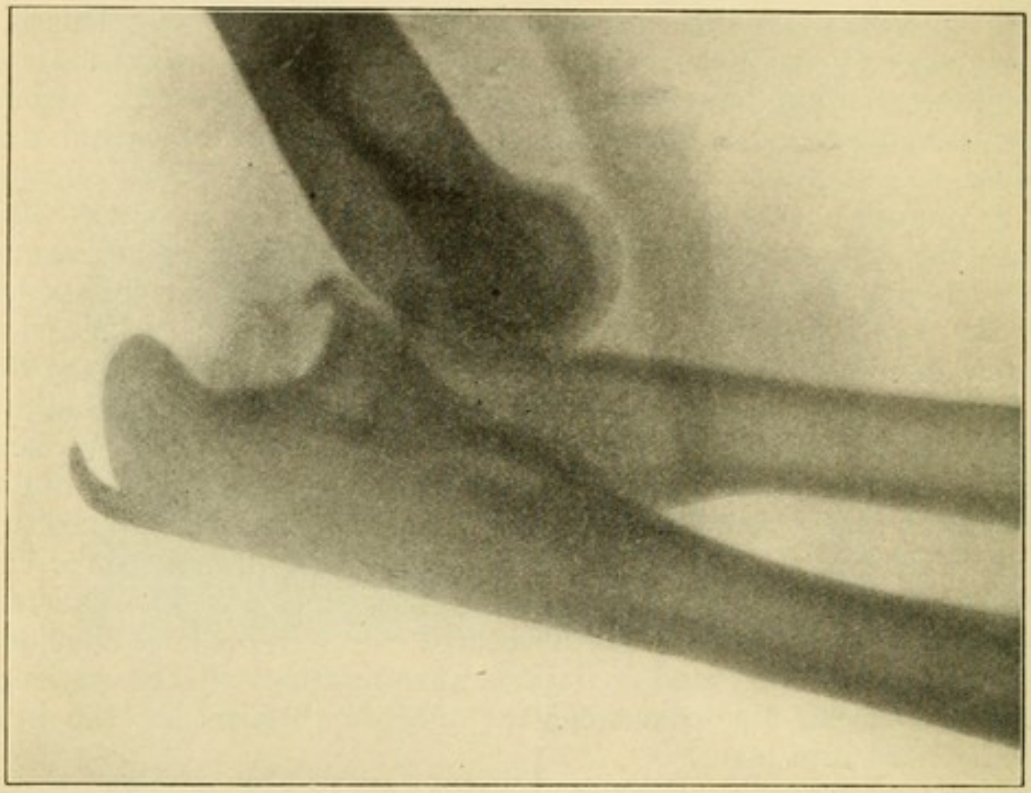

FIG. 402.—Old unreduced posterior dislocation of elbow, with evidences of hypertrophic arthritis. Episcopal Hospital.

Symptoms.—The deformity usually is quite apparent. The forearm, usually pronated, is carried at an obtuse angle with the arm, and motion is painful and restricted. The radius and ulna may be displaced directly backward, but often there is also slight lateral displacement. The olecranon is found displaced posteriorly and upward in relation to the condyles, and the greater sigmoid fossa of the ulna often can be felt between the tense triceps and posterior surface of the humerus (Fig. 402). The head of the radius is absent from its normal place just in front of the external condyle and can be felt posteriorly. Anteriorly the lower extremity of the humerus fills the flexure of the elbow. The diagnosis from supracondylar fracture, referred to at p. 341, should present no difficulties, and in case of doubt, the lesion is much more likely to be a fracture than a dislocation. If the lesion is recognized, and the luxation promptly reduced, recovery is rapid, and in most cases nearly perfect function is secured.

Treatment.—In recent cases, especially in children, reduction without an anesthetic is easy, by reversing the steps by which the lesion was produced: first hyperextend the elbow, until the tip of

the olecranon strikes the humerus, and the coronoid is freed from the trochlea; then make extension and counter-extension in the axis of the arm, pushing the lower end of the humerus backward; and finally acutely flex the elbow, when the bones will be replaced with a snap. Often the pressure of the thumbs over the lower end of the humerus, and that of the clasped fingers over the posterior surface of the olecranon, is sufficient to secure reduction (direct method); or the knee may be placed in the bend of the elbow and used as a fulcrum to lever the bones of the forearm away from the humerus by traction on the wrist with one hand, while the humerus is pushed backward with the other hand (Fig. 403). The elbow is dressed in hyperflexion (p. 347), for a week, and then carried in a sling for another, and after two weeks guarded active use is encouraged.

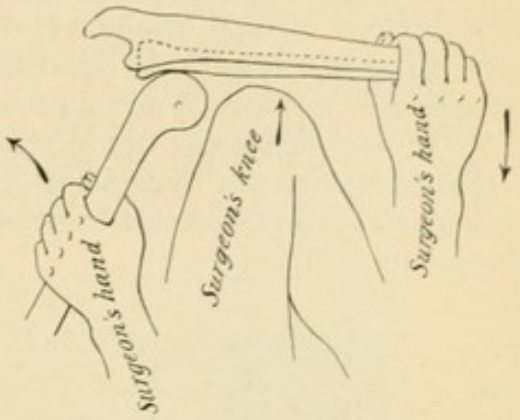

FIG. 403.—Mechanism of reduction of posterior dislocation of elbow by aid of the knee.

Lateral Dislocation.—*External* dislocation often is due to direct violence, usually is incomplete and complicated by fracture of the external condyle, and extensive rupture of the internal lateral ligament

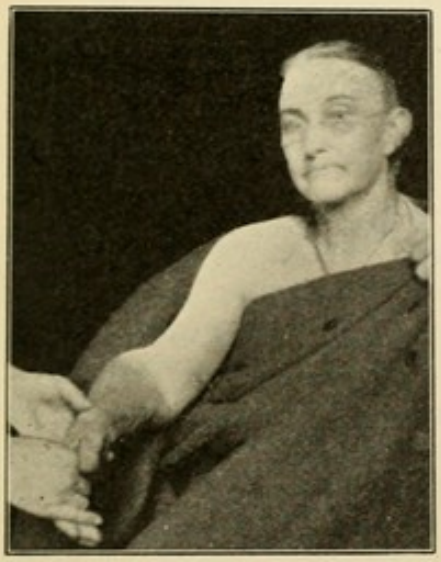

FIG. 404.—External lateral dislocation of elbow, with fracture of external condyle, and rupture of internal lateral ligament and fracture of epitrochlea. Dr. W. Walker's case. Episcopal Hospital.

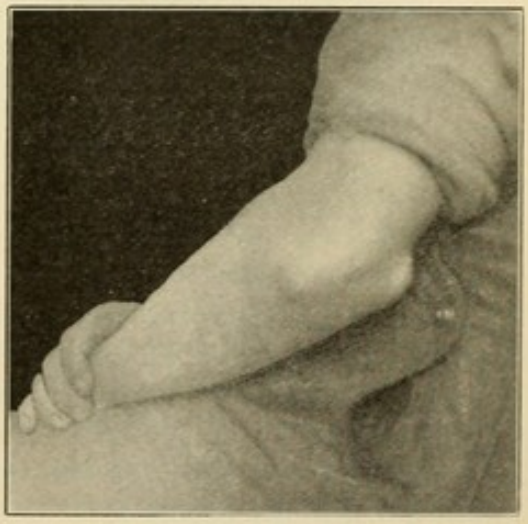

FIG. 405.—Inward dislocation of ulna and radius. Dr. De Tar's case. Patient fell and while lying on left elbow train struck him upon buttocks. Reduction easy under anesthetic.

(Fig. 404). *Internal* dislocation is rarer than external, and fracture is a less usual complication (Fig. 405). In both forms the deformity is so extreme and the bony processes so easily palpable that, if careful examination is made before swelling obscures the landmarks, the

diagnosis should not be difficult. Reduction is easier to secure than to maintain, especially if fracture exists. The elbow should be dressed in hyperflexion and treated as a fracture.

Forward Dislocation.—Forward dislocation of both bones at the elbow is very rare; even including seven cases in which the olecranon was broken off and remained in place, the total number on record, according to Stimson, is less than twenty-five. Fracture of the epitrochlea is a frequent accompaniment. Reduction is not difficult, as both lateral ligaments are lacerated.

Dislocation of the Ulna Alone from the humerus is most often posterior; the symptoms and treatment are much the same as when both bones are so displaced.

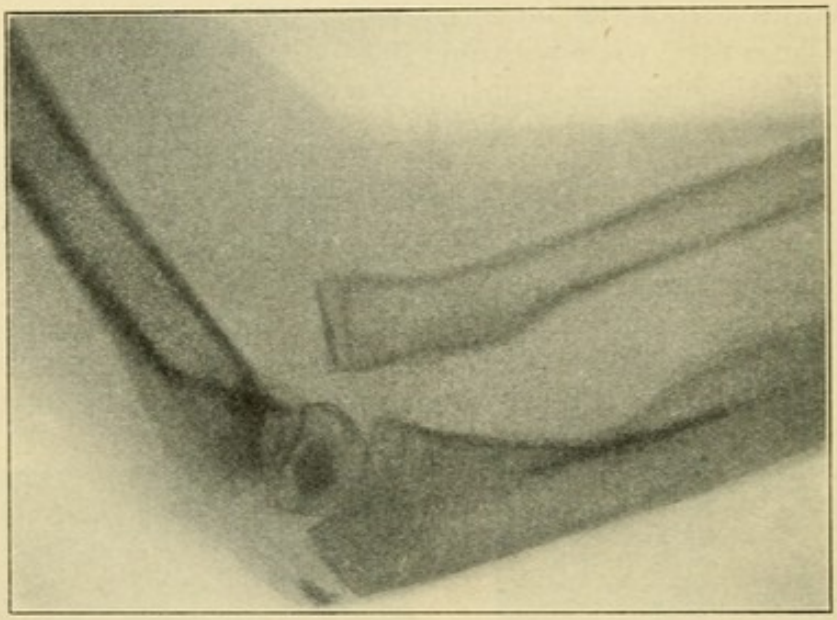

FIG. 406.—Anterior and outward dislocation of head of radius, with fracture of shaft of ulna. Four months after injury. Episcopal Hospital.

Dislocation of the Head of the Radius usually occurs in an anterior direction. The orbicular ligament may remain intact, the radius slipping out of its grasp, and subsequently being displaced forward by the pull of the biceps; often it is the result of a fracture of the upper part of the shaft of the ulna, from direct violence, the continuance of the fracturing force driving the head of the radius forward (Figs. 406 and 407). This combined lesion is so frequent that the recognition of either a dislocation of the radial head or a fracture of the upper end of the ulna should make the surgeon suspect the existence of the complicating lesion. Examination may detect a hollow in front of the external condyle, and the head of the radius a little forward from its normal position; flexion of the elbow beyond a right angle may be prevented by contact of the radius with the humerus. Reduction sometimes may be secured by full supination and direct pressure upon the displaced bone; and flexion will then become possible.

Reduction should be obtained at all hazards, by arthrotomy if necessary. Only after reduction of the radial dislocation has been secured can the fracture of the ulna be reduced. If re-dislocation of the radial head occurs after keeping the elbow hyperflexed (p. 347) for several weeks, it may be assumed that the radial head had not been replaced within the orbicular ligament; and an operation may be necessary to hold it in place. In cases of complete dislocation it is very unlikely that reduction can be secured without operation. In old unreduced luxation, excision of the radial head may be done to permit flexion of the elbow, but in children this should be avoided if possible, since removal of the epiphysis will interfere with development.

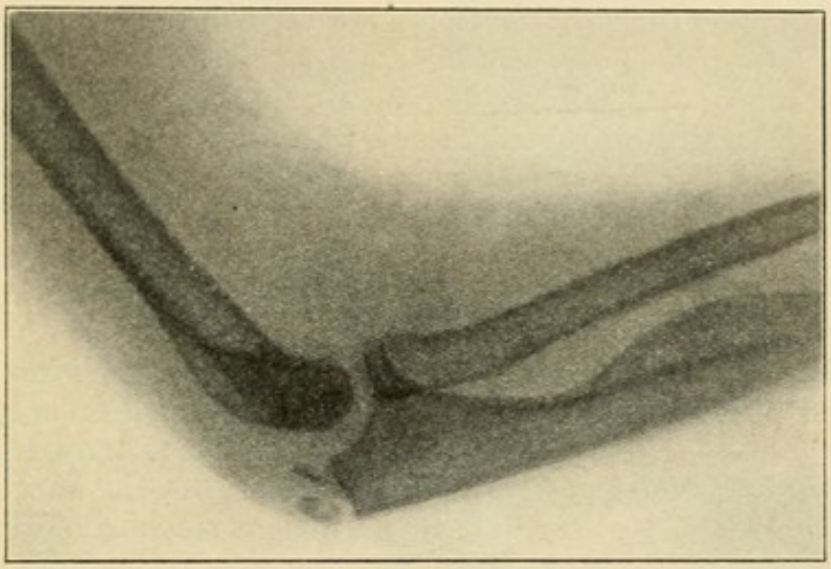

FIG. 407.—Anterior and outward dislocation of head of radius, three months after reduction by arthrotomy and capsulorrhaphy. Episcopal Hospital.

In young children a *subluxation* known as "pulled elbow" occurs: this is due to vertical traction on the forearm, often produced as the caretaker helps or lifts the child across an obstruction in the street. If the forearm is supinated the vertical traction tends to bring the forearm and arm into a straight line, causing momentary loss of the carrying angle; or forced pronation may pry the radius forward over the ulna as a fulcrum. Symptoms of pulled elbow are rather indefinite, and in many cases no definite history of trauma can be obtained; it is merely noticed that the arm is not used properly, and that there is tenderness around the elbow. *Treatment* of "pulled elbow" consists in securing reduction of the subluxated bone by the same methods employed in cases of complete dislocation, and in preventing recurrence (which is not very rare) by keeping the elbow at rest for a week.

Wrist.—Dislocation of the radio-carpal joint, usually consisting in dorsal displacement of the carpus, is very rare; Stimson classes Barton's fracture (p. 355) more as a complication of this dislocation than as an independent lesion. It is produced usually by the same injuries as Colles's fracture, and the differential diagnosis is

not always easy; but if it is possible to feel the styloid processes of the radius and ulna still attached to their respective bones, and to ascertain that the length of the bones of the forearm remains the same on both sides of the body and to feel the very abrupt eminence on the dorsum caused by the displaced carpal bones, confusion between fracture and dislocation is not apt to occur. Besides, the luxation is reduced by an elastic snap, without crepitus, and without tendency to recurrence. I have seen one case myself, easily diagnosed clinically by attention to these details. The diagnosis may be confirmed by a skiagraph.

Spontaneous Subluxation of the Wrist (*Madelung's Disease*).—See p. 542.

Dislocations of the carpal bones are not very uncommon, particularly *forward dislocation of the semilunar*, associated or not with fracture of the scaphoid. The bone is palpable under the flexor tendons, and there is a gap on the extensor surface between the os magnum and radius. The other carpal bones, most often scaphoid or os magnum, usually are dislocated backward. If reduction is not easily secured, the displaced bone should be excised.

Metacarpus.—The metacarpal bones rarely are luxated, the displacement usually being posterior.

Phalanges.—The *proximal phalanx of the thumb* not infrequently is dislocated posteriorly on the head of its metacarpal bone by hyperextension, sometimes in a fight, a fall, or in the effort to push a tight stocking off the heel of the foot. The deformity is quite characteristic (Fig. 408), the phalanx in well-marked cases making a distinct angle with the metacarpal bone, the head of which is easily palpable in front; the distal phalanx remains flexed, owing to tension on the flexor longus pollicis, which is displaced to one side or other, usually the ulnar side of the metacarpal. The head of the metacarpal is "button-holed" through the anterior ligament; the tendons of the flexor brevis blend with the lateral ligaments, and it is the tension of these lateral ligaments, which fit like a collar around the neck of the metacarpal, that may render reduction impossible. In some cases reduction can be effected without anesthesia, (1) by pressing the metacarpal bone toward the palm, so as to relax the short thumb muscles; (2) by sliding the base of the phalanx over the head of the metacarpal, *keeping the phalanx in hyperextension* until the head of the metacarpal has been cleared. If reduction is impossible, an incision is made along the radial border of the flexor surface of the

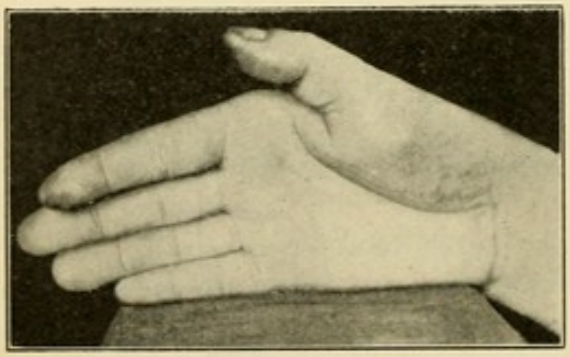

FIG. 408.—Dislocation of metacarpo-phalangeal joint of thumb. Reduced by arthrotomy. Episcopal Hospital.

prominent head of the thumb metacarpal, and the external lateral ligament is divided close to the phalanx.

Dislocations of the interphalangeal joints of the fingers almost always takes place posteriorly, from hyperextension, in falls or blows on the finger tips (Fig. 409). Reduction usually is easy, but a joint fracture of the proximal bone may exist, and some deformity may result. Treatment is the same as for fracture of a phalanx. *Lateral dislocation* usually is incomplete (Fig. 410).

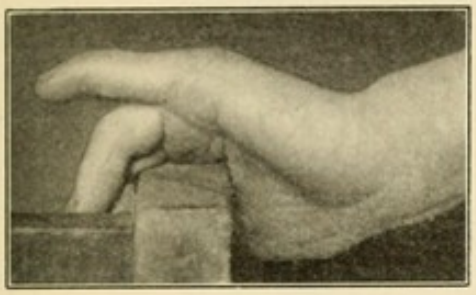

FIG. 409.—Posterior dislocation of middle phalanx on proximal of fifth finger. Episcopal Hospital.

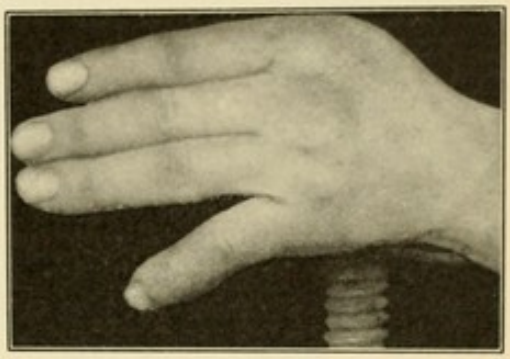

FIG. 410.—Lateral dislocation of middle on proximal phalanx. Episcopal Hospital.

Sacro-iliac Joints.—Complete luxation is rare, but subluxation, from sprain or long-continued strain is not unusual. Motion occurs antero-posteriorly around a transverse axis, and the usual displacement is of the upper end of the sacrum backward. Cricks and stitches in the small of the back, or severe backache may follow strain on these joint ligaments from stooping, from malposition in sitting or standing, or simply from lying long flat on the back, when the muscular support is weakened by anesthesia or constitutional disease. Relaxation of these joints sometimes is seen, and is best treated by orthopedic apparatus, gymnastics, etc. (p. 535).

Hip.—Dislocation of the hip is a rare and rather a serious injury. The head of the femur is held in the acetabulum by a capsular ligament which is reinforced above and below by band-like ligaments, leaving the capsule weak anteriorly and posteriorly. The upper band-like ligament (ilio-femoral ligament of Bertin, 1754) is especially strong, and is known as the Y-ligament of Bigelow (1869); it is scarcely ever ruptured, no matter what the force that produces the luxation. Indirect violence is the usual cause, the femur being forced beyond its normal range either in flexion and adduction, or in extension and abduction, and the head of the bone being pried out of the acetabulum by leverage. In the cadaver luxations are most easily produced by hyperabduction, forcing the great trochanter against the posterior lip of the acetabulum, and using it as a fulcrum by which the head is lifted out of its socket; the capsule is then ruptured anteriorly below the ilio-femoral ligament, and the head of the bone passes on to the *anterior plane*[1] of the innominate bone (Fig. 411). In patients, how-

[1] Nélaton's line divides the innominate bone into two planes (Allis, 1896).

ever, the history of the injury generally indicates another mechanism, the femur having been in flexon and adduction, and the force having been received through an upward thrust in the long axis of the femur, or by a heavy weight falling on the pelvis from behind. In such cases it is probable that the strong ilio-femoral ligament has been wound around the neck of the femur (inwardly rotated), acting as a sliding fulcrum; or possibly that the neck of the femur has been forced against the horizontal ramus of the pubis, and that the head has been pried out of the acetabulum over this as a fulcrum. The capsule here is ruptured posteriorly, and the femoral head passes on to the *posterior plane* of the innominate bone. Owing to the immense length of the distal arm of the lever (the whole lower extremity), it is not at all unusual for a dislocation primitively anterior to be converted into one of the posterior variety secondarily; in such cases the capsule may be widely lacerated, but in almost every case the ilio-femoral ligament remains intact, and the lower extremity is circumducted and rotated on it as a pivot.

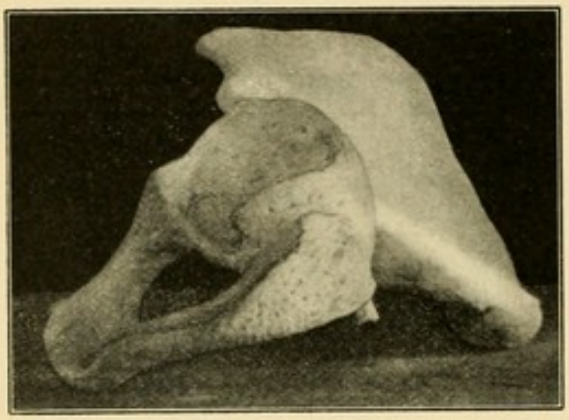

FIG. 411.—Innominate bone showing the anterior and posterior planes. University of Pennsylvania.

In general, then, two main types of dislocation at the hip may be recognized, *anterior* and *posterior;* and of each type there are several varieties, according as the head of the femur rests high or low on the anterior or posterior plane of the pelvis (Fig. 412).

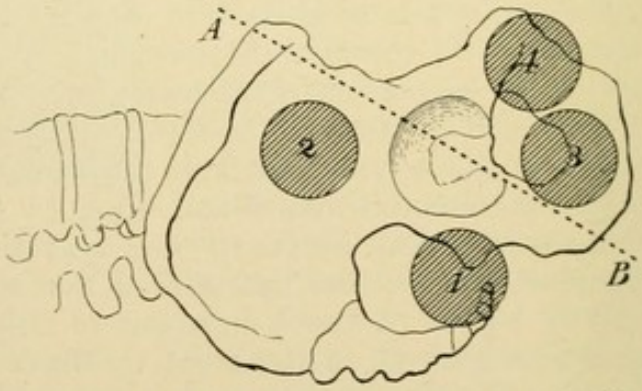

FIG. 412.—Usual sites of dislocation at the hip. *A* to *B*, Nélation's line. Posterior dislocations are (1) low; (2) high. Anterior dislocations are: (3) low; (4) high. See text.

Posterior Dislocations of the Hip, more frequent than anterior, are classed as *high* ("dislocation on the dorsum ilii," or "above the tendon" of the obturator internus), and *low* ("dislocation into the sciatic notch" of Sir Astley Cooper, 1822; or "below the tendon" of Bigelow 1869); and of these two the high luxation is much more frequent, though this may be only a secondary displacement, the head of the femur having emerged from the capsule lower than the sciatic notch, and having been displaced upward when the limb was extended.

Symptoms.—There is loss of normal mobility; there is shortening, with flexion, adduction and internal rotation at the hip; and in standing the toes of the injured side rest on the dorsum of the other foot (Fig. 413). The lower the position of the femoral head on the posterior

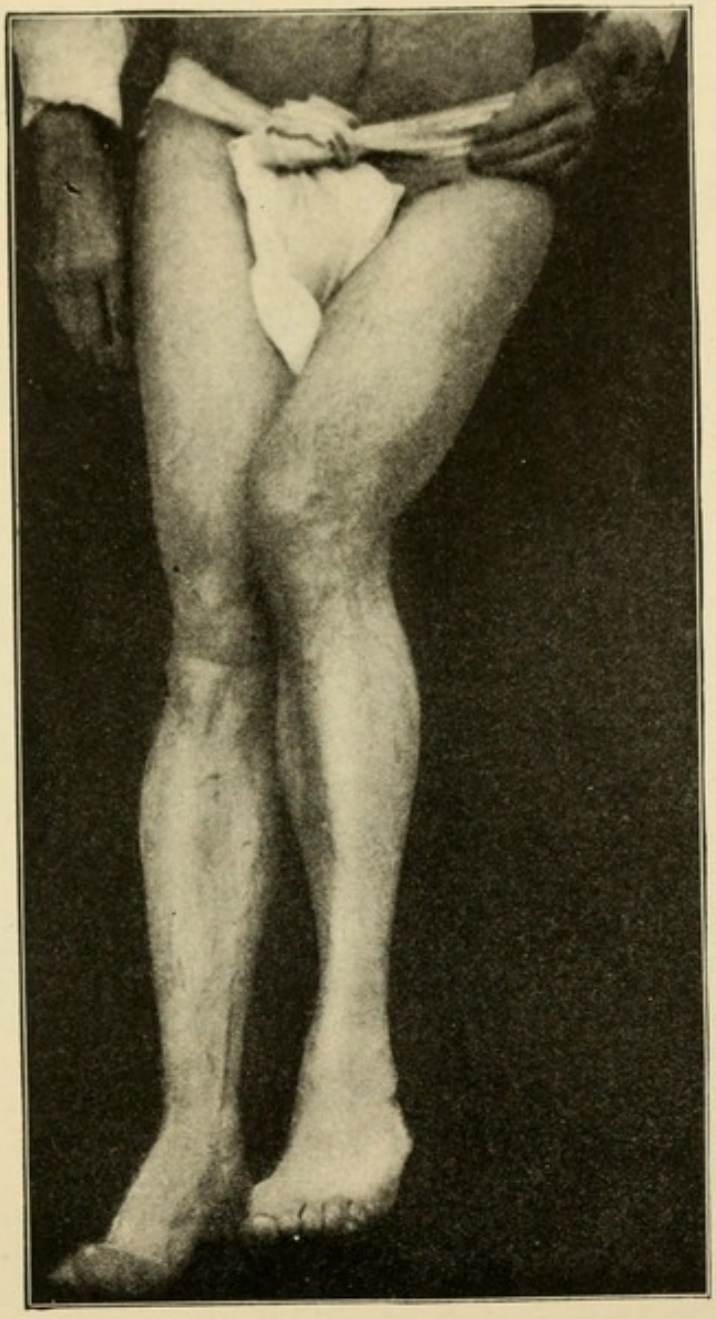

FIG. 413.—Posterior (dorsal) dislocation of the hip. (Stimson.)

plane, the more marked will be the shortening, flexion, adduction, and inward rotation. The head of the femur[1] can no longer be felt below Poupart's ligament, beneath the femoral artery, but sometimes

[1] A good working rule to remember is that the position of the internal condyle corresponds to that of the head of the femur, while that of the external condyle corresponds to that of the great trochanter (G. G. Davis, 1910).

can be detected posteriorly under the gluteal muscles; the trochanter is unduly prominent, is rotated forward, and is above Nélaton's line.

Anterior Dislocations of the Hip are classed as *high* ("pubic"), or *low* ("thyroid"), the latter, in which the head rests in the obturator foramen, probably being the primitive form in most cases; in the pubic form, the head rests against the horizontal ramus of the pubis; an exaggerated form of the high dislocation is the "suprapubic," and an exaggerated form of the low dislocation is the "perineal," the head of the bone passing inward beyond the thyroid foramen and across the ischium into the perineum.

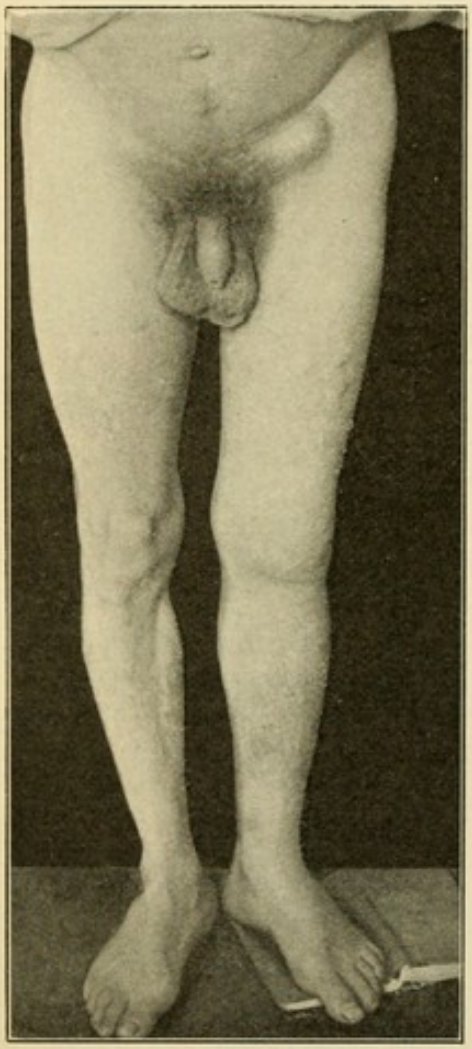

Fig. 414.—Anterior (thyroid) dislocation of hip. Pennsylvania Hospital.

Symptoms.—All these anterior dislocations are characterized by immobility, flexion, abduction, and eversion of the limb (Fig. 414); in the low forms there may be apparent lengthening, but in the high cases there usually is actual shortening. The head of the femur generally can be felt beneath the pectineus or adductor muscles, and often forms a visible prominence; the trochanter is rotated backward, and is less prominent than normally.

Other Atypical or "Irregular" Dislocations of the Hip occur, but are extremely rare, and are either secondary modifications of those described above, or are caused by such violent trauma as frequently to cost the patient his life. The so-called "central dislocation of the hip" is discussed at p. 325.

Prognosis.—If reduction is effected promptly, and without additional trauma, restoration of function is rapid, and generally complete; but the longer reduction is delayed, and the greater the force required in accomplishing it, the more unfavorable the outlook. But even in some cases of irreducible luxation, especially of the thyroid type, very fair use of the limb may be secured.

Treatment.—Reduction of dislocation of the hip is accomplished either by the *direct* or *indirect* method.

Direct Method.—In this, systematized by Allis (1896), the head of the femur is first brought into the position in which it burst through the capsule, and is then pushed or pulled into the acetabulum. As in both anterior and posterior dislocations the head leaves the

acetabulum in its lower part, and as the capsule probably is widely torn below, the method of direct reposition is nearly the same for both varieties. The patient should be anesthetized and laid on his back on a mattress on the floor, with the pelvis firmly fixed: flex the thigh on the pelvis to a right angle, thus bringing the head of the femur toward the lower part of the acetabulum; flex the knee to a right angle, to relax the hamstring muscles and sciatic nerve, and to aid in rotating the thigh. Hold the ankle with one hand, and pass the other hand beneath the flexed knee or sling a towel under the knee and over your own shoulders, to aid in the upward traction required. In *backward* dislocation have the thigh slightly *adducted*, to free the head from the rim of the acetabulum and to relax the anterior branch of the

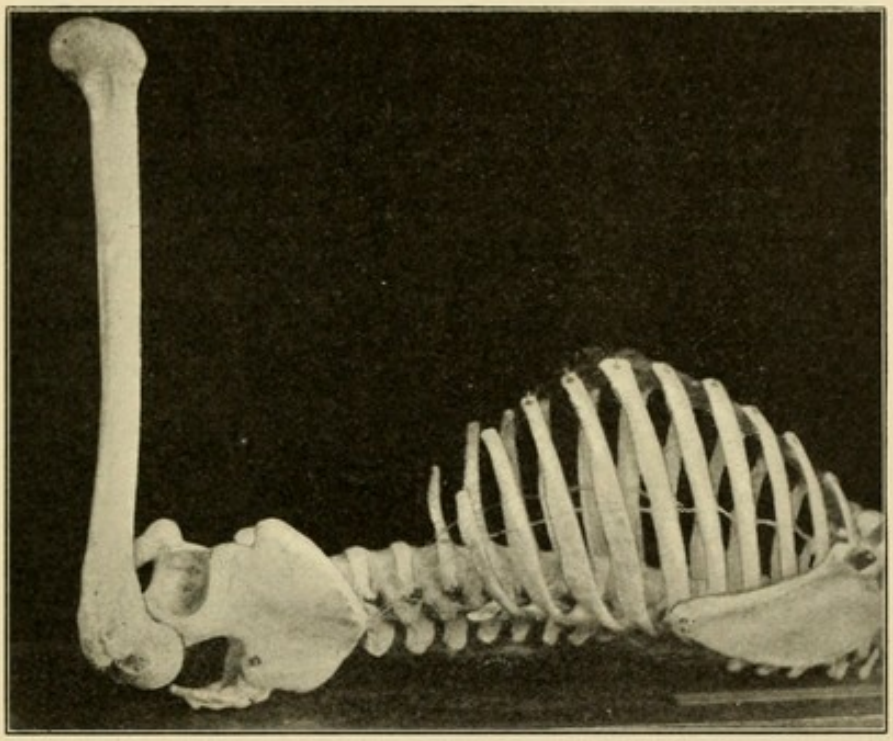

FIG. 415.—Position of bones in reduction of posterior dislocation of hip by direct method. University of Pennsylvania.

Y-ligament; then make vertical traction on the thigh upward and a little *inward*, and the head may jump into the acetabulum (Fig. 415). If it does not, rotate the thigh gently in and out (do not circumduct it), to make the capsule gape widest, and try to pull the head over the rim of the acetabulum in the various positions of rotation. An assistant may help by direct pressure upward and inward on the great trochanter. The head usually will jump into the acetabulum with an audible snap. In *forward* dislocation, have the thigh slightly abducted, to free the head from the antero-inferior margin of the acetabulum, and to relax the posterior branch of the Y-ligament; then make vertical traction upward and slightly outward, and the head often will jump into the acetabulum (Fig. 416). If not, gentle rotation may be tried, until the capsule gapes its widest;

and an assistant may aid by pushing the trochanter upward and slightly outward.

In Stimson's application of the direct method (1889) for posterior dislocation, the patient lies prone, with the affected thigh hanging vertically downward: the knee of the dislocated side is flexed, and the ankle held by the surgeon; in most cases the weight of the limb is sufficient to reduce the dislocation within a few minutes without pain and almost imperceptibly; if necessary, weight may be added to the knee, and gentle rotation practiced, as when the patient lies on his back.

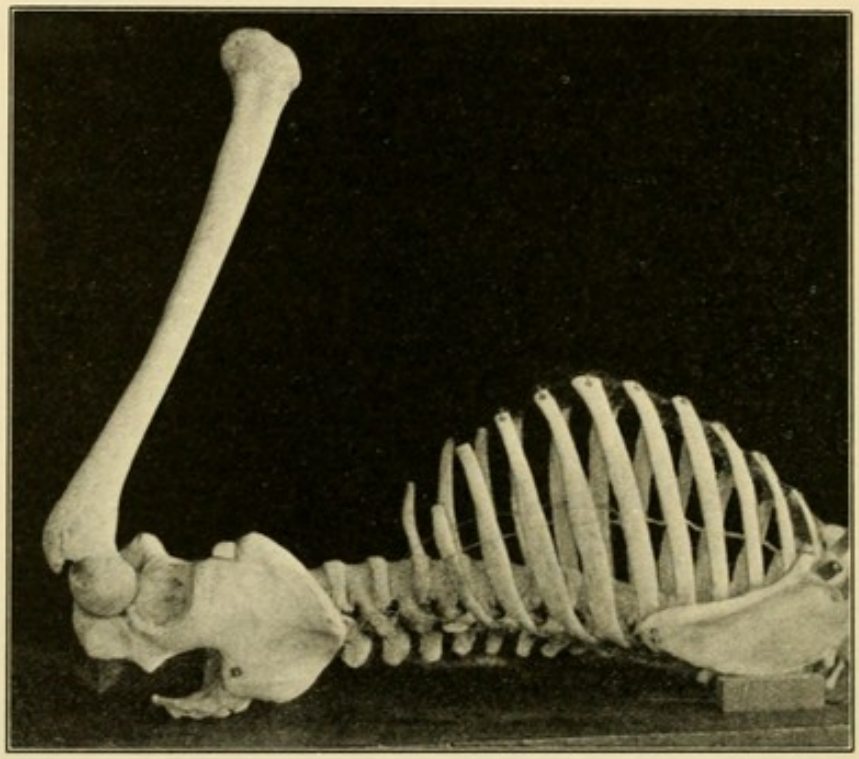

FIG. 416.—Position of bones in reduction of anterior dislocation of hip by direct method. University of Pennsylvania.

Indirect Method.—Reduction by manipulation alone was taught and practised by Hippocrates, N. R. Smith (1831), and Dèspres (1835), and was systematized by W. W. Reid (1851); they regarded the muscles as the chief obstacles to reduction; but it remained for Moses Gunn (1853) and especially for Bigelow (1869) to demonstrate that even with muscular contraction abolished by anesthesia, the capsule still remained the supreme obstacle, and that manipulation was successful only when the action of the Y-ligament was appreciated and employed as an aid. It is used as a sliding fulcrum over which the head of the femur rides into the acetabulum. The patient is anesthetized, and laid on his back on a mattress on the floor; with the pelvis firmly fixed, the thigh is flexed on the pelvis to relax the Y-ligament and to bring the head of the bone down to the lower part of the acetabulum near the rent in the capsule; and the leg is

flexed on the thigh to aid in the manipulation, and to relax the hamstrings and sciatic nerve. In *posterior* dislocations the limb is brought up *in the position in which it is found* (adduction), and is gently circumducted and rotated outward after the thigh has been flexed to more than a right angle with the pelvis; as outward circumduction is continued (Fig. 417), the head of the bone is swung downward and inward by tension on the posterior branch of the Y-ligament, and finally as the limb is brought down to the position of full extension and very slight abduction, the head rides over the rim of the acetabulum and sinks into its socket. *If the abduction is too great* as the thigh is brought down to extension, the head will slide across to the anterior plane of the pelvis, and a secondary thyroid luxation will be produced. Rarely in this excursion the sciatic nerve may be caught up over the neck of the femur. *If abduction is not great enough,* the head will slide up again on the outer side of the acetabulum, and the high posterior luxation will be reproduced. Rarely as it slides up it may

FIG. 417.—Reduction of backward dislocation of femur. (Bigelow.)

FIG. 418.—Reduction of downward and forward dislocation of femur. (Bigelow.)

catch under the tendon of the obturator internus. In *anterior* dislocations the limb is brought up *in the position in which it is found* (abduction), and is gently circumducted and rotated inward after the thigh has been flexed to more than a right angle with the pelvis; as inward circumduction is continued (Fig. 418), the head of the bone is swung downward and outward by tension on the anterior branch of the Y-ligament; and finally as the limb is brought down to the position of full extension and very slight adduction, the head rides over the rim of the acetabulum into its socket. *If the adduction is too great,* a secondary posterior dislocation may be produced; and *if it is not great enough,* the head will slide up the inner side of the acetabulum to a pubic position.

Reduction is known to have been accomplished when the head of the bone is felt to snap into place, and it can be felt rotating in its socket by the fingers below Poupart's ligament; when normal extension of the hip is possible, and when a skiagraph shows the bones in place.

After-treatment.—The patient should be kept in bed with moderate weight-extension for a couple of weeks, and should resume use of the limb with caution.

Patella.—See page 279.

Knee.—Traumatic luxations of the knee are extremely rare, and usually caused by very severe injuries. The displacement of the head of the tibia may be backward, forward, lateral, or rotatory. Wise (1909) refers to 270 cases of dislocation of the knee, 114 of which were anterior. Most of the displacements are incomplete, the lateral almost invariably. Forward dislocation is caused by sudden violent hyperextension, by indirect or direct violence; the tibia slides up on the front of the condyles, but usually maintains the same axis as the femur, not being flexed or hyperextended. Backward dislocation usually follows direct force applied to the front of the tibia, and the leg becomes hyperextended on the thigh. In many of these luxations injuries to the popliteal vessels or nerves are present, and the intra-articular cartilages and ligaments may be ruptured. Usually reduction is not very difficult, owing to stretching or laceration of the lateral ligaments. Prognosis as to function is not very good even in uncomplicated cases, some deformity (flexion, valgus, etc.), generally persisting through life; and for complications, amputation may be required.

Fracture or Subluxation of the Semilunar Cartilages (*Internal Derangement of the Knee-joint*, Hey, 1803). In these cases there may be a sprain, or slight twist of the knee, which, while the patient is walking, suddenly becomes locked in a flexed position; at the same time excruciating pain may be felt, and sometimes a palpable lump appears below the internal condyle. The lesion usually consists in detachment of the internal semilunar cartilage from the head of the tibia; sometimes a piece of it is broken off, and slipping outward, locks the knee-joint. As a rule gentle manipulation and gradual passive extension so far as possible, followed by sudden acute flexion of the knee will reduce the deformity, and restore the movements of the joint. The same train of symptoms, however, frequently recurs, and may be due not to detachment or fracture of a cartilage, but to the presence of "joint mice" (p. 461), the result of chronic articular disease.

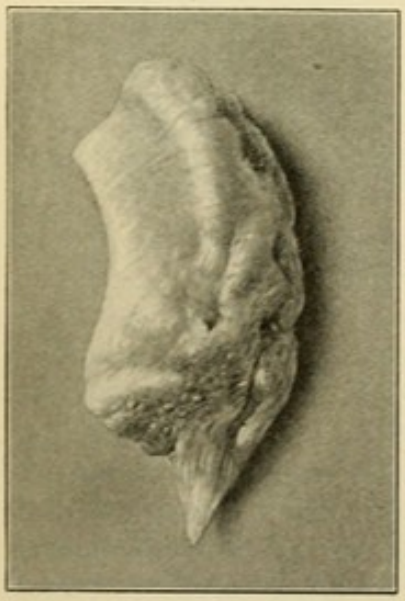

FIG. 419.—External semilunar cartilage removed from knee, for dislocation. Episcopal Hospital.

Treatment.—After reduction of the deformity some appliance must be worn to limit motion in the knee, and to prevent rotation. If the patient is anxious for a radical cure, arthrotomy may be done

preferably through a transverse incision directly over the luxated cartilage, which is caught in a sharp hook or volsellum forceps and removed (Fig. 419). Attempts to suture it in place are not advisable. Function nearly always is completely restored. Arthrotomy for the removal of "joint mice" is best done by a longitudinal incision along the inner border of the patella, which may then be displaced outward, as the knee is flexed, widely exposing the joint.

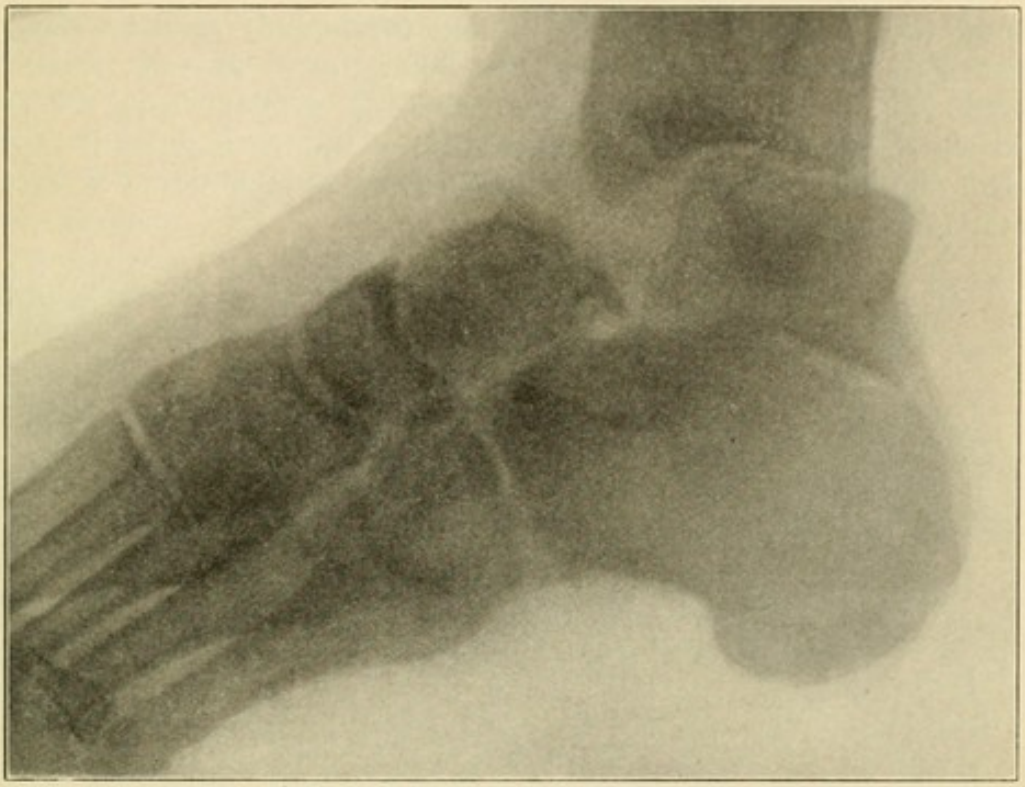

FIG. 420.—Skiagraph of fracture-dislocation of astragalus. Age forty-five years. From fall of eight feet, landing on feet. Irreducible. Both fragments excised. Excellent result. Episcopal Hospital.

Ankle. (*Tibio-tarsal Joint*).—Except in connection with fracture of the leg bones, dislocations at the ankle-joint are exceedingly rare. Wendel (1898) collected 108 cases without fracture. *Posterior* luxation usually follows forced plantar flexion of the foot, with rupture of the lateral ligaments of the ankle, the astragalus sliding backward off the tibio-fibular mortise as dorsal flexion is regained. *Anterior* luxation, much rarer, usually occurs when the foot is in extreme dorsal flexion, the leg bones being forced backward against the tense tendo Achillis either by a blow from above or by a fall on the heel. *Lateral* dislocation is that in which the astragalus and with it the foot, leaves the tibio-fibular mortise, and is displaced externally or internally, there being little or no rotation of the foot. A less unusual displacement is that in which the astragalus rotates around an antero-posterior axis, so that the sole of the foot looks either inward (*supination dislocation*) or outward (*pronation dislocation*). If, on the other hand, the astragalus rotates around a vertical axis, it may remain

in the tibio-fibular mortise, but the entire foot may rotate with it the toes looking inward and the heel outward in *dislocation by inversion*, and the opposite being the case in *dislocation by eversion*. Dislocation *upward* (the astragalus separating the tibia and fibula) is known by Nélaton's name, though his case was complicated by fracture. Unless swelling obscures bony landmarks, these various forms can be distinguished clinically; but in all cases it is desirable to have skiagraphs made in at least two planes. These dislocations about the ankle-joint frequently are compound, and as already remarked, fracture of some of the bones involved very rarely is absent (Fig. 384). Reduction is not always possible without incision, and should be accomplished on the day of injury if possible. The longer the bones remain out of place, the less favorable will be the prognosis for function.

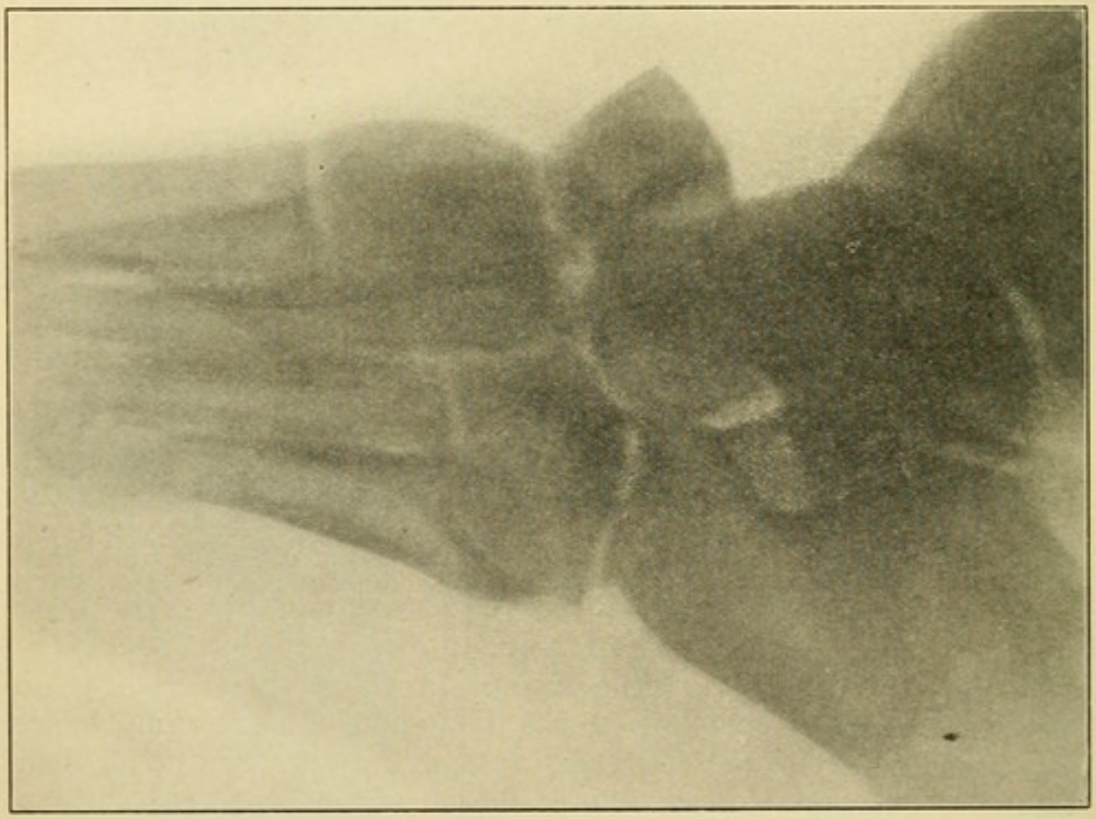

Fig. 421.—Skiagraph of upward dislocation of tarsal scaphoid. Age fifty-four years. Episcopal Hospital.

Tarsus.—The *astragalus* may be the subject of an isolated dislocation forward or backward, the latter being much rarer, and the forward displacement usually being somewhat inward or outward as well; or the astragalus may be rotated in any axis, remaining *in situ*. If reduction is not possible by manipulation, aided perhaps by tenotomy of the tendo Achillis, arthrotomy should be done, and the astragalus removed unless reduction is easy. Good function followed astragalectomy for fracture-dislocation in the case represented in Fig. 420. Isolated dislocation of the other tarsal bones

may occur (Fig. 421); unless reduction is easy, the displaced bone should be excised. *Subastragalar dislocation* of the foot, of which Wise (1909) has collected 87 examples (50 inward, 21 outward, 8 anterior, and 8 posterior), consists of displacement of the entire foot from the astragalus, which remains in the tibio-fibular mortise. Reduction usually is possible by manipulation, and may be aided by tenotomy of the tibialis anticus, or by incision, if necessary. For compound dislocations amputation may be required.

Dislocation at the *medio-tarsal joint* is rare. Skillern (1913) reports what he considers the thirteenth authentic case on record. The anterior tarsus may be displaced toward the flexor or extensor surface. Reduction usually is possible by manipulation under an anesthetic.

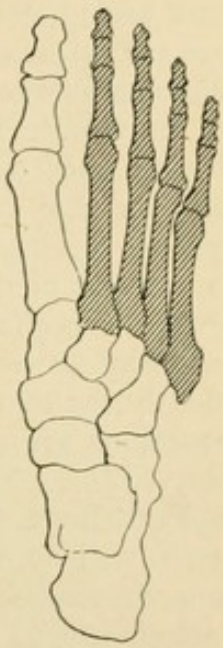

FIG. 422.—The structural portions of the foot concerned in metatarsal dislocations. (Quénu and Küss.)

Metatarsus.—Dislocations of the metatarsals have been studied at length by Quénu and Küss (1909); they collected 35 cases, and believe that systematic radiographic study will show it to be rather a frequent lesion of the foot. It frequently is complicated by fracture, and usually is due to direct violence or to falls on the toes. They show that the foot may be divided into two structural parts, as in Fig. 422, of which the main weight-bearing part is composed of the tarsus and the first metatarsal with its phalanges, while the four outer metatarsals serve as a balance. The most frequent luxations are (1) one in which the balancing portion is displaced externally and toward the dorsum of the foot (*external dorso-lateral dislocation*), and (2) one in which there is a displacement of the balancing portion outward and of the first metatarsal inward (*divergent dislocation*). Diagnosis depends largely on radiography. If reduction is impossible by manipulation, operation may be done; this cannot be made to conform to any type, but may involve tenotomy, arthrodesis, removal of fragments, etc. But even in cases not reduced, fair use of the foot may be regained after several months or a year.

Phalanges.—Dislocation of the phalanges of the toes are rare, usually due to direct violence, and hence often compound. Reduction and treatment are the same as in the fingers.

CHAPTER XIV.

DISEASES OF BONE.

DYSTROPHIES OF BONE.

THERE are numerous affections of bone of whose nature pathologists are still in ignorance. Some of them are known to be associated with changes in the organs of internal secretion; some of them may be due to remote infections, to chronic toxemias or intoxications; but all that is certain is that they depend on *disturbances of nutrition*, and for that reason it is convenient to group them together as *dystrophies*. In most cases the osseous system alone is not affected, but is more conspicuously diseased than the soft tissues. The diseases in question range from atrophic to hypertrophic forms, but in many both atrophy (softening) and hypertrophy (hardening) are present coincidently, or at different stages of the same disease. Congenital malformations are mentioned in the chapter on Orthopedic Surgery (Chapter XVI).

Atrophy of Bone.—This may be *concentric* or *eccentric* (Fig. 423). In the former variety, which begins at the periosteal surface, the size of the bone decreases, but its length (due to cartilaginous growth) is little affected, and what once was a strong shaft becomes a mere spindle. In eccentric atrophy the changes begin in the marrow, and, though the bone may not change in size, it becomes weaker and more porous. In both forms the pathological changes consist in absorption of the bony trabeculæ by giant cells (osteoclasts), with the deposit of fat in the lacunæ (*lacunar resorption*). If the bone becomes fragile and brittle, there is said to be *osteopsathyrosis*, or *fragilitas ossium;* if it merely becomes light and porous, without tendency to fracture, the condition is known as *osteoporosis*.

Causes.—Causes of bone atrophy are disuse (as in amputation stumps, paralyzed limbs, etc.); chronic disease, especially of the nervous system; and old age. In most cases disuse is the paramount cause. Atrophy from pressure is also seen, as in tumors, aneurysms, etc.

Osteogenesis Imperfecta.—Osteogenesis imperfecta, the so-called "idiopathic fragilitas ossium," is considered a definite disease; it is congenital, may be hereditary, and patients seldom reach adult life. Lovett and Nicholls found it associated with changes in the adrenals (1906). Naturally the long bones of the limbs are those most often fractured, usually from no recognizable injury; union occurs without difficulty, but usually with deformity owing to the

frequent lack of splinting. The calvaria may remain membranous throughout, or scattered bone islets may develop.

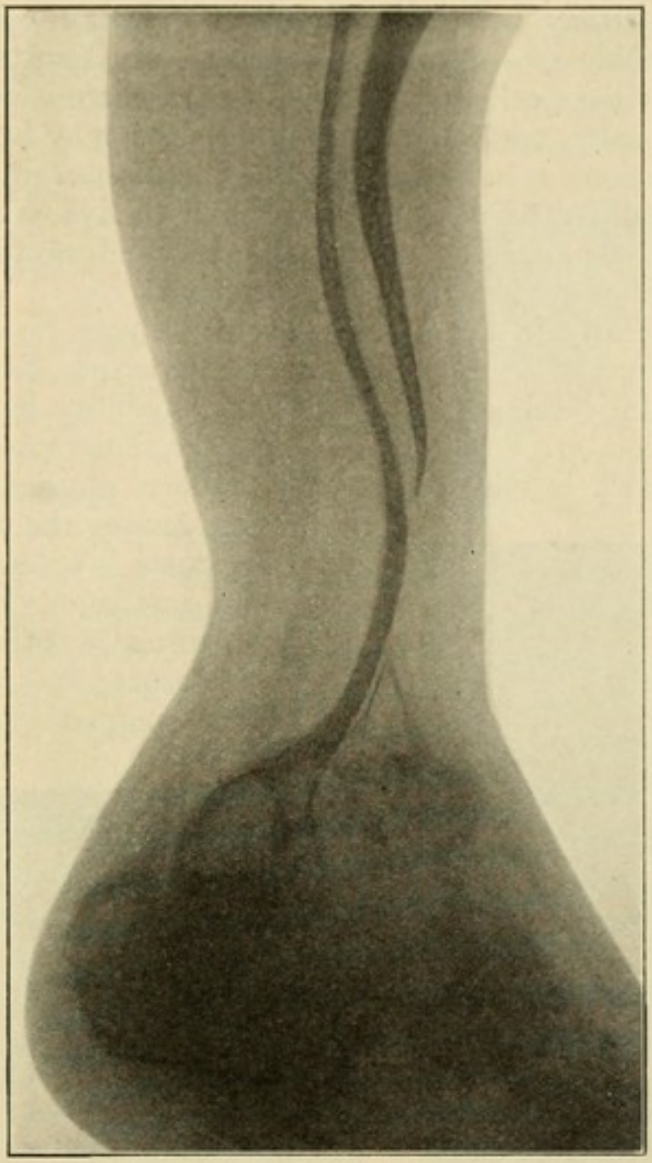

FIG. 423.—Extreme bone atrophy, occurring in hereditary syphilis, in a girl, aged eighteen years, who had not walked for five years. The continuity of the tibia is lost, that of the fibula preserved (concentric atrophy). The tarsal bones and articular extremities of the tibia and fibula show eccentric atrophy. Episcopal Hospital.

Achondroplasia. — Achondroplasia is a congenital affection in which the epiphyses of the long bones become ossified abnormally early, preventing growth of these bones in length, and giving these patients a typical appearance: normal-sized body, with dwarf-like extremities. The calvaria (of membranous development) usually is unaffected. Shattuck classes it as a para-cretinous condition, and found it associated with changes in the thyroid.

Rachitis.—This is a disease apparently dependent on malnutrition, and having its chief manifestations in the osseous system. It begins almost exclusively in young children (under three years of age), but seems never to be congenital. The patients usually are not

breast-fed, but have been brought up on improper milk mixtures. The osseous changes occur chiefly in the epiphyseal cartilages, and consist in irregular over-growth of cartilage cells; some of these cartilaginous islets may be displaced into the metaphysis, and cause subsequent trouble (see Multiple Cartilaginous Exostoses, p. 443). Though the cartilage cells form osteoid tissue, there is deficient deposition of lime salts, and such as are deposited may be removed by lacunar resorption, resulting in marked osteoporosis. When the disease passes off, after lasting from three to five years, the bone becomes hard, dense, and eburnated, and deformities developed during the earlier period become permanent.

Symptoms.—Early in the disease, attention may be drawn to the infant on account of constant fretfulness, sweating about the head, backwardness in walking or even crawling, inability to sit up alone, delayed dentition, etc. In extreme cases the limbs are very painful, and pseudo-paralysis may be present. When physical signs begin to develop, among the most constant and conspicuous is enlargement of the epiphyseal cartilages (Fig. 424), appreciable especially at the wrist, ankle- and costo-sternal joints, the deformity in the last named situation being

FIG. 424. — Rachitis. Age five years. Scarcely able to walk alone. Children's Hospital.

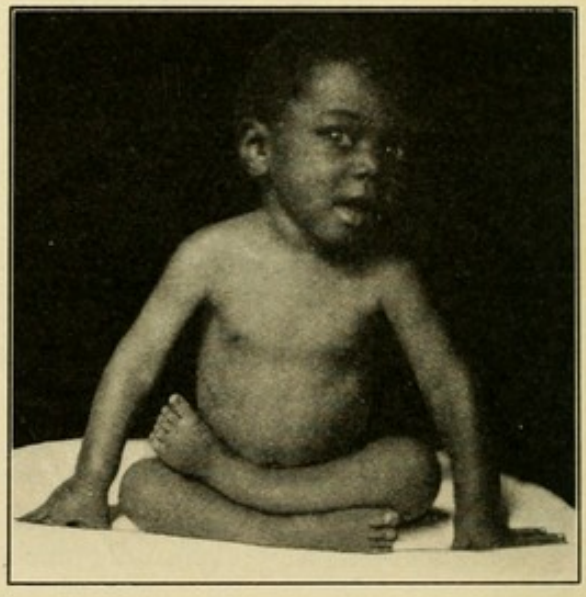

FIG. 425. — Rachitis. Age two years. Showing how bow-legs develop from persistent malposition. Children's Hospital.

called the "rachitic rosary." The head appears square, the forehead is high, and the fontanelles remain open to the third or fourth year. The thorax may present a transverse depression (Harrison's groove, 1820) from the constant tug of the diaphragm on the softened ribs. The child is "pot bellied," and there may be a long, rounded kyphosis of the spine, which disappears completely on hyperextension; the spine

is nowhere rigid. Various deformities of the extremities develop, due to malposition and pressure (Fig. 425). "Knock-knee" or *genu valgum* usually is due to changes in the lower femoral epiphysis, with overgrowth of the internal condyle, increasing the normal outward deviation of the leg; "out-knee" or *genu varum* is a less usual deformity than "bow-legs," in which the main deformity is in the leg bones. Knock-knee and bow-leg may coexist (Fig. 426), generally due to the mother carrying the child constantly on the same arm (that side on which knock-knee develops) instead of alternating on the right and left. *Anterior curvature of the tibiæ* is a conspicuous deformity, but very slightly disabling. Rachitic *coxa vara* is one of the less usual deformities. *Rachitic deformity of the pelvis* may interfere with parturition.

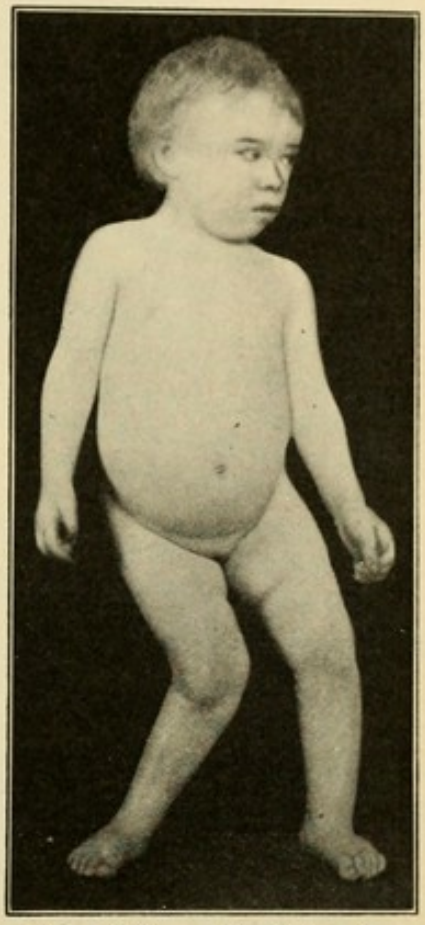

Fig. 426. — Rachitic legs: knock-knee on right, bow-leg on left, from being carried constantly on the mother's right arm. Orthopædic Hospital.

Treatment.—In early stages constitutional treatment is most important, and may be successful in preventing development of deformities. The diet must be regulated, and as soon as the child can be weaned, a generous mixed diet, with plenty of vegetables, is preferable to continuance with milk; of all tonics, exclusive of fresh air, cleanliness, and sunlight, which of course must be provided, none is so good as cod liver oil; this (not an emulsion, but the pure Norwegian oil) may be given three times daily in doses from 30 minims up to any quantity that can be absorbed. In the very exceptional cases in which this is not tolerated, the syrup of the iodide of iron may be substituted; and in many cases phosphates should be given in addition. Locally, beginning deformity in the limbs may be overcome by daily gentle manipulation in the mildest cases; or by splinting, or the use of gypsum cases renewed every few weeks with the legs in a corrected position. The use of *braces*, which is preferable when the patient can afford to purchase them, usually will overcome slight deformities within eighteen months or two years, if applied while the bones are still soft (before the age of two years and a half). Bow-legs show a greater tendency to spontaneous cure, and improve much more rapidly under treatment by braces than do knock-knees. Good types of braces are shown in the accompanying illustrations (Figs. 427 and 428); the *modus operandi* of braces is not to overcome the deformity forcibly, but to prevent growth in other than the proper direction; they

require constant repair and readjustment, and the surgeon should see that they are in repair and properly adjusted every third or fourth week. Usually they need not be worn at night in bed.

After the age of three years, and occasionally earlier, very little improvement can be expected from conservative measures, and an operation should be undertaken. *Manual correction* may be attempted by Anzoletti's method (1909): plaster of Paris is moulded very accurately to the extremity, from beyond the toes well up to the groin, so as to prevent all motion, and the patient is kept in bed on low diet for four or five weeks, so as to promote bone atrophy; at the end of this time the gypsum is removed, and the softened bones sometimes may be bent in the hands to the desired shape without

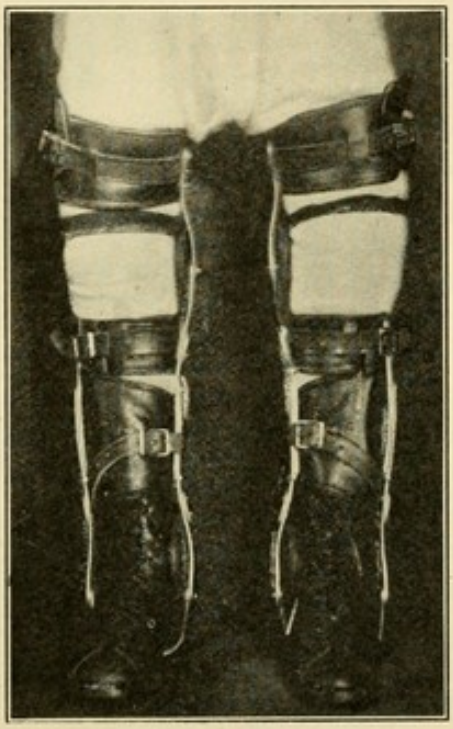

Fig. 427.—Bow-leg braces. Pads over internal condyles and internal malleoli, with leather apron over apex of deformity. Orthopædic Hospital.

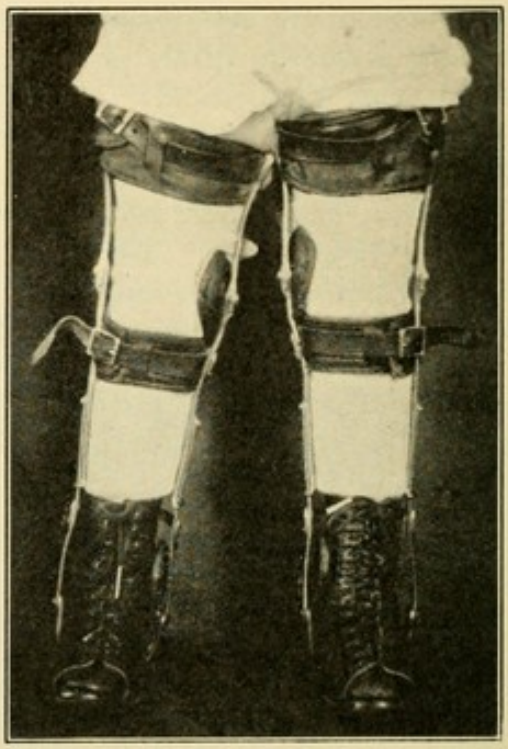

Fig. 428. — Knock-knee braces. Pads over internal condyles and internal malleoli. Orthopædic Hospital.

anesthetizing the patient. Plaster of Paris is then applied in an over-corrected position, and the patient encouraged to walk about, being fed up, and given cod liver oil; at the end of four or five weeks the bones will be hard enough to go without support. I have tried the method several times, but think it suitable only for acute cases, especially those of bow-legs; in cases of long duration it is better to resort to osteoclasis or osteotomy. *Osteoclasis,* or breaking the bone, is accomplished by use of the osteoclast (Fig. 429), the patient being anesthetized; the limb is then put up in plaster of Paris in over-corrected position, and is treated as a fracture. *Osteotomy,* or division of the bone by an osteotome (Fig. 451, 4), which may be described as a chisel bevelled on both edges, so as to cut straight

ahead, is done through a minute incision which divides the periosteum. The osteotome is introduced through the periosteum, is turned transversely to the long axis of the limb, and is driven through

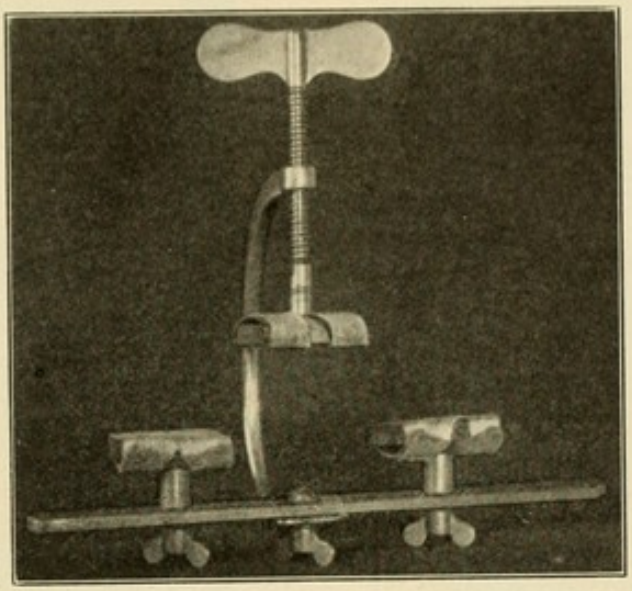

Fig. 429.—Hopkins's osteoclast. Orthopædic Hospital.

the bone by a mallet in such a way as to divide it transversely all except a few fibres at the further side; several cuts in the bone (all at the same level) may be necessary, but they are all made through the one skin incision, making practically a subcutaneous operation. The

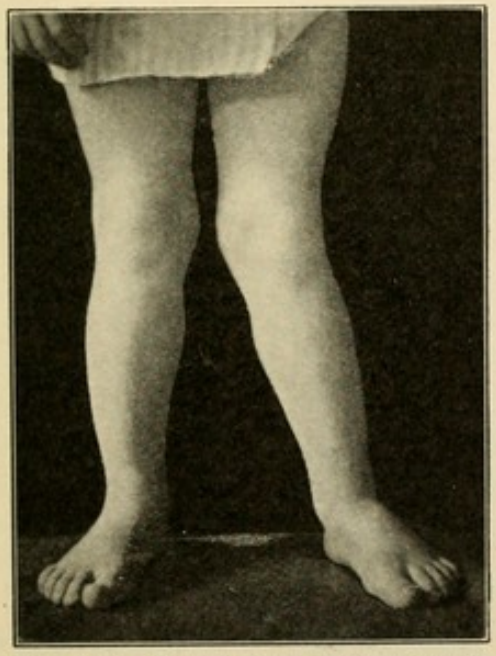

Fig. 430.—Knock-knees, osteotomy of both femurs. (See Fig. 431.) Orthopædic Hospital.

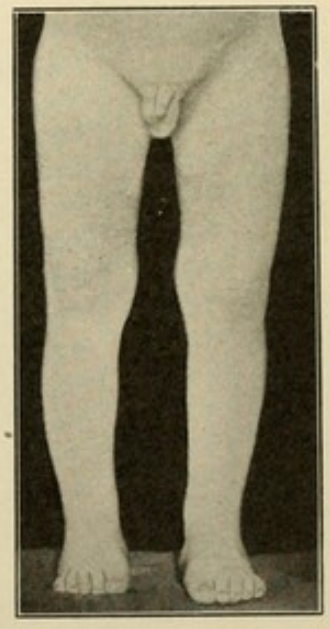

Fig. 431.—Result of osteotomy of femurs for knock-knees. Orthopædic Hospital.

remaining bone fibres are then fractured by hand, the incision closed with one suture, and the limb is put up in plaster of Paris in an *over-corrected* position. For knock-knee the osteotomy is done a finger's

breadth above the epiphyseal line of the femur, usually on the outer side of the bone (Figs. 430 and 431); for bow-legs it is done at the

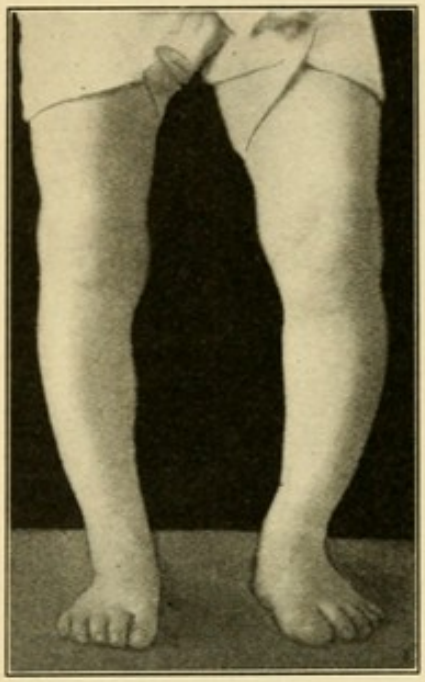

FIG. 432.—Bow-legs, osteotomy of both tibiæ. (See Fig. 433.) Orthopædic Hospital.

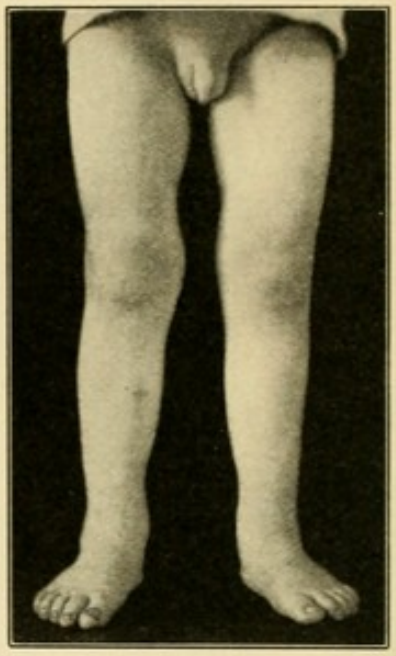

FIG. 433.—After osteotomies for bow-legs. Orthopædic Hospital.

apex of the deformity, usually only the tibia being divided, the fibula bending or being broken by hand (Figs. 432 and 433). The correc-

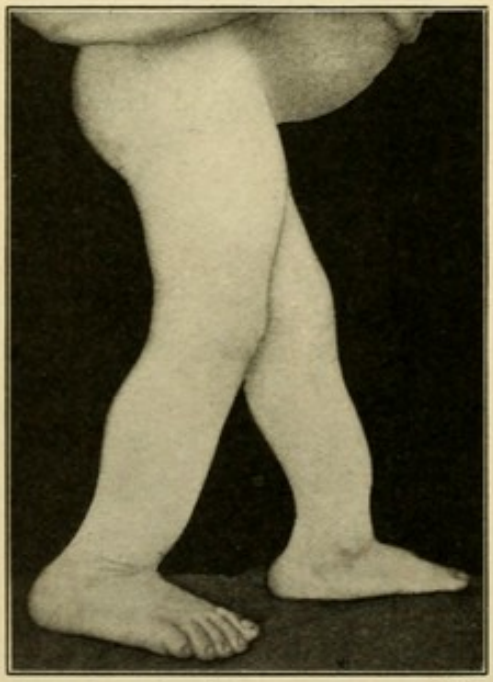

FIG. 434.—Anterior curvature of tibiæ in rachitis. (See Fig. 435.) Orthopædic Hospital.

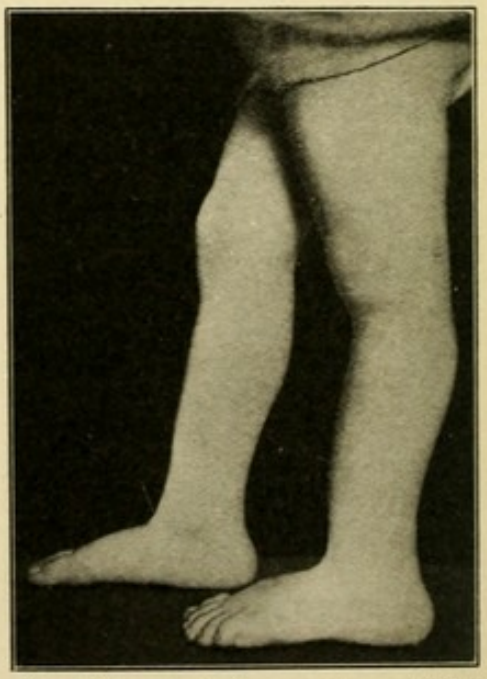

FIG. 435.—Anterior curvature of tibiæ after osteotomy. Orthopædic Hospital.

tion of anterior curvature is more difficult (Figs. 434 and 435). The patient is not allowed to walk for six or eight weeks.

Scurvy.—Scurvy, which may complicate rachitis or occur independently, should be borne in mind as a possible cause of symptoms of bone disease in infants. Tenderness of shafts of long bones, with skiagraphic evidences of subperiosteal hemorrhages, in association with other scorbutic symptoms, should make one suspicious of this condition. The diagnosis from tuberculous or subacute septic osteomyelitis is not always easy. Constitutional anti-scorbutic treatment is indicated.

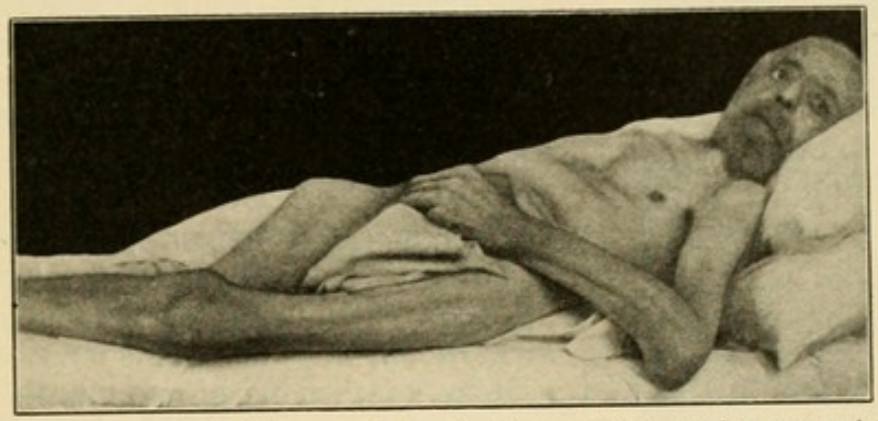

FIG. 436.—Osteomalacia (five years' duration) in a patient, aged seventy-eight years. Confined to bed for six months. Fracture of right femur occurred the day before the photograph was taken, and death from asthenia two days later. Dr. F. W. Sinkler's case. Episcopal Hospital.

Osteomalacia.—Osteomalacia, or softening of the bones, is an affection occurring mostly in women, often in those who have borne several children in rapid succession. It is believed to be associated with ovarian disease. Scarcely ever does it occur before puberty. Deformity is progressive and marked, involving the pelvis, the vertebral column, and later the extremities. "Spontaneous fracture" (Fig. 436) may occur, but is not frequent. The disease has been treated by oöphorectomy, but some surgeons (Bastianelli) claim that the benefit from such operations has been due to the chloroform inhalation used for anesthesia; and they now induce such anesthesia without doing an operation (W. J. Mayo, 1910). According to Mayo, also, different Italian observers have found an identical and specific diplococcus in the periosteum in this disease, in rachitis, and in osteitis deformans; when a culture of this diplococcus was injected into rats it produced rachitis in the very young animal, and osteomalacia in adult rats. The relation of thyroid diseases to osteomalacia is not clear.

Osteitis Deformans (*Paget's Disease of the Bones*, 1876) occurs in adult life, patients usually not applying for treatment until well past forty years of age. It runs a very chronic course, lasting many years, and growing progressively worse, though intermissions and exacerbations may occur. It is characterized in its earlier stages by osteoporosis, causing flexibility and deformity of the bones; but later the bones hypertrophy and become markedly thickened. Fracture is rare. The lower extremities are affected earliest, resulting

in general outward and anterior bowing of the knees and legs; the spine shows a long, rounded kyphosis, and the calvaria becomes very much thickened. At times the bones are very painful, but often progressive enlargement of the head is what first calls the patient's attention to his condition. Eventually loss of height is observed, the attitude resembling that of anthropoid apes, with bowed head, disproportionately long arms, and a waddling gait (Fig. 437). Some weakness and stiffness usually exist, but death occurs only from intercurrent disease, usually pulmonary, or from advanced arteriosclerosis which is a prominent feature of the malady.

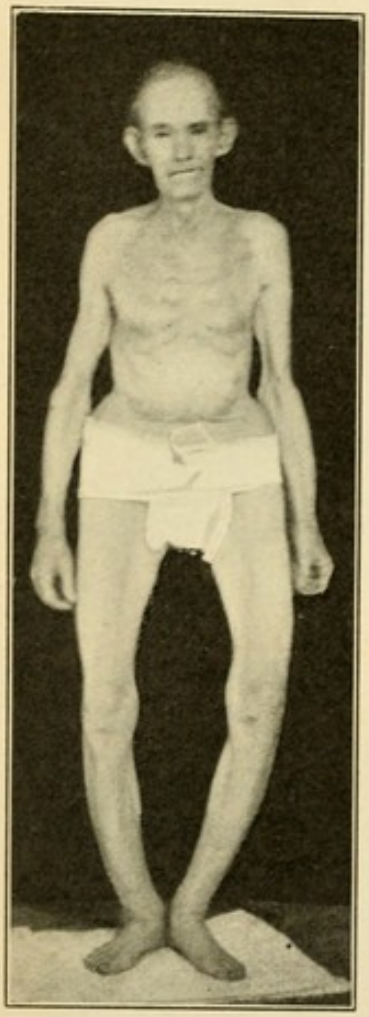

FIG. 437.—Osteitis deformans (Paget's disease) in a patient, aged seventy-two years. Duration twelve years. Orthopædic Hospital.

Treatment.—Treatment is chiefly hygienic and dietetic. Thymus or thyroid extract may be of value. Pain may be relieved by application of proper orthopedic apparatus.

Hypertrophy of Bone.—This may be compensatory, as when one of two parallel bones is removed for disease, the other may become hypertrophied. Or it may be the result of chronic irritation, as in thickening of a tibia underlying an old leg ulcer. Increase in thickness and weight is commoner than increase in length, though the latter occurs to a marked degree in some amputation stumps, (p. 200); sometimes, too, after fracture or tuberculous or inflammatory lesion of bone, actual increase in length may occur, or at least the affected bone may grow faster than the corresponding bone on the other side of the body.

Leontiasis Ossea (Virchow, 1865) is a disease usually arising in youth, characterized by hypertrophy of the face bones, giving the face a leonine expression, due to the gradual obliteration of its features. The foramina in the base of the skull may be narrowed, causing exophthalmos, blindness, and paralysis of the various cranial nerves. Hypertrophy of the calvaria causes pressure on the brain, with headaches, convulsions, etc. No treatment is of avail.

Acromegaly (P. Marie, 1886) is a disease of youth or early adult life, characterized by hypertrophy, enlargement and thickening of the apices and extremities of the skeleton—fingers, toes, chin, nose, etc.; while similar soft tissues also may enlarge—lips, tongue, ears, and even penis and clitoris. A rounded kyphos develops in the dorsal spine. Headache is the chief subjective symptom. The disease often is caused by changes, usually neoplastic, in the hypo-

physis cerebri; a skiagraph may demonstrate enlargement of the sella turcica, and pressure symptoms from hypophyseal growth may develop later. Treatment by pineal, thyroid, thymus, or other extracts may be tried, but the only hope of cure consists in removal of the hypophysis (see p. 584).

INFECTIONS OF BONE.

Infection of a bone usually occurs through the blood-stream, some *locus minoris resistentiæ*, generally due to injury, determining localization of the infection. Those who have a general blood-infection (furunculosis, typhoid fever, syphilis, tuberculosis, etc.), therefore, are predisposed to bone infection. Infection of bone also occurs in compound fractures, but as in these the products of inflammation are readily discharged from the broken surfaces and through the wound of the soft parts, the disease seldom assumes such serious proportions as when infection arises in the unbroken bone; in the latter instance the very structure of the bone prevents swelling, so that strangulation and necrosis occur very early.

Acute Periosteitis.—Acute periosteitis rarely occurs as an isolated affection; in almost every case there are also osteitis and osteomyelitis, and it is probable that the infection is localized first in the medulla, and is propagated to the periosteal surface of the bone through the Haversian canals. In convalescence from *typhoid fever*, however, subperiosteal abscess may occur, and in most such cases there is no appreciable involvement of the medulla, and at most only a superficial caries of the cortex. The lesion occurs oftenest in the long bones and the ribs; relief of symptoms (pain, tenderness, swelling, fever, etc.), and rapid cure usually follow incision of the periosteum and scraping the carious bone (Fig. 438).

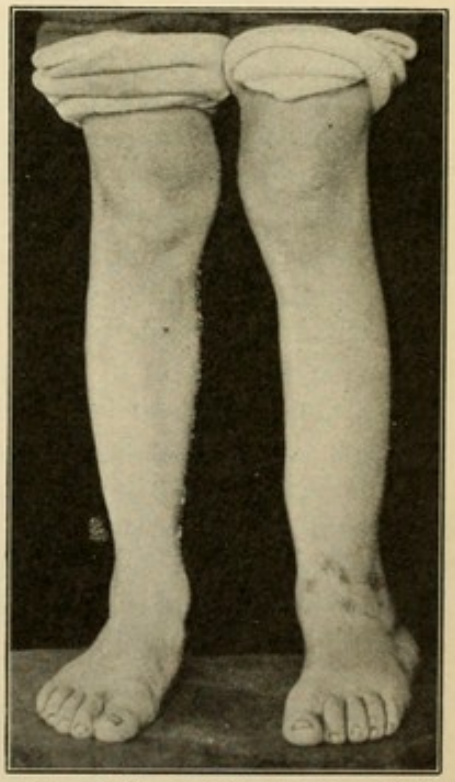

Fig. 438. — Periosteitis of left tibia nine months after typhoid fever. Age nine years. Episcopal Hospital.

Chronic Periosteitis.—Chronic periosteitis is a frequent lesion, occurring in many of the dystrophies already described, or as the result of contusions of bone, from chronic inflammation of overlying soft tissues, and in chronic infections, especially syphilis (Fig. 460). The long bones are most often affected: the periosteum is raised from the shaft by the formation of new bone, and the resulting deformity may be very evident on inspection. Distinct periosteal

nodes may form, or the thickening may be diffuse. Usually there is a good deal of aching, but no very acute pain; the osteoscopic (bone-tiring) pains become worse after exertion and when the warmth of bed induces hyperemia of the diseased parts. The treatment is much the same as for syphilitic periosteitis (p. 442).

Osteitis.—Osteitis scarcely ever occurs as a recognizable affection apart from accompanying osteomyelitis.

Osteomyelitis.—This is an acute septic infection of bone marrow, usually due to the Staphylococcus aureus, and affecting mostly the long bones of the extremities, especially the tibia, femur, and ulna, in their juxta-epiphyseal portion, which is named by Kocher the metaphysis. It occurs almost exclusively in children from six to sixteen years of age, and often follows slight trauma, or exposure to cold and wet, as in frequent swimming expeditions. Predisposing causes are malnutrition, convalescence from the exanthemata or other general infections.

Owing to the dense bony case in which the inflammation occurs, it is extremely rare for an abscess to form; instead a true phlegmon of bone results, infection spreading up and down the medulla. The cortex is affected secondarily, and in most cases periosteitis results from transmission of infection through the Haversian and Volkmann's canals. The process rarely extends into the joints, even in adults, and in children nearly invariably is arrested at the cartilage of the epiphyses. Swelling being impossible, the medullary tissues become strangulated, and death of the bone in large masses follows (necrosis), its extent depending on the destruction of the marrow cells within, and on the amount of separation of periosteum on the surface. Sometimes the entire shaft of the bone becomes necrotic, is spontaneously detached at its epiphyses, and floats in pus beneath the unruptured periosteum. Usually, however, before this stage is reached drainage is instituted by operation, or the periosteum is perforated by the pus with formation of a *parosteal abscess* in the soft tissues. The periosteum is raised from the cortex, and new subperiosteal bone is formed; this at first is plastic but later becomes sclerotic and is known as the *involucrum;* and such portions of the bone marrow as survive form new bone within, so that eventually the necrotic portion of bone, known as a *sequestrum,* is more or less completely surrounded by new-formed bone but still communicates with the surface through orifices in the involucrum known as *cloacæ*, and through these a discharge of pus continues. Several sequestra may form, each having its own cloaca or cloacæ, and discharging on the skin surface through numerous sinuses (Fig. 439). When this stage of the disease is reached, it assumes a chronic form usually described by the term Necrosis (p. 431).

Symptoms.—These are both general and local, the former often so over-shadowing the latter that without attention to the history and careful physical examination the disease has been mistaken for toxemia resulting from typhoid fever, pneumonia, meningitis, etc.

The disease may be ushered in by a chill, with sudden rise in temperature to 105° F. or higher, the child appearing very ill and making little complaint of the extremity affected. In these hyperacute cases death from septicemia may occur within a day or two in spite of active treatment. In most cases, however, the affected limb becomes *painful, helpless,* and *swollen;* redness may not be evident. Tenderness is extreme, extending throughout the shaft of the affected bone, but most intense at one spot. Indeed, tenderness usually is so great

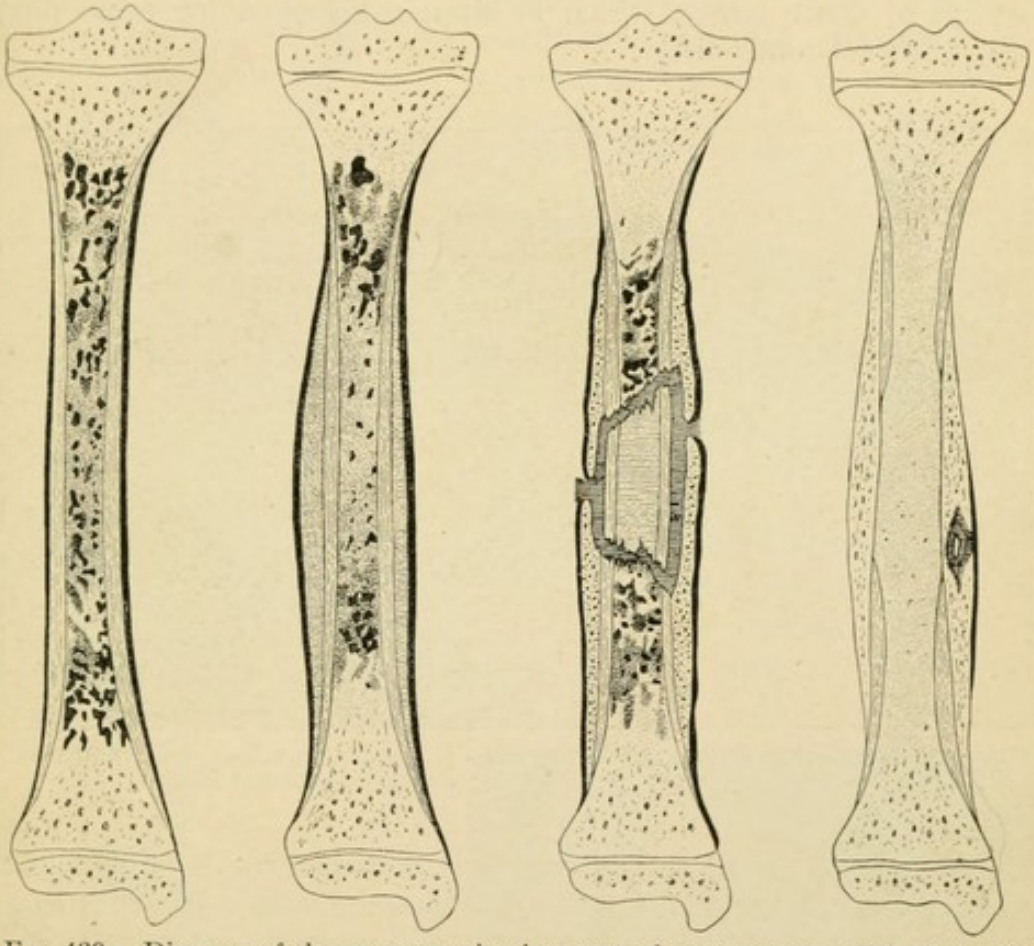

FIG. 439.—Diagram of changes occurring in a case of acute osteomyelitis of the tibia. In the *first figure,* there is diffuse suppuration in the medulla of the diaphysis. In the *second figure,* the products of inflammation are seen, filling the space between the cortex and the periosteum. In the *third figure,* new subperiosteal bone has been formed, and within this involucrum is seen a large sequestrum, surrounded by pus, which discharges through openings in the involucrum, known as cloacæ. In the *fourth figure,* only a small cortical sequestrum remains, the involucrum has become very dense, and the medullary cavity is replaced by eburnated bone. (de Quervain.)

as absolutely to prevent palpation at the seat of greatest disease. Even if the remainder of the shaft be not tender to palpation or tapping, prolonged gentle pressure even at a distance will eventually and *suddenly* become acutely painful; this is a valuable diagnostic point (Nichols, 1907). The disease is often mistaken for acute rheumatic arthritis, with most disastrous results; but in osteomyelitis the joints are not involved, while the bones are; and multiple lesions, common in acute rheumatic fever, are rare so early in the course of

osteomyelitis, though quite frequent later. The distinction between deep-seated suppuration of bone, and serous joint effusion should not be difficult if physical examination is thorough. The mistake is most apt to occur in the case of bones which are not subcutaneous (femur, radius, humerus), but ignorance and carelessness may err even in the case of the tibia or ulna. At later stages, if the patient survives, edema of the skin, with redness, and even fluctuation, make a mistake absolutely unpardonable. Throughout the course of the disease the surgeon should be on the lookout for secondary invasion of other bones, which is often overlooked for some days, owing to a subacute onset.

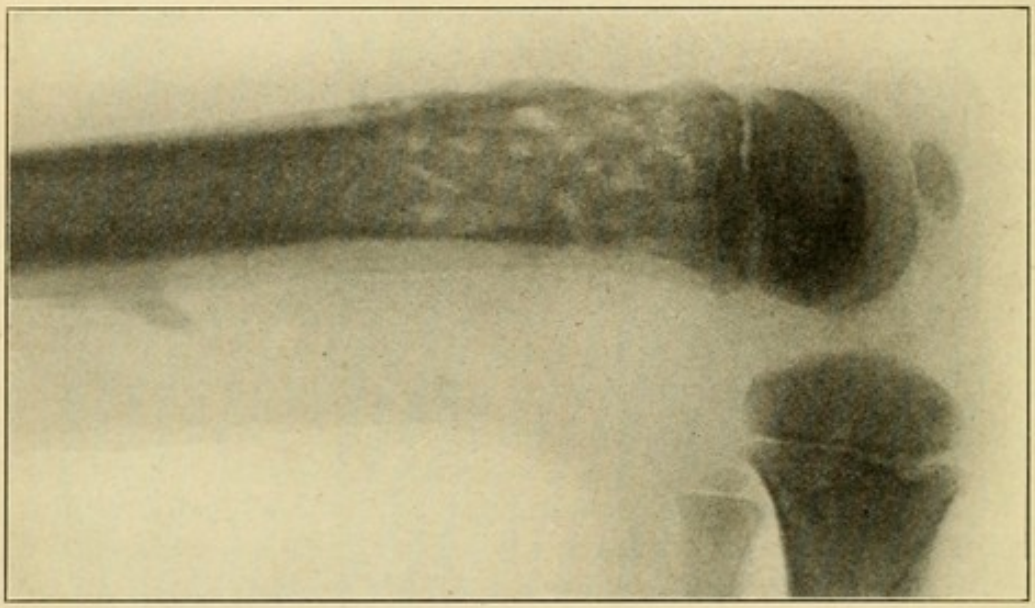

FIG. 440.—Skiagraph of acute osteomyelitis of femur; age seven years; treated at home for "typhoid fever" for four weeks. Episcopal Hospital.

Treatment.—As soon as the diagnosis is made, the bone should be opened. Delay even of a few hours is dangerous in very acute cases, leading to widespread necrosis, pyemia, and multiple secondary foci of osteomyelitis in other bones. In a case of which I have cognizance, the patient was treated during four weeks for typhoid fever, with the result that not only was he gravely ill for many months with pyemia, but he lost his entire ulna, and developed secondary lesions in one tibia, and both femora (Fig. 440). The patient should be anesthetized, the limb elevated until bloodless, and an Esmarch band applied well above the diseased area; a free incision is then made dividing the periosteum where subcutaneous or after exposure through the proper intermuscular space. Usually the periosteum is found more or less widely detached from the cortex by pus; the cortex then may look white and dead, but generally a few minute bleeding-points (Volkmann's canals) may be seen. If the periosteum is detached from the cortex throughout, and the shaft is loosened at its epiphyseal attachments, the entire shaft may be removed, either in one

piece, or by wrenching each end free after sawing the bone across its centre; in the case of the femur and humerus, however, where no parallel bone exists to act as splint, it will be better, even under these circumstances, to leave the shaft in place until an involucrum has formed dense enough to maintain the form of the limb. Where the periosteum is only partly detached from the bone, or where the infection has not yet extended from the marrow out through the cortex, the cortical bone may appear normal; but *in all cases the surgeon should open the medulla to provide drainage.* The periosteum should be carefully detached from a sufficient area, and the medulla exposed by trephine or gouge and mallet. The marrow usually is found softened, grayish yellow, or even purulent; but failure to find frank pus by no means indicates that septic osteomyelitis is absent. If the operation is done sufficiently early the inflammation may not have progressed to the stage of suppuration; and in certain cases of subacute infection (perhaps tuberculous), there is what is known as *albuminous osteomyelitis* (Ollier, 1872), the exudate being serous or at most sero-purulent. In such cases, or if the diagnosis is doubtful,

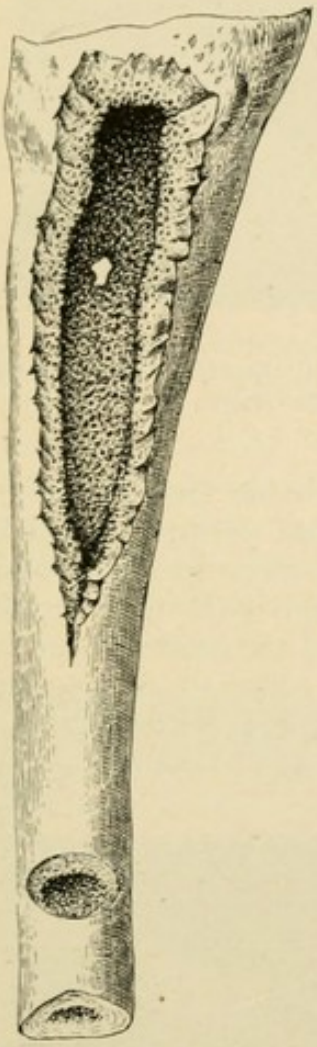

FIG. 441.—Specimen of tibia excised for osteomyelitis; below is seen the trephine opening made for exploration; above, the large opening made by gouge and mallet. Finally the entire diaphysis was excised. Episcopal Hospital.

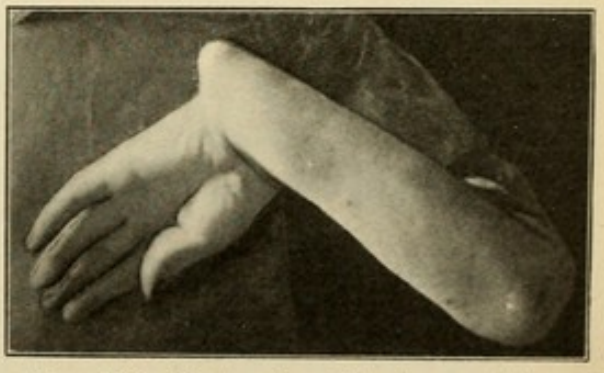

FIG. 442.—Deformity following excision of radius twenty-five years ago for osteomyelitis; useful hand; man works as laborer. Episcopal Hospital.

the marrow may be exposed by drill holes. If the medulla is found widely infected, a second button of bone may be removed at a distance from the first, to determine the extent of medullary implication; and the intervening bone may then be removed by gouge and mallet, cutting a long gutter in the cortex, and widely exposing the medulla. It never is proper to curette the marrow or attempt its removal in

any way, any more than it is proper to curette an acute phlegmon of the soft parts (p. 51); it is probable that all the marrow cells are not destroyed, and such as still are living are very important agents in forming new cortical bone. The periosteum alone is not always capable of forming an entire new shaft. In exceptional cases total resection of the diaphysis, even if this is not wholly necrotic, may be done when a parallel bone exists to act as splint, if the osteo-

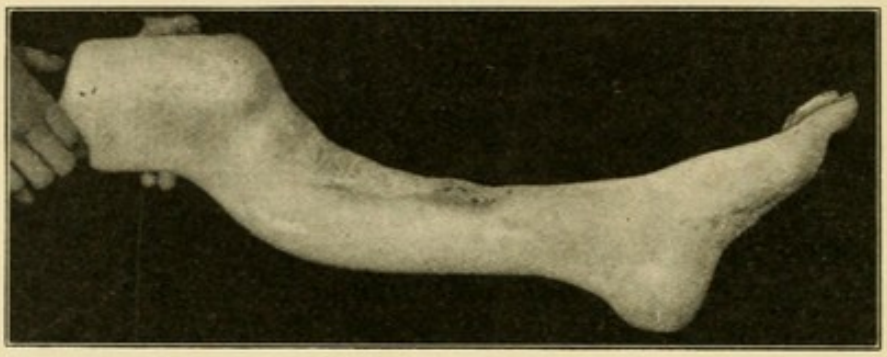

FIG. 443.—Deformity from excision of tibia for osteomyelitis. Operation two years ago. Now fourteen years old. Ankylosis of knee. Only upper and lower epiphyses of tibia remain, with about three inches of shaft above malleolus. Cannot stand on leg. Episcopal Hospital.

myelitis is so widespread as to render probable total necrosis later, or if the patient's condition is so septic that prompt convalescence is demanded (Fig. 441); but such removal often leaves a deformed (Fig. 442) or helpless limb (Fig. 443), which later may require an orthopedic operation (p. 504). In the case of the humerus and femur, where the disease is not very acute, it is sufficient to trephine the bone at the limits of inflammation, and pass a drainage tube from one opening to the other through the medulla. If guttering has been

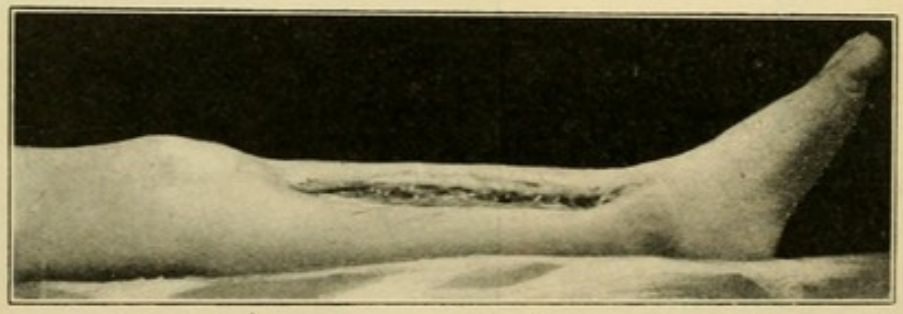

FIG. 444.—Granulating wound two months after guttering (*évidement*) of tibia for osteomyelitis. Children's Hospital.

done, the marrow cavity is firmly packed with iodoform gauze, the wound is left widely open, and is allowed to heal by granulation (Fig. 444). If the entire diaphysis has been removed, the same course may be pursued, or the periosteum may be sutured lightly together, obliterating the cavity, as advised by Nichols (1904).

If operation has been done early enough, necrosis of the shaft may not occur, and permanent healing will follow the primary intervention.

In most cases, however, portions of the cortex become necrotic, are exfoliated as sequestra, and may require subsequent operation for their removal.

Chronic Osteomyelitis.—This is rarer than the acute form of the disease and is due to a less virulent infection. The bone is infiltrated with purulent material, its lime-salts are more or less absorbed and the narrow cavity obliterated. *Treatment.*—Free drainage should be provided, and, if possible, all the diseased bone should be gouged away. Recurrences are frequent unless radical operation is done. Eventually hypertrophy, sclerosis, and eburnation occur.

Necrosis.—Necrosis is the term applied to the chronic stage which succeeds acute or subacute osteomyelitis. It implies the presence of a *sequestrum*, more or less detached; of an *involucrum*, more or less developed; and of *cloacæ*, usually communicating with the surface of the limb by sinuses through which bare bone may be felt. **Caries** is that condition of bone comparable to an ulcer of the soft parts, there being no actual sequestrum (slough), but only death of bone in molecular masses. It occurs chiefly in tuberculous bone disease (p. 439). A sequestrum may be due to necrosis of the superficial cortical layers (Fig. 445), or there may be a total or "tubular" sequestrum (Fig. 446) The superiosteal bone is soft and plastic when newly formed, and possesses great powers of regeneration; if, however, a sequestrum remains beneath it long enough, the involucrum

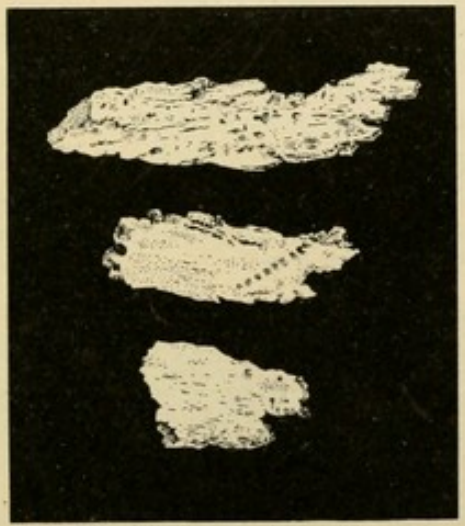

FIG. 445.—Cortical sequestra following osteomyelitis of femur. Episcopal Hospital.

FIG. 446.—Necrosis of humerus, showing tubular sequestrum, involucrum, and cloacæ. Osteoporosis above. Episcopal Hospital.

gradually loses its regenerative powers, and becomes dense and sclerosed; sometimes so dense that the finest steel makes no impression on it. Therefore, it is better, whenever possible, to remove

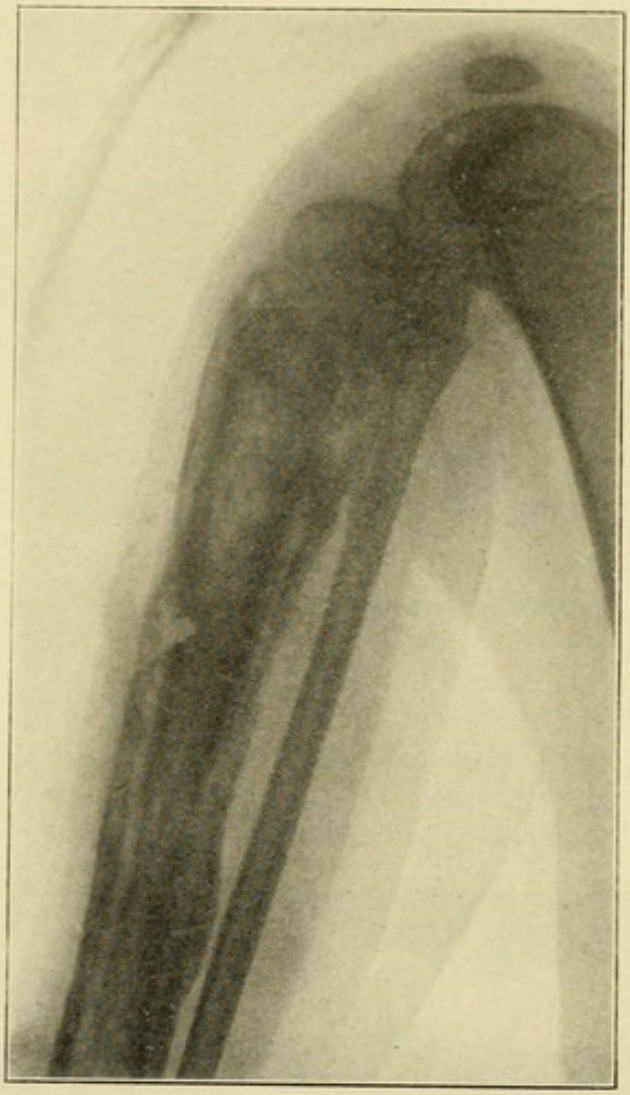

FIG. 447.—Skiagraph of necrosis of tibia, showing large sequestrum within involucrum. Episcopal Hospital.

FIG. 448.—Sequestrum of radius ulcerating out eleven months after compound comminuted fracture. Episcopal Hospital.

sequestra while the involucrum is still plastic, so that the cavity left will be filled up promptly by periosteal proliferation. This stage usually ceases about two or three months after the primary infection.

The plastic condition of the subperiosteal bone may be determined by sticking a needle through it, close to a sinus, when crackling will occur, and the needle will be arrested by the necrotic shaft underneath; or it may be possible to see the new-formed bone in a skiagraph (Fig. 447). If there is a parallel bone present, as in the forearm and leg, removal of the sequestra may be undertaken so soon as the patient convalesces from the first operation, and prompt regeneration even of an entire shaft may be anticipated; but when the femur or humerus is affected, it is better to delay secondary operation until a fairly strong involucrum has formed. This is about two or three months after the onset of the disease; the strength of the involucrum may be determined by skiagraphy, and its *total thickness* should approximate half that of the normal bone. In some cases sequestra will work themselves loose, and eventually may be discharged spontaneously (Figs. 448 and 449), but this may require many years, and in most cases ultimate cure is much accelerated by operation.

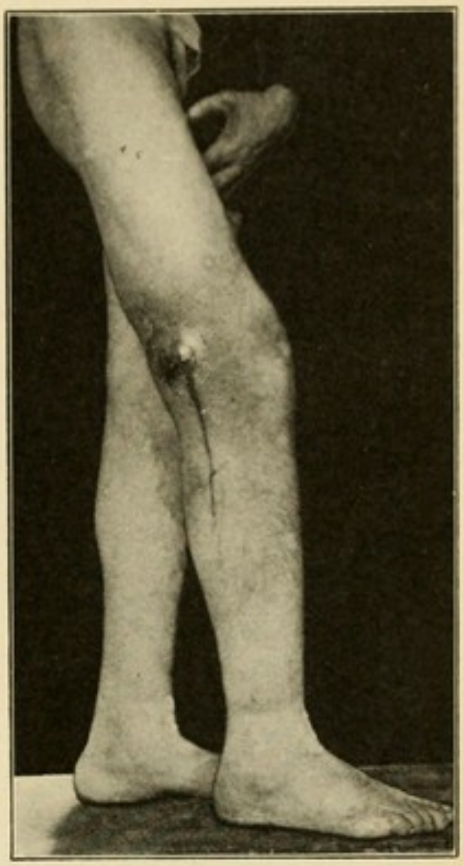

FIG. 449.—Chronic osteomyelitis of femur; age forty-three years, onset seven years ago. No symptoms for several years until a few weeks ago, when a sequestrum began to work loose; sequestrum extracted through sinus, which promptly healed. Episcopal Hospital.

Sequestrotomy, as the operation for the removal of sequestra is called, is done under Esmarch anemia: a rubber bandage is applied from the fingers or toes to above the upper limit of disease (Fig. 450), thus removing most of the blood from the limb; an Esmarch band is then applied just above the termination of the elastic bandage, which is then removed, leaving a bloodless field for operation. This is important because hemorrhage from the involucrum and medulla may be free, and unless the wound is dry it is difficult to distinguish dead from living bone. The limb is then incised, including as many sinuses as possible in the line of incision, or excising the scar of previous

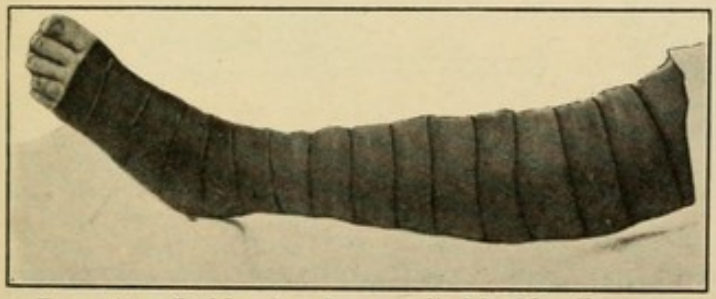

FIG. 450.—Rubber bandage applied for bloodless operation. The Esmarch band is then applied above the knee, and the rubber bandage is removed from the leg, exposing the seat of operation (sequestrotomy of tibia). Episcopal Hospital.

operation. If the subperiosteal bone is still plastic it is incised with a heavy knife and carefully reflected from the underlying necrotic shaft, which is then removed piecemeal or in mass. If a dense involucrum is present, it is searched for cloacæ, and the location of sequestra determined, enough of the overlying bone being removed to permit of their removal; they are more apt to be completely detached from surrounding

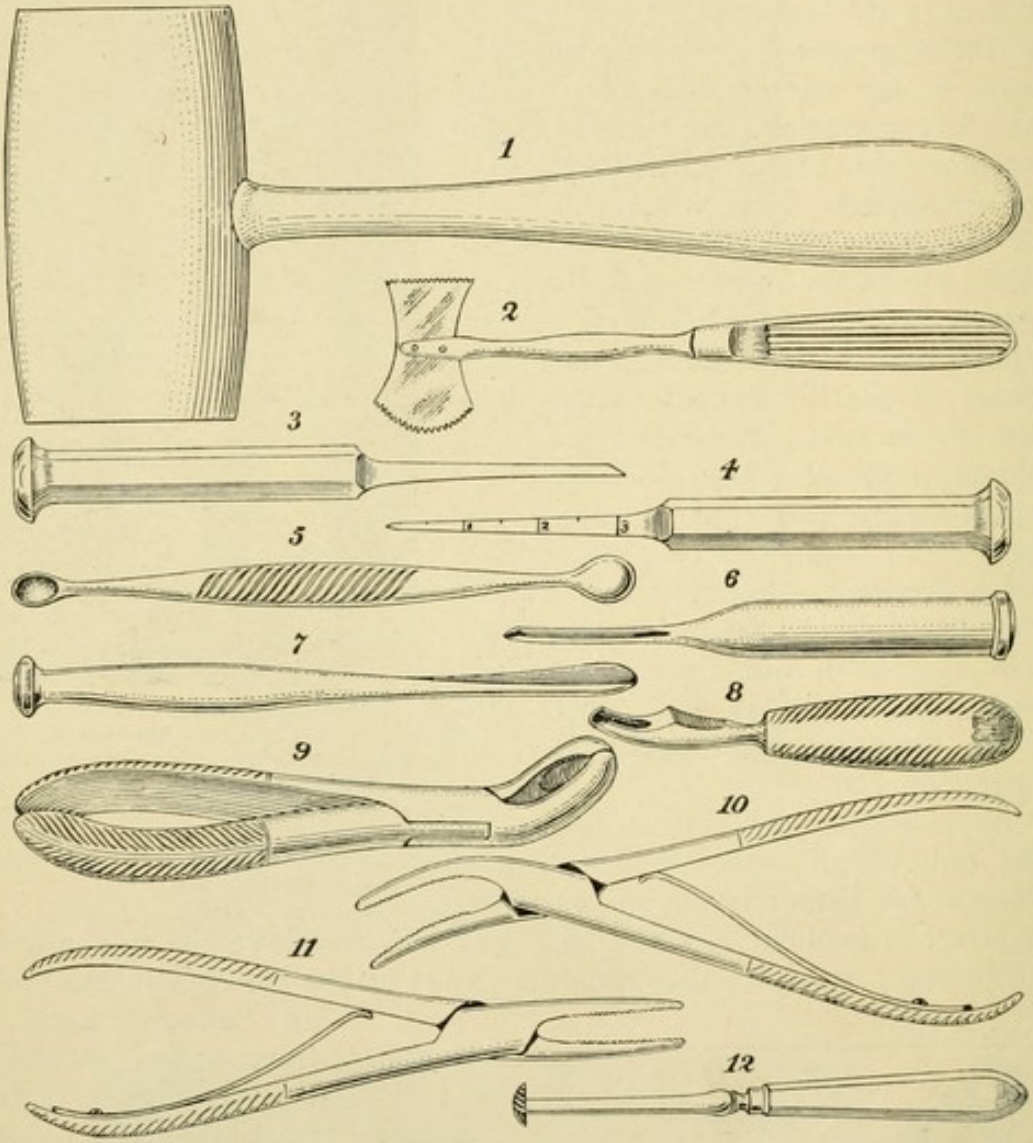

Fig. 451.—Instruments for operation on bones: 1, wooden mallet; 2, Hey's saw; 3, chisel; 4, osteotome; 5, Volkmann's sharp spoon or bone curette; 6, Jones's gouge; 7, gouge bevelled on its convexity; 8, thumb gouge; 9, gouge forceps; 10, 11, sequestrum forceps; 12, burr.

healthy bone than at an earlier stage. When the sequestrum is not completely detached, suspected bone should be removed by gouge and mallet until healthy bone is reached. This is known by the fact that minute blood spots on the bone (Haversian canals) cannot be washed away in living bone, whereas rinsing a chip of dead bone in water will remove all blood from its surface.

If the operation is done before sclerosis of the involucrum the cavity,

if small, may be allowed to fill with blood-clot, and this probably will be converted into bony tissue by sub-periosteal proliferation (Fig. 452). When, however, the involucrum is dense, any cavity left will remain a cavity, unless filled with some substance to stimulate ossification. Probably the best substance for such purposes is the

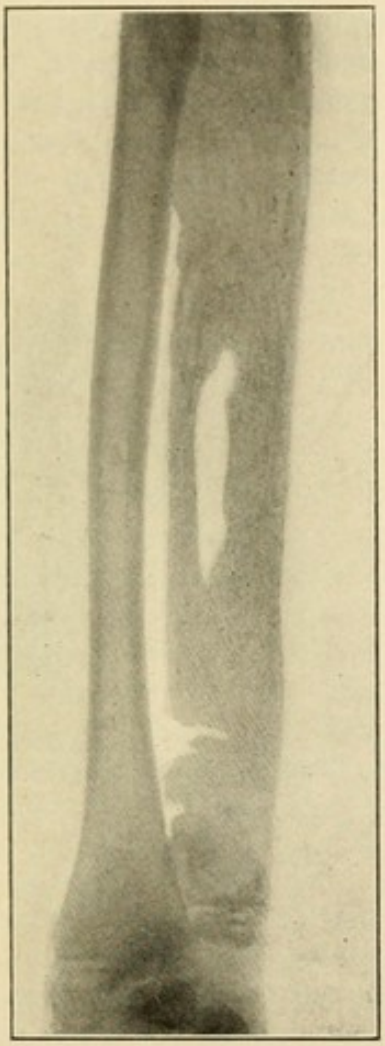

FIG. 452.—Skiagraph showing involucrum of ulna, after removal of sequestra. Note numerous cloacæ. Age fourteen years. Episcopal Hospital.

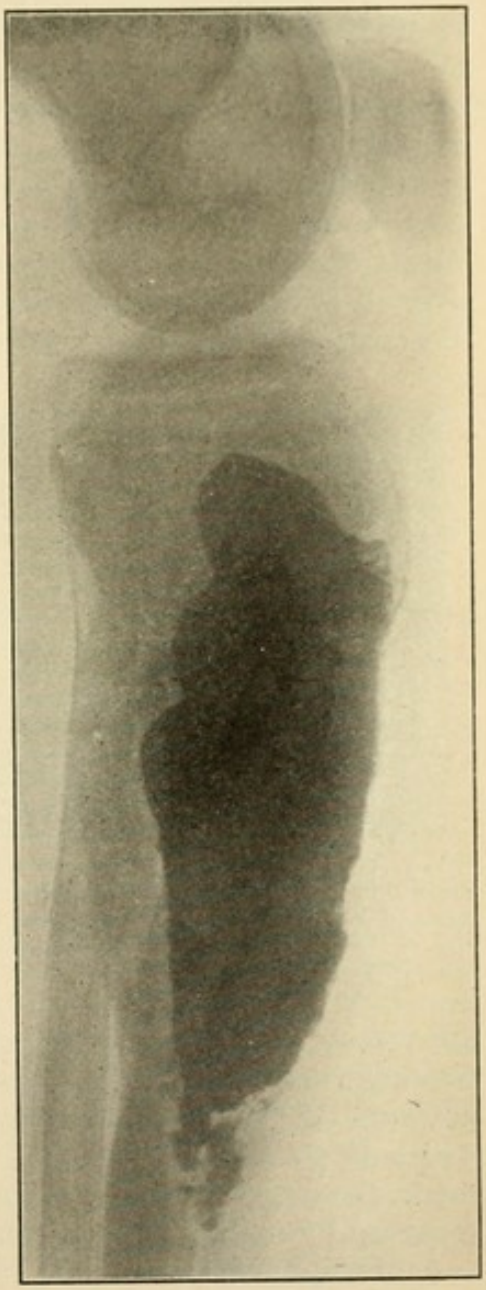

FIG. 453.—Iodoform bone-wax in cavity of tibia (*plombage*). Episcopal Hospital.

iodoform bone wax of Mosetig-Moorhof (1903): iodoform, 60 parts; spermaceti and oil of sesame, each 40 parts. This is heated to 100° C. while being mixed, and again heated to 50° C. before being poured into the bone cavity. Such an operation is termed *plombage* (Fig. 453). I have used as much as three ounces of this wax at one time

(in a girl of seventeen years), but others have reported symptoms of iodoform poisoning from less quantities. The best results follow when the cavity is dried and sterilized by a hot air blast before pouring in the wax; or by the actual cautery, taking care only to sear and not to char the bone. If this cannot be done, the cavity may be swabbed out with strong antiseptics and dried with sterile gauze. In these chronic cases there is only an attenuated infection. The soft tissues are sutured tight over the wax as it cools, no drainage being employed; and though some of the wax may be discharged eventually through a sinus, convalescence is much less tedious than if no bone filling had been employed. Beck's bismuth paste (p. 484) may be employed in small quantities instead of iodoform bone wax, but is less suitable. In cases where the cavity left is exceedingly large, it is better to resort to the old operation of *évidement*, in which the entire anterior and most of the lateral walls of the involucrum

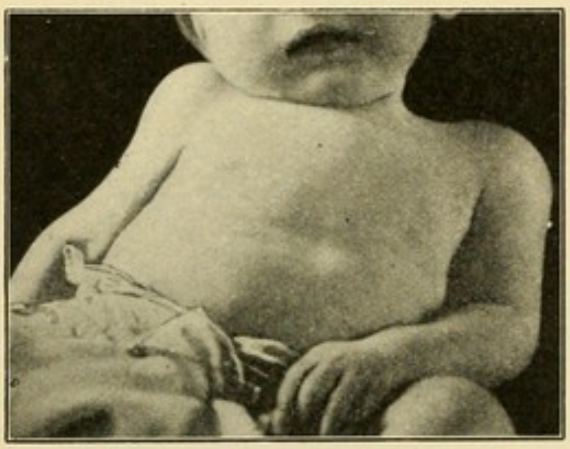

FIG. 454.—Acute epiphysitis of left humerus, upper end; age eight months. Admitted with diagnosis of scurvy. Temperature rose to 105° F., and at operation epiphysis was found separated. Recovery. Children's Hospital.

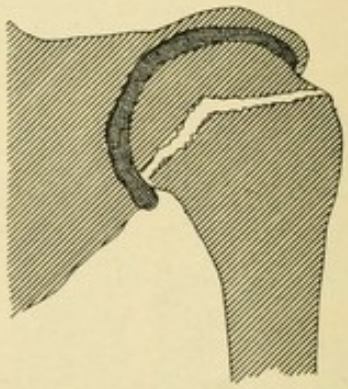

FIG. 455.—Diagram showing the relation of the upper epiphysis of the humerus to the shoulder-joint.

are removed by gouge and mallet, so that only a superficial trough remains representing the posterior wall of the involucrum, thus allowing the soft parts to grow down and across the cavity (Fig. 444), which is packed with gauze. Though healing may take a year or more, the cure eventually is complete. Neuber (1896) tried to hasten recovery by nailing flaps of soft tissues in the gutter left by *évidement*.

Acute Epiphysitis.—While in children osteomyelitis is apt to begin and to manifest its greatest intensity in the metaphysis, in infants it occurs almost exclusively in the epiphysis (Fig. 454), and owing to certain special features requires separate mention. The condition frequently is overlooked, from neglect of physical examination; and the closeness of a lesion to a joint (the shoulder and hip are especially liable to the disease) may render it likely to be confused with acute rheumatic arthritis or joint-injury; indeed, as the epiphysis becomes detached from the shaft quite early in the disease, the resemblance to fracture is considerable. Infection of the joint is frequent, owing to

the position of the epiphyseal line which even at the shoulder is partly intra-articular (Fig. 455), thus affording scarcely any chance for extra-articular drainage.

Treatment.—Treatment consists in early incision, exposing the septic focus with curette, and draining the cavity with gauze. If pyarthrosis develops, the joint also should be drained. Deformity from interference with growth, flail-joint, or pathological luxation (especially at the hip) may follow. Ankylosis is rare.

Bone Abscess.—As a result of osteomyelitis a residual abscess (p. 805) may form in bone, most frequently in the tibia (*Brodie's abscess*, 1824). Very rarely such an abscess may be the primary lesion, no diffuse osteomyelitis having preceded it; such cases usually are tuberculous. A bone abscess is confined by a dense wall of sclerosed bone, and may remain latent for many years, causing intermittent attacks of pain and limping, and being finally roused to acute stage by trauma or constitutional affection.

Diagnosis.—The diagnosis depends on the history, persistent localized bone tenderness, and *x*-ray examination.

Treatment.—The dense wall should be cut away, the pus evacuated, the cavity sterilized, and treated as other bone cavities (p. 435). If the abscess is small, and if its outlines can be well defined by *x*-ray examination, it may be possible to excise it in one mass, by cutting through healthy bone on all sides.

Fibrous Osteitis.—By this term is understood a condition regarded by all more recent investigators as an inflammatory disease of bone "in which the medullary tissue is replaced by a new formation of connective tissue with or without cyst formation." (Bloodgood, 1910.) Its relations to bone cysts and myeloma (p. 445) are not well defined. It occurs in children, affects oftenest the humerus, femur, and tibia, and begins insidiously; in very many cases spontaneous fracture or the deformity resulting from such an unrecognized fracture is what first calls attention to the condition. There may be pain and increase in the size of the bone, but the disease usually is easily distinguished from malignant neoplasms of bone by the long duration of symptoms. Unless the patient is seen for fracture, the swelling and pain, neither very marked, usually exists for a year or more before the surgeon is consulted. Diagnosis is much aided by the *x*-ray, which will exclude sarcomatous change, and may show cyst formation.

Treatment.—The treatment consists in removal of all diseased tissue by gouge or curette, the cavity being treated as one following sequestrotomy.

Tuberculosis of Bone.—Tuberculosis rarely affects the diaphyses of long bones, its lesions being confined almost exclusively to the region of the epiphyseal cartilages; but in short bones (hands, feet, vertebræ), diffuse medullary involvement is common. There are good anatomical reasons for this. As noted in Chapter III, tubercle bacilli usually find lodgement in the lymph nodes, and only when

these caseate and rupture do the bacilli escape into the blood-stream. Infection of bone, therefore, occurs through the blood, the lesion being an infarct or embolus which has successfully passed through the pulmonary capillaries. There are three sets of arteries supplying long bones—one, the main nutrient artery, enters the diaphysis, and branches in both directions; a second enters the metaphysis, while the epiphyseal arteries form the third group; now all these arteries send their terminal branches to the region of the epiphyseal cartilage (which is bloodless), and they do not inosculate with each other. It is in this region, therefore, that bacterial emboli lodge, no matter by which of the three arterial systems they enter the bone. In short bones, however, the main nutrient artery breaks up into small branches almost as soon as it enters the cortex, and tuberculous emboli are arrested in the medulla. It is denied by some that trauma, in creating a *locus minoris resistentiæ*, has any influence in determining the localization of tuberculous foci in bone; but clinically it is a well established fact that any site of lessened resistance is prone to invasion by tuberculosis, whether the primary change is traumatic or infectious. According to Ely (1911) the reason that tuberculosis develops in the neighborhood of the epiphyses, and not in other regions (as the brain) which are supplied by end-arteries, is because in the epiphyses the soil is suitable for the growth of tubercle bacilli, while elsewhere it is not (see p. 476). If the tuberculous process begins on the shaft side of the epiphyseal cartilage of a long bone (*i. e.*, in the metaphysis), the resulting lesion resembles a very subacute type of septic osteomyelitis; this condition appears to be more common in Great Britain and on the continent of Europe than in this country. Its existence was recognized by Volkmann in 1879, and Stiles has recently (1912) called renewed attention to it. If, however, the tuberculous embolus lodges on the joint side of the epiphyseal cartilage the joint is quickly invaded; and this often occurs even when the metaphysis is first involved, especially in joints where the epiphyseal cartilage is largely inside the joint capsule.

The affected area undergoes caseation, the bony framework melting away in the centre, while proliferation may take place under the periosteum. In favorable cases the disease may become latent, by encapsulation of the tuberculous focus; or softening may extend, the cold abscess may rupture into a neighboring joint (very frequent in case of long bones), may work its way to the skin surface through a sinuous tract, or may cause gradual expansion of the cortex, without rupture (especially in the phalanges). Secondary pyogenic infection may occur, especially after sinus formation, and an osteomyelitis originally purely pyogenic may become secondarily infected by tuberculosis. For such cases more or less formal operation (sequestrotomy, plombage, évidement), may be required. Joint infection is so very frequent in the case of long bones (especially the femur, tibia, and humerus) that it is best to study epiphyseal tuberculosis in connection with tuberculosis of joints (p. 476). This is also the

case in the bones of the carpus and tarsus. Vertebral tuberculosis is considered in Chapter XVIII.

In the metacarpal bones and phalanges a diffuse tuberculous osteomyelitis follows the arrest of tuberculous emboli, and the lesions are the same in kind as, though running a much less acute course than in pyogenic osteomyelitis. *Tuberculous dactylitis*, as this form is called, occurs almost exclusively in infants and young children (Figs. 37 and 456); it may affect several digits, and may be accompanied by tuberculous bone disease elsewhere. Caries of facial bones in infants usually is tuberculous. Local rest and cleanliness, and general hygienic measures usually cure the disease, though the finger may be deformed from extrusion of sequestra, ankylosis, etc.

FIG. 456.—Tuberculous dactylitis, early stage; age three years; duration seven months. Episcopal Hospital.

Caries of the skull from tuberculosis is not very rare in adults (Fig. 457). The diagnosis depends on the discovery of tuberculosis

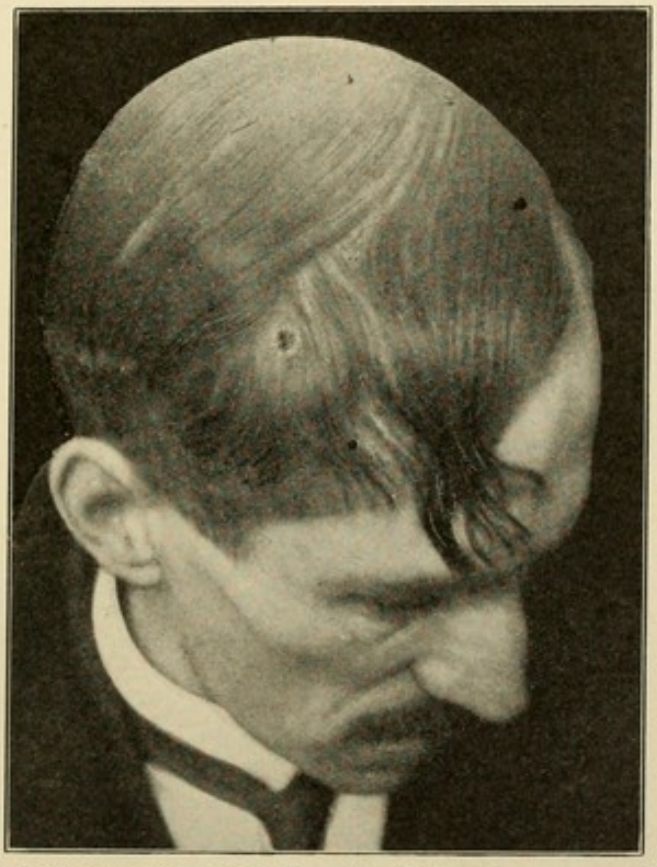

FIG. 457.—Tuberculous caries of skull. Age thirty-nine years. Phthisis for eight or nine years. Present trouble began by swelling like wen, nine months ago. Six months ago this ruptured and has been moist or scabbed even since. Depression in bone palpable. Has another area still in *wen* stage, fluctuating and red. Episcopal Hospital.

elsewhere in the body (notably the lung), on the exclusion of syphilis, and on the chronic and indolent course of the affection.

Syphilis of Bone.—Osseous manifestations of syphilis occur late in the disease, with the exception of fugacious attacks of periosteitis

Fig. 458.—Syphilitic dactylitis. Age twenty-eight years; duration five months. Five years after chancre. Pathological fracture of phalanx. (See Fig. 459.) Episcopal Hospital.

Fig. 459.—Skiagraph of finger shown in Fig 458. (Syphilitic dactylitis.) Note pathological fracture of phalanx. Episcopal Hospital.

in the secondary stage. The lesions resemble those occurring in the other infectious granulomas, involving softening and caries, or proliferation and eburnation. Both processes frequently occur at once in different parts of the same bone.

In *hereditary syphilis* the earliest bone-lesions are those in the cranium and phalanges, occurring mostly in young infants. In the cranium softening, caries, and suppuration are frequent, with circumferential periosteal over-growth, forming the so-called Parrot's nodes (1879); or mere thinning of the skull from malnutrition and pressure may occur, affecting especially the occipital bone. Caries of the bony nasal septum and palate bones also is seen. *Syphilitic dactylitis* is difficult to distinguish from tuberculous dactylitis, but usually may be recognized by the family history, existence of specific lesions elsewhere, and results of anti-syphilitic remedies; it occurs in acquired as well as in congenital syphilis (Figs. 458 and 459). In tuberculous dactylitis microscopical examination or inoculation may reveal the nature of the process. Constitutional anti-syphilitic treatment of the mother, if the infant is nursing, always should be employed in connection with local treatment.

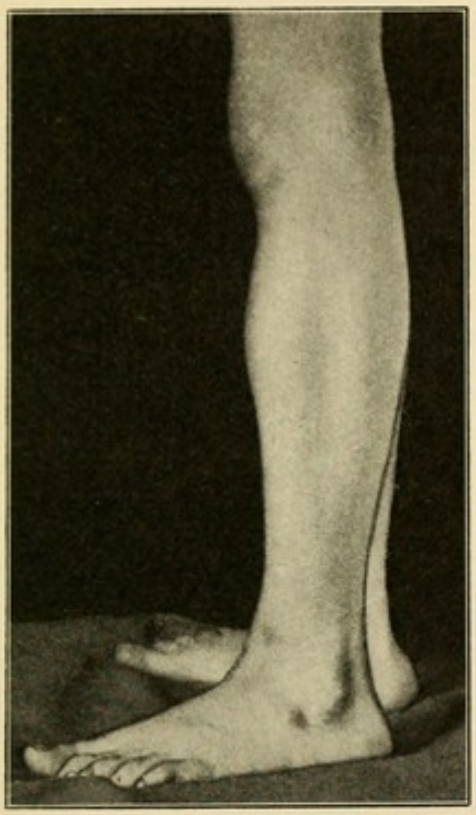

FIG. 460.—Syphilitic periosteitis of left tibia, early stage; duration three months. Hereditary syphilis, patient also having Hutchinson teeth and interstitial keratitis and marked genu valgum. Age thirteen years. (See also Figs. 461, 462, and 463.) Orthopædic Hospital.

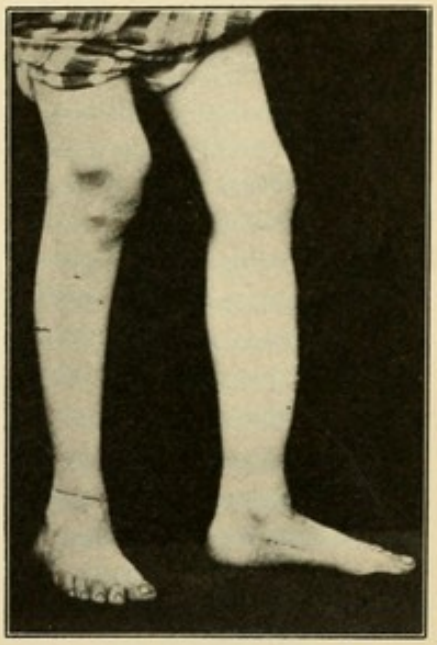

FIG. 461.—Same patient as Fig. 460: Sabre-blade tibia (left), from photograph two years after Fig. 460. Note also syphilitic arthritis of right knee. Orthopædic Hospital.

From one to six years of age there are few manifestations of hereditary syphilis, but after this period disease of the long bones is frequent, especially of the tibiæ, one or both of which develop a periosteitis, at first more or less well defined (Fig. 460), but later

diffuse and producing characteristic "sabre-blade deformity" (Fig. 461). The bone may be softened early in the affection, but later thickening and elongation occur, and the bone is markedly sclerosed (Figs. 462 and 463). If the pain does not yield to anti-syphilitic remedies, the bone may be drilled in various places, thus relieving tension; while during the stage of osteoporosis much comfort may be derived from support by braces. The deformity is incurable.

FIG. 462

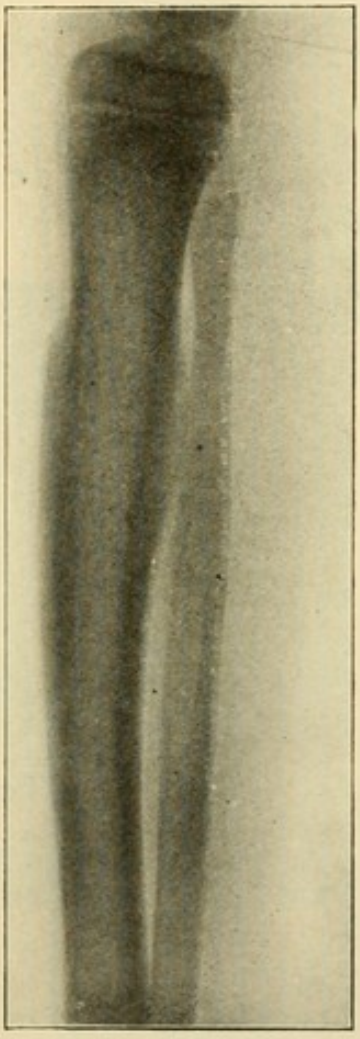

FIG. 463

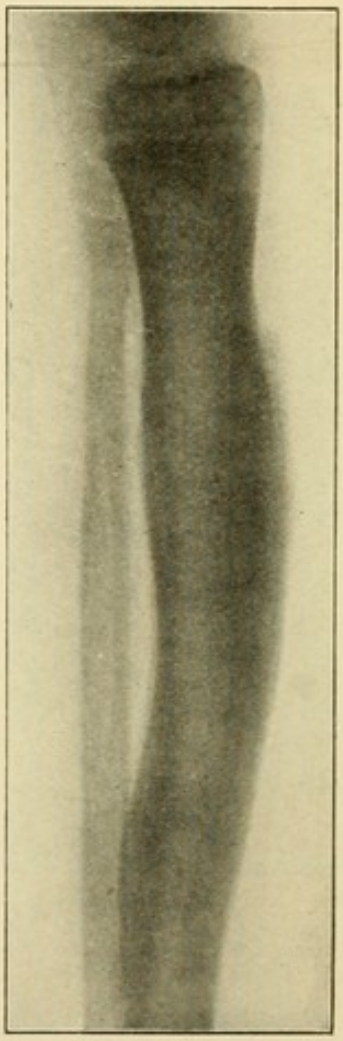

FIGS. 462 and 463.—Skiagraphs of syphilitic periosteitis of tibiæ, showing "sabre-blade" deformity with hypertrophy and sclerosis of the bones. Age nine years. Episcopal Hospital.

Osteomyelitis rarely is due to syphilis, but in children gummatous epiphyseal lesions may occur, and cause marked local over-growth (Post, quoted by Nichols, 1907); or by softening and invasion of the joint may produce tuberculous-like arthritis (p. 503).

In *acquired syphilis* the chief bony manifestation of the disease is the periosteal gumma, which may begin with pseudo-inflammatory symptoms, and occasionally breaks externally; under proper anti-syphilitic treatment, however, it is apt to be absorbed, leaving a depressed area on the surface of the bone (calvaria, nasal bones, palate, sternum, tibia) due to dry caries and lacunar resorption,

with a thickened margin due to periosteal proliferation. If the process is arrested before softening of the gumma occurs, periosteal nodes or exostoses may remain instead of depression due to caries. Rarely a distinct sequestrum forms; this is characteristically worm-eaten in appearance and may require many years for exfoliation. In all cases where sinus formation occurs, secondary pyogenic infection is frequent, and sequestrotomy, etc., may be necessary; in other cases constitutional treatment alone often is sufficient to relieve symptoms and arrest the progress of the disease. Painful exostoses may be removed, or eburnated bone (Fig. 464) drilled.

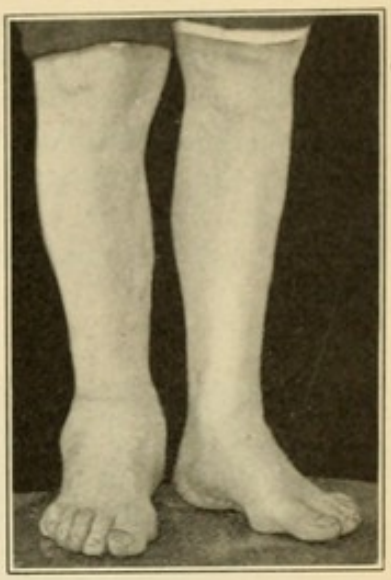

FIG. 464.—Syphilitic osteitis causing eburnation of the tarsal bones. Patient had a chancre eighteen years ago, and has pulmonary emphysema which may possibly be an etiological factor in the bone disease.

TUMORS OF BONE.

Here may be recognized diseases which comprise what Adami calls blastomatoid conditions (p. 107), as well as true neoplasms of bone. In the former category belong, perhaps, certain of the diseases described as dystrophies of bone, as well as many forms of exostosis, hyperostosis, etc.

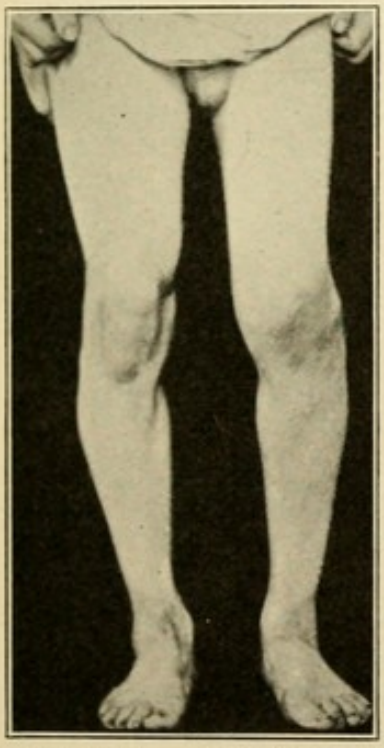

FIG. 465. — Cartilaginous exostosis of outer tuberosity of left tibia growing into popliteal space. Begun at age of sixteen years, and was removed three years later. Recurrence noted first five weeks ago.

Among the *exostoses* (p. 112) several clinical types are recognizable, and deserve short mention here. They are divided into the cartilaginous and fibrous forms. *Cartilaginous exostoses* are single or multiple out-growths arising from epiphyseal cartilages or in the neighborhood of epiphyseal lines; they are most frequent at the upper end of the tibia (Fig. 465) or lower end of the femur (Fig. 466), and may cause trouble by pressure on structures in the popliteal space. Excision is the proper treatment, removing also the portion of bone from which they grow, as recurrence is frequent. One typical affection, usually described by the term *Multiple Cartilaginous Exostoses* (Fig. 467), is thought by some to be a distinct disease; but it seems probable that it may follow any form of chronic inflammation, infectious or toxic, whose lesions are located in the bones, and it is certain that it may be associated with, if not caused by, rachitis or syphilis, may affect several

in the same family, and extend through several generations (Lippert, 1903). It appears usually about the age of puberty, though I have seen one case in an infant; and it may exist for some years before the patient's attention is attracted by the out-growths. These affect especially the long bones of the extremities, occur mostly at or near epiphyseal lines (p. 110), and seldom cause symptoms except rom pressure. If this exists the offending exostoses may be removed.

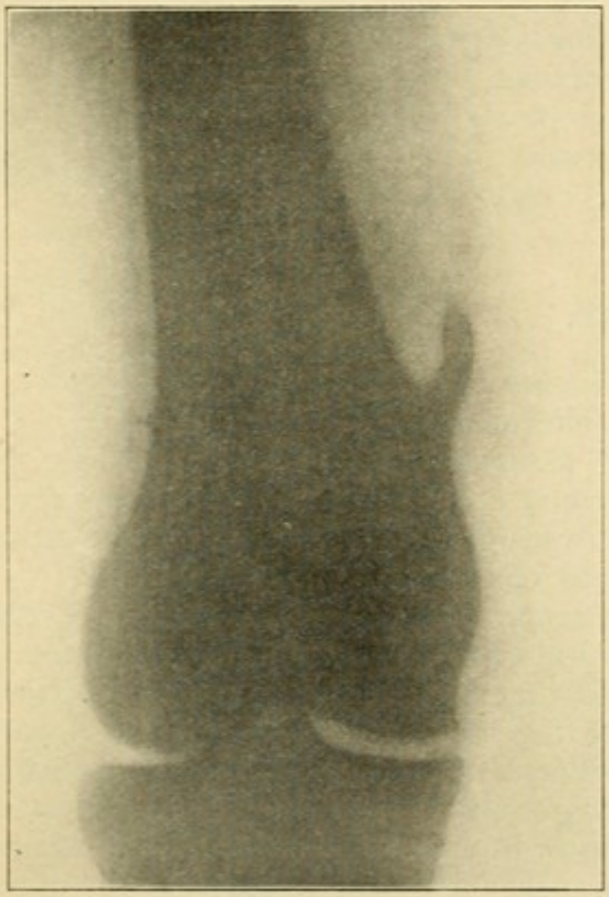

FIG. 466.—Skiagraph of exostosis of femur springing from region of epiphysis and growing toward diaphysis. Girl, aged sixteen years. Duration two years. Began three months after injury from runner of sled. Orthopædic Hospital.

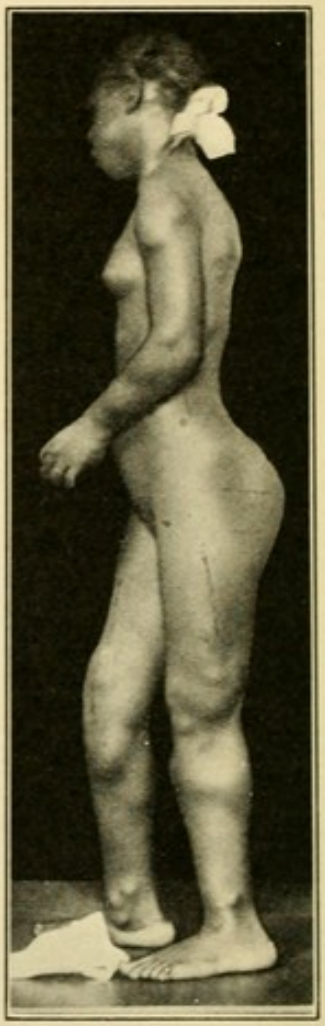

FIG. 467.—Multiple cartilaginous exostoses, in a negro girl, aged thirteen years. Children's Hospital.

Patients sometimes claim that a certain exostosis has appeared more or less suddenly, or that another has decreased in size. Disturbances of growth, distortions, subluxations, etc., are frequent in the long bones (Bessel-Hagen, 1891). *Fibrous exostoses* arise either from periosteum or its attached fascia or tendons. Several clinical types are well known, including the *ivory-like exostosis of the skull* (mentioned at p. 112); *subungual exostosis*, found almost solely on the great toe; *exostoses of the facial bones*, especially the nasal process of the maxilla (leontiasis ossea may commence thus), and the mandible;

and exostoses in connection with *tendinous insertions* (see myositis ossificans traumatica, p. 274), where a bursa may develop (*exostosis bursata*) in which cartilaginous bodies may float.

Fibromas, arising from periosteum, are rare; they form one variety of polypi in the nasopharynx, and on the jaw constitute the "fibrous epulis."

Chondromas and *Osteomas* have been sufficiently described in Chapter IV.

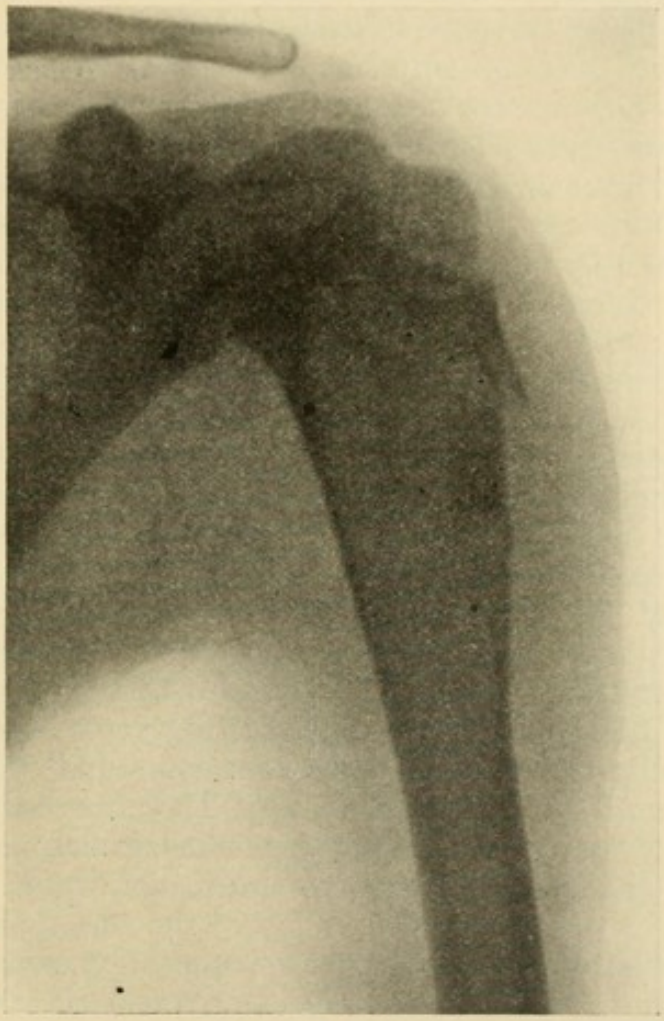

FIG. 468.—Bone cyst of humerus, duration fifteen months; recent fracture from slight injury. Cured by evacuation and scraping; and crushing in the thin wall of the cyst to obliterate the cavity. Episcopal Hospital.

Bone Cysts.—These have been carefully studied by Bloodgood (1910), who collected 89 cases; 69 of these had some relation to osteitis fibrosa (p. 437). The cyst usually is single, and contains thin, dark brown fluid, never distinctly hemorrhagic, and never under great tension; there usually is a distinct fibrous lining inside the bony shell, and even when this is absent, evidences of fibrous osteitis can be found microscopically. Unless the cysts are huge and of very long duration, or there has been a pathological fracture (Fig. 468) there is no alteration in the overlying periosteum. Small islets of cartilage may

exist in the cyst wall, and a few giant cells may be present; but neither occurs in sufficient amount to render likely confusion with degenerated chondromas or with myelomas. The *symptoms* for which these patients seek relief, as well as the proper treatment, have been given in connection with fibrous osteitis (p. 437). The *diagnosis* from other forms of cyst (degenerated chondromas, echinococcus disease, etc.), which are rare, is not very important clinically, as the same treatment is required. In *bone abscess* there usually is a history of previous osteomyelitis, and the *x*-ray shows the abscess surrounded by sclerosed bone. From *myeloma*, except in cases of very short duration, distinction usually may be made by *x*-ray; myeloma expands the bone rather abruptly, may cause periosteal proliferation, does not extend far up or down the medullary cavity, sometimes shows trabeculæ, and has no fibrous lining beneath the cortex; the benign bone cyst causes little expansion of bone, extends for some distance up and down the medulla, and usually a faint, fibrous lining can be detected. Myeloma occurs in young adults past twenty years of age; and spontaneous fracture is rare. Bone cysts occur mostly in children, and spontaneous fracture is frequent. *Sub-periosteal hematoma* may resemble a bone cyst if encapsulated by new-formed sub-periosteal bone. The cortex may be slightly eroded, but the medulla never is involved. Such cysts are not uncommon in the cranial bones of infants, from obstetrical injury, but may arise elsewhere from contusion of bone.

Giant-celled Myeloma.—This tumor is described at p. 113; its differential diagnosis from benign cyst has just been discussed.

Bone Aneurysms, so-called, usually are of the type of *false osteoid aneurysm* mentioned at p. 113. Usually they are medullary sarcomas of highly malignant type (spindle- or even round-celled), but they may arise from a giant-celled myeloma. They are distinguished from benign bone cysts by the frankly hemorrhagic nature of their contents, which are under pressure; by much more rapid growth, early perforation of the cortex and invasion of the soft tissues; and when this stage has been reached, by expansile pulsation, sometimes accompanied by bruit. Giant-celled myeloma rarely presents any cystic centre, and if one exists it is relatively small, and surrounded by typical myelomatous tissue; whereas in the pulsating sarcomas of bone, the blood-cyst comprises the main tumor, and the sarcoma cells exist in a thinned-out layer around the periphery.

Treatment.—The treatment is prompt disarticulation above the affected bone. Local recurrence or internal metastases usually occur in a few months, and death follows within a year.

Sarcoma.—Bone is one of the most frequent sites of sarcoma, and sarcoma is the most frequent tumor of bone. It is oftenest found in the femur, tibia, and pelvis. The tumor may grow from any connective tissue cells in the bone, but not from myeloplaxes nor blood-forming cells (p. 113). Bone sarcomas are classified clinically as *periosteal* and *medullary*, and either form may be composed of round

cells or spindle cells; round-celled sarcomas of bone most frequently are derived from medullary tissues, where round cells (lymphocytes, etc.) are found normally; while periosteal growths are most frequently spindle-celled in type (see p. 116).

Not every sarcoma growing in bone tends to form osseous tissue; many of them remain unossified throughout, and some do not have even calcareous deposits: (1) If the sarcoma arises from connective tissue cells in bone (not osteoblastic in type) it is properly called an *osteo-sarcoma* (*a sarcoma growing in bone*); (2) such as are derived from bone-forming cells (osteoblasts) alone deserve the name *ossifying* or *osteoid sarcoma* (*malignant osteoma*); whereas if a preëxisting benign tumor of bone (osteoma, chondroma, myeloma?) becomes sarcomatous by anaplasia, it is termed an *osteoma* (*chondroma*, etc.) *sarcomatodes*. In the first and last varieties no true bone is formed by the tumor cells, such bone as is present being either the original bone invaded by the tumor cells, or, according to Borst (1902), may be newly formed bone due to stimulation of osteogenetic cells by the adjacent tumor cells (such a stimulation is denied by Adami). The histological differentiation of these types is difficult, and a clinical distinction usually is impossible; but as the *prognosis* depends more upon the type of cell from which the tumor is derived than on the form of the cell, it is important to be informed that a pathological distinction exists between these forms of bone sarcoma. The most malignant growths are composed of the most highly undifferentiated cells. Thus the more bone in a sarcoma, the less malignant it is.

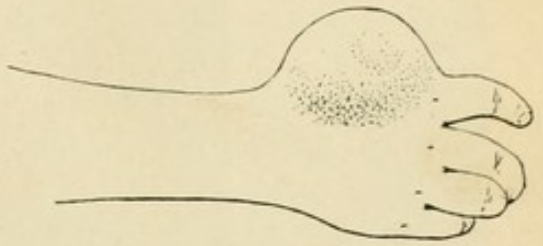

FIG. 469.—Periosteal ossifying sarcoma of index metacarpal. Age forty-eight years; duration six weeks. Amputation of forearm. Death thirty months later, after three months' illness from pulmonary metastases. Episcopal Hospital.

Symptoms.—The symptoms of sarcoma in general are given at p. 117. *Medullary* or *central sarcoma* usually grows in the metaphyses of the long bones, and for a time is prevented by the epiphyseal cartilage from invading the joint. The patient generally applies for pain before much deformity is present. Slight uniform expansion of the bone end may be found, but the joint is not implicated; in early stages joint motions are painless, and the tumor pains most at night, not during exercise. These points serve to distinguish it from arthritis. Pathological fracture is common, and may be the first symptom. It is a question whether fracture ever precedes and predisposes to sarcoma formation. A skiagraph shows total destruction of the bone end, but a normal joint; yet even the epiphysis disappears as the disease advances. *Periosteal sarcoma*, usually osteoid in character, generally affects the diaphyses of long bones, early causing a visible swelling, fusiform in outline,

but situated mostly on one side of the bone, not encircling it. It is firm but not bony to the touch, thus being easily distinguished from the medullary tumors which are bony hard until they thin the cortex (stage of *spina ventosa*) or break through it. In a skiagraph the periosteal tumor is seen to be caused by periosteal proliferation, this membrane being raised from the shaft rather abruptly, and showing newly formed bone in the wedge-shaped chink between itself and the cortex. The cortex is more or less eroded in the centre of the tumor area, and in advanced cases the medulla is invaded. Radiating spicules of newly formed osteoid tissue placed at right angles to the shaft are present between the cortex and raised periosteum, in the centre of the tumor.

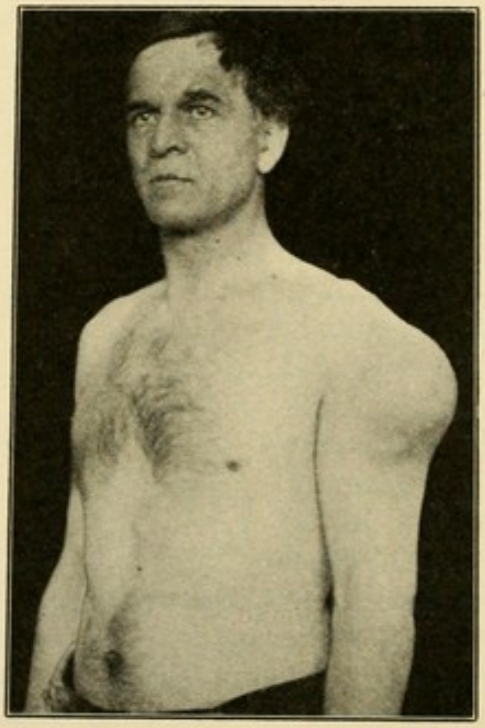

FIG. 470.—Periosteal chondroma sarcomatodes. Age fifty years. Tumor for twenty-five years, sudden growth for three months, following injury. (See Fig. 471.) Refused any operation. Episcopal Hospital.

Diagnosis.—A rather rapidly growing (weeks and months) tumor in bone, in a young adult, sometimes following trauma, and attended by increasing pain, deformity, and disability, usually is a sarcoma. Local heat, enlarged veins, tense shiny skin, etc., are present in advanced cases. In case of doubt it is well to measure the limb's circumference accurately at intervals of a few weeks; steady and progressive increase in circumference denotes a malignant neoplasm. Any benign tumor of bone, even if in existence for many years, which, from trauma or no known cause, begins suddenly to grow rapidly, should be considered malignant (Figs. 470 and 471).

Treatment.—The usual advice is to do amputation as early as possible, the limb being removed at the nearest joint above the disease. But to one who considers the ultimate results, it is question-

able whether anything is gained by this but relief of pain. Internal metastases must often be present when the patient first comes to the surgeon, since they appear with such uniformity even after removal of the limb; and local recurrence is so apt to follow excisions or amputation in continuity, that there is no class of cases so dis-

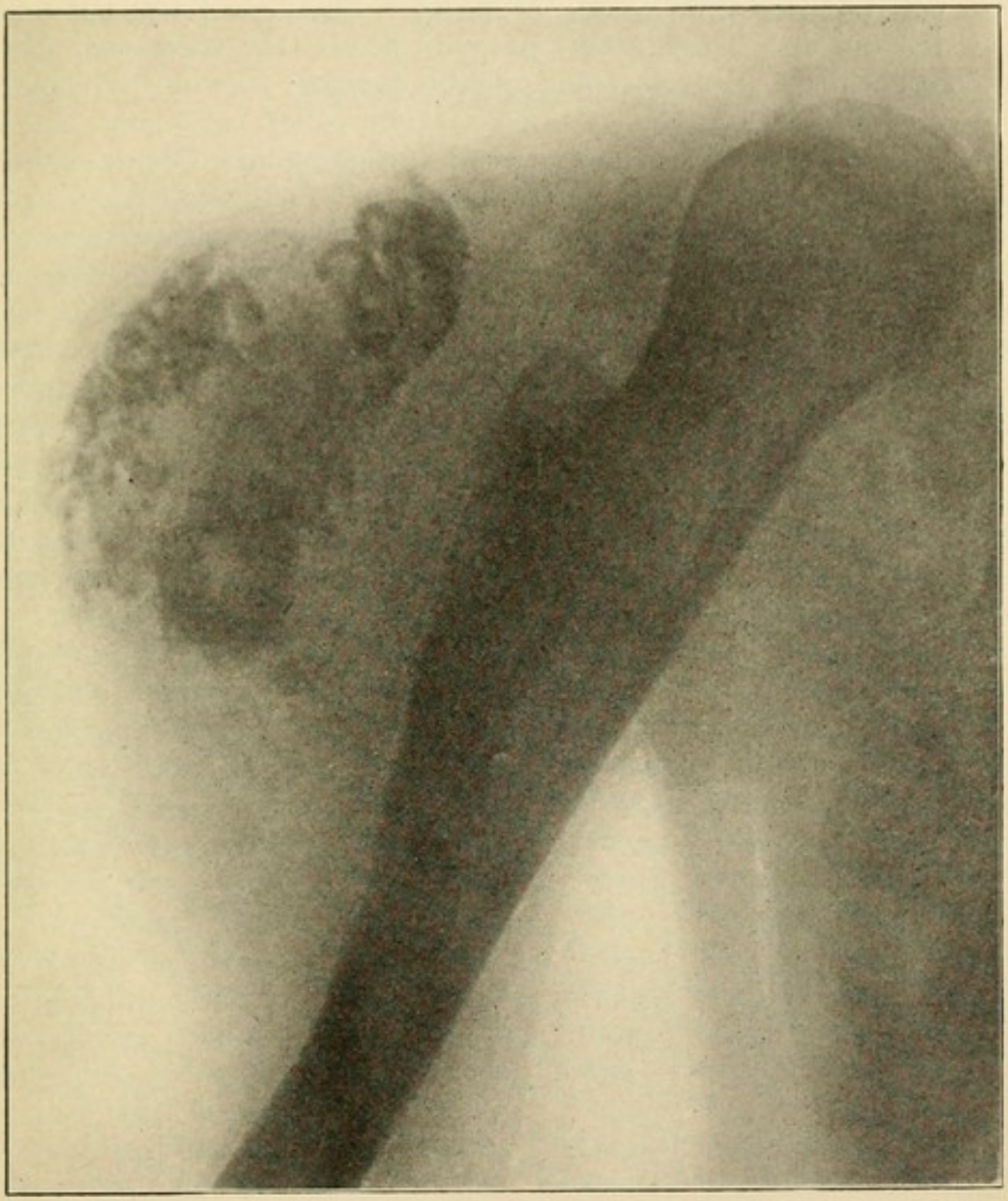

FIG. 471.—Skiagraph of periosteal chondroma sarcomatodes. Same case as Fig. 470. Tumor for twenty-five years, hard, adherent to bone. Three months ago the tumor was broken from humerus by a fall. Since then there has been rapid growth, and much pain. The tumor has grown fast again to the humerus. Episcopal Hospital.

heartening. Most patients die within two or three years from the first appearance of symptoms of the disease. The object of any operation is to remove all of the tumor, and this usually but not always implies disarticulation. This is always preferable to a long and bloody excision or to any operation which will leave a useless limb. If the patient regains some measure of health and comfort even for

a few months, before visceral metastases make their presence known, the operation cannot be said to have been done in vain. Coley's fluid (p. 117) should be employed as a routine, since at least it can do no harm, and may be of value; the following figures give Coley's own experience (1910) with its use in sarcoma of long bones: of 52 cases in which it was used, 10 (6 myeloid and 4 periosteal) patients were well for over three years; of 38 cases in which it was not used, 5 (3 myeloid and 2 periosteal) patients passed the three-year limit in good health. But as some of the myeloid sarcomas included probably should have been classed as giant-celled myelomas, not as sarcomas, the results are not as good as they seem. Opiates should be administered freely in the latter stages.

Carcinoma.—Carcinoma of bone occurs as a metastatic growth, being especially frequent in cases of prostatic and thyroid carcinoma, but is also seen in carcinoma of the mammary gland, uterus, etc. In the long bones the first symptom frequently is pathological fracture, and this occurrence always should lead to search for primary carcinoma, past or present. The fractures usually unite without difficulty. In the spine, secondary carcinoma usually is a direct extension from mammary or visceral carcinoma. Local treatment is useless. The intolerable pain of vertebral invasion should be relieved by opium given until effective; or the dorsal roots of the nerves may be divided intraspinally.

CHAPTER XV.

DISEASES OF JOINTS.

DYSTROPHIES OF JOINTS.

It was pointed out in the last chapter, in the section dealing with *Dystrophies of Bone*, that some of these conditions at times were associated with changes in the organs of internal secretion. Thus, Acromegaly is very constantly associated with changes in the hypophysis cerebri; Achondroplasia has been found associated with pathological alterations in the thyroid; Osteogenesis Imperfecta, with changes in the adrenals; Osteomalacia, with changes in the ovaries, while the administration of thymus or thyroid extract sometimes is of benefit in cases of Osteitis Deformans.

As in the case of bone diseases, so in those which affect the joints, there is a class of chronic affections not definitely inflammatory, though possibly due to remote or attenuated infection, to toxemias or intoxications, or to changes in the organs of internal secretion. Until more definite knowledge concerning them is gained, it is convenient to class them as *dystrophies*, since at least it is certain that their more immediate cause is to be sought in *disturbances of nutrition*. If it be asked why disorders due to disturbances of nutrition affect the bones and joints rather than the soft parts, it may be replied that the bones and joints have a less free and active circulation than the soft parts, and like the hair, nails, teeth, etc., give early evidence of circulatory disturbance; moreover, the soft parts themselves are affected, but less conspicuously than the bones and joints. Slight constantly recurring injuries, moreover, show their effects more on the joints than the soft parts, and sometimes have a very marked influence in localizing trophic lesions in one joint or set of joints rather than in others.

The pathological changes in these dystrophic joints are those of *atrophy* and *hypertrophy;* they may exist separately or together, but in almost every case one change or the other predominates so that the disease can be classed either as *atrophic* or *hypertrophic* in type. It is possible that the atrophic type is a more acute manifestation of the same disease which in subacute or chronic form corresponds to what is described as the hypertrophic type. The les ons may affect the synovial membrane only, or, as is much more frequently the case, the bones and cartilages as well; and in most cases it is these structures which are first involved, the synovial membrane being implicated secondarily. One joint or many may be affected, the disease being classed as *monarticular* or *polyarticular*.

The nomenclature of these diseases is much confused: two terms, Rheumatoid Arthritis and Arthritis Deformans have been employed indiscriminately by many writers, and have been applied to various different diseases; so that if a surgeon today refers to a disease by either of these terms, no one knows to what disease he refers unless he further defines his meaning. Speaking generally, however, the term *rheumatoid arthritis* usually has been applied by English-speaking physicians to chronic joint diseases in which synovial lesions were believed to predominate; and *osteo-arthritis*, or *arthritis deformans*, a term introduced by the Germans, to those forms in which bony changes are preëminent. The relation of these joint dystrophies to affections of the organs of internal secretion is by no means so evident as in some of the bone dystrophies, to which reference was made above. But the favorable influence exerted by a long course of treatment of thymus gland extract upon atrophic joint lesions is well recognized, and the development of hypertrophic joint lesions, in women, at a time when ovarian and thyroid changes are frequent, is a fact to which Llewellyn Jones recently has called attention.

It is customary to speak of all these joint affections as different forms of arthritis, though this term implies an inflammatory rather than a degenerative condition. Yet these dystrophic joint diseases have certain features which distinguish them from infections of joints, and which it is very important to bear in mind. Our present knowledge of the subject is due largely to the investigations of Goldthwait, Nathan, and Llewellyn Jones (1909). The dystrophies begin insidiously, are not attended by marked phenomena of inflammation nor by constitutional reaction; they gradually progress, invading other joints one by one; may exhibit slight remissions and exacerbations; but the joints once affected never entirely recover, and there is no definite end to the disease. The infections have a definite and easily remembered commencement; are attended by the usual inflammatory phenomena and constitutional reaction, even if slight in degree; usually all the joints affected are attacked at or about the same time; and when once the infection has run its course, the disease is gone, and the joints recover, or retain permanent but never progressive disability.

Atrophic Joint Lesions.—Here is placed a disease named "atrophic arthritis" by Goldthwait (1905), and "metabolic osteoarthritis" by Nathan (1906); it is the same as the "rheumatisme noueux" of Trousseau (1868), the "chronic progressive articular rheumatism" of Charcot (1874), the "arthritis nodosa" of Waldmann (1884), the "arthritis deformans" of Baumler (1897), and the "primary progressive chronic joint rheumatism" of Pribram (1902). It is a polyarticular, symmetrical affection, occurring in women oftener than in men, and generally beginning in the fingers and hands, where it may be localized by repeated slight trauma. It is seen oftenest in young adults, but sometimes occurs in children. It affects first the smaller joints of the hands and feet, especially the proximal

interphalangeal joints of the fingers; it progresses through many years, invading the wrists, elbows, shoulders, ankles, knees, spine, and maxillary joints. The hips seldom are affected.

The pathological change first noted is a localized subchondral atrophy of the joint ends, giving them a "punched out" appearance in a skiagram (Fig. 472); these are minute bone cysts, due to osteoporosis and lacunar resorption (Nathan,[1] 1909). Later the overlying cartilage degenerates, becomes invaded by connective tissue from the underlying spongiosa, and a so-called cartilaginous decubitus (pressure

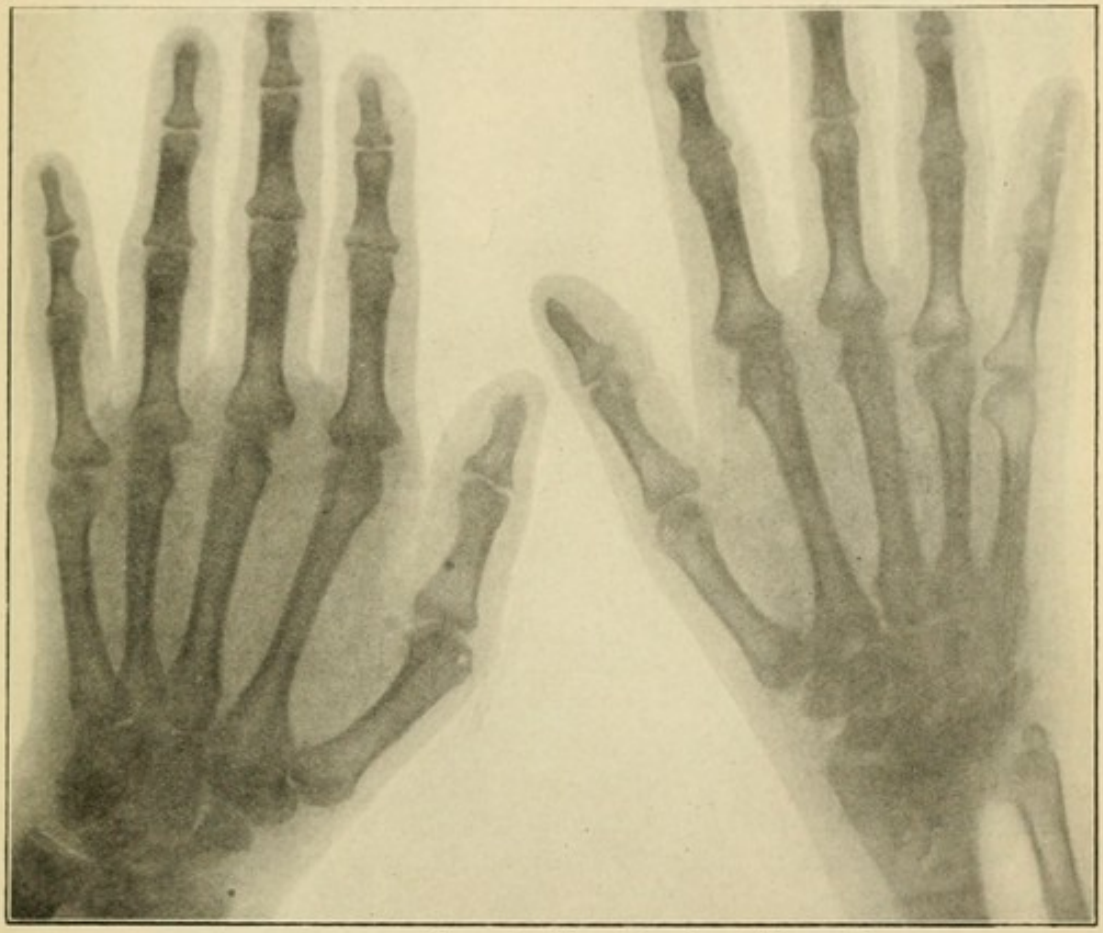

FIG. 472.—Skiagraph of atrophic arthritis of hands. Girl, aged twenty-one years; duration two years. Note bone cyst in distal end of proximal phalanx of middle finger of left hand; absorption of heads of metacarpal bones in both hands; and atrophic changes in bones of right carpus. Orthopædic Hospital.

sore) is produced by pressure of the opposing bone. The cartilage becomes completely absorbed, the joint cavity is lost, being filled by loose and vascular connective tissue which shows no tendency to contraction, and ankylosis (p. 467) rarely or never occurs. In skiagraphs of advanced cases the joints appear to be ankylosed, because the bones are in immediate contact or overlap, no clear cartilaginous area intervening (Fig. 473). The joints become distorted, and subluxated from muscular contraction; and in weight-bearing joints, as

[1] Poncet considers such changes characteristic of one form of "tuberculous rheumatism" (see p. 474).

the knee, the bone ends may become broadened and mashed out rather flat, owing to their atrophic state. No reactionary phenomena are visible; no attempts at repair are made; no ecchondroses or osteophytes are formed.

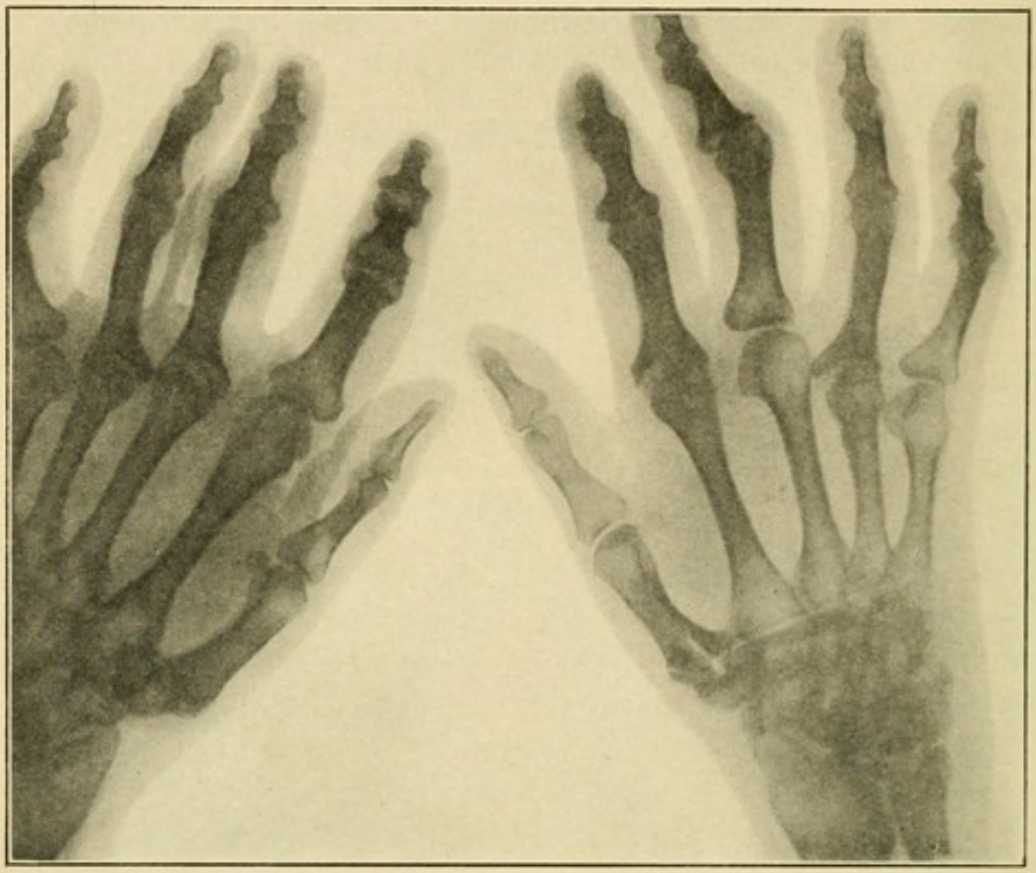

Fig. 473.—Skiagraph of atrophic arthritis of hands. Woman, aged thirty years; duration five years. Changes more advanced than in Fig. 472. Subluxations and apparent ankyloses. (See Fig. 474.) Orthopædic Hospital.

Symptoms—The pathological changes shown in Fig. 472 may have existed for many months before subjective symptoms arrest the patient's attention. Usually the first complaint is of stiffness in

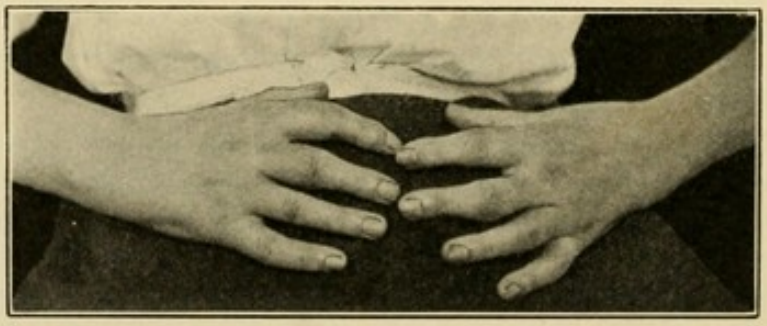

Fig. 474.—Atrophic arthritis. Duration six years. Same patient as in Fig. 473.

the fingers, worse in the morning and gradually passing away after use; and the patient is dosed for "rheumatism." But on examination this is found not to be real stiffness, but rather weakness, passive

motion being free and often painless. Muscular atrophy is pronounced, and often increased the swollen appearance of the joints (Fig. 474). Synovial effusion is rare, except from over-exertion or trauma; it may be attended by considerable pain, but both pain and effusion subside when the joints are put at rest. Joint deformity follows destruction of bone ends and muscular contraction; but though motion may be limited or even abolished by periarticular changes it is free within the range allowed. Motion is most limited

FIG. 475.—Skiagraph of atrophic arthritis of hands, advanced stage. Woman, aged sixty-five years; duration forty-five years. Marked bone absorption, many subluxations. Two years later skiagraphs showed scarcely any bone left in shafts of metacarpals. (See Fig. 476.) Episcopal Hospital.

in the larger joints; in advanced cases the smaller joints may become flail-like, and the skin covers the phalanges like a wrinkled glove (Figs. 475 and 476). Lateral deviation, flexion, or hyperextension of the phalanges may occur, and several different deformities may exist in the same hand. The only constitutional symptoms are those of slight cachexia and secondary anemia.

Prognosis.—The prognosis is gloomy. The disease steadily progresses, and in most cases the patient eventually becomes a helpless cripple.

Treatment.—Good feeding and hygiene are required; the only favorable results I have seen have been in patients under the care of Pemberton, whose plan of treatment is based on metabolic studies, and is largely dietetic in nature (1913). Medicines are of little value, but Nathan reports increasingly favorable results from thymus extract, in doses of 10 to 20 grains three times daily. Guaiacol carbonate sometimes is useful, in doses of from 5 to 15 grains three times daily, continued for at least a year. This should be combined with potassium iodide and tonics. Rest is necessary when exacerbations occur from trauma or over-use; it often is best enforced by use of orthopedic apparatus. Massage, hot baths, baking, etc., and exercise short of fatigue, are of some value. After subsidence of acute symptoms, deformity should be corrected by weight-extension and tenotomy, or even by forcible manipulation, though this is more apt to fracture the bones than overcome periarticular contractures.

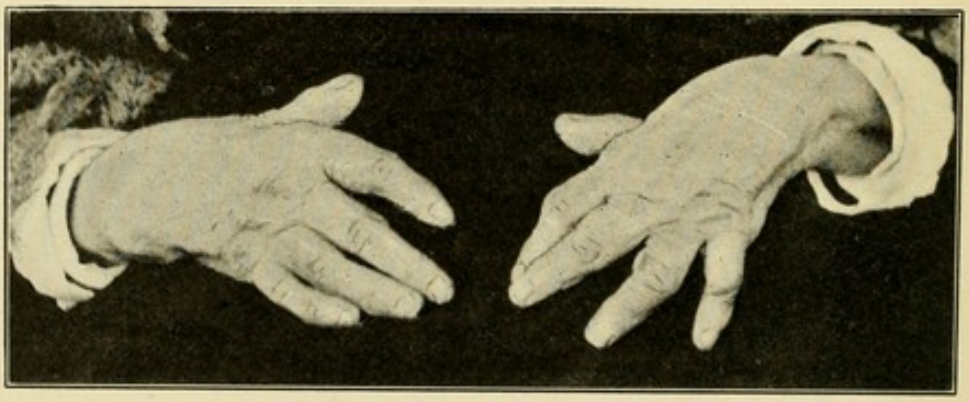

FIG. 476.—Atrophic arthritis (advanced stage). Same patient as Fig. 475. Episcopal Hospital.

Hypertrophic Joint Lesions.—These, as pointed out at p. 550, are not rare as results of attenuated or remote infections; but there are also certain forms of hypertrophic joint disease which seem to be pure disorders of nutrition. In the *polyarticular form*, "Heberden's nodes" (1804) are found; these consist essentially in hypertrophies of the bases of the distal digital phalanges, often accompanied by lateral deviation of the terminal phalanx (Fig. 477). The thumb rarely is affected. The *monarticular form* is of more interest to surgeons. It is the "arthritis deformans" of Volkmann (1882), Schüller (1900), and Hoffa (1906), the "chronic partial rheumatism" of Charcot (1874), and the "hypertrophic arthritis" of Goldthwait (1905). In this disease the influence of trauma frequently is conspicuous, hypertrophic lesions developing in a joint injured perhaps many years before (Fig. 402), or in one which constantly is subject to slight injury or strain. *Static strain*, from imperfectly reduced fracture, or faulty attitudes, often is a cause. The disease affects men more than women, usually those past forty years; and arteriosclerosis seems to be a predisposing factor. Sometimes the affection is called *senile arthritis*, and when the hip is attacked, it is known as "morbus coxæ

senilis." As a matter of fact, however, the knee is more often affected than the hip, especially in women; in men the hip and spine are oftener attacked. In the spine the disease is called "spondylitis deformans" (p. 616).

The earliest pathological change is said to occur in the joint cartilage; this shows attempts at proliferation, but the cartilage cells which border on the joint cavity are discharged into the synovial fluid, and the underlying cartilage is worn down by attrition of the opposing bone, producing a "cupping" of the joint surface; while

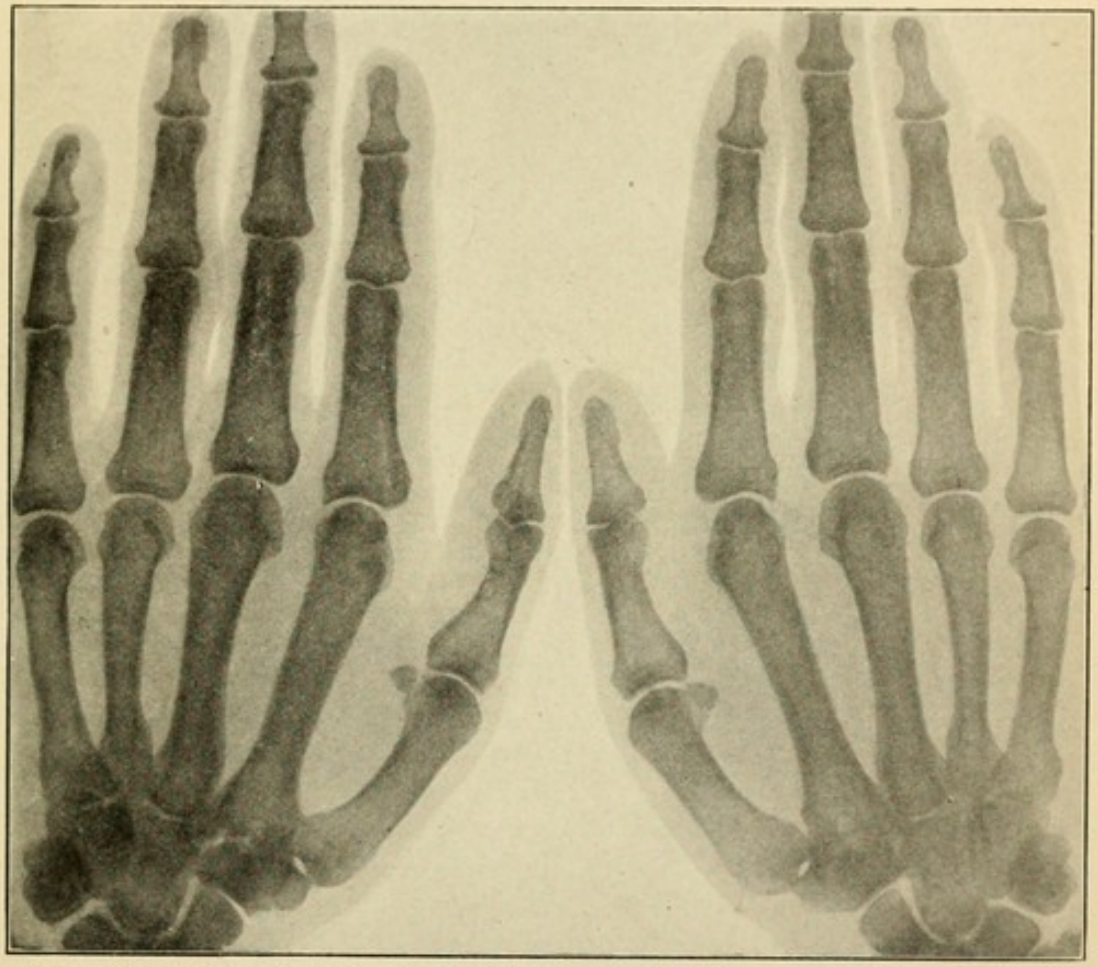

FIG. 477.—Skiagraph of hands of patient, aged sixty-three years, with polyarticular hypertrophic arthritis. Insidious onset, many years ago. Note hypertrophies of bases of distal phalanges ("Heberden's nodes") and periosteal proliferations along shafts of proximal and middle phalanges. Orthopædic Hospital.

the more fortunate cartilage cells not subjected to such pressure proliferate into the attachments of the capsule, and so produce spurs, ecchondroses, and osteophytes, which cause a "lipping" at the joint margins. The bone ends themselves often are the seat of porosis, and in weight-bearing joints, especially the hip, very marked alterations in the shape of the bone ends may occur; thus the head of the femur may be worn away, the acetabulum enlarged upward and backward ("wandering acetabulum"), while the base of the femoral neck and the acetabular borders become studded with osteophytes.

The angle between the neck and shaft of the femur is decreased, and coxa vara results. The earliest skiagraphic evidences of these bone changes are observed in sharper angularity of the bone margins. The edges of the tibial condyles become sharp, the patella becomes square, the astragalus and scaphoid lose their gentle curves, and eventually distinct exostoses are observed (Figs. 478 and 479). These occur especially at points of strain, where ligaments or tendons are attached; they are not always confined to the immediate neighborhood of joints. The joint ligaments may be gradually destroyed by the

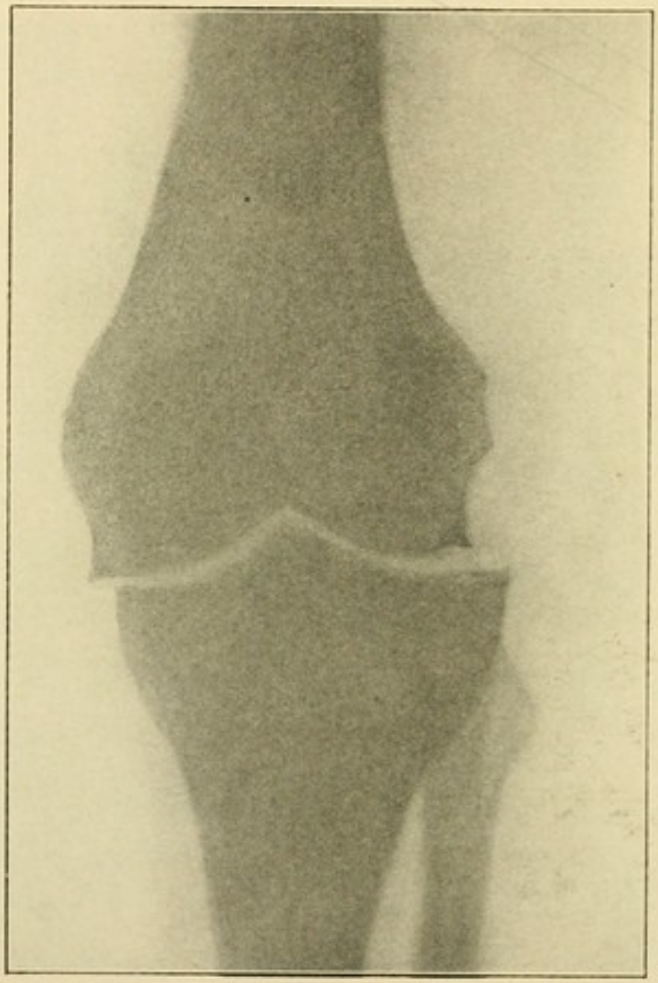

FIG. 478.—Skiagraph of monarticular hypertrophic arthritis of knee. Woman, aged forty-nine years. Duration two years. Insidious onset; no injury. (See Fig. 479.) Orthopædic Hospital.

degenerative process, and, according to Marsh, the joint may become weakened, loose, even flail-like; this occurs oftenest in the knee. Usually, however, for a time at least, limitation of motion is observed owing to periarticular fibrous changes or the interlocking of osteophytes, but ankylosis rarely or never occurs. If the obstructing osteophytes are removed, free motion may be restored for a time. In the shoulder-joint the long tendon of the biceps may fuse with the underlying bone.

Symptoms.—The patient complains of weakness and stiffness in the affected joint. It creaks on motion, and motion commonly is

limited. Severe referred pain as well as local pain may be felt. The general health is not materially impaired. If the small joints are affected they present Heberden's nodes, but rarely give subjective symptoms. The disease typically is monarticular in the beginning, and often remains so; but other joints may be involved in time. The *diagnosis* depends on excluding an infectious origin, which often is difficult, and sometimes impossible; on observing the localization of the process to one of the larger joints which has been injured or is the seat of constant strain or repeated slight trauma; and on the

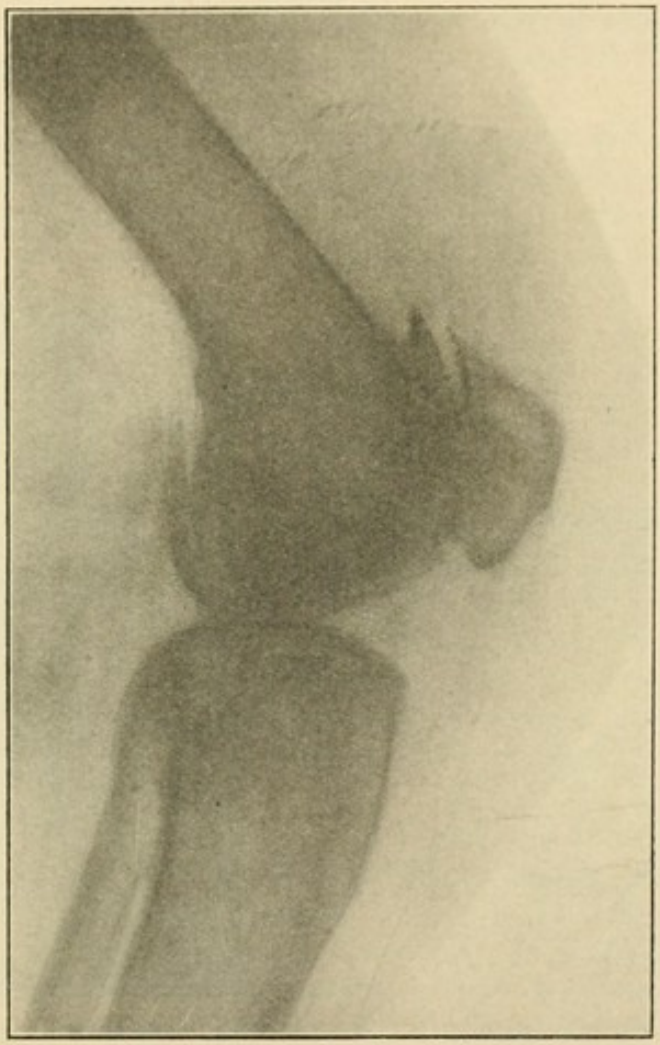

FIG. 479.—Hypertrophic arthritis of knee, lateral view. Same patient as Fig. 478. Orthopædic Hospital.

results of skiagraphic examination. Atrophic arthritis is polyarticular, affects first the smaller peripheral joints, and spreads centripetally, and occurs in women in early adult life. Hypertrophic arthritis is monarticular, affects a large joint, and occurs in persons past middle life. Both have an insidious onset, are chronic from the start, run a long and tedious course, and neither is accompanied by inflammatory or constitutional symptoms.

Treatment.—Sometimes it may be possible to prevent the development of hypertrophic lesions by relieving a joint from strain,

protecting it from injury, or by active treatment of an underlying condition, such as internal derangement of the knee-joint (p. 412). In the cure of the disease, a painful joint should be put at rest. Confinement to bed seldom is necessary, the use of plaster of Paris splints, braces, etc., usually being sufficient. Immobilization should not be absolute, however, nor should it be continued too long, since this promotes stiffness. Such exercises as can be taken without too great fatigue should be encouraged. Occasionally one or more bony spurs which markedly limit motion, or cause pressure symptoms, may be removed by saw or chisel. Arthrodesis (p. 528) has been employed in some cases, especially at the hip (Figs. 480 and 481) and the knee, to relieve pain by permanent joint-fixation. General hygienic treatment is of value, but no drug has much influence on the disease.

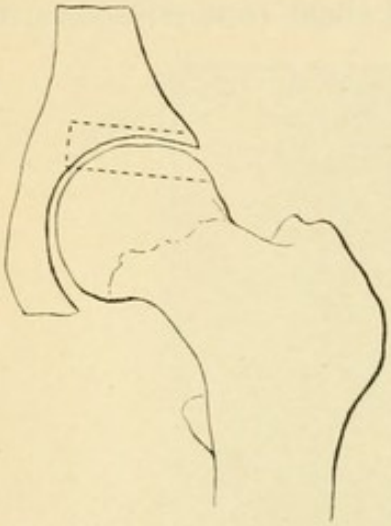

FIG. 480.—Albee's method of arthrodesis of the hip (See Fig. 481.)

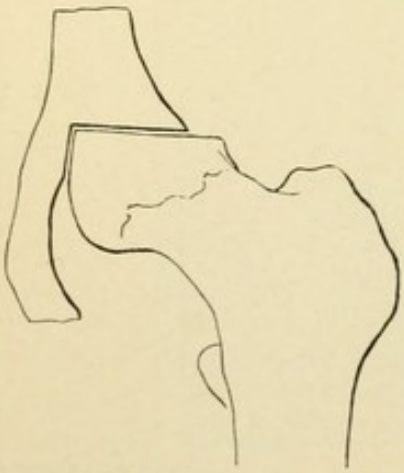

FIG. 481.—Albee's method of arthrodesis of the hip.

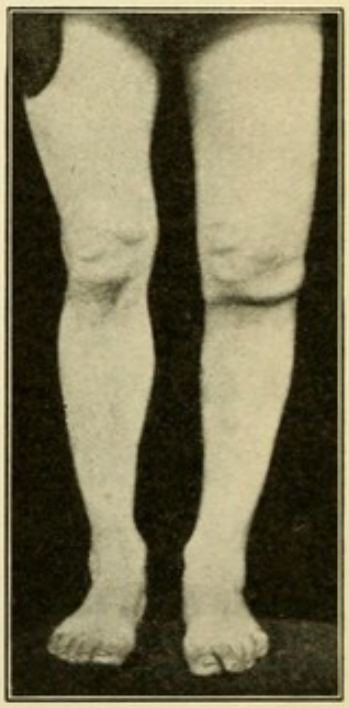

FIG. 482.—Charcot joint. Age fifty-one years. Duration, three months; followed sprain while climbing. Lost knee-jerks and Argyll-Robertson pupils. Orthopædic Hospital.

Neuropathic Joints (Charcot, 1868).—In *tabes dorsalis* the joints are subjected to unusual strain, as deep sensation is lost, and the patient is not aware of the injury he inflicts upon them in walking, pulling himself up stairs, etc.; the nutrition of the bones also is disturbed, predisposing them to distortion and fracture. So-called spontaneous fracture is not rare, and sometimes occurs some time

before definite tabetic symptoms develop. As a rule only one joint is affected by the dystrophy, most often the knee; but the shoulder, elbow, ankle, and hip sometimes are affected. Painless effusion may be the first symptom, and this may exist so long as to induce relaxation of the ligaments, or even a flail-joint, before the patient realizes its condition (Fig. 482). The bone ends become distorted from pressure, and pieces may be broken off and lie free in the joint. Osteophytes frequently grow in the fibrous tissues surrounding the joint.

Diagnosis.—The diagnosis depends on the detection of constitutional symptoms of tabes, associated with a nearly painless dystrophy of one of the larger joints, with effusion and abnormal mobility. In *syringomyelia* similar changes may occur, usually in the upper extremity.

Treatment.—This consists in care of the general tabetic condition, and support to the diseased joint; massage may improve the condition of the surrounding muscles. In some cases arthrodesis may be done, in the endeavor to restore stability. Very rarely amputation may be required.

LOOSE BODIES IN JOINTS.

This condition has many of the same symptoms as *internal derangement of the knee-joint*, referred to at p. 412, but the pathogenesis is different. The knee is affected in the vast majority of cases. The loose bodies, or "joint mice" as they are called, may be entirely free, or may remain attached to the capsule by a pedicle. They may be derived from hypertrophied synovial fringes, from organized blood-clot, flakes of fibrin, etc.; from detached chips of bone or cartilage; or from ecchondroses, osteophytes, etc., developed in hypertrophic arthritis. One or an innumerable number of such bodies may be present.

Symptoms.—The symptoms are those of the underlying disease (villous, or hypertrophic arthritis), or of old injury, with occasional locking of the joint from impaction of the loose body. This often is followed by an attack of acute synovitis. If the loose bodies are large, or present in sufficient numbers, they may be detected by palpation, and sometimes they are dense enough to be detected in a skiagraph. Care should be taken not to mistake a normal sesamoid bone or other extra-articular structure for a loose body.

Treatment.—Usually nothing short of arthrotomy and removal of the bodies will give relief, unless the joint is kept immobilized; and even after such an operation the joint lesion which caused the formation of the loose bodies will require its appropriate treatment.

INFECTIONS OF JOINTS.

Pathology.—Infection may reach a joint through external wound, directly through the blood-stream, or from a neighboring focus of

inflammation, usually in bone. Wounds of joints have been considered in Chapter XIII. Most joint infections secondary to bone lesions are tuberculous in origin; these are discussed at (p. 476). In this place it is desired merely to enumerate briefly the main pathological changes which occur in joints as the result of infection.

Synovitis is the earliest stage; the synovial membrane is congested and swollen, and minute ecchymotic areas may be present in it; effusion into the joint cavity occurs, due both to increase in the natural synovial secretion and to the formation of inflammatory lymph. Fluid collects in the joint because it is a free surface, and wherever a free surface exists effusion predominates over edema. In mild infections, and in aseptic inflammations such as sprains, contusions, etc., the effused fluid usually remains serous in type; but infections due to pyogenic cocci usually, and those caused by the pneumococcus, gonococcus, etc., often end in suppuration, constituting the condition of *pyarthrosis* or *empyema articuli* (Fig. 483). *Arthritis* is a clinical term used, in contradistinction to synovitis, to imply predominant involvement of structures of the joint other than the synovial layer of the capsule; and *osteo-arthritis* signifies involvement

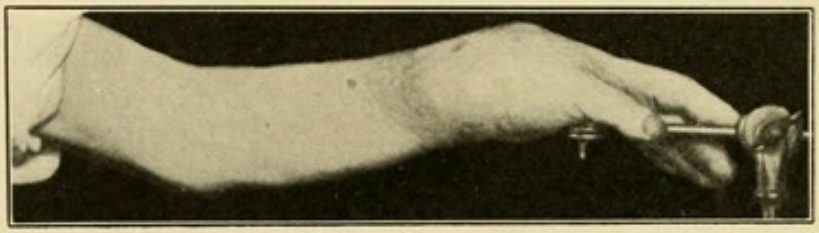

FIG. 483.—Pyarthrosis of wrist. Residual abscess three months after complete healing of infected hand and forearm. Orthopædic Hospital.

of the bone ends. In some cases of subacute infection no marked effusion occurs, but proliferation of the synovial villi is the main feature, producing *villous arthritis;* this is believed by some to be caused by a specific diplococcus, discovered in 1900 by Schüller.

If recovery ensues while the effusion is still serous, little subsequent trouble may be experienced; often, however, the fluid is not entirely absorbed, and *chronic serous synovitis* (*hydrops articuli*, p. 464) develops. When the exudate has been sero-fibrinous some organization of the inflammatory material usually occurs, and the joint cavity is more or less obliterated by bands of adhesions, which may restrict motion. When suppuration has occurred, more or less destruction of the cartilages, ligaments, etc., is inevitable; complete disorganization of the joint may occur; and as gradual repair by organization and cicatrization sets in, the bones become welded together, more or less firmly, and frequently in bad position, in a condition of *ankylosis* (p. 467). Ankylosis may be entirely bony, or due to fibrous adhesions allowing a very limited range of motion; limitation of motion due to periarticular changes (contraction of capsule, ligaments, tendons; locking of osteophytes, etc.) is not spoken of as ankylosis, which term

always implies *loss of motion from intra-articular adhesions*, fibrous or osseous in character. Owing to the distention of the capsule during the stage of effusion, and to changes in the bone ends, *pathological dislocation* of the joint may occur, from muscular action, or the force of gravity.

Symptoms.—Joint effusion is shown by increase in circumference, with bulging of the capsule at its weakest parts. In the knee the patella is floated up from the condyles, and when the quadriceps extensor is relaxed, the patella can be made to tap against the bone; the capsule bulges on each side of the quadriceps tendon, and the quadriceps bursa is distended (Fig. 484). When much fluid is present fluctuation can be elicited. In the elbow the capsule bulges on both sides of the triceps tendon; in the ankle, beneath the tendo Achillis and anteriorly. In the wrist swelling is more marked on the dorsum; while in the hip and shoulder effusion is more difficult to appreciate. Any joint which is the seat of effusion tends to assume a position in which the capsule is most relaxed; this usually is in moderate flexion, and in the hip slight abduction as well as flexion is characteristic. Great pain is felt in the affected joint, and from pressure of the effusion on neighboring nerves referred pain may exist. Muscular spasm is present, and may cause starting or jumping pains in the joint, from time to time, especially during sleep. Joint motion is painful, and the joint itself is tender. As a rule, the bone ends are not tender in simple synovitis nor in arthritis not secondary to osseous disease; but crowding the bones together causes pain. The affected joint may be hot even in simple synovitis, but unless suppuration is present there is not much constitutional disturbance, nor is the affected joint red. Suppuration may be ushered in by a chill, or there may be no change except in the temperature. In pyarthrosis of the larger joints the patient becomes gravely ill, and all the constitutional signs of septicemia or pyemia develop. The joint becomes more tense and painful, exquisite tenderness develops, dusky redness with edema of the skin may be present, and unless the pus is evacuated it may perforate the capsule and invade the soft parts. Spontaneous dislocation is most frequent in the hip.

If villous arthritis develops, the joint does not present fluctuation, but is doughy, and the capsule does not bulge but presents a more uniform enlargement, and it is evident that this is due partly to periarticular thickening. The condition becomes subacute or chronic, and is then characterized by creaking and crackling on motion, slight permanent loss of full extension, and moderate disability.

Treatment.—The treatment of acute synovitis consists in local rest of the joint, secured by proper splinting, and in the case of the lower extremity by rest in bed, usually with weight extension. If this treatment is instituted promptly, apparent recovery may ensue in a few days; but the joint, especially the knee, should be protected for several weeks by a light plaster case, as recurrence of effusion, and development of hydrops is much to be feared. Massage of the

surrounding muscles, not of the joint itself, is of value for restoration of function after all inflammatory symptoms have been absent for several weeks. When the patient comes under observation at a later stage, with the joint in bad position, or suppuration threatening, weight extension should be applied as well as splinting; the latter alone sometimes is sufficient for the upper extremity. The joints should be kept in the position which will be least useless should ankylosis occur: the shoulder in slight abduction; the elbow and ankle at a right angle; the wrist and knee in full extension; and the hip in full extension and slight abduction, but without either external or internal rotation. The forearm should be kept nearly in full supination.

Suppuration is treated by aspiration (which may be used as a diagnostic measure) and injection of 2 per cent. formalin-glycerin solution, the joint meantime being kept at rest, and such constitutional measures being used as the patient's condition demands. Aspiration and formalin injection may be repeated a number of times, though the injection may be very painful; and usually the infection may be controlled in this way, the fluid gradually becoming serous, and the joint inflammation subsiding with preservation of a fair degree of motion. Should, however, improvement not be secured after two or three aspirations, the joint should be incised, and treated as detailed for septic arthritis following trauma (p. 387).

Villous arthritis, when acute, is treated as synovitis, by rest, and antiphlogistic or sorbefacient applications. In its more usual subacute or chronic stage, benefit is derived from massage, passive motion, baking, hot and cold douches, passive congestion, etc. Any source of infection (see p. 476) should be removed, and the patient's general health improved. Painful joints should be supported by suitable apparatus.

Acute Arthritis of Infants (T. Smith, 1874) almost invariably suppurative, occurs as a hematogenous infection, and probably always is secondary to acute epiphysitis (p. 436). The diagnosis is not always easy, unless the condition is constantly in mind; when the pus has perforated the capsule, making beneath the muscles a tense, hot, painful swelling, with enlarged veins, a diagnosis of sarcoma has often been made. I saw such an error in an infant with arthritis of the shoulder, when I was house-surgeon at the Episcopal Hospital. The disease seldom results in ankylosis, but leaves a deformed, flail-like joint.

Chronic Serous Synovitis, or **Hydrops Articuli,** occurs oftenest in the knee, usually the result originally of slight trauma causing acute synovitis with effusion, which has never entirely subsided, owing to inefficient treatment, for which the patient is more often to be blamed than the surgeon. The condition is maintained either by recurring slight trauma, or by some remote or attenuated infection. Sometimes hydrops seems to be chronic from the start; in such cases careful search should be made for any site of infection

which may maintain a toxemia and thus interfere with joint metabolism.

The joint is distended, but rarely tense; floating of the patella and fluctuation are detected easily; and no signs of acute inflammation or constitutional disturbance are present (Fig. 484). If pain is entirely absent, the existence of a Charcot joint should be suspected (p. 460). The patient complains of weakness and insecurity in the knee, of its tiring easily, of a feeling of fulness and discomfort on partial flexion, and of inability to flex the joint completely. He stands usually with the knee not quite fully extended, though passive extension may produce no discomfort. There may be a moderate degree of villous hypertrophy, and "joint mice" may develop; indeed such conditions themselves may maintain a state of chronic synovitis by the constant irritation they produce. Increase in the pads of subpatellar fat is not unusual (see *Lipoma Arborescens*, p. 503); and the neighboring bursæ may be chronically inflamed.

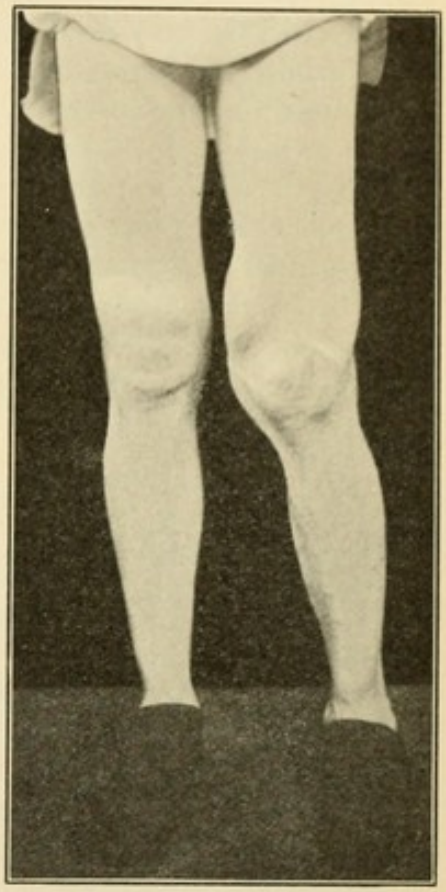

FIG. 484.—Hydrops articuli of left knee, slight of right. Gonorrheal arthritis of left knee twelve years ago. Knee always swollen since. Orthopædic Hospital.

Treatment.—Any source of infection which can be detected should be cured, and intestinal putrefaction and toxemia should be overcome if present. Locally, treatment should be instituted as for acute synovitis, by putting the joint at absolute rest for several weeks. This, with moderate uniform pressure by plaster of Paris or adhesive strapping, may cause the effusion to disappear. Counter-irritation may assist absorption. It may now be possible to detect a loose cartilage or other form of "joint mouse" which is partly responsible for continuance of the condition. Rarely aspiration of the fluid may be employed for the same purpose, and to hasten absorption; it should be followed by injection of 2 per cent. formalin glycerin solution. I once did arthrotomy, finding the under surface of the patella and opposing femoral cartilage roughened, and placed a drainage tube across beneath the patella; the patient recovered perfect function in a few weeks, and in the eight years he was under observation there was no return of the condition, which had resisted conservative treatment for months. Such a plan rarely is proper, because the disability never is total, and the disease entails no risk to life. If rest and immobilization fail to secure absorption of the fluid, or if, as is usual, effusion recurs when joint function is resumed,

the patient may be allowed to walk about in a gypsum case or brace; and hot and cold douches, vigorous massage of the joint and leg and thigh muscles during many months, and elastic compression may bring a certain measure of relief. When joint mice are present, they may be removed by arthrotomy, in the hope that they are the cause of the recurring effusion. It is rare for a permanent cure to be obtained.

Intermittent Hydrarthrosis is a very obscure affection of joints, generally believed to be of vaso-motor origin. The effusion occurs suddenly, within a few hours, and subsides as rapidly, or within a day or two; the attacks occur at more or less regular intervals, perhaps daily for a certain portion of each year, or every few months. Almost any joint may be affected, and men as well as women are subject to the disease. *Treatment* is purely symptomatic.

Periarthritis.—Periarthritis is a vague term under which it is convenient to group various subacute or chronic periarticular conditions until their true pathology can be determined. These lesions seem to be more frequently a cause for complaint around the shoulder than elsewhere, though they occur sometimes in other joints. They usually are caused primarily by trauma (sprains, subluxations, etc.), and are maintained either by static strain (especially in the sacro-iliac joint), or frequently recurring trauma. The condition was mentioned at p. 268 and 385. Codman (1906) has drawn attention to the subdeltoid bursa as the main factor in such disability; while T. T. Thomas (1911) thinks cicatricial contraction of the axillary portion of the capsule, resulting from sprain or self-reduced subluxation, is a more frequent, if not the only cause of the condition at the shoulder. The neighboring nerves (axillary plexus, sacral plexus and sciatic nerve) may be involved in periarticular adhesions, and thus complicate the case.

Symptoms.—The symptoms are pain and disability, and in the shoulder especially limitation of abduction and external rotation. Tendinous or bursal crackling often is present. "Sprain fracture" of the greater tuberosity of the humerus sometimes exists. Each case requires careful individual study to determine the original cause, and if possible the pathological lesion present. *Subdeltoid bursitis* is characterized by tenderness below and in front of the acromion when the arm hangs by the side, this tenderness disappearing when the arm is abducted and the bursa disappears beneath the acromion; in chronic cases with adhesions abduction is impossible, and the diagnosis is more difficult, but usually there are no physical signs in the axilla. *Implication of nerves* is recognized by symptoms of neuritis, and sometimes trophic changes in the fingers. My own experience leads me to coincide with Thomas's views, that in most cases the main lesions are in the axillary region of the joint, and not in the subdeltoid bursa.

Treatment.—Massage, passive motion, baking, hot air douche, etc., may all be tried. Improvement is slow. In resistant cases the

patient should be etherized, the adhesions forcibly ruptured, and the arm dressed in abduction. Improvement in the nutrition of the hand may follow such treatment. If it be certain that the subdeltoid bursa is the seat of adhesions which cannot be ruptured by manipulation, the bursa may be opened and the adhesions cut or the bursa excised. Dissection may relieve an intractable neuritis, especially of the sciatic nerve.

Ankylosis.—This is a fixation of joints by intra-articular adhesions. According to the character of these adhesions ankylosis is classed as *fibrous* or *bony*. It is worth while to repeat here again that limitation of motion from extra-articular causes is not ankylosis; it has been called "false ankylosis." Thus in the dystrophies of joints discussed in the opening paragraphs of this chapter, there is limitation of motion, but not ankylosis. True ankylosis, whether fibrous or bony, probably always is the result of infectious arthritis or of trauma. Complete bony ankylosis rarely occurs except from trauma, most cases of bony ankylosis due to arthritis presenting only a few bands or processes of bone uniting the articulating surfaces, the remainder of the joint cavity being filled up by fibrous adhesions. If only fibrous ankylosis is present it usually is possible to detect a few degrees of motion if the joint is carefully examined under an anesthetic.

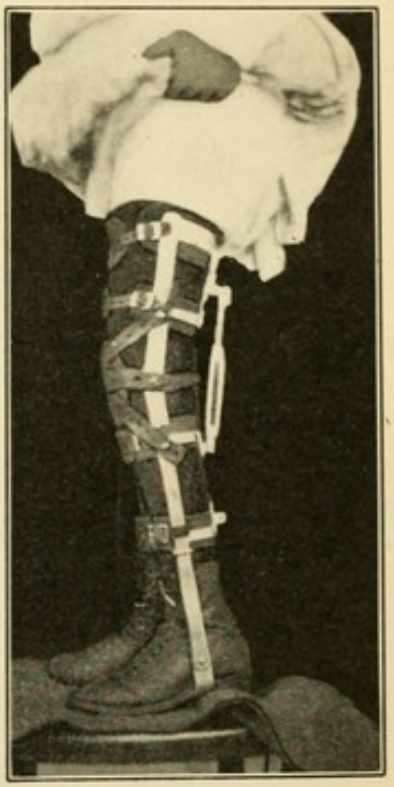

Fig. 485. — Brace for knee with Stromeyer screw, to produce gradual extension. Orthopædic Hospital.

Treatment.—The treatment of ankylosis in tuberculous arthritis is considered at p. 487. What is said here applies to ankylosis due to other forms of infection (pyogenic, pneumococcic, typhoid, etc.), or to trauma. If ankylosis occurs with the limb in good position, no treatment may be advisable, especially in the aged, those with visceral disease, etc. A stiff hip is largely compensated for by mobility in the lumbar spine; a stiff elbow, if the hand can be brought to the mouth, may be useful enough; and movements of the scapula on the trunk largely compensate for ankylosis in the scapulohumeral joint; but almost any joint which is in bad position will be improved by treatment. With very few exceptions, however, no operation should be undertaken until all signs of active disease have long since subsided. In cases of fibrous ankylosis, where the disease is still subsiding, the use of weight extension or of elastic compression against a splint, or of a splint with Stromeyer screw (Fig. 485), may secure improved position; and in cases of fibrous ankylosis and false ankylosis in which definitive healing has occurred, the surgeon may

make attempts to secure improved position by rupture of adhesions under an anesthetic (*arthrolysis* or *brisement forcé*), always making movements of flexion before those of extension (to avoid damage to the important periarticular structures in the flexures of joints), and seeking to rupture adhesions by abrupt movements of small excursion rather than by prolonged or violent pressure. The joint should then be immobilized in improved position until inflammation subsides, when gentle passive movements should be begun and active use encouraged. While such measures often secure improved position and sometimes a moderate range of motion in cases of false or fibrous ankylosis, in bony ankylosis open operation is required.

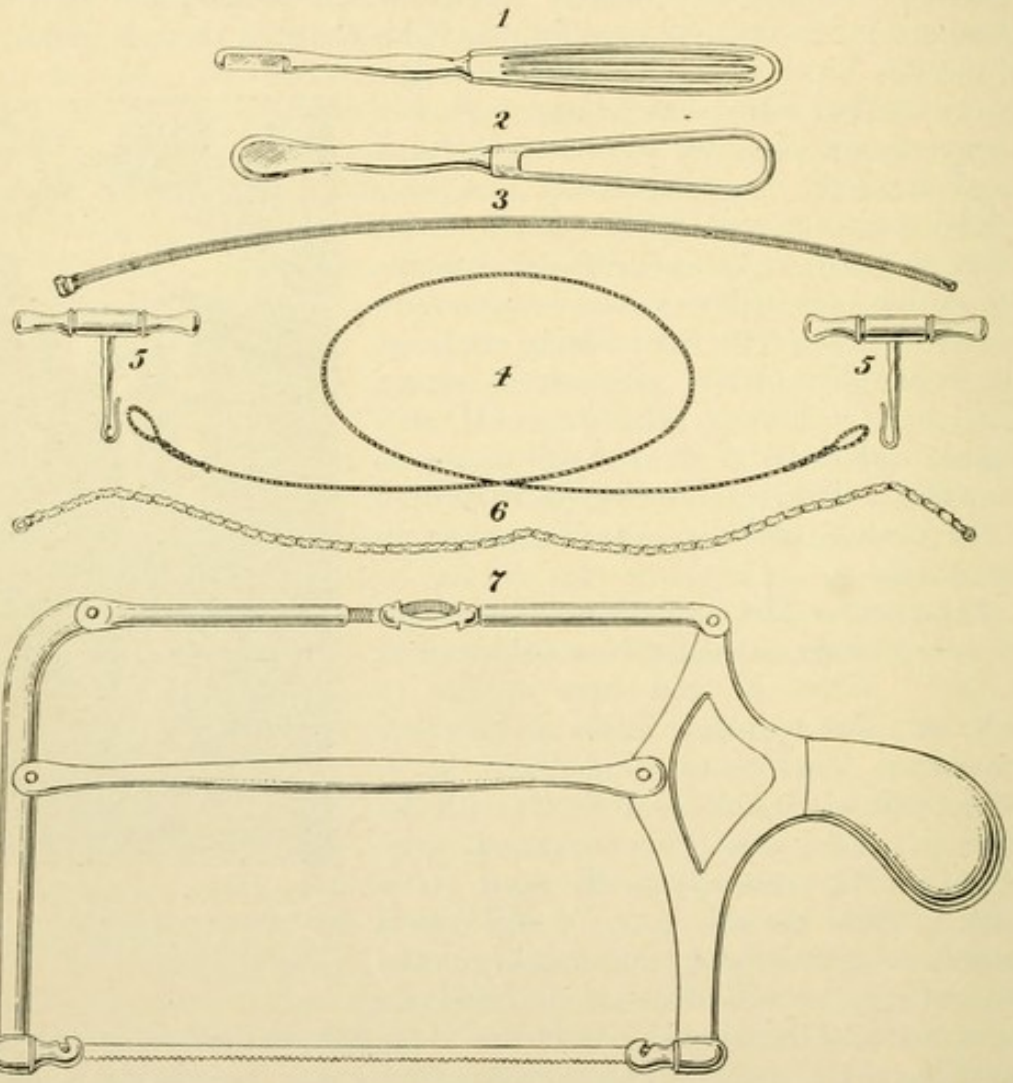

FIG. 486.—Instruments used in excision of joints: (1) Blunt-pointed resection knife. (2) Periosteal elevator. (3) Guide for Gigli wire saw (4), and (5) handles. (6) Chain saw. (7) Butcher's saw, the blade of which can be reversed, so as to cut upward.

If it is not desired to restore motion to the joint, simple *osteotomy* may suffice to secure good position. This is seldom employed except at the hip. Here the neck of the bone may be divided (Adams, 1871), but as this often is distorted by disease, subtrochanteric osteotomy of the femur (Gant, 1872), is preferable (p. 487). *Excision* of joints

for ankylosis is employed to correct deformity where osteotomy will not suffice, as at the knee, shoulder, and elbow. In the latter situations a movable joint is sought, but at the knee the object of excision is to secure ankylosis in full extension, the most useful position. *Excision of the knee* is done *without an Esmarch band* by a transverse incision, slightly convex downward, across the front of the joint from the posterior edge of the base of one condyle to that of the other; the skin is dissected up until the upper border of the patella is exposed and the quadriceps tendon is divided at its insertion into the patella; the knee-joint is acutely flexed, and the intra-articular ligaments are divided. The condyles of the femur being thus cleared, the saw is applied to them and a section about half an inch thick is removed, *not* at right angles to the long axis of the femur, but obliquely from without inward, from before backward, and from above downward; in other words, in such a manner that the posterior internal portion of the sawn surface shall be the longest, and the anterior external the shortest. The tibial condyles are then sawed across at right angles to the long axis of the leg, but somewhat bevelled antero-posteriorly so as to correspond to the section of the femur. The tibial condyles with the attached patella are then removed in one mass (*Ashhurst's operation*, 1884). Barely enough of the femur and tibia are removed to allow the limb to come straight; the posterior ligaments always, and the lateral ligaments whenever possible, are left intact. The periarticular tissues are sutured with chronic catgut, and the skin is closed with provision for drainage for twenty-four hours. The limb is dressed in plaster of Paris and immobilization continued for six or ten weeks until union is firm. If complete bony ankylosis (in bad position) is present already, it is sufficient to excise a wedge of bone to restore the axis of the limb (Figs. 487 and 488). In all cases of excision of the knee,

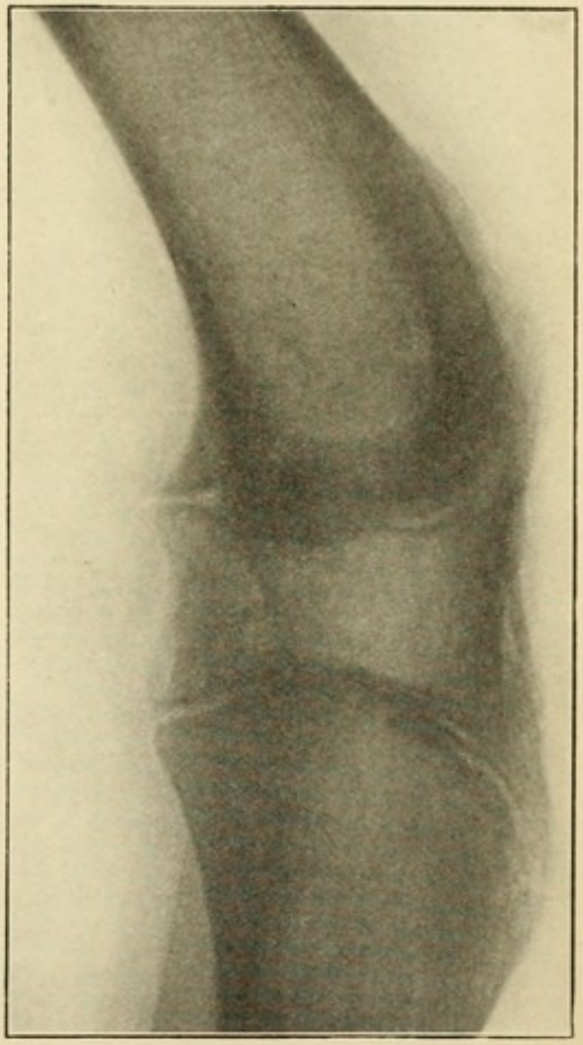

FIG. 487.—Ankylosis of knee in flexion, in a girl of twelve years; result of arthrectomy for tuberculosis nine years previously. (See Fig. 487.) Episcopal Hospital.

the limb should be supported by a brace for a year afterwards. The *elbow is excised* through a straight posterior incision splitting the triceps muscle near the inner border of the olecranon, and carefully separating its tendinous expansion from the olecranon. Injury of the ulnar nerve should be avoided; it is most liable to injury just below the level of the joint close to the inner border of the olecranon. After the lateral ligaments have been divided the joint may be luxated. Enough bone is removed (leaving the radial insertion of the biceps) to ensure a false joint being established; a space of at least one inch and a half should exist between the humerus and bones of the forearm, to ensure free motion. The limb is immobilized only until the soft parts heal; active use is then encouraged. Return of function depends largely on preservation of the periosteum into which the triceps inserts, and its fibrous expansion over the radius. The *shoulder is excised* through an anterior incision in the hollow between the coracoid and acromion processes, thus avoiding injury to the branches of the circumflex nerve. The long tendon of the biceps is pushed to one side. The capsule is opened as in shoulder-joint amputations, and the muscles inserted into the tuberosities are divided as there described. Usually the section of the humerus is made through the surgical neck; but it is better to remove more bone from the glenoid than from the humerus, since restoration of function depends largely on the preservation of the muscular insertions in the latter. After-treatment is the same as in excision of the elbow. In all these excisions, it is well, if possible, to open up the line of the old articulation first, by breaking adhesions and sawing across bridges of bone, and then to remove from the bone ends so much as is necessary. Attempts to excise a joint in one block, except by experienced surgeons, result in the removal of too much or too little bone. *Excision of the wrist* seldom is required; in most cases an erasion (p. 486) suffices.

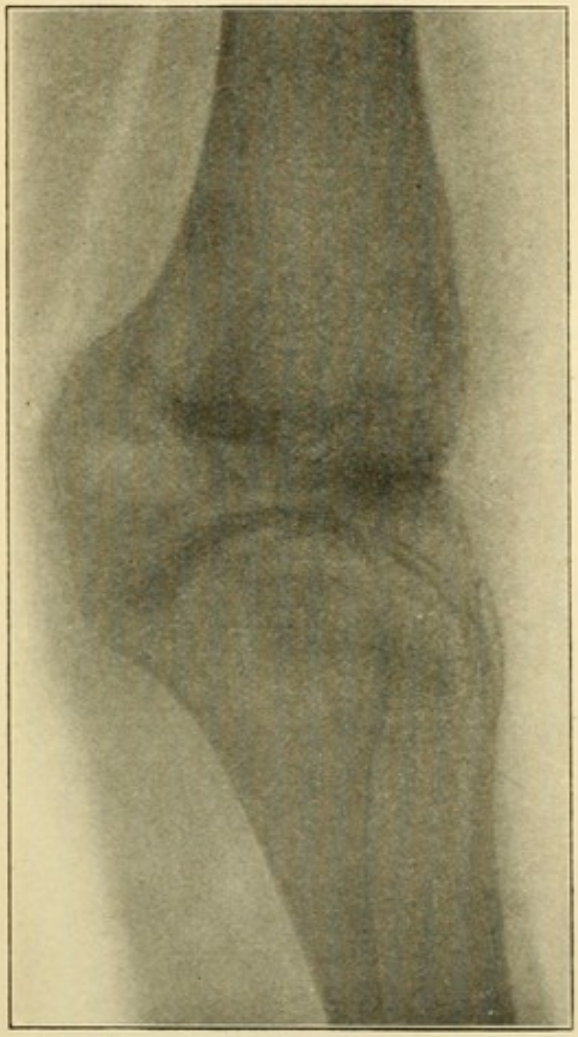

FIG. 488.—Result of cuneiform resection of the knee shown in Fig. 486. The epiphyseal lines have been carefully preserved. Episcopal Hospital.

If formal excision is done, the best incision is that of Mynter (1894), splitting the dorsum of the hand between the index and middle fingers. Ankylosis is the desired result.

Arthroplasty is an operation designed to secure a movable joint with the minimum amount of bone resection, by interposition between the bone ends of pedicled flaps of fat, fascia, or muscle. This operation has been practised with success by Murphy (1904), Huguier (1905), G. G. Davis (1908), and others. It permits the formation of a good movable joint at the knee if the lateral and patellar ligaments are preserved and the bone ends so shaped as to prevent luxation; and in the elbow and shoulder it preserves the free motion secured by the ordinary resection, at the same time rendering the joint more stable, because less bone has to be removed. But the operation is difficult, requires special training and experience in joint surgery, and is not always successful. Baer (1909) uses pig's bladder instead of autoplastic flaps. Lexer (1908) has successfully transplanted, from amputated limbs, entire joints with their attached capsule and ligaments.

SPECIAL INFECTIONS OF THE JOINTS.

The special infections of the joints usually can be differentiated clinically from pyemic infections, and from each other, but bacteriological study of the joint fluids or capsule may be necessary. Pyemic infections of joints are referred to at p. 74.

Pneumococcic Infection usually is a complication of pneumonia (70 per cent. of cases), but may occur from other sources, especially otitis media. The knee and shoulder are most often attacked. There is purulent effusion, and the signs of acute arthritis are present. *Treatment* consists in aspiration of the fluid and injection of 2 per cent. formalin-glycerin solution, and use of weight extension. Arthrotomy and drainage should be done if symptoms are severe or persist. The mortality is about 33 per cent. (K. Bulkley, 1914). Ankylosis is not unusual, but formation of sinuses is rare.

Gonococcic Infection usually is secondary to a gonococcal urethritis or its local complications. It occurs in less than 2 per cent. of cases, and mostly in the male sex; almost invariably the joint condition appears in the end of the third week (eighteenth to twenty-second day) after the onset of gonorrhea. The polyarticular form is rheumatic (*i. e.*, synovial) in character, somewhat resembling acute rheumatic arthritis; but the monarticular form is more like a septic arthritis. In the former the small joints of the hands and feet are oftenest affected; sometimes the sterno-clavicular joint. In the monarticular, form the knee, ankle, wrist, and elbow are oftenest invaded. The joints become extremely painful, swollen, red, and doughy to the touch. There is not much effusion. Endocarditis is an occasional complication. Spontaneous fistulization is rare. After gonococcic arthritis the joints are left in a more or less damaged

and sometimes seriously deformed state. Bony ankylosis is not unusual.

Treatment.—If rest of the affected joints (the patient always being confined to bed, and the primary infection receiving proper attention) does not secure marked improvement within forty-eight hours, the joints should be opened, and irrigated with saline or formalin-glycerin solution, and closed without drainage. There is too little effusion,

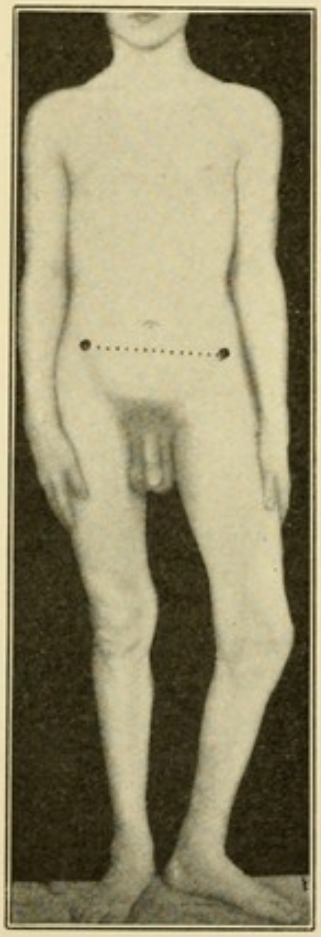

FIG. 489.—Post-typhoid ankylosis of left hip, in a lad of sixteen years. Dr. Harte's case. (See Fig. 490.) Orthopædic Hospital.

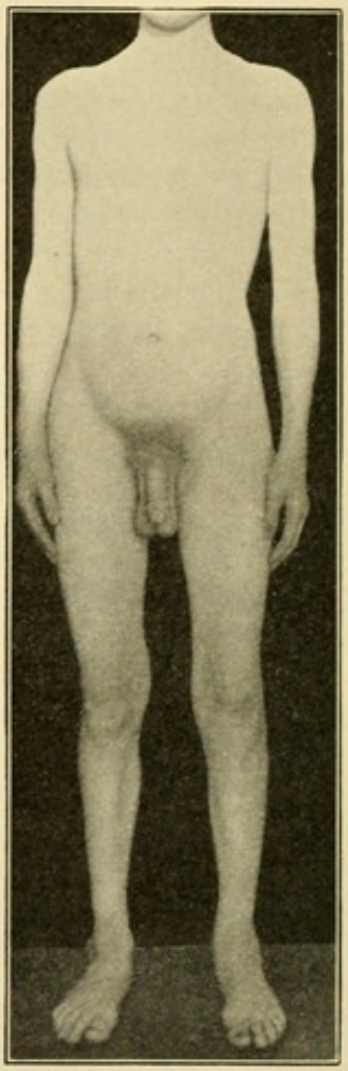

FIG. 490. — Result of subtrochanteric osteotomy of left femur for bony ankylosis in bad position. (See Fig. 489.) Orthopædic Hospital.

as a rule, for mere aspiration and injection to be efficient. Usually the disease is much shortened by joint irrigation; under conservative measures the joints may remain acutely painful for weeks, and the patient's health often is gravely affected, hectic fever and emaciation developing. Vaccine therapy is of considerable value. Fuller (1905) has proposed and practised drainage or extirpation of the seminal vesicles which some regard as the focus which maintains the infection.

Typhoid Arthritis occurs during or after convalescence from typhoid fever, usually about the third or fourth week of the disease. Its

development may be overlooked, owing to the patient's apathetic state. The hip is most often affected (Figs. 489 and 490); suppuration and sinus formation are not unusual (perhaps from mixed infection), though as in pneumococcic and gonococcic arthritis ankylosis may follow without frank suppuration. Pathological luxation may occur. *Typhoid spondylitis* (p. 615) sometimes is seen, though a true inflammation of the vertebral joints is much rarer than a periarticular fibrosis.

Subpyemic and Cryptogenous Arthritis.—In addition to these special infections of joints, and to tuberculous and syphilitic joint diseases, which are considered at p. 476 and 503, there are a number of other systemic infections, the etiological organisms of which are not known in all cases, but which sometimes are accompanied or followed by inflammation of one or more joints, and in which it is very evident that the general infection is responsible for the local inflammation, either by direct action of its bacteria, or through the toxins derived from these microbes. Such articular infections may be grouped together conveniently, as is done by Marsh, as *subpyemic infections*, some of them having a more or less evident etiology and symptomatology (arthritis and scarlet fever, influenza, dysentery, etc.); while in others, such as "acute articular rheumatism," the joint infection itself seems almost to constitute the disease. *Acute rheumatic arthritis*, unless some efficacious serum or vaccine is secured soon, will become a surgical disease when physicians become thoroughly convinced that it is a form of pyemia. Immediate removal of the pharyngeal tonsils, thought by some to be the portal of infection, has been adopted in a few cases. Or the surgeon may open, irrigate, and close the first joint affected; or aspiration and injection with formalin-glycerin solution (2 per cent.) may be done.

Probably the form of metastatic arthritis most often encountered is that following *infections of the pharynx, naso-pharynx,* or *tonsils.* The joint manifestations occur so long (several weeks) after the primary lesion has healed that their inter-relation usually is overlooked. The patients come to the surgeon with bony ankylosis, and tell him their physician has been treating them for rheumatism. The history is that very soon after exposure to cold or wet,[1] sudden pain developed in one or more joints; probably a chill occurred; the joint became swollen, red, and tender; the patients lay in bed a long time in one position; and finally when in the course of several weeks the acute symptoms subsided, one or more joints were found to be stiff, and have remained so since. A skiagraph will show bony ankylosis. Now, acute rheumatic arthritis does not cause ankylosis, its symptoms are rapidly relieved by salicylates, and the disease does not last more than two or three weeks.

These acute metastatic joint infections should be treated by *weight-extension* (to prevent deformity and if possible ankylosis), by *aspira-*

[1] This is to be regarded merely as the *localizing* cause of the joint lesions. The infection which occurred two or three weeks previously is the original cause.

tion of the joint contents (to relieve pressure on the synovial membrane thus preventing its destruction), and *by injection of* 10 *to* 15 *c.c. of a* 2 *per cent. formalin-glycerin solution* (to sterilize the joint). This injection may have to be repeated once or twice after intervals of a few days (Murphy, 1913).

There is, moreover, a still more obscure group of joint diseases, which clinically give every evidence of being infectious, but the true pathogenesis of which has not been established from a bacteriological stand-point. These may be called *cryptogenous infections* of joints, and include various "rheumatoid" conditions, which clinically resemble infectious as distinguished from dystrophic arthritis (p. 452). Among these, *chronic rheumatic arthritis*, a disease whose existence I do not doubt, holds an important place; by it I understand the

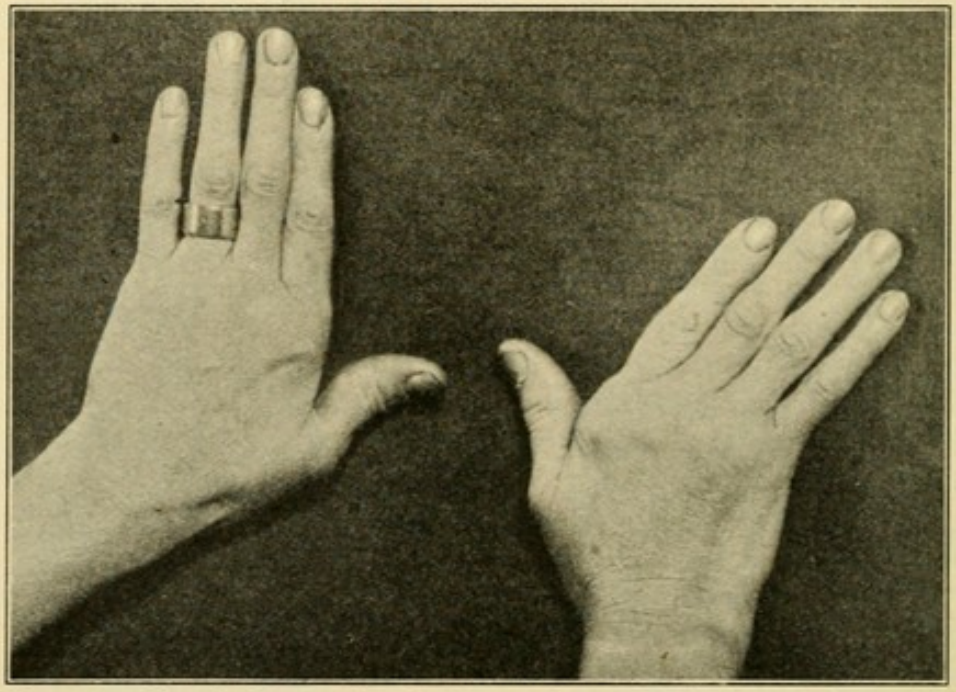

FIG. 491.—Chronic rheumatic arthritis; age fifty years; had acute rheumatic arthritis as child and as girl. Orthopædic Hospital.

damaged condition of joints which may persist after one or several attacks of "acute articular rheumatism;" on such a joint may be grafted, as on to any joint or set of joints whose resistance is below par, dystrophic lesions. I believe Fig. 491 represents such a condition. *Still's Disease* (1897), a chronic polyarticular affection of young childhood, resembling atrophic arthritis in many respects, and accompanied by enlargement of the lymph nodes and spleen, and involvement of the cervical spine, probably belongs among the cryptogenous infections. So does the *tuberculous rheumatism* of Poncet (1903), which is a subacute polyarticular infection, somewhat resembling in onset "acute articular rheumatism," but probably due to endogenous toxins of tubercle bacilli (Figs. 492 and 493). In this group of cryptogenous infections also belong certain cases of arthritis which cease to

trouble the patient when he is cured of some source of infection which may have been neglected for years; such are dental caries, pyorrhea

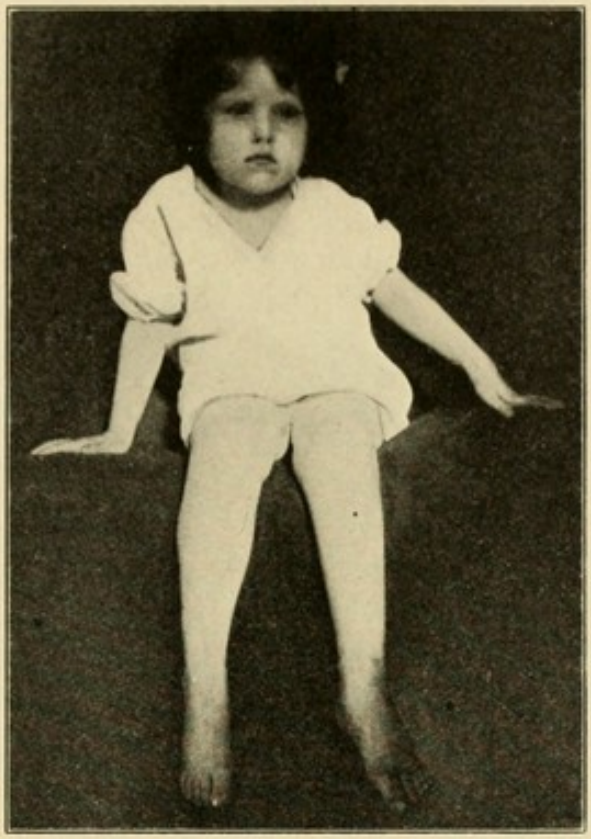

FIG. 492.—Tuberculous rheumatism in a girl of five years. Acute onset in left ankle, some weeks after an attack of scarlatina. Six months later left knee, wrist, and shoulder became similarly affected; reacted to tuberculin. Photographed one year after onset. (See Fig. 493.) Orthopædic Hospital.

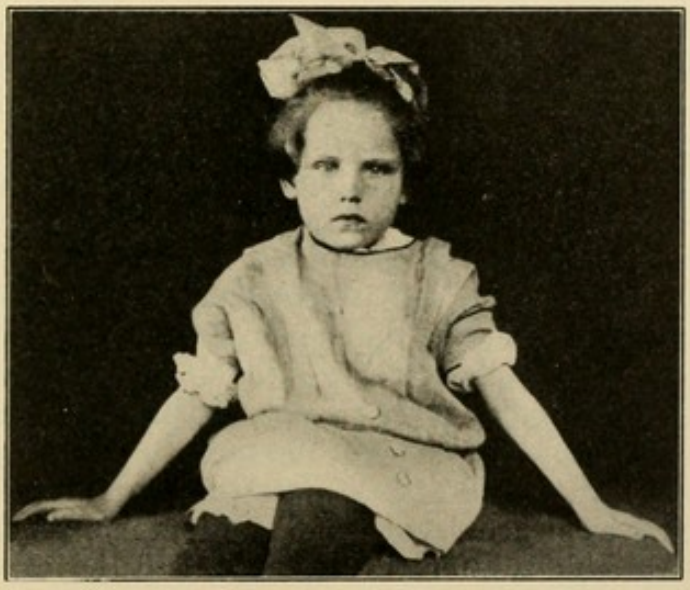

FIG. 493.—Patient shown in Fig. 492, one year later. Normal extension in left wrist. Knee still in plaster of Paris, and four years later not yet quiet. Orthopædic Hospital.

alveolaris; sinus diseases; affections of the tonsils; empyema thoracis (Fig. 494); affections of the lungs (here belongs *pulmonary osteo-*

arthropathy), intestines, appendix; genito-urinary diseases in both sexes, especially chronic semino-vesiculitis or prostatitis in the male, and cervical lacerations in the female, etc. Cases of joint disease concerned with one or more of the above infections are constantly being seen, and are recognized by intelligent physicians; and some remarkable results obtained by cure of the primary infection have been reported by Marsh, Goldthwait, and others.

In chronic rheumatoid conditions always look for a source of infection.

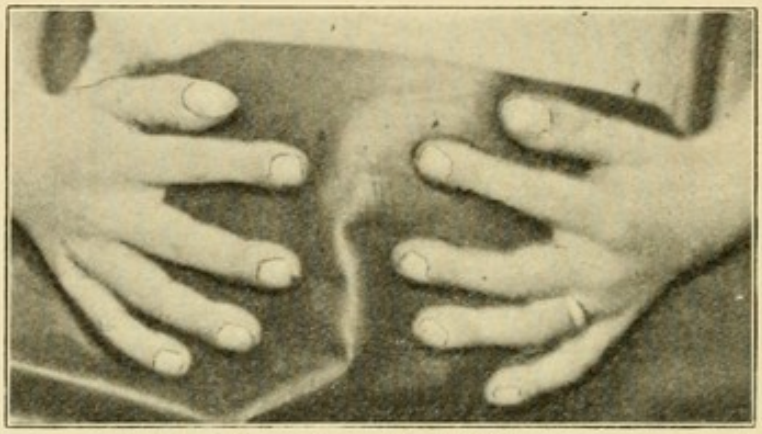

FIG. 494.—Pulmonary osteoarthropathy. Clubbed fingers four years after operation for empyema (unhealed). Age ten years. Children's Hospital.

Tuberculosis of Joints.[1]—**Pathology.**—In tuberculous arthritis the primary lesion in almost all cases, especially in children, is in the adjacent bone, and the synovial membrane lining the joint cavity is invaded only secondarily. This was first definitely shown by Nichols, of Boston, in 1898. The bacilli reach the bone ends through the blood-stream, presumably from a preëxisting focus in the bronchial or mesenteric lymph nodes; and they lodge in the region of the epiphyseal cartilage rather than in the diaphysis of the bone for the anatomical reasons stated at p. 438. The disease begins on one side or other of the epiphyseal cartilage. An additional, and perhaps a better reason for this localization of the bacilli is suggested by Ely (1911): he recalls the well known fact that tubercle bacilli flourish where red marrow exists (as in the epiphyses of growing bones), whereas bone which contains yellow marrow (adult bones throughout, and the diaphyses of juvenile bones) is almost immune to tuberculous invasion; he also suggests that the immunity of cartilage and fascia to tuberculous invasion is due to the fact that only in connective tissues which have epithelial, epithelioid, or lymphoid cells, do tubercle bacilli find a suitable soil for development, and that in this way the marked affinity of tuberculosis for synovial membrane is to be explained. This theory of Ely's also explains why primary synovial tuberculosis is so much less unusual in adults than in children, since

[1] The tuberculous nature of these diseases was first clearly demonstrated by Volkmann, in a classical paper published in 1879.

the bones of the former do not afford a suitable soil for the development of tuberculosis, owing to the absence of red marrow.

In tuberculosis of an epiphysis the lesion exists in the marrow, the cells of this structure being grouped around the invading bacilli in the form of histological tubercles; the bony trabeculæ are then destroyed, the centre of the tuberculous focus undergoes caseation, and *caries* of the bone is said to exist; if actual liquefaction occurs a *cold abscess* of bone is formed. The entire bone end is the seat of a rarefying osteitis, the bony trabeculæ being much decreased in size and strength, while the marrow spaces are increased. Formation of sequestra is rather unusual; when found they are small, and typically worm-eaten in appearance. Often there is a zone of sclerosed bone immediately around the sequestrum or the central caseous area, while outside of the sclerotic bone the rarefying osteitis, above described, continues. *Caries Sicca* is a term used by Volkmann (1867) to describe a rare form of joint disease now recognized as tuberculous, which is seen oftenest in the shoulder and in which gradual, quiet, fibrous ankylosis occurs, without swelling or other evidences typical of tuberculous arthritis.

The articular cartilage resists for a long time invasion by the spreading tuberculous process, and when the joint finally is entered it is more often at the site of attachment of the capsule than in the centre of the articular cartilage. But as the disease progresses the articular cartilage is gradually covered in by the tuberculous granulation tissue or "pannus," and is perforated in numerous places, giving (Fig. 495) it a typical sieve-like (Volkmann, 1882) or "pepper-pot" appearance; and in advanced cases the cartilage may be entirely destroyed.

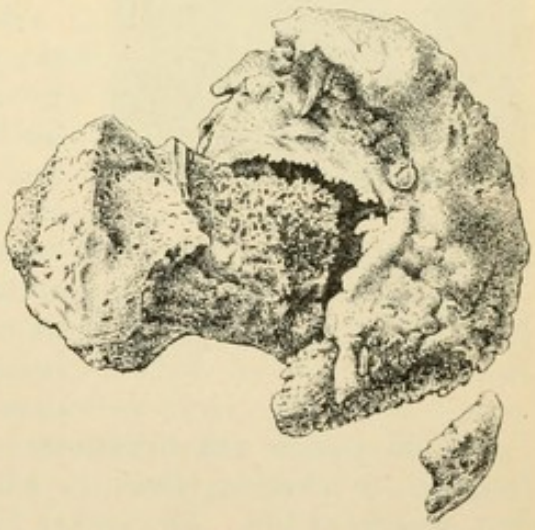

Fig. 495.—Head and neck of femur excised for tuberculosis. Note "pepper-pot" appearance of cartilage covering head of femur; pathological fracture of neck; and small sequestrum below. Children's Hospital.

Before actual tuberculous invasion of the joint cavity, there may be slight serous synovitis with effusion, from irritation due to the focus in the neighboring bone end. When the synovia has once been invaded, or in the rare cases of primary synovial disease, the tuberculous process spreads rapidly throughout the joint, attacking and perhaps destroying the ligaments, reaching out along adjacent tendon sheaths and bursæ, and causing a pulpy, gelatinous hyperplasia of all the serous tissues attacked (*gelatinous arthritis*, Ashhurst, 1871). Usually there is very little effusion, though "tuberculous hydrops" occasionally occurs (Fig. 496). Either by condensation of fibrinous

flakes, or by detachment of the tips of the villous synovial fringes, so-called "rice-bodies" or "melon-seed bodies" may develop in tuberculous joints. By most authorities these are regarded as highly characteristic of the tuberculous nature of the joint lesions: tubercle bacilli frequently have been found within the rice-bodies, and their inoculation into susceptible animals causes generalized tuberculosis.

If the tuberculous process extends to the skin surface, and a cold abscess of bone discharges itself through a sinus, secondary infection with pyogenic cocci is extremely apt to occur. Before such secondary invasion the walls of a sinus communicating with a tuberculous focus are not themselves the seat of tuberculosis; but when secondary infection is present the connective tissue which forms the walls of such a sinus are studded with tubercles (Ely, 1911). Secondary invasion with pyogenic cocci may occur through the blood-stream before any sinus forms; such a complication is apt to hasten the disintegrating process and encourage formation of sinuses.

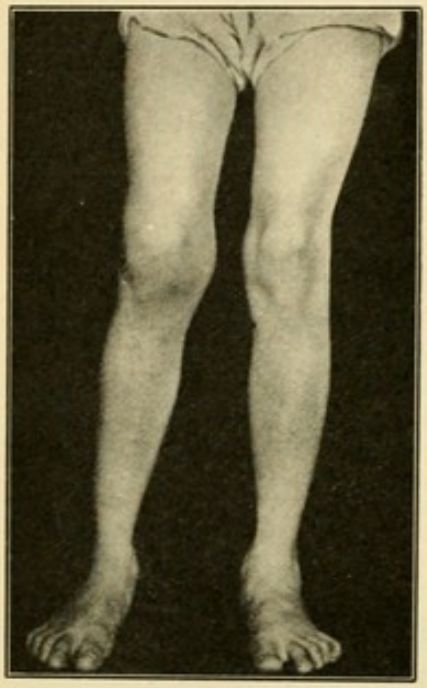

FIG. 496.—Tuberculous hydrops of right knee. Age eight years. Duration six months. For persistence of symptoms, excision of knee was done five years later. (Dr. Dickson's case.) Orthopædic Hospital.

Healing occurs by the encapsulation of the tuberculous focus or its replacement by fibrous tissue. If the joint cavity has been invaded this implies more or less firm fibrous ankylosis. In most cases the tuberculous process merely becomes latent, and is prone to become active again if the joint is subjected to unusual strain, or if the general health becomes impaired, particularly by the development of pulmonary tuberculosis.

Clinical Course and Symptoms.—Joint tuberculosis is much more frequent in children than in adults, arising especially during the first decade of life. The spinal joints are those most often affected; the knee and hip come next in order of frequency; while the joints of the foot, elbow, and wrist are more frequently diseased than the shoulder. In about one-third of the cases in children a history of traumatism can be obtained, two or three weeks previous to the onset of joint symptoms; and this generally is regarded as having a distinct etiological relation to the development of the disease. But it must be remembered that nearly all children sustain slight joint injuries, yet comparatively few develop tuberculous arthritis; so that it is necessary to assume a predisposition to tuberculosis and the existence of a primary focus elsewhere in the body. The injury which precedes the tuberculous joint symptoms rarely is severe; fractures scarcely ever are followed by tuberculosis, and fractures

in the tuberculous heal normally. Two explanations are offered for this: one is that the more severe injury arouses better defensive action on the part of the patient; the other is that severe lesions require careful and prolonged treatment, and healing, therefore, is more apt to occur than after a trivial injury which often is neglected.

Among the earliest subjective symptoms of tuberculous arthritis are disability and pain. The joint is used less, the joint is "favored," and it gives evidence of being more easily tired than the normal joint. Stiffness present on getting out of bed in the morning may wear away during the day; but toward evening the joint again becomes disabled, and this is evidenced by slight limp, and complaints of pain. Pain may be almost absent except when the joint is used; but frequently a joint which is painless when the child is awake will trouble it at night, causing restlessness, and on falling asleep and relaxing its muscles the child will experience "starting pains" which will rouse it momentarily from sleep with a "night-cry." Instead of pain being felt at the diseased joint, it may be *referred* to the peripheral distribution of the nerve supplying the joint: thus in tuberculous spondylitis pain frequently is present in the epigastrium (intercostal nerves), and in tuberculosis of the hip pain is referred to the knee (obturator nerve).

Examination of the diseased joint at this early stage shows slight but persistent muscular spasm. The muscles surrounding a joint are supplied by the same nerve that supplies the joint, and irritation of the joint causes reflex irritation of the adjacent muscles (Hilton's law, 1877). The joint may be held absolutely rigid by the patient, but in the earliest stages the most that can be detected is limitation of motion in all directions: there is neither full extension, flexion, abduction, adduction, nor rotation; and forcing any of these motions causes pain. Comparison with movements of the corresponding unaffected joint is imperative. The joint is held in the most comfortable position and is consistently protected by the patient: a sore wrist or elbow is supported by the other hand, and if the hip or knee is involved the sound foot may be put under the ankle of the diseased limb and be used as a splint to prevent motion in the painful joint.

There is tenderness to palpation directly over the joint, and persistent tenderness of a bone end with evidences of articular irritation is a valuable sign. Unless the disease is advanced, or primarily synovial in origin, there is rarely much thickening of the capsule or synovial effusion. In superficial joints (knee, elbow, ankle) more or less heat usually is appreciable, but in the hip this seldom can be detected. Muscular atrophy, an evidence of disuse, is a valuable confirmatory sign of tuberculous arthritis; in early stages it sometimes can be detected only by measurement, but in later stages, where articular thickening is present and accentuates the atrophy, it is apparent at a glance (Fig. 523).

With these local signs there is seldom much constitutional reaction.

The temperature may be raised 1° or 2° in the evening, and loss of appetite and malaise may be present; but there is no acute inflammatory state such as is seen in cases of septic arthritis.

As the disease progresses, the joint thickening increases, being of a doughy, boggy consistency, and typically spindle-shaped in outline. The skin is pallid, and the affection well deserves the name "white swelling" which has been applied to it for so many years. Spastic contraction of the surrounding muscles passes into true contractures, which will maintain deformity even if ankylosis is absent. Progressive joint disintegration may lead to partial or complete dislocation; and this usually is attended by relief from pain. Finally, by rupture of cold abscesses, sinuses may develop, and usually this complication is quickly followed by secondary infection, resulting in hectic fever, and the gradual but progressive decline of the patient's general health.

Diagnosis.—Symptoms of subacute arthritis in a child, from no apparent cause, or following slight injury, and without marked constitutional reaction, but persisting in spite of temporary rest, always should excite a suspicion of tuberculosis. This suspicion is strengthened by a family history of tuberculosis, either pulmonary or osseous, and is made nearly positive if there is persistent elevation of temperature of 1° or 2°, if the tuberculin tests (p. 81) are positive, and if there is no leukocytosis. Skiagraphic examination rarely will reveal any bony focus so early in the disease as to be of much value in doubtful cases, but a squaring of the epiphyses, particularly at the knee, is regarded as characteristic of tuberculosis.

A *sprain* will cease to cause acute symptoms if the joint is put to rest for two or three weeks; but a tuberculous arthritis always will be roused to activity if joint function is resumed in so short a time. A *septic arthritis* is more violent in its onset, is attended by much more constitutional disturbance, and progresses to early suppuration and joint disintegration; its course is run in days and weeks, while that of a tuberculous arthritis extends over months and years. *Acute rheumatic arthritis* is in most cases a polyarticular affection, is characterized by high temperature, cardiac or pleural complications, hyperleukocytosis, and marked local inflammatory reaction. It is rare in young children. In *syphilitic arthritis* other signs of syphilis nearly always can be detected.

A positive diagnosis of tuberculosis always can be made if tubercle bacilli can be found in the synovial membrane, rice-bodies, joint-fluid, etc., or if inoculation with these substances causes tuberculosis in a susceptible animal.

Prognosis.—The most favorable cases are those of apparent osseous origin in children, in which efficient treatment is instituted before evidences of invasion of the synovia are demonstrable, and in which the symptoms are so slight as scarcely to warrant a positive diagnosis. These are the cases in which patients recover with joints which are to all intents and purposes normal. After joint invasion is once

demonstrable, and in cases primarily synovial, the most that can be hoped for is recovery with more or less impairment of motion; and the more firm the ankylosis the less apt will the patient be to have recurrence of the disease. After secondary infection the prognosis is gloomier both as to function and life; and in adults all forms of tuberculous arthritis are much more serious than in children. In general terms it may be stated that from one-third to one-half of patients with tuberculous arthritis die as a result of their joint lesions; few indeed as a direct consequence (then mostly from hectic, amyloid degeneration of the viscera, etc.), but many from tuberculous meningitis, phthisis, or some intercurrent malady from which healthier persons would have recovered. In cases ending in apparent recovery, which often is merely latency of the tuberculous process, the course of treatment must last from one to five years or longer; and other patients must continue treatment until death removes them from the surgeon's care.

Treatment.—The *constitutional treatment* of surgical tuberculosis was discussed at p. 82; its value in tuberculous arthritis is inestimable, and never should be forgotten. The most efficient local treatment frequently is powerless to check the disease; and sometimes constitutional treatment alone is able to restore a patient to health. The surgeon must not overlook the fact that it is better to have a healthy body with a stiff or deformed joint, than to have a straight and comely joint without a body capable of sustaining life. If the general health is good, joint function can be restored subsequently by an orthopedic operation. Every hospital should have an open air ward or at least a porch available for tuberculous joint cases, where the advantages of constitutional and local treatment may be combined for those most requiring such care.

Local treatment may be summed up almost in one word: Rest. It is not known definitely how this acts, but a plausible theory is suggested by Ely (1911): he contends that cure is effected by abolishing joint function, because thus both red marrow and synovia become atrophic and in the case of ankylosis entirely disappear; and where they are not, tubercle bacilli cannot exist.

There are two chief methods by which joint rest is obtained: *fixation* and *traction*. *Fixation* is secured by the use of splints, plaster cases, braces, etc., the sole object being to abolish motion at the diseased joint as effectually as possible; this not only relieves pain, but has direct influence in checking the tuberculous process. By *traction* is understood not so much actual extension on the limb sufficient to pull the joint surfaces apart, as cessation of weight-bearing and relief of pressure: it acts by relieving pain and securing rest, but also prevents deformity which is prone to occur when the weight of the body is borne on the softened bone ends. Traction is applied chiefly to the knee, hip, and spine; fixation alone usually is sufficient for the upper extremity.

Whenever possible in the spine and lower extremity the advantages

of fixation and traction should be combined. This is best accomplished by bed-treatment, so long as acute symptoms persist, regardless of the stage of the disease. Recumbency at once removes the weight



FIG. 497.—Bradford frame. See text.

of the body from the diseased joints, and fixation is much more readily secured. In children, the use of a Bradford frame (1890) (Fig. 497) to which the body is strapped, provides fixation for spine, hip, or



FIG. 498.—On the roof garden of the Orthopædic Hospital. Showing Bradford frames with head and foot extension.

knee, in the most efficient manner. This frame is made of gas-pipe, and is covered with tightly stretched canvas; it should be a little longer than the patient and as wide as from one armpit to the other. The child is fastened to it by a broad canvas apron covering chest

and abdomen, or by straps crossing the shoulders.[1] The frame thus becomes a part of the child, and the two together can be carried about from room to room, or from ward to roof garden (Fig. 498), thus preventing the painful and harmful joint-movements necessitated by carrying the child in the arms or transferring it to a stretcher and back again to the bed. Weight-extension usually is a desirable adjuvant in securing joint fixation, and is the most effectual method of overcoming pain and muscular spasm, to which latter factor deformity in the earliest stages is due. Weight-extension always should be applied in the axis of the deformity (Fig. 512), and as spasm lessens the direction of the extension can be gradually changed until the normal position is secured. Great care must be exercised during recumbent treatment to keep the foot at a right angle with the leg, preventing the development of talipes equinus.

When all symptoms of arthritis (limitation of motion from spasm, pain, fever, etc.) have been absent for a month or more, recumbent treatment may be discontinued. This stage is reached after two to six months in cases coming under observation in the early stages of the disease. If local treatment (fixation and traction) are now recklessly discontinued in the erroneous idea that the joint is cured, and if the patient is allowed to resume joint function, it will be only a few weeks before all symptoms of arthritis return, and possibly in aggravated form. It is absolutely imperative to guard the joint against injury and strain by continuing for a long period fixation or traction, or both, during ambulatory treatment. By the use of plaster of Paris cases, braces, crutches, etc., both fixation and traction (in modified forms) can be continued; and this should be done until, by allowing gradual return of function (first limited motion, then weight-bearing), the surgeon proves that the joint lesion has become so thoroughly encapsulated as not to be liable to cause recrudescence of the disease. This period of ambulatory after-treatment extends always through several months, usually through a year or more, and often for many years. Only by making haste slowly can permanent good results be achieved. If there is any reason (there are few good reasons) why recumbent treatment is impossible when the patient first is seen, ambulatory treatment with fixation and traction may be employed from the start; but this is apt to promote ankylosis, and deformity is very difficult to prevent. Moreover, in many cases the symptoms are so acute that rest in bed is an absolute necessity. Yet I believe with Coudray (1911), that in no case should a manifest tendency toward ankylosis be hindered; the joint should be kept in good position, but attempts to preserve motion are extremely apt to keep the disease active. The surest and most lasting cures are those which follow ankylosis.

Treatment of Cold Abscesses.—If the joint be put at rest, and the patient kept in the open air, the threatening abscess may cease to

[1] G. G. Davis uses also an upper frame, well padded and moulded to the body, to hold the child against the lower frame.

enlarge, and in not a few cases gradually will disappear. Hence these conservative measures should be given full trial. If the abscess continues to enlarge, and threatens to approach the skin, with the consequent danger of infection from the skin cocci, even before spontaneous rupture makes such an infection sure, I think it is best to expose the abscess wall by careful dissection through overlying healthy tissues, to incise the abscess, evacuate its contents, and wipe the abscess cavity gently but thoroughly with iodoform gauze. I cannot see that anything is to be gained by curetting the walls of the abscess cavity, nor by attempts to "excise the sac," which in many cases is an impossibility. The incision to reach the abscess is sutured in layers, without drainage. Children should be etherized, but in adults, local anesthesia is sufficient. In most cases (fifty-one out of sixty, according to Starr, 1907), the incision heals without breaking down at any point, and in only a very few cases does the abscess refill and require a second evacuation. It is dangerous to leave a cold abscess to itself until the overlying skin has become adherent and reddened, since secondary infection from skin cocci is frequent, and rapid joint disintegration, hectic, amyloid disease, etc., follow; and it is still more dangerous to open a cold abscess without perfectly aseptic technique, or to drain it by tube or gauze after incision, or to allow it to discharge itself spontaneously. But sometimes the patient is not seen until spontaneous rupture threatens, and secondary infection already is present. Under such circumstances the abscess should be evacuated by a small incision where it is pointing, but should not be drained; the puncture should be occluded with aseptic gauze, and in many cases little or no subsequent discharge will occur, the "hot" will gradually resume its character of "cold" abscess, and eventually may be absorbed. Thus the formation of sinuses and prolonged suppuration may be prevented.

Aspiration of a cold abscess is inferior to formal incision, because it cannot be done satisfactorily until the pus is very close to the surface and unless it is very fluid. A certain number of cures, however, will follow aspiration and injection of a 10 per cent. iodoform-glycerin emulsion.

Treatment of Sinuses.—In tuberculous arthritis sinuses nearly invariably are an indication of secondary infection: if no secondary infection is present (a fact which bacteriological investigation will demonstrate), they usually will heal under rest and constitutional treatment. I have had exceptionally good results from *heliotherapy:* the sinuses are exposed to direct sunlight, beginning with periods of five minutes twice daily, and increasing the length of the exposures as rapidly as possible without producing sunburn. If the sinuses fail to heal, and if discharge of pus is not profuse, they should be filled with the bismuth paste of Beck (1905): one part of bismuth subnitrate (arsenic free) to two parts of sterile amber vaselin. This is heated in a water bath until fluid, and is injected into the sinuses by a syringe which after being boiled, is rinsed in alcohol and

allowed to dry before it is filled with the liquid paste. The sinuses are filled as full as possible. A skiagraph, made after distending the sinuses with this paste, will show their origin and ramifications (Fig. 499). If pus should be dammed up behind the paste, the increased

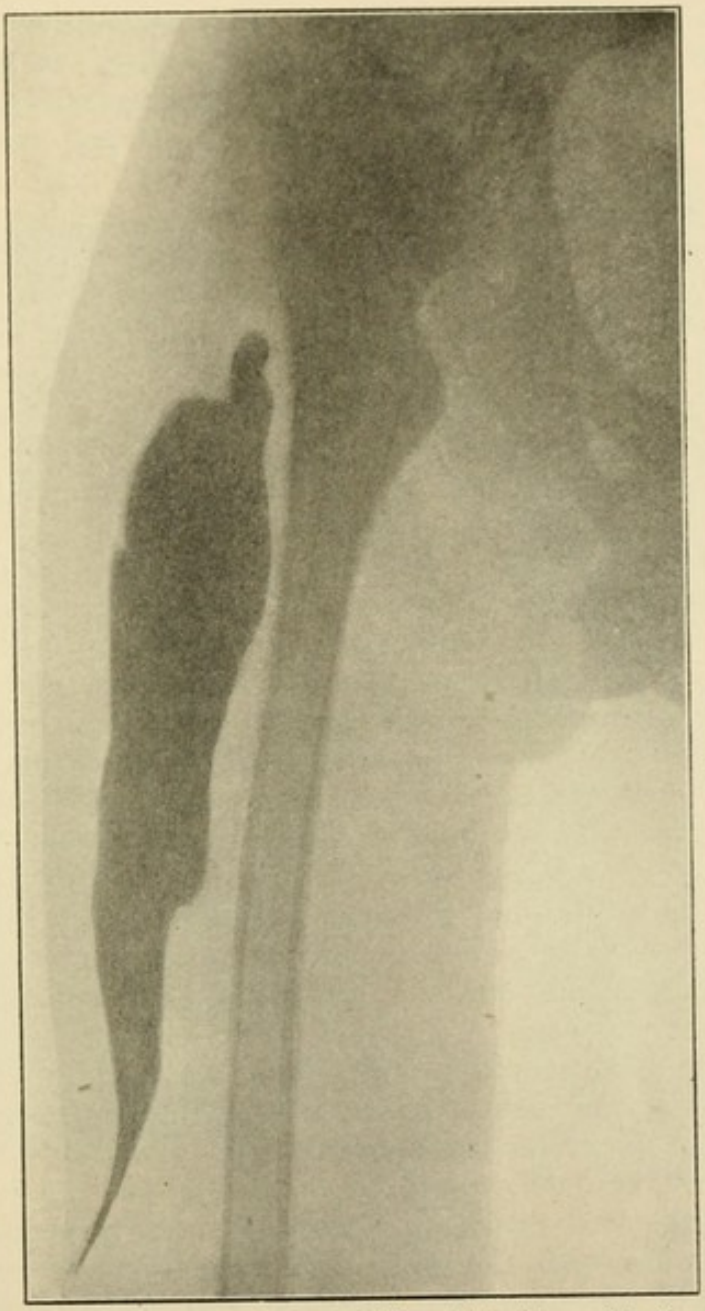

FIG. 499.—Skiagraph of tuberculous arthritis of left hip, with sinus discharging on outer surface of thigh; sinus has been distended with Beck's bismuth paste. Boy, aged ten years; coxalgia for six years. Abscess punctured three months before skiagraph was made, because it was pointing and because there was secondary infection from skin cocci. Orthopædic Hospital.

local heat will cause the paste to melt, and it will be extruded from the sinus spontaneously. The mode of action of bismuth paste is not certainly known, but it causes marked improvement, the discharge diminishing and the sinuses often closing in a comparatively short time. If a firmer injection mass is desired, the following formula

(Beck's paste No. II) may be employed: Bismuth subnitrate (arsenic free), 30 parts; amber vaselin, 50 parts; paraffin, 10 parts. Or Mosetig-Moorhof's iodoform bone-wax may be used (p. 435). Bismuth poisoning has been observed in a few instances, so not more than four or six ounces of Beck's paste should be employed in a child.

If profuse suppuration persists in spite of conservative measures, it is probable that a sequestrum is present, and this may be removed by curette or gouge. Formal operation in children rarely is advisable. Injections of alcoholic solutions of iodin (2 to 10 per cent.) are useful in overcoming secondary infection.

Operative Treatment in Tuberculous Arthritis.—It might be thought that early excision of the diseased area would abort the disease, but unfortunately it scarcely ever is possible to locate by skiagraphy or otherwise an extra-articular focus; nor would what might be considered total extirpation of the focus amount to much more than removal of the centre of an area infected far beyond what is indicated by gross appearances. When once the joint itself is involved, only a formal excision could remove all the disease, and in children such an operation, which implies removal of the epiphyses, is productive of such marked deformity and disability as to be generally condemned by intelligent surgeons. Moreover, in children, the results of conservative treatment thoroughly carried out, as outlined above, are so satisfactory, that operation presents no advantages in the early stages of the disease. In adults, on the other hand, the results of conservative treatment have proved so disheartening, chiefly through their inability to endure confinement to bed, and their tendency to develop phthisis, that joint excision or even amputation is the accepted form of treatment. Ely (1911) claims that an excision which will produce ankylosis and thus permanently abolish joint function is all that is necessary to effect a cure; he asserts that it matters not how little bone is removed, nor how much tuberculous material is left, so long as ankylosis is obtained, as this in itself will cause disappearance of synovia, which is the joint tissue on which in adults tubercle bacilli almost solely subsist. But hitherto it has been the habit of surgeons to remove as much diseased tissue as possible. In children, excisions, if done, should be limited to the epiphyses of the bones, the epiphyseal cartilages being rigorously respected, and any focus in the metaphysis should be evacuated by the curette through a perforation of the epiphyseal cartilage, and not by sawing off the bone end until all diseased tissue disappears. *Arthrectomy* or *erasion of joints*, adapted especially to the knee, was introduced by Wright, of Manchester (1881), and in this country by J. Ashhurst, Jr. (1889), as a substitute for excision in children; it aims to remove all the diseased soft tissues (synovia, ligaments, cartilages) without invading the bones; and may be employed for the purpose of effecting ankylosis when conservative measures fail to secure subsidence of symptoms. Like excision, there is nothing specific in its action; it is merely a method of joint disinfection.

Treatment of Ankylosis from Tuberculous Arthritis.—As has already been indicated, ankylosis following tuberculous arthritis often implies merely a latency of the disease, though no doubt definitive cure sometimes occurs. But owing to the frequency with which slight trauma, even many years after ankylosis has occurred, may rouse the dormant lesion into activity, the surgeon should be extremely cautious in efforts to restore joint motion. If ankylosis has occurred in good position, especially in the joints of the lower extremity, no

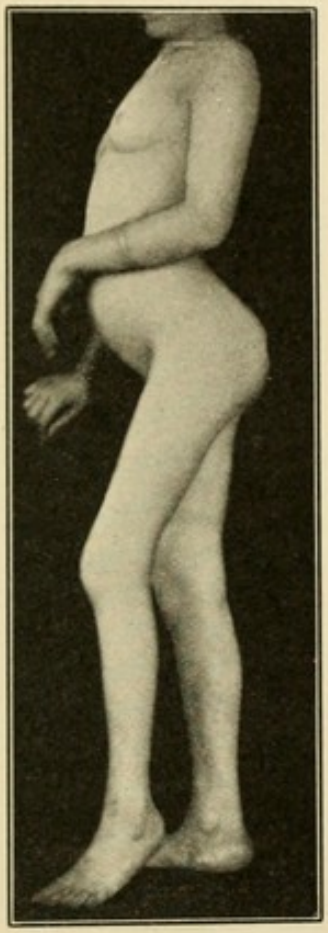

FIG. 500.—Ankylosis of hip from old coxalgia, age thirteen years. Orthopædic Hospital.

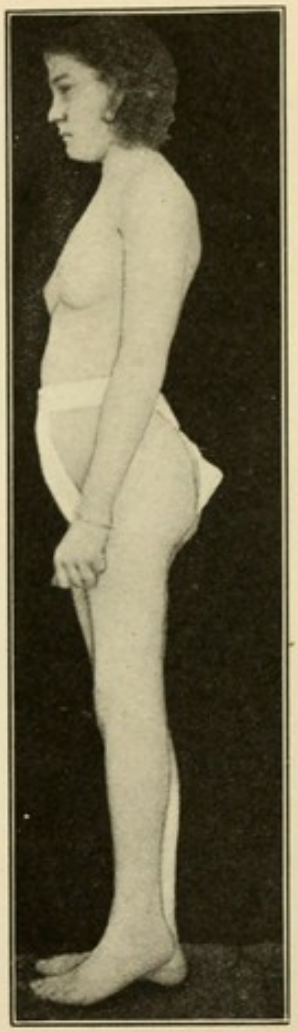

FIG. 501.—Same patient as Fig. 500; one year after subtrochanteric osteotomy of femur. Orthopædic Hospital.

treatment should be adopted, as a rule. For deformity at the hip, subtrochanteric osteotomy (p. 468) is the best treatment, as it divides the bone where healthy (just below the lesser trochanter), and there is very little risk of rousing the old disease, especially if the bone section is made with a saw instead of by osteotome and mallet. A puncture is made about two inches below the great trochanter, on the outer side of the femur, with Adams's knife; this is passed directly to the bone, and is then carried across its anterior surface, and along this knife as a guide, Adams's saw is passed; the knife

is then withdrawn, and the femur is divided by very gentle sawing. The limb is then brought into a position of abduction and nearly full extension (Figs. 500 and 501). Tenotomy of the adductors may be necessary to secure abduction. The limb is then fixed in this position in plaster of Paris, and is treated as a recent fracture. At the knee, formal excision (p. 469) usually will secure a useful and straight limb, though still ankylosed; attempts at arthroplasty in tuberculous knees are to be condemned. An ankylosed elbow causes great disability even if ankylosis has occurred at the best possible angle, and excision may properly be done with the aim of restoring motion. The same is true of the shoulder.

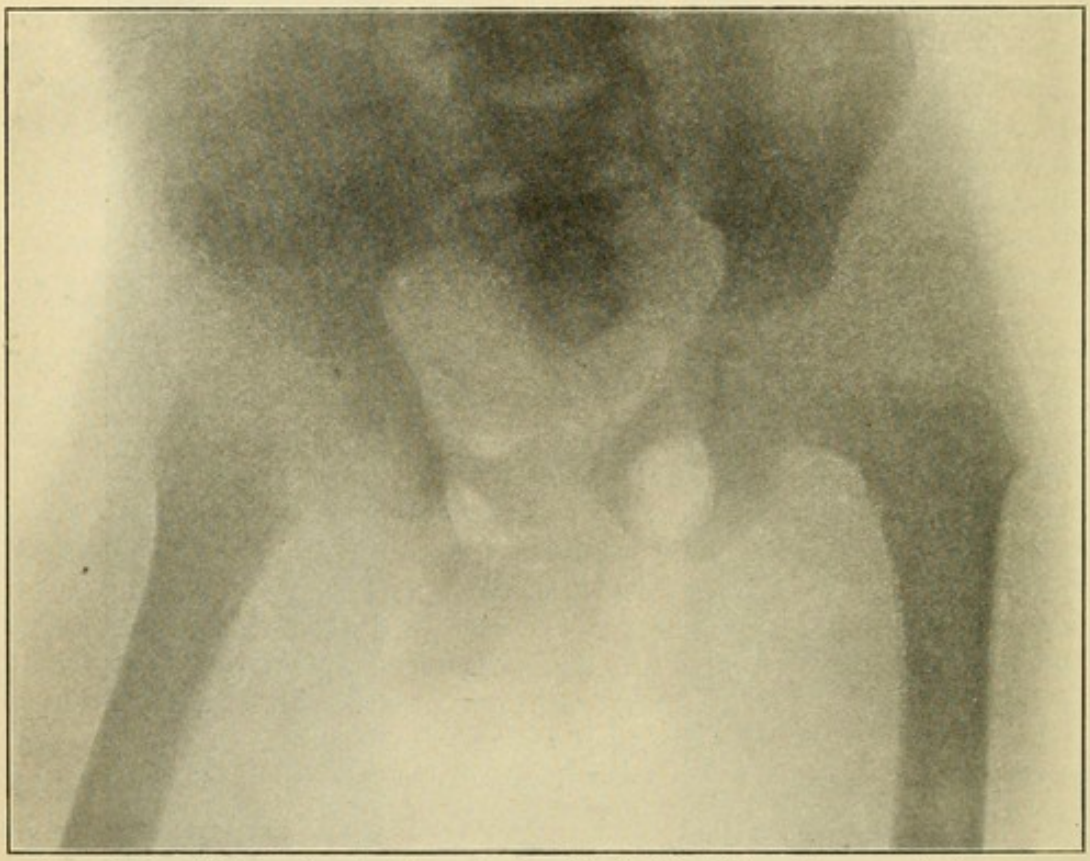

FIG. 502. — Skiagraph of tuberculosis of left hip-joint. Boy, aged five years, duration five months. Note abduction and flexion of thigh; absorption of head of femur and involvement of acetabulum. Orthopædic Hospital.

Tuberculosis of the Hip.—Pathology —The primary lesion is in the neck or head of the femur in most cases, but occasionally the acetabulum or synovia is first involved. Acetabular and synovial disease are intra-articular from the beginning; and a femoral lesion very soon penetrates the joint, the epiphysis of the head being intra-articular. Thus in all cases invasion of synovia occurs early, and in many the acetabulum remains healthy for only a short period. There is marked rarefaction of the bone, nearly all calcareous matter disappearing; the skiagraphic picture (Fig. 502) is not unlike that of round-celled sarcoma of bone in the total obliteration of all land-

marks. If weight-bearing is continued, the acetabulum may be enlarged upward and backward ("wandering acetabulum"), and pathological luxation may occur; if this is an early symptom in cases in which weight-bearing has not been allowed, it generally is due to rupture of the capsule from intra-articular effusion. The head of the femur may become very much altered in shape, or entirely absorbed; and when secondary pyogenic infection is present, pathological fracture of the neck is not very rare (Fig. 495). The best result in such cases is firm ankylosis (Fig. 503).

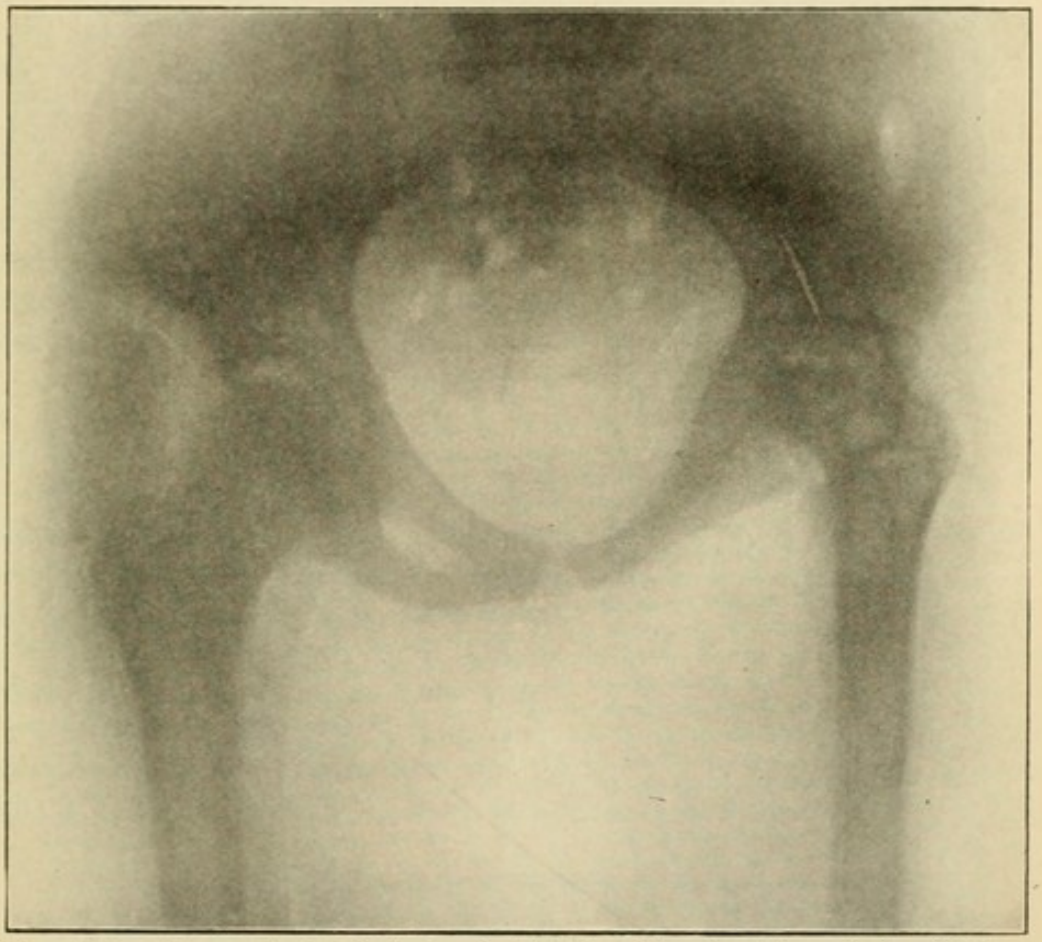

FIG. 503.—Skiagraph of ankylosis of right hip following tuberculosis. Girl, aged thirteen years; coxalgia at nine years; no symptoms for two years; healed sinus present in groin. Note obliquely contracted pelvis. Orthopædic Hospital.

Symptoms and Clinical Course.—When early symptoms of tuberculous joint disease (p. 479) point to the hip, the patient should be attentively examined after removal of all clothing from the waist down. Nearly 90 per cent. of cases are in children under ten years of age. First the gait (bare-footed) should be studied: usually a slight limp will be noted; and in the early stages the thigh is held in slight *flexion* and *abduction*, causing *flattening of the buttock* and *obliteration of the gluteal fold* on the affected side (Fig. 504). The patient is then laid flat on his back on a firm table: measurements from the navel to the malleoli may show *apparent lengthening* of the affected extremity; this is due to its abduction, but if the healthy limb is placed in a

similar degree of abduction the discrepancy will disappear. Unless there is marked bone deformation or dislocation there can be no actual change in the length of the limbs. Examination usually is best begun by testing the motions of the normal limb, making all the tests with extreme gentleness, and aiming to gain the child's confidence. Usually the affected thigh is kept slightly flexed (Fig. 505), and when an attempt is made to bring it out straight, the lumbar spine rises from the table (Fig. 506) because the hip is held rigidly in flexion, and motion is transferred to the spine. First rotate the lower extremity gently to and fro in its own axis, comparing the motion in the two limbs; there will be little or at least limited rotation on the diseased side, and it will be painful. Then try abduction of the thigh, still keeping the limb as fully extended as possible; on the diseased side abduction usually is markedly limited by the muscular spasm. The range of flexion is next investigated, first, by bringing the sound thigh up against the abdomen, and then comparing this with flexion in the diseased joint; this usually is somewhat limited, but not so markedly as rotation and abduction. Next, abduction with the thigh flexed to a right angle may be tested; this is always

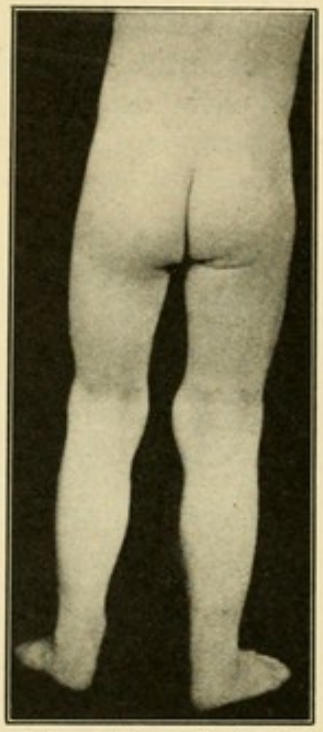

FIG. 504.—Tuberculosis of the left hip. First stage: flexion and abduction; flattening of buttock and obliteration of the gluteal fold. Age five years; duration two months. Orthopædic Hospital.

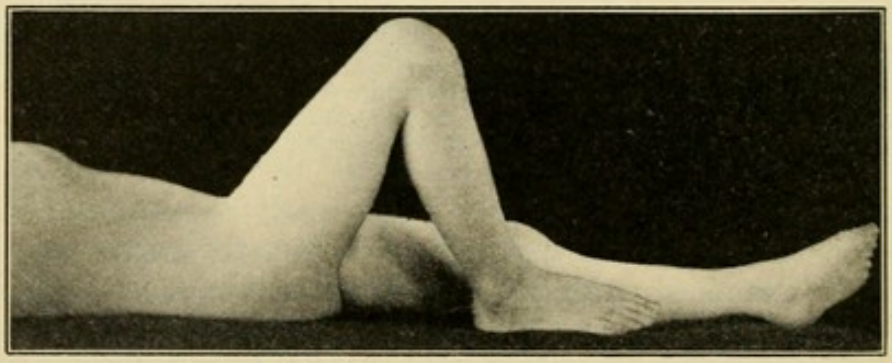

FIG. 505.—Tuberculosis of right hip for nine months. Age three years. The hip is held in a flexed position by muscular spasm, and the lumbar spine lies flat on the table. (See Fig. 506.) Orthopædic Hospital.

much decreased on the diseased side. Then the child is turned over on its stomach, and the range of hyperextension is tested in each hip by raising the knee from the table; this movement always is

limited on the diseased side, and where marked flexion deformity is present, it is manifestly unnecessary to test hyperextension. If any of these motions are persistently, even if only very slightly

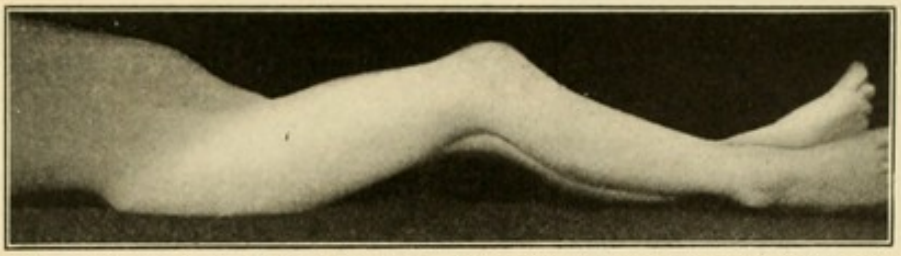

FIG. 506.—Tuberculosis of right hip (see Fig. 505), showing arching of lumbar spine when attempt is made to bring the knee down on the table. Motion occurs in the lumbar spine, not in the hip-joint. Orthopædic Hospital.

limited, and if there is a history typical of the onset of tuberculous arthritis, the diagnosis may be considered established; and if an exami-

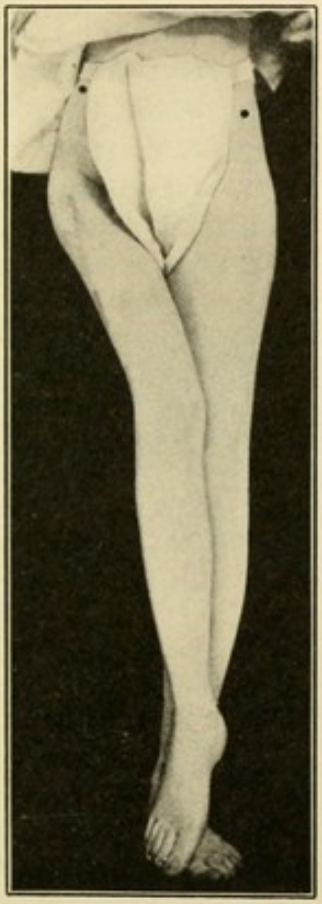

FIG. 507.—Deformity, following tuberculosis of hip: adduction and shortening (six inches). Age sixteen years; onset of disease at three years; healed sinuses. No symptoms for the last eight years. Orthopædic Hospital.

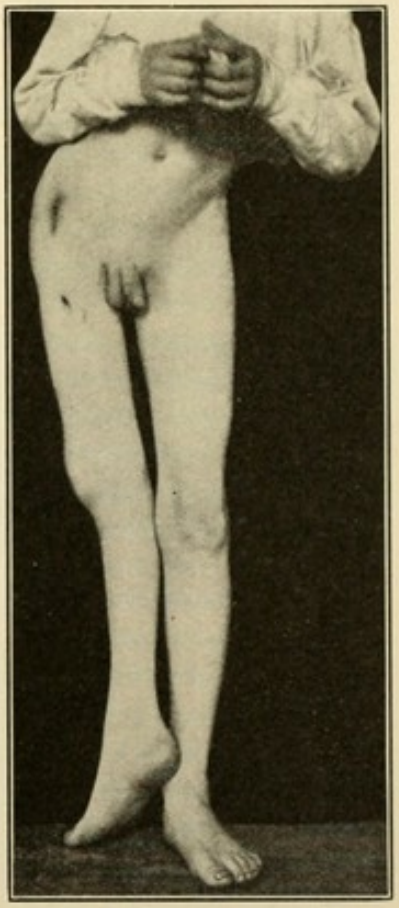

FIG. 508.—Extreme exterior rotation following tuberculosis of hip. Age twelve years. Duration four years; sinuses still open. (Dr. Alexander's case.) Episcopal Hospital.

nation such as above indicated were systematically made by the physician first called to attend the patient, and if proper treatment were instituted, valuable time would be saved. Only too frequently

the family physician makes no physical examination at all, or only a partial one, hampered by the patient's clothing; and treatment for a sprain or for rheumatism is prescribed, when a very little more trouble would have enabled a correct diagnosis to be made. In the rare cases where the signs are so slight as to render a positive diagnosis hazardous, the surgeon will consult his own and the patient's interests much better by enjoining recumbent treatment for a week or two, than by making light of the malady.

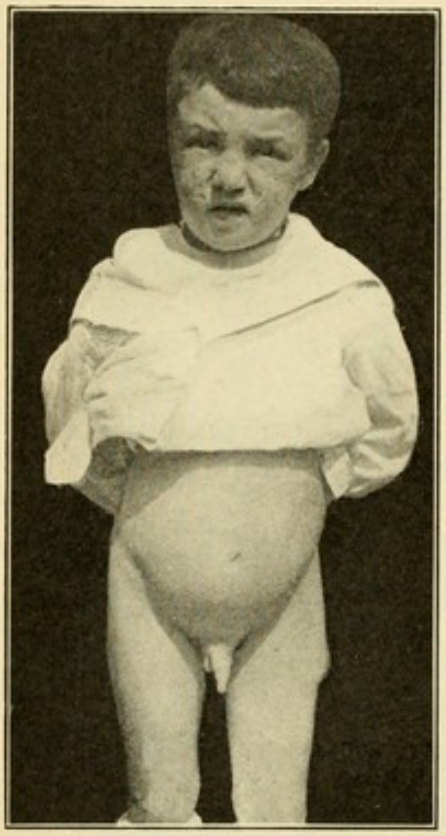

FIG. 509.—Cold abscess of left thigh, from tuberculosis of hip. Sequestrum discharged later. Age four years; duration three years. Orthopædic Hospital

At a later stage of the disease, the early deformity of abduction is replaced by *adduction*, possibly owing to atrophy of the iliopsoas which lies closest to the joint, and the unapposed action of the adductors. In efforts to walk the patient has to bring the lower extremities parallel, and as the diseased limb is fixed in adduction, the healthy limb must be abducted to correspond; this causes a descent of the pelvis on the unaffected side, and *apparent shortening* of the diseased extremity. But if the healthy limb is placed in a similar attitude of adduction, the measurements will be found the same, unless bone destruction or dislocation is present. The deformity of flexion and adduction, in this which is called the second stage of "coxalgia," may be due in part to intra-articular

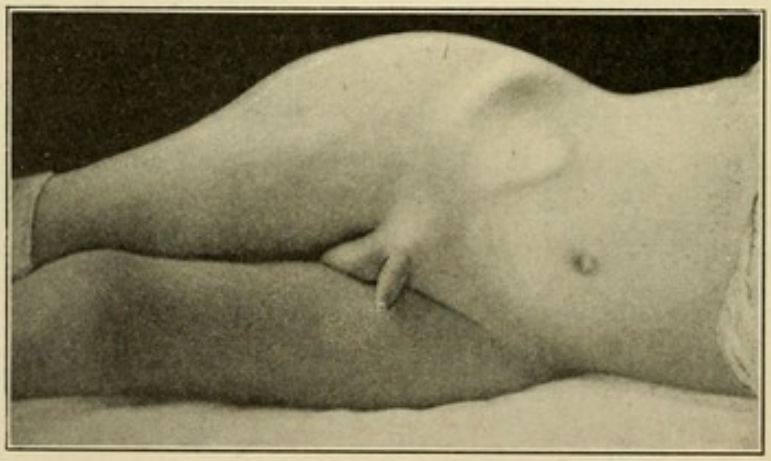

FIG. 510.—Gluteal abscess in coxalgia. (Dr. Hodge's case.) Children's Hospital.

changes, but most of it is due to muscular contractures which may be overcome by joint fixation and traction.

At a still later stage of the disease the patient may come under observation with cold abscess or sinuses, and with ankylosis in almost any position (Figs. 507 and 508), or with pathological luxation. Cold abscesses and sinuses usually are in direct communication with the joint cavity, but occasionally are due to extra-articular perforation of the bone. The abscess may point at any part of the thigh, but

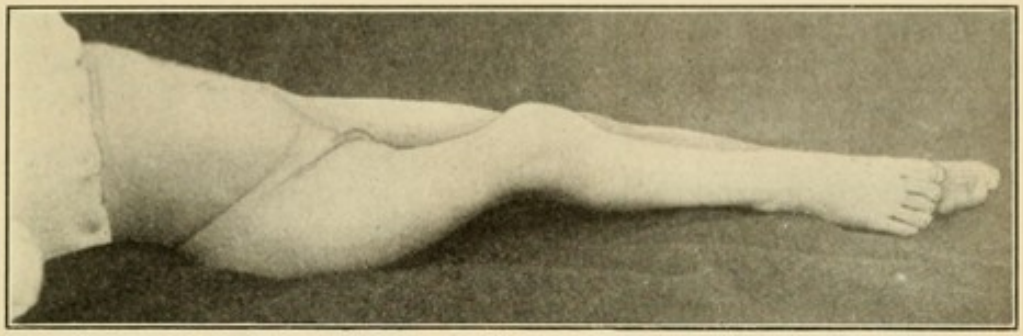

FIG. 511.—Adductor abscess in coxalgia. Age six years. Coxalgia for one year. Abscess for four weeks. Orthopædic Hospital.

the most frequent site is on the outer side (Fig. 509); or a gluteal abscess (Fig. 510) may occur, usually from perforation of the posterior capsule. Abscesses or sinuses in the adductor region (Fig. 511) usually are an evidence that the acetabulum is involved, as, according to Vincent (1895) is the occurrence of adduction as the primary deformity.

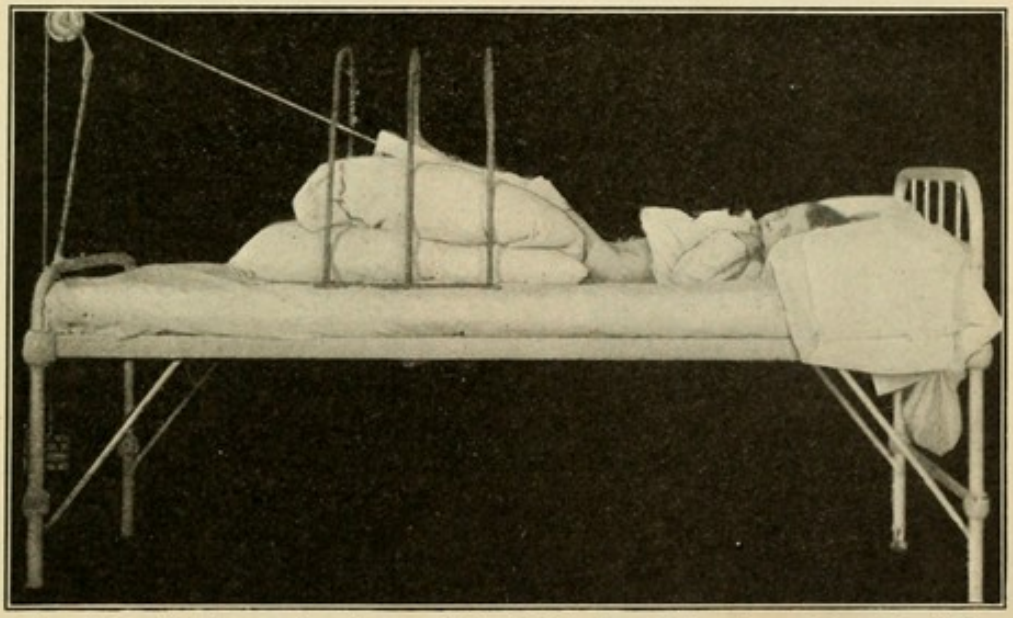

FIG. 512.—Bed extension for coxalgia with flexion deformity. Note the high cradle to keep the bed-clothes off the foot. Episcopal Hospital.

Diagnosis.—Not every case of arthritis of the hip is tuberculous, even in children, and where doubt exists as to the etiological factor, other aids may be called in to assist the clinical diagnosis, such as the tuberculin tests, estimation of the leukocytes, and skiagraphy. Nor

should the surgeon forget that other affections besides arthritis may cause rigidity, flexion, adduction, etc. Among such may be mentioned inguinal or femoral adenitis, psoas abscess (p. 607), and even appendicitis. Attention to the clinical history and physical signs will exclude such affections as fracture of the cervix femoris, congenital or traumatic dislocation of the hip, coxa vara, and deformity from infantile arthritis.

Treatment.—Recumbency should be insisted on in all early cases, with weight extension of two or three pounds applied in the axis of the deformity (Fig. 512). Sufficient fixation usually is secured by

Fig. 513.—Thomas hip brace. Episcopal Hospital.

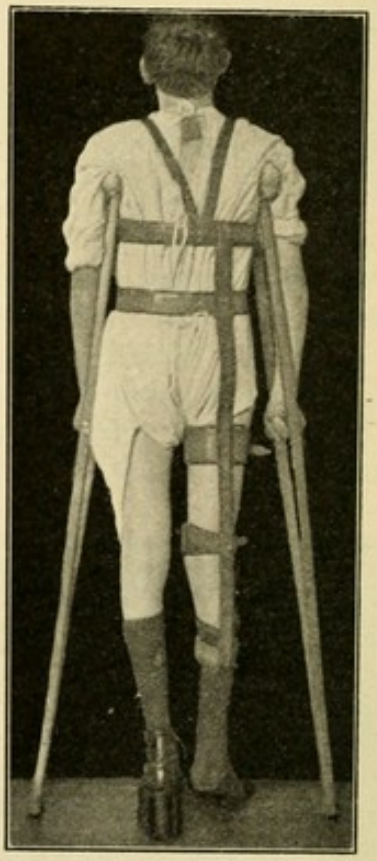

Fig. 514.—Thomas hip brace; rear view.

strapping the body to a Bradford frame. If this cannot be procured, a binder's-board splint or light plaster cast may be applied to the hip and pelvis, weight-extension being used in addition. In most cases, after a week or two, muscular spasm disappears and full extension may be secured. The temperature should be recorded twice daily, in this as in all acute tuberculous conditions; it forms a valuable guide as to the progress of the local lesion. After one or two months of recumbency examination may disclose an apparently normal joint, and the temperature curve may be quite satisfactory; but this merely indicates that the disease is latent, not that it is cured.

When symptoms have been absent for a month or more, ambulatory treatment may be cautiously tried. In this, joint fixation may be gradually relaxed, but weight-bearing should be prevented for a long time to come. Various braces are in use for this stage of treatment: with all, a high shoe is worn on the healthy side, and crutches are used, allowing the diseased limb to swing free of the ground. The brace of H. O. Thomas (1875) (Figs. 513 and 514), provides *fixation* at the hip, and traction is secured by the weight of the limb; but it is impossible for the patient to sit down with the brace on, and the limb may rotate within the brace, giving rise to unsuspected

FIG. 515.—Taylor hip brace. Episcopal Hospital.

FIG. 516.—G. G. Davis's brace for coxalgia. Orthopædic Hospital.

deformity. About 1855 H. G. Davis introduced the method of *traction* in ambulatory splints; a modification of this, introduced in 1873 by C. F. Taylor (Fig. 515), consists of a pelvic band, passing around the pelvis between the anterior superior iliac spines and the level of the great trochanters, to which is attached a long outside iron extending below the foot beneath which it forms a stirrup; to the stirrup traction straps are fastened from the foot, counter-extension being provided by a perineal strap. Movements of flexion and extension are permitted at the hip, as the outside iron is jointed below the pelvic band; this allows a sitting posture to be assumed. A more efficient brace

is that of G. G. Davis (Fig. 516), in which besides a perineal strap for counter-extension, as in the Taylor brace, an inside iron is added which supports a well-padded bar passing from one side iron to the other beneath the tuber ischii; on this bar the patient sits, absolutely preventing weight-bearing on the diseased joint, while the foot extension keeps the lower extremity taut, aiding the weight of the limb in securing traction. If braces cannot be secured, a spica bandage of plaster of Paris may be applied to the thigh and pelvis, preferably fixing the knee and ankle also; and with a high shoe on the sound side, and crutches, the patient may do well, though a well-fitting brace is much more cleanly and comfortable. Usually it is well for the brace to be worn night and day at first, until it is certain that no recurrence of symptoms is to be feared, when it may be left off at night. While a patient is wearing a brace, he should be seen by the surgeon every two or three weeks; and the surgeon should himself see, personally, that the brace fits comfortably and is efficient. If he is unwilling or unable to undertake the responsibilities of mechanical treatment, he should retire from the case.

If it is found that under ambulatory treatment symptoms of coxitis return, recumbent treatment should be resumed, and carried out as already indicated. When, however, ambulatory treatment succeeds, joint fixation may be gradually dispensed with. If eight months or a year are passed without any symptoms whatever of joint trouble, it probably will be safe to discard the brace, but a high shoe on the sound side and the use of crutches should be insisted on for a much longer period. Then the high shoe may be abandoned, and crutches alone used, until by very gradual stages weight-bearing is proved safe.

I am well aware that some orthopedic surgeons at present are opposed to such conservative measures, and prefer to follow the example of Lorenz (1906), in treating all early cases of coxalgia by weight-bearing, fixing the joint in the attitude of deformity by a gypsum splint, and abolishing recumbency and traction entirely from their plan of treatment. But the plan here recommended seems to me the most rational when the pathology of the lesions is considered, and is still employed by the majority of judicious surgeons in this country, Great Britain, and France; and I am convinced that if rigorously employed from the earliest stage, it will cure a much larger proportion of patients without ankylosis than will the method of Lorenz, though the course of treatment may be longer.

The treatment of *cold abscess* and *sinuses*, with secondary infection, has been so fully discussed at p. 484, that little need be said here. In almost all cases recumbent treatment, and heliotherapy, alone or with bismuth or iodin injections, will cause sinuses to close eventually. Very rarely it may be necessary to remove a sequestrum or some carious bone by the curette; then the cavity should be filled with iodoform bone-wax (p. 435). Almost never is formal excision necessary or desirable in children, and then only to avert death from sepsis, and

as a less severe remedy than amputation. I have done only two excisions of the hip, employed as a last resort in cases of profuse suppuration and prolonged hectic: one boy (Fig. 495) recovered with the usual shortened and deformed, though useful limb (Figs. 517 and 518); the other, though temporary improvement was secured (Fig. 32), died two months later from tuberculous meningitis. Excision of the hip for tuberculosis should be regarded merely as a method of joint

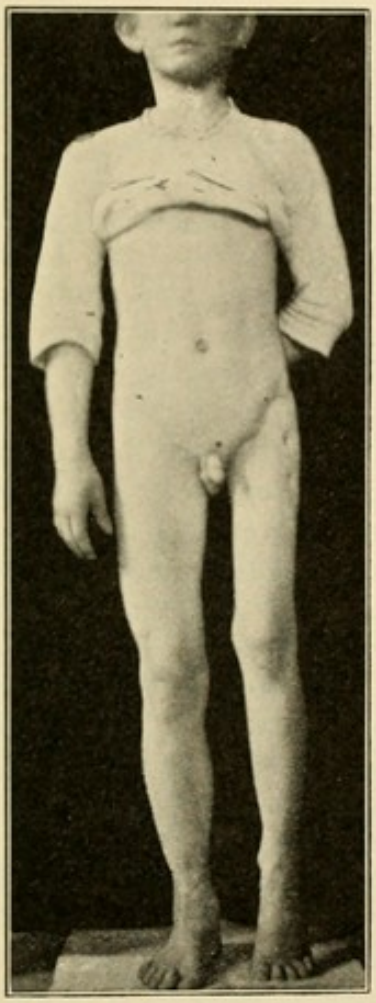

FIG. 517.—Result of excision of hip for tuberculosis, in a boy of fourteen years, one year after operation. (Dr. H. C. Deaver's case.) (See Fig. 518.) Episcopal Hospital.

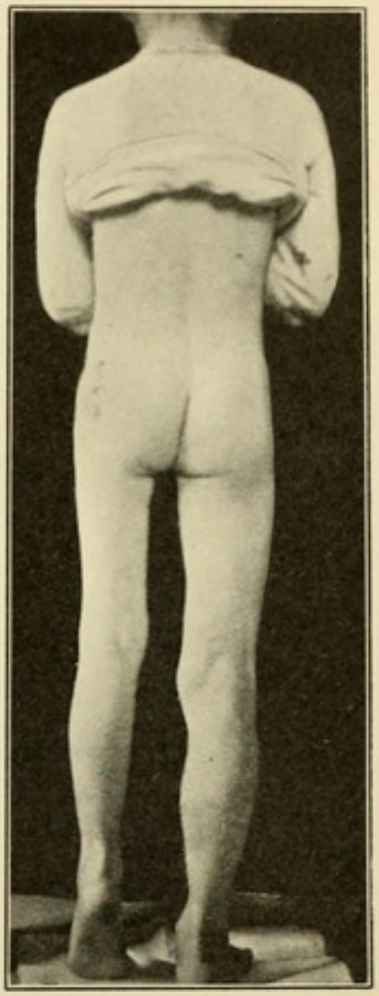

FIG. 518.—Excision of left hip for coxalgia; age fourteen years. Left hip in slight adduction; apparent shortening three inches, actual shortening one and a half inches; still uses crutches; wound dry but scabby; one year after operation. Episcopal Hospital.

disinfection (Coudray, 1911), and should be as conservative in extent as is possible with such end in view. An anterior incision is best, as originally advocated by Hueter (1878), and later adopted by R. W. Parker; this incision is made on the outer side of the sartorius, displacing the rectus and ilio-psoas to the inner side (Barker, 1888); as much synovia should be removed as possible. In very septic cases the posterior longitudinal incision is preferable. This was used by C. White, of Manchester (1769), and was known during the nineteenth

century by Langenbeck's name. After detaching the muscles from the great trochanter the femur is divided below this process, the entire upper end being removed; the acetabulum also is gouged away if necrotic. Though the immediate mortality of the operation is only about 5 per cent., yet when employed for the cases here described as suitable for such treatment, the ultimate death rate is from 20 to 25 per cent. If employed in less severe cases in which it is not necessary, the death rate will, of course, be less. Amputation occasionally may save a life after excision and re-excision have failed. After the operation recumbent treatment with fixation and traction is continued until latency of symptoms indicates the propriety of passing to ambulatory treatment. Ankylosis should be encouraged. Ely (1911) thinks the benefit of excision in hip disease is due to the luxation of the femur which often results, thus permanently abolishing the joint as such, as effectually as would ankylosis (p. 481).

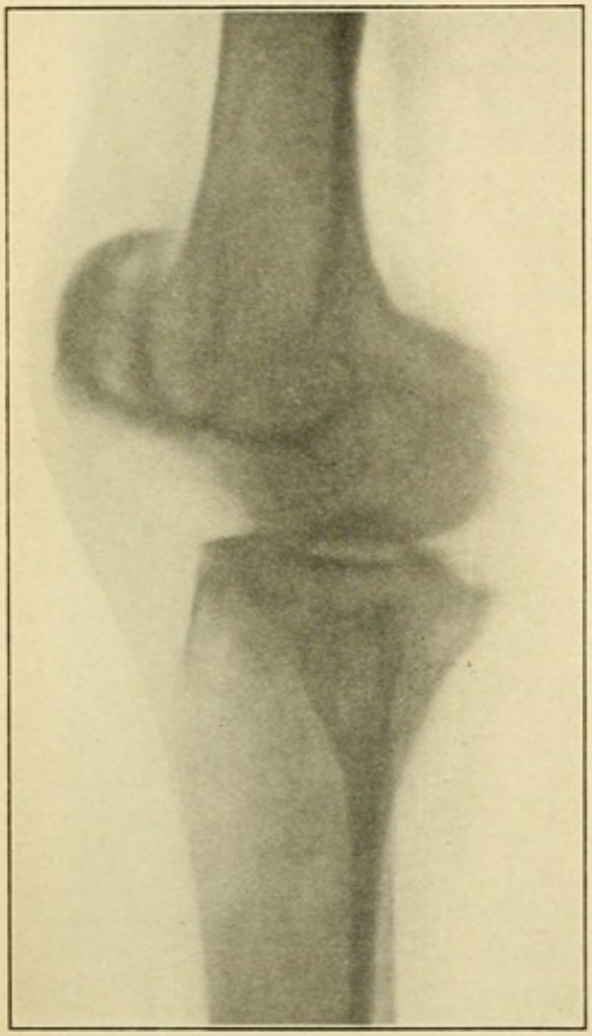

Fig. 519.—Skiagraph of tuberculous arthritis of knee; age thirty-seven years; duration seven years. Same patient as in Fig. 520. Episcopal Hospital.

In adults, in whom tuberculosis of the hip is rare, excision is more often required, but, fortunately, the resulting disability is less.

Tuberculosis of the Knee.—This is the most frequent form of tuberculous joint disease in adults, in whom the primary lesion often is synovial; but the knee is often attacked in children also, and in them usually the femur, tibia, or patella is first involved. In the knee, as in the elbow, local signs of arthritis are much more marked than in the hip, consisting in heat, dusky redness, typical fusiform swelling, and occasionally in intra-articular effusion. Usually, however, enlargement of the joint is due to fungus granulation tissue, and though it may seem as if fluctuation was present, aspiration will fail to demonstrate fluid. The patella does not float, but early becomes fixed more or less firmly to the condyles of the femur (Fig. 519). The knee is flexed, and contractures of the hamstrings develop.

In advanced cases posterior subluxation of the tibia occurs, usually accompanied also by rotation outward. Starting pains are very annoying, and the patient lies curled up on the diseased side, his whole attention apparently concentrated in protecting the painful joint from injury or motion. Cold abscess is rarer than in hip disease, and sinuses more frequently are of extra-articular origin.

Treatment.—The treatment consists in local rest, secured in acute cases by recumbency with splinting and weight-extension. In less severe cases the fixation by plaster of Paris without traction may suffice, and if the gypsum is renewed every four or five weeks gradual decrease of the deformity may be secured. Weight-bearing usually should be allowed before motion at the knee, but for some months after ambulatory treatment is commenced it is safer to employ a traction brace, much the same as in hip disease, with a high shoe on the healthy foot, and crutches. If conservative treatment is persisted in for a year, and the disease fails to become latent, the question of operative treatment may arise: in children below the age of puberty all that should be attempted is erasion of the joint (arthrectomy, p. 486); and though by resort to this operation the disease may not be permanently cured, and though, as is frequent, flexion deformity develops after operation, it may be possible by its aid to tide the patient over the years of childhood until formal excision can be safely done. In adults the results of conservative treatment are very disappointing (Fig. 520); if, after judicious trial of this for some months, no improvement occurs, or if the disease constantly lights up afresh when ambulatory treatment is adopted, excision of the knee should be done; and in

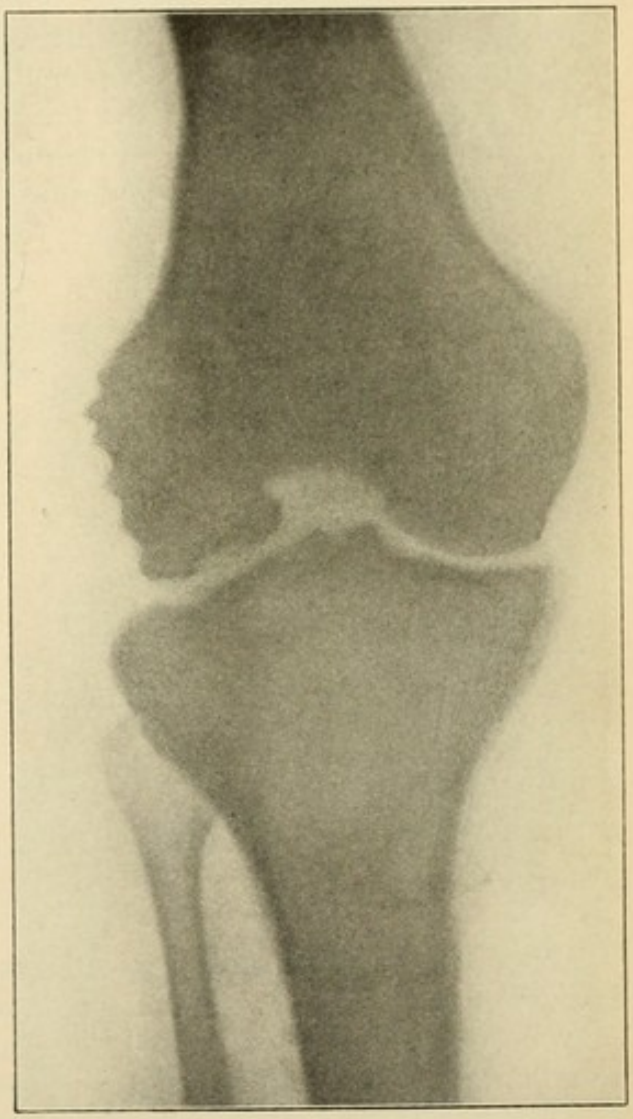

FIG. 520.—Skiagraph of tuberculous arthritis of knee, showing destruction of external condyle of femur, external tuberosity of tibia and perforation of cartilage of tibia. Age thirty-seven years; duration seven years. Probably synovial in origin. Treated by excision. Episcopal Hospital.

practically all cases in adults with sinuses or secondary infection, early excision will give the best results (Fig. 521). The operation has been described at p. 469. Ankylosis should be firm in eight to ten weeks. Even if excision fails to cure the disease at once, which rarely is the case, the surgeon must not conclude that immediate amputation is necessary; by persistence in conservative measures, firm ankylosis and healing of sinuses may yet occur; or a re-excision may be more successful. Amputation should be regarded as the last resort, chiefly adapted to the very old. By excision the limb will be shortened from one-half to two inches. During convalescence from operation the tendency to development of genu varum must be guarded against, as well as the tendency of the femur to ride forward on the tibia. The patient should wear an orthopedic apparatus to fix the knee for a year. The immediate mortality of the operation is about 5 to 10 per cent.

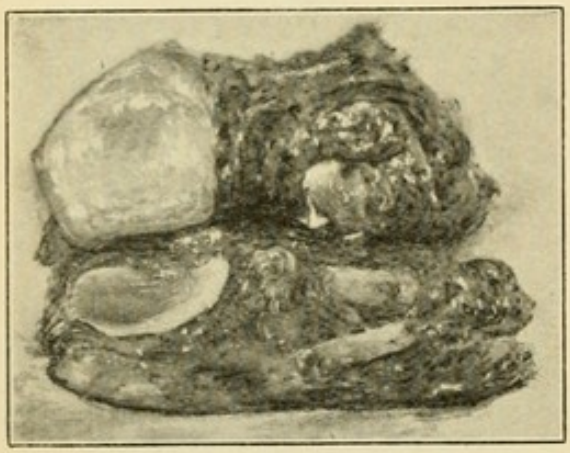

FIG. 521.—Specimen from excision of left knee for tuberculosis. (See Figs. 519 and 520.) Episcopal Hospital.

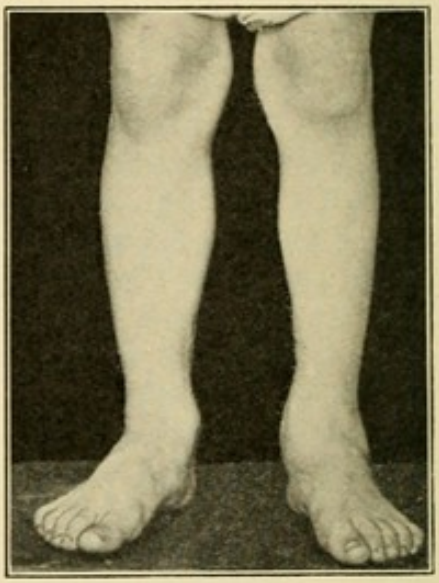

FIG. 522.—Tuberculosis of left ankle-joint. Episcopal Hospital.

Tuberculosis of the Ankle and Tarsus.—The diagnosis sometimes is difficult in children or adolescents, in whom painful flat-foot (p. 547) may be the primary symptom. The astragalus and calcaneum are the bones most often affected, but owing to the proximity of so much synovial membrane (Fig. 165), early joint invasion occurs (Fig. 522), and fistulization with secondary infection is very common.

Treatment.—Treatment, even when the diagnosis is only tentative, should be by rest and cessation of weight-bearing, secured by a gypsum case and use of crutches. This usually is sufficient in children, in whom sinuses soon close, and erasion rarely is required. If motion is prevented by a suitable brace, weight-bearing may be resumed a few months after cessation of active symptoms. In adults, on the other hand, time should not be lost in conservative treatment unless improvement is progressive; if the disease seems stationary, and especially if the foot grows worse, erasion or excision should be resorted

to without delay. The entire astragalus should be removed, and as much of the tuberculous soft parts as possible. Usually the surgeon

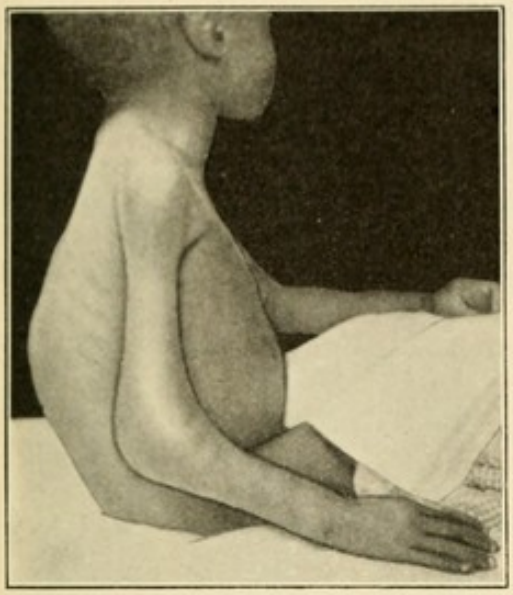

FIG. 523.—Tuberculosis of elbow in a child of four years, showing typical fusiform swelling; also tuberculous spondylitis, and tuberculous osteomyelitis of left forearm and hand with sinuses. This condition is euphoniously described as the "moist rot." Children's Hospital.

FIG. 524.—Tuberculosis of elbow. Age seven years; duration four years; sinuses for four months. Also tuberculous cervical adenitis. (See Fig. 525.) Orthopædic Hospital.

finds that he has delayed too long, and that while this conservative operation may improve matters for a while, amputation eventually will be necessary.

Tuberculosis of the Elbow is much more frequent in children than in adults. The primary lesion is more often in the ulna or humerus than in the radius. Joint invasion is rapid, and typical fusiform enlargement results (Fig. 523). Fistulization is difficult to prevent (Fig. 524), and cure seldom occurs except by ankylosis, and it is better, especially in children, to encourage ankylosis and closure of sinuses than to resort to precocious excision (Fig. 525). No effort should be made to restore motion until all symptoms have been absent for many months. Then an excision or arthroplasty may be done.

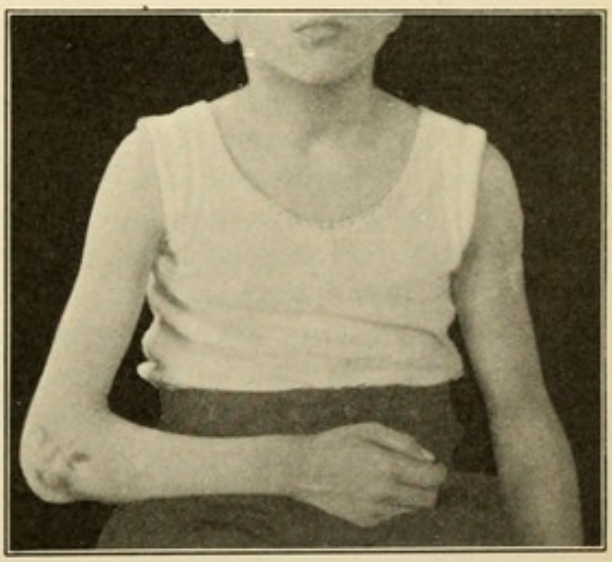

FIG. 525.—Tuberculous elbow, fibrous ankylosis, sinuses healed. Age ten years. Three and a half years after Fig. 524.

Tuberculosis of the Wrist.—This is rare in children; immobilization promptly employed and long continued usually produces a cure with only moderate limitation of motion. In adults sinuses are prone to form, and amputation is the usual termination, though erasion should be tried first. Formal excision of the wrist is very rarely advisable (p. 470); firm fibrous ankylosis is sought, and the hand seldom is very useful.

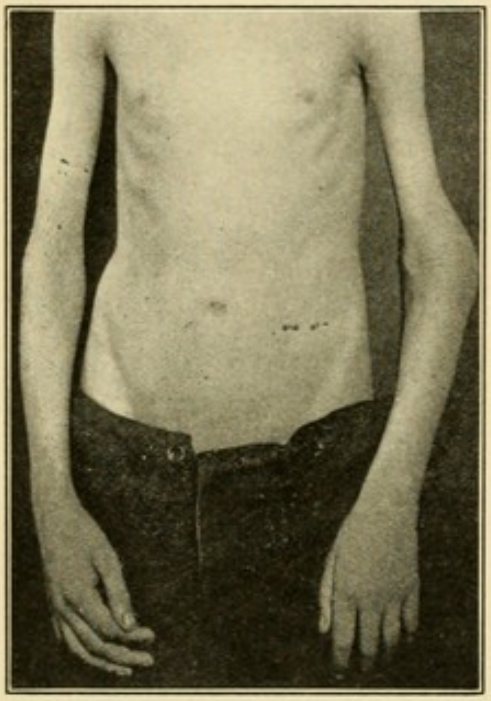

FIG. 526.—Syphilitic arthritis of left elbow. Age fourteen years; duration two years. Also interstitial keratitis and slight sabre-blade tibia. Orthopædic Hospital.

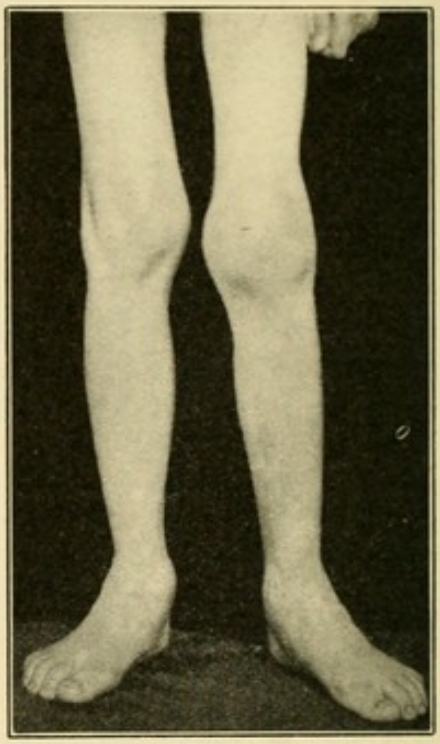

FIG. 527. — Syphilitic arthritis of both knees. Age thirteen years; duration five months. Orthopædic Hospital.

Tuberculosis of the Sacro-iliac Joint is very rare, especially in children. The *symptoms* are pain, sometimes radiating down the sciatic nerve, localized tenderness over the affected joint, and a peculiar feeling of insecurity in the pelvis on attempts to walk. When standing, the body is inclined away from the diseased side, as in "sciatica." Examination shows no involvement of the hip or vertebræ; hyper-flexion of the hip on the diseased side occurs to the normal extent unless the knee is kept extended, when it will be impossible to flex the hip as far on the diseased as on the healthy side, since muscular spasm will be roused by traction on the ischium through the tense hamstrings. Pressing the iliac crests together, and attempts at antero-posterior motion in the pelvic joints cause pain. In advanced cases swelling over the dorsal or pelvic surface of the joint occurs, and suppuration may develop, with sinuses posteriorly or in the inguinal or adductor regions.

Treatment.—Recumbency, with weight-extension for many months, is required. No form of apparatus is satisfactory in preventing weight-bearing at the sacro-iliac joint, and recurrence of symptoms

is not unusual when ambulatory treatment is attempted. A few recoveries have been reported after resection of the joint, but even in adults this should be reserved until conservative measures have proved ineffectual. Picque (1910) reports seven resections of the sacro-iliac joint for tuberculosis: two patients were cured, three were recovering ("nearly cured"), one died of cachexia, and the last had amyloid degeneration of the viscera and death was anticipated.

Syphilis of the Joints.—Syphilitic arthritis is not very rare in cases of hereditary lues, but often, especially in the acquired form of the disease, is not recognized. In its clinical aspects the disease much resembles tuberculous arthritis, especially of the primary synovial type, but pain is less severe. The diagnosis usually is made from concomitant evidences of syphilis (Figs. 526 and 527), and is confirmed by the Wassermann reaction and results of antisyphilitic treatment. If the joint is painful, suitable apparatus should be provided.

TUMORS OF JOINTS.

Tumors of the joints, except those developed from the neighboring bones, are quite rare.

Lipoma Arborescens is the name given by Volkmann (1882) to a synovial or subsynovial growth in which fatty deposits occur. It is observed oftenest in the knee, along one side of the tendo patellæ, but also occurs in the shoulder. It is regarded by Poncet, Marsh, Ely, and Whitman as tuberculous in nature, and there is no doubt that sometimes it is; but it is better to consider it, with Nichols (1907), a hypertrophic synovial change which may occur in various joint affections. The fatty out-growth is more or less pedunculated, is palpable through the skin as an ill-defined mass, and interferes with the functions of the joint without producing very acute symptoms. The best treatment is excision of the growth.

Sarcoma.—Primary sarcoma (endothelioma) of joints is rare. It begins in the synovia or subsynovial connective tissue. Lejars and Rubens-Duval (1910) have collected 16 cases, 13 of which occurred in the knee. This is one of those neoplasms where transition from epithelioid to sarcomatoid tissue is best observed. The clinical symptoms somewhat resemble a subacute infectious arthritis, and the diagnosis usually depends on microscopical examination of an excised specimen. If the tumor recurs after local extirpation, amputation should be done.

CHAPTER XVI.

ORTHOPEDIC SURGERY.

Orthopedics, from the Greek words ὀρθός and παῖς, meaning literally a *straight child*, is that part of surgery which deals with the correction of deformities, either congenital or acquired. So many surgeons, during the last fifty years or more, have devoted their exclusive attention to this subject, that the practice of orthopedic surgery is now recognized as a specialty of equal rank with gynecology or genito-urinary surgery. In the limits of a text-book on general surgery, therefore, it is manifestly impossible to do more than provide an outline of the subject, and inculcate the general principles which underlie its practice.

CONGENITAL DEFORMITIES.

Congenital Absence of Bones is not very rare. Those most often deficient are the radius, and the tibia or fibula. Sometimes the outer portion of the foot is absent along with the fibula, or a portion of the hand absent with the radius. The exact diagnosis often depends on skiagraphy. The hand or foot deviates toward the side where its support is lacking. In infancy malposition may be prevented or corrected by splints, or other apparatus. Often during childhood or adolescence it becomes necessary to operate for the correction of deformity, or to improve function. In the foot, some form of arthrodesis (p. 528) usually will be required to give stability in walking,[1] while in the upper extremity it may seem desirable to lengthen contracted muscles and tendons, and do osteotomy or resection of the existing bone for cosmetic effect, though function can seldom be improved.

Osteoplastic Operations.—After resection of a large part of the diaphysis of a bone, for osteomyelitis or tumor, the limb often is left in a helpless condition, much as in the cases of congenital deformity noted above. When the shaft of the tibia has been excised, and fails to regenerate, the upper end of the fibula may be moved over later to a socket cut in the upper epiphysis of the tibia (Hahn, 1884); in cases reported by Nichols (1904), Huntington (1905), and others, the fibula underwent hypertrophy and supported the weight of the body very well. In other cases a portion of the diaphysis of the femur,

[1] Wille (1909) in a case of congenital absence of the fibula did arthrodesis by driving a fibula (obtained from an amputated leg) up from the sole, through the calcis, astragalus, and tibia, and obtained a fair result.

humerus, or other long bone, has been replaced immediately by transplanting a portion of the patient's tibia, cut long enough to fill the defect, and about half an inch in diameter. This "transplant" must be brought into contact, at least at one end, with healthy bone, containing Haversian systems, so that the osteoblasts lining these may grow along the channels in the transplant, and thus lay down new bone in place of that contained in the transplant, which is slowly absorbed by the osteoclasts. If the transplant is not brought into contact with a healthy Haversian system, it will not be permeated by osteoblasts, but will be gradually absorbed and the operation will be a failure (Murphy, 1912). Many surgeons prefer to preserve the periosteum of the transplant, thinking it favors bone growth. I have always removed the periosteum before cutting the transplant.

FIG. 528.—Congenital absence of costal portion of right pectoralis major, in a girl of six years. No disability. Slight scoliosis. Orthopædic Hospital.

Congenital Absence of Muscles (Fig. 528), which is quite rare, seldom entails much disability; when it does, it usually is possible to improve function by tendon transplantation (p. 525), or insertion of artificial ligaments (p. 529).

FIG. 529.—Supernumerary digits, six toes on each foot. Age seven months. Also had six fingers on each hand, but the extra fingers were amputated at birth. Episcopal Hospital.

Supernumerary Fingers or Toes (Polydactylism) (Fig. 529) usually require amputation; special care should be paid to hemostasis, as deaths in infants from secondary hemorrhage have been reported.

Malformations involving the metacarpal or metatarsal bones seldom can be appreciated without a skiagraph (Fig. 530), and require special types of operation.

Fig. 530.—Skiagraph of the left hand of a patient, aged nineteen years, showing polydactylism and syndactylism. The right hand was similarly affected. Episcopal Hospital.

Webbed Fingers (Syndactylism) (Fig. 531) may be treated by several forms of plastic operation. Didot's method (1850) is sufficiently indicated by the accompanying figure (Figs. 532). There is great tendency for the web to re-form, and it always is well to carry the incisions far down between the heads of the metacarpal bones. For this reason Agnew's operation (Fig. 533) is preferable, as it provides a flap of healthy skin over the web.

Congenital Contraction of a Finger may require some form of plastic operation, after excision of dense bands of connective tissue. In the case represented in Fig. 534, full extension became possible only when the anterior ligament of the interphalangeal joint was divided.

Congenital Dislocations.—**Congenital Dislocation of the Hip** is the most frequent of these congenital luxations. Some authorities believe that the displacement of the bones may not always date

Fig. 531.—Webbed fingers; age fourteen years. Orthopædic Hospital.

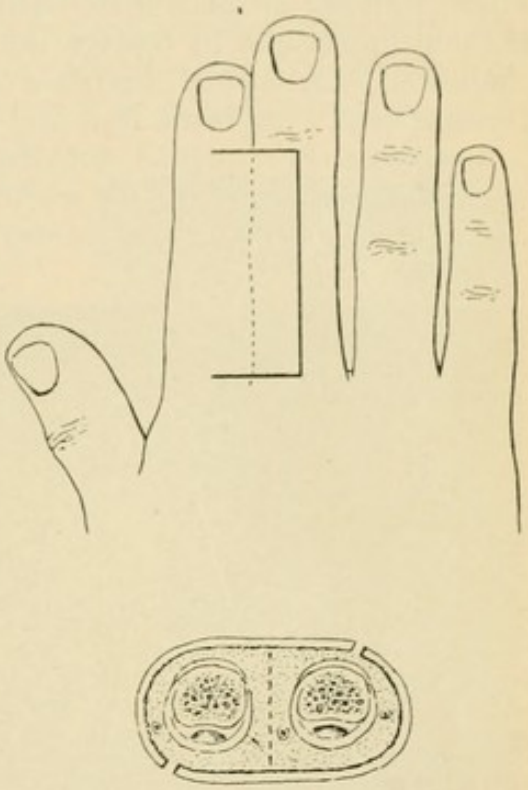

Fig. 532.—Didot's operation for webbed fingers.

from fetal existence, but may be produced by uterine contractions during birth (Allis, 1907), or after birth by injudicious attempts to extend the baby's thighs; however, it is very generally agreed

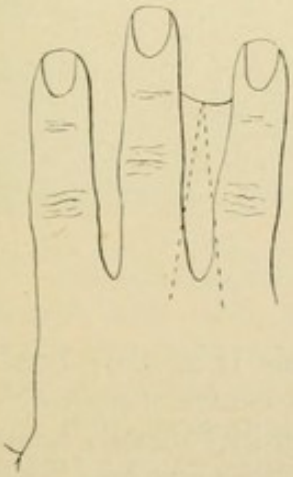

Fig. 533. — Agnew's operation for webbed fingers.

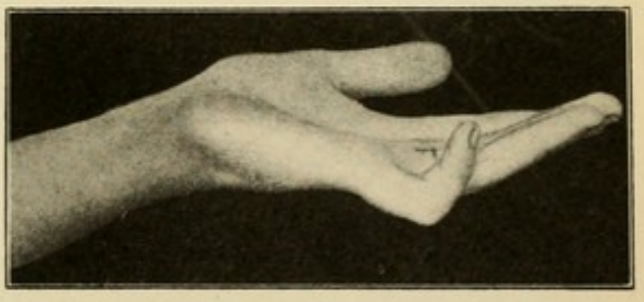

Fig. 534.—Congenital contracture of fifth finger; age sixteen years. Episcopal Hospital.

that there is a congenital malformation of the acetabulum and of the head of the femur or both, possibly due to malposition within the uterus. The deformity is more common in female (85 per cent.) than in male (15 per cent.) children, and more often unilateral (63 per

cent.) than bilateral (36 per cent.). The dislocation is *posterior* in the overwhelming majority of cases. The longer the dislocation stays unreduced the more does the capsule contract around the acetabulum, forming an hour-glass-shaped channel through which it may become impossible to replace the head. The acetabulum, which is shallower than normal, becomes more so as life advances unless the femoral head is replaced in it and normal weight-bearing is restored.

Symptoms.—Frequently nothing abnormal about the child is noted until walking is attempted, when a limp is visible in the unilateral cases (Fig. 535), and a characteristic waddle in the double dislocations.

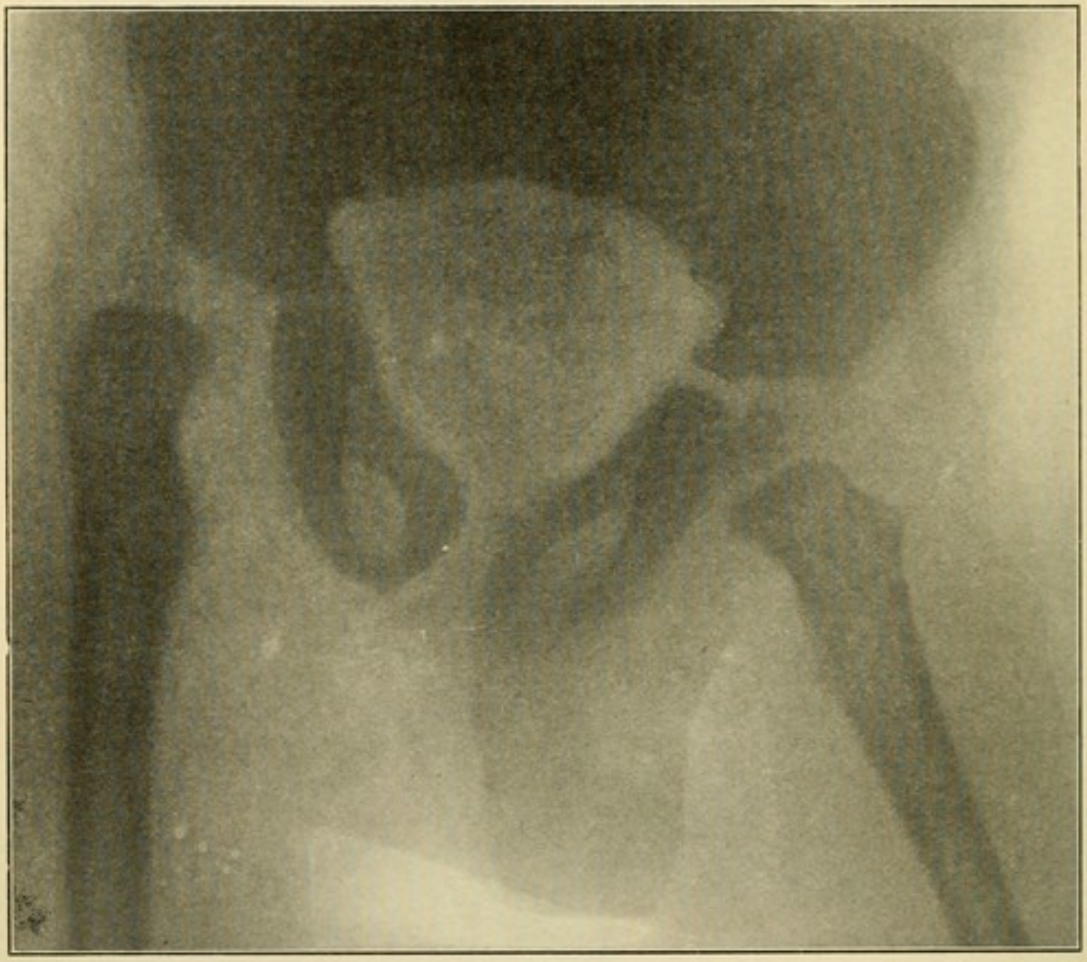

FIG. 535.—Congenital dislocation of left hip, in a boy of two years. Limp first noted on attempts to walk at the age of fifteen months. Episcopal Hospital.

In the latter there also develops marked lordosis (Fig. 536), because the centre of support is displaced posterior to the centre of gravity. If the dislocation is not reduced, deformity and disability usually increase with age; and in most cases adolescents and adults must lead a semi-invalid existence. The *diagnosis* is made from the history, from the symptoms noted above, and from the physical examination. This shows moderate shortening of the extremity affected (Fig. 537), elevation of the trochanter above Nélaton's line, and absence of the femoral head from its socket. By alternately pulling and pushing on the fully extended lower extremity, while the pelvis is fixed, the great trochan-

ter will be found to slide up and down. When the two thighs are flexed to a right angle, with the knees bent, and the child on its back, the thigh on the affected side is found shorter. There is diminished abduction, especially when the thigh is flexed to a right angle. Flexion and extension are free and painless, facts which together with the history readily serve to distinguish this affection from traumatic dislocation. In coxa vara the head of the bone is in the acetabulum; and in coxalgia there is an acute arthritis, or its resultant deformity. Confirmation of the diagnosis of dislocation is obtained by skiagraphy, which usually shows more or less *anteversion* of the head of the femur: that is, instead of pointing inward toward the pelvis, the neck of the femur lies more nearly in the sagittal plane, the head pointing forward even when the lower limb is not rotated outward.

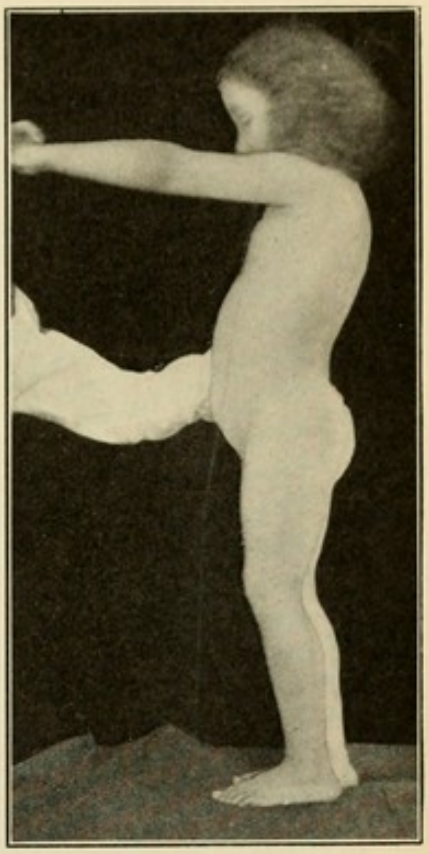

FIG. 536.—Lordosis from double congenital dislocation of hips, in a girl of seven years. Orthopædic Hospital.

Treatment.—Reduction should be accomplished as soon as the diagnosis is made. In very young children, reduction is not difficult to secure by the usual methods for dislocation of the hip (p. 408); but in all cases reduction is very difficult to maintain owing to the shallowness of the acetabulum, the deformation and anteversion of the head, and the resiliency of the soft parts. After the age of eight or nine years it is very difficult and sometimes impossible to obtain reduction without open operation, which is called by the Germans the "bloody" as distinguished from the "bloodless" method of reposition. Paci, of Pisa (1888, 1894), was an early exponent of the bloodless method, which he systematized, and Lorenz (1895) abandoned his bloody method to take up a modification of Paci's operation, which he has popularized all over the world. The child being etherized and the pelvis fixed, the surgeon flexes and then abducts the thigh until the adductor tendons become tense; these are then ruptured subcutaneously by blows from the ulnar side of the hand, or by violent massage. The limb is then forcibly hyperflexed, with the knee extended, until it lies alongside the body, with the foot beside the patient's head. When all resisting soft structures on the anterior portion of the joint have been ruptured, reduction is attempted: the trochanter is placed over a wedge-shaped block, and by hyperabduction of the flexed thigh the surgeon pries the head of the femur into its socket. The clenched fist may be used as a fulcrum instead of Lorenz's wedge; but either method is liable to fracture the

cervix femoris (Fig. 539). According to Bade (1909), nerve injury, resulting in paralysis, has occurred in 67 out of 2204 cases of bloodless reposition; and many surgeons have produced one or more fractures of the femur, myself included (in a patient over eight years of age). A much safer and equally efficient method is that of G. G. Davis (1907), in which the patient is placed prone on the table, and the thigh is flexed until it lies alongside the chest, with the knee in the axilla; this brings the head of the femur below but still posterior to the acetabulum; then the adductors are gradually stretched by manual pressure downward on the great trochanter (Fig. 540); when these

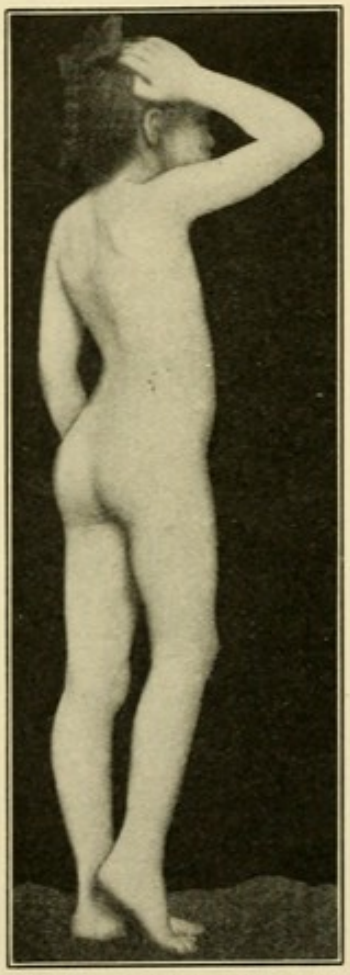

FIG. 537.—Congenital dislocation of right hip, in a girl eight and a half years old. (See Fig. 538.) Orthopædic Hospital.

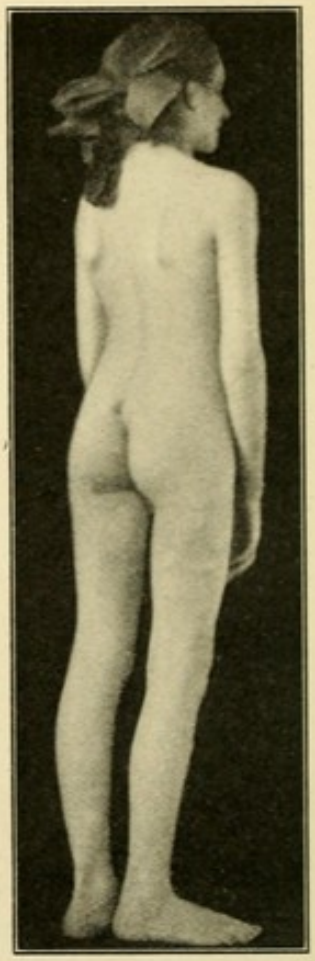

FIG. 538.—Congenital dislocation of right hip. Three and a half years after reduction. Same patient as Fig. 537. Orthopædic Hospital.

structures have been stretched enough to allow the groin to come in contact with the table, the head of the femur may jump from the posterior to the anterior plane of the pelvis with an audible and palpable click. If not, the flexion of the thigh is slightly diminished (*i. e.*, it is drawn a little away from the chest) and its abduction is slightly increased, by raising the knee a short distance from the table. Pressure downward on the trochanter is continued until the head of the femur can be felt by the finger in the groin. If reduction cannot be secured at the first attempt without the use of unjustifiable force, it is better to dress the limb in the fullest abduction possible and

make another attempt several weeks later if necessary, after subcutaneous division of the adductor muscles, close to the pubis.

When reduction has been secured, this fact may be determined (1) by hearing or feeling the femoral head jump into the acetabulum; (2) by observing that the knee can no longer be fully extended, since the ascent of the femur from the posterior plane of the innominate

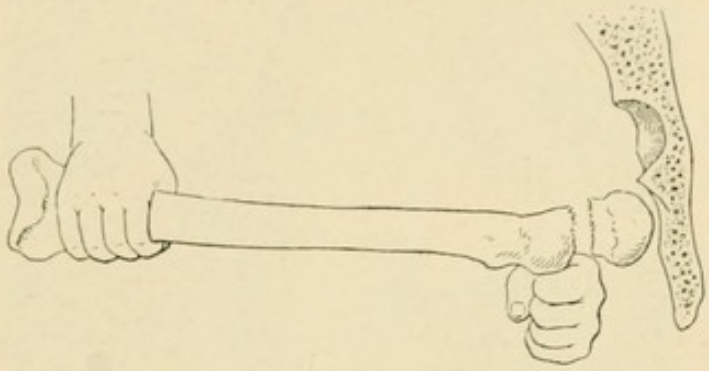

FIG. 539.—Fracture of neck of femur when hyper-abduction is attempted according to Lorenz's method.

bone to the acetabulum has caused a relative shortening of the hamstrings; (3) by palpating the head of the femur in its socket below Poupart's ligament; (4) by reproducing the luxation and again reducing it; and (5) by skiagraphy. Sometimes an "anterior transposition" only is secured: in this the head, instead of jumping into the acetabulum, passes above it to a position just below the anterior superior spine

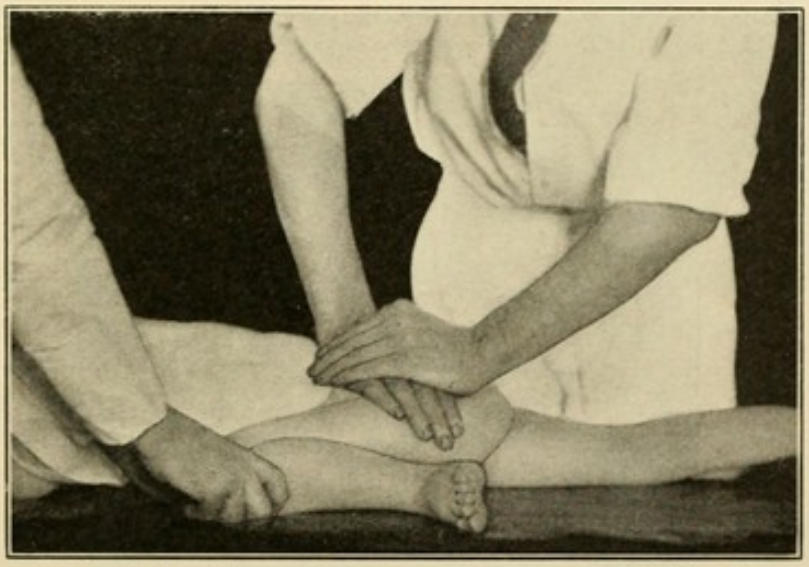

FIG. 540.—G. G. Davis's method of reducing congenital dislocation of hip. Orthopædic Hospital.

of the ilium; of course this is not so favorable a result as an "anatomical reposition," but it is better than a persistence of the dislocation, since it transfers the weight-bearing point to the centre of gravity.

After reduction the head of the femur is not at all stable in its ill-formed socket, and the chief difficulty and tedium in the care of these cases arises in the after-treatment, in efforts to prevent relapse. The limb should be dressed in plaster of Paris in *the most stable position;*

usually this is with the thigh flexed to a right angle and abducted beyond the coronal plane; that is, so that the knee is in a plane *posterior* to the symphysis pubis (Fig. 541). This, the "primary position,"

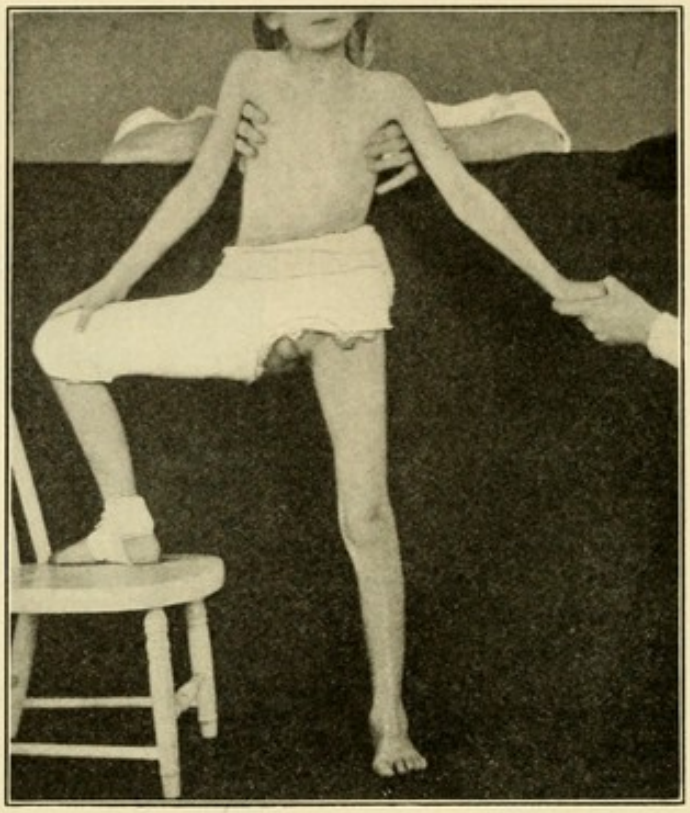

FIG. 541.—Congenital dislocation of right hip; primary dressing. Photographed two weeks after operation. Same patient as Figs. 537, 538, and 543. Orthopædic Hospital.

FIG. 542.—Frog position after reduction of congenital dislocation of both hips. Orthopædic Hospital.

called also the "frog position" when both hips are concerned (Fig. 542), must be maintained for from four to six months. During this time the child must be encouraged to walk about, with support, as weight-bearing favors the deepening of the acetabulum. At the end of this time, unless reluxation has occurred or is imminent, the abduction and flexion may be diminished gradually, and the thigh dressed in a less awkward position (Fig. 543), in which locomotion is easier. Sometimes greater stability is secured by dressing the limb with the patella looking directly forward, without any external rotation of the thigh. Immobilization of the hip must be continued, except in very young children, for from nine to eighteen months after the primary reposition, and for a similar or longer period after any recurrence of dislocation and secondary reposition. After this time external support may be discontinued, and gentle passive motion and massage may be prescribed. The younger the child, the sooner, as a rule, can external support be dispensed with, and the sooner will function return.



FIG. 543.—Congenital dislocation of right hip in walking cast. Same patient as Figs. 537, 538, and 541. Orthopædic Hospital.

If reluxation recurs persistently, and in cases where bloodless reposition is impossible, a resort to open operation usually is proper. The best approach is by an anterior incision, along the inner border of the sartorius. Hoffa (1890) used a posterior incision with temporary resection of the great trochanter, but later abandoned this method. Lorenz (1892) used an incision from the anterior superior iliac spine to the great trochanter, passing between the tensor vaginæ femoris and gluteus medius; I have used this method with satisfaction. Ludloff (1908) uses an internal incision, passing between the adductors and pectineus. In all cases the capsule is widely opened, preserving the Y-ligament; and the acetabulum is cleared out sufficiently to hold the head of the femur. Structures preventing reduction should be divided; but in adults, where utmost efforts sometimes fail to secure reduction, it may be sufficient to form a new socket above the acetabulum (G. G. Davis, 1908). A certain measure of relief will be secured if the head of the femur becomes more firmly fixed, in any position, than it was before operation.

Congenital Dislocation of the Shoulder.—In many cases it is probable that the displacement occurs during obstetrical delivery. The dislocation nearly always is subspinous (Fig. 544); the attitude is characteristic; and the diagnosis easy. Reduction rarely is possible

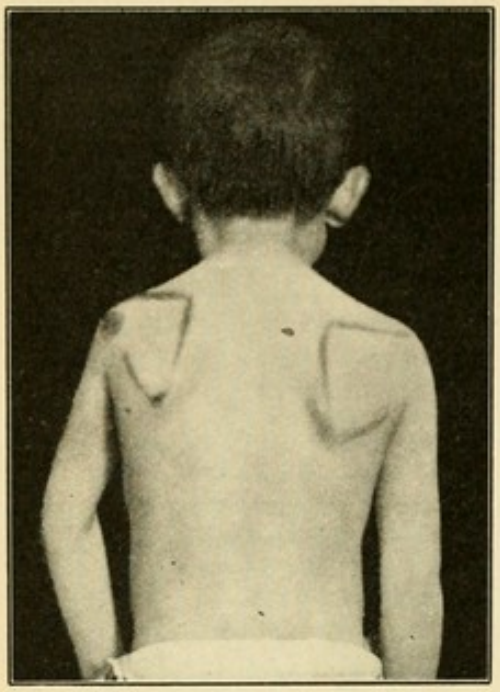

Fig. 544.—Congenital dislocation of the left shoulder. Age seven years. Orthopædic Hospital.

without open operation. This dislocation not infrequently accompanies the condition designated "brachial birth palsy," and according to T. T. Thomas, the dislocation is the essential lesion (p. 283).

Congenital Elevation of the Scapula, Sprengel's Deformity (1891).—The upper extremity develops as an appendage of the cervical spine, and if normal descent of the scapula fails to occur, it remains in the cervico-dorsal region, more or less deformed, often being fixed to the vertebral spines by a process of bone or cartilage. The subject has been studied recently by A. E. Horwitz (1908), who analyzed 136 cases. In the patient under my own care (Fig. 545), who also presented

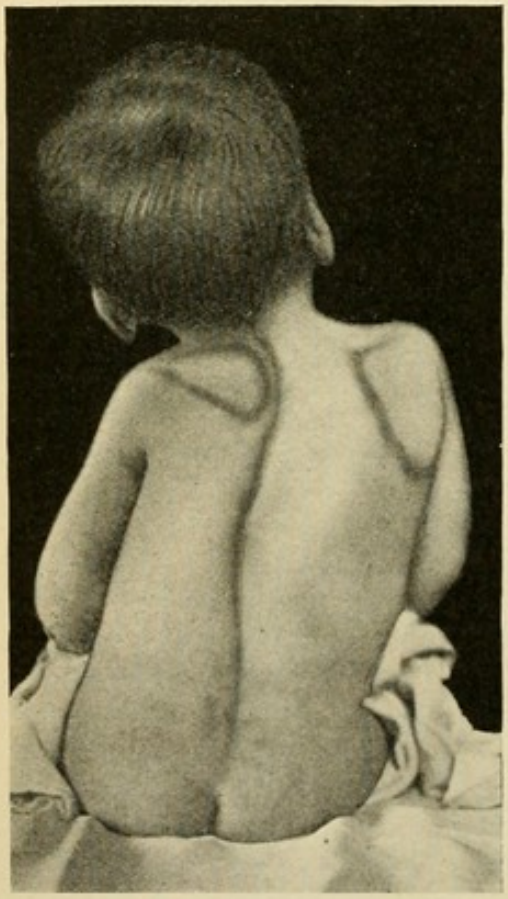

Fig. 545.—Congenital elevation of left scapula in a boy of three years; before operation. Orthopædic Hospital.

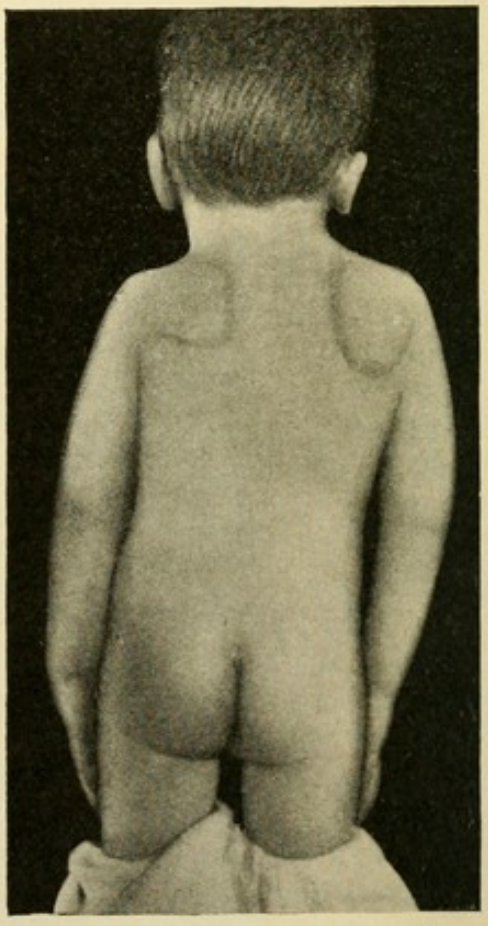

Fig. 546.—Congenital elevation of left scapula, three months after operation. Orthopædic Hospital.

congenital scoliosis and absence of several ribs, marked improvement resulted from open section of the muscles attached to the vertebral border of the scapula, depression of the scapula, and re-attachment of the rhomboids to the upper angle of the bone (Fig. 546).

Congenital Dislocation of the Knee is quite rare, and usually is anterior in direction, the leg being hyperextended on the thigh. The patella may be absent. The use of splints or orthopedic apparatus usually secures a return to the normal position, with moderate range of flexion, before the age for walking arrives.

Congenital Talipes.—The cause of congenital foot deformities is unknown, though they often are attributed to malposition in the uterus. The hands sometimes are the seat of similar deformities (*Club Hands*). The deformity may affect one or both feet. There are several distinct types of deformity, though usually more than one is present. *Talipes Equinus* is "pointed toe" deformity in which the front of the foot is depressed and the heel elevated, the patient walking on the toes, as a horse, whence the name. In *Talipes Calcaneus* the heel is depressed and the toes elevated. In *Talipes Varus* the anterior part of the foot is adducted, and the foot is inverted (supinated); the inner border of the sole is shortened and elevated, and the patient walks on the outer border. In *Talipes Valgus* the anterior part of the foot is abducted, the foot is everted and pronated, the sole is flat, and the inner border of the foot is convex. In *Talipes Cavus* or *Arcuatus* ("hollow foot") the arch of the foot is high, and the foot is shortened antero-posteriorly, without being either pronated or supinated.

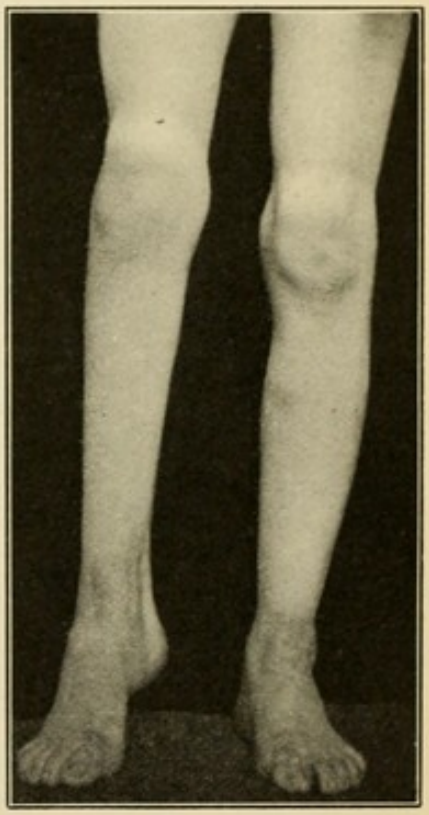

FIG. 547. — Congenital talipes equinus, with slight cavus deformity in a boy of thirteen years. Orthopædic Hospital.

At birth there seldom is appreciable bony deformity, but contractures of tendons and ligaments as well as of the skin and subcutaneous tissues are present. If the deformity is not overcome while the bones are soft, these will become deformed, adapting their form to the altered function required by weight-bearing and locomotion.

Equino-varus. — The most frequent combination of congenital deformities is that of *equinus* and *varus*, forming the ordinary "club-foot" (Fig. 548); there often is slight *cavus* as well. The feet turn in, the soles face each other, the tibial border of the sole is concave and shortened, and the heel is elevated. There is no natural tendency for the deformity to correct itself; on the contrary, if patients

are neglected and allowed to walk, the deformity constantly increases until in extreme cases they may have to walk on the dorsum of the foot (Fig. 549). The tibialis anticus and posticus are short, and keep the foot inverted; the tendo Achillis raises the heel; the plantar fascia is contracted and arches the foot, and the flexors of the toes aid in causing cavus deformity. The calcaneum long remains small and ill-formed, and the calf muscles are poorly developed, because of disuse; and the extensors of the toes and the peronei, which work at marked disadvantage, are weak and totally unable to overcome the deformity.

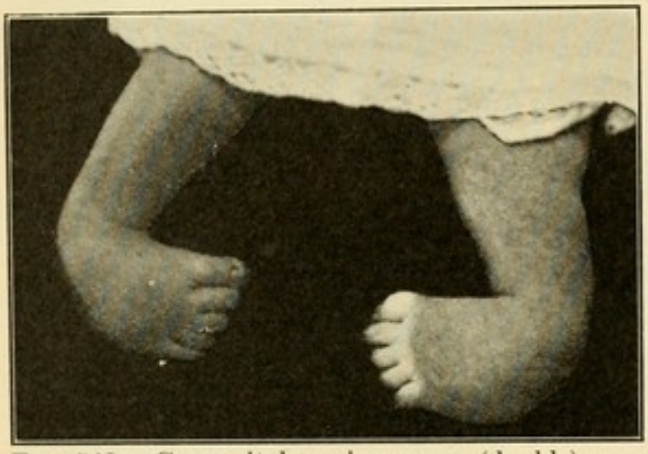

FIG. 548.—Congenital equino-varus (double), age seven months. (See Fig. 549.) Orthopædic Hospital.

Treatment.—In earliest infancy manual correction alone may suffice, if it is applied intelligently and at least twice daily. Holding the leg bones at the malleoli in one hand, the other hand forcibly abducts the foot, so as to stretch the shortened tissues on the inner side of the sole. This is repeated from ten to twenty times, morning and night. When the adduction can be overcome, and the foot brought into a straight line with the leg, but not before, attempts are made to bring the heel down by dorsi-flexing the foot in the sagittal plane. By no means should the tendon of Achilles be divided so long as there remains the slightest tendency to varus; without the calcaneum as a fixed point (made so by the attachment of the Achilles tendon) it is impossible to overcome by manipulation the adduction of the foot. From the age of a few weeks until the child begins to stand, the foot should be held in the best position obtainable at each manipulation by being bandaged to a posterior right-angled splint, or in plaster of Paris. If plaster of Paris is used, the case should be renewed every two or three weeks and the foot put up again in the improved position secured by renewed manipulation. Sometimes it is necessary to anesthetize the baby to apply manipulation effectively.

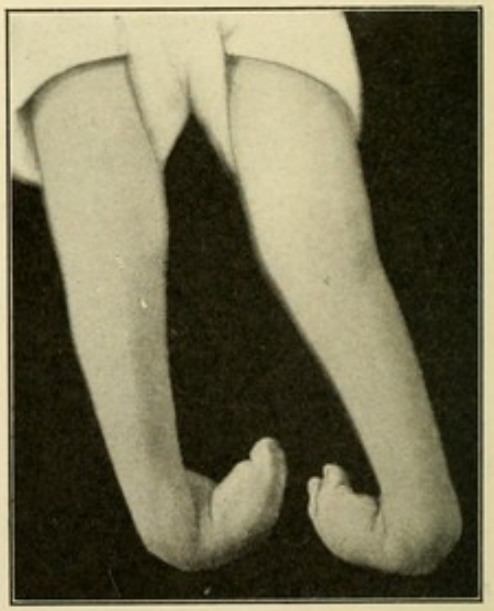

FIG. 549.—Inveterate varus. Same patient as Fig. 548, three years later. Has received no treatment; walks on the dorsum of his feet. Orthopædic Hospital.

If this treatment is faithfully carried out there are very few cases

of club feet in which the feet will not be in sufficiently good position for weight-bearing when the age for walking arrives. At this stage braces may be applied, to be worn night as well as day, but removed daily for washing and manipulation; and these must be continued until there is no further tendency to relapse. The main factors in such apparatus are a strong laced shoe, open to the toe, so that the foot can be inserted easily; an instep strap to hold the foot against the sole, and keep the heel from rising; side irons to prevent inversion of the foot; and an elastic strap from the outer side of the foot to the outer side iron, to keep the ankle dorsi-flexed and the foot everted. Apparatus is not designed to overcome deformity, but acts merely as do splints in the case of fractured bones, to maintain proper position after this has been secured by other means. These braces (as all

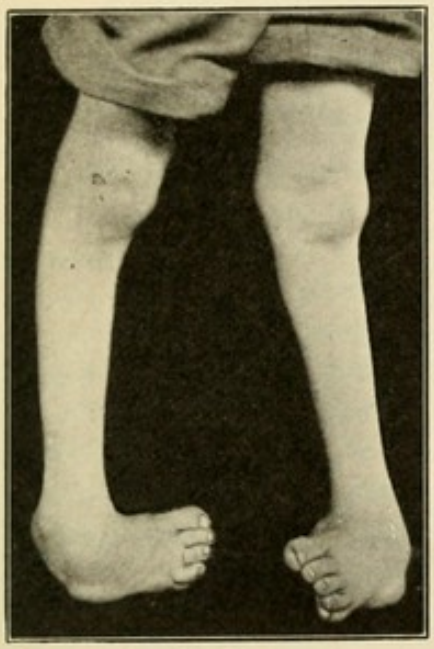

FIG. 550. — Double equino-varus (congenital). Age seven years. Relapsed case, from neglect of treatment. Orthopædic Hospital.

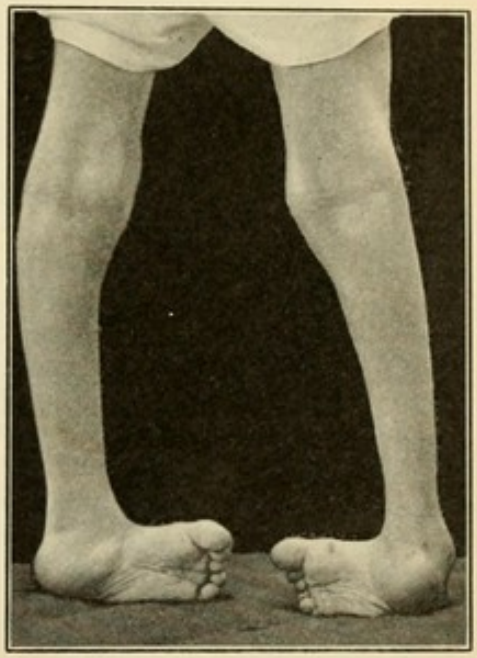

FIG. 551.—Relapsed varus. Rear view of patient in Fig. 550. (See Fig. 556.) Orthopædic Hospital.

other orthopedic apparatus) will require constant oversight and adjustment, and this must not be shirked by the surgeon who undertakes the treatment of such cases. Braces present the great advantage over gypsum that they permit muscular action, and so favor development of the limb. Usually they should extend to mid-thigh, for greater security; and where internal rotation of the foot is persistent, it may be necessary to add a pelvic band, so as to have some fixed point by which to evert the entire lower extremity.

In cases in which proper treatment has been neglected, and in relapsed cases (Figs. 550 and 551), mere manipulation usually is powerless to overcome the deformity. Here the patient must be anesthetized, and more forcible stretching done, as indicated in the accompanying illustrations (Figs. 552, 553, 554 and 555). The foot is

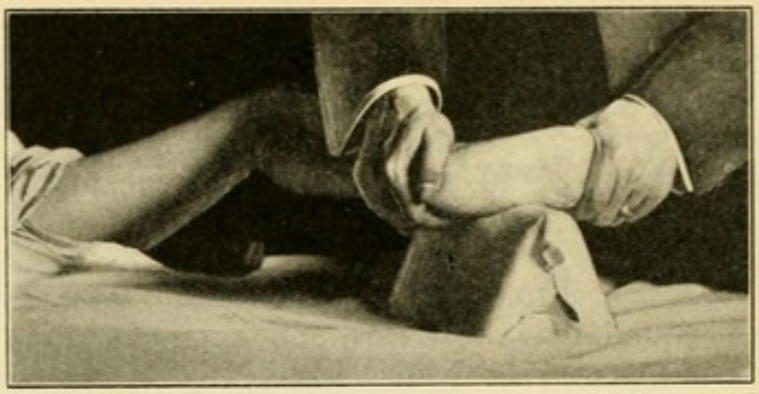

FIG. 552.—Club-foot wedge in use, overcoming varus. Orthopædic Hospital.

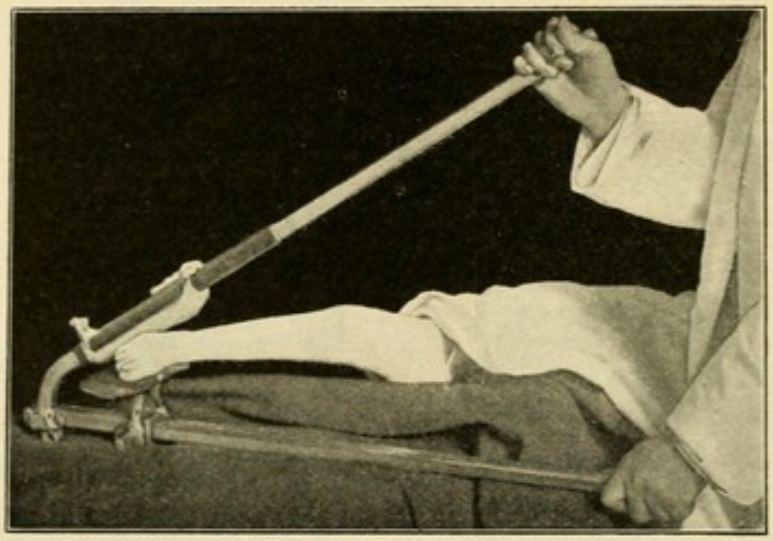

FIG. 553.—G. G. Davis's tarsoclast in use. Orthopædic Hospital.

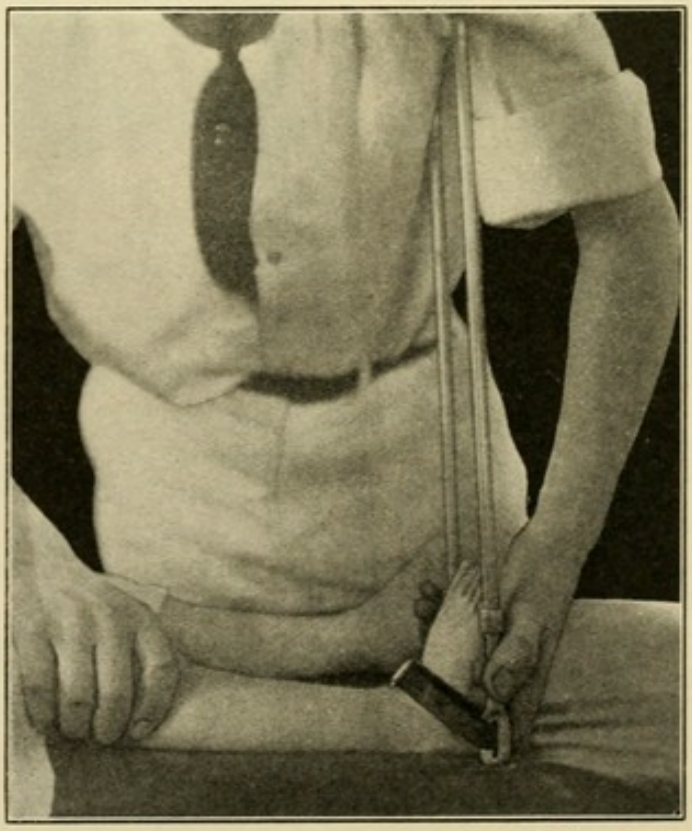

FIG. 554.—Use of G. G. Davis's lever to stretch tendo Achillis. Orthopædic Hospital.

dressed in over-corrected position in plaster of Paris and the patient stays in bed several days after the operation, and for the first twenty-

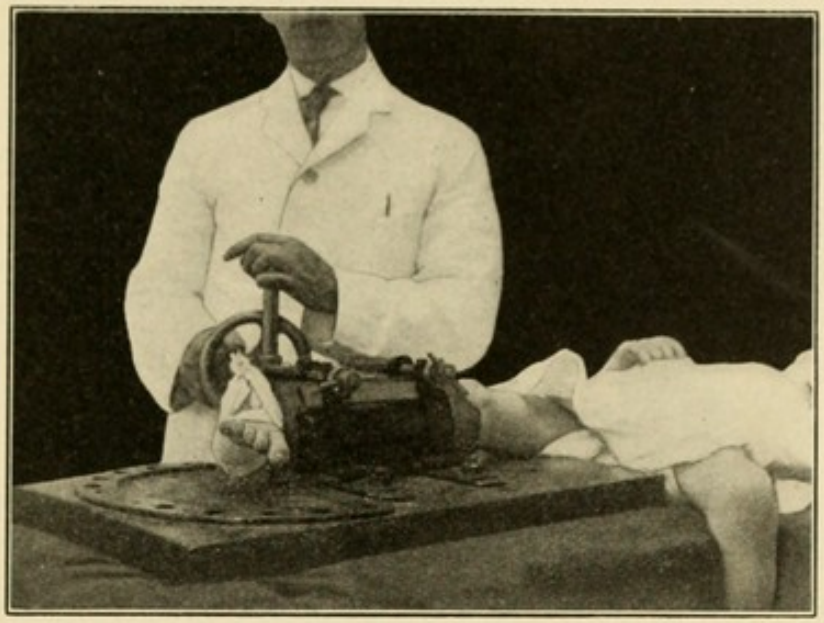

Fig. 555.—G. G. Davis's varus machine in use. Orthopædic Hospital.

four hours the foot is kept elevated to prevent edema. Walking in the gypsum case is then allowed. If the stretching (*redressement forcé*) is skilfully done, evil consequences are very unusual, though rarely a superficial slough may form over the dorsum of the foot. The plantar fascia often is tense, and usually should be divided; but tenotomy of the tendo Achillis or other tendons seldom is advisable. **Tenotomy** usually is done by the subcutaneous method (Stromeyer, 1831): a puncture is made by a sharp-pointed tenotome (Fig. 557) just to one side of the tense tendon and where it is most accessible; a blunt-pointed tenotome is then inserted beneath the tendon, and while this is kept taut, it is divided from within out-

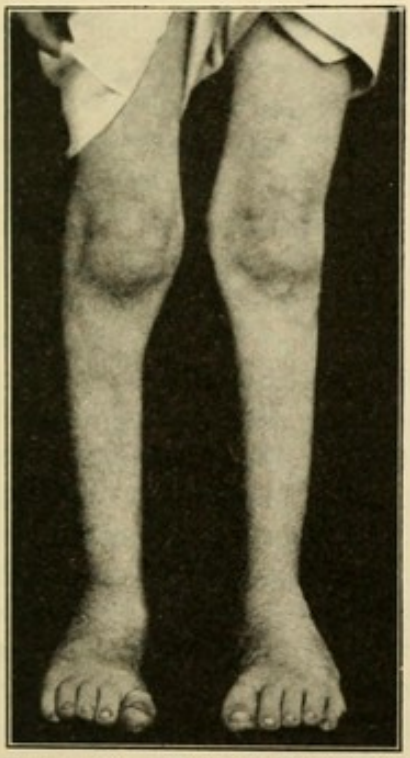

Fig. 556. — Double equino-varus after use of instruments shown in Figs. 552 to 554. Same patient as Figs. 550 and 551. Orthopædic Hospital.



Fig. 557.—Sharp and blunt-pointed tenotomes.

ward by a gentle sawing motion; any oozing of blood is checked by pressure and an aseptic dressing applied with the limb as much

over-corrected in position as is possible; and this position is maintained by a fixed dressing for four to six weeks. The tendo Achillis is divided about an inch above its insertion; the tibialis anticus below the annular ligament; the tibialis posticus between the internal malleolus and its

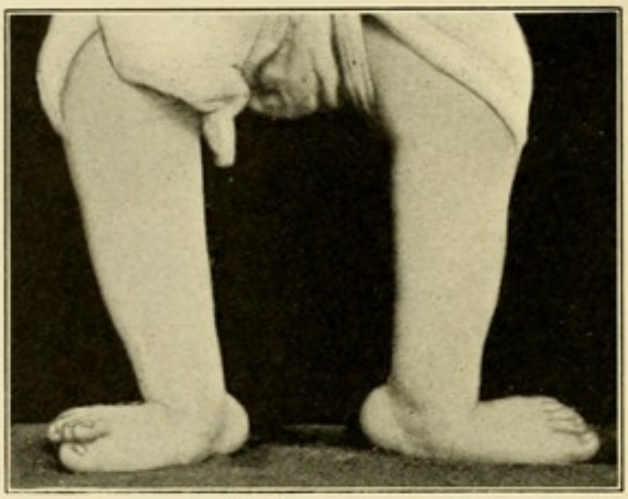

FIG. 558.—Double congenital talipes valgus. Age two and a half years. Orthopædic Hospital.

point of insertion; and the peroneal tendons behind and above the external malleolus.

In cases in which bony deformity has developed, which cannot be overcome by forcible manipulation as above indicated, it may be necessary to do some formal cutting operation. Phelps (1881) divided all the structures (skin, muscles, tendons, ligaments) on the contracted side, in the same plane, until the astragalo-scaphoid joint was widely opened, and dressed the foot in over-corrected position, packing the wound with gauze. While this is efficient in overcoming deformity at the time, relapses are not unknown, and the foot is stiff and functionally impaired at the best. Ogston (1892), Mencière of Rheims, and Barlow, in the case of very young children, have adopted a method called by Mencière "*modelage par évidement;*" this consists in excavating all but a shell of the calcis, astragalus and cuboid, by means of a small curette, and then forcibly correcting the deformity, a procedure which is rendered easy by the temporary weakness produced in the bones. In most cases of bony deformity in children or adults, the best method

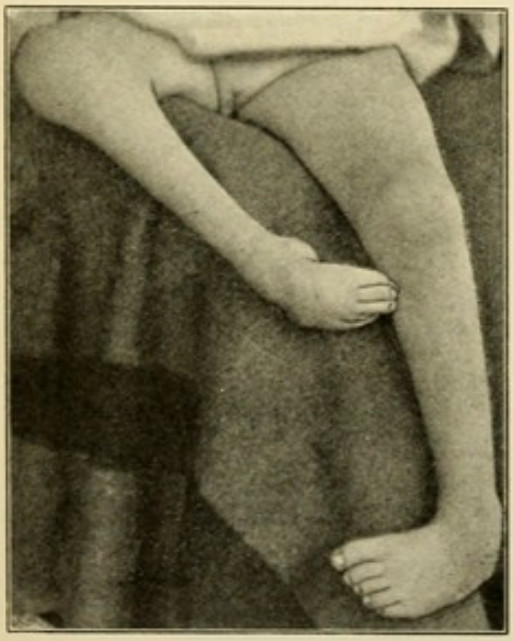

FIG. 559.—Congenital club-feet and contracture of knee. Age three years. Episcopal Hospital.

of overcoming the deformity is to do **cuneiform tarsectomy**, or wedge-shaped resection of the tarsus (R. Davy, 1881): in this operation a wedge of bone (regardless of the outlines of the individual bones), with its base on the dorsum and its apex on the sole, is removed from across the tarsus; the portion excised being sufficiently large to allow over-correction of the deformity. **Astragalectomy**, which is preferred by many surgeons, is more difficult of execution, and leaves a less shapely foot than does cuneiform tarsectomy.

Other forms of congenital talipes (Fig. 558), as well as club-hand, contracted knee (Fig. 559), etc., are so rare that it seems unnecessary to discuss them here, as the principles of treatment are the same as in equino-varus.

PARALYTIC DEFORMITIES.

Acute Anterior Poliomyelitis.—Paralytic Talipes.—Most of the paralytic deformities which require orthopedic treatment are the result of "infantile paralysis," though cases occasionally are encountered the effect of cerebrospinal meningitis, diphtheria, or other rarer infections. The vast majority of cases of infantile palsy involve one or both lower extremities, especially the feet. The extent of the paralysis is very variable; it may affect only one muscle group, or a single muscle; or it may affect both lower extremities in their entirety, forcing the child to walk on his hands, using the feet merely as props (Fig. 560), or occasionally inducing a quadrupedal gait; or the trunk also may be paralyzed, rendering the child helpless. Infantile palsy affecting one side of the back, is an occasional cause of scoliosis (Fig. 579). In some cases there is only slight tendency to contractures of the unparalyzed muscles, the paralyzed part remaining entirely flaccid; while in others, contractures are an early and prominent symptom. In nearly every case deformity eventually develops.

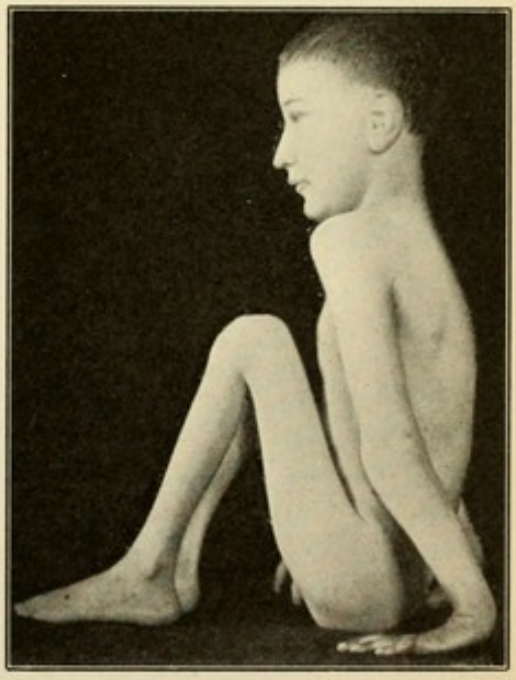

FIG. 560.—Infantile palsy of both lower extremities. Position assumed in walking on hands. Age four years. Orthopædic Hospital.

When it has been ascertained that paralysis exists, it is important to institute mechanical treatment at once, to prevent, so far as possible, the development of deformity, and to encourage return of function. Even the weight of the bed-clothes on the toes may be injurious, predisposing to equinus deformity. The foot should be

supported at a right angle with the leg, and the knee and hip should be kept fully extended, by suitable splints or apparatus. Meanwhile, massage and electric treatment (galvanism) should be employed, and use of the limb encouraged, provided that proper posture is maintained. Usually after a month or two the extent of the paralysis will be fairly well defined, but under conservative measures, further improvement may occur for two or three years. If proper treatment (orthopedic support, massage, electricity) has been instituted promptly, and faithfully pursued, usually there will be no further improvement after the lapse of this time. But in all cases where such treatment has not been employed, the surgeon should delay resort to operative methods until trial has been made of mechanical support, massage, etc., for at least two years.

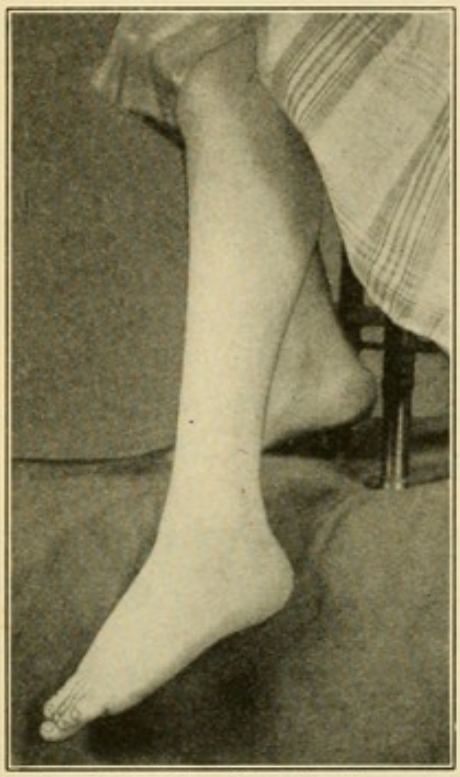

FIG. 561.—Paralytic foot-drop, in a girl of fourteen years. Orthopædic Hospital.

If deformity develops from neglect of, or in spite of, proper support by apparatus, various forms of *paralytic talipes* may be present. These are distinguished from the deformities of *congenital talipes* by the history of their being acquired, usually during the second or third year of life, as the result of an acute, even if slight, febrile attack, after which the child began to limp; by their flaccid character, some muscles being noticeably paralyzed, while others by overaction cause persistent deviation of the foot; by reactions of degeneration in the paralyzed muscles when their electrical contractility is investigated (these never exist in congenital talipes); and by marked atrophy of the paralyzed limb.

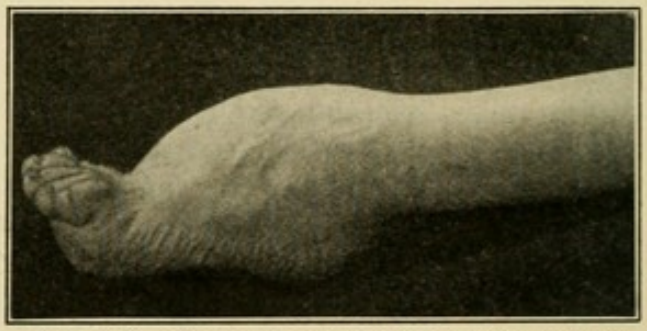

FIG. 562.—Paralytic equinus, age twenty years, deformity growing steadily worse since childhood. Orthopædic Hospital.

The most frequent deformity is *equino-varus*, due to paralysis of the peroneal muscles, often associated with loss of power in the extensor longus digitorum and extensor longus hallucis; the tibialis anticus and posticus act as strong inverters of the foot, and the unopposed flexors and calf muscles maintain foot-drop (Fig. 561), producing a potential equinus which if long uncorrected may become a fixed deformity

(Fig. 562). In other cases there is no marked contracture of the active muscles, but owing to the paralysis, the foot easily turns into a position of extreme deformity (Fig. 563), rendering locomotion almost impossible without apparatus. *Paralytic Calcaneus* (Fig. 565)

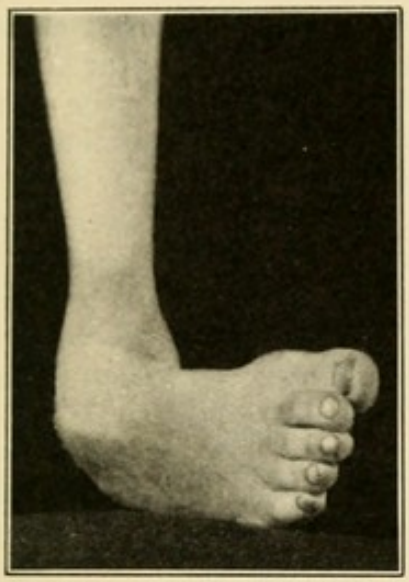

FIG. 563.—Paralytic varus before operation. Age fifteen years; duration eight years. (See Fig. 564.) Orthopædic Hospital.

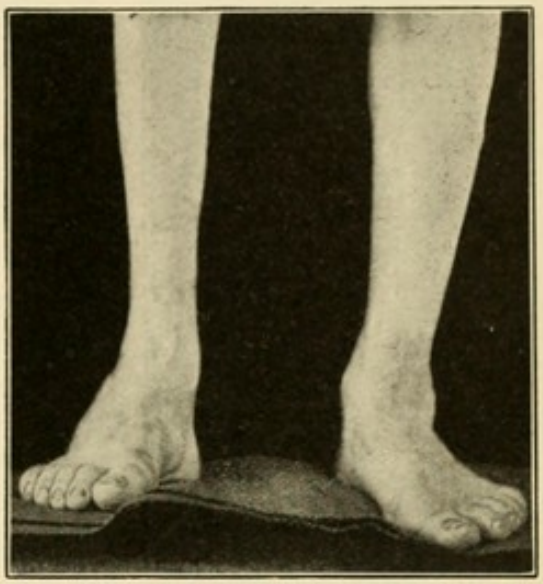

FIG. 564.—Patient shown in Fig. 563, after transplantation of tibialis anticus to base of fifth metatarsal bone. Orthopædic Hospital.

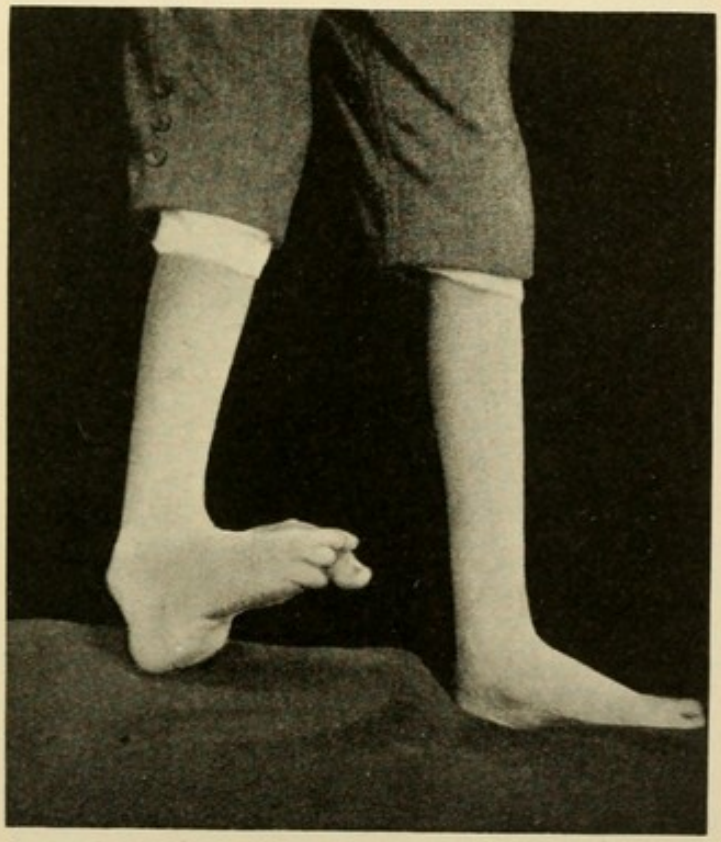

FIG. 565.—Paralytic calcaneus, showing attitude assumed in walking. Aged twelve years; duration eight years. Left foot assumed similar attitude as soon as any attempt at motion was made, but patient could not balance himself long enough with both feet in action for a photograph to be taken. (See also Fig. 566.) Orthopædic Hospital.

is due to paralysis of the calf muscles; the unopposed extensors cause the toes to fly into the air at each step; sometimes there is dislocation of the peroneal tendons anterior to the external malleolus. Calcaneus deformity usually is combined with marked *cavus* (Fig. 566), though this may exist alone, from contracture of the plantar fascia and extensors of the toes, when the short foot muscles (interossei and lumbricals) have been paralyzed (Fig. 571). *Paralytic Valgus* (Fig. 569) is much more common than a similar congenital deformity; usually the two tibial muscles are paralyzed, and sometimes the flexors of the toes as well. Usually the peronei are contracted.

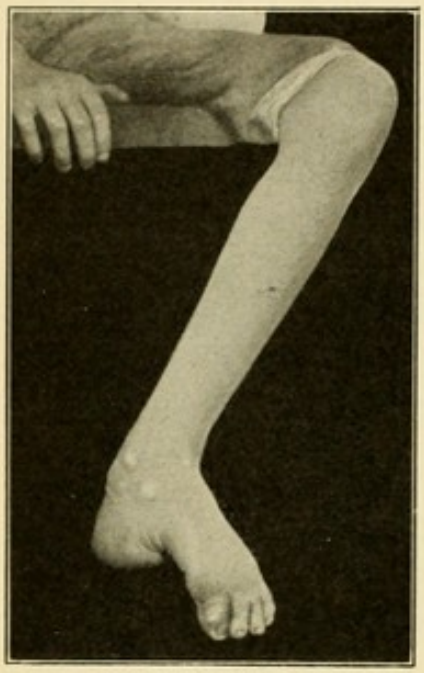

Fig. 566.—Paralytic calcaneus, showing secondary cavus, when toes were forcibly flexed. Same patient as Fig. 565.

When it has been ascertained that no further improvement is to be expected without operation, the aim of the surgeon should be to devise some means by which apparatus may be discarded. Whenever there are a sufficient number of healthy muscles for the purpose, it is

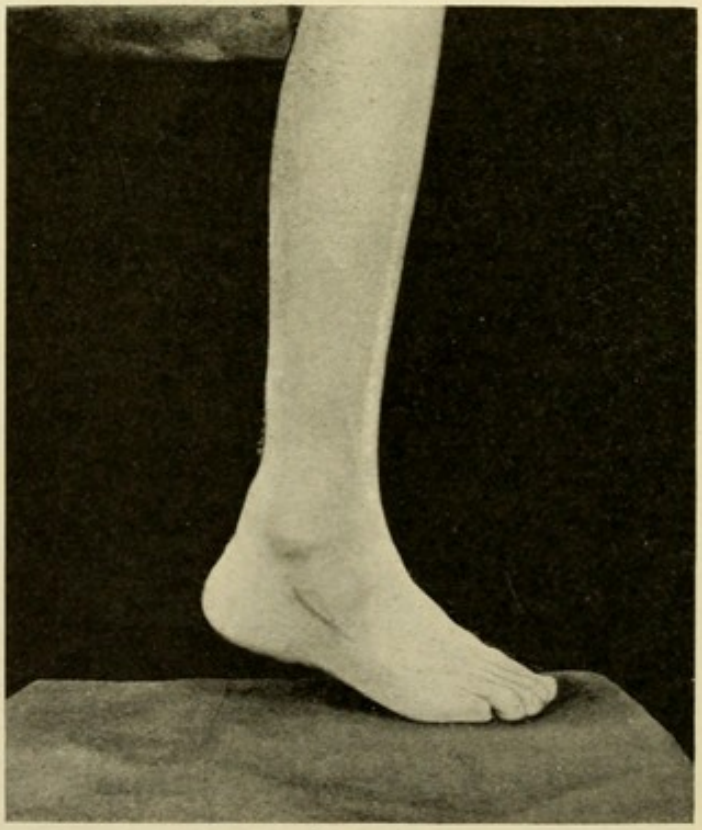

Fig. 567.—Paralytic calcaneus after transplantation of the peronei and tibialis posticus into the calcaneum, showing power of raising the heel. (See Figs. 565, 566, and 568.) Orthopædic Hospital.

possible, by changing the points of insertion of one or more, so to distribute the muscular power which remains as to secure to the patient a well balanced foot. This operation is known as **Tendon Transplantation.** It seldom is advisable to employ it before the age of six years, since before this age it is very difficult to be certain which muscles are functionally active, because this is a point ascertained much more accurately by clinical observation than by investigation of the electrical reactions. Before tendon transplantation is attempted, it is important to overcome all deformity, and this may require repeated manipulation under an anesthetic, *redressement forcé* (as in congenital talipes, p. 518), or even tenotomies; only when the foot can be held

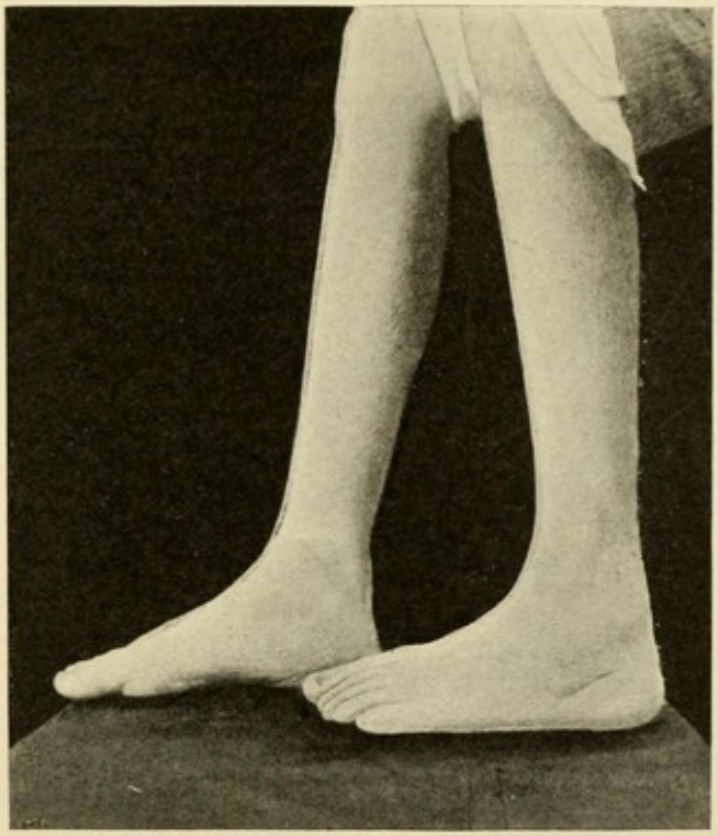

FIG. 568.—Paralytic calcaneus two months after tendon transplantation. (See Figs. 565, 566, and 567.) Orthopædic Hospital.

in the over-corrected position by the pressure of one finger, will it be safe to resort to operation. The best method of tendon transplantation is the periosteal insertion of Lange (1898); this may be succinctly described by a concrete example, namely, the transplantation of the tibialis anticus to the base of the fifth metatarsal bone, for the relief of varus due to paralysis of the peroneal muscles. Under Esmarch anemia the tibialis anticus is divided at its insertion, and is drawn out of its sheath through a second incision made over its course above the annular ligament; a subcutaneous channel is then burrowed from above the annular ligament to the tuberosity of the fifth metatarsal bone, and through a third incision at the

latter point the tendon of the tibialis anticus is drawn down, and under the utmost possible tension is sutured to the periosteum by several

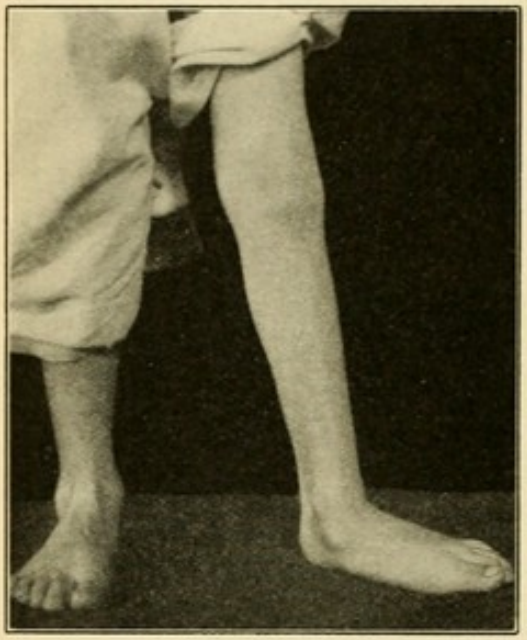

FIG. 569.—Paralytic valgus, age seven years; treated by tendon transplantation. (See Fig. 570.) Orthopædic Hospital.

FIG. 570.—Patient shown in Fig. 569. After transplantation of peroneus brevis and tertius to insertion of tibialis anticus.

mattress sutures of strong chromic catgut. The foot is immobilized in over-corrected position (valgus), in gypsum, for eight weeks; function is then gradually resumed. The tibialis anticus being now inserted on the outer side of the foot will act as an everter, largely replacing the paralyzed peronei, and rendering the further use of apparatus unnecessary.

FIG. 571. — Paralytic cavus, age eleven years, showing over-action of the extensor longus hallucis. Orthopædic Hospital.

In similar manner, for other deformities, various other tendons may be transplanted, as will occur to the mind of any ingenious surgeon. For paralytic valgus it is best to transplant the extensor longus hallucis to the insertion of the tibialis anticus; when the extensor longus hallucis is paralyzed also, one of the peronei may be transferred to the insertion of the tibialis anticus (Figs. 569 and 570), or if the extensor longus digitorum is active, the *distal* end of the tibialis

anticus (divided above the annular ligament) may be sutured to this healthy tendon. For paralytic cavus, the extensor longus hallucis, which is usually the deforming factor (Fig. 571), may be attached to the head of the first metatarsal. For paralytic calcaneus the peronei and tibialis posticus may be transplanted into the insertion of the tendo Achillis (Figs. 565 to 568). For paralysis of the quadriceps femoris one or more of the hamstrings may be transplanted into the patella; and for paralysis of the internal rotators of the thigh, the tensor fasciæ femoris may be transplanted into the great trochanter (G. G. Davis, 1911).

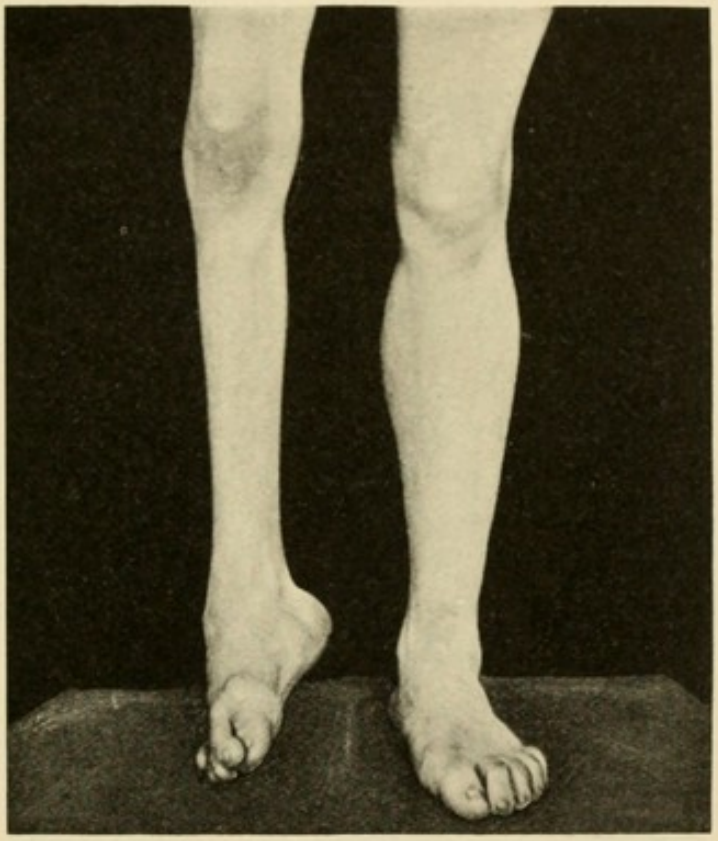

FIG. 572.—Paralytic flail-foot, age eighteen years; duration fourteen years. (See Fig. 573.) Orthopædic Hospital.

In many cases it is possible by *shortening paralyzed tendons* to enable them to act as ligaments in maintaining better position, or when slight power remains, to enable them to use it to better advantage. If a healthy tendon is too short to be available for purposes of transplantation, silk strands may be attached to its end in an imbricated manner, and the tendon thus lengthened the required amount.

Nerve Anastomosis has been employed in some cases of paralytic deformities of the feet, but not with much success. It should be reserved for those cases in which the entire distribution of one nerve is paralyzed, but in which the entire distribution of a neighboring nerve is intact. I employed it in one case in which the entire distribution of the anterior tibial nerve was paralyzed, but in which that of the musculo-cutaneous was unaffected, anastomosing the peripheral

end of the anterior tibial into the musculo-cutaneous; but no power was regained.

Arthrodesis.—When so many muscles are paralyzed that none are available for transplantation, it is possible to convert a "dangle-foot" with flail-joints (Fig. 572) into a firm and useful support by producing an artificial ankylosis (Fig. 573). This operation, known as arthrodesis (Fig. 574), should not be undertaken before the age of nine years at least, since the bones of younger patients are still too cartilaginous for firm union to follow a joint resection. For "foot-drop," arthrodesis of the ankle-joint is done: through a small transverse incision over the front of the joint, displacing the tendons, the articulating surfaces of the astragalus, tibia, and fibula are removed.[1]

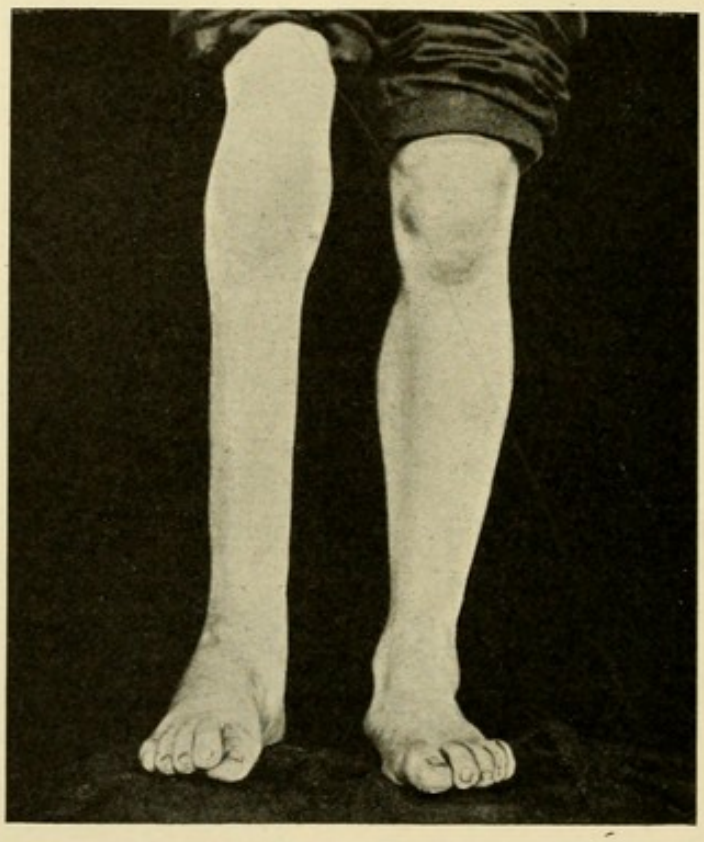

FIG. 573.—Result of arthrodesis of ankle, and subastragalar joints for paralytic flail-foot (Fig. 572). (See Fig. 574.) Orthopædic Hospital.

For lateral mobility, subastragalar arthrodesis is done; in eight cases I have found a single external incision, above the peroneal tendons, sufficient to remove the articulating surfaces of astragalus and calcaneum, as well as those of astragalus and scaphoid (Fig. 165). The wounds are closed without drainage, and the foot is fixed in gypsum for eight weeks, when walking may be resumed; but a light brace should be worn for a few months more.

[1] To secure closer apposition, Goldthwait (1908) advises osteotomy of the fibula just above the malleolus, with inward displacement of this process against the astragalus.

In some cases before the patient is old enough to have arthrodesis done, a flail-joint may be rendered more or less firm by the insertion through the bones of *strong silk sutures, to act as ligaments* (Lange, 1903).

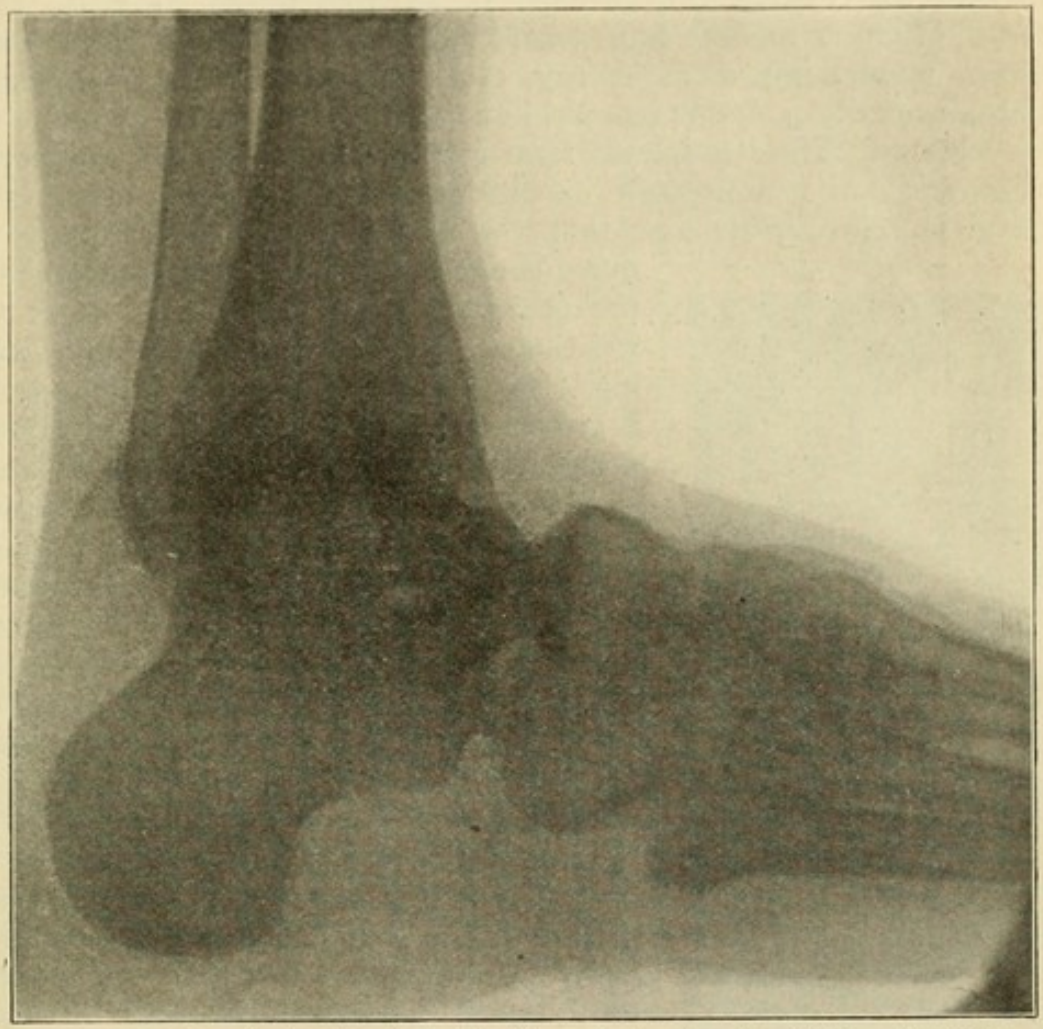

FIG. 574.—Result of arthrodesis of ankle and subastragalar joints. (See Figs. 572 and 573.) Orthopædic Hospital.

Infantile Paralysis of the Upper Extremity (Fig. 575), much rarer than paralytic affections of the lower limbs, is treated on the same general principles. Transplantation of muscles has been done chiefly at the shoulder where a portion of the trapezius or of the pectoralis major has been used to supplement the deltoid. Nerve anastomosis has given no better results than in the leg.

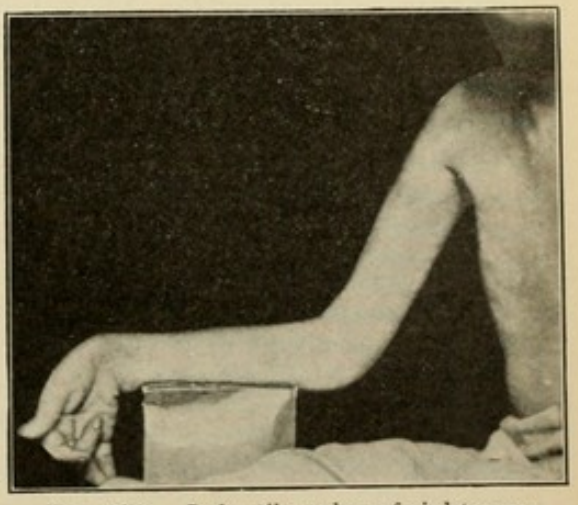

FIG. 575.—Infantile palsy of right arm. Children's Hospital.

Cerebral Palsies.—These result from cortical or meningeal hemorrhages, or from congenital defects, such as porencephalon. Spasticity is their main characteristic, and by this factor it usually is possible to distinguish them from infantile paralysis, which is flaccid. In children they usually occur from injury at birth, and there often is mental impairment (p. 576). In adults they may follow cranial injuries, apoplexy, etc. The paralysis is hemiplegic, paraplegic, diplegic, or monoplegic, according to the site of the cerebral lesion. The hemiplegic form is most frequent, the paraplegic next, while the monoplegic or diplegic types are quite rare. The flexor muscles are stronger than the extensors, and the deformity is quite characteristic: the arm is adducted, the elbow flexed, the forearm pronated, the wrist flexed and the hand clasped tight; the hip is flexed and adducted, the knee slightly flexed, and the foot in the equino-varus position, there being a tendency to walk on the toes (Fig. 576). By gradual steady pressure it usually is possible to correct these contractures, but as soon as pressure is released they recur, the patient having very little if any voluntary control of the affected limbs. In the course of time the deformity becomes permanent, unless malposition is prevented by orthopedic means.

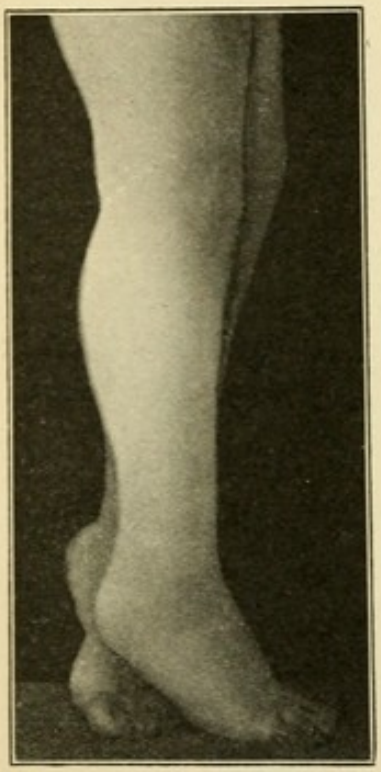

FIG. 576.—Infantile spastic paraplegia, age three years. Attitude in attempting to walk. Orthopædic Hospital.

Treatment.—The treatment consists in the use of massage and manipulation to prevent the contractures from becoming permanent. Malposition should be prevented by splints or braces. Tenotomy will improve position temporarily, but relapses are common. A longer intermission before relapse, and better prospects of permanent functional improvement are offered by intra-perineural *neurotomy* after the method of Nutt (1909): the nerves supplying the spastic muscles are divided and at once reunited by suture; temporary paralysis of all the spastic muscles follows, injurious peripheral impulses are abolished; and return of power to the muscles paralyzed by the neurotomy is so slow that the weaker antagonistic muscles are given a chance to recuperate. Förster (1908) has practised intradural division of the sensory nerve roots (*Rhizotomy*) supplying the affected extremity, but the operation is dangerous and the results very uncertain. Schwab and Allison (1909) have used intraneural alcohol injections. In most cases the disability is lasting, and no form of treatment is of much avail.

LATERAL CURVATURE OF THE SPINE.

Lateral Curvature of the Spine, or **Scoliosis,** is an affection of childhood. It is convenient to distinguish between *functional or postural lateral curvature* and true *organic* or *structural scoliosis.* The former is due simply to malposition, and there is a general (single) curvature of the spinal column, usually convex to the left. Round shoulders often coexist. If neglected, these children may develop true structural scoliosis, as the bones still are soft and their shape is readily altered by long continued unequal pressure. The diagnosis of postural lateral curvature is easily made by dropping a plumb-line from the vertebra prominens, and noting the deviation of the spinous processes. The child may be brought for examination on account of stooping, round shoulders, or general relaxation of the joints. Proper gymnastics, attention to hygiene, manner of supporting the clothing, etc., usually effect a cure in from one to two years. The clothing should not be supported by the points of the shoulders, but as far as possible from the pelvis, or from the slope of the neck; any ordinary gymnastic and calisthenic exercises are efficient; over-study and tire should be avoided, and an active out-of-door life encouraged.

In *organic* or *structural scoliosis* there is, in addition to *lateral deviation of the spinal column* (Fig. 577), also *rotation* of the bodies of the vertebræ, the transverse processes of the vertebræ rotating backward on the convexity of the curve, and forward on its concavity. This rotation is best appreciated by having the patient bend the body horizontally from the hips (Fig. 578).

Scoliosis may be due to a number of causes: (1) It may develop, as already mentioned, as a sequel of *postural lateral curvature;* this probably is the most frequent cause. Sometimes it is convenient to recognize as a predisposing cause, in cases beginning this way, a rachitic or other dystrophic softening of the bones, to account for the rapidity with which structural changes occur in the spinal column. (2) *Congenital anomalies of the spine* (studied at length by Mouchet and Rouget in 1910); there may be a supernumerary wedge-shaped vertebra; or a portion of one or more vertebræ, with or without their attached ribs, may be absent. The deformity in these cases is recognized in early infancy, and the bony lesion usually can be detected in a skiagraph. (3) *Infantile paralysis* or other muscular lesion, allowing unopposed contraction of the muscles on the unaffected side (Fig. 579), is a rather unusual cause. (4) *Empyema,* causing collapse of the thorax on the affected side, is a frequent cause (Fig. 762). (5) *Torticollis,* and other deformities of neighboring parts, such as *ankylosis of the hip in bad position,* causing *tilting of the pelvis,* should also be remembered as occasional causes of this deformity.

In most cases, as already mentioned, the deformity arises from faulty attitudes in sitting, standing, sleeping, etc. It develops most frequently between six and ten years of age, and occurs in girls in over 75 per cent. of cases. The child carries heavy books or a heavy baby

habitually on one arm; sits at school or at home at a desk or table disproportionately high, requiring habitual undue elevation of the right shoulder; one leg may be a trifle shorter than the other, or the patient may sit on a cushion higher on one side than on the other, inducing obliquity of the pelvis—in short, from causes, which often cannot be defined, the patient is brought to the surgeon (unfortunately seldom until the deformity has existed for some years) complaining of asymmetry, with projection of one shoulder and one hip, usually the right. Such patients should be examined with the back bare from

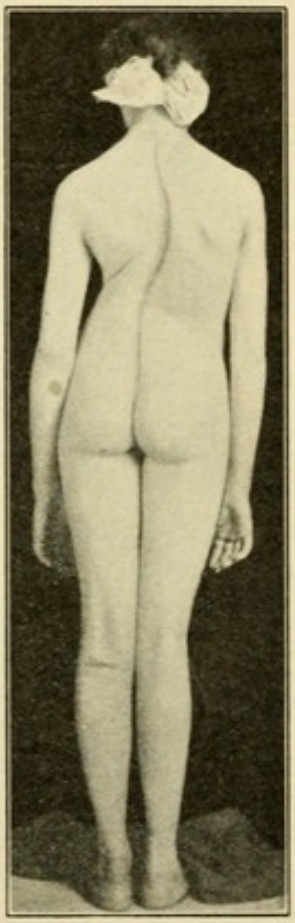

FIG. 577.—Scoliosis, in a girl of sixteen years; left shoulder droops, right thorax (convex curve) is prominent. (See Fig. 578.) Orthopædic Hospital.

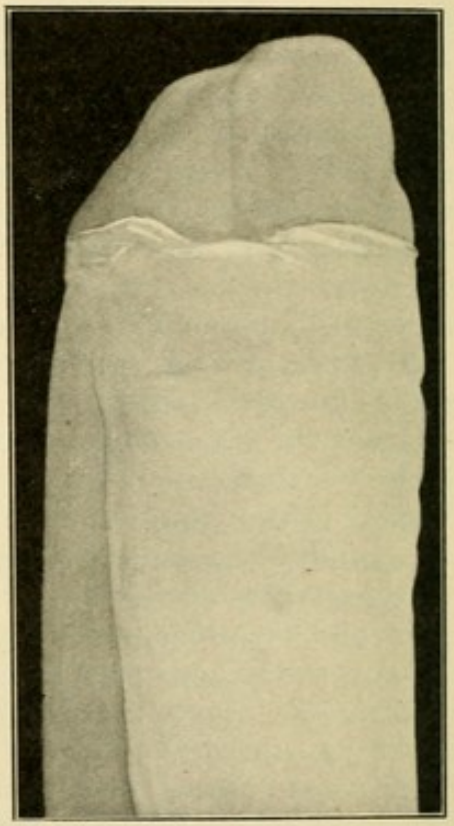

FIG. 578.—Patient in Fig. 577, stooping to show posterior rotation at the side of the convexity of the curve. Orthopædic Hospital.

neck to pelvis, and without shoes on their feet. Even if no asymmetry is evident at a glance, it is extremely likely that after standing a few minutes the slouching attitude will come on, and reveal the deformity. In the immense majority of cases there is a curve convex to the right in the thoracic region, which compensates a curve convex to the left in the lumbar region, the latter being regarded as the primary curve. (If the case is one of postural scoliosis only, there seldom is more than one curve, which usually is convex to the left; placing a lift under the left foot usually causes the curve to disappear.) The line of the waist is more cut in on the left side, a distinct fold

often existing (Fig. 577); and when the patient stoops forward at the hips the right thorax becomes prominent, the left loin projects, and the right loin falls away (Fig. 578). In extreme cases the anterior surface of the thorax is deformed also, the left lower ribs becoming very prominent, and the apex of the right lung being markedly compressed; sometimes the liver is proptosed, and the heart displaced to the left. Valvular incompetency is frequent in cases of great deformity. Besides the deformity, the patient complains of tiring easily, of weakness, or of marked disability.

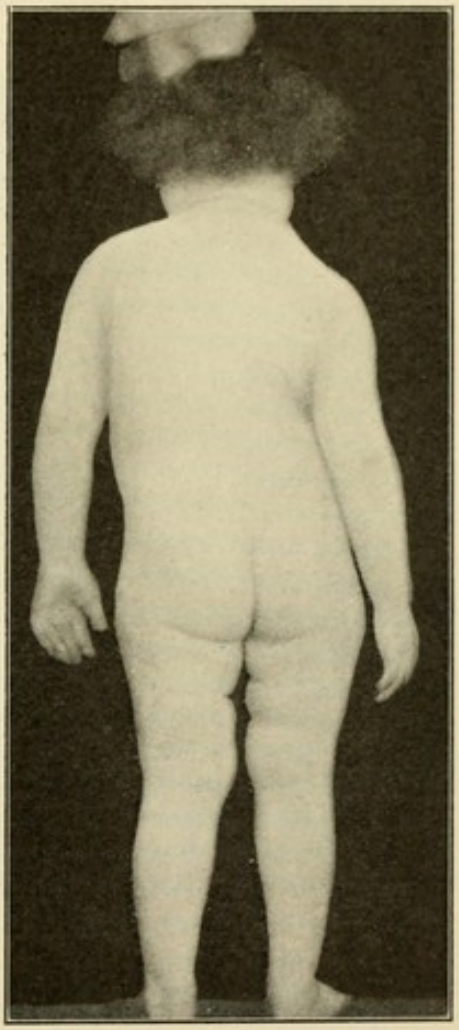

Fig. 579.—Incipient scoliosis, following infantile palsy one year ago. Age four years. Left side paralyzed. Orthopædic Hospital.

Diagnosis.—In cases of very slight degree it is difficult sometimes to be certain that the affection is scoliosis and not incipient tuberculosis of the spine. In the latter condition there may be lateral deviation of the spine without any kyphosis; but the lateral deviation is more abrupt than the gentle curve of scoliosis (Fig. 639); there is painful rigidity of the spine as detected by flexion, hyperextension, and lateral bending; there usually is tenderness localized to the seat of disease; there may be constant, slight, evening rise of temperature; and the tuberculin test probably will be positive. A skiagraph may reveal a tuberculous lesion; but in cases of scoliosis, except those easily recognized as such clinically, will show no bony change. If the slightest doubt as to the nature of the trouble persists, treatment for Pott's disease (p. 609) should be instituted until its absence is proved.

Treatment.—The mildest grades of rotatory scoliosis may be overcome by correction of habitual malposition and special gymnastic exercises under the supervision of a competent orthopedic surgeon. The patient should sleep on a hard, flat bed, without a pillow, and either supine or prone; she should spend at least one hour each day lying flat on her back on a hard level couch or on the floor; and should give up habits of writing, reading, sewing, etc., which require a cramped posture. Where pain or disability is marked, recumbent treatment, with head and foot extension, as for Pott's disease should be instituted. The exercises prescribed for scoliosis cannot be detailed here; they form almost a sub-specialty in orthopedic practice,

and are of a highly technical nature. They should be taken daily (at least three times weekly) for from one to three hours for a period of nine months up to one or two years. It is folly to expect permanent improvement sooner. In most cases, certainly in those in which noticeable rotation is present, the patient should be provided with some form of spinal support; for all severe grades of deformity this is more important than gymnastics, as it is futile to expect to correct bony deformity by muscular exercise. As H. Bigg (1905), Lovett and Seever (1911), and other recent writers, point out, the deformity should be treated on the same principles that guide us in treatment of other bony deformities, such as bow-legs and club feet.

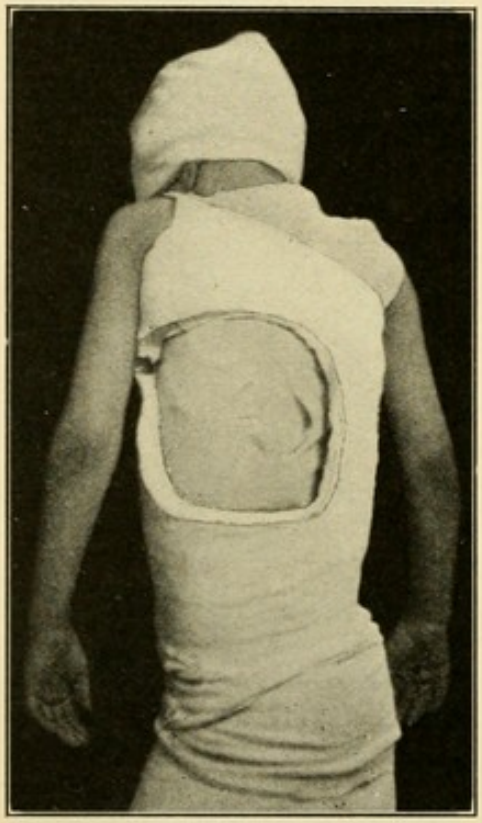

FIG. 580.—Plaster of Paris jacket applied according to Abbott's method for the treatment of scoliosis (curve convex to right in thoracic region). Large window cut over the hollow region; the left shoulder held high and forward; the right shoulder forced down and backward; the pelvis rotated forward toward the right. Orthopædic Hospital.

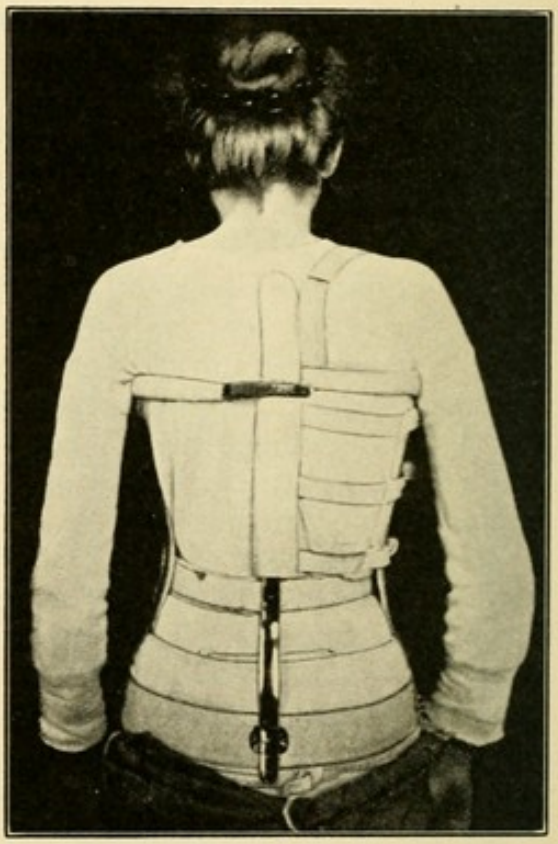

FIG. 581.—G. G. Davis's brace for scoliosis. Orthopædic Hospital.

The most efficient corrective apparatus is a gypsum jacket, applied according to the method of Abbott (1912) with the patient lying supine on a canvas sling, attached at each end to a special frame. This sling is cut on the bias at one end, so that when one side of the sling is pulled taut the other is relaxed. The taut side of the sling is placed under the prominent side of the thorax, and the patient's head and thighs are thoroughly flexed. Then bands are attached to the sides of the frame to assist over-correction of the deformity, and the plaster of Paris is applied and moulded carefully to the body,

which has been padded with saddler's felt until approximately symmetrical in form. When the plaster has set, large windows are cut over the compressed portions of the thorax (usually over the left scapula and lower ribs posteriorly, and the right mammary region anteriorly), and the pads over these compressed portions are removed, while increasing pressure is brought to bear on the prominent portions of the thorax by inserting, at intervals of a few days, broad felt pads between the thorax and jacket (Fig. 580). The same jacket may be worn for a period of from two to three months. A new jacket then is applied for a month or six seeks longer; and this treatment is continued until *over-correction* of the deformity has been obtained. This form of treatment is the most efficient yet devised. When over-correction has been secured and maintained for a few weeks, symmetry is restored by gymnastics. Treatment by gypsum jackets as formerly applied, had to be continued indefinitely, as relapses were frequent and very prompt after apparently complete cures. In Abbott's method, however, the reduction of deformity is reasonably rapid and if over-correction can be secured, appears to be lasting. In less severe cases removable jackets or spinal braces (Fig. 581) may be used, constructed to act on the same principles as above described; but they are less efficient than irremovable gypsum jackets even though they permit coincident use of gymnastics.

STATIC DISORDERS OF THE LUMBAR SPINE AND PELVIS.

These were studied in 1901 by Goldthwait, and are frequent causes of neurasthenia, backache, and general disability, especially in women. After childbirth, or during convalescence from some wasting disease, or simply from malnutrition, overwork, etc., the tone of the pelvic and lumbar muscles is lowered, and undue strain is thrown on the ligaments. Similar symptoms may occur after prolonged anesthesia, during which the patient has lain on her back without support to the lumbar spine; some cases of "lumbago" are due to similar conditions; and most patients with what has long been called "neurotic spine" have some static disturbance with ligamentous strain as the basis of their trouble.

The most frequent condition is a loss of the normal lumbar lordosis; occasionally, however, somewhat similar symptoms follow increase of the lordosis, caused by wearing very high-heeled shoes, by ankylosis of the hip in a flexed position, etc. Flatness of the back often is associated with weak or pronated feet (p. 547), and is relieved by treatment of the foot condition.

The normal lumbar lordosis disappears at first merely when the patient is supine; later it is absent also in the erect posture. The sacro-iliac joints and symphysis pubis may become relaxed, and pain may be referred down the sciatic nerves; while at each step the patient may feel discomfort and may obtain relief only by lying prone, or supine with the lumbar spine supported by a pillow. One sacro-iliac

joint frequently is more relaxed than the other. By placing one hand over the joint while the other palpates the symphysis pubis, it usually is possible to detect abnormal mobility as the patient stands first on one foot then on the other. Or with the patient lying prone, the sacro-iliac joints may be made to move by hyperextending the thighs.

Treatment.—The treatment in mild cases consists in massage of the lumbar muscles, with gymnastic exercises. In severe cases it may be necessary to put the patient to bed with weight extension to the lower extremities; later some form of spinal and pelvic support must be provided. For sacro-iliac relaxation the application of a firm

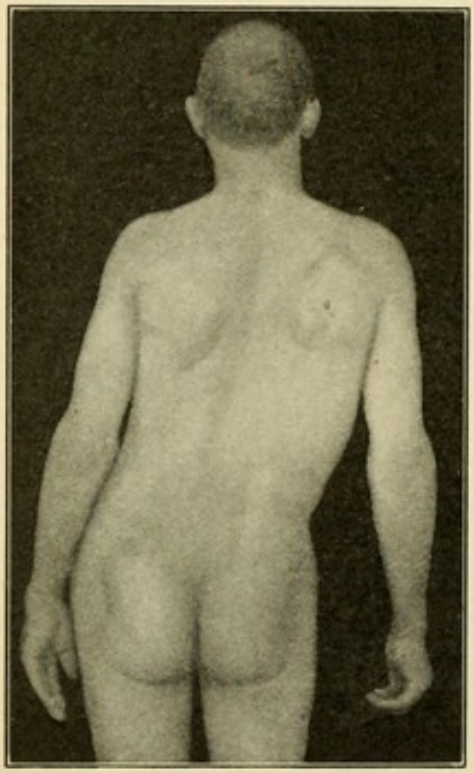

FIG. 582.—Sacro-iliac sprain, with relaxation (left side). For eight months pain in left hip, back, and down sciatic. Diagnosed Pott's disease, elsewhere. Orthopædic Hospital.

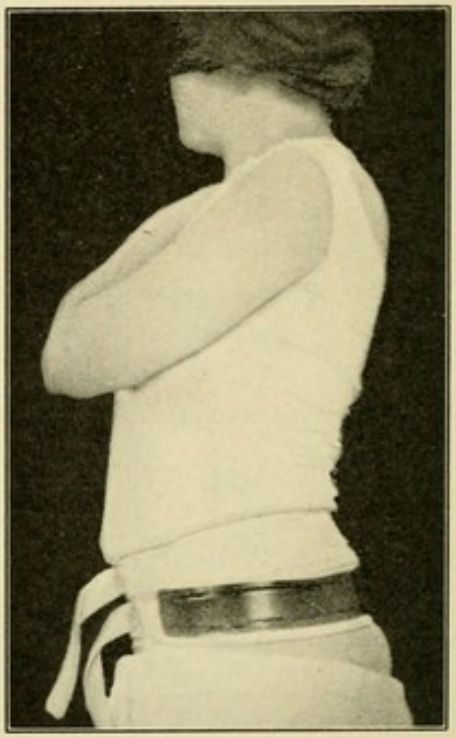

FIG. 583.—Belt for sacro-iliac relaxation. Orthopædic Hospital.

pelvic belt between trochanters and iliac crests often is all that is required (Fig. 583). Where the lumbar spine also is involved, it will be necessary to support this also: this may be accomplished by the application of a light gypsum jacket, with the patient lying prone on a hammock, as in Pott's disease (p. 611), or by some form of orthopedic corset which will maintain hyperextension of the lumbar spine.

Spondylolisthesis is the term given to subluxation of the last lumbar vertebra forward on the sacrum; occasionally the fourth lumbar vertebra is displaced forward on the fifth. The affection is commonest in young adult females, but occurs also in growing girls and in youths and young men. There is a depression above the sacrum,

over the last lumbar vertebra, and sometimes a prominence can be felt above the sacral eminence by a finger in the rectum or vagina. The symptoms and treatment are much the same as for static strains of the lumbar spine, of which, indeed, spondylolisthesis may be considered the terminal stage.

DEFORMITIES OF THE HEAD AND NECK

Torticollis, Caput Obstipum, or Wry-neck, sometimes is due to injury at birth, rupturing some of the fibres of the sternomastoid or other cervical muscle. It is uncertain whether the cases of *hematoma of the sterno-mastoid muscle* sometimes seen in infants are a result of the rupture of the muscle because it was congenitally short, or are themselves the cause of wry-neck by causing subsequent cicatricial contraction of the muscle. Often the deformity is not noticed until the child is several months old, and then it is difficult to be certain whether the affection is congenital or acquired. As a rule, the congenital affection is painless, while the acquired form has a more or less acute onset. Torticollis may be symptomatic of certain other diseases, as astigmatism, or cervical Pott's disease (p. 603), fracture-dislocation of the cervical spine, cervical rib, cervical adenitis (Fig. 584), "rheumatic stiff neck," toothache, ear-ache, tonsillitis, or other affection which may irritate the spinal accessory or upper cervical nerves, causing spasticity of the muscles concerned in the production of the deformity. These are especially the sternomastoid, the trapezius, and the scalenus anticus, especially the sterno-mastoid.

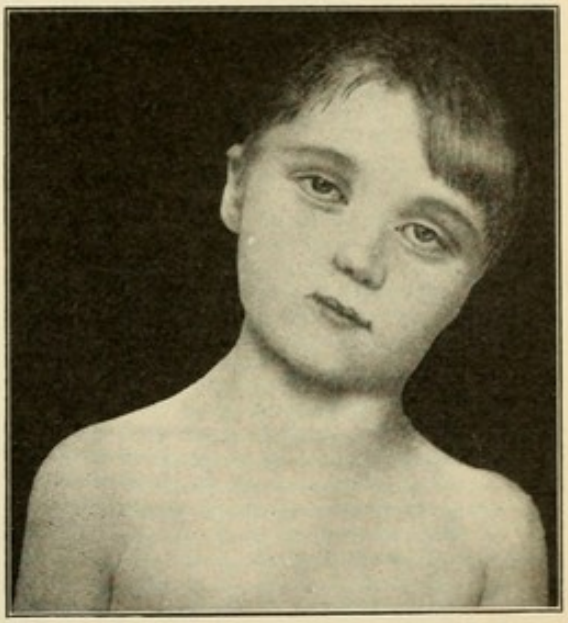

FIG. 584.—Torticollis from cervical adenitis. Children's Hospital.

Symptoms.—The head is rotated to the opposite side, the chin pointing to the unaffected shoulder, while the ear approaches the shoulder of the affected side (Fig. 585). If the deformity continues long uncorrected, it may lead to facial asymmetry, scoliosis, or other secondary deformities which cannot be remedied.

Treatment.—The surgeon should first ascertain that the deformity is not of the symptomatic variety; if it is, removal or proper treatment of the cause of irritation usually will cause the wry-neck to disappear. If no cause other than a shortening of the muscles can be found, attempts may be made by massage, gymnastics, or apparatus to overcome the deformity. If these fail, as in most cases they do,

the surgeon may resort to division of the contracted structures. In cases of short duration this usually is quite efficient, but in many patients the most that can be expected is a lessening of deformity. It is better to divide all resisting structures by open section than to attempt a subcutaneous operation; very dense cicatricial bands, which may exist in the cervical fascia, should be excised, and the muscles may be divided transversely and left unsutured, or some form of muscle lengthening, analogous to the lengthening of tendons may be employed. The head is then dressed in an over-corrected position, maintained by a gypsum case (Fig. 586), or orthopedic apparatus.

FIG. 585.—Congenital torticollis with acquired scoliosis. Note asymmetry of face. Children's Hospital.

Spasmodic Torticollis, a form of *Tic Convulsif*, is an affection of obscure origin, consisting essentially in sudden tonic involuntary, and usually painful contraction of the neck muscles, momentarily turning the head into a wry-neck position. The extent of the spasm, and the number of muscles involved, varies greatly. The disease usually begins insidiously, in young adult life, but progresses without intermission until almost the entire body may be involved; any effort to move or speak, and especially any excitement, brings on a spasm, and the patient may curl up in a knot, as it were, on the side affected, being absolutely helpless and unable to straighten himself out. Many surgical measures have been tried, but none have had permanent good effect; but as the same can be said for medical measures, the temporary relief which follows operation should not be despised. Division of the nerves supplying the cervical muscles

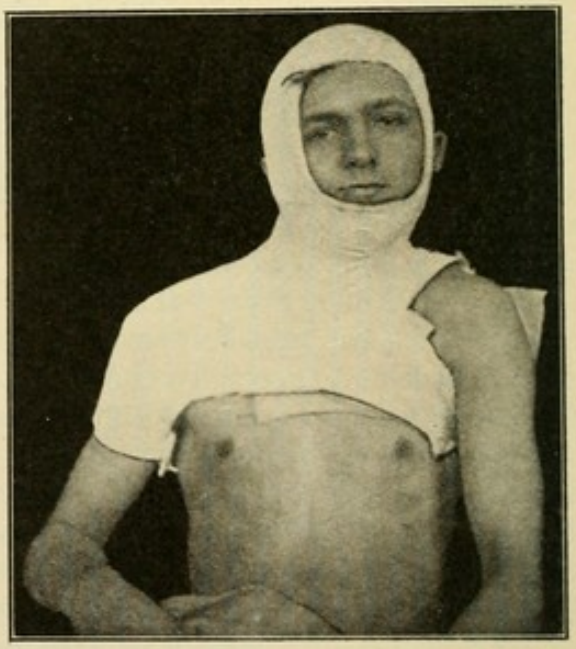

FIG. 586.—Gypsum dressing after operation for left-sided congenital torticollis. Age nineteen years. Orthopædic Hospital.

most affected is the operation usually done, especially division of the spinal accessory or upper cervical nerves (Keen, 1891).

Cervical Ribs.—On one or both sides of the neck a rudimentary rib may be formed, usually attached to the seventh cervical vertebra, but occasionally to the sixth. The affection is said to be bilateral in 75 per cent. of cases, and occurs in females three times as often as in males. If the rib is very short, no symptoms may be produced, but usually it is long enough to reach to the subclavian artery, which passes over the rib, and may be compressed, causing symptoms of numbness, tingling, etc., in the extremity affected. Pressure on the brachial plexus, cervical sympathetic or pneumogastric nerves may

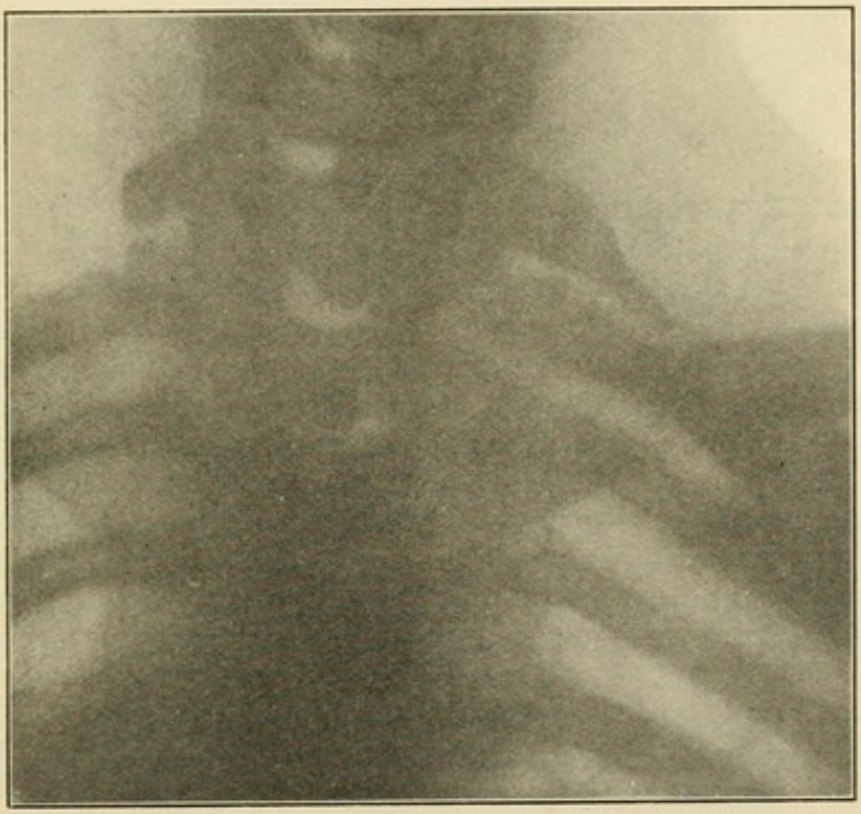

FIG. 587.—Cervical rib (left); age eighteen years. Numbness, tingling, etc., for four months. (Dr. W. J. Taylor's case.) Orthopædic Hospital.

also occur. Usually no trouble is experienced until adult life (Fig. 587). In most cases the rib is palpable in the neck; and the abnormal position of the artery, as well as changes in the radial pulse, may simulate aneurysm. Rest for a few weeks, with elevation of the arm, usually causes subsidence of acute symptoms. When these recur, and are disabling, excision of the abnormal rib should be done. The operation may be very difficult, from the altered relations of blood-vessels, nerves, and muscles, and from the proximity of the pleura. Complete recovery is the rule, even if temporary paralysis occurs from careless handling of the nerves.

ACQUIRED DEFORMITIES OF THE UPPER EXTREMITY.

Cubitus Valgus, or increase of the normal "carrying angle" of the upper extremity, sometimes follows rachitis, but most often is the result of a fracture of the lower end of the humerus. It is less frequent and less disabling than **cubitus varus,** which almost always is due to fracture, especially supracondylar fractures of the humerus. Either deformity may be treated by supracondylar osteotomy of the humerus. Some surgeons prefer to dress the arm in full extension after the operation: if this is done, for valgus deformity the forearm should be kept in supination, which relaxes the muscles passing from the external supracondylar ridge; while for varus the forearm is dressed in full pronation, making these muscles tense, and, therefore, restoring the carrying angle. If the elbow is dressed in hyperflexion, as in a recent supracondylar fracture, the precautions mentioned at page 346 against varus and valgus deformities should be observed.

Ischemic Contracture (Stromeyer, 1838; Volkmann, 1869) is due to muscle and nerve degenerations following ischemia caused by pressure of splints or bandages applied for a fracture of the elbow or forearm. Very rarely it has followed injury in which no splint or dressing of any kind had been used. It has been reported as affecting the lower extremity also. Bardenheuer (1911) in his recent elaborate study of the question, concluded that the degenerative changes were due to venous stasis, the muscle cells being poisoned by metabolic products in the blood, and that the primary cause is not an anemia of the parts. Nerve involvement in cases of ischemic contracture has been emphasized by J. J. Thomas (1909). The hand swells and becomes cyanosed, and the parts are extremely painful; but the constriction is not sufficient to cause gangrene. After a few days the pain ceases, and swelling may subside. The damage is done within a few hours, and cannot be repaired merely by removal of the splints; it is far better to be sure in the first place that the dressing used does not interfere with the circulation. Usually the condition develops in what appears an insidious manner only because the surgeon is not on the lookout for it; if interference with the circulation persists for several hours there is already nerve and muscle degeneration, and if the surgeon was sufficiently attentive he would discover it at the next dressing, and not be surprised when subsequent deformity develops.

The deformity is quite characteristic (Fig. 588), resembling that of ulnar paralysis; nor is this resemblance surprising since the ulnar nerve often is involved (Fig. 589). But even if the symptoms of neuritis are present, and they are not in all cases, there are also symptoms of fibrous degeneration of the muscles on the flexor side of the forearm. The joints are not affected, motion being limited merely by muscular contracture: thus, when the wrist is fully flexed, extension of the fingers becomes possible; but efforts to straighten the wrist at once cause flexion of the fingers. Frequently there are

pressure sores in the skin, and the resulting cicatrices aid in fixing muscles, tendons, and nerves, in one almost inextricable mass of adhesions.

Treatment.—Very little can be done until the ulcers have healed, except to prevent further deformity. No remedial treatment should be undertaken until acute symptoms have subsided. Then trial may be made of massage and passive motion; but usually very slight if any improvement is secured. R. Jones (1908) applies a malleable

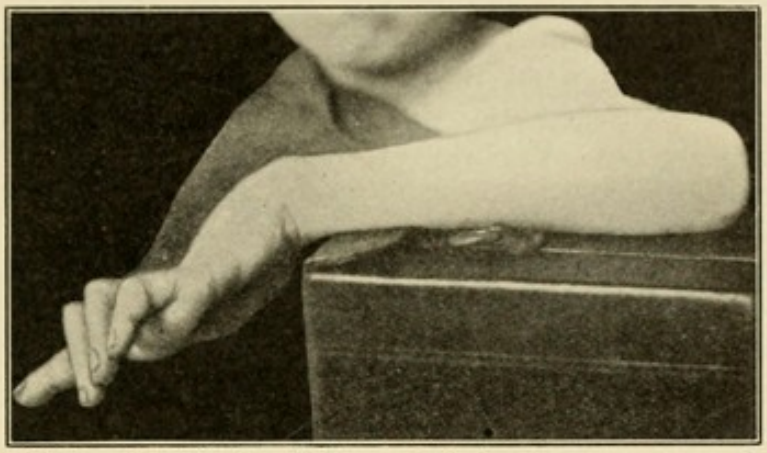

FIG. 588.—Deformity following Volkmann's ischemic contracture and paralysis of ulnar nerve after fracture of elbow. Orthopædic Hospital.

metal splint to each finger up to the carpal joints, first with the wrist in full flexion, a position which usually permits nearly full extension of the fingers; the wrist flexion is gradually diminished and the finger extension progressively increased by changing the angle of the finger splints; and in the course of several months the contracted tissues may be sufficiently relaxed to permit fair function. In most cases, however, especially in those complicated by nerve changes, operation

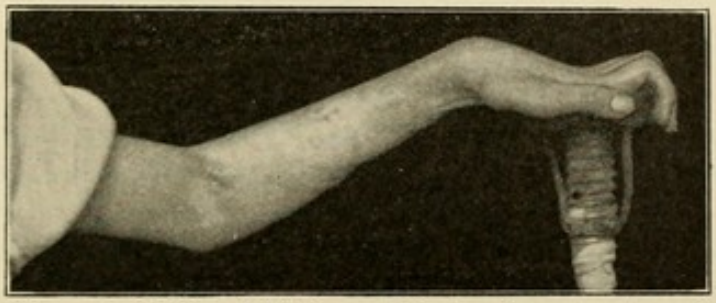

FIG. 589.—Ulnar paralysis and Volkmann's ischemic contracture after fracture at the elbow. Episcopal Hospital.

is required. This consists in a free dissection of the muscles, tendons, and nerves; in muscle and tendon lengthening (Anderson, 1889; Littlewood and Page, 1898), and in preventing, so far as possible, formation of new adhesions, by interposing flaps of fascia or pieces of Cargile membrane[1] between the various structures. Some brilliant

[1] This is thin gold-beaters' skin, made from the peritoneum of an ox, first used by an Arkansas physician named Cargile, and introduced to professional notice in 1902 by R. T. Morris.

results have been secured by these methods (Dudgeon, 1902; G. G. Davis, 1908), but in many cases the operation has to be repeated a number of times Binet (1910) has studied 141 cases of Volkmann's contracture, and prefers to treat them by resection of the radius and ulna, shortening the forearm until the tendons become relaxed sufficiently to straighten the fingers (Colzi, 1892; Henle, 1896; Froelich, 1909); but while good results have followed this method it is better in every case to make sure that the nerves are freed from adhesions.

Spontaneous Subluxation of the Wrist or Manus Valga (Madelung's Disease, 1878).—The symptoms of this affection usually are manifested about the age of puberty; it affects particularly females; involves both wrists in about 50 per cent. of cases; is characterized by dorsal projection of the lower ends of the ulnæ, by slight radial deviation of the hand, and in its more advanced stages by subluxation of the wrist forward at the radiocarpal joint (Fig. 590). Especially characteristic in radiograms is the widening of the interosseous space, due to incurvation of the lower end of the radius, the normal flexor concavity of which becomes much exaggerated. The hand thus is carried forward with the articular surface of the radius, while the ulna, which is not displaced forward, appears to be unduly prominent. Siegrist (1908) collected 62 cases, only 10 of which were in males.

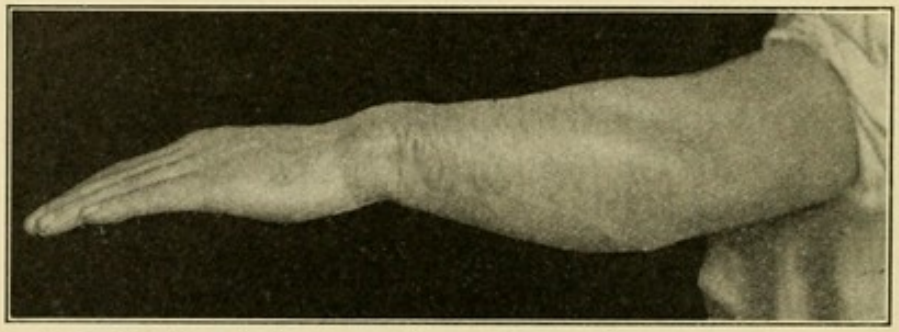

FIG. 590.—Madelung's disease; male, aged twenty-four years. Began about eight years of age. Episcopal Hospital.

The affection has been attributed by some to adolescent rachitis; others are satisfied to describe it as an obscure form of osteitis affecting the radius. In the last few years there has been a tendency to regard it as a congenital deformity, to which attention is first directed at an age when local over-exertion and constitutional malnutrition exert their influence. In addition to the deformity there often is discomfort from pain or ache, and some disability from loss of extension and circumduction at the wrist. Usually these are relieved by splinting, or orthopedic apparatus, with constitutional treatment. In severe cases osteotomy of the radius may be done to overcome deformity.

Contraction of the Palmar Fascia (Dupuytren's Contraction, 1832).—This affection occurs in adults past middle life, particularly men, and in some cases seems to be caused by slight recurring trauma from the handles of tools, canes, etc. The patients often are gouty. In about half the cases both hands are affected, usually the right before

the left. The fascia is the seat of chronic inflammatory changes,[1] with secondary contraction; it becomes densely adherent to the skin; and the resulting deformity may totally disable the patient. The thumb and index finger are the last to succumb.

FIG. 591.—Dupuytren's contracture of the palmar fascia; early stage. Age sixty-six years. Episcopal Hospital.

Temporary relief may be secured by *tenotomy* of the tense fascial bands, introducing the tenotome between the skin and fascia and cutting downward (Adams, 1879); the fingers should be dressed on a splint in full extension for three weeks, and this splint should be worn at night for three weeks longer. But recurrence of the deformity is usual. *Excision* of the contracted bands was introduced by Kocher (1887), and Keen (1906) reflected a skin flap, including the adherent fascia, which was then dissected off the skin before this was replaced. The fascia is so densely adherent that some sloughing is liable to occur. Lexer and others have excised skin and fascia in one piece, and filled the gap by a flap of skin transplanted from elsewhere.

Trigger Finger.—Trigger finger is a condition in which there is some obstacle to voluntary flexion or extension of the finger, which flies "shut" or "open" when passively moved past the position where it catches. The usual obstacle is a fusiform thickening of one of the flexor tendons, and the hitch occurs where the deep tendon perforates the superficial. If rest on a splint for some weeks, followed by massage, proves ineffectual in relieving the condition, the tendon sheath may be opened and the thickening of the tendon excised. Cotton (1911) refers to 160 cases, in about 40 of which operation was done.

ACQUIRED DEFORMITIES OF THE LOWER EXTREMITY.

Coxa Vara.—Normally the neck of the femur forms an angle of about 135 degrees with the shaft; when this angle is notably decreased

[1] These are classed by the Lyons surgeons as a form of inflammatory tuberculosis.

(115 degrees or less) *coxa vara* is said to exist. The deformity consists in elevation of the great trochanter and a relative depression of the femoral head, which, however, retains its position within the

FIG. 592.—Coxa vara, the result of injury during infancy. Age six years. Episcopal Hospital.

FIG. 593.—Skiagraph of double coxa vara (rachitic). Note rachitic pelvis—acetabula pressed together. Orthopædic Hospital.

acetabulum. Coxa vara may result from trauma, especially epiphyseal separation of the head or fracture of the cervix in children (Fig. 592); from rachitic softening of the bones, when the deformity usually is bilateral (Fig. 593); or from no well very defined causes, chiefly in adolescents. (See Rottenstein and Houzel, 1910; Calvé, 1910.)

Symptoms.—The symptoms are those of the underlying or preceding condition; slight limp, limitation of abduction, because the trochanter strikes the pelvis; marked prominence of the trochanter when the thigh is flexed (Fig. 594); increased range of adduction, especially when the thigh is flexed; elevation of the trochanter above Nélaton's

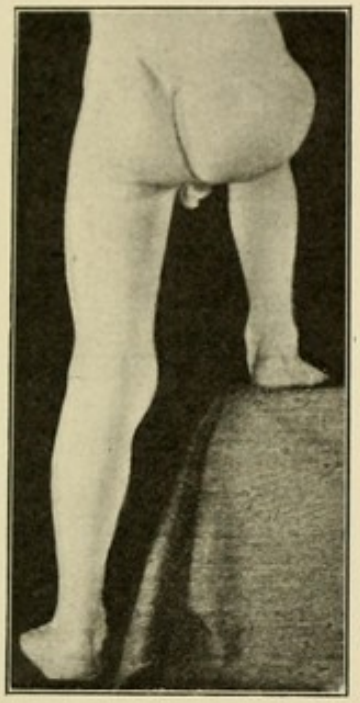

Fig. 594.—Coxa vara from fracture of cervix femoris as infant. Note prominence of great trochanter when thigh is flexed. Episcopal Hospital.

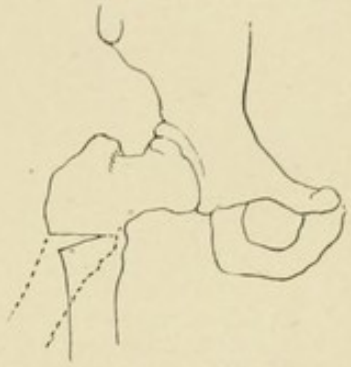

Fig. 595.—Whitman's wedge-shaped osteotomy of the femur for coxa vara.

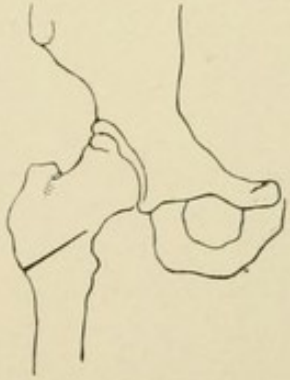

Fig. 596.—Whitman's operation for coxa vara. Consolidation has occurred in the abducted position.

line; and, in cases due to trauma, usually external rotation of the lower extremity. There is moderate shortening, but seldom much pain, relief being sought for the limp and deformity.

Treatment.—In many cases no treatment is required; in some, the addition of a lift to the heel brings relief by overcoming shortening. In cases with great deformity a cuneiform osteotomy of the femur may be done, as advised by Whitman (1901), removing a wedge with its apex at the lesser trochanter; or simple linear osteotomy may suffice. The thigh is dressed in extreme abduction, and when consolidation is complete, adduction will restore approximately the normal relations of neck and shaft (Figs. 595 and 596). In recent cases of impacted fracture of the head or neck in children or adolescents,

the deformity may be overcome by forcible abduction under an anesthetic.

Coxa Valga (Fig. 597) is a much rarer condition, in which the neck of the femur makes with the shaft an angle of more than 135 degrees. The trochanter is less prominent than normally, abduction is increased and adduction diminished. There usually is outward rotation of the lower extremity. The deformity may be congenital and usually is observed in limbs which never have borne any weight. Efforts may be made to increase the adduction by manipulation under an anesthetic.

FIG. 597.—Coxa valga, apparently congenital, in a girl of twelve years. Angle between neck and shaft is 165 degrees on the right; on the left (normal) it is 130 degrees. Episcopal Hospital.

Snapping Hip (*die schnellende Hüfte, la Hanche à Ressort*). This affection has been the subject recently of an elaborate study by L. Heully (1911), who has collected 57 cases. He proposes the term "*ressaut fascio-gluteal*," as explaining what he believes to be the pathology of the condition which has been recognized since 1859, though dispute as to its nature has always existed. Perrin, who reported the first case, believed it to be a form of voluntary luxation of the hip; but the study of Heully confirms the opinion of Morel-Lavalleé,

Chassaignac, and others, that it is due to sudden slipping of the fascia lata (altered by injury or congenitally deformed) over the surface of the great trochanter. The phenomenon occurs especially during flexion and internal rotation of the thigh, but in some cases slight movements of the pelvis on the lower extremity are sufficient to produce it. In traumatic cases the lesion is separation of the upper part of the tendon of the gluteus maximus from its insertion in the linea aspera, and the snap occurs involuntarily and is painful; while in congenital cases it is not painful and usually is under voluntary control, possibly being due to abnormally low insertion of the gluteus tendon in the linea aspera (Heully). The defect may be repaired by suturing the tendon to the periosteum of the great trochanter and aponeurosis of the vastus externus.

Anterior Metatarsalgia.—T. G. Morton in 1876 described a condition which was believed by him to be due to pinching of a nerve between the heads of the fourth and fifth metatarsal bones ("Morton's toe"). A sudden unendurable cramp in the anterior metatarsus occurs while the patient is walking, and he is forced to remove the shoe at once, rub and manipulate the foot, and flex and extend the toes, until the pain passes. This series of events may be repeated a number of times, but except in the most aggravated cases the attacks never come on except when walking, and with a shoe on the foot. More recent observations, especially by Goldthwait and Whitman, have shown that *weakness in the transverse arch* of the foot is an important factor, and may cause various minor symptoms before metatarsalgia develops. Callosities may form on the sole over the heads of the metatarsals, especially the second and third; and pain may be caused by lateral compression by a shoe which would be comfortable if the normal convexity of the arch was maintained. Relief usually may be obtained by wearing broader shoes, or by applying a small longitudinal pad beneath the sole to support the centre of the transverse arch, or a support may be worn in the shoe (beneath the insole) just back of the heads of the metatarsals, thus relieving them from strain; such an application is known as an *anterior heel*. The patient should actively exercise the toes in flexion, and may benefit from massage. Morton excised the head and neck of the affected metatarsal.

Flat-foot (*Pes Planus*).—This very frequent affection is an evidence of weakness in the foot. In a foot that is merely weak, however, the antero-posterior arch may still be preserved, but a tendency to *pronation* exists: when weight is put on the foot the internal malleolus descends and rotates backward, causing a relative outward displacement of the anterior part of the foot; the patient walks with the toes well turned out, and to bring the two feet parallel it may be necessary to rotate both entire lower extremities inward, so that the patellæ look toward each other rather than anteriorly. In truly flat feet the arch is depressed, and in aggravated cases the scaphoid may rest on the floor (Fig. 598). The affection is common at all ages, and may be very disabling. In adolescents painful flat-foot often is an

early evidence of tuberculosis of the tarsus, and this diagnosis always should be carefully considered. In young children the foot remains perfectly flexible, but if the condition persists for years unrelieved, great rigidity may develop; and in adults more or less rigidity is the rule. In cases where rigidity is absent much may be done by proper exercises, even without mechanical support. The patient should rise on to the toes of both feet simultaneously, from ten to twenty times, morning and night; he should then attempt to supinate his feet the same number of times by flexing his toes and contracting the tibialis anticus and posticus muscles; and flexion exercises of the toes with the feet off the ground also should be prescribed. Walking on the toes, and on the outer side of the soles is another valuable exercise. In most cases, however, it is desirable to support the arch in walking: for this purpose the first thing is to secure a pair of strong

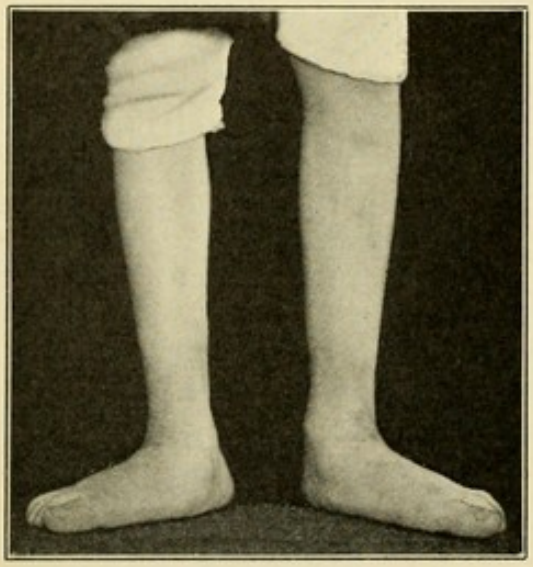

FIG. 598.—Flat feet, in a boy of eight years. (See Fig. 599.) Orthopædic Hospital.

FIG. 599.—Flat feet foot-prints. Same patient as Fig. 598. Orthopædic Hospital.

shoes, made on a straight or nearly straight last, with broad toes, low heels and a wide shank; the shoes should be "high" shoes, laced. Many sole plates are sold in the stores for the purpose, but as they scarcely ever fit the foot to which they are applied, it rarely is proper to use them. If a sole plate is to be used it should be made for the individual patient, moulded on a cast of this foot taken in the resting position. An easier and as efficient method, I believe, is to have a shoemaker insert a steel strip in the shank of the shoe, and then to build up the arch, to any height desired, by properly cut felt pads placed beneath the inner sole. The height of this pad may be increased or decreased at will. In very rigid feet, benefit is derived from massage, passive movements, and baking. Sometimes "Mobilisierung" under an anesthetic, with tenotomy of the tendon of Achilles or of the peroneal tendons, may be necessary; after such an operation the foot

is dressed in plaster of Paris in the varus position for several weeks, when proper apparatus may be applied.

Hammer Toe.—Hammer toe (*Digitus malleus*) is a deformity of extension at the metatarso-phalangeal joint and flexion at the proximal interphalangeal joint (Fig. 600). It is commonest in the second toe, which, being the longest, suffers most from short and narrow shoes. The condition usually begins in childhood. A corn forms over the prominent phalangeal joint, and the end of the toe becomes club-shaped. If massage, application of adhesive plaster strapping, etc., do not relieve symptoms, tenotomy of the contracted tendons (extensor and flexor) may be done; and in relapsed cases, the toe may be amputated.

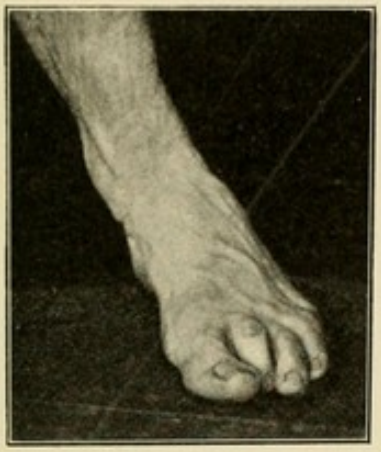

FIG. 600.—Hammer toe in a man of twenty-six; duration since childhood. Episcopal Hospital.

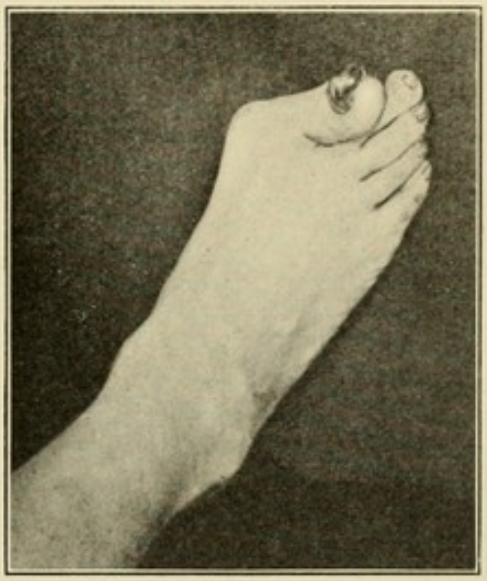

FIG. 601.—Hallux valgus, with a bunion over the head of the first metatarsal bone. Age sixty-nine years. Orthopædic Hospital.

Hallux Valgus.—Hallux valgus is a deformity in which the great toe is abducted, often lying on the top of the other toes. This results in marked prominence of the first metatarso-phalangeal joint; and over this a bursa is formed by friction of the shoe (Fig. 601). In some cases, the primary cause of the deformity is adduction of the first metatarsal bone, due to the presence of a congenital anomaly, a bone known as the intermetatarseum (J. K. Young, 1910); but I have seen the intermetatarseum present without hallux valgus, and in most cases no such bone exists, the deformity being caused by ill-fitting shoes. If proper shoes, which do not abduct the toes, do not secure relief, excision of the projecting head of the first metatarsal may be done. C. H. Mayo (1908) preserves the bursa and inserts it between the bones.

Painful Heel.—Painful heel may be due to a variety of causes. Trauma may cause rupture of some fibres of the tendo Achillis, or produce inflammation in the retrocalcaneal bursa (Achillobursitis),

or in a bursa sometimes present between the Achilles tendon and the skin; or it may cause strain on the attachment of the plantar fascia, as is common in flat feet. Subsequently, exostoses may develop at these points of strain. *Infections*, especially gonococcic, and some forms of sub-pyemic or cryptogenous infection (Fig. 602) may cause exostoses to form on the calcaneum or other tarsal bones; or similar changes may be an evidence of *hypertrophic arthritis* (p. 456).

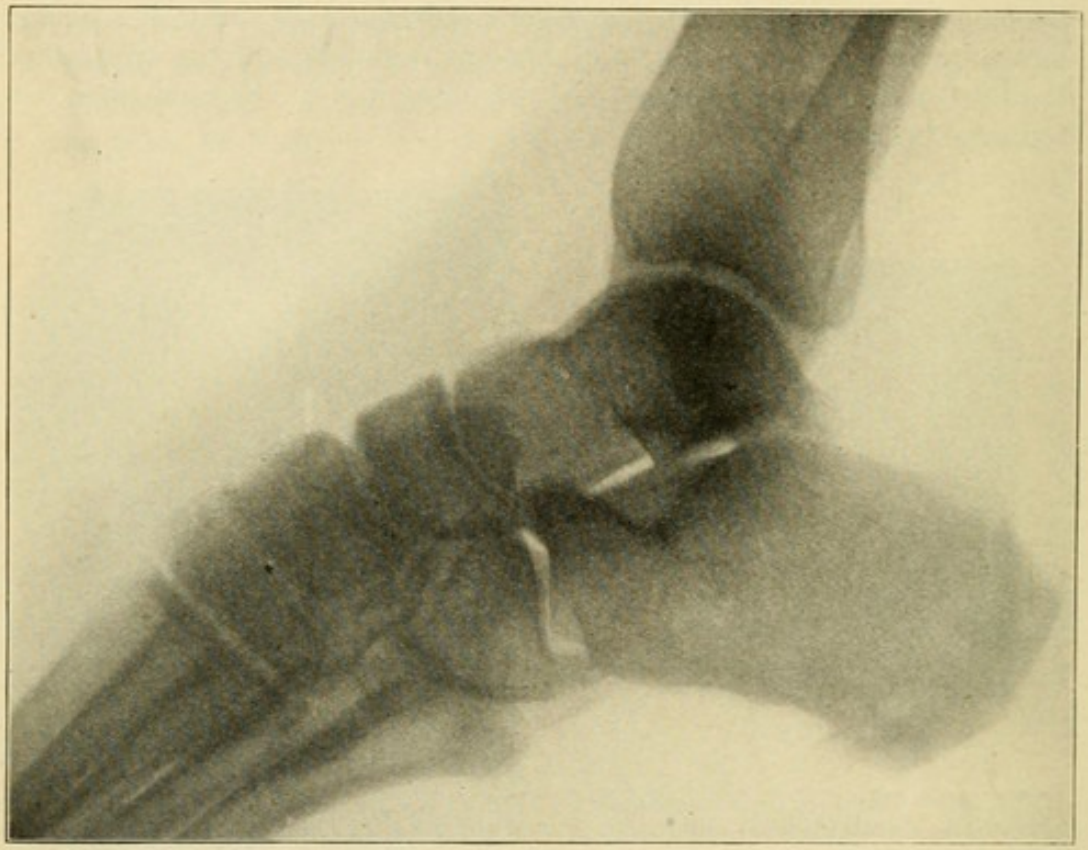

FIG. 602.—Exostoses of calcaneum at attachments of plantar fascia and tendo Achillis, in a patient aged forty-four years. Duration of symptoms, over two months. Also has incipient hypertrophic arthritis of hip. Orthopædic Hospital.

Treatment.—The treatment consists in care of the underlying condition (sprain, flat-foot, gonorrhea, etc.); local rest by proper orthopedic shoes, etc.; and, in cases which resist conservative measures, in excision of the exostoses.

CHAPTER XVII.

SURGERY OF THE HEAD.

SURGICAL AFFECTIONS OF THE SCALP.

Birth Injuries.—During parturition that portion of the scalp which protrudes into the birth canal may become edematous from pressure on surrounding parts; this condition, which is known as *caput succedaneum*, may be recognized by the history of prolonged or difficult labor, by the facts that it is present at birth, that the affected area pits on pressure and presents no signs of inflammation; while it may be distinguished from cephalhematoma (see below) by the fact that the swelling is not limited to the outline of one bone. The swelling disappears in a few hours or days, and usually no treatment is necessary. *Cephalhematoma* is an extravasation of blood beneath the pericranium; it is encountered in about one labor out of two hundred. Usually the right parietal is the bone affected, and it is probable that in many cases the bone itself is directly injured, either bent or broken (p. 564). As the pericranium is attached at the sutures, the hemorrhage never passes the limits of the bone affected; generally the condition is not noticed for a day or two after birth, and at this time the blood at the periphery may have become clotted or organized, so that the scalp presents an indurated ring with a softened or fluctuating centre. Occasionally thin plates of subperiosteal bone develop, and the bone crackles on palpation. In most cases no treatment is required, but if no evidence of absorption is seen after two weeks the fluid may be evacuated by puncture; pressure should then be applied to prevent re-accumulation. Should infection of the hematoma occur, from the deep skin cocci or through the blood stream, it should be drained (Fig. 603).

FIG. 603.—Suppurating cephalhematoma in an infant of five weeks. Incised. Death in four days. Children's Hospital.

Contusions.—Contusions of the scalp are frequent at all ages. If the head is examined immediately after the injury the impress of the vulnerating body may be detected; but swelling occurs very quickly,

and usually the only signs are those of edema, and possibly hematoma. The blood usually is extravasated in the subcutaneous tissues, superficial to the aponeurosis of the occipito-frontalis. It may be difficult to distinguish such cases, after the lapse of a few hours, from depressed fractures of the skull as the contusion presents a soft depressed centre, surrounded by an indurated area due to inflammatory reaction and commencing organization; but firm pressure in the centre detects solid bone at the same level as the surrounding cranial surfaces, and there is no irregular outline to the depressed area, such as is commonly present in fracture; moreover, the elevated margin moves with the scalp upon the bone beneath. In cases of doubt the scalp should be incised and the skull inspected. A hematoma beneath the occipito-frontalis is widely diffused, and may be of great size. In most cases hematomas of the scalp subside under pressure by bandages, application of cold, and rest in bed; if no diminution in size is evident after ten days, or if infection occurs, the hematoma should be incised, and pressure applied, when the cavity will heal by granulation.



FIG. 604.—Lacerated wound of the scalp, with subaponeurotic cellulitis; the result of sealing the wound with a cotton and collodion dressing. Forty-eight hours after injury the cellular infiltrate had gravitated into the temporal region where it was arrested by the attachment of the temporal fascia to the zygoma. Episcopal Hospital.

Wounds.—Wounds of the scalp may result from blunt force, as well as from cutting instruments, as the scalp is very readily split on the underlying bone. Bleeding is free, as the bloodvessels are unable to contract and retract, being enmeshed in the firm fibrous processes which bind the skin to the aponeurosis. This also renders it difficult to catch the bleeding points in hemostats, or to apply ligatures; and the surgeon often must depend on sutures to arrest the bleeding. Temporary control of hemorrhage is easily secured by pressure on the margins of the wound; and during an operation hemostasis sometimes may be secured by applying an Esmarch band or other form of elastic tourniquet around the crown of the head. Wounds which divide the occipito-frontalis aponeurosis transversely gape much more than longitudinal wounds; and when the loose subaponeurotic areolar tissue is opened there is much greater danger of infection arising, especially if the wound is closed without drainage (Fig. 604). Owing to the great vascularity of the parts large portions of the scalp may be avulsed and yet retain their vitality when properly cleansed and sutured in place. When the skull has been denuded of its pericranium over large areas, some caries is very apt to occur, but if the soft parts are promptly replaced no such result need be anticipated unless infection is present.

In all scalp wounds a large surrounding area should be shaved, all foreign bodies removed from the wound, and this should be cleaned with antiseptics. Silkworm gut sutures should be used, and if there is any risk of a hematoma forming, or if the subaponeurotic space has been opened, the wound should be drained for a few days.

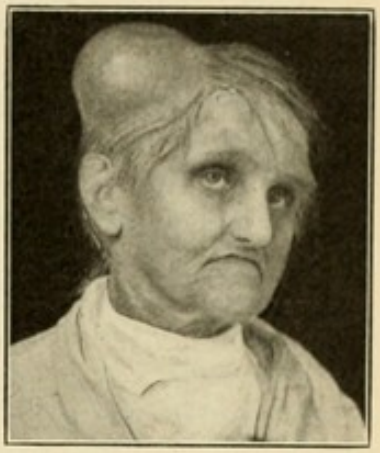

FIG. 605.—Sarcoma of scalp. Death a few months after photograph was made. (Dr. W. L. Rodman's case.) Presbyterian Hospital.

Tumors. — Tumors of the scalp apart from *sebaceous cysts*(Fig. 223, p. 265) are not very frequent. In infancy *dermoid cysts* (Fig. 226, p. 266) sometimes are seen; these usually grow in the region of the embryonal clefts, occurring in or near the orbit, at the glabella, or over one of the fontanelles; usually they are more or less immobile, deep-seated, and are not attached to the epiderm, being thus easily distinguished from ordinary wens. If not removed in infancy, the underlying bone may be absorbed from pressure, and the growth may become adherent to the dura mater, making its removal more difficult. *Papillomatous growths* of the scalp should be eradicated by cauterization, or excised, as they are prone to undergo epitheliomatous change. *Epithelioma* often develops in scars from burns, syphilitic ulcers, etc. *Sarcoma* may arise in the scalp or the cranial bones, and the latter are rapidly invaded by tumors which at first were superficial (Fig. 605). Usually no operation is of any use.

SURGICAL AFFECTIONS OF THE SKULL

Congenital Malformations.—Cephalocele.—Occasionally at or soon after birth a fluctuating tumor of the head is found which evidently protrudes through the skull and is composed of cranial contents. The growth occurs oftenest in the region of the posterior fontanelle (*occipital cephalocele*), though it may also protrude at the root of the nose (*sincipital cephalocele*), or very rarely at the anterior fontanelle or through one of the cranial sutures. The tumor usually is wholly or partly reducible by pressure, which if excessive may cause symptoms of cerebral compression (p. 573); and it becomes more prominent and tense when the child cries. It frequently is possible to detect the defect in the cranium through which the protrusion occurs. If the protrusion is composed solely of the meninges, with subarachnoid fluid, it is called a *meningocele;* an *encephalocele* contains also some brain substance; while a protrusion formed by a diverticulum of one of the ventricles is called a *hydrencephalocele* or an *encephalocystocele.* It formerly was believed that the most frequent form was the meningocele; but, though the protrusion resembles this macroscopically, histological study has proved that most cases

really are encephalocystoceles, as the cavity of the cyst is lined by ependymal cells, which are directly continuous with those of the ventricles of the brain, while the cyst walls are formed by an attenuated layer of cerebral tissue.

The *diagnosis* usually is not difficult, though deep lying dermoids, in contact with the dura mater, and having its motions transmitted to them, sometimes are mistaken for cephaloceles. The prognosis is poor, most infants either dying soon after birth, or presenting in later life evidences of cerebral defects (porencephalon, hydrocephalus, idiocy, etc.). Spina bifida often coexists.

Treatment.—Protection should be afforded the tumor, to prevent excoriation and infection. In most cases little else can be done; but if there is only a small channel of communication with the cranial cavity, and if the child's mentality appears normal, removal of the tumor may be attempted, with closure of the skull defect by transplanting a bone flap from a neighboring portion of the skull.

Microcephalus.—When the skull is abnormally small, the child often is idiotic or feeble-minded. Keen (1890), Lannelongue (1891) and others have done linear craniotomy for this condition, on the theory that premature ossification of the cranial sutures caused compression of the brain, and that division of the cranium in a line parallel with the sagittal suture would allow the brain to expand. But the modern belief is that the smallness of the skull is the result of lack of cerebral development, and is not the cause of it. Agnew said the operation was no more use than cutting a piece out of a turtle's shell, to make him grow larger; and this is the general belief of surgeons of today. There is no surgical treatment for idiocy.

Hydrocephalus.—This is a symptom of some disease of the brain or its membranes, interfering with the normal circulation of the cerebrospinal fluid, and causing it to collect in abnormal amounts on the surface of the brain or within its ventricles. Hydrocephalus thus is classified as *external* and *internal;* and it may be acute or chronic, congenital or acquired.

External Hydrocephalus, in which the fluid collects in the subarachnoid space, is very rare; many cases designated by this name really are properly classed as other conditions. There may be acute edema of the subarachnoid tissues, as the result of trauma; the "acute serous meningitis" of Quincke (1893) belongs here, as also does "hydrops ex vacuo," in which fluid collects and fills the space left by skrinkage of the brain from injury or disease.

Internal Hydrocephalus.—This is met with in two distinct forms, the *congenital* and the *acquired.*

Acquired Hydrocephalus usually results from obstruction or actual occlusion of the foramina at the base of the brain, by which the cerebrospinal fluid leaves the ventricles; and the most frequent cause is a basal meningitis, generally tuberculous (p. 579). Each lateral ventricle communicates with the third ventricle through a foramen of Monro; while in the roof of the fourth ventricle (which

drains the third ventricle through the aqueduct of Sylvius) are found the foramina of Key and Retzuis, and that of Magendie, which are the channels of communication between the ventricular cavities and the subarachnoid space of the brain, this being continuous with the subarachnoid space of the chord. Occlusion of one foramen of Monro may cause unilateral hydrocephalus. Though most cases of acquired internal hydrocephalus are due to basal meningitis, yet ependymal inflammations, or pressure of a brain tumor causing obstruction of the veins of Galen sometimes are responsible for the condition by producing edema from venous stasis. The *symptoms* of the acquired form of internal hydrocephalus are those of the causative condition complicated by cerebral compression (p. 573); and the *treatment* consists in relieving the compression, as removal of the cause of the obstruction usually is out of the question. Lumbar puncture (p. 157) is useless, as the occlusion of the basal foramina prevents evacuation of the ventricles by this route; and such treatment may prove quickly fatal by withdrawing the support of the cerebrospinal fluid from beneath the medulla, and allowing the superincumbent pressure to crowd this down into the foramen magnum (p. 574). But as a palliative measure repeated tapping of the lateral ventricles may be done (v. Bergmann, 1888) through a trephine opening at Keen's point (1888): this is 3 cm. behind and an equal distance above the external auditory meatus; the needle is entered through the posterior part of the first temporal convolution, and is directed toward the summit of the opposite pinna; the ventricle should be reached at a depth of about 4 cm. Kocher's point (1894), is 2.5 cm. to 3 cm. from the median line and 3 cm. anterior to the precentral fissure (see Cranio-cerebral Topography, p. 567); the needle is directed downward and backward and enters the ventricle at a depth of 4 or 5 cm. Fig. 606 illustrates the relative position of the lateral ventricles to the surface of the brain. Or a large area of bone may be removed from the cranium, relieving the ventricular pressure by allowing hernia cerebri as in the operation of decompression for brain tumor (p. 589).

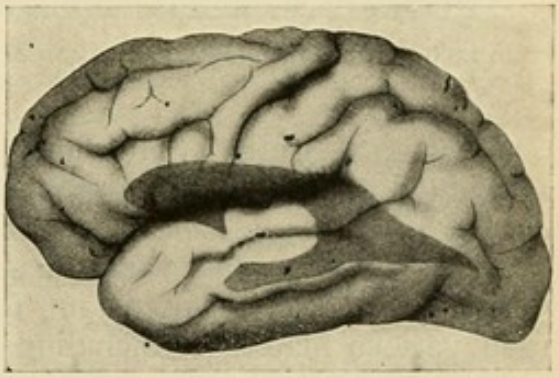

FIG. 606.—Shaded portion on surface of the brain indicating the position of the lateral ventricle within. (Campbell.)

Congenital Hydrocephalus.—In these cases there is no obstruction or obliteration of the foramina at the base of the brain, but for some reason the cerebrospinal fluid collects in excessive quantities, and as this condition supervenes in fetal existence, or soon after birth before the cranium is ossified, there are no symptoms of cerebral compression, but progressive enlargement of the cranium occurs, and the typical hydrocephalic head is produced (Fig. 607). A fair

degree of intelligence may be preserved, but in cases of extreme deformity the size and weight of the head may render the child helpless, and in most cases death from malnutrition occurs within the first two years of life. Spina bifida sometimes complicates the case, and paralyses of the limbs are not uncommon. Rarely is the disease arrested spontaneously.

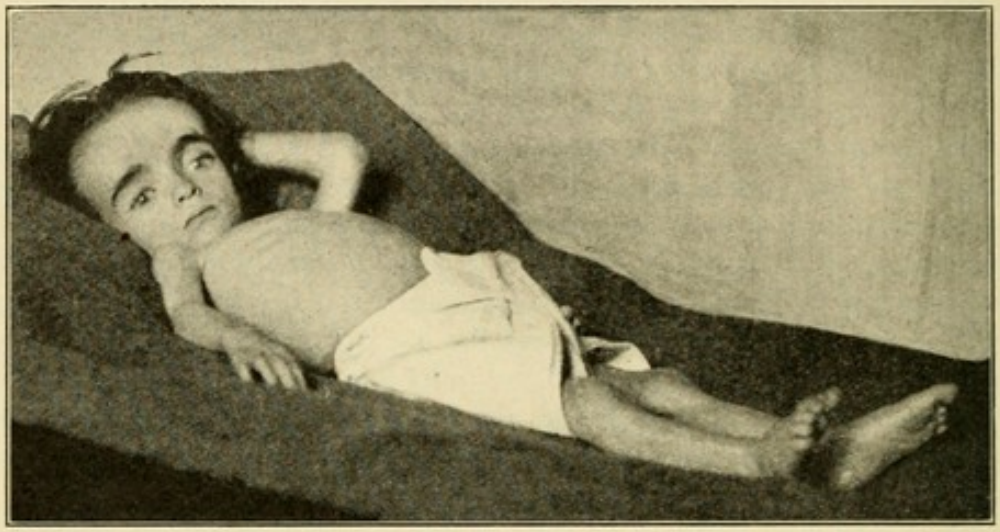

FIG. 607.—Congenital internal hydrocephalus of moderate grade. Age seventeen months. Episcopal Hospital.

Treatment.—Keen (1891) and Sutherland and Cheyne (1898) attempted to drain the ventricles into the subarachnoid space (*intracranial drainage*), whence they thought the fluid could readily be absorbed by the veins which discharge into the longitudinal sinus. Cheyne used strands of catgut for this purpose, and others have used various materials, including gold and silver tubes. N. Senn (1903) drained into the *subcutaneous tissues*. But the immediate mortality was unduly high, and no permanent benefit was secured in those patients who recovered, so that the operation has been abandoned. Cushing (1908), having due regard for the fact that in these congenital cases there rarely is any obstruction to the circulation of the cerebrospinal fluid at the base of the brain, inferred thence that the obstruction must be where the cerebrospinal fluid enters the blood vascular system (*i. e.*, in the region of the longitudinal sinus); on this account he held it to be useless to attempt to establish an outflow by Keen's and Cheyne's method; but he proposed, after ascertaining that the ventricles could be drained by puncture of the lumbar spine, to divert the fluid thence into the *retro-peritoneal tissues* by means of a silver tube passed through the body of one of the lumbar vertebræ. He has done this operation twelve times "with a considerable measure of success." Heile (1910), in an infant of two days old, successfully employed Handley's operation (p. 270), connecting the sac of a spina bifida with the peritoneal cavity by means of subcutaneous silk threads; a complicating hydrocephalus also disappeared. On the theory that the excess of cerebrospinal fluid

is not due to damming up but to hypersecretion, Stiles (1905) has practised *ligation of both common carotid arteries*, at an interval of three weeks, and feels encouraged by the results.

INJURIES OF THE SKULL.

Wounds.—Occasionally one sees incised wounds of the cranial bones, without fracture; sabre wounds sometimes occur in war, and in civil life a pen-knife or other sharp instrument may be stuck into the skull. Such injuries require no special treatment beyond removal of the foreign body, if still present, and antiseptic care of the wound. If the implement is so firmly embedded in the skull that it cannot be withdrawn, as was the case with a pen-knife wound of the skull which I treated when interne at the Episcopal Hospital (the point of the blade having broken off), and if it is certain that the cranial cavity has not been penetrated, it will be safe to wait a few hours until reactive processes in the surrounding bone have begun, when the implement may be extracted easily. Otherwise the surrounding bone must be removed with gouge, and the object extracted.

Fractures.—For practical purposes the skull may be considered a sphere, possessed of a considerable degree of elasticity. For it to be fractured, a good deal of force is necessary, and this acts in two main ways: (1) the skull may be compressed between two diametrically opposite forces, or (2) it may be struck a violent blow. In the latter case the effect is the same whether the head is struck, or whether it strikes against another object; the only counter-pressure in the former case is that offered by the inertia of the head and the resistance of its attachments to the trunk, while in the latter there is also the momentum of what Archibald happily terms the "after-coming head." Between the diffused crush and the localized blow, there may be all grades of violence, varying from the puncture made by a pick-axe, or the blow from a black-jack, to a knockout by a sand-bag, or a crush between two heavy beams.

When the cranium is compressed in one diameter it naturally expands in the diameter at right angles to the first (Saucerotte, 1769); Victor Bruns (1854) and Angus McLæan (1912) measured this compensatory expansion experimentally, finding that it amounted to several millimeters. The first and most obvious result of this compression was illustrated by Ali Krogius (1907) by cracking a hazelnut by lateral compression (Fig. 608): fissures are produced which represent meridians of longitude in relation to the points of compression which are regarded as poles; these fissures gape widest in the equatorial region, and when compression is relaxed they may close again completely. In the skull such fissures are very frequently seen as the result of diffused violence, and in them may be caught, as in a vise, hairs from the scalp, portions of felt from a hat, and strangest of all, foreign bodies may even pass through the fissure while it momentarily gapes, and thus be entirely hidden from view inside

the cranium when the closed fissure is examined by the surgeon. These are called *bursting fractures* (von Wahl, 1883).

Another result of the compensatory expansion of the skull in the diameter at right angles to that in which it is compressed, is that at the poles there occurs an *inbending* of the skull (Figs. 609 and 610); that such should be the case at the point of impact of localized violence, is not difficult to understand, but that a fracture from inbending may occur at a point more or less remote would be unthinkable unless the elasticity of the skull and ordinary physical laws were kept in mind. This is the *fracture by counter-stroke* (*contrecoup*), which formerly was explained solely on the basis of vibrations which were set up by the blow, and spreading in all directions from the

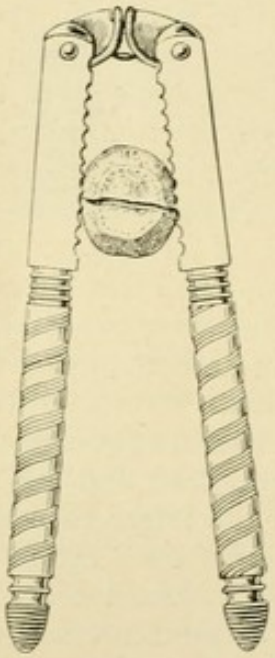

FIG. 608.—Mechanism of fracture of the skull by lateral compression: a *meridional bursting fracture.*

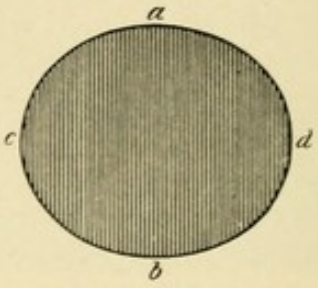

FIG. 609.—Diagram to illustrate the elasticity of the skull. When the skull is compressed between *a* and *b*, these points approach each other while the points *c* and *d* become more widely separated. (See Fig. 609.)

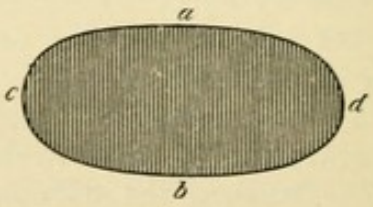

FIG. 610.—Mechanism of fracture of the skull by counter-stroke: when the skull is compressed at *a*, *a* and *b* approach each other, and a fracture by *inbending* may occur at *b* as well as at *a;* or fracture by *outbending* may occur at *c* or at *d*.

point of impact met finally at the polar point and there disrupted the skull. Though the bursting theory, originated by Chopart and other French surgeons in the eighteenth century, and re-introduced and elaborated by Felizet in France (1873), by Messerer and von Wahl in Germany, and by Dulles in America, in the eighth decade of the last century, has largely superseded the vibratory theory as an explanation of fissured fractures and fractures by counter-stroke, there can be no doubt, as pointed out by Nancrede (1884), that vibrations do occur, and are most violent where the bone is thickest, that is, at the base of the skull, where most of the fractures by counter-stroke occur.

When localized violence is applied to the skull the force of the blow expends itself mostly by depressing the bone at the point struck;

this is the *inbending fracture* referred to above. Now, this point being regarded as a pole, there are produced in the surrounding inert but elastic skull, concentric areas of compression, or *outbendings*, which represent parallels of latitude; and at the points where the inbending and outbending[1] areas meet, a circular fissure or *ring fracture* may result (Fig. 611). Occasionally a long fissure occurs at the equatorial region when the skull is diffusely crushed, and, according to Archibald, this must be explained as a fracture by outbending, as must certain fissures which run at right angles to the meridional bursting fissures (Fig. 612).



FIG. 611.—Ring fracture of skull. From a specimen in the Mütter Museum of the College of Physicians of Philadelphia.

In addition to the usual classification of fractures, as simple, compound, depressed, etc., there are important clinical distinctions between fractures of the vault of the skull and those of its base.

Fractures of the Vault of the Skull.—Most fractures of the vault are due to direct violence, the parietal and temporal bones being most often injured. Almost always the injury acts from outside the

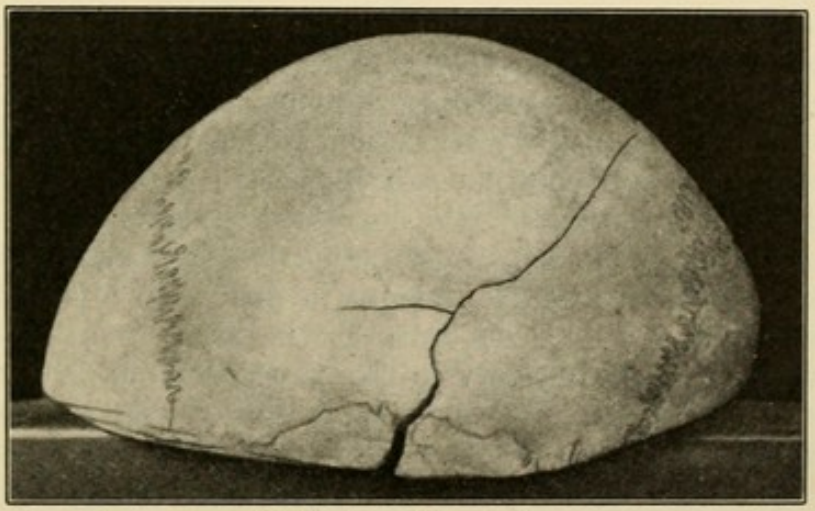

FIG. 612.—Bursting fracture of skull from diffused violence on vertex: fissure radiating to base and widest at equator (temporal region); with outbending fracture (just below parietal eminence) at right angles to main fissure. From a specimen in the Mütter Museum.

skull, so that the inner table is in the line of extension (Fig. 613), and, therefore, is more widely fractured than the external table

[1] The Flachbiegung und Krumbiegung of Treub (1884).

(Teevan, 1864). Indeed, so elastic is the skull that a fracture of the vitreous table may occur without any fracture of the outer table. In the rare cases, mostly suicidal pistol shots, in which the cranial vault is fractured from violence within the skull, the outer table is more widely fractured than the inner. It is very unusual for the external table to be fractured without injury of the internal; it is then depressed into the diploë. In 1909 I trephined for such an injury, in a boy, aged thirteen years, at the Episcopal Hospital, Philadelphia. The amount of splintering is in inverse ratio to the momentum of the body fracturing the skull; but in the case of gunshot wounds, as pointed out at p. 188, the "explosive action" is manifested at close range.

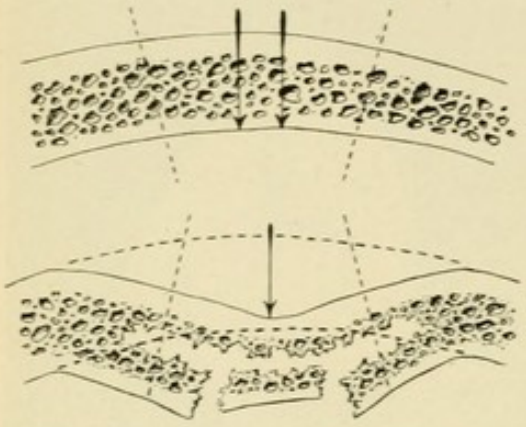

FIG. 613.—Teevan's diagram to show that the inner table often is more extensively damaged than the external, because it is in the line of extension.

Symptoms.—Apart from those due to intracranial complications (p. 569), there are no symptoms specially indicative of a fracture of the vault of the skull. The *diagnosis* rests on the history of injury, on the symptoms due to complicating intracranial lesions, and on physical signs. A skiagraph may be of value. If there is no scalp wound, the entire calvaria must be palpated carefully and persistently to discover any evidence of fracture; if a mere fissure exists, without depression or separation, nothing will be detected beyond the signs of contusion of the scalp (p. 551). The error of mistaking a hematoma for a depressed fracture must be guarded against. If there is a depressed fracture it usually is possible to feel it through the scalp, recognizing its jagged outline and its actual depression below the surrounding bony surfaces; the depressed fragments may not be impacted, and injudicious pressure may drive them against the brain. If the existence of a fracture remains in doubt, no hesitancy should be felt in making an incision down to the bone, under proper antiseptic precautions, and inspecting the bared cranium. In compound fractures it may be necessary to enlarge the existing wound for the same purpose. A normal suture may be distinguished from a fissured fracture by its anatomical position, its greater irregularity of outline, and by the fact that a fracture cannot be washed clean of blood. In children there may be diastasis of suture lines instead of, or in addition to, fissured or depressed fracture of the skull.[1]

Prognosis.—This is good, so far as the fracture alone is concerned. It is only intracranial complications that render the outcome doubtful. Excessive loss of bone seldom occurs, and complications affecting the scalp (erysipelas, etc.) are very rare with antiseptic methods.

[1] See footnote, p. 561.

Treatment.—Every case of head injury, no matter how trivial in appearance, should be treated with extreme circumspection. It is the custom of many cautious surgeons, and for years has been mine, to urge all patients with injuries of the head to remain under constant surgical observation, preferably in the hospital, for several days. It is most important to prevent infection; and, as a rule, it is well to shave the entire scalp, as this often renders diagnosis easier, and always promotes asepsis. Shaving the scalp, or at least a wide area around the injury, therefore, usually is the first step in treatment.

If only a simple fissured fracture exists, without depression, and without any evidence of intracranial mischief, it is sufficient to keep the patient in bed for six to eight days, with an ice bag to the head; the bowels should be well opened, preferably by calomel, as this has a specific action upon the meninges and brain, exerting what was known in the last century as an "anticipatory antiplastic action," that is, preventing excessive inflammatory reaction, probably by its antiseptic properties. Urotropin is used for the same purpose, as it has been found to circulate in the cerebrospinal fluid; it must be given in very large doses. If the simple fissured fracture was caused by localized violence, which is rarely the case, it will be safer to ascertain whether or not the inner table is splintered, by removing a button of bone with the trephine. If such splintering exists, the case is treated as a depressed fracture.

If the fissured fracture is compound the surgeon should make very certain that no hair or other foreign body is caught in the fissure, or has passed through it, before he decides against operation. If there is any doubt as to the surgical cleanliness of the fissure, the surgeon must take means to render it aseptic as soon as the patient recovers from the shock of the accident. Sometimes little tufts of hair are found sticking up out of almost invisible fissures (G. G. Davis, 1910), and a gouge must be employed to remove them and their containing bone; in other cases a trephine may be used to perforate the skull, and then the entire septic fissure is gnawed away into healthy bone by rongeur forceps.[1]

If the fracture is depressed I believe operation always in indicated, to relieve pressure on the brain; and *if it is compound, whether it is depressed or not*, operation usually is necessary to secure asepsis of the wound. But operation has no virtue of its own, being only a mechanical means of fulfilling plain therapeutic indications. Loose

[1] In 1907 I operated on a boy of eleven years, at the Episcopal Hospital, Philadelphia, for extensive bursting fracture due to crush; there were compund comminuted depressed ring-fractures in the right parietal and the left temporal bones, the poles of impact; and these areas were connected across the vault by a meridional fissure which was deflected into the suture lines, causing diastasis of the right temporo-parietal suture and the entire coronal suture, with rupture of the longtudinal sinus. The loose fragments were removed, the depressed fragments elevated, and the separated sutures cleaned of hairs and clot by gnawing away both margins of bone. From the left temporal region a fissure ran to the base, thus practically separating the skull into antero-posterior halves. There was no injury to the brain, and the boy recovered.

fragments are removed, and the elevator (Fig. 614, 3) is passed under the depressed fragments and these are pried up into place. Search is then made by Horsley's dural separator (Fig. 614, 2) for loose fragments which sometimes are driven under the neighboring intact portions of cranium, and these are removed. All fragments completely detached should be removed entirely; they will not reunite if left in place, and may undergo necrosis or cause infection. At best they would act only as decalcified bone might, as an inorganic basis into which surrounding osteoblastic cells might grow. If the fragments are impacted, so that none of them can be removed, and there is no crack into which the elevator can be insinuated, a button of bone must

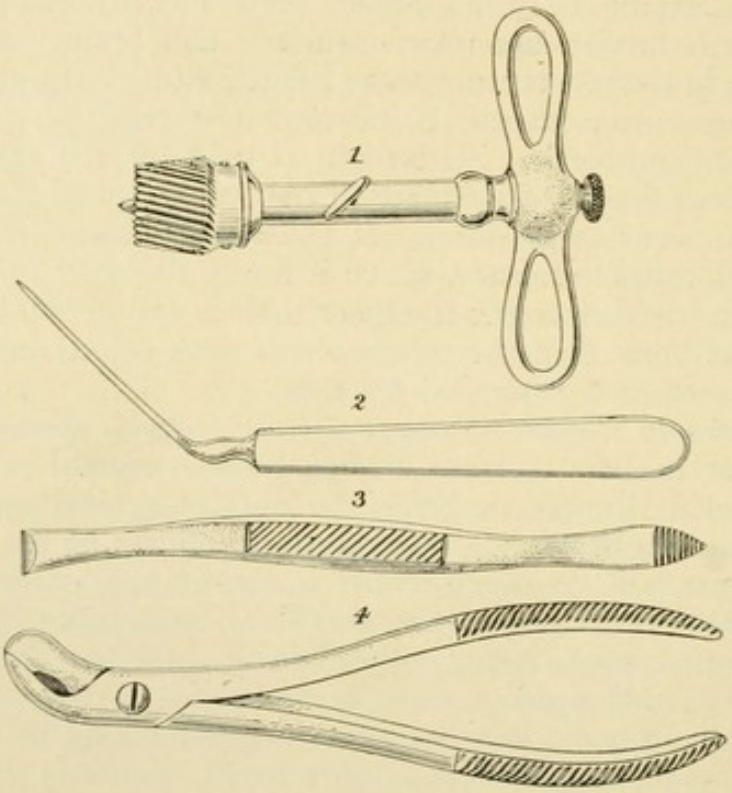

FIG. 614.—Instruments used in operating for fracture of the skull: 1, Crown trephine; 2, Horsley's dural separator; 3, bone elevator; 4, Hopkins's rongeur forceps.

be removed by the crown trephine (Fig. 614, 1), and the remaining depressed fragments elevated through the opening thus made. Next, the bone must be disinfected. Usually this is best accomplished by biting off ragged edges of bone with the rongeur forceps (Fig. 614, 4), thus completely removing all suspicious areas in which foreign particles may have been caught. In *fractures of the frontal sinuses* the outer wall alone may be fractured; but as the sinuses are of uncertain extent, even when developed, and as the fracture always is compound, either from within or on the skin surface, it is proper to explore the region affected, and to remove sufficient bone to render the wound surgically clean.

After any operation for fracture of the skull, a copious dressing

should be securely applied (Fig. 615), as the patient may be delirious, and requires mechanical protection to the site of operation.

Rupture of the longitudinal sinus is a not infrequent complication of fractures of the cranial vault. H. R. Wharton (1901) collected 70 case reports. Bone fragments may be embedded in its walls, or it may be torn accidentally in elevating or removing depressed fragments. Hemorrhage may be profuse, but it is readily controlled by packing, as the blood-pressure is low. Attempts to suture the rent rarely are successful, the sutures tearing out; and the profuse hemorrhage may cost the patient his life before the attempts to suture are abandoned. Packing is quicker and safer. The gauze should be removed in three or four days.

FIG. 615.—Dressing for fracture of skull. Episcopal Hospital.

Trephining the Skull.—The trephine is applied first with the centrepin protruded; with this as a pivot a circular groove is cut by alternately supinating and pronating the hand, and when this groove is of sufficient depth to steady the trephine without the aid of the centrepin this is withdrawn, and the trephining is continued very cautiously, using scarcely any pressure for fear of plunging the instrument into the brain. The use of Galt's conical trephine[1] renders this accident unlikely, if ordinary prudence is exercised. When the diploë is reached, the trephine cuts more easily, and the bone bleeds more; as the vitreous is approached the surgeon, from time to time, should test the depth of his groove with the flat end of a probe, as the skull is not of uniform thickness and incautious trephining may rupture the dura at one side before the vitreous table is cut through on the other. If the button of bone does not come away in the crown of the trephine, it is pried out by the elevator. The trephine never should be applied on the depressed fragment, but on the surrounding intact cranium, so that no further impaction or cerebral injury may be produced. Nor should the trephine be applied directly over the longitudinal or lateral sinuses.

Hudson's Trephine (1909) is a modification of Doyen's burr (1896), an instrument like a carpenter's brace and bit; the burrs of Hudson's

[1] This was a revival of an old instrument. Galt's pattern was first used by Sayre in 1861: the spiral grooves on the periphery act as a wedge so long as there is counter-pressure by bone on the oblique teeth of the crown; when resistance ceases, the spiral grooves act as a screw, and the trephine binds. Hudson's trephine (p. 588) is constructed on the same principle.

instrument (Fig. 628) are made with spiral cutting grooves, so that unless something solid like bone is pressed upon by the point, the instrument will bind, thus rendering impossible an injury to the dura. This is the same principle on which Galt constructed his conical trephine.

Fractures of the Skull in the Newborn.—Indentations of the semi-membranous skull of the baby may occur from injury during labor, or at a later age from blows, falls, etc. The bone is so flexible that true fracture during labor is rarer than bending. The depression usually corrects itself within ten days; if it does not, and immediately if it produces symptoms of cerebral compression (p. 576), operation should be done. Nicoll's operation (1903) consists in excision of the cup-shaped depression, and its replacement with the dural (convex) surface beneath the skin. Usually it is sufficient to pry the bone up by an elevator introduced through a neighboring fontanelle or suture. The bone is soft and easily cut by scissors. Some surgeons use a corkscrew for an elevator. The danger of leaving such fractures untreated is that cortical lesions may result, leading to spastic paralysis, epilepsy, imbecility, etc. Commandeur (1910) has collected 46 such operations, with three deaths from infection. In older infants fracture may split the cranial bone radially in the usual line of ossification.

Fractures of the Base of the Skull.—Most of these are the result of bursting force, a fissure extending from the point of injury on the vault to the base of the skull, usually along definite lines. The recognition of this fact is due chiefly to Aran (1844), who claimed that in every fracture of the base the fissure began in the vault. This, however, is not literally true, as the fracture sometimes begins at the base and may or may not extend to the vault. Falls on the feet or on the buttocks may fracture the base by force applied through the condyles of the occipital bone. When fracture of the base occurs as part of a bursting fracture from diffused force applied to the calvaria, the fissure extends to the base by the shortest anatomical route, avoiding buttresses such as the mastoid, the external angular process of the frontal bone, etc. Thus it is found that in *fractures from lateral compression*, usually on the parietal bones, the fissure crosses the middle fossa of the skull in the majority of cases (23 out of 32 cases recorded by Archibald). *From*

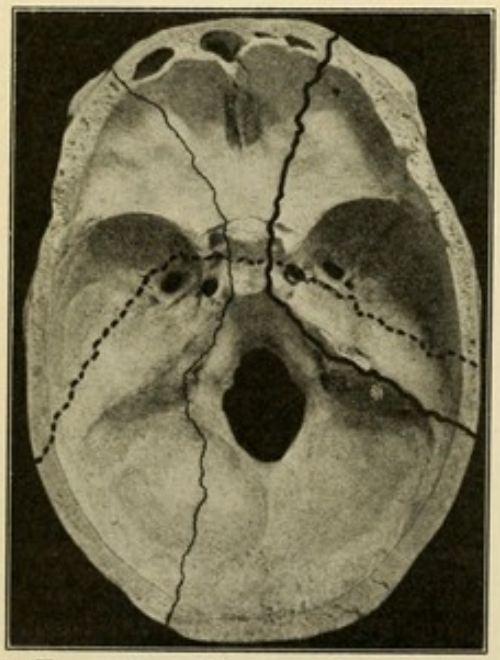

FIG. 616. — Diagram showing the usual course taken by fissured fractures of the base of the skull.

occipito-frontal compression, a fissure results which passes usually through one orbital plate of the frontal, through the body of the sphenoid, and the sella turcica, along the petro-occipital suture to the jugular foramen, and perhaps up again to the vault along the masto-occipital suture; or if the fissure passes down the occipital bone, it skirts the side of the foramen magnum, and so to the sella turcica (Fig. 616). Rawling found the sphenoidal sinus fractured in 70 per cent. of his cases. These basal fractures very often are compound, through the naso-pharynx or middle ear. Displacement is very slight.

Punctured fractures of the base of the skull are exceedingly serious lesions; they occur from such implements as umbrella tips, pencils, pipe-stems, etc., which may penetrate the orbit or naso-pharynx, sometimes entering one of the fissures or foramina at the base of the brain with little damage to the surrounding bone.

Symptoms.—These depend, as in fractures of the vault, much more upon cerebral injury than upon the mere existence of fracture. The *diagnosis*, therefore, depends in large measure on circumstantial evidence derived from certain physical signs, and from a knowledge of the mode of injury. Fractures of the *anterior fossa* may be accompanied by bleeding into the retrobulbar tissues of the orbit, subconjunctival ecchymosis appearing some days after the injury, and spreading from behind forward; exophthalmos is a rare sign. Bleeding from the nose or mouth is as often due to extracranial as to cranial lesions. Brain substance or cerebrospinal fluid rarely is discharged. Blood may be swallowed and vomited. Fractures of the *middle fossa* frequently are compound through the middle ear, and though bleeding from the ear may be due merely to rupture of the tympanic membrane, when persistent or profuse it has usually an intracranial source; it may enter the throat through the Eustachian tube. A clear liquid discharge may occur from the mastoid cells or from the membranous labyrinth, but any such discharge in large amount is more apt to be cerebrospinal fluid. Paralysis of one or more of the cranial nerves is more frequent in fractures of the middle fossa than in those of the anterior or posterior fossæ. The seventh and eighth nerves are those most often injured, usually from laceration or secondary edema. Ferron (1908) collected 339 instances of nerve lesion, with 33 deaths. Fractures of the *posterior fossa* frequently are not recognized, because of lack of physical signs. Ecchymosis over the mastoid, appearing some days after the injury, is of some significance; as is the occasional involvement of the ninth, tenth, and eleventh nerves.

Prognosis.—This depends upon the presence of intracranial lesions and upon the development of complications, especially meningitis. Without these, the prognosis is no worse than in fracture of the vault. As a general rule, about one out of three or four patients with fracture of the base will die within a week or ten days.

Treatment.—The general treatment is the same as in fractures of the vault: physical and mental rest, in a cool, darkened room;

and purgation to remove material which might cause toxemia or bacteremia and hence increase the danger of sepsis. Urotropin should be administered (15 grains three times daily, with an interval of one day at the end of each three-day period), and liquid diet should be continued until danger of complications has passed. The naso-pharynx and external auditory meatus should be cleansed, but repeated irrigation is more apt to encourage sepsis than to prevent it. If bleeding is profuse it may be necessary to pack the naso-pharynx or auditory meatus; in all cases it is well to keep a little sterile absorbent cotton in the latter channel to absorb discharges. If bleeding is very persistent, and especially if packing produces symptoms of cerebral compression, attempt should be made, by trephining the skull low in the temporal region, to reach the source of hemorrhage and deal directly with it. If symptoms of compression arise, whether there is external hemorrhage or not, decompression should be done (p. 589). Nassau (1912) not only does decompression, but opens the dura, and lightly packs the arachnoid spaces with gauze; he claims that this is the only efficient method of controlling intradural hemorrhage (p. 575). Four days later the patient is again anesthetized, the gauze is removed, the dural flap sutured, and the scalp closed. Lumbar puncture may be employed as a diagnostic measure to ascertain the presence of blood in the cerebrospinal fluid; occasionally it is curative also.

FIG. 617.—Loss of bone after fractured skull; four months after operation. (Dr. Mutschler's case.) Episcopal Hospital.

Osteomyelitis.—Osteomyelitis of the cranial bones is rare, and extremely fatal; usually it follows contusion of the bone, secondary infection occurring through the blood-stream or from an overlying hematoma. It is rarer still as a complication of compound fracture or a scalp wound, as in such cases drainage is free. The *diagnosis* rests on the appearance of septic symptoms, after injury to the skull, with the development locally of the "puffy tumor" of Percival Pott (1768), which is "a circumscribed, flattened, elevated swelling," due to infiltration of the scalp with serum, and indicates "a subjacent suppurative periosteitis, denuded bone, and in many instances subcranial suppuration with separation of the dura mater" (Nancrede, 1885).

Treatment.—Treatment consists in removal of all diseased bone, by trephine and rongeur, with free drainage. Death is the usual outcome of the disease, from meningitis and encephalitis, except where very early operation is done.

Repair of Cranial Defects.—Usually after operation for fracture or other lesion of the skull, in which a large area of bone is removed, the defect produces little inconvenience, being filled in by dense fibrous tissue. There is no tendency to hernia cerebri (Fig. 631) unless intracranial tension is increased; on the contrary, the area usually is depressed (Fig. 617). Sometimes, from dural adhesions, or other cause, this depressed area is a source of constant annoyance, and may subject the brain to slight injuries. If the symptoms are so severe as to demand relief, a pedunculated osteoplastic flap, composed of scalp and outer table of the skull, may be raised by chisel from the neighboring healthy bone, and implanted into the defect (König, 1890), the denuded cranium being covered by a Wolfe graft; or, as done by Frazier in a recent case at the Episcopal Hospital, a free transplant, consisting of the outer table, may be removed from another portion of the skull.

SURGICAL AFFECTIONS OF THE BRAIN AND MENINGES.

Cranio-cerebral Topography, which implies a knowledge of the relation of intracranial structures (cerebral fissures and convolutions, blood-sinuses, meningeal vessels, etc.) to the overlying skull, is not now regarded as of so much importance as some years ago. This is so both because these relations exhibit variations in different persons, and because modern surgical technique enables the surgeon to raise a large bone flap from the cranium, and expose the underlying structures over a sufficiently wide area to permit of his recognizing them rather by their relations to each other than by their relations to the surface of the cranium. But there are a few landmarks which it is indispensable for the surgeon to know.

The *longitudinal sinus* runs beneath the sagittal suture from the root of the nose to the inion; it lies within the falx cerebri, and extends, with its annexed blood-lakes, for nearly an inch each side of the median line, being broader behind than anteriorly. Usually it extends further to the right than to the left of the median line.

The *lateral sinus* runs on each side, along the attachment of the tentorium cerebelli, from the inion to the base of the mastoid; here it passes downward, following the petro-mastoid suture to the jugular foramen (Fig. 619). The anterior and upper margin of the curve where the horizontal and descending (sigmoid) portions of the lateral sinus meet, known as the knee (genu) of the lateral sinus, is about 2.5 cm. (1 inch) above and nearly 4 cm. (about 1½ inches) behind the centre of the external auditory meatus. The sinus is about 12 mm. (½ inch) or more broad, and the "dangerous area," over which a trephine or chisel should not be applied, includes a strip of bone nearly 2.5 cm. (1 inch) wide, overlying the course of the sinus.

The *upper limit of the cerebral hemispheres* corresponds to the position of the superior longitudinal sinus. Their *lower limit* reaches, in front to the upper margin of the orbit; laterally it passes from a

point 12 mm. ($\frac{1}{2}$ inch) above the external angular process of the frontal bone, to the upper margin of the external auditory meatus, and thence to the inion, along the upper border of the lateral sinus.

The *fissure of Rolando* runs from a point about 12 mm. ($\frac{1}{2}$ inch) behind the mid-point between glabella and inion, forward for nearly 8.5 cm. ($3\frac{1}{2}$ inches), at an angle of about 70° with the sagittal suture. If a square of paper (90°) is folded diagonally, so as to make two angles of 45° each, and one of these folds is again doubled on itself, so as to make two angles of 22.5° each, it will be possible, by adding one of these latter angles to the 45° angle, to construct off-hand an angle of 67.5°, or three-quarters of the original right angle. If, then, this

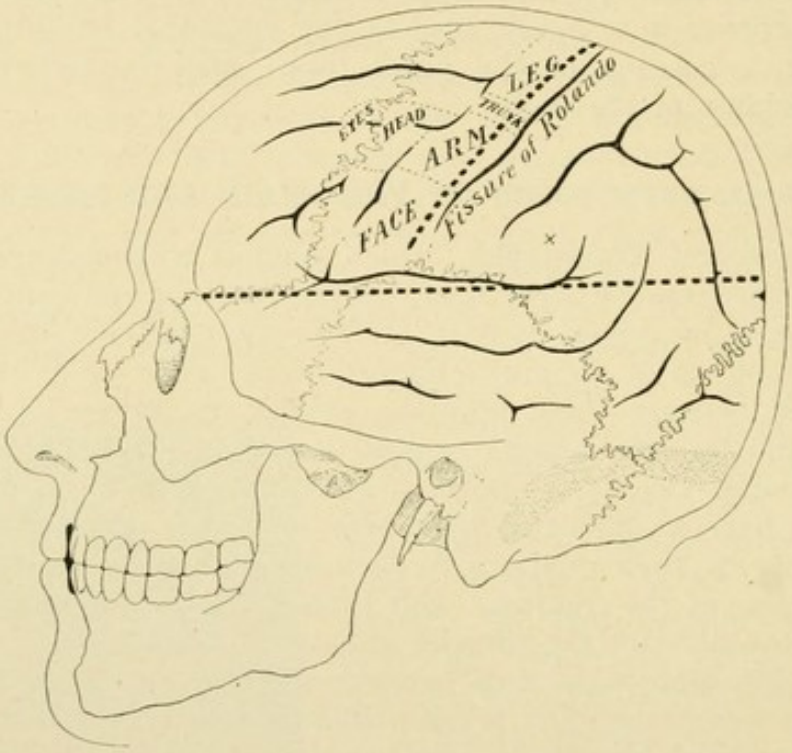

Fig. 618.—Relation of the chief fissures and convolutions of the brain to the surface of the skull. The dotted line which is nearly horizontal indicates the fissure of Sylvius; this line runs from the external angular process of the frontal bone through a point 2 cm. below the parietal eminence (x), and its middle third corresponds roughly with the Sylvian fissure. Note the positions of the cranial sutures.

angle (67.5°) is placed on the sagittal suture, so that its apex lies 12 mm. ($\frac{1}{2}$ inch) behind the mid-point between glabella and inion, the course of the Rolandic fissure will be approximately indicated (Chiene, 1888). The relation of the other chief fissures and convolutions is sufficiently indicated in Fig. 618.

The *middle meningeal artery*, entering the skull by the foramen spinosum, divides almost immediately into two branches. The anterior branch runs forward and upward and crosses the anterior inferior angle of the parietal bone, near the pterion; thence it runs upward toward the sagittal suture, lying behind and more or less parallel to the coronal suture. Near the pterion it lies usually in a bony groove or canal, and is frequently torn by splinters of bone, or ruptured

by inbending or bursting fractures at this point. It may also be injured at this point by a trephine, so it is safer to expose it by a trephine opening in the middle of the temporal fossa, say 4 cm. ($1\frac{1}{2}$ inches) posterior to the external angular process of the frontal bone, and 2.5 cm. (1 inch) above the zygoma (Fig. 619). The posterior branch runs horizontally backward across the squamous plate of the temporal bone, and crosses the temporo-parietal suture within about 2 cm. ($\frac{3}{4}$ inch) of its posterior end; it may be exposed by a trephine opening about 2.5 cm. (1 inch) below the parietal eminence.

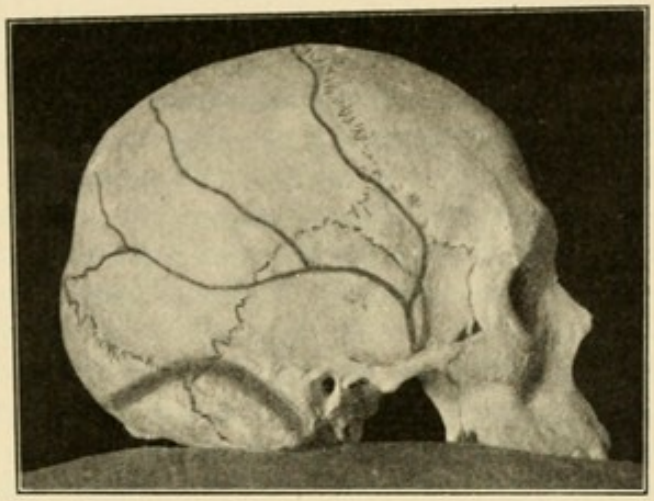

FIG. 619.—Course of middle meningeal artery and lateral sinus, outlined upon the surface of the skull.

Concussion and Contusion of the Brain.—The brain is an incompressible structure suspended within a bony case by fibrous partitions, chief of which are the falx and tentorium; it is held relatively immobile at its base by the cranial nerves, bloodvessels, and processes of dura mater, which pass through the base of the skull. It is surrounded by a small amount of cerebrospinal fluid, which is in greater quantity toward the base, especially around the medulla; and its ventricles, which are directly continuous with the subdural spaces (p. 555), are filled with the same fluid. A blow upon the head causes not so much a vibration or tremefaction of the brain substance, as a sudden displacement of the brain as a whole; it is flung, as it were, against the opposite side of the skull, and usually it is contused most at the point of impact, or the polar point, or at the base, where the greatest strain comes. The cerebellum is relatively little affected, because of its protected position beneath the tentorium, because it floats on a greater amount of cerebrospinal fluid, and because of the possibility of downward displacement by crowding the medulla into the foramen magnum. Some blows on the head, severe enough to cause symptoms, produce symptoms which are so momentary and fleeting that it always has been difficult to believe that they were attended by structural change. And until modern methods of histological study were developed, it happened not rarely that postmortem

examination failed to disclose any lesion in the brains of those who had actually died with symptoms due to "concussion." But it has come to be recognized, largely through the investigations of Sir Prescott Hewett (1870), that the condition of these brains is not one of "concussion," as was formerly taught, but is the result of concussion, and is characterized by *contusion, compression, extravasation, laceration,* or *inflammation* in varying degrees. Of course, it cannot be asserted categorically that histological changes always are present in patients who recover at once from the symptoms of concussion, because there is no opportunity of submitting their tissues to microscopical examination at the time of injury; but the belief is quite general, and I believe quite justified, that even when the symptoms produced are the most insignificant, definite lesions exist, and that these vary from temporary arrest of cell-action, with capillary stasis, or the slightest grades of contusion, with punctate hemorrhages, to distinct laceration, ecchymosis, exudation, and edema of the brain and pia-arachnoid. Kocher teaches that the immediate and temporary symptoms are the result of cerebral anemia, while unconsciousness which lasts for hours or days is due to cellular changes.

Symptoms.—As in all cases of injury, some degree of shock is present, and it often is difficult to distinguish the symptoms of this condition from those due to concussion of the brain. After a blow on the head only such symptoms as dizziness, or disturbances of vision (sparks, specks, etc.), may be observed. In more marked cases there is momentary loss of consciousness, the patient falling as one dead; or, when striking the head in a fall, lying motionless for a few seconds, and then regaining consciousness and rising to his feet before assistance can reach him. In typical cases, two distinct stages may be recognized:[1] (1) The patient at first lies motionless, senseless, nearly pulseless, pale and cold, breathing feebly but naturally; the pupils dilated or contracted, fixed or acting freely; perhaps with involuntary discharge of feces and urine. He will swallow if food is put into his mouth. From this first stage, which may last many days, the patient may recover without further trouble, or he may gradually sink and die without reaction; or the first stage may last a few moments only, the patient having passed into the second stage before the surgeon sees him. The disappearance of the first stage, whether by passing into the second or by direct recovery, commonly is marked by vomiting. (2) In the second stage the patient is no longer unconscious, though much indisposed to speak or pay attention to surrounding objects. If roused by a question, he will answer, but peevishly or angrily, turning away as if displeased at the interruption. His posture is peculiar: he lies habitually on his side, curled up, with all his joints more or less flexed, and if a limb is touched he draws it away with an air of annoyance. The eyelids are kept firmly closed. The pulse, at first slow and weak, gradually

[1] This description is copied, almost verbatim, from the Principles and Practice of Surgery of John Ashhurst, Jr.

becomes more frequent and stronger; the breathing is easier, and the surface regains its natural warmth and color. This stage gradually subsides, after several hours or days, and as the patient regains ability and willingness to communicate with those around him, he complains almost invariably of severe headache. If the cerebral lesions have been marked, they may leave the patient with his mental faculties permanently impaired; usually, however, in such an event, the earlier symptoms will have been those of *compression of the brain* rather than those recognized as due to concussion.

Treatment.—The patient should be laid horizontal, with the head slightly elevated, in a darkened room; and throughout his illness he should be protected from all noise. During the first stage, stimulation for shock may be necessary. So soon as shock is recovered from, the bowels should be evacuated, the urine drawn if necessary; and moderate amounts of liquid nourishment should be administered. During the second stage, cold should be applied to the head, while restoration of cerebration may be hastened by the administration of calomel, one-sixth of a grain every four hours, for its "anticipatory antiplastic effect" (p. 561); and this may be continued for many days, or until the patient is clear in his head. Should restlessness or delirium supervene, it is well to administer, with each dose of calomel, two or three grains of Dover's powder. The use of the mind, in conversation, reading, etc., should be resumed very gradually, and convalescence should be prolonged, the patient living by rule for many months after apparent recovery, and remaining under surgical observation until by the lapse of time the absence of complications from unrecognized cerebral lesions is assured.

Compression of the Brain.—As already stated, the brain is an incompressible structure; its bulk can be reduced only by loss of its fluid constituents; if compressed in one direction it must expand in another. Experimental compression of the brain produces first a stasis in the smaller venous channels; the longitudinal sinus collapses; the blood cannot escape from the skull. If pressure increases the arterioles may be affected. Normally changes in intracranial vascular pressure are compensated for by the ebb and flow of the cerebrospinal fluid. This drains away into the veins, and these in turn empty mostly into the longitudinal sinus and certain emissary veins through the diploë. Increase in vascular pressure from the arterial side is easily and rapidly compensated for by venous absorption of cerebrospinal fluid; and obstruction to the venous outflow (often seen in cases of cervical or thoracic neoplasms) does not prove injurious so long as the collateral diploic veins are open, or so long as the cerebrospinal fluid can pass into the spinal canal and escape into the venous circulation by that channel. But if the pressure on the venous side becomes so great as to dam the blood back into the capillaries, these side escapes become blocked, the brain may be forced down until the medulla chokes off the outlet for cerebrospinal fluid through the foramen magnum, and symptoms of "compression" appear.

It was shown experimentally by Althann, in 1871, and since his time by numerous other investigators, that "the effect of space diminution in the skull was identical with that of any other process which hindered cranial circulation" (Archibald, 1908); so that, as pointed out by von Bergmann (1880), the symptoms of "compression" are due not to actual compression of nerve elements, but to *cerebral anemia.*

The maintenance of life depends on the functioning of the chief medullary centres, vasomotor, vagus, and respiratory; and it is to interference with the circulation of these centres that the most striking symptoms of cerebral compression are due. Localized compression produces the so-called *focal symptoms, i. e.*, paralysis; while generalized compression, which may develop independently of, or may succeed, local compression, is particularly characterized by *bulbar symptoms:* interference with the centres already named; but in generalized compression there also usually is unconsciousness, from cortical compression.

So soon as anemia affects the medulla, the vasomotor centre is stimulated, blood-pressure is raised higher than intracranial (extravascular) pressure, blood again reaches the medulla, and life is prolonged, at least temporarily (von Schulten, 1885). But the stimulus of anemia then being removed, blood-pressure sinks somewhat, as intracranial pressure continues to increase, and anemia of the medulla again occurs; whence renewed stimulation of the vasomotor centre, a further rise in blood pressure, and again a temporary relief of the medullary anemia. Cushing (1902, 1903) has been able to follow these successive periods of anemia and return of circulation by observation of the cerebral cortex of monkeys through a trephine opening; and his experiments justify the conclusion that similar changes occur in the medulla.

This alternate stimulation and depression of the medullary centres explains the more or less periodic phases observed in the blood-pressure and respiration curves obtained from such patients. They are known as Traube-Hering waves. The respiratory phases closely resemble the Cheyne-Stokes type, the stage of apnea occurring when the respiratory centre is deprived of blood, and the hyperpnea developing when circulation is restored by increase in blood-pressure. This "life and death struggle," as von Schulten termed it, may continue until blood-pressure reaches enormous heights; Cushing raised it experimentally to 290 mm. Hg.; but unless intracranial pressure is relieved, the medullary centres in time will cease to react, and sudden fall of blood-pressure will occur, followed by death. "Death probably always occurs from primary failure of the vasomotor centre, rather than from that of the respiratory, as has been asserted by some. The vasomotor centre holds the key to the position. Its defeat involves that of the respiratory and vagus centres; and with their defeat the whole army is devoted to slaughter." (Archibald, 1908.)

Causes.—Anything which increases intracranial pressure may cause symptoms of compression of the brain. This includes: (1) Foreign bodies driven against or into the brain (bone fragments, bullets, etc.); (2) hemorrhage, subcranial, subdural, or intracerebral; (3) products of inflammation (serous effusion, lymph, pus); (4) tumors of the brain; (5) acquired internal hydrocephalus, etc.

Symptoms.—Very slowly induced compression may not produce symptoms for a long period; and even in cases of rapid compression there often is a "*stage of compensation*" from rise in blood-pressure, during which no symptoms may be observed. During the *stage of manifest compression* two periods may be recognized: (1) *Early symptoms:* There is irritation of the cortical and medullary centres, due to venous stagnation; slight quickening of respiration, and rise in blood-pressure; headache, dizziness, restlessness, roaring in the ears, disturbed sleep; moaning and groaning; and at times delirium. Sometimes circulatory changes in the fundus oculi can be detected, but these disappear in a few hours. (2) *Late symptoms:* The gradual increase in the compressing force finally overcomes the blood-pressure, and cerebral anemia results. This stimulates the vasomotor centre which raises blood-pressure yet higher by causing peripheral capillary constriction, especially in the splanchnic area. The patient lies somnolent, stuporous, even comatose; with slow, full, bounding pulse; there is labored respiration, which in the last stages approaches the Cheyne-Stokes type; the cheeks are passively puffed out at each expiration ("smoking his pipe," the French call it); the pupils react sluggishly or not at all. The more dilated pupil usually is on the side of greatest compression. Sometimes the patient can be partially roused from his coma by pressure on the supra-orbital nerve; then slight convulsive movements of the extremities may occur, and hemiplegia, or localized paralysis may become evident. Irregularity of the respiration is one of the earliest and surest signs of approaching exhaustion of the medullary centres; and unless blood-pressure can be measured periodically by the manometer, respiration is a more reliable guide as to prognosis than the quality of the pulse; for the "vagus pulse," slow, regular, and strong, continues practically unchanged until very near the fatal ending.

Diagnosis.—If the early symptoms of the stage of manifest compression were borne in mind, the condition often could be diagnosed and measures for relief instituted, before the later stage, complicated by unconsciousness, is reached. When an unconscious patient is examined, the existence of an adequate cause for cerebral compression always should be excluded before dismissing this as the cause of the symptoms. Many a patient suffering from cerebral compression has been sent away from accident wards as "drunk," when a very little time spent in examination would have detected focal symptoms (pupillary, facial, or lingual paralysis; monoplegia, hemiplegia, etc.); while bulbar symptoms probably could have been discovered if they had been specifically looked for. In any case of doubt, keep the

patient under observation; if the cause of symptoms is compression, this soon will become evident.

Prognosis.—This depends very largely upon the cause of the compression, and the time at which treatment is instituted. In many cases of brain tumor, for instance, it may be impossible to remove the cause of compression, so that cure is out of the question; but symptoms may be relieved and life prolonged by removing the counter-pressure caused by the skull. But even in cases where the cause of compression can be removed, treatment may not be instituted until the last stages of compression, and the medullary centres may not recover; or even though they recover, the focal compression may have done so much damage to the cerebrum as to impair the patient's mental or physical ability throughout life.

Treatment.—From what has been said above it is very evident that the two main indications are to maintain blood-pressure at a higher point than intracranial (extravascular) pressure, and to relieve the compression by surgical means. The full, bounding pulse, the singing in the ears, etc., of the early stages, do not by any means indicate that the patient should be bled, or that aconite should be administered; they are an index of his compensatory powers and all that will save his life is to keep his blood-pressure high, and to relieve the intracranial pressure as quickly as possible. Theoretically the latter point may be gained by lumbar puncture of the subdural space of the cord; but draining away cerebrospinal fluid, by removing the brain's support from below, may serve only to allow the superincumbent pressure to force the medulla down into the foramen magnum, thus strangulating it and causing instant death. The most imperative indication is to "decompress" the brain by removing some of the overlying cranium, on one or both sides. This may be done by the trephine, the opening being enlarged by rongeur forceps, or a bone-flap may be raised (p. 586). At the same time that decompression is done, the cause of compression, whenever possible, should be removed. The site of the cranial opening depends on the cause of compression and on the existence of focal symptoms; when not contraindicated the subtemporal operation of Cushing (p. 590) is very satisfactory.

In the most advanced stages of cerebral compression emergency measures are necessary to raise the blood-pressure until operation can be undertaken; these are such methods as artificial respiration, lowering the patient's head, bandaging his extremities, compression of the abdomen, and the administration of strychnin, adrenalin, etc. After decompression it should be remembered that the stimulating effect of recurring anemia upon the vasomotor centre is lost; and if this centre shows signs of exhaustion, it must be stimulated by strychnin, or repeated doses of adrenalin.

Subcranial or Extradural Hemorrhage may be due to bleeding from the diploë or cranial sinuses, in cases of fracture of the skull, but in the vast majority of cases it is due to rupture of the middle

meningeal artery. *Middle meningeal hemorrhage* may occur with or without fracture of the skull, and upon the side of injury or on the opposite side (from "contre-coup"). The anterior branch of the artery is most often ruptured, usually near the pterion, where it passes through a bony groove or canal; but it may be torn off at its exit from the foramen spinosum (by concussion, or by a bursting fracture), or lacerated by bone fragments at other parts of its course. The bleeding which results slowly separates the dura from the cranium, and the resulting clot may spread over an entire hemisphere (Fig. 620).

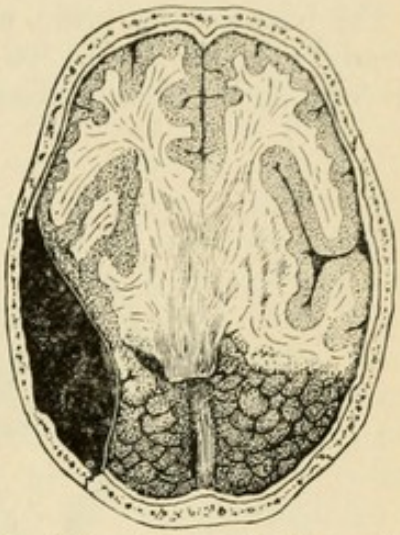

FIG. 620. — Subcranial hemorrhage from rupture of the posterior branch of the middle meningeal artery. No fracture of the cranium. Man, aged fifty-one years, was found lying on the street, unconscious. Taken to police station. Operation about forty hours after injury. Blood-pressure fell from 170 mm. before operation to 110 mm. a few hours later. Recovery. Episcopal Hospital.

Diagnosis.—The usual history is that after an injury to the head the patient experiences momentary symptoms of concussion, then recovers more or less completely; but some hours or even days later signs of compression appear, sometimes gradually, sometimes with alarming suddenness. What is particularly characteristic is the so-called "free interval," between the injury, when rupture occurs, and the time when the accumulating clot brings on symptoms of compression.

Treatment.—The treatment consists in exposing the main trunk or anterior branch of the artery, removing the clot, tracing the bleeding to its source, and ligating the artery by passing a fine suture around it by means of a round-pointed needle. T. R. Neilson (1903) plugged the foramen spinosum with a match-stick. If the hemorrhage does not come from the anterior branch, the posterior should be exposed. If all focal signs are absent, and no cause for compression is found on the side of the skull first opened, it is justifiable to open the other side, as rupture may occur from counter-stroke.

Intradural Hemorrhage.—Bleeding into the meshes of the pia-arachnoid, which is much more frequent than the extradural form, almost invariably is of traumatic origin, venous in character, and complicated by extensive cranial and cerebral injury (Fig. 621). Usually the blood is widely diffused, and the fluid removed by lumbar puncture may be blood-tinged. The *symptoms* are those of cerebral compression; "it is safe to say," writes Cushing, "that in any serious cranial injury in which unconsciousness has been present from the first, subdural bleeding is taking place, either from the fracture itself or from some laceration of the brain." *Treatment* consists in decompression if symptoms of compression continue for more than a

few hours or are well marked at first. Seldom is it possible to find any distinct bleeding point, but exposure to the air, or gentle irrigation with very hot saline, may be sufficient to arrest the hemorrhage. Drainage is provided by strips of rubber tissue. The operation, unless another opening is indicated by focal symptoms, should be by Cushing's subtemporal route (p. 590) which gives ready access to the base of the brain whence the bleeding usually arises. As already mentioned (p. 566), Nassau tampons the subdural tissues for four days, then replaces the dural flap.

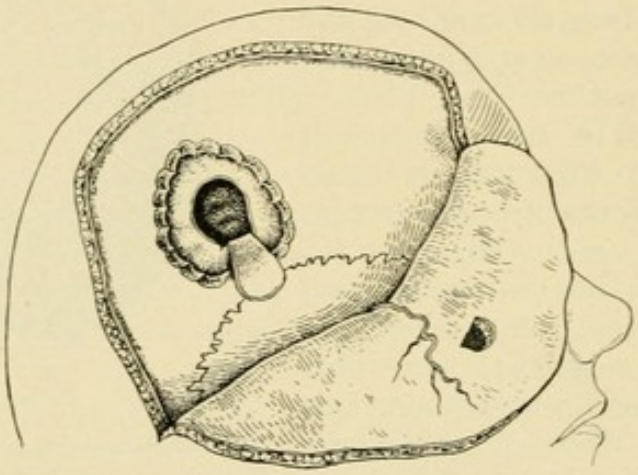

FIG. 621.—Intradural hemorrhage. A boy of five years had a large flap of scalp torn loose. Parietal bone bent inward, but no fracture. Operation three hours later (for continued unconsciousness and left hemiplegia) showed extensive intradural hemorrhage, the brain being 4 cm. distant from the dura. After removal of compression respiration improved, but death occurred in a few hours. Episcopal Hospital.

Intracranial Hemorrhages in the Newborn.—These occur usually from a rupture of a vein in the pia-arachnoid, near the longitudinal sinus, as the result of trauma during birth. The *diagnosis* is not always easy, at least until signs of compression of the brain appear; lumbar puncture may show bloody cerebrospinal fluid; and cerebral irritability and irregularity of respiration are suggestive. The *prognosis* is bad; nearly 80 per cent. die from cerebral compression within a few days; while of those that recover most are mentally deficient or afflicted with spastic paralysis (p. 530), athetosis, nystagmus, etc. *Treatment:* Operative relief, proposed by Keen in 1901, was first employed in 1904 by Cushing, who has reported (1908) nine operations, with four recoveries. A large osteoplastic flap, which can be cut out with strong scissors, is raised, the dura is opened, the clots removed by gentle irrigation, and the wound closed without drainage.

Intracerebral Hemorrhage occurs chiefly as the result of vascular disease (ordinary "apoplexy"), or from degenerative changes in brain tumors. Wounds are occasionally causes of localized cortical hemorrhage. The suggestion by Leonard Hill (1896) that surgery by effecting decompression, or even by evacuation of the clot, might be of use in these cases, was acted upon with success by Borsuk and

Wizel (1897) in a traumatic case. Cushing (1908) has operated on four cases of spontaneous hemorrhage, one operation (subtemporal decompression and evacuation of the clot) being successful. Under expectant treatment the mortality is nearly 90 per cent., in these cases of acute severe apoplexy, in which alone is operation to be considered.

Sinus Thrombosis.—This arises, in the vast majority of cases, by extension of septic inflammation from the air sinuses of the skull, especially the mastoid cells. Pyogenic inflammation of the scalp or erysipelas are rare causes, the infection spreading along the diploic emissary veins. The *diagnosis* depends on recognizing a focus from which septic inflammation may be derived, on local signs such as edema of the overlying scalp, and distention of its veins, together with evidences of constitutional sepsis, and perhaps cerebral compression. The *longitudinal sinus* may be thrombosed from frontal, ethmoidal, or sphenoidal sinusitis, or rarely from erysipelas of the scalp, etc. Thrombosis of the *cavernous sinus*, which is very rare, may arise from extension of inflammation along the facial and angular veins (carbuncle of upper lip, etc.), or along the petrosal sinuses (from the sigmoid sinus), and is particularly characterized by the resulting exophthalmos.

The *lateral sinus*, especially its sigmoid portion, is that which is involved in by far the largest number of cases, and almost always as the result of middle-ear disease, the infection coming along the emissary veins or directly invading the sinus wall after destruction of the intervening bone. The *symptoms* are those of the preëxisting disease (mastoiditis), of sepsis (repeated chills, sweating, hectic temperature), and cerebral irritation or compression (rare); but such symptoms often do not appear until the sinus thrombosis has been in existence for some days, and may indicate a softening of the clot and dissemination of emboli. Naturally the lungs are most often attacked in this way. Thrombosis is prone to extend to the internal jugular vein, and often this can be felt as a tender cord in the neck. The head may be tilted to the affected side. In meningitis, which is much commoner in infants than adults as a result of middle-ear disease, cerebral symptoms (vertigo, vomiting, hebetude, delirium) are more marked, there is retraction of the neck and paralysis of the ocular muscles, with choked disk; fever is higher and more regular; Kernig's sign is present; and lumbar puncture shows turbid cerebrospinal fluid, from which organisms may be recovered. In brain abscess cerebral symptoms, without those of meningitis, predominate; temperature is subnormal; there is evidence of cerebral compression; and emaciation is rapid. In neither meningitis nor in uncomplicated cases of brain abscess is there thrombosis of the internal jugular vein.

Treatment.—The first step is to clear out the mastoid, and this merely preliminary measure should not be done with too great deliberation (see Chapter XIX). The shell of bone which overlies the sigmoid sinus is then removed by gouge or burr, and the sinus well

exposed; plenty of room should be gained by use of the rongeur. The sinus is next incised: *if bleeding occurs* the sinus is compressed first on the torcular side; and, if it continues, also on the jugular side of the incision. Persistence in bleeding, when pressure is made at both these points, indicates a return flow from the mastoid emissary or superior petrosal sinus. These should be separately tested. If the petrosal is not thrombosed it is probable that the entire system is healthy. *If no bleeding occurs* when the sinus is opened, it should be slit up toward the torcula until a return flow is obtained; this is controlled by packing; the clot is then removed as far as the original incision, and, after temporary pressure has been made on both jugulars in the neck, a similar procedure is carried out at the bulbar end of the sinus. If no return flow can be obtained from this end of the sinus, it is a sign that the thrombus extends into the jugular, and resection of this vein should be done. It is to be performed as a primary operation, before exposing the sinus, when a diagnosis of jugular thrombosis is made in advance. *Resection of the Internal Jugular Vein:* The vein is exposed and doubly ligated low in the neck; it is divided between these ligatures and dissected upward, clamping and tying each branch encountered. Thrombosed branches should be excised. When the vein has been traced up as far as possible, it is ligated and cut across. The neck wound is tamponed with gauze and not closely sutured. If the jugular vein is too densely adherent to be removed safely, it should be slit open, and the wound packed with gauze. The *general mortality* of thrombosis of the lateral sinus is about 25 per cent.

Meningitis.—**External Pachymeningitis**, usually purulent and localized (*subcranial abscess*), affects the external layer of the dura, and may result from osteomyelitis of the cranium (p. 566) with or without fracture of the skull, or from neighboring sinus thrombosis. *Treatment* consists in removal of the overlying bone, with drainage.

Internal Pachymeningitis is a rare disease, of subacute or chronic character, in which membranous lymph, easily detachable, is deposited on the inner layer of the dura. It is microbic in origin, occurs sometimes in general infections (typhoid fever, pneumonia), and sometimes is hemorrhagic in type. The symptoms are not very characteristic, being those of slowly increasing cerebral irritation or compression; and the diagnosis is difficult. *Treatment:* operation, comprising removal of the false membrane or hemorrhagic exudate, offers the only hope of cure or prevention of insanity (Munro, 1902).

Leptomeningitis.—Inflammation affecting the pia-arachnoid may be due to a number of bacteria; the form known as *epidemic cerebrospinal meningitis*, caused by the Diplococcus intracellularis, is a specific contagious disease, usually coming under the physician's care. Early use of Flexner's serum (1906) is most important. As the ultimate cause of death is purely mechanical, being due to cerebral compression from acute internal hydrocephalus (p. 554), surgical treatment may be advisable when purely medical measures have

failed. Lumbar puncture, used for diagnosis, is of no therapeutic value when hydrocephalus supervenes; the only remedy is single or repeated puncture of the ventricles.

Leptomeningitis also may be caused by ordinary pyogenic cocci, pneumococcus, B. tuberculosis, etc. Especially in *tuberculous meningitis*, which is so uniformly fatal under medical treatment, it seems as if almost any surgical risk were justifiable. Lumbar puncture will relieve the intracranial tension, due to accumulation of seropurulent exudate, so long as the medulla is not driven down like a cork into the foramen magnum, or so long as the foramina in the roof of the fourth ventricle are patulous (p. 554). But when acute internal hydrocephalus develops, the only hope of relief lies in tapping the ventricles (p. 555) or their permanent drainage into the subdural space (p. 556).

Serous or Amicrobic Meningitis is a form of the affection in which clear, sterile serous fluid collects in the intradural spaces (Eichhorst, 1887). Some cases are traumatic in origin, but most are regarded as due to bacterial infection localized elsewhere in the body, thus being analogous, as pointed out by Archibald (1908), to the sterile serous effusion of pleurisy secondary to subphrenic abscess. Sometimes this affection complicates sinus thrombosis or mastoiditis.

Diagnosis.—The diagnosis is difficult, the serous character of the effusion being discovered first at operation undertaken to relieve pressure symptoms thought to be due to subcranial or intradural suppuration, or to brain abscess.

Treatment.—In traumatic cases lumbar puncture may suffice to evacuate the fluid; in others craniotomy should be done. If serous meningitis is found, undue persistence should not be exercised in searching for a brain abscess which may not exist.

Syphilis of the Leptomeninges.—Practically all the intracranial lesions of syphilis arise in the meninges and involve the brain only secondarily, by pressure. They are found most often in the arachnoid tissues, especially in the frontal region and at the base. The diagnosis from cerebral tumors is not easy, but the treatment is much the same (p. 585).

Encephalitis or Cerebritis, except as it complicates traumatic lesions, concerns surgeons little, unless in localized form (*Brain Abscess*). There is supposed to be an epidemic form, analogous to acute anterior poliomyelitis, of which, probably, more will soon be heard.

Brain Abscess.—This is due in about equal proportions to *trauma*, especially penetrating and punctured wounds, and to *suppurative disease* of the mastoid cells, middle ear, or other air sinuses of the cranium. It occurs also in pyemia, but very much less frequently. The *site* of the abscess in the brain depends largely on the focus of infection. Frontal abscess results from disease of the frontal sinuses, ethmoid and sphenoid cells, cavernous sinus, thrombosis, etc. Middle-ear disease is the chief cause of abscess in the temporo-sphenoidal

lobe; while cerebellar abscess usually is secondary to mastoid disease or lateral sinus thrombosis. The causative condition frequently has been in existence for months or even years, before brain abscess develops. The cerebrum is affected more than twice as often as the cerebellum. The abscess almost always is in the subcortical area of the brain, and seldom has any macroscopical connection with the

FIG. 622.—Cerebral abscess from middle-ear disease; *initial stage:* headache, nausea, chilliness, and fever. (G. Laurens.)

FIG. 623.—Cerebral abscess from middle-ear disease; *manifest stage:* persistent headache, mental hebetude, and other symptoms of compression. (G. Laurens.)

source of infection, having arisen from embolism (rare), or by progressive thrombosis of minute venous channels. Usually, if not invariably, however, there exists a microscopic connection between the source of infection in the cranial bones and the abscess cavity; the abscess has been compared to a mushroom, growing by a stalk from the neighboring carious bone.

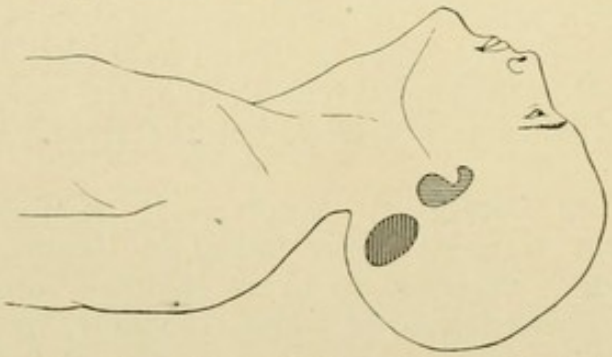

FIG. 624.—Cerebellar abscess from middle-ear disease, simulating meningitis (retraction of the head, occipital headache, etc.). (G. Laurens.)

Symptoms.—When the abscess follows middle-ear disease, which is its most frequent single cause, and may be taken as the type, it is usual for there to have been some recent exacerbation of the chronic symptoms. The course of a typical case is well sketched by Cushing: after the exacerbation of the old symptoms, arise those of the *initial stage* of brain abscess (headache, nausea, chilliness, and fever) (Fig.

622); these may subside, but rarely disappear entirely, for a period of a week or ten days (*latent stage*); then, with more or less sudden cessation of discharge from the ear, symptoms of intracranial sepsis and pressure become evident (persistent headache, mental hebetude, vomiting, slow pulse, subnormal temperature, and leukocytosis (*manifest stage*) (Fig. 623). Usually there are no distinct focal symptoms, other than marked tenderness of the overlying skull, and sometimes facial paralysis. Rapid emaciation is a very significant sign. If the abscess is in the cerebellum, meningitis may be simulated (Fig. 624). The distinction between abscess and tumor of the brain seldom is difficult (p. 583).

Treatment.—The abscess must be drained as early as possible. Do not delay overnight if you suspect an abscess. Some surgeons prefer to do a tympano-mastoid exenteration first, and then wait a few days, to see if the symptoms suggestive of brain abscess will subside; but if an abscess is present, any delay is dangerous. Many operators prefer to open the intact cranium (Macewen, 1893) over the supposed site of abscess, and to proceed to exenteration of the tympano-mastoid only after evacuating the abscess. For *abscess in the temporo-sphenoidal lobe* trephine at a point one inch above the supra-meatal spine. The *cerebellum* is exposed by trephining below the lateral sinus and posterior to its sigmoid portion. Most aurists think it safer to approach the brain abscess through the middle ear or mastoid, because by this avenue one is most certain to cross the meninges where adhesions exist, and can follow on to the abscess along its "stalk." When the cortex is exposed, in either case, measures should be taken to prevent contamination of the meninges, unless the diseased area is isolated already by adhesions. The brain is then explored by a grooved director, and when pus is found the overlying cortex is incised on the director, sufficiently to secure drainage. This is difficult to maintain, as the semifluid brain tends to block the tube. Should damming up of pus be suspected the wound must be reopened. Even in the hands of the most skilled and expert surgeons, operation for brain abscess is attended by a mortality of about 50 per cent.; but as all patients will die, and quite as soon, if no operation is done, this should not deter one from trying to save even moribund patients.

Brain Tumor.—Any growth within the cranium, whether a true neoplasm or an infectious granuloma, is considered clinically a "brain tumor," because productive of the same general signs. *Tuberculoma* is the most frequent growth in childhood; these tumors occur with special frequency in the cerebellum, and often are multiple. *Syphiloma* is more common in adults, being usually a meningeal growth which compresses the brain secondarily. These two types of growth from a larger class of brain tumors than do the true neoplasms. Of the latter, the most frequent are *endothelioma* and *glioma*. The former grows from the meninges, usually is encapsulated and easily enucleated from the cup-shaped depression it produces in the

surface of the brain; the glioma, on the other hand, usually is an infiltrating growth of the subcortical area, and is with difficulty distinguishable macroscopically from normal brain tissue. *Sarcoma*, which is less usual, grows from the connective tissue of the meninges, frequently invading the bone; or may arise in the cortex, whence it sometimes can be shelled out, owing to peripheral degenerative changes. Often it is multiple, and is a more frequent form of metastatic growth than *carcinoma*. *Fibroma* is seldom seen except in the cerebello-pontine angle. *Cysts* occur in the brain; some are of parasitic origin (echinococcus, cysticercus), others are the result of hemorrhages into the brain substance, or arise as degenerative changes in a glioma. The latter is the usual cause of cerebellar cysts.

Symptoms.—Tumors grow in the brain oftener than in any other part of the body. Hale White (1885) estimated that a tumor is found in the brain in one among every 59 autopsies. They may exist for years and cause no symptoms, if in a silent region or if of very slow growth. They occur mostly between the ages of fifteen and fifty. In old age and infancy they are rare. It is usual to discuss the symptoms of brain tumor under two headings, general symptoms, and localizing symptoms.

General Symptoms.—The *syndrome of brain tumor* comprises the three cardinal symptoms, *headache*, *vomiting*, and *papilledema*. *Headache* at first is intermittent, but when constant, and especially when referred persistently to one region, which is tender to percussion or pressure, must be regarded as highly significant; probably it is due, as pointed out by Cushing (1908), to pressure upon or distortion of the falx or tentorium, as the brain itself is insensitive. The *vomiting*, perhaps due to irritation of the pneumogastric nerve, is projectile in character, may occur independently of meals, and be unattended by nausea. *Papilledema, optic neuritis*, or *choked disk*, is a characteristic change in the eye-grounds, commonly believed to be due to damming up of the cerebrospinal fluid in the sheath of the optic nerve, as the result of increased intracranial tension. If this pressure is not relieved, hemorrhages may occur in the nerve head and retina, resulting in permanent blindness. Usually both optic nerves are affected, but unequal involvement of the two nerves does not indicate that the compressing lesion is on the side where papilledema is greatest, unless only one nerve is appreciably involved. Papilledema often is more marked in subtentorial lesions than others. The importance of examining the eye-grounds in all suspected cases of intracranial lesion cannot be too much emphasized, as acuity of vision may persist even when papilledema is moderately far advanced. On the other hand, this sign may be entirely absent throughout the course of the disease. Cushing recently has called attention to changes in the *color fields*, detected by expert ophthalmological examination, as one of the earliest of the general signs of brain tumor. No *bulbar symptoms*, such as occur in compression of the brain from trauma, are observed in cases of brain tumor, because the increase in pressure

is so very gradual. Occasionally a brain tumor, previously unsuspected, makes its presence known first by the occurrence of a hemorrhage into the tumor, the symptoms resembling those of ordinary apoplexy; and in a young adult such an occurrence should rouse the suspicion of a brain tumor.

Localizing Symptoms.—These are interpreted through anatomical knowledge of the seat of the cerebral functions. As the increase in pressure occurs very slowly, *it is the rule for the development of paralytic symptoms to be delayed, usually being preceded by irritative symptoms* (Jacksonian epilepsy, p. 590); and a very slowly growing tumor in a silent region of the brain may produce no localizing symptoms until by encroachment it involves the nearest physiologically recognizable centre, causing "neighborhood" as distinguished from true "focal" symptoms. Thus a tumor in the frontal lobe may make its presence known only by general symptoms (headache, vomiting, papilledema), until so large as to interfere with the motor functions; and when paralysis of motion at last occurs, the incautious observer may jump to the conclusion that the tumor is growing in the motor region; instead of recognizing the fact, as he would have done if an accurate history of the progress of the disease had been obtained, that the growth evidently was primary elsewhere, and had compressed the motor region only secondarily.

Diagnosis.—This involves not only the determination *whether a tumor exists at all*, but also the recognition of the *kind of tumor* present, and *its location.*

1. Brain tumor may be closely simulated by the cerebral symptoms of *chronic nephritis;* the urinary changes in the latter condition are the chief distinction, but as a brain tumor may coexist, the patient should be watched for the development of localizing symptoms. *Abscess of the brain* usually may be distinguished from brain tumor by the history of trauma, bone disease, etc., which is absent in the latter affection; as well as by the more acute course of the disease in cases of brain abscess. *Acquired internal hydrocephalus* (p. 554) is to be distinguished by the usual bilateral distribution of any localizing signs. Sometimes a brain tumor may be detected by aid of a skiagraph.

2. *The kind of tumor* is very difficult and usually impossible to determine. The existence elsewhere in the body of a *tuberculous* process naturally would suggest a tuberculoma as the cause of the cranial symptoms; as would a history of syphilis or evidence of past or present syphilitic lesions the existence of a *syphiloma.* The tuberculin tests and the Wasserman reaction are also available. The use of antisyphilitic remedies, as a method of exclusion, though quite habitual, should not be persisted in for more than six weeks (Horsley, 1890), unless relief of symptoms is secured sooner; because, in the first place, few intracranial syphilomas are permanently influenced by medication, and, secondly, other forms of tumor may undergo temporary regression under antisyphilitic treatment, only to cause

renewed symptoms later. Moreover, it is quite characteristic of the intracranial lesions of syphilis to undergo spontaneous retrogression and recrudescence, even in the absence of treatment. Lumbar puncture may aid the diagnosis by showing the constant lymphocytosis so characteristic of syphilis, or by revealing the tuberculous nature of the affection by appropriate pathological methods. Nothing certain can be said of the diagnosis of glioma, endothelioma, sarcoma, etc.

3. *The Site of the Tumor.*—If in the *frontal lobe* no localizing symptoms will be recognized, but there may be certain alterations in intellect appreciable by the patient's family or intimates. Frontal lobe tumors often are found at autopsy on the insane. A certain degree of incoördination may be present, affecting the equilibrium in standing or walking, and causing resemblance to cerebellar tumors. A tumor in the *motor area* (anterior to the Rolandic fissure) will produce first Jacksonian epilepsy (p. 590), and later motor paralysis of the opposite side, first of the centres nearest the growth, and later of the entire motor cortex of the hemisphere involved. In the *parietal lobe* (just posterior to the fissure of Rolando) sensory disturbances (such as loss of muscle sense, posture sense, etc., or word blindness) will precede Jacksonian fits and loss of motion, which latter phenomena will result when the tumor reaches such a size as to press upon the cortex or subcortical fibres in front of the fissure of Rolando. A tumor in the superior parietal convolution may cause astereognosis. A tumor of the *occipital lobe*, or posterior part of the parietal lobe, should be suspected if vision is affected early (homonymous hemianopsia, sometimes preceded by visual hallucinations, such as flashes of light, seeing objects upside down, etc.). Tumors in the *temporosphenoidal lobe* give rise to deafness, loss of taste and smell, and the convulsions which occur often are preceded by a sensory aura. Tumors at the *base of the brain* are particularly characterized by paralysis of the different cranial nerves, as well as by hemiplegia, hemianesthesia, etc. Tumors of the *hypophysis cerebri* may produce symptoms of hyperpituitarism (gigantism in infants, acromegaly in adults) or of hypopituitarism (adiposity, with infantilism in children, and loss of sexual characteristics in adults), according as the anterior or posterior portions of the hypophysis are involved; in either case, the general symptoms of brain tumor are present, together with bitemporal hemianopsia from pressure on the optic chiasm. A good skiagraph may demonstrate increase in size of the sella turcica. *Subtentorial tumors* may be within the cerebellum or may grow from the meninges. The general symptoms occur early, and are constant and severe; and in addition to the cardinal symptoms of brain tumor already mentioned, these subtentorial growths are characterized especially by vertigo, cerebellar ataxia, nystagmus, etc. Most symptoms occur on the same side as the lesion. Of the *extracerebellar tumors* those growing in the *cerebellopontine* angle are most frequent; usually they are fibromas, growing from the sheath of the

eighth cranial nerve, and cause persistent tinnitus aurium, and deafness of the same side; while at a later stage they cause paralysis of the fifth, sixth, and seventh nerves, and may finally simulate tumors within the cerebellum (Fig. 625). They are lightly attached by a small pedicle, and usually can be enucleated easily. *Intracerebellar tumors* are characterized by the early development of vertigo, changes in the eye-grounds (sometimes blindness before papilledema), and sensations of motion of self or of surrounding objects; the head is tilted, usually toward the side of the lesion, and there is staggering gait, with tendency to fall constantly in one direction, often toward the side of the lesion. The ataxia is not increased by shutting the eyes. It is more marked in tumors of the vermis than in those of the hemispheres. Tumors of the *pons and medulla* are rapidly fatal, are not amenable to operative treatment, and often cannot be distinguished from cerebellar growths.

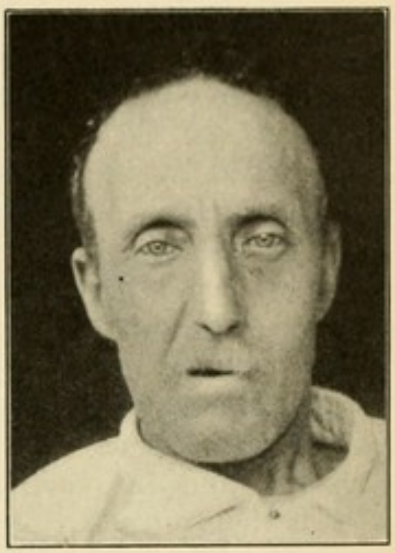

FIG. 625. — Tumor in right cerebello-pontine angle. Age forty-nine years. Symptoms began two or three years ago; worse for last six to eight months, since which time there have developed ataxia, deafness, facial paralysis, and loss of eyesight. (Paralysis of sixth, seventh, eighth nerves, paresis of ninth, and double choked disk.) (Dr. F. W. Sinkler's patient.) Orthopædic Hospital.

Treatment.—An untreated brain tumor uniformly leads to death. Purely medical treatment is ineffective even in controlling the most distressing symptoms, pain and blindness. Operation, merely by removing the overlying cranium and thus relieving the brain of pressure (*decompression*) may cause disappearance of all symptoms for an indefinite period, even restoring sight; and in some cases the tumor can be removed, effectually curing the patient. A radical operation, including removal of the tumor, of course, always is to be preferred; but when an unlocalized tumor exists, making its presence known only by the "syndrome of brain tumor," the surgeon should not hesitate to relieve the headache, check the vomiting, and prevent the development of blindness or possibly to restore sight which has failed, by means of the palliative operation. This operation also is employed when a tumor is found which cannot be removed, either because of its situation, its size, or its infiltrating character.

A tumor in one of the *cerebral hemispheres* is exposed by the formation of a bone-flap (the so-called osteoplastic craniotomy, p. 586), the bone being replaced after the removal of the tumor. If no tumor is found, or if it cannot be removed safely, the bone is removed from the flap, thus converting the operation into one of decompression. Indeed, Horsley never replaces the bone-flap even after the tumor has been successfully removed. But where decompression is planned in advance, the subtemporal operation of Cushing is to be preferred

(p. 590). A tumor *beneath the tentorium* is exposed by removal of bone from one or both occipital fossæ; and the bone is not replaced. A tumor of the *hypophysis* grows either toward the brain, or toward the vault of the pharynx; this usually may be determined by skiagraphy. If the tumor appears accessible from within the cranium, it is best approached across the anterior fossa of the skull, by means of a *frontal* bone-flap, according to Frazier's modification of McArthur's method (1912): a large bone-flap with external base is elevated from the right frontal region, and the supra-orbital margin and roof of the orbit are temporarily resected. The dura covering the frontal lobe is then elevated from the base of the anterior fossa, and is incised directly over the pituitary body. The sella turcica may also be approached by the *lateral route*, elevating the temporal lobe from the base of the skull after removal of nearly the entire side of the calvaria (Horsley); or by the *naso-frontal route* of Giordano, employed by Schloffer (1907), and von Eiselsberg (1910); or by the *infra-nasal method* of Kanavel (1909), employed by Halstead (1910) and by Mixter (1910). In Halstead's operations a preliminary tracheotomy was done, and the pharynx was tamponed. Raising the upper lip, an incision is made through the mucous membrane of the superior alveolus, and the cartilaginous septum of the nose is divided. The nose is then retracted upward. After the bony septum and turbinates have been excised, the anterior wall of the sphenoidal sinus is exposed at the bottom of the wound. This wall being broken through, the posterior wall is identified. This lies at a distance of from 70 to 83 mm. from the anterior nasal spine, and often is thinned by the growth of the tumor within the sella turcica. As soon as the latter cavity is opened, the tumor tissue, which usually is fluid, is evacuated and the cavity is lightly curetted. The tumor cavity and the entire wound are then packed with iodoform gauze, which emerges through the nostrils; the nose is replaced and retained by a suture or two, and finally the alveolar mucous membrane is sutured.

Osteoplastic Craniotomy, or *Temporary Resection of the Skull for Brain Tumor.*—The strictest aseptic technique is requisite. Hemorrhage from the scalp may be controlled by an elastic band passed around the occipito-frontal circumference of the head. The "head-high" position lessens venous congestion. A skin-flap is outlined with a narrow base in the temporal region, the flap being so situated as to overlie the supposed site of the tumor. The tissues of the scalp are not separated from the underlying bone, which is cut through in the same lines as the skin incision. Various methods are employed for dividing the bone: Frazier makes a trephine opening at each side of the base of the flap, and cuts the margins of the bone-flap by Cryer's spiral osteotome (1897), which is a side-cutting rotatory fraise, propelled by a dental engine (Fig. 626); Cushing drills holes in the bone at the four corners of the bone-flap, and divides the bone along the top and each side of the quadrangular flap by means of the Gigli wire saw (1897), which cuts from within outward (Fig. 627);

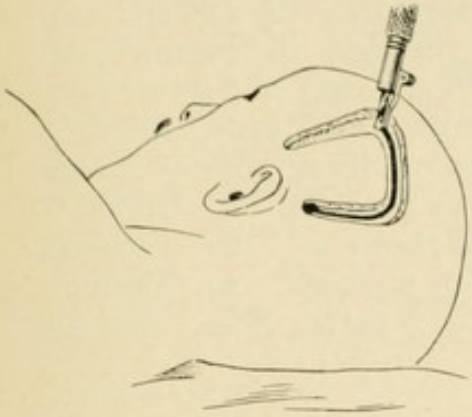

FIG. 626.—Cutting the bone-flap by means of Cryer's spiral osteotome.

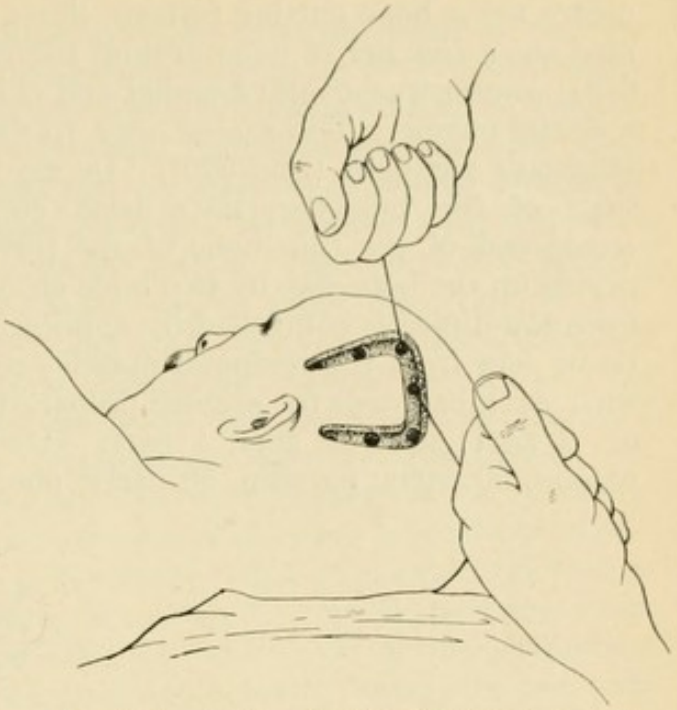

FIG. 627.—Cutting the bone-flap by means of the Gigli wire saw. (See Fig. 486.)

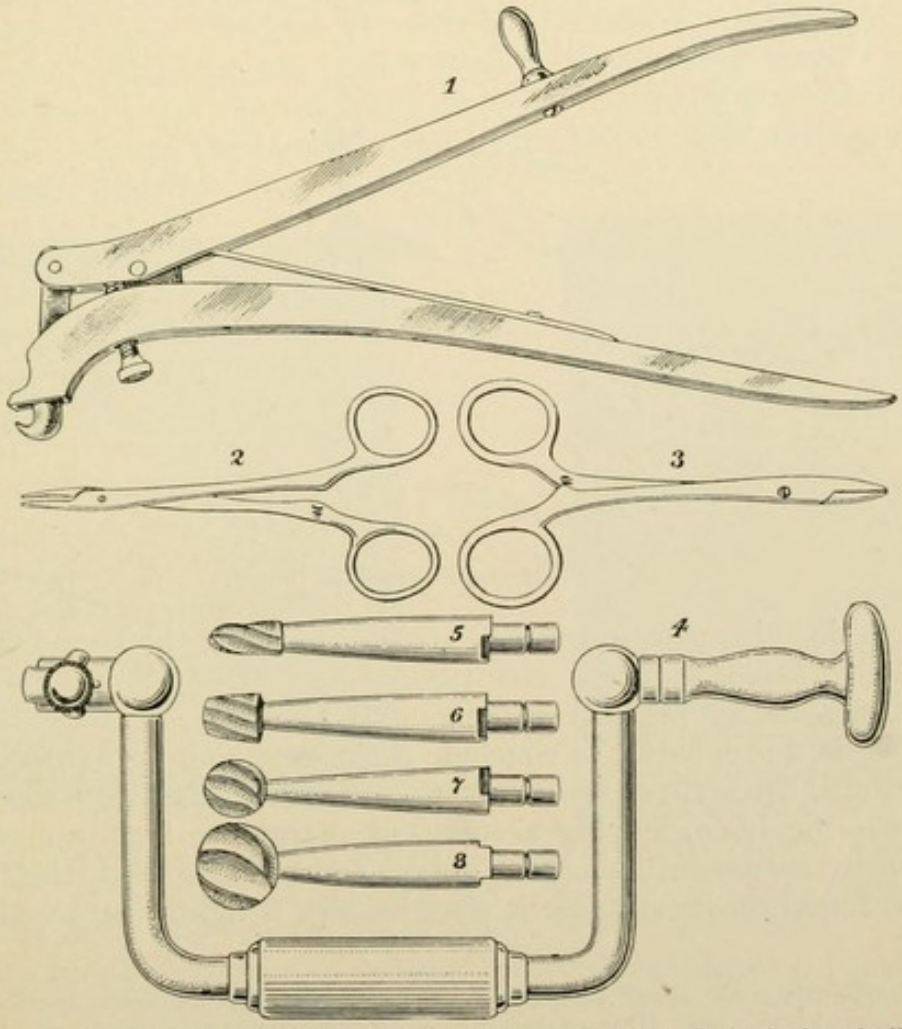

FIG. 628.—Instruments used in making an osteoplastic flap of the skull: 1, De Vilbiss's forceps; 2, mosquito hemostat; 3, ordinary hemostat; 4, Hudson's trephine (see p. 563), with four bits: 5, the perforator; 6, 7, 8, burrs to enlarge the original perforation. (See Fig. 629.)

others use a bone cutting forceps, like a very narrow rongeur, which nips out a channel of bone around the margin of the bone-flap (Fig. 628); some surgeons use a mallet and chisel, or a circular saw run by a dental engine. The easiest way to drill the holes is by means of Hudson's trephine (Fig. 629). In any case, after the top and two sides of the bone-flap have been cut through, its narrow base (composed of the thin bone of the temporal fossa) is fractured by prying up the bone-flap by two bone elevators (Fig. 614, 3). Bleeding from the diploë is controlled by application of minute slips of muscle tissue (cut from the temporal muscle) or by plugging with Horsley's wax. Archibald uses the original preparation: beeswax, 7 parts; almond oil, 1 part; salicylic acid, 1 part. Hartley preferred this formula: vaselin, 50 parts; paraffin, 50 parts; phenyl, 5 parts. Some surgeons

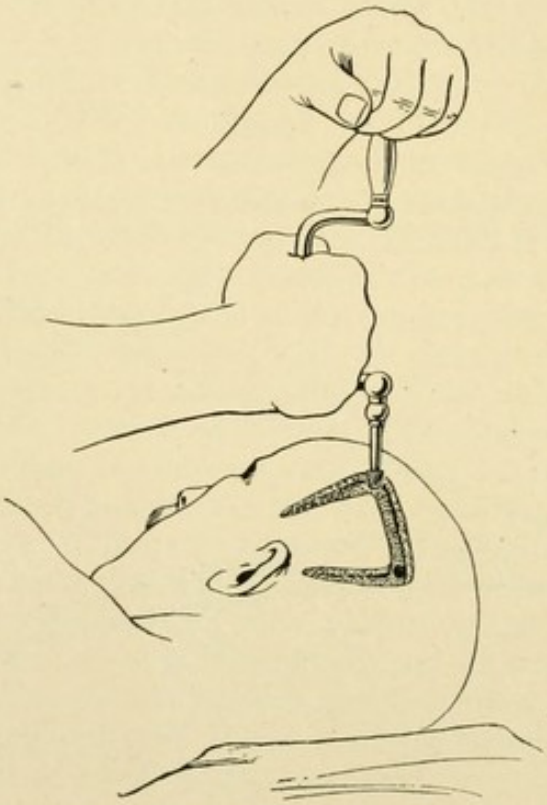

FIG. 629.—Hudson's trephine in use.

prefer to do this operation in two stages, replacing the bone-flap and postponing exploration for the tumor until some days later; but unless unexpected difficulty or delay has attended the formation of the bone-flap, it is better to conclude the operation in one sitting.[1]

The dura, being thus exposed over a wide area, is incised concentrically with the bone, leaving a sufficient margin to facilitate closing it again by suture. When the cerebral cortex is exposed, the tumor may be found on its surface; it then usually is lightly attached, and

[1] Cushing has found that the second stage of such an operation may be conducted without the use of any anesthetic, except "primary anesthesia" for suturing the skin-flap at the end of the operation, since the dura and cortex are totally insensitive to gentle manipulation.

may be enucleated. If no tumor is visible, it is justifiable to explore the subcortical region. It is extremely important to control hemorrhage from the pial vessels; any bleeding points should be caught in mosquito hemostats (Fig. 628) and ligated or sutured with very fine silk. Sometimes it is sufficient to apply minute slips of muscle tissue. To explore the subcortical region an incision with scalpel is made in the middle of a convolution free of vessels, and if an encapsulated tumor is found it is shelled out by blunt dissection; a cyst should be evacuated and its lining wall removed if this is possible without trauma. A diffusely infiltrating growth should not be removed. I have seen a surgeon scoop out spoonful after spoonful of tissue from one cerebral hemisphere which was pronounced by several distinguished neurologists who were present to be typically gliomatous in appearance; yet microscopical study proved the tissue removed to be normal cerebral substance, while at autopsy the tumor was found in a totally different part of the brain. Hemorrhage from the brain substance is controlled by extremely gentle irrigation with hot (115° to 120° F.) saline solution, or by light pressure with pledgets of dry absorbent cotton, or the application of muscle tissue. The dural flap is then sutured as accurately as possible; the bone-flap is replaced, and the skin is sutured tightly with closely set interrupted sutures of silkworm gut, which control all bleeding from the scalp. Never hurry, and use only extremely gentle manipulations in brain surgery. Keep the wound free from blood, and avoid drainage whenever possible.

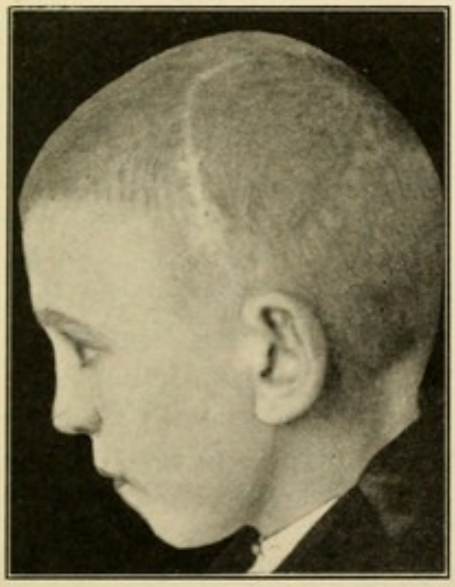

FIG. 630.—Cicatrix of operation by osteoplastic flap, for middle meningeal hemorrhage. Age fourteen years. (Dr. Frazier's case.) Episcopal Hospital.



FIG. 631. — Hernia cerebri three months after operation for cerebral tumor. (Dr. W. J. Taylor's case.) Orthopædic Hospital.

Decompressive Operation for Brain Tumor.—As stated already, an osteoplastic craniotomy may be converted into a decompressive operation by removal of bone from the flap, replacing only the tissues

of the scalp. The dural flap which has been turned down for the purpose of exploration, is replaced but is not sutured, and the brain bulges into the opening, relieving the intracranial pressure, and is covered only by the tightly sutured scalp. Such a protrusion, known as hernia cerebri, may be very unsightly (Fig. 631), and as the tumor continues to grow the hernia may become immense, and may cause sloughing of the overlying scalp, with secondary infection of the cerebral substance. A better operation, when decompression is planned in advance, is the *subtemporal decompressive operation* of Cushing: in this a flap of skin is turned down over the temporal fossa, exposing the temporal muscle covered by its aponeurosis; these structures are then divided down to the bone in a straight line parallel to the muscular fibres, from temporal ridge to zygoma; by retracting the muscle a fairly large area of cranium is exposed; this is trephined, and the opening is enlarged by rongeur forceps and the dura is incised around the margin of the skull opening. The muscle and the skin-flap are then sutured, without drainage. The hernia cerebri, which results, protrudes beneath the temporal muscle, which acts as support, rendering the deformity much less conspicuous. Frazier employs a similar decompressive operation on the occipital bone, in cases of inoperable cerebellar tumors. It may be impossible to close the scalp, in some cases of inoperable brain tumor, after decompression has been accomplished, owing to the protrusion of the hernia cerebri; but if necessary this may be diminished by elevating the patient's head, or even by lumbar or ventricular puncture.

Patients may live for months or years after a decompressive operation, being symptomatically relieved until rapid death results from some incurable complication.

Fungus Cerebri should be distinguished from *hernia cerebri*, mentioned above. The former is an old term which it is convenient to retain to describe granulations ("proud flesh") springing from cerebral substance exposed in a wound, and developing as the result of infection. Fungus cerebri may occur in cases of compound fracture, with rupture of the dura and protrusion of brain substance; or in cases of hernia cerebri secondarily infected from sloughing of the overlying scalp. The treatment consists in antiseptic and astringent applications, of which alcohol is the most effective. This gradually causes the granulations to shrivel up. If the fungus is cut off with scissors it will soon return unless the infection is controlled and the wound begins to cicatrize and contract.

Focal or Jacksonian Epilepsy, named after Hughlings Jackson, who particularly studied the condition in 1873, was referred to at p. 584, as an occasional symptom of brain tumor. It is characterized by convulsive attacks beginning in one muscle or group of muscles, gradually spreading until finally a generalized convulsion ensues. Consciousness may persist until the convulsions become general, or it may not be lost at all. It is thus distinguished from ordinary ("idiopathic") epilepsy, in which the fits are general from the first,

and in which unconsciousness ushers in the attack.[1] Jacksonian epilepsy is believed to be due either to some localized cortical lesion, or, rarely (and then most often in children and women), to some peripheral sensory irritation, arising from a painful cicatrix or other lesion such as eye-strain, dental disorders, genital affections, etc.

In cases due to cortical lesion the most frequent cause, apart from tumor, is the result of old trauma; this may have been a depressed fracture, or a meningeal hemorrhage producing a meningo-cortical adhesion, a cyst, or a cicatrix. Similar lesions may be the result of intracranial infections, especially in children, in whom focal epilepsy may develop after an attack of meningitis, poliomyelitis, etc.

Treatment.—As there is no medical cure for these cases, it is perfectly justifiable to consider what benefits may be gained from surgical intervention if a definite lesion can be located. Nor should the surgeon hesitate to operate for any surgical condition in another part of the body in an epileptic patient merely because occasional fits occur; for it happens occasionally that cure of a lesion not suspected of having any causal relation with the epilepsy results in freedom from, or at least in a lessening in frequency of the convulsions.

If a meningeal or cortical lesion is suspected, the centre controlling the muscle group first affected is exposed by an osteoplastic flap. Depressed bone is removed; adherent dura is excised, and the reformation of adhesion is prevented by the interposition of Cargile membrane, silver foil, or similar substance. Free transplants of fascia lata have been used with success. Little can be done for lesions in the cerebral substance. The proper centre may be identified by faradization of the cortex. Kocher (1899) believed a decompression operation alone was of benefit. The sooner any operation is done after the development of focal epilepsy, the more apt is it to be curative; and if all head injuries received efficient treatment at the time of the original accident, the number of cases of Jacksonian epilepsy would be much decreased.

[1] Advances in knowledge constantly are diminishing the number of cases of true "idiopathic" epilepsy, and it is not impossible that only our ignorance prevents a recognition of an organic lesion in all such cases.

CHAPTER XVIII.

SURGERY OF THE SPINE.

Spina Bifida, or Hydrorrachis.—Under these names are included several forms of congenital malformation of the spine, due to failure of proper coalescence in the embryonal medullary plates. *Myelocele,* or *Rachischisis,* is the most complete form. In this the skin is deficient, and there is exposed on the back of the infant, usually in the lumbar region, a dark red area covered by endothelium, which is continuous above and below with the central canal of the spinal cord. The infant often presents other serious malformations, and usually is stillborn or dies within a few days from continual leakage of cerebrospinal fluid, or from infection. *Syringomyelocele:* Here the central canal of the spinal chord is distended with fluid, the surrounding chord is compressed and atrophic, and protrudes as a cystic tumor through a defect in the vertebral laminæ. The protrusion, which is covered by skin, or membrane, usually occurs to one side, and not in the midline. *Meningomyelocele* is by far the commonest of these deformities, occurring in nearly two-thirds of all cases of spina bifida. The cystic protrusion is formed by fluid which collects in the meshes of the arachnoid, and the roots of the spinal nerves are spread out over the walls of the sac. If the sac presents a dimple or furrow on its surface it is probable that the cord itself is adherent. The laminæ of one or several vertebræ may be deficient. *Meningocele,* in which the protrusion involves only the spinal membranes, and never the nerve roots or the cord itself, occurs only in about 8 per cent. of cases. The tumor is small, covered throughout with healthy skin, never presents a dimple or a furrow, and usually is more or less pedunculated, its orifice of communication with the spinal canal being small. In meningomyelocele, on the contrary, the protrusion is large, sessile, and communicates with the spinal canal through a large defect; and while healthy skin may extend upward from its base some distance, the summit of the protrusion usually is covered by membrane which easily becomes inflamed and sloughing is frequent. Paralysis of the parts below the tumor points to a condition of meningomyelocele rather than of pure meningocele. If there is a defect in the bony wall of the vertebral canal, without the protrusion of any of its contents, the condition is known as *Spina Bifida Occulta;* this usually is accompanied by hypertrichosis of the region affected. In very rare cases there has been a defect in the anterior portions of the vertebral canal, constituting *Spina Bifida Anterior.*

Symptoms.—Besides the presence of a cystic growth, usually in the lumbar or sacral regions of the spine, it may be possible to ascertain

by palpation or skiagraphic examination that a defect exists in the vertebræ. Compression of the spina bifida usually causes increased tension in the cranial fontanelles, and may produce convulsions. Tension of the cyst is increased during expiration, and when the child is in the upright position.

Treatment.—1. *If there are other serious malformations*, or *extensive paralysis*, no radical treatment should be adopted, as most of these patients will die within the first year under any circumstances. Efforts to avoid infection should be made, by preventing excoriation of the sac. If such patients survive more than five years, operative treatment, as detailed below, will be proper. 2. *If there are no other serious malformations and no paralyses*, the treatment to be adopted depends upon the condition of the coverings of the spina bifida: when these are healthy, as in most cases of pure meningocele, operation should be postponed until the child is five years of age; when the coverings are thin or membranous, the risk from delay is as great as, if not greater than that from early aseptic operation. Immediate operation may be required at any time for rupture of the sac, but when a choice is possible, operation during the second or third month of life is to be preferred (Lovett, 1907).

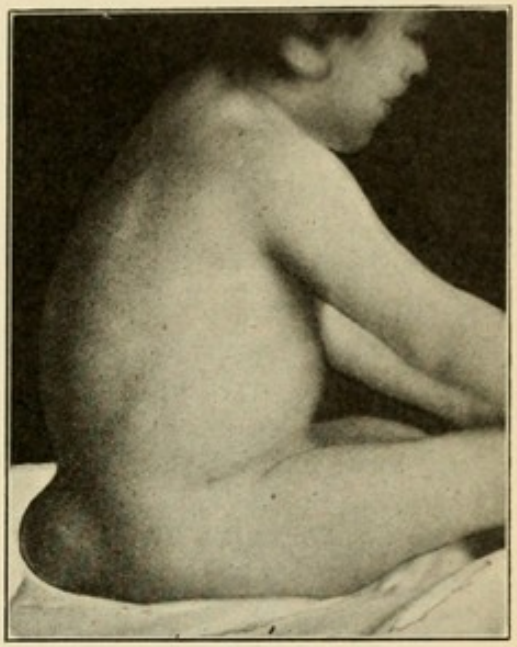

FIG. 632.—Spina bifida. Age eighteen months. Orthopædic Hospital.

Operation usually consists in excision of the sac, preserving healthy skin coverings, and carefully dissecting free adherent nerves, but cutting away those that cannot be preserved, as they probably are functionless (Carson). The sac walls are then overlapped, as in radical cure of umbilical hernia, and the muscles and skin are sutured in separate layers, and the wound is closed tightly without drainage. The death rate following operation is from 25 to 35 per cent., and hydrocephalus sometimes develops as a result. Reference was made at p. 556 to Heile's employment of drainage of the sac into the peritoneal cavity by means of subcutaneous silk threads, with coincident cure of a complicating hydrocephalus.

Sacro-coccygeal Tumors.—See Chapter IV.

INJURIES OF THE SPINE.

Strains.—Strains of the back, affecting the muscular and aponeurotic structures, are much more frequent than true **sprains** affecting the spinal joints. According to the severity of the injury, these patients

are to be treated by rest in bed, or as ambulatory cases, support being provided during the painful stages by adhesive plaster strapping or plaster of Paris jackets. Restoration of function may be aided later by massage.

Sprain-fracture.—Sprain-fracture of the transverse processes of the lumbar vertebræ, unilateral, occasionally occurs from muscular action. Tanton (1910) has collected 17 cases of this injury. Skillern (1913) has reported a case of sprain-fracture of a spinous process.

Static Lesions of the Lumbar Spine and **Spondylolisthesis** are discussed in Chapter XVI.

Concussion of the Spinal Cord.—This term has been used to define a condition supposed to be more or less analogous to concussion of the brain (p. 569). It implies that there has been injury to the spinal cord without lesion of the vertebral column; and while some hold that the symptoms which follow a supposed injury have no pathological basis for their existence, being merely one form of neurosis, other authorities believe that actual changes in the cord have taken place, and have left more or less irreparable damage. Many of these patients receive their injury in railroad accidents, and the condition which ensues is popularly known as "Railway Spine," or, because of the improvement which usually follows the settlement of a suit for damages, as "Litigation Spine." As a matter of fact it is probable that most of these cases should be considered severe strains or sprains of the back, and the surgical treatment is the same. For the hysterical symptoms which sometimes ensue, the patients should be referred to a neurologist.

Hematomyelia.—Hematomyelia, or hemorrhage into the substance of the spinal cord, sometimes occurs from sudden twists or angulations of the vertebral column, perhaps from a self-reduced subluxation, without discoverable gross lesion of the spinal column. It is seen oftenest in the lower cervical region (Thorburn, 1889), and causes paralysis depending upon the extent of the lesion. Usually the lower extremities recover from the paralysis more or less rapidly, though they may remain spastic, while the flaccid paralysis of the upper extremities continues. There is dissociated anesthesia below the level of the lesion: that is, while tactile sensation is preserved, temperature and pain sense are diminished or lost. Spinal puncture shows no blood in the cerebrospinal fluid.

Stab Wounds.—Stab wounds, involving the spinal cord are very rare. From unilateral lesion a monoplegia may result. It is best in civil life to explore such wounds, by laminectomy (p. 601), as it may be possible to repair the injury.

Fractures and Dislocations of the Spinal Column.—Fracture and dislocation occur as a combined lesion in about 60 per cent. of cases of injury of the spinal column, while isolated fractures and dislocations form each about 20 per cent. of these injuries. The spine is most subject to injury where its mobile and immobile portions meet, that is, in the lower cervical and the dorso-lumbar regions. Pure

dislocations are very rare except in the cervical region, as the form of the articular processes renders fracture almost a necessary complication in other portions of the vertebral column. Fractures of the laminæ or spinous processes usually occur from direct violence, as in gunshot wounds, or in falls from a height directly upon the back, impinging on a stone, fence rail, etc. The most common lesion is a crushing fracture of the bodies of one or more vertebræ, attended by forward dislocation of the vertebra next above, the disjunction of the articular processes taking place on one or both sides (Fig. 633). Such cases generally are caused by sudden hyperflexion, with twist, of the spinal column, as falls from a height on to the feet or the buttocks, crushing injuries from above acting upon the shoulders, or from a dive into shallow water. Violence acting upon the head or neck usually produces a lesion in the lower cervical region, and that acting from below determines lesions in the dorso-lumbar portion of the spine.

Fig. 633.—Fracture dislocation of eleventh and twelfth thoracic vertebræ. From a specimen in the Mütter Museum of the College of Physicians of Philadelphia.

Symptoms.—These may be divided into those due to injury of the vertebral column, and those caused by accompanying lesions of the spinal cord. It is said that the cord escapes injury in about one-third of the cases.

Symptoms from Injury of the Vertebral Column.—Of these, *deformity* is of most value. This may consist in a *depression* at the point of injury, especially when the fracture is from direct violence, the spines and laminæ being driven forward; or it may indicate that there is a partial forward dislocation of the vertebra whose spine is depressed. Such a depression is most apt to be found in a dorso-lumbar injury. In some cases there is *angular deformity*, a well defined kyphos existing

at the point of injury and indicating the collapse of a vertebral body, causing separation of the spinous processes. *Rotatory deformity* is seen oftenest in the cervical region, in cases of unilateral dislocation: the head is twisted away from the side which is luxated, and this side may be unduly prominent; the sterno-mastoid muscle on the uninjured side is more tense than is that on the injured side. Other symptoms of fracture, such as mobility and crepitus, seldom are present; but persistent localized tenderness is very suggestive of vertebral injury, and in the cervical region muscular spasm, producing rigidity of the neck, is a very usual symptom, especially in lesions of the vertebræ without injury of the cord. A good skiagraph may be necessary to assure the diagnosis in obscure cases.

Symptoms from Injury of the Spinal Cord. Motor Symptoms.—Motor paralysis is the most striking and one of the most constant symptoms, and involves all the muscles below the seat of the lesion. Usually it follows the injury immediately, and then indicates extensive destruction of the cord, as a rule from crush due to displaced bone (Fig. 634). If the onset of the paralysis is delayed, it probably is the result of hemorrhage either within the cord (*hematomyelia*) or in the arachnoid spaces. The former has been considered above; in the latter, which is known as *hematorrachis*, paralysis of motion usually is more marked than is that of sensation, and gradually extends upward, perhaps in the course of a few hours. In all cases the primary paralysis is flaccid, and the patient is free from pain, at least in the early stages. If the paralysis becomes spastic very soon (12 to 24 hours) after the injury, and if the reflexes are present, it usually indicates only partial destruction of the cord, from contusion, pressure from displaced bone, hematorrachis, etc. Paralysis which first develops some days after a spinal injury usually is due to inflammatory exudation or blood-clot. But lumbar puncture rarely shows blood in the cerebrospinal fluid.

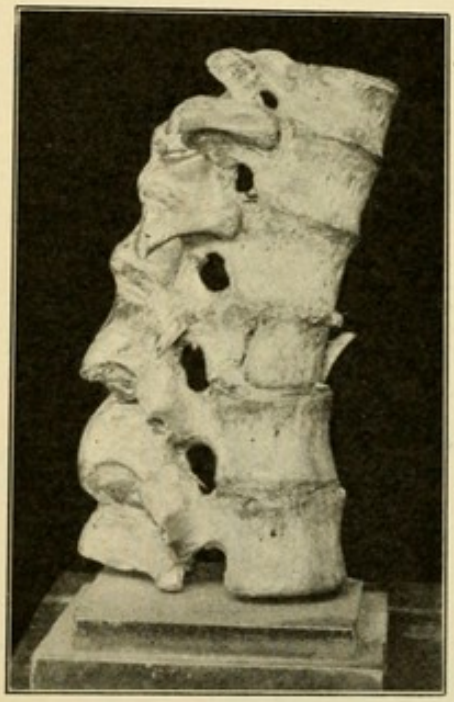

FIG. 634. — Crushing fracture of first lumbar vertebra. Mütter Museum.

In the cervical region, symptoms of cord injury may be obscured at first by those due to cerebral concussion, caused by the same injury. If the lesion is above the fourth cervical segment, causing paralysis of the diaphragm, immediate or rapid death is usual. Symptoms from paralysis of the cervical sympathetic may be present. Characteristic attitudes may be assumed owing to unopposed action of intact muscles (Fig. 635).

If the lesion is below the second lumbar vertebra, paralysis may be absent or only partial, owing to the fact that the spinal cord itself does not extend beyond this level, and the injury may involve only some of the branches of the cauda equina. In rare cases only unilateral (homolateral) paralysis may exist; this is much more usual in stab and gunshot wounds than in cases of fracture-dislocation.

At a later date (after a week or ten days) it is very usual for the patient to experience painful spasms in the paralyzed limbs; and as cicatricial changes in the cord progress the type of paralysis becomes spastic, and contractures develop (Fig. 244).

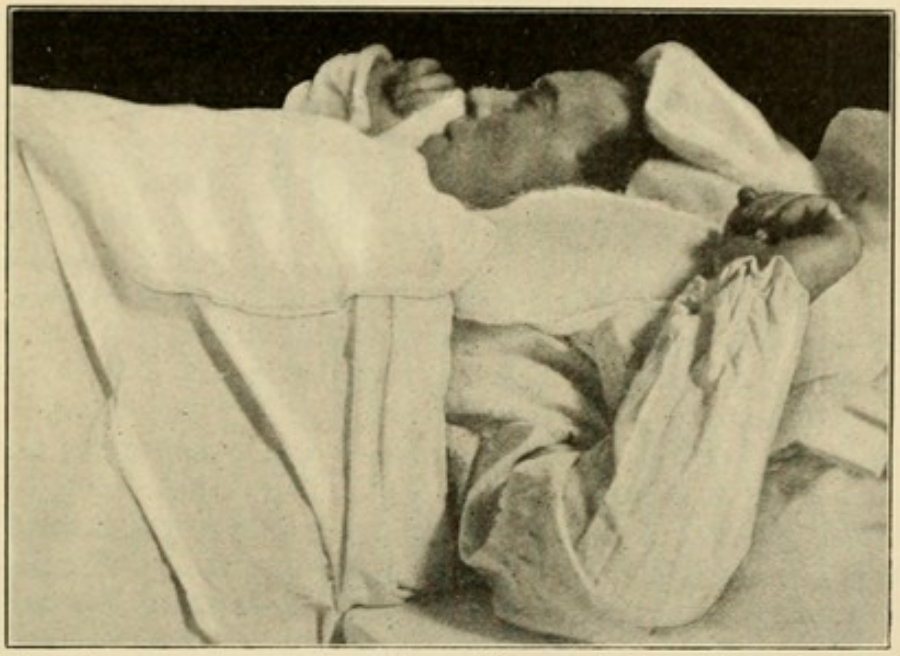

FIG. 635.—Fracture of cervical vertebræ. Characteristic position of arms when the lesion is above the fourth cervical segment. (Thorburn's position.) (See Fig. 636.) Episcopal Hospital.

Sensory Symptoms.—Sensation is lost over an area corresponding to that of paralysis of motion, and the upper limit of the motor and sensory paralysis is sharply defined, thus determining the level of the injury (Fig. 636). Pain rarely is severe, though a zone of hyperesthesia is not infrequent at the upper border of the anesthetic area. Shooting pains, from irritation of the sensory nerve roots, are more common in partial cord lesions, and often occur when recovery from severer lesions is beginning. Dissociated anesthesia, as already mentioned, is frequent in hematomyelia.

Bed-sores, especially over the sacrum and heels, are very prone to develop in cases of spinal injury, being described as due to trophoneurotic disturbances. Whatever is the true explanation, the probability of their early development (within two or three days) always should be borne in mind, and preventative measures instituted.

Abdominal and Vesical Symptoms.—Owing to the motor paralysis affecting the muscles of the abdominal wall, and perhaps the muscular tunics of the intestines, tympanites develops. If, as is usual, the lesion

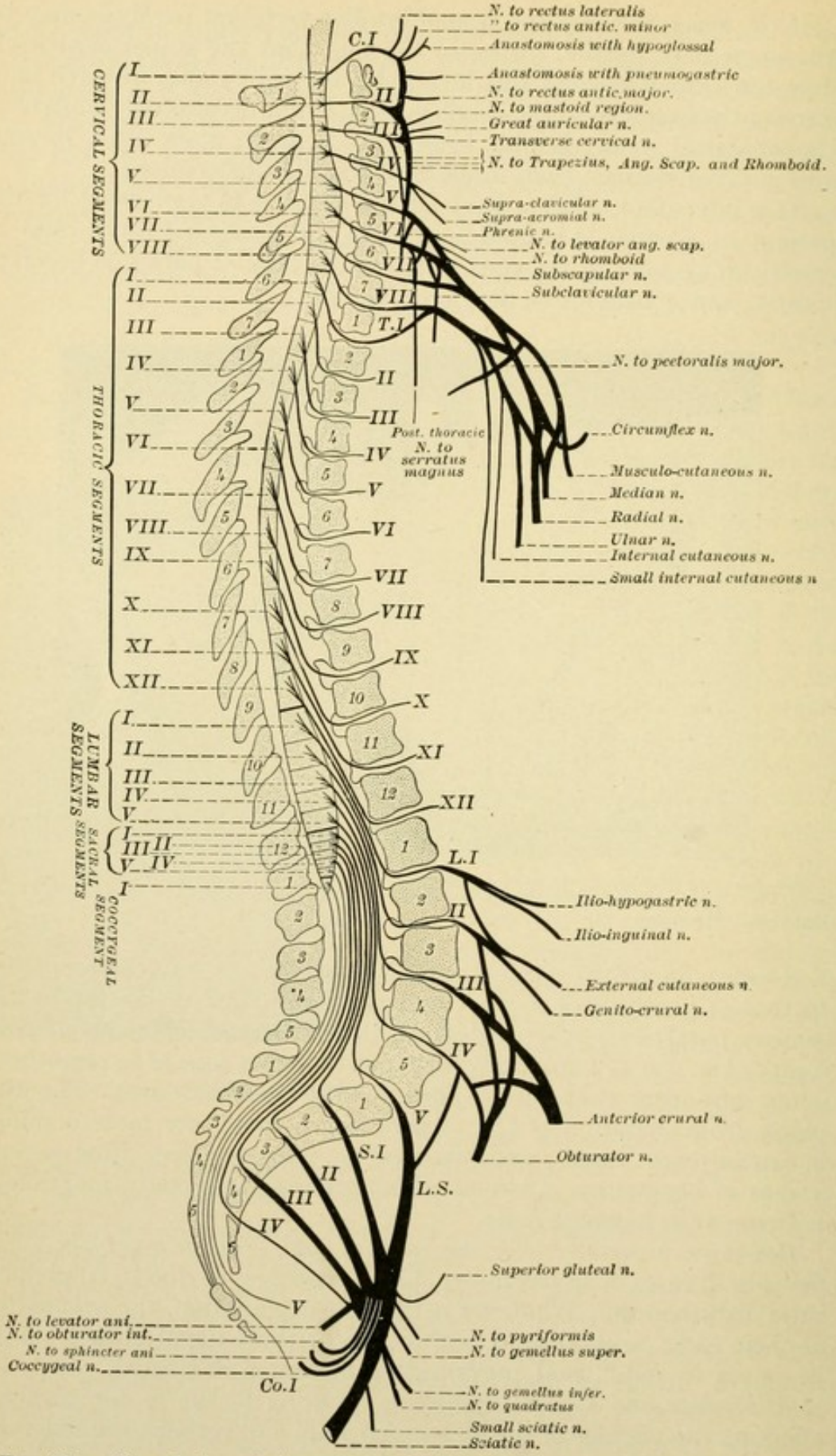

FIG. 636.—The relation of the segments of the spinal cord and their nerve roots to the bodies and spines of the vertebræ. (Dejerine et Thomas, Mal. d. l. Moelle Epinière, Paris 1902.)

is above the spinal centres for the bladder and rectum (in the second, third, and fourth sacral segments), there is *retention with overflow* of the urine and feces, as the voluntary impulses from the cerebrum cannot reach the spinal centres, and the sphincters remain tonically contracted until overflow occurs. The bladder becomes distended, and only the surplus urine dribbles away; feces accumulate in the rectum, and this is emptied only by enema, or finally by exhaustion of the sphincter. If, however, what is very rare, the lesion is so low as to damage these centres themselves, or the nerves between them and the bladder or rectum, then true *incontinence* of urine and feces occurs, the bladder remaining empty, while the urine and feces are passed involuntarily, and more or less continuously. *Cystitis* is very hard to prevent, as a consequence of the habitual use of the catheter which is required as long as retention persists. *Priapism*, occurring soon after the injury, is common, especially in younger patients, and is said to be more frequent in severe and high lesions than in those at a lower level, or those in which there is only partial destruction of the cord.

Prognosis.—It long has been a rule of thumb that when the fracture is in the cervical spine the patients will live a week, those with fracture of the thoracic spine a month, and those with fracture of the lumbar spine a year; and this may still be considered a fairly accurate prognosis when there is evidence of complete transverse lesion of the cord. But in the cervical region it is not unusual for the cord to escape injury, mainly owing to the large size of the spinal canal. J. and A. Boeckel (1911) have collected 36 such cases. In injuries of the thoracic and lumbar regions, life may be preserved indefinitely if such complications as bed-sores, cystitis, and pyonephrosis can be prevented; and if the cord is not totally destroyed, careful nursing may enable a certain amount of power to be regained.

Treatment.—No hesitancy should be felt in reducing any deformity present, especially in the cervical region; but this should be done judiciously, and with a clear idea of the mechanism of the injury. The fact that one or more such attempts have resulted in the patient's immediate death, demonstrated nothing, as pointed out by Malgaigne, as long ago as 1843, but that the attempts were unskilfully made by an incompetent person. In studying nearly 400 cases of spinal injury, John Ashhurst, Jr. (1867) found that in the treatment of dislocations in the cervical region the mortality had been nearly four times greater when no attempts were made to reduce the deformity, than when this was undertaken by extension, rotation, etc. Walton (1892) systematized the reduction of these injuries, omitting attempts at extension (longitudinal traction), which he demonstrated to be useless, and employing only "retro-lateral flexion and rotation," in the unilateral cervical dislocations, which are the most frequent cases. Reduction is accomplished, after etherizing the patient, in this manner: the surgeon stands behind the seated patient, and grasps the head between his hands; the head is then

tilted backward, and flexed slightly away from the dislocated side, so as to release the dislocated articular process from the intervertebral foramen of the vertebra next below, where it is usually caught. The head is then rotated so as to carry the dislocated side backward. Reduction of the deformity may be attended by an audible or palpable click. The patient should remain in bed, with the head and neck immobilized by plaster of Paris dressings, or by sand-bags with weight extension (as in cervical Pott's disease, p. 609) for a couple of weeks, and some retentive appliance should be worn for some weeks longer, or until the ruptured ligaments have had a chance to heal. Bilateral cervical dislocations may be reduced by the same method, applied to each side separately. The deformity from fracture, seldom present except in the thoracic and lumbar regions, usually is best corrected by hyperextension of the spine.

In every case with cord injury, the patient should be kept on a water bed, with head and foot extension, as in tuberculosis of the spine (p. 609); and the utmost care should be taken to prevent the development of bed-sores (p. 62). The bladder should be drained by an inlying catheter, if there is retention of urine; and the bowels generally have to be moved by enemas. In most cases nothing further can be done than to keep the patient comfortable by careful nursing. If life is preserved, efforts must be made to maintain the nutrition of the paralyzed parts by massage; the development of deformities from contractures (Fig. 244) should be guarded against, though these may be corrected later by tenotomies; and eventually such orthopedic apparatus as is indicated should be provided, as in this way patients otherwise nearly helpless may regain some power of locomotion.

The Question of Operation.—In cases where, after the first few days, it seems that the cord has not been completely destroyed—as evidenced by persistence of reflexes, early development of spasticity, with shooting pains, spasmodic contractions, etc.—it is justifiable to expose the injured cord by laminectomy, in the hope that evacuation of blood-clot (almost always extradural) or even the removal of counter-pressure on the cord by the laminæ and arches, may accelerate the cure. But it is in just such cases as these that a fair amount of improvement may occur without operation; yet as this cannot be certain beforehand, and as operation in such carefully selected cases does not increase the mortality, I think it should be employed. Very early operation (on the day of injury, if possible), is proper in all cases where the spines and laminæ have been driven inward against the cord by direct violence; since in such cases it is reasonably sure that the displaced fragments continue to compress the cord, or that hematorachis will develop later. The same is true of gunshot wounds of the vertebral column, in civil life, involving the arches; these should be treated by laminectomy and removal of displaced fragments, whether or not there are cord symptoms.

In other cases, with symptoms of complete transverse lesion, in most of which the osseous lesion is collapse of the vertebral bodies, it

is extremely probable that the cord has been crushed by the displaced bone at the time of the accident, but that there is no continuing pressure from the bone; and even did such pressure exist, it is extremely improbable that relief of the cord from it would in any way promote recovery of function.

It is argued by some that all fractures of the vertebræ should be treated by immediate operation, as in the case of fractures of the cranium. But the cases are not similar; for in fractures of the cranium we do not operate to repair damage to the brain (which is irreparable), but for the purpose of preventing infection, preventing or relieving intracranial pressure (from effused blood or displaced bone), or preventing the subsequent development of Jacksonian epilepsy. In the case of vertebral fractures, infection is very little to be feared, none of these fractures except those from gunshot wounds being compound; while intraspinal pressure, in the sense in which we speak of intracranial pressure, scarcely exists, save in the rare cases of rapidly ascending paralysis from hematorachis. In spinal fractures, therefore, operation should be undertaken, not to repair irreparable damage to the cord, but as indicated above only when it is probable that some extramedullary lesion (displaced bone, blood-clot) causing continuing pressure can be removed.

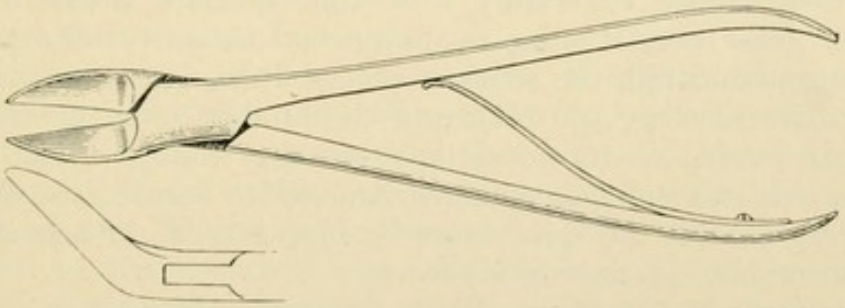

FIG. 637.—Large bone cutting forceps for laminectomy, with blades angled on the flat.

Laminectomy.—The patient lies prone. A skin-flap is turned aside, exposing the spinous processes, and the muscles are detached by blunt dissection from the laminæ of one side. Hemorhage, which is profuse, is readily controlled by pressure of hot gauze. Hemostats are useless. The laminæ of the other side are then cleared. When the requisite number of arches (usually three or four) have been thus exposed, the supraspinous ligament connecting the lower spinous processes is divided, and a large bone cutting forceps, with blades angled on the flat (Fig. 637), is passed into the opening and the requisite number of spinous processes is removed from below upward. A crown trephine is then employed to open the spinal canal, and the opening thus made is enlarged by rongeur forceps, biting away the laminæ as far as the articular processes. This method is quicker and safer than the use of chisel and mallet. When the wound is dry the dura is opened by a median longitudinal incision, allowing the cerebrospinal fluid to escape slowly. The cord is inspected, and spicules of

bone, blood-clot, etc., may then be removed. Usually it is not possible to tell from the appearance of the cord whether or not it is the seat of a complete transverse lesion. Some days or weeks after the injury the cord, above and below the lesion, may seem swollen. If the cord is completely severed, attempts should be made to suture it[1] with fine chromic catgut, introduced as mattress sutures with a fine curved needle. The dura should not be tightly sutured, and it usually is well to leave a gauze wick for drainage down to the dural surface. The wound is then closed in layers.

Traumatic Spondylitis (Kümmel, 1891).—Under this term is described a rarefying osteitis of the vertebræ, which develops after severe contusion or fracture, and gives rise to a gradually increasing kyphosis. Mauclaire and Burnier have recently (1912) collected one hundred such cases. In spinal injuries, long after-treatment (plaster of Paris jackets, body braces) is necessary to prevent the development of such a deformity. It is treated as is tuberculosis of the spine.

Osteomyelitis.—Osteomyelitis of the vertebræ is rare. Symptoms of general sepsis may obscure the local affection, so that this may not be detected until abscesses form, unless symptoms of compression of the spinal roots or the cord sooner call attention to the vertebral column. The mortality is about 60 per cent. The affected area should be exposed; almost invariably it is the vertebral bodies that are diseased. The cervical spine is approached by an incision posterior to the sterno-mastoid, the thoracic region by an operation known as costo-transversectomy (p. 614), and the lumbar spine by the retro-peritoneal route, as in operations on the kidney. The abscess is evacuated, and sufficient bone is removed to secure free drainage. If recovery ensues, the spine must be supported as in convalescence from tuberculosis of the vertebræ.

Tuberculosis of the Spine; Pott's Disease.[2]—More than one-third of the osseous lesions of tuberculosis are located in the vertebral column. Children, from two to ten years of age, are affected oftenest, and the disease is comparatively rare in adults. Two-thirds of the cases begin in children under five years of age. The lesions are situated almost exclusively in the vertebral bodies, and affect the thoracic vertebræ oftenest (over 50 per cent. of cases), and the cervical region least often (about 15 per cent.). Destruction of the vertebral bodies by caseous softening, with continuance of weight-bearing function, explains the development of various deformities. Cold abscesses are a notable feature of the disease, forming its most important complica-

[1] Harte and Stewart (1902) reported a case of suture of the spinal cord after excision of the damaged area (three-fourths of an inch in extent), caused by bullet wound; there was return of fair function in the paralyzed lower limbs. A. R. Allen (1911) has suggested immediate median longitudinal section (2 to 3 cm.) of the spinal cord in the area believed to be damaged, on the theory that paraplegia results from secondary compression from intramedullary edema rather than from actual destruction of the cord tissue by the original injury.

[2] Paraplegia resulting from this affection was first carefully studied by Percival Pott in 1779.

tion. Paraplegia, much less frequent, and probably no more serious in its results, is the other main complication.

Symptoms.—The first symptoms to attract attention may be mere listlessness, a desire to sit still and to hold on to the tables and chairs in walking around the room. Usually slight alterations in the gait, in the manner of stooping, etc., are observed very soon. The patient, like Agag in the presence of Samuel, walks "delicately," fearful to make any sudden movement lest the spine be jarred. The body may be held persistently to one side. In trying to pick anything off the floor, instead of stooping like the normal child, by flexing the lumbar spine and the pelvis, the patient holds the spine rigid and upright, and by flexing his knees and hips brings his buttocks almost in contact with the ground. In standing, the patient may lean forward and support his body by resting his hands on the thighs; in sitting he will prop himself up on his hands; and in disease of the cervical region may hold the chin in the hands and turn the whole body around, or merely roll his eyes, instead of turning his head. At night the child is restless, and sleep may be disturbed by starting pains, with their attendant night-cries (p. 479). "Belly-ache" often is one of the earliest complaints, being due to pain referred along the intercostal nerves. Pain occasionally is referred to the buttocks or the knees, when the lumbar spine is diseased.

Physical Examination, thorough and systematic, is indicated whenever any symptoms point to a possibility of spinal disease. Have all the patient's clothing removed, and let him walk barefoot to and fro, studying the gait in all aspects. Let him stoop forward, flexing the lumbar spine and pelvis, but keeping the knees extended, until the tips of the fingers touch the floor. Note any indications of discomfort so produced, and especially any break in the normal contour of the flexed spine, which should be one continuous curve. Muscular spasm, from underlying disease, will cause loss of this rounded contour, and the process of straightening up again may be attended by jerky movements. Then let the patient sit on the floor or on a firm couch, and bend his body well down between his fully flexed thighs, so as to flex the spine as far as possible; and note any irregularity in the contour. Then lay the patient prone, and gently elevate the feet in one hand, thus hyper-extending the spine (Fig. 638). Note here also any area which lacks normal flexibility, or which is painful. Then raise the head and shoulders from the bed, to test the flexibility of the cervical and upper thoracic spine in the same manner.

When typical deformity once has appeared, diagnosis is comparatively easy. But earlier types of deformity should be recognized when present. In the cervical spine, wry-neck may often be symptomatic of tuberculosis; in the thoracic region a posterior angular curvature (kyphosis) is nearly pathognomonic; and in the lumbar region an exaggerated lordosis, with protuberant abdomen, may first attract attention. Lateral deviation of the spine is seen chiefly in disease in the dorso-lumbar or lumbo-sacral regions (Fig. 639) and may

be due to unilateral spasm of the psoas, from incipient cold abscess. Careless observation may mistake this deviation for lateral curvature

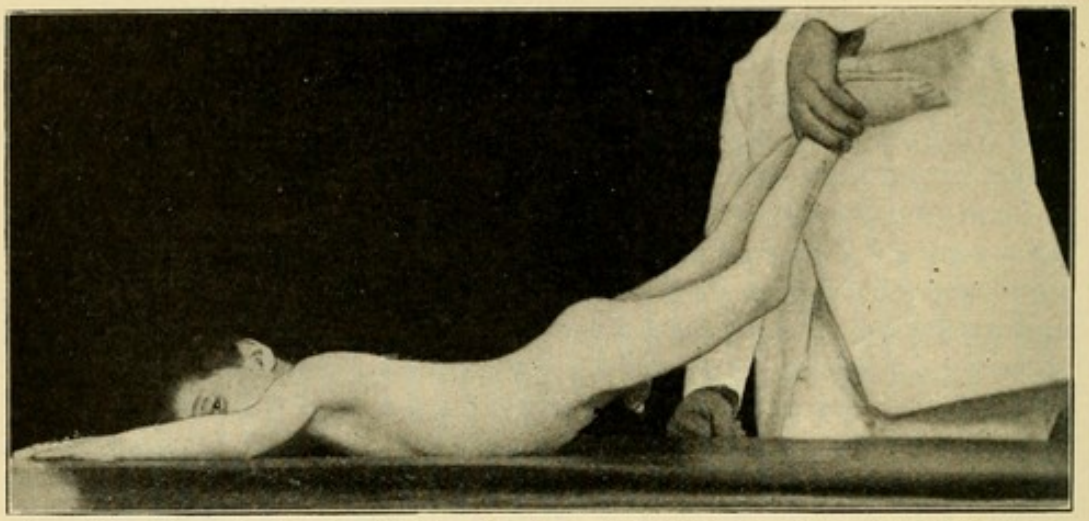

FIG. 638.—Examination for rigidity of spine in Pott's disease: the patient lies prone and the spine is hyperextended by raising the feet. Orthopædic Hospital.

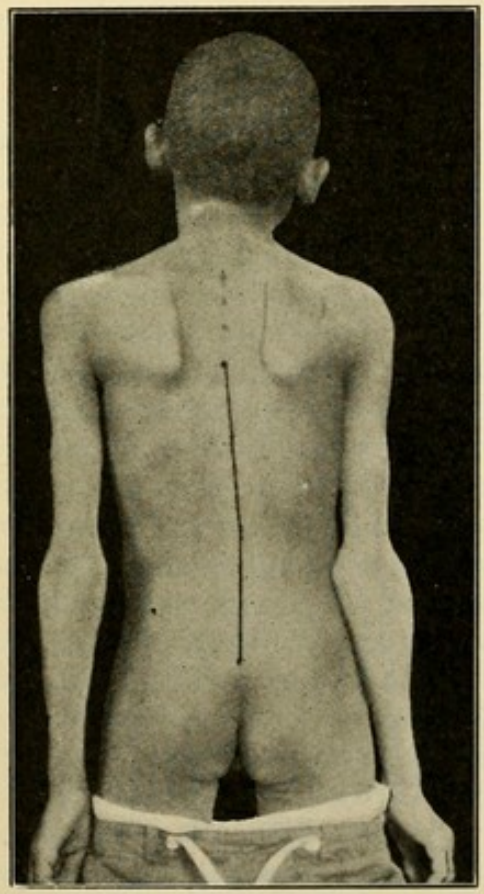

FIG. 639.—Pott's disease, showing lateral deviation to left. Age thirteen years. Duration seven months. Orthopædic Hospital.

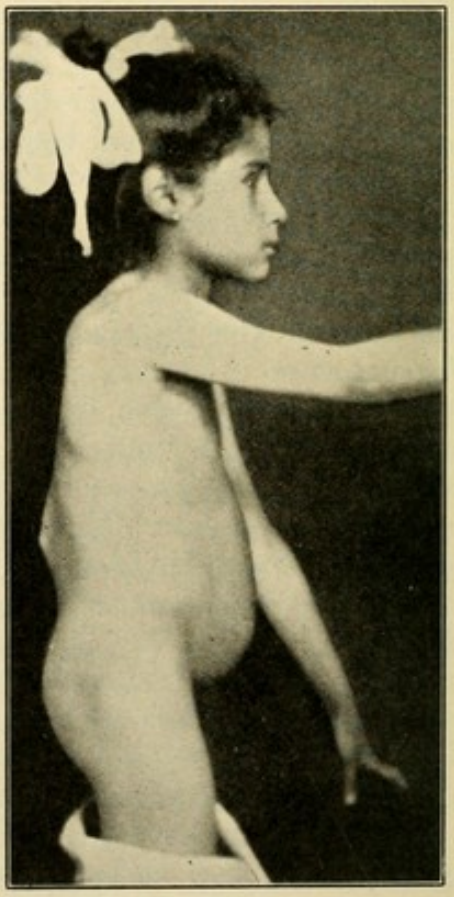

FIG. 640.—Pott's disease. Age seven years. Duration one year, showing angular kyphos. Orthopædic Hospital.

of the spine (p. 533); but pain usually is absent in the latter deformity, and physical examination will detect neither tenderness (abscess?) nor muscular spasm. In cases where the diagnosis remains doubtful,

the tuberculin test (p. 81) may be tried; and under any circumstances the patient should be kept under strict observation until further development of symptoms makes the diagnosis certain.

Deformity.—This requires further discussion. In the thoracic region, as already noted, the deformity is characteristically angular and sharp (Fig. 640); as the disease progresses the kyphos becomes more rounded (Fig. 641). In children it is rather an early development, and rarely is absent after the lapse of a few months. In adults, on the other hand, as the vertebral bodies contain much more calcareous matter, the disease may exist for many months, sometimes for years, before any noticeable kyphos develops. In low lumbar and sacral tuberculosis

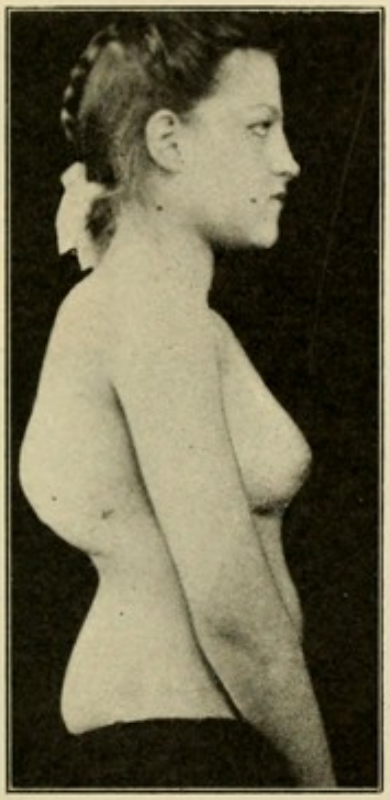

FIG. 641.—Old Pott's disease, age sixteen years; duration since three months old, showing rounded kyphos. Orthopædic Hospital.

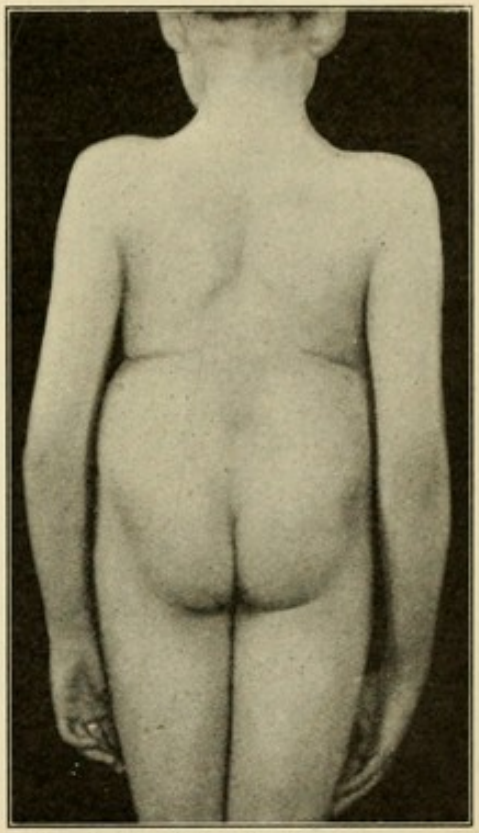

FIG. 642.—Old Pott's disease. Age twelve years; duration ten years. Showing stunting of patient's height. Orthopædic Hospital.

the deformity at any age is much less conspicuous than in the thoracic and cervical regions, and may manifest itself only in a stunting of the patient's height (Fig. 642). In the cervical and lumbar regions, where lordosis normally exists, the disease rarely causes more than an obliteration of this anterior concavity, rendering the affected spine straight. When a kyphos high in the thoracic region is well marked, a compensatory lumbar lordosis may develop, giving the patient a strutting, self-important air, while the lower ribs may be depressed until they rest on the iliac crests, markedly flattening the chest (Fig. 643). In dorso-lumbar disease, on the contrary, the ribs are elevated, marked "chicken-breast" develops, and the outlet of the pelvis may be much

contracted antero-posteriorly, owing to the rotation of the sacrum around a transverse axis (Fig. 641).

Abscess.—As the disease affects almost exclusively the bodies of the vertebræ, any cold abscess that develops will be found beneath the anterior common ligament. This structure prevents the pus from extending forward, with the result that it gravitates along various planes of fascia, and comes to the surface in rather typical locations. Only in the rare cases of disease of the vertebral arches is the abscess apt to point posteriorly, and then usually in the median line.

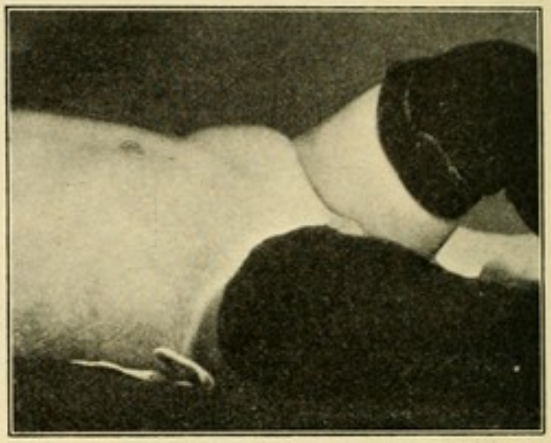

FIG. 644.—Psoas abscess from Pott's disease. Age three years; Pott's disease for one year; abscess for several months. Orthopædic Hospital.

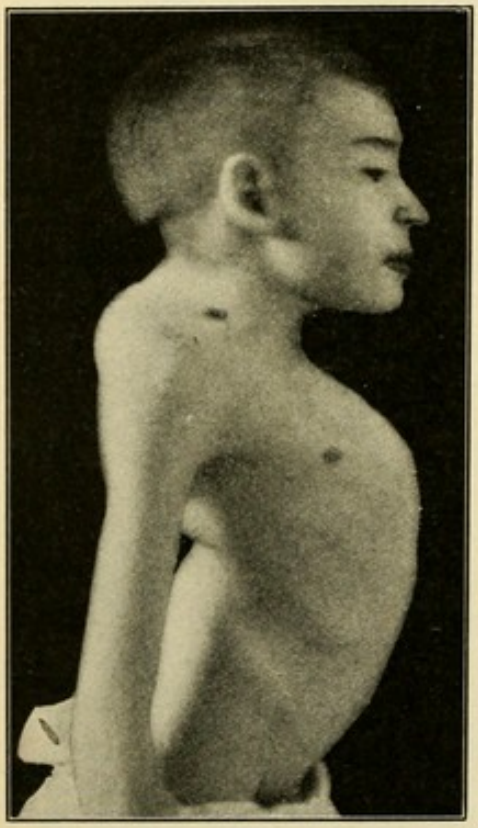

FIG. 643.—Cervico-dorsal Pott's disease with retro-pharyngeal abscess. Age twelve years; duration of disease ten years. Developed dyspnea and dysphagia; and sinus formed on right side of neck posterior to the sterno-mastoid muscle; through this sinus liquid food has been discharged, for the last six months, whenever the patient swallows. Orthopædic Hospital.

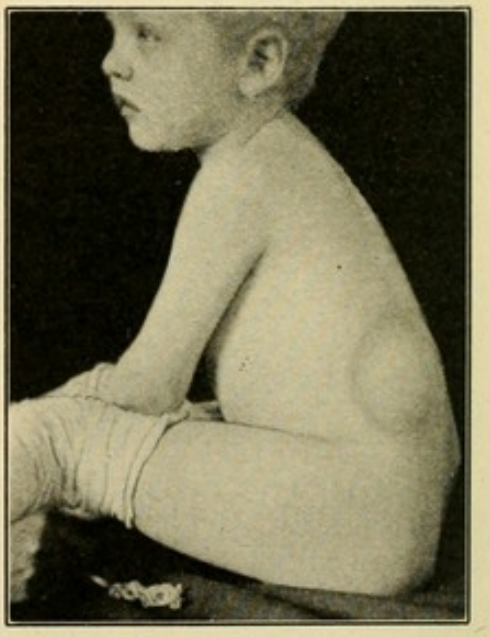

FIG. 645.—Left lumbar abscess in Pott's disease. Age four years; Pott's disease for one year; abscess several months. Abscess treated by operation, as advised in text. No return of abscess, and patient in good health five years after operation. Orthopædic Hospital.

When suppuration occurs in disease of the cervical spine, it forms a *retro-pharyngeal* abscess; this may cause dysphagia, dyspnea, or even alterations in the voice if the pus sinks so far as to compress the

larynx or distort the vagus nerve or its laryngeal branches. As such an abscess increases in size, it may rupture into the pharynx and cause sudden death by suffocation; or, as is much more usual, may make its way to the lateral aspect of the spine, and point in the neck, usually behind the sterno-mastoid muscle (Fig. 643); rarely it may follow the cords of the brachial plexus into the axilla. In the lower cervical and upper dorsal regions, the abscess bulges into the posterior mediastinum, and may track along the aorta and external iliac artery until it points below Poupart's ligament; or, as is less usual, may track outward along the ribs, pointing usually near their angles, and simulating costal caries (p. 731), which indeed may complicate the spinal condition. In the lower dorsal and lumbar regions the pus usually passes beneath the internal arcuate ligament of the diaphragm, invades the psoas muscle (*psoas abscess*), and points in Scarpa's triangle on the outer

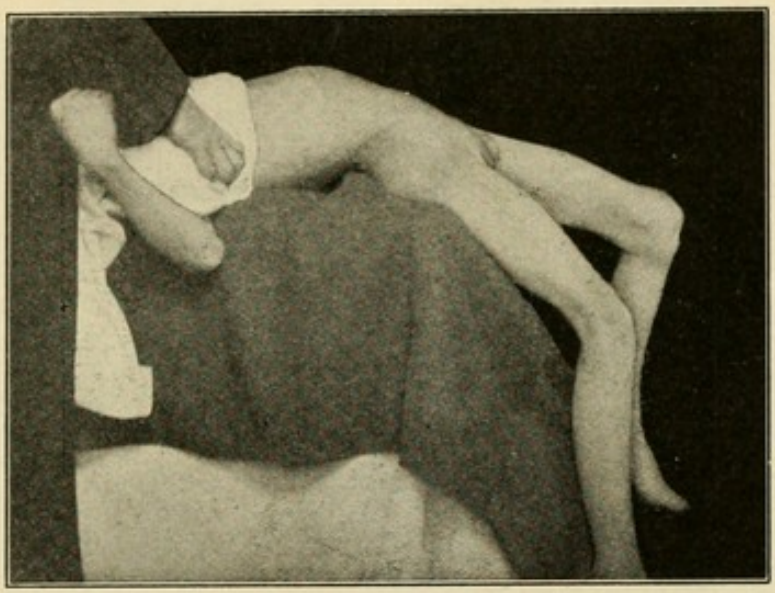

FIG. 646.—Early psoas contraction from left iliac abscess. Age eleven years. Pott's disease for four years. Abscess for eight months. Orthopædic Hospital.

side of the femoral vessels (Fig. 644). Usually such an abscess may be detected while still in the iliac fossa, when it is known as *iliac abscess*. Sometimes, instead of entering the psoas sheath, the pus passes beneath the external arcuate ligament, and points in the lumbar region (*lumbar abscess*), simulating a perinephric abscess (Fig. 645). Very occasionally an abscess may leave the pelvis through the sacro-sciatic notch and point in the buttock (*gluteal abscess*); and an *ischio-rectal abscess* sometimes may be traced to the spine.

Diagnosis of Abscess.—These various forms of abscess should be watched for. Their development may account for contractures (especially of the psoas muscle), for an apparently inexplicable exacerbation of symptoms (pain, fever, disability), and very occasionally (when the abscess ruptures into the spinal canal) for suddenly developed paraplegia or meningitis.

Psoas contraction is best demonstrated by placing the child on its back, with its lower limbs hanging over the end of the table: the normal

limb will drop below the horizontal, while one with psoas contraction will remain flexed at the hip, in spite of compensatory lordosis (Fig. 646). Or, with the child prone, the hip-joints may be tested for hyperextension, as in the examination for coxalgia (p. 490). There is little difficulty in distinguishing between coxalgia and psoas contraction secondary to Pott's disease; in the former, the motions of the hip are limited in all directions, not only in extension; and there are no evidences of spinal disease. An iliac abscess usually is palpable, a distinct fulness, which is absent on the normal side, being present along the course of the psoas muscle. Intraperitoneal abscesses, as from appendicitis, are of much more acute development, with symptoms of peritonitis, and are attended by leukocytosis.

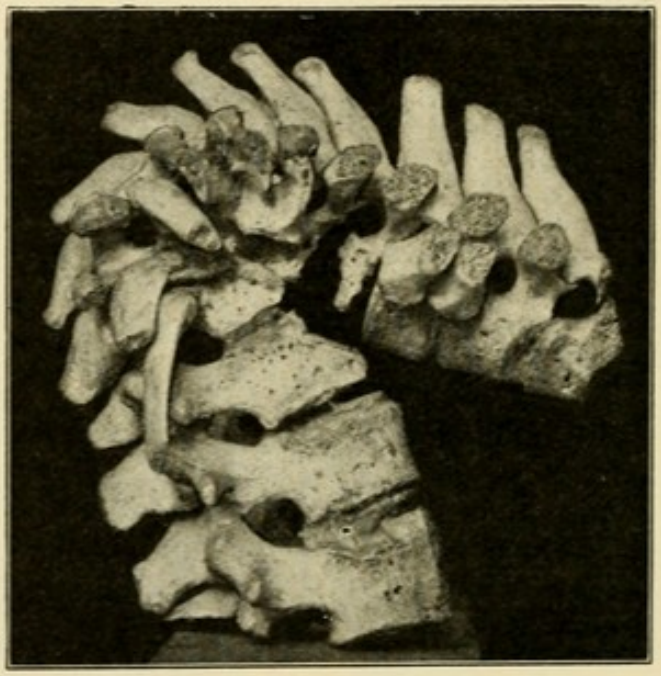

FIG. 647.—Pott's disease with extreme angulation, but not sufficient to cause paraplegia. Note that there are present the spines of fourteen vetebræ—bodies of only seven; in other words, seven bodies have been destroyed. From a specimen in the Mütter Museum of the College of Physicians of Philadelphia.

Paraplegia from Pott's disease, is the effect of a "transverse myelitis," or degeneration of the spinal cord from pressure. This pressure very seldom is caused by bony deformity from extreme angulation (Fig. 647). Almost always the pressure is due to tuberculous granulation tissue, usually extradural in situation. Rarely the rupture of a cold abscess into the spinal canal will cause paraplegia, which in these circumstances generally appears suddenly. In most cases the paraplegia is slow in onset, the patients first becoming spastic, and only gradually losing the power of locomotion. Sensation is not often lost entirely, even when motion is entirely abolished; but hypesthesia and paresthesia are frequent. Complete flaccid paralysis is rare. Interference with the functions of the bladder and rectum occurs as in fracture dislocations of the spine.

Meningitis.—See p. 579.

Prognosis.—The disease is seldom cured; in adults scarcely ever. It may be arrested in childhood, and many a "hump-back," even with marked deformity, is enabled to lead for years an active and useful life. But recurrence of symptoms always is to be feared. Very few patients die as a direct result of the disease, and then mostly from complications, such as tuberculous meningitis or amyloid degeneration of the viscera; but before the disease becomes latent probably one patient out of every three affected will die from intercurrent maladies which would have been survived, had not the viscera, particularly the heart and lungs, been so distorted by the spinal deformity. Neither an unopened abscess nor the onset of paraplegia seems to render the prognosis more grave; but the rupture of an abscess, with the secondary infection which this entails, opens a door, as Calot says, through which death soon enters.



FIG. 648.—Extension from head and both feet for Pott's disease. Orthopædic Hospital.

Treatment.—To secure rest for the diseased spine recumbent treatment is almost indispensable, and in the acute stages is imperative. This at once removes the superincumbent weight. The use of the Bradford frame (Fig. 497), to which the child is strapped, largely prevents motion in the spine, and immobility is further favored by head and foot extension (Fig. 648). Meanwhile, the patient should be kept in the open air, night as well as day whenever possible, and all the general measures useful in surgical tuberculosis should be adopted (p. 82). During recumbency it is especially important to prevent "pointed-toe deformity," which is very apt to develop if the foot is

unsupported and kept constantly in the equinus position by the weight of the bed-clothes. Careful trained nursing is indispensable. A nurse trained especially in this work is desirable whenever her services can be obtained.

If recumbent treatment can be instituted before deformity develops, it may be possible to secure arrest of the disease, and to prevent the occurrence of subsequent deformity. As in the case of tuberculous coxitis, the only patients I have seen whom I could consider really cured of the disease, without impairment of function, were those in whom such treatment was adopted before the diagnosis was entirely certain. When once a kyphos has developed it is very seldom that surgery can do anything better than to prevent increase of deformity. Whitman prefers to treat early cases on a frame which keeps the spine hyperextended; this treatment is not applicable when fixed deformity already exists, and is open to the theoretical objection that it prevents collapse of the diseased vertebral bodies and thus hinders ankylosis, which should be encouraged, as the only chance of permanent cure. At one time Calot (1896) was an advocate of forcible correction of any existing deformity, the patient being anesthetized; but a thorough trial of the method has caused it to be abandoned not only by other surgeons but by Calot himself. It was found that the death rate was markedly increased (shock, traumatic pneumonia, miliary tuberculosis, spinal meningitis, etc.), and that the ultimate cure of the disease was not accelerated nor the final deformity diminished.

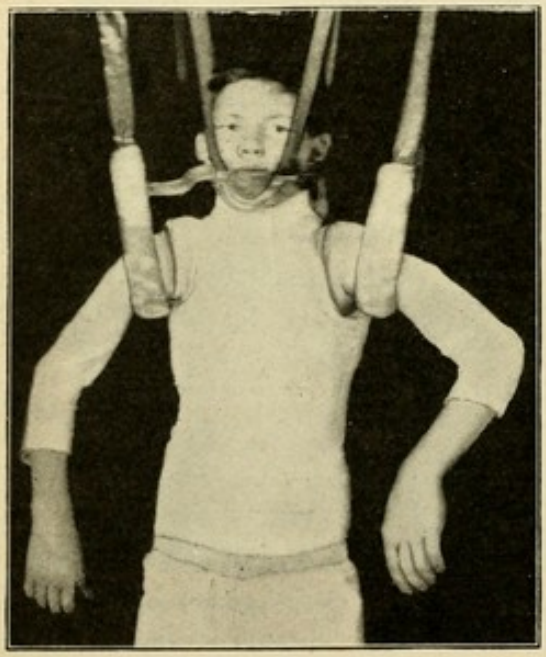

Fig. 649.—Application of plaster jacket with patient suspended. Orthopædic Hospital.

When all symptoms of the disease have been absent for two or three months at least, ambulatory treatment may be tried with great caution, and *never without efficient support to the spine*. The **plaster jacket**, when properly applied, is a most efficient support. It may be applied with the patient recumbent, or suspended by the head and shoulders, the heels just clearing the floor (Fig. 649). For most cases of thoracic and lumbar disease I think the prone position is preferable (Fig. 650): the child lies on a sling attached at both ends, by a bar and ratchet, to a Bradford frame; the sling is left just lax enough to allow slight hyperextension of the spine, and is included in the plaster bandages, being slipped out after the plaster jacket has dried. With a seamless undershirt next the skin, and all bony prominences (pelvis, kyphos, axillæ) well padded with saddler's felt, such a

jacket may be worn for several months in comfort. The surgeon should smell the cast all over every few weeks, and thus may detect very early any evidence of excoriation. As an additional guard against

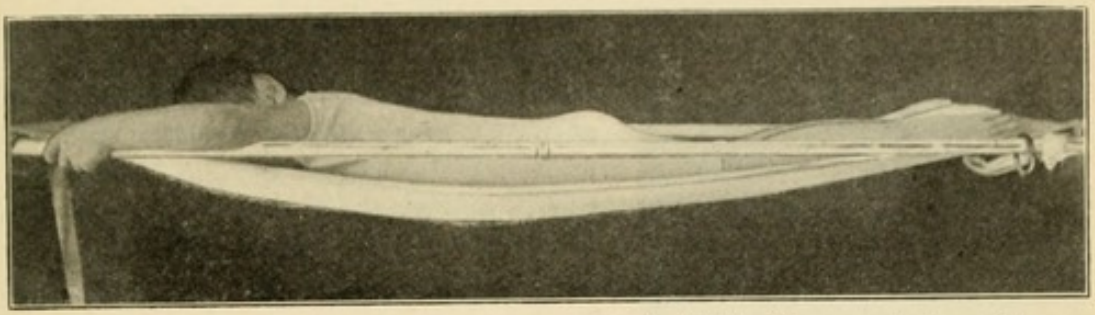

Fig. 650.—Position for applying plaster jacket in Pott's disease. Orthopædic Hospital.

such an occurrence, "scratchers" may be inserted next the skin before the jacket is applied: these are long pieces of bandage, with their protruding ends sewed to each other, and are to be drawn up and down every day or so, to keep the skin in good condition. For high dorsal (above the eighth thoracic vertebra) or cervical disease the head and neck must be immobilized also; and in such cases it is more convenient to apply the jacket with the patient suspended. The front of the cast should be cut away to diminish its weight (Fig. 651).

Fig. 651.—The plaster of Paris jacket for upper dorsal disease. The jacket is trimmed away above and below, and the large abdominal window is cut to allow of free breathing and feeding. (Cheyne and Burghard.)

Braces.—These depend more on fixation (limitation of movement) than on support in the sense of relief of weight-bearing. Davis's brace (Fig. 652) (1898) takes a fixed point of support at the pelvis (between iliac crests and great trochanters) by means of a malleable steel band; over the iliac crests pass well-padded straps, attached behind and in front to the pelvic band, which effectually prevent the brace from sliding downward. Up from the pelvic band on each side of the spine runs a light steel bar, connecting through a cross-bar above with crutch pieces under the axillæ; these are supported below by steels attached to the pelvic band in the mid-axillary line. Nothing passes over the shoulders, as the object is not to hang the apparatus from the shoulders, but to support the weakened spine from below. The brace is thus fixed below at the pelvis and above at the

shoulders, and presses forward on the transverse processes at the level of the kyphos, thus tending to hyperextend the spine and relieve pressure on the bodies of the vertebræ. If the lesion is above the eighth thoracic vertebra it usually is desirable to support the head also, by an attachment to the spinal uprights. When ambulatory treatment is first commenced, the apparatus should be worn at night as well as during the day, of course being removed once daily for bathing; but the patient *never should be in any other than the recumbent position except when the spinal support is in place.* It should be taken off only after he lies down and should be put on again before he even sits up.

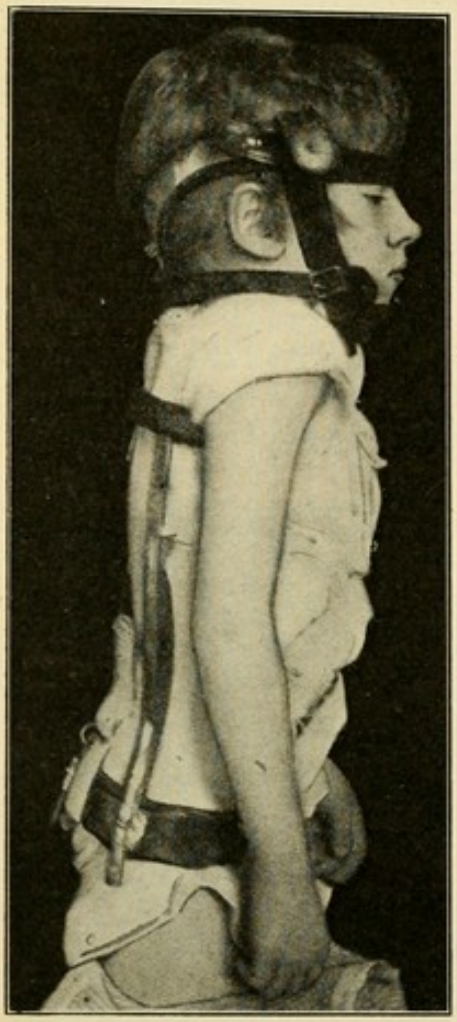

FIG. 652.—Brace for cervical or high dorsal Pott's disease. Orthopædic Hospital.

Some support of this kind scarcely ever can be dispensed with; when it is abandoned *symptoms nearly invariably return.* This has been demonstrated to be a fact in so many cases that it is almost foolhardy for a surgeon to tell a patient to throw away his braces and go without support. Only after many long months of freedom from symptoms is it desirable to dispense with the crutch pieces of the apparatus, the brace then consisting merely of a pelvic band, spinal uprights, and shoulder-straps. Such an apparatus gives practically no support, but prevents dangerous degrees of movement in the spine.

Operative fixation of the spine, in recent cases of Pott's disease, has been employed by several surgeons. Lange inserts two steel bars, one on each side of the spinous processes, and fastens them above and below to the transverse processes of healthy vertebræ. Albee splits the spinous processes of vertebræ over the seat of disease and of two more above and below, and inserts in the cleft a sliver chiselled off the patient's tibia; when this grows fast firm ankylosis is secured. Hibbs chisels partly through the spinous processes at their base, turns each one down until it comes into contact with the base of the spinous process next below, and thus covers the diseased region of the spine with a solid bridge of bone. Of these various measures I believe Albee's operation of bone transplantation is the best. I have employed it in seven cases, and apart from one death from pneumonia, all the patients have shown marked improvement; but in one (Fig. 653) the

transplant later became loosened at its lower extremity, and a new kyphos developed.

Treatment of Abscess.—The general principles which should guide surgeons in the treatment of tuberculous abscesses and sinuses have been discussed in Chapter XV. If recumbency and immobility do not cause retrogression of the abscess, and still more so if it continues to enlarge, it should be incised through healthy overlying tissues, should be carefully evacuated, its cavity should be thoroughly wiped out with iodoform gauze, and the incision should be tightly closed by several layers of sutures (see Fig. 645). A *retropharyngeal abscess*

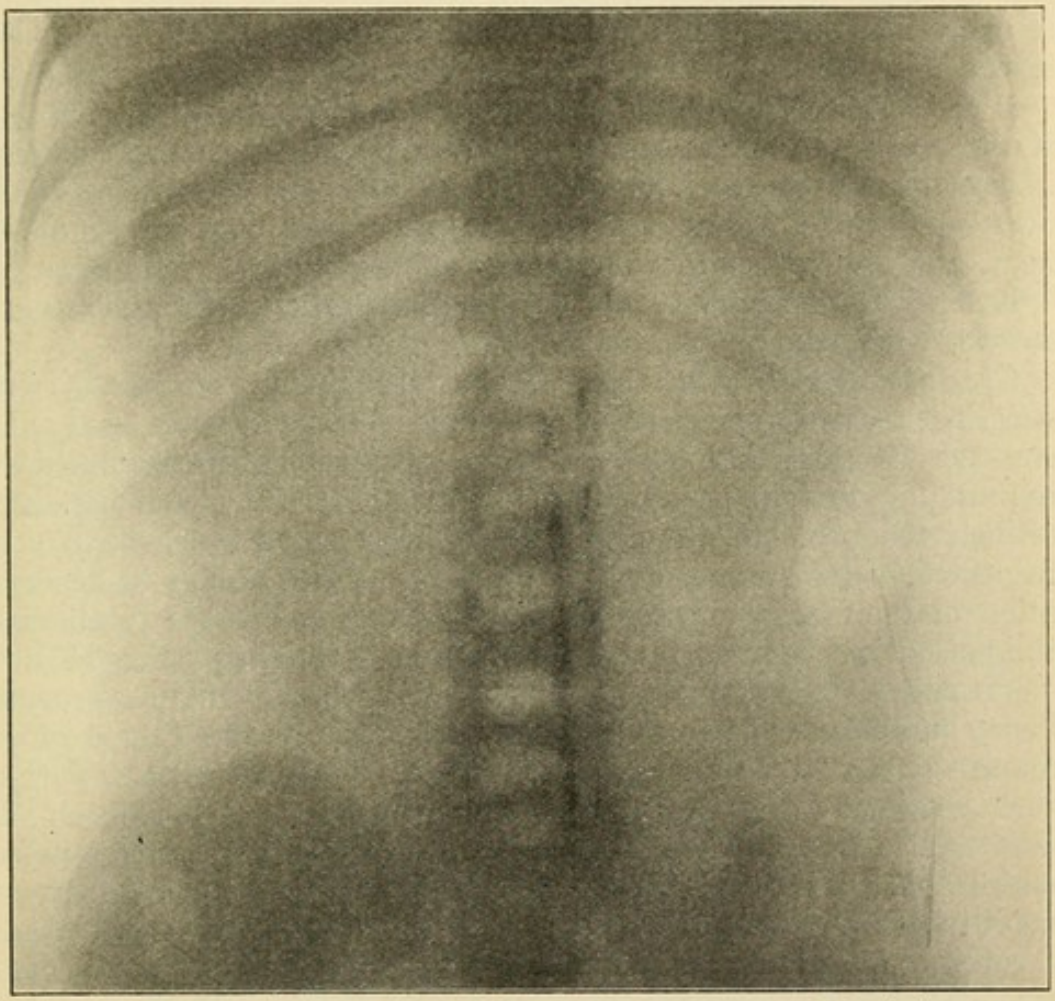

FIG. 653.—Bone transplant in lumbar spine. Episcopal Hospital.

requires early evacuation, to prevent rupture into the pharynx or secondary infection from the same source. In adults local anesthesia is sufficient. An incision is made, in the lines of the skin, at the posterior border of the sterno-mastoid muscle, and this is defined and drawn forward; usually the bulging abscess is found just beneath the muscle, and may be opened by Hilton's method (p. 51). The abscess wall, the muscle, the platysma, and the skin, should be sutured if possible in separate layers. An abscess in the *posterior mediastinum* rarely requires drainage; it is exposed by excision of the heads and necks of the ribs, with the corresponding transverse processes of the diseased

vertebræ (**costo-transversectomy**). Injury to the intercostal nerves, and especially to the pleura should be avoided. An *iliac abscess* may be opened by a small McBurney muscle-splitting incision as in appendicitis (p. 820), without fear of invading the peritoneum if the incision is made close to the ilium and the dissection keeps close to iliac fossa. After evacuation, and thorough wiping of the abscess walls with iodoform gauze, the wall of the abscess cavity and the structures of the abdominal wall are sutured in layers. A *psoas abscess* does not admit of such secure closure, after evacuation just below Poupart's ligament; but the abscess wall, the fascia lata, and the skin usually can be closed in separate layers. A *lumbar abscess* is approached as in operations on the kidney, and usually the abscess wall, the lumbar fascia, and the skin, can be sutured separately.

If the abscess is giving no symptoms, does not tend to enlarge, and is not so near the skin as to make probable the occurrence of secondary infection from skin cocci, it should be left alone, and the patient should be treated as if it did not exist. Constant watch, however, should be kept, and proper treatment promptly adopted whenever required.

It seems unnecessary to add anything as to the *treatment of sinuses* to what was said in Chapter XV.

Treatment of Contractures.—Often recumbent treatment, with weight extension applied first in the axis of the deformity, will allow contractures gradually to be overcome. Occasionally tenotomies are required (adductors, psoas, rectus femoris, tensor fasciæ femoris, hamstrings, tendo Achillis, etc.). But in many cases which have been neglected, sinuses exist, with secondary infection; amyloid degeneration of the viscera is present; and nothing remains but to alleviate the patient's miserable state until death ends the scene (Fig. 243).

Treatment of Paraplegia.—In almost every case in childhood recumbency will cause disappearance of paraplegia in the course of six months or a year. In such cases, then, it is only after the failure of such treatment that the question of operation need be raised. In adults, also, recumbency in most cases will cause return of power within that time. If after eight months or a year of recumbent treatment in adults no improvement is noticed and spasticity still persists, I think laminectomy (p. 601) should be done, and the tuberculous granulation tissue excised; the dura should not be opened, as tuberculous meningitis probably would ensue; and it is quite useless, and perhaps not always harmless, to curette away carious bone from the vertebral bodies. Only when the paraplegia is of *sudden onset* do I think laminectomy should be undertaken as an early operation. In ordinary cases the symptoms come on very gradually, and the ultimate complete or nearly complete recovery, even after many months of complete abolition of the motor functions, is due to this very feature, as the cord gradually accustoms itself to the condition of pressure. But when the onset is sudden or very rapid (complete paraplegia developing in a few days in a patient previously not even spastic), the cord has not the time to so accustom itself, and there is

great danger that it may be damaged irretrievably unless the pressure is promptly relieved. In cases with such rapid onset, as already noted, it is probable that the cause is rupture of an abscess into the spinal canal.

Other Forms of Infectious Spondylitis.—*Typhoid Spondylitis* was referred to at p. 473. When a patient has lain long in bed, with any wasting disease, his spine is apt to become affected from static strain; lying flat on the back, the normal lumbar lordosis may be lost, and the thoracic kyphosis may be increased. As a consequence, when he first assumes the erect posture, or even during convalescence in bed, complaints of stiff back may be made. This condition is not very infrequent after long and serious attacks of typhoid fever, but though it is called colloquially by the name of "typhoid spine," it should not be confused with true typhoid spondylitis. The latter condition is much rarer, and is due, as suggested in 1889 by Gibney, and as demonstrated in 1906 by McCrae, to definite lesions in the vertebræ, similar to those occurring in the long bones as a sequel to typhoid fever (p. 425). Only a few vertebræ are involved, usually in the lower thoracic or lumbar region. The onset is very acute, resembling the most severe cases of Pott's disease, with great pain, which may radiate along the spinal nerves, and perhaps with cramps in the extremities. Any motion is painful. Sometimes a kyphos develops. *Treatment* is the same as for tuberculous spondylitis; though ankylosis may result, recovery usually is complete in a few months.

The spine may be affected also by *gonococcic* and *pneumococcic* infection, as well as by that due to *influenza*, *tonsillitis*, etc. The symptoms are subacute in onset, are typical of an infectious as distinguished from a dystrophic process (p. 452); and the diagnosis depends on the recognition elsewhere in the body of the original infective focus. According to Painter, the entire vertebral column, or the greater part of it, is affected at once, the lesions not being confined to any one region, as is so frequently the case in hypertrophic arthritis of the spine. There is spinal rigidity, but not much deformity, unless this be a slight lateral deviation, or inclination to round shoulders. From involvement of the costal articulations, respiration is hampered. *Treatment* implies cure of the infecting focus, whenever this can be discovered, with support to the spine during the period of acute symptoms, and counter-irritation, massage, and gymnastics at a later date. The spine may also be affected by what were described in Chapter XV as *Subpyemic* and *Cryptogenous Infections*. (See below.)

Dystrophies of the Vertebral Column.—These affections conform more or less closely to the two main types of dystrophic arthritis discussed in Chapter XV. The term *Spondylitis Deformans* is quite as indefinite as is arthritis deformans, since it may include both types, or be limited, as it is by some, to the hypertrophic form.

In *atrophic spondylitis* the vertebræ seldom if ever are affected unless

the small peripheral joints have been attacked previously; the spinal changes, therefore, occur merely as an advanced stage of atrophic arthritis as described at p. 452. Fig. 654 depicts the typical attitude assumed by these patients. Great care should be exercised to exclude any infectious origin for stiffness of the spine, before presuming to make a diagnosis of atrophic spondylitis. In what have been described as the subpyemic and cryptogenous infections, the vertebral column, when affected, seldom presents the rounded kyphosis (Fig. 654) which characterizes the dystrophic conditions; usually it becomes abnormally straight, and the patient often has been described as having a "poker-back." The *treatment* of atrophic spondylitis has been discussed sufficiently in connection with atrophic arthritis (p. 456).

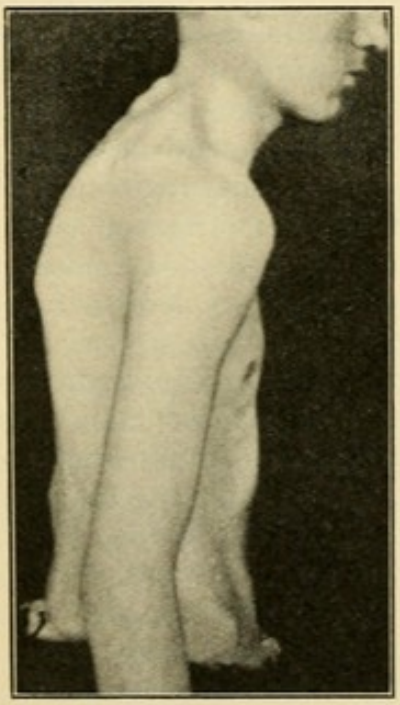

FIG. 654.—Atrophic arthritis of spine; age sixteen years; duration one year. Fingers, right knee, and left shoulder are involved also. Orthopædic Hospital.

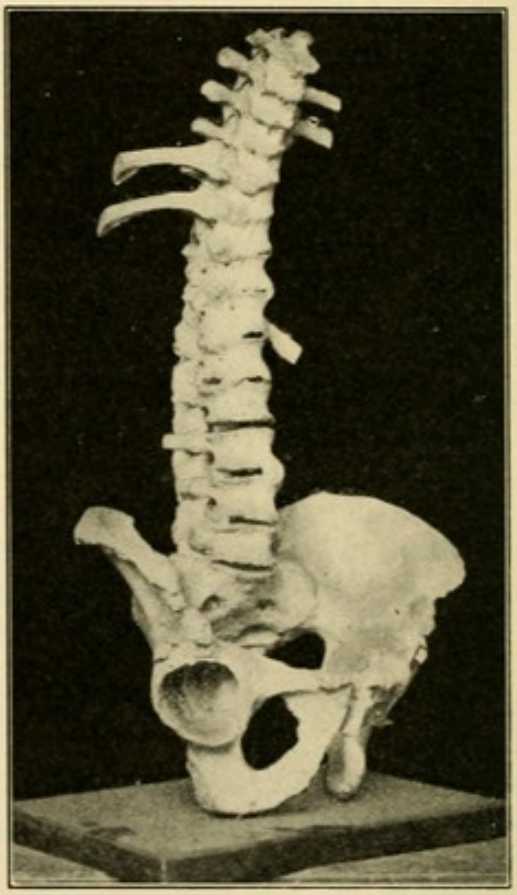

FIG. 655.—Hypertrophic spondylitis; involvement also of acetabulum and pelvis. From a specimen in the Mütter Museum of the College of Physicians of Philadelphia.

In *hypertrophic spondylitis,* the spine may be affected alone, or in association with one or more of the larger joints of the extremities. As in hypertrophic arthritis affecting such joints alone, so in the vertebral disease, a history of previous trauma or of actual static strain usually may be obtained. As a rule only a limited portion of the vertebral column is affected, especially the lumbar region, frequently in conjunction with hypertrophic arthritis of the sacro-iliac or

hip-joint of one side. The pathological changes closely resemble those encountered in the joints of the limbs, and exostoses or osteophytes frequently may be detected in skiagraphs. Early in the disease there is softening of the vertebral bodies (rarefying osteitis), and considerable deformity may occur, in the form of a more or less rounded kyphosis. As the affection progresses, however, the new-formed periosteal outgrowths tend to cover the vertebral bodies with a more or less continuous bridge of bone, rendering the spine absolutely immobile (Fig. 655). Usually this bony coating is situated to one or other side of the median line, and there may be a corresponding lateral deviation of the spinal column. If any of the spinal nerves are compressed there may be neuralgic pains in the parts supplied, and sometimes there are secondary muscular atrophies. This complication was described by Bechterew (1892) as a special type of the disease. When one or more of the "root joints" (*i. e.*, hip, shoulder) of the limbs were involved in the hypertrophic changes, the affection was considered by Marie (1898) a separate disease, and was described by him as "spondylose rhizomélique." In many cases of hypertrophic spondylitis the affection progresses so quietly that the patients never apply for treatment, and the deformity is discovered by incident or only at autopsy. In others, pain, stiffness, and considerable disability demand relief. *Treatment* is to be conducted as in cases where other joints are involved in hypertrophic arthritis (p. 459).

Intraspinal Tumors.—Usually these are small, more or less encapsulated growths, springing from the meninges, and intradural in location nearly as often as extradural. Very rarely has an intramedullary tumor been found. In most of the reported cases the tumors were sarcomatous, but fibroma, endothelioma, echinococcus cysts, and other growths have been found; and it is not unlikely that in some of the cases classed as sarcomatous the microscopical diagnosis was in error.

Symptoms.—Pain of a rheumatic or neuralgic character, localized to one limb or to one of the intercostal nerves, usually is the first symptom. This pain may subside under treatment but is prone to recur, and after a few months or even years is accompanied by a numbness or heaviness in the affected extremity. Though unilateral at first, the symptoms nearly invariably become bilateral before complete paralysis develops. The ensuing paraplegia conforms to the ordinary type due to "pressure myelitis;" there is spasticity at first, but later complete flaccidity develops. As physical signs of a tumor (deformity, rigidity of the spinal muscles, tenderness) usually are absent, the *diagnosis* depends largely on the history, on the slowly developing paralysis, and on exclusion of other forms of medullary compression. A neurological consultation is desirable to aid in determining the spinal segment involved. It scarcely ever is possible to determine before operation the nature of the tumor, whether or not it is extradural, or even whether or not it is intramedullary.

Treatment.—Immediate resort should be had to laminectomy when once the diagnosis is reasonably certain, as the prognosis is absolutely

bad unless pressure on the cord is relieved. The usual mistake, on the part of both neurologists and surgeons, has been to expect to find the tumor at too low a level. Hence the surgeon should expose first that region of the cord which is supposed to be affected; and if the growth is not found there, he should search upward until the cause of compression is found. In 1905 I collected for Harte records of 92 operations for intraspinal tumor; in only 5 of these cases did the surgeon fail to find the tumor, and in three of these it was learned subsequently that it was situated only a very little higher than the region exposed at operation. Elsberg has pointed out that in some cases where an intramedullary or subpial tumor cannot be removed at the primary operation, it will be found to have been spontaneously extruded a few days later.

The mortality of the operation has been about 25 to 30 per cent., but is less in more recent times. Of those patients who survived nearly 60 per cent. were classed as cured; 34 per cent. as improved; and in only 6 per cent. was no improvement secured.

Chronic Serous Spinal Meningitis usually is a complication of chronic serous cerebral meningitis (p. 579), but may occur independently (Krause, 1906), as a localized collection of serous fluid, possibly the result of a previous infection which has caused adhesion of the pia to the dura over a limited area (Spiller, 1906). It produces symptoms closely resembling those of intraspinal tumor, and the treatment is the same.

CHAPTER XIX.

SURGERY OF THE FACE, MOUTH, AND NECK.

SURGERY OF THE NOSE.

Epistaxis or **Nosebleed** may occur spontaneously or from trauma. Probably many cases of nosebleed thought to be spontaneous really are due to slight trauma, in "blowing" or "picking" the nose. High arterial tension, from renal or cardiac disease, is a predisposing cause. The patient should lie flat with the head slightly elevated, and should refrain from blowing the nose. It should not be thought that hemorrhage has ceased merely because no blood runs out of the nostril, since the patient may be swallowing the blood as it runs backward into the pharynx. Later such blood may be vomited. Cold applications are efficient in checking the hemorrhage in most cases. It often is possible to check bleeding temporarily by raising the arms above the head, thus diminishing the venous pressure; but bleeding may recur when they are lowered. A hot mustard foot bath may be tried. Applying a small roll of gauze between the upper lip and the alveolar process, in the midline, and compressing the lip over this pad, sometimes will control the bleeding by pressure on the coronary vessels of the lip or the arteria septi nasi. In almost every case the bleeding comes from this artery as it travels upward along the cartilaginous septum just within the nostril. By raising the tip of the nose, and with light reflected from a head-mirror, it often is possible to see this bleeding-point, especially if the nostril is sprayed with cocain solution (2 per cent.) or swabbed with adrenalin (1 to 1000). These agents, or hydrogen peroxide, frequently are effective in checking the hemorrhage. If bleeding persists, and as a last resort, the tampon must be resorted to. If a Simpson splint (made of Bernays's sponge, which when moistened swells to eight times its previous size) is available, it may be inserted within the nostril, and usually is very efficient. If bleeding occurs from further back in the nostril, it may be necessary to plug the posterior as well as the anterior nares. This is done by attaching a string to the end of a soft rubber catheter, and passing this (string end first) along the floor of the nostril until the catheter emerges in the pharynx; both ends of the string are then pulled out through the mouth, and to one end is tied a tampon of size sufficient to plug the posterior naris of the bleeding side (Fig. 656). As the catheter is withdrawn from the nose this tampon is pulled by the string into the mouth, around the posterior margin of the soft palate and into the posterior nasal opening. The other end of the string is left long, hanging from the mouth, to

facilitate withdrawal. The anterior naris is then plugged from the front. These tampons should not be left in place more than twenty-four or thirty-six hours, as they are apt to excite suppuration, and perhaps maxillary or frontal sinusitis, or even otitis media. A cannula expressly for plugging the posterior nares was invented by Bellocq, and is useful if at hand.

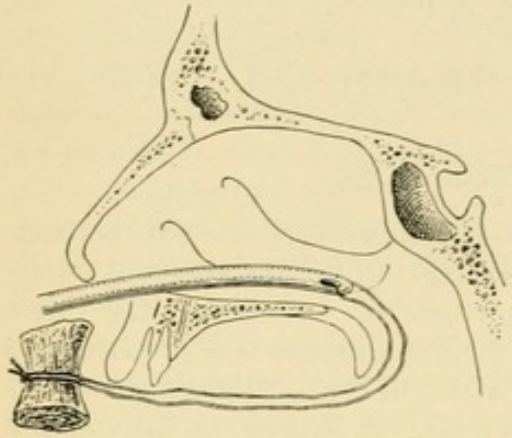

Fig. 656.—Plugging the posterior nares.

Foreign Bodies in the Nose usually may be extracted by fine forceps or scoop, under good illumination. If, however, the foreign body lie not on the floor of the nose, nor anteriorly, it will be easier and safer to dislodge it by syringing warm boric acid or saline solution through each nostril alternately.

Acne Rosacea.—Acne rosacea in its early stages, comes under the care of the dermatologist; but when through long duration and neglect of proper treatment the skin and subcutaneous tissues of the nose have become hypertrophied (*Acne Hypertrophica, Rhinophyma*), then surgical treatment is necessary for a cure. The nose is now enlarged, erythematous, covered with dilated venules or arterioles; and nodules of various sizes and shapes make the patient conspicuous (Fig. 657). *Treatment:* Frequent steaming of the parts, after application of green soap or a soap poultice, or ointments containing sulphur or salicylic acid, may somewhat improve the nutrition of the skin; but in most cases the over-growths require to be removed. Simply shaving off these excrescences may suffice, the denuded areas being left to heal by granulation; or excision may be done, and the wound covered with Wolfe skin grafts.

Fig. 657.—Rhinophyma, or hammer nose. (Tillmanns.)

Rhinoplasty.—The formation of a new nose, wholly or in part, may be required for various reasons. The deformity known as Saddle Nose (Fig. 937), occurring as the result of syphilis, old fracture, or other lesion, may be remedied by implanting beneath the skin a suitably shaped bridge of silver or bronze-aluminum. Subcutaneous injections of paraffin have also been employed. Kolle uses paraffin with a melting-point of 102° to 115° F., and makes the injections (by means of a special syringe with a screw piston) with the paraffin cold; this obviates danger of embolism. No anesthetic is required if the injection is made slowly, and if only a small quantity is injected at any one time.

If the nose is completely destroyed from injury, lupus, syphilis, etc., a new one may be constructed by plastic operations. In the *Indian method of rhinoplasty*, used by the native surgeons of India for many centuries, and introduced into England in 1816 by Carpue, a flap is taken from the forehead, and is twisted around a pedicle which contains the angular, frontal, and supraorbital arteries of one side (Fig. 658). The flap is made a quarter of an inch larger on all sides than desired, as it is sure to shrink. The edges of the nasal opening are then freshened, and all bleeding is controlled by very fine catgut ligatures. The frontal flap is then rotated and is sutured in place by tongue and groove sutures (Fig. 659). A columna may be formed from the upper lip, if thought desirable, after a week or ten days, but usually the orifice of the new nose contracts so much that it is undesirable to subdivide it. The pedicle is not cut through for about a month after the primary operation. The denuded frontal area may be left to heal by granulation or may be covered by Wolfe grafts. C. Nélaton and Ombredonne (1904) introduced a valuable modification of the Indian method, in which a piece of the eighth costal cartilage is first transplanted

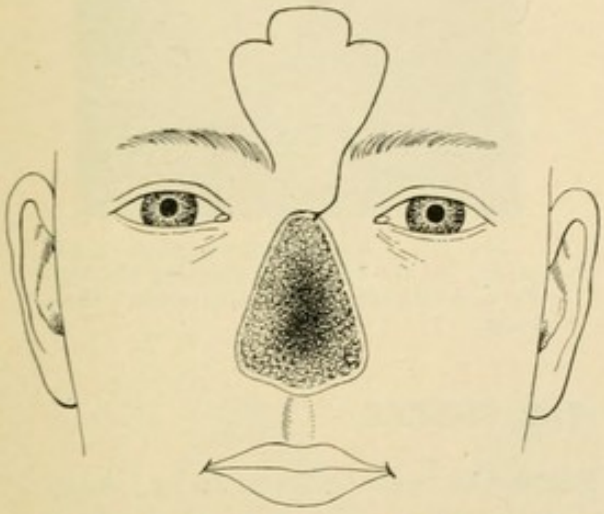

FIG. 658.—Outline of frontal flap for rhinoplasty by the Indian method.

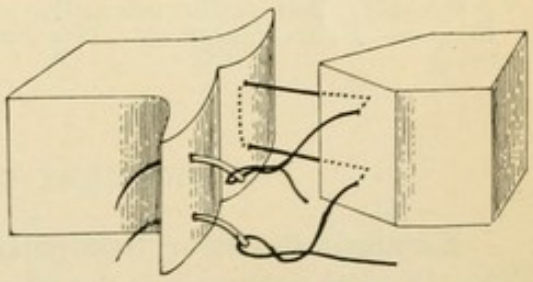

FIG. 659.—Tongue and groove sutures.

beneath the skin of the forehead. Six weeks later the flap containing this cartilage is cut and turned down over the nose. A cutaneous lining for the nose is also formed by inverting a small flap from the glabella and another from each side of the nose. The *Italian Method of Rhinoplasty*, widely employed by Taliacotius in the sixteenth century, consists in transferring a flap from the arm. At the first operation the flap is marked out and is partially detached; when it is sufficiently vascularized and thickened, after the lapse of about ten days, this flap is stitched to the freshened edges of the remaining nasal structures, and the arm and head are securely bandaged together. A plaster of Paris dressing is desirable. About ten days or two weeks later the flap is cut away from the arm; and a columna may be formed then, or subsequently.

Rhinoplasty has also been done by transplanting a phalanx of the finger or toe, or a piece of costal cartilage, into the subcutaneous tissues of the nose; but such methods are applicable only when there is suffi-

cient healthy skin already over the nose to ensure complete burial of the transplanted structure. The "transplant" must be brought into contact with bone denuded of periosteum, so that the Haversian systems extending from this may permeate the transplant (p. 505).

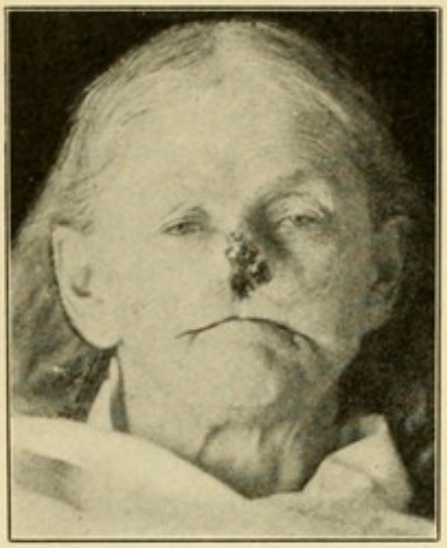

FIG. 660.—Patient with destruction of the nose. Before rhinoplasty. (See Fig. 661.)

FIG. 661.—Same patient after rhinoplasty by the Indian method by the late Prof. Ashhurst, 1894. University Hospital.

SURGERY OF THE CHEEKS.

Keratosis Senilis or **Seborrheic Patch** has been referred to in Chapter IV as a precancerous condition of the skin. The skin of the face of elderly persons, especially those who have been exposed much to the weather, may present a number of slightly raised, greasy, yellowish-brown patches, due to hypertrophy of the epidermal cells, and accumulation of sebaceous matter on the surface. If these patches are picked off and a small bleeding erosion is revealed, this lesion probably is a superficial epithelioma; if no bleeding occurs the lesion may still be in its precancerous stage. Beyond recognizing this fact and acknowledging the possibility that proper treatment by a skilled dermatologist might prevent or at least delay the development of epithelioma, neither pathologist nor clinician can go. Before there is any suspicion of malignancy, careful treatment of the skin should be adopted. The face should be well steamed over a bucket of hot water, at least once daily; after thoroughly drying, a little salicylic acid ointment (10 grains to the ounce) should be rubbed into the seborrheic patches. Sometimes green soap (Tinctura Saponis Viridis, U. S. P.) should be used instead of ordinary toilet soap. D. W. Montgomery, who has studied these cases most carefully, wipes off the skin with glacial acetic acid, and in rebellious cases uses trichloracetic

acid, after curetting the lesion; then the *x*-rays are employed. He points out that when the cheeks or other portions of the face are widely affected radical excision is not to be considered even if the

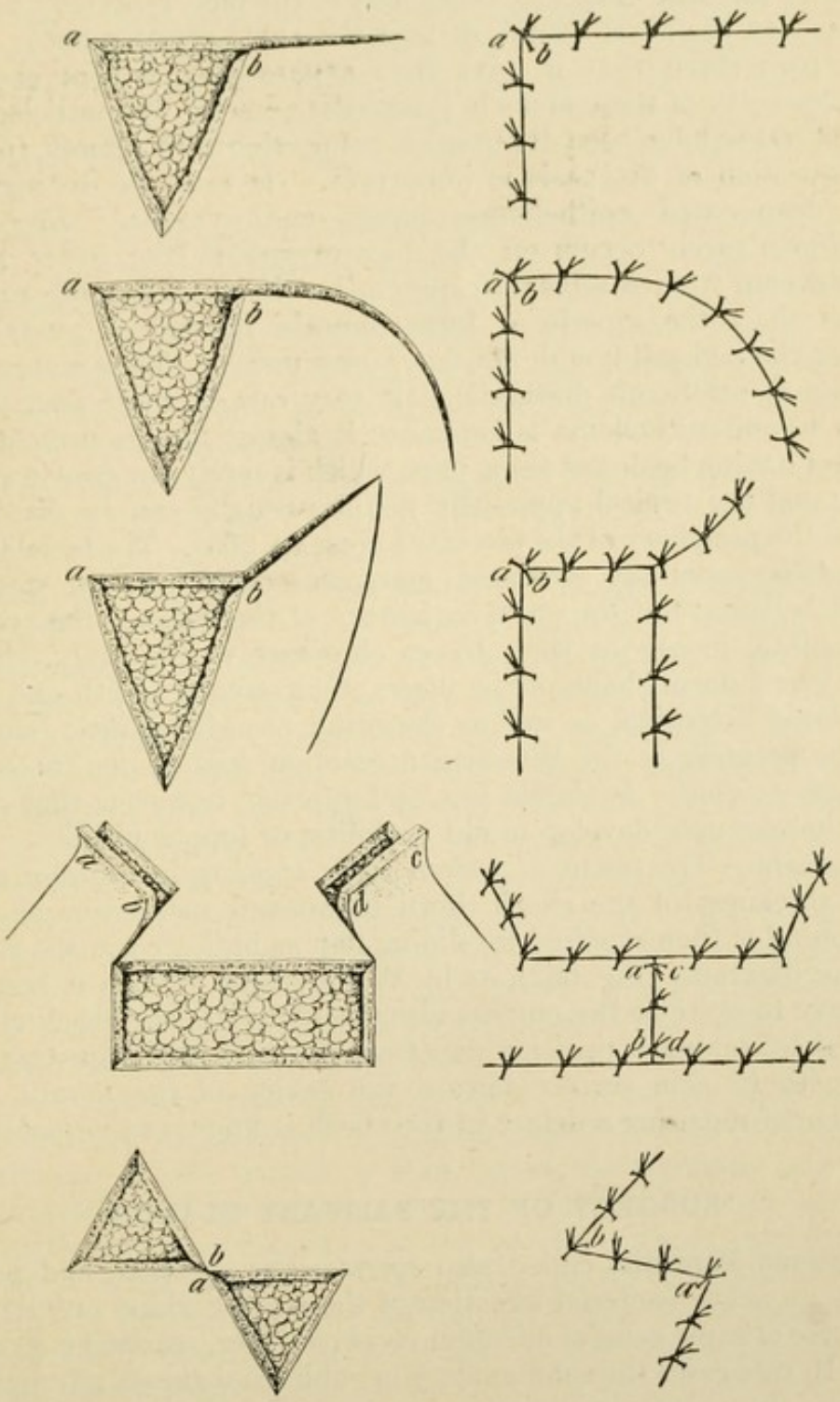

FIG. 662.—Typical plastic operations.

epitheliomatous nature of the lesions is recognized; and any flaps used to repair defects left by partial excision will themselves be the seat of these precancerous growths, and will in time develop into epithelioma, causing an apparent local recurrence. If only one or

two patches exist, they should be treated by excision, as in fully developed epithelioma.

Superficial Epithelioma or **Rodent Ulcer** occurs more often on the cheeks or forehead than any other part of the face, especially near the ala nasi, on the lower eyelid, or near the angle of the mouth. Some authorities claim that it owes its comparatively benign character to the poverty of these areas in lymphatic vessels. Its pathology and clinical course have been discussed in connection with tumors, (p. 123). The question of diagnosis is important. It must be distinguished from deep-seated epithelioma, lupus, and syphilis. *Deep-seated epithelioma* rarely occurs on the face except on the lower lip; it may develop from a seborrheic patch, but it is much more rapid in growth than the superficial form (months instead of years), and invades the regional lymph nodes. *Lupus* usually affects young adult patients of scrofulous diathesis; it is very rare in those past middle life in whom epithelioma is common; it almost always presents evidence of having healed at some part, which is rarely the case in epithelioma; and the typical apple-jelly nodules usually can be discovered around the periphery of the ulcerated areas (p. 263). The facial lesions of *syphilis*, especially ulcerated gummas, sometimes are mistaken for epithelioma; but the previous history of the patient, the presence of syphilitic lesions or their traces elsewhere in the body, the circinate or reniform shape of the ulcers, their greater depth and much more rapid extension, as well as the result of antisyphilitic remedies, and the presence of the Wasserman reaction, will render the correct diagnosis evident. It should not be forgotten, however, that malignant changes may develop in old syphilitic or lupous ulcers.

Treatment.—Treatment of rodent ulcer consists in excision of the entire thickness of the cheek down to mucous membrane or bone. The wound is then repaired by sliding flap as indicated in the accompanying diagrams (Fig. 662), or by Wolfe grafts. When it has been necessary to sacrifice the mucosa also, the defect in the cheek may be repaired by taking a pedicled flap from the neck and adjusting it in place with its skin surface toward the cavity of the mouth. The operation of repairing a defect in the cheek is known as *meloplasty*.

SURGERY OF THE SALIVARY GLANDS.

Infectious Parotitis, called also *symptomatic parotitis*, and *parotid bubo*, is an acute bacterial infection of the parotid gland occurring in the course of some general infection (typhoid fever, scarlatina, pyemia, etc.). In rare cases the submaxillary or sublingual glands are similarly affected. In contradistinction to epidemic parotitis (mumps), only one parotid usually is affected, and suppuration is frequent. Cases of this nature may also follow abdominal or other operations, but rarely, if ever, unless general anesthesia has been induced. In all such instances, as in typhoid fever and other wasting diseases, there is abundant opportunity for a direct ascending infection from the

mouth along Stenson's duct; and while infection through the blood-stream cannot be denied, it probably is rare. In the substance of the parotid gland, between its lobules, there are numerous minute lymph nodes; and it is possible that some cases classed as parotitis really are instances of lymphadenitis of these nodes. Prophylaxis is important, and consists in measures to promote cleanliness of the mouth and prevent drying of the mucosa around the orifice of the parotid duct. Mechanical injury of the glands should be avoided during anesthetization.

Treatment.—Local applications (ice bag, painting with iodin, mouth washes) may be useful before suppuration occurs. This should be treated promptly by incision parallel with the branches of the facial nerve. A probe is then inserted, and an endeavor made to secure drainage of all pockets of pus through the one opening; but owing to the dense fibrous stroma of the gland each suppurating lobule may have to be incised separately.

Tuberculosis sometimes attacks the parotid lymph nodes, but very rarely affects the gland itself. Excision of these nodes is difficult without injuring the facial nerve.

Tumors of the Parotid.—The peculiarity of parotid tumors is that they usually are of the "mixed" variety (p. 106). This may be due to the situation of the parotid in the region of the first branchial cleft of fetal life. These tumors are very apt to contain cartilage, with areas of myxomatous degeneration; rarely cysts may form. They occur in young adults, and grow with extreme slowness; often no change is appreciable from year to year (Fig. 663). At first they are fairly well encapsulated, but owing to the deep relations of portions of the parotid gland, they appear to be fixed at an early stage of development. Though the tumor may grow to an immense size, the facial nerve seldom is affected; but the lobe of the ear becomes displaced, outward and upward. If rapid growth develops, as it usually does in time, malignancy should be suspected (Fig. 664). In very advanced cases, secondary enlargement of the cervical lymph nodes may occur. Similar growths may occur in the *submaxillary salivary glands*, but are much rarer, and seldom are distinctly cartilaginous.

Treatment.—If the patient is seen before the tumor is large, and before rapid growth has commenced, it often is possible to enucleate the growth from the substance of the parotid without injury to the facial nerve or Stenson's duct. Operation should be urged before the tumor grows very large. The incision should be made parallel with the branches of the facial nerve, nearly as high as the zygoma, and the knife should pass at once to the tumor, with no dissection of the superficial structures, as this is apt to injure the facial nerve. The growth is then enucleated, and the wound closed by buried and superficial sutures. In malignant cases wide-sweeping excision must be practised if any operation is undertaken, but an attempt should be made to preserve the facial nerve by exposing its main trunk before it enters the tumor. Preliminary ligation of the external carotid

artery often is advantageous. Blunt dissection should be avoided. The parts should be freely exposed, and nothing should be cut that cannot be seen. The operation is tedious, difficult, and dangerous. If the tumor extends far into the retro-maxillary fossa and appears densely adherent there, as ascertained by preliminary examination through the mouth, usually no operation should be done. (See also remarks on Excision of Tumors, p. 131).

FIG. 663.—Mixed tumor of parotid, age forty-two years; duration twenty-two years. Very slow growth. Episcopal Hospital.

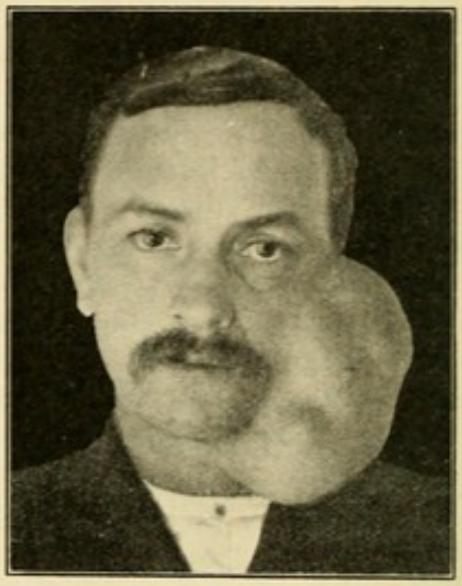

FIG. 664.—Mixed tumor of parotid (sarcomatous); twenty-one years' duration. Weight of tumor two pounds. Removed by the late Prof. Ashhurst, 1896. University Hospital.

Mikulicz's Disease (1892) is a rare affection characterized by painless, slowly developing, chronic, symmetrical enlargement of the parotid and lachrymal glands; sometimes the submaxillary and sublingual glands are involved also. In some cases there is general lymphatic involvement and enlargement of the spleen. There may be fever. If such constitutional remedies as arsenic and iodide of potash are ineffectual, extirpation may be justifiable for cosmetic reasons, or to relieve pressure on neighboring structures. The cause of the disease is unknown.

Salivary Fistula.—This usually arises in the parotid gland, especially in its main duct, as the result of injury (operative or accidental) or suppuration. The secretion discharges on the cheek which is kept constantly moist, especially while food is being masticated. The skin may become very much irritated. The mouth feels dry. The patient is rendered both conspicuous and miserable.

Treatment.—If the orifice is in front of the masseter muscle the fistula is not so difficult to cure. A cannula may be passed from the mucous surface of the cheek through the fistula on to the cheek where it makes two punctures, about one centimeter apart; a fine wire (of silver, iron, or bronze-aluminum) is then passed through these two

artificially made mucous orifices (Fig. 665), and is tied on the mucous surface (Fig. 666). The edges of the cutaneous orifice are then freshened, and it is closed by suture. The parotid secretions then find their way along the wire to the mouth, and by the time the wire cuts out and establishes an internal opening the cutaneous orifice has healed. If the fistula is situated over the masseter muscle, attempts should be made to construct a channel forward in the cheek to its anterior edge, either

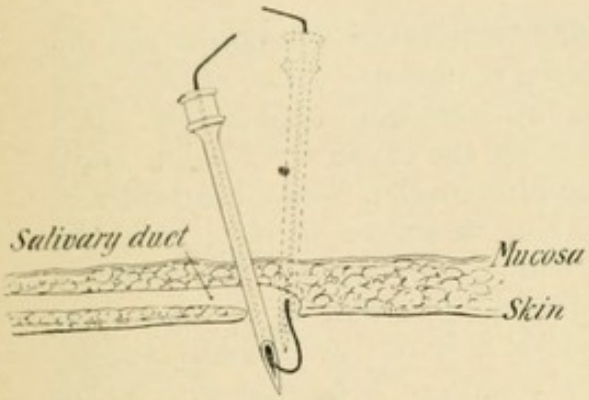

Fig. 665.—Operation for salivary fistula: both ends of a wire are conducted to the mucous surface of the cheek through puncture made by a cannula.

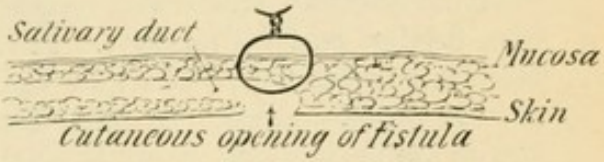

Fig. 666.—Operation for salivary fistula: the wire is tied on the mucous surface.

by establishing a seton, as in the method just described, or by a formal plastic operation. Occasionally partial excision of the parotid gland will be necessary to cause cessation of discharge. If no infection is present, simple ligation of the main duct on the central side of the fistula may result in atrophy of the gland.

Sialo-lithiasis or **Salivary Calculus** is not a very uncommon condition. In 1908 Bendixen referred to 216 cases. The calculous formation is due to bacterial action on the secretion of the glands, as in the pathogenesis of biliary calculi. The calculus usually obstructs the excretory duct, causing secondary enlargement of the glands, with mild inflammatory symptoms. Occasionally recurrent attacks of colic occur. The affection is much more common in the submaxillary than in either the parotid or sublingual gland. Often the calculus is palpable in the floor of the mouth, just beneath the mucosa. *Treatment* consists in removal of the stone by incision in the floor of the mouth; if the calculus is in the body of the gland, and especially if there is suppuration or a cutaneous fistula, it is better to excise the entire gland, by an incision beneath the mandible.



Fig. 667.—Chronic inflammation of submaxillary and sublingual salivary glands and of submaxillary lymph nodes. Episcopal Hospital.

Chronic Inflammation may affect the submaxillary and sublingual salivary glands. The affection may simulate a neoplasm in its gradual

onset and indolent course. Usually the glands are found to contain minute abscesses, and there is increase in the connective tissue. Extirpation is the proper treatment (Fig. 667).

SURGERY OF THE EAR.

Foreign Bodies.—It is necessary first to ascertain whether or not the foreign body still is present. In children the history is not always very clear, and much harm may be done by incautious exploration. If a probe or forceps is pushed blindly along the canal, the foreign body may be driven further in. Under good illumination from a head-mirror, and by drawing the pinna upward and backward to straighten the external auditory canal, the surgeon will be able to detect the presence of a foreign body (Fig. 668). In children the use of an ear speculum seldom is necessary, but where the canal is hairy, as in many adults, this is indispensable. In most cases persistent syringing with warm sterile saline solution or weak antiseptic will be successful in removing the foreign body; but if this is a pea or bean the soaking may cause it to swell up and thus render its removal more difficult. For such bodies, therefore, and for all others where syringing has failed, delicate forceps or scoop should be employed. The same methods should be employed in cases of *impacted cerumen*.

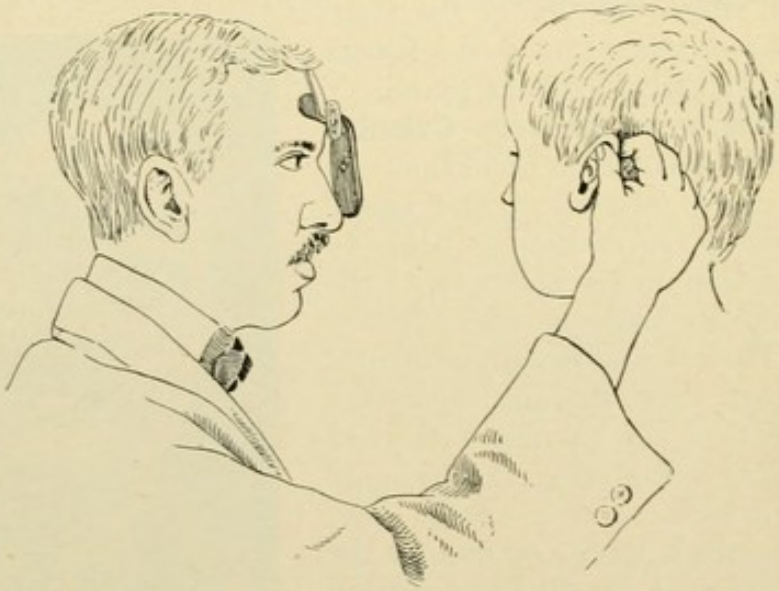

FIG. 668.—Examination of external auditory canal by light reflected from a head-mirror.

Furuncle.—Furuncle of the auditory canal is an exceedingly painful condition which requires prompt incision. Even though the sharpest knife is used, and the incision made with great delicacy, the pain is excruciating, but if the auriculo-temporal nerve, just in front of the tragus, is infiltrated with a few drops of a 2 per cent. novocain solution complete anesthesia is secured (Skillern, 1913). After opening, the crater of the furuncle should be touched with a drop of tincture of

iodin or pure carbolic acid; and a small pledget of cotton should be introduced, and an aseptic dressing then bandaged to the auricle.

Hematoma Auris or **Othematoma** usually is the result of a blow. It is not uncommon in patients in insane asylums, who can give no account of its appearance; and on this account it has been thought to have some occult connection with unsoundness of mind. If it ever develops spontaneously, it probably is to be attributed to arterio-sclerotic changes. The effused blood separates the skin from the cartilage, usually over the pinna; and unless proper treatment is instituted the auricle will become conspicuously deformed from organization and cicatrization of the thrombus. The blood may be aspirated by a hypodermic needle in very recent cases; but usually the blood is semi-clotted, and an incision is necessary. This should be made along the helix (Fig. 669), and after the blood is evacuated the skin should be reapplied very carefully to the underlying cartilage and should be held against it by accurate adjustment of small pads and a firm bandage. Unless this coaptation is very firm and exact, re-accumulation of blood will occur. After a few days massage should be employed.

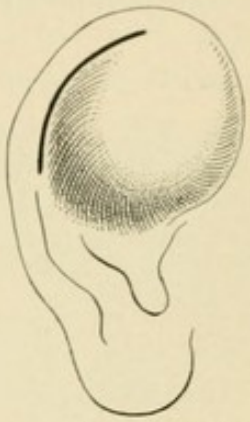

FIG. 669.—Proper incision to evacuate an othematoma.

Prominence of the Auricle, either congenital or acquired, may be remedied by suitable plastic operation. In the usual congenital form the pinna hangs down like a hood, and the condition is named "lop-ear." Generally it is sufficient to remove an ellipse of skin from the posterior surface of the auricle and adjoining scalp, and then to suture the ear against the head and keep it in place by a firm bandage. Some such support should be worn for several weeks. Occasionally it is necessary to excise some of the cartilage of the auricle also.

Supernumerary Auricles are not very rare. Excision is the proper treatment.

Otitis Media.—The middle ear is a mucous-lined cavity, draining into the pharynx through a long and narrow channel, the Eustachian tube. Infection usually ascends from the pharynx, which often is septic, especially if adenoids are present. Occlusion of the Eustachian tube or of either of its orifices renders the middle ear a closed chamber where microbes are prone to multiply and increase in virulence. The middle ear in these respects resembles the vermiform appendix. In cases of middle-ear disease or its complications, the services of an otologist are desirable; but as these cannot always be obtained in emergency, the general surgeon may be called upon to treat the acute stages of such lesions. Only emergency treatment, therefore, is considered in this work.

Catarrhal inflammation of the middle ear frequently develops after an attack of measles, pneumonia, scarlatina, or other infectious

disease. It is accompanied by ear-ache, slight deafness, a sense of fulness in the ear, slight feverishness, and probably some dysphagia. Inspection of the drum membrane, with reflected light, through a speculum, shows it reddened and swollen, and sometimes bulging, especially in the posterior part. By moving the patient's head back and forth it may be possible to see the undulation of fluid through the semi-transparent drum membrane. Later the membrane becomes opaque.

In *acute purulent inflammation* of the middle ear the symptoms are the same in kind though usually more severe in degree. The affection usually is purulent from the first, and does not follow catarrhal inflammation. In children the affection may run its course almost without pain, although pressure on the tragus usually is painful, as the bony canal is still incomplete, and movements of the auricle are communicated to the middle ear. Often only a sudden rise of temperature will show any deviation from the normal. This is so frequently the case in children that any sudden rise of temperature during convalescence from the exanthemas, influenza, bronchitis, etc., demands examination of the ears. If such examination is neglected, the first thing to attract attention to the ear may be the discharge of pus following spontaneous perforation of the drum membrane.

Treatment.—Simple "ear-ache," which may be due to referred pain from pharyngeal or dental affections, or may be a mild form of catarrhal otitis media, usually may be relieved by instillation into the external auditory canal of a few drops of hot water. This is quite efficient as hot laudanum or other drug. It is the heat rather than the drug that is effective. If there is evidence of accumulation of fluid within the tympanic cavity, especially if there is any bulging of the membrane, this should be incised (*myringotomy*): after suitable cleansing of the canal by dilute hydrogen peroxide and aseptic syringing, the incision is made in a curved line around the entire posterior circumference of the drum membrane, thus forming a flap, which allows much more free and prolonged drainage than a mere puncture. The point of the knife should not do more than penetrate the membrane, as the tympanic cavity may be very shallow. The ear is drained by a small strip of gauze extending just as far as the drum membrane; this should be renewed as often as it becomes soaked with discharge—several times an hour if necessary. Several times daily, not oftener than every two or three hours, the canal should be irrigated gently with a weak antiseptic solution. Heat to the mastoid will be grateful, and sedatives may be requisite to allay the pain. The patient must be confined to bed for several days. The nasopharynx, whence the infection usually has come, should receive appropriate treatment.

Acute Mastoiditis.—Invasion of the mastoid cells, by extension of inflammation from the middle ear through the aditus and the antrum, occurs in many cases of acute purulent otitis media. Prompt treatment of the middle-ear disease by myringotomy will permit

recovery in many cases without permanent damage to the antrum or mastoid. If the discharge of pus persists long, and is profuse, in spite of proper conservative treatment of the middle ear, it usually indicates that there is involvement of the mastoid cells. This is a chronic condition, however, and does not concern us here. Not infrequently, shortly before symptoms of *acute* mastoiditis appear, an ear which had been "running" for months or years suddenly ceases to discharge. The patient has pain in and behind the ear; there is fever, perhaps chilliness or an actual chill; headache and general malaise. The mastoid is tender, not only at its tip, as sometimes occurs in cases of simple otitis media, but especially over the emissary vein and the antrum; and in some cases there is evidence of periosteitis. In children pus often makes its way outward along the petro-mastoid suture, bulges beneath the periosteum, and causes the auricle to stand away from the head in a very characteristic manner (Fig. 670). In rarer cases an abscess forms deep in the neck beneath the sterno-mastoid muscle (*Bezold's abscess*). In adults movement of the auricle is not painful; this is an important differential sign from furunculosis of the external auditory meatus. But in children, in whom the bony canal is less well developed, movement of the auricle is communicated to the middle ear and hence usually causes pain.

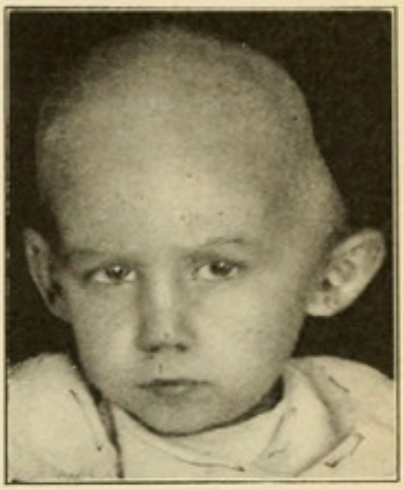

FIG. 670. — Mastoid abscess (left) pointing through petro-mastoid suture. Age three and a half years. (Dr. Gibbs's case.) Episcopal Hospital.

Diagnosis.—This rests on the previous history of the case, namely, onset of ear trouble usually in convalescence from an acute infectious disease; on the existence, past or present, of chronic otitis media; and on physical examination of the ear, showing mastoid tenderness, redness, and edema, perhaps with protrusion of the auricle.

Prognosis.—If the infecting organism is the staphylococcus or even the pneumococcus, recovery without operative treatment (other than myringotomy) may occur in a fair proportion of cases. Where the streptococcus or the Bacillus mucosus capsulatus is found, bone destruction is apt to be much greater, and very seldom can operation be avoided.

Treatment.—In cases which develop soon or immediately after the first appearance of an otitis media, operation on the mastoid may be delayed one or two days, to ascertain what effect the myringotomy will have on the mastoid symptoms. But if the B. mucosus capsulatus is found in the discharge from the middle ear no delay in operating should be permitted; operation should not be postponed even until the next day. When the streptococcus is found delay never should be longer than one week, even when clear signs of mastoiditis are

lacking. Prompt drainage of the infected bone is demanded. There is great risk of sinus thrombosis (p. 577) or brain abscess (p. 579) if there is delay, especially in cases occurring as exacerbations of long standing middle-ear disease with inefficient drainage.

Operation for Acute Mastoiditis.—An incision is made from the tip of the mastoid process upward, parallel with and about 5 mm. posterior to the attachment of the auricle, for a distance of two or three inches. This incision passes directly to the bone, but as in children the bone is very soft, great care should be taken not to cut too deeply. If the posterior auricular artery is divided, it should be clamped and ligated at once. The periosteum is then separated from the bone throughout the length of the incision, for a space of nearly an inch in width, exposing the posterior wall of the external auditory meatus, and the *suprameatal spine of Henle.* The sternomastoid muscle is

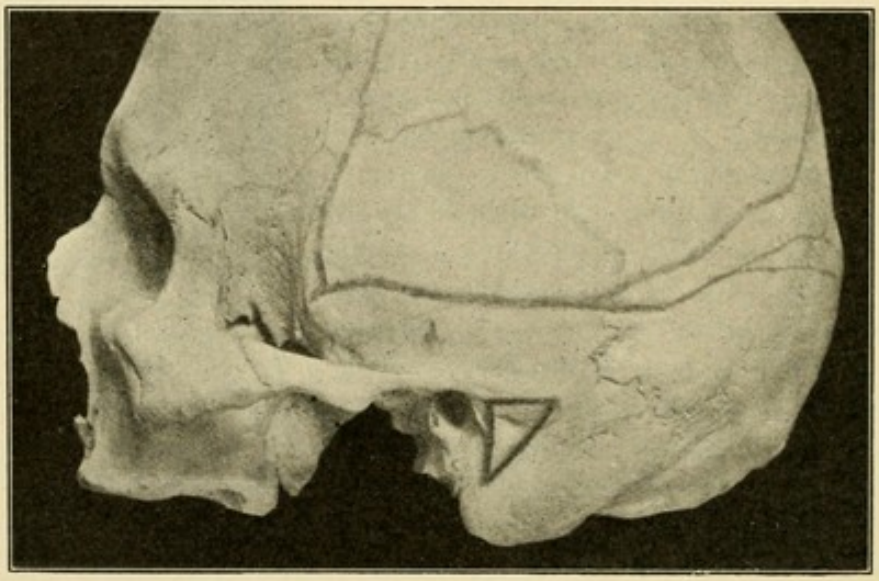

FIG. 671.—Macewen's triangle, outlined on the skull; and the suprameatal spine of Henle.

then detached from the mastoid tip, cutting it close to the bone. If more room is required at any stage of the operation an incision is carried backward from the centre of the post-auricular incision, and the two triangular flaps so formed are elevated from the bone. The surgeon next identifies the *suprameatal triangle* (Macewen, 1893), which lies above and behind the external auditory meatus; it is bounded in front by the bony wall of this canal and the suprameatal spine, above by the posterior root of the zygoma, and posteriorly by a line joining these two (Fig. 671). This triangle is the guide to the situation of the antrum, over which it lies. In children the antrum lies at a higher level than in adults, in whom it is more behind than above the meatus. Usually the bone directly covering the antrum is perforated by minute venous channels, and the antrum may be located in this way. The antrum may be opened first (Fig. 672), as advised by Macewen; or the surgeon may first remove the cortex overlying

the mastoid cells, from the tip of the mastoid up to the antrum. If a dental engine is available, a rotary burr is a very satisfactory instrument. Usually, however, a gouge and mallet are used to remove the cortex, and then the pneumatic cells are excavated by a bone curette or fine gouge forceps. In young children a strong curette will remove the cortex also. The instruments should be made to cut from within outward, unless the parts are fully exposed. The entire mastoid, including its tip, should be removed; and in most cases all the pneumatic cells which are accessible, wherever situated, should be removed, including any in the posterior zygomatic root. As the pneumatic cells may extend along the petrous portion of the temporal bone even to its apex, it manifestly is impossible to remove all in every case, and in cases where the patient is extremely septic it undoubtedly is better merely to secure free drainage, and to leave the completion of

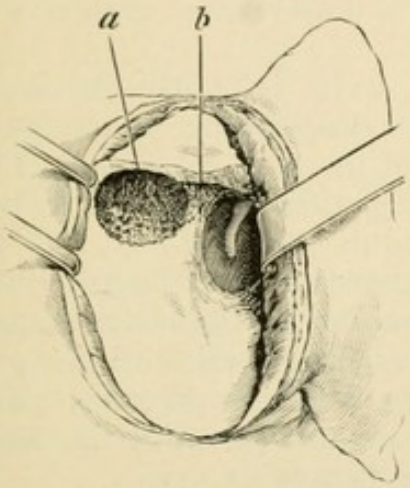

FIG. 672.—Operation upon the mastoid antrum. The antrum (*a*) has been laid open and gouged out, and the bridge of bone (*b*) between it and the external auditory meatus is seen. (Cheyne and Burghard.)

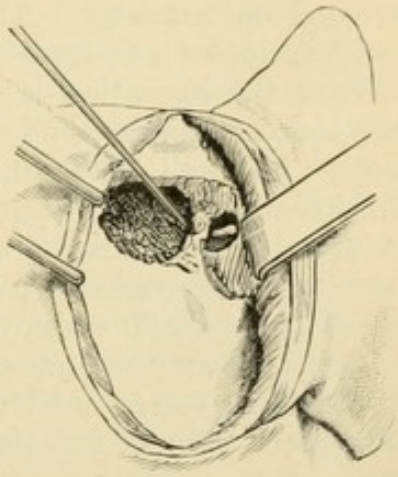

FIG. 673.—Operation upon the mastoid antrum. A bent probe has been introduced from the antrum to the middle ear. (Cheyne and Burghard.)

a radical operation for another occasion. But in every case, without exception, it is necessary to open the antrum, and thus accomplish the purpose of the operation, the securing of free drainage of this region of the middle ear through the mastoid. As the bone is being removed it should be repeatedly examined by the probe; the antrum is recognized by the probe passing first upward, then forward and inward into the middle ear (Fig. 673). A probe introduced into the middle ear through the perforated tympanic membrane may be an aid in locating the antrum.

The structures in most danger of injury are the *sigmoid sinus*, *the facial nerve*, and the *horizontal semicircular canal*. If a gouge is used, cutting from without inward, it should be bevelled on its convex surface, and should be applied very obliquely to the surface of the skull, so that if the lateral sinus is exposed it will be pushed ahead of the gouge and not wounded. Usually the inner

(vitreous) layer of the mastoid process, which separates the sinus from the pneumatic cells, may be recognized when the latter have been cleared away. If there is reason to suspect sinus thrombosis, this bone must be removed also, and the sinus treated as recommended at page 577. The facial nerve is in most danger as it passes outward and slightly backward beneath the floor of the *aditus ad antrum*. The horizontal semicircular canal projects into the median wall of the *aditus ad antrum*. The curette should not be used in either of these situations. The roof of the antrum and the aditus is very thin, and the *middle cranial fossa* lies directly above it; but this will not be opened if no bone is removed above the line of the temporal ridge (continuation of the posterior root of the zygoma). The condition of the bone forming the tegmen antri should be ascertained by very gentle probing. If it is carious or perforated it should be removed gently with curette or gouge forceps, since there may be an extradural abscess above it requiring drainage. The treatment of intracranial abscess has been considered at page 581.

When the operation is concluded the cavity is lightly tamponed with iodoform gauze, and the skin incision closed except at the lower angle. An aseptic dressing is applied, and the head bandaged. The after-treatment requires great care. The patient is confined to bed for several days; and the wound is dressed on the third day, and the gauze packing renewed. Not until firm granulations have formed should syringing be employed, but the sinus left by the operation and the external auditory meatus may be gently cleansed with pledgets of absorbent cotton moistened with dilute hydrogen peroxide. The subsequent care is that for any granulating surface. In the most favorable cases healing is complete in from four to six weeks.

SURGERY OF THE LIPS AND PALATE.

Hare-lip and Cleft Palate.—These, which are conveniently considered together, are the most frequent congenital deformities of the face. They are best understood by reference to the accompanying diagram (Fig. 674), which represents an embryo of three weeks. The fronto-nasal process (*a*) is descending between the maxillary processes (*b b*). The eyes are represented by *c c*, and the mandibular processes by *d d*. Failure of the embryonal maxillary processes to coalesce in the median line leaves a fissure of varying extent in the upper lip and palate.

If the fissure is single, it does not occupy the median line but corresponds to the line of junction between the intermaxillary bone (fronto-nasal process) and the superior maxilla. But a cleft of the soft palate, and one of the back part of the hard palate is in the median line, as the frontal process (intermaxillary bone) does not extend backward so far. In a complete double cleft of the palate, therefore, the fissure is Y-shaped, double in front, and single behind.

If the fissure is double, the intermaxillary bone usually projects in front of the lip (Fig. 675), and the fissures may involve both palate and lip, or either one to the exclusion of the other. As a general rule it may be said that cleft palate without hare-lip is very rare, while hare-lip without accompanying deformity of the palate is fairly common.

The proper age for operation always has been a matter of discussion. As the existence of cleft palate is a more serious disability than that of hare-lip, it should take precedence in matter of operation. Where there is no deformity of the palate, the best time for operation on the lip is from six weeks to three months after birth. Those surgeons who have most experience with these deformities have come to share the opinion of Brophy, of Chicago, who since 1900 has been urging that the best age for operation on the palate is between the age of two weeks and three months. When not contraindicated, the hare-lip may be repaired at the same time. But the palate should be repaired before the lip. Infants with cleft palate and hare-lip usually are stronger soon after birth than subsequently, owing to the difficulty of suckling them. In such young patients operation may be done without an anesthetic if absolutely necessary; they have no apprehension of pain or suffering to come, nor any memory of it after it has past.

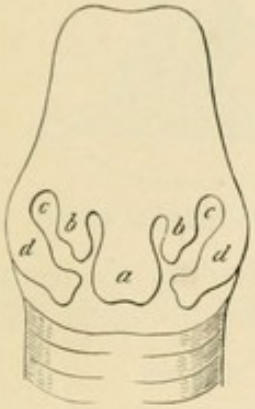

FIG. 674.—The head of an embryo of three weeks. (See text.)

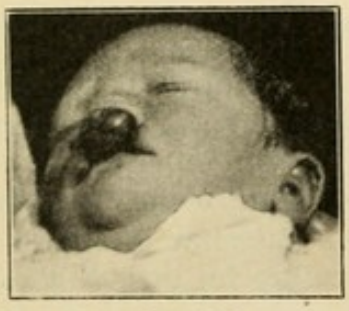

FIG. 675.—Double hare-lip and cleft palate. Age two days. Note the projecting intermaxillary bone. Orthopædic Hospital.

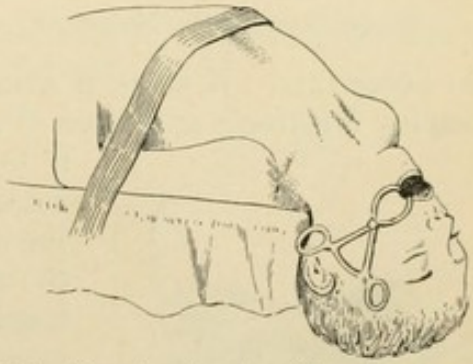

FIG. 676.—Hanging head position, for operations on the palate.

But in most cases there is no contraindication to the use of ether or chloroform. Ether is preferable in older children and in adults. It is administered in the "hanging head" position (E. Rose, 1874), and the surgeon stands at the patient's head, thus getting a good view of the inverted palate (Fig. 676). The use of a mouth tube for anesthetization is a great convenience.

Hare-lip.—*Single hare-lip* varies from a mere notch to a fissure extending into the nostril, and perhaps continuous with a unilateral

cleft of the palate. The principle of the operation consists in freshening the edges of the fissure and suturing them together. The lip is

Fig. 677

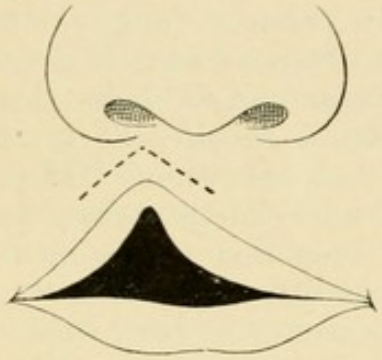

Fig. 678

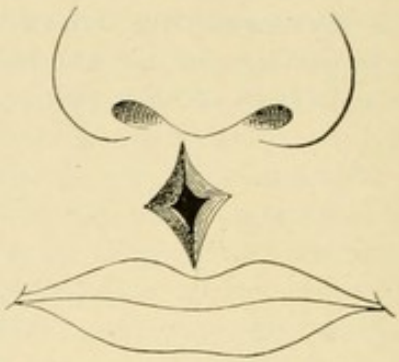

Figs. 677 and 678.—Nélaton's method for incomplete single hare-lip.

first freely separated from the upper jaw, by dividing the frenum or other adhesions. Bleeding should be controlled promptly by mos-

Fig. 679

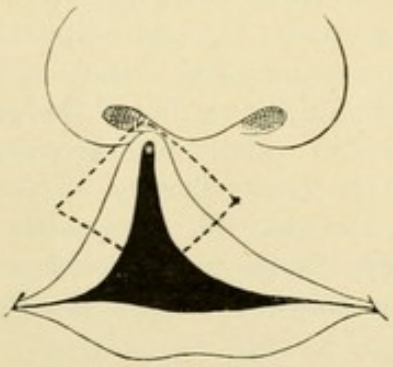

Fig. 680

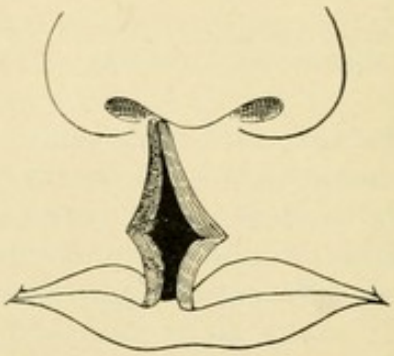

Figs. 679 and 680.—Malgaigne's method for complete single hare-lip.

quito hemostats. If there is a mere notch in the lip it is sufficient to employ Nélaton's operation (Figs. 677 and 678); usually, however, it is better to pare both edges of the fissure in a line slightly concave toward the median line. The knife is entered at the apex of the fissure for denuding each margin; and care is taken that these incisions unite above the apex of the fissure and that enough of each flap is left at the free border of the lip to ensure a *projection* on the vermilion border when the edges are united (Figs. 679 and 680; Malgaigne's operation, 1844); if the vermilion border is sutured flush, the contraction of the cicatrix soon will cause a depression. Interrupted sutures of fine silkworm gut or horsehair are used. They are introduced from the cutaneous surface down to but not through the mucous membrane.

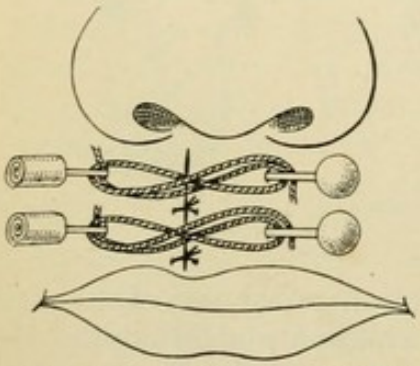

Fig. 681.—Hare-lip pins in use with twisted suture; points of pins cut off and wrapped in adhesive plaster.

Or hare-lip pins and a twisted suture may be used for the main support, with superficial interrupted sutures to secure accurate coaptation

FIG. 682 FIG. 683

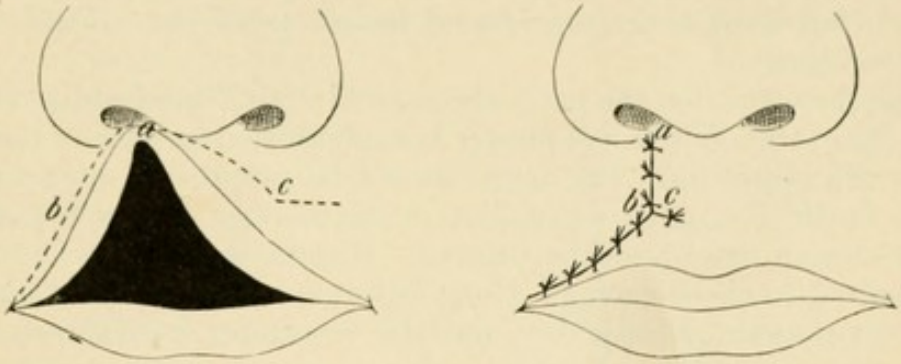

FIGS. 682 and 683.—Owen's method for complete single hare-lip.

(Fig. 681). If the fissure is larger than a mere notch, it is better to adopt some form of plastic operation, as indicated in Figs. 682 and

FIG. 684 FIG. 685

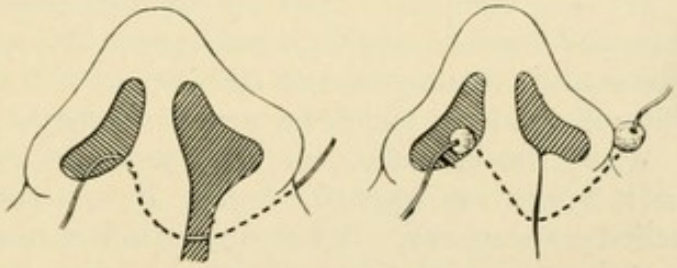

FIGS. 684 and 685.—Method of improving the shape of the nostril. (Stone.)

683. *To improve the nostril*, a wire suture shotted at both ends may be passed as indicated in Figs. 684 and 685.

FIG. 686 FIG. 687

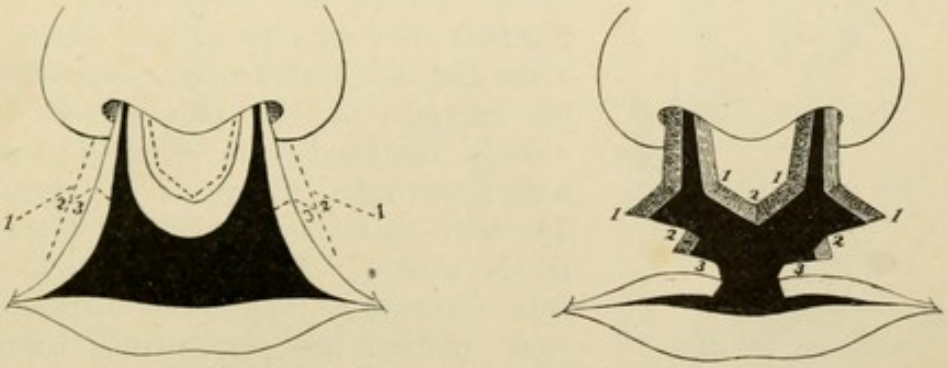

FIGS. 686 and 687.—Hagedorn's method for double hare-lip.

Double Hare-lip.—The operation here is the same as in cases of single hare-lip, the margins of each fissure being freshened and sutured separately; but often it is well to bring a small flap from the larger side across beneath the intermaxillary bone, to form the prolabium; and

if there is sufficient tissue a second still smaller flap from the other side may be introduced between this flap and the intermaxillary bone If the intermaxillary bone protrudes and cannot be pushed back into place even by division of its attachment to the septum, it may be excised; but as it bears the central incisor teeth this should not be done recklessly.

After the operation the parts are painted with Whitehead's varnish,[1] and a long strip of adhesive plaster is applied from one ear to the other across the upper lip. The baby should be put to the breast or fed from a bottle as soon as convenient, as the motions involved in sucking tend to lessen tension on the sutures. Minute doses of paregoric may be required to check crying. Every alternate stitch may be removed about the fourth or sixth day, and the remainder from the eighth to the tenth day.

Cleft Palate.—If the operation is done in early infancy the maxillary bones are cartilaginous, and may be brought into apposition by moderate pressure. This permits suture of the vivified margins of the cleft without tension, and restoration of normal relations of the parts concerned in phonation before the child begins to talk. If the operation is not done until after the age of two years, and particularly in older children and adults, a much more difficult and tedious method will have to be employed, and the patient will have acquired improper habits of speaking which he never will be able completely to abandon. When the operation for cleft palate is confined to the soft palate, it is known as *staphylorrhaphy;* if it involves the hard palate it is called *uranoplasty.* Before operation is undertaken it is important that the patient be free of coryza, pharyngitis, or other inflammatory conditions of the upper respiratory tract.

Early operation.—This consists essentially in passing sutures of heavy wire across the cleft (above the horizontal process of the palate bone) from the buccal surface of one maxilla to that of the other (Fig. 688). These sutures are then twisted tightly together over perforated lead plates; and when the maxillæ are thus approximated the margins of the palatal cleft (previously denuded) are sutured together with interrupted sutures of silkworm gut. The wire sutures are removed after four to six weeks. Though some slight pressure ulceration may occur beneath the lead plates no permanent harm is done.

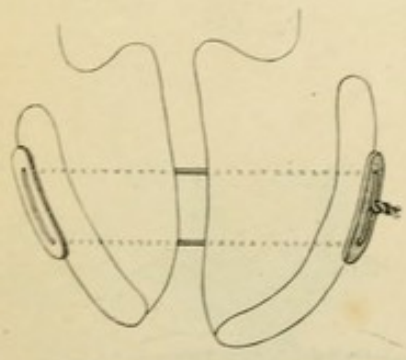

FIG. 688.—Wire sutures passed, for uranoplasty in infancy.

Late Operation.—Here the maxilla cannot be approximated, and it is necessary to close the cleft solely by means of the soft parts. The

[1] Whitehead's varnish is made by substituting for the spirit ordinarily used in the preparation of "Friar's Balsam" (compound tincture of benzoin), a saturated ethereal solution of iodoform, adding one volume in ten of turpentine.

margins of the cleft are freshened first; usually they cannot be made to meet even under great tension. Then an incision is made through the mucous membrane and periosteum of the hard palate close to the alveolar process; this is not carried so far posteriorly as to divide the trunk of the descending palatine artery as it emerges from the posterior palatine foramen, and it is placed so close to the alveolus as to leave most of the branches of this artery on the median side of the incision. Bleeding, which usually is very free, is controlled by packing the incision with gauze which is allowed to remain, while a similar incision is made in the palate of the other side. The mucous membrane and periosteum are now separated from the hard palate by suitable periosteal elevators from these lateral incisions to the median cleft (Fig. 689). Even when these flaps have been thus freed, it may be impossible to make the edges of the cleft meet in the median line without undue tension. The higher the arch of the palate the easier will it be to make the flaps meet, when thus separated from the palate above. To overcome the remaining tension it may be

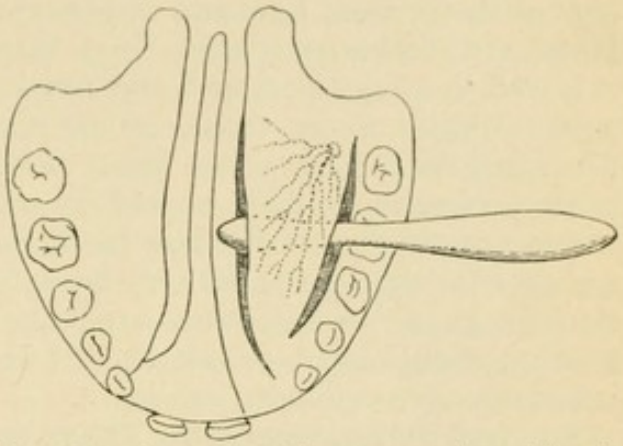

FIG. 689.—Separating the muco-periosteal flap in the operation for cleft palate.

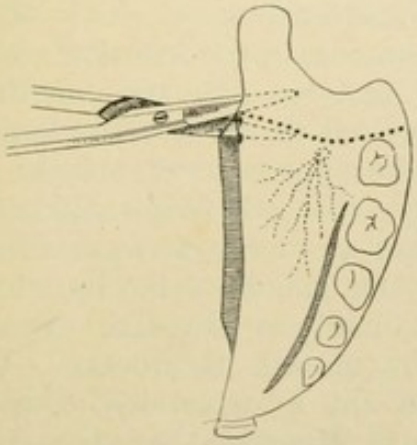

FIG. 690.—Cutting the aponeurosis of the velum at its insertion in the hard palate.

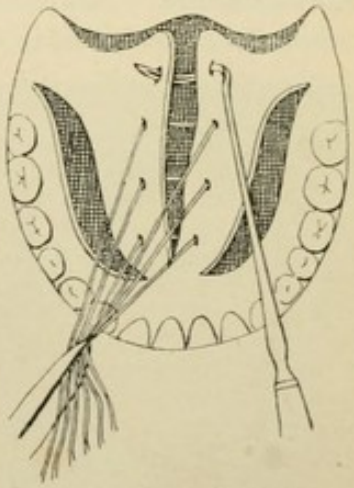

FIG. 691.—Introduction of sutures, in the operation for cleft palate.

necessary to divide the aponeurosis of the soft palate at its attachment to the hard palate. This is accomplished by use of scissors bent on the flat almost to a right angle; one blade is inserted between the detached mucoperiosteum and the under surface of the back of the hard palate, and the other along the nasal surface of the soft palate

(Fig. 690). The freshened edges of the cleft are finally united by interrupted sutures of silkworm gut, passed by means of special mounted needles, as indicated in Fig. 691. The sutures may be secured by clamping perforated shot over their ends. The wound is then covered by Whitehead's paint.

In the *after-treatment* the patient, especially if an infant, must be kept with the head low, and so placed that vomited matters, mucus, blood, etc., find a ready exit. If no marked opposition is encountered it is well to spray the mouth and nasal cavities with some weak antiseptic solution every three or four hours. Speaking should not be permitted for a week at the least. Liquid diet, meat juices, or broth being preferable to milk, should be employed until after removal of the sutures, when soft diet may be allowed. The sutures should not be removed for ten days unless they begin to cut out sooner. If the operation is not a success, from partial or complete sloughing, another attempt should not be made for at least a month, so as to allow the inflammatory swelling to subside.

Acquired Perforations of the Palate, the result of syphilis, of trauma, or of sloughing following infection, are very difficult to close by operation, and none should be attempted until the parts are in healthy condition. Usually a flap of mucous membrane must be inverted from one or both sides of the perforation. These are sutured together and the denuded area left to heal by granulation. In cases not admitting of operative relief some form of obturator should be worn in the form of a plate attached to the teeth. The obturator never should be introduced into the perforation itself, as this would surely cause it to grow larger by atrophy from pressure.

Macrocheilia.—Abnormal size of the lips, usually the lower, may be due to a congenital condition of lymphangiectasis. This often does not cause marked deformity until the age of puberty. Or the condition may be acquired as the result of hypertrophy following recurrent attacks of cellulitis (Fig. 692). It frequently is accompanied by an adenomatous condition of the mucous glands of the lip which may be palpable as shot-like nodules beneath the mucous membrane. The *treatment*, if any is demanded, consists in excision of a wedge-shaped section all across the lip, with suture of the mucous to the cutaneous border.

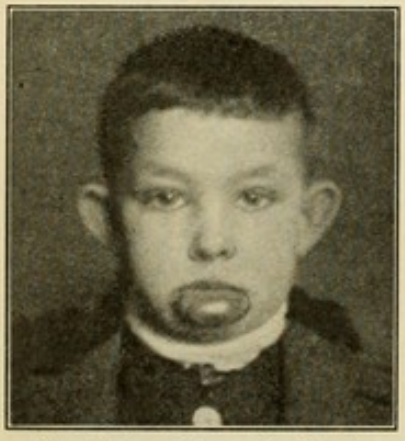

FIG. 692.—Macrocheilia in a boy of seven and a half years; not congenital; followed cellulitis from injury at eighteen months of age. Orthopædic Hospital.

Cysts.—Cysts of the labial mucous glands form small, rounded, submucous tumors. They may follow biting the lip. If punctured the cysts are apt to refill, so it is better to excise the anterior wall and cauterize the lining membrane.

Carbuncle.—Carbuncle, when it affects the upper lip, is an unusually serious form of the disease, from the danger of intracranial complications by thrombosis and embolism through the facial and angular veins. Bullock recently has collected notes of 27 cases, with six deaths, a mortality of 22 per cent. He advocates and practised with success in one case, early ligation of the facial veins about half an inch below the inner canthus of each eye. Early and free incision of the carbuncle is important, regardless of apparent deformity, as this may be remedied later by skin-grafting or plastic operation.

Epithelioma.—Epithelioma of the lip is a frequent condition, and for successful treatment requires early recognition. Frequently it follows chronic local irritation, notably the heat from a short-stemmed clay pipe; the explanation is that the moistened epithelium sticks to the absorbent clay and is peeled off the lip as the pipe is removed. An exfoliation results, with a tendency to keratosis. Less than 9 per cent. of cases of epithelioma of the lip occur in women; in men there is only one case in the upper lip to 45 in the lower, while in women there is one in the upper to every 7 in the lower lip (Butlin). The lesion usually begins to one side of the median line on the vermilion border of the lip (muco-cutaneous junction), and almost without exception is of the more malignant deep-seated type of epithelioma. An epithelioma beginning on the cutaneous surface of the lip often is of the less malignant superficial type (rodent ulcer).

The deep-seated epithelioma growing on the vermilion border of the lip may arise in a seborrheic patch, or as a primary papilloma. The former is much commoner. The lip is supplied by a row of sebaceous glands which often are visible in lips that appear to be normal, "as a slightly shaded or as a glittering band that stretches like a bow across the front of the lips between one corner of the mouth and the other," about half a centimeter above the cutaneous border (Montgomery). Somewhere on this line, crusts tend to form, and a typical seborrheic patch develops. Early invasion of the regional lymphatics occurs; but they are microscopically infected long before they become palpable. They should be searched for carefully, the finger of one hand being placed in the floor of the mouth, and the fingers of the other hand beneath the chin. The submental nodes are those first affected, then those around the submaxillary salivary glands (both sides), and finally the deep cervical lymph nodes along the great vessels. The nodes at first are indurated, and usually painless; but rarely are they distinctly palpable until the labial ulcer has existed for many months. As already remarked, long before they are palpable, probably within three or four months of the appearance of the lip lesion, microscopical examination of the submental nodes will show the presence of carcinoma cells.

As time goes on, the labial ulcer becomes a foul, fungating, stinking crater; the cervical lymphatics form conspicuous tumors; they adhere to the skin and form secondary ulcers of the same foul character as in the lip. The patient cannot eat; the stench renders him loathsome

to himself and every one near him; strength gradually fails; hemorrhages from the growth may occur; the trachea or esophagus may be compressed; and he dies a miserable and painful death, but not as rapidly as he could wish.

Diagnosis.—The diagnosis seldom offers much difficulty. Epithelioma occurs very rarely in patients under middle age; it is predisposed to by exposure to weather, by chronic local irritation of any kind; the area affected is covered with adherent crusts, which reveal a small bleeding ulcer when removed; from the surface of the ulcer it may be possible to squeeze out the epithelial pearls and columns of cancer cells lining the sebaceous ducts; the crusts soon form again; and the regional lymph nodes are not palpably enlarged until the lesion has existed for a number of months. A *chancre* of the lip is of much more acute development; may occur at any age; is frequent on the upper lip; presents parchment-like induration; does not tend to scab but has a macerated or sloughy surface which is very little inclined to bleed; a history of contagion usually can be elicited; lymphatic enlargements occurs within a few weeks, the nodes being soft and juicy on palpation; microscopic examination of smears from the lesion usually will reveal the presence of the Treponema pallidum; in due time skin lesions make their appearance; and antisyphilitic treatment is curative. A *gumma* of the lips is quite rare; it is painless; there is no lymphatic enlargement; the history or evidence of other syphilitic lesions usually can be obtained; and antisyphilitic treatment is rapidly effective.

Prognosis.—The expectation of life in cases in which no operation is done is from three to five years from the commencement of the disease, and about eighteen months from the time of diffuse lymphatic involvement. If radical operation is done before the lymphatics are perceptibly enlarged, from 50 to 60 per cent. of patients will be free from recurrence three years later; of those in whom recurrence takes place a small proportion can be permanently cured by a second operation, and the others will have an expectation of life dating from the period of recurrence. Recurrence is much more apt to develop in the lymphatics than in the lip; and a growth which develops in the lip may not be a recurrence, strictly speaking, but a development of a new epithelioma from a seborrheic patch in the neighboring skin used in forming the new lip at the first operation.

Treatment.—A lesion on the lower lip which is merely suspected of being carcinomatous should be excised, with a margin of at least a quarter of an inch on all sides, and subjected to microscopical examination. If there is no evidence of malignancy this operation may be regarded as sufficient. If the patient refuses to have the suspected patch excised, treatment as for keratosis senilis (page 622) may be instituted; but the surgeon should not forget that he is dealing in the lower lip with a very different form of epithelioma from the rodent ulcer where such treatment is in a few cases successful. There need be no anticipation of success if the growth on the lower lip is really an epithelioma. If such a lesion is either clinically or microscopically

malignant, it is necessary to remove the adjacent lymph nodes also. The growth on the lower lip should then be excised with a margin of at least a half inch on each side, by incisions at right angles to the line of the lip, not by a V-shaped incision.

The operation introduced by Grant, of Denver (1899), usually is employed now (Figs. 693 and 694). After excision of the lesion, usually including most of the lower lip, in form of a rectangle, incisions are carried downward and outward from the lower angles of this rectangle, so as to expose the submaxillary region on each side. These regions are then cleared of lymph nodes, ligating the facial vessels if necessary. Finally the submental lymph nodes are removed through a separate median incision. By drawing together in the median line the flaps outlined by the two lateral incisions, the lower lip is well restored without further plastic procedure. The other chief merit claimed

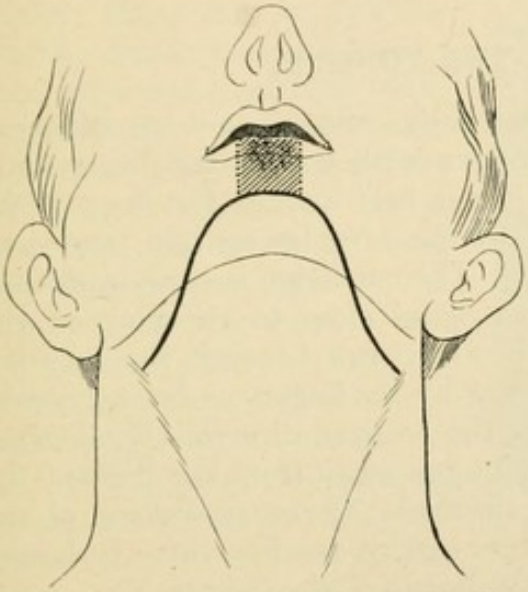

FIG. 693.—Grant's operation for epithelioma of the lower lip.

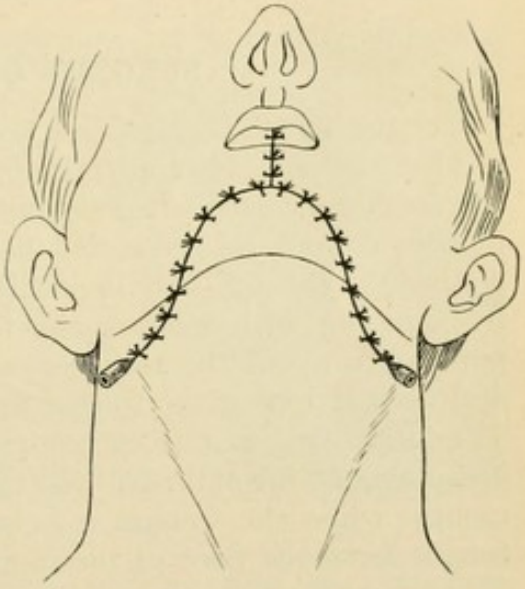

FIG. 694.—Grant's operation completed.

for this operation is that it leaves the point of the chin untouched, and that this serves as a firm basis of support for the new lower lip. But it will be noted that this method of operation does not remove the labial growth in one mass with its related lymphatics, but extirpates the diseased tissue in three or four separate sections. Moreover, the cavity of the mouth is opened as the first step in the operation, exposing the entire wound to contamination during the tedious dissection of the submaxillary and submental regions.

For these reasons I think it is better to commence the operation by the removal of the submental and submaxillary lymphatics. These regions are well exposed by making a long curved incision which corresponds to those incisions of Grant's operation which are represented by solid lines in Fig. 693. The skin over the point of the chin may be left attached by carrying this first incision a little lower than indicated. The flap thus outlined is dissected downward, including with the skin

only the platysma, and leaving the fatty and lymphatic tissues *in situ*. When the submental and both submaxillary regions have been exposed in this way they are cleared of lymphatics and fat by dissection from below upward; and the diseased structures are removed. Incisions are then made upward into the mouth on each side of the labial growth, and the lower lip is excised. The submental flap is then sutured to the point of the chin, and the lateral flaps are united in the median line as in Grant's operation. It is well to drain both submaxillary regions from the outer angles of the lateral incisions for several days. Where the dissection has been very extensive it is better to carry a tube from the submental region in the median line through the floor of the mouth, draining the buccal secretions directly into the dressings, and thus lessening the chance of infecting the suture lines. The portions of the skin incisions not drained should be painted with Whitehead's varnish (p. 638).

SURGERY OF THE TONGUE.

Tongue-tie.—It happens occasionally, though not so often as mothers believe, that an infant is born with congenital shortness of the *frænum linguæ*. The tongue then is held against the floor of the mouth, cannot be protruded beyond the alveolar margin, and may occasion slight difficulty in suckling. The condition is easily remedied by snipping with scissors the tense band close to the floor of the mouth (to avoid the ranine vessels which run beneath the tongue), and then stripping the tongue upward by the fingers as far as needed. The bifid blade at one extremity of the grooved director (Fig. 706) is a convenient retractor to hold the tongue away from the floor of the mouth, while the frenum is being divided. If the separation of the tongue from the floor of the mouth is carried too far, there is danger of the baby being suffocated by "swallowing" the tongue.

Macroglossia.—Abnormal enlargement of the tongue, when not dependent upon constitutional causes, such as cretinism, may be congenital or acquired, as in the pathologically analogous condition of macrocheilia (p. 640), and from similar causes. In congenital cases the patients usually are mentally deficient. The protruding tongue becomes inflamed and dry from exposure to the air, resulting in stomatitis, with collection of sordes, fetor of the breath, etc. In time the incisor teeth of both jaws are pressed forward and the alveolar processes are distorted; but this deformity rarely becomes permanent before the tenth year.

Treatment.—Treatment consists in partial excision, usually of a wedged-shaped portion of the tip of the tongue, with suture of the remaining lateral flaps in the mid-line. Or, as the thickness of the tongue usually is more obnoxious than its breadth, a transverse resection may be done, making superior and inferior flaps. Preliminary ligation of the lingual arteries may be advisable if the tongue is very large, and Armstrong recommends the use of silver wire instead of

silkworm gut for suturing the tongue. The best time for operation is from the third to the sixth year.

Ranula.—Ranula is a cystic tumor between the tongue and the floor of the mouth. It is a clinical term, possibly descriptive of the frog-like appearance of patients when the growth is very large. Though occasionally congenital, in the vast majority of cases it is acquired; usually it is considered a retention cyst of one of the sublingual glands or its duct. It is not improbable that its pathogenesis is similar to that of galactocele (p. 703). Occasionally a salivary calculus may be the cause of obstruction of the duct, but as a rule no cause can be found. The cyst in most cases is of slow development and chronic in duration. It is unilocular. Conditions described as *acute*, and as *intermittent ranula* are also recognized, though very rare. In the acute cases a swelling suddenly appears beneath the tongue, the mucous membrane lining the floor of the mouth is raised above the dental border, salivation is profuse, speech, deglutition, and even respiration are interfered with, and suffocation may threaten. Astringent washes usually are sufficient to relieve the symptoms, and the cystic swelling may disappear as rapidly as it came, as was the case in the only patient with this rare affection I have seen; but sometimes incision is required. In the chronic cases the cyst, though unilateral at first, may spread so as to involve the entire sublingual region; very seldom at the present day is it allowed to grow so large as to project in the submental region. The mucous membrane slides freely over it, and its surface often is covered with dilated and tortuous veins (Fig. 695); it is semi-translucent, and the contents are a viscid, ropy, mucus. Ranula is most likely to be confounded with dermoid cysts, which, however, are rare; a dermoid cyst has thicker walls, pits on pressure, and is not translucent.

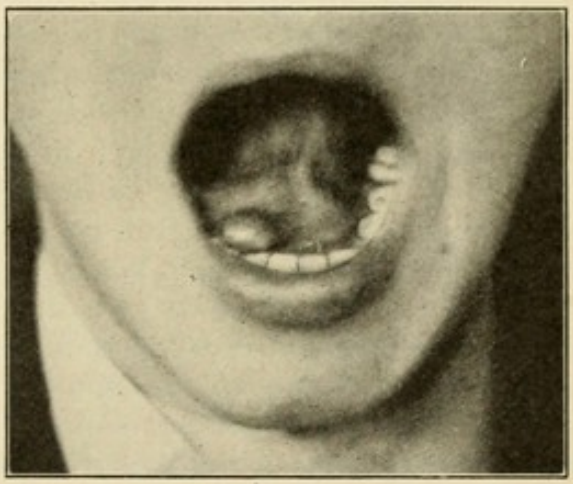

FIG. 695.—Ranula. Age eleven years; duration over one year. Projecting cyst is dark blue from overlying vein. Episcopal Hospital.

Treatment.—Excision of the anterior wall of the cyst, and scraping or cauterizing the remaining portion of the lining membrane, and packing the cavity with gauze until healing by granulation takes place, usually effect a cure. But unless a thorough operation is done and the after-treatment efficiently conducted, recurrence will take place. The operation can be done under cocain anesthesia, through the mouth.

Ludwig's Angina, or **Angina Ludovici,** is a condition first accurately described by Ludwig in 1834. It is an acute septic inflammatory

process involving the *cellular tissues of the floor of the mouth and the submaxillary region of one or both sides of the neck.* It is important to note that in this definition the main clinical features of the disease are indicated. It affects the connective tissue spaces, being a cellulitis, as asserted by G. G. Davis (1906), not a lymphangitis; the lymph nodes and the submaxillary and sublingual salivary glands are not primarily diseased, but may be invaded secondarily. It involves both the floor of the mouth and the cervical tissues. It is not confined to either. Usually it owes its origin to infection from dental lesions, and often commences after the extraction of teeth; but it may begin in the tonsil or other intrabuccal structure. The cellulitis spreads with great rapidity from the floor of the mouth around the posterior border of the mylo-hyoid muscle, a route to which attention was called by T. T. Thomas in 1907. Both sides of the neck are affected. The submaxillary gland and lymph nodes usually are found more or less intact in the centre of a necrotic area of cellular tissue.

It is not unusual for groups of patients to be affected nearly simultaneously, but the disease does not seem to be contagious.

Symptoms.—The onset of the disease is marked usually by difficulty in talking and swallowing, pain in the floor of the mouth, salivation, and finally dyspnea. The patient becomes profoundly septic, but gives evidences of little or no constitutional reaction. The temperature often is not very high, nor is there marked leukocytosis. Edema of the glottis may occur at any time, and T. T. Thomas believes this is the usual cause of death; but in many cases death seems to be due to toxemia, and suffocative symptoms are entirely absent.

Diagnosis.—The diagnosis depends on recognizing a possible cause; on demonstrating a cellulitis both in the floor of the mouth and in the upper cervical regions, perhaps extending to the clavicle, and often more marked on one side; and on the rapid progress of the disease to a fatal termination unless relieved by efficient treatment.

Treatment.—As soon as the diagnosis is made, and without waiting for the development of more serious symptoms, the parts should be incised. This may be done under local anesthesia; general anesthesia may be out of the question, owing to the suffocative symptoms. An incision is made directly in the median line in the submental region, between the genio-hyoid muscles; the knife is pushed up into the floor of the mouth, emerging just behind the symphysis menti. There are no structures of importance in the median line. A drainage tube is then drawn through from the submental region to the floor of the mouth. An incision is then made in one or both submaxillary regions, and a tract is made by thrusting a hemostat into the mouth through the mylohyoid muscle. Tubes are then inserted in these additional tracts; or one long tube may be made to pass from one submaxillary region to the other across the floor of the mouth above the mylohyoid muscle (Fig. 696). In addition, if the sublingual tissue is markedly edematous, it is well to incise the mucous membrane of the floor of the mouth from the mid-line to the second molar tooth, as advised by J. W.

Price (1908), and gently to curette wherever a soft spot is found. Usually little or no pus is found, the infection being so severe that the tissues are unable to react. The parts are dressed with hot, moist antiseptic gauze, to form a poultice. Concentrated nutriment and stimulants should be given. Tracheotomy is required when edema of the glottis occurs. The mortality of the affection has varied from 20 to 40 per cent., in different series of cases.

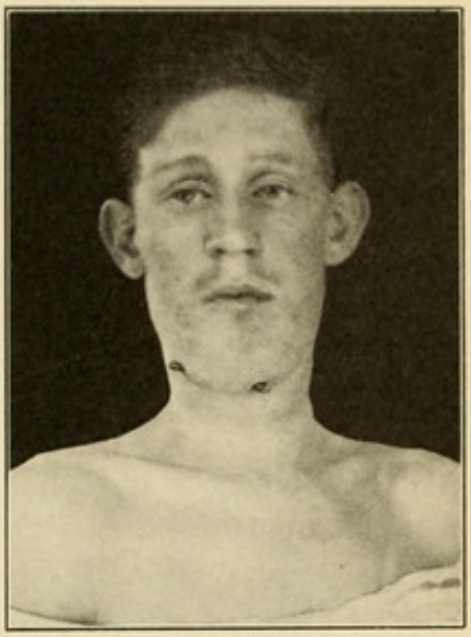

Fig. 696.—Ludwig's angina, in a patient of twenty-two years. After operation. (Dr. J. W. Price, Jr.'s case.) Episcopal Hospital.

Glossitis.—Acute Superficial Glossitis may follow burns, scalds, or other injuries, and the lesion may be catarrhal in character, or associated with destruction of the mucous membrane and the formation of one or more ulcers. Stomatitis of similar form may coexist. Healing readily occurs, as a rule, under the influence of alkaline mouth washes. An indolent ulcer may be touched with a drop of pure carbolic acid.

Acute Parenchymatous Glossitis, in which the tongue suddenly becomes immensely swollen, threatening suffocation, is described by systematic writers. It is an infectious process, analogous to but rarer than Ludwig's angina, and not affecting the sublingual nor the cervical tissues. Treatment consists in incising the dorsum of the tongue to the depth of 5 to 10 mm., each side of the median raphe, for a distance of about two inches. This rapidly relieves the swelling.

Abscess of the Tongue may be acute or chronic. Either form is rare, and the chronic form may be indistinguishable from a deep gumma of the tongue. If fair trial of antisyphilitic treatment causes no improvement, an exploratory incision should be made. Incision is the proper treatment also for acute abscess.

Chronic Superficial Glossitis is known by various other names, more or less descriptive of different stages of the disease. The best known and most used is *Leukoplakia*. Other names are Leukoma, Leukokeratosis, Smokers' Patches, Psoriasis, and Ichthyosis of the Tongue. These conditions derive their surgical importance from the fact that they are recognized as *precancerous diseases*, analogous to the senile keratosis of the skin discussed at page 622. The pathological change in the tongue consists in a proliferation of the epithelial cells, collection of leukocytes, and scar formation immediately beneath the epithelial layer. The patches may occur on the tongue alone, on the cheeks and lips alone, or on both tongue and other buccal surfaces. They are seen oftenest on the dorsum of the tongue near its tip, but not in the median line. They never occur behind the circumvallate

papillæ. They may be small or large, irregular, circular, circinate, or "geographical" in outline; they always spread, and different patches frequently coalesce. Early in the disease the patches appear as red, shiny, smooth areas on the tongue, surrounded by a distinctly furred area of mucous membrane (Smokers' Patches). Later these patches become bluish white, but retain their characteristic smoothness (Leukoplakia). Still later some evidences of thickening and induration are present, the patches are furrowed, and the fissures may be ulcerated (Leukokeratosis). This stage borders on the development of carcinomatous changes.

Cause.—The cause of this affection is not known, but is definitely related to several forms of chronic irritation. Of these the most important is smoking or the use of tobacco in any form; probably it is the chemicals in the tobacco, combined with the mechanical irritation, and, in the case of smoke, the heat, that renders its use so harmful. But many cases occur in those who have never used tobacco. Other predisposing causes are syphilis, when its tertiary stage is reached; psoriasis, or ichthyosis, elsewhere in the body; the presence of broken, or decayed teeth; irritation from badly fitting vulcanite dental plates, etc.

Symptoms.—The earliest symptom, which may be overlooked for many months, is smarting in the tongue after excessive smoking or drinking; later, pain is felt whenever highly seasoned or hot food is taken. But the patient may discover the patches accidentally, on looking in the mirror; or they may be called to his attention by his dentist or physician before any definite symptoms have arisen.

Treatment.—The use of tobacco *in any form* should be absolutely prohibited until entire disappearance of the lesions. Any other form of irritation, whether due to dental conditions or dietary indiscretions, should be remedied, and unirritating, preferably alkaline, mouth washes should be ordered. Cauterization of the lesions usually makes them worse. If there is a single, small, localized lesion, it may be excised. If epithelioma is suspected, a portion of the patch should be excised for microscopical examination.

Tuberculosis.—Tuberculosis of the tongue is rare. The lesion commences as a tuberculoma, but very seldom is it seen until this has broken down, leaving an ulcer. Usually the lesion is secondary to tuberculous disease elsewhere (lungs or larynx), and this gives the clue to the diagnosis. The tuberculous ulcer appears at the tip or edges of the tongue, rarely on the dorsum; it is superficial and lies in the long axis of the tongue; it is not indurated; has not raised or thickened borders; secretes thick and yellowish pus; and may be surrounded by caseous foci. It is commonest in men and in adults (Plate IV, Fig. 1). The ulcer is very painful. Early invasion of the cervical lymph nodes is usual.

Treatment.—In the very rare cases where tuberculosis is primary in the tongue it is proper to excise the lesion together with the enlarged lymph nodes. In most cases, however, nothing can be done save to

PLATE IV

FIG. 1

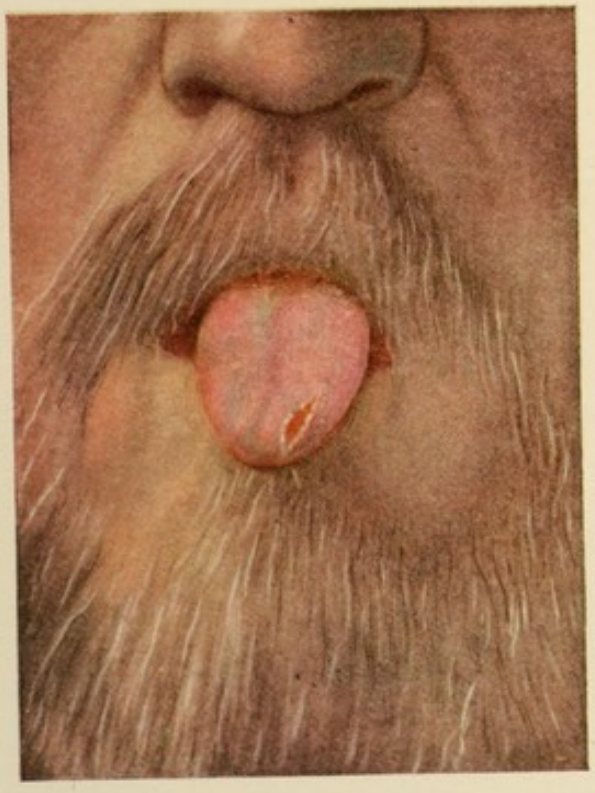

Tuberculous ulcer of the tongue, in a patient aged 47 years; has also tuberculous laryngitis. Episcopal Hospital.

FIG. 2

Diffuse gummatous glossitis in a woman aged 55 years, duration 4 years; chancre 25 years ago. Episcopal Hospital.

FIG. 3

Carcinoma of the tongue, in a man aged 59 years; duration 5 months. Excision of tongue. Recovery. Episcopal Hospital.

relieve the pain by local use of cocain or other anesthetic. Armstrong says spraying the affected area with a 1 per cent. solution of carbolic acid, to which a little sodium bicarbonate has been added, sometimes is soothing.

Syphilis.—Syphilis of the tongue is of most surgical interest in the gummatous stage. *Chancre* and *mucous patches* of the tongue and mouth present the same characteristics as these lesions elsewhere, and their diagnosis seldom is difficult. *Gumma* of the tongue may be single or multiple, superficial or deep. The lesions occur chiefly on the dorsum of the organ; they soon break down, and are apt to coalesce, forming large irregular, nearly painless ulcers with overhanging edges and covered with an adherent slough. The ulcers do not tend to bleed when the slough is pulled away; they are not indurated; they are not accompanied or followed by enlargement of the cervical lymph nodes; a history of previous syphilitic lesions usually can be obtained; and they rapidly improve under the administration of the iodides. These features serve to distinguish them from carcinomatous ulcers (p. 650). *Diffuse gummatous glossitis* as it heals leaves a characteristically fissured and furrowed tongue (Plate IV, Fig. 2).

Sarcoma.—Sarcoma of the tongue is very rare. Serafini, in 1910, reported what he believed was only the thirty-second case on record.

Carcinoma.—In the tongue this occurs almost invariably in the form of epithelioma, though a few cylindrical-celled carcinomas have been recorded. It is much more common in men than in women (about 15 to 1), and quite unusual before middle life. Frequently it seems to be brought on by chronic irritation, such as that from a broken tooth, from tobacco smoke, or the stem of a pipe (Plate IV, Fig. 3). The pre-cancerous lesions of the tongue already have been discussed (p. 647), and Butlin demonstrated not long ago that many lesions, previously considered by him and others as pre-cancerous, prove on microscopical examination to be actually malignant.

Usually the epithelioma begins in a fissure, an ulcer, or a patch of leukoplakia. Sometimes, but rarely, it appears first as a wart or papilloma; and any such growth on the tongue which does not disappear very promptly after removal of a recognized source of irritation should be considered malignant. The epithelioma commonly appears on the lateral margin of the tongue, very rarely at the tip, and almost never on the dorsum. It begins occasionally as a submucous growth, but even in such cases it is very seldom seen until an ulcer has formed; and in the vast majority of instances it develops in a preëxisting erosion or ulcer. It may begin in the floor of the mouth, but it is more usual for this to be invaded secondarily. A cancer in the *anterior third of the tongue* tends to spread to the floor of the mouth and mucous membrane covering the alveolus; it early invades the submental and submaxillary lymph nodes, first those on the same side as the growth, but later the involvement is bilateral. Next the deep cervical chain is invaded. The submaxillary and sublingual salivary glands usually are not invaded. A cancer in the *posterior two-thirds*

of the tongue tends to spread to the soft palate and pharynx; it invades the lymphatics of both sides very early; first the submaxillary, then the deep cervical. When the latter have been invaded by cancer arising in any part of the tongue, the growth spreads up their chain to the base of the skull and downward to the clavicle. Distant metastases occur very late and are quite unusual. In the vast majority of cases the disease is distinctly limited to the face and neck. When once the cervical lymph nodes are invaded, the tumor may grow in them with alarming rapidity, and these secondary growths may quite over-shadow the original trouble. The same progressively fatal course, but even more rapidly, is observed here as in the cervical growths following carcinoma of the lip (p. 641).

Symptoms.—Pain and smarting in the diseased area, especially on smoking, drinking alcoholic beverages, or eating hot or highly seasoned food, usually are the first things to attract the patient's attention. The tongue, or the whole mouth, may feel sore. There is difficulty and pain in swallowing, and the patient refrains from eating. Later even liquids can scarcely be taken. The tongue feels thick and clumsy. Speech becomes indistinct. Salivation is increased. Pain may be referred to the ear if the growth is far back in the tongue. Very rarely is pain altogether absent; but occasionally the patient is unaware of his condition until the tumor is inoperable. From inability to eat, sleepless nights, and constant pain, the patient rapidly becomes emaciated. If secondary infection occurs, there will be added feverishness, chilliness, and increased secretion from the tumor, with horrible fetor of the breath. Hemorrhages may occur from the mouth or from secondary ulcers in the neck. Death may occur from such a complication or from septic inhalation pneumonia, but more often follows a short period of delirium due to toxic absorption.

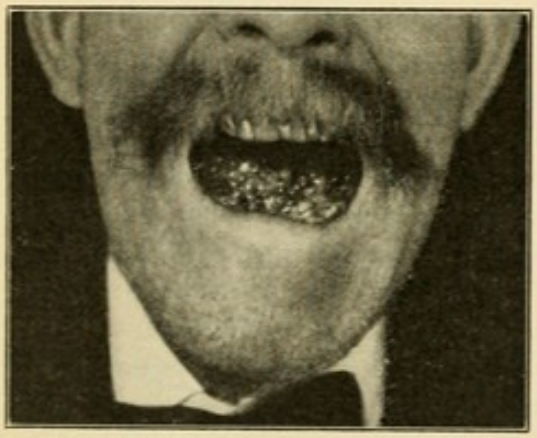

FIG. 697.—Recurrent carcinoma of floor of mouth. Excision of tongue by intrabuccal method in September, 1909, three months after appearance of growth. Recurrence in November, 1909. Photograph February 14, 1910. (Dr. H. C. Deaver's case.) Episcopal Hospital.

Diagnosis.—Carcinoma of the tongue must be distinguished chiefly from tuberculous and syphilitic ulcerations. The characteristics of these have been considered already (p. 648); but it should not be forgotten that carcinoma frequently develops in a syphilitic lesion. In carcinoma the main diagnostic points are the hardness of the ulcer's base; the thickness of its margins, the bleeding when the adherent slough is removed, exposing an uneven floor; the patient's age; and the existence of some chronic form of local irritation. Any ulcer even suspected of being carcinomatous should be subjected to micro-

scopical study. A portion of the ulcer may be removed easily by pulling the tongue far out of the mouth and injecting a few cubic centimeters of eucain solution (6 per cent.) beneath the ulcer; a *portion of the indurated margin of the ulcer* is then pinched up in forceps and cut off with scissors. Enlargement of the lymph nodes never should be depended upon for a clinical diagnosis. Long before they are palpable they are microscopically diseased. Yet the presence of enlarged lymph nodes points to carcinoma rather than to a tertiary syphilitic lesion.

Prognosis.—In cases entirely untreated, the expectation of life is not more than eighteen months from the time the growth is recognized. In many cases death occurs in less than nine months. By radical surgical treatment the expectation of life is almost doubled, and a certain number of patients (25 per cent. in Butlin's statistics), in whom early operation is done, remain free of recurrence for many years or until death from some other malady. Even in cases where recurrence takes place, this is almost always in the neck, and the patient is still able to take nourishment and does not suffer nearly so much pain as if the tumor was still growing in the mouth. The immediate mortality after radical operation is in general from 15 to 20 per cent. It is lower in uncomplicated cases, and much higher when part of the mandible or pharynx has to be removed.

Treatment.—Owen well says that most of these patients come to the surgeon when the tumor is so far advanced, that if he considered only his own peace of mind he would decline to undertake any operation. But whenever it is not inoperable, radical removal of the growth and the ralated lymph nodes is the only rational treatment. In deciding for or against operability, the surgeon should examine especially the local extent of the disease, and the range of lymphatic involvement. A cancer of the tongue cannot be considered inoperable merely because it has invaded the floor of the mouth or has eaten into the mandible. But if the entire floor of the mouth, on both sides, is densely infiltrated, and especially if the growth has extended along the anterior pillar of the fauces to the soft palate or pharynx, it generally will be impossible to cut wide enough of the growth to ensure freedom from local recurrence. In regard to lymphatic involvement, the surgeon should examine carefully and repeatedly the deep cervical lymphatics extending up to the base of the skull. If these are manifestly involved, and certainly if they are immovably adherent to the spinal muscles or the skull itself, he should decline to interfere with them. Involvement of the lymphatics downward is not so serious a matter, since it is very seldom that the disease process passes beyond the subclavian triangle; and the contents of this triangle and those above it can be removed with comparative facility by modern methods.

Most surgeons prefer to do in two stages whatever form of operation is undertaken. Armstrong, however, removes both the lymph nodes and the tongue at the same sitting. Usually the lingual growth is removed first; and after a week or ten days the cervical lymphatics

are dissected out. In early cases (3 to 5 months' duration) it may be sufficient to remove the lymphatics only from the bifurcation of the carotid up to the tongue and base of the skull; in more advanced cases the dissection must commence as low as the clavicle. If only the anterior third of the tongue is involved, most surgeons consider it sufficient to remove the submental nodes and the cervical nodes of the same side as the lingual lesion; but Da Costa urges that even in such cases the cervical lymphatics also on the other side should be excised, as he has found them involved at a very early stage. Nearly all authorities are agreed that, when the tumor involves the posterior part of the tongue, the lymphatics from both sides of the neck ought to be removed. This may require the division of the operation into three stages. Owen recommends, if the lymph nodes are increasing very rapidly in size, that the first operation should consist in extirpating them, since if the tongue is removed first, and the operation on the lymph nodes postponed for a couple of weeks, they may have become inoperable by that time.

The questions of the *preparation of the patient* and of the *anesthetic* are of importance. For several days previously special attention should be given to cleansing the patient's mouth,[1] and improving so far as possible, his general health. No operation should be done while there is an acute bronchial or pulmonary lesion. The anesthetic, preferably ether, should be given by a skilled anesthetist; wherever possible (and this should be the case in every well appointed hospital) the method of intratracheal insufflation (p. 154) should be employed. This minimizes or altogether prevents the chance of pulmonary complications, and permits the operation to be done in the head-high position, which markedly decreases the quantity of blood lost. If this method cannot be used, one of the other methods recommended at p. 153 for operations on the head and neck should be employed. A hypodermic of morphin and atropin should be given shortly before beginning the operation.

The *cervical lymphatics* are well exposed by the incisions recommended by Butlin (Fig. 698). The two triangles outlined are dissected free, the flaps being composed of skin alone, especially in the submental and submaxillary regions. If necessary another incision may be carried outward along the clavicle. All the fat and lymphatic tissues are then cleared out in one mass, beginning at the clavicle and working upward along the great vessels and forward to the region of the jaw. The common carotid artery may be temporarily clamped, close to the subclavian. The sternomastoid muscle may be divided or excised with the deeper structures to facilitate the dissection. The internal

[1] I have used Talbot's iodo-glycerole mouth wash with good effect before and after operation:

℞—Zinci iodidi (pur.),	3	parts
Water,	2	"
Iodin crystals,	5	"
Glycerin,	10	"

jugular vein may be excised if the growth is densely adherent; and the vagus nerve, and even the common carotid artery may be extirpated if necessary. But in those past fifty years of age removal of the carotid is inadvisable on account of the danger of softening of the brain and paralysis (Crile).

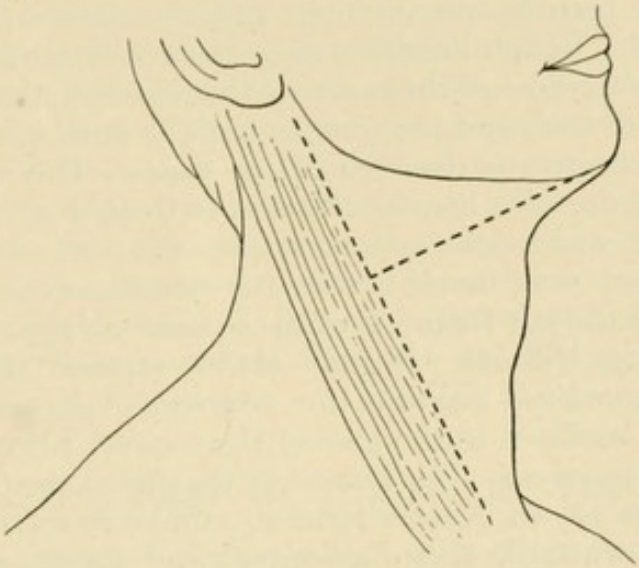

FIG. 698.—Butlin's incisions for extirpation of the cervical lymphatics.

For partial or complete *removal of the tongue*, various methods are in use.

Intrabuccal Method (Whitehead's Operation, 1881).—The tongue is held within the mouth chiefly by the frenum and the anterior pillars of the fauces. If these, and the mucous membrane between the tongue and the mandible, are divided, the tongue can be pulled far out of the mouth (Roux, 1839). In growths involving only a small area on the anterior part, it usually is sufficient to remove the half of the tongue diseased. A stout linen ligature is passed through the tip of the tongue on the healthy side, and after dividing the frenum and the mucous membrane on the diseased side of the floor of the mouth, the tongue is split down the middle by scissors, and the half to be removed is cut squarely across at least three-quarters of an inch behind the growth. The arteries are caught as they are cut: the lingual in the floor of the mouth, and the dorsalis linguæ as it spurts from the stump. They are tied securely, and the mucosa of the remaining half of the tongue is sutured to the border left attached to the mandible of the diseased side. If the entire tongue is to be removed by this method, each half of the tongue is removed separately, as above described, the precaution being taken to secure the stump of the tongue (glosso-epiglottidean fold) by a strong linen ligature before the second half is removed. This ligature is useful in controlling hemorrhage, and should be left hanging out of the mouth for a few days, to aid in overcoming any respiratory difficulty.

Method by Division of the Symphysis Menti.—This operation was introduced by Sédillot (1844), and a few years later by Syme. Kocher

has recently adopted it as his normal method. It is used for removal of the entire tongue in cases where the floor of the mouth is involved. The lower lip is divided in the mid-line, and this incision is carried down to the hyoid bone. The mandible is then drilled in two places on each side of the mid-line, to facilitate its subsequent wiring. The symphysis is then sawed through, and the halves of the mandible are separated. Rough handling may cause a fracture. The mucous membrane on the floor of the mouth is then divided, the lingual arteries are caught and tied, and the tongue, with as much of the floor of the mouth as necessary, is removed in one mass. The stump, with the two spurting dorsales linguæ arteries, is treated as in Whitehead's method, over which this operation presents few advantages. The exposure is not very much better, the wound left is very prone to infection, and the jaw frequently fails to unite solidly.

Submaxillary Methods.—Regnoli (1838) exposed the tongue by a transverse *suprahyoid incision*, for removal of its anterior portion. For a growth confined to the base of the tongue, Kocher has adopted *subhyoid pharyngotomy*. For tumors at the side of the tongue invading the floor of the mouth, Kocher formerly employed an incision from the symphysis downward, then backward, and finally upward to the mastoid; this is still known as *Kocher's method*. The skin-flap thus outlined is turned upward, the lymphatic tissue in the upper part of the neck is removed, and the external carotid artery and facial vein are ligated if necessary. The submaxillary salivary gland is removed, because though seldom itself invaded, there usually are lymph nodes imbedded in its lobules. The mouth is opened at the posterior border of the mylohyoid muscle, and the attachments of the tongue to the hyoid bone are severed. Then the tongue is drawn down into the wound, and its base is cut across. The wound must be freely drained, by a large tube passing from the buccal cavity out at the incision in the neck. *Langenbeck's Method* (1875) consists in making an incision from the angle of the mouth downward to the level of the thyroid cartilage, with division of the mandible between the first and second molar teeth, thus approaching the tongue from the side.

When it is necessary to *excise a portion of the mandible* along with the tongue and the floor of the mouth, Crespi and Bastianelli's modification (1890) of Langenbeck's method is to be preferred. The lower lip is divided in the median line, and the incision is carried backward to the mastoid, well below the jaw, as in Kocher's method. After clearing the upper cervical region, and ligating the external carotid artery and the facial vein, the mandible is divided well in front and behind the growth, and the tongue and floor of the mouth are removed in one piece with it. A similar operation gives the best exposure for cancer arising in or involving secondarily the floor of the mouth, whether or not excision of the mandible is required. To remedy the defect in the floor of the mouth, the remaining half of the tongue (if it has not required removal) may be split parallel with the floor of

the mouth, and thus can be spread out far enough to be sutured to the mucous membrane of the cheek, above the alveolus (v. Eiselsberg, 1904; W. Bartlett, 1907). If the mandible is not already edentulous the teeth may be pulled, and any mucous membrane still adherent to the jaw may be dissected away.

After removal of the tongue the patient still can make himself understood, and swallowing is not interfered with.

Palliative Operations sometimes are possible, even when the disease is too far advanced to afford hope of cure. The most important of these methods is *extirpation of the external carotid arteries*, on both sides, as introduced by Dawbarn (1903), to effect starvation of the lingual growth. Or they may be injected with paraffin. These methods are not applicable to cases where the lymphatic involvement over-shadows the original growth. The use of radium emanation and of the *x*-ray may be valuable in allaying pain, and in diminishing fetor and secretion.

OPERATIONS ON THE AIR SINUSES.

The air sinuses are mucous-lined cavities draining into the nasal passages, and like the middle ear are prone to become infected when their drainage is obstructed. The cure of adenoids, deflected septum, hypertrophied turbinates, and other seemingly minor conditions, therefore, becomes important as a prophylactic against more serious ailments. Acute infections of these accessory sinuses usually are treated successfully by the rhinologist by the intranasal route, and are by no means so important surgically as chronic infections, which require radical operation for their relief. These chronic lesions may consist merely of *empyema* of the sinus affected, or there may be *exuberant granulation tissue*, or even *mucous polypi*. As all these affections are rightly considered a part of the specialty of nose and throat diseases, it seems inexpedient to do more here than outline in the briefest possible manner the nature of the operations at present employed in their treatment. An acute exacerbation of a chronic lesion may occur at any time, and may be quickly fatal, especially in the case of the frontal, ethmoidal, and sphenoidal sinuses, unless immediate adequate drainage is provided.

The *diagnosis* of chronic sinusitis is not always easy, but depends in large measure upon persistent discharge of pus, found by intranasal examination to enter the nasal passages in the region where the suspected sinus normally drains. There are in addition, when drainage is inefficient, usually headache and localized tenderness. In *ethmoidal disease* the pain usually is referred to the bridge of the nose and the eyeball; in *sphenoidal sinusitis* it usually is between the eyes and in the occipital region; in *frontal sinusitis* the pain and tenderness are localized to the region above the root of the nose and the inner margin of the orbital cavity, and occasionally the pus perforates anteriorly and forms an abscess at the root of the nose; in *maxillary*

sinusitis the pain may be referred to the teeth, the nose, or all over the head, but tenderness usually is localized to the maxillary bone.

As a preliminary to all these operations, preparation of the nasal passages by a course of conservative treatment is essential to success. This usually comprises removal of the anterior portion of the middle turbinate bone which almost invariably is thickened and interferes with intranasal drainage. In cases of patients acutely ill it often is better to do an operation which is incomplete from the specialist's standpoint, consisting merely in securing adequate drainage by the most accessible route, and to postpone the ideal radical operation to another occasion, as in the parallel cases of acute mastoiditis (p. 632). Drainage tubes or gauze, employed in these nasal operations never should be allowed to remain in place more than forty-eight hours. Careful after-treatment, preferably conducted by a rhinologist, is necessary to complete the cure.

The **maxillary antrum** communicates with the nasal cavity through its middle meatus, and the opening is some distance above the floor of the sinus so that drainage is very imperfect. Infection may follow nasal disease or be due to extension upward from a carious tooth. When conservative measures fail, the surgeon may break through the outer wall of the nasal fossa, in the inferior meatus, thus establishing drainage at the level of the floor of the antrum. This may be done in emergency by firm pressure with the blunt ends of the blades of scissors curved on the flat. Usually it is preferable to open the maxillary sinus by gouge and mallet through the canine fossa, after incising and reflecting the mucous membrane and periosteum. A large opening in the outer wall of the sinus should be made, and its cavity should be cleared of polypi, necrotic bone, etc. Then the inner wall of the sinus is broken down as far as the level of its floor, working across its cavity. The nasal mucous membrane is preserved, is formed into a flap attached along the floor of the nose, and is turned outward to cover the floor of the maxillary sinus, which is thus freely drained into the inferior meatus of the nose. This mucous flap is held in place by packing introduced from the nasal cavity, and the incision in the alveolar tissues is closed by suture.

The **frontal sinus** is readily exposed by applying a small trephine just to one side of the glabella. As the size of these sinuses is extremely variable, not only in different individuals, but also on the two sides of the same individual, the surgeon always should make an opening which is small and close to the root of the nose, so as to run no danger of entering the cranial cavity. This opening may then be enlarged with gouge or rongeur. A tract for drainage into the middle meatus of the nose can be made by enlarging the infundibulum with curette. Such drainage, by a tube passed from the inner angle of the frontal incision down into the nose, is sufficient in emergency. Killian's operation, described below, is preferable as a method of radical cure.

The **anterior ethmoidal cells** frequently are diseased along with the frontal sinus, as they usually drain into the upper part of the infun-

dibulum; and they are best evacuated across the opened frontal sinus. The **middle and posterior ethmoidal cells drain** into the middle meatus and the superior meatus, respectively. They may be reached by resection of the os planum, after exposing the inner wall of the orbit. There may be a fistula in this situation, or even an abscess between the os planum and the eye-ball. Drainage into the nasal cavity and from the external wound is provided for. For radical cure, Killian's operation is preferable.

The **sphenoidal sinus** seldom can be drained effectively by the intranasal route, and as the ethmoidal and frontal sinuses frequently are involved also, the method of treatment for radical cure usually employed now is that known as **Killian's Operation** (1902), which involves an approach across the frontal sinus. This includes removal of the anterior wall of the frontal sinus and of its floor (the roof of the inner part of the orbit), leaving a bridge of bone (supra-orbital ridge) between these two openings to support the soft parts when sutured and thus prevent deformity. After evacuating the frontal sinus, and thoroughly exposing all its angles, the frontal process of the superior maxilla is removed. (This should be done without injury to the mucosa of the nasal cavity, which is to be preserved as a flap to line the excavated frontal sinus and establish a free communication between this cavity and the nose.) The ethmoid cells which are thus exposed are then cleaned away, and the anterior wall of the sphenoidal sinus is removed by gouge or gouge forceps. Removal of part of the nasal bone of the side affected may be necessary to secure better exposure. The flap of nasal mucosa finally is turned outward across the lower wall of the large cavity, and this is lightly packed with gauze which emerges into the nasal fossa. The external wound is then completely sutured.

SURGERY OF THE JAWS.

Alveolar Abscess.—Alveolar abscess almost always is secondary to dental disease. Before the stage of suppuration, peridental inflammation is denoted by tenderness, which usually is relieved by firm pressure on the gum, accompanied by moderate swelling. At this stage proper disinfection of the root canals of the teeth, which are infected from the cavity in the crown, usually causes arrest of the process. Later the entire side of the jaw may be swollen, and tenderness is exquisite. Sometimes the pus escapes at the side of the tooth, but in many cases it spreads beneath the periosteum of the jaw, and unless promptly evacuated, osteomyelitis and necrosis may result, or in the upper jaw, involvement of the maxillary sinus. Occasionally the pus breaks through the skin below the body of the mandible (Fig. 699), or will form an abscess in the cheek (Fig. 700). Secondary infection of the salivary glands or of the cervical lymph nodes may occur.

Treatment.—Early free incision of the alveolar border, down to the bone, followed by detergent mouth washes usually is promptly curative, and even if no pus is found this incision quickly relieves pain and markedly accelerates recovery.



FIG. 699.—Alveolar abscess of lower jaw, pointing over body of mandible. Four days after extraction of tooth. Episcopal Hospital.



FIG. 700.—Abscess of left cheek, following pulling of teeth on upper and lower jaw, thirteen days previously. Episcopal Hospital.

Acute Osteomyelitis of the jaws is not common even in the mandible, and in the maxilla is decidedly rare. The general septic symptoms render differentiation from alveolar abscess easy.

Treatment.—Treatment consists in free incision, both inside and outside the mouth. The inflammation may be confined to the alveolar border, but it is better to open the body of the jaw by trephine or gouge if there is any doubt as to the limits of the disease. Free drainage is the most essential factor.

Necrosis of the Jaws affects the mandible in most cases, and follows acute osteomyelitis, or may be due to phosphorus poisoning, with subacute or chronic onset. In the latter instance the disease seldom appears until the patient has been working in phosphorus for several years, and it may not appear for several years after the patient has quit his work in phosphorus. Phosphorus poisoning produces changes of a chronic ossifying nature in the periosteum in all parts of the body, resulting in increased density of the bone, decrease in the size of the marrow cavity, and lessened circulation. These changes are particularly marked in the mandible. If secondary infection does not intervene, as in the mandible it usually does from carious teeth, the later stages of the process (rarefaction and pathological fracture) are seen. Workers in phosphorus should have their teeth inspected and cleaned by a competent dentist, at frequent intervals. Necrosis

of the jaws occasionally results from the constitutional effects of *arsenic poisoning*, or from *mercurial stomatitis*.

Treatment.—Treatment consists in providing free drainage by incision of the soft parts and involucrum, when the latter is present. Great conservatism should be exercised in extraction of sequestra. It is best to wait until they are freely movable by probes introduced through neighboring cloacæ, and until the involucrum has developed sufficiently to maintain the form of the jaw. Though the teeth usually are lost, the ultimate outcome as regards function usually is satisfactory.

Ankylosis of the Temporo-maxillary Joint may be unilateral or bilateral, but even unilateral involvement renders the jaw immovable. The condition may result from various forms of arthritis or from fracture of the condyle; or false ankylosis may occur from periarticular contractures, due to cicatrices from burns, etc. If the ankylosis occurs before full development of the mandible, *retrognathism*, or *micrognathy* is the result (Fig. 701), from loss of function. In unilateral ankylosis the affected side of the mandible seems smaller than the sound side, but stands out normally from the neck, whereas the healthy side appears flattened; the chin usually is deviated toward the affected side (Kirstein, 1910).

FIG. 701.—Retrognathism from ankylosis of jaw due to post-scarlatinal arthritis in infancy. Now eight years old. Orthopædic Hospital.

Treatment.—Some form of arthroplasty (p. 471) is necessary to restore motion. The joint is best exposed by turning down from above a skin-flap with temporary resection of the zygoma (Lilienthal, 1911). The condyle of the mandible is then excised, and a flap turned in from the temporal muscle or masseter. By turning down the zygoma, with attached masseter muscle, any damage to the facial nerve, parotid gland, and duct, is avoided. The periosteal insertion of the external pterygoid muscle should be preserved. The older operations of resection of a wedge from the body of the mandible in front of the angle seldom succeeded in restoring permanent motion. For false ankylosis from *cicatricial contractures* a plastic operation is necessary. Murphy (1913) uses a flap of mucous membrane from the hard palate. The mandible may be *lengthened* by osteoplastic operation on both sides, dividing the body in sigmoid fashion and sliding the lower segment forward.

Facial Hemiatrophy is a very rare condition of obscure origin, but one whose existence should be known to the surgeon, for diagnostic purposes (Fig. 702). The atrophy affects bones as well as soft parts. It may be associated with neuritis of the trigeminal nerve, but usually is not painful. Neurologists treat it by electric currents and general hygienic measures.

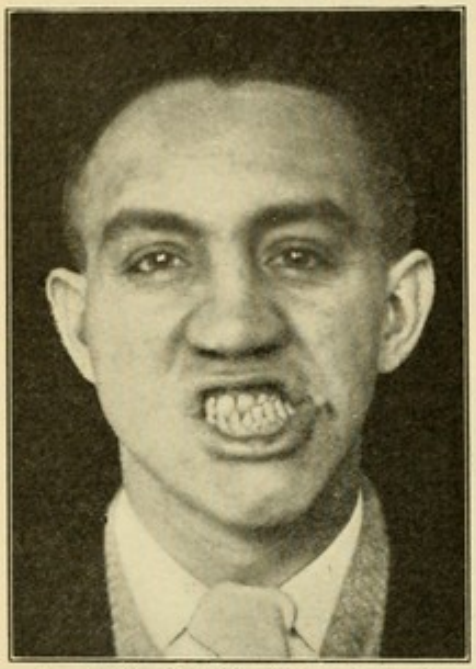

FIG. 702.—Left facial hemiatrophy. Male twenty-six years old. Duration ten months. No injury, but he was a "boxer" and deformity was mistaken for that due to impacted and united fracture of ascending ramus of lower jaw. Notice over-lapping of teeth. Episcopal Hospital.

Tumors of the Jaw.—These may arise from the alveolar border or from the body of the bone.

Tumors of the Alveolar Border.—There are three of these alveolar growths of considerable frequency: Epulis, Ossifying Periosteitis, and Carcinoma.

1. **Epulis.**—Epulis, a connective tissue tumor, is the most frequent growth of the alveolus. Pathologically it is either (*a*) a fibroma or an angeio-fibroma, or (*b*) a tumor containing giant cells, resembling a myeloma or myeloid sarcoma. This appears to be the only region in the body where giant cells spring from periosteum. Epulis seems to be more nearly related to inflammatory processes than to true neoplasms. The giant-celled form often arises above an old root or beside a decayed tooth, and is reddish brown in color; but the fibrous form may occur where the teeth appear normal, and is whiter in color. Epulis is painless, but in spite of this fact often has been mistaken for an alveolar abscess. It occurs in children or young adults, is soft and elastic, but does not fluctuate. Ulceration may occur eventually, but is very long delayed.

Treatment.—Treatment consists in local extirpation by knife and gouge forceps, through healthy tissues. The raw surface left should be seared with the actual cautery. Recurrence may take place if the surgeon is too conservative. Yet even after repeated recurrence no metastasis occurs. It never is necessary to excise the whole thickness of the bone; removal of the portion of the alveolus affected is sufficient.

2. **Ossifying Periosteitis** forms a diffuse bony enlargement of the alveolus. It may be due to chronic infection (as pyorrhea alveolaris). Subperiosteal resection may be done, without fear of recurrence.

3. **Carcinoma.**—Carcinoma is commoner on the upper (Fig. 703) than the lower jaw (Fig. 704). It is sufficiently distinguished from epulis by its occurrence only in older patients, by its early ulceration, the marked induration of the borders of the ulcer, and the ultimate

involvement of the lymph nodes. Extirpation, together with wide excision of the lymphatics of the same side as the lesion, is the proper treatment.

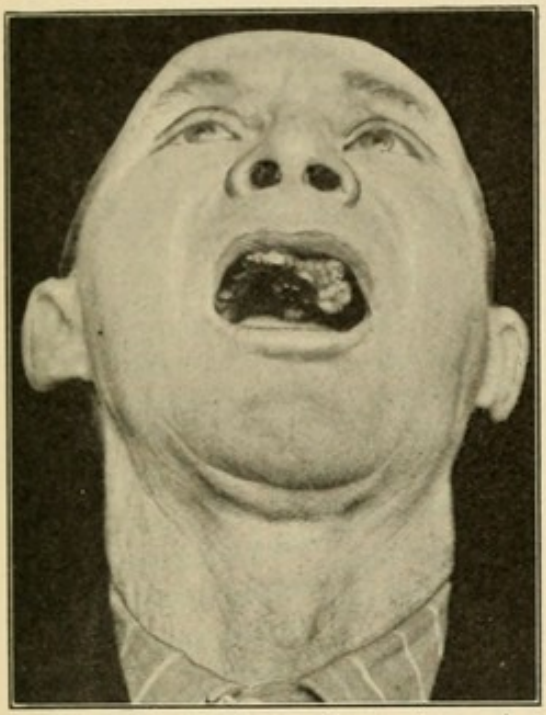

FIG. 703.—Carcinoma of upper jaw. Age seventy-three years; duration six months, now inoperable. Was struck on this side of mouth one year ago by handle of "release" while running engine. Episcopal Hospital.

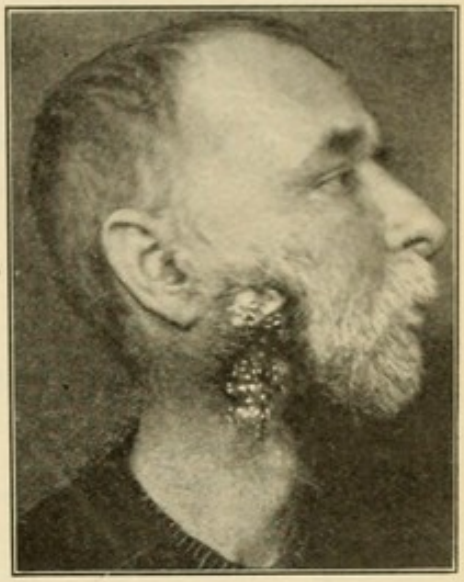

FIG. 704.—Recurrent carcinoma of inferior maxilla. Partial excision of mandible in September, 1906. Photograph March 1908. Now inoperable. (Dr. H. C. Deaver's case.) Episcopal Hospital.

Tumors of the Body of the Jaw.—Some of these are benign, and some are malignant. Among the former are *dentigerous cysts*, especially the adamantinoma. These were discussed at p. 112. Of the malignant tumors (*sarcomas*) there are various forms. Until recently the giant-celled form of epulis, affecting the alveolus, was classed as a sarcoma. True sarcoma may affect the body of either the upper or lower jaw. Usually it is periosteal in origin, and grows as a firm or even a bony tumor. It does not present egg-shell crackling, which is common in the admantinoma, and occurs in older patients than those in whom dentigerous cysts usually are seen. According to Bloodgood sarcoma of the lower jaw in front of the angle usually is of a less malignant nature than the forms which occur at the angle and rapidly invade the ramus. The former (less malignant) growths are "mixed sarcomas," that is, partly bony, fibrous, or myxomatous, and are rare after the age of twenty-five years. The more malignant varieties, which are rare before the age of twenty-five years, are spindle- and round-celled sarcomas. These latter quickly invade the soft parts, extending in the upper jaw to the antrum (where, indeed, they may originate), to the orbit, and to the temporo-maxillary fossa; and in the lower jaw invading the pharynx and soft structures of the neck. The differential diagnosis is best made from an excised specimen.

Treatment.—In the less malignant forms of sarcoma, the surgeon aims to remove the entire growth, with a small margin of healthy tissue on all sides. In the lower jaw this usually necessitates a resection of the entire thickness of the bone, though very occasionally the alveolar border may be left as a splint to maintain the form of the bone. In the upper jaw it usually is possible to preserve the orbital plate, and often the hard palate also. It is doubtful whether any operation, even the most radical, is of any use whatever in the more malignant forms of sarcoma.

Excision of the Superior Maxilla.—The typical operation, though seldom done at present for tumors arising in the maxilla itself, sometimes is required as a preliminary to the removal of growths in the naso-pharynx. Preliminary ligation of the external carotid artery is advisable if the operation is for exposure of such a tumor. The incision shown in Fig. 705, enters the nostril and outlines a flap which is reflected outward, the knife being kept close to the periosteum. The mucous membrane of the hard palate is divided in the median line, and the attachment of the soft palate to the bone severed transversely. The mucous membrane of the gingivo-labial fold is divided clear of the disease, and that in the floor of the nose is divided in the median line. After extraction of the central incisor tooth on the involved side, the alveolus and palate are divided by a phalangeal saw (Fig. 139, 6), introduced through the nostril. The tissues of the orbit are then displaced upward, the spheno-maxillary fissure is identified, and the attachment of the maxilla to the malar bone is divided with saw. Then the nasal process of the maxilla is divided from orbital to nasal cavity, and the bone is grasped in lion-jawed forceps and pulled downward, any remaining attachments, including the junction of the pterygoid processes with the maxilla, being severed with bone-cutting forceps or chisel. Hemorrhage is then controlled, if necessary by the actual cautery. The mucosa of the cheek is then sutured to that of the palate, and the skin wound closed with interrupted sutures, after packing it loosely with iodoform gauze, which is made accessible through the nostril. Frequent syringing through the nostril or any opening in the roof of the mouth is required during convalescence. *Temporary resection of the superior maxilla* is done by the same skin incision, but the flap is not separated from the bone; this is divided as above described except at its malar attachment, which is used as a hinge, after fracture by leverage outward.

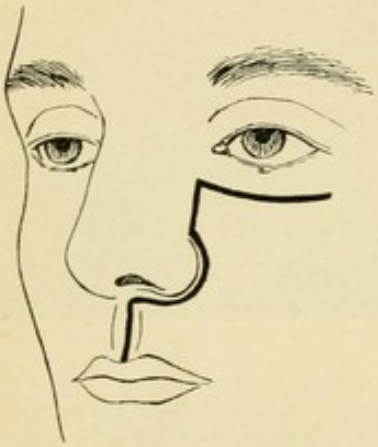

FIG. 705.—Fergusson's incision for excision of upper jaw.

Excision of the Inferior Maxilla.—The typical operation involves only half the mandible. An incision is made from the middle of the lower lip down to the hyoid bone, and from this point back as far as

the angle of the jaw, the submaxillary structures are dissected free, and the soft parts are separated from the outer surface of the bone, respecting the branches of the facial nerve, but ligating the facial and the lingual arteries and veins. Most of the external surface of the ramus is thus exposed. The symphysis is then divided with saw and the structures of the floor of the mouth cut with scissors, from before backward. An incision is then made along the mucous membrane on each side of the ascending ramus of the jaw; the bone is forcibly depressed, and the insertion of the temporal muscle into the coronoid process is divided with scissors. The jaw is then turned somewhat outward, and the pterygoid muscles cut close to their insertions. The lingual nerve should be preserved if possible, but, of course, the inferior dental must be sacrificed. The temporo-maxillary joint may then be opened, the few remaining attachments severed, and the bone removed. After careful control of all hemorrhage, the pterygoids are sutured to the masseter muscle, and the mucous membrane of the cheek united to that of the floor of the mouth. Finally the skin wound is closed, with provision for drainage externally. *Partial excision* involves removal only of the portion of bone affected, after its division in front of and behind the growth.

Prosthesis after Excision of the Inferior Maxillary Bone.—If the periosteum can be preserved, a shell of bone sufficient to prevent excessive deformity may be formed in time. While the wound is healing the remaining portions of the bone should be held in proper position by stout silver wire, used as a bridge across the gap left by excision of the diseased portion. A sinus usually persists until the wire is removed, but by that time the bone may be sufficiently firm. Claude Martin, of Lyons, since 1878, has employed after excision of either upper or lower jaw, a temporary prosthesis made of hard rubber, previously constructed to fit into the contemplated defect. This prosthesis is riddled with channels, and though it is implanted into the wound through the buccal aspect (no attempt being made to close anything but the skin), the wound and the appliance may in almost all cases be kept clean until healing occurs by irrigation through its numerous channels. When healing is complete a permanent prosthesis is constructed.

SURGERY OF THE TONSIL AND PHARYNX.

Peritonsillar Abscess or **Quinsy** usually is a sequel of parenchymatous amygdalitis. The systemic symptoms of sepsis may be marked. Locally, in addition to the signs of the preceding tonsillitis, may be observed a diffuse swelling of the soft palate at the upper border of the tonsil. At no time is a distinct sense of fluctuation obtainable. Early evacuation is the only satisfactory treatment. Thrust a grooved director through the most prominent part of the swelling (usually through the soft palate), after painting it with 10 per cent. cocain (Fig. 706). The tract made by the grooved director may be enlarged

by inserting the closed points of a pair of dressing forceps, and withdrawing the instrument with the blades opened. The relief is immediate, and under the use of simple alkaline mouth washes convalescence usually is established in twenty-four to thirty-six hours. If a peritonsillar abscess is left to burst of itself, it may do so during sleep, and has caused death from suffocation. In very young children it is better to open it in the head-low position.

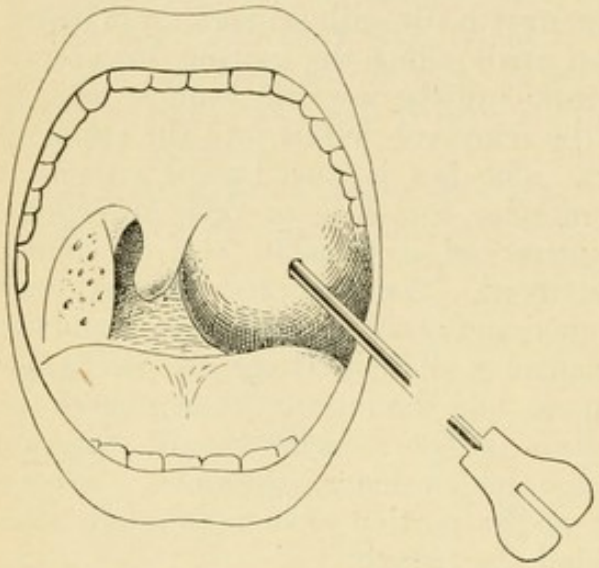

FIG. 706.—Puncture of peritonsillar abscess through soft palate.

Malignant Tumors of the Tonsil. — Either carcinoma or sarcoma may occur in the tonsil. Diagnosis is not easy. Any unilateral tonsillar enlargement in an adult should be regarded with suspicion. The possibility of syphilitic lesions of the tonsil (chancre and ulcerated gumma) should be kept in mind, and their presence excluded by the history of the case, the existence of evidences, past or present, of the disease elsewhere in the body; as well as by the use of laboratory and therapeutic tests. In most cases a specimen of the growth should be excised for microscopic study. In carcinoma the diagnosis usually is easily made by this means, but in sarcoma the histological picture may not be convincing.

Symptoms.—The symptoms are chiefly those of obstruction, in sarcoma, with pain on deglutition; the lymph nodes seldom become enlarged until late in the disease, after ulceration has occurred. Local extension to the palate and pharynx is much more common in carcinoma, and in this affection the submaxillary and deep cervical lymph nodes are involved early, though not palpably so for a number of weeks.

Treatment.—If the diagnosis is made very early in the disease, by means of microscopic study, it may be possible to enucleate the tonsil from within the mouth. Usually, however, and particularly in the case of carcinoma, the growth should be approached from the neck. In *lateral pharyngotomy* an incision is made from the mastoid well forward under the body of the jaw; after clearing the submaxillary and cervical regions, the facial artery is ligated close to its origin, so as to control its tonsillar and ascending palatine branches; the wall of the pharynx is incised on a sound introduced through the mouth, and the diseased area excised with scissors. Temporary resection of the mandible may be requisite. Approach to the tonsil, the epiglottis, and the pharynx may also be gained by *suprahyoid pharyngotomy* (Jeremitsch, 1895; von Hacker, 1906); in this operation a transverse

incision, convex forward, and about three or four inches long, is made above the hyoid bone, and all the muscles passing upward from this bone are divided, including both genio-hyoids, the mylo-hyoid, genio-hyoglossus, and hyo-glossus; sometimes also the stylo-hyoid and anterior belly of the digastric on the side of the lesion. Enough tissue should be left attached to the hyoid bone to facilitate subsequent suture. By hyperextension of the neck, and pulling the chin upward, wide exposure of the base of the tongue and the lateral pharyngeal walls is secured. Usually the facial and lingual arteries on the more diseased side must be ligated; the hypoglossal nerve should be preserved if possible. *Subhyoid pharyngotomy* (Vidal de Cassis, 1826; Sklifosovsky, 1892) is a somewhat similar operation, but there is more danger of injuring the superior laryngeal nerve, without compensating advantages. When the malignant growth has been excised, the severed cervical tissues are carefully re-united by many rows of buried sutures, and the wound is freely drained. These operations are dangerous, seldom employed, and difficult even for skilled operators with accurate anatomical knowledge.

If the case is inoperable, palliative measures, such as the "starvation" method of Dawbarn (p. 655), may be tried, with the use of the *x*-ray, and, in the case of sarcoma, of Coley's fluid.

Tumors of the Naso-pharynx.—These usually are soft fibromas, occur in young adults from fifteen to twenty-five years of age, and in many cases assume a character which clinically is malignant, though microscopical examination rarely shows a typical sarcoma. They spring from the submucous tissues at the base of the skull, and grow into the nasal passages, invade the maxillary sinus, the orbit, the temporal fossa, and may open even the cranial cavity. Occasionally they seem to spring from the antrum and grow backward into the naso-pharynx. Unless removed, death is practically certain from obstruction to respiration and deglutition. The growth is apt to recur after partial removal, and complete extirpation is a serious and often a bloody operation, demanding usually excision of the superior maxilla (p. 662) to gain access to the growth, even if this bone is not itself invaded by the disease. Preliminary ligation of the external carotid artery is advisable, and the actual cautery may be required to check the bleeding even after this precaution.

SURGERY OF THE AIR PASSAGES.

Foreign Bodies.—Foreign bodies are especially apt to enter the larynx, trachea, or bronchial tubes in young children, who thoughtlessly place various objects in the mouth, and by a sudden act of inspiration, in laughing or coughing, draw them into the larynx. In anesthetized patients, or those in a drunken stupor, vomited matters may be similarly aspirated into the air passages. Severe paroxysms of choking ensue, but very rarely does rapid death from asphyxia occur. Apart from asphyxia, the chief danger is due to secondary pulmonary inflam-

mation. Occasionally a foreign body is arrested in the larynx, but in most instances it passes down into the trachea, and thence usually into one or other bronchus.

Symptoms.—Symptoms depend on the site of the foreign body, and on the time which has elapsed since the accident. The first symptoms, or those of *obstruction*, seldom last very long. They are succeeded by those of *irritation*, denoted by a short croupy cough, with retrosternal pain, and later by mucous or bloody expectoration; paroxysms of dyspnea occur from time to time when the foreign body is forced upward into the larynx. If impacted in the larynx, symptoms of obstruction persist, and there usually is aphonia. If impacted in a bronchus, or if immovably fixed at any point by a sharp projection catching in the mucous membrane, the symptoms of irritation are not very marked; and auscultation over the region of the lung obstructed usually detects very weak or absent respiratory murmur, but no dulness is found on percussion until inflammatory changes arise. If the foreign body moves freely about in respiration, the symptoms of irritation are very pronounced, and occasionally the foreign body can be heard flapping about.

Diagnosis.—The diagnosis in small children must be made from "croup" or diphtheria, and in the absence of a clear history, and where there is no evidence of diphtheritic membrane in the pharynx, this is difficult, without laryngoscopic examination. When a foreign body is present dyspnea occurs particularly in expiration, while in laryngeal obstruction from other causes, inspiratory dyspnea is found. Moreover, if the foreign body is sufficiently dense (a pebble or some metallic toy), its presence will be revealed by the *x*-ray. In the case of foreign bodies impacted in the pharynx or esophagus there rarely is so much dyspnea, and swallowing will be difficult or impossible. A foreign body in the pharynx usually can be reached by a finger introduced into the mouth.

Treatment.—1. *In emergencies*, any physician may open the trachea and extract the foreign body if it can be found. If impacted in the larynx, high tracheotomy or crico-thyrotomy should be preferred. In other cases low tracheotomy is better. Even if the foreign body is not found it is more apt to be discharged spontaneously through a tracheotomy wound than by the natural passages.

2. *When there is no emergency*, the services of a skilled laryngologist should be procured. He may be able, by means of a bronchoscope introduced through the mouth (*upper bronchoscopy*) to see and extract the foreign body (Fig. 707). If it is situated too low to be reached successfully from above, the same method may be employed, the instrument being introduced through a "low tracheotomy" wound (p. 670), the procedure then being known as *lower bronchoscopy* (Fig. 708). Bronchoscopy was introduced by Killian in 1897, and has been highly developed by Guisez in France, and by Chevalier Jackson in this country. R. T. Morris and Huber (1910) have employed it very successfully in conjunction with fluoroscopic inspection of the foreign

body during the manœuvres of extraction. General anesthesia usually is required. In early cases upper bronchoscopy may be successful, but when pulmonary complications exist lower bronchoscopy is to be preferred.

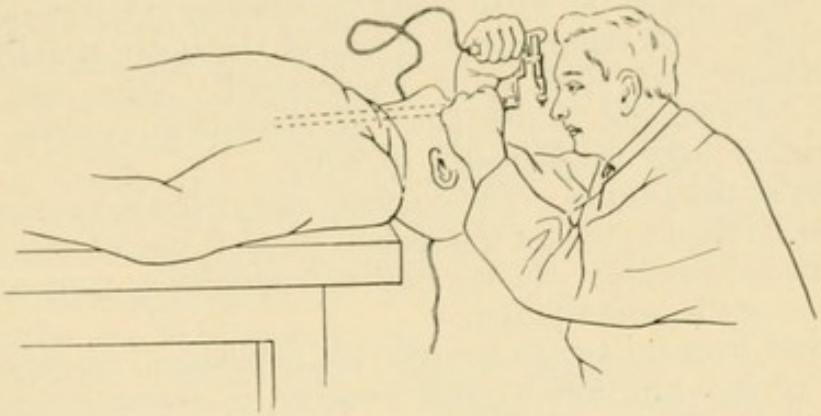

FIG. 707.—Upper bronchoscopy.

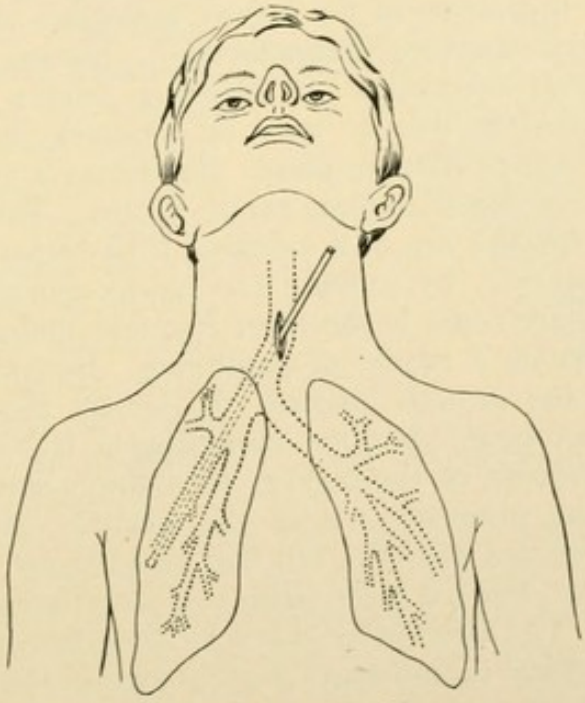

FIG. 708.—Lower bronchoscopy.

Fracture of the Larynx is rare. The thyroid is the cartilage most often involved. Michel (1910) has studied 40 cases recently reported. Among these there were 17 deaths. Seven of these patients died suddenly, without operation, at periods varying from a few hours to six days after the accident. The mortality in non-operative cases is 42 per cent. In very severe injuries, where the fracture is compound internally (hemoptysis, threatening asphyxia from edema of the glottis) tracheotomy should be done, and the deformity corrected. In very mild cases, no operation is required, it being sufficient to apply a light immobilizing dressing. In intermediate cases, especially if there is any emphysema, tracheotomy should be done as a precautionary

measure, since experience shows that in such cases sudden death is apt to occur from edema of the glottis.

Edema of the Glottis.—Above the true vocal cords there is abundance of loose areolar submucous tissue, prone to edema from trauma or infection. Below the vocal cords the mucosa is tightly applied to the cartilage. The symptoms of edema of the glottis usually develop very suddenly and often quite unexpectedly. They are those of asphyxia. Treatment, which must be immediate, consists in cricothyrotomy or high tracheotomy (p. 670).

Tumors of the Larynx.—These belong rather to the province of the laryngologist than to that of the general surgeon, except when external operations are required. In any case it is well for surgeon and laryngologist to act in consultation.

The most frequent *benign tumor* is the papilloma. It may occur in patients of any age, but is most frequent in young adults. Early symptoms of hoarseness, with recurrent attacks of laryngitis, finally will be followed by those of respiratory obstruction. The diagnosis is confirmed by inspection of the larynx through a mirror introduced above its superior aperture (*laryngoscopy*). Benign growths usually are pedunculated; ulceration or bleeding points to malignancy. Pedunculated growths usually may be removed by intra-laryngeal methods, in the hands of a specialist. Papilloma is very apt to recur, but other forms of benign tumors rarely return. The performance of tracheotomy, with the use of a tracheal tube sometimes has served to prevent recurrence, by putting the larynx completely at rest.

Carcinoma.—Carcinoma is the most frequent malignant tumor. It is said to be rare as a sequel of papilloma. Sarcoma is very rare. In many cases the growth involves the larynx secondarily, having originated in the tongue, pharynx, or esophagus; this form is described as *extrinsic carcinoma* of the larynx, as distinguished from *intrinsic carcinoma*, arising primarily within the larynx. The *symptoms* are the same as in benign growths, but the patients are older (it is rare before fifty years), there is more pain, and sometimes there is spontaneous bleeding. The *diagnosis* is made by laryngoscopy, and if necessary by microscopical examination of an excised portion of the growth. The disease usually is more extensive than it seems. Tuberculosis and syphilis have to be considered, but usually may be excluded by the history of the case, by clinical examination, and by laboratory tests. The *prognosis* of carcinoma of the larynx is bad. Without operation death usually occurs within three years, and it is a very painful death. *Treatment* should be radical whenever possible, and it is best accomplished by external operation.

OPERATIONS ON THE AIR PASSAGES.

Intubation of the Larynx.—This operation, introduced by O'Dwyer in 1885, consists in the introduction into the larynx, by special instru-

ments passed through the mouth, of a hollow tube which is allowed to remain, suspended from the false vocal cords, until the symptoms of laryngeal stenosis, for which the operation was done, have subsided. It is employed almost solely for laryngeal obstruction resulting from diphtheria. The armamentarium comprises a set of hollow hard rubber *tubes* of various sizes suitable for any age up to twelve years. The approximate size is determined beforehand by means of a scale. Each tube is provided with a hole at its upper end through which a long thread is passed; the thread is left hanging out of the patient's mouth and enables the tube to be quickly withdrawn if necessary. The tube is then fitted over the *obturator*, which is screwed securely to the *introducer*. A *gag* is placed in the left side of the mouth, and the child (not anesthetized) is held upright in the nurse's arms, with head steadied and slightly extended. The surgeon then introduces his left forefinger and draws the tip of the epiglottis forward. The introducer is then passed backward by the right hand and the tip of the tube is guided into the larynx by the fingers of the left hand (Fig. 709). The tube is then quickly pushed off the obturator by means of the sliding shaft on the introducer, and the latter with the obturator still attached is withdrawn. The thread fastened to the tube is left hanging out of the mouth, until it is certain that the tube will be well borne. If the tube has been passed into the esophagus by mistake, it should be withdrawn at once, cleansed, and properly reinserted. If dyspnea is not relieved when the tube is in the larynx, a larger tube should be inserted. If the tube is well borne, the thread may be removed after a few hours. When necessary the tube may then be removed by the *extractor*, reversing the steps employed in its introduction.

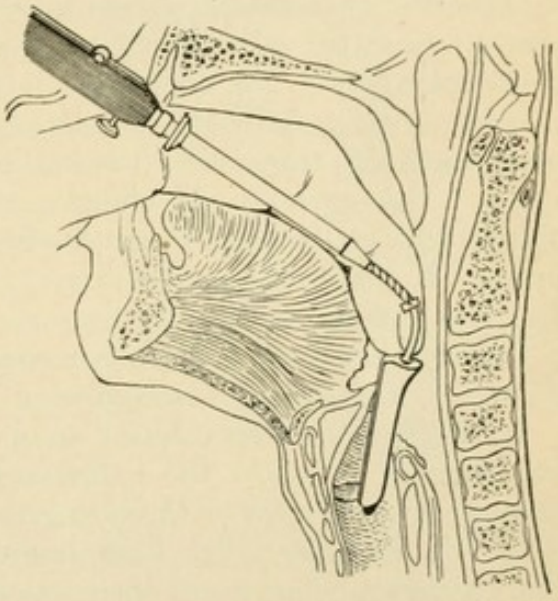

FIG. 709.—Intubation of larynx.

The *mortality* due to the operation itself is very inconsiderable, but death may occur in spite of the operation. Intubation should be preferred to tracheotomy in all cases in which it is applicable. When it fails to relieve the obstruction, tracheotomy may still be done, and a tube inserted below the obstruction.

In **cutting operations** upon the air passages the patient should be in the "hanging head position" (Fig. 676); this not only renders the parts more accessible, but avoids so far as possible aspiration of blood or gastric contents. In cases where partial asphyxia is present, no

anesthetic is required; in others local anesthesia usually is sufficient except where the soft parts have been invaded by malignant disease. Shortly before extensive operations (thyrotomy, laryngectomy) a hypodermic injection should be given of morphin (gr. $\frac{1}{6}$) and atropin (gr. $\frac{1}{100}$), to diminish secretion and paralyze inhibitory impulses. Local use of cocain, even when a general anesthetic is employed, is advisable for the latter purpose also.

Crico-thyrotomy, in which an incision is made in the crico-thyroid membrane, occasionally is done for acute laryngeal obstruction in adults. The wind-pipe is here most accessible, and in emergencies there is no other method by which it may be so quickly opened. But there is some danger of injuring the recurrent laryngeal nerve, and as the larynx itself is opened it is not considered a proper operation for diphtheritic obstruction, as the false membrane may extend below the seat of operation. But in cases of edema of the glottis this objection does not apply. No anesthetic is required. The surgeon fixes the cricoid cartilage between the thumb and finger of his left hand, and makes a small transverse incision in the skin over the crico-thyroid space. The sterno-hyoid muscles are then separated, and the blade of the knife is entered transversely through the crico-thyroid membrane. If the crico-thyroid artery is wounded, it should be clamped and tied before opening the larynx. Occasionally it is of large size. A tracheotomy tube is then introduced, and the after-treatment conducted as in a case of tracheotomy.

Tracheotomy.—The trachea may be opened either above (*high tracheotomy*) or below the isthmus of the thyroid gland (*low tracheotomy*). Usually two or three rings are accessible above, and as many below the isthmus. The high operation usually is to be preferred if the indication is laryngeal obstruction, but, as already mentioned, low tracheotomy is preferable for the removal of a foreign body in the bronchi. The higher the trachea is approached, the nearer does it lie to the surface of the neck; and in the suprasternal region access to it is obscured by numerous veins, which are markedly engorged in cases of respiratory obstruction, and render the operation much more difficult (Fig. 710). No anesthetic is required. Partial asphyxiation renders the patient almost insensible to pain, and the first incision cuts all the sensory nerves. Most surgeons still employ a longitudinal skin incision, but I believe with O. Franck a transverse one is better, as it is less liable to subsequent infection, gives better exposure and leaves an inconspicuous scar. If the skin is pinched up in the fingers, the anterior jugular veins do not come with it, and there is almost no bleeding. The interspace between the sterno-hyoid muscles is identified, and these as well as the underlying sterno-thyroids are separated, exposing the trachea. This is then fixed in the wound by a sharp tenaculum. Unless this precaution is taken it may be very difficult to cut the cartilages, especially in an adult, as the knife is apt to push the trachea deeper into the neck or to one side. Two or possibly three cartilages are then divided, in the long axis

of the trachea, strictly in the median line, and a tracheal dilator (Fig. 711) is introduced. Or the trachea may be opened transversely, between two rings; it will gape, owing to the hyperextension of the neck. In this way the operation may be completed with no other instrument than the knife.

The operator should take care, especially in cases of diphtheria, that the violent paroxysms of coughing, which follow opening the trachea, do not spatter his face with false membrane. Any membrane presenting in the wound should be carefully withdrawn. A *tracheotomy tube* (Fig. 712) is then inserted, and fastened in place by tapes tied behind the patient's neck. This tube is provided with an inner cannula which is removed frequently and cleansed, without disturbing the outer tube. As long as the tube remains in place, the patient should be kept in a moist warm atmosphere; this is best secured by employing a croup tent, and by the use of a kettle of hot water, on the surface of which is floated a small quantity of compound tincture of benzoin. It is an advantage to have the outer tracheotomy tube constructed with a window on its convex surface, so that when the inner tube is withdrawn, tests can be made from day to day of the possibility of laryngeal respiration. In emergencies, where a tracheotomy tube is not available, one may be constructed out of a soft catheter or rubber drainage tube. It rarely is possible to remove the tube permanently before the third or fourth day. In cases of stenosis from cicatrix or neoplasm it may be necessary to wear a tracheal cannula permanently. In these cases a tube with a ball valve, permitting inspiration but preventing expiration through the tube, may enable the patient to employ his larynx in speaking.

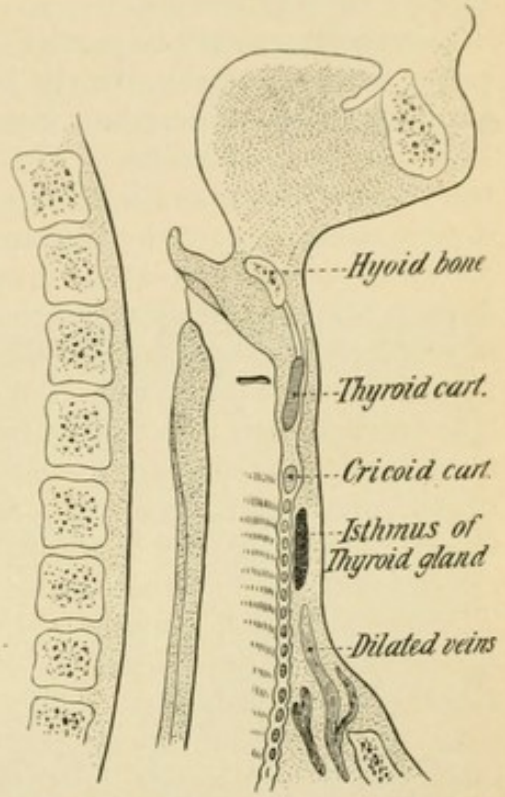

FIG. 710.—Sagittal section of neck, showing anatomical landmarks involved in operations on the larynx and trachea.

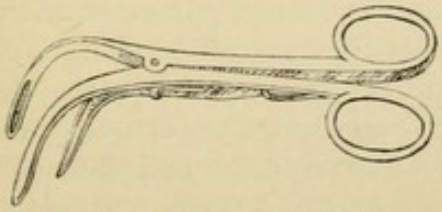

FIG. 711.—Elsberg's three-bladed tracheal dilator.

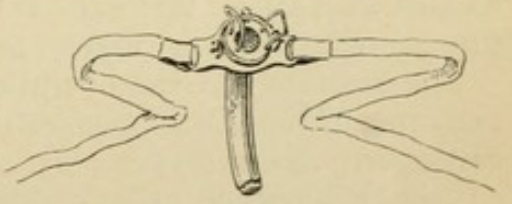

FIG. 712.—Tracheotomy tube.

Thyrotomy or **Laryngo-fissure** consists in splitting the thyroid cartilage in the mid-line, turning aside the halves, and exposing the interior of the larynx. It is used to remove sessile benign growths, and as an exploratory operation in cases not certainly malignant. When malignancy exists the exploration should be followed immediately by laryngectomy.

Laryngectomy may be partial (*Hemilaryngectomy*) or complete (*Extirpation of the Larynx*). In the latter operation Hartley, of New York, employs (1908) a cross-bow incision, analogous to that used in operations on the cerebullum. The transverse incision passes just below the level of the hyoid bone, and the longitudinal extends far enough downward to expose the isthums of the thyroid gland. The platysma, sterno-hyoid and omo-hyoid muscles are turned down in the triangular flaps. All superficial veins and both superior thyroid arteries are ligated, the latter close to their origin; and the superior laryngeal nerves are cut, after application of cocain to block inhibitory impulses. The trachea then is cut away from the cricoid, is turned forward, and is sutured end-on into the lower angle of the incision. Division of the thyroid isthmus and free separation of the trachea from the esophagus may be necessary. A tracheotomy tube is then introduced, and the anesthetic subsequently administered by this route. The sternothyroid muscles are then divided below the larynx. The pre-laryngeal and lateral laryngeal lymph nodes are then raised, together with the larynx and attached sterno-thyroid muscles, and the pharynx is incised transversely behind the larynx, and the larynx, including the epiglottis, is removed. All bleeding having been controlled, the pharynx is completely closed by sutures (over a stomach tube, passed through the nose, and used as a guide);[1] the musculocutaneous flaps are replaced and sutured, and the wound is drained from one or both lateral angles. After-treatment is conducted as in cases of tracheotomy. The patient should lie in the head-low position, and should not swallow anything for three days. Until then he may be fed liquids through the tube passed by the nose into the esophagus at the time of operation. Crile (1913) points out that the chance of infection may be lessened by a preliminary operation in which the suprasternal space is widely opened on both sides of the trachea and is packed with gauze. After several days when the wound is covered with firm granulations, the surgeon proceeds to extirpation of the larynx.

The mortality of the operation is about 20 per cent. Nearly 50 per cent. of those who recover remain free of recurrence for one year or longer. About 20 per cent. of those who recover are permanently cured. Recurrence usually takes place, if at all, within one year. If the deep cervical lymphatics are involved, no radical operation is of any use.

Hemilaryngectomy is done by turning down a triangular flap on one side only. A tube is inserted in the trachea well below the cricoid, and after preliminary laryngo-fissure, the diseased half of the thyroid cartilage is removed, with its related lymph nodes.

[1] This tube should be allowed to remain.

SURGERY OF THE NECK.

Wounds.—These may be incised, lacerated, gunshot, or stab wounds. The chief immediate danger is hemorrhage or edema of the glottis. Injuries of nerves, if undetected and not repaired, may lead to lasting disability. In suicidal *cut-throat*, the patient often loses his courage when blood begins to flow, and the damage may not be nearly so great as appears at first sight. If the trachea, larynx, or pharynx are wounded, it frequently is safer to insert a tracheotomy tube at once, to prevent asphyxia should edema of the glottis occur. Usually no anesthetic is necessary. Hemorrhage should be controlled by exposing, clamping, and ligating the bleeding points. Venous bleeding may cease after respiratory obstruction has been relieved by tracheotomy. The superior laryngeal and the hypoglossal nerves are those most frequently severed in suicidal attempts. No prolonged attempts should be made to repair the nerve injury unless the patient's condition is favorable. A lodged bullet need not be removed unless very easily accessible. Severed muscles should be sutured. The wound should be drained freely, as it is in a region very prone to infection.

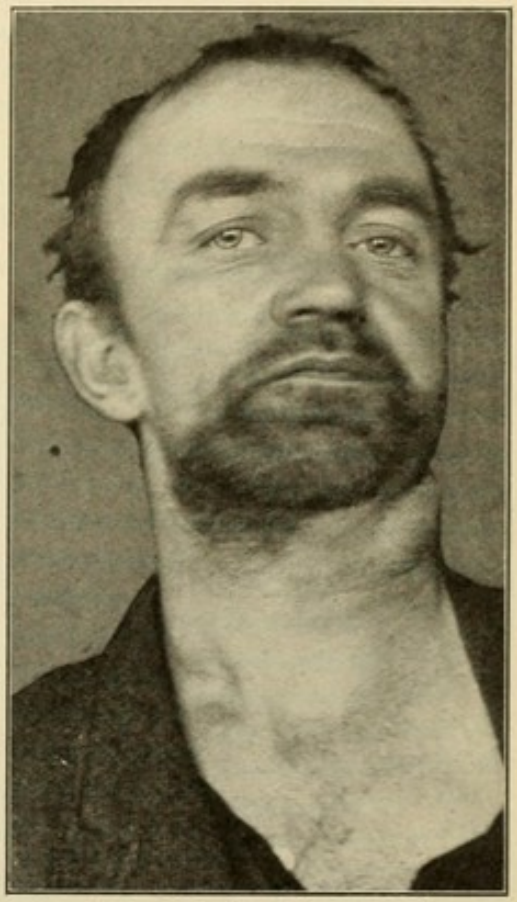

FIG. 713.—Woody or ligneous phlegmon of neck. Struck by steel two months ago. Slow, painless onset of induration, which extends from mandible nearly to clavicle, and from larynx to anterior border of trapezius. Skin red, slight edema, and pitting on pressure. No tenderness. Poulticed for three days, then incised. Rapid recovery. Episcopal Hospital.

Woody or Ligneous Phlegmon of the Neck (Reclus, 1893).—This is a slow and indolent inflammation, probably due to attenuated bacterial infection, the portal of entrance of the infection being uncertain. The inflammatory process is said usually to begin below the jaw in the submaxillary or submental region, and extends to the clavicle, usually on one side only. It converts the normally supple neck into a dense board-like structure, neither painful nor tender, and not attended by noticeable constitutional reaction. There may be an erythematous blush in the skin, and possibly some pitting on very firm pressure, but there is no evidence of suppuration. The affection, which seems to be a cellulitis, begins insidiously and may last for weeks before medical attention is sought (Fig. 713).

Treatment.—The board-like area should be incised in several places, and the neck should be poulticed. After suppuration is established, the indurated tissues quickly soften, and recovery usually is uneventful. This disease must not be confused with actinomycosis; the chief point of resemblance is the board-like induration.

Lymphadenitis.—Inflammation of the lymph nodes probably occurs oftener in the neck than in any other portion of the body. The cavities of the nose, mouth, and pharynx constantly breed hordes of microbes, and whenever the virulence of these is increased, or the resistance of the patient lowered, they or their toxins are absorbed, largely through carious teeth or the tonsils, and secondary enlargement of the cervical lymph nodes follows. The scalp also is a very prolific source of infection for the cervical lymph nodes. Every year I see a number of patients with cervical adenitis due to the infection instituted by head lice.

It is of the utmost importance not to regard the lymphadenitis as the main feature of the disease. The focus of infection always should be looked for, and usually can be found if the examination is thorough. If it is found and properly cared for, the lymphadenitis may subside spontaneously. Examine the scalp, ear, teeth, lips, tonsils, nose, and naso-pharynx, and do not be satisfied until some source of infection has been discovered. The *anatomical connections* of the various groups of cervical lymph nodes should be remembered. Around the upper part of the neck, as a collar, are arranged, from before backward, the *submental, submaxillary, subparotid, post-auricular* and *occipital* lymph nodes, draining corresponding areas of the face and head. The submaxillary nodes receive the drainage from all of the other groups mentioned except the occipital, and sometimes the submental; and *all these groups directly, or indirectly through the submaxillary,* drain into the upper portion of the *deep cervical lymph nodes,* which form a chain along the internal jugular vein from mastoid nearly to clavicle. These deep cervical lymph nodes sometimes are infected directly from the primary focus of the teeth, tonsils, scalp, etc., without implication of the intermediary group, but in most cases the latter is infected first. The deep cervical lymph nodes are also connected with the *supraclavicular lymph nodes,*

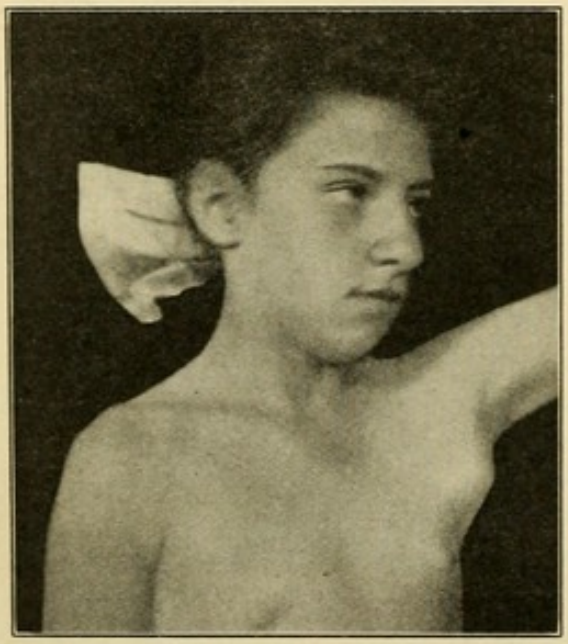

FIG. 714.—Tuberculous cervical and axillary adenitis, in a girl of fifteen years; duration nearly one year. Has had two operations on neck, both probably incomplete; last, one year ago. Episcopal Hospital.

which drain the surfaces of the upper arm and axilla, and sometimes the occipital portion of the scalp and the mammary gland. These supraclavicular lymph nodes may be infected through the deep cervical lymph nodes, or may in turn infect them. The deep cervical and supraclavicular nodes are themselves drained into the subclavian vein at its junction with the internal jugular. The deep lymph nodes of the neck lie beneath the sternomastoid muscle, and upon the fascia which covers the prevertebral muscles (scaleni, levator anguli scapulæ, etc.); their efferent vessels do not pass into the mediastinal nodes, but occasionally they receive afferent lymphatics from this source. Occasionally the axillary lymph nodes become involved by infections travelling down the neck and through the supraclavicular nodes (Fig. 714).

Acute Lymphadenitis.—The affected nodes are swollen, tender, palpable, and sometimes visible as a diffuse swelling (Fig. 715). The more acute the process the less distinctly can the individual node be outlined, and in many cases the affection is so acute that suppuration has occurred before the surgeon is consulted. In the earlier stages, attention to the focus of infection, and application of ichthyol, belladonna and mercury, or compound iodin ointment to the side of the neck affected usually cause subsidence of acute symptoms, and the nodes cease to be palpable.

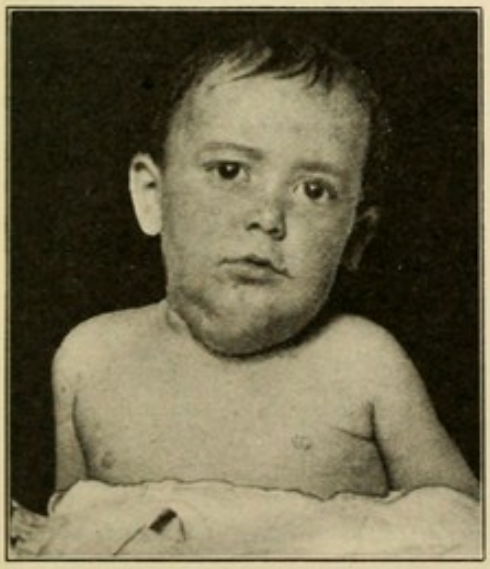

FIG. 715.—Acute submental lymphadenitis. Children's Hospital.

FIG. 716.—Submaxillary abscess from acute lymphadenitis (not tuberculous), due to carious teeth. Age eleven years. Two months later other abscesses formed, were incised and curetted. One year later, formal operation for tuberculous lymph nodes, evidently secondary to previous inflammation. (See Fig. 36.) Episcopal Hospital.

Abscess from cervical lymphadenitis (Fig. 716) requires the same treatment as an abscess elsewhere; but as in many cases the abscess is quite deeply seated, it often is best to open it by **Hilton's Method**; a small superficial incision is made in the skin, under local anesthesia if necessary, and then a grooved director is cautiously insinuated through

the intervening structures until pus begins to flow; a pair of dressing forceps is then passed along the grooved director, with its blades closed; when it has entered the abscess cavity the blades are opened, and the forceps is withdrawn, thus dilating the tract previously made. In this way there is no danger of injuring important bloodvessels or nerves.

Chronic Lymphadenitis.—Chronic lymphadenitis usually follows repeated acute attacks, the nodes retaining some inflammatory hyperplasia after each new infection. In the vast majority of cases, under these circumstances, the nodes become secondarily infected with tubercle bacilli. It is possible, of course, that the primary infection may have been tuberculous, since even in cases which clinically are thought not to be tuberculous microscopical study nearly always reveals the characteristic lesions of tuberculosis; and in some cases where no histological indication of tuberculosis was found, inoculation experiments have been positive.

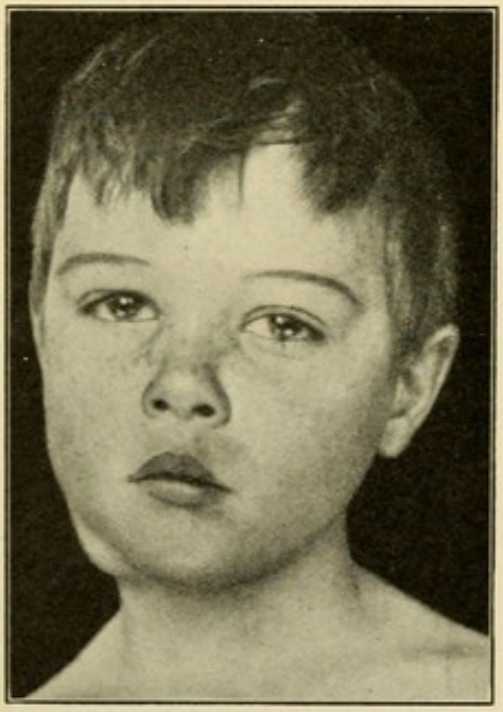

FIG. 717.—Tuberculous cervical adenitis (submaxillary and subparotid). Duration six months. No softening yet. Children's Hospital.



FIG. 718.—Tuberculous cervical adenitis. Age twenty-five years; duration three years, no sinus. From carious teeth. Orthopædic Hospital.

Tuberculous Lymphadenitis.—Tuberculous lymphadenitis in the neck is an exceedingly common affection. For anatomical reasons, the subparotid and submaxillary lymph nodes, draining the tonsils, teeth, and anterior portions of the scalp, are those most often primarily involved (Fig. 717). Thence the disease spreads to the upper deep cervical lymph nodes, travels along those accompanying the internal jugular vein to the clavicle, and often invades the supraclavicular group. Tuberculous cervical adenitis occurs oftenest in those from fifteen to twenty years of age, and is commoner in those under fifteen than in

those past twenty-five years of age. It may affect one or both sides of the neck. Usually, as noted above, there have been one or more attacks of acute adenitis—seldom so acute as to lead to suppuration, and often so subacute as to have required no medical attention, the child being "doctored" at home with ham fat or goose grease. Such attacks often date from the period of convalescence following measles or other acute exanthem. Finally the nodes become so conspicuous, or so constantly tender, even if invisible to a casual glance, that medical attention is sought. The nodes are now more or less discrete, movable, elastic, but tender; they do not feel hot, and give no evidence of fluctuation. They vary from pea-size to that of a walnut, seldom larger. Almost always there are a great many more present than can be detected by clinical examination. When the affection is of still longer duration the surgeon finds, instead of discrete, elastic, and movable nodes, that there are ill-defined, more or less immovable masses, evidently composed of several coalesced nodes (Fig. 718); in one or two places there may be evidence of softening. At a still later stage, cold abscesses form, spontaneous fistulization may occur, and the neck is riddled with sinuses, each separate and distinct node as it softens discharging through a new orifice (see Fig. 36). If secondary pyogenic infection occurs, a hectic state may develop.

The *diagnosis* must be made from Hodgkin's disease and from malignant or syphilitic enlargements. A differential diagnosis from *chronic non-tuberculous inflammation* usually is impossible, at least in the early stages of tuberculosis, except from the results of treatment, or by laboratory examination of an excised specimen. If cure of the infecting focus and non-operative care of the neck causes nodes to become no longer palpable, it may be assumed that the condition was not tuberculous, or only very slightly so. *Hodgkin's disease* usually is easily recognized by the firmness of the nodes, their tendency to enlarge without coalescing or softening, and by involvement of other groups of lymph nodes as well as the cervical. *Carcinoma* is secondary to a growth elsewhere, though this growth may have been excised many years previously, and there may be no local recurrence and an inconspicuous scar. Such lymph nodes are hard and not tender, and the patients are very rarely indeed of an age when tuberculous adenitis is frequent. *Sarcoma* of the cervical lymph nodes is rare. In its early stages it resembles clinically a case of Hodgkin's disease, but affects only the cervical lymph nodes; it never suppurates, but tends to involve the skin, and to form a fungous ulcer. It is important to recognize the existence of *syphilis*, particularly the hereditary form, in cases of the cervical lymph nodes. It occurs about puberty, and its syphilitic nature should be suspected from the presence of other signs of the disease (Fig. 938).

Prognosis and Treatment.—The *prognosis* of tuberculous cervical adenitis is bad, unless it is properly treated. Not only does the local condition go from bad to worse, but the patient's general health steadily deteriorates. Statistics collected in 1905 by Dowd, and so

far as I know not since contradicted, showed that without operation, but with medical treatment only, from 21 to 25 per cent. of these patients ultimately develop phthisis. This is small wonder, when the drainage of the cervical lymph nodes into the right heart is remembered. In 1909 Dowd traced ninety-six patients on whom he had operated more than three years previously. He found nearly 94 per cent. apparently cured; one death; and five patients with recurrence which could be cured by operation. No other form of treatment gives such satisfactory results. Even in children, in whom temporizing and medical methods often are regarded as more legitimate in this affection than in adults, the prognosis is better if the diseased lymph nodes are removed by operation. But in every case *the source of infection must be cured.* No matter how thorough the operation, if the infecting focus

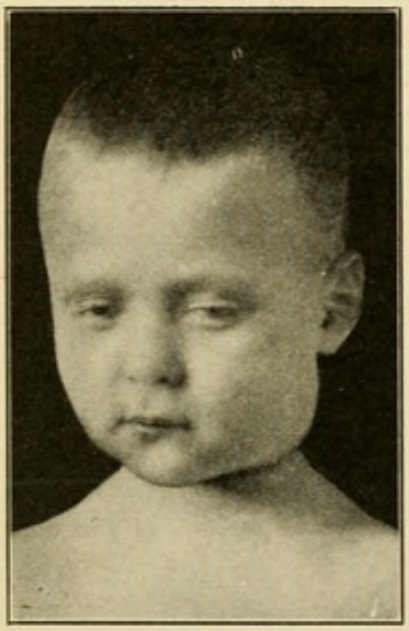

FIG. 719. — Tuberculous cervical lymph nodes; duration six months, following measles. (See Figs. 719, 720, and 721.) Children's Hospital.

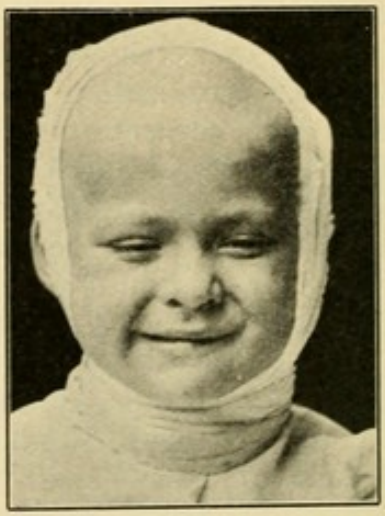

FIG. 720.—Same patient as Fig. 719, after operation, showing temporary paralysis of depressor anguli oris. (See also Figs. 721 and 722.) Children's Hospital.

remains in scalp, tonsil, pharynx, or elsewhere, other nodes not detected at the first operation will become diseased, and the patient will be no better off than before the first operation. If there are chronically enlarged lymph nodes in the neck, the first thing to do is to cure the source of infection; the lymph nodes may then cease to give symptoms. If they do not, they almost certainly are tuberculous, and should be removed. Occasionally the lymphatic invasion is so much more disabling than the source from which the infection is derived, that it is justifiable to do the operation on the cervical lymphatics first, and to postpone cure of the nasal or tonsillar or dental or scalp condition, until comparative health has been restored; but in many such cases a recurrence in the neck will take place because the infecting focus is too long neglected. Seldom or never is it advisable to undertake a nose or throat operation at the same time that the neck opera-

tion is done. If there are adenoids, enlarged tonsils, etc., it is better to attend to them one or two weeks before the neck operation is done; and a week or ten days usually should elapse between operations if both sides of the neck are involved. The neck operation frequently is one of great difficulty, and if properly done always is tedious and lengthy (Figs. 719, 720, 721, and 722).

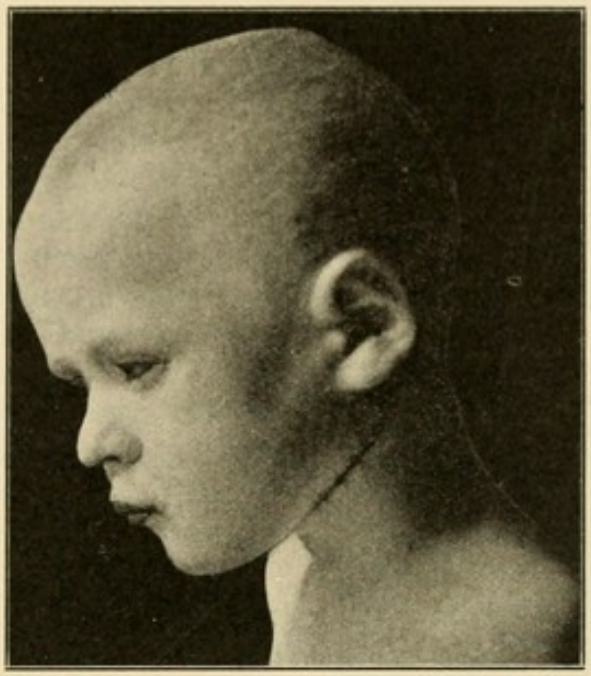

FIG. 721.—Same patient as Fig. 719, showing Dowd's incision for cervical adenitis. Children's Hospital.

Operation.—If the nodes only in the *upper portion* of the neck are involved, they may be reached conveniently through Dowd's upper incision, which runs in the direction of the folds of the neck an inch or more below the jaw (Fig. 721). Cut through the platysma and deep



FIG. 722.—Mass of tuberculous lymph nodes removed entire, showing groove for great vessels (three-fourths natural size). (See Figs. 719, 720, and 721.) Children's Hospital.

fascia before reflecting the margins of the wound, so as to avoid injury to the branch of the facial nerve which supplies the depressor labii inferioris; this nerve runs between the deep fascia and platysma, about a finger's breadth below the mandible, and is the only branch of the

facial nerve exposed to injury (Fig. 720). Then identify the anterior border of the sterno-mastoid muscle, and work under its margin until the carotid sheath is exposed below the enlarged lymph nodes. These should then be removed by careful dissection (not blunt tearing) from below upward, *in one mass* (Fig. 722). The chief dangers are hemorrhage from large branches of the internal jugular vein, especially the facial and temporo-maxillary veins; and injury to important nerves, notably the hypoglossal and spinal accessory.

If the *lower deep cervical lymph nodes* are involved, a second transverse incision, parallel to the first, and several inches lower, may be added. These nodes are most easily exposed along the posterior border of the sterno-mastoid muscle. As one works along this from below upward, the first nerves encountered are branches of the superficial cervical plexus, emerging about the middle of the posterior border of the sterno-mastoid; and about an inch higher up the spinal accessory is encountered as it leaves this muscle and crosses the posterior cervical triangle to the trapezius muscle. The sensory nerves may be sacrificed, but the spinal accessory should be preserved.

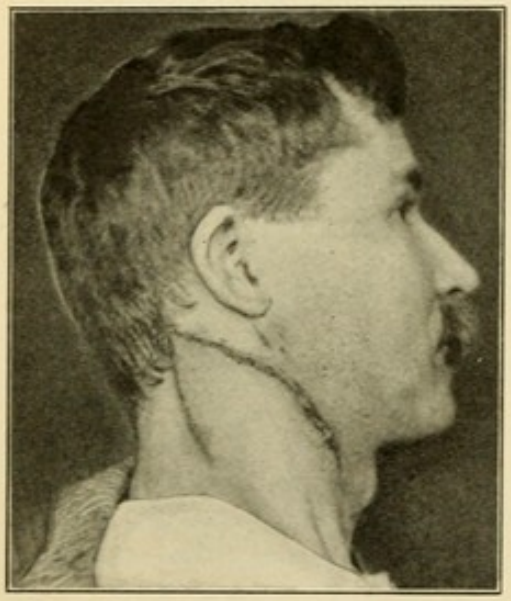

Fig. 723.—Flap incision for cervical adenitis four months after operation. (Scars emphasized in reproduction.) Episcopal Hospital.

In cases where there is *very extensive involvement*, including the supraclavicular nodes, and where the tissues are densely adherent, it is better to turn down a large triangular flap, as indicated in Fig. 723. This flap is turned downward and forward, the posterior incision being extended forward above the clavicle if necessary. The dissection is begun at the clavicle and proceeds upward, the diseased tissue being removed in one mass. If the surgeon can once lay bare the prevertebral muscles he will be able to remove the entire lymphatic area of the neck. In exceptional cases transverse division of the sternomastoid muscle may be necessary. The existence of a cold abscess or even of a sinus, if uninfected, does not interfere with repair of the wound.

The wound should be closed with two layers of sutures, the first to the platysma and fascia, and the second in the skin. Neglect to suture the platysma separately allows stretching even of a transverse scar. Drainage should be provided for by small tube, for the first few days; and after extensive operations the patient's head should be immobilized by sand-bags until healing is well under way.

Tumors of the Carotid Body or **Gland** usually are clinically malignant. Pathologically they are peritheliomas or endotheliomas. The

tumor occurs in young adults, and is slow-growing, painless, dense, and non-inflammatory. Its clinical course extends through many years, but sudden growth may develop at any time. Eventually the growth surrounds and compresses the carotid arteries, and causes symptoms from pressure, especially from pressure on the sympathetic, hypoglossal, and vagus nerves. The *diagnosis* is made chiefly by exclusion. The tumor is situated at the bifurcation of the common carotid artery, and receives transmitted pulsation; but this pulsation is not expansile, and there is no thrill nor bruit. Compression of the common carotid artery does not affect the tumor. The absence of primary growth elsewhere, the long duration, and the younger age of the patient, exclude carcinoma. Sarcoma grows much more rapidly, and tends to soften and ulcerate.

Treatment.—If seen very early, extirpation may be undertaken; but very soon the operation becomes one of the utmost difficulty and great danger. The mortality thus far is about 25 per cent. Operation usually involves ligation of the common carotid artery below and of the external and internal carotids above the growth, for it cannot be separated from them safely. Other structures should be preserved if possible. In one case it was necessary to remove part of the base of the skull to secure the internal carotid above the growth; and irreparable damage has been done to both recurrent and superior laryngeal nerves, to the hypoglossal and even the facial nerve. If it appear improbable that the operation can be completed, it should not be attempted, or if begun, should be abandoned in good time.

FIG. 724.—Thyro-glossal cyst: at birth size of walnut; steady growth since. Age four years. Orthopædic Hospital.

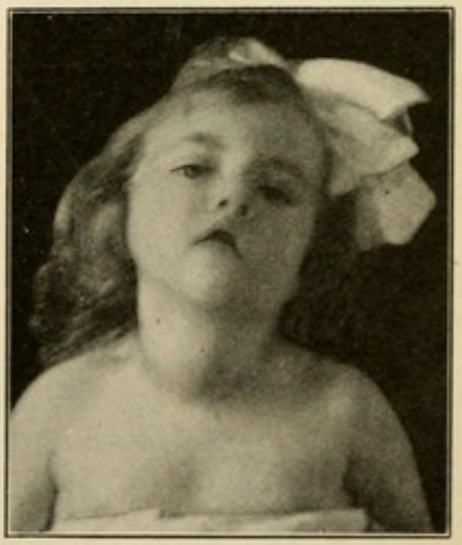

FIG. 725.—Thyro-glossal cyst; age four years. Orthopædic Hospital.

Thyro-glossal Cysts and Fistulæ.—The thyro-glossal duct in the embryo runs from the foramen cecum of the tongue through or behind the hyoid bone, in the mid-line of the neck, to the thyroid gland. If the duct fails to be obliterated, any portion which remains may become

dilated and form a cyst; and if the cyst ruptures externally a fistula will result. These cysts and fistulæ always are in the median line of the neck. They may be above the hyoid bone, over it, below it, or the entire thyro-glossal duct may be persistent. Usually these cysts are noted in childhood (Figs. 724 and 725), but sometimes no trace of them is observed until puberty (Figs. 726 and 727). The cyst slowly and painlessly increases in size, and relief is sought for deformity or pressure effects. A thyro-glossal fistula secretes a little mucoid matter; pain may result from retention of its contents if the orifice becomes scabbed. Suprahyoid cysts are lined by stratified squamous epithelium; those arising lower in the thyro-glossal tract are lined by columnar (sometimes cilated) epithelium.

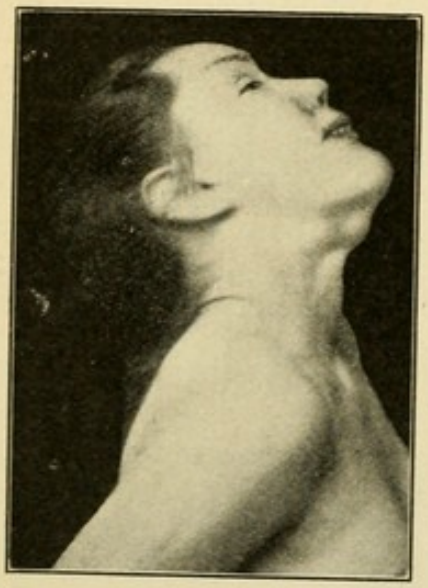

FIG. 726.—Thyro-glossal cyst, age fourteen years; duration one year. Episcopal Hospital.

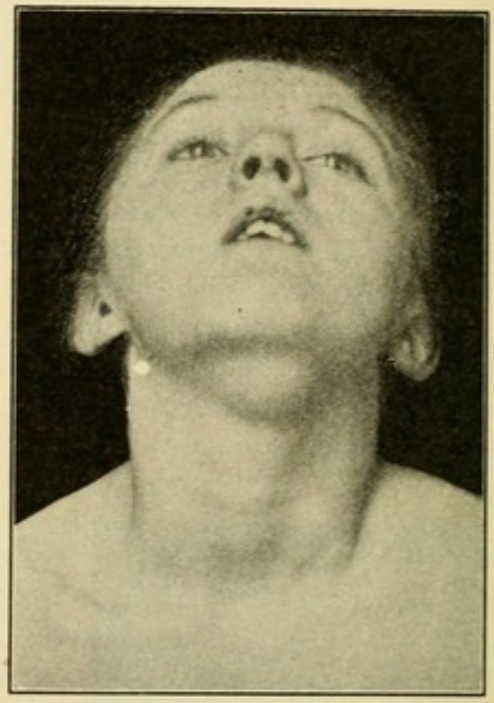

FIG. 727.—Thyro-glossal cyst. Same patient as Fig. 726. Episcopal Hospital.

Treatment.—Extirpation should be done, removing carefully every trace of the duct wall. Recurrence will take place if any portion remains. The dissection is difficult and should not be undertaken by an unskilled operator.

Branchial Cysts and Fistulæ.—These result from maldevelopment of the branchial arches and clefts of embryonic life. They are situated laterally in the neck, and thus are easily distinguished from the median thyro-glossal remains. Branchial fistulæ usually open along the anterior border of the sterno-mastoid muscle, and may extend as far as or even into the pharynx. The condition is congenital, but the patient may not seek relief until adult life, and the cysts may be of insignificant size until the occurrence of some injury (Fig. 728). If the cyst lies near the pharynx it will have lymphoid tissue in its walls.

Treatment.—Extirpation, which is the only successful treatment, involves a very much more delicate dissection than that of the median cysts already mentioned; and even skilled dissectors may have to repeat the operation a number of times. Distending the sinus with paraffin, which is injected hot and allowed to harden *in situ*, is a valuable aid.

Branchiogenic Carcinoma (Langenbeck, 1861; Volkmann, 1882).—Occasionally a carcinoma develops in a branchial cleft. Diagnosis before operation is difficult. It may resemble a tumor of the carotid body, but occurs in older persons, its duration is measured by weeks or months, not by years, and it is adherent to the skin. *Treatment* involves extirpation of the tumor with the overlying skin.

FIG. 728.—Branchial cyst of neck; age eighteen years; duration seven months; followed a fall. Orthopædic Hospital.



FIG. 729.—Cystic fibroma of cheek and neck; twenty-five years' duration. Weight of tumor three pounds and five ounces. Excised by the late Prof. Ashhurst, 1896. University Hospital.

Hygroma.—This is an old clinical term used to describe cervical cysts of different nature. The subject has been studied recently by Dowd (1913). Some are *lymphangeiomatous* in character: these are congenital, usually occupy the posterior triangle, seldom cause disability, often grow smaller and may even disappear as the patients grow older. Their removal is difficult and dangerous, and should not be attempted unless pressure symptoms render relief imperative. Often the most that can be done is to excise the anterior and parts of the lateral walls of the cyst, and pack its cavity with gauze, looking for a cure by granulation, cicatrization, and contraction. Occasionally the cyst extends into the axilla. *Hemorrhagic cysts* may result from traumatic or spontaneous hemorrhage into a preëxisting cyst. *Bursal cysts*, occurring in preëxisting bursæ around the hyoid bone or thyroid cartilage, result from effusion due to trauma or constitutional disease.

Lipoma is frequent in the neck. **Fibroma** is rather unusual; it generally springs from the deep fascia, is slow growing; may in time undergo degenerative changes (Fig. 729), and reaches an immense size.

SURGERY OF THE THYROID GLAND.

Inflammation.—Inflammation of the normal thyroid gland is comparatively rare. It is described as *thyroiditis*, and must be distinguished from *strumitis*, or inflammation of a goitrous gland (p. 688). *Acute thyroiditis*, seldom leading to abscess, occurs by infection through the blood-stream in general infections such as typhoid fever, scarlatina, etc. The entire gland is enlarged and tender, and pressure symptoms are usual. If suppuration is suspected an incision should be made. If multiple abscesses exist, or if necrosis occurs, partial excision should be done. *Chronic thyroiditis* is much less unusual than the acute, and usually is chronic from the start, seldom following an acute attack. It occurs usually in alcoholic or arteriosclerotic adults, and may be caused by syphilis (gummatous form), tuberculosis, or prolonged use of iodin. Operation may be required for diagnosis in cases of asymmetrical involvement of the gland, or to relieve pressure. *Ligneous* or *woody thyroiditis* (Riedel, 1896) is believed by Delore and Alamartine (1911) at times to be one of the manifestations of what Poncet calls inflammatory tuberculosis. Clinically the diagnosis from carcinoma is difficult, and pathologists interpret the histological pictures differently. Compression of the trachea is frequent, and demands intervention. This should consist merely in resection of the thyroid isthmus. Radical operation is nearly impossible and is not necessary. The use of the *x*-ray may hasten regression of the disease.

Goitre.—This is a clinical term used to describe an enlargement of the thyroid gland. It is derived from the Latin word for throat (guttur). The thyroid is an epithelial gland which in embryonic life had a duct, the thyroglossal duct. The presence or absence of a goitre, and the existence or non-existence of constitutional symptoms in connection with it, depend on the inter-relation of secretion and absorption in the thyroid gland. In fetal life there is little or no evidence of secretion. At puberty the thyroid becomes more active, and, as noted below, sometimes enlarges. In adult life whatever secretion is produced is normally absorbed by the body tissues. In abnormal states there is excess of secretion, and this is either not so absorbed, and accumulates in the thyroid ("cystic" goitre); or else is absorbed and produces toxemia (hyperthyroidism). Whenever hyperthyroidism exists there is an increase in the secreting surface of the thyroid; this results either in a parenchymatous hypertrophy (without cyst formation), or in intracystic papillomatous out-growths (if the change occurs in a thyroid previously cystic). When instead of parenchymatous hypertrophy, there is marked increase in the interglandular connective tissue, the amount of secreting surface is relatively decreased; this is the case in the thyroids of cretins (hypothyroidism)

and the term hypertrophic fetal thyroid is applied. If in a fetal type of thyroid the epithelial (secreting) elements are in excess, we have an adenomatous thyroid, and symptoms of hyperthyroidism may or may not be present. Patients in whom atrophy of secreting cells has occurred, usually as the result of pressure from accumulated and not absorbed secretion (chiefly, therefore, in cases of cystic thyroid), are those who are spontaneously cured of their toxic symptoms; in some such cases the final state may be one of hypothyroidism (MacCarty, 1910).

Physiological enlargement of the thyroid gland often occurs in girls at puberty (Fig. 730), the enlargement persisting for a year or more and then gradually subsiding. Sometimes enlargement recurs at every menstrual period or during pregnancy; and occasionally the enlargement which appeared at puberty never subsides. The gland is uniformly and symmetrically enlarged. No symptoms are present and the patient may not be aware of the existence of a goitre. No treatment is required.

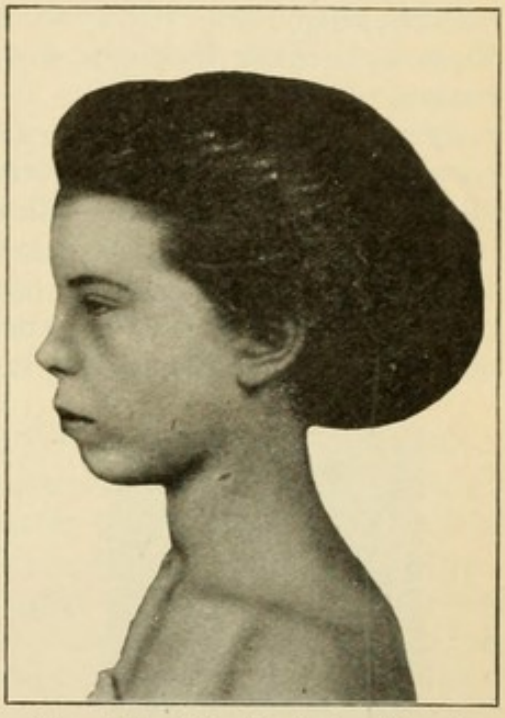

FIG. 730.—Physiological goitre, in a girl of thirteen years. Orthopædic Hospital.

Pathological enlargement of the thyroid gland is endemic in certain regions, notably in Switzerland; it is frequent in French Canada, and in some other parts of North America. It is generally believed that this enlargement is associated in some way with the drinking water of the patients; and it seems probable that the cause is some qualitative change in the iodin constituents of the drinking water. The enlargement may be *diffuse* or *circumscribed* ("*nodular*"). This classification of Kocher is in general use, and is very convenient for purposes of clinical study.

Diffuse enlargement involves both lateral lobes and isthmus proportionately. It usually is due to more or less uniform increase in all the elements of the thyroid (*follicular* and *parenchymatous goitre*) or to disproportionate increase in the colloid material (*colloid goitre*). In the latter and more frequent form, the consistency of the swelling is harder, and the individual lobules appear larger and are more easily defined. A *diffuse vascular goitre* is one of any form in which vascularity is marked. A *diffuse fibrous goitre* is the result of inflammation and cicatricial changes in any of the forms mentioned, and is very rare. There is also a form of *diffuse adenomatous goitre* which it is better to classify among malignant growths.

Circumscribed or *nodular enlargement* may occur in any of the principal forms already mentioned: follicular, colloid, or adenomatous. The colloid or "cystic" goitre is by far the most frequent form. Nodular goitre is characterized (1) by the irregularity and inequality of the enlargements; and (2) by their tendency to undergo degenerative changes, such as colloid, hyaline, calcareous, etc., and to intracystic hemorrhages. Single nodules are most common in one of the lower poles of the lateral lobes; occasionally they occur in one of the upper poles; and very rarely in the isthmus or in the pyriform lobe when the latter is present. Multiple nodules may exist. As the nodules increase in size they displace the remaining normal gland structure, and may become more or less encapsulated. Occasionally a diffuse colloid goitre is converted into a goitre with multiple cystic nodules; these have little tendency toward degeneration or internal hemorrhages.

Symptoms and Diagnosis.— *Diffuse goitre* retains the shape of the normal gland, and rarely attains very large size. The tumor, as in all thyroid affections, rises with the larynx in the act of swallowing and in coughing. It is movable laterally, but scarcely at all up and down. Pressure symptoms are rare. Sometimes venous engorgement is visible over the root of the neck or upper thorax. In *nodular goitre* the relation of the swelling to the thyroid is determined by its location in the neck over the normal site of the thyroid, and by its movement with the larynx in deep breathing, swallowing, and coughing. The swelling is close to the median line of the neck, but usually is distinctly lateral in its attachment. As it increases in size it may become pendulous (Fig. 731). It pushes forward the sub-hyoid muscles, and displaces the sterno-mastoid muscle and great vessels of the neck laterally, so that the vessels may be palpable at the posterior border of this muscle; it may distort or compress the trachea and esophagus; and may cause symptoms from pressure on the sympathetic, recurrent, or superior laryngeal nerves. Rarely a goitre may grow down behind the sternum, when its presence may be detected by percussion. Finally, a goitre may produce disturbance of the heart and circulation, either directly by pressure on the great vessels, or through interference with respiration; or in some instances from hyperthyroidism (p. 688). Intermittent pressure on the great vessels of the neck may produce giddiness and other evidences of disturbances in the intracranial circulation.

FIG. 731.—Cystic goitre, of sixteen years' duration in a patient of thirty-seven years. Pennsylvania Hospital.

In *diffuse follicular* and in *parenchymatous goitres* the diagnosis

rests on the soft, flabby consistency, palpation of the small but rather distinct lobules, and the vascularity. Early symptoms of hyperthyroidism may be present, and these usually will be increased by the administration of iodin. The *diffuse colloid goitre* is relatively firm, the lobules are much larger, and some are quite hard; iodin causes no diminution in size. The *diffuse fibrous* goitre is harder, and there are symptoms of hypothyroidism.

In *nodular colloid goitre* (cystic goitre) the diagnosis often is made at a glance. The surface of the cyst is smooth, its form is oval or rounded, and its consistency elastic. The *adenomatous goitre* is recognized by its circumscribed character, and its soft and doughy feel.

Treatment.—In many cases of diffuse goitre, judicious medical treatment, with attention to hygiene, will cause diminution or complete subsidence of the swelling. Operation is required only for cosmetic effect, to relieve pressure symptoms, or to check progressive growth or a tendency toward hyperthyroidism. In most cases of nodular goitre operation is indicated at an early stage, for the same reasons which render its adoption advisable at a later stage in the diffuse form. This is particularly true of nodules undergoing degenerative changes, and especially of the nodular adenomatous form, since in this the tendency to malignant change is well marked. Finally, it may be stated in general terms, that any goitre of rapid growth or tender on pressure should be referred to the surgeon.

The *operation* consists in excision of the affected lobe; or in case of one or two large nodules, in their *enucleation;* as the nodules usually are fairly well encapsulated the remainder of the gland may be left intact, to prevent development of symptoms of hypothyroidism. Enucleation is indicated especially where it is probable that very little healthy functionating gland tissue remains. In diffuse goitre it usually is found sufficient to excise one lobe, with a part of the isthmus; the remaining lobe may then cease to cause symptoms. Should these continue, a part or whole of the second lobe may be removed subsequently. *Kocher's incision* is a transverse incision, slightly convex downward, crossing the neck over the prominence of the thyroid, from one sterno-mastoid muscle to the other. In operations on one lobe only, the incision need be only half as long. The flaps, including platysma and fascia, are then dissected upward and downward, exposing the pre-thyroid muscles. These may be divided near the hyoid bone, if necessary, thus preserving their nerve supply, and the tumor may then be dislocated into the wound. In all thyroidectomies, partial or complete, hemorrhage should be scrupulously avoided, by clamping and ligating veins as they are encountered, and securing the superior and inferior thyroid arteries of the affected lobe before its excision is begun. Both arteries should be secured close to, or after entry of their branches into the gland. This is especially important in case of the inferior thyroid, so as to avoid interference with the circulation of the inferior parathyroid glandule (p. 691). Then the capsule of the gland is split open along its lateral

aspect, and the lobe is removed, leaving part of it adherent to the posterior portion of the capsule, so as to avoid injury to the parathyroid glandules and the recurrent laryngeal nerve. The occasional presence of a thyroidea ima artery should be remembered. The isthmus is clamped and is ligated, in the groove made by the clamp, before it is divided. Severed muscles are then sutured, and the wound is closed with ample drainage.

Strumitis.—Inflammation of a goitrous thyroid is less unusual than that of the normal gland. The diagnosis rarely is difficult, and the treatment is the same as for corresponding forms of thyroiditis.

Hypothyroidism.—In persons from whom the entire thyroid gland is removed there usually develops a condition of acquired cretinism, known as *myxedema*, or *cachexia thyreopriva*. The signs of this condition need not be detailed here. A knowledge of the condition is sufficient to warn the operator not to remove all the functionating thyroid tissue. If this course has to be pursued in the eradication of malignant disease, the patient should ingest daily a sufficient quantity of thyroid extract to keep the myxedematous symptoms in abeyance. Transplantation of thyroid tissue, from man and from some lower animals, has been tried in such cases, and in some instances with encouraging results. The portions of thyroid gland have been implanted subcutaneously, in the subserous tissues, in the splenic pulp, and in the bone marrow. In most cases, even if the graft functionates properly for a time, it eventually is absorbed, and myxedematous symptoms again develop.

Hyperthyroidism (*Exophthalmic Goitre, Graves's Disease* (1835), *Basedow's Disease* (1840), *Thyrotoxicosis*).—Administration of thyroid extract in excess to normal persons causes the development of certain symptoms which are also present in some diseased states of the thyroid gland. These symptoms are the direct antithesis of those observed in myxedema. They may be grouped in four main categories: (1) Local changes in the thyroid. (2) General circulatory symptoms. (3) Nervous symptoms. (4) Metabolic changes. There should also be mentioned exophthalmos, which usually is present, but sometimes is not associated with other typical symptoms.

The affection is much commoner in women than in men (about 6 to 1), and occurs usually between the ages of fifteen years and thirty-five years; it is less rare after thirty-five years than before puberty. It appears to be induced by physical or mental exhaustion, worry, anxiety, fright, fear, etc. Sometimes it develops very acutely; in others very rapidly, but not suddenly; at other times its onset is insidious. In the cases which develop rapidly, the goitre usually makes its first appearance at the time that the thyrotoxic symptoms develop; in the chronic cases, with slow onset, a goitre usually has been present for months or years before hyperthyroidism ensues.

Local Changes.—The thyroid usually is enlarged symmetrically and diffusely. Its vascularity is increased, giving it a soft feel; but deep pressure detects a gland firmer than normal. Nodular goitre

rarely is associated with thyro-toxic symptoms. The more acute the onset, the more marked are the local changes. In cases of long duration, especially when medical treatment has been prolonged, the gland becomes smaller and firmer, but the vascular phenomena may be demonstrated again after excitement. In some cases no local changes are perceptible, and the diagnosis depends on other signs.

Circulatory Symptoms.—Tachycardia is the most prominent symptom: the pulse is abnormally frequent, quick, usually of high tension, and extremely irritable (A. Kocher). These changes may be acute in onset, or very gradually develop. Excitement always accentuates them.

Nervous Symptoms.—Restlessness of mind and body is exceedingly characteristic. The patient inclines to be hysterical, and weeps without provocation; there is insomnia; tremor, especially marked in the hands, tongue, and lips; and various psychoses may develop.

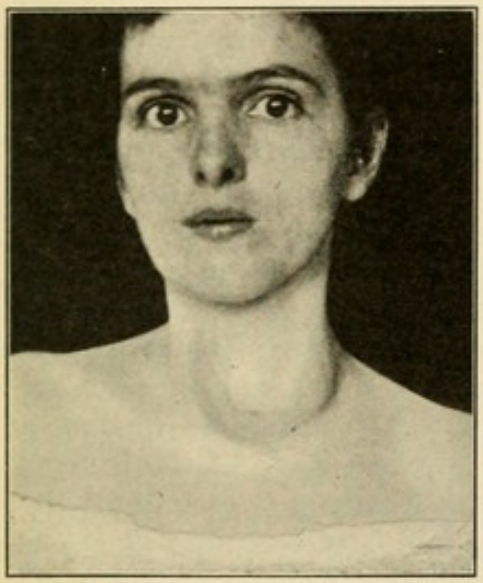

FIG. 732.—Exophthalmic goitre. Duration seven years; twenty-eight years old. Has had seven children. Goitre has grown rapidly during the last year. No tachycardia or nervousness. Exophthalmos not noticed by patient. Episcopal Hospital.

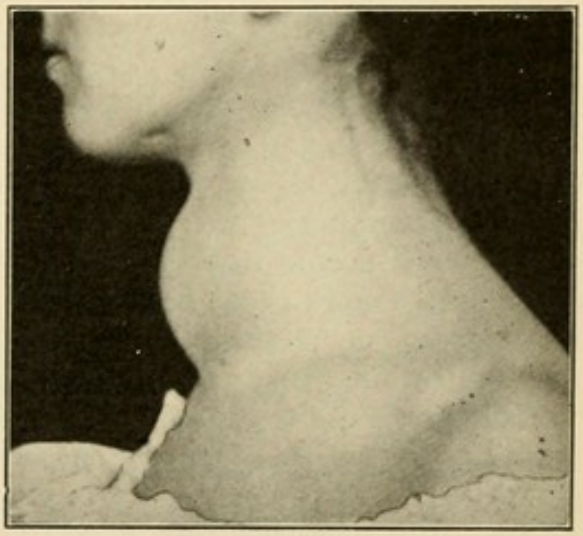

FIG. 733. — Exophthalmic goitre. Same patient as Fig. 732. Episcopal Hospital.

Metabolism.—In general terms, all metabolic activity is increased. The skin is warm and moist; the temperature slightly raised; the amount of urine increased; weight is lost, and in advanced stages emaciation may occur. Brown atrophy of the heart and degenerations of the other viscera develop eventually, and render recovery impossible. There is great weariness quite early in the disease. Frequent attacks of diarrhea may occur. Capillary hemorrhages are not infrequent. The blood-changes are said by Kocher to be characteristic, and almost pathognomonic: there is slight leukopenia, but marked increase in the actual and proportional number of lymphocytes, which may outnumber the neutrophile leukocytes; the red blood cells and hemoglobin remain unaltered.

Exophthalmos is not a necessary feature of hyperthyroidism. It may be present, and associated with a goitre, without any of the circulatory, nervous, or metabolic symptoms which are characteristic of the disease (Fig. 732). Its pathogenesis is not understood. It may be absent when other symptoms of the disease are very pronounced.

Diagnosis.—This depends on recognizing the circulatory, nervous, and metabolic symptoms which have been detailed above; and on the blood-changes, on which great stress is laid by Kocher. The existence of a palpable goitre and exophthalmos are confirmatory signs, but by no means necessary for a diagnosis. The histological diagnosis, as pointed out at p. 684, depends on the recognition of increase in the secreting surface of the gland, quite apart from other changes which may be present.

Prognosis.—Theoretically, hyperthyroidism is a self-limited disease; but the disease may kill the patient before it burns itself out. In rare cases the thyrotoxic symptoms subside, perhaps aided by medical treatment, and those of hypothyroidism succeed. The thyroid thus may destroy itself by hypersecretion. But in most cases the disease grows progressively worse. The more acute its onset, the more rapid is its course. Acute exacerbations characterize some rather subacute cases. In these and in the hyperacute cases, death may occur in a paroxysm, with rapid cardiac exhaustion (*delirium cordis*), general edema, albuminuria, fever, dyspnea, etc. In other, more chronic, cases, death occurs from intercurrent maladies, such as influenza or tonsillitis; it may occur merely from administration of an anesthetic for operative purposes, since viscera damaged by the long continuance of intoxication cannot functionate under these additional demands.

Treatment.—As the disease is due to intoxication from the thyroid gland, there are two logical remedies: one is removal of part of the gland, the other is the preparation and administration of an antitoxic serum. The latter has been tried by Beebe and Rogers, but not with the uniform success which has attended operative treatment, and must be continued indefinitely as the cause of the symptoms is not removed. In the hyperacute cases usually no treatment is of use, and death occurs in a short time. In the subacute cases, in which the thyrotoxic symptoms and the goitre appear simultaneously, medical treatment should be tried before resort to operation, as by procuring absolute rest for mind and body it is possible to ameliorate the patient's condition. In most cases confinement to bed is imperative, in isolation. Local cold is of great value in quieting the tachycardia. Kocher thinks iodin internally is of much value. The bowels and kidneys must be looked to, and a milk diet may be beneficial. Belladonna or atropin, with an occasional course of bromides, are useful in controlling circulatory disturbances. If no improvement is evident within a couple of weeks, it is useless to pursue this treatment further, and operation should be undertaken, as it should even earlier if the patient continues to grow worse, and in the more chronic cases where it may be employed safely without such careful preparative treatment.

The Parathyroids.—In all operations injury of the parathyroids should be avoided; for though Shepherd attaches little importance to them, other surgeons of equal or greater experience (Kocher, C. H. Mayo, Crile, Halsted) entertain the greatest respect for their powers of good and evil. These little glands, of uncertain function, usually are four or more in number; they are situated two on each side of the neck behind the thyroid gland, and separated from it by the posterior portion of its capsule. The lower pair are in relation with the terminal branches of the inferior thyroid artery, and are the more constant in position. The upper parathyroids are supplied either from the superior thyroid artery or from communicating branches from the inferior thyroid. Removal or destruction of all the parathyroids is supposed to be the cause of post-operative tetany, which has been seen in a few cases. As it is impossible to identify the parathyroids except by histological examination (macroscopically they cannot be distinguished from lymph nodes), the only safe course is to keep clear of the site where they normally are found. This is best done in excisions by leaving the posterior portion of the capsule and, if necessary, a layer of thyroid tissue adherent to it.

Operation.—In severe cases it is the custom first to diminish the thyrotoxic symptoms by ligating one or more of the arteries supplying the gland; and to proceed to partial excision within a week or ten days, before the favorable effect of the preliminary operation has passed away. In very acute cases the patient will be so much worried and excited by the anticipation of any operation, that Crile has adopted the ingenious plan of instituting a course of very strict pre-operative treatment, repeated every morning, and embodying the essential steps in preparation for operation, as if they in themselves constituted the treatment. Every morning the patient's neck is washed as if for operation, and dressings are applied; every morning she inhales some essential oil, to simulate an anesthetic. Then some favorable morning, in the course of usual routine, a real anesthetic is given, and the operation is completed without the patient being aware of any change from the daily routine. In Kocher's hands, the mortality of operation in 200 severe cases was 4.5 per cent.; and there were 85 per cent. of cures. In cases with advanced visceral degenerations operation is useless.

Ligation.—Most surgeons follow Kocher in ligating one or both superior thyroid arteries. But Delore and Alamartine (1911) have pointed out that the circulation is much better controlled if the superior and inferior thyroids on the same side are ligated. Halsted (1913) now ligates both inferior thyroids. The *superior thyroid artery* is exposed by a small transverse incision over the upper pole of the lateral lobe, which usually is palpable through the skin; the sterno-mastoid is drawn backward and the omo-hyoid forward, and the pole of the gland itself is ligated extracapsularly, in two places. This "polar ligation," introduced in 1909 by Jacobson and Stamm, and adopted by C. H. Mayo, is valuable as it does not interfere with the

blood-supply to the superior parathyroids, which would be jeopardized if the main trunk was ligated; and because it controls the veins and lymphatics and also destroys most of the vasodilator nerves entering the lateral lobe. This polar ligation thus becomes what Delore and Alamartine call an angeio-neurectomy. The *inferior thyroid artery* is best ligated at its origin from the thyroid axis, since it divides into numerous branches before entering the gland, and separate ligation of these is difficult and exposes the recurrent laryngeal nerve and inferior parathyroid to injury. The artery is exposed by an incision parallel to the clavicle at the posterior border of the sternomastoid; the anterior scalene muscle is located, and the thyroid axis found just to its median border.

Thyroidectomy.—As in the case of simple goitre (p. 687) only one lateral lobe is to be removed. If symptoms persist, half of the remaining lobe may be removed at a second operation. Great care in hemostasis must be exercised, and the wound must be freely drained.

Sympathectomy (Jaboulay, 1896).—Excision of both superior ganglia of the cervical sympathetic, effective in overcoming the exophthalmos, has been abandoned by most surgeons, because it has very little influence on the other symptoms.

Malignant Tumors of the thyroid are not very rare, especially in goitrous regions. Carcinoma is commoner than sarcoma; endothelioma also occurs. Clinically, the distinction is not of much importance, since, as A. Kocher says, "By the time malignant goitre reveals its two chief characteristics it is too late for a radical cure." He adds that if the thyroid continues to enlarge after puberty, in spite of appropriate internal treatment, and in the case of any thyroid which begins to grow without any apparent cause after the thirty-fifth year of life, malignant change should be suspected. The two chief characteristics of these malignant tumors are irregular growth, and change in consistency. Instead of the nodules being more or less uniform in distribution and size, a few of them will begin to project to an abnormal degree beyond the others, and they will lose their elastic consistency and become firmer and more flesh-like. Pressure symptoms occur earlier than in benign enlargement, because of development of adhesions to surrounding structures. Spontaneous pain is not an early symptom, but occurs in malignant growths much sooner than in benign.

Prognosis.—The prognosis is bad. Metastasis occurs early, and may be the first evidence of malignancy. In carcinoma, and even in histologically benign diffuse adenoma, metastasis to bones is frequent; and Shepherd has observed pulmonary invasion by carcinoma through the internal jugular veins.

Treatment.—Very early extirpation is the only method that offers any hope of cure. Shepherd says he has completely excised over a dozen thyroids, and never save in one case (repeated operations for recurrence) has seen any evil effects attributable to injury of the parathyroids though he has taken no care to preserve them. But the

prophylactic administration of parathyroidin is recommended, and the use of thyroid extract may be necessary to prevent myxedema. Tracheotomy may be necessary in far advanced inoperable cases; it may prove a difficult operation.

SURGERY OF THE THYMUS GLAND.

In some infants acute or chronic dyspnea is due to enlargement of the thymus gland, which compresses the trachea. Usually the enlarged gland may be detected by percussion, and its presence should be suspected when tracheotomy fails to relieve the dyspnea. Then the incision may be extended down to the episternal notch, when the thymus (much like an enlarged lymph node) will protrude from the anterior mediastinum, and may be drawn up into the neck. In some cases it has been sutured to the sterno-mastoid muscle to keep it from again becoming wedged in the thoracic opening, but it is better to enucleate it from its capsule and remove as much of it as is easily detachable. The wound should not be drained, for drainage implies infection, and this means death. If the respiratory obstruction is relieved in time, recovery follows. Olivier (1912) has studied the results of 42 thymectomies; of the 15 deaths, 7 were not due to the operation, and 8 were attributed to the secondary tracheotomy. He concludes that subtotal, subcapsular thymectomy is the best treatment.

SURGERY OF THE ESOPHAGUS.

Foreign Bodies.—There are three points at which a foreign body is apt to be arrested: (1) At the level of the cricoid cartilage; (2) where the left bronchus crosses the esophagus; (3) at the cardiac orifice of the stomach. All sorts of things may be swallowed: children's playthings, false teeth, pieces of bone, and in the insane, even spoons, forks, etc. Large bodies usually are arrested in the pharynx, and often may be extracted with the finger. Bodies with sharp prongs may catch in the esophageal wall at any point, and much damage may be done by forcible attempts at extraction.

The *diagnosis* depends on the history, which in infants and the insane may be very uncertain; on the presence of dysphagia; and on the results of examination with esophageal instruments and the *x*-ray. It is important to make the diagnosis *as soon as possible*, before inflammatory softening or perforation of the esophageal wall occurs. Do not postpone thorough examination until the next day, thinking the diagnosis will be easier then. It will not be. The esophagoscope should be employed whenever available, and if used early, before the mucous secretion is excessive, the foreign body usually can be seen. This is an instrument analogous to the bronchoscope and cystoscope. It is very much safer in skilled hands than the insertion of a bougie, but this may be the only instrument obtainable.

Treatment.—By means of an esophagoscope and the special instruments employed with it, one skilled in the use of such apparatus frequently will be able to extract the foreign body under the control of the eye. If this is not possible, the surgeon must employ the older and less satisfactory method of introducing an esophageal forceps, probang, or coin-catcher and thus endeavoring to remove the foreign body by the sense of touch. A general anesthetic is required. A coin usually lies transversely in the esophagus, and may be caught by a

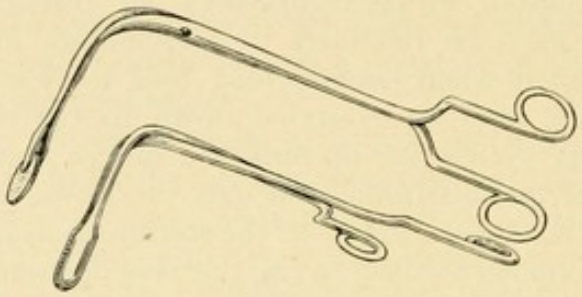

FIG. 734.—Forceps for removing foreign bodies from the esophagus.

forceps whose blades open in this direction (Fig. 734). If the coin lies very far down in the esophagus the old fashioned "coin-catcher" (Fig. 735) may be more useful. Occasionally a lodged foreign body may be advantageously pushed on into the stomach. It is not safe to make violent or too prolonged efforts at extraction, especially when more than thirty-six hours have elapsed. When all reasonable efforts have failed, or at once if the nature of the impacted body forbids attempts at extraction through the mouth, the surgeon should



FIG. 735.—Esophageal instruments: 1, Olive tipped bougie; 2, horse-hair probang; 3, coin-catcher; 4, esophageal forceps.

resort to external esophagotomy if the foreign body is well above the cardiac orifice; if impacted at the latter site, extraction should be attempted by gastrotomy (p. 876). Under the best modern methods it might be possible to perform transpleural esophagotomy.

External Esophagotomy.—Through an incision along the anterior border of the left sterno-mastoid, with division or downward displacement of the omo-hyoid, the esophagus is exposed behind the trachea and on the median side of the great vessels It should be freely

separated from the surrounding tissues, and incised on a sound passed from the mouth, after pulling it up into the wound and isolating it with gauze. The foreign body is then extracted with finger or forceps. The incision in the esophagus is tightly sutured with at least two rows of chromic gut sutures, and a drainage tube is passed down to the site of suture, and is not removed for a week. The remainder of the wound is closed in layers. No food should be swallowed for a week or ten days; rectal feeding should be employed, especially saline solution as in peritonitis, but in the case of very weak patients food may be introduced into the stomach by a stomach tube. The prognosis is good if the foreign body has been removed within the first thirty-six hours.

Stricture of the Esophagus usually results from lye burns, and is especially frequent in small children who drink a cupful of the nice white fluid, mistaking it for milk. It may occur also in adults, from ingestion of corrosive poisons. *Symptoms* of stricture may not develop for several months after the accident. Sometimes they appear rather suddenly, but usually there is a gradual but progressive increase in dysphagia, at first for solids, then for liquids, and finally regurgitation occurs through the nostrils as soon as food is swallowed. In time a pouch may form, and then regurgitation may not occur for half an hour or more after food is ingested. Any inflammatory attack is apt to produce complete obstruction. Weight is constantly lost, and emaciation may become extreme. There is a decided tendency to bronchial and pulmonary disease, owing to regurgitation of decaying food, and death may occur from such intercurrent malady.

Diagnosis.—The diagnosis is made from the history of the accident, from the symptoms, and from examination of the esophagus. This should be done by the esophagoscope; but if this is not available, an olive-tipped bougie (Fig. 735) may be passed very gently and cautiously; and the existence of a stricture and its site may be thus determined. The *x*-ray will detect the existence of a pouch if this is filled with bismuth gruel.

Treatment.—1. If the stricture is easily permeable to liquid food, it usually will be possible to secure passage of a bougie, especially if this is done under control of vision through the esophagoscope. Many strictures impermeable to blind instrumentation are not impermeable with esophagoscopy. The danger of perforation, especially if there is a thin walled pouch, always should be kept in mind. Such an accident generally results fatally in a few days from septic pneumonia or mediastinitis. If a bougie can be passed, *gradual dilatation* often is possible, as in the case of permeable urethral stricture; but hazardous as is the employment of any force in urethral instrumentation, it is absolutely harmless compared to its use in esophageal work. The safest esophageal sound, when one is used without the esophagoscope, is the olive-tipped bougie, but it is relatively safe only because of its size. The smaller the stricture, the more flexible should be the instrument. Gradual dilatation may be aided by internal esopha-

gotomy through the esophagoscope, the edge of the stricture being divided under full view. Subsequent dilatation always should be conducted under control of esophagoscopy.

2. If the stricture is impermeable to instruments, the treatment depends somewhat upon the amount of nourishment the patient can take. If sufficient nourishment is taken to maintain weight, various expedients may be tried to get through the stricture. The patient may be made to swallow a silver ball (Abercrombie, 1830) or perforated shot (Socin, 1889) attached to a string; after resting on the stricture for some hours these may pass through, and thus from day to day larger balls may be used, until a bougie can be passed. These methods are not more effective than esophagoscopic instrumentation, but may be tried when this is not available. External esophagotomy rarely can be recommended, even when the upper end of the stricture is accessible through the neck. It is not likely that this method will be successful when esophagoscopy has failed, and it cannot be known that the stricture does not extend all the way down to the cardiac orifice. If weight is being lost, it is useless to postpone a resort to gastrostomy (p. 877). When the stomach is opened, attempts may be made to pass an instrument through the stricture from below, and these occasionally are successful. But if the patient is very weak it is better not to prolong the operation, but merely to establish an opening in the stomach as rapidly as possible. Stamm's or Senn's method is the best for these cases. It usually happens that the stricture becomes permeable after the esophagus has had a rest for some weeks, while food is being introduced through the gastric fistula. This is analogous to the usual course of impermeable urethral strictures after the performance of Cock's operation (p. 1026). When the stricture becomes permeable, a string may be passed through it from the mouth; then by extracting the other end through the gastric fistula, the stricture may be cut by a sawing motion, while the esophagus is kept taut to prevent damage to its walls (Abbe's method, 1893); or the surgeon may adopt von Hacker's method (1894) of retrograde dilatation by drawing through the stricture gradually increasing sizes of rubber tubing, at intervals of a few days ("Sondierung ohne Ende").

3. If the stricture remains impermeable even after gastrostomy, there are still several plans of treatment which may be adopted. Maffei (1906) in two cases successfully exposed the esophagus by the transpleural route, and found that the stricture became permeable as soon as he had released the peri-esophageal adhesions; the esophagus was not opened at all. Roux (1907) and Herzen (1908) have formed an artificial esophagus by transplanting beneath the skin of the sternum a loop of the upper jejunum, excluded from the intestinal tract. This is to be attached above to the cervical esophagus, and below to the stomach. Herzen's name for this delicate procedure, which is completed in several sittings, is "ante-thoracic esophago-jejuno-gastrostomy." Willy Meyer (1913) has followed Jianu and

Roepke in utilizing a flap from the greater curvature of the stomach, to construct a new pre-sternal esophagus.

Congenital Imperforation of the Esophagus is a rare malformation in which the gastric end of the esophagus usually empties into the bronchus, and the pharyngeal end terminates in a blind pouch. The baby suffers from recurring attacks of suffocation due to regurgitation of gastric contents into the air passages; food swallowed is at once regurgitated. The best *treatment* is performance of *jejunostomy* (p. 878), for the purpose of introducing nourishment, as advised by Demoulin (1904). Should the infant survive (which is unusual) treatment as for impermeable stricture of the esophagus should be attempted later.

Diverticula of the Esophagus may be congenital or acquired. The acquired diverticula are due either to traction from without (usually from adhesions to bronchial lymph nodes, etc.), or to pressure from within. The *traction diverticula* rarely produce symptoms, as their lumen is oblique or horizontal and the orifice is directed downward (Zenker, 1878); food is not apt to collect in them, and often they are found unexpectedly at autopsy. But occasionally during life perforation occurs. *Pressure diverticula*, well studied by Halstead in 1904, constantly produce symptoms during life, from accumulation and regurgitation of food. Sometimes during meals a palpable tumor appears in the left side of the neck, and can be emptied by pressure. Often the earlier part of a meal will be swallowed more easily than the latter part, because gradual filling of the pouch causes obstruction of the esophagus. The pouch is found most often to spring from the posterior wall of the esophagus in the median line, just below the pharynx. A bougie sometimes will be arrested in the pouch, and sometimes will pass on into the stomach, and thus the condition may simulate a spasmodic stricture. But if one bougie is arrested in the pouch, it may be possible to pass another alongside of it into the stomach. The diagnosis is aided by esophagoscopy and by the use of the *x*-ray after filling the pouch with bismuth gruel.

Treatment.—If the diverticulum is accessible from the neck, it should be exposed from the left side, and excised. The stump is treated as the appendix stump (p. 857), and the wound treated as in external esophagotomy (p. 694).

Dilatation of the Esophagus, as a whole, usually is secondary to what has been described as cardiospasm, which is now believed to be not a spastic condition of the cardiac orifice of the stomach, but of the esophagus just above the cardia. The cause of the "cardiospasm" has not always been determined, but in some cases gross esophageal lesions (ulcer, carcinoma, etc.) have been found.

Symptoms.—The symptoms are those of slowly oncoming and never entirely complete obstruction to food. In the early stages there is a feeling of fulness after eating, with an uneasy sensation in the epigastrium or behind the sternum; the patient eats very slowly, and requires much liquid to wash the food down; final entrance of

food to the stomach may be accomplished only after the patient has retired to a corner and urged the food down by deep breathing, gulping, or curious contortions of the arms and body. Later, regurgitation occurs immediately after swallowing; but when full dilatation has developed food may be retained for several hours. The regurgitated food is not sour, as it would be if vomited after lying in the stomach.

Diagnosis.—Diagnosis is based on the symptoms, and on the exclusion of organic stricture by esophagoscopy or by passage of a bougie. A bougie may be arrested near the cardiac orifice, but usually passes through after temporary arrest. A skiagraph, made after ingestion of bismuth gruel, also is helpful.

Treatment.—The most satisfactory treatment is forcible divulsion of the cardia. This can be done by instruments passed by mouth, as in the methods of Sippy and of Plummer. The apparatus consists of a rubber bag about 10 cm. long, encased in a silk bag which limits the possible distention to a circumference of 15 cm. Dilatation is produced by an air-pump. The treatment usually must be repeated several times before complete relief is secured. No anesthetic is necessary. In some cases divulsion of the cardia may be done after gastrostomy.

Carcinoma.—Carcinoma is the most frequent disease of the esophagus. It occurs oftenest in males, in the decline of life. About 50 per cent. of cases are near the cardia, 40 per cent. at the bifurcation of the trachea, and only 10 per cent. at the cricoid cartilage. It probably often develops in an ulcer or erosion. Its onset is insidious, but when once symptoms develop, they progress rapidly. The chief characteristic is increasing difficulty in deglutition, for which no cause can be found in the patient's clinical history. Syphilitic stricture is rare but must be excluded. The diagnosis from aortic aneurysm often is exceedingly difficult. In carcinoma very early and great enlargement of the bronchial lymph nodes may occur; there often are pressure palsies of the recurrent laryngeal or sympathetic nerves; and dyspnea may exist. Referred pain is common, and erosion of the vertebræ and even paraplegia may develop before symptoms of esophageal obstruction are marked. Pulmonary complications are frequent. Passage of a bougie may provoke hemorrhage. Esophagoscopy is important. The *prognosis* is very bad. Death usually occurs in a year from the date of diagnosis.

Treatment.—When thoracic surgery becomes better developed, and especially by the use of anesthesia by intratracheal insufflation, it will be possible to explore the seat of disease, with the hope of doing a radical operation. This has been accomplished once successfully, by Torek (1913). In most cases only the palliative operation of gastrostomy is successful, but this should not be employed so long as liquids can be swallowed. Whenever possible, before this operation is done, the intestinal tract should be cleared of the masses of stagnant feces usually present.

CHAPTER XX.

SURGERY OF THE BREAST, THE CHEST WALL, THE LUNGS, AND THE DIAPHRAGM.

SURGERY OF THE BREAST.

Congenital Anomalies.—The only one of these that is of much surgical interest is the existence of supernumerary breasts, a condition known as *polymastia*. Either sex may be affected, but it is said to be slightly more common in males. The extra glands may be situated almost in any part of the trunk, most often near the axilla or groin (Fig. 736), or in a line joining these two sites. The accessory glands may be of various sizes. Sometimes only a supernumerary nipple is present (*polythelia*), (Fig. 737), and sometimes a mass of mammary tissue without a nipple exists in the subcutaneous tissues. In men this resembles a lipoma; but in women its true nature is revealed by its increase in size during menstruation, or pregnancy, or lactation. Any supernumerary mamma which causes annoyance should be excised.

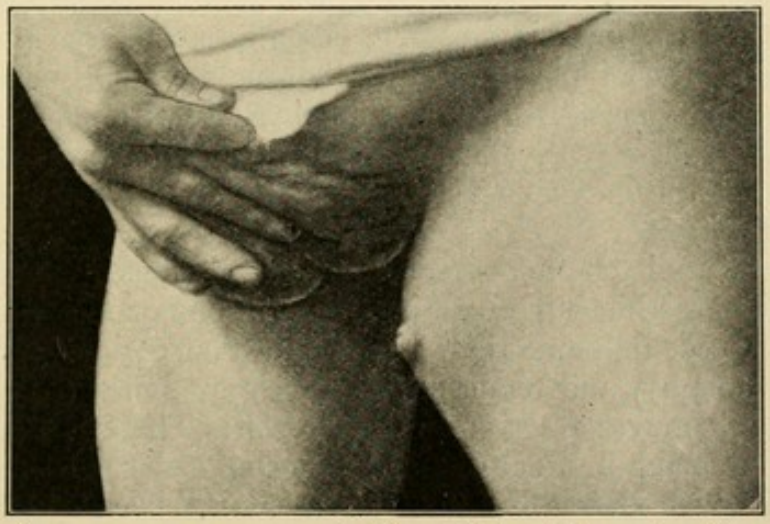

FIG. 736.—Supernumerary mamma (or lipoma?) in adult male. Since puberty has had this mass which at times used to discharge a little whitish fluid. Note the nipple-like projection, but absence of pigmentation. Episcopal Hospital.

Affections of the Nipple.—Sometimes a nipple fails to develop properly, especially where tight underclothing is constantly worn. During pregnancy care should be taken to favor its development by drawing it out, gently; and it should be further prepared for suckling by frequent cleansing and application of astringent washes, of which none is better than dilute alcohol. During lactation,

not only should the condition of the infant's mouth be watched, but the nipple should be washed with warm water and castile soap before and after suckling, and if any tendency to irritation exists it should be dusted with boric acid or borated talcum powder after cleansing after each act of nursing. *Fissures* and *excoriations* of the nipple, which are extremely painful and interfere with suckling, should be treated by unremitting attention to cleanliness. The use of a nipple shield or breast pump, so as to prevent direct contact of the child's mouth, is necessary, and in most cases the act of suckling must be discontinued temporarily. The excoriations and fissures, after gentle cleansing, should be painted with dilute tincture of iodin (1 part to 5 of water), or a weak glycerite of tannin, and then dusted with boric acid powder. The use of ointments is injurious.

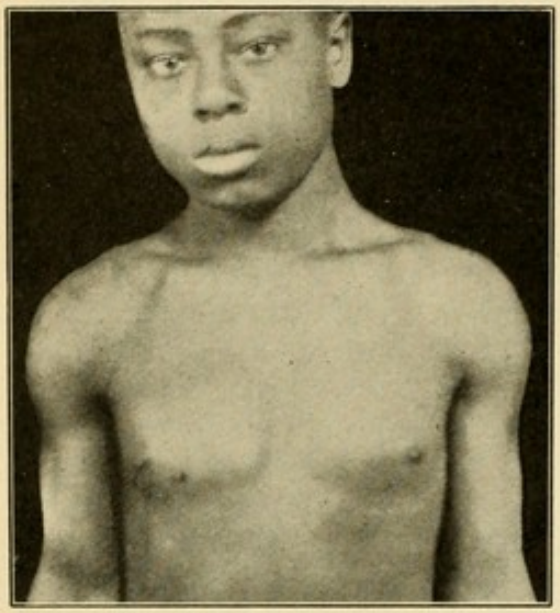

FIG. 737.—Polythelia; a supernumerary nipple near right nipple. Orthopædic Hospital.

Acute Mastitis.—Though inflammation of the breast occasonally develops in the newborn, and in boys and girls at puberty, it occurs oftenest in nursing women, being in most cases an ascending infection from the nipple by way of the ducts or the lymphatics. It is most frequent in primiparæ, especially in those with poorly developed nipples, which have received insufficient attention during pregnancy. It occurs most often within a few days of delivery, or not until the end of lactation.

Acute mastitis is characterized by the usual signs of inflammation, which are confined in almost all instances to one or more lobes of the gland. Diffuse inflammation is rare. The regions affected feel tough and doughy, and tenderness is not very marked. The skin is unaltered and moves freely over the breast. There is a heavy feeling, with dull pain, and occasionally shooting pains. In a puerperal woman this stage is described as "*caked breast,*" because of the accumulation and inspissation of the milk owing to obstruction of the galactophorous ducts by the inflammatory changes.

Treatment.—Treatment consists in attention to the nipple, which may be fissured or excoriated, and to the patient's general health. The child should not be allowed to suckle from the affected breast until resolution is complete. Daily light massage of the area affected usually is efficacious in overcoming the stagnation and promoting resolution without suppuration. Some ointment with lanolin as a basis should be used in connection with the massage. In the

intervals the breast should be covered with belladonna and mercury or other sorbefacient ointment, and well supported with a compressory bandage or binder. Meantime a breast pump must be employed. Another valuable aid in resolution is passive hyperemia, according to Bier's method, with a cupping glass applied over the nipple, as originally introduced by Chassaignac.

Mammary Abscess.—Mammary abscess usually develops as a sequel of stagnation mastitis (caked breast). The area affected becomes more tender; dusky redness appears in the skin; this becomes adherent to the deeper structures; and the abscess is ready to be opened (Fig. 738). Before this occurs, however, destruction of the mammary tissue may be very extensive, and it is very important to recognize the onset of suppuration as early as possible. The fluid expressed from the nipple by massage, in the stage of caked breast, should be collected from time to time on gauze. The milk will be absorbed; but if there is any pus in the fluid, it will remain on the surface of the gauze and stain it yellow. This is known as Budin's sign. As soon as suppuration is suspected, the inflamed area should be incised. This incision should be made directly over the area affected, and in a line radiating from the nipple, so as to injure as few of the milk ducts as possible and thus decrease the chance of a lacteal fistula developing. The earlier and more freely this incision is made, the less danger there is of the pus burrowing among the glandular tissue. If delayed, various pockets of pus will be found, and these will have to be broken open by the finger to ensure free drainage. Tube drainage is desirable until the discharge of pus ceases. An abundant dressing of hot moist gauze (soaked in boric acid or normal saline solution) is required to absorb the discharge. After drainage is discontinued the wound closes rapidly in most cases, if incision has been made early enough; if it has been delayed or not sufficiently free, secondary abscesses may form. Very rarely, when the breast is riddled with abscesses and discharging sinuses, amputation is required.

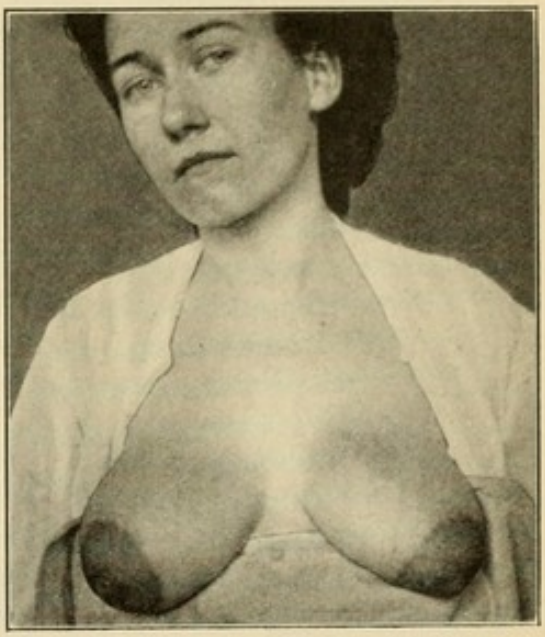

FIG. 738.—Abscess of left breast in a primipara. Age twenty years, nursing a baby three months old. Duration of mastitis ten days. Incised and drained by tube; in nine days only a granulating surface remained. Episcopal Hospital.

Chronic mammary abscess is not very rare; it may be subacute or frankly chronic. The former usually arises during lactation, as the result of an unresolved stagnation mastitis; or after an imperfectly

drained acute abscess. Those which develop independently of lactation are much more unusual, and may be due to suppuration in a hematoma (from trauma), or to excoriations, patches of eczema, etc., on the nipple or in the inframammary fold. The *symptoms* are those of chronic mastitis (see below), but the *physical signs* resemble more those of a neoplasm (p. 711), and the *diagnosis*, which often is impossible, rests on the history of the case, and the detection of some source of infection. *Treatment:* Exploratory incision, best by the submammary incision (p. 711), usually is necessary for diagnosis; and the abscess wall which often is thick and indurated, should then be removed in entirety.

Submammary Abscess.—Suppuration may occur in the cellular tissue between the pectoral muscle and the breast. Usually this is caused by an abscess in a deep lying lobe of the mammary gland, where pointing occurs through the deep layer of superficial fascia in which the gland lies, instead of through the overlying skin; indeed, prolongations of the gland may extend normally into the retromammary space. In a few cases, however, submammary abscess is secondary to axillary lymphadenitis or to diseases of the pleura, caries of the ribs, etc., which usually are tuberculous in nature. The *diagnosis* of submammary abscess is not always easy; the gland is prominent, raised away from the chest by the suppuration beneath; but owing to the deep seat of the suppuration the ordinary physical signs of an abscess may not be present. The abscess may simulate a small hard tumor, especially as axillary adenitis often is present. *Treatment* consists in evacuation of the pus by a curved incision beneath the breast, with free drainage until the discharge ceases.

Subpectoral Abscess.—See p. 730.

Chronic Mastitis.—In addition to the acute infectious mastitis, already described as most frequent in puerperal women, there occurs a form of circumscribed subacute or chronic mastitis, probably also infectious in origin, in women at almost any age, but usually in those between twenty and thirty, or in those approaching the menopause, and among the unmarried nearly as frequently as in those who have borne children. They come to the surgeon complaining of a painful and tender area in the breast, about which they not infrequently seem unduly alarmed. Examination shows slight or no enlargement of the breast, and palpation of the gland with the hand, pressing it flat against the chest wall, makes it clear that there is no tumor present. If the gland is examined between the thumb and fingers, one or more irregularly-shaped, ill defined masses may be felt; these usually seem to radiate from the nipple, and undoubtedly are in the glandular tissue. The overlying skin is unaltered, and the breast moves freely upon the chest wall. The mass may be exquisitely tender, and the seat of shooting or neuralgic pains. The overlying skin may be highly hyperesthetic. To such a condition in neurotic women, the term *mastodynia* or *neuralgia of the breast* has been applied. This is the "irritable tumor of the breast" of Sir Astley Cooper (1829),

though it is also possible that such a condition might be caused by a false neuroma (p. 293) as in other portions of the body. Pain referred to the breast in cases of intercostal neuralgia should not be confused with true mastodynia. *In most cases of mastodynia both breasts are affected*, but only one out of a number of such lumps may give symptoms. They may produce symptoms during menstruation or pregnancy, and not at other times.

The *cause* of these changes is obscure, and the subject is not much clarified by the various hypotheses which have been advanced. If the woman has borne children, the natural assumption is that these masses are the result of changes occurring during lactation; they may be the remains of an area of stagnation mastitis (caked breast) which was so slight as to have been overlooked at the time. In virgins, it may be assumed that the breast has been subject to forgotten trauma; or that its condition is connected with some functional derangement of the pelvic organs.

The *pathological anatomy* of the condition is practically unknown, as operation has been undertaken very seldom. Lecène (1911) examined a fragment of tissue from such a specimen, and found lesions which corresponded to a functional hypertrophy of the acini, with lymphatic stasis, and slight degree of congestion; he concluded that they were trophic or vasomotor in origin, and in no way truly inflammatory.

The *clinical course of the disease* is various. Usually the symptoms subside under conservative treatment, and the masses do not enlarge or give any other evidence of their presence; in many cases they almost disappear. In some cases, however, a cystic transformation supervenes, the pathogenesis of which is uncertain; probably it is neoplastic in character, and not due to inflammatory compression of the gland ducts (p. 712).

Treatment.—Firm support, by bandaging or binder, or even by adhesive plaster strapping, should be provided, unless the tenderness is so excessive as to render this impossible. Belladonna and mercury, compound iodin or ichthyol ointment, applied to the breast, leaving the nipple uncovered, is useful in relieving tenderness. When tenderness subsides, gentle massage should be given. The condition of the pelvic organs should be determined, and suitable treatment instituted. Tonics, good food, and general hygienic measures should not be neglected.

In addition to this circumscribed form of chronic mastitis, some writers recognize a *diffuse chronic mastitis*. I have discussed this subject at p. 709.

Galactocele.—Closely related pathologically with chronic mastitis is the condition described as galactocele, formerly considered a retention cyst of the breast. The cyst wall, however, is not composed of secreting cells, but is formed by a condensation of surrounding connective tissues. Lecène (1911) holds that it is merely a chronic abscess into which milk ducts have opened secondarily; others, with

less probability as it seems to me, contend that the primary condition was dilatation of the lactiferous tubules, and that the cyst is formed by their rupture into the surrounding tissues. Galactocele is quite rare, and occurs most often during lactation. A small lump forms quite suddenly; usually it is in the region of the areola, but may be more deeply seated. Sometimes several cysts exist. The mass is not tender or painful, feels semi-cystic, and is quite movable beneath the skin and on the underlying pectoral fascia. In many cases pressure on the swelling causes milk to exude from the nipple, and the cyst may thus be emptied. In other cases its contents become inspissated, and resemble butter or cheese, when there may be pitting on pressure, which is a very characteristic sign. *Lacteal calculi* have been described in some of these cases, but modern writers consider the reports apocryphal.

Treatment.—A galactocele should be excised, and the wound sutured. Incision, followed by packing, is followed by tedious cure, and the cicatrix is more conspicuous.

Tuberculosis of the Breast is a rare affection. It occurs almost solely in women from thirty to fifty years of age, usually those who have borne children. The infection may be an ascending one from the nipple, by way of the ducts or lymphatics; may be hematogenous; or may arise by extension from an adjacent focus in the ribs, submammary lymphatics, or pleura. Many scattered nodules may be found, or one or two large masses. The tendency toward the formation of cold abscess and toward spontaneous fistulization is more common in the latter form. Until this stage is reached the diagnosis is nearly impossible clinically, and even after these developments it is not always easy. The axillary lymphatics usually are enlarged. If secondary infection follows fistulization, the general health rapidly deteriorates.

Treatment.—The only satisfactory treatment is amputation of the breast, and extirpation of the axillary lymphatics. The operation resembles that for carcinoma, but it is not necessary to remove the pectoral muscles unless they are manifestly diseased.

Syphilis.—Syphilis may affect the skin over the breast, or the mammary gland itself. A *chancre* presents the same characters here as elsewhere; it occurs almost exclusively in women who act as wet-nurses to foundlings or other infants with congenital syphilis; the lesions may be multiple and often both breasts are affected. Prophylaxis usually is possible, and a syphilitic child never should be nursed by another than its own mother, who is immune to infection in this way, according to Colles's law (p. 998). Secondary lesions of syphilis, especially *mucous patches*, often may be found in the submammary fold when not visible elsewhere. Sometimes in this stage of syphilis the mammary glands become swollen and painful, the condition being known as *diffuse syphilitic mastitis*. *Gumma* is the most frequent lesion of syphilis which affects the glandular tissue of the breast. It is quite rare, however, and is difficult to distinguish

from some benign tumors unless a distinct history of syphilis can be obtained, or the Wassermann test is positive, or when the beneficial effect of antisyphilitic treatment becomes apparent. Fortunately the iodides are very rapidly curative.

Tumors of the Breast.—The subject of tumors of the mammary gland usually is a difficult one for the student, because owing to the complexity of its structure the tumors growing in it are of many different kinds derived from epithelial or fibrous tissues. Thus there may be adenomatous, papillomatous, epitheliomatous, cystic, and even sarcomatous tumors. And as in most of these tumors both the epithelial and fibrous elements seem to participate almost equally in the blastomatous transformation, it is rare for a pure adenoma, or a pure fibroma to develop. Instead we find many combinations of fibrous, adenomatous, cystic, papillomatous, and other conditions. The following classification, based in part on that of J. Collins Warren (1905), seems to me the most satisfactory. The relative frequency of the different growths is indicated by the attached percentages.

Blastomatoid Conditions
- (*a*) Fibro-adenomatosis, .2 per cent.
- (*b*) Cyst-adenomatosis, 15.8 per cent.

} 16 per cent.

Benign Tumors
1. Fibro-adenoma, 9.6 per cent.
   - (*a*) Periductal fibroma { Intracanalicular / Pericanalicular
   - (*b*) Periductal myxoma
   - (*c*) Periductal sarcoma

   } 12 per cent.
2. Cyst-adenoma, 2.4 per cent.
   - (*a*) Fibro-cystadenoma
   - (*b*) Papillary-cystadenoma
3. Simple Adenoma
4. Lipoma
5. Angeioma
6. Endothelioma
7. Enchondroma

} 1 per cent.

Malignant Tumors
1. Sarcoma, 1 per cent.
2. Carcinoma, 70 per cent.
   - (*a*) Adenocarcinoma
   - (*b*) Solid-celled Carcinoma
     1. Scirrhous Carcinoma
     2. Carcinoma Simplex
     3. Medullary Carcinoma
   - (*c*) Paget's Disease of the Nipple
   - (*d*) Carcinomatous Cyst

} 71 per cent.

Before discussing blastomas, or tumors proper, it is necessary to say something of certain *blastomatoid conditions* which occur in the breast. The general characters of these conditions were discussed in Chapter IV.

In the mammary gland there occur lesions the true nature of which is still in much dispute. As to one condition especially, while it may be said that surgeons acknowledge its existence and are agreed on

its clinical features; and while pathologists agree on the histological picture; yet the former cannot agree on a name which they consider descriptive, and the latter cannot agree on the interpretation of what they see under the microscope. This condition is known in some quarters by the name "chronic cystic mastitis." Another condition the classification of which is disputed, is described as "idiopathic hypertrophy" of the breasts. Now when one looks at the classification of tumors given above, he sees that under the benign growths the two main types, which are fibro-epithelial in character, are (1) Fibro-adenoma, and (2) Cystadenoma. Were he to look around for blastomatoid conditions in his patients corresponding to these tumors, he would find that such conditions actually occur; and it would be a matter of surprise that no one had previously recognized that idiopathic hypertrophy of the breasts corresponds to a fibro-adenomatosis, and that chronic cystic mastitis corresponds to a cystadenomatosis. Let us look then at these two conditions more narrowly, and see what they are:

Fibro-adenomatosis.—Diffuse or "idiopathic hypertrophy" of the breasts may appear first during pregnancy; but the disease in most cases affects virgins soon after the age of puberty. Albert (1910) has collected 18 cases of the former and 52 of the latter variety. It is doubtful whether the conditions are pathologically the same: in the cases which develop during pregnancy the glandular elements are markedly increased, whereas in the virginal form it is a pure fibromatous over-growth, the undeveloped glandular elements being practically unchanged. This difference may be due merely to the undeveloped condition of the virgin breast.

Both breasts are enlarged in almost all cases (62 out of 70 cases collected by Albert), and they may reach an immense size. In Durston's historic case, recorded in 1669, the weight of one breast, removed postmortem, was 64 pounds. Seldom, however, does the weight exceed 8 to 12 pounds. There are no symptoms other than discomfort from the size and weight, but the breasts may increase and decrease slightly in size from time to time. The form which arises during pregnancy sometimes subsides spontaneously when the pregnancy and lactation are ended; but the virginal form progressively increases. The growth is slow, and the disease extends over many years. Very rapid enlargement of one breast alone, though it bear the character of a simple hypertrophy, always should rouse suspicion of malignancy, especially sarcoma.

Treatment.—Treatment of the condition which arises during pregnancy always should be palliative; this consists in the recumbent position, with elevation and compression of the breasts; the use of sorbefacient ointments locally; the internal administration of potassium iodide or thyroid extract; repeated catharsis, and a dry diet. If no improvement is noted after pregnancy has terminated, and in the virginal cases as soon as the diagnosis is assured, one of the breasts should be amputated. In a few cases the remaining breast has then

somewhat decreased in size. If it does not, it should be removed subsequently.

Cystadenomatosis or **Abnormal Involution of the Breast.** — In 1883 Reclus described in detail a "cystic disease of the breast," which he had studied first over twenty years before, and which had been recognized by F. König (1875), by Brodie (1846), and by Sir Astley Cooper (1829). In more recent times it has been studied by Schimmelbusch (1890), who named it *cystadenoma;* by König (1893), who called it *mastitis chronica cystica;* by J. C. Warren (1905), for whom it is an *abnormal involution of the breast;* and by Bloodgood (1906), who called it *senile parenchymatous hypertrophy.* These are only a few of the names by which it is known. It matters little by what name it is called, so long as people understand what is referred to; and I have not had the temerity to select a new name for it, but have followed Warren, who restored it to the position in the nosology of breast lesions to which it was originally assigned by Sir Astley Cooper: a pathological change similar in nature to that of diffuse virginal "hypertrophy," though characterized by epithelial (cystic) growth, where the latter is characterized by fibrous.

The disease is very frequent, but may exist for years without producing symptoms Though seen oftenest in women from thirty to fifty years of age, this is no proof that it has not had an obscure beginning at a much earlier age. Occasionally it comes under observation shortly after puberty, when the mammary glands begin to develop; but is much more frequently seen when their functional activity is drawing to a close. It is rare after the menopause. In most cases both breasts are diseased, though only one may produce symptoms. The disease appears to be as common in the unmarried and in those who have borne no children as in those in whom the mammary glands have been functionally active.

Symptoms and Clinical Course.—The woman consults a physician usually because she has an uncomfortable feeling in the breast, and perhaps because she has noticed that it has grown larger, or because by accident she has felt a lump in it. On examination the breast generally is found enlarged, but not unduly pendulous. No lump or tumor is visible. If the gland is picked up in the thumb and fingers, it may seem that there is a considerable tumor in it, but if the hand presses the gland flat against the chest it is evident that there is no tumor at all. There should now be undertaken what Astley Cooper calls a very careful and nice manipular examination. What is detected is very characteristic: seemingly each individual lobule can be felt distinctly, enlarged and hardened, and moving freely upon the other lobules. The breast feels as if it were full of lead shot, varying in size from pin-head to grape-size. Early in the disease no large masses are felt. These little, hard masses are mostly in the centre of the gland, beneath the nipple and areola. Pressure on the breast causes no pain, but an occasional shooting pain occurs. The overlying skin is normal. There is no discharge from the nipple. The axillary

nodes are not palpable. If now the other breast be examined, almost invariably a similar condition, perhaps not so pronounced, will be found in it.

If such a breast is amputated, it is found that the shot-like particles which felt so hard, and which were distributed through all parts of the gland, are not solid at all, as one might imagine; they are minute cysts, tensely filled with clear or slightly yellow or even brownish fluid. The cyst walls are smooth; there are no intracystic growths. Microscopical examination shows that the cysts are lined with glandular epithelium, which shows little if any tendency to proliferation beyond the capacity of the basement membrane; seldom in any place is there more than one row of cells on the basement membrane, and never is there any papillomatous out-growth into the cavity of the cyst. The stroma of the breast is a dense white mass of fibrous tissue, and there is no single area in the entire breast which can be said to be free of disease. The change is not one of tumor formation, but a general blastomatoid over-growth.

If no treatment is instituted the disease may progress; or after a few years, a secondary atrophy may set in, the breast decreasing in size, all symptoms subsiding, and the patient remaining well. This, however, is rare; in most cases the disease is progressive. In one portion of the breast a larger, more clearly outlined mass may be felt, and sometimes there are two or three such masses. They may be visible as rounded projections beneath the skin. When very large they may give a sense of fluctuation. They are cysts; and have formed by the gradual distention of one or more of the small cysts which have been present for years. In other parts of the breast these small cysts may still be felt on "nice manipular examination." At this latter stage of the disease, there sometimes is a glairy or clear yellowish discharge from the nipple; pressure on the cysts may cause this fluid to appear. The cysts may oscillate in size from month to month, and at times the axillary lymph nodes may become palpable, and again this swelling may subside. Pathological examination at this stage may show the cysts still simple in nature, with smooth lining wall, but in the vast majority of cases the cysts, at least the larger ones, contain intracystic papillomatous out-growths.

If still no treatment is instituted, some of the clinical characteristics of malignancy may be noted. The nipple may seem retracted into the gland, but usually can be drawn out easily, the skin may become adherent, not by cellular infiltration, but by condensation of the intervening tissues; and at last one of the cysts may grow so large as to cause pressure necrosis of the overlying skin. The contents of the cyst will then be discharged, and the cyst, if it contains no papillomatous out-growths, may collapse, and in rare cases healing may occur. If the cyst contains papillomatous out-growths, these may protrude through the opening formed in the skin by sloughing, and a fungus growth will develop which it may be very difficult to distinguish from a malignant tumor. At the present day, however,

it is almost an unknown thing for the disease to be allowed to reach this advanced stage, as the breast is removed at an earlier period.

Another, and probably more frequent contingency may arise. Instead of the disease taking on a cystic type of development, which usually is quite benign, it may undergo an adenomatous transformation, in-growths occurring from the ducts or cyst walls into the surrounding stroma; and *in about* 10 *or* 15 *per cent. of cases the disease terminates as a carcinoma* (Speese, 1910). It is on this account that its early recognition and proper treatment are so important.

Diagnosis.—In its onset this affection of the breasts resembles *chronic mastitis*, and by many it is still considered infectious in origin There seems to be no doubt that previous attacks of mastitis predispose the patient to the development of this disease. And in some cases it is nearly impossible to say off-hand that this is a case of diffuse chronic mastitis and not one of "abnormal involution," or *vice versa*. I have preferred to discuss the disease entirely in one place, and for this reason have described only a localized and not a diffuse form of chronic mastitis (p. 702). From *cystadenoma* of the breast (p. 712) its differentiation also is difficult especially in the later stages; but as a rule even in such cases the diffuse nature of the process is evident. While the cystadenoma is at first a localized growth, it increases in size much more rapidly than does the breast which is the seat of diffuse cystadenomatosis; and only after the latter condition has existed for many years will cysts be present commensurate in size with those of a cystadenoma of some months' duration. As in this stage the treatment for both affections is the same (amputation of the breast), the distinction is not of great importance.

Treatment.—1. If the woman is young (under thirty-eight years), the cystadenomatoid change recently discovered and presumably of slow growth, she should be kept under strict surgical observation, a careful manipular examination of the breasts being made at monthly intervals. Meantime such general hygienic measures, changes in clothing and habits of life, and attention to menstrual derangements should be enforced as seem indicated. Local treatment has little value, but such as was recommended for chronic mastitis (p. 703) is at least harmless. If the condition remains stationary, or, still better, if it seems to subside, well and good; no operation is required. If it continues to progress, the breast (often both of them) must be operated on. The operation may be begun by an exploratory incision, as in the method of "plastic resection" of the breast (p. 711); when the gland tissue is exposed and incised, the subsequent course of the operation will depend on what is found. If only one or two fairly large cysts are found, and no suspicion of malignancy exists, it is sufficient to excise the cysts and leave the greater portion of the gland intact. If a number of cysts are present the entire breast should be amputated, as described below. If any suspicion of malignancy exists, the axilla should be exposed, cleared, and its contents should be

removed in one mass with pectoral muscles, mammary, gland, and overlying skin.

2. If the woman is past the age of greatest functional activity of the mammary glands (and this age varies in individuals as in different races), it is better to remove the breasts at once, since the probability of actual or subsequent malignant change is much greater at this period of life.

Whenever the breast is removed it should be most scrupulously examined macroscopically; any and every area suggesting malignancy should then be studied microscopically by a competent pathologist. Such areas are intracystic papillomatous growths, or areas of greater density or of ulceration in the cyst walls. Only one very minute area such as this may be present in the entire gland, and it is very easily overlooked. The question of malignancy should be decided, as it is vital for prognosis and the patient's peace of mind.

I place no reliance at all on diagnoses made during the progress of the operation from microscopical study of frozen sections; yet I know that Rodman and other experienced surgeons still deem this method of value. The macroscopical appearance of the breast should be a better guide to the surgeon, and my own judgment agrees with that of Bloodgood and others, that no surgeon should be satisfied to operate on these borderline cases unless he has the skill and knowledge to differentiate clinically at the time of operation between growths certainly benign and those possibly malignant.

Amputation of the Breast.—An incision is made in the submammary crease, from the anterior axillary fold inward to the parasternal line. The lower edge of the pectoralis major is exposed, and the mammary gland thrown upward on the patient's chest. The gland can then be explored from the posterior surface. If amputation, instead of plastic resection or radical ablation, is determined upon, a curved incision is then made above the breast, joining the ends of that already made. The flaps are dissected up sufficiently to ensure complete removal of all glandular tissue. The wide area over which this may be spread should be remembered (p. 721). The surface of the pectoralis major is then exposed above and the fascia is dissected from it downward. Bleeding points, chiefly branches of the intercostals, are clamped as severed. The superficial fibres of the muscle are removed, and the mammary gland is excised in one piece with the nipple and overlying skin, the surrounding fat, and the pectoral fascia. Hemorrhage being controlled by ligature, the wound is closed with interrupted sutures, and provision is made for drainage for a few days.

Benign Tumors.—Benign tumors of the breast are rare. They occur mostly in young women, from fifteen to thirty years of age, and in almost all cases are fibro-epithelial in type (Ribbert, 1901). They are conveniently divided, as is done by Warren, into two subdivisions: (1) Those in which the fibrous element predominates *fibro-adenoma;* and (2) those in which the epithelial element is conspicuous—*cyst-adenoma.*

1. **Fibro-adenomatous Tumors.**—These are particularly characterized by neoplastic growth of the stroma which surrounds the gland ducts; hence they are all described as *periductal tumors.* If the tumor is mostly pure fibrous tissue, like that found in the virgin breast, it is called a *periductal fibroma;* and the fibromatous change may be either *intra-canalicular* in type, or *pericanalicular:* in the former case the fibromatous tissue compresses and distorts the ducts, so that these appear as curved slits or chinks in the microscopical field; while in the peri-canalicular form the normal appearance of the ducts is largely preserved. In most cases, instead of a pure fibromatous tumor, there is myxomatous degeneration of the fibroma, and the growth is known as a *periductal myxoma;* this is the form most frequently encountered, though probably at an earlier stage the tumor was more purely fibromatous. In rare cases, the stroma of the tumor instead of being fibromatous or myxomatous is sarcomatous, and the growth is called *periductal sarcoma.*

Symptoms and Clinical Course.—Usually occurring in young unmarried women, these growths well deserve the name "chronic mammary tumor" bestowed upon them by Sir Astley Cooper. They present few symptoms other than the presence of a "lump in the breast," which usually is discovered accidentally, and may be attributed to injury. When of long duration a visible swelling may exist. This swelling or lump is in the central portion of the gland, but not close to the nipple. It feels hard, is well defined from the rest of the gland, is not tender, and seldom is movable except in one mass with the breast. Palpation of the breast with the flat hand, pressing it against the chest, demonstrates the presence of an actual tumor; the lump does not vanish as does that due to chronic mastitis, when this manœuvre is adopted. The overlying skin is not affected, nor are the axillary nodes enlarged. The tumor grows very slowly, and may remain for years in much the same condition. Occasionally, however, rapid growth occurs; this, of course, is a bad omen. But in most cases the prognosis is absolutely good.

Treatment.—The tumor should be removed. It is encapsulated, and by exposing the posterior surface of the mammary gland, as described below, the growth can be enucleated, the breast replaced, and no visible scar will remain. This method of *plastic resection of the breast,* introduced in 1882 by T. Gaillard Thomas, has been revivified by J. Collins Warren. It is thus performed: An incision is made from the anterior axillary fold inward in the submammary crease, as far as the inner lower quadrant of the breast. This incision is deepened to expose the pectoralis major, and the mammary gland is dissected from its surface and is thrown upward on the patient's chest. As the main blood-supply of the gland enters it from its superficial surface, near its upper border, no fear of sloughing need be felt. The posterior surface of the gland being thus brought to view, the region of the tumor is exposed by an incision radiating from the centre; the tumor is enucleated, and the cavity is obliterated by

catgut sutures, thus restoring the contour of the breast. This is then replaced on the pectoral muscle, and the deep layer of the superficial fascia carefully sutured, so as to retain the breast in place; and the skin is closed with provision for drainage.

2. **Cystadenomatous Tumors.**—These seem to represent a later development of the fibro-adenomatous tumors just described; and as nearly all growths in the breast at the present day are removed soon after their presence is discovered, it results that cystadenomatous tumors are much more rare now than fifty or one hundred years ago. At that time the curious combination of fibrous and epithelial proliferation, resulting in solid (perhaps sarcomatous) tumors filled with cysts, was productive of great confusion as regards nomenclature. This class of tumor was described by Astley Cooper as *hydatid disease* of the breast; Brodie called it *sero-cystic sarcoma;* Paget named them *proliferous mammary cysts;* and Johannes Müller used the term *cysto-sarcoma phyllodes*, both the latter observers laying special stress on the occurrence of intracystic papillary out-growths. To the present day the French call it *adeno-sarcoma.*

The growth consists, in fact, of a cystic tumor, with a more or less abundant fibrous stroma—a *fibrocystadenoma.* The cysts are of various sizes, usually some of them quite large. Their lining membrane may be quite smooth, as if from pressure atrophy. Almost invariably from one or more areas of the cyst wall, papillomatous growths project—*papillary cystadenoma.* These intracystic growths have a solid core of fibrous tissue, and they may completely fill the cyst and even cause its distention. It seems as if the proliferation of the stroma had converted the semi-circular chinks or slits of the intracanalicular fibroma into actual cysts formed by the pressure of papillary out-growths into the duct lumen. This impression is confirmed by the fact that the papillomas are covered with cells which present the characteristics of ductal rather than of acinal epithelium. The small amount of fluid which the cysts contain may be colorless, slightly tinged with yellow or green, but usually is brownish or hemorrhagic in nature.

Symptoms and Clinical Course.—These tumors occur in older women than do the fibro-adenomatous growths. The average age in Warren's patients was fifty-two years. Indeed, in most cases where cysts are found in the mammary gland it is an indication that this organ has reached its full maturity before the tumor began to grow. Cystadenoma grows more rapidly than the solid benign tumors, and if not removed, may reach a large size. The growth is situated in the central part of the breast, beneath the nipple or areola, and at first presents much the same features as the fibro-adenoma. In the course of a few years, however, the presence of cysts usually may be suspected from the lobulated nature of the tumor, and sometimes from distinct fluctuation. But the latter rarely occurs, since the cysts are apt to be filled with the papillary out-growths, which give them a solid feel. The overlying skin is not altered, the axillary nodes

are not enlarged, and seldom is the general health affected. Very often there is a bloody discharge from the nipple. In very advanced cases the skin overlying one of the cysts may become thinned, and a semitranslucent appearance may be present. The breast may be covered with a network of distended veins. Finally, as in the most advanced stages of cystadenomatosis (p. 707) perforation of the skin may occur, with the protrusion of the intracystic papillomas as a fungus growth. *At any stage of the disease malignant changes may occur.* These may develop in the epithelial elements (carcinoma), or rarely in the stroma (sarcoma.)

Diagnosis.—The diagnosis must be made from fibro-adenoma, and from cystadenomatosis. From the former, cystadenoma usually may be distinguished by the greater age of the patient, by the less dense feel and less definite outline which the growth presents; as well as by its more rapid enlargement and its eventually cystic character. From cystadenomatosis of the breast the distinction is difficult only in the later stages, when the primarily local tumor (cystadenoma) has grown so large as to occupy nearly the entire area of the mammary gland.

Treatment.—Ablation of the breast, pectoral muscles, and axillary lymphatics, as for carcinoma, is the safest treatment in patients over thirty-eight or forty years of age. In younger patients, in whom malignant changes are less likely, amputation of the breast is sufficient.

Other benign tumors occur in the breast, but are extremely rare, and present only pathological interest. A pure *adenoma* has been described by S. W. Gross (1880) and by Rodman: it is a soft, succulent, nodular, rather rapidly growing tumor, not very well encapsulated, and affecting young women. *Lipoma* may occur in the interlobular tissues of the mammary gland, in the subcutaneous fat overlying it, or in the submammary tissues. Cases of *angeioma* and *endothelioma* have also been recorded. *Enchondroma* is another rare growth, developing here, as in the salivary glands, in the form of a "mixed tumor," with areas of cartilage and calcareous matter. The *diagnosis* of these rare growths sometimes is not made until after removal, which is the proper *treatment.*

Malignant Tumors of the Breast.—The general character of malignant as distinguished from benign tumors was indicated in Chapter IV, and it is not necessary to repeat this discussion here. It is enough to say that over 70 per cent. of tumors of the breast are malignant, and that in women approaching or past the menopause every tumor should be regarded as malignant, and should be treated accordingly.

Sarcoma.—Sarcoma is very rare. It occurs in less than 3 per cent. of cases of mammary neoplasm. Reference was made at (p. 711) to a form of *periductal sarcoma,* which is classed among the benign tumors. This forms about 80 per cent. of the cases of sarcoma of the breast on record, a fact which emphasizes the exceeding rarity of true mammary sarcoma. This truly malignant form of sarcoma which

forms only 20 per cent. of the recorded cases of mammary sarcoma, is of the spindle- or round-celled type, and epithelial proliferation is scanty or absent. The tumor affects women at any age, probably most often those between forty and fifty years. At first it is a well defined, small, indolent mass, which may cause no symptoms for years. Eventually, however, rapid growth sets in, the tumor breaks through its imperfect capsule, infiltrates the mammary gland, causes distention, redness, and sloughing of the overlying skin, and in a few months or even weeks there is a protruding, fungus, bleeding mass (fungus hematodes). The *diagnosis* is difficult in the early stages; when seen at this time the growth may be mistaken for a benign tumor. *Treatment* consists in early amputation of the breast; the axillary lymphatics very rarely are involved, but in patients past thirty-eight or forty years it is a wise precaution to substitute ablation for amputation, as in cases of carcinoma.

Carcinoma.—Carcinoma is the most frequent affection of the breast. Only about 1 per cent. of cases occur in the male breast (Fig. 739). Most tumors of the breast in women over forty years of age are carcinomatous, but the disease is not at all infrequent at an earlier age. The older the patient, the more apt is a tumor to be carcinomatous. The left and right breasts are affected with about equal frequency. Very rarely are both breasts simultaneously attacked (in about 1 per cent. of cases), but the disease may spread from one gland to the other through the lymphatics (Fig. 740). Heredity has little influence in the clinical etiology of the affection, nor has race. It is more frequent in married than unmarried women, particularly in those who have borne and suckled children. The influence of direct trauma seldom is noted (Plate V).

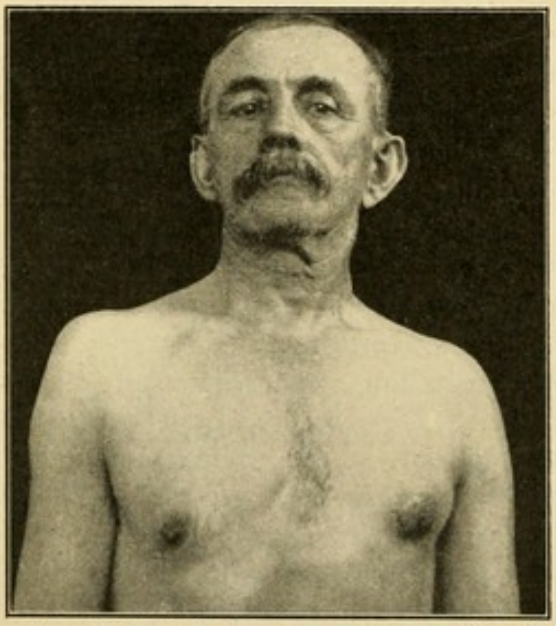

FIG. 739.—Scirrhous carcinoma of male breast, age fifty-nine years; duration three years; rapid growth for one year. Axillary nodes palpable. (Dr. J. P. Hutchinson's case.) Pennsylvania Hospital.

Pathology.—A tumor of the mammary gland may begin as a carcinoma, or carcinoma may develop in a previously existing benign tumor. The latter is much the rarer; it oftenest succeeds the change described as abnormal involution of the breast (p. 707) and assumes the type of *adeno-carcinoma*, or "duct cancer" (p. 125). In this form the tumor lies near or beneath the nipple, which is not retracted; the growth is soft, shows little tendency to infiltrate, but early breaks through the skin, and appears as an ulcer without the

PLATE V

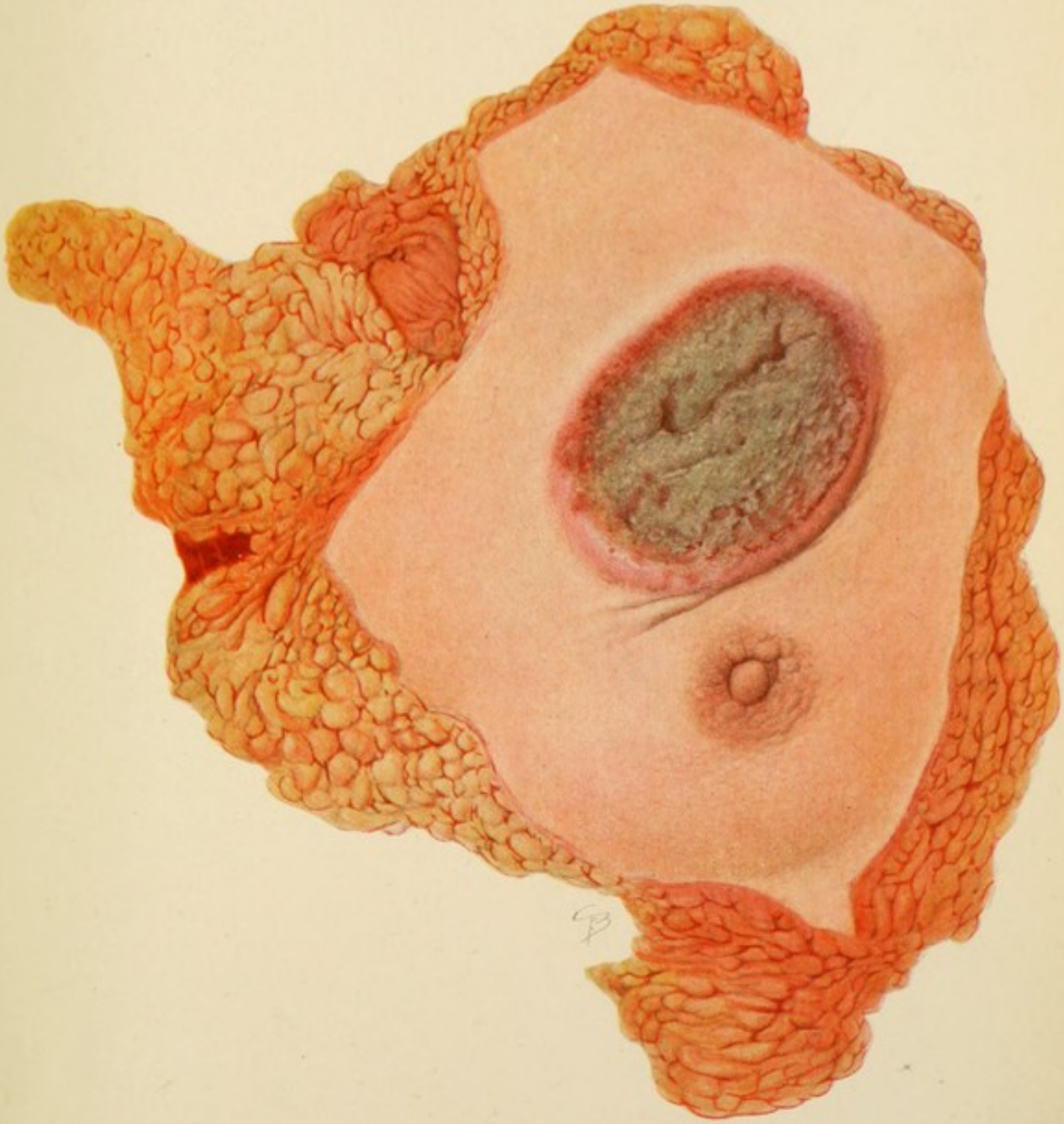

Scirrhous Carcinoma of Breast.

Specimen (half natural size) from excision of right breast for carcinoma. Aged 45 years; duration 2½ years, ulcerated 6 months. Tumor developed a few months after direct trauma. Note the "rose ulcer" in the upper outer quadrant, measuring 3 x 2 inches and covered with adherent gray-green slough; beneath this was a hard tumor the size of a goose egg (Plate VI), not attached to chest wall. Visible mass in axilla. Tumor, pectoral muscles, and axillary structures removed in one mass. Episcopal Hospital.

hard and thickened margins so characteristic of the commoner types of carcinoma, and having its surface not depressed but rather elevated above the surrounding skin. Rarely does this growth long preserve the relatively benign character of an adeno-carcinoma; it soon proliferates in an atypical manner like the *solid-celled carcinoma.* The latter, which is the usual form of carcinoma seen in the breast, arises in an atypical proliferation of the epithelial cells lining the acini of the gland, and thus is distinguished from the rarer and less malignant duct-cancer by the term acinous carcinoma.

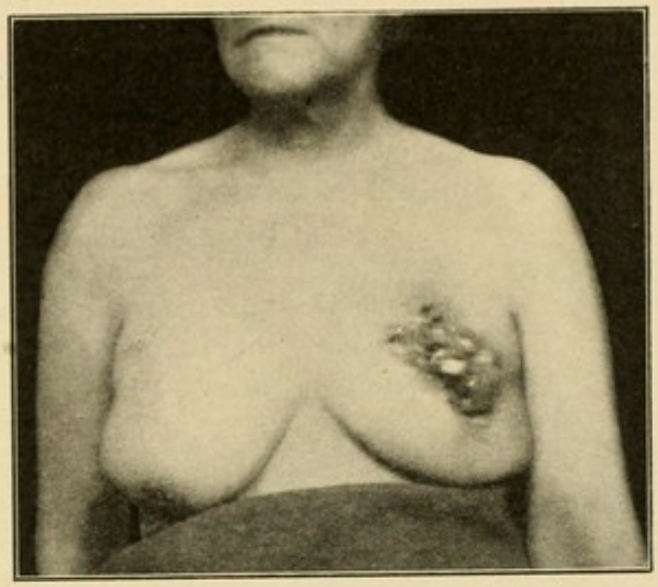

FIG. 740.—Carcinoma simplex of both breasts, age sixty-six years. Growth in left breast for five years, ulcerated five months; large sloughing ulcer; axillary nodes palpable. Growth in right breast for two years: skin red and adherent; nipple retracted; axillary nodes palpable. Palliative amputation of both breasts in October, 1909, with prolonged after-treatment by *x*-rays. (Dr. Thos. S. Stewart.) In September, 1911, a metastatic growth appeared in right thigh. In August, 1913, mediastinal and pulmonary metastases, but no local recurrence. In January, 1914, feeble, but little discomfort. Episcopal Hospital.

The microscopical features of adeno-carcinoma and solid-celled carcinoma were considered at (p. 125). Clinically, the usual type of mammary carcinoma, that classed as solid-celled, is encountered in three varieties dependent upon the relative amount of stroma present: Scirrhous Carcinoma, in which stroma is very abundant and cellular elements scanty; Carcinoma Simplex, in which stroma and epithelial elements exist in equal amount; and Medullary Carcinoma, in which the epithelial elements are very abundant and the stroma is scanty. The clinical features of these three forms may now be briefly considered.

Scirrhous Carcinoma, or simply **Scirrhus,** is the most frequent form of mammary cancer. Owing to the abundance of the stroma the tumor is quite hard; it seems as if the surrounding tissues were endeavoring to stifle the growth of the epithelial elements. On section the tumor is found to be absolutely continuous with the surrounding tissues; there is not the slightest indication of a capsule; it is impossible to remove the tumor from the gland. It is hard,

and creaks when cut by the knife. Usually *both the cut surfaces are found to be concave;* it is as if the tumor was too small for the tissues in which it grew, and tended to contract further at the first opportunity. The surface of the section often has been likened to that of an unripe pear: it is pale and shiny, grayish white at first, but becomes pinkish on exposure to the air. Usually there are yellow dots scattered over the surface of the tumor; these are either spots of fatty degeneration, or areas of fatty tissues not yet strangulated by the fibrous stroma. On scraping the section with the knife, "cancer-juice" is produced; but this is no longer regarded as particularly characteristic of carcinoma.

Symptoms and Clinical Course.—The patient finds a lump in her breast, but rarely are there any subjective symptoms. There may be occasional lancinating pains, but the tumor is not tender, a fact which distinguishes it from all inflammatory swellings. This lump in most cases lies *in the periphery of the mammary gland,* not near the nipple; and is found oftenest in the upper outer quadrant. It is hard, but not definitely outlined, when felt between the thumb and fingers; and it is still palpable as a dense nodule when the breast is pressed by the palm of the hand flat against the patient's chest. This distinguishes it from non-neoplastic thickenings of the mammary gland. Owing to the abundance of the fibrous stroma and its tendency to contract, *the size of the breast usually is diminished* in cases of scirrhus; when this contraction is extreme, the condition is named *atrophic or withering scirrhus* (Fig. 741). An early and valuable sign due to this contracting tendency has been pointed out by Halsted: this is *limitation of the excursions on the chest wall of the affected mamma* as compared with the normal gland. If the breast is pulled from side to side, and up and down, even in the case of a small, deeply seated, and almost impalpable nodule, it will be found that the excursions of the affected breast are diminished, especially in a direction away from the axilla. The cancer cells extend along planes of fascia in all directions, and the abundant fibrous stroma follows them up, as if in the endeavor to strangle them by its contraction. This extension and subsequent contraction limits the excursions of the breast, pulls the nipple down into the gland (*retraction of the nipple*), and, through the ligamenta suspensoria of Sir Astley Cooper, causes the typical

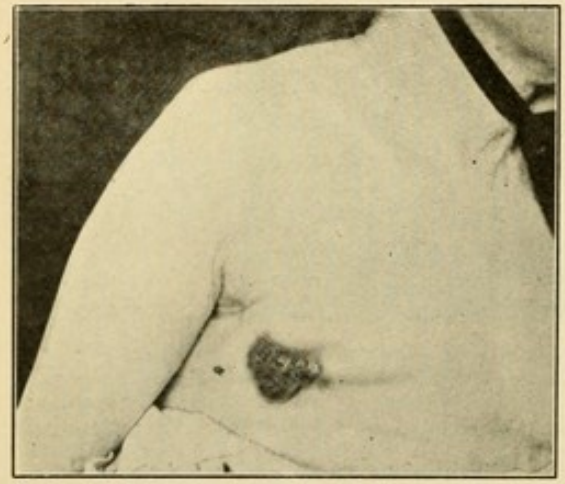

FIG. 741.—Atrophic or withering scirrhus of breast. Age seventy-five years; growth noticed only a little over a year ago; ulcerated for six months. Has had no treatment, and the growth is now adherent to the ribs and inoperable. Episcopal Hospital.

PLATE VI

Scirrhous Carcinoma of Breast.

The tumor shown in Plate V has been sectioned longitudinally, and the sternal half of the section is here represented. Note dense tumor underlying ulcer and adherent to pectoral muscles At the right of the picture is seen the tissue excised from the epigastric region. (Half natural size.) Episcopal Hospital.

dimpling of the overlying skin resembling an orange or pig skin. Thus quite early the overlying skin becomes fixed to the growth, and the growth becomes fixed to the pectoral fascia. The *axillary lymphatics* are not palpably enlarged early in the disease, but they are microscopically invaded long before they become palpable. The diagnosis should be made before this complication or ulceration of the skin develops. *Ulceration* is a late stage of the disease, usually not appearing for one or two years after the development of the tumor. In some cases (atrophic scirrhus) ulceration may never occur. When it develops it is due to gradual invasion of the skin by the cancerous growth; a small ulcer first appears, and this gradually increases in size. The scirrhous ulcer is quite typical: it is more or less circular in outline, fixed to the chest wall, red, dry, and quite dense; colloquially it is known as the "*rose ulcer*" (Fig. 742). Occasionally as a

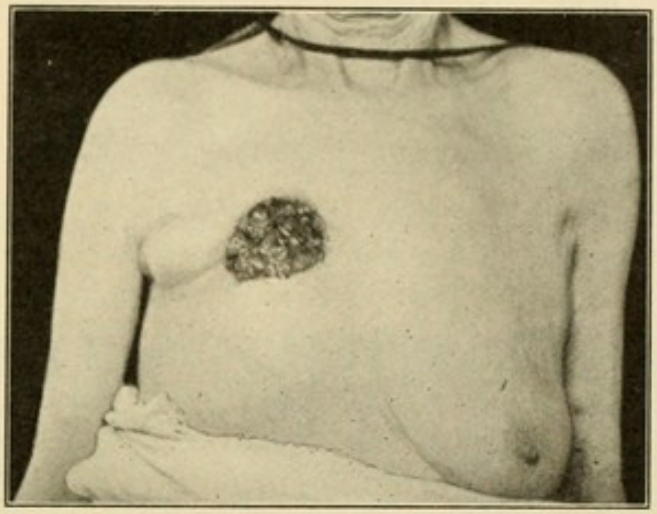

FIG. 742.—Scirrhous carcinoma of breast showing typical "rose ulcer." Age sixty-eight years; duration three years; ulcerated six months. Has had no treatment, and growth is now adherent to ribs and inoperable. Two years and six months later, there was a large stinking ulcer, patient was extremely emaciated, hardly able to stand, and suffered dreadful pain. Episcopal Hospital.

primary growth, but more often as a recurrence after operation, carcinoma grows either in many apparently isolated spots over the chest wall, or widely diffused in the skin; this is known as "*squirrhe en cuirasse*," as if the patient was covered with a "coat of mail" composed of carcinomatous nodules (Fig. 744).

Prognosis and Treatment.—Owing to the slow growth and few subjective symptoms produced by the tumor, the patient often does not seek surgical advice until fixation and perhaps ulceration have occurred. The average duration of life in untreated cases of scirrhus is from two and a half to three years. The more atrophic the type, the longer will death be delayed; sometimes the patient drags out a painful existence for twenty years. If radical operation is done before fixation of the tumor, so that it is possible to remove all of the disease, freedom from recurrence for three years or more (which is classed as "ultimate cure") will result in from 50 to 70

per cent. of cases so treated. The reasons why operation should be urged, even with no better prospects, are stated at p. 725; and the

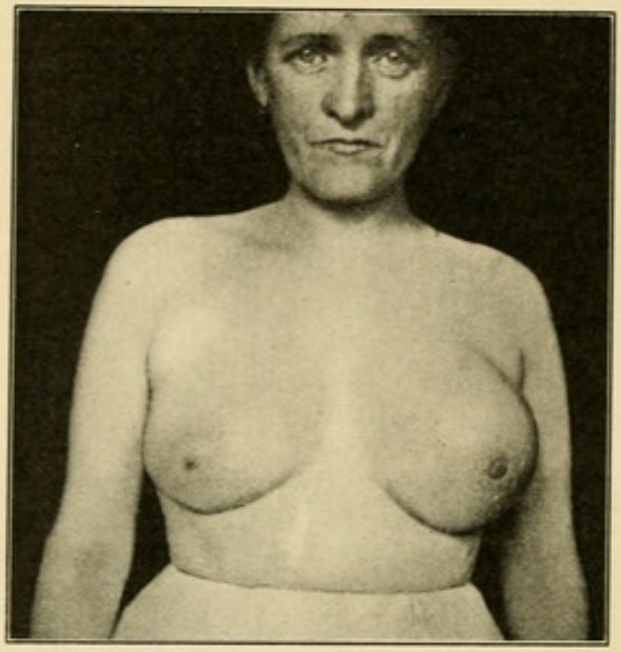

FIG. 743.—Carcinoma simplex of left breast. Age forty-four years; duration seven months, from recurring trauma from work in mill. Note pig-skin dimpling, retraction of nipple, breast standing out from thorax; emaciated face, and anxious expression. (See Fig. 744.) Episcopal Hospital.

FIG. 744.—Recurrent carcinoma of breast one year after excision. Note cancer *en cuirasse*, fatter face and less anxious expression since being under hospital care; edema of left arm; involvement of right axilla. Two and a half years after operation, condition no worse, growth seemingly held in check by constant *x*-ray treatments. (Dr. Thos. S. Stewart.) No pain, less edema of arm. Episcopal Hospital.

question of operability is discussed in the same place. In inoperable cases palliative treatment, as outlined in Chapter IV, is indicated.

Carcinoma Simplex or Acute Scirrhus is an intermediate form between the scirrhous and medullary types. The tumor causes increase in the size of the breast, and grows rapidly; the axillary lymphatics are palpably involved quite early in the disease, and all local symptoms (limitation of excursion of the breast, retraction of the nipple, orange skin dimpling) occur sooner than in the scirrhous form (Fig. 743). Ulceration also develops earlier and the ulcer is deeper but is not fixed to the chest wall; its surface is covered with sloughs, there is more discharge, and hemorrhages may occur (Fig. 740).

Prognosis and Treatment.—On account of the more rapid growth of the tumor, the patient usually seeks advice sooner than in the scirrhous form, and therefore radical treatment more often can be undertaken with a hope of cure.

Medullary Carcinoma is much rarer than either scirrhus or carcinoma simplex. The tumor occurs in younger women, and is of extremely rapid growth, often simulating a phlegmonous process. The overlying skin is red and tense; the breast is covered with dilated veins, and feels hot on palpation; soft areas resembling suppurating cysts or abscesses may be felt; and in the course of a few weeks the whole surface of the tumor breaks down, and a foul, sloughing mass protrudes. Hemorrhages are frequent, and large clots may cover the surfaces of the mass (Fungus Hematodes). On section the tumor often resembles softened brain matter, whence it sometimes is called *encephaloid;* it is friable and pulpy. An extreme type of medullary carcinoma, with most alarmingly rapid growth, is described as *carcinomatous mastitis.* This often involves both breasts.

Prognosis and Treatment.—Death usually occurs within a few months, even early radical operation proving ineffectual in preventing recurrence. Those tumors developing during pregnancy are the most malignant of all.

Paget's Disease of the Nipple.—This was described by Sir James Paget, in 1874, as a form of dermatitis or eczema predisposing to carcinoma of the breast. It is a rare disease, and while almost all cases occur in the nipple of the female breast, a few have been recorded as occurring in other parts of the body. The exact nature of the affection is still disputed by pathologists. Most authorities consider it carcinomatous from the beginning, but its point of origin is undetermined. Some hold that it arises in the galactophorous ducts and invades the skin secondarily; others believe that it originates in the epidermis and invades the ducts secondarily. Microscopically the characteristic feature is the presence of large transparent multinucleated cells ("Paget cells") in the deeper layers of the epidermis. *Clinically* the disease affects women of the cancer age; it begins as a scaly affection of the nipple, typically eczematous in nature but totally uninfluenced by local remedies usually effectual in relieving eczema in other parts of the body. As the disease progresses, the areola is involved, and the erosion or excoriation continues to spread superficially for months before the glandular tissue is noticeably affected.

The area usually is moist, but some psoriasis-like cases have been reported. The subjective symptoms are itching, tingling, and burning; but the general health is not impaired.

Treatment.—Treatment consists in amputation of the breast as soon as the disease is recognized; if the disease is extensive or of long duration, it is safer to do a radical operation as for carcinoma.

Cancer Cyst.—This is the rarest form in which malignant disease of the breast occurs. It has been studied by Bloodgood (1907). Usually occurring as a single cyst, it grows slowly, and presents few clinical signs of malignancy. Exploratory operation being undertaken, the cyst is found to contain bloody fluid, and there is no intracystic papillomatous out-growth to account for this fact; but usually an indurated or ulcerated area is found in the cyst wall. Any cyst which is opened at operation, and is found to contain hemorrhagic fluid, should be looked upon as carcinomatous unless there is an intracystic papilloma to account for the blood.

Treatment consists in radical operation as for other forms of carcinoma.

Extension of Mammary Carcinoma.—*Local extension* occurs especially to the overlying skin, to all portions of the mammary gland and its ramifications, and to the surrounding adipose tissue. The deep fascia overlying the pectoral muscles and as far down as the epigastrium is widely infiltrated, and early invasion of the pectoralis major muscle may occur, as demonstrated by Heidenhain (1889).

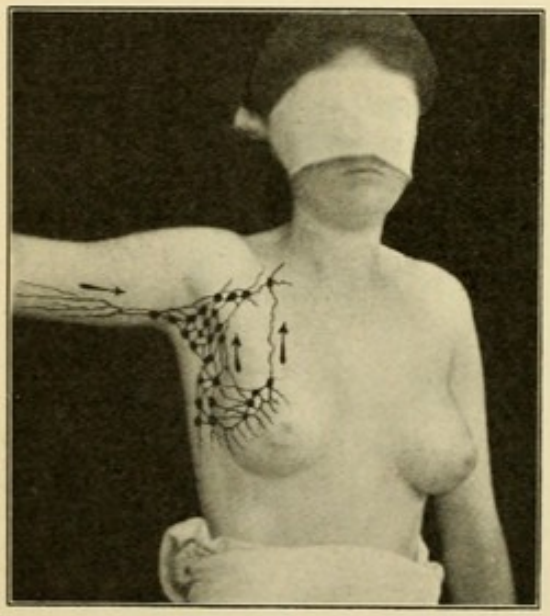

FIG. 745.—Lymphatics of the breast and axilla, involved in mammary carcinoma. Episcopal Hospital.

Lymphatic extensions are directly continuous with the main growth by fine columns of cancer cells. As the primary tumor in most cases is in the upper outer quadrant it is the axillary lymphatics that are first invaded as a rule, and this invasion occurs long before the nodules are palpable. In most cases the nodes which first become palpable are those on the side of the thorax, about midway between the axillary folds. Let the patient's arm hang by her side, so as to relax the axillary fascia, and then palpate gently and attentively in this region. But in the case of a growth in the extreme upper and outer part of the gland, early extension may occur to the nodes highest in the axilla, and these rarely can be palpated. In time all the axillary lymphatics are involved, and even the supraclavicular nodes may become enlarged. In advanced cases lymphedema of the arm results

from the axillary lymphatic obstruction; venous obstruction may also contribute to the edema; and pain from compression of the axillary nerves may be a very distressing symptom. Lymphatic extension may also occur to the mediastinum, especially if the tumor grows in one of the inner quadrants of the breast; or extension may occur across the middle line of the body to the other breast, or even to the other axilla. Both breasts and both axillæ always should be examined attentively. Finally reference must be made again to cancer *en cuirasse*, due to widespread carcinomatous lymphangeitis of the skin.

Distant metastases by way of the blood-stream are denied by modern pathologists. Cancer cells in the blood excite thrombosis, and the thrombus as it organizes usually destroys or renders them harmless (Handley). Handley has also indicated that bone lesions (confined to the bones of the trunk, the proximal ends of the limbs, and the skull) are in direct continuity with the main growth; their site often is suggested by the presence of subcutaneous nodules over the affected bone, even before bone pains, or pathological fracture demonstrate their existence. In cases of scirrhus this sad event occasionally occurs before the local tumor is noted; and it is a rule always to consider the possibility of already present metastases before operating on a case of scirrhus, and always to inquire into the condition of the mammary gland in the case of obscure malignant growths in the bones or viscera.

Radical Operation for Mammary Carcinoma.—*Ablation of the Breast.*—The general principles on which a radical operation for malignant disease is based were discussed in Chapter IV (p. 132). The development of the technique of the modern operation for carcinoma of the breast is due largely to the teaching of C. H. Moore, Volkmann, Heidenhain, Stiles, Halsted, and Handley. Moore (1867) was one of the earliest to discard the theory of a cancerous diathesis, and to look upon it as a disease of purely local origin; in consequence he urged wide excision of the breast and all involved structures (pectoral fascia and muscle and enlarged lymphatics) in one mass. Volkmann (1875) always excised the pectoral fascia and emphasized the necessity of removing the surface of the pectoral muscles when diseased, and established the "three year limit," all patients free from recurrence after this interval being reckoned as "cures." Though recurrences (or perhaps new carcinomas) may grow after intervals of ten and even twenty or more years, it is found by the best operators today that recurrence after a free interval of three years occurs in only about 20 per cent. of patients. Heidenhain (1889) urged removal of the surface of the pectoralis major muscle in all cases, even when not visibly diseased, as on microscopic examination he found it always invaded by cancer cells. Stiles (1892) called renewed attention to the importance of wide local excision, showing the great area over which the mammary gland was spread out—sending processes to the clavicle above, to the axilla laterally, and well below the lower border

of the pectoralis major, on to the serratus magnus, rectus, and external oblique muscles. Halsted (1894) introduced removal of the pectoralis major as a measure of routine, to facilitate clearing the axilla, in every case, whether the axilla was manifestly diseased or not; and he also insisted that the supraclavicular lymph nodes should be excised, and that the entire diseased tissue should be removed in one piece. Willy Meyer in the same year urged removal of the pectoralis minor in every case, and renewed the advice of Gerster (1885), who had advocated commencing the operation by the axillary dissection, which was left by others for the last step, and usually was undertaken only after the main tumor mass had been cut away. Finally, Handley, in his Astley Cooper prize essay (1905), demonstrated anew the importance of the deep fascia as the main highway by which the carcinoma cells spread in all directions from the common centre of disease, and has shown the necessity of removing it in a wide circle on all sides of the growth, which should be taken as a centre, the circumference to which excision should extend having as radius the distance from the tumor to the clavicle. This excision extends laterally to the latissimus dorsi, medially well beyond the middle line, and inferiorly at least two inches below the ensiform process.

The operation thus comprises removal of a very wide area of skin, the mammary gland with surrounding fat, the deep fascia, both pectoral muscles, and axillary lymphatics, *in one mass*. If this diseased mass is cut into at any point the contained cancer cells will be given a chance to escape into the surrounding healthy tissues, and recurrence will be very apt to follow. For the same reason all rough handling and tearing the tissues apart by blunt dissection should be avoided.

FIG. 746.—Jackson's incision for carcinoma of the breast, suitable for early cases. The rectangular flap is turned downward and the axillary flap upward in closing the wound. Episcopal Hospital.

Skin Incision.—So long as this removes a sufficient area of skin, its particular form is immaterial. A wound which cannot be closed completely is less likely to be the seat of recurrence than one which can, because there is less likelihood of diseased tissue remaining. I prefer Jabez N. Jackson's (Fig. 746) incision (1906) for early cases with little apparent involvement of the skin. For the average case Rodman's incision is as good as any (Fig. 747). Only a portion of the incision is made at first, sufficient for the dissection of the axilla, which should constitute the first step in the operation. To postpone this to the last, as in Halsted's method, leaves the entire thoracic

wound exposed during the most tedious part of the operation; whereas, if the axilla is cleared first (and this may require two hours or more in difficult cases) the remainder of the operation may be completed in about fifteen minutes. Moreover, the blood-supply is controlled much more effectively if each branch going to the tumor mass is secured at its origin.

The pectoralis major muscle is exposed first, its upper border identified, clamping or protecting the cephalic vein. A finger is then passed beneath the muscle, and it is divided close to its humeral attachment. The clavicular fibres of the pectoralis major are next cut close to the bone. This exposes the pectoralis minor, which is similarly divided close to the coracoid process, and the axilla is fully exposed. If there are palpably enlarged lymph nodes at the apex of the axilla, the skin incision should be extended upward across the clavicle, and the supraclavicular nodes explored. If enlarged they should be removed. Unfortunately it is not feasible to remove them in one mass with the axillary lymphatics, and they must be excised separately. Then the axilla is cleared from above downward, working along the axillary vessels to the lower border of the latissimus dorsi. Arterial and venous branches are clamped and cut close to the main trunks. Whenever the supply of hemostats is exhausted, all clamped points should be ligated, thus releasing the hemostats for future use. The main nerve trunks are carefully preserved, as is the median (long) subscapular nerve which supplies the latissimus dorsi; injury to this will affect the usefulness of the arm. Sensory nerves may be cut without compunction. When the vessels once have been dissected free the operation may proceed with greater rapidity. The entire axillary contents are turned toward the chest, and the lateral thoracic wall, from behind forward, is denuded of fascia; here the long thoracic nerve (external respiratory) should be looked for and preserved. The axillary wound is then filled with gauze.

FIG. 747.—Rodman's incision for carcinoma of the breast, suitable for most cases. The triangular flap below the clavicle is pulled downward, and the undermined skin on the lateral surface of the thorax is pulled upward, the wound being sutured in the form of the letter T, the long limb lying in the long axis of the breast. Episcopal Hospital.

The skin incisions are gradually extended to outline the breast, and are extensively undermined, on all sides, leaving attached to them only enough superficial fat to prevent sloughing. The axillary contents and pectoral muscles are then turned toward the median

line, and the dissection of the chest is continued from the lateral wall to the sternum. Here the perforating branches of the intercostals and internal mammary arteries will be encountered, and may cause troublesome bleeding if allowed to retract below the intercostal muscles before being clamped. The tumor mass now being free above, the dissection is continued downward, removing the deep fascia over the upper portion of the rectus muscle in the epigastric region.

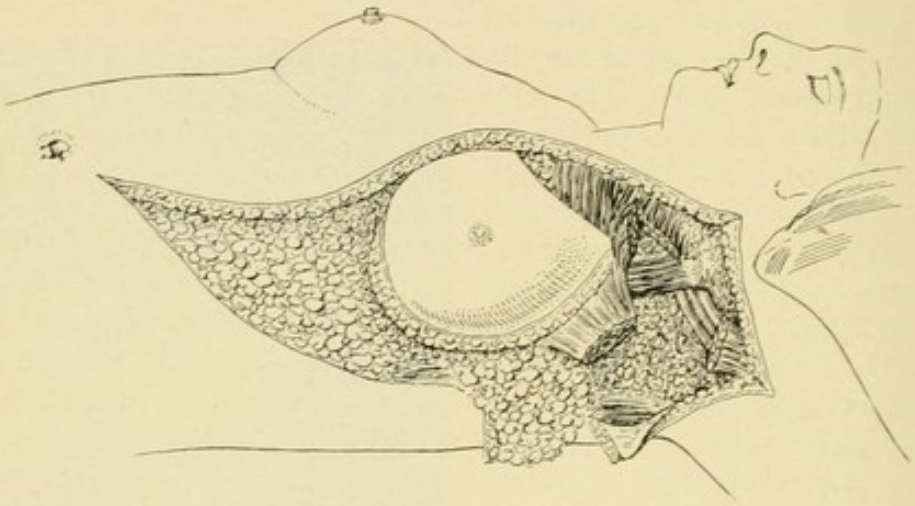

FIG. 748.—Ablation of the breast: the pectoralis major has been cut near its humeral insertion, and its clavicular fibres have been divided, exposing the pectoralis minor. The entire skin incision (indicated in the drawing) is not made at one time, but only as the operation proceeds.

The tumor being thus removed, a puncture for drainage is made in the skin of the axilla, and a tube introduced. This is allowed to remain four or five days. The skin is then sutured, closing the wound as far as can be done without undue tension. The arm is dressed in a fully abducted position; this permits more accurate apposition of the skin to the axilla, prevents accumulation of wound discharges here, and facilitates return of the function of the upper extremity. When the skin is accurately adjusted to support the axillary structures, it is very seldom that disability follows from cicatricial contraction. Lymphedema may develop after the operation, especially when a thorough removal of the axillary lymphatics has been accomplished. It may be treated by Handley's operation (p. 270). Excellent motion is retained by the arm in spite of removal of both pectoral muscles, and the patient is little if at all inconvenienced by their loss. Murphy retains them as pads to fill up the hollow of the axilla, and removes the breast before beginning his axillary dissection. Few or no surgeons any longer approve of this method of operating. Tansini slides a musculo-cutaneous flap from the back across to the thoracic wound, permitting of its complete closure in every case.

The *immediate mortality* of the extensive operation described above is very low—not more than 1 per cent. in skilled hands. Deaths are caused almost solely by visceral complications, such as pneumonia, cardiac disease, or uremia.

After-treatment.—When the incision cannot be sutured completely, some surgeons prefer to do skin-grafting at the conclusion of the operation; while others postpone this until granulation has commenced. Personally I believe it is better to do neither, but to expose the granulating surface to the *x*-ray at suitable intervals. If this treatment is conducted by a skilled röntgenologist, there seems much less tendency to recurrence, and where inoperable recurrence takes place this treatment greatly relieves the pain, diminishes the discharge and fetor, and keeps the patients comfortable (Figs. 740 and 744).

Examination of the wound for recurrence should be insisted upon, at first monthly; then every three or four months, until the three year period has elapsed. After this time the patient should report to her surgeon at least once a year, or immediately if any symptoms arise.

End Results of the Radical Operation for Carcinoma of the Breast.—If the operation is done in favorable cases (before there is palpable axillary involvement and before the tumor is fixed or the overlying skin ulcerated), about 70 per cent. of patients will be "cured" in Volkmann's sense; that is, they will remain free of recurrence for a period of three years. And of these clinical "cures," only about one-fifth will have a recurrence at a later date. If axillary invasion has occurred before the operation is done, about 25 per cent. of patients will be in good health after three years. These figures are conservative, as better results are reported by those who do most of these operations.

But the advantages of the operation are great even if recurrence or metastasis eventually occurs. At the very worst, the patient will enjoy a number of months, perhaps several years, of good health, and will have hope of ultimate cure. Even if recurrence takes place a cure may still be possible by aid of a second or third operation. Finally, if metastasis occurs, and death results from this cause, it will be a very much less painful death than that from local recurrence, and the operation at least will have prolonged life and afforded an interval of comfort and of hope.

Inoperable Cases.—Usually no operation should be undertaken in cases in which it is manifestly impossible to remove all of the disease. In most patients with the supraclavicular nodes palpably enlarged, no operation, however radical, will effect a cure; but if the tumor is not otherwise inoperable, the radical operation may be done, these nodes being removed at a second operation ten days or two weeks later. Only if they are very slightly involved is it safe to prolong the original operation for their immediate removal.

Recurrences are to be treated on the same principles as the primary growth. Even fixation to the chest wall does not necessarily contraindicate excision; the portions of ribs invaded may be removed.

Palliative operations sometimes are done in inoperable cases. Very occasionally mere "*amputation*" *of the breast* (p. 710), to remove a sloughing ulcer, followed by *x*-ray treatment, will promote the

patient's comfort and prolong life even when cure is out of the question (Fig. 740). *Cauterization* with the actual cautery, or with chemicals, such as chloride of zinc solution (5 per cent.), sometimes will relieve discomfort by sterilizing the surface of a sloughing growth. *Double oöphorectomy,* introduced by Beatson of Glasgow, in 1896, has been employed in a number of advanced cases, and in some patients shrinkage of the breast tumor and considerable relief has followed. *Amputation at the shoulder-joint* was employed by Esmarch (1883) as a primary operation in one far advanced case, and has been practised a number of times since in cases of recurrence; and even *interscapulothoracic amputation* has been employed in cases of recurrence (Dent, in 1897, and later by others). Others have employed rhizotomy (p. 530), with marked relief of pain.

SURGERY OF THE CHEST WALL.

Congenital and Acquired Malformations.—These are of interest from a diagnostic point of view, but little can be done in the way of treatment. *Birth injuries* occasionally result in deformities which persist through adult life (Fig. 749), but seldom entail any disability. The diagnosis is made from the history. *Rachitic deformities,* reference

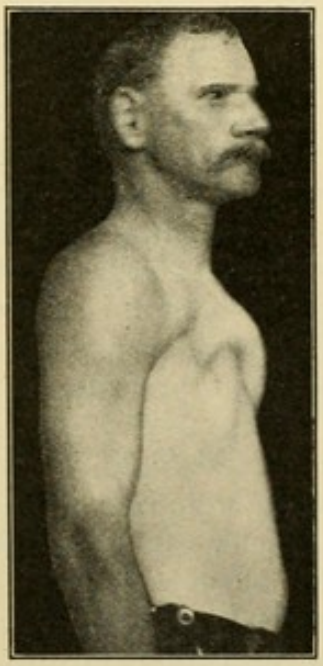

Fig. 749.—Birth injury of thorax. Orthopædic Hospital.

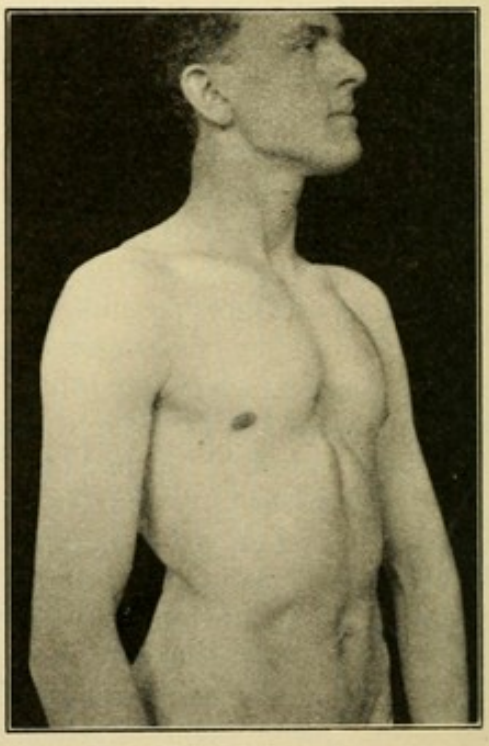

Fig. 750.—Funnel breast (rachitic). Orthopædic Hospital.

to which was made at p. 418, develop during infancy or early childhood, and are recognized by coincident symptoms of rachitis. The most frequent deformities are the "rachitic rosary," Harrison's groove, and pigeon breast; these seldom persist past the age of puberty. Funnel breast, however, may last through life (Fig. 750).

Some of these deformities may be improved by gymnastic exercises, or by the use of orthopedic apparatus, if treatment is begun in early childhood; but the disability is so slight in adult life that no active interference is required.

Injuries.—The most frequent injury is fracture of the ribs. This was considered at p. 323. Simple contusions require no special notice. Severe lacerated wounds, with compound fracture of the ribs, usually are attended by visceral injuries (for which see p. 733). They are caused by crushing injuries, explosions, etc., and often are fatal. If the patient survives, convalescence is prolonged, and severe deformity may ensue (Fig. 751).

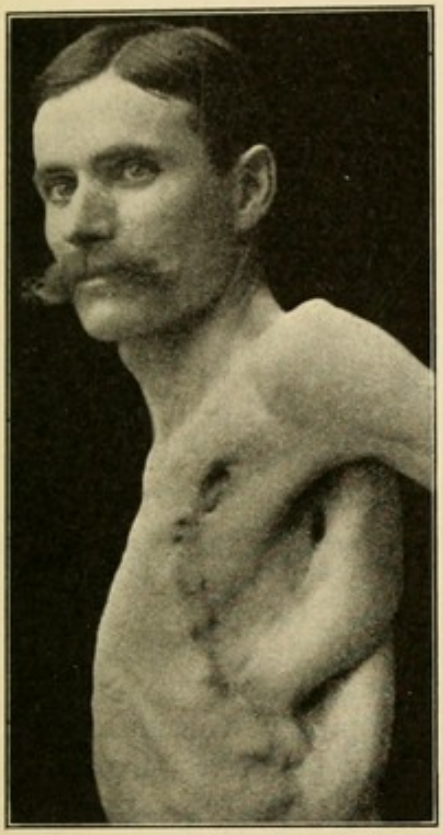

Fig. 751.—Deformity of thorax following injury by explosion in coal mine. Episcopal Hospital.

In some cases a phenomenon known as *traumatic asphyxia*, or *stasis cyanosis*, follows sudden violent compression of the chest (or abdomen) of short duration. This state is characterized by marked cyanosis of the head, face, and neck, usually sharply delimited a

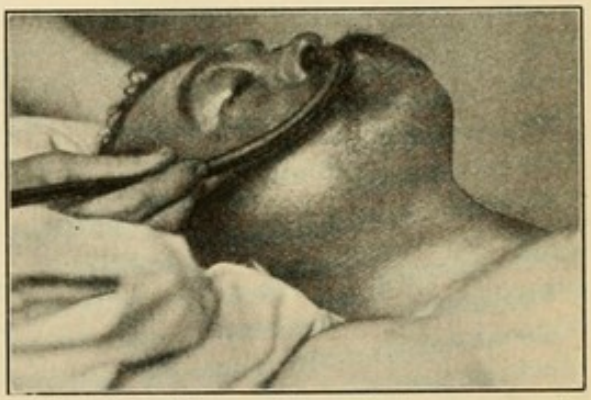

Fig. 752.—Traumatic asphyxia; oxygen inhalations. Death in twelve hours. Episcopal Hospital.

short distance above the clavicle, apparently by the collar. The patient looks as if he had been strangled (Fig. 752): the eyes are bloodshot, and the eye-lids may become edematous; there may be hemorrhages from the naso-pharynx or ears; convulsions or unconsciousness may occur. In addition to shock, there is irregularity or entire failure of respiration. The cyanosis, which is petechial in appearance, may be due to extravasation of blood (true traumatic asphyxia) or to dilatation of the capillaries with blood stasis (stasis cyanosis). It is difficult to differentiate the conditions, which, indeed, often coexist. The mechanism by which this state is produced is believed to be sudden compression of the thorax with the glottis closed, causing violent reflux of blood from the right heart. There may be interstitial and subpleural hemorrhages in the lungs, with

interstitial emphysema; and in some cases cerebral congestion and hemorrhages have been found postmortem.

Treatment.—Treatment comprises measures to overcome shock, with artificial respiration, and inhalations of oxygen. The pulmotor, a mechanical device for artificial respiration employed in cases of poisoning by illuminating gas, may be used with advantage.

Surgical Emphysema.—Surgical emphysema is a term used to describe the escape of air into the subcutaneous tissues. As previously noted (p. 301) it may occur in the face in connection with fractures of the nose, etc. The most usual form, however, is that due to thoracic injury; and the air escapes across the pleura from the lungs which have been punctured by a broken rib or ruptured by the compressing force. If the emphysema appears first at the root of the neck, and not at the site of injury, it is probable that the rupture of the lung is entirely subpleural, and that the air has escaped into the loose cellular tissues surrounding the bronchi, and eventually reaches the neck by way of the mediastinum. This subcutaneous emphysema may occur without any clinical evidence of severe intra-thoracic injury, but as auscultation and percussion are much interfered with by its development, it is probable that the deeper lesions often are overlooked. Occasionally a wound of the pleura, without injury of the lung, may cause the development of emphysema, the outside air being sucked into the wound by the negative intra-thoracic pressure.

The air may spread far over the body, up to the scalp, down to the groin, and even out along the limbs; the eyes may be closed up, and the patient may become so bloated that recognition will be impossible. Subjective symptoms, except those due to visceral lesions, are insignificant. Palpation of the areas affected produces typical crackling; the skin feels as if floated up from the muscles or bones by an effervescing liquid; the air may be driven from one place to another by the fingers, and pitting on pressure is apparent. The larger the source of supply, the more rapid will be the development and spread of the emphysema. In some cases only a very limited area is affected, and attentive examination is required to detect it; in others the emphysematous area increases rapidly in size as the patient is watched.

Treatment.—Mild cases require no treatment; but usually, whether or not there is fracture of the ribs, the injured side of the thorax should be strapped, as limitation of the respiratory excursions will diminish the spread of the air. Where the emphysema is very marked, it has been recommended that multiple punctures be made with a fine pointed bistoury, or tenotome, whereupon air will escape with a hissing noise, and the swelling will partly subside. As a matter of fact, if any treatment is necessary, it is much better to aspirate the pneumothorax, since as long as this continues air will escape from it into the subcutaneous tissues. The chief danger is infection of the subcutaneous tissues, with widespread cellulitis. Apart from this and visceral lesions, the prognosis is good.

Axillary Abscess.—This may be *superficial* or *deep*. The former, which is more frequent and less serious, arises in connection with the hair follicles or sebaceous glands, as a furunculosis; the process occurs superficially to the axillary fascia. Usually suppuration starts in several different points, but if incision is not made promptly these may coalesce to form one abscess (Fig. 753). *Treatment* consists in incision and drainage.

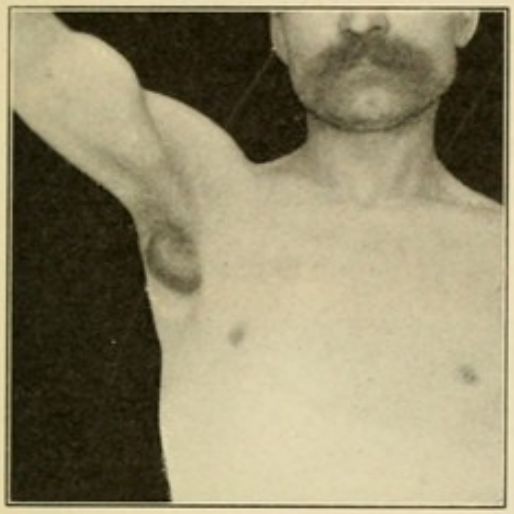

FIG. 753.—Abscess superficial to deep fascia of axilla. Episcopal Hospital.

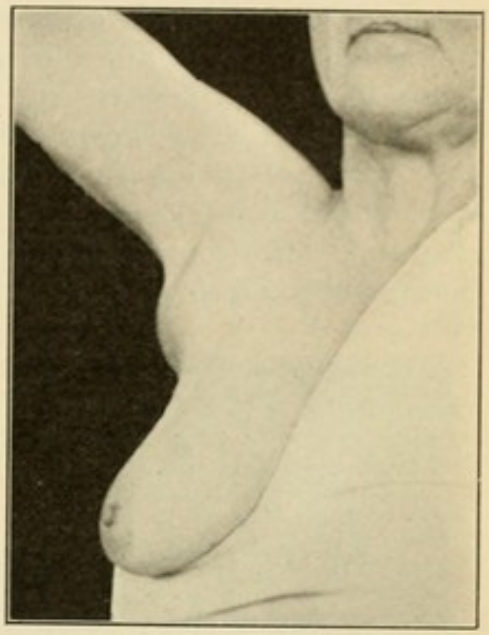

FIG. 754.—Deep axillary abscess, following lymphadenitis; duration six weeks. Episcopal Hospital.

Deep or True Axillary Abscess arises in the tissues of the axilla underneath the axillary fascia; it begins as lymphadenitis (Fig. 754), and usually is due to a primary infection in the hand, or rarely in the breast. Occasionally these deep axillary abscesses point through the thin (cribriform) portions of the axillary fascia and present beneath the skin. Rarely the pus may travel upward along the sheath of the axillary vessels and point at the root of the neck. Owing to the deep seat of the inflammation, and to the pus being covered by the dense axillary fascia, distinct evidences of suppuration often are absent. The surgeon should not wait for fluctuation, or even for redness and edema of the overlying skin, or other classical signs of abscess. The subjective symptoms, pain, tenderness, and loss of function of the arm, are so severe as to suggest serious trouble, and the constitutional evidences of infection may be marked. Therefore no time should be lost in draining the axilla. Usually an anesthetic is desirable. An incision is made from the outer border of the axilla inward to the chest wall, midway between the anterior and posterior axillary folds. After the skin is incised the knife should be kept fairly close to the thorax. When the axillary fascia has been incised, if pus does not flow, further exploration should be conducted according to Hilton's method (p. 51). The axilla is drained by a tube, and the arm is carried in a sling.

Subpectoral Abscess.—This is an abscess between the pectoralis major muscle and the pectoralis minor, or one beneath the latter muscle, at the extreme apex of the axilla. Probably in most cases it is caused by direct contusion or strain of the pectoral muscle, producing a small hematoma which subsequently is infected through the blood-stream. It may arise in suppuration of the subclavian lymph nodes, which lie on the anterior surface of the pectoralis minor or clavipectoral fascia. Sometimes this follows infected wounds of the thumb or index finger or radial aspect of the forearm, since the lymphatics from these regions may pass directly to these nodes along the cephalic vein; whereas the lymphatics from other regions of the hand and forearm enter the axilla with the brachial vessels. Rarely a subpectoral abscess is caused by caries of the ribs, or by bronchial or pleural infection; in such cases the abscess often is chronic and is due to tuberculosis (Fig. 758).

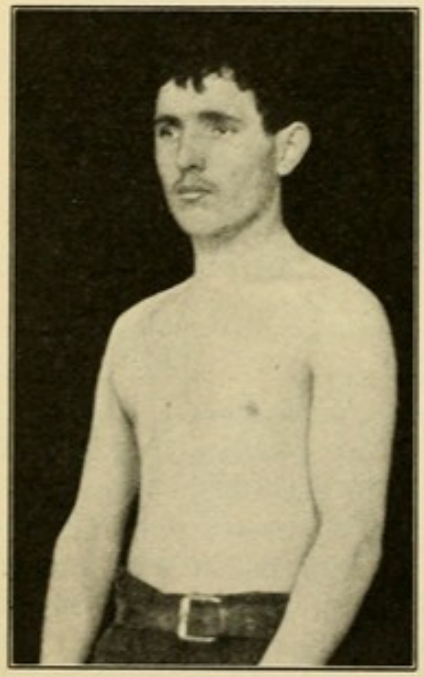

FIG. 755.—Right subpectoral abscess; duration three weeks. No cause discoverable. Episcopal Hospital.

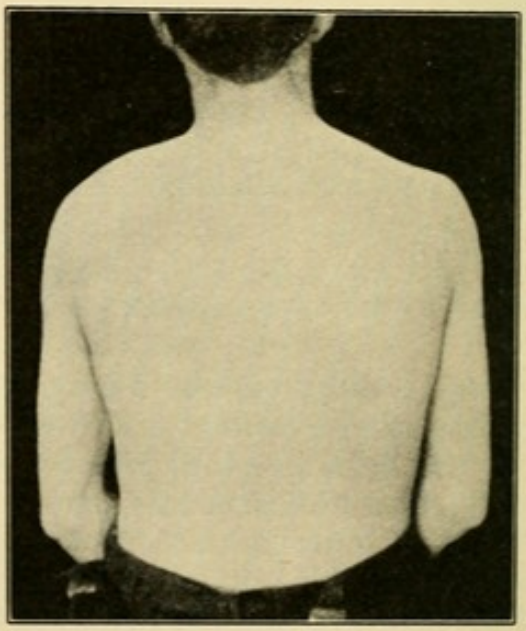

FIG. 756.—Abscess in left supraspinous fossa; duration one week; cause unknown. Incision evacuated six to eight ounces of pus. Healed in six days. Episcopal Hospital.

Symptoms.—A subpectoral abscess forms a rounded, tender, painful swelling below the inner part of the clavicle; it tends to point at the lower border of the pectoralis major (Fig. 755), or rarely may burrow through an intercostal space into the pleura. It is differentiated from axillary abscess by its position nearer the median line of the body, and by the relaxed condition of the axillary fascia and freedom of the axilla; and from arthritis of the shoulder by the slight impairment of the movements of the joint, which are quite free within a limited range. I have seen the condition mistaken for tuberculosis of the shoulder-joint.

Treatment.—The abscess should be opened by an incision along the lower border of the pectoralis major, and should be drained with a tube. Musser collected 23 cases with 13 deaths.

Subscapular Abscess.—This is quite rare. The pus forms in the space betwen the serratus magnus and the posterior thoracic wall. It cannot point anteriorly because of the attachment of the serratus magnus to the lateral aspect of the thorax; it cannot escape internally because of the spinal connections of the scapula. The pus, therefore, spreads either upward, and points beneath the trapezius, which is unusual; or downward to the angle of the scapula.

If the existence of this condition is remembered, the diagnosis rarely will be difficult. The abscess should be opened at the lower angle of the scapula, and drained. In some cases the body of the bone may be trephined.

Suprascapular Abscess.—Suppuration in the supraspinous fossa is another unusual condition (Fig. 756). Unless the condition is borne in mind, the swelling may be mistaken for a sarcoma. The onset usually is subacute, and may follow the formation of a hematoma in the supraspinatus muscle as the result of trauma; or the lesion may be tuberculous and arise in the bone. The abscess should be opened and drained, unless it is thought to be tuberculous, when it should be treated as a tuberculous abscess elsewhere in the body (p. 483).

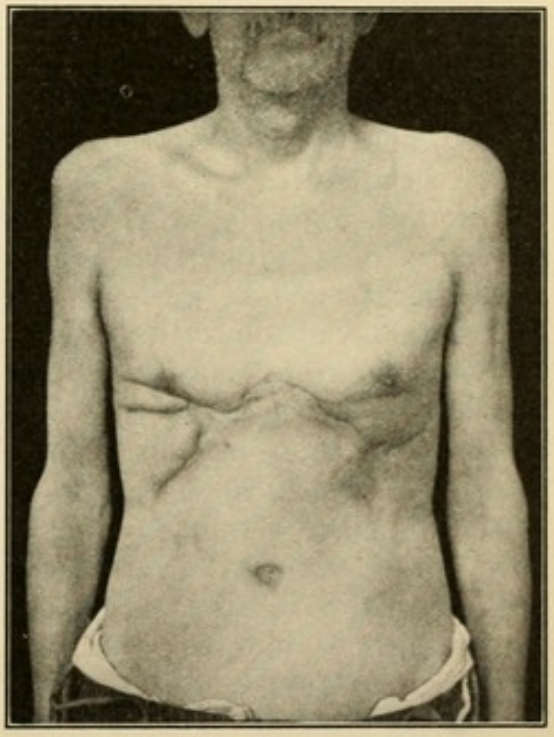

Fig. 757.—Extensive scars of both hypochondriac regions from previous operations for necrosis of ribs. Episcopal Hospital.

Caries of the Ribs.—This usually is tuberculous in nature. It may be due to extension from a focus in the vertebræ, or from a tuberculous pleurisy; or the disease may be primary in the ribs. In the latter case development of the affection often follows injury. Usually the patients are adults, and there often is pulmonary tuberculosis or a tuberculous lesion in the bones, joints, or lymph nodes. Early formation of a cold abscess occurs, and this presents itself as a fusiform swelling along the course of one or more of the ribs. The ribs from the third to the eighth are oftenest affected, near the chondral or the vertebral joints. The disastrous results of spontaneous fistulization and secondary infection are as prominent here as elsewhere in the body where tuberculous disease is concerned. Interminable suppuration ensues, with numerous fistulæ, and constant pocketing

of "hot" pus, which requires evacuation (Fig. 757). If seen before rupture occurs, the abscess should receive the treatment advised for cold abscess in general (p. 483).

Tuberculosis may also affect the joints of the *sternum;* at the junction of the manubrium and gladiolus its development has been mistaken for fracture (N. B. Carson).

Acute septic osteomyelitis of the ribs may occur, but is rare; also rare is *typhoid periosteitis* of the ribs, which may not develop for months or years after the attack of typhoid fever. Osteomyelitis may result in necrosis of the ribs, and resection of the portions affected may be required; in cases of typhoid origin, however, curettement of the carious surfaces usually is sufficient.

SURGERY OF THE ANTERIOR MEDIASTINUM.

Affections of the anterior mediastinum offer up to the present a very limited field for surgical care.

Acute Mediastinitis.—Acute mediastinitis is the term used for a cellulitis of the mediastinum. It may follow a stab or gunshot wound, or may result from extension downward of a cervical cellulitis. There are pain, tenderness on pressure over the sternum, and constitutional symptoms of sepsis. Signs of cardiac, pulmonary, or tracheal compression may arise. Usually in the course of time pus is formed, and this seeks an exit for itself through an intercostal space close to the sternum, or possibly by rupture into a bronchial tube or the pleura. *Lymphadenitis of the mediastinum* usually is tuberculous. The onset of symptoms is less acute than in mediastinitis.

Treatment.—When medical measures, with cold locally, fail to relieve the symptoms, and especially when symptoms of respiratory obstruction arise, surgical intervention is called for, even before pointing of an abscess occurs. The operation consists in trephining the sternum, enlarging the opening with rongeur forceps, and evacuating the pus by Hilton's method (p. 51). An abscess may be opened where it points, but even then it is usually necessary to cut away part of the sternum to secure free drainage.

Mediastinal Tumors.—These give evidence of their presence by compression symptoms, and by an abnormal area of dulness on percussion. Tuberculous lymphadenitis is the most frequent non-neoplastic growth. The lymphadenoid enlargements of Hodgkin's disease and sarcoma are not so frequent as secondary desposits of carcinoma. Benign tumors, especially dermoids, also occur. As a rule no surgical treatment offers any prospect of cure; but palliation may be offered by splitting the sternum longitudinally to lessen the symptoms of compression. Should a benign tumor be found, it might be removed successfully. Friedrich recommends transverse section of the sternum above the third rib. Enlargement of the thymus gland is referred to at p. 693.

SURGERY OF THE LUNGS AND PLEURA.

Subcutaneous Injuries.—Subcutaneous injuries of the thoracic viscera usually are accompanied by fractures of the ribs or sternum; but sometimes the lung is ruptured without there being any coincident injury of the elastic thoracic cage. In most cases the lung is directly crushed, but it is possible for it to be injured by wrenching from its pedicle, or by being torn loose from pleural adhesions. The extent of the lesion varies from mere bruising to extensive laceration, and the resulting hemorrhage may be slight or very severe. In the mildest cases the visceral pleura is not ruptured, and the symptoms are those of a localized pneumonia, possibly with the development of subcutaneous emphysema commencing at the root of the neck (p. 728). When the visceral pleura is ruptured, hemorrhage occurs into the pleural cavity, and the air also usually escapes from the lung, forming a pneumo-hemothorax.

Diagnosis.—The diagnosis depends on ascertaining the history of an injury; on the symptoms, which do not differ from those of penetrating wounds of the lung (see below); and on the physical signs of pneumothorax and surgical emphysema. The differential diagnosis from traumatic diaphragmatic hernia may be difficult; this is discussed at (p. 751).

Treatment.—The treatment consists primarily and chiefly in rest, either in the recumbent or sitting posture, whichever is more comfortable to the patient. I believe the administration of opium in some form is decidedly beneficial, allaying the annoying cough, slowing the respiration, and, therefore, diminishing the bleeding. In many cases the bleeding stops of itself. The blood-pressure in the pulmonary system is only one-third of that in the systemic. If bleeding does not cease, as indicated by persistent symptoms of internal hemorrhage, and by gradual increase in the amount of pleural effusion, it must be checked by operative means, as described below in connection with penetrating wounds of the lung. If the pneumothorax persists and causes dyspnea, the air may be aspirated; for this a very fine needle should be used, as less liable to cause subcutaneous emphysema. The surgeon should not resort to this measure unnecessarily, since relief of the pneumatic pressure on the lung may cause recurrence of bleeding.

Prognosis.—The prognosis is grave except in the case of trivial lesions. Möller, in 1910, reported 23 cases from Körte's clinique; no operation was attempted in any case, and none would have been of any avail in the 9 fatal cases.

Penetrating Wounds of the Thorax.—These are chiefly gunshot or stab wounds. The former have been considered at (p. 189). In most cases of stab wounds the lung is injured, but penetration of the parietal pleura without visceral injury is possible. In the latter case intrapleural hemorrhage (hemothorax) may occur from injury of a vessel in the thoracic wall; and there usually is pneumothorax,

air being sucked into the pleural cavity at each inspiration. Complicating injuries of the diaphragm and abdominal viscera are frequent. If the lung has been wounded there may be considerable *shock*, with *dyspnea*, *cough*, and usually spitting of blood (*hemoptysis*). In many cases there are the symptoms of severe *internal hemorrhage* (p. 227). The physical signs are those of pneumothorax, or hemopneumothorax; sometimes there is hemorrhage from the wound. Escape of air from the wounded lung through the external wound occasionally occurs; it is known as *traumatopnea*, and should not be confused with the mere aspiration of air into the pleural cavity such as was described as occurring even when no pulmonary injury is present. Prolapse of the lung through the wound is a rare occurrence; this should not be confused with subcutaneous hernia of the lung, which is described at p. 736.

Diagnosis.—Usually this is not difficult. But it should be remembered that alarming intrapleural hemorrhage may occur from injuries of the internal mammary and intercostal arteries, without wound of the lung; and the possibility and extreme seriousness of complicating stab wounds of the diaphragm (p. 749) should be kept in mind.

Treatment.—The constitutional treatment is the same as for gunshot wounds or subcutaneous rupture of the lung. Under no circumstances should the wound be explored with finger or probe. The surrounding skin should be painted with 3 per cent. alcoholic solution of iodin, the wound should be covered immediately with sterile gauze, and the side of the chest affected should be firmly strapped as in the case of fractured ribs. This materially alleviates the patient's pain, though probably it has little influence on the progress of the wound in the lung.

The *question of the propriety of early operative interference* in thoracic injuries has been the subject of much discussion during the last few years; and some surgeons are very uncompromising in their attitude for or against intervention. The debate is waged chiefly over the subject of stab wounds, the propriety of non-interference in the case of gunshot wounds, except for positive indications, being very generally recognized. In the case of subcutaneous injuries, also, a decision for or against operation is not very difficult, because the symptoms either are so trivial as never to raise the question, or the lesions are so manifestly lethal in extent as to render operation useless. But in the case of stab wounds there are those who teach that operation is never or hardly ever required; and there are others, equal in experience and authority, who maintain that every patient with a stab wound of the thorax, seen within the first twelve hours, should be taken at once to the operating room, and that the question of operative or non-operative treatment should be decided only after an exploratory operation has been done to determine by inspection the extent of the lesions. Zeidler, of St. Petersburg, with an immense experience in this class of cases, takes the latter ground; and his assistant Lawrow (1911) has exposed his views very

thoroughly. Other things being equal, this no doubt is the logical position to take; but the fact remains that if it is adhered to, a great many unnecessary operations will be done; and in many cases the patients will be made worse or will be killed by the exploration.

Most surgeons recognize that stab wounds which might involve the diaphragm or abdominal viscera should be explored; and the fact that 55 out of 121 stab wounds of the thorax (Lawrow) came within this category should be borne in mind. It is recognized, moreover, that wounds which probably injure the heart should be explored (p. 236); according to Lawrow's figures only one out of ten stab wounds of the thorax implicates the heart. But when these two classes of stab wounds are excluded, there certainly remains a large number of cases in which it is at least extremely probable that only the lung has been injured, or that even though the pleura has been penetrated there is no visceral injury whatever; and it is interesting to compare the results secured in the case of uncomplicated pulmonary wounds in Zeidler's service, where every patient who consented was subjected to early operation, with those reported (1910) by Möller from Körte's clinique, where no operations were done in such cases. According to Zeidler's immediate exploration plan the mortality in 52 uncomplicated cases was 27 per cent.; whereas Körte treated 19 such cases without one death. And the significance of this comparison I believe is not altered by the fact that in 78 per cent. of the cases explored by Zeidler and his assistants some visceral injury or bleeding from an intercostal vessel was found.

From a consideration of these facts I think it is evident that no hard and fast rules can be laid down for treatment, but that each individual case must be treated on its own merits. In fully equipped hospitals, I believe exploratory operation for stab wounds of the thorax will be indicated more often in the future than in the past; certainly more often than in the case of gunshot wounds or crushes. But I cannot believe that exploration in every case is necessary or desirable. If there is a possibility of injury of the heart, or of the diaphragm or abdominal viscera, exploration is imperative; but if this possibility seems remote, it is better to treat the patient expectantly.

As *indications for operation*, then, may be recognized the following factors:

1. Possibility of injury to the heart, to the diaphragm, or abdominal viscera.

2. Active hemorrhage from the wound.

3. Signs of internal hemorrhage, recognized by constitutional symptoms, and by steady increase in the amount of the hemothorax. It makes no difference whether this comes from the wounded lung or from a parietal vessel. The bleeding must be stopped.

4. Pneumothorax which develops suddenly some days after the injury. As pointed out by Möller this indicates sloughing or reopening of the wound in the lung; and immediate drainage of the pleura is

required to prevent sepsis. Primary pneumothorax scarcely ever will be so severe as to demand relief; but if necessary the air may be aspirated through a fine needle. If this fails, the only relief lies in thoracotomy, by which the pressure within the pleura may be reduced to that of one atmosphere.

Operation.—Usually a general anesthetic is required. Ether is the best, and if possible it should be administered by intratracheal insufflation (p. 154). The wound is carefully explored, cutting down layer by layer, until it is ascertained that the pleura has been entered. Then the incision is extended to a length of six or eight inches in the wounded interspace. By strong retraction of the ribs (for which the rib-spreader of Mikulicz is convenient) it may be possible to complete the operation without resecting any of the ribs. Resection of one or both ribs bordering on the primary incision may be done later if necessary. A bleeding intercostal vessel, which may be the only source of hemorrhage, should be looked for and ligated. The pleura having been widely opened, the thoracic cavity is tamponed (by fine silk tampons or those of handkerchief gauze if these are available), and the diaphragm is inspected, unless there is good reason to believe that it has not been injured. If a wound is found, it should be treated as described at p. 750. If bleeding continues, the lung is caught in volsellum forceps, and is drawn into the thoracic incision. This fixes the mediastinum, promotes cardiac action, and ventilates the other lung. The lung is then searched for wounds, and these are sutured with mattress sutures of fine chromic gut, introduced close to the border of the wound, passed deeply, but not drawn very tight. Round-pointed needles should be used. A wound of exit as well as one of entrance should be looked for. If the wounds cannot be sutured, they should be packed; or a very extensive wound may be "exteriorized" by suturing its margins to the edges of the parietal wound. After the pulmonary wound has been sutured the lung will expand if intratracheal insufflation is being employed, and the blood which has collected in the pleural cavity will be forced out of the thoracic incision. If it is not, the pleura should be wiped dry. No irrigation should be employed. The parietal wound is then closed in layers (pleura, intercostal muscles, and skin), *without drainage.* If the anesthetic has been administered in the usual way it will be safer to leave a drainage tube in the incision for a few days; this should be just long enough to enter the pleura. In 22 cases where the wound was closed without drainage, subsequent drainage for empyema or abscess was required in only 13 (Stuckey); the other 9 patients recovered without any complication, and if all had been drained, all would have had empyema.

Hernia of the Lung is rare. When congenital it may be due to defect in the chest wall, or may develop at the root of the neck. Acquired cases usually follow some months or years after injury of the thorax, the lung bulging out beneath the cicatrix. The swelling is sponge-like in consistency, crepitates on pressure, and is reducible;

it increases in size during forced expiration, may disappear spontaneously during inspiration, and gives an impulse on coughing.

Treatment.—Treatment seldom is required. If support by pads or adhesive plaster does not secure relief, an operation may be undertaken, dissecting out the cicatrix, and repairing the wound by overlapping its edges in several layers. The pleural cavity need not be opened.

Pneumothorax.—The presence of air in the pleural cavity as a complication of injuries of the thorax has been alluded to. Occasionally the condition arises from disease of the lung, usually tuberculous; but such cases have little surgical importance. The pneumothorax may be open or closed: that is, there may or may not be a wound of the thoracic parietes producing a communication between the pleura and the outer atmosphere. If there is no external wound (when the pneumothorax is due to escape of air from the wounded or diseased lung), or if the thoracic wound is small or valvular, the pressure of the air in the pleura may be increased at each respiration, and a "tension pneumothorax" is said to exist.

Symptoms.—The symptoms depend upon the rapidity with which the pneumothorax develops, and on the air pressure. A very suddenly produced pneumothorax may cause immediate death from distortion of the mediastinum, and interference with the action of the heart or the other lung. One of very slow onset may produce no appreciable symptoms. When traumatic in origin, the symptoms often are obscured by those of shock, internal hemorrhage, etc. Unless the lung is bound down by adhesions, the air fills the entire pleural cavity, and the entire side of the chest affected becomes tympanitic on percussion. There is absence of respiratory movements, no breath sounds are heard, and vocal fremitus is absent. If the air is under extremely high pressure a dull note may be obtained on percussion; this is rare. Almost always there is dyspnea; there may be cyanosis; the cardiac action may be embarrassed, and the pulse usually is weak, not very rapid, and may be irregular.

Treatment.—In most cases of *closed pneumothorax* the air will be absorbed spontaneously within a few days, and no treatment is required. If dyspnea is severe the air may be aspirated. For this a very fine needle should be used, so as not to produce subcutaneous emphysema. In cases of *open pneumothorax* relief of symptoms usually follows closure of the external wound by suture or occlusive dressing. This restores the piston action of the diaphragm, ventilates the other lung, and facilitates heart action. If for any reason the wound cannot be closed, and the symptoms of a tension pneumothorax supervene, it is better to enlarge the parietal wound or to introduce a drainage tube, thus reducing the intrapleural pressure to that of one atmosphere.

Hemothorax.—Blood in the pleural cavity almost invariably is the result of injury to the thorax, either subcutaneous or penetrating. The hemorrhage may be derived from the lung or from the

internal mammary or one of the intercostal vessels. Bleeding from parietal vessels is not likely to stop of its own accord, owing to the negative pressure within the pleural cavity. If the bleeding comes from the lung it will not cease until the intrapleural pressure equals the blood-pressure within the lung; but as this is only one-third as great as that in the systemic circulation, intrapleural hemorrhage from a lung wound will stop of itself much sooner than will bleeding from an intercostal artery.

The *physical signs* are those of pleural effusion. The symptoms of internal hemorrhage indicate the nature of the effusion, and this may be proved by aspiration. The blood does not clot very readily, and forms an excellent culture medium for bacteria. Hence there is great danger of secondary empyema. If infection does not occur, and the blood finally clots and becomes organized, extensive and perhaps disabling pleural adhesions may develop. I have operated on a patient with calcification of the entire pleura, the result of injury many years previously.

Treatment.—This depends upon the rapidity of the hemorrhage as well as upon its extent. Rapid bleeding (indicated by the symptoms of internal hemorrhage and by rapid increase in the amount of fluid in the pleura) usually indicates an extensive pulmonary lesion, and demands operation, as described under stab wounds of the lung (p. 736). If the bleeding is slower, it is better not to interfere unless the upper level of the dulness (in the sitting posture) ascends as high as the spine of the scapula, or unless the symptoms of hemorrhage are very pronounced.

Pneumo-hemothorax.—Pneumo-hemothorax is more frequent than either pneumothorax or hemothorax separately. The air rises to the upper part of the pleural cavity, and the blood gradually accumulates below. The physical signs are those of pyo-pneumothorax, which are described in every text-book of general medicine. The diagnosis depends on a recognition of these, and on a history of recent injury and on the symptoms of internal hemorrhage. Aspiration of the fluid proves its hemorrhagic nature. Differentiation from diaphragmatic hernia (p. 751) may be difficult. *Treatment* has been discussed sufficiently under the separate headings pneumothorax and hemothorax.

Chylothorax.—Chylothorax usually is due to rupture of the thoracic duct, which may occur as a complication in some cases of fracture of the spine. The effusion is left-sided, but owing to more serious injuries often is overlooked. Rapid emaciation is characteristic, but the diagnosis cannot be certain until some of the fluid has been withdrawn by aspiration; and microscopical and perhaps chemical study may be necessary then to determine its nature, as an effusion similar in macroscopical appearances sometimes occurs in cases of malignant disease of the pleura. *Treatment* is unsatisfactory. In some cases repeated aspiration has been followed by recovery.

Hydrothorax.—Hydrothorax is the term used to describe a collection of non-inflammatory fluid (transudate) in the pleural cavity. It presents little surgical interest.

Pleurisy or **Pleuritis** is an inflammation of the pleura, almost invariably of bacterial origin, and in the vast majority of cases due to infection transmitted from the lung. It may result from hematogenous infection, but this is rare. It is always present in some degree in cases of penetrating wounds of the thorax. In the early stages of the inflammation a plastic exudate is formed, and if the process stops here, recovery with more or less extensive pleural adhesions may occur. Such cases form about one-fifth of the total cases of pleurisy (Fraley, 1907) and seldom come under surgical care. In about three-fifths of cases serous effusion occurs, and in about one-fifth more this effusion finally becomes purulent (pyo-thorax). If adhesions have formed early, or in a previous attack of pleurisy, the effusion may be *encapsulated;* its site then may be between the lung and the parietal pleura, between two lobes of the lung, or between the lung and diaphragm. In cases where there are no adhesions the fluid lies free in the pleural cavity and forces the lung upward and backward into the spinal gutter. The *symptoms* of pleurisy with effusion are detailed in every text-book on general medicine, and need not be recounted here. The diagnosis is confirmed by exploratory puncture with an aspirating syringe.

Treatment.—If the effusion is large and if no tendency to reabsorption is manifested, and particularly if the constitutional symptoms indicate suppuration, the fluid should be aspirated, as described at p. 147. The needle is passed close to the upper border of the rib, in the sixth, seventh, or eighth interspace, usually in the posterior axillary line or below the angle of the scapula. The site may be anesthetized by a hypodermic injection of cocain or by ethyl chloride spray. Seldom is it necessary to withdraw all the fluid, as the relief of tension secured by aspiration of a portion may hasten absorption of the remainder.

Pyothorax, or **Empyema Thoracis,** is a collection of pus within the pleural cavity. It is the suppurative stage of pleurisy with effusion; but in many cases suppuration occurs so rapidly that no anterior stage of serous effusion can be recognized. In no case is there any sharp line of distinction to be drawn between the two conditions, as the serous exudate (when one exists) gradually becomes sero-purulent, and this in turn assumes the usual character of pus. The pus may sink to the bottom of the pleural cavity as a heavy flocculent sediment, and the supernatant liquid may remain comparatively clear.

Pyothorax is most frequent in children, especially as a complication or result of croupous pneumonia, the infecting organism being the pneumococcus. Pneumonia if followed by empyema in from 5 to 10 per cent. of cases. In adults men are affected much oftener than women, and the empyema results less often from a frank pneumonia;

in many cases the staphylococcus or streptococcus is the infecting organism, and these may appear as secondary infections in cases originally caused by the pneumococcus, which is a short-lived organism.

Unless the pus is evacuated early, the parietal and visceral pleuræ become thickened, and a fixed cavity is produced, which will hinder expansion of the lung even when the contained fluid has been removed. Adhesions may also occur, within the pleura, and much oftener than in cases of serous effusion the empyema is *encapsulated* either on the surface of the lung, between its lobes, or between the lung and diaphragm. In rare cases the pus may evacuate itself through one of the bronchial tubes, or may perforate the diaphragm and form a subphrenic abscess. In children it is not unusual for a neglected empyema to break through an intercostal space and to point subcutaneously. In adults this is rare (Fig. 758). This condition is described as an *empyema necessitatis*. If the empyema ruptures externally, which is very unusual, a pleural fistula is left, and this scarcely ever heals spontaneously.

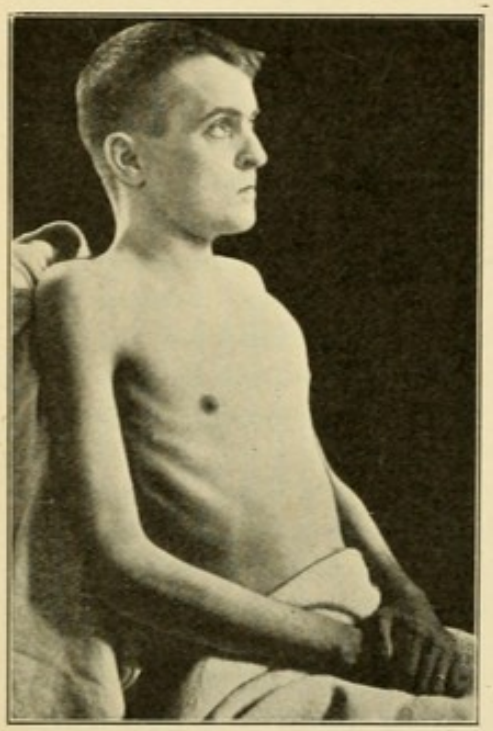

FIG. 758.—Empyema necessitatis, pointing beneath left pectoral muscles. Age thirty-two years; phthisis for two years; pneumonia seven months ago. "Abscess in thorax" for five weeks. (Dr. Harte's case.) Pennsylvania Hospital.

Symptoms and Diagnosis.—Usually the empyema is secondary to some thoracic condition (pneumonia, bronchitis, injury) for which the patient has been under treatment. *In children*, in whom the condition is most frequent, an empyema very frequently is mistaken for an unresolved pneumonia; but this condition is rare in children, and if an aspirating syringe is used, as it should be, for exploration in such cases, the diagnosis will be quickly cleared up. The physical signs in children may be very misleading, as the breath sounds may be quite clearly heard; this, with the persisting dulness on percussion, causes the resemblance to unresolved pneumonia. There may be Skodaic resonance above the dull area. But tactile fremitus is decreased, and the mere fact of a lingering pneumonia in a child should make one suspect an empyema. Nor should failure to draw pus at the first puncture make the physician conclude that it is absent, if the constitutional signs of sepsis persist. The pus may be too thick to run through the needle employed, or the collection may be encapsulated, and may not have been reached by the needle. In advanced cases, however, the diagnosis is easy; the temperature

continues elevated, and though remissions may occur daily or oftener, the normal is not reached. The apex beat of the heart may be displaced by large effusions; the interspaces of the affected side may bulge; dilated veins may cover this side of the thorax; and it may seem larger than the healthy side, though its respiratory excursions are less than normal or absent (Fig. 759). In *adults* the diagnosis of pleural effusion does not present the same difficulties, but the presence of pus rarely can be asserted positively unless paracentesis is done.

Treatment.—A child almost *in articulo mortis* may be saved by prompt evacuation of the pus, but the evacuation should not be too rapid in any case where there is marked dyspnea, cyanosis, etc., as abrupt change in the intrapleural pressure may cause sudden death. In any case of massive effusion (one extending as high as the spine of the scapula) it is well to withdraw half or three-fourths of the fluid by aspiration before proceeding to drain the chest.

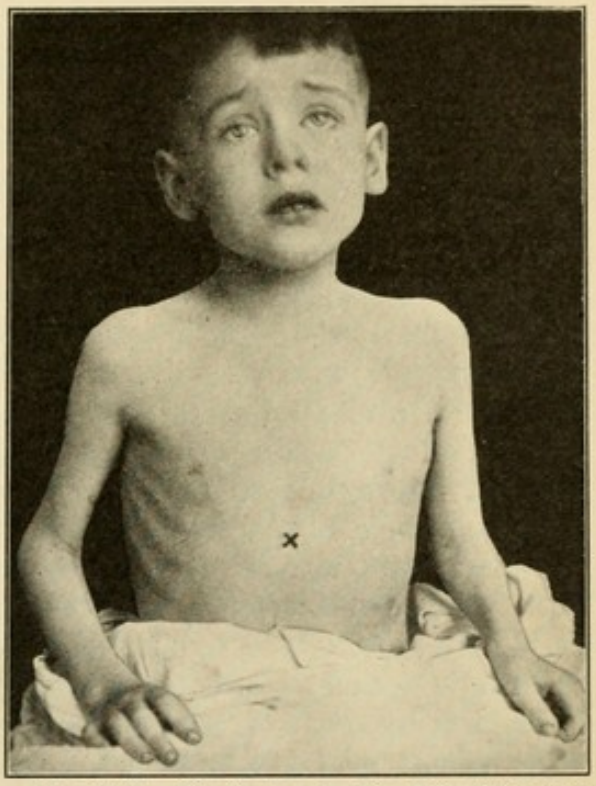

FIG. 759.—Pyothorax on the left, following pneumonia. Age seven years; duration two weeks. Note *x* on apex beat, displaced to right; dyspneic expression; bulging of left intercostal spaces, and well marked intercostal depressions on right. Children's Hospital.

Murphy's Method. — Murphy aspirates the pus and at once injects two or three ounces of a 2 per cent. solution of Liquor Formaldehydi (U. S. P.) in glycerin. This solution should have been made up at least twenty-four hours previously, so as to allow it to become thoroughly mixed and sterile. A week later the fluid is aspirated again, and it is found less purulent and more serous; another injection of the formalin-glycerin solution is given, and at the third or fourth aspiration the fluid is found to be pure serum. *This fluid is allowed to remain* in the pleural cavity, and is very gradually absorbed, as the lung expands and the chest wall sinks in. A year or more may elapse before all the fluid is absorbed, but as it is sterile the patient is in no way inconvenienced by its presence.

Few other surgeons have adopted Murphy's plan of treatment, most preferring still to open the pleural cavity and drain the abscess. Naturally the earlier Murphy's method is employed, the more successful it will be; if employed as soon as the first evidences of suppuration appear in a pleural effusion, one injection may suffice for a cure. But in cases of long standing, where the pleura is much thickened

and the lung is bound down by adhesions, I think thoracotomy, as described below, is to be preferred.

Thoracotomy or Pleurotomy.—This is the operation of opening the thoracic cavity for the purpose of draining an empyema; a portion of a rib is excised to ensure free drainage (König, 1878). The rib selected depends on the location of the pus, if this is encapsulated; if the pus is free in the pleural cavity the surgeon chooses the sixth rib in the anterior axillary line, the seventh in the mid-axillary line, or the eighth rib in the posterior axillary line. It is said that if a lower rib is chosen, the ascent of the diaphragm may interfere with drainage; and if too high a rib is selected it may be above the level of the pus, and the lung may be injured. T. T. Thomas (1913) advocates resection of the eleventh rib close to the angle to secure dependent drainage, and secure prompt closure of the sinus. In children some surgeons prefer an intercostal incision, without resection of a rib, but I believe even in these cases convalescence is more rapid if a larger opening is made.

The operation may be done under local anesthesia if necessary: after anesthetizing the skin and subcutaneous tissues as usual, the needle is inserted in the intercostal space at the dorsal extremity of the proposed incision, and is pushed in until it strikes the rib, its point is then manipulated until the lower border of the rib is found, whereupon it passes through the elastic resistance offered by the external intercostal muscle; it is then pushed still a little further in, and about 2 c.c. of a 1 per cent. solution of cocain are injected around the intercostal nerve. This procedure is repeated in the interspace next below; and after a few minutes the intervening rib may be painlessly resected. In many cases, especially in children, a general anesthetic (ether) is to be preferred. Dyspnea should be relieved by aspirating most of the pus before beginning the operation. The patient is not to be turned over on the healthy side, as this may cause arrest of respiration or cardiac action. By bringing the body well over the side of the table the operation may be done without much difficulty, as the patient lies supine. Of late I have always followed Elsberg's suggestion to have the patient lie prone; respiration is perfectly easy in this position and the operative pneumothorax causes less pulmonary collapse than in the usual position.

An incision of about three inches is made along the rib selected, and the knife is carried directly down to the bone. Bleeding-points are clamped. The periosteum is incised and is stripped from the outer surface of the rib throughout the length of the incision, by means of a periosteal elevator. On the upper surface of the rib strip the periosteum from behind forward, and on the inferior surface strip it from before backward. Then the periosteum is also stripped from the deep (pleural) surface of the rib, keeping the instrument close to the bone. By this means the intercostal vessels, which are separated from the rib by its periosteum, are pushed aside with the soft parts. When the rib has been thus denuded throughout its entire circumfer-

ence for a distance of about two inches, a bone-cutting forceps or a special costotome is used to divide the rib at one end of the incision. The portion of rib to be excised is then grasped in forceps, and the rib is divided at the other end of the incision (Fig. 760), and the intervening portion is removed. This should be at least an inch and a half long. The parietal pleura, still covered by the deep layer of the periosteum, then presents in the wound; these structures should be divided in the axis of the rib for an inch or more. In some cases of long standing empyema the parietal pleura may be half an inch thick. There is little danger of wounding the lung, but it is well to take the same precautions as in opening the peritoneum (p. 821). The intercostal vessels often are thrombosed, and may not bleed if wounded; if the periosteum has been stripped carefully from the rib before this is excised, and if the deep incision is made nearer the upper than the lower border of the rib, these vessels will not be wounded. If they are wounded, bleeding from them is controlled more easily by a mass suture than by a ligature.

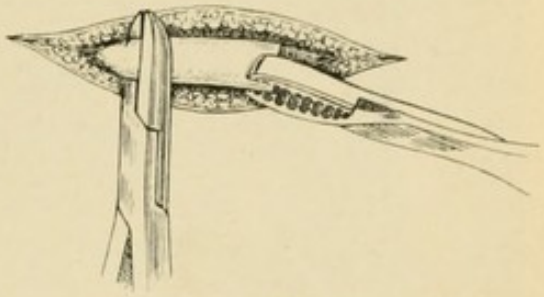

FIG. 760.—Excision of a rib for empyema.

As soon as the pleura is opened the anesthetic may be stopped. Usually only a few minutes are required for the whole operation. The pus should be allowed to escape slowly. Violent paroxysms of coughing may occur. The surgeon should introduce his finger from time to time, to assist the discharge of masses of lymph. If the empyema is of long duration, it is well to break up adhesions between the chest wall and lung, so as to facilitate its subsequent expansion. In such old cases the infection is not very virulent, and septic absorption is not to be feared. In acute cases, where the infection is more active, the lung is not firmly bound down, and its release, therefore, is not necessary.

A large rubber tube (at least half an inch in diameter) is then passed just within the parietal pleura, and is fixed by a stitch to the margin of the skin wound. If not thus fixed it may fall into the pleural cavity or be pulled out of the wound accidentally. An extremely abundant dressing of gauze and absorbent cotton is applied, and the patient is returned to bed.

After-treatment.—The dressing may require changing several times daily at first. Masses of lymph blocking the tube should be removed with forceps. No irrigation of the cavity should be employed. In some instances this has caused death. As soon as agreeable the patient should be propped up in bed, and measures must be adopted to promote expansion of the lung. Every time the clock strikes the hour the patient should be instructed to take a half dozen or more deep respirations, and several times daily he should blow water from

one Wolff's bottle to another (Fig. 761). Children may exercise their lungs by blowing up toy balloons, sounding trumpets, etc. Patients should be got out of bed as soon as possible.



FIG. 761.—Blowing through Wolff's bottles to expand lung after thoracotomy for empyema. Episcopal Hospital.

Convalescence often is tedious, and may be interrupted by pneumonic or pleuritic attacks, with evidences of septic absorption. This sometimes is due to interference with drainage of the wound. In favorable cases the tube does not require to be replaced when once removed at the expiration of ten days or two weeks. As judged by the results of operation, the mortality from empyema is about 20 to 25 per cent.; but as practically all patients die unless operated on, and as the death rate from the primary pneumonia is very high, the operation must be regarded as a distinct life-saving measure.

Bilateral Empyema.—Bilateral empyema is most frequent in children. Fabrikant (1911) has collected 118 cases, with a mortality of 37 per cent. The second side should be operated on a few days after the first.

Pleural Fistula.—Pleural fistula may persist for years after the evacuation of an empyema, unless properly treated, and may lead to death from exhaustion, amyloid degeneration of the viscera, secondary tuberculosis, or some intercurrent disease. If the empyema has been recognized early, and has been evacuated promptly, the resulting sinus closes in a few months or less. It is in cases of chronic empyema, where the lung is bound down by dense adhesions, that a large thoracic cavity remains. From this a pint or more of pus may be discharged daily; and when saprophytic infection is added, the discharge is exceedingly putrid, and the patient is loathsome to himself and to all around him. The thorax becomes deformed, curvature of the

spine develops (Fig. 762), and the patient is a helpless cripple. Clubbing of the fingers is frequent (Fig. 494), and other joint changes may add to his misery (pulmonary osteoarthropathy (p. 476).

Treatment.—Treatment depends upon the extent and duration of the sinus. A small and recent sinus, which does not discharge very much pus, often may be made to heal by bismuth paste injections (Ochsner, 1909), as used for tuberculous sinuses (p. 484). This method, with skiagraphy, is valuable in determining the size of the cavity within the thorax.

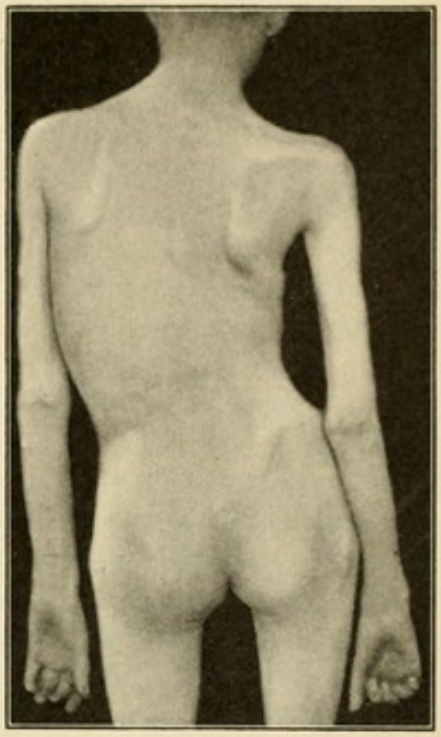

Fig. 762.—Scoliosis, nine months after operation for empyema; fistula still discharges eight ounces of pus daily. Episcopal Hospital.

When there is much purulent discharge it is desirable to check this before instituting any formal operation; and this is best accomplished by irrigation which may be employed with safety in these chronic cases. Potassium permanganate solution is very satisfactory. The cavity should be cleansed at least once daily in this manner.

Sometimes the sinus is kept from healing by the presence of a drainage tube which has been lost inside the wound. This may be detected by a skiagraph, and its removal constitutes the first step in treatment.

If drainage is not free, the sinus should be enlarged, under an anesthetic, and the surgeon should break up with his finger the adhesions between the lung and parietal pleura; and if the cavity is large, he should resect another rib at its most dependent portion, and drain from the lower opening.

Information derived from use of the *x*-ray may be an aid in the prognosis: if the collapsed lung is permeable to air the *x*-ray will show decreased density during forced expiration; and if the lung shows a tendency to expand during coughing, it is probable no further operation will be required (Destot and Violet, 1904). For cases in which the lung is permeable, but where no tendency to expansion is apparent, decortication or discission, as described below, should be done. If the lung neither shows a tendency to expand nor is permeable to air, the only way to efface the pleural cavity is to resect the bony thoracic cage overlying it, and thus to allow the soft parts to fall in against the lung (Estlander, Schede).

Decortication of the Lung (Fowler, Delorme, 1893).—This consists in opening the old cavity of the empyema by an intercostal incision or the resection of a rib, obtaining sufficient exposure to enable the

surgeon to explore the entire interior of the empyema cavity. The most important step is to free the lung thoroughly from its attachments to the parietal pleura. This is best done by making an incision through the latter close to the outer or posterior margin of the lung along the spinal gutter. The fingers are then inserted between the posterior thoracic wall and the lung, and the latter is gradually freed. Its natural elasticity and tendency to expansion aid in this manœuvre. When the lung is thus freed posteriorly it may be possible to peel the remains of the abscess wall off its surface. The thoracic wound is then closed with drainage, and the case is treated as one of recent empyema. The results are very satisfactory, the lung expanding and the abscess cavity becoming obliterated.

Discission of the Pleura (Ransohoff, 1903) is adopted in cases where decortication proves difficult or impossible. If the dense membrane overlying and compressing the lung is scored by the knife, down to the lung tissue proper, the incision will gape widely; and if a number of such incisions are made in parallel and criss-cross lines, each incision will gape so widely that the lung will expand to a very surprising degree.

Thoracoplasty, Estlander's Operation (1877).—This consists in the resection of several ribs (three to five), for a considerable extent, directly over the old empyema cavity, in order to allow the soft parts of the thoracic wall to fall in against the collapsed and non-expansile lung. The cavity is thus wholly or in part obliterated. In very large cavities the operation may not effect a cure, but the result is "the difference between having a large abscess discharging a great quantity of pus, and a small sinus which weeps a little thin fluid." (J. Ashhurst, Jr., 1894.) The operation may well be combined with free separation of the lung from its parietal adhesions, especially posteriorly—a modified form of decortication. *Schede's Operation* (1890) consists in resection of nearly the entire bony wall of the side of the thorax affected. This is exposed by reflecting an immense flap extending from the second costal cartilage anteriorly, to the costal margin below, and to the spine of the scapula posteriorly. After removal of the ribs, this flap is applied against the exposed lung. This operation has a high mortality and is rarely done at the present day, when earlier and more thorough treatment of the acute empyema enables the patients to recover without such immense cavities. In no cases should it be attempted until decortication and Estlander's operation have failed.

Tuberculosis of the Pleura, usually secondary to that of the lung or bronchial lymph nodes, presents little surgical interest except in cases with effusion. Most painless, slowly developed, and apparently causeless cases of pleural effusion in adults are tuberculous. The condition is recognized by the physical signs of pleural effusion, and the nature of the fluid may be suspected from the patient's history. Diagnostic puncture reveals straw-colored or slightly turbid fluid, rarely blood-tinged. Tubercle bacilli seldom can be

discovered, but a high lymphocyte count may suggest the tuberculous nature of the fluid, and inoculation experiments usually will confirm the diagnosis. The condition is to be regarded as one of cold abscess. Secondary infection, from the perforation of a tuberculous cavity in the lung into the pleura, is not very uncommon, forming a pyo-pneumothorax. Secondary infection may also occur through the blood or from the unruptured lung.

Treatment.—Local treatment is entirely secondary in importance to the general treatment of the tuberculous patient. Only if the effusion is massive, and causes dyspnea, should any of the fluid be withdrawn by aspiration. If much fluid is withdrawn damage may be done to the diseased lung, or a recently closed communication with the lung may be reopened. After some of the fluid is withdrawn the remainder may be gradually absorbed. If on aspiration the fluid is found to be verging on suppuration (from secondary infection), an ounce or two of formalin-glycerin solution (2 per cent.), should be injected. Under no circumstances should the pleura be opened by incision, or drainage be established: such a course surely invites secondary infection, with an external pyo-pneumothorax, and death usually occurs in a few weeks. *Secondary tuberculosis in an open empyema cavity* may occur, but is not so quickly fatal as a primary tuberculous pleurisy secondarily infected. It should be treated as other cases of open pneumothorax following empyema, with special attention to the patient's general health.

Tuberculosis of the Lungs.—Surgery of this condition may be said to be still in an experimental stage, and has been applied mostly to advanced stages of the disease otherwise incurable.

In 1898 Murphy introduced to surgical notice in this country, a plan of treatment, previously advocated (1882) by Forlanini, consisting in *injections of nitrogen gas* into the pleural cavity, to cause collapse of the lung and thus to induce rest and promote healing of the pulmonary lesions. Nitrogen is said to be more slowly absorbed than any other gaseous substance. *Pneumonotomy*, to drain cavities in the lung, has been done on numerous occasions; the first formal operation is the historic one of Baglivi in 1643. It is conceivable that with the present improvements in the technique of pulmonary surgery such operation may find a legitimate field in the future for the rare cases in which an apical cavity is not draining well, and in which no other discoverable tuberculous lesions exist. Partial *pneumonectomy* was done by Tuffier in 1891; he removed the apex of one lung, containing an early focus of tuberculosis. The patient recovered and was in good health four years later. Medical and hygienic treatment will cure such patients, and no operation should be done. *Estlander's Operation* was suggested in 1891 by O. H. Allis as a means by which collapse of a pulmonary cavity might be secured, with improved chance of its healing; and this operation has been employed by Quincke and others. Friedrich (1909) has employed *Schede's method* for the purpose of causing collapse of a tuberculous lung,

the other lung being healthy, or exhibiting no evidence of active disease. Freeman (1909) resected the upper ribs, and after the wound had healed adjusted a hernial truss over the apex of the lung to cause obliteration of a tuberculous cavity. Freund's operation of chondrectomy, as in cases of pulmonary emphysema, has also been employed in cases of pulmonary tuberculosis, to overcome the thoracic rigidity which prevents aëration of the lung. Freund in 1910 referred to 8 such operations in patients with pulmonary tuberculosis.

Pulmonary Emphysema.—W. A. Freund, having recognized since 1858 that some of these cases are caused by fixation of the chest wall due to ossification of the chondral cartilages, proposed in 1906, the operation of *chondrectomy* for their treatment. The costal cartilages of the second, third, and fourth ribs on both sides of the thorax are excised with their perichondrium, so as to prevent their regeneration. The operation appears to have been employed in nearly fifty cases, with a fair measure of success.

Abscess and Gangrene of the Lung, which are not very frequent, may be regarded as different stages of the same affection. Most cases occur in adults, and follow pneumonia; some cases follow a pulmonary infarct from a septic focus elsewhere in the body; and some follow the lodgement of foreign bodies. The patients usually are in a very poor physical condition, with degenerations of the viscera, before the pulmonary condition develops.

Symptoms.—Usually these develop rather suddenly as a complication of the preëxisting disease. There is profound sepsis. Physical examination reveals a localized consolidation in the lung, which may give the signs of cavity after expectoration of its contained sputum. The sputum from an abscess is great in quantity, and consists of thick yellow pus, not malodorous at first. The older the abscess the more fetid does the pus become, owing to saprophytic infection. In cases of gangrene, which usually is a sequel to abscess formation, this fetid character of the pus is very pronounced. If there is elastic tissue in the sputum it is not probable that gangrene is present, since saprophytic bacteria soon destroy it. Pleurisy, with adhesions, frequently occurs and may prevent perforation of the abscess into the pleural cavity with development of a putrid empyema. The use of the *x*-ray is of much value in localizing the abscess. If exploratory puncture is done, it should be followed at once by operation.

Treatment.—Operation should not be delayed if gangrene is present. The patient gets no stronger by waiting even for one day. Without operation 80 per cent. of cases of gangrene of the lung die. In Körte's 28 operations for abscess or gangrene, the mortality was 28.5 per cent. (1909). In Lenhartz's 111 operations for gangrene the mortality varied from 27 to 38 per cent. (1908). If the abscess drains well through a bronchus, operation may be postponed. Whenever possible the operation should be done under anesthesia by intratracheal insufflation, though Körte administered the anesthetic in the usual way. The ribs overlying the site of the abscess

(which should be determined beforehand) are resected subperiosteally, for a distance of three or four inches. If the lung is not adherent to the pleura it should be sutured to it by interrupted mattress sutures of chromic catgut, applied in a circle around the supposed site of the abscess. Sometimes the site of the abscess can be detected by palpation, being denser than the surrounding lung tissue. If the patient is not in very serious condition the second stage of the operation is postponed for a couple of days. If the lung is already adherent to the parietal pleura, or if the patient's condition is precarious, the surgeon proceeds at once to open the lung. This is done by Hilton's method, first thrusting a grooved director into the lung, and when pus is found dilating the tract with dressing forceps. Some surgeons use the actual cautery for opening the abscess. Any loose necrotic masses of lung tissue should be removed, but if even lightly adherent they should not be disturbed The abscess is drained by a tube.

Bronchiectasis.—For this condition surgeons do an operation similar to that for abscess of the lung; but though the condition is not curable by medical means, the cure by surgery may be worse than the disease. The persistence of the bronchiectatic cavity may not materially shorten the patient's life, and the risk of operation is very great. In Körte's 17 patients the mortality of the operation was 73 per cent.

Tumors of the Pleura and Lung may be primary, or secondary to growths elsewhere. Primary growths are rare and very difficult to diagnose. Most of them are malignant in nature. Endothelioma and sarcoma occur in both lung and pleura, carcinoma only in the lung. Tumors of the pleura invade the lung, and those of the lung soon attack the pleura. Of the secondary growths carcinoma is more frequent than sarcoma.

Symptoms.—The symptoms are not clearly defined. Some cases of primary carcinoma of the lung are mistaken for tuberculosis. There is dulness on percussion, and the breath sounds are absent or may be heard distantly. Exploratory puncture may reveal a bloody pleural effusion, or there may be a dry tap. Blood in a pleural effusion signifies either tuberculosis or malignant disease. There is no fever and no leukocytosis. The increase in the physical signs is rapid. Cachexia appears early and is pronounced.

Treatment.—There is little to do. If the pleura fills with fluid, and this causes dyspnea, thoracentesis may be done. A few cases of excision of portions of the lung have been recorded, the patients surviving the operation (Lenhartz).

SURGERY OF THE DIAPHRAGM.

Stab Wounds of the Diaphragm.—In the majority of cases the stab wound is received in the thorax, by a downward thrust, and a complicating wound of the pleura exists. This is almost always the

case in stab wounds inflicted by Slavs, but Italians frequently stab their antagonists by an upward thrust, the stiletto entering the abdomen first. The left side is more often injured than the right. There are no characteristic *symptoms*, and the diagnosis can be made with certainty only by exploratory operation, except in the rather unusual cases in which the omentum or one of the abdominal viscera protrudes through the thoracic wound. It is the frequency of injury to the abdominal contents which renders these wounds so serious. In 55 out of 121 consecutive stab wounds of the thorax, recorded by Lawrow (1911), the diaphragm and abdominal organs were involved. The wound usually is in one of the lower intercostal spaces, especially between the seventh and tenth; but stab wounds as high as the second interspace have caused injury to the diaphragm. The liver is the most frequently injured of the abdominal viscera, then the stomach or spleen (Magula, 1910).

Treatment.—Treatment is by immediate exploratory operation in every case in which a lesion of the diaphragm is suspected. The mortality without operation is nearly 90 per cent., and those patients who have survived the immediate injury have perished eventually from strangulation of a diaphragmatic hernia or other lesion which a prompt operation could have prevented. *Thoracotomy* is the operation of choice, because by laparotomy it is very difficult if not impossible (1) to reduce the herniated organs, owing to the negative pressure within the thorax, (2) to repair the wound of the diaphragm, (3) to suture wounds of the cardia or fundus of the stomach, or (4) to repair damage to the lung. The technique of the operation is much the same as that for diaphragmatic hernia (p. 752). If the stab wound is abdominal, and *laparotomy* is employed as the primary operation, secondary thoracotomy may be necessary before the herniated organs can be replaced or the diaphragm sutured; such an operation is described as *thoraco-laparotomy*. By the term *combined operation* is understood one in which the thoracic and abdominal cavities are opened by the same incision: this is best made in the eighth interspace, dividing the ninth costal cartilage and the diaphragm as far as necessary to secure free exposure.

If the case is not complicated by injury to the viscera, the mortality with prompt operation is less than 20 per cent.; in complicated cases it is about 65 per cent. (Magula).

Gunshot Wounds of the Diaphragm, except when complicated by injury to the viscera, are so rare as to have little surgical interest, unless strangulation of a hernia occurs subsequently through the opening in the diaphragm. In most cases injuries of the thoracic and abdominal organs exist, and the surgeon has to employ either thoraco-laparotomy or the combined operation.

Rupture.—Rupture of the diaphragm, a subcutaneous injury, is very rare. As extensive lesions of the abdominal organs are frequent, Deaver and Ashhurst advise laparotomy as the primary operation, so that hemorrhage and intestinal leakage may be controlled. If

it is difficult to reduce the organs which have been herniated into the thorax, thoracotomy should be done also; this usually is required to facilitate repair of the diaphragm.

Diaphragmatic Hernia may be due either to congenital or to traumatic defect in the diaphragm. Owing to the negative pressure within the thorax, it is always the abdominal organs which prolapse through the opening. The most frequently herniated viscera are the stomach, colon, omentum, small intestine, liver, duodenum, and kidney—in the order named. Though a congenital defect may be present at birth, the hernia may not appear until adult life, and may produce no noteworthy symptoms until strangulation occurs. In over 90 per cent. of cases the hernia is on the left side, because the liver acts as a protection on the right. Most of the cases occur in the fetus, or in infants stillborn or dying soon after birth. In adult life sudden death from cardiac failure is a frequent termination, and the possibility of a diaphragmatic hernia always should be remembered in considering the causes of sudden death.

Symptoms.—Subjective symptoms often are lacking, the malformation being found unexpectedly at autopsy. In the newborn, cyanosis and dyspnea are prominent, the left thorax does not expand properly, there is dextrocardia, and death usually results in a few hours. The adult patient may have suffered from mild indigestion, with distress after meals; but no alarming symptoms may arise until sudden cardiac failure or perhaps death occurs from acute overdistention of the herniated stomach. Strangulation is a frequent termination, being due to any sudden strain which forces a larger portion of the abdominal contents through the diaphragmatic opening.

The *physical signs* of diaphragmatic hernia are much more precise in theory than in practice. Diagnosis of the condition in life, except by the aid of the *x*-ray, is exceptional. The lower chest on the affected side is tympanitic, the breath sounds are very feeble and distant, vocal fremitus is lost, expansion is decreased, and the heart is dislocated away from the affected side. The same signs exist in pneumothorax; but in diaphragmatic hernia the diaphragm does not descend on deep inspiration, and causes which may produce pneumothorax nearly always may be absolutely excluded. Moreover, distention of the stomach with liquid will change the physical signs in a case of diaphragmatic hernia; but in pneumothorax the thoracic tympany and other signs will not be affected. Aspiration is to be condemned as a method of diagnosis, owing to the great danger of septic pleuritis or peritonitis. A history of sudden onset following severe strain (sometimes childbirth) or crushing injury, or occurring some years after a stab or gunshot wound of the thorax, is highly characteristic of diaphragmatic hernia. Finally the relation of the stomach to the diaphragm may be determined by the use of skiagraphy after filling the stomach with bismuth emulsion or introducing a stomach tube filled with mercury. From the rare or congenital condition known as *eventration of the diaphragm*, which is associated with

hypoplasia of the left lung, diaphragmatic hernia sometimes may be distinguished by the history of the case, and by recognizing through skiagraphy that the diaphargm in the former condition remains still above the abdominal organs no matter how far upward into the thoracic cavity these may protrude.

Treatment.—Immediate operation is required for recent diaphragmatic hernia of sudden development, because the danger of strangulation is very great. Unfortunately most such cases are first seen by the surgeon after strangulation has developed, and the patient is too ill to justify the prolonged examination and numerous tests recommended in seeking to reach a correct diagnosis. But if the surgeon can ascertain that the patient has had a severe injury (crush, or penetrating wound of the lower thorax or upper abdomen) even many years previously, the diagnosis and indications for treatment may become very apparent. If the true condition is recognized *thoracotomy* (Permann and Postempski, 1889) should be done. In many cases incision in the eighth intercostal space, without resection of ribs, has given adequate exposure. After packing off the lung with fine silk or handkerchief gauze tampons, any rupture or perforation of the abdominal viscera should be repaired, and they should be replaced within the abdominal cavity. Then the opening in the diaphragm should be sutured; when this is not possible the omentum may be stitched to its margins, or as a last resort the opening may be tamponed. If the operation has been done under differential pressure or with intratracheal insufflation anesthesia, the pleura may be closed without drainage. In other cases a tube should be left in for a few days.

If no diagnosis other than intestinal obstruction has been made, laparotomy will be the operation employed; but if reduction of the hernia from below proves impossible, no hesitation should be felt in proceeding to thoracotomy.

CHAPTER XXI.

HERNIA.

A **hernia** is a protrusion of a viscus through an abnormal opening in the walls of the cavity within which it is naturally contained. This is a general definition, and may be applied to a hernia of a muscle through a rupture in its sheath, to a hernia of the brain through an artificial opening in the skull, or to a hernia of an abdominal viscus through an abnormal opening in the abdominal walls. By long usage, however, the term hernia, when standing by itself, is applied only to protrusions of the abdominal viscera. This protrusion usually occurs through an aperture of the abdominal wall which transmits bloodvessels or nerves, through a congenital defect, or through one acquired as the result of operation or disease. If this protrusion occurs through a *normal* opening it is not called a hernia, but a prolapse; as a prolapse of the rectum through the anus, or of the uterus through the vagina. The term hernia also implies that the protruding structures are still covered by skin: thus when omentum or other structure protrudes through an incised wound of the abdomen, it is not called a hernia but a prolapse.

In the great majority of cases of abdominal hernia, the viscus which protrudes carries before it a pouch of the parietal peritoneum, which is called the *sac* of the hernia; and since this sac may remain as a protrusion even when it contains none of the abdominal viscera, a hernia has been defined as "a protrusion of peritoneum liable to contain, containing at times, or permanently containing any viscus or part of a viscus from the abdominal cavity." (Da Costa.) But as the abdominal organs sometimes protrude through a part of the abdominal wall which has no parietal peritoneum (*e. g.*, a hernia of the bladder), or slide down behind the parietal peritoneum, instead of carrying it before them as a protrusion (*e. g.*, sliding hernia of the colon), I think it is better to cling to the old definition. If the sac protrudes and is empty that patient has either a *reduced* or a *potential* hernia, according to whether or not the sac has before been the seat of a hernia. A sac may exist for many years without a hernia developing in it (p. 754).

Nomenclature.—A hernia receives its name (1) from the *region in which it appears*, as epigastric, lumbar, umbilical, inguinal, etc.; (2) from its *contents*, as a hernia of intestine (enterocele), of omentum (epiplocele), of bladder (cystocele), of rectum (rectocele), etc.; (3) from its *condition*, as reducible, irreducible, inflamed, strangulated, etc.; and (4) from its *mode of development*, whether of sudden develop-

ment or slowly acquired. Various other terms, used in describing hernia, will be explained as they are encountered.

Causes.—The *predisposing causes* of a hernia may be either general or local.

General Predisposing Causes.—(1) *Age.* Most herniæ appear in infantile or early adult life; the longer one lives the less apt he is to have a hernia. But the number of old people alive is so much less than that of young adults and children, that among the aged hernia is relatively more common. (2) *Sex.* Men and boys are much oftener afflicted with hernia than women. There are two main reasons for this: first because of the weakness of the inguinal region in the male sex from the descent through it of the testicle; and, second, from the more active life men lead, and the greater frequency with which they are subjected to great abdominal strains. (3) A distinct *hereditary tendency* toward hernia is recognized, probably from the persistence of anatomical defects at points of greatest strain.

Local Predisposing Causes.—(1) *Weakness of the abdominal wall.* After an abdominal operation, a hernia may develop in the scar (incisional hernia, p. 772); or as a consequence of injury to the motor nerves of the inguinal region from an operation elsewhere, an inguinal hernia subsequently may develop (Figs. 774, 788, and 792). Sometimes a hernia appears first after a debilitating illness or pregnancy. (2) *Increased strain upon the parietes* by the abdominal contents. The gradual deposition of fat in the omentum and mesentery increases the intra-abdominal tension, causes stretching of the parietal peritoneum, opens up the hernial orifices, and thus predisposes to the development of a hernia. The same train of events may occur in cases of ascites, of intra-abdominal tumors, of pregnancy, etc. (3) A hernia may be the *effect of repeated efforts*, in coughing, in straining at stool, in urinating (when there is some urinary obstruction) (Fig. 798). (4) The existence of a congenital sac predisposes the patient to the development of a hernia, though observations in the dissecting room show that many patients with preformed sacs pass through life without any evidence of a hernia.

Structures Composing a Hernia.—In a typical case a hernia is composed of a pouch of parietal peritoneum, called the *sac;* of the *contents* of the sac; and of its *coverings*, which are the structures of the abdominal wall, muscles, fascia, and skin (Fig. 763).

Sac.—The sac, as noted already, sometimes is wholly or in part deficient. Typically it is composed of a *neck* (that part which communicates with the peritoneal cavity), and a *body* (that part which surrounds the protruding viscera). The apex of the sac is its *fundus*. The sac may be *congenital* or *acquired*. I believe, with Russell and Murray, that the sac is congenital in a far larger proportion of cases than is commonly thought. This preformed sac renders the patient the potential possessor of a hernia; but until the hernia develops ("comes down" is the colloquial expression), the presence of the sac in most cases cannot be determined (p. 1058, congenital hydrocele).

The *congenital sac* is found oftenest in inguinal hernia, but occurs frequently also in the femoral form, and sometimes in umbilical hernia. It may be very large, but usually is quite small until distended by the protruding abdominal contents. The *acquired sac* usually is slowly developed from gradual stretching of the parietal peritoneum: at first the neck of the acquired sac is its widest part, but as the sac increases in size it becomes more or less pear-shaped, the neck being relatively narrow; then the sac continues to increase in size by the pressure of the contained structures, but, as a rule, the neck does not enlarge at the same rate but remains relatively small. The wall of the sac, at first like the neighboring parietal peritoneum may become much thickened from inflammation, and its neck may undergo cicatricial contraction. The sac usually becomes densely adherent to the surrounding parts, especially at its fundus; and though the contents of the sac may be returned to the abdomen, as long as the empty sac remains recurrence of the hernia is to be expected. In hernia of long duration the neck of the sac may be shifted, by the pull of its contents, downward and toward the median line of the body.

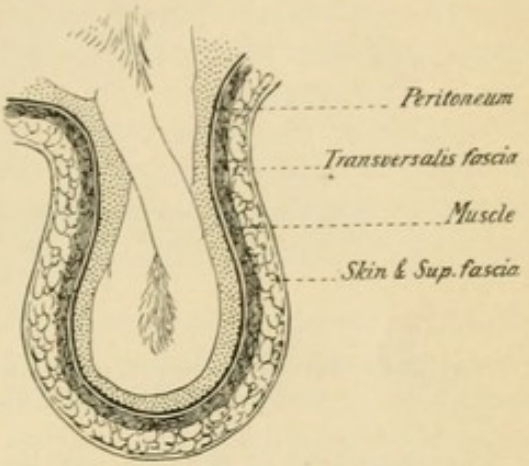

FIG. 763.—Diagram to show a hernial sac, its contents and coverings.

The **Contents of the Sac** may be almost any of the abdominal viscera, but the most frequently herniated structures are the *intestine* (enterocele), and the *omentum* (epiplocele). In infancy and young childhood the omentum seldom is found in a hernia, owing to its undeveloped state; but in adults, particularly those who are obese, it is the most frequently found of all structures. The lower ileum is the portion of the bowel most often found in a hernia, because it has the longest mesentery and lies nearest the inguinal and femoral openings. Hernia of the large bowel is infrequent, owing to its relatively short mesenteric attachments. The cecum may be drawn into a hernia by a coil of ileum already there; but the sigmoid is sufficiently mobile to find its own way into a hernia. A single coil or several coils of intestine may be found in the sac, or the hernia may be formed only by a portion of the wall of the intestine; this latter condition (Fig. 764) is described as *Richter's hernia* (1778). A hernia of Meckel's diverticulum (Fig. 765) is known as *Littré's hernia* (1700). When the herniai contents remain long in the sac, they usually become adherent to its walls and often are matted together. In this way a hernia may become irreducible. When both omentum and intestine are in the sac (entero-epiplocele), it usually is the omentum which enters it first. The omentum generally lies in

front of, or even completely surrounds the bowel, and the bowel may be caught in apertures or depressions in the mass of omentum and thus may become strangulated. Unless the hernia is inflamed or strangulated there is little or no serum within the sac.

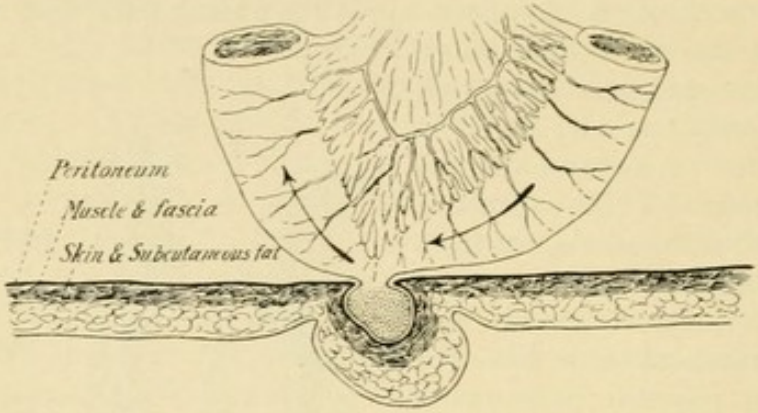

FIG. 764.—Partial enterocele, or Richter's hernia. Drawing made from a case of strangulated hernia in the Episcopal Hospital.

The **Coverings of the sac** will be described in connection with each particular form of hernia.

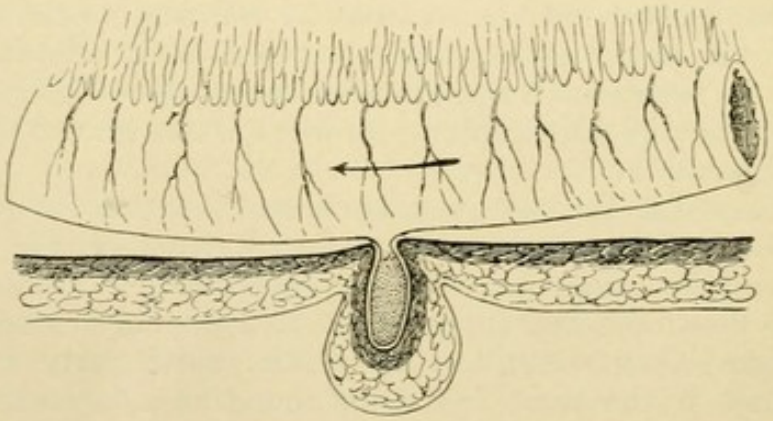

FIG. 765.—Littré's hernia—a hernia of one of the intestinal diverticula (Meckel's diverticulum).

Reducible Hernia.—This is one in which the contents can be replaced within the abdominal cavity. It is the most frequent variety, since almost every hernia is reducible when it first appears, and becomes irreducible only after the lapse of years. For months or years before the hernia appears the patient may have felt a weakness in the region where the protrusion afterward develops. If the hernia develops gradually, there may be at first the merest bulging of the parts during straining efforts; later a small rounded tumor may be seen. This can be reduced easily by the pressure of a finger, and usually disappears spontaneously when the patient lies down. In cases of hernia present at birth, or of sudden though later development, or of long duration before seen by the surgeon, the protrusion often is of considerable

size. In time the greater part of the abdominal contents may descend into the sac.

The outline of a hernia is more or less rounded or oval, usually being less broad at the neck of the sac than elsewhere. The hernia increases in size when the patient stands up, coughs, or strains; it disappears either spontaneously or by gentle pressure when he lies down; and in most cases it reappears again if he once more stands up and coughs. When he coughs there usually is a distinct impulse transmitted to the hernia, and this often can be seen and almost always can be felt.

Enterocele.—If the sac contains intestine only, the hernia is smooth, feels elastic, often gurgles on palpation, and usually is resonant on percussion. The impulse is well marked. Reduction usually is accompanied by a distinct gurgle and by a characteristic sensation well described as a "flop."

Epiplocele.—An omental hernia feels denser, more fibrous or doughy to the touch than an intestinal hernia; it is irregular in outline; gives little or no impulse on coughing; and is dull on percussion. Reduction is not accompanied by any gurgle, nor by the "flop" so characteristic of bowel slipping back into the abdomen.

In the *entero-epiplocele* the symptoms of the two separate forms are combined.

It seldom is possible to ascertain what portion of the gut forms the hernia. In umbilical hernia the transverse colon is most often found; and in inguinal and femoral hernia, the ileum. The cecum is much more frequent in right-sided inguinal hernia than elsewhere, but is not very unusual in a left inguinal hernia. In femoral hernia the omentum and small bowel are most often found.

Treatment.—It is necessary for a hernia to be cured, whenever possible, because of the grave danger which may accrue to the patient from the occurrence of strangulation. A cure can be obtained only by an operation, by which the sac of the hernia is removed, its neck closed, and the structures of the abdominal wall repaired in such a manner as to prevent recurrence of a hernia. This is the best treatment in every case in which an operation is not contraindicated; but the operation requires skill for its performance, and sometimes is very difficult. It should not be attempted by the occasional operator. Even if the best treatment (that which results in cure) is contraindicated or is refused, it is still necessary that the hernia be treated. An untreated hernia tends constantly to grow larger and to become irreducible. It is possible to keep a hernia reduced by the use of apparatus (known as a truss) which exerts pressure over the neck of the empty sac, and prevents descent of the hernial contents.[1] It used to be taught that in some cases the prolonged use of a truss might cause obliteration of the hernial orifice by exciting adhesions of the

[1] I mention only to condemn the attempts of some charlatans to cause closure of the neck of the hernial sac by injecting paraffin in the surrounding tissues (Fig. 766).

opposing layers of peritoneum. This occasionally occurs in infants, but in the vast majority of cases, though a truss may keep the hernia reduced so long as the truss is in place, no obliteration in the neck of the sac is caused, and its contents tend to return at once when the truss is removed. If the neck of the sac becomes constricted from prolonged use of a truss (and this is not unusual), the hernia will be more apt to become strangulated, if it comes down, than if no truss had been worn. If no treatment at all is undertaken, the hernia constantly increases in size, is very apt to become irreducible, and the patient must endure the discomforts of this condition as well as run the added risk of strangulation which an irreducible hernia entails.

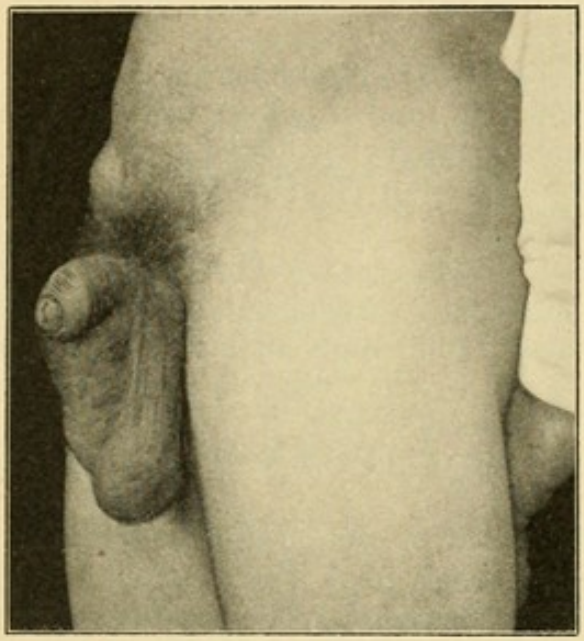

FIG. 766.—Masses of paraffin in inguinal canal and scrotum, injected on two occasions, several months ago, in effort to cure a hernia of twelve years' duration. Patient aged thirty-eight years. Hernia now in scrotum. Episcopal Hospital.

The *contraindications to operation* in the case of a reducible hernia are only those which contraindicate any operation, however trivial (p. 760). There are no local conditions which contraindicate operation in cases of reducible hernia. Even immense size of the hernial orifice, with excessively weak abdominal walls, is a condition that may be overcome by proper methods (p. 774).

A **truss** is an apparatus designed to support a hernia. It should keep a reducible hernia reduced. It is applied around the body, and has a pad which makes pressure over the hernial orifice. Most trusses are for inguinal or femoral hernia, and are applied around the pelvis between the iliac crests and the trochanters of the femora (Fig. 792). A truss may be made of steel covered with leather or hard rubber, causing elastic pressure over the hernial orifice; or it may be made entirely of leather, and depend on the tension with which it is buckled in place to retain the hernia. Trusses are also used for umbilical herniæ; and the abdominal belts, used to support ventral and incisional hernia may be considered a form of truss.

There are certain features which every truss should possess: it should retain its position without extraneous aid; it should keep the hernia reduced in all positions of the body, and during coughing, sneezing, defecation, etc.; it should not cause irritation of the skin overlying the hernia or elsewhere; and it should be easily kept clean. The patient must have at least two trusses, in case one of them is

broken. The trusses suitable for the different forms of hernia will be described under special herniæ (p. 786).

De Garmo says a patient who wears a truss is a chronic invalid, and though this statement is somewhat of an exaggeration, it is absolutely true that such a patient must observe certain rules of conduct if he wishes to continue in good health. He should be kept under his physician's observation. A truss requires as strict oversight as any other orthopedic appliance (p. 517). The truss must always be applied while the patient is recumbent, after reduction of the hernia; it need not be worn at night, but it should be reapplied every morning before the patient gets out of bed. It must never be taken off except when he is lying down. When he takes a bath he must wear the truss in the tub. He must not make any sudden exertion or strain at any time. He must lift no heavy weights. He must not go swimming. He should be debarred from all athletics except the lightest exercises. If he wants to be cured of his hernia, let him be operated on. Otherwise he must endure the limitations which truss-wearing requires. The possibility of strangulation of his hernia should be ever present in his mind. Should it occur it will force him almost always to an immediate operation to escape death; and he will be unable to choose either the time, or the place, or the surgeon for such an operation.

Irreducible Hernia.—The commonest causes for irreducibility of a hernia are inflammatory adhesions affecting its contents. These may be between the sac and its contents, or adhesions of the coils of bowel to each other, to the omentum, etc. The most frequent cause is adhesion of the omentum to the sac. The bowel rarely becomes adherent to the sac.

Intravisceral adhesions often prevent reduction even when no adhesions to the sac wall exist, because the contents are amalgamated into a mass too large to pass through the neck of the sac. A hernia may be apparently irreducible, because manipulation cannot force back in a short time, through a small orifice, a large mass of intestines or omentum which have taken years to descend. There is no strangulation present in an irreducible hernia, though a strangulated hernia may be irreducible. The *diagnosis* of an irreducible hernia depends upon recognizing that the protrusion is at one of the usual hernial orifices, on ascertaining the history of its development, and on the physical signs, which are the same as in a reducible hernia, with a few self evident exceptions. An irreducible hernia presents an impulse on coughing; it constantly tends to become larger, and the patient suffers from a sense of dragging, from digestive disturbances, and often from intermittent attacks of constipation and diarrhea. Thoûgh a patient may live for many years with an irreducible hernia, he is in constant peril because the prolapsed viscera are exposed to trauma, and are liable to repeated attacks of inflammation or obstruction; and strangulation is much more apt to occur than in the case of a hernia which is retained by a truss.

Treatment.—The cure of an irreducible hernia is more difficult and dangerous than that of a simple hernia, and can be secured only by operation. Except in the very old, or those with severe constitutional or organic disease, or those with most enormous herniæ, operation always should be urged upon the patient. It is extremely desirable to reduce the size of these large herniæ before any operation is undertaken, and even if no operation is done the patient may secure much relief from the preliminary treatment. This plan is to keep the patient in bed, on spare diet, with a course of mild purging, and frequent enemas, so as to secure complete evacuation of the bowels. Abstinence and rest will reduce the amount of fat in the omentum and mesentery; and recumbency, combined with elevation of the foot of the bed, will bring the force of gravity to aid in securing reduction in the size of the hernia. This method appears first to have been advocated by Sir Astley Cooper in 1828. In most cases a partial reduction at least can be secured by resort to taxis (p. 766) after a couple of weeks of this preparatory treatment, and sometimes the entire hernia can be reduced. In these cases of immense hernia, if the surgeon thoughtlessly undertakes an operation without such preparatory treatment, he may find it impossible to make the viscera enter the abdomen even after this has been opened. If the hernia can be reduced to ordinary size before operation is attempted, this should be as successful in obtaining a cure as in cases of reducible hernia.

If the patient refuses operative treatment, the application of some form of support, in the nature of a "bag-truss" or suspensory may somewhat alleviate the symptoms.

Inflamed and Obstructed Hernia.—These conditions are met with almost solely in cases of irreducible hernia. *Inflammation* may occur from accidental trauma, from unskilled or violent attempts at reduction, from the pressure of an ill-fitting truss, or from changes in the contents of the sac. Among the latter attention may be called to the occasional presence of the vermiform appendix in the sac, with the possibility of appendicitis. *Obstruction* of a hernia is said to occur when the normal course of gas or feces through the herniated bowel is interrupted; this may result from intestinal indigestion with accumulation of flatus, or from fecal impaction (p. 889). The *symptoms* of inflamed and obstructed hernia are much the same, consisting in local pain, tenderness, nausea, and perhaps vomiting; the hernia still gives an impulse on coughing; and flatus is passed by the anus, though there may be constipation. The symptoms are decidedly less severe than in the case of strangulation.

Treatment.—The patient should be put to bed, and should lie in a position which relaxes the hernial orifice; an ice bag should be applied locally; an enema should be administered; *nothing whatever* should be given by mouth; and if the symptoms are severe or if they do not subside in the course of a few hours, operation, as in cases of strangulation, becomes imperative. In any case where the condition of strangulation cannot be positively excluded, immediate operation should be done.

Incarcerated Hernia.—This is one which, though ordinarily reducible, has for some reason become temporarily irreducible (De Garmo). This complication occurs most often in large herniæ, and usually is due to unskilful attempts at reduction, resulting in some slight twist in the bowel which renders the hernial orifice relatively too small to allow reduction. While there may be some local pain and tenderness, there are no symptoms of strangulation present.

Treatment.—Treatment consists in rest in bed, with the foot of the bed elevated and the patient so placed as to relax the hernial orifice. An ice bag or cold coil should be applied to the hernia, and the surgeon should not attempt to reduce the hernia until the acute symptoms have had a chance to subside; he may find then that the hernia has been spontaneously reduced, or that its reduction by taxis (p. 766) is easy. If the symptoms do not subside within a few hours, taxis should be tried, and if this fails, operation should be done as in cases of strangulated hernia.

Strangulated Hernia.—This is one in which the circulation of blood is obstructed or entirely arrested. This serious occurrence is liable to bring on all the usual consequences of strangulation, which are studied at p. 762.

The **cause** of strangulation of a hernia is not always evident. It is clear that a constriction exists, pressing upon the protruded structures and interfering with their circulation. This constriction may be either in the sac wall, in the surrounding structures, or inside of the sac. *Constriction by the sac itself* is rare, especially in children; the site of constriction usually is at the neck of the sac, particularly in the case of patients who have long worn a truss and in whom the sac and its neck have undergone cicatricial contraction. In some cases of congenital sacs points of constriction may exist elsewhere than at the neck (Fig. 780); and in some cases constriction may occur from bands of inflammatory adhesions formed within the sac. *Extra-saccular constriction* is by far the most frequent form and usually occurs at the abdominal opening in fascial or tendinous tissue through which the sac and its contained viscera pass. *Intra-saccular constriction*, which is rarest of all, may be due to torsion of the contents of the sac, or to the bowel being caught in an aperture or pocket in the omentum.

Mechanism of Strangulation.—As the neck of the sac and the abdominal opening through which the hernia passes are not muscular, but fibrous, and hence have no power of active contraction, it is evident that in cases of extra-saccular as in those of intra-saccular constriction the prime cause of strangulation lies in the contents of the sac. If the hernia previously was reducible, these changes in the contents of the sac usually begin as the state already described as incarceration of the hernia; in the case of irreducible hernia the first changes usually are those described as inflammation or obstruction of the hernia, and they may be brought on by the unwelcome intrusion into the sac of a coil of gut or a plug of omentum never before present. In some patients a hernia which is suddenly developed becomes stran-

gulated immediately on its first appearance; such a strangulation is apt to cause rapid and very serious changes in the contents of the sac. A similar chain of events usually occurs when a hernia suddenly protrudes into a sac which has long been empty, especially if the use of a truss has caused cicatricial contraction in the neck of the sac. This form of strangulation may be described as *acute* to distinguish it from that of more *chronic* onset, which usually is preceded by incarceration, inflammation, or obstruction of the hernia.

All irreducible herniæ are more liable to strangulation than those which are reducible and are retained by a truss. An irreducible umbilical hernia is especially liable to strangulation; and, of all forms, a femoral hernia is most prone to strangulation. Ventral and incisional herniæ very rarely become strangulated.

Structural Changes Occurring in Strangulation.—Probably in every case the first change is obstruction of the venous circulation of the contents of the sac; the arterial circulation is less rapidly affected because of the higher blood-pressure in the arteries and their more resistant walls. Arrest of the venous circulation causes the blood to be dammed back into the capillaries while these are still receiving blood from the arterial side. The result is stagnation of the blood, and edema of the extravascular tissues. Almost at once the hernia becomes too large to be returned through the orifice by which it had escaped. If intestine is strangulated, intestinal obstruction (p. 884) is present as well as strangulation, and usually precedes it.

Strangulation of bowel causes the rapid outpouring of serum which may distend the sac; it will be greater in amount if the strangulation is very slow in onset than if the entire circulation is arrested immediately. At first this fluid is pale yellow, clear, and sterile, and perhaps should be considered a transudate rather than an effusion; but very soon it becomes inflammatory in character, turning cloudy from the increase in the number of leukocytes present, and often is bloody, and in later stages of strangulation, brownish or black. Bacteria soon penetrate the walls of the obstructed bowel. If the strangulation is not promptly relieved, the bowel, which at first is congested, bright red, soggy, and with its natural lustre but slightly impaired, becomes purplish or even black in color, and may be covered with patches of inflammatory lymph. Actual gangrene quickly follows: the intestine loses its lustre entirely, and becomes soft, doughy, and grayish black; the peritoneal coat strips easily, the muscular coats are friable, and the bowel is very easily torn. In many cases definite rings of constriction are found at the points of strangulation: usually the constriction ring at the distal (anal) end of the strangulated loop is more pronounced than that at the proximal (gastric) end. The bowel below the constriction is nearly normal in appearance, or if anything rather paler than normal and collapsed; that proximal to the constriction is distended, congested, and more nearly resembles the gut which has occupied the hernial sac. When the bowel becomes necrotic, or even before, merely as the result of intestinal obstruction, death from

toxemia may occur. If life is prolonged, the slough may separate from the intestine, resulting in intestinal perforation into the hernial sac, which then becomes the seat of a fecal abscess. The overlying tissues may next become inflamed, and in rare instances this fecal abscess has opened spontaneously through the skin. In many cases septic inflammation spreads to the peritoneal cavity, and general peritonitis is the cause of death. This may occur from perforation of the bowel at the point of constriction (Fig. 767), with escape of fecal contents into the peritoneal cavity, or from propagation of inflammation along the coats of the bowel above the constriction. There may be a volvulus of the intestine leading up to the hernial ring, within the abdominal cavity.

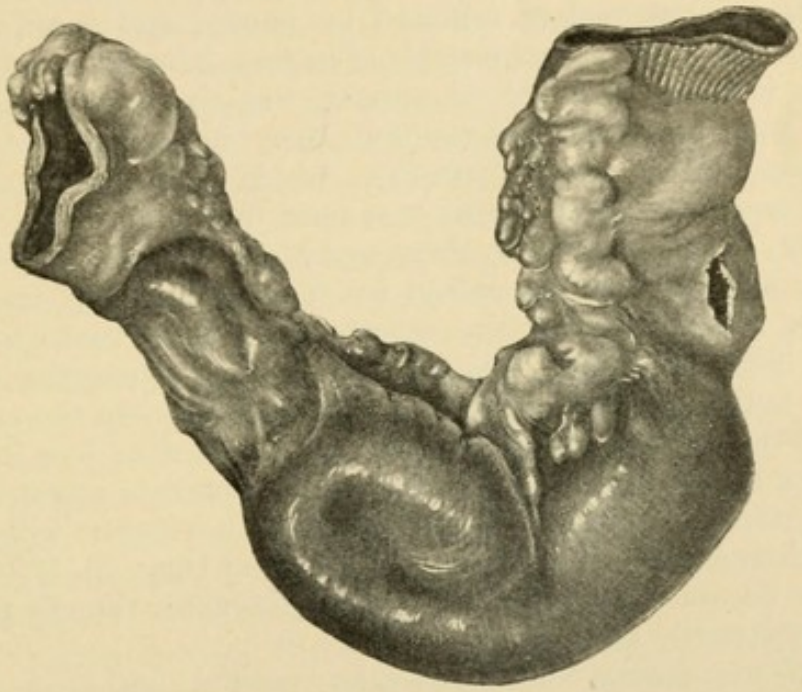

FIG. 767.—Specimen of gangrenous small intestine resected in a case of strangulated femoral hernia. Age seventy-one years; hernia strangulated for two weeks before operation. Fecal abscess in sac, bowel ruptured just above proximal constriction. Death twelve hours after operation (spinal anesthesia). Episcopal Hospital.

If omentum is strangulated there is not much serum effused in the sac. The omental veins are found distended, dark blue or black, and perhaps thrombosed. The omental fat becomes pinkish red at first, feels denser than normal, and does not bleed readily if incised; later it becomes grayish white and perhaps necrotic.

Symptoms of Strangulated Hernia.—In almost every case the patient has had a hernia for some time before it becomes strangulated. Usually following a muscular strain (perhaps merely a mis-step, exuberant laughter, etc.) a sudden pain is felt at the site of the hernia. If the hernia was not down at the time of the accident, it slips out suddenly, even escaping from under a truss if one was worn. If the hernia was down already at the time of the accident, whether irreducible or not, it feels to the patient as if it had increased in size from the protrusion

of additional bowel or omentum. If the pain is very severe the patient may fall to the ground in a state of shock. The pain is followed very soon by a general abdominal pain which at first is colicky, becomes progressively worse, and which later is constant, not intermittent. *If not checked by opiates this pain does not leave the patient until gangrene has occurred or until the strangulation is relieved.* Spontaneous cessation of pain therefore is a bad sign; it is accompanied by a false sense of security, and is soon followed by extreme prostration, and signs of impending death as in cases of intestinal strangulation from other causes.

If the hernia is an **enterocele**, the usual symptoms of *intestinal obstruction* (p. 885) develop very soon after the occurrence of the strangulation. The initial colicky pain, in almost all cases but not always, is accompanied or followed by nausea and vomiting. The vomiting, which at first is the result of nausea, later becomes typically projectile in type, due not to nausea, but to reversed peristalsis. First the gastric contents are vomited; then bile-stained matter; later the contents of the upper intestine, which is brownish and sour-smelling; and in the final stages true fecal or stercoraceous vomiting may occur. Coincident with these symptoms there is absolute constipation, and no flatus is passed by the rectum. An enema may empty the rectum of what was already there or in the sigmoid; but after the lower bowel has been emptied, no further movement can be obtained, and in no case is there passage of flatus. In the case of an **epiplocele** the symptoms are the same though often less in degree, there being seldom absolute constipation or complete arrest of flatus.

If the intestinal obstruction is not relieved, *peritonitis* will develop, with its characteristic symptoms and physical signs (p. 805). Until this event occurs the temperature is not elevated, though the pulse slowly but steadily increases in rapidity.

Physical examination shows a tender, painful, and tense swelling at the site of the hernia. In the case of a large hernia long irreducible, these signs are not so apparent, but usually it is evident that the swelling is somewhat more tense and painful than before the onset of the symptoms of strangulation. In an omental hernia the swelling is boggy, rather than tense. There is *no impulse* in a strangulated hernia when the patient coughs. Palpation of the abdomen usually reveals rigidity of the abdominal muscles near the site of the hernia; it is a voluntary rigidity, not like that which results from peritonitis. Auscultation of the abdomen detects sounds of borborygmi characteristic of peristalsis; usually these peristaltic noises are exaggerated, and sometimes they may be traced up to the site of obstruction, where they are arrested with a distinct click.

Diagnosis of Strangulated Hernia.—This depends on recognizing, in addition to the symptoms of intestinal obstruction, the existence of a hernia with the signs characteristic of strangulation. If the latter condition is present, it is not necessary to wait for full development of symptoms of intestinal obstruction before making a diagnosis. I

have several times found a gangrenous patch on the bowel in cases where neither nausea nor vomiting had been present, although the strangulation had lasted for from six to eight hours. In very fat patients it may be impossible to detect with certainty a very small hernia. All the usual sites of hernia should be carefully examined, and corresponding parts of the body should be compared most diligently in obscure cases. A feeling of greater resistance over one hernial ring than at the corresponding point on the other side of the body may be the only physical sign discernible in a case of partial enterocele (Richter's hernia); but such small herniæ may become gangrenous much sooner than larger herniæ. If *two herniæ*, both irreducible, are present, it may be difficult to decide which of the two is strangulated; usually the physical signs (absence of impulse on coughing, greater tension and tenderness in the neck of the strangulated hernia) will be of more aid in such cases than the history and subjective symptoms. An irreducible hernia may be present and there may be *peritonitis* from some other cause. The distinctions between intestinal obstruction and peritonitis cannot be too often insisted upon; they are detailed at p. 809. In strangulated hernia peritonitis is a late symptom, all the early signs indicating intestinal obstruction. There may be an irreducible hernia and yet there may be *some other cause for intestinal obstruction:* here again physical examination will show an impulse on coughing unless the hernia is strangulated; while a careful history of the case may throw much light on the diagnosis as it may indicate previous attacks of peritonitis, leaving crippling bands or adhesions as the true cause of the symptoms. If no conclusion can be reached after careful study, the surgeon should expose the hernia before proceeding to exploratory laparotomy. The *vomiting of pregnancy* may be confusing, if an irreducible hernia is present; but the negative physical examination of the hernia, and the fact that there is no evidence of intestinal obstruction, should be sufficient evidence of the true condition. In some cases of inguinal hernia, confusion is caused by the presence of an *inflamed lymph node* in the groin, and in infants by an *inflamed hydrocele of the cord*. When, as often in these cases, physical examination is unsatisfactory, and the history is unknown or negative, a differentiation may be impossible. An undescended testicle need not be mistaken for a strangulated hernia if the surgeon is cautious enough to examine the scrotum before reaching a diagnosis.

Treatment of Strangulated Hernia.—The object of treatment is to relieve the strangulation. This may be accomplished (1) by pushing the strangulated bowel or omentum back into the abdominal cavity by means of *Taxis;* or (2) by *operation*—dividing the constriction, inspecting the bowel, and treating it appropriately before restoring it to the abdomen. In most cases this operation may be completed by repair of the abdominal wall so as to prevent recurrence of the hernia. *The physician never should leave his patient until the strangulation has been relieved,* or until he has made arrangements for immediate surgical treatment.

Taxis.—This is a term derived from the Greek, and implying *arrangement* or *adjustment*. It is used in surgery in a technical sense to describe various manipulations by which the surgeon seeks to secure reduction of a hernia. The patient should be placed on a bed, with his shoulders and pelvis raised, so as to relax the abdominal muscles. The surgeon then surrounds the hernial orifice with the thumb and fingers of his left hand, while with the right he endeavors by very gentle but persistent compression to empty the herniated bowel of some of its gaseous and fluid contents. When this has been accomplished, he employs his right hand in the most gentle and patient kneading movements, in the attempt to make the bowel recede into the abdomen. The direction of pressure must correspond to that by which the bowel came down. Success is manifested by the bowel slipping back into the abdomen with an audible gurgle and a characteristic flop. If these signs are absent, even though the hernia appears to have been reduced, it is most probable that this is not really the case, but that *reduction in mass* has occurred. This term implies that the contents of the sac have been pushed upward until they lie on the inner aspect of the abdominal wall, but have carried before them the neck of the sac, which is the seat of constriction; and that the hernia, still strangulated, rests between the abdominal wall and parietal peritoneum. If the symptoms of strangulation persist, operation should be done immediately.

Contraindications to the Taxis.—(1) Taxis never should be employed if anyone else already has attempted it; because there is no telling how much damage may have been done to the gut, and in its present state even the very gentlest manipulation may rupture it or cause other disastrous consequences. (2) Taxis never should be employed in very acute cases; it is suitable only to such as begin with symptoms of incarceration or obstruction of the hernia. (3) Taxis never should be employed while the patient is anesthetized, as there is too much risk of using unjustifiable force. (4) Taxis never should be persisted in for more than fifteen minutes.

Operation.—The operation for strangulated hernia is one which any medical man may be called on to perform in emergency. It is not nearly so difficult as is the taxis, and is incomparably more efficient in securing the end in view—that of relief of strangulation. If operation were resorted to in every case within the first twelve hours, and with modern aseptic methods, the mortality of strangulated hernia would be only from 3 to 5 per cent., or less than half that of typhoid fever; instead of as high as that of pneumonia, or fracture of the base of the skull, as it is now, when in many cases the obstinacy of the patient or still worse the ignorance of the family physician postpones operation until gangrene and peritonitis have developed. The mortality when operation is employed under such circumstances varies from 10 to 50 per cent., according to the constitutional resistance of the patient. If no operation is done, spontaneous cure by sloughing and formation of a fecal fistula may result in as many as 2 per cent. of cases, while 98 per cent. will terminate in death.

The operation, which is known as *herniotomy* or *kelotomy*, consists essentially in making an incision through the overlying structures until the neck of the sac is exposed; then the sac is opened, and the constriction causing strangulation is divided. For this deep incision many surgeons still use Cooper's herniotome (Fig. 768) which has the advantages of a blunt point which can be slipped under the constriction and a short cutting edge. The contents of the sac are then replaced within the abdomen if they are in good condition, and the wound is repaired as in an operation undertaken for the "radical cure" of hernia. If the contents of the sac are not in good condition they are treated as described below (see Treatment of Complications).

FIG. 768.—Cooper's herniotome.

In former times, before the days of aseptic surgery, there was great danger of peritonitis developing after such an operation, and much more stress was laid upon the employment of taxis, and even in operating many surgeons followed the method of Petit (1760), who divided extra-saccular constrictions and then reduced the hernia *without opening the sac*. But for the last twenty years at least, the taxis has been falling increasingly into disfavor; and especially since the development of methods of inducing local anesthesia, and spinal analgesia, have surgeons been more ready to resort to operation. And I am convinced that it should be clearly understood that no patients however moribund in appearance (unless *in articulo mortis*) should be refused the hope of recovery which operation always affords. If the patient is too ill to endure a general anesthetic, and if no facilities exist for administering local or spinal anesthesia, there is no reason in the world why the operation should not be done without any anesthetic whatever. Our surgical ancestors operated thus for many generations, and in not an insignificant proportion of cases recovery followed.

TREATMENT OF COMPLICATIONS.—As the surgeon cuts through the overlying tissues he may find that they are edematous. This may be the result of trauma inflicted during attempts at taxis, or rarely may be due to inflammation spreading from a fecal abscess in the sac. The sac usually is recognized by its transulucent and bluish appearance. Usually it is impossible, and never is it requisite for the surgeon to recognize the various layers of tissue overlying the sac. Each of the deeper layers as it appears should be cut through cautiously, as one opens the peritoneum, after raising it in forceps from the underlying structures. In this way there is very little danger of injury to the contents of the hernial sac. In most cases there is some fluid in the sac; if it is clear and limpid, it is not likely that the condition of the bowel is very bad. When the sac is opened and the constriction relieved, more of the bowel should be drawn out of the abdomen, and

its condition should be carefully observed. (In serious cases the anesthetic, if given by inhalation, may be suspended at this point in the operation.) If the bowel was merely nipped in the hernial orifice, and has fallen back into the abdomen as soon as the constriction is relieved, the surgeon never should neglect to draw it out again into the wound to ascertain its condition. The next step is the application to the bowel of hot (115° F.) sterile hot water or saline solution. The hot fluid should not be poured over the bowel with any force, but should be allowed to flow gently over the bowel so as to avoid the trauma even of a current of water. Nor should the bowel be subjected to massage or to irritation by gauze sponges. The bowel should be examined for its *lustre*, its *color*, and its *elasticity*. Though the color when first exposed may be bright red, bluish, dark blue, purple, or even black, it may return to normal after relief of the strangulation and application of hot solutions for a varying time up to half an hour. If the gut is entirely gangrenous when first seen, of course it is hopeless to expect its recuperation; but recovery may occur from any stage short of gangrene; and a patch of seeming gangrene which at first appears so large as to demand resection, may be so much diminished in size by hot applications as to permit of retention of the bowel after inversion of the worst portions. If the lustre of the peritoneal coat is preserved, as a rule the color will return to the normal and the bowel will survive. If the mesenteric vessels cannot be felt pulsating the bowel will not survive. If the bowel fills out with its contained air and retains its normal cylindrical form, it is more apt to be healthy than if it has lost its resiliency and retains any indentation or crease accidentally produced during manipulation. Careful inspection should be made also of the circular constrictions on the bowel at the points of strangulation, if such constrictions exist. There may be a threatening perforation here, while the intervening portion of bowel which was not directly compressed, but had its circulation impaired only by pressure on its mesentery, may be fairly normal.

If the bowel returns to its normal condition, it should be replaced, and the wound should be closed. If a suspected spot remains, it often is possible to cover it in by inverting it and suturing neighboring healthy portions of bowel over it, as indicated in the accompanying diagrams. Even though the entire lumen of the gut appears to be obstructed by the amount of its wall inverted, recovery without any untoward symptom may occur (Fig. 769). The sero-serous suture is used, as in other intestinal operations (p. 830). If the circular constriction at the point of strangulation has been very tight, it will have crushed all the coats of the bowel except the peritoneum at this point, just as if a compression forceps had been applied to the gut previous to the application of a ligature. In such circumstances the ring of constriction sometimes may be covered in by producing a partial intussusception of the bowel (Fig. 770).

Only if there is actual gangrene is resection desirable; and even in such cases, if the patient's condition is very bad, or if the operator is

inexperienced, it will be quite sufficient to leave the gangrenous coil of intestine lying in the sac, after relieving the constriction, and packing sterile gauze around the bowel, which should then be opened and drained. If the proximal (afferent) bowel is very much distended, or if the strangulation has existed a long time, it always is well to *evacuate the contents of the proximal loop* (which in such cases are regarded as highly toxic), instead of allowing these contents to pass on down through the intestinal canal, whence absorption may occur, causing increased toxemia.

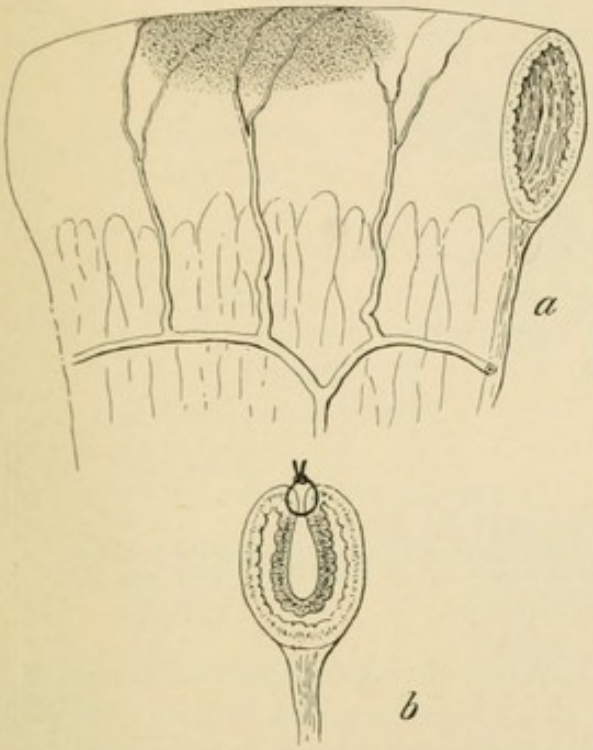

FIG. 769.—Gangrenous spot on bowel (*a*), inverted into lumen by sutures (*b*). From a patient in the Episcopal Hospital. Recovery.

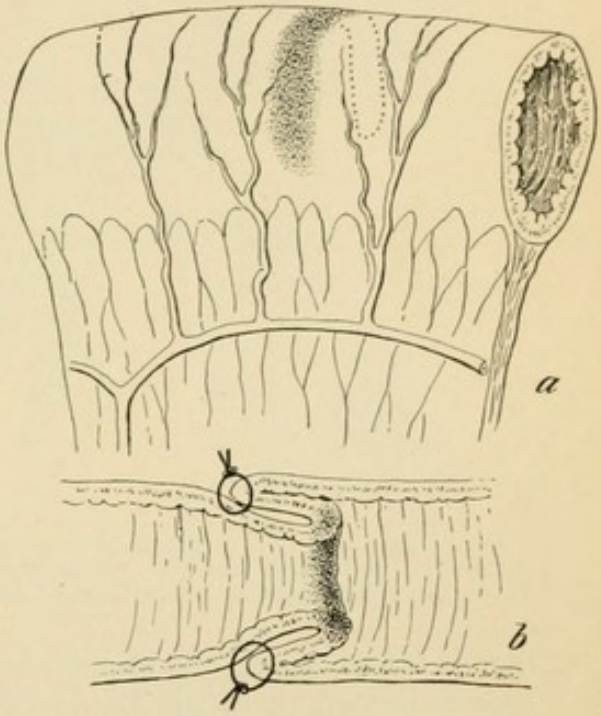

FIG. 770.—Gangrenous area involving nearly whole circumference of bowel (*a*), successfully treated by producing a partial intussusception (*b*). Episcopal Hospital.

Where resection of the bowel is done the surgeon may terminate the operation either by establishing a false anus in the wound, or by completing an intestinal anastomosis. The former should be selected in all cases where a prolongation of the operation is not desirable, unless the site of resection is very high in the intestinal canal. When an anastomosis is done it may be either an end-to-end anastomosis or a lateral anastomosis (p. 833). In these cases no further prolongation of the operation is desirable, so no attempt at a "radical cure" of the hernia should be made; it is sufficient to close the wound, usually with drainage, in the simplest and most expeditious manner.

The *treatment of omentum* found in the sac demands a few words of explanation. If there is no serious change in this structure, it may be replaced; but if there is any doubt about its condition, it should be

excised, after tying it off where normal by a series of interlocking ligatures, below which it is cut away, leaving a sufficient stump to ensure that the ligatures will not slip. Each ligature should include no more than a pencil's thickness of the omentum, and the omentum should be excised before the ligatures are cut short, so that the surgeon may use them to hold the omental stump in the wound for careful inspection, to make sure that hemorrhage is controlled. The omental bloodvessels have no muscular coats, and do not retract or contract and allow spontaneous cessation of bleeding. Not unfrequently the omentum protrudes in a loop, into the hernial sac (Fig. 771), and unless

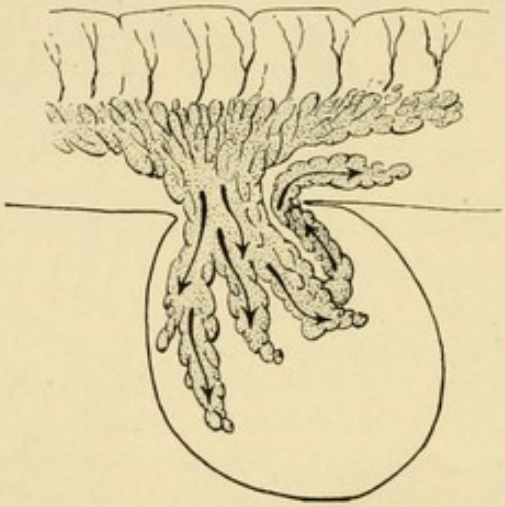

FIG. 771.—Loop of omentum protruding into hernial sac, but having its free end within the abdominal cavity. Complications might ensue if this free end was not drawn out before ligating and cutting off the omentum.

care is taken to pull the end of the loop out of the abdomen before its base is ligated there will be danger of its necrosing and causing peritonitis or obstruction later. The omentum is so seldom normal when it has been long in a hernial sac, even if not strangulated, that I believe it is much better to excise it under all circumstances, unless the condition of the patient is such as to render any prolongation of the operation unjustifiable. If it is restored to the abdomen it is quite likely to cause subsequent trouble either by adhesions or by favoring recurrence of the hernia (Lucas-Championnière).

The *after-treatment* is the same as after other operations for intestinal obstruction. If the wound has not been securely repaired, the patient should be operated on after complete recovery, to obtain a radical cure; or a truss should be worn to prevent reappearance of the hernia.

SPECIAL HERNIÆ.

Classification.—There are only three forms of hernia of frequent occurrence; all the others are rare. The most frequent form is the *inguinal*, which occurs in about 73 per cent. of cases; then comes the *femoral*, in about 18 per cent. of cases; and lastly the *umbilical*, which occurs in about 8.5 per cent. of cases. This leaves about 1 per cent.

for the rarer forms (lumbar, obturator, etc.). In this reckoning, however, incisional hernia is not included. To afford a perspectus of the subject to the student, there is no more serviceable classification of hernia than the following:

HERNIÆ OF THE EPIGASTRIC REGION.

1. Diaphragmatic.
2. Epigastric.

HERNIÆ OF THE MESOGASTRIC REGION.

1. Ventral
2. Incisional—These may occur also in other regions.
3. Umbilical.
4. Lumbar.

HERNIÆ OF THE HYPOGASTRIC REGION.

1. Inguinal.
    1. Indirect (or Oblique).
    2. Direct.
2. Femoral or Crural.
3. Pelvic.
    1. Anterior—obturator.
    2. Inferior { (1) Perineal. (2) Pudendal. (3) Vaginal.
    3. Posterior { (1) Ischiatic. (2) Gluteal.

These various forms will now be discussed in turn. *Diaphragmatic Hernia* has already been considered (p. 751). *Internal Hernia* is discussed in Chapter XXII.

Epigastric Hernia.—By this term is understood one or more small protrusions, usually of omentum only, occurring in or near the median line of the abdomen (linea alba) between ensiform process and umbilicus. It is a rare condition, first well studied by Terrier in 1886. A much more frequent abnormality, and one which often is mistaken for a ture hernia, is the protrusion of small portions of the *preperitoneal fat* through apertures between the transverse fibres of the sheaths of the recti muscles which go to form the linea alba. According to Tillaux (1894) it is more frequent in men. The patient complains of pain, and on examination a small mass can be felt the size of a marble or thereabouts, and generally irreducible. It simulates an epiplocele.

Treatment.—If the application of firm pressure by adhesive plaster or an abdominal belt does not afford relief, the fatty tumor may be excised, after exposing and ligating its pedicle. If the linea alba is carefully sutured there is not apt to be a recurrence.

Ventral Hernia.—This hernia may occur in any part of the abdominal wall, but does not protrude through one of the usual apertures such as the umbilicus, the inguinal or femoral canals, etc. It is a very rare form of hernia, though by many surgeons it is not distinguished from incisional hernia (see below). The usual cause is injury resulting in partial rupture of the abdominal muscles, from a direct blow or merely by muscular strain. In some cases no distinct history of injury can be obtained, the abdominal wall seeming to have yielded spontaneously at the site where the hernia appears (Fig. 772). No true sac exists, the parietal peritoneum merely bulging a little when the patient strains.

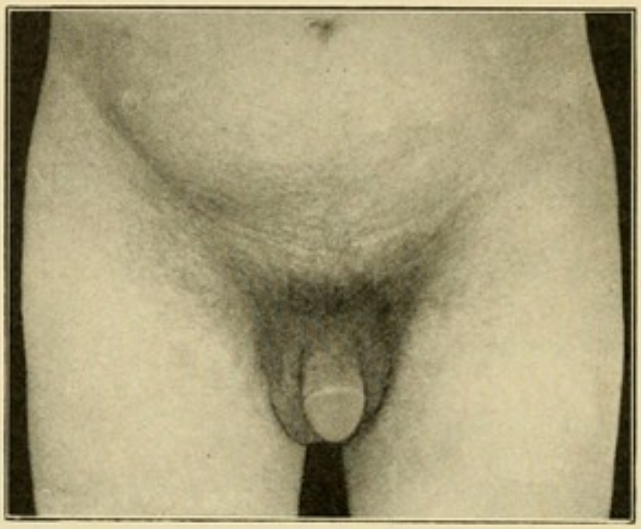

FIG. 772.—Ventral hernia through right oblique muscles. (Dr. Neilson's case.) Episcopal Hospital.

Under the heading of ventral hernia may be included also protrusion due to *diastasis of the recti muscles* in the mid-line. A slight degree of diastasis is normal above the umbilicus, but pathological diastasis usually is seen in the hypogastric region, and occurs in women who have borne many children and who are emaciated. A similar condition is frequently seen in infants and young children, as a congenital deformity.

Symptoms.—The symptoms of ventral hernia are a feeling of weakness at the site of the protrusion, and dragging sensations within the abdomen. The diagnosis is not difficult, if the possible existence of the condition is remembered.

Treatment.—Usually symptomatic relief is secured by wearing a firm abdominal belt. In children with diastasis of the recti the use of adhesive plaster strapping as advised in cases of umbilical hernia usually effects a cure. Even in adults the hernia is not liable to complications, but if desired the patient can secure permanent relief by an operation as for incisional hernia.

Incisional Hernia.—This is much more frequent than a true ventral hernia, and receives its name from its development in the cicatrix of an operative incision. One cannot too much insist upon the impor-

tance of placing the incision so as to do as little damage as possible to the structures of the abdominal wall (see p. 818). Incisional hernia was much more frequent formerly when less care was taken in the repair of abdominal wounds. An incisional hernia is very rare in a clean wound which is closed completely by tier suture. If the wound is drained, a hernia is much more apt to develop.

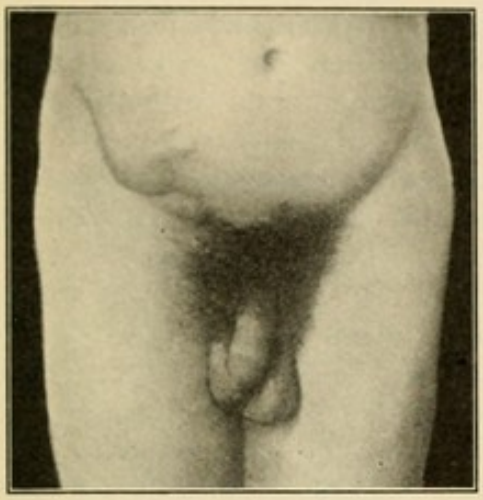

FIG. 773.—Incisional hernia, in scar of operation for appendicitis seven years ago (incision in right semilunar line). Episcopal Hospital.

FIG. 774.—Incisional hernia, in scar of operation for typhoid perforation of intestine nine years ago (right rectus incision). Two years ago a right inguinal hernia also developed. Age thirty-six years. (Dr. Harte's case.) Episcopal Hospital.

This form of hernia may be of any size, and if large may cause very great disability. Usually there is no true peritoneal sac, but the abdominal viscera lie in direct contact with fascia or skin, and almost always are closely adherent to their coverings. Owing to this fact

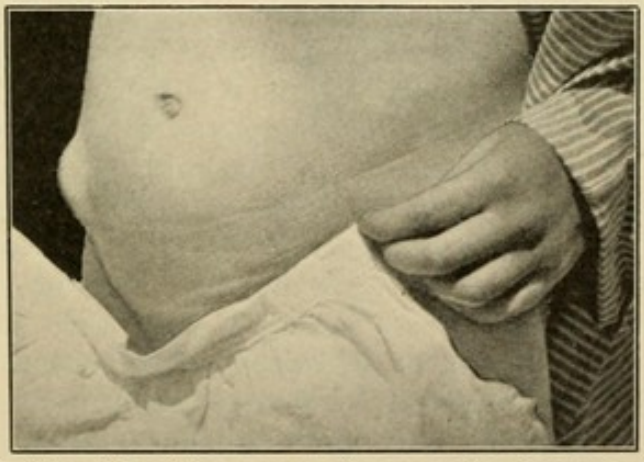

FIG. 775.—Incisional hernia one year after operation for appendicitis (right rectus incision). Children's Hospital.

there is no chance for spontaneous cure even if the hernia is kept reduced by suitable appliances. As the abdominal opening is relatively large, strangulation or other lesser complication is rare; though incarceration may occur if the aperture is small.

The *symptoms* are the same as in ventral hernia.

Treatment.—If the patient is healthy, operation should be done. If this is contraindicated, an abdominal belt, as in cases of pendulous abdomen (Fig. 875), may relieve the worst symptoms. When operation is done it should be remembered that the cicatrix is usually very thin and the hernial contents adherent. The surgeon, therefore, begins by an incision at the periphery of the hernia, and opens the abdomen not directly through the old cicatrix, but through healthy tissues above or below or to one side of the hernia. Here there will be no adhesions to the parietal peritoneum. The hernial contents are then cautiously dissected free from the overlying abdominal wall, the cicatricial tissue is excised, and the herniated structures reduced. In cases of very large hernia with many adhesions between the prolapsed intestines and omentum it is not desirable to separate these more than is required to free the different layers of the abdominal wall. Redundant or diseased omentum should be excised. The various layers of the abdominal wall, especially the aponeuroses, should be dissected free, exposing enough of each for accurate suture, and if possible for overlapping. Then the wound should be repaired as a recent abdominal incision (p. 821). The most important layer of the abdominal wall to suture accurately is the anterior sheath of the rectus or the aponeurosis of the external oblique. Hemostasis should be absolute, and the wound should not be drained. The patient should remain in bed for at least three weeks, and if the hernia was large should wear an abdominal belt and avoid straining efforts for a year after operation. Bartlett (1903) and other surgeons have implanted silver wire filigree in these wounds, with a view of rendering them stronger. Recent experience has shown that free flaps of fascia lata can be transplanted to supply the defect.

Umbilical Hernia.—This is a frequent affection, especially in infants and stout adults past middle life. Three forms are to be distinguished, the *Congenital*, the *Infantile*, and the *Adult*.

Congenital Umbilical Hernia is rare, occurring once in five or six thousand births. It is classed as *embryonic* and *fetal*. The former is due to failure of development of the abdominal wall, and the hernia, or rather eventration, may be very extensive, containing beside intestine also stomach, liver, heart, etc. The *fetal* variety develops after the third month of intra-uterine life, and the sac is lined by peritoneum and seldom is very large. Infants with large embryonic hernia usually are stillborn, or die so soon after birth as to offer little chance for repair of the defect by surgical means. The smaller fetal hernia usually is covered only by a translucent membrane through which the herniated viscera can be seen. Other malformations, especially of the bladder or rectum, may be present.

Treatment.—The hernia should be repaired by operation so soon as possible. The general mortality is about 30 per cent., but is less after operation done on the first day of life than later.

Umbilical Hernia in Infants and Children is very frequent. It develops at any time after complete cicatrization of the navel, and seldom

appears first after the close of the second year of life. The hernia seldom is very large, is covered by normal skin, and usually appears not directly under the umbilical cicatrix, but slightly above and to one side. Pressure by a finger reduces the hernia easily, and when the child cries or strains it becomes larger and more tense (Fig. 776).

TREATMENT.—If the hernia is small and the child is young, there is some chance of cure without operation. With the child lying down, one end of a strip of adhesive plaster, about two inches wide is fixed in one lumbar region; then the surgeon draws the opposite side of the belly forward, so as to form a longitudinal fold in the region of the

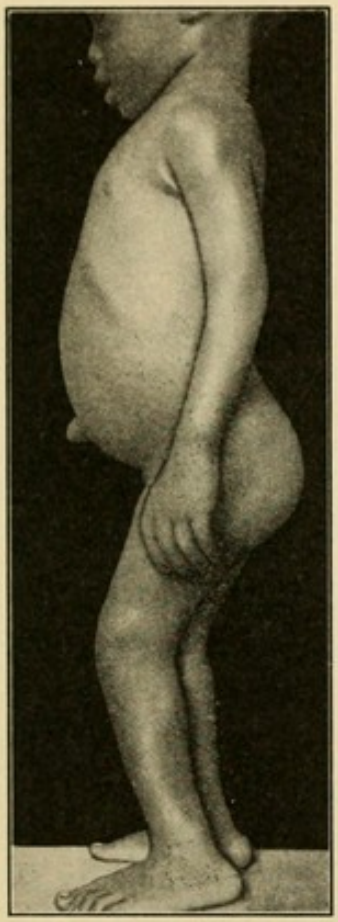

FIG. 776.—Umbilical hernia in a rachitic negro boy. Children's Hospital.

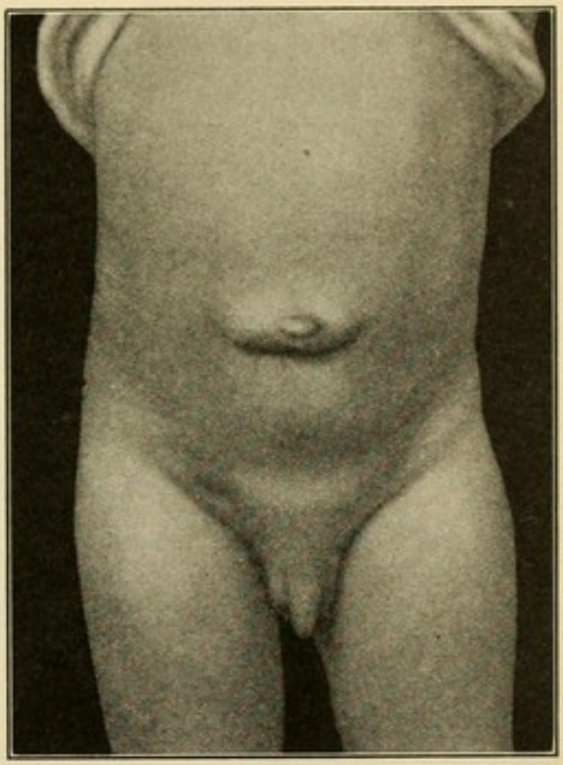

FIG. 777.—Result of operation for umbilical hernia with preservation of the navel. Children's Hospital.

linea alba. The adhesive plaster is then drawn across the relaxed belly and is tightly applied to the loin on the other side. It is well to reinforce this first strip by one or two others. It is better not to place a button, or a coin, or pad, or anything else over the hernia, as these tend to keep open the hernial ring. The adhesive plaster should be renewed about once a week, or as often as it comes loose. Care must be taken to keep the hernia reduced by the finger while the plaster is being changed. Attention is necessary to prevent excoriations of the skin. If the plaster is applied too tightly it may encourage the development of inguinal hernia. If this method of strapping an

umbilical hernia is faithfully continued for a year, a cure will result in a large number of cases if the hernia is small and of short duration. If no improvement is apparent within four or six months, operation probably will be necessary.

Operation for infantile umbilical hernia is best done after the child is two years old. This will allow a fair trial of conservative treatment. I think it is well in children, especially in boys who are exposed more than girls to ridicule for any abnormality, to do an operation which permits *preservation of the navel,* as advised by Stone. I make a semilunar incision, below the umbilicus, in the direction of the folds of the skin, and turn this skin flap upward, exposing the hernial ring, which is treated as in adults; when the skin flap is replaced, the patient's aspect is quite normal (Fig. 777).

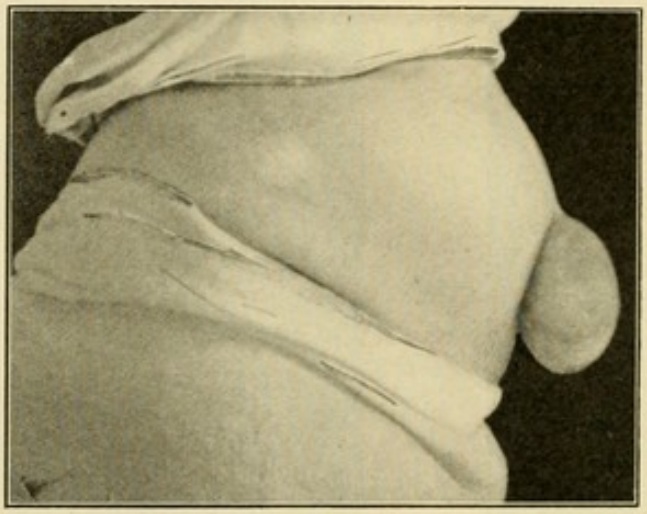

FIG. 778.—Umbilical hernia in adult. Age fifty-two years; duration two years. Episcopal Hospital.

Umbilical Hernia in Adults.—This may be a sequel or recurrence of the infantile form, or may develop first in adult life. It is more frequent in women, being predisposed to by repeated pregnancies. As in infants and children, the protrusion usually occurs slightly above the umbilical cicatrix. Omentum is almost always present in the sac, and generally becomes adherent, rendering the hernia irreducible at least in part. When the hernia is allowed to grow large, it becomes pendulous (Fig. 778), and usually contains transverse colon and often small intestine also. Incarceration is frequent, and strangulation not unusual. Strangulation often is intra-saccular, a coil of gut being caught in the matted and hypertrophied omentum. The *coverings of the hernia* are skin, subcutaneous fat, a thin layer of fascia, preperitoneal fat, and peritoneum; the latter forms the sac, which is acquired, not congenital. The pressure of the hernia causes atrophy of the tissues overlying it, and the contents of the sac usually lie very close to the skin, at least over the fundus of the sac. In most cases there is also considerable diastasis of the recti muscles, both above and below the ring.

TREATMENT.—The best treatment is by operation. Before this is attempted, however, it is very important to secure reduction of as much of the hernia as is possible, by the means described at p. 760.

A transverse incision is made, outlining an ellipse of the redundant skin, including the umbilicus. This incision should extend from one semilunar line to the other, and in very fat patients may have to be even longer. This incision exposes the anterior sheaths of the recti muscles on all sides of the hernial ring, and at some distance from it. The fat is then dissected off the aponeurosis up to the borders of the ring, and at this point the sac is cautiously opened, with the usual precautions against wounding its contents. This is very hard to avoid, if an attempt is made to open the sac at its fundus. The sac is then cut away with scissors at the margins of the hernial ring, on the finger as a guide, and the parietal peritoneum as cut is caught in clamps to prevent it from retracting out of sight. The reducible contents of the sac are then replaced in the abdomen. Usually a good deal of omentum has to be excised; this should be done with the precautions recommended at p. 769. The skin containing the umbilicus, circumscribed by the original incision is removed in one piece with the hernial sac (*Omphalectomy*). When all the hernial contents have been replaced, a gauze pack is inserted to plug the opening and keep them from protruding again. The next step is *closure of the hernial ring:* a transverse incision is made outward for about one inch from the hernial ring through the anterior sheath of each rectus muscle. Usually there is diastasis of these muscles, and for a distance of one inch or more on each side of the mid-line the anterior and posterior sheaths of the recti may be in contact. The anterior sheaths alone are to be incised, and are dissected upward and downward until a flap of this strong aponeurosis is formed both above and below the hernial opening. The margins of the neck of the hernial sac (parietal peritoneum), still caught in forceps, are next to be closed with sutures. This may be accomplished by applying a purse-string (p. 829) if the ring is small; but if it is large it is better to use interrupted sutures. The sutures should include also the transversalis fascia and the posterior sheaths of the recti muscles. Before the last suture is tied the gauze pack is removed. The peritoneal cavity being thus closed, the surgeon catches in Allis forceps the free margins of his aponeurotic flaps already formed from the anterior sheaths of the recti muscles. These flaps are then overlapped, the lower one being pulled up between the upper flap and the deeper structures, and they are sutured together by interrupted mattress sutures of chromic catgut, as indicated in Fig. 779. The free margin of the upper flap may then be sutured to the superficial surface of the anterior rectal sheaths.

Transverse suture of the wound in repair of umbilical hernia is preferable to longitudinal suture because patients with umbilical hernia usually have quite a pendulous abdomen, and there is much more slack in the tissues and less tension on the sutures if transverse suture is adopted. Frequently it is very difficult if not impossible to

bring together the edges of the recti by a longitudinal suture, because of their diastasis; but if the transverse suture with overlapping is employed the approximation of the recti is unnecessary. The principle of overlapping fascial layers in the repair of hernia, first introduced in 1881 by Lucas-Championnière, was adopted by W. J. Mayo (1899) in the case of umbilical hernia, and the operation as above described is known by his name. He has since adopted modifications of the technique introduced by Ochsner: no attempt is made to suture the neck of the sac separately, nor are transverse incisions made in the rectus sheaths for the purpose of forming fascial flaps. The opening in the abdomen is closed simply by three mattress sutures so introduced as to draw its lower margin well up beneath its upper. I have

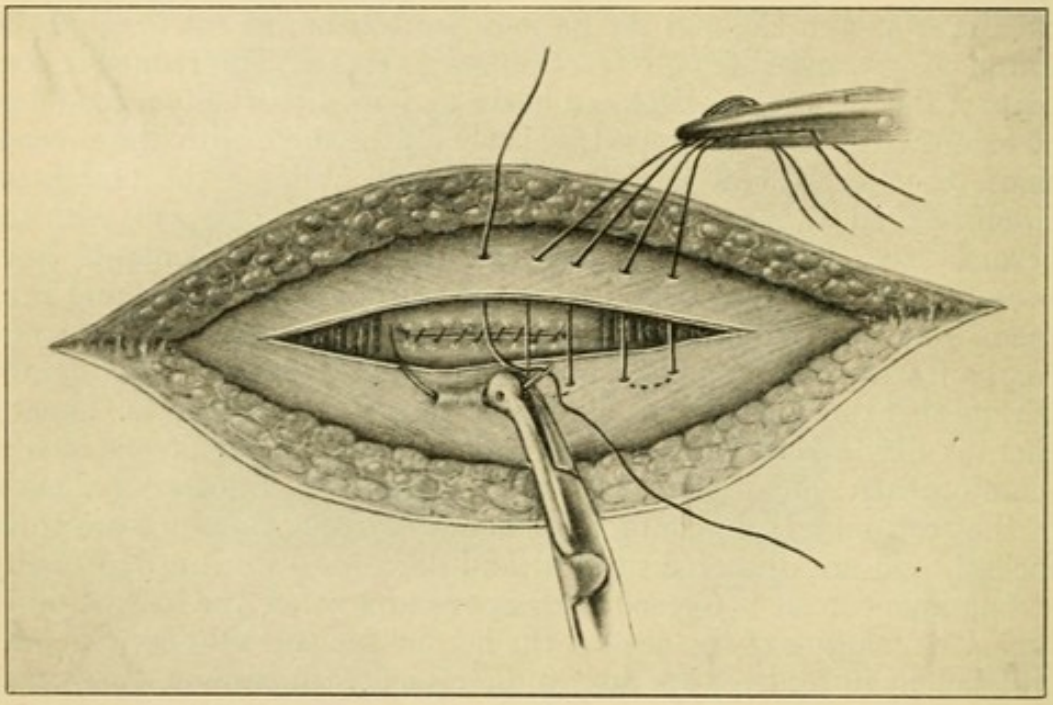

FIG. 779.—Radical repair of umbilical hernia. The parietal peritoneum has been sutured, and the lower aponeurotic flap (anterior sheaths of the recti muscles) is being drawn up underneath the upper flap by means of mattress sutures.

always used the original method, and believe it is preferable except where the hernial orifice is quite small. The patient should be confined to bed at least for three weeks; and if the hernia was very large or the abdomen very pendulous, an abdominal belt should be worn for several months. Recurrence is very unusual.

Strangulated Umbilical Hernia.—This is a very serious condition; the patient frequently is old, feeble, asthmatic, fat, and arteriosclerotic. The hernia in most cases is already irreducible; strangulation usually begins with symptoms of incarceration, and the development of complete strangulation is difficult to recognize, owing to the frequency of intra-saccular strangulation. Taxis should not be persisted in unless the patient absolutely refuses operation. Operation usually is too long delayed. When done, no attempt should be made

to complete the procedure by repair of the hernial orifice if the hernia has been long irreducible, or if the patient's condition is bad. It is sufficient to relieve the strangulation, and the herniated structures may be left adherent to the sac, and should not be reduced.

Lumbar Hernia.—This is quite rare. The protrusion occurs through Petit's triangle,[1] which is bounded below by the crest of the ilium, in front by the external oblique and behind by the latissimuss dorsi muscle. The floor of this triangular space is formed by the internal oblique muscle or its posterior aponeurosis, which is continuous and identical with the lumbar aponeurosis, with which the transversalis muscle and transversalis fascia are here fused (Fig. 916). The coverings of the hernia are skin, superficial fascia, lumbar aponeurosis (or internal oblique), preperitoneal fat, and peritoneum.

Most of the cases of lumbar hernia on record have been either congenital (probably due to abnormal size of Petit's triangle), or the result of trauma. The condition presents the usual symptoms and physical signs of a reducible hernia (p. 756), and must be distinguished from a cold abscess, as well as from a lipoma. There is no distinct neck to the sac. Strangulation is unusual.

Treatment.—If the patient wears a well-fitting truss for a year or more, there is fair probability that a small hernia may cease to protrude. In most cases, however, operative treatment is preferable. This consists in dissecting out the layers of the abdominal wall, and overlapping them by suture whenever this is possible. Dowd (1907) turned up a flap from the fascia lata covering the gluteal region, to aid in closure of the opening.

Inguinal Hernia.—Of the three usual forms of hernia, inguinal, femoral, and umbilical, inguinal hernia is by far the most frequent. It comprises about three-fourths of all cases of hernia, and is much more frequent in men than in women. In males, 96 per cent. of herniæ are inguinal, about 2.5 per cent. are femoral, and only 1 per cent. are umbilical. In females, 50 per cent. are inguinal, 33 per cent. are femoral, and 16 per cent. are umbilical (De Garmo).

Nomenclature.—If the hernia emerges from the peritoneal cavity at the internal abdominal ring, traverses the inguinal canal, and appears at the external abdominal ring, it is called an *indirect* or *oblique inguinal hernia*. If it passes directly through the abdominal wall on the median side of the deep epigastric artery, and thus appears at the external ring without traversing the inguinal canal, it is called a *direct inguinal hernia*. This is much rarer than the indirect form. If the hernia remains above the brim of the pelvis, it is called an *incomplete inguinal hernia*, or a *bubonocele;* if it descends beyond the brim of the pelvis it is called a *complete inguinal hernia*. A complete inguinal hernia in the male enters the scrotum and is termed a *scrotal hernia*; in the female it enters the labium majus and is called a *labial hernia* (this should not be confused with a pudendal hernia, p. 800).

[1] Lumbar hernia was first described by J. L. Petit in 1783.

Oblique Inguinal Hernia.—Inguinal hernia is more frequent in the male because of the greater size of the inguinal canal and because of the existence of the vaginal process of peritoneum which accompanies the testicle in its descent into the scrotum. These facts account also

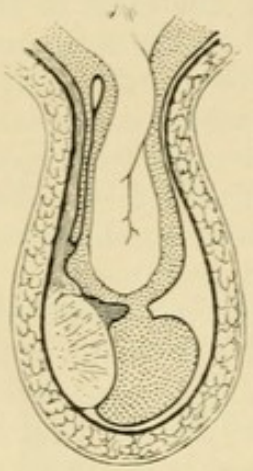

FIG. 780.—Incomplete obliteration of the funicular process of peritoneum, just above the testicle. Found at operation on a patient aged thirty-two years; duration of hernia sixteen years. Episcopal Hospital.

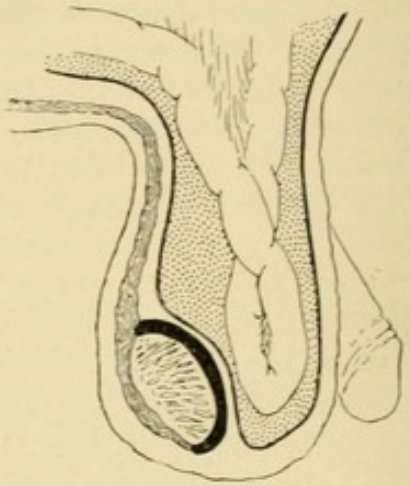

FIG. 781.—Ordinary adult type of inguino-scrotal hernia: fundus of sac separate from testicle, and easily enucleated. Hernia usually slowly developed.

for the greater frequency of oblique than of direct inguinal hernia. It is gradually coming to be recognized, largely owing to the teaching of Hamilton Russell (since 1899), and of R. W. Murray, that most

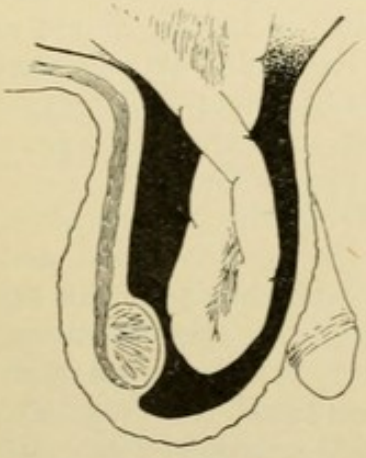

FIG. 782.—Hernia into patulous processus vaginalis: there is no separate tunica vaginalis. So-called "congenital hernia." A hernia of sudden formation.

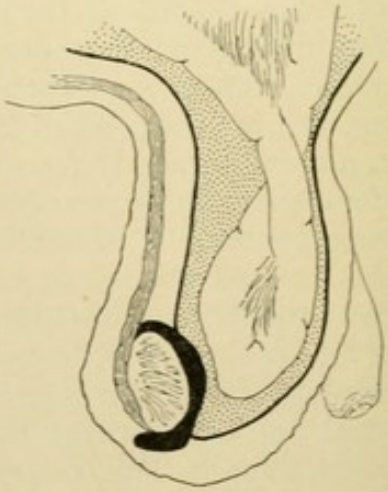

FIG. 783.—Hernia into funicular process: fundus of sac adherent to tunica vaginalis. So-called "infantile hernia." A hernia of sudden formation.

cases of hernia are due to the existence of a preformed sac. The probability of the existence of such a sac is greatest in the inguinal region; and formerly it was the custom in describing oblique inguinal hernia to lay great stress on the different varieties of sac which might be

present, according to the stage of development which had been reached by the vaginal process of peritoneum during fetal life. These distinctions have little more than academic interest; but a reference to the accompanying illustrations will explain the five forms which may be encountered. Occasionally *incomplete obliteration of the funicular process* occurs at one or more points, forming fibrous bands or strictures in the serous sac (Fig. 780); this accounts for cases of bilocular hydrocele (p. 1060), and is of some importance because strangulation may occur at any of these points, as well as at the neck of the hernial sac. The fact of greatest importance to bear in mind is that it is the existence of a preformed sac which predisposes to development of hernia, and that it is the *extirpation of the sac which is the most important step* (especially in children and young adults) in the operation for the cure of hernia. A. H. Ferguson pointed out that in some patients the

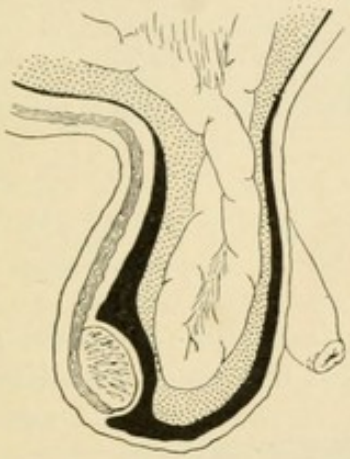

FIG. 784.—Hernia encysted into the tunica vaginalis. The "encysted hernia of Sir Astley Copper." Funicular process closed only at the internal ring. An acquired hernia of slow formation.

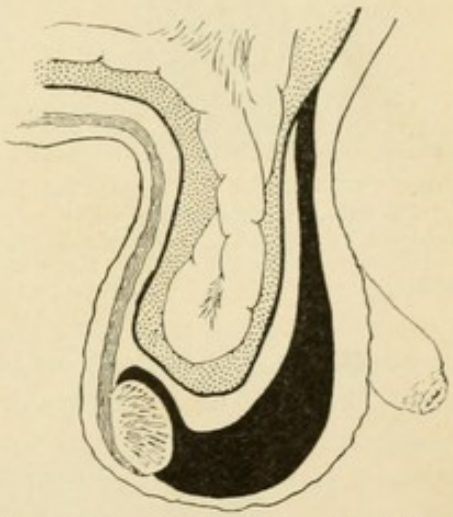

FIG. 785.—Hernia encysted between tunica vaginalis and testicle. "Encysted hernia of Hey, of Leeds." Due to same congenital defect as Fig. 784, but parietal peritoneum has yielded just posterior to upper obliterated end of funicular process.

internal oblique muscle does not have an origin from Poupart's ligament, as is normally the case, and that this renders the region of the internal abdominal ring very weak. Apart from these anatomical factors, the predisposing and exciting causes of inguinal hernia are the same as those of hernia in general (p. 754).

If the hernia is *present at birth* it is one usually described as congenital (Fig. 782); but of course a "congenital" sac may be present but no hernia develop until adult life. If the hernia appears at any time after birth, and is of *sudden formation*, it is probable that there was a preformed sac, and that the sudden appearance of the hernia is caused by muscular effort forcing some of the abdominal contents into this sac (Fig. 783.) If the hernia is of *slow formation*, which is rare except in adults, it is still possible that a small preformed sac may have existed.

If the hernia occurs into a sac formed by the patulous vaginal process of peritoneum (Fig. 782), whether the hernia is present at birth, appears during infancy or childhood, or does not appear until

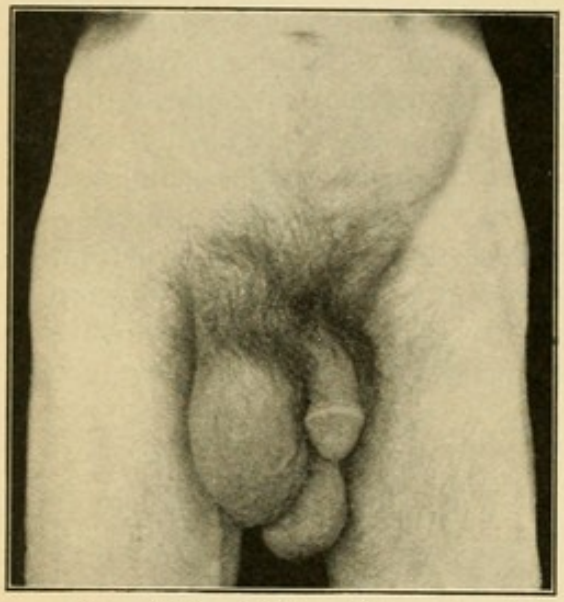

FIG. 786.—Right oblique inguino-scrotal hernia. Congenital sac, but hernia developed in adult life. Outline of testicle obscured. (See Fig. 782.) Episcopal Hospital.

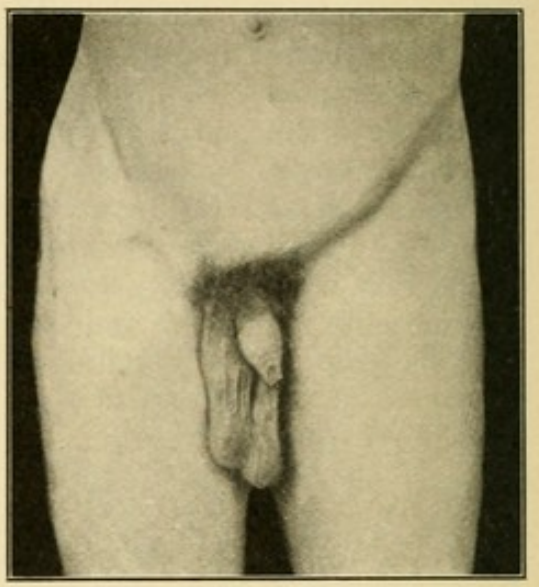

FIG. 787.—Right oblique inguino-scrotal hernia, funicular type (infantile). Age sixteen years. Outline of testicle distinct from that of hernia. (See Fig. 783.) Episcopal Hospital.

late adult life, *the contents of the hernia will obscure the outline of the testicle* (Fig. 786). If, however, the testicle has its own tunica vagi-

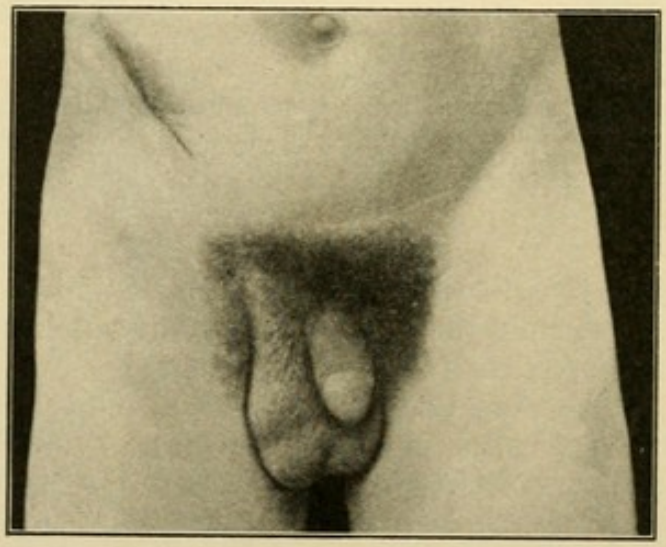

FIG. 788.—Right oblique inguino-scrotal hernia; age sixteen years; slowly acquired three years ago. McBurney incision for appendicitis eight years ago. (See p. 754.) Outline of testicle distinct from that of hernia. (See Figs. 781 and 791.) Episcopal Hospital.

nalis (Figs. 781 and 783), *the hernia and the testicle can be perceived as separate swellings in the scrotum* (Figs. 787 and 788). This distinction is of some clinical importance, when operative treatment is under-

taken (p. 789). In all cases, with very few exceptions, the hernia lies in front of the spermatic cord, and even if the hernia is irreducible, the cord usually can be palpated behind it.

Symptoms and Diagnosis.—An oblique inguinal hernia is more common on the right side. It appears first at the internal abdominal ring, and may or may not descend into the scrotum. In its descent it always passes through the inguinal canal. The longer its duration and the larger the hernia, the less oblique becomes its passage through the abdominal wall, as the internal ring gradually enlarges and shifts its position nearer to the spine of the pubis. When in the scrotum the hernia is not attached to the testicle, and in most cases can be reduced within the abdomen. This reduction is attended by characteristic signs (p. 757). If the hernia is irreducible the diagnosis may be more difficult; but always, unless strangulated, the hernia transmits an impulse when the patient coughs. The differential diagnosis of direct inguinal hernia is considered at p. 792, and that of femoral hernia at p. 794.

An *incomplete inguinal hernia* must be distinguished from: (1) *Hydrocele of the cord* (p. 1060). If this is inflamed, it may closely resemble a strangulated inguinal hernia, unless a clear history can be obtained. But there are no signs of intestinal obstruction. (2) *Inflammatory Lymphadenitis*, or *Inguinal Bubo* (p. 269), is inflammatory in nature, is irreducible; gives no impulse on coughing; and usually a source of infection in the genitals, lower extremity, or buttocks can be found. (3) *Tuberculosis of the Inguinal Lymph Nodes* may resemble an irreducible epiplocele; but there is no impulse on coughing; the history of the onset of the two affections is different; the swelling lies superficial to the inguinal canal, and does not extend into the scrotum even if of long duration; suppuration is frequent. (4) *Cold Abscess*, the result of tuberculosis of the spine, occasionally makes its appearance in the inguinal canal; it may transmit an impulse when the patient coughs, and often is reducible when he lies down; but the abscess presents no gurgling on reduction, and it is dull on percussion, which an enterocele is not; moreover, examination of the spine usually will reveal the true condition. (5) *Undescended Testicle* (p. 1050). This is recognized because the scrotum on the affected side is empty, and because of the sickening pain produced by handling the tumor, which is irreducible.

A *complete inguinal hernia* must be distinguished from: (1) *Vaginal Hydrocele*, (p. 1059), which appears first, not at the internal abdominal ring, but in the scrotum; which rarely extends into the inguinal canal; which is attached to the testicle and is irreducible; which though cystic on palpation is dull, not resonant, on percussion, and which transmits light. (2) *Congenital Hydrocele* (p. 1058); this may be distinguished from a hernia because the inguinal canal seems empty except for the cord; because when reduction occurs there is no gurgling or flop of intestine; because of the extreme slowness with which the scrotum refills when the patient stands up; and because the hydrocele is dull

on percussion and is translucent. (3) *Varicocele* (p. 1061). This appears first in the scrotum, not at the internal abdominal ring; it may not extend into the inguinal canal; it gives a very different impression from a hernia when palpated; and though usually the swelling disappears when the patient lies down and the scrotum is elevated, this occurrence is not attended by any of the signs which indicate the reduction of a hernia. (4) *Sarcocele* (p. 1056). This is formed by an enlargement of the testicle itself; it appears first in the scrotum; is irreducible; is dull on percussion even if partly cystic; and though thickening of the spermatic cord may occur from extension of the disease, this does not present the characteristics of a hernia.

Oblique Inguinal Hernia in the Female.—In women only the round ligament passes through the inguinal canal. It carries with it a process of peritoneum (the canal of Nuck), which may remain patulous and predisposes to the formation of a hernia. The internal oblique muscle in the female, as a rule, has a larger origin from Poupart's ligament than in the male, and no doubt this lends additional strength to the region of the internal abdominal ring and the inguinal canal. In children a hernia usually is arrested in the canal of Nuck (Fig. 789), but in adults it often descends into the labium majus, though rarely attaining very large size.

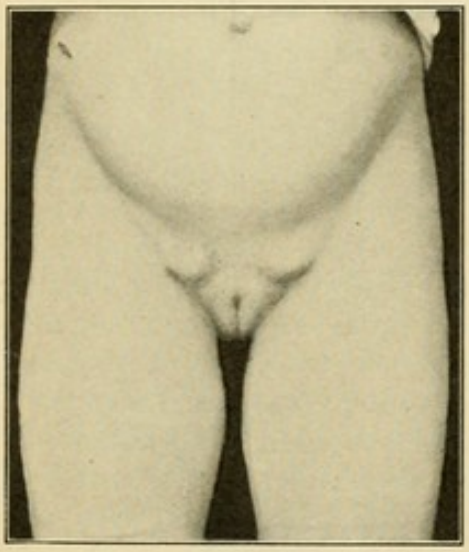

FIG. 789.—Double oblique inguinal hernia into the canal of Nuck, in a girl of nine years. Children's Hospital.

Strangulation of Oblique Inguinal Hernia may occur in the neck of the sac, at the internal ring, or at the external ring. The external ring should be divided first whenever strangulation is present; the sac is then opened; and if strangulation is not relieved by this means, the neck of the sac and the internal ring must be divided also.

Rare Forms of Oblique Inguinal Hernia.—A hernia may make its appearance at the internal abdominal ring, but for some reason be arrested in its journey downward to the scrotum. This may be due to the obstruction offered by an undescended testicle (occasionally an ovary in the female), or from the partial constrictions in the lumen of a preformed sac, to which reference was made at p. 781. (1) If the hernia is arrested just outside of the internal abdominal ring and forms for itself a diverticulum out of the sac wall, between the parietal peritoneum and the abdominal muscles, it is called an *inguinal properitoneal hernia* (first well described by Krönlein in 1880). This hernia usually spreads toward the median line of the body. (2) If it forms a sac for itself between the muscular planes of the abdominal wall it is called an *interstitial* or *interparietal hernia;* this is the least

unusual form, and the hernia generally spreads outward toward the crest of the ilium. (3) If the hernia occupies a diverticulum in the subcutaneous tissues, outside of the external abdominal ring, upon Poupart's ligament, or overhanging the upper part of Scarpa's triangle, it is known as a *superficial inguinal hernia* or an *inguino-crural hernia;* this is the rarest of these unusual forms of hernia.

These herniæ are very liable to strangulation, but the exact diagnosis of the condition seldom is made before operation.

Unusual Contents of Oblique Inguinal Hernia.—The *usual contents* are small bowel and omentum. The presence of **large bowel** is unusual. When present it usually forms what is known as a **sliding hernia,** as the bowel usually slides down retroperitoneally, carrying a peritoneal pouch down with it, covering only its anterior aspect. In this pouch small bowel and omentum may be contained, and when these are reduced at operation, the surgeon will find that the posterior wall of the hernial sac covers the large bowel (Fig. 790). A *sigmoid hernia,* occurring on the left, is considered more frequent than a *cecal hernia* on the right. Occasionally a cecal hernia occurs on the left; in such cases it is probable that the cecum has been drawn into the sac by the traction of the ileum already in the sac. The presence of the *vermiform appendix in the hernial sac* is of considerable importance, as it may become the seat of acute inflammation, gangrene, etc. Such cases have been carefully studied by Jacquemin (1905) and by Massoulard (1906). An *undescended testicle* usually is accompanied by a hernial sac; this subject is discussed at p. 1050. Occasionally in the female the *ovary,* the *tube,* or even the *uterus* (pregnant or non-pregnant) is found in the sac of an inguinal hernia; F. T. Andrews (1905) has tabulated 366 cases of this nature.

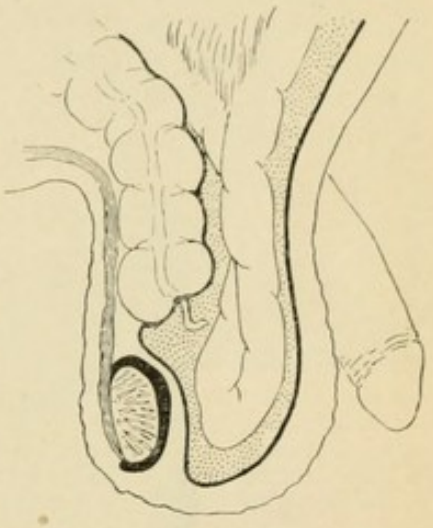

Fig. 790.—Sliding hernia of the cecum: small intestine in the hernial sac. Age thirty-one years; duration two years. Episcopal Hospital.

Treatment of Oblique Inguinal Hernia in Adults.—A cure without operation is all but unknown in adult patients. The *mortality* of the operation is very low, scarcely one in three or four hundred cases; and the deaths scarcely ever are due to the operation itself, but to complications, which may follow any operation. *Recurrence of the hernia* takes place in very few cases; according to Coley, permanent cure is effected by proper operation in about 95 per cent. of cases. But when for any reason operation is contraindicated, or when the patient refuses operative treatment, the surgeon should know what measure of relief may be effected by mechanical treatment, and should be able to order intelligently the proper form of truss, and to see that it accomplishes the purpose for which it is designed.

Trusses for Inguinal Hernia.—The *pad of the truss* is to be applied over the inguinal canal, so as to hold its superficial and deep walls in contact, and thus to close the channel by which the hernia descends. The pad must not be placed only over the external ring, still less over the spine of the pubis, as this allows the hernia to slide past the truss (Fig. 791). The pad should not be set at an angle with the spring of the truss (as in the bad type of truss introduced in 1837 by Dr. Heber Chase, and still in use), but should be directly beneath the spring, so as to ensure its remaining in place and exerting direct pressure on the canal. The *counterpressure* is over the sacral region or the posterior part of the buttock of the opposite side, just lateral to the posterior superior spine of the ilium. In young adults, where the hernia is small and easily retained, the **cross-body truss** (Fig. 792) is the most serviceable type. According to De Garmo this type was introduced by an English firm of instrument-makers toward the

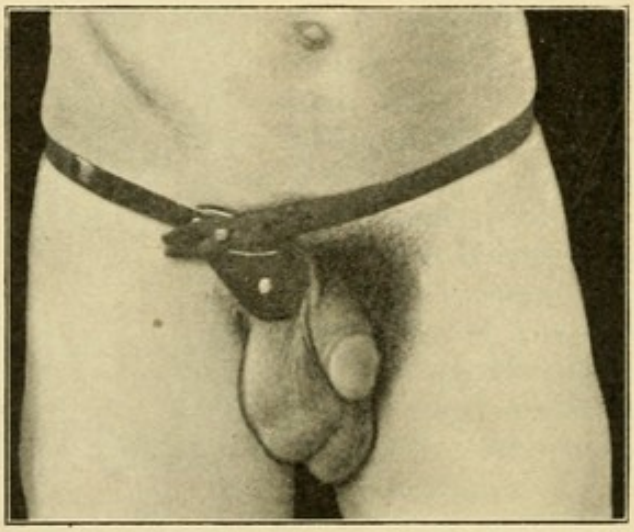

FIG. 791.—Badly fitting truss of French-German type. Pad is placed over spine of pubis, and the hernia is now in the scrotum. Same patient as Fig. 788. Has worn truss this way more than two years, in hope of being cured. Episcopal Hospital.

close of the eighteenth century. The spring is complete in front; beginning at the pad over the inguinal canal, it passes across the pubis from the affected to the unaffected side, and is continued around three-fourths of the pelvis to the buttock of the affected side. The strap holding the ends of the spring together thus lies on the same side of the pelvis as the hernia. The pressure made by the pad is inward and slightly upward. If the hernia is less easily retained, or if the patient is older and obsese, a truss with *double pads* gives better support; the best is the **Hood type** of truss, introduced about seventy years ago by Dr. J. W. Hood, of Kentucky. The spring is solid in front, and supports adjustable pads, one over each inguinal canal (Fig. 793), and is continued posteriorly on each side to within a few inches of the spine, where it is supplied with two pads for counterpressure; the ends of the spring are connected across the spine by a short strap. This is also the best type of truss for double inguinal

hernia. The truss is so secure that very little elastic spring pressure is needed to keep it in place and to retain the hernia, a fact which renders it very comfortable for the patient to wear. Other forms of truss, the English rat-tail truss, and the French and German trusses are much less efficient.

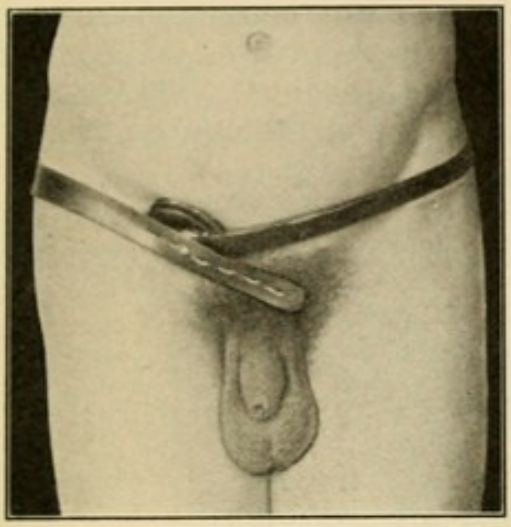

FIG. 792.—Cross-body truss, fitting well. Age twenty-two years. Appendicitis operation (rectus incision) one year ago; hernia developed six months later. Episcopal Hospital.

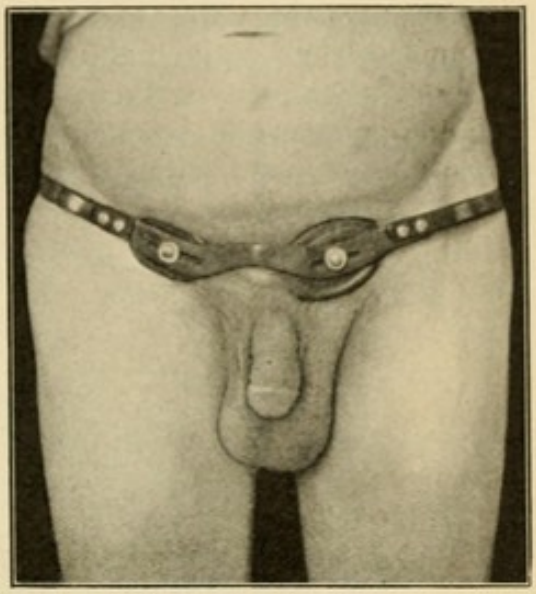

FIG. 793.—Double hood truss, applied for large left inguinal hernia; light pad also on right side. Age fifty-nine years. This truss maintains reduction even in severe coughing. Episcopal Hospital.

OPERATION FOR OBLIQUE INGUINAL HERNIA.—Almost every surgeon who operates on many cases of inguinal hernia develops certain modifications of technique peculiar to himself. Many of these have been published as original operations, though few of them are real improvements on the universally accepted type of operation which is that introduced in 1885 by Bassini. This is the best operation for the average case, and if it is well learned the operator can introduce such improvements as suggest themselves in special cases as he increases in experience. It is not often that two cases of hernia are as alike as two peas.

Bassini's Operation.—The incision runs above and parallel to Poupart's ligament from the internal to the external abdominal ring. This incision passes at once to the aponeurosis of the external oblique; the deep layer of the superficial facia (Scarpa's fascia) sometimes is mistaken for this aponeurosis. There will be cut in this incision at least two veins—the superficial epigastric and the superficial circumflex iliac veins. The four bleeding-points should be clamped *and ligated*. Any other bleeding-points should be clamped *and ligated*. Every bleeding-point encountered during the operation should be clamped *and ligated*. It is not sufficient to trust to forcipressure for permanent hemostasis. The success of the operation depends on the aseptic healing of the wound, and the development of a very small hematoma may nullify the entire work.

When the aponeurosis is exposed, the external abdominal ring should be identified. If not readily apparent it is easily found by raking upward with the handle of the scalpel in the neighborhood of the pubic spine (Fig. 794). An incision is next made through the external oblique aponeurosis from the region of the internal ring into the external ring; this incision runs parallel to Poupart's ligament and at least half an inch above it. Do not make the incision too near Poupart's ligament or there will be no free margin of the external oblique aponeurosis to facilitate subsequent suture. There is no advantage in not cutting through the pillars of the external ring.

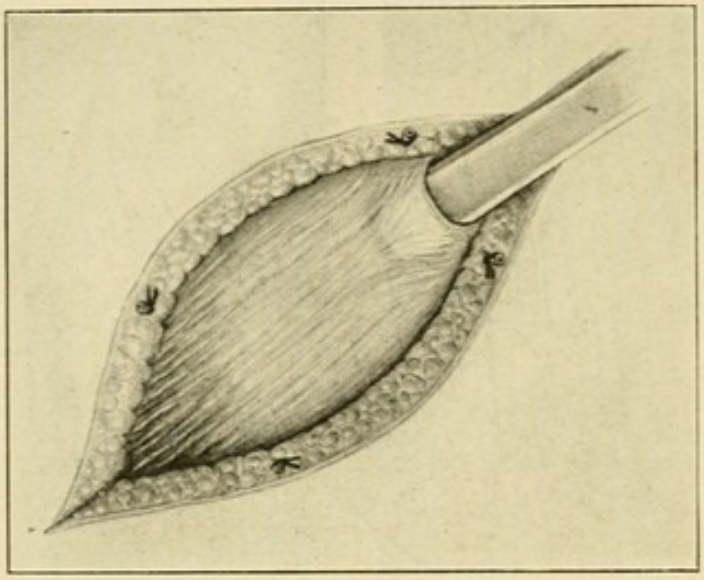

FIG. 794.—Operation for inguinal hernia: superficial fascia incised and bleeding-points located. Aponeurosis of external oblique exposed, and external abdominal ring identified by handle of scalpel.

When the external oblique aponeurosis has been incised, its cut margins are retracted, by blunt dissection with the handle of the scalpel, until the inner shelving margin of Poupart's ligament is well exposed below, and the arching fibres of the internal oblique can be easily seen on the upper (umbilical) side of the wound. The ilio-inguinal nerve should not be injured. The index finger is then passed down on the outer side of the inguinal canal, close to Poupart's ligament, and hooks up all the structures of the canal, including the hernial sac and the spermatic cord (Fig. 795). By a little skilful dry dissection the end of the finger can be passed entirely through, beneath these structures from the lower to the upper side of the wound. Holding these structures upon the left index finger, the surgeon strips its various coverings off the hernial sac by wiping them away with gauze or by the use of dissecting forceps. As little cutting as possible should be done, as this increases bleeding. The names of these deep *coverings of the hernia* (intercolumnar fascia, *i. e.*, external oblique; cremasteric fascia, *i. e.*, internal oblique, and fascia propria, *i. e.*, transversalis fascia, have little more than academic interest.

The sac is least adherent to surrounding structures in the upper part of the inguinal canal, and it is best to isolate it here first.

When the sac is finally bared, it may be opened, and its contents reduced. Then with one finger inside the sac, the surgeon proceeds to complete its enucleation from the surrounding tissues.[1] The sac sac is separated from the cord, and the dissection is continued upward to the internal ring, *until parietal peritoneum is reached.* This is known by the presence of pre-peritoneal fat, and by the peritoneum becoming whiter, denser, and more fibrous; and the operator should not be satisfied until such peritoneum has been reached. If he desists before parietal peritoneum is reached he will leave the upper part of the sac behind, in the form of a pouch, which will predispose to recurrence. The operation is not always easy. When the parietal peritoneum has

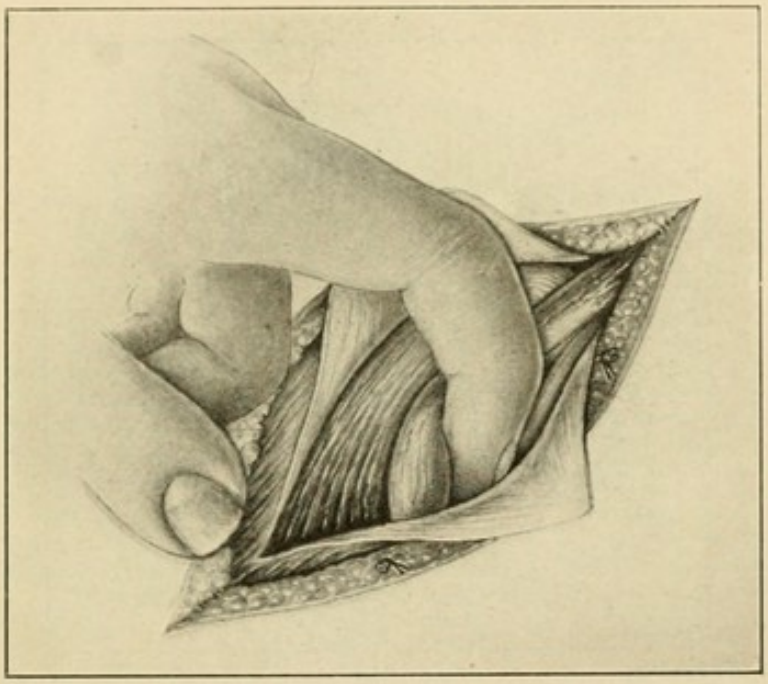

FIG. 795.—Operation for inguinal hernia: the inguinal canal has been exposed by an incision through the aponeurosis of the external oblique. The finger is passed down close to Poupart's ligament and hooks up all the structures in the canal.

been exposed, the neck of the sac is closed by a purse-string suture, or if large by continuous suture, as in the case of any abdominal wound. It is not sufficient merely to ligate the sac as one ligates an artery; such a ligature is very apt to slip off the neck of the sac. When the neck of the sac has thus been securely sutured, the sac is cut away, *but the ends of the suture are left long;* the neck is now allowed to recede into the upper angle of the wound, and is carefully inspected for bleeding; if this is found the neck of the sac is drawn again into full view by the attached suture, and the bleeding-point is ligated or

[1] If the sac is of the "congenital" type (Fig. 782), its complete enucleation is impossible. The fundus should be left attached to the testicle, and may be sutured, to form a tunica vaginalis. If very much of the fundus is left a secondary hydrocele may form.

controlled by an additional suture. When it has been ascertained that there is no bleeding, the ends of the suture are cut short, and the surgeon proceeds to close the inguinal canal.

The spermatic cord is held out of the way, and the *first row of deep sutures* is introduced. These sutures are to approximate the arching fibres of the internal oblique and the conjoined tendon to the inner shelving margin of Poupart's ligament, so as to form a new floor to the inguinal canal, upon which the transplanted cord is to lie. This is the essential feature of Bassini's operation. In passing these sutures there is considerable danger of wounding the femoral vessels, especially the vein, beneath Poupart's ligament. These are mattress sutures of chromic catgut (No. 2 or No. 3). The first suture is passed at the upper end of the inguinal canal just below the internal ring. The round-pointed curved needle is entered from the superficial aspect of

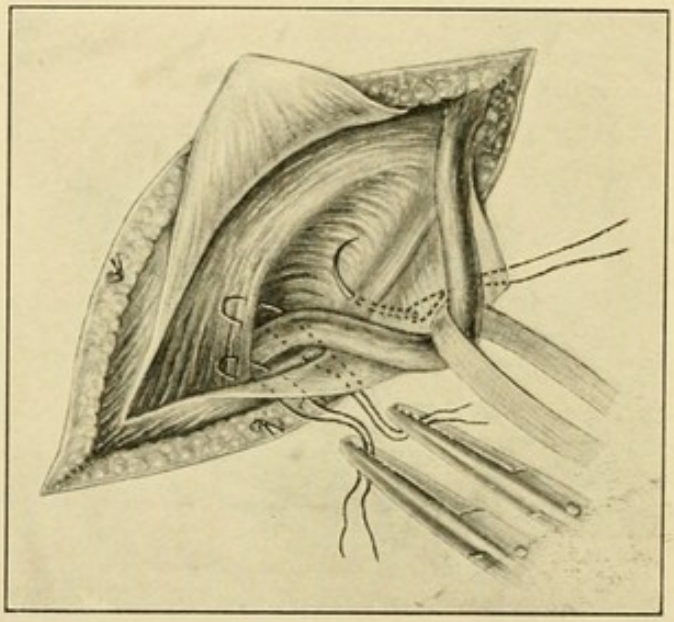

FIG. 796.—Operation for inguinal hernia: suturing the arching fibres of the internal oblique (beneath the cord) to Poupart's ligament.

Poupart's ligament (Fig. 796), and emerges (on the surgeon's index finger as a guide) on the deep and shelving border of this ligament in the inguinal canal. It is better to prick your finger than to injure the femoral vein. The needle is then passed beneath the spermatic cord, and takes a firm hold of the internal oblique, passing through it from below upward. The course of the needle is then reversed, passing first through the internal oblique from above downward, then across the inguinal canal beneath the cord, and finally through Poupart's ligament from within outward, to emerge about half a centimeter from its original point of entrance. This completes the first mattress suture. Usually three or four other similar sutures are required, the last sutures drawing the conjoined tendon down against the lower and inner end of Poupart's ligament. If the upper end of the canal seems weak, it is well to pass the first suture through Poupart's

ligament and the internal oblique just on the lateral (flank) side of the internal ring. By passing all these deep sutures as described, the knots are brought entirely outside the inguinal canal. This is an advantage.

The spermatic cord is now replaced on the superficial surface of the internal oblique, and the cut margins of the external oblique aponeurosis are then sutured, over the cord, with a continuous suture (*the second row of deep sutures*) from above downward, leaving an opening below (the new external ring) just large enough to transmit the cord (Fig. 797). The skin wound is then closed in the usual way. The patient should remain in bed two weeks, and if the hernia was large, or if more than one hernia was operated on, for three weeks or longer.

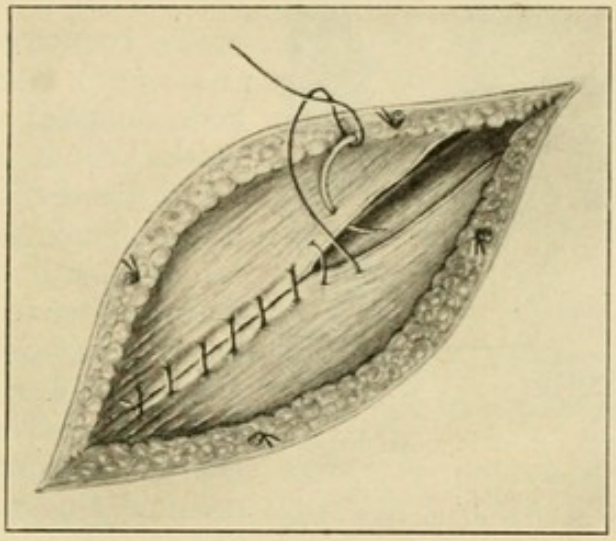

FIG. 797.—Operation for inguinal hernia: the aponeurosis of the external oblique is sutured over the cord.

In **women** the operation is simpler, since there is no cord in the way. The canal may be completely closed, the round ligament being included in the sutures.

In **infants** the use of a truss for a year or more will cure a small hernia in a fair proportion of cases—De Garmo says in 95 per cent. But this means that the truss fits, that it is changed from time to time as the child grows, that the patient is under constant surgical supervision, and that the truss is employed with all the precautions enumerated at page 759. Unless these conditions are fulfilled, and they rarely are, a cure need not be expected. But, as a rule, it is not desirable, though perfectly possible, to resort to operation on a child until it has learned to control its bladder and bowels. The youngest patient I have operated on was a boy, six weeks old, with strangulated hernia; he was not confined to bed after the operation, and did perfectly well. In young children complete extirpation of the sac is sufficient to ensure against recurrence; it is not necessary to transplant the cord, and if it is short it may be impossible to do so. If the inguinal canal seems

weak, the other steps of the operation are the same as in the Bassini operation. This form of operation, without transplanting the cord, was employed also in adults by A. H. Ferguson (1899), and is known as Ferguson's method.

Direct Inguinal Hernia.—This hernia is one which protrudes through the abdominal wall on the median side of the deep epigastric artery, just to the outer side of the spine of the pubis, and directly behind the external abdominal ring. This is the space known as Hesselbach's triangle. Direct hernia is seen about once in every 30 to 40 cases of indirect inguinal hernia. It is least rare in adults and occurs oftener in men than in women. It is a hernia of slow formation, and there is no well defined neck to the sac. In most cases it may be recognized at a glance (Fig. 798). Strangulation is very unusual. It is distinguished from oblique inguinal hernia by the fact that when it has been reduced, pressure over the internal abdominal ring does not prevent its reappearance. It should not be forgotten that a large indirect inguinoscrotal hernia may cause the position of the internal abdominal ring to shift until it lies directly behind the external ring; but a direct hernia never descends far into the scrotum. Sometimes when the hernia is reduced, it is possible to palpate the deep epigastric artery on the lateral margin of the hernial orifice. If there is any doubt about the nature of the hernia, it probably is an indirect inguinal hernia.

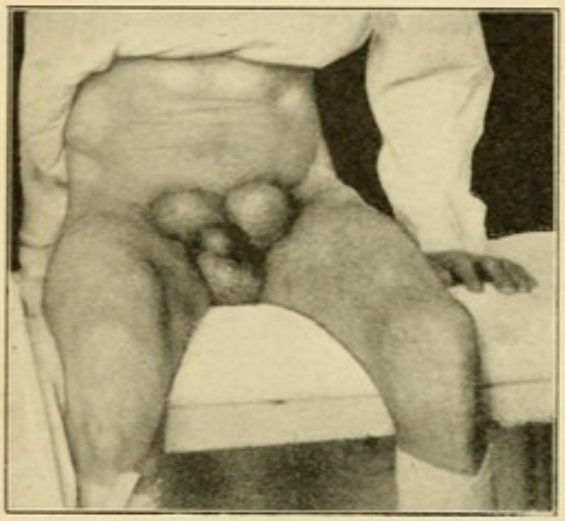

FIG. 798.—Double direct inguinal hernia, age sixty-eight years; duration thirty years. Of slow onset, from constant straining in urination. Has strictures of urethra, and enlarged prostate. Operation on herniæ contraindicated until urinary obstruction is relieved. Episcopal Hospital.

A direct hernia usually protrudes through the conjoined tendon, which is carried forward as one of its coverings. Occasionally, however, it passes to the outer side of the conjoined tendon. In most cases the spermatic cord lies on the outer side of the sac.

Rare Forms of Direct Inguinal Hernia.—Sometimes the sac of a direct inguinal hernia occupies (1) a properitoneal position near the bladder; or after protruding through the conjoined tendon on the median side of the obliterated umbilical vein, it may lie (2) between the conjoined tendon and the external oblique aponeurosis, or (3) in a subcutaneous position in front of the external oblique aponeurosis. For these rare varieties of direct inguinal hernia Reich, in 1909, proposed the name of *Supravesical Hernia*. He collected 16 cases of the first variety, which he calls internal supravesical hernia; and 26 cases of the second and third varieties, which he terms external supravesical hernia.

Treatment of Direct Inguinal Hernia.—If a truss is used, it must have a large pad, as the hernia is difficult to control. Repair of the defect by operation is also more difficult and is less sure in preventing recurrence than in indirect inguinal hernia. The parts are exposed in the same way, and the sac is isolated. In doing this the surgeon should remember that the bladder frequently protrudes into Hesselbach's triangle, and that its extraperitoneal surface is with difficulty distinguished from preperitoneal fat. Any fatty mass toward the median side of the hernial orifice should be avoided. When the sac has been opened and its contents have been reduced, it will be found that an opening is left which it is difficult to suture firmly, owing to the relaxed and atrophied condition of the various layers of the abdominal wall. After the parietal peritoneum has been sutured, the internal oblique and conjoined tendon should be drawn down if possible and sutured to Poupart's ligament, underneath the spermatic cord, as in the *Bassini operation* (p. 787). In cases where the internal oblique and conjoined tendon are very weak, the median reflected flap of the external oblique aponeurosis may be included in the sutures with them, and be drawn down and sutured to Poupart's ligament beneath the spermatic cord; then the lateral reflected flap of the external oblique is sutured over the cord (*E. Wyllys Andrews*, 1895). If the cremaster is well developed it may be employed as an additional layer in suturing the canal. Another plan may be adopted where the conjoined tendon is so thin that it will not hold the sutures; an incision is made through the transversalis fascia along the lateral border of the conjoined tendon, raising it and the anterior sheath of the rectus off this muscle, whose fibres are then drawn over and sutured to Poupart's ligament (*Bloodgood*, 1898). When, as is often the case, the sac is blended with the much relaxed overlying structures, no attempt should be made to separate them, but *G. G. Davis's operation* (1905) should be employed: these blended tissues are divided transversely, and are overlapped from above downward, much as in Mayo's operation for umbilical hernia (p. 778). This gives very satisfactory closure. The use of silver filigree or of a free fascial flap, as noted at p. 774, may be desirable in some cases.

However the deeper structures are sutured, the skin is closed in the usual way, and after-treatment is conducted as after operations for indirect inguinal hernia.

Femoral Hernia.—**Femoral** or **Crural Hernia** has also been termed **merocele.** The hernia protrudes through the femoral canal, beneath Poupart's ligament, on the median side of the femoral vein. As already noted, it is commoner in women than in men, especially in women after the menopause. In childhood it is rare. Though in most cases there is a preformed sac, this may not always be a congenital deformity,[1] but may be a traction diverticulum probably due to the

[1] According to Lockwood, a congenital sac in the femoral canal is to be attributed to traction by aberrant strands of the gubenernaculum testis.

fact that some of the preperitoneal fat is forced into the femoral canal and gradually draws the peritoneum after it. Such a sac may exist for many years before a hernia forms; Murray found this condition in 48 out of 200 cadavers. Most of the femoral herniæ I have seen have been of sudden formation, clearly indicating the previous existence of a sac.

As the hernia develops, it carries before it preperitoneal fat (*septum crurale*) and transversalis fascia (*crural sheath*). While still in the femoral canal it is known as an *incomplete femoral hernia*. Increasing in size, it leaves the femoral canal, causes bulging of the cribriform fascia, and curves upward over the falciform process of fascia lata, and lies beneath the skin of the groin (*complete femoral hernia*). It seldom grows very large. The only contents of the sac often is omentum, but neither this nor intestine is likely to become irreducible without becoming at the same instant strangulated. Strangulation probably is more frequent in femoral than in any other form of hernia, and gangrene occurs more rapidly, owing to the sharp margins of the femoral canal. Small intestine is much more frequently present in the sac than the colon, but the cecum sometimes is found; A. C. Wood (1906) has collected 100 cases in which the vermiform appendix was the only structure in the sac.

Rare Forms of Femoral Hernia.—The sac of a femoral hernia may have one or more diverticula, and such cases have been described as separate forms of femoral hernia: there are recognized (1) *a diverticulum through the cribriform fascia*, or hernia of Hesselbach (1816); (2) *a diverticulum through the superficial fascia*, or hernia of Cooper (1807); (3) *a properitoneal diverticulum*, or hernia of Tessier (1834). A more frequent, but still very rare variety, is called a *pectineal hernia*, or hernia of Cloquet (1814); in this the sac passes from the femoral ring between the pectineus muscle and its sheath, instead of anterior to the latter as in the usual form; if large the sac may extend outward beneath the femoral vessels. Ulrichs (1911) refers to 15 cases of this variety of femoral hernia which was well studied in 1907, by Dege. This hernia is to be distinguished from another rare variety, in which the sac enters the sheath of the femoral vessels, and passes into the thigh behind them (*hernia retrovascularis*). There have been recorded also a few cases of femoral hernia *external to the femoral vessels*, between the ilio-pectineal ligament and the femoral artery (hernia of Partridge, 1846). A hernia through an opening in Gimbernat's ligament was described first by Laugier (1833) and is known by his name; it is on the median side of the obliterated umbilical artery.

Diagnosis.—A femoral hernia is to be distinguished from other forms of hernia, from enlarged lymph nodes, from subcutaneous lipoma, from varices of the saphenous vein, and from psoas abscess.

1. An *inguinal hernia* appears first above Poupart's ligament, and can be retained within the abdomen, after reduction, by pressure over the inguinal canal. A femoral hernia always makes its first appearance below Poupart's ligament, and it will not be retained within the

abdomen if pressure is made only over the inguinal canal. If the hernia is irreducible the diagnosis is more difficult; but if an imaginary line is drawn from the spine of the pubis to the anterior superior spine of the ilium, it is safe to say that a hernia whose chief bulk lies below that line (which corresponds to Poupart's ligament) is a femoral hernia (Fig. 799).

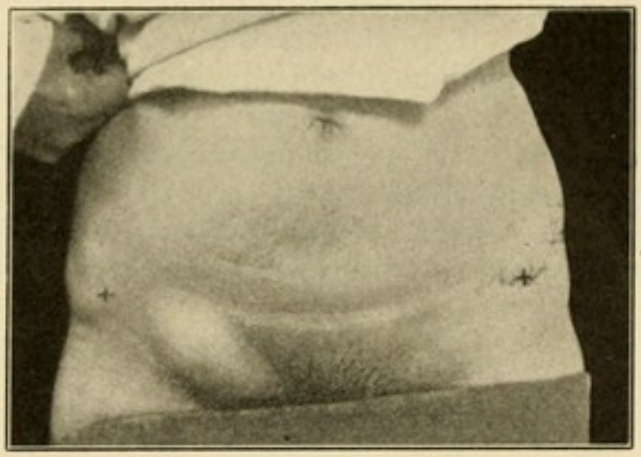

FIG. 799.—Right femoral hernia. Episcopal Hospital.

2. If an *obturator hernia* is present, the femoral canal will be empty, which is never the case if a femoral hernia exists.

3. In *femoral adenitis* the swelling may occur over the femoral canal, but it transmits no impulse on coughing; moreover, it presents signs of inflammation and a primary source of infection usually can be found. But as a strangulated femoral hernia may be present behind inflamed lymph nodes, it is safer to operate in cases of doubt. The same is true in cases of *fatty or other tumors* overlying the femoral canal.

4. A *varicosity of the long saphenous vein* may protrude over the femoral canal. It transmits an impulse when the patient coughs, but though, like a hernia, it disappears when the patient lies down, its reduction is not attended by gurgling, nor when the patient stands up will its reappearance be prevented by pressure over the femoral canal.

5. A *psoas abscess* is secondary to tuberculosis of the spine, which usually may be detected by proper examination. When the abscess descends below Poupart's ligament it usually appears on the outer side of the femoral vessels. Though it may transmit an impulse on coughing, and may be reducible, this reduction is not attended by the gurgling so characteristic of hernia.

Treatment of Femoral Hernia.—The use of a truss is unsatisfactory even in retaining the hernia within the abdomen, as it is impossible to obliterate the femoral canal; the most that a truss can do is to close its lower (*crural*) opening. No cure without operation need be anticipated; and in no form of hernia is a cure so necessary, owing to the great frequency with which strangulation occurs.

1. The usual operation is done by the *femoral route*. The skin incision may be straight, in the long axis of the body, directly over the

femoral canal, or a flap may be outlined, convex outward, so that the line of skin sutures will be far removed from the genitalia (Fig. 800). The incision should commence well above Poupart's ligament, and should expose also the fascia lata and cribriform fascia over the upper part of Scarpa's triangle. Care should be taken not to wound the long saphenous vein. When the skin and subcutaneous tissues have been reflected, the sharp margin of the falciform process of the fascia lata is to be located. Beneath this the femoral artery will be felt pulsating, and to the median side of this is the femoral vein which is in constant danger of injury. On the median side of the wound the surgeon should identify the pectineus muscle and its fascia. Then the sac may be opened. If the hernia is large and irreducible, which is seldom the case, it may be impossible to identify these various structures until the sac has been opened and its contents reduced.

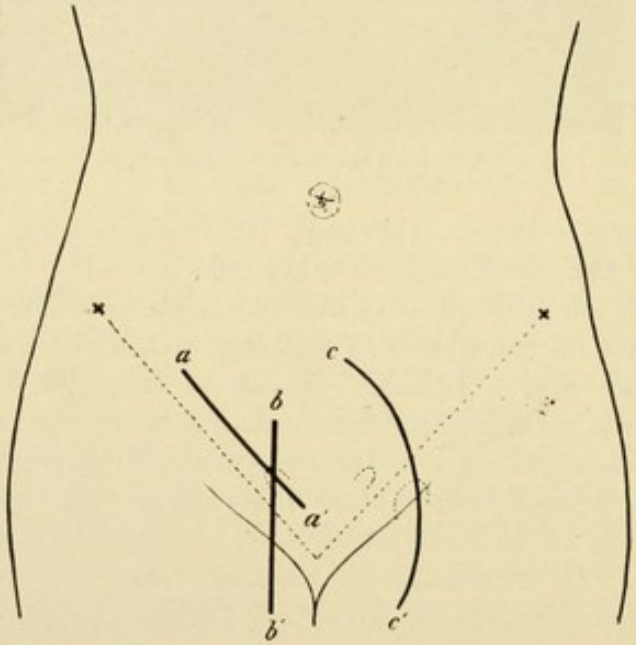

FIG. 800.—Incision for femoral hernia: *a a'*, for the inguinal method; *b b'*, longitudinal incision for the crural method; *c c'*, flap incision for the crural method.

Under such circumstances the operator must cut down layer by layer until the sac is opened. It is seldom possible to identify the various coverings of the hernia. The omentum in an irreducible femoral hernia nearly always requires to be excised in entirety. When the contents of the sac have been reduced, the sac must be traced up into the femoral canal under Poupart's ligament until parietal peritoneum is reached. This is known by its being whiter, denser, and more fibrous than the walls of the hernial sac. The opening in the parietal peritoneum is then closed with a purse-string suture, and the sac is cut away, with the usual precautions against overlooking hemorrhage from the stump (p. 789). From recent observations (Ochsner) it seems probable in most cases of femoral hernia, except where the femoral canal is widely dilated, that accurate suture of the parietal peritoneum is a sufficient preventative of recurrence, even without any attempt to close

the femoral canal by suture. But in most cases it is not very difficult to insert one or more sutures so as to obliterate the canal. The needle (curved and round pointed), threaded with chromic catgut, is entered on the superficial surface of Poupart's ligament, close to the femoral vein, and is made to emerge in the femoral canal, catching some of the fibres of the sheath of the femoral vein if possible to do this without puncturing the vein. The needle is again gripped in the needle-holder, and is passed transversely inward, taking a firm hold of the pectineal fascia and underlying muscle, and is again gripped in the needle-holder. The needle is then passed through Poupart's ligament from below upward, near its inner end, and emerges finally near its original point of entrance on the superficial aspect of Poupart's ligament. This completes the first purse-string suture of the femoral canal (Fig. 801). If there is room, a second similar suture may be passed nearer the lower

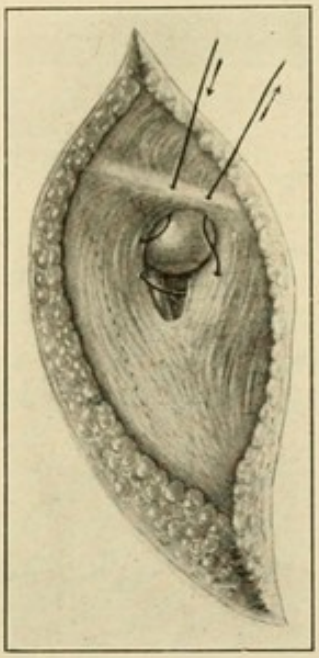

FIG. 801.—Crural operation for femoral hernia: closing the femoral canal.

(crural) orifice of the femoral canal. When these sutures are tied, Poupart's ligament is pulled down against the pectineal fascia, and the femoral canal is closed. The needle always should be introduced first on the side of the canal where the femoral vein lies, as there is thus less danger of injury to this important structure. The skin wound is then closed in the usual way.

2. The *inguinal route* for operation in cases of femoral hernia, introduced, in 1892, by Ruggi, does not seem to have been employed much in this country, though it possesses many advantages, which I shall mention after briefly describing the operation. The skin incision is the same as in the operation for inguinal hernia (Fig. 800, *a a'*), and the external oblique is divided, freely exposing the inguinal canal. The lower border of the internal oblique and the conjoined tendon (with the spermatic cord or round ligament) are then pulled upward and toward

the median line by a retractor, drawing the transversalis fascia tense, and exposing the superficial aspect of Hesselbach's triangle—bounded below by Poupart's ligament, internally by the conjoined tendon, and on the outer side by the deep epigastric artery (Fig. 802). The

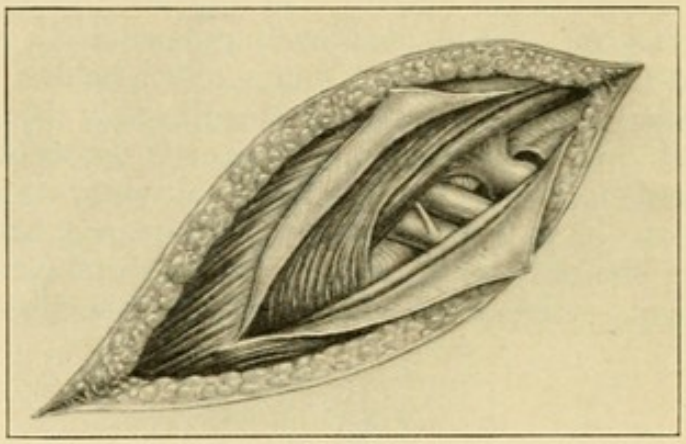

FIG. 802.—Inguinal operation for right femoral hernia: the aponeurosis of the external oblique has been divided, exposing the inguinal canal. The transversalis fascia has been divided, exposing the sac of the hernia entering the femoral ring.

transversalis fascia is then incised on the inner side of, and parallel to, the deep epigastric vessels. This at once exposes the pouch of peritoneum, as it enters the upper (abdominal) orifice of the femoral canal, to form the femoral hernia. It lies just to the median side of the external iliac vein, in full view. The hernial sac is then drawn out

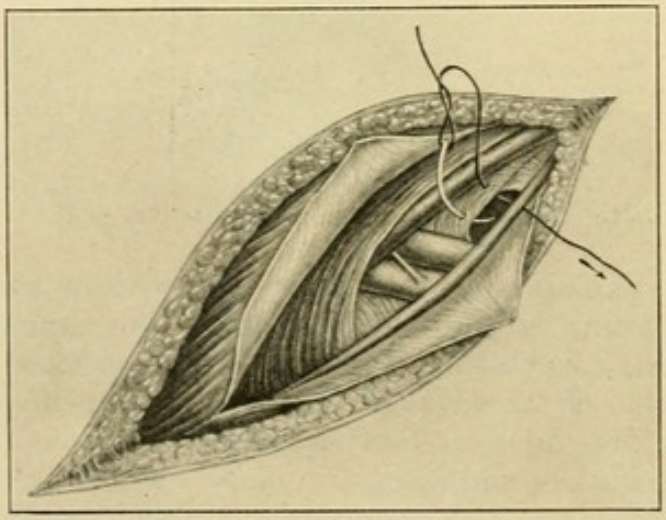

FIG. 803.—Inguinal operation for right femoral hernia: the sac has been removed and the parietal peritoneum sutured; Poupart's ligament is now being sutured to Cooper's ligament. Gimbernat's ligament in full view.

of the femoral canal, and into the inguinal wound. It is opened and its contents are reduced. It is then easy to close by suture the opening in the parietal peritoneum well above the neck of the sac. These steps having been accomplished, the surgeon may insert a purse-string

suture in the femoral canal, precisely as in the crural method of operation, except that the steps of this suturing are under better control of the eye. Poupart's ligament is pulled down by the sutures against Cooper's ligament, firmly closing the femoral canal at its abdominal opening (Fig. 803). The internal oblique and conjoined tendon are then allowed to fall back in place; Parlavecchio and Dujarier suture them to Cooper's ligament, over the spermatic cord. If the inguinal canal appears weak they may be sutured beneath the cord either to Cooper's or to Poupart's ligament. The operation is then concluded, as in cases of indirect inguinal hernia.

I have employed this inguinal method for the treatment of femoral hernia for a number of years, and regard it as superior in every way to the femoral route. It is simpler, easier, and I believe also safer. In uncomplicated cases it enables the surgeon to excise all of the sac, the whole of which is readily drawn up into the inguinal wound; and it ensures closure of the parietal peritoneum without leaving a pouch which will predispose to recurrence. In complicated cases it gives much freer exposure of the parts, and renders the surgeon master of the situation: if there is strangulation, the constriction is much more readily found and easily divided; if there is an anomalous distribution of the obturator artery, it is easily discovered, and accidental hemorrhage may be promptly controlled; if the gut is gangrenous, and intestinal resection or anastomosis is required, these may be done much more rapidly and safely than by the femoral method. By the latter route Gimbernat's ligament, the usual point of constriction, cannot be divided under control of the eye; it may be impossible, owing to shortness of the mesentery, to draw down enough healthy bowel to perform a resection, and even when the anastomosis is accomplished, if one is required, it may be impossible to return the gut through the narrow femoral canal. The only alternative in such cases is to divide Poupart's ligament, a procedure which renders recurrence of the hernia almost certain, and in a form which it is extremely difficult to cure. Should there be a fecal abscess in the sac, however, it should be drained through a femoral incision before the inguinal operation is begun. The peritoneal cavity also should be well protected by gauze-packs before the gangrenous gut is reduced. If it proves impossible to draw the sac up into the inguinal canal, its neck should be opened and its contents should receive appropriate treatment. Under these circumstances the fundus of the sac may be allowed to remain in the femoral canal.

Obturator Hernia.—This is very rare. Berger found it once among 10,000 cases of hernia. About 200 cases are on record. It is most frequent in elderly women. It is a hernia of slow formation. The sac leaves the pelvis through the obturator foramen, and protrudes in the upper inner part of Scarpa's triangle, underneath the pectineus muscle, where the hernia can be more easily felt than seen. The thigh should be flexed, adducted, and rotated slightly outward: then the surgeon places his finger against the descending ramus of the pubis

behind the adductor longus, and palpates carefully for the swelling (Macready). The two limbs should be compared. Sometimes both sides are affected. The sac usually contains bowel, but the tube and ovary have been present in a few cases. The existence of a hernia seldom is recognized until strangulation occurs, and even then the true cause of the symptoms may be overlooked.

Diagnosis.—The diagnosis in a case of strangulation, apart from the symptoms of intestinal obstruction, would depend on the history of previous attacks of incarceration of the hernia, with relief of pain coincident with the sensation of something slipping back into the pelvis; the onset of the present symptoms with sudden pain in the region of the obturator foramen; on the radiation of pain in the distribution of the obturator nerve; and on the discovery of a tender swelling beneath the pectineus muscle, by the mode of examination already indicated, together with palpation of the inner surface of the obturator foramen through the vagina or rectum.

Treatment.—Treatment consists in laparotomy and reduction of the hernia, with closure of the obturator canal by suture. The mortality has been about 85 per cent., largely because the condition has not been recognized in time.

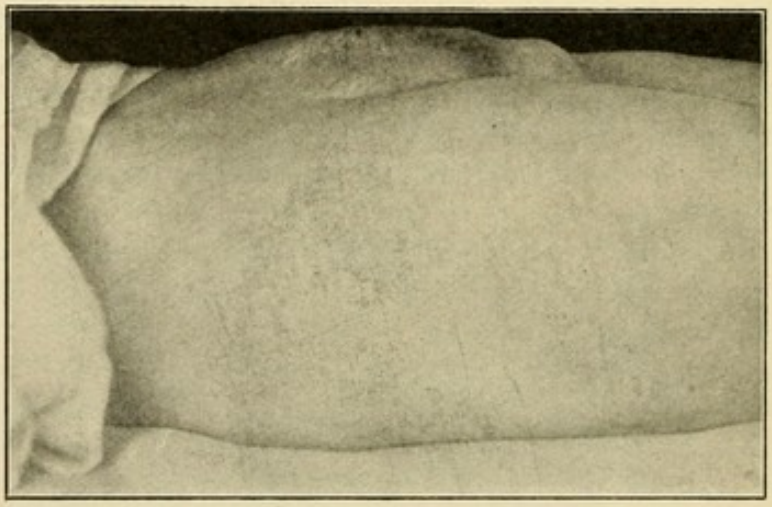

Fig. 804.—Left pudendal hernia, containing ovary, in a woman of eighty years. Diagnosis at operation (symptoms of strangulation). Recovery. Episcopal Hospital.

Perineal, Pudendal, and Vaginal Herniæ.—These are extremely rare. It is probable that congenital anomalies of the pelvic peritoneum (possibly preformed pouches) predispose to the development of these herniæ. They occur about six times as often in women as in men. *In the male* the protrusion occurs in the perineum (*perineal hernia*), between rectum and prostate, or rarely in the ischio-rectal fossa. It may be associated with prolapse of the rectum. *In the female* the hernia may leave the pelvis behind or in front of the broad ligament. In the former case the protrusion may occur in the perineum, in the ischio-rectal fossa, or in the posterior vaginal wall (*vaginal hernia*). Vaginal hernia usually is associated with procidentia uteri. If

the hernia leaves the pelvis in front of the broad ligament, as is more often the case, it enters the labium majus (*pudendal hernia*, Fig. 804), where it must be distinguished from (1) an inguino-labial hernia, which passes above the brim of the pelvis, through the inguinal canal; and from (2) a femoral hernia, which also leaves the abdomen above the brim of the pelvis, and which has the neck of its sac external, not internal, to the descending ramus of the pubis.

Treatment.—Treatment usually is palliative, by the application of a suitable pessary, T-bandage, or other appliance. Strangulation is rare. Operation is undertaken only when the hernia forms a complication of another condition, such as prolapse of the rectum, vagina, or uterus.

Ischiatic Hernia.—These are also extremely rare forms of hernia. Köppl (1908) has collected 23 cases. He prefers Waldeyer's classification: (1) Hernia Ischiadica Suprapyriformis. (2) Hernia Ischiadica Infrapyriformis. (3) Hernia Ischiadica Spinotuberosa. The first and second forms occur through the greater sacrosciatic foramen (11 cases above, and 7 below the pyriformis muscle); the third form (only one case recorded) occurs through the lesser sacrosciatic foramen. In four of the recorded cases the particular form was not described.

These herniæ occur into a preformed sac, either congenital, or formed by the traction of a gluteal lipoma, myxoma, or other tumor. They make their external appearance along the perineal border of the gluteus maximus muscle, and it is difficult to distinguish them from perineal hernia. If strangulation occurs, the swelling should be explored and drained from below; then the abdomen should be opened, and the gut reduced. The general mortality of the reported cases is 34 per cent.

CHAPTER XXII.

ABDOMINAL SURGERY IN GENERAL, AND INJURIES OF THE ABDOMINAL VISCERA.

THE PERITONEUM.

The large serous sac known as the peritoneum is of immense importance in surgery. It forms the omentum and mesenteries, and covers closely the gastro-intestinal tract, and less completely the liver, gall-bladder, and pancreas, as well as the spleen, kidneys, bladder, and female organs of generation. Its total area is said to exceed that of the skin which covers the surface of the body. There is present normally a small amount of fluid, just sufficient to lubricate the endothelial surfaces. This fluid or any extraneous material introduced into the peritoneal cavity is absorbed largely in the region of the upper abdomen, especially through the peritoneum lining the under surface of the diaphragm. It is believed that a constant upward current exists from the peritoneal cavity through the diaphragm to the mediastinal lymph nodes; and absorption of intraperitoneal exudates occur much more rapidly by this route than through the mesenteric lymph nodes which drain the mucous surfaces of the abdominal viscera. Absorption from the peritoneal cavity is hindered largely by a faculty which the peritoneum possesses in common with all serous membranes—that of forming adhesions. Advantage of this is taken in surgery whenever any operative procedure becomes necessary on organs covered with peritoneum. Isolation of an infected area is favored by the insertion of gauze packs, which will within a few days excite adhesions of sufficient strength to wall off the general peritoneal cavity. The slight mechanical trauma inflicted by the insertion of sutures arouses sufficient reaction in the apposed serous surfaces to ensure their adhesion if contact is maintained by the sutures for a week or ten days; hence such sutures always are inserted in such a manner as to bring serous surfaces into contact with each other. In cases of infection of the peritoneum by bacteria and their toxins, the injury to the endothelial surface of the peritoneum is sufficient in most cases to cause adhesion between adjacent serous surfaces, and it is in this way that infectious processes are localized. While this results in encapsulation of an infecting focus, it also entails a certain amount of impairment of function in interference with peristalsis.

Peritonitis.—Inflammation of the peritoneum is one of the most frequent abdominal conditions met with in surgery. It is caused by

bacterial infection. The existence of "idiopathic" peritonitis is no longer recognized. Even if we cannot find the portal of infection, we can at least identify the microörganisms which are the ultimate cause of the peritonitis; and it may be accepted as an axiomatic truth that in practice no peritonitis exists unless it has been caused by bacteria. Experimentally an aseptic peritonitis may be produced by the intraperitoneal injection of irritating but sterile chemicals; and theoretically when any incision into the peritoneal cavity is repaired the process of union which occurs is a form of peritonitis; but what is understood by the term peritonitis standing alone, is a *bacterial infection of the peritoneum.*

Causes.—The bacteria and their toxins gain access to the peritoneum in various ways. (1) In the immense majority of cases they come from the gastro-intestinal tract, which always is swarming with bacteria; these escape from the intestinal tract as the result of lesions which will be studied in the next chapter (appendicitis, intestinal obstruction, cholecystitis, etc.). (2) In a large proportion of cases in the female the infection comes from the internal genitalia. (3) In a few cases infection is carried from without by injury; but in these cases the infection which results from injury of the intraperitoneal organs is much more serious than that which is carried into the wound by the vulnerating body. (4) In a small proportion of cases the infection is believed to be hematogenous in origin. (5) In exceptional cases peritonitis develops from extension of inflammation from some focus in kidney, bladder, diaphragm, abdominal wall, or other neighboring structure.

The microbes most frequently encountered are the staphylococcus, streptococcus, and colon bacillus, in enterogenous infections; the gonococcus and streptococcus in genital infections; and the tubercle bacillus or the pneumococcus in those apparently of hematogenous origin.

Pathology.—As a rule, peritonitis begins as a more or less localized process in the immediate neighborhood of the atrium of infection whether this be the vermiform appendix, the gall-bladder, the Fallopian tube, an ulcer in the gastro-intestinal tract, or any other lesion (Plate VII, fig. 1). Peritonitis always is either increasing or decreasing; it does not remain stationary. It is not a state but a process; it runs a more or less definite course, sometimes of infinite complexity, owing to changes which will be studied in detail later. The disease progresses either to recovery or to death of the patient, as surely as does inflammation of any other structure in the body, as pointed out in Chapter I. Its course is so very markedly influenced by treatment that this important fact sometimes is overlooked.

The *omentum* plays a much more conspicuous part in the process of peritonitis than is generally recognized. This structure may be regarded as an aggregation of phagocytes enmeshed in fat. The endothelial cells which line its surface are highly phagocytic. The omentum is the chief source of the reactive processes which are aroused

by peritoneal infection. By chemotactic attraction it is drawn to the point of attack, and it envelops the infecting lesion in the endeavor to localize it. Other adjacent structures also become adherent to each other. When the peritonitis has been thus localized the further progress of the inflammation is the same as that which occurs elsewhere when the protective forces are in the ascendant: the phagocytes accomplish their task, the bacteria are killed and their toxins neutralized, and the patient recovers from his attack of peritonitis. *But the omentum remains adherent to the diseased area;* and more or less extensive intestinal adhesions persist. There may or may not be the formation of an **abscess** beneath the omentum, or in the midst of intestinal adhesions (Plate VII, fig. 3). If one is formed, it will run the same pathological course as an abscess in other situations; it will tend to point and to rupture at the site of least resistance, and this may be into the surrounding peritoneal cavity, into the bowel, bladder, etc., or rarely through the overlying abdominal wall. The frequency and great danger of intraperitoneal rupture makes it incumbent on the surgeon to recognize and to drain such an abscess as soon as possible.

If intraperitoneal rupture of such an abscess is followed by a slight attack of peritonitis only, which at once becomes localized in the form of a second abscess; and if this abscess ruptures in turn and a third abscess is formed, and so on until multiple abscesses exist, then the condition corresponds to the **progressive fibrino-purulent peritonitis** of Mikulicz (1889). A large part of the peritoneal cavity may be invaded in this way, the intestines, omentum, and neighboring structures being matted together in an inextricable mass of adhesions among which are found numerous minute abscesses. This occurrence is rare.

If the primary infection is very severe the bacterial toxins may be diffused within the peritoneal cavity before the omentum has an opportunity to encapsulate the source of infection. Then you will find on opening the abdomen that the omentum appears to have dissolved itself into an exudate which is rich in anti-bodies and which on culture you will often find sterile. The bacteria are enclosed in phagocytes, or are adherent to the omentum, or to the parietal or visceral peritoneum. The omentum, as I said, seems to be dissolving in fluid; it feels extremely slimy, and you cannot tell where omentum ceases and where the fluid begins; if you hold the omentum up it will almost drip this fluid from its meshes. There are no adhesions anywhere. Everything is covered by serous slime. This is the stage of the process which is recognized as **spreading** or **diffuse peritonitis** (Plate VII, fig. 2). The bowels are not much altered: those nearest the seat of disease may be red, their lustre may be slightly diminished, and they may even feel a little sticky; but that is all. The battle between the attacking and repelling forces is as yet undecided; the process is very acute, and it changes with alarming rapidity. This change may be either for the worse or the better. If the latter, then the anti-bodies gradually overcome the toxins, evidences of systemic poisoning (toxemia) subside; the peritoneal exudate becomes thicker

PLATE VII

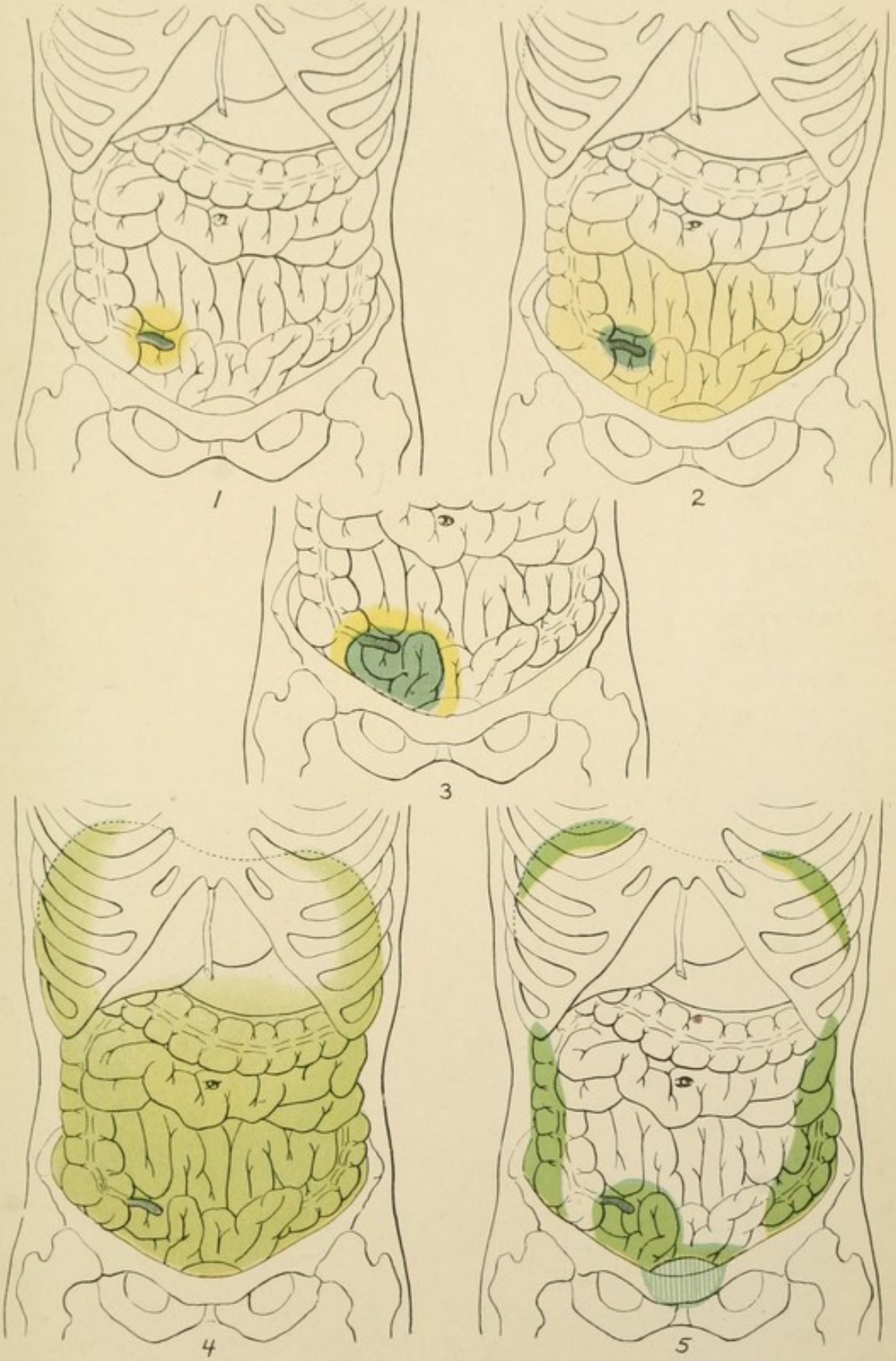

Peritonitis.

1. Acute local peritonitis, from appendicitis. 2. Acute diffuse peritonitis. 3. Single, primary abscess. 4. General peritonitis. 5. Multiple, residual abscesses. (After de Quervain.)

and more sticky; lymph covers the inflamed intestines where their endothelial covering has been destroyed; frank pus begins to collect in dependent situations and pockets of the peritoneal cavity; and as the reparative process continues the infectious material is localized in one or many regions, which are shut off from the rest of the peritoneal cavity by adhesions between the coils of intestine, the omentum, the parietal peritoneum, and neighboring structures, such as bladder, uterus, stomach, gall-bladder, diaphragm, etc. The result of such an attack of peritonitis is the formation of multiple **residual abscesses.** Many surgeons confuse this condition, which is frequent, with that described by Mikulicz as progressive fibrino-purulent peritonitis. The pathogenesis of the latter form of peritonitis, which is rare, has been described above; I believee the idea that it is of frequent occurrence rests on faults of observation. Purulent exudates collect, and residual abscesses form chiefly in the dependent portions of the peritoneal cavity, especially the pelvis, the iliac fossa, the lumbar gutters, or in the subphrenic regions (Plate VII, fig. 5).

If the resistive powers of the patient prove unequal to the task of localizing an attack of peritonitis after it has reached the diffuse stage, the infection continues to spread, until what may be called **general peritonitis** is present (Plate VII, fig. 4). From this patients seldom recover. They die of toxemia or septicemia before the invading forces have been overcome. And if the virulence of the infecting organisms is very high, or if the patient's resistance is very much below par, the peritoneal infection may spread with alarming rapidity from the very first. In such cases little or no exudate is formed, but, on the contrary, the bacterial poisons are quickly absorbed, and the patient dies with a dry peritoneum, without adhesions, without exudate, but with the intestines red, friable, and on the verge of disintegration. This usually is described as **septic peritonitis,** though the term of A. O. J. Kelly (1896), **toxic peritonitis,** is preferable. When there is a tendency for minute hemorrhages to occur, either in the subserous tissues, or free into the peritoneal cavity, rendering the scanty exudate blood-tinged, the condition is sometimes called **hemorrhagic peritonitis.**

Clinical Course and Diagnosis.—The symptoms of oncoming peritonitis are so inextricably bound up with those of the condition to which it is secondary, such as appendicitis, or intestinal perforation, that it is difficult to distinguish between the two, especially as peritonitis is rightly regarded not as a distinct disease, but as itself a complication of the underlying disease. However, it is convenient to describe the clinical picture which a patient with peritonitis presents to the observer, and then to study more in detail the physical signs on which a diagnosis of peritonitis is based.

Acute Local Peritonitis.—The initial more or less diffuse and colicky pain of the primary lesion (in the appendix, Fallopian tube, gall-bladder, etc.) is succeeded within a few hours by a pain which is burning, intense, and local. This is increased by movement, by pressure, by coughing, or deep breathing. The affected area of the abdomen

becomes extremely tender, the muscles overlying it are rigid, peristalsis is arrested in the immediate vicinity of the lesion, and there is local tympany due to paresis and distention of the bowel most affected by the peritonitis. These factors account for the persistent constipation, and the nausea and vomiting. There is moderate elevation of temperature, leukocytosis, and a rapid, hard, wiry pulse.

Acute Diffuse Peritonitis.—This usually is a sequal to the local form, but in cases of gastric or intestinal perforation may exist from the very first. All the symptoms are aggravated, and at the onset there often is marked shock. The pain is almost unendurable, constant, burning, or boring, and spreads widely over the abdomen.[1] The abdomen is of board-like rigidity throughout, and exquisitely tender. The patient's respiration is entirely thoracic, and the flat or even scaphoid abdomen moves not at all, even in deep inspiration. The patient lies on his back or side, with knees drawn up to relax the abdominal muscles. The constipation is absolute; no flatus is passed; peristalsis is entirely absent; vomiting is almost continuous, the patient regurgitating with little effort, every few minutes, small amounts of offensive prune-colored liquid. The symptoms of this stage pass almost imperceptibly into those of *general peritonitis.* The evidences of systemic poisoning become pronounced: there is more fever, greater leukocytosis, rapid, shallow respiration; the eye is bright, the expression anxious, and the skin from being rough and dry becomes covered with a clammy moisture. The pulse grows very rapid, running, weak, and almost uncountable. The abdomen begins to become distended, rigidity lessens and then disappears; extreme distention finally develops. In the last stages tenderness and leukocytosis may be absent. Death is preceded by delirium, great restlessness, cyanosis, air hunger, sweating, subsultus tendinum, carphologia, and finally exhaustion. In rare cases of very severe infection, from the first, and not infrequently before death, the abdomen is soft, and there is diarrhea ("septic diarrhea").

The history of the case is of great value in diagnosing the primary lesion, but in peritonitis, as in most other acute lesions, much more reliance can be placed on physical signs than on the clinical history or the symptoms. It is well, therefore, to consider in more detail some of the physical signs which were enumerated above.

Rigidity of the Abdominal Wall.—This is due to reflex (involuntary) muscular contraction, brought about by stimulation of the spinal segments, whence arise both the nerves supplying the diseased abdominal viscera (sympathetic fibres) and those which supply the overlying muscles of the abdominal wall. So long as the peritonitis is localized, the rigidity will remain local; spread of rigidity is an indication that the peritonitis is spreading in a similar manner. In some

[1] Peritonitis limited to the area occupied by the small intestine, and confined beneath the omentum, may run its course without any of the usual symptoms, so long as parietal peritoneum is nowhere affected; it is only the parietal peritoneum which has pain sense, according to Lennander, while that covering the viscera is insensitive.

cases the stimulus seems to affect the sensory as well as the motor nerve filaments of the abdominal wall, and hyperesthesia of the skin overlying the diseased viscus is present. Conversely, inexpert palpation of the abdominal wall with a cold hand, or with fingers lacking in skill and gentleness, will stimulate these sensory cutaneous filaments, and will cause contraction of the abdominal muscles, and thus may make the careless examiner think that rigidity due to peritonitis is present, when he has himself caused this rigidity by his inexpert examination. The true reflex rigidity of the abdominal muscles can be recognized only by experience, and many physicians never learn to recognize it, owing to indifference and lack of practice. It is the *tactus eruditus*, the *experienced touch*, that counts, and the only way to gain this experience is to palpate with attention and care the abdomens of hundreds of patients with and without peritonitis.

Palpation for muscular rigidity should be made with the finger tips, but with the utmost gentleness. Place the tips of all four fingers of both hands very lightly on the surface of the abdomen at some point far removed from the region suspected of disease and palpate the normal abdominal wall first. Do this gently and circumspectly in every case, and you will gain your patient's confidence, and further palpation will be easier. Having placed the fingers barely in contact with the abdomen, arrange them so that alternate pressure with each hand will be in a direction parallel to the course of the fibres of the muscle you are about to palpate. Then, without at any time raising your fingers from the surface of the abdomen, and with extreme gentleness, bear down for a fraction of a second first with one hand and then with the other. Repeat this manipulation a number of times before passing to another region of the abdomen, and accomplish this transfer of your hands without raising them from the abdominal wall, so as to spare the patient the shock of a new contact. Having reached another region, repeat your manipulations here, and so on until the entire abdomen has been covered. This should include the rectus muscle of each side both above and below the umbilicus, and the oblique muscles not only in the iliac and hypogastric regions, but in the flanks and in the loins as well. In this way you will very quickly learn the different sensation conveyed to the palpating finger by a rigid or a normally relaxed muscle. Do not be in a hurry, and be more gentle than you think anyone else can be. This is not at all the same kind of palpation that is desirable when one is seeking to discover a mass within the abdomen. It is this latter form of palpation that most physicians attempt when they seek for rigidity, with the result that they usually fail to recognize its presence. Here the hand is laid flat on the belly, and by gentle and rocking pressure alternately with the heel of the hand and the pulps of the fully extended fingers, the examiner seeks to depress the abdominal wall until the underlying structures can be palpated.

If rigidity is present, it is a clear indication that some degree of peritonitis exists. Slight rigidity usually indicates a mild grade of

peritonitis so long as the abdomen is not distended; and marked rigidity indicates peritonitis of much more serious import. So, too, the extent of the rigidity on the surface of the abdomen is a fair indication of the area of peritoneum involved. But if the patient is excessively fat, or if the muscles are very much atrophied, no rigidity may be palpable.

Tenderness on palpation is of almost equal importance with rigidity. Cutaneous hyperesthesia, which was referred to above, is described as *superficial tenderness;* what is to be studied now is known as *deep tenderness*. When this is exquisite it usually signifies pus under tension, whether the pus is localized as an abscess or free in the belly as in diffuse peritonitis. Rigidity scarcely ever is present without tenderness, though the latter may not be elicited by very gentle palpation in the case of a very muscular or extremely rigid abdominal wall. But tenderness frequently persists after rigidity has given way, as in time it usually does, to abdominal distention. This persistence of tenderness is a very important sign, often indicating that gangrene has occurred in the organ diseased. Palpation through the rectum often is of great value, in discovering tenderness in the recto-vesical pouch.

Percussion of the abdominal wall should succeed palpation. It should be done with the utmost gentleness, and not over any area which is very tender. It is possible by percussion, much more safely than by palpation, to determine the presence of an abscess, or of an inflammatory mass due to adherent omentum. These will give a dull note on percussion, and will be surrounded by areas of tympany. The existence of an effusion which is settling in the pelvis or the loins may also be ascertained by percussion.

Finally, *auscultation* should not be neglected. In cases of diffuse peritonitis the abdomen is quiet; no peristaltic sounds are heard unless at a great distance from the focus of infection.

Distention of the abdomen is a late sign of peritonitis, and of bad prognostic import. A diagnosis which is delayed until the abdomen is distended is of little use. The onset of distention occurs *pari passu* with the disappearance of abdominal rigidity. The distended abdomen may be tense from tympanites, but it never is rigid. The distention is the result of two factors: the first is paresis of the intestinal nerves and of those supplying the abdominal wall, as a result of poisoning by the absorption of toxins; this relaxes the muscular tunic of the intestines and makes the belly wall soft. The second factor causing distention is the occurrence of fermentative and putrefactive changes within the intestines, producing tympanites. The constipation which has already been noted, and the distention of the abdomen which is here discussed, are the consequence and not the cause of the patient's illness. He is not ill because his abdomen is distended, but his abdomen is distended because he is ill.

Differential Diagnosis.—Peritonitis must be distinguished from the colic of acute gastro-enteritis, from pleurisy and pneumonia, and from

intestinal obstruction. Other conditions with which it is sometimes confounded will be discussed in connection with the several lesions which may cause peritonitis.

Acute Gastro-enteritis.—In mild cases this is attended by sudden, sharp, stabbing pain, which varies in intensity from time to time—*intestinal colic.* The pain is relieved by pressure on the abdomen. There is no tenderness, no rigidity, no change in pulse or temperature, and no leukocytosis. Vomiting is unusual, but if it occurs it is not repeated when the stomach has been emptied. In severer cases there is vomiting, and general abdominal pain and tenderness. There may be fever, with increase in the pulse rate, but there is no rigidity of the belly wall; and there is diarrhea, which is rare in peritonitis. In cases where doubt remains after a thorough examination, visit the patient again after an interval of three or four hours, and keep him in constant surveillance until the nature of the disease is manifest.

Pleurisy and pneumonia often are attended by pain referred to the abdomen, and in children this may be the only complaint. There is no nausea or vomiting; only slight rigidity of the upper abdomen, and only superficial tenderness (cutaneous hyperesthesia) are present. There is no deep tenderness. If the chest were examined in all cases of acute abdominal disease, whether the presence of pulmonary complications be suspected or not, the surgeon would be saved many an error and the patient an unnecessary operation. Even if the pulmonary lesion is so deep-seated as to give no distinct physical signs, a diagnosis of peritonitis usually may be excluded by the absence of physical signs in the abdomen, and by the presence of symptoms, such as rapid respiration, dyspnea, slight cyanosis, etc., which are characteristic of thoracic disease.

Intestinal Obstruction frequently is complicated by peritonitis in its later stages, just as peritonitis may be followed at any time by intestinal obstruction. A differential diagnosis often is impossible when either condition has existed for some days, because then both conditions may be present. But at the outset the two affections present very different symptoms and physical signs. In intestinal obstruction, attentive study of the patient's history usually will reveal a cause for the obstruction in some previous attack of peritonitis. The attack of intestinal obstruction begins with colicky pains, and these are more or less relieved by pressure on the abdomen. The pain is intermittent, and *between the paroxysms the patient may feel quite comfortable and may appear very well.* In peritonitis the patient is decidedly ill from the very commencement of the attack, and there are no remissions. In obstruction the intervals between the pains rapidly shorten, but the pain does not for a long time become constant; in peritonitis it is constant from the beginning. In obstruction there is absolute constipation, as in peritonitis, and no flatus is passed by rectum; vomiting occurs early, is persistent, and soon becomes of the projectile type (p. 885), with rather long intervals between the attacks of vomiting. In peritonitis, on the contrary,

the patient vomits oftener, the vomitus is small in quantity each time; and the vomiting is not projectile but regurgitant in type (p. 806). In obstruction, as in peritonitis, the contents of the upper bowel are vomited after the stomach has been emptied; but in obstruction the rejected matters finally become fecal, which never is the case in peritonitis. In obstruction there is no rigidity of the abdominal wall, and distention occurs early—often within a few hours. Rigidity is the most valuable early sign of peritonitis, but distention seldom occurs until after the lapse of eleven or twelve hours. The distention of obstruction may at first be localized to the area immediately above the obstruction. Auscultation in obstruction detects extremely active and disordered peristalsis; sometimes peristaltic waves can be clearly seen through the distended belly wall. In peritonitis the abdomen is silent. In obstruction the temperature is not elevated, while in peritonitis it almost always is above normal. Leukocytosis is rare in obstruction, unless strangulation has occurred; but in peritonitis it is the rule. In both affections a steady increase in the pulse rate occurs, and is a most valuable sign.

Treatment.—This is not the place to discuss the prevention of peritonitis; but that it may be prevented often by prompt operation will be pointed out time and again in the following pages. What concerns us here is how to treat the patient after peritonitis has developed; and I here exclude from consideration pelvic peritonitis in connection with gynecological affections.

1. *In the early stages*, before the peritoneal inflammation has become diffuse, surgeons are in perfect accord in recommending immediate operation, to remove the source of infection, and thus prevent the development of diffuse peritonitis. This is a much surer and far safer course to pursue than to trust to the unaided powers of nature to isolate and overcome the infection. If the source of infection is the appendix, it can be entirely removed; if it is a perforation of the intestine, it can be sutured, and the further discharge of infectious material prevented; if there is a lesion which cannot be treated in either of these ways (as in acute pancreatitis) the surgeon can at least isolate the source of infection by gauze packs, providing drainage, and thus preventing further intra-abdominal contamination. The details of operation, which should be completed quickly, will be described in connection with the various lesions which cause peritonitis.

2. *When the peritonitis is in the diffuse stage* surgeons are divided into two camps. There are those who think, with Ochsner, that it is safer to undertake no operation in cases of spreading peritonitis, but to trust to such measures as are detailed below to aid nature in isolating the infection, and to wait until a residual abscess has been formed before instituting drainage. Neither Ochsner nor anyone else, however, ever claimed that the patient could be cured without any operation; the only question is whether the operation shall be immediate or postponed. Then there are other surgeons who believe, so long as the evidences of toxemia are not very marked, and *so long as the*

degree of abdominal rigidity is greater than its distention, so long, in short, as it is evident that the patient is still reacting to the infection, that throughout this period it will be more to the patient's ultimate advantage to institute drainage as soon as possible, and at the same time to treat the focus of infection by excision, suture, or tamponade, provided this secondary part of the operation can be carried through without unduly prolonging the procedure or entailing too great shock. My own belief and my practice, founded on a not very limited experience with all forms of peritonitis, is that operation under these circumstances is not only justifiable but imperative. Ochsner and others limit the time within which immediate operation is to be done to the first thirty-six hours from the beginning of the illness. No doubt this is a convenient rule of thumb, but one patient will reach at the end of twelve hours a stage of peritonitis which will not be reached by another for two or three days. So that I think it is safer to decide the question in favor of or against immediate operation not on the mere lapse of time, but, as I have done above, *on the patient's physical condition*. Especially valuable, I believe, is *the persistence of rigidity or the onset of distention*. Statistics might be quoted to support the views of surgeons on both sides of this question; but the fallacy of trusting to such figures is obvious. Only those who open the abdomen in all these cases know the state of affairs inside; those who do no operation give statistics founded on impressions, not on visual inspection of the peritoneum, and they are quite as likely to reckon as non-operative survivals, patients whose peritonitis never became widespread, as the really serious cases.

3. *When diffuse peritonitis has so far advanced that rigidity has disappeared*, and marked distention is present, the patient being very toxic and perhaps delirious, and constantly regurgitating the upper intestinal contents, almost all surgeons are in agreement with Ochsner that operation is more apt to hasten death than to give the patient a chance of recovery. In these cases, however, a well defined course of treatment must be pursued, and occasionally even a seemingly moribund patient will improve, one or more abscesses will form, and if these are drained at a propitious time recovery may yet ensue. This treatment, about to be described, is known as *the Ochsner treatment of peritonitis*, because so warmly espoused by this surgeon ever since 1900. It should be adopted in every case of peritonitis so soon as the diagnosis is made, whether or not operation is to be undertaken. If operation is to be done, this treatment will be of short duration, but it will aid materially in securing a good result; and the same treatment always is continued after operation until the peritonitis subsides. The most important features of this non-operative or preparatory treatment are: (1) *abstinence from everything by mouth* (hence it sometimes is called "starvation treatment"); (2) *instillation of fluids by the rectum;* and (3) *the head high position.*

The patient is placed in bed either in Fowler's position (1900), lying flat on the back, and with the head of the bed raised twelve

to fifteen inches from the floor; or else in the so-called exaggerated Fowler position, that is, in a semi-sitting posture in the bed (Fig. 805). This aids the gravitation of fluids to the pelvis and keeps them away from the subphrenic region, whence absorption is so rapid, thus diminishing toxemia; and it lessens the chances of pulmonary complications. The patient is very apt to slide down in the bed unless supported. A special chair-like bed frame is the best support, but in emergencies a sand-bag may be passed beneath the mattress below the buttocks, or the patient may sit in a sling formed by tying the ends of a sheet to the two upper posts of the bed.

FIG. 805.—Exaggerated Fowler position. One week after suture of a duodenal perforation. Note slight elevation of reservoir for enteroclysis solution. Episcopal Hospital.

Nothing whatever is given by mouth, not food, not water, not ice; nothing is permitted. Anything taken into the stomach rouses peristalsis, and this spreads infection more widely in the peritoneum. Moreover, it increases nausea and provokes vomiting. The only thing ever to be introduced into the stomach is a stomach tube, which should be used every six hours or less often, to relieve the stomach of regurgitated intestinal contents. A patient who has once experienced the relief which lavage of the stomach affords under these circumstances is only too anxious to have the procedure repeated as soon as he feels his stomach refilling.

To replace the fluids lost by intraperitoneal effusion, the patient is given saline solution or tap water by the rectum, as already described in Chapter V. This does not excite peristalsis, is quickly absorbed, allays thirst, restores blood-pressure, dilutes circulating toxins, and after operation seems to promote drainage from the wound.

No drugs are required as a rule. Stimulants, such as camphorated oil, atropin, digitalis, or strychnin, seldom are indicated and do not seem to have much effect. Morphin very rarely is required; the pain soon ceases if nothing is taken by mouth and if nausea is controlled by lavage. Unless there is pain, sleep is not much interfered with. But I do not believe that morphin does any harm, and there is no reason why it should not be administered if it promotes the patient's comfort.

This treatment should be continued until the peritonitis subsides. This period seldom is longer than three days, but it may be a week.

The more absolute the treatment from the first, the sooner will its effect become manifest. Under this form of treatment many patients who would die under any other form of treatment, or after operation, will survive the peritonitis, and as the abdomen gradually softens, the surgeon will find evidences of one or more collections of pus. Very rarely a patient will recover from what appears to have been a diffuse septic peritonitis without effusion; when the abdomen is opened later to remove the cause of the disease, few adhesions and no pus may be found. I have seen only two such cases. Other patients will die in spite of this treatment; but it is not too much to say that the Ochsner treatment is the only form of treatment which gives these bad cases of peritonitis even a fighting chance.

After the peritonitis subsides the patient is still far from convalescent. As the abdomen becomes softer auscultation will detect commencing peristalsis, and it will be painless; flatus will be passed, and the bowels may move spontaneously or by simple enema. At this time small amounts of liquid food may be allowed by mouth; but if this is attempted too soon it will cause vomiting, rouse active peristalsis, break up newly formed adhesions, rupture an abscess which is just localizing, and perhaps cause intestinal obstruction. The patient must be very carefully nursed, and progress must be sure rather than rapid. When the abdomen has become entirely soft in parts removed from the seat of disease, when the bowels are acting normally, and the patient is approaching convalescence, then it is time to drain the abscesses which have formed. If these are neglected, and intraperitoneal rupture occurs, the patient seldom survives even immediate drainage.

Residual Peritoneal Abscesses. — So long as an intraperitoneal abscess is present, the patient is in constant danger. No delay should be permitted in instituting drainage when once it is ascertained that the patient can withstand the intervention. The abscess should be incised and drained, if possible without opening the uninvolved peritoneal cavity; nothing else should be attempted. Do not make any search for the cause of the peritonitis, but be content to secure drainage. Make sure, however, that you find all the abscesses. Plate VII, fig. 5, shows the most frequent sites in which residual abscesses form. In most cases a secondary and more formal operation is indicated some weeks or months later, to complete the cure by removal of the diseased organ (appendix, gall-bladder), closure of a fecal fistula, etc.

Pelvic abscess sometimes may be drained by puncture through the rectum, or through the vagina. Unless the anterior rectal wall bulges and fluctuation is unmistakable it is safer usually to make a suprapubic incision. This always should be preferred when there is also an *iliac abscess;* and always after opening an iliac abscess the surgeon should make sure that a separate pelvic abscess is not overlooked. A *lumbar abscess* is drained by an incision in the flank or loin.

Subphrenic abscess is of great importance, because, though less frequent, it is so often overlooked. It may occur either (1) to the right

or (2) to the left of the falciform ligament of the liver; or (3) behind the right coronary ligament; or (4) in the lesser peritoneal cavity. Abscesses on the extraperitoneal surfaces are rare, and usually are secondary to hepatic abscess, in connection with which they are discussed (p. 936). Of the four sites of subphrenic abscess mentioned above, that most frequently the seat of suppuration is the space behind the right coronary ligament and extending around its free margin to the subhepatic space. Most abscesses in this situation are secondary to appendicitis; the abscess tends to point through the lower intercostal spaces, except when intraperitoneal or intrapleural rupture occurs. Most of the abscesses in association with the left lobe of the liver in front of the left coronary ligament are due to gastric or duodenal lesions; those in the lesser peritoneal cavity may follow gastric or pancreatic lesions; while those far to the left are rare and generally secondary to splenic affections or are the result of diffuse peritonitis. The *diagnosis* of subphrenic abscess is based: (1) On the history of the illness, indicating a possible cause for the formation of an abscess in the subphrenic region; perforated gastric or duodenal ulcers cause almost one-third of these cases, appendicitis over one-sixth, hepatic affections about one-sixth, and the remaining one-third are due to miscellaneous affections (Barnard, 1908). (2) On abdominal signs and symptoms of an abscess—dulness, tenderness, mass, possibly rigidity. (3) On thoracic signs and symptoms, especially slight pleural frictions or effusion, or upward displacement of the lung with increased dulness over the liver. (4) On general signs and symptoms of suppuration—fever, leukocytosis, chills and sweats, and especially progressive emaciation. The *treatment* of subphrenic abscess involves drainage by operation; nearly every patient not operated on dies. In most cases of right-sided abscess the operation is by thoracotomy, as in operations for abscess of the liver (p. 937). Rarely an abdominal incision is proper. The general mortality is about 37 per cent.

Peritoneal Adhesions.—This condition, which has been referred to (p. 802), often is described as chronic peritonitis; it is rather the result of a former peritonitis. There is no inflammatory process. The adhesions which developed during the existence of active inflammation remain, and by their interference with peristalsis cause symptoms of which pain and obstipation are the most constant. The drag of adherent structures on the parietal peritoneum, the mesenteries or the female genitalia may render life miserable, and the patient may become an invalid. Purgation is apt to rouse such active peristalsis as to increase pain, and sometimes causes intestinal obstruction; and the usual symptoms of coprostasis are an annoyance unless the bowels are opened normally.

There are other cases in which peritoneal adhesions develop as the result of such an attenuated infection that the origin of the affection cannot be traced. Such are many cases of Lane's kink, of Jackson's membrane, and other forms of peritoneal disease which have been recognized only within recent years. These are discussed at p. 896.

The surgeon is powerless to prevent the formation of adhesions in cases of acute peritonitis, and, indeed, often hails them with delight as aids to the patient's immediate recovery; but he is careful when he opens the abdomen in other cases to avoid manipulations which will encourage the formation of useless and disabling adhesions. He does not handle the parts not concerned in the operation; he withdraws from the abdomen as little of the intestine as possible, and prevents it from becoming dried while it is exposed; and he is careful to cover all denuded serous surfaces by inversion with sero-serous sutures or by stitching the omentum over the defect. Various attempts have been made to prevent peritoneal adhesions by the use of oily substances, but without much success. In recent laboratory work, however, Saxton Pope (1914) has found that a 2 per cent. solution of sodium citrate in a 3 per cent. (hypertonic) sodium chloride solution possesses great power in preventing peritoneal adhesions.

Treatment.—In the treatment of peritoneal adhesions, it is only by experience that a surgeon can learn when to let well-enough alone. If the adhesions are broken up the new adhesions that form may be still more disabling, in spite of patient suturing and omental grafting. Unless the adhesions produce symptoms it is better, as a rule, not to interfere with them. Of course, if intestinal obstruction occurs, this must be overcome.

Pneumococcic Peritonitis.—This occurs oftenest in children, particularly girls under the age of six years. Most cases are secondary to a pneumococcic infection of the lungs; but the primary focus may be situated elsewhere, as in the middle ear or the female genitalia. The infection probably is more often enterogenous than hematogenous. The physical signs are those of acute diffuse peritonitis (p. 806), but the patient's general condition is not so much affected as when the peritonitis is due to the ordinary organisms, and the death rate is much lower. In most cases there is a good deal of effusion, and this usually becomes encysted within the course of a few days or a week. It should then be opened and drained.

Tuberculosis of the Peritoneum.—The tubercle bacilli may reach the peritoneum through the blood-stream, from the mesenteric lymph nodes, directly from the intestinal tract, or from the Fallopian tube. In almost all cases there are other tuberculous lesions elsewhere in the body. Tuberculosis of the lungs frequently preëxists, and in a large proportion of adult patients this will develop later if not already present at the time the signs of peritoneal tuberculosis are noted. As a complication of Pott's disease of the spine, tuberculosis of the peritoneum is not very rare.

As a part of a general miliary tuberculosis (blood infection), tuberculosis of the peritoneum has no surgical interest. The cases of most surgical importance are those in which a removable focus of tuberculosis exists in the abdominal cavity. This is most often the *Fallopian tube* in women, and the *vermiform appendix* in men. In children tuberculosis of the *mesenteric lymph nodes* is more frequent. In many

cases a tuberculous ulcer of the small intestine is the point of peritoneal infection. Here, as in the appendix, the tubercle bacilli penetrate the thinned floor of the ulcer, and usually without a macroscopical perforation, escape into the peritoneal cavity, which becomes widely covered with miliary tubercles. These feel like minute shot or sand-like particles, projecting from the serous surfaces. They are yellowish-gray in color. The same course of events occurs when the infection arises in the Fallopian tube, whence it may escape through the abdominal ostium, or by a minute perforation. It is not improbable (Baumgartner) that the lesion is not really primary in the Fallopian tube, but that this has been infected from its peritoneal surface; but at all events, the tuberculous process is most active here for the time being, presumably because the bacilli have found a fertile soil for development. Tuberculosis of a *hernial sac* is not very rare. Usually it is secondary to some intra-abdominal focus.

The changes in the peritoneum are those characteristic of other forms of peritonitis, only very much milder in degree. Usually there is a moderate amount of exudate formed. This may be clear, yellowish, greenish, turbid, or even purulent; not seldom it is bloody. When the disease has lasted for many months, adhesions form, and may be very extensive, causing kinks, and leading to intestinal obstruction. The omentum becomes thickened and forms lumpy masses which often can be felt through the abdominal wall. As the omentum and mesentery both may become retracted from thickening and tuberculous infiltration, these masses usually are situated in the left hypochondrium. The intestines lie mostly below and to the right, and their tympanitic state adds to the distention of the abdomen. Among the adherent intestinal coils small collections of puruloid matter may occur. Rarely there is a large encysted collection of fluid. Caseous changes in the mesenteric lymph nodes are a late occurrence. The intestinal walls become very friable, and internal (entero-enteric) fistulæ may form; occasionally an external fecal fistula develops spontaneously. In infants a tuberculous abscess may discharge through the umbilicus, as in a case under my care some years ago at the Children's Hospital.

Symptoms and Diagnosis.—The disease is one of early adult life, and of early childhood. Before five years of age it is not infrequent. It is rare after thirty-five or forty years. Most cases occur in women between eighteen and thirty years of age.

Tuberculous peritonitis may begin rather acutely, or it may be chronic from the beginning. In the former case, after a few weeks of malaise and gastro-intestinal derangements (colics, attacks of constipation and diarrhea, nausea) the first thing to attract the patient's attention is enlargement of the abdomen, due to serous effusion. This may persist unchanged for months, but usually there are times when the abdomen seems to become smaller. As time goes on, adhesions begin to form, and if spontaneous recovery takes place (and it is not unknown) the abdomen becomes softer, the bowels act normally,

the general health improves, and the patient convalesces. Or an encysted collection of fluid may form, and be cured by evacuation.

In cases which are chronic from the beginning the prodromal symptoms may have existed for many months; there rarely is much effusion; often none can be detected. Omental masses may be palpable, and they may change their site and their form from time to time, in the course of weeks or months, from no appreciable cause. Usually the subjective symptoms are slight, unless the adhesions cause intestinal obstruction, or secondary infection produces hectic fever. So long as the patients lie quiet in bed and are carefully nursed little change in their condition may be appreciable from month to month (Fig. 806).

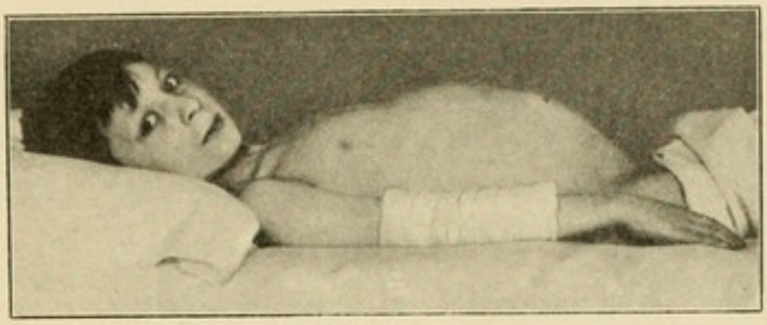

FIG. 806.—Tuberculosis of the peritoneum with effusion. Episcopal Hospital.

The diagnosis of peritoneal tuberculosis will be strengthened by finding any tuberculous focus elsewhere in the body. Tuberculosis of the bones usually will be easily detected; but examination should also be made of the lungs, testicles, prostate, seminal vesicles, and kidneys, as incipient lesions in these structures often are overlooked.

Treatment.—The general hygienic treatment already recommended (p. 82) for patients with tuberculosis is most important in cases of tuberculous peritonitis. A fair proportion of cases, as pointed out by Fenger (1901), tend toward spontaneous recovery. If improvement under general hygienic treatment is progressive, no operation is indicated. In other cases, however, effusion persists; the patient does not gain ground, and may grow progressively worse. In these patients, the propriety of operative interference must be considered. Operation has been found, empirically, to be of most value in cases with effusion. Tapping and aspiration of the fluid never have produced as good results as formal incision and evacuation. Probably this is for the same reasons that incision and evacuation of cold abscesses in connection with joint tuberculosis are more successful than is aspiration; the peritoneal effusion of tuberculosis is similar to a cold abscess elsewhere, and it is important to prevent the occurrence of secondary infection, either from the surface of the body or from within the intestinal tract. The abdomen should be opened in women, as if for an operation on the uterine appendages; in men, over the appendicular region; as these are the most frequent sites of primary foci. Whenever possible, without inflicting damage on the intestines, a tuber-

culous appendix in men should be removed; in women not only should one or both tubes be removed if affected, but a diseased appendix also. If adhesions are present the utmost caution should be used if any attempts to separate them are made. It is very easy to tear a hole in the intestine, and very difficult to repair it. Even if the intestinal sutures can be made to hold, union very seldom occurs, and a fecal fistula is the nearly inevitable result. Only if the bowel has been torn should the abdomen be drained. In other cases it should be closed tightly, to prevent any possibility of secondary infection from the surface of the body.

In general it may be said that the immediate mortality following operation is very small, if proper precautions are taken against injuring the intestines. The ultimate prognosis is better when some focus such as the appendix or tube has been removed. Cure occurs much oftener in the ascitic than in the dry cases. If the patients are traced, nearly half the number will be found to die within a few years, and there will be many recurrences. But the prognosis is better with than without operation, and even a few years of comparative freedom from discomfort are not to be despised.

OPERATIONS ON THE ABDOMEN.

Laparotomy, or **Abdominal Section,** is a general term used to describe any operation which involves opening the peritoneal cavity.[1] Definite operations are described more accurately by specific names, such as *gastro-enterostomy*, *cholecystectomy*, *entero-anastomosis*, etc. These terms will be defined in the proper place. They are sufficiently descriptive of the operation when they stand alone, and it is not necessary to complicate them by the prefix *laparo-* as is done by some surgeons; though all such operations include that of laparotomy.

Abdominal Incisions.—In planning an incision through the abdominal wall, the surgeon must have in mind not only ready and sufficient exposure of the abdominal viscera concerned in the operation, but also must endeavor to inflict as little injury as possible on the structures through which he cuts. There are three things to be considered in this connection—the bloodvessels, the muscles with their aponeuroses, and the motor nerves.

The *blood-supply* is so free that injury or ligation of any one of the main arterial trunks entails no danger of sloughing; but such injury should be avoided whenever possible because time is lost in checking the hemorrhage, and the wound is more liable to become infected if not kept dry. The deep epigastric artery is the most important; the superior epigastric is much smaller; and the deep circumflex iliac is not often encountered.

[1] Laparotomy is derived from λαπαρὰ the Greek word for the soft parts between the ribs and pelvis. Celiotomy is used as an equivalent by some writers, but is considered less correct, as the Greek term κοιλία from which it is derived was used for a cavity of any kind—a joint, the heart, as well as the abdomen.

Muscles should be split in the course of their fibres whenever possible. Transverse section of muscle fibres is to be avoided; when this is unavoidable, the muscle must be repaired by suture. The resulting cicatrix in the muscle will resemble one of the lineæ transversæ in the rectus abdominis muscle; this will not impair much the muscle's contractility, but it complicates the operation and is undesirable. The fibres of the three oblique muscles of the abdomen cross each other's course at various angles, and transverse division of one or two of these muscles can be avoided only in small incisions, such as the gridiron incision of McBurney (p. 820), where each muscular layer is split in the direction of its fibres. Incisions through the rectus muscle can be made of any length by splitting its fibres parallel to their course. An incision through muscular tissue is preferable to one through the linea alba or the linea semilunaris, because where several layers of tissue are traversed, as in cutting through a muscle and its sheath, much firmer union can be secured by suturing the wound in several layers, than where only one aponeurotic structure is available.

The *motor nerves* are the most important of all structures to preserve, since they are so small that they cannot be sutured if cut, and the muscles supplied by them are paralyzed, and permit marked bulging of the abdominal wall in spite of accurate repair of muscular and aponeurotic structures by suture. These nerves are branches of the lower intercostals (6th to 12th) and they run more or less transversely forward from the intercostal spaces between the transversalis and internal oblique muscles, giving off branches to these and the external oblique; finally they perforate the posterior sheath of the rectus muscle and supply it by numerous fine twigs. Any incision which will divide these nerves is to be avoided whenever possible. An incision through the semilunar line will cut the nerves supplying that portion of the rectus muscle between the incision and the linea alba. Hence any longitudinal incision, unless quite short, should be made as near the linea alba as possible. If an incision is planned for any other part of the abdominal wall, it should, so far as possible, run parallel to and between two of the motor nerves.

Section of nerves, as mentioned above, results in bulging of the abdominal wall from muscular paralysis (Fig. 807). This may entail great disability; and unlike incisional hernia (p. 772), with which it should not be confused, it cannot be cured by operation. All that can be done is to apply some form of abdominal support, as in cases of pendulous abdomen (p. 898).

For *operations on the stomach, intestines,* and *female generative organs* surgeons usually employ a longitudinal incision splitting the fibres of the rectus muscle close to the linea alba on the right or left, whichever appears to give readiest access to the seat of disease. An epigastric incision of course is used in stomach operations (Fig. 808), and one in the hypogastrium for pelvic operations. For operations on the small intestines the incision usually is made to the left of the median line, just below the umbilicus; thus it may be extended upward

past the umbilicus without injuring the round ligament of the liver, which lies to the right.

For *operations on the gall-bladder* the usual incision is a longitudinal one through the outer third of the right rectus muscle, from the costal margin downward for four inches; if more room is needed the incision is extended obliquely upward along the costal border to the ensiform process (*Mayo Robson's incision*). Though this incision necessarily divides a number of motor nerves the resulting disability is much less than when an incision of similar length is used in the lower abdomen, where the tension is greater.

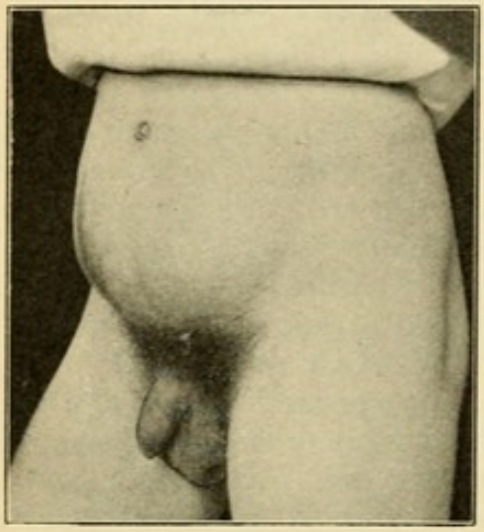

FIG. 807.—Bulging of right side of abdomen from paralysis of motor nerves as result of long incision in right rectur muscle. Episcopal Hospital.

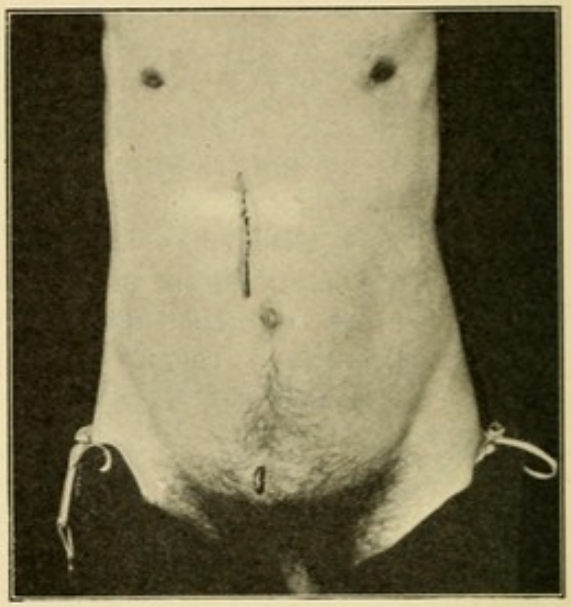

FIG. 808.—Incision for perforated duodenal ulcer. Cicatrix three and a half inches. Suprapubic stab wound for drainage. Episcopal Hospital.

For *operations on the appendix* a lateral incision is employed. If only a small incision is required, the *muscle-splitting* or *gridiron incision*, introduced in 1893 by McBurney, is preferred by many operators.[1] It is centred over *McBurney's point*, which is "from one and a half to two inches" from the right anterior superior iliac spine, and on a line from that point to the umbilicus. The skin incision is made parallel to Poupart's ligament, and the aponeurosis of the external oblique is divided in the same direction, parallel to its fibres. The fibres of the internal oblique are thus exposed. They run nearly at right angles with the previous incision, and are split in this direction. The fibres of the transversalis at this point run in the same direction as those of the internal oblique, and are split with them in the direction of their course. The peritoneum is opened by an incision parallel to that through the skin. This gridiron incision cannot well be made more than three or four inches long. Many surgeons expose the appendix by a longitudinal incision splitting the outer

[1] It had been used previously by L. L. McArthur.

fibres of the right rectus muscle; this has been called *Deaver's incision;* he calls it the "simple incision." Or, after opening the anterior sheath of the rectus and displacing the fibres of this muscle toward the median line (passing around the lateral border of the muscle without splitting its fibres), the posterior sheath of the rectus, together with the transversalis fascia and peritoneum, may be incised, as proposed by Battle in 1895, by Jalaguier and by Kammerer in 1897, and by Lennander in 1898. Both this and Deaver's incision necessarily divide a number of nerves to the rectus muscle unless the incision is short. For this reason I prefer the *transverse incision* of G. G. Davis (1906), which is described at p. 854.

Making the Abdominal Incision.—The skin and superficial fascia are divided down to the aponeurotic layer (external oblique aponeurosis, anterior sheath of rectus). Bleeding-points are clamped. The aponeurotic layer is then divided throughout the length of the incision. Do not forget that in the lower abdominal wall the aponeurosis of the external oblique does not blend with the rectus sheath at the semilunar line, but passes as a separate structure for some distance toward the median line before blending. Therefore an incision in the lower abdomen just to the median side of the semi-lunar line must divide the external oblique aponeurosis and the rectus sheath as separate structures before the muscular fibres of the rectus will be exposed. When the muscular fibres are exposed they are to be split parallel to their course. This is best done by the handle of the scalpel, followed by the fingers of the surgeon. In the hypogastric region the rectus fibres should be split from below upward, and in the epigastric region from above downward, so as in each case to brush aside rather than break off the branches of the epigastric arteries which run in the directions named—from the epigastrium down, and from the hypogastrium up. When the transversalis fascia and peritoneum are exposed they should be caught up in two hemostats, applied about a centimeter apart, and should be drawn away from the underlying viscera; then the surgeon should divide these structures cautiously, with the flat (not the point) of the knife, held sideways (Fig. 809). If the peritoneal cavity is not opened at once, another hold should be taken of the intervening tissues, and thus the surgeon should cut down layer by layer until the peritoneum has been opened. As soon as this is accomplished, the scalpel is laid aside, and the peritoneal opening is enlarged by a blunt pointed scissors passed on the finger as a guide. The peritoneum is opened to the full length of the abdominal wound.

Closing the Abdominal Incision.—The cut margins of the peritoneum (including the transversalis fascia, and where present the posterior sheath of the rectus) are caught in hemostats, and drawn into the wound until visible. The abdominal viscera are kept from protruding by the insertion of a gauze pack. Then the peritoneum is closed with a continuous catgut suture, applied so as to evert the peritoneum into the wound (Fig. 810). This brings endothelial surfaces together, favors rapid union, and lessens the chances of omentum becoming

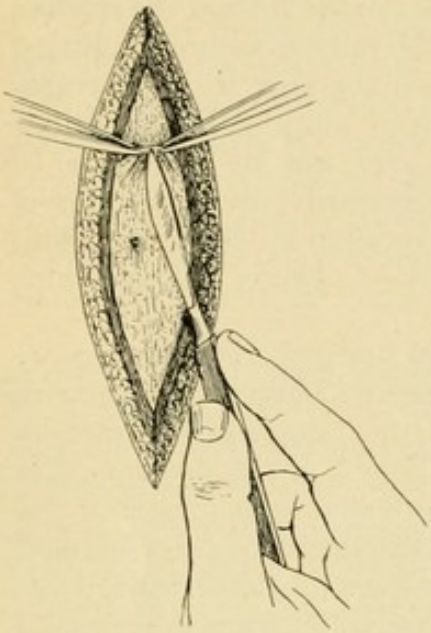

FIG. 809.—Incising the parietal peritoneum.

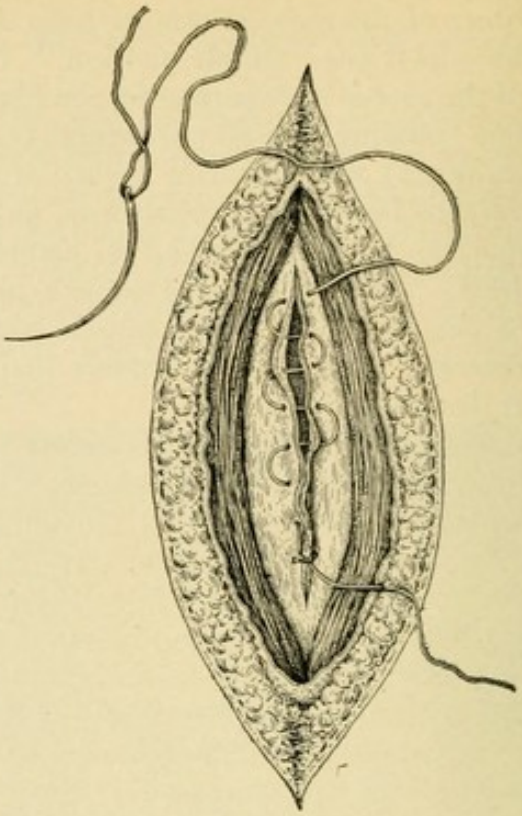

FIG. 810.—Suturing parietal peritoneum (Deaver and Ashhurst.)

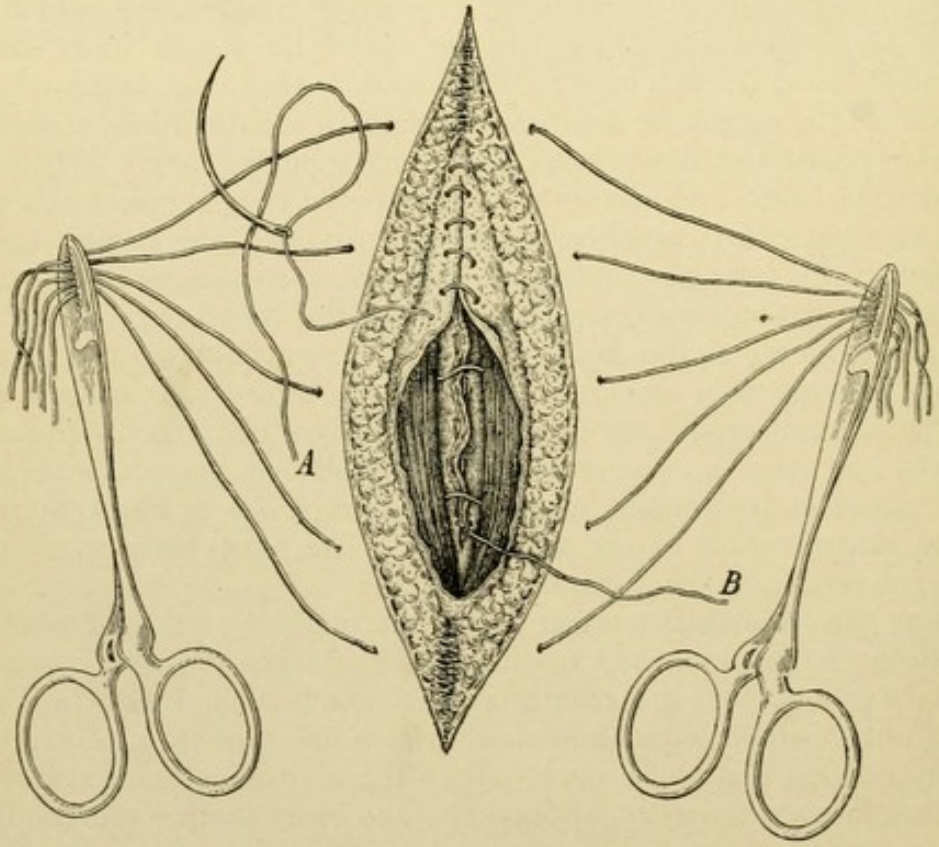

FIG. 811.—The "splint sutures" have been inserted, and their ends are clamped. The anterior sheath of the rectus is being sutured. (Deaver and Ashhurst.)

adherent to the abdominal surface of the cicatrix. Before the last peritoneal suture is drawn tight, the gauze pack is removed.

If the wound is large or if the patient is very fat, several "relaxation" or "splint sutures" are next inserted; these are interrupted sutures of non-absorbable material, silkworm gut, linen, or wire. Each splint suture is passed from the skin surface down through all structures of the abdominal wall to the peritoneum (which has already been sutured) across the wound, and out through all structures of the abdominal wall on the other side, to the skin surface. None of these sutures is tied at this time.

Next the aponeurotic layer is sutured with a continuous stitch of chromic catgut (Fig. 811). The split muscle fibres fall together naturally and do not require a separate suture. If there is much subcutaneous fat, a continuous suture of plain catgut may be used to appose it. Finally the splint sutures are pulled taut and tied, not with very much tension, but just tight enough to obliterate all dead spaces in the wound. A few superficial skin sutures may be required to secure accurate closure. If the patient is not fat, and the wound small, the splint sutures may be omitted.

In *wounds which are drained* it is safer to use interrupted sutures throughout, so that should one stitch become infected it may be removed without destroying the entire row of sutures.

General Technique of Abdominal Operations.—There are so many technical points that are common to different abdominal operations, that it is convenient to describe them together. I shall consider here **preparation for operation,** and **after care**; as well as **intestinal localization, methods of intestinal suture, intestinal resection,** and **entero-anastomosis.**

In all abdominal operations the parts especially concerned in the manipulations are walled off from the rest of the viscera by gauze "packs" or "pads." These are made by stitching together a number of layers of gauze (four to six thicknesses is sufficient) so as to give the packs a certain bulk, and prevent ravellings from escaping into the wound. These packs are made of convenient sizes; for a major laparotomy, they should be about 8 by 14 inches; for a minor laparotomy they may be much smaller. Most important is it not to allow one of the gauze packs, or a sponge, or an instrument, to become lost in the wound. Such accidents sometimes occur, but with care and system are avoidable in almost all cases. It is best to have a tape attached to one corner of each pack, and to leave this tape hanging out of the wound, clamped by a hemostat; if a piece of gauze never is placed entirely within the abdomen, it is not likely that it will slip in unperceived. Some operators employ a continuous roll of gauze, which is unrolled only as it is inserted into the abdomen. Many surgeons use these packs, and all gauze employed within the abdomen, only after it has been moistened in hot saline solution. I prefer to keep them dry.

Preparation of Patient for Abdominal Operation.—Unless immediate operation is demanded, as in emergency cases, the preparation of the patient should begin at least twenty-four hours before the time set

for the operation. It is well that he should learn to pass his urine while lying on the flat of his back (Atlee); it may save him much discomfort after operation. Other general preparation is the same as for any major operation. The intestinal tract should be well cleared by a purge and this should be administered sufficiently early on the day before the operation for it to act before night, so that the patient's sleep may not be disturbed. On the day of operation, and at least two hours before the time set for operation, the patient should be given an enema of warm soapsuds. Even in emergency cases it often is well to administer an enema just before operation.

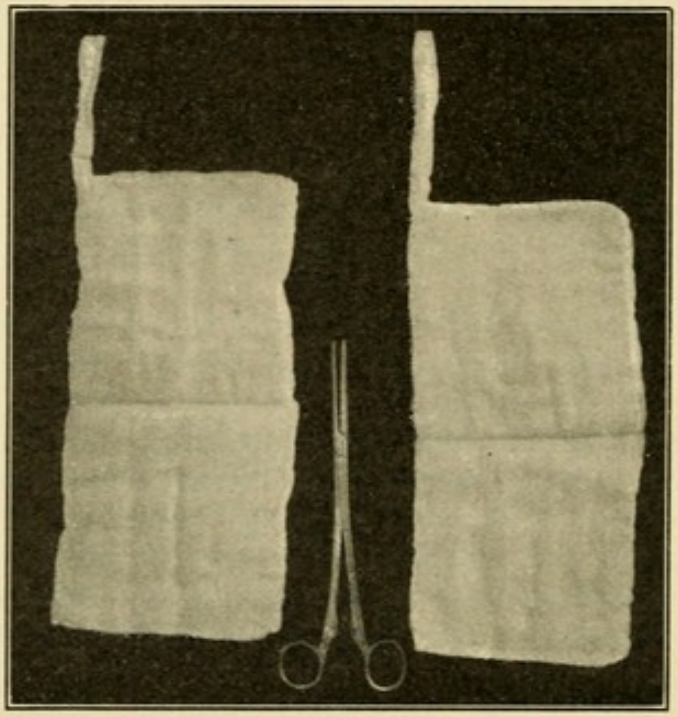

FIG. 812.—Gauze packs, for a major laparotomy; with "sponge forceps."

The abdomen should be shaved, including the pubic hair, and should be washed with green soap, rubbed with alcohol (60 per cent.), and with bichlorid of mercury (1 to 2000). Then a dry sterile dressing should be applied. This preparation is best done in the evening of the day before operation; unless done at least three or four hours before operation, the skin will not be sufficiently dry at the time of operation for the use of iodin to be effectual (p. 141). If iodin is not used, the entire abdomen should be washed again, after the patient is etherized, as at the first preparation. In emergencies it is sufficient to paint the abdomen (previously shaved dry) with 3 per cent. iodin twice, allowing the first coat of iodin solution to become thoroughly dried before the second is applied and waiting until the second has dried before making the incision.

On the evening before operation the patient should eat only a light, semi-solid meal Only cooked (sterile) food should be taken for at least two days before operation. The mouth and teeth should be

carefully cleansed. On the day of operation nothing but water should be allowed, unless the operation is to be late in the afternoon. Then a little liquid, preferably not milk, should be given for breakfast. Water may be taken until two hours before operation, but not in excessive quantities.

After-treatment in Abdominal Operations.—Very little except careful nursing is required in uncomplicated cases. If there is no vomiting, a drachm of hot water (not luke-warm) may be given every few minutes after eight to twelve hours. I am quite convinced that really hot water is less apt to cause nausea than is ice or ice-water. After eighteen to twenty-four hours small quantities of liquid diet may be given; soft diet may be begun on the third or fourth day. If the stomach has been the seat of operation mouth-feeding should not be begun for from twenty-four to thirty-six hours after operation. Vomiting is treated by total abstinence from mouth-feeding; by sitting the patient up in bed; by the administration of a glass of hot water; and finally by lavage. The treatment of peritonitis has already been considered (p. 810).

The surgeon should not be in too great a hurry to have the patient's bowels moved. Unless they move spontaneously, an enema may be given on the third or fourth day. Owing to the pre-operative catharsis, and the abstinence from food after operation, it is futile to expect a free evacuation any sooner. Cathartics should not be given after operation unless the enema proves ineffectual. Calomel in divided doses, followed by a saline purge, usually is preferred.

The patient may be turned on his side (this does not mean that he may turn himself) on the second day after operation if he desires it. He should be made comfortable. If there is peritonitis he will be in the sitting posture (Fig. 805) and will not need to be turned over to ease his back.

It is not well for the patient to leave bed until several days after the sutures have been removed. Rarely should an abdominal patient spend less than two weeks in bed. If the incision was large, or the operation very extensive, it may be advisable for the patient to remain in bed three weeks or longer. Only the very old should be hurried out of bed; and even they, if they can be made comfortable in a sitting position in bed, do just as well in bed as in a chair.

Intestinal Localization.—Often during the course of an abdominal operation it becomes important to distinguish large from small bowel, or even to identify more or less accurately different areas of the latter as belonging to the upper jejunum, the middle of the small gut, or the lower ileum. In cases of peritonitis or intestinal obstruction, the small intestine may be so distended as to equal or exceed the size of the colon, so that mere size is no criterion. In many cases the longitudinal bands on the colon may be recognized, or even the sacculation of the large intestine; but inflammatory changes or distention may obscure such means of identification. The large intestine in fat adults is covered by epiploic appendages; but in children and emaciated

adults these are absent. The safest and most constant distinction is the attachment of the intestine to the posterior abdominal wall by its mesenteries (Da Costa, 1894). The small intestine is attached by its mesentery obliquely across the lumbar spine: the coils of small bowel rarely can be brought very far laterally in the abdominal cavity, but usually occupy its middle portion. The large intestine is attached to the posterior abdominal wall on the right and left of the abdomen, and transversely above. If all the intra-abdominal structures are pushed away from the right side by the use of gauze pads, the bowel which it will be impossible to push away, will be the cecum and ascending colon. In inserting the hand, if the fingers be made to follow the peritoneum on the right across the flank, into the loin, and toward the median line, the first bowel they encounter attached to the posterior abdominal wall, will be the ascending colon. The same condition of affairs exists on the left side: the descending colon and the sigmoid have their posterior attachments further to the left than any of the intestines, and after all the movable bowels have been packed away from the left side, the immovable intestine, which remains relatively fixed, will be the descending colon or sigmoid. The sigmoid often has a long mesentery, and the sigmoid loop may prolapse into a right inguinal incision. The same is true of the transverse colon, which may be easily accessible from either iliac region or the hypochondrium. But the transverse co on is easily distinguished from other portions of the large bowel because it has the great omentum attached to it. The sigmoid and cecum are readily distinguished from each other by their mesenteric insertions.

The mesentery of the small intestine, as already noted, crosses the lumbar spine obliquely, beginning above on the left, and ending at the cecal region on the right. The *direction* in which a coil of small bowel is running (*i. e.*, which end is nearer the duodeno-jejunal juncture) can be ascertained by paying attention to the attachment of its mesentery. The coil of bowel to be investigated should be withdrawn from the abdomen, spread out, and untwisted, until the fingers can follow the mesentery down to its origin or root along the lumbar spine. If the bowel is not rotated on its mesentery, it is evident that it is running in the same direction as the root of the mesentery, and hence that its upper (duodenal) end is nearer the epigastrium than is its lower (cecal) end. The *upper end of the jejunum* is readily found by lifting the great omentum and with it the transverse colon out of the abdomen, and turning these structures upward on the patient's thorax. This makes the transverse mesocolon taut, and the jejunum is seen emerging from its lower layer just to the left of the spinal column. This is the duodeno-jejunal juncture. The duodenum here is retroperitoneal, and the first intraperitoneal coil of gut is the origin of the jejunum. This is an important landmark in gastro-jejunostomy. The *lower end of the ileum,* or the ileo-cecal juncture, is readily found by running the fingers upward along the external iliac vessels as they lie at the brim of the true pelvis. The structure which arrests

the fingers in the neighborhood of the right sacro-iliac joint, will be the termination of the mesentery of the ileum where this passes into the cecum. With a little practice it is not difficult to scoop up into the wound, on the finger tips, the ileo-cecal loop, and thus to bring the

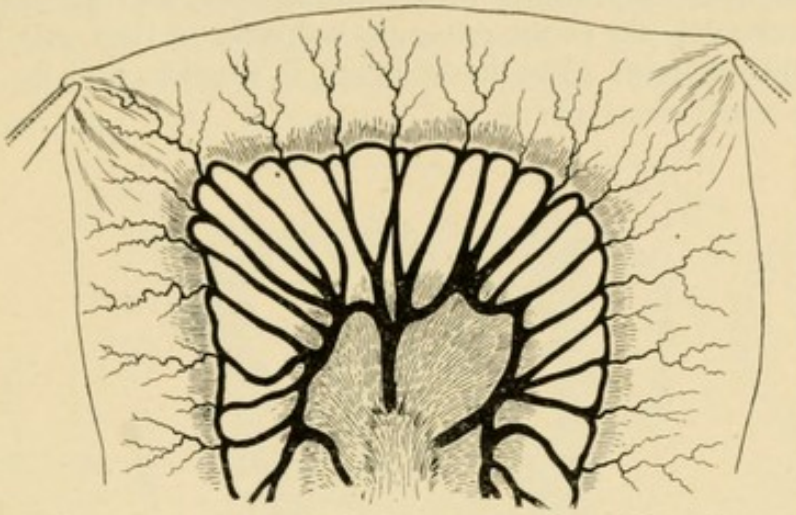

FIG. 813.—The mesenteric arteries in the upper portion of the jejunum. There are only primary vascular loops, and the vasa recta are long.

appendix vermiformis into view. Monks (1903) conducted studies in the hope of being able to differentiate at operation between different portions of the jejuno-ileum, without the necessity of tracing the entire small intestine downward from its origin or upward from its termination. Chief reliance is placed on the arrangement of the

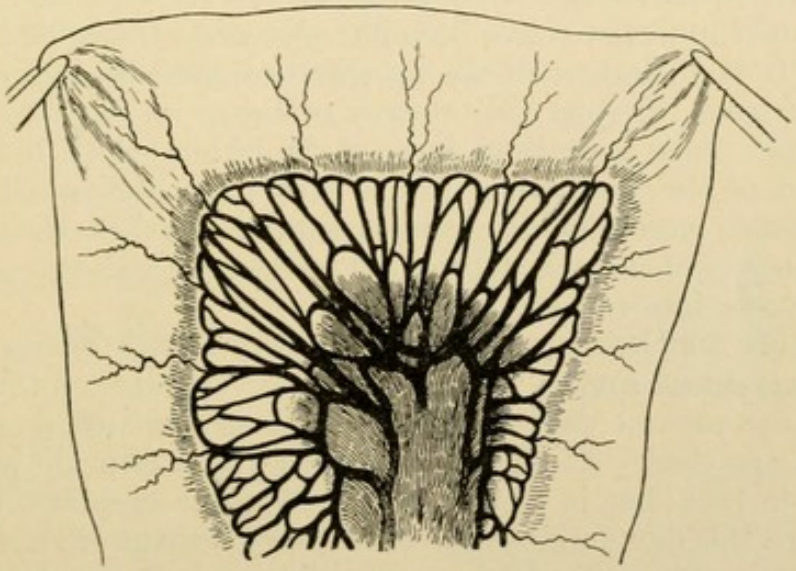

FIG. 814.—The mesenteric arteries in the middle of the jejuno-ileum. Secondary loops are well-developed, and the vasa recta are shorter.

mesenteric bloodvessels. High in the jejunum there are only primary vascular loops, with perhaps an occasional secondary loop, and the vasa recta are from 3 to 5 cm. long (Fig. 813). Midway, say at ten feet from either end, the secondary loops are a prominent feature of

the mesenteric vessels, and the vasa recta are shorter (Fig. 814). In the lower ileum the vessels are much less easily distinguished, owing to the deposition of fat in the mesentery; the loops, if visible, are much more complex, and the vasa recta are short and irregular (Fig. 815). The upper jejunum is larger in diameter, its walls are thicker, and often the valvulæ conniventes are palpable, or they may be visible by transmitted light. The lower ileum is smaller, and its walls are thinner.

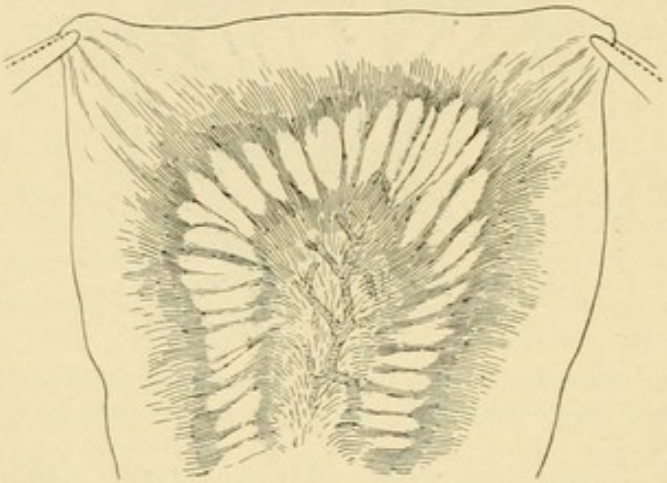

FIG. 815.—In the lower ileum the mesenteric bloodvessels can hardly be distinguished, owing to the deposit of fat. The preparations shown in Figs. 813, 814, and 815 are from the laboratory of operative surgery in the University of Pennsylvania.

Intestinal Sutures.—The underlying principle in suture of organs covered with peritoneum is to bring serous surfaces into contact. This principle appears to have been introduced by Jobert de Lamballe in 1824. It is analogous to the principle adopted in surgery of the vascular system (Chapter X), always to bring intima into contact with intima. Such apposition, both of the intima which lines bloodvessels and of the peritoneum which covers the abdominal viscera, results in much more rapid and certain union than where the muscular or fibrous layers of these structures are sutured without bringing their serous surfaces into contact.

Any suture which brings serosa into contact with serosa may be called a **sero-serous suture.** There are many varieties of this suture in use at the present day, to which the names of various surgeons have been attached. As already mentioned, this principle was used by Jobert in 1824; but in 1826 its application was simplified by Lembert, and to this day an interrupted sero-serous suture is known as a **Lembert suture** (Fig. 816). If the suture did not hold well he included tissues down to the mucous coat of the bowel, and Halsted, in 1887, renewed this injunction. It is said that it is easy to tell by the sensation imparted to the surgeon's hand, when the needle has caught up the tough submucous tissue. As a matter of fact the needle often, if not indeed usually, penetrates all the coats of the intestine; and this makes no difference so long as no fecal leakage occurs along the needle

track. This is prevented by the use of (1) round-pointed needles, and (2) linen celluloid thread (Pagenstecher's suture, 1900), which possesses no capillarity. This suture material becomes encapsulated and remains permanently.

For additional security in intestinal wounds, and especially to check bleeding from the cut margins of the bowel, it is the rule to employ also a **through-and-through suture,** which passes through all the coats of the intestine. This is inserted before the sero-serous suture, is

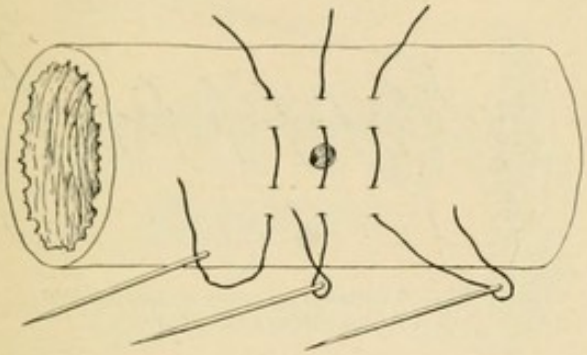

FIG. 816.—Perforation of the bowel, being closed by three Lembert sutures.

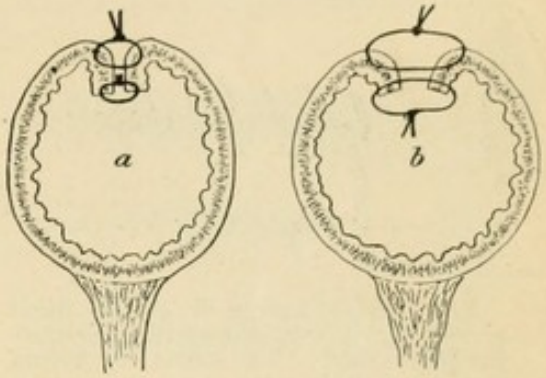

FIG. 817.—*a*, Czerny-Lembert suture; *b*, Albert-Lembert suture. (See the text.)

knotted within the lumen of the bowel, and should be of absorbable material so that it will ulcerate out into the intestinal canal when union is firm. Chromic catgut (No. 0 or No. 1) is the best material. The principle of the through-and-through suture knotted within the lumen of the bowel we owe to Albert. A diagram of the Albert-Lembert suture is shown in Fig. 817, *b*. Czerny's suture did not penetrate the mucosa, and was not knotted within the bowel (Fig. 817, *a*).

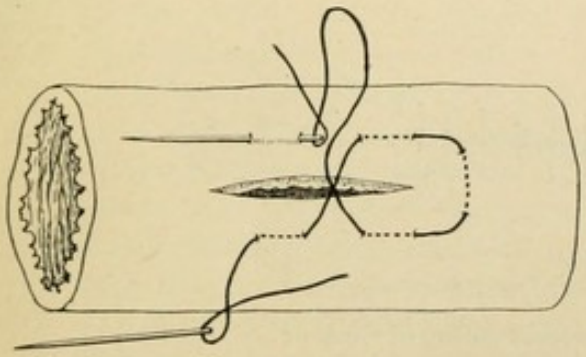

FIG. 818.—Gély's suture.

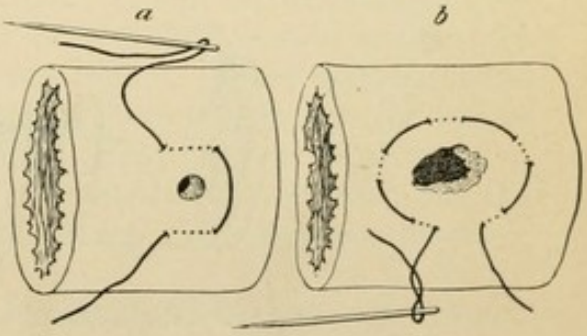

FIG. 819.—*a*, The first points of a Gély suture, used to close a puncture. *b*, a purse-string suture, used to close a perforation.

Suture of Punctures and Perforations.—A mere puncture may be inverted by a couple of Lembert sutures (Fig. 816) or by the first points of a Gely suture (1844) (Fig. 818). A perforation usually may be closed by a purse-string suture (Fig. 819, *b*), but if it is large it must be sutured as a wound in a direction either transverse or parallel

to the long axis of the intestine, whichever puckers the bowel less. As there seldom is bleeding from the edges of a perforation it is not usually necessary to use a through-and-through suture, the sero-serous suture being sufficient.

Suture of Incisions or Wounds.—Gunshot wounds resemble perforations and require the same treatment. Ruptures, lacerated and incised wounds, especially operation wounds, usually require first a through-and-through suture to check hemorrhage. This may be

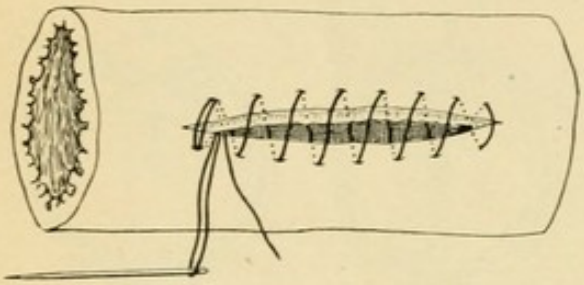

FIG. 820.—Closure of an intestinal wound by a continuous through-and-through suture. The knots lie within the lumen of the gut.

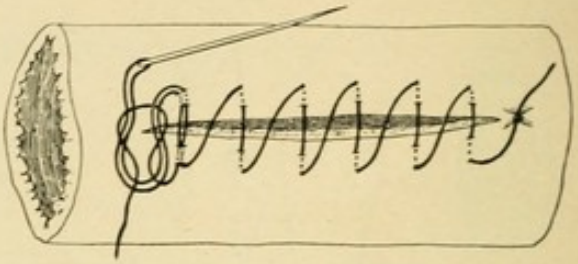

FIG. 821.—Continuous sero-serous suture (Dupuytren's suture).

either interrupted or continuous. The needle is entered at one end of the incision, from the mucous surface, emerges on the peritoneal surface, crosses to the opposite side of the incision, and there again penetrates all the coats of the bowel from the serous to the mucous surface. It is then knotted; the knot thus lies within the lumen of the bowel. If an interrupted suture is desired, both ends of the thread are cut short, and other sutures introduced about one-half a centimeter apart until the wound is closed. If a continuous suture is preferred, only the free end of the thread is cut short, and the needle is

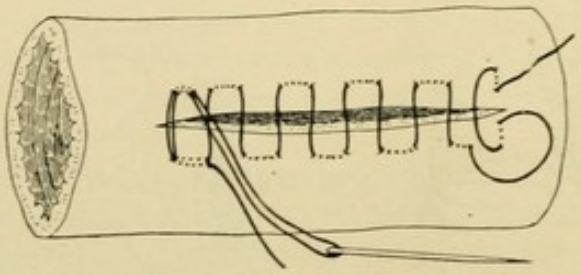

FIG. 822.—Right-angled sero-serous suture of Cushing.

re-introduced on one side of the wound *from its mucous surface*, and traversing all the coats of the bowel, emerges on the peritoneal surface. The needle is then carried across the wound to its opposite lip; here enters the serous surface of the bowel, traverses all its coats, and emerges on the mucous surface. This completes the second stitch, and the thread is then drawn taut, carefully inverting the lips of the wound as this is done. Each similar stitch is pulled taut until the other end of the wound is reached, when the suture is knotted and the

knot is allowed to retract within the lumen of the bowel (Fig. 820). To reinforce this through-and-through suture, a *continuous sero-serous suture* (known also as Dupuytren's suture) is applied (Fig. 821). Any point which seems weak may be reinforced again by an interrupted suture. When there is much tension on the parts a sero-serous suture, inserted as shown in Fig. 822, usually holds better; it is known as the *right-angled sero-serous suture* (also by the name of Hayward W. Cushing, 1889). Or a *mattress suture*, either interrupted (Fig. 823) or continuous (Fig. 824) may be employed; this is known by Halsted's name (1887).

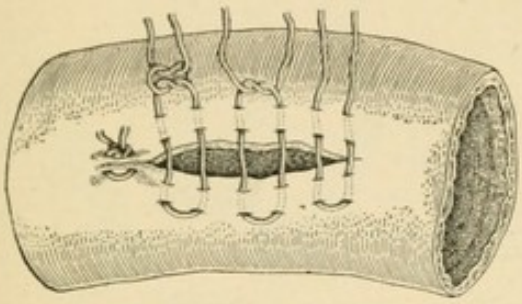

FIG. 823.—Interrupted mattress suture. (Deaver and Ashhurst.)

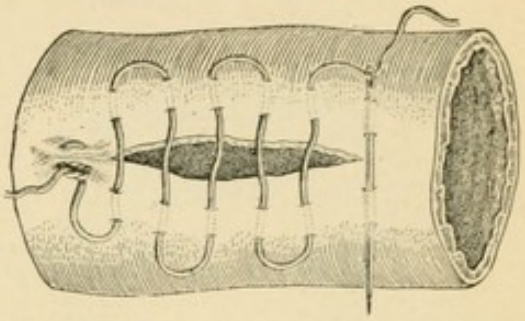

FIG. 824.—Continuous mattress suture. (Deaver and Ashhurst.)

Intestinal Resection.—When it is necessary to resect a portion of the intestinal canal, the mesentery is first tied off. This is done by a series of interlocking ligatures applied about an inch from the intestinal attachment of the mesentery, and never over quite as wide an area as the length of gut to be removed, for fear of endangering its vitality. The gut above and below the diseased area is then double clamped: suitable clamps, with their blades covered by rubber tubing, introduced into surgery by Rydygier (1881), and popularized by Doyen (1900), may be applied to healthy bowel, and if clamped only tight enough to appose the mucous surfaces may remain in place for an hour or more without inflicting any injury. These clamps should have light, elastic blades, which meet at their tips before the bodies of the blades come together (Fig. 825). They prevent fecal extravasation and also serve the purpose of temporary hemostasis, like the elastic band of Esmarch used in amputating. In emergency pieces of tape may be tied around the bowel.

Such clamps should be applied to the healthy bowel an inch or more above and below the proposed limits of resection. Any ordinary clamp forceps are then applied at the limits of the diseased area, which is thus cut at each end between two pairs of clamps (Fig. 826), so that no fecal extravasation occurs.

The subsequent procedure depends upon whether it is desired to restore the continuity of the intestinal canal by *anastomosis*, or to establish a *false anus* in the wound. The best way to establish a false anus after intestinal resection is to suture the two coils of bowel together like a double-barrelled shotgun—"*en canon de fusil*," as the

French call it. This is easily accomplished by a few sero-serous sutures. Then the circumference of each intestinal coil is sutured to the parietal peritoneum, leaving about an inch of each gut protruding from the wound. The clamps used for resection may be left

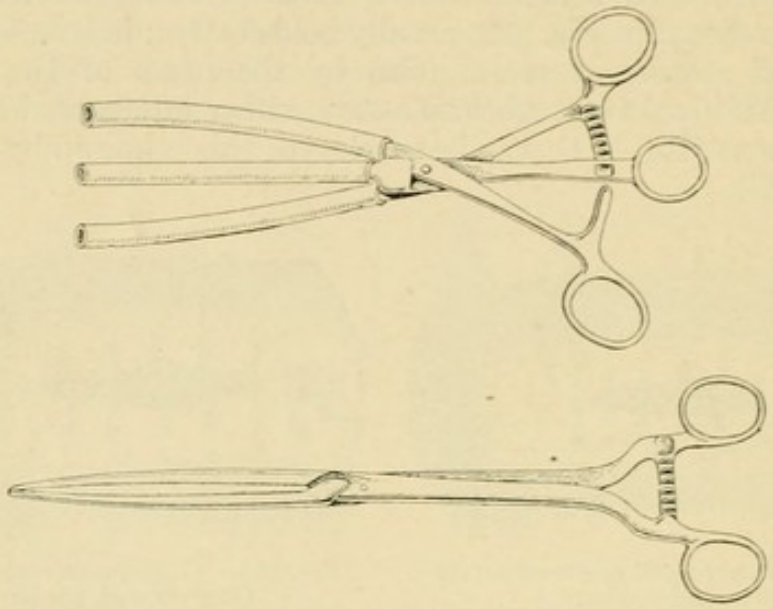

FIG. 825.—Clamps used in gastric and intestinal surgery. Note the form of the blades; in the upper (three-bladed) forceps the rubber tubing is in place.

on the protruding ends for a few days (or until the peritoneal cavity is shut off by adhesions), if there is no urgent need to secure a fecal evacuation; or the ends may be simply ligated and be left to open themselves when the slough separates. Other methods of forming a

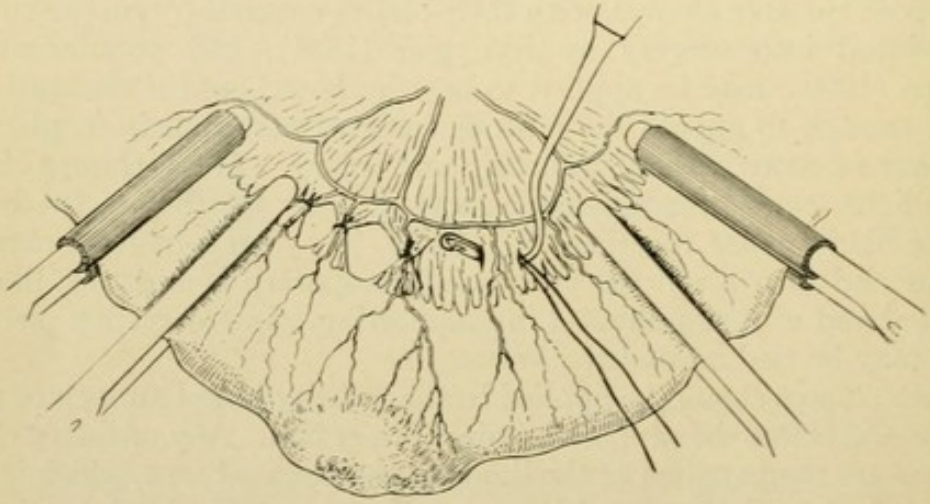

FIG. 826.—Intestinal resection. After the mesentery has been ligated and cut close to the bowel, the resection clamps are applied, and the diseased bowel is cut away.

false anus are discussed at p. 914; and the treatment of this condition is considered at p. 894.

Intestinal Anastomosis.—This may be accomplished by uniting the gut *end-to-end* (**circular enterorrhaphy**); or, after closing the open ends

of the intestines, these may be placed *side by side* and a **lateral anastomosis** may be established (N. Senn, 1889). By an **implantation** is understood an operation in which the end of one bowel is sutured into the side of another, much as the ileum is implanted into the cecum.

End-to-end Anastomosis.—The rubber-covered clamps employed during the intestinal resection are left in place. By bringing them parallel to each other, the ends of the gut are approximated; these then look at the surgeon like a double-barrelled shot-gun. This brings four layers of intestinal wall to view, two of which are apposed.

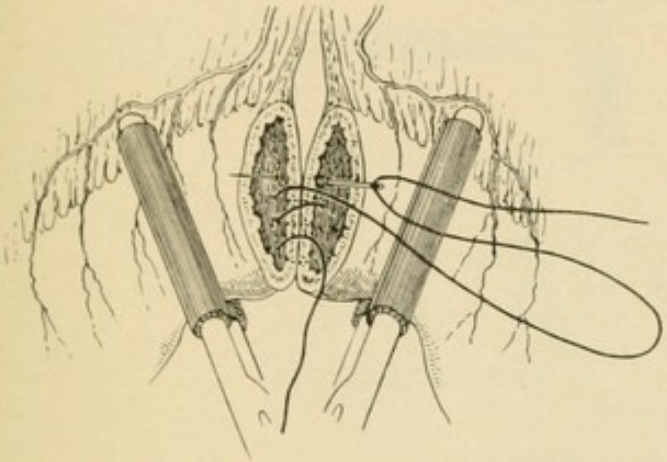

FIG. 827.—End-to-end anastomosis. The through-and-through suture has been started.

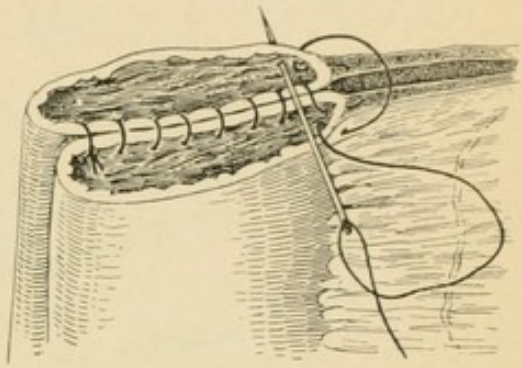

FIG. 828.—End-to-end anastomosis. Passing the through-and-through suture at the mesenteric attachment.

1. First, a continuous through-and-through suture of chromic catgut is applied: this is begun by introducing the needle from the mucous surface of that coil of gut on the operator's right, at the antimesenteric point. The needle is pushed through the apposed intestinal walls from the lumen of one gut into that of the other, where it emerges on the mucous surface, having in its course traversed all intervening layers of both guts: of the first coil from the mucous to the serous, and of the second coil from the serous to the mucous surface. The first stitch is then tied, the knot coming within the lumen of the bowel. The end is left long. The suturing is then continued (Fig. 827) toward the mesenteric attachment, and when this is reached the suture is passed as indicated in Fig. 828. The suture is continued around the margin of the gut, always passing from the mucous to the serous surface of the first coil and from the serous to the mucous surface of the second coil of bowel. When the point of beginning is reached at last, the suture is terminated by knotting it to the original end, which was left long for this purpose. When both ends are cut short, the knot disappears into the lumen of the bowel.

2. The clamps may then be removed, and the operation is completed by passing a continuous sero-serous suture around the entire anastomosis, thus reinforcing the through-and-through suture.

3. The mesentery will become redundant when the intestinal ends are approximated; its free border may be stitched to the anastomosis.

Maunsell (1892) thought it facilitated the operation of circular enterorrhaphy to evaginate the divided ends through a longitudinal incision in one of the coils of intestine. After suture of the divided ends has been thus completed, from their mucous surface, they are replaced, and the intestinal incision through which they were withdrawn is closed. A partial intussusception of the sutured ends remains (Fig. 829).

M. E. Connell (1892) advocated only interrupted mattress sutures, penetrating all the coats of the bowel, and tied on their mucous surface.

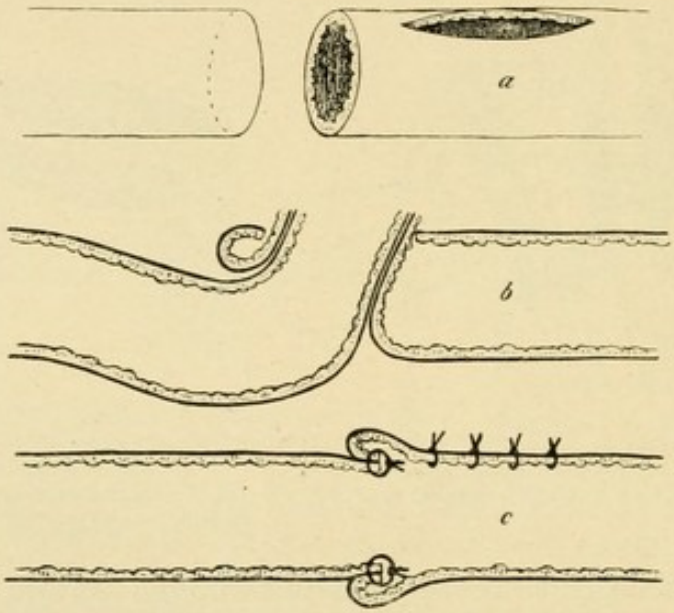

FIG. 829.—Maunsell's method of circular enterorrhaphy. *a*, the incision in one coil of intestine; *b*, the open ends of both coils evaginated through this incision, to facilitate suturing; *c*, the operation completed.

Lateral Anastomosis.—The open ends of the resected bowel must first be closed. If the lumen of the gut is small, it is sufficient to apply a ligature in the groove made by a crushing clamp, as in the operation of appendicectomy (p. 856) and to invert this ligature by a purse-string sero-serous suture. When the guts are to be left in or near the wound after the lateral anastomosis has been completed (as in some cases of resection for strangulated hernia), it is sufficient to apply a strong ligature, as above described, without a secondary inverting purse-string suture. Thus time is saved. In most instances, however, and especially where the lumen of the resected gut is of large size, it is safer to close the end of the bowel by two layers of sutures, the first being a continuous through-and-through suture of chromic catgut, and the second a linen sero-serous suture.

Lateral anastomosis should be made in an iso-peristaltic direction (Fig. 830); though where afferent and efferent loops are sutured together *en canon de fusil*, and an anastomosis is subsequently established, the antiperistaltic direction of the anastomosis appears to make little difference (Fig. 831).

The formation of a lateral anastomosis is much facilitated by the use of rubber-covered intestinal clamps. The three-bladed "Roosevelt clamp," or one of similar pattern, is very convenient (Fig. 825). The

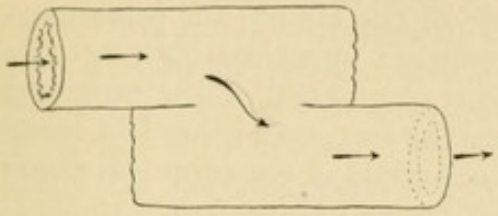

FIG. 830.—Lateral anastomosis with intestinal coils in iso-peristaltic relation.



FIG. 831.—Lateral anastomosis with intestinal coils in anti-peristaltic relation.

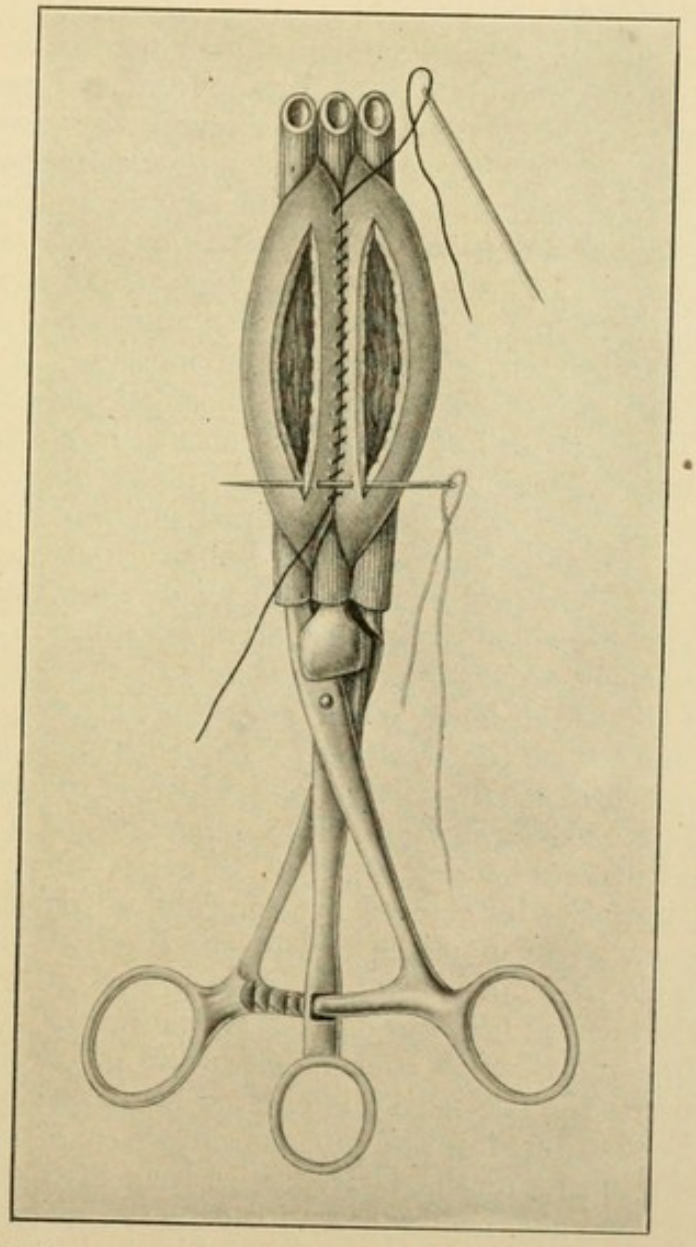

FIG. 832.—Lateral anastomosis: the clamp has been placed; the sero-serous suture has been inserted, close to the middle blade of the forceps; and the coils of intestine have been opened. At the near angle of the intestinal incisions the needle is entered for the commencement of the through-and-through suture.

clamp should be applied so as to embrace a considerably greater area of bowel than that concerned in the anastomosis. The anastomosis is made on the free (antimesenteric) border of the intestinal loops.

1. The first step consists in the insertion of a continuous linen sero-serous suture close to the median blade of the clamp, for a distance a little longer than the size of the proposed intestinal opening, say about 8 to 10 cm. This suture is begun at one end of the proposed intestinal opening, where it is knotted, the free end being left long; it is continued in a straight line to the other end of the proposed anastomosis, uniting the two coils of intestine, as indicated in Fig. 832. When this point is reached the suture is not cut, but the needle, still threaded, is laid aside temporarily, to be used again before the close of the operation. This needle and thread will be referred to as *the sero-serous suture.*

2. The surgeon then makes a longitudinal incision in one of the coils of bowel, about one centimeter distant from and parallel to the sero-serous suture already applied, and about 6 to 8 cm. in length. This incision divides first the serous and muscular coats of the gut; as these retract the mucosa pouts into the incision. The mucosa is cautiously opened at one point, so as not to wound the opposite wall of the bowel. Any discharge from the lumen of the bowel is wiped carefully away. Then the opening in the mucosa is enlarged by scissors to the full extent of the intestinal incision. If the mucosa seems redundant, as is often the case in the small intestine, it should be excised. The other coil of gut is then opened in a similar way for an equal distance. There are now exposed in the wound two apposed loops of intestine, each with a longitudinal incision in its antimesenteric border. Each of these incisions has two lips, an anterior and a posterior. The two posterior lips are fairly close together, while the anterior lips are some distance apart. For purposes of description it is convenient to apply definite names to these structures: we may speak of the coil of bowel on the operator's right as the *first gut,* and that on his left as the *second gut* (frequently it is impossible to know which of these is the afferent and which is the efferent loop); each of these guts has an incision with *an anterior* and a *posterior lip;* the posterior lips are closely apposed to each other. Where the anterior and posterior lip of each incision join, is found the angle of the incision; one angle is at the end of the intestinal incision away from the operator (*the far angle of the incision*) and the other is at the near end of the incision (*the near angle of the incision*).

3. A through-and-through continuous suture of chromic catgut is now to be inserted. The needle is entered at the near angle of the incision in the first gut, from its mucous surface, and traverses all its coats, emerging on its serous surface; it is then inserted at the near angle of the second gut, passing from its serous to its mucous surface. This stitch is then tied, the knot coming within the lumen of the bowel. The end of the suture is left long; it should not be confused with the end of the sero-serous suture (linen), which also was left long. The

through-and-through chromic catgut suture is continued away from the operator, uniting the posterior lips of the intestinal incisions, as shown in Fig. 833, until the far angles of the incisions are reached. During this time the needle is passed always from the mucous surface of the first gut through all its coats to its serous surface, and immediately into the serous surface of the second gut, emerging on the mucous surface of the second gut. Then the thread is drawn taut; the needle is carried back to the side from which it started, and again enters the mucous surface of the first gut, traverses all its coats to emerge on its serous surface, and at once enters the serous surface of the second gut, and, traversing all its coats, emerges on its mucous surface in the lumen of the second gut. This is accomplished each time by one push of the needle, which is enabled to pass through the walls of both guts "all at one bite," because the posterior lips of the intestinal incisions are so closely approximated. When, however, the far angles of the intestinal openings are reached, it is no longer possible for the needle to pass through the walls of both guts all at one bite, but it is necessary for it to be passed through each separately. But the same method of suturing may be continued: thus the needle always enters the first gut from its mucous surface and emerges on its serous surface; it then is carried across to the free margin of the second gut (at its far angle or on its anterior lip), and always enters its wall from the serous surface and emerges on its mucous surface. This is readily understood by reference to Fig. 833. This method of suturing is continued along the anterior lips of the intestinal incisions toward the operator until the near angles of the incisions are reached, when a complete circumference will have been traversed by the through-and-through chromic catgut suture, which is finally knotted to its original end, which was left long for this purpose at the starting-point, the near angles of the intestinal incisions. As this suture is being inserted in the anterior lips these should be carefully inverted so as to ensure accurate contact of their serous surfaces. If there is difficulty in securing proper inversion of the anterior lips, it is a very good plan to use for this part of the operation a continuous right-angled suture

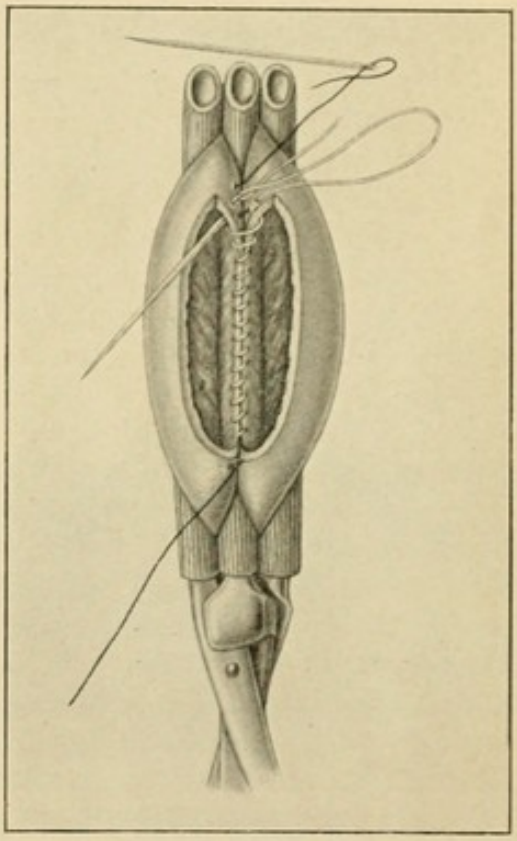

FIG. 833. — Lateral anastomosis: the through-and-through suture has united the posterior lips of the intestinal incisions, and the far end of these incisions has been reached.

similar to the sero-serous suture of Cushing (Fig. 822), except that here the right-angled suture should penetrate all the coats of the intestine, *leaving the loop of the suture always on the mucous surface of the bowel* (Fig. 834). This is known as C. H. Mayo's suture (1905). It is nothing else than a right-angled through-and-through suture.

4. When the application of the through-and-through suture has been completed, the rubber clamps may be released, but should not be removed from their position, as they serve to keep the parts accessible for the application of the final suture. This is a continuation of the sero-serous suture first applied, the needle of which, still threaded, was laid aside temporarily before the application of the through-and-through suture was commenced. This sero-serous suture is now continued over the inverted anterior lips of the intestinal anastomosis, further inverting them and burying from sight the through-and-through suture. The sero-serous suture is finally arrested at the near angle of the anastomosis, where it is knotted to its own original free end, which was left long for this purpose. The clamps are then entirely removed; the anastomosis is inspected on all sides, any weak spot being reinforced by one or two additional interrupted sero-serous sutures. The intestines are then replaced within the abdomen.

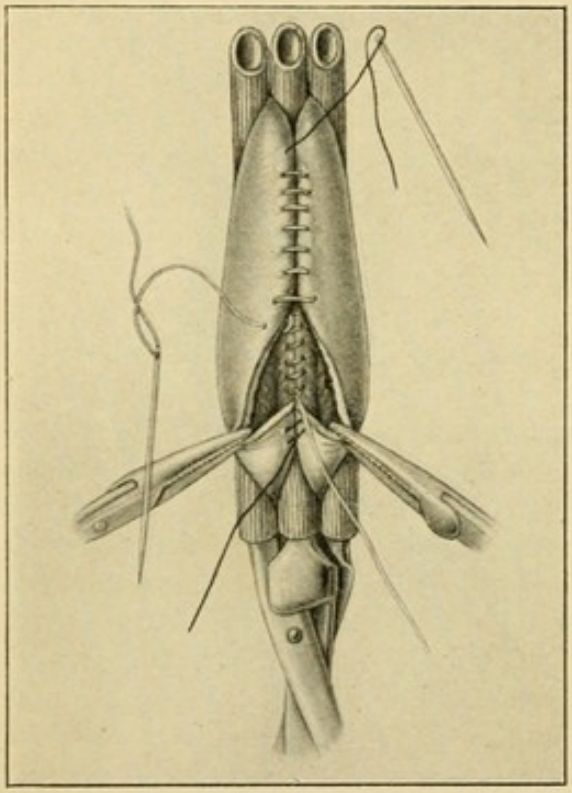

FIG. 834. — Lateral anastomosis: the far angles of the intestinal incisions have been sutured, and the anterior lips of the incisions are now being united by the through-and-through suture which is passed in a manner similar to the sero-serous suture shown in Fig. 822.

The advantages of lateral over end-to-end anastomosis are the following: the opening may be made of any desired size; there is no mesenteric attachment to be included in the sutures, and no fear of leakage at this weak point. The chief disadvantage is the additional time required for its performance, when it is employed after intestinal resection, because then it involves also closure of two ends of bowel. After lateral anastomosis following intestinal resection the coils of bowel involved tend to straighten out, so that after some years little or no trace of the anastomosis can be found, even when it was made in an antiperistaltic direction. Lateral anastomosis I believe should be preferred (1) whenever the large bowel is concerned, as this has a relatively large extraperitoneal surface and, therefore, usually is not well adapted for an end-to-end anastomosis; (2) in cases where the

two coils of gut to be anastomosed differ much in diameter, though by careful suture or by cutting the smaller intestinal loop obliquely it is possible to employ end-to-end anastomosis even under such circumstances; and (3) in cases where the intestinal walls are altered from inflammatory changes, as in most cases of acute intestinal obstruction, strangulated hernia, etc. End-to-end anastomosis I think is best limited to resections of small intestine not undertaken in the presence of *acute* disease.

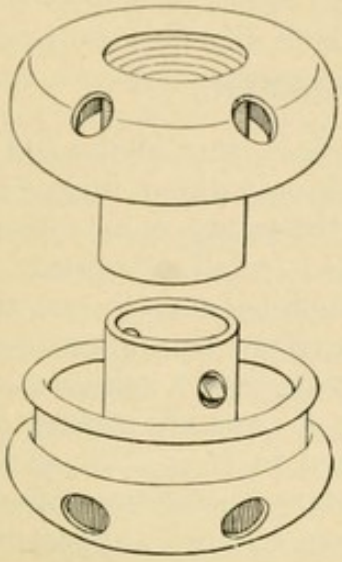

FIG. 835.—The Murphy button for intestinal anastomosis; above, the female half; below, the male half of the button.

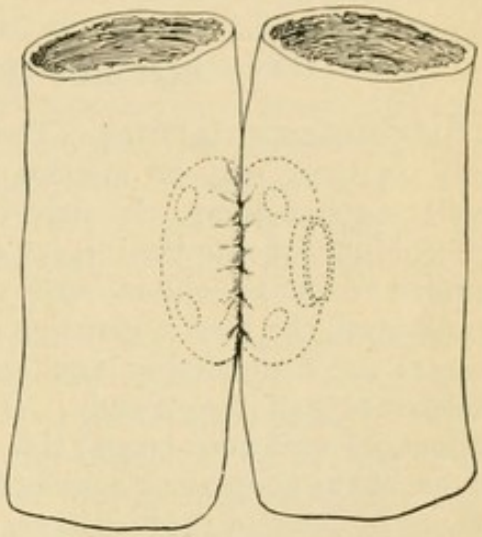

FIG. 836.—Two coils of intestine anastomosed by means of the Murphy button.

Mechanical devices for intestinal anastomosis are not much used by surgeons any more. The *Murphy button*, introduced by J. B. Murphy, in 1892, is still the most popular in this country, as is the somewhat similar contrivance of Jaboulay, in France, and Mayo Robson's bone bobbin, in England. The Murphy button is a very ingenious contrivance, made of metal, nickel-plated; it consists of two parts (Fig. 835), one of which is inserted through a small incision into each of the loops of bowel to be anastomosed, and is held in place by a purse-string suture which puckers the bowel around the half of the button inserted. The projecting shanks of each end of the button are then forced together, the male within the female; the two halves of the button are thus held together automatically by a spring. Serous surfaces are thus brought into broad apposition (Fig. 836). The union may be reinforced by a few interrupted sero-serous sutures. The button is provided with a lumen in its centre, and if all goes well it ulcerates into the lumen of the intestine in ten days or two weeks and is passed by rectum. During the application of the button its lumen may be filled with cocoa butter, which will prevent fecal extravasation temporarily, but melts as soon as the intestines are returned to the abdomen. I have never used any mechanical device in effecting intestinal anastomosis, but believe the Murphy button better than any other such appliance. It is particularly indicated where the parts concerned in the operation

cannot be brought into the wound so as to render accurate suture possible, or where very rapid conclusion of the operation becomes imperative. The chief danger from the use of the button is that its mechanism may be defective, so that it may ulcerate out too soon, allowing fecal extravasation and causing death from peritonitis. It should be an invariable rule for the surgeon himself personally to test the mechanism of the button thoroughly and several times before the operation is commenced. Occasionally the button has caused intestinal obstruction.

INJURIES OF THE ABDOMEN.

Subcutaneous Injuries.—These may affect the abdominal wall only, or there may be visceral injury with or without injury of the overlying structures. In almost all cases the injury is by direct violence, blunt force in the form of a blow, a kick, a fall, or a crush, being applied to the abdominal wall. If the abdominal muscles are rigidly contracted, the blow a glancing one, the force not very great, and the viscera not distended or weakened by disease, only a **contusion of the abdominal wall** may result. If the force is greater, **rupture of the abdominal wall** may occur; this was referred to at p. 273. Rupture of one of the abdominal muscles from voluntary contraction sometimes occurs in cases of typhoid fever; I have seen one case, apparently of this nature, complicating pneumonia.

When there is **visceral injury** it usually is because the abdominal muscles have been taken off their guard, or because they are very flabby and weak. Then the force need not be very great, especially if the hollow viscera are distended or the solid viscera enlarged by disease. In these cases no macroscopic evidence of injury to the abdominal wall may be found. Visceral injury without injury of the abdominal wall is much more frequent than rupture of the abdominal wall without visceral injury. The gravity of the injury, as pointed out at p. 181, depends largely upon the momentum of the vulnerating body: a mere tap on the abdomen from a heavy swinging crane, or block and tackle, will do much more damage than a smart blow with a stick. Sometimes a fall inflicts injury by indirect violence, one of the abdominal viscera being torn from its moorings by the jar when the patient lands on his buttocks or feet; but this is very rare.

Most cases of abdominal injury occur in men during active adult life, or in children. An irreducible hernia is an important predisposing factor: not so much that the structures in the hernial sac are injured, but because the intra-abdominal organs are held taut, and thus are unable to escape from a crushing force. This was the case in two out of five patients upon whom I have operated for subcutaneous rupture of the abdominal viscera.

The *intestinal tract* is most often injured. Its more fixed portions (duodeno-jejunal juncture, lower ileum and cecum) are most exposed to injury. The injury may be a mere contusion, which may or may

not terminate in gangrene and perforation; rupture may occur; or the bowel may be torn loose from its mesentery. Ruptures usually occur on the anti-mesenteric border of the gut, and seem to be caused by over-distention of the intestine with a resulting explosive injury, a coil of gut being compressed so as to dam up its contents against an obstruction, such as the ileo-cecal valve or a kink between adjacent intestinal loops. A few cases of rupture of the large bowel have been reported from the injection of compressed air into the rectum. Ruptures of the stomach have occurred from too forcible lavage, and from artificial distention with Seidlitz powders; this is especially to be feared in cases of gastric carcinoma, and in unconscious patients. Spontaneous rupture of the stomach has been reported as a result of vomiting, fermentative distention, etc. Complete transverse ruptures occur oftenest at the duodeno-jejunal juncture. *Crushes* of the intestine result from pressure between the body which inflicts the injury and the sacral promontory or lumbar spine. In this way the lower ileum is often torn loose from its mesentery.

The *solid organs* are less often the seat of injury than is the gastro-intestinal tract. The spleen and liver are much more frequently injured than is the pancreas, which is in a protected situation. The liver or spleen may be penetrated by the fragments of broken ribs, but usually the lesion is a rupture from diffuse compression. The rupture may be entirely subcapsular, or may extend to the surface of the organ.

Symptoms and Diagnosis.—Often there is considerable shock; usually there is vomiting; local pain causes shallow and thoracic respiration. Pain is the most constant symptom, and where fecal extravasation occurs it may be agonizing. The abdominal wall is very rigid, and physical examination is unsatisfactory.

If there is only a *severe contusion of the abdominal wall*, without visceral injury, the general condition of the patient is not much affected, even at first, and it rapidly improves. The pain is not very great, but tenderness and rigidity usually are very pronounced. It is very difficult to exclude visceral injury certainly, and in most cases exploratory laparotomy is indicated. If there is a large *rupture of the gastro-intestinal tract*, permitting fecal extravasation, the pain is extremely severe; but if the rupture is very small it may be occluded by the mucosa,[1] and there may be comparatively little pain. Serious symptoms follow intra-abdominal hemorrhage even when there is no injury of the gastro-intestinal tube. A significant symptom in cases with visceral injury is a steady increase in the pulserate; usually the temperature also rises, and leukocytosis develops. Later the signs of peritonitis develop. If there is a rupture of one of the solid organs, or of the omentum or mesentery, signs of internal hemorrhage usually precede the onset of peritonitis. Emphysema of the abdominal wall (a valuable but very rare sign), indicates rupture of a hollow viscus.

[1] In all injuries sustained during life the mucosa is everted into the rupture; this is not the case if the rupture takes place after death (Whitney).

The only certain way to exclude visceral injury is by exploratory laparotomy, and usually this is postponed too long.

Ruptures of the gastro-intestinal tract almost always are due to injury from the front. Apart from the very severe pain, mentioned above, the occurrence of repeated vomiting, of widespread tenderness and rigidity, or of blood in the stools, indicates injury of a hollow viscus.

Rupture of the liver is due to injury to the right hypochondriac region or lower thorax. As noted above, fracture of the ribs may be present, with puncture of the liver by a fragment. The rupture usually is in the right lobe, involves the capsule of Glisson, and permits intraperitoneal hemorrhage. The chief symptoms are those of internal hemorrhage. Jaundice may develop after several days. Rupture of the *gall-bladder* or *bile-ducts* allows extravasation of bile, and peritonitis develops early or late according to the infectiousness of the bile.

Rupture of the spleen is most frequent in cases of malarial hypertrophy, and under such circumstances may occur from very slight trauma, or even spontaneously. Other enlargements of the spleen also predispose it to rupture. This occurrence during typhoid fever is rare, and usually fatal. Rupture of the normal spleen usually is due to severe injury directly over the left hypochondriac region, lower thorax or loin; but if the spleen is enlarged it may be ruptured or torn loose from its supports by indirect violence.

Rupture of the Kidney.—See p. 984.

Rupture of the Bladder.—See p. 971.

Treatment.—If there is reasonable doubt as to the presence of visceral injury, the patient should be carefully studied for three or four hours after the accident. If there is only contusion of the abdominal wall, distinct improvement usually occurs within this time. If no improvement occurs, I believe exploration is imperative, even if the patient does not seem to be growing worse. The mortality without operation is 96 per cent. The earlier the operation the more chance there is of its being successful; isolated case reports show that the death rate after operation within twenty-four hours of injury is about 55 per cent. The general mortality after operation, in consecutive series of cases, is about 85 per cent. (Meerwein, 1907). Until operation is done, the shock should be treated; and, *after making a diagnosis*, morphin may be administered to allay pain. In cases of mere contusion an ice bag or hot water bag locally may be soothing. *After operation*, treatment as for peritonitis is indicated (p. 810).

Operation.—Unless there are definite indications of the seat of the lesion, a left paramedian incision should be made just below the umbilicus. Do not let the intestines escape from the wound. If there is free air in the peritoneal cavity, or if gastric or intestinal contents are found, it is clear that the gastro-intestinal tract is ruptured. If the abdomen is full of blood, it probably comes from a solid organ or from the omentum or mesenteries. If the operation has been delayed, the presence of recent adhesions, lymph, etc., will

serve as a guide to the seat of rupture. If these are absent, the intestine must be examined in detail, beginning at the ileo-cecal juncture, and passing upward toward the duodenum. Not more than two or three feet of small intestine should be outside the abdomen at any one time. Most ruptures are in the lower ileum. If active hemorrhage is found, this should be checked before anything else is done. For this purpose it is best to pack all the intestines away first to one side of the wound and then to the other and examine all structures in turn on the right and on the left, from the spinal gutter forward and from diaphragm to pelvis. Eventration of the intestinal tube does not facilitate the search; it is best to keep the intestines inside the abdomen as much as possible. Do not hesitate to make your incision large enough to facilitate rapid operating.

Intestinal Tract.—A rupture of the antimesenteric border usually can be repaired by suture, as described for perforations (p. 829); resection of the intestine should be avoided if possible. A complete transverse rupture should be treated by lateral anastomosis, or, as a last resort, and only when the rupture is low in the intestinal tract, by establishment of a false anus. At the duodeno-jejunal juncture, where lateral anastomosis is impossible, end-to-end union should be attempted; if this proves impossible, the duodenal end should be closed, and the upper end of the jejunum united to the stomach by lateral anastomosis (gastro-jejunostomy, p. 879). In Moynihan's case the regurgitation of the bile and pancreatic juice into the stomach caused no disability. Meerwein successfully supplemented this operation by uniting a lower loop of the jejunum to the descending duodenum (anterior antecolic duodeno-jejunostomy). If the intestine is torn loose from its mesentery at any point, it should be resected; it will be best then to fix the intestinal loops in the wound, *en canon de fusil* (p. 834), after ligating their ends and establishing a lateral anastomosis, as advised in cases of resection for strangulated hernia. Irrigation should not be employed, even if there is fecal extravasation. A large rubber or glass drainage tube should be carried to the floor of the pelvis, and subsequent treatment should be conducted as in cases of peritonitis.

Liver.—If injury of the liver is suspected, the incision should be made through the upper right rectus. As the blood-pressure in the liver is low, hemorrhage is not difficult to control if the site of rupture is accessible. If possible, the injury should be sutured. Mattress sutures of chromic catgut will hold in most cases, if they are not drawn too tightly. If they cut out, they should be tied over strands of catgut, used as the quills in the old-fashioned quill suture (Fig. 105). If direct suture proves impossible, the omentum may be sutured into the rupture, as a tampon, or gauze may be used. Blood-clots should be scooped out of the pelvis and spinal gutters, or wiped up with sponges; but irrigation is not advisable. The pelvis should be drained, and subsequent treatment conducted as in peritonitis. The mortality after operation is from 75 to 80 per cent. (Boljarski).

Spleen.—The incision is best made in the upper left rectus muscle. The operative mortality is about 38 per cent., but many patients die before operation can be undertaken. If the spleen is not much disorganized, it may be possible to suture the rent, or to tampon it, or even to compress the spleen against the diaphragm by firmly applied gauze packs; but suture is difficult, owing to the friability of the splenic pulp, and in many cases, especially if the lesion is at all extensive, splenectomy (p. 957) should be done. Sheldon (1910), as the result of animal experimentation, advises clamping the pedicle of the spleen with rubber-covered forceps; these are loosened in four hours, and if hemorrhage does not recur they are subsequently removed. The splenic wound itself is ignored. This method is more applicable to cases of stab wound than to rupture, since the spleen often is quite disorganized in the latter cases.

Stab Wounds of the Abdomen.—The symptoms alone are not sufficiently characteristic to warrant a diagnosis. They are those of any abdominal injury: shock, vomiting, pain, and rigidity. The important question to decide in these cases is whether or not the abdominal cavity has been penetrated. Under no circumstances[1] should this be left in doubt until the development of peritonitis renders it certain. The question as to which viscus is injured is of quite secondary importance. If protrusion of omentum, prolapse of bowel, or escape of intestinal contents renders the fact of penetration certain, no hesitancy need be felt in freely opening the peritoneal cavity. This should be done by a para-median incision.

If the external wound is small, and there is doubt as to whether the blade actually has entered the peritoneal cavity, cautious exploration should be undertaken. The wound should not be explored by sound or finger. It should be stuffed with gauze and the patient should be prepared as for an abdominal operation. The surgeon should then dissect down layer by layer and thus follow the tract of the wound. If difficulty is experienced in tracing a small stab wound, it is best first to lay bare the abdominal aponeurosis (sheath of rectus, aponeurosis of external oblique) over a wide area, and search it for the stab wound. If this cannot be found, and it is known that the blade was very short (that of a pen-knife, for example), and if there are no other symptoms of penetration, the skin incision may now be closed. If, however, it be ascertained that the blade has penetrated the aponeurosis, the surgeon should next lay bare the transversalis fascia and peritoneum, but should not open the latter until he is sure it has been penetrated. I am thus insistent upon this cautious approach to the peritoneal cavity, when the fact of its penetration is in doubt, because it often happens on opening the abdomen widely in these cases that inspection shows no evidence of intra-abdominal lesion, and very extensive search becomes necessary to exclude the

[1] This statement, of course, does not refer to wounds received in warfare. These require the same treatment as abdominal gunshot wounds in military life (p. 191).

possibility of visceral injury; and if none be found to exist, and it is shown that the vulnerating weapon itself never had opened the peritoneal cavity, the surgeon will have subjected his patient to a quite unnecessary and by no means trivial operation. If, however, the fact of abdominal penetration has been determined by the method just described, the surgeon will be quite justified in his extensive intra-abdominal manipulations, even though no lesion be found more serious than hemorrhage from an omental vein (Deaver and Ashhurst).

If some of the abdominal contents protrude through a wound their condition will determine their proper treatment. If viable,[1] they should be cleansed, any visceral wounds should be repaired, and the viscera should be replaced. For this purpose it may be necessary to enlarge the abdominal wound. Omentum which protrudes from an abdominal wound should be excised, as should portions of prolapsed intestine which appear certain to become gangrenous.

The abdominal structures most often wounded are the following: small intestine, colon, omentum or mesenteries, liver, stomach, and diaphragm.

After opening the abdomen, the first thing to do is to control hemorrhage. Each intestinal lesion should be repaired as it is discovered, and should not be put aside with the idea of repairing it later in the operation. Careful search of the entire intestinal tract is necessary, as the lesions often are multiple, and in about one-third of the cases which terminate fatally postmortem examination shows this result to be due to the presence of one or more perforating wounds which were not discovered at operation. The general mortality after operation is about 50 per cent.; it is much higher if no operation is done. When operation is done within the first twenty-four hours the mortality is less than 10 per cent.

Gunshot Wounds of the Abdomen.—In addition to the general account of these injuries given in Chapter VII, some more particular account of the operative treatment may be given in this place. The probability of penetration is so great that in civil life every case should be subjected to exploratory laparotomy at as early an hour as possible. The incision should be made close to the median line, in that portion of the abdomen injured. The wound of entrance of the bullet may be disregarded, unless there is hemorrhage through it from a vessel in the abdominal wall; then the wound of entrance should be opened and the bleeding arrested. But it is much better to enter the abdomen through healthy structures, and at the most convenient point, than to make the exploration through the infected bullet tract. The bullet wound, however, should be swabbed out with iodin (3 per cent.) and packed with gauze.

Gunshot wounds of the *intestinal tract* usually are perforating, the bullet producing wounds of entrance and exit in each coil of intestine which it injures. Sometimes as many as four or six perforations

[1] See Strangulated Hernia, p. 768.

will be found within a few inches of each other in one coil of bowel. In such cases it may be necessary to excise the segment of gut wounded; but whenever possible suture should be preferred, and even if the repair of the perforations by suture seems to cause some obstruction to the lumen of the gut, I believe it is better to run this risk than to undertake resection. The omentum may be sutured over the damaged area, to reinforce the sutured perforations; or the damaged coil of bowel may be fixed in the wound, to preclude damage from intraperitoneal leakage of intestinal contents, if there is doubt about the sutures holding. If the mesentery is so much damaged as to impair the vitality of a segment of intestine, resection can hardly be avoided. Each lesion should be repaired as it is found; it is only a waste of time to pass over a perforation thinking to find and repair it at a later stage of the operation.

Gunshot wounds of the *stomach* require special mention. The "head-high" (reversed Trendelenburg) posture, with a sand bag under the patient's lower dorsal spine, is a great help in exposing the field of operation. The stomach is best found by identifying first the left lobe of the liver, and passing the fingers from its under surface over the gastro-hepatic omentum on to the anterior wall of the stomach. Usually there is both a wound of entrance and one of exit. The wound first found should be repaired at once. If no other wound is found on the anterior wall, the gastro-colic omentum should be divided, between hemostats, on the colonic side of the gastro-epiploic arteries, and for a distance *at least* of three inches. The existence of a perforation on the posterior wall usually will be indicated by extravasation within the lesser peritoneal cavity. W. Martin (1907) found that among the cases he studied failure to suture the bullet-hole in the posterior gastric wall had not materially influenced the mortality. A perforation should be sutured if found; if inaccessible from the posterior wall of the stomach the surgeon may open the anterior wall of this organ and suture the posterior perforation from inside the stomach. If more room is required to expose a perforation in the cardiac region of the stomach, temporary resection of the costal margin may be adopted; if the line of section is kept in the cartilages (not invading the bony structure of the ribs), the pleural cavity will not be opened (Auvray). Drainage of the lesser peritoneal cavity should be secured by a wick of gauze emerging through the gastro-colic omentum; hemorrhage from this structure, which has been controlled during operation by hemostats, is permanently arrested by suture. Drainage through the left loin seldom is required; but some form of drainage of the lesser peritoneal cavity never should be neglected, particularly in cases where the pancreas has been injured. Another drain should be placed anterior to the stomach, and in cases where gastric or intestinal contents have been diffused in the abdomen, the pelvis should be drained also through a suprapubic opening.

Gunshot wounds of the *duodenum* are rare, scarcely ever uncompli-

cated by other lesions, and usually fatal. Proper exposure is difficult and it may be impossible to suture or even to discover a perforation on the retroperitoneal surface. Usually it will be well to drain the sutured area, especially if it is retroperitoneal. Drainage always should be employed, preferably through the loin, if a retroperitoneal perforation is suspected but not definitely located, or if one is located in an inaccessible position. Resection with end-to-end anastomosis may be required. In many instances it probably will be safer to close both ends of the duodenum, and do gastro-jejunostomy or duodeno-jejunostomy (Deaver and Ashhurst).

Gunshot wounds of the *liver* often bleed profusely. There usually is little difficulty in checking bleeding by suture or tampon, and if hemorrhage is arrested in good time, the immediate prognosis is reasonably good; though secondary complications, such as hepatic or subphrenic abscess, empyema, or pneumonia, are much to be feared. The general mortality after operation is from 35 to 40 per cent.; in a series of 37 cases uncomplicated by injuries of other viscera, the mortality was only 16 per cent. (Patel and Loaëc, 1912).

Gunshot wounds of the *spleen*, as in the case of subcutaneous injuries, frequently cause so much disorganization as to require splenectomy.

Gunshot wounds of the *pancreas* almost always are complicated by injuries of surrounding viscera. The best exposure is gained through the gastro-colic omentum. Tamponade is more successful than attempts at suture. Drainage always should be employed. If the injury is undiscovered, death is practically certain. The death rate after operation is about 43 per cent. (Diehl, 1911).

CHAPTER XXIII.

SURGERY OF THE GASTRO-INTESTINAL TRACT.

SURGERY OF THE APPENDIX VERMIFORMIS.

Appendicitis.—Inflammation of the vermiform appendix of the cecum is the most frequent form of abdominal disease seen by the surgeon. Its symptoms were described even by authors of classic times; but no one, except perhaps Mélier, in 1827, considered disease of the vermiform process as the chief, if not the sole cause of these symptoms until it was proved, about thirty years ago, by Matterstock in Germany that almost all abscesses in the right iliac fossa were associated with a perforated appendix; and by Fitz in America that in cases of so-called typhlitis (inflammation of the cecum) and in cases of appendicitis the symptoms were identical. The term appendicitis was introduced by Fitz in 1886.

Pathogenesis.—The anatomy of the appendix predisposes it to inflammation. It is filled with fecal matter charged with bacteria; it contains a long mucous canal which opens by a narrow orifice into the cecum; usually it is more or less kinked or twisted, owing to the shape of its mesentery; and the slightest swelling of its walls at any point may cause complete obliteration of its lumen, converting its distal segment into a closed cavity whose naturally infectious contents are thus markedly increased in virulence. In addition to these factors, the appendix possesses a precarious blood-supply: it possesses no collateral circulation; its arteries are "end-arteries;" and the slightest swelling or constriction or kinking of the organ may cut off the blood-supply completely, resulting in partial or total necrosis.

The infection, in the vast majority of cases, is *enterogenous;* but *hematogenous* infection sometimes occurs (p. 850). In enterogenous infection the bacteria swarming in the fecal contents of the appendix produce a sub-epithelial reaction, which is known as the *primary focus* (Primarinfekt) of Aschoff (1908). This occurs in the depths of one of the mucous crypts of the appendix, and consists of a collection of neutrophile leukocytes. The epithelium itself, which overlies the primary focus, may be destroyed very early in the process, its place being taken by a plug of fibrin. *Usually a number of these primary foci develop simultaneously.* The inflammatory reaction spreads very quickly toward the serous coat of the appendix, and peritonitis may develop before the mucous surface is seriously diseased. In almost every case, the primary infection is due to the streptococcus; but invariably the colon bacillus invades the walls of the organ secondarily,

and soon over-grows the streptococcus, so that cultures of the latter are lost.

If resolution does not occur at this very early stage of appendicitis, these intramural foci become confluent, and the condition is known as *simple phlegmonous appendicitis*. The existence of a primary catarrhal appendicitis, with ulceration as its result, is denied by Aschoff; what was formerly described as catarrhal appendicitis is now recognized as phlegmonous (intramural) in nature. This phlegmonous stage is present, with few exceptions, whenever the disease has lasted more than twelve hours. Even should resolution occur at this early stage of the disease, the appendix will not return to its normal state; cicatricial tissue remains, strictures may form, and the organ is more than ever predisposed to infection. If resolution does not occur early in the phlegmonous stage of the disease, intramural abscesses develop, miliary in size. These are prone to perforate the serous coat of the appendix (*miliary perforations*), causing peritonitis without macroscopic perforation of the appendix. Or they may rupture into the lumen of the appendix, producing ulcers. *Ulcerative appendicitis* never is the primary stage; it follows the phlegmonous, whether or not this has progressed to the stage of suppuration. In this ulcerative stage the mucous membrane frequently is *hemorrhagic;* but the most serious complications of this stage are (1) **ulcerative perforation** (macroscopic), which usually occurs on the anti-mesenteric border of the appendix; and (2) **necrosis** of the wall of the appendix. This necrosis may be the result of anemia from vascular thrombosis, or it may be due to the direct toxic influence of bacteria on the appendicular wall. In either case secondary invasion of the necrotic area by putrefactive microbes (from the fecal contents of the appendix) leads to **gangrene.** Separation of the slough formed in this manner produces yet another variety of perforation.

Every attack of appendicitis passes through all the stages described unless arrested spontaneously or unless the appendix is removed.

If resolution occurs early in the phlegmonous stage of the disease, and if the appendix suffers a number of such mild attacks (which may be so mild as to pass unnoticed), a condition described as **chronic appendicitis** may develop.[1] This term implies not so much a chronic inflammation, as defined at p. 35, as it does the result of previous inflammatory attacks. The lesions are fibrotic and sclerotic in nature, and are most marked in the distal portion of the appendix, especially behind a stricture. In some cases repeated mild attacks lead to obliteration of the lumen of the organ, through the process of adhesion between its apposed granulating walls. This **appendicitis obliterans** (Senn, 1894) usually affects only the tip of the organ, but as the patient ages the entire lumen may be obliterated.

[1] This is the teaching of Aschoff, whose studies of the pathology of appendicitis are the most recent and accurate. Other authorities have held that an acute attack seldom occurs except in an appendix already the seat of chronic appendicitis. Both views are harmonized if we admit that chronic appendicitis always begins with a definite attack which is acute pathologically, no matter how mild clinically.

Strictures, or actual **occlusion** of the lumen of the appendix may occur at various points. If a stricture only is present, it is usual for a **coprolith** or fecal concretion to develop behind it (Fig. 837), or between two strictures. If complete occlusion exists the tip of the appendix beyond the occlusion or the segment lying between two occluded points may become the seat of an **empyema**, during an acute attack; or if the infection dies out a **cyst** may succeed the empyema. Not infrequently in an acute attack temporary occlusion (from edema or kinking) occurs close to the cecum and the whole appendix is converted into an abscess sac. Fecal concretions found in the appendix at operation almost surely are the result of a previous attack of appendicitis; after they are once formed they predispose, by their mechanical action, to further attacks and especially to perforation, which occurs oftenest behind the concretion. *Foreign bodies* which are rare in the appendix, act in much the same way as do the fecal concretions: they may lie in the lumen of the appendix for years without producing any symptoms.

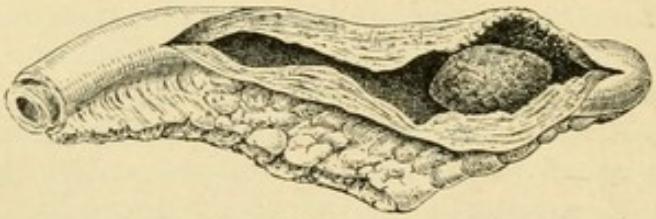

FIG. 837. — Gangrenous appendix with fecal concretion near tip. Note thickness of walls, indicating previous attacks; stricture on proximal side of concretion; and impending perforation near tip. Episcopal Hospital.

Causes.—Appendicitis is commonest between the ages of ten and thirty years, when all infectious disorders are most prevalent. Streptococci, especially diplococci, are the bacteria most often directly responsible for an attack of the disease; but why it is that they produce the attack at any given time is a mystery. The great frequency of *enterogenous* infection has already been noted; and it is probable that stagnation of the contents of the appendix from kinking is the main predisposing cause. Digestive derangements increase the virulence of bacteria in the intestinal canal, or are the result of this increased virulence; and disordered peristalsis may force fecal matter containing these highly virulent organisms into the appendix. There is no good proof that appendicitis arises as the extension into the appendix of a catarrhal inflammatory process in the cecum. It is probable that intestinal parasites found in the appendix (Fig. 838) have no etiological significance.

In some cases it is possible that infection occurs through the bloodstream (*hematogenous*). In this connection attention has been called (by Kellynack, Kretz, and others) to the histological resemblance of the appendix to the faucial tonsils, both of them containing much lymphoid tissue; and it has been held that appendicitis is an abdominal angina. But neither the clinical history of the patients, nor the

histological examination of the diseased appendices supports the theory of hematogenous infection, except in extremely rare instances.

One attack of appendicitis predisposes to another. Nearly 85 per cent. of 3000 patients under Deaver's care had had a previous attack.

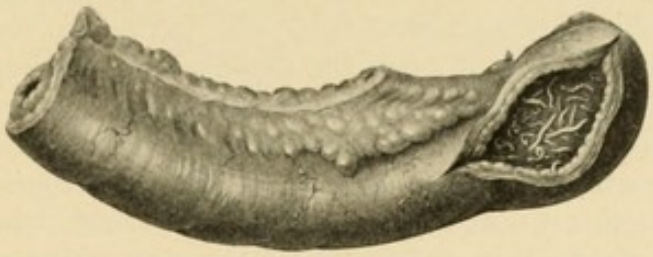

FIG. 838.—Acute appendicitis, appendix containing oxyuris vermicularis. (Natura size.) Episcopal Hospital.

Acute Appendicitis.—SYMPTOMS AND CLINICAL COURSE.—*Pain, nausea*, and *vomiting* followed by *tenderness* and *rigidity:* These are the cardinal symptoms of acute appendicitis. Usually without previous warning the patient develops a sudden colicky pain, more or less diffused throughout the abdomen or localized to the umbilical region. This pain is due to the disordered peristaltic action of the appendix in attempts to empty itself against resistance. It is analogous to the pain of biliary, intestinal, or renal colic; like them it excites nausea and vomiting. The vomiting is reflex, and suffices only to empty the stomach. It is not repeated unless peritonitis develops, when it assumes the type already described at p. 806. This primary nausea and vomiting follows and does not precede the initial pain of appendicitis; to this rule there are very few exceptions. At this time there is no special tenderness in the abdomen; indeed, as in intestinal colic, pressure may relieve the pain. But usually within twelve hours the character of the pain changes; it is no longer diffuse and colicky, but becomes localized to the right iliac region, where the diseased appendix is found. The pain is now burning, constant, and intense. Simultaneously with this localization of the pain to the right iliac fossa there develop both tenderness and rigidity, which also are confined to the region of the appendix. Palpation now reveals a normal abdomen elsewhere, but over the right iliac fossa the muscles (particularly the right rectus) are rigid, and tenderness is so marked that even slight pressure causes extreme pain. *This localized rigidity is the most important single symptom of appendicitis.* Roughly speaking, all these symptoms of appendicitis are localized around **McBurney's point,** which was described by its author in 1891 as a point from one and a half to two inches distant from the anterior superior spine of the right ilium on a line drawn between this spine and the umbilicus.

When this stage of the disease has been reached it is possible in all but the most exceptional cases to make an accurate diagnosis of appendicitis. The condition is clinically one of localized peritonitis, as described at p. 805, and that this is the pathological state is evident from the account of the pathogenesis of appendicitis already given.

Appendicitis is localized peritonitis; all the signs of this condition are present: tenderness and rigidity, arrest of peristalsis in the immediate vicinity of the lesion, local tympany from paresis and distention of the ileo-cecal coil of the intestinal canal; and persistent constipation. The development of complications should not be awaited before making an accurate diagnosis.

In a small proportion of cases the attack does not begin with acute pain, but with a gradually increasing discomfort in the neighborhood of the appendix; and in such cases, the physical signs of appendicitis often develop without any nausea or vomiting. Hence it is, that in appendicitis as in all other acute abdominal lesions when the history of the case is atypical, it is safer to rely on the physical examination than on the history, in reaching a diagnosis.

No mention has been made hitherto of the *temperature, pulse,* or *leukocytosis,* in connection with appendicitis. They are of quite secondary importance. Usually the temperature is slightly elevated from the first, and the pulse quickened, as in all febrile states. There also is leukocytosis in most cases, the white blood cells numbering anywhere from 10,000 to 40,000. The white-blood count is of more value in prognosis (p. 859) than in diagnosis.

When the stage of localized symptoms described above has been reached, the disease pursues either one of two courses: It subsides, or complications develop. In the former case the pain gradually lessens; the tenderness changes to mere "soreness," rigidity disappears, flatus is passed normally, the temperature curve reaches the normal, and the leukocytosis gradually subsides. The course of such an attack lasts on the average from three days to a week. If the attack does not subside, complications develop; they are frequent and almost countless. Among the more important are perforation and gangrene of the appendix, and abscess formation or diffuse peritonitis with all its dire consequences. The symptoms, diagnosis, and treatment of these complications are considered at p. 857.

Diagnosis.—The diagnosis of appendicitis usually is easy. It is the most frequent of all acute abdominal diseases, and should be ever in the surgeon's mind. In *intestinal colic* the pain is general and does not become localized to the region of the appendix; pressure relieves it; nausea and vomiting are by no means constant, and often precede the onset of the pain; active peristalsis is audible; and diarrhea is the usual outcome. At no period of the attack is there muscular rigidity. Fever is unusual. Leukocytosis is absent. In *biliary colic* the pain is situated in the right hypochondrium and often radiates to the right shoulder. A history of many previous attacks often is obtainable, and jaundice may have been present at some time. Tenderness and rigidity if present are confined to the gall-bladder area. If the patient is past forty years of age the attack probably is biliary, not appendicular. In *acute cholecystitis* the symptoms somewhat resemble those of biliary colic. Tenderness and rigidity are constant, but are confined to the upper right abdominal quadrant, unless the gall-bladder

is displaced. The characteristics by which an enlarged gall-bladder is recognized are stated at p. 920. In *renal colic* from disease of the right kidney, the symptoms may closely simulate those of appendicitis, particularly when a calculus is lodged in the ureter. Yet the radiation of the pain, the urinary findings, and the absence of gastro-intestinal symptoms suffice in most cases to make the diagnosis clear. Skiagraphy is a valuable aid. In *acute salpingitis*, especially affecting the right tube, the peritoneal symptoms are confined to the pelvis and gastro-intestinal symptoms are absent. Tenderness is too low and too near the median line, for appendicitis; it is not at McBurney's point, but about over the middle of Poupart's ligament. Vaginal examination confirms the diagnosis. Some cases of *typhoid fever* begin with rather acute abdominal pain, and this may be accompanied by nausea and vomiting. Usually, however, strict inquiry reveals that the actual onset of the disease occurred several days previously, with malaise, headache, feverishness, etc. The temperature is too high (103° F. or more) and the pulse too slow (100 or lower) for appendicitis; and there is leukopenia not leukocytosis.

In none of the affections mentioned, nor in any of the score or more other diseases which may be exceptionally confused with appendicitis, is the clinical history typical of the latter: *sudden* pain, first diffuse, then settling to the right iliac fossa; *followed* by vomiting; and the extremely important *localized tenderness* and *rigidity*.

Prognosis.—The appendix is the *fons et origo mali*, and if it is removed before complications develop, the prognosis is brilliant. The mortality of operation at this stage of the disease is so low that hundreds and hundreds of such simple cases are cured without a death. Once in several hundred operations it may happen that a patient dies of pneumonia or some other unforeseen complication; but this minimal risk stands in no sort of relation with the risk run by delaying operation to determine whether or not complications are about to develop. As a matter of fact, even under the most approved non-operative treatment, complications develop in at least 10 per cent. of cases. It was justifiable to delay operation only in the days before the development of aseptic surgery; until that time the only form of intra-abdominal disease successfully amenable to surgical treatment was localized suppuration. It was then and it is now absolutely impossible to control the course of the disease in the appendix by any means known to medical science.[1] Unless the appendix is removed the patient is left to the unaided efforts of nature. Never should the surgeon call for aid from beneficent Nature until he has exhausted his own resources. Apollo would not help the teamster until the latter had whipped up his horses and put his own shoulder to the wheel. The mere diagnosis of appendicitis should be an indication for immediate operation. I am conceited enough to believe that I can recognize, as well as anyone else, the occurrence of perforation or suppuration

[1] I am speaking of disease *in the appendix*, not of the peritoneal complications of this disease.

in appendicitis, but I frankly confess my utter inability to feel sure one hour that neither of these events will occur during the next, so long as an acutely inflamed appendix remains within a patient's belly. It is possible to argue on probabilities, and to defer operation in cases that appear mild; but sooner or later the surgeon will encounter a case which will make him regret his procrastination, and will convince him that he has lost the life of his patient through over-confidence in his own powers of prognostication. Even if life be not lost, it will be surely jeopardized by the development of peritonitis, localized or diffused, with the possibility of its lethal sequels, such as gangrene of the bowel, intestinal obstruction, pylephlebitis, etc. It is strange that well-meaning physicians, and even some apparently intelligent surgeons will delay operation, trusting to be warned of impending danger by well-defined symptoms in time to employ an operation, when the best time for operation is before alarming symptoms arise. Only in the very aged, or in those with extremely serious visceral lesions (cardiac or renal) is delay justifiable.

TREATMENT.—The abdomen should be shaved and cleansed and the bladder emptied (by catheter if necessary) as before any abdominal operation. No other preparation is required, but in many cases it is well to empty the lower bowel by enema.

Operation.—I prefer, and habitually employ, the transverse *incision* of G. G. Davis. Other incisions for appendectomy have been described in Chapter XXII. This transverse incision is so planned that its centre lies over the right semilunar line, at the level of the anterior superior spine of the ilium. In simple acute cases the incision is from one and a half to two inches long (Fig. 839). The skin and subcutaneous tissues are divided, exposing the aponeurosis of the external oblique. This, and the anterior sheath of the rectus are incised in the same transverse direction throughout the inner half of the wound. The muscle fibres of the rectus are thus exposed, and are to be retracted toward the middle line. In this way the posterior sheath of the rectus and the transversalis fascia are exposed. The peritoneal cavity is next opened in the usual way, in a transverse direction. The left forefinger is then inserted into the peritoneal cavity, and hooks up the abdominal wall on the outer side of the opening already made. With blunt scissors the operator then splits the internal oblique and transversalis muscles outward in the direction of their fibres (which here run directly transversely), thus passing parallel to the motor

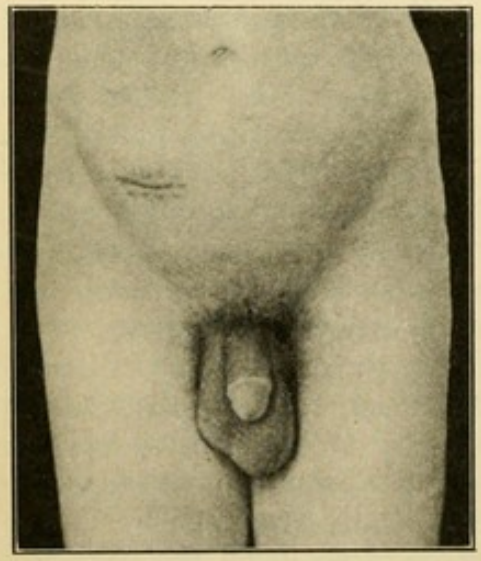

FIG. 839.—Transverse incision for appendectomy; two weeks after operation. Episcopal Hospital.

nerves of the abdominal wall. The transversalis fascia and peritoneum are then cut in the same direction, throughout the whole extent of the wound. If more room is needed toward the median line, the anterior and posterior sheaths of the rectus may be incised as far as the linea alba, but the muscle itself need not be cut, as it can be drawn far to the left with a retractor. If more room is needed to the outer side, the oblique and transversalis muscles may be cut as far as the iliac spine, or further if necessary, without any damage to the abdominal nerves. Some branches of the deep circumflex iliac artery may be cut if the wound is extended outward, but the only muscular fibres which will be cut across are those of the external oblique; but in most cases the incision involves only the aponeurosis of this muscle, not its muscular fibres.

Locating the Appendix.—First Method.—Place two fingers of the left hand inside the abdominal wound and follow the parietal peritoneum of the anterior abdominal wall downward to Poupart's ligament; then carry the fingers upward along the brim of the pelvis (recognized by the pulsations of the external iliac artery) until they are arrested. The structure which arrests them will be the mesentery of the ileo-cecal region. Usually the appendix can be recognized in this position by the sense of touch, and if not adherent can be drawn out of the abdominal wound between the index and middle fingers. *Second method:* Pass the fingers of the left hand along the parietal peritoneum on the outer side of the wound, and let them follow the parietal peritoneum inward across the iliac fossa. The structure which arrests them will be the cecum or ascending colon with its mesentery. Draw the cecum into the wound and trace its longitudinal bands downward until they converge at the base of the appendix which is then delivered. *Third method:* This is less brilliant than those just mentioned, but it is the surest method of all. Pack all the abdominal contents to the patient's left, by inserting gauze sponges. When all the movable structures have been thus carried away from the seat of operation, only the immovable will remain. This is the cecum, attached to the posterior abdominal wall by its short mesentery. When the cecum is thus found, draw it out of the wound, and trace it downward until the appendix is delivered.

Removal of the Appendix.—(1) Pass an aneurysm needle, carrying No. 1 chromic catgut, through the meso-appendix close to the base of the appendix and tie this ligature around the free border of the meso-appendix as far away from the appendix as possible. If the meso-appendix is very thick or long, it is safer to tie it in two or three sections. (2) Cut the meso-appendix as close to the appendix as possible, thus leaving enough tissue beyond the ligature to prevent its slipping (Fig. 841). (3) Clamp the appendix at its juncture with the cecum, and clamp it again about a centimeter distant. Remove the first clamp and ligate the base of the appendix in the groove crushed by the clamp, using No. 1 chromic catgut (Fig. 842). (4) Cut the appendix between the ligature and the distal clamp. The stump of

the appendix may be touched with phenol and with alcohol, but I regard this as an unnecessary refinement of technique. (5) Insert

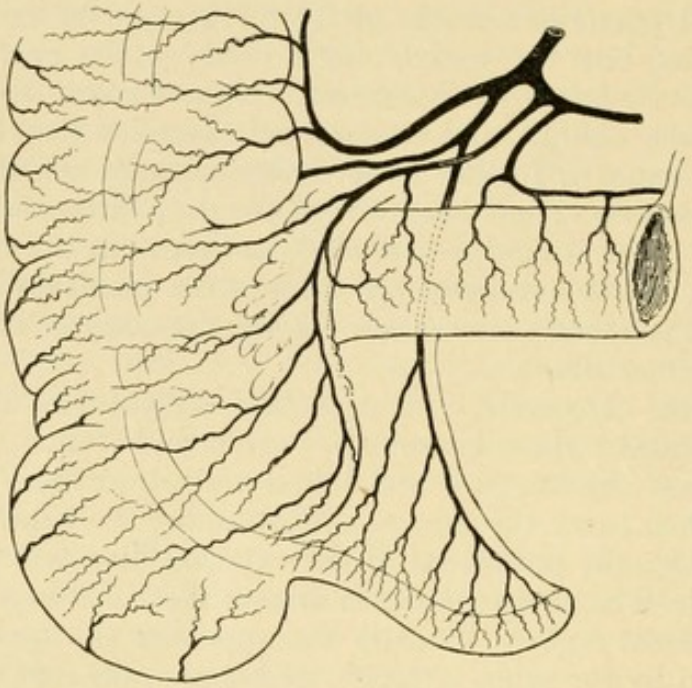

FIG. 840.—The blood-supply of the cecum and appendix.

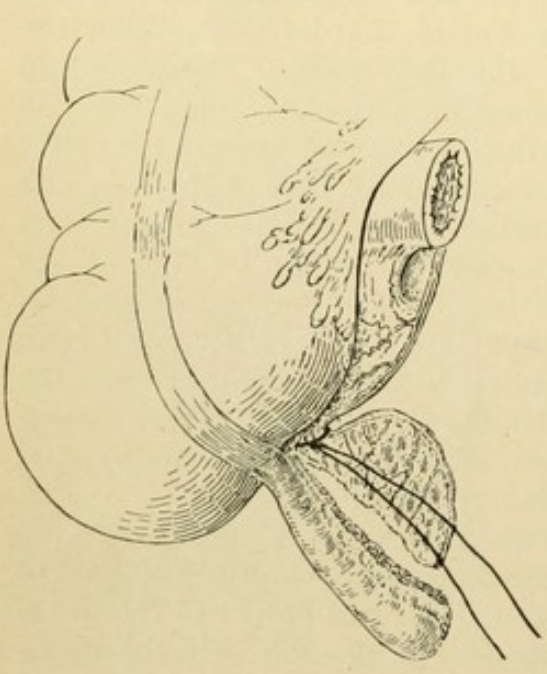

FIG. 841.—Appendectomy: the meso-appendix has been tied close to the base of the cecum, and then divided close to the appendix.

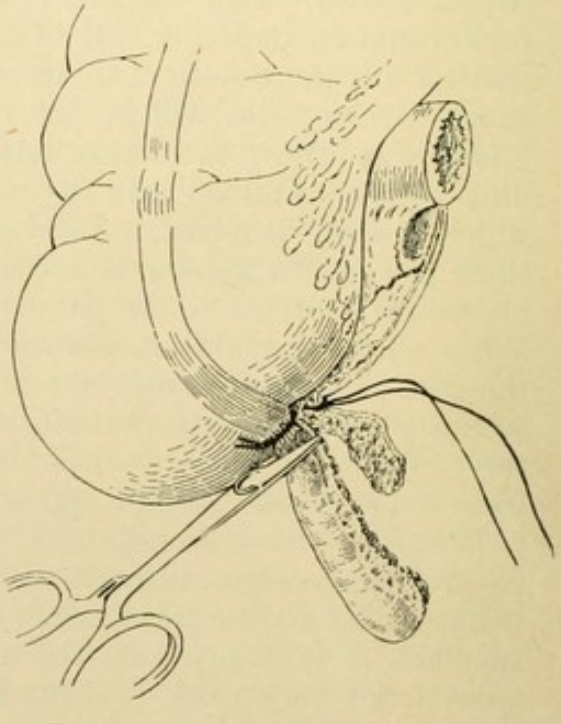

FIG. 842.—Appendectomy: the base of the appendix has been ligated in the groove made by clamping a hemostat; a second hemostat is left in place.

a purse-string suture of linen thread in the cecum about 2 cm. away from the stump of the appendix (Fig. 843); then cut the ends of the appendicular ligature short, and as the stump of the appendix is

pushed inward, tie the purse-string suture, thus completely burying the stump. (6) Look at the meso-appendix to make sure that the ligature has not slipped, and then cut the ligature short. (7) Finally, close the abdominal wound, suturing (*a*) the peritoneum and posterior sheath of the rectus; (*b*) the anterior sheath of the rectus and the internal oblique and transversalis muscles; (*c*) the external oblique aponeurosis. Each layer is sutured with a continuous suture of chromic catgut. Tie any bleeding points in the superficial fascia; and then close the skin wound with interrupted sutures of silkworm gut.

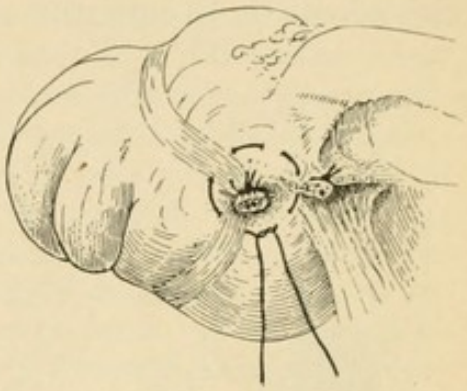

FIG. 843.—Appendectomy: the appendix has been cut off, and a purse-string suture has been inserted in the cecum.

In *uncomplicated cases* of appendicitis no drainage is required, and no special after-treatment is to be pursued. The patient may have hot water, in amounts of a half ounce (15 c.c.) or less, every fifteen to thirty minutes, by mouth, *after twelve hours*. Liquid diet is begun after twenty-four hours and is continued for three days, when soft diet is allowed. Full diet may be given after the tenth day, when the wound is first dressed and the skin sutures removed. If the bowels do not move spontaneously by the third or fourth day, an enema should be given, and only when this proves ineffectual is a purge required. I prefer to keep my patients in bed at least two weeks, but many surgeons allow them to be up in a week or ten days.

If operation cannot be done, then, so soon as a diagnosis is made, treatment should be instituted as already advised for cases of diffuse peritonitis (p. 810). By adherence to the strictest code of the Ochsner treatment, it usually will be possible to prevent the development of widespread peritonitis; but even under the best circumstances, an abscess will form or some other complication develop in about 10 per cent. of cases. *Nothing is so surely productive of complications as the administration of purgatives.*

Complications of Appendicitis.—From a clinical point of view the most frequent complications of appendicitis are **abscess, diffuse peritonitis,** and **gangrene of the appendix.** There is no greater fallacy than to suppose, as is done by many physicians, that neither abscess nor peritonitis can occur unless there is a **macroscopical perforation** of the appendix. Macroscopical perforations are comparatively rare, and even when present usually are of secondary importance to the abscess or the diffuse peritonitis which dominates the clinical picture.

Among the complicated cases of appendicitis under my own care, the following lesions have been the cause of the predominating symptoms:

		Mortality.
Primary abscess	in 19.1 per cent.	0.0 per cent.
Residual abscess	11.2 "	20.0 "
Gangrene	24.7 "	13.6 "
Diffuse peritonitis	44.9 "	17.5 "

The general mortality for the entire series of complicated cases of appendicitis is 13.5 per cent. Not one of these patients would have died if operation had been done within twenty-four hours of the onset of the disease, and even those patients among the complicated cases who recovered would have been saved the discomforts and prolonged convalescence attending a drained wound.

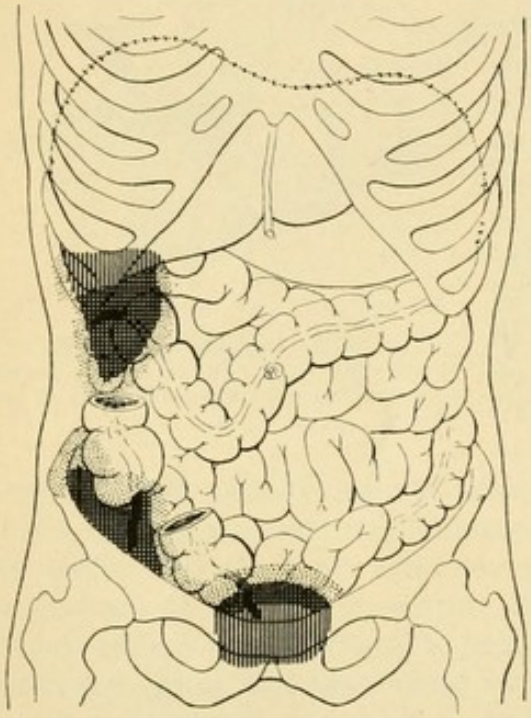

FIG. 844.—Usual sites of appendicular abscess: 1, in the right iliac fossa; 2, in the pelvis; 3, in the right kidney pouch.

PRIMARY APPENDICULAR ABSCESS.—This is the least dangerous of the complications of appendicitis. The reaction of the peritoneum to the appendicular infection is adequate, and the infection remains localized to the immediate neighborhood of the appendix. The most frequent site of such abscess is in the right iliac fossa. Other frequent sites are the pelvis and the right flank or loin, depending upon the position of the appendix (Fig. 844). An abscess on the median side of the cecum, or among the coils of small intestines is unusual; one

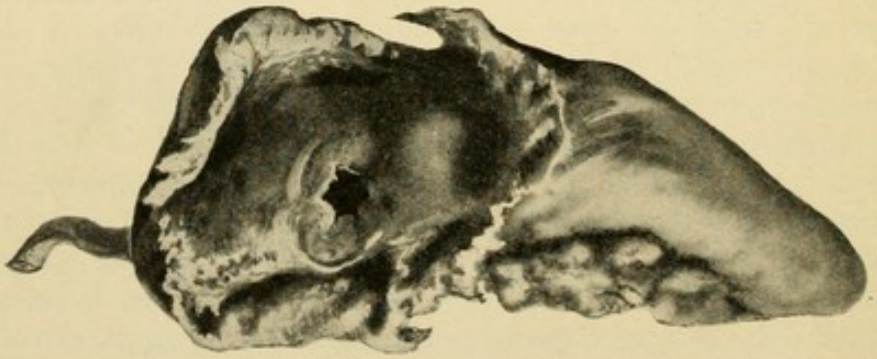

FIG. 845.—Perforated appendix, forming part of an abscess wall; perforation into adhesions. Episcopal Hospital.

between the layers of the mesentery of the ileum, or elsewhere in the retroperitoneal tissues, is very rare. In most cases the wall of the abscess is formed by the parietal peritoneum of the iliac fossa, pelvis

or flank, on one side; by the cecum, adherent omentum or anterior abdominal wall, in front; while its medial wall is formed by omentum or coils of small intestine. The appendix usually forms a part of the abscess wall at some point (Fig. 845), but may lie entirely within the abscess cavity. It may or may not present a macroscopical perforation.

Symptoms.—So long as the pus is under tension there are the usual symptoms of toxic absorption, such as elevation of temperature, increase in the pulse rate, and leukocytosis. If a differential count shows more than 90 per cent. of the white-blood cells are polynucleated, it usually indicates the presence of pus provided there is hyperleukocytosis. A high white count, with a low polynuclear percentage, indicates poor resistance on the part of the patient. If leukocytosis is not marked and the polynuclear percentage is low, it indicates either that the abscess is completely localized and that no absorption is occurring, or that the patient is overwhelmed by the infection. The clinical picture must be relied upon to distinguish between these two states. When only a small abscess has formed, and has become well localized so that no absorption is occurring, a careless observer may be led to think that the patient has entirely recovered. In such cases secondary leakage of the abscess may occur, resulting in diffuse peritonitis.

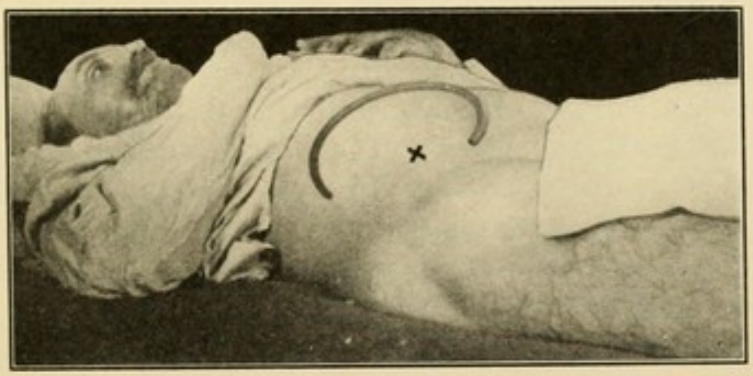

FIG. 846.—Large appendicular abscess two weeks after onset. *X* on anterior superior spine of ilium. Outlines of abscess indicated by a drainage tube. Episcopal Hospital.

The *physical signs* present depend upon the duration of the abscess and upon its size. Soon after the formation of an abscess, the rigidity and tenderness so characteristic of appendicitis in its earlier stages may persist to such a degree that recognition of a mass by palpation may be impossible. But by percussion it usually is possible to demonstrate an area of dulness in the right iliac fossa. Such dulness, however, frequently is due to a mass of adherent omentum; and it is not safe to assume that a mass, even if distinct and papable, contains much pus. The quantity of pus may vary from a few drops up to a pint or more. Seldom does the abscess contain more than 10 to 15 c.c. of pus. Palpation through the rectum may discover a bulging, tender mass in the rectovesical pouch, or in women behind the uterus. Rectal touch is particularly valuable in small children, for in them a large pelvic abscess may pass unnoticed if this examination is neglected.

If the appendicular abscess has been in existence for several days, it usually is possible to define its outlines by palpation, and in cases of very long duration the abscess may be visible at a glance as a large rounded tumor (Fig. 846).

Residual Appendicular Abscess.—This is one which forms after the subsidence of diffuse peritonitis caused by appendicitis. It has also been termed a *post-Ochsner abscess*, because localization of the infection has been brought about by adherence to the Ochsner treatment (p. 811). The pathogenesis, symptomatology, and treatment of these conditions have been discussed in Chapter XXII.

Treatment of Appendicular Abscess.—An appendicular abscess should be evacuated, and unless the patient is very gravely ill the appendix should be removed at the same operation. But if it is very difficult to find the appendix, or if it is extremely adherent, it need not be removed. Deaver says it is better to have a live patient with his appendix still in, than a dead patient without one. Operation for abscess should be undertaken as soon as possible after the diagnosis is made. There is nothing to be gained by delay, and in many cases, especially of residual abscess, there is danger that the adhesions limiting the abscess may give away, and that diffuse peritonitis may follow the leakage of pus.

It is the teaching of Deaver, and many surgeons are in accord with him, that it is best always to open the appendicular abscess at the place where it comes in contact with the parietal peritoneum. To my mind there are serious objections to this teaching: (1) in the vast majority of cases there is no way of telling beforehand whether or not the abscess is in direct contact with the abdominal wall, and as a matter of fact in a great many cases no such direct contact exists; (2) in cutting down upon the point where the abscess is supposed to be in contact with the abdominal wall, one cannot be sure that he will not extend his incision too far in one direction or the other and so trespass upon uninfected peritoneum at the same moment that he gives exit to the pus, thus running the grave risk of spreading infection within the peritoneum; (3) in an endeavor to prevent this error in technique it is necessary to make a funnel-shaped wound in the abdominal wall—very large in its superficial part and very small in the depths; the surgeon has to work in a confined space at the bottom of a deep wound; often the appendix cannot be found, and a second operation is necessary to remove it; and in any event the large wound (made fortuitously according to the site of the abscess, and not with respect to the anatomy of the abdominal wall) must be left open almost in its whole extent, and post-operative hernia is the rule; (4) last, but by no means least, in evacuating an abscess in this way the surgeon cannot be sure that he has not ruptured the abscess wall on the opposite side—that toward the general peritoneal cavity—thus causing leakage of pus into uninfected areas. Only when the abscess is almost ready to burst through the abdominal wall, or rarely through the rectum, and the patient is gravely ill, am I in the habit of incising directly into the

abscess cavity. In such cases, which are mostly residual abscesses, I make no attempt to remove the appendix at the first operation, which need consume only about five minutes and may be done under local anesthesia or under nitrous oxide.

In the ordinary cases of appendicular abscess I believe, with Murphy, that it is much safer first of all to open the healthy peritoneal cavity on the median or upper side of the abscess mass, and to isolate the entire diseased area by gauze packs. Then one may extend the incision to as great a length as seems desirable (Fig. 847); and, after evacuating the abscess at leisure and with perfect control of the infective material, may complete the operation by removal of the appendix, and may close the greater part of the abdominal wound, leaving only sufficient space unsutured for the emergence of the drains. With such treatment hernia is a very rare sequel, and no secondary operation is required.

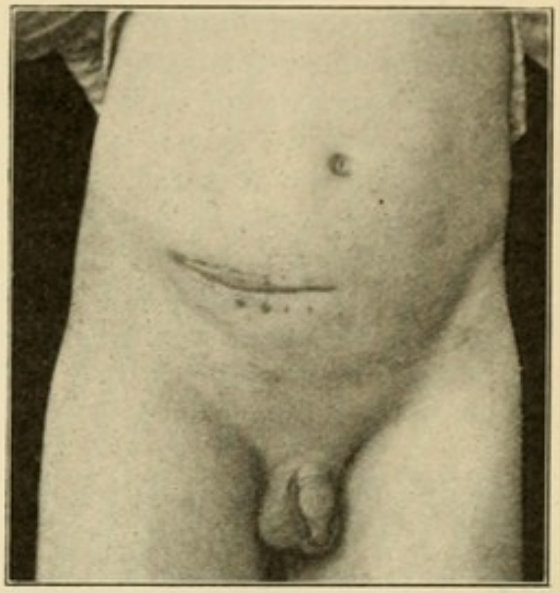

FIG. 847.—Very large transverse incision in a case of appendicular abscess, drained from its outer end. Two months after operation. Episcopal Hospital.

In all operations for appendicular abscess the surgeon should make sure that no pelvic collection of pus is overlooked. This is determined by passing a glass tube, along the fingers as a guide, to the bottom of the pelvis; through the lumen of the glass tube a rubber tube is then inserted to the floor of the pelvis, and by means of a syringe attached to its outer end suction is exerted, and any fluid in the pelvis will be drawn into the syringe. If the abscess occupies the iliac fossa or loin, and no pus is found in the pelvis when it is explored as just indicated, it will be safe usually to be content with drainage extending only to the base of the appendix and the site of the abscess cavity. In cases where pus has been found in the pelvis, or in other cases if there is any uncertainty as to the efficiency of the drainage, it is proper to drain the pelvis also. For this purpose a rubber tube suffices, and acts as a better drain than does a wick of gauze. The drain should emerge at the outer angle of the transverse incision, or at the lower angle of a longitudinal wound. The drain should not be removed for at least four days, and it is better then to shorten it by degrees. Too early removal of the drainage frequently leads to the damming up of pus and the formation of a residual abscess. Though such collections usually can be opened by inserting a finger into the wound, without a general anesthetic, sometimes formal operation is necessary.

GANGRENOUS APPENDICITIS.—Though an appendix associated with an abscess or with diffuse peritonitis frequently is necrotic wholly

or in part, there is a clinical distinction between such cases and those classed as gangrenous appendicitis. In the latter class, necrosis of the appendix occurs with such rapidity, usually as the result of vascular thrombosis, that no adequate peritoneal reaction develops, and the necrotic organ lies free from limiting adhesions or protecting omentum in an almost normal abdomen. Unless such an appendix is removed promptly, it will separate as a slough from the cecum and fecal extravasation will cause very severe septic (toxic) peritonitis, often costing the patient his life.

There are no certain *symptoms* by which the occurrence of gangrene may be recognized; but *sudden* cessation of pain, especially if extreme tenderness persists, should make one suspect the occurrence of gangrene. The fact that gangrene has occurred, thus checking absorption of toxins, may also explain rather abrupt disappearance (unfortunately only temporary) of systemic symptoms of infection.

The only efficient *treatment* is immediate removal of the appendix. It is wise to drain the wound in every case.

Diffuse Peritonitis.—The pathogenesis, symptomatology, and indications for operation have been discussed at p. 806. In cases deemed suitable for operation, the surgeon must aim to make the operation as short as possible (Fig. 848). After opening the peritoneum, the appendix is sought, and if readily found is brought into the wound and removed. Then a glass drainage tube is passed to the bottom of the pelvis, and any fluid which has collected there is removed by suction as described under the treatment of pelvic abscess (p. 861). If the head of the operating table is raised after evacuating the pelvis, the fluid which lay in the patient's flanks will trickle over the brim of the pelvis and may be removed thence by suction. A gauze wick is carried down to the pelvis behind the glass tube, and both the glass tube and the gauze wick are allowed to remain for drainage. The patient is returned to bed in the head high position, and the usual treatment for peritonitis (p. 811) is continued. The glass tube should be exhausted once or twice daily, and at each dressing should be rotated slightly so as to prevent its fixation by adhesions. When the discharge ceases to be purulent, usually about the third or fourth day, the glass tube should be substituted by one of rubber. The rubber tube should be inserted as far as the floor of the pelvis through the lumen of the glass tube, which is then withdrawn over it; if the glass tube is with-

Fig. 848.—Small right rectus incision, in a case of diffuse peritonitis from appendicitis. Episcopal Hospital.

drawn before the rubber tube is in place, the drain tract will collapse and it will be impossible to insert the rubber tube. The gauze wick is removed from the fourth to the tenth day, and the rubber tube is gradually shortened, allowing the sinus to heal by granulation.

If the appendix is not removed at the first operation, the patient should be strongly urged to have this done so soon as convalescence is complete. The frequency of second attacks of appendicitis is great, and they are attended by all the dangers of the first. Even should no such acute attacks occur, the presence of the diseased organ and of the adhesions which surround it often seriously impairs the patient's comfort and may render him a semi-invalid; moreover, the appendix may undergo malignant change.

Chronic Appendicitis.—The pathogenesis of this condition was discussed at p. 849. The *symptoms* are many and various. Pain is the most constant symptom and is one without which the diagnosis cannot be made accurately. In most cases the pain is localized to the region affected, but it may be referred through the pull of adhesions to various parts of the abdomen. Gastric dyspepsia is frequent, and may be the predominant symptom. The stomach, as W. J. Mayo points out, is the mouth-piece of the gastro-intestinal tract. Disorders anywhere in this tract are constantly calling attention to their presence through disorders of the stomach. This is true, of course, especially of gastric and duodenal lesions; but it is equally true of gall-stones and of chronic appendicitis, as well perhaps as of other less frequent lesions. The characteristics of the dyspepsia due to chronic appendicitis are sufficiently distinct to enable a diagnosis to be made in most cases. The gastric symptoms occur with no regularity as regards ingestion of food, nor is relief obtained by eating. Indeed, eating usually aggravates the indigestion, but with no constancy or regularity. The patient complains of general abdominal pain, mostly below the umbilicus. The patient usually is about thirty years of age. Patients past thirty-five years much more often suffer from dyspepsia due to gall-stones, and those past forty years from that due to gastric ulcer or its sequels. Apart from the symptoms of chronic appendicitis, a good deal of reliance should be placed on the *history* of the case, and particularly on the *physical examination.* Usually there will have been one or two attacks of abdominal pain or distress sufficiently acute to have laid the patient up for a day or so, even if not so acute as to have been recognized at the time as attacks of appendicitis. Even when such a history is lacking, deep palpation of the abdomen over the right iliac fossa almost invariably detects marked localized tenderness even when none is complained of by the patient.

TREATMENT.—The treatment of the disease consists in removal of the appendix. Often this contains a fecal concretion, and evidences may be found of past inflammation within the appendix (strictures, obliteration of its tip), or without it (peritoneal adhesions, kinks, etc.).

Primary Carcinoma of the Appendix is found in about 1 per cent. of cases which come to operation or necropsy. Without microscopical examination the lesion usually is overlooked. It causes no symptoms which suffice to distinguish it from chronic appendicitis, with which it often is associated. Its frequency is an argument for the removal of the appendix as an incident in the course of other abdominal operations.

Tuberculosis of the Appendix is scarcely less frequent than carcinoma. If any symptoms are produced they are indistinguishable from those of chronic appendicitis, except when the tuberculous infection has spread so far as to give rise to the clinical picture of *tuberculosis of the peritoneum* (p. 815). The appendix should be removed unless the disease is so widespread as to make this unusually difficult.

Intussusception of the Appendix has been recorded in a few cases. The *symptoms* are those of acute appendicitis and the treatment is the same.

SURGERY OF THE STOMACH AND DUODENUM.

Gastric and Duodenal Ulcer.—It is probable that these ulcers, as well as others in the gastro-intestinal tract, are toxemic in origin. In practically all toxemias there are gastro-intestinal ulcers, and in practically all cases of gastro-intestinal ulceration there is present some form of toxemia (Dieulafoy, Gandy, 1899). The toxemia is of infectious origin, and the infection may arise in a chronically inflamed appendix, in the biliary tract, or in some other situation which is readily overlooked. Oral sepsis usually is present, and no doubt has etiological relation; constant swallowing of pathogenic microbes impairs the vitality of the stomach, and its acid secretions render it more vulnerable. Mechanical indigestion, from rapid eating ("bolting" unmasticated food), is another important cause.

The earliest stage in these gastro-intestinal lesions is ecchymosis; then follow hemorrhagic infarct, slough, and hemorrhagic erosion; next is developed the "exulceratio simplex" of Dieulafoy; then comes the true ulceration with hemorrhagic borders; and then the final stages, *perforation, chronic ulcer with thickened border and little tendency to heal,* or a *cicatrix.* These local effects probably are due to the action of *hemorrhagins,* which erode the endothelial lining of the bloodvessels, and of *mucolysins,* which destroy the gastric mucosa. Ecchymosis, the first stage, is produced by hemorrhagins alone; when mucolysins also act an erosion is produced, and in time a fully developed ulcer will be formed, unless anti-bodies are formed by the organism to hold these cytolysins in check (Hort, 1908). These ulcers are not formed alone in the stomach and duodenum though they are most frequent here. Other similar lesions, not so apt to produce symptoms, may exist in the jejunum or ileum or large intestine, but they are comparatively rare. In the mucous membrane of the stomach there are small collections of lymphoid tissue, and these

are in greatest number along the lesser curvature and in the pre-pyloric region. It seems not improbable that inflammation of these structures, occurring in general infections, may have an etiological relation to gastric and pyloric ulcer.

An ulcer in the stomach or duodenum, when once formed, is difficult to heal, partly owing to trauma from ingested food, and to want of rest due to constant peristalsis, but largely owing to chemical changes in the gastric secretions, producing *hyperchlorhydria*.[1]

Duodenal ulcers are more frequent than gastric (as 3 to 2), and of gastric ulcers those near the pylorus and along the lesser curvature of the stomach are much the most frequent.

At first "acute," "round," or "open" in type, the ulcer through long duration becomes callous, with thickened borders; and if healing finally occurs, in part or wholly, the resulting cicatrix will distort the stomach, and perhaps cause pyloric stenosis.

Acute Gastric Ulcer, or **Open Ulcer,** is not very frequent in this country. It affects especially anemic young people, especially women, from eighteen to twenty-five years of age, and is as much a symptom of their disease as the anemia itself. It is apt to give rise to *hemorrhage* and to *perforation*. The ulcers usually are multiple; are round; appear punched out of the gastric wall; and usually are from 0.5 to 1 cm. in diameter.

Symptoms.—The characteristic *symptoms* are severe burning pain soon after eating, relieved by evacuation of the stomach either through the pylorus or by vomiting. The pain seems to be due to the increased acidity of the gastric juice caused by the process of digestion, as well as to peristaltic movements and mechanical trauma by the food. There is hyperacidity even of the empty stomach. Antacids thus relieve the pain. An area of tenderness in the epigastrium is commonly present, usually to the right of the median line; sometimes a similar tender area is found just to the left, more rarely the right of the last two dorsal vertebræ. Vomiting is frequent, often being self-induced to relieve pain. The vomitus often is streaked with blood, and quite independently of the ingestion of food hematemesis may occur. Profuse and prostrating hemorrhage usually is due to an erosion or an exulceration; more moderate bleeding, especially if frequently recurrent, generally is due to the round open ulcer.

Chronic Gastric and Duodenal Ulcer; Cicatrizing or Callous Ulcer.—This may be a later stage of the open ulcer already described, but it seems clinically often to have been chronic from its commencement, whatever its pathological origin. It is a much more frequent disease in this country. It is this type of ulcer which is more often duodenal than gastric. Mayo has established the position of the pyloric vein

[1] The normal acidity of the gastric juice is equivalent to 0.48 per cent. hydrochloric acid. If a patient is reported to have a gastric acidity of 60, this signifies that there is hyperchlorhydria. If, on the other hand, the total acidity is reported as 30 or 20, the acidity is clearly below normal. The "free" acid of the gastric juice normally varies between 0.1 and 0.2 per cent.

as the dividing line, and classes the portion of the duodenum above the bile papilla as gastric rather than intestinal in nature.

The ulcer, which usually is single, has thickened borders, and is quite irregular in outline. Cicatrization leads to contraction, and *pyloric stenosis* (p. 868) is the most frequent result. If the ulcer is situated on the lesser curvature, it often extends on both anterior and posterior walls of the stomach (saddle ulcer); and its cicatrization may produce *hour-glass stomach* (p. 871). The chronic inflammatory changes around the periphery of the ulcer are frequent forerunners of *carcinoma of the stomach* (p. 873).

Symptoms.—These last a long time before relief is sought from surgery, so that the patients usually are thirty-five to forty years of age or older when first seen. The affection is commoner in men than in women. Symptoms of dyspepsia overshadow everything else. These dyspeptic attacks, characterized by flatulence, pain, palpitations of the heart, epigastric distress, belching, sour eructations, nausea and even vomiting, occur in periods which last several weeks at a time. During the intervals the patient suffers less, but is not entirely free from symptoms. The pain and distress do not begin until three or four hours after meals, and are relieved by ingestion of more food (*hunger-pain* of Mayo Robson). This is because the excess of acid is neutralized by food. Patients are unwilling to go without food for more than a few hours at a time. This constant and regular recurrence of gastric dyspepsia several hours after meals is particularly characteristic. The dyspepsia due to chronic appendicitis (p. 863) is both inconstant and irregular in its occurrence, and is not relieved by eating. In chronic gastric or duodenal ulcer, however, the distress from indigestion may finally become so extreme, that a patient will be unable to eat his full meals. He may be reduced to carrying a bottle of milk around with him, taking a sip every little while, to relieve the burning sensation in his stomach. *Hemorrhage*, as has been remarked, is less usual in chronic than in acute ulcer, and rarely is large in amount. If the ulcer is duodenal, blood in the stools (melena) is more frequent than hematemesis; the bleeding may be occult or visible to the naked eye.

Physical examination is of much less assistance at this stage of the disease, than later, when pyloric obstruction has developed. Tenderness is rather diffuse; and occasionally a mass may be felt in the pyloric region, and may be mistaken for carcinoma.

Prognosis and Treatment of Gastric and Duodenal Ulcer.—Hemorrhage kills about 5 per cent. of patients, and perforation about 15 per cent. Of the 80 per cent. which remain, prompt, efficient, and prolonged medical treatment will cure perhaps three-fourths; but this cure seldom is permanent. From 30 to 50 per cent. of patients so cured have relapses, and though they may be "cured" a number of times by resort to medical treatment, the cure usually is attained with greater difficulty and is less lasting, after each new relapse. Meanwhile the patient is subjected to the danger of hemorrhage and per-

foration; and the development of pyloric stenosis, hour-glass stomach, or carcinoma is the usual termination in those patients who survive.

Medical treatment aims to encourage healing of the ulcer largely by reducing the acidity of the gastric juice. This is accomplished by regulation of the diet and the ingestion of antacids. Surgical treatment aims to effect a cure either by excision of the diseased structures, or by altering the composition of the gastric juice more or less permanently by admitting the alkaline duodenal secretions (bile and pancreatic juice) into the stomach through a gastro-intestinal anastomosis. The latter method, which still is more widely employed than excision, and which is more widely applicable, is attended by an operative mortality of 3 per cent., or less, in the hands of skilled abdominal surgeons; and from 75 to 80 per cent. of the patients who recover are permanently relieved of symptoms (Deaver and Ashhurst). It is generally conceded, therefore, in patients whose symptoms recur after one or several "medical cures," that surgical treatment is indicated; and especially is this true of patients with recurring hemorrhage. Perforation of course calls for immediate operation.

Operation.—If the stomach is not bound down by adhesions, removal of the entire ulcer-bearing area (Rodman, 1900), as in cases of carcinoma, is preferred by many surgeons; this is especially desirable when there is much inflammatory thickening around the base of the ulcer. The technique of this operation (partial gastrectomy) is detailed at p. 881. Excision of an isolated ulcer may also be done. In both cases a complementary gastrojejunostomy is done. The mortality, even in skilful hands, is higher than that of simple gastrojejunostomy (p. 879), and I believe in most cases the latter operation is to be preferred, unless the stomach is freely movable or unless carcinoma is suspected. If there is no pyloric stenosis, it is well to plicate the pylorus when gastrojejunostomy is done, since this seems to accelerate the cure. It is well also to invert the ulcer by a few sutures, as a prophylactic against subsequent perforation.

Perforation of Gastric or Duodenal Ulcer.—In most cases, unless the patient is too ill to talk, he gives a history characteristic of the disease. Perforation may be *acute*, *subacute*, or *chronic*. An acute perforation is one which occurs into the free peritoneal cavity, the base of the ulcer having been unprotected by adhesions. A subacute perforation is one which occurs into such protecting adhesions. A chronic perforation occurs into an adherent viscus, such as pancreas, liver, colon, gall-bladder, etc.

Acute perforation is characterized by very sudden, extremely severe epigastric pain, often attended by shock. The patient doubles up with pain, clutching at his abdomen, and even after being got to bed may be found rolling around in agony, groaning constantly and securing no relief. Vomiting may or may not occur. Collapse is recognized by the anxiety of countenance, the cold and clammy surface, the sudden pallor and the guarded breathing. The pulse is feeble but may be either slow or rapid at first. The abdomen presents truly a

"board-like" rigidity, and as a consequence deep palpation is valueless. If the patient is not seen soon after the occurrence of perforation, the effused gastric contents may have travelled down the right flank to the cecal region, and the case may be mistaken for appendicitis. After six or eight hours, the abdomen becomes distended, secondary vomiting commences, the pulse quickens and becomes more feeble, and other signs of diffuse peritonitis (p. 806) arise.

Treatment consists in immediate laparotomy through the upper right rectus, and suture of the perforation, which usually is near the pylorus. If suture is impossible, the perforation should be tamponed with gauze. If operation is done within a few hours of perforation and especially if suture stenoses the pylorus, or if the sutures tear out, posterior gastrojejunostomy should be done at the same time. In many early cases the abdominal fluid is sterile, particularly if perforation occurred in a fasting stomach, and perhaps because of the hyperacidity of the gastric juice; but in all cases the pelvis should be drained (through a suprapubic incision) as well as the upper abdominal wound. Subsequent treatment is the same as after any operation for diffuse peritonitis. If operation is done within the first few hours of perforation, the mortality is only about 15 per cent.; if postponed, the death rate rises to 33 and to 50 per cent.

Subacute Perforation may be attended by the same type of symptoms, though less severe, as in acute perforation; or the condition may be found unexpectedly at operation for the underlying disease. If a subacute perforation is suspected in such a case, it is safer to do gastrojejunostomy without disturbing the adhesions more than is necessary. It may be very difficult to secure efficient closure of such a perforation by suture.

In *chronic perforation* no additional symptoms are produced at the actual moment when the gastric wall ceases to form the floor of the ulcer and its place is taken by pancreatic tissue or by firm fibrinoplastic material, so that the symptoms which first call attention to the changed condition are not those of perforation nor of peritonitis, but of sepsis due to some form of perigastric or subphrenic abscess, or to some internal fistula. Treatment involves drainage of such an abscess and operative cure of the gastric lesion.

Hemorrhage in Gastric and Duodenal Ulcers.—The diagnosis usually is not difficult, but the diagnosis of gastric ulcer has been made in cases of bleeding from esophageal varices. Treatment during continuance of bleeding should be purely medical: morphin hypodermically, an ice bag to the epigastrium, and nothing whatever by mouth. Operation at this time is too dangerous to be recommended; the mortality is from 60 to 80 per cent. When the hemorrhage has ceased, however, and the patient has regained some measure of health, operation should be done to cure the ulcer. Especially important is this when repeated hemorrhage occurs.

Pyloric Obstruction.—This includes three distinct affections: Infantile Pyloric Stenosis; Pylorospasm; Gastric Dilatation.

Infantile Stenosis of the Pylorus.—The baby usually is healthy at birth, but within a week or so develops the condition described as **hyperemesis lactantium.** Unless arrested, the affection progresses until gastric peristalsis can be seen through the emaciated abdominal wall, and a pyloric tumor can be felt. The obstruction usually is due to excess of muscular tissue about the pylorus. The cause of this change is not certain, but probably is hypertrophic. In most cases medical treatment brings relief before complete obstruction develops; but unless loss of weight is checked very soon operation should be done. Posterior gastrojejunostomy is the operation usually employed. Nicoll (1906) has had much success with a special form of pyloroplasty.

Pylorospasm.—This is an intermittent or constant contraction of the pyloric sphincter, attended by more or less evident symptoms. It is itself only a symptom of a lesion which may be in the stomach or elsewhere. Pylorospasm not infrequently accompanies gallstone colic or appendicitis. In many cases the pain is not very great, amounting merely to a lively sense of discomfort in the epigastric region, and being overshadowed by symptoms of "peristaltic unrest of the stomach" (Kussmaul, 1880): when the pylorus contracts spasmodically the stomach meets with an insuperable obstacle to its evacuation; peristaltic unrest ensues, flatulence develops from fermentation and from swallowed air; and, finally, when the limit of endurance is reached, the pylorus relaxes and gastric contents pass out into the duodenum or the patient is relieved of his distress by vomiting. Secondary gastric dilatation may ensue. *Treatment* is that of the causative condition.

Gastric Dilatation.—Acute Dilatation of the Stomach (Hilton Fagge, 1872) is met with as a complication in various infectious diseases, notably typhoid fever and pneumonia; as well as after some operations, not always involving the abdomen. Though not caused by pyloric obstruction, it seems best to mention the condition in this place.

The stomach fills nearly the whole abdomen, and the site of apparent obstruction usually is found at or near the duodenojejunal angle. A physiological fact pointed out by Kelling (1900) may have some bearing on the condition: this is that so long as the duodenum is distended the stomach is unable to empty itself. Many surgeons still support the theory of Hanau-Albrecht (1899), that acute dilatation of the stomach is caused by constriction of the transverse duodenum by the superior mesenteric artery, from the drag of the small intestines (**gastro-mesenteric ileus**).

Vomiting is profuse and repeated, and there is little nausea; immense quantities of fluid are brought up in this way, demonstrating hypersecretion by the stomach. Gaseous distention is extreme, and the outlines of the stomach may be recognized through the abdominal wall. When the stomach tube is passed there is an abundant escape of odorless gas, with a gushing or gurgling sound, at times almost an explosion. Marked flattening of the abdomen follows this evacuation,

but soon the stomach refills with fluid and air. Signs of collapse, largely due to deprivation of the tissues of so much liquid, quickly follow. Occasionally spontaneous relief occurs, and profuse diarrhea ushers in convalescence.

Treatment.—Treatment consists in repeated use of the stomach tube; and in placing the patient prone or on the left side, with the foot of the bed elevated, with a view to overcoming an obstruction at the duodenojejunal angle. Or the patient may assume the knee-chest posture. Operation to relieve a kink, or to perform gastrojejunostomy should be the last resort.

Secondary Gastric Dilatation.—This is not a distinct disease, but is the terminal stage of some preëxisting disease which causes pyloric obstruction. The most frequent causes are carcinoma, chronic gastric or duodenal ulcer, or perigastric adhesions usually due to disease of the biliary tract. Benign pyloric obstruction usually is due to contraction of ulcers near the pylorus. Occasionally in the earlier stages of ulceration such hyperplastic reaction occurs as to cause temporary obstruction of the pylorus; if gastrojejunostomy is done at this stage the pylorus may subsequently become patulous, just as it might have done if no operation had been employed. But when cicatricial stenosis once develops the prognosis is hopeless without operation.

Symptoms.—Three stages are recognized: In the *stage of compensation* it is only after an unusually heavy meal that distress is experienced; gaseous distention becomes oppressive, the clothing is perhaps unconsciously loosened, and relief eventually is obtained by the belching of gas and the eructation of a little sour fluid. Finally the wearied stomach empties itself into the duodenum. This stage may last for months or years, but eventually the *stage of stagnation* is developed: here the stomach is unable completely to evacuate its contents between meals, except in the long interval at night. A sense of fulness persists from one meal to the next, and anorexia develops. Weight may not be lost, but none is gained. In the *stage of retention* emaciation commences and may become extreme. The stomach is not emptied even during the night; lavage before breakfast will detect food particles still in the stomach, and the gastric contents will be sour, rancid, and usually very acid. The evidences of fermentation are pronounced, and production of gas may continue after the stomach contents have been removed, as is evidenced by their separation into three typical layers on standing. Because fluids are not absorbed from the stomach, and because in this stage they are late in reaching the small intestine, if they reach it at all, there is more or less constant thirst. As retention becomes extreme, the stomach occasionally makes an attempt to empty itself by the act of vomiting; though generally incomplete evacuation is secured, temporary relief is obtained. Copious and cumulative vomiting which occurs every few days is very good evidence that the stomach is dilated. Occasionally tetany occurs.

Physical Signs.—The capacity of the stomach is seen to be increased not only from the large amount of the vomitus, but by lavage. Skiagraphy at various intervals after the ingestion of bismuth gruel will demonstrate the gastric retention, and dilatation. The greater curvature almost always is below the umbilicus and may reach to the pelvis. The stomach may be cautiously distended with air by a hand bulb attached to the stomach tube. The outlines can then be determined by percussion. Analysis of the feces shows the solid matter reduced to less than half the normal of 4 to 6 oz. in twenty-four hours; while the proportion of water falls as low as 40 or even 30 per cent. of normal. The urine also is diminished in quantity.

Diagnosis.—The diagnosis is based on a history indicative of a previous disease which might cause pyloric obstruction, and upon the existence of the symptoms and physical signs mentioned above. In *gastroptosis*, though the stomach may be dilated, there is no clinical history characteristic of gastric ulcer or gall-stones.

Prognosis and Treatment.—This is the terminal stage of a serious disease. Gastric dilatation due to benign obstruction is less serious than gastric carcinoma only because patients with the former disease die more slowly than do those with cancer. Cancer usually kills in a shorter time, but death in benign dilatation is quite as sure even if longer delayed. The starvation is slow, and it is barely possible that the patient will not recognize the fact that he is starving to death; yet he should be told that surgery affords the only escape from death. A measure of comfort may be secured, in the earlier stages, by periodic gastric lavage and careful regulation of diet; but no true improvement takes place. What the surgeon urges is that operation shall be undertaken while yet there is sufficient recuperative power left in the body cells of the wretched patient. The choice of operation lies between gastrojejunostomy, which is preferable in most cases; partial gastrectomy, which is indicated if malignancy is suspected; and some form of pyloroplasty, which is not to be recommended except in patients whose gastric motility is only slightly impaired.

Hour-glass Stomach.—As more than two pouches may exist, the term *segmented stomach* (Wölfler, 1895) is preferable, though little used. The deformity usually is the result of contraction of an ulcer, but perigastric adhesions may be the cause, or even carcinoma (Fig. 849). The pouches may be of various sizes, or diverticula may exist. The *symptoms* seldom can be distinguished from those of pyloric obstruction, which often is present as an additional complication; and the *diagnosis* depends chiefly on the use of the stomach tube, and filling the stomach with air or water, by means of which the existence of more than one compartment may be detected in many cases. Often where no such abnormality exists, a skiagraph will show what is apparently an hour-glass constriction. *Treatment* consists in some form of operation to overcome the obstruction. In *gastroplasty* (Fig. 850) an incision is made through the constriction in the long axis of the stomach and is sutured transversely; the operation is analogous

to pyloroplasty (p. 878). In *gastrogastrostomy* (Fig. 851) a lateral anastomosis is made between the adjacent pouches. *Gastro-anasto-*

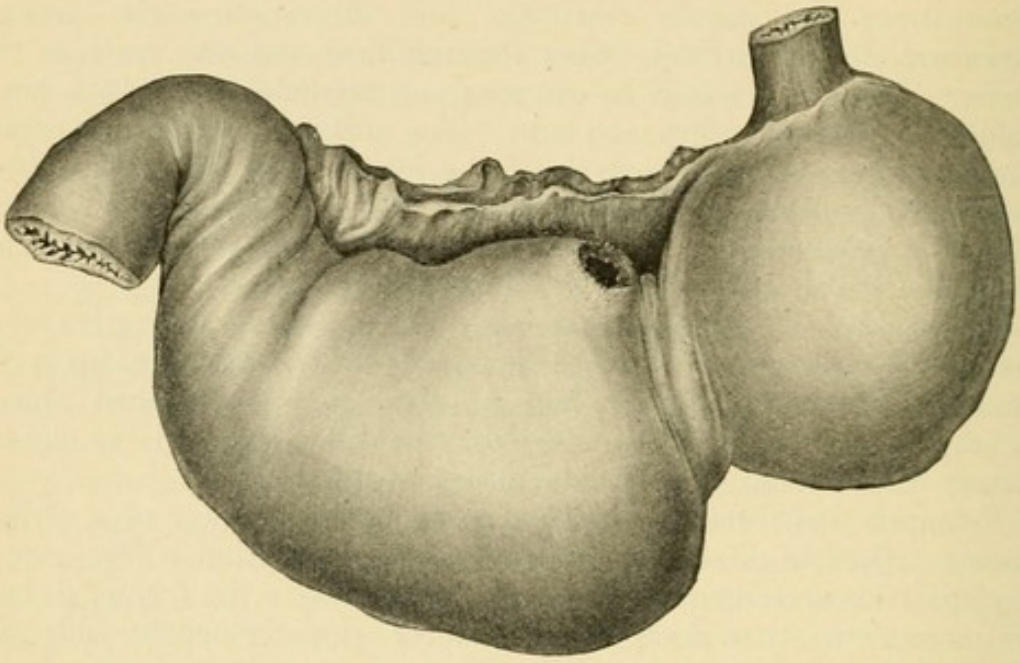

FIG. 849.—Hour-glass stomach from carcinomatous "saddle" ulcer on lesser curvature, with perforation; death from peritonitis (half natural size). (Deaver and Ashhurst.) Episcopal Hospital.

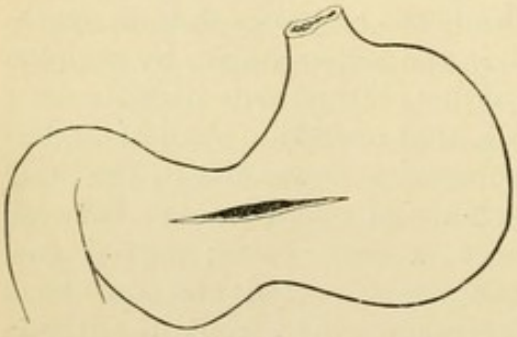

FIG. 850.—Gastroplasty. (Deaver and Ashhurst.)

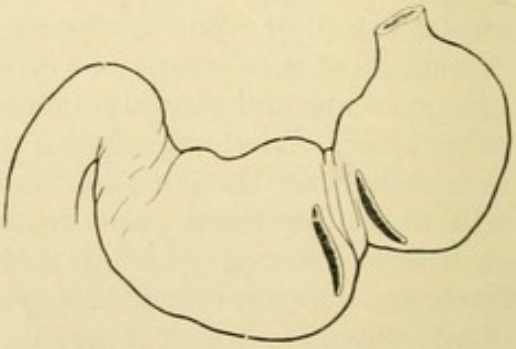

FIG. 851.—Gastro-gastrostomy. (Deaver and Ashhurst.)

mosis (Fig. 852) is analogous to Finney's pyloroplasty (p. 879). In the majority of cases *gastrojejunostomy* in the cardiac pouch is to be preferred to the operations just mentioned. As the cardiac pouch may be so small as to pass unperceived, the entire stomach should be examined before any operation is done. If pyloric stenosis also is present, it may be necessary to do pyloroplasty in addition, or even to make a second anastomosis, between the jejunum and the pyloric pouch.

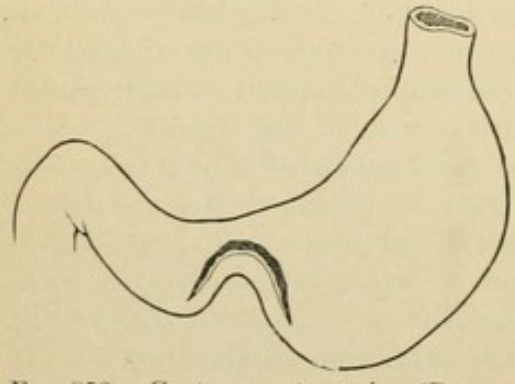

FIG. 852.—Gastro-anastomosis. (Deaver and Ashhurst.)

Plastic Linitis (*Cirrhosis of the Stomach, Zuckergussmagen, Magen-*

schrumpfung, etc.)—This is a diffuse sclerosis of the stomach, especially of the submucous tissues, leading to marked thickening of the gastric walls and diminution in the capacity of the stomach. It may be benign or malignant in nature, and probably may arise in several different diseases, such as carcinoma, syphilis, polyserositis, lymphatic obstruction, etc. Thomson and Graham (1913) have reviewed the subject at some length, and prefer to term the condition a "fibromatosis." If the change is recognized early enough, partial gastrectomy may be attempted; as a palliative measure gastro-enterostomy may be done, or even duodenostomy or jejunostomy.

Gastroptosis.—See Visceroptosis, p. 898.

Carcinoma of the Stomach.—This is a very frequent disease, but it seldom is recognized in time to save the patient's life. About 75 per cent. of cases of gastric carcinoma can be shown by microscopic study to have had their origin in chronic ulcer of the stomach. This is an unanswerable argument in favor of prompt and lasting cure of such ulcers by surgical means. This class of patients with incipient gastric cancer has been recognized only recently. Hitherto they have been treated for chronic gastritis, dyspepsia, etc., and it was not until frequent surgical intervention became the rule in such cases that it was proved that the change from the benign to the malignant state manifests itself by no clinical symptoms.

Cancer of the stomach presents clinically two forms. In one a patient past middle life, without having suffered previously from indigestion, suddenly loses appetite, especially for meats, grows progressively weaker and more emaciated, develops epigastric pain and possibly a palpable mass, becomes subject to vomiting spells every few days, which bring up a quantity of coffee-ground material, foul smelling and fermented; and quickly develops the cancerous cachexia. This is the classical picture of gastric carcinoma, and it is still seen; but it is very rare when compared with that other course of development which I have just mentioned. Gastric carcinoma appears with sudden onset in not more than 10 per cent. of cases. The second and much more frequent course is found in patients who have been long sufferers from dyspepsia. Medical treatment has given relief at times, but indigestion recurs again and again. Appetite may be preserved, but digestion is torture; so abstemiousness becomes the rule. There may or there may not have been some period when gastric ulcer was suspected or actually diagnosticated. Usually there have been no very definite symptoms. Finally these patients die; and at autopsy a wide-spreading carcinomatous ulcer is found.

Pathology.—Carcinoma of the stomach occurs oftenest between the ages of forty and seventy years, and affects the sexes about equally. The growth occurs at the pylorus in about 60 per cent., and at the lesser curvature in about 10 per cent. of cases. Carcinoma of the body or fundus is rare.

Histologically three types of gastric cancer are recognized: (1) Spheroidal-celled carcinoma, composed of cells like those normally

lining the gastric tubules; (2) Cylindrical-celled or adeno-carcinoma, composed of cells similar to those normally lining the gastric glands; and (3) Colloid carcinoma, a tumor whose chief characteristic is myxomatous degeneration of epithelial cells and stroma, which may occur either in the spheroidal-celled or cylindrical-celled varieties. Clinically carcinoma may be classed as scirrhous or medullary.

Lymphatic extension occurs early. The main paths invaded are indicated in Fig. 853. Our knowledge of these lymphatics is due almost entirely to Cunéo (1900), and to Jamieson and Dobson (1907). Carcinoma, beginning as it usually does along the lesser curvature close to the pylorus, invades first the lymphatics along the lesser curvature, even up to the coronary artery close to the cardiac orifice of the stomach. Hence it is evident that every radical operation for gastric

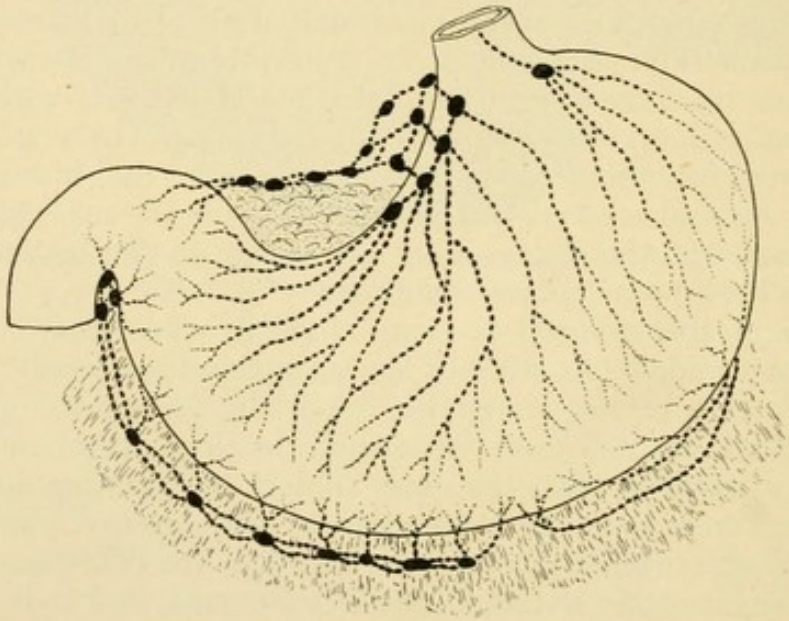

Fig. 853.—Paths of lymphatic extension in carcinoma of the stomach. After Jamieson and Dobson.

cancer must remove the entire lesser curvature of the stomach. Moreover, so soon as the carcinoma is at all extensive, the lymph nodes in the gastro-colic omentum, for a variable distance away from the pylorus, are involved. Therefore *Hartmann's line for gastrectomy* (1901) was made to pass from the coronary artery to a point directly below it on the greater curvature (Fig. 860). A third point of the greatest importance is that whereas the carcinomatous invasion extends rapidly and for an indefinite distance away from the pyloric region of the stomach, it invades the duodenum only rarely. The removal of the first inch (2.5 cm.) of the duodenum nearly invariably enables the surgeon to get beyond the limits of the growth. Palpable induration stops with the area of mucosa involved, but in the submucosa the invasion will have advanced considerably further. The resection must extend from 5 to 8 cm. away from the macroscopical tumor on the cardiac side of the growth, and from 1.5 to 2 cm. from it on the

intestinal side. Early lymphatic extension, according to Jamieson and Dobson, also occurs along the pyloric and hepatic arteries to the suprapancreatic lymph nodes.

Apart from the lymph nodes, gastric carcinoma extends oftenest to the liver, which is affected in one-third of the cases examined at autopsy. This invasion occurs along the radicles of the portal vein. In scirrhous carcinoma, and in all forms which cause marked pyloric stenosis, invasion of the liver is long delayed. Invasion of the great omentum may be followed by grafting of cancer cells on the pelvic organs. Invasion of the left supraclavicular lymph nodes, by permeation along the thoracic duct, is a very late sign.

Symptoms.—Early diagnosis from symptoms alone is so difficult as to be usually impossible. Almost always, by the time classical symptoms have developed, the disease has passed beyond the stage curable by excision, which is the only means of cure at present known.

Pain, vomiting, and tumor; loss of weight, anemia, and changes in the gastric secretion are the classical symptoms. But their development is so late that they do not bring the patient to the surgeon in a curable stage.

Carcinoma should be suspected when chronic gastric catarrh exists without any discoverable cause (such as abuse of food, of alcohol, or of drugs; circulatory disturbances of the heart or liver; or diseases such as cholelithiasis, gastric ulcer, etc., which cause definite lesions in the region of the stomach); especially if the chronic gastritis is in a patient over forty years of age, and if it is attended by loss of appetite for meats. If a tumor exists, the diagnosis is less difficult; but the tumor must be distinguished from a distended gall-bladder, from a growth of the colon, pancreas, etc. In obscure cases distention of the stomach with air should not be neglected; this may render a hidden tumor palpable, and the characteristic shape of a pyloric growth (apex toward the duodenum and indistinct base toward the body of the stomach) frequently can be recognized (Kocher). Occult blood in the stomach contents and feces is the most valuable of the laboratory findings. In non-malignant ulcerations of the stomach, rest in bed with milk diet will cause the disappearance of occult blood. In cancer no treatment has any effect (Deaver and Ashhurst).

Diagnosis.—The diagnosis can be only surmised in most cases still in the operable stage; only when the abdomen has been opened (and not always then) can the surgeon be sure carcinoma is present. If a distinct tumor is present, it generally can be recognized as carcinomatous by its irregular shape, its "knotty" feel, and by diffused induration into surrounding structures.

Treatment.—Whenever there is evidence of an anatomical lesion in the stomach which is not relieved by a few weeks of judicious medical treatment, exploratory operation should be undertaken even though an exact pathological diagnosis of the lesion has not been reached. Partial gastrectomy (p. 881) should be done even on suspicion of malignancy. The immediate mortality of this operation is

about 25 per cent. in the hands of the average surgeon; even in the hands of Robson, Mayo, Deaver, and other skilled abdominal surgeons the mortality is from 5 to 10 per cent. The remote results indicate that from 10 to 20 per cent. of patients with carcinoma of the stomach who survive radical operation are cured of the disease, passing the three and five year limits without recurrence. This is a creditable showing considering that no other form of treatment offers even the shadow of a chance for cure. Moreover, even if the patient ultimately dies from recurrence or internal metastasis, his life is prolonged on the average for eighteen months and most of this time is passed in comparative comfort, and death finally comes in less hideous form: the patient dies not of starvation but of cancerous cachexia. Even when removal of the entire disease by operation seems impossible, many abdominal surgeons think that life is prolonged and comfort promoted by removal of the foul sloughing mass, discharging into the stomach. It is well recognized that gastro-enterostomy is not a good operation for such cases; the immediate mortality is very high (15 to 25 per cent.), and if the immediately fatal cases are included, the reckoning shows survival is shorter than if no operation had been employed, while the patients who survive suffer more than before the operation and may live a longer time than if the abdomen had been closed without doing gastro-enterostomy. Other palliative operations have been employed: in carcinoma of the cardiac orifice gastrostomy has been done, but I believe it is contraindicated so long as the patient can swallow fluids. Jejunostomy and even duodenostomy (above the bile papilla) may be employed as euthanasial measures in cases where the body of the stomach is widely infiltrated and the patient is starving. In employing such operations the precarious state of the patient must be remembered; the surgeon should know before beginning the operation just what he intends to do, and then should do it without any unnecessary intra-abdominal exploration.

OPERATIONS ON THE STOMACH.

Gastrotomy.—The operation of opening the stomach may be required for the removal of foreign bodies within the stomach or impacted in the lower end of the esophagus; or for purposes of exploration. The *abdominal incision* is made through the upper left rectus muscle, close to the median line. The stomach is located by finding first the left lobe of the liver and tracing the gastro-hepatic omentum down to the lesser curvature of the stomach. If a foreign body is to be removed, it should be located if possible before opening the stomach. After isolating the stomach with gauze packs, hold the foreign body against the anterior wall of the stomach and cut directly down upon it, making the incision just long enough to remove the foreign body. Then repair the gastric incision with at least two rows of sutures (p. 830), and close the abdominal incision without drainage.

Gastrostomy.—The establishment of a gastric fistula, for the purpose of introducing food, is required most often in cases of impermeable stricture of the esophagus (p. 695). The fistula should be made in the pyloric antrum, and not in the fundus of the stomach. Several methods of operating are in common use.

1. *Stamm's* (1894) *or E. J. Senn's* (1896) *Method.*—The anterior gastric wall is drawn into the wound, and a small incision is made, just large enough to admit the end of a good-sized catheter (No. 26 French). The catheter (its outer end clamped) is inserted for about 2 or 3 cm. inside the cavity of the stomach, and is fixed to the gastric wall by a single catgut suture. Then a purse-string suture of linen is taken in the stomach wall, circularly around the catheter and about 2 cm. distant from it; as this suture is tightened the catheter is pushed toward the cavity of the stomach and carries with it the gastric wall, which is thus inverted so that the catheter lies in a serous channel (Fig. 854). Two other purse-string sutures are similarly passed, and as each is tightened the inverted cone of gastric wall is lengthened, so that finally the catheter lies in a channel over 5 cm. in length. The stomach is then sutured to the parietal peritoneum on both sides of the abdominal wound, and this is closed around the catheter.

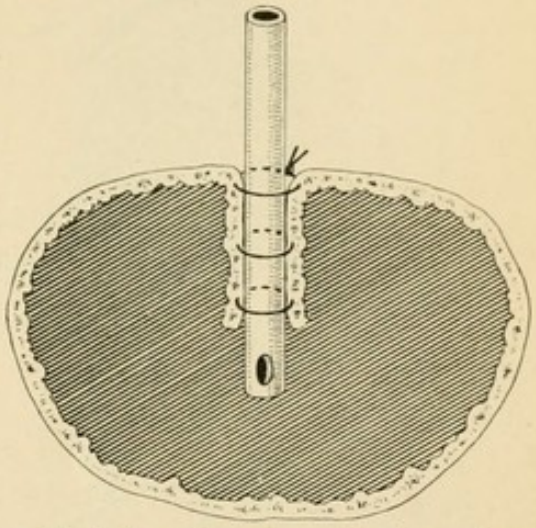

FIG. 854.—Gastrostomy by Stamm's method.

2. *Kader's method* (1896) is the same as Senn's except that the puckering sutures to invert the gastric wall around the tube are not passed as purse-strings, but as parallel sutures, one on each side of the tube.

3. In *Witzel's method* (1891) the tube is buried in an oblique manner in the gastric wall, by means of Lembert sutures. After these sutures are all tied, an opening is made in the gastric wall just large enough to admit the end of the tube; and after this has been introduced and fixed to the wall of the stomach with one catgut stitch, its point of entrance is covered by a few additional Lembert sutures of linen.

The channel formed from the cavity of the stomach to the skin in all these operations is absolutely continent so long as the catheter is in place; when it is removed leakage may occur, but if the catheter is left out for a long time the channel tends to close spontaneously, owing to the adhesion of its serous surfaces. Liquids may be introduced into the stomach through the tube at once if the patient is much emaciated. During the intervals between feedings the tube should be clamped, and it should be withdrawn for cleaning at least once daily after the first few days.

Jejunostomy (p. 876) sometimes is employed as a substitute for gastrostomy. Karewski (1896) adopted the technique employed by Witzel for gastrostomy, while Maydl (1898) employed a Y-anastomosis (p. 881).

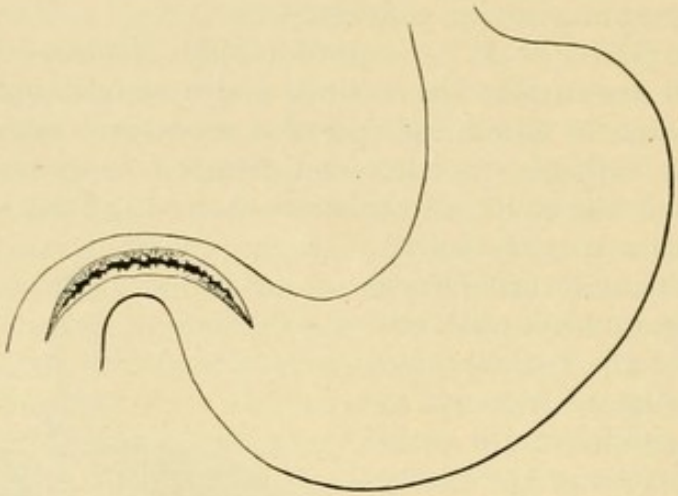

FIG. 855.—Incision for pyloroplasty. (See Fig. 856.)

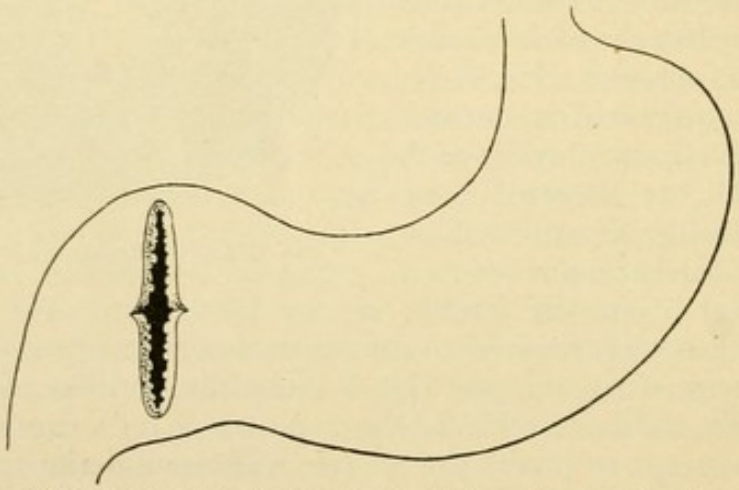

FIG. 856.—Pyloroplasty, the incision through the pylorus ready for suturing.

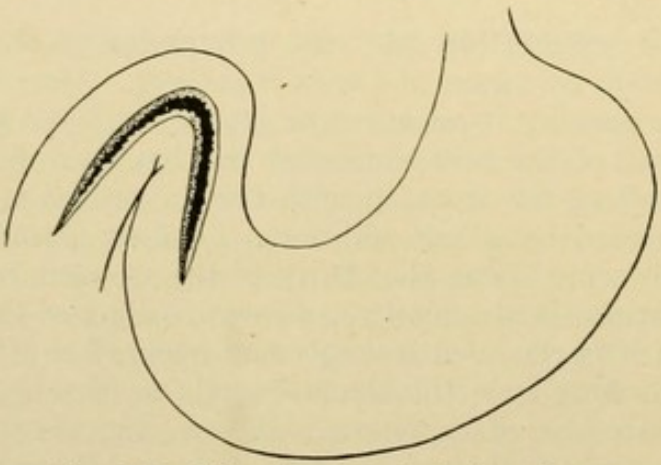

FIG. 857.—Finney's method of pyloroplasty.

Pyloroplasty.—The operation for pyloric stenosis devised independently by Heinecke and Mikulicz is seldom employed at present.

It consists in incising the pylorus in its long axis and then suturing this incision transversely (Figs. 855 and 856). The incision should extend from the stomach clear through the pylorus into the duodenum. The operation is inefficient in preventing recurrence of stenosis, and is undesirable because it is necessary to work in diseased tissues. The latter objection applies also to **Finney's pyloroplasty** (1902) which is more efficient, however, because it approaches the type of a lateral anastomosis between stomach and duodenum (Fig. 857).

Gastrojejunostomy.—An anastomosis between the stomach and small intestine was first done in 1881 by Wölfler at the suggestion of his assistant Nicoladoni. The jejunum was anastomosed with the anterior wall of the stomach, for malignant obstruction of the pylorus. In 1885 von Hacker adopted a method of posterior gastrojejunostomy, by anastomosing a loop of the upper jejunum with the posterior gastric wall through an opening made in the transverse meso-colon. Most surgeons have now adopted posterior gastrojejunostomy as the method of choice, and use a jejunal loop as short as possible, as advised in 1901 by Petersen, the assistant of Czerny (Fig. 858).

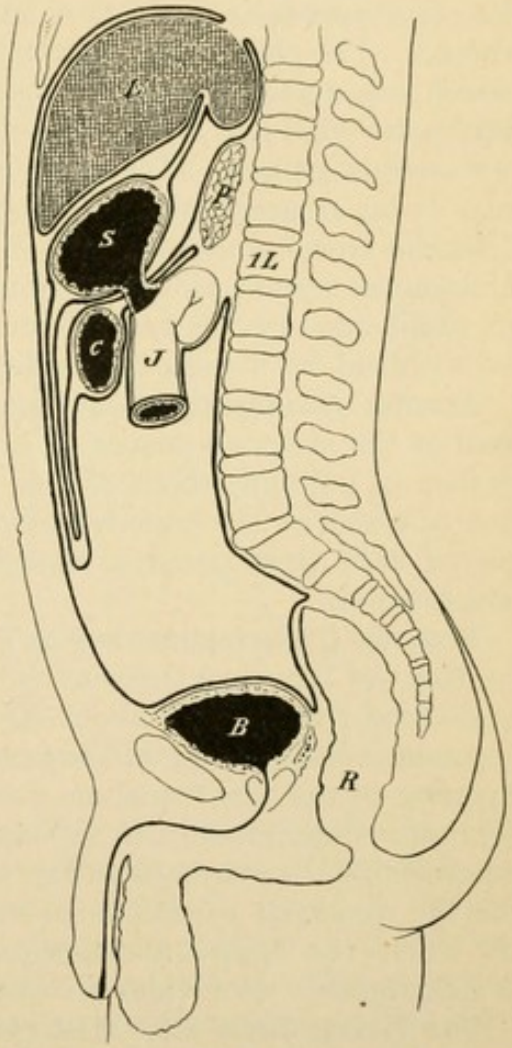

FIG. 858.—Posterior retrocolic gastrojejunostomy. Note the absence of a loop between the origin of the jejunum and the site of anastomosis and the slight distortion of the organs when the operation is completed.

The *indications* for gastrojejunostomy have already been considered.

The *abdominal incision* is made through the upper right or left rectus muscle close to the linea alba. After careful exploration, the great omentum and attached transverse colon are drawn out of the wound and pulled upward to the patient's right, thus putting transverse meso-colon on the stretch, and bringing the origin of the jejunum into sight. The transverse meso-colon is next torn through in a bloodless area, by means of dissecting forceps, and the opening is enlarged by the fingers in an antero-posterior direction until it is from 8 to 10 cm. in length. The posterior gastric wall is thus exposed and is made to protrude through the meso-colon, whereupon it is grasped in an anastomosis forceps

with rubber covered blades. At least 7.5 cm. of the gastric wall should be grasped in this way. The portion grasped should be in the pyloric antrum, and the forceps should be applied more or less transversely to the long axis of the stomach. The jejunum, just below the duodenojejunal juncture, is now brought forward, and a similar fold of it is grasped in the other portion of the anastomosis forceps. The jejunal loop should be applied to the stomach in such a way that its aboral end is next the greater curvature of the stomach, and its oral end next the lesser curvature. Moynihan prefers to have the jejunum slant toward the patient's right; while Mayo turns it toward the left. The gastric wall and jejunum being thus apposed, a typical *lateral anastomosis* (p. 834) is made between them with needle and thread. The clamps are then released, and the edges of the opening which was made in the transverse meso-colon are carefully sutured to the gastric wall just above the anastomosis by three or four interrupted sero-serous sutures. If this is neglected, a hernia of the small intestine may occur alongside the anastomosis, into the lesser peritoneal cavity. The abdominal contents are then replaced in proper position, and the abdominal wound closed without drainage. Liquids may be given in small amounts in twelve hours, but even semi-solid food should be withheld for a week or ten days.

Anterior Gastrojejunostomy may be required when the posterior wall of the stomach proves inaccessible on account of adhesions, etc. A loop of jejunum about 35 cm. (14 inches) long must be used, so as not to constrict the transverse colon. If the operation must be completed with great speed, a Murphy button may be employed for the anastomosis.

Posterior Gastrojejunostomy in Y.—This, which was adopted in 1897 by Roux of Lausanne, presents advantages in some cases: the jejunum is divided transversely about 35 cm. below its origin, and its aboral segment is implanted into the posterior wall of the stomach through an opening in the transverse meso-colon. Then the oral segment of the jejunum is implanted into the aboral segment about 15 cm. below the gastro-jejunal anastomosis (Fig. 859). In this way there is no chance for the duodenal secretions to reach the stomach, as they constantly do when the usual anastomosis is done. The principle of the Y-anastomosis is of value in certain other intestinal anastomoses.

The Vicious Circle after Gastrojejunostomy is rarely seen at present. When a long jejunal loop was used it was not infrequent. Probably the cause is obstruction of the duodeno-jejunal loop at the point of anastomosis. The patient vomits persistently after operation, and if repeated lavage proves ineffectual the abdomen may have to be re-opened to relieve the obstruction. The best treatment is an entero-anastomosis between the afferent and efferent limbs of the jejunal loop. The pylorus also should be occluded by a purse-string suture, if still patulous.

A peptic ulcer of the jejunum occasionally forms at or below the gastrojejunal anastomosis. It is seldom recognized except by hemor-

rhage or perforation. Treatment of these complications is the same as that of gastric or duodenal ulcer. It may be necessary to make a new gastrojejunostomy opening. This complication is rare after the no-loop method of posterior gastro-enterostomy.

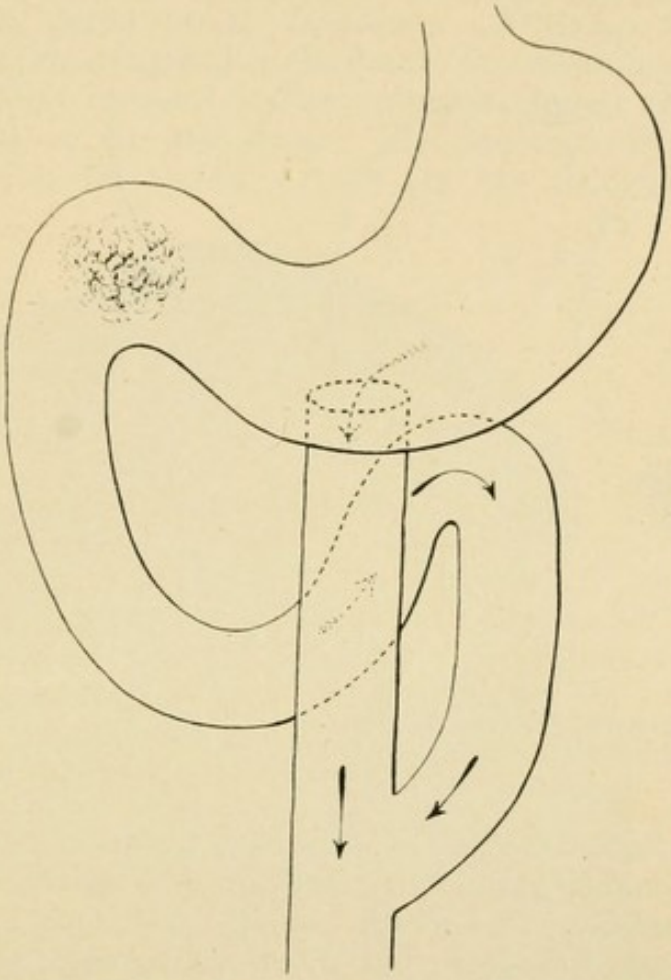

FIG. 859.—Diagram of posterior gastro-jejunostomy in Y.

Gastrectomy.—A portion or the whole of the stomach may be removed. In **pylorectomy** the pylorus and some of the pyloric antrum are removed; this operation is employed only in cases of benign disease. In every case of malignant disease the whole of the lesser curvature ought to be removed, and the operation is called a **partial gastrectomy**, the stomach being divided at the Hartmann or Mikulicz line (Fig. 860). If the stomach is removed as far as the Mayo line, the operation is known as **subtotal gastrectomy**; while if the entire stomach is removed from esophagus to duodenum, the procedure is worthy the name of **total gastrectomy. Circular** or **cylindrical gastrectomy** designates an operation by which the central portion of the stomach, including the entire circumference, is removed.

Partial Gastrectomy.—*Billroth's First Method* (1881).—This operation is very rarely employed. After removal of the diseased area, an end-to-end anastomosis is made between the duodenum and the remaining portion of the stomach (Fig. 861). As the circumference of the latter

is much greater than that of the duodenum leakage is very apt to occur at the "angle" of the suture lines. Kocher (1891) modified the Billroth I technique by implanting the duodenum into the posterior wall of the stomach, thus avoiding the deadly angle, and completely closing the cut surface of the stomach.

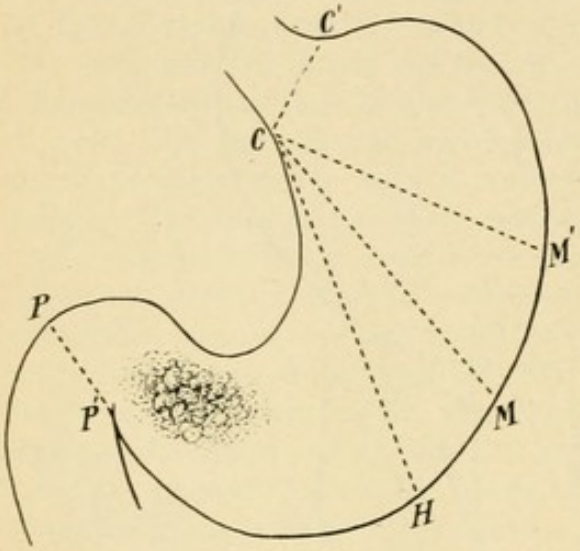

FIG. 860.—Stomach, showing the Hartmann (*H*), Mikulicz (*M*), and Mayo (*M'*) lines.

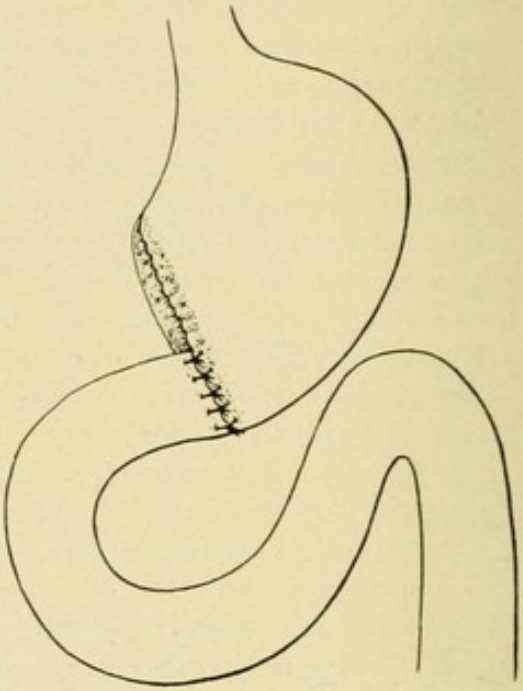

FIG. 861.—Partial gastrectomy by Billroth's first method.

Billroth's Second Method.—In this both the duodenum and stomach are closed completely, and the operation is terminated by a typical gastrojejunostomy. In Billroth's original technique an anterior gastrojejunostomy was done; but whenever possible posterior gastrojejunostomy is preferable.

The stomach is exposed through the usual right rectus incision, and is isolated with gauze. "The coronary artery is identified, doubly ligated and divided, close to the cardiac orifice of the stomach. The finger is passed through the gastrohepatic omentum into the lesser peritoneal cavity, and the gastrohepatic omentum is ligated in sections fairly close to the transverse fissure of the liver. By cutting through the gastro-hepatic omentum the surgeon reaches the pyloric artery, which is doubly ligated and cut. The finger is then passed down behind the pylorus, and the right gastro-epiploic artery is identified below the pylorus; this artery is ligated but not cut. Hemostatic forceps are then applied to the gastro-colic omentum, and as they are applied this structure is divided between them, beginning at the pylorus and passing along the upper border of the transverse colon until the point is reached at which it is proposed to divide the stomach. This point should be two inches to the left of the visible malignant growth. When this point has been reached the left gastro-epiploic artery is ligated just to the left of the proposed gastric incision. In

placing the hemostats on the gastro-colic omentum, great care is to be taken to avoid the middle colic artery and its branches. The portion of stomach to be removed is now completely freed along its curvatures, and remains attached only to the duodenum and the body of the stomach. The lesser peritoneal cavity can now be protected thoroughly by sterile gauze compresses. A clamp with rubber-covered blades is now applied to the duodenum about one inch beyond the portion visibly diseased, and an ordinary clamp is applied just to the pyloric side of the first clamp. The duodenum is then divided between the two, the section cutting also the right gastro-epiploic

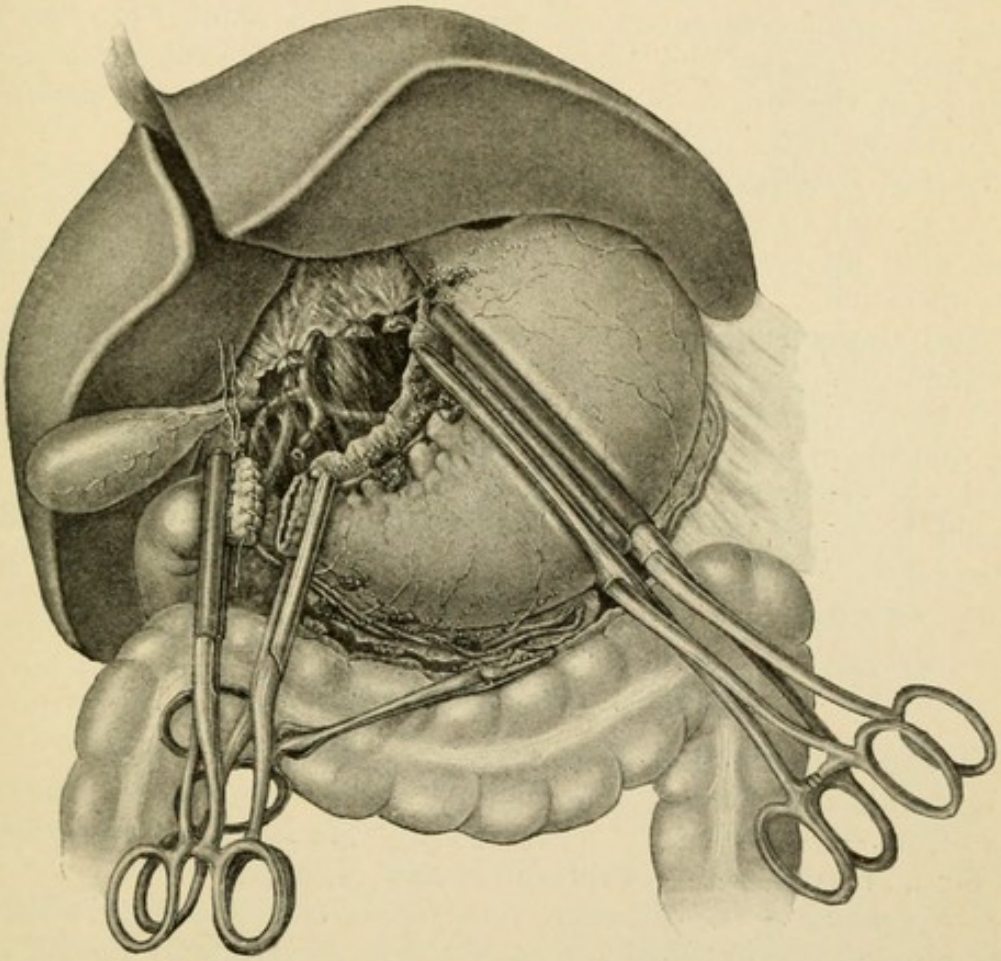

FIG. 862.—Partial gastrectomy: the duodenum has been divided, and the clamps are in place for the gastric section. (Deaver and Ashhurst.)

artery (already ligated) below the pylorus. The entire portion of the stomach to be excised can now be turned to the patient's left. The duodenal stump is closed first by a through-and-through iodized catgut suture; before the occluding clamp has been removed a purse-string suture of linen is applied on the distal (duodenal) side of the clamp; the clamp is then removed, and by catching the duodenal wall in two places with dissecting forceps the sutured end of the duodenum is inverted and the purse-string suture is drawn tight and tied (Fig. 862). The gastro-colic omentum is then ligated, and the hemostatic forceps removed. Rubber-covered gastrectomy clamps are then applied

across the stomach from the greater to the lesser curvature, at least two inches to the left of the visible malignant growth. Clamps with a screw lock at the end of the blades, as in Kocher's clamps, are safest. About three-fourths of an inch to the right of this occluding clamp an ordinary forceps is applied, and the stomach is divided between the two with the thermo-cautery. The excised portion being removed, a through-and-through suture of iodized catgut is inserted through the margins of the gastric walls which protrude from between the blades of the rubber-covered clamp. It is well to grasp these margins at one or more points with forceps to prevent their retracting. When the through-and-through sutures have been completed, the clamp is removed, and a continuous sero-serous suture is applied burying the first row." (Deaver and Ashhurst.) A posterior gastrojejunostomy is then done, the viscera replaced, and the great omentum is drawn up to cover the space left by the removal of the stomach.

Subtotal Gastrectomy differs from the operation just described only in the greater amount of stomach removed. Sometimes this is so great that only an anterior gastrojejunostomy can be done to complete the operation.

Total Gastrectomy proceeds along the same lines as partial gastrectomy; the duodenum should be sutured to the esophagus (end to end) before the stomach is completely cut away from the latter. If the duodenum, even after mobilization (p. 933) cannot be made to reach the esophagus without undue tension, a loop of the jejunum should be employed instead, being drawn through the transverse meso-colon. The Y-anastomosis of Roux is valuable under such circumstances.

SURGERY OF THE INTESTINES.

Intestinal Obstruction, or **Ileus,** may be caused by:

1. *Paralysis* of the muscular tunic of the bowel (*adynamic obstruction*) from bacterial toxins, as frequently seen in cases of peritonitis (p. 808), or from lesions of the spinal cord (p. 597).

2. *Spasticity* of the muscular tunic (*dynamic obstruction*) which is very rare, and occurs chiefly in cases of lead or tyrotoxicon poisoning.

3. *Occlusion* of the intestine by (*a*) Changes within the lumen of the bowel, such as impaction of feces, a gall-stone, or other foreign body (*obturation*). (*b*) Changes in the wall of the bowel, such as congenital malformations, or gradual occlusion by a tumor or contracting cicatrix. (*c*) Pressure from the outside, by tumors of neighboring organs.

4. *Strangulation* of the intestine by (*a*) Peritoneal bands or adhesions. (*b*) Intussusception. (*c*) Volvulus. (*d*) Internal Hernia.[1]

Cases of intestinal obstruction are conveniently divided into two classes, *acute* and *chronic*. Though cases of chronic obstruction frequently become acute, and though acute cases very rarely may

[1] Strangulation of external hernia has been considered at p. 761.

become chronic, there is in most cases no difficulty in distinguishing one from the other. The acute cases are those due to *strangulation* or to *obturation* from the sudden impaction of foreign bodies. The chronic cases are almost solely those due to gradual occlusion of the lumen of the bowel by a tumor or cicatrix or from pressure from without. Dynamic obstruction is scarcely a surgical affection, while adynamic obstruction has been sufficiently discussed with the subject of peritonitis. Obstruction from congenital malformations usually occurs at the rectum or anus, and is discussed at p. 901. Affections of Meckel's diverticulum are discussed at p. 891.

Acute Intestinal Obstruction.—The gravity of this condition depends not merely upon the arrest of the fecal current but upon constitutional symptoms. The higher the obstruction occurs in the intestinal tract the more quickly developed and the more pronounced are these constitutional symptoms. The collapse and other constitutional symptoms of acute dilatation of the stomach have already been noted (p. 869). The exact cause of such constitutional symptoms has not been determined, in spite of much recent experimental work by Draper, Hoguet, and others.

Symptoms.—The **local symptoms** are well marked and easily recognized: they are pain; vomiting; obstipation, with no passage of flatus by the rectum; disordered peristalsis which is always audible when the ear is placed on the belly, and may be visible if the abdominal wall is thin; and finally distention of the abdomen. The *pain* is characteristic; it is sudden in onset, very severe, often causes the patient to cry out, and is intermittent. When it ceases the patient feels and may look perfectly well, but it returns unexpectedly and with great suddenness. In most cases, within a day or so, the pain becomes constant, and is more or less localized to the seat of obstruction. Sudden cessation of a fixed pain usually indicates the occurrence of gangrene. The vomiting is projectile in type: there is little or no nausea, and the patient, unprepared by previous nausea, suddenly and unexpectedly spues forth a quantity of vomitus all over everything. At first the vomiting is not very frequent; the gastric and duodenal contents are rejected first, later the upper intestinal contents, and shortly before death matter that appears fecal may be vomited. Though repeated enemas may secure an evacuation from the bowel below the obstruction, no normal movement occurs, and no flatus is passed by rectum at any time. Eventually the abdomen becomes tympanitic and distended and the peristaltic movements sometimes may be observed to be arrested at a fixed spot, where the obstruction is located. The bowel above the obstruction becomes much dilated and undergoes the changes already described in strangulated hernia; that below the obstruction is collapsed. The virulence of the bacteria above the obstruction is much increased, and the altered intestinal wall is more readily traversed by them, and thus peritonitis supervenes even before gangrene or perforation of the strangulated bowel takes place. Not until this time is

the temperature noticeably elevated, and though at this time also the pulse becomes rapid and wiry, in the early stages of intestinal obstruction the pulse often is fuller and slower than normal. In this advanced stage the diagnosis is difficult between peritonitis with secondary obstruction, and primary obstruction terminating in peritonitis. The clinical picture is that of the late stages of peritonitis (p. 806). In cases of acute intestinal obstruction, unrelieved by operation, death usually occurs within a week.

Diagnosis.—The impaction of a *biliary calculus* or other foreign body may be suspected from the history of the case, and from the intermittent character of the symptoms, since the obstruction seldom is absolute at first, the gall-stone shifting its position within the lumen of the gut from time to time. It is most apt to become impacted in the lower ileum. Obstruction from *peritoneal adhesions*, resulting in kinks of the intestine or constriction beneath a band of organized lymph is most frequent in children or young adults who give a history of one or more attacks of peritonitis or of an abdominal operation. The symptoms usually are very severe and collapse is marked. *Intussusception* is rare in those more than two years of age; usually it results

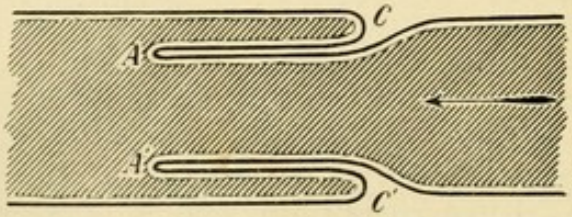

FIG. 863.—Diagram of an intussusception: *A*, the apex of the intussusceptum; *C*, the collar of the intussuscipiens.

from violent peristalsis induced by enteritis; the presence of intestinal parasites, polypi, or enlarged mesenteric lymph nodes may act as predisposing causes. The most frequent form of invagination is the ileo-cecal. The portion of intestine which is sucked down into the lumen of that below is known as the *intussusceptum*, while that which receives it is called the *intussuscipiens* (Fig. 863). The *apex* of the intussusceptum is that part which leads the way in the lumen of the bowel (in an ileo-cecal intussusception the apex of the intussusceptum is formed by the ileo-cecal valve); while the *neck* is the portion which enters the *collar* of the intussuscipiens. The characteristic symptom of this form of intestinal obstruction is the constant desire to defecate, with the passage of blood and mucus from the rectum. Occasionally the finger introduced into the rectum will feel the apex of the intussusceptum; and in many cases it is possible to recognize a sausage-shaped tumor in the right or left hypochondrium, the right iliac region being flattened (*Dance's sign*, 1826), owing to the migration of the invaginated bowel along the course of the ascending and transverse colon. *Volvulus* is most frequent in adults, especially in the aged, and is said to occur oftenest in the sigmoid flexure; but in my own

experience the small intestine has been oftenest involved. The obstruction is due to twisting of the bowel around its mesentery; unless an arc of three-fifths of a circle is described strangulation does not occur. The twist usually takes place in contra-clockwise direction, the oral limb of the bowel passing above and to the right of the aboral limb. Volvulus is predisposed to by elongation of the mesentery or by fixation of the intestine at any point by adhesions, thus permitting active peristalsis to throw the oral limb over the aboral portion which is fixed. Rectal examination sometimes reveals a distended coil of bowel in the recto-vesical pouch; or the distended loop may be palpable through the abdominal wall. *Internal hernia* may occur in any of the recesses or pockets of the peritoneum, especially the duodeno-jejunal fossæ; less often in the pericecal fossæ or the meso-sigmoid fossa.

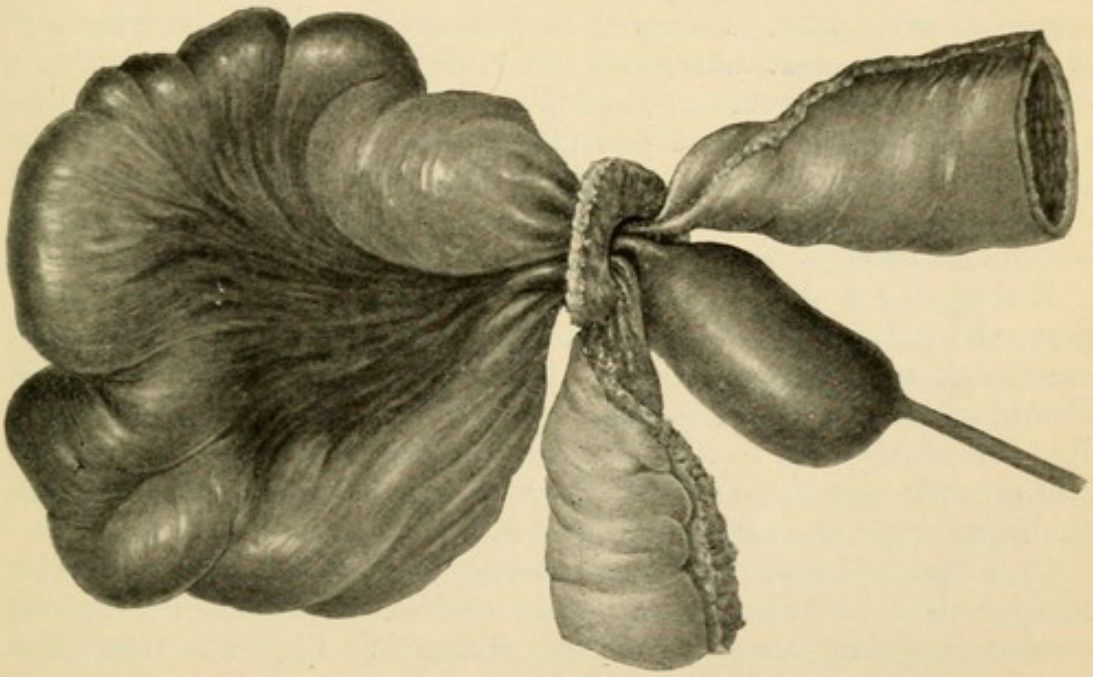

Fig. 864.—Strangulation of a loop of ileum through a hole in its mesentery. A Meckel's diverticulum, adherent to the anterior abdominal wall prevented more intestine from passing through the mesentery. Episcopal Hospital

Hernia through the foramen of Winslow is rare, as is a hernia through a congenital or acquired opening in the mesentery of the small intestine (Fig. 864). The possibility of a hernia through the transverse mesocolon after the operation of gastro-jejunostomy has been mentioned (p. 880). The diagnosis of these internal herniæ is difficult; usually the symptoms are gradual in onset, and many cases belong to the category of chronic rather than to that of acute obstruction. Sometimes as the hernia increases in size it may be discovered on palpation, or borborygmi and subjective symptoms may point to the region of the abdomen involved.

Treatment.—The first and most important item of treatment is *to avoid purgatives*. Even if the presence of obstruction is uncertain, the administration of any form of laxative or purge is absolutely con-

traindicated, so long as the possibility of acute intestinal obstruction cannot be excluded. It is perfectly proper to use enemas, in order to secure an evacuation; but purgatives are not only useless, in that they never relieve the obstruction, but they are intensely harmful. They arouse peristalsis, which results in increase of the strangulation, and they increase the amount of the intestinal contents above the obstruction. Some surgeons recommend the use of eserin, in cases of obstruction seen early; they argue that while it arouses peristalsis it does not cause an exudation into the intestinal canal as most other purgatives do; and they believe that it will do good in cases of adynamic obstruction, and that where the nature of the obstruction is uncertain its use will aid the surgeon in reaching a diagnosis, since if nothing is accomplished or the patient is made worse it may be assumed that the obstruction is not adynamic but mechanical. This teaching I regard as pernicious. Though I have seen eserin blow the wind out of a belly with great activity, I have failed to observe that such an occurrence hastens recovery; and I have also seen intestinal perforation caused by the violent peristalsis induced by eserin. It cannot be too strongly impressed upon the student that in cases of adynamic obstruction the patient is not ill because his abdomen is distended, but his abdomen is distended because he is ill.

If there is any doubt as to the diagnosis, much less damage will be done the patient by resort to immediate laparotomy than by procrastination; and when operation is once seen to be indicated, there should be no delay. The patient will not get any better by waiting. But it is always well to wash out the stomach before operation. This will prevent vomiting and perhaps aspiration of gastric contents into the lungs while the patient is under ether.

Operation.—Unless the site of obstruction is definitely known, the incision should be median, below the umbilicus. Do not let the distended intestines escape from the abdomen. Find the transverse colon; it is recognized by the attached omentum. If it is distended, the obstruction is lower, probably in the sigmoid or rectum, rarely at the splenic flexure; if it is collapsed, the obstruction probably is in the small intestine. Try to find some collapsed small intestine and trace it upward to the obstruction. If evisceration becomes necessary, the eviscerated intestines should be covered in hot wet towels, and these should be kept hot and wet by constant irrigation with saline solution at a temperature of about 115° F. If the bowel above the obstruction is very much distended it should be emptied of its highly infectious contents by aspiration or incision. Monks advocates passing a glass tube up the lumen of the distended intestine, and crowding as many coils of bowel upon it as possible, to aid in securing evacuation. I have tried this method on several occasions, but have not found it effectual. If the condition of the patient is very bad, the operation may be terminated by establishing a false anus above the obstruction, as in cases of acute obstruction superimposed upon chronic obstruction (p. 890); and in almost moribund patients life is occasionally saved

by opening the first distended coil of intestine which presents itself without making any search whatever for the obstruction; this constitutes the old operation of *enterotomy*. It has recently been revived by Krogius (1911). If obstruction is due to the *impaction of a foreign body*, it should be dislodged if possible and removed through an incision in healthy intestine.

If the obstruction is due to *kinking from adhesions*, these usually may be separated with the fingers or gauze dissection; distinct bands must be cut. The denuded areas on the intestines should be inverted by sero-serous sutures, or should be covered with omentum. If the adhesions are very widespread and the bowel very friable, a short-circuiting operation (p. 895) may be necessary.

In cases of *intussusception*, efforts at reduction should be made by pushing the intussusceptum back, not by attempts to pull it out from above. The latter method rarely is successful, and may be productive of much damage. If reduction proves impossible, the intussuscipiens may be incised longitudinally and the intussusceptum removed, the incision being closed, and the neck and collar of the invaginated bowel being sutured together as in Maunsell's method of end-to-end anastomosis (Fig. 829). Enterectomy rarely is justifiable in this or any form of acute obstruction; the establishment of a false anus above the obstruction (if this is not too high in the intestinal tract) or a short-circuiting operation will be preferable. Occasionally the gangrenous intussusceptum separates as a slough and is discharged by rectum. The operative mortality is about 33 per cent.

In cases of *volvulus*, the bowel should be untwisted, and if the condition of the patient permits, it is well to take a reef in the redundant mesentery or to attach the sigmoid to the parietal peritoneum, so as to prevent recurrence.

Chronic Intestinal Obstruction.—This is most often the result of fecal impaction, benign or malignant stricture, or widespread peritoneal adhesions which interfere with peristalsis without causing strangulation.

In **fecal impaction**, which occurs oftenest in the rectum or sigmoid, rarely in the transverse colon or cecum, there is obstinate constipation, with slight intermittent colicky pains from disordered peristalsis; sometimes a mass can be felt through the abdominal wall, which is recognized as fecal from its doughy consistency. Vomiting (never stercoraceous) may occur during an acute attack; and watery diarrhea often follows relief of the obstruction. *Treatment* comprises the use of repeated enemas, administered in the Trendelenburg or knee-chest posture, and evacuation of fecal masses from the rectal ampulla by the finger if necessary. When once the impaction is relieved, it is safe to give purges; as long as any acute symptoms persist opium and belladonna may be of use in relaxing intestinal spasm.

In chronic obstruction from a **cicatrix** or **tumor** of the intestine, the symptoms are much the same as in fecal impaction, but as a rule

no tumor can be felt. After many attacks of partial obstruction, this is prone to become acute and complete at the last. If palliative treatment (enemas) proves unavailing the surgeon should open the abdomen, and in the presence of acute obstruction should content himself with making a false anus above the seat of the tumor; if there is no evidence of acute obstruction the tumor or cicatrix may be resected, but such a course almost always leads to death from peritonitis unless the bowel above the tumor is unobstructed. If the tumor is in the rectum, a sigmoid anus may be made in the left iliac region (Littre's operation, 1710); but if the tumor is higher in the large intestine cecostomy (Fig. 865) should be done in the right iliac region (Pillore, 1776). For obstruction in the small intestine, which is rare, a short-circuiting operation is preferable (entero-enterostomy).

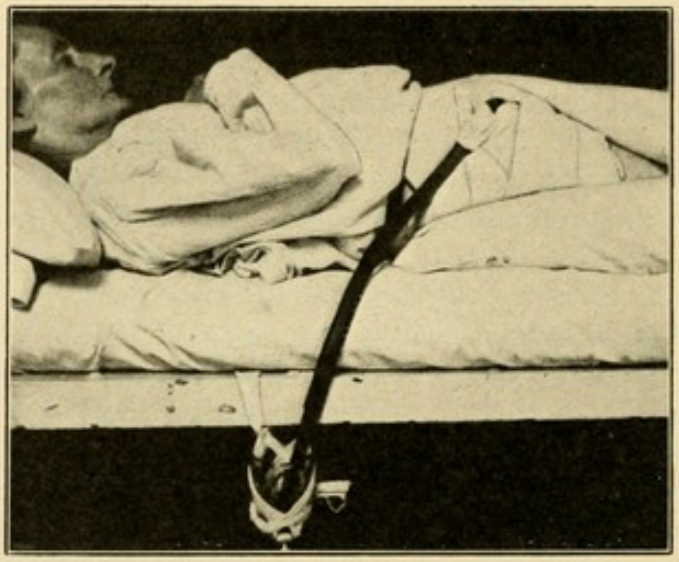

FIG. 865.—Cecostomy, for acute intestinal obstruction, of one week's duration, supervening on chronic obstruction of twelve years' standing. Paul's tube in cecum. Stricture of sigmoid, in woman of fifty-three years, following injury in childbirth thirteen years ago. (See page 911.) Episcopal Hospital.

Mesenteric Thrombosis and Embolism.—Thrombosis of the mesenteric vessels occurs in many cases of intestinal obstruction, as the result of strangulation. But thrombosis, and rarely embolism, may occur as a primary condition, from the same causes which produce similar conditions in other parts of the body. The *symptoms* are not unlike those of acute intestinal obstruction, except that pain occasionally is inconspicuous in cases of thrombosis; peritonitis develops more rapidly than in intestinal obstruction; and there are evidences of hemorrhage into the intestinal tract, with bloody diarrhea or vomiting. *Diagnosis* is difficult. *Treatment* comprises immediate laparotomy and resection of the affected bowel, which quickly becomes gangrenous. Among 22 complete operations collected by Zesas (1910), there were 7 recoveries. If the condition of the patient renders resection impossible, the gut may be tamponed, or may be drained; but incomplete operations almost always terminate fatally.

Meckel's diverticulum, the remains of the omphalo-mesenteric duct, is found in about 2 per cent. of bodies which come to autopsy. It is attached to the lower ileum, within a few feet of the cecum, and usually springs from the anti-mesenteric border of the gut. It is about the size of the finger, and may be unadherent, or may be attached to the umbilicus (see Umbilical Fistula) or to some other point in the abdomen. It is most apt to cause trouble if adherent, acting as a band under or around which the intestine becomes strangulated. If adherent to the umbilicus, volvulus of the small intestine is frequent, causing torsion and perhaps strangulation of the diverticulum (Fig. 866). If unattached, its chief affection is acute inflammation, which in its pathogenesis, symptomatology and treatment resembles appendicitis.

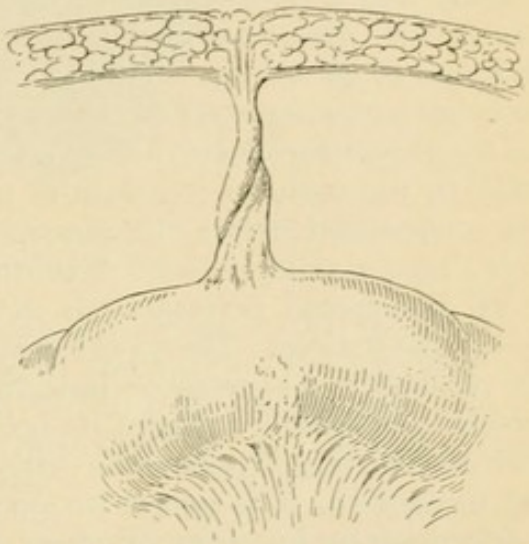

FIG. 866.—Strangulation of Meckel's diverticulum, adherent to umbilicus. Age forty-six years; duration two days. Episcopal Hospital.

Diagnosis.—The presence of a Meckel's diverticulum may be suspected if the umbilical cicatrix is abnormal. I have twice been able to make the correct diagnosis before opening the abdomen, by heeding this maxim. Trouble is especially apt to arise about the age of puberty.

Treatment.—It is best to excise the diverticulum, at the same time doing what is necessary to the strangulated intestine.

Umbilical Fistula.—If the omphalo-mesenteric duct remains patulous, a fistula is present at the umbilicus. This may discharge feces, or if very small only mucus. In some cases the discharge resembles gastric juice and it is uncertain whether the mucosa from which the discharge comes is an excluded part of Meckel's diverticulum, or neoplastic (adenomatous) in nature (Denucé, 1908). The best *treatment* is extirpation of the diverticulum.

Affections of the **Urachus** are discussed at p. 963.

Internal Fistulæ of the Intestinal Tract usually are the result of peritonitis, malignant disease, or tuberculosis. Occasionally they result from injury. The existence of a fistula between the *gall-bladder* and the intestine may be inferred if a large gall-stone is passed by rectum or lodges in the intestine; such fistulæ often close spontaneously and rarely cause symptoms. A *gastro-colic* fistula gives evidence of its presence chiefly by the development of lienteric diarrhea and fecal vomiting. Other forms of internal fistula are rare and do not cause characteristic symptoms. Gastro-colic fistulæ scarcely ever close spontaneously, and early operation is indicated. The best plan is to separate the stomach and colon and repair the perforation in

each. But this is not always possible. Alternate methods are (1) section of the colon on each side of the fistula, and *bilateral exclusion* (p. 895) of the portion of bowel containing the fistula, leaving it as a pouch attached to the stomach, and reuniting the colon above and below the seat of disease; (2) short-circuiting the fecal current by a colo-colostomy (above and below the fistula) or by ileo-sigmoidostomy; but neither of these plans is very satisfactory.

Intestinal Perforation in Typhoid Fever occurs in about 2.5 per cent. of cases. It is most frequent during the third or fourth weeks of the disease and is predisposed to by a mixed infection in the intestinal tract. The great majority of perforations occur in the ileum, within a few feet of the cecum. The important **symptoms** are *abdominal pain, localized muscular rigidity, increase in the pulse rate,* and often a *fall in the temperature* immediately after the perforation. But the patient may be too toxic to complain of pain, and the other symptoms may pass unnoticed unless the physician and nurse are constantly alert. Very soon rigidity is lost, distention commences, and often it is not until widespread peritonitis is developed that the surgeon is asked to see the patient. The sooner operation is done, the better the chance of recovery. Consent for immediate operation should be obtained before perforation occurs if its occurrence seems probable. If a pre-perforative stage (peritonitis without symptoms of perforation) can be recognized, it is proper to open the belly then, and to prevent perforation by inverting all ulcers which threaten to perforate. Even if no lesion is found (*laparotomie blanche*) the patient is none the worse for the exploration.

The **operation** may be done under spinal or local anesthesia, but I prefer a general anesthetic (ether or gas). The incision, about 3 inches long, is made through the right rectus muscle, below the umbilicus; and the lowest loop of ileum is pulled into the wound and traced upward until the perforation (there may be more than one) is found or until healthy bowel is reached. When a perforation is found it should be closed by a purse-string or other appropriate suture (p. 829) in such a way as not to stenose the bowel. If the patient is desperately ill (no such patient is too near death for operation to offer a chance of recovery) it is sufficient to drain the intestine above the area of disease, by a Paul's tube (p. 915), tamponing the necrotic bowel. Drainage to the pelvis always should be employed, but I consider irrigation of the peritoneal cavity harmful. Subsequent treatment is the same as for peritonitis.

In collective statistics (Harte and Ashhurst, 1904) the mortality is nearly 75 per cent.; but a few individual operators report a death-rate well below 60 per cent. (Montreal General Hospital, Johns Hopkins Hospital). In my own hands the mortality has been 62.5 per cent.; this includes one patient who recovered after cholecystectomy for *perforation of the gall-bladder* during typhoid fever (Fig. 867), and a case of recovery after removal of an acutely inflamed *appendix* during typhoid fever.

Intestinal Hemorrhage in Typhoid Fever is of surgical interest, chiefly in connection with the diagnosis of perforation. In hemorrhage, though there may be marked shock, increase of pulse rate and fall of temperature, there seldom is pain or marked abdominal rigidity; and usually the blood appears in the stools within an hour or so.

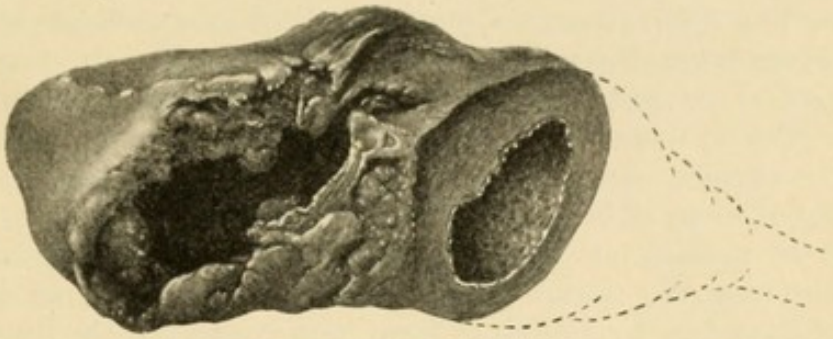

FIG. 867.—Gall-bladder removed by cholecystectomy, showing typhoid perforation. (Natural size.) Episcopal Hospital.

In severe recurring hemorrhages, which usually are fatal, Harte (1909) advocates laparotomy; he succeeded in finding the bleeding spot by the aid of transmitted light, and in checking the bleeding by suture. Though his patients eventually succumbed, he has indicated the proper course to pursue in such cases.

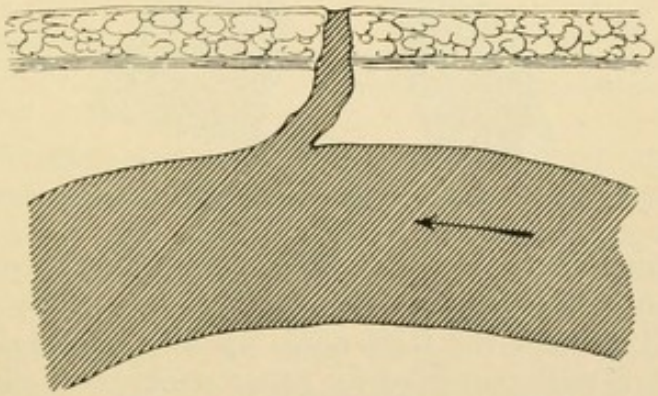

FIG. 868.—Diagram of a fecal fistula.

Fecal Fistula and False Anus.—If only a small portion of the intestinal contents (perhaps only flatus) is passed from the bowel through the opening in the abdominal wall, the patient is said to have a *fecal fistula* (Fig. 868); but if practically the entire intestinal contents are discharged in this way, a *false anus* (Fig. 869) is said to exist.

A **fecal fistula** sometimes develops in a drained abdominal wound a few days after operation in cases where the bowel was gangrenous, but the fecal discharge usually ceases spontaneously after removal of the drainage, as the wound granulates. Its closure is aided by confining the patient to as dry a diet as possible, and by securing an evacuation through the rectum every day by means of an enema.

Purges are contraindicated. To prevent excoriation of the skin around the fistula, it may be painted with collodion, with Whitehead's varnish (p. 638), or covered with zinc oxide ointment. Mineral bases should be used in all such ointments, as animal bases sometimes are digested by the intestinal juices.

A **false anus** usually is an artefact, intentionally produced by the surgeon (Fig. 885); though it may also develop spontaneously, by the gradual formation of a spur in a case of fecal fistula. It shows no tendency to heal, owing to the presence of this firm spur between the afferent and efferent loops of bowel; operation almost always is necessary to secure its closure. In some cases, where it is certain that the afferent and efferent loops of bowels are in close apposition, it is safe to destroy the spur by passing one blade of a clamp into each opening and gradually tightening the clamp throughout a period of several days until pressure has caused a slough to form, and converted the lumen of the two intestines into one. Dupuytren's enterotome is the type of instrument employed. If this can be satisfactorily accomplished the

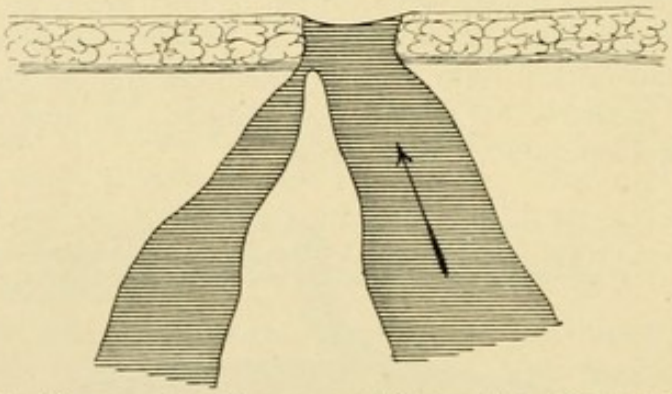

FIG. 869.—Diagram of a false anus, with formation of a marked spur.

external opening of the fistula usually closes spontaneoulsy. In most cases, however, a radical operation must be done. This consists in dissecting widely around the false anus, opening the healthy peritoneal cavity, which is well protected by gauze packs, and closing the opening in the bowel by inversion of its margins where this is possible; and in other cases by resection of the affected bowel, and restoration of the continuity of the intestinal tract by end-to-end or lateral anastomosis.

Tumors of the Intestine, except of the sigmoid and rectum (for which see page 913), are quite rare. Benign tumors are almost unknown with the exception of mesenteric cysts (see below). Hyperplastic tuberculosis and malignant tumors (sarcoma and carcinoma) produce symptoms by obstructing the bowel. Sometimes melena or enterorrhagia occurs. If the tumor is recognized as soon as symptoms of chronic obstruction appear, it is usually possible to remove it by intestinal resection with fair prospect of ultimate recovery. Lymphatic extension generally occurs late. In malignant tumors of the small intestine resection with end-to-end or lateral anastomosis may be done.

In carcinoma of the cecum (which sometimes gives a palpable tumor before obstructive symptoms arise) it is best to resect the entire ileo-cecal coil of intestine as high as the distribution of the middle colic artery. The continuity of the intestinal tract is restored by implanting the ileum into the transverse colon or the sigmoid. If resection is impossible in any case (and it never should be attempted when acute obstruction has developed) a false anus may be established above the site of obstruction; or a **short-circuiting operation** (Fig. 870) or an **intestinal exclusion** (Fig. 871) may be performed.

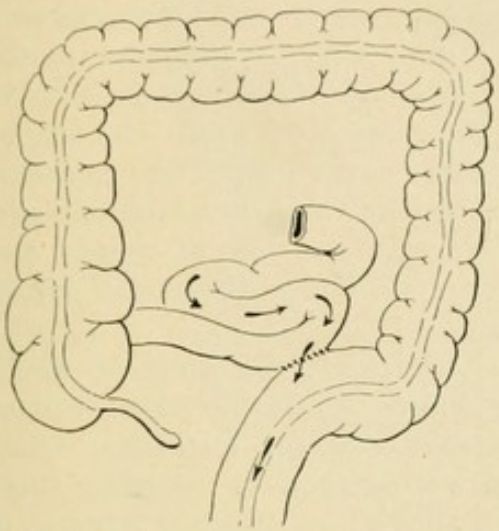

FIG. 870.—Ileo-sigmoidostomy, a typical "short-circuiting" operation.

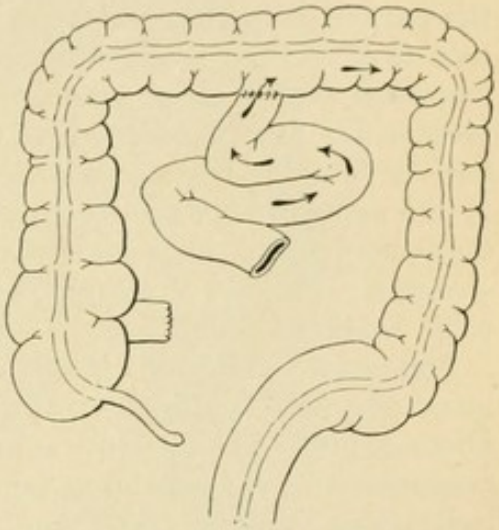

FIG. 871.—Unilateral exclusion of the ascending colon, by implantation of the ileum into the transverse colon.

Mesenteric Cysts usually are of embryonal origin, and are endotheliomatous in nature. Hydatid cysts, and cystic degenerations of malignant tumors, also occur. Adhesions are common, but the tumor usually is movable laterally; it is surrounded by a tympanitic area, and may be crossed by a band of tympany. Its most frequent site is in the mesentery of the lower ileum. H. C. Deaver collected 40 cases in 1909. The proper treatment is extirpation, which often involves resection of the overlying intestine.

Omental Cysts of the same nature occasionally occur.

SURGERY OF THE COLON AND SIGMOID.

Colitis.—Three types of this disease may be recognized: (1) Ordinary "*catarrhal*" *colitis* or entero-colitis, without known specific cause, due originally to errors in diet, exposure, etc. (2) *Bacillary dysentery*, due to the B. dysenteriæ of Shiga, which usually is an acute disease and often rapidly fatal, and which is the common epidemic form of dysentery which devastates camps, prisons, etc. (3) *Amebic dysentery* caused by the amœba dysenteriæ (A. coli), which even if acute or subacute at first almost always terminates as a chronic disease. It is almost solely with the latter group of cases that surgery

is concerned, since except in the rare event of perforation or abscess formation the first and second are best treated medically.

In amebic dysentery the entire colon or only parts of it may be affected. As the sloughs are cast off ulcers are left, and these may cicatrize or perforate, while new ulcers are forming in other parts of the colon. The sloughs may be passed by rectum in large masses (membranous dysentery). The amebæ are carried quite constantly in the portal circulation to the liver, and hepatic abscess (p. 936) is a frequent sequel.

Symptoms.—The disease may begin acutely or so insidiously that the patient is unaware of its existence and comes under the surgeon's care first for the liver complication. A history of residence in the tropics is then a great aid in diagnosis, though those who have never been in the tropics may suffer from the disease. Usually the ameba may be found in the stools, especially after purgation. The symptoms of the acute stages are frequent and copious watery and bloody discharges from the bowel, with much pain and loss of weight and strength. Periods of remission are common, but recurrence of symptoms is almost inevitable.

Treatment.—The indications are (1) to destroy the parasites which infest the bowel, and (2) to procure healing of the intestinal lesions. Dieting, intestinal antiseptics, and rectal and colonic irrigations, which comprise the medical treatment, rarely succeed in meeting these indications, though they may secure alleviation or even latency of symptoms. If symptoms recur persistently, it is best to resort to the operation of *cecostomy*, or that of *appendicostomy* (Weir, 1902); when a fistula is thus established in the caput coli, irrigations can be much more effectively used, and thus the operation affords a means of killing the parasites and of curing the intestinal lesions. Cecostomy is done by the method of Senn or Witzel, for gastrostomy (p. 877); appendicostomy is accomplished by detaching the meso-appendix in part, and suturing the appendix in the abdominal wound (Fig. 900).

Pericolitis, etc.—Of late years numerous cases have been observed at operation in which there existed more or less definite symptoms of chronic intestinal obstruction, of chronic appendicitis, etc., but in which the main pathological changes consisted in the presence of broad bands or membranes, binding the cecum to the parietal peritoneum, holding the lower ileum in a kinked position, or fixing the sigmoid so as greatly to interfere with its function. These membranes were well described by Jabez N. Jackson in 1909 and are generally known by the name of **Jackson's membrane.** The **kink of the ileum** (Fig. 872) is especially associated with the name of Lane.

It is usually assumed, rather by exclusion than from any definite reasons, that these membranes are the result of low grade infection. Some are thought to be congenital in origin. But their exact pathogenesis is not known.

Symptoms.—The symptoms are subacute or chronic in type, and, according to Jackson, consist essentially in pain and tenderness, con-

stipation, mucous discharge from the bowel, meteorism, loss of weight, gastric symptoms, and "neurasthenia."

Treatment.—Treatment consists in division of the adhesions and careful peritonization of all denuded surfaces. A diseased appendix or gall-bladder, or other source of infection should be treated appropriately at the same time.

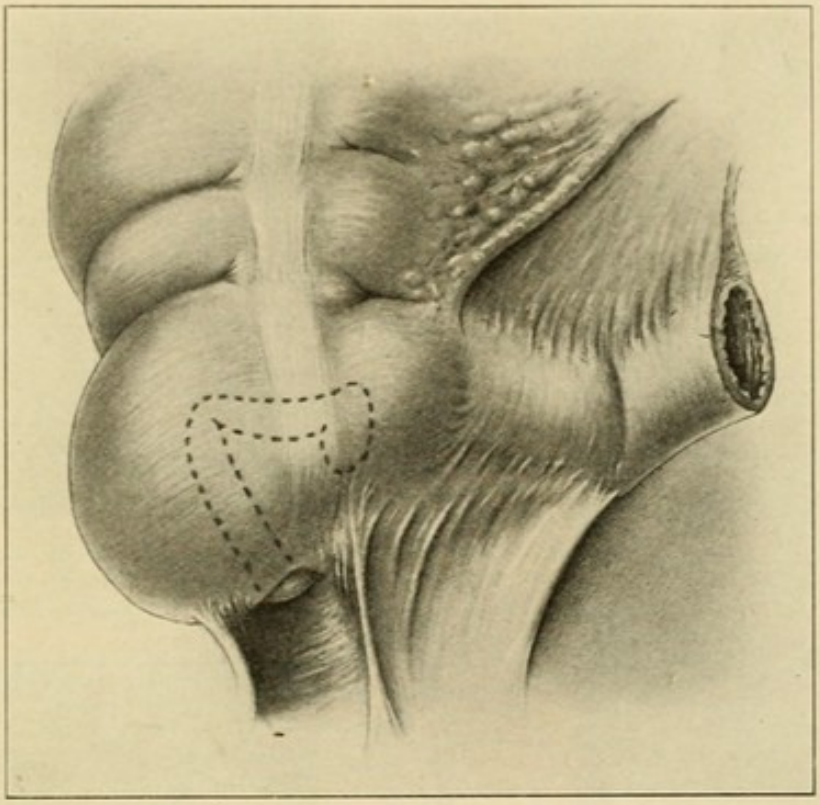

FIG. 872.—Kink of the ileum due to membrane binding it to the cecum, and associated with chronic appendicitis. The appendix was much twisted and occupied a deep subcecal fossa. From a patient in the Episcopal Hospital.

Pericolitis Sinistra.—When the sigmoid is affected the cause almost always is inflammation of one or more of the diverticula so commonly found there, and the pathological changes are somewhat different from those encountered about the cecum and ascending colon. The classification I suggested in 1907 includes: (1) **Sigmoiditis,** an inflammatory hyperplasia of the walls of the sigmoid, converting it into a rigid tube, and usually causing a certain amount of obstruction. This is comparatively rare. It may be caused by inflammation of a diverticulum buried in the intestinal wall or in an epiploic appendage. (2) **Perisigmoiditis,** which usually is the result of inflammation of a diverticulum projecting into the free peritoneal cavity. This may or may not lead to perforation or abscess formation. The symptoms resemble those of appendicitis, except that they occur on the left side, and the treatment is the same, viz., excision of the diverticulum and drainage of the abscess, or in rare cases resection of the diseased portion of the sigmoid, especially if there is any suspicion of malignancy. Sigmoid diverticulitis has been particularly studied by Mayo (1907)

and by Brewer (1907). (3) **Mesosigmoiditis**: This again is most often due to inflammation of a diverticulum lying within the layers of the meso-sigmoid, or to an ulcer in the sigmoid. Sometimes a distinct tumor is formed by the secondarily enlarged lymph nodes (Fig. 873); and sometimes the meso-sigmoid becomes contracted and distorted, causing secondary obstructive symptoms (Ries, 1907).

Cecum Mobile.—An unduly movable cecum may be the cause of many of the symptoms just described, according to Wilms (1908). This condition may be associated with Lane's kink or with Jackson's membrane, constricting the ascending colon or hepatic flexure, and is to be treated by suspension of the cecum by suture to the parietal peritoneum after removal of the appendix and any adventitious membrane present.

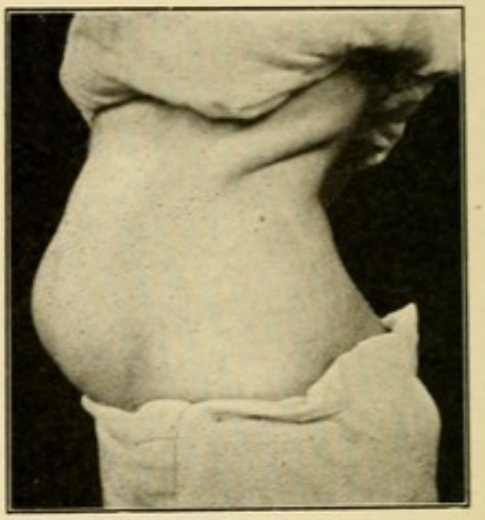

FIG. 874. — Pendulous abdomen: complaints of backache and invalidism for years. Episcopal Hospital.

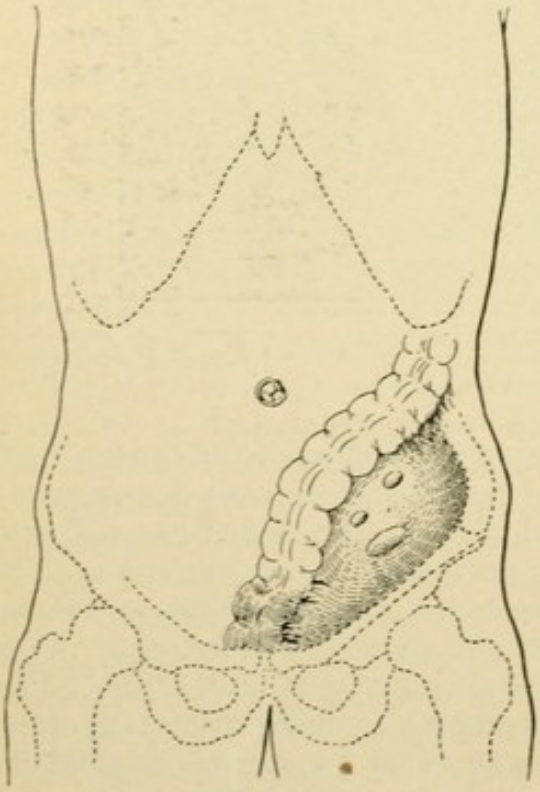

FIG. 873.—Meso-sigmoiditis, in a child of seven years. Recovery after exploratory laparotomy. Children's Hospital.

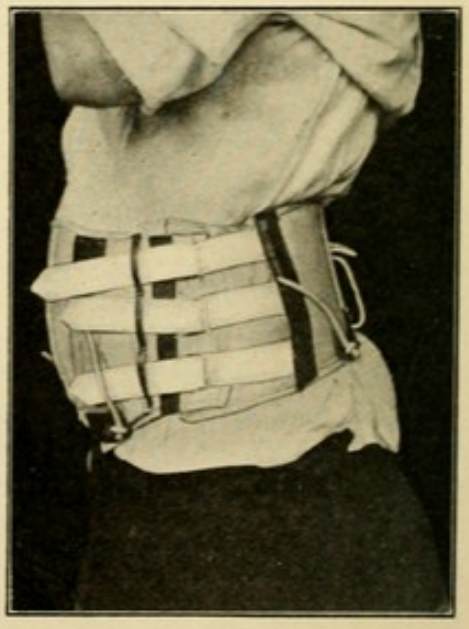

FIG. 875.—Same patient as Fig. 874. All symptoms relieved by wearing suitable belt.

Visceroptosis.—Glénard, in 1885, drew attention to general visceral prolapse, involving the hollow viscera, usually the right kidney, and sometimes the liver and spleen as well. The deformity is more common in women, and may or may not be associated with *pendulous abdomen*. It is recognized now as not very rare in children, and is often held

responsible for chronic constipation. Gastroptosis, already mentioned at p. 871, usually is a part of general visceral prolapse. In cases of pendulous abdomen symptoms of sacro-iliac relaxation (p. 535) may arise, and much comfort often be derived from the use of an abdominal belt (Fig. 875) or properly fitting corset, though skiagraphs made (after the use of bismuth gruel by mouth or enema) before and after the application of such a support do not show any noticeable change in the position of the hollow viscera. Relief probably is secured by overcoming static strain in the pelvic joints and lumbar spine.

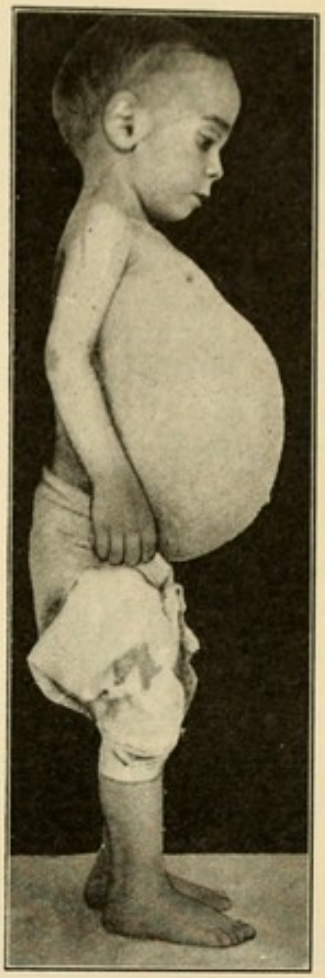

FIG. 876.—Congenital megacolon. From a patient under the care of the late Prof. Ashhurst in the University Hospital.

Chronic Constipation, which often is due to some mechanical factor, such as visceroptosis or one of the types of pericolitis above described, is treated by Lane by means of exclusion of the colon by ileo-sigmoidostomy.[1] In some cases the entire colon is excised at the same time or subsequently. Codman warns against accepting without question the evidence of skiagraphs made after the ingestion of bismuth gruel as indicating true obstructive kinks in the large intestine, since it has been found by Hertz that fluoroscopic examination demonstrates no obstruction to the onward course of the intestinal contents even when the kinks appear very pronounced. In most cases of chronic constipation the delay occurs in the pelvic colon, and not at the hepatic or splenic flexures where kinks are most apparent.

[1] According to Lane's theory most human ailments are due to "chronic intestinal stasis:" the primary condition is some obstruction in the descending colon or sigmoid; this results in cecal dilatation, and in attempts to overcome the obstruction adventitious attachments are formed around the cecum and lower ileum which should be regarded as nature's efforts to fix the bowel in a more effective position. Unfortunately this usually results in obstruction in the lower ileum; the weight of the retained secretions in the jejuno-ileum causes a kink at the duodeno-jejunal juncture, and again in an effort to overcome this nature produces adhesions around the origin of the jejunum which may increase the obstruction, and by leading to dilatation of the duodenum may be responsible for the development of duodenal ulcer. Gastro-enterostomy Lane holds is effective merely because suspension of the first jejunal loop to the stomach relieves obstruction at the duodeno-jejunal juncture; the gastro-jejunal anastomosis is of no use whatever. The only rational treatment for all these conditions he contends is section of the lower ileum and union of its proximal end with the sigmoid below the last obstruction. In this way he claims to have cured such diverse lesions as exophthalmic goitre, tuberculosis of the hip, trifacial neuralgia, etc., all of which he attributes to a primary auto-intoxication from chronic intestinal stasis.

Congenital Megacolon.—This is believed by most pathologists to be really of congenital origin, as indicated by the name selected for it by Hirschsprung in 1886. It is also known as *Hirschsprung's Disease*. Whether or not there is always a mechanical obstruction, or whether the dilatation of the colon is of neuropathic origin, are questions still in dispute. The sigmoid flexure is usually, and the entire colon often, involved; while the rectum and the small intestine almost always escape the dilatation. Most patients come under observation between the ages of two and ten years. Obstinate constipation exists from very early life; the abdomen becomes immensely distended (Fig. 876); the colon is packed with feces; tympany may be extreme at times; and the usual symptoms of fecal impaction are present. The general health is impaired, and the child's growth may be arrested.

Treatment.—Treatment in mild cases, and especially in very young patients, should be palliative, as for any ordinary case of chronic constipation. In others, operative treatment, which offers the only hope of permanent cure, should not be delayed too long. Cecostomy I believe is the operation of choice; this is to be followed by free irrigations of the bowel through the fistula, and when the colon has been well cleansed and the patient's health is improved, the entire portion of bowel affected is to be resected.

Tumors of the Sigmoid and Pelvic Colon are considered in connection with those of the rectum (p. 913).

SURGERY OF THE RECTUM AND ANUS.

Examination of the Anus and Rectum.—Digital examination may be employed with the patient on his back with thighs flexed, or standing in a stooping posture. The gloved finger, well lubricated with green soap, is gently insinuated until both sphincters are passed, when its tip will be in the rectum, which normally contains no feces. In men the prostate and seminal vesicles can be felt beneath the anterior rectal wall, and in women the cervix of the uterus usually can be felt. Most pathological changes occur in or near the anal canal, and they often are overlooked because the examiner expects to find them too high in the rectum. If visual inspection is desired, it is necessary to dilate the sphincter; this is best done under a general anesthetic. First one index finger then the other is introduced, and by gradually separating them in various diameters, the sphincter is dilated. Usually it is desirable to dilate it until the finger comes into contact with the tuberosity of the ischium on each side. The mere fact of dilatation renders the anal canal visible, but to inspect the rectum high up, a speculum (proctoscope) is necessary. Fig. 877 shows some convenient types. The patient should lie on his back, with thighs well flexed on the pelvis. The speculum is introduced gently, with the obturator in place, and when introduced to its full depth the obturator is removed, any fecal matter or mucus is sponged away, and as the speculum is

slowly withdrawn the mucosa which prolapses into its end is carefully inspected for ulcers, dilated hemorrhoidal veins, orifices of fistulæ, etc. A sigmoidoscope is similar to a proctoscope, but much longer (10 to 14 inches): it is inserted with great care until its tip gets well beyond the hollow of the sacrum, and the bowel is examined (by light reflected from a head mirror, or preferably by means of an incandescent bulb at the point of the instrument) from above downward, as the instrument is withdrawn. In most cases the instrument does not really enter the sigmoid, but the entire rectal canal is readily seen, especially if the pelvis is raised so that the rectum balloons.

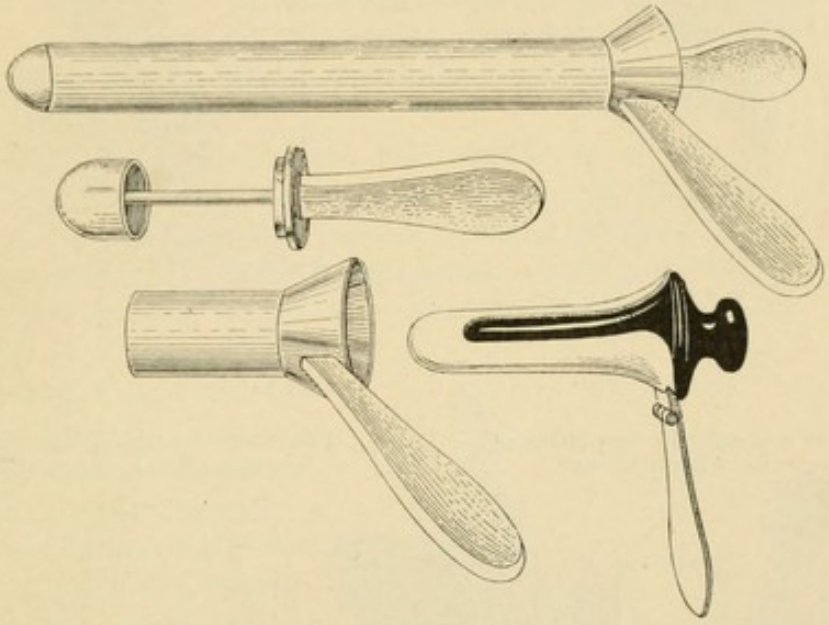

FIG. 877.—Two forms of proctoscope, and a sigmoidoscope.

Congenital Malformations.—These are due to failure of proper union between the primitive proctodeum and the rectum (Figs. 878, 879, and 880). The most important classification is into those infants with absolute occlusion of the rectal canal, and those in whom there exists some form of fistulous exit for the meconium. In these latter cases the rectum may empty into the urethra or the bladder, or in the female into the vagina. In all except the last mentioned variety the condition usually is recognized at birth, or within a few days, and demands immediate operation. When the opening is into the vagina no obstruction may occur, and the malformation may pass unnoticed until adult life.

In any case the proctodeum may be present, as a dimple or shallow sinus at the normal site of the anus, the occlusion being above; or there may be no evidence of an anus. The most serious cases are those in which the proctodeum is present and the occlusion so high in the rectum or sigmoid that it cannot be recognized from below, but is only inferred when symptoms of obstruction have been present for a number of days. In such cases I believe it is safer to open the cecum than the sigmoid, since the obstruction may be in the latter.

I demonstrated in 1907 that there are exceedingly few of these cases in which the bowel cannot be reached by a perineal operation; and as the mortality of this operation is very much less than that of iliac colostomy (Littré's operation, p. 890) which is the usual substitute, it cannot be too strongly emphasized that perineal proctoplasty almost always may be successfully accomplished. An antero-posterior incision is made in the perineum, over the normal site of the anus,

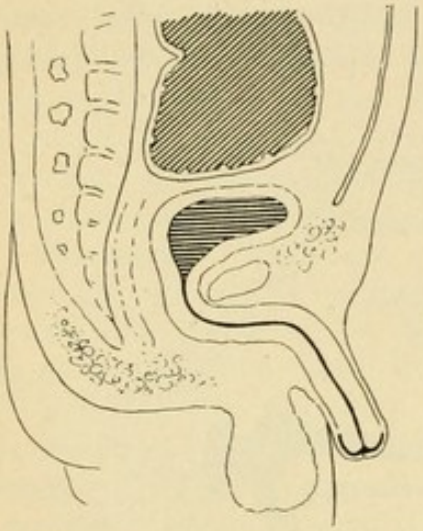

FIG. 878.—Congenitally imperforate rectum, proctodeum absent.

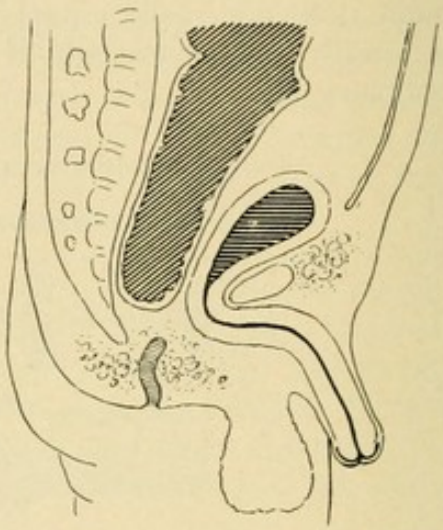

FIG. 879.—Congenitally imperforate rectum, proctodeum present.

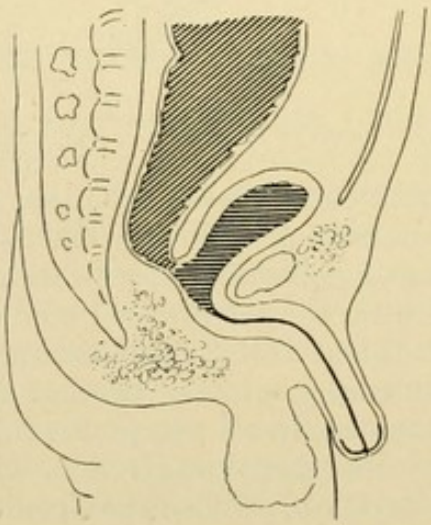

FIG. 880.—Congenitally imperforate rectum, the bowel opening into the urinary tract.

from the base of the scrotum to the coccyx, and this is deepened, keeping in the median line and following the curve of the sacrum, *until the rectal pouch is found.* (I may go further, and advise, with Stromeyer, even if the rectum cannot be found from below, that the peritoneal cavity be opened through the perineum and any distended loop of bowel found.) When the bowel is found, it is opened, and its margins are drawn down and sutured to the skin. In newborn infants

the promontory of the sacrum is only 3 to 5 cm. (1½ to 2 inches) distant from the anus, and I have on several occasions carried the dissection as far as this and succeeded in finding the rectum; and none of the patients so treated (one of whom was two weeks old when brought for operation) has died. On the other hand, the only patient on whom I have been forced to do iliac colotomy (cecostomy) died of inanition; this was a case in which no obstruction could be felt from below, and where the autopsy showed there was agenesis of a portion of the sigmoid, producing obstruction. In cases where the bowel opens into the bladder or urethra it almost surely will be possible to reach the rectal ampulla from below. If nothing more radical can be done the surgeon can at least establish a common perineal opening for feces and urine, thus preventing temporarily ascending infection of the urinary tract. When the child is older a more radical operation may be attempted.

When the bowel opens into the vagina, it is best to dissect the rectum free, transplant the fistulous opening in it to the normal site of the anus, and repair the vaginal opening (Rizzoli, 1856).

Abscess Around the Rectum and Anus.—This is a frequent affection, and the abscess may occur in various situations (Fig. 881): (1) *Subtegumental* or *perianal*, which is between the skin and the external sphincter; (2) *ischio-rectal*, the most frequent of all, which occupies the ischio-rectal fossa, between the skin and the levator ani muscle; (3) *submucous* between the mucous membrane of the rectum and the internal sphincter; (4) *pelvi-rectal*, which develops above the levator ani muscle, just outside the muscular wall of the bowel; and (5) *retrorectal*, which is similar to the last named, except that it develops in the hollow of the sacrum. As will be seen by reference to the diagram all of these abscesses have their origin in the region of the anus between the sphincters, and almost always they are the result of slight trauma, from hardened feces, perhaps combined with exposure to wet and cold. The patient complains of burning and scalding in the rectum and great pain on defecation; it pains him to sit down; and he may have retention of urine.

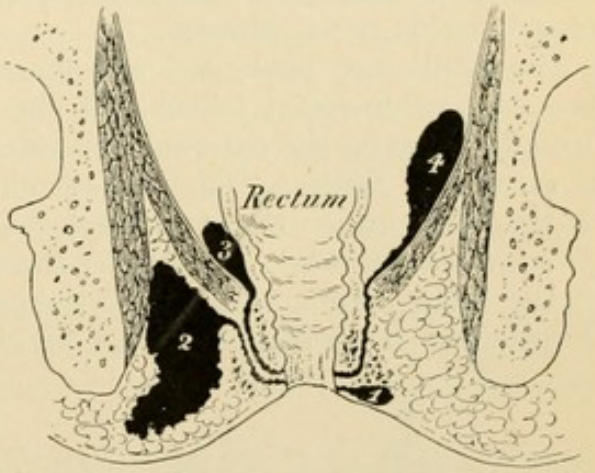

FIG. 881.—Perianal abscesses. (See text.)

Ischio-rectal Abscess is most frequently seen. Examination in the earliest stages shows merely a sense of resistance close to the sphincter ani, with extreme tenderness. Later the whole ischio-rectal region on one side may be tumefied, red, edematous, and pitting on pressure. Occasionally the abscess bursts spontaneously into the

rectum (between the external and internal sphincters) or on the surface; but usually it is so painful that surgical treatment is sought quite early. Treatment consists in opening the abscess by an incision radiating from the anus in the case of very small abscess; or by an anteroposterior incision if the abscess is large. The incision must be much longer than seems necessary, since it contracts very rapidly when the pus is discharged. The cavity is drained by a wick of gauze, and is allowed to heal by granulation. Great care in dressing is requisite to prevent damming up of pus. The affection is not usually a serious one, but I have seen a few fatal cases in alcoholics and patients otherwise unable to withstand infection. The sinus may be very slow in healing, and *fistula in ano* is a frequent result, especially if rupture into the bowel takes place.

The other forms of abscess mentioned require the same treatment, but in those which lie above the external sphincter (**submucous**) it is desirable to divide this also, as in *fistula in ano*, to secure better drainage. A **pelvi-rectal abscess** should be opened by an incision in the ischio-rectal fossa, after which the abscess is freely opened and drained by puncturing the levator ani and then dilating it by Hilton's method (p. 51).

Fistula in Ano.—The most frequent cause of a fistula about the anus is ischio-rectal abscess.

The fistula may have two openings, one on the skin surface (usually over the ischio-rectal fossa) and the other on the mucous surface (usually between the external and internal sphincters); this is known as a *complete fistula*. Only one opening may exist, and this may be on the skin surface (*blind external fistula*), or on the mucous surface (*blind internal fistula*). Sometimes there are two or more skin openings to the same fistula, which may then resemble a horseshoe in form. Occasionally several independent fistulæ exist.

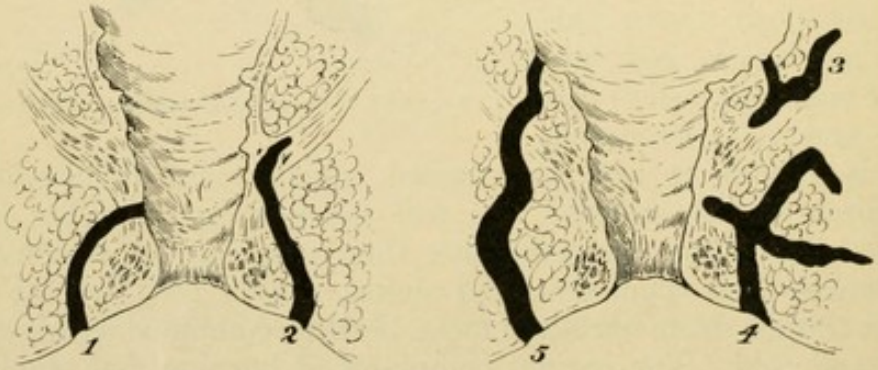

FIG. 882.—Fistulæ in ano: 1, complete fistula (usual form); 2, blind external fistula (usual form); 3, blind internal fistula; 4, blind external fistula with suppurating tracts; 5, complete fistula entering the bowel above the internal sphincter.

Symptoms and Diagnosis.—The patient complains of a discharge of pus, or an irritation of the skin around the anus. The external orifice of the fistula usually is easily detected when the buttocks are separated; it may be marked by a granulation or a tab of skin. The internal orifice

sometimes can be felt by a finger in the rectum as an indurated spot, or it may be made visible by means of a rectal speculum. The suppurating tract which connects the two may be very devious. If it is desired to probe the fistula without giving a general anesthetic, the finger should be introduced into the rectum before the probe is passed into the sinus. Every fistula around the anus is not a *fistula in ano;* it may be a pilo-nidal sinus (p. 266) or the opening of a cold abscess in connection with disease of the pelvic bones or vertebral column; or, more probably, a fistula resulting from a peri-urethral abscess (p. 1027).

Treatment.—If the fistula is of very recent formation, palliative treatment may be employed. Cauterization with silver nitrate or chloride of zinc, or injections of bismuth paste sometimes bring temporary relief, but permanent cure without operation is very rare. The classical operation consists in laying open the fistula from one orifice to the other, by division of the external anal sphincter. A grooved director is passed into the external opening of the fistula, is caught by a finger as it emerges in the anal canal or rectum, and its point is bent down and brought out of the anus, which is then slit up on the director as guide. In the case of external blind fistulæ the director is passed into the sinus and is made to perforate the rectal mucous membrane where this seems thinnest. A blind internal fistula may be opened up in similar manner after exposing its internal orifice. When the fistula is once laid open, the cicatricial tissue lining it is cut or scraped away, and the raw surface is packed and allowed to heal by granulation. The sphincter should be cut transversely, not obliquely to its fibres, and in not more than one place at the same operation, even if several fistulæ exist, for fear of producing incontinence of feces.

Of late years many surgeons have had much success in curing fistula in ano by formal excision of the tract followed by immediate closure by buried absorbable sutures; but the practice is not yet very common.

Some of these fistulæ are **tuberculous** in nature; usually they develop very insidiously, and usually a tuberculous focus exists elsewhere in the body. Unless the other lesions are very far advanced, tuberculous fistulæ should be treated by excision and suture, as those of simple inflammatory nature. Scraping and leaving the wound open is apt to result in recurrence.

Fissure of the Anus.—If a lump of hardened feces tears down one of the anal valves, the trauma is very apt to result in an indolent ulcer, lying in the grasp of the external sphincter. The ulcer is placed longitudinally in the anal canal, almost always at its posterior midportion, and usually extends on to the skin surface. Almost unbearable burning pain at the anus, after every act of defecation, and lasting for an hour or more, is a highly characteristic symptom; and inspection of the anus confirms the diagnosis. Digital examination of the anal canal should not be made until the surgeon is ready to treat the lesion. Very occasionally a recently formed fissure can be made to heal by

cauterization, application of a stimulating ointment, and scrupulous cleanliness; but in most cases operation is required. This consists in division of the sphincter through the base of the ulcer, under a general anesthetic. Healing is then prompt under ordinary dressings.

Hemorrhoids or Piles.—A varicose condition of the rectal veins is a very frequent affection. The *inferior hemorrhoidal veins* drain into the internal pudic; the *middle hemorrhoidals* into the internal iliac or one of its branches; while the *superior hemorrhoidals* are tributaries of the portal system through the inferior mesenteric vein. These veins lie beneath the mucosa in loose areolar tissue, possess no valves, and are therefore especially subject to the effects of gravity; there are free anastomoses between the superior and the middle and inferior hemorrhoidal veins, so that dilatation of one set is quickly succeeded by dilatation of the others. In addition to the effect of gravity, which is always acting, these veins are liable to distention from the pressure of the contents of the rectum and sigmoid, from disturbances in the portal circulation (which occur during every period of digestion, and which pathological states frequently render constant), and from pressure on the pelvic veins in cases of ovarian, uterine, or prostatic disease. Straining in urination (as from stricture) as well as that due to chronic constipation, is a frequent cause.

Hemorrhoids are classed as *internal* (which are covered with mucous membrane) and *external* (covered by skin), or as *intero-external*, according to their relation to the sphincters. Hemorrhoids are further classed as *bleeding*, *inflamed*, *thrombosed*, etc., terms which sufficiently explain themselves.

The affection is commonest in adults, but is not very rare in the young and the aged. **External piles** appear as protrusions of small size, close around the anus; they are covered with normal skin, unless inflamed, when they become purplish or red, swollen and very tender. Suppuration may occur, and clotting of the contained blood is not very unusual; in this way a phlebolith may develop. The skin around the anus may become much macerated, and at first glance the condition may be mistaken for mucous patches; but the latter usually are not the only signs of syphilis present, and frequently occur elsewhere as well as around the anus. **Internal piles** are arranged in a circle just within the sphincters; occasionally some are found higher up. They are bluish-black protrusions beneath the mucous membrane, and are easily compressible unless partly organized or thrombosed from repeated attacks of inflammation. The piles become worse when the patient is constipated, and may protrude only when he strains at stool or may come down on the slightest effort (Fig. 883), leading eventually to prolapse of the rectum. There is a sense of fulness and discomfort in the rectum almost all the time, and during a "fit of the piles," when these structures become inflamed, the pain may be almost unendurable and may radiate in various directions. Free bleeding from the dilated veins usually brings relief, and is a rather frequent occurrence, especially at the end of a bowel movement. The

blood is bright red, and appears spread over the fecal masses, not mingled with them, as is blood which comes from higher up in the intestinal tract, and which is apt to be brown and clotted before it is passed.

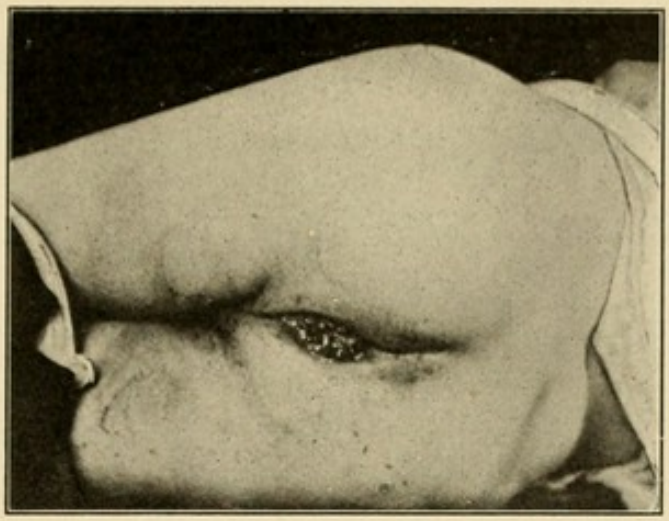

FIG. 883.—Internal hemorrhoids, protruding and bleeding. Episcopal Hospital.

Treatment.—Any cause which can be discovered should be removed if possible. In mild cases it is sufficient to attend to the state of the bowels, procuring at least two free and soft motions daily by means of dieting and mild laxatives, such as salines in the morning, senna, rhubarb, etc. Active purges have little therapeutic effect though they may be required to unload the rectum. Scrupulous cleanliness must be preserved by irrigation or injections of cold water; protruding piles should be pushed back after defecation; and some astringent ointment (as one of equal parts of gall and stramonium ointment, U. S. P.) may be applied to the anus. Should inflammation occur, the patient should be confined to bed, with the pelvis slightly elevated; and an ice bag or dry hot cloths may be applied locally. Moist heat should be avoided. Much relief may be secured by the administration of the following: ℞—*Ext. rhamni pursh. fl.*, f℥ss; *ext. ergot. fl.*, f℥j; *ext. hamamelis fl.*, f℥iss.—M. S.—*Teaspoonful in water three or four times daily.* Sometimes suppositories of opium, with acetate of lead or tannic acid, prove useful. If thrombosis occurs and the pile is excessively painful, it may be punctured and the clot evacuated. Usually it is best to postpone more formal operative treatment until the inflammation has subsided. Some surgeons employ palliative operations, especially the injection of carbolic acid into the base of each of the piles (one or two at each sitting) which are thus thrombosed and may eventually shrivel up. I have no experience with this method myself, but believe that as commonly employed it is neither efficient nor entirely safe. Wallis prefers a 10 per cent. solution of carbolic acid in glycerin and water; 3 to 8 minims are injected into the pile, according to its size. He found his patients secured temporary relief.

Several radical operations are in common use for cases of hemorrhoids, the chief of which are **ligation, clamp and cautery operation**

and **excision.** For the average operator there is no doubt that the first of these is the method of choice both for safety and for certainty of cure. For internal hemorrhoids I think it is preferable to cauterization, though the latter is widely employed for these as well as for external piles. Excision, the most radical of all, is a more formidable operation, and though sufficiently simple to a skilled operator, entails more risk to the patient.

Ligation of Hemorrhoids.—The anus is dilated as described at p. 900, and each pile mass is caught in suitable forceps. Hemostatic forceps are not efficient, as they usually tear loose. The Allis forceps or a special ring forceps may be used. Unless all the piles are clamped in this way at one time, there will be danger of dislodging the ligatures already placed while the remaining piles are being sought for. If there is any pile which has a cutaneous margin (intero-external hemorrhoid) a groove should be cut around its base through the skin with scissors; this prevents the ligature from slipping, and by severing the skin nerves reduces the discomfort after operation. A groove may be cut also in the mucous membrane, all around the base of the pile, exposing its pedicle, but this is not necessary. Then a curved needle carrying a long, stout, linen thread is made to transfix the base of the pile, in the long axis of the rectum; the loop of the thread is cut and the pile is ligated in two sections, the ligatures interlocking and being tied in the groove already out. The protruding portion of the hemorrhoid is then cut away leaving enough stump to prevent slipping of the ligature. The ends of the latter should be left long until it has been ascertained that no bleeding occurs. Each pile mass (usually there are not more than five) is treated in the same way. Finally the surfaces of the amputated piles are dusted with iodoform powder, and a sterile pad is applied to the anus and held in place by a T-bandage. Usually the bowels move spontaneously by the fourth day. If they do not they should be opened by a dose of castor oil. An enema should not be given. Particular attention to local cleanliness and efficient drying should be enforced for two weeks; usually the patient may leave bed in a week or ten days after operation.

Clamp and Cautery for Hemorrhoids.—After dilating the sphincter and grasping all the piles in suitable forceps as already advised a special pile clamp is applied to one of the masses, in the long axis of the bowel, and is screwed so tight as to crush the base of the pile. The protruding tissue is cut away, and the stump in the grasp of the pile-clamp is cauterized with the cautery at a dull (cherry) red heat. Though the pile-clamp usually has its under surface faced with ivory, to prevent radiation of the heat to the surrounding tissues, it is well as an additional safeguard to surround it with damp cloths while the cautery is in use. Each pile mass in turn is treated in similar fashion, and subsequent treatment is conducted as already described.

Excision of Hemorrhoids (Whitehead, 1882).—An incision is made in a circle around the muco-cutaneous juncture of the anus, and the mucous membrane including the pile-bearing tissue is dissected

upward with snips of the scissors and gauze pressure, until healthy mucous membrane is reached on all sides. The diseased cuff of mucous membrane is then excised, and the mucous membrane above is united to the skin below by a continuous suture of chromic catgut. If properly done there is very little hemorrhage, as the varicose veins themselves are not opened; and there is little chance of stricture resulting unless infection occurs. Frequently the mucous membrane and skin separate slightly at one or more points, but this does not occur until granulation tissue has formed.

Prolapse of the Rectum.—This develops as the result of repeated straining efforts, as in cases of hemorrhoids with constipation or in severe diarrhea with rectal tenesmus, or sometimes as the result of whooping cough. The loose mucous membrane protrudes from the anus at first only during defecation, and may recede spontaneously when the patient stands up. Later, however, the bowel may protrude at other times and may require to be replaced manually. Occasionally reposition becomes impossible; in such cases usually the muscular wall of the rectum has prolapsed also (*procidentia recti*).

The condition is most common in young children, but occurs also in adults, and sometimes during old age when it often seems to depend on loss of muscular tone. In every such case examination should be made to exclude the presence of polypus, stricture, or carcinoma higher up in the bowel.

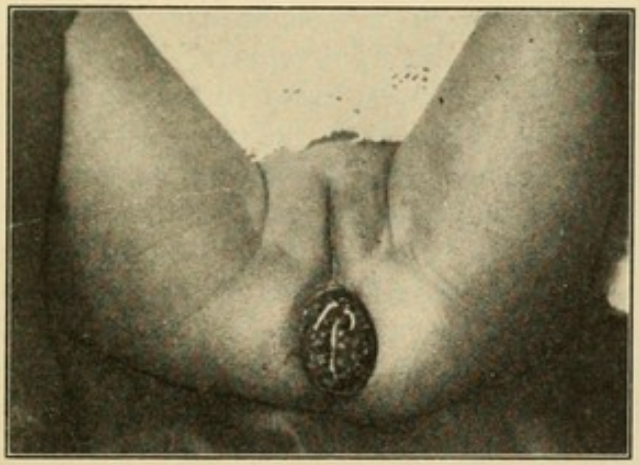

FIG. 884.—Prolapse of rectum. Children's Hospital.

Symptoms.—In the ordinary form (*prolapsus recti* or partial prolapse) the mucous membrane of the rectum is seen protruding from the anus as a red or purplish ring. Usually the condition is unmistakable (Fig. 884). In complete prolapse (*procidentia*) the protrusion may be several inches in depth, and there is a clearly recognized groove between the mucous membrane and the anus. Prolapse causes a sense of weight and weakness, and often some disturbance of the urinary functions. Strangulation is rare, but is seen occasionally at the first onset of the prolapse; when the condition becomes chronic the sphincters are much relaxed.

Treatment.—Reduction usually may be secured by moderate pressure with an oiled cloth or the gloved hand, while the patient is lying prone. In cases of strangulation it may be necessary to divide the sphincter. Recurrence often may be avoided by having the bowels opened only when the patient is lying down flat on his back. Moreover, the buttocks should be strapped together by adhesive plaster, which is removed only after the bowels have acted, and is at once replaced when the parts have been cleansed. In the case of most children, in whom the condition is not of very long standing, a cure results if the child is kept in bed with proper regulation of diet and bowels. Cod-liver oil is valuable as a tonic for these purposes. If operation is required trial should first be made of cauterization as in the case of hemorrhoids, clamping, excising, and cauterizing longitudinal folds of mucous membrane down to within a half inch of the anal margin. Or Whitehead's operation may be done. In *Gersuny's operation* (1893) the anal canal is dissected free of all attachments and is twisted on itself until a feeling of resistance is encountered and then is sutured in its new position.[1] In *Schomacker's operation* a part of each gluteus maximus is transplanted around the anus, one in front and one behind; the muscular flaps are then sutured to each other. *Mummery's operation* (1910) consists in opening the space between the rectum and sacrum by a transverse incision, packing it full of gauze, and allowing it to heal by granulation. The patient should remain in bed for a month. Mummery had complete success with this method in four cases of severe procidentia. After recovery the posterior rectal wall is firmly attached to the hollow of the sacrum by fibrous tissue. Sutures were used (instead of gauze packing) by Verneuil (1889), Fowler (1897), and recently by Ekehorn (1909). *Sigmoidopexy*, or suspension of the sigmoid to the anterior abdominal wall, first employed in 1889 by Verneuil, is the most radical of these operations for procidentia; but it is wise to combine it with a plastic operation below, as recurrence has taken place in more than half the cases treated by sigmoidopexy alone (Pachinio, 1905). Jeannel's operation included also the formation of a false anus.

Proctitis.—Inflammation of the rectum may be *traumatic* (from impaction of feces, frequent use of enemas, foreign bodies, etc.) or *infectious* (dysenteric, septic, gonococcic, etc.). The **symptoms** are a sense of heat, tenesmus, frequent, small, watery stools, often with blood and mucus. There may be considerable fever and much constitutional disturbance. Examination through a speculum shows inflamed mucous membrane, and frequently patches of lymph covering ulcers which bleed readily when touched. **Treatment** involves removal of the cause when this is possible and known; also cleansing and antiseptic applications through a speculum. After an ordinary cleansing

[1] Chetwood (1902) employs a similar operation for fecal incontinence; and it was for this purpose that Gersuny's operation was originally devised, based on his experience (1889) with enuresis.

enema, in severe cases, the patient may be etherized, and a 2 per cent. solution of silver nitrate swabbed all over the inflamed surfaces, through a speculum. Then the rectum is irrigated with boric acid solution (half saturated), and finally an injection is given of a few ounces of some demulcent solution (flaxseed or slippery elm), containing 10 drops of laudanum (Abbe); this is to be retained as long as possible. In most cases two or three such treatments at intervals of a few days arrest the disease. But in cases where colitis also exists (dysenteric, tuberculous), recurrence is the rule unless the ulcers above can be made to heal by appropriate treatment (p. 896).

Strictures of the Rectum.—These are a frequent result of dysenteric ulceration and of trauma in childbirth (Fig. 865). Malignant ulceration causing obstruction is considered under the heading Tumors of the Rectum (p. 913). Inflammatory changes in neighboring structures (vagina, broad ligaments of uterus, pelvic connective tissue, prostate, etc.) frequently extend to the fibrous tissue in the layers of the rectal wall and they may cause a *submucous* or *perirectal* stricture which is the same in its effects as one which arises in ulceration of the mucous membrane, since no ulceration of the mucous membrane which does not involve the fibrous tissue can produce a stricture. Other causes than those already mentioned are rare, though tuberculous and syphilitic and other specific ulcerations and strictures do occur. Syphilitic stricture, formerly considered frequent, is now acknowledged to be quite rare. When these specific ulcerations occur their pathology is much the same as that of septic or traumatic ulceration, since secondary infection from the intestinal contents is the rule.

Almost all strictures occur within three or four inches of the anus; those which occur higher, in the sigmoid or colon produce the symptoms of chronic intestinal obstruction (p. 889). The stricture may be single or multiple, marginal or annular, of large or small calibre. The simple inflammatory stricture, according to Tuttle, usually occupies only a portion of the circumference of the bowel, stands out abruptly from the rectal wall, usually is close to the anus, and has a smooth surface covered with epithelium. A syphilitic stricture presents a gradual funnel-shaped contraction, there is a bluish-white cicatrix around the edges of the ulcer, and the floor of the ulcer is excavated; the edges of a tuberculous ulceration always are undermined and its base is elevated (Tuttle). Secondary ulceration, from fecal impaction, occurs above the stricture, so that when these patients come for treatment the rectum almost always is ulcerated as well as strictured, though the ulcers which were the original cause of the stricture may have healed long since.

Symptoms.—These may not develop for years after the proctitis which is the original cause of the stricture. The patient may come complaining of frequency of urination with a sense of weight in the perineum, and the importance of thorough local examination cannot be too often emphasized. There is a history of the primary rectal condition, followed by a latent period, and then gradually developing

but steadily increasing difficulty in obtaining complete evacuation of the rectum. As secondary ulceration develops, blood and mucus are discharged with the stools, or frequently alone, the stricture retaining the fecal mass above it. The diagnosis of simple from malignant stricture is made by observing the long duration of the simple stricture and the comparatively slight impairment of the general health; and by direct examination of the rectum, when the smooth, hard, but not nodular character of the stricture determines it to be non-malignant. Malignant stricture is very rare before thirty-five or forty years of age; its course is rapid and progressive (two to three years); loss of flesh and strength appears early; the tumor is nodular to the touch and bulges into the lumen of the bowel as well as causes fibrous thickening of its coats; and the odor of the discharge is gangrenous, never simply fecal (Tuttle).

Treatment.—Permanent cure cannot be hoped for from *palliative treatment* with rectal bougies; they are of benefit even temporarily only when the stricture is of recent formation; they must be passed at intervals throughout the patient's life; and in many cases serve only to aggravate the patient's discomfort by producing bleeding and further ulceration, even if skilfully and gently passed. An ordinary wax candle, molded by heat to suitable shape, makes as good a bougie as any, provided the stricture is not very small and is close to the anus. In other cases it is best to use the hollow bougie of Wales, which is introduced through a speculum passed up to the face of the stricture, and by means of which irrigation may be practised above the stricture. Before *operative treatment* is undertaken it is important to cleanse the bowel above the stricture. If this cannot be accomplished from below (by repeated enemas or colonic irrigations through a Wales's bougie, aided by the use of olive oil or gentle saline purges by mouth), it is necessary to do colostomy (sigmoidostomy). After the entire fecal current has been diverted in this manner, and the lower segment of the bowel thoroughly evacuated and brought into a healthy state by irrigations, direct treatment of the strictures may then be attempted. *Posterior proctotomy* (Verneuil), or incision of the posterior rectal wall, including the sphincters and everything down to the bone, is not to be recommended unless the stricture is close to the anus; but it is a good operation in cases where septic proctitis accompanies stricture, as it secures free drainage and relieves the acute symptoms though it does not produce a cure. The hemorrhage is not alarming and may be controlled by packing gauze around a large rectal tube. It is necessary to continue the passage of bougies subsequently for an indefinite period. In the case of a single high stricture it may be possible to perform *sigmoido-proctostomy*, making an anastomosis by the Murphy button between the sigmoid and the rectum below the stricture; the spur between the strictured and the anastomotic opening may be removed later by Dupuytren's enterotome. In the worst cases of stricture formal *excision of the rectum*, as for malignant disease, is the most satisfactory treatment.

Recto-urinary and Recto-genital Fistulæ.—Formerly these were frequent results of difficult parturition, following the separation of sloughs caused by pressure of the fetal head or by instruments; but owing to improvements in the obstetric art they are now comparatively rare. Occasionally they result from operative injury, or from the rupture of an abscess into both the intestinal and genito-urinary tract, or as the result of specific or malignant ulceration. The fistula may connect the intestinal tract with the bladder or urethra (*recto-vesical* and *recto-urethral fistulæ*) or with the vagina (*recto-vaginal*), rarely the uterus (*recto-uterine fistula*). Vesico-vaginal and vesico-uterine fistulæ are results of similar causes and require similar treatment, though the intestinal tract is not involved. The **diagnosis** is made by observing the discharge of urine or feces (sometimes only of flatus) through an abnormal channel, and by direct examination with sound or endoscopic instrument (cystoscope, proctoscope) in the bladder or rectum. The only satisfactory **treatment** is by operation, which consists essentially in dissecting up the borders of the fistula and closing the opening in the wall of each viscus involved, by means of separate sutures. In the rare cases of recto-uterine or vesico-uterine fistulæ hysterectomy may be necessary (Chapter XXIX).

Tumors of the Rectum and Sigmoid.—*Benign tumors* are comparatively rare. *Adenoma* is the least unusual. It occurs most often in children in the form of *rectal polypus*, and presents symptoms similar to those of hemorrhoids, for which or for prolapsus it is often mistaken. Usually when the child strains the polypus comes down in reach of the examining finger, or it may prolapse through the anus. Treatment consists in excision after transfixion and ligation of its base. In adults adenoma and papilloma are quite rare growths, and usually are pre-carcinomatous in nature. The tumor is rather soft, seldom is ulcerated, and is freely movable on the underlying rectal wall. It should be freely excised. In the disease known as *multiple adenoma* the entire colon may be invaded by small polypoid growths, though usually the rectum is the part most involved. The symptoms are persistent bloody diarrhea, with tenesmus, and gradual loss of flesh and strength. If removal of the numerous rectal growths is followed by their persistent recurrence, or if there is a suspicion of malignancy excision of the rectum should be done; or if the entire colon is diseased a false anus may be established in the cecum.

Carcinoma.—Carcinoma is the most frequent tumor of the rectum. It occurs (1) *at the anus* (squamous-celled carcinoma), which is rare; (2) *just above the sphincters* (adeno-carcinoma, often encephaloid), which is not unusual; or (3) *above the reach of the examining finger* in the upper rectum or pelvic colon, at the level of the promontory of the sacrum (adeno-carcinoma, often scirrhus); in this latter situation about two-thirds of rectal cancers are found. The rectum frequently is invaded by carcinoma originating elsewhere (prostate, cervix uteri). Anal carcinoma causes secondary invasion of the inguinal lymphatics, and clinically resembles epithelioma of the lower lip. True rectal

carcinoma extends in the submucous tissues of the rectal wall rather than directly through it to neighboring structures; and invades the lymph nodes in the hollow of the sacrum, but seldom higher than the promontory of the sacrum. Except in the more highly malignant forms, death is more apt to occur from intestinal obstruction than from local extension or metastasis.

Symptoms.—The symptoms are hemorrhage (especially in younger patients), alternating diarrhea and constipation, and eventually loss of weight and foul discharge with highly characteristic odor. These symptoms, however, may not appear for months after the development of the tumor, particularly if the latter is high in the rectum. Often the growth is found absolutely inoperable when no symptoms of note have ever existed.

Diagnosis.—Diagnosis is not difficult at the stage when most patients consult a surgeon. The tumor is irregular in outline, nodular, with raised margins and ulcerated centre; and it is fixed to the bowel wall if not to the surrounding structures. If any doubt exists, a piece should be excised from the base, for microscopical study. If the growth is too high to be accessible for diagnosis from below, laparotomy should be done.

Treatment.—The first question to decide is whether or not radical operation can be done, and, if this is impossible, whether the establishment of a false anus will promote the patient's comfort. *The growth may be considered inoperable* (1) when the patient's condition forbids an operation with a mortality varying from 10 to 50 per cent.; (2) when the growth is found to be fixed even when examined under anesthesia; or (3) when distinct metastases exist. In such cases *palliative treatment* aims to reduce the amount of fecal discharge and decrease its irritating qualities by attention to diet and administration of intestinal antiseptics; to secure free evacuation of the bowels by gentle purging and by enemas administered if possible by a tube passed above the growth; by local treatment of the ulcerating area by irrigation with permanganate or creolin solution; and finally to keep the patient as comfortable as possible by administering plenty of opium. In rare instances advantage is to be derived from scraping and cauterizing the surface of a cauliflower-like growth. If acute obstruction occurs (it is rare except in carcinoma of the sigmoid) a false anus should be established in the sigmoid, or if the obstruction has existed very long, in the cecum, where the gut is healthier. Unless obstruction is present or death only a matter of a few months, many patients will prefer to suffer rather than be relieved at the expense of an iliac anus; but if the latter is properly constructured and cared for, it produces very little disability, and relieves the patient of untold discomfort by producing latency of rectal symptoms.

Formation of a False Anus.—Through a left-sided McBurney incision a loop of sigmoid is drawn out, and its afferent limb drawn taut. If this precaution is neglected prolapse of the descending colon may occur through the false anus. Then the afferent and efferent

loops are stitched together along their mesenteric borders, for a distance of about six inches, so as to form an efficient spur. The loop of bowel is then replaced and sutured in the abdominal wound at the level of the mesentery (Fig. 885). If the operation is done for acute obstruction a Paul's tube should be fixed in the proximal loop immediately. Otherwise it is not necessary to open the gut for several days; the opening is then accomplished by a transverse incision. Subsequent treatment involves occasional irrigation of the rectal loop through the false anus, to clear it of discharges (which are much diminished after diversion of the feces from the ulcerating area), and regular daily irrigation of the colon through the upper opening. If the colon is thoroughly flushed out every morning, by a pint or more of warm water, and if this injection is retained for about twenty minutes, free evacuation of the bowel is secured by turning face downward and exerting pressure over the cecum. "The patient is then quite comfortable and clean for the rest of the day" (Wallis).

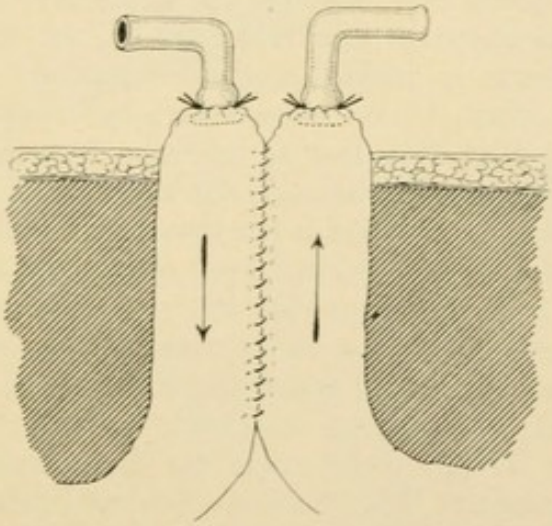

FIG. 885.—Establishment of a permanent false anus by suturing the afferent and efferent loops together "en canon de fusil." A Paul's tube has been tied in each end.

RADICAL OPERATION.—About a week is required to get the intestinal tract in proper shape for operation, and commencing the night before large doses of deodorized tincture of opium should be given (Tuttle). In cases of acute obstruction, or if the sphincters will have to be removed, a preliminary colostomy (as above described) should have been done about two weeks before radical operation. Opportunity should also be taken, when the abdomen is opened, to palpate the liver for metastatic growths.

1. *Where the growth invades the sphincters,* these and the rectum as high as the sacral promontory are removed; and the pelvic end of the rectum is closed and allowed to drain through the previously established iliac anus. The perineal wound is completely closed, with drainage to the hollow of the sacrum. The inguinal lymphatics should be extirpated also.

2. *For a growth just above the anus,* in which the sphincters can be preserved, I think the perineal operation as modified by Peck (1909) should be done: The anus is closed by a purse-string suture; then an incision is made from coccyx to rectum and is carried forward on each side of the anus in Y-shape. The coccyx may be excised, but further removal of bone from the sacrum (Kraske, 1885) does not materially facilitate the operation. Both of the levator ani muscles are cut just above the anus; the rectum is separated all around its circumference and is doubly ligated, below the growth, divided between the (linen) ligatures and the cut surfaces are seared with the actual cautery. The peritoneum is then opened, the rectum is freed anteriorly from bladder and prostate, as well as laterally and posteriorly, and is drawn down until an area well above the growth is exposed. It is here again doubly ligated, divided and cauterized, and the tumor is removed. The occluding suture is then removed from the anus, the sphincter is split posteriorly, and the anal mucous membrane is excised. The proximal segment of bowel, still closed by ligature, is then drawn down until it projects well beyond the sphincter, which is sutured around it. The peritoneum and levatores ani are then repaired, the hollow of the sacrum is drained, and the unopened bowel is left protruding from the anus. When several days have passed, and granulation has begun, so that little fear of infection remains, the redundant bowel (perhaps sloughing in parts) is cut away, and fecal discharge is allowed. Fair sphincter control is preserved; the immediate mortality of such an operation is from 10 to 20 per cent.; and from 20 to 60 per cent. of patients pass the three-year interval without recurrence.

3. *For high rectal carcinoma* (all tumors above easy reach of the finger), a combined abdominal and perineal extirpation is the accepted procedure, though the primary mortality even in skilled hands is very high (25 to 50 per cent.), and the permanent cures average only about 16 per cent. This method was first introduced by Maunsell, and has been popularized in France by Quénu and Hartmann (1897), and in this country by Tuttle and the Mayos. I believe Weir's modification (1901) of the method, in which the sphincter is preserved, is better than the plan of Quénu in which the entire rectum is removed and an iliac anus established, though the latter is the method preferred by Tuttle and Mayo. The surgeon commences by opening the abdomen in the mid-line and examining the parts. If the tumor is high enough in the sigmoid an ordinary intestinal resection may be done, with end-to-end union, or where possible by lateral anastomosis, which is safer. If the tumor is too low to make this possible, the sigmoid is divided a safe distance (6 inches) above the growth, both ends being closed at once by suture. The meso-rectum is then divided, and, after ligation of the superior hemorrhoidal artery, the rectum and fatty and lymphatic tissue behind it can be stripped off the sacrum quickly, and with very little hemorrhage (Fig. 886). The rectum is then doubly clamped below the growth, divided, cauterized, and the diseased bowel removed. Next the sigmoid and perhaps the descending colon must

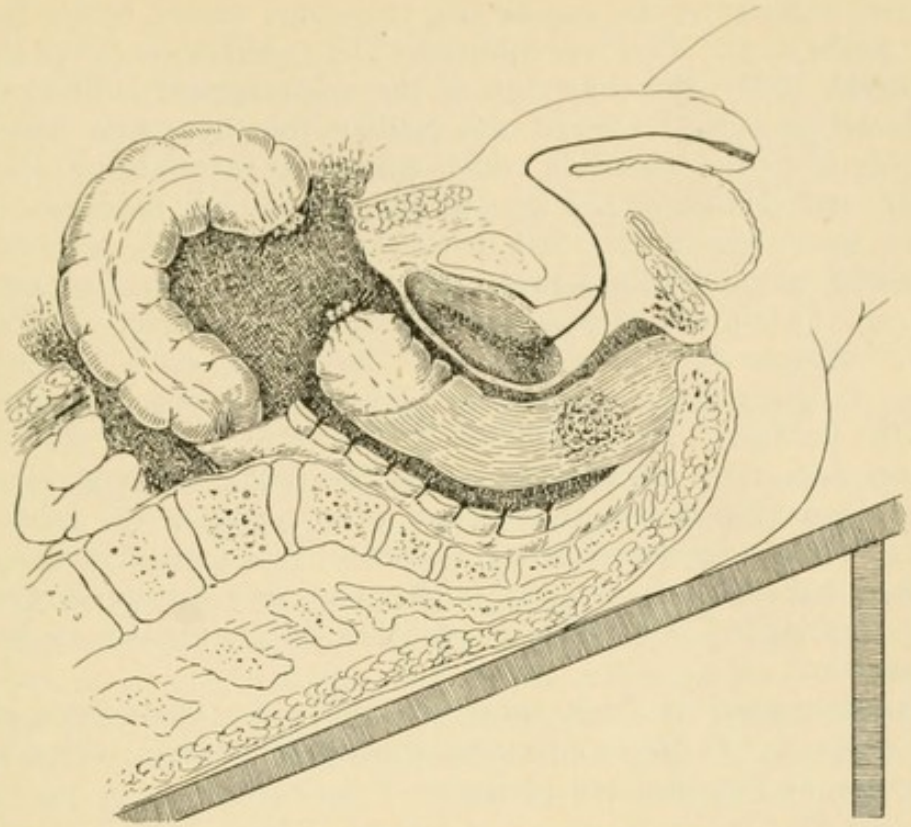

FIG. 886.—Abdomino-anal operation for carcinoma of the rectum: the sigmoid has been divided and both ends closed: the rectum has been freed from the hollow of the sacrum.

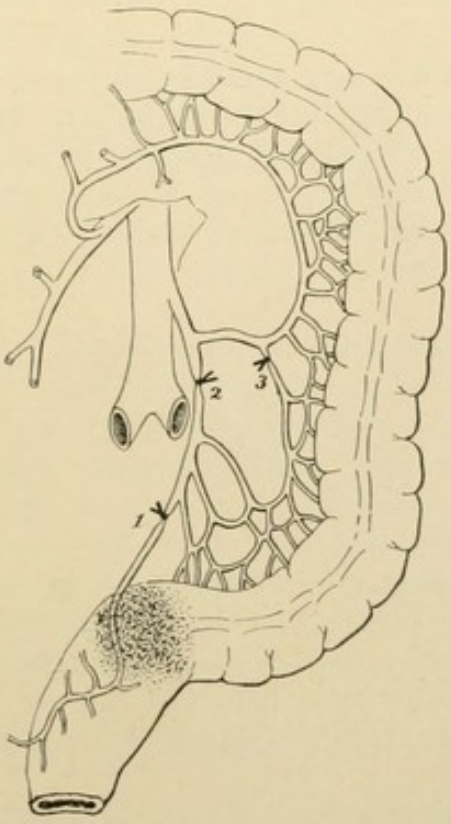

FIG. 887.—Blood-supply of the pelvic colon and rectum: 1, ligature on the superior hemorrhoidal artery; 2, ligature on the inferior mesenteric; 3, ligature on a descending branch of the left colic artery.

be freed sufficiently to enable the remaining bowel to be brought down to the anus. This is accomplished by *mobilization* of the sigmoid (P. Duval, 1902): the outer leaf of the meso-sigmoid is divided, and the bowel is turned toward the median line by gauze dissection, restoring it to the condition which existed in intra-uterine life. By ligation and section of the sigmoid arteries, and if necessary of the inferior mesenteric itself, close to the root of the meso-sigmoid (Fig. 887) sufficient circulation is preserved through the loops of communication from the left colic or even from the middle colic artery (Archibald, 1908). Ample slack of sigmoid and descending colon having been secured in this manner, an assistant introduces forceps into the anus from the perineum, and evaginates the lower segment of the rectum; next he pulls down through its lumen the upper segment (sigmoid). The abdominal wound is then closed, after repair of the pelvic peritoneum. The evaginated rectum and sigmoid are then securely sutured together, and are finally replaced in the pelvis by reducing the evagination. Drainage of the pelvis is provided by an incision in front of the coccyx.

If an iliac anus has been made previously, for obstruction or any other reason, it is better to excise the entire rectum, including the sphincters, and to close the perineum.

CHAPTER XXIV.

SURGERY OF THE GALL-BLADDER, LIVER, PANCREAS, AND SPLEEN.

SURGERY OF THE GALL-BLADDER AND BILE-DUCTS.

Infections of the Gall-bladder and Bile-ducts.—It has been shown by Adami and others that bacteria are constantly being transmitted from the intestinal tract through the *portal circulation* to the liver. The liver is endowed with antibacterial and antitoxic properties, and under normal conditions the bacteria received in the way described are destroyed in the liver. But if the virulence of the bacteria is increased, or the destructive action of the liver lessened, then such bacteria are excreted from the liver with the bile. The gall-bladder is a suitable place for bacteria to multiply, both from its anatomy, and from certain characteristics which are easily acquired. The bile tends to stagnate in the gall-bladder because of the tortuosity of the cystic duct, because the fundus of the gall-bladder is lower than its outlet, and above all because persons of sedentary habits and those who wear tight corsets do not aid the expulsion of bile from the gall-bladder by active exercise of the diaphragm and abdominal muscles. It is possible also, and not very infrequent, for the gall-bladder to be infected by way of the *systemic circulation*, through the cystic artery. This is probably the case in typhoid fever, in which disease the infecting bacillus usually can be obtained in pure culture from the gall-bladder. An infection by way of the *common bile-duct*, ascending from the duodenum is rare.

If the infection which reaches the gall-bladder either through its contained bile, or through the blood-stream, is very severe, the resulting changes in the gall-bladder are acute in type. The pathology of acute inflammation of the gall-bladder (*cholecystitis*) corresponds to that already discussed in connection with the appendix. The walls of the gall-bladder are the seat of round-celled infiltration (*phlegmonous inflammation*) and this may lead to gangrene or to perforation of the organ. If the infection which reaches the gall-bladder is very mild, a slight catarrhal inflammation occurs, and the interaction of the cholesterin set free in this way with the salts contained in the bile results in the formation of concretions known as gall-stones or biliary calculi.

Cholecystitis.—The pathogenesis of this condition has been described It is rare except as a complication of gall-stone disease (*cholelithiasis*, p. 922). Swelling of the spiral folds of mucous membrane lining the

cystic duct converts the gall-bladder into a closed cavity, and the virulence of the infection is thus increased. If suppuration occurs within the gall-bladder the condition is described as **empyema** of the gall-bladder. If inflammation spreads to the surrounding peritoneal structures, **pericholecystitis** is said to exist. Even if the disease is arrested before gangrene or perforation occurs a return to normal does not ensue; pericholecystitis leaves as a legacy pericholecystic adhesions which bind the gall-bladder to the duodenum, pylorus, or omentum, and which may cause kinking of the bile-ducts; while changes in the wall of the gall-bladder and in the cystic duct impair still more its drainage facilities, and stricture or occlusion of the cystic duct may convert the gall-bladder into a permanently closed cavity with contents of very low infectious power, a condition described as **hydrops** of the gall-bladder. **Chronic cholecystitis** may occur as a sequel of an acute attack, or if the infection is mild the cholecystitis may be chronic from the beginning. It is very rare except in cases of cholelithiasis.

Symptoms of Acute Cholecystitis.—The patient usually is an adult in early middle life. The affection is rare before thirty years of age, and not very frequent in those over forty years, unless previous attacks have occurred. The attack usually begins with *biliary colic* (p. 924) which may be mild or severe. It is a mistake to suppose that biliary colic occurs only when gall-stones are present; as in the case of the appendix, the intestine, and the kidney, the colic is a sign of disordered and violent peristalsis in an effort of the organ to empty itself against resistance. The resistance may be formed by a gall-stone impacted in the neck of the gall-bladder or in one of the ducts, but it often is formed by inflammatory occlusion of the cystic duct, or by an exceedingly viscid and tarry state of the bile which is a frequent condition in the stagnant gall-bladder. In many cases of cholecystitis the pain is not very severe at first, and is felt in the epigastrium, or is diffused through the abdomen; soon, however, it settles to the gall-bladder region, to the right of the epigastrium or in the right hypochondrium. Sometimes referred pain is felt in the right shoulder, under the scapula, or in the right iliac fossa. If the gall-bladder lies low in the abdomen the attack may be confused with appendicitis. *Nausea and vomiting* usually occur, but may be entirely absent. *Muscular rigidity* and *tenderness* over the site of the gall-bladder are constant and very valuable signs. The *gall-bladder becomes enlarged* and usually can be outlined by percussion, and if rigidity and tenderness are not very great, it may be palpable as a smooth rounded tumor beneath the costal margin *continuous with the liver dulness* and *moving in respiration* unless fixed by adhesions from previous disease. *Jaundice* does not occur in uncomplicated cases of cholecystitis; it implies involvement of the common or hepatic ducts. There usually is *fever*, but the temperature seldom is very high; there is polynuclear leukocytosis. If there is much constitutional reaction, and if the elevation of temperature continues for several days and is high, *empyema* or

threatening gangrene should be suspected. *Perforation* into the free peritoneal cavity is very rare (Fig. 867), and is unusual even into preformed pericholecystic adhesions. It may be recognized in some cases by sudden severe pain, perhaps with symptoms of shock, fall of temperature, rise of pulse rate, and occasionally by the sudden disappearance of a gall-bladder tumor previously palpable. Unless the upper abdomen is well protected by adhesions, spreading peritonitis ensues. In the former case a pericholecystic, subphrenic or, rarely, a perinephric abscess results. Spontaneous perforation through the abdominal wall (*external biliary fistula*), or into the gastro-intestinal tract (*internal biliary fistula*) is very rare.

Diagnosis.—Acute cholecystitis must be distinguished from appendicitis (p. 852), gastric or duodenal perforation (p. 867), intestinal obstruction (p. 886), and acute pancreatitis (p. 945). In most cases the correct diagnosis is easy, owing to localization of the signs and symptoms to the gall-bladder region, and the recognition of the enlarged gall-bladder.

Treatment.—The patient should be treated by rest in bed, in the semi-recumbent position; absolute prohibition of food or liquid by the mouth; hot or cold applications to the upper right quadrant of the abdomen; and proctoclysis of saline fluid or tap water. Most mild cases of cholecystitis will subside within a day or two under this treatment. If anything is taken into the stomach peristalsis is aroused, and there is danger of spreading the infection from the gall-bladder to the bile ducts or to the surrounding peritoneal structures. When all acute symptoms have been absent for a day or so, sodium phosphate in hot water may be given by mouth, and then feeding may be cautiously resumed. If the attack does not subside promptly, suggesting the probable occurrence of suppuration within the gall-bladder, the organ should be drained (*cholecystostomy*, p. 930).

Cholangeitis.—Cholangeitis, or inflammation of the bile-ducts, is rare except as a complication of gall-stone disease, or as a sequel of catarrhal gastro-duodenitis ("catarrhal jaundice"). In this condition the duodenal mucous membrane around the bile-papilla, and that in the lower end of the common duct, swell up and cause obstruction of the biliary outlet, resulting in the development of jaundice. In many of these cases it is probable that swelling of the head of the pancreas also occurs and compresses the common bile duct, which is known to transverse its substance in two out of three cases. If the attack of jaundice occurs in the young, it usually is due to gastro-duodenal catarrh; jaundice in middle aged or old patients usually is due to gall-stone disease, pancreatitis, or malignancy. In the latter conditions pain is more marked (usually it is entirely absent in catarrhal jaundice); the jaundice is of longer duration (usually it subsides in a week or ten days in cases of gastro-duodenal catarrh); it varies in intensity unless there is obstruction by a malignant growth or pancreatitis; and attacks of chills and fever are much more common than in attacks of catarrhal jaundice. **Chronic catarrhal cholangeitis** and

suppurative cholangeitis are very rare except in connection with gall-stone disease.

Treatment.—Cholangeitis due to gastro-duodenal catarrh subsides promptly under appropriate medical treatment. In other cases the treatment is that of the causative condition.

Cholelithiasis.—The formation of gall-stones has already been alluded to. The chief predisposing condition is stagnation of bile in the gall-bladder. As the **stagnant gall-bladder** is more frequent in women than in men, so is the occurrence of gall-stone disease. The stagnated bile becomes viscid, ropy, and very dark in color. It invites infection, and when such infection occurs, in attenuated form, the union of cholesterin derived from the mucous membrane, with bile salts, results in the formation of concretions (**gall-stones**). **Biliary sand,** composed of minute cholesterin crystals, is found not very infrequently in such a gall-bladder, which is otherwise apparently normal. This sand clings to the mucosa of the gall-bladder and cannot be detected with the finger because so fine and so well covered by mucus; it can be seen glistening on the gauze which has wiped the gall-bladder cavity. Such a gall-bladder has been described by Moynihan as the "*Cholesterin Gall-bladder,*" and by Wilson, of the Mayo's clinique, as the "*Strawberry Gall-bladder,*" from the appearance of the minute yellow specks on the inflamed mucous membrane. It is held by Aschoff and Bacmeister (1909) that a concretion composed of pure cholesterin may be formed in the gall-bladder without the presence of bacterial infection; they teach that this stone precedes the formation of all other varieties, which may be numerous.



Fig. 888.—Radial cholesterin stone; spontaneous fracture in gall-bladder. Female, aged fifty years, with empyema of gall-bladder. Recovery. (See Fig. 889.) Episcopal Hospital.

The following varieties of gall-stones may be recognized: (1) The **pure cholesterin stone** (Figs. 888 and 889) usually is of fairly large size and oval in shape; it is soft when first formed but becomes hard and brittle on drying; is white, yellowish, or brownish black on the surface, but white and crystalline on section. It is not stratified, but is composed of radiating crystals around a comparatively soft centre, which in the dried specimen may be hollow. (2) **Laminated cholesterin stone.** Laminations indicate that secondary deposits of bile salts have occurred around the primary radial cholesterin stone. (3) **The common gall-stones,** or **mixed cholesterin calculi,** vary greatly in number and size

and usually are faceted; the surface color usually is yellowish. They are all formed at or about the same time, and are pressed into their faceted shape while still soft (Fig. 890). (4) **Mixed bilirubin-calcium stones** are less usual, generally occur singly, or in groups of three or four, on section show concentric layers of dark reddish-brown material; and on drying usually contract with the formation of fissures. (5) **Pure bilirubin-calcium stones** also occur, as do certain still rarer forms.



FIG. 889.—Cholesterin gall-stone, with polished facet at each end. Same stone as Fig. 888, after fragments had been glued together. Episcopal Hospital.

Gall-stones are the result of previous disease in the gall-bladder, and may form so silently that little indication of their presence is given until some acute infection arises, causing acute calculous cholecystitis, or cholangeitis. They are formed in the gall-bladder, not in the liver or bile ducts, and so long as they remain in a gall-bladder free from infection may produce no noteworthy symptoms. This state is described as **Simple Cholelithiasis.** But the presence of the concre-



FIG. 890.—Common gall-stones, from a gall-bladder removed for acute calculous cholecystitis, in a woman, aged thirty-seven years. Dyspepsia for years, and much belching after meals. Wakened one midnight by epigastric pain; two days later enlarged gall-bladder palpated; admitted for operation on third day; cholecystectomy; recovery. Episcopal Hospital.

tions predisposes the gall-bladder to infection, and if one or more of the calculi wander from the gall-bladder and enter the cystic or the common duct, very serious symptoms may arise. At operation these ducts are found to have been invaded by one or more calculi in nearly 40 per cent. of cases (Deaver and Ashhurst).

Simple Cholelithiasis.—This has been defined above. The gall-stones have remained quiescent in the gall-bladder since the time of their first formation, perhaps many years previously. The symp-

toms are due to a *chronic catarrhal cholecystitis,* and the pathological changes in the gall-bladder are not very marked. The bile is thick and tarry, but so long as no acute infection occurs the patients are not much troubled. But certain **symptoms** are present by which the disease may be recognized, and they can be discovered by studying carefully the history of the case. These symptoms usually are considered gastric in origin, and the patient attributes to "indigestion" fleeting attacks of pain, dull, boring, or grasping in character, which occur in the epigastrium, but which are irregular in their occurrence and are dependent on no recognized factor. Pylorospasm may occur, but vomiting is rare, as is acute pain. If slight pressure over the gall-bladder region relieves the discomfort it is probable that pericholecystic adhesions are present. In cases of simple cholelithiasis there may be tenderness over the gall-bladder, and various special points of tenderness (corresponding to McBurney's point in appendicitis) have been described, but I have not found them of practical significance. With the patient sitting and leaning forward, the surgeon may stand behind him, with one hand hooked under each costal margin at the ninth costal cartilage. If at the end of deep inspiration, which forces the gall-bladder against the finger tips, the patient experiences a sudden severe pain, it is the opinion of some that gall-stones are present. This is known as Murphy's test for cholelithiasis; I have repeatedly found it unreliable. With the patient recumbent, the right loin may be supported with the left hand, while with the finger tips of the right the gall-bladder is palpated beneath the costal margin. Sometimes at the end of deep inspiration it can be felt and if diseased usually is tender and painful. There is also very commonly a tender spot to the right of the twelfth dorsal vertebra (Boas's area).

Biliary Colic.—Biliary colic usually has occurred once or oftener before patients come to the surgeon for operation. As stated already, it may occur where no calculi are present. In the mildest cases the pain may be fleeting, and the patient may forget its occurrence unless closely questioned, especially as the earlier attacks of colic usually cause pain in the mid-epigastrium and not over the gall-bladder. In other cases, however, the initial attack is severe. A man, believing himself to be in the enjoyment of excellent health, except for slight gastric symptoms which have never incommoded him, may suddenly have a dreadful cramp in his upper abdomen; he bends forward pressing his hands or the back of a chair into his belly; breaks out in a cold sweat; becomes deathly pale and feels faint; is nauseated; and sometimes his distress is relieved by vomiting. Or he may writhe around his bed, or even on the floor in utmost agony. When the obstruction is relieved by the calculus falling back into the gall-bladder or by the cystic duct becoming patulous, pain ceases instantly. If obstruction continues pain does not vanish, but continues for hours or days, but not so intense as at first. The pain now shifts to the gall-bladder region, and may be referred to the back or shoulder through filaments of the fourth cervical nerve, from which the phrenic

is derived. When there is complete obstruction of the cystic duct, colicky pain quickly disappears.

Acute Calculous Cholecystitis is a frequent occurrence in cases of simple cholelithiasis. The symptoms do not differ from those of non-calculous cholecystitis (p. 920), and it is largely on the *recurrence* of symptoms that the diagnosis of gall-stones is based.

Migrated Gall-stones.—In many cases of cholelithiasis it is possible to determine whether the calculi remain in the gall-bladder or have escaped into the bile ducts, and especially whether or not the common duct is involved. As only a few of the calculi usually leave the gall-bladder the clinical picture may be somewhat confusing.

Stone in the Cystic Duct.—As soon as a stone enters the duct, typical gall-stone colic results and paroxysms of pain recur until the stone either passes through the duct, returns to the gall-bladder, or is arrested permanently in the duct. If in the latter case obstruction is complete, colic gradually ceases, and usually the gall-bladder becomes distended and enlarged, causing at first *empyema*, and later, if the infection becomes attenuated, *hydrops*. In many cases, however, when a stone is lodged in the cystic duct, it forms a diverticulum for itself and bile can still enter and leave the gall-bladder. *Perforation* incases of cholelithias is occurs usually at or near the origin of the cystic duct; while in non-calculous cholecystitis it occurs oftenest at the fundus of the gall-bladder.

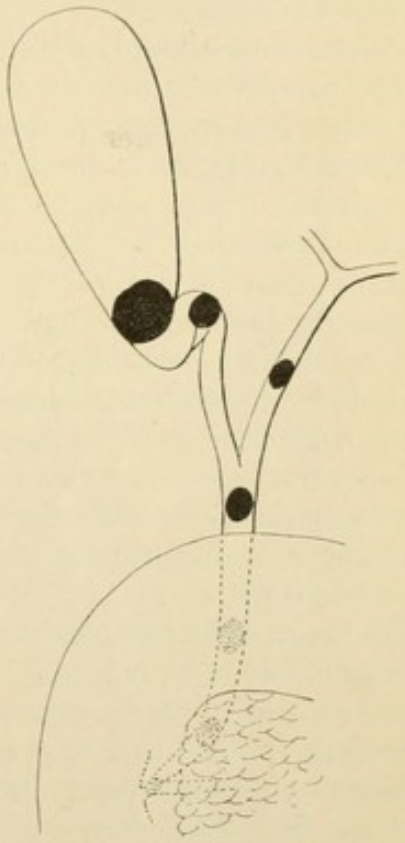

FIG. 891.—Sites of lodgement of migrated biliary calculi: in the neck of the gall-bladder; in the cystic duct; in the hepatic duct; in the common duct (supra-duodenal, retro-duodenal, or pancreatic portion), or at the papilla of Vater.

Stone in the Common Duct.—It is rare for a stone to pass completely through the choledochus. The larger stones are arrested in its supra-duodenal portion, and the smaller in its retroduodenal or in the ampulla of Vater. Complete obstruction, when it occurs, seldom lasts more than a week or ten days, the acute attack then subsiding and perhaps not recurring again for weeks or months. Each attack of colic is characterized by *jaundice*, *fever*, and *marked constitutional disturbance*. These are absent in simple biliary colic. They are due to recurrent attacks of cholangeitis, causing temporary complete occlusion of the choledochus with damming up of bile and pus, very seriously threatening the integrity of the liver, and frequently bringing

the patient to death's door. The calculus does not float around free in the bile-duct, acting as a ball-valve, as described by Fenger (1896): at operation it usually is found firmly fixed, sometimes in a diverticulum. The fever rises abruptly to 104° F. or higher, and falls again as rapidly to normal or subnormal. It is known as "Charcot's intermittent fever," and Moynihan describes the temperature record as a "steeple" chart, from its sudden variations. The jaundice also is intermittent, or at least lessens from time to time, and stercobilin is never very long absent from the feces. Persistence of jaundice, with its accompanying constitutional condition, known as **cholemia**, is a very dangerous feature, and the tendency to hemorrhage becomes very marked, owing to the prolongation in the clotting time of the blood.

When there is calculous obstruction of the common duct, the gall-bladder is found to be contracted in 80 per cent. of cases; and in 90 per cent. of cases where the gall-bladder is enlarged, the obstruction is due to causes other than stone, usually malignant disease. This is known as **Courvoisier's Law** (1890). The explanation is that the gall-bladder has been diseased so long before the stones migrate into the common duct, and has become so contracted and thickened as a result of disease, that it can no longer dilate under the influence of back pressure.

Stone in the Hepatic Duct.—Calculi are found in the hepatic duct only when they have floated upward from the common duct, or when, the common duct being already full of stones, others descending from the gall-bladder have to pass into the hepaticus. Gall-stones (except biliary sand) are not formed in the liver except when the choledochus and common hepatic duct are already filled. The symptoms of stone in the hepatic duct cannot be distinguished from those due to common duct calculus.

Treatment of Cholelithiasis.—In cases of **simple cholelithiasis** operative treatment should be urged, unless any operation is contraindicated by extreme age, or by visceral disease. There is no medicine which will cause the solution of the stones, though charlatans often deceive patients by administering olive oil in large quantities and telling them that the fecal concretions so produced are the biliary calculi. But it is possible by strict medical treatment, such as diet, hygiene, etc., to keep the disease latent for many years in some cases; and most patients who can afford such a life will be satisfied to adopt this procedure rather than operation. But they should be informed that, as Mayo writes, the danger of the development of carcinoma in such a gall-bladder (see p. 942) is five times as great as is the mortality following operation for the relief of simple gall-stone disease, when performed by a competent surgeon. And Kehr says "the slight dangers of early operation stand in no sort of a relation with the great dangers of the disease itself; even the latent cholelithiasis we should always regard with suspicious eyes, for the quiet work of gall-stones is often the most destructive. *In malignancy and insidiousness,*" concludes Kehr, "*no*

disease of man compares with cholelithiasis." If, after their attendant has stated the facts of the case, the patients still will not be operated on, that is their own look-out. The mortality following operation in these simple cases, in competent hands, is less than 5 per cent.

The proper operation in the vast majority of cases of simple cholelithiasis is removal of the calculi and drainage of the gall-bladder (*cholecystostomy*, p. 930); only if the gall-bladder is so altered by disease as to be functionally useless, is it desirable to remove it (*cholecystectomy*, p. 931). Recurrence of gall-stones after cholecystostomy is very unusual, and generally the stones that are found subsequently are not newly formed, but were overlooked at the first operation. The mortality of cholecystectomy is slightly higher than that of simple drainage, but in cases of **acute calculous cholecystitis** it is to be preferred, as also in every case *where the gall-bladder is much contracted or thickened* and in cases of the "*cholesterin gall-bladder.*" Cholecystectomy is also to be done in cases of **obstruction of the cystic duct by a calculus**, since stricture, with resulting hydrops, is the almost inevitable result of removal of such a stone. In cases of **hydrops** and **gangrene** always, and in most cases of **empyema** or **perforation** removal of the gall-bladder is indicated.[1]

In cases of **stone in the common duct** the patients may come under observation either during an attack of obstruction with cholangeitis, or during a free interval. In the latter contingency there is no need to postpone operation, and removal of the stone or stones should be undertaken. In the presence of acute complete obstruction of the common duct, however, it is the teaching of nearly all surgeons that operation should be delayed until under medical treatment (as for acute cholecystitis, p. 921) complete obstruction has subsided. Deaver and Ashhurst contend, on the other hand, that by waiting the patient runs the risk of cholangeitis, cholemia, with the gravest form of sepsis; not to mention perforation of the common duct or the formation of almost inoperable adhesions, or the indefinite persistence of chronic jaundice with its dangerous hemorrhagic tendencies. The fact that the mortality of operations during persistence of complete obstruction is very much higher than that of interval operations is not a valid argument against immediate operation, since the question is not the death rate from operation, but the death rate from the disease. Deaver says "while many times there has been cause to regret not operating during the stage of acute obstruction, never yet has there been cause to regret prompt relief of the obstruction by operation."

The operation consists in removal of the stones in the common duct (by **choledochotomy**, p. 932), thorough exploration of the common and hepatic as well as the cystic duct, and drainage of the common

[1] Individuals known as "*typhoid carriers*," in whom the gall-bladder acts as a store-house for typhoid bacilli which are discharged with the feces, and who often cause epidemics of typhoid fever, may be surely relieved of their infecting qualities by removal of the gall-bladder. No medicines are of any value, and anti-typhoid vaccination has been tried without success.

duct and the gall-bladder by separate tubes. Occasionally the gall-bladder has to be removed.

Obstruction of the Common Duct may result from stricture, the result of previous operative interference, or from tumor formation, as well as from lodgement of calculi. If the stricture is benign in nature, the bile should be short-circuited into the intestinal tract by an anastomosis between the gall-bladder and duodenum or stomach. If the gall-bladder has been removed, and *cholecystenterostomy* is therefore impossible, an anastomosis will have to be made between the dilated duct above the obstruction and the intestine (*choledocho-enterostomy, hepatico-enterostomy*). If the obstruction is due to malignant disease, no operation beyond exploration should be done, unless the disease can be completely removed. Carcinoma of the gall-bladder and bile-ducts is considered at p. 942.

In cases of **postoperative external biliary fistula** the gall-bladder should be removed, if the common duct is patent; if the gall-bladder has already been removed there is almost certainly obstruction of the common duct. In either case obstruction of the common duct is to be treated as above indicated.

OPERATIONS ON THE GALL-BLADDER AND BILE-DUCTS.

The deeper structures may be made much more accessible by placing a sand-pillow (about four to six inches in thickness) beneath the patient's spine, at the level of the liver, thus throwing the upper abdomen forward, and allowing the intestines to fall toward the pelvis. The head and shoulders should be suitably supported so as to facilitate administration of the anesthetic. In very difficult cases the foot of the table may be lowered (reversed Trendelenburg posture) as originally advised by Elliot, of Boston, who introduced in 1895 the position above described.

The **incision** in common use for biliary operations is that known as *Mayo Robson's* (Fig. 893); in simple cases only the longitudinal incision through the rectus muscle is necessary. In cases which promise to be very difficult *Czerny's Winkelschnitt* (1892) is to be preferred: this runs from 5 to 7 cm. in the mid-line, above the umbilicus, and bends to the right just below the umbilicus, cutting the rectus transversely. Kehr has abandoned (1912) his original bayonet incision (*Wellenschnitt*) and now employs an angular incision somewhat like Czerny's. Sprengel's *transverse incision* which divides the right rectus muscle directly across at whatever level seems desirable, and which may be extended in the same direction if necessary, is gaining favor in Europe; Gosset in France and Körte in Germany have adopted it. Before suturing any of these incisions, the support should be removed from beneath the patient's spine.

After the abdomen has been opened the parts concerned in the operation must be well protected by gauze pads. One is placed in the subhepatic space or right kidney pouch, a second presses the stomach

out of the way toward the left, a third is placed over the gastro-hepatic omentum just below the liver, and a fourth is packed down toward the cecum. Sometimes another pad is placed between the right lobe of the liver and the diaphragm. In many operations it is possible to draw the liver, and with it the gall-bladder, partly out of the wound. If the lower border of the liver is drawn slightly downward and then lifted upward into the abdominal incision, slightly rotating the organ so as to turn its inferior surface toward the patient's left, it fully exposes the gall-bladder and brings the cystic and common ducts very near the surface. In this way the cystic duct forms almost a straight line with the common duct, which is therefore more easily found. An assistant should hold the liver in this position with the aid of gauze sponges. Too much force must not be used. I have torn the liver in trying to deliver it.

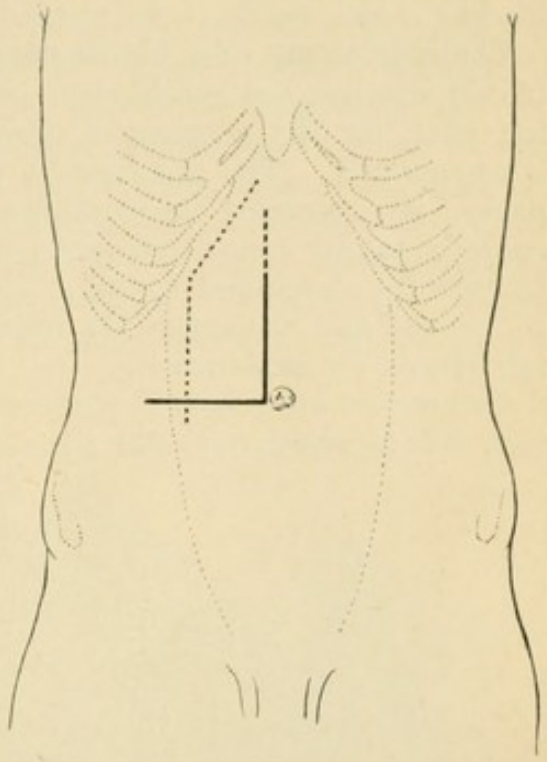

FIG. 892.—Mayo Robson's and Czerny's incisions for operations on the biliary tract. (See text.)

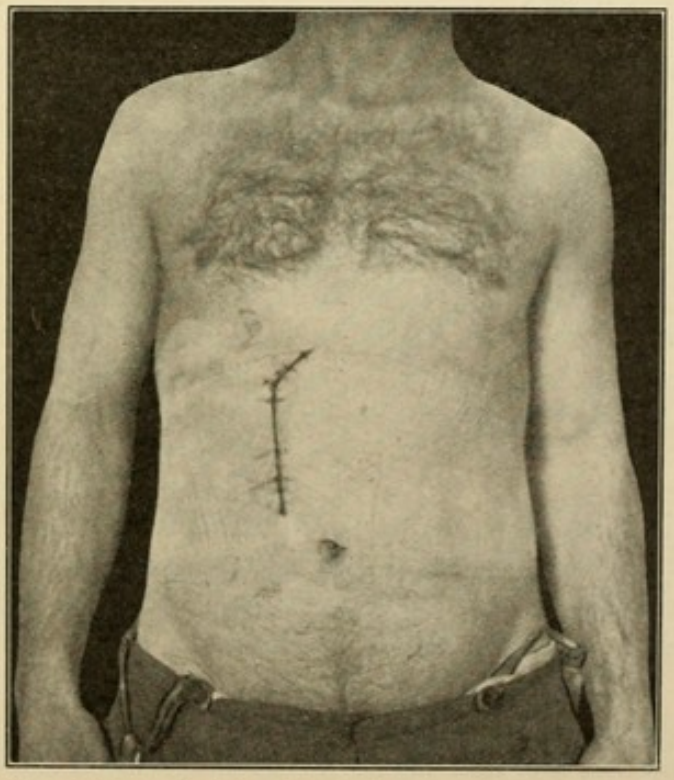

FIG. 893.—Mayo Robson incision for cholecystostomy. Episcopal Hospital.

Cholecystendysis is the name given to the operation in which after opening the gall-bladder for removal of calculi, it is at once sutured and the abdominal wound closed without drainage. The operation is scarcely ever done at present, and is not to be commended. A gall-bladder which needs to be opened needs also to be drained.

Cholecystotomy and Cholecystostomy.—The former term implies merely opening the gall-bladder, while the latter indicates that it is left open for the purpose of drainage. The terms often are used synonomously. The gall-bladder is exposed and isolated by gauze packs. If distended the contained fluid is removed by trocar and cannula, taking care to prevent contamination of surrounding structures or the abdominal wound. The gall-bladder is then pulled into the wound and opened at the fundus with scissors, and the finger is introduced for exploration.

Gall-stones are removed with scoop, forceps, or spoon. Thick and tarry bile is wiped out, and the surgeon makes sure that no calculi remain in the neck of the gall-bladder or the cystic duct by palpation with a finger on the outside and a sound in the lumen of the duct. Unless the patient's condition forbids, the surgeon should then explore the common duct and the head of the pancreas, while the gall-bladder is temporarily plugged with gauze. These manipulations are described at p. 932 (*Choledochotomy*). When it is certain that no stones remain, a purse-string suture of catgut is inserted in the fundus of the gall-bladder about an inch from the opening. A drainage tube open on the side as well as at the end, or cut in fish-tail fashion[1] is passed into the gall-bladder for about an inch, and is stitched to the gall-bladder with two or more catgut sutures. The tube is then pushed into the gall-bladder, inverting its edges around the tube, and the purse-string suture is pulled taut and tied. With this valve-like closure of the opening the biliary fistula does not remain open long after the tube is removed. If the gall-bladder cannot be inverted in this manner the opening should be sutured tightly around the tube, and in such cases or whenever there is a possibility of leakage around the tube it is

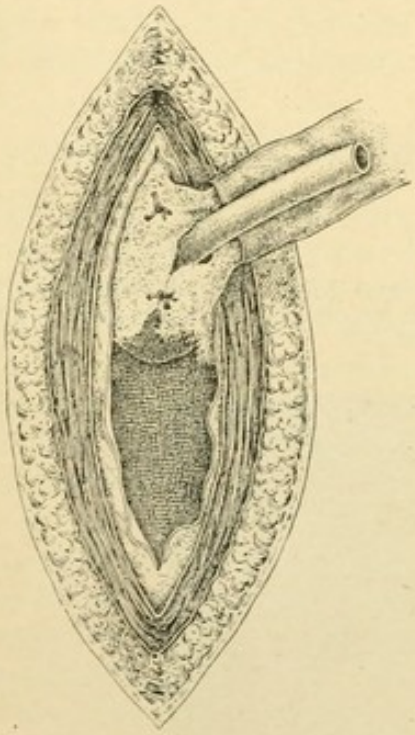

FIG. 894.—Cholecystostomy: the gall-bladder tube is surrounded with gauze from a cigarette drain. (Deaver and Ashhurst.)

[1] It is convenient to have this tube wrapped in gauze and the gauze again surrounded by rubber dam, so that the sutures holding it to the gall-bladder will not tear out.

safer to insert also a small cigarette drain beside the gall-bladder (Fig. 894). The gauze pads are then removed and the abdominal wound is closed around the drainage. The tube in the gall-bladder remains until it comes away of itself, which is usually about the end of the second week. The fistula in such cases ceases to discharge bile very soon after the tube is removed. *When prolonged drainage is desired*, as in cases of cholangeitis, pancreatic lymphangeitis, etc., the gall-bladder should not be inverted around the tube, but should be closed tightly around it without inversion of its wall; then the gall-bladder should be sutured to the parietal peritoneum, or even to the anterior sheath of the rectus muscle; and biliary drainage should persist for from four to six weeks at the least. In some cases of pancreatic disease many months are required before it will be safe to allow the fistula to close.

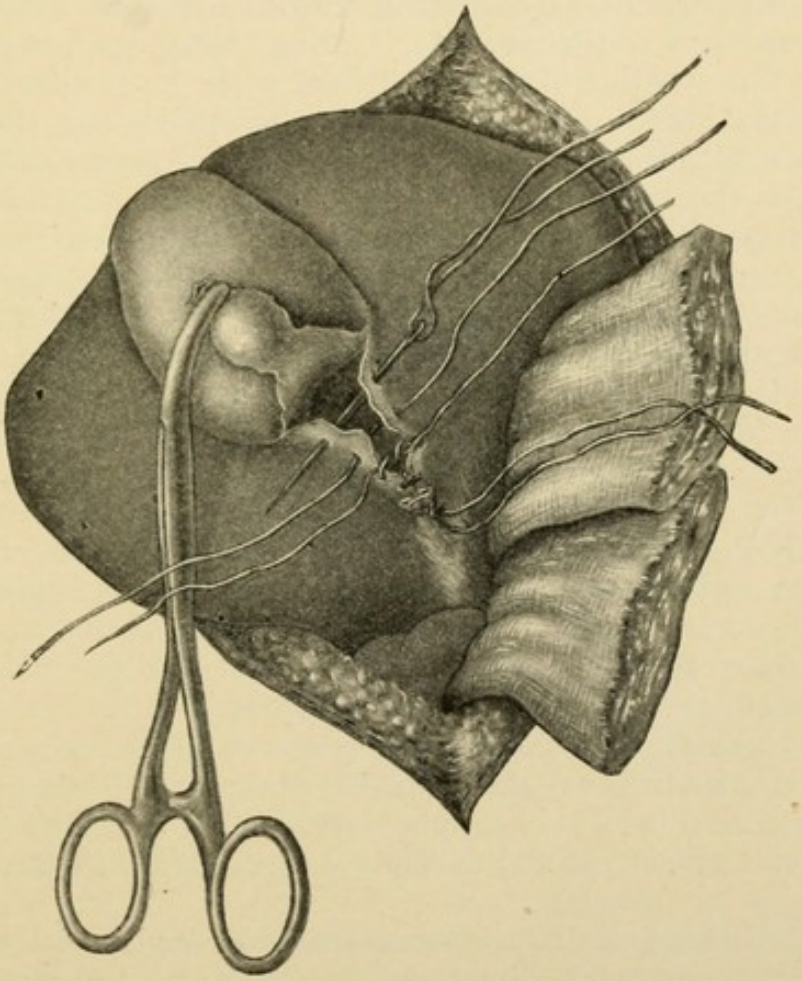

FIG. 895.—Cholecystectomy: the cystic duct and the cystic vessels have been clamped and ligated, and the gall-bladder is being enucleated from its bed under the liver. The method of suturing the peritoneal folds is indicated. (Deaver and Ashhurst.)

Cholecystectomy.—After exposure and isolation of the parts in the usual way, the cystic duct is identified, and the peritoneum overlying it is incised, and is separated from the cystic duct by gauze dissection until the common duct is reached. The cystic duct is then

grasped with two hemostatic forceps and is divided between them. The cystic artery and vein which lie above and to the inner side of the duct are then clamped with two hemostats and divided between. The cystic vessels may be ligated now or later. The gall-bladder is then enucleated from its attachments to the liver, leaving a peritoneal fold on each side (Fig. 895). When the gall-bladder has been removed these peritoneal folds are sutured together; but if there is much bleeding from the denuded liver surface, or in cases of marked infection, it is safer to put a cigarette drain in the bed of the gall-bladder and suture the peritoneal folds over it.

If on opening the abdomen the surgeon encounters very dense adhesions, it may not be practicable to proceed as above indicated. In such cases **Terrier's operation** (1905) is to be preferred: the anterior margin of the liver is identified, and the fundus of the gall-bladder found. The gall-bladder is opened at its fundus and its lower wall is cut open little by little by snipping with fine scissors. This incision is continued into and through the cysticus, right down to the choledochus. The splitting of the cystic duct is the most difficult part of the operation, because it cannot be distinguished from the outside, on account of adhesions, and it is only by following its lumen, as one follows the strictured lumen of the urethra in external perineal urethrotomy without a guide, that the choledochus can be reached.

Before concluding the operation of cholecystectomy, the common and hepatic ducts should be sounded, through the stump of the cystic duct, to make certain that no calculi have been overlooked. A drainage tube is then passed into the stump of the cysticus, and up the hepaticus for about 1 cm., and is stitched in position with No. 0 chromic catgut. The subhepatic space should also be drained by a tube, and these two tubes must be carefully distinguished (by color, by insertion of two safety pins instead of one, or in some other way), so that no subsequent confusion can arise. The abdominal wound is then closed around the drainage. The tube to the subhepatic space may be removed on the second or third day, but that which drains the hepaticus should be allowed to remain at least for two weeks. If there has been much hemorrhage or escape of bile into the subhepatic space it is safer to use a glass tube for drainage of this region. This tube is replaced by a rubber tube within a few days, and the subsequent treatment conducted as when a glass tube has been used to drain the pelvis (p. 862).

Choledochotomy and Choledochostomy are employed interchangeably as are the corresponding terms relating to the gall-bladder, since at present almost every operation involving an incision into the choledochus is supplemented by drainage of that structure. When the gall-bladder is present it serves as a guide to the common duct, which is brought into the wound, when possible, by the method noted at p. 929, after the gall-bladder has been opened and cleared of stones as previously described. The common duct often is much dilated and it may be difficult to distinguish it from the portal vein. For

this purpose a hypodermic needle may be used, as advised by Terrier and by Deaver. The index finger is passed into the foramen of Winslow, while the thumb is placed on the free border of the gastrohepatic omentum and the supraduodenal portion of the choledochus is palpated. If a stone is found it scarcely ever is possible to push it back through the cysticus into the gall-bladder, but sometimes the scoop or forceps may be passed down from the gall-bladder through the cysticus for removal of the stone. In most cases, however, it is necessary to incise the duct over the stone to extract it. This incision is made in the long axis of the duct and of convenient length. If the duct is large enough the finger makes the best probe to search for other stones. Any stones detected by finger or scoop or sound, should be pushed toward the opening in the choledochus; if impacted in the retroduodenal portion of the duct a stone may be crushed between the fingers or broken up by the scoop, and the fragments extracted from the incision in the supraduodenal portion or pushed into the duodenum through the ampulla of Vater. As a last resort *retroduodenal choledochotomy* may be necessary; or if a calculus is impacted in the lower end of the common duct very close to the duodenum, *transduodenal choledochotomy* may be necessary. These operations are described below.

When all stones have been removed, the common duct is drained by passing a rubber tube large enough to fill its lumen up toward the hepatic duct for 1 to 2 cm. (**Hepaticus drainage, Kehr's operation.**) The tube is fixed in the common duct, as described in connection with cholecystectomy; and the gall-bladder is drained by a separate tube. (If cholecystectomy is necessary the stump of the cysticus may be closed with suture). The operation is concluded by drainage of the subhepatic space, as after cholecystectomy.

In cases where the gall-bladder is absent, choledochotomy may be a very difficult operation if many adhesions are present, as there is no guide to its location. In such cases Desjardins recommends that the surgeon commence by exposing the retroduodenal portion of the choledochus by mobilization of the duodenum, as described below. Or the surgeon may open the duodenum and identify the choledochus by retrograde catheterism through the ampulla of Vater. I believe the former method is preferable.

Retroduodenal Choledochotomy.—If an incision is made through the parietal peritoneum on the right of the descending duodenum, this coil of intestine may be separated by blunt dissection from the posterior abdominal wall, and restored to the condition it occupied in fetal life. By turning the duodenal loop to the left (*mobilization of the duodenum*, Jourdan, 1895) the head of the pancreas and the retroduodenal portion of the common duct are brought into view (Fig. 896), and an impacted calculus may be removed by direct incision (Fig. 897). As in most cases in which this operation is necessary the supraduodenal portion of the choledochus has already been opened, this may be used for drainage, and the incision in its retroduodenal portion sutured. It

is wise, however, to leave a drain in the retroduodenal space, for fear of leakage.

Transduodenal Choledochotomy (McBurney, 1891) is applicable to a calculus impacted in the ampulla of Vater or very close to the duodenal wall. The duodenum is opened through its anterior wall, and the bile papilla identified. If a calculus is caught in the ampulla it usually is possible to extract it by dilating or incising the papilla.

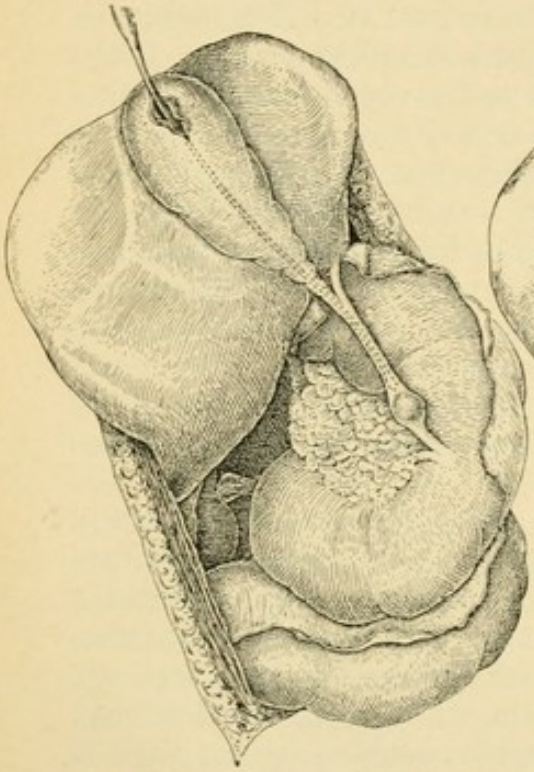

FIG. 896.—Retroduodenal choledochotomy: after mobilization of the duodenum, a stone is exposed at the site of obstruction to the sound. (Deaver and Ashhurst.)

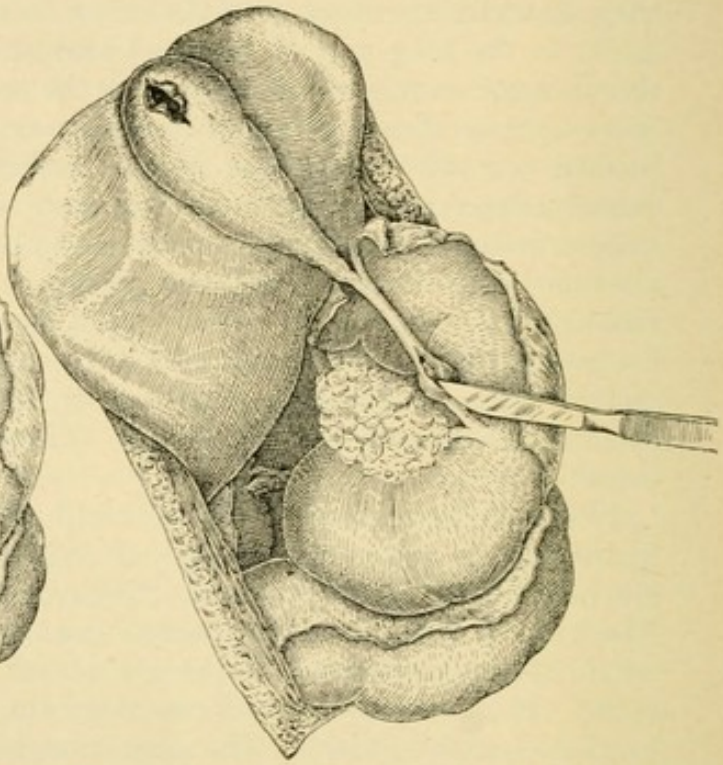

FIG 897.—Retroduodenal choledochotomy: the choledochus is incised over the impacted calculus. (Deaver and Ashhurst.)

If it is impacted in the common duct just outside the duodenal wall, it is necessary to incise also the posterior wall of the duodenum over the calculus, and then to open the choledochus and remove the stone. The opening in the choledochus is then sutured to the incision in the posterior duodenal wall, to ensure adequate drainage of the choledochus; this is Kocher's operation of *duodeno-choledochostomy* (1895). The incision in the anterior wall of the duodenum is then sutured as any intestinal wound, and the abdominal incision is closed in the usual way.

Cholecystenterostomy.—The anastomosis may be made with the duodenum (cholecysto-duodenostomy) or with the stomach (cholecysto-gastrostomy). A lateral anastomosis, about an inch long, by suture (p. 834), is the best method, but if it is impossible to apply rubber-covered clamps to prevent fecal extravasation during the operation, a small sized Murphy button may be used for the anastomosis.

SURGERY OF THE LIVER.

Anomalies of Shape and Position.—Except in rare cases of congenital, diaphragmatic, or umbilical hernia the position of the liver seldom is altered unless **hepatoptosis** (falling of the liver) exists in connection with *visceroptosis* (p. 898). Apart from rather vague pains hepatoptosis produces no characteristic symptoms and the diagnosis must be made by recognition of the liver in its abnormal position. Usually it descends somewhat toward the median line, and is recognized as a large tumor to the right of the umbilicus of the size and consistency of the liver; often a notch can be felt. When displaced there is resonance over the normal site of the liver dulness, and pulmonary resonance and intestinal tympany may merge. It is distinguished from a *movable* or *enlarged kidney* by the absence of urinary symptoms, by the fact that the liver moves in respiration, while the kidney does not, and that it lies in front of the colon, not behind it.

Treatment.—Treatment should consist in reposition of the liver, when this is possible, with the patient recumbent, and the application of an abdominal belt as in cases of pendulous abdomen (Fig. 875). If palliative treatment proves ineffective, the abdomen may be opened and the anterior margin of the liver stitched to the costal border, with mattress sutures of heavy chromic catgut.

Changes in the Shape of the Liver usually are acquired, and are of two main varieties. In one, the so-called **corset liver** (Fig. 898), the plastic liver has become indented by compression through the costal margin. This tends to distort the cystic duct, causing stagnation of bile, with its consequences already discussed (p. 922). In the other form the anterior margin of the liver is drawn down in a tongue-shaped protrusion, known as **linguiform** or **Riedel's lobe** (1888). Usually disease of the biliary tract exists and has produced the deformity by gradual traction from adhesions or the weight of an enlarged gall-bladder. *Treatment* involves operative cure of the biliary lesion, after which the enlarged lobe usually shrinks (Terrier); in rare instances amputation of the lobe may be desirable.

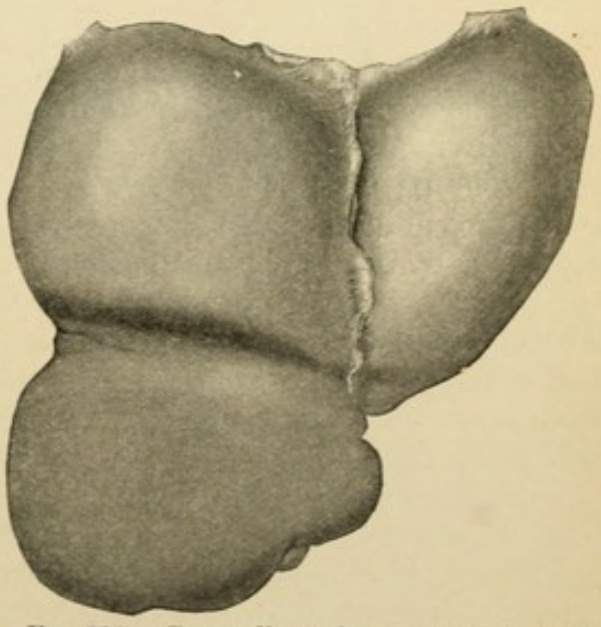

FIG. 898.—Corset liver, from a patient aged fifty-seven years. Death from perforation of a malignant ulcer of the stomach. (See Fig. 849.) Episcopal Hospital. (Deaver and Ashhurst.)

Suppurative Hepatitis.—There are three main varieties of suppuration which occur in the liver: (1) Abscess the result of trauma; (2) pyemic or embolic abscess; and (3) tropical or amebic abscess.

1. **Traumatic Abscess** is rare; it may occur as the result of a penetrating wound, or from secondary infection (through the blood or bile) of a hematoma which has resulted from subcapsular rupture (p. 841), usually is single and may be of large size. The diagnosis depends on the history of the case, and development of symptoms of pus formation; and the treatment is the same as for tropical abscess.

2. **Pyemic or Embolic Abscess,** when of surgical interest, almost invariably is the result of infection through the portal circulation, and is termed **suppurative pylephlebitis.** Especially frequent as causes are appendicitis and typhoid fever, but any infection in the distribution of the portal vein may be the cause; and cases of suppurative cholangeitis involving the finer intrahepatic bile-ducts often cannot be distinguished either during life or at autopsy from cases of suppurative hepatitis caused by hematogenous infection. When occurring from appendicitis or other acute infection the symptoms (pain, high but irregular fever, chills, sweats, tenderness, and enlargement of the liver, sometimes jaundice) usually develop within a week or two of the primary affection. In such cases the liver is riddled with abscesses of various size, and operative treatment is out of the question. Every such case is fatal. When resulting from typhoid fever, however, and, according to Quénu and Mathieu (1911), occasionally as the result of appendicitis, the symptoms do not appear until convalescence is established. The average fever-free interval in typhoid fever, according to Melchior (1910), is fourteen days. Such cases resemble somewhat amebic abscess, and treatment is the same.

3. **Tropical or Amebic Abscess** takes its name from its occurrence especially in the tropics, and as the result of infection with the Amœba coli. The patient usually gives a history of residence in tropical or semi-tropical climes, and almost always has suffered from dysentery; but as the symptoms of amebic colitis sometimes are very insignificant (p. 896) too much faith should not be put in the patient's history. The hepatic abscess, which usually is single (in 60 per cent. of cases) and of large size, may not develop or at least may not begin to produce symptoms until many years after the occurrence of the primary infection. The ameba is transported to the liver through the portal circulation, and the destructive process begins in the hepatic cells. The abscess usually is in the right lobe of the liver, but even when the abscess is very large the shape of the liver may not be noticeably altered. The abscess develops silently, like a cold abscess, and it often produces no symptoms until secondary infection has occurred. When uninfected by pyogenic organisms the contents are reddish brown in color and vary in consistence from fluid to gelatinous. Amebæ often cannot be found except in scrapings from the wall of the abscess, or after it has been discharging for several days.

Symptoms.—In one-third of the cases, according to Rouis, there are no symptoms noticed by the patient until rupture occurs, usually into the lungs, pleura, or peritoneal cavity. When symptoms exist, they may not be referred to the liver for months after malaise, lassitude, and increasing weakness are noted. Jaundice is rare. When local symptoms are noted they frequently are referred to the base of the right lung or the pleura. Fever is another valuable sign, though the temperature may not be high except in the evening; in malaria the temperature usually rises in the daytime. Enlargement of the liver, and pain (local and referred to the right shoulder) may not occur until late. Diagnosis is aided by purging the patients with salines and searching the stools for amebæ, which usually can be found in the third or fourth watery stool. A high leukocyte count in the afternoon is regarded as an indication of the presence of secondary infection. The most common mistakes in diagnosis are (1) failure to recognize the presence of disease of any description; (2) misinterpretation of the significance and nature of basic pneumonia; (3) attributing the fever to malaria; and (4) mistaking other diseases for abscess of the liver, and *vice versa* (Manson, 1904). In tropical abscess the spleen is not enlarged.

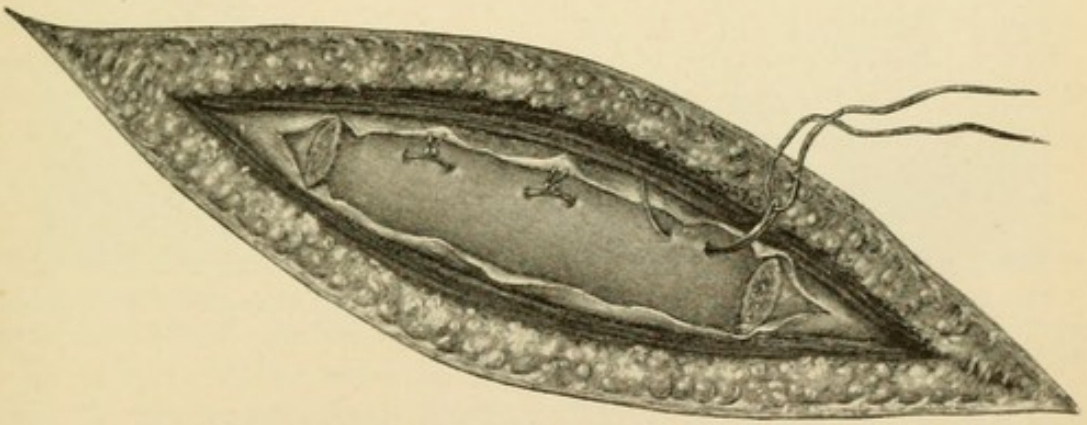

FIG. 899.—Transpleural operation for abscess of the liver: a portion of rib has been excised, subperiosteally; and the diaphragm is being sutured to the tissues or the costo-phrenic sinus. (Deaver and Ashhurst.)

Treatment.—Treatment involves drainage of the abscess. At the same time proper treatment of the colitis (p. 896) must be instituted. The operation of **hepatotomy** for drainage of a liver abscess resembles that for subphrenic abscess (p. 814). If the abscess cannot be localized by the physical signs, laparotomy should be done and its position determined. No attempt should be made to localize the abscess by aspiration, except after the liver has been exposed to view. If the abscess is found to be near the convex surface of the liver or if this fact can be determined without opening the abdomen, the abscess should be drained by the transpleural route (Knowsley Thornton, 1885) as in the operation for subphrenic abscess: Excise (subperiosteally) four inches of the eighth, ninth or tenth rib in the mid-axillary line; then suture the diaphragm to the tissues of the costo-phrenic

sinus (deep layer of costal periosteum, both layers of pleura), without opening the pleura, by three or four interrupted sutures of chromic catgut (Fig. 899). Then make an incision along the upper border of the next lower rib, through all structures, diaphragm included, until the liver is exposed. In acute cases the liver is bluish, soft and pulpy, and may bulge into the wound. Adhesions usually shut off the peritoneal cavity, but it is well to isolate the parts with gauze. Where these adhesions are the densest, usually the abscess is found. It is opened by a stab with a bistoury, and the tract enlarged by dressing forceps followed by the finger. It is drained by a double tube of rubber, and not until four or five days at least have elapsed should irrigation be employed. The sinus may take many weeks to close.

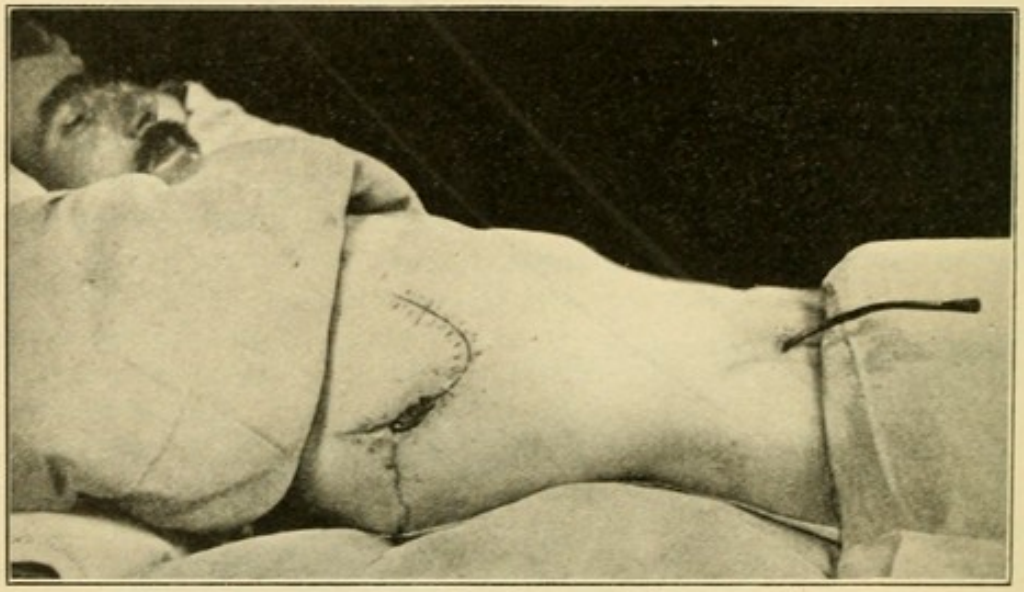

FIG. 900.—Hepatic abscess exposed by flap method. Appendicostomy for accompanying colitis. Catheter in the appendix. Recovery. (Dr. C. H. Frazier's case.) Episcopal Hospital.

Echinococcus Cyst.—Hydatid cyst is the result of infection by the Tenia echinococcus, a parasite found in the intestinal tract of dogs, sheep, and other animals. The ova enter the intestinal tract of man with food or drink, or possibly as the result of handling or being licked by an animal infested by the parasite. The capsule is digested in the intestinal tract of the patient, and the embryo is liberated. It bores into the intestinal wall, and in most cases is carried by the portal system to the liver. Hydatid cysts of other organs or tissues are rare and often secondary to a primary growth in the liver. After the parasite (in larval state) reaches the liver, it loses its hooklets and enters the immature or cysticercus stage. Inflammatory changes cause a connective tissue encapsulation, so that the cyst wall consists of two layers; an outer laminated layer or capsule, and an inner granular or germinal layer. The contents are clear, colorless fluid, unless secondary infection occurs, when the fluid is purulent; sometimes it is bloody or bile-stained. Hydatid fluid contains a poisonous ptomain,

which may cause convulsions, rapidity of the pulse and respirations, dilated pupils and collapse. Unless the parasite dies daughter cysts develop within the original parent cyst. The heads or scolices of the parasites cling to the germinal layer in pedunculated vesicles known as brood capsules. These are similar to the primary cyst. The scolices may become detached and lie free in the brood capsule, or if this ruptures they may float free in the parent cyst. Degeneration, calcification, and death of the parasites may occur. Hydatid cysts usually occur in the right lobe of the liver and in 90 per cent. of cases the cyst is solitary.

Symptoms.—The clinical course of the disease much resembles that of tropical abscess of the liver. So long as secondary infection is absent, and until the cyst grows so large as to project from the surface of the liver, symptoms are inconspicuous. The average duration of the disease before treatment is sought is from five to seven years. Attacks of urticaria are not uncommon. There is danger of rupture (spontaneous or from trauma), into the bile passages, the peritoneal cavity, the gastro-intestinal tract, or the thorax; as well as from secondary infection.

Diagnosis.—The diagnosis can be made only when a palpable cystic enlargement of the liver is detected. The condition must be distinguished from *carcinoma* of the liver, which is a solid growth, and usually secondary to a tumor elsewhere; from *tropical abscess* (p. 936); from *empyema thoracis* and *subphrenic abscess;* and from *gummatous growths* (syphilitic) of the liver, which are much more common in this country than hydatid cysts.

Treatment.—There is no cure without operation. Most cysts grow downward and are best exposed by laparotomy. The best plan is that of Quénu; after exposure of the cyst its contents are aspirated by means of a *very fine* trocar and cannula. It is well to insert the trocar through the rubber tube used to drain the fluid from the cannula (Fig. 901), as in this way no danger of leakage occurs. Then a solution of formalin (1 per cent.) is allowed to run into the cyst cavity and to distend it. This is permitted to remain for five minutes so as to sterilize its contents. It was demonstrated by Dévé (1901) that each of the parasitic elements is capable of reproducing the primary lesion, and Quénu found (1902) that formolization as above described sterilized the contents of the cyst absolutely. The cyst is then emptied, its wall is incised, and the germinal membrane is removed. Then the cyst may be closed by sutures, without drainage, but it should be attached to the abdominal wound so that an intracystic effusion of bile or blood

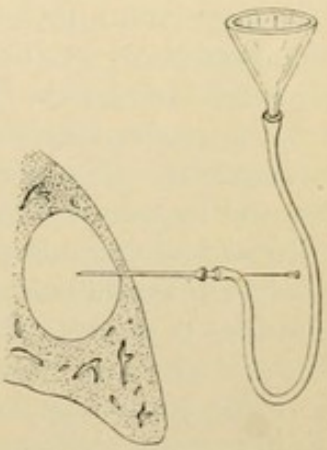

FIG. 901.—Quénu's method of formolization of hydatid cysts of the liver.

can be evacuated easily should either complication occur later. If the old plan of marsupialization (opening, packing with gauze, and suturing to the abdominal wound) is employed without formolization, the condition is analogous to that of a cold abscess opened and drained—secondary infection is almost unavoidable, biliary effusion is frequent, and the sinus takes very long (months) to close.

Cirrhosis of the Liver.—Pathologists distinguish between *portal cirrhosis*, in which the cause is transmitted by the portal circulation, and the obtrusive symptoms are those of portal obstruction; and *biliary cirrhosis* in which the essential lesion is a radicular cholangeitis, and the conspicuous clinical feature is jaundice (A. O. J. Kelly). The latter has not, so far, become amenable to surgical treatment, though proper operative treatment of diseases of the gall-bladder and bile-ducts may often prevent its development; and in the former surgery is able only to modify or lessen the distressing symptoms, without in any way bringing about a cure of the underlying disease.

The main symptoms of portal cirrhosis of the liver are (1) *gastro-intestinal hemorrhages*, from obstruction of the portal vein, and (2) *ascites* from peritoneal changes which accompany the disease. Pure portal obstruction is said not to produce ascites, which it is believed is caused almost solely by changes in the endothelium of the peritoneum; it is in the nature of a chronic serositis, probably due to the toxemia of disordered hepatic function. Cases of portal cirrhosis sometimes are complicated by tuberculosis of the peritoneum, or by a chronic polyserositis associated with cardiac disease; and in such cases it may not be the hepatic toxemia, but the complicating disease which is responsible for the peritoneal effusion. Most of the operative methods proposed for the relief of ascites are based on the idea that this occurs as a direct transudate from the portal system. Such is not the case, and a rational operation must seek to alter the nutrition of the peritoneal endothelium; operations which seek to establish a collateral circulation for the obstructed portal system are rational only when gastro-intestinal hemorrhages are present or threaten.

Paracentesis.—The ascitic fluid may be removed by repeated tappings, and in rare instances the fluid finally ceases to re-accumulate. The trocar and cannula should be thrust into the abdomen in the midline between umbilicus and pubes, after it has been ascertained that the bladder is empty. No anesthetic is necessary, though in nervous patients or when the abdominal wall is thick, a local anesthetic may be used. The patient should be in the semi-recumbent position, and as the fluid is evacuated concentric pressure should be made on the abdomen by means of a many-tailed bandage, so as to prevent syncope by the sudden relief of pressure on the large abdominal bloodvessels. If the amount of fluid is very great, it is best not to remove all of it at once. The puncture is sealed with collodion, and the abdomen kept tightly bandaged, in an effort to prevent re-accumulation.

Laparotomy with gauze abrasion of the serous surfaces of the liver, spleen, and diaphragm, in an effort to alter their nutrition, and check

the formation of the ascitic fluid, which is simultaneously evacuated, is a more effectual method of treatment, and much of the good attributed to epiplopexy (see below) is no doubt due to these steps which form an integral part of that operation.

Epiplopexy, introduced by Talma (1889) and Morison (1894), consists in suturing the omentum to the parietal peritoneum on both sides of the abdominal incision, or between the peritoneum and the posterior sheath of the rectus muscle, in the effort to establish a collateral circulation. As already noted, abrasion of the serous surfaces of the liver, spleen, diaphragm, and of the parietal peritoneum forms an integral part of this operation, the idea being that a collateral circulation will be established in the adhesions thus produced. The surest manner of establishing a collateral circulation for portal obstruction is to make an anastomosis between the portal vein and vena cava (*Eck's fistula*); this was done by Vidal (1903) in a patient almost exsanguinated by gastro-intestinal hemorrhages; but though these were cured, the ascites was not, and death ensued four months later from acute general infection, evidently enterogenous; the portal blood-stream had been short-circuited and the liver was no longer interposed to the hordes of microbes constantly absorbed from the bowels.

After epiplopexy the abdomen is not drained, though this formerly was considered essential. Symptomatic relief has been secured in from one-third to one-half the cases.

Tumors of the Liver, Gall-bladder, and Bile Ducts.—Benign tumors are very rare and have little surgical interest.

Carcinoma of the Liver may be primary, but in almost all cases is secondary to a growth in the distribution of the portal system. The usual type, whether primary or secondary, is nodular or multiple carcinoma. If this is a primary growth most of the nodules are metastases from one original focus which usually is in or near the gall-bladder (Beadles, 1896); while in secondary carcinoma the nodules are scattered all over the liver uniformly, and not massed about the fossa of the gall-bladder. The nodules are whitish, gray, or yellowish masses, from the size of a pinhead to that of an orange, but seldom larger than a walnut. They stand out from the surface of the liver, frequently cause perihepatitis with resulting adhesions; and when large often become umbilicated as the result of interstitial hemorrhages. If the growth is primary, gall-stones usually are present.

Symptoms are not characteristic, and the diagnosis rarely is made until enlargement of the liver, with palpable nodules, and the development of ascites and sometimes of jaundice, indicate that the disease has passed the operable stage. The symptoms of the secondary growth in the liver frequently overshadow those due to the primary focus in pancreas, stomach or intestinal tract, and even at autopsy it may be difficult to find the primary growth.

Treatment in almost all cases must be palliative; very occasionally a primary growth may be excised, but in most patients the prognosis

is hopeless, and death ensues in from five to seven months after recognition of the condition.

Sarcoma of the Liver almost always is secondary, usually to a growth in the eye or the soft tissues of the limbs; but many years occasionally elapse between removal of the primary tumor and evidence of hepatic involvement.

Carcinoma of the Gall-bladder and Bile-ducts is much more common than carcinoma of the liver. Secondary carcinoma is rare and of little surgical importance.

Primary Carcinoma of the Gall-bladder is found in about 2 per cent. of specimens removed by cholecystectomy; and almost invariably gall-stones are present and are regarded as the predisposing cause. The growth begins at the fundus or near the neck of the gall-bladder, and extension occurs to the liver. The early *symptoms* are those of cholelithiasis; later a hard nodular tumor of the gall-bladder is recognized, but by this time hepatic involvement frequently renders the case inoperable. The most favorable cases are those where a thick-walled gall-bladder removed at operation is discovered to be the seat of carcinoma only when microscopically examined. Such patients may survive several years, whereas those in whom the correct diagnosis is made before or during operation usually die within a year.

Treatment consists in extirpation of the growth whenever possible. This always should include excision of the entire cystic duct with the gall-bladder and may necessitate removal of the adjoining liver tissue also. Methods of suture of the liver have already been considered (p. 843).

Primary Carcinoma of the Bile Ducts presents much the same symptoms as carcinoma of the head of the pancreas, notably obstructive jaundice, of slow or sudden but almost always painless onset, never remitting but gradually deepening to a bronze or almost black hue. If the growth is in the choledochus, the gall-bladder becomes distended and enlarged, and is palpable through the abdominal wall in half of the cases. If the growth is in the hepaticus (which is rare), no enlargement of the gall-bladder occurs. Disturbance of the pancreatic functions indicates obstruction at the papilla of Vater.

Treatment.—Exploratory operation is proper in all but manifestly hopeless cases. If a radical operation cannot be done, *the abdomen should be closed without doing anything further.* Palliative operations for malignant obstruction of the common duct have a very high primary mortality (hemorrhage from cholemia) and do not prolong the patient's life nor promote his comfort. If complete extirpation can be done, the drainage of bile into the intestine must be restored by some form of biliary-intestinal anastomosis (p. 928). Retroduodenal resection of the choledochus in 18 operations collected by Oppenheimer (1912), gave an immediate mortality of 50 per cent. Occasionally a growth at the papilla of Vater can be excised by a transduodenal operation (Czerny, 1901). The immediate mortality of

this operation, according to Oppenheimer, is 33 per cent. The most radical operation of all for growths at the lower end of the choledochus resembles that of cephalic pancreatectomy (p. 951).

SURGERY OF THE PANCREAS.

Infections of the Pancreas.—Theoretically infection may reach the pancreas, as it may any other organ, (1) through the blood-stream; (2) along its excretory ducts; (3) through its lymphatics; or (4) by contiguity, from neighboring structures.

1. *Infection through the blood* is comparatively rare. The pancreas is seldom affected in pyemia; but the occurrence of pancreatitis as a complication of acute parotitis (mumps) though unusual is well recognized (Deaver and Ashhurst tabulate 61 cases); and a few cases of involvement of the pancreas have been reported in cases of scarlatina, influenza, and other acute infections. In chronic interacinar pancreatitis, also, which is a frequent accompaniment of arteriosclerosis and which usually results in diabetes, the causative agent is conveyed to the pancreas in the blood-stream; and it is probable, as pointed out below, that acute pancreatitis is the result of some toxin which exerts its action first on the endothelial lining of the bloodvessels.

2. *Infection through the ducts* has been produced experimentally by injection of bile, gastric juice, and other irritants, resulting in acute inflammation; but it is not probable that such occurrences are frequent in life, though Opie recorded a case in which a small gall-stone blocked the orifice of the ampulla of Vater and allowed retrojection of bile into the pancreatic duct.

3. *Infection through the Lymphatics.*—The lymph nodes around the head of the pancreas drain the lymph from the gall-bladder and bile-ducts, as well as (more or less directly) from the pylorus, the appendix, and other common sites of intra-abdominal infection. The lymphatics from the remainder of the pancreas are more or less independent of those about its head, and do not drain such common sites of infection as those already mentioned. The chronic infections of the pancreas are almost always confined to the head of the gland, and the fibrous tissue which forms is interlobular in distribution, thus corresponding to the lymphatic tissue; it is true that the blood-channels also are interlobular, but if in these cases of chronic pancreatitis the infection was conveyed by the blood-stream the entire gland should be involved, which is not the case in chronic interlobular pancreatitis, the common form; though it is the case in the rarer interacinar form, in which, as already indicated, the causative agent probably is blood-borne. That the infection does not originate in the excretory ducts, in cases of interlobular pancreatitis, is indicated by the local distribution of the resulting fibrosis, which is neither scattered diffusely throughout the gland, as are the ducts, nor yet situated close about the parenchyma of the gland in the portion which is affected. It is

thus evident, as pointed out by Maugeret (1908), that the condition commences as a pancreatic lymphangeitis, the term suggested by Arnsperger (1911), and adopted by Deaver and Pfeiffer (1912), who have been particularly instrumental in securing recognition of the disease in this country.

4. *Infection by contiguity* is rare, except when a gastric ulcer or carcinoma becomes adherent to or perforates into the pancreas.

Acute Pancreatitis.—*Acute catarrhal pancreatitis* is of little importance surgically; it may accompany acute gastroduodenitis, and catarrhal cholangeitis, aiding in producing the obstructive jaundice which is the common expression of these conditions. *Acute parenchymatous pancreatitis* is classified as *hemorrhagic, suppurative,* and *gangrenous* (Fitz, 1889), terms which indicate the stage of the disease. The suppurative and gangrenous stages frequently are classed as *subacute pancreatitis.*

Acute Hemorrhagic Pancreatitis is the commonest form of acute pancreatitis. The adjective hemorrhagic is attributive, not qualifying; hemorrhagic inflammation may occur in any organ, but it is especially frequent, and the hemorrhagic tendency is especially marked in the case of the pancreas. It is probable, as long ago indicated by Truhart, that the process commences as an autodigestion of the pancreas. It is true that under normal conditions the pancreatic juice is activated by a kinase with which it comes in contact only after leaving the pancreas; but under abnormal conditions, as pointed out by Carnot (1908), a kinase may be generated within the pancreas itself by the action of leukocytes or bacteria or toxins. These, probably, are conveyed to the organ through the blood-stream, for the lesions in acute pancreatitis are scattered here and there, and are not confined to any particular segment of the gland. The results of the infection are caused by extravasation of the pancreatic juice, whether this is confined to the pancreas itself or escapes into the retroperitoneal tissues or into the free peritoneal cavity: the trypsin causes **hemorrhages** and the steapsin causes areas of **fat necrosis.**

The disease is more frequent in men than in women, and most patients are of middle or later life, and rather obese. Recurring slight attacks are not very rare, though the surgeon often is not consulted until a fulminating attack occurs, and so far the existence of the disease in milder forms has scarcely ever been recognized. Trauma has in some cases seemed a predisposing cause; in them a hematoma probably had formed, and only when it ruptured and allowed extravasation of pancreatic juice, did the symptoms of acute pancreatitis arise. If the abdomen is opened very early in the attack there may be nothing to indicate the pancreas as the seat of disease; after the lapse of a few hours, however, there is found a sero-purulent exudate usually blood-tinged and areas of fat necrosis in the omentum, mesentery, or peripancreatic fat. Hematomas may be observed in the same situations. The areas of fat necrosis occur as minute whitish specks or flakes, dense and rigid, often surrounded by a hemorrhagic

zone, and not raised from the surface of the surrounding fat, a fact which aids in distinguishing them from miliary tubercles. Disorganization of the pancreas occurs very early, and microscopical study seldom is satisfactory, a fact which accounts for the uncertainty that still exists as to pathogenesis. If the patient lives, gangrene of the pancreas may follow, and the entire lesser peritoneal cavity may be converted into an abscess containing foul-smelling, purulent, chocolate colored exudate, with pieces of necrotic pancreas floating around loose in the fluid.

Symptoms and Clinical Course.—Usually symptoms arise so suddenly and are of such an overwhelming nature that the patient can give no history of previous milder attacks. In most cases seen by the surgeon the disease runs its course in from five to eight days, death occurring within a week, unless prompt operation is done. *Pain*, *vomiting*, and *collapse* are the most prominent symptoms. The pain is intense, excruciating, and may cause collapse; it is neuralgic, and colicky in nature, and resembles that due to acute intestinal obstruction, though the latter often begins with mere twinges and becomes severe only after the lapse of hours. The pain of pancreatitis does not shift, it remains epigastric. Collapse may not occur until the hemorrhagic exudate breaks through the capsule of the pancreas. Vomiting is so frequently repeated that it resembles that which occurs in cases of intestinal obstruction; but in the latter the vomiting is projectile and regurgitant and there is little or no nausea. Hiccough is frequent and very persistent. Dyspnea is said to be present rather often. *Physical examination*, early in the course of the disease, is unsatisfactory, owing to tenderness and abdominal distention. Muscular rigidity is not very great. After the subsidence of the most acute symptoms, toward the third or fourth day, it usually is possible to detect an ill defined tumefaction in the epigastrium, and there frequently is tenderness and perhaps palpable resistance in the left loin. The patient continues to be gravely ill; the stomach is unretentive; emaciation is rapid; slight jaundice is frequent; the pulse is weak and running, and the temperature is elevated and perhaps hectic in type. The patient will now die of exhaustion, sepsis, or secondary peritonitis, unless promptly relieved by operation.

Diagnosis.—Acute pancreatitis must be distinguished from perforation of the stomach or duodenum, biliary colic, intestinal obstruction, appendicitis, and poisoning by drugs which have been swallowed. In most cases which might be confused with pancreatitis, a history of the affection can be obtained and will lead to a correct diagnosis. Acute pancreatitis is the disease which cannot be recognized as any other affection and which is apt, therefore, to pass undiagnosed.

Treatment.—The abdomen should be opened promptly for purposes of exploration, by an epigastric incision; isolate the upper abdomen by gauze packs; if a collection of fluid is found in the lesser peritoneal cavity, evacuate it by aspiration; expose the pancreas (preferably through the gastro-colic omentum), and if it presents no gross lesions

do not incise it, but merely tampon the lesser peritoneal cavity; if there is an abscess or hematoma in the pancreas incise its capsule, and with a blunt instrument carry the incision into the substance of the gland, to secure drainage of all pockets of pus, etc. Then tampon the incision into the pancreas, using a large rubber tube for drainage in the centre of the tampons. In some cases, especially of subacute pancreatitis, a counter-incision in the left loin should be made. Complications in the biliary tract (which are not frequent) should not be treated at this time, except for very positive indications.

Abscess or Gangrene of the Pancreas usually is a sequel of acute pancreatitis. The recognition of the condition depends upon attention to the clinical course of the disease, and the detection of evidence of deep-seated tumefaction in the region of the pancreas. The abscess frequently points in the left loin, and if this is the case, it should be opened in this place. In other cases an epigastric incision is made first, and the upper abdomen is explored, and a counter-opening is made wherever it seems most desirable. Guinard (1907) commends the thoracic route (left side), similar to that employed in cases of hepatic or subphrenic abscess.

Pancreatic Fistula sometimes persists for a long time after an operation for acute pancreatitis. The discharge is exceedingly irritating and the skin should be protected by ointments with mineral base. Antidiabetic diet should be insisted upon, as advocated by Wolgemuth (1912); usually the discharge decreases rapidly after a week or ten days, and the fistula then closes.

Chronic Pancreatitis.—This may be *catarrhal* or *interstitial* in distribution. The former is believed by Mayo Robson and others to be of frequent occurrence, though it is of slight surgical significance; it frequently accompanies chronic interstitial pancreatitis, and when duct-borne infection was regarded as frequent the catarrhal was believed to be a forerunner of the interstitial form. *Chronic interstitial pancreatitis* occurs in two main forms: *interacinar* and *interlobular*. The former was mentioned at p. 943, as accompanying arteriosclerotic changes in the pancreas; the lesions involve the entire pancreas (head, body, and tail), the nutrition of the islands of Langerhans is affected early, and diabetes often results. It is not amenable to surgical treatment.

The only variety of this disease of surgical importance is **chronic interlobular pancreatitis.** As already pointed out this begins as a **pancreatic lymphangeitis**, the primary focus usually being in the gall-bladder or ducts, or in the pyloric region of the stomach or duodenum. If the primary focus of infection can be recognized and properly treated before the process in the pancreas has advanced to the stage of organization and cicatrization (*true chronic interlobular pancreatitis*), there is every reason to believe that the pancreas will not be permanently damaged. The disease is commonest in adult males between thirty and fifty years of age.

Symptoms and Clinical Course.—The symptoms of pancreatic lymphangeitis are those of the causative lesion, and the local pancreatic changes are not recognized until after the abdomen has been opened. Then the head of the pancreas is found enlarged, firmer than normal, and the individual lobules are distinctly palpable, which is not the case in the normal pancreas. In true interlobular pancreatitis, the advanced stage of pancreatic lymphangeitis, the head of the pancreas (the body and tail are scarcely ever affected, for reasons already pointed out) is enlarged and hard with a nodular surface; on section, tense bands of fibrous tissue traverse the cut surfaces, accounting for the formation of the well-marked lobules. In some cases the enlargement of the head of the organ can be detected through the abdominal walls. The symptoms are those of the underlying malady, accompanied by certain additional symptoms and physical signs and certain changes in the digestive functions which characterize the condition as one of *pancreatic insufficiency*. Moreover, whenever the enlarged head of the pancreas obstructs the common bile duct (which traverses it in two-thirds of cases), there are added symptoms of *biliary insufficiency*, namely, obstructive jaundice, and its accompanying digestive derangements. The consequences of *pancreatic insufficiency* are chiefly steatorrhea, and azotorrhea:

Steatorrhea is an excess of fat in the feces. In health the feces contain about 20 per cent. of fat, which represents from 7 to 11 per cent. of the fat taken as food. After suppression of the bile alone the feces contain 60 per cent. of fat; after suppression of the pancreatic secretion, 70 per cent. of fat; and after suppression of both bile and pancreatic juice they contain 90 per cent. of fat (Carnot). Not only is the proportion of fat in the feces much increased, but very little of the ingested fat is absorbed: instead of only about one-tenth being unabsorbed, as is normally the case, as much as one-third may be unabsorbed when bile is absent from the intestinal canal, and when both bile and pancreatic juice are absent 90 per cent. of the ingested fat may be recovered from the feces. Thus where both bile and pancreatic juice are lacking the ingested fat is used hardly at all, and instead of the normal chemical changes in the ingested fat (whereby from 35 to 40 per cent. of it is converted into split fats), chemical examination of the feces shows that split fats are reduced at least to one-fifth of normal (R. Gaultier, 1905). It is seldom that excess of fat in the feces is visible to the naked eye. In well marked cases of steatorrhea the passages are bulky, of a silver, gray, or asbestos-like color, and the fat may float on the surface like oil droplets or particles of butter. But such stools occasionally occur in health after ingestion of large quantities of fatty food; and in slighter degrees steatorrhea may be caused by biliary deficiency, diarrhea, and other intestinal derangements, so that too much reliance cannot be placed on it as an indication of pancreatic insufficiency.

Azotorrhea.—This is an excess in the feces of undigested proteid material. In health about 5 or 6 per cent. of the nitrogen ingested

as food is excreted in the feces, whereas in cases of pancreatic disease various investigators have recovered from the feces as much as 32, 45, and even 70 per cent. of the ingested nitrogen. This condition occurs, according to Fitz, only when there is extreme diminution of the pancreatic juice, and is significant only when gastric digestion is normal, when the diet contains no excess of meat, and when there is no diarrhea. *Schmidt's test* consists in determining that the nuclei of the muscle cells of the ingested meat fibres are still intact, as they are digested only by the pancreatic juice. *Salomon's* test depends on the fact that lecithin is present in unusual quantities in the feces of patients with pancreatic disease; accordingly if such patients are put on an egg diet, from 0.4 to 1.2 grams of lecithin are excreted in the feces daily, instead of 0.1 gram or less, which is the normal.

The presence of *stercobilin* in the feces indicates that there is not complete obstruction to the discharge of bile into the intestines. In cases of obstructive jaundice due to chronic pancreatitis and common duct lithiasis the obstruction is rarely absolute, and a distinct though often subnormal reaction for stercobilin may be obtained: but in carcinoma of the head of the pancreas it is entirely absent or present only in very faint traces.

Urinary Changes.—As already noted glycosuria seldom occurs in interlobular pancreatitis and when present in this condition appears only very late and usually indicates an incurable lesion. "*Alimentary Glycosuria*" (that which occurs when an excess of sugar is ingested) is much more apt to occur, and may be a constant phenomenon, if there is serious disease of the pancreas (*Wille's test*). In interacinar pancreatitis glycosuria is a very frequent and an early symptom, but this disease is not amenable to surgical treatment.

A "*pancreatic reaction*" in the urine has been described by Cammidge, which he considers of very great value in the diagnosis of pancreatic lesions. The reaction consists in the crystallization from the urine of an unknown substance, possibly a pentose. Some of those who have most practical experience with the "improved test" of Cammidge speak favorably of its diagnostic value, though it is sometimes present in other abdominal diseases. But Deaver and Ashhurst say, "In our own practice we have gradually come to regard it as of less and less value." In a series of 351 tests made by Kinney for Deaver, it was found that, "roughly speaking, in all the cases in which the condition of the pancreas was determined accurately at the time of operation, this supposedly specific pancreatic reaction was obtained only about two and a half times as frequently when the pancreas was affected as when it was not."

Diagnosis of Chronic Pancreatitis.—The confidence of clinicians in their ability to diagnose chronic pancreatitis corresponds to their faith in the accuracy and reliability of the various tests for pancreatic function, particularly the Cammidge reaction. The pancreatitis, however, is to be regarded as a complication of some other disease rather than as an independent affection, and it cannot be too often

emphasized that the curable stage of the pancreatic affection vanishes when the lymphangeitic infiltration and edema give place to an interlobular sclerosis which can be no more curable than chronic nephritis or cirrhosis of the liver.

From the symptoms and physical signs, localization of the disease to the pancreatico-hepatic region almost always can be made, but in the differentiation of chronic pancreatitis from disease of the bile ducts there always is a large amount of doubt in the minds of those clinicians whose experience with the Cammidge reaction has been unsatisfactory and disappointing.

Treatment.—This may almost be summarized in the expression treat the cause. In most cases the cause is in the gall-bladder or bile-ducts, and prolonged drainage of the biliary tract allows subsidence of the pancreatic swelling, by overcoming the focus of infection to which it was due. It is not an uncommon thing for a biliary fistula to remain open for months, or for symptoms to recur if it closes too early, in cases of chronic pancreatitis. Mayo Robson and some other surgeons prefer to adopt cholecystenterostomy (p. 934) as a primary operation in such cases; but it seems more logical to attempt to relieve the biliary infection which is present by external rather than by intestinal drainage. The gall-bladder should be sutured to the parietal peritoneum or the anterior sheath of the rectus, as described at p. 931, and the resulting fistula should be kept open for several months; and it is important at the time of operation to make sure of the patency of the common duct by passing a sound through it into the duodenum.

In some cases of pancreatitis no primary lesion, not even a slight one, can be found in the biliary tract. The pyloric region of the stomach or the duodenum may then be the focus of infection, and if this is determined to be the case, such lesions should receive appropriate treatment. When no other lesion can be discovered Vautrin advocates attacking the pancreas directly, and especially urges drainage of the retropancreatic tissues after exposing this region by mobilization of the duodenum (p. 933).

Pancreatic Calculi.—These are of such rarity and so seldom produce recognizable symptoms, that they are of comparatively slight surgical importance. The pathogenesis of the stones is similar to that of biliary calculi, but their composition is very different, most pancreatic calculi being formed largely of calcium carbonate or phosphate. They are not crystalline, usually occur in large numbers strung along the pancreatic ducts like the beads of a chain, and are faceted only on their ends. They occur five times as often in men as in women, but have been diagnosed during life in very few recorded instances. There may be symptoms of coincident (and perhaps causative) biliary disease, or of pancreatic insufficiency; and as the calculi are impermeable to the *x*-ray it might be possible to recognize their shadows in a skiagraph; pancreatic colic, if it occurs, can scarcely be distinguished from that due to biliary disease.

Treatment.—Link (1911) collected six operations for pancreatic calculi, and reported a seventh operation by himself. He performed pancreastostomy (analogous to cholecystostomy) drawing the tail of the pancreas out through the transverse mesocolon, splitting the gland longitudinally, removing the calculi, and stitching a rubber drainage tube in the principal duct. The fistula was still open several months after the operation, but the patient was in good health.

Carcinoma.—Carcinoma is the most frequent tumor of the pancreas. It affects the head of the organ in more than half the cases, corresponding thus with chronic interlobular pancreatitis, though there is so far no proof that the latter disease is an etiological factor in the production of carcinoma. The tumor begins as a very small localized growth, usually as scirrhus, and sometimes gives metastases to the liver before it grows large enough to be readily recognized; hence many cases of secondary carcinoma of the liver are considered primary until a minute primary nodule is found in the pancreas. If the growth occurs in such a situation as to block the excretory duct of the pancreas and to occlude the common bile-duct the resemblance to other causes of obstructive jaundice (common duct lithiasis, chronic pancreatitis, tumors or strictures of the choledochus) is very close, and differential diagnosis may be difficult. In most cases, however, of malignant obstruction of the common duct the gall-bladder becomes enlarged (*Courvoisier's Law*, p. 926), and in very many cases can be easily recognized through the abdominal wall as a globular tumor, moving with respiration, and continuous with the liver dulness which often also is greater than normal.

Symptoms and Diagnosis.—There are no pathognomonic symptoms. The original clinical description, given by Bard and Pic (1888) (which comprised *steadily increasing jaundice*, *enlargement of the gall-bladder* and *rapid emaciation*), constitutes a syndrome or group of symptoms common to any lesion which causes obstruction at the papilla of Vater (Fig. 902). A carcinoma of the pancreas may grow in situations other than the head of the gland without producing this syndrome, and various other conditions may cause obstruction at the papilla of Vater and thus give rise to this same group of symptoms. In the typical case of carcinoma in the head of the pancreas, a patient, usually over forty years old, complains for an indefinite period of vague upper abdominal symptoms having no localizing character. Then jaundice appears painlessly, and continuously deepens; the gall-bladder enlarges, and the patient loses weight and strength very rapidly. Pain may or may not be a conspicuous feature. Fever usually is absent. Jaundice never lessens, but continuously grows deeper; signs of pancreatic insufficiency are present, and stercobilin is persistently absent from the feces.

When the abdomen is opened and the pancreas is examined directly by sight and touch it often is impossible to differentiate carcinoma and pancreatitis. In most cases reliance must be placed on the clinical history of the disease. In pancreatitis the usual cause is biliary infec-

tion, which seldom is present in carcinoma. In pancreatitis there are recurrent attacks of pain, fever, jaundice, characteristic of stone in the common duct; while in carcinoma the onset is insidious, the course of the disease is chronic, and there are no periods of remission. In pancreatitis the gall-bladder is contracted and friable, and usually is surrounded by adhesions; in carcinoma it is enlarged and distended, and is much more tough and resistant than in cases of pancreatitis.

Treatment.—Medical treatment is the only palliative treatment that is to be countenanced. *Palliative operations* (cholecystostomy and cholecystenterostomy are those available) neither prolong the patient's life nor promote his comfort, and should be done only when there is a probability that the condition is not malignant, and that prolonged drainage of the biliary tract may succeed in overcoming the obstruction of the common duct. *Radical operation*, which scarcely ever is possible, consists in excision of the head of the pancreas (**cephalic pancreatectomy**). This implies also resection of the descending duodenum, as removal of the pancreas jeopardizes its blood-supply. The technique, which has been systematized by Desjardins (1907) and Sauvé (1908), comprises section of the pylorus, mobilization of the duodenum, section of the duodenum on the right of the superior mesenteric artery, division of the pancreas (well beyond the growth), and section of the common bile-duct. Then it remains to reëstablish the continuity of the gastro-intestinal tract by gastrojejunostomy; to implant the choledochus into the intestine or stomach; and finally to drain the remaining portion of the pancreas into the intestine (**pancreatoenterostomy**, Coffey, 1909). If the tumor is in the body of the pancreas, the organ may be resected and its two ends reunited, as done by Finney; or if the tail only is involved, it may be removed and the stump closed.

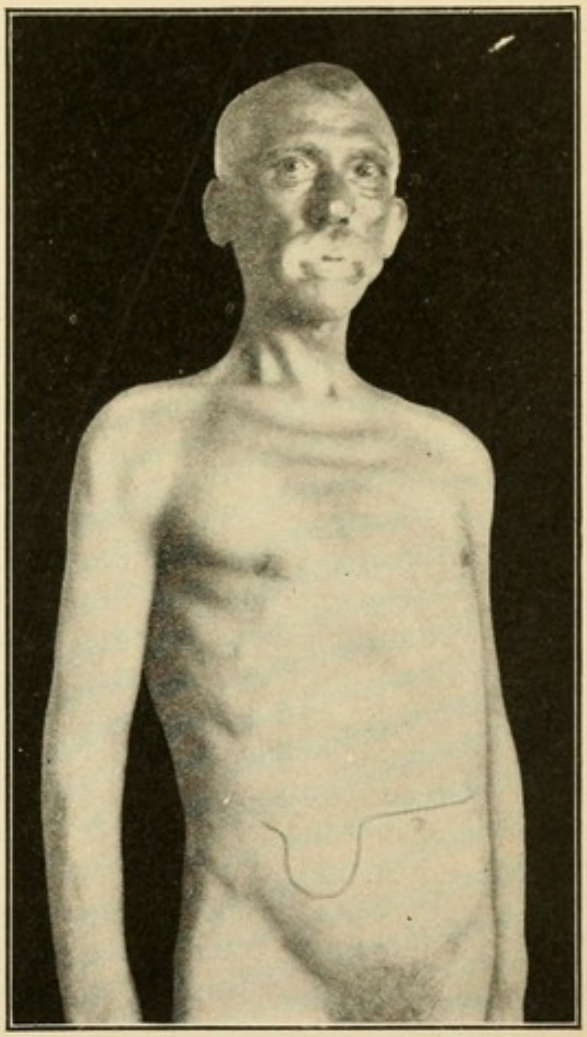

FIG. 902. — Obstructive jaundice: enlargement of the gall-bladder and liver, probably from carcinoma of the head of the pancreas. An inoperable case. German Hospital. (Deaver and Ashhurst.)

Cysts of the Pancreas.—These are classed as *true cysts* (those due to retention, cystic neoplasms, hydatid cysts, etc.) and *pseudo-cysts* (cysts which arise in close association with the pancreas and involve it secondarily). Pseudo-cysts are more frequent than true cysts, and usually are formed by effusions which result from abdominal injuries.

The affection is commonest in early adult life, and in many cases a history of traumatism can be obtained, though it may have occurred several years previously. The existence of *retention cysts*, the result of occlusion of the ducts by calculi or chronic pancreatitis, is so rare that it is of pathological interest only. *Cystic new growths* also are rare, whether benign or malignant, and the cysts which result seldom are large. *Traumatic cysts* form the vast majority of cases seen by the surgeon, and they are frequently situated in the lesser peritoneal cavity, having only secondary connections with the pancreas. The contents of the cyst usually are light brown, being tinged by the blood in the original hematoma, or from hemorrhage into the cyst at a later period; and examination often detects the presence of one or more of the pancreatic ferments.

Symptoms and Diagnosis.—Apart from rather vague digestive symptoms and recurring attacks of acute epigastric pain, which seldom are entirely absent, there is little on which to base a diagnosis until a *tumor* can be detected, or at least until it is of such size as to cause *pressure symptoms*. The latter comprise gastric symptoms, with recurring attacks of pain and vomiting; jaundice from biliary obstruction; and constipation from pressure on the colon. Symptoms of pancreatic insufficiency are rather unusual. The tumor which finally develops may present through the *gastro-colic omentum*, through the *gastro-hepatic omentum*, or *below the transverse colon*. The relation of the stomach and colon to the cyst may be determined by percussion, after distending these organs with air. In rare cases the cyst may grow backward into either flank. Most cysts transmit the pulsations of the aorta, but this ceases when the patient assumes the knee-chest posture. Disappearance of a cyst may result from its rupture into the intestinal tract, whereupon large quantities of saliva-like fluid are discharged from the bowel; usually the cyst refills.

Diagnosis.—A pancreatic cyst must be distinguished from *mesenteric* and *omental cysts;* from *kidney*, *suprarenal* and *hepatic cysts;* from *an enlarged gall-bladder;* from *ovarian cysts;* from *cysts of the spleen;* and from *aneurysm of abdominal aorta*. As a rule the history, the relation existing between the stomach and colon and possibly signs of pancreatic insufficiency, make the diagnosis fairly certain in most cases.

Treatment.—Operation is indicated, as there is no hope of spontaneous cure. If the cyst is small and pedunculated (which is rare) it may be possible to extirpate it completely. In most cases marsupialization must be done—the cyst being evacuated and its cavity being drained with gauze and tube. Closure of the resulting fistula may be accelerated by adherence to an antidiabetic diet.

SURGERY OF THE SPLEEN.

Most of the conditions which are of surgical interest cause an **enlargement of the spleen**, and it is important to be able to differentiate an enlarged spleen from other abdominal tumors.

General Diagnosis of Abdominal Tumors.—**Splenic Tumors.**—These may be almost of any size, even filling the greater part of the abdomen. In most cases, however, the enlargement is greatest on the left side, and the spleen unless fixed by adhesions, moves with respiration. The enlarged spleen is so closely applied to the abdominal wall that it is impossible to insinuate the hand between its upper margin and the costal border; it has a sharp inner border which is almost always interrupted by one, two, or three notches. Splenic tumors always grow forward; they never produce fulness in the loin. The dulness on percussion extends up to the sixth rib or higher in the mid-axillary line. The colon is first displaced downward, and later lies behind the enlarged spleen, so that any resonance due to it will be in the flank or loin. In many cases of splenic enlargement the blood examination aids in making a diagnosis.

Kidney Tumors rarely come into close contact with the anterior abdominal wall, and even when they do, they also cause marked bulging in the loin. They have a rounded contour, with no sharp, notched anterior border. The range of motion is much less than in the case of the spleen, and the tumor does not move with respiration. In all but the very largest tumors the hand can be insinuated between the costal margin and the upper border of the kidney. The descending colon overlies the anterior surface of the kidney and is pushed forward when the kidney enlarges. Thus there is resonance anterior to the tumor and dulness in the loin, which is the reverse of what is present in the case of a tumor of the spleen. Other important differential signs are obtained by cystoscopy, catheterization of the ureters, and examination of the urine.

Suprarenal Growths give much the same physical signs as kidney tumors, but the colon often is pushed downward instead of forward. Hematuria is frequently present.

Periphrenic Abscess, apart from evidences of suppuration, resembles enlargement of the kidney rather than splenic tumor.

Ovarian Tumors.—In the case of a wandering spleen of nearly normal size, which has become fixed in the pelvis, confusion might arise unless a distinct notch could be felt. In other cases ovarian and splenic tumors could scarcely be confused. The upper border of an ovarian tumor is very seldom in actual contact with the left costal margin unless it reaches also to the right costal margin. Ovarian tumors grow upward from the pelvis; they do not move with respiration; and have no sharp border with one or more notches. They extend further across the middle line and cause more symmetrical enlargement of the abdomen. Vaginal examination shows the tumor in close association with a normal sized uterus, and frequently the pedicle of the cyst

can be felt through the rectum. There is usually an area of resonance between the upper border of dulness over an ovarian tumor and the normal area of splenic dulness.

Growths of the Colon at the Splenic Flexure.—Most of these tumors cause intestinal obstruction before a palpable tumor develops, but occasionally a diffuse non-obstructing carcinoma occurs which may have to be differentiated from an atypical enlargement of the spleen. A tumor of the colon has not the definite shape of an enlarged spleen, nor has it the same close apposition to the abdominal wall throughout its extent. It usually is dull to superficial and resonant to deep percussion. It seldon moves much during respiration, but unless fixed by adhesions changes its position to a marked extent with changes in the patient's posture. Sooner or later intestinal obstruction and metastasis develop, but exploratory laparotomy should be done before this stage is reached.

Tuberculous Peritonitis.—In this condition, already studied in Chapter XXII, tumors of various sizes and shapes may form in the abdomen, and one which forms in the left hypochondrium, particularly if adherent to the spleen, may closely simulate a splenic tumor. But the range of motion is limited by adhesions, and although the anterior border of such a mass may feel quite sharp and well defined, it seldom exhibits a notch similar to those on the spleen. Moreover, other foci of tuberculosis often can be detected, and the tuberculin test may be of value.

Retroperitoneal Tumors are comparatively rare. The least unusual variety is a *diffuse lipoma*, which is clinically semi-malignant, tending to recur after partial extirpation. Complete extirpation is not possible. *Sarcoma* also occurs as a retroperitoneal tumor, usually arising in the lymph nodes. These retroperitoneal tumors usually present within the circle formed by the large bowel, offering to percussion a dull note surrounded by intestinal tympany. Inflation of the stomach and colon, and exmination in the Trendelenburg and knee-chest positions should be employed in obscure cases.

Causes of Enlargement of the Spleen.—There are two groups of cases associated with splenomegaly: (1) Those in which the blood changes are distinctive (which include most cases of malaria, the leukemias, pernicious anemia, splenomegalic polycythemia, typhoid fever, and kala-azar). (2) Those in which they are not distinctive. A positive diagnosis cannot be made without a blood examination. With the exception of certain cases of malaria, *splenectomy is absolutely contraindicated in cases included in the first of these two groups.* In the second group (no characteristic blood changes) are included.

1. *Cases in which splenectomy may be necessary* (movable spleen, cysts, tumors, tuberculosis, abscess, Banti's disease).

2. *Cases in which splenectomy is contraindicated* (congestion, infarct and thrombosis, infectious fever, Hodgkin's disease, cases of portal obstruction, amyloid disease, pseudo-leukemia, hereditary and family forms of splenomegaly, etc.).

Movable Spleen.—This occurs oftenest in women, as in the somewhat analogous condition of hepatoptosis, already described. Increased weight, from enlargement, prediposes the spleen to ptosis, but in many cases of enlarged spleen adhesions hold the organ in place. A movable spleen is of surgical importance chiefly because of the accidents to which it is subject, notably *acute torsion of its pedicle.* This is accompanied by paroxysmal pain, with reflex vomiting, shock, and perhaps by the later development of gangrene of the spleen and peritonitis. In *chronic torsion* the twist of the pedicle is tight enough only to cause congestion of the spleen which leads to perisplenic adhesions. Recurrent acute attacks may lead to the same results, and the spleen may become fixed in an abnormal position, a condition described as *dislocated spleen.*

Diagnosis.—The diagnosis of a movable spleen is made by recognizing in the movable tumor the size, consistency, and shape of the normal spleen, and by the possibility of the reduction of the spleen to its normal position when the patient is recumbent. The diagnosis of a dislocated spleen is difficult, owing to the adhesions which obscure its shape.

Treatment.—If no symptoms are produced it is sufficient for the patient to wear an abdominal support which will tend to keep the spleen in place. In most cases where symptoms are present, splenectomy is indicated. Splenopexy does not give satisfactory results.

Cysts of the Spleen.—Hydatid cysts are extremely rare. By far the greater number of splenic cysts are non-parasitic in type, and most are the result of traumatism, though lymphangeiomatous and sequestration cysts may occur, as well as cystic degenerations following embolism.

Symptoms.—The symptoms are those usual in cases of splenomegaly and the diagnosis depends on recognition of the cystic character of the enlargement.

Treatment.—The most satisfactory treatment is splenectomy.

Abscess of the Spleen may occur in pyemia, but cases of surgical interest usually develop in the course of some infectious fever, especially malaria, and rarely typhoid, dysentery, influenza, and dengue. These abscesses usually are single and of large size. The *diagnosis* depends on recognition of enlargement of the spleen with general and local signs of suppuration. *Treatment* usually must be confined to incision and drainage, since perisplenic adhesions render splenectomy difficult or impossible.

Splenic Anemia, or **Banti's Disease,** described by Banti in 1888, is characterized by great chronicity and three definite clinical and pathological stages: (1) *Simple enlargement of the spleen.* (2) *Enlargement with secondary anemia.* (3) *Cirrhosis of the liver with splenomegaly.* The cause of the disease is unknown, but it is believed to be infectious in origin. The great majority of cases begin in early adult life, and the sexes are about equally affected. The disease extends over a period of from five to twenty-five years, and always terminates fatally unless the spleen is removed.

Pathology.—The spleen enlarges steadily but retains its normal shape. The average weight is from 1500 to 1750 grams. Usually numerous and dense perisplenic adhesions develop, and the capsule and fibrous trabeculæ of the spleen undergo hypertrophy, but the most notable change is hyperplasia of the reticular fibres without any marked change in the cellular elements. The Malpighian corpuscles are overgrown with connective tissue, and there is proliferation of the endothelium of the sinuses. Often fairly normal areas of the splenic tissue remain in certain places. The amount of endothelial proliferation may be so great as to cause the characteristic change known as *Primitive Endothelioma of the Type of Gaucher*. The splenic vein is always more or less sclerosed, and this change may also affect the portal vein. Cirrhosis of the liver does not develop until late in the second stage of the disease, and from this time on the changes cannot be distinguished from those of Laennec's atropic cirrhosis.

Symptoms and Diagnosis.—The *first stage* (simple enlargement of the spleen) develops insidiously and lasts a long time. There is enlargement of the spleen which may not be discovered until it is of great size, but no other symptoms exist. In *the second stage* there are added to the splenic enlargement symptoms of anemia (pallor, weakness, dyspnea, palpitation). The anemia is of the chlorotic type—diminution of red blood cells and hemoglobin with a low color index. There is also leukopenia with relative lymphocytosis. But the symptoms of anemia may be out of all proportion to the blood changes. The amount of urine is decreased, and it contains urobilin and albumin intermittently. Finally the liver begins to enlarge, and subsequently or even previous to palpable enlargement of the liver, gastro-intestinal hemorrhages (particularly hematemesis) occur. This second stage of the disease lasts from eighteen months to several years. With the approach of the *third stage* the liver diminishes in size, ascites develops, the hemorrhages increase, the urine is still further diminished and contains urobilin and at times bilirubin, the skin develops pigmentation and sometimes toward the end of the disease true jaundice occurs.

Much dispute as to minor points still exists, but the above description gives the essentials of the clinical course of the disease. The **diagnosis** usually is impossible in the first stage, which often is classed as "*idiopathic splenomegaly*." Even after the appearance of anemia differential diagnosis may be difficult. In *cirrhosis of the liver* gastro-intestinal hemorrhages and ascites with decrease in size of the liver usually appear before enlargement of the spleen. In *pernicious anemia* the anemia is greater than in Banti's disease, the color index is high, and nucleated red blood cells and poikilocytes are present. In Banti's disease the hemoglobin seldom is below 40 per cent. unless there has been a recent severe hemorrhage, as in Morris Lewis's case. In *malarial splenomegaly* the parasite usually can be found in the blood, the history of the case is different, and quinine may be curative. *Leukemia* is disclosed by the blood examination. *Splenomegaly in childhood* (Fig.

903) is very difficult to distinguish from Banti's disease. Some of the cases probably are Banti's disease. The *pseudoleukemia infantium* of von Jaksch usually appears in the second year of life, is characterized by very grave anemia (red blood cells, 1,000,000; normoblasts; poikilocytosis), by leukocytosis (15,000 to 20,000) and lymphocytosis. There is marked splenomegaly and usually moderate enlargement of the liver. Banti's disease must also be distinguished from *syphilitic splenomegaly*, *amyloid spleen*, and from *family types of splenomegaly in childhood*. *Hemolytic splenomegaly*, recently described by Banti, which resembles both Banti's disease and hemolytic jaundice, is cured promptly by splenectomy.

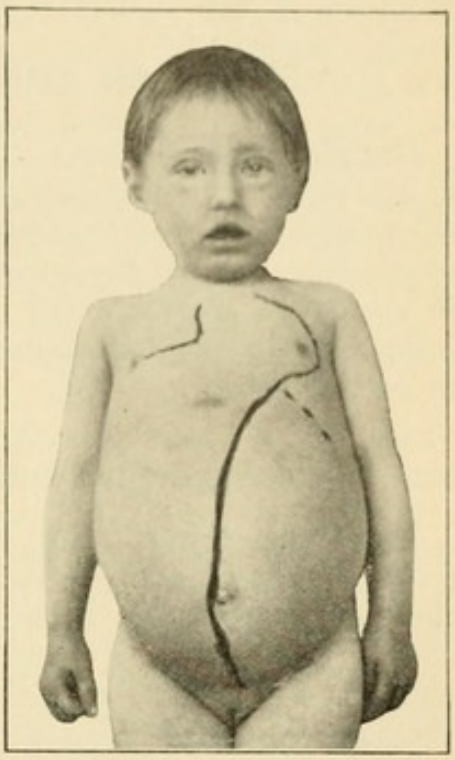

FIG. 903.—Splenomegaly in a child aged three and a half years. (Dr. Newlin's case.) Pennsylvania Hospital.

Treatment.—The only treatment which has any effect on the disease is removal of the spleen, and this is effective only if done before cirrhosis of the liver (third stage of disease) develops. The presence of slight ascites, with enlargement of the liver, which occurs in the end of the second stage of the disease is not a contraindication to splenectomy, as these symptoms do not indicate irremediable changes in the liver. The immediate mortality of splenectomy is lowest in the first stage of the disease, and increases the longer the operation is postponed. The average immediate mortality is about 25 per cent.; permanent cure results in almost all cases where operation is done in the first stage, in from 50 to 75 per cent. of those in the second stage, and in few or no cases in the third stage.

Splenectomy.—The best incision is one on the left corresponding to Czerny's gall-bladder incision (Fig. 892). If no adhesions are present the operation is not difficult. The most important point is the control of hemorrhage. The capsule of the spleen and the veins in its pedicle are easily torn. It is best if possible to separate adhesions first, and to cut the lienophrenic ligament and then rotate the spleen toward the mid-line. If the hand can be introduced gently between the spleen and diaphragm, the former may be drawn down into the wound. If the vessels in the pedicle are not too large they should be clamped close to the spleen, and the spleen removed after cutting between the clamps and the spleen. In some cases the tail of the pancreas is cut off also (Mayo), but if carefully sutured no fistula will result. Unless there is enough tissue left in the pedicle for the safe application of ligatures it is best to leave the clamps in place for several days. In most cases it is well to leave a gauze drain in the wound.

CHAPTER XXV

SURGERY OF THE BLADDER AND KIDNEYS.

GENITO-URINARY surgery has been developed into such a specialty of late years that it is impossible in a text-book such as this to do more than indicate in the briefest possible manner the general principles of diagnosis and treatment of most of the affections, and to describe in somewhat greater detail, but by no means at full length, those conditions of common occurrence which are constantly encountered in general practice.

GENERAL DIAGNOSIS OF URINARY DISORDERS.

The surgeon must study the urine or other secretions discharged from the urethra, and examine the genito-urinary organs themselves. A thorough examination includes macroscopical and microscopical study of urethral discharges (both those which are apparent, and those obtained after stripping the prostate and seminal vesicles, p. 1013); chemical and microscopical study of the urine, which should be collected in three glasses for macroscopical inspection; instrumentation with sound or catheter; and cystoscopic examination. In many cases bacteriological study of the urine, pus, etc., also is necessary.

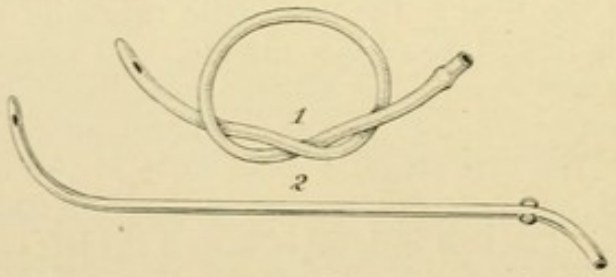

FIG. 904.—1, soft rubber catheter. 2, metal catheter.

Catheters.—Catheters are hollow tubes designed to draw off the contents of the bladder (Fig. 904). If they are of *metal* (usually nickel-plated) they must have a curve corresponding to that of the urethra. Sir Henry Thompson's instruments were curved at the point through an arc which corresponds to the fourth of the circumference of a circle whose diameter is three and one-quarter inches. *Flexible catheters* have no fixed curve; they are of two principal kinds: the soft rubber catheter (Nélaton's), and the English catheter. The latter is made of webbing and is covered with shellac. It is provided with a stylet, and when used with this in place, is fairly rigid; or if used without the

stylet, as is safer and customary, may be made to retain any curve for a short time by moulding it in warm water and then quickly plunging it into cold water when it becomes stiff. A catheter should be ten or eleven inches long, and provided with one or two large, smoothly finished eyes near its vesical extremity; all catheters should be solid from the eye to the point, thus leaving no pocket for the accumulation of decomposing blood or inspissated pus. An English catheter should have the eye woven in its manufacture, not punched out after the catheter has been made; and if used with the stylet, great care must be taken not to have the stylet so long that there is danger of its protruding from the eye. The calibre of urethral instruments usually is based on the French scale, which gives the diameter in thirds of a millimeter (practically the circumference in millimeters). The sizes in common use range from 10 to 40; the average adult urethra accommodates a sound of from 30 to 32 Fr. A rigid instrument smaller than No. 10 is dangerous and should not be used.

Introduction of the Catheter.—The greatest damage may be inflicted from neglect of proper antiseptic and aseptic precautions. Metallic and soft rubber instruments may be boiled just before use; but as webbing instruments will be ruined by heat, they should be soaked in a 5 per cent. solution of formalin (cold) for twenty minutes and before being used should be rinsed in cold sterile water, as the formalin solution might cause urethritis. The patient should be lying down; and the surgeon after washing his own hands (and wearing gloves if possible) should retract the patient's foreskin, and wash the glans well with soap and water and rinse it in alcohol. The instrument should be well lubricated with some sterile oil, such as a preparation of Irish moss, or glycerin; and it often is well to distend the urethra by injecting the lubricant directly into it from a syringe. A soft catheter is introduced by inserting its point in the meatus and gently pushing it onward into the bladder little by little, always holding it close to the glans penis. A metallic instrument is most easily inserted while the surgeon stands at the patient's left. After raising the penis in the left hand the surgeon gently inserts the tip of the instrument within the meatus, while its shaft lies along the left groin. Then without raising the shaft from the plane of the body, it is carried over to the mid-line, as the tip of the instrument sinks into the penile urethra; it should enter by its own weight and should not be forced. Not until the point has reached the bulbous urethra should the handle be raised from the patient's abdomen. As the handle is gently raised the point glides under the pubis, traverses the prostate, and enters the bladder (Fig. 905). If the handle is raised too soon the point will catch in front of the triangular ligament. When the point has successfully passed this region, and the handle of the instrument is nearly vertical, the left hand may be placed on the convexity of the instrument, in the perineum, and thus guide it into the bladder. When the catheter has entered the bladder it can be rotated freely in the urethra, on its own axis, and its shaft lies between the patient's

thighs making an angle of 45° or less with the horizon. An instrument may also be passed from the patient's right side by the manœuvre known as the *tour de maître:* the instrument is introduced with its convexity upward, and as its point reaches the bulb the shaft is swept around toward the abdomen, and is raised to the vertical and then depressed between the patient's thighs as the instrument enters the bladder.

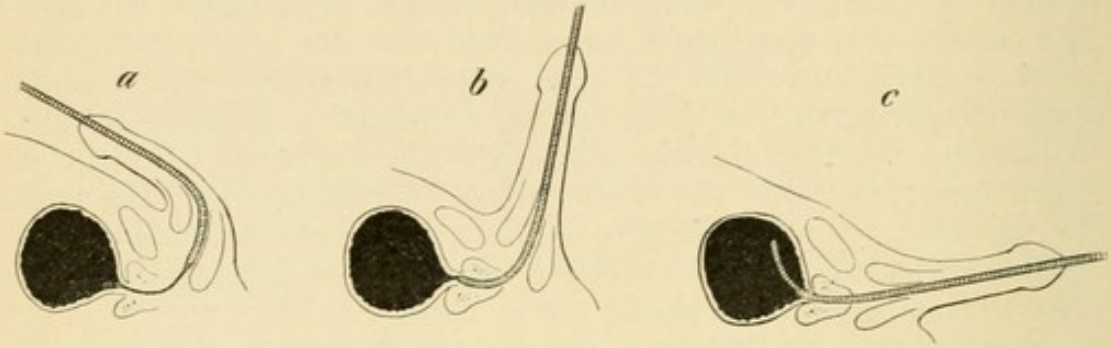

FIG. 905.—Method of introducing a metal catheter.

Cystoscopes.—A cystoscope is an instrument designed to permit visual inspection of the interior of the bladder. In the female it is possible to accomplish this by direct vision, using a narrow speculum (Kelly's cystoscope) and placing the patient in the knee-chest or exaggerated Trendelenburg position so as to allow the bladder to become distended with air so soon as the speculum is introduced. In

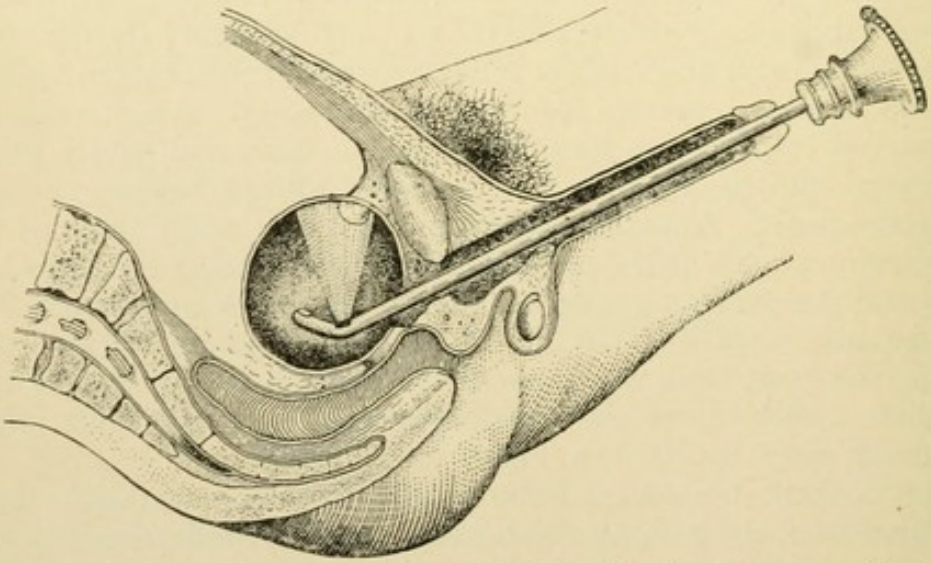

FIG. 906.—Illumination of anterior vesical wall by Nitze's cystoscope. (Park.)

men, however, it is necessary to have an instrument somewhat resembling a catheter, provided with an electric light at its vesical extremity and a series of lenses by which the image is transferred to the outer end of the instrument where the examiner's eye is placed (Fig. 906). In most cystoscopes, the system of lenses reverses the image, but by inserting another lens, the image may be righted again; this, however,

makes the apparatus more complicated and cuts down the amount of light. Cystoscopic examination requires skill and practice, and should not be attempted without ample training. In many cases it may be accomplished after anesthetizing the deep urethra with a 4 per cent. solution of eucain, but sometimes a general anesthetic is required. Before the cystoscope is inserted the bladder should be emptied of urine, and irrigated if necessary to cleanse it of blood or pus; about four ounces of solution are left in the bladder. Then the cystoscope (sterilized in carbolic acid or formalin solution—it cannot be boiled) is introduced, and after its point is within the bladder, the electric current is turned on, and the examiner proceeds to inspect the interior of the bladder. The ureteral orifices may be seen and the swirl of urine discharged from each may be readily recognized, as also the discharge of blood or pus instead of urine. The condition of the vesical mucous membrane is also studied; foreign bodies, tumors or calculi are searched for; the presence and situation of the orifices of diverticula are located, etc. Some cystoscopes are provided with slots through which a fine catheter may be passed, for the purpose of catheterizing the ureters; and through some it is possible to insert delicate instruments and under the control of vision make applications to ulcers, cauterize or snare off tumors, remove small foreign bodies, etc. An **endoscope** is an instrument similar to a cystoscope, but designed to examine the interior of the urethra.

Estimation of the Functional Capacity of the Other Kidney.—Always before one kidney is removed, and in a great many other cases, it is necessary for the surgeon to determine the functional capacity of the healthy (or less diseased) kidney. The simplest way to do this is by **chromoureteroscopy**, by means of the indigo-carmine test; this was introduced in 1903 by Völcker and Joseph, and has been popularized in this country by B. A. Thomas: 20 c.c. of a 0.4 per cent. solution, or 4 c.c. of a 4 per cent. solution of indigo-carmine are injected hypodermically, and a cystoscope is introduced. The urine is stained blue, and if the kidney is healthy the stain will appear in the urine as it is discharged from the ureter of the kidney in question within nine minutes of the time it was injected hypodermically. A delay of more than twenty minutes in the appearance of the stain indicates serious incompetency.

Other methods involve the collection of urine from each kidney separately. This is best accomplished by **catheterization of the ureters.** Then one may use, in addition to the ordinary chemical and microscopical tests of the separate urines, also what is known as the *phenolsulphonephthalein test,* which is highly commended by H. H. Young: "The patient is given three glasses of water to drink, and is then catheterized and the bladder washed out just before inserting 1 c.c. of fluid containing 6 mg. of the drug intramuscularly or intravenously. The time of the appearance of the first faint pinkish tinge as the urine escapes from the catheter into the test-tube, made alkaline by adding a drop of 25 per cent. NaOH solution, is noted as the beginning of the

test." In healthy patients the drug appears in the urine about seven minutes after it is administered; 40 to 60 per cent. is excreted in the first hour, and from 20 to 25 per cent. in the second hour. The *phloridzin test* is less accurate: this is based on the power of the normal kidney to excrete sugar within a given time; the diseased kidney loses in part or entirely its permeability to sugar. After the ureteral catheters are in place, 20 minims of a 1 per cent. solution of phloridzin are injected hypodermically; glycosuria should appear within from fifteen to thirty minutes, and usually disappears after three hours. *Cryoscopy*, the estimation of the freezing-point of the blood and urine, is rather a complicated test, and of uncertain value.

SURGERY OF THE BLADDER.

Exstrophy of the Bladder is a congenital deformity due to a defect in the closure of the hypogastric region of the abdominal wall. The pubic bones often are ununited, and epispadias (p. 1045) and sometimes inguinal hernia may also be present. The deformity is much commoner in male than in female children. The anterior wall of the bladder being absent, the intra-abdominal pressure forces out the posterior wall, and the mucous surface presents itself as a red, moist protrusion, often with the ureteral orifices readily visible. Urine dribbles constantly, the mucous membrane and surrounding skin become much inflamed, and ascending infection of the kidneys almost invariably follows; it is said that in about half the cases death ensues from this complication before the tenth year.

The only effective **treatment** is by operation, of which there are two main classes:

1. Those which aim to cover in the protruding bladder wall by some form of *plastic operation*. Of these methods the best is that of John Wood (1865), in which a cutaneous flap from below the umbilicus is inverted over the bladder, and is covered by two flaps slid inward from the groins, or by one large "bridge flap" from the scrotum (Richard). Though this does not restore sphincteric control, it narrows the opening for the discharge of urine and makes it possible for the patient to be kept clean by wearing a urinal; but in many cases cystitis occurs and vesical calculi form, and ascending kidney infection causes death. Moreover, if hairs grow on the inverted skin surface they cause additional trouble.

2. The other plan of operation, and that which is most in favor at the present day, consists in *transplanting the ureters* or, preferably, the base of the bladder containing the ureteral orifices, into the large bowel (rectum or sigmoid), thus allowing the urine to collect in the rectum where it may be retained by the sphincter several hours at a time. Here also, however, there is great danger of ascending kidney infection, even when the valve-like insertion of the ureters in the bladder wall remains intact in the transplanted segment; and the primary mortality is even higher than in the autoplastic methods.

Urachal Cysts and Fistulæ.—If the allantoic duct of the embryo fails to close at the umbilicus a **fistula** remains which may discharge urine if it is patent all the way down to the bladder, or which if closed at its vesical end may discharge only mucoid fluid. Sometimes a fistula of the urachus will close spontaneously after obstruction to the natural outflow of urine is removed, but in most cases excision of the fistulous tract is required. If the urachus closes at both ends, a **cyst** may form in its course. These urachal cysts seldom give rise to recognizable symptoms, and usually are found unexpectedly at operation. Excision is the proper treatment.

Cystitis.—Inflammation of the urinary bladder in almost all cases is caused by bacteria, which are introduced from without or which reach it through the urine delivered from the kidneys. Unless there is obstruction to the outflow of urine through the urethra it is difficult to infect the healthy bladder with germs of ordinary virulence, and *bacteriuria* (see below) may exist a long time without the occurrence of cystitis. An ordinary mild attack of cystitis tends to spontaneous recovery; but the occurrence of congestion of the bladder (from internal medication, exposure to cold, instrumentation, etc.) predisposes it to infection, as does the presence of foreign bodies (calculi). Unclean, or even clean catheterization, if frequently repeated, is the most frequent cause of cystitis; but extension backward of an acute or chronic urethritis, or the descent from the kidney of urine contaminated with tubercle or typhoid bacilli, are other usual causes. Colon bacilli are those most often introduced by instrumentation.

The usual changes met with in inflammation of mucous surfaces are present: an abundant mucous secretion, desquamation of epithelium, and if the infection is severe, ulceration of the bladder. Perforation is excessively rare. In cases of long standing, infiltration of the bladder wall occurs, the muscular coat is more or less replaced by fibrous tissue, and as this contracts the capacity of the bladder is much decreased and its elasticity is destroyed.

Symptoms.—*Pain, frequency of urination*, and *changes in the composition of the urine*, are the cardinal symptoms of cystitis. The pain, which is felt mostly in the perineum or behind the pubis, varies with the acuteness of the attack, and may be present only during urination, or there may be a constant burning or sense of weight. The urine is passed frequently, in small quantities, and with considerable tenesmus; it is clouded by pus and mucus, and occasionally is blood-stained. The pus will cloud all the urine, whether this is collected in one, two, or more glasses. *In acid urines* are found the B. coli communis, B. tuberculosis, B. typhosus, pneumococcus, and gonococcus; *in alkaline urines*, staphylococci, streptococci, B. proteus, etc. Constitutional symptoms are unusual except in very severe grades of acute cystitis, and they often indicate renal complications.

Treatment.—As already noted, most cases of cystitis tend to spontaneous recovery unless there is urethral obstruction, or unless the infecting source continues active. The first point in treatment is to

determine the source of infection and remove it. If no exterior source can be determined, and if no urinary obstruction exists, it is probable that the kidney is at fault. If cystoscopy cannot be done the fact that the cystitis has its origin in an infected kidney often must be surmised only by exclusion of all other factors, and by noting pain and tenderness over, and perhaps enlargement of the kidney.

In the Acute Stages.—Put the patient to bed and keep him on a liquid diet, with plenty of water, and some demulcent such as flaxseed tea. An alkaline diuretic should be given, especially citrate or acetate of potash; and when the most acute symptoms subside, some antiseptic such as phenyl salicylate or hexamethylenamine may be administered. Watson says the urine should be made alkaline before these are employed, to avoid too great irritation of the bladder; others think hexamethylenamine is valueless so long as the urine is alkaline. If there is much pain or violent tenesmus, no hesitation should be felt in giving opium and belladonna by rectal suppositories or hypodermically. Local hot applications (sitz-baths) are grateful to the patient; and in case retention of urine (p. 1015) occurs, every such method should be tried before resorting to catheterization, and if this becomes necessary only a soft instrument should be used.

When the *chronic stage* is reached much good may be accomplished by irrigation of the bladder. Saline or boric acid solution may be used in ordinary cases, and in more rebellious cases permanganate of potash (1 to 8000) or silver nitrate solutions (1 to 2000 to 1 to 100). **Irrigation of the Bladder** is best accomplished through a soft catheter, to the outer end of which a small funnel is attached; the fluid is then allowed to run in gently by the force of gravity. By inserting a nozzle just within the meatus, and raising the reservoir to a height of from three to five feet, it is possible to overcome the sphincter and irrigate the bladder without the introduction of a catheter; but unless very skilfully done this method is more painful. Not more than a couple of ounces should be introduced at first, but after several sittings which should take place every second or third day, the amount may be increased up to the tolerance of the bladder. The surgeon should not imagine, however, that he is operating by a species of hydraulic mining, and no force whatever must be employed. In chronic cystitis with urinary obstruction it often is well to let the catheter remain in place, thus securing better drainage; and as a last resort it may be necessary to perform suprapubic or perineal cystotomy to secure free drainage.

Bacteriuria.—Bacteriuria is a condition in which bacteria are found in large quantities in the urine, but in which local symptoms are slight or absent. The bacteria most often encountered are the colon and typhoid bacillus and the Staphylococcus albus. The source which supplies the bacteria (kidney, prostatic urethra) should be determined and suitably treated. Bladder irrigations are of no use; but deep injections into the prostatic urethra, or irrigation of the kidney pelvis after catheterization of the ureter, usually prove efficient.

When no source of infection can be detected, a prolonged course of urinary antiseptics, or administration of autogenous vaccines may prove curative.

Diverticula.—Diverticula of the bladder sometimes occur in cases of chronic cystitis, usually as the result of back pressure from urethral obstruction. They are most frequent on the extraperitoneal surface of the bladder. The urine which collects in them stagnates, and calculi frequently form. Occasionally perforation occurs. The diagnosis is best made by cystoscopy; but occasionally the presence of a diverticulum may be suspected if residual urine is found sometimes but is entirely absent at other times, or if after washing out the bladder until the solution returns clear, a sudden gush of purulent urine occurs.

Treatment.—The only satisfactory *treatment* is excision of the diverticulum; at the same time, or previously, all causes of urinary obstruction should be overcome. If operation is refused, temporary improvement may be secured by vesical irrigation and treatment of the urinary obstruction.

Tuberculosis.—Tuberculosis of the bladder almost always is secondary to the disease elsewhere in the body, especially in the kidney or epididymis. Although constantly exposed to infection when the secretions of these organs enter it, the bladder successfully resists infection for a long time, and even when infected is able for a long time to recover its health spontaneously if the source of infection is removed. If this source is the kidney, the vesical lesion begins around the ureteral orifice; while if infection is received from the ejaculatory ducts through the urethra, the vesical trigone is the part first affected. The affected areas are at first mere patches of congestion; then whitish tuberculous nodules appear, break down, and form small round ulcers which tend to preserve this typical rounded form even when they have coalesced. Advent of mixed infection causes rapid spread of the lesions

Symptoms.—Frequency of urination is the earliest, and for a long time may be the only subjective symptom, though blood in microscopic quantities usually will be found in the urine if looked for. As the process advances, urination becomes excessively painful, there is great and incessant tenesmus, and the pain is referred to the end of the penis, the thighs, and the perineum. The urine is acid, increased in quantity, and in time becomes intermittently or constantly bloody and shreddy. By this time signs of tuberculosis elsewhere in the body usually have appeared. The finding of tubercle bacilli in the urine may be very difficult, but innoculation experiments may serve to confirm the diagnosis.

Treatment.—In addition to the general treatment suitable in every case of tuberculosis, it usually is possible to cause arrest or even complete cure of the vesical lesion, if the primary focus (kidney, testicle, etc.) is removed. Even if both kidneys are diseased, it seems that the removal of the more diseased organ improves the condition,

not only of the bladder, but of the remaining kidney. In cases in which the disease seems primary in the bladder, local treatment may be relied on. Bransford Lewis recommends injections into the bladder of iodoform emulsion, or distention of the bladder by air. As a last resort suprapubic drainage may be adopted to promote euthanasia.

Tumors of the Bladder, except papilloma and carcinoma, are rare. In children sarcoma sometimes is seen. Pathologically, **papilloma** is a benign neoplasm, but clinically it resembles malignant tumors in its tendency to recurrence, and according to some authorities it frequently undergoes carcinomatous transformation. So long as it is benign clinically it forms a more or less pedunculated villous tumor, with a base which moves freely on the muscular wall of the bladder. **Carcinoma** is hard, nodular, infiltrating, and becomes fixed to surrounding structures, such as prostate or vagina.

Symptoms.—The earliest symptom of a vesical tumor is hematuria, which is usually painless at first, and characterized by the irregularity of its occurrence. It may be profuse, and eventually causes grave secondary anemia. Malignant tumors may be excessively painful, so that examination without a general anesthetic may prove impossible. The usual occurrence of cystitis adds its symptoms to those due to the vesical tumor itself. The diagnosis is best made by cystoscopy, taking means to secure a clear medium by the local use of adrenalin to check bleeding or by constant irrigation. If this is impossible, suprapubic cystotomy, which often is required for treatment, may be used for diagnosis.

Treatment.—Small and well pedunculated papillomas may be removed by the operating cystoscope by snaring and cauterization of their bases. Larger or recurrent growths require suprapubic cystotomy, with wide excision of mucosa with the pedicle, the wound being cauterized and the bladder drained. Malignant growths require excision of the entire thickness of the bladder wall. Sometimes this involves extirpation of the bladder, with transplantation of the ureters into the rectum or the skin of the loin; or bilateral nephrostomy may be done. The mortality is about 30 per cent., and about half the patients have recurrence within a year. Fulguration is efficient in many benign tumors, and may be repeated in case of recurrence, and often is useful as a palliative measure in otherwise inoperable conditions.

Vesical Calculus.—The pathogenesis of urinary calculi is discussed in connection with kidney stones (p. 977). The majority of vesical calculi have descended from the kidneys where they were originally formed. Such stones are composed of *uric acid,* having been formed in acid (uninfected) urine. But while lying in the bladder they may subsequently become encrusted with *triple phosphates,* if the urine is alkaline and cystitis is present. Pure phosphatic calculi may also be formed in the bladder, under the conditions just mentioned. Calculi of *amorphous phosphates,* however, are formed in urine which is alkaline or neutral when it leaves the kidney, and are not caused by vesical

infection and alkaline decomposition of urine in the bladder as are those composed of triple phosphates. Calculi of *oxalate of lime* (called *mulberry calculi* from their appearance) are next most frequent to calculi composed of uric acid and triple phosphates, which together form 90 per cent. of all urinary calculi, more than half of all calculi being uric acid.

Vesical calculus is more frequent in men, and in children, than in women. In women and children phosphatic calculi are very rare. Calculi vary in size from those just too large to be passed spontaneously to those which fill the bladder. Calculi small enough to be passed through the urethra (usually less than 1 gram in weight) are classed as gravel. A calculus weighing more than a few ounces is rare. Usually only one calculus is present, and very seldom are there more than five or six.

The chief *predisposing causes* for the formation of calculi in the bladder are *urinary obstruction* and *vesical infection*. Hence most phosphatic calculi are met with in cases of stricture of the urethra and enlargement of the prostate. Foreign bodies in the bladder (broken ends of catheters, etc.) usually become encrusted with phosphates owing to the development of cystitis. If there is no obstruction and the urine remains acid, stones very rarely form in the bladder, and those which descend from the kidney may be passed by urethra.

Symptoms.—*Pain* and *hematuria* are the chief symptoms. The pain is characterized by two features: (1) It is made worse by motion, exercise, jolting in a carriage, etc.; and (2) it occurs especially at the end of urination, when the bladder contracts on the calculus. The pain is felt in the neck of the bladder and is referred mostly to the glans penis, and sometimes to the perineum, rectum, or thighs. Persistent tenesmus may produce prolapse of the rectum or hemorrhoids. Sometimes hyperacid urine, in the absence of calculi, may cause similar symptoms; and sometimes a calculus lodged in a diverticulum or behind an enlarged prostate may be so fixed as to cause no distinctive symptoms. Bleeding occurs irregularly, rarely being profuse. It is increased by motion, and seldom appears except at the end of urination. The blood is bright red, as if recent.

Diagnosis.—The diagnosis of vesical calculus depends upon detecting the stone by a sound, by cystoscopy, or by skiagraphy (Fig. 907). A vesical sound, or stone searcher (Fig. 910) resembles an ordinary urethral sound except that its shaft is smaller and longer, and its beak shorter and more abruptly curved. Before sounding about 4 ounces of fluid should be injected into the bladder, if this has been recently emptied. First explore the centre of the bladder and then turn the beak to each side in turn, giving gentle taps by quickly rotating the instrument between thumb and finger. Finally depress the shaft between the patient's thighs, reverse the beak, and explore the *bas-fond* of the bladder, particularly in cases of enlarged prostate, by gently raising the shaft again. The presence of more than one calculus may be ascertained by catching one in the blades of a lithotrite (Fig. 908), and then

striking the other with the instrument. If the calculus is lodged in a diverticulum, or covered by mucus or blood clot, it may be impos-

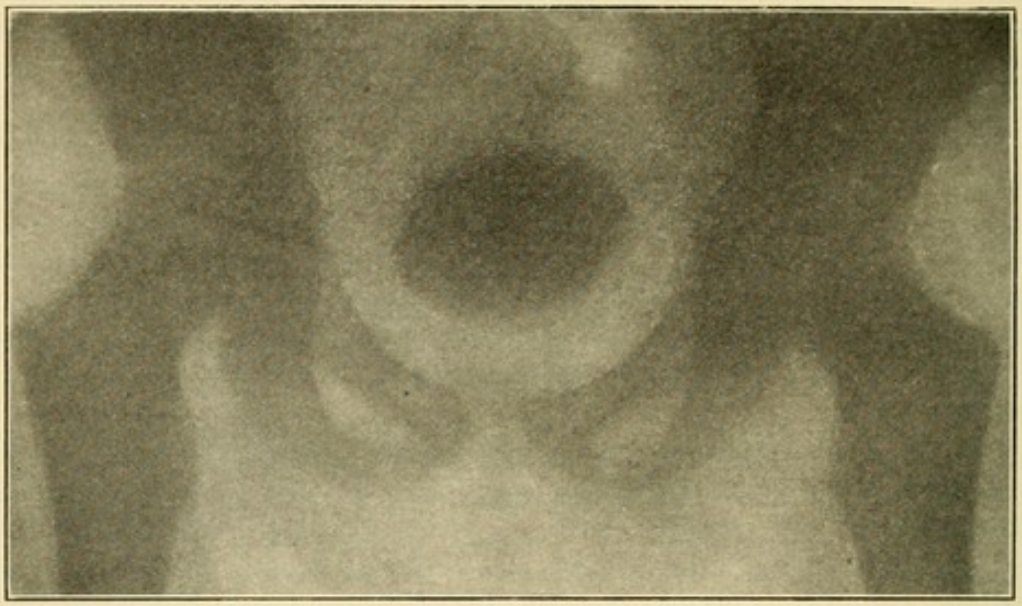

FIG. 907.—Vesical calculus in a boy aged four years. (Dr. J. P. Hutchinson's case.) Children's Hospital.

sible to detect it by a sound; and sometimes phosphatic incrustations on the bladder wall are mistaken for a calculus.

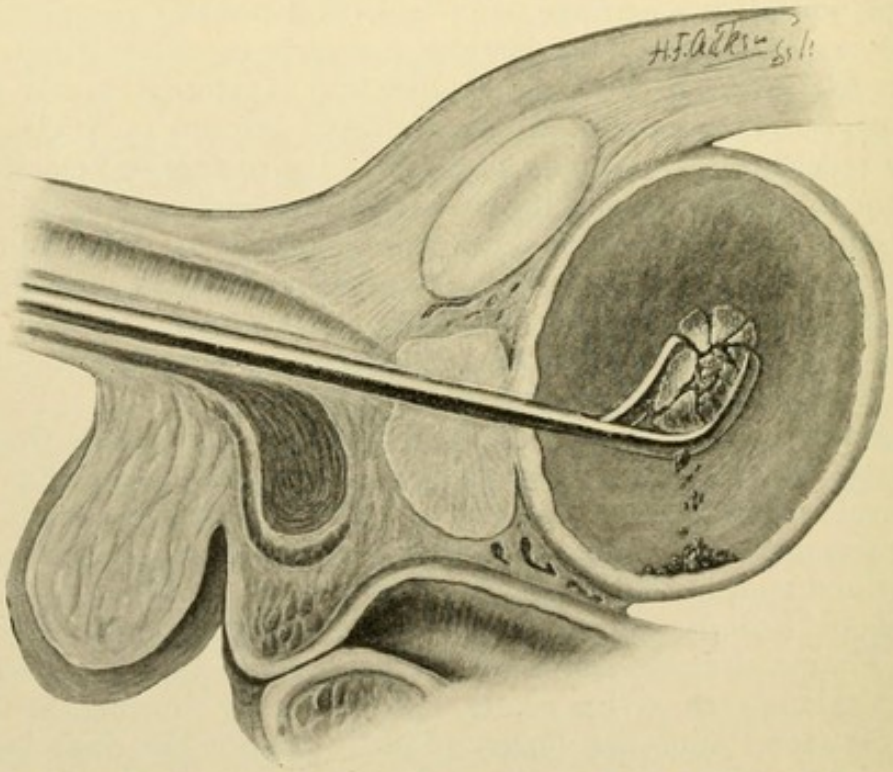

FIG. 908.—Lithotrite crushing stone. (Watson and Cunningham.)

In most cases skiagraphy is available, and will demonstrate the number and size of all but the softest stones. Cystoscopy is not often

required, but if the surgeon possesses a cystoscope and knows how to use it, no method is so satisfactory.

Treatment.—The stones must be removed. There is no solvent treatment.

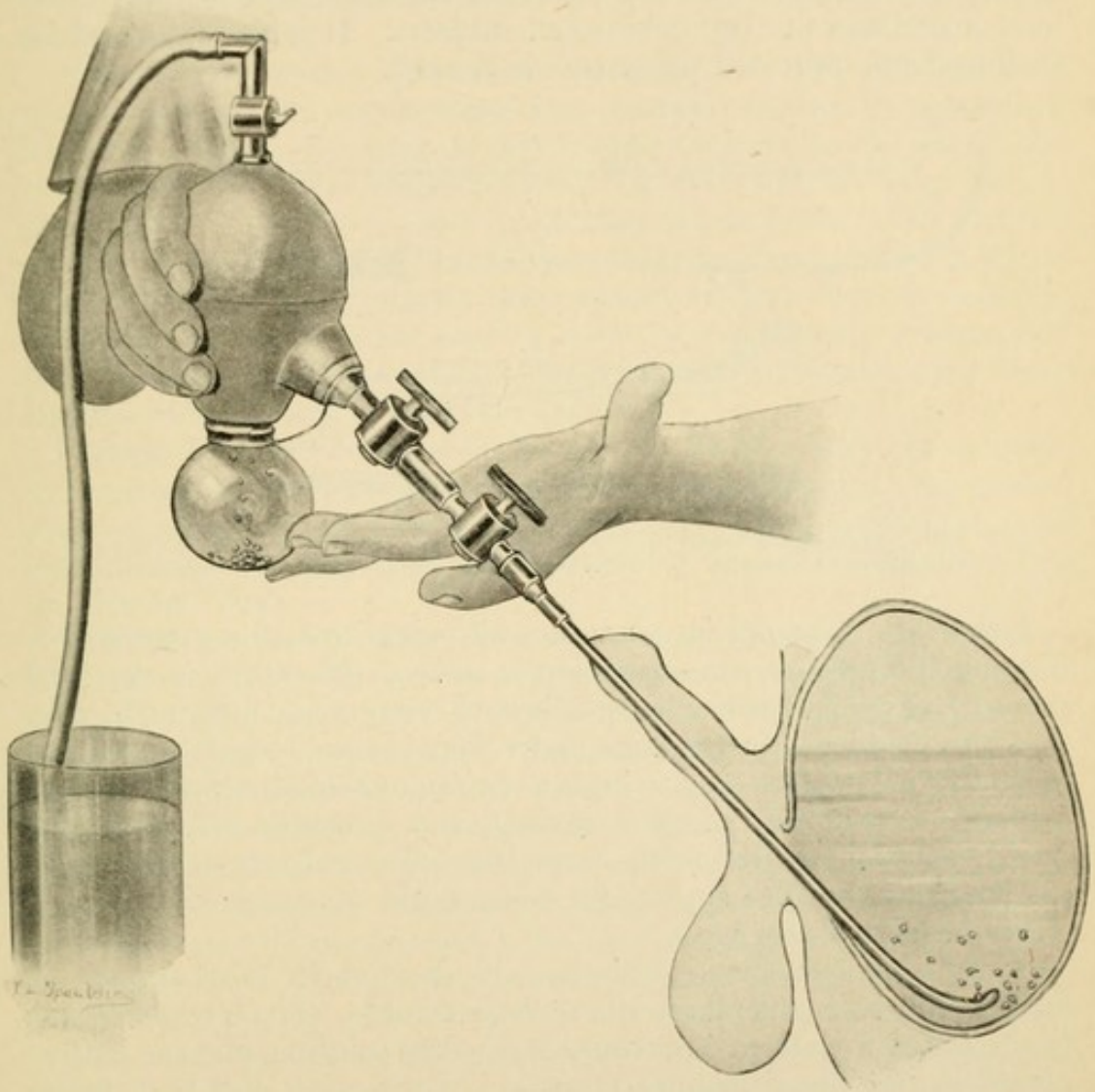

FIG. 909.—Bigelow's evacuating apparatus withdrawing fragments of calculus from the bladder. (Watson and Cunningham.)

Lithotrity and Litholapaxy.—Unless the stones are very hard (mulberry calculus) they may be broken up into gravel inside the bladder by means of the lithotrite, the operation being known as **lithotrity** (Civiale, 1824); the fragments are left to be passed spontaneously. It is much better to adopt Bigelow's plan (1878) or immediate evacuation of the fragments (**litholapaxy**). This is accomplished by gentle kneading of the rubber bulb attached to the evacuating apparatus (Fig. 909), which procedure creates a swirl in the intravesical fluid, as a result of which some fragments are drawn into the bulb at each motion, and by the force of gravity fall into the glass receptacle immediately beneath the rubber bulb. The operation of litholapaxy is

not now in general use, because the mortality of cutting operations is less than it was when Bigelow's operation was introduced, and because recurrence of stone formation is frequent (18 per cent.), either because all the fragments are not removed at first, or because urinary obstruction and vesical infection are not relieved. But the primary mortality is very low (under 5 per cent.), and the operation may be done under local anesthesia in very debilitated subjects. It is best reserved for such patients, provided no cystitis is present.

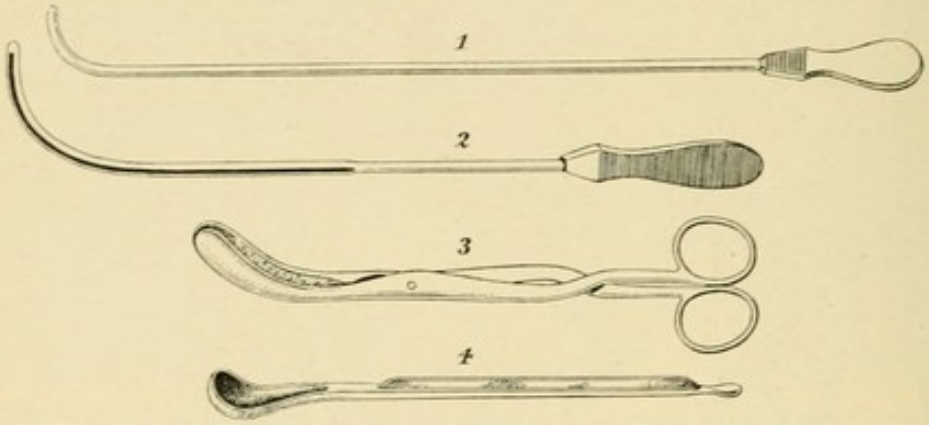

FIG. 910.—Instruments used in lithotomy: 1. Stone searcher. 2. Grooved staff. 3. Lithotomy forceps. 4. Lithotomy scoop (probe gorget at other end).

Lithotomy.—Though in women small calculi may be extracted by dilating the urethra (the operation is termed *lithectasy*), in the large majority of cases of either sex, it is best to remove calculi by an incision into the bladder. In patients under fifty years of age the primary mortality is low; it is easy to ensure the removal of all calculi, efficient drainage is provided when necessary, and prostatic obstruction, if present, may be treated at the same time. Several cutting operations are available, but the suprapubic route is the operation of choice, in either sex and at any age.

Suprapubic Cystotomy.—This may be done under local anesthesia, but in children a general anesthetic is preferable. The bladder should be distended with from 4 to 6 ounces of saline solution, and the patient placed in the Trendelenburg position. An incision of 2 to 3 inches is made through one or other rectus muscle, close to the median line and extending right down to the pubis, opening the space of Retzius. The fingers then draw upward the prevesical fat and fold of peritoneum. The bladder is recognized by its bluish color. Large veins should be avoided. A traction suture is inserted in the bladder wall on each side of the site of the proposed vesical incision, and the bladder is then opened by the knife which cuts downward toward the pubis. Before all fluid escapes the finger is inserted and the cavity of the bladder explored. The stone is then removed with suitable forceps. Be careful to remove all the stones and not to overlook one in a diverticulum. (If indicated the prostate may now be removed. See p. 1038.) If there is no cystitis (which is seldom the case) the bladder incision may be closed completely, care-

fully inverting its edges so as to prevent prolapse of mucous membrane. In doubtful cases it is better to drain by inserting a tube as in the operation of cholecystostomy (p. 930), carefully inverting the mucous membrane. In *all* cases, a small wick of gauze should be placed in the space of Retzius. The vesical tube should be allowed to come away of itself, which it usually does in the second week. The urinary fistula is then encouraged to close.

Perineal Lithotomy.—The *lateral operation*, in which the bladder is opened through the membranous and prostatic urethra by an incision which passes from the base of the scrotum outward to the left ischiorectal fossa, is seldom employed now. A grooved staff (Fig. 910) in the urethra is used as a guide in making the incision. The primary mortality is low, especially in children, but the deep incision is apt to injure the ejaculatory ducts, only calculi of less than 2 inches in diameter can be removed, and it requires considerably greater skill than the suprapubic operation. *Median perineal lithotomy* has a much higher mortality, and affords still less room.

Foreign Bodies.—Foreign bodies in the bladder may be removed by experts with the operating cystoscope. In the hands of the general surgeon more success attends suprapubic cystotomy; though small objects may be successfully extracted by a perineal urethrotomy incision (p. 1022).

Injuries of the Bladder are rare. Most frequent are ruptures. These may involve the intraperitoneal or the extraperitoneal surfaces, or both. They occur most often in men, and the chief predisposing cause is alcoholic intoxication: this increases the quantity of urine, obtunds the sensibilities so that an overloaded bladder is neglected, and renders its subjects quarrelsome, helpless, and prone to injury. The chief symptoms are *abdominal pain* and *bloody anuria:* the patient desires to urinate, but only a little blood is passed. *Extraperitoneal rupture* frequently complicates a fracture of the pelvis, and is difficult to distinguish from rupture of the urethra on the pelvic side of the triangular ligament (see p. 1017). In *intraperitoneal rupture* peritonitis soon follows, as the urine seldom is aseptic. The diagnosis should be made before this time by means of physical examination. A catheter should be passed (extreme asepsis!) and any bloody urine present should be evacuated. Then at least one quart (in the adult) of sterile saline solution should be injected, unless the development of a suprapubic mass corresponding to the unruptured bladder appears sooner. Then this fluid should be withdrawn. Unless all the injected fluid is regained, it is evident that it has passed out of the bladder. If more fluid than was injected into the previously emptied bladder is returned, it is evident that fluid is being drained from the peritoneal cavity. In either case, the abdomen should be opened, the rent in the bladder sutured (inverting its edges with sero-serous sutures), and the peritoneal cavity drained. It is also well to leave a catheter in the bladder, draining it through the urethra. The mortality is about 23 per cent. (Ashhurst, 1906).

SURGERY OF THE KIDNEYS.

Anomalies of Form and Position.—One of the commonest congenital malformations of the kidney is the so-called **horseshoe kidney**. Here the two organs are fused together, usually at their lower poles. This is found once in about a thousand cases. It increases the difficulties of diagnosis and treatment of kidney lesions. The **ureters** may or may not be normal in such cases; but even with normal kidneys abnormalities of the ureters are not very rare. The commonest abnormality is the existence of two ureters to the same kidney; each may spring from a separate renal pelvis, or both may leave the same pelvis. The diagnosis of such conditions sometimes is made before operation by skiagraphy after catheterization of the ureters with instruments impervious to the *x*-ray or after distending them with collargol. **Anomalies of the blood-supply** of the kidneys are frequent. The most important are extra arteries to the upper or lower pole of the kidney, or an artery which crosses in front of the ureter, and which may be a cause of hydronephrosis by intermittent pressure or by causing kinking of the ureter. The kidney may be **congenitally misplaced** in almost any position in the abdomen, but this is very rare.

Nephroptosis, or Movable Kidney, usually is regarded as an acquired condition, but some investigators have found it in a definite proportion of patients in early infancy. It is more common in women than in men (4 to 1), and is predisposed to by anything which increases the capacity of the lower abdomen (repeated pregnancies, removal of pelvic tumors), or which diminishes the room beneath the diaphragm (tight lacing, scoliosis), and which at the same time causes relaxation of the normal support of the kidney (general poor health, or wasting diseases with absorption of fat). Nephroptosis usually is present in cases of visceroptosis (p. 898), but frequently exists alone. It is more common on the right than the left side, but both kidneys often are affected.

Symptoms.—The patients usually are thin, long-waisted, run-down women from thirty to fifty years of age. In most cases the condition is unknown to the patient, and is discovered as an incident in an abdominal examination. When symptoms exist the chief complaint is weakness and dragging sensations in the loin; but no acute symptoms arise unless the kidney becomes twisted on its pedicle, resulting in sudden congestion from venous stasis or blockage of the ureter with temporary hydronephrosis. Such acute attacks are known as *Dietl's crises* (1864). The *diagnosis* depends on recognizing by palpation the movable kidney. Three grades are recognized: (1) When the kidney is merely *palpable;* (2) where it is *movable;* and (3) where it is *floating*. Examination is conducted with the patient recumbent, and the thighs flexed to relax the abdominal muscles. The surgeon places one hand beneath the loin, and presses downward firmly but gently with the other hand in the flank, until the two hands are approximated. Then when the patient takes a long breath the lower pole of the kidney, if it is palpable,

is forced down against the examining hand. If the kidney is truly *movable* it can be felt also when the patient stands and leans forward, resting her hands on the edge of the bed. The examiner now stands behind her, and works his hand gently upward from the iliac fossa toward the flank; whereupon, during deep inspiration, a movable mass may be recognized, which slips back to the loin, during expiration. A *floating* kidney can almost be grasped in the fingers, and may be found in the iliac fossa or the pelvis. Fixation of such a floating kidney in abnormal position, by adhesions or otherwise, constitutes a *dislocated kidney*. This is a very rare condition. A Dietl's crisis is recognized by its occurrence in a patient with a floating or movable kidney, by the sudden increase in size of the tumor, by the attending constitutional disturbance (nausea, vomiting, shock, perhaps chills and fever), by the absence of intestinal or peritoneal symptoms, and by prompt subsidence of symptoms when the kidney becomes untwisted on lying down or by manipulation. Subsequently microscopical study of the urine may show blood.

Treatment.—If no symptoms exist, no treatment is indicated beyond building up the patient's general health. If symptoms are present they often are relieved by a rest-cure, with forced feeding, or by the application of an abdominal belt such as was advised for cases of pendulous abdomen. It rarely is desirable to use a special pad over the kidney. If recurrent attacks of torsion occur, or if palliative treatment fails to relieve chronic symptoms which are *undoubtedly* due to the mobility of the kidney, this organ may be fixed in its proper position by operation (**nephropexy**). Various methods are employed. In all it is important to secure the kidney in a position as nearly normal as possible, avoiding particularly excessive rotation of the organ in any direction. One of the most satisfactory operations is to incise the capsule along the convexity of the kidney, to peel the capsule back in two leaves, and to suture these to the lumbar aponeurosis (Edebohls, 1901). The lumbar wound is closed in layers without drainage. Another method is to support the kidney in the depths of the wound by two slings of gauze, one under each pole; the gauze is left in place for a week or ten days, and the adhesions which result in the extensive granulating wound are supposed to hold the kidney in place. Da Costa employs slings each of which is made by suturing together with catgut, end-on, two pieces of gauze, the sutured portion is placed around the kidney, and when the catgut has been absorbed, the ends of the slings are easily removed.

Infections of the Kidneys arise in most cases either from the bloodstream or as ascending infections from the bladder or genitalia.

Hematogenous Infections.—The kidneys receive from the body and discharge through the urine great quantities of toxins, and in many cases large numbers of bacteria (*bacteriuria*, p. 964). If the resistive power of the kidneys is weakened (previous renal disease, urinary obstruction, trauma, etc.) or if the toxins or bacteria are of extraordinary virulence, inflammation of the kidneys (*nephritis*) results.

There are various forms of nephritis, which are best classed as *acute* and *chronic*. Only some of these need concern us here.

Cases of **toxic nephritis** due to mineral poisons, and those cases due to toxemia (as in scarlatina, diphtheria, influenza, etc.) or auto-intoxication (as in chronic intestinal stasis, pregnancy, etc.), may be acute but frequently are chronic from the beginning, and usually are cared for by the physician. Of late years, however, it has become possible to relieve some of these patients by operative means. Puncture of the kidney or incision of its capsule was advocated by R. Harrison in 1897, by Ferguson and Edebohls in 1899, and the latter in 1901 reported a number of cases in which he had practised **decapsulation** of the kidneys. By stripping the capsule from the contracted and sclerosed kidney its nutrition is improved by relief of tension and perhaps by development of collateral circulation. There is no doubt that in many cases vast improvement occurs: the amount of the urine increases, the edema and ascites vanish, casts disappear from the urine, and previously bed-ridden patients are enabled to resume a certain degree of activity. In favorable cases this improvement has lasted several years, though evidences of chronic nephritis persist. In other patients, however, no improvement occurs or the state is made worse. The operation is still on trial. The kidney is exposed as for other kidney operations (p. 985), it is brought into the wound, and its capsule is incised along the convexity; the flaps of the capsule are then stripped off the organ to the hilum on each side, and are excised; the kidney is replaced and the wound closed without drainage, but not too tightly. It is better to postpone operation on the second kidney for a week or ten days. Brewer recommends the operation in cases of severe acute nephritis, following the exanthemas, etc.

Septic Nephritis.—What are commonly recognized as surgical infections of the kidney, of hematogenous origin, are cases of acute nephritis due to septic embolism. In a large proportion of cases only one kidney (usually the right) is affected, and the lesions vary from hemorrhagic infarcts (which soon heal, leaving minute cicatrices) to diffuse suppuration. Several foci of suppuration may coalesce and form distinct abscesses. Extension to the pelvis of the kidney, causing *pyelitis*, is frequent; extension to the fatty capsule of the kidney and surrounding structures (perinephritis) is less usual. In cases where pelvis and kidney are diffusely involved (*pyelo-nephritis*) it may be impossible to distinguish the pathological changes from those caused by an ascending infection.

Symptoms.—The recognition of acute unilateral hematogenous infection of the kidney is due mainly to the work of Brewer. Over 80 per cent. of the cases occur in women, frequently as a sequel of some known general infection (pneumonia, tonsillitis, furunculosis, etc.). The onset and course of the disease may be very acute, subacute, or comparatively mild. The severe cases usually begin with a chill, temperature of 104° or 105° F., rapid pulse and high leukocytosis. From the first the symptoms of toxemia are marked, and the local

condition may be overlooked, the disease resembling perhaps influenza, lobar pneumonia, or one of the exanthemas. Subsequently attention is directed to the kidney region by pain and discomfort in the abdomen or flank, and these may be mistaken for signs of cholecystitis or appendicitis. Compensatory action of the healthy kidney may obscure urinary changes (red-blood cells, albumin, pus) unless especially looked for. "The one pathognomonic sign present in all cases," adds Brewer, "is a marked unilateral costovertebral tenderness."

Treatment.—In the severe cases, with high temperature and progressive toxemia, nephrectomy should be done without unreasonable delay; death is the almost invariable result of such delay or of palliative operations. In the milder cases, which Brewer describes as those where the temperature begins to fall within forty-eight hours, decapsulation of the kidney may be done, or nephrotomy if there is evidence of much tension or localized suppuration. In the mildest type, where the diagnosis may be uncertain, medical treatment may be persisted in, and any chronic pyelonephritis which remains may be subjected to appropriate surgical treatment subsequently.

Ascending Infections.—Ascending as well as hematogenous infection is predisposed to by previous renal disease (especially renal calculus) or the occurrence of trauma; but even in such circumstances it rarely occurs unless there is obstruction to the urinary outflow. In women, pressure from pelvic tumors or the gravid uterus is a cause of urinary obstruction which leads not infrequently to ascending kidney infection. In men such obstruction is due in most instances to enlargement of the prostate or stricture of the urethra. Back pressure of urine within the bladder first compresses the ureteral orifices, damming the urine back into the ureters and kidneys; inflammatory infiltration of the bladder wall from cystitis may impair the sphincteric action of the ureteral orifices; and if extreme dilatation of the bladder occurs the ureteral orifices may become constantly patulous, by the approximation of their course through the bladder-walls to a straight line. It is probable also that infection extends up the walls of ureters to the kidney pelvis, and thus produces pyelitis and pyelo-nephritis, which are the usual results of obstruction in the presence of infection. In some cases the ureters appear unaffected, but in most they are dilated, pouched and perhaps strictured. The pyelo-nephritis arising from ascending infection is commonly spoken of as **surgical kidney.** The renal cortex is thinned, the pelvis enlarged, and the kidney substance is riddled with abscesses of various sizes.

Symptoms.—Surgical kidney is more frequent in the aged than in the young, and occurs very much oftener in men than in women. It may be acute or chronic, but as acute attacks tend to be prolonged by chronic symptoms, and as the chronic condition frequently is interrupted by acute attacks, the symptomatology is best considered together. The onset usually is acute, and often follows exposure to cold or wet, the passage of a catheter, sounding for stone, or dilatation of a urethral stricture. The patient has a chill, is nauseated, his

temperature rises, and for a few hours he may be very ill. In many cases these symptoms cannot be distinguished from those of so-called urethral fever (p. 1026), but the diagnosis of pyelitis is probable if fever continues, and becomes almost a certainty if there is a dull ache in one or both loins and if an enlarged, tender kidney can be palpated. The urine contains pus, sometimes blood, and usually is alkaline. The pus settles slowly to the bottom of the receptacle, whereas the pus of cystitis settles very quickly.

One or both kidneys may be affected. If only one is affected and the ureter is completely blocked, the urine may be fairly normal, while the patient's condition will grow worse; on the other hand, if free drainage of the kidney is present the patient may feel quite comfortable in spite of the infected character of his urine. In the average chronic case, so long as the kidney drains freely, the patient may be little troubled by subjective symptoms unless an exacerbation occurs from renewed irritation of the urinary passages, or indiscretions in diet, etc. Recurrence of acute attacks is common, as the kidney, unlike the bladder, has no great tendency to sterilize itself spontaneously.

Treatment.—In the acute cases put the patient to bed, and ensure free drainage of urine from the bladder by an inlying catheter if necessary. Keep the patient on a milk diet, and make him drink plenty of water. Give 15 grains of urotropin three times daily. Treat threatening uremia by diuretics, cathartics, sweating, and if necessary venesection. If the urine is nearly normal, or anuria is present, and the kidney enlarged and tender, nephrotomy or rarely nephrectomy may be required; but whenever possible radical operation should be postponed until the acute attack subsides. When the chronic stage is reached, radical treatment of the obstructing cause (stricture, enlarged prostate, etc.) may succeed in curing the pyelitis. Before nephrectomy is done, in any case, the functional capacity of the other kidney must be proved adequate (p. 961).

Hydronephrosis.—This is hydrops of the kidney due to urinary obstruction, in the absence of infection. The condition may be unilateral or bilateral. Causes of unilateral hydronephrosis are recurrent torsion of the ureter by the vagaries of a movable kidney; impaction of a stone in the ureter without complete blocking of the canal; or stricture of the ureter. Bilateral hydronephrosis is due to obstruction of both ureters, either directly, as by a tumor of the bladder involving both ureteral orifices, pressure of a pelvic tumor, etc., or indirectly by enlargement of the prostate, stricture of the urethra, etc. The *symptoms* occur as a sequel to those due to the obstructing lesion; the kidney becomes enlarged and may reach an immense size. If temporary relief of the obstruction occurs, the accumulated urine is discharged, with polyuria and disappearance of the tumor. This, however, may soon refill (*intermittent hydronephrosis*).

Treatment.—Treatment comprises removal of the obstruction when this is possible. A movable kidney may be fixed; a stone in the ureter removed; a stricture of the ureter treated by dilatation, ureteroplasty

(analogous to pyloroplasty) or by resection and end-to-end suture; a pelvic tumor may be excised. Finally, if no obstruction can be found, or if it cannot be removed, and the kidney is functionless, nephrectomy may be done.

Pyonephrosis.—Pyonephrosis occurs as the end-result of pyelonephritis, or it may be due to the infection of a preëxisting hydronephrosis. If the other kidney is functionally sufficient, nephrectomy should be done. Nephrotomy with drainage rarely is beneficial, and in most cases nephrectomy and death are the only alternatives, and death may follow nephrectomy.

Perinephric Abscess.—This is suppuration in the fatty capsule of the kidney. I have already mentioned the occurrence of perinephritis as a sequel of septic nephritis; and though perinephritis often results in suppuration there are many other causes for perinephric abscess; hence the term perinephritic abscess should not be used, the kidney being at fault only in about one-fifth of the cases (M. B. Miller, 1909). In most cases the source of infection is in the lower genito-urinary tract, and extension to the perirenal tissues occurs along the lymphatics. Trauma may be a predisposing cause. Pulmonary complications are frequent.

Symptoms.—Symptoms often are subacute in onset, and the patient may not be laid up until a week or more has elapsed. He complains of local pain and tenderness, walks guardedly, with his body bent toward the affected side; and the thigh is slightly flexed; there is localized muscular rigidity, and a tender spot between the twelfth rib and iliac crest posteriorly. Later there may be moderate or high elevation of temperature; leukocytosis usually is high (average is 25,000); and still later distinct evidences of suppuration develop. Sometimes, however, the onset is very acute, with chill, high fever, and extreme prostration. The diagnosis is not always easy, even if the condition is kept in mind. A source of infection should be looked for. Confusion with a lumbar abscess, due to Pott's disease of the spine, should not arise unless such a cold abscess is secondarily infected and signs of spinal involvement are absent.

Treatment.—Treatment consists in evacuating the abscess by a lumbar incision; and this should not be postponed if the symptoms are acute, even if the diagnosis is uncertain.

Nephrolithiasis or Renal Calculus.—The urine of many persons may contain crystalloids in abnormal amount, yet so long as they are held in solution by the action of colloids, no stone will be formed. If, however, the crystalloids are present in excess of the power of the colloids to hold them in solution by means of what is known as adsorption, then the crystalloids (uric acid, acid urates, calcium oxalate, etc.) go out of solution and are deposited on the colloids as a matrix. If the colloids are what are known as reversible colloids, such as mucin, both they and the mineral deposited on them may be redissolved by more water. If, however, the colloid is irreversible, such as fibrin, it cannot be re-dissolved. The colloid mostly concerned in the forma-

tion of urinary calculi is believed to be fibrin; and as this is a product of inflammation and infection, it is not unreasonable to suppose that calculi may form as the remote result of an attenuated infection of the urinary tract, much as gall-stones are formed in the biliary tract. But the influence of infection in these cases has not been proved, and it is customary to regard such calculi (uric acid, oxalate of lime; rarely cystin, etc.) as *primary calculi*, in contradistinction to those undoubtedly the result of bacterial infection of the urinary tract, which are termed *secondary calculi*. These latter usually are composed of triple phosphates and result from bacterial decomposition of the urine. Phosphatic deposits may occur as laminations on primary calculi, as concretions on the mucous membrane lining the urinary tract, or as distinct calculi.

Renal calculus is most common between twenty and forty years of age, affects men somewhat oftener than women, and the right kidney a little oftener than the left. Both kidneys are involved in from 20 to 50 per cent. of cases. The prevention of calculus formation concerns the physicians; when stones have formed in the kidney the case becomes surgical.

The classification of urinary concretions as *sand*, *gravel*, and *calculi*, has already been mentioned (p. 967). Sand may be productive of no definite symptoms; gravel gives rise to repeated attacks of renal colic as the small stones pass into or through the ureter; while a calculus so large as to be relatively immovable may be symptomless. The smaller the calculi, as a general rule, the greater is their number and the more apt are they to produce symptoms.

Symptoms.—These may be divided into those of **simple nephrolithiasis** and those of **complications** of the disease, such as renal colic, hydronephrosis, pyelitis, and its sequels.

In *simple nephrolithiasis* (which corresponds to simple cholelithiasis) the stones remain in the kidney and infection is absent. There may be no symptoms to call attention to the kidney. What symptoms the patient complains of usually are referred to the bladder, and are the effect of passage of urine altered in quality or quantity. Especially valuable as suggestive of renal disorder is the occurrence of blood in the urine, usually in microscopic amount. It may be present only after the patient has been up and about, and may disappear if he lies quiet in bed. Unless secondary infection occurs, or unless the kidney is unduly movable, and therefore liable to congestion or to hydronephrosis, it is unusual for much pain to be felt in the kidney region itself or for macroscopical hematuria or pyuria to occur. But sometimes complaint is made of a dull ache in the lumbar region, and quite frequently there is tenderness on pressure here, or over the lower pole of the kidney in the flank. Sometimes the kidney is palpably enlarged. Murphy places special reliance on fist percussion over the lower ribs, using one hand as plessimeter and thumping it with the other fist as plessor. He claims that in the presence of a renal calculus this always produces severe pain. Subjective symptoms, such as pain

over the kidney, frequently disappear as soon as the patient goes to bed; and after his admission to a hospital ward the diagnosis may seem doubtful. The *x*-ray is of inestimable value in the diagnosis of renal calculus, but unfortunately it may be difficult, or impossible, to secure a skiagraph which will show calculi of pure uric acid (Fig. 911). Fortunately few calculi are composed of uric acid or urates without some admixtures of other salts. No plate should be considered satisfactory unless the shadow of the psoas muscle is clearly visible. Confusion arises from defects in the plate, shadows of fecal concretions, and, in the case of ureteral stone, from those of phleboliths, calcification around ligatures left at previous pelvic operations, etc. The functional capacity of the other kidney (p. 961) should be ascertained in every case of renal calculus.

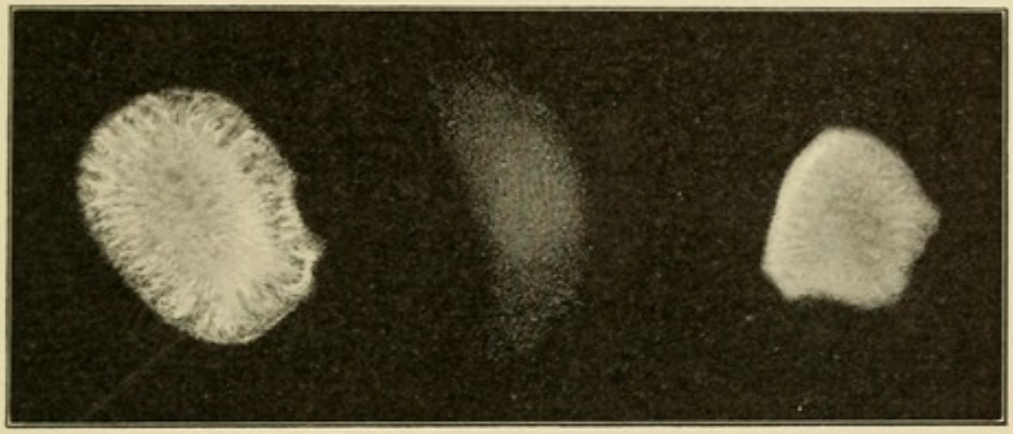

FIG. 911.—Shadows cast in a radiogram by different renal calculi: on the left, phosphatic; in the centre, uric acid; on the right, oxalate of lime. (Rothschild.)

Renal colic is the most frequent symptom of complicated cases of nephrolithiasis, but it may be caused by other factors than the passage of a calculus through the ureter. The symptoms are the same as in cases of Dietls's crisis (p. 972), but in the latter condition the kidney always is movable, which is not often the case in nephrolithiasis. Pain is referred along the course of the ureter, into the testicle, and down the thigh, and sometimes to the end of the penis. The pain usually begins and ends suddenly; but if the stone is impacted in the ureter the pain ceases gradually and light attacks of colic recur often. There may be nausea and vomiting, but there seldom is much constitutional disturbance, unless the kidney is infected, when the symptoms of pyelitis, etc., arise. These have already been considered. During the continuance of the colic the urine may be diminished or entirely suppressed; crebruria, with tenesmus, is frequent, and blood usually is found in the urine.

Diagnosis of Nephrolithiasis.—This is not certain unless the stones are seen in a skiagraph (Fig. 912); and even then, as noted above, sources of error are not infrequent. If gravel has been passed, and colic persists, it is a fair inference that other stones remain; and the diagnosis is very probable if repeated colic occurs, with hematuria

and occasionally pyuria, with symptoms of pyelitis. The chief conditions from which renal calculus must be distinguished are biliary colic, appendicitis, and intestinal obstruction. The diagnosis of these has already been considered.

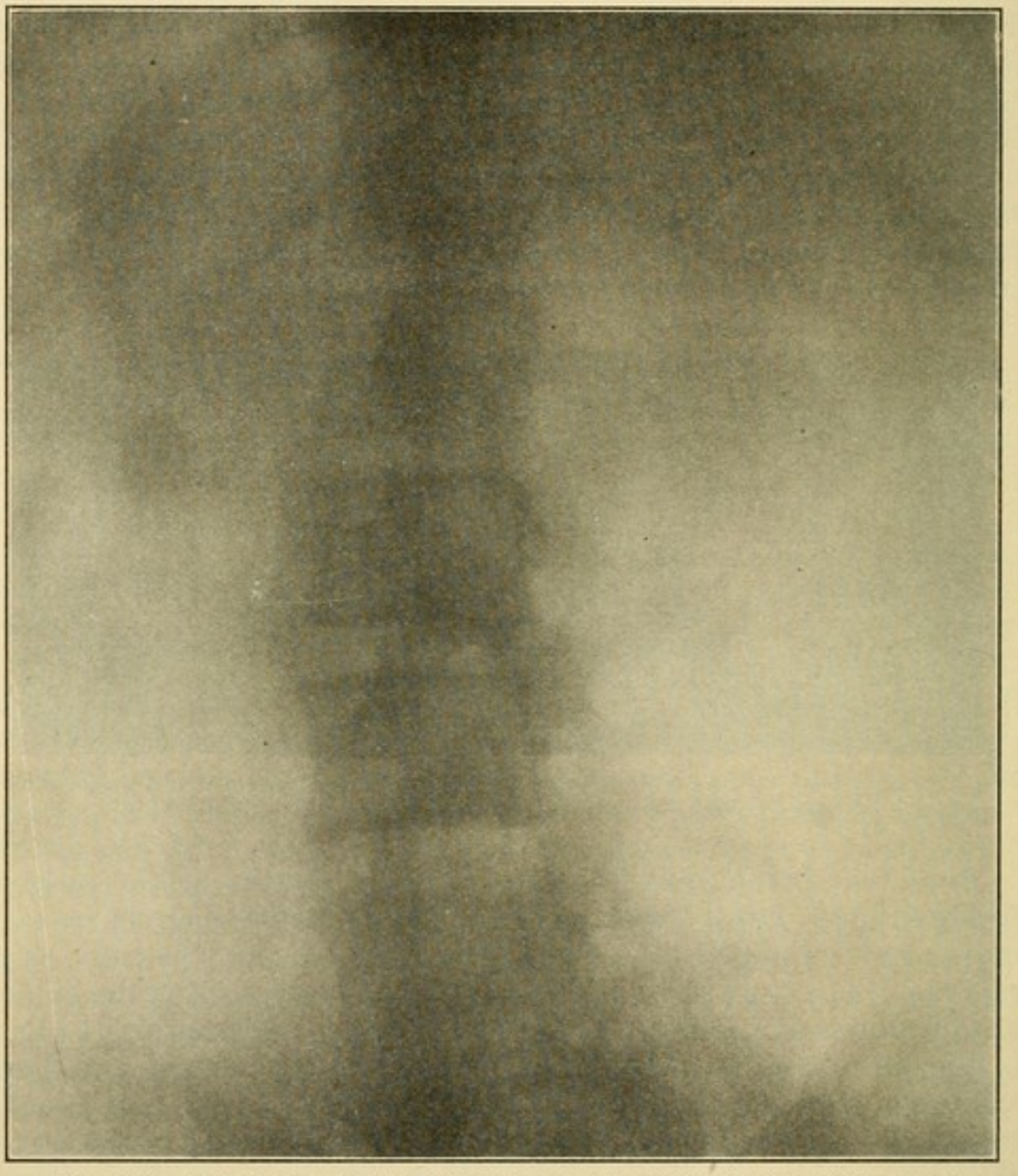

FIG. 912.—Skiagraph of calculus in kidney. The faint shadow of the psoas muscle is barely visible. Episcopal Hospital.

Treatment.—If the stones are shown by skiagraphy to be merely gravel, and if such have already been passed successfully, it is sometimes advisable to trust to medical treatment to prevent the formation of other calculi, and to allow the patient to pass such as already exist *per vias naturales* (Fig. 913). Any stone too large to be passed requires removal by operation; especially is this true when pyelitis is present and fails to clear up under palliative treatment.

If the stones lie loose in the kidney pelvis, a fact which cannot be determined before the kidney is exposed, they should be removed by *pyelotomy;* if they are fixed in the cortex, *nephrotomy* (nephrolith-

otomy) should be done. These operations are described at p. 986. If the presence of calculi is uncertain it is better to incise the kidney sufficiently to explore its interior than to endeavor to locate the stone by "needling" the kidney. In all cases a sound or ureteral catheter should be passed down the ureter to the bladder, to make certain that no obstruction has been overlooked.



FIG. 913.—Renal calculus of uric acid passed by urethra. (Scale in inches.) Orthopædic Hospital.

Ureteral Calculus.—The *x*-ray has shown that calculus is more frequent in the ureter than in the kidney (C. L. Leonard). In nearly all cases the stone has descended from the kidney. It lodges by preference (1) just below the renal pelvis; (2) at the brim of the true pelvis; or (3) just outside the bladder wall. Blockage of the ureter in the first position causes symptoms similar to those of renal calculus; in the last position, those resembling cystitis. Stones arrested at the brim of the pelvis frequently are mistaken for chronic appendicitis, and the appendix is removed in vain.

Complete blockage of the ureter may bring on *calculous anuria*. This may be due to the functionally useless state of the second kidney; to blockage of both ureters at once; to the existence of only one kidney, or of a horseshoe kidney with a single ureter; or to what is called "reflex inhibition" of the healthy kidney. Unless relieved by operation, calculous anuria usually terminates in uremia and death; occasionally death occurs suddenly without uremic symptoms. The free interval varies from one to sixteen days, but rarely is it longer than three or four days.

Treatment.—A stone in the upper part of the ureter often can be worked backward into the kidney pelvis; if not, it must be exposed by enlarging the lumbar wound, and removed by direct incision of the ureter (*ureterolithotomy*). If in the middle portion of the ureter, the stone is best exposed extraperitoneally through a McBurney or similar incision. As the peritoneum is stripped up from the iliac fossa, it carries the ureter with it. Gibbon places a finger inside the peritoneal cavity to aid in bringing the ureter into the wound. A stone very near the bladder may be reached extraperitoneally by the suprapubic route (C. L. Gibson); vaginal and perineal operations are less satisfactory. A calculus in the intramural part of the ureter may be extracted by suprapubic cystotomy, or even by means of the operating cystoscope.

Calculus anuria requires active treatment to prevent uremia; hot baths, sweating (pilocarpin); morphin and atropin to allay pain and

spasm. Unless the anuria is relieved within thirty-six or at the most forty-eight hours, operation should be done. There is no time to undertake an elaborate search for the site of obstruction in the ureter; so unless this is known (when ureterolithotomy by the proper route is indicated) the diseased kidney should be exposed and drained, the radical operation being postponed until convalescence.

Tuberculosis of the Kidney.—Tuberculosis of the genito-urinary tract usually develops first in the kidney (66 per cent. of cases), or the epididymis (30 per cent.); in a few cases it appears first in the Fallopian tubes, the prostate, testis, uterus or seminal vesicles (Watson and Cunningham). In nearly all cases the infection is blood-borne and is secondary to a focus elsewhere in the body (bronchial or mesenteric lymph nodes). The bladder, as pointed out at p. 965, scarcely ever is the first portion of the genito-urinary tract to be invaded, and as a consequence ascending tuberculous infection of the kidney is exceedingly rare. Secondary pyogenic infection, however, frequently ascends from the bladder and causes rapid disintegration of the tuberculous kidney.

In most cases only one kidney (the right and left about equally) is affected at first, and the other kidney may remain intact for a long time. The lesions commence in the cortex, but the pelvis is invaded when rupture of the caseous foci occurs. The ureter may remain healthy long after the infection has secured a foothold in the bladder.

The disease is most frequent in early adult life, and the sexes are about equally affected. At the time patients come to operation the disease is still confined to one kidney in more than half the cases, and even at autopsy the second kidney is free in about one out of three cases. In the large majority of cases of bilateral disease the second kidney is only very slightly involved.

Symptoms.—There are both *constitutional symptoms* characteristic of a tuberculous lesion, and *local symptoms* referable to the urinary tract. Among the former may be mentioned afternoon pyrexia, nervousness, sleeplessness, anorexia, and loss of weight. Though the patient seems ill, no definite cause is apparent. After weeks or months, urinary symptoms appear. At first these are referred to the bladder; the urine is passed frequently; its quantity is increased, and its specific gravity lessened; it contains pus and microscopical amounts of blood. Frank hematuria is rare. Vesical irritability may be extreme before the tuberculous lesion has spread to the bladder. Secondary pyogenic infection of the kidney causes hectic fever, night sweats, emaciation, and rapid loss of strength. Not until this stage is reached is the acidity of the urine lost.

Diagnosis.—Vesical symptoms should not divert attention from the kidney. Pus in the urine does not necessarily mean cystitis. In cystitis the urine almost always is alkaline; but in renal tuberculosis it remains acid until pyogenic infection is far advanced. Occurrence of remissions in the severity of the symptoms is highly characteristic of tuberculosis, but is unusual in renal calculus. In the latter, exacer-

bation of symptoms usually follows exercise; but in renal tuberculosis this constant relation of cause and effect is not seen. Renal calculus usually may be excluded by skiagraphy. In tuberculosis the temperature chart (even in the absence of pyogenic infection) should rouse suspicion of the nature of the infection. The hypodermic use of tuberculin and inoculation experiments with the centrifugated urinary sediment, are valuable aids in diagnosis. Cystoscopy usually reveals appearances around the ureteral orifice on the diseased side which are considered by experts highly characteristic. Ureteral catheterization is the surest way of determining the healthy condition of the second kidney. In many cases inoculations and examinations of the urine for tubercle bacilli have to be repeated on several occasions, as the results are not always constant.

Treatment.—Most surgeons are in accord in recommending removal of the diseased kidney as the only hope of cure; even if the other kidney is slightly diseased, the tuberculous process may become latent in it after the more diseased organ has been removed. The excellent effect of nephrectomy on vesical tuberculosis has already been mentioned (p. 965). The immediate mortality of nephrectomy for tuberculosis is from 5 to 10 per cent.; and about 26 per cent. of patients are cured of the disease and remain well for three years or longer. In most others great improvement occurs. But if the second kidney is incompetent, nephrectomy should not be done, and hygienic treatment alone must be employed. If pyonephrosis is present, relief may be afforded by nephrotomy and drainage, if nephrectomy is contraindicated.

Tumors of the Kidney.—These are conveniently classed as solid tumors and cysts.

Solid Tumors of the Kidney.—*Hypernephroma* is the commonest (p. 127). Other solid tumors are *sarcoma* and *carcinoma*. Benign solid tumors are very rare. Solid tumors occur oftenest in adult life, especially from forty to sixty years of age; but *sarcomas*, *embryonic tumors* and *tumors of the adrenal gland* are seen in children.

The physical signs of all these solid tumors are much the same, and have been considered under the differential diagnosis of enlargements of the spleen (p. 953). Hypernephroma may grow to immense size, but the other malignant tumors kill before they reach great size. Symptomatic varicocele and severe referred pain are usual results, and ascites is an unusual result of pressure by kidney tumors. The chief characteristic, apart from the presence of a tumor, is hematuria, which often is painless, usually is profuse, and occurs without vesical symptoms. Bright red blood is passed from the urethra when the patient expects urine. Bleeding may be so profuse as to produce faintness, recurs at irregular intervals, and is not made worse by exercise as is the less marked bleeding which attends renal calculus. If the ureter is blocked by a clot the urine is clear, but diminished in amount, and severe pain may be felt in the loin. When hemorrhage occurs and back pressure on the kidney is relieved the patient may feel better. Tumor of the adrenal sometimes may be distinguished from tumors of the kidney

proper by attention to certain details: it is most frequent in children, and anorexia, listlessness, loss of weight and strength may be noted weeks or months before the tumor is discovered; the tumor grows beneath the diaphragm, pushes the kidney down, causes early referred pain and paresthesia, and sometimes is accompanied by bronzing of the skin and precocious puberty; hematuria is very rare. The skeleton always should be examined for metastases.

Prognosis.—Hypernephroma generally leads to death within three of four years. Sarcoma and carcinoma terminate fatally within a year or less, as do tumors of the adrenal in children.

Treatment.—Nephrectomy should be done whenever possible. If the growth is large the transperitoneal route is the best. The immediate mortality of operation is about 25 per cent. and most patients who survive succumb to metastases within two years.

Cystic Tumors of the Kidney are rare and of little surgical interest. Polycystic disease sometimes appears to be hereditary; it is seen oftenest in early infancy or in middle life; usually both kidneys are affected, and hence nephrectomy which otherwise would be proper, is contraindicated. Simple serous cysts of the kidney also occur, but are exceedingly rare.

Injuries of the Kidney.—Rupture from falls, kicks, etc., is more frequent than stab or gunshot wounds. The latter are recognized by the course of the missile, bleeding into the bladder, and sometimes the discharge of urine from the wound, Subcutaneous injury varies from contusion, to fragmentation, or complete disruption (pulpefaction) of the kidney. There is hematuria, and in most cases a hematoma forms in the flank. Intraperitoneal hemorrhage is rare. There is much local pain and tenderness, and if bleeding is profuse or long continued even in small amount the usual consequences ensue.

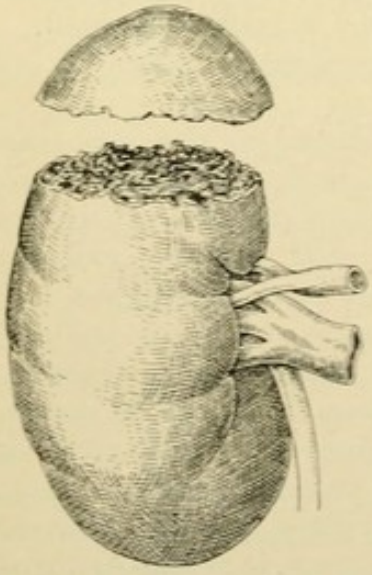

FIG. 914.—Rupture of right kidney (anterior view). Woman, aged thirty-two years, fell, striking loin on a step. Operation for increasing hematoma four hours after injury. Fragment sutured to kidney. Recovery. Episcopal Hospital.

Treatment.—In cases of gunshot or stab wound the kidney should be exposed and the wound tamponed or closed by suture. There is little prospect of spontaneous arrest of hemorrhage. In subcutaneous injuries, on the other hand, bleeding frequently ceases when the patient is kept quiet in bed, with ice locally and morphin internally. Salol or urotropin should be given. If bleeding is very profuse, and particularly if the lumbar hematoma continues to increase in size, the kidney should be exposed and the wound tamponed, or, better, closed with mattress sutures of chromic gut,

deeply inserted and including the fibrous capsule. Nephrectomy is to be avoided; even a portion of the kidney completely detached may be sutured in place (Fig. 914), and if even only one-tenth of what is saved retains its functional activity, the patient is just so much better off than if it had been removed.

OPERATIONS ON THE KIDNEY.

Position of the Patient.—In **lumbar operations** the patient should lie prone, with a sand-bag or other support between the costal margin and pelvis. When the kidney has been exposed the patient may be drawn toward the foot of the table, while the sand-bag is kept immovable. Thus it compresses the lower thorax, enforces abdominal breathing, and the kidney tends to prolapse into the wound (Edebohls). In the **abdominal approach** the position is similar to that employed in operations on the bile-ducts, but with the patient turned a little toward the healthy side.

Incisions.—The usual incision for *lumbar operations* runs parallel to the last rib, and about an inch below it, from the outer border of the erector spinæ mass for four or five inches downward and forward. This incision may be extended forward in the course of the motor nerves of the abdominal wall (Fig. 915). The iliohypogastric and ilioinguinal nerves lie just below this incision between the transversalis fascia and the oblique muscles, and should not be injured. If more room is desired at the upper angle of the wound, the lateral arcuate ligament which binds the twelfth rib to the transverse process of the first lumbar vertebra and the quadratus lumborum, may be cut and the rib thus mobilized. By keeping close to the rib there is not much danger of wounding the pleura. This oblique incision divides, at the spinal end, the latissimus dorsi; at the abdominal end, the oblique abdominal muscles at their origin from the lumbar aponeurosis. This aponeurosis itself is divided as far backward as the erector spinæ mass. Then the transversalis fascia is divided. These structures are shown diagrammatically in Fig. 916. When they have been incised the peri-renal fat, enclosed in the fascia of Gerota, is exposed. In infected cases this fatty capsule may be dense, but usually it is easily displaced by the finger, exposing the kidney covered by its true capsule.

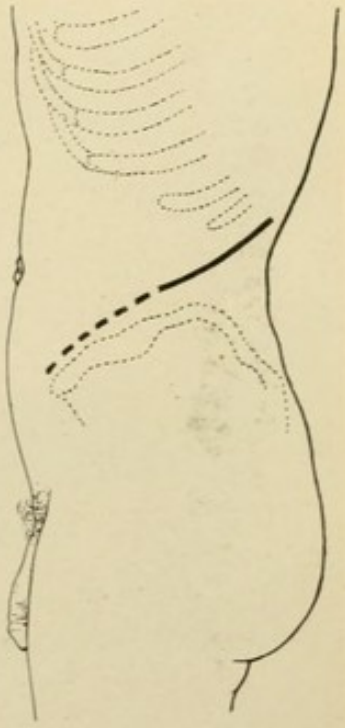

FIG. 915.—Incision for exposure of kidney by lumbar route.

In exposure of the kidney by the *abdominal route*, the best incision is one parallel to the motor nerves, beginning at the semi-lunar line at the level of the umbilicus and running back toward the flank as far as necessary.

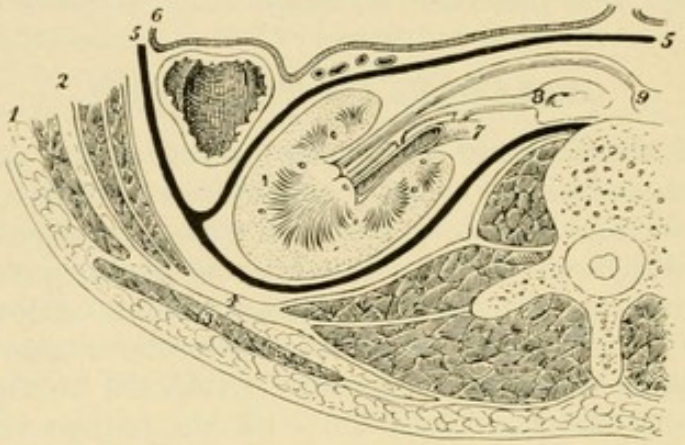

FIG. 916.—Cross-section of left lumbar region, to show structures concerned in operations on the kidney (diagrammatic). 1. External oblique muscle. 2. Internal oblique and transversalis muscles. 3. Latissimus dorsi. 4. Lumbar aponeurosis. 5. Perirenal fascia. 6. Peritoneum. 7. Ureter. 8. Renal artery. 9. Renal vein.

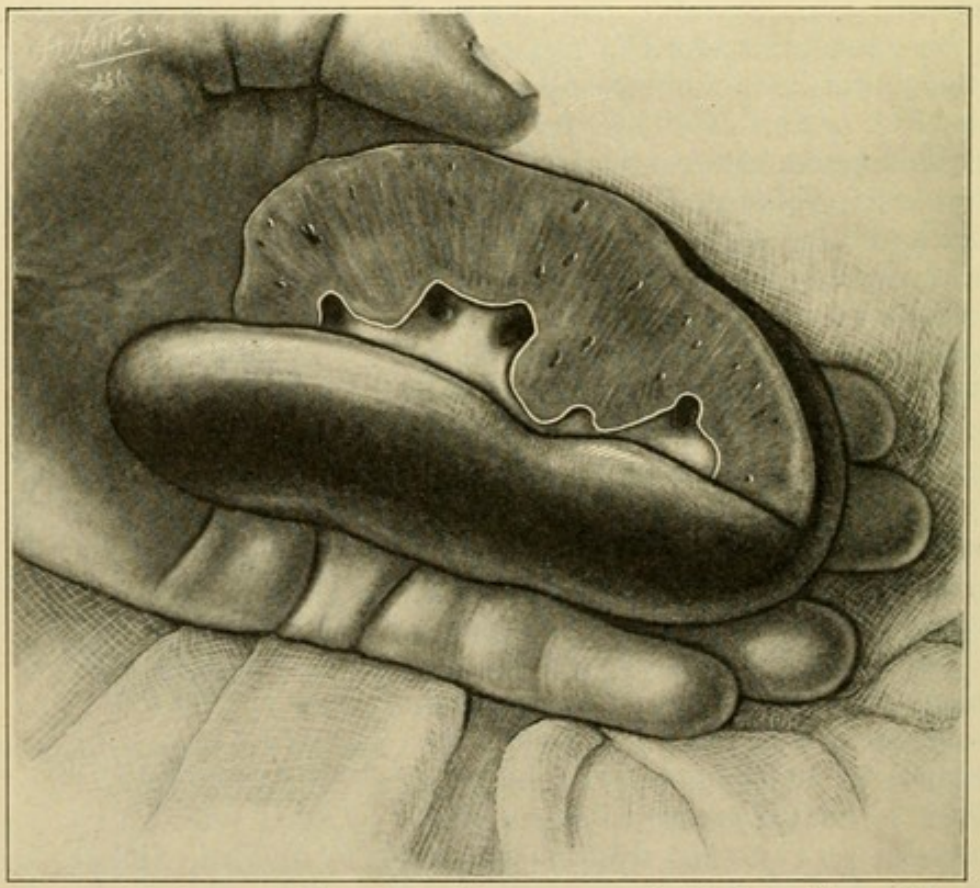

FIG. 917.—Nephrotomy: The kidney drawn out on the back and its pedicle compressed with the fingers. The splitting of the kidney here shown illustrates the operation. (Watson and Cunningham.)

Nephrotomy.—After exposure of the kidney by a lumbar incision, as indicated above, proceed to enucleate it from its fatty capsule.

Free both poles as well as the anterior and posterior surfaces by blunt dissection with the finger, and do not attempt to deliver the kidney into the wound until it has been thoroughly freed. In infected cases it may be impossible to free the kidney, on account of adhesions; hemorrhage may then be controlled by clamping the pedicle with rubber-covered forceps while the kidney is opened. If the kidney can be delivered, control the pedicle between the fingers (Fig. 917). Incise it longitudinally a little posterior to the convex border, in the bloodless zone, so as to avoid Brödel's white line which overlies the principal vessels supplying the renal cortex. Brewer opens the exposed kidney by Hilton's method (p. 51), so as to avoid hemorrhage. Cullen uses a wire which is passed from one pole of the kidney to the other, and is then made to saw its way out through the convex border.

If the operation is for the removal of calculi (**nephrolithotomy**) a large cortical incision is desirable, so as to expose all the calices and the pelvis and allow probing of the ureter. If the operation is done merely for drainage, the opening need not be so large.

If the stones are known to lie in the kidney pelvis, **pyelotomy** should be preferred to nephrolithotomy. The pelvis is exposed by turning the kidney forward and clearing off by gentle blunt dissection the fat which covers the posterior surface of the kidney pelvis. The pelvis is then incised a short distance from the kidney. After removal of calculi and probing of the ureter, the fatty tissue overlying the pelvis is sutured back in place, as this tends to prevent leakage. Drainage should be by rubber tissue, not by gauze.

Nephropexy has been sufficiently described (p. 973).

Nephrectomy.—The kidney is exposed, and, if possible, is delivered through the wound. The pedicle is attacked from below. Clamp the proximal and ligate the distal portion of the ureter, cut between, and leave the ligature long. Expose the renal arteries and vein by blunt dissection, from the front of the kidney; if not too bulky, ligate the pedicle *en masse*, or transfix and tie on both sides. Leave the ligature long. Then catch the pedicle between the kidney and the ligature in forceps, and cut between the kidney and the forceps, removing the kidney, but leaving the forceps on the pedicle, In case bleeding occurs (it may be profuse) the pedicle can be drawn into the wound, and another ligature applied. If it is impossible to expose the pedicle satisfactorily, it may be clamped and the kidney cut away. Never tie the ligature while the clamp is in place, since when the clamp is released and the pedicle retracts the ligature may be forced off. It is permissible to hold the pedicle in a clamp while the ligature is being passed (Fig. 918), but before the ligature is tied the clamp must be released. If this is impossible, the clamp must be left in place for four or five days.

The kidney being removed and all hemorrhage checked, the ligature on the ureter is pulled upon, and the ureter drawn into the wound. As much as possible of it should be resected, and the end securely ligated. In septic or tuberculous cases it is well to inject 10 drops

of carbolic acid, thus ensuring obliteration of its lumen. In cases of nephrectomy for tuberculosis, where pyogenic infection is absent, it is best if possible to close the wound without drainage. In all cases of pyogenic infection drainage is essential.

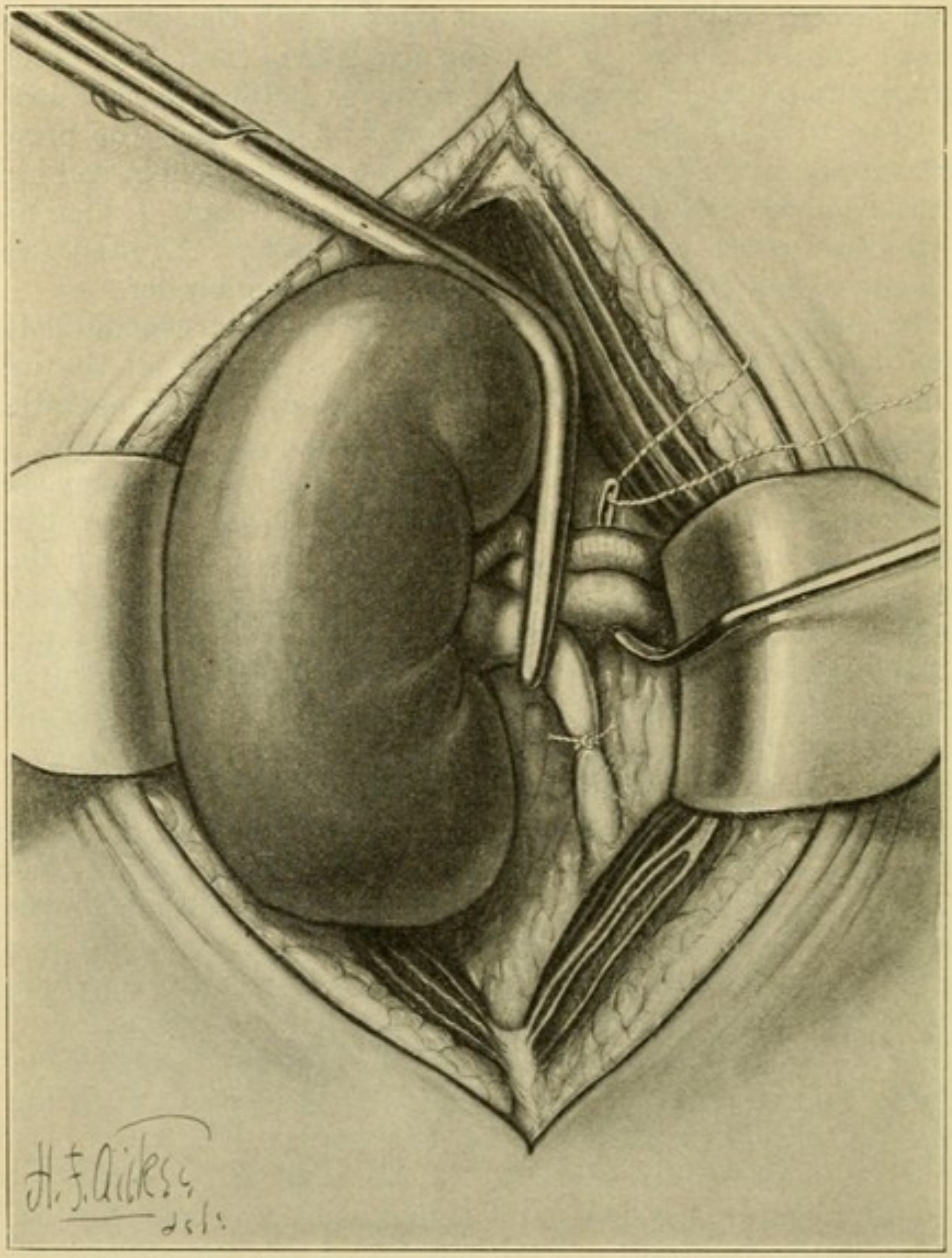

FIG. 918.—Nephrectomy: Manner of clamping and tying the pedicle of the kidney. (Watson and Cunningham.)

Closure of the Wound.—In all operations on the kidney, whether drainage is employed or not, the same care in suturing the wound should be taken as in abdominal operations. Hernia is not very infrequent if suturing is carelessly done.

CHAPTER XXVI.

VENEREAL DISEASES.

SYPHILIS.

The pathology of syphilis is discussed in Chapter III.

Contagion.—The disease may be inherited (congenital syphilis) as well as acquired. The only pathological difference between these two forms of the disease is that in the inherited form there is no primary lesion (chancre), the infecting organism having entered the infant's body through its mother's blood or with the semen of the father.[1] The lesions of syphilis from which the disease may be contracted are the primary lesion (chancre), and the secondary lesions (especially mucous patches). Tertiary lesions seldom if ever convey the contagion. In nearly all cases there is at the point of inoculation a pre-existing abrasion, crack, or fissure in the epithelium of the patient inoculated; inoculation through the intact skin is very rare.

The occurrence of *immediate* and *mediate* contagion was also mentioned in discussing the pathology of syphilis. In most cases syphilis is acquired by immediate contagion, during sexual intercourse. Hence it is classed as a venereal disease.[2] The sores from which the virus is derived being situated on the genitalia, the sore produced by inoculation likewise develops on the genitals. If the disease is not contracted during coitus, the primary lesion usually is not on the genitalia (though it may be), but on the lip, face, or other exposed portion of the body; and is due to direct contact with contagious sores in another individual (immediate contagion) or to mediate contagion through infected towels, eating and drinking utensils, etc. Such patients being regarded as innocent, the disease in them is sometimes termed *syphilis insontium*. In such cases mediate contagion may conceivably cause inoculation in the genitalia; but the presumption is strong that a genital sore has been acquired during the venereal act. Yet it is well to remember that such occurrences are at least possible, and care should be taken not to wound the feelings of others

[1] It has not been found possible to produce a similar form of the disease experimentally (using monkeys), since the treponema is destroyed by phagocytosis when injected directly into the blood. According to Levaditi and Roché, however, syphilis without any primary lesion has been produced by injecting the organisms into the testicle where they are able to develop. In these cases the first manifestations of the disease corresponded to secondary syphilis, and in so far resembled the congenital form.

[2] Until Ricord, in 1836, pointed out the clinical differences between chancre and gonorrhea, these two affections were not distinguished, both, as well as chancroid, being considered lesions of "the venereal disease" (syphilis).

and perhaps cause domestic unhappiness by expressing an unguarded opinion, which, after all, may prove erroneous (J. Ashhurst, Jr.).

Symptoms and Diagnosis of Chancre.—A chancre develops from three to five weeks after exposure, and occurs first as a reddish-brown papule; but usually when first seen exfoliation of the overlying epithelium has occurred. The chancre appears as a superficial erosion, which is common, or as a deep excavated ulcer (Hunterian chancre), which is rare.

Fig. 919.—Multiple chancres (penis and abdomen), the result of simultaneous inoculation. Episcopal Hospital.

In the male, chancre usually develops on the prepuce, frenum, or glans penis; less often on the body of the penis, the abdomen, or elsewhere. In the female it occurs on the labia, within the vagina, or on the cervix uteri; occasionally around the anus or in the perineum. In men it usually attracts attention as soon as it develops, on account of its exposed position; in women, for the contrary reason, it is generallyo verlooked, and they come under treatment first when secondary lesions develop.

In almost all cases the chancre is *solitary;* if more than one is present, *all have been inoculated at the same time,* usually from numerous secondary lesions (Fig. 919). The chancre is not *auto-inoculable;* a person who has a chancre has developed a constitutional disease which runs a regular course, and he is immune to re-inoculation (from his own sores or sores of others) until the disease is absolutely eradicated.

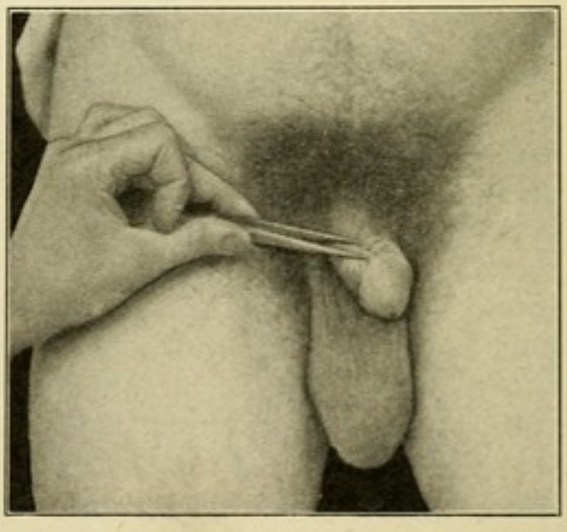

Fig. 920.—Chancre, duration one day; exposure two weeks ago. (Also left vari cocele.) Age twenty-one years. Note induration. Ulcer can be picked up in forceps without folding on itself. Episcopal Hospital.

In all cases the chancre is *indurated,* at some time in its development. Sometimes induration appears before erosion of the epithelium occurs, and usually it persists after the ulcer has cicatrized. The induration of a chancre causes it to feel like a piece of parchment or a split pea in the skin, and often the chancre can be picked up, as it were, without causing it to fold on itself or wrinkle (Fig. 920). In cases where induration is less evident, it is best detected by slight

rigidity of the prepuce as this rolls back from the corona glandis (Fig. 923). This is not an inflammatory induration: the outlines of a chancre (almost invariably round or oval) are sharply defined; and there is no redness, heat, swelling, or abundant secretion from the eroded or ulcerated surface. The surface of a chancre on a mucous membrane may be moist, and covered with a thin pellicle of fibrin; but one on an exposed surface usually is covered with a dry brownish scab.

FIG. 921.—Scar from chancre on glans penis, seven months previously. Age twenty-two years. (Note also small punched-out ulcer back of prepuce from a healed chancroid.) Episcopal Hospital.

The duration of a chancre is self-limited. It heals spontaneously in a few weeks or months unless complications arise. It leaves a very characteristic *cicatrix*, which usually but not always, may be identified years later by its circular, shiny, slightly depressed appearance (Figs. 921 and 922).

A **mixed chancre** is a sore in which both the syphilitic and chancroidal viruses have been inoculated.[1] Usually both poisons have been inocu-

FIG. 922.—Scar on body of penis from chancre two years previously. Age twenty-six years. Episcopal Hospital.

[1] Until Bassereau in 1852 pointed out the clinical differences between chancre and chancroid, they were not distinguished, both being regarded as the initial lesion of syphilis. Rollet in 1866 was the first to explain the essential nature of "mixed chancre."

lated at the same time, but this is not always the case. A chancre may be inoculated subsequently with chancroidal virus, or *vice versa.*

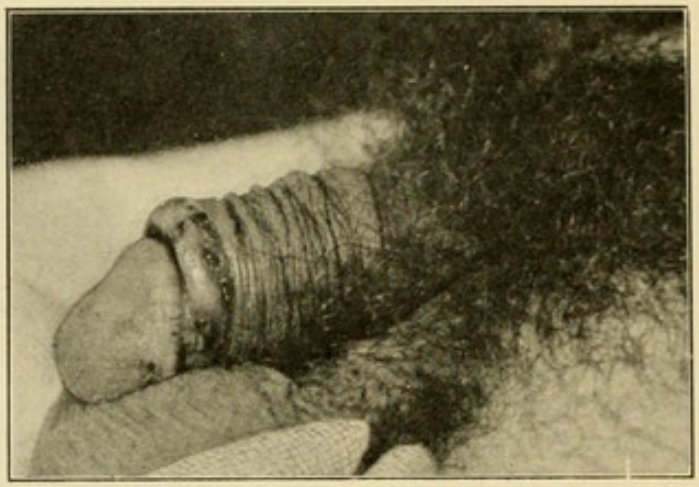

FIG. 923.—"Mixed chancre." Multiple chancroids, appeared four weeks ago, four days after coitus. Induration present for last week only. Note stiffness of prepuce as it is rolled back from corona glandis. Episcopal Hospital.

In most cases the early symptoms and history indicate that the lesion is a chancroid; and it may be only when the ulcer fails to heal and induration commences (Figs. 923 and 924), or even not until symptoms of secondary syphilis appear, that the true condition is recognized.

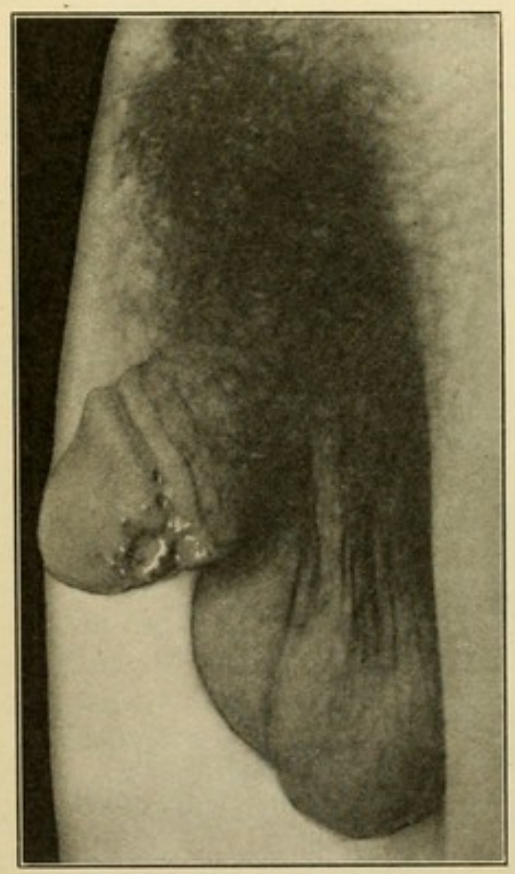

FIG. 924.—Mixed chancre. Lesion appeared five weeks ago, four days after coitus. Episcopal Hospital.

Syphilitic Bubo.—Very soon after the appearance of the chancre, the related lymph nodes (usually the inguinal) become enlarged and indurated. Many nodes are affected (*polyganglionic*), and if the

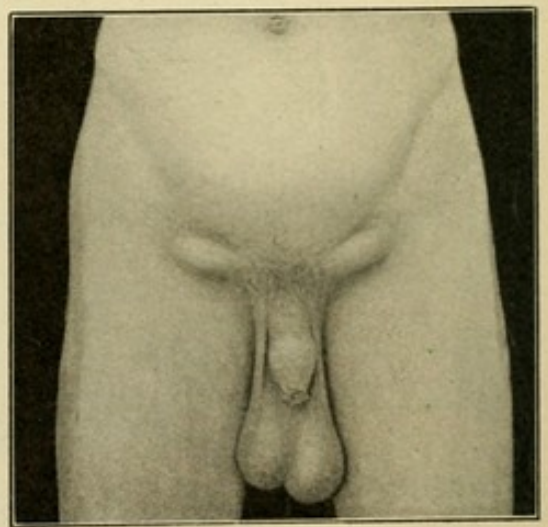

FIG. 925.—Syphilitic buboes. Age seventeen years. Coitus January 15, chancre of glans penis developed February 7. Photographed March 22, 1909. Episcopal Hospital.

inguinal region is involved, almost invariably the affection is *bilateral*. Usually the enlargement is moderate (Fig. 925), but occasionally I have seen great lumps the size of oranges develop. The individual nodes do not tend to coalesce, they remain discrete; their outlines are recognizable on palpation; they are neither especially painful nor very tender; they show *no evidences of acute inflammation*, and *never suppurate*. These features serve to distinguish syphilitic from *chancroidal bubo*, which is *unilateral*, *inflammatory*, very painful; and in which *suppuration* is frequent.

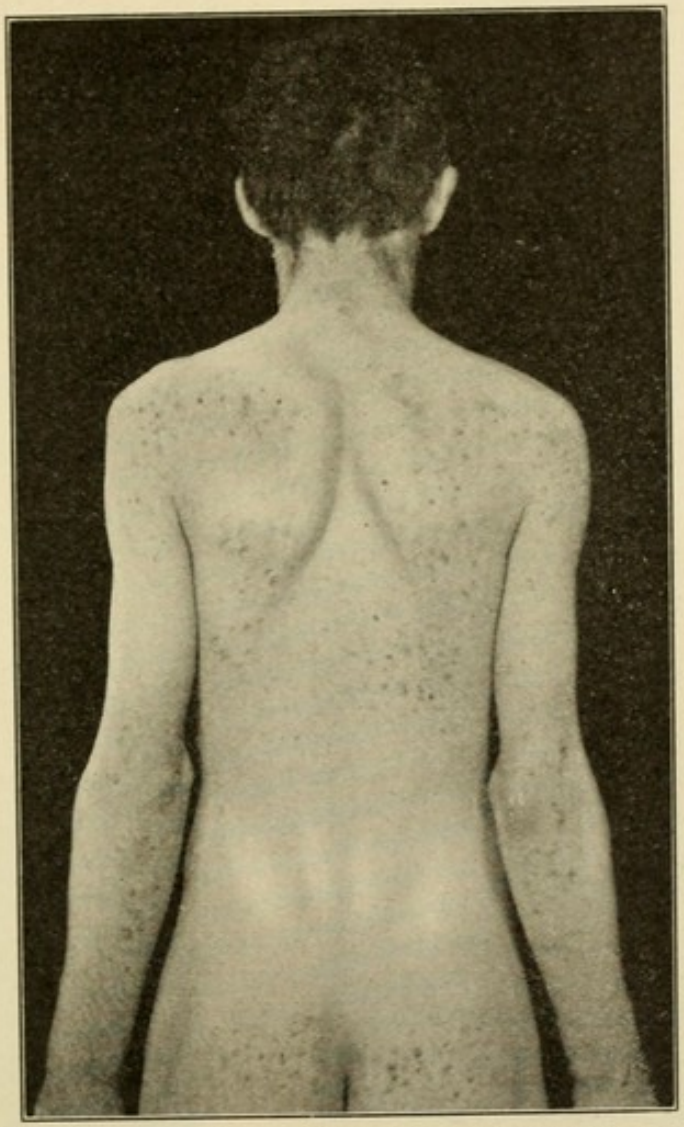

FIG. 926.—Macular syphiloderm; duration seven days; chancre three months ago. Episcopal Hospital.

Symptoms and Diagnosis of Secondary Lesions.—As noted in Chapter III, various prodromal symptoms (fever, malaise, headache, vague "rheumatic" pains) often occur during the period between the development of the chancre and the appearance of secondary lesions. This period lasts, on the average, *about six weeks*. At the end of this time, often before the chancre has healed, sometimes after its existence has been almost forgotten, and occasionally as the first recognized

symptom of syphilis (the chancre having passed unnoted), there appear skin rashes which, though multiform and various, possess certain characteristics by means of which their syphilitic nature usually may be recognized. About this same time the lymph nodes all over the body become enlarged, especially the posterior cervical and epitrochlear groups. This lymphatic involvement is very characteristic, and often can be relied on for diagnosis when the skin rashes are too faint or fleeting for recognition. There is also falling of the hair (alopecia syphilitica); and sore throat, from development in the pharynx of lesions which correspond to the skin rashes. Affections of the eye, especially iritis, sometimes occur.

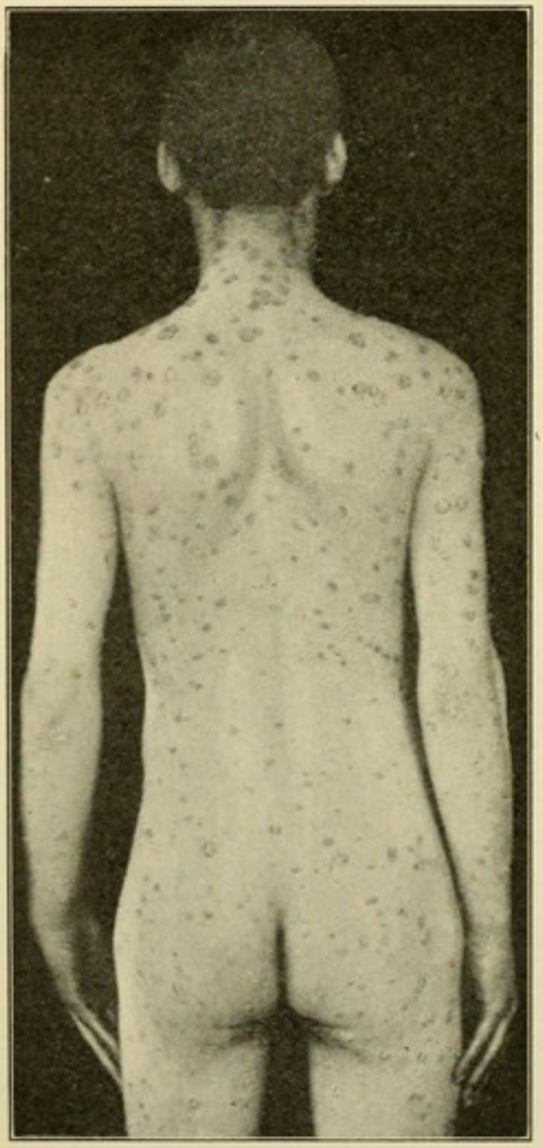

FIG. 927. — Papular syphiloderm, scaling (syphilitic psoriasis); duration one month; chancre three months ago. Episcopal Hospital.

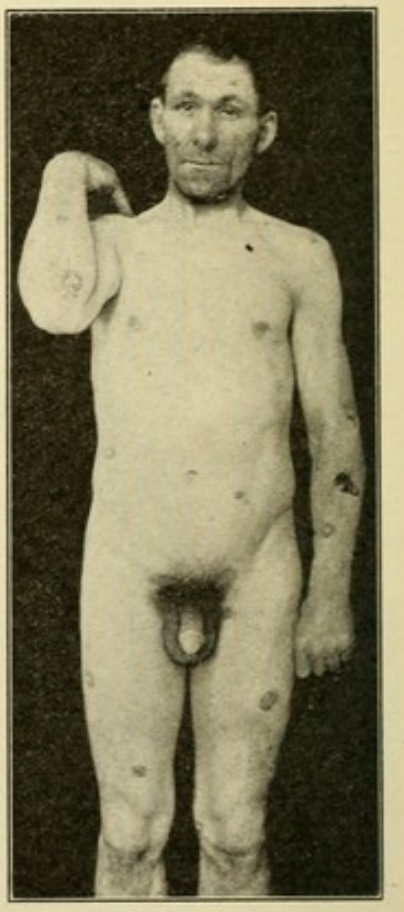

FIG. 928. — Papulo-squamous syphiloderm; chancre seven months ago. Episcopal Hospital.

The occurrence in combination of *skin rashes, lymphatic enlargement, falling of the hair,* and *sore throat* is almost pathognomonic of secondary syphilis.

Syphilodermas.—The skin rashes of secondary syphilis require more extended description. They are characterized (1) by the so-called *protean* nature of the eruption, or the appearance simultaneously, or

in quick succession, or more than one variety; (2) by their appearance *symmetrically*, all over the body; (3) by the *absence of subjective symptoms*, the lesions causing no sensation of itching, burning, etc.; and (4) by the *ham-red* or *coppery color* of the lesions, especially as they fade away. They are distinguished from the skin lesions of *tertiary syphilis:* (1) by their appearance within a more or less definite interval after the primary lesion; this is not true of tertiary lesions; (2) by their general and symmetrical distribution; tertiary skin lesions are local and asymmetrical; (3) they do not spread centrifugally and hence do not assume the circinate and serpiginous character of tertiary lesions; (4) they tend to disappear spontaneously after lasting a few weeks or months, even without treatment; and their disappearance is markedly hastened by mercurial treatment.

Macular rashes (erythema and roseola) usually are the first to appear (Fig. 926); they may become apparent only after the patient's body has been exposed to the air. Examination in a good light is necessary.

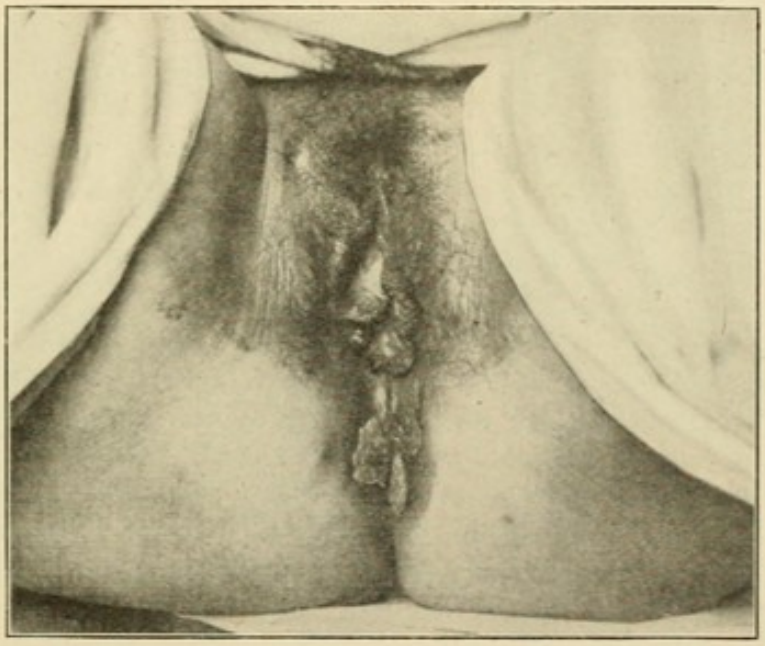

FIG. 929.—Mucous patches around the labia and anus of a colored woman. Pennsylvania Hospital.

Papular rashes also occur early. Papules which are exposed tend to scale, and the lesion may resemble psoriasis (Fig. 927). A papular eruption which occurs late is more deeply situated in the skin, and bears a slight resemblance to tertiary lesions (Fig. 928). Papules which occur in a group on the forehead, just below the hair line, tend to become confluent and are termed the *corona Veneris*. Papules which occur on mucous membranes, or on skin surfaces which are moist and warm (anus, scrotum, labia, infra-mammary folds) have their epithelial covering destroyed by maceration; they are known as **mucous patches**, or if confluent, as **condylomata lata** (Fig. 929).[1] They

[1] The *condyloma latum*, or flat wart, is so-called to distinguish it from the ordinary venereal wart or *condyloma acuminatum* (p. 1049).

should be looked for in the situations named, as well as in the buccal mucous membrane (cheeks, palate, fauces, tonsils, tongue).

Pustular rashes occur later than the macular and papular, usually several months after the primary lesion. The chief varieties are ecthyma, acne, and impetigo. If deep ulcers are formed, characteristic round, white, shiny cicatrices are left.

Symptoms and Diagnosis of Tertiary Syphilis.—Usually there is an interval of a few or many years between the disappearance of secondary symptoms and the occurrence of those of the tertiary stage. Occasionally, however, no interval elapses, tertiary symptoms appearing while the skin rashes of the second stage still are present. In many cases no tertiary symptoms ever appear, especially if active treatment has been persisted in throughout the secondary period.

Tertiary lesions may affect almost any tissue in the body. Those which occur in the skin, mucous membranes, subcutaneous tissues, eye, nervous and vascular systems, muscles and fascia, bones and periosteum, and certain of the solid viscera, are of most importance in surgery.

The **skin lesions** of tertiary syphilis are deep and destructive. They appear at no definite interval after the primary lesion, they are localized and not symmetrical in distribution, they tend to spread centrifugally and to assume a serpiginous form, they show no inclination toward spontaneous cure, and treatment by mercury alone rarely is very effective. Their chief forms are the *tubercular* (not tuberculous; see p. 77), *squamous*, and *rupial*.

Syphilitic tubercules are at first reddish or coppery papules, which tend to early ulceration; as those in the centre heal, the tubercules at the periphery become ulcerated, producing a serpiginous lesion (Fig. 930) which usually is easily recognized. Syphilitic tubercules occur frequently about the eye and nose; where it is important to distinguish them from lupus, and rodent ulcer. The scar which results from a tubercular ulceration is large and quite characteristic (Fig. 931); it will be noted, in the patient represented in this photograph, that although both knees (symmetrical portions of the body) have been affected, the lesion on the left side developed seventeen years after that on the right.

Squamous lesions often attack the palms and soles, where cracks and fissures are frequent, and may be very painful.

Rupia may occur in one or many patches, following a bullous eruption (Fig. 932).

In the **mucous membranes** syphilitic ulceration may cause great destruction. Gummatous lesions of the tongue have been described in Chapter XIX. The *palate, fauces, pharynx*, etc., may suffer severely; perforation of the palate is not unusual; "*falling in*" of the nose is frequent; and sometimes the soft palate grows fast to the vault of the pharynx, completely shutting off the nasal passages from the oropharynx. Strictures of the *esophagus, larynx, trachea*, and occasionally of the *intestinal canal* occur.

In the **subcutaneous tissues** the most frequent lesion is the syphilitic gumma (Fig. 933). Its clinical characters have been described in Chapter III.

In the **eye** the most frequent lesion is syphilitic iritis.

In the **nervous system** the lesions affect chiefly the brain and spinal cord, or their membranes. Lesions of the peripheral nerves are rare. Any lesion of the central nervous system which occurs in a patient who has had syphilis, even many years previously (Fig. 934), should be regarded as syphilitic until the contrary can be proved.

In the **arterial system** the influence of syphilis in causing aneurysm has been pointed out in Chapter X.

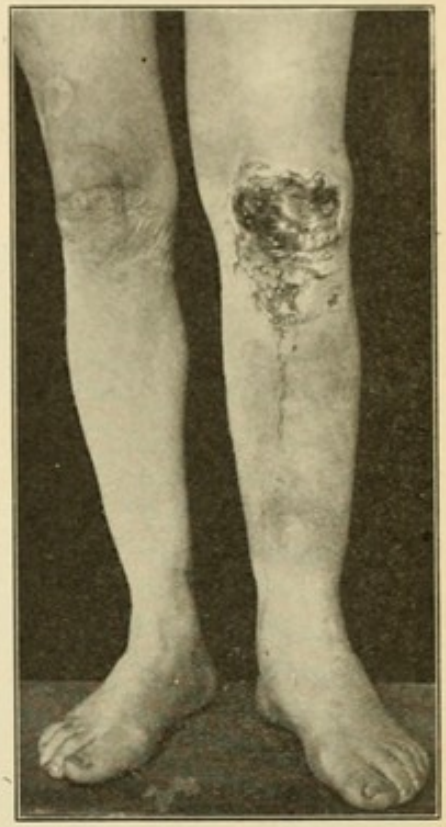

Fig. 931. — Left knee, active tubercular ulceration of tertiary syphilis in a woman aged fifty years, twenty years after the primary lesion. Right knee and thigh show cicatrices of similar tubercular lesions which developed seventeen years previously and were three years in healing. Episcopal Hospital.

Fig. 930.—Tuberculo-crustaceous lesion, in tertiary stage of syphilis. Duration nine months. Episcopal Hospital.

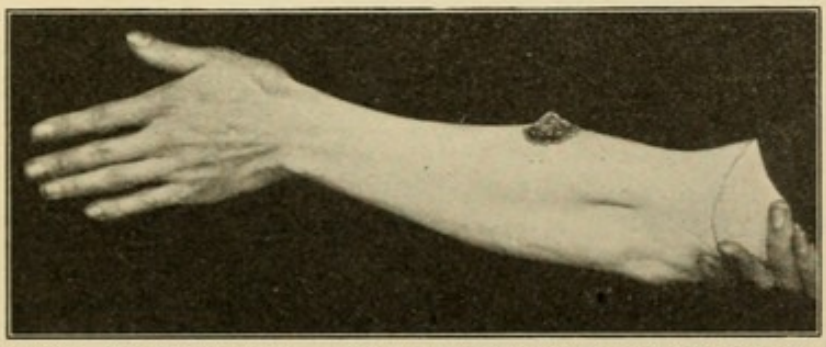

Fig. 932.—Syphilitic rupia. Age twenty-six years; duration five weeks. Chancre one year ago. Episcopal Hospital.

In the **muscles, bursæ, tendons,** and **fascia** gummatous tumors are not unusual, limiting function by their bulk, by ulceration, or by

the cicatrices which are the result of healing. Syphilitic *panaris* and *dactylitis* (Fig. 935) have been described in Chapter XIV.

Syphilis of the **bones** has been considered in Chapter XIV.

Of the **solid viscera,** the lesions of tertiary syphilis affect particularly the *liver,* where gummas may simulate nodular carcinoma. The diagnosis depends on the history of the case, the recognition of other signs (past or present) of syphilis, and the result of medication. At operation gummas usually may be recognized by central softening, if recent, or by the stellate fibrous cicatrix which results when healing has been uninterrupted. Excision may be desirable if calcification occurs. Syphilis of the *spleen* is rare and of little surgical interest. Syphilis of the *testicle* is considered in Chapter XXVIII.



FIG. 933.—Gumma of neck and of lower eyelid, duration six weeks. Patient aged forty-five years, had gonorrhœa twenty-five years previously, no history of chancre. Rapid improvement under mixed treatment. Episcopal Hospital.

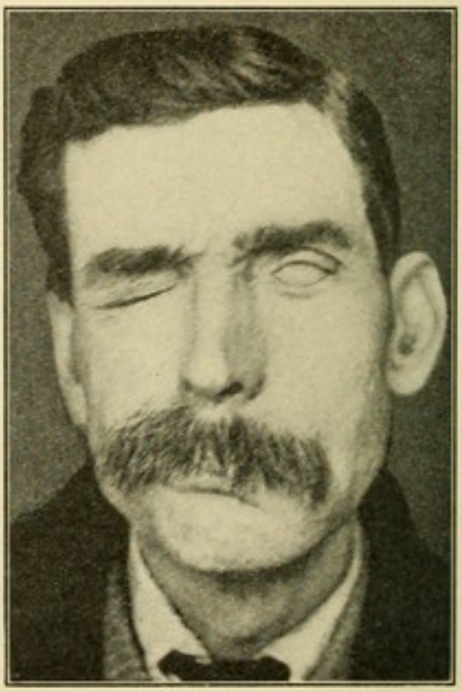

FIG. 934.—Paralysis of left facial nerve from intracranial lesion, thirty years after chancre. Paralysis of sudden onset ten days ago. Episcopal Hospital.

Hereditary Syphilis.—It has already been stated that this differs from the acquired form of the disease chiefly in having no primary lesion. It may be inherited (1) from both parents; (2) from the mother, infected either before conception or during pregnancy; or (3) from the father at the time of conception. As the mother in the latter circumstances is able to suckle her syphilitic child without acquiring syphilis herself (**Colles's law,** 1837), it was formerly taught that she had acquired immunity from the fetus; but as such a mother reacts positively

to the Wassermann test (p. 1001), it is now taught that she has acquired syphilis from her fetus, and that her refractoriness to inoculation is due to the fact that she already has the disease, though in latent form.

Profeta's law (1865), to the effect that a healthy child of syphilitic parents is unable to contract syphilis, is now also explained by the child having the disease in latent form, since such children give a positive Wassermann reaction. Both Colles's and Profeta's laws are merely an expression of the fact stated at p. 990, that any patient who has developed syphilis is immune to re-inoculation until the disease is absolutely eradicated.

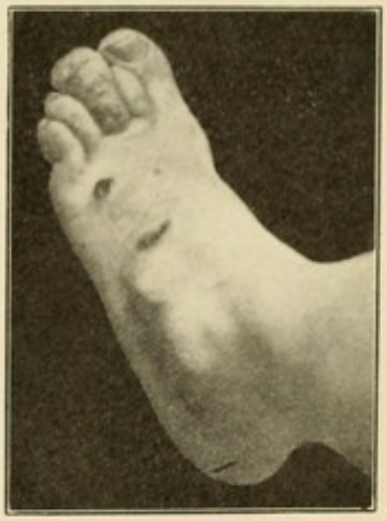

Fig. 935.—Syphilitic dactylitis, in a patient aged forty-one years, twelve years after chancre. Episcopal Hospital.

Pregnancy, in the case of syphilis, usually terminates in abortion, in miscarriage or in still-birth at term. The more attenuated the infection, the more probable is the birth of a living child at term. The child often shows no evidences of syphilis at birth; but if the disease is truly hereditary and not acquired after birth, lesions corresponding to those of the secondary stage almost invariably appear before the age of two weeks.

Fig. 936.—Hereditary syphilis; aged twelve years. Hutchinson teeth; interstitial keratitis; sabre-blade tibiæ. Orthopædic Hospital.

The *earliest symptoms* are bullous skin eruptions (pemphigus), mucous patches, and coryza ("the snuffles"). The baby suffers from

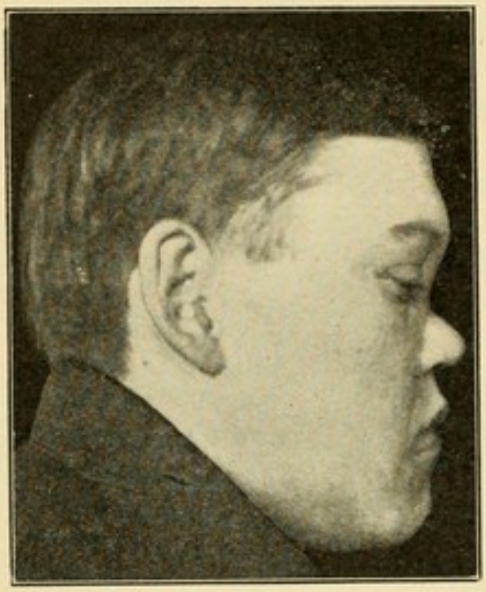

FIG. 937.—Saddle-nose in hereditary syphilis. Age twenty-four years. Also has genital infantilism and chronic otitis media. Episcopal Hospital.

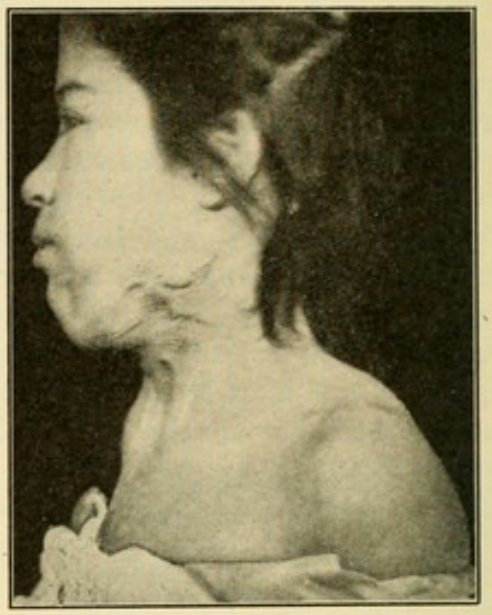

FIG. 938.—Hereditary syphilis. Age fourteen years; superficial gummata wrongly diagnosed as tuberculosis and eight operations done during last five years. (Dr. W. Walker's case.) Episcopal Hospital.

malnutrition and looks wrinkled and prematurely aged. If the period of infancy is survived, further lesions seldom appear until the age of six years or older. The most characteristic of these lesions are *interstitial keratitis*, "*Hutchinson's teeth*" (Fig. 936) (a peculiar notched and inverted wedged-shaped condition of the permanent upper central incisors, first recognized as syphilitic by Jonathan Hutchinson, 1861), *rhagades* or *linear cicatrices* at the corners of the mouth, *saddle-nose* (Fig. 937), *dactylitis*, and *sabre-blade tibia* (Fig. 461). Superficial gummata may be mistaken for tuberculosis of the cervical lymph nodes. (Figs. 938 and 939). Syphilis of the *joints* (p. 503) is common in the hereditary form of the disease. In many cases *genital infantilism* may exist even if the body is large and reasonably well formed.

FIG. 939.—Hereditary syphilis, same patient as Fig. 938, three months after a course of anti-syphilitic treatment. Episcopal Hospital.

Diagnosis of Syphilis.—This has been based for many years solely on the clinical findings, and as laboratory aids (particularly the complicated Wassermann test, 1906) often are not available, it is very important for the surgeon to be able to recognize and attach due significance to the multiform symptoms of the disease, especially as these often are developed without apparent regularity and are constantly modified by previous treatment or extraneous circumstances. Often very little assistance can be obtained from the patients themselves, who may be wilfully deceptive in their answers or who may really have failed to notice symptoms sometimes trivial in themselves and frequently spread over a long term of years.

The distinction between **chancre** and **chancroid** is of great importance, and usually is possible clinically by attention to the points enumerated at p. 1007; but the existence of **mixed chancres** must be remembered, and also that both chancre and chancroid may be inoculated simultaneously but in different parts of the body. Moreover, a person already having syphilis may subsequently acquire a chancroid, and this may be modified by the syphilitic soil in which it is planted. Valuable information may be derived from "confrontation," or the examination of the individual from whom the disease was contracted; but this is seldom possible in this country.

Extragenital Chancre, particularly on the lips and tongue, must be distinguished from carcinoma. This usually may be done clinically by observing the early palpable enlargement of the neighboring lymph nodes in chancre, and the effect of antisyphilitic treatment. Microscopical study of a section of the suspected ulcer is a sure method, but like other laboratory aids is not always available.

In the diagnosis of **secondary** and **tertiary lesions** the surgeon must rely not upon any one or two symptoms, but upon the coexistence of a number, and especially upon their course and order of development. A surgeon meeting with a case of iritis or of cutaneous eruption, or of periosteal "rheumatism," in a person of notoriously lax morality, should not at once jump to the conclusion that the disease is syphilitic; for to do so would be as unphilosophical as it might be unjust. If, on the other hand, a patient should suffer from frequent attacks of recurrent iritis, copper-colored eruptions of various forms, post-cervical engorgement, alopecia, and occasional development of mucous patches; or from osteoscopic pains, indolent nodes and gummatous tumors of the areolar tissue—even though such a patient should appear as virtuous as Joseph or as wise as Penelope—the surgeon might reasonably conclude that he had to deal with a case of syphilis, and should direct his remedies accordingly (J. Ashhurst, Jr.).

Laboratory Aids to Diagnosis.—In many of the ulcerated lesions of syphilis, especially the chancre and mucous patches, it is possible to find the Treponema pallidum by microscopical study of smears with dark field illumination, or after proper staining. The *Wassermann* or *complement-fixation test* for syphilis is now in almost universal use, and is considered perfectly reliable within certain limits. The

test is of highly technical nature, and requires long practice and vast experience for its proper performance; many of the tests are useless because these exacting conditions are not fulfilled. Then the test sometimes is not positive during the earliest stage of syphilis (chancre), nor as a rule during the secondary stage if the patient has been under active antisyphilitic treatment. It is of greatest value in the third stage of the disease, and in para-syphilitic affections, since here the patient usually has not been under active treatment for a long time, and if the test is positive it may be considered conclusive evidence that the patient is still suffering from syphilis. Even this does not prove, however, that *the lesion in question* is necessarily syphilitic. In the case of hereditary syphilis, also, a positive Wassermann reaction may indicate that a child of syphilitic parents is itself actively infected, or it may indicate merely that the child has syphilis in a latent form, in accordance with Profeta's law. Whether or not a positive Wassermann test may be obtained in the third or fourth generation of patients suffering from latent syphilis is not certain; but I am inclined to believe that it may. Certainly the fact that the test is positive often is the only evidence, however remote, which can be obtained to indicate that the patient or his ancestors ever were infected with syphilis.

Treatment of Syphilis.[1]—As syphilis is a general infection, constitutional treatment is much more important than local. It has been found by several centuries of experience that the most useful internal remedies are mercury and the iodides. The first of these is antiseptic, and probably acts directly on the parasite which causes the disease, thus being specially indicated during the active stages of syphilis; while the iodides, which aid elimination, are chiefly beneficial (either alone or combined with mercury) in the tertiary stage. Since the discovery of the microbic cause of syphilis, renewed efforts have been made to secure some drug which shall once and for all destroy the parasites which cause the disease and thus produce rapid cure. At first it was thought that this *Sterilisatio Magna* had been provided in the arsenical compound known as *Salvarsan*, the six hundred and sixth ("606") chemical synthetically prepared by Ehrlich, with this end in view, and furnished to the public in 1909. To this remedy has succeeded, lately, *neosalvarsan*. But it has become evident that while these preparations are of exceedingly great efficacy in certain cases, their use only supplements and does not supplant that of mercury and the iodides.

Throughout the continuance of the disease, strict rules of hygiene must be observed. In alcoholics, nephritics, and the tuberculous, the prognosis is bad. In otherwise healthy patients the disease is not only curable, but often rapidly so. The patient must not drink any alcoholic liquors. He must not smoke nor chew tobacco, as these habits favor the development of mucous patches. He should have his

[1] The question of venereal prophylaxis is mentioned at p. 1011.

teeth put into good order, and should keep them in good condition throughout the disease. He must take great care of his skin, bathing frequently and paying special attention to regions where mucous patches are apt to develop. He must be careful in his diet. He must not kiss any one on the lips; must sleep alone; must never use a common towel, drinking cup, or other utensil likely to spread contagion.

Treatment of the First Stage.—Unless the diagnosis of chancre is positive, I believe it is improper to administer constitutional treatment until the appearance of secondary symptoms renders the existence of syphilis certain. The reason for this is that, if the sore is not a chancre, no secondary symptoms will appear under any circumstances, and if the sore is wrongly suspected of being a chancre, and constitutional treatment is administered, the subsequent failure of secondary symptoms to appear may be attributed to the treatment employed, and both physician and patient will still entertain the erroneous opinion that syphilis is present. Hence is apparent the extreme importance of reaching an accurate diagnosis in the first stage of the disease, by careful clinical study and laboratory work.

If in any manner the diagnosis of chancre is incontestable, then the patient should be put upon constitutional treatment at once, since there is very little doubt that this will render the subsequent course of the disease less severe. The best way to administer mercury internally is in the form of the protiodide (hydrargyri iodidum flavum) in doses of from $\frac{1}{8}$ to $\frac{1}{4}$ grain (0.008 to 0.016 gram). The tolerance of the patient for this drug must be ascertained, and the dose must be kept just below this point. Usually it is well to combine a tonic, such as iron, with the mercury. Whenever mercury is being taken the patient should be directed to snap his teeth together occasionally, to ascertain the first occurrence of tenderness of the gums; the dose is then reduced slightly. Should salivation, unfortunately, occur, the drug must be stopped at once, and cleansing mouth washes used.

Locally, little need be done for the chancre, beyond keeping it clean and dusting it occasionally with some inert powder. Cauterization is not only useless but harmful; and the uselessness of excision with a view of arresting the disease, was pointed out in Chapter III. If the buboes which attend a chancre are painful, they may be covered with ichthyol or belladonna and mercury ointment, and slight pressure may be applied by a firm bandage.

Treatment of the Second Stage.—If constitutional treatment has been begun in the first stage, no secondary manifestations may appear; but it will still be necessary to continue treatment since experience has shown that not only may its discontinuance be followed by the appearance of secondary lesions, but that the occurrence of tertiary lesions is more certain and their character more severe, while after prolonged and proper treatment during the second stage they usually are mild if they appear at all. A continuation of the internal administration of mercury is the least distasteful treatment for the patient, and if the protiodide has been given successfully during the first stage

it may be continued into the second; or what is probably better, the bichloride or the biniodide of mercury (hydrargyri iodidum rubrum) may be given in doses of from $\frac{1}{16}$ to $\frac{1}{8}$ grain (0.004 to 0.008 gram), three times daily in pill form. If a tonic seems indicated, a mixture may be made up with the compound tincture of gentian, the compound syrup of sarsaparilla, or the tincture of the chloride of iron.

If the patient first comes under treatment *when the second stage is fully developed*, there is no better method to gain prompt control of the symptoms than by **inunctions of mercury**; indeed, I much prefer this method of administration in all cases, but patients often object to it as uncleanly. About a dram of the Unguentum Hydrargyri is to be rubbed into a non-hairy part of the body once daily. The same part of the body should not be employed again except after an interval of several days: this is accomplished by using in succession the two sides of the thorax, the two flanks, and the epigastrium. The patient should make the inunctions himself; if made by another, gloves should be worn to prevent absorption through the hands. The patient should wear the same underclothing for a week before bathing and removing the excess of mercury. When the symptoms are thoroughly under control (usually within a few weeks) inunctions may be discarded if the patient desires, and mercury may be administered by mouth, as above described. Should active symptoms recur, it is best to resume inunctions temporarily.

The *hypodermic administration of mercury salts* has been tried but abandoned by most who were at one time enthusiastic advocates of the method. It has been found painful, dangerous, and unreliable. *Intramuscular injections* are hotly advocated by E. L. Keyes, Jr.; he prefers a mixture of hydrargyri salicylatis 3 parts, and alboline (or benzinol) 30 parts. From 5 to 10 cgm. are injected once or twice weekly into the gluteus maximus. *Mercurial fumigations* are used by some, but never have been widely adopted.

Administration of mercury in some form should be continued at least for two years and a half after the initial lesion. Some follow the intermittent method: give mercury for six months, then stop for a month; then give it for three months, then stop for two months. This includes the first year. During the second year mercury is given for eight months at intervals. Continuous administration is preferable; and after cessation at the end of two and a half or three years, the administration of mercury should be resumed if symptoms recur, or if a positive Wassermann reaction develops; and should then be continued at intervals until this reaction remains constantly negative, even after treatment has been stopped for some months.

Treatment of the Third Stage.—Here the iodides should be taken, usually in combination with mercury, which markedly enhances their effectiveness. Potassium or sodium iodide may be given in doses beginning with 5 or 10 grains, thrice daily, and increased to a point just short of iodism. In deep lesions, especially of bone, immense doses are tolerated. Local treatment of external lesions in this stage

is an important adjuvant to constitutional treatment, but without the latter is absolutely inefficient.

Treatment of Hereditary Syphilis.—If either parent is syphilitic the mother should be treated during pregnancy. This reduces the chance of miscarriage, and favorably influences the course of the disease in the child Treatment of the mother should be continued throughout lactation for the infant's sake, quite apart from any indication for treatment on her own part. Inunction is the safest and surest method of administering mercury to the baby; a few grains of blue ointment may be spread on the infant's binder, daily, and allowed to work its way into the skin by the baby's movements. For later lesions (bones and joints) iodides also should be given. In most cases tonics are indicated, especially iron and quinine.

Treatment of Syphilis by Salvarsan.—This is a powerful antiseptic, and rapidly kills any syphilitic parasites with which it is brought into direct contact. It has no eliminative action like the iodides, and is useless for lesions to which it cannot be conveyed directly through the blood-stream. It is administered by intravenous injection. The usual dose is 0.6 gm., in 40 c.c. of freshly prepared and sterile physiological salt solution. This mixture is rendered alkaline by adding, drop by drop, 1 c.c. of a 15 per cent. solution of sodium hydrate, constantly agitating the mixture. Then enough salt solution is added to make 300 c.c. Thus each 50 c.c. of the entire mixture contains 0.1 gm. of salvarsan.

Though occasional deaths, and a few cases of blindness and serious lesions of the central nervous system have been recorded as following its use, and presumably caused by it, no hesitation need be entertained in its employment in any case where a rapid amelioration of symptoms is imperative. That it is absolutely curative in some cases is indicated not alone by the sudden and permanent disappearance of all symptoms, but also by the persistently negative Wassermann tests, and in a few instances by the fact that patients have lost their immunity to syphilis and have again acquired the disease. In most cases it is necessary to continue the use of mercury and the iodides after the injection of salvarsan, even if this has been repeated one or more times, as it may be at intervals of not less than one week.

CHANCROID.

The **Chancroid,** or **Ulcus Molle** (to distinguish it from the syphilitic chancre or *ulcus durum*), is now generally believed to be caused by infection with the Bacillus of Ducrey (1889). According to Sovinsky (1904) a pure culture of this bacillus will produce chancroids in man and in animals. The infection is strictly local, and always is acquired by inoculation from a similar sore. Usually it is acquired in coitus, but mediate transmission is possible. The lesion is auto-inoculable; from its first appearance and so long as it remains unhealed, other chancroids

may be inoculated from the pus which flows over the surrounding skin.

Chancroid occurs oftenest on the genital organs—especially on the prepuce, corona glandis, frenum, and urinary meatus in the male; and in the female on the labia or os uteri. But any part of the body exposed to the contagion may be inoculated. It is not very rare for inoculation to occur through unbroken skin; but usually some minute abrasion or excoriation is already present.

Clinical Course and Symptoms.—There is no distinct period of incubation. Usually the next day after exposure the patient feels an itching or tingling at the point of inoculation; a minute papule rapidly forms, and this in another day becomes a vesicle, then a pustule which either ruptures and exposes an ulcer, or becomes scabbed. Thus by the fourth to sixth day the lesion is fully developed. An ulcer which appears later than the tenth day after exposure is not a chancroid. In about 80 per cent. of cases multiple chancroids are present. These may have been inoculated simultaneously, or may have been inoculated one after the other from the single original lesion.

A chancroid appears as a rounded or oval ulcer, apparently punched out of the skin, with sharply defined and undermined margins (Fig. 924). It varies in size from less than 0.5 cm. to 1.5 cm. in diameter; it is not adherent to the underlying tissues, is surrounded at first by a reddened area of inflammatory reaction, discharges profusely pus which is auto-inoculable, and is covered by an adherent grayish slough. There is a certain amount of inflammatory induration about the base of a chancroid, but it is not sharply limited and does not resemble the parchment-like induration so characteristic of true chancre.

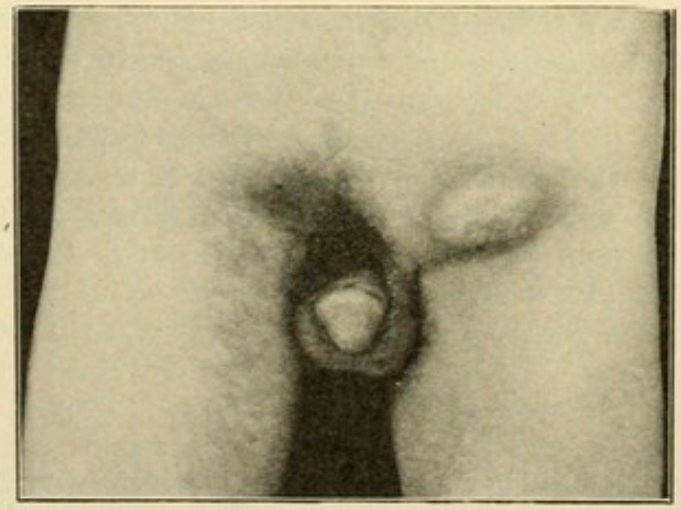

FIG. 940.—Left inguinal bubo, one week after development of chancroid on frenum. No bacillus of Ducrey found in pus, and bubo healed promptly after incision. Episcopal Hospital.

Chancroidal Bubo.—In many cases, but not in all, the related lymph nodes become inflamed, and suppuration is very frequent. This complication usually develops within the first two weeks, but occasionally not for several weeks after the chancroid has healed. Suppura-

tion in the bubo may result from secondary infection of the chancroid with pyogenic microbes (the bubo being then similar to the ordinary *bubon d'emblée*, p. 269), or may de due to direct absorption through the lymphatics of the Bacillus of Ducrey. Absorption of toxins produced by this bacillus is not a sufficient explanation. It is believed, however, that the Bacillus of Ducrey is self-destroyed by the toxins it produces in the bubo, and this is held to explain the difficulty of obtaining cultures or smears of the organism from the abscess.

A chancroidal bubo almost always is *unilateral* (Fig. 940), usually on the same side of the body as the chancroid itself. It is *distinctly inflammatory* in character from the first, and in no way resembles the indolent syphilitic bubo in which many separate lymph nodes are palpable.

Phagedenic Ulceration occasionally occurs in chancroid, especially in patients who are in poor constitutional condition from alcoholic or venereal excesses, or who are tuberculous. **Serpiginous ulceration** also is rare; usually it is seen in the case of inguinal buboes which have been opened without due attention to cleanliness, and have become secondarily infected with the discharges from the original chancroid (Fig. 942).

Other complications are *phimosis, para-phimosis, balanoposthitis, coexistence of syphilis* or of *gonorrhea*, etc.

Diagnosis of Chancroid.—*Herpetic eruptions* on the genitalia develop almost immediately after coitus, do not form ulcers by the third or fourth day, but disappear spontaneously. They are not auto-inoculable. Yet a chancroid may develop in an herpetic vesicle, and therefore a distinction before the third or fourth day is not always possible. A *chancre* appears about three weeks after coitus, not within a few days; it is single, unless multiple from the first, whereas chancroids usually are multiple even if single at first. A chancre is a superficial erosion or an ulcer with hard, elevated, sloping edges, not a punched-out ulcer with undermined edges; it presents a peculiar parchment-like induration and is not surrounded by a reddened inflammatory base; it is almost invariably accompanied by double inguinal bubo, which rarely if ever suppurates, while chancroid often has no bubo and if one occurs it is unilateral and almost always suppurates; a chancre has an innate tendency to heal but is followed by constitutional symptoms of syphilis, while a chancroid has no innate tendency to heal and is never followed by syphilis unless a mixed chancre (p. 991) is present. One attack of chancroid affords no protection against subsequent attacks.

Treatment of Chancroid.—Some mild chancroids may heal under ordinary antiseptic dressings.[1] It is possible, however, that such

[1] T. R. Neilson recommends the following:

℞—Hydrargyri chlorid. corros.,	gr. ½
Zinci sulphat.,	gr. ix
Acid. boric.,	ʒ j
Glycerini,	ʒ iij
Aquæ,	fʒ vj

M.—S.—Apply on absorbent cotton.

sores are not true chancroids but only herpetic ulcerations infected by pyogenic cocci. In most chancroids the surest and occasionally the only way to secure healing is to destroy the specific microbes by cauterization. For this purpose I have never found anything so efficient as fuming nitric acid. Some surgeons much prefer carbolic acid, or even the actual cautery. If the chancroid is large, or the patient very timid, it may be necessary to administer an anesthetic. But in the average dispensary case (and it is only in the lowest class of such patients that chancroids are seen—it is a disease of filth) no anesthetic is necessary. Cauterization should not be employed unless the diagnosis is certain; it produces induration and makes difficult a distinction from the initial lesion of syphilis. When it is employed, thoroughness is requisite. The best way to apply nitric acid is by means of a stick about the size of a pencil smoothly rounded off at one end. The surrounding healthy skin should be protected from the acid by smearing it with olive oil or vaselin, and the ulcer is dried. The stick is then dipped in the acid, and is vigorously rubbed into the ulcerated surface, overlooking no corner or cranny. This destroys the specific microbes, and when the resulting crusts separate it will be found that a healthy granulating surface is left which will soon heal under ordinary antiseptic dressings or ointments. If healing does not proceed normally, cauterization must be repeated, but this is very seldom necessary if it has been properly done in the first place.



Fig. 941.—Dorsal slit of prepuce to expose chancroids of mucous surface of prepuce. Note inflammatory thickening of prepuce. Episcopal Hospital.

If the chancroid is inaccessible on account of phimosis, the foreskin should be slit up the dorsum (Fig. 941), under cocain; then the cut edges and the exposed chancroids are to be cauterized. I have never seen a case where an efficient dorsal slit did not give enough exposure.

Treatment of Chancroidal Bubo.—It is useless to attempt to treat the bubo until the infecting focus (chancroid) has been cured, since fresh inoculation will constantly occur through the lymphatics. Prompt treatment of the chancroid itself, as indicated above, fre-

quently is sufficient to cause the bubo to disappear, even when suppuration appears to threaten.

I do not think it is advisable to open a chancroidal bubo until suppuration is very evident; the longer the pus remains in the abscess, the more apt it is to sterilize itself of the chancroidal virus. Yet spontaneous rupture of the abscess is to be avoided at all hazards, especially if the chancroid itself is unhealed; since then the opened bubo will become infected by the discharges from the chancroid, and

FIG. 942.—Chancroidal ulcer. Age fifty-five years. Duration ten weeks. Bubo developed soon after chancroid of glans, and was allowed to rupture spontaneously; the ulcer then became infected with the chancroidal virus, and showed no tendency to heal. Treated by excision. Episcopal Hospital.

will be converted into a chancroidal ulcer (Fig. 942). When the bubo is to be opened, this should be done with careful antiseptic precautions. Where this precaution has been taken, and where the original chancroid was no longer a source of infection, I have never seen any bubo that did not heal promptly under ordinary antiseptic dressings. If the bubo after it is opened becomes converted into a chancroidal ulcer, as indicated above, it must itself be treated as the original chancroid; or the ulcer may be excised and the resulting wound cauterized.

GONORRHEA.

Gonorrhea is a local infection of mucous membranes caused by *gonococcus* (Neisser, 1879; Bumm, 1887). This is a diplococcus which is a pure parasite, growing best at body temperature and soon perishing when discharged from the body. It is readily killed by heat, and does not survive long in dried secretions. Mucous membranes with cylindrical-celled epithelium are much more easily infected by the gonococcus than are those covered with pavement epithelium. The gonococcus is found in the purulent exudate, within the leukocytes,[1] and invades the submucous tissues easily; it spreads through the lymphatics,

[1] Some pathologists hold that unless the diplococci in question are intracellular they cannot be certainly classed as gonococci; legal proof requires the growth of a pure culture.

enters the blood stream, and may produce a **general infection** (a mild form of pyemia). In the latter circumstances secondary localizations in serous membranes are frequent. One such localization, *gonococcic arthritis*, has been studied in Chapter XVI; *gonococcic endocarditis* is treated by the physician; and *gonococcic iritis* by the ophthalmologist. Whether or not *gonococcic conjunctivitis* (gonorrheal ophthalmia) ever occurs by infection through the blood-stream is disputed; certainly in most cases infection occurs by mediate contagion through soiled towels, etc.

Gonococcic Urethritis.—Urethral inflammation due to infection by the gonococcus is the commonest venereal disease. In the female the infection localizes itself especially in the vulvovaginal canal, not so much in the urethra. In man the infection, acquired in sexual intercourse, becomes localized in the anterior urethra, especially the fossa navicularis; unless there is phimosis, causing retention of secretions, the glans penis and prepuce usually escape infection owing to the character of their epithelial covering. From the anterior urethra the inflammation usually spreads throughout the entire canal, and is especially apt to remain localized, in chronic form, in the deep urethra and prostate. Throughout the urethra the submucous tissues are invaded, and inflammation of the glands of Littré is common; these may be converted into abscesses, which rupture into the urethra or rarely externally. Inflammation of Cowper's glands is more apt to result in external rupture. and is the chief cause of periurethral abscess (p. 1027) and periurethral urinary fistulæ. The healing of these patches of inflammation or follicular abscesses may result in the formation of urethral strictures (p. 1019).

Symptoms and Clinical Course.—1. In **Acute Gonococcic Urethritis,** vulgarly known as *the clap,* the first symptoms usually appear on the third or fourth day after contagion, and consist in tingling and itching of the urinary meatus. On inspection the lips of the meatus are found swollen, and there is a slight glairy discharge which causes them to adhere between the acts of urination. A scalding sensation in passing water is very frequent. One or two days later a profuse purulent, sometimes blood-stained discharge appears; the *ardor urinæ* lessens; painful erections are frequent; and edema of the foreskin may occur with phimosis or paraphimosis (Fig. 973) and resulting balano-posthitis. Later, during erection, the penis may be bent downward or laterally (*chordee*); this painful symptom is due to the inability of the spongy portion of the penis, which surrounds the inflamed urethra, to become elongated to the same extent as the cavernous bodies. *Epididymitis* (p. 1052) is another frequent complication. In almost all cases of gonorrhea the inflammation extends within a week or ten days to the *posterior urethra.* This event may pass unnoticed, or may be evidenced by increasing frequency of micturition, vesical tenesmus, and sometimes by temporary lessening of the discharge. Then as these symptoms abate, the discharge may again increase. Even in severe cases, constitutional symptoms usually are absent.

Acute gonococcic urethritis tends to run a self-limited course, almost all symptoms disappearing within six to ten weeks, no matter what treatment is employed, or even if no treatment is employed; but proper treatment usually hastens subsidence of symptoms. In almost all cases, however, subsidence of acute symptoms does not indicate that the disease is cured, but merely that it has become chronic or latent. The gonococci remain localized in the deep urethral crypts, in the prostatic utricle, prostate gland, or seminal vesicles, and after any excess in eating or drinking, after excessive coitus, and sometimes from no ascertainable cause, a urethral discharge containing gonococci will appear, may cause a temporary renewal of acute symptoms, and is capable of conveying contagion to another individual.

2. **Chronic Gonococcic Urethritis,** known also as *the gleet*, is a very frequent sequel of acute posterior urethritis. The symptoms are insignificant, the most constant being slight mucous or purulent discharge (perhaps only a drop or two) from the meatus, observed when the patient wakens in the morning. After defecation, or during sexual excitement, a similar slight discharge may occur. If a sound is passed into the penile urethra, the chronically inflamed urethral glands often may be detected as small nodules, by running the finger along the under surface of the penis. Sometimes vesical tenesmus is annoying at intervals. There may be frequent erections and nocturnal pollutions, and the seminal discharge sometimes is blood-stained.

Diagnosis.—The diagnosis of *acute gonorrhea* usually may be made clinically, but it is always well to stain a smear of the discharge and examine it for gonococci. If the anterior urethra only is involved, and the patient's urine is collected in two glasses, the second portion will be clear, as the urine first passed will have washed away all the secretions. If, however, the posterior urethra is involved, the second glassful of urine will be cloudy or will contain shreds of mucus, since the pressure of accumulated secretions pent up in the deep urethra can force the vesical sphincter and allow the urethral discharge to mix with the urine in the bladder. In *chronic gonorrhea* it is indispensable to examine the urethral discharge for gonococci. If no secretion is readily available, the prostate and seminal vesicles should be given gentle massage, as indicated at p. 1013, to force their contents into the urethra. A number of laboratory examinations may be necessary before gonococci can be found. In chronic urethritis the second urine constantly contains shreds.

Treatment.[1]—Certain **general directions** should be given a patient suffering from gonorrhea. He should be warned of the danger of con-

[1] The prevention of venereal disease is to be regarded as a scientific and not simply a moral problem. It is self evident that the simplest means of prevention (abstention from impure coitus) is the most efficient, but cannot always be enforced upon patients. In the case of enlisted men in the army and navy it has been found advisable to adopt definite rules of venereal prophylaxis. Holcomb and Cather (1912) report the results in the United States Navy, where the following rule was enforced after every exposure to venereal disease: (1) Wash the penis (head and shank and under frenum) with 1 to 5000 bichloride of mercury solution, using a

tagion, especially of gonorrheal ophthalmia; the possibility of complications, especially epididymitis, should be called to his attention; and he should be instructed as to precautions concerning diet, rest, hygiene, and cleanliness. He should drink plenty of water, and should take no alcoholic liquor at all, unless a confirmed drinker. He should wear a suspensory bandage, and if possible during the acutely inflammatory stage he should remain in bed with the scrotum elevated. The discharge should not be kept dammed up in the urethra by dressings; but the lips of the meatus should be greased with vaselin and the discharge collected in loosely applied absorbent cotton which is changed frequently. The presence of phimosis may add the complication of balano-posthitis, and a dorsal slit of the foreskin may be advisable to secure free drainage, especially if chancroids are thought to coexist. Paraphimosis seldom requires treatment.



FIG. 943.—Urethral syringe. (Watson and Cunningham.)

If the patient is seen in the earliest stages of the disease, before profuse discharge has commenced, it may be possible to secure prompt arrest of the disease by what is called *abortive treatment*. This consists in the use of antiseptic injections into the urethra, the usual substances employed being protargol (2 to 5 per cent.) or argyrol (5 to 10 per cent.); silver nitrate, in strength varying from 1 to 2000 up to 4 per cent., is also used. The patient should urinate before taking the injection, which is administered by means of a glass urethral syringe with blunt nozzle (Fig. 943). This is carefully introduced into the meatus, and the lips of the meatus are closed tightly around the nozzle by the fingers of the left hand, as the piston of the syringe is pushed home with the right. From 2 to 5 c.c. of the solution is injected twice, the second injection being held in the urethra for several minutes. These injections are to be used three or four times daily, except in the case of the very strong silver nitrate solutions, which should be used only once daily and by the surgeon himself, one or two injections often sufficing. In many cases in which this abortive treatment is promptly instituted, the results are excellent; though the urethral discharge may be temporarily increased, it soon decreases again, becoming glairy and perhaps blood-stained, and then ceasing entirely, within a week or ten

cotton sponge. (2) Pass the urine; and take urethral injection of 2 per cent. protargol solution and hold it in the urethra until 60 has been counted. (3) Rub 50 per cent. calomel ointment well into foreskin, head, and shank of penis, especially the frenum. They found that: 1385 exposures treated as above in the first eight hours, gave 19 infections, or 1.37 per cent.; 731 exposures treated as above in eight to twelve hours, gave 25 infections, or 3.4 per cent.; 920 exposures treated as above in twelve to twenty-four hours, gave 46 infections, or 5 per cent.

days. In other cases some discharge persists, and further treatment, as in the chronic stage, must be instituted.

If the patient is seen first during the **inflammatory stage** of gonorrhea, it is not advisable to use injections, and they should be discontinued if previously employed. In this stage the patient should remain in bed if possible, with the scrotum well elevated, especially avoiding sexual excitement. The penis should be immersed in hot water several times daily, as the heat not only allays the inflammation but is germicidal to the gonococci. Internally, capsules containing Ol. copaibæ ♏vij, and Oleores cubeb. ♏iij may be given, with or without methylene blue (gr. ij) and sandalwood oil (♏ij). Not until the decline of the inflammation should injections be resumed, and as the discharge loses its purulent character and becomes mucoid the stronger antiseptics may be abandoned and astringents given by injection, such as zinc or copper sulphate, lead acetate, etc. The following is the formula of the remedy known as "brue:" ℞—Plumbi acetat. gr. xxx; Zinci sulphat. gr. xvj; Ext. krameriæ fl. f℥iv; Tinct. opii f℥iij; Aquæ destillat. q. s. ad f℥vj. Internally such drugs as salol or urotropin are indicated. As the discharge lessens the strength of the astringent injections should be gradually diminished.

The treatment of **chronic gonococcic urethritis** involves discovery, if possible, of the habitat of the remaining germs, and their destruction. For this purpose examination with the endoscope often is advisable. Through this it may be possible to detect superficial ulcerations or erosions of the urethra, the orifices of inflamed urethral glands, etc.; or by the use of bulbed sounds the presence of a stricture of large calibre (p. 1021) may be determined; or with the cystoscope the prostatic utricle and orifices of the ejaculatory ducts may be investigated. Chronic prostatitis and seminovesiculitis are frequent complications, and it may be impossible to discover gonococci in a chronic urethral discharge until after massage of these structures, as described below.

For *lesions of the anterior urethra*, it is best to give **irrigations** three times weekly. The solution (silver nitrate, 1 to 10,000; potassium permanganate, 1 to 10,000; protargol, 1 to 2000) is allowed to enter the urethra from a fountain syringe, by the force of gravity. After the urethra has been well cleansed in this manner, a soft catheter is passed into the bladder, and this is filled with the solution; the catheter is then withdrawn, and the patient allowed to empty his bladder, thus cleansing the entire lower urinary tract (Horwitz). Strong applications are then made to the erosions through the endoscope. If there is much periurethral infiltration, the passage of large-sized sounds twice weekly is of benefit. Stimulating ointments may be employed by smearing them over the sound and then gently rubbing the corpus spongiosum while the sound is in place.

If lesions persist in the deep urethra it is well to make **instillations** of silver nitrate (0.5 per cent.) or protargol (0.25 to 2 per cent.) through a deep urethral syringe (Fig. 944) after **massage of the prostate**, which is accomplished by introducing the index finger into the rectum, and

gently stroking the vesicles and each lobe of the prostate downward toward the ejaculatory ducts. Too violent massage may set up a prostatitis or even a proctitis. It is usual to have the patient stand in a stooping posture for massage of the prostate, the surgeon standing behind him; but if the surgeon has a little practice and not too short a finger, it is more convenient to have the patient lying supine. Any urethral discharge which follows massage of the prostate should be examined for gonococci, and if these are found persistently absent



FIG. 944.—Keyes' deep urethral syringe. (Watson and Cunningham.)

at a number of examinations made at intervals after stopping all treatment, the urethritis may be considered cured. Sometimes prolonged treatment causes a *non-gonococcic urethritis*, and cessation of local treatment and attention to the patient's general health may be successful in stopping a discharge which seems otherwise incurable. Microscopical examination of the discharge in such cases may show the presence of staphylococci, streptococci, or colon bacilli. The use of **autogenous vaccines** may be of use in such cases, as well as in chronic gonococcic urethritis.

CHAPTER XXVII.

SURGERY OF THE URETHRA AND PROSTATE.

SURGERY OF THE URETHRA.

Bougies and Sounds (Fig. 945) may be regarded as *solid catheters* (p. 958). They are used in the diagnosis and treatment of urethral strictures. The **bougie** (so-called because originally made of wax) is flexible; the old French *bougie à boule* is inferior to the modern bulbous-tipped French bougies made of webbing, like English catheters. The best have a core of lead which gives them sufficient weight to facilitate their introduction. *Filiform bougies* are made of whalebone, and should be perfectly flexible and highly polished. **Sounds** are metallic instruments; they should be highly polished or nickel-plated, of sufficient weight to sink into the urethra easily, and provided with

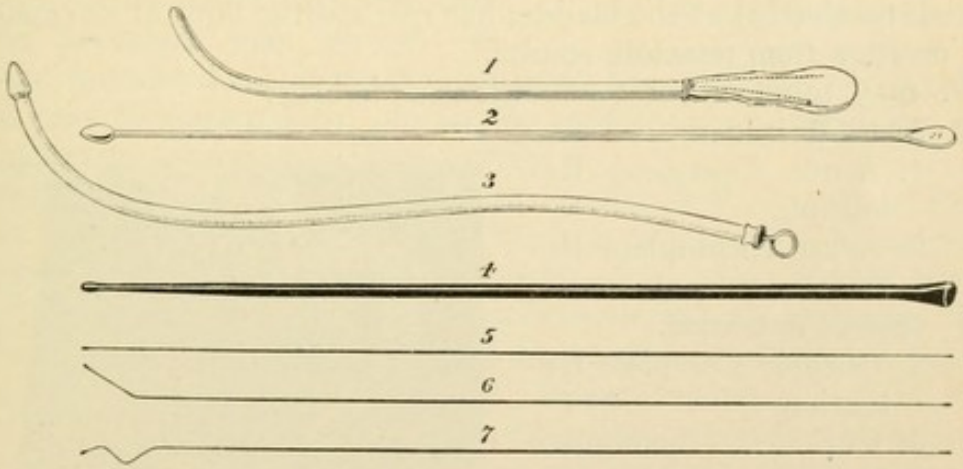

FIG. 945.—Urethral sounds and bougies: 1. Steel sound. 2. Bulbed sound. 3. Bougie à boule. 4. Olive tipped bougie, made of webbing, with a leaden core. 5, 6, 7, Filiform bougies, made of whalebone.

a suitable handle, to prevent slipping. They are introduced in the same way as metal catheters (Figs. 946 and 947). *Bulbed sounds* correspond to the *bougies à boule;* they are of use in determining the extent and site of a stricture, by the sensation they impart to the examiner's hand when the bulb catches on the anterior or posterior face of the stricture.

Retention of Urine.—Retention of urine is a condition which occurs so often in affections of the urethra, that it is convenient to enumerate its varieties at the outset. First there is (1) **Acute Complete Retention:** the patient, previously able to evacuate his urine wholly or in part, suddenly becomes unable to do so; *all* the urine is retained, and the

condition is *acute*. (2) **Acute Incomplete Retention** occurs when the patient is just able to void a few drops, with much effort; the condition is acute, but a little of the urine is passed. (3) **Chronic Complete Retention**, where the patient depends absolutely upon the catheter for emptying his bladder, though the condition is chronic, and the catheter has been required for months or years. (4) **Chronic Incomplete Retention** *without distention of the bladder*, where a certain portion of urine is constantly retained, but where the major portion is evacuated voluntarily; a chronic condition, where, without the bladder being over-filled, **residual urine** exists. Finally there is (5) **Chronic Incomplete Retention** *with distention of the bladder*, where so much of the urine is retained that the bladder has reached the limit of its capacity, and **overflow from retention** results.

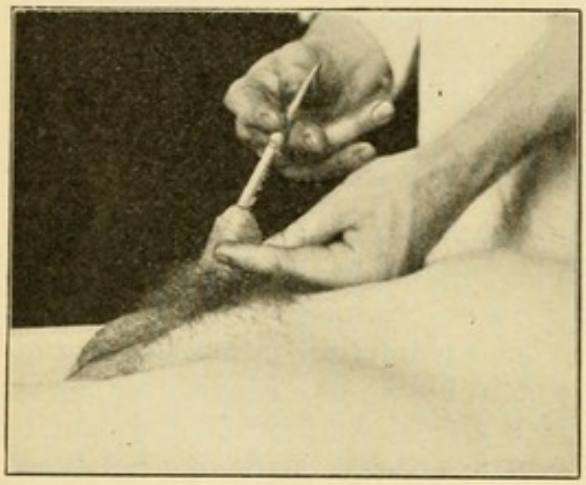

FIG. 946.—Passing a sound from the patient's right side. Observe how the sound is held in the fingers, and note that no force can be used. Episcopal Hospital.

We may tabulate these conditions as follows:

I. **Acute Retention.**
   1. Acute Complete Retention.
   2. Acute Incomplete Retention.

II. **Chronic Retention.**
   3. Chronic Complete Retention.
   4. Chronic Incomplete Retention *without distention of the* bladder.
   5. Chronic Incomplete Retenfion *with* distention of the bladder.

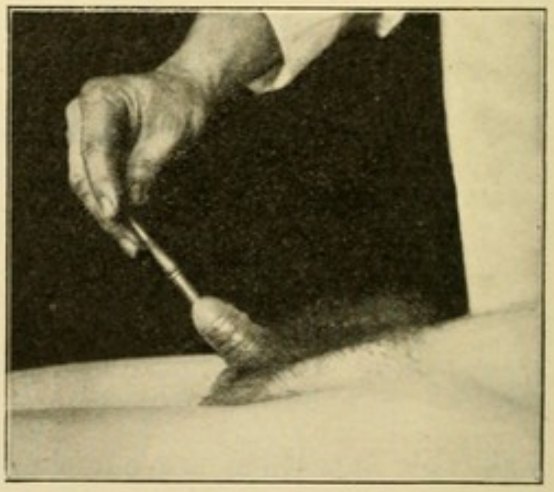

FIG. 947.—The urethral sound fully introduced. Note the angle it makes with the horizon. Episcopal Hospital.

The **first** of these conditions occurs oftenest as a complication of **stricture of the urethra**; the **second** in cases of **urethritis**; the **third, fourth,** and **fifth** are seldom seen except in cases of **enlargement of the prostate.**

Foreign Bodies.—Foreign bodies may enter the urethra from the bladder (calculi, etc.) or from without. The end of a catheter or filiform bougie occasionally breaks off; and sometimes a patient passes implements into the urethra to relieve some fancied obstruction, and the instrument breaks off or escapes from his fingers. There is danger

of such bodies escaping into the bladder, and they may seriously traumatize the urethra. It is very important not to introduce a sound incautiously for the purposes of diagnosis, since it is apt to push the foreign body up into the bladder, or to embed it in the urethral wall. It is better to make the diagnosis by means of the *x*-ray, whenever this is available. It is rare for foreign bodies to produce complete urinary obstruction, but they scarcely ever can be washed out by the stream of urine. Fortunately sufficient time usually is available to send the patient to a well equipped hospital. There it may be possible to extract the foreign body by the aid of the endoscope, or even by alligator forceps (Fig. 948) introduced closed and opened when they are felt to come into contact with the foreign body. Occasionally a pencil or similar article may be worked out step by step by forcing the penis down over it as it is fixed with the fingers through the perineum or the penile urethra. A hat pin, introduced into the urethra head first may be extracted by protruding its point through the body of the penis, reversing it, and pushing it out head first. If all other methods fail external urethrotomy (p. 1022) should be done; an incision in the penile urethra should be sutured, but one in the perineum may be left to heal by granulation. If the foreign body has escaped into the bladder it may be removed by suprapubic cystotomy, if extraction with the operating cystoscope is impossible.

FIG. 948.—Urethral forceps.

Traumatic Rupture of the Urethra usually is the result of direct injury (falls, kicks, etc.) to the perineum; occasionally it occurs as a complication of fracture of the pelvis. The lesion almost always is in the subpubic urethra, at the bulbo-membranous juncture. The diagnosis depends on the history of traumatism, and the passage of bloody urine or on the symptom of "bloody anuria" (p. 971). In most cases **urinary extravasation** occurs after twenty-four hours. If the rupture occurs anterior to the superficial layer of the triangular ligament, the urine passes first into the perineum and being confined by Colles's fascia rapidly forces its way through the cellular tissues of the scrotum on to the abdominal walls, through the abdomino-scrotal opening. If rupture occurs above the triangular ligament, the symptoms resemble those of extraperitoneal rupture of the bladder, but the history of injury to the perineum, with resulting ecchymosis, etc., points to the urethra as the seat of the lesion. If urinary extravasation is unrelieved, extensive sloughing will occur, especially if the urine was previously unhealthy; constitutional symptoms of sepsis are frequent, and death may ensue from this cause.

Treatment.—Treatment consists first in guarded attempts to enter the bladder with a soft catheter. If this succeeds, as it may very soon after the injury, before urinary extravasation has occurred, the catheter should be left in the bladder for four or five days, while

urinary antiseptics are administered. If extravasation of urine is already present when the patient is seen, the urethra should be opened, immediately, in the perineum, with the aid of a sound passed down to the site of rupture. Numerous incisions in the perineum, scrotum, and skin of the abdominal wall may be necessary to secure free drainage and avert threatening sepsis. Usually there need be no fear that the patient will be unable to empty the bladder through the wound, and it is not necessary to drain the bladder by a catheter; but if the vesical end of the urethra is readily found this may be done. In a case of rupture of the urethra above the triangular ligament I successfully employed Demarquay's operation (1858): this consists in dissecting down to the site of rupture through a curved incision (convexity forward) as in the modern operation of perineal prostatectomy (p. 1040). Some surgeons advocate suture of the ruptured urethra; but in all the cases which have come under my care, the local condition precluded such a step. When the perineal wound begins to granulate, it is usually possible to pass a sound through the penis into the bladder, and if this is done once or twice weekly, the perineal wound soon closes. The danger of subsequent stricture formation, however, is very great. **Traumatic stricture** forms rapidly after injury and the palliative methods and even the usual operations employed for stricture the result of gonorrhea seldom prevent recurrence, owing to the dense nature of the scar and its extent. Unless the patient can have bougies passed at least once monthly for many years (perhaps throughout life), it is better to excise the strictured area and to unite the healthy urethra above and below by sutures, over a catheter which is left in place for several days or until the urethral wound is healed. I employed this method with most happy results in the case of the boy shown in Fig. 953. Though only ten years old, his urethra easily admitted a No. 18 Fr. sound one year after operation.

Non-gonococcic Urethritis occasionally occurs, the chief causes being instrumentation, stricture, ingestion of irritating drugs, excessive coitus, or masturbation, etc. If the condition is chronic it probably is kept up by a stricture or a focus of inflammation in the prostatic urethra or its adnexa. The acute form usually subsides so soon as the cause is removed. The treatment of the chronic form is the same as for chronic gonococcic urethritis (p. 1013).

Prolapse of the Urethra is rare. It occurs oftenest in female children, from straining efforts (coughing, defecation, micturition). The protrusion, which seldom involves more than the mucosa, may be excised, and bleeding checked by pressure, cauterization, or suture.

Stricture of the Urethra.—Several varieties of urethral stricture are recognized:

I. **Inorganic Strictures.**—1. *Inflammatory Stricture*, or obstruction of the urethra from acute inflammation. This is the form which occasionally occurs during the acute stage of gonorrhea, resulting in acute complete retention of urine; it also occurs from pressure outside the

urethra, from an inflamed prostate, periurethral abscess, etc. It is to be *treated* by palliative measures such as indicated under spasmodic stricture, or incision and drainage through the perineum of prostatic or periurethral abscesses. Introduction of a catheter should be avoided whenever possible; if retention persists, the bladder may be aspirated above the pubis. (2) *Spasmodic Stricture:* This is no stricture at all, merely a spasm of the urethra, though it occurs most often in patients with organic stricture. It occurs also as the result of psychic influence (as where an individual cannot urinate in the presence of others), in cases of inflamed hemorrhoids or of seminovesiculitis, after surgical operations, in the course of the infectious fevers, etc. Spasm usually occurs in the membranous urethra, from the contraction of the deep transversus perinei muscle. *If retention is complete,* and of eight hours or more duration, a catheter should be used; *if incomplete or recent* palliative measures may be tried for some hours. Among the most effective is a hot bath, the patient attempting to urinate in the bath; enemas of laudanum, followed by a purge, may also be used. Recurrence of spasm must be prevented by attending to the condition of the urine, and relieving any local cause, especially organic stricture

II. **Organic Strictures.**—(1) *Traumatic Stricture* has been described at p. 1018. (2) *Congenital Stricture* is less rare than usually supposed, but may produce no symptoms until the age of puberty or later. (3) *Stricture from Cicatrices following Urethritis,* almost always the result of gonorrhea, is the type most often seen, and what is said in the following pages refers especially to it.

Strictures result from submucous round-celled infiltration, which passes through the usual stages of organization, cicatrization, and contraction. As gonococcic urethritis is most frequent about the age of twenty years, strictures are seen oftenest in early adult life; they seldom present symptoms for the first time after forty years of age. They may occur in any portion of the urethra, but are most frequent in the subpubic portion, especially the bulbous urethra, but are not rare in the penile urethra. Stricture of the membranous and prostatic urethra is rare. Strictures usually are *multiple* (Fig. 949), and may be of *various forms* (Fig. 950). Their *calibre* varies from that which is impassable to the finest instrument, up to those which barely constrict the urethral lumen and which may be detected only by the aid of a bulbed sound. The *orifice* of the stricture may be central or eccentric.

Symptoms and Clinical Course of Stricture.—The early symptoms of stricture usually are insignificant, but occasionally acute retention of urine is the first indication of trouble. In most cases the patient complains first of slight gleety discharge, with pain in the deep urethra during and following urination; he finds the calls to urinate more frequent, the stream is diminished in size, and a longer time is required to empty the bladder. Attacks of acute retention are frequent, from inflammatory changes or plugging of the stricture by a pellet of mucus

or pus. Retention with overflow is another frequent sequel. From straining in micturition, hemorrhoids or prolapse of the rectum may develop. The urethra immediately behind the stricture becomes dilated, and as backward pressure continues, changes occur in the bladder. The bladder at first may hypertrophy, but in most cases a condition of atrophy (fibroid degeneration) sets in eventually, so that the bladder loses its power of contraction. This is predisposed to by cystitis, which is prone to develop (owing to stagnation of urine) as the result of instrumentation or as a descending infection from the kidney. Pressure diverticula may form in the bladder, and eventually dilatation of the ureters and renal pelves may occur, with hydronephrosis, pyonephrosis, or surgical kidneys. Other complications and sequels are frequent. The most important (Retention of Urine, Urethral Fever, Extravasation of Urine, Periurethral Abscess, Urinary Fistulæ) are discussed in the following pages.

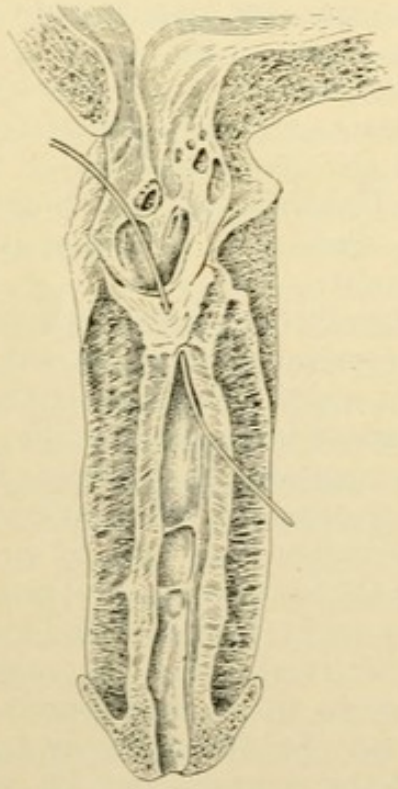

FIG. 949.—Strictures of the urethra. A probe has been passed through a false passage in the bulbous urethra. (After Albarran.)

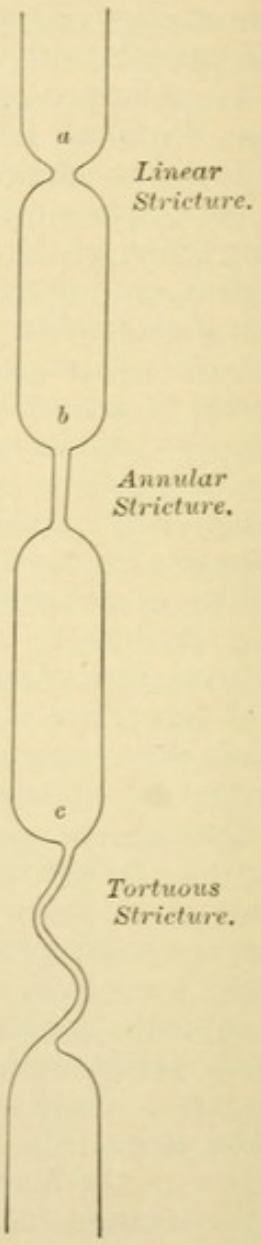

FIG. 950.—Diagram of different forms of stricture. (Watson and Cunningham.)

Diagnosis of Stricture.—While the existence of stricture usually may be surmised from its symptoms enumerated above, or from its

various sequels, verification of the diagnosis depends on instrumental examination of the urethra. The calibre of the normal urethra corresponds with the circumference of the penis: a circumference of 3 inches implies a urethral calibre of 30 mm. of the French scale (p. 959); $3\frac{1}{4}$ inches corresponds to 32 Fr.; $3\frac{1}{2}$ inches corresponds to 34 Fr., etc. The *average urethra* admits a No. 32 Fr. sound, but the meatus usually is smaller than the urethra within. Strictures of large calibre are best detected by passage of a bulbed sound. Such strictures require treatment only if productive of definite symptoms. Strictures of medium or small calibre will cause the arrest of an ordinary steel sound of average size. It is always well to commence the examination by passing a full sized sound, and then to try smaller sizes in turn until one is passed into the bladder. It is not safe to use an inflexible sound smaller than No. 10 Fr., for fear of making a false passage.

Treatment of Stricture.—There are two main classes of strictures, the treatment of which it is convenient to consider separately: these are *permeable* and *impermeable* strictures. By the former is meant a stricture through which an instrument can be passed; and by the latter one through which no instrument of any size or form whatever can be passed. This distinction is relative, since a stricture which a surgeon finds impermeable on one occasion may not be so on another occasion nor for another surgeon.

I. Treatment of Permeable Stricture.—1. The best treatment is that by **gradual dilatation.** A sound just large enough to be grasped by the stricture is passed about twice weekly, and the size of the sounds passed is very gradually increased. Thus if No. 14 Fr. has been passed with a little difficulty on the first occasion, it is well to begin the second *séance* with No. 12 Fr., and not to push dilatation beyond No. 16 Fr. At the third sitting Nos. 14, 16, and 18 Fr., probably can be passed. It is then desirable in the average case to continue dilatation until a number on the scale is reached which is two or three points higher than that which is considered normal for that patient. But in the case of multiple or fibrous strictures, or in a patient who is old or feeble, or prone to urinary fever or other complication, it is best to be satisfied with keeping a canal patulous for No. 22 or 24 Fr. If *over-dilatation* can be secured gradually, and if it can be maintained for several months, it is probable that no further trouble will be experienced. Absorption of the cicatricial tissue will have occurred, and unless a new stricture forms the patient may consider himself cured. In cases where it is impossible to push the dilatation up to normal and beyond, it is necessary for the patient to have a sound passed once monthly for the rest of his life. Neglect of this precaution will allow the stricture to recontract, and relief of the patient will then be more difficult.

2. Treatment by **rapid dilatation** or **rupture** of the stricture is, I believe, best adapted to strictures of large calibre, such as sometimes cause persistence of a chronic urethritis; though even in these cases gradual dilatation often is sufficient. Rupture is accomplished by

various forms of instruments which are first passed through the strictures and then expanded by some mechanical device (Fig. 951).



FIG. 951.—Kollman's urethral dilator. (Watson and Cunningham.)

3. **Incision of the Stricture (Urethrotomy)** is the best treatment for strictures too dense and fibrous to be treated successfully by gradual dilatation; or for those which tend persistently to recur, even after a long course of such treatment. But it should never be forgotten that it may be more judicious to persist in conservative treatment in the old and feeble, even if it be not curative, than to resort even to a trivial operation which may suddenly snuff out life.

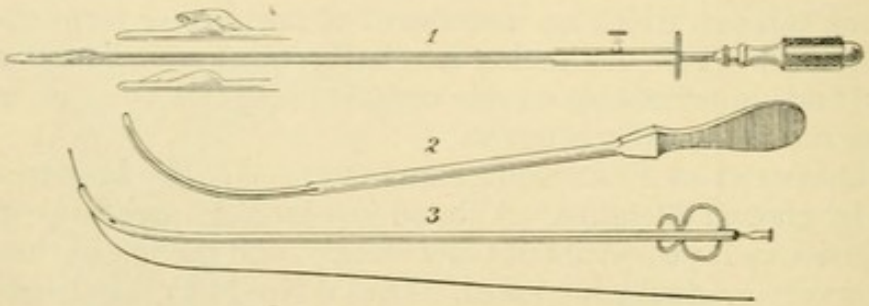

FIG. 952.—1. Civiale's urethrotome; a model which will cut the stricture from *behind forward*, or from *before backward*. 2. Syme's grooved staff for external perineal urethrotomy. 3. Tunnelled catheter, threaded over a filiform bougie.

(*a*) *Internal Urethrotomy* (Amussat, 1824) is especially applicable to strictures of the penile urethra: it is accomplished by introducing an instrument through the stricture and then withdrawing from the instrument a concealed blade (Fig. 952, 1), which cuts the stricture on the roof of the canal from *behind forward* (Civiale's urethrotome, 1849), or from *before backward* (Maisonneuve's urethrotome, 1855). The operation may be done under local anesthesia (10 per cent. eucain), but a general anesthetic is preferable. After either of these operations it is best to retain an inlying catheter for three or four days, the penis being bandaged to it if there is much hemorrhage (which is unusual); and after the catheter is removed, dilatation must be maintained by passage of sounds for several weeks, or longer if a tendency to recontraction is evident.

(*b*) *External Urethrotomy.*—This operation is safer than internal urethrotomy for strictures in the deep urethra. It was popularized by Syme in 1843, and is commonly known as **External Perineal Urethrotomy with a Guide**, or *Syme's operation:* A guide is passed through the stricture from the meatus, and the bulbo-membranous urethra is

then opened from the perineum upon the guide behind the stricture, and the stricture is divided from behind forward. Syme used a guide provided with a groove upon its convexity and a shoulder which rested against the face of the stricture (Fig. 952, 2). After division the stricture should be fully dilated by passage of steel sounds and the bladder drained by a perineal tube for several days, when the passage of sounds may be commenced, and the perineal wound allowed to heal by granulation.

II. Treatment of Impermeable Stricture.—Very few strictures are really impermeable; indeed, it has been asserted by several eminent authorities that any stricture which would permit urine to escape from above would also admit an instrument from below. But as their experience increased they were forced to acknowledge that they themselves had encountered strictures which remained impermeable to their best efforts. If the patient is able to pass his urine, there is plenty of time available for attempts to render the stricture permeable. Hence it is convenient to discuss the treatment of impermeable stricture according as it is not or is accompanied by *retention of urine.*

1. *Impermeable Stricture without Retention of Urine.*—The first efforts of the surgeon should be devoted to rendering the stricture permeable. It is not safe to let a patient with impermeable stricture continue as he is; the risks of retention, urinary extravasation, etc., are too imminent. After trying the usual *steel sounds*, and finding it impossible to pass the stricture with any, down to No. 10 Fr. (no smaller inflexible instrument is safe) the surgeon should next try fine *flexible bougies* (those filled with a leaden core are best) which on account of their very flexibility may be enabled to pass through a tortuous stricture which is absolutely impermeable to a rigid instrument.[1] If such an instrument cannot be passed (even a No. 1 Fr. may be used without fear of damaging the urethra), *filiform whalebone bougies* should be employed. These should be sterilized in the same way as the flexible bougies and catheters, in a cold 5 per cent. formalin solution (p. 959). The filiform bougie is passed down to the face of the stricture, where it may be arrested, or may enter a false passage produced by previous instrumentation. In any event it should be left in place, and other filiforms should be passed down beside it, until all the false passages are filled and the face of the stricture is covered by the points of the bougies. Then as the last filiform is introduced it may slide at once through the stricture and into the bladder, the orifice of the stricture being the only point unoccupied.[2] Usually not more than six filiforms are introduced at once; by withdrawing each in turn about an inch, and again passing it down against the face of the

[1] As noted at p. 959, passage of a bougie usually is easier after distending the urethra with the lubricant by means of a syringe.

[2] If an endoscope is available, it may be possible to pass a filiform through the stricture under control of direct vision.

stricture with a slight twist, the surgeon seeks to insinuate one of the filiforms into the orifice of the stricture. After working a while on one side of the patient's bed, it sometimes is possible to accomplish more by passing to the other side and commencing all over again, as the surgeon insensibly works the filiforms toward himself on whichever side he stands (J. H. Brinton). If a filiform finally is passed through the stricture, *it should be allowed to remain in place.* This applies to any instrument which has been passed through a stricture with great difficulty. The continuous dilatation of the stricture thus produced will render easier the later passage of a larger instrument. When a filiform has been successfully passed through a stricture, all the other filiforms may be withdrawn; and a tunnelled catheter (popularized by Gouley about 1873) may be passed over the filiform into the bladder, and retained in place of the filiform; this acts as rapid dilatation or rupture of the stricture. Some filiforms are provided with a cap and screw thread at their outer ends, so that a larger bougie may be screwed on and pushed through the stricture as the filiform is pushed into the bladder where it curls up.

In a case a stricture remains impermeable in spite of repeated efforts to pass an instrument, resort must be had to **operation.** As in this operation no guide can be passed through the stricture (as is a prerequisite for performing Syme's operation), it is known as **External Perineal**[1] **Urethrotomy without a Guide,** or **Perineal Section.**[2] Here a sound is passed down to the face of the stricture, and the urethra is opened on this as a guide, *in front of the stricture,* by an incision through the perineum. The margins of the opened urethra are then caught in guy sutures and pulled taut, while the surgeon endeavors to pass a probe or filiform bougie through the stricture whose face is thus exposed to view (Arnott, 1822). By forcing a few drops of urine out of the bladder, the orifice of the stricture may become visible. If a probe can be passed through the stricture, the operation is completed as in Syme's method, by dividing the stricture on the guide. But if the stricture cannot be entered, the surgeon proceeds to complete the perineal section, dissecting cautiously backward, strictly in the median line, until he has divided the stricture and opened the dilated urethra behind it. This is the part of the operation which gives it the name of **perineal section.**[3] It is an operation which may prove long and difficult, but with a good light and steady hand it is not dangerous. An alternative method is to open the bladder above the pubis, introduce a sound into the vesical orifice of the urethra

[1] External urethrotomy scarcely ever is necessary for strictures of the *penile* urethra because these very rarely are impermeable; but it may be employed if requisite, the bladder being drained by an inlying catheter, and the incision in the under surface of the penis being allowed to heal by granulation.

[2] Or the "*old operation,*" the "*London operation*" (as distinguished from the Edinburgh operation, or Syme's).

[3] This method, according to Wiseman, was first employed in 1652 by Molins; according to Guthrie it was adopted by Sir Astley Cooper in 1793. The operation was systematized by Jameson, of Baltimore, in 1824.

and make it protrude in the perineum behind the stricture; the urethra is then opened on this guide, through the perineum, and the stricture is cut from behind forward. This method of "**retrograde catheterization,**" I regard as an unnecessary complication; though it may shorten the operation, it does not lessen its mortality or improve its results, rather the reverse. It is also possible to open the urethra at the apex of the prostate (behind the stricture) by **open dissection of the perineum** (Guthrie, 1834; Demarquay, 1858) and then to divide the stricture from behind forward; or to perform **Cock's operation** (p. 1026) and complete it as did John Hunter (1788) and Guthrie (1834) by division of the stricture from behind forward. But the best operation in impermeable stricture without retention of urine, is the perineal section, as systematized by Arnott and Jameson. After the stricture has been cut (by whatever method) it should be fully dilated, and the bladder drained for a few days through the perineum.

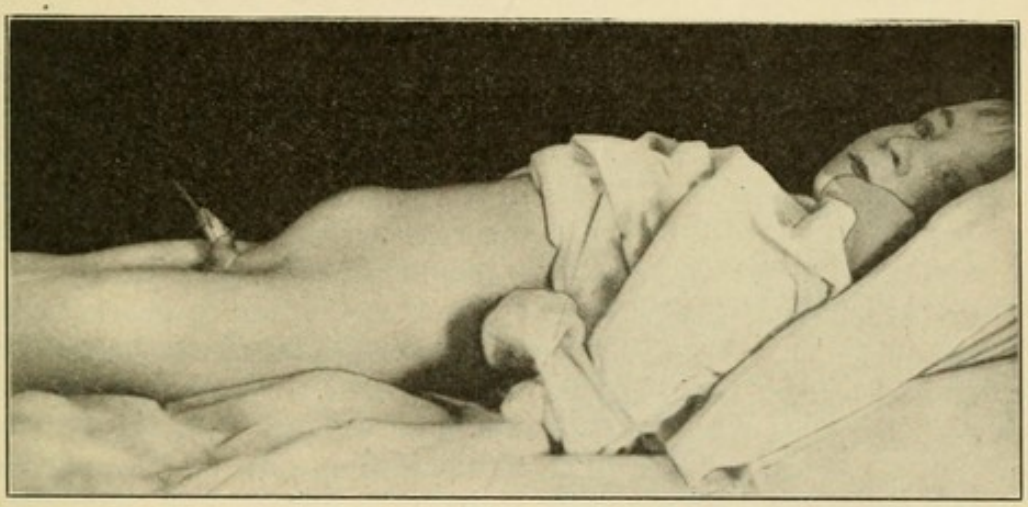

FIG. 953.—Acute complete retention of urine from traumatic stricture of urethra. Filiform bougie tied in the urethra. Age nine years, injury six weeks previously. Bladder drained iteslf alongside filiform in forty-eight hours. Treated by excision of stricture. (See p. 1018.) Episcopal Hospital.

2. *Impermeable Stricture with Retention of Urine.*—Here there is no time for long delay. There is danger of urinary extravasation, rupture of the bladder, etc., and uremia generally impends from renal complications. Not more than thirty minutes should be spent in attempts to pass an instrument through the stricture; if a filiform can be passed, the bladder will drain itself alongside the bougie within twenty-four to forty-eight hours (Fig. 953) and immediate operation is unnecessary. If no instrument can be passed, and if the bladder is much distended, temporary relief may be secured by tapping it suprapubically; and occasionally after the bladder is emptied the stricture becomes permeable. In many cases, however, the bladder is thickened and contracted from cystitis, and is not accessible above the pubis; and even if it is possible to aspirate it in this position, more permanent drainage is required than can be secured in this way. Hence relief of retention is best accomplished by **Tapping the Urethra at the**

Apex of the Prostate, known as **Cock's operation.**[1] The surgeon introduces his gloved left forefinger into the rectum and places it upon the apex of the prostate. Then he cuts steadily but boldly through the median line of the perineum toward his finger as a guide; when the knife is felt to approach the finger, it is made to cut obliquely, opening the dilated urethra at the apex of the prostate, *behind the stricture.* The knife is then withdrawn, and a grooved director takes its place, the left forefinger being kept in the rectum to serve as a guide until the director is in the bladder. The finger is then withdrawn from the rectum, and the glove removed. The left hand then holds the grooved director while the right hand passes a catheter along it into the bladder, where it is retained for several days. After this lapse of time the stricture usually becomes permeable. The main object of the operation, as I recommend it, is to *relieve acute complete urinary retention in cases of impermeable stricture.* When the patient has been put out of jeopardy by this means, other suitable measures may be adopted to cure the stricture. In many cases it is feasible to follow Hunter's and Guthrie's advice, and complete the primary operation by division of the stricture from behind forward. In other cases the patient is in such desperate condition when first seen that any prolongation of the operation is injudicious. Cock's operation has often been described as "dramatic in its simplicity," and it is its extreme simplicity and the rapidity with which it may be done that commend it.

Urethral or **Urinary Fever** is a form of sepsis due to absorption of bacteria or their products from erosions or abrasions of the urethra. In some patients it is a frequent sequel to the passage of a sound or catheter. Symptoms usually do not appear until after the first act of urination, subsequent to the instrumentation. In most cases there is only a feeling of chilliness, with anorexia or nausea, and some elevation of temperature; but there may be a frank chill. In rare cases true pyemic symptoms develop, with acute monarticular or polyarticular effusion.

Treatment.—Treatment consists in the internal use of urinary antiseptics for some time before urethral instrumentation, and the administration of a full dose of quinine and opium as soon as the instrumentation is completed. In case of severe and recurrent attacks, it may be desirable to drain the bladder by the perineum, until the urethra becomes healthier.

Extravasation of Urine has been referred to (p. 1017) as a complication of rupture of the urethra, and its clinical features were pointed out in that place. It occurs not infrequently, also, in cases of urethral stricture, either spontaneously, or as the result of false passages made by careless instrumentation. That false passages are not more often

[1] This is a variety of the old bouttonnière operation, revived in 1856 by Mr. Cock, of Guy's Hospital, as a treatment for *impermeable stricture complicated by urinary fistulæ*, and popularized by him in 1866; he found that when the urine was diverted from the strictured urethra through the perineum, the fistulæ tended to heal spontaneously, and the stricture usually became permeable.

accompanied by urinary extravasation is no doubt attributable to the fact that the false passages have their orifices directed away from the bladder. Extravasation of urine occurs sometimes in cases where no stricture exists. One of the worst cases I ever saw was in an old man of seventy-three years, in whom no urethral obstruction existed, and in whom no instruments had been passed. In such cases it is probable that perforation of the urethra occurs as the result of unrecognized ulceration or the rupture of a peri-urethral abscess. Treatment, as already advised, consists in perineal urethrotomy, and free incisions wherever required to drain the extravasated urine or remove sloughs.

Peri-urethral Abscess.—Peri-urethral abscess was mentioned at p. 1010 as a complication of gonococcic urethritis. Usually one or both Cowper's glands are involved, and a tender swelling appears to one side or other or the median raphé of the scrotum at its junction with the perineum (Fig. 954). The condition is distinguished from perianal or ischio-rectal abscess by its less acute symptoms, the history of urethral disease, and the location of the swelling in the perineum rather than close to the anus.

FIG. 954.—Peri-urethral abscess, on the patient's right. Episcopal Hospital.

Treatment.—Treatment consists in incising the abscess as soon as it is recognized, in the endeavor to prevent its rupture into the urethra, as this latter result almost invariably entails the subsequent formation of a urinary fistula in the perineum.

Urinary Fistulæ.—Urinary fistulæ usually are the remote result of gonococcic urethritis, or of neglected cases of extravasation of urine. Usually the fistulæ occur in the perineum, but they may be located in the scrotum, in the penis (floor of the urethra), in the adductor region of the thighs, or in the buttocks. In almost all cases the communication with the urethra is on the vesical side of a stricture, and proper *treatment* of the stricture often allows the fistulæ to close. In cases where no stricture exists, however, and especially where the fistula is indurated and lined with mucous membrane, it is necessary to do a formal operation. The use of an inlying catheter, and cauterization of the fistulous orifices seldom is efficient. The urethra should be drained behind the internal orifices of the fistulæ by Cock's or by Syme's technique, according as there is or is not an impermeable stricture; a stricture if present should be cut; and the fistulous tracts should be excised, and if possible closed by suture. Perineal drainage of the bladder may be dipensed with after a week and full sized sounds should be passed regularly until the fistulæ have healed.

SURGERY OF THE PROSTATE.

Acute Prostatitis and Abscess of the Prostate.—Usually this is a complication of posterior urethritis (gonococcic), involvement occurring by direct extension. In rare cases acute prostatitis may result from the trauma of frequent or careless instrumentation; and occasionally prostatic abscess occurs as a metastatic infection in the course of the exanthemas, typhoid fever, pneumonia, etc.

Symptoms.—The symptoms are both general and local. General symptoms (high fever, typhoid state, muttering delirium) if severe, may completely mask the local condition, which causes intense burning pain in the rectum, with rectal tenesmus and usually retention of urine. Examination by a finger in the rectum (extremely painful) detects the enlarged tender prostate. One or both lobes may be involved. Only if an abscess is very near the surface can a soft area or fluctuation be detected by rectal palpation.

Treatment.—Treatment should be palliative at first. A brisk purge should be given, and the urine rendered alkaline (Watson). Some relief may be secured from hot rectal irrigations and sitz baths. Urinary antiseptics should be administered, and if there is urinary retention it is better to allow a soft catheter to remain constantly in the bladder than to pass it frequently. **Operation** should be done after twenty-four or forty-eight hours unless relief is obtained sooner; but if suppuration is suspected operation should be immediate. Only if the abscess is manifestly pointing in the rectum should it be opened by this route; in such cases a drainage tube should be passed within the sphincter ani, but need not enter the prostate. Whenever possible it is better to expose the prostate as in perineal prostatectomy, incising one or both lobes and draining the retroprostatic space by tube or gauze. Even if pus is not found, relief is prompt and lasting. During convalescence it is well to resort to regular prostatic massage.

Chronic Prostatitis—Chronic prostatitis is a still more frequent complication of posterior urethritis than is the acute form of the disease. Usually it is gonococcic in origin, but as a rule secondary infection has occurred, and only the pyogenic cocci or the colon bacillus can be found. It is insidious in onset, and patients may not come under treatment until many years after the causative urethritis has ceased to cause annoyance.

Symptoms.—The main local symptom is a chronic, gleety, urethral discharge. General neurasthenic symptoms are frequent, and referred pain may be felt in the back, thighs, buttocks, groins, etc. The diagnosis is confirmed by examination of the rather abundant secretion obtained by massage of the prostate (p. 1013). Soon after the primary lesion gonococci or other bacteria are found; but at later periods the secretion is composed almost entirely of pus cells, and even these may not be found until after massage has been employed for the third or fourth time.

Treatment.—The best treatment is regular prostatic massage, about three times weekly, followed by urethral and vesical irrigations, and occasionally by instillation of 5 per cent. silver nitrate or the application of stimulating ointments to the deep urethra. The use of the Kollman urethral dilator (Fig. 951, p. 1022) may also prove of value.

Enlargement of the Prostate—This often is spoken of as **hypertrophy** of the prostate, but in a pathological sense there is no true hypertrophy, and I prefer to retain the term enlargement simply because the actual pathological process at work in these cases is still in dispute,

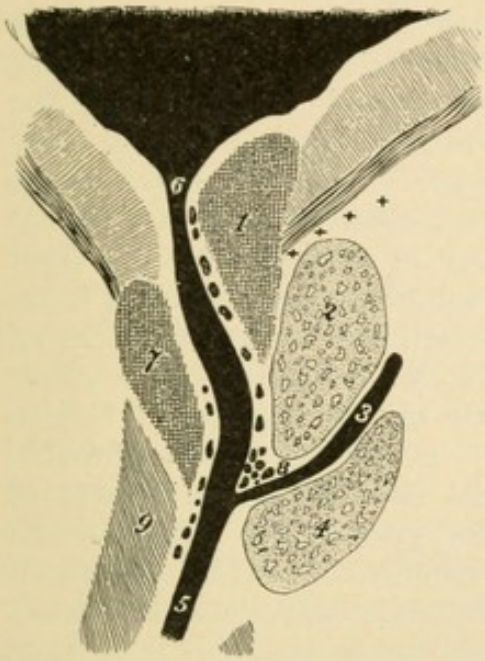

FIG. 955.—Diagram of a sagittal section through the prostatic urethra: 1. Sphincter of bladder (internal), posterior segment. 2. Pre-spermatic portion of prostate. 3. Ejaculatory ducts. 4. Retro-spermatic portion of prostate. 5. Urethra. 6. Vesical orifice of urethra. 7. Internal sphincter of bladder, anterior segment. 8. Suburethral or paraurethral glands (group of verumontanum). 9. External sphincter of the bladder. (After Cunéo.)

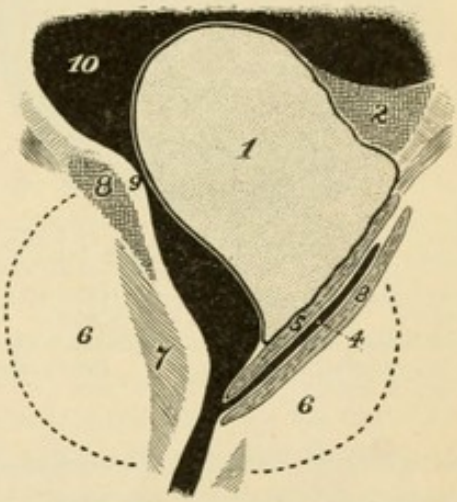

FIG. 956.—Diagram of a sagittal section of the prostatic urethra, in a case of "enlargement of the prostate:" 1. Enlargement (adenoma) of the suburethral glands (Fig. 955, 8). 2. Internal sphincter of the bladder, posterior segment. 3. Retro-spermatic portion of the prostate. 4. Ejaculatory ducts. 5. Pre-spermatic portion of prostate. 6. Lateral lobes of tumor (adenoma of suburethral glands). 7 External sphincter of bladder. 8. Internal sphincter of bladder, anterior segment. 9. Neck of bladder. 10. Bladder. (After Cunéo.)

and because it is the mechanical effect of the enlargement of the gland (*urinary obstruction*) which makes the condition important surgically. The modern hypothesis, put forward by Motz and Péréarnau in 1905, and supported by researches of E. Marquis (1910) and Cunéo (1913), is to the effect that so-called enlargement of the prostate is not an affection of the prostate at all, but of the **suburethral glands**, lying beneath the urethra immediately on the vesical side of the ejaculatory ducts (Fig. 955). According to this theory, the change is truly neoplastic (adenomyoma), and the tumor displaces and condenses the prostate beneath and around it as a sort of capsule (Figs. 956 and 957). Though this is in accord with the facts that in

"enlargement of the prostate" the ejaculatory ducts are depressed far toward the rectal aspect of the tumor, and that the lengthening of the urethra occurs solely in that portion between the verumontanum and the bladder (there is no lengthening of the segment of the prostatic urethra on the distal side of the verumontanum), nevertheless this theory has not yet gained very wide acceptance.

Clinically there are two seemingly distinct forms of enlargement of the prostate: in one the change in the prostate appears to be **adenomatous** in character, and the prostate becomes large, soft, or of only moderate hardness; while in the other a **sclerosis** exists, as if caused by a chronic inflammatory process, and the prostate does not become very large. I believe there is no good evidence that this fibrous type of enlargement is a later stage of the adenomatous form, though this is the teaching of Moullin and some other authorities on the subject. I believe it is much more probable that the adenomatous form of enlargement is an "*adenomatosis*" of the prostate (or rather of the suburethral glands), or even a true adenomyoma; while the small sclerotic prostate is the *result of chronic infection*, and should be classed entirely apart. Ciechanowski (1900) and others since his time have sought to show that all cases of enlargement of the prostate were originally inflammatory in origin, the main causative factor being the gonococcus.

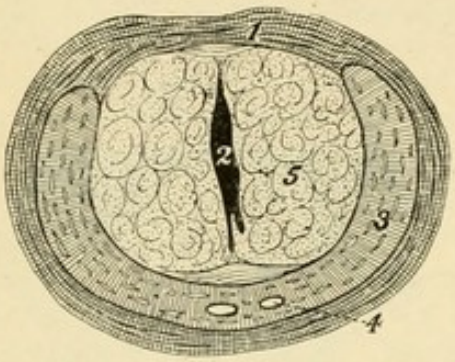

FIG. 957.—Diagram showing in transverse section the relation of the periurethral adenoma to the prostate: 1. Capsule of the prostate. 2. Urethra. 3. Prostate, compressed and pushed aside by the new growth. 4. Ejaculatory ducts. 5. Adenomyoma (After Cunéo.)

A prostate which is the seat of the adenomatous type of enlargement usually presents on section numerous "prostatic tumors" which compress the surrounding stroma into a capsular envelope, and which grow in the direction of least resistance (toward the bladder); here they often project beneath the mucous membrane posterior to the urethral orifice, and are termed (wrongly) "median lobe" enlargements. In some cases the enlarged prostate presents no such distinct tumor masses in its interior, but exhibits general glandular or fibrous enlargement, or a combination of the two forms. The small, hard, sclerotic prostate usually is densely adherent to surrounding structures, and these evidences of former peri-prostatitis lend support to the view that such prostates have been altered by chronic inflammatory changes.

Any prostate weighing more than six drams (23 grams) may be considered abnormal. From this size they range up to 12 ounces or more. The average weight of prostates removed at operation is about 3 ounces. Enlargement occurs chiefly in an anteroposterior direction,

and, as the apex of the prostate is fixed against the triangular ligament, growth occurs chiefly toward the vesical cavity. The two lateral lobes usually are not equally enlarged, and this accounts for a rather constant deviation of the urethra to one or other side. The two lateral lobes may project into the bladder in such a form that the urethral orifice resembles the os uteri; or as already mentioned, a "prostatic tumor" may force its way through the capsule of the prostate and project beneath the vesical mucous membrane as a nipple-like obstruction or as a pedunculated out-growth behind the vesical orifice of the urethra.

Clinical Pathology.—As the prostate gland enlarges, various changes are produced in the urethra, bladder and rectum; and less directly in the urine, kidneys, and general health.

Changes in the Urethra.—The length of the normal urethra averages 8 inches; but in enlargement of the prostate the *length may be* 14 *or* 16 *inches,* the increase occurring in the prostatic portion of the canal, especially in that portion on the vesical side of the ejaculatory ducts. This fact also explains the *elevation of the vesical orifice of the urethra* and the *increased curve* of the prostatic urethra, necessitating a special curve to inflexible instruments (Fig. 958, 3 and 4). *Lateral deviation* of the urethra has been mentioned above. In some cases a pedunculated enlargement at the vesical orifice produces a Y-shaped channel. Increase in length of the posterior wall of the prostatic urethra may increase its antero-posterior diameter and consequently its capacity, so that it may hold an ounce or two of urine; this is rare, but should be remembered as a possibility, since evacuation of a small amount of urine from the dilated prostatic urethra may lead the inexperienced to think the catheter has entered the bladder.

The most important *change in the bladder* is the formation of a *post-prostatic pouch,* due to combined elevation of the urethral orifice and descent of the vesical floor. The greater the obstruction to the outflow of urine the larger this pouch becomes, and the more **residual urine** collects in it. Residual urine is that which remains in the bladder after the patient has expelled all he can. At first some hypertrophy of the vesical walls may occur, but if obstruction is unrelieved dilatation and atrophy ensue, and the quantity of residual urine gradually increases. This state of chronic incomplete retention of urine without distention of the bladder (*stage of residual urine*) is finally succeeded by the same condition with distention of the bladder, and when the limit of the bladder's capacity has been reached, overflow occurs (*retention with overflow*). The distinction between the latter condition and true incontinence of urine has been explained at p. 599. But cystitis may occur, and then the bladder does not dilate; its walls become thickened and its capacity diminished. Vesical irritability demands frequent evacuation, and retention with overflow is rare. The adenomatous type of enlargement usually is associated with a dilated bladder; while where cystitis and contraction of the bladder are present the prostate usually is small and fibrous.

The *effects on the kidneys and ureters* are those usual in other cases of urinary obstruction, with or without infection (p. 975).

The *residual urine* almost invariably become alkaline, and invites the occurrence of cystitis, but if acute retention does not occur, and catheterization is avoided, the occurrence of cystitis may be long postponed. Phosphatic calculi frequently form, but as they are more or less fixed in the retroprostatic pouch may cause no characteristic symptoms.

Effects on Urination.—Residual urine diminishes the capacity of the bladder; hence urination must be more frequent. Frequent urination increases the existing congestion; this in turn may bring on retention of urine; catheterization is resorted to, once or oftener, and cystitis is the usual consequence. The retention and the infection produce nephritis, the quantity of urine is increased, and this causes still more frequent calls to evacuate the bladder. In this way a vicious circle is produced, and unless the original cause of all this woe, urinary obstruction, is removed, the patient's general health quickly deteriorates. Dilatation of the bladder and changes in its walls cause feeble power of expulsion, and slowness in completing the urinary act; while the inability of the vesical neck to act properly and the interference with the action of muscles around the membranous urethra cause the last portions of urine to be voided in dribbles, no power remaining of evacuating it in spurts.

Effects on the Rectum.—The rectum may be obstructed by an enlarged prostate, causing increasing difficulty in defecation; and the constant straining in micturition is a frequent cause of hemorrhoids and prolapsus.

Symptoms and Clinical Course.—Symptoms seldom are observed before the age of fifty years, but usually enlargement is present for some time before notable symptoms are produced. Usually the disease is insidious in onset, and the first abnormality noted is *nocturnal frequency of urination.* Urination probably is as frequent by day, but does not arrest attention. Sometimes involuntary dribbling of urine is the first sign of trouble, usually due to retention with overflow. Occasionally acute retention is the first symptom. *Starting the stream is difficult,* because there is both increased obstruction to be overcome, and decreased expulsive power; *the stream tends to drop vertically from the meatus; a longer time than usual is required to pass the urine,* though the amount evacuated each time may be small; and the *urine dribbles at the end of the act of urination. Retention of urine* is noticed by the patient only when acute, or when the chronic form is accompanied by overflow. The symptoms of *cystitis* and *renal complications* need not be detailed here. *Hematuria* seldom occurs spontaneously, but may follow the most gentle catheterization, from rupture of varicose urethral or vesical veins.

Patients with enlarged prostates may be divided roughly into three classes (Deaver and Ashhurst, 1905): in *the earliest stage* the chief complaint is nocturnal frequency of urination; in *the second stage*

patients suffer occasionally from complete retention, but are not much troubled by cystitis and enjoy fairly good health; while in *the third stage* urinary retention is nearly absolute, the bladder cannot be evacuated without a catheter, the kidneys are markedly diseased, and the patients are on the verge of the grave.

Diagnosis.—Diagnosis of enlargement of the prostate cannot be made from the symptoms alone; physical examination is required. The first and most important sign to be looked for is a distended bladder; neglect to observe this sign, and the hasty and injudicious introduction of a catheter in cases of long standing retention with overflow may cause immediate syncope (from decrease of intra-abdominal pressure), and may lead in a few days to the patient's death from renal congestion and uremia. The proper treatment of retention with overflow is given at p. 1035. Having noted the absence of a distended bladder, request the patient to pass all the urine he can, and note the facility with which he starts the stream, the force with which it is expelled, and the presence or absence of dribbling at the end of urination. The amount of urine passed should be measured, and the habitual frequency of urination noted. A patient who passes four ounces of urine, more or less, every two hours, probably has no serious renal lesion. If he passes four ounces only every three or four hours, either the normal amount is not excreted by the kidneys or the quantity of residual urine is rapidly increasing. If on the other hand half an ounce or an ounce is passed every ten or fifteen minutes, the kidneys will be excreting from 50 to 150 ounces of urine daily, and retention with overflow probably exists. If the bladder is not distended, the surgeon should next insert a catheter, to ascertain the quantity of residual urine. For diagnostic purposes (not for treatment by catheterism, p. 1034) I prefer a metallic instrument, since it acts also as an exploratory sound. As this is passed, note the presence or absence of strictures, any deviation of the subpubic urethra, the height to which the vesical orifice is raised, and the distance from the external urinary meatus at which urine begins to flow. *The following facts favor the diagnosis of enlarged prostate:* if the shaft has to be depressed unduly between the patient's thighs before urine flows, indicating elevation of the vesical orifice of the urethra; if the urinary distance (that from the meatus to the point at which urine commences to flow) is increased above 8 inches; if the catheter deviates laterally in the prostatic urethra; or if the catheter meets an obstruction more than 7 inches from the meatus, showing the obstruction is further back than the usual site of strictures. A small amount of urine evacuated from the dilated prostatic urethra should not deceive the examiner into thinking the bladder has been reached.

The amount and character if the residual urine are now noted; and finally a few ounces of saline solution are injected into the bladder, and the metal catheter is used very gently as a sound to explore the condition of the vesical walls and to search for calculi in the post-prostatic pouch. Before the catheter is removed, insert a finger into

the rectum and palpate the prostate; the intravesical instrument can then be regarded as a very long finger, and the prostate can be palpated between this and the finger in the rectum.

Treatment.—This may be discussed under the headings: (1) General treatment; (2) palliative treatment, which includes catheterism and certain palliative operations; and (3) radical treatment by prostatectomy.

1. GENERAL TREATMENT is important. Especial attention should be paid to diet, to hygiene, and to securing free evacuation of the bowels. Cascara or some similar laxative is to be preferred. Atropin never should be given long at a time, for fear of increasing vesical atony; hence the popular A. B. & S. pills should be avoided. Drugs are not of much value for the prostatic condition, but during an accession of prostatic and vesical congestion the use of a prescription such as that advised at p. 907, for a "fit of the piles," often procures marked relief. The urine should be kept acid, by administration of benzoic acid in 5 grain doses, with twice the quantity of sodium borate to ensure solution; and if the urine is not too acid urotropin is the best antiseptic. For excessively acid urine it is best to increase the ingested fluid, to decrease the sugars, and to administer alkaline salts of potassium or sodium.

2. PALLIATIVE TREATMENT.—**Catheterism** consists in periodical evacuation of the residual urine by use of a catheter. This will cure no patients, but may promote their comfort, and in the very aged or feeble may even prolong life. As the expectation of life, however, in patients treated by catheterism is in the average no more than four or five years, it is clear that the life of the *average* patient is shortened by such treatment. I do not recommend it except when prostatectomy is contraindicated. The frequency of catheterization depends entirely upon the distress occasioned by residual urine, *provided the latter is not increasing in quantity.* As a general rule a patient with 4 ounces of residual urine requires to be catheterized once in twenty-four hours; the best time is just before going to bed. If 6 ounces are present, use the catheter twice, night and morning, and add one more catheterization for each additional 2 ounces of urine up to six times daily. When the required number of catheterizations exceeds this limit, some other form of treatment is urgently demanded, even though catheterism appears to maintain the patient's general health.

Catheters for use in cases of enlarged prostate should be 14 to 16 inches long. If there is difficulty in introducing the usual soft rubber catheter, it is possible usually to insert a *Mercier catheter;* this is one made of webbing, like the English catheter (p. 958), but having the point set at an angle of 110 degrees with the shaft (Fig. 958, 1). This elbow facilitates the point of the catheter riding over the prostatic obstruction, the point of the instrument being made to follow the roof of the urethra. A *double elbowed* catheter may be useful at times. If neither of these can be inserted, an English catheter, moulded to the proper "prostatic curve," as advised at p. 959, may be used. If it will not pass without

the stylet, it should be reintroduced with the over-curved stylet in its interior; when the obstruction is met, the stylet may be withdrawn about half an inch, thus raising the point of the instrument over the obstruction (Physick, 1818) (Fig. 958, 3). A metal prostatic catheter is advisable only where the tissues are so hard and resistant from long-standing inflammation, that flexible instruments are not strong enough to push apart the sclerosed structures. If the patient has to catheterize himself a metal catheter never should be allowed; the best instrument is the soft rubber catheter, next the Mercier or the English. The patient should be drilled frequently in the necessary aseptic technique, care of the catheters, and their introduction. Only intelligent and careful patients, willing to devote the necessary time to the matter, will succeed in avoiding the prompt occurrence of cystitis, which is eventually nearly inevitable.

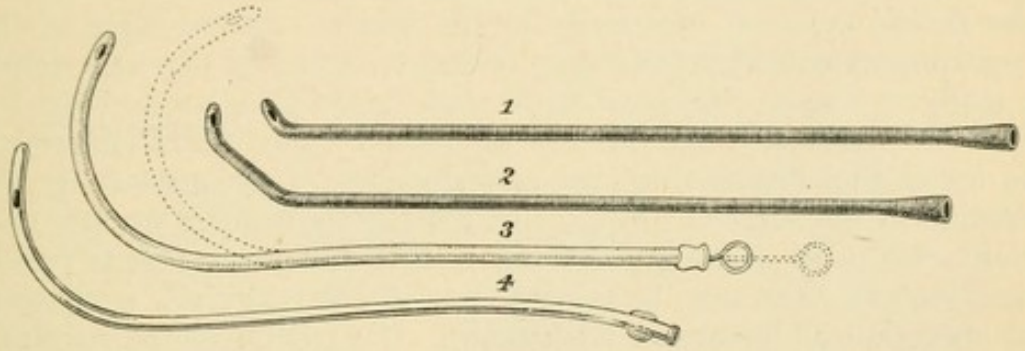

FIG. 958.—Prostatic catheters: 1. Mercier's *coudé* (elbowed) catheter. 2. *Bi-coudé*, or double elbowed catheter. 3. English catheter mounted on an over-curved stylet; when the stylet is partly withdrawn the catheter assumes the form indicated by the dotted lines. 4. Metal catheter, with prostatic curve.

Besides the occurrence of cystitis, the treatment of which is discussed at p. 963, certain other complications are not unusual. *Acute complete retention of urine* is treated by immediate catheterization. There is great danger in delay, and the chance of the retention being overcome by palliative measures is very much less than in cases of acute retention from stricture. In *chronic complete retention of urine* the bladder should be drained by a permanent catheter, in the hope that the cause is atony of the bladder, which may be relieved by constant drainage. If retention persists after atony has been relieved in this way, or if atony is not relieved by the drainage, it will be advisable either to remove the prostate or to establish a suprapubic vesical fistula (see below). The treatment of *residual urine* (chronic incomplete retention of urine, without distention of the bladder) has been considered at p. 1034. Finally there may be *retention with overflow* (chronic incomplete retention of urine with distention of the bladder): here immediate and complete withdrawal of the urine from the bladder is considered inadvisable, since experience has shown that sudden relief of intravesical pressure usually is followed by hematuria from rupture of veins in the bladder walls, and is frequently followed by the development of surgical kidneys, uremia, coma, and death, within

a few days. It is probable that the danger in such cases lies in the intermittent catheterization that has usually been employed, since this increases the chances of infection, and since Cabot (1903) showed that constant drainage by the use of an inlying catheter was able to avert threatening fatalities from such causes. Hence the surgeon either should adopt Cabot's plan or should adhere to the time-honored custom of evacuating such over-distended bladders by degrees, withdrawing only a few ounces at a time; or if all the urine is drawn at once, and an inlying catheter is not retained, he should replace most of the fluid withdrawn from the bladder by saline solution.

Among **palliative operations** the formation of a **suprapubic fistula** holds first place. This was popularized in 1888 by Hunter McGuire; the operation resembles that of suprapubic cystotomy (p. 970). Where urethral obstruction is marked, there is no likelihood of the suprapubic fistula closing, but when this tendency is observed a rubber tube should be worn constantly in the fistula. At the time of the operation any calculi present may be removed, but no attempt should be made to remove the prostate in such feeble patients as those for whom this palliative operation is advisable. Siter (1912), however, has found that **dilatation of the vesical orifice of the urethra**, by the insertion of the surgeon's finger through the suprapubic wound, may secure almost as much relief (even if only temporary) as a formal prostatectomy, and may be resorted to without materially prolonging the operation or increasing its gravity. If a pedunculated prostatic out-growth is found acting as a ball-valve against the vesical orifice of the urethra, it should be removed; if no other urethral obstruction exists (a point readily determined by passing a soft catheter) this may effect permanent relief of all symptoms. In some cases where the prostate is small and atrophic, and the bladder thickened and contracted, much relief may be secured by median perineal cystotomy, with incision of the prostate and dilatation of the prostatic urethra (**perineal prostatotomy**); a perineal tube is retained until a permanent fistula is assured. After either suprapubic or perineal drainage a fair measure of continence is secured; and constant drainage by an inlying catheter will be available whenever demanded by the occurrence of cystitis.

The **Bottini operation** was introduced in 1874, but little used until popularized by Freudenberg in 1897. It consists in making incisions in the prostate by a galvano-cautery introduced through the urethra. The subsequent cicatrization and contraction of these incisions may reduce the size of the prostate and thus overcome urinary obstruction; or they may fail to do so. The operation is uncertain in its results, the good effects sometimes secured are not permanent, and the mortality is no lower than that of prostatectomy in skilled hands.

3. Radical Treatment consists in removal of the prostate. It is the treatment of choice, and should be adopted in every case except where distinct contraindications exist. The chief contraindications are severe cystitis and renal insufficiency; and these usually may be

overcome by preliminary treatment, which may include some of the palliative operations already discussed, notably suprapubic drainage of the bladder. Extreme age is not a contraindication, but if such patients can be kept comfortable by catheter life, it will not be advisable to resort to prostatectomy.

Two methods of operation are in common use: the *suprapubic*, introduced in 1887 by McGill of Leeds, and improved and popularized in 1901 by Freyer, of London; and the *perineal*, which was a gradual development of the practice of perineal prostatotomy (a common practice in the early part of the last century), and which was employed first in cases of malignant disease during the decade from 1870 to 1880. Its modern development is due largely to the labors of the French school, headed by Albarran, and to its exploitation in this country by Dr. H. H. Young, of Johns Hopkins University.

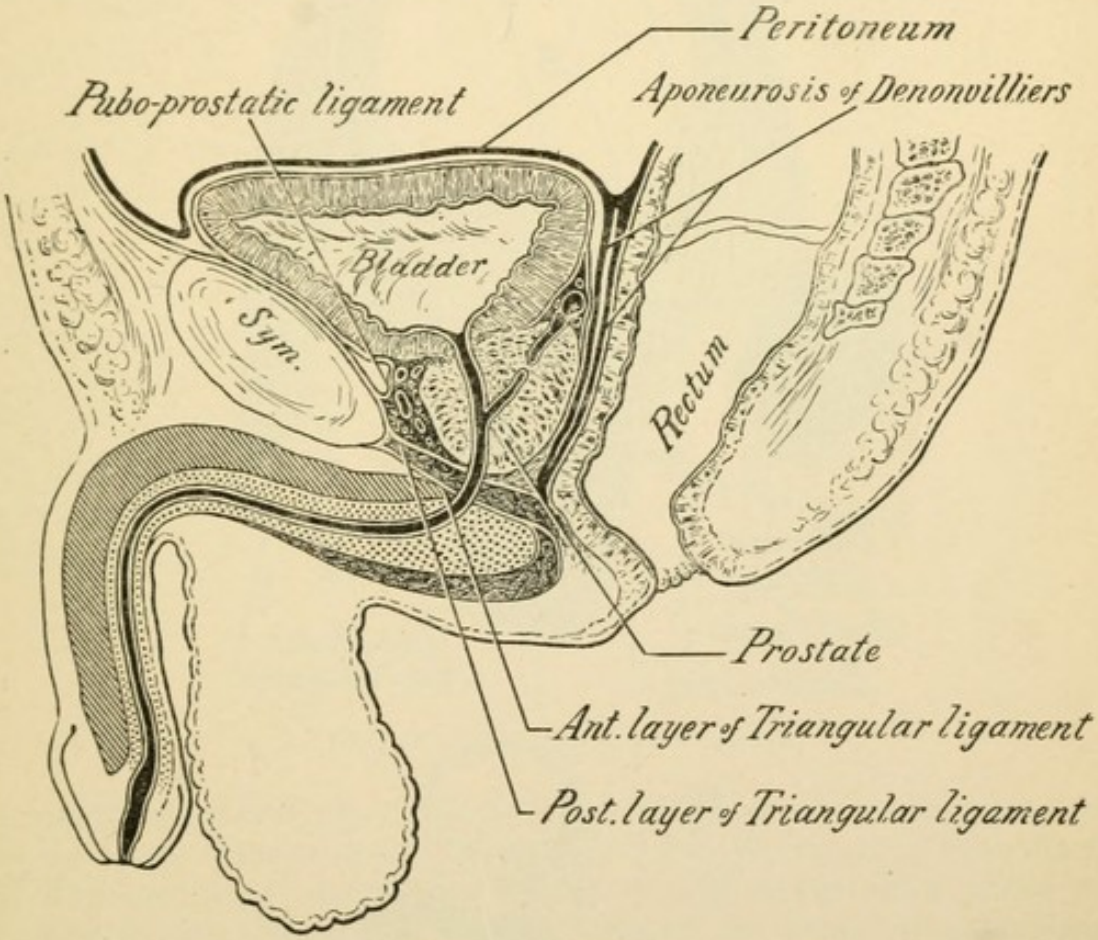

FIG. 959.—Sheath of prostate in sagittal section (diagrammatic). (Deaver and Ashhurst.)

For cases of enlarged prostate of the adenomatous type (the immense majority) suprapubic prostatectomy (Freyer) is preferable; but where the prostate is dense, and adherent to surrounding structures, and where the bladder is small and contracted, the operation is best done through the perineum, as it will be impossible to shell out the organ as is done in the suprapubic operation.

Suprapubic Prostatectomy.—The prostate lies upon the triangular ligament and above the aponeurosis of Denonvilliers (Fig. 959); neither of these structures, so important in completing the floor of the pelvis, is divided when the prostate is lifted off them and delivered into the cavity of the bladder. When the prostate is adenomatous its enucleation in this manner is accomplished with surprising

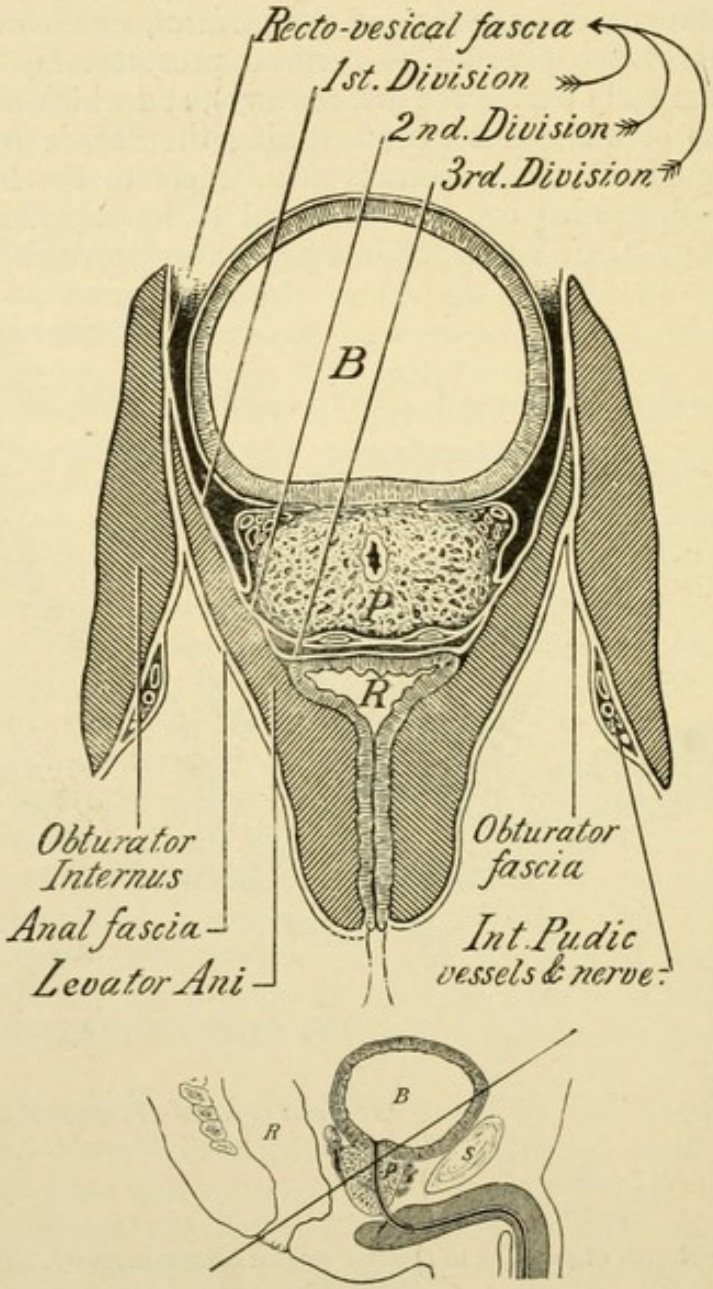

FIG. 960.—Sheath of prostate in transverse section. Line of section shown in the lower drawing (diagrammatic.) (Deaver and Ashhurst.)

ease. The enlarged prostate projects into the bladder, and is covered only by mucous membrane or at most by attenuated muscular tissue which is as much prostatic capsule as it is vesical wall. Enucleation takes place theoretically between the proper prostatic capsule (condensed by the eccentric enlargement of the "prostatic tumors")

and its sheath, formed by partitions of the rectovesical fascia (Fig. 960). It is not unlikely, however, that in many cases the enucleation takes place within the layers of the true prostatic capsule, much as the heart of an onion may be shelled out, leaving the outer layers intact.

The bladder is opened as in suprapubic cystotomy (p. 970), and to assist subsequent manipulations the index and middle fingers of one hand (gloved) are passed into the patient's rectum (the sphincter having been well stretched previously) and are made to push the prostate up toward the suprapubic wound (Fig. 961). The surgeon then inserts a finger of the other hand into the vesical orifice of the urethra, and breaks through the mucous membrane covering the enlarged prostate. The natural line of cleavage is found without much trouble. The

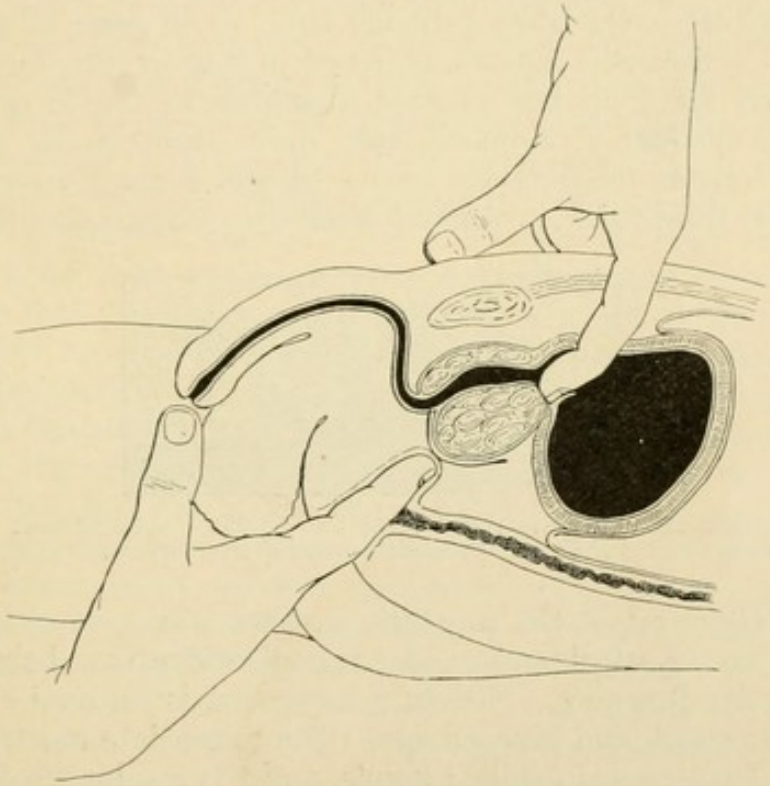

FIG. 961.—Suprapubic prostatectomy.

finger should first pass to the outer side of the lateral lobe first attacked, since here the attachment of the prostate to its sheath is least dense. Then the finger cautiously but not timidly works down under the lateral lobe toward the neighborhood of the posterior commissure and the ejaculatory ducts. Next the posterior and inferior surfaces are separated from the sheath; and finally when the lobe is pretty well outlined the finger may pass along the lateral and inferior surfaces to the apex of the lobe and free this from the triangular ligament. At times the lateral lobe first attacked comes away alone, leaving the urethra still attached to the other lobe. More often the vesical mucous membrane tears during this enucleation, and the vesical orifice of the urethra becomes entirely detached by extension of the tear across the trigone of the bladder. Then the enucleating finger

will pass across to the other lobe, beneath the posterior commissure of the prostate. Finally, when enucleation of the second lobe has been completed, the prostate is found fully detached from surrounding structures, except where the urethra annexes it to the triangular ligament. At this stage it is said the prostatic urethra may slip out of the prostate, remaining attached to the triangular ligament; but what usually occurs is that it tears off just on the vesical side of the verumontanum, and is removed with the prostate. The anterior commissure of the gland may give away during these manipulations, but in most cases the prostate is removed in one mass (Fig. 962). It is then withdrawn from the bladder, and the cavity from which it has been enucleated rapidly contracts. Bleeding rarely is alarming, and usually is rapidly controlled by hot douching.[1] The bladder is then closed around a large drainage tube, as in cases of suprapubic cystotomy. The tube may be removed in four or five days, and the patient may leave his bed as soon thereafter as proves agreeable to him. The bladder is irrigated once daily through the suprapubic wound as long as this remains open. Should it show no tendency to close by the third week, a catheter should be passed once daily by the

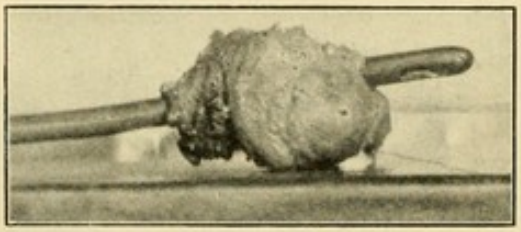

FIG. 962.—Enlarged prostate removed by suprapubic prostatectomy. Catheter in urethra pointing toward bladder. Prostate on its inferior surface. Episcopal Hospital.

urethra. Removal of the prostatic urethra will have shortened the urethral channel considerably, the vesical orifice now being close to the triangular ligament. Stricture formation is unusual. The chief dangers are shock and hemorrhage. The immediate mortality varies from 5 to 7 per cent. in skilled hands, and the results are exceedingly good. Voluntary urination is restored; no residual urine remains; and the patient's life is lengthened by many years.

Perineal Prostatectomy I think is best reserved for small fibrous prostates. The best exposure is gained by the technique of the French school, elaborated by Proust (1903). The patient lies on his back with his buttocks raised on a sand pillow, and thighs flexed on the abdomen as far as possible, thus inverting the pelvis and bringing the perineum nearly horizontal. A staff is fixed in the urethra, and through a transverse incision, with convexity forward, extending from one ischiatic tuberosity to the other, the perineal centre is exposed. Then the attachment of the external sphincter ani to this is divided, and the

[1] In cases of persistent bleeding the bed of the prostate may be packed with gauze, held in place by a few sutures of catgut passed through the free edges of mucous membrane forming the roof of the cavity. One end of the gauze projects from the suprapubic wound, and the packing can thus be removed as soon as the catgut sutures are absorbed (Deaver and Ashhurst).

dissection continued posterior to the transverse perineal muscles. By drawing the anus toward the coccyx, the recto-urethralis muscle is put on the stretch; and by dividing this close to the membranous urethra (which is not opened), the surgeon opens the space between the two layers of the aponeurosis of Denonvilliers (Fig. 959), known as the "*espace décollable rétroprostatique.*" The rectum now falls away from the anterior structures and appears like a loop of intestine floating free in the peritoneal cavity; it is covered by the posterior layer of this aponeurosis, while the anterior layer still covers the prostate and seminal vesicles. It is to be recalled that the aponeurosis of Denonvilliers really is an obliterated sac of peritoneum, analogous to the processus vaginalis of the testicle.

Beyond the anterior layer of the aponeurosis of Denonvilliers the prostate can now be indistinctly felt, floating away as soon as touched. The urethra therefore is opened, at the apex of the prostate; a prostatic tractor is inserted into the bladder, and its blades are turned so as to catch on the vesical surface of the prostate. The prostate being thus steadied, its sheath (anterior layer of the aponeurosis of Denonvilliers) is opened over one of the lateral lobes of the prostate, by an incision parallel to the urethra. By the finger or a blunt dissector, this sheath is then stripped from each lateral lobe, with utmost thoroughness. Proust says that time apparently lost at this stage of the operation will be found to accelerate matters considerably at a later stage. When the prostate is thus freed of all its attachments except to the urethra and ejaculatory ducts, the prostatic tractor is removed, and the floor of the urethra is split open from the apex of the prostate back to but not into the neck of the bladder. This cut hemisects the prostate as well, and each lateral lobe in turn is dissected off the lateral and upper aspects of the urethra, by scissors. If possible, each lateral lobe is removed entire, not by *morcellement.* Proust ligates the ejaculatory ducts, thinking this lessens the chances of orchitis. The bladder is drained by rubber tube, and the floor of the prostatic urethra is sutured over this as a guide, as far forward as the triangular ligament, where the tube emerges. The perineal wound is drained by gauze wicks, and is partly closed by buried sutures.

Young introduced in 1903, and has practised in a large series of cases with surprising success and wonderfully low mortality, an operation which he calls "conservative" perineal prostatectomy. The technique is much the same as that of the French school, except that an attempt is made to preserve the ejaculatory ducts by leaving intact the posterior commissure of the gland, in which they run. It seems very doubtful whether this feature of the operation is of any value.

Atrophy of the Prostate and Contracture of the Neck of the Bladder (Chetwood, 1901).—Usually these occur together, and are the result of long continued inflammatory changes. The sclerotic type of prostatic enlargement, already described, can with difficulty be separated from atrophy of the gland. The symptoms are similar to those seen in enlargement of the prostate, since the sclerosis of the tissues interferes with urination. Especially frequent, according to Young, are

chronic inflammatory changes in the prostatic utricle. Another frequent factor in urinary obstruction in these cases is a "*bar at the neck of the bladder*" (Guthrie, 1834) usually in the form of a dense fibrous ring around the vesical orifice of the urethra. Chronic prostatitis usually coexists. The *diagnosis* is made by recognizing the small sclerotic prostate on rectal examination, and by use of the cystoscope which usually shows an abnormal condition of the prostatic urethra and vesical neck.

Treatment.—Treatment even by specialists in genito-urinary surgery, is not always satisfactory. The condition of the urine should be attended to; and methods already advised in cases of chronic prostatitis may be tried. Best results follow direct treatment of the prostatic urethra through the cystoscope. If a bar at the neck of the bladder is found, it may be punched out by one of the modern instruments copied after Mercier's original prostatotome and prostatectome (1837), or relief may be secured by the Bottini galvano-cautery operation. Prostatectomy (by the perineal route) may be considered the last resort.

Carcinoma of the Prostate is now recognized as much more frequent than formerly supposed. It probably occurs in not less than 10 per cent. of patients who complain of symptoms of urinary obstruction from prostatic disease. The malignant growth appears to originate usually in that portion of the prostate posterior to the urethra and below the ejaculatory ducts. It tends to infiltrate upwards invading the vasa deferentia and seminal vesicles long before it spreads into the prostatic tissues immediately adjacent to the neck of the bladder. Patients seldom come under observation while the growth is still operable. In some cases the earliest indication of trouble is not the occurrence of local symptoms, but the discovery of metastasis in the bones of the pelvis, trunk, or thighs. Usually it is found that a hard, nodular, fixed tumor occupies the region of the prostate, and that the rectal mucous membrane does not glide easily over the enlarged organ as is the case in benign enlargement. Referred pains are frequent in advanced cases.

Treatment.—Treatment usually must be palliative. A radical operation, involving removal of the prostate and seminal vesicles, resection of the neck of the bladder, and suture of the membranous urethra to the remaining vesical wall, has been devised and practised by Young, with fair success. Where such a radical operation is impracticable, he has practised a partial perineal prostatectomy with preservation of the urethra and vesical mucosa; he thinks that in about 60 per cent. of cases excellent functional results may be expected which will be maintained so long as the patient lives.

Sarcoma of the Prostate is rare. A tumor in a child or young person probably is sarcomatous; it grows very rapidly, and almost always is inoperable. The earliest symptom often is complete retention of urine; less often do symptoms of incomplete urinary obstruction occur, or rectal symptoms. Death occurs within three months to two years.

CHAPTER XXVIII.

SURGERY OF THE MALE GENITAL ORGANS.

SURGERY OF THE PENIS.

Congenital Deformities.—Hpyospadias.—The most frequent of these is hypospadias, in which there is a defect in the floor of the urethra, extending from the meatus a variable distance backward. It occurs once in about 300 males, and is due to failure of coalescence between the two lateral portions of the penis on its under surface. In *glandular hypospadias* the urinary meatus is displaced only slightly, and unless it is as low as the region of the frenum no treatment usually is required. In *penile hypospadias* (Fig. 963) the opening usually occurs at the junction of the penis and scrotum (peno-scrotal hypospadias) but may be anterior to this site. In the most marked deformity the

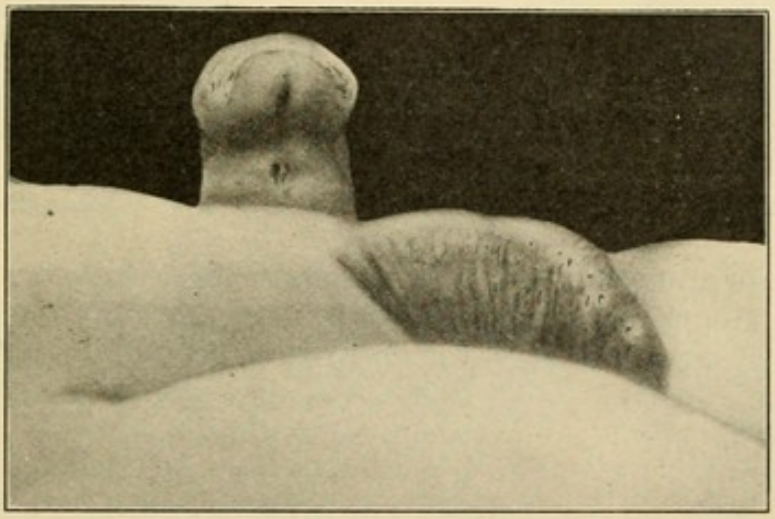

Fig. 963.—Penile hypospadias. Episcopal Hospital.

opening is in the *perineum*, there is usually *cleft scrotum*, the penis is rudimentary, and there is resemblance to the condition known as hermaphrodism. In all cases of hypospadias there is downward incurvation of the penis, and the prepuce usually is abnormal in form or attachment.

Treatment.—Treatment involves some form of plastic operation, and the best time for this is about the age of six years. It is very important to employ only such skin in plastic operations as will remain free from hair throughout life. In most cases the bladder should be drained through the perineum during the first week after operation, or until the sutured structures have firmly united. In glandular

hypospadias Beck's operation (1907) is the best (Figs. 964 and 965): the urethral orifice and about an inch of the urethra are dissected free, and

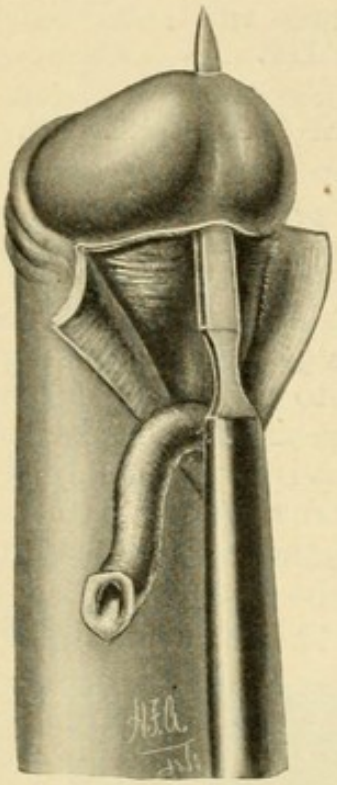

FIG. 964.—Beck's operation for hypospadias. (Watson and Cunningham.)

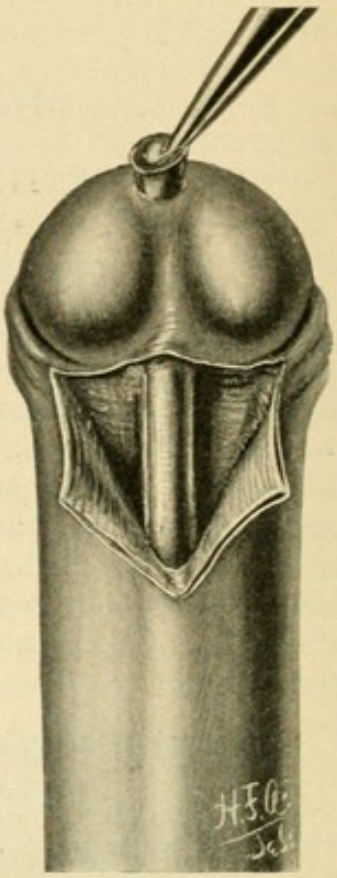

FIG. 965.—Beck's operation. (Watson and Cunningham.)

the glans is perforated from base to summit by a bistoury, this tract is dilated, and the previously mobilized urethra is drawn through and the meatus sutured in its normal position. A similar operation may succeed when the urethral opening is in the penis not too far from the glans; but in most cases of penile and in all cases of peno-scrotal and perineal hypospadias, it is necessary to construct a new urethra by skin flaps. A good method in cases of peno-scrotal hypospadias is to outline two corresponding rectangular flaps from the under surface of the penis and the anterior median raphé of the scrotum, respectively, as indicated in Fig. 966. The denuded edges are sutured together, and after several weeks, when union is firm, the penis with the adherent scrotal raphé (which forms the floor of the new urethra) are cut free from the scrotum, and the raw surfaces are covered in by sliding

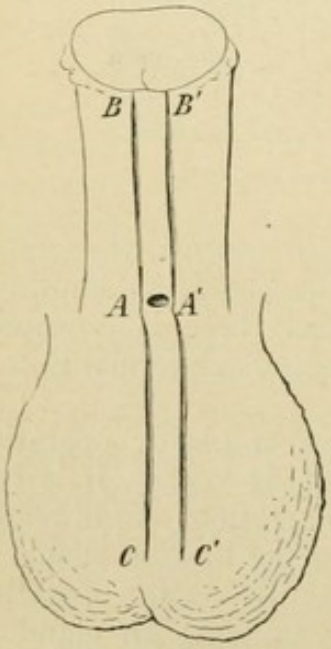

FIG. 966.—Bucknall's operation for penoscrotal hypospadias (1907).

flaps together from the sides, or by bringing the redundant prepuce over the under surface of the penis as a bridge. After a penile urethra has been constructed in this way, it may be transplanted into the glans, according to Beck's operation, on a subsequent occasion. Cantas (1911) used a plastic flap, with pedicle, from the thigh, containing a section of the long saphenous vein, which served as the new urethra.

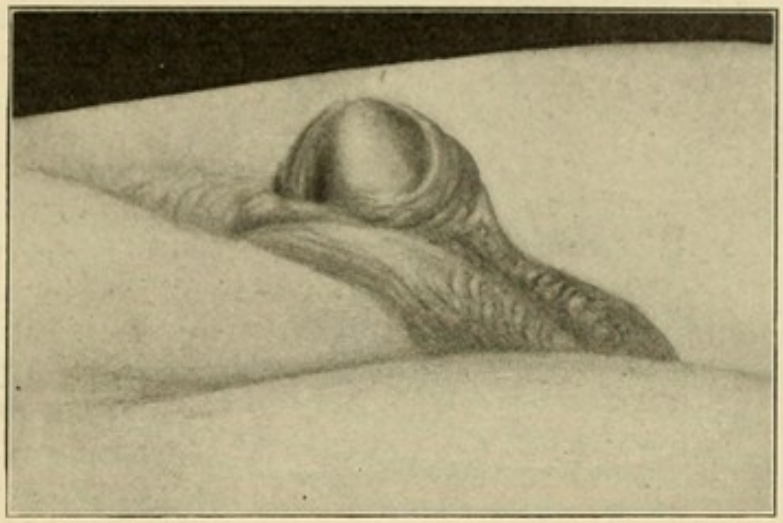

FIG. 967.—Epispadias; age six years. Episcopal Hospital.

Epispadias.—In epispadias the roof of the urethra is deficient for a greater or less distance back from the normal site of the meatus (Fig. 967). It is treated by operations analogous to those employed for hypospadias. Cantwell's operation (1895) is commended by Binnie (Fig. 968).

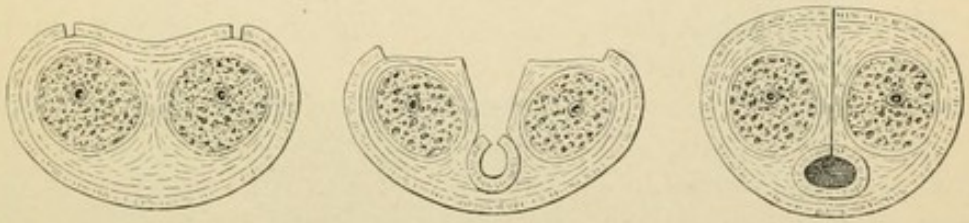

FIG. 968.—Cantwell's operation for epispadias: a new urethra is formed by inverting skin-flaps; the corpora cavernosa are then separated in the mid-line; the new formed urethra is placed in the floor of the channel thus made; and finally the cavernous bodies are sutured together over the new urethra.

Hermaphrodism.—This is a condition in which an individual possesses the generative organs of both sexes. It is excessively rare; in the vast majority of cases only *false hermaphrodism* exists: a male with a perineal hypospadias, cleft scrotum, rudimentary penis, and undescended testicles may resemble a female on casual inspection; or a female with abnormally large clitoris and congenital absence of the vagina may resemble a male hypospadiate. *Treatment* involves operative cure of the predominant deformity, when this is possible.

Phimosis.—Phimosis is the condition in which the prepuce cannot be retracted over the glans. It is rare as a congenital deformity, most

cases so classed being merely instances of **adherent prepuce** the result of balano-posthitis: in these retraction is possible, though difficult. Cure follows daily retraction, cleansing, and application of zinc oxide ointment to the inflamed parts. Most cases of true phimosis (Fig. 969) are the result of neglect of the parts in infancy and early childhood, the preputial orifice remaining infantile in size while the penis has continued to grow. Mere *elongation* or *redundancy* of the prepuce usually is congenital (Fig. 970). In many cases phimosis develops as a temporary condition in adult life, as a complication of balano-posthitis from chancroids or gonorrhea.

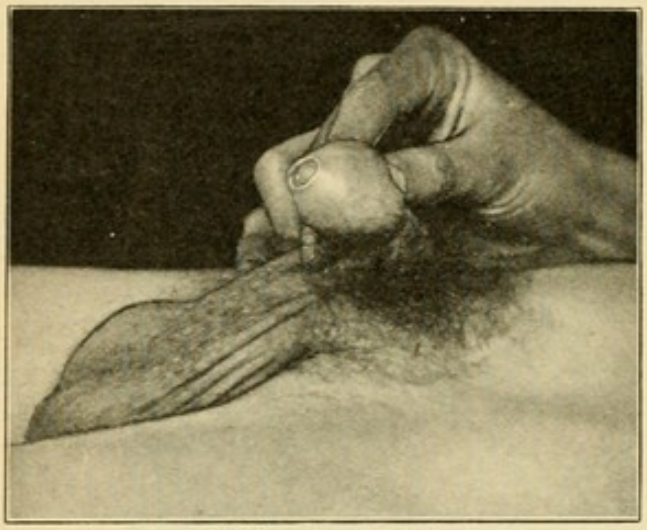

FIG. 969.—Phimosis. Age sixteen years. Episcopal Hospital.

Treatment.—Treatment may be by *incision*, *excision*, or *circumcision*. Incision (dorsal slit of the prepuce) was mentioned at p. 1008; it is used mostly in cases complicating balano-posthitis. Excision of a wedge shaped portion of the prepuce is seldom or never employed. *Circumcision* is the typical operation. Various special forceps have been devised to simplify the operation but their place is readily supplied by clamping the foreskin between the handles of a pair of scissors, the redundant foreskin being cut off with another pair (Fig. 971). The section should be made obliquely, removing more tissue from the dorsum of the penis than from the region of the frenum. The clamp should be applied at a level which corresponds with the sulcus behind the corona glandis, and the skin should be drawn well in front of the glans before the clamp is tightened. When the redundant tissue is cut away and the clamp is removed it will be found that the skin surface of the prepuce retracts, while its mucous layer still covers the glans. The mucous layer is then slit up the dorsum, with scissors, as far as the corona glandis. It is not necessary to trim off the triangular flaps of mucosa thus formed, as by careful suturing no redundant tissue is left. Next *every bleeding*

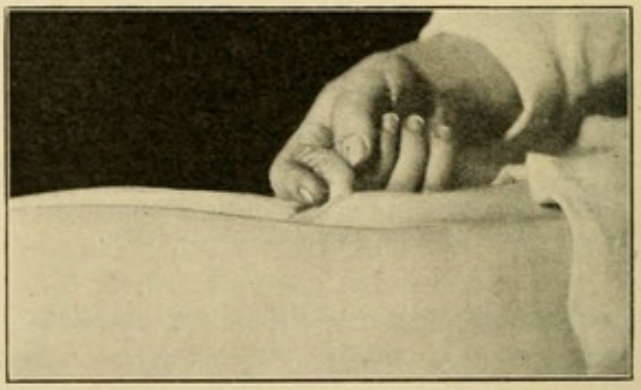

FIG. 970.—Redundant prepuce. Children's Hospital.

point should be caught in hemostats and ligated with fine catgut. Neglect of this precaution usually results in formation of a hematoma and breaking down of the wound. Finally the skin and mucous layer of the prepuce are sutured together with interrupted sutures of chromic catgut. The first suture is introduced at the frenum, the second in

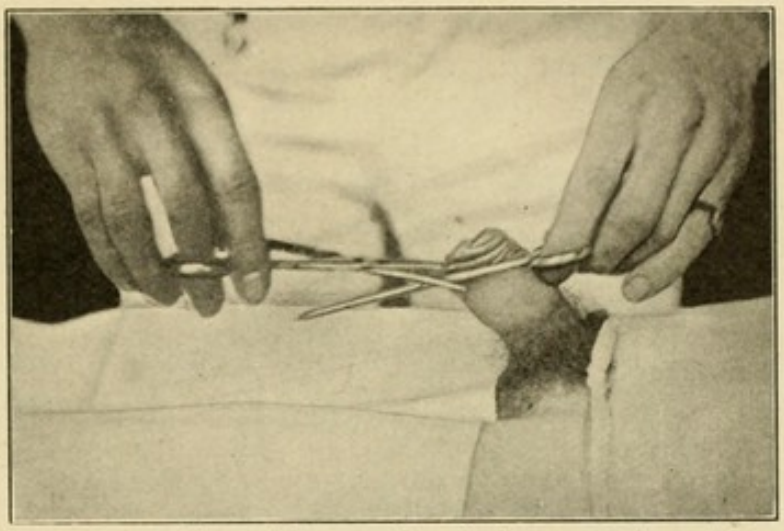

FIG. 971.—Circumcision with two pairs of scissors. Episcopal Hospital.

the mid-line on the dorsum of the penis, the third and fourth at the midpoints on the right and left sides, and such other intervening sutures as are required to secure neat apposition. *The ends of all these sutures are left long after tying*, and the dressing (a thin roll of gauze) is held in place by knotting the free ends of the sutures over it

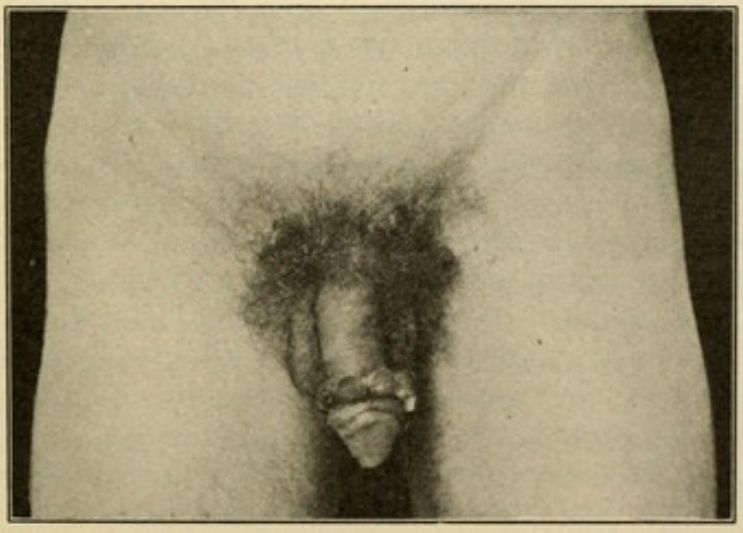

FIG. 972.—Dressing for circumcision. Episcopal Hospital.

(Fig. 972). This roll of gauze should be applied a little slack, so as not to produce strangulation should erections occur. No other dressing is used. In the course of ten days or two weeks this gauze may be peeled off, as the chromic catgut sutures will have been absorbed. In the meantime the seat of operation requires no treatment.

Paraphimosis.—Paraphimosis is the condition in which the foreskin has been retracted over the glans and cannot be replaced owing to swelling of the glans or edema of the foreskin (Fig. 973). The tightest band of constriction, back of the corona, may become ulcerated from pressure; this always occurs before there is danger of strangulation of the penis.

Treatment.—In recent cases it is usually possible to reduce the paraphimosis by pushing the glans upward with the thumbs, while the index and middle fingers of both hands, applied behind the corona, pull the foreskin forward. If reduction is not accomplished in this way, it is often advised that the constricting band be divided; but as a matter of fact usually no treatment is required beyond bathing the parts in hot water and keeping the penis elevated to favor reduction of the edema. In the course of a few days the foreskin can be drawn down again in most cases, but sometimes permanent thickening from lymph-edema persists and may require excision or circumcision.

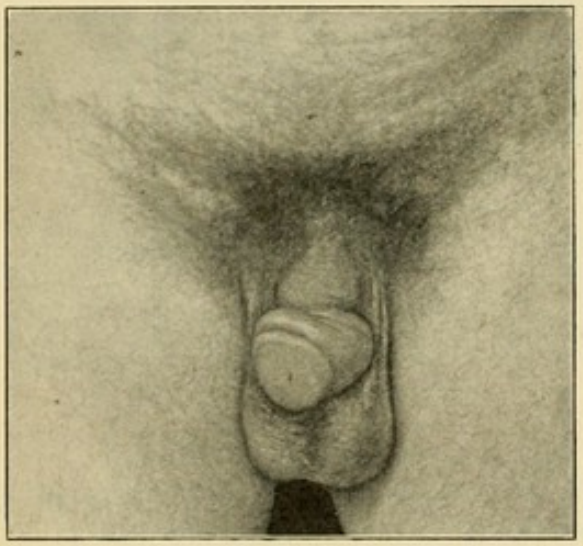

FIG. 973.—Paraphimosis from gonorrhea; nine days' duration. Episcopal Hospital.

Balanitis and Balano-posthitis.—**Balanitis** is inflammation of the glans penis; **posthitis** is inflammation of the prepuce. Usually both glans and prepuce are inflamed (**balano-posthitis**). In children this condition is a frequent complication of adherent prepuce; in adults it occurs as a complication of gonorrhea or chancroids, being predisposed to by phimosis or elongation of the prepuce. In the aged, formation of a *preputial calculus* is an occasional complication.[1]

Treatment.—In cases with phimosis or adherent prepuce, dorsal incision of the prepuce, or circumcision should be done, the former being preferable in gonorrheal or chancroidal cases. Inflammation may be reduced before and after operation by instillations of weak silver nitrate solution between glans and prepuce.

Herpes Progenitalis.—Herpetic vesicles sometimes develop on the penis, especially on the mucous layer of the prepuce; they may occur seemingly spontaneously, or soon after coitus. The vesicles resemble those seen in cases of herpes occurring elsewhere on the body. The

[1] Under the name of "the fourth venereal disease" Corbus and Harris (1909) have described a form of erosive balanitis due to symbiosis of a spirochete and a vibrio. The spirochete is identical with that of Vincent's angina, found in the mouth, and the infection is believed to be conveyed to the prepuce and glans by unnatural sexual practices.

affection appears first as one or several minute reddish papules which turn into vesicles in the course of a few hours. Often they assume a crescentic outline. There is some itching and tingling, and after the vesicles rupture contact with the urine causes burning pain. Patients usually are subject to recurring attacks.

Treatment.—The general health should be given attention, and any local source of irritation (phimosis, etc.) should be appropriately treated. If the herpetic vesicles are kept clean and dry, they usually heal within a few days. Astringent washes (1 per cent. sulphate of zinc, or acetate of lead) should be applied once daily, the parts being then thoroughly dried, and powdered.

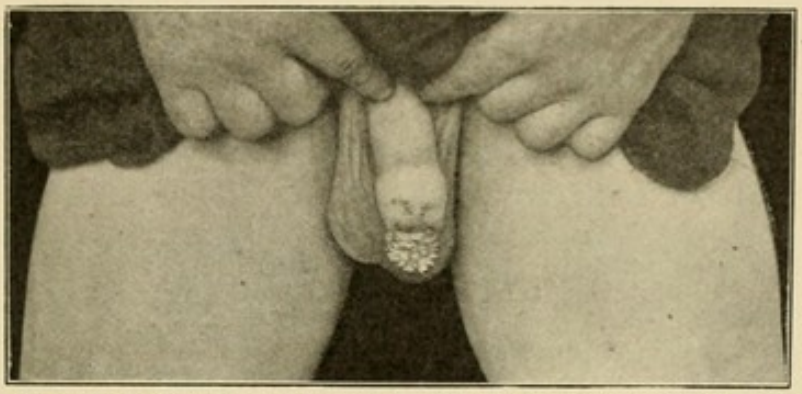

FIG. 974.—Venereal warts from phimosis. Duration seven months. No venereal disease. Episcopal Hospital.

Venereal Warts (Verrucæ Acuminatæ).—This affection was mentioned at p. 259. It has no necessary connection with venereal disease. The warts usually occur in persons with phimosis or redundant prepuce, and are the result of uncleanliness (Fig. 974).

Treatment.—In mild cases it is sufficient to apply caustics (fuming nitric acid) every day or so until the warts shrivel up and drop off; but in cases complicated by phimosis this should be relieved by appropriate means, and the warts should be excised and their bases cauterized.

Carcinoma.—Carcinoma is the only tumor of frequent occurrence on the penis. It may develop in an old venereal scar; is predisposed to by the existence of phimosis or balano-posthitis;[1] but often no cause is evident. It presents the same characteristics as carcinoma in other regions of the body. Usually it arises on the glans or the prepuce. The squamous-celled type is not highly malignant. A papillary form is more usual, is much more malignant, and presents irregular projections, resembling venereal warts except for the hardness of their bases and margins, and the presence of ulceration, which occurs early. The inguinal lymph nodes on both sides are involved early in the papillary variety, not until later in the squamous-celled type of carcinoma. Invasion of the pelvic nodes also occurs.

Treatment.—If the carcinoma has not spread beyond the glans, amputation of the penis is sufficient; but if the corpora cavernosa have

[1] Leukoplakia of the glans is recognized as a pre-cancerous condition.

become infiltrated extirpation of the entire penis is necessary. In *all* cases the inguinal lymph nodes should be excised; usually this may be done at the same time as the operation on the penis, and then always as the first step of the operation; but if the tumor is very septic, it is best to postpone removal of the inguinal lymph nodes until the lower wound has healed.

Amputation of the Penis involves removal only of the phallic portion of the penis: a rubber tube is tied around the base of the organ, to control bleeding; a circular incision is made through the skin well behind the seat of disease, and the skin is allowed to retract. The corpora cavernosa are then divided at the base of the skin-flap and closed transversely by sutures. The urethra (with the corpus spongiosum) is dissected free for a centimeter or more in front of this point, and is divided. "The urethra is then slit up in three places, one below and two above; the three square flaps so formed are then turned back and their corners cut off. This makes three small triangular flaps which when spread out form one large triangle. The skin is then sutured accurately to the edges of this triangle, and no raw surface is left" (G. G. Davis, 1897).

Extirpation of the Penis.—The scrotum is slit open from the penoscrotal juncture to the perineum, and the bulbous urethra is isolated and divided, and its vesical end fixed to the skin of the perineum, being split on its under surface for at least half an inch. The incision is next carried around the base of the penis, the suspensory ligament is divided, the crura cut, and the entire penis is removed. A catheter is left in the bladder. In advanced cases it is necessary to remove both testicles and spermatic cords as far as the internal abdominal ring, so as to permit complete extirpation of the inguinal lymphatics.

SURGERY OF THE TESTICLES, SCROTUM, AND SPERMATIC CORD.

Congenital Anomalies.—In some rare cases one or both testicles may be absent. A much more usual anomaly is **non-descent of the testicles,** on one or both sides, called respectively *monorchidism* and *cryptorchidism.* The affection is more frequent on the right. The testicle may be retained in the abdominal cavity or may be lodged in the inguinal canal or at the external ring. Inguinal hernia often is present as a complication. Rarely the testicle is *misplaced,* being found in the perineum or on the thigh. In most cases the diagnosis of non-descent or misplacement is readily made by observing the absence of the testicle from the scrotum, and its presence in the inguinal canal or elsewhere. Sometimes the testicle is *wandering,* slipping up into the inguinal canal when the cremaster contracts, and at other times remaining in the scrotum (Figs. 975 and 976).

Treatment.—A testicle which remains in the inguinal canal or at the external ring is constantly exposed to injury; one which comes and goes dilates the inguinal canal and predisposes to the development

of hernia, and is itself liable to torsion (see below). The condition should be remedied by operation, and the best age for this is about six years. The undescended testicles, according to Corner, possess the power of producing spermatozoa only for a short time, usually from the age of twenty to twenty-two years, though their function of internal secretion may be sufficient to ensure the acquirement of secondary sexual characteristics at the usual age of puberty. In any case, their removal is contraindicated unless they are actually diseased. The main therapeutic indication is to place the testicle in a situation where it shall not be exposed to injury. If possible it should be brought down into the scrotum; but if this cannot be done, it should be replaced within the abdominal cavity.[1] The operation is begun by opening the inguinal canal, as in the hernia operation. The testicle is exposed, and a hernial sac if present is excised and the opening in the parietal peritoneum is closed. If the cord is not long enough to enable the testicle to be replaced in the scrotum, it often

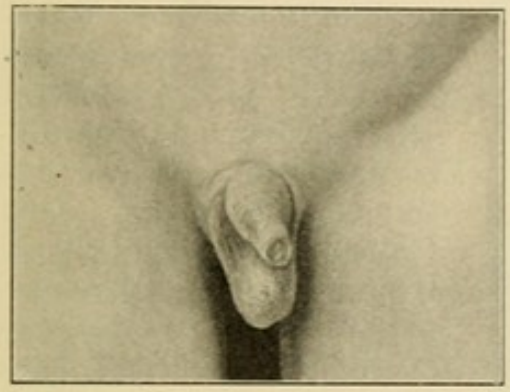

FIG. 975.—Wandering testicle: testicle now in inguinal canal. Age fifteen years. Episcopal Hospital.

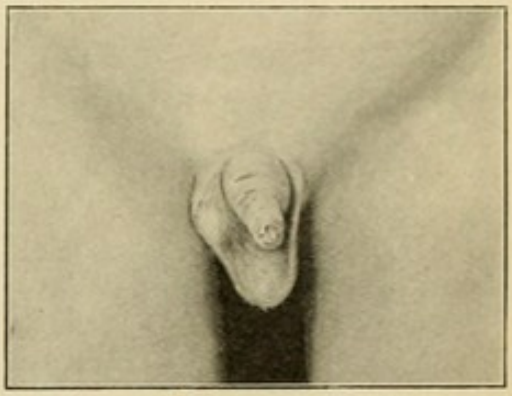

FIG. 976.—Wandering testicle: testicle now in upper part of scrotum. Episcopal Hospital.

is possible to lengthen it (Bevan, 1903) by careful division of fibrous bands and freeing the structures well around the internal ring, by ligation and division of the cremasteric artery, or even by excision of all the constituents of the cord except the vas and its accompanying vessels; *the latter step seldom is necessary*, but according to Bevan sacrificing the spermatic vessels will not lead to gangrene of the testicle. When the organ has been brought down into the scrotum, it should be fixed by sutures to the median scrotal septum. The cord should not be transplanted as in the Bassini hernia operation, but should be treated as in Ferguson's method (p. 792).

[1] The supposition that a mal-placed testicle is more prone to the development of malignant tumors than the normally situated organ, is cited by some as justification for orchidectomy (castration) in these cases. But this supposition rests on inconclusive facts; and even if it were true, it would not be the mal-position which created the predisposition to malignant disease, but some developmental defect in the organ itself and the occurrence of malignant changes would be no more frequent if the testicle were retained in the abdomen than if it were replaced in the scrotum.

Torsion of the Testicle, generally traumatic in origin (straining efforts, contortions of the body, etc.), occurs usually in children with unduly movable testicles. In most cases the tunica vaginalis extends up to the internal ring, and congenital hydrocele (p. 1058) may be present. The *symptoms* are acute, sickening pain in the inguinal canal or scrotum according to the site of the testicle; the testicle becomes a little swollen, and is extremely tender. The *diagnosis* must be made from strangulated inguinal hernia and from inflamed hydrocele of the cord. In these conditions a normally placed and symptomless testicle usually is present. *Treatment* is by operation, which consists in uncoiling the twist and fixing the testicle in normal position by means of sutures; or in castration if gangrene of the testicle has occurred.

Inflammation of the Testicle.—**Orchitis** implies inflammation of the testis proper; while inflammation of the epididymis is called **epididymitis.** In most cases both component parts of the testicle are affected (**epididymo-orchitis**), but almost invariably one or the other affection dominates the clinical picture. Apart from trauma, which is not a very frequent cause, the disease is oftenest due to infection carried by the blood-stream (orchitis) or extending from the urethra through the vas deferens (epididymitis). **Orchitis** is much more frequent in boys than in adults, and occurs as a complication of mumps (Fig. 977), tonsillitis, influenza, etc. The attack lasts about four days. Usually the right testis is affected, but occasionally both sides are attacked one after the other. Some atrophy may occur subsequently. Suppuration often occurs in cases complicating typhoid fever. **Epididymitis** usually is a complication or sequel of gonorrhea, occurring from the third to the sixth week of the disease. Sometimes it occurs after the passing of a sound or catheter, especially in cases of prostatic enlargement. The left side is affected oftener than the right, but both sides may be involved in turn.

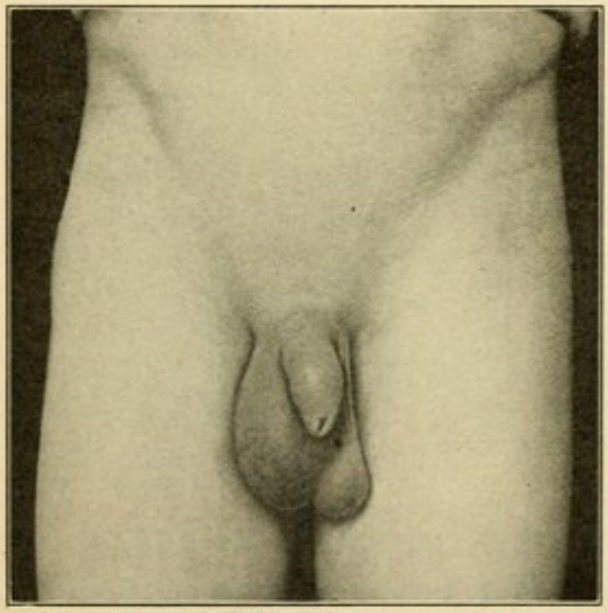

FIG. 977.—Orchitis following mumps. Age fourteen years. Mumps one week ago, followed first by left orchitis, which subsided; then by right orchitis, which has lasted for three days. Episcopal Hospital.

Symptoms.—Symptoms of orchitis and epididymitis are of rather sudden onset, but prodromes (malaise, headache, nausea, creepiness, and chilliness) may occur. The earliest symptoms may be referred to the abdomen, and may be mistaken for those of appendicitis.

The testicle becomes acutely painful, excessively tender, and swollen; most of the swelling is due to inflammatory effusion into the tunica vaginalis (*acute hydrocele*). The scrotum may become red and edematous. The temperature sometimes is high, and the patient may appear very ill, at least for a time. If the patient keeps on his feet, and particularly if the testicle is allowed to hang unsupported, all the symptoms are aggravated, and there may be dragging abdominal pains. The **diagnosis** between orchitis and epididymitis may be made by noting the history of the case and the probable cause of the scrotal swelling; by observing that in epididymitis the swelling begins in the globus minor, spreads to the globus major, and that when the entire epididymis is affected it forms a "boat-shaped" enlargement on the outer and back part of the testis. Most of the scrotal enlargement, as already remarked, is caused by acute hydrocele of the tunica vaginalis. In orchitis the smooth globular form of the testicle is felt, and the epididymis is not palpably enlarged.

Treatment.—The patient should be put to bed, and the scrotum elevated. Heat, especially in the form of a flaxseed poultice, is better than cold as a local application. If injections have been in use, for gonorrhea, they should be stopped. Some urinary antiseptic should be given. Puncture of the tense tunica albuginea in one or several places, with a fine tenotome, is the most efficient way of relieving pain. No anesthetic is required. The scrotum is painted with 2 per cent. iodin solution, and is drawn tensely over the testicle, and the puncture is made at the seat of greatest swelling. This plan is said to have been suggested by Petit, and widely employed by Vidal de Cassis, and by H. Smith, during the last century. As an open operation the method has been recently revived by Bazy, Belfield, and Hagner; for this, a general anesthetic is advisable: the tunica vaginalis is incised, its contents evacuated, and the inflamed epididymis is punctured in one or several places; the scrotal wound is then packed with gauze. If no operation is done acute symptoms begin to subside in four or five days; then sorbefacient ointments, especially those containing guaiacol and ichthyol, should be applied, and when only a painless induration remains resolution may be favored by strapping the testicle with adhesive plaster or with a broad strip of rubber tissue. In the most acute cases of gonorrheal epididymitis suppuration may occur, requiring incision and drainage of an abscess; occasionally castration is required. In almost all cases cicatricial changes occur in the body or globus minor of the epididymis, which prevent discharge of semen into the vas deferens; and if both sides have been affected the patient may be rendered sterile. To overcome this condition, which is said to occur in about 40 per cent. of cases of bilateral epididymitis, Edward Martin (1902) has practised with success an anastomosis between the globus major and the vas deferens (epididymo-vasostomy). Cases of *recurrent epididymitis* often are caused by infection from the seminal vesicles, and can be cured only by proper treatment of this focus of infection.

Neuralgia of the Testicle.—Under this name is described a condition in which the testicle, usually the left, is persistently tender and afflicted with lancinating pains. This condition must be distinguished from referred pain due to lesions elsewhere, notably renal calculus and varicocele. If no cause for referred pain exists, and a history of epididymitis, or orchitis is obtained, it is probable that the neuralgia is due to compression of the testicle by sclerosis and contraction of the tunica vaginalis or albuginea; under such circumstances continuance of palliative measures (use of a suspensory, hot and cold douches, occasional passage of a cold sound, or instillations of argyrol into the deep urethra, etc.) probably will prove useless, and it is best to expose the testicle and excise the tunica vaginalis.

Semino-vesiculitis or Spermato-cystitis.—This may be *acute* or *chronic*. The acute form almost invariably occurs as a complication of gonorrhea. Chronic semino-vesiculitis usually is a sequel of the acute form, but the condition may be chronic from the start and may be due not to gonorrhea but to non-gonococcic posterior urethritis or prostatitis. In most cases only one vesicle is affected at first, but the second rarely escapes eventual infection. In the acute form the vesicle is distended with purulent exudate, but inflammatory infiltration of surrounding tissues may occur to such a degree that the vesicles cannot be recognized by palpation through the rectum. The **symptoms** of the acute form are pain in the perineum or rectum, especially after defecation or seminal ejaculation. The semen often is blood-stained, and may be colored blue from the admixture of indigo. Sexual excitability is pronounced, and frequent and painful erections are characteristic. In the chronic form the symptoms are those of the gleet (p. 1011); recurrent attacks of epididymitis often occur.

Treatment.—In *acute semino-vesiculitis* the patient should be confined to bed, and all local treatment of the urethral condition should be discontinued. A hot water bag may be applied to the perineum, or hot rectal injections may be given if they lessen discomfort. Urinary antiseptics should be given, and the bowels should be opened by a laxative. If pain is excessive, and particularly if constitutional symptoms exist, the occurrence of suppuration should be suspected: the patient then should be anesthetized and the rectum explored; if any signs indicating suppuration are found, the vesicle should be exposed through the perineum (by the method advised for perineal prostatectomy), opened and drained. The treatment of *chronic semino-vesiculitis* has already been considered in connection with chronic urethritis. In cases of recurrent epididymitis, Belfield opens the vas deferens below the external abdominal ring and irrigates the seminal vesicle by injecting not more than 2 c.c. of the irrigating fluid. As noted at p. 472, Fuller drains the seminal vesicles through the perineum in cases of gonococcic arthritis.

Tuberculosis of the Testicle.—This probably is caused in most cases by hematogenous infection. Keyes, however, maintains that it is always secondary to tuberculosis of the prostate and seminal

vesicles. The lesion in the testicle begins in the globus major of the epididymis[1] and invades the testis secondarily. The patients usually are between twenty and thirty years of age, and as a rule only one testicle is affected at first, but extension to the other side is frequent, probably by way of the seminal vesicles and ejaculatory ducts through the vas deferens.

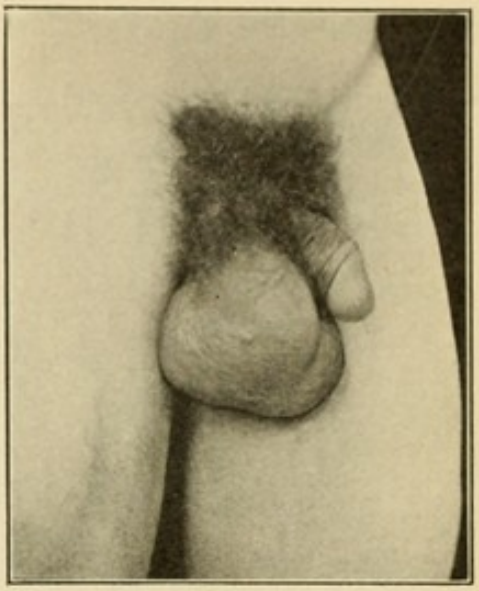

Fig. 978.—Tuberculosis of both testicles, duration four months; age nineteen years. Right testicle adherent to skin, and abscess palpable. Both seminal vesicles enlarged and nodular. Episcopal Hospital.

Symptoms.—The onset usually is insidious, and the patient may be scarcely aware of his condition until he discovers by accident a hard nodule in the epididymis, or until suppuration has occurred with fistulization of the scrotum. In the rare cases with acute onset the condition at first somewhat resembles gonorrheal epididymitis; but unlike this affection it does not subside in the course of a week or two. In most cases the clinical diagnosis must be considered uncertain until areas of softening have formed; usually this is quickly followed by implication of the skin of the scrotum, which becomes adherent to the testicle (Fig. 978); then the cold abscess ruptures and cheesy pus is constantly discharged from the fistula (Fig. 979). At this stage the diagnosis may be confirmed by finding tubercle bacilli in the discharge; at earlier stages focal reaction to a tuberculin test may be relied on.

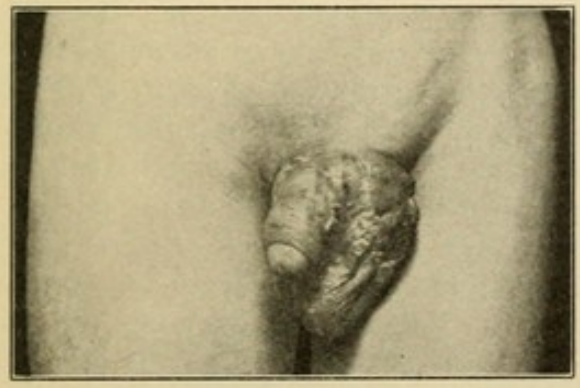

Fig. 979.—Tuberculosis of left testicle, duration two years; age thirty-three years. Operation for left hydrocele eighteen months ago; fistulæ in scrotum for last six months. (See Fig. 980.) Episcopal Hospital.

Treatment.—There is much dispute among surgeons as to the proper treatment of these patients. Some advise immediate castration in all cases; others condemn all operative interference and trust entirely to hygienic measures and vaccine therapy. My own feeling is that so long as suppuration and fistulization do not occur there is no need to remove the testicle. A nodule in the epididymis may remain unchanged for years provided excellent hygienic life conditions are

[1] In gonococcic epididymitis the globus minor is attacked before the globus major.

present, as has been shown by Watson and Cunningham. Under such circumstances (and if tuberculous lesions exist elsewhere in the body, even if the local lesion is advanced) minor operative measures may be of benefit to the local condition and may promote the patient's comfort. Epididymectomy sometimes is done, leaving the testis intact, with or without anastomosis between it and the vas deferens. According to Barney (1911) the semen is sterile in 85 per cent. of patients even before epididymectomy. A cold abscess may be treated on the same principles recommended when dealing with cold abscesses in association with bone disease. But when fistulization has occurred, and particularly if secondary infection is present, I feel quite sure it is best, especially in the average hospital patient, to remove the testicle and spermatic cord as far as the internal ring. The operation is described below. If only one testicle is diseased and is removed, only about 9 per cent. of patients die of genito-urinary tuberculosis, the other testicle becomes involved subsequently only in about 26 per cent., and cure follows in about 45 per cent. of patients; if double castration is necessary, 15 per cent. of patients die within the first three years after operation, but 56 per cent. are permanently cured (Haas).

FIG. 980.—Specimen removed by castration from the patient shown in Fig. 979: testicle and adherent skin of scrotum, with spermatic cord and inguinal lymph nodes in one mass. Episcopal Hospital.

Castration or Orchidectomy.—Open the inguinal canal, as in the operation for hernia. Transfix and ligate the spermatic cord at the internal abdominal ring. Cut the cord below the ligature and turn it down over the scrotum with its annexed fatty tissue and lymph nodes. Close the inguinal wound (except at the lower angle where the cord emerges) as in the operation for hernia, and cover it with sterile gauze. Then proceed to remove the testicle in one mass with the adherent scrotum, by extending the original incision downward, cutting wide of all infiltrated tissue. In this way the inguinal wound runs no risk of being infected, since it is closed before the suppurating scrotal tissues are attacked, and all the diseased tissue is removed in one mass. Usually it is well to leave a small drain in the scrotal end of the incision for a couple of days.

Syphilis of the Testicle.—Sarcocele.[1]—Sarcocele is a manifestation of the third stage of syphilis. The lesion almost always is in the

[1] This is an old term still in use, signifying a fleshy or solid tumor; by long usage it is applied exclusively to enlargements of the testicle.

testis, not in the epididymis; the most frequent form, clinically, is a gummatous deposit in one or several spots. Pathologically a diffuse sclerosis of the tunica albuginea and septa of the testis is a very frequent lesion, but it is seldom recognized clinically. In most cases of the gummatous form of the disease only one testis is involved; softening of the gumma with ulceration of the skin scarcely ever occurs. The affection is extremely indolent. The testicle grows slowly and never reaches a very large size; it presents smooth, rounded nodules almost of woody hardness and not at all tender. If the epididymis is involved the testis feels like a stone lying in a clam shell, the sharp edges of the hardened epididymis embracing the testis (Keyes). Frequently a hydrocele of the tunica vaginalis is present. The only subjective symptoms are those due to the increased weight of the organ. A history of syphilis usually can be obtained; the Wassermann test will be positive; and antisyphilitic treatment will prove rapidly curative. The **diagnosis** must be made from *tuberculosis* and from *tumors* of the testicle. In the former the epididymis is affected, and invasion and fistulization of the skin are frequent. In the latter, most of which are instances of malignant disease, the testicle grows rapidly, attains a much greater size than in syphilis, there is more pain and discomfort, and invasion of the skin is frequent, with the protrusion of a fungus growth.

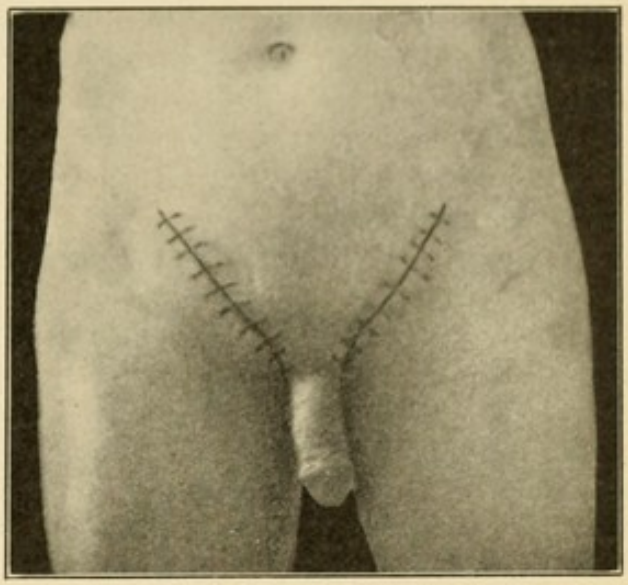

FIG. 981.—Scars from double orchidectomy for tuberculous sarcocele. Age forty-six years. Episcopal Hospital.

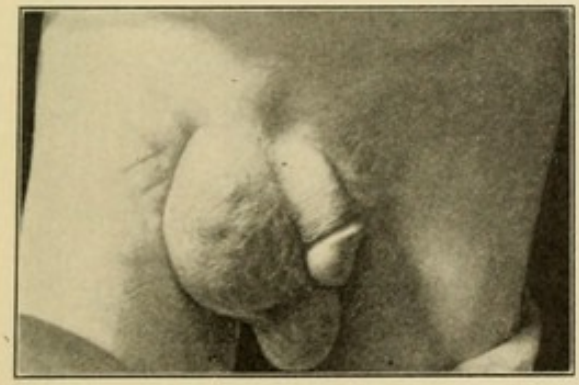

FIG. 982.—Sarcoma of right testicle. Age seventy-four years, duration five months. Diagnosis made after tapping hydrocele (four ounces of bloody fluid), which permitted palpation of hard nodular growths. Episcopal Hospital.

Treatment.—In every case of sarcocele, where the diagnosis is doubtful, it is well to try antisyphilitic treatment before any operation is recommended. If the disease is syphilitic, mixed treatment will be quickly effectual.

Neoplasms of the Testicle are not very rare, except benign tumors. Most of the tumors are extremely malignant, and are classed loosely

as sarcomas. Chevassu (1910), in a careful study of 100 cases, found carcinoma (seminoma) in 47, true sarcoma in 3, and mixed tumors in 50 cases. Such tumors may occur at any age, but are most frequent in middle life. Growth is rapid (weeks), and the tumor may become several times as large as the normal testicle. In most cases hydrocele of the tunica vaginalis develops, and its contained fluid usually is blood-stained (Fig. 982): if there is no history of injury the presence of blood in hydrocele fluid always suggests malignancy. Extension occurs early along the spermatic cord, and to the lumbo-aortic lymph nodes, and especially to a lymph node at the bifurcation of the common iliac vein.

Treatment.—By the ordinary method of castration, as described in connection with tuberculosis of the testicle, surgery succeeds in saving about 20 per cent. of patients.[1] *Radical operation* implies removal of the tumor in one mass with its anatomically related lymph nodes. Chevassu has devised a technique by which the lumbo-aortic nodes may be reached: the incision passes along the inguinal canal and up the abdominal wall *outside* the semilunar line as far as the false ribs, and if necessary is extended forward along the costal border. The parietal peritoneum is dissected inward, without opening the peritoneal cavity, and when the perirenal fascia is reached its anterior layer is incised, and the dissection continued in front of the kidney, until the renal vessels and aorta are exposed. In 1910 Chevassu collected records of 11 such operations, with no immediate mortality; in 8 the operation was carried to a successful conclusion, but in 3 others had to be abandoned (inoperable).

FIG. 983.—Congenital hydrocele (left). Age five months. Children's Hospital.

Hydrocele.—This is a collection of serous fluid in the tunica vaginalis.

In **congenital hydrocele** (Fig. 983) there is a communication between the tunica vaginalis and the peritoneal cavity. Usually the orifice of communication is too small for the development of a hernia. The condition is noted first in infancy, but may persist until adult life, even without the development of a hernia. When the scrotum is elevated the fluid disappears within the abdominal cavity, usually very slowly, and as slowly reappears when the erect posture is resumed. *Treatment* is the same as for inguinal hernia in infants.

[1] Out of 100 patients with malignant disease of the testicle treated by the ordinary method of castration, Chevassu found 81 died in less than four years, while 19 survived in good health for periods varying from four to ten years after operation.

Acquired Hydrocele of the tunica vaginalis is seen oftenest in childhood and in middle adult life (Figs. 984 and 985). The pathogenesis of the lesion is uncertain, but the fluid probably is in the nature of an exudate, due to trauma or some form of infection of low grade. As already mentioned, gonorrheal epididymitis and most other infections of the testicle are accompanied by the development of acute hydrocele, and such a lesion may lay the foundation for the subsequent pathological change in the serous membrane which leads to chronic serous effusion. It is possible that many adult hydroceles are unrecognized manifestations of tuberculosis (Fig. 979) or syphilis. In some cases rice bodies are found, and the sac may become calcareous. Most of the adults affected are arteriosclerotic.

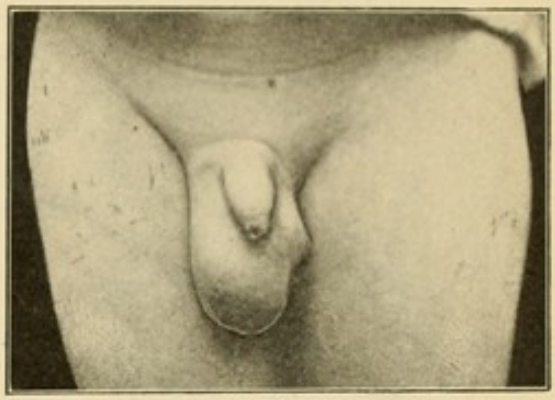

FIG. 984.—Hydrocele of the right tunica vaginalis, in a child of three years. Children's Hospital.

Symptoms.—The swelling commences at the bottom of the scrotum, and gradually increases in size. At first it is soft and fluctuating, but eventually may become very tense and hard. The patient has little or no discomfort except from the size and weight of the swelling. Usually relief is sought before a very great size is attained. Rarely the sac extends into the inguinal canal, and from the existence of constrictions (similar to those encountered in some cases of inguinal hernia—see p. 781) an hour-glass or bilocular hydrocele may result (Fig. 986). The same appearance may be caused by the coexistence of a vaginal hydrocele and a hydrocele of the cord.

FIG. 985.—Hydrocele of tunica vaginalis. Age fifty-two years; duration nine years; tapped eight times. One quart withdrawn after making photograph. Episcopal Hospital.

The *diagnosis* is made from the history of the case, and from observing that most hydroceles are translucent when examined by transmitted light; old hydroceles, with thickened walls, and those into which hemorrhage has occurred, however, are opaque. The diagnosis from hernia was considered at p. 783.

The best *treatment* is by operation; but in adults who refuse operation or in whom operation is contraindicated for any reason, it is sufficient to withdraw the fluid from time to time by tapping the hydrocele.

The testicle almost always is at the back part of the swelling, but its position should be ascertained by palpation and by examination with transmitted light. The tumor is then grasped in the left hand, and the skin is drawn tightly over it, when with a quick thrust a trocar and cannula are pushed into the most prominent part of the swelling, avoiding large veins. The trocar is then withdrawn and the contents of the hydrocele allowed to flow. When all the fluid has been evacuated the cannula is withdrawn and the puncture is sealed with cotton and collodion. No anesthetic is required and the patient need not be confined to bed. He should wear a close-fitting suspensory in an endeavor to prevent too rapid re-accumulation of the fluid. It is well to examine the testicle carefully after the hydrocele fluid has been evacuated, as in many cases it is found diseased. Some surgeons recommend the injection into the emptied sac of some irritating or caustic fluid in the hope of causing obliteration of the cavity; but the alleged advantages of this practice do not compensate for the dangers of uncontrollable inflammation and excessive pain. In most cases in which simple tapping is done, re-accumulation of the fluid occurs at progressively shorter intervals.

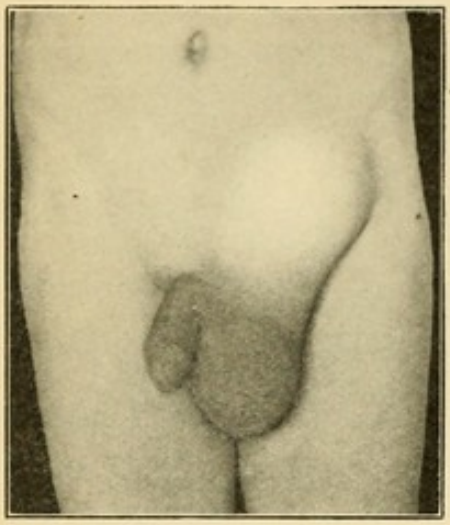

FIG. 986.—Bilocular hydrocele. Age twenty-three years; duration since infancy. (Dr. C. F. Mitchell's case.) Pennsylvania Hospital.

Operation.—In most cases, especially in children and young adults, it is best to resort to operation. The incision should be made just below the external abdominal ring, not in the scrotum, as this is difficult to sterilize. The operation most often done, known by the name of Jaboulay (1895), consists in evacuating the contents of the sac by incision, and *everting the walls of the tunica vaginalis* around the testicle so that the serous surface of the tunica vaginalis lies against the subcutaneous tissues. If the incision in the tunica vaginalis is made just large enough to push the testicle through, no sutures are required to hold the everted tunica vaginalis in place; this is known as the "bottle operation." I have had one recurrence after this operation in a child, and know of others; and, therefore, prefer *excision of the sac* (von Bergmann). In cases with much thickening of the tunica vaginalis it is well to scrape the testicular portion of the tunica vaginalis with Volkmann's sharp spoon, as it cannot be removed with the knife without damage to the testicle.

Hydrocele of the Cord is a collection of serous fluid in an unobliterated portion of the funicular process of peritoneum. If the sac communicates with the peritoneal cavity, the condition is known as *funicular hydrocele;* if the sac is closed at both ends, it is an *encysted*

hydrocele of the cord (Fig. 987). *Hydrocele of the canal of Nuck* is the corresponding condition in the female sex. If inflammation of the sac occurs from any cause, and no accurate history can be obtained, the condition may be readily mistaken for strangulated hernia. *Treatment* of hydrocele of the cord consists in excision of the sac.

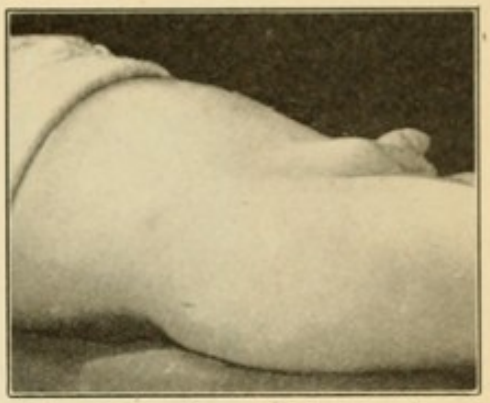

FIG. 987.—Encysted hydrocele of the cord. Age two and a half years. Children's Hospital.

Spermatocele. — Spermatocele, known also as *encysted hydrocele of the tunica vaginalis*, is a cyst which develops about the globus major of the epididymis and contains spermatic fluid. Its pathogenesis is disputed. It occurs oftenest in young adults, and forms a slowly growing but tense cystic tumor at the upper and back part of the testicle. It may project into the tunica vaginalis or grow behind it. The diagnosis often is not made until operation is done. Proper treatment is excision of the sac.

Hematocele.—A collection of blood in the tunica vaginalis may result from injury or disease; there may or may not have been a pre-existing hydrocele. In many cases seemingly of spontaneous origin, hematocele is symptomatic of malignant disease of the testicle. The physical signs are the same as those of vaginal hydrocele, except that the swelling is opaque to transmitted light.

Treatment.—In acute traumatic cases the blood should be withdrawn by tapping. In other cases the treatment is that of the underlying cause (hydrocele, sarcocele).

Varicocele.—A varicose condition of the veins of the spermatic cord (the pampiniform plexus) occurs in about 10 per cent. of males, usually commencing about the age of puberty. In almost all cases the left side is affected, occasionally both sides, very seldom the right alone. This predilection for the left side is attributed (1) to the pressure of the sigmoid on the spermatic vein; (2) to the fact that the left spermatic vein enters the left renal at a right angle, while the right spermatic enters the vena cava obliquely; (3) to the absence of valves on the left side; (4) to the lower position of the left testicle in the scrotum; and (5) to the habit most men have of "dressing left." Seldom or never can any exciting cause be found. The rather rapid onset of a varicocele usually is symptomatic of some abdominal neoplasm obstructing the venous circulation.

Symptoms.—Symptoms may be entirely absent even in cases where the varicocele is very large. Often, however, the patient complains of vague dragging pains and discomfort in the left side of the scrotum, and there may be occasional lancinating pains in the testicle and along the cord. Atrophy of the testicle is mentioned as a possible sequel, but I never observed it. In rare cases the patient may be "neuras-

thenic." Examination shows a relaxed state of the scrotum, with the left testicle hanging very low, and above it, extending up to the inguinal canal, a soft mass of dilated veins which feel like a bunch of earthworms (Fig. 988). These veins may be emptied by having the patient lie down and elevating the scrotum; they will become distended again when he stands up, even if pressure is made over the inguinal canal.

FIG. 988.—Varicocele, age thirty-six years. Episcopal Hospital.

Treatment.—Treatment seldom is required. There is nothing serious in the condition and it often disappears spontaneously later in life. If the patient is uncomfortable he will feel better for wearing a suspensory bandage, particularly in warm weather. Cold douches sometimes are soothing. If marked discomfort persists, the varicocele is easily cured by a simple operation. An incision is made just below the external abdominal ring, and the cord is brought out of the wound. The dilated veins are separated from the vas deferens and its accompanying vessels, and the varicose veins are ligated close to the external ring, and again about two inches lower. The ends of these ligatures are left long, and after the section of veins lying between the ligatures has been removed, the ligature on the proximal end is tied to that on the scrotal end of the cord, thus shortening the cord and elevating the testicle. The wound is closed without drainage (careful hemostasis), and the patient stays in bed a week or ten days.

Elephantiasis.—Elephantiasis occurs oftenest in the scrotum, as pointed out in Chapter XI, and the disease may spread thence to the penis. As the result of lymphatic obstruction and repeated attacks of dermatitis, the skin and subcutaneous tissues become enormously hypertrophied, deep creases and folds form, and in them dirt and macerated epithelial cells collect, emitting nauseating odors, and predisposing to ulceration and renewed attacks of dermatitis, eczema, erysipelas, etc. In tropical countries the scrotum may become so immense that the patient has to push it around before him on a wheelbarrow. In this latitude the disease is very seldom seen. The best

treatment is excision. The operation may prove difficult, and bleeding usually is free; but if asepsis can be maintained, great relief is afforded.

Tumors of the Scrotum are unusual. The occurrence of **dermoids** (sequestration cysts) was mentioned in Chapter IV (Fig. 78). **Papillomas** are more frequent, and often undergo malignant degeneration (Fig. 989). In former years **epithelioma** of the scrotum was frequently seen in chimney sweepers, from the irritation of the soot which accumulated on the scrotum in these persons of none too cleanly habits. At the present day workers in tar and paraffin are subject to the same affection. The proper **treatment** of these tumors is excision; this scarcely ever requires castration, as the malignant growth spreads widely in the skin before attacking the testicles.

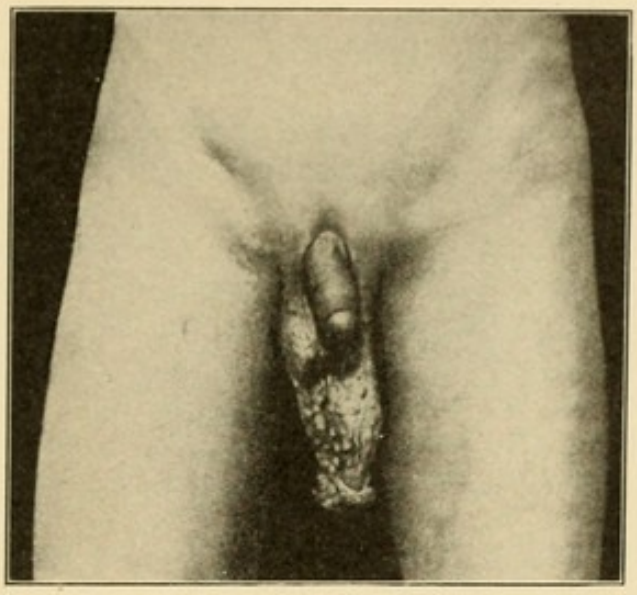

FIG. 989.—Ulcerating papilloma of scrotum (epitheliomatous). Age thirty-six years; duration three and a half years. Episcopal Hospital.

CHAPTER XXIX.

SURGERY OF THE FEMALE GENITALS.

General Remarks on Examination of the Female Pelvic Organs. —**Position of the Patient.** — The woman usually is examined in the "lithotomy position," that is, lying on her back, with knees and hips flexed, and the soles of the feet resting on the bed or table where she lies (Fig. 990). Sometimes the "Sims position" is preferred: here the woman lies on her left side, with her left arm behind her back, thus throwing her right shoulder forward; her right thigh is flexed upon her abdomen as fully as possible, so that the right knee rests upon the table, while the left lower extremity is flexed only to a moderate

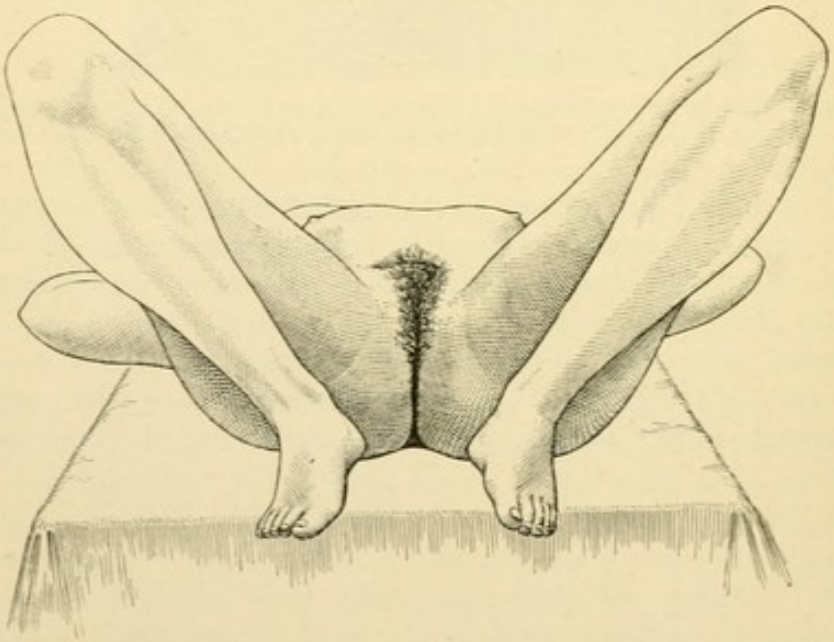

FIG. 990.—Lithotomy position. (Findley.)

degree (Fig. 991). Sometimes, but not very often, it is desirable to examine the patient in the standing position, or even in the knee-chest position (Fig. 992). In a virgin, vaginal examination should be made only when the patient is under the influence of a general anesthetic. A rectal examination may suffice.

An examination of the female pelvic organs should include (1) *inspection of the external genitalia*, (2) *examination with the speculum*, and (3) *bimanual examination of the internal genital organs*. The bladder and rectum should be empty.

External Genitalia.—Note the condition of the labia: inflammatory changes, as in acute gonococcic vulvitis and vaginitis; the existence of a labial abscess; the presence or absence of mucous patches; edema from pregnancy or pelvic tumors; excoriations and hypertrophy in cases of pruritus. Observe the state of the hymen; the position of the

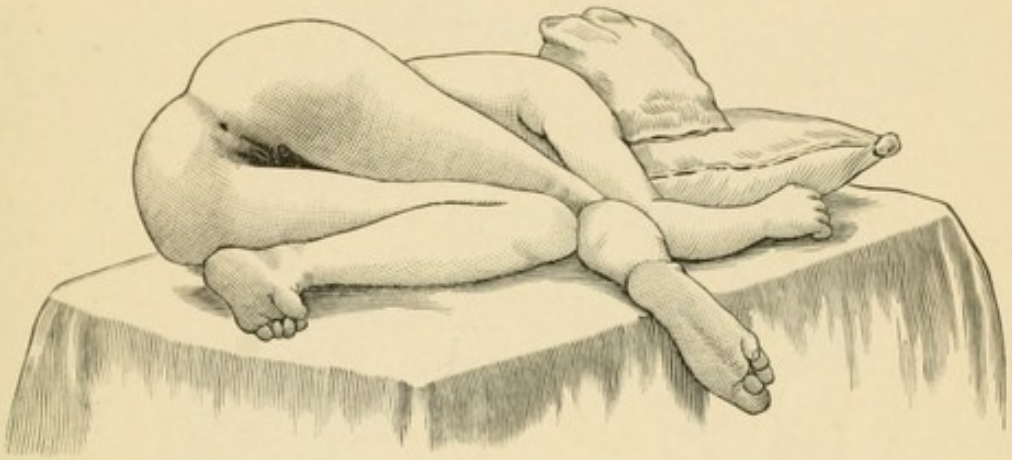

FIG. 991.—Front view of Sims' position. (Findley.)

carunculæ myrtiformes, if present; and the condition of the vulvar opening, whether normally closed or widely gaping as in multiparous patients with relaxed vaginal outlet. The position and condition of the urethral orifice should be noted, especially the presence of a gonorrheal discharge, or the existence of a caruncle.

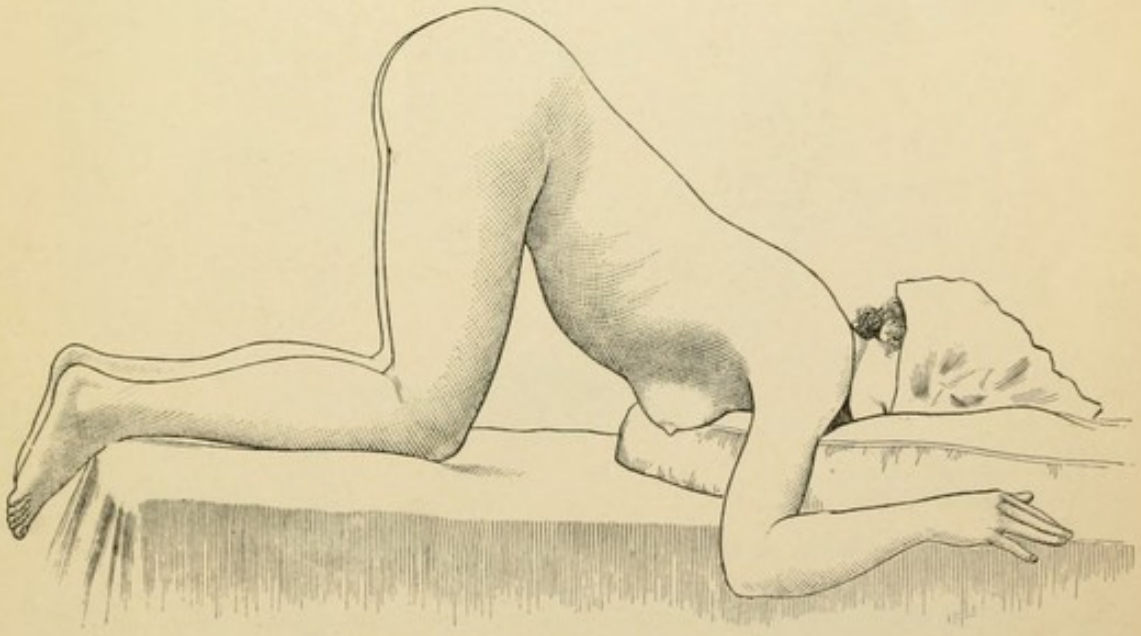

FIG. 992.—Knee-chest position. (Findley.)

Speculum Examination.—If the patient is in the Sims position, the *duck-bill vaginal speculum of Sims* (1845) should be used (Fig. 993, 2). This is inserted with the blade in the sagittal plane, and as soon as

the vagina is entered the blade is turned transversely, and is pushed forward until the stem catches on the fourchette; then the speculum is drawn backward, displacing the posterior vaginal wall and rectum into

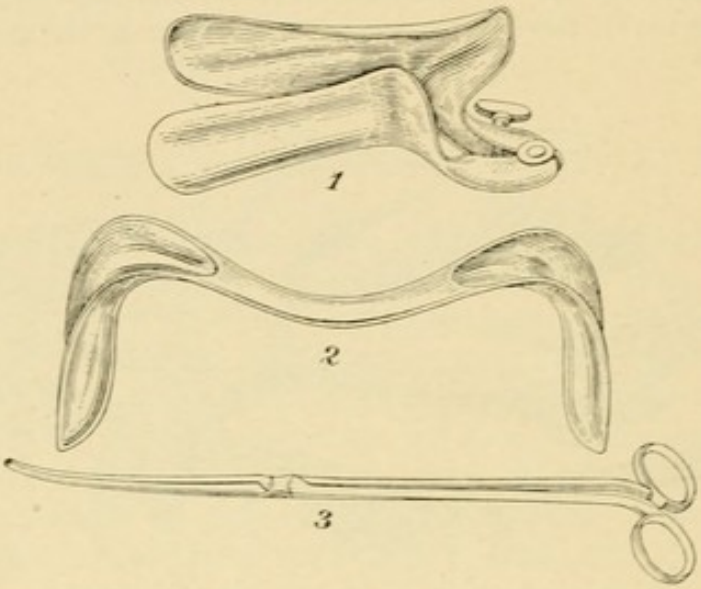

FIG. 993.—1, Bivalve vaginal speculum. 2, Sims' duck-bill speculum. 3, Speculum forceps.

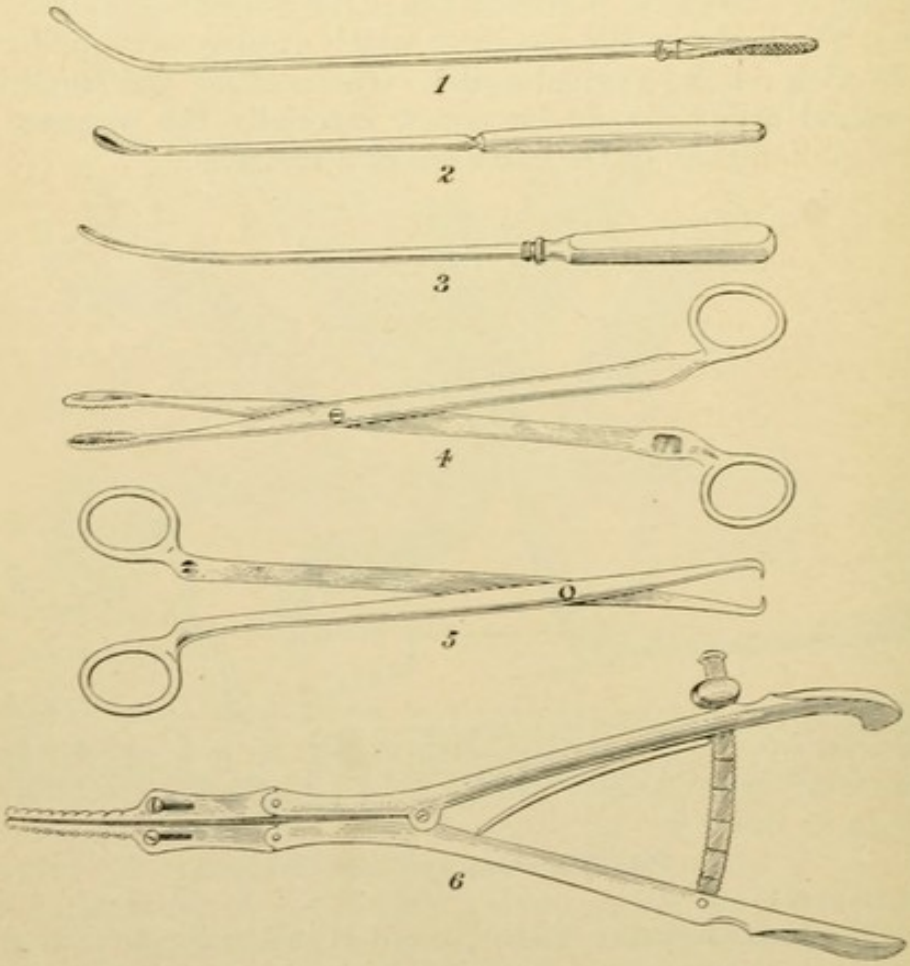

FIG. 994.—1, uterine sound. 2, sharp uterine curette. 3, dull uterine curette. 4, placental forceps. 5, double tenaculum forceps. 6, cervical dilator.

the hollow of the sacrum, and causing the vagina to be ballooned with air. This usually renders the cervix visible. In the dorsal and lithotomy positions it is more convenient to use a *bivalve speculum* (Fig. 993, 1): this is inserted closed, with the blades in the sagittal plane; as soon as the vagina is entered the speculum is turned transversely, but the blades are not opened until the speculum has entered its full

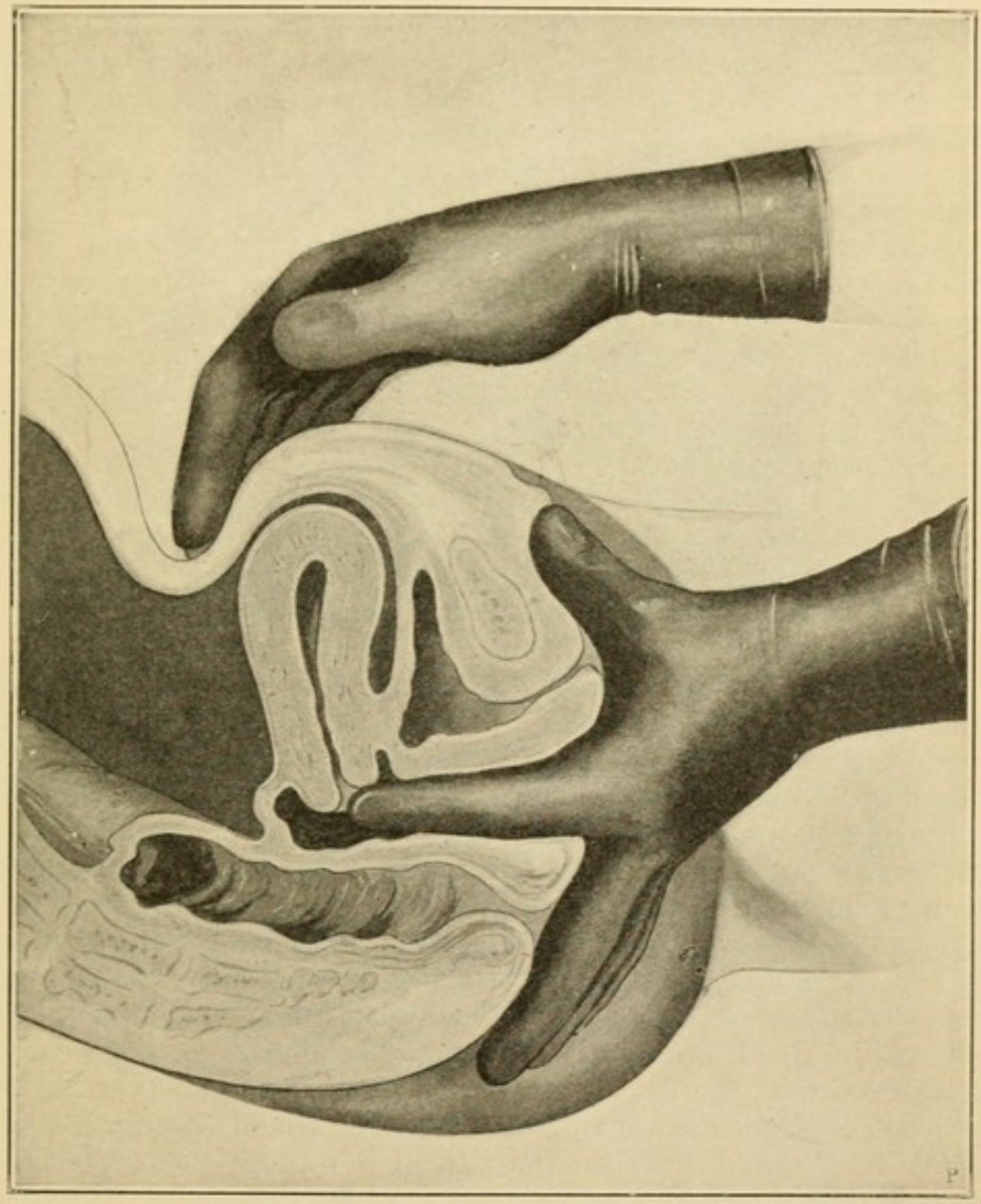

FIG. 995.—Bimanual vaginal examination. (Dudley.)

length. When the blades are finally separated, the surgeon endeavors to bring the cervix into view between them. If the speculum is too small or too short this may prove difficult. Several sizes should be available. When the cervix is exposed, examine its size, its shape, and its position; note the presence or absence of lacerations, erosions, ulcerations; observe the condition of the os, whether characteristic

of a nulliparous or parous patient; and especially note the presence or absence of a cervical discharge and its character—mucous, purulent, bloody, etc. In suspicious cases smears should be taken from vagina, from urethra, and from cervix for microscopical examination.

Bimanual Examination.—After withdrawing the speculum, insert two fingers of the gloved hand into the vagina. The beginner will do best to use both right and left hands, alternately, on the same patient; with the left hand he will be able to feel lesions on the left side of the pelvis which might easily escape detection if the right hand only was used. First examine the condition of the posterior vaginal wall and perineum. Then locate the cervix, and note its condition (soft and characteristic of pregnancy; hard, with scar tissue from previous pregnancies, lacerations, etc.), its size, its position (whether or not displaced by pelvic lesions), and its mobility, or fixation. With the aid of the other hand above the pubes (Fig. 995), then endeavor to palpate the fundus of the uterus, and note its position, whether or not it is displaced, whether movable or fixed, and finally the size and consistency of the uterus. Note the presence or absence of a mass in the pouch of Douglas; its consistency, fixation, and tenderness. Palpate in turn each tube and ovary by passing the vaginal fingers first to one side and then to the other side of the cervix, and endeavor to locate and outline, between these and the fingers of the abdominal hand, the uterine adnexa. No matter what the age, social condition, or history of your patient, *always exclude pregnancy before reaching a final diagnosis.*

Preparation for Operation and After-care.—Enough has been said on this subject in Chapter XXII in reference to abdominal operations. But a few words are necessary in regard to vaginal operations. It is desirable to have all such patients in bed, and to have the parts thoroughly cleansed by douching twice daily for several days before operation. No operation should be done while the parts are acutely inflamed, nor during a menstrual period unless immediate operation is imperative. The bowels should be thoroughly opened by a purge given early in the day before that set for operation, and a cleansing enema should be given at least six hours before the time of operation (the previous evening if necessary). If a purge is not given until the night before operation, the bowels may be so loose as to move during the operation and soil the wound. The bladder should be emptied just before the operation. When the patient is in position on the table the vagina is thoroughly washed with soap and hot water, wiped out with alcohol, and douched with bichloride solution.

After operation the patient should remain in bed for at least two weeks, often longer. The bowels should not be locked up by opiates, and if they do not move by the fourth day castor oil should be given; whenever possible an enema should be avoided. The urine should not be drawn by catheter unless retention occurs; after the patient has urinated the vulva should be gently douched with some hot antiseptic solution and gently dried and powdered.

Congenital Malformations.—The vulva may be **congenitally imperforate**, but the condition is more often due to adhesion of the labia minora as the result of vulvitis in childhood (Fig. 996). In most cases, whether congenital or acquired, the occluding membrane is very thin, and is readily ruptured by pulling the labia apart or by rupturing adhesions with a grooved director; occasionally the use of scalpel or scissors is necessary. Reunion should be prevented by dressing the raw surfaces with boric acid ointment and the daily introduction of a fold of lint.

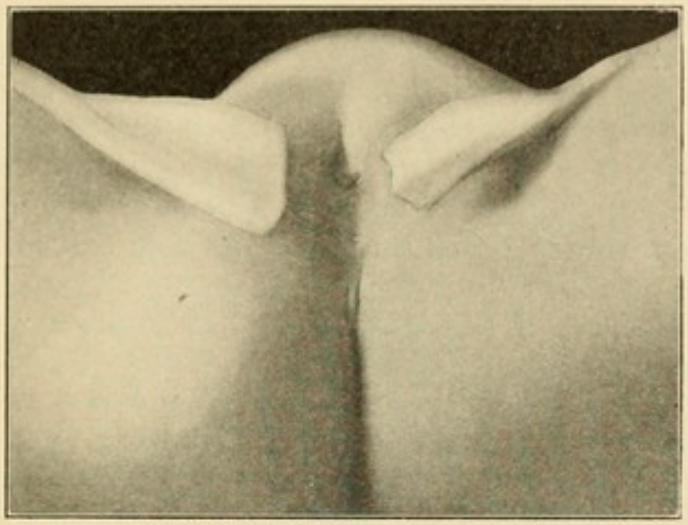

FIG. 996.—Adhesion of labia from vulvitis in infancy. Age three years. Children's Hospital.

Imperforate Hymen.—Imperforate hymen seldom is recognized until after the age of puberty, when the non-appearance of the menstrual flow, and its ultimate damming up in the vagina (*hematocolpos*) and in the uterus (*hematometra*) cause a local examination to be made. If these conditions continue unrelieved for several years a large pelvic tumor may develop, and some danger exists of peritonitis from rupture of the uterus or tubes or from leakage of the uterine contents through the fimbriated extremity of the tubes. *Treatment* consists in incision and drainage, and if necessary in some form of plastic operation to prevent cicatricial contraction.

Absence of the Vagina.—Absence of the vagina usually is a congenital defect, but occasionally the vagina becomes obliterated by cicatricial contraction. If the presence of a uterus and adnexa can be demonstrated (exploratory laparotomy may be necessary), attempts may be made to construct a new vagina. Various external plastic operations have been employed, but usually without permanent success. The plan introduced by Baldwin (1907) though the mortality is higher, has given much better results: a loop of the small intestine is excluded from the intestinal tract, and still attached to its mesentery (which must be sufficiently long) is sutured in place between bladder and rectum, opening below at the vulvar orifice, and being closed above

around the cervix uteri. The continuity of the intestinal tract is then restored by end-to-end or lateral anastomosis.

Stenosis of the Cervix.—Stenosis of the cervix, usually from congenital hypoplasia and accompanied by **anteflexion of the uterus**, is a frequent cause of dysmenorrhea in girls and young women. The dysmenorrhea is of the obstructive type, that is, it is greatest preceding the flow which often is delayed and usually is scanty. The patient usually is sterile, and proper treatment often is followed by conception. The kink in the uterus favors retention of secretions, and causes venous congestion, with resulting endometritis. Examination shows an undersized but lengthened (conical) cervix with pin-point os, firm and unyielding to the touch, and the fundus uteri close beneath the symphysis.

Treatment.—Forcible dilatation, the patient being anesthetized, is seldom productive of permanent cure, even if the operation is many times repeated. It is better to incise the cervix posteriorly in the mid-line almost up to the internal os and recto-uterine fold of peritoneum; a small wedge of tissue is cut out on each side (Fig. 997), and

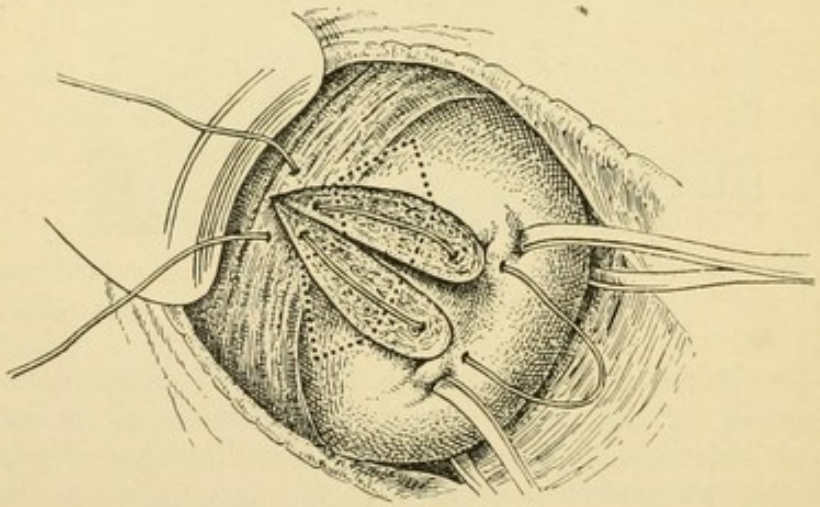

FIG. 997.—Dudley's operation for anteflexion. Patient in the Sims position. (Findley.)

the cut surface on each side is then folded on itself so as to pull the anterior lip of the cervix backward (*Dudley's operation*, 1891). If the anterior lip is very long it may be excised. Or *Pozzi's operation* may be done: this consists in dividing the cervix bilaterally, hollowing out and infolding upon itself each of the four denuded surfaces.

Malformations of the Uterus.—Malformations of the uterus are not very rare. Ectopic pregnancy may occur in one of the rudimentary horns of a uterus bicornis. In cases of double uterus (uterus didelphys) it is best,usually, to remove one uterus by hysterectomy, to prevent complications during a possible pregnancy.

Gonorrhea in the Female.—As noted at p. 1071, the occurrence of gonococcic infection of the genito-urinary tract in the female often is not attended by very acute symptoms. The gonococci are deposited at the vulvar orifice or in the vagina by mediate or immediate contagion, and within a few days may produce *acute urethritis, vulvitis,*

and *vaginitis*. Frequently, however, no acute symptoms develop, but the gonococci lodge and proliferate in the vulvo-vaginal glands (*Bartholinitis*) and in the cervical glands (*endo-cervicitis*) and are exceedingly difficult to dislodge. When the disease reaches a chronic stage, it persists indefinitely, causing no particular disability at times, but at others producing local and distant disturbances which render life a burden. Moreover, the patient is a constant carrier of infection, and this may be conveyed to innocent persons, especially children, by mediate contagion. Recrudescences of the infection occur from time to time, and with each new attack the germs travel higher in the genital tract, spreading from the cervix to the uterus (*endometritis*), where the infection does not linger, to the tubes, ovaries, and peritoneum; here occur *acute and chronic salpingitis, pelvic peritonitis, pyosalpinx, tubo-ovarian abscess*, etc. These complications frequently develop first in the puerperium, especially after miscarriages or abortions.

Urethritis.—The urethra almost always is affected when gonorrhea attacks the female, but the course of the disease is much less acute in its symptomatology, and residual foci of infection are much less frequent than in the male. Occasionally a focus of infection remains in the *suburethral glands of Skene*, but abscess formation is extremely rare. These abscesses (one in each gland) protrude just below the external urinary meatus, and pressure on them will make pus exude from their orifices in the floor of the urethra, about 0.5 cm. within the meatus. They should not be confused with *urethral caruncles*, which are inflammatory hypertrophies or angeiomatous out-growths of the urethral mucous membrane, protruding from the urinary meatus, not beneath it through the anterior vaginal wall. Some caruncles bleed or are excessively painful; such should be excised, with a wide area of the mucosa from which they spring, as recurrence is frequent.

Treatment.—The treatment of gonococcic urethritis in the female is subordinate to that of the vulvitis and vaginitis with which it is accompanied.

Vulvitis and Vaginitis.—These are exceedingly common in infants and little girls, usually resulting from mediate contagion through soiled towels, etc. In them the symptoms may be very acute, as is also the case in the young nullipara, but in the case of women who have borne many children the vaginal mucous membrane is much less easily infected and gonococcic vaginitis is rarely seen. The patient complains of burning pain, worse during urination and defecation; the labia minora are red, edematous, and tender; there is a profuse purulent exudate, in which gonococci are readily found; the vaginal walls may be fiery red, and in rare instances exfoliation of epithelium and ulceration may occur. The vulvo-vaginal glands of Bartholin are exceedingly prone to harbor the infection for a long time, and abscess formation is very common (Fig. 998); indeed it may be the first symptom to bring the patient to a physician. The **vulvo-vaginal abscess** points at the posterior part of the vulvar opening, between the labium majus and minus, and is to be treated by early and free incision, with excision

of the anterior wall of the abscess sac, or if possible by extirpation of the entire gland, as recurrence is very common unless radical treatment is adopted at the first. Occasionally as the result of very attenuated infection, or from cicatricial closure of the duct, a **cyst of Bartholin's gland** develops (Fig. 999); this is to be treated by excision.

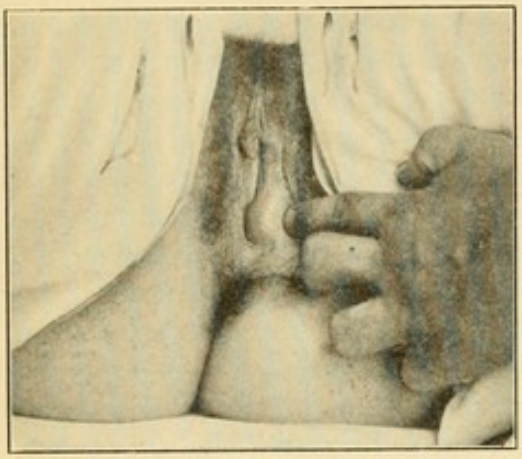

FIG. 998.—Abscess of the vulvo-vaginal gland of Bartholin. Duration three days. Acute gonorrhea in a patient aged twenty-two years. Pennsylvania Hospital.

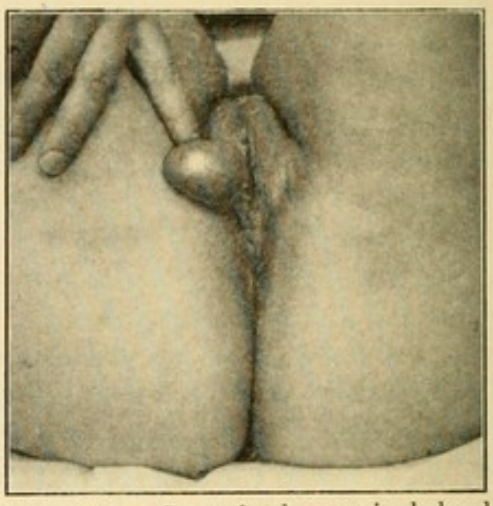

FIG. 999.—Cyst of vulvo-vaginal gland of Bartholin. Age thirty-six years; duration fourteen years. Attached by two pedicles to right labium minus. Episcopal Hospital.

Treatment.—The treatment of acute gonococcic vulvitis and vaginitis is best conducted with the patient in bed, until the most acute symptoms subside. Great care must be taken to prevent infection of the eyes, as well as conveyance of contagion to other patients by instruments, dressings, etc. There is very little use in local treatment, since injections, irrigations, etc., are very apt to spread the infection further up the genital tract. The patient should be confined to liquid diet at first, especially drinking plenty of water; urinary antiseptics should be administered; and the accumulation and crusting of the purulent discharge should be prevented by douching the vulva frequently with hot permanganate of potash solution, or some other antiseptic. The heat of the solution is beneficial in itself. It may be well to leave a rubber tube in the vagina, to promote drainage. As the discharge lessens and tenderness becomes less, the rubber tube may be substituted by a glycerin tampon, changed daily. When the chronic stage is reached the infection probably will be found to be localized in the cervix or the Fallopian tubes; the local treatment of these affections is discussed below.

Chronic Gonococcic Vaginitis, especially in children, is most successfully combated by the use of vaccines; without their use a leucorrheal discharge may persist indefinitely, and though no gonococci may be found by microscopical examination on many occasions, any local irritation may bring them from their hiding places. In both children and adults a so-called "cure" of the disease usually means only latency of symptoms. Some authorities teach that a woman once infected with gonococci is always infected.

In the use of vaccines for chronic gonococcic vaginitis in children, I have followed the directions of B. W. Hamilton (1910): give 50,000,000 killed gonococci by hypodermic injection every fifth day, increasing the dose by 10,000,000 until five injections have been given, the last dose being 90,000,000 gonococci. After a ten-day interval repeat the same treatment if necessary. In recent cases Hamilton found that six injections usually cured.

Endocervicitis.—This usually is gonorrheal in origin, mixed infection occurring subsequently and aggravating the condition. The chief symptom is a leucorrheal discharge, thick and purulent. Menstruation occurs irregularly, and usually the flow is greater than normal. Examination through the speculum usually reveals a plug of tenacious muco-pus protruding from the os. Microscopically, the glands which line the cervical canal are seen to be swollen and cystic, and much increase in the stroma may occur, leading to hypertrophy or elongation of the cervix. The cervix may have erosions or actual ulcerations on its vaginal surface.

Treatment.—Treatment by palliative means (douches, tampons, local applications or argyrol, iodin, etc.) rarely is efficient. Even thorough scraping of the cervical canal, the patient being anesthetized, generally fails to effect a cure. The best treatment is formal excision of the diseased tissue, with plastic restoration of the cervical canal: the cervix is split bilaterally, and a wedge of tissue (including the cervical mucosa) is removed from each lip; then the cervical flaps are folded upon themselves and their free borders sutured to the mucosa at the internal os (*Schroeder's operation*, Figs. 1000 and 1001).

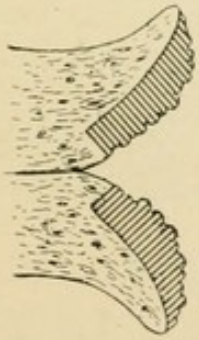

FIG. 1000.—Schroeder's operation: the shaded areas are excised.

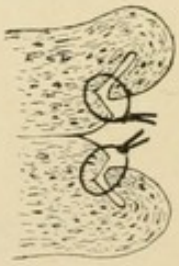

FIG. 1001.—Schroeder's operation: the flaps are sutured.

Endometritis.—Endometritis is a much rarer affection than commonly believed. Most patients said to have endometritis have an entirely different lesion as the main cause of their symptoms. The symptoms of which they complain are painful, prolonged and irregular menstruation, leucorrheal discharge between their periods, a certain amount of backache, etc. Examination shows the existence of endocervicitis, or salpingitis, or both; and it is some such lesion, and not a possibly accompanying but relatively insignificant endometritis, which is responsible for the symptoms. Endometritis which exists as the most important lesion usually results from infection following

abortion, miscarriage, or labor. Occasionally the disease occurs in the nullipara or in the aged; in these instances it usually is caused by stenosis of the os, or displacements of the uterus which cause congestion or interfere with proper drainage. If the disease continues long untreated, the entire uterine body may become affected (*metritis*). The *diagnosis* of endometritis, except in the rare virginal and senile forms, depends upon the recognition of the symptoms mentioned above occurring after a miscarriage or a prolonged convalescence from labor.

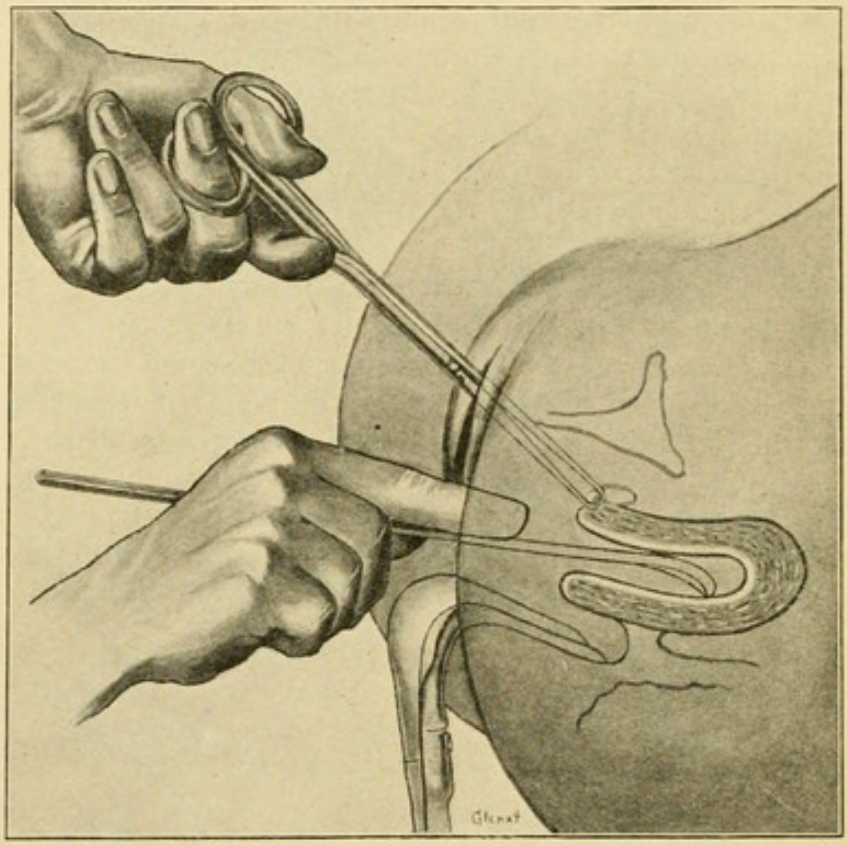

FIG. 1002.—Curettage of the uterus. (Findley.)

Treatment.—Much can be done to prevent the development of endometritis by avoiding infection in the puerperium, but when the disease is fully established, treatment is not very satisfactory. The first essential is to secure free drainage, by dilatation of the os, maintained by introduction of a glass drainage tube (Wylie's drain); the hypertrophied and diseased endometrium should be removed at the same time by curette (Fig. 1002), but this step is quite useless unless free drainage is provided after the operation. The tube should be retained for several weeks, and may be replaced later if necessary. If other lesions (endocervicitis, salpingitis) exist they should receive appropriate treatment.

Acute Metritis.—Acute metritis is seldom seen except in cases of puerperal sepsis (p. 1092).

Chronic Metritis.—Chronic metritis, as noted above, usually is a sequel of neglected cases of endometritis. At first the uterus is large, soft and boggy, but later becomes sclerosed, though usually retaining some enlargement. Hyaline degeneration is not infrequent, and malignant changes may occur. The *symptoms* resemble those of chronic endometritis, but usually are more severe and often are accompanied by pseudo-hysterical phenomena. Menorrhagia is excessive, and the patients become chronic invalids. The *diagnosis* from small interstitial or submucous fibroids may be difficult. The only efficient *treatment* is hysterectomy. The condition is no more curable by medicine or palliative local treatment than sclerosis of any other organ.

Salpingitis.—Inflammation of the Fallopian tubes usually is due to the local action of gonococci, the infection travelling upward by gradual steps from its resting places in the vulva and cervix. **Tuberculosis** of the Fallopian tubes has been mentioned in Chapter XXII.

Acute Salpingitis.—Acute salpingitis is most frequent in nulliparæ; it may occur during an acute attack of gonorrhea (vulvo-vaginitis and urethritis) or may arise later as the result of some factor which lessens the resistance of the pelvic organs. There is always a certain amount of peri-salpingitis (*pelvic peritonitis*) accompanying acute inflammation of the tubes, and pathologically the condition is not unlike an attack of appendicitis, except that the infecting organism is the gonococcus and not the more deadly streptococcus or colon bacillus. The *symptoms* are those of peritonitis localized to the pelvic region, usually more marked on one side than on the other, and not attended by notable gastro-intestinal symptoms. The tenderness is close to Poupart's ligament, too low and too near the median line for typical appendicitis; and the history of the case and vaginal examination almost always indicate the true condition.

Treatment.—Keep the patient in bed, and treat her as for diffuse peritonitis (p. 811); there is no fear of gangrene or perforation of the tube, as there is when the appendix is acutely inflamed; and the acute attack subsides almost invariably within a few days. The exceptions are a few cases of salpingitis of puerperal origin; but most of these, even, subside under proper conservative treatment. The mortality following early operation is high; but if recurrent attacks of pelvic peritonitis occur in spite of conservative treatment it may become necessary to operate before the chronic stage has been reached. The operation consists in removal of the affected tube (*salpingectomy*, p. 1080) and of the ovary also if this is involved. But whenever possible no operation should be done for several months after the subsidence of an acute attack; after such an interval the virulence of the microbes is very much attenuated, and often the pus in the tube is found to be sterile.

Chronic Salpingitis.—Chronic salpingitis is a term used to describe a condition which is not so much a chronic inflammation of the tubes, as it is the result of a previous acute inflammation. The tubes and ovaries are bound down in adhesions, often involving omentum,

sigmoid, cecum and appendix, and less often the pelvic coils of small intestine. There is difficulty, and often pain, in securing evacuation of the bowels; an aching sensation, or dragging pain, is nearly constant in the lateral pelvic regions, especially when the patient is on her feet; referred pains (small of back, thighs, groins) are frequently present; there usually is leucorrhea, with painful, profuse, and irregular menstruation, and the woman becomes a chronic invalid. Examination shows the uterus and adnexa more or less fixed by adhesions; considerable tenderness is present; and the pelvic organs cannot be clearly outlined.

Treatment consists in removal of the focus or rather foci of infection (*salpingo-oöphorectomy*), releasing the adhesions, and covering denuded peritoneal surfaces by infolding or by omental grafts. The appendix usually should be removed also.

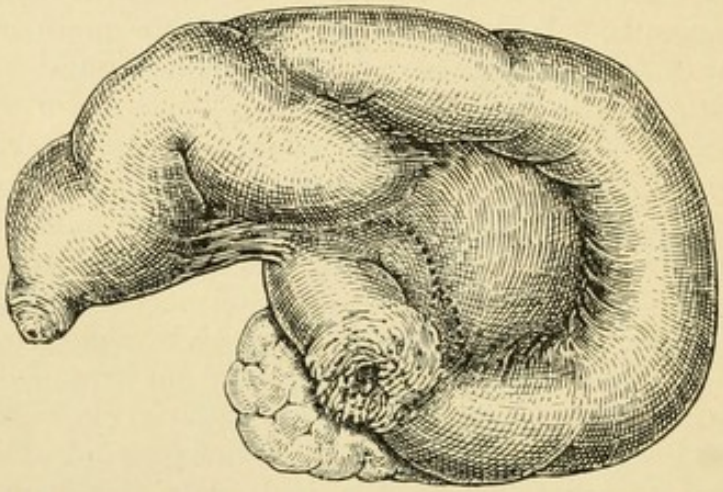

Fig. 1003.—Right pyosalpinx, seen from posterior aspect. The tube is distended, pouched, and surrounds the ovary. Episcopal Hospital.

Pyosalpinx, or **Pus-tube,** results from accumulation of the products of inflammation within the lumen of the Fallopian tube, owing to inflammatory occlusion of the fimbriated and uterine extremities (Fig. 1003). The exciting cause almost always is the gonococcus, and the condition usually is a remote sequel of acute salpingitis. It has been noted already that gonococcic infection of the tubes becomes attenuated soon, and that after several months the contents usually are sterile. A patient with pus-tubes (both sides usually are diseased) as a rule gives a history of having passed through several attacks of pelvic peritonitis; and in many cases a distinct history of the primary infection can be secured. A pus-tube often follows the first childbirth in cases where the patient has been inoculated with not very virulent gonococci; thereafter the woman usually is sterile. If the pus-tube in such a woman first begins to cause symptoms a number of years after the last childbirth, it may be mistaken for a case of ectopic gestation (p. 1090). Frequently pus-tubes exist for years without causing notable symptoms; but in most cases there is an annoying leucorrhea, and the patient may be completely disabled by painful

adhesions to the intestinal tract, by recurrent attacks of pelvic peritonitis from leakage of the contents of the sac, etc. On examination it is usual to find the cervix displaced, and a mass in the recto-uterine pouch, sometimes clearly demonstrable as springing from one side or other of the uterus; a similar but smaller mass, not large enough to occupy the pouch of Douglas, may be present on the other side of the uterus. Pus-tubes usually are fixed by adhesions, but they may be very movable, and their existence should not be ruled out on the ground of mobility alone. A low, immobile mass, especially if it results from puerperal infection, almost always is a pelvic abscess; pus-tubes form a high, not a low mass.

Treatment. — If symptoms are present the diseased structures should be removed. If the woman is young and the ovary healthy, it should be left, only the tube being removed, but in many cases the ovary is degenerated ("cystic degeneration" from chronic oöphoritis, p. 1078) and will prove useless or even harmful if preserved. The entire tube should be removed, excising its interstitial part from the uterine cornu; in some cases, in addition to the removal of both tubes and ovaries it is necessary to remove the uterus also, either to facilitate the operation, or because this organ itself is diseased (*chronic metritis*). The operation of salpingo-oöphorectomy is described at p. 1079. If the woman complains of no particular symptoms, it often is best to do no operation. I have known a woman with an undeniable pus-tube pass through a normal pregnancy and puerperium and give birth to a healthy child.

Rupture of a pus-tube is rare while its contents are still highly infectious; when it occurs, it is followed by diffuse peritonitis, which is best treated not by immediate operation, but by strict adherence to the rules laid down in Chapter XXII for the non-operative treatment of diffuse peritonitis. Immediate operation has a very high mortality, but if the patient is treated expectantly the infection almost always becomes localized again, frequently in the form of a *pelvic abscess*.

Tubo-ovarian Abscesses.—This is an abscess which involves both tube and ovary (Fig. 1004). Usually the primary condition is that of pyosalpinx, and the ovary becomes invaded by direct extension. It is rare for an ovarian abscess to exist alone, or for it to spread to the tube secondarily. But when a small ovarian cyst or corpus luteum bursts into an adherent pus-tube, infection of the whole ovary may result, the tube and ovary then forming one mass. Sometimes tube and ovary are in communication only through an intervening pelvic abscess. It is difficult to distinguish a tubo-ovarian abscess from an ordinary pus-tube before operation, as the symptoms and physical signs are almost identical.

Treatment is the same as for pyosalpinx.

Hydrosalpinx.—Hydrosalpinx, or a collection of serous fluid in the tube, sometimes develops as a terminal stage of pyosalpinx; often, however, the collection of fluid appears to have been serous from the beginning. Hydrosalpinx frequently develops on one or both sides

in cases of uterine fibroids. **Treatment** is that of the complicating condition.

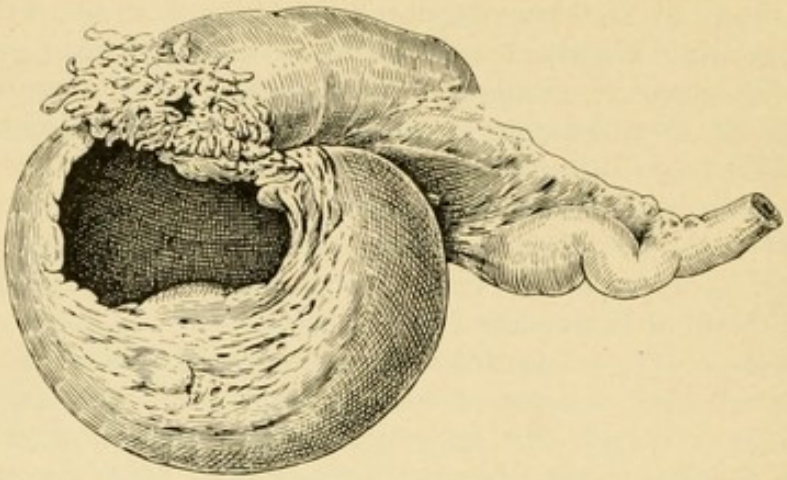

FIG. 1004.—Left tubo-ovarian abscess, seen from posterior aspect. Ruptured before operation, causing fatal peritonitis (colon bacillus). Episcopal Hospital.

Oöphoritis or **Ovaritis** is much less frequent and produces much less conspicuous symptoms than salpingitis. Like the latter condition, of which it is almost always a direct sequel, it may be acute or chronic. The **symptoms** cannot well be differentiated from those of the complicating salpingitis. In *acute ovaritis* the ovary is swollen, tender, and often prolapsed into Douglas's pouch; *abscess of the ovary* is rare unless it is the result of secondary infection of a preëxistent ovarian cyst, or occurs in the form of a tubo-ovarian abscess, already described.

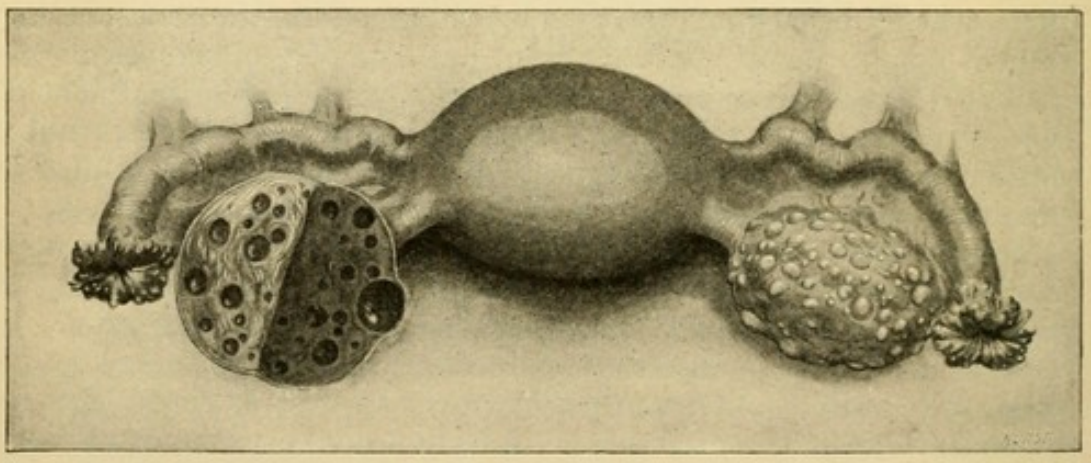

FIG. 1005.—Microcystic degeneration of the ovary; the ovary to the right shows numerous small cysts scattered over the surface; these are Graafian follicles which have undergone cystic degeneration, and which it is said may take on excessive growth and develop into large tumors, or may remain as here represented; on the other side is shown a similar condition of the ovary in section. (Dudley.)

Treatment.—In acute ovaritis the treatment should be the same as in cases of acute salpingitis. If suppuration occurs, the proper treatment is oöphorectomy. In chronic ovaritis the ovary is the seat of "cystic degeneration," and should be removed along with the tube if this is diseased (Fig. 1005); since both ovaries usually are affected,

it is well, if the patient is a young woman, and a portion of the ovary remains healthy, to leave it as a transplant in the abdominal wound; there are fair prospects that it will possess sufficient function to prevent an artificial menopause.

Salpingo-oöphorectomy.—The abdomen is opened by a paramedian incision about three or four inches long, above the pubes. In any case in which there is any possibility of pus being present, the surgeon should wall off the small intestines with gauze packs as soon as the peritoneum is opened, and *before the pelvis is explored.* Place the first gauze pack on the right or left side of the pelvic cavity, not in the

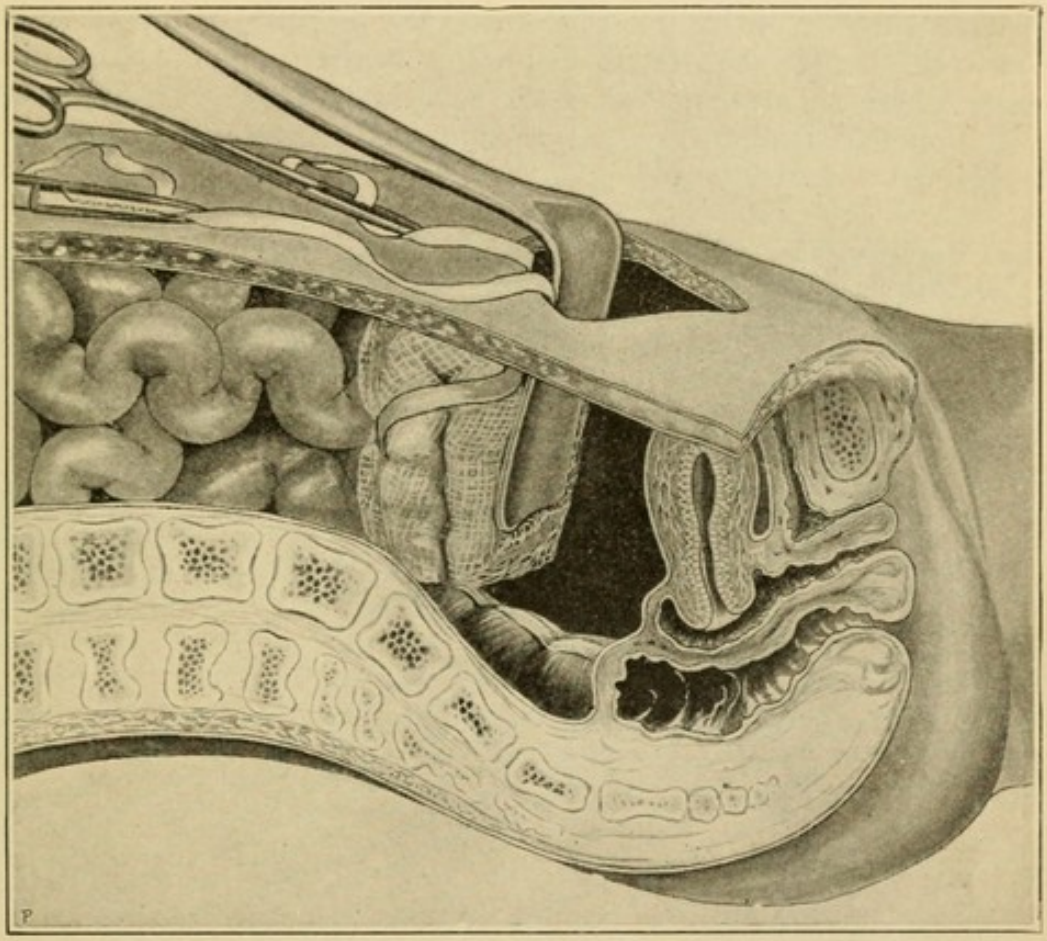

FIG. 1006.—Isolating the pelvic cavity by the use of gauze packs. (See Fig. 812.) (Dudley.)

mid-line; if the first pack is inserted in the mid-line the intestines will prolapse into the pelvis on both sides of it, and it will be more difficult to control them. The second gauze pack is placed in the mid-line, and the third on the left, thus pushing the troublesome small intestines completely out of harm's way (Fig. 1006). If it is known to be a clean case it will facilitate these manœuvres to place the patient in the Trendelenburg (high pelvic) position as soon as the abdomen has been opened; but if there is any danger of infection, it is safer to isolate the general peritoneal cavity by gauze while the patient's body is still horizontal, and then to raise it into the Trendelenburg position.

If many adhesions are present it may be difficult at first to recognize anatomical landmarks. First locate the fundus of the uterus. Sometimes it is covered by omentum or sigmoid. Then cautiously and gently work your fingers down behind it until Douglas's cul-de-sac is reached. Then endeavor to isolate the tubes and ovaries by blunt dissection with the fingers, working from the mid-line outward and pushing the omentum and intestine away from the pelvic organs rather than enucleating the latter from the intestines. It is not very difficult to tear a hole in the intestines if undue haste or force is employed. From time to time mop up the clotted blood which collects in the pelvis as the result of rupture of adhesions. When at last the posterior surfaces of the broad ligaments are outlined, turn your attention to their anterior surfaces, beginning at the fundus of the uterus again, where the attachments of the tube and of the round ligament form valuable landmarks, and then work out toward the sides of the pelvis.

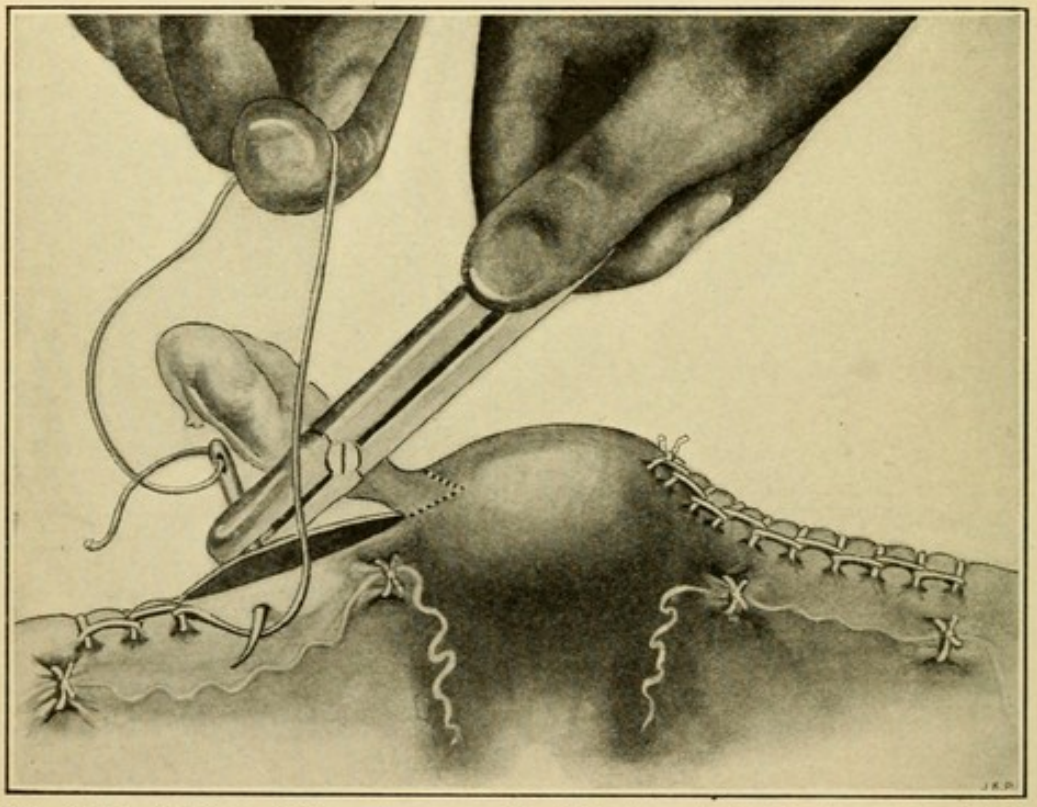

FIG. 1007.—Salpingo-oöphorectomy: on the right the suturing has been completed; on the left the method of resecting the uterine cornu is indicated. (Dudley.)

If few or no adhesions are present, the tube and ovary from each side can be brought into the wound without difficulty. If the tube only is diseased, it alone should be removed (**salpingectomy**); or if the tube is healthy and the ovary diseased, **oöphorectomy** should be done. In most cases both tube and ovary are removed together. The blood supply is readily controlled by a ligature around the ovarian artery, at the lateral margin of the broad ligament, and another close

to the uterus, just below the tube, where the uterine and ovarian arteries anastomose. The tube and ovary are then cut free from the broad ligament and any oozing points temporarily clamped in hemostats. The tube should be removed by resecting a wedge-shaped piece of the uterine cornu, unless the uterine tissue is very friable, and will not hold sutures, when it is sufficient to ligate the uterine stump of the tube. The cut edges of the broad ligament are then sutured by a lock stitch of chromic catgut, controlling any venous oozing (Fig. 1007). The ends of the ligatures on the ovarian, and uterine arteries are then tied together, thus shortening the broad ligament, and retaining the fundus in proper position. Usually it is well to invert the edges of the broad ligament by another row of sero-serous sutures, burying the first row and covering the uterine stump of the tube. This lessens the chance of post-operative adhesions.

In some cases it is safer to leave a tube or gauze to drain the floor of the pelvis, but where there has not been much soiling of the pelvic structures, and no oozing persists, the abdominal wound may be closed without drainage.

Birth Injuries.—Lacerations of the cervix and perineum are the most frequent obstetrical injuries, and often produce such distressing symptoms as to demand operative relief.

Lacerations of the Cervix may be unilateral or bilateral; anterior or posterior lacerations are rare, as are stellate lacerations. When these patients reach the surgeon healing has occurred, but it is healing with deformity: the cervical mucosa becomes everted, and resembles an ulcerated surface; erosions frequently form on the vaginal portion of the cervix, and annoying leucorrhea frequently is present. If the lacerations are very wide and deep, subsequent pregnancies may terminate in miscarriages from very slight provocation, or conception may not occur at all. Moreover, carcinoma of the cervix seldom occurs except in the scar of an old laceration; and this is the chief argument in favor of habitual operative treatment. But before any operation is done for laceration of the cervix, it is important to remedy inflammatory conditions in the uterus and adnexa, since the interference with free drainage which may result from repair of a cervical tear may cause retention of uterine secretions, thus aggravating a chronic endometritis and perhaps indirectly leading to the development of salpingitis. At the time of operation the uterine cavity should be cleansed by the curette, and immediately after repair of the cervix the tubal lesion, if any exists, should be treated by laparotomy.

Treatment.—The operation for the repair of a lacerated cervix is known as **trachelorrhaphy** ("*trachelorrhaphy*," Emmett, 1869). It consists in denuding the torn surfaces, excising the cicatricial tissue, and restoring the cervix to normal shape by sutures. The technique is sufficiently indicated in the accompanying illustration (Fig. 1008). In some cases where the lacerations are very extensive, or the cervix

hypertrophied, **amputation of the cervix** is required. Schroeder's method has already been illustrated (p. 1073).

Lacerations of the Perineum and Pelvic Floor usually produce more discomfort than lacerations of the cervix. The levator ani muscles are composed typically of three portions: a posterior portion, entirely beneath the rectum, which is not of importance in the present connection; a middle portion, which is closely applied to the sides of the rectum; and an anterior portion, which meets with the corresponding fibers from the opposite side, at the perineal centre. In *superficial tears* little more is torn than the juncture of these anterior fibers, and some of the fibres of the transversus perinei, at the perineal centre. In *complete tears* the rupture extends down through the perineal centre and involves the sphincter ani, almost always entailing fecal incontinence. Neither a superficial nor a complete tear of the perineum necessarily involves the *pelvic floor proper*, so there is not much loss of support to the pelvic organs; it is only when the tear extends up one or both lateral sulci of the vagina, rupturing the middle fibres of the levator ani and detaching them from the sides of the rectum that there develops a tendency to hernia of the pelvic contents through the vulvar orifice.

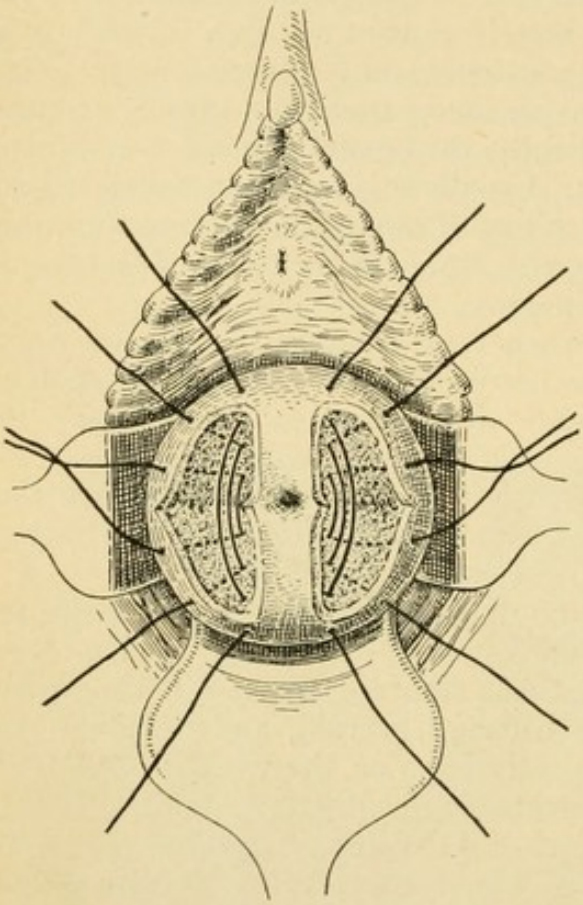

FIG. 1008.—Trachelorrhaphy: after excision of the cicatricial tissue, sutures of No. 2 chromic catgut are passed, beginning at the apex. (Findley.)

The *symptoms* due to this loss of support in the pelvic floor are chiefly a feeling of weakness in the pelvis when the patient stands or walks; and dragging sensations in the lower abdomen, with pains referred oftenest to the ovarian or lumbar regions. In typical cases the vulvar orifice gapes, the anus falls backward toward the coccyx, and descends to a lower plane, no longer being placed in a well marked cleft between the nates. In many cases the anterior wall of the rectum protrudes beneath the posterior vaginal wall, forming a *rectocele* (Fig. 1009); and in connection with this there often develops an *anterior colpocele* or a *cystocele* (p. 1088). If the condition is neglected it frequently leads to *prolapse* or to *procidentia of the uterus*.

Treatment.—The operation for the repair of a lacerated perineum is known as **perineorrhaphy.**[1] Its nature and extent depend on the character of the tear. If *both lateral sulci of the vagina are involved,* the best operation is of the type devised by Emmett (1883): this consists in denuding the relaxed areas, reuniting the levatores ani muscles to the lateral rectal and posterior vaginal walls, and restoring the external perineum by transverse sutures, known as "crown sutures." The manner in which the denudation is accomplished is of little moment; many surgeons follow Emmett in employing scissors. Personally, I prefer the scalpel, and I am in the habit of proceeding as follows:

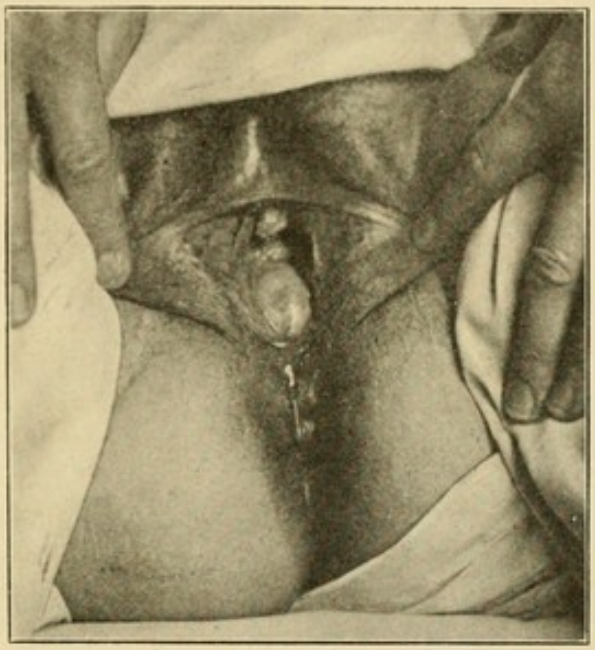

FIG. 1009.—Rectocele and cystocele. Pennsylvania Hospital.

1. *Denudation.*—A tenaculum is placed at the lowest myrtiform caruncle on each side, and these points are well retracted exposing the rectocele. A point on this is selected, which when drawn forward by tenaculum will reach almost but not quite to the urinary meatus (Fig. 1010). When these three tenacula are placed in apposition the normal form of the vulvar opening is restored. A fourth tenaculum is then placed in the mid-line at the mucocutaneous juncture. Point *b* (Fig. 1010) is then drawn upward and point *f* downward, making the line *b f* taut. The vaginal mucosa is incised from *b* to *f*, and the mucocutaneous border from *f* to *e* and from *f* to *d*. The flap *b f e* is then dissected up with scalpel until *c*, the apex of the lateral vaginal sulcus, is reached; this point becomes apparent when the points *b* and *e* are drawn widely apart, forming the lines *b c* and *e c* (Fig. 1011). When

[1] It was Parvin's teaching that the terms *trachelorrhaphy* and *perineorrhaphy* should be limited to immediate repair of birth injuries; and that the operations when done at later periods should be called *tracheloplasty* and *perineoplasty*. The usual operation for repair of a lacerated perineum involves also the vagina, whence the term *posterior colporrhaphy* or *colpo-perineorrhaphy*.

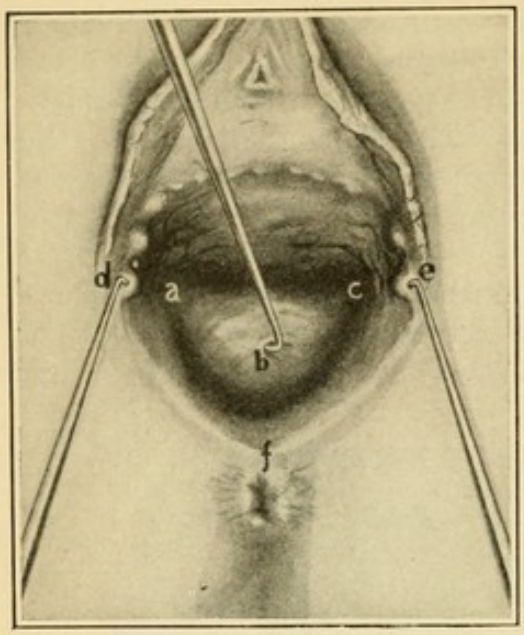

FIG. 1010.—Typical incomplete laceration of the perineum. The tenaculum hooked into the crest of the rectocele at point *b* draws it slightly forward. The other two tenacula are hooked into the lowest remains of the hymen, points *d* and *e* (carunculæ myrtiformes). The three tenacula if approximated would bring into coincidence points *b*, *d*, and *e*, and would show what surfaces should be united. (Dudley.)

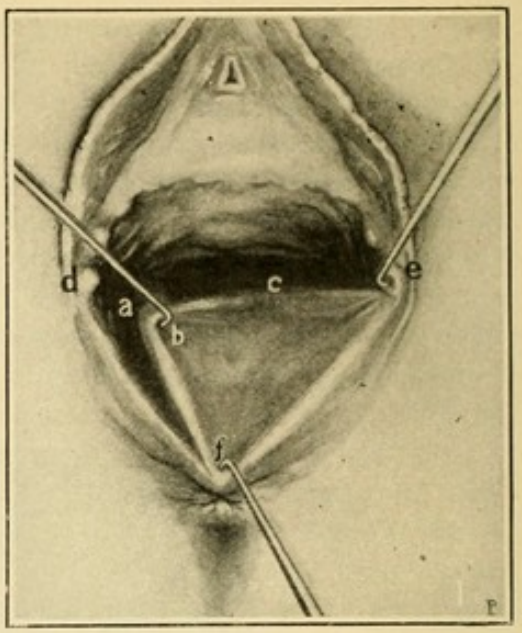

FIG. 1011.—Same as 1010. Tenaculum at *d* removed and placed at *f*. Tenacula *b*, *e*, and *f* make traction so as to render tense, lift up and expose for denudation the torn sulcus of the left side. The ridges formed by the structures drawn taut indicate the outline of the surface to be denuded. (Dudley.)

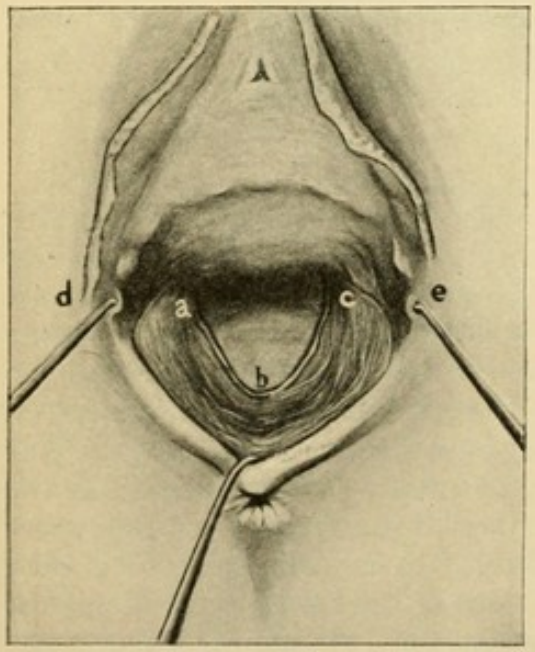

FIG. 1012.—This shows the surfaces denuded and ready for suturing. Some operators prefer to expose the surface on both sides for denudation in the manner in which they are exposed in this illustration. In the use of either method it is desirable to denude on each side somewhat further back into the sulcus than is here shown. (Dudley.)

the dissection has been carried as high as these lines, the flap of mucous membrane is cut free by dividing it along *e c* and *b c* with straight scissors. The same procedure is then carried out on the patient's right side, until the lines *d a* and *b a* are reached, when the flap is cut free by scissors passed along these lines. The denuded surfaces now have the appearance represented in Fig. 1012.

2. *Suture.*—The method of inserting the sutures is important: in a typical Emmett operation the lateral vaginal sulci are sutured first, beginning at the apex of the denuded area and working toward the vaginal outlet (Fig. 1013). Finally the crown sutures, usually of silkworm gut, are passed from the skin surface deeply into the tissues of the perineum from one side to the other, uniting the

levatores ani in the median line. Dudley modifies this method by making separate suture of the levatores ani with buried sutures and then closing the vaginal sulci (Fig. 1014). Finally the skin of the perineum is closed.

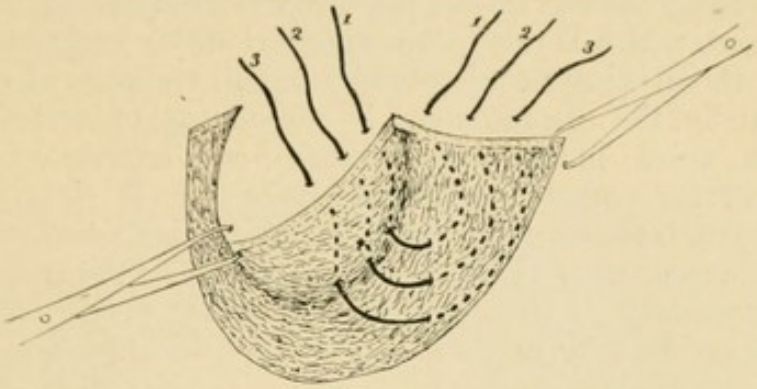

FIG. 1013.—Perineorrhaphy: method of passing sutures in one of the lateral sulci.

In cases where the *chief damage is at the vulvar outlet*, it is sufficient to suture the levatores ani alone. They are easily exposed through an incision about two or three inches in length along the mucocutaneous border, from the lowest myrtiform caruncle on one side to that on the other. The vaginal mucous membrane is then raised by blunt dissection, the levator ani on each side is identified and drawn into the wound with forceps, and is united to its fellow of the opposite side by buried mattress sutures of chromic gut. The skin incision is then closed.

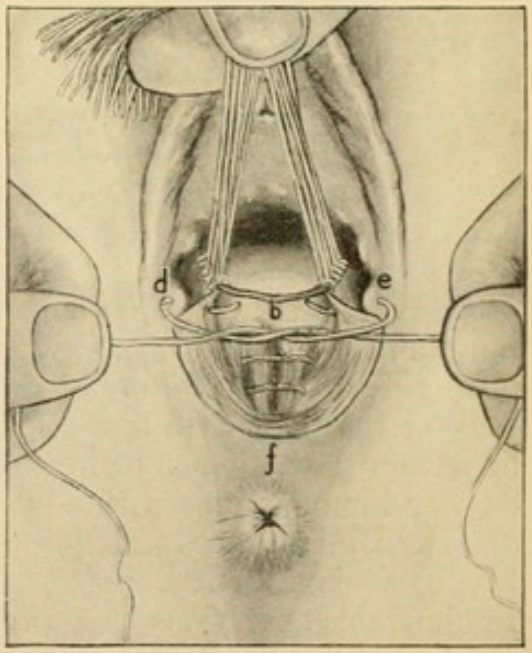

FIG. 1014.—All the sutures in the two lateral sulci have been introduced and tied. The levatores ani have been united in the median line by buried sutures. The crown suture, which brings together the two carunculæ myrtiformes and the posterior vaginal wall, is being tied. This completes the intravaginal part of the operation. (Dudley.)

In cases of *complete laceration of the perineum*, it is necessary, in addition to the other operative procedures indicated, also to reunite the retracted ends of the ruptured sphincter ani; these should be exposed through a transverse or inverted V-shaped incision in front of the anus, should be accurately identified, and sutured to each other by buried sutures. The retracted ends of the ruptured sphincter produce dimples in the skin of the anus, and the skin between the retracted ends is not puckered as is the rest of the skin surrounding the anus. When these retracted

ends have been sutured to each other the skin is puckered normally around the whole circumference of the anus.

Displacements of the Uterus.—Anterior Displacement.—*Anteflexion,* involving a bend in the axis of the uterine canal, frequently accompanies stenosis of the cervix, and requires the same treatment (p. 1070). In *anteversion,* which is rarer than anteflexion, the cervix is displaced backward, there being no abnormal bend in the axis of the uterine canal. Usually the displacement is caused by, or at least is associated with, pelvic inflammatory disease, and is relieved by proper treatment of the complicating condition.

Posterior Displacement is common; and here also *retroflexion* is more usual than *retroversion.* In extreme degrees the fundus occupies the pouch of Douglas. If the displacement follows pelvic inflammatory disease the uterus may be fixed in its malposition by adhesions, and may cause much discomfort. In cases due to relaxation of the pelvic floor, following pregnancy, no noteworthy symptoms may be caused unless relaxation is so extreme as to permit prolapse of the uterus, with its complicating lesions.

Treatment.—In many cases following pregnancy (*subinvolution of the uterus*), unattended by complicating lesions, and causing no severe symptoms, permanent restoration of the uterus to its normal position may be secured by mechanical treatment. The fundus should be replaced manually by the surgeon several times weekly, and its retention in normal position favored by inserting a tampon behind the cervix after the fundus has been brought forward. Sometimes a pessary is employed for this purpose. The woman should do no heavy lifting or arduous work for months; should keep her bowels freely opened, avoiding constipation and its attendant straining in defecation; and should wear no tight clothing which causes downward pressure on the pelvic organs. If the uterus is subinvoluted, it is well for the patient to spend much time in bed at first. She should lie flat on the abdomen or in the Sims posture for several hours each day, and may assume with advantage the knee-chest posture for ten or fifteen minutes several times daily. In most cases no operative treatment is required, unless demanded by complicating lesions. Innumerable operations have been devised to hold the uterus forward (*hysteropexy*). *Shortening of the round ligaments in the inguinal canal* (Alexander, 1882) presents the disadvantage that it does not permit treatment of accompanying pelvic lesions; there are exceedingly few cases in which it is indicated. *Intraperitoneal shortening of the round ligaments* is preferable. The operation may be done as follows: A forceps is thrust through the broad ligament from its posterior surface, just beneath the tube and close to the uterus. This forceps then grasps the round ligament about two inches from its uterine end, and draws it through the broad ligament (Fig. 1015). The other round ligament is treated similarly, and then the two round ligaments are sutured to each other and to the posterior wall of the uterus just back of the fundus (Webster, 1901; Baldy, 1903). If they

are sutured too low on the uterus they will pull the cervix forward and increase the retro-displacement of the fundus. *Ventro-suspension of the uterus* consists in suturing the fundus to the anterior abdominal wall, with absorbable sutures; if non-absorbable sutures are used, the operation is known as *Ventro-fixation*. The operation should not be done in any patient who has not reached the menopause. It is very seldom indicated except as an incident in the operative treatment of genital prolapse in the female.

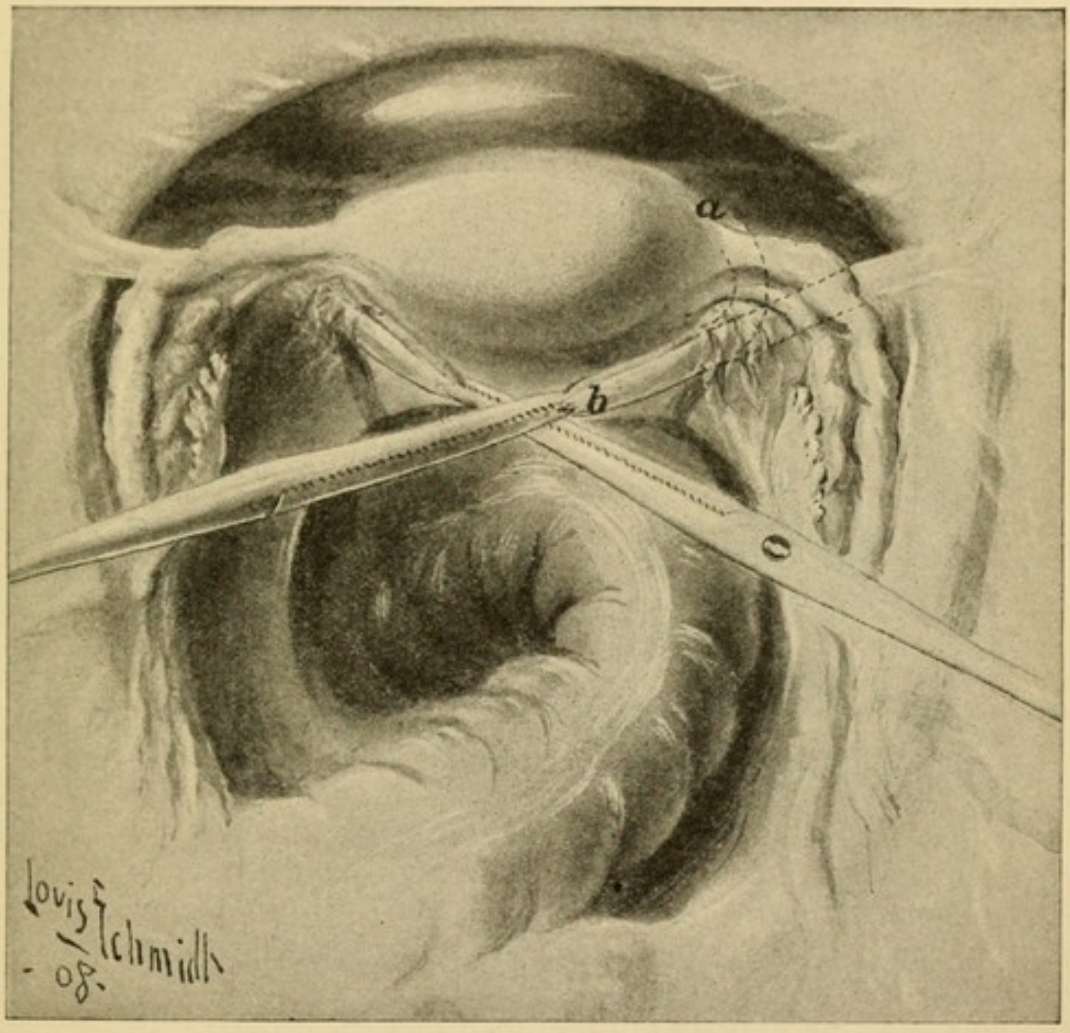

FIG. 1015.—Hysteropexy: both round ligaments have been pulled through the broad ligaments, and are about to be sutured to each other and to the fundus of the uterus. (Baldy.)

Downward Displacement.—Usually this is a sequel of retrodisplacement. When the axis of the uterus is changed so that it corresponds with that of the vagina, descent is almost invariably the sequel. It is predisposed to by loss of support, the result of lacerations of the pelvic floor and perineum, or of the atrophy which sets in about the time of the menopause; and by increased pressure from above, such as tumors of the uterus or abdominal organs, obesity, tight lacing, straining in defecation, etc. Several degrees of descent of the uterus

are recognized: in *prolapse* the uterus still remains in the vaginal canal, usually pushing before it a cystocele or rectocele (Fig. 1016); while in *procidentia* the uterus protrudes from the vulva (Fig. 1017). The cervix becomes hypertrophied from passive congestion and friction, and frequently is ulcerated. The anterior vaginal wall is pushed or pulled down by the prolapsing uterus, and *anterior colpocele*, or even *cystocele* (prolapse of the bladder through the anterior vaginal wall) results. Residual urine collects in the bladder pouch, and digital pressure may be necessary to secure evacuation of urine. The occurrence of posterior colpocele and rectocele has been discussed at p. 1083.

FIG. 1016.—Prolapse of the uterus; large rectocele; also hemorrhoids. Pennsylvania Hospital.

FIG. 1017.—Procidentia uteri and ulceration of the cervix. Patient, aged thirty-six years, has had eight children, including one set of twins. Pennsylvania Hospital.

Treatment involves (1) repair of the anterior vaginal wall; (2) repair of the pelvic floor and perineum; and frequently also (3) some intra-abdominal operation to secure the uterus in a position of anteversion, thus restoring the normal relation of the axis of the uterus to that of the vagina; (4) if the cervix is very large it should be amputated as the first step of the operation (p. 1073).

Repair of the anterior vaginal wall may be done by making a median incision from just back of the urinary meatus to a point about an inch in front of the cervix; here the incision diverges in two branches, so as to form an inverted Y. This incision is carried through the mucosa exposing the muscular wall of the bladder. The mucous flaps are then reflected laterally by gauze dissection, until the operator's finger can detect the margins of the rent in the vesico-vaginal fascia through which the hernia of the bladder has occurred. These fascial margins are then sutured together in the mid-line by buried mattress sutures of chromic gut, taking care not to penetrate the bladder. If no such margins can be detected, the sutures should at any rate be passed as far laterally as possible, through the outer layers of the vesical wall,

infolding this upon itself and thus overcoming the prolapse of the bladder. The flaps of vaginal mucosa are now to be sutured; if redundant the excess may be excised.

The *operation for the repair of a cystocele never is efficient unless supplemented by repair of the pelvic floor and perineum*, as already described (p. 1083).

In cases where the uterus is diseased and has to be removed, great care should be taken to implant the stumps of the broad and round ligaments into the remains of the cervix or the vaginal vault, to prevent prolapse. In severe or recurrent cases the cervical stump may be implanted in the abdominal wall.

Genital Fistulæ.—Most cases of genital fistulæ in the female result from separation of sloughs which have been produced by prolonged or excessive pressure during parturition. They are rare at the present day, owing chiefly to the advances in obstetrics. Some occur as the result of careless operating (Fig. 1018), and others from ulceration due to inflammation or malignant disease. All except the latter usually may be cured by operative treatment. By far the commonest form of fistula is the *vesicovaginal;* other fistulæ (*vesico-uterine, recto-vaginal, recto-uterine, uretero-cervical,* etc.) are comparatively very rare. The **diagnosis** depends on the recognition of the leakage of urine or fecal matter (or even merely flatus) into the genital tract. Injection of the bladder or rectum with colored fluids (milk, methylene blue, etc.) renders this fact certain. In most cases the fistula can be brought to view by use of a speculum. Uterine fistulæ, however, cannot be thus exposed.

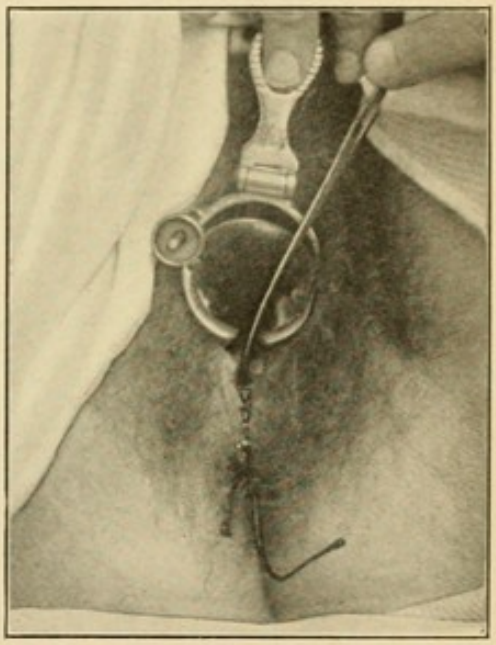

FIG. 1018. — Recto-vaginal (recto-vestibular) fistula following attempted repair of a laceration of the perineum. Pennsylvania Hospital.

Treatment.—Preparatory treatment before operation is of the utmost importance. The phosphatic deposit of urinary salts around the margins of the fistula must be removed gently, and their reformation prevented by rendering the urine acid. The patient must drink plenty of water; copious hot vaginal douches should be given to cleanse the parts, and the dermatitis of the vulva and adjacent skin should also be relieved by appropriate remedies. After operation the patient remains in bed about three weeks, and for the first two weeks constant vesical drainage is assured by the use of an inlying catheter (preferably glass, with appropriate curve), which must be changed frequently.

1. *When the fistulous tract can be exposed from below*, it is usually possible to close it by a plastic operation. The edges of the fistula

are pared obliquely, at the expense of its vaginal surface, and in an oval form (Fig. 1019). The flap-splitting method seldom is required.

2. *When the fistulous tract cannot be exposed from below,* as is usually the case in fistulæ which involve the uterus, laparotomy becomes necessary. The bladder is carefully separated from the uterus, and the opening in each repaired separately. Hysterectomy may render the operation easier or the cure more certain.

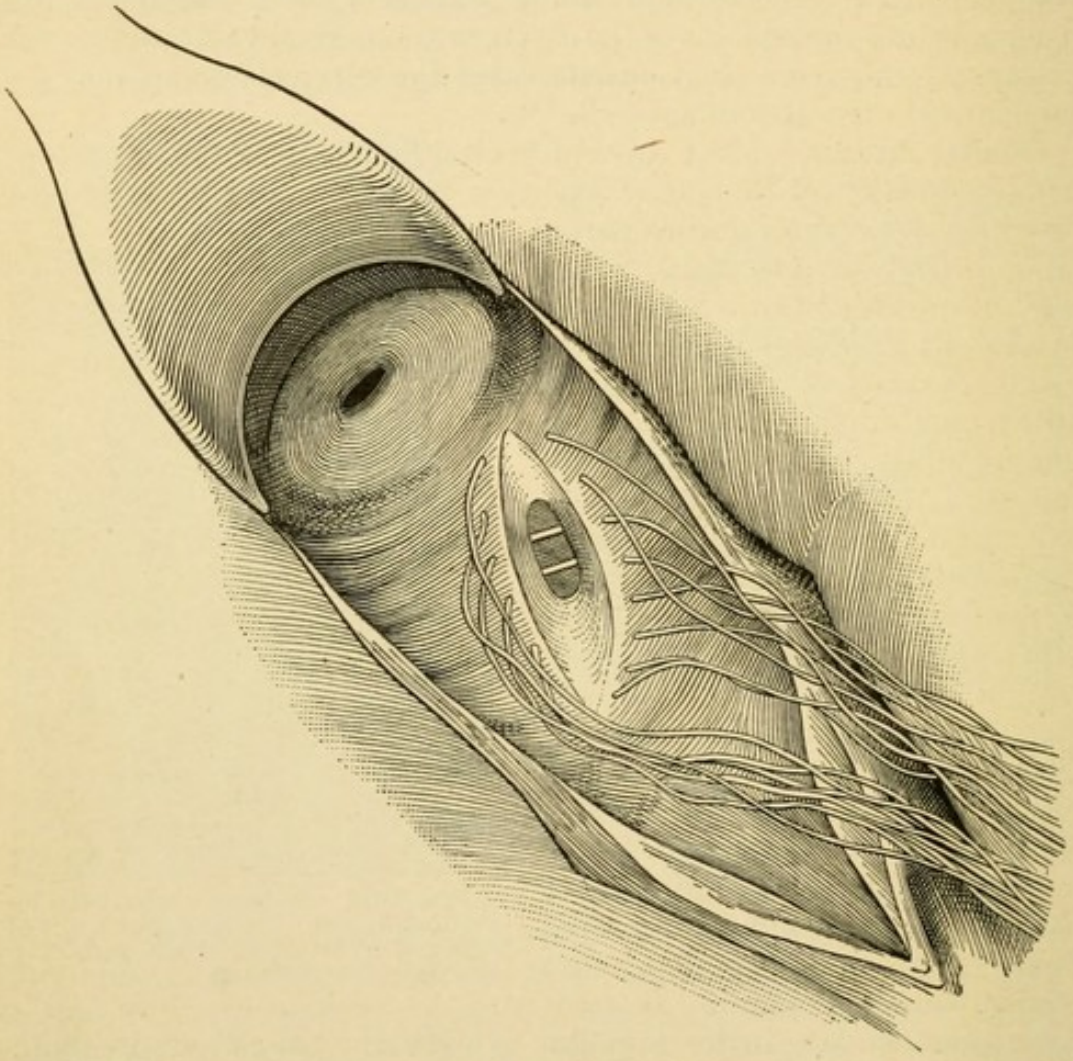

Fig. 1019.—Vesico-vaginal fistula, showing the proper area of denudation. Left lateroprone position; exposure by Sims' speculum. (Dudley.)

Extra-uterine Pregnancy.—Ectopic gestation usually occurs in the tube, and in most cases *rupture* of the tube occurs, or the embryo is discharged into the peritoneal cavity through the fimbriated extremity of the tube (*tubal abortion*), from the sixth week to the third month pregnancy. Occasionally rupture occurs into the cellular tissue of the broad ligament; this is least unusual when pregnancy occurs in the tube close to the uterine wall (*ampullar pregnancy*), or as an *interstitial pregnancy* in that portion of the tube within the uterine wall. In the latter case an intra-uterine abortion may occur. After rupture or tubal abortion the embryo usually dies, but in rare

cases it continues to grow (secondary abdominal pregnancy) almost to full term.

The **causes** of extra-uterine pregnancy are obscure. It occurs oftenest in women who have been sterile for five years or more, and is thought to be predisposed to by previous attacks of salpingitis, or congenital peculiarities of the tube (long and tortuous, with small lumen or with diverticula).

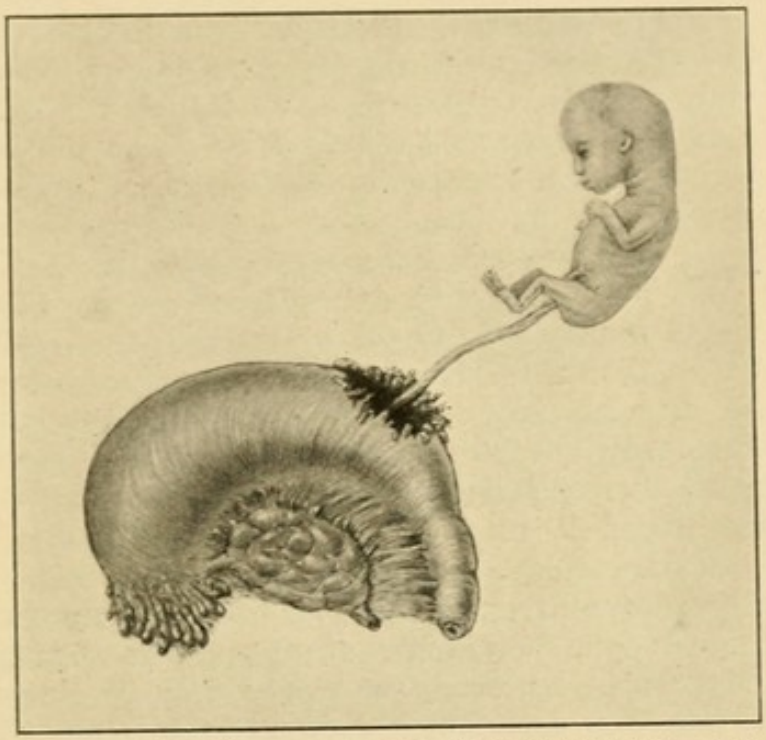

FIG. 1020.—Ruptured tubal pregnancy; an eight weeks' fetus. Age twenty-three years, one childbirth, four years ago; had missed one period, and had had premonitory symptoms for three days. Admitted to hospital with diagnosis of peritonitis; pulse, 150; temperature, 98° F.; leukocytes, 45,000; polynuclears, 94 per cent.; hemoglobin, 35 per cent. Correct diagnosis based on anemia. Operation fifteen hours after rupture. Recovery. Episcopal Hospital.

Symptoms and Diagnosis.—The usual early symptoms of normal pregnancy may or may not be present; these include particularly, morning sickness, increase in size of breasts, perhaps with pigmentation. In almost all cases there is a disturbance of the normal menstrual periodicity: often one period is missed and this is followed in a week or so by irregular and scanty bleeding. Painful cramps may or may not occur in the uterus. If vaginal examination is made, the presence of a mass in the tube usually can be determined. It may be difficult to distinguish this from a pyosalpinx, but in the latter there should be no concomitant symptoms or signs of pregnancy. In ectopic gestation the uterus usually is somewhat enlarged and the cervix is softened. In the vast majority of cases the patient does not come under the care of a physician until rupture of the tube occurs. This is attended by agonizing pain, frequently so severe as to cause faintness, and is followed by more or less profuse internal hemorrhage evidenced by the usual signs. Indeed, symptoms of severe internal

hemorrhage in a woman previously in good health almost always are due to the rupture of an ectopic gestation sac. In a minority of cases the bleeding occurs so slowly that no very acute symptoms are produced, and the blood collects in the pelvis in the form of a pelvic hematocele.[1]

Treatment.—If the condition is recognized before rupture or tubal abortion occurs, the affected tube should be removed at once. Exactly the same treatment is required when rupture has occurred. Some authorities, notably Simpson of Pittsburgh, contend that the hemorrhage always will cease of itself, and that no operation should be done until the symptoms indicate that this has taken place. The majority of surgeons and gynecologists, however, still believe that less risk is run by immediate operation, even in the presence of profound shock from hemorrhage, than by delay. Very little anesthetic is required. The abdomen is rapidly opened above the pubes, the hand is introduced and feels for the uterine appendages; usually there are no adhesions, and it is very easy to tell by the sense of touch which is the affected tube, even if this has not been ascertained before opening the abdomen. The ruptured tube is brought into the wound and the bleeding temporarily checked by the fingers. The diseased tube, usually with its corresponding ovary, is then removed; the clotted and semi-fluid blood is removed by forceps and gentle sponging, but no irrigation is employed. It is well to pass the hand into each kidney pouch and evacuate the clots which have accumulated there. If the operation is done soon after rupture, and if most of the effused blood and clot can be removed, the wound may be closed without drainage. In late cases, especially if there is any suspicion of secondary infection of the clot from the adjacent intestinal tract (not very rare) it is safer to drain the pelvis for a few days. *Bilateral tubal pregnancy* may occur, and it is always desirable to examine both tubes before closing the abdomen.

Puerperal Sepsis.—Many cases of septic infection develop from the genital tract during parturition and the puerperium. This is owing chiefly to the ignorance and carelessness of midwives or incompetent general practitioners; but sometimes it is unavoidable, being due solely to a preëxistent infection, or to self-induced abortion. The *prevention* of such infection is in the realm of obstetrics; but its *treatment* frequently falls to the lot of the general surgeon, and it behooves him to be prepared to do the best that is known for these unfortunate patients.

The infection usually takes its origin at the placental site or in the lacerated cervix; occasionally from lacerations in the vagina or at the vulvar orifice. If fetal products are retained, and become infected by putrefactive microörganisms, *sapremia* develops (p. 75). This

[1] *Rupture of a retention cyst of the ovary* occasionally is followed by severe internal hemorrhage which may be indistinguishable from that due to ruptured tubal gestation (p. 1097). I have encountered two such cases. The treatment is the same as for ruptured extra-uterine pregnancy.

is commoner than invasion by pathogenic bacteria, resulting in *septicemia;* the latter may arise as a secondary condition in a case of sapremia, but more often is a primary condition. Finally, if septic thrombosi occurs, with the lodgement of secondary emboli, the condition is described as *puerperal pyemia.*

Retained Secundines. — It may happen after labor (particularly in cases of miscarriage or abortion) that some of the fetal tissues are retained. The question arises whether their expulsion shall be left to nature, or whether they shall be removed by a surgeon. While there is no doubt that in a great many such cases the unaided power of nature is sufficient, yet I think surgical intervention hastens convalescence, and is to be recommended provided it is certain that secundines have been retained for several days. If this fact is uncertain, as it is in a great many cases, it is better to wait several days longer and to evacuate the uterus surgically only when evidences of sapremia become manifest.

Sapremia.—Local changes are confined mostly to the endometrium (*putrid endometritis*) which is covered with brownish-gray pulpy sloughs, with exceedingly foul odor. Sapremia occurs oftenest after full term labors or miscarriages near term. Symptoms usually do not appear until the fourth day or later, and consist essentially in elevation of temperature (perhaps as high as 105°) and other phenomena of fever, with foul smelling discharge from the cervix.

Treatment.—As soon as such symptoms manifest themselves, the uterus should be completely evacuated.[1] This is best done by the gloved finger, covered with gauze, or with the placental forceps, if the cervix will not admit the finger easily. If a curette is used, it should be the dull curette, but even a dull curette is dangerous under such circumstances. It is very easy to perforate the puerperal uterus, especially if diseased. The surgeon should adopt some system in cleaning out the uterus, and should make sure that no large mass of decomposing tissue is left behind. On several occasions I have been forced to repeat the operation for persistence of symptoms, removing large masses of foul smelling necrotic placenta which had been overlooked by the previous operator. If bleeding is free, the uterine cavity should be packed with iodoform gauze, which is left in place for two days; and a full dose of ergot should be administered. If no noteworthy bleeding occurs, a gauze wick may be left within the cervix, or if this tends to contract too much to permit free drainage, a rubber tube should be passed through the cervix into the uterine cavity.

After prompt evacuation of such a uterus the temperature rapidly falls, and uninterrupted convalescence is the rule (Fig. 31, p. 74).

If perforation of the uterus is suspected, the uterine cavity should be lightly packed with gauze, and subsequent developments awaited. *If perforation is certain,* and especially if the operator has dragged

[1] It is needless to say that all such patients should be sent to a well-equipped hospital and put in charge of a competent surgeon. But etherization is not always necessary.

down bowel, mistaking it for retained placental tissues, the abdomen should be opened at once (by a competent surgeon), and the damage repaired.

Septicemia.—This may occur after full term parturition (especially if instrumental), but is most frequent as the result of criminal abortions in the early months of pregnancy. There is *septic endometritis*, with adherent false membrane over denuded areas, and purulent blood-stained discharge, almost always accompanied by *acute septic metritis*, evidenced by an edematous boggy uterus. Infection may spread to the peritoneum (*perimetritis, acute septic pelvic peritonitis*, Fig. 1021) and to the subperitoneal cellular tissues (*parametritis, acute septic pelvic cellulitis*). The blood sinuses in the uterine walls become the seat of *septic thrombosis*, and this may extend to the uterine and ovarian veins, resulting eventually in *puerperal pyemia* (see below). *Perivascular lymphangeitis* may occur, and if extension of the thrombus to the external iliac and femoral veins takes place, "milk leg" results (p. 240).

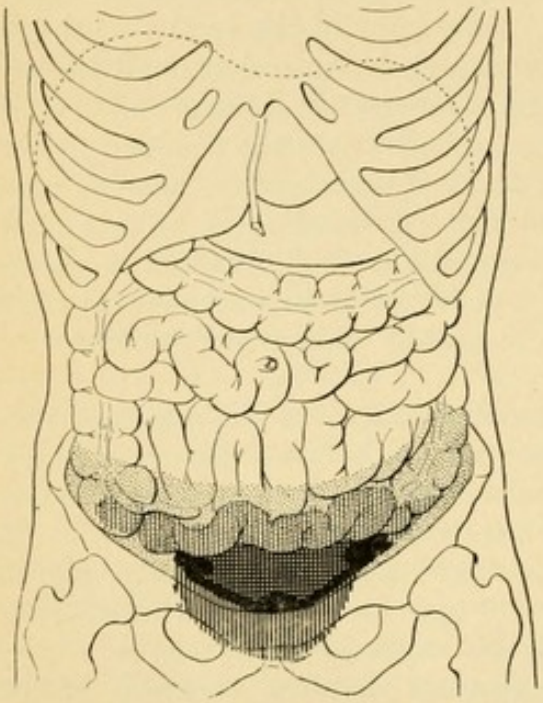

FIG. 1021.—Puerperal sepsis: Pelvic peritonitis with suppurative perimetritis, and parametritis. (After de Quervain.)

Symptoms.—The onset of puerperal septicemia occurs earlier than that of sapremia, usually on the second or third day after delivery. The disease often is ushered in by a chill, and the constitutional symptoms are much more severe than the local. The temperature rises to great heights and falls again rapidly and at irregular intervals (Fig. 28, p. 72); the pulse is persistently rapid and weak. Chills may occur only once or twice in the course of the disease, or several times daily, but at irregular intervals. Frequent chills usually indicate pyemia. Unless peritonitis sets in, and except during the chills, the patient suffers little; often she feels quite well, except for weakness, even when most gravely ill. There may be little found in the pelvis to account for the symptoms: usually the uterus is larger than normal, and the discharge may be purulent, but it does not possess the foul odor characteristic of putrefaction, unless sapremia was the primary condition. Early in the disease the uterus is not fixed, and the abdomen usually is soft and full. Only if salpingitis or pelvic peritonitis exists is there local rigidity and tenderness. It is when the infection is confined to the extraperitoneal structures (pelvic cellulitis), that the patient feels so well subjectively. By the end of the first week of the disease,

rarely earlier and often much later, the uterus may become fixed, and a pelvic mass may be detected. In some cases during the second or third week the thrombosed uterine and ovarian veins may be palpated in the broad ligament.

Treatment.—In every case I believe it is well to make sure that the uterus retains no necrotic material. Indeed it must be confessed that the diagnosis between sapremia and septicemia often cannot be made until after the uterine cavity has been explored. If necrotic material is found, and rapid improvement follows its removal, it usually is safe to assume that the condition was one of sapremia; if on the other hand, septic symptoms continue it is evident that the infection has entered the uterine walls and has become systemic. Attempts have been made to eradicate the entire focus of disease in these cases by prompt removal of the uterus; but the mortality following the operation is too high to justify its employment at this stage. Some weeks or months later hysterectomy may be necessary, to remove a uterus riddled with abscesses.

As early as possible cultures should be made from the interior of the uterus. In most cases the streptococcus is the infecting organism; and if the patient is seen early enough (within two or three days of onset) it may be worth while to employ large doses of antistreptococcic serum, or a polyvalent serum. But unless massive doses (50 to 150 c.c. in twenty-four hours) are employed early in the disease, this remedy appears to be useless.

Further than this, nothing remains but to provide careful nursing; to ensure the taking of plenty of proper nourishment and abundance of water (continuous proctoclysis, hypodermoclysis, etc.); and to watch the pelvic condition. Vaginal examinations should be made not oftener than once in three days; great gentleness should be used, and note should be made of the mobility of the uterus, the presence of a mass, or of thrombosed ovarian veins. *A pelvic mass* under these circumstances is placed low in the pelvis, fixed to the uterus, and usually on one side or the other, though often extending behind the cervix. Often the abscess tends to point above Poupart's ligament (Fig. 1022). Many authorities consider that all such abscesses have their origin in the pelvic cellular tissues, and are entirely extraperitoneal. Some of them I am sure are ordinary residual pelvic abscesses, the sequel of diffuse peritonitis. The distinction is of little practical importance, but a very important point is to open all such masses *without invading the healthy peritoneal cavity.* A pelvic mass the result of gonococcic infection (pyosalpinx, tubo-ovarian abscess) is placed higher in the pelvis, and its onset does not date from an instrumental delivery or a miscarriage (Fig. 1023). Such an abscess may be opened transperitoneally with safety, providing the operation is not done for three or four months after the acute onset (p. 1075). But abscesses which result from puerperal infection usually are streptococcic in origin, and if the peritoneum is opened, even many years after the acute onset, fatal peritonitis frequently develops. The abscess should be incised through

the posterior vaginal vault, or above Poupart's ligament. No operation should be undertaken as a mere exploration, but only when the existence of suppuration is fairly certain.

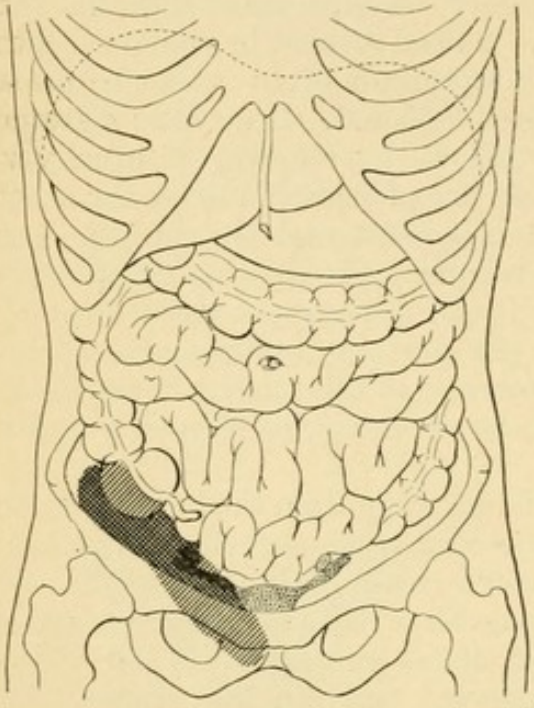

FIG. 1022. — Puerperal sepsis: pelvic abscess extending low in the pelvis and pointing above Poupart's ligament. (After de Quervain.)

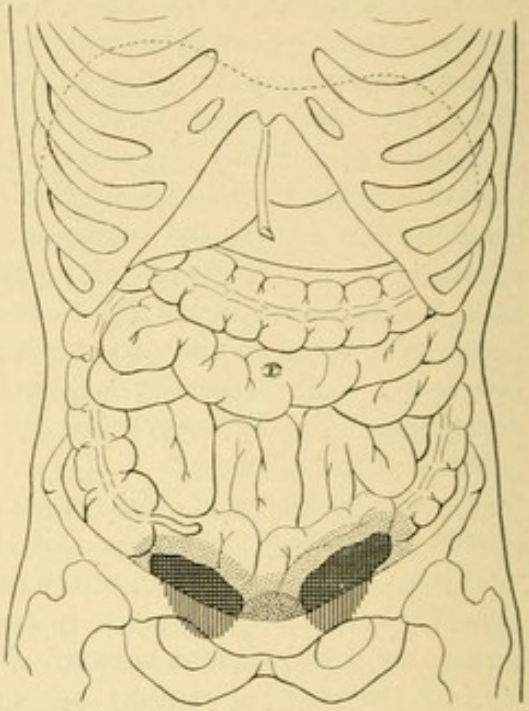

FIG. 1023.—Double pyosalpinx, with moderate serous perisalpingitis. The masses are placed higher in the pelvis than those which result from puerperal sepsis. (After de Quervain.)

Vaginal Puncture.—The cervix is pulled down and forward by volsellum forceps, and a transverse incision is made about two inches long, just posterior to the cervix. When the vaginal wall has been incised, the knife is laid aside, and the abscess is opened by the finger, or by Hilton's method (p. 51). The cavity is drained by gauze and rubber tube.

Extraperitoneal Incision.—If the abscess points near Poupart's ligament, it is easily evacuated through a small McBurney incision. When the layers of the abdominal wall have been incised, great care is required not to injure the peritoneum, or to break up isolating adhesions if the abscess is intraperitoneal in origin. The surgeon should burrow down cautiously along the pelvic wall until pus is found. The abscess cavity is then drained by rubber tube and gauze.

Pyemia.—Puerperal pyemia, as already noted, results from the detachment of septic emboli in the peri-uterine veins. Repeated chills, and the appearance of metastatic foci of infection are the two main diagnostic points. Embolic pneumonia is frequent. Other foci are less usual, but recovery may ensue after multiple arthritis, conjunctivitis, subcutaneous abscesses, and even after cerebral embolism.

Treatment.—When thrombosed ovarian veins can be felt on vaginal examination, and the clinical symptoms of pyemia, especially recurring chills, are present, it has been proposed to open the abdomen and ligate the veins above the limits of thrombosis, or even to excise the infected thrombi, as is done in jugular thrombosis (p. 240). The operation, though it may be difficult, is seldom impossible; but sometimes the thrombus is found to extend so high (to the renal veins or vena cava) or may involve so many trunks (internal, common and external iliac), that the operation will have to be abandoned. But as the mortality following this operation, in collected statistics, varies from 20 to 55 per cent.,[1] and the general mortality of the condition for which it is recommended is from 55 to 80 per cent., in cases treated without operation, it is apparent that in carefully selected cases it is a procedure worthy of careful consideration.

TUMORS OF THE FEMALE GENITAL TRACT.

Ovarian and Parovarian Cysts and Tumors.—**Ovarian Cysts** may be classified as *retention cysts* and *cystadenomas*. *Dermoid cysts* (*teratomas*) are discussed at p. 1101.

Retention Cysts of the Ovary.—Reference has already been made, at p. 1078, to *cystic degeneration* of the ovaries, usually associated with chronic ovaritis, and probably due to thickening of the stroma; the cysts usually are small, multiple, and appear not only on the surface of the ovary, but are scattered throughout its structure (Fig. 1005). Apart from the associated lesions, they produce no symptoms and require no treatment.

A retention cyst of the *Graafian follicle* usually is larger than the cysts found in cystic degeneration of the ovary; it almost always is single, and is attached to the ovary by a rather wide base. It is lined by cylindrical epithelium, but in the larger cysts this becomes atrophied from pressure. If it is large enough to produce symptoms, the differential diagnosis from tubal and other ovarian enlargements becomes important. Usually it is found to be the size of a hen's egg or small orange, and freely movable in the pelvis, though attached by a pedicle to the uterus. Its contents are clear, unless blood-stained from intracystic hemorrhage. Intraperitoneal rupture, with or without bleeding, may occur; and if bleeding is profuse the condition resembles that seen in ruptured ectopic pregnancy and requires the same treatment. Excision of the cyst and suture of the defect in the ovary is the proper treatment for the unruptured cyst; removal of the entire ovary is undesirable unless the patient has reached the menopause.

The *corpus luteum cyst* is another type of retention cyst of the ovary. The contents usually are dark and tarry, and the cyst wall is not tense. Without histological examination, which shows typical lutein cells (pigmented round cells) but no epithelium in the lining membrane,

[1] Michels in 1909 collected 64 such operations, with 31 deaths (48 per cent.); but J. W. Williams (1909) reported 5 cases in his own experience with only 1 death.

the diagnosis from the Graafian follicle cyst is uncertain. The cyst should be excised and the defect in the ovary sutured.

Tubo-ovarian Cysts may occur in connection with any variety of ovarian cysts, but are especially frequent in the case of retention cysts. They may follow *tubo-ovarian abscess* (p. 1077).

Cystadenomas of the Ovary.—These are true neoplasms. Two main varieties are recognized: the *simple (pseudomucinous) cystadenoma*, and the *papilliferous cystadenoma*.

Simple Cystadenoma.—These are the typical "ovarian cysts." Nowadays they rarely reach the immense size formerly encountered, when the tumor not infrequently weighed more than the patient, since operation is resorted to while the cysts are still of reasonable size.

Usually only one ovary is affected. The cyst originally is multilocular, but the smaller cysts frequently coalesce to form larger compartments, and incomplete partitions may be the only evidence of the former multilocular state. The cyst walls are lined by cylindrical epithelium in a single layer; stratification of the epithelium is rare and may indicate a malignant tendency. In the cyst walls are found downgrowths of epithelium, forming simple or compound gland tubules. The fluid within the cysts is viscid, glairy, or mucinous, and its color varies from clear yellow to turbid or brownish. From their contents the cysts often are termed *pseudomucinous*. The ovary is compressed, atrophied, and may be entirely destroyed by the pressure of the cyst. The two most frequent **complications** are *rupture* of the cyst, and *torsion of its pedicle*. If **rupture** occurs there may be marked shock, but this is rare; usually the fluid is absorbed, and temporary polyuria may be noted; in other cases peritonitis develops. Occasionally after rupture portions of the cyst lining become engrafted in various parts of the abdominal cavity, and numerous small cysts develop (*pseudomyxoma peritonei*). **Torsion of the pedicle** is a very serious accident, which occurs in about 10 per cent. of cases. It is especially frequent in dermoid cysts (p. 1101). The symptoms are severe pain, shock, and sudden increase in size of the tumor (perhaps previously not known to exist). This sudden increase in size results from venous obstruction in the pedicle, causing serous and bloody transudation in the cyst. If the twist is tight enough, gangrene, with slowly developing peritonitis, may occur. Prompt operation is indicated in all cases.

Even if no complications occur, the clinical course of an ovarian cyst is invariably toward the death of the patient. Ovarian cysts grow rapidly, and usually life is terminated within comparatively few years unless the cyst is removed by operation.

Papilliferous Cystadenoma.—This growth frequently affects both ovaries, is more often unilocular than multilocular, often develops between the layers of the mesosalpinx, and rarely attains very large size. The cyst wall is lined by cylindrical-celled epithelium, usually not stratified, but always bearing intracystic papillomas. The contained fluid is thin and serous, rarely blood-tinged. At the time of operation fully 50 per cent. of these tumors are already carcinomatous,

and it is highly probable that all would become malignant if not removed. The continuous growth of the intracystic papillomas leads to distention of the cyst and frequently causes its rupture, whereupon the growth becomes grafted on neighboring structures in the abdomen, and ascites frequently results. Secondary myxomatous or calcareous degeneration may occur.

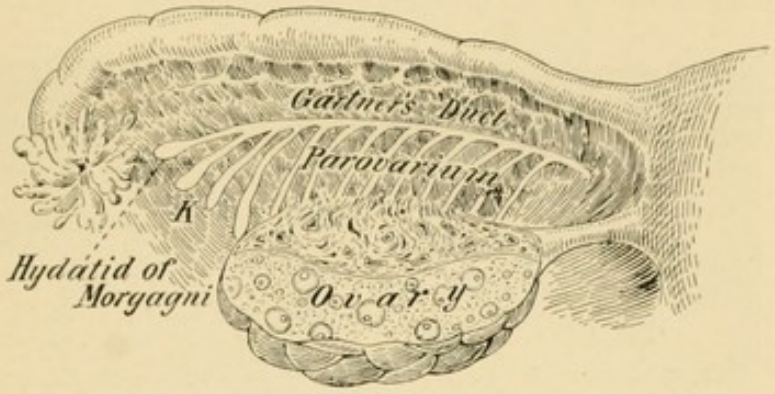

FIG. 1024.—Diagram of ovary and parovarium.

Parovarian Cysts.—The *parovarium* or *epoöphoron* lies in the broad ligament between the ovary and Fallopian tube. It is formed by the remains of the Wolffian body (Fig. 1024), and is composed of a longitudinal tube (*Gärtner's duct*), and transverse tubules which run from the hilum of the ovary to join the longitudinal tube. The *Hydatid of Morgagni*, which is present in about 50 per cent. of females, is recognized as the lateral continuation of the longitudinal duct; it enters the broad ligament on its anterior surface between Fallopian tube and ovary. *Kobelt's tubules* are the aberrant tubules of the Wolffian body between the hydatid of Morgagni and those tubules which enter the hilum of the ovary. Any of these tubular structures may become the seat of cystic formation. Cysts arising from the hydatid of Morgagni and from Kobelt's tubules usually are small, are attached to the lateral border of the broad ligament by a more or less distinct pedicle, and seldom produce symptoms; they are to be distinguished from myxomatous and cystic degeneration of the fimbriæ of the Fallopian tube.

The *typical parovarian cyst* forms about 10 per cent. of all cases of ovarian cyst. It develops and spreads within the folds of the broad ligament (hence it is known as the "broad ligament cyst"), almost always is unilocular, grows slowly, and seldom attains very great size. Its contents are clear, "like spring water," and the cyst wall is lined with a single layer of cylindrical epithelium. It is easily distinguished from an ovarian cyst because it is independent of the ovary, is covered by peritoneum, possesses a double layer of vessels on its surface (one belonging to the peritoneum and the other to the cyst wall), usually is easily enucleated (rarely forming adhesions), possesses no distinct pedicle, and almost invariably has the Fallopian tube stretched out over its surface at some distance from the ovary.

Symptoms and Diagnosis of Ovarian and Parovarian Cysts.—Few symptoms are present unless the cyst is of such a size as to become impacted in the pelvis, or unless it is so large and of such long duration as to have induced cachexia, when the typical *facies ovariana* is seen (Fig. 1025). In most cases the cyst is discovered by accident, or the woman comes to the surgeon because of increase in size of the abdomen. Ovarian cysts are commonest from forty to fifty years of age.

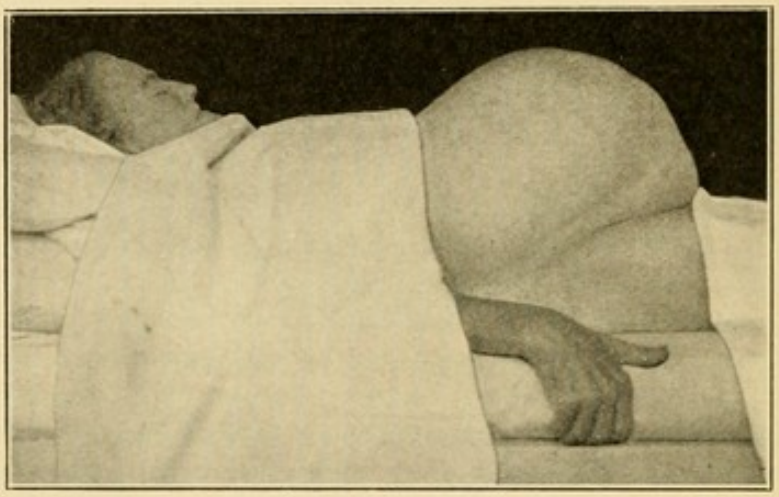

FIG. 1025.—Malignant suppurating ovarian cyst in a woman, aged fifty-seven years; duration of illness seven years. Was tapped for ascites several years ago. Tumor cystic with solid masses; abdominal circumference, with patient recumbent, was 49 inches. Weight 149 pounds (normal weight 126 pounds). Inoperable. Episcopal Hospital.

If the tumor is small it is felt as a smooth, round, tense, fluctuating, movable, and usually painless tumor, attached to the uterus by a pedicle. Differential diagnosis from other tubo-ovarian lesions depends chiefly on the clinical history.

If the tumor is of medium size (fetal to adult head) it usually rises out of the pelvis and is appreciated as an abdominal growth. The diagnosis must be made from uterine fibroid and other pelvic tumors. The cyst lies posterior to the uterus (a distended bladder lies in front), and it often is possible to determine that the uterus is of normal size. In most cases the pedicle of an ovarian cyst can be detected, but this may require abdomino-rectal palpation, while one assistant draws the uterus down into the vagina by a tenaculum and another assistant draws the tumor as far as possible out of the pelvis into the abdomen. If a pedicle is absent (intraligamentary cyst) the distinction from a subperitoneal fibroid may be very difficult, depending chiefly on the clinical history.

When the tumor becomes very large, ascites is the chief condition which simulates it. But in ascites there usually is some organic cause for the condition, and the latter has developed suddenly; the abdomen is flat on the top and bulging in the flanks; its outline does not rise abruptly from the pubis as is the case in ovarian cyst (Fig. 1025); the umbilical area is resonant, the navel pouts, and there is shifting dulness in the flanks.

Dermoid Cysts (**Teratomas**) develop from the germinal cells of the ovary. Under this term are classed both *simple* dermoid cysts, which contain only normal skin products (secretions of sweat and sebaceous glands, hair, nails, and teeth), and *complicated dermoid cysts*, in which may be found also bones, cartilage, muscle, and other more or less fully formed structures (**embryomas**). Dermoid cysts frequently affect both ovaries, and may begin to grow at any age (often in children and young girls). When growth begins it usually is rapid; but if the cyst remains small it may cause no symptoms unless it becomes infected or undergoes carcinomatous change (both are frequent complications) and may last for a lifetime. Usually the cysts are adherent and should be treated as if malignant.

Solid Tumors of the Ovary are comparatively rare. They are frequently bilateral. The most important are the *malignant tumors:* the carcinomas clinically resemble the papilliferous cystadenomas; in many cases they are secondary to carcinoma elsewhere (stomach, breast, uterus, liver, etc.) being grafted on the germinal epithelium of the ovary through the medium of the omentum. Blood-stained ascitic fluid is frequently present. Sarcoma usually occurs at a younger age. Of the *benign tumors*, fibroma is most often encountered; it may occur at an early age, but seldom causes symptoms except from its weight or from pressure if impacted in the pelvis.

Treatment.—All such growths should be removed, unless clearly inoperable.

Ovariotomy.—This is the classical operation for the removal of an ovarian cyst (Ephraim McDowell, 1809). If the cyst is so small as to be delivered easily through an ordinary abdominal incision, the operation resembles that described as oöphorectomy[1] or salpingo-oöphorectomy (p. 1079); the tube may or may not be removed with the diseased ovary. But in cases where the tumor is very large, the technique of the operation is different. A hypogastric paramedian incision is made, and the peritoneal cavity opened; if the cyst is thought to be malignant (papilliferous cystadenoma, dermoid) every effort should be made to prevent its rupture; these cysts seldom are immensely large, and usually may be delivered through an incision of moderate size. In every case of malignancy both ovaries should be removed. In the case of an immense cyst, however (usually a simple cystadenoma), it is best to tap the tumor so as to enable it to be removed through an incision of ordinary size. After the cyst wall is exposed, the presenting surface of the tumor is isolated by gauze packs, and a large blunt pointed cannula (at least 1 cm. in diameter) with rubber tube attached, is thrust into an avascular area of the cyst wall, and the contents are removed by syphonage. If the cyst is multilocular it may be necessary to tap several loculi; usually a sufficient number may be reached from the interior of that first emptied without withdrawing the cannula. As the cyst walls collapse they are to be drawn

[1] This of course is a more correct term etymologically, but long usage sanctions the use of the term *ovariotomy* for the typical operation for large ovarian cysts.

into the wound with volsellum forceps, and an assistant is to make pressure on the flanks, so as to prevent leakage into the abdominal cavity. When the entire tumor has been withdrawn the pedicle comes into view. If there are adhesions, the operation is much more difficult, and careful dissection may be required to free the tumor from omentum, mesentery, intestine, etc. When the pedicle has been brought into view, it should be caught in strong crushing forceps, and ligated by transfixion in the groove thus made. The pedicle usually is composed of broad and round ligaments, Fallopian tube, and infundibulo-pelvic ligament. Great care should be taken to see that hemostasis is complete; when they can be identified the ovarian and utero-ovarian arteries should be tied separately. Finally the stump of the infundibulo-pelvic ligament should be united to the stump of the tube, and denuded areas should be covered by peritoneum. Before closing the abdomen always examine the other ovary.

If the intestines are carefully protected from exposure and the patient's bodily heat maintained, the operation is attended by very little shock. The mortality in expert hands is below 5 per cent.

Fibroids of the Uterus.—These tumors are fibro-myomas; those with an excess of fibrous tissue justly merit the term fibroids, but in general this term and myoma or fibromyoma are used indiscriminately, regardless of the amount of fibrous tissue present in the tumors. The tumors usually are multiple, and spring from the uterine wall, probably, it is believed, from the walls of bloodvessels. They occur with greatest frequency in the body of the uterus, fibroids of the cervix being comparatively rare. By some the affection is considered a widespread disease, with one of its local manifestations in the uterus; and they explain the frequently accompanying myocardial changes in this way. Some authorities teach that the tumors always have a congenital origin; it is undisputed, however, that they seldom begin to produce symptoms or are discovered until well into the child-bearing period, from thirty-five to forty-five years of age. A woman with fibroids usually is sterile, and it is disputed whether sterility is to be regarded as a cause or a result of the existence of fibroids. If pregnancy occurs it is very apt to result in abortion or miscarriage. Fibroids are especially common in the negro race.

The tumors begin as *interstitial* growths, within the walls of the uterus; they may remain in the uterine wall even when attaining very large size, but usually they tend to push their way through to the *subperitoneal* or the *submucous* surface of the uterus. In many cases tumors are found in all three locations. They may present beneath the peritoneum or mucosa as sessile growths, but not infrequently a pedicle forms. Then the tumor, if subperitoneal, may become adherent to neighboring abdominal structures, as the result of attacks of congestion and inflammation from torsion of the pedicle; and in rare instances these secondary adhesions may become so firm that the pedicle ruptures and the migrated fibroid continues to receive its nourishment through the adhesions alone. Submucous fibroids

frequently develop pedicles, and present in the uterine cavity or protrude from the cervix in the form of *polypi*. Usually only one polypus is present, springing from the cervix or near it, and mostly fibrous in

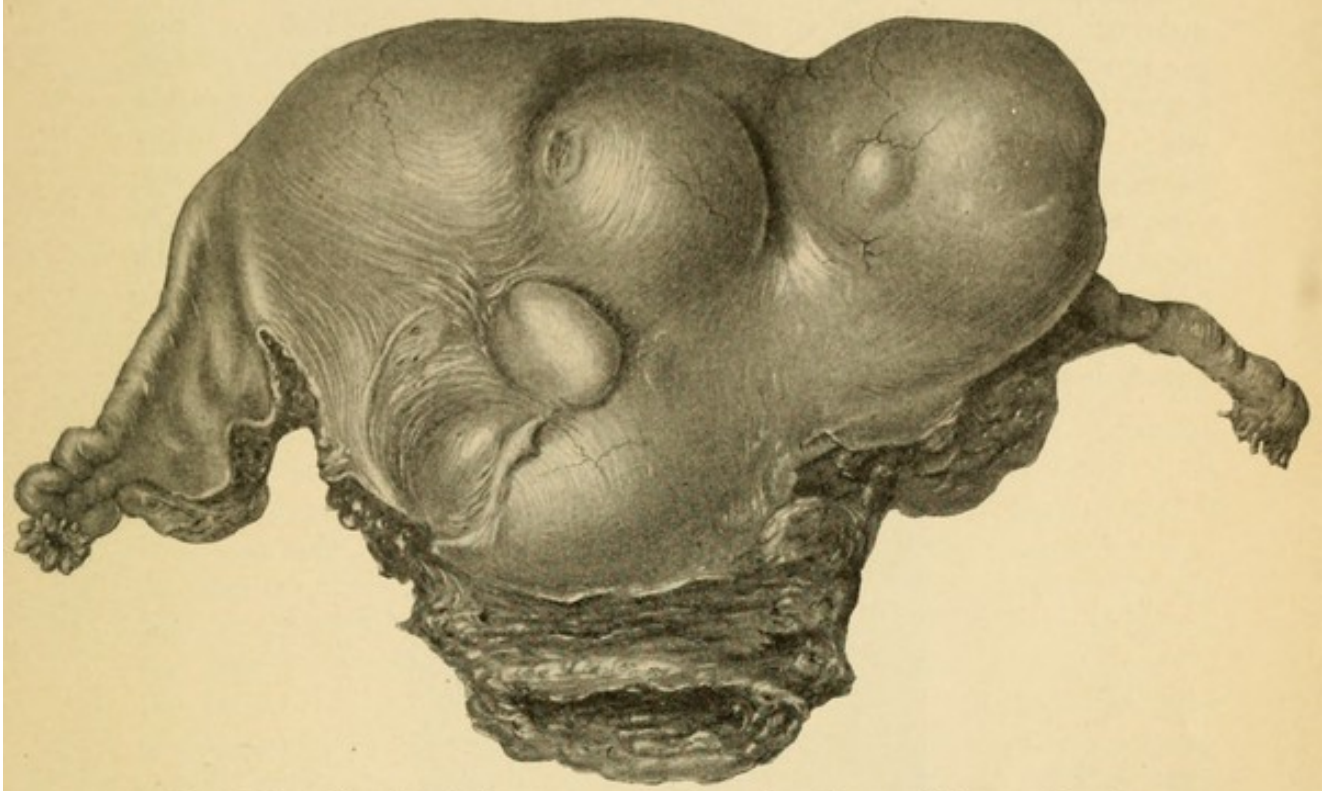

FIG. 1026.—Fibroids of the uterus, subperitoneal and interstitial; age fifty-three years. (See Fig. 1027.) Episcopal Hospital.

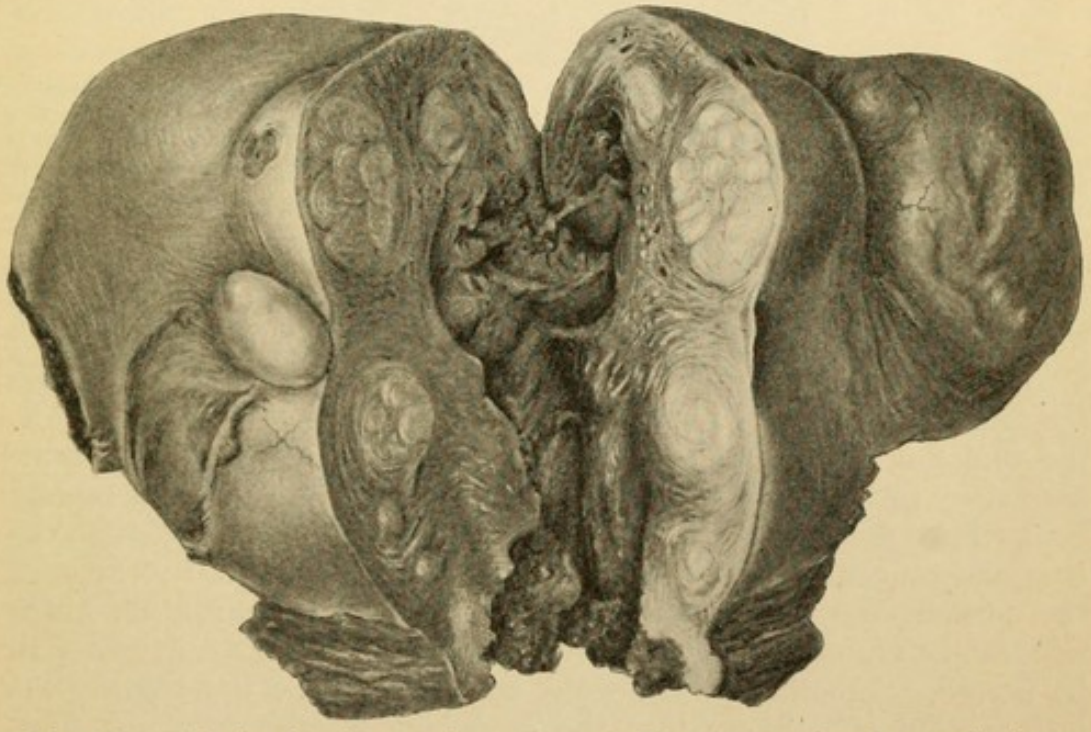

FIG. 1027.—Uterine fibroids, specimen shown in Fig. 1026 sectioned, exposing interstitial growths, one of which has undergone cystic degeneration. Note also carcinoma of the cervix, with its crater-like excavation; a rare complication of fibroid tumors. Episcopal Hospital.

structure. If a polypus springs from the fundus of the uterus, the uterine wall becomes thinned at the point of attachment, and *inversion of the uterus* may occur.

Symptoms.—In many cases no symptoms whatever are produced until the tumors become so large as to cause *pressure effects.* Among the most usual of these are vesical irritability, hemorrhoids and interference with defecation, pain in the sacrum and coccyx, varicose veins or edema from interference with the circulation of the lower extremities, renal disturbances from pressure on the ureters, etc. *Interstitial growths* may cause no noticeable change in the form of the uterus, though it may be much larger than normal, and the depth of its cavity will be increased; but a sound should not be introduced without due consideration, particularly until the possibility of pregnancy has been absolutely eliminated. Dysmenorrhea is present in

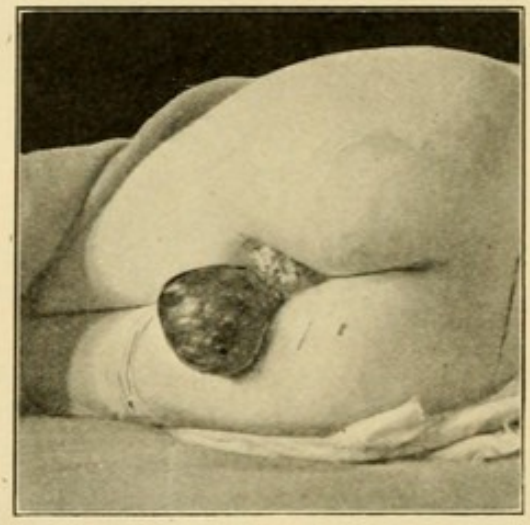

FIG. 1028.—Prolapse of submucous fibroid (strangulated) with complete inversion of vagina—uterus not inverted. Age forty-three years. Had normal childbirth two years ago, and no symptoms from fibroid until prolapse occurred, twenty-three hours before operation (vaginal hysterectomy). Death from peritonitis five days after operation. Episcopal Hospital.

some cases of interstitial growths. *Subperitoneal growths* usually may be recognized by bimanual palpation; they may be of various sizes and shapes, but are attached to the uterus, move with it, and usually are high in the pelvis, not in the position where pus tubes are found; unless the tumor is very large, or impacted in the pelvis, the tumor is not fixed. *Submucous growths* are particularly characterized by profuse and prolonged menstrual bleeding; intermenstrual hemorrhage is rare, though bleeding may last from one period to the next and continue through this; then an intermission may occur until the normal time for the occurrence of the next menstruation which will also be unduly prolonged. Anemia is a frequent result and may be severe. Sometimes submucous tumors may be detected by the introduction of a finger into the os, which frequently is patulous. Attacks of colicky pain may be caused by efforts of the uterus to force the tumor through the cervix. *Complications:* Occasionally a

large submucous fibroid *prolapses* through the vagina, and may cause *inversion* of this structure or even of the uterus itself. *Strangulation* of the prolapsed fibroid may occur, resulting in *gangrene*, a very serious complication (Fig. 1028). Fibrous polypi are less serious than larger myomatous submucous tumors, rarely causing alarming bleeding. Yet the presence of any submucous growth predisposes to infection of the endometrium, and this readily extends to the tubes, so that hydrosalpinx, as already noted (p. 1077), is a frequent complication, Or infection may spread directly to the tumor mass, causing a very serious form of septic metritis.

Diagnosis.—This is made from attention to the history of the case, from observation of the symptoms, and, most important of all, from the physical examination. It is especially important in every case to *exclude the presence of pregnancy:* a large interstitial myoma, particularly if softened as the result of passive congestion with edema, may so closely simulate pregnancy as to deceive even the elect. Too much reliance should not be placed on the history in such cases, if it is impossible to corroborate the patient's tale; many women would be pleased to be relieved of a pregnancy by hysterectomy, and are wilfully deceitful. Usually, however, in pregnancy the cervix is softer, the uterus feels more cystic, the menses are absent, and always (if the policy of "waiting and watching" is followed) indisputable signs of pregnancy will declare themselves in time. An *ovarian cyst* may closely resemble a fibroid of the uterus if it is very tense, and particularly if intraligamentary; in some cases nothing short of an exploratory operation will clear the diagnosis. In the case of *pyosalpinx* the history is different; the mass usually is posterior to the uterus and fixed; there is more leucorrhea than in fibroids, and menstruation is irregular rather than prolonged or profuse. The diagnosis from *carcinoma* and *other malignant tumors* rarely is difficult.

Adenomyoma of the uterus occurs in 5 per cent. or more of cases. The glandular elements are derived either from the endometrium (Cullen, 1903), or from remnants of the Wolffian body in the walls of the uterus (von Recklinghausen, 1896). The tumors frequently are infiltrating in character, but occasionally subperitoneal more or less encapsulated growths develop, or even polypi. Cyst formation is the only form of degeneration which is common. The *symptoms* are much the same as in cases of ordinary fibroids, and the *diagnosis* seldom is made except in the pathological laboratory. The existence of this variety of myoma may be suspected, however, if the tumor is very adherent, and particularly if it is cystic and the contents of the cysts are chocolate colored (menstrual fluid). The proper *treatment* is hysterectomy.

Prognosis.—The prognosis of uterine fibroids is not good. Until some symptoms are produced, the growths often pass undiscovered. But, when symptoms of any kind once have appeared, it is rare for the patient ever again to be free from discomfort. The menopause is indefinitely deferred, and the tumor usually continues to grow.

Not to mention various degenerations (calcareous, myxomatous, cystic, hyaline, malignant) of the tumors, which occur in about 20 per cent. of cases, and the ever-threatening degeneration of the cardiac muscle, which is almost inevitable, the woman is subject to the dangers of hemorrhage, miscarriage, sepsis, inversion of the uterus, etc.

Treatment of Uterine Fibroids.—We hear reports lately of favorable results secured by *x*-rays and radium treatment, just as some years ago much was heard of the electric treatment advocated by Apostoli, and even before that time of the curative value of ergot. Whether these new departures will prove more lasting than their predecessors time alone can show; but for the present and immediate future at least, the treatment advised and practised by rational surgeons is operative. *The tumors should be removed.* In some comparatively young women who are anxious to bear children, it may be justifiable to remove the individual tumors, leaving the main bulk of the uterus intact. This is especially the case when a polypus is present, without other demonstrable growths. Polypi may be removed through the vagina after the division of the pedicle by scissors or by formal excision from the uterine wall. Temporary division of the cervix may be necessary. Bleeding from the stump of the polyp rarely is severe and may be controlled by packing if suture is impossible. Isolated subperitoneal growths may be removed by excision and enucleation through an abdominal wound; the operation is known as *myomectomy*. The objections to it (largely theoretical) are that other tumors almost surely are overlooked and will subsequently give rise to trouble; that even should pregnancy follow it is very apt to be terminated prematurely; and that should pregnancy continue to term, grave complications may arise during parturition or the puerperium from other fibroids which have grown during the pregnancy. But in a small proportion of cases, carefully selected, the operation is of value.

In the great majority of cases removal of the uterus (*hysterectomy*) is preferable. This may be accomplished by the vaginal route (*vaginal hysterectomy*) if the uterus is small; but in most cases the abdominal operation is required. If the uterus is amputated above the cervix the operation is known as *supravaginal hysterectomy;* if the cervix also is removed the proper term is *pan-hysterectomy*. In most cases the tubes and ovaries are removed also (*complete* supravaginal or pan-hysterectomy).

Abdominal Hysterectomy.—The fundus of the uterus is drawn through the abdominal wound by volsellum forceps, and one broad ligament is exposed by drawing the tumor well to the other side. Clamps may then be applied to both sides of the proposed section, leaving the adnexa attached to the uterus if they are diseased (Fig. 1029). In many cases it is simpler to ligate the ovarian vessels at once, applying clamps only to the uterine side of the broad ligament. Hemorrhage being thus controlled, the broad ligament is divided with scissors down to the level of the cervix, but not far enough to

wound the uterine artery, which has not yet been secured. The round ligament is then ligated close to the uterus, and divided between the ligature and uterus. The tumor is then pulled to the patient's other side, and the broad and round ligaments are divided as on the first side. This frees the uterus so that in most cases the cervix can be drawn up into the abdominal wound. The tumor is then turned backward, and an incision is made from one round ligament to the other somewhat above the vesical reflection of peritoneum. The peritoneal flap thus formed is pushed away from the cervix by gauze dissection, until at the sides of the cervix the uterine vessels are exposed. These

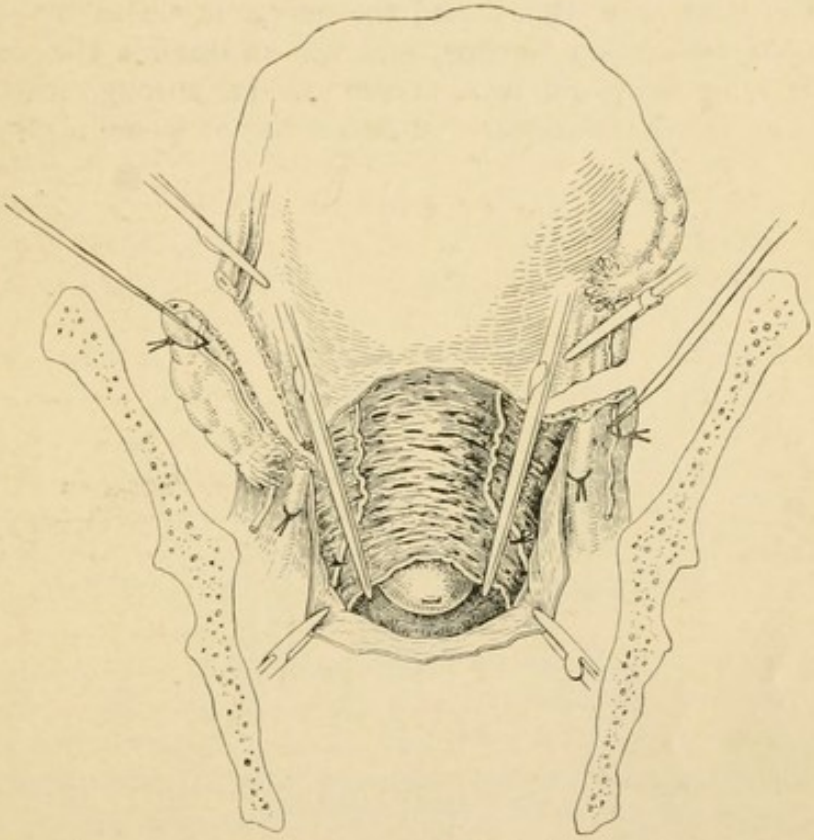

FIG. 1029.—Diagram to show technique of abdominal panhysterectomy: on the right of the picture the left ovary and tube are being removed with the uterus; the right ovary is not being removed. Ligatures have been placed on the ovarian and uterine arteries and on the round ligaments on both sides, and the tissues close to the uterus have been clamped. The anterior vaginal fornix has been opened exposing the cervix.

are clamped close to the uterus and ligated not more than half an inch distant; the ureter crosses under the uterine artery about three-quarters of an inch (2 cm.) distant from the cervix. The uterine vessels are then divided on both sides, between clamp and ligature. The uterus is then turned well forward over the pubes, and an incision is made across its body above the pouch of Douglas, from one broad ligament attachment to the other; and the peritoneal flap thus formed is pushed downward by gauze dissection. Finally the cervix is cut through with scissors in funnel shape, and the uterus is removed. The cervical canal is then closed with catgut sutures, and the stumps

of the round and broad ligaments are sutured to it, so as to support it in proper position. Then the peritoneal flaps front and back are united over the cervical stump, closing in all areas denuded of peritoneum. In most cases the abdomen is closed without drainage.

If it is desired to remove the cervix also, the dissection must be carried a little deeper; then the vaginal vault is divided. The surgeon must look for bleeding from the vaginal arteries and secure a dry field before proceeding. Finally, the stumps of the round and broad ligaments are implanted into the vaginal vault.

Vaginal Hysterectomy.—This is suitable only in cases where the tumor is small, and the vagina sufficiently relaxed. A self-retaining speculum is used (Fig. 1002), and the cervix is closed by sutures or by a double tenaculum forceps, and drawn outside the vulva. An incision is next made all around the cervix, through the mucosa; the incision in the anterior cul-de-sac is deepened, pushing the

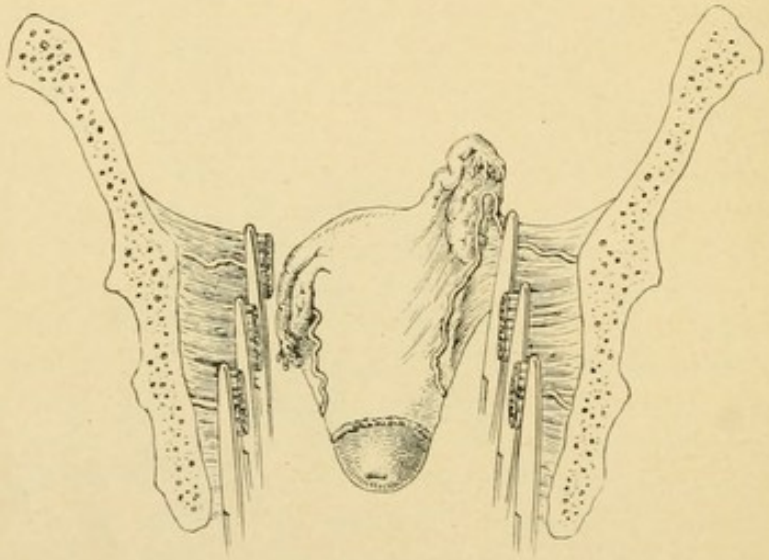

Fig. 1030.—Diagram of vaginal hysterectomy, showing application of clamps to the broad ligaments.

bladder wall and with it the ureters well upward and forward, until the peritoneal cavity is opened. A finger is then inserted into the pelvic cavity and passed behind the cervix, and on this finger as a guide the posterior vaginal cul-de-sac is further incised until the peritoneal pouch of Douglas is opened. Gauze is then packed into this opening to keep the intestines from prolapsing into the wound. Any bleeding is easily controlled by hemostats. If the tumor is not too large, the fundus of the uterus may now be hooked down by the finger and brought out through the incision in the anterior vaginal cul-de-sac. If this can be accomplished the broad ligaments may then be ligated from their ovarian border downward to the cervix, as in supravaginal hysterectomy. If the fundus of the uterus cannot be delivered in this way, the broad ligaments are clamped from below upward, not more than half an inch distant from the cervix, removing the tubes and ovaries also if they are diseased (Fig.

1030). The broad ligaments are then cut through between the clamps and the uterus; and the peritoneum is closed, the gauze pack being removed as the last peritoneal suture is tied. After carefully ligating the broad ligaments, their stumps are sutured to the vaginal vault. A gauze drain is left in the vagina. The operation may be done also without ligatures, leaving the clamps on the broad ligaments for several days. Special clamps, with detachable handles, have been devised for this purpose.

Carcinoma of the Uterus.—This is exceedingly common, especially in the cervix. Only about 5 to 10 per cent. of cases occur in the body of the uterus. In the cervix the growth almost always is a squamous-celled epithelioma, though carcinoma of the glandular type (adenocarcinoma) sometimes occurs; while in the body of the uterus the tumor, with a very few rare exceptions, is an adenocarcinoma. Most patients are in the fourth decade of life, approaching or past the menopause; almost all have borne children, and many have had lacerations of the cervix which have not received proper treatment.

Carcinoma of the Cervix occurs in two forms: (1) as an *everting, vegetating, proliferating*, or *cauliflower-like growth;* or (2) as an *inverting, infiltrating*, and *contracting growth*. At an early stage of the disease these two types are quite distinct, but later the carcinomatous tissue tends to become necrotic, and when sloughs have been shed the cervix is represented only by a crater-like cavity filled with purulent débris (Fig. 1027). The everting type is more easily recognized at an early date, owing to the papillary excrescences which form; whereas in the infiltrating type very extensive invasion of the cervical tissues may occur before there is much alteration in the appearance of its vaginal surface.

Extension occurs to all surrounding tissues, but in no definite order. The bases of the broad ligaments frequently are invaded early, so that the uterus becomes fixed; the ureters are surrounded and may become compressed by the growth; the pelvic lymphatics up to and even beyond the bifurcation of the aorta are invaded; sometimes extension to the inguinal lymphatics occurs; the growth extends locally into the vaginal vault, and the bladder and even the rectum may be infiltrated, so that late in the disease distressing vesico-vaginal fistulæ (rarely recto-vaginal) may form. In most cases the uterine body remains free of disease, the carcinomatous growth rarely extending above the level of the internal os.

Symptoms.—These usually are absent or are overlooked until the disease is quite far advanced; only from 10 to 20 per cent. of patients applying for treatment are susceptible of cure. The most important symptom, and usually the earliest, is *bleeding*, especially intermenstrual or occurring after the menopause. Usually this bleeding occurs spontaneously, and is moderate or apparently insignificant in amount; it may follow coitus or defecation; occasionally it is profuse and prostrating. Such a sudden and alarming hemorrhage almost always is due to carcinoma and not to fibroids. The bleeding is painless as a

rule, and unless the woman notes its occurrence and submits to vaginal examination, she may go along for months before anything further occurs to call attention to her condition. There may be, indeed there usually is, a certain amount of *leucorrhea;* and the serous, watery, or blood-stained character of this, and at a later period its fetor, may arrest her attention. *Pain* is a late and unimportant symptom; it rarely is severe until the sacral plexus is involved and the tumor entirely inoperable.

The disease may thus be divided clinically into *three stages:* (1) the *stage of occasional hemorrhage;* (2) the *stage of gradual decline of health, with fetid leucorrhea;* and (3) the *inoperable, hopeless stage*, with excruciating pain, and disgusting odor, the patient's condition being loathsome to herself and all about her. The average duration of the disease from first symptoms to death averages from fifteen to twenty months.

Carcinoma of the body of the uterus presents the same symptoms, but they develop at a much later period, and are not attended by any definite physical signs, except slight enlargement of the uterus. It is much more frequent in women who have borne no children than carcinoma of the cervix.

Diagnosis.—Every woman whose symptoms suggest the mere possibility of the disease should be submitted to a competent surgeon for a most painstaking vaginal examination; any alteration in the cervix, especially if bleeding is easily aroused, should be regarded as suspicious, and a section should be taken for microscopic study. This is easily done after swabbing the cervix inside and out with 10 per cent. eucain solution; the section (removed with knife or scissors) should extend from the cervical canal into apparently healthy tissue, and should be submitted to a pathologist for prompt report. If a carcinoma of the uterine body is suspected, the curette should be used, and the scrapings mounted and examined histologically.

Treatment.—A radical operation, similar in scope to that practised in cases of carcinoma of the breast, and involving removal of the pelvic lymph nodes and connective tissues in one mass with the diseased uterus, was systematized in 1895 by Ries, elaborated by Sampson, and popularized by Mackenrodt, Wertheim, and others; but while in theory this procedure is correct, it is found that the immediate mortality even in the hands of skilled gynecological operators is about 25 per cent. An inexperienced surgeon will not be able to do a complete operation, and in his attempt to be ultra-radical probably will do more harm than good. Many investigators claim that a truly radical operation is impossible, and point out that autopsies have shown that whenever carcinomatous lymph nodes were removed at operation, others were overlooked. It seems to me that we must look upon these radical methods as still upon trial, and only to be attempted by exceptionally skilled and experienced operators in carefully selected cases. *When the uterus is not fixed* its removal by the ordinary method of pan-hysterectomy (p. 1106), paying special attention to wide excision of the vaginal vault, but without attempts

to dissect the pelvic lymph nodes, is an operation not attended by an unjustifiable primary mortality; and many patients so treated will be restored temporarily to health and enjoyment of life; and when recurrence or metastasis takes place, as it almost surely will, the condition will be much less distressing than if no operation had been performed.

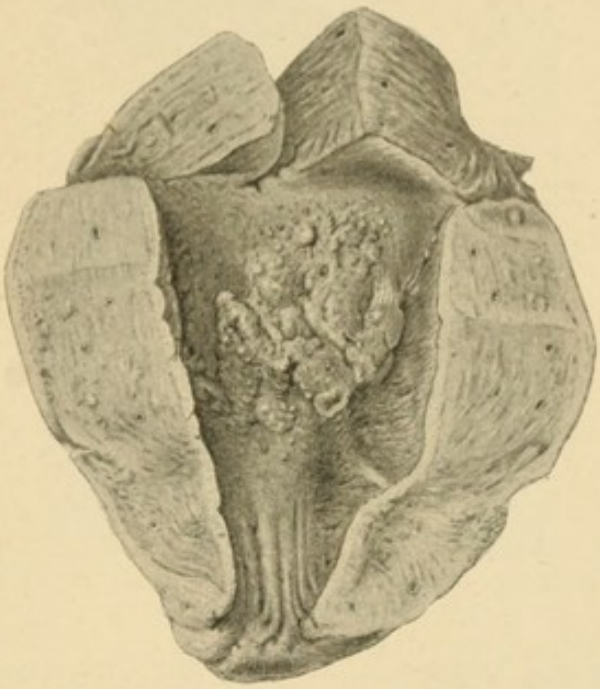

FIG. 1031.—Chorio-epithelioma malignum, in a patient aged forty-two years. Diagnosis made from microscopical examination of scrapings from endometrium ten days after an abortion. Immediate hysterectomy. Episcopal Hospital.

When the uterus is fixed, and its removal appears impossible, the patient's comfort may be greatly promoted and her life prolonged by scraping away the cervical growth with a curette, and cauterizing its base thoroughly with the actual cautery. This palliative operation may be repeated every few months, and may be used in cases of recurrence after hysterectomy. It deserves to be employed with more enthusiasm than is usually accorded to palliative operations.

Chorio-epithelioma, or **Deciduoma Malignum** (Sänger, 1888), is an exceedingly malignant tumor growing in the body of the uterus after pregnancy. The pregnancy frequently is terminated before term, and the most favorable cases are those in which the diagnosis is made by the pathologist from examination of retained tissues removed in such cases (Fig. 1031). Such examination never should be neglected. The tumor probably arises from the chorionic and not from the decidual tissues; it behaves like the most malignant types of sarcoma, giving early venous metastasis, especially to the lungs (78 per cent.) and vagina (54 per cent.) (Dorland). Vaginal growths may be the only evidences of the disease. The chief *symptoms* resemble those of uterine carcinoma, namely bleeding, and watery leucorrhea. The proper *treatment* is pan-hysterectomy, if the diagnosis is made

before distant metastases occur. Removal of vaginal growths in cases where the uterus appears free from the disease, has occasionally proved successful.

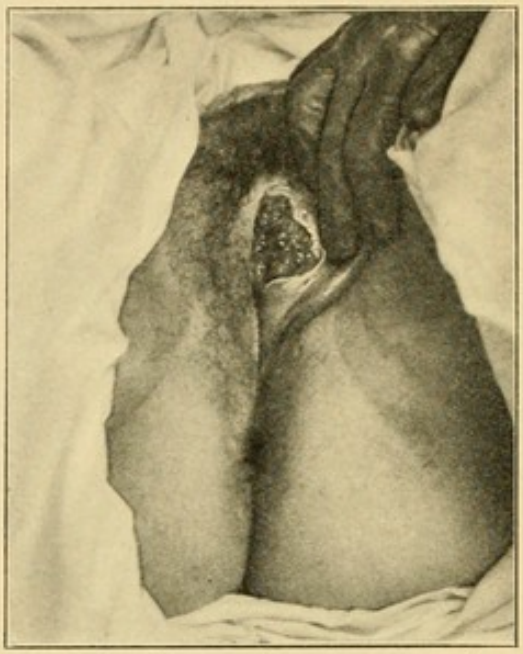

Fig. 1032.—Carcinoma of vulva; age forty-five years; duration eight months. Pennsylvania Hospital.

Carcinoma of the Vulva is not very rare (Fig. 1032). Extension occurs to the inguinal lymph nodes, and radical operation requires the extirpation of these on both sides, the technique being similar to that adopted in cases of carcinoma of the external genitals of the male.

INDEX.

A

Abdomen, gunshot wounds, 191
treatment, 845
injuries, 840
operation, 842
operations, 818
stab wounds, 844
Abdominal incisions, 818
operation, after-treatment, 825
preparation of patient, 823
technique, 823
section, 818
surgery, 802
tumors, diagnosis, 953
wall, contusion, 840
rupture, 840
Ablation of breast, 721
Abortion, tubal, 1090
Abrasions, 159
Abscess, 26, 47
acute, 47
treatment, 50
Hilton's method, 51, 675
alveolar, 657
appendicular, 858
treatment, 860
axillary, 729
Bezold's, 631
bone, 437
brain, 579
Brodie's, 437
chronic, 47
cold, 47, 79
treatment, 483
digital, 279
gluteal, 607
iliac, 607, 813
ischiorectal, 607, 903
liver, 936
lumbar, 607
lung, 748
mammary, 700
chronic, 701
metastatic, 73
neck, 675
ovary, 1078
palmar, 279
pancreas, 946
pelvic, 813, 1077, 1096
extraperitoneal incision, 1096
vaginal puncture, 1096
pelvirectal, 904
Abscess, peri-anal, 903
perinephric, 977
peritonsillar, 663
peri-urethral, 1027
phlegmonous, 47
pointing, 48
prostate, 1028
psoas, 607
residual, 805
peritoneal, 813
retropharyngeal, 606
scrofulous, 47
secondary, 73
spleen, 955
subcranial, 578
submammary, 702
subpectoral, 730
subphrenic, 813
subscapular, 731
tongue, 647
tubo-ovarian, 1077
vulvo-vaginal, 1071
Acapnia, 172
Achillodynia, 267
Achondroplasia, 417
Acne hypertrophica, 620
Acromegaly, 424
Acromioclavicular dislocation, 394
Actinomycosis, 84
Acupressure, 229
Acupuncture, 142
Adamantinoma, 112
Adenitis, 269
cervical, 674
Adenocarcinoma, 125
Adenoma, 119
of breast, 713
of rectum, 913
Adenomatosis, 119
Adenomyoma of uterus, 1105
Adenosarcoma, 106
Adherent prepuce, 1046
Adhesions, peritoneal, 814
Ainhum, 64
Air-hunger, 227
Air passages, foreign bodies, 665
operations, 668
surgery, 665
sinuses, operations, 655
Albert-Lembert suture, 829
Albert's disease, 267
Albumosuria (Bence-Jones), 113
Alexander's operation, 1086

Alexins, 23
Alimentary glycosuria, 948
Allis's sign, 364
Alveolar abscess, 657
border, tumors, 660
Amebic dysentery, 895
Amicrobic meningitis, 579
Amputating knives, 195
Amputations, 192
ankle-joint, 211
arm, 207
Ashhurst's, 212
Billroth's, 216
breast, 710
Chopart's, 211
cinematoplastic, 202
circular method, 197
conditions requiring, 192
dressing, 196
elbow, 207
elliptical method, 199
fingers, 205
flap method, 199
foot, 210
forearm, 206
Gritti's, 213
Guthrie's, 214
Hancock's, 214
hand, 205
Hey's, 210
hip-joint, 214
instruments, 192
interilioabdominal, 216
intermediate, 203
interscapulo-thoracic, 210
knee-joint, 213
Larrey's, 215
Lee's, 212
leg, 212
Lisfranc's, 210
medio-tarsal, 211
metacarpal, 206
methods, 197
modified circular method, 199
mortality, 203
multiple, 200
operative procedure, 195
oval method, 199
penis, 1050
Pirogoff's, 211
primary, 203
secondary, 203
Sédillot's, 212
Senn's, 215
shoulder-joint, 207
Skey's, 210
special, 205
subastragalar, 211
supracondylar, 213
Syme's, 211
Textor's, 211
thigh, 213
transcondylar, 213
traumatic, 192
wrist-joint, 206
Anaplasty, 225
Anastomosis, intestinal, 832
end-to-end, 833
lateral, 834
Murphy button, 839
nerve, 286
Anatomical tubercle, 76
Anel's ligation, 254
Anemia, splenic, 955
Anesthesia, 148
accidents, 151
chloroform, 152
ether, 149
ethyl chloride, 152
general, 148
administration, 153
choice, 152
in head operations, 153
infiltration, 156
in intrathoracic operations, 153
intratracheal insufflation, 154
local, 155
in neck operations, 153
nerve blocking, 157
nitrous oxide, 152
primary, 150
spinal, 157
vein, 158
Anesthetics, 148
Aneurysm, 247
by anastomosis, 247
Anel's ligation, 254
bone, 446
Brasdor's ligation, 255
cirsoid, 247
classification, 249
dissecting, 249
electrolysis, 256
extirpation of sac, 256
false, 248
osteoid, 113, 446
filipuncture, 256
Hunter's ligation, 254
ligation, 254
Matas's operation, 257
racemose, 247
saccular, 249
traumatic, 233, 247
treatment, 253
non-operative, 253
operative, 253
true, 248
tubular, 249
varicose, 235
venous, 233
Wardrop's ligation, 255
wiring, 256
Aneurysmal bruit, 252
varix, 235
Aneurysmoplasty, 258
Angeioleucitis, 268
Angeioma. *See* Hemangeioma
of breast, 713
Angeiotripsy, 229
Angina Ludovici, 645
Ankle dislocation, 413
tuberculosis, 500

Ankle-joint amputation, 211
Ankylosis, 467
treatment, 467
tuberculous, 487
Anoci-association, 148
Anteflexion uteri, 1086
Antethoracic esophago-jejuno-gastrostomy, 696
Anteversion uteri, 1086
Anthrax, 87
treatment, 89
Antibacterial sera, 45
Antisepsis, 36, 139
Antiseptic methods, 141
Antiseptics, 36
Antitoxic sera, 45
Antitoxins, 23
Antyllus, operation of, 255
Anuria, calculous, 981
Anus, carcinoma, 913
false, formation of, 914
fissure, 905
surgery, 900
Apoplexy, 576
Appendicitis, 848
acute, 851
causes, 850
chronic, 863
complications, 857
diagnosis, 852
gangrenous, 861
obliterans, 849
operation, 854
pathogenesis, 848
peritonitis, 862
simple phlegmonous, 849
symptoms, 851
treatment, 854
ulcerative, 849
Appendicostomy, 896
Appendicular abscess, 858
treatment, 860
Appendix, carcinoma, 864
coprolith, 850
cyst, 850
empyema, 850
fecal concretion, 850
foreign bodies, 850
intussusception, 864
removal, 855
stricture, 850
surgery, 848
tuberculosis, 864
Arm, amputation, 207
Arrow-wounds, 170
Arsenic poisoning, bones in, 659
Arterial embolism, 242
thrombosis, 241
varix, 247
Arteriectasis, 248
Arteries, ligation, 230
methods, 231
rules for, 230
Arteriosclerosis, 241
Arteriovenous wounds, 235
Arteritis, 241
Arthrectomy, 486
Arthritis, 462
acute, of infants, 464
rheumatic, 473
atrophic, 452
cryptogenous, 473
deformans, 452
gonococcic, 471
hypertrophic, 456
metastatic, 473
nodosa, 452
pneumococcic, 471
rheumatoid, 452
senile, 456
subpyemic, 473
syphilitic, 503
tuberculous, 476
operation in, 486
typhoid, 472
villous, 462
Arthrodesis, 528
Arthrolysis, 468
Arthroplasty, 471
Ascites, 940
Asepsis, 36, 139
Aseptic fever, 70
methods, 141
Ashhurst's amputation, 212
excision of knee, 469
Aspiration, 147
Astragalectomy, 521
Astragalus, dislocation, 414
fracture, 383
Auditory canal, furuncle, 628
Auricle, prominence of, 629
supernumerary, 629
Autotransfusion, 175
Axillary abscess, 729
infusion, 144
Azotorrhea, 947

B

Bacillary dysentery, 895
Bacteria in inflammation, 18
pathogenic, 18
pyogenic, 28
saprophytic, 19
toxins, 19
Bacteriemia, 70
Bacteriolysins, 23
Bacteriuria, 964
Balanitis, 1048
Balano-posthitis, 1048
Bandage, figure-of-eight, 135
many-tailed, 135
plaster of Paris, 137
recurrent, 135
of Scultetus, 135
spiral, 135
reversed, 135
T-, 135
varieties, 135
Bandaging, 133
Banti's disease, 955

Bartholin's gland, cyst of, 1072
Bartholinitis, 1071
Barton's fracture, 355
Basedow's disease, 688
Bassini's operation, 787
Bayonet wounds, 170
Bazin's disease, 264
Beck's bismuth paste, 484
operation, 1044
Bed-sore, 62
Bezold's abscess, 631
Bier's hyperemia, 40
Bile-ducts, carcinoma of, 942
infections, 919
operations, 928
surgery, 919
Biliary calculus, formation of, 919
colic, 924
fistula, post-operative, 928
sand, 922
Billroth's amputation, 216
gastrectomy, 881
powder, 219
Birth injuries, 1081
"Birth-mark," 244
Bismuth paste, 484
Bistoury, 49
Bites, 170
Bladder, calculus in, 966
carcinoma, 966
diverticula, 965
exstrophy, 962
foreign bodies, 971
injuries, 971
irrigation, 964
papilloma, 966
post-prostatic pouch, 1031
rupture, 971
surgery, 958
tuberculosis, 965
tumors, 966
Blank cartridge wounds, 186
Blastoma, 104
Blastomatoid growths, 107
Blastomycosis, 86
Blood-vascular system, diseases, 237
surgery, 227
Bloodvessels, gunshot wounds, 186
subcutaneous injuries, 233
suture of, 234
wounds, 233
Boas's area, 924
Boil, 261
Bone abscess, 437
aneurysm, 446
atrophy, 416
carcinoma, 450
caries, 431
congenital absence, 504
cysts, 445
diseases, 416
felon, 280
fibromas, 445
gunshot wounds, 186
infection, 425
lacunar resorption, 416
Bone necrosis, 431
osteomyelitis, 426
Paget's disease, 423
sarcoma, 446
syphilis, 440
transplantation, 504
tuberculosis, 437
tumors, 443
wax, 435
Bottini operation, 1036
"Bottle operation," 1060
Bougie à boule, 1015
Bougies, 1015
filiform, 1015
Braces, 611
Bradford frame, 482
Brain abscess, 579
treatment, 581
compression, 571
concussion, 569
contusion, 569
cysts, 582
endothelioma, 581
sarcoma, 582
surgical affections, 567
syphiloma, 581
tuberculoma, 581
tumor, 581
decompressive operation, 589
treatment, 585
Branchial cysts, 682
Branchiogenic carcinoma, 683
Brasdor's ligation, 255
Breast, ablation of, 721
abscess, 701
adenoma, 713
adeno-sarcoma, 712
amputation, 710
angeioma, 713
caked, 700
cancer cyst, 720
carcinoma, 714
cauterization, 726
extension, 720
inoperable, 725
medullary, 719
oöphorectomy, 726
operation, radical, 721
end-results, 725
recurrence, 725
scirrhous, 715
simplex, 719
congenital anomalies, 699
cystadenoma, 712
cystadenomatosis, 707
cystic disease, 707
cystosarcoma phyllodes, 712
enchondroma, 713
endothelioma, 713
fibro-adenoma, 711
fibro-adenomatosis, 706
fibrocystadenoma, 712
gumma, 704
hydatid disease, 712
hypertrophy, idiopathic, 706

Breast, hypertrophy, senile parenchymatous, 707
involution, 707
irritable tumor, 702
lipoma, 713
myxoma, 711
neuralgia, 702
papillary cystadenoma, 712
plastic resection, 711
sarcoma, 713
scirrhus, 715
sero-cystic sarcoma, 712
surgery, 699
syphilis, 704
tuberculosis, 704
tumors, 705
benign, 710
malignant, 713
Brisement forcé, 468
Broad ligament cyst, 1099
Brodie's abscess, 437
Bronchiectasis, 749
Bronchoscopy, 666
Bryant's line, 364
Bubo, 269
chancroidal, 1006
parotid, 624
syphilitic, 992
Bubon d'emblée, 269
Bubonocele, 779
Budin's sign, 701
Bulbar symptoms, 572
Bullet wounds, 183
Bunion, 259
Burns, 217
duodenal ulceration, 218
electric, 222
treatment, 219
wounds, 266
x-ray, 222
Bursitis, 267

C

Cachexia in malignant growths, 103
thyreopriva, 688
Caked breast, 700
Calcaneum, fracture, 383
Calculous anuria, 981
Calculus, biliary, formation of, 919
varieties, 922
lacteal, 704
pancreatic, 949
preputial, 1048
renal, 977
salivary, 627
ureteral, 981
urinary, formation of, 977
vesical, 966
Callositas, 259
Callous ulcer, 55
Callus, 304
Cammidge reaction, 948
Cancer cyst of breast, 720
Cancrum oris, 63
Capillary nevi, 244
Caput obstipum, 537
succedaneum, 551
Carbolic acid gangrene, 60
Carbuncle, 261
of lip, 641
Carcinoma, 119, 123
anus, 913
appendix, 864
basal-celled, 123
bile-ducts, 942
bladder, 966
bone, 450
breast, 714
cauterization, 726
extension, 720
inoperable, 725
operation, radical, 721
end-results, 725
recurrence, 725
cecum, 895
cervix, 1109
columnar-celled, 125
cylindrical-celled, 125
encephaloid, 126
epiblastic, 119
esophagus, 698
gall-bladder, 942
glandular, 125
hypoblastic, 119
jaw, 660
kidney, 983
larynx, 668
liver, 941
lymph nodes, 273
medullary, 125
pancreas, 950
penis, 1049
permeation, 120
prostate, 1042
rectum, 913
scirrhous, 125
simplex, 126
solid-celled, 125
squamous-celled, 121
stomach, 873
thyroid, 692
tongue, 649
tonsil, 664
treatment, 127
uterus, 1109
vulva, 1112
Cardiolysis, 237
Caries of ribs, 731
sicca, 477
of skull, 429
Carotid gland, tumors of, 680
Carpus, dislocation, 404
fracture, 359
Castration, 1056
Catarrhal jaundice, 921
Catheter, double-elbowed, 1034
introduction, 959
Mercier, 1034
Catheterism, 1034

Catheters, 958
Cauterization, 142
Cavernous angeiomas, 245
sinus thrombosis, 577
Cecal hernia, 785
Cecostomy, 896
Cecum, carcinoma, 895
mobile, 898
Cellulitis, 66
pelvic, 1094
Cephalhematoma, 551
Cephalocele, 553
Cerebral palsies, 530
Cerebritis, 579
Cervical ribs, 539
Cervix, carcinoma, 1109
laceration, 1081
stenosis, 1070
Chancre, 83, 989
Hunterian, 83
mixed, 991
superficial erosion, 83
of tongue, 649
Chancroid, 1005
treatment, 1007
Chancroidal bubo, 1006
treatment, 1008
Charbon, 87
Charcot's intermittent fever, 926
joint, 460
Chauffeur's fracture, 355
Cheeks, epithelioma, 624
keratosis senilis, 622
lupus, 624
plastic operations, 623
rodent ulcer, 624
seborrheic patch, 622
surgery, 622
Cheloid, 109
Chemotaxis, negative, 21
positive, 21
Chest wall, injuries, 726
malformations, 726
rachitic deformities, 726
surgery, 699
Chilblain, 222
Chloroform anesthesia, 152
Chloroma, 114
Cholangeitis, 921
Cholecystectomy, 931
Cholecystendysis, 930
Cholecystenterostomy, 934
Cholecystoduodenostomy, 934
Cholecysto-gastrostomy, 934
Cholecystitis, 919
calculous, 925
chronic, 920
treatment, 921
Choledocho-enterostomy, 928
Choledochostomy, 932
Choledochotomy, 932
retroduodenal, 933
transduodenal, 934
Cholelithiasis, 922
Murphy's test, 924
simple, 923
Cholelithiasis, treatment, 926
Cholemia, 926
Cholesteatoma, 129
Cholesterin, gall-bladder, 922
Chondrectomy, 748
Chondroma, 110
Chondrosarcoma, 116
Chopart's amputation, 211
Chordoma, 114
Chorio-epithelioma, 106, 1111
Chromoureteroscopy, 961
Chyle duct, wounds of, 268
Chylothorax, 268, 738
Chylous ascites, 268
Cicatrization, 30, 53
Cigarette drain, 52
Cinematoplastic amputation, 202
Circumcision, 1046
Cirrhosis, liver, 940
of stomach, 872
Cirsoid aneurysm, 247
"Clacking jaw," 392
Clavicle, dislocation, 392
fracture, 326
Clavus, 259
Cleft palate, 634, 638
operation, 638
scrotum, 1043
Cloacæ, 426
Cloquet's hernia, 794
Club foot, 515
hands, 515
Cocain anesthesia, 155
Coccygodynia, 325
Coccyx, fracture, 325
Cock's operation, 1025
Coin-catcher, 694
Cold abscess, 79
effects of, 221
Coley's fluid, 117
Colic, renal, 979
Colitis, 895
Collapse, 172
Colles's fracture, 351
law, 998
Colon, surgery of, 895
Colostomy, 915
Colpocele, 1082
anterior, 1088
Colpo-perineorrhaphy, 1083
Colporrhaphy, posterior, 1083
Common duct, obstruction, 928
stone in, 925
Compression of brain, 571
treatment, 574
Concussion of brain, 569
of spinal cord, 594
Condylomata lata, 995
Congenital absence of bone, 504
deformities, 504
megacolon, 900
talipes, 515
Congestion, 20
Constipation, 899
Contracture, palmar fascia, 542
Volkmann's, 540

Contractures of muscles, 276
Contused wounds, 167
Contusion, 159
abdominal wall, 840
brain, 569
joints, 385
nerves, 282
scalp, 551
Cooper's hernia, 794
Corn, 259
Cornu cutaneum, 260
Corona veneris, 995
Corpus luteum cyst, 1097
Corset liver, 935
Costo-transversectomy, 614
Counter-irritation, 142
Courvoisier's law, 926
Coxa valga, 546
vara, 543
Coxalgia, 488
Cranial defects, repair, 567
Craniocerebral topography, 567
Craniotomy, osteoplastic, 586
Cricothyrotomy, 670
Critical discharges, 31
Crural hernia, 793
Crushed limbs, treatment, 294
Crutch-palsy, 282
Cryoscopy, 962
Cryptogenous arthritis, 473
Cryptorchidism, 1050
Cubitus valgus, 346, 540
varus, 346, 540
Cuneiform tarsectomy, 521
Cushing's decompressive operation, 590
suture, 831
Cut-throat, 673
Cylindroma, 128
Cyst or cysts, 129
appendix, 850
Bartholin's gland, 1072
bone, 445
brain, 582
branchial, 682
broad ligament, 1099
corpus luteum, 1097
dentigerous, 112, 661
dermoid, of ovary, 1101
of scalp, 553
extravasation, 129
Graafian follicle, 1097
hydatid, 131
kidney, 984
lip, 640
liver, echinococcus, 938
mesenteric, 895
omental, 895
ovary, 1097
dermoid, 1101
pancreas, 952
parasitic, 131
parovarian, 1099
pilo-nidal, 130, 266
retention, 129
sebaceous, 265
of scalp, 553
Cyst or cysts, sequestration, 130
spleen, 955
thyro-glossal, 681
tubo-ovarian, 1098
urachal, 963
Cystadeno-carcinoma, 125
Cystadenoma, 119
breast, 707, 712
ovary, 1098
papilliferum, 119
Cystadenomatosis of breast, 707
Cystic duct, stone in, 925
Cystitis, 963
Cystocele, 1082, 1088
operation, 1088
Cystoscope, 960
Cystotomy, suprapubic, 970
Czerny's suture, 829
Winkelschnitt, 928

D

Dactylitis, syphilitic, 441
tuberculous, 439
Dance's sign, 886
"Dangle-foot," 528
Deaver's incision, 820
Deciduoma malignum, 106, 1111
Decompression, 574
Decompressive operation, 589
Decortication of lung, 745
Decubitus, 62
Deformities, congenital, 504
of head, 537
of neck, 537
paralytic, 521
Delirium cordis, 690
traumatic, 173
tremens, 174
Demarquay's operation, 1018
Dentigerous cyst, 112, 661
Dermatitis, *x*-ray, 222
Desmoids, 277
Determination of blood, 20
Diacondylar fractures, 341
Diapedesis, 20
Diaphragm, eventration, 751
gunshot wounds, 750
hernia, 751
rupture, 750
stab wounds, 749
surgery, 749
Dietls's crises, 972
Digital abscess, 279
Dilatation of esophagus, 697
of stomach, acute, 869
secondary, 870
Discission of pleura, 746
Disinfection, iodin, 141
Dislocated kidney, 973
spleen, 955
Dislocation of acromio-clavicular joint, 393
ankle, 413

Dislocation of astragalus, 414
carpal bones, 404
clavicle, 392
elbow, 399
fingers, 405
hip, 405
congenital, 507
humerus, 394
knee, 412
congenital, 515
mandible, 391
mediotarsal joint, 415
metacarpus, 404
metatarsus, 415
nerves, 283
patella, 279
phalanges, 404
radiocarpal joint, 403
radius, head of, 402
sacro-iliac joints, 405
scapula, 394
shoulder, 394
congenital, 513
spine, 594
sternoclavicular joint, 392
tarsus, 414
tendons, 278
tibiotarsal joint, 413
vertebræ, 594
wrist, 403
Dislocations, 387
causes, 388
complicated, 391
compound, 390
congenital, 507
consecutive, 388
old, 391
pathological, 388
primitive, 388
recurrent, 391
reduction, 390
special, 391
spontaneous, 388
subastragalar, 415
traumatic, 388
treatment, 390
Dissecting aneurysm, 249
Diverticulum of bladder, 965
of esophagus, 697
Diverticulitis, sigmoid, 897
Drainage tube, 51
Dressing forceps, 49
wounds, 166
Dudley's operation, 1070
Duodenum, ulcer, 864
in burns, 218
chronic, 865
hemorrhage, 868
perforation, 867
treatment, 866
Dupuytren's contracture, 542
suture, 831
Dysentery, amebic, 895
bacillary, 895
Dystrophies of bone, 416
of joints, 451

E

Ear, foreign bodies in, 628
surgery of, 628
Ear-ache, 630
Ecchondroma, 110
Ecchymosis, 159
Echinococcus cyst of liver, 938
Eck's fistula, 941
Ectopic gestation, 1090
Edema of glottis, 668
Edematous ulcer, 54
Elbow, amputation, 207
dislocation, 399
excision, 470
tuberculosis, 501
Electric current injuries, 217
Elephantiasis Arabum, 271
of scrotum, 1062
Embolism, 73, 237
arterial, 241
mesenteric, 890
post-operative, 178
pulmonary, 178, 241
retrograde, 73
Embolus, 73
Embryoma, 106
Empyema of appendix, 850
articuli, 462
gall-bladder, 920
necessitatis, 740
thoracis, 739
bilateral, 744
Emphysema, pulmonary, 748
surgical, 728
Emphysematous gangrene, 65
Encephalitis, 579
Encephalocele, 553
Encephalocystocele, 553
Enchondroma, 110
of breast, 713
Endo-aneurysmorrhaphy, 257
Endocervicitis, 1073
Endometritis, 1073
putrid, 1093
septic, 1094
Endosteoma, 111
Endostosis, 112
Endothelioma, 127
of brain, 581
of breast, 713
Endotoxins, bacterial, 19
End-to-end anastomosis, 833
Enostosis, 112
Enterocele, 755
Entero-epiplocele, 755
Enterorrhaphy, circular, 832
Epicondylitis, 342
Epidemic cerebrospinal meningitis, 578
Epididymitis, 1052
Epididymo-orchitis, 1052
Epididymo-vasostomy, 1053
Epigastric hernia, 771
Epignathus, 106
Epilepsy, focal, 590
Jacksonian, 590

Epiplocele, 755
Epiphyseal separation, 296
Epiphysitis, acute, 436
Epispadias, 1045
Epistaxis, 619
Epithelioma, 121
of cheeks, 624
deep-seated, 121
of lip, 641
papillary, 123
pearly bodies, 122
of scalp, 553
superficial, 123
Epitrochlea, fracture, 344
Epulis, 660
Erasion of joints, 486
Erethistic shock, 173
Erysipelas, 67
phlegmonous, 69
treatment, 69
Erythema induratum, 264
nodosum, 264
Esmarch anemia, 433
Esmarch's elastic band, 194
Esophagotomy, external, 694
internal, 695
Esophagus, carcinoma, 698
dilatation, 697
diverticulum, 697
foreign bodies, 693
imperforation, 697
stricture, 695
surgery, 693
Estlander's operation, 746
Ether anesthesia, 149
Ethmoidal disease, 655
Ethyl chloride anesthesia, 152
Eucain anesthesia, 155
Eventration of diaphragm, 751
Évidement, 436
Excision of elbow, 470
of hip, 497
of inferior maxilla, 662
of joints for ankylosis, 469
of knee, 469
of shoulder, 470
of superior maxilla, 662
of wrist, 470
Excoriation, 159
Exophthalmic goitre, 688
Exostoses, cartilaginous, 443
fibrous, 444
subungual, 444
Exostosis, 112
bursata, 445
Exploring needle, 49
Exstrophy of bladder, 962
Extradural hemorrhage, 574
Extra-uterine pregnancy, 1090

F

Facial hemiatrophy, 660
False anus, 831, 893, 914
Farcy, 89

Fat-embolism, 178
necrosis, 944
Fecal fistula, 893
impaction, 889
Felon, 280
Female genitals, surgery of, 1064
Femoral hernia, 793
treatment, 795
Femur, fracture, 362
shaft of, fracture, 368
Fever, 70
aseptic, 70
surgical, 71
Fibrin, 24
Fibro-adenoma, 119
of breast, 711
Fibro-adenomatosis of breast, 706
Fibroid, 114
recurrent, 116
of uterus, 1102
treatment, 1106
Fibroma, 108
bone, 445
molluscum, 108
neck, 684
Fibromatosis nervorum, 114
Fibromyoma of uterus, 1102
Fibromyxoma, 109
Fibrosarcoma, 109, 116
Fibula, fracture of, 379
Filaria sanguinis hominis, 271
Filariasis, 271
Filiform bougies, 1015
Filipuncture in aneurysm, 256
Fingers, amputation, 205
congenital contraction, 506
supernumerary, 505
webbed, 506
Finney's pyloroplasty, 879
Fissure of anus, 905
of nipple, 700
of Rolando, 568
Fistula, 48, 52
in ano, 904
biliary, 921
postoperative, 928
blind, 52
branchial, 682
Eck's, 941
gastro-colic, 891
genital, 1089
pancreatic, 946
pilo-nidal, 266
pleural, 744
recto-genital, 913
recto-urethral, 913
recto-urinary, 913
recto-uterine, 913, 1089
recto-vaginal, 913
salivary, 626
suprapubic, 1036
thyro-glossal, 681
treatment, 52
umbilical, 891
urachal, 963
uretero-cervical, 1089

Fistula, urinary, 1027
vesico-uterine, 913, 1089
vesico-vaginal, 913, 1089
Fixed dressings, 137
Flat-foot, 547
Floating kidney, 973
Fluxion of blood, 20
Focal epilepsy, 590
symptoms, 572
Foot, amputations, 210
fracture, 382
Forearm, amputations, 206
fractures, 355
Foreign bodies in air passages, 665
in appendix, 850
in bladder, 971
in ear, 628
in esophagus, 693
in nose, 620
in soft parts, 169
Fowler's position, 811
Fracture, acetabulum, 325
astragalus, 383
Barton's, 355
calcaneum, 383
carpus, 359
chauffeur's, 355
clavicle, 326
coccyx, 325
Colles', 351
elbow, 338
face bones, 320
femur, 362
shaft, 368
fibula, 379
forearm, 355
hip, 362
humerus, 331
shaft, 336
larynx, 667
leg, 376
malar bone, 320
mandible, 321
maxilla, 321
metacarpus, 361
metatarsus, 384
by muscular action, 297
nasal bones, 320
olecranon, 348
patella, 372
phalanges, 362, 384
pelvic bones, 323
Pott's, 380
radius, 350
ribs, 323
scapula, 330
skull, 557
spine, 594
sternum, 322
supracondylar, of humerus, 339
tarsus, 382
tibia, 376
trochanter, 368
ulna, 348
vertebræ, 594
zygoma, 320
Fractures, 294
after-care, 309
badly united, treatment, 315
callus, 304
causes, 297
classification, 294
comminuted, 294
complete, 294
complicated, 295
treatment, 312
compound, 294
treatment, 312
delayed union, 306
depressed, 296
diagnosis, 301
double, 294
green-stick, 294
gunshot, 186
impacted, 296
incomplete, 294
mechanism, 297
multiple, 295
pathological, 298
process of union, 303
ring, 559
simple, 294
treatment, 307
operative, 310
skiagraphy, 302
special, 319
spontaneous, 298
sprain, 298
symptoms, 298
treatment, 306
ununited, 306, 316
treatment, 317
Fragilitas ossium, 416
Frazier-Spiller operation, 292
Friar's balsam, 638
Frost-bite, 221
Fungus cerebri, 590
Funnel breast, 726
Furuncle, 261
auditory canal, 628

G

Galactocele, 703
Gall-bladder, carcinoma, 942
cholesterin, 922
empyema, 920
hydrops, 920
infections, 919
operations, 928
perforation, 921
strawberry, 922
surgery, 919
Gall-stones, formation of, 919
in common duct, 925
in cystic duct, 925
in hepatic duct, 926
migrated, 925
varieties, 922
Galt's trephine, 563
Ganglion, 281

Ganglion, gasserian, extirpation of, 291
Gangrene, 58
arterial occlusion, treatment, 62
causes, 59
carbolic acid, 60
diabetic, treatment, 61
dry, 60
emphysematous, 65
foudroyante, 65
hospital, 63
line of demarcation, 60
of separation, 60
of lung, 748
moist, 60
of pancreas, 946
senile, 59
treatment, 61
spreading, 65
symmetrical, 64
symptoms, 60
traumatic, 65
treatment, 61
varieties, 60
Gangrenous stomatitis, 63
Gärtner's duct, 1099
Gasserian ganglion, extirpation of, 291
Gastrectomy, 881
Billroth's, 881
Hartmann's line, 874
partial, 881
subtotal, 884
total, 884
Gastric ulcer, 864
Gastro-anastomosis, 872
Gastro-colic fistula, 891
Gastrogastrostomy, 872
Gastro-intestinal tract, rupture of, 842
Gastrojejunostomy, 879
Gastroplasty, 871
Gastrostomy, 877
Gastrotomy, 876
Genital fistula, 1089
Genitalia, female, examination, 1065
Genitals, female, surgery of, 1064
male, surgery of, 1043
Gersuni's operation, 910
Gestation, ectopic, 1090
Glanders, 89
Gleet, 1011
Glioma, 114
brain, 581
Gliosarcoma, 116
Glossitis, 647
Glottis, edema of, 668
Gluteal abscess, 607
Goitre, 684
colloid, 685
cystic, 686
diffuse, 685
exophthalmic, 688
nodular, 686
operation, 687
parenchymatous, 685
treatment, 687
Gonococcic joint infection, 471
urethritis, 1010
Gonorrhea, 1009
female, 1070
treatment, 1011
abortive, 1012
autogenous vaccines, 1014
prophylactic, 1011
Graafian follicle cyst, 1097
Granulation tissue, 26, 30
tuberculous, 79
Granulations, 30, 53
Granuloma, infectious, 19, 76
Graves's disease, 688
Gritti's amputation, 213
Gumma of breast, 704
of testicle, 1057
of tongue, 649
Gummas, 84, 997
Gunshot wounds, 180
of abdomen, 191, 844
of bloodvessels, 186
of bones, 186
of diaphragm, 750
of head, 188
of intestine, 845
of joints, 186
of liver, 847
of lungs, 189
of nerves, 186
of pancreas, 847
of spine, 189
of spleen, 847
of stomach, 846
of thorax, 189
Guthrie's amputation, 214
Gypsum, 137

H

Hallux valgus, 549
Halsted's suture, 831
Hammer toe, 549
Hancock's amputation of, 211
Hand, amputation, 205
Hare-lip, 634
double, 637
single, 635
Harrison's groove, 726
Hartmann's line for gastrectomy, 874
Head deformities, 553
gunshot injuries, 188
operations, anesthetic, 153
surgery of, 551
Heart, foreign bodies in, 237
injuries, 236
massage, 237
rupture, 236
wounds, 236
Heat, effects of, 217
prostration, post-operative, 179
Heberden's nodes, 456
Hectic fever, 75
Heliotherapy, 484
Hemangeio-endothelioma, 128
Hemangeioma, 244
Hemarthrosis, 387

Hematocele, 1061
Hematocolpos, 1069
Hematoma, 160, 233
auris, 629
Hematometra, 1069
Hematomyelia, 594
Hemiatrophy, facial, 660
Hemilaryngectomy, 672
Hemophilia, 227
Hemorrhage, 227
apparent, 227
arterial, 227
concealed, 227
constitutional signs, 227
extradural, 574
internal, 227
intestinal, in typhoid, 893
intracerebral, 576
intradural, 575
middle meningeal, 575
operative, 176
primary, 177
reactionary, 177
secondary, 177, 232
treatment, 232
subcranial, 574
subcutaneous, 227
treatment, 228
acupressure, 229
cold, 229
forcipressure, 229
heat, 229
ligation, 229
position, 228
pressure, 228
styptics, 229
torsion, 229
venous, 227
Hemorrhagic pancreatitis, 944
peritonitis, 805
Hemorrhoids, 906
treatment, 907
Hemothorax, 737
Hepatic duct, stone in, 926
Hepatico-enterostomy, 928
Hepaticus drainage, 933
Hepatitis, suppurative, 936
Hepatoptosis, 935
Hepatotomy, 937
Hermaphrodism, 1045
Herpes progenitalis, 1048
Hernia, 753
causes, 754
cecal, 785
cerebri, 590
classification, 770
of Cloquet, 794
of Cooper, 794
crural, 793
diaphragmatic, 751
enterocele, 755
entero-epiplocele, 755
epigastric, 771
epiplocele, 755
femoral, 793
operation, 795
Hernia, femoral, rare forms, 794
strangulation, 799
treatment, 795
of Hesselbach, 794
incarcerated, 761
treatment, 761
incisional, 772
inflamed, 760
inguinal, 779
complete, 783
direct, 792
treatment, 793
incomplete, 783
nomenclature, 779
oblique, 780
operation, 787
treatment, 785
properitoneal, 784
strangulation, 784
truss, 786
inguino-crural, 785
irreducible, 759
treatment, 760
ischiatic, 801
labial, 779
Laugier's, 794
Littré's, 755
lumbar, 779
lung, 736
muscle, 274
nomenclature, 754
obstructed, 760
obturator, 799
Partridge's, 794
pectineal, 794
perineal, 800
preperitoneal fat, 771
pudendal, 800
recurrence, 785
reducible, 756
treatment, 757
retrovascularis, 794
Richter's, 755
sac, 754
contents, 755
sigmoid, 785
sliding, 785
special, 770
strangulated, 761
operation, 766
taxis, 766
treatment, 765
supravesical, 792
taxis, 766
of Tessier, 794
truss, 758
umbilical, 774
adult, 776
congenital, 774
infantile, 774
strangulated, 778
vaginal, 800
ventral, 772
Hesselbach's hernia, 794
Hey's amputation, 210
Hilton's method of opening abscesses, 675

Hip, central dislocation, 325
dislocation, 405
congenital, 507
excision, 497
fracture, 362
tuberculosis, 488
Hip-joint amputation, 214
Hirschsprung's disease, 900
Hodgkin's disease, 114, 271
Hollow foot, 515
Horn, 260
Horse-shoe kidney, 972
Horsley's wax, 588
Hospital gangrene, 63
Hour-glass stomach, 871
"Housemaid's knee," 267
Hudson's trephine, 563
Humerus, dislocation, 394
fracture, 331
shaft, fracture, 336
Hunterian chancre, 83
Hunter's ligation, 254
Hutchinson's teeth, 1000
Hydatid cyst of liver, 938
disease of breast, 712
of Morgagni, 1099
Hydrarthrosis, intermittent, 466
Hydrencephalocele, 553
Hydrocele, 1058
acquired, 1059
acute, 1053
of canal of Nuck, 1061
congenital, 1058
of the cord, 1060
encysted, of cord, 1061
of tunica, 1061
funicular, 1060
operation, 1060
treatment, 1060
vaginal, 1059
Hydrocephalus, 554
acquired, 554
congenital, 555
Hydronephrosis, 976
Hydrophobia, 96
furious, 97
paralytic, 97
Pasteur treatment, 99
Hydrops articuli, 462
of gall-bladder, 920
Hydrorachis, 592
Hydrosalpinx, 1077
Hydrothorax, 729
Hygroma, 683
Hylomas, 106
Hyperemesis lactantium, 869
Hyperemia, active, 20
passive, 20
Bier's, 40
Hypernephroma, 127, 983
Hyperostosis, 112
Hypertrophy of bone, 424
of prostate, 1029
Hyperthyroidism, 688
treatment, 690
Hypodermic injections, 143
Hypodermoclysis, 144
Hypoleukocytosis, 31
Hypospadias, 1043
Hypothyroidism, 684, 688
Hysterectomy, abdominal, 1106
vaginal, 1108
Hysteropexy, 1086

I

Ichthyosis of tongue, 647
Idiopathic fragilitas ossium, 416
splenomegaly, 956
Ileus, 884
Iliac abscess, 607
Imperforate anus, 902
esophagus, 697
hymen, 1069
rectum, 902
vulva, 1069
Incarcerated hernia, 761
Incised wounds, 160
Incision, abdominal, 818
closure, 821
Czerny's, 928
Davis's, 821, 854
Deaver's, 821
gridiron, 829
Kehr's, 928
kidney, 985
McBurney's, 820
Mayo Robson's, 820, 928
muscle-splitting, 820
Sprengel's, 928
transverse, 821, 854, 928
Incisional hernia, 772
Indian rhinoplasty, 621
Indigo-carmine test, 961
Infantile paralysis, 521
Infants' arthritis, 464
Infectious granulomas, 19, 76
Infiltration anesthesia, 156
Inflammation, 17
alexins, 23
antitoxins, 23
bacteriolysins, 23
causes, 18
bacteria, 18
exciting, 18
predisposing, 18
toxins, 19
cellular infiltrate, 22
chronic, 35
cure, 37
diapedesis, 20
diseases resulting from, 47
extension, 27
fever, 70
fibrin, 24
fibroblasts, 22
leukocytes, 22
lymphization, 23
lymphocytes, 22
lymphogenesis, 23
margination, 20

Inflammation, migration, 20
modified forms, 76
nervous system, 27
pathology, 19
summary, 29
phlegmonous, 26
pyrexia, 70
regeneration, 30
repair, 29
resolution, 23
resulting affections, 70
subacute, 35
symptoms, 31
heat, 33
impaired function, 34
local, 32
modification of nutrition, 35
muscular rigidity, 34
pain, 33
referred, 33
redness, 32
swelling, 33
tenderness on pressure, 34
terminations, 27
treatment, 35
alteratives, 44
Bier's hyperemia, 40
cathartics, 42
cold, 37
compression, 40
constitutional, 41
counter-irritants, 39
diaphoretics, 43
diet, 41
diuretics, 43
douches, 39
drugs, 42
heat, 38
hygiene, 41
incision, 40
irrigation, 38
local, 37
bleeding, 39
massage, 41
narcotics, 39
operation, 40
position, 37
prophylaxis, 35
rest, 37
sedatives, 42
serum therapy, 44
stimulants, 43
stimulation of phagocytosis, 44
tonics, 44
vaccines, 44
venesection, 39
Inflammatory fever, 71
lymph, 24
Infusion, axillary, 144
intravenous, 145
Ingrowing toe-nail, 260
Inguinal hernia, 779
complete, 783
direct, 792
treatment, 793
incomplete, 783
Inguinal hernia, oblique, 780
properitoneal, 784
strangulation, 784
Inguino-crural hernia, 785
Injuries, 159
general effects, 172
local effects, 159
Insect-stings, 170
Intestinal anastomosis, 832
end-to-end, 833
lateral, 834
Murphy button, 839
localization, 825
stasis, 899
sutures, 828
tract, internal fistulæ, 891
Intestine, gunshot wound, 845
hemorrhage of, in typhoid, 893
obstruction, 884
acute, 885
chronic, 889
diagnosis, 886
operation, 888
treatment, 887
perforation of, suture in, 829
in typhoid, 892
resection, 831
rupture, 843
surgery, 884
tumors, 894
wounds, 830
Intoxication, 70
Intracerebral hemorrhage, 576
Intracranial hemorrhage in newborn, 576
Intradural hemorrhage, 575
Intrathoracic operations, anesthetic, 153
Intratracheal insufflation, 154
Intravenous transfusion, 145
Intubation, 668
Intussusception, treatment, 889
Involucrum, 426
Iodin disinfection, 141
Irreducible hernia, 759
Ischemic contracture, 540
Ischiatic hernia, 801
Ischio-rectal abscess, 607, 903
Italian rhinoplasty, 621

J

Jacksonian epilepsy, 590
Jackson's membrane, 896
Jacob's ulcer, 123
Jaw, carcinoma, 660
fractures, 321
osteomyelitis, 658
necrosis, 658
sarcoma, 661
surgery, 657
tumors, 660
Jejunum, peptic ulcer, 880
Joint, Charcot's, 460
mice, 461
Joints, ankylosis, 467
atrophic lesions, 452

Joints, contusions, 385
diseases, 451
dystrophies, 451
erasion, 486
gunshot wounds, 186
hypertrophic lesions, 456
infection, 461, 471
gonococcic, 471
metastatic, 473
pneumococcic, 471
injuries, 385
loose bodies in, 461
neuropathic, 460
sarcoma, 503
syphilis, 503
tuberculosis, 476
tumors, 503
wounds, 386

K

Kader's gastrostomy, 877
Kehr's incision, 928
operation, 933
Keloid, 109
Kelly's cystoscope, 960
Kidney, anomalies, 972
calculus, 977
carcinoma, 983
cyst, 984
dislocated, 973
floating, 973
functional capacity, 961
gunshot wound, 984
horseshoe, 972
hydrops, 976
infections, 973
injuries, 984
movable, 972
needling, 981
operations, 985
incisions, 985
sarcoma, 983
stab wound, 984
stone, 977
surgery, 958, 972
surgical, 975
tuberculosis, 982
tumors, 983
diagnosis, 953
Killian's operation, 657
Kink, Lane's, of ileum, 896
Knee, dislocation, 412
congenital, 515
excision, 469
tuberculosis, 498
knee-joint, amputation, 213
Knock-knee, 421
Knots, 166
Kobelt's tubules, 1099
Kraske's operation, 916

L

Lacerated wounds, 167
Laceration of cervix, 1081
Laceration of perineum, 1082
Lacteal calculus, 704
Lacunar resorption, 416
Laminectomy, 601
Lane's kink, 896
Laparotomy, 818
Larrey's amputation, 215
Laryngectomy, 672
Laryngo-fissure, 672
Laryngoscopy, 668
Larynx, carcinoma, 668
extirpation, 672
fracture, 667
intubation, 668
papilloma, 668
tumors, 668
Lateral anastomosis, 834
sinus, 567
thrombosis, 577
ventricles, tapping, 555
Laugier's hernia, 794
Leeching, 147
Lee's amputation, 212
Leg, amputation, 212
fractures. 376
ulcer, 55
Leiomyoma, 114
Lembert suture, 828
Leontiasis ossea, 424
Lepidomas, 106
Leptomeninges, syphilis of, 579
Leptomeningitis, 578
Leukocytosis, 31
Leuko-keratosis, 647
Leukoma, 647
Leukopenia, 31
Leukoplakia, 647
Ligaments, shortening round, 1086
silk, 529
Ligation, 229
for aneurysm, 253
Lightning strokes, 222
Line of demarcation, 60
Linitis, plastic, 872
Lip, carbuncle, 641
cysts, 640
epithelioma, 641
surgery, 634
Lipoma, 107
arborescens, 503
of breast, 713
of neck, 684
Lipomatosis, 107
Liquor puris, 26
Lisfranc's amputation, 210
Lithectasy, 970
Litholapaxy, 970
Lithotomy, 970
perineal, 971
Lithotrity, 969
Litigation spine, 594
Littré's hernia, 755
Liver, abscess, 936
anomalies, 935
carcinoma, 941
cirrhosis, 940

Liver, corset, 935
cyst, echinococcus, 938
gunshot wounds, 847
linguiform lobe, 935
Riedel's lobe, 935
rupture, 842
operation, 843
sarcoma, 942
surgery, 935
tumors, 941
Lockjaw, 90
Longitudinal sinus, rupture, 563
thrombosis, 577
Ludwig's angina, 645
Lumbar abscess, 607
hernia, 779
Lumpy jaw, 85
Lung, abscess, 748
decortication, 745
gangrene, 748
hernia, 736
injuries, 733
surgery, 669, 733
tuberculosis, 747
tumors, 749
Lupus vulgaris, 263
of cheeks, 624
Luxations, 387
Lymph, inflammatory, 24
Lymphadenitis, 269
of neck, 674
tuberculous, 676
Lymphangeio-endothelioma, 128
Lymphangeioma, 270
Lymphangeioplasty, 270
Lymphangeitis, 268
Lymphangiectasis, 269
Lymphatic varicocele, 269
Lymphatics, wounds, 268
Lymphedema, 270
Lymphization, 23
Lymphocytes, origin, 22
Lymphoma, 114
sarcomatodes, 272
Lymphomatosis, 114, 271
Lymphorrhea, 268
Lymphosarcoma, 116, 272
Lyssa, 96

M

McBurney's incision, 820
point, 820
Macrocheilia, 640
Macroglossia, 644
Macromelia, 270
Madelung's deformity, 542
Madura foot, 86
Malar bone, fracture, 320
Malignant lymphoma, 271
pustule, 87
Mallein test, 90
Mammary abscess, 701
chronic, 701
gland. *See* Breast.
Mandible, dislocation, 391
Mandible, excision, 662
fracture, 321
tumors, 660
Mania a potu, 174
Manus valga, 542
Margination, 20
Marjolin's ulcer, 123
Mastitis, acute, 700
carcinomatous, 719
chronic, 702
cystic, 706
stagnation, 700
syphilitic, 704
Mastodynia, 702
Mastoiditis, acute, 630
operation, 632
Matas's operation, 257
Mattress suture, 831
Maunsell's operation, 834
Maxilla, excision, 662
fracture, 321
tumors, 660
Mayo Robson's incision, 820, 928
Mayo's operation, 244
Meckel's diverticulum, 891
Mediastinitis, 732
Mediastinum, anterior, surgery of, 732
Medio-tarsal joint, amputation, 211
dislocation of, 415
Megacolon, congenital, 900
Melanoma, 129
Melon-seed bodies, 478
Meloplasty, 624
Meninges, surgical affections of, 567
Meningitis, 578
amicrobic, 579
epidemic cerebrospinal, 578
serous, 579
spinal, 618
tuberculous, 579
meningocele, 553, 592
Meningomyelocele, 592
Mercier catheter, 1034
Merocele, 793
Mesenteric cysts, 895
embolism, 890
thrombosis, 890
Mesosigmoiditis, 898
Mesothelioma, 127
Metacarpal amputation, 206
Metacarpus, dislocation, 404
fracture, 361
Metastatic abscess, 73
Metatarsalgia, anterior, 547
Metatarsus, dislocation, 415
fracture, 384
Metritis, 1074
acute, 1074
chronic, 1075
septic, 1094
Michel's clamps, 166
Microcephalus, 554
Microdactylia, 275
Micrognathy, 659
Middle meningeal hemorrhage, 575
Migration, 20

Mikulicz's disease, 626
"Miner's elbow," 267
Minor surgery, 142
Mixed chancre, 991
tumors, 106
Molecular death, 59
Molluscum fibrosum, 293
Momburg's hemostasis, 216
Monorchidism, 1050
Morbus coxæ senilis, 456
Mortification, 58
Mosetig-Moorhof bone-wax, 435
"Mother's mark," 244
Mouth-wash, iodo-glycerole, 652
Movable kidney, 972
spleen, 955
Mucous patches, 995
Mummery's operation, 910
Murphy button, 839
Muscle, congenital absence, 505
contracture, 276
rupture, 274
tumors, 277
wounds, 273
Muscular hernia, 274
Myelogenous leukemia, 113
Myeloma, 113
giant-celled, 113
Myelomatosis, 113
Myocarditis, postoperative, 177
Myoma, 114
malignant, 116
of uterus, 1102
sarcomatodes, 116
Myomectomy, 1106
Myo-sarcoma, 116
Myositis, 274
ossificans progressiva, 275
traumatica, 274
traumatic, 274
Myringotomy, 630
Myxedema, 688
Myxo-lipoma, 108
Myxoma, 109
Myxo-sarcoma, 109

N

Nasal bones, fracture, 320
Naso-pharynx, tumors, 665
Neck, deformities, 537
fibroma, 684
ligneous phlegmon, 673
lipoma, 684
lymphadenitis, 674
operations, anesthetic, 153
surgery, 673
woody phlegmon, 673
wounds, 673
Necrosis, 58, 431
jaws, 658
liquefaction, 59
Needles, 164
operative, removal of, 169
Needling kidney, 981
Negri bodies, 97
Nélaton's line, 364
Neoplasm. *See* Tumors.
Nephrectomy, 987
Nephritis, septic, 974
toxic, 974
Nephrolithiasis, 977
simple, 978
treatment, 980
Nephrolithotomy, 980
Nephropexy, 973, 987
Nephroptosis, 972
Nephrotomy, 980, 986
Nerve anastomosis, 286
for talipes, 527
blocking, 157
contusion, 282
dislocation, 283
gunshot wounds, 186
laceration, 283
regeneration, 287
rupture, 282
stretching, 283
tumors, 293
wounds, 284
Nervous system in inflammation, 27
Neuralgia, 288
of breast, 702
sciatic, 292
trifacial, 289
Neuralgic ulcer, 54
Neurectasis, 288, 292
Neurectomy, 288
Neurinomas, 293
Neuritis, 287
Neurofibromatosis, 293
Neurolysis, 288
Neuroma, 114
amputation, 114
false, 114
Neuropathic joints, 460
Neuroplasty, 286
Neurorrhaphy, 285
Neurotomy, 288
intra-perineural, 530
Nevoid lipoma, 246
Nevus pilosus, 245
vasculosus, 244
Newborn, intracranial hemorrhage, 576
Nipple, affections, 699
excoriation, 700
fissures, 700
Paget's disease, 719
Nitrous oxide anesthesia, 152
Noma, 63
pudendi, 63
Non-union in fractures, 316
Nose, acne rosacea, 620
foreign bodies, 620
saddle, 620
surgery of, 619
Nose-bleed, 619

O

Obstruction, choledochus, 928
intestinal, 884

Obstruction, intestinal, acute, 885
treatment, 887
chronic, 889
pyloric, 868
Obturator hernia, 799
Ochsner treatment, 811
Odontomas, 112
Olecranon, fracture, 348
Omentum, cyst, 895
Omphalectomy, 777
Onychauxis, 260
Onychia, 260
Oöphorectomy, 1080
Oöphoritis, 1078
Operation, 818
ablation of breast, 721
adenectomy, 677
Agnew's, 506
air passages, 668
Alexander's, 1086
amputations, 192
breast, 710
anastomosis, intestinal, 832
Anel's, for aneurysm, 254
anesthesia, 148
aneurysmoplasty, 258
ante-thoracic esophago-jejuno-gastrostomy, 696
Antyllus, 255
appendicectomy, 855
appendicostomy, 896
arthrectomy, 486
arthrodesis, 528
arthroplasty, 471
astragalectomy, 521
Ashhurst's amputation, 212
excision, 469
Bassini's, 787
Beck's, 1044
Berger's, 210
bile-duct, 928
Billroth's amputation, 216
gastrectomy, 881
Bottini's, 1036
"Bottle," 1060
Brasdor's, for aneurysm, 255
castration, 1056
cecostomy, 896
cholecystectomy, 931
cholecystendysis, 930
cholecystenterostomy, 934
cholecysto-duodenostomy, 934
cholecysto-gastrostomy, 934
cholecystostomy, 930
cholecystotomy, 930
choledocho-enterostomy, 928
choledochostomy, 932
choledochotomy, 932
chondrectomy, 748
Chopart's amputation, 211
cleft palate, 638
Cock's, 1025
colostomy, 915
colpo-perineorrhaphy, 1083
colporrhaphy, 1083
craniotomy, 586
Operation, Cushing's decompressive, 590
cystocele, 1088
cystotomy, 970
Demarquay's, 1018
Didot's, 506
Dudley's, 1070
Dupuytren's amputation, 209
endo-aneurysmorrhaphy, 257
epiplopexy, 941
erasion of joints, 486
esophagotomy, 694
Estlander's, 746
excision, ankle, 500
elbow, 470
hip, 497
knee, 469
mandible, 662
shoulder, 470
superior maxilla, 662
of tongue, 651
tumors in general, 131
urethral stricture, 1018
wrist, 470
extirpation, aneurysmal sac, 256
Finney's pyloroplasty, 879
Frazier-Spiller, 292
gastrectomy, 881
gastro-anastomosis, 872
gastrogastrostomy, 872
gastrojejunostomy, 879
gastroplasty, 871
gastrostomy, 877
gastrotomy, 876
Gersuni's, 910
goitre, 687
Gritti's amputation, 213
Guthrie's amputation, 214
Hancock's amputation, 211
hemilaryngectomy, 672
hepatico-enterostomy, 928
hernia, 787
Hey's amputation, 210
Hunter's, for aneurysm, 254
hysterectomy, 1106
hysteropexy, 1086
intestinal anastomosis, 832
Kader's gastrostomy, 877
kidney, 985
Killian's, 657
Kraske's, 916
laminectomy, 601
laparotomy, 818
Larrey's amputation, hip, 215
shoulder, 209
Le Conte's amputation, 210
Lee's amputation, 212
Ligation for aneurysm, 254
of arteries, 230
Lisfranc's amputation, 210
lithectasy, 970
litholapaxy, 969
lithotomy, 970
lithotrity, 969
Littre's, 902
Matas's, for aneurysm, 257
Maunsell's, 834

Operation, Mayo's, 244
Mummery's, 910
nephrectomy, 987
nephrolithotomy, 980
nephropexy, 987
nephrotomy, 980
neurectomy, 288
neurorrhaphy, 285
neurotomy, 288
omphalectomy, 777
oöphorectomy, 1080
orchidectomy, 1050
orchidopexy, 1051
osteoplastic, 504
osteotomy, 420
ovariotomy, 629
pancreatectomy, 951
paracentesis for ascites, 940
Peck's, 916
pericardiotomy, 237
perineal section, 1024
peritonitis, 862
pharyngotomy, 664
Phelps's, 520
phlebectomy, 244
phlebotomy, 147
Pirogoff's amputation, 211
pleurotomy, 742
pneumonectomy, 747
pneumonotomy, 747
Pozzi's, 1070
proctotomy, 912
prostatectomy, 1036
prostatotomy, 1036
pyelotomy, 980
pylorectomy, 881
pyloroplasty, 878
rhinoplasty, 620
Ruggi's, 797
salpingectomy, 1080
salpingo-oöphorectomy, 1079
Schede's, 243
Schomacker's, 910
Schroeder's, 1073
Sédillot's amputation, 212
Senn's amputation, 215
sequestrotomy, 433
Siter's, 1036
Skey's amputation, 210
skin-grafting, 224
Spence's amputation, 209
splenectomy, 957
Stamm's gastrostomy, 877
staphylorrhaphy, 638
Stokes's amputation, 213
stomach, 876
Syme's amputation, 211
urethrotomy, 1022
sympathectomy, 692
Teale's amputation, 207, 212
tenotomy for talipes, 519
Terrier's, 932
Textor's amputation, 211
Thomas's plastic resection of breast, 711
thoracoplasty, 746
Operation, thoracotomy, 742
thyroidectomy, 692
thyrotomy, 672
tongue, 653
tracheloplasty, 1081
trachelorrhaphy, 1081
tracheotomy, 670
Trendelenburg's, 243
trephining skull, 563
uranoplasty, 638
ureterolithotomy, 981
urethrotomy, 1022
vaginal hysterectomy, 1108
ventro-fixation of uterus, 1087
Wardrop's for aneurysm, 255
Warren's, 711
Whitehead's, hemorrhoids, 908
tongue, 653
wiring aneurysm, 256
Witzel's gastrostomy, 877
Young's, 1041
Opsonic index, 45
theory, 44
Opsonins, 23
Orchidectomy, 1056
Orchidopexy, 1051
Orchitis, 1052
Orthopedic surgery, 504
Osteitis, 426
deformans, 423
fibrous, 437
Osteo-arthritis, 452
metabolic, 452
Osteoclasis, 420
Osteogenesis imperfecta, 416
Osteoma, 111
malignant, 447
sarcomatodes, 447
Osteomalacia, 423
Osteomyelitis, 426
albuminous, 429
chronic, 431
jaw, 658
ribs, 732
treatment, 428
vertebræ, 602
Osteophyte, 112
Osteoplastic craniotomy, 586
operations, 504
Osteoporosis, 416
Osteopsathyrosis, 416
Osteosarcoma, 116, 447
Osteotomy, 420
for ankylosis, 468
subtrochanteric, 487
Othematoma, 629
Otitis media, 629
Ovariotomy, 1101
Ovaritis, 1078
Ovary, abscess, 1078
cyst, 1097
dermoid, 1101
retention, 1097
cystadenoma, 1098
papilliferous, 1098
embryomas, 1101

Ovary, teratoma, 1101
tumors, 1101
diagnosis, 953

P

Pachymeningitis, 578
Paget's disease of bone, 423
of nipple, 719
Painful heel, 549
Palate, perforations of, 640
Palmar abscess, 279
fascia, contracture of, 542
Palsy, brachial birth, 783
cerebral, 530
crutch, 282
infantile, 521
post-anesthetic, 282
Panaris, 279
Pancreas, abscess, 946
carcinoma, 950
operation, 951
cysts, 952
fistula, 946
gangrene, 946
gunshot wounds, 847
infections, 943
surgery, 943
Pancreatectomy, 951
Pancreatic calculi, 949
insufficiency, 947
lymphangeitis, 946
reaction, 948
Pancreatitis, acute, 944
chronic, 946
treatment, 949
hemorrhagic, 944
Pancreato-enterostomy, 951
Pan-hysterectomy, 1106
Papilloma, 118
of bladder, 966
intracystic, 118
of larynx, 668
Papillomatous growths of scalp, 553
Paralytic talipes, 521
Paraphimosis, 1048
Parathyroids, 691
Paronychia, 279
Parotid bubo, 624
tuberculosis, 625
tumors, 625
Parotitis, infectious, 624
symptomatic, 624
Parovarian cyst, 1099
Partridge's hernia, 794
Patella, dislocation, 279
fracture, 372
Peck's operation, 916
Pectineal hernia, 794
Pelvic abscess, 1077, 1096
bones, fracture, 323
cellulitis, 1094
Pelvi-rectal abscess, 904
Pelvis, bimanual examination, 1068
static disorders, 535
Penis, amputation, 1050
carcinoma, 1049
congenital deformities, 1043
extirpation, 1050
surgery, 1043
Peptic ulcer of jejunum, 880
Perforating ulcer, 261
Perforation of gall-bladder, 921
of intestine, 829
typhoid, 892
of uterus, 1093
Periarthritis, 466
Pericarditis, cardiolysis in, 237
Pericardiotomy, 237
Pericholecystitis, 920
Pericolitis, 896
sinistra, 897
Perimetritis, 1094
Perineal hernia, 800
prostatectomy, 1040
Perineoplasty, 1083
Perinephric abscess, 977
Perineum, laceration, 1082
Perinorrhaphy, 1083
Periosteal sarcoma, 447
Periosteitis, acute, 425
alveolar border, 660
chronic, 425
Perisigmoiditis, 897
Perithelioma, 128
Peritoneal adhesions, 814
Peritoneum, 802
tuberculosis, 815
Peritonitis, 802
acute diffuse, 806
local, 805
causes, 803
clinical course, 805
diffuse, 804
operation, 862
distention, 808
fibrino-purulent, 804
general, 806
hemorrhagic, 805
idiopathic, 803
Ochsner treatment, 811
operation, 862
pathology, 803
pneumococcic, 815
rigidity, 806
septic, 805
spreading, 804
starvation treatment, 811
symptoms, 805
tenderness, 808
toxic, 805
treatment, 810
Peritonsillar abscess, 663
Peri-urethral abscess, 1027
Pernio, 222
Pes planus, 547
Petechia, 159
Phagedenic ulcer, 54
Phagocytes, 23
Phagocytosis, 23
Phalanges, dislocation, 404

Phalanges, fracture, 362, 384
Pharyngotomy, lateral, 664
subhyoid, 665
suprahyoid, 664
Phelps's operation, 520
Phenol-sulphonephthalein test, 961
Phimosis, 1045
treatment, 1046
Phlebectasis, 242
Phlebectomy, 244
Phlebitis, 238
post-operative, 240
treatment, 240
Phleboliths, 238
Phlebosclerosis, 238
Phlebotomy, 147
Phlegmon, 26, 47
Phosphorus poisoning, bones in, 658
Picric acid dressing, 219
Pigmented mole, 245
Piles, 906
Pilo-nidal cyst, 266
fistula, 266
Pirogoff's amputation, 211
v. Pirquet's test, 81
Plaster jacket, 610
Plaster of Paris, 137
Plastic linitis, 872
surgery, 225
Pleura, discission, 746
injuries, 733
surgery, 733
tuberculosis, 746
tumors, 749
Pleural fistula, 744
Pleurisy, 739
Pleuritis, 739
Pleurotomy, 742
Plexiform neuroma, 293
Plombage, 435
Pneumococcic joint infection, 471
peritonitis, 815
Pneumo-hemothorax, 738
Pneumonia, post-operative, 177
Pneumonectomy, 747
Pneumonotomy, 747
Pneumothorax, 737
Points douloureux, 289
Poisoned wounds, 170
Poliomyelitis, anterior, 521
Polydactylism, 505
Polymastia, 699
Polypus, naso-pharyngeal, 665
rectal, 913
uterus, 1103
Polythelia, 699
"Port-wine" stain, 244
Post-anesthetic palsy, 282
Post-operative deaths, 176
embolism, 178
fat-embolism, 178
heat prostration, 179
myocarditis, 177
phlebitis, 240
pneumonia, 177
sepsis, 177
Post-operative status lymphaticus, 178
Pott's disease, 602
abscess, 606
treatment, 613
contractures, treatment, 614
operative fixation of spine, 612
paraplegia, 608
treatment, 609
fracture, 380
Pozzi's operation, 1070
Pre-cancerous changes, 121
Pregnancy, extra-uterine, 1090
treatment, 1092
Prepuce, adherent, 1046
redundancy, 1046
Probe, eyed, 49
Procidentia recti, 909
uteri, 1088
Proctitis, 910
Proctoclysis, 144
Proctoscope, 901
Proctotomy, 912
Profeta's law, 999
Prolapse of rectum, 909
of urethra, 1018
of uterus, 1088
Properitoneal inguinal hernia, 784
Prostate, abscess, 1028
adenomatosis, 1030
atrophy, 1041
carcinoma, 1042
enlargement, 1029
operation, 1036
treatment, 1034
radical, 1036
hypertrophy, 1029
sarcoma, 1042
surgery, 1028
Prostatectomy, 1036
perineal, 1040
suprapubic, 1038
Prostatotomy, perineal, 1036
Prostatitis, acute, 1028
chronic, 1028
"Proud flesh," 53
Psammoma, 128
Pseudoleukemia infantium, 957
Psoas abscess, 607
Ptomains, 19
Pudendal hernia, 800
Puerperal pyemia, 1093
sepsis, 1092
"Pulled elbow," 403
Pulmonary embolism, 178, 241
osteo-arthropathy, 475
Punctured wounds, 169
Pus, 25
absorption, 26
encapsulated, 26
gummatous, 84
Pus-tube, 1076
rupture, 1077
Pyarthrosis, 462
Pyelitis, 974
Pyelo-nephritis, 974
Pyelotomy, 980

Pyemia, 73
puerperal, 1096
symptoms, 74
treatment, 74
tuberculous, 80
Pylorectomy, 881
Pyloroplasty, 878
Finney's, 879
Pylorospasm, 869
Pylorus, obstruction, 868
stenosis, 869
Pyogenesis, 25
Pyogenic bacteria, 28
membrane, 26
Pyonephrosis, 977
Pyosalpinx, 1076
Pyothorax, 739
Pyrexia, 70

Q

Quinsy, 663

R

Rabies, 96
Racemose aneurysm, 247
Rachitic rosary, 726
Rachischisis, 592
Rachitis, 417
osteoclasis, 420
osteotomy, 420
Radio-carpal joint dislocation, 403
Radius, fracture, 350
head of, dislocation, 402
Railway spine, 594
Rankenneurom, 293
Ranula, 645
Ray fungus, 84
Raynaud's disease, 64
v. Recklinghausen's disease, 293
Rectocele, 1082
Recto-genital fistula, 913
Recto-urethral fistula, 913
Recto-urinary fistula, 913
Recto-uterine fistula, 913, 1089
Recto-vaginal fistula, 913
Rectum, adenoma, 913
carcinoma, 913
false anus, 914
radical operation, 915
examination, 900
malformations, 901
polypus, 913
prolapse, 909
stricture, 911
surgery, 900
tumors, 913
Redressement forcé, 519
Regeneration, 30
Renal calculus, 977
colic, 979
Repair, 29
in fractures, 303
in incised wounds, 161
Resection of breast, 711
Resection of intestine, 831
Residual peritoneal abscess, 813
Restitutio ad integrum, 30
Retained secundines, 1093
Retention of urine, 1015
Retroflexion of the uterus, 1086
Retrognathism, 659
Retrograde catheterization, 1025
Retroversion of the uterus, 1086
Reverdin's skin-grafting, 224
Rhabdomyoma, 106, 114
Rhagades, 1000
Rheumatic arthritis, 473
Rheumatism, tuberculous, 474
"Rheumatisme noueux," 452
Rheumatoid arthritis, 452
Rhinoplasty, 620
Rhinoscleroma, 87
Rhizotomy, 530
Ribs, caries, 731
cervical, 539
fracture, 323
osteomyelitis, 732
Richter's hernia, 755
Riedel's lobe, 935
Ring fracture, 559
Rodent ulcer, 123
of cheeks, 624
Roller bandage, 133
Rose ulcer, 717
Round ligaments, shortening of, 1086
Rupture of abdominal wall, 840
bladder, 971
diaphragm, 750
gastro-intestinal tract, 842
heart, 236
liver, 842
muscle, 274
nerve, 282
pus-tube, 1077
spleen, 842
tendon, 278
urethra, 1017

S

St. Anthony's fire, 67
"Sabre-blade deformity," 442
tibia, 1000
Saccular aneurysm, 249
Sacro-iliac joint, dislocation, 405
tuberculosis, 502
Saddle nose, 620
Saline solution, 143
Salivary calculus, 627
fistula, 626
glands, surgery, 624
Salomon's test, 948
Salpingectomy, 1080
Salpingitis, 1075
Salpingo-oöphorectomy, 1079
Sapremia, 71, 75, 1093
chronic, 75
Sarcocele, 1056
Sarcoma, 114

Sarcoma, alveolar, 115
bone, 446
of brain, 582
of breast, 713
classification, 115
giant-celled, 113
of jaw, 661
of joint, 503
of kidney, 983
large round-celled, 115
of liver, 942
medullary, 447
mixed-celled, 115
osteoid, 447
periosteal, 447
of prostate, 1042
pure, 116
of scalp, 553
small round-celled, 115
spindle-celled, 115
of thyroid, 692
of tonsil, 664
tubular, 115
Sarco-sepsis, 71
Scalds, 217
Scalp, birth-injuries, 561
contusions, 551
cyst, dermoid, 553
epithelioma, 553
papillomatous growths, 553
sarcoma, 553
surgical affections, 551
tumors, 553
wounds, 552
Scapula, congenital elevation, 514
dislocation, 394
fracture, 330
Scar tissue, 24
Schede's operation, 243
thoracoplasty, 746
Schmidt's test, 948
Schomacker's operation, 910
Schroeder's operation, 1073
Sciatica, 292
Scirrhus of breast, 715
Sclavo's serum, 89
Scoliosis, 531
treatment, 533
Scrofula, 76
Scrofuloderma, 264
Scrotum, elephantiasis, 1062
epithelioma, 1063
papilloma, 1063
tumors, 1063
Scurvy, 423
Sebaceous cyst, 265
Semilunar cartilage, subluxation, 412
Sédillot's amputation, 212
Semino-vesiculitis, 1054
Senile arthritis, 456
Senn's amputation, 215
gastrostomy, 877
powder, 219
Sepsis, 36, 70
post-operative, 177
puerperal, 1092
Septic diarrhea, 806
nephritis, 974
peritonitis, 805
Septicemia, 71
puerperal, 1094
Sequestrotomy, 433
Sequestrum, 426
Sera, 45
Sero-serous suture, 828
Serpiginous ulceration, 53
Serum, antistreptococcic, 45
therapy in inflammation, 44
Shock, 172
electric, 222
erethistic, 173
insidious, 173
prevention, 174
psychical, 173
secondary, 173
torpid stage, 173
treatment, 175
Shoulder dislocation, 394
congenital, 513
excision, 470
Shoulder-joint, amputation, 207
Sialo-lithiasis, 627
Sigmoid diverticulitis, 897
hernia, 785
surgery, 895
tumors, 913
Sigmoiditis, 897
Sigmoidopexy, 910
Sigmoidoproctostomy, 912
Silicate of sodium dressing, 139
Silk ligaments, 529
Silverfork deformity, 351
Simple ulcer, 54
Simpson splint, 619
Sims's position, 1064
speculum, 1065
Sinus, 48, 52
thrombosis, 577
treatment, 52
tuberculous, 80
Sinusitis, 655
frontal, 656
maxillary, 656
Siter's operation, 1036
Skey's amputation, 210
Skiagraphy in fractures, 302
Skin, surgery, 259
Skin-grafting, 57, 223
Reverdin's method, 224
Thiersch's method, 223
Wolfe-Krause method, 225
Skull, caries, 439
congenital malformations, 553
dangerous area, 567
fractures, 557
base, 564
bursting, 558
by counterstroke, 558
ring, 559
treatment, 561
vault, 559

Skull, injuries, 557
newborn, fracture, 564
osteomyelitis, 566
surgical affections, 553
temporary resection, 586
trephining, 563
wounds, 557
Sliding hernia, 785
Sloughing, 58
phagedena, 63
ulcer, 54
Small-shot wounds, 185
Smoker's patches, 647
Snake bites, 170
Snapping hip, 546
Sounds, urethral, 1015
Spasmodic tic, 292
torticollis, 292
Speculum examination, 1065
Spermatocele, 1061
Spermato-cystitis, 1054
Sphacelus, 58
Spina bifida, 592
anterior, 592
occulta, 592
ventosa, 113
Spinal anesthesia, 157
cord, concussion, 594
meningitis, 618
Spine, dislocation, 594
fractures, 594
gonococcic infections, 615
gunshot wounds, 189
injuries, 593
lateral curvature, 531
lumbar static disorders, 535
pneumococcic infection, 615
sprain-fracture, 594
stab wounds, 594
strains, 593
surgery, 592
tuberculosis, 602
tumors, 617
Spirochæta pallida, 82
Spleen, abscess, 955
cysts, 955
dislocated, 955
enlargements, 954
gunshot wounds, 847
movable, 955
rupture, 842
operation, 844
surgery, 953
tumors, 953
Splenectomy, 957
Splenic anemia, 955
Splenomegaly, 955
Spondylitis, atrophic, 615
deformans, 615
hypertrophic, 616
traumatic, 602
typhoid, 615
Spondylolisthesis, 536
Spondylose rhizomélique, 617
Sprain, 385
"Sprained ankle," 385
Sprain fracture, 298
of spine, 594
Sprengel's deformity, 514
incision, 928
Squirrhe en cuirasse, 717
Stab wounds, 170
of abdomen, 844
of diaphragm, 749
of spine, 594
of thorax, 733
Stagnant gall-bladder, 922
Stamm's gastrostomy, 877
Staphylorrhaphy, 638
Starch dressing, 139
Stasis cyanosis, 727
Status lymphaticus, 178
Steatoma, 265
Steatorrhea, 947
Stenosis of cervix, 1070
Sterilization, 140
Sterno-clavicular dislocation, 392
Sternum, fracture, 322
tuberculosis, 732
Still's disease, 474
Stomach, carcinoma, 873
cirrhosis, 872
dilatation, acute, 869
secondary, 870
fibromatosis, 873
gunshot wounds, 846
hour-glass, 871
linitis, 872
operations, 876
segmented, 871
surgery, 864
ulcer, 864
acute, 865
chronic, 865
hemorrhage, 868
open, 865
operation, 867
perforation, 867
treatment, 866
Strains, back, 593
tendon, 279
Strangulated hernia, 761
Strangulation, 160
Strapping, 385
Strawberry gall-bladder, 922
Stricture of esophagus, 695
of rectum, 911
of urethra, 1018
Strumitis, 688
Stumps, diseases of, 200
end-bearing, 202
structure, 200
Styptics, 229
Subastragalar amputation, 211
dislocation, 415
Subcranial abscess, 578
hemorrhage, 574
Subinvolution of uterus, 1086
Subluxation of jaw, 392
semilunar cartilage, 412
wrist, spontaneous, 542
Submammary abscess, 702

Subpectoral abscess, 730
Subscapular abscess, 731
Subtrochanteric osteotomy, 487
Subungual exostosis, 444
Supernumerary fingers, 505
toes, 505
Suppuration, 25
without bacteria, 27
Suprapubic fistula, 1036
prostatectomy, 1038
Suprascapular abscess, 731
Supravesical hernia, 792
Surgical fever, 71
infections, 76
kidney, 975
technique, 133
Sutures, 162
absorbable, 162
Albert-Lembert, 829
buried, 163
chain, 163
Connell's, 834
Cushing's, 831
Czerny's, 829
deep, 163
Dupuytren's, 831
Gely's, 829
Halsted's, 831
hare-lip, 636
interrupted, 162
intestinal, 828
knots, 166
Lembert, 828
lock, 163
mattress, 831
Mayo's, 837
non-absorbable, 162
overhand, 163
quilled, 163
quilt, 163
sero-serous, 828
subcuticual , 165
superficial, 163
through-and-through, 829
tongue and groove, 621
twisted, 636
Syme's amputation, 211
operation, 1022
Symmetrical gangrene, 64
Sympathectomy, 692
Syncope, 173
Syndactylism, 506
Synovitis, 462
chronic serous, 462
treatment, 463
Syphilis, 989
bone, 440
breast, 704
chancre, 83
complement-fixation test, 1001
condylomata lata, 995
contagion, 989
diagnosis, 1001
gummas, 84
hereditary, 998
insontium, 989
Syphilis, joint, 503
leptomeninges, 579
mucous patches, 995
pathology, 83
period of incubation, 83
pregnancy, 999
rashes, 995
salvarsan, 1005
secondary lesions, 83, 993
skin lesions, 996
symptoms, first stage, 990
second stage, 993
third stage, 996
tertiary, 996
testicle, 1056
tongue, 649
treatment, 1002
treponema pallidum, 1001
Wassermann test, 1001
Syphilitic bubo, 992
dactylitis, 998
panaris, 998
rupia, 996
tubercle, 996
Syphilodermas, 83, 994
Syphiloma, brain, 581
Syringomyelia, 461
Syringomyelocele, 592

T

Talbot's iodo-glycerole mouth wash, 652
Talipes, congenital, 515
nerve anastomosis, 527
paralytic, 521
tenotomy in, 519
Tarsus, dislocation, 414
fracture, 382
tuberculosis, 500
Telangiectases, 244
Temporo-maxillary joint ankylosis, 659
Tendon-sheaths, tuberculosis, 279
Tendons, dislocation, 278
gunshot wounds, 186
rupture, 278
strains, 279
transplantation, 525
wounds, 277
Tenotomy for talipes, 519
Tenosynovitis, 279
Terato-blastoma, 105
Teratomas, 104
monsters, 105
fetal inclusion, 105
ovary, 1101
sacral, 106
Terrier's operation, 932
Tessier's hernia, 794
Testicle, congenital anomalies, 1050
gumma, 1057
inflammation, 1052
misplaced, 1050
neoplasms, 1057
neuralgia, 1054

Testicle, non-descent, 1050
sarcoma, 1058
surgery, 1050
syphilis, 1056
torsion, 1052
tuberculosis, 1054
tumors, 1057
wandering, 1050
Tetanus, 90
antitoxin, 94
carbolic acid injections, 96
chronic, 93
cryptogenetic, 91
nascentium, 91
pathology, 91
symptoms, 92
treatment, 94
Textor's amputation, 211
Thecitis, 279
Thiersch's skin-grafting, 224
Thigh, amputation of, 213
Thoracoplasty, 746
Thoracotomy, 742
Thorax, gunshot wounds, 189
operations, 736
stab-wounds, 733
wounds, 733
Thrombosis, 237
arterial, 241
cavernous sinus, 577
lateral sinus, 577
longitudinal sinus, 577
mesenteric, 890
sinus, 577
venous, 238
Thrombus, 160
Thymus gland, surgery, 693
Thyro-glossal cysts, 681
fistula, 681
Thyroid, carcinoma, 692
enlargement, 684
inflammation, 684
sarcoma, 692
surgery, 684
tumors, 692
Thyroidectomy, 692
Thyroiditis, 684
Thyrotomy, 672
Thyrotoxicosis, 688
Tibia, fracture of, 376
Tibio-tarsal joint dislocation, 413
Tic convulsif, 292
douloureux, 289
Toe, supernumerary, 504
Tongue, abscess, 647
carcinoma, 649
chancre, 649
excision, 651
gumma, 649
ichthyosis, 647
sarcoma, 649
surgery, 644
syphilis, 649
tuberculosis, 648
Tongue-tie, 644
Tonsil, surgery, 663
Tooth wounds, 170
Torsion, 229
Torticollis, 537
spasmodic, 292, 538
Tourniquet, 194
Toxemia, 70
cryptogenetic, 71
Toxic nephritis, 974
peritonitis, 805
Toxins, bacterial, 19
Trachelorrhaphy, 1081
Tracheloplasty, 1081
Tracheotomy, 670
Transcondylar amputation, 213
Transfusion, direct, 145
Transplantation, bone, 504
tendon, 525
Transverse myelitis, 608
Traube-Hering waves, 572
Traumatic asphyxia, 727
delirium, 71, 173
fever, 71
Trendelenburg's operation, 243
Trephine, Galt's, 563
Hudson's, 563
Trephining, skull, 563
Treponema pallidum, 82
Trichiniasis, 276
Trigger finger, 543
Trochanter, fracture, 368
Truss, 758
for inguinal hernia, 786
Tubal abortion, 1090
Tubular aneurysm, 249
Tubo-ovarian abscess, 1077
cyst, 1098
Tubercle, 77
Tuberculin, 78
test, 81
focal reaction, 81
Tuberculoma, brain, 581
Tuberculosis, 76
ankle, 500
appendix, 864
bladder, 965
bone, 437
breast, 704
carpus, 502
cutis, 263
diagnosis, 80
elbow, 501
hip, 488
joints, 476
kidney, 982
knee, 498
lungs, 747
lymph nodes, 269, 676
parotid, 625
pathology, 77
peritoneum, 815
v. Pirquet's test, 81
pleura, 746
ribs, 731
sacro-iliac joint, 502
skin, 263
spine, 602

Tuberculosis, spine, abscess, 606
sternum, 732
tarsus, 500
tendon sheaths, 279
testicle, 1054
tongue, 647
treatment, 82
wrist, 502
Tuberculous cavity, 80
dactylitis, 439
granulation tissue, 79
gumma, 79
lymphadenitis of neck, 676
meningitis, 579
peritonitis, 815
pyemia, 80
rheumatism, 474
sinus, 80
ulcer, 80
Tufnell's treatment for aneurysm, 253
Tumors, 101
abdominal, diagnosis of, 953
adenoma, 119
of alveolar border, 660
of appendix, 864
of bile-ducts, 942
of bladder, 966
blastoma, 104
blastomatoid, 107
of bone, 443
of brain,581
of breast, 705
cachexia, 103
capsule, 102
carcinoma, 119
cartilaginous, 110
of carotid gland, 680
characteristics, 101
chloroma, 114
cholesteatoma, 129
chondroma, 100
chordoma, 114
classification, 104
consistency, 102
cylindroma, 128
cyst formation, 103
sequestration, 130
cystadenoma, 119
cystoma, 129
definition, 101
desmoid, 277
embryoma, 106
endosteoma, 111
endothelioma, 127
epithelioma, 121
excision, 131
fibroid, 114
fibroma, 108
fibro-myxoma, 109
fibro-sarcoma, 109
form, 101
formation, Cohnheim's theory, 103
parasitic theory, 104
Ribbert's theory, 104
of gall-bladder, 942
Tumors, glioma, 114
growth, 102
hylic, 106
malignant, 114
hypernephroma, 127
of intestine, 894
intraspinal, 617
of jaw, 660
of joints, 503
keloid, 109
of kidney, 983
of larynx, 668
lepidic, 106
benign, 118
malignant, 119
transitional, 127
lipoma, 107
of liver, 941
of lung, 749
lymphoma, 114
lymphomatosis, 114
malignancy, 103
mediastinal, 732
melanoma, 129
mesothelioma, 127
metastasis, 103
mixed, 1C6
of muscle, 277
myeloma, 113
myelomatosis, 113
myoma, 114
myxoma, 109
myxo-sarcoma, 109
of naso-pharynx, 665
of nerve, 293
neuroma, 114
odontoma, 112
osteoma, 111
ostoses, 112
of ovary, 1101
of pancreas, 950
papilloma, 118
of parotid, 624
perithelioma, 128
of pleura, 749
psammoma, 128
of rectum, 913
recurrence, 103
rhabdomyoma, 114
sarcoma, 114
of scalp, 552
of scrotum, 1063
of sigmoid, 913
of spleen, 953
of stomach, 873
terato-blastoma, 105
teratoma, 104
of testicle, 1057
theories of formation, 103
of thyroid, 692
xanthoma, 108
Tyloma, 259
Typhoid arthritis, 472
carriers, 927
hemorrhage, 893
perforation, 892

Typhoid periosteitis, 425
spine, 615
spondylitis, 615

U

Ulcer, 53
callous, 55
duodenal, 864
chronic, 865
hemorrhage, 868
perforation, 867
treatment, 866
edematous, 54
gastric, 864
acute, 865
callous, 865
chronic, 865
hemorrhage, 868
open, 865
operation, 867
perforation, 867
treatment, 866
healthy, 54
indolent, 55
inflamed, 54
irritable, 54
Jacob's, 123
leg, 55
strapping, 56
syphilitic, 57
Marjolin's, 123
neuralgic, 54
perforating, 60, 261
phagedenic, 54
repair, 53
rodent, 123
simple, 54
sloughing, 54
tuberculous, 80
varicose, 58
warty, 58
weak, 54
Ulceration, 26, 53
serpiginous, 53
Ulcus molle, 1005
Ulna, fracture, 348
Umbilical fistula, 891
hernia, 774
strangulated, 778
Union in fractures, 303
in incised wounds, 161
Urachal cysts, 963
fistulæ, 963
Uranoplasty, 638
Ureter, catheterization, 961
Ureteral calculus, 981
Uretero-cervical fistula, 1089
Ureterolithotomy, 981
Urethra, foreign bodies, 1016
prolapse, 1018
rupture, 1017
stricture, 1018
congenital, 1019
dilatation, 1021
Urethra, stricture, incision, 1022
inflammatory, 1018
inorganic, 1018
organic, 1019
perineal section, 1024
spasmodic, 1019
symptoms, 1019
traumatic, 1019
treatment, 1021
surgery, 1015
Urethral fever, 1026
Urethritis, female, 1071
gonococcic, 1010
non-gonococcic, 1014
Urethrotomy, 1022
Urinary extravasation, 1017
fever, 1026
fistula, 1027
Urine, overflow with retention, 1016
residual, 1016
retention, 1015
Uterus, adenomyoma, 1105
anteflexion, 1086
anteversion, 1086
carcinoma, 1109
chorio-epithelioma, 1111
deciduoma malignum, 1111
didelphys, 1070
displacements, 1086
downward displacement, 1087
fibroid, 1102
fibromyoma, 1102
hysteropexy, 1086
malformation, 1070
myoma, 1102
perforation, 1093
polyp, 1103
procidentia, 1088
prolapse, 1088
retroflexion, 1086
retroversion, 1086
subinvolution, 1086
ventrosuspension, 1087

V

Vaccination, 143
Vaccines, 45
in inflammation, 44
Vagina, absence, 1069
Vaginal hysterectomy, 1108
operations, preparation, 1068
Vaginitis, 1071
chronic, 1072
Valsalva's treatment for aneurysm, 256
Varicocele, 1061
operation, 1062
Varicose aneurysm, 235
veins, 242
ulcer, 58
Varix, 242
Vein, anesthesia, 158
entrance of air, 234
Venereal diseases, 989
warts, 259, 1049

Venous aneurysm, 233
nevi, 245
Ventral hernia, 772
Ventricles, tapping lateral, 555
Ventro-fixation of uterus, 1087
Ventrosuspension uterus, 1087
Verruca, 259
Verrucæ acuminatæ, 1049
Vertebra, dislocation, 594
Vertebræ, fracture, 594
osteomyelitis, 602
Vertebral column, dystrophies, 615
Vesical calculus, 966
Vesication, 142
Vesico-uterine fistula, 913, 1089
Vesico-vaginal fistula, 913, 1089
Vicious circle, 880
Villous arthritis, 462
Visceroptosis, 898
Volkmann's contracture, 540
Volvulus, treatment, 889
Vulva, carcinoma, 1112
imperforate, 1069
Vulvitis, 1071
Vulvo-vaginal abscess, 1071

W

Wardrop's ligation, 255
Wart, 259
venereal, 1049
Warty ulcer, 58
Wassermann reaction, 1001
Wax, Horsley's, 588
Mosetig-Moorhof's, 435
"Weaver's bottom," 267
Webbed fingers, 506
Wen, 265
Whitehead's excision of tongue, 653
hemorrhoid operation, 908
varnish, 638
Whitlow, 279
Wille's test, 948
Wiring aneurysm, 256
Witzel's gastrostomy, 877
Wolfe-Krause skin-grafting, 225
Wool-sorter's disease, 87
Wounds, arrow, 170
arterio-venous, 235
bayonet, 170
bites, 170
blank cartridge, 186
bloodvessels, 233
bullet, 183
of bursæ, 266
contused, 167
drainage, 165
dressing, 166
gunshot, 180
of abdomen, 191, 844
of bloodvessels, 186
of bones, 186
character, 182
of diaphragm, 750
Wounds, gunshot, of head, 188
of intestine, 845
of joints, 186
of liver, 847
of lung, 189
of nerves, 186
of pancreas, 847
of spine, 189
of spleen, 847
of stomach, 846
of tendons, 186
of thorax, 189
of heart, 236
incised, 160
dressing, 166
healing, 161
intestinal suture, 830
of joints, 386
lacerated, 167
of muscles, 273
of neck, 673
of nerves, 284
open, 160
poisoned, 170
punctured, 169
of scalp, 552
of skull, 557
small shot, 185
snake bites, 170
stab, 170
of abdomen, 844
of diaphragm, 749
of thorax, 733
subcutaneous, 160
suture, 165
of tendons, 277
tooth, 170
Wrist, dislocation, 403
excision, 470
subluxation, 542
tuberculosis, 502
Wrist-joint amputations, 206
Wry-neck, 537
Wyeth's method, 214

X

Xanthoma, 108
Xiphodynia, 322
X-ray dermatitis, 222
in fractures, 362
therapeutic uses, 223

Y

Young's operation, 1041

Z

Zuckergussmagen, 872
Zygoma, fracture, 320