

## **The stomach and sophagus : a radiographic study / by Alfred E. Barclay.**

### **Contributors**

Barclay, Alfred E. 1876-1949.  
Augustus Long Health Sciences Library

### **Publication/Creation**

New York : Macmilliam : 1913.

### **Persistent URL**

<https://wellcomecollection.org/works/hs26sv23>

### **License and attribution**

This material has been provided by This material has been provided by the Augustus C. Long Health Sciences Library at Columbia University and Columbia University Libraries/Information Services, through the Medical Heritage Library. The original may be consulted at the the Augustus C. Long Health Sciences Library at Columbia University and Columbia University. where the originals may be consulted.

This work has been identified as being free of known restrictions under copyright law, including all related and neighbouring rights and is being made available under the Creative Commons, Public Domain Mark.

You can copy, modify, distribute and perform the work, even for commercial purposes, without asking permission.

**wellcome  
collection**

Wellcome Collection  
183 Euston Road  
London NW1 2BE UK  
T +44 (0)20 7611 8722  
E [library@wellcomecollection.org](mailto:library@wellcomecollection.org)  
<https://wellcomecollection.org>

COLUMBIA LIBRARIES OFFSITE  
HEALTH SCIENCES STANDARD



HX64131360


RC816 .B23


The stomach and soph


**RECAP**

RC 816


B23







The Stomach and Œsophagus



Digitized by the Internet Archive  
in 2010 with funding from  
Open Knowledge Commons

# THE STOMACH AND ŒSOPHAGUS

A Radiographic Study

BY

ALFRED E. BARCLAY, M.A., M.D., B.C. (Cantab.),  
M.R.C.S., L.R.C.P.

*Medical Officer to the x-Ray and Electrical Departments of the  
Manchester Royal Infirmary ;  
Late Clinical Assistant, Electrical Department, London Hospital.  
Council of Electro-Therapeutic Section of the Royal Society of Medicine.*

THE MACMILLAN COMPANY  
64-66, FIFTH AVENUE  
NEW YORK  
1913



January  
19-26567

RC 816  
B23

## PREFACE

This little volume is, in essence, a thesis.\* Sir Clifford Allbutt, Sir William Osler, Dr. R. Hutchison, and others who read it were kind enough to suggest that it was worthy of publication, and these pages are re-printed with some alterations and additions from the *Medical Chronicle* by the courtesy of the Editor, Dr. E. M. Brockbank. The chief alteration is the inclusion of Chapter VIII on the *Ætiology* of Gastric Ulcer, which was conceived and written after correcting the rest of the proofs of this volume. To Dr. J. Gow I am indebted for the Index, and to Prof. Dr. Gocht for the Bibliography.

*March, 1913.*

\* Submitted for the degree of M.D., at Cambridge, in April, 1912, and placed prox. access. Horton Smith prize.



## CONTENTS.

	PAGE
Chapter I. INTRODUCTION - - - - -	1
Chapter II. TECHNIQUE - - - - -	5
<i>Fundamental principles, methods of examination, protection of the patient, protection of the observer, position of the patient, preparation of the patient, foods used, special methods.</i>	
Chapter III. THE DIAGNOSIS OF AFFECTIONS OF THE ŒSOPHAGUS	13
<i>The causes of œsophageal obstruction, the stages of œsophageal obstruction.</i>	
Chapter IV. THE NORMAL STOMACH - - - - -	22
<i>Position, shape, capacity, tonic action, peristalsis, control of the pylorus, control of peristalsis and tonic action, notes on cases operated on.</i>	
Chapter V. THE PATHOLOGICAL STOMACH - - - - -	30
ATONY - - - - -	30
PYLORIC OBSTRUCTION - - - - -	33
NOTES ON CASES - - - - -	36
HYPERSECRETION - - - - -	37
NOTES ON CASES OF ULCERS OF PYLORIC REGIONS	37
Chapter VI. GASTRIC ULCER AND HOUR-GLASS STOMACH - - -	39
ULCER OF THE FUNDUS - - - - -	39
ULCERS OF THE PYLORUS - - - - -	39
ULCERS OF THE BODY OF THE STOMACH - - - - -	40
NOTES ON CASES - - - - -	43
CARCINOMA OF THE STOMACH - - - - -	46
NOTES ON CASES - - - - -	48
AEROPHAGY - - - - -	49
POST OPERATIVE EXAMINATIONS - - - - -	50
INCIDENCE OF LESIONS OF THE STOMACH - - - - -	53
Chapter VII. SMALL INTESTINE - - - - -	54
DUODENAL ULCER - - - - -	54
NOTES ON CASES - - - - -	55
Chapter VIII. THE ÆTIOLGY OF GASTRIC ULCER - - - - -	62
Chapter IX. CONCLUSIONS - - - - -	73
Chapter X. TABULATION OF CASES - - - - -	77
Class 1. NORMAL - - - - -	79
Class 2. DUODENAL IRRITATION - - - - -	81
Class 3. ULCERS OF PYLORIC REGION - - - - -	84
Class 4. ULCERATION OF THE BODY OF THE STOMACH - - -	85
Class 5. CARCINOMA OF THE STOMACH - - - - -	88
Class 6. PYLORIC OBSTRUCTION - - - - -	89
Class 7. ADHESIONS - - - - -	95
Class 8. POST OPERATIVE EXAMINATIONS - - - - -	96
BIBLIOGRAPHY - - - - -	99
INDEX - - - - -	123

## LIST OF ILLUSTRATIONS.

FIG.		FACING PAGE
1. Diagram.	Course of the œsophagus - - - - -	15
2. „	Slight bulging of aortic arch - - - - -	15
3. „	Large aneurism causing œsophageal obstruction	15
4. „	Growth in posterior mediastinum causing obstruction - - - - -	15
5. „	œsophageal obstruction - - - - -	15
6. „	œsophageal obstruction at cardiac orifice - - -	15
7. Radiogram.	œsophageal obstruction due to small ulcer - - -	19
8. „	Cardiospasm - - - - -	19
9. Diagram.	Air in the fundus of the empty stomach - - -	23
10. „	Air in the fundus of a stomach that already contained food - - - - -	23
11—14. „	Illustrating the manner in which the normal stomach accommodates the food - - - - -	23
15. „	Bismuth food entering a stomach that already contains food - - - - -	31
16. „	Bismuth food entering an empty atonic stomach	31
17. „	Bismuth food entering an atonic stomach that already contains food - - - - -	31
18. Radiogram	of an extremely atonic stomach (pyloric obstruction) - - - - -	32
19. „	of an atonic stomach showing the rugæ - - - - -	32
20. „	of an atonic stomach with retained food. Type 1 of chronic pyloric obstruction - - - - -	35
21. „	of an atonic stomach with retained food. Type 2 of chronic pyloric obstruction - - - - -	35
22. „	of typical upper sac of an hour-glass stomach - - -	40
23. Diagram	of hour-glass stomach with atony - - - - -	40
24. Radiogram	of an hour-glass stomach with small penetrating ulcer (Haudek) - - - - -	40
25. Diagram	of hour-glass stomach with atony - - - - -	40
26. Radiogram	of an hour-glass stomach - - - - -	43
27. „	of stomach with chronic penetrating ulcer giving rise to no symptoms - - - - -	43
28. Diagram	of a case of carcinoma of the stomach - - - - -	47
29. Radiogram	of a case of carcinoma of the stomach - - - - -	47

## CHAPTER I.

### INTRODUCTION.

THE diagnosis of gastric and intra-abdominal lesions is perhaps the most intricate and difficult branch of medicine, and even in experienced hands the condition found post-mortem or on the operating table is often very far different from that which was suspected from a full consideration of all the various signs, symptoms, and clinical tests available. Therefore the importance of any new method that will be of assistance in the diagnosis of these cases cannot be over-estimated. The application of the *x*-rays in the diagnosis of these conditions has been productive of excellent results in this respect.

In the early days of *x*-ray diagnosis one expected that by merely seeing the shape of the shadow of the food in the stomach a diagnosis could at once be formed. It was only after a number of failures that one was driven to the obvious conclusion that a thorough study of the normal stomach was essential. A better knowledge of the limitations of the method must be arrived at before undertaking the examination of the pathological cases. The difficulties of interpreting the shadows cast by the bismuth meal in the stomach are great; for not only is the organ absolutely different in shape during life from the pictures one would expect from the study of anatomy, but also even slight alterations in tonic action will produce a picture that *appears* to be very different. Again, the conditions found at operation were often quite the reverse of what one expected from the *x*-ray examination. For instance one reported, after *x*-ray examination, a stomach of normal size, and the surgeon at the operation found a large flaccid sac and *vice versa*. And in the study of the normal great difficulty was experienced, for it was found that even in healthy subjects the stomach apparently varied to an amazing extent, not only in shape and position but also in the manner

in which the muscular walls appeared to act. Another difficulty was presented by the fact that the pictures seen when the patient was in the upright position differed completely from those obtained when the patient was examined lying on the couch. One was also occasionally confronted with such phenomena as that of a healthy subject whose stomach seemed to conform to all one's ideas of what a healthy organ should be on one examination, while on the following day a picture that seemed to bear little or no resemblance to the previous one was seen.

Up till the last two years it was often a matter of speculation as to whether one would be able to obtain *x*-rays of sufficient power to penetrate the abdomen of any but the thinnest patients, and in a great number of the early cases one had the utmost difficulty in obtaining even a rapid glance of the shadow before the force of the currents used wrecked the *x*-ray tube. It was very seldom that one could study the pars pylorica. Moreover, it was only when the apparatus was working at its most efficient pitch, and when the *x*-ray tube happened to be in exactly the right condition, that a radiograph could be taken, and even then the exposure had to be of such lengthy duration that all detail was lost owing to the peristaltic movements of the walls.

During the last two years, however, one has been able to rely upon obtaining a satisfactory screen examination in nearly all cases, and it is only in the study of the pars pylorica that one could often have wished for greater clearness in the screen image. Radiographs have often been taken but they have seldom, if ever, revealed greater detail than could be made out by the screen examination, owing to movements during the lengthy exposures that were necessary. In the last few months, however, the introduction of the intensifying screen has reduced the exposures to a matter of a second or so, with the result that whenever it is not possible to see exactly what is going on, a picture may be taken that will be of considerable assistance in the diagnosis.

Such are some of the difficulties which have beset the earlier stages of this work, but apart from the technical

difficulties one conclusion stands out with great clearness; no one picture can be taken to represent the normal stomach, and no detailed study of a small number of normal subjects can be of great value in itself; it is only by the consideration of a very large number of cases that a clear conception of the possible variations of the normal stomach can be obtained, and it is only after this knowledge has been obtained that the value of the *x*-ray method of examination in the diagnosis of pathological conditions of the stomach becomes of value.

I have been much impressed by the fact that frequently the symptoms of the severity in relation to extent of lesion appear to bear very little relation to the extent of the disease found at the operation—the nervous condition of the patient apparently being responsible for the accentuation of subjective sensations that in a phlegmatic subject would be accounted of little moment. In this respect the contrast between hospital and private patients has been very marked.

The whole alimentary canal, but especially the stomach, is an exceedingly sensitive muscular organ, and spasmodic conditions have been found (and during the last two years recognised) in a large proportion of pathological cases. These spasmodic contractions have been a source of much trouble in diagnosis, and it was not until I realised that they entered into and complicated almost every active lesion involving the mucous membrane that I appreciated their importance, not only in complicating the diagnosis but in interfering with the gastric functions, in many cases causing complete functional bilocations of which no suggestion was found at the operation. It was found that the extent and severity of the spasmodic element of organic lesions did not bear any relation to the size or appearance of the ulcerations, and the suggestion is that the severity of the spasm depends rather on the irritability of the ulcer than upon any other factor.

In this thesis, therefore, I propose to deal chiefly with the explanation of the various difficulties met with in the normal and pathological cases examined, and to lay down the signs on which the diagnosis of morbid conditions may be given. Full use has been made in every case of the clinical history



and such other evidence as was available before giving a diagnosis, and although one is so thoroughly convinced of the enormous value of this method—especially in indicating those cases that are suitable for operation—one must urge that the *x*-ray method is only one of the means at our disposal, and that if we do not use all the evidence available, the use of this method by itself will lead to mistakes in diagnosis, and we will be doing less than justice not only to the means of diagnosis at our disposal but also to the patient.

I am quite conscious of having received many suggestions from writers on the subject but, as will be seen, the thesis is based almost exclusively on my own examinations. It is of considerable size, and I have therefore omitted the historical outline and summary of the work done by others in this branch of medicine.

It was Cannon who first initiated the study of the intestinal movements in dogs and cats by means of giving large doses of bismuth, but as applied to the examination of the human alimentary canal, Rieder of Munich was the pioneer, for it was he who first demonstrated that the large doses necessary for these examinations were quite harmless, although previously Roux and Balthayan had attempted diagnosis by means of 5 drachm doses. Many observers have written on the subject but the following names stand out most prominently:—Holzknecht and Jonas of Vienna, Jolasse, Leven and Barrett, Haudek, Groedel, Rosenthal, Kaestle and Hertz.

My own work on this subject commenced in 1906, and since then I have availed myself of every opportunity of examining both normal and abnormal subjects. I have notes of nearly 900 patients examined\* and there are many others of whom I have no records, either owing to the rush of hospital work, or, as in many of the normal cases, because nothing worthy of note was found at the examination. As a routine practice, I see each patient two or three times during the first hour after the meal has been taken and then re-examine after 24 hours, so that the actual number of examinations must be very large.†

\* Up to December, 1912, 1,280 cases had been examined. A proportion of these were examined in conjunction with my partner, Dr. Bythell.

† The double bismuth meal saves time, but I do not use it as there is less likelihood of overlooking abnormalities, especially of the small intestine, when one follows the whole process from the beginning.

## CHAPTER II.

### TECHNIQUE.

#### 1. FUNDAMENTAL PRINCIPLES.

The *x*-rays penetrate all substances to a greater or lesser extent, the resistance that is offered to their passage being approximately in direct proportion to the specific gravity. The walls of the alimentary canal do not differ from the rest of the abdominal contents in this respect, and consequently they give no distinctive shadow on the fluorescent screen or radiogram.

The method therefore depends on filling the cavities with some substance that differs as widely as possible in density from that of the tissue structures, *i.e.*, something very heavy, such as a bismuth salt, or by inflating them with air or gas. In the former case the contents obstruct the rays and therefore a dark shadow is thrown upon the fluorescent screen, whereas in the latter, the air allows the rays to pass more freely and therefore the screen is more brilliantly illuminated. This latter method is, however, of very limited value.

#### 2. METHODS OF EXAMINATION.

The examination should be undertaken with the patient standing with his abdomen pressed against the screen, and the passage of the first mouthfuls should always be carefully observed from the cardiac orifice to the lowest point. I have found that examinations made in the upright position yield infinitely more information than those conducted with the patient lying down, and as these latter examinations give a different picture which may be very misleading, I have purposely omitted any description of them in order to avoid confusion.

Radiographs are of comparatively little use except for demonstration purposes, as they represent the picture at one particular moment only, and give little indication as to how the stomach receives the food, etc. Radiographs

are therefore expensive, and in many cases unnecessary luxuries except for demonstration purposes, but a good radiogram of the pars pylorica will reveal more detail than can be made out on the screen. It must be understood that the shadow represents only such of the contents as contain bismuth, and will therefore give the outline of the cavity only in so far as it is filled by this food. Consequently, where the tone is good and the organ contracts upon its contents, the bismuth shadow represents the true shape of the cavity, except in the upper part (which usually contains some air, showing as a light area beneath the left dome of the diaphragm), but when the tone is defective all the food falls to the lowest part, and it is only this portion of the stomach that is outlined.

### 3. PROTECTION OF THE PATIENT.

It is the soft rays, the ones which are easily stopped and are therefore useless for this type of examination, that produce *x*-ray dermatitis. For this reason the patients have worn a dressing-gown or other garment, and in practice this has been found quite sufficient protection, as not a single case of reddening of the skin has been noted, although many of the examinations—especially for demonstration purposes—have been very prolonged. Moreover, repeated examinations have been necessary in practically every case, some of the early ones being examined as many as eleven times.

### 4. PROTECTION OF THE OBSERVER.

From the outset—in 1906—it has been evident that a radiograph of the stomach contents, no matter how perfect, could be of little value in diagnosis, just as a photograph would be useless in depicting an ataxic gait. Therefore examinations have invariably been conducted by means of the fluorescent screen, and this has necessarily involved a great deal of exposure to the rays on the part of the observer. Great difficulty has been experienced in devising apparatus for self-protection that would yet allow of easy manipulation of the patient. When examining with the subject lying on a couch there was little difficulty, as one was not in the direct path of the rays,

but for examination in the upright position the observer is necessarily in front of the tube. A protective diaphragm was therefore made by the hospital staff of carpenters, and the quantity of rays that now penetrates is infinitesimal.

At all times *x*-ray proof gloves and apron have been worn and no dermatitis has been sustained. In the early days, before the fluorescent screen was covered with *x*-ray proof glass, irritation of the eyes was of frequent occurrence, but no permanent ill-effects have resulted.

During periods of heavy work, before the operator was efficiently protected, it was found that excessive weariness and mental inertia were the immediate result of a series of screen examinations, but since the addition of the protective diaphragm, already referred to, this effect has not been noted to the same extent. The only ill-results now encountered, even on the busiest days, being slight weariness and headache, which are probably not due to *x*-rays but to working in a dark unventilated room in which the air is in a partially ionised condition. (Recently a ventilating fan has been placed in the wall, and now there is apparently no undue weariness even after the busiest morning's work.)

##### 5. POSITION OF THE PATIENT.

(a) *In gastric cases.* It was at once apparent that posture had an extraordinary effect on the gastric contents, and it became a matter of choice whether to examine the patient standing or lying down, as the limitations of time prevented a routine use of both positions. In many cases, however, both were employed, but the horizontal position practically never yielded any information that one had not already obtained, and its use was abandoned except for post-operative cases where the patient was too weak to stand and it was necessary to determine by what route the food left the stomach. For this purpose the horizontal position sufficed, but it is not capable of yielding reliable data as to the stomach walls, and for this reason I think it futile to attempt ordinary *x*-ray diagnosis unless the patient can be examined in the upright position. Another point that determined the use of

this posture was the fact that it is the usual position during digestion, and it is while this process is going on that the *x*-ray examination is made.

The best view of the stomach is obtained with the abdomen against the screen, but in certain cases it was found that the pyloric portion seemed to turn somewhat backwards and its shadow was thus foreshortened, but, by rotating the patient slightly, this portion came into full view. The pylorus itself is the most difficult portion to see clearly, not only on account of the small quantity of food that it usually contains but also because of the superimposed shadow of the vertebral column.

(b) *In œsophageal cases.* The upright position is the easiest and most useful as well as the most natural for œsophageal cases. In the direct antero-posterior position the vertebral column and heart form a very heavy shadow through which it is impossible to see the œsophagus clearly, but if the patient is slowly rotated so that the front of the right shoulder is against the screen, a certain angle is found at which these two shadows become separate; a comparatively clear space representing the posterior mediastinum is opened up, and it is through this space that the œsophagus passes. In this position the whole œsophagus is seen, from the pharynx to the cardiac orifice.

#### 6. PREPARATION OF THE PATIENT.

Patients should be prepared for all abdominal examinations as if for an anæsthetic by means of purgatives, in order that the stomach may be empty and that there may be no shadows in the intestines to confuse the picture. This also makes the abdomen much more translucent to the rays, consequently the picture of the stomach full of bismuth has a much sharper outline than if no preparation had been made. These patients are frequently taking some bismuth mixture; this should be discontinued some days previously.

No special preparation is of course necessary for œsophageal examination.

## 7. FOODS USED.

(a) *In gastric examinations.* The essential feature of the food is that it should be of sufficient difference in specific gravity from the abdominal contents to cast a definite shadow. This is attained by embodying in it a salt of one of the heavy metals. Bismuth subnitrate was used in the early cases, as much as 4 ozs. being taken with no ill-effects. Reports of cases of poisoning were published\* and the carbonate of bismuth was subsequently used, the proportion being approximately 1 ounce to 2 or 3 ounces of the excipient. For stout patients the quantity was increased if necessary in order to get a denser shadow. The oxychloride of bismuth was tried, but I could find no difference in the behaviour of the stomach, although this salt is more correct theoretically as it is not acted upon by hydrochloric acid. In practice I have never noted the evolution of CO<sub>2</sub> into the stomach from the use of the carbonate, and I find that patients prefer it to the oxychloride, which has moreover a tendency to settle out from the food, making the detection of hypersecretion impossible.† The excipient used has been bread and milk, thoroughly mashed up, or porridge. Other excipients, such as mucilage of tragacanth, pounded biscuits, cake, bread and butter, mince meat, vegetables, etc., have been tried with more or less success, but the composition of the food seems to be of no practical moment, provided it does not nauseate the patient. The addition of raspberry syrup has been of some service in obviating this difficulty, but it is seldom that patients find the crude mixture too distasteful.

No fixed quantity has been given, but sufficient has been used in each case to dilate the potential cavity of the stomach to such an extent that the condition of the walls could be deduced. The quantity, therefore, has varied from 2 ozs. to

\* At least two cases of poisoning occurred in America, but I have been unable to trace the references. Bennecke and Hoffman ("Münchener Medizinische Wochenschrift," 1906, No. 19) recorded a fatal case, the symptoms being suggestive of nitrite poisoning, and nitrites were found both in the blood and pericardial fluid. Later Bohmie proved that the administration of bismuth sub-nitrate was followed by the appearance of nitrites in the faeces and urine, but not in the blood.

† Specially prepared Barium Sulphate is now often used and is quite satisfactory, except that it appears to be rather stimulating to the gastric muscle and makes the detection of the duodenal irritation less certain.

$\frac{3}{4}$  pint—in one case of delusions as to the shape of the stomach a patient took 4 pints of custard mixed with bismuth carbonate (8 ozs.) with no ill-effects.

It is quite unnecessary to give purgatives in order to clear out the bismuth after the examination. In large doses the salt passes through unaltered and gives rise to neither constipation nor diarrhœa.

(b) *In œsophageal cases.* The same food stuffs have usually been employed in œsophageal cases, but the consistency has been varied according to the patient's statement as to the character of food with which he has difficulty. Cachets and capsules of bismuth have been discarded, as it was found that they gave quite unreliable evidence; in a healthy subject a gelatine capsule was delayed half an hour at the cardiac orifice in spite of copious draughts of water, while a delay of many minutes was sometimes seen behind the aortic arch. The passage of a solid bougie was watched in one case, but its use appeared to be so dangerous that I have never again employed this method.

#### 8. SPECIAL METHODS.

(a) *Physical methods.* The most useful special method employed is the application of abdominal massage. This practice, which I introduced about three years ago, has been of the greatest service, since by its use it is almost invariably possible to distinguish between alterations in the outline of the stomach due to organic lesions and those due to spasm, and where, as so frequently happens, there is a combination of these two factors, a great deal of information may usually be obtained as to the respective parts played by each in determining the shape of the resulting shadow.

Manipulation either by hand or more safely with a wooden spoon (as suggested by Holzkecht) during the examination, has frequently given information as to the fixity or otherwise of various parts of the stomach, but care is needed in making deductions as it is exceedingly easy to mistake displacement of the contents for displacement of the stomach wall itself.

Inflating the stomach by means of sodium bicarbonate and tartaric acid distends the fundus, and has occasionally yielded information as to this portion of the cavity, but, owing to the impossibility of excluding gastric ulcer, it has seldom been used.

In the early cases, when good definition of the greater curvature could not be obtained, I found that injecting air per rectum was of some value, and in a few cases this method showed up small irregularities that would otherwise have escaped notice.

A mixture of bismuth and lycopodium has been tried for more clearly demonstrating the level of fluids, but its use was unnecessary and it has been abandoned.

Capsules made of gold-beater skin containing bismuth have been given, in order to test the digestive power of the gastric juice (suggested by Schwartz). I found that it was not possible to determine at what time the capsules ruptured and also that very frequently they were broken during deglutition. As no other bismuth could be given until the observations on these capsules were completed their use has been abandoned.

(b) *Actions of drugs.* The only drugs that have been examined to any extent have been sodium bicarbonate, belladonna, valerian, asafoetida, and alcohol.

Valerian and asafoetida have been found to diminish tonic action in proportion as patients found them distasteful. Those who disliked the smell or taste most showed the greatest loss of tone. Alcohol, on the other hand, tended to increase tonic action, the increase being more or less proportionate to the patient's appreciation of the alcohol (whisky) used in the experiments.

Belladonna acted in an uncertain manner. In some cases of spasm it caused complete relaxation, while in others it had little or no effect. In one or two cases of excessive peristalsis this symptom was checked by its action. No cases of excessive secretion have been tested with this drug as yet.

Sodium bicarbonate has also been found to check excessive



and painful peristalsis in a wonderful way in a proportion of cases, while in others it has produced no effect. I have also lately introduced the use of this drug for testing, in a very rough but handy manner, the quantity of free acid in the stomach. In healthy subjects there is well-marked evolution of carbon dioxide, but in every case of marked hypersecretion there has been much more profuse production of gas.

## CHAPTER III.

DIAGNOSIS OF AFFECTIONS OF THE  
ŒSOPHAGUS.

Possibly none of the many striking conditions that are revealed by *x*-rays is so dramatic as the demonstration of œsophageal obstruction. A dogmatic positive or negative diagnosis is expected and is freely given by the radiographer, and it is usually accepted by the physician, for it is a generally accepted axiom that it is a case of either 'guilty' or 'not guilty,' and that if the bismuth food passes freely down the œsophagus there cannot be any obstruction. This is not the case, for 'obstruction' is a relative term and depends on three distinct factors, *i.e.*, (1) the consistency of the food in relation to (2) the degree of obstruction and (3) the power of the œsophageal peristalsis, aided by the action of gravity.

The œsophagus, unlike the rest of the alimentary tract, has approximately only one function namely to act as a highway from the mouth to the stomach, and anything that interferes with this function causes the symptom of œsophageal obstruction, which may arise from a variety of causes. It is frequently the first and only sign of such serious conditions as new growths and aneurisms, while comparatively innocent lesions may give rise to precisely the same trouble. I am convinced that in some of these latter, the patient's life would have been saved by a gastrostomy if the operation had not been put off too long on the supposition that it was due to malignant disease, and that it was not worth operating except to avert death from starvation.

*The methods of investigation* available and their limitations.

Of the bougie it is difficult to write with patience. It is an act of crude barbarity to pass such an instrument for diagnostic purposes into a tube whose walls may be the seat of simple or malignant ulceration or even eroded by an aneurism, if other

less dangerous methods are available. The bougie is a most useful surgical instrument, and in a large proportion of cases it is the right instrument to employ for surgical purposes, but for diagnosis there is no other such barbaric relic in the whole of medicine or surgery. Plummer's method\* of passing a bougie, threaded on a swallowed string, seems to be the only safe way of employing this instrument.

The œsophagoscope, on the other hand, reveals the whole of the track down which it travels but that is all. It is blind to conditions around the œsophagus and may be passed, all unsuspectingly, within a fraction of an aneurism or growth that by its pressure is causing difficulty in swallowing.

The *x*-ray method shows the shadow of the food in the œsophagus. It does not show the œsophagus itself, but it reveals the presence of aneurisms and large new growths, while from the shape and behaviour of the food shadow much may be learned as to the nature of the lesion that gives rise to the symptom. Moreover, it has two very great advantages, it is entirely free from danger and it involves no distressing manipulative procedure.

#### THE CAUSES OF ŒSOPHAGEAL OBSTRUCTION.


1. Those due to pressure from without.
2. Those due to changes in the walls themselves.
3. Foreign bodies.
4. Reflex causes.

(1) *Due to external pressure.* (Œsophageal compression.)

- (a) Aneurism.
- (b) New growth in the neck, mediastinum, or lungs.
- (c) Enlarged glands.
- (d) Spinal abscess and new growths arising from the vertebral column.
- (e) Bronchocele.

The diagnosis of these conditions does not fall within the scope of this thesis and is therefore omitted.

\*H. S. Plummer, "Journal of American Medical Association," August, 1908, and June, 1910; J. S. Mayer, *ibid.*, October, 1910.



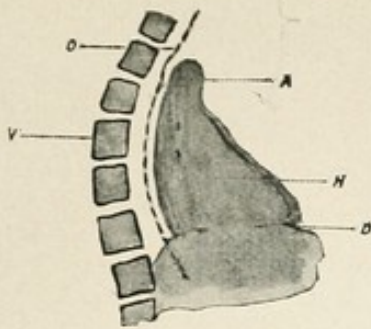


Fig. 1.

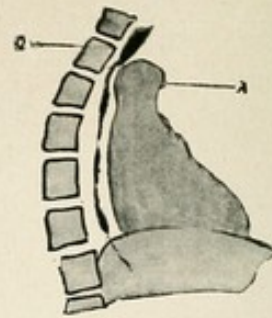


Fig. 2.

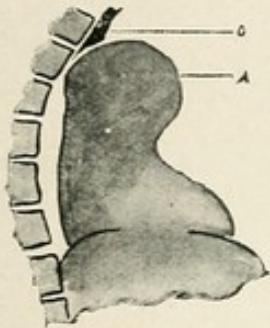


Fig. 3.

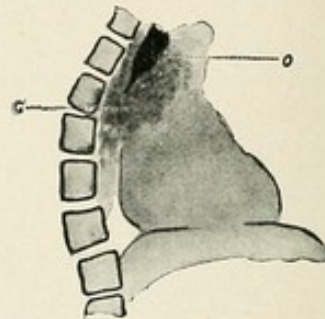


Fig. 4.

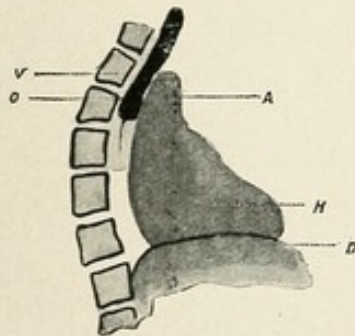


Fig. 5.

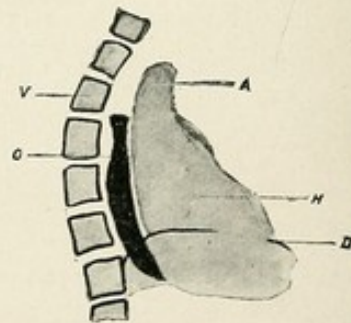


Fig. 6.

Fig. 1. Diagrammatic representation of the semi-lateral view of the posterior mediastinum with the normal course of the oesophagus indicated by the dotted line. (A. Aorta. H. Heart. D. Diaphragm. O. Oesophagus. V. Vertebral column.)

Fig. 2. Slight dilatation of aortic arch with delay of bismuth above it. No real obstruction.

Fig. 3. Large aneurism of aortic arch with oesophageal obstruction.

Fig. 4. Growth in the posterior mediastinum surrounding and obstructing the oesophagus.

Figs. 5 and 6 represent obstruction behind the aortic arch and at the cardiac orifice respectively.

(2) *Due to causes on the walls themselves.*

(a) New growths.

(b) Ulceration, with spasmodic contraction.

(c) Cicatrization, following ulceration from caustics and acids, syphilis, etc.

It is seldom that these cases can be separated from one another. The growths are usually too small to cause any distinct shadow, while cicatrization, ulceration, and spasmodic contractions give exactly similar appearances. Belladonna is of some value in relaxing the spasmodic element in these cases I find, but it is not sufficiently reliable in causing relaxation of spasm to be of much value in diagnosis.

In this group of causes there are nearly always two factors to consider, *i.e.*, the organic and the spasmodic, and I cannot too strongly insist on the importance of this latter element which is often responsible for almost the whole of the symptomatic disturbance.

The œsophagus, like the rest of the alimentary tract, is highly sensitive, and a small abrasion or ulceration may set up a spasm of such severity and persistence that complete obstruction may result. The severity of the spasm appears to depend, not on the size of the ulcer, but upon its irritability, for I examined a case on the day following operation for removal of an eroded penny that had been lodged in the œsophagus for four months, and found only the slightest delay with quite thick food, whereas in another case, which was examined by the œsophagoscope, I found complete obstruction with dilatation although only a very small ulcer was seen. I believe that simple, or peptic ulceration of the œsophagus is of far more frequent occurrence than is commonly taught.

It is in this type of case that the stage of dilatation with leakage or temporary recovery is sometimes seen, and a certain number of cases of simple ulceration are met with in which the passing of a bougie may so stretch the base of the ulcer that healing and complete relief of all symptoms may follow, as I have seen on two occasions, one of the patients being a man of over seventy.

The use of the bougie should never be attempted unless the bismuth shadow shows a definite funnel-shape at its lower end; a bougie may wander in an amazing fashion far away from the opening into the passage. Force must never be used, and even with the gentlest manipulation a round-nosed bougie may pass into an ulcer and down between the mucous and muscular coats, giving a sense of absence of obstruction that, in one of the cases I examined, led to the death of the patient from direct septic extension to the lungs.

(3) *Foreign bodies in the œsophagus.*

Most foreign bodies that are found in the œsophagus are opaque to the *x*-rays and the bismuth method of examination is unnecessary for their detection. Plum-stones, fish-bones, and certain kinds of tooth-plates however, throw no shadow that can be distinguished, and in a few of these cases I have been able to demonstrate their presence by observing the behaviour of the bismuth food as it found its way past them. In some cases the stream was divided, in others portions of bismuth were left adherent to, or in pockets about, the foreign body. On the whole, however, the detection of these translucent bodies has not been satisfactory.

(4) *Reflex causes.*

- (a) New growths and inflammatory lesions of the larynx and in the neck.
- (b) Ulceration and new growths of the cardiac end of the stomach.
- (c) Neurotic and hysterical.

(a) New growths and inflammatory lesions of the larynx and in the neck are readily diagnosed by other methods, and it is very exceptional that the *x*-ray examination is of any value except in demonstrating that, although the food enters the pharynx, it does not get into the œsophagus.

(b) Ulceration and new growths of the cardiac end of the stomach, when situated close to the cardiac orifice may give rise to very marked obstruction. (figs. 6 and 8.) In one case a healed ulcer, two inches from the orifice, was the only pathological condition noted post-mortem in a case where the

patient showed all the signs of extreme dilatation of the œsophagus. This had led to such weakness that the patient died from the shock of the operation of gastrostomy. In another case, where marked dilatation had taken place and no food appeared to enter the stomach, advanced carcinoma was found, but it did not involve the orifice which appeared to be quite patent and normal in all respects. In both these cases, although dilatation of the œsophagus had occurred, the post-mortem reports state that the œsophagus was not dilated.

*\*(c) Neurotic and hysterical.* I have seen no cases in which this diagnosis was confirmed, but neurotic patients frequently gave trouble by stating that they could not swallow. Persuasion and distraction of the attention, however, usually overcame this difficulty and demonstrated the nature of the case.

#### THE STAGES OF ŒSOPHAGEAL OBSTRUCTION.

Whatever the cause the result is the same and there are three definite stages, not only in the *x-ray* appearances, but also in the clinical history of the cases.

*Stage 1. Difficulty in swallowing.* (Most marked in upper part of the œsophagus.)

This is the stage of difficulty in swallowing. The patient has not lost weight but gives a history of some difficulty in swallowing, especially when he tries to eat his food fast and without mastication. Usually there is little or no pain, provided he masticates carefully and eats slowly, but he often states that he has to force each mouthful down separately.

On examination with the ordinary type of bismuth porridge it is probable that, at the most, a little delay is noted at one particular part. If, on the other hand, we make up

\*Recently I saw a case in which it was evident that the patient had to push each mouthful down the œsophagus by sheer forceful deglutition as far as the level of the clavicle. There was evidently no obstruction beyond this point, the food passed down quite freely and easily and not a trace was left adhering to the walls, while in the upper third traces of the food remained for a long time. It was quite clear there was paralysis in the upper third, while the lower two-thirds were quite normal. On making enquiry from Professor Elliott Smith, I found that he had just traced out a dual nerve supply arising from two separate nuclei in the medulla, while the same observation had been made by Van Gehuchten and Molhant 6 months previously ("Le Nevraxe," June, 15, 1912, p. 55).



our bread and milk with lumps in it and make the patient eat it quickly, we may find that there is definite delay at this same point, and occasionally one sees a violent peristaltic wave squeeze the food almost into a ball and force it through the obstruction.

The œsophagus is called upon to do an excessive amount of work, consequently hypertrophy occurs—it is the stage of compensatory hypertrophy, and for the time being compensation is established.

*Stage 2. Pain after swallowing.* (Not so well-marked in the lower as in the upper parts of the œsophagus.)

This is the stage of painful deglutition and the patient has begun to lose flesh. He states that he cannot swallow solids at all and that even gruel sometimes regurgitates into his mouth but he never actually vomits. The pain *after* swallowing of food is the main feature, and it is his dread of eating, far more than the actual obstruction, that leads to the wasting, for although the food he eats is eventually forced through, yet the pain is such that he prefers starvation.

On examination there is definite delay at the point of obstruction; there is seldom any mistake in the diagnosis unless some such thin mixture as milk and bismuth is used, which may pass through unobstructed. The food is held up, it cannot pass on, and the œsophageal walls bring all their peristaltic power to bear on the obstruction, and as the powerful waves move downwards, the food being unable to pass through the obstruction escapes upwards in a narrow stream through the descending contraction. When one sees the picture one is not surprised that it is the stage in which pain is the marked feature—it is sometimes so marked that it suggests a life and death struggle. The waves are not a continuous succession of contractions; it is a case of one great effort followed by a period of comparative rest while the muscle braces itself up for another powerful contraction. This curious intermittent feature of the contractions is, I believe, characteristic of failing compensation, not only in the



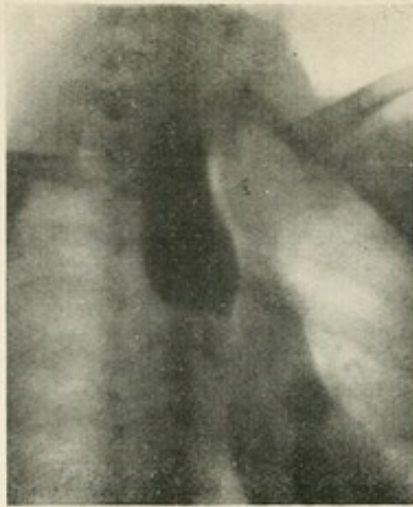


Fig. 7. Radiogram of oesophageal obstruction at the level of the 6th dorsal vertebra. The cause in this case was a small peptic ulcer. The spasm that caused the obstruction was only brought on by giving dry bread. It was after this procedure that the bismuth food was given, and the radiogram indicates the complete obstruction that has resulted.

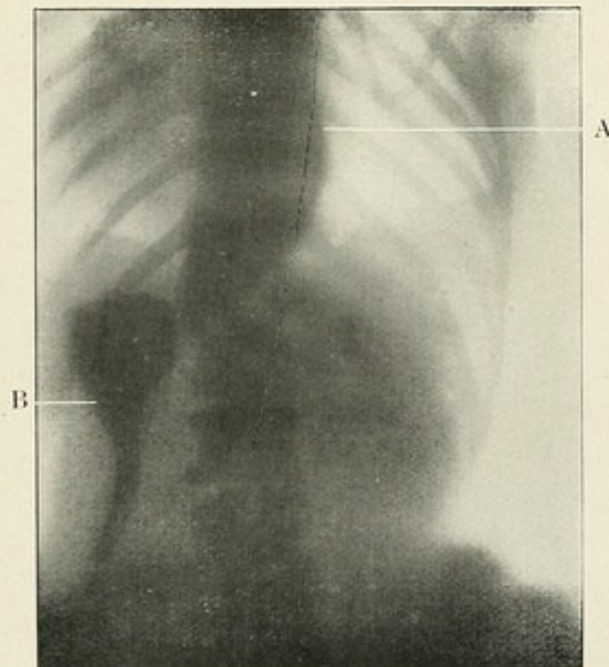


Fig. 8. Spasmodic oesophageal obstruction (cardiospasm). (a) The dilated oesophagus, (b) Bismuth food that entered the stomach more or less in a rush, indicating the spasmodic nature of the lesion very clearly in this case.

œsophagus but also in the stomach, in certain stages of pyloric obstruction.

In this stage the compensation is failing and hypertrophy is about to give place to dilatation.

*Stage 3. Dilatation.*

(Naturally, in cases where the obstruction is high up and the œsophagus has no room to dilate, this stage is not so well marked as in the lower two-thirds of its course.)

Clinically, it is the stage of starvation and the patient is rapidly losing flesh, but the pain and difficulty in and after swallowing are comparatively slight, so that the patient feels and often becomes better for a time. There is no longer any actual difficulty in making the food pass down, but sooner or later it is brought up again—the lower down the obstruction and the greater the degree of dilatation the longer will the food be retained, so much so that in marked cases a diagnosis of pyloric obstruction is not at all infrequently made. In one of these cases quite considerable quantities of bismuth were found in the dilated pouch that extended above the diaphragm two days after it had been given, and the patient gave a history of having recognised in his vomitus, food that he had taken some days previously. Indeed, in a few cases, it is absolutely impossible to recognise whether the trouble is œsophageal or gastric, for the food returned from such a pouch has the same acid smell as gastric vomit, and fermentation takes place just as readily in a dilated œsophagus as it does in the stomach in pyloric obstruction. Moreover, the stomach tube may give most misleading information, for instead of stopping at the obstruction it may just as readily pass into the pouch, whose thin walls give little sense of resistance. I have seen a tongue,  $1\frac{1}{2}$  inches long, pushed out from a sac over the dome of the diaphragm by the sheer weight of the tube in a fraction of a second, in a case where an entry in the notes stated that bougies had been passed into the stomach. On more than one occasion I have found complete obstruction in cases diagnosed as carcinoma of the stomach,

on the evidence of the chemical examination of a test meal that could not possibly have been in the stomach.

It would be expected that this state of affairs could not last long, but when the cause is in part spasmodic, the complete relaxation of the tone that allows the dilatation also relaxes the spasm, and this is often the most important element in the obstruction. When the cause is not rapidly progressive, a cycle may be established reverting between the second and third stages. Such cases are sometimes due to simple or peptic ulceration, which I believe to be of more frequent occurrence than is commonly supposed. The ulcer causes a spasmodic obstruction that follows through the usual three stages till dilatation is established. After a time the œsophagus is too worn out to keep up its spasmodic contraction in spite of the source of irritation, and relaxation takes place so that food passes through. Soon the muscle recovers its power and contracts on the ulcerated surface and again the spasm is produced. In the larger number of cases however, a compromise is effected and there is no definite cycle, a more or less permanent condition of dilatation with leakage being the result, so that the patient lives in comparative comfort but in a state of semi-starvation.

On examination, no matter what the consistency of the food, it simply flows into the œsophagus and lies in the dilated sac, for there are no peristaltic waves of sufficient force to disturb it. If the sac is called upon to hold more than a certain quantity, either the patient must vomit or the sac must dilate still further. Sometimes dilatation is carried to an extreme, especially in the lower part of the œsophagus. The pouch distends along the line of least resistance which is by displacement of the lung and burrows forward over the dome of the diaphragm, occasionally even displacing the heart to some extent.

Pathologically, it is the stage where compensation has failed. The fight in which the musculature has called up all its reserves has ended in defeat. The hypertrophied wall is dilated, thinned out, and incapable of effective contraction. One would expect that at the post-mortem we should find this

state of affairs as in life, but it is very seldom that it is recorded in the post-mortem notes. The only explanation I can suggest is, that although the œsophagus has been so distorted during life, in death the same conditions do not exist. Probably rigor mortis and the contraction of the elastic elements of the muscle restore the œsophagus to a semblance of the normal.

Like all involuntary muscles the œsophagus has a wonderful power of recovery, and even a grossly dilated œsophagus may completely recover its activity and tone in a very short time if rest can be secured, *i.e.*, if the obstruction can be reduced or feeding carried on by some other method. In one patient, a woman, in whom the œsophageal shadow was noted as two inches in diameter, the obstruction yielded of its own accord, and when I saw her a week later it was impossible, even with solid food, to note any abnormality.

## CHAPTER IV. THE NORMAL STOMACH.

The anatomy of the soft parts, as seen in the dissecting room, is not necessarily a true index to the condition found in life, and although the stomach is retort-shaped after death or on the operating table, it is a very different organ as it fulfils its functions in life and with the patient in the upright position. Like the rest of the alimentary canal it is tubular, more or less J shaped, and almost entirely to the left of the middle line. The lowest part reaches to about the level of the umbilicus\* and the pylorus is perhaps an inch higher and slightly to the right of the middle line, but these data are approximate only, as in practice it is found that even in patients who do not know what indigestion is, the shape of the shadow differs widely. Generally speaking, this is due to defective tonic action, and therefore it is essential that this property of the gastric muscle should be grasped before any attempt is made to detect pathological changes.


The increased capacity for food is obtained by lateral expansion of the tube, which should hold its contents up against the action of gravity at a fixed level, and it is the tonic action (see page 24) of the gastric muscle that is responsible for this maintenance of the fluid level in the upright position.

The lowest border should not move with respiration, and compensation for diaphragmatic movement is automatically taken up by the stomach walls.

In a paper † before the Electro-therapeutic section of the Royal Society of Medicine, I showed that the contents are not churned up but take up their positions according to their specific gravities, except in the pars pylorica when the peristalsis is active; consequently air always occupies the fundus,

\* The level of the umbilicus is practically the same as that of the iliac crests, so that there is no need to place a coin or other mark on this point to show its position.

† "Proc. Roy. Soc. Med.," Feb., 1909.





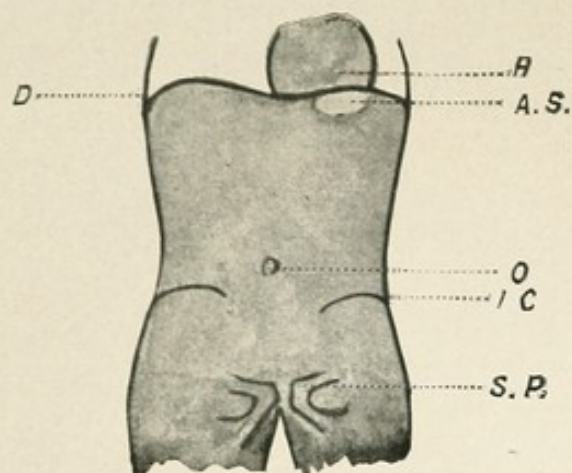


Fig. 9.

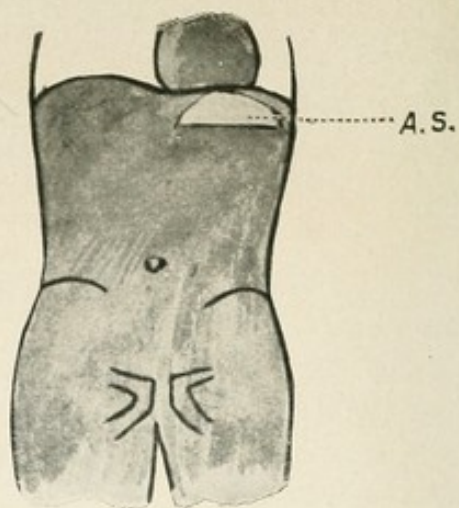


Fig. 10.

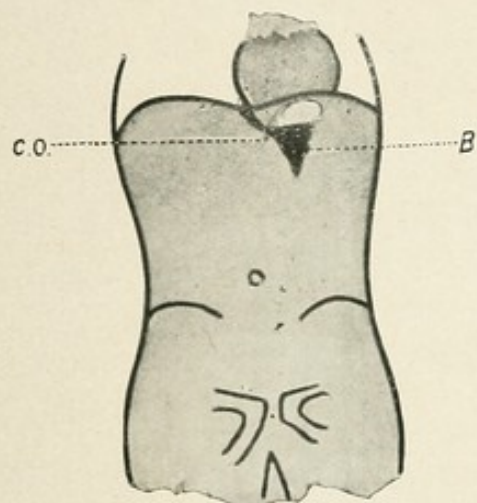


Fig. 11.

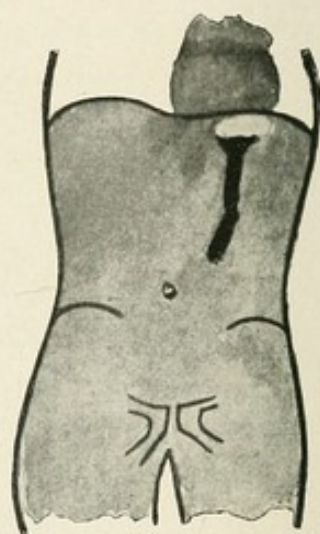


Fig. 12.

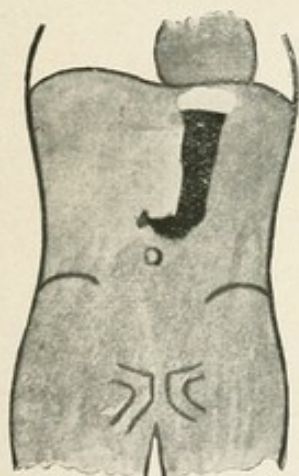


Fig. 13.

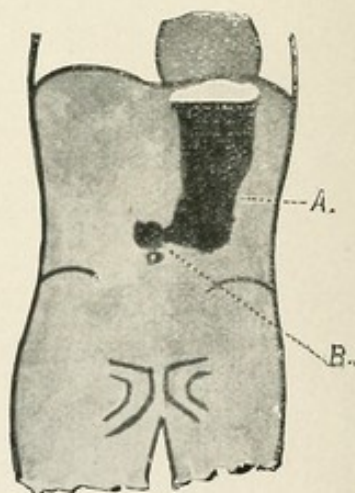


Fig. 14.

Fig. 9. Air in fundus of the empty stomach (A.S.). H. : Heart. D. : Diaphragm. O. : Umbilicus. I.C. : Iliac crest. S.P. : Symphysis pubis.

Fig. 10. Air in the fundus (A.S.) of a stomach that already contains fluid.

Figs. 11, 12, 13, 14.

Diagrams illustrate the filling of a normal stomach B. : Bismuth food. C.O. : Cardiac orifice. A. and B. in Fig. 12 indicate peristaltic waves.

and the heavier food gravitates to the lowest part. Hence the bismuth food outlines the lowest border in all cases.

The fundus occupies the left cupola of the diaphragm and usually contains air which shows as a light area below the shadow of the heart.

If the stomach is empty, the air appears as an oval shadow, while if there is a quantity of food in the stomach, the shadow represents the arc of a circle, its lower border being a straight line which can be demonstrated as fluid by watching the ripples on its surface on shaking the patient.

The empty stomach is a potential space, and into it the bismuth food passes. The weight of a single mouthful may not be sufficient to canalize the potential cavity for a little time and hence the food stays in the upper part just below the air, but as more is given the shadow is seen passing downwards to the lowest point, and after a short time the pyloric antrum is filled. After two or three mouthfuls have been swallowed the shape of the shadow should be like the letter 'J,' and as more food is given the increased capacity is obtained by the lateral expansion of the shadow, and not by any appreciable drop in the position of the lowest border, or raising of the upper level of the shadow.\*

It has been stated that the shadow of the bismuth filled stomach does not represent the normal shape; that the actual weight of the food causes a distorted appearance. This, however, can be easily disproved by giving an ordinary meal and then watching a thin watery suspension of bismuth permeate the ordinary food. The shape of the organ obtained in this way differs in no detail from that obtained with the usual bismuth method.

I have found that in infants the shape of the organ is much more globular and during the first year of life is comparatively spherical, but as the child assumes the upright

\* The description of the normal stomach is purposely vague—it is as fruitless to apply the precision of descriptive anatomy to such an organ as it would be to give exact figures and shapes for an indiarubber balloon. Its capacity varies from zero to many pints, while its shape is determined not only by its tonic action and the quantity of food it contains but also by the pressure of the other intra-abdominal organs, particularly by the presence or absence of gas in the splenic flexure.

*Hyperbolic  
curvature*

position the stomach elongates. It is not, however, till near the age of puberty that the lower border descends to the umbilicus.

The stomach is not a fixed organ and it is easily displaced by even slight forces. For instance if the splenic flexure is distended with gas the stomach may be displaced to the right, or if the patient's abdomen is pressed upon, the lowest border may be moved upwards by two inches or more.

This is the description of the normal stomach, but, as I have already said, it is by no means always found in persons who have never suffered from any gastric trouble. It is a fact that the stomach may present *an appearance* that is far from normal and yet fulfil its functions perfectly. The part played by tonic action or defective tonic action in the appearances seen is the key note to correct interpretation in these cases, and will therefore be considered.

*Tonic action.*

The upper border of the contents should be about the cardiac orifice, and the increased capacity for more food should be obtained by a widening of the tube. (See figs. 11 to 14.) Tonic action, therefore, may be defined as the constant contraction of the stomach which maintains the contents in tubular form, *i.e.*, it is an automatic contraction that counterbalances the action of gravity on the stomach contents. In the recumbent position therefore, the tonic action is not called upon to anything like the same extent, and it seems reasonable to suppose that the benefit received by patients suffering from atony from rest in bed is due, in part at least, to the relief of the constant strain on this function.

A thorough understanding of this property of the muscle is invaluable in gastric radioscopy. Tone is a property of the living muscle, and is therefore not seen either in the post-mortem room or as a rule on the operating table. It is under the control of the central nervous system, and may alter very rapidly. For instance, everyone knows the sinking feeling that accompanies nausea, sudden fear, and disgusting smells, and in these conditions I have invariably found that this sinking sensation in the abdomen is accompanied by an actual

relaxation of the tone, and consequently by a drop in the level of the lower border of the stomach, while an increase in the tone accompanies the actual process of vomiting and retching. I have made many experiments on tonic action with various drugs such as valerian and asafœtida, and the loss of tone seemed to be in direct proportion to the disgust in almost every case.

Loss of tone is often associated with loss of appetite, while appreciation of food tends not only to stimulate the flow of gastric juice, as we know, but also to increase the tone.

*Peristalsis.*

It should be possible to make out the peristaltic movements in all except very stout patients, and they appear to be always present from the time food enters the stomach till it is empty. The waves start opposite the cardiac orifice and sweep along the greater curvature, gaining in force as they approach the pylorus.

On the lesser curvature the waves are not seen so high up. When they actually segment the bismuth shadow, some distance from the pylorus, the peristalsis is more powerful than normal, but peristalsis is so variable that no conclusions should be drawn from this sign, unless the waves are persistently noted as excessive on several occasions.

The persistent absence of peristalsis in a stomach otherwise normal in appearance but containing retained food, is associated with extensive ulceration—usually malignant—involving the pyloric region and giving rise to obstruction.

Naturally, in a thinned out atonic stomach, the peristalsis is likely to be much less powerful than in a normal stomach, but even in extreme cases, when the lowest part is almost in the pelvis, peristalsis can always be elicited by massage. In these cases it is difficult to observe the movements, the shadow of the sacrum and ilium obstruct the view, and unless the *x*-ray tube is working well it may be impossible to make certain of this point.

Reverse peristalsis is very seldom seen in this country and when met with it indicates gross pathological changes, usually at the pylorus, but I have only seen it in six cases.

*The control of the pylorus.*

By means of giving sodium bicarbonate and observing the evolution of carbon dioxide, the acidity of the gastric contents can be roughly estimated, and it is certainly not in those cases in which the evolution of gas is greatest that the pylorus opens most freely, but in the class of case that I have styled 'duodenal irritation' (p. 55). In this type of case the food is seen passing out almost at once into the duodenum and continuing to pass on until the stomach is empty; one does not see any hypersecretion and the evolution of gas is not more than in healthy people. It looks therefore as if the degree of acidity of the gastric contents is not the determining factor.

Such evidence as I have seems to prove that fatty foods tend to remain longer in the stomach than the carbohydrate and proteid meals usually employed, but I have not noted any difference in this respect between the porridge and bread and milk bismuth meals.

The rapid emptying in the duodenal cases is most striking. Not only does the food go through more rapidly but also the pyloric relaxation seems to be much more complete than in the healthy subject, with the result that quite large quantities pass through at a time and are easily seen on the fluorescent screen, in contrast with the finer division and thin stream in which the food leaves the stomach in perfectly healthy subjects, which can only be detected on the fluorescent screen under the most favourable conditions. In a certain number of these I have also noted that the pylorus did not open at once and no food was seen passing through for perhaps ten minutes, but when once shadows were seen in the duodenum, the stomach began to empty rapidly as if the mere presence of food in the duodenum brought about pyloric relaxation. In every case of actual ulceration of the duodenum this rapid emptying has been noted, whether the meal was made up of bread and milk or of porridge. Distending the duodenum does not bring about closure of the pylorus, rather the reverse, so far as I can tell from observations on a limited number of cases in which this portion of the intestine has been overloaded either artificially by giving

a very large meal, or pathologically by reason of cicatrization.

These observations suggest very strongly that the control of the pylorus is regulated by some sensory mechanism in the duodenum, and an irritable state of this part of the gut, whether intrinsic or reflex, tends to abnormal pyloric relaxation. In two cases this relaxation was so marked that I actually pressed a large quantity of food through the sphincter by manipulating the stomach through the abdominal wall.

*The control of peristalsis and tonic action.*

As I have pointed out,\* I believe that tonic action and peristalsis are entirely separate and independent muscular functions. The evidence on which this opinion is based is that even in the cases where atony was most marked, peristalsis was quite well seen, while in a limited number of instances (type 2 of chronic pyloric obstruction)† an exactly opposite state of affairs was found, *i.e.*, perfect tonic action with complete and persistent absence of peristalsis.

That both of these functions are influenced by the central nervous system has been demonstrated in a variety of ways. For instance, tonic action and even spasmodic contractions have been relaxed when patients have been frightened. When patients have become faint I have nearly always had warning by seeing a sudden relaxation of tonic action—an observation that has sometimes saved the patient from a nasty fall. If there are a number of observers present the patient tends to become nervous, and often I have failed to demonstrate excessive peristalsis and hypertonic conditions that were invariably present when I carried out the observations by myself. The influence of nauseating smells in causing relaxation of tone has already been referred to.

\* Proc. Roy. Soc. Med., Electro-Therapeutic Section, Feb., 1909, p. 9.

† In advanced cases of pyloric obstruction two definite and widely differing types are met with and will be discussed in detail later (p. 33):—

Type 1. Is far the most common. The stomach is extremely atonic and sags down into the pelvis. Peristalsis may be quite active and yet the food may be retained for days.

Type 2. Is rare. The stomach is normal in shape, but distended with retained food, and the bismuth is seen in the stomach for 24 hours or longer. Frequently in these cases no peristalsis is seen and no movement can be evoked by massage.

In the early stages of pyloric obstruction, as we should expect, peristalsis is more marked than in health, but the phenomenon of very active peristalsis and hypertony, in association with an abnormally patent pylorus in cases of duodenal ulcer and duodenal irritation, suggest that these functions of the musculature are also influenced by some reflex connection with the duodenum.

In the cases referred to as type 2, of chronic pyloric obstruction, we have complete absence of peristalsis. Neither massage nor electrical stimulation seem to be of any avail in eliciting contractions. In these cases also an almost hypertonic condition persists and is quite uninfluenced by attempting to induce nausea. It is most striking that it is only in this class of case that neither of these functions can be influenced by any means I have tried, and the inference is that the nerve supply which regulates them is cut off. The actual pathological lesion found has always been of an extensive nature involving the lesser curvature in the pyloric region, and presumably this is where the nerve supply passes into the stomach from the duodenum, either directly or through sympathetic ganglia. The injury to these nerves produces a complete absence of peristalsis while tonic action is very pronounced, a condition that is in marked contrast to the usual atonic condition found in type 1 of chronic pyloric obstruction. It looks, therefore, as if tonic action is an intrinsic muscular endowment, or that there are centres controlling this function in the stomach wall itself or connecting with the vagus and acting in a similar manner to the centres in the lumbar enlargement for the regulation of micturition. In the vast majority of chronic pyloric obstruction cases, I have found that peristalsis is present and that the stomach is atonic. In some of these the pathological conditions were precisely similar to those found in the rarer type of case. If therefore my deductions are correct, it seems probable that the production of one or other type depends on whether or not these communicating nerve fibres are interfered with by the progress of the disease.

NOTES ON CASES IN WHICH THE OPERATION REVEALED A  
NORMAL STOMACH. (*Cases on p. 79*).

In the cases filed under this head are included only those in which no abnormality involving the stomach was found at the operation, with the exception of the duodenal cases, and those in which the *x*-ray picture of 'duodenal irritation' was present, which have been tabulated under a separate heading.

For a description of the normal stomach, see p. 22.

In many apparently normal stomachs a certain degree of spasmodic contraction of the middle of the body was noted, but in most of them the application of massage to the abdomen relaxed the spasm at once, while in a small number, notably Nos. 369 and 398, the contraction was thought to be organic in origin as it could not be relaxed by massage or the administration of belladonna. In case 398 this spasm persisted, and was so definite that at my instance the surgeon again explored and found nothing whatever to account for it; while in case 369 the simple manipulation of the stomach at the operation was sufficient to effect a perfect cure, and re-examination after the laparotomy showed no trace of the contraction previously noted.

Displacement of the lower part of the stomach is often met with. The most common cause is distention of the colon with air or faeces, and the examination 24 hours later will nearly always make this point quite clear. Adhesions and new growths are also factors in displacements, and the detection of these conditions depends, as a rule, on manipulation of the organ, preferably when the colon is also filled with bismuth. Under this heading are tabulated only those cases in which the stomach itself was not involved by the lesion.

Case 296 is curious, in that several observers detected a definite abdominal tumour near the pylorus. Radiographically I found no evidence of any abnormality, and no tumour could be found at the operation.

Slight or even marked atony was noted fairly frequently but was regarded rather as deficient physiological contraction than as a pathological condition.



## CHAPTER V.

## THE PATHOLOGICAL STOMACH.

**ATONY.\***


Atony, the failure of the muscle to maintain the tubular form against the action of gravity, is a complication of many pathological conditions of the stomach, and the part played by atony in the resulting shadow of the bismuth meal must be appreciated before we can diagnose other lesions of which the atony is merely a complication.

In the mildest degree of atony, so frequently met with, the food is held up for a short time, and then gradually gravitates to the lowest part; there is, however, always some evidence of the tubular formation remaining, even after a prolonged period. In marked cases the food straightway gravitates to the lowest part, and it is only the lowest border that is outlined. The picture of a really atonic stomach as seen upon the screen shows that the bismuth meal, instead of being held up in tubular form, sinks at once to the lowest point, where it lies as in a sac. The whole bismuth meal quickly finds its level in the lowest part, forming a more or less crescentic shadow low down in the abdomen, and in extreme cases even on a level with the pubes.

In such cases it is often difficult to persuade the patient to take more than a very small quantity of the bismuth food, but if he can be prevailed upon to do so, it is found that the increased capacity is obtained by an increase in the vertical depth of the shadow. In other words the stomach does not contract upon its contents but appears to remain inert.

The manner in which the food enters the stomach suggests that the walls of the upper part are in contact, *i.e.*, it flows down in a thick stream. Sometimes, at the junction of the middle and the upper third, the stream breaks off in thick

\* Strictly speaking atony should be considered with the normal stomach for it is a defective physiological action rather than a pathological condition.



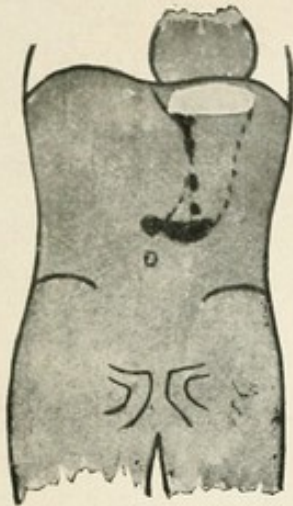


Fig. 15.

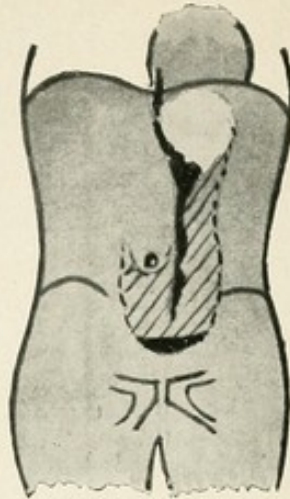


Fig. 16.

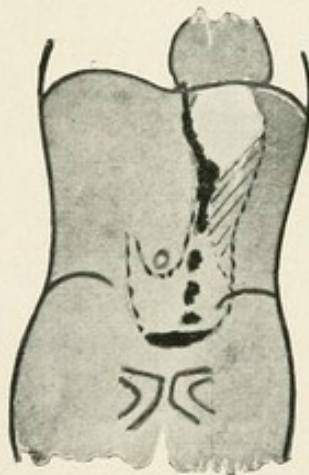


Fig. 17.

Fig. 15. Diagram of bismuth food entering a stomach that already contains food or fluid, possibly secretion.

Fig. 16. Diagram of food entering an empty atonic stomach. The shaded area represents the collapsed walls as I imagine them to be.

Fig. 17. Diagram of food entering an atonic stomach which already contains food.

'blobs' which drop to the lowest point, like tar falling through water, showing that there is already some food in the lower part of the stomach keeping the walls apart, and through which the bismuth food sinks.

*Fallacies in the diagnosis of atony.*

That the bismuth shadow only outlines the lowest part of the stomach after a time does not necessarily indicate loss of tone, for it must be remembered that the stomach itself will be secreting juice, which, being lighter than the bismuth food, will consequently rise above it. Hence, although the tubular form may be maintained, yet the upper part of the tube will throw no shadow, because it contains none of the bismuth mixture, for, as I have already said, there is no churning action in the stomach except close to the pylorus.

For the same reason an atonic condition is suggested when the stomach already contains food; the bismuth mixture rapidly sinks through the stomach contents, which cannot be seen, and hence only the lower border is outlined. The fact of a full stomach is always suggested, however, before the bismuth food is given by the shape of the air space, bounded below by the upper margin of the fluid. Also, when the bismuth food enters, it passes down more rapidly than when canalizing a passage between the collapsed walls, and in a manner that at once suggests a heavy substance falling through a lighter. Moreover, when a considerable quantity has been given, the shadow indicates that it is only the lower part of a column that we see, and further information on this point is easily obtained by pressing the stomach contents upwards.

The lowest border of the stomach is well below the umbilicus in atony, but this is no proof that the stomach is atonic, for the whole organ is displaced when the diaphragm is below its usual level. This condition—visceroptosis—is most important, as it gives rise to severe gastric symptoms in some cases.

In a certain number of cases where we find the lowest border of the stomach far below the umbilicus, the tonic action

appears to be quite good. This condition is known as *gastroptosis*, and it is said by Goldthwaite\* that faulty posture is the chief factor in its production. Certainly it can be greatly improved by abdominal massage and exercises that tend to increase the normal lumbar concavity, as I have proved on several occasions.

It is a condition that places the gastric peristalsis at considerable disadvantage. Since the pylorus is well above the lowest part there is a tendency towards retention of food in the stomach, which in its turn will lead to a constant strain on the tonic action, and if this gives way, the lower border falls still further with the result that there may be delay in emptying.

Moreover, the transverse colon is attached to the lower border of the stomach by the transverse mesocolon, and it follows that in these cases this portion of the large intestine is also found below the usual level. It is seldom that the ascending and descending colon have any mesentery and consequently there is a tendency to kinking of the large intestine at both the splenic and hepatic flexures, although I am not convinced that it actually occurs. As these patients appear to suffer from constipation it is probable that mechanical obstruction may play a part, and Goldthwaite believes that this condition with its resulting constipation is the cause of many diseases, such as rheumatoid arthritis. He records most encouraging cases in support of the treatment by massage and exercises. In extreme cases he advises a short-circuiting operation.

Frequently at operations the stomach which has appeared at the *x*-ray examination to be quite normal is found as a large flaccid sac, and *vice versa*. My explanation of this discrepancy is that nausea, disgust, and fear, bring about relaxation of tonic action, *i.e.*, the stomach will tend to become a large atonic sac, whereas I have always found that in the act of retching or vomiting it is contracted up. Anæsthetics inhibit the action of the involuntary muscle of the stomach, and consequently the condition found at the operation is that

\* Goldthwaite. "Boston Med. and Surg. Journal," 1904 and May, 1906.

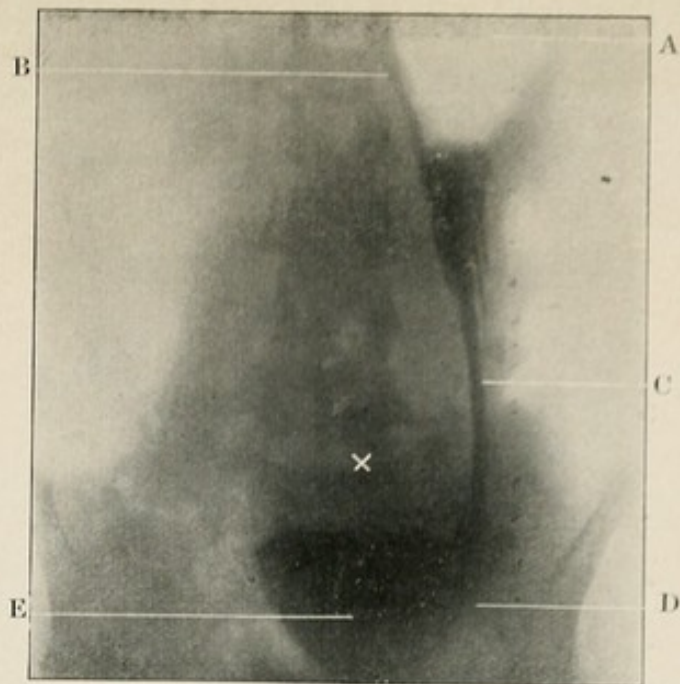


Fig. 18. Radiogram of a case of extreme atony in which the lowest part of the stomach extended nearly 6" below the umbilicus. A little food has just been given, and is seen extending from the cardiac orifice to the mass of food in the lowest part. Note how this is held up to some extent in the upper part by the walls of the stomach being in apposition. (a) air, (b) cardiac orifice, (c) food sliding down, (d) a peristaltic wave showing as a feeble concavity in the shadow, and (e) the mass of food in the lowest part, (x) umbilicus.

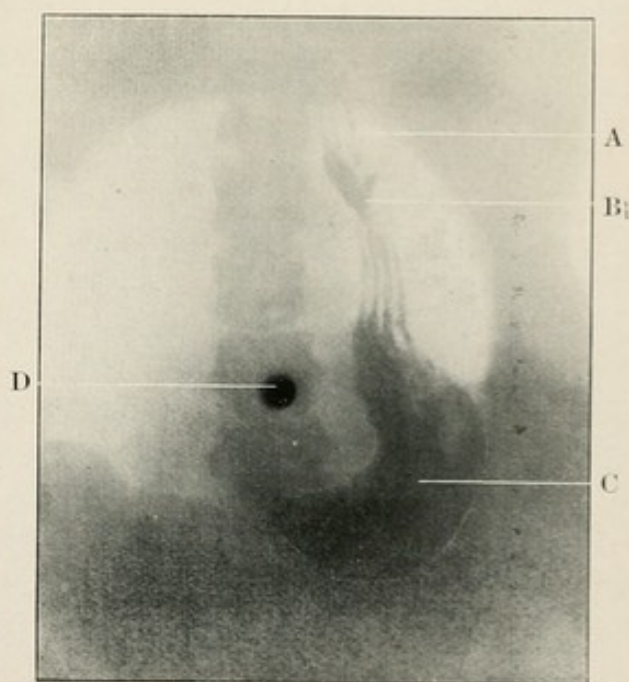


Fig. 19. Radiogram of an atonic stomach. Pressure has been applied to the abdomen so that the food has been forced upwards. The photo was taken as the food was again taking up its position in the lower part and shows the distribution of the rugae in parallel lines coinciding with the axis of the stomach. (a) air, (b) food held up between the collapsed walls and passing down through the rugae to the mass of food, (c); (d) umbilicus. A suspension of bismuth was used to obtain this result.



in which the muscle happened to be when the anæsthetic acted upon it, and is a most unreliable index to the natural condition.

### **PYLORIC OBSTRUCTION.**

Obstruction is a relative term and depends not only on the narrowing of the canal through which the food has to pass, but on the *vis a tergo*. These are the two main factors, but when the stomach is atonic there is also the static disability resulting from the fact that the lowest part, in which the food collects, is far below the pylorus.

It seems impossible at present, even with detailed notes of all these 84 cases before me, to analyse with certainty the various stages, as I have done in the case of œsophageal obstruction—the part that loss of tonic action plays is so difficult to determine. In the large majority the loss of tone is a marked feature, but in a small number perfect tonic action persists in spite of the most striking retention, hardly any of the bismuth food having passed on in 24 hours. Apart from these rare cases, which I shall refer to later, the stages are not so difficult to separate, although there is no definite dividing line between them:—

#### *A. In acute cases.*

- (1) It is very seldom that a really acute case is seen. I have only seen two, but in both of these the writhing and twisting of the stomach in its efforts to pass the food out was a sight that is not readily forgotten. In both of them it was a carcinoma of the pylorus that was the cause of the trouble. The struggle seems to be over in a short time and the picture becomes that of a chronic obstruction in its third stage, but whether under type 1 or type 2 I cannot tell.

#### *B. In chronic cases.*

- Type 1.* (1) A normal stomach that exhibits rather active peristalsis persistently and yet shows no signs of emptying in, say, three-quarters of an hour. Such a picture is rather suggestive of slight obstruction




but far from diagnostic. In a certain number of these cases hypersecretion has been noted. (See p. 37.)

- (2) A normal stomach that occasionally shows very powerful waves (or successions of waves) of peristalsis with periods of inactivity between, is suggestive that peristaltic action is becoming worn out, and if this sign is observed on one or two occasions it is practically certain that obstruction is present. I have seen such peristalsis entirely checked both by tr. belladonnæ and sodium bicarbonate, but the action of neither of these drugs is constant in this respect.

There may be some delay in emptying but it is seldom as long as six hours. These are the cases most frequently met with in private practice and that give most trouble in diagnosis.

- (3) Retention of food is found when the peristalsis fails to empty the stomach, and the patient nearly always complains that he feels his 'food lying on his stomach' for hours. Tonic action is called into play continuously, for the stomach is never empty, and by degrees the organ becomes atonic. Owing to the failure of tone, the stomach becomes stretched, the muscle is thinned out and cannot produce peristaltic waves of the same power as formerly. Not only so, but the work it is called upon to do in lifting the food to the pylorus increases as the greater curvature sags down towards the pelvis. Even when the stomach becomes quite atonic, its lowest border sometimes as low as the symphysis pubis, I have very seldom, if ever, failed to see evidence of peristalsis, provided the apparatus was working efficiently. In one of these atonic cases I found quite a quantity of bismuth food in the stomach five days after it had been given, in spite of persistent vomiting. (Figs. 18 and 20)

*Type 2.* I have no evidence whether or not the early stages in these cases are the same as in type 1, but



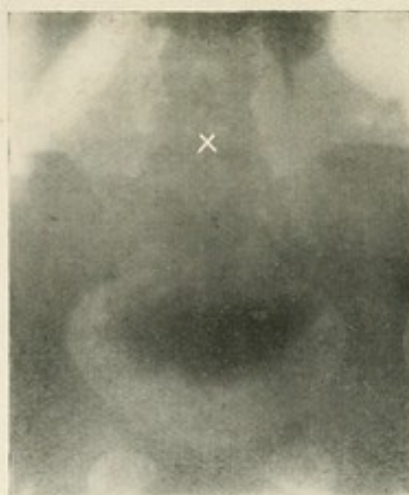


Fig. 20. Radiogram of a typical case of chronic pyloric obstruction, Type 1. The plate was taken 24 hours after the food was given, and the bismuth is seen lying about 5 inches below the level of the umbilicus. None of the food appears to have reached the cæcum. A little more food has been given and can be seen sliding down between the collapsed walls of the upper part of the stomach. The radiogram does not happen to show any of the "blobs" of bismuth food falling from this point into the lower part of the stomach.

X is the position of the umbilicus.

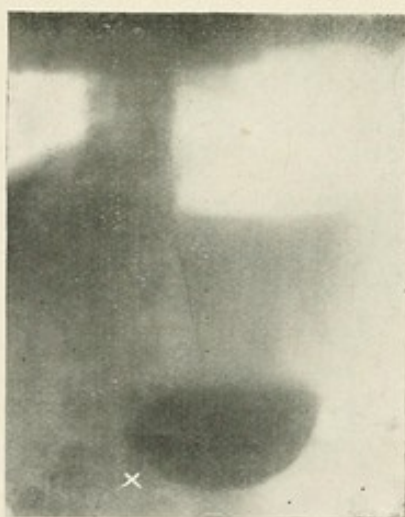


Fig. 21. Radiogram of Type 2 of pyloric obstruction. The plate was taken 24 hours after the bismuth food had been given and none of the food seems to have left the stomach. Note the perfect tonic action, the absence of peristalsis, the wide column of fluid above the bismuth shadow and the fluid line forming the lower margin of the air shadow. X is the position of the umbilicus.

the resulting *x*-ray picture is a most striking contrast. Perfect tonic action is always present and yet the stomach is invariably full of fluid, and presumably this fluid is food. Peristalsis is entirely absent, or there may be an occasional powerful wave. The delayed emptying is just as marked as in the atonic cases, and on examining the operative findings I see that out of eight cases, six showed carcinoma of the pylorus (20, 31, 80, 309, 682, 698), while of the two others one (208) is reported as an extensive ulcer of the lesser curvature close to the pylorus, and the other (313) showed marked cicatricial contraction, the pylorus being one mass of fibrous tissue; precisely similar lesions were found in some of the atonic cases. Fig. 21 is a good example of this type.

In the latter stages then, pyloric obstruction gives rise to *retention of food*, and the diagnosis rests on the determination of this fact. The detection of retained food in the stomach when the bismuth examination is made is of some importance and will therefore be considered.

If the tone of the stomach is good we can see a broad fluid line below the air, which ripples and splashes when the patient is shaken, even though he has been starved for several hours previously. On giving bismuth food a stream of dense shadows is seen falling from the cardiac orifice down to the lowest part of the stomach—like pitch dropping through water. Naturally, only the lower border is outlined, and on giving more food it is noted that the shadow suggests that the bismuth is only indicating the lower part of the vertical column of the stomach contents. The peristaltic waves are sometimes excessive and when we see very powerful waves that are followed by a period of inactivity it is practically certain that obstruction is present, but of course all such observations must be confirmed.

When the tone of the stomach is defective the retained food sinks to the lower part and there is nothing, except the

way in which the food drops to the lowest part (see fig. 17, p. 30), to indicate the presence of the retained food. The picture is simply that of an atonic stomach in which peristalsis is more violent than one would expect in a thinned-out organ.

Retention of bismuth food is the result of pyloric obstruction and Rieder laid it down that the whole of a bismuth meal should have left the stomach within five hours. For diagnostic purposes this is a good enough guide, but I never report definite obstruction unless the delay is well marked. In hospital practice eight hours retention is my standard, but, in the vast majority of the cases recorded, some food was still present in the stomach after 24 hours. In private practice six hours is my standard, but I always repeat the observation on at least one occasion to verify this finding when the margin of delay is so small. It is quite possible that in the early stages there may be rapid emptying as was noted in case 126 in which an operation nine months later showed quite well marked pyloric obstruction.

Bad teeth and septic conditions of the mouth must be attended to before any reliance can be placed on these data. I have seen a case cured by removal of carious stumps in which quite a large quantity of food was still present in the stomach after 24 hours.

#### NOTES ON CASES OF PYLORIC OBSTRUCTION.

(Cases on p. 89.)

The large number of cases that fall under this head is most striking. In 84 out of 270 cases included in this tabulation, pyloric obstruction was verified by the operative findings.

No attempt has been made to separate out the malignant cases from the non-malignant, as so large a number were on the border line, and nothing but a microscopic examination would have determined the cause of the obstruction. As yet, the *x*-ray examination reveals the mere fact of obstruction, and does not give any definite clue as to the nature of the lesion except when a portion of the gastric cavity is obliterated—such cases have been tabulated in Class 5. From the surgical point of view, however, the nature of the disease is

of secondary importance as compared with the knowledge that there is obstruction present and that the patient can almost certainly be relieved, for a time at any rate, no matter what the cause may be. It is worthy of note in this connection, that in some cases that were undoubtedly malignant, the patient's general condition improved in a manner that was quite as striking as in the non-malignant cases. Not only so but the patients have, in one or two instances, been in perfect health when enquiry was made six months and even two years later.

The large number of instances of spasmodic and organic contractions of the body of the stomach, in connection with pyloric obstruction, is discussed on p. 46.

#### ***HYPERSECRETION.***

I have met with a number of cases in which all the appearances of a normal stomach were present but, after perhaps a quarter of an hour, all the bismuth food occupied the lower part of the stomach, while the upper part contained nothing but thin fluid—the gastric secretion. Such a picture indicates excessive secretion, and in the few cases that have been submitted to operation an ulcer near the pylorus has been found. The marked acidity of these excessive secretions is very readily demonstrated by giving sodium bicarbonate and watching the rapid increase of the air space in the fundus. The active secretion cannot be detected when there is atony. Fig. 15 represents the appearance seen when secretion is very excessive.

#### NOTES ON ULCERS OF THE PYLORIC REGION.

*(Cases on p. 84.)*

The pars pylorica contains comparatively little of the bismuth food at a time and its shadow is therefore not so easy to see as that of the large mass in the body of the stomach. Moreover, the opacity of the vertebral column is superimposed and renders it almost impossible to make certain of details. As yet, I have never seen a case in which I obtained any definite evidence of ulceration from the appearance of the pars

pylorica itself, but there are several signs that point towards the presence of an active ulcer in this region. There is no hard and fast line between the cases of ulceration with spasm and those of organic obstruction of the pylorus, and in the following list of cases I have included only those in which there was either no really excessive peristalsis, no delay in emptying, or no marked cicatrization of the pylorus found at the operation.

In some of the earlier cases no indication of any pathological condition was recognised. Most of these have remained in their original class (Class iv), *i.e.*, under ulcers of the body of the stomach. It is only recently that I have made the observation that hypersecretion can be easily detected radiographically. The number of cases that have been operated on so far is comparatively small, but in those cases where this phenomenon was well marked the operative findings have shown active ulceration close to the pylorus. Unfortunately there are degrees of hypersecretion, and in the less marked cases the sign certainly does not necessarily indicate ulceration; moreover, the ulceration of malignant disease will give rise to the same sign. At the present time I am investigating this subject and have found, as expected, that on neutralising the secretion with a solution of sodium bicarbonate, there is apparently a far less profuse liberation of  $\text{CO}_2$  in the carcinomatous cases than in those which are probably due to ulceration. Although the number of cases is rather small I have now little hesitation in suggesting a diagnosis of pyloric ulceration if:—(1) the stomach is normal, (2) the peristalsis is rather active, (3) no shadows are seen passing through the duodenum, (4) there is very rapid secretion which gives off  $\text{CO}_2$  freely.

It will be noted that the picture, as stated, differs widely from that seen in duodenal ulceration. (p. 54.)

## CHAPTER VI.

## GASTRIC ULCER AND HOUR-GLASS STOMACH.

(Organic and spasmodic.)

(1) Ulcers of the fundus of the stomach are rare but two cases that I examined came to the post-mortem room. One was a small cicatrized ulcer about two inches from the cardiac orifice on the anterior wall, the other a malignant ulceration of the fundus that did not involve the cardiac orifice. In both of these cases the only symptom noted at the time of examination was œsophageal obstruction and in both there was very marked distension of the lower end. In one of them a large quantity of bismuth food remained in the œsophagus and was found there 24 hours later and this in spite of the fact that the patient had been 'vomiting' and that at the post-mortem there was no trace of obstruction or of any pathological change at the cardiac orifice itself. I think it is highly probable that many of the cases of 'cardio-spasm' recorded by Plummer\* and others are in reality due to ulcers near the cardiac orifice.

(2) Ulcers of the pylorus give rise to spasmodic contraction of the pylorus. The actual obstruction in some cases is so marked and so persistent that the stomach may become completely atonic, extending to 4 or 5 inches below the umbilicus, while only a very small quantity of the food is passed out in 24 hours. Later on the ulceration leads to cicatrization but as yet the *x*-ray method does not yield us any information as to the importance of one or other factor in the production of the obstruction. In a few cases of active ulceration close to the pylorus one has noted very marked and rapid secretion of gastric juice, which is very easily detected as it lies above the bismuth food. (See p. 37.)

\* H. S. Plummer, "Journal of American Medical Association," August, 1908 and June, 1910; J. S. Mayer, *ibid.*, October, 1910.



(3) An ulcer of the body of the stomach is nearly always in an irritable condition and as a result it gives rise to a spasmodic contraction of greater or less severity, the effect, radiographically, being an hour-glass appearance that can only with difficulty be distinguished from the cicatricial hour-glass to which it ultimately gives rise.

That the stomach is an exceedingly sensitive muscular organ is evidenced by the frequency with which spasmodic conditions are met with, quite apart from organic lesions, while it is very rare to meet with any active ulcerative condition that is not complicated by a spasmodic element that, from the functional point of view, is of far greater importance than the actual lesion itself. For instance a small ulcer of the greater curvature may cause an hour-glass contraction that prevents the food passing into the lower part of the stomach as in cases 207, 389, 400 and 406 where a gastro-jejunosomy had failed to relieve the symptoms.

The contractions of the stomach most frequently met with are about the junction of the middle and upper third, and the picture given by the bismuth meal is that the food descends to this point and assumes a cone shape. Comparatively suddenly the spasm may relax and the bismuth food passes on into the lower portion, often in a thick stream, giving a somewhat bilocular appearance for a time.

When the bismuth food is held up in the upper portion of the stomach I have found that rubbing the abdomen very frequently relaxes the spasm so that the contents pass down at once. When the tone of the whole organ is good the resultant shadow is that of a normal stomach with possibly a small indentation to mark where the spasm had occurred; but if the tone is defective, as is common in these cases, the contents drop into the lower part, possibly leaving a small quantity at the point where the obstruction was noted. Further abdominal massage usually causes the whole shadow to gravitate to the lowest part, but if traces are observed for a considerable length of time, in spite of massage and a drink of milk, it is practically certain that there is definite ulceration or cicatrization at this point giving rise to the spasm. The

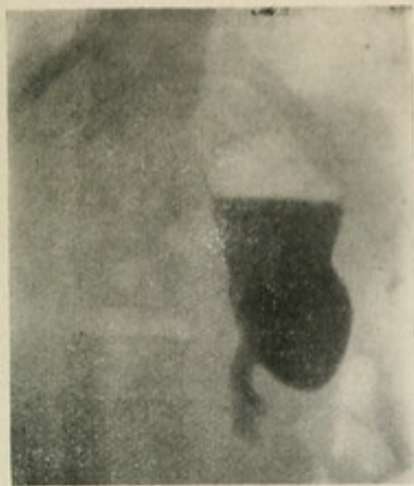

Fig. 22.

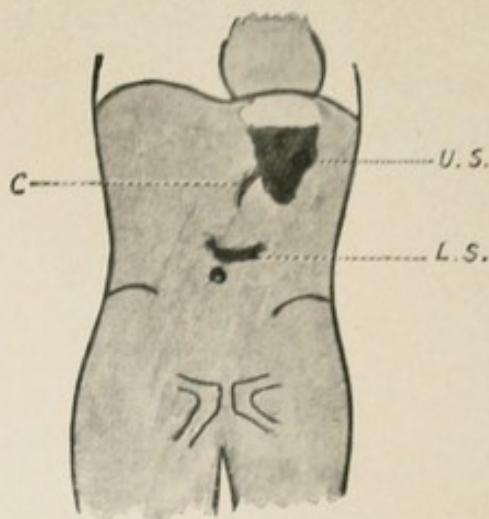


Fig. 23.

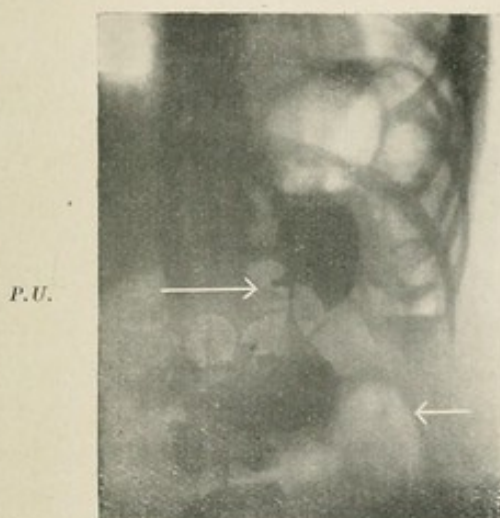


Fig. 24.

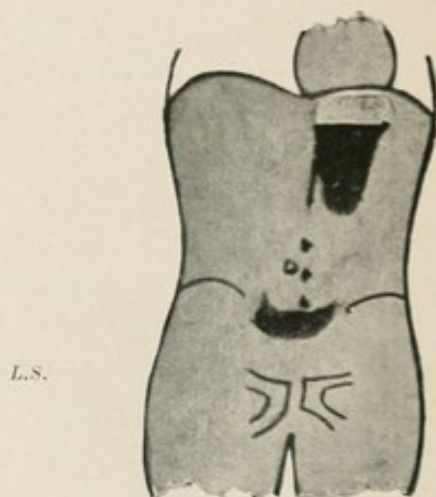


Fig. 25.

Fig. 22 Radiogram of typical upper sac of an hour-glass stomach. This was a cicatricial hour-glass stomach.

Fig. 23. Hour-glass stomach. *U.S.* Upper sac. *L.S.* Lower sac. *C.* Passage leading to lower sac.

Fig. 24. Radiogram of an hour-glass stomach. Massage made no impression. Note the small pocket to the inner side of outlet from the upper sac (*P.U.*): this is one of the penetrating ulcers described by Haudek. (*L.S.*) Indicates the lower sac. Extensive cicatrization of the stomach forming a very typical hour-glass contraction.

Fig. 25. Hour-glass stomach is often associated with pyloric obstruction. The bismuth food is passing through the channel and falling in drops through the retained food in the lower sac.



more persistent the spasm in spite of massage, the more probable becomes the diagnosis of actual ulceration or cicatrization. Acute pain on deep pressure at the site of the constriction is very suggestive of the presence of an ulcer.

In a certain proportion of cases small pockets are formed by chronic penetrating ulcers, as pointed out by Haudek,\* and these often hold their bismuth food for quite a long time after the rest of the food has passed on (fig. 24). In one patient I examined recently I found a very marked pocket on the lesser curvature (fig. 26). There is no doubt that it was due to a chronic penetrating ulcer although the patient had no gastric symptoms at all. The interesting point in this case is that the patient had no gastric symptoms probably *because* the ulcer did not give rise to any spasmodic contraction, *i.e.*, it was not irritable. On the other hand I saw a case in which only a few ounces of food could be forced into the stomach, forming a small funnel-shaped shadow, and after 24 hours all this bismuth food was still in the same position. This patient was operated on and there was nothing abnormal to be noted about the stomach except a fairly large ulcer high up on the greater curvature that was threatening to perforate. There was no cicatrization.

These two extreme cases indicate the importance of the spasmodic contraction resulting from ulceration, and all my observations on this subject strongly support Hertz's views on the subject of pain due to gastric ulcer: "I believe that tension is the only cause of true visceral pain."† The importance of examining while symptoms are present is obvious.

Belladonna has a marked influence on some of the spasmodic contractions. Relaxation may be startlingly sudden in some, while in others no effect is noted, although the massage test has proved the condition to be spasmodic. In a very marked hour-glass contraction, which was thought to be partly organic, I found that this drug practically removed the obstruction between the upper and lower parts of the stomach.

\* M. Haudek, "Arch. of the Röntgen Ray," June, 1911.

† A. F. Hertz, "The Sensibility of the Alimentary Canal," 1911. p. 47.

Acting on the suggestion of this examination, one patient has lived in perfect comfort for the past eighteen months, taking small doses of *tr. belladonnæ* from time to time.


The shape of the upper sac in organic contractions is nearly always as in fig. 22, but it is not diagnostic.

The shape depends on the fact that of the two curvatures of the stomach the lesser is the more fixed: consequently any contraction that takes place is towards the lesser curvature. If however an ulcer occurs in some other part and produces adhesions, the site of the ulcer itself becomes fixed and the stomach is contracted to this part as in fig. 27 where the ulcer on the posterior wall was adherent to the pancreas.

It is not easy in many cases to distinguish between a functional and an organic hour-glass contraction. In both cases the bismuth is held up in the upper sac, and it may possibly be noted that retained food is also present in it. It is always suggestive of a bilocular condition if the lowest part outlined by the bismuth does not reach nearly to the level of the umbilicus without showing some indication of turning to the right as if towards the pylorus.

On watching carefully it is generally seen that some portion of the shadow is passing on, either in drops or as a thin pencil, and falling into the lower sac. If this is not seen, the patient should be persuaded to take some more of the bismuth meal, or a drink of milk, and this is often sufficient to increase the intragastric pressure, so that the passage will be canalized.

If, on rubbing the patient's abdomen, it is found that the greater part of the shadow descends into the lower sac, the condition is certainly spasmodic. But if manipulation makes little or no difference in the rate at which food leaves the upper sac, a true organic hour-glass condition is probably present. A careful examination of the upper sac will usually reveal the presence of peristalsis on the greater curvature, starting almost under the diaphragm—that is to say, much higher up than usual. I used to consider that the presence of peristalsis in the upper sac was one of the diagnostic points between a



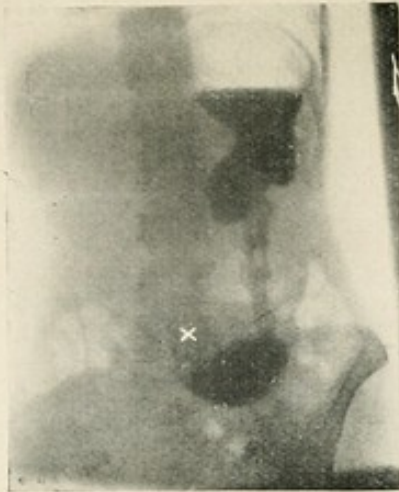


Fig. 26. Radiogram of an hour-glass stomach. The opening from the upper sac is not in the usual position on the inner side, but from the posterior wall. Pyloric obstruction is also present, and the food seen in the lower sac had been given 6 hours previously while that in the upper sac had only just been taken. The condition was due to a very dense mass of cicatrization adherent to the pancreas (accounting for the position of the neck of the hour-glass) and marked thickening of the pylorus. X umbilicus.

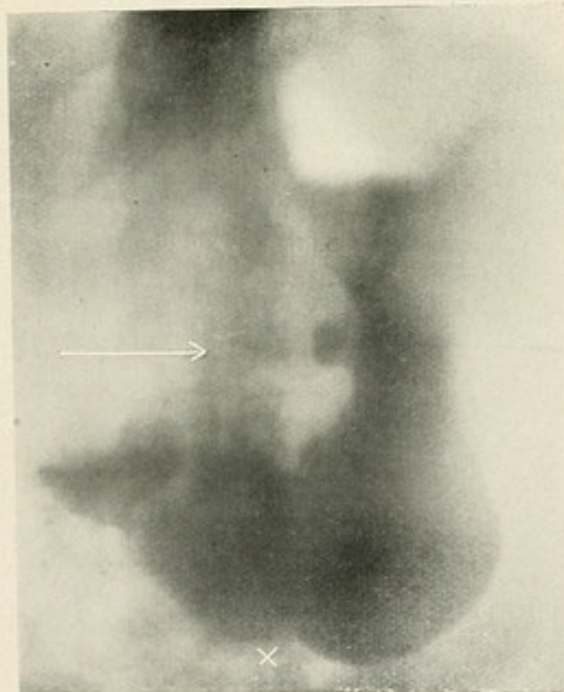


Fig. 27. Radiogram of case referred to on p. 42, and a normal stomach with the exception of the pocket on the lesser curvature, indicated by the arrow, due to a chronic penetrating ulcer (Haudek). X umbilicus.

true organic and a spasmodic obstruction, but this is not the case.

It must be emphasized once again that there will be a spasmodic element in almost all organic lesions, and that the functional disability will not depend so much on the lesion itself as upon the spasmodic contraction to which it gives rise.

Moreover there are occasional cases of spasmodic hour-glass contractions which give all the typical appearances, and yet at the operation there is no gross lesion to be found to account for the spasm. I believe that the spasmodic nature of these cases can be diagnosed if the massage test is thoroughly used. Since I have employed it I have been misled only once, although I have seen several cases that would formerly have been diagnosed as organic lesions. *The greatest safeguard, however, is the re-examination of the patient on one or two other occasions;* for spasmodic contractions are not necessarily always present, whereas organic contractions can never completely relax.

In the lower sac the food may show a variety of pictures, but most frequently the shadow is well below the umbilicus, and both atony and pyloric obstruction are present. In 22 out of 38 cases of ulceration of the body of the stomach there was also evidence of a lesion at the pylorus. (see p. 47.)

NOTES ON THE CASES OF ULCERATION OF THE BODY OF THE STOMACH. (Cases on p. 85.)

HOURLASS STOMACH.

Ulceration gives an entirely different *x*-ray picture in the body of the stomach to that seen when the pars pylorica is involved, and I have therefore separated these cases from one another.

An hour-glass appearance of the stomach is of very frequent occurrence, and in the early cases one made many mistakes through not recognising the fact that the stomach is a highly sensitive organ, and is often the seat of spasmodic contractions that may have all the appearance of organic lesions. It was only when I discovered that gentle, or if necessary forcible massage led to relaxation of spasm, that



mistaken diagnosis from this cause ceased to be of frequent occurrence. Tincture of belladonna was also employed, but, although it relieved the spasm in some cases, it absolutely failed in others. Many cases of purely spasmodic contraction have been met with, but there are four to which I wish to draw special attention: Class i, No. 369, and Class viii, Nos. 41, 363, and 398. In these the spasmodic contractions were so marked that I diagnosed the presence of a definite organic lesion, while the operation failed to reveal any underlying cause.

*Case 369.* A marked contraction near the pylorus that exactly simulated a carcinoma: patient only examined once. The manipulation of the stomach at the operation cured the patient and no trace of the spasm was afterwards seen when he was re-examined.

Cases 41, 363, 398 had been operated upon and the gastro-jejunosomy had failed to relieve the symptoms. In all of them an hour-glass contraction had been noted before the operation, and no trace of biloculation or ulcer had been found to account for it, and when re-examined after the operation the same appearance was noted. All these patients either vomited or retched while under observation and it was evident that it was because of the biloculation, for as soon as all the food had passed down into the lower sac this tendency to vomit ceased and the pain became less severe.

The most searching scrutiny of the outside of the stomach failed to reveal any abnormality, although I think it probable that some minute erosion or irritable point must have been present. In another case (Class vi, No. 713), at which only one examination was possible before the operation, I found a very marked hour-glass in association with an early stage of pyloric obstruction. In this case, although no lesion could be found to account for the spasm, the patient stated that relief of his 'hunger pain' (a typical description) occurred as the food canalized the 'middle sphincter.' I quite expect to find that this patient is not cured by the gastro-jejunosomy.\*

\* See footnote on p. 65.

Turning to the records in which a definite ulcer or evidence of old ulceration was found, I have in the following list tabulated 42 cases, and in 38 of them the lesion was indicated radiographically by the hour-glass appearance that was due in part to cicatrization, but to a greater extent as a rule to the induced spasmodic contraction. It is not possible to classify the findings as these have varied widely, from a little cicatrization about an ulcer to a constriction that completely divided the cavity, but the *x*-ray picture has almost always shown a very much narrower channel than was found at the operation. In some cases this has been very marked indeed; quite a small ulcer on the greater curvature with just a little puckering around, has given rise to a contraction so severe and so persistent under massage that only a thin stream could find its way down, and, on the other hand, a well marked cicatricial hour-glass with an indurated ulcer might relax to a great extent with massage, leaving a channel that appeared to be more or less the same size as that found at the operation. There was a greater or lesser degree of spasm in all these cases, and, so far as I can gather from my notes, the severity of the spasmodic element does not depend on the size of the ulcer but rather, one would suppose, on its irritability. Hence the functional disability resulting from an ulcer of the body of the stomach, apart from the stenosis of very marked cicatricial contraction, cannot be gauged by the appearance found at the operation.

In all these 42 cases there are only four in which an ulcer of the stomach failed to give rise to a contraction that was easily detected on the screen.

*No. 24.* Large ulcer of lesser curvature near pylorus—one of the early cases in which the pars pylorica was not well seen, and no records of secretion or peristalsis were made.

*No. 193.* A small ulcer of the lesser curvature, one inch below the cardiac orifice.

*No. 418.* Large ulcer of lesser curvature. Cicatrices of the duodenum.

*No. 760.* Cicatrix of lesser curvature, two inches from the pylorus.

It will be noted that in all these cases the ulcer was on the lesser curvature, near one or other of the orifices.

With the exception of these four cases therefore, ulceration of the body of the stomach has given rise to an hour-glass contraction (about 90·5 per cent.).

The association of these hour-glass contractions with pyloric obstruction is very marked. In 14 cases out of the 38 this condition was also present, and it is probable that the four cases in which the gastro-jejunostomy had failed to relieve the symptoms (Nos. 206, 266, 389, and 400) should also be added to the number. Ulceration of the pylorus was also met with in four cases (Nos. 335, 599, 717, 720) and presumably these would eventually have become cases of pyloric obstruction. In at least a half of the cases of ulceration of the body of the stomach therefore, there was also a lesion at the pylorus.


Among the cases of pyloric obstruction will be found many cases where spasmodic contractions of the middle of the stomach were well marked, but in a far larger number, slight spasmodic contractions were easily recognised as such, and were not recorded. This association cannot be accidental, but whether both conditions depend on some other unrecognised condition within the abdomen, or whether the contraction of the body of the stomach depends on the pyloric lesion I cannot say, but am inclined to the former view.

In two cases (Nos. 418 and 420) cicatrization of the duodenum was also noted.

In four cases ((Nos. 207, 389, 400, and 406) a gastro-jejunostomy had failed to relieve the symptoms, and a further operation showed the presence of an organic hour-glass contraction above the stoma, as suggested by the *x*-ray examination.

#### **CARCINOMA OF THE STOMACH.**

New growths in the abdomen throw no shadows which can be distinguished from the general abdominal opacity; they can however often be demonstrated by reason of displace-



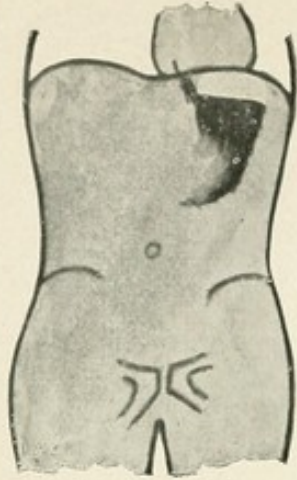


Fig. 28. Carcinoma of the stomach. The whole of the pyloric portion and a part of the lesser curvature are invaded.

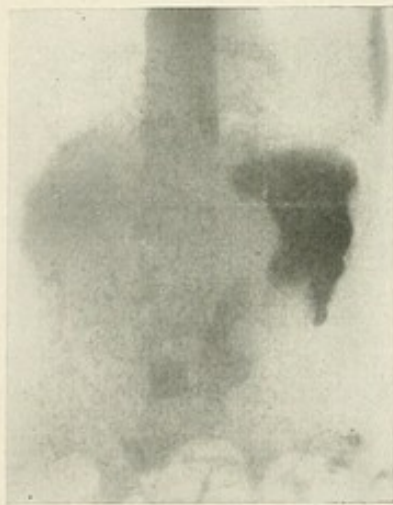


Fig. 29. Radiogram of a case of carcinoma of the stomach. The pyloric portion of the cavity is almost completely obliterated. In some cases the shape of the remaining cavity is most irregular.

ments of viscera, irregularities caused by the inroads of the growth into the stomach, and by obstruction to the passage of the food, all of which may be shown by giving the patient a bismuth meal. If the pylorus is involved, obstruction may be noted, but this form of obstruction cannot as a rule be distinguished from pyloric obstruction due to other causes.

Apart from pyloric obstruction, the diagnosis of carcinoma depends upon the irregularities caused by the inroads of the growth.

The inroads may be quite small, like the outline of a piece of coral, or there may be more or less marked obliteration of the cavity by the growth which displaces the bismuth and consequently gives rise to deficiency in the normal shadow. Such inroads may suggest peristaltic waves at first sight, but on further observation it is noticed that they are permanent, and that peristaltic waves sweep up to these notches, are lost to sight, and reappear on the further side of them. In advanced cases the greater part of the gastric cavity may be completely obliterated. (See figs. 24 and 25.)

Growths involving the anterior or posterior walls sometimes invade the stomach so that bismuth is displaced and a clear space is seen in the midst of the shadow. These clear spaces may appear and disappear as peristaltic waves sweep past, or on pressing the abdomen against the screen, but they must not be confused with similar appearances caused by, say, curds of milk which contain no bismuth. This fallacy is always guarded against by making radiograms on two successive days and a comparison of these will give the clue to the real interpretation.

Spasmodic contractions may simulate the appearance of growths and therefore massage should be employed, and even if there is no doubt a subsequent examination should be undertaken for confirmation.

We cannot exclude the presence of new growths by this method, but it is seldom that there is no clue to the diagnosis if the new growth actually invades the stomach.

NOTES ON CASES OF CARCINOMA OF THE BODY OF THE  
STOMACH. (*Cases on p. 88.*)

To place all the cases of carcinoma of the stomach under one head was quite impossible as such a large number of the pyloric cases were on the border line, and in many cases the surgeon could not tell whether the thickening was due to inflammatory causes or to new growth. All cases of pyloric obstruction, whether due to growth or cicatrization, have therefore been placed together in Class 4, and in the following list are included only those in which the growth invaded the body of the stomach.

In the diagnosis of carcinoma of the stomach reliance must be placed on the displacement of the bismuth food by the growth. In the large majority of cases a considerable portion of the cavity was involved and there was no doubt as to the diagnosis. In a smaller number definite inroads of growth were noted, often difficult to distinguish from peristaltic waves, especially when the apparatus was not working well. Adhesions in some cases gave rise to indentations that were mistaken for carcinoma, and in one case (recorded under Class 1, No. 369) a pure spasmodic contraction gave rise to the same mistake.

An hour-glass appearance is sometimes caused by the obliteration of part of the cavity (fig. 25), and it may be difficult to distinguish a carcinomatous biloculation from the cicatricial condition, as in case 59, but when the growth is sufficiently advanced to give rise to such an appearance, an abdominal tumour can almost invariably be detected.

Clear spaces in the bismuth shadow have been noted on several occasions (case 58 is the only one in the tabulation, but in my notes I have records of eight such observations in patients whose clinical symptoms left no room for doubt as to the diagnosis). The chief source of error is the presence of boluses of ordinary food or even curds of milk, but a confirmatory examination will clear up this point. These clear spaces are often only demonstrated by pressing the patient's abdomen against the screen, and they tend to appear and disappear as peristaltic waves pass over them.

The movements of the diaphragm are sometimes, but not often, restricted, and on many occasions I have found the liver enlarged and the diaphragm pushed up on the right side, indicating secondary growth in the liver. In no single instance have I found secondary deposits in the lungs, in fact the only instance of this complication I have met with in association with abdominal cancer was in a case where I reported the stomach as normal and in which carcinoma of the rectum was subsequently discovered.

Twenty-three cases only are tabulated out of a much larger number in which the diagnosis has been perfectly plain, often both clinically and radioscopically. In many of them the *x*-ray report showed that operative interference would be useless. This probably accounts for the presence of only five cases of this type in the last 300 cases examined.

**AEROPHAGY** (*air-swallowing*).

Air-swallowing is not an uncommon condition, and one which may give rise to severe gastric symptoms.

On giving bismuth food the outline of the stomach may be perfectly normal, or it may suggest an atonic condition; but it is always noticed that as the patient swallows his food a certain amount of air passes down the œsophagus with each mouthful, and the air space gradually increases and may even extend down even as far as the umbilicus unless eructations occur. The cardiac portion may be dilated like a great bubble, occupying the whole of the left hypochondriac region and even displacing the diaphragm upwards. Such patients swallow more air with liquids than they do with solid or semi-solid food, so that any case where this condition is suspected should be tested with a glass of water.

In well-marked cases violent and persistent eructations may take place, and it is noted that the air shadow, instead of becoming smaller, remains the same, or even becomes greater in extent. Sometimes the air distends the lower part of the œsophagus to some extent.

On more than one occasion I have seen the air apparently sucked down the stomach to the level of the umbilicus. It



looks as if this is only possible when the lower part of the stomach is anchored down by adhesions, but I have not been able to satisfy myself on this point.

I have noted the occurrence of slight ærophagy in connection with appendicitis on a considerable number of occasions when gastric symptoms were apparently due to this cause.

**ADHESIONS.** (*Cases on p. 95.*)

For the diagnosis of adhesions we have to depend on the fact that under normal conditions it is possible to manipulate the stomach through the abdominal wall and to determine more or less accurately the fixity or otherwise of the organ. Some cases are more or less obvious, *e.g.*, adhesions of the lesser curvature to the lower border of the liver but, like all other observations on the stomach, one must repeat the observation at a subsequent examination, for on more than one occasion I have found that the confirmatory examination revealed a perfectly normal stomach in cases where I had been quite confident that there were adhesions.

In some cases they cause inroads into the gastric cavity that are almost impossible to distinguish from carcinomatous inroads, and in case 699 this mistake was made, while in case 408 the stomach was segmented by a band of adhesions near the pylorus and other small indentations were noted that suggested this diagnosis, although there was some doubt in my mind as to whether the case was or was not one of carcinoma.

In case 151 the persistence of atony (or ? gastroptosis), in spite of massage and exercises, led me to suspect the presence of adhesions fixing the transverse colon in the pelvis, as it was impossible to raise the stomach by manipulation although it could be pushed sideways, while the transverse colon appeared to be fixed. The operation in this case showed the presence of an old appendicitis and a cord-like adhesion to the transverse colon.

**POST-OPERATIVE EXAMINATIONS.** (*Cases on p. 96.*)

Many patients in whom a gastro-jejunosomy has been performed have been examined, but in this table are included only those in which the operation had failed to relieve the

symptoms. In the cases in which a cure was effected I have not come across a single instance in which the stoma was closed. In a small number, about one-quarter of these cases, the bismuth food was observed passing through both the stoma and the pylorus.

In only one case (524) was the appearance of the formation of a vicious circle noted (*i.e.*, the continued presence of a shadow in the duodenum) and at the operation it was found that the stoma was occluded by adhesions and the duodeno-jejunal flexure kinked. It seems probable, therefore, that the theory of vicious circle vomiting is at least an extremely rare cause of failure, since not a single instance was found in the cases recorded.

In seven cases (44, 416, 470, 471, 483, 524, 530) the *x*-ray examination showed that, either there was obstruction of the small intestine just beyond the stoma, or that no food passed through this opening, and in each of these the operation showed the presence of adhesions, the obstruction as a rule being due to kinking.

In seven cases, although the stoma was working perfectly, there was a well marked hour-glass condition present, and in most of them it was evident at the *x*-ray examination that the patient vomited from the upper sac, and that so soon as all the food had passed into the lower sac the discomfort and inclination to vomit passed off. An exploratory operation was performed in six of these cases with the following results:—

41. No cause found to account for the hour-glass condition. Patient unrelieved, and still shows hour-glass condition.
207. Cicatrix of greater curvature with active ulcer, and partial organic hour-glass.
257. Adhesion (extra gastric) forming hour-glass.
266. Cicatricial hour-glass with active ulcer.
363. No cause found to account for the condition. Patient unrelieved.
398. No cause found to account for the condition. Patient relieved five weeks after operation, but this also occurred after the previous operation. On this occasion the appendix also was removed.

In one of the two cases of active ulceration the surgeon noted at the time of the previous operation that a small ulcer was present on the greater curvature, but it appeared to be so insignificant that he did not excise it, in the expectation that healing would take place when the pyloric obstruction was relieved by means of a gastro-jejunostomy. Remarks on the three cases of spasmodic hour-glass condition will be found on reference to p. 44.

In two cases (209 and 357) an hour-glass condition had been found at the time of the operation and the upper sac united to the jejunum. In both of these cases pyloric obstruction also was present with the result that food lodged in the lower sac. Excision of the lower sac was performed in both with complete relief of symptoms.

In case 419 the stoma was situated further from the pylorus than in any other case I have seen. There was marked pyloric obstruction and the peristalsis seemed to squeeze the food into the pars pylorica, and this appearance coincided with the pain. At the operation a growth of the pylorus was found and excised. This relieved the patient, for a time at any rate.

Cases 689 and 756 (entered in Class 6) were both sent for examination because the symptoms persisted, in spite of an operation, at which it was said a gastro-jejunostomy was performed. In both cases the *x*-ray findings were most suggestive of an ordinary pyloric obstruction, and no trace of a stoma could be seen. At the operations it was found that no gastro-jejunostomy had been performed.

In case 10 it was impossible to detect the cause of the delay in emptying of the stomach, which was almost as marked after as before the operation. The stomach was completely atonic and, with the inefficient apparatus then in use, it was impossible to make certain of details in the pelvis.

In case 594 the stoma was working perfectly, and no cause for the persistence of symptoms was seen. On reopening the abdomen it was found that the stomach was adherent to the anterior abdominal wall, and the breaking down of these adhesions brought about a cure.

**INCIDENCE OF LESIONS OF THE STOMACH.**

It is interesting to note the sex incidence of diseases of the stomach as shown by figures taken from the tables included in this thesis. The extraordinary preponderance of ulcers of the body of the stomach in females is most marked, almost 5 to 1, while from lesions of the pylorus, including both simple and malignant, the male sex appears to suffer most frequently in the proportion of 9 to 7. The male sex also suffers most frequently from carcinoma of the stomach (excluding pyloric cancer), in the proportion of 2 to 1.

The number of cases is comparatively small but the figures are somewhat striking.

	Ulcers of the body of the Stomach.	Pyloric Lesions.	Carcinoma of the Stomach.	Total.
Male .....	8 .....	54 .....	16 .....	78
Female ...	39 .....	42 .....	8 .....	89
<hr/>				
Total ...	47 .....	96 .....	24 .....	167

Amongst the cases in which the symptom complex of duodenal irritation was seen (see p. 54, *et seq.*) there are 30 males and only 8 females. In these cases although the symptoms were gastric, the lesions were for the most part secondary or referred. If these cases are included in the tables the proportion of incidence of gastric symptoms is nearly equal in the two sexes.

It would appear that success from operative treatment was more probable in men than in women, for out of the 29 cases in which the symptoms had recurred or in which the operation had failed to give complete relief only 7 were males while 22 were females, but in two of the latter the subsequent operation revealed the fact that no gastro-enterostomy had been performed.

## CHAPTER VII.

## SMALL INTESTINE.

The food passes through the small intestines very rapidly, it is squirted through the pylorus and sometimes, though I do not consider it normal, it may be seen going round the loop of the duodenum. The manner in which the food passes on is peculiar. If a bolus can be seen in the jejunum, it can be made out that it is tossed backwards and forwards, gradually passing onwards. Together with these peristaltic movements there is continual segmentation of the bolus going on, so that almost immediately it is shredded into minute sub-divisions and mixed with the secretions of digestion to such an extent that, beyond a general impression of opacity in the abdomen, no trace of the bismuth is seen until the shadow appears near the cæcum. An instantaneous radiogram, however, will show the fine division of the food that has gone on.

In tubercular peritonitis and other forms of adhesive peritonitis, I find that the segmentation contractions, if one may call them by such a name, are defective, with the result that definite shadows are seen in various coils of small intestine. Several instances of lesions of the jejunum have been met with and in each of them, besides the evidence of obstruction, a well marked duodenal symptom-complex has been noted.

**DUODENAL ULCER.**

This condition cannot be definitely determined by *x*-ray examination, but there is a symptom-complex which is very strongly suggestive, if not of actual ulceration, at any rate of irritation of the duodenum. The various points that are noted are:—

(1) The stomach always exhibits good tone, even if ptosis is present. Hypertonus is often noted.

(2) The peristalsis is more active than normal, especially when the food has commenced to pass through the duodenum.

(3) The food begins to leave the stomach almost at once and as a rule continues to pass out very rapidly until the stomach is empty.

(4) The pyloric relaxation is so complete that large masses of food are seen passing through the duodenum—instead of the fine, almost imperceptible stream, that can only be detected with certainty by means of an instantaneous radiogram. In certain cases a separate bolus is seen remaining, apparently in a pocket, in the duodenum.

#### NOTES ON CASES OF DUODENAL IRRITATION.

(Cases on p. 81.)

I have separated these cases out from among those which I had at first classified as normal because, although the stomach appears to be quite normal both radiographically and on the operation table, yet they appeared to show certain radiographic features that I have learned to regard as a symptom-complex.<sup>1</sup> It is quite possible that my own technique (*i.e.*, giving only a comparatively small quantity of bismuth food made with *bread and milk*) is more favourable for demonstrating this symptom-complex than that of some other observers, as one worker (Dr. Thurstan Holland, of Liverpool) has told me privately that he sometimes obtains the signs I have described in perfectly normal subjects. On the other hand, Hertz<sup>2</sup> has arrived at the same conclusions and also Rowden,<sup>3</sup> of Leeds, who examines Mr. Moynihan's cases.

The symptom-complex consists of the following signs:—

- (1) A normal stomach but always more or less hypertonic.
- (2) Active peristalsis.
- (3) Rapid emptying of the stomach.
- (4) Food seen passing through the duodenum with, or without a persistent shadow in some part of the duodenum.

1. "B. M. J.," Sept., 1910; "Archiv Rontgen Ray," Oct., 1910.

2. A. F. Hertz. "Sensibility of the Alimentary Canal," 1911, p. 59.

3. B. G. A. Moynihan. "Lancet," January, 6, 1912.

(1) The stomach is invariably 'J' shaped and not a trace of atony is observed. In fact hypertony is often so marked that it may require quite a large quantity of food to canalize the empty stomach. Such cases are at first suggestive of an hour-glass contraction, and in two of them (Nos. 97 and 273) I actually suspected the presence of an organic lesion half-way down the stomach, because of the way in which the contraction of the walls resisted the passage of the food.

The action of gravity is an important factor in canalizing the empty stomach, and it frequently happens that at the lowest part of the organ there is a considerable pause in the progress of the food before it enters the pars pylorica. H. M. W. Gray, of Aberdeen,<sup>1</sup> interpreted this sign as an indication that there is normally a sphincter at this point, probably indicated by the incisura of His, and on this theory laid it down that the stoma of a gastro-jejunosomy should be made beyond this point.

(2) *Active peristalsis.* This feature is often not observed till the first food has entered the duodenum. One would not describe the waves of contraction as excessive, but, on the other hand, they are much more active than usual and segment the shadow perhaps three inches from the pylorus. Such peristalsis is seen in early stages of pyloric obstruction, but in duodenal irritation there is no obstruction, in fact the pylorus allows the food to pass on more rapidly than usual.

(3) *The rapid emptying.* The early observations I made on cases of duodenal ulceration proved one point conclusively, namely, that the stomach began to empty itself extremely rapidly and in a manner that was not observed in the normal healthy subject. In some cases a meal of half a pint of bismuth food had left the stomach in less than half an hour and it was exceptional to find more than a very small quantity in the stomach after three-quarters of an hour. In only one

1. "Lancet," February 22, 1908, p. 549, and July 25, 1908, p. 224, and December 3, 1910, p. 1610.

case (No. 66) was any delay in emptying noted, and in this the duodenal canal was stenosed by the cicatrization.<sup>1</sup>

Not only does the food pass out rapidly from the stomach but it seems to reach the large intestine in an extraordinarily short time. I noted shadows in the cæcum in half an hour in one case. It is likely that this activity of the whole tract accounts for the frequent clinical history "My food does not do me any good."

(4) *Food seen passing through the duodenum.* In the healthy subject I do not expect to see the food passing through the duodenum—it leaves the pylorus in such a fine stream that it is only by means of an instantaneous radiogram that it can be detected with certainty, whereas in these cases one sees quite large shadows pass through the duodenum, and even the untrained observer has no difficulty in tracing the progress from the pylorus to the duodeno-jejunal flexure, although from this point onwards the sub-division of the food proceeds so rapidly that no trace of it is seen on the screen. The appearance is as if there were sudden intermittent relaxations of the pylorus that allowed more food to pass through than the duodenum was capable of dealing with.

It is not after every peristaltic wave that the pylorus opens in this way, nor is it necessarily in response to a specially powerful wave, although it is always as a ring of contraction forces the food against the pylorus that the shadow is seen passing through the duodenum.<sup>2</sup>

1. Although the food begins to pass out rapidly it does not necessarily follow that the stomach is emptied quickly, for in several instances there has been a little food still present after 5 hours, although no pelvic lesion could be found at the operation; only the duodenal ulcer.

2. This appearance can be produced artificially by giving a large quantity of food rapidly, and on one occasion I even obtained distension of the duodenum, but this was in a patient whose mental state was not stable. He wished to prove that his stomach was abnormal, and although he had been operated on, and although I had examined him previously on two separate occasions, he would have me make an observation when he had 'quite filled' his stomach. He swallowed four pints of custard mixed with 8 oz. of bismuth carbonate, and this distended the stomach, probably causing some pressure on the duodeno-jejunal flexure, with the result that the duodenum also was distended. (No constipation or pathological effect was noted as the result of this huge dose of bismuth.) Dr. A. C. Jordan recently read a paper before the Electro-Therapeutic Section of the Royal Society of Medicine ("Proc. Roy. Soc. Med.," Dec., 1911), in which he described kinking of the duodeno-jejunal flexure, and I believe that in the majority of his cases his technique approximated to the above observation. He has told me privately that with the ordinary methods he failed to obtain the appearances he described. In my list of cases only one (No. 498) showed obstruction at the duodeno-jejunal flexure.



Where the ulcer or cicatrix is situated on the lower border of the first part of the duodenum, it is sometimes found that there is a definite shadow of retained food in this position which appears to be almost continuous with the gastric shadow. It is, however, unaffected by the peristalsis of the stomach. When gastric peristalsis is well marked, it forms a complete ring towards the pylorus, cutting off a portion of the shadow which gradually diminishes in size as the constricting ring passes on, the food escaping back into the stomach. The shadow of food retained in the duodenum, on the other hand, is unaffected by the peristalsis, and is always present until after the stomach is empty. This picture is only suggestive of duodenal ulcer in one position and is not diagnostic, since it may be due to puckering of the duodenum from other causes, such as carcinoma and cicatricial conditions in this region, *e.g.*, cholecystitis.

Examination of the patient, in the recumbent position, may demonstrate a similar condition on the posterior wall of the duodenum, and it is usual to examine all these cases in the horizontal as well as in the upright position, because the passage of food through the duodenum can be better seen with the patient lying down than when he is standing up.

Very frequently a 'caput duodeni,' a shadow just beyond the pylorus, is constantly noted until the stomach is empty, but this is not I think of pathological significance; it is often seen in cases where the duodenal symptom-complex is not present. The appearance suggests that there may be, in certain subjects at any rate, a second sphincter just beyond the pylorus that is supplementary to the pylorus in regulating the supply of food to the duodenum.

Apart from this 'caput duodeni,' a separate shadow seen in the duodenum is very suggestive of the formation of a pocket by spasmodic contraction, cicatrization, adhesions, or growth. The appearance is not typical of any one condition. In two of the cases (81 and 92) this feature was only detected when the patient lay down.

*Exceptions and anomalies.*

In two cases only (Nos. 240 and 241) a duodenal ulcer was

said to be present (by the same operator) when the symptom-complex was not noted, but case No. 241 died from an occult hæmorrhage a few days subsequently, and at the post-mortem not only was no cause found for the bleeding, but also there was a complete absence of even a suspicion of ulceration, although grey patches were observed on the peritoneum. Case 241 is therefore placed under the normals, while case 240 remains in this class, although somewhat discounted by the post-mortem on case No. 241. Slight atony was noted in only one case (No. 501) although all the other features were well marked, while gastropstosis with absence of all the features of the symptom-complex occurred in case 730.

In all these cases a certain train of appearances was established, and on analysis I found:—

Duodenal ulceration	- - -	14 cases.
Cicatrization of the duodenum	- - -	7 „
Adhesions about duodenum (generally in connection with gall-bladder)	- - -	13 „
Carcinoma in this region	- - -	3 „
Appendicitis, abscess	- - -	1 „
Appendix fixed by adhesions near to duodenum	- - - - -	1 „

I used to record only the actual gastric lesion in my own notes and did not appreciate the possible importance of evidence of old appendicitis or other abdominal inflammation as a possible primary cause of the trouble.

It seems probable that many different lesions in the abdomen may give rise to what I believe to be irritation of the duodenum, and will give rise to this symptom-complex although it is most frequently found in association with actual pathological lesions affecting the duodenum itself.

It often looks as if the 'duodenal irritation' was the result of some other lesion within the abdomen (as in case 658), and that the presence or absence of actual ulceration was more or less accidental. This is entirely in accord with Moynihan's view:—'I have long held the view that the diseases of the stomach, duodenum and gall-bladder, with which the surgeon deals, are not primary but secondary.' (*Lancet*, Jan. 6, 1912.) It is for this reason that I have termed this the symptom-

MB

complex of 'duodenal irritation,' as I feel confident that further investigation will prove that duodenal irritation and ulceration are generally, if not always, secondary conditions.

In case 658 the symptom-complex was found in association with a tubercular ulcer of the jejunum, this lesion being discovered at the operation in consequence of the *x*-ray report, while in a more recent case the same appearances were seen in connection with an early carcinoma of the jejunum about twelve inches from the duodeno-jejunal flexure. This case is of particular interest as the symptoms were extremely vague, and it was purely on the *x*-ray diagnosis of a lesion of the jejunum that the operation was undertaken. Unfortunately the patient died, from delayed chloroform poisoning it is supposed, and the condition of the mucous membrane of the duodenum showed that there had been some general inflammation (duodenal irritation) of which no trace could be seen on the peritoneal surface.

(January 1913.) Since writing the above, 4 more cases of lesions of the small intestine have been operated on, and in each of them I had noted a very marked duodenal symptom-complex as well as the accumulation of shadows in the small intestine resulting from the obstruction and defective movement caused by the lesion. I have also noted the symptom-complex several times in association with mucous colitis. In a recent case it was very markedly seen in a patient who had a mouthful of septic teeth, and it was when looking for a cause for the *x*-ray appearances, which gave one the impression of secondary gastric trouble, that the teeth were noted. At the operation there was absolutely no evidence of present or past disease to be found in the abdomen. It is also present, to some extent at any rate, in appendicitis, if the symptoms are at all gastric. I also noted similar appearances in a lady who had quite severe symptoms, and in this case again one had the impression that the symptoms were secondary. A few weeks later the patient (aged 45) developed slight delusions and her gastric symptoms disappeared.

The multiplicity of conditions then, in which duodenal irritation, or even ulceration is noted, makes one more and

more convinced that in the large majority of cases the duodenal trouble is, in the first place at any rate, secondary. It is as if the duodenal region were the storm centre for the alimentary tract to which disturbances in other parts, or possibly even in the nerve centres, might be referred, in many cases before any local manifestations had developed. Another interesting and suggestive phenomenon is the association of spasmodic and organic hour-glass stomach with pyloric obstruction (see p. 46); as if the lesions were complementary the one to the other or, more likely, both secondary to some common cause to which we have as yet not found the clue.

E. H. S. under

eg. Vomiting in  
appendicitis -  
obstruction

## CHAPTER VIII.

## THE ÆTIOLOGY OF GASTRIC ULCER.

The ætiology of gastric ulcer has always pertained to the department of the pathologist. Unfortunately the pathologist can only study the dead subject and, as we know, the stomach as it fulfils its functions differs widely from the flaccid sac that we see in the post-mortem room or even on the operating table. That morbid anatomy does not always give a true picture of the cause of symptoms has been indicated on many occasions and in the pages of this book there are references to several cases that bear upon the point. For instance on p. 16 a case of obstruction of the œsophagus is described in which the patient was almost dead from starvation and the œsophagus was dilated to a great extent. Yet the post-mortem showed no sign of the obstruction that had been almost complete nor of the dilatation that had followed, and this in an extreme case in which the bismuth food was still found in the œsophagus after 24 hours. Instances of spasmodic contractions of the stomach of which no trace could be found at the operation are very numerous. Special note is made of three cases on p. 44 in which a gastro-enterostomy had failed to relieve symptoms and in which a very marked and persistent hour-glass contraction was noted. In all these cases the patient vomited from the upper sac and it was evident that the hour-glass contraction was the cause of the trouble, and yet no pathological change could be found to account for abnormalities that were causing symptoms which made life a burden. It is clear that in many cases morbid anatomy tells but half the tale, that half which relates to tissue changes and infers that the functional disturbance is due entirely to these changes. As I have already said (p. 40) it is often the smaller ulcers (just as it is often the smaller renal calculi) that give rise to the severest symptoms. On the other hand cases have

been met with in which gross pathological changes have certainly been present in the stomach wall with practically no symptoms. A chronic penetrating ulcer is mentioned on p. 41 as giving, and of having given, practically no trouble. One of the most completely fibrous hour-glass contractions I have seen had not given rise to very severe symptoms. In fact the morbid anatomy does not necessarily give the clue to the actual disturbance and, apart from the patient's symptoms, we have no guide to the functional effects of a lesion of the stomach or intestines except by the *x*-ray method of examination which in its turn has its own limitations, for although it shows us the functional results it is only by inference that we diagnose the underlying cause, attempting to separate the factors of spasm and morbid process that have produced the effect.

It was while reading the final proofs of this book that the ideas embodied in this chapter forced themselves upon me. The interpretation of the pathology of the living assumed an importance that I had not previously attached to it, even though I was so fully conscious of the importance of the spasmodic element as a complication of organic lesions. And this is just the crux of the whole argument. At the operation one saw a small ulcer of the stomach whereas at the *x*-ray examination one had seen a typical and persistent hour-glass contraction which must necessarily have been spasmodic. One took it for granted that it was cause and effect, the ulcer being the cause and the spasmodic contraction the effect produced. And yet on looking back one found cases where we had the effect apparently without the cause, the spasmodic contraction without ulceration, and it was this that set me thinking that perhaps cause and effect had been confused and that possibly the ulceration was the effect of the spasm and that the spasm was due in the first place to some other cause although it could also be produced by the ulceration.

It was not a case of evolving a theory and setting to work to prove it; the hypothesis forced itself upon me and it was simply a case of analysing the various impressions that have, I believe, opened up the solution of a problem that I had no

thought of investigating. It is hardly likely that my observations cover the whole of the ground, but I am fully convinced of the accuracy of the deductions as far as I have been able to carry them during the few weeks that have elapsed since I arrived at this new conception of their significance.

The observations on which the deductions are based are as follows :—

(1) The stomach is very sensitive and many cases of spasmodic contraction have been met with ranging from those that were readily relaxed by massage to contractions that were actually mistaken for organic lesions. Quite a large number of spasmodic hour-glass stomachs have been examined and found at operation to show no trace of ulceration or other abnormality that, by local action, would cause the spasm. These spasmodic contractions have been met with in the body of the stomach and also at the pylorus. On several occasions I have seen that the vomiting took place from the upper sac and as soon as the food passed down the tendency to vomit and the pain ceased. They are often present one day, absent the next; they can usually be relaxed by massage or manipulation to some extent and are not necessarily found at subsequent examinations. There is no pain over the site of the spasm on deep palpation.

(2) Identical contractions have been met with, in fact are almost invariably met with, in association with even quite small ulcers, and I have always believed that the severity of the spasm resulting from an ulcer was dependent on its irritability and not on the size of the ulcer since small lesions gave just as, if not more, marked contractions than the large florid ulcerations.

(3) I have seen pyloric obstruction—as indicated by seeing the greater part of the food still in the stomach after 24 hours—permanently *cured* by removing bad teeth (p. 36). In an out-patient with many decayed stumps practically the whole of the food was still present in the stomach after 24 hours. On admission he was made to use a tooth brush and when I examined him a few days later practically all the food had passed out of the stomach in five hours. He was a fairly intelligent man and

had tried careful dieting before he was admitted to the hospital with no effect.

(4) In two cases I have been so much impressed by the irritable appearance of the stomach that, in spite of fairly well-marked clinical evidence I reported that I thought the symptoms were secondary, the condition of the teeth being in my opinion sufficient to cause the radiographic appearances noted; this in spite of the fact that some retention of food was noted on one occasion. In neither of these cases was any evidence found at the operation of gastric or other intra-abdominal lesion of any kind.

(5) An irritable condition of the stomach, or even an hour-glass contraction, is frequently noted when there is severe constipation.

(6) Spasmodic contractions, forming hour-glass stomachs have been noted as being not so marked or entirely absent after the bowels have been moved in cases of severe constipation.<sup>1</sup>

(7) In taking brief clinical histories of approximately 1400 cases I have been struck with the frequency of a history of constipation and also by the presence of bad teeth or a history of having had bad teeth removed after the onset of the symptoms.

(8) In fully a half of the cases of ulceration of the body of the stomach there was also evidence of retention of food behind the pylorus and in the large majority of these latter there was actual thickening of the pylorus. In two cases in which no thickening of the pylorus was detected at the operation a gastro-jejunosomy to the upper sac failed to cure and a subsequent examination showed the bismuth retained in the lower sac. A further operation showed well-marked thicken-

1. Case 713, quoted on p. 44, is instructive in this respect. There was a very marked hour-glass condition in association with pyloric obstruction. Nothing was found to account for the hour-glass contraction, but the pylorus was thickened and therefore a gastro-enterostomy was performed. I expected that this patient would not be cured, but a year later he writes: "I have put on two stone in weight and can eat everything. I was always very costive, in fact I never had a motion without opening medicine, but have never had a dose since the operation." In the light of other cases it looks as if the operation had relieved the constipation and that this was the cause of the spasmodic hour-glass contraction.



ing of the pylorus, and excision of the lower sac cured the patient.

(9) In a very large number of the cases of pyloric obstruction a more or less marked spasmodic contraction was noted in the body of the stomach. The relationship between spasm or even ulceration of the body of the stomach and pyloric obstruction is so marked that it can hardly be accidental. I have often remarked that it looked far more as if lesions in these two sites were dependent on some common cause than on one another.

(10) Moynihan put into words a belief that had gradually been taking shape in my own mind—"the diseases of the stomach, duodenum, and gall-bladder, with which the surgeon deals are not primary but secondary" (*Lancet*, Jan. 6, 1912). I had been much impressed by what I called the interdependence of abdominal conditions, *e.g.*, when one found an irritative condition of the large bowel, *e.g.*, mucous colitis, one usually found the appearances and often the symptoms of duodenal ulcer, while in one case there was a gastric ulcer with hour-glass contraction. The duodenal appearances and symptoms were also noted in several cases of lesions of the small intestine (carcinoma, tubercular ulcer and adhesions) in which the actual site of the disease was indicated to the surgeon solely by the *x*-ray examination. In one of these a typical ulcer of the duodenum was also found, while in another, who died a few days after the operation, the mucous membrane was injected and inflamed although there was no evidence of this on the peritoneal surface. In appendicitis, when there were gastric symptoms, these same appearances indicating duodenal irritation were also noted from time to time at the *x*-ray examination.

(11) The excessive and rapid formation of gastric secretion has been noted in all the later cases in which a pyloric ulcer has been found, except those in which marked retention of food was also present, this feature making it impossible to detect the hypersecretion. Well-marked hypersecretion has been noted in cases where there was slight delay in emptying (six hours), and under medical treatment not only has the

delay in emptying disappeared but also no hypersecretion could afterwards be detected. The hypersecretion seems to be the accompaniment of pyloric lesions and disappears with the pyloric "irritation." I have not yet seen hypersecretion in association with an ulcer of the body of the stomach unless there was an actual lesion of the pylorus also present.<sup>1</sup> In one instance I found what was evidently the upper sac of an hour-glass contraction of cicatricial type, and during the half-hour I had the patient under observation (the surgeon was waiting to operate) only a very small quantity of food found its way through into the lower sac but there was profuse secretion into the upper sac and, as suspected, this indicated an active ulcer of the pylorus. At the operation there was only a very narrow channel connecting the upper and lower sacs so that the secretion must have been poured out from the cardiac end, suggesting very strongly that the hypersecretion of pyloric ulcer is a general secretory activity, probably reflex, and not a local hypersecretion dependent on the direct irritation of the ulceration. Whether the pyloric lesion is the result of the hypersecretion or vice versa one cannot say, but I suspect that they are both dependent on a common cause and not necessarily on one another.

(12) In operations for gastric and duodenal ulcer there is very frequently evidence of old appendix trouble.

(13) Gastric symptoms—the old symptom-complex of gastric ulcer—have been cured by short circuiting the large intestine in a case of severe constipation. (*Lancet*, February 8, 1913. Paris correspondent.)

(14) My own personal experience of oral sepsis indicates that this is always worse when I am run down and improves as soon as I take a holiday. Occasionally when I am below par I have acid risings into my mouth, probably indicating an excessive formation of gastric juice such as I have frequently noted in association with pyloric ulcer in marked cases, with "pyloric irritation" in the less marked cases.

1. If the stomach is emptying rapidly one has not the same chance of detecting the presence of hypersecretion.

On two occasions I have been conscious of retention of food for a prolonged period and once I actually brought up a mouthful that contained fragments taken on the previous day. A more thorough and persistent use of an antiseptic mouth wash relieved this unpleasant symptom within the course of a couple of days.

Occasionally I am also troubled with slight hunger pain.

I am certain I do not suffer from any gastric lesion for I have perfect digestion in the ordinary course of events and do not know what indigestion is nor does the radiographic examination reveal any abnormality.

(15) The experimental production of gastric ulcer in animals shows that these always tend to heal very rapidly and a typical chronic ulcer has not yet, I believe, been produced, even by causing local thrombosis.

(16) I know that there is considerable literature on the subject but I have seen no case in which ulceration has taken place at the site of a gastro-enterostomy; and yet at this point the mucous membrane is comparatively roughly joined, and one would certainly expect that if ulceration was caused by the action of the gastric juice this would be a *very common* sequence to the operation, especially when we remember that in most of the operations a clamp is used that must produce a certain amount of bruising. This is certainly not the case in the hospital with which I am connected<sup>1</sup> and it is inconceivable that the mucous membrane is brought into perfect apposition in every case.

(17) In the duodenum the conditions do not appear to be exactly the same as in the stomach. Observations show that in every case of duodenal ulcer, and also where there is duodenal irritation, the stomach begins to empty itself very rapidly and one can easily see quite large shadows pass

1. Neither the pathologist nor any of the surgeons at the Manchester Royal Infirmary have seen a single case of ulcer occurring at the site of the stoma (gastro-jejunal ulcer) nor have they seen a jejunal ulcer. The only case of ulceration occurring in this region was an acute ulcerative process that almost separated the jejunum from the stomach, but this was four years after the operation had been performed.

through the duodenum. In some cases there is a separate bolus persistently present in some part as if a pocket was formed but, in spite of large quantities passing through, I have very seldom observed obstruction, and whenever this has been seen there has been definite cicatrization or some external cause found at the operation to account for the retention. It seems therefore as if spasm, as seen in the stomach, is not associated in the same way with duodenal ulceration and I think it likely that some other influence is at work in these cases. The conditions that obtain in the stomach and duodenum during life are as yet only partly understood and the various factors that control the passage of the food through the pylorus are by no means clear. I have given my reasons (p. 26) for believing that the control of the pylorus is influenced by the duodenal condition. In all cases of duodenal ulcer and of duodenal irritation one sees very abnormal pyloric relaxation as evidenced by the passage of large masses of food, whereas in the normal subject it is practically impossible to see the food passing through the duodenum, so fine is the stream that passes through the pylorus, and so rapid the segmentation and shredding of the food. The appearances suggest that the segmentation contractions that normally shred the food in the small intestine are absent in the duodenum when there is ulceration or irritation, otherwise the large shadows would not be seen in the duodenum. We know, therefore, that the pylorus is abnormally relaxed in these cases and one suspects that the relaxation extends to the duodenum and that the relaxation is sufficient to counterbalance whatever tendency towards spasmodic contraction the ulceration might give rise to. The absence of a spasmodic contraction in these cases would account for the fact that they frequently heal spontaneously, but the causation of these ulcers does not appear to be the same as in gastric ulcer.

Taking all these observations together I think that they become intelligible on the following hypothesis:—

Septic conditions in the mouth or other sources of swallowed septic matter, constipation, mucous colitis and a variety of other conditions are capable of producing spasmodic

contractions of various parts of the stomach. The spasm produces a narrowing of the lumen that is of great functional importance, causing a definite obstruction to the passage of food. By an indiscretion of diet or want of mastication something too large to pass easily through the channel has to be forced through by powerful peristalsis. This leads to an abrasion at the point where the lumen is narrowed and where there is the constant irritation of food passing over it. Also a surface is exposed that is not structurally fitted to withstand the action of the gastric juice. In this way an ulcer is formed which in its turn perpetuates the original spasm that determined the site of the ulcer. A vicious circle is established, the ulcer now being actually the cause of spasm that prevents healing so that even if the original cause of the spasm is removed there is little if any improvement in the local condition.

The stomach and duodenum are, as it were, the storm centre for the alimentary tract to which peripheral stimuli are referred, the result being either a general irritable condition of the stomach and duodenum or spasmodic contractions of one or more parts of the stomach. These stimuli are referred to the stomach and duodenum either directly, from swallowed septic matter, or indirectly from lower parts of the tract as in the case of lesions of the small intestine as indicated radiographically and proved by operation; as in the mucous colitis cases and constipation cases as indicated radiographically and also by the subsequent history of the cases.

Appendix dyspepsia is too well known to need mention. Radiographically it is indicated as a rule by duodenal irritation and Moynihan tells of the very large percentage of duodenal ulcer cases in which there is evidence of old appendicular trouble.

Now these spasmodic contractions give rise to all the radiographic appearances of actual lesions—on more than one occasion a surgeon has re-opened an abdomen at my suggestion because of the persistent hour-glass contraction that has been noted above the stoma of a gastro-enterostomy which was

functioning perfectly. Three of these patients were actually observed vomiting from the upper sac of the hour-glass contraction, the pain and tendency to vomit disappearing when once the food had passed down into the lower sac, and yet no cause was found at the operation to account for the contraction. In several cases where I have reported definite pyloric obstruction the surgeon could find nothing to indicate gastro-enterostomy, and in two of them a subsequent operation showed thickening of the pylorus. There are many cases of various types all pointing in no uncertain manner to the obvious conclusion that the spasmodic contraction is of as great importance functionally, as the organic, and that these apparently purely spasmodic contractions are replaced by actual organic lesions has been actually noted in some two or three cases in which a second operation has been undertaken. (This has been noted only at the pylorus as yet.)

That ulcerations of the alimentary tract are irritable and give rise to spasmodic contractions I have seen proved time and again, *e.g.*, ulcers of the œsophagus that only caused symptoms (and obstruction) after the patient took dry bread crumbs. (The ulcers were actually seen through the œsophagoscope afterwards.) The same has been noted in the stomach very frequently. Hour-glass contractions with retention of food in the upper sac have often been found, at operation, to be due to quite small ulcers with practically no cicatrization.

If my contention is correct that purely spasmodic contractions are capable of producing functional obstruction which leads to trauma of the mucous membrane, and that this ulcer or abrasion is itself capable of producing a similar spasmodic contraction, it follows that when once an ulcer is formed it will perpetuate the spasmodic contraction even if the primary cause of the spasm is removed. Hence it is clear that removing the primary cause will not cure the patient, for the ulcer when once formed continues to induce a spasm that tends to the perpetuation of the ulcer. If on the other hand an ulcer or abrasion has not occurred, the removal of the primary cause whether it be teeth, nasal discharge or swallowed pulmonary discharge, stagnation of fæces, appendix

inflammation or some other cause, will probably bring about a rapid and lasting cure of the patient. It is probable therefore that the chief factor in the production of gastric ulcer is a physical one, but the connection between the various primary conditions and the spasmodic contractions they produce is a problem that is beyond the reach of radiography.

This theory covers the whole of the many and varied observations I have detailed and I believe accounts satisfactorily for them all, including the failure to produce gastric ulcers artificially that are comparable to those met with in man. To what extent the gastric juice is responsible I cannot say, but it seems reasonable to suppose that when once an abrasion is formed a surface is exposed that is not adapted to withstand the action of the gastric juice and will therefore tend towards the extension of the ulceration.

CHAPTER IX.  
CONCLUSIONS.

The progress that has been achieved in the diagnosis of gastric disorders by means of the bismuth method, has been very marked during the five and a half years in which the material for this thesis has been collected. I have been present at as many of the operations as possible, but have had to take my records from the operation books in a very large proportion of cases, and during the first two and a half years the work was anything but encouraging. The opinions I gave as the result of the *x*-ray examination were as often wrong as right, and in many of the failures in diagnosis it seemed that I was hopelessly beside the mark; so much so, that at times I had little confidence in the work and little hope of ever becoming successful, the results were seemingly so contradictory. During the next eighteen months, however, the apparent inconsistencies gradually became fewer in number, but even so it seemed doubtful if the results obtained were worth the time and labour involved, especially when one had to choose between this branch of investigation and others which one knew would yield satisfactory results if one had time to develop them. I had much encouragement from the physicians and surgeons of the Manchester Royal Infirmary and Ancoats Hospital, who have in this and other matters always been most helpful to both my partner, Dr. Bythell, and myself, when we have been carrying out any work. During the last eighteen months the results have been much more satisfactory, and the operative findings have seldom shown anything that had not been indicated by the *x*-ray examination, although of course I did not always read the signs aright. Some of the failures in diagnosis were in connection with ulceration involving the lesser curvature, which occasionally seems to give rise to no spasmodic contraction; as if some ulcers in this region were either not



irritable or interfered with the nerve fibres that should set up localised spasm.

Purely spasmodic contractions have been another cause of failure, but these have very seldom given rise to mistaken diagnosis if the massage test was properly applied, and if the patients were re-examined as a routine procedure, a condition that is often difficult to hold to in hospital practice owing to the pressure on accommodation of the surgical beds.

The pars pylorica is still the most difficult region of the stomach about which to obtain reliable information, and the appearances of this part very seldom reveal such details as will assist in the diagnosis. One has therefore to rely almost entirely on the deductive evidence obtained from the rate at which the food leaves the stomach, the tonic action, the peristalsis, secretion, and so forth.

The point has not yet been reached at which it is possible to say, 'there is no active pathological lesion of the stomach walls'—one has so often to make reservations as to the pars pylorica; but, on the other hand, evidence is accumulating that will I believe very soon lead to the possibility of always making a definite positive diagnosis of pyloric ulcers, and when this becomes possible, one will be able to give a definite negative diagnosis in the large number of cases of suspected gastric trouble in which the dyspepsia is functional or secondary to some other trouble.

The certainty with which pyloric ulcers (or, if one may say it, pyloric irritation) may be distinguished from duodenal ulcers (or duodenal irritation), is in marked contrast to the clinical differentiation of these cases.

Defective tonic action is also rather troublesome in making a negative diagnosis, but the appreciation of the changes brought about by defect of tone becomes intuitive after a time, and I am now seldom troubled by the appearances it causes.

The connection between the train of symptoms, which I have discussed under the head of duodenal irritation (p. 55), with other lesions of the intestinal tract is most striking, and confirms the impression that I took from Mr. Moynihan's

lecture before the Manchester Pathological Society,\* that duodenal ulcer is probably often a secondary lesion. As I write I have a patient under observation in whom this train of symptoms is well marked, and the examination I have just made (20 minutes after the food was taken) reveals a large collection of bismuth in the jejunum, and, if confirmed, is almost certainly indicative of adhesions or, as in the last similar case, an ulcer of the jejunum, while the clinical evidence only suggests duodenal ulceration.

In taking notes of all the cases the persistent recurrence of a history of severe constipation, especially in women, seems to indicate that the association of gastric lesions with this trouble is more than a coincidence. In many cases also, chiefly men, the teeth have been in a bad state, sometimes actually at the time of the examination, and on several occasions the cleaning up of the mouth has brought about a wonderful change not only in the patient's condition, but also in the *x*-ray appearances. Cases that have been diagnosed clinically and confirmed radiographically as duodenal ulcer, cases of pyloric obstruction with marked delay in emptying and spasmodic contractions of the stomach, have all been cured by attention to the teeth and bowels. I have little doubt now that constipation and bad teeth are two of the main factors in determining the onset of ulceration of the stomach and duodenum. Whether or not they are the actual causes I cannot say but they are both capable of giving rise to spasmodic contractions which have almost all the appearances of pathological changes in the stomach walls. One is more and more impressed with the importance of the physical element of spasm, not only in the causation of true visceral pain but also perhaps in the actual production of some of those lesions of the alimentary canal that were at one time regarded as primary.

Statistics are of course worth very little, nevertheless I thought it would be instructive to take at random from my files the records of thirty consecutive cases and summarise the results. In 19 I gave a definite report that was entirely

\* "Lancet," February 24, 1912.

in accord with the operative findings. In six the diagnosis was quite correct, but I could not give such a definite report, *e.g.*, suggesting that there was probably an ulcer or growth present, but that the *x*-ray evidence was not sufficiently definite to justify the diagnosis. Of the remaining five, I find as follows:—(1) a case of extraordinary extensive adhesions to the liver, which I had diagnosed definitely as a carcinoma obliterating the gastric cavity; (2) a case which I only had the opportunity of seeing on one occasion, I mistook a spasmodic hour-glass for an organic lesion, but also suggested the probability of an ulcer at the pylorus, which was found at the operation; (3 and 4) in two cases I found no evidence of ulceration, and the operation showed the presence of an ulcer of the lesser curvature, in one case at the cardiac end, and in the other near the pylorus (two of the four cases met with in which an ulcer failed to set up a spasmodic contraction); (5) one case in which I gave a report that there was probably an ulcer in the pyloric region. The operation revealed a perfectly healthy stomach.

There is no useful purpose to be served in comparing these results with those obtained by clinical methods in the same series of cases, as the requisition cards are usually made out by the house-surgeons or house-physicians, and are probably filled in at random before an exhaustive clinical examination has been made.

One conclusion is quite clear; the more time one spends on a case and the more one considers the *x*-ray findings in connection with the clinical history, the more accurate will be the diagnosis. The *x*-ray method is of some value by itself, but when it is taken in conjunction with all the other available means of investigation, it becomes the greatest of all aids we possess in the diagnosis of diseases of the walls of the intestinal tract.

That the work is of value is evidenced by the fact that last year (1911) I examined nearly 350 in-patients by means of the bismuth method at the Royal Infirmary. But perhaps the most noticeable feature is the fact that one no longer hears of the successful diagnoses but of the failures.

## CHAPTER X.

## TABULATION OF CASES.

To attempt the classification and tabulation of the eight or nine hundred cases of which I have notes was obviously a labour that would yield no definite information. I have therefore only tabulated those in which the actual condition was discovered either on the operating table or in the post-mortem room, and have classed them according to the actual pathological lesion found, and not according to the *x*-ray findings. Even so, the task was not easy, for there are many cases in which the operation yields indefinite information as to the exact nature of the lesion. This is especially the case in pyloric obstruction, and for this reason all cases of this nature, whether simple or malignant, are placed under one heading.

Again, description of the operative findings is often so meagre and so lacking in detail that one had to rely in many cases on the memory of the surgeon or house-surgeon for important information. A number of cases have been rejected from this tabulation on the ground of insufficient data as to the operative findings.

*Class 1.* Cases in which the gastric symptoms were not directly due to a lesion of the stomach or duodenum.

*Class 2.* Cases in which the symptom-complex of duodenal irritation was found, or in which an actual lesion of the duodenum was discovered.

*Class 3.* Cases of ulcer of the pars pylorica.

*Class 4.* Cases of ulceration of the body of the stomach with or without the formation of a definite hour-glass contraction.

*Class 5.* Cases of carcinoma of the body of the stomach—not including pyloric carcinoma.

*Class 6.* Cases of pyloric obstruction—whether simple or malignant.

*Class 7.* Cases in which the stomach was distorted by adhesions—apart from actual disease of the walls.

*Class 8.* Cases in which surgical interference had not been altogether successful.

I have added introductory remarks to each division with a special note of any case, or class of case, to which I wished to draw attention.

Strictly speaking, classes 1 and 2 should be under one heading, but the symptom-complex of duodenal irritation seems so clear that it will be readily seen why these cases are classed separately.

The clinical diagnosis is taken from the requisition cards which are filled up in the wards.

Tables of Cases



## CLASS I. (See p. 29.)

## NORMAL.

No. Age. Sex.	Clinical Diagnosis.	X-ray Findings	Operative Findings.	Remarks.
6 53 M.	?	Nil.	No evidence of ulcer.	Gastro-jejunostomy did not relieve symptoms
25 46 F.	? Carcinoma of stomach.	Nil when standing; bismuth segmented over growth when lying down.	Carcinoma of pancreas, etc.; stomach not invaded.	
28 35 F.	? Gastric ulcer; ? carcinoma of stomach.	Slightly atonic; nil else.	No abnormality found.	
54 35 F.	—	Nil but visceroptosis.	Nil in stomach; nephropexy.	Patient no better.
60 33 F.	? Carcinoma; ? gastric ulcer.	Nil except slightly active peristalsis.	Nothing found.	
86 35 M.	Pyloric ulcer.	Excess peristalsis; nil else.	No evidence of abnormality.	
102 22 F.	? Gastric ulcer.	Nil except rather active peristalsis.	Nil except slight adhesions near pylorus; no gastro-jejunostomy.	Relieved.
125 39 F.	—	Stomach normal; nil except some air swallowing.	Nil found; kidneys fixed.	No benefit.
154 40 F.	?	Stomach appeared to be twisted upon itself; nil else.	Nil found; no gastro-jejunostomy.	Patient cured
171 60 M.	Carcinoma of stomach.	Nil abnormal.	Carcinoma of pancreas.	
182 22 M.	?	Nil abnormal.	Tubercular peritonitis around appendix.	
241 41 M.	Duodenal ulcer.	Nil abnormal.	Surgeon described duodenal scarring, and patient died 3 days later from occult hæmorrhage for which no cause was found.	No duodenal ulceration found at post-mortem
248 70 M.	Carcinoma.	Nil abnormal found.	Abscess near appendix.	
249 40 F.	Carcinoma of stomach.	Stomach atonic; some visceroptosis.	No abnormalities found, but gastro-jejunostomy performed.	
284 25 M.	?	Normal, except rather marked air swallowing.	Appendix removed.	Cured.
296 35 F.	Abdom. tumour	No abnormalities found; no evidence of displacements.	No abnormalities found.	
311 35 M.	? Gastric.	Nil abnormal found.	Appendix thickened with adhesions.	
333 28 F.	Gastric ulcer.	Gastroptosis, but nil else.	Nil in stomach; kidneys low down; nephropexy.	



No.	Age.	Sex.	Clinical Diagnosis	X-ray Findings.	Operative Findings.	Remarks
337	38	M.	? Gastric ulcer.	Stomach not involved by the growth.	Growth of splenic flexure, adherent to stomach.	
369	44	M.	Dilat. stomach.	Stomach normal, except marked contraction near pylorus; looked like carcinoma.	Nil found; no gastro-jejunostomy.	Spasm cured by laparotomy.
372	24	F.	Dilat. stomach.	Aerophagy; spasm of middle.	Nil found.	
398	38	F.	Dilat. stomach; ? Gastric ulcer.	Hour-glass marked; vomiting from upper sac.	Nothing to account for the hour-glass; appendix removed.	Cured 5 weeks after operation, but relapsed.
402	33	F.	Gastric ulcer.	Nil except active peristalsis.	Appendix removed; nil in stomach.	
405	50	F.	Dilat. stomach.	Nil found.	Nil.	
423	47	M.	Carcinoma ? of stomach.	Nil, stomach displaced, but not involved.	Growth of colon.	
476	38	M.	? Gastric ulcer.	Nil peristalsis rather active.	Nil in stomach; chronic appendix.	
478	27	M.	Gastric ulcer	Nil abnormal.	Nil; old appendix.	
481	64	M.	Carcinoma of stomach.	Nil abnormal noted.	Stone gall-bladder.	
485	30	M.	—	Slightly atonic.	Appendix removed; nil in stomach.	
489	48	M.	Gastric ulcer?	Nil.	Stomach normal; appendix removed.	
497	26	F.	Gastritis.	Irregular card; end looked like adhesions.	Nil.	
555	59	F.	Carcinoma of stomach.	Growth displacing stomach.	Growth of gall-bladder.	
593a	47	M.	Pyloric obstruction.	Nil abnormal.	Gall-stones.	
706	57	M.	Duodenal ulcer.	Nil abnormal.	Growth of pancreas.	
612	47	M.	Duodenal ulcer.	Normal.	Few adhesions duodenum to gall-bladder.	
716	27	F.	? Gastric ulcer; ? appendix.	Gastroptosis; nil else.	Stomach normal; inflamed appendix.	
721	36	F.	? Tumour; ? gastric.	Tumour not in relationship to stomach.	Growth of kidneys; stomach not involved.	
761	49	M.	Carcinoma of stomach.	Œsophagus obstructed, with pouching; stomach looks normal.	Stomach normal; gastrostomy.	
772	47	M.	Carcinoma of stomach.	Stomach normal.	Carcinoma of hepatic flexure.	
791	34	F.	? Gastric ulcer.	Stomach normal; rather active secretion; active peristalsis.	Nil found in stomach.	

## CLASS II. (See p. 55.)

## DUODENAL IRRITATION.

By "normal stomach" in these cases I mean that the organ exhibits either perfect tonic action or more often, hypertonics. The separate bolus in the duodenum refers to the large food shadows seen passing through the duodenum, not to the stationary shadows.

Age. Sex.	Clinical Diagnosis.	X-ray Findings.	Operative Findings.	Remarks.
30 30 M.	Dilat. stomach.	Stomach normal, rapid emptying; peristalsis active; separate bolus in duodenum.	Adhesions of duodenum to liver.	
66 31 F.	Gastric ulcer ?	Stomach normal; peristalsis active; separate bolus in duodenum; stomach emptied rather slowly.	Definite cicatrization of duodenum; posterior gastrojejunostomy.	Cured.
70 37 M.	Duodenal ulcer.	Stomach normal; peristalsis active; rapid emptying; separate bolus in duodenum.	Cicatrization round duodenum; posterior gastrojejunostomy.	Cured.
78 28 M.	Tumour.	Stomach normal; rapid emptying, peristalsis active; separate bolus in duodenum.	Extensive carcinoma not involving stomach.	
81 51 M.	Duod. ulcer ?	Stomach normal; rapid emptying, peristalsis active; separate bolus in duodenum, when patient lay down.	Ulcer upper surface duodenum.	Cured.
92 35 M.	Duod. ulcer ?	Stomach normal; rapid emptying, peristalsis active; separate bolus only when patient lay down.	Duodenal ulcer.	Cured.
97 34 F.	? Gastric ulcer.	Stomach normal; peristalsis active; rapid emptying; separate bolus in duodenum; spasm middle stomach.	Cicatrization about duodenum; nil in body of stomach.	Much better, but not cured.
101 62 M.	Duodenal ulcer.	Stomach normal; rapid emptying, peristalsis active; separate bolus in duodenum.	Duodenal ulcer.	Cured.
120 56 M.	Neurosis.	Stomach normal; rapid emptying, peristalsis active; separate bolus in duodenum.	Few adhesions; nil else.	Patient developed G.P. 1.
184 42 M.	Duod. ulcer ?	Stomach normal; rapid emptying, peristalsis active; separate bolus in duodenum.	Duodenal ulcer; gastrojejunostomy.	Cured.
218 34 M.	Duod. ulcer ?	Stomach normal; peristalsis active; no separate bolus in duodenum; rapid emptying.	Ulceration both sides of pylorus; adhesions to liver.	Relieved, but not cured.
219 22 M.	Gastric ulcer ?	Stomach normal; rapid emptying; peristalsis active; no separate bolus in duodenum.	Appendicular abscess; adhesions.	Patient not cured.

No. Age. Sex.	Clinical Diagnosis.	X-ray Findings.	Operative Findings.	Remarks.
240 36 M.	Dilat. stomach.	Visceroptosis; slight atony; peristalsis active.	Duodenal ulcer.	
289 46 M.	Pyloric obstruction.	Stomach normal; rapid emptying; peristalsis active; separate bolus in duodenum.	Growth of lesser curvature.	Duodenum not explored.
307 31 F.	Stomach? kidneys?	Stomach normal, except displaced; rapid emptying; peristalsis active; separate bolus in duodenum.	Adhesions to distended gall-bladder.	
314 37 F.	Duodenal ulcer.	Stomach normal; rapid emptying; peristalsis active; separate bolus in duodenum.	Cicatrix round 1st part duodenum.	
401 51 M.	—	Stomach normal; rapid emptying; peristalsis active; separate bolus in duodenum.	Adhesions of duodenum to liver.	
412 54 M.	Gastric ulcer.	Stomach normal; rapid emptying; no active peristalsis; no separate bolus in duodenum.	Duodenal cicatrization.	
417 54 F.	Pyloric obstruction.	Stomach normal; rapid emptying; peristalsis active; no separate bolus in duodenum; small intestine overloaded.	Adhesions of duodenum to liver; small intestine not examined.	
418 50 M.	Carcinoma.	Stomach normal; separate bolus in duodenum; rapid emptying.	Large ulcer lesser curvature, and duodenal ulcer.	No indication of the gastric ulcer.
451 30 M.	Duodenal ulcer.	Stomach normal; rapid emptying; peristalsis active; separate bolus in duodenum.	Adhesion duodenum to gall-bladder; gastro-jejunosomy	
468 38 M.	Dilat. stomach.	Stomach normal; peristalsis active; no rapid emptying; no separate bolus in duodenum.	Scar on duodenum; gastro-jejunosomy.	
475 37 M.	Pyloric ulcer.	Stomach normal; peristalsis active; rapid emptying; separate bolus in duodenum.	Duodenal ulcer; gastro-jejunosomy.	
477 35 M.	Gastric ulcer?	Stomach normal; peristalsis active; rapid emptying; separate bolus in duodenum.	Pericholitis; adhesion to gall-bladder, etc.	
486 34 F.	? Gall-bladder.	Stomach normal; peristalsis active; rapid emptying; separate bolus in duodenum.	Post-mortem, stone gall-bladder.	
498 22 M.	Gastritis.	Stomach normal; rapid emptying; peristalsis active; separate bolus in duodenum; obstruction at duodeno-jejunal flexure.	Pericholitis; duodenal ulcer; adhesions at duodeno-jejunal flexure.	

No.	Age.	Sex.	Clinical Diagnosis.	X-ray Findings.	Operative Findings.	Remarks.
501	30	M.	Gastric ulcer.	Slight at; rapid emptying; peristalsis active; separate bolus in duodenum.	Cicatrical duodenum.	
561	27	M.	Gastric ulcer.	Stomach normal; peristalsis active; rapid emptying; separate bolus in duodenum.	Duodenal ulcer; gastro-jejunostomy.	
586	40	M.	Duodenal ulcer.	Stomach normal; peristalsis active; rapid emptying; separate bolus in duodenum.	Thickening of duodenum.	
587	23	M.	Gastritis.	Stomach normal; peristalsis active; rapid emptying; separate bolus in duodenum.	Duodenal ulcer; gastro-jejunostomy.	
588	35	M.	Gastric ulcer?	Stomach normal; peristalsis active; rapid emptying; separate bolus in duodenum.	Adhesions duodenum to gall-bladder and colon.	
589	31	M.	Duodenal ulcer.	Stomach normal; peristalsis active; rapid emptying; separate bolus in duodenum.	Duodenal ulcer.	
613	50	M.	Duodenal ulcer.	Stomach normal; peristalsis active; rapid emptying; bolus in duodenum, which does not move on.	Cicatrices of pylorus and duodenum.	
619	36	M.	Gall-stones.	Stomach normal; peristalsis active; rapid emptying; separate bolus in duodenum.	Gall-stones; adhesions.	
638	29	M.	Dyspepsia.	Stomach normal; peristalsis active; rapid emptying; separate bolus in duodenum.	Long appendix fixed by adhesions very high up.	
658	24	M.	? Duod. ulcer.	Stomach normal; peristalsis active; rapid emptying; coils of jejunum seen in left iliac fossa.	Duodenal ulcer and ring ulcer of jejunum (tubercular).	Duodenal ulcer and ring ulcer of jejunum.
730	49	F.	Dilat. stomach.	Gastroptosis; nil else.	Nil in stomach; adhesions to duodenum.	
749	56	F.	Dyspepsia.	Stomach normal; peristalsis active; rapid emptying; no separate bolus in duodenum.	Gall-stones and adhesions.	

## CLASS III. (See p. 37.)

## ULCER OF PYLORIC REGION.

No.	Age.	Sex.	Clinical Diagnosis.	X-ray Findings.	Operative Findings.	Remarks.
143	55	F.	? Pyloric obstruction; dilated stomach.	Large atonic stomach; retained food; no delay in passing food out.	Cicatrization about pylorus; small active ulcer.	Cured.
308	42	M.	Pyloric ulcer.	Large atonic stomach with retained fluid; no marked delay emptying.	Cicatrix near pylorus.	
335	39	F.	? Gastric ulcer.	Hour-glass; secretion into upper sac; delay in emptying lower sac (24 hours).	Typical hour-glass stomach; ulceration and cicatrization of pylorus.	Secretion into upper sac.
396	44	M.	Dilat. stomach.	Atony; hypersecretion.	Thickening of pylorus; gastro-jejunosomy.	
579	40	F.	Gastric ulcer.	Hour-glass; cicatrization; hypersecretion to upper sac.	'As though string had been tied round stomach'; also pyloric ulcer.	Hypersecretion with pyloric ulcer.
593	31	M.	Duodenal ulcer.	Stomach normal; hypersecretion; peristalsis active; no food seen passing through duodenum; ? delay emptying.	Thickening about pylorus and lesser curvature.	Hypersecretion with ulcer of pylorus.
666	32	M.	Carcinoma.	Slight atony; nil else noted.	Ulcer posterior wall 1 inch from pylorus.	
717	36	F.	Gastric ulcer	Hour-glass; excessive secretion upper sac.	Cicatricial hour-glass; ulcer of pylorus.	
720	40	F.	Gastritis.	Well-marked hour-glass; pyloric obstruction; rapid secretion.	Mass of adhesions, middle lesser curvature; thickened pylorus with active ulcer; inflamed appendix.	Rapid secretion with ulcer of pylorus.
723	32	M.	Duodenum? appendix?	Hour-glass (spasmodic); pain relieved when food passed through; active secretion; active peristalsis.	No hour-glass; no ulcer; many adhesions about pylorus and ? ulcer pylorus; adhesions appendix.	
724	24	M.	? Gastric ulcer; ? carcinoma pylorus.	Normal; active secretion; peristalsis active.	Cicatrix about pylorus; active ulcer.	
777	32	M.	Dilat. stomach.	Stomach normal; excessive secretion; active peristalsis.	Ulcer pyloric portion on posterior wall.	

## CLASS IV. (See p. 43.)

## ULCERATION OF THE BODY OF THE STOMACH.

## HOURLASS CONTRACTIONS.

No. Age. Sex.	Clinical Diagnosis.	X-ray Findings.	Operative Findings.	Remarks.
24 50 M.	? Gastric ulcer.	Slight delay in emptying; nil else.	Large ulcer middle lesser curvature; thickening about pylorus.	Patient cured by gastro-jejunosomy.
35 32 F.	? Pyloric obstruction.	Definite hour-glass and pyloric obstruction.	Typical hour-glass; contraction and thickening of pylorus.	Cured by gastroplasty and gastro-jejunosomy.
37 34 M.	—	Hour-glass, partly spasmodic.	Ulcer lesser curvature; some cicatrization.	Excised.
79 52 M.	Gastric ulcer.	Spasmodic hour-glass, which relaxed leaving indentation.	Ulcer anterior wall; excised.	
83 48 F.	Obstruction of pylorus.	Definite hour-glass small channel; definite delay in lower sac.	Cicatricial hour-glass; cicatricial pylorus; gastroplasty and gastro-jejunosomy.	Cured.
89 47 M.	Growth ?	Atonic with spasm about middle.	Large stomach; cicatrix on lesser curvature; gastro-jejunosomy.	Cured.
91 42 F.	Pyloric obstruction ?	Cicatricial hour-glass (funnel-shaped); no pyloric obstruction.	Ulcer greater curvature; cicatricial hour-glass, with adhesion.	Cured.
93 41 M.	œsophageal obstruction.	Huge pouching just above diaphragm.	Post-mortem, small ulcer anterior surface near cardiac orifice.	No dilatation of œsophagus and no obstruction found post-mortem.
137 42 F.	Dilatation.	Hour-glass stomach; upper sac only seen.	Cicatricial hour-glass.	Patient died suddenly 3 weeks later.
193 59 F.	Gastric ulcer.	Atonic; slight delay emptying; some obstruction duodenum.	Ulcer 1 inch below cardiac orifice; ulcer just beyond pylorus with cicatricial contraction.	
203 63 F.	—	Hour-glass, and distorted by adhesions; lower sac in right iliac fossa; delay in emptying of lower sac.	Ulcers and cicatrices middle of stomach; growth at pylorus.	
207 30 F.	Gastric ulcer; gastro-jejunosomy 1908.	Well-marked cicatricial hour-glass; stoma working perfectly.	Stomach not explored, but kidney fixed November, 1909.	Unrelieved; entered also in Class VIII.

No. Age. Sex.	Clinical Diagnosis.	X-ray Findings.	Operative Findings.	Remarks.
207 31 F.	Same case one year later.	Exactly same picture as above.	Stomach almost divided by marked contraction.	Cured.
230 39 F.	? Stenosis of pylorus.	Hour-glass stomach, and definite delay in emptying.	Ring of ulceration of greater curvature; constriction of pylorus.	
239 40 F.	Gastric ulcer.	Funnel-shaped hour-glass; inverted peristalsis in lower sac; delay in emptying (24 hours).	Multiple scars forming trilocular stomach; growth at pylorus.	
266 43 M.	Old gastro-jejunostomy.	Hour-glass stomach well marked; stoma working perfectly.	Hour-glass, with active ulcer.	Cured by gastroplasty; a small ulcer of body had been noted at time of 1st operation.
286 39 F.	Dilat. stomach? gastric ulcer.	Hour-glass stomach; no pyloric obstruction.	Hour-glass; probably active ulcer.	
299 23 F.	Gastric ulcer.	Hour-glass stomach, partly spasmodic; no pyloric obstruction.	Large ulcer lesser curvature; some puckering; gastro-jejunostomy to upper pouch.	
310 40 F.	Gastric ulcer; ? pyloric obstruction.	Hour-glass stomach; definite delay emptying.	Trilocular stomach; cicatricial pyloric obstruction.	
331 29 F.	Gastric ulcer.	Division of stomach near pylorus.	Hour-glass stomach.	Lower sac quite large.
335 39 F.	? Gastric ulcer; ? carcinoma.	Hour-glass; secretion into upper sac; delay in emptying lower sac (24 hours).	Typical hour-glass stomach; ulceration and cicatrization of pylorus.	Secretion into upper sac; also entered in Class III.
364 37 F.	Pyloric stenosis	Spasmodic hour-glass; no pyloric obstruction.	Cicatricial hour-glass, with active ulcer.	
367 43 F.	Dilat. stomach.	Hour-glass, chiefly organic; no pyloric obstruction.	Large; gastro-jejunostomy lesser curvature, with cicatrization.	
371 39 F.	Gastric ulcer.	Hour-glass; no pyloric obstruction.	Hour-glass; gastro-jejunostomy to lower sac.	
389 40 F.	Gastric ulcer; old gastro-jejunostomy.	Hour-glass marked; stoma patent.	Hour-glass, with ulcer; gastroplasty.	
400 33 F.	Gall-stone? kidney; old gastro-jejunostomy.	Perfect hour-glass; stoma patent.	Cicatricial hour-glass.	

No.	Age.	Sex.	Clinical Diagnosis	X-ray Findings.	Operative Findings.	Remarks.
406	26	F.	Old gastro- jejunostomy.	Hour-glass, chiefly spasmodic; stoma patent.	Hour-glass, cicatricial, above stoma.	
418	50	M.	Carcinoma.	Nil; separate bolus in duodenum.	Large ulcer lesser curvature; cicatrix in duodenum.	
420	53	F.	? Stomach; ? Kidneys.	Spasmodic hour-glass, and separate bolus in duodenum.	Hour-glass and duodenal ulcer.	
455	48	F.	—	Cicatricial hour-glass.	Cicatricial hour-glass.	
461	39	F.	Gastric ulcer.	Marked hour-glass.	Cicatricial hour-glass.	
465	39	F.	Gastric ulcer.	Incomplete hour-glass; delayed emptying lower sac.	Pyloric obstruction; old cicatrices anterior walls of stomach.	
482	29	F.	Gastric ulcer; pyloric obstruction.	Hour-glass (cicatricial); no pyloric obstruction.	Cicatricial hour-glass. Thickening of pylorus.	
490	24	F.	Dilat. stomach.	Spasmodic hour-glass; delayed emptying lower sac.	Cicatrix of greater curvature and also at pylorus.	
492	31	F.	Neurosis.	Hour-glass, and delayed emptying lower sac.	Hour-glass, adherent to liver; pyloric obstruction.	
493	45	F.	Abdominal tumour.	Hour-glass; no evidence of growth.	Typical hour-glass; no pyloric obstruction or growth.	
573	18	F.	Gastric ulcer.	Hour-glass; some pyloric obstruction.	Ulcer lesser curvature; thickened pylorus.	
579	40	F.	? Gastric ulcer.	Hour-glass, cicatricial; hypersecretion to upper sac.	'As though string had been tied round stomach'; also pyloric ulcer.	Hypersecretion with pyloric ulcer.
583	28	F.	Gastric ulcer.	Spasmodic hour-glass.	Large ulcer middle stomach.	
589	39	F.	Pyloric stenosis	Hour-glass, cicatricial.	Cicatricial hour-glass.	
618	36	M.	Gastric ulcer.	Hour-glass, chiefly spasmodic.	Ulcer greater curvature.	
686	34	F.	Gastric ulcer?	Hour-glass, partly spasmodic; no pyloric obstruction.	Large ulcer lesser curvature; cicatrization.	
695	45	F.	Dilat. stomach; gastric ulcer?	Hour-glass, cicatricial, penetrating ulcer; retained food (24 hours).	Mass of adhesions middle stomach; hour-glass; pylorus normal; anterior gastro-jejunostomy.	
717	36	F.	Gastric ulcer.	Hour-glass; excessive secretion upper sac.	Cicatricial hour-glass; ulcer of pylorus.	
720	40	F.	Gastritis.	Well-marked hour-glass; pyloric obstruction; rapid secretion.	Mass of adhesions middle lesser curvature; thickened pylorus with active ulcer; inflamed appendix.	No pyloric obstruction, although retained food.
760	42	F.	Gastric ? kidney.	Gastroptosis; pylorus dropped 2 inches; nephroptosis.	Cicatricial ulcer lesser curvature, 2 inches from pylorus.	Hypersecretion with ulcer of pylorus.
782	65	F.	Gastric ulcer.	Pyloric portion sacculated and bound to liver; upper portion suggested hour-glass contraction	Mass of adhesions of pyloric portion stomach to liver; old ulceration; ulcer of pylorus	Rapid secretion with ulcer of pylorus.



## CLASS V. (See p. 48.)

## CARCINOMA OF THE STOMACH.

No.	Age.	Sex.	Clinical Diagnosis.	X-ray Findings.	Operative Findings.	Remarks.
7	43	M.	Carcinoma of stomach?	Very excessive peristalsis; pars pylorica obliterated. No delay in emptying.	Annular growth of pylorus.	Excised growth; patient died 18 months later.
8	35	M.	Carcinoma of stomach.	Stomach invaded; small irregular cavity only left.	Advanced carcinoma; inoperable.	
9	43	M.	Carcinoma of stomach.	Inroads of growth well defined.	Inoperable carcinoma.	
21	45	M.	—	Irregularity in outline of greater curvature.	Inoperable carcinoma.	
40	37	M.	? Carcinoma.	Irregularities of outline.	Advanced carcinoma.	
42	53	F.	? Carcinoma of stomach.	Inroads of growth near pylorus; retention of food.	Carcinoma of pylorus; gastro-jejunostomy.	
48	52	F.	Carcinoma of stomach.	œsophageal obstruction at cardiac orifice; no evidence of growth of stomach	Post-mortem six weeks later; growth of lesser curvature 5" x 6"; cardiac orifice not involved.	No contraction of cardiac orifice post-mortem.
58	54	M.	? Carcinoma of stomach; ? aneurism.	Light areas in midst of bismuth shadow.	Inoperable carcinoma; posterior wall chiefly.	Patient died 3 months later.
64	39	M.	? Carcinoma of stomach.	Irregular in outline.	Advanced carcinoma.	
170	58	M.	? Carcinoma of stomach.	Inroads of growth giving hour-glass appearance.	Inoperable carcinoma.	
233	53	F.	? Carcinoma of stomach.	Definite irregularities of outline.	Mass of growth in lesser curvature.	
289	46	M.	? Pyloric obstruction.	Stomach normal; shadows well seen in duodenum; active peristalsis.	Plaque of growth on lesser curvature; duodenum not explored.	No evid. of growth of stomach.
297	34	M.	Pyloric ulcer.	Irregular in outline.	Growth lesser curvature.	
300	29	F.	? Carcinoma of stomach.	Large atonic stomach; nil else.	Operation six months later; large mass involving anterior wall.	
342	66	F.	Carcinoma of stomach.	Gastric cavity obliterated, except along greater curvature.	Post-mortem; massive carcinoma involving whole stomach.	
366	55	F.	Abdom. tumour	Obliteration of all the cavity, except greater curvature.	Large mass extending from lesser curvature.	
380	43	M.	Duodenal ulcer.	Stomach cavity small and irregular; back pressure œsophageal dilatation.	Stomach one mass of growth.	
385	55	F.	Carcinoma of stomach.	Nil abnormal made out.	Growth lesser curvature, size of Tangerine.	
403	50	M.	—	Irregularity of pyloric portion.	Post-mortem; carcinoma.	
469	66	M.	? Carcinoma.	Cavity nearly obliterated.	Large growth; inoperable.	
582	52	F.	Carcinoma of ascending colon.	Cavity nearly obliterated; right side diaphragm pushed up.	Growth involving colon and stomach, secondary in liver.	
614	60	M.	? Carcinoma of pylorus.	Irregularities near pylorus; no obstruction.	Carcinoma of pylorus.	
776	47	M.	? Gastric ulcer; ? pyloric stenosis.	Marked inroad of pyloric portion; retained food.	Carcinoma of lesser curvature and pylorus	Patient died 36 hours later, cause unknown.

## CLASS VI. (See p. 36.)

## PYLORIC OBSTRUCTION.

No. Age. Sex.	Clinical Diagnosis	X-ray Findings.	Operative Findings.	Remarks.
10 35 F.	Dyspepsia.	Complete atony; bismuth seen in stomach for 5 days after examination.	Pyloric obstruction (cicatrical); gastro-jejunostomy.	Not cured.
20 52 M.	? Carcinoma.	Normal stomach, full of fluid; bismuth in stomach after 24 hours.	Carcinoma of pylorus with ulceration.	
24 50 M.	Gastric ulcer.	Slight delay in emptying.	Ulcer of lesser curvature and thickening of pylorus; gastro-jejunostomy	Cured. See also under Class IV.
29 54 M.	? Carcinoma of stomach.	Marked atony; retained fluid; slight delay.	Ulcer surrounding pylorus; gastro-jejunostomy	
31 55 F.	? Carcinoma of stomach.	Retained food; tone perfect; bismuth retained 24 hours.	Extensive carcinoma involving pylorus; gastro-jejunostomy	Patient cured.
41 32 F.	—	Hour-glass, partly spasmodic; peristalsis of upper sac; delayed emptying of lower sac.	Pyloric thickening; no ulcer of body.	Not cured; patient persisted in vomiting from upper sac.
56 44 F.	? Gastric ulcer.	Visceroptosis; delay in emptying; marked peristalsis.	Thickening of pylorus; gastro-jejunostomy.	Cured.
65 25 F.	? Gastric ulcer.	Some delay in emptying, in spite of excessive peristalsis; some visceroptosis.	Thickening about pylorus; gastro-jejunostomy	Relieved by operation.
72 61 F.	Gastric ulcer.	Extreme atony; marked peristalsis; delayed emptying (24 hours).	Thickening about pylorus; gastro-jejunostomy	Cured.
80 46 M.	? Pyloric obstruction.	Retained food; perfect tone; defective peristalsis; delayed emptying (24 hours).	Large mass about pylorus	
88 47 F.	Carcinoma of pylorus.	Stomach atonic; marked delay emptying (24 hours).	Growth at pylorus; huge stomach; gastro-jejunostomy.	'Cured' 2 years later.
94 32 M.	Dilat. stomach.	Definite delay in emptying (12 hours); some atony.	Thickening of pylorus	Cured.
98 43 F.	? Gastric ulcer.	Large atonic stomach with retained food; slight delay in emptying; marked peristalsis.	Adhesions along lesser curvature and pylorus; ? as to obstruction.	Cured.

No. Age. Sex.	Clinical Diagnosis	X-ray Findings.	Operative Findings.	Remarks
126 46 M.	Duodenal ulcer.	Nil, except rather active peristalsis; stomach emptying rapidly.	9 months later pyloric obstruction found.	Rapid emptying noted in early stage.
175 42 M.	Gastric ulcer.	Definite delay in emptying; some atony.	Ulcer of pylorus; adhesions to liver.	Cured.
179 34 F.	—	Very atonic stomach; active peristalsis; slight delay emptying.	Pyloric thickening and ulcer; stomach very large.	Cured.
192 51 M.	—	Retained food; delay in emptying.	Growth about pylorus and liver.	
201 48 M.	? Duod. ulcer; ? malignant.	Definite delay (24 hours); stomach normal; retained food; peristalsis not active.	Cicatrix of pylorus; gastro-jejunosomy.	Cured.
205 36 M.	Duodenal ulcer.	Stomach normal; violent peristalsis occasionally; slight delayed emptying (10 hours).	Old cicatrices about pylorus and duodenum; gastro-jejunosomy.	Patient died 3 days after operation; no cause known.
208 35 M.	Pyloric obstruction.	Retained food 24 hours; perfect tone; peristalsis absent.	Ring of ulceration round pylorus.	Cured.
217 36 F.	Carcinoma of stomach.	Huge atonic stomach; definite delay in emptying (24 hours).	Huge stomach; growth around pylorus.	
220 49 M.	Duodenal ulcer.	Stomach normal; very active peristalsis; occasionally some delay emptying.	Adhesion of pylorus and duodenum to gall-bladder; ? Pyloric obstruction.	
226 29 M.	Duodenal ulcer.	Stomach toneless; definite delay (24 hours).	Thickening of pylorus and scarring of duodenum.	Cured.
230 39 F.	? Pyloric stenosis.	Hour-glass stomach and definite delay in emptying lower sac.	Ring of ulceration greater curvature and constriction of pylorus.	
239 40 F.	Gastric ulcer.	Funnel-shaped hour-glass; inverted peristalsis in lower sac; delay in emptying (24 hours).	Multiple scars forming trilobular stomach; growth at pylorus.	
250 49 M.	Dilat. stomach.	Huge distended stomach full of food; marked delay (48 hours).	Large growth of pylorus.	
269 40 F.	? Dilated stomach; pyloric stenosis.	Complete atony; delay in emptying (24 hours); incomplete hour-glass.	Cicatrices about pylorus and smaller one on greater curvature.	Cured.
272 43 M.	Duodenal ulcer.	Stomach, normal, but occasionally active peristalsis.	Adhesions and glands malignant? about pylorus.	
293 35 F.	Dilat. stomach.	Extreme atony; delay emptying.	Growth at pylorus; gastro-jejunosomy.	Patient cured (6 months).

No.	Age	Sex.	Clinical Diagnosis.	X-ray Findings	Operative Findings.	Remarks.
294	43	M.	Gastric ulcer.	Slight atony; occasional violent waves of peristalsis; no marked delay emptying.	Thickening pylorus; gastro-jejunosomy.	Cured.
295	50	M.	? Carcinoma of stomach.	Definite delay in emptying; occasional violent peristalsis; inroads of growth at pylorus.	Growth about pylorus.	
309	56	M.	? hour-glass.	Retained fluid; perfect tone; peristalsis absent; definite delay (24 hours).	Large growth around pylorus; gastro-jejunosomy	
313	34	M.	—	Retained fluid; stomach normal; no peristalsis; delay emptying (24 hours).	Cicatrices; stenosis of pylorus.	
320	37	M.	Gastric ulcer.	Rather active peristalsis; some atony; delay in emptying.	Mass adherent to pylorus.	Stomach the flabbiest surgeon had handled.
330	47	M.	Pyloric obstruction.	Retained food; active peristalsis, but no marked delay in emptying (10 hours).	Thickening about pylorus.	
335	39	F.	? Gastric ulcer; ? carcinoma.	Hour-glass; secretion into upper sac; delay in emptying lower sac (24 hours).	Typical hour-glass stomach; ulceration and cicatrization of pylorus.	Secretion into upper sac.
338	40	M.	Dilat. stomach.	Atonic stomach; delay in emptying (24 hours).	Thickening of pylorus.	
340	65	M.	Dilat. stomach.	Atonic stomach; retained food; delay emptying (24 hours).	Large cicatrix.	
342	42	M.	Dilat. stomach; ? carcinoma.	Retained food; occasional active peristalsis; inroad near pylorus; slight delay emptying.	Inoperable carcinoma of pylorus.	
355	65	M.	? Gastric carcinoma; ? gastric ulcer.	Delay in emptying; irregularities near pylorus.	Pyloric thickening; adhesions to liver.	
359	60	F.	Carcinoma of stomach.	Atonic stomach; retained food; delay in emptying.	Pyloric thickening; huge stomach.	Patient died 1 week later, ? cause.
370		M.	—	Retained food; violent peristalsis; no atony.	Pyloric obstruction; large stomach.	
373	49	F.	Pyloric obstruction.	Atonic; delay in emptying (24 hours).	Carcinoma of pylorus; gastro-jejunosomy	
375	41	F.	Pyloric obstruction.	Atonic; delay in emptying (24 hours).	Pyloric obstruction; gastro-jejunosomy.	

No.	Age.	Sex.	Clinical Diagnosis.	X-ray Findings.	Operative Findings.	Remarks.
383	59	M.	Abdom. tumour	Atonic; delay in emptying; no inroads.	Growth of pylorus.	
399	33	M.	Gastralgia.	Atonic; retained food; slight delay in emptying (6 hours)	Large ulcer pylorus.	
410	63	M.	?	Retained food; delayed emptying; tone perfect.	Ulcer pylorus; gastro-jejuno-ostomy.	
411	36	M.	Gastroptosis.	Delay in emptying (10 hours).	Thickening pylorus.	
421	58	M.	Duodenal ulcer.	Irregularities near pylorus; delay in emptying (24 hours); tone fair.	Carcinoma of pylorus.	
422	57	F.	Pyloric obstruction.	Irregularities; delay in emptying (24 hours).	Carcinoma of pylorus; thin stomach walls.	
460	57	M.	Pyloric obstruction; growth?	Delay in emptying (6 days); stomach atonic.	Growth of pylorus and duodenum.	
465	39	F.	Gastric ulcer.	Incomplete hour-glass; delayed emptying lower sac.	Pyloric obstruction; old cicatrix; anterior wall of stomach.	
470	36	F.	Gastric ulcer.	Atonic; slight delay in emptying; active peristalsis.	Pyloric ulcer; gastro-jejuno-ostomy.	Cured.
487	21	F.	Dilat. stomach.	Delayed emptying; atonic stomach; retained food.	Growth of pylorus; gastro-jejuno-ostomy.	
490	24	F.	Dilat. stomach.	Slight delayed emptying; spasm middle stomach.	Large stomach; cicatrix near pylorus and also ulcer on greater curvature; gastro-jejuno-ostomy.	
492	31	F.	Neurosis.	Hour-glass, and delayed emptying lower sac (24 hours).	Hour-glass; adhesion to liver; pyloric obstruction.	
494	48	M.	Duodenal ulcer.	Stomach displaced; retained food; delayed emptying.	Large saddle-shaped ulcer about pylorus; adhesions to liver.	
500	46	M.	Gastritis.	Atonic; delayed emptying (24 hours).	Growth of pylorus.	
512	47	F.	Pyloric obstruction.	Atonic; retained food; delayed emptying (24 hours).	Thickening about pylorus; gastro-jejuno-ostomy	
523	42	F.	Gastric ulcer; dilated stomach.	Atonic stomach; retained food; delayed emptying.	Thickening about pylorus; gastro-jejuno-ostomy	
531	42	M.	—	Atonic; retained food; delayed emptying (24 hours).	Stomach very large; cicatrix about pylorus.	
573	18	F.	? Gastric ulcer.	Hour-glass (cicatricial); hypersecretion to upper sac; delayed emptying of lower sac.	'As though string had been tied round stomach'; also pyloric ulcer.	Hypersecretion with pyloric ulcer.
580	43	F.	Pyloric obstruction; dilated stomach.	Atonic; retained food; delayed emptying.	Thickening of pylorus; malignant.	

No.	Age	Sex.	Clinical Diagnosis.	X-ray Findings.	Operative Findings.	Remarks.
582	29	M.	?	Delayed emptying (6 hours); stomach atonic.	Thickening of pylorus.	
583	54	M.	Abdom. tumour	Atonic; delayed emptying (24 hours); no irregularities.	Carcinoma of pylorus.	
584	42	F.	Pyloric obstruction.	Atonic; delayed emptying (24 hours).	Post-mortem; thickened pylorus.	
585	43	M.	Duodenal ulcer.	Retained food; some delay in emptying (8 hours).	Thickened pylorus; gastro-jejunosotomy.	
585a	44	F.	Pyloric obstruction.	Stomach normal; active peristalsis; hypersecretion; slight delay in emptying?	Adhesions and cicatrix about pylorus and duodenum	
586a	62	F.	—	Atonic; delay in emptying (24 hours).	Carcinoma of pylorus.	
590	21	F.	Dilat. stomach.	Atonic stomach; active peristalsis; excessive secretion.	Growth at pylorus; gastro-jejunosotomy.	
592	33	M.	Gastralgia.	Atonic stomach; delay in emptying; retained food.	Large ulcer at pylorus; stomach large; gastro-jejunosotomy.	
600	40	F.	Visceroptosis.	Atonic; delay in emptying.	Thickening of pylorus; carcinoma?	
687	60	M.	? Carcinoma of stomach.	Atonic; delay in emptying (24 hours); retained food.	Cicatrix of pylorus.	
682	27	M.	Pyloric tumour.	Tone good; delay in emptying; no peristalsis; obliteration of pylorus.	Carcinoma of pylorus.	
752	40	M.	? Duod. ulcer.	Atonic; retained food (24 hours).	Ulcer of pylorus; adhesions.	
753	25	M.	Gastric ulcer.	Atonic; retained food; displaced pyloric portion; active peristalsis.	Large ulcer pylorus.	
545	23	M.	Hodgkin's disease; pyloric obstruction.	Stomach normal; occasional excessive peristalsis; excessive secretion; gave off little CO <sub>2</sub> .	Carcinoma at pylorus; many secondary glands.	
664	28	M.	Gastric ulcer; pyloric obstruction.	Stomach normal; occasional excessive peristalsis; excessive secretion; gave off little CO <sub>2</sub> ; retained food.	Large growth of pyloric region and secondary glands.	
689	30	F.	Gastric ulcer.	Stomach atonic; retained food; delayed emptying (24 hours).	Pyloric obstruction marked; old ulcer.	Patient was examined 2 months before and very slight, if any, delayed emptying was noted.

No. Age. Sex.	Clinical Diagnosis.	X-ray Findings.	Operative Findings.	Remarks.
698 45 M.	? Carcinoma of pylorus.	Retained food; tone perfect; peristalsis absent.	Carcinoma of pylorus.	
713 32 M.	Gastric ulcer.	Delayed emptying; spasm middle.	Ulcers about pylorus and cicatrices.	
753b48 F.	Carcinoma of stomach?	Retained food; stomach atonic; delayed emptying (24 hours).	Carcinoma of pylorus fungating into stomach.	
756 35 F.	Old gastro-jejunostomy.	Stoma not working; some delay emptying; looks like pyloric obstruction	No gastro-jejunostomy had ever been performed; cicatrix of pylorus; gastro-jejunostomy.	
764 47 F.	Pyloric obstruction.	Retained food; slight delay emptying (10 hours).	Pyloric obstruction; gastro-jejunostomy.	

## CLASS VII. (See p. 50).

## ADHESIONS.

No. Age. Sex.	Clinical Diagnosis.	X-ray Findings.	Operative Findings.	Remarks.
151 38 F.	Neurasthenia.	Stomach atonic; held down to colon by adhesions; transverse colon fixed in pelvis.	Old appendix; adhesions of colon.	Not cured 18 mos. later much better.
251 10 M.	T.B. peritonitis	Bilocular stomach; food retained in many pockets of small intestines.	Tuberculosis; peritonitis; multiple adhesions.	Relieved.
408 61 F.	Gastric ulcer.	Bands divided stomach, and as in Case 251.	Multiple adhesions; old ulcer below cardiac orifice.	
472 60 M.	Old perforated duodenal ulcer.	Adhesions to liver, etc.	Adhesions anterior wall and liver.	
479 42 F.	Old strangulated hernia; ? adhesions.	Stomach bound down in pelvis.	Adhesions small intestine, stomach and colon.	
591 28 M.	Dyspepsia.	Nil, except stomach displaced to right.	Appendix adhesions on right side; stomach normal.	Long appendix fixed up towards right hypochondrial region.
699 56 M.	? Carcinoma of stomach or œsophagus.	Stomach cavity represented by 3 sacs, very small, bound to liver; back pressure œsophageal dilatation.	Mass of adhesions stomach to liver; anterior gastro-jejunostomy.	




## CLASS VIII. (See p. 50.)

## POST OPERATIVE.

No. Age. Sex.	Clinical Diagnosis.	X-ray Findings.	Operative Findings.	Remarks.
10 35 F.	Old gastro-jejunostomy (see Class VI.).	No increase in tone; food still delayed in stomach longer than 24 hours.	—	
19 55 F.	Pyloroplasty.	Hour-glass condition: no obstruction, stoma working perfectly.	—	Patient unrelieved.
26 19 F.	Perforated gastric ulcer.	Food through stoma quite freely.	—	
35 32 F.	Old gastro-jejunostomy (see Class IV.).	Stoma working perfectly.	—	
41 32 F.	(See Class VI.)	Hour-glass marked, but stoma works perfectly when food reaches it.	Nil found to account for hour-glass.	Patient persisted in vomiting from upper sac.
44 25 F.	Gastro-jejunostomy.	Obstruction in duodenum.	Adhesions.	
206 23 F.	Old gastro-jejunostomy.	Stoma working perfectly.	—	Patient spoken to severely and completely cured.
207 30 F.	Old gastro-jejunostomy 1908.	Gastro-jejunostomy working perfectly; marked spasm middle of stomach forming hour-glass.	Marked cicatrix above stoma; gastro-gastrostomy.	Unrelieved.
209 31 F.	Old gastro-jejunostomy for hour-glass.	Stoma from upper sac working perfectly, but food retained in lower sac 24 hours after.	Well-marked pyloric obstruction; lower sac excised.	Patient cured.
257 49 F.	Old gastro-jejunostomy.	Adhesions forming hour-glass; stoma working perfectly.	Adhesions broken down.	Cured.
263 41 F.	5 weeks after gastro-jejunostomy.	Stoma working perfectly.	—	
266 43 M.	Old gastro-jejunostomy.	Hour-glass stomach; well-marked; stoma working perfectly.	Hour-glass, with active ulcer.	Cured by gastroplasty, a small ulcer of body had been noted at time of first operation.
357 52 F.	Old gastro-jejunostomy to upper sac of hour-glass.	Delayed emptying of lower sac; stoma from upper sac works well.	Thickening of pylorus; lower sac excised.	Cured.

No.	Age.	Sex.	Clinical Diagnosis.	X-ray Findings.	Operative Findings.	Remarks.
363	41	F.	Old gastro- jejunostomy.	Spasmodic hour-glass; stoma working perfectly.	Nil found to account for hour-glass.	Unrelieved.
398	38	F.	—	Hour-glass; marked vomiting from upper sac.	Nothing to account for the hour-glass; appendix re- moved.	Cured five weeks after operation.
416	47	M.	Old gastro- jejunostomy.	Adhesions about jejunum and stomach.	Many adhesions.	
419	22	F.	Old gastro-je- junostomy 2 months after operation.	Stoma working perfectly, but placed far from pylorus.	Growth of pylorus; adherent to gall-bladder; growth excised.	The pain ap- peared to be due to the con- tractions of the stomach on the food in the pyloric portion; re- lieved by operation. Cured.
470	36	F.	3 weeks after gastro- jejunostomy.	Jejunum kinked behind stomach.	Jejunum stitched up.	
471	30	F.	Gastro- jejunostomy.	Stoma not patent.	Adhesions.	
483	30	M.	Old gastro- jejunostomy.	Kink 6 inches from stoma.	Adhesions with kinking of jejunum.	
524	46	F.	Gastro-jejunos- tomy 5 years ago.	Stomach atonic; excessive peristalsis; stoma not work- ing; obstruction at duodeno- jejunal flexure.	Cicatrization about stoma jejunum, and adhesions.	
539	35	M.	Old gastro- jejunostomy 1 year after operation.	Food passing freely both ways; excessive peristalsis; stoma 5 inches from py- lorus.	—	
563	36	F.	Old gastro- jejunostomy 2 years ago.	Stoma working perfectly.	—	
580	47	M.	Old gastro- jejunostomy 10 months.	Adhesions blocking jejunum.	Many adhesions dissected out.	Patient died.
594	45	M.	Old gastro- jejunostomy; duodenal obstruction.	Stoma working perfectly; hypersecretion.	Adhesions anterior wall.	Cured.
599	50	F.	Gastro-jejunos- tomy 2 years.	Both stoma and pylorus patent.	—	
689	30	F.	Gastro-jejunos- tomy 6 weeks after operation	Stoma not working; looks like pyloric obstruction.	No gastro-jejunostomy had been performed; cicatrix of pylorus.	Cured.
56	35	F.	Old gastro- jejunostomy.	Stoma not working; slight delay emptying.	No gastro-jejunostomy had been performed; cicatrix of pylorus; gastro-jejunos- tomy.	
57	34	M.	Old gastro- jejunostomy.	Stoma working well; slight obstruction in jejunum.	—	



## Bibliography

1870

## BIBLIOGRAPHY.

The following bibliography is taken direct from Prof. Dr. Hermann Gocht's recently published volume, "Die Röntgen-Literatur," by kind permission of the author. A few additions have been made.

### THE ŒSOPHAGUS.

- ABRAMS (San Francisco), Eructations and Skiagraphy. Glasgow fever and Small-Pox hosp., 31. V. 1898. Ref.: Lancet 1899, Vol. II, p. 785.
- ALBERS-SCHÖNBERG (Hamburg), Über die Anwendung des Wehnelt'schen elektrolytischen Unterbrechers im Röntgeninstrumentarium. Sternum- und Osophagusdarstellung. Fortschr. a. d. Geb. d. Röntgenstr. 1901, Bd. V, Heft 1, S. 1.
- Osophagusdarstellung. Aus: Albers-Schönberg, Röntgentechnik, 3. Aufl., 1910, Kap. 26.
- ARCCLÈRE, Radiographie de l'oesophage. Lyon méd. 1908, p. 770. Ref.: Journ. de radiologie (Belge) 1908, Bd. II, Nr. 12, S. 522.
- V. BERGMANN (Berlin), Über einen Fall von Blindsack der Speiseröhre. Freie Vereinigung d. Chirurgen Berlins, 9. VII. 1906. Ref.: Fortschr. a. d. Geb. d. Röntgenstrahlen, Bd. XI, Heft 1, S. 66.
- BERTOLOTTI, Un nuovo metodo di radioscopia esofagea. R. Acad. de Torino 1905, Nr. 11 und 12. Ref.: Fortschr. a. d. Geb. d. Röntgenstr., Bd. X, Heft 2, S. 122.
- BERTOLOTTI und BOIDI (Trotti), Fall von enormer Osophagusdilatation. Arch. d'électr. méd. 1907, Nr. 220. Ref.: Fortschr. a. d. Geb. d. Röntgenstr., Bd. XII, Heft 1, S. 71.
- La radiodiagnostic dans un cas de dilatation paralytique de l'oesophage. Ztschr. f. ärztl. Fortbildung. Ref.: Fortschr. a. d. Geb. d. Röntgenstr., Bd. XII, Heft 4, S. 291.
- CAHN, A. (Strassburg), Über die diagnostische Verwertung der Röntgenstrahlen und den Gebrauch der Quecksilbersonde bei Speiseröhrenerkrankungen. Naturwissenschaftl. med. Verein Strassburg, 9. VI. 1905. Ref.: Münchener med. Wochenschrift 1906, Nr. 2, S. 101.
- DAWSON, BERTRAND, Roentgen rays as an aid to the diagnosis of stricture of the oesophagus. (Schlundstriktur). Lancet 1907, Vol. II, p. 1144. Ref.: Ztschr. f. Elektrologie u. Röntgenkunde, Bd. X, Heft 8, S. 319.
- DOYEN (Paris), Application de la radiographie pour déterminer le siège et la forme d'une dilatation oesophagienne. Académie de méd., 12. X. 1897.
- EHRlich (Stettin), Münze in der Speiseröhre lokalisiert. Wissenschaftl. Verein d. Ärzte zu Stettin, 6. XII. 1898. Ref.: Berliner klin. Wochenschr. 1899, Nr. 3, S. 66.

- EIJKMAN (Scheveningen), Der Schlingakt, dargestellt nach Bewegungsphotographien mittels Röntgenstrahlen. Arch. f. d. gesamte Physiol., Bd. XCIX. Ref.: Fortschr. a. d. Geb. d. Röntgenstr., Bd. VII, Heft 3, S. 160.
- EINHORN, M., Stretching of the cardio- in the treatment of cardio-spasm. Am. Journal of Med. Sciences, Oct. 1910.
- Additional remarks on cardio-spasm. Med. Record, March 1, 1913.
- V. EISELSBERG (Wien), Über zwei Fälle von Fremdkörpern im Osophagus, in welchem jedesmal die Diagnose mit Hilfe des Röntgenschirmes leicht gelang, worauf die Fremdkörper durch Osophagotomie mit Erfolg entfernt wurden. Verein für wissenschaftl. Heilkunde, Königsberg, 22. XI. 1897. Ref.: V.-B. d. Deutschen med. Wochenschr. 1898, Nr. 24, S. 174.
- Demonstration eines dreissigjährigen Mannes mit Osophagusdivertikel. K. k. Gesellschaft d. Ärzte in Wien, 8. III. 1907. Ref. Fortschr. a. d. Geb. d. Röntgenstr., Bd. XI, Heft 2, S. 129.
- EWALD (Berlin), Röntgenbilder von tiefsitzenden Osophagusdivertikeln und Dilatationen. Berliner med. Gesellsch., 14. III. 1906. Ref.: Fortschr. a. d. Geb. d. Röntgenstr., Bd. X, Heft 1, S. 62.
- EWALD (Heidelberg), Über ein Röntgenogramm von einer Stenose des Osophagus. Berliner med. Gesellsch., 1908. Ref.: Fortschr. a. d. Geb. d. Röntgenstr., Bd. XII, Heft 5, S. 352.
- FIRMANDEAU, A., Radioskopische Diagnostik der Osophagusstenosen. Arch. d'électr. méd. 1911, Nr. 312. Ref.: Fortschr. a. d. Geb. d. Röntgenstr., Bd. XVII, Heft 5, S. 340 und Journ. de radiologie (Belge) 1911, vol. V, fasc. 4, p. 393.
- FLESCH und PÉTERI (Budapest), Bedeutung der Radiologie bei der Untersuchung von narbigen Osophagusstrikturen bei Kindern. Jahrb. d. Kinderheilkunde, Bd. XXIII, Heft 6. Ref.: Deutsche med. Wochenschr. 1911, Nr. 33, S. 1535.
- GARD et ORCELIN, Radiographies d'oesophage. Société des sciences méd. Lyon, 17. VI. 1908. Ref.: La presse méd., 1. VII. 1908, Nr. 53 und Ztschr. f. Elektrologie u. Röntgenkunde 1909, Bd. XI, Heft 7, S. 241.
- GLAS, Zur ösophagoskopischen Diagnose der idiopathischen Speiseröhrenerweiterung. Wiener klin. Wochenschr. 1907, Nr. 14. Ref.: Fortschr. a. d. Geb. d. Röntgenstr., Bd. XI, Heft 3, S. 222.
- GLÜCKSMANN (Berlin), Demonstration von Lichtbildern aus dem Gebiete der Speiseröhrenerkrankungen. Berliner med. Gesellsch., 20. Dez. 1905. Ref.: Fortschr. a. d. Geb. d. Röntgenstr., Bd. IX, Heft 6, S. 401.
- GOCHT, H. (Halle), Erkrankungen des Schlundes. Aus: „Handbuch der Röntgenlehre“, 3. Aufl. 1911, S. 373.
- GUISEZ, Valeur de l'oesophagoscopie au point de vue diagnostique et thérapeutique. La presse méd., Nr. 13, 12. II. 1908. Ref.: Ztschr. f. Elektrologie u. Röntgenkunde, Bd. X, Heft 8, S. 318.

- HILDEBRANDE (Marburg), Wertvolle Aufschlüsse bei Speiseröhrenverengung mittels Röntgenstrahlen. Arch. f. physik. Medizin u. med. Technik, Bd. II, Heft 1 und 2. Ref.: Berliner klin. Wochenschr. 1907, Nr. 48, S. 1558.
- HOLLAND, CHARLES THURSTAN (Liverpool), Stricture of the oesophagus and bismuth. Arch. of the Roentgen Ray, Nov. 1904, Vol. IX, p. 134.
- HOLZKNECHT (Wien), Zur Diagnose der Oesophagusstenose. Deutsche med. Wochenschr. 1900, Nr. 36.
- Besprechung einer Modifikation der röntgenoskopischen Untersuchung des Oesophagus. Gesellsch. f. innere Medizin u. Kinderheilkunde, Wien, 11. I. 1906. Ref.: Fortschr. a. d. Geb. d. Röntgenstr., Bd. X, Heft 4, S. 253.
- Modifikation der bisherigen Röntgenuntersuchung des Oesophagus. Gesellsch. f. innere Medizin u. Kinderheilkunde, Wien, 7. VI. 1906. Wiener med. Wochenschrift 1906, Nr. 28, S. 1420. Fortschr. a. d. Geb. d. Röntgenstr., Bd. X, Heft 4, S. 251.
- Röntgenaufnahmen der Speiseröhre mit Hilfe von Wismutbrei. Gesellsch. f. innere Medizin u. Kinderheilkunde, Wien, 7. VI. 1906. Ref.: Fortschr. a. d. Geb. d. Röntgenstr., Bd. XI, Heft 1, S. 66.
- HOLZKNECHT, G., und ALBERT, D., Die Atonie der Speiseröhre (Dysphagia atonica: Pseudo-ösophagismus). Ztschr. f. klin. Medizin 1910, Bd. LXXI, Heft 1 und 2. Ref.: Ztschr. f. Röntgenkunde u. Radiumforschung 1911, Bd. XIII, Heft 4, S. 151.
- JORDAN, ALFRED, London, The Roentgen Ray examination of the oesophages. Arch. of the Roentgen Ray 1911, Nr. 127, p. 348.
- Oesophageal peristalsis. Arch. of the Roentgen Ray 1911, Nr. 131, p. 26.
- KAUFMANN und KIENBÖCH, Über Erkrankungen der Speiseröhre. Wiener klin. Wochenschrift 1909, Nr. 35—38. Ref.: Fortschr. a. d. Geb. d. Röntgenstr., Bd. XV, Heft 6, S. 383.
- KAYSER, Röntgendiagnose der Oesophaguserkrankungen. Ärztlicher Verein in Hamburg, 23. XI. 1909. Ref.: Deutsche med. Wochenschr. 1910, Nr. 6, S. 290.
- KEEN (Philadelphia), A case of dilated oesophagus. Philadelphia Med. Journal 1900, Nr. 1.
- KIENBÖCK (Wien), Radiogrammskizzen zu Fällen von Oesophaguserkrankung. K. k. Gesellsch. d. Ärzte, Wien, 31. I. 1908. Ref.: Fortschr. a. d. Geb. d. Röntgenstr., Bd. XII, Heft 3, S. 209.
- Über das Zenkersche Divertikel der Speiseröhre. Arch. f. physik. Medizin u. med. Technik, Bd. VI, Heft 1. Ref.: Fortschr. a. d. Geb. d. Röntgenstr., Bd. XVII, Heft 6, S. 411.
- KÖHLER, ALBAN (Wiesbaden), Speiseröhre. Aus: Köhler, Lexikon der Grenzen des Normalen, 1910, S. 155.
- KOVÁCS, F., und STOERK, O. (Wien), Über das Verhalten des Oesophagus bei Herzvergrößerung. Wiener klin. Wochenschr. 1910, Nr. 42. Ref.: Fortschr. a. d. Geb. d. Röntgenstr., Bd. XVII, Heft 2, S. 114.



- KRAUSE, PAUL, Über einen interessanten Röntgenbefund bei Oesophaguskarzinom, welcher einen Oesophagusdivertikel vortäuschte. Ztschr. f. Elektrologie u. Röntgenkunde, Bd. XI, Heft 10. Ref.: Fortschr. a. d. Geb. d. Röntgenstr., Bd. XV, Heft 2, S. 122.
- Differentialdiagnose des Oesophagusdivertikels im Röntgenbilde. Niederrheinische Gesellsch. f. Natur- u. Heilkunde in Bonn. 21. II. 1910. Ref.: Deutsche med. Wochenschr. 1910, Nr. 32, S. 1511.
- LANGE (Sidney, Cincinnati), The Roentgen examination of the oesophagus. Arch. of the Roentgen Ray 1908, Vol. XIII, Nr. 103, p. 231, and The Lancet Clinic, 7. XI. 1908. Ref.: Arch. of the Roentgen Ray 1909, Vol. XIII, Nr. 106, p. 353.
- The early recognition of oesophageal stricture. Med. Record, 3. I. 1909. Ref.: Fortschr. a. d. Geb. d. Röntgenstr., Bd. XIV, Heft 6, S. 452.
- LEVY-DORN (Berlin), Demonstrationen: Diverticulum et tumor oesophagi etc. Zentralblatt f. Chirurgie, Nr. 42, 1908. Freie Vereinigung d. Chirurgen Berlins, 13. VII. 1908. Ref.: Vereinsbeil. d. Deutschen med. Wochenschr. 1908, Nr. 47, S. 2051.
- LINDEMANN (Hamburg), Demonstration eines Falles von Oesophagusspasmus durch Röntgenstrahlen. Ärztlicher Verein in Hamburg, 29. XI. 1898. Ref.: V.-B. d. Deutschen med. Wochenschr. 1899, Nr. 12, S. 70.
- MEISENBURG, Ein Fall von Divertikel des Oesophagus. Deutsche med. Wochenschr. 1907, Nr. 8, S. 301.
- OLBERT (Marienbad) und HOLZKNECHT (Wien), Oesophagusatonie (Pseudoösophagismus). Verhandl. d. Deutschen Röntgenges. 1910, Bd. VI, S. 72.
- OPPLER, Oesophagusabknickung. Med. Sektion d. Schlesischen Gesellsch. f. vaterl. Kultur, Breslau, 19. V. 1905. Ref.: Fortschr. a. d. Geb. d. Röntgenstr., Bd. IX, Heft 2, S. 143.
- PERUSSIA (Mailand), Beitrag zur radiologischen Semiotik der ösophagealen Neubildungen. Fortschr. a. d. Geb. d. Röntgenstr., Bd. XVII, Heft 3, S. 149.
- PFAHLER (Philadelphia), The diagnosis of carcinoma of the oesophagus by means of the Roentgen rays. Arch. of diagnosis, New York, Jan. 1909.
- PIRIE (Dundee), The diagnosis of the oesophageal stricture. Arch. of the Roentgen Ray 1908, Vol. XIII, Nr. 96, p. 41.
- POELCHEN (Zeitz), Vorführung eines Röntgenbildes eines von ihm operierten Oesophagusdivertikels. 29. Kongress d. Deutschen Gesellsch. f. Chirurgie, 18.—21. IV. 1900. Ref.: Wiener klin. Wochenschr. 1900, Nr. 12, S. 444.
- PRZEWALSKI (Charkow), Über ein Oesophaguskarzinomsymptom. Fortschr. a. d. Geb. d. Röntgenstr., Bd. XIV, Heft 3, S. 178.
- REITZENSTEIN (Nürnberg), Zur Kenntnis und Diagnose der tiefen Oesophagusdivertikel. Münchener med. Wochenschr. 1898, Nr. 12.
- RÖSLER, ALFRED (Leipzig), Zur Diagnostik der hochsitzenden Pulsionsdivertikel mittels des Röntgenverfahrens. Fortschr. a. d. Geb. d. Röntgenstr., Bd. XVI, Heft 3, S. 218.

- ROSENHEIM, Über idiopathische Speiseröhrenerweiterung. Berliner med. Gesellsch., 26. II. 1902. Ref.: V.B. d. Deutschen med. Wochenschr. 1902, Nr. 11, S. 83.
- RUMPEL (Hamburg), Die klinische Diagnose der spindelförmigen Speiseröhrenerweiterung. Münchener med. Wochenschr. 1897, Nr. 16, S. 420.
- SCHMILINSKY (Hamburg), Über die Anwendung der Röntgenstrahlen bei Oesophagusstrikturen. Arztlicher Verein in Hamburg, 8. I. 1901. Ref.: V.-B. d. Deutschen med. Wochenschr. 1901, Nr. 8, S. 62.
- SJÖGREN (Stockholm), Zur Röntgendiagnostik der Speiseröhrenerweiterung. Fortschritte a. d. Geb. d. Röntgenstr., Bd. X, Heft 5, S. 270.
- Beitrag zur Kenntnis von Divertikeln in der Speiseröhre. Fortsch. a. d. Geb. d. Röntgenstr., Bd. XIV, Heft 2, S. 117.
- TILMANN (Köln), Über Oesophagusdivertikel. Allgemeiner Arztlicher Verein in Köln, 9. III. 1908.
- WALSHAM (London), The diagnosis of carcinoma of oesophagus by X-rays. Arch. of the Roentgen Rays 1899 and 1902.
- Two cases of carcinoma of the Oesophagus. Arch. of the Roentgen Ray 1903, Vol. VII, Nr. 7, p. 114.
- WHITE, A foreign body in the oesophagus detected and located by the Roentgen rays. Univer. Med. Mag. VIII, 9, 1896.
- WILLIAMS, H., X-ray examination of Stricture of the Esophagus. Boston Medical and Surgical Journal, 5. V. 1910, Ref.: Arch. of the Roentgen Ray 1910, Bd. XV, Nr. 123, S. 202.

## THE STOMACH.

- ADLER, Diagnose des Ulcus ventriculi et duodeni mittels Röntgenstrahlen. Journ. of Amer. Assoc., 12. XI. 1910, Vol. LV, Nr. 20. Ref. Deutsche med. Wochenschr. 1910, Nr. 49, S. 2308.
- ASHBURG, HAVARD, E. (Baltimore), Röntgenbefunde bei Ulcus ventriculi und duodeni. Amer. Roentgen Ray Society 1910. Ref.: Fortsch. a. d. Geb. d. Röntgenstr., Bd. XVII, Heft 6, S. 392.
- AUBOURG, PAUL, Gastro-Entero-Anastomose, in radiographischer Darstellung. Bull. et mém. de la société de radiologie méd. de Paris, Juli 1910. Ref.: Fortsch. a. d. Geb. d. Röntgenstr., Bd. XVI, Heft 4, S. 303.
- Radiographies de quelques estomacs pathologiques. Bull. et mém. de la société de radiologie méd. de Paris, janvier 1911. Ref.: Journ. de radiologie (Belge) 1911, vol. V, fasc. 4, p. 372.
- Zur Radiographie des Magens. Bull. et mém. de la société de radiologie de Paris, Nr. 21. Ref.: Fortsch. a. d. Geb. d. Röntgenstr., Bd. XVII, Heft 1, S. 50.
- Fonctionnement d'une gastro-anastomose dix années après l'intervention. Radiographie montrant le mode d'évacuation de la bouche. Radiographie d'intestin grêle. Bull. et mém. de la société de radiologie de Paris, 18. X. 1910. Ref.: Journ. de radiologie (Belge) 1911, vol. V, S. 151.

AUBOURG, PAUL (*continued*).

- Radiographie rapide et radioscopie de l'estomac. La presse méd., Nr. 7, 25. I. 1911.
- Über Sanduhrmagen. Bull. et mém. de la société de radiologie de Paris 1911, Nr. 23. Ref. : Fortschr. a. d. Geb. d. Röntgenstr., Bd. XVII, Heft 3, S. 182.
- Diagnostic chirurgical d'une biloculation de l'estomac reconnue par l'examen aux rayons X. Bull. et mém. de la société de radiologie méd. de Paris, mars 1911. Ref. : Journ. de radiologie (Belge) 1911, vol. V, fasc. 4, p. 376.

AUBOURG et LEBON, Electrification directe de l'estomac par une sonde sous le contrôle des rayons X. Pariser Académie de méd., 11. IV. 1911. Ref. : La presse méd., Nr. 29, 12. IV. 1911 und Ztschr. f. Röntgenkunde u. Radiumforschung 1911, Bd. XIII, Heft 10, S. 412.

BACHER (Olmütz), Zur Radiologie der benignen Magenerkrankungen. Prager med. Wochenschr. 1909, Nr. 12. Ref. : Zentralbl. f. innere Medizin 1909, Nr. 49, S. 1201.

BADE, PETER (Hannover), Eine neue Methode der Röntgenphotographie des Magens. Deutsche med. Wochenschr. 1899, Nr. 38, S. 627, und Münchener med. Wochenschrift 1899, Nr. 41, S. 1351.

BAISCH, B., Radiologische Untersuchungen des gesunden und kranken Magens. Med. Klinik 1908, S. 613. Ref. : Zentralbl. f. Chirurgie 1908, Nr. 20, S. 783, und Naturhist.-med. Verein in Heidelberg, 4. I. 1908. Ref. : Fortschr. a. d. Geb. d. Röntgenstr., Bd. VIII, Heft 1, S. 48.

BARCLAY (Manchester), Normale und pathologische Magenformen und Lagen. British Med. Assoc. Electr. Section. Ref. : Fortschr. a. d. Geb. d. Röntgenstr., Bd. XIII, Heft. 3, S. 170.

— Skiagramme des normalen und kranken Magens. 8. Jahresversamml. der British Med. Assoc. 1910 (London). Ref. : Münchener med. Wochenschr. 1910, Nr. 39, S. 2063.

— Gastric radioscopy. Arch. of the Roentgen Ray 1910, Nr. 123, S. 167. Ref. : Fortschr. a. d. Geb. d. Röntgenstr., Bd. XVI, Heft 5, S. 400.

— Gestalt des Magens im Röntgenbilde. Brit. Med. Journ., 27. Aug. Ref. : Deutsche med. Wochenschr. 1910, Nr. 37, S. 1722.

— The diagnosis of gastric and oesophageal affections by X-ray methods. Med. Chronicle, Jan. and Feb. 1913.

BARJON, F. (Lyon), Radiographie de l'estomac. Société méd. des hôpitaux, Lyon, 26. XI. 1907. Ref. : La presse méd., Nr. 98, 4. XII. 1907. Ztschr. f. Elektrologie u. Röntgenkunde, Bd. X, Heft 8, S. 318.

— Examen radiologique de l'estomac. Journ. de radiologie (Belge) 1908, vol. II, Nr. 7, p. 78.

BARRET und LEVEN, Sanduhrmagen. Bull. et mém. de la société de radiologie de Paris, Nr. 22. Ref. : Fortschr. a. d. Geb. d. Röntgenstr., Bd. XVII, Heft 2, S. 112.

- BARRET und LEVEN (*continued*).
- Der Magen im Stehen und im Liegen. Bull. et mém. de la société de radiologie de Paris 1911, Nr. 25. Ref.: Fortschr. a. d. Geb. d. Röntgenstr., Bd. XVII, Heft 5, S. 343.
  - Biloculation gastrique par distention gazeux de l'estomac et du côlon; déformation considérable indépendante de toute lésion organique. Bull. et mém. de la société de radiologie méd. de Paris, février 1911. Ref.: Journ. de radiologie (Belge) 1911, vol. V, fasc. 4, p. 377.
- BAUDEL, Die Röntgenuntersuchung des Magens. Arztl. Verein Nürnberg, 17. I. 1907. Ref.: Fortschr. a. d. Geb. d. Röntgenstr., Bd. XI, Heft 4, S. 291.
- BECHER, WOLF (Berlin), Bestimmung der unteren Magengrenze vermittlems Röntgendurchleuchtung. Deutsche med. Wochenschr. 1901, Nr. 2, S. 22.
- Röntgenologische Diagnostik der Magenerkrankungen, an einigen Fällen erläutert. (Diskussionsbemerkung.) Verhandl. d. Deutschen Röntgenges. 1905, Bd. I, S. 68.
- BÉCLÈRE (Paris), Demonstration eines typischen Falles von Pyloruskarzinom. Bull. de la société de radiologie, Paris, vol. I, Nr. 5. Ref.: Fortschr. a. d. Geb. d. Röntgenstrahlen, Bd. XIV, Heft 3, S. 224.
- BLOCH, WILLY (Berlin), Belastungsproben des Magens. Berliner klin. Wochenschr. 1910, Nr. 17, S. 716.
- DE BOM (Anvers), Ein Fall von Sanduhrmagen. Journ. de radiologie (Belge) 1910, vol. IV, fasc. 21, p. 232. Ref.: Fortschr. a. d. Geb. d. Röntgenstr., Bd. XVI, Heft 1, S. 72.
- BORN, H. H. (St. Louis), Un cas d'estomac biloculaire. (Magen.) Journ. de radiologie 1910, vol. IV, fasc. 21, p. 232.
- BOSQUIER et DESPLATS, Essai séméiologique de radioscopie de l'estomac. Application aux dilatations, ptoses et atonies gastrique. (Magen.) Journ. des praticiens, 1. V. 1909. Ref.: Journ. de radiologie 1909, vol. III, Nr. 6, p. 559.
- BRAUNER (Wien), Röntgenologische Diagnostik der Magenerkrankungen einigen Fällen erläutert. Verhandl. d. Deutschen Röntgenges. 1905, Bd. I, S. 66.
- Über eine Röntgenmethode zur Magenuntersuchung. Berliner klin. Wochenschr. 1905, Nr. 29, S. 930.
  - Ein kasuistischer Beitrag zur radiologischen Frühdiagnose des Magenkarzinoms. Arch. f. physik. Medizin u. med. Technik 1906, Bd. I, S. 11.
- BRÄUNING, Die Untersuchung des Magens mit Röntgenstrahlen. Wissenschaftl. Verein d. Ärzte in Stettin, S. XII. 1908. Ref.: Fortschr. a. d. Geb. d. Röntgenstr., Bd. XIV, Heft 2, S. 142.
- Untersuchungen über die Beziehungen zwischen dem Tonus, der Salzsäureproduktion und der Lage des tiefsten Punktes des Magens. Münchener med. Wochenschr. 1910, Nr. 14. Ref.: Fortschr. a. d. Geb. d. Röntgenstr., Bd. XV, Heft 4, S. 227.

- BULLRICH und ROJAS, Exploracion radiologica del estomago. Revista de la soc. méd. Argentina, Vol. XVI, Nr. 93. Ref. : Zentralbl. f. Chirurgie 1910, Nr. 19, S. 692.
- CANNON, Magenbewegung. Amer. Journ. of Physiology 1898, I, 3, p. 359.
- Röntgenographie der Passage verschiedener Nahrungsmittel durch den Magen. Journ. of Amer. Assoc. 1905, Nr. 1. Ref. L.-B. d. Deutschen med. Wochenschr. 1905, Nr. 6, S. 237.
- CHILAUDITI, DEMETRIUS, Über langsame Entleerung mancher Magen. Bull. et mém. de la société de radiologie de Paris, Novbr. 1910. Ref. : Fortschr. a. d. Geb. d. Röntgenstr., Bd. 16, Heft 5, S. 406.
- COHN, M. (Berlin), Sanduhrmagen. Freie Vereinigung der Chirurgen Berlins, 9. V. 1910. Ref. : Fortschr. a. d. Geb. d. Röntgenstr., Bd. XVII, Heft 2, S. 108.
- Zur Untersuchung des Magens mit Wismutkapseln. Berliner klin. Wochenschr. 1910, Nr. 39, S. 1780.
- COLE, LEWIS, GREGORY, The complex motor phenomena of various types of unobstructed gastric peristalsis. Arch. of the Roentgen Ray 1911, Nr. 137, p. 242.
- CORDUA (Hamburg), Ulcus ventriculi callosum. Arztlicher Verein Hamburg, 11. IV. 1911.
- CRANE (Kalamazzo, Mich.), X-ray evidence in gastric ulcer. Transactions of the Amer. Roentgen Ray Society. Ninth Annual Meeting, New York, 28.—30. XII. 1908. Ref. : Fortschr. a. d. Geb. d. Röntgenstr., Bd. XIV, Heft 6, S. 446.
- DALTON and REID, The diagnosis of gastric dilatation and gastroptosis by the X-rays. (Magenerweiterung.) Clinical Society of London, 24. III. 1905. Ref. : Lancet 1905, Vol. I, p. 861.
- DESTERNES, Un cas de dilatation d'estomac avec spasme médiogastrique et ptose du duodénum. Bull. et mém. de la société de radiologie méd. de Paris, janvier 1911. Ref. : Journ. de radiologie (Belge) 1911, vol. V, fasc. 4, p. 375.
- DIETLEN, H. (Strassburg i. E.), Beobachtungen über Magenperistaltik. Verhandl. d. Deutschen Röntgenes. 1911, Bd. VII, S. 66.
- Radiologische Studien über die Magenfüllung. (Diskussionsbemerkung.) Verhandl. d. Deutschen Röntgenes. 1911, Bd. VII, S. 80.
- DREYER (Breslau), Zur Frage der Differentialdiagnose zwischen Magengeschwür und Magenkarzinom. (Diskussionsbemerkung.) Verhandl. d. Deutschen Röntgenes. 1911, Bd. VII, S. 78.
- EINHORN, Roentgenographie of the stomach. New York Med. Record, 13. X. 1906. Ref. : Arch. of the Roentgen Ray 1907, Vol. XI, Nr. 9, p. 265, and Nr. 12, p. 351.
- EINHORN und COLE, Über Röntgenphotographie des Magens. Wiener klin. Rundschau 1907, Nr. 30. Ref. : Ztschr. f. Elektrologie u. Röntgentechnik, Bd. X, Heft 8, S. 319.

- V. EISELSBERG (Wien), Das Röntgenbild eines verschluckten Talers in der Magengegend. Verein f. wissenschaftl. Heilkunde, Königsberg, II. XII. 1899. Ref.: Fortschr. a. d. Geb. d. Röntgenstr. 1900, Bd. III, Heft 5, S. 196.
- EISLER, F., und KAUFMANN, R (Wien), Radiologische Studien über die Magenfüllung. Verhandl. d. Deutschen Röntgenes. 1911, Bd. VII, S. 69 und 82.
- ELISCHER (Budapest), Röntgenuntersuchung des Magens. Orvosi Hetilap, Nr. 42. Ref.: Deutsche med. Wochenschr. 1911, Nr. 47, S. 2196.
- ENRIQUEZ, Ptose et dilatation atonique de l'estomac. (Magen.) La presse méd., II. I. 1908, Nr. 4. Ref.: Ztschr. f. Elektrologie u. Röntgenkunde, Bd. X, Heft 8, S. 318.
- Radiographie rapide et hyperkinésie gastrique. Pariser Société méd. des hôpitaux, 23. XII. 1910. Ref.: La presse méd., Nr. 104, 28. XII. 1910 und Ztschr., f. Röntgenkunde u. Radiumforschung 1911, Bd. XIII, Heft 6, S. 232.
- FABER, P. H., Röntgenuntersuchung und normale Lage des Magens. Hospitalstid., Nr. 41. Ref.: Deutsche med. Wochenschr. 1911, Nr. 47, S. 2196.
- FAULHABER (Würzburg), Röntgenuntersuchung des Magens. Arch. f. physik. Medizin u. med. Technik, Bd. III, Heft 3, 4 und 5 und Bd. IV, Heft 1 und 2. Ref.: Journ. de radiologie (Belge) 1909, vol. III, Nr. 2, p. 141.
- Zur Röntgendiagnostik des tiefgründigen (kallösen) Ulcus ventriculi. Münchener med. Wochenschr. 1910, Nr. 40, S. 2073.
- Über den jetzigen Stand der Diagnose des Ulcus ventriculi. Würzburger Arzteabend, 12. VII. 1911. Ref.: Münchener med. Wochenschr. 1911, Nr. 46, S. 2476.
- Die Bedeutung der Röntgenuntersuchung für die Diagnose des Magenkarzinoms. Deutsches Arch. f. klin. Medizin, Bd. CI, Heft 1 und 2. Ref.: Ztschr. f. Röntgenkunde u. Radiumforschung 1911, Bd. XIII, Heft 3, S. 129.
- FINKH, EBERHARD, Die röntgenologische Diagnostik chirurgischer Magenerkrankungen. Med.-naturwissenschaftl. Verein, Tübingen, 15. XI. 1909. Ref.: Fortschr. a. d. Geb. d. Röntgenstr., Bd. XV, Heft 4, S. 222.
- FLESCH und PÉTERI (Budapest), Ergebnisse und Magenuntersuchungen mittels Röntgenstrahlen im Säuglings- und späteren Kindesalter. Ztschr. f. Kinderheilkunde, Bd. II, S. 263, 1911. Ref.: Berliner klin. Wochenschr. 1911, Nr. 34, S. 1572.
- FORSSELL, GÖRTA (Stockholm), Quelle est la forme réelle de l'estomac? Intern. Kongress f. Radiologie u. Elektrologie, Brüssel, September 1910.
- Die Bewegungen des menschlichen Magens. (Eine röntgenologische Studie.) Nord. Med. Archiv 1911, Abt. I, Heft 1—4, Festschr. f. Prof. J. Berg. Ref.: Münchener med. Wochenschr. 1911, Nr. 31, S. 1690.

- FOVEAU DE COURMELLES (Paris), Première radiographie totale de l'estomac par le lait de bismuth. Académie de méd. de Paris, Mai 1899.
- Mode de l'exploration de l'estomac par les rayons X. Académie de méd., 23. V. 1899.
- L'existence d'un rétrécissement bi-trapézoidal de l'estomac, constaté par les rayons X. Académie de méd., 23. V. 1899. La semaine méd. 1899, Nr. 23, p. 179.
- FRÄNKEL, ARTHUR (Berlin), Röntgendiagnosen und Röntgenfehldiagnosen beim Magenkarzinom, diagnostischer Fortschritt durch Röntgenkinographie. Berliner med. Gesellsch., 6. XII. 1911. Ref.: Deutsche med. Wochenschr. 1911, Nr. 51, S. 2401.
- FRANKL, Beitrag zur Pathologie der Magengeräusche. Wiener klin. Wochenschr. 1909, Nr. 18. Ref.: Fortschr. a. d. Geb. d. Röntgenstr. 1910, Bd. XV, Nr. 6, S. 382—383.
- FRIEDRICH (Marburg), Bedeutung des Röntgenverfahrens für Diagnose der Nachwehen des Magengeschwürs. Arztl. Verein Marburg, 17. II. 1910.
- \*GAULTIER, R., Les dilatations de l'estomac: sémiologie et thérapeutiques des distentions gastriques. J. B. Ballière et fils, Paris 1909.
- GOCHT, H. (Halle), Erkrankungen des Magens. Aus „Handbuch der Röntgenlehre“, 3. Aufl. 1911, S. 373.
- GODART (Dauhieux), Le diagnostic de l'estomac biloculaire. Polyclinique 1908, Nr. 15. Ref.: Fortschr. a. d. Geb. d. Röntgenstr., Bd. XIV, Heft 2, S. 152.
- \*GOLDAMMER (Hamburg), Die röntgenologische Diagnostik der Erkrankungen des Magendarmkanals. Lucas Gräfe & Sillem, Hamburg 1909. Archiv u. Atlas Bd. XV.
- GRAY, H. M. W., Motor functions of the stomach: (a) in normal cases, (b) after gastroenterostomy, as demonstrated by X-rays. Lancet, Nr. 4430. Ref.: Berliner klin. Wochenschrift 1908, Nr. 34, S. 1578.
- GROEDEL III, FRANZ M. (Bad Nauheim, Frankfurt a. M.), Die Verwendung der Röntgenstrahlen zur Diagnose der Magenkrankheiten und zum Studium der Morphologie und Physiologie des Magens. Münchener med. Wochenschr. 1907, Nr. 22, S. 1068.
- Zur Topographie des normalen Magens. Deutsches Archiv f. klin. Med. 1907, Bd. XC.
- Über den schädlichen Einfluss des Schnürens auf den Magen. Med. Klinik 1907, Nr. 20. Ref.: Ztschr. f. Elektrologie u. Röntgenkunde, Bd. X, Heft 2, S. 88.
- Gibt es eine Ptose des Magens? Med. Klinik 1908, Nr. 9. Ref.: Fortschr. a. d. Geb. d. Röntgenstr., Bd. XII, Heft 6, S. 441.
- Die röntgenologisch nachweisbaren Merkmale der Gastrektasie und der Pyloroptose. Berliner klin. Wochenschr. 1908, Nr. 15.
- Die Ausgestaltung der Riederschen Röntgen-Wismutmethode für Magenuntersuchungen. Die Magenorthodiagraphie. Verhandl. d. Deutschen Röntgenges. 1907, Bd. III, S. 74.
- Die Form des pathologischen Magens. Deutsche med. Wochenschr. 1910, Nr. 15, S. 701.

- GROEDEL III, FRANZ M. (*continued*).  
 — Einige Streitfragen aus der Röntgenologie des Magens. Archiv. f. Verdauungskrankheiten 1910, Bd. XVI, Heft 5. Ref.: Fortschr. a. d. Geb. d. Röntgenstr., Bd. XVI, Heft 4, S. 305.
- GROEDEL III, FRANZ M. und LEVI, A., Über intermittierende Sanduhrmagen. Fortschr. a. d. Geb. d. Röntgenstr., Bd. XVII, Heft 2, S. 55.
- GRUNMACH, E. (Berlin), Röntgenologische Diagnostik der Magen-erkrankungen an einigen Fällen erläutert. (Diskussionsbemerkungen.) Verhandl. d. Deutschen Röntgenges. 1905, Bd. I, S. 68.  
 — Röntgenologische Diagnostik der Magentumoren. (Diskussionsbemerkung.) Verhandl. d. Deutschen Röntgenges. 1907, Bd. III, S. 83.
- \*GULLON, L'exploration radiologique de l'estomac chez l'homme sain, étudiée au point de vue anatomique et physiologique. Thèse, Paris 1907. Ref.: La presse méd., Nr. 69, 28. VIII. 1907 und Ztschr. f. Elektrologie u. Röntgenkunde, Bd. X, Heft 1, S. 28.
- HAENISCH (Hamburg), Die Röntgenstrahlen bei der Früdiagnose des Magenkarzinoms. Amer. Roentgen Ray Society 1910. Ref.: Fortschr. a. d. Geb. d. Röntgenstr., Bd. XVII, Heft 6, S. 393.  
 — Über Peristaltik des Magens. (Diskussionsbemerkung.) Verhandl. d. Deutschen Röntgenges. 1911, Bd. VII, S. 80.
- HÄRTEL, FRITZ, Die Gastroenterostomie im Röntgenbilde. Deutsche Ztschr. f. Chirurgie, Bd. 1909, Heft 3/4, S. 317.
- HARTUNG (Dresden), Röntgenkinematographie des Magens nach Rieder. Gesellsch. f. Natur- und Heilkunde, Dresden, 21. I. 1911. Ref.: Deutsche med. Wochenschr. 1911, Nr. 29, S. 1371.
- HAUDEK (Wien), Über die radiologischen Kriterien der Pylorusstenose. Wiener med. Wochenschr. 1910, Nr. 36. Ref.: Berl. klin. Wochenschr. 1910, Nr. 40, S. 1845.  
 — Zur röntgenologischen Diagnose der Ulzerationen in der Pars media des Magens. Münchener med. Wochenschr. 1910, Nr. 30, S. 1586 und Verhandl. d. Deutsch. Röntgenges. 1910, Bd. VI, S. 146.  
 — Das penetrierende Magengeschwür und der Wert seines Nachweises. 82. Versamml. deutscher Naturforscher u. Ärzte, Königsberg, Septbr. 1910. Ref.: Deutsche med. Wochenschr. 1910, Nr. 41, S. 1935.  
 — Röntgendiagnose der Pylorusstenose. Gesellsch. f. innere Medizin u. Kinderheilkunde zu Wien, 30. VI. 1910. Ref.: Berliner med. Wochenschr. 1910, Nr. 34, S. 1606.  
 — Röntgendiagnose eines kallösen Ulcus ventriculi mit sekundärer eitriger Perigastritis. Gesellsch. f. innere Medizin u. Kinderheilkunde, Wien, 20. X. 1910. Wiener med. Wochenschr. 1910, Nr. 52 und 1911, Nr. 8. Ref.: Berliner klin. Wochenschr. 1911, Nr. 4, S. 179.  
 — Radiologische Beiträge zur Diagnostik des Ulcus und Carcinoma ventriculi. Münchener med. Wochenschr. 1911, Nr. 8, S. 399.  
 — Zur Differentialdiagnose des Ulcus penetrans im Röntgenbild. Berliner klin. Wochenschr. 1911, Nr. 39, S. 1783.



HAUDEK (*continued*).

- The Roentgen diagnosis of chronic gastric ulcer. Arch. of the Roentgen Ray 1911, Nr. 131, p. 6.
- Röntgenplatten zur Differentialdiagnose zwischen Magengeschwür und Magenkarzinom. 40. Versamml. d. Deutschen Gesellch. f. Chirurgie, Berlin, April 1911. Ref.: Münchener med. Wochenschr. 1911, Nr. 19, S. 1040.
- Demonstration von Röntgenplatten zur Differentialdiagnose zwischen Magengeschwür und Magenkarzinom. Verhandl. d. Deutschen Röntgenges. 1911, Bd. VII, S. 74.
- Differentialdiagnose zwischen penetrierendem Magengeschwür und penetrierendem Magenkarzinom. (Diskussionsbemerkung.) Verhandl. d. Deutschen Röntgenges. 1911, Bd. VII, S. 80.

HAUDEK und STIGLER, Radiologische Untersuchungen über den Zusammenhang zwischen Austreibungszeit des normalen Magens und Hungergefühl. Arch. f. d. gesamte Physiologie 1910, Bd. CXXXIII, S. 145. Ref.: Fortschr. a. d. Geb. d. Röntgenstr., Bd. XVII, Heft 4, S. 250.

HEMMETER, JOHN, Photography of the human stomach by the Roentgen method, a suggestion. Boston Med. and Surg. Journ. 1896, 134, 25.

- Neue Methoden zur Diagnose des Magengeschwürs. Arch. f. Verdauungskrankheiten, Bd. XII, Heft 5. Ref.: Fortschr. a. d. Geb. d. Röntgenstr., Bd. XI, Heft 3, S. 220.

HERTZ, The diagnose of hour-glass stomach with the X-rays. Arch. of the Roentgen Ray, Sect. 1910, Nr. 122, p. 127. Ref.: Fortschr. a. d. Geb. d. Röntgenstr., Bd. XVI, Heft 4, S. 303.

- Duodenal ulcer. Guy's Hospital Gazette, 1909.
- Motor functions of the stomach. Quarterly Journ. of Med., July 1910.
- Functional hour-glass stomach. Proc. Roy. Soc. Med., vol. V, Medical Section, 1912.
- The anatomy of the normal stomach. Brit. Med. Journ., Sept. 1912.

HESSE, A. (Kissingen), Geben uns die in der Radiologie zur Verwendung kommenden Metallsalze ein falsches Bild von Form und Grösse des Magens? Berliner klin. Wochenschr. 1911, Nr. 21, S. 931.

HESSE, OTTO (Bonn), Dauerheilung eines Magensarkoms nach Resektion vor 7½ Jahren. Therapie der Gegenwart, Berlin, Juni 1911. Urban & Schwarzenberg.

HILLER, Röntgenuntersuchung über Form und Lage des Magens. Physiolog. Verein Kiel, 30. XI. 1908. Ref.: Fortschr. a. d. Geb. d. Röntgenstr., Bd. XIII, Heft 5, S. 341.

HOFFMANN, Bericht über Röntgenuntersuchung am Magen. Med. Klinik 1905, Nr. 14, S. 338. Ref. Fortschr. a. d. Geb. d. Röntgenstr., Bd. VIII, Heft 6, S. 455.

HOFFMANN, KLAUS (Heidelberg), Röntgenologische Grössenbestimmung des Magens. Fortschr. a. d. Geb. d. Röntgenstr., Bd. XVI, Heft 4, S. 263.

- HOFFMANN (Leipzig), Magebeobachtung mit Röntgenstrahlen und die chronische idiopathische Magenblase. Med. Gesellsch. zu Leipzig, 14. II. 1905. Ref.: Fortschr. a. d. Geb. d. Röntgenstr., Bd. IX, Heft 1, S. 68.
- HOLLAND, CHARLES THURSTAN (Liverpool), A note on the X-rays appearances in certain cases of hour-glass stomach. Arch. of the Roentgen Ray 1911, Nr. 129, p. 416. Ref.: Fortschr. a. d. Geb. d. Röntgenstr., Bd. XVII, Heft 3, S. 175.
- HOLZKNECHT (Wien), Enteroptose und Magenerweiterung. Relaxatio ventriculi. Mitteil. aus meinem Laboratorium, 1906.
- Der normale Magen, nach Form, Lage und Grösse. Mitteil. aus meinem Laboratorium, 1906, Heft 1.
- Die diagnostische Röntgendurchleuchtung des Magens mit besonderer Berücksichtigung der Anfangsstadien des Magenkarzinoms. Berliner med. Gesellsch., 10. I. 1906. Ref.: Münchener med. Wochenschr. 1906, Nr. 4, S. 190.
- Derzeitiger Stand der röntgenologischen Diagnostik der Magentumoren. Verhandlungen d. Deutschen Röntgenges. 1907, Bd. III. Ref.: Münchener med. Wochenschr. 1907, Nr. 16, S. 805.
- The Roentgen diagnosis of the stomach. Arch. of the Roentgen Ray 1911, Nr. 136, p. 206.
- Die Röntgendiagnostik des Magens. Jahreskurse f. ärztl. Fortbildung, August 1911. Ref.: Fortschr. a. d. Geb. d. Röntgenstr., Bd. XVII, Heft 6, S. 411.
- HOLZKNECHT und BRAUNER, Die radiologische Untersuchung des Magens. Wiener klin. Rundschau 1905, Nr. 16, 18, 19, 21, 22, 23. Ref.: Fortschr. a. d. Geb. d. Röntgenstrahlen, Bd. IX, Heft 2, S. 151.
- Die Grundlagen der radiologischen Untersuchung des Magens. Mitteil. aus dem Laboratorium f. radiologische Diagnostik u. Therapie im k. k. allgem. Krankenhaus in Wien 1906, Bd. I, Heft 1. Ref.: Fortschr. a. d. Geb. d. Röntgenstr., Bd. IX, Heft 6, S. 410.
- HOLZKNECHT und HAUDEK, Projektionen aus dem Gebiet der Radiologie des Magens. Verhandl. d. Deutschen Röntgenges. 1910, Bd. VI, S. 148.
- HOLZKNECHT und JONAS, Zur radiologischen Diagnostik raumbeengender Tumoren der Pars pylorica. Mitteil. a. d. Laboratorium f. radiologische Diagnostik u. Therapie im k. k. allgem. Krankenhaus in Wien. Ref.: Fortschr. a. d. Geb. d. Röntgenstr., Bd. IX, Heft 6, S. 410.
- Die Differentialdiagnose zwischen extra- und intraventrikulären Tumoren. (Magen.) Röntgenowsky Wiestnick 1908.
- \*— Die radiologische Diagnostik der intra- und extraventrikulären Tumoren und ihre spezielle Verwertung zur Frühdiagnose des Magenkarzinoms. Moritz Perles, Wien 1908.

HOLZKNECHT und JONAS (*continued*).

— Die Röntgenuntersuchung des Magens und ihre diagnostischen Ergebnisse. Ergebnis der inneren Medizin und Kinderheilkunde, Bd. IV, X. Ref.: Fortschr. a. d. Geb. d. Röntgenstr., Bd. XV, Heft 5, S. 316.

\*— Die Röntgenuntersuchung des Magens und ihre diagnostischen Ergebnisse. Julius Springer, Berlin 1910.

HOLZKNECHT und KAUFMANN, Die Peristaltik am Antrum pylori des menschlichen Magens. Mitteil. aus Holzknechts Laboratorium 1906, Heft 1.

JAMIN (Erlangen), Die zur Röntgenuntersuchung des Magens gebräuchlichen Methoden. Physik.-med. Sozietät Erlangen, 25. II. 1908. Ref.: Fortschr. a. d. Geb. d. Röntgenstrahlen, Bd. XIII, Heft 1, S. 50.

JOLLASSE (Hamburg), Über den derzeitigen Stand der Röntgendiagnostik bei Magen und Darmkrankheiten. Ärztlichen Verein in Hamburg, 11. VI. 1907 und 25. VI. 1907. Ref.: V.-B. d. Deutschen med. Wochenschr. 1907, Nr. 47, S. 1974 und Nr. 48, S. 2021.

— Zur Motilitätsprüfung des Magens durch Röntgenstrahlen. Fortschr. a. d. Geb. d. Röntgenstr., Bd. XI, Heft 1, S. 47.

— Beitrag zur Röntgendiagnose des Sanduhrmagens. Fortschr. a. d. Geb. d. Röntgenstrahlen, Bd. XI, Heft 5, S. 312.

— Magendarmdiagnostik mittels Röntgenstrahlen. Intern. Kongress f. Radiologie u. Elektrologie, Brüssel, 13.—15. IX. 1910.

JONAS (Wien), Über Antiperistaltik des Magens. Deutsche med. Wochenschr. 1906, Nr. 23.

— Über die nach Gastroenterostomie auftretenden Beschwerden und das radiologische Verhalten des anastomosierten Magens. (Suffizienz und Insuffizienz der Anastomose.) Arch. f. Verdauungskrankheiten 1908, Heft 6.

— Über die physiologische und pathologische Kleinheit des Magens und den radiologischen Nachweis der Magenschrumpfung. Arch. f. Verdauungskrankheiten, XIII, Heft 6. Ref.: Fortschr. a. d. Geb. d. Röntgenstr., Bd. XII, Heft 5, S. 436.

— Zur Diagnose des Schrumpfmagens. Mitteil. d. Vereins f. innere Medizin u. Kinderheilkunde in Wien 1909.

— Über die Entwicklungsstadien der Pylorusstenose und ihre klinisch-radiologische Diagnostik. Wiener klin. Wochenschr. 1909, Nr. 44. Ref.: Fortschr. a. d. Geb. d. Röntgenstr., Bd. XV, Heft 6, S. 383.

— Die radiologische Feststellung gewisser Krankheitsbilder des Magens. Med. Klinik 1910, Nr. 22, S. 854. Ref.: Ztschr. f. Röntgenkunde u. Radiumforschung 1911, Bd. XIII, Heft 4, S. 154 und Fortschr. a. d. Geb. d. Röntgenstr. 1910, Bd. XV, Nr. 6, S. 382.

KAESTLE (München), Bioröntgenographische Darstellung der Magenbewegung. Verhandl. d. Deutschen Röntgenkongresses. 1909, Bd. V, S. 154.

KAESTLE (*continued*).

- Versuch einer neuen Methode zur Prüfung der Verweildauer von Flüssigkeiten im Magen. Münchener med. Wochenschr. 1910, Nr. 35, S. 1837.
- Radiologische Studien über die Magenfüllung. (Diskussionsbemerkung.) Verhandlungen d. Deutschen Röntgenges. 1911, Bd. VII, S. 79.
- KAUFMANN und KIENBÖCK (Wien), Über den Rhythmus der Antrumperistaltik des Magens. Münchener med. Wochenschr. 1911, Nr. 29, S. 1237.
- Über Schichtung der Speisen im Magen. Med. Klinik 1911, Nr. 30. Ref.: Fortschr. a. d. Geb. d. Röntgenstr., Bd. XVII, Heft 5, S. 338.
- Über Schichtung der Speisen im Magen. Verhandl. d. Deutschen Röntgenges. 1911, Bd. VII, S. 65.
- Über den Rhythmus der Antrumperistaltik des Magens. Verhandl. d. Deutschen Röntgenges. 1911, Bd. VII, S. 66.
- KIEFFER, Etude comparative de l'examen du siège et de la forme de l'estomac par l'exploration externe et par la radioscopie. Ann. intern. d. chir. gastro-intestinale 1907, Nr. 2. Ref.: Zentralbl. f. Chirurgie 1907, Nr. 20, S. 568.
- KLYNENS, J., Estomac en sablier. Société belge de radiologie, 24. IV. 1910. Ref.: Journ. de radiologie 1910, vol. IV, fasc. 20, p. 194.
- Grand ulcère calleux juxtapylorique avec diverticule prévertébral. Société belge de radiologie, 2. V. 1911. Ref.: Journ. de radiologie (Belge) 1911, vol. V, fasc. 4, p. 350.
- KÖHLER, ALBAN (Wiesbaden), Magen. Aus: Köhler, Lexikon der Grenzen des Normalen, 1910, S. 157.
- KONRIED, Ein Fall von Pseudotumor des Magens. Wiener klin. Wochenschr. 1908, Nr. 6. Ref.: Fortschr. a. d. Geb. d. Röntgenstr., Bd. XII, Heft 3, S. 211.
- KRAFT (Strassburg), Röntgenologische Diagnostik der Magenerkrankungen an einigen Fällen erläutert. (Diskussionsbemerkung.) Verhandl. d. Deutschen Röntgenges. 1905, Bd. I, S. 68.
- KRAUS (Karlsbad), Mitteilung über eine Reihe nicht abgeschlossener Untersuchungen über die motorische Funktion des Magens. Gesellsch. f. innere Medizin, Wien, 2. IV. 1903. Ref.: Fortschr. a. d. Geb. d. Röntgenstr. 1903, Bd. VI, Heft 5, S. 243.
- KRAUSE, PAUL (Bonn), Über Salzsäureprobe ohne Magenschlauch. Verhandl. d. Deutschen Röntgenges., 1907. Bd. III. Diskussion.
- Magensarkom. (Diagnostik.) Niederrheinische Gesellsch. f. Natur- u. Heilkunde, Bonn, 20. II. 1911. Ref.: Deutsche med. Wochenschr. 1911, Nr. 44, S. 2058.
- KRETSCHMER (Berlin), Zur Differentialdiagnose des benignen und malignen Sanduhrmagens. Berliner klin. Wochenschr. 1911, Nr. 29, S. 1319.
- KÜMMELL (Hamburg), Magenerkrankungen im Röntgenbilde. XV. Internat. med. Kongress, Lissabon, 19.—26. IV. 1906. Ref.: Wiener med. Wochenschr. 1906, Nr. 42, S. 2069.

KÜMMELL (*continued*).

- Die Anwendung der Röntgenstrahlen bei Magenerkrankungen. Verhandl. d. Deutschen Gesellsch. f. Chirurgie, Berlin 1906. Ref. : Fortschr. a. d. Geb. d. Röntgenstr., Bd. X, Heft 6, S. 372.
- KUPFERLE (Freiburg i. B.), Die Röntgendiagnose des Ulcus ventriculi. Freiburger med. Gesellsch., 4. VII. 1911. Ref. : Deutsche med. Wochenschr. 1911, Nr. 30, S. 1423.
- LANGE, SIDNEY, The X-ray examination of the stomach. Ohio State Med. Journ., March 1910.
- LEVEN, Röntgenologische Magenuntersuchung bei Schmerzen am Mac Burneyschen Punkt. Société de thérapeutique, Nov. 1909. Ref. : Fortschr. a. d. Geb. d. Röntgenstrahlen, Bd. XV, Heft 1, S. 47.
- LEVEN und BARRET, Bestimmung der Magengrösse mit Hilfe der Röntgenstrahlen. Société de biologie, 24. XII. 1903. Ref. : Wiener med. Wochenschr. 1904, Nr. 34, S. 1588.
- Radioscopie gastrique. Forme, limite inférieure et mode de remplissage d'estomac. Presse méd. 1906, Nr. 9, p. 63. Ref. : Fortschr. a. d. Geb. d. Röntgenstr., Bd. X, Heft 4, S. 259 und Ztschr. f. Elektrologie u. Röntgekunde, Bd. IX, Heft 1, S. 38.
- Röntgenuntersuchung des Magens. Presse méd. 1907, p. 66. Ref. : Wiener med. Wochenschr. 1907, S. 1153.
- Définition de la dilatation de l'estomac basée sur la radioscopie gastrique. La presse méd., Nr. 46, 8. VI. 1907. Ref. : Ztschr. f. Elektrologie u. Röntgenkunde, Bd. IX, Heft 9, S. 340.
- Diagnostic radioscopique du cancer de l'estomac. Pariser Soc. anat., 10. I. 1908. Ref. : La presse méd., Nr. 5, 15. I. 1908 und Ztschr. f. Elektrologie u. Röntgenkunde, Bd. X, Heft 8, S. 321.
- Diagnostic radioscopique d'un cancer de l'estomac. Pariser Société méd. des hôpitaux, 31. I. 1908. Ref. : La presse méd., Nr. 11, 5. II. 1908 und Ztschr. f. Elektrologie u. Röntgenkunde, Bd. X, Heft 8, S. 321.
- Le diagnostic radioscopique de l'aérophagie méconnue. Son importance en clinique. Bull. et mém. de la société de radiologie md. de Paris, vol. I, Nr. 4, juillet 1909. Ref. : Journ. de radiologie 1909, Bd. III, Nr. 6, p. 564 und Fortschr. a. d. Geb. d. Röntgenstr., Bd. XV, Heft 1, S. 61.
- Région pylorique atteignant le point de Mac Burney. Les faux diagnostics d'appendicite. Bull. et mém. de la société de radiologie méd. de Paris, Sept. 1909. Ref. : Journ. de radiologie 1909, vol. III, Nr. 6, p. 562.
- Heilung eines Falles von Sanduhrmagen durch antiluetische Therapie. Bull. de la société de radiologie de Paris, 2, 1. Ref. : Fortschr. a. d. Geb. d. Röntgenstr., Bd. XV, Heft 1, S. 56.
- Die radiographische Untersuchung des Magens mit neuen Ergebnissen. Arch. d'électr. méd., Nr. 293, Oktober 1910. Ref. : Fortschr. a. d. Geb. d. Röntgenstr., Bd. XVI, Heft 4, S. 300.
- La chorée de l'estomac. Bull. et mém. de la société de radiologie de Paris, mai 1910. Ref. : Journ. de radiologie 1910, vol. IV, fasc. 21, p. 291 et Presse méd., 2. VII. 1910, Nr. 53. Ref. : Journ. de radiologie (Belge) 1911, vol. V, p. 148.

- LEVEN und BARRET (*continued*).  
 — Sanduhrmagen. Bull. et mém. de la société de radiologie méd. de Paris, Juli 1910. Ref.: Fortschr. a. d. Geb. d. Röntgenstr., Bd. XVI, Heft 4, S. 303.  
 — Notions nouvelles introduites en médecine par l'examen radiologique de l'estomac. Journ. de radiologie (Belge) 1911, vol. V, p. 159.
- LEVY-DORN (Berlin), Röntgenbild eines in die Leber durchgebrochenen Ulcus ventriculi Hufelandische Gesellsch., 9. II. 1911. Ref.: Berliner klin. Wochenschr. 1911, Nr. 11, S. 494.
- LINDEMANN (Hamburg), Röntgenbilder des normalen und erweiterten Magens. Deutsche med. Wochenschr. 1897, Nr. 17, S. 266 und Hamb. ärztl. Verein, 16. II. 1897. Ref.: Münch. med. Wochenschr. 1897, Nr. 8, S. 213 und Nr. 17, S. 453.
- LION, A propos de l'examen radiographique de l'estomac. La presse méd., Nr. 9, 1. II. 1911. Ref.: Ztschr. f. Röntgenkunde u. Radiumforschung 1911, Bd. XIII, Heft 8, S. 319.
- LOSSEN (Königsberg), Über die idiopathische Erweiterung des Oesophagus. Grenzgeb. d. Medizin u. Chirurgie 1903. Ref.: Fortschr. a. d. Geb. d. Röntgenstr., Bd. VII, Heft 5, S. 290.
- MARKOWIC, A., und PERUSSIA, F., Die Entleerungszeit des Magens in rechter und linker Seitenlage und ihre diagnostische und therapeutische Bedeutung bei Hypermotilität, Pylorusinsuffizienz, Atonie und Pylorusstenose. Med. Klinik 1910, Nr. 14.
- MAUNZ (München), Mechanismus der Magenentleerung bei Magenoperierten. Beitr. z. klin. Chirurgie, Bd. LXX, S. 343—349.
- MINETTI, ADOLFO (Genua), Sull indagine Roentgenologica dello stomaco. Clinica medica 1907.
- DE NOBELE (Gand), Le radiodiagnostic de l'ulcère chronique de l'estomac. Société Belge de radiologie, 24. I. 1911. Ref.: Journ. de radiologie (Belge) 1911, vol. V, fasc. 4, p. 334.
- DE NOBELE et DAUWE, L'exploration radiologique de l'estomac. Annales de la société de méd. de Gand 1908. Ref.: Zentralbl. f. innere Medizin 1909, Nr. 35, S. 870.
- NOWAK, Radiologische Diagnose der chronischen Magengeschwüre. (Kasuistik.) Casop. lék. cesk, Nr. 45.
- OESTERNES, Variationen der Magenform und Magenlage. Bull. et mém. de la société de radiologie de Paris, Nr. 26. Ref.: Fortschr. a. d. Geb. d. Röntgenstr., Bd. XVII, Heft 5, S. 343.
- OTTINGER et BONNIOT, Contracture spasmodique du pylore dans certains ulcus gastriques. Bull. et mém. de la société radiologie méd. de Paris, juin 1910. Ref.: Journ. de radiologie (Belge) 1910, vol. IV, fasc. 22, p. 306.
- PAUCOAST, HARRY K., The radiographic examination of the gastrointestinal tract from a practical standpoint, especially in connection with diagnosis and treatment of gastro-enteroptosis. Internat. Clinic, vol. III, 19 series, Dec. 1908.
- PERUSSIA, F. (Mailand), La diagnosis radiologica del carcinoma gastrico. Policlinico sez. med. 1911, XVIII, 9. Ref.: Zentralbl. f. Chirurgie 1911, Nr. 51, S. 1682.

- PESCI, GIACOMO (Genua), Sull indagine Roentgenologica nelle malattie dell' esofago e dello stomaco. *Giornale di Elettricità Med.* 1907, Nr. 6 et II. Congrès intern. de physio-thérapie, Rom. Okt. 1907. Ref. : *Journ. de radiologie (Belge)* 1907, vol. I, p. 330.
- PFAHLER (Philadelphia), The diagnosis of the size, form, position and motility of the stomach and bowel by means of the X-ray. *Arch. of Physiological Therapy*, Juli 1905. Ref. : *Fortschr. a. d. Geb. d. Röntgenstr.*, Bd. IX, Heft 5, S. 368.
- The Roentgen rays as an aid in the diagnosis of carcinoma of the stomach. *Transaction of the Amer. Roentgen Ray Society. Ninth Annual Meeting, New York, 20.—30. XII. 1908.* Ref. : *Fortschr. a. d. Geb. d. Röntgenstr.*, Bd. XIV, Heft 6, S. 446 und *Journ. the Amer. Med. Assoc.*, 13. III. 1909, Vol. LII, Nr. 11. Ref. *Journ. de radiologie* 1909, vol. III, Nr. 5, p. 454.
- The Roentgen rays in the diagnosis of carcinoma of the stomach. *New York Med. Journ.*, 21. VIII. 1909. Ref. : *Fortschr. a. d. Geb. d. Röntgenstr.*, Bd. XIV, Heft 6, S. 453.
- X-ray as means of diagnosis of carcinoma of the stomach and bowels. *Med. Record*, March 25, 1911.
- Gastric and duodenal adhesions in gall-bladder region and their diagnosis by the Roentgen Rays. *Journ. of Amer. Med. Assoc.*, June 17, 1911, p. 1777.
- PFÖRRINGER (Regensburg), Zur Röntgendiagnostik der Magenerkrankungen. *Fortschr. a. d. Geb. d. Röntgenstr.*, Bd. XII, Heft 1, S. 24.
- POTTER, Button-hook in the stomach shown by the Roentgen rays. *Kensington Infirmary*, 13. I. 1898. Ref. : *Lancet* 1898, Vol. I, pp. 786 and 791.
- DE QUERRAIN (Basel), Zur Röntgendiagnostik des runden Magengeschwürs. *Münchener med. Wochenschr.* 1911, Nr. 17, S. 884.
- RANZI, E. (Wien), Röntgenaufnahmen von Strumen. *Demonstration in der k. k. Gesellschaft der Ärzte. Wiener klin. Wochenschr.* 1906, S. 168.
- REICHE (Hamburg), Zur Diagnose des Ulcus ventriculi im Röntgenbild. *Fortschr. a. d. Geb. d. Röntgenstr.*, Bd. XIV, Heft 3, S. 171.
- Röntgendiagnose des penetrierenden Magengeschwürs. *Münchener med. Wochenschrift* 1911, Nr. 1, S. 30.
- RENAUX, E., Die radiologische Diagnose des Ulcus ventriculi. *Journ. de radiologie (Belge)* 1911, vol. V, p. 129. Ref. : *Fortschr. a. d. Geb. d. Röntgenstr.*, Bd. XVII, Heft 3, S. 181.
- REITZENSTEIN (Nürnberg), Über Magendurchleuchtung. *Ärztlicher Verein in Nürnberg*, 2. III. 1899. Ref. : *Fortschr. a. d. Geb. d. Röntgenstr.* 1899, Bd. III, Heft 1, S. 34.
- RIEDER (München), Die Röntgenuntersuchung des Magens. *Allgemeine Zeitung* 1908, Nr. 31.
- Das chronische Magengeschwür und sein röntgenologischer Nachweis. *Münchener med. Wochenschr.* 1910, Nr. 48, S. 2508.
- \*— Die Sanduhrformen des menschlichen Magens. *J. F. Bergmann, Wiesbaden* 1910.

- RIBAS y RIBAS, The motility of the stomach after gastro-enterostomy. Arch. of the Roentgen Ray 1911, Nr. 126, p. 283.
- RIBAS y RIBAS, COMAS und PRIÓ, Motilidad gástrica del gastro-enterostomizado: estudio radioscópico. Ztschr. f. Röntgenkunde u. Radiumforschung 1911, Bd. XIII, Heft 2, S. 62.
- Motilidad gástrica del gastro-enterostomizado estudio radioscópico. Thomas, Barcelona 1911. Ref.: Zentralbl. f. Chirurgie 1911, Nr. 44, S. 1465.
- ROSENFELD, G. (Breslau), Beiträge zur Magendiagnostik. Ztschr. f. klin. Medizin 1898, Bd. XXXVII, Heft 1 und 2.
- Zur Diagnostik der Magenkrankheiten. Schlesische Gesellsch. f. vaterländ. Kultur, 25. XI. 1898.
- Klinische Diagnostik der Grösse, Form und Lage des Magens. Zentralbl. f. innere Medizin 1899, Nr. 1. Ref.: Fortschr. a. d. Geb. d. Röntgenstr. 1899, Bd. II, Heft 4, S. 163.
- Zur Topographie und Diagnostik des Magens. Münchener med. Wochenschr. 1900, Nr. 35.
- Zur Diagnostik des Sanduhrmagens. Zentralbl. f. innere Medizin 1903, Nr. 7.
- Die Röntgendurchleuchtung des Magens. Deutsche med. Presse 1905, Nr. 8.
- ROUX et BALTHAZARD, Sur les fonctions motrices de l'estomac. (Magen.) Société de biologie, 10. et 24. VII. 1897. Arch. de physiologie 1898, X, p. 85.
- RUDIS-JICINSKY (Iowa), Türks Gyromele und die X-Strahlen in der Diagnose der Magenkrankheiten. The Amer. X-Ray Journ., Okt. 1901.
- Emanation of the stomach with gyromel in situ. (Magen.) Roentgen S. Meet. Buffalo. Casopis lékarski ceskych 1903.
- SALOMON (Wien), Frau mit funktionellem Sanduhrmagen. Gesellsch. f. innere Medizin u. Kinderheilkunde in Wien, 7. III. 1907. Ref.: Fortschr. a. d. Geb. d. Röntgenstr., Bd. XI, Heft 3, S. 217.
- SCHLESINGER, EMMO, Zur Diagnostik der sekretorischen Funktion des Magens mittels Röntgenstrahlen. Deutsche med. Wochenschr. 1910, Nr. 9. Ref.: Fortschr. a. d. Geb. d. Röntgenstr., Bd. XV, Heft 4, S. 228.
- Zur Motilitätsprüfung des Magens mittels Röntgenstrahlen. Berliner klin. Wochenschrift 1910, Nr. 7, S. 280.
- Die Grundformen des normalen und pathologischen Magens und ihre Entstehung. Berliner klin. Wochenschr. 1910, Nr. 43, S. 1977.
- Zur Differentialdiagnose des Ulcus penetrans im Röntgenbilde. Berliner Hufelandische Gesellsch., 15. VI. 1911. Berliner klin. Wochenschr. 1911, Nr. 36, S. 1645.
- Eine Aziditätsbestimmung des Mageninhalts mittels des Röntgenverfahrens. Verein f. innere Medizin u. Kinderheilkunde, Berlin, 15. V. 1911. Ref.: Deutsche med. Wochenschr. 1911, Nr. 26, S. 1242.



- SCHLESINGER, EMMO (*continued*).  
 — Eine Aziditätsbestimmung des Mageninhalts mittels des Röntgenverfahrens. Deutsche med. Wochenschr. 1911, Nr. 30, S. 1391 und Nr. 40, S. 2095.
- SCHLESINGER und NATHANBLUT, Über Erfolge und Aussichten einer konservativen Therapie des Sanduhrmagens, nebst Beiträgen zur röntgenologischen Diagnostik desselben. Mitteil. a. d. Grenzgebieten, Bd. XXII, S. 787—794. Ref.: Ztschr. f. Röntgenkunde u. Radiumforschung 1911, Bd. XIII, Heft 10, S. 404.
- SCHMIEDEN, V. (Berlin, Bonn), Magenerkrankungen im Röntgenbilde. Berliner klin. Wochenschr. 1908, Nr. 49, S. 2180 und Verhandl. d. Deutschen Gesellsch. f. Chirurgie 1909, S. 47.  
 — Die Differentialdiagnose zwischen Magenschwür und Magenkrebs, die pathologische Anatomie dieser Erkrankungen in Beziehung zu ihrer Darstellung im Röntgenbilde. Archiv f. klin. Chirurgie 1911, Bd. XCVI, Heft 2. Ref.: Münchener med. Wochenschr. 1911, Nr. 52, S. 2800.
- SCHMIEDEN, V., und HÄRTEL, F., Röntgenuntersuchung chirurgischer Magenkrankheiten. Berliner klin. Wochenschr. 1909, Nr. 15, S. 669; Nr. 16, S. 721 und Nr. 17, S. 773.
- SCHMILINSKY (Hamburg), Eine mit Schrot gefüllte Magensonde zeigt sich auf dem Röntgenbilde. Arztlicher Verein zu Hamburg, 28. XI. 1899. Ref.: Fortschr. a. d. Geb. d. Röntgenstr. 1900, Bd. III, Heft 4, S. 158.  
 — Sanduhrmagen. Arztlicher Verein zu Hamburg, 28. XI. 1899.
- SCHÜLE, Studien über die Bestimmung der unteren Magengrenzen mit besonderer Berücksichtigung der Radiographie. Arch. f. Verdauungskrankheiten, Bd. XI, Heft 6. Ref.: Fortschr. a. d. Geb. d. Röntgenstr., Bd. IX, Heft 4, S. 303.
- SCHÜLLER, L. (Würzburg), Klinische und experimentelle Untersuchungen über die Funktion des Magens nach Gastroenterostomie und Pylorusresektion. Mitteil. a. d. Grenzgeb. d. Medizin u. Chirurgie, Bd. XXII, Heft 5. Ref.: Fortschr. a. d. Geb. d. Röntgenstr., Bd. XVII, Heft 4, S. 254.
- SCHWARZ, GOTTWALD (Wien), Röntgenologische Methode zur Prüfung der Magenfunktion. Ztschr. f. ärztl. Fortbildung 1906, Nr. 12. Ref.: Fortschr. a. d. Geb. d. Röntgenstr., Bd. X, Heft 5, S. 304.  
 — Über Salzsäureprobe ohne Magenschlauch. Verhandl. d. Deutschen Röntgenes. 1907, Bd. III, S. 68. Ref.: Münchener med. Wochenschr. 1907, Nr. 16, S. 806.  
 — Röntgenogramme von 4 Fällen mit Verengerung der Pars media ventriculi. K. k. Gessellsch. d. Ärzte in Wien, 22. I. 1909. Ref.: Fortschr. a. d. Geb. d. Röntgenstr., Bd. XIII, Heft 4, S. 264.  
 — Ein Fall von narbiger Pylorusstenose mit Röntgenbefunden. Wiener klin. Wochenschrift 1910, Nr. 10. Ref.: Fortschr. a. d. Geb. d. Röntgenstr. 1910, Bd. XV, Heft 6, S. 384 und Journ. de radiologie (Belge) 1910, vol. IV, fasc. 21, p. 282.  
 — Zum Reicheschen Röntgenbefund bei tiefgreifendem Ulcus ventriculi. Wiener med. Wochenschr. 1911, Nr. 4 und Nr. 14. Ref.: Fortschr. a. d. Geb. d. Röntgenstrahlen, Bd. XVII, Heft 6, S. 412.

- SCHWARZ, GOTTWALD (*continued*).  
 — Röntgendiagnose eines Ulcus ventriculi. *Gesellsch. f. innere Medizin u. Kinderheilkunde*, Wien, 22. (23.) II. 1911. Ref.: *Berliner klin. Wochenschr.* 1911, Nr. 13, S. 601 und *Wiener klin. Rundschau* 1911, Nr. 13.  
 — Zur Aziditätsbestimmung des Mageninhaltes mittels des Röntgenverfahrens. *Deutsche med. Wochenschr.* 1911, Nr. 35, S. 1608.  
 — Versuch eines Systems der physiologischen und pathologischen Magenperistaltik. *Fortschr. a. d. Geb. d. Röntgenstr.*, Bd. XVII, Heft 3, S. 128.
- SCHWARZ, GOTTWALD und HAUDEK (Wien), Röntgendiagnose des Ulcus ventriculi. *Wiener med. Wochenschr.* 1911, Nr. 14.
- SCHWARZ und KREUZFUCHS, Über radiologische Motilitätsprüfung des Magens. *Wiener klin. Wochenschr.* 1907, Nr. 15. Ref.: *Fortschr. a. d. Geb. d. Röntgenstr.*, Bd. XI, Heft 3, S. 222.
- SGOBBO, Die Elektrisierung des Magens, beobachtet am Röntgen-  
 schirm. *Giornale di Elettività Medica*, Januar-Februar 1909.  
 Ref.: *Zschr. f. Elektrologie u. Röntgenkunde* 1909, Bd. XI, Heft 10, S. 362.
- SICILIANO (Florenz), Sanduhrmagen. *Fortschr. a. d. Geb. d. Röntgenstr.*, Bd. XIII, Heft 1, S. 37.
- SICILIANO, L., et BEVERINI, F., Quelques observations sur la radioscopie gastrique. *Fortschritte a. d. Geb. d. Röntgenstr.*, Bd. XIV, Heft 3, S. 202.
- SICK (Stuttgart), Zur Pathologie der Magenbewegungen. XXVIII. *Deutscher Kongress f. innere Medizin*, Wiesbaden, April 1911. Ref.: *Münchener med. Wochenschr.* 1911, Nr. 19, S. 1037.
- SILVAGNI, Radiologic researches on the evacuation of the stomach in gastro-enterostomy. *Bulletino delle Scienze Mediche*, July 1909.
- \*SIMMONDS (Hamburg), Über Form und Lage des Magens unter normalen und abnormen Bedingungen. *Gustav Fischer*, Jena 1907.
- SKINNER, H. E. Duodenal diagnosis and X-ray consideration. *Arch. Inter. Med.*, Nov. 1911, p. 574.
- STANMORE, E., Examination by the Roentgen rays of stomach. *Manchester Med. Society*, 4. III. 1908. Ref.: *The Lancet* 1908, Vol. I, p. 862.
- STEYRER, Über Lage und Gestalt des Magens. *Gesellsch. d. Charité-ärzte*, Berlin, 2. XI. 1905.
- STIERLIN, EDUARD (Basel), Die Röntgendiagnose der geschwürigen und indurativen Prozesse des Magendarmkanals. *Med. Gesellsch. Basel*, II. V. 1911. Ref.: *Berliner klin. Wochenschr.* 1911, Nr. 22, S. 1011.
- STILLER (Budapest), Kritische Glossen eines Klinikers zur Radiologie des Magens. *Boas Archiv*, Bd. XVI, Heft 2, S. 121. Ref.: *Berliner klin. Wochenschr.* 1911, Nr. 3, S. 127.
- STRAUSS, H., und BRANDENSTEIN, J., Über Ulcus penetrans ventriculi und Sanduhrmagen. *Berliner klin. Wochenschr.* 1911, Nr. 28, S. 1269.
- TALMA, S., Röntgenographische Bestimmung der Lage des Magens. *Berliner klin. Wochenschr.* 1911, Nr. 22, S. 976.

- TREPLIN (Hamburg), Magenerkrankungen im Röntgenbilde. Deutsche Gesellsch. f. Chirurgie, XXXV. Kongress, 1906. Ref.: Fortschr. a. d. Geb. d. Röntgenstr., Bd. X, Heft 6, S. 372.
- TUFFIER et AUBORG, Examen de quelques estomacs à l'aide des rayons de Roentgen. (Magenuntersuchung.) Société de l'intern. des hôpitaux de Paris, 24. X. 1907. Ref.: Lt presse méd., Nr. 90, 6. XI. 1907 und Ztschr. f. Elektrologie u. Röntgenkunde, Bd. X, Heft 4, S. 160 et La presse méd., Nr. 100, 11. XII. 1907. Ref.: Ztschr. f. Elektrologie u. Röntgenkunde, Bd. X, Heft 7, S. 284.
- TURNER, DAWSON (Edinburgh), The Roentgen rays in a case of chronic varicose ulcer and of non healing ulcer. (Ulcuscruris.) Edinburgh Med.-Chirurg. Society, 21. XII. 1904. Ref.: Lancet 1905, Vol. I, p. 92.
- WENCKEBACH (Groningen), Stereoscopic Roentgenography in the diagnosis of internal diseases. (Magendarmuntersuchung.) Arch. of the Roentgen Ray 1908, Vol. XIII, Nr. 100, p. 172.
- WIESNER, BERNARD (Aschaffenburg), Eine Verbesserung der Durchleuchtungsblende speziell für die Zwecke der Magenuntersuchung. Münchener med. Wochenschr. 1907, Nr. 32.
- WITTE, J. Hannover), Moderne Magendiagnostik. Berliner klin. Wochenschr. 1909, Nr. 47, S. 2103. ...
- WULACH (Düsseldorf), Die Verweildauer der verschiedenen Nahrungssubstanzen im Magen. Münchener med. Wochenschr. 1911, Nr. 44, S. 2319.

## Index

The following is a list of the names of the persons who have been mentioned in the text of this book. The names are arranged in alphabetical order.

A. B. C. D. E. F. G. H. I. J. K. L. M. N. O. P. Q. R. S. T. U. V. W. X. Y. Z.

The names are arranged in alphabetical order.

INDEX

100

## Index

- Adhesions, 50.  
Aerophagy, 49.  
Air, injection of, 11.  
Anæsthetics, action on stomach, 32.  
Appendicitis, 66.  
— with aerophagy, 50.  
Appendix dyspepsia, 70.
- Bougies, 13, 16.
- Capsules, gelatine, 10.  
— gold-beater skin, 11.  
"Caput duodeni," 58.  
Carcinoma of stomach, 46.  
Constipation, 65, 75.
- Dermatitis, 6.  
Drugs, 11.  
— alcohol, 11.  
— belladonna, 11, 15, 41.  
— bicarbonate of soda, 11, 26, 37.  
— valerian, 11.
- Duodenal irritation, notes on cases, 55.  
— — peristalsis in, 56.  
— ulcer, 54.  
Duodenum, food seen in, 57.  
— second sphincter in, 58.  
— segmentation of food in, 69.  
Dysphagia, 17.
- Enteroptosis, 32.
- Foods, 9, 17, 26.  
Free acid in stomach, 12.  
Fundamental principles, 5.
- Gastric ulcer, 39.  
— — ætiology, 62.  
— — notes on cases, 43.
- Gastro-jejunosomy, examinations after, 52.  
Gastroptosis, 32.  
Gravity, action of, 56.
- Hour-glass stomach, 39, 44.  
Hypersecretion, 26, 37, 66.  
Inflation of stomach, 11.
- Jejunum, ulcer of, 60.  
— after gastro-enterostomy, 68.
- Massage, 10, 25, 40.  
Method of examination, general, 5.  
— — of œsophagus, 13.  
Mucous colitis, 66.
- Normal stomach, 22.  
— — operation in, 29.
- Œsophageal obstruction, 13.  
— pouch, 19.  
Œsophagoscope, 14.  
Œsophagus, dilatation, 19.  
— foreign bodies, 16.  
— peptic ulcer, 20.  
— power of recovery, 21.  
— spasm of, 15.
- Penetrating ulcers, 41.  
Peristalsis, absence of, 28.  
— in carcinoma, 47.  
— in duodenal irritation, 56.  
— nervous control, 27.  
— in pyloric obstruction, 34.
- Position of patient, 7.  
Post-operative examinations, 50.  
Preparation of patient, 8.  
Protection from rays, 6.  
Pyloric obstruction, 33.  
— — notes on cases, 36.  
— — peristalsis in, 34.  
— — retention of food in, 35.  
— ulcer, diagnosis, 38.  
— — notes on, 37.
- Pylorus, carcinoma, 35.  
— control of, 26.
- Results after operation, 53.
- Septic conditions, 69.  
Shadow, clear spaces in, 48.  
— pyloric, 8.  
Small intestine, 54.  
Soft rays, 6.  
Spasmodic contraction, 47.

Stomach, adhesions, 50.  
— anatomy, 22.  
— atony, 30.  
— carcinoma, 46.  
— displacement, 29.  
— hour-glass contraction, 39.  
— hypersecretion, 26, 37.  
— incidence of lesions, 53.  
— inflation, 11.  
— nervous control, 24.  
— normal, 22.  
— peristalsis in, 25, 27.  
— physiology, 22.  
— rapid emptying, 26, 56.

Stomach (*continued*),  
— retention of food in, 36.  
— reverse peristalsis in, 25.  
— shape, 23.  
— spasm, 29, 39, 44, 62, 64.  
— tone, 24, 27, 35.

Tabulation of cases, 77.

Teeth, carious, 64, 75.

Upright position, 5.

Visceroptosis, 31.

Vicious circle, 51.

