

A short manual of surgical operations.

Contributors

Barker, Arthur E. J. 1850-1916.
Augustus Long Health Sciences Library

Publication/Creation

London : Longmans, Green, 1887.

Persistent URL

<https://wellcomecollection.org/works/ez7kyxm9>

License and attribution

This material has been provided by This material has been provided by the Augustus C. Long Health Sciences Library at Columbia University and Columbia University Libraries/Information Services, through the Medical Heritage Library. The original may be consulted at the the Augustus C. Long Health Sciences Library at Columbia University and Columbia University. where the originals may be consulted.

This work has been identified as being free of known restrictions under copyright law, including all related and neighbouring rights and is being made available under the Creative Commons, Public Domain Mark.

You can copy, modify, distribute and perform the work, even for commercial purposes, without asking permission.

**wellcome
collection**

Wellcome Collection
183 Euston Road
London NW1 2BE UK
T +44 (0)20 7611 8722
E library@wellcomecollection.org
<https://wellcomecollection.org>

COLUMBIA LIBRARIES OFFSITE
HEALTH SCIENCES STANDARD



HX64055205

RD32 B24

A short manual of su

RECAP

RD32

B2A

Columbia University
in the City of New York

College of Physicians and Surgeons



Given by
Miss Gussie Ellison
in memory of
Dr. Ernest William Auzal

1918

EX LIBRIS

ERNEST
WILLIAM
AUZAL

E. W. Husar
San Francisco
Calif
1887.

3.25-

MEDICAL AND SURGICAL WORKS

PUBLISHED BY

MESSRS. LONGMANS, GREEN, & CO.

A DICTIONARY OF MEDICINE. By Various Writers.

Edited by R. QUAIN, M.D. F.R.S. &c. Twelfth Thousand. With 138 Woodcuts. Medium 8vo. 31s. 6d. cloth, or 40s. half-russia; to be had also in 2 vols. 34s. cloth.

THE SCIENCE AND ART OF SURGERY: being a Treatise

on Surgical Injuries, Diseases, and Operations. By JOHN ERIC ERICHSEN, F.R.S. With 984 Illustrations. 2 vols. 8vo. 42s.

ON CONCUSSION OF THE SPINE, NERVOUS SHOCKS,

and other Obscure Injuries of the Nervous System. By JOHN ERIC ERICHSEN, F.R.S. Crown 8vo. 10s. 6d.

A SYSTEM OF SURGERY, Theoretical and Practical, in

Treatises by Various Authors. Edited by TIMOTHY HOLMES, M.A. and J. W. HULKE, F.R.S. 3 vols. royal 8vo. £4. 4s.

QUAIN'S ELEMENTS OF ANATOMY. The Ninth Edition.

Re-edited by ALLEN THOMSON, M.D. LL.D. F.R.S.S. L & E., EDWARD SCHÄFER, F.R.S. and GEORGE DANCER THANE. With upwards of 1,000 Illustrations engraved on Wood, of which many are Coloured. 2 vols. 8vo. 18s. each.

ANATOMY, DESCRIPTIVE AND SURGICAL. By HENRY

GRAY, F.R.S. late Lecturer on Anatomy at St. George's Hospital. With 569 Woodcut Illustrations, a large number of which are coloured. Re-edited by T. PICKERING PICK, Surgeon to St. George's Hospital. Royal 8vo. 36s.

NOTES ON PHYSIOLOGY FOR THE USE OF STUDENTS

PREPARING FOR EXAMINATION. With 120 Woodcuts. By HENRY ASHBY, M.D. Lond. Fcp. 8vo. 5s.

A MANUAL OF OPERATIVE SURGERY ON THE DEAD

BODY. By THOMAS SMITH, Surgeon to St. Bartholomew's Hospital. A New Edition, re-edited by W. J. WALSHAM. With 46 Illustrations. 8vo. 12s.

THE ESSENTIALS OF HISTOLOGY, Descriptive and

Practical. For the use of Students. By E. A. SCHÄFER, F.R.S. With 281 Illustrations. 8vo. 6s. or Interleaved with Drawing Paper, 8s. 6d.

THE HANDBOOK FOR MIDWIVES. By HENRY FLY

SMITH, M.B. Oxon. M.R.C.S. late Assistant-Surgeon to the Hospital for Sick Women, Soho Square. With 41 Woodcuts. Crown 8vo. 5s.

CLINICAL LECTURES AND ESSAYS. By Sir JAMES

PAGET, Bart. F.R.S. D.C.L. &c. Edited by F. HOWARD MARSH, Assistant-Surgeon to St. Bartholomew's Hospital. 8vo. 15s.

LECTURES ON SURGICAL PATHOLOGY. By Sir JAMES

PAGET, Bart. F.R.S. D.C.L. &c. Re-edited by the AUTHOR and W. TURNER, M.B. 8vo. with 131 Woodcuts. 21s.

A MANUAL OF PATHOLOGY. By JOSEPH COATS, M.D.

Pathologist to the Western Infirmary and the Sick Children's Hospital, Glasgow. With 339 Illustrations engraved on Wood. 8vo. 31s. 6d.

~~~~~  
London: LONGMANS, GREEN, & CO.

**HANDBOOK ON DISEASES OF THE SKIN.** With especial reference to Diagnosis and Treatment. By ROBERT LIVEING, M.A. and M.D. Cantab. Fifth Edition, Revised and Enlarged. Fcp. 8vo. 5s.

**NOTES ON THE TREATMENT OF SKIN DISEASES.** By ROBERT LIVEING, M.A. and M.D. Cantab. 18mo. 3s.

**A TREATISE ON GOUT AND RHEUMATIC GOUT (RHEUMATOID ARTHRITIS).** By Sir ALFRED BARING GARROD, M.D. F.R.S. With 6 Plates, comprising 21 Figures (14 Coloured), and 27 Illustrations engraved on Wood. 8vo. 21s.

**THE ESSENTIALS OF MATERIA MEDICA AND THERAPEUTICS.** By Sir ALFRED BARING GARROD, M.D. F.R.S. New Edition, revised and adapted to the New Edition of the British Pharmacopœia, by NESTOR TIRARD, M.D. Crown 8vo. 12s. 6d.

**A TREATISE ON THE CONTINUED FEVERS OF GREAT BRITAIN.** By CHARLES MURCHISON, M.D. LL.D. &c. Revised by W. CAYLEY, M.D. Physician to the Middlesex Hospital. 8vo. with numerous Illustrations, 25s.

**CLINICAL LECTURES ON DISEASES OF THE LIVER, JAUNDICE, AND ABDOMINAL DROPSY.** By CHARLES MURCHISON, M.D. LL.D. &c. Revised by T. LAUDER BRUNTON, M.D. and Sir JOSEPH FAYRER, M.D. 8vo. with 43 Illustrations, 24s.

**PULMONARY CONSUMPTION: its Etiology, Pathology, and Treatment.** With an Analysis of 1,000 Cases to Exemplify its Duration and Modes of Arrest. By C. J. B. WILLIAMS, M.D. LL.D. F.R.S. F.R.C.P. and CHARLES THEODORE WILLIAMS, M.A. M.D. Oxon. F.R.C.P. Second Edition, Enlarged and Re-written by Dr. C. THEODORE WILLIAMS. With 4 Coloured Plates and 10 Woodcuts. 8vo. 16s.

**ON RENAL AND URINARY AFFECTIONS.** By W. HOWSHIP DICKINSON, M.D. Cantab. F.R.C.P. &c. With 12 Plates and 122 Woodcuts. 4 vols. 8vo. £3. 4s. 6d.

**GUNSHOT INJURIES; their History, Characteristic Features, Complications, and General Treatment.** By Surgeon-General Sir T. LONGMORE, C.B. F.R.C.S. With 58 Illustrations. 8vo. 31s. 6d.

**THE DIAGNOSIS AND TREATMENT OF DISEASES OF WOMEN, INCLUDING THE DIAGNOSIS OF PREGNANCY.** By GRAILY HEWITT, M.D. New Edition, in great part re-written and much enlarged, with 211 Engravings on Wood, of which 79 are new in this Edition. 8vo. 24s.

**LECTURES ON THE DISEASES OF INFANCY AND CHILDHOOD.** By CHARLES WEST, M.D. &c. 8vo. 18s.

**THOMSON'S CONSPECTUS.** Adapted to the British Pharmacopœia of 1885. Edited by NESTOR TIRARD, M.D. Lond. F.R.C.P. New Edition, with an Appendix containing notices of some of the more important non-official medicines and preparations. 18mo. 6s.

**A TEXT-BOOK OF ORGANIC MATERIA MEDICA.** Comprising a Description of the Vegetable and Animal Drugs of the British Pharmacopœia, with other non-official Medicines, arranged systematically and especially designed for the use of Students. By ROBERT BENTLEY, M.R.C.S. Eng. F.L.S. With 62 Illustrations on Wood. Crown 8vo. 7s. 6d.

~~~~~  
London: LONGMANS, GREEN, & CO.

SURGICAL OPERATIONS

PRINTED BY
SPOTTISWOODE AND CO., NEW-STREET SQUARE
LONDON

A SHORT MANUAL
OF
SURGICAL OPERATIONS

BY

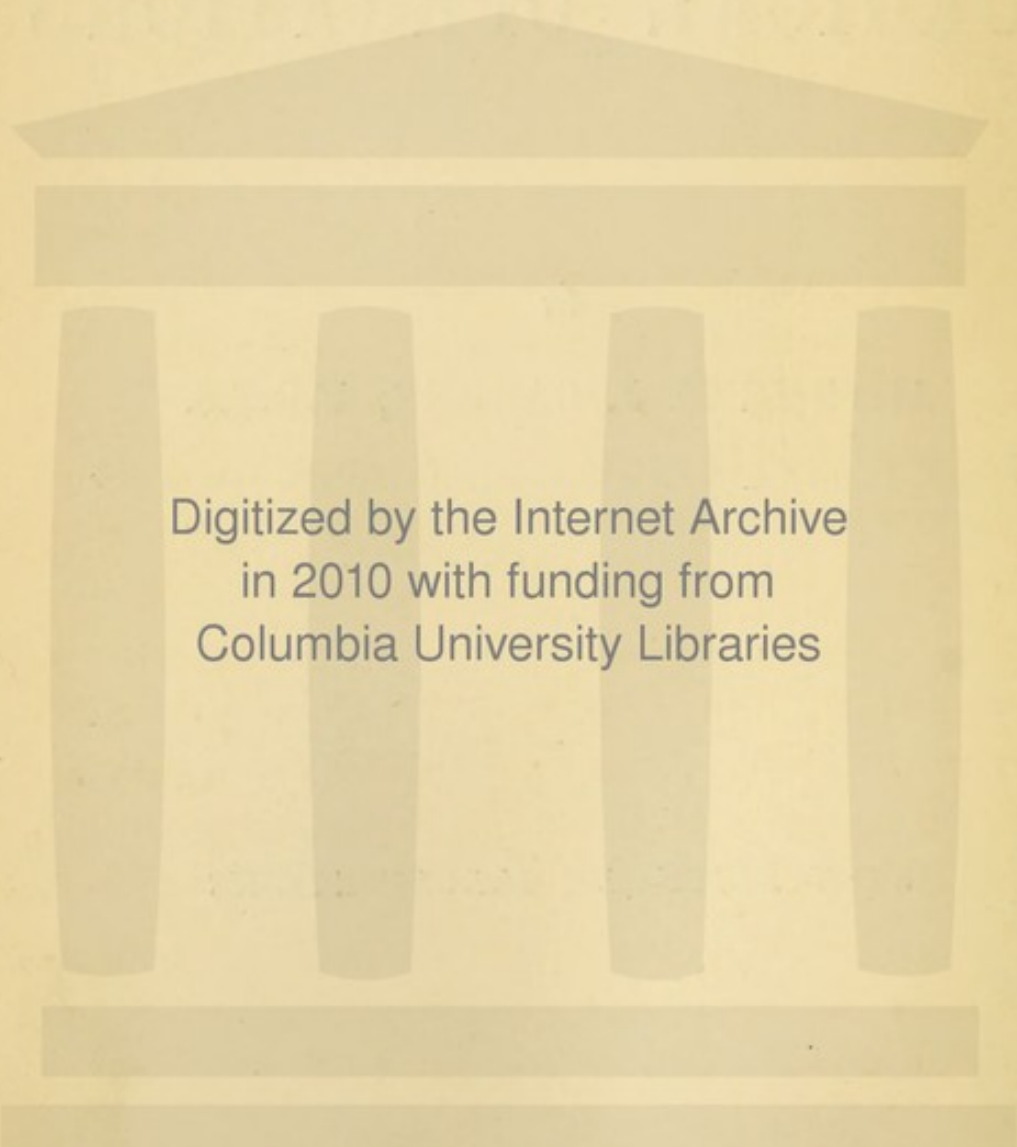
ARTHUR E. J. BARKER, F.R.C.S.

SURGEON TO UNIVERSITY COLLEGE HOSPITAL; ASSISTANT-PROFESSOR OF
CLINICAL SURGERY AND TEACHER OF PRACTICAL SURGERY
IN UNIVERSITY COLLEGE, LONDON

WITH SIXTY-ONE ILLUSTRATIONS

LONDON
LONGMANS, GREEN, AND CO.
AND NEW YORK : 15 EAST 16th STREET

1887



Digitized by the Internet Archive
in 2010 with funding from
Columbia University Libraries

PREFACE.



IN writing this small work at the request of some better qualified to judge of the need of a Short Manual of Operative Surgery than himself, the author has fully recognised the difficulty of the task. On the one hand, Operative Surgery has made such vast strides of late, owing to the recognition of the antiseptic régime, that a book which should give an account of *all* its most recent achievements alone would have to be large; while, on the other, many of the older procedures, which are gradually being supplanted by newer operations, could not yet be left out of any manual which in the least aspired to completeness. The difficulty, in short, appeared to resolve itself into one of the selection of those of the newer procedures which ought to be familiar to all practitioners, and of those older ones which, for a time at least, are not likely to fall into disuse. In carrying out this selection the author has striven to describe the older and presumably better known operations as shortly as possible, so that in dealing with the newer and less familiar procedures more space might remain for detailed description. But even here it has been necessary to exercise much self-denial, and to condense the account of many important

operations, sometimes much more than inclination would prompt.

To the defects incidental to this plan of treatment of such a wide subject the author is fully alive. But it is hoped that these short sketches from the hand of one who has been in the midst of operative surgery for many years may be of use to others, and may be none the less so that they are coloured in almost every case largely by his own personal experience.

For any faults in the little figures and diagrams the author is alone responsible, all of them, with eight or nine exceptions, being of his own drawing. Whatever has been lost in artistic finish by constituting himself his own draughtsman has perhaps been compensated for by the figures representing the author's own ideas, and being thus more in harmony with the text than if drawn by another.

A. E. B.

HARLEY STREET, W.:

September 10, 1887.

Errata.

After Fig. 25 *read* 'after Lister (adapted).'

„ „ 36 „ 'after Quain (adapted).'

A MANUAL
OF
SURGICAL OPERATIONS.



CHAPTER I.

*PRELIMINARY REMARKS ON SURGICAL
OPERATIONS IN GENERAL.*

IN approaching the consideration of the surgical operations of the present day, it is assumed throughout this work that each and all are conducted upon the strictest principles of what is now known as the 'antiseptic' or 'aseptic' system of wound treatment. It is taken for granted once for all that whatever the operation may be, whether great or small, whether for injury, disease, or deformity, the field of operation shall be rendered ideally clean beforehand, not only by ordinary ablutions, but by careful washing in one or other of the many valuable germicides now in use. Again, it is understood that the hands of both the operator and his assistants, all instruments, sponges, and utensils, and whatsoever is likely to come in contact in any way with the wound during or after operation, shall be similarly cleansed immediately before use. Further, that on the completion of the operation the wound shall be enveloped in some of the many forms of antiseptic dressings designed

as to shape and material to receive and distribute the first sanious discharge whether little or much, and protect the latter as well as the wound from access of ferment-laden air, and, in the presence of this, to neutralise its putrefactive influence ; and also so designed and arranged as to provide an even elastic support to the parts engaged in the field of operation, and thus give rest and check oozing. Finally it is insisted on that the same precautions in manipulation and dressing shall be observed until the termination of the case.

It is necessary to start with this understanding because many operations are considerably modified both in design and execution by the acceptance or rejection of the principles advocated and formulated by Sir Joseph Lister. With the more detailed modes of carrying out these principles in practice, by the use of one or other antiseptic material for washes and dressings, or by the employment or rejection of the spray apparatus, we are not concerned in this work ; but the principles must be understood to be insisted on if the procedures detailed in the following pages are to be clearly intelligible. Starting on this understanding, descriptions of operations can be made briefer than otherwise, and many repetitions can be avoided.

Turning now to the more immediate question of operative procedure, it will be found convenient to follow a certain common plan in considering our line of action in each case. The surgeon is advised to attend carefully to the following points before commencing an operation :—

He should personally overlook (1) the collection and arrangement of the instruments and other mechanical requisites for the operation and their condition ; (2) the position of the patient's body ; (3) his own position and that of his assistants in relation to the patient ; (4) he should have clearly in his mind's eye the direction and

length of the first incision, and the landmarks for the operation from its commencement to its completion.

The habit of reviewing these matters carefully beforehand in all operations will conduce to their rapid and accurate execution, and so will often materially influence their result. If it be true that rapidity of execution is not now of such paramount importance as in the days before anæsthetics and the elastic tourniquet, it is also equally true that accuracy of detail should be more than ever one of our chief aims in operating.

In the following pages these points will be considered in relation to each group of operations at the head of special sections, but, where necessary, they will be reviewed in respect to particular procedures besides.

It is sometimes implied that to carry antiseptic principles into practice efficiently involves the preparation of an elaborate paraphernalia of dressings, &c. Experience is disproving this more and more every day, and is demonstrating that the surgeon thoroughly imbued with the principles may content himself with a very simple practice in most cases and be thoroughly successful in attaining to perfect asepsis in operating. The author ventures to think that the following brief sketch of what he finds, after a long trial of various methods, to be that best suited for the management of most ordinary recent wounds, may prove of use, at all events, to those operating alone who cannot command more elaborate methods.

The first care of the surgeon should be to see for himself that his sponges, ligatures, and dressings are in the best possible condition for use.

The preparation of sponges is a little troublesome, but well repays all the care bestowed. The best sponges for surgical purposes are undoubtedly the finest 'Turkey' varieties, ranging from the size of the fist downwards, but

other coarser sorts may also be used. They should vary in shape from the spheroidal to the thinnest, flattest form that can be procured. They are first soaked for a few days in diluted hydrochloric acid until all the minute shells and the calcareous sand which they contain are dissolved out, when they will be found to be much softened. They are then rinsed in hot water and stored in a five per cent. solution of pure carbolic acid (absolute phenol). During operation they should go straight from the wound into water, in order that the blood may be rinsed out of them before they are washed in the carbolic solution and used again. After the operation they should be immediately well soaked in warm water, then for a day or so in a solution of borax soap powder or of common rock-salt. This will remove the last traces of blood from them, after which they are again well rinsed in warm water and placed in the carbolic solution as before. Wide-mouthed glass or stone jars, well covered, are the most convenient vessels for their storage. They should never be put away in these except in an absolutely pure state; a sponge which is not in this condition is one of the most dangerous materials which could approach a fresh wound, and where a patient's life is concerned we must of course spare no pains to eliminate every risk. It is very remarkable how tenacious sponges are of blood and other albuminous fluids, and nothing but the most thorough treatment of them at once will suffice to extract these; any delay renders the difficulty of cleansing them, and the probability of their becoming the soil for the growth of organisms, very great.

The choice of ligatures and sutures for most ordinary operations lies nowadays practically between catgut, either carbolised or chromicised, silver wire, and carbolised silk. Of these excellent substances the author gives the preference decidedly to the last. The two first are not


always easy to be procured of good quality, and are often unreliable as to the amount of their absorbability: the latter is easy to obtain all over the world, simple to prepare, and, though it is not soon absorbed, it is, if absolutely aseptic, perfectly innocuous when left in any of the tissues of the body. It is easy to thread through the smallest needles, is strong even when very fine, and the knot made by tying it is more secure than that of catgut. Having experimented on the preparation of several of the very best kinds of silk, the author gives the preference to the hardest twisted varieties, for many practical reasons. The mode of preparing it is very simple. It is first tested as to its general strength and the presence of possible flaws or knots, by straining it with the hands in lengths. It is then wound up on a glass rod or strip (a microscopic slide-glass answers very well) and boiled in a beaker of 5 per cent. solution of absolute phenol (carbolic acid) for half an hour. It is now ready for use, but if not required immediately may be kept for an indefinite time in the same solution in a stoppered glass jar. It does not appear to lose its strength in the least when thus prepared, but becomes somewhat closer in the grain and more wiry, a property which has several advantages. Thus prepared and introduced into the tissues without subsequent contamination or undue violence in tying the knot, silk will remain in any part of the body without producing the slightest irritation, whether it be used for arteries or veins, or for the suture of skin, intestine, or other deeper tissues. Except in the case of arteries it is well not to tie this silk very tight. If this is done, there may be a little strangulation of tissue and consequent irritation. One has often noticed the difference when the edges of the skin, for instance, have been very sharply nipped by a ligature, and when simply brought together. In the first place, the ligature has tended to cut

its way out, and this has often been erroneously set down to impurity in the material, when it was really a question of strangulation; in the last, it has remained quiescent for weeks, and then come out perfectly dry. Silk of this kind has all the good properties of silver wire without its drawbacks.

While claiming much catholicity of taste in the matter of dressings, the author has of late years employed salicylic wool more and more for all ordinary fresh wounds. Where there is likely to be much fluid secretion of any kind, as, for instance, in the case of the drainage of an empyæma or psoas abscess, it is less suitable than some of the coarser fabrics, such as carbolised gauze, jute, or waste silk; but for amputation wounds, or those made for the removal of tumours or other clean cuts into soft tissues, I would personally give it the preference to all other textures for several reasons combined. Among these may be mentioned that its antiseptic properties are quite equal to the demand made upon it in the class of wounds alluded to; it is elastic and takes the form of a part without losing its elasticity and 'caking'; it may be kept an indefinite time without spoiling; it is relatively cheap. When it is to be used the author finds it most convenient to have one of the ordinary packets unrolled flat and as much as is required cut with scissors into strips about two and a half inches broad and a foot long. These strips, about an inch in thickness, can then be laid in any direction along the edges of the wound without dispersing the acid, which is irritating to the air-passages both of patient and surgeon. In using these strips the author finds it best first to apply one on each edge of the wound, so that a small crevice shall be left between them corresponding to the latter, and no obstruction shall be offered to the escape of the first ooings. Over these first strips others are placed at various angles until a thick pad

is formed, through which graduated pressure can be brought to bear on all parts of the wound. The bandaging of these is a matter which requires some experience. On the one hand, the pressure must be firm and even, and on the other, not too great. The aim should be in every case to bring the deeper parts of the wound into apposition while leaving the points suited for drainage without much pressure. The mode just described of adjusting the wool in strips is preferable to applying it in one or more large masses at once, not only because the pressure can be better graduated, but also because there are more interspaces provided thus for the reception of discharges if present. Of course other antiseptic fabrics may be used in the same way, both iodoform and sal alembroth wool, for instance; but the first of these at all events is much more expensive without possessing any corresponding superiority as an antiseptic, except in the case of very free and foul discharges, and in this case it is a question whether wool of any kind is a good dressing.

Next to working with absolutely pure materials and implements, the rendering of the wound perfectly dry before it is finally closed comes next in importance. Every visible blood-vessel has first to be closed, either by forcipressure, torsion, or ligature—then every other kind of oozing can be checked, as a rule, by pressure. The most convenient way of applying this is by means of sponges laid well into the wound and held there until this end is attained. When it is seen that the bleeding has ceased at all points the suturing of the edges is proceeded with. But while the stitches are being introduced one or more sponges should be still left in the wound, only to be removed at the last moment. With this end in view all the stitches may be inserted, but not tied; then the sponges are drawn out, and while an assistant presses on the edges and surround-



ings of the wound and brings its deeper surfaces into contact as well, the surgeon rapidly ties the whole row evenly and steadily. All this time the pressure over the part is not relaxed, and should not be until replaced by the graduated pressure of the dressing. In this way all oozing within the wound is prevented, and the deeper surfaces are kept accurately in contact. If, in place of this, a space is left under the skin and among the deeper structures, oozing of blood or serum is certain to take place into it, and either healing is delayed, or at all events a most favourable soil for the propagation of septic organisms is spread out among the planes of the wound. In most cases a drain-tube should be inserted, to allow the escape of possible effusion. But it must be remembered that this is not always necessary, and that a clean dry wound, even though deep and wide-reaching, will often heal *per primam* without a drain-tube. Nothing but experience, however, can teach us what cases demand a tube and what may be trusted to heal without one, so that it is better to follow the rule of employing one from the first in all serious wounds, watching always for those cases where it can be removed very early, and for others in which it may be dispensed with altogether. Sometimes a strand of carbolised gut or horsehair inserted in the angle of a wound will suffice for the drainage of the serum or blood first effused; but it is better to aim at preventing this effusion altogether, and this can often be done to a large extent by graduated elastic pressure, and that rest of the part which is secured by a permanent elastic dressing.

A covering properly applied as above, on fresh wounds, should not need to be removed for several days, or perhaps for weeks. It must be remembered that the only object in taking away a dressing such as this would be to get rid of material soaked with discharge, to allow of the escape of

pent-up fluid, to remove a drain-tube or stitches. Now, if there be but a trace of blood or serum in the dressings, the latter often need not be disturbed at all until the end of the case. If the effusion be moderate, the dressings may still be left for two or three days intact; the patient and the wound in the meantime having the benefit of rest. Where there is much effusion or suppuration, of course the dressing will have to be changed early. The surest guide in all cases is the temperature, when studied with the patient's general condition. A rise of two or even three degrees within the first couple of days, unaccompanied by malaise, anorexia, headache, thirst, throbbing or tenderness about the wound, or tenderness over the nearest lymphatic glands, need not excite any uneasiness, or call for removal of the dressings. But if these subjective phenomena are present, together with even a slight rise of temperature, the part must be inspected at once, and pent-up fluid must be sought for. With due attention to these points, it has been my custom for a long time past to leave the wool dressings intact, as a rule, for many days, in most cases, and I have thus accumulated a long series of cases in which even deep wounds have been perfectly healed in one, two, or three dressings. Permanent antiseptic wool dressings are destined to play an important part in operative surgery henceforth; but their use will not prove a safe or successful practice except in the hands of those who have mastered the details of the antiseptic system. As to the removal of stitches, this may often be postponed until the end of the case, if good silk be employed. I have not unfrequently demonstrated them weeks after operation, lying perfectly without reaction in the edges of the skin, and perfectly dry when ultimately removed.

CHAPTER II.

OPERATIONS ON THE ARTERIES.

LIGATURE OF ARTERIES IN THEIR CONTINUITY.

GENERAL CONSIDERATIONS.

The Instruments required for ligature of arteries are few and of the simplest kind, whether the vessel be large or small, deep-seated or superficial. The most troublesome to deal with will rarely require more than are contained in the following list:—A medium-sized scalpel; dissecting and artery forceps; blunt hooks and broad metal retractors; a grooved director; an aneurism-needle; ligatures; needles; dressings.

These should all be arranged within reach of the operator in trays containing enough carbolic solution (1 in 20) to cover them completely.

Of the ligatures only is it necessary to make a few general remarks. The choice at the present day of material for these lies between prepared catgut, either carbolised or chromicised, kangaroo-tendon or ox-aorta tissue prepared likewise with carbolic acid, and twisted silk boiled and preserved in carbolic solution (1 in 20) (*vide* p. 5). All these are excellent in their way, but the author gives the preference to the last. The first are not always to be obtained of good quality, and are often unreliable as to their degree of absorbability. The third and fourth are likely to gain

favour in time ; but good silk is very easy to procure, and though it does not appear to be easily absorbed, it is, when thoroughly aseptic, quite innocuous in the tissues, where it becomes encapsuled at first, and ultimately absorbed in all probability ; furthermore it is easy to tie, and the knot holds better than is the case with any of the other substances.

Whatever material is used, our antiseptic ligatures are now always cut short and left in the wound. The older practice of leaving them hanging from the latter until they had cut their way out is almost universally abandoned since the general adoption of the principles of antiseptic surgery.

The Position of the Patient is another point which should be specially attended to in all operations on arteries, the success and comfort in dealing with them depending in a great measure on this detail. For most of the formal operations the matter is simple : the patient is placed supine. The only exceptions would be for the gluteal, sciatic, and popliteal arteries ; but ligature of these may almost be regarded as obsolete operations. But though the body lies supine for all, the best position for the limbs and head will vary for almost every procedure, and will be considered specially before the description of each.

The Position of the Operator and his **Assistants** is also a matter of importance and will be indicated in discussing each operation.

The Position of the Knife in the Operator's Hand is a point next to be considered. For the first incision through the skin the best is that known as the 'dinner knife position.' In this the end of the handle rests in the palm, between the heads of the metacarpals of the index and middle fingers, the shoulder of the knife being grasped by these two fingers and the thumb, the pulp of the index resting upon the back. For the deeper part of the dis-

section the 'writing position' is better suited, *i.e.* the knife is held for cutting as the pen is for writing. When dividing the skin the blade is held as perpendicular as possible both at the beginning and end of the cut, so that there may not be any 'tailing off' of the wound. The superficial structures under the skin are divided in the same way, but on reaching the sheath of the artery much caution is necessary. This structure is best divided by pinching up a small portion in a dissecting-forceps and cutting it towards the instrument with the knife-blade held flat. If it is to be further opened, this may be done on a director, or by still cutting on the forceps. Any forcible tearing in this situation is to be avoided, lest the nutrition of the artery or vein be damaged. Nor is the artery to be separated widely from its sheath. It should be cleaned to a limited extent, sufficient for the easy passage of the needle underneath, but dealt with very gently.

The skin incisions made by young operators in ligaturing arteries are usually too short. It would perhaps be well if some regular standard were adopted, fairly representing the general opinion. Thus we might have a two-inch, a three-inch, and a four-inch incision for adults. Then we should have no difficulty in remembering that at the ankle a two-inch incision was always required, and in the leg, thigh, and pelvis a three-inch incision; again, for the wrist and forearm two inches would be the length, and for the arm, axilla, and neck always three inches. The aorta, if tied, will require a five-inch cut in the skin.

The Landmarks for Incision and Operation.—In deligation of arteries, more almost than in any other species of operation, the landmarks on the surface of the body should be studied and remembered. These are usually derived from bony points, or the outline of prominent muscles or

tendons. They will be described in dealing with each separate artery.

It should be remembered that the aneurism-needle as a rule is passed under the artery from the side at which the greatest danger lies, *e.g.* the presence of a vein or nerve. When the ligature has been passed under an artery, the latter should be compressed for a moment between it and the finger, while pulsation is felt for at a point lower down, to make sure that the circulation is quite controlled before the thread is finally knotted. Then the fingers are carried down close to the vessel along the ligatures so that the strain on the threads shall not drag on the artery while the knot is being formed. In making the second part of the knot the strain should not be so great as in the first, as the thread is apt to cut upon itself, especially if of silk.

The first dressing after ligature of arteries is, in the case of the larger vessels, the formal Listerian gauze packing, &c. But in some of the smaller arteries, where only shallow wounds are made, the latter may be accurately stitched up at once and covered with a dry, permanent antiseptic dressing, *e.g.* a pad of iodoform or salicylic wool, deep as well as superficial union by first intention being aimed at.

It should be borne in mind throughout the whole operation that in order to have a dry wound during the healing process, as well as for the sake of finding the artery readily and safely, all bleeding points should be attended to at once and closed by catch-forceps before any further dissection is proceeded with.

Although questions of special treatment are as far as possible to be limited in this work, the after-management of a limb, or ligature of its main artery, must be noticed as almost part of the operation. The first danger in a case

of the kind being gangrene of the part from arrest of its blood-supply, the whole limb should be protected against any further accidents which may interfere with its vitality. It should, in the first place, be well wrapped up in cotton-wool, and thus shielded against alternations of temperature. Hot bottles (in winter) may be placed in the bed, but not near the limb. The latter should be kept in a state of absolute rest. Light nutritious diet, which will not increase arterial tension, is demanded, and the strictest quiet, mental and physical, is to be enjoined. If a permanent dressing is used there will be of course less risk of disturbance about the seat of ligature throughout the after-treatment of the case; but if other methods are employed which require frequent changing of dressing, every care must be taken on each occasion not to move the limb or handle the immediate neighbourhood more than is absolutely necessary, especially during the second week. As a rule, such operation wounds heal by first intention throughout.

LIGATURE OF THE ABDOMINAL AORTA, BY MEDIAN INCISION.

Sir A. Cooper.

Instruments as above, with the addition of a very long-handled aneurism-needle.

Position of Patient.—Supine, with the thighs slightly flexed over a pillow.

Position of Operator and Assistants.—The surgeon stands on the right side of the patient, with one assistant at his left hand, another standing on the opposite side of the body.

Landmarks for Incision and Operation.—The aorta divides at a point (fig. 1, +) situated about an inch below and a little to the left of the umbilicus, and corresponding to the lower part of the left side of the body of the fourth lumbar vertebra. The median incision will therefore begin

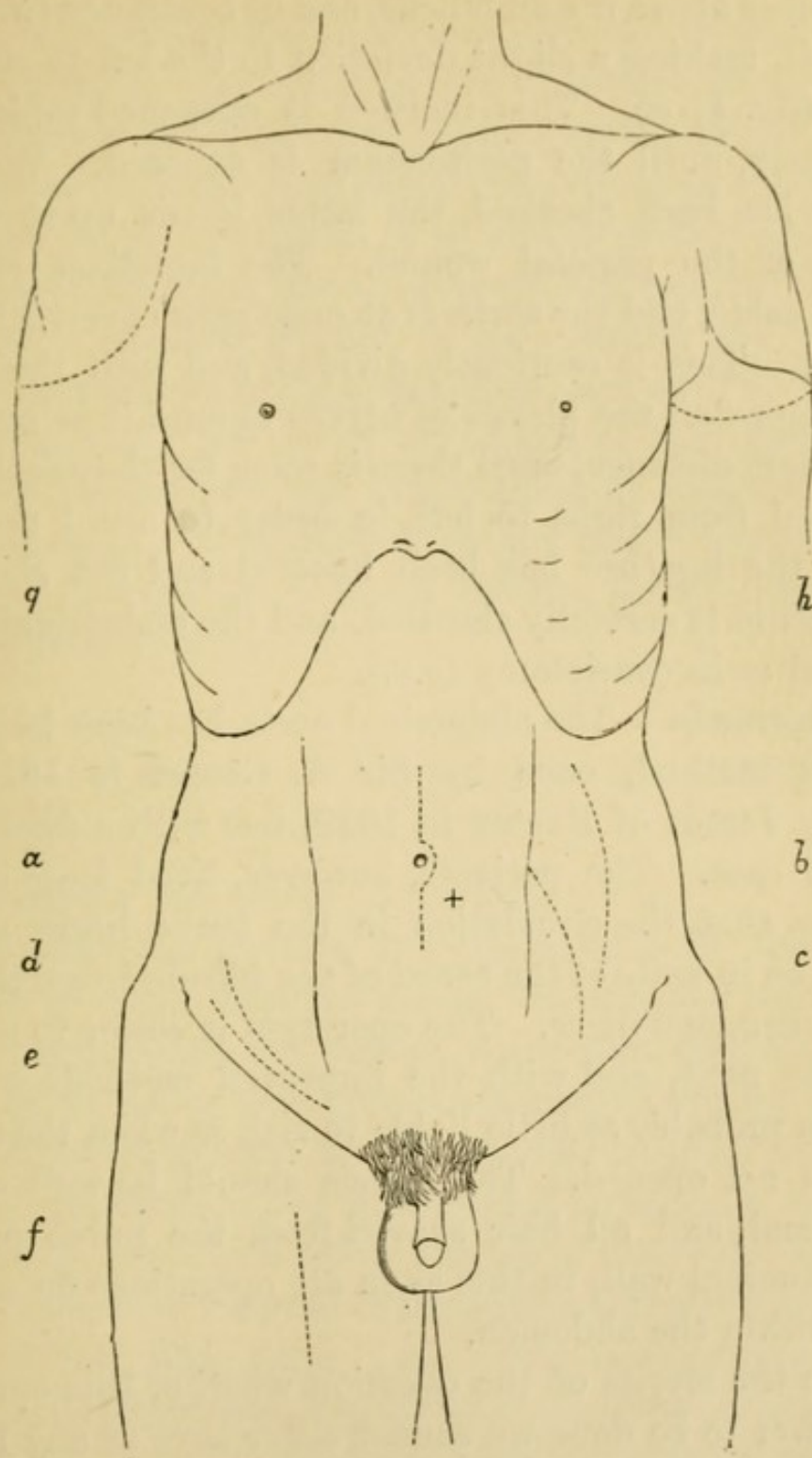


FIG. 1.—INCISIONS FOR LIGATURE OF ARTERIES.

+, Point of bifurcation of abdominal aorta; *a*, Sir Astley Cooper's incision for ligature of abdominal aorta; *b*, Murray's incision for ligature of abdominal aorta; *c*, common iliac; *d*, external iliac (Abernethy's); *e*, external iliac (Sir A. Cooper's); *f*, superficial femoral in Scarpa's triangle; *g*, incision for flap amputation at the shoulder-joint; *h*, incision for amputation at shoulder-joint by oval method.

two inches above the umbilicus, and be continued two inches below it, making a slight deviation to the left to avoid the navel (fig. 1, *a*). This incision is deepened rapidly, but cautiously, until the peritoneum is exposed. When all oozing has been checked, the latter is slit up to the full extent of the parietal wound. The intestines are now turned aside, and the aorta is at once seen covered by peritoneum. This is cautiously divided, and with the forceps and finger-nail the plexus of nerves around it is separated for a short distance, until there is room for the needle; this is passed from right to left, in order to avoid the vein. When the ligature has been knotted and cut short, the peritoneum is carefully cleansed, and the abdominal wound is closed as in ovariectomy (*q.v.*).

Memoranda.—The abdominal aorta has been twice tied by this method, once by Sir A. Cooper in 1817, and once by James of Exeter in 1829, but with a fatal result in each case. The patients, however, lived long enough to show that the circulation in the lower limbs may be carried on in spite of the arrest of the blood-stream through the two common iliacs. The operation is easier to perform than the next, and with the improved methods of anti-sepsis is probably as little liable to risk as when the peritoneum is not opened. The bowels should be well cleared beforehand, and all hair shaved from the pubic parts of the abdominal wall, in this as in all operations on arteries lying within the abdomen.

Into the merits of the question whether this operation ought ever to be done we cannot enter here at any length. It is enough to remark that cases have been met with in which surgeons of the greatest eminence have considered it to be their duty to tie the abdominal aorta as the best means within their reach of averting great danger from their patients. That it may one day be successful is pos-

sible ; nevertheless, the most serious objection to the operation will probably never be removed, namely, that when an aneurism of the iliac vessels has grown to such a size that nothing but ligature of the abdominal aorta will check the flow of blood through it, it is almost certain that the latter vessel too will be gravely diseased and unfitted by the degenerative changes present in its coats for the plastic processes necessary for the permanent closure of its lumen at the point tied. In the earlier stages of the disease no surgeon at the present day would think of ligaturing the abdominal aorta. If performed for wounds of branches of the latter, the operation would have a better chance of success if done in time.

LIGATURE OF ABDOMINAL AORTA, BY LATERAL INCISION.

Murray's Method.

Instruments, &c., as for the last operation.

Landmarks for Incision and Operation.—In this case the aim is to reach the aorta without opening the peritoneal sac, thus minimising the risk of peritonitis, and avoiding the intestines, which may give much trouble during operation by the other method, as was the case with Mr. James's patient. An incision five inches long is made on the left side from about an inch below the tip of the tenth rib to a point an inch or so internal to the anterior superior spinous process of the ilium (fig. 1, *b*). This is rapidly carried down to the peritoneal lining, which is then stripped off from the abdominal wall behind, until the vessel is reached from the side. Holding the peritoneum over to the right with broad retractors, the assistant hooks his finger in the external lip of the wound, and so makes room for the operator. The latter now endeavours to clear the vessel of

nerves and the peritoneum with his finger-nail, having due regard to the inferior vena cava on the right side. This part of the operation is 'tedious rather than difficult.' When cleared, the vessel is ligatured by means of a long needle, and is closed as tightly as possible. The union of the wound in the parietes by deep-reaching sutures completes the operation. A drain-tube should be inserted in the lower angle.

Memoranda.—This operation, first planned by Murray in 1834, has been performed in six or perhaps seven cases, but in all with a fatal result. In one case, operated on by Dr. Monteiro of Rio Janeiro, however, the patient lived for ten days without any untoward symptoms or affections of the lower limbs. In this instance the ligature was found to have ulcerated through the artery, the cause of death being secondary hæmorrhage. It seems possible that with antiseptic precautions and perfectly pure ligatures, a better result may be obtained in the future, ulceration of ligatures through the arterial coats being nowadays an exceptional occurrence. But the presence of disease in the arterial walls will remain the great objection to the operation. If the abdominal wound be not accurately brought together, there will be a great tendency to hernia. The bowels should be carefully unloaded by enemata, and the abdominal wall cleansed and shaved before operation in all cases.

LIGATURE OF THE COMMON ILIAC ARTERY.

Instruments, &c., as above.

Position of Patient.—Supine, with the thighs extended and the skin of the groin tense at first; later, the thigh is flexed a little to allow relaxation of the structures over the artery.

Position of Operator and Assistants.—The operator may stand on the left side of the patient for both arteries, the incision being then made from below upwards in each case. One assistant stands on his left, the other at the opposite side of the body.

Landmarks for Incision and Operation.—The arteries are found on either side of the body, in a line slightly curved outwards, running from a point (fig. 1, +) an inch below and to the left of the umbilicus, to the middle of Poupart's ligament; that is, from the lower border and left side of the fourth lumbar vertebra to a point midway between the anterior superior iliac spine and the spine of the pubis. The first incision (fig. 1, *c*) is to commence an inch and a half above and external to this latter point, and run upwards with a curve an inch and a half external to the line indicated for fully four inches. It divides the skin and superficial fat, and exposes the external oblique muscle. The latter is now divided to the same extent, either with or without a director. With a steady hand and good light the latter method is to be preferred. The internal oblique is divided in a similar manner, but the transversalis is more safely opened up on a director. The fascia transversalis is now exposed and notched at one end of the incision, by pinching it up in the forceps and cutting with the knife held flat. The director is introduced through this opening, and the fascia is cleared by a little lateral movement of the instrument, and raised so as to be safely slit up to the end of the incision. The knife is not to be carried quite to the end of the groove in the director, as the peritoneum may overlap this a little. The latter is now separated by the finger and pressed inwards and is thus held by a broad copper spatula, another drawing the outer lip of the wound towards the crest of the ilium. The artery is easily found as it lies on the prominent bone,

and its sheath is cleared. The latter is then seized in a forceps and opened by a short stroke with a knife cutting on its points. Through the button-hole opening thus made the aneurism-needle, armed with a carefully chosen ligature, is passed under the vessel from right to left, whether on the right or left side of the body. When the eye protrudes from underneath the artery the ligature is caught in a forceps, and the needle is withdrawn with as little disturbance as possible of the parts. The ligature is then knotted firmly with the points of the fingers.

Memoranda.—The vessel has so short a course that we must be careful to place the ligature as near its middle as possible. Both common iliacs have their vein to the right and on a plane posterior to themselves. They are crossed by the ureters at their termination, but these are usually quite out of the way, being carried inwards with the peritoneum, to which they adhere, as do also the spermatic vessels. In closing the wound in the parietes the sutures should include the muscles and fasciæ, and a drain-tube should be inserted deeply.¹

This operation was first performed by Gibson of Philadelphia, and has since been frequently repeated, but with very discouraging results. In 1860 a collection of all the cases of ligature of the common iliac artery known was published in the 'American Journ. of Med. Sciences,' by S. Smith.² Of these, thirty-two in number, only seven recovered. The operation is at the present day regarded with much disfavour, especially as increased experience in the treatment of aneurism without ligature has shown how much can be done in this way.

¹ The bowels should be unloaded by enemata, and the abdomen cleansed and shaved before operation.

² Quoted in Holmes's *System of Surgery*, vol. iii. p. 146.

LIGATURE OF THE INTERNAL ILIAC ARTERY.

This is a very rare operation, and only called for on account of unmanageable hæmorrhage from wounds or aneurisms of the gluteal or sciatic arteries. The incision necessary for reaching the vessel and the various stages of the operation are essentially the same as in the case of the common iliac, and need no special description here.

LIGATURE OF THE EXTERNAL ILIAC ARTERY.

Abernethy's Method modified.

Instruments, Position of Patient, Operator, and Assistants as for the common iliac artery.

Landmarks for Incision and Operation.—Remembering the direction of the common and external iliac arteries as given above, and feeling for the vessel as it passes into the thigh, two points are marked, one an inch above and an inch external to the middle of Poupart's ligament, the other an inch above and internal to the anterior superior spinous process of the ilium. A four-inch curved incision is made with its convexity downwards (fig. 1, *d*) uniting these two points, starting or terminating at the lower one, according as the surgeon stands on the right or left side of his patient. The surgeon may stand on the left side for both arteries, in which case the incision would always start from below. This wound is, as a rule, clear of the deep epigastric and circumflex ilii arteries, and does not open the inguinal canal. It should sever the skin and superficial fat at once and expose the external oblique muscle. The latter is now divided to the same extent, either by a firm steady cut with a free hand, or on a director slipped carefully under it. The internal oblique and transversalis are similarly dealt with, the latter being

always severed on a director, as it is very thin. The transversalis fascia is now laid bare, usually covering some sub-peritoneal fat, and is taken up with care on a director throughout the whole extent of the wound, the instrument being insinuated with slight lateral movements. The knife, in running along the groove to slit up the fascia, is not carried quite to the end, which may be overlapped by the peritoneum. The latter is now pressed gently inwards by an assistant with a broad metal retractor, while the operator's finger seeks the vessel. This is easily found running along the brim of the pelvis, having its vein to the inner side and the genital branch of the genito-crural nerve lying upon it. When it has been cleared by a little scraping with the back of the knife, the needle is passed under it from within outwards, avoiding the vein, the genital branch of the genito-crural nerve anteriorly, and the anterior-crural internally. The artery should be exposed as little as possible, only the eye of the needle being brought forward on the outer side far enough for the ligature to be seized. As the needle is withdrawn, its back being towards the peritoneum, it is not likely to wound the latter or the vein. The operation is completed by the knotting of the ligature and closure of the parietal wound by deep sutures as above.

Memoranda.—From its origin usually opposite the sacro-iliac synchondrosis to its termination at Poupart's ligament, this artery gives off no named branches except the deep epigastric and circumflexa ilii which rise as a rule within half an inch from the ligament. Sometimes these have a higher origin, in which case the ligature must be placed higher up. It is usually applied a little below the middle of the vessel. Some twigs of the superficial epigastric artery are usually divided in the first incision, and must be attended to before the deeper part of the dissection

is proceeded with, in order that the field of operation may not be obscured. Some operators prefer to tear the transversalis fascia open with the fingers rather than divide it with a knife, and this has its advantages. It may be easily done in fat patients. In a perfectly aseptic dry wound a notch of the peritoneum is not of much consequence, though of course it should be avoided most carefully. Here, too, the bowels should be thoroughly unloaded, and the abdominal wall cleansed and shaved before operation.

The external iliac artery was first ligatured by Abernethy in 1796, and since then the operation has been frequently repeated with success. According to Norris and Cutter's tables, quoted by Holmes,¹ out of 153 cases in which the artery was ligatured, 47 died, 43 at least as the result of the operation. Of these 17 succumbed to gangrene of the limb and 3 of sloughing of the sac; 9 died of hæmorrhage, 5 of peritonitis, 1 of pelvic abscess, 1 of diffuse inflammation, 3 of exhaustion, 1 of pleurisy, 2 of tetanus, and 1 of delirium tremens; 2 were unaccounted for. It will be seen from these tables that death in half the cases which succumbed was due to causes which might probably have been prevented by careful attention to anti-septic details, and that consequently we may expect much better results in the future.

LIGATURE OF THE EXTERNAL ILIAC.

Sir A. Cooper's Method.

Preliminaries as in the last operation.

Here the inguinal canal is opened up and the whole incision is placed lower down and more internally than in the last operation.

¹ *System of Surgery*, vol. iii.

Landmarks for Incision and Operation.—From a point half an inch to the outside of the external abdominal ring and half an inch above Poupart's ligament, an incision (fig. 1, *e*) three inches long is made in the direction of the fibres of the external oblique muscle outwards and upwards to a point an inch internal to the iliac spine. When the muscle is exposed it is opened below by a small notch with a knife, raised on a director and slit up to the full extent of the incision. The upper edge of this wound being raised, the cremasteric fibres and transversalis fascia are torn through with a director and forceps opposite to the internal inguinal ring, until the finger can be thrust through the latter, and the cord drawn upwards and inwards. The wound in the internal oblique and transversalis fascia is now extended outwards, while the cord and peritoneum, and with them the epigastric artery, are drawn inwards and upwards with a broad spatula. The iliac artery may now be felt with the finger, surrounded with some condensed areolar tissue. This has to be carefully torn through before the needle can be passed under the vessel from within outwards, care being taken not to include the genital branch of the genito-crural nerve. The rest of the procedure does not differ materially from the last.

Memoranda.—This operation has the advantage of coming directly down on the vessel without much disturbance to the peritoneum, and with less weakening of the abdominal wall. It has the disadvantages that without much care the deep epigastric and circumflex arteries and vein may easily be wounded, and if ligatured their valuable anastomoses be lost; further, the main artery is not as fully exposed as is desirable, and if so the prolongation of the incision upwards is not so satisfactory as in the last operation.

LIGATURE OF THE COMMON FEMORAL ARTERY.

This operation may now be considered as almost obsolete, having been abandoned in favour of either ligation of external iliac or superficial femoral. It will not therefore be described.

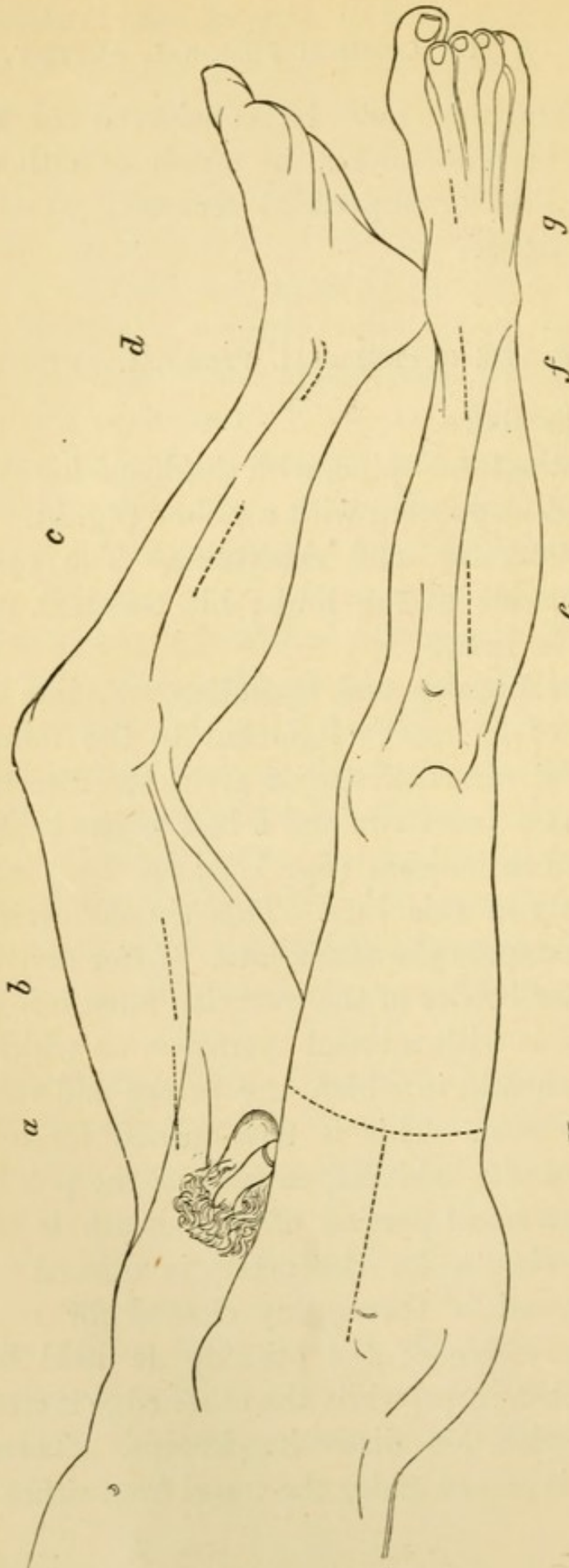
LIGATURE OF THE SUPERFICIAL FEMORAL ARTERY.

Instruments as above.

Position of Patient.—Supine, with thigh and leg slightly flexed and everted, supported with a pillow (fig. 2).

Position of Operator and Assistants.—The operator stands on the outside of the limb; his assistant on the opposite side of the body.

Landmarks for Incision and Operation.—A line drawn from the middle of Poupart's ligament to the most prominent part of the internal condyle gives the direction of the artery. From a point two and a half inches below the ligament, a four-inch incision (fig. 1, *f*; fig. 2, *a*) is made downwards directly in this line. This should divide the skin and fat, and expose the fascia lata. After division of the latter the inner border of the sartorius muscle is found and drawn outwards with a broad retractor, on which the common fascial sheath, in which the artery and vein are contained, is well seen. This is now opened for a little distance with the knife held flat, cutting on the point of a forceps in which a small portion of the sheath is seized. Then the special sheath for the artery is opened in the same way, the vessel is thoroughly cleared for a short distance, and one edge of the opening is held by an assistant in a catch-forceps, while the other edge is steadied by the surgeon with his dissecting-forceps. Then the needle, unarmed, is passed under the vessel from either side,



H

FIG. 2.—INCISIONS FOR LIGATURE OF ARTERIES OF LOWER LIMB.

a, Femoral in Scarpa's triangle; *b*, Femoral in Hunter's canal; *c*, Post. tibial in middle of the leg; *d*, Post. tibial behind inner angle; *e*, Ant. tibial in upper third of leg; *f*, Ant. tibial in front of ankle; *g*, Dorsalis pedis;

H, Amputation at hip by combined circular and vertical method.

but usually from within outwards, keeping close to the artery in order to avoid the vein which lies behind. No force should be used, nor should more than the eye be protruded at the far side, in order that the nutrition of the arterial walls should not be disturbed more than is necessary. When the ligature is drawn under the vessel the finger should be pressed upon the latter, while the circulation below is observed. If this is satisfactorily arrested the ends are securely knotted, care being taken not to include the long saphenous nerve which may be found crossing over the sheath from without inwards at about the level of the border of the sartorius muscle. The ligature should never be applied higher than four inches below Poupart's ligament, the point selected as a rule being about five inches below, unless a branch be found immediately at this spot. All bleeding from small twigs should be arrested before any attempt to open the sheath of the vessels is made, otherwise the field of operation is obscured to a dangerous extent.

Memoranda.—If the first incision is not directly over the vessel, but to its inside, the adductor longus may be exposed instead of the sartorius, and give rise to a little embarrassment. Remembering that the sartorius fibres run downwards and inwards, and those of the adductor downwards and outwards, the surgeon may correct this error even though his incision be found to be a little misplaced. Another danger of an incision inside of the guiding line is wound of the saphena vein, but this is not very likely to occur.

A small drain-tube should be inserted into the wound so as to reach under the edge of the sartorius muscle, but will not be required, probably, after the second day. After the operation the whole limb should be enveloped in cotton-wool, and placed on pillows in the same slightly flexed

everted position adopted for the operation, every care being taken to keep the patient quiet.

LIGATURE OF THE FEMORAL ARTERY IN HUNTER'S CANAL.

Preliminaries as for the last operation.

Landmarks for Incision and Operation.—The same guiding line is taken for this as for the last operation, but here the incision is made about half an inch internal to it, so that the edge of the sartorius be struck with certainty. The canal lying in the middle of the thigh underneath this muscle, it is important that the latter be defined from the first. A four-inch incision (fig. 2, *b*) therefore is made exactly in the middle of the thigh, and a little internal to the line of the artery as described, and should at once penetrate to the fascia lata. When this is opened the sartorius is found and drawn inwards with a broad spatula, exposing the strong fibrous wall of Hunter's canal. This is pinched up in a forceps and opened for about an inch, when the sheath of the vessels will be seen, and probably also the long saphenous nerve crossing to the inside. Avoiding this, the sheath is opened to a small extent over the artery, and the latter is cleared thoroughly. Then steadying the sheath with forceps on either side, the needle is passed from without inwards, with due regard for the vein, which lies on a posterior plane and a little towards the outer side.

Memoranda.—The incision should not be made below the middle of the thigh, or there is danger of wounding the saphena vein and of coming down upon the fibres of the vastus internus instead of the sartorius, and so missing the artery. There is also the danger of mistaking the anastomotic for the femoral, or otherwise of placing the ligature too close to the former. More care is required here than

above in order to avoid the vein. The operation is not a favourite one, ligature of the vessel in Scarpa's triangle being preferred.

In reference to this operation Mr. Holmes says¹ that out of 204 cases collected by Norris² 50 died. Of these 50 the cause of death is not given in 4. Of the remaining 46 exactly half died of gangrene of the limb, and 8 of hæmorrhage. The rest, it will be seen, on reference to the paper, succumbed to affections which might have been prevented by attention to rigid antisepsis. It is quite probable, too, that the 8 deaths from hæmorrhage might have been prevented in a similar way. In Mr. Holmes's own list of 'primary' ligation of the femoral artery for the ten years preceding 1874, there are 77 cases, of which only 11 died, showing a very marked improvement on former statistics. Indications are already given in more recent collections of cases that the chief dangers of the operation are gradually being eliminated. Thus Mr. Syme ligatured this artery 37 times without a single death, and future results will probably approach more to his experience than to those of the statistics just given.

LIGATURE OF THE POPLITEAL ARTERY.

Instruments as above.

Position of the Patient.—Prone, with legs extended.

Position of Operator and Assistants.—The operator stands on the left side of the patient, with his assistant opposite to him.

Landmarks for Incision and Operation.—The middle line of the space gives the direction of the incision, which should reach from the outer border of the semi-membranosus

¹ *System of Surgery*, vol. iii.

² *American Journal of Medical Science*, 1849, vol. xviii.

muscle downwards for quite three inches. After the skin and fascia have been divided, the internal popliteal nerve is first exposed and is drawn outwards, while the muscle is drawn inwards. Then the vein appears superficial and a little external to the artery, but closely applied to it. This is separated with the utmost caution, and is held outwards while the needle is passed between it and the artery. The needle should be threaded.

Memoranda.—Any formal operation on this artery is rarely or ever called for, ligature of the femoral in Scarpa's triangle being always preferred, except in cases of injury of the vessel, when the existing wound is utilised as far as possible to reach the bleeding point. If it is to be tied the point selected should be as high as possible. Were the vessel to be tied low down the relations of the artery, vein, and nerve would be reversed from without inwards while remaining the same as to depth. There would here be an extra element of danger in the presence of the short saphena vein at its termination.

After the operation the patient is placed supine, with the limb flexed over a pillow.

LIGATURE OF THE POSTERIOR TIBIAL ARTERY IN THE MIDDLE OF THE LEG.

Instruments as above.

Position of Patient.—Supine, inclining a little to the affected side, the thigh and knee being flexed and everted over a pillow, and the leg lying on its outer side.

Position of Operator and Assistant.—The operator stands on the affected side of the patient, his assistant opposite to him.

Landmarks for Incision and Operation.—The direction of the artery is given by a line running from the centre of

the popliteal space to a point midway between the internal malleolus and the tendo Achillis. Bearing this line in mind, the inner border of the tibia in its middle third is felt for and an incision (fig. 2, *c*) three inches long is made, parallel to, and from half an inch to an inch behind, it. The gastrocnemius, if seen, is drawn outwards, exposing the tibial origin of the soleus. This is carefully divided to the full extent of the first incision, when the deep fascia comes into view and under it the artery, with its venæ comites and the nerve lying to its outer side. The fascia is carefully slit up, and the needle is passed from without inwards, avoiding the veins and nerve.

Memoranda.—This operation is rarely called for as a formal procedure. In making the deeper part of the dissection we try to avoid, on the one hand, the edge of the gastrocnemius, and, on the other, getting in among the fibres of the soleus and mistaking its tendinous bundles for the deep fascia.

LIGATURE OF THE POSTERIOR TIBIAL AT THE ANKLE.

Instruments, Position of Patient, of Operator, and Assistants as for the last operation.

Landmarks for Incision and Operation.—The internal malleolus is the only guide needed here. Half an inch from its posterior margin and following the line of the latter a semilunar incision (fig. 2, *d*) is made for two inches. This should expose the annular ligament at once, under which the artery with its venæ comites on either side will be easily made out. On dividing the ligament the veins are separated from the vessel and the needle is passed from behind forwards, thus avoiding the nerve as well as the veins.

Memoranda.—If the incision be made too close to the

internal malleolus, the sheath of the tibialis posticus may be opened, leading to some embarrassment. Sometimes the artery divides into its plantar offsets above the middle of the ligament, in which case both branches are tied, if the operation is done for wound of the foot, as is usually the case.

LIGATURE OF THE ANTERIOR TIBIAL ARTERY IN THE UPPER THIRD.

Instruments as above.

Position of Patient.—(1) Supine, with legs and feet extended, or (2) with the knee flexed and the sole of the foot planted firmly on the table, the leg being now vertical (Heath).

Position of Operator and Assistants.—The surgeon in the first case stands on the outer side of the limb; for the second position he sits in front of the shin, his assistant in either case being opposite to him.

Landmarks for Incision and Operation.—A line drawn from a point midway between the head of the fibula and tuberosity of the tibia to the middle of the ankle-joint is the best guide to the general course of the artery. In the upper third of this line an incision (fig. 2, *e*) is made three inches long, dividing the skin and superficial fat. Then the deep fascia of the leg is slit up on a director and the interval between the tibialis anticus and extensor communis digitorum is sought for with the handle of the knife, which is made to separate them. Holding them apart with broad spatulæ, the artery is found lying on the interosseous membrane, with the nerve to the outside and its veins on either hand. The needle is passed from within outwards.

Memoranda.—The division between the two muscles must not be sought for with the edge of the knife, lest their substance should be opened up and the artery missed. It

should be searched for with the finger and knife-handle, working rather towards the tibia than the fibula. This operation is rarely called for.

LIGATURE OF THE ANTERIOR TIBIAL ARTERY IN THE
LOWER THIRD.

Instruments, Position of Patient, Operator, and Assistants as for the last operation.

Landmarks for Incision and Operation.—The same line is our guide as in the last operation. The incision (fig. 2, *f*) is made in this case in the lower third of the leg just over the annular ligament. It should be three inches long and lie half an inch from the external border of the tibia outside the tibialis anticus muscle. On dividing the fascia the latter will be seen accompanied by the tendon of the extensor pollicis longus, which must be drawn outwards. The artery will now be exposed, accompanied by its veins, and with the nerve usually on its external aspect. The needle should be passed from the side at which the nerve lies.

Memoranda.—If the outer border of the tibialis anticus be not exposed by the first incision, a valuable guide is lost, and the interval between the flexor pollicis and extensor communis may be opened up instead.

LIGATURE OF THE DORSALIS PEDIS ARTERY.

Instruments, Position of Patient, Operator, and Assistants as in the last operation.

Landmarks for Incision and Operation.—A line drawn from the middle of the ankle-joint to the space between the bases of the two first metatarsals gives the direction of the artery. A two-inch incision (fig. 2, *g*) is made along this, commencing below the annular ligament, and running

along the outside of the extensor pollicis tendon, between which and the tendon of the common extensor the artery is easily found, having the nerve, as a rule, on its outside. The needle is passed from the side on which the nerve lies, which is not constant.

LIGATURE OF THE INNOMINATE ARTERY.

On general grounds and from the results which have attended the ligature of this vessel hitherto, it is doubtful whether it will not be considered unjustifiable from henceforth. It has been ligatured, according to Mr. Holmes,¹ at least sixteen times up to the present, and, in every case but one, with a fatal result. Besides this, it has been exposed for the purpose of ligation four times, the operation having gone no further on account of disease of the vessel, or of insuperable difficulties. Should it be attempted, the same incisions and the same dissection practically will be required as for ligature of the common carotid artery in its inferior stage (*q. v.* p. 36). Here, however, it will always be necessary to make the second transverse incision (fig. 3, *e*) outwards along the upper border of the clavicle from the termination of the first, and also to divide the sternal attachment of the sterno-mastoid muscle. It may also be desirable, as was done by Cooper of San Francisco, in both cases to resect the sternal end of the clavicle in order to gain easier access to the very deep-lying artery.

LIGATURE OF THE COMMON CAROTID ARTERY BELOW THE OMOHYOID MUSCLE.

Instruments as above.

Position of Patient.—Supine, with a pillow under the shoulders and neck. The head should be moderately extended, and the face turned towards the sound side.

¹ *System of Surgery*, vol. iii.

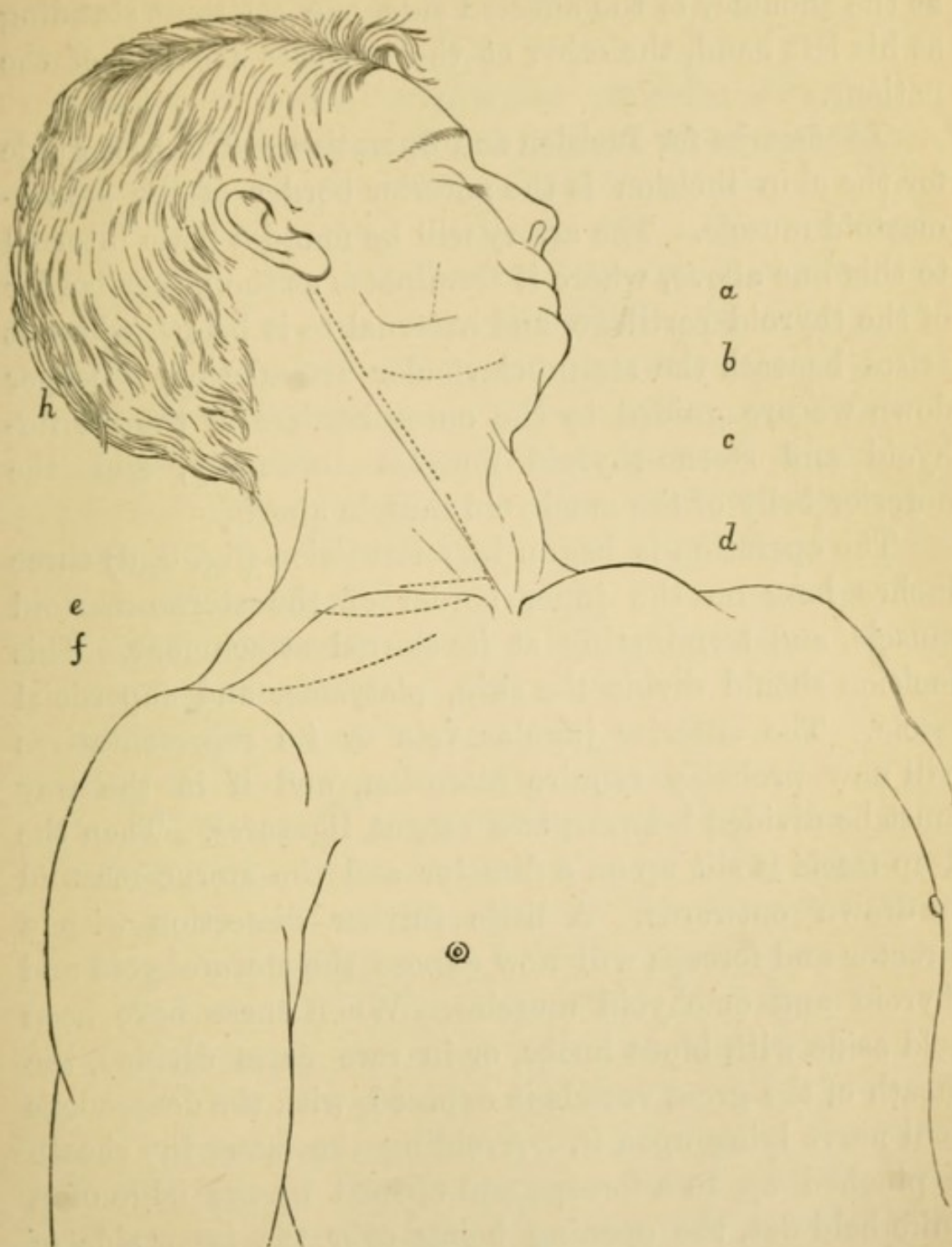


FIG. 3.—INCISIONS FOR LIGATURE OF ARTERIES ABOUT THE NECK.

a, Ligature of facial artery ; *b*, Lingual artery ; *c*, Carotid artery above the omohyoid ; *d*, Carotid below the omohyoid ; *e*, Taken with *d*, Incision for Ligature of Innominate ; *f*, Subclavian in third stage ; *g*, Axillary artery in first stage ; *h*, External Carotid.

Position of Operator and Assistants.—The surgeon stands at the shoulder of the affected side, one assistant standing at his left hand, the other at the opposite shoulder of the patient.

Landmarks for Incision and Operation.—The best guide for the skin incision is the anterior border of the sterno-mastoid muscle. The artery will be found a little internal to this line above, where it terminates at the upper border of the thyroid cartilage, and external to it below, where it arises beneath the sterno-clavicular articulation. Deeper down we are guided by the outer borders of the sterno-hyoid and sterno-thyroid muscles internally, and the anterior belly of the omohyoid muscle above.

The operation is begun by an incision (fig. 3, *d*) three inches long on the inner border of the sterno-mastoid muscle, and terminating at its sternal attachment. This incision should divide the skin, platysma, and superficial fascia. The anterior jugular vein or its representatives will now probably require attention, and if in the way must be divided between two catgut ligatures. Then the deep fascia is slit up on a director and the sterno-mastoid is drawn outwards. A little further dissection with a director and forceps will now expose the sterno-hyoid and thyroid and omohyoid muscles. When these have been held aside with blunt hooks, or in rare cases divided, the sheath of the great vessels is exposed, with the descendens noni nerve lying upon it. Avoiding the latter the sheath is pinched up in a forceps and opened by the edge of a knife held flat, the opening being over the inner side of the artery. When the latter has been very carefully cleaned with the back of the knife-point and forceps the aneurism-needle, threaded, is passed beneath it from without inwards, keeping very close to the artery, so as not to include the vagus nerve, which lies behind it and a little to the outside.

The ligature is then seized in a forceps and the needle withdrawn, after which the knot is made in the usual manner.

Memoranda.—In some cases the later steps of the operation are facilitated by a second incision running outwards from the lower end of the first and dividing the lower attachments of the sterno-mastoid muscle (fig. 3, *e*); but this is not always called for. Sédillot's incision, which was directed so as to open up the interval between the sternal and clavicular attachments of the muscle, has little to recommend it and is universally abandoned. The common carotid artery, having no named branches, can be tied at any point in its course, but either just below or just above the omohyoid muscle are the points of election. The only difficulty likely to arise in the course of dissection down to the artery will be due to the presence of small veins and consequent oozing if they be wounded, the field of operation being thus obscured. This must be carefully guarded against by drawing the veins gently aside, and where there is the slightest difficulty in doing this by ligaturing them twice and dividing them between the ligatures. The tying of a vein even when of considerable size in an aseptic wound is a simple and safe measure. There is usually no trouble from the internal jugular vein, which is frequently not seen at all during the whole operation, especially on the right side. On the left it is more likely to come into view having a closer and more anterior relation to the lower part of the artery. By opening the sheath over the inner and front aspect of the artery the danger of including the vein is avoided, as it lies in its own special compartment of the sheath. The surface of the artery at the spot selected for ligature should be thoroughly cleaned, otherwise the needle will not pass easily around it.

LIGATURE OF THE COMMON CAROTID ABOVE THE OMOHYOID
MUSCLE.

This operation differs very little from the last except that the ligature is applied above the omohyoid muscle, but as close to it as possible. The first incision (fig. 3, *c*) through the skin has the same length and direction as in the last case, but its mid point here corresponds to the level of the cricoid cartilage. Otherwise the operations are practically the same.

Ligature of the common carotid artery is *per se* not a very serious operation, if antiseptic precautions are taken to the fullest extent. The artery having no named branches, there is but little risk of secondary hæmorrhage, if the ligature be perfectly pure and unirritating. Cerebral disturbance more or less permanent has been observed in several cases; but apart from these two dangers there is little to be feared nowadays, though formerly the results were frequently not good. Statistics gathered from old and recent sources would be misleading as to the results of the operation and are omitted. And we need a much larger number of recent cases from which to draw conclusions than could be collected at present.

LIGATURE OF THE EXTERNAL CAROTID ARTERY.

Instruments, Position of Patient, Operator, and Assistants as for the common carotid (*q.v.*)

Landmarks for Incision and Operation.—The direction of the first incision (fig. 3, *h*) is given in this case also by the anterior border of the sterno-mastoid muscle. It should be three inches long and commence just below the lobe of the ear. In the deeper dissection the posterior belly of the digastric muscle is our guide.

The operation begins with the above incision, which should divide the skin, superficial fascia, and platysma at once, and expose the anterior border of the sterno-mastoid muscle. The deep fascia spreading off from this is now slit up, with due regard to the external jugular and temporo-facial veins, which must be doubly ligatured and divided if they cannot be easily drawn aside. A little blunt dissection will now expose the parotid gland and the posterior belly of the digastric, which is drawn a little upwards with blunt hooks, exposing the hypoglossal nerve and external carotid artery. The needle is passed from before backwards, keeping very close to the vessel.

Memoranda.—This artery is not often tied as a formal operation, ligature of the common carotid being usually preferred for those conditions which require the arrest of blood-flow through its branches. The latter lie so close together as to render the formation of a firm clot on either side of the ligature doubtful. The chief points of difficulty in the operation are the avoidance of the veins in the first instance and then of the hypoglossal and superior laryngeal nerve, the first lying upon the latter underneath the artery.

LIGATURE OF THE LINGUAL ARTERY IN THE DIGASTRIC SPACE.

Instruments, Position of Patient, Operator, and Assistants as in the last operation.

Landmarks for Incision and Operation.—Three points guide us for the first incision (fig. 3, *b*): the symphysis menti, the great cornu of the os hyoides, and the edge of the sterno-mastoid muscle. For the deeper part of the dissection we are guided by the tendon of the digastric muscle primarily, and then by the posterior margin of the hyoglossus muscle. The operation is begun by an in-

cision (fig. 3, *b*) commencing at a point a little below and internal to the symphysis menti, and running outwards across the great cornu of the os hyoides to the edge of the sterno-mastoid muscle. This incision may be straight or, better, a little curved downwards, and should be quite three inches long. It should divide the skin, superficial fascia, and platysma, after which the deeper fascia is opened up until the lower border of the sub-maxillary gland is exposed. On turning up the latter, the tendon of the digastric is seen, having the hypoglossal nerve a little above it and on a deeper plane. Between the two, and still a little deeper, the lingual artery will be seen as it passes under the hyoglossus muscle. The nerve and lingual vein being drawn upwards, the muscle covering the artery may be divided a little, in order to clear the latter. The needle carrying the ligature is then passed under the vessel from above, downwards.

Memoranda.—Some surgeons prefer to tie the lingual artery just below the posterior belly of the digastric muscle, *i.e.* outside its triangle. This may be done through the same incision, but it must be remembered that here the relations are different. In this case the digastric tendon is above the nerve, below and deeper than either is the artery, below and deepest of all is the vein. For all the purposes for which this artery requires ligature, however, the first operation is to be preferred. The relative colours of the nerve and tendon of the digastric should be studied before passing the ligature.

LIGATURE OF THE FACIAL ARTERY.

Preliminaries as in the last operation.

Landmarks for Incision and Operation.—The anterior border of the masseter muscle is here our guide. Along

this an incision (fig. 3, *a*) is made for an inch or so, just on the border of the jaw. The artery is easily found with its vein behind it, and the needle is passed underneath it from behind forwards.

LIGATURE OF THE SUBCLAVIAN ARTERIES.

Operations on these vessels in any but their third stages are not now generally considered desirable, and are by most surgeons condemned as unjustifiable. On the left side, the almost vertical course of the vessel, its deep relations to the pleura, thoracic duct, pneumogastric and phrenic nerve in its first stage, offer difficulties to the operator of the first order, while the close proximity of branches to the ligature if applied in the second stage render the formation of a firm clot at either side of it very problematical, even where the difficulties and risks of the operation can be overcome. And on the right side, although the artery is, in its first stage at all events, more accessible, its ligation, owing to its relations, is still surrounded with great difficulty and risk, and there is even less probability of clotting around the seat of ligature. Of the eleven cases on record of ligation of the first stage of the subclavian artery the result has been fatal in all (Holmes¹). All died either of the immediate effects of the operation or of hæmorrhage. Mr. Holmes advises that, if this operation should ever be undertaken again, the vertebral and carotid arteries should be tied at the same time, in order to diminish the risks of secondary hæmorrhage from the distal side of the ligature. The procedure in ligation of the subclavian artery is practically the same as that for reaching the first stage of the common carotid in its lower stage (*q.v.*). But here it will *always* be necessary to make

¹ *System of Surgery*, vol. iii.

the transverse incision (fig. 3, *e*) over the inner end of the clavicle and divide the attachments of the sterno-mastoid, which is not always indispensable in dealing with the latter vessel.

LIGATURE OF THE SUBCLAVIAN ARTERY IN ITS
THIRD STAGE.

Instruments, &c., as above.

Position of Patient.—Supine, with the shoulders and head a little raised on pillows and the face turned towards the sound side (fig. 3). The clavicle is well depressed by drawing down the arm and fixing it against the side.

Position of Operator and Assistants.—The operator stands at the elbow of the affected side, having one of his assistants at the shoulder facing him, and another at the opposite side of the patient.

Landmarks for Incision and Operation.—The outer border of the sterno-mastoid muscle and the line of the clavicle are our best guides at first; later on the scalenus tubercle of the upper rib, with the muscle attached to it. The omohyoid muscle may or may not be seen, but if so should be drawn upwards.

The skin over the clavicle is first drawn down with the left hand and steadied while the skin-incision (fig. 3, *f*) is made by cutting firmly on the clavicle for three inches, the inner end of the wound lying over the outer border of the sterno-mastoid muscle. The skin being now released, the wound will lie a little above the clavicle. In it may be seen the external jugular vein or its representatives. So far as possible, any or all of these veins which are in the way should be drawn aside. But if this cannot be easily done, there should be no hesitation in dividing them between two fine catgut or silk ligatures. All bleeding

points must be carefully closed at every stage of the operation before the dissection is proceeded with, in order that a clear view of the structures involved may be secured. The deep fascia is now divided on a director to the full extent of the first incision, after which the tubercle on the first rib is felt for with the finger. If seen, the omohyoid muscle is drawn upwards. To the outside of the tubercle the artery will be felt, and may be cleared by a little blunt dissection as it lies on the first rib, having the brachial plexus above and behind, and the vein below and anteriorly. The aneurism-needle, threaded, is now passed between the nerves and artery from above, downwards, rather than between the vein and the latter, on account, in the last case, of the difficulty in depressing the handle of the needle sufficiently to bring the point into view, clear of the nerves.

Memoranda.—The first point to be attended to is the depression of the clavicle, which is essential to reaching the vessel easily. But this is sometimes very difficult when the aneurism thrusts the bone up from below. In such a case it has been proposed to divide the clavicle. The transversalis humeri below and the transversalis colli arteries above are usually not seen, but may be enlarged and in the way; their veins are, however, more likely to give trouble. The subclavian vein itself ought not to cause any embarrassment with due care. Portions of the brachial plexus have been tied more than once in mistake for the artery. Several other preliminary incisions have been employed both at home and abroad, but that just described is the one usually chosen as adequate in every way. If that portion only of the artery which lies upon the first rib be manipulated, there is little or no danger of injury to the pleura; but if the upper edge of the bone be transgressed, the pleura may be opened with very serious, if not fatal, results. And even where the sac has not been

actually opened, pleurisy has been set up, in many cases, by damage to the subpleural tissues.

When performed for the cure of aneurism of the innominate artery, this operation is shown to be very successful, but results in high mortality when undertaken for axillary aneurism, owing to the unsound state of the vessel at the seat of ligature. From Mr. Holmes's careful examination of the question, we learn that for the latter affection it should never be performed unless both intermittent and continuous pressure under an anæsthetic have proved unavailing; also in cases of traumatic aneurisms the old operation of laying open the sac and tying the vessel above and below is to be preferred. In large aneurism of the axillary artery, amputation at the shoulder is probably the best chance for the patient, if anything at all is done.

LIGATURE OF THE VERTEBRAL ARTERY.

This operation was performed for the first time by Smyth of New Orleans on account of secondary hæmorrhage following ligature of the innominate artery. It has been revived within the last few years by Alexander of Liverpool for the relief of epilepsy, and has been performed by this surgeon and others with considerable success as far as the operation is concerned.

Instruments, Position of Patient, of Operator, and Assistants as for ligature of the carotid artery.

Landmarks for Incision and Operation.—Our guides here for the first incision are the posterior border of the sterno-mastoid muscle, deeper down the inner border of the scalenus anticus muscle and the transverse process of the sixth cervical vertebra.

A three-inch incision is first made along the posterior border of the sterno-mastoid muscle commencing at the

clavicle. On drawing the muscle inwards, the scalenus anticus with the phrenic nerve are seen, and must be drawn outwards. Then the transverse process of the sixth cervical vertebra is felt for, and below it, with its vein lying anteriorly, the artery is found, and is cleared by blunt dissection in the interval between the scalenus and longus colli muscles. The vein is drawn to the outside, and the needle is passed under the artery from without inwards.

Memoranda.—At first sight this may appear a formidable dissection, but with due care in the checking of bleeding all the steps may be easily accomplished. The vessel is crossed by the inferior thyroid artery below, but this is drawn inwards without trouble. On the left side the thoracic duct also crosses the vessel, but is avoided in the blunt dissection. The chief dangers are wound of the phrenic nerve and internal jugular vein, but they are easily avoided.

LIGATURE OF THE AXILLARY ARTERY.

As in the case of the subclavian, ligature of this vessel is very rarely performed in its first two stages, and for similar reasons. The difficulties of operation are great, in the first place, and where these are overcome the presence of branches close to the point of ligature renders the formation of a sound clot very doubtful. A description of the first operation is given here for completeness' sake, but it should be borne in mind that the operator's choice lies really between ligature of the axillary artery in its third stage, or of the subclavian in its third stage. These are both simpler in performance and less dangerous than either of the intermediate operations.

LIGATURE OF THE AXILLARY ARTERY.

First Stage.

Instruments as above.

Position of Patient.—Supine, with the shoulder raised and the arm at first fully abducted and rotated a little outwards (fig. 4), to put the pectoral muscles on the stretch; later the arm should be brought to the side and inverted (fig. 3, *g*), to allow the relaxation of the muscles and other structures in the field of operation.

Position of Operator and Assistants.—Between the affected arm and the patient's side, the assistants standing, one at the affected, the other at the opposite shoulder.

Landmarks for Incision and Operation.—The clavicle and anterior margin of the deltoid muscle are our guides for the first incision; deeper down the coracoid process and upper border of the pectoralis minor muscle help to the position of the vessel.

A three-inch curved incision (fig. 4, *h*) is first made half an inch below the clavicle, commencing a little internal to the border of the deltoid, so as to avoid the cephalic vein, and ending close to the sternal end of the bone. This divides at once the skin and superficial fascia with the descending branches of the cervical nerves. The pectoral muscle is now divided to the same extent, and the coraco-clavicular ligament and lesser pectoral muscle are exposed. The lower edge of the wound being held well down with a broad spatula, the coraco-clavicular ligament is torn through with a director close to the coracoid process and upper border of the minor pectoral. The arm being now brought to the side (fig. 3, *g*), the parts are relaxed and can be drawn a little downwards, so rendering the exposure of the vessel easier. It lies with the brachial plexus to the outer and its vein to the inner side, and on a plane a little

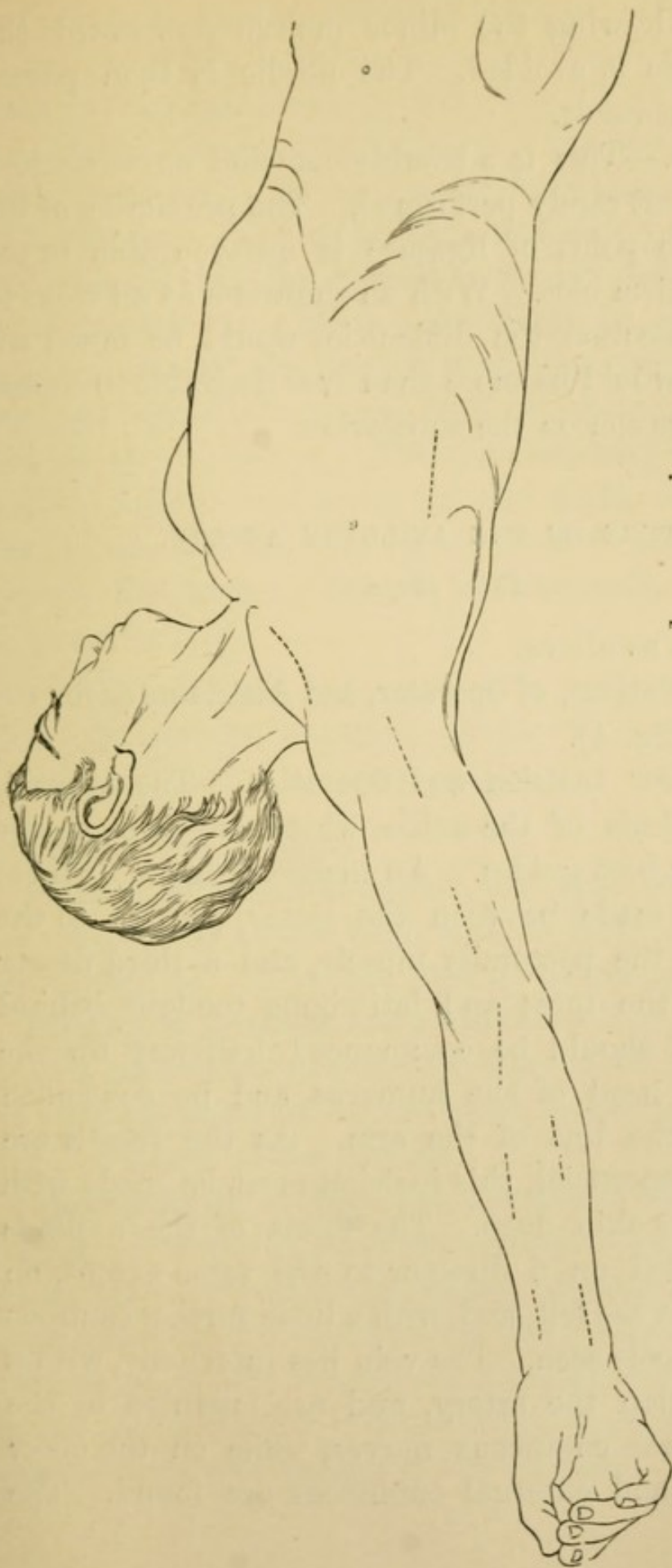


FIG. 4.—INCISIONS FOR LIGATURES OF ARTERIES.

a, Radial artery at the wrist; *b*, Ulnar artery at the wrist; *c*, Radial artery in forearm; *d*, Ulnar artery in forearm; *e*, Brachial artery at elbow; *f*, Brachial artery in arm; *g*, Axillary artery in third stage; *h*, Axillary artery in first stage; *i*, Incision for drainage of empyæma.

a
b

c
d

e

f

g

h

i

anterior. By drawing the minor muscle downwards the acromio-thoracic is avoided. The needle is then passed from within outwards.

Memoranda.—This is a troublesome and unsatisfactory operation and but rarely performed. The proximity of the branches to the point of ligature is unfavourable to the formation of a firm clot. With an aneurism at all close to the field of dissection the difficulties would be much enhanced, and it would be more than ever desirable to choose the higher operation on the subclavian.

LIGATURE OF THE AXILLARY ARTERY.

Third Stage.

Instruments as above.

Position of Patient, of Operator, and Assistants as for the last operation (fig. 4).

Landmarks for Incision and Operation.—The anterior and posterior folds of the axilla, which are now on the stretch, are our best guides. An incision (fig. 4, *g*) three inches long is made between the latter, parallel to the lower border of the pectoralis muscle, and a third nearer to it than to the teres and latissimus tendons behind (Heath). This should be commenced half-way up the axilla, over the head of the humerus, and be continued downwards in the line of the arm. As the vessels are comparatively superficial, this incision must be made with caution, and only skin deep. The fascia of the axilla is now to be divided on a director to the same extent, on which the vessels are felt, and, with a little further cautious dissection, distinctly seen. The vein lies internally, with a tendency to overlap the artery, and accompanied by the ulnar and internal cutaneous nerves, while on the outer side the median and external cutaneous are found. The

needle is to be passed between the vein and artery from within outwards, keeping close to the latter and thus avoiding the musculo-spiral nerve behind, and the median and external cutaneous externally. The point of ligature should be chosen as far as possible from the branches.

Memoranda.—After the skin and fascia of the axilla have been divided, the dissection should be performed as far as possible with blunt instruments in order to avoid wounding any of the smaller glandular twigs of vessels, bleeding from which would tend to obscure the further steps of the operation. The incision may be made in a direction towards the trunk on the right side and away from it on the left. In every case it should be well towards the pectoral margin of the axilla rather than the posterior fold.

LIGATURE OF THE BRACHIAL ARTERY IN THE MIDDLE OF THE ARM.

Instruments as above.

Position of Patient.—Supine, the arm being extended and abducted to a right angle with the body and somewhat everted (fig. 4). It is thus held by an assistant.

Position of Operator and Assistants.—The operator may stand or sit beside the patient's body on the affected side. One assistant holds the arm as above, standing at the elbow, the other stands at the shoulder.

Landmarks for Incision and Operation.—The first guide is the inner border of the biceps muscle. If for any reason this be not easily made out, a line running from the head of the humerus in the middle of the axilla to the middle of the bend of the elbow will give the direction of the vessel. A three-inch incision (fig. 4, *f*) in the middle of the arm is carried along the above line. This should be

made cautiously so as to divide the skin and superficial fascia only, which are here thin. Avoiding the basilic vein, which usually dips at about this point under the deep fascia, the latter is divided freely. The muscle can then be drawn a little outwards, exposing the artery and its venæ comites. The median nerve lying on the vessel must be drawn outwards, and to avoid it the aneurism-needle is carried from without inwards.

Memoranda.—It is better to have the arm held in the position named than to allow it to rest on a table, which has a tendency to make the triceps overlap the artery. The profunda artery and vein must be avoided in carrying the needle underneath the main vessel. The incision may be made from below upwards on the right and from above downwards on the left.

LIGATURE OF THE BRACHIAL ARTERY AT THE BEND OF THE ELBOW.

Instruments as above.

Position of Patient.—As above (fig. 4), the arm resting on a table.

Position of Operator and Assistants.—The surgeon stands on the outside of the elbow, an assistant sitting opposite to him, steadying the arm and forearm on the table.

Landmarks for Incision and Operation.—The artery lies midway between the condyles of the humerus, but the best guide to take is the tendon of the biceps. Half an inch internal to the latter a three-inch incision (fig. 4, *e*) is made, the lower end lying over the neck of the radius. This ought to just stop short of the median cephalic vein, and to course along the outer side of the basilic. It divides the skin, superficial fascia, and a few nerve-filaments, and exposes the bicipital fascia. The latter is now divided on a

director and the vessel with its venæ comites is exposed, lying upon the brachialis anticus muscle and with the biceps tendon to its outer, the pronator teres to its inner side. The median nerve also lies internal to the artery, but is not in contact with it. The needle is passed under the vessel from within outwards.

Memoranda.—This operation is rarely performed, the higher one being, as a rule, preferred.

LIGATURE OF THE ULNAR ARTERY IN THE MIDDLE OF THE FOREARM.

Instruments as above.

Position of Patient.—As above, with the arm abducted and forearm extended and supine (fig. 4).

Position of Operator and Assistant.—The operator sits or stands on the ulnar side of the forearm, his assistant on the radial side, holding the forearm and hand steady on the table.

Landmarks for Incision and Operation.—Our guide here is the outer border of the flexor carpi ulnaris muscle, or a line from the internal condyle of the humerus to the radial border of the pisiform bone, along which the two lower thirds of the artery may be found. A two-inch incision (fig. 4, *d*) is made in the middle of the forearm along this line down to the aponeurosis; this is divided to a similar extent, exposing the interval between the flexor sublimis and flexor carpi ulnaris. On opening this interval, which inclines towards the ulna, the artery is found lying upon the deep flexor with its veins on either side, and the ulnar nerve approaching it from within. The needle is passed from within outwards.

Memoranda.—This is not a favourite operation. The most likely error to fall into is that of dissecting too far outwards and so opening up the space between the palmaris

longus and flexor sublimis. This may be avoided by noting the direction of the interspace, the one sought for inclining towards the ulna, the wrong one towards the radius.

LIGATURE OF THE ULNAR ARTERY ABOVE THE WRIST.

Instruments, Position of Patient (fig. 4), **of Operator and Assistants, and Landmarks, &c.**, as above.

A two-inch incision (fig. 4, *b*) is made here, commencing half an inch above and a little internal to the pisiform bone. This should divide the skin and aponeurosis of the forearm at once, after which a fascia of greater or less thickness is met with, stretching across the vessels and ulnar nerve, which lies next the tendon. This fascia is slit up on a director, and the needle is passed from within outwards between the nerve and artery.

LIGATURE OF THE RADIAL ARTERY IN THE MIDDLE OF THE FOREARM.

Instruments, &c., as for the last operation, fig. 4.

Landmarks for Incision and Operation.—A line drawn from the middle of the bend of the elbow-joint to the base of the styloid process of the radius gives the direction of the artery or the edge of the supinator longus muscle. Along this line an incision (fig. 4, *c*) is made for two inches in the middle of the arm, which should expose the aponeurosis of the arm at once. This must then be slit up to the same extent, and the supinator longus be drawn outwards, on which the artery with its venæ comites will be exposed, having the radial nerve to the outside and lying on the insertion of the pronator teres. The needle is passed from without inwards.

Memoranda.—The more muscular the arm, the more inclination is there to place the incision too far towards the ulnar side.

LIGATURE OF THE RADIAL ARTERY ABOVE THE WRIST.

Instruments, &c., as for the last operation, fig. 4.

Landmarks for Incision and Operation.—An incision (fig. 4, *a*) is made between the tendons of the supinator longus and flexor carpi radialis for two inches, dividing the skin only. Then the fascia is carefully opened on a director, after which the artery is easily found. The needle may be passed from either side, there being no nerve in relation to the artery and the venæ comites lying on both sides probably.

Memoranda.—This is one of the easiest of operations, but it is not often required. The artery may be slit up by the first incision, if due care be not observed.

LIGATURE OF THE RADIAL ARTERY ON THE DORSUM
OF THE WRIST.

Instruments as above.

Position of Patient.—Supine, with arm abducted and forearm half-way between pronation and supination, resting on a table.

Position of Operator and Assistants.—The operator may sit opposite the affected hand, looking up the forearm. His assistant sits outside the forearm, grasping the latter and the hand to steady them.

Landmarks for Incision and Operation.—The tendons of the extensor ossis metacarpi and secundi internodii pollicis, as they pass over the end of the radius, are our guides. A two-inch incision is first made along the outer border of the tendon of the last-named muscle, dividing the skin and some of the radicles of the cephalic vein. Through this the artery is very easily found before it sinks between the heads

of the first dorsal interosseous muscle and bases of the two metacarpal bones.

Memoranda.—This operation is of comparatively little value, and is not often performed. It has the disadvantage, too, that if there should be any inflammation about the wound the tendons of the thumb may be more or less fixed by plastic matter, and the member be damaged in its functions.

CHAPTER III.

OPERATIONS ON THE VEINS.

GENERAL CONSIDERATIONS.

OPERATIONS on veins, apart from simple puncture with the object of abstracting blood, have always been regarded with considerable apprehension, on account of the danger of septic phlebitis, so apt to occur. But lately, since the thorough recognition of the value of antiseptics, these operations have come to be held to involve few or no special risks, and are widely practised. Nothing, however, but the most scrupulous attention to antiseptic precautions will justify premeditated interference with the veins of the body. Thus safeguarded they may be incised for the abstraction of blood, excised if involved in tumours or hypertrophied and dilated as in the case of various varices, or sutured if accidentally opened in their long axis, or completely ligatured for the purpose of obliterating them in their continuity.

PHLEBOTOMY OR VENESECTION.

Instruments, &c.—A lancet; a broad tape a yard long; a pad of some antiseptic fabric; a stick to be held in the patient's hand during the operation.

Position of Patient.—Seated, with the arm abducted extended and inclined downwards.

Position of Operator.—Standing to the right of the arm to be operated on, grasping the elbow with his left hand, the thumb of which is placed across the vein, just below the point selected for puncture.

Landmarks for Incision and Operation.—The median basilic vein is usually the vessel selected, being easily seen when engorged. The operator first takes the tape in both hands, places its centre on the front of the arm above the elbow, and brings both ends firmly but lightly round, to cross behind the arm and to be tied tightly on the front again with a slip knot. The patient is then given the stick to hold in his hand and to move the fingers upon. Grasping the limb as above and holding the lancet between his right forefinger and thumb, the operator now transfixes the anterior surface of the swollen vein above his thumb, with which it is steadied, and opens it freely by an oblique cut, leaving its posterior surface intact. The thumb is now removed and the vein is allowed to bleed as long as necessary, the patient manipulating the stick all the time. An antiseptic pad is then laid upon the opening, and is retained there by the left thumb while the tape is removed with the right hand. Then the middle of the tape is laid obliquely upon the pad, and its ends are brought round the elbow in a figure of 8 two or three times, and finally tied securely over the pad. The arm is put up in a sling in the flexed position for a few days.

OPERATIONS FOR VARICOSE VEINS.

Varices rarely require operations except in the scrotum and lower extremity, and it will suffice therefore to describe some of the methods employed for their cure in these two

situations. The principles in all cases are the same: we seek to obliterate the veins at one or more points by producing in them a simple plastic phlebitis. In addition to this, in some cases we interrupt the continuity of the vessels, either by simple division or by removing a portion between two ligatures. All this requires absolute exclusion from the vein or wound of anything capable of producing decomposition.

FOR VARICOCELE. RESECTION OF VEINS.

For the cure of this condition a very simple procedure is rapidly coming into use, which promises to supplant the numerous older, less certain, and more dangerous methods, and this will be first described.

Instruments.—A scalpel; aneurism-needle; ordinary suture-needles; dissecting-forceps.

Position of Patient.—Supine.

Position of Operator and Assistants.—At opposite sides of the body, the assistant pressing on the inguinal ring lightly to produce distension of the vein. The operator stands at the affected side.

Landmarks for Incision and Operation.—In the line of the spermatic cord, below the external ring an incision is made for about an inch and a half in the tissue of the scrotum. This may be done either by direct cut or transfixion of a fold of skin. The veins are now sought for and are easily isolated, aided by a few touches of the knife. An aneurism-needle, threaded with fine carbolised catgut or silk, is then passed under them, and the double thread is held while the needle is withdrawn. The threads are now separated about three quarters of an inch, and are tightly tied and cut short. If very massive, the intervening portions of the veins may be excised completely,

but if moderately so it is only necessary to divide between the ligatures. The scrotal wound is now closed, a strand of catgut being inserted in the lower angle for drainage. A little iodoform is dusted over it, and it is covered with antiseptic wool packed over the whole scrotum and perineum and secured firmly with a bandage passing round the thigh in a figure of 8 and forming a St. Andrew's cross over the perineum. This dressing should not need changing until the wound is quite healed.

Memoranda.—In dissecting out and ligaturing the veins, great care must be taken to avoid injury to the nerves and arteries of the cord and vas deferens. One of the great advantages of this operation over the older procedures is that these structures are easily pushed aside, and that the veins above are included in the ligature. In this way all risk of sloughing of the tissues of the scrotum and of atrophy of the testicle is avoided. It is well to remember that strong carbolic lotion should be used sparingly for cleansing the scrotum, otherwise an acute eczematous condition is often produced. The part should be previously well washed with warm soap and water. For some time before the operation the patient should be obliged to stand up before a fire in order that the veins may be swollen and easily seen, so that no time may be lost in finding and isolating them cleanly.

Some other methods of treating varix, whether in the scrotum or the leg, are still in common use and may now be briefly noticed. But those who have had experience in the treatment of these conditions will give the preference to simple excision of the vein just described.

OPERATION FOR VARICOCELE BY SUBCUTANEOUS LIGATURE.

The scrotum and surrounding parts are first thoroughly cleansed with antiseptics. Then the enlarged veins are

felt for with the operator's left finger and thumb, and are separated from the vas deferens and held up in a fold of scrotal skin. A straight needle, threaded with fine carbolised catgut or silk, is then made to perforate this fold of skin from side to side, passing between the veins in front and the vas deferens behind. The veins are then allowed to slip backwards, the skin being held as before between the finger and thumb. The needle is now passed back again through the same punctures in the skin, the veins being in this case behind it. The double ligatures emerging at the original point of entry now include the veins between them, and are separated from each other and tied as far apart on the vein as possible and cut short. The knots then slip through the puncture and disappear in the scrotal tissue.¹ The veins by this method are doubly ligatured, but, of course, other structures of more or less importance may be included as well.

Memoranda.—Great care must be taken to separate the vas deferens before the puncture is made, and also to avoid wound of the veins. If catgut is used there is a probability of the veins becoming pervious again. For this reason alone silk is preferable, and if carefully prepared with carbolic acid it is quite safe not to provoke any suppuration.

VIDAL DE CASSIS' OPERATION FOR VARICOCELE.

This operation is still performed by some surgeons, but has obviously many drawbacks. It must be accompanied by suppuration, and this is not always limited to the immediate neighbourhood of the operation, but may extend through the scrotal tissues, if not into the veins. It also requires special apparatus, which is an objection to a

¹ The wounds are dusted with iodoform and covered with a tuft of wool secured with collodion.

measure which may be effected otherwise with the ordinary instruments always at hand.

Instruments.—A scalpel; a fine steel rod with a sharp removable point, and bored transversely at either end; a long, straight needle to carry thick silver wire.

Operation.—The veins are caught up between the left finger and thumb in a fold of scrotal skin, leaving the vas deferens as far as possible at the back of the scrotum. Then a short incision is made in the skin thus held, as broad as the blade of the scalpel. Through this the steel pin is passed behind the veins, and on emerging its point is unshipped. The long needle, carrying a silver wire screwed into its blunt end, is now entered through the same opening as its fellow, but is carried in front of the veins and out at the same aperture of exit as the first. The ends of the wire are now threaded through the transverse holes in either end of the first pin and are drawn tight. The steel pin is then twisted on its axis so as to further compress the veins between itself and the wire by rolling the latter round itself. By this means the veins are strangulated and begin soon to inflame, and finally the pin and wire cut their way out by ulceration and are withdrawn.

Memoranda.—The only special dangers to be avoided in this operation are inclusion of the vas deferens and puncture of the veins. The great objection to it is that it induces suppuration, and that some of the nerves and arteries of the cord may be destroyed with the veins.

FOR VARICOSE VEINS OF THE LEG.

The procedure recommended for this condition is essentially the same as that first described for varicocele, namely, the excision of a portion of the dilated vein (usually the

saphena in this case) at one or more points in its course, according to the extent of the varix present. The skin wounds are generally made in the long axis of the limb over the contorted and enlarged vein. Here, too, the vessel, and it alone, is to be cleared, ligatured, and divided, or partially excised, between the ligatures. When excision of an inch or so of the vessel is performed at more than one point in its course it is impossible for the condition to return in that vein, and the resulting scars are soft and hardly to be noticed. This operation should never be done if there is the slight suspicion of phlebitis—acute, sub-acute, or chronic—in any part of the track of the vein. Even if there be a trace of inflammation about the ankle, it would be improper to operate on the veins above the knee, and the surgeon must wait until this has entirely disappeared.¹

FOR VARIX OF THE LEG. COMPRESSION WITH
HARELIP PINS.

In this operation the vein is compressed between harelip pins passed through the skin and under the veins, and a piece of catheter secured by a figure of 8 of thick silk thrown over it and round the projecting ends of each pin.

The patient is encouraged to stand about opposite the fire before the operation in order to make the veins prominent. An ordinary stout harelip pin is then taken and is entered about an inch from the line of the vein at the upper end of its most dilated part, and is made to dip under the vessel and emerge at about an inch from it on the opposite side. A stout silk thread is then carried round the projecting ends of the pin and over a piece of

¹ The author has performed this operation in a considerable number of cases without any mishap, and with the best results. In the great majority of cases the wounds have healed absolutely by first intention.

catheter or a roll of sticking-plaster laid obliquely across the vessel, and is made to compress it between the pin and the latter. The same manœuvre is practised on the vein at one or more points lower down. In the course of a few days a certain amount of swelling is noticed at the points compressed, which is in fact due to plastic phlebitis and periphlebitis. When this is seen the silk threads are cut through and the pins are withdrawn, the punctures being dusted with iodoform and covered with wool and collodion. The patient should remain in bed for a week or ten days after this, and endeavour to move the limb as little as possible.

Memoranda.—Great care is necessary to avoid wounding the vein in using the harelip pin. If by accident this is done, the pin should be withdrawn and passed under the vessel higher up.

TRANSFUSION OF BLOOD.

This is usually performed now by the direct or immediate method, i.e. by establishing a direct communication between the veins of the donor and recipient by means of one or other form of india-rubber pumping apparatus armed with a cannula at one or both ends. The simplest contrivance for this purpose is that of Dr. Aveling, and consists of an india-rubber bag to contain about half an ounce, running off at either end into a short piece of rubber tubing, terminating in a fine silver cannula. The median basilic veins of both donor and recipient, having been compressed above and exposed, are opened by an oblique slit sufficiently to admit the ends of the cannulæ. Before these are introduced, however, the pump is filled from end to end with a warm saline solution, and its taps are closed. When the cannulæ have been inserted in the veins and secured there with fine carbolised silk, the taps are opened, and the thumb is

pressed upon the soft tubing near the donor's end ; then the pumping bag is squeezed slowly until empty, when the thumb is transferred to the opposite end while the bag fills again. Then the same manœuvre is repeated until enough blood has been transferred to the patient, when the cannulæ are withdrawn and the wounded veins treated in the usual manner. An instrument equally efficient may be constructed out of a piece of india-rubber tubing and two small pieces of silver or glass tube. Other more complicated apparatuses have been recommended from time to time, but have not shown themselves superior to that just described. Blood may also be transferred from one person to another by means of a common hydrocele syringe, having first been drawn off into a clean basin and defibrinated by beating in the usual manner. This method is more troublesome and dangerous than the first, as opening a way for the admixture of air and impurities with the blood transfused.

Of late a solution of phosphate of soda has been used for transfusion, either alone or mixed with fresh blood. It should always be prepared fresh for the occasion, and consists of one ounce of phosphate of soda to twenty ounces of warm distilled water recently boiled. Some authorities consider the best fluid for transfusion to consist of one part of this solution, mixed with three parts of fresh blood.

CHAPTER IV.

OPERATIONS ON THE NERVES.

OPERATIONS FOR NERVE-SUTURE.

NERVES may require to be sutured, either immediately after their division, or after the lapse of some considerable time. Wherever possible, immediate suture should be the rule, but even when very long periods have elapsed since the section, union and a restoration of the functions of a nerve may take place, if the operation be carried out with care. In either case the procedure is practically the same. It should be borne in mind that, even after the most careful suture of a nerve, its functions may not be completely restored for months. In the meantime, the nutrition of the parts supplied by the nerve should be kept up by friction and the use of electricity.

Instruments, &c.—A scalpel; dissecting-forceps; blunt hooks; round curved needles and fine catgut.

Operation.—The nerve-ends having been exposed, are cleaned for a short distance to allow of manipulation, but otherwise should be disturbed as little as possible. In the case of a freshly divided nerve, its ends, if clean cut, are immediately adapted to one another, but where they are torn they must be first squared by the removal of as much of their lacerated tissue as is necessary to secure a sound,

clean surface for immediate union. Where a considerable period has elapsed since the nerve was wounded, the divided ends will be found much altered. The distal portion will usually be seen to be distinctly atrophied and blunted, the proximal will end in a bulbous fibrous swelling of greater or less thickness. The proximal end will therefore be easily found, while the distal may require very close search. When both have been laid bare, they are divided transversely at a point which is judged to contain true nerve-tissue, as little being removed as possible. More must be taken away from the proximal end which is bulbous, than from the distal which is dwindled. The removal of the bulb approximates the two ends in size more or less.

They may now be sutured in several ways. In the first place, the needle may be carried directly through one end of the nerve from without inwards, and through the other in the reverse direction, at about a quarter of an inch from their point of section, the catgut being knotted so as to bring the cut surfaces into contact. Again, the perineurium alone may be taken up by the needle at either side and similarly used to draw the ends together, or, finally, both methods may be combined. In all cases a needle (Hagedorn's) should be chosen without sharp edges, which may cut the fibres transversely; nor should the sutures be drawn tight enough to produce any strangulation of the ends.

When the latter are brought together the parts around must be disposed about them as accurately as possible, and thoroughly cleansed of all blood-clots. The external wound is then sutured and a firm elastic dressing is applied. Great care must be given to the disposal of the limb in the best position to relax the nerve and to secure absolute rest for the part.

The most suitable dressing in most cases of nerve-suture is one of dry antiseptic wool, the great aim being to obtain

union by first intention; and as there is but little likelihood of oozing, drainage may often be dispensed with.

NERVE-STRETCHING.

Stretching may be required in several regions of the body both for sensory, motor, and mixed nerves. It may be said, as a rule, to be a simple procedure when once the nerve to be dealt with has been found. The class of affection for which this operation may be required is well illustrated in the case of sciatica affecting the main nerve-trunk of the thigh, and *tic spasmodique* depending presumably upon some morbid condition in the nucleus of the facial nerve in the medulla oblongata. The operations on these two nerves will now be described, as examples of what may be required for many others.

STRETCHING THE SCIATIC NERVE.

Instruments.—A scalpel; dissecting-forceps; broad flat retractors; blunt hooks.

Position of Patient.—Prone; the thighs and legs extended.

Landmarks for Incision and Operation.—The first skin incision is placed above the middle of the thigh, and a little internal to its axis. It should be about four inches long, and reach at once down to the muscles. The edges of the wound are now drawn apart with a broad copper spatula, and the interval between the biceps and semi-tendinosus muscles is sought for with the fingers. When these muscles are held apart the nerve is at once seen, and is hooked upon the operator's right index finger. It is then firmly strained, first outwards through the wound, and then from above downwards, and from below upwards.

The amount of force applied should be very considerable. It has been found that the breaking strain of the sciatic nerve is always above eighty pounds. When stretched, the nerve is replaced in its bed and the wound is brought together in the usual way, the greatest care being taken to secure union by first intention. No vessels of any importance are wounded, and if evenly applied pressure is employed in the dressing, no drain-tube will be required, but a strand of ordinary carbolised catgut may be inserted at one angle of the wound for the purpose of the little drainage required during the first day or two.¹

STRETCHING THE FACIAL NERVE.

Having had no experience of this procedure, I have taken the description of it from a paper by Dr. Sturge and Mr. R. J. Godlee² on a case of *tic spasmodique* in which the operation was performed by the latter gentleman with the best results. Four other cases had been previously operated on in the same way by different surgeons, and with ultimate benefit as in this case. The nerve was cut down upon in the following way, adopting the method first described by Baum. An incision was begun behind the ear about opposite the meatus, and was carried downwards and forwards to a point immediately below the lobule, and then almost perpendicularly, but slanting a little forwards, nearly to the angle of the jaw. A small transverse incision was also made below the pinna. After exposing the edge of the sterno-mastoid and the parotid gland, these structures were separated deeply and were pulled respectively backwards and forwards. As soon as the edge of the digastric

¹ In the only case in which the author has had occasion to perform this operation he was struck with its great simplicity and the small amount of time necessary for its completion.

² *Clin. Soc. Trans.*, vol. xiv. p. 44; vol. xvi. p. 220.

appeared the knife was discarded and the structures above and parallel to the upper border of the muscle were, one after the other, pulled up with a blunt hook or forceps, and cleaned with a steel director. When the nerve was reached and raised on the hook the twitching at first increased; a somewhat firmer pull arrested it for a time, but it began again on relaxing the tension; a still firmer pull not only stopped the twitching, but caused the right side of the face to pass into a state of complete paralysis. After this had occurred, one or two further pulls were given and the wound was closed. The operation was conducted in every way antiseptically, and the wound healed without suppuration in nine days.

Memoranda.—The following note in regard to the method of operating is made by Mr. Godlee. ‘The line of the nerve is exactly parallel with the upper edge of the digastric, and it will be found about half-way down that portion of the mastoid process which is exposed in the wound—viz., the free anterior border. The great auricular nerve will in part be divided. The posterior auricular vein often occupies a position which would involve its division in the first incision. No normal artery of importance is likely to be met with in the deep parts of the wound, though considerable hæmorrhage may arise from glandular branches. The posterior auricular artery may be divided in cleaning the structures below the ear, but can give no trouble. In fact, as long as the operator keeps in the same plane as the digastric muscle, he can scarcely wound any vessel of importance. It must not be forgotten that the deep part of the dissection approaches very closely to the internal jugular vein. The trickling of blood into the wound makes the operation somewhat difficult, and necessitates good assistance in keeping the edges apart and in sponging.’

CHAPTER V.

OPERATIONS ON TENDONS AND FASCIÆ.

TENOTOMY FOR CLUB-FOOT.

UNDER the name of 'club foot' a number of perfectly distinct conditions are commonly grouped, which have, however, this in common, that they frequently require for their cure the division of certain tendons acting on the foot, as well as fascial bands which have adapted themselves to the vicious position of the latter. These are divided in different ways by different operators, but the mode now to be described is that most usually adopted.

The exact age most suitable for operation is still a matter of debate, but the general consensus of opinion is in favour of interference during earliest infancy. Another debated point was formerly whether the foot should at once be brought into position after tenotomy, or whether it should be left in its old position until plastic matter had been formed between the divided ends of the tendon. It is now settled that delay beyond a day or two after operation is unnecessary, and some surgeons now make it a practice to put up the foot at once in the proper position with one or other of the many appliances for retaining it thus. Among these perhaps the favourite is the small tin splint which may be altered from time to time to suit the changed

position of the foot. The leg and plantar portions of this are united by a stiff rod of copper or brass, sufficiently soft to be twisted in any direction by the adult hand, but strong enough to control the movements of the infant's foot. Some operators prefer to put the foot up at once in plaster of Paris, and to change this every week or so. In all cases great care is necessary to avoid chafing the soft skin of the little foot, and all splints must be well covered to this end. It must never be forgotten that though the tendons be properly divided, the result will not be good unless the closest attention is given to the frequent adjustment of the splint for many months after operation.

For the division of tendons various knives have been used at different times. We are accustomed now to employ either a sharp or blunt pointed tenotome, the sickle-shaped variety having been abandoned, in this country at all events. The first two mentioned should have blades at least an inch long and an eighth of an inch broad. Some operators discard the blunt-pointed tenotome altogether, and complete the operation with the sharp-pointed instrument. In dividing the tendon the knife is now usually inserted underneath it on the flat, and is then turned with its edge outwards so as to cut towards the skin. Some surgeons, however, prefer to enter the knife between the skin and tendon and cut through the latter to the bone.

In every case the foot should be very carefully washed with soap and warm water and soaked in an antiseptic solution before operation.

The chief varieties of club-foot will now be considered in the order of their relative frequency.

OPERATION FOR TALIPES VARUS.

The tendons principally at fault here are those of the tibiales and to a minor degree the tendo Achillis.

The patient, usually a child, is best placed prone, either on a table or the nurse's lap, the sound leg being flexed and held out of the way. The limb to be operated on is grasped firmly by an assistant and the foot in the operator's left hand. The bony points round the internal malleolus being kept clearly in his eye, the operator enters the tenotome in front of the malleolus, where it is bounded by the tibialis anticus tendon, and slips it under the latter on the flat. The foot is now forcibly abducted and rotated inwards, so as to render the tendon as tense as possible. Then the edge of the knife is turned towards the skin and the tendon is divided by a sawing motion until it is felt to give way suddenly. Too much strain should not be put on the foot at the last moment, lest the knife, being suddenly released, should cut through the skin as well. When the tendon is quite cut through, the knife is turned again on the flat and withdrawn, while with the left hand the surgeon applies a pad of antiseptic wool over the puncture. This is retained in place with collodion or plaster. The foot is then turned a little over, for the division of the tibialis posticus. This is best done about three-quarters of an inch above the internal malleolus, where in some cases a small irregularity in the bone can be made out, and where the tendon can be often felt when put on the stretch. Here the knife is to be inserted almost vertically to the bone and with the plane of its edge in the line of the tendon, between which and the tibia it is made to enter. When a sufficient aperture has been made into the sheath of the tendon, a blunt-pointed instrument is substituted for the first, and is immediately turned with its edge backwards towards the latter. This is then stretched strongly by flexing and everting the foot, and with a gentle sawing movement the tense tendon is divided, the flexor longus being often at the same time unintentionally severed. With care there

is no risk of the posterior tibial artery being divided, but if it be, no bad result need be anticipated if a pad be firmly applied over it. This wound is treated in the same way as the last.

The foot and leg are now covered with a bandage, in order to maintain the pads in position over the wounds.

FOR TALIPES VALGUS.

The tendons very rarely require division for this condition, but if they should do so the tenotome is introduced in front of the ankle-joint at the inner side of the extensor longus, and from this can be made to divide the tendon of the latter muscle, and that of the peroneus tertius, when they have been rendered tense by extension of the ankle.

FOR TALIPES EQUINUS.

When this condition is uncomplicated there is no simpler operation than that for its relief, the tendo Achillis being divided about an inch above its insertion. The tenotome is in this case inserted on either side of the tendon, usually on the outside in the case of the right foot, and on the inside in that of the left, the child lying on its face and the surgeon standing behind.

When this condition is associated with varus, as is frequently the case, it is best to defer the division of the tendo Achillis until the varus has been cured, the foot requiring the support of the latter tendon during the treatment.

FOR DIVISION OF THE PALMAR AND PLANTAR FASCIAE.

These fasciæ occasionally require to be divided, on account, in the first case, of that condition known as 'Dupuytren's contractio palmaris,' and in the latter case when the plantar fascia has shrunk to accommodate itself to the dis-

torted shape of the foot in talipes equino-varus. In both states the mode of division and after-treatment is precisely the same. A very narrow short-bladed tenotome is here required, and is entered between the skin and the bands which have been put on the stretch by forcible extension, and is then made to divide them at one or more points by steady pressure, combined with a slight sawing movement. It is often necessary to repeat this section at a number of different points of the palm or sole; the knife, indeed, should be used until complete relaxation is possible. The punctures are covered with clean pads and collodion, and the parts are put upon the stretch from the first.

FOR DIVISION OF THE HAMSTRINGS.

Section of the hamstring tendons is but rarely called for nowadays, owing to the improvement which has taken place in the treatment of early joint-disease. It may, however, be necessary to remedy deformity, the result of neglect in the management of synovial disease of the knee, and is a simple procedure.

The only muscles calling, as a rule, for division, are the biceps and semi-tendinosus, and if the tenotome be kept close to the tendon, neither the nerves nor vessels of the popliteal space are endangered.

Operation.—The patient having been placed upon his face, and the leg extended so as to stretch the hamstrings as fully as possible, a point is selected a little above the joint, on the inner side of the biceps tendon, and here a puncture is made with a sharp knife. Through this a blunt-pointed tenotome is passed down and under the tendon, which is then divided towards the skin. If the use of the knife be thus limited, there is little or no danger of wound of the external popliteal nerve. The same directions will serve for the division of the semi-tendinosus tendon.

Memoranda.—On no account are the fibrous bands which spring into prominence at the sides of the popliteal space, on section of the hamstrings, to be interfered with by the knife. The relations of parts have been so altered by disease, that the surgeon may wound important structures if tempted to break this rule. Moreover, these fascial bands will readily stretch in course of time, and thus little would be gained by their section. The limb is only gradually extended after this operation, the best appliance, perhaps, for the purpose, being Thomas's knee-splint.

DIVISION OF THE TENDON OF THE STERNO-MASTOID MUSCLE.

When torticollis depends upon a permanent contraction of the sterno-mastoid muscle, it may be necessary to divide the tendon of the latter, and this operation requires considerable care, on account of the deep relations of the muscle at the point of its insertion.

Operation.—The tendon having been put upon the stretch, a puncture is made with a sharp-pointed tenotome just over the inner border of the attachment of the muscle to the sternum. Through this opening a director is passed, and carried behind the tendon. Then a narrow, blunt-pointed tenotome is slipped along this, with its blade flat against the latter, and is finally turned so as to divide it in a direction outwards towards the skin. For the section of the clavicular portion, a second puncture is made in the interval between the sternal and clavicular insertions of the muscle, and a director is passed behind the latter, along which a blunt-pointed tenotome is carried, to be finally used for division of the tendon, towards the skin, as in the first case.

Memoranda.—The tenotome in each instance must be inserted with great care close behind the muscle, so as to

avoid the vessels beneath, and on approaching the outer border of the clavicular division of the muscle, the external jugular vein must be protected against injury.

In dividing the last fibres of the tendon, care must be taken that the blade of the knife does not spring suddenly forward and sever the skin.

Extension of the head and neck is to be made gradually after the operation, by means of splints specially prepared for the purpose.

OPERATION FOR THE CURE OF WEBBED FINGERS.

It might seem at first sight a simple matter to remedy the defect in question, but experience has shown that it is one which tests the surgeon's skill to the utmost. Simple division of the web uniting the fingers is invariably followed by a return of the condition, the union of the divided surfaces steadily advancing upwards from below. It is necessary then to devise some means by which the raw surfaces produced by the division of the tissues between the fingers shall be at once covered in by skin, leaving nothing to granulate up, or, if this is not feasible, at least to cover in the proximal end of the cleft in such a way that the two edges shall not come in contact. There are two methods for accomplishing one or other of these objects now in use, which have yielded good results, and these are now described.

Didot's Operation.

This is only likely to give really good results in those cases in which the web between the fingers is thick and full.

Operation.—The parts having been thoroughly cleansed, an incision reaching through the whole thickness of the skin is made straight down the middle of the *back* of one

of the fingers involved, and another down the middle of the *front* of the other finger (fig. 5, index and middle). Both of these incisions must reach from the level of the free margin of the web to a point corresponding nearly to the metacarpo-phalangeal joint. From both

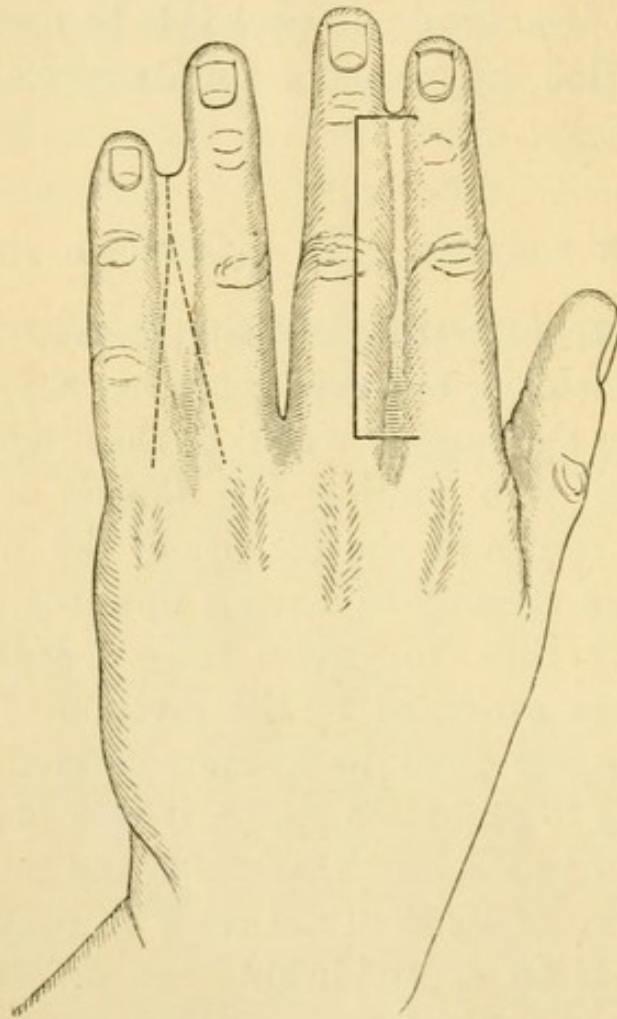


FIG. 5.—BACK VIEW OF HAND, WITH FLAPS OF TWO OPERATIONS FOR WEBBED FINGERS MARKED OUT.

Didot's on the index and middle, Zeller's (dotted line) on the ring and little fingers.

ends of each a short incision is now made at right angles, reaching to the middle line of the opposite finger. In this way two long three-sided rectangular flaps are marked out, one on the back of the web, the other on the front, and having their free margins on opposite fingers.

These are now dissected back to their bases, each taking up half the thickness of the web; any few remaining fibres uniting the fingers are now severed, and the latter are free. The two flaps are now wrapped round the fingers to which they are attached—one from behind, the other from

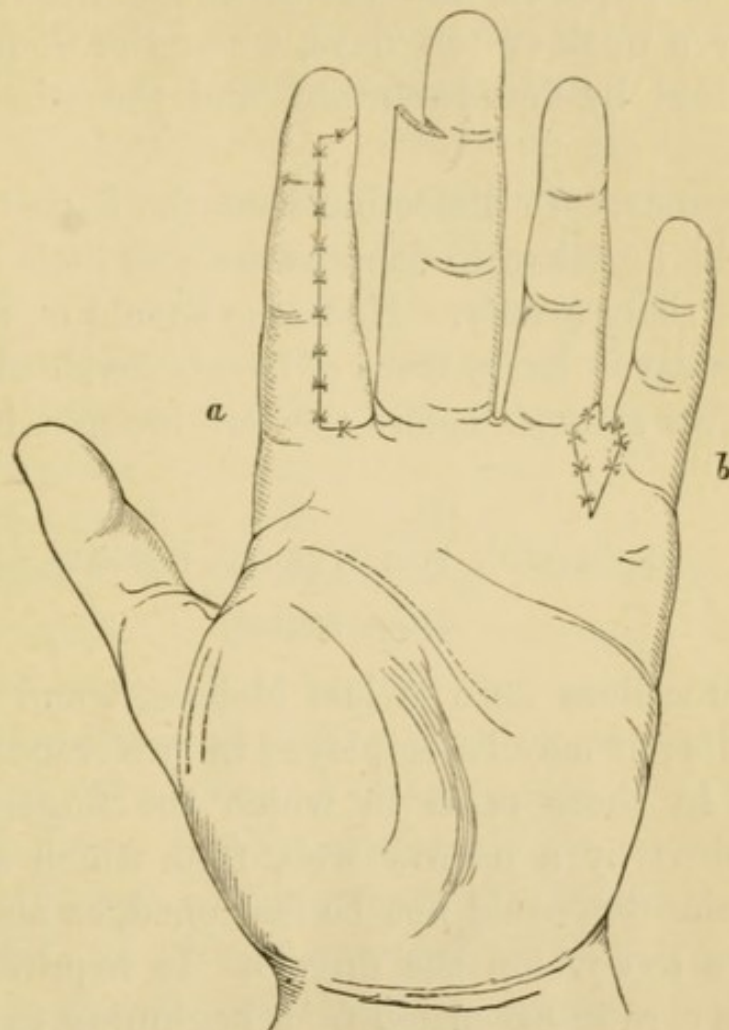


FIG. 6.—FRONT VIEW OF HAND, WITH FLAPS OF THE TWO OPERATIONS FOR WEBBED FINGERS.

In Didot's one of the flaps, *a*, is stitched in place, the other is free.
In Zeller's, *b*, the single flap is stitched in position.

the front (fig. 6, *a*, index and middle)—and each should completely cover in the raw surface left by the dissection off of its fellow from the opposite aspect of the finger. In their new position they are carefully united with fine carbolised silk, so that every part of the raw surfaces is com-

pletely covered, special attention being given to the angle between the fingers. The wounds are then dusted with iodoform, and covered with antiseptic wool, packed well between the digits. If the whole procedure has been carried out antiseptically, and abundance of wool be used, no splint is required, and the dressings need not be disturbed for a week or ten days, when the wounds will be found united by first intention, and the stitches can be removed.

Memoranda.—In dissecting back the flaps, the greatest care should be taken to damage them as little as possible, and to cut them evenly. No tissue should on any account be taken away. Every trace of blood-clot should be wiped from the raw surfaces before they are brought into contact.

OPERATION FOR WEBBED FINGERS.

Zeller's Method.

The procedure here is less elaborate, and gives very good results; it may be employed in preference to Didot's operation in those cases in which the fingers are very closely united by a narrow web, from which an anterior and posterior flap could not be fashioned, as above, of sufficient size to envelop the fingers. It requires the same scrupulous care in execution from beginning to end as the last operation.

Operation.—A triangular flap (fig. 5) is first mapped out on the dorsal aspect of the web, its base forming a line between the metacarpo-phalangeal joints of the two fingers, and its apex reaching nearly to the free margin of the web (fig. 5, ring and little finger). This is dissected up, and turned back, and the remaining tissues of the latter are then divided down the middle line, nearly as far in front as the palmar aspect of the interval between the

heads of the metacarpal bones. All bleeding having been arrested, the posterior flap is doubled over between the fingers, and its apex is carefully inserted between the edges of the anterior incision, and is fixed there with a few points of carbolised silk (fig. 6, *b*, ring and little finger). The edges of the flap are also similarly secured to the raw surfaces between the fingers. If there be any loose skin obtainable from the anterior layer of the web it is now made to cover as much of the raw surfaces on the sides of the fingers as possible, by stitching of the edges. Any portion uncovered will granulate up in the usual way.

The wound is treated as in the last case, and may be left for several days without change of dressing if the operation has been done with every antiseptic precaution. When the dressing is changed, the flap will probably be found to have united by first intention.

Memoranda.—The triangular flap should be as thick and as little injured in dissection as possible. The object of carrying its base and the anterior incision to receive its apex so low down is to allow for a certain amount of shrinkage which will take place in every instance. Of course the wound between the fingers must not be carried far enough into the palm to endanger the bifurcation of the digital arteries. In a case operated on by the author, by this method, a good deal of shrinking eventually took place, even though the new web, for a considerable time after the wounds were quite healed, was much below the level of the normal fissures between the other fingers. The patient, however, had eventually a very useful hand and fingers.

CHAPTER VI.

OPERATIONS ON THE BONES.

It would be difficult to name any direction in which surgery has advanced more rapidly during the last few years than in the operative treatment of bone affections. Delivered from the great fear of septic processes, so terribly fatal when attacking bones, surgeons have advanced further and further in dealing with the skeleton, until numbers of new operations have sprung up, and until the older procedures have been extended to almost every bone in the body.

One of the most remarkable of all the newer operations, and the one, perhaps, of the widest application, is that for the remedy of genu valgum, and as it furnishes a good example of the method in use in dealing with the skeleton and the extent to which interference may be carried with impunity, it is first described.

OSTEOTOMY FOR GENU VALGUM.

Macewen.

In this country, at the present time, practically but one operation is performed for genu valgum by the great majority of surgeons—namely, that designed by Dr. Macewen of Glasgow, and this will be first described here, the next in favour being subsequently alluded to.

Instruments.—A scalpel; artery forceps; strong chisels; and a mallet.

Position of Patient.—Supine, inclining slightly towards the affected side, the limb to be operated on being flexed at both hip and knee.

Position of Operator.—On the outside of the right leg for that side, at the left hip for the left side; an assistant stands in front of the operator on the same side, in both cases holding the limb firmly.

Landmarks for Incision and Operation.—The upper border of the patellar articular surface of the femur is the best guide for the incision in the skin, and the point of section of the bone. This is easily felt on flexing the knee, and the thumb is fixed on it, to mark its position. The limb is then placed in a slightly flexed position, and laid partly on its outer side. The operator then enters the point of the knife on the inner aspect of the knee in front of the adductor magnus tendon, and at the level of the patellar articular border, and thrusts it down to the bone at once. He then cuts upwards in the line of the axis of the femur for about an inch, dividing everything down to the bone to that extent at once. Through this wound the chisel is inserted, and when it reaches the bone it is rotated until its edge lies across the axis of the femur, and its plane is parallel to that of the epiphysis, half an inch above which it should divide the bone (fig. 7). Giving the chisel a slight tap with the mallet to steady it, the surgeon should look to see that it is directed across the femur, parallel to a line touching the lower borders of the condyles of the latter, and not that it is at right angles to the axis of the shaft (*vide* fig. 7). When sure of this, he directs his assistant to steady the knee by grasping the thigh above and leg below, and then strikes the chisel sharply a few times with the mallet. Without being withdrawn the tool is then levered a little across its own plane, so as to widen the wound in the bone (fig. 7, *arrow*), and is then struck

again until it divides two-thirds or so of the latter. It is then withdrawn, while a sponge is held firmly on the opening, and the remaining third is fractured. To do this

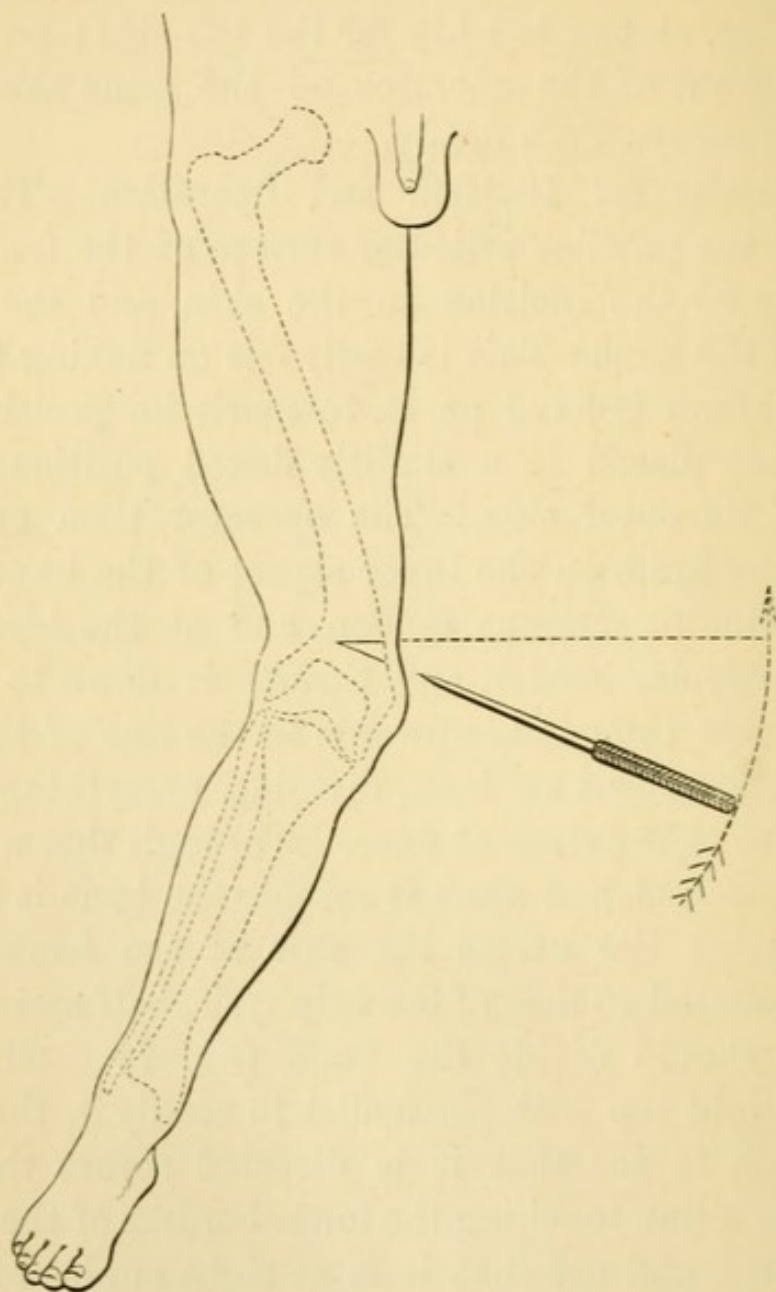


FIG. 7.—MACEWEN'S OPERATION.

The direction in which the chisel is here placed is that in which it is struck with the mallet. The direction of the arrow is that in which the chisel is levered up and down when in the bone, so as to form a wide gap in the femur, as in the figure.

the surgeon grasps the thigh and leg, and strongly adducts the latter with the whole limb in the extended position.

In young patients this fracture is rarely complete, and is more of the nature of a bending or infraction which leaves the periosteum intact on the outer side, a manifest advantage during the process of repair.¹ Sometimes enough of the bone has not been cut by the chisel, though it appears to have entered fully two-thirds of the diameter of the femur; this is due either to narrowness of the tool employed, or to its being placed a little too far to the front or back, leaving the opposite aspect of the bone consequently undivided. This is remedied by replacing it in the opening, but a little to the front or back of the bone, according as it is felt to be undivided, and then giving it a few extra blows with the mallet. Whenever the chisel is about to be withdrawn, it should be lapped round with a carbolised sponge and brought away through this while the hand presses the sponge on the surface of the wound, during the efforts to straighten the limb. In this way no air or impurities can be drawn into the soft parts during the manipulation.

When finally brought into a straight line or, better still, when given a little curve inwards, the limb is put up in one or other of the retaining apparatuses according to the fancy of the operator. The author prefers to wrap the whole thigh and leg from the iliac crest to the toes in ordinary dressmaker's cotton wadding of even thickness, with salicylic wool in the neighbourhood of the wound, over which iodoform has been sprinkled, and then to apply a plaster of Paris bandage in the usual way from foot to groin. This is left on for fourteen days or so, after which the plaster is removed and the limb may be allowed to rest between sand-

¹ This was shown to be the case in a patient of Dr. Macewen's, who died of diphtheria ten days after osteotomy for genu valgum. The external fibres of bone and the periosteum were bent and stretched, but not severed.

bags in bed without any special apparatus, unless the patient be restless, in which case an outside splint should be applied.

Memoranda.—In the wound of the soft parts no vessels of any importance are wounded, as a rule. Occasionally some articular twigs may bleed a little, but this need not delay the operation, as the bleeding will probably cease before the bone is divided. The skin incision should be left unsutured, and should not require a drain-tube. If the knee be kept in the semi-flexed position during the section of the bone the popliteal vessels are relaxed and out of the way of the chisel, and are in no danger unless the latter is used carelessly. All examination as to the depth of the wound should be made with the chisel itself rather than with a probe or the finger, which should never be introduced. But, as a rule, the depth of the incision in the bone can be gauged with sufficient accuracy as the chisel is driven in, and it will not require to be reintroduced at all.

This is one of the most successful operations in surgery, and with antiseptic precautions almost totally devoid of risks. In proof of this it may be stated that of 330 patients operated on for various osseous deformities of the lower limb by Dr. Macewen, there were no deaths as the result of the operation. Three died in hospital, 1 of pneumonia contracted before the treatment was begun, 1 died of tubercular meningitis, 1 of diphtheria. Among these 330 patients, besides 367 limbs operated on for genu valgum, other osteotomies, bringing up the total to 835, were performed. Such results after serious operations find hardly any parallel in surgery.

The author has performed this operation some scores of times without a single *contretemps*, and with the best results as to usefulness of the affected limbs.

OSTEOTOMY FOR GENU VALGUM.

Ogston.

In this operation the knee-joint is opened and the relations of the condyles are altered by obliquely sawing off the internal one without removing it. This interference with the joint appears to be the radical defect in the procedure which has led to its being practically abandoned in this country in favour of Macewen's operation.

Instruments.—A scalpel ; long blunt-pointed tenotome ; artery-forceps ; a narrow-bladed Adams' saw.

Position of Patient.—Supine, with the affected limb flexed at hip and knee, the sole of the foot resting on the table.

Position of Operator and Assistants.—The operator stands in every case on the left side of the patient, steadying the knee with the left hand. One assistant presses the sole of the foot upon the table and steadies the leg ; another is ready with sponges.

Landmarks for Incision and Operation.—The upper border of the patellar articular surface of the femur is our guide here, as in the last operation. About an inch above this and on the anterior and inner aspect of the femur, a short incision is made down to the bone in the direction of the interval between the condyles. Into this incision the tenotome is thrust, and is made to divide all the structures including the periosteum underneath the quadriceps expansion in a straight line towards the intercondyloid notch, but only sufficiently freely for the narrow blade of the saw to enter the joint. This saw is now thrust along the track made by the tenotome and should point directly towards the crucial ligaments (fig. 8). With it the internal condyle is sawn through directly backwards until it is felt to be loose, when the instrument is withdrawn. The knee is

now extended and the leg is forced into a straight line with the femur. While this is being done the cut surface of the internal condyle is felt to glide upwards upon the cut surface of the femur.

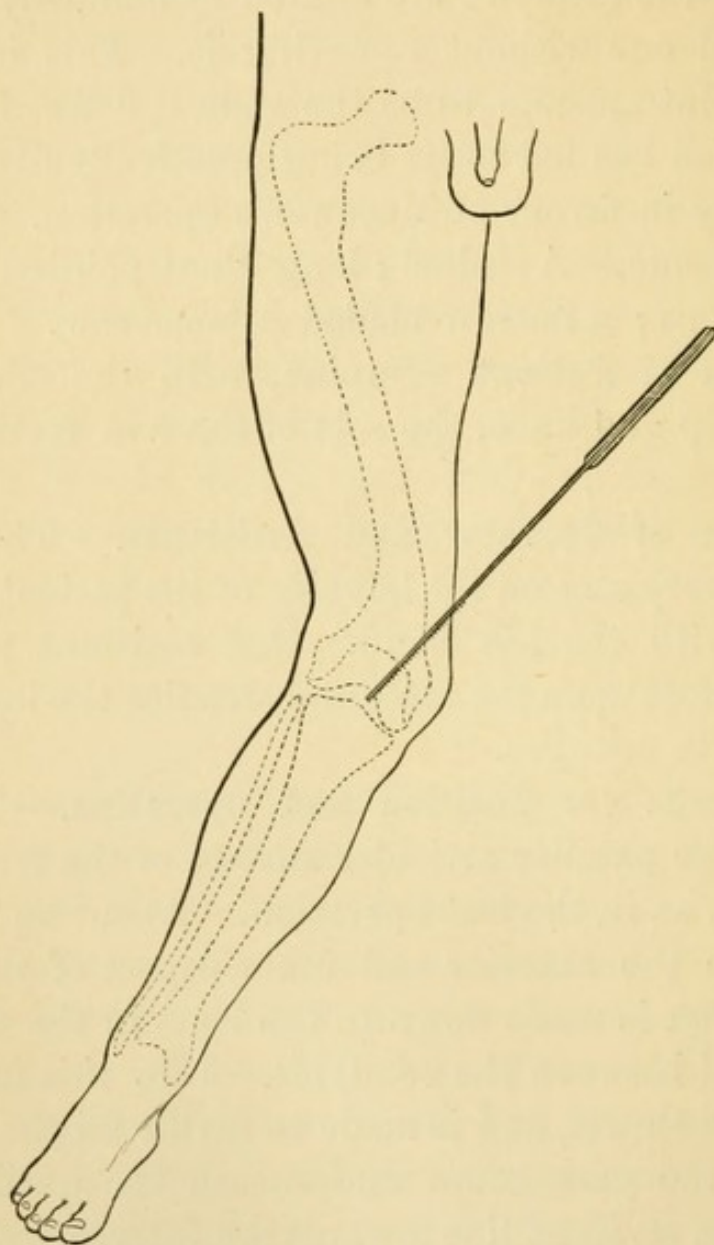


FIG. 8.—OGSTON'S OPERATION.

The saw is represented as it lies on the anterior aspect of the inner condyle ready for section of the latter in a direction backwards.

The wound is now dried, dusted with iodoform, and dressed, as in the last case, with antiseptic wool or gauze. No drain-tube is required, and no stitches. The limb is

either secured in position with a splint such as Gooch's, or at once put into plaster of Paris, a course preferred by the author.

Memoranda.—No vessel of any importance ought to be wounded in this operation, but there may be a good deal of oozing from the cut surface of the bone. This bleeding into the joint and the presence of sawdust in it constitute a strong objection to the operation. In using the saw care must be taken not to cut into the popliteal space, and not to lacerate the soft parts.

The results of the operation are often very good, but in no way better than those following Macewen's procedure, in which the joint is not opened and in which consequently no adhesion can form within.

OSTEOTOMY FOR BENT TIBIA.

Whenever this operation is required, which is very rarely, it is performed on the same general principles and with the same precautions as in the case of the last operations. In the earlier procedures for the cure of the condition a wedge-shaped portion of bone was generally removed from the tibia at the point of greatest convexity; but this, though still the practice of some, is now considered by many unnecessary. It is often quite enough to divide the tibia either straight across or, better still, obliquely. The plane of this oblique line of section varies with the direction of the tibial curve. If convex inwards the bone is divided from above downwards, and from before backwards; if curved forwards the plane of section should be from above downwards and from within outwards. Only very rarely will the fibula require to be cut or broken. The lines of section just given admit of the bone being brought into a

straight line with the least possible displacement of the fractured surfaces.

The division may be affected either with a saw or chisel. If the former is used Gowan's osteotome will be found the most convenient instrument, the saw with it being applied so as to produce the least possible laceration of the tissues around and the greatest accuracy of section.

OSTEOTOMY FOR ANKYLOSED HIP.

In certain cases of hip-joint disease followed by bony ankylosis the position of the limb, owing to faulty treatment, is such that progression is interfered with seriously, as well as other important functions of the body. The most usual deformity is extreme flexion with great adduction and some inversion. Such deformity is rarely met with at the present day, owing to improved methods of treatment during the acute stage, but when present may be remedied with comparatively little risk and trouble. The patient will usually be anxious about two things—first, to have the limb straightened; second, to have the movements of the joint restored. The first of these demands is easily met by the surgeon; the second is a matter of much difficulty, requiring as it does the most careful and prolonged after-treatment, and a considerable amount of fortitude on the part of the patient.

Instruments as for genu valgum, with the addition of a narrow-bladed Adams' saw for certain cases.

Position of Patient.—Lying upon the sound hip.

Position of Operator and Assistants.—The surgeon stands behind the patient, beside the affected thigh, his assistant at the opposite side.

Landmarks for Incision and Operation.—The first skin incision will vary, of course, according to the point chosen

for section of the bone. This latter is in some cases divided below the lesser trochanter, in others through the neck. In the first instance a longitudinal incision about an inch in length is made over the outer aspect of the femur just below the level of the lesser trochanter. In the second case an incision of the same size and direction is made above the great trochanter in the axis of the neck. Both should go straight down to the bone at once. In either case the chisel is then introduced through the wound, and on reaching the femur is turned on its axis so that its cutting edge is across that of the bone. It is then struck sharply with the mallet until the latter is almost or completely divided. It is well in this case not to trust too much to fracturing an uncut portion of the femur, as is done for genu valgum. Here we are aiming at complete solution of continuity of the bone and periosteum in a straight line; in the case of genu valgum the opposite is desired as far as possible. Consequently the assistant who is in charge of the limb must not bear too heavily upon it, lest he fracture the last internal portion obliquely, and thus form a spike of bone which would give rise to much trouble both in after-treatment and probably also by injuring the future movements of the limb. When the bone is completely severed it is brought into the straight line and thus retained by weight-extension, passive movement being begun from the very first in all cases. The small incised wound requires no sutures or special drainage, and is dressed with a simple antiseptic dressing. Some surgeons prefer the narrow-bladed saw for the division of the bone. If used, it is introduced through the same openings as those described for admitting the chisel, and the bone is sawn across transversely. It has no special advantages over the chisel, and has the disadvantage that it leaves bone-dust in the wound. In other cases Gowan's osteotome may be

used, and will be found very convenient to the operator, though open to the same objection.

Memoranda.—This is one of the simplest operations, the only difficulties arising out of hardness of the bone, occasionally present to an extreme degree. In such a case it is more than ever necessary to carry the saw or the chisel straight through the bone, in the latter case by well-directed, decided blows. The tool has been broken more than once by clumsy handling of the mallet. The chisel should be stout and tapering towards its edge, and the latter must be rounded at either side. If it should become locked in the bone it may be loosened a little by lateral movements across the axis of the latter, but all levering should be avoided, as calculated to break off portions of the steel of the thin edge of the instrument.

OSTEOTOMY FOR FAULTY ANKYLOSIS OF THE KNEE.

In cases, yearly becoming rarer, in which the knee has been allowed to undergo osseous ankylosis in a flexed position, it may be considered desirable to restore the limb to good position by division of the bone. This has been done in various ways, but the procedure now in use is so much superior to the older methods in simplicity of execution and immunity from risk as to have superseded them. This, then, will alone be described here.

Instruments, &c., as for genu valgum.

Position of Patient.—Supine, with both thighs flat on the table, and the knees hanging over the end of the latter.

Position of Operator and Assistant.—The operator stands on the right side of the patient for both limbs, his assistant on the opposite side.

Operation.—A short one-inch transverse incision is

made through the skin and soft parts down to the bone, about half an inch above the patellar articular facet of the femur; through this a full-sized chisel is inserted, and is carefully adjusted to a right angle with the axis of the bone. It is then struck sharply with a mallet until the bone is nearly divided through. Then it is withdrawn a little and shifted to one side and another, and similarly driven with the mallet nearly through to the posterior surface. The gap thus made on the front of the bone is widened by levering the chisel backwards and forwards until a wide opening is made anteriorly. When nothing remains undivided except the posterior lamella of the bone, the chisel is withdrawn finally, a sponge immediately taking its place, and the knee is forcibly extended until the remaining part of the osseous tissue gives way, and the gap in the bone is closed by the straightening of the femur.

The limb is then covered with an absorbent antiseptic dressing and is put up on a Macintyre's splint or in plaster of Paris in a very slightly flexed position. If properly treated the dressing will probably not require to be disturbed until union in the improved position has taken place.

Memoranda.—Unless this operation is performed with every possible antiseptic precaution it is not justifiable. Thus done, however, it is as simple as other subcutaneous osteotomies. Care is required not to encroach on the popliteal space in driving the chisel through the bone, the axis of which must be kept closely in the eye of the operator. Great care should be taken not to use any violence in straightening the limb, lest damage be done to the popliteal vessels and nerves. It must be remembered further that this operation is only to be done in selected cases where the tissues behind the knee are sound and sufficiently mobile to justify the hope that both vessels

and nerves will accommodate themselves to the altered relations of tension produced by the operation. In some cases where the popliteal tissues are tense it may be better, after dividing the bone, to use gradual extension of the knee by weight for a few days rather than to straighten the limb forcibly at once. Occasionally, too, a wedge of bone may be removed from the anterior aspect of the condyloid portion of the femur to facilitate the straightening of the limb.

OSTEOTOMY FOR BADLY-UNITED FRACTURE.

For badly united fractures, where a patient is decidedly anxious for the cure of an angular deformity, nothing better can be done than osteotomy on the lines described above. The bone may be divided either on the concavity or convexity of the curve, according to the relation of important structures to it. Preference, however, should be given to division from the concave aspect where there is a choice, for in this case the last portion of the bone on the convexity can be fractured without any disturbance of its periosteum and the adjacent textures, and the tendency will be for them to hold the fragments together from the first, besides which the limb, as it is brought into a straight line, will be somewhat more lengthened than if the bone were cut on the convexity of the curve. In these cases the bone should not be completely divided with the chisel, but a portion should be left to be fractured by strain steadily applied so as to do as little damage to the soft parts around as possible when the bone snaps. When brought into a straight line the limb should be immobilised as completely as possible for several weeks in plaster of Paris applied over its whole length after the method described as suitable in cases of genu valgum where the bone has been divided. Of course other apparatuses may be

used for fixing the part, but none will do this so completely and so comfortably for the patient as the plaster of Paris case, applied over a thick even layer of cotton *wadding*. The wound must of course be first carefully cleansed and dressed with an antiseptic covering before the latter is applied. The author prefers to dust it with iodoform, and then cover it with strips of salicylic wool so arranged as to allow of the escape of the first slight serous discharge.

WIRING OF BONES FOR UNUNITED FRACTURE OR FALSE JOINT.

Although a fracture of any of the long or short bones may fail to unite, the same rules will guide us in wiring them together wherever the lesion be, and it is therefore unnecessary to point out here much more than the general principles which are to guide the operator.

In the first place the most rigid antisepsis is to be practised if these operations are to be undertaken at all.

Next, the aspect of the limb chosen for the incision down upon the bone, which must be very free, should be that at which the least important structures lie, that point too being selected if possible at which they are shallowest.

When the bone is reached the periosteum should be carefully raised from that portion which is to be removed without disturbing its relation to the soft structures around or to the ends to be united.

When the relations of the fractured surfaces to one another have been made out, it is well to drill the holes for the wires before cutting off the ends. In this way the liability of the latter to split during the use of the drill is lessened. The line of section, however, should be determined on beforehand, and should be so planned that the ends will rest more or less against one another in such a

way as to oppose shortening. The wires when introduced are to be bent round one half of the circumference of the bone and twisted tightly. The ends are then cut off close and hammered flat against the bone. They may not require ever to be removed, and are a source of strength to the part, but in some cases may be cut down upon after consolidation of the fracture and withdrawn. In a perfectly aseptic wound this will not be necessary (*vide* a case by the author, 'Transactions of the Clinical Society,' 1886).

The wire used for suture should be of silver and of various thickness. For the olecranon it should be about $\frac{1}{25}$ of an inch, for the patella $\frac{1}{16}$, for the femur $\frac{1}{10}$ in thickness.

FOR WIRING AFTER FRACTURE OF THE PATELLA.

The general question as to the class of cases in which this operation is demanded and those in which it is not necessary will not be discussed here; the matter is still *sub judice*. It is enough now to remark that the weight of opinion appears to be in favour of trusting, as a rule, in all recent cases, to one or other of the fixed appliances, and especially to the plaster of Paris case after aspiration of blood from the joint, as recommended by Mr. C. Heath, and of reserving the use of the wire stitch for those in which, for one reason or another, the above treatment has failed, and wide separation of the fragments of the patella has taken place, with the result of serious impairment of the functions of the limb. Under these circumstances there can be no doubt of the justifiability of the operation if undertaken by one versed in the details of the antiseptic treatment of wounds, or of the excellent results which have been obtained. It is right, however, to state that so high an authority as Sir J. Lister is in favour of suture of the

patella in recent cases of fracture, and he has argued the case with his usual moderation and ability.¹

It must not be forgotten, however, that the condition of

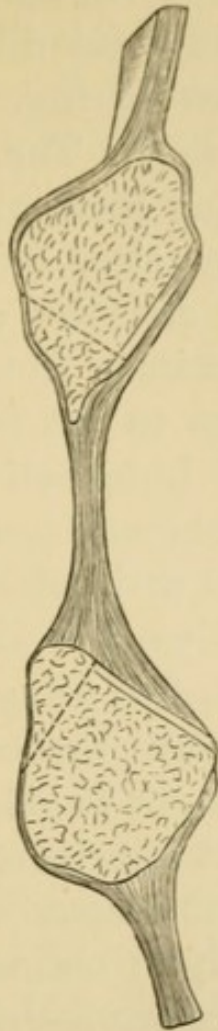

FIG. 9.—OLD FRACTURE OF THE PATELLA WITH FIBROUS UNION.
(From a preparation in University College Museum.)

The tilting out of the fragments is well seen, also the fibrous material between them, especially on their cartilaginous aspect. Mammillated processes of new bone are seen springing from the fractured surfaces. The dotted lines indicate the planes of the fresh surfaces to be cut in the operation, and nearly correspond with the original line of fracture. The cartilaginous covering of each fragment is tilted somewhat towards its fellow.

the parts involved is totally different in recent and old fractures of the patella. In the first the interval between the broken surfaces is filled up with firm blood-clot and fibrous shreds, but beyond clearing this material away and

¹ *Brit. Med. Journ.* Nov. 3, 1882.

cleansing the joint, but little has to be done before the fragments are bored and wired together. They are probably only moderately separated, are non-adherent to parts around, and the fractured surfaces are fresh. But with old fractures the case is quite different. Here the fragments are widely separated (fig. 9), are united to one another by fibrous tissue. The broken surfaces have thrown out bone, forming more or less mammillated processes running into the latter (*vide* fig. 9). The fibrous material may cover the articular cartilage of the patella fragments as in the specimen from which I have drawn (fig. 9), and unite them to the femur at various points. It is necessary therefore in operating under these circumstances to cut away the fibrous tissue between the fragments to release the latter from their adhesion, so as to be able to draw them into apposition, and also to cut a fresh plane surface on each portion before bringing them together. Of the two operations, therefore, that on recent fractures is the least complicated, and ought to give the best results. But whether for old or recent injuries of the patella the mode of procedure is practically the same.

Instruments.—A scalpel; ordinary carpenter's boring-awls, or an Archimedean screw-drill with various 'bits;' chisels; a mallet; a narrow-bladed fine saw; Fergusson's lion-forceps; pure soft silver wire $\frac{1}{16}$ inch thick.

Position of Patient.—Supine, with the affected limb fully extended.

Position of Operator and Assistants.—The operator stands on the outer side of the knee to be operated on, his assistant facing him and steadying the limb.

Landmarks for Incision and Operation.—It is only necessary to keep the middle line of the patellar fragments in view over the gap separating them. In this line an incision is made reaching from a full inch above the upper

to an inch below the lower fragment. This should divide all the soft parts fully, when they can be drawn aside. When thoroughly exposed, but without interference with their periosteum, the two portions of the patella are drilled with an awl in a line reaching obliquely from the corresponding edges of their cartilaginous surfaces to the superficial aspect of their attached margins (fig. 10). One such

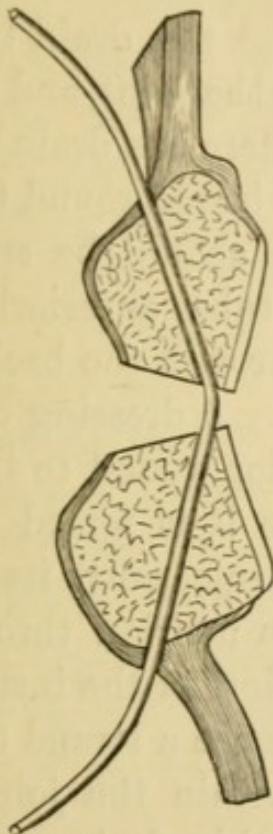


FIG. 10.

Fragments cut square, cleared of all fibrous covering between their cartilaginous surfaces, and drilled for the silver wire. The latter is shown in place.

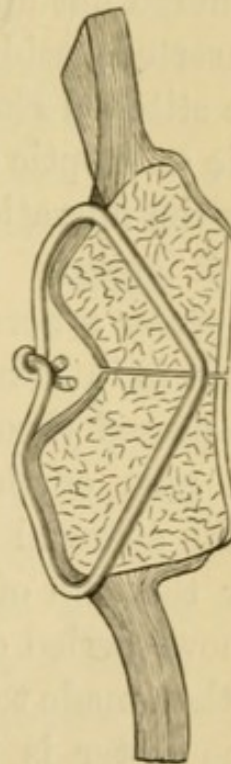


FIG. 11.

Fragments in apposition, with the wire twisted, and its knob hammered flat.

hole carried in the direction of the axis of the limb will usually be sufficient, but two may be necessary, one at either side. The fractured surfaces must now be freshened and cut square, either with the edge of a chisel or saw, each fragment meanwhile being grasped in the lion-forceps, laterally if necessary. All fibrous tissue covering the joint-surfaces of the bones should also be pared away. The wires are now

inserted (fig. 10), and the fragments are brought together as accurately as possible, after the whole field of operation and the joint have been thoroughly cleaned from *débris* and blood by washing and drying out with sponges. When the bony surfaces are in apposition, the wires are bent over and carefully twisted one or two turns (fig. 11), so as to secure the greatest amount of immobility. Then the ends of the wire are cut away and the twisted stump is bent over laterally and hammered flat upon the bone. A fine drain-tube may now be inserted beside the bone into the joint, and the skin wound be stitched closely, except where the drain lies. A soft elastic antiseptic dressing firmly bound round the joint completes the operation. The limb should be supported on a back splint. Instead of a tube anteriorly, some surgeons prefer a horsehair drain through the back of the joint. This is introduced as follows. A dressing or sinus-forceps is passed through the anterior wound to the outer and back part of the joint. Here it is forced straight through the synovial tissues and capsule, until its point is felt under the skin of the ham. An incision through the latter is now carried down to the points of the instrument, which is then made to protrude and seize a strand of horsehair. The latter is brought well within the joint as the forceps are drawn back, and with this drain posteriorly the anterior wound may be completely stitched up without any drainage aperture being left. This is probably the best routine treatment.

Memoranda.—Next to absolute cleanliness throughout the whole procedure the most important point is the accuracy of adjustment of the bony surfaces and of the wires. The drainage of the joint is also very important. If there is no effusion after the first twenty-four hours the tube or horsehair may be removed and the wound allowed to close. The wires should be allowed to remain in the bone perma-

nently. Throughout the whole procedure the aim of the operator should be to disturb the soft structures around the fragments and the periosteum as little as possible, so as not to interfere with the vascular supply of the part so necessary for its repair. In cases of old fracture with wide separation of the fragments it may be necessary to partially divide the rectus muscle in order to admit of the latter being brought together. This may either be done by an inverted V-shaped incision in the middle of the muscle, the limbs of the Λ not reaching quite to its margins, or by two or more parallel oblique lateral incisions starting from opposite borders of the rectus, and not completely dividing it across, as recommended by Dr. Hector Cameron, of Glasgow, at the British Medical Association Meeting, 1887.

The statistics of this operation are very encouraging so far. Out of 50 cases collected by Mr. Turner¹ 22 operations were done for recent fractures, 28 for old cases. Of the first group none were fatal, of the second two died of pyæmia. Of the first group 16 resulted in good movement of the joint; of the second there was a similar result in 10; and in 2 and 4 respectively there was partial movement.

Following recent fractures the operation resulted in ankylosis in 3, following old fractures in 9 cases.

OSTEOTOMY FOR HALLUX VALGUS.

It may occasionally happen that this condition is sufficiently aggravated to call for operation, but rarely or ever ought it to be so severe as to demand excision of the metacarpo-phalangeal joint, though this has sometimes been

¹ *Clin. Soc. Trans.*, vol. xvii. 1884.

done. The simple operation for its remedy now to be described was proposed to the author some years ago by one of the students at University College Hospital on the spur of the moment, and was at once employed in a case under treatment for hallux valgus at the time.

Instruments.—An osteotomy chisel and mallet; a narrow-bladed scalpel.

Position of Patient.—Lying on the affected side; the foot to be operated on being supported on a sandbag, with its inner border turned upwards.

Position of Operator and Assistant.—The surgeon stands over the foot, which is steadied by an assistant.

Landmark for Incision.—The head of the metatarsal bone of the great toe is defined by feeling with the fingers, and an incision about an inch long is made on its inner side, commencing over the margin of the cartilage and dividing everything down to the periosteum to the full extent of the incision. Through the latter the chisel is inserted, and then turned so that its edge shall lie across the neck of the bone at a point about half an inch from the head. A few strokes of the mallet will now divide the bone almost through, the remainder being left for forcible fracture. The chisel is then withdrawn, while a sponge is pressed round its blade, and with the sponge still pressed tightly on the wound, the toe is forcibly brought inwards into a straight line. A light antiseptic dressing, covered by a straight splint for the inside of the foot, to which the toe is secured, completes the procedure. If there be any difficulty in bringing the toe into a straight line, a small wedge may be removed from the bone, instead of its simple section, after which the difficulty will disappear.

Memoranda.—There are no structures of importance divided, and no sutures or ligatures are necessary as a rule. In some instances, however, one or two points of suture

would be desirable, in which case a strand of catgut may be inserted in the angle of the wound for drainage.

OSTEOTOMY FOR TALIPES.

In some cases of very bad club-foot, where other orthopædic treatment has failed, an operation has been proposed and practised of late years which bids fair to make a permanent place for itself in surgery. This procedure consists in removing a wedge-shaped portion of the tarsus in such a manner that the cut surfaces of the remaining parts of the foot being brought together, the latter is restored to a straight line, while the sole is made to look downwards. This is done with as little injury to the soft parts of the foot as possible. The latter is, of course, shortened in every case, but the patient henceforth treads on the sole of the foot, which is strong and elastic.

The pioneers of this operation were Mr. Solly, who removed the cuboid bone, in 1854, for the remedy of talipes equino-varus, and Mr. Davies-Colley, who took away a wedge-shaped piece of the tarsus, in 1878, with the same object in view. But it is to Mr. R. Davy¹ that we owe the fuller development of the procedure and the best analysis of its results.

Instruments.—A scalpel; a probe-pointed narrow-bladed saw; a 'kite-shaped director'; a 'parallel wire director'; bone-forceps; sequestrum-forceps; artery-forceps; scissors.

Position of Patient.—Supine, with the thigh and knee bent, and the sole of the foot resting on the table.

Position of Operator and Assistant.—The surgeon stands on the outer side of the limb. His assistant places himself opposite, grasping the foot and ankle to steady both.

¹ *Trans. Med. Chir. Soc.*, 1885.

FOR TALIPES EQUINO-VARUS.

Landmarks for Incision and Operation.—The outer aspect of the cuboid bone is the guide for the first incision. When this is made out, an oval piece of skin is cut away over it by two curved incisions, starting on the dorsal aspect of the bone and ending on its under-surface. The skin removed should include the bursa which usually forms from pressure at this spot, and should be nearly as broad as the base of the wedge about to be removed from the tarsus; the subcutaneous structures should be left intact. The surgeon now turns the foot somewhat outwards, and fixing the situation of the astragalo-scaphoid joint in his eye, makes a straight incision over it from the lower to the upper dorsal border of the scaphoid bone. This incision is likewise only skin-deep. The foot is now planted firmly on its sole again, and the tendons and all other soft structures above them are raised from the dorsum of the tarsus by means of a leaf-shaped elevator, introduced through the external oval skin-wound and working towards the internal vertical incision. In this way a triangular surface is cleared on the dorsum of the tarsus, corresponding to the base of the wedge to be removed. The 'kite-shaped' director with its grooves downwards is now passed from the large external skin-wound, beneath the tendons, &c., until its point projects just through the internal vertical incision. Then the probe-pointed saw is thrust along the groove of the director nearest the toes until it projects well through the internal incision. With it the tarsus is divided from its dorsal to its plantar aspect in a line at right angles to the metatarsal bones. Without moving the kite-shaped director, the saw is now withdrawn and is thrust along the groove nearest the ankle until its point emerges at the same spot as before. The tarsus is then sawn through

again from dorsum to under-surface, in a line at right angles to the long axis of the os calcis. Between these two saw-cuts lies the wedge-shaped portion of bone to be removed. This is now seized with the sequestrum-forceps and is drawn out, any ligamentous shreds still adherent to it below being cautiously divided with scissors or probe-pointed knife. The sawn surfaces and the whole wound are next washed of all *débris* and wiped dry, and the former are adapted one to the other so as to give the best shape possible to the foot. The internal wound may then be stitched up completely; the external, all but its lower angle, in which a drain should be placed for a while. Then the foot is placed either upon a special splint designed by Mr. Davy, or is put up at once in plaster of Paris, having been first dressed with salicylic wool.

In some cases, especially where there is little or no thickening of the skin over the cuboid bone, a straight incision, running along the outer surface of the bone from the neck of the os calcis to the base of the fifth metatarsal bone, may be substituted for the removal of the oval piece of skin described above.

OPERATION FOR TALIPES EQUINUS.

Not having performed this operation himself, the author prefers to describe it in Mr. Davy's own words (*loc. cit.*):

‘Taking the line of the transverse tarsal joint again as a guide, on the outer and inner sides of the foot, immediately over the joint, two wedge-shaped pieces of skin are removed, equal in extent to the amount of bone demanded. The soft structures are freed on the dorsum of the foot in the way previously described; but as the base of the osseous wedge for equinous cases is at the dorsum and its apex at the sole, the parallel wire director, instead of the

kite-shaped varus one, is used. The saw is successively inserted in its grooves, and by keeping in mind the idea of a key-stone, a clean wedge of bone is cut out from the dorsum to the sole of the foot. This wedge is easily extracted in one piece, and consists of the component bones of the transverse tarsal joint, and in severe cases of portions of bone anterior to it.'

The splint used is the same as that for varus, or plaster of Paris may be employed.

Memoranda.—The first great point to be kept in view in these operations, is the protection of the soft parts from all bruising and laceration during the process of clearing the bones. This is best effected by observing to keep close to the latter. Then, in using the saw, care should be taken not to cut too far through, and so injure the plantar structures. The relative depth of the tarsus on its inner and outer aspect must be borne in mind while the saw is being used, and the first evidence of mobility in the wedge be looked for as a guide to its separation. The clearing of the soft parts on its plantar aspect is best deferred until the wedge has been sawn.

The portions of bone included in wedges of ordinary size belong usually to the astragalus, os calcis, scaphoid, and cuboid, but in larger wedges parts of all the tarsal bones have been found.

The place which these operations are to take in surgery has yet to be determined. That no one ought to think of performing them except in inveterate cases is clear and must be insisted on. In Mr. Davy's hands the procedure has been very successful. He tells me that he has now performed the operation thirty-three times in bad cases; of these one died and the rest have all walked well and gained their livelihood. In one case of talipes equinovarus in which I performed the operation myself, I was

much impressed with the ease with which it could be carried out, and with the excellence of the result.

OSTEOPLASTIC OPERATIONS FOR THE REPAIR OF
DEFICIENCIES IN LONG BONES.

Several operations have been devised for the filling up of deficiencies in the shafts of long bones, the result of disease, injury, or operation. It occasionally happens that after acute neurosis the whole or greater part of the diaphysis comes away as a sequestrum, leaving nothing but the two epiphyses united by a fibrous cord. Again, after compound comminuted fracture, portions may necrose and leave a deficiency between the broken ends only filled up by soft tissue. Finally, after resection of part of the shaft of a bone for new growth, a limb is often rendered practically useless. In any of these cases a properly devised osteoplastic operation may be the means of restoring the continuity of the bone with little or no diminution of its length, provided the patient be young and healthy enough for the processes of repair to be carried on with energy. Supposing then a defect of about two inches in a long bone otherwise quite sound, one of the following operations may be performed with good results. Greater deficiencies are probably better treated by transplantation of bone from another healthy individual.

The first method, called by Ollier that 'par glissement,'¹ is carried out as follows:—

A longitudinal incision is carried down to the deficiency between the ends of the bone. The fibrous material between the latter is then divided transversely (fig. 12), and a thin slip (*b, b*) is then cut off each of the ends of the bones with a fine saw in order to make fresh surfaces on them. These

¹ *Traité des Résections*, 1885, vol. i.

slips are cut from right to left in one case, and from left to right in the other. They are left attached to their respective bones by their external periosteum and the surrounding soft parts (fig. 13). From one of the ends is then cut an oblique portion (*c*), the line of section starting from that border of the freshened end opposite to the attachment of the

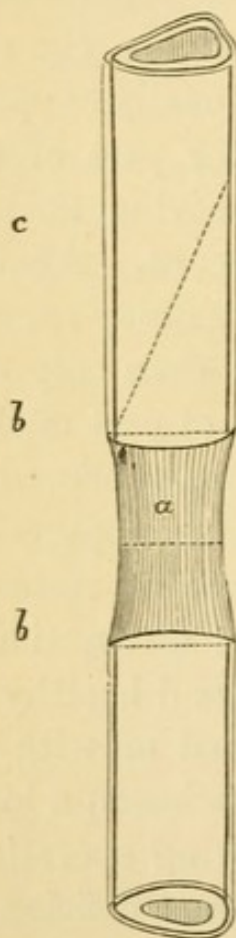


FIG. 12.

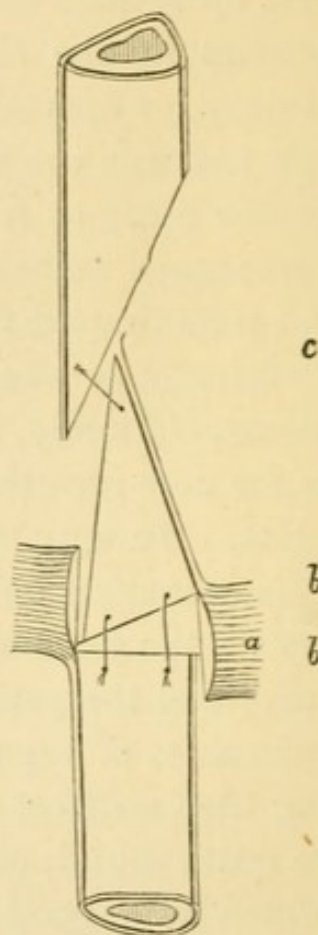


FIG. 13.

OPERATION 'PAR GLISSEMENT.'

a, Fibrous tissue between the broken ends; *b, b*, lines of transverse section to freshen the ends; *c*, oblique line of section to set free the fragment for filling the gap.

slip (fig. 13, *b*). The triangular portion thus released from the shaft, but still attached everywhere to its surrounding periosteum and soft parts, is made to glide downwards towards the freshened surface of the other part of the diaphysis until its base rests upon the latter (fig. 13), and its apex lies upon the oblique saw-cut of the bone from

which it was taken (fig. 13). In this position it is secured by a few silver wires passed through holes previously drilled. The little slips of bone first cut from the ends of the bone now serve more or less to fill up the angles between the fragments, and to furnish osseous material. The whole operation must be done with as little

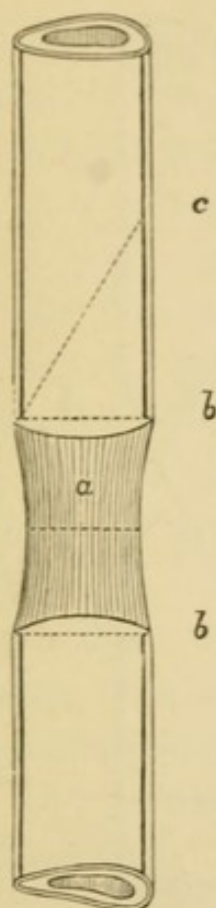


FIG. 14.

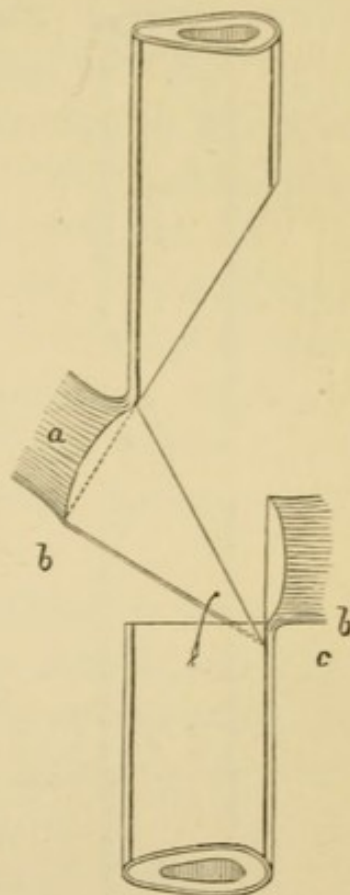


FIG. 15.

OPERATION 'PAR RENVERSEMENT.'

a, Fibrous tissue between the broken ends; *b, b*, lines of section to freshen the lower end; *c*, oblique line of section of upper fragment to set it free, to be turned down towards the lower one.

disturbance to the relation of the various fragments of the bone to their soft parts as possible. And before closing the wound, the whole of its cavity must be cleansed from every trace of blood-clot or saw-dust. A fine twisted gut or silk drain and an antiseptic dressing complete the procedure.

This operation may be modified by cutting triangular pieces from both ends of the bones and uniting them by their bases, instead of taking one only from a single bone.

The next method is that described by Ollier (*loc. cit.*) as that of 'renversement.'

The ends of the bones having been exposed as before,

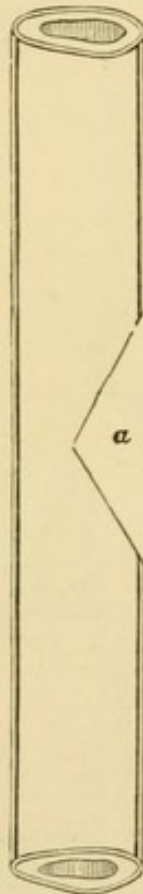


FIG. 16.

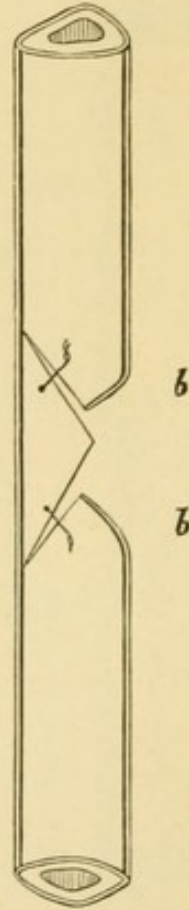


FIG. 17.

OPERATION 'PAR APPROCHE.'

a, Portion to be cut out of the adjacent bone; *b, b*, fresh surfaces cut on the ununited ends, with the fragment from *a* in situ and wired.

and the fibrous bond of union (*a*) divided with due regard for the soft parts and the periosteum, one of them is freshened by cutting from it a thin strip with a saw (fig. 15, *b*). This may be left attached by its periosteum as in the last case, and turned to one side. From the other portion of the bone a large triangular portion (*abc*) is loosened by

cutting obliquely across it towards one edge of its extremity (fig. 14, *c*) where it is left attached by its periosteum and the surrounding soft parts. The point of this fragment (*c*) is now turned down across the gap, between the two bones, and is there secured with wire (fig. 15). The wound is then thoroughly dried of all blood, drained with horsehair, and closed.

A third method, known as the 'procédé par approche,' is only suitable where two bones run side by side (*e.g.* radius and ulna), and where one has a deficiency to be filled up. Here the separated ends of the broken bones are freshened by paring them obliquely (fig. 14, *b b*). From the side of the opposite sound bone a wedge-shaped portion (*a*) is then cut out, without detaching it from the soft parts, and it is turned round so that its sawn surface can be adjusted to the freshened surfaces of the extremities of the deficiency. It is then secured in the usual manner with wire (fig. 17).

But where there is a great distance between the two ends of a bone, none of these methods is suitable, and the only prospect of uniting them is by actual transplantation of portions of bone from another individual by the method now to be described.

FOR TRANSPLANTATION OF BONE.

This operation has been done in various ways to remedy the effects of suppurative periostitis, and consequent loss of more or less of the shaft of one of the long bones. It is only likely to succeed in young subjects whose osteogenic energies are still thoroughly active. The tissues, too, into which the grafts are to be implanted must be quite sound, and the grafts themselves be taken from young and healthy bone. It was for some time thought that grafts consist-

ing of periosteum alone would be sufficient for the reproduction of new bone; but this is now held by the best authorities to be erroneous, and portions of the bone underlying the periosteum are always included in the fragments implanted. The latter must be small and thin, not exceeding a quarter of an inch in length, and one quarter in breadth. In Professor Macewen's cases they were taken from wedges of bone just removed from the bent tibiæ of children ranging from five to nine years of age, whose conditions required osteotomy for the straightening of their limbs. These wedges were split up into chips of the above size by means of a chisel, and were kept wrapped in antiseptic sponges until required. Great care was taken to preserve the periosteum from injury of any kind.

In the case of a child aged three years, in whom the whole diaphysis of the humerus had been lost in the course of an acute neurosis, the operation was performed as follows, fifteen months after the removal of the sequestrum. There was no trace of bone left between the head and the condyloid portion, and the limb was perfectly useless.

The small pointed stump of the upper fragment connected with the head of the humerus was exposed by dissection between the muscles, during which anatomical knowledge was the only guide. The soft parts were elevated from the end of the bone with the periosteum, and a furrow of about an inch and a half long was made from the tip of the bone downwards. Into this furrow a carbolised sponge was pressed, and was there left to arrest oozing. In the mean time, the wedge of bone, the result of an osteotomy in another child, was split into small pieces, each having its portion of periosteum undisturbed. The sponge being removed, and with it all traces of clot, these small portions of bone were placed carefully at regular intervals along the groove in the soft parts leading from the stump

of bone above. The wound was then closed accurately, a horsehair drain running to its deeper part. At the end of two months an addition of one inch to the length of the bone was found to have taken place from the growth of the grafts. Four months after the first operation, a second, similar in every way, was performed, starting from the tip of the new bone. Here the grafts were made a little larger, but without any advantage. Indeed some of them necrosed, and came away in the third week. Notwithstanding, a mass of new bone was formed, and at the end of two months after the second operation, a gain of an additional one inch and a quarter was proved. A third operation of a similar kind was then performed four months after the second, but this time starting below from the condyloid fragment of the humerus. The effect was equally good, although here, too, four of the grafts came away necrosed: the resulting new bone measured about an inch and three quarters in length. The upper and lower portions of the humerus were now long enough to touch one another, and four months after the last operation they were exposed, freshened by cutting away a little of their opposed surfaces, and united. A little later the process of union was hastened by inserting two pegs, and leaving them four or five weeks *in situ*. At the end of this period union was found complete, and the humerus measured only half an inch shorter than its fellow. The arm continued to grow, and became thoroughly useful in every way, though previously quite useless.¹

TREVES'S OPERATION FOR CARIES OF THE LUMBAR VERTEBRÆ.

In certain cases of caries affecting the lumbar, and possibly the last dorsal, vertebra, it may be considered

¹ *Traité des Résections*, 1885, vol. i.

desirable to open up a way for the escape of morbid products directly through the loin, and especially for the removal of necrosed portions of bone if present. Surgery is indebted to Mr. F. Treves for first proposing this measure as a formal operation and for formulating the procedure.

Instruments.—A scalpel ; artery-forceps ; retractors ; director ; sharp spoons ; sequestrum-forceps.

Position of Patient.—Lying on the left side, with the knees drawn up, a thick sandbag being placed under the left side.

Position of Operator and Assistants.—Standing behind the patient.

Landmarks for Incision and Operation.—The last rib, the crest of the ilium, and the edge of the erector spinæ muscle are the guides we look for. A vertical incision is made from the last rib to the crest of the ilium at the outer border of the erector spinæ muscle, *i.e.* at about two and a half inches from the spinous processes. This ought to pass at once through skin and fat, and reach the posterior layer of the lumbar aponeurosis. The latter is then incised in the same line for about two inches, so exposing the fibres of the erector spinæ muscle. These are drawn outwards with a broad spatula, and the middle layer of the lumbar aponeurosis, forming the front of the sheath, is similarly slit up at a point a little external to its attachment to the transverse processes. The quadratus lumborum now comes into view, and is cautiously divided in the same vertical line, with due regard to the lumbar arteries, the abdominal divisions of which usually pass posterior to it. Then the anterior thin layer of the fascia lumborum is seen separating the quadratus from the psoas fibres, and both are divided or torn with the finger, which will now rest upon the diseased bone. If any sequestra are present they are removed with a forceps, but if only a

carious cavity is met with, it is to be scraped with sharp spoons. In all cases free drainage of the carious area is to be provided for by large tubes passing to its deepest parts, and brought out of the lumbar skin wound. The latter is then partially closed by a stitch or two at either end, and is well packed with gauze, or other loose antiseptic dressing, in the usual way.

Memoranda.—No vessels of importance are cut in this dissection, but care is required to avoid the abdominal branches of the lumbar arteries while the quadratus is being divided. The best safeguard here is to keep close to the transverse processes, between which the division of the vessels takes place. Either loin may be chosen, but the right is to be preferred. As a matter of fact, the operation on the living subject is usually much simpler than above described, owing to the abscess being met with before the dissection has been carried as deeply as the psoas.

CHAPTER VII.

AMPUTATIONS AND DISARTICULATIONS.

GENERAL CONSIDERATIONS.

THE objects to be constantly kept in view in amputating the whole or a portion of a limb are the following :

1. To secure absolute cleanliness of the part and its surroundings before, during, and after operation by washing with warm soap and water, and shaving them, and the use of the best antiseptic materials available.

2. To completely remove the damaged portion with as little sacrifice of sound tissue as possible.

3. To prevent hæmorrhage, and to deal as gently as may be with the cut surfaces so as to reduce the amount of shock at the time and the subsequent vascular reaction to a minimum.

4. To provide from sound tissue a well-fitting and adequate covering for the ends of the bones left in the stump, and in such a way as to place the resulting scar out of the way of pressure.

5. In suturing the wound, to secure at one or more dependent points a free escape for any effusion from its surfaces, and to bring the latter as far as possible into perfect apposition throughout their entire extent, aided by pressure and position so as to favour union by first inten-

tion, not only at the edges of the wound but also in its deeper parts.

1. In most primary amputations, and in many for disease, as the incisions pass through sound tissues, it is not difficult to secure the first of these objects by close attention to antiseptic principles. And even where amputation is performed for injury, and the tissues have been more or less exposed to the access of impurities, it is not difficult in most cases to restore them to absolute cleanliness by careful wiping and sponging with carbolic acid, chloride of zinc, or corrosive sublimate solutions. This is more difficult when dealing with suppurating structures, but should always be aimed at.

2. To attain the second object much judgment is required, inasmuch as each case has to be considered on its own merits. As a rule, in amputation for new growth or other disease it is better to err upon the side of free removal than to leave tissue behind which is a source of risk to the immediate or ultimate result. The dangers of shock have been so much reduced of late years, through the saving of blood by the use of the elastic bandage and by the perfecting of anæsthetics, that we are justified in going further in this direction than formerly.

3. To prevent bleeding one or other form of tourniquet is used nowadays in most amputations, but some surgeons still prefer digital compressions of the main artery. The tourniquet most in use is that known as Esmarch's, consisting simply of a strong piece of india-rubber cord or tubing wound a few times round the upper part of the limb. Before this is applied, however, the latter is emptied of its blood either by compression with an india-rubber bandage carried in the usual way from below upwards, or, as recommended by Sir J. Lister, by keeping the limb vertical for four or five minutes while it is stroked down-

wards with the hand. The first method has the merit of saving time and rendering the limb quite bloodless, but it is unsuited in cases of soft new-growth, or where there is much purulent infiltration, on account of the great risks of driving morbid elements centripetally into the lymphatic spaces or vessels. It has the further drawback that it is usually followed by considerable vascular atony, leading to much oozing from the surfaces of the wound after its removal. This may be met to some extent by pressure and irrigation with iced water or galvanism, but there still remains the inherent defect in the method. To remedy this Sir J. Lister proposes simple elevation of the limb, which he has found, from experience, is followed not only by emptying of the veins, but also by contraction of the arteries and arterioles, reaching its maximum in about four minutes. If, at the end of this time, the elastic band is applied at the upper part of the limb the advantages of Esmarch's bloodless method are obtained without its drawbacks.

4. To provide adequate covering for the cut ends of the bones several modes of dividing the soft parts have been devised. These can all be brought under the heads of 'circular,' 'oval,' or 'flap' amputations.

The circular amputation is most suited for limbs with single bones, but may be done at any part of the upper or lower extremity. It has the great merits, that it sacrifices a minimum of bone, and that the muscles and vessels are divided at right angles to their course, and retract evenly and well. It has the disadvantages, however, that the scar will probably be directly over the end of the bone. This objection is of less weight in these days of union of wounds throughout by first intention than formerly, when the scar was almost certain to be fixed by inflammation to the end of the bone, and to be thin and tender.

The circular method, more or less modified, is consequently coming again into favour.

The ordinary way of performing the operation is as follows: the surgeon stands on the right side of the limb and grasps it with his left hand above the point of section, drawing the skin upwards as much as possible at the same time. Then with a knife, the blade of which should be in length once and a half the diameter of the part to be removed, he makes one even circular cut round the limb, dividing the skin and fat down to the deep fascia. While doing this the operator stoops a little, passes his hand and the knife under the limb, turns the point of the latter towards his own face, and lays its cutting edge on the anterior surface of the limb. Then, commencing at the heel, its edge is swept steadily round and is carried into the first part of the incision without leaving the hand or ceasing to cut. The skin and fat are next everted, seized in the left hand and drawn upwards, while the knife is employed with its edge directed vertically to the muscles, to dissect up the sleeve-like flap by a series of strokes at right angles to the axis of the limb. The point ought not to be used for this, but the centre of the blade. By these means the skin, and its nerves and vessels, are injured as little as possible, and the latter are divided transversely and only once. If the point of the knife be used the vessels may be notched in more than one place, and thus much time and blood be lost in securing them. This dissection of the flaps is the only tedious part of the proceeding, and if the limb is rapidly tapering it may be a matter of some difficulty to reflect the skin over the bulkier part higher up. But when this is accomplished the muscles are divided by two or three circular strokes as before at right angles to the bone. The latter is now further cleared of the remains of the muscle-fibres to a point a little higher up by

retraction, and is divided with a saw in the usual way, commencing of course with a back stroke from heel to point, the blade being steadied with the nail of the operator's left thumb. The skin is then brought over the face of the bone and is united in one straight line, which may have any direction, but is usually transverse.

The difficulties of everting and reflecting the skin after circular division without damage to its nutrition and in a reasonable time have led to a modification of the method, which consists in making two very short antero-posterior skin flaps instead of the single circular line of incision, then drawing the skin up and dividing the muscles as just described. This 'modified circular amputation,' as it is called, is particularly useful about the knee and elbow. It yields too a more shapely stump than the circular, and the skin is more easily and safely retracted.

The oval method of amputation is as follows. The surgeon, standing at the right of the limb but facing towards the patient's trunk, enters the point of the knife perpendicular to and directly over the axis of the bone at a point a little below that at which the latter is to be divided. From this he cuts downwards, gradually leaving the mid line of the bone, and, bringing the knife-edge down on to the soft parts, he sweeps round the member transversely and then upwards again to the starting-point. Then, drawing up the soft parts, the bone is divided a little above the upper angle of the wound. The latter is sutured in the direction of the line of the limb. This method is particularly well suited for removing the digits wholly or in part, and has also been practised at the shoulder and hip joints with advantage.

The flap amputations are of great variety. Thus the flaps may be cut single or multiple, one long and one short, oval or square, lateral or antero-posterior, consisting

of skin alone or of skin and muscle. They may also be fashioned from within by transfixion from their base or from without by simple dissection from point to base.

When made from without inwards the point of the knife is entered perpendicularly through the skin at one side of the base of the flap to be formed, and is made to cut directly downwards for a short distance, and then in a curve downwards and across until the front of the limb is passed, when it travels up to a point opposite to that of entry. In this way the full depth of both skin and fat are preserved to the very edge of the flap. The latter is then reflected with its fat or with more or less muscle. When transfixion is preferred, the soft parts are pinched up between the operator's left thumb and fingers at the point selected for the base of the flap, and the point of the knife is thrust in with its back towards the nail of the former, and is made to traverse the limb in front of the bone and emerge close to the fingers. It will require to be depressed a little after crossing the bone in order to reach the latter. When completely through the limb it is made to cut by a gentle sawing movement downwards and then outwards, rather abruptly through the skin, so as to give the latter its full depth at its edge. This first flap being reflected, the second is similarly formed by transfixion at the same point, the knife passing behind the bone in this case.

If rectangular flaps are desired, Teale's method is that usually chosen. This consists in forming long and short square flaps, the shorter one to contain the great vessels, the longer to lie opposite to it, and consequently, as a rule, on the dorsum of the limb. The dimensions of these flaps, which may consist of skin alone or of muscle besides, are as follows:—Half the circumference of the limb at the point of section of the bone gives the length and breadth of the long flap. The shorter one has the same breadth,

but is to be only one quarter as long as its fellow. When the bone is divided at the base of these flaps the longer one is doubled over so that its end can be adapted to that of its shorter fellow.

Each of these various methods of performing amputation has its special merits, as will be seen lower down ; but it should not be forgotten that in these days more depends upon close attention to details in the treatment of the tissues involved in the operation, as regards the checking of bleeding, cleanliness, drainage, and the bringing of all the wounded surfaces into firm apposition, than on the particular shape or size or mode of cutting the flaps.

The statistics of amputations and disarticulations as regards success and mortality are not attempted in this work. The introduction and full recognition of the antiseptic system of wound treatment is so comparatively recent that statistics of cases treated strictly under it would be relatively scanty. Moreover, it would still be very difficult to avoid mixing up cases in which the antiseptic treatment was not fully carried out with those in which it was. Without exercising this discrimination, statistics such as would enable the surgeon to choose between one operation and another can hardly be compiled. It is enough for the present to know that at the present date antiseptic surgery has reduced the mortality after every kind of amputation and disarticulation enormously, by almost annihilating septic infection from without, while chloroform and the elastic tourniquet have greatly diminished the shock of operations. The mortality percentages of the older statistics must therefore be largely discounted at the present day, but how much in the case of any individual operator will depend upon his care in attending to surgical cleanliness, general hygiene, and avoidance of shock in his operations.

AMPUTATIONS OF THE UPPER EXTREMITY.

Here especially nothing should be sacrificed for the sake merely of making a neat and formal operation. Every fraction of the limb is of importance, and it is wonderful what excellent results are obtained, especially in the case of the hand, in healthy individuals by what might fairly be called patchwork operations, where simple trimming up of the injured bones has been resorted to, and irregular flaps have been taken wherever they could be obtained. In the case of the fingers, however, it is undesirable, as a rule, to amputate anywhere except at the base of the distal phalanx or metacarpo-phalangeal joint. Removal between these points leaves a stump uncontrolled by tendons, and always more or less in the way. This does not apply to the thumb, every atom of which should be saved that can be, in order to serve as an opponent to the other fingers.

THE FINGERS AND HAND.

For operations on the upper extremity the body should be in all cases supine on the table, and the arm in most cases abducted to a right angle. Amputations about the shoulder will require in addition that the upper part of the body should be raised somewhat on pillows. If the spray is used it is well to wrap the trunk in some warm covering, especially in the case of children and feeble persons, to protect the chest against its chilling influence. Perhaps the best material for this is ordinary cotton-wool swathed round the whole trunk and secured with a roller bandage.

THE FINGERS.

Only two operations, that by oval incision and that by a single long anterior flap, will be here described as applicable to every finger with very slight modifications.

Instruments.—A straight, sharp-pointed bistoury; artery-forceps; bone-forceps; needles.

Position of Patient.—Supine, with the arm abducted to a right angle and the hand prone, for the oval and flap operations, unless the latter is done by transfixion, when the hand is placed supine.

Position of Operator and Assistants.—The operator faces and grasps the diseased part in his left hand. An assistant stands opposite to him with his back to the patient's side holding the adjacent fingers apart or flexed, as the case may be.

Landmarks for Incision and Operation.—In removing the fingers the best guide to the joint surface is the palmar flexure in each case. It is particularly necessary to remember this when operating from the dorsal aspect, otherwise we are apt to cut on the head or neck of the bone instead of into the joint.

The flap amputation is done from without (fig. 18, *a*), or by transfixion. In the first case, the hand being prone, the knife-edge is laid across the dorsum of the joint just below its most prominent part when flexed, or opposite to the flexure-fold. With one sweep the articulation is opened, aided by flexion, and the lateral ligaments are divided. Then the edge is turned downwards behind the loosened bone, and a long oval flap is made, by a sawing movement, from the soft parts in front of the portion to be removed. This flap is then turned up and united to the dorsal edge of the wound after torsion or ligature of the digital arteries.

In the second case, the hand being held supine, the soft parts in front of the finger are transfixed across the flexure-fold, and a palmar flap is cut, as above; this is then turned up, and the knife-edge is laid across the front of the joint, which is then forcibly extended. One stroke of the knife ought now to sever the lateral ligaments passing between

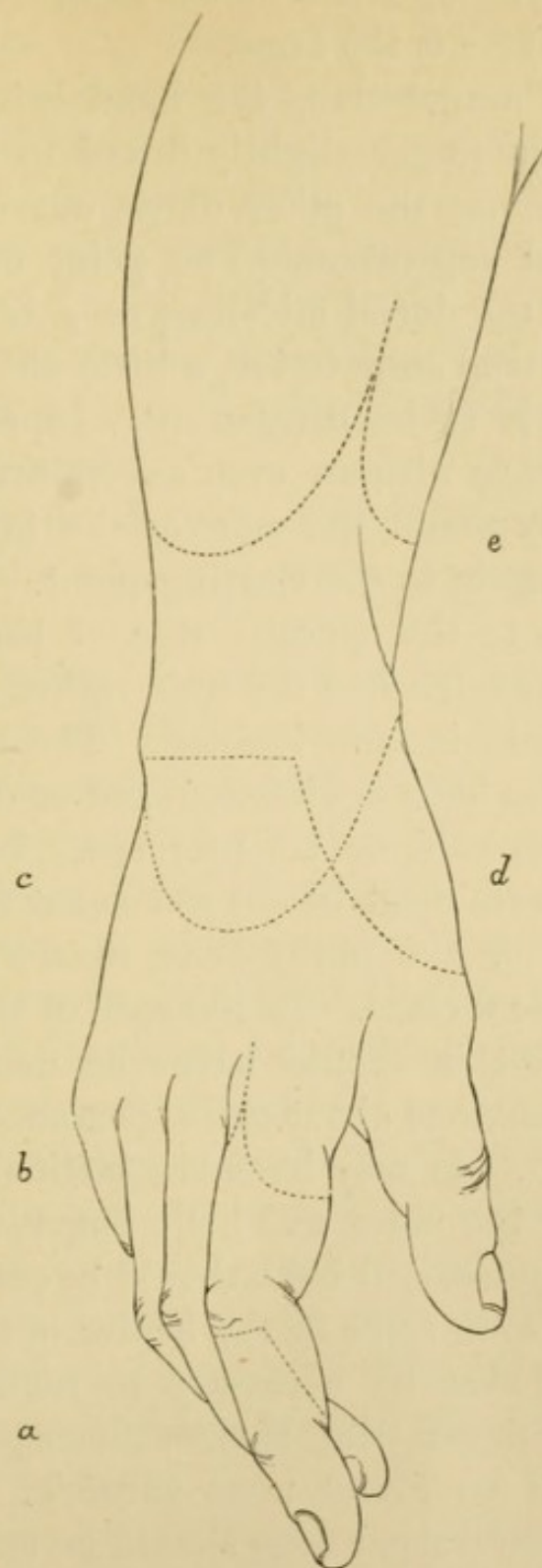


FIG. 18.—INCISIONS FOR AMPUTATIONS.

a, For removal of the finger by anterior flap; *b*, for removal of the finger by the oval method; *c*, for amputation through the wrist-joint by dorsal and palmar flaps; *d*, for amputation at the wrist by Dubreuil's method; *e*, for amputation through the forearm by antero-posterior skin flaps.

the bones and through the dorsal skin. The resulting wound in both cases is the same.

In the oval amputation, the hand being prone, the operator holds the finger slightly flexed in his left hand, an assistant keeping the other digits out of the way by flexion or forced separation. The point of the knife is then entered in the dorsal mid-line, or a little above the knuckle, or, if a true amputation, a little above the spot at which the bone is to be divided (fig. 18, *b*). From this an incision is made with an even sweep, first downwards, and then laterally round the side of the finger across its web, and so up again to the starting-point. It is better to change the knife to the opposite side of the finger when the first stroke has reached the web, rather than to try to complete the whole in one incision. The soft structures being divided, the bone is disarticulated or divided, as the case may be, with knife or bone-forceps. In the first instance the soft parts must be cut somewhat fuller, to allow a good covering for the bulky head, than when the latter is removed by the forceps. In the case of the metacarpophalangeal joint this should never be done, unless the patient is more anxious about the appearance of the hand than its strength. It may be more justifiable after complete removal of the index and little finger, in which case the head of the metacarpal bone should be cut off obliquely, so as to give an even slope to the border of the hand.

If it should ever be necessary to remove the whole thumb or little finger with their metacarpal bones, this oval method will be found most suitable. In each case the base of the metacarpal bone should be left if possible.

AMPUTATION AT THE WRIST-JOINT.

1. By two semilunar flaps, dorsal and palmar.
2. By one long palmar flap.

3. By one lateral flap (*Dubreuil's method.*)

Instruments.—A short, straight-backed amputation knife; a saw; artery-forceps; needles.

Position of Patient.—Supine, arm abducted, hand prone for 1 and 3, supine for 2.

Position of Operator and Assistants.—The operator stands facing the patient, holding the damaged member in his left hand and flexing the wrist a little. An assistant, having his back to the patient's shoulder, draws up the skin of the forearm.

Landmarks for Incision and Operation.—The styloid processes of the ulna and radius guide us for the first dorsal incision.

1. Flexing the wrist, the operator enters the point of the knife at the styloid process to his left, and cuts at first well downwards, and then with a curve across and up to the opposite styloid process (fig. 18, *c*). The skin flap thus formed being reflected with all its subcutaneous fat by the assistant, the surgeon cuts through the tendons, and flexing the wrist forcibly divides the lateral ligaments. Then the knife is placed transversely behind the carpus with its edge downwards, and is made to cut a flap from the palmar structures somewhat longer than on the dorsum. In doing this care should be taken not to lock the edge of the knife in the pisiform bone. It may best be avoided by forcing the carpus back as much as possible after division of the ligaments. The palmar flap may also be formed from without before disarticulation. The wound is drained at its angles.

2. This operation is mentioned by Sir J. Lister, but is not often performed. In it the dorsal incision is made concave upward with the point of the knife, corresponding with the curve of the joint. The long palmar flap is cut from without from apex to base.

3. Dubreuil's operation by lateral flap is suited for those cases in which the dorsal and palmar structures are diseased or injured, leaving the skin on the radial border of the metacarpal bone of the thumb sound.

Holding the hand prone and flexed, the surgeon enters the point of the knife opposite the middle of the dorsal border of the radiocarpal articulation. From this he cuts downwards half-way to the web of the thumb, then across over the back of the latter, round its radial border, and so up again on its palmar aspect to a point over the front of the wrist-joint, opposite to that on the dorsum from which it started. The oval lateral flap (fig. 18, *d*) thus formed being turned up, the remaining two-thirds of the skin of the wrist and tendons are divided by a circular sweep of the knife at the level of the articulation. Then the ligaments are severed, and the lateral flap is laid transversely across the joint, its edges corresponding to the circular incision.

AMPUTATION OF THE FOREARM.

Instruments, Position, &c., as above. The surgeon stands in all cases on the right side of the limb.

Any of the circular or oval methods (*vide* pp. 115 to 118) may be employed here, but the choice will usually lie between the ordinary circular, modified circular, or short skin flap operations (fig. 18, *e*) as described above. Any of these will give good results, and will sacrifice a minimum of bone. If flaps are chosen they must always be antero-posterior.

EXARTICULATION AT THE ELBOW-JOINT.

Instruments, Position, &c., as above. The surgeon stands on the right side of the limb in all cases.

This is not a common operation, but when necessary is

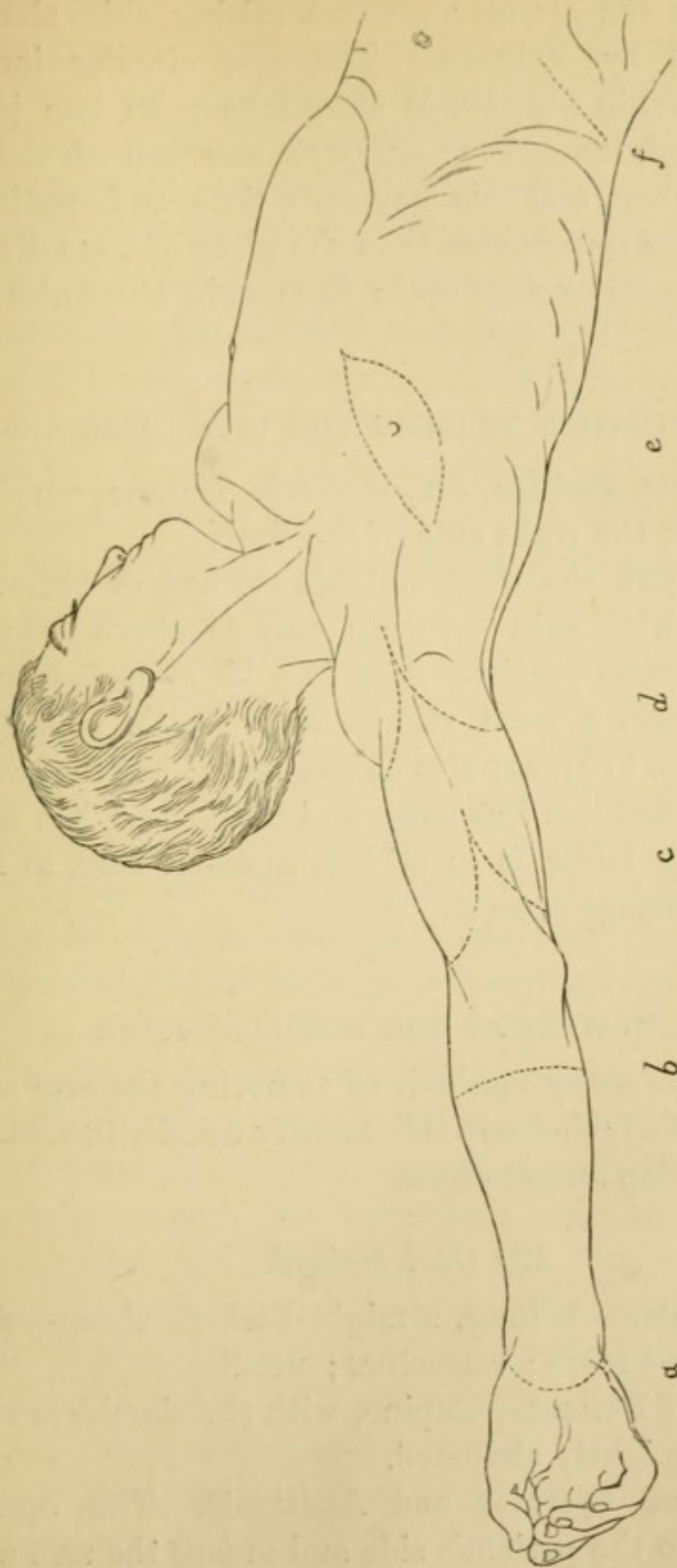


FIG. 19.—INCISIONS FOR AMPUTATIONS.

a, Amputation at the wrist-joint by antero-posterior flap ; *b*, exarticulation at the elbow, circular skin-flap ; *c*, amputation of the arm by antero-posterior flaps ; *d*, amputation at the shoulder-joint by deltoid flap ; *e*, amputation of the breast ; *f*, incision for nephrotomy.

best done by the circular method, raising skin alone, as recommended by Velpeau. The first circular incision through the skin (fig. 19, *b*) should be quite two inches below the condyles. Some operators saw through the base of the olecranon, and this may save time and cutting of tissues of more importance than the piece of bone divided.

Antero-posterior flaps made from skin alone also give good results.

AMPUTATION THROUGH THE UPPER ARM.

Instruments, Position, &c., as above. The surgeon stands in all cases on the right side of the limb.

For this part the most suitable method of removal is the circular, with skin covering only as above described (p. 116). Antero-posterior flaps (fig. 19, *c*) made by transfixion also form a good stump, and Teale's rectangular method (*vide* p. 119) may also be practised; but the circular amputation sacrifices less bone, and if the scar lies across the end of the latter it is of less moment here, as there will be no pressure upon it.

AMPUTATION AT THE SHOULDER-JOINT.

Among the many methods of removing the arm at the shoulder-joint our choice in this country usually lies between the oval and flap amputations.

The Oval Method.

Instruments.—A long, straight-backed, sharp-pointed knife; artery-forceps; retractors; needles.

Position of Patient.—Supine, with the shoulders raised and the arm slightly abducted.

Position of Operator and Assistants.—The operator stands close to the patient's side and grasps the arm above

the elbow with his left hand. If the limb be heavy an assistant standing behind him holds it by the wrist and elbow and follows his movements. Another assistant stands facing the surgeon at the shoulder, and either commands the vessels from the first with an elastic tourniquet, or is ready to slip his thumb on to them as soon as the soft parts are sufficiently cleared to do so.

Landmarks for Incision and Operation.—The coracoid process is felt for, as the best guide for the commencement of the incision. A little outside of this point the knife is entered and is carried downwards for quite four inches, cutting deeply and then rather abruptly outwards, merging into a circular sweep until it reaches the postero-internal aspect of the limb (fig. 1, *h*). The operator now transfers the knife to the front and inner aspect of the latter, and placing its edge in the termination of the circular incision, finishes it and then turns upwards obliquely into the first part of the cut anteriorly. This inner part of the incision should only divide the skin and fat. The edges of the anterior wound being now drawn apart by the assistant at the shoulder, the arm is forced backwards and the head of the bone upwards and forwards, as it is exposed by a few further touches of the knife. The latter is then made to cut firmly upon the head of the bone, by which the capsule and rotator muscles are freely divided and the head can be forced out. The blade is now laid behind the bone and is carried downwards through the structures remaining uncut on the inner side. It is followed by the thumbs of the assistant at the shoulder, who seizes the vessels and compresses them as the blade makes its final stroke towards the thorax in the line of the circular part of the skin incision. Both artery and vein are now tied and the edges of the wound are united, the drain-opening being below.

Memoranda.—If the knife be not kept close to the bone and out of the way of the deltoid, the posterior circumflex artery is likely to be wounded early, and blood and time are lost.

Amputation by Deltoid Flap.

Instruments, Position, &c., as in the last case.

This operation may be performed by transfixion or by cutting from without, which is generally to be preferred, as securing greater accuracy in shaping the flap.

In the latter case the arm is grasped by the surgeon above the elbow and is carried inwards. Then the point of the knife is entered, either at the base of the acromion or at the coracoid process, according to the side operated on, but always to the surgeon's left (fig. 1, *g*, and 19, *d*), and is carried downwards and to the right, round the insertion of the deltoid, and then upwards again, to form an external flap out of that muscle. This is now reflected up, and the arm is carried backwards and inwards while the knife cuts on the head of the bone and divides the capsule and its muscles. Then the blade is swept downwards on the inner side of the bone (fig. 19, *d*), keeping close to it, and is finally brought abruptly inwards towards the thorax. But while this is done the assistant at the shoulder slips his thumb behind the knife, and grasps the main vessels in the flap before they are divided.

If transfixion is employed to fashion the deltoid flap the arm must be strongly abducted, or even raised (fig. 19, *d*), after which the surgeon grasps the deltoid and skin over it with his left hand, and enters the knife at the coracoid process for the right limb, and root of the acromion for the left. It is then thrust straight through in a line between these two points with its edge towards the insertion of the deltoid, and opens the capsule as it passes the head of the bone. It is now made to cut downwards and outwards through

the insertion of the deltoid, forming a long oval flap. When this is thrown up on the shoulder the rest of the operation is completed as in the last case.

AMPUTATIONS OF THE LOWER EXTREMITY.

For these the patient is always placed supine, and should be drawn down until the buttocks rest on the end of the table. The same precautions as to avoidance of chill by warm coverings should be taken as in operations about the shoulder (*vide* p. 121), shock being in these cases often severe, especially if the abdomen be left exposed and the spray be employed.

AMPUTATIONS OF THE TOES.

The rules which guide us here are practically the same as those for removal of the fingers. But wherever possible a scar on the sole of the foot must be avoided. It should be remembered also that, except in the case of the great toe, it is useless to preserve any of the members, so that removal should always take place at the metatarsophalangeal joint or the smaller digits. Beyond noticing these points it is only necessary to add that the oval method is preferable when possible, whether the metatarsal bone is taken away with the toe or not. The incision should be commenced on the dorsal aspect about half an inch above the point at which the bone is to be divided or disarticulated (fig. 20, *a*).

When a toe with its metatarsal bone is to be removed, it is usually better to divide the latter with forceps at its base, than to disarticulate, especially where the metatarsal of the great toe is in question. In all cases care should be taken to keep as close to the bone as possible and thus out

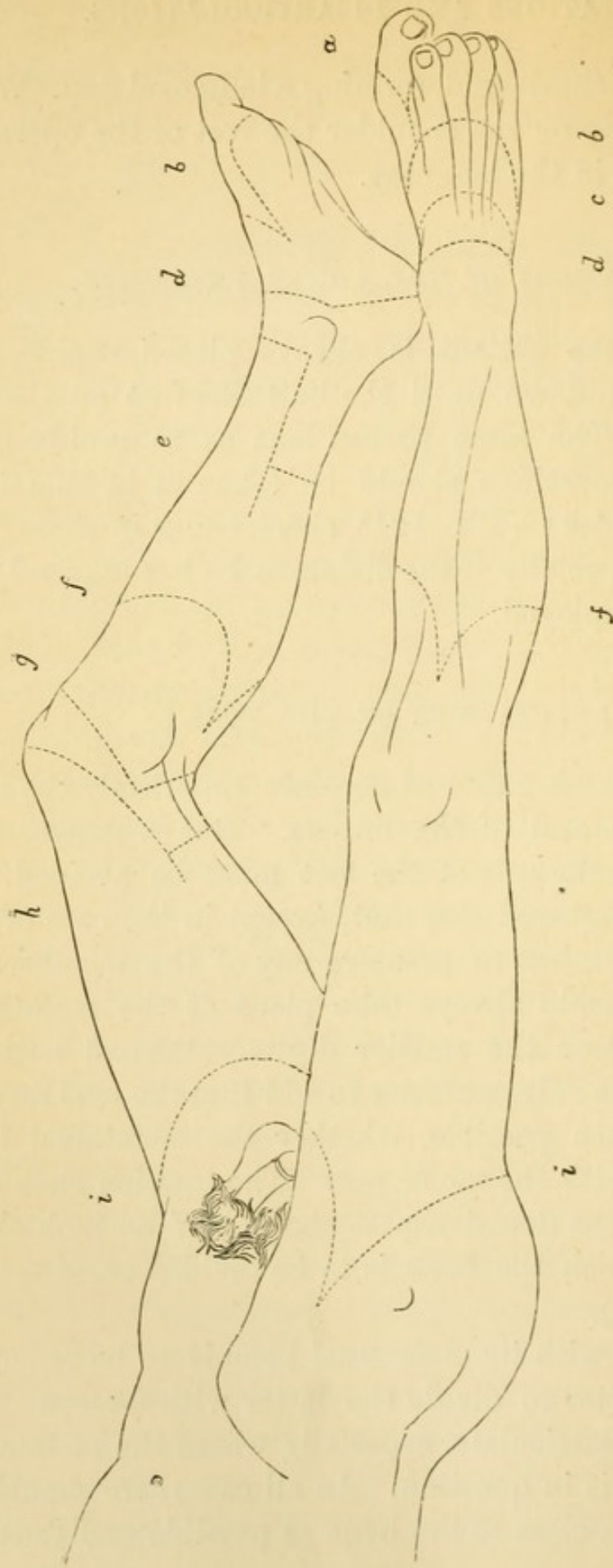


FIG. 20.—INCISIONS FOR AMPUTATIONS OF THE LOWER EXTREMITY.

a, Amputation of the great toe by the oval method; *b*, Hey's amputation through tarso-metatarsal joint; *c*, Chopart's amputation through the tarsus; *d*, Syme's amputation at the ankle-joint; *e*, Teale's method applied to the leg; *f*, Stephen Smith's amputation through the knee-joint; *g*, Carden's amputation through the condyles; *h*, Spence's amputation by long anterior flap; *i*, amputation through the hip-joint by antero-posterior flaps.

of the way of the vessels. In removing the toes alone the great bulk of the heads of the metatarsals should be borne in mind, and the flaps cut well on to the sides of the phalanges, otherwise they will prove too scanty.

AMPUTATION OF THE FOOT AT THE TARSO-METATARSAL JOINT.

Hey's Operation.

Although amputation at the point above indicated is usually described as Hey's, it is rarely performed quite as originally described by that surgeon, Lisfranc's modification of it being found to give better results and to be easier.

Instruments.—A medium-sized, straight-backed amputating knife; a Butcher's saw; a bone-forceps; artery-forceps; needles.

Position of Patient.—Supine, with the legs brought well over the end of the table, the affected limb being flexed, and resting on its heel on the edge of the table.

Position of Operator and Assistants.—The surgeon stands facing his patient; an assistant steadies the flexed limb, on the outside of which he stands facing the operator.

Landmarks for Incision and Operation.—The bases of the first and fifth metatarsal bones are the guide for the first incision (fig. 20, *bb*), which passes with a good downward curve from one to the other, across the dorsum of the foot, forming a flap which should reach well over the metatarsus and contain all the soft tissues. When this is turned up the operator separates the metatarsus from the tarsus by forcibly bearing upon the former while the heel rests on the table, and dividing the tense ligaments, remembering the deep setting of the second metatarsal bone. Then the knife is placed transversely behind the

metatarsus as the latter is drawn forwards by the surgeon's left thumb, and is made to cut downwards to the roots of the toes. The long plantar flap thus formed is now cut across, either from side to side, or by transfixion from its centre, first on one side, then on the other, the knife being held vertically in each case. It should be a little longer on its inner than on its outer side. Some operators prefer to fashion the plantar flap before separating the bones. Others again recommend cutting through the base of the second metatarsal bone with a bone-forceps to avoid the trouble of disarticulating it; or, again, division of all the bones straight across with a saw just below their bases. In amputation for injury the latter method gives excellent results, where the treatment is distinctly aseptic.

AMPUTATION OF THE FOOT THROUGH THE ASTRAGALO-
SCAPHOID AND CALCNEO-CUBOID JOINTS.

Chopart's Amputation.

This operation, which removes the foot in the line between the astragalus and os calcis behind and scaphoid and cuboid in front, is not often performed now. It has been found that though it preserves the tarsus, the latter is often drawn back in process of time and the scar is brought into contact with the ground. Further, in cases of disease of the tarsus, the risks of leaving behind some focus of inflammation determines most surgeons to prefer removal of the foot at the ankle-joint, which gives a better stump with no increase of danger.

Instruments, &c., as for the last operation.

Position of Patient.—Supine, with the lower limbs extended and separated, the leg being flexed on the sound side.

Position of Operator and Assistants.—The surgeon stands opposite the sole of the foot and steadies the heel

with his left hand as below. The assistant, facing him, grasps the toes and holds the foot elevated and at a right angle to the leg.

Landmarks for Incision and Operation.—The tubercle of the scaphoid and a point midway between the prominent end of the fifth metatarsal bone and the external malleolus are marked by the operator's left thumb and fingers. From these points a long plantar, almost quadrilateral flap, reaching to the heads of the metatarsal bones, is marked out and cut by keeping the knife close to the bones. From the same points a curved dorsal incision (fig. 20, *c*) is made, reaching well down on the instep. Raising the flap thus formed, the line of the joint is opened above the scaphoid and cuboid bones; and, bearing firmly on the foot to stretch the ligaments, the surgeon completes their separation from the astragalus and os calcis.

Memoranda.—Unless due care is taken to cut into the ligaments close to the ankle-joint, the articulation below the scaphoid may be opened and the true line of separation missed. Some surgeons prefer to divide the bones of the tarsus irrespective of the joints in cases of injury.

AMPUTATION THROUGH THE ANKLE-JOINT.

Syme's Amputation.

Instruments, Position, &c., as in the last operation.

Landmarks for Incision and Operation.—The points to be remembered are the tip of the external malleolus and a point half an inch below and behind the internal malleolus. Keeping his thumb and forefinger on these points and steadying the heel with the palm of the hand, the operator unites them by a deep-cut incision across the under-surface of the heel, inclining a little backwards (fig. 20, *d d*). The flap thus marked out is now dissected off the os calcis, the

knife being kept close to the bone and the soft parts guarded by the left thumb-nail. Then, grasping the foot in his left hand from above, the surgeon unites the extremities of the first incision by a transverse cut across the dorsum of the foot, dividing everything to the bone. A second stroke divides the ligaments of the joint, which are put strongly on the stretch, and the lateral attachments are also rendered tense by rotation and severed. Nothing remains but to divide the tendo Achillis from above, and saw off the lower ends of the tibia and fibula, about a quarter of an inch above their trochlear surface. The hood-shaped flap is then brought up to the edge of the anterior wound.

Memoranda.—If due care is not observed, the posterior flap may be notched and scored by the knife and its nutrition be thus imperilled. In cases of disease this may best be avoided by clearing off the soft parts from the bone by means of an elevator working under the periosteum, as recommended by Esmarch.

AMPUTATION THROUGH THE ANKLE-JOINT AND OS CALCIS.

Pirogoff's Amputation.

Instruments, Position of Patient, Operator, &c., as for Syme's operation.

Landmarks.—As in the last operation, a point is marked half an inch below and behind the internal malleolus, and another on the tip of the external malleolus. The operator, steadying the heel, unites these two points by a plantar incision inclining well forwards and going down to the bone at once. He then grasps the foot from above in the palm of his left hand as above, extends it forcibly, and unites the ends of the first incision by a firm stroke of the knife, passing straight across the dorsum and dividing everything down to the bone. The ankle-joint is now easily opened,

and, the ligaments being divided, the foot is drawn forwards. A narrow-bladed saw is then laid upon the upper surface of the os calcis, behind the astragalus, and the bone is sawn through from above downwards and forwards in the line of the first skin incision. The ends of the tibia and fibula are now sawn off just above the articular surface, a little more being removed posteriorly than anteriorly. The heel flap is then brought up until the sawn surfaces of the bones are in contact. Stout catgut stitches are then introduced through holes bored in the edges of the apposed bones in order to keep the os calcis from being drawn backwards by the strong calf muscles before union has taken place. Suture of the skin-wound completes the operation.

This operation is rarely desirable in disease of the tarsus, where it is rare to find the os calcis sound enough to justify any portion of it being left. It is well suited, on the other hand, for injury of the foot.

Le Fort's Operation.

Le Fort has modified Pirogoff's operation by making longer anterior and plantar flaps, and then sawing the os calcis horizontally from behind forward, from its posterior to its anterior facet, the tibia and fibula being treated as in the last operation. When the two cut surfaces of the bones are adjusted and secured, the flaps are sutured, the result being a stump with the heel in the normal position.

AMPUTATION OF THE LEG.

Instruments.—A medium-sized, sharp-pointed amputating knife; a saw; artery-forceps; needles.

Position of Patient.—Supine, with the leg brought well over the end of the table.

Position of Operator and Assistants.—The surgeon

stands in each case on the right side of the limb, his left fingers marking the base of the flap. The assistant stands on his right, holding the foot to be removed.

This is usually done by one long anterior flap, or by a long anterior and short posterior. In the latter case Teale's method (*vide* p. 119, and fig. 20, *e*) may be chosen, and gives good results. But the long, rounded, anterior, single flap, half the circumference of the limb in breadth and a little more in length, should be chosen where there is room for it.

Flaps cut from the calf are to be avoided, as they are heavy and usually form an adherent cicatrix on the edge of the tibia, so tender as to interfere with locomotion. In all cases the flaps should be cut from without rather than by transfixion.

Stephen Smith's operation, by lateral hooded flaps (*vide* p. 140), may also be performed on the leg when there is no room for antero-posterior flaps.

AMPUTATION BELOW THE KNEE. 'SEAT OF ELECTION.'

Instruments, Position of Patient and Surgeon, as for the last operation.

Landmarks for Incision and Operation.—Two points are fixed by the surgeon's left thumb and index finger two inches below the level of the tuberosity of the tibia on the inner and outer aspect of the limb. These are united by a curved incision, forming a short anterior semilunar flap. A corresponding flap is formed between the same points behind by elevating the limb and cutting from without. The skin is then drawn up, so as to expose the bone an inch below the tuberosity, and the muscles are divided by circular strokes at the same level. Then the bone is divided, the anterior edge being rounded, either at once

by the use of Butcher's saw, first cutting obliquely and then directly across, or subsequently, after the use of an ordinary saw, by bone-forceps. The section of the fibula should always be completed before that of the tibia is finished, and this may best be done by raising or depressing the heel of the saw according to the side operated on. The tibio-fibular joint should not be opened. The skin-flaps thus formed will give a good covering for the bone, and the cicatrix be out of the way of pressure, as this is borne by the tuberosity of the tibia, now flexed. It should be noted that some surgeons of eminence still prefer to make the posterior flap by transfixion.

AMPUTATION THROUGH THE KNEE-JOINT.

This operation has lately been revived for injury or disease of the leg, and is now advocated as warmly by many surgeons as it was formerly condemned.¹ It has been done by a single long anterior flap (Pollock²), by lateral hooded flaps (Stephen Smith³), or by anterior and posterior flaps (Nathan Smith, E. Markoe). Finally it has been performed by what has been termed the oval (Baudens and Sédillot), or the oblique circular method (Hardie⁴). Of all of these, Stephen Smith's operation, with the addition of Brinton's modification—*i.e.* the preservation of the semilunar cartilages of the knee *in situ*—appears to be regarded with most favour.

Instruments, Position of Patient, &c., as in the last operation.

¹ This whole question is ably discussed by Mr. Bryant in a paper in the *Trans. Roy. Med. and Chir. Soc.* 1886, p. 163.

² The history of amputation at the knee-joint is sketched very fully by Mr. Pollock in *Trans. Roy. Med. and Chir. Soc.* 1870, p. 1.

³ *New York Journ. of Med.* 1852, and *Amer. Journ. of Med. Science*, 1870.

⁴ *Proceed. Roy. Med. and Chir. Soc.*, Dec. 8, 1885.

Stephen Smith thus describes his method (fig. 20, *ff*):—

‘The incision is commenced about an inch below the tubercle of the tibia (middle line), and carried downward and forward over the most prominent part of the side of the leg until it reaches the under surface, when it is curved towards the median line. When that point is reached, it is continued directly upward to the centre of the articulation. A second incision begins at the same point as the first, and pursues a similar direction upon the opposite side of the leg and meets it in the median line in the posterior part. The following points should be remembered, viz., the incisions should incline moderately forwards down to the curve of the side of the leg, to secure ample covering for the condyles; and that upon the internal aspect should have additional fulness for the purpose of ensuring sufficient flap for the internal condyle of the femur, which is longer and larger than the external. In the dissection of the skin, fascia and cellular tissue are raised, and the ligamentum patella is divided, allowing the patella to remain.’ ‘The extremity of the femur is already completely covered, and the line of union of the flaps will be between the condyles and over the intra-condyloid notch. When cicatrisation is complete, the cicatrix sinks into this notch, and disappears from the face of the stump, and offers no point of contact with the artificial appliance. The appearance of the stump is good. In the process of repair, it will be found that the drainage is so perfect that all the anterior portion of the wound remains dry, and frequently heals by immediate union.’

In performing the above operation, the semilunar cartilages should be separated from the tibia and left (with all their lateral attachments undisturbed) on the surface of the femur, as recommended, first by Brinton, and since by Bryant, *loc. cit.*

Memoranda.—The chief advantages claimed for this

operation are, that the flaps are not so liable to slough at their edges as when anterior and posterior; that the drainage of the wound is very perfect; that the end of the stump is covered with skin accustomed to bear the weight of the body, the scar being drawn up behind the condyles; that there is no opening up of bone-tissue or muscular planes, and finally that the end of the stump has a broad surface of bone to rest on. The patella and semilunar cartilages, having been left undisturbed, serve to round off the stump in a way that enables it to sustain the weight of the body remarkably well. Besides this, the skin and soft parts, being left undisturbed in their deeper relations to the semilunar cartilages, &c., are not so liable to retraction as when the latter are removed, and are less liable to slough than when dealt with by antero-posterior flaps.

Hardie's Method.

In this operation the knife-edge is placed transversely on the point of the leg two and a half inches below the tuberosity of the tibia, and is drawn with a sweep round, and then obliquely upwards to a point in the centre of the ham, a little higher than the starting-point in front, and then round the opposite side of the limb to the latter. In this way, when the soft parts are stripped off the tibia as far as the joint, the end of the femur is covered by a hooded flap hanging down in front. This flap should contain the patella and semilunar cartilages (Brinton), and should be united longitudinally behind, room being left for drainage. The scar eventually is drawn up on the back of the thigh.

AMPUTATION THROUGH THE CONDYLES OF THE FEMUR.

Carden's Method.

Instruments.—A long, sharp-pointed, straight-backed knife; a saw (Butcher's by preference); artery-forceps; needles.

Position of Patient.—Supine, the buttocks being brought to the edge of the table, with the thighs extended, the affected limb bent to a right angle at the knee.

Position of Operator and Assistants.—The surgeon stands on the right side of the limb, gauging the base of the anterior flap with the fingers of his left hand; his assistant, kneeling, holds the affected leg, bent to a right angle.

Landmarks for Incision and Operation.—The upper borders of the condyles are our guide for the ends of the first incision, forming the anterior flap, and the insertion of the ligamentum patellæ for the lower border of the latter. Defining the upper borders of the condyles with his left fingers and thumb, the operator enters his knife at the tip of the index finger, and sweeps it horizontally round the knee below the insertion of the patellar ligament, and brings it up to the point on which his thumb rests (fig. 20, *g*). The flap thus cut, containing skin and fat only, is reflected upwards, and the knife is entered at the thumb in the angle of the wound, and is thrust across the limb behind the bone, emerging at the opposite angle. Then its edge is turned downwards, and all the soft structures behind the knee are divided by one straight stroke. The bone is now cleared, and is sawn across just above the condyles. The hood-shaped anterior flap falls over the end of the bone, and gives a good covering, the scar being behind.

A modification of the above method proposed by Gritti consists in leaving the patella and extensor muscles in the anterior flap, but removing the articular cartilage of the patella with a saw. The cut surface of this bone is then applied to that of the femur, and is fixed to it with strong catgut passed through its edges. There is no special advantage in this operation, which is not often performed now.

Sir J. Lister has designed and practised an operation

at the same spot as that chosen for Carden's amputation, which contrives the low division of the bone with the skin-flap from the front of the knee, without the drawback incidental to the last method of operating, namely, that there is a tendency to sloughing in the edges of the long anterior flap, no matter how skilfully formed. He describes it thus :

'The surgeon first cuts transversely across the front of the limb from side to side at the level of the tuberosity of the tibia, and joins the horns of the incision posteriorly, by carrying the knife at an angle of forty-five degrees to the axis of the leg, through the skin and fat. The limb being elevated, he dissects up the posterior skin-flap, and proceeds to raise the ring of integument as in a circular operation (*vide* p. 116), taking due care to avoid scoring the subcutaneous tissue, and dividing the hamstrings as soon as they are exposed ; then, bending the knee, he finds no difficulty in exposing the upper border of the patella. He then sinks his knife through the insertion of the quadriceps extensor, and having cleared the bone immediately above the articular cartilage, and holding the limb horizontal, he applies the saw vertically, and at the same time transversely to the axis of the limb (not of the bone), so as to ensure a horizontal surface for the patient to rest on. The popliteal artery and vein are then secured, and any articular branches that may require it.'

AMPUTATION ABOVE THE KNEE.

In this situation there is a choice of three excellent amputations. Teale's, by rectangular flaps ; Spence's, by one long anterior flap ; and Syme's, by a modified circular operation.

The rules for making the flaps in the first of these have been already given (*vide* p. 119). The objections to it

are that the anterior flap is necessarily very long, being half the circumference of the thigh, and its corners are apt to slough, also that more of the bone is sacrificed than is necessary.

In Spence's operation (fig. 20, *h*), also by anterior flap, these objections are met by making a somewhat shorter oval anterior flap, and compensating for its diminished length by free retraction of the muscles, before division of the bone. The operation is practically the same as Carden's, except that, on reflecting the skin and fat as far as the upper border of the patella, the rest of the flap is made to include a considerable quantity of muscle from the front of the limb. Then when the base is reached, the posterior skin and muscles are cut obliquely upwards from about an inch and a half below, to the base of the anterior flap, and, the soft parts being well retracted, the bone is divided through or immediately above the condyloid portion.

Benjamin Bell practised a similar operation, but formed the anterior flap by transfixion, and the posterior by one single stroke from without, counting much upon the retraction of the muscles at the base of both.

Syme's modified circular amputation above the knee is commenced by the formation of two short semilunar anterior and posterior flaps consisting of skin and fat only. These are reflected, and the skin above them is first dissected up as in the circular method, for two inches above their bases. Then the anterior muscles are divided by one sweep of the knife at the same level, and the posterior at point at which they were first uncovered in forming the posterior flap. This method of dividing the muscles allows for the greater contraction on the posterior aspect of the limb. All the structures are further retracted before the bone is sawn across. The operation has the advantages of the circular method without the difficulty of dissecting up

the skin, and the risks of injuring its vascular supply, which in a very tapering limb are often great.

AMPUTATION IN THE MIDDLE THIRD OF THE THIGH.

This is best done by antero-posterior flaps, and these are usually made by transfixion, except in the case of tumours, when it is better to cut from without.

Instruments.—A long straight-backed knife; a saw; artery-forceps; needles.

Position of Patient.—Supine; the buttocks resting on the end of the table, with the affected thigh extended, the sound limb being abducted and flexed, its heel resting on the table.

Position of Operator and Assistants.—The surgeon stands on the right side of the limb, the assistant holding the latter is on his right, another assistant maintaining the sound limb in the position described.

Landmarks for Incision and Operation.—Two points are marked on the inner and outer aspects of the thigh, showing half its circumference at the spot where the bone is to be divided. With his left hand the surgeon pinches up the soft parts just above these, and transfixes the limb from side to side, anteriorly to the bone, at the points marked. He then cuts downwards and, later, abruptly outwards, forming a long anterior flap. The knife is then made to transfix the limb again at the same points, but this time passing behind the bone, and a corresponding somewhat longer flap is made posteriorly. The bone is now cleared by a circular sweep and is sawn across, care being taken to finish the division of the linea aspera by elevating the heel of the saw before the nearest side of the bone is completely sawn through, otherwise the linea aspera is inclined to split obliquely, and to form a spike, which may be overlooked until it has done damage.

AMPUTATIONS AT THE HIP-JOINT.

Out of the numerous operations for removal of the lower limb at the hip-joint, only two will be described here. In every case possible Esmarch's elastic tourniquet should be used to control the vessels of the thigh.

1. *Amputation by Long Anterior and Short Posterior Flaps by Transfixion.*

Instruments.—A pointed knife with a straight back, having a length one and a half times the diameter of the limb at the point of section; artery-forceps; needles for silk; long needles for inserting supporting stitches of silver wire through the whole depth of the stump.

Position of Patient.—Supine, with the buttocks resting on the edge of the table. The opposite thigh and leg are flexed and abducted out of the way, the heel resting on the table.

Position of Operator and Assistants.—The operator stands on the outside of the thigh, whether right or left. One assistant, kneeling, holds the affected thigh slightly flexed at first; another stands beside the patient on the same side as the operator, prepared to control hæmorrhage and take the anterior flap as it is formed. A third stands beside the sound thigh and holds it as above, and may also command the aorta with a large horse-shoe compressor. This will not be necessary if the elastic tourniquet or Davy's rectal lever are used.

Landmarks for Incision and Operation.—The point selected for entering the knife for transfixion is midway between the anterior superior spinous process and the tip of the trochanter (fig. 20, *ii*). From this it is thrust with its edge downwards across the capsule of the joint, just grazing

the head of the bone until it emerges on the inner side of the thigh. Then with a sawing motion it is made to cut a long anterior flap, while assistant No. 2 slips his fingers under the cut surfaces and grasps the vessels, before the knife is finally brought out through the vessels and skin. This long flap is now turned upwards, and the capsule is further cleared with the knife while assistant No. 1 forcibly extends the limb, but without abducting it. When the head springs out anteriorly the knife is placed behind it and the trochanter (which should be rotated a little forwards), and by a stroke downwards and backwards a somewhat shorter posterior flap is made from all the soft structures, and the operation is completed. The gluteal vessels are then first secured, and subsequently the femoral, both artery and vein.

The flaps after suture must be very carefully drained and finally supported by accurate padding and bandaging, so as to bring all the deeper surfaces into apposition as much as possible. A few deep wire supporting stitches with shields may also be introduced from before backwards, through the bases of the flaps, with advantage, for the same purpose.

2. *Amputation by Combined Circular and Vertical Incision.*

Instruments, Position, &c., as for the last operation.

This operation is recommended by Esmarch, and is thus described by him :

By a single, strong, circular sweep of the knife five inches below the tip of the trochanter, all the soft parts of the thigh are divided completely to the bone, and the latter is at once sawn across.

The vessels are then ligatured.

The bone is now seized in a lion-forceps and steadied, while a second incision is made, commencing two inches

above the tip of the trochanter, and carried down along the latter, to terminate in the first circular cut. The two borders of this incision being held apart by an assistant, the bone is cleared of the soft parts by the use of an elevator inserted under the periosteum, and by the knife where the muscle-insertions are too firm for the latter. When the capsule is reached it is divided, and the head is dislocated in the usual way. The rest of the operation is as above.

This method has the advantage that all vessels of any note are cut transversely, and that the surface necessarily divided is reduced to a minimum. It may be modified by making the vertical incision first and giving it a slight inclination outwards below, until it gradually merges into a circular sweep which comes up behind and internally, to terminate in the first part. The bone also need not be sawn across in some cases, but be cleared and dislocated.

I have done a similar operation to this in two acts, and have been surprised at the ease of performance and good result (*vide* 'Brit. Med. Journal,' 1880).

AMPUTATION OF THE BREAST.

In performing this operation the following points should be kept clearly in the mind's eye. First, to eradicate the diseased structures as completely as possible. Second, to do so with as little violence to the remaining tissues as may be. Thirdly, to aim at bringing about union by first intention in the deepest as well as the most superficial parts of the resulting wound.

In dealing with benign tumours it is easy to attain all these objects. But with malignant growths the case is different. Here it is necessary to remove the whole breast, and not only this, but it is now considered by many experienced operators indispensable to clear out all the lym-

phatic glands from the axilla in every operation, whether they can be felt to be enlarged or not. And, moreover, the skin overlying the breast should be removed very freely in all cases of malignant disease. Palliative operations for cancer of the breast are doubtless not only justifiable, but desirable; but radical operations have of course a far higher aim. And that the latter can only be successful when early and very free excision of breast, axillary glands, and skin is practised, is abundantly shown by experience. The great risks of very wide-reaching operations may not be justifiable where the extent of the growth forbids the hope of anything but palliation, but are fully so when there is a prospect of thoroughly eradicating an otherwise inevitably fatal disease.

The second object is easily attained by free cutting, instead of violent tearing of the tissues. In the axilla it is not well to use the knife much; but this is not necessary, as the glands can easily be enucleated with their surrounding areolar tissue as far up as the clavicle, by careful sweeping movements of the fingers aided by an occasional snip of the scissors. This is especially true of early operations.

The third requirement is met by adequate drainage, by introducing numerous closely set stitches, by accurate padding and by firm bandaging.

Instruments.—A full-sized scalpel; at least 12 artery-forceps (Wells's pattern); needles.

Position of Patient.—Supine, with the arm on the affected side abducted to a right angle.

Position of Operator and Assistants.—The surgeon may stand in each case on the side to be operated on, or, for the left breast, may lean over the patient from the opposite side. His assistant is best placed at the shoulder of the affected side in either case.

Landmarks for Incision and Operation.—The only guides needed are the nipple and the anterior axillary fold. Two semilunar incisions, the first below, the next above the nipple, are commenced (fig. 19, *e*), some inches to its inner side and as far above it as possible, and meet behind the anterior fold on the middle of or inner aspect of the axilla. These should be made with the knife held perpendicular, and should divide skin and fat at once. Catch-forceps having been applied to the bleeding vessels, which are usually numerous, the margins of the gland are felt for and cleared by steady sweeps of the knife, as it is elevated from the pectoral muscle. Where the glands are to be removed the author has found it best not to complete this deep dissection at the axillary aspect of the mamma, but, having cleared it in all other directions, to dissect the axillary glands and fat away with the breast without breaking their continuity. This may easily be done with the fingers as far as the clavicle if necessary, and ensures less bleeding and more complete removal than if the breast were first excised and then the contents of the axilla. It is necessary of course to be cautious in clearing the glands from the neighbourhood of the axillary vessels; but if the dissection be done deliberately, without the use of any sharp instrument, very little bleeding is produced, and thus the structures are well seen and are easily separated.

While the axilla is being cleared out, the cavity left by the removal of the mamma should be filled with soft carbolised sponges pressed tightly into it. Then after the excision is completed these are changed, and those substituted for them are not withdrawn until the stitching of the edges of the wound has been nearly completed, when they are drawn out, while compression over the skin covering the cavity is kept up from without. The stitches in

the skin ought not to be more than half an inch apart, and may be placed closer than this where there is any tension on the edges. In the latter case, too, a few deep supporting stitches, formed of silver wire with lead buttons, may be inserted with advantage, so as to draw the farthest parts of the flaps nearer to one another and thus diminish the strain on the edges. Where a large extent of skin has been removed with the breast there may be much difficulty in getting the edges of the wound together. Short of plastic operations this difficulty is best met by dissecting up the upper and lower flaps for a considerable distance from the pectoralis muscle, after which they will be found much more elastic and more readily drawn together. A drain-tube should be inserted at one or both angles of the wound. The latter is now covered with a soft absorbent dressing of one kind or another, the author preferring salicylic wool, and the arm is brought to the side and pressed firmly over this, the forearm lying across the front of the chest pointing towards the shoulder. Then the hollow in front of the arm and forearm is filled up with more wool, and a quantity is also placed in the hollow behind the arm to exercise pressure on the posterior part of the axilla. Firm bandaging over the arm, forearm, and thorax completes the procedure. These dressings so applied may often be left undisturbed for a week or ten days, when the wound will be found almost or entirely united except at the drain-openings.

Memoranda.—In making the first skin-incisions their general direction should be as much transverse to the axis of the body as possible, so that when the patient lies recumbent in bed the outer angle of the wound may be dependent for drainage. The lowest of the two incisions should be so directed that its outer end can be prolonged up into the axilla and open the latter sufficiently for the

easy removal of all the lymphatic glands there, whether indurated or not, as far up under the clavicle as can be reached with the fingers. Due regard of course must be had to the vessels, and especially the axillary and subscapular veins, but if necessary these may both be freely exposed.

In very fat patients it is well to remove most of the adipose tissue which surrounds the breast in excising the latter, so that the skin may be brought into direct contact with the pectoral muscle. The vitality of fat is low, and shreds of it are apt to necrose if left, and prevent immediate union. The wound should be perfectly dry and free from blood-clots before being finally brought together. It may be stitched for the greater part of its extent over sponges, the latter only being removed when the last few threads are being knotted, and their pressure being at once replaced by another large sponge laid over the whole area of the wound. When the flaps are completely sutured care must be taken that they are everywhere brought into contact with the pectoral by the arrangement of the dressings and bandages.

CHAPTER VIII.

EXCISIONS OF JOINTS.

GENERAL REMARKS.

THE history and statistics of excision of joints, as performed with all antiseptic precautions, and with all the improvements of the so-called sub-periosteal methods, have yet to be written. It is sufficient here to say that results and statistics of mortality compiled from mixed lists in which advanced cases, with abscesses and open sinuses, of long standing and often putrid, are ranged side by side with others at an early stage where no open wounds have ever existed, and where every possible precaution has been taken to guard against putrefaction and to preserve the periosteum and muscle-attachments around the immediate seat of the operation, are perfectly unreliable and misleading. When the last class alone come to be analysed, the mortality will be found to be much lower and the results as to usefulness of limb immeasurably better than in former days. Already much has been done; but this is probably as nothing compared to what is still to be achieved in this very wide field of surgery. Every day adds to our knowledge of the pathology of joint-disease, and develops our methods of dealing with it. Perhaps the greatest advance of all has been made in the modes of treatment of the diseased synovial membrane by operation. Instead of leaving it to take care of

itself after the bony surfaces of the joint have been removed, as was formerly the case, this tissue is now, in many cases, formally excised in its whole extent without any interference with the bones of the articulation. This operation, which it is now the fashion to call arthrectomy, to distinguish it from excision, in which bone is removed, may be considered before the latter, being distinctly a more conservative operation and giving better results when performed in proper cases: moreover, it ought to be considered an essential part of every excision.

EXCISION OF THE DISEASED SYNOVIAL MEMBRANE OF
JOINTS (SO-CALLED ARTHRECTOMY OR ERASION).

This operation is a recent development of modern antiseptic surgery and the outcome of the great advance which the pathology of joint-affections has made within the last few years. Such an operation as the dissection out of the entire synovial membrane—*e.g.* of the knee-joint—would not be considered a justifiable operation by any who had not confidence in the newer antiseptic methods of wound-treatment and the possibility of obtaining union by first intention even in the deepest part of large wounds. Nor would it appear ever to be called for except to those who are convinced of the general and local infective properties of scrofulous or tubercular material. It is to completely remove the latter in the earlier stages of its formation, and so to save the system from its generalisation and the bones from local infection, that we undertake arthrectomy. The latter operation has moreover the advantage over the older and more formal excisions that, the epiphyses of the bones being left intact, the growth of the latter is not affected. The procedure so far has most frequently been applied to the knee as a definite operation, and will only be described in detail

as employed for that joint. A good deal remains to be done in formulating methods of operation on the same principles for other joints.

Instruments.—A scalpel; dissecting-forceps; vulsellum and artery ditto; scissors; sharp spoons and gouges.

Position of Patient.—Supine, the affected limb, which will usually be more or less flexed, resting with the sole of the foot on the table. After elevation of the limb for five minutes an Esmarch's bandage is applied as high up in the thigh as possible.

Position of Operator.—Always on the right side of the limb, his assistant standing opposite and grasping the thigh above and the leg below, so as to prevent rotation.

Landmarks for Incision and Operation.—The mid plane of the thigh on either side and the middle of the ligamentum patellæ below, are our guides for the first incision. This is commenced on the side of the thigh opposite to that on which the operator stands, and about two or three inches above the patella. From this it is carried straight downwards across the middle of the patellar ligament and up to a corresponding point on the other side. The oval flap thus formed includes everything down to the bone at its lower end, but is cut with caution at the sides. When cleared below it is turned upwards and the joint is thus freely exposed. The limb is now forcibly flexed to a right angle, and all the diseased synovial membrane, together with any softened ligamentous tissue, is dissected from around the bones. In doing this, great care is necessary lest the posterior ligaments of the joint be cut through and the popliteal space be opened up. The disease rarely extends early in this direction, and this operation is only intended for relatively early cases. But the semilunar and lateral ligaments will almost always require to be freely excised as well as the pulpy tissue around them, and not unfrequently the

crucial ligaments as well. Then all the synovial membrane running over the front of the joint must be carefully removed from the anterior flap, and as far as possible in one continuous mass, so that no part may escape. This dissection of and about the subcrureal bursa is an extensive one, but must be carried out systematically. Then the surfaces of the two bones are carefully examined for signs of disease. If the cartilage is normal no interference will be necessary, but if, as is often the case, it is pitted and eroded in patches the diseased tissue should be pared off. If, in addition to this, the bone be softened at certain points where the cartilage is eroded it should be scooped or gouged away until perfectly sound tissue is reached. But in doing this all interference with the epiphysis should be avoided as far as possible so that the growth of the bone be not damaged.

When a sound surface has been reached everywhere over the field of operation the latter is thoroughly cleansed from all *débris* and blood-clot, and any vessels are twisted which may be seen. The limb being brought straight, the anterior flap is then laid down in its place and the cut surfaces of the ligamentum patellæ are sewn together with a few points of silk suture. The patella is treated as the other bones. Then the edges of the wound are evenly stitched, only about half an inch at the upper angle on both sides being left open for drainage. In these angles a decalcified bone-tube or a thick strand of catgut is inserted for drainage if there is any threatening of oozing. A strip of protective is then placed over the wound, and this is covered with one or other form of antiseptic dressing, which is firmly bandaged round the part before the Esmarch bandage is taken off. The mode of dressing preferred by the author is as follows. Around the incision iodoform is first dusted. Then long strips of salicylic wool are laid on each border of the wound so that the interval between the strips

corresponds with the latter. Similar strips are carried round the limb from the foot of the groin until the whole member is enveloped in an even covering an inch or two in thickness. This is then firmly bandaged from the instep to the groin, with a little extra pressure over the area of operation, an assistant holding it perfectly straight in the mean time. The limb is then supported behind on a piece of scored (Gooche's) splint reaching from the heel to the fold of the nates and firmly bandaged over the first dressing. The patient is then placed in bed and the limb is kept in an almost perpendicular position for the first few days, during which the dressing, if firmly applied, should not need to be disturbed. It is then taken off, and a fresh covering is replaced as before, over which the same splint may be re-applied, or the whole limb may be put up in plaster of Paris if union by first intention seems likely to take place.

Memoranda.—In dissecting up the synovial tissues on the inner aspect of the knee, care must be taken not to encroach too much upon the opening in the adductor tendon, lest the femoral artery or its branches be wounded. In the bloodless condition of the limb produced by elevation and the use of the elastic tourniquet, any considerable arterial twig, although empty, can be seen and can be twisted. The elastic tourniquet ought not to be removed until the limb is fully dressed and bandaged. Any oozing which may then occur will be checked by the firm pressure of the wool. This is one of the operations which shows the advantage of permanent dressing perhaps better than any other. In several cases the author has left on the first dressing for a couple of weeks or more, and on its removal has found complete union throughout the whole area of operation. If drain-tubes can be avoided there will be very little reason for re-dressing the wound until it is quite

healed. Out of a considerable number of these operations which have been performed at University College Hospital the author has seen no bad result. In his own cases, amounting to some six or seven in number, which alone he has been able to follow up, healing has taken place almost entirely by first intention in all; there has been no recurrence of the disease, and the functions of the limb have been excellent. In some cases there has been a little movement left, with manifest advantage to the patient.

EXCISION OF THE HIP-JOINT BY ANTERIOR INCISION.

R. W. Parker's Operation.

It is assumed here that this operation is performed at a comparatively early stage of hip-joint disease, that is, before much destructive change has taken place within the articulation, but not before all other means have been tried and failed to check the progress of the affection. In almost every case, early or late, there will be flexion of the thigh. In the less advanced cases there will be eversion and abduction besides, while with marked bone-disease we shall find shortening, inversion, and adduction as well as flexion. It is to be hoped, however, that in the future surgeons will not wait for the latter condition to be reached before operating. This anterior operation now to be described is not easy on the dead body or in the case of certain gunshot injuries of the joint, but has few difficulties in cases of tubercular disease, and gives remarkably good results.

Instruments.—An ordinary scalpel; a narrow-bladed Adams' saw or Gowan's osteotome; broad retractors; sharp spoons; artery-forceps; ligatures; sequestrum-forceps; a periosteal elevator.

Position of Patient.—Supine, with both thighs extended as much as possible.

Position of Operator and Assistants.—The surgeon stands in every case on the right side of the patient; one assistant, facing him, holds the affected thigh, another stands beside and to the left of the operator.

Landmarks for Incision and Operation.—The only guides necessary are the anterior superior spinous process of the ilium and the outer border of the sartorius muscle near its origin.

The operation begins with a three-inch incision starting half an inch below and external to the anterior superior spinous process, and running downwards and slightly inwards (fig. 21). This incision should be made boldly, and pass at once deeply between the tensor vaginæ femoris and lesser glutei muscles (*a, b*) on the outside, and the sartorius and rectus (*c, d*) internally. If the first stroke does not actually reach the capsule of the joint, a second is made in the same line, and the latter is opened. The opening being enlarged, a finger can be passed into the cavity for examination. When the state of the bone has been made out, the narrow saw, or Gowan's osteotome, is introduced above the neck and the latter is divided from above downwards without any further disturbance of the parts. The head can now be lifted out with the finger or a sequestrum-forceps. Then the whole cavity of the joint must be scraped out carefully, so as to remove not only any carious bone in the acetabulum, but also any broken-down, softened, tuberculous synovial tissue and granulations in a state of caseation. Great care should be taken to thoroughly clear the acetabulum of all the latter.

The cavity must now be freely syringed out with chloride of zinc solution or other antiseptic, then *wiped dry* and well dusted within with iodoform. It is drained

with a full-sized tube brought out of the lower angle of the skin-incision. The latter is drawn together with a stitch

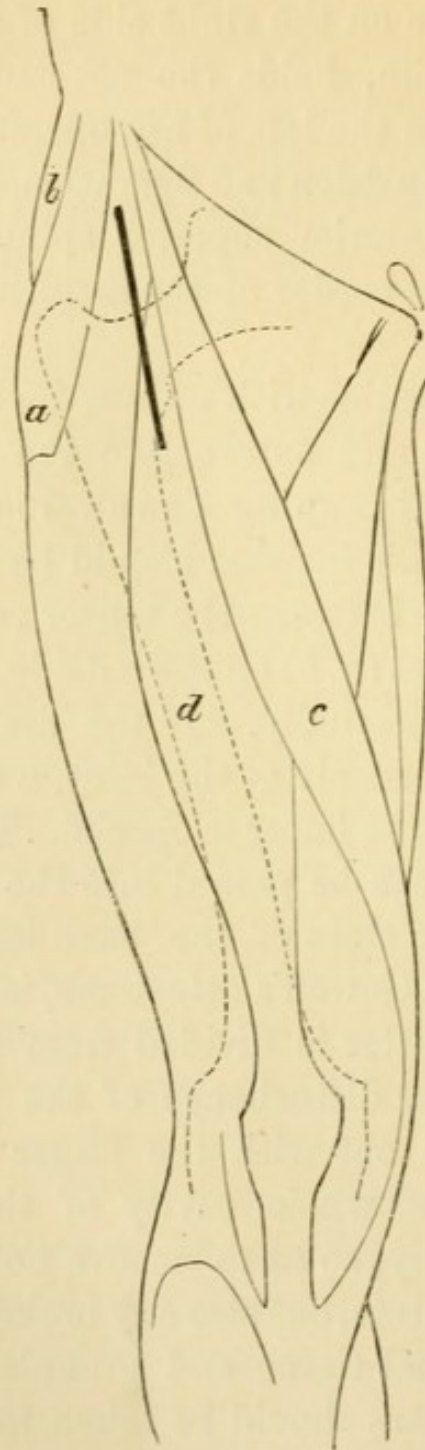


FIG. 21.—EXCISION OF HIP BY ANTERIOR INCISION.

a, Tensor vaginæ femoris muscle ; *b*, glutæus muscle ; *c*, sartorius muscle ; *d*, rectus muscle. The black line indicates the position of the incision down to the neck of the femur.

or two above, but is left open below. The operation is now completed, unless any arterial twigs require attention, which is rarely the case. If there be thorough destruction of the capsule, with the formation of abscesses in the buttock, a drain-tube can be passed from the joint through the soft parts behind and externally, a simple thrust of a sinus-forceps preparing the way for it, and a button-hole opening in the skin being made with a scalpel.

Memoranda.—Should dislocation have already taken place, the deeper part of the wound ought not to be carried quite as low down as the first incision, lest the anterior circumflex artery be divided; otherwise only a few twigs of the anastomosis between the circumflex ilii and gluteal artery are wounded. Thus no vessels of any importance are cut in this operation, and no muscles or nerves. The nutrition therefore of the parts around is not impaired, nor are the powers of the joint much weakened; the drainage is good, even though the opening be anterior. In dividing the bone the greatest care should be exercised to disturb the adjacent periosteum as little as possible. On no account should the head of the bone be wrenched out of the incision, by forcible extension and eversion of the limb, before being cut off, lest the periosteum be stripped off beyond the line of section. If this stripping take place, death of a certain amount of the bone is almost certain to follow. In cases of very early disease a little difficulty may be experienced in opening up the capsule unless the thigh be well flexed; but a large opening is not required for the use of the saw, which divides the bone in the direction of the first incision. It is well not to divide the capsule transversely to the axis of the femur, so that the ileo-femoral ligament may be left as much intact as possible, this structure being of great importance to the strength and future usefulness of the joint.

No splint is required immediately after the operation, the limb lying in good position, as a rule, if left to itself, no muscles having been divided. If there be any tendency to displacement a weight-extension will be the most suitable means of correcting it in the first instance. As the wound lies in front and is small, there is no difficulty in dressing it without moving the patient in the least, hence another reason for discarding splints at first. But when the wound is in a fair way to heal, the author is in the habit of putting the patient upon a double Thomas's splint, in which he can be removed from bed and be carried out for change of air without the least disturbance of the limb or of the dressing on the wound. This dressing should consist for the first few days of antiseptic gauze, then of iodoform powder and salicylic or iodoform wool.

After a considerable experience of this operation, which was introduced to the profession by Mr. R. W. Parker, the author regards it as superior in every way to the older method, and as likely to become the operation *par excellence* in all early cases of hip-joint disease.

There is, however, one other method highly spoken of by so good an authority as Dr. Macewen, of Glasgow, which is likely to rival that just described: it may be called the excision by the superior incision, and was proposed, I believe, first by Ollier. It needs but a very brief description, differing from the last operation only in the direction of the first incision.

EXCISION OF THE HIP BY SUPERIOR INCISION.

Ollier.

Instruments, &c., as for the last operation.

Landmarks for Incision and Operation.—The first point to be made out is the tip of the trochanter, the next the

direction of the neck of the femur as it runs towards the acetabulum. From the upper border of the latter a straight incision is now made to the middle of the upper edge of the trochanter. This should go right down to the bone at once and expose the neck. The soft parts are then held aside and the state of the joint is examined. If there is any want of room for this inspection, the trochanter is split in the direction of the first incision, and its two halves are drawn apart without disturbance of their lateral attachments. All diseased material is now removed from the joint by the aid of the narrow saw dividing the neck of the femur, and the gouge or sharp-spoon operating on the acetabulum and synovial membrane. When nothing but sound tissue is left, the edges of the wound, including the two halves of the trochanter, are brought together and are closed above, a drain-tube occupying the lower angle and reaching well into the acetabulum. Few or no vessels require any special attention, and as the attachments of the muscles are spared, as in the last operation, the future strength of the joint is secured.

This operation seems well suited for the very earliest stages of hip-joint disease in young persons, and is deserving of wider trial than has yet taken place.

EXCISION OF THE HIP—POSTERIOR INCISION.

Instruments.—A stout scalpel; two broad copper retractors; dissecting, sequestrum, and artery forceps; a narrow-backed saw (Adams's—Gowan's osteotome may be used instead of the latter); gouges; two sharp-spoons; ligatures; sutures.

Position of Patient.—Lying on the sound side of the body.

Position of Operator and Assistants.—The surgeon stands

behind the patient's thighs, facing towards his head. One assistant grasps the affected limb by the knee and ankle; the other stands on the opposite side of the body prepared to use the retractors.

Landmarks for Incision and Operation. The upper and posterior border of the trochanter are the only guiding points necessary to remember.

The operation commences by a firm, deep incision beginning midway between the anterior superior spinous process of the ilium and the top of the trochanter, and sweeping backwards and then downwards behind its posterior margin for about three inches, maintaining a distance of about an inch from the border of the bone throughout (fig. 22). This incision should divide the skin and muscles at one stroke, and reach to the neck of the bone. According to the older fashion, the limb should now be forcibly adducted and inverted by the assistant in charge of it until the head of the bone is thrust out of the wound sufficiently to be sawn off with an ordinary flat saw, or a Butcher's resection saw. But this practice should be and indeed is carefully avoided by most operators at the present day. If it be thus thrust out of the wound there will almost certainly follow, as a consequence, a stripping off of the periosteum from the bone beyond the point of section, and further necrosis is very apt to follow. From a considerable experience of operations on the hip, the author has found it to be quite unnecessary thus to force out the bone, and quite easy to divide it *in situ*, with a narrow-bladed saw, or osteotome, and afterwards remove the several portions with a sequestrum-forceps. If the trochanter is also involved, it is equally easy to divide the bone below it in the same manner *in situ*, but it is to be hoped that in the future all cases will be operated on long before this stage of disease has been reached. As to re-

moving the trochanter simply because it is said to retain the discharges of the wound, and itself to project from the latter, this is an unnecessarily severe procedure to get over a difficulty otherwise not hard to overcome. In adults, the trochanter is not likely to be involved ; in children it

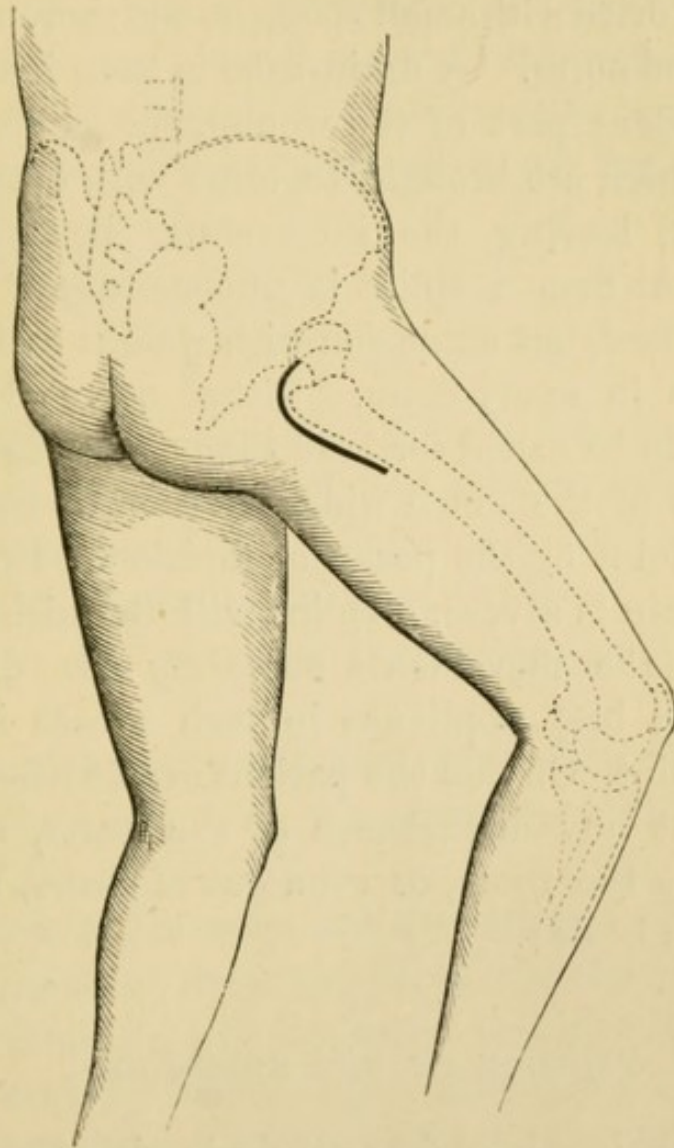


FIG. 22.—EXCISION OF THE HIP BY POSTERIOR INCISION.

The dark line indicates the position of the incision sweeping round the trochanter.

may be either primarily, or secondarily, if the case has been allowed to run on ; but under any circumstances as little bone should be taken away as possible compatibly with thorough removal of the diseased portions.

When the head of the femur has been excised, the acetabulum should be examined with the finger, and, if diseased, must be carefully scraped with a sharp-spoon, or gouged until only sound tissue is left behind. The softened degenerated synovial and capsular structures should also be scraped away, and the joint then washed out with chloride of zinc, then dried with small sponges, and thoroughly dusted over with iodoform. A drain-tube is then inserted in the most dependent part of the wound, the upper and lower angles of which are brought together with deep carbolised silk sutures, leaving the intervening portion open for drainage. At first a splint is unnecessary if a Listerian dressing is used, but extension with weight and pulley will be desirable in many cases. Either one or the other is more likely to be called for here than after the last operation, in view of the much wider division of the soft parts around the joint by the posterior incision. In those cases where the pain is severe, a splint will diminish the suffering during the movements necessary for dressing the wound. The best appliance in such a case is a double Thomas's splint. On this the patient can be lifted or turned over without any disturbance of the parts, and can be carried about the room, or even out of doors, long before the wound is healed.

EXCISION OF THE KNEE-JOINT.

This operation, in so far as it deals with diseased bones, is becoming rarer and rarer every day as a formal procedure. Increased knowledge of the pathology of the diseases affecting the joint is leading to their earlier recognition and treatment at a stage when a complete excision is uncalled for. Thus in many cases in which formerly the whole process would have been allowed to run on to exten-

sive destruction of all the surfaces before an operation would have been considered justifiable, we now consider it our duty to step in early, open the joint more or less freely, and remove tissues in a relatively early stage of disease. This we do, knowing now the danger of local and general infection of the system on the one hand, and on the other having learned the great immunity from immediate risk of operations performed bloodlessly and antiseptically. Only two of the many methods of excising the knee-joint will be mentioned here: 1, that by anterior oval flap, and 2, that by H-shaped incision.

1. *By Oval Anterior Flap.*

Instruments, &c.—A large scalpel; retractors; a broad-bladed saw; Butcher's saw; lion-forceps; artery-forceps; gouges and sharp-spoons.

Position of Patient.—Supine, with the knee semi-flexed, unless the joint be straight and stiff, as is mostly the case.

Position of Operator and Assistant.—The surgeon places himself on the right side, the assistant on the left side of the limb.

Landmarks for Incision and Operation.—The outer and posterior borders of the condyles of the femur are felt for with the operator's left forefinger and thumb, and a deep incision is made from one to the other, curving downwards so as to pass across midway between the patella and the tuberosity of the tibia, with one stroke opening the joint. The semilunar flap so formed, which is made a little longer if necessary by commencing the lateral incision a little higher up, is now seized with the left hand, and dissected up to its base with a few touches of the knife. It consists of all the soft parts down to the front of the femur, and

has the divided ligamentum patellæ at its apex. The knee is now forcibly flexed, and the lateral and crucial ligaments are divided, the edge of the knife cutting towards the femur in each case, so as to avoid the popliteal vessels. Clearing the end of the femur as far as possible with his finger, the operator then places the edge of the broad saw on its anterior aspect at right angles to its long axis, and near the upper margin of its cartilaginous surface. The bone is then divided directly backwards, or perhaps, as some prefer, a little more is taken off behind than in front. If Butcher's saw is used, the cutting is done from behind, forwards, in the same plane. The next step is to clear the end of the tibia, from which a slice is also similarly taken away in a plane parallel to its articular surface. The excised portions of both bones should be as small as possible. If on either of the cut surfaces any diseased patches be discovered, they must be gouged out if limited, or, if otherwise, an extra slice may be removed with the saw. The latter measure should be avoided as far as possible, especially in young subjects, lest the epiphysial lines be encroached upon. The ends of the bones will bear much gouging of their cancellous tissue without injurious effects, either immediate or remote. All diseased synovial membrane should now be dissected away with knife or scissors, and all sinuses be scraped clean, so that only healthy tissue be left on all aspects of the joint. Then all the wounded surfaces are carefully sponged with a strong antiseptic solution, and wiped dry and clean, after which the cut surfaces of the bones are brought into apposition. They should fit accurately when the femur and tibia are in a straight line or, according to some, when there is a very slight bend at the knee. The flap is now brought down and fixed in its place by interrupted sutures; but before this is done, the patella, if diseased, should be either gouged or dissected

out very carefully, so as not to injure the soft tissues around; if not diseased, the bone is best left undisturbed. The flap should be stitched from its centre to its base at either side, a drain-tube being inserted at the angles of the wound. If the surfaces of the large wound be tolerably clean cut after removal of the diseased synovial structures, a good deal of union by first intention may be brought about in its deeper parts by careful, even pressure applied through the medium of some soft elastic dressing such as salicylic or iodoform wool. Firm bandaging over this will bring the various surfaces into apposition, and maintain them so in a state of rest. As for the varieties of splint which may be used for the after-treatment this is not the place to discuss them. Until the first dressing is changed, no elaborate splint will be required, the firm pressure of the thick layers of soft material almost giving sufficient support of themselves to the limb. After this everything depends on the presence or absence of suppuration. If the wound is healing by first intention, nothing can be better than a plaster of Paris casing with or without windows. This should be applied over a thick layer of antiseptic wool, and if evenly put on will be more comfortable than any other appliance. And even where there is a little discharge from the drain-openings, this casing with windows may be used with advantage. Where there is free discharge, the knee must be left free, whatever splint is used. In this, more than in other allied operations, infrequent antiseptic dressing is an enormous gain.

Memoranda.—The chief points to be kept in view in excision of the knee are the following: α , to remove all the diseased bone, but only so much as is absolutely necessary; β , to divide both the femur and tibia, so that the planes of the saw-cuts shall be as nearly as possible at right angles to the axes of both bones: γ , to avoid wounding the vessels

at the back of the joint with knife or saw; δ , in young patients to leave the epiphysial line intact if possible: ϵ , before closing the wound, to remove any diseased portions of synovial structures around the field of operation, and to scrape clean all sinuses. In some cases it will be found convenient, in dividing the femur, to do so in a curved line following the outline of the condyles, and to make a corresponding line of section in the tibia to receive the femur. This helps to keep the tibia from slipping backwards on the femur.

No vessels of importance ought to be divided, but a few articular twigs may require attention. Some difficulty may be experienced in fixing the cut surfaces of the bones in good position, but this should be done once for all, leaving nothing for subsequent dressings. Some operators (Esmarch), to avoid shifting of the bones, wire the femur and tibia together at one or two points, or secure them with stout catgut. Others again advocate securing the two bones together by driving ivory or steel pins obliquely through them; but if the limb be put up straight in plaster of Paris once for all, there will be no tendency to displacement before union has taken place.

2. *By H-shaped Incision.*

The preparations for and details of this operation are identical with those of the last, except as regards the incisions in the soft parts. These consist of two long straight cuts on the inner and outer aspects of the joint, commencing two inches below the articular surface and running upwards for four or five inches, and of another uniting these two across the front of the ligamentum patellæ. All these incisions should go straight to the bone at once and open the joint, after which the square flaps are turned

upwards and downwards respectively, and the rest of the operation is completed as just described.

Memoranda.—The inner incision should not be placed too far behind, or the saphena vein will be divided; and the outer one should not begin below the head of the fibula lest the peroneal nerve be cut.

This operation is now rarely practised.

EXCISION OF THE ANKLE-JOINT.

This is one of the rarest operations in this country, Syme's amputation being preferred to it, as a rule, after scraping of the diseased area and free drainage have failed to arrest the disease. Still it may be called for in special cases and yield good results. Its use should be limited to very early disease which has resisted treatment and is still advancing, and of compound dislocation or bullet-wound.

The method of operation now described is Langenbeck's, which is itself an amplification of that of Hancock. Its chief aim is to remove the diseased portions of bone without injury to the periosteum. Where the morbid process is limited to the bone alone this is, of course, a most desirable end to keep in view; but where the synovial and capsular structures participate, it is hard to see any great advantage in it.

Instruments.—A scalpel; periosteal elevators; a narrow-bladed saw; lion-forceps; sequestrum-forceps; artery-forceps.

Position of Patient.—Supine, with the foot laid on its side.

Position of Operator and Assistant.—The surgeon stands on the outer side of the limb, steadying the latter with his left hand; his assistant stands opposite to him.

Landmarks for Incision and Operation.—The outlines of the malleoli are the best guide on both sides of the

joint. The first incision commences two and a half inches above the tip of the external malleolus and on its posterior border, runs down along the latter round the tip, and follows the anterior border upwards for about an inch. It should reach to the bone at once (fig. 23).

An elevator is now introduced, and the periosteum with the overlying soft parts is separated to the full extent of the incision, until a narrow saw can be introduced behind the fibula at the upper angle of the latter. With this the bone is divided transversely and, being seized with a lion-

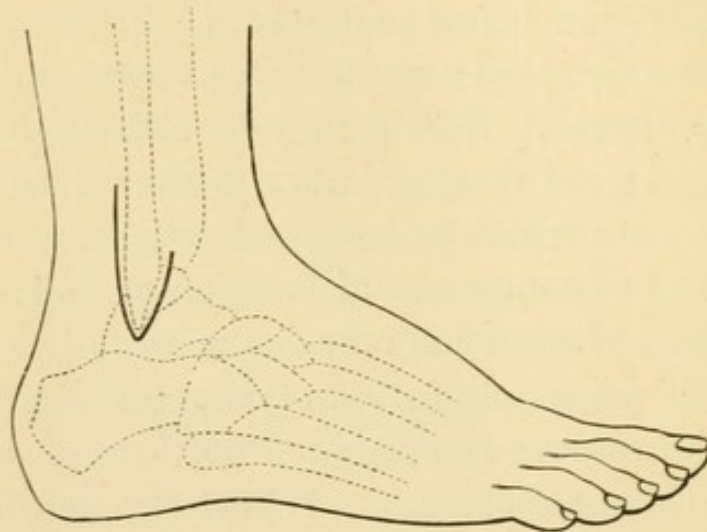


FIG. 23. (After Esmarch.)—EXCISION OF THE ANKLE.
Incision over external malleolus.

forceps, is elevated out of its bed, every effort being made to spare the interosseous ligament and periosteum from injury. The external ligaments are divided close to the bone as the latter is removed.

The foot is now laid upon its outer side, and a second incision (fig. 24) is made, circumscribing the lower border of the internal malleolus for about an inch and a half. From the mid-point of this, which is opposite to the tip of the ankle, a third cut runs directly upwards for two inches, forming with the last the figure of an anchor. Both these

incisions are carried boldly down to the bone at once. The periosteum and soft parts are separated with an elevator from the tibia as before, and the deltoid ligament is severed close to the latter. This is now sawn across transversely with a narrow saw at the upper end of the vertical incision, and the bone is removed with the same care for the periosteum and interosseous ligament as before. In removing the upper part of the astragalus, which is the next step, the saw is made to work in the line of the curved incision, the sole of the foot being pressed flat on the table to steady the parts.

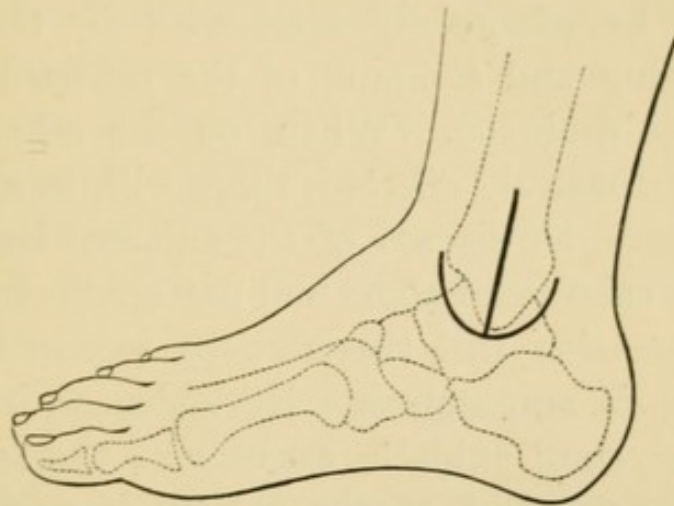


FIG. 24. (After Esmarch.)—EXCISION OF THE ANKLE.
Incision over inner malleolus.

All diseased synovial tissue is now carefully clipped and scraped away, and the edges of both wounds are brought together, except where a drain-tube crosses the joint completely. Nothing then remains but to fix the foot securely at a right angle to the leg, with the periosteal tubes left by the removal of the bones gently stretched. This is best done with one or other form of plaster of Paris apparatus, with windows opposite the drain-openings, and strengthening bands of metal in front and behind.

Memoranda.—No vessels of importance ought to be cut in the above incision, and if the elevator is skilfully used

the tendons and their sheaths suffer very little damage. In some cases, where the astragalus is deeply diseased, it will be better to remove the whole bone. This may easily be done with an elevator working within the periosteum. The result in such a case is remarkably good in young persons.

EXCISION OF THE OS CALCIS.

The conditions under which this operation is called for are very rarely met with. Caries of the bone, when very limited, can be adequately dealt with by thorough and careful gouging and scraping of the softened parts, followed by free drainage. When, on the other hand, the os calcis is extensively affected, there will, in a large proportion of cases, be disease of the adjacent bones, and removal of the calcaneum alone will not eradicate it; a more extensive operation will therefore be required, as a rule, such as Syme's amputation. Nevertheless, in some few cases among young subjects excision of the os calcis may offer the best prospect to the patient if performed subperiosteally. This should be a *sine quâ non*. If the disease spreads beyond the periosteum the case is unsuited for this operation.

The following incisions have been found by the author in two cases to be quite extensive enough for the removal subperiosteally of the whole os calcis. They are similar to, but more limited than, those described by Mr. Holmes.

On the outer side of the foot a cut is made, reaching from the external border of the tendo Achillis to the calcaneo-cuboid joint, and at the level of the upper border of the cuboid bone. Another incision extends downwards from the anterior end of the first for about an inch, towards the sole of the foot. In each instance the knife is carried

boldly down to the bone, making way for the elevator, with which the rest of the operation is completed for the most part. The periosteum is simply stripped off the bone all round, and elevated with the soft parts until the whole os calcis can be lifted out of its bed. When this is accomplished, the resulting cavity is thoroughly dried out, sprinkled, with iodoform, and left to granulate up, the skin wound being closed except posteriorly, where a drain-tube is inserted.

The foot is then enveloped in antiseptic dressings and encased in plaster of Paris, care being taken to set it at a right angle with the leg and to leave a window in the plaster for drainage.

Memoranda.—The author has only found it necessary to perform this operation thrice. In each case it was done as above, and without difficulty, and gave excellent results in two; the third has been operated on too recently to judge.

EXCISION OF THE ASTRAGALUS.

This operation may be required in some rare cases and be followed by excellent results, as the author has seen in one or two of his own patients and in some operated on by his colleague Prof. Heath. Existing sinuses should always be utilised if present, but in enlarging them it is well to follow a definite line of incision as far as possible. This will run from just above the tip of the external malleolus forwards and a little inwards, curving towards the dorsum of the foot. It will cross a space between the peronei tendons, in which no structures of much importance are found, and may go straight to the bone at once. If the foot is now turned well inwards and extended, the astragalus is easily exposed and examined. Should the state of the bone be found to require it, excision can now be performed by

grasping it in a strong sequesterum or lion forceps and twisting it round backwards and forwards, while the elevator is inserted as much under its periosteum as possible and clears its attachments. The author has been much struck by the ease with which the bone can be enucleated in this way, and with the good results obtained as regards healing and progression. The resulting cavity should be afterwards well scraped, dried, and sprinkled with iodoform, and drained.

The foot is best fixed at a right angle in a plaster of Paris splint, with a window over the wound. This splint should be well varnished, to protect it from the discharges escaping from the windows. A very good varnish, which may be spread freely over all the dressings and even the wound itself, is friar's balsam—the Tr. Benzoini Comp. of the British Pharmacopœia.

Formal descriptions of modes of excision of the other bones of the foot are not required. Occasionally they may need to be excised, but in such a case a short incision over the bone in the long axis of the foot will give room for the use of the elevator sub-periosteally. The same direction must be chosen for incisions for the removal of the metatarsals. But in almost all cases a better operation may be performed for disease in this region by simply making an incision large enough to scrape away morbid material from the bone with sharp-spoons of various sizes. When this is done thoroughly all the advantages of resection are obtained without the disadvantages of opening joints, sheaths, and areolar planes.

EXCISION OF THE SHOULDER BY ANTERIOR INCISION.

Excision of the shoulder is a rare operation in civil practice, and when required is usually performed on older patients than are either resection of the hip or elbow.

There can be little doubt that where the surgeon has a choice the above operation by anterior incision is the best, although that by deltoid flap may be suitable in special cases. But in speaking of the operation we mean the most recent development of the procedure—i.e. with all the improvements of the so-called subperiosteal method, which aims at leaving all the insertions of the capsular muscles intact.

Instruments as above (*vide* Hip).

Position of Patient.—Supine, with the shoulders resting on a pillow. The arm, held straight by the side, should be turned so that its external condyle looks forwards; in this position the bicipital groove looks inwards.

Position of Operator and Assistant.—The operator places himself beside the affected arm, looking towards the shoulder; his assistant stands behind him, grasping the hand and arm and steadying them.

Landmarks for Incision and Operation.—The coracoid process and the bicipital groove alone need be noticed.

The operation begins with a four-inch incision commencing a little external to the coracoid process and running straight down the arm. This divides the inner border of the deltoid muscle and exposes the bicipital groove. Into this the knife is now slipped and carried upwards until the capsule is opened freely. The tendon is then lifted out of its bed and held inwards. Next the periosteum with its attachment to the capsule and muscle-insertions is stripped off the neck of the bone, the latter being rotated inwards and outwards by the assistant as may be required for that purpose. When the bone is sufficiently cleared to give room for the narrow saw to work in sound tissue, the head is sawn off *in situ*. The acetabulum and the rest of the joint are now scraped clean of all diseased tissue, and syringed out with chloride of

zinc solution. The cavity is then dusted well with iodoform and a drain-tube is inserted. Only the upper angle of the wound will require one or two stitches; the lower part is left open for drainage. After the operation the patient should remain in bed until the healing process is well established, but should then get up and employ active movement very early, the arm being supported in a sling, and good drainage being kept up until the final closure of the cavity.

Memoranda.—If the external condyle is turned quite outwards the bicipital groove will look directly forwards, and the incision will have to be placed more externally. In the case of a perfectly healthy bone or on the dead subject the elevation of the periosteum and muscle-insertions is a matter of great difficulty. But when the tissues are inflamed, especially if the patient be young, the task may be completed with comparative ease. The importance of leaving the muscles as far as possible attached to the periosteum and capsule cannot be overrated. And as this adds but little to the difficulty of operation in most cases, it should always be aimed at. The head of the bone should never be forced out of the wound, in order to be sawn off, but should be removed with a narrow saw, cutting it *in situ*. In this way all unnecessary stripping off of the periosteum will be avoided. No vessels of any importance are divided in this operation.

EXCISION OF THE SHOULDER BY DELTOID FLAP.

This operation is rarely employed for disease of the shoulder, but in certain cases it may appear to offer special advantages. It is quite justifiable in extensive injury to the joint—such, for instance, as that often produced by gunshot, although an unnecessarily severe measure for

ordinary cases. As might be expected, it leaves a weaker limb than does the operation by anterior incision just described.

Instruments, &c., as for the last operation.

Position of Patient.—Supine, inclining a little towards the sound side, and with a pillow under the shoulders ; the arm is kept parallel with the side.

Position of Operator and Assistant.—The surgeon stands on the outside of the affected limb, his assistant standing beside him, grasping the elbow and wrist.

Landmarks for Incision and Operation.—The outline of the deltoid muscle is our best guide. The operation consists in cutting an oval flap of skin and muscle by one steady sweep of the knife corresponding nearly to the deltoid, but a little narrower at the base, which is of course above. This flap is turned up on the shoulder, and the joint is thus exposed. The rest of the operation is completed by opening the capsule and removing all the diseased bone with as little disturbance of the attachments of the muscles and periosteum as possible. No regular rule can be given for this part of the operation in the living subject ; the surgeon's best guide is the state of the bone and soft parts, which, on the one hand, must be spared as much as possible, and on the other must be thoroughly cleared of all diseased material. The flap is now turned down and stitched everywhere accurately except below, where a drain-tube should usually be inserted. The whole is covered with an antiseptic dressing firmly supported by bandaging.

The after-treatment consists in supporting the arm on pillows during the time the patient lies in bed, but this should not be for long. As soon as the healing process is established, he should be allowed to rise and carry the arm in a sling, and, moreover, use it as early as possible.

Memoranda.—In clearing the head of the bone the elevator should be used subperiosteally as much as possible. And in stitching the flap the needle should be passed deeply, so as to promote complete union of the deltoid muscle in its former position. But though this be done the strength of the shoulder will be much impaired in most cases. No vessels of any importance ought to be divided. As this operation would probably only be chosen for cases of extensive disease or injury, it will not often be possible to procure union throughout the deeper parts of the wound by first intention; but where the cavity can be thoroughly cleansed of all damaged tissue, a permanent elastic dressing should be tried with this object in view.

EXCISION OF THE ELBOW BY STRAIGHT POSTERIOR INCISION.

Instruments.—A strong scalpel; artery-forceps; elevators; Butcher's saw; a second narrow-bladed saw; bone-forceps; metal retractors.

Position of Patient.—Supine, but inclining a little to the sound side, the affected arm being held nearly vertical, with the forearm flexed and nearly horizontal.

Position of Operator and Assistants.—The surgeon stands beside the patient's hip on the affected side; one of his assistants stands at the shoulder grasping the diseased arm and forearm, and presenting the elbow to the operator; the other assistant stands on the sound side.

Landmarks for Incision and Operation.—The middle line of the olecranon and the humerus are our guide for the first incision. The ulnar nerve lying in the groove between the inner condyle and the olecranon is to be carefully protected throughout the whole operation. An incision between three and four inches long is carried over the ulna

and up on to the humerus, or in the reverse direction, a little internal to the middle line, and having its mid-point opposite to the tip of the olecranon. This cut should be made firmly and be carried down to the bone and through the periosteum at once. Then with the elevator the latter and soft parts are separated from the bone posteriorly and laterally, with due regard to the ulnar nerve, which is protected by the thumbnail of the operator. Very little aid from the knife is called for at this stage of the operation. When sufficiently cleared the olecranon is sawn off with a narrow-bladed saw, or in the case of a slender bone is nipped across with bone-forceps, the soft parts on either side being protected with retractors. The joint is now forcibly flexed and is thus opened freely from behind, when the humerus is similarly cleared with a blunt elevator, working as close to the bone as possible, and, if necessary, aided occasionally with a few touches of the knife. When cleared, the broad end of the bone is cut off transversely with the Butcher's saw from before backwards, just above its trochlear surface. Great caution is necessary here to avoid injuring the ulnar nerve, but more still in the next step of the operation, which consists in clearing the ends of the radius and ulna and removing them just below the sigmoid notch in the latter bone and the capitellum of the radius. If the stripping of the bones is done subperiosteally this danger is reduced to a minimum. At the origin and insertion of the muscles and lateral ligaments, a little difficulty may be experienced with the elevator; but even here the author finds it possible to clear the bone without using the knife, provided the edge of the elevator be not too blunt. The advantages of so doing can hardly be over-rated. Besides the preservation of the periosteum, which is of such importance for the repair of the joint, the attachments of the muscles and ligaments are in a great

measure preserved, especially the expansion of the triceps and the insertion of the brachialis anticus, and thus the future strength of the new joint is increased.

After the section of the bones all the diseased soft tissues around must be carefully removed by scissors and sharp-spoons until the whole surface of the wound is clean. Then the bleeding is thoroughly arrested, and the edges of the incision are brought together after the whole surface of the wound has been lightly dusted with iodoform. Free drainage is provided at the upper angle of the wound, and the arm is put up in the straight position at first, on one or other of the splints, having a joint corresponding to the elbow for extension and flexion. The apparatus designed by Mr. Heath may be used here with advantage. Some surgeons prefer, however, to treat the case from the beginning to the end without any splint.

Memoranda.—In removing the diseased bone the operator has to guard, on the one hand, against taking away so much as to produce a more or less 'flail-like' condition in the new joint, and, on the other hand, to remove enough to secure free mobility. As a rule, working by the subperiosteal method, the error is more likely to be committed of leaving too much bone behind, in which case much disappointment arises from the want of movement in the new joint and possibly persistence of the disease. No vessels of importance are likely to be divided in any part of the operation.

EXCISION OF THE ELBOW BY T-SHAPED INCISION.

This operation only differs from the last, which is most generally in use, in the fact of a transverse cut being added to the longitudinal one along the inner border of the olecranon. This transverse wound is placed over the tip of the olecranon, and reaches to the external condyle. It has

the advantage of giving freer access to the parts involved, but has the drawback of dividing fibres from the triceps to the fascia of the forearm, and also of leaving a transverse scar over the spot at which the greatest mobility is demanded from the skin.

EXCISION OF THE WRIST.

This is an operation on the whole rarely performed, the selection of cases suitable for it being a matter of much difficulty. In very early disease of the wrist in young subjects all surgeons are averse to a formal operation of the kind, trusting rather to other measures, while in advanced cases few trust to excision for the complete removal of the local condition. The difficulty of seizing the right moment for interference, which lies between these two extremes, is recognised by all, and is one cause of the rarity of the operation. Again, the results in the bulk of those cases operated on has not been extremely encouraging. Finally the method of thoroughly gouging and scraping away the diseased areas of tissue as they are discovered in the neighbourhood of the wrist has offered sufficiently good results to contrast favourably with the formal excision of the joint, and it seems probable that the latter operation will become rarer as the former procedure becomes more developed.

Excision of the wrist may be performed in various ways, but it is proposed here only to describe the two most usual methods. The first of these is that generally employed in this country, the second that more in favour in Germany.

EXCISION OF THE WRIST.

Sir Joseph Lister's Method.

The results of this operation depend so much upon attention to minute details, and these are so elaborate, that

it is safest to give the description of the procedure, as nearly as possible, in Sir J. Lister's own words, slightly abridged (*vide* 'Lancet,' April 1, 1865).

Before operating, adhesions are broken down by moving the articulations of the hand forcibly and freely. A radial

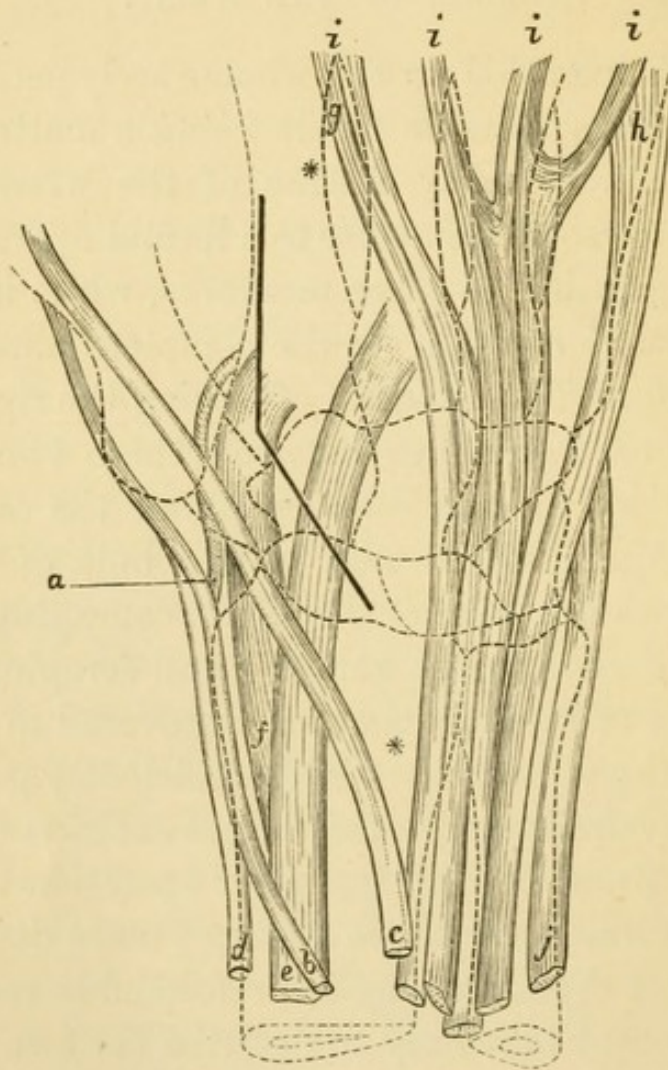


FIG. 25.—EXCISION OF THE WRIST. (Sir J. Lister's operation.)

Tendons and outlines of bones on back of wrist, with lines of incision for Lister's and Langenbeck's operation. *a*, Radial artery; *b*, tendon of ext. primus internod. pollicis; *c*, secund. internod. pollicis; *d*, exten. ossis metacarp. pollicis; *e*, ext. carp. rad. brevior; *f*, ext. carp. rad. longior; *g*, ext. indicis; *h*, ext. min. digit.; *i*, ext. communis; *j*, ext. carp. ulnaris. Two dark lines, forming an obtuse angle, give the Listerian radial incision; **, a line drawn from one asterisk to the other will give Langenbeck's single incision.

incision is then made in the direction of the thick line in the diagram (fig. 25) on the back of the hand. It is planned

so as to avoid the radial artery and tendons of the extensor secundi internodii pollicis and extensor indicis, and commences on the middle of the dorsal aspect of the radius, on a level with the styloid process; thence it is at first directed towards the inner side of the metacarpo-phalangeal joint of the thumb, running parallel in this course to the tendon of the extensor secundi internodii pollicis. But on reaching the line of the radial border of the second metacarpal bone it is carried downwards longitudinally for half the length of the bone, the radial artery being thus avoided as it lies somewhat farther to the outside of the limb. The soft parts at the radial side of the incision are next detached from the bones with the knife guided by the thumbnail, so as to divide the tendon of the extensor carpi radialis longior at its insertion into the base of the second metacarpal bone, and raise it along with that of the extensor carpi radialis brevior, previously cut across, and the secundi internodii, while the radial artery is thrust somewhat outwards. The next step is the separation of the trapezium from the rest of the carpus by means of cutting pliers applied in the direction of the longitudinal part of the incision. The removal of this bone is reserved until the rest of the carpus has been taken away, when it can be dissected out without difficulty or danger to the radial artery. The soft parts on the ulnar side of the incision are now dissected up from the carpus as far as convenient, the hand being bent back to relax the extensors. The complete separation of the latter, however, is best effected from the ulnar incision, which must be very free. For this the knife is entered at least two inches above the lower end of the ulna, immediately anterior to the edge of the bone, and is carried downwards between it and the flexor carpi ulnaris and on in a straight line as far as the middle of the fifth metacarpal bone on its palmar aspect. The dorsal lip of

this incision is then raised, and the tendon of the extensor carpi ulnaris is cut at its insertion and is dissected up from its groove in the ulna, care being taken to avoid isolating it from the integuments. The extensors of the fingers are then raised from the carpus, and the dorsal and internal lateral ligaments of the wrist-joint are divided, but the connexion of the tendons with the radius are left purposely undisturbed. The anterior surface of the ulna is now cleared by cutting towards the bone, so as to avoid the artery and nerve; the articulation of the pisiform bone is opened and the flexor tendons are separated from the carpus, the hand being depressed to relax them. While this is being done the knife is arrested by the process of the unciform bone, which is chipped through at its base. Care is taken to avoid carrying the knife farther down the hand than the bases of the metacarpal bones, lest the deep palmar arch be wounded. The anterior ligament of the wrist-joint is also divided, after which the junction between the carpus and metacarpus is severed with cutting pliers, and the carpus is extracted by seizing it from the ulnar incision in a pair of sequester-forceps and touching with a knife any ligamentous connexions that may remain undivided. The hand being now forcibly abducted, the ends of the radius and ulna will protrude at the ulnar incision and are carefully examined and treated according to their condition. If sound or only superficially affected, the articular surfaces alone are removed. The ulna is divided obliquely with a small saw, so as to take away the cartilage-covered rounded part over which the radius sweeps, while the base of the styloid process is retained. The ulna is thus left of the same length as the radius, and this greatly promotes the symmetry and steadiness of the hand, the angular interval between the bones being soon filled up with fresh ossific deposit. The end of the radius is then cleared sufficiently

to permit a thin slice to be sawn off parallel to the general direction of the inferior articular surface. For this purpose it is scarcely needful to disturb the tendons in their grooves, the bevelled, ungrooved part of the bone being enough to remove, and thus the extensor secundi internodii pollicis may never appear at all. This may seem a refinement, but the freedom with which the thumb and fingers can be extended even within a day or two after the operation, when this point is attended to, shows that it is important. The articular facet on the ulnar side of the bone is then chipped away with bone-forceps applied longitudinally. If, on the other hand, the bones prove to be deeply carious, the pliers and gouge must be used with the greatest freedom, for it is of course far better to take away too much bone than too little, and a useful hand will result in spite of a very extensive excision. The metacarpal bones are next dealt with on the same principle, each being in turn closely investigated. If sound, the articular surfaces only are clipped off, the little facets by which they articulate with one another being removed by the longitudinal application of the pliers. If the shaft is softened its cancellous tissue is drilled or scooped out freely.

The trapezium is next dissected out with care, to avoid the radial artery and the tendon of the flexor carpi radialis, which is firmly bound into the groove on its palmar aspect. The first metacarpal bone is then cleared and its articular facet removed in all cases. Lastly, the articular surface of the pisiform bone is clipped off, the rest of the bone being left, unless unsound, as it gives attachment to the *f. carp. ulnaris* and anterior annular ligament. It may be observed that the extensors of the carpus are the only tendons divided; the *f. carp. radialis*, being attached to the second metacarpal bone below its base, escapes. No vessel of any importance requires attention,

and the incisions are now stitched, the radial completely, the ulnar at both ends, leaving the middle open for drainage.

The limb is placed on a special splint designed by Sir J. Lister, which supports the hollow of the hand in the most suitable position.

The after-treatment requires very great care. The principal objects to be kept in view are to maintain flexibility of the fingers by frequently moving them, and at the same time to procure firmness of the wrist by keeping it securely fixed during the process of consolidation. The passive motion of the fingers is commenced on the second day, whether the part is inflamed or not, and is continued daily until it ceases to be necessary. In executing these movements each finger is both flexed and extended to the full degree which is possible in health, care being taken that the metacarpal bone concerned is held quite steady, to avoid disturbing the wrist. Active movements of the fingers too are encouraged from the first.

When the wrist is becoming firm, passive movement must be begun with it, and gradually increased in extent.

The hand and wrist will require a support to be worn habitually for a considerable time after operation. This is best made of moulded leather laced at one side.

EXCISION OF THE WRIST BY SINGLE DORSAL RADIAL INCISION.

Langenbeck's Method.

Instruments as above.

Position of Patient.—Supine, the arm fully abducted, the hand also abducted, lying prone on a small table.

Position of Operator and Assistants.—The operator sits opposite the extremities of the fingers; his assistant also,

seated at the elbow of the affected arm, grasps it and the wrist firmly.

Landmarks for Incision and Operation.—The dorsal aspect of the metacarpal bone of the index finger and the tendons of the extensor secundi internodii pollicis and extensor indicis are felt for, and are our best guide for the first incision. The latter begins on the dorsal aspect of the end of the radius, and runs downwards for about four inches along the inner border of the metacarpal bone of the index finger nearly parallel with the tendon of the extensor indicis, dividing skin alone (fig. 25 **). Avoiding the last-named tendon the incision is carried down to the bone, and severs the annular ligament between this tendon and that of the secundi internodii pollicis. The capsule is now opened in the same direction, and the ligamentous structures are separated from the bones as follows. The extensor tendons of the thumb and wrist, with as little damage to their sheaths as possible, are separated from the grooves on the back of the radius by means of an elevator, aided slightly by the knife, and are pushed outwards *en masse*. In the same way the common extensors of the fingers are separated and thrust inwards, being elevated from the bone with the periosteum and surrounding fibrous structures as a whole.

The hand is now flexed and the small bones of the joint are exposed. The first row of these are now freed from their ligaments and gently removed with a small elevator in the following order: scaphoid, semilunar, and cuneiform. Leaving the trapezium and pisiform bones undisturbed, the trapezoid, os magnum, and unciform bones are taken out together, by seizing the head of the os magnum and dividing the metacarpo-carpal ligaments on the dorsal aspect of each, while the metacarpal bones are strongly flexed.

The ends of the radius and ulna are now thoroughly cleared, but only so far as is necessary to remove the diseased portions of each completely, and are sawn off. At this stage of the operation great care is necessary to avoid the terminal portion of the radial artery as it turns over the trapezium to sink into the first metacarpal interspace.

For the after-treatment of the case Esmarch (from whose description the above outline is drawn) recommends regular extension of each separate finger by means of plaster strips attached to each, and fastened by cords to a weight in the usual way. The counter-extension is provided for partly by the weight of the forearm resting on an inclined plane at the upper end of which the pulley for the extension of the fingers is placed, and partly by a counter-extending strip of plaster attached to the forearm in the usual way, and drawn upon behind the elbow by an elastic band or ring fixed to the lower part of the rest or to the bed.

Memoranda.—Throughout the whole of the operation great care must be taken to encroach as little as possible upon the structures lying upon the palmar surface of the hand, and also to preserve the periosteal attachments of the bones not removed with all care. Finally, the tendons and other structures are to be replaced and adjusted around the new joint before the skin wound is brought together.

CHAPTER IX.

*OPERATIONS ON THE LIPS, FACE, PALATE, AND
TONGUE.*

OPERATIONS ON THE LIPS.

THESE are very frequently called for, and among them the commonest are required for the remedy of the deformity of hare-lip. Numerous operations have been designed for the latter, but only those most in use will be here described.

HARE-LIP.

Several rules guide us in dealing with these deformities, which may be briefly mentioned here.

1. The condition should always be operated on early in life, and most authorities are agreed that about the beginning of the third month of infancy is the most suitable age.

2. The child's general health should be good at the time of operation, and it should be free from cough or any other cause for straining.

3. Every particle of tissue should be saved in the area of deformity that can possibly be left.

4. In paring the edges of the clefts, good broad-cut surfaces should be made for union one with the other.

5. These surfaces should be free from blood-clot and

all impurity before being brought together, and should be accurately and securely adjusted. The borders of the cleft will need occasionally to be separated from the mucous membrane of the jaw for a little distance on either side before being drawn together, so as to permit adjustment without strain, but this is not the rule.

Instruments.—A narrow-bladed sharp-pointed scalpel; fine-pointed artery-forceps; compressors for the upper lip at either side; harelip pins; soft silk for use with the latter; strips of gauze; cheek-compressors; collodion.

Position of Patient.—Supine, with the head raised on a pillow.

Position of Operator and Assistant.—The operator stands in front of the patient, or on the right side; his assistant behind the head, to steady it and support the cheeks. Some operators prefer to place themselves behind the patient's head, and manipulate the lips, so to speak, upside down. This method has some advantages, especially that the blood from the cut surfaces runs into the roof of the pharynx away from the larynx, and does not tend to choke the little patient. But without a great deal of practice it is difficult to form a symmetrical lip when the operator has to view the parts upside down.

FOR SINGLE HARE-LIP NOT REACHING THE NOSTRIL.

The operation for this condition is one of the simplest. The coronary arteries on both sides being controlled, either with clamps or by the fingers of an assistant, the red border of the fissure is seized in an artery forceps. When stretched and steadied by means of this instrument, the point of the knife is entered a short distance from the true margin of the lip towards which its back is turned, and is made to pierce the whole thickness of the structure. It is

then made to cut upwards parallel to the margin of the fissure round the apex of the latter and down to a point corresponding to that at which it entered on the other side (fig. 26 *a*). The fringe of tissue thus separated is then drawn down, leaving a lozenge-shaped hole (fig. 26 *β*) in the lip, the opposite edges of which are brought together in the usual way. This consists in inserting two or more hare-lip pins across the opening, which enter and leave the skin

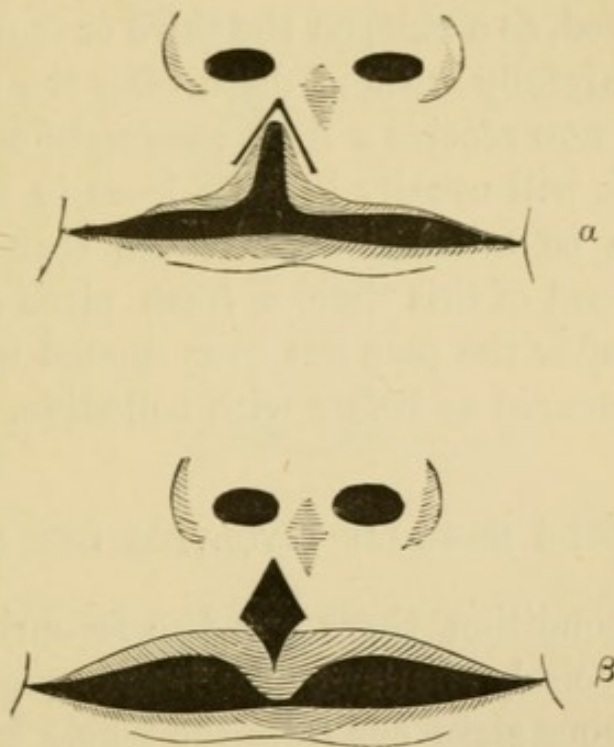


FIG. 26.—SINGLE HARE-LIP. (First method).

a, Single hare-lip not reaching the nostril, with line of incision marked out ;
β, the same after section, the double flap turned down ready for suture.

about half an inch from its margins, and are carried through all the tissue of the lip except the mucous membrane, emerging on its cut surfaces close to the latter. A figure-of-eight of soft silk carried over the ends of these pins will draw the cut surfaces together, and at the same time compress the vessels of the lip against the pins. The edges of the fold of tissue, separated from the margin of the fissure, will not need the support of a pin, but may be

drawn together with a point of silk or catgut suture. When brought together they will tend to fill up the depression, and if, after union has taken place, they are found redundant, can easily be pared away. A strip of gauze reaching from cheek to cheek across the wound should now be laid over the silk, and secured to it and the skin on either side by collodion. This will tend to distribute the strain over the parts on either side of the fresh cut, and will hold the latter in a state of rest until united. If pins are used they may be removed, as a rule, on the third or fourth day, being twisted out carefully without disturbing the silk or gauze, which should now receive a fresh coating of collodion. The gauze and silk will usually become loose in about a week, and may then be taken away. If the scar is not found secure at the end of this time, a fresh piece of gauze may be reapplied after the part has been dusted with iodoform, and may be secured as before with collodion.

FOR SINGLE HARE-LIP INVOLVING ONE NOSTRIL.

For this condition there are two favourite operations. The first is precisely similar to the last, except that instead of one continuous strip cut from the whole margin of the cleft, two flaps are cut one from each side of the latter having their attached bases below and their free tapering ends above at the nostril. These are turned downwards, precisely as in the last case, and are adapted one to the other, while the freshened edges of the lip proper are brought together from the nostril down to their bases. The mode of securing the wound is the same in every respect as that used in the last operation.

The second operation is a slight variation on the last. Here a thin strip is cut completely away from the mesial border of the cleft downwards from the nostril nearly to the

free margin of the lip, and then outwards along its lower border (fig. 27 *a*). On the other side of the cleft a flap is cut from the nostril downwards nearly to the free margin, and is left attached by its base (fig. 27 *a*). It is then turned downwards, and when the upper part of the cleft is brought together by its freshened edges this flap is adjusted to the cut surface on the lower margin of the lip on the opposite side, and thus forms part of the free border

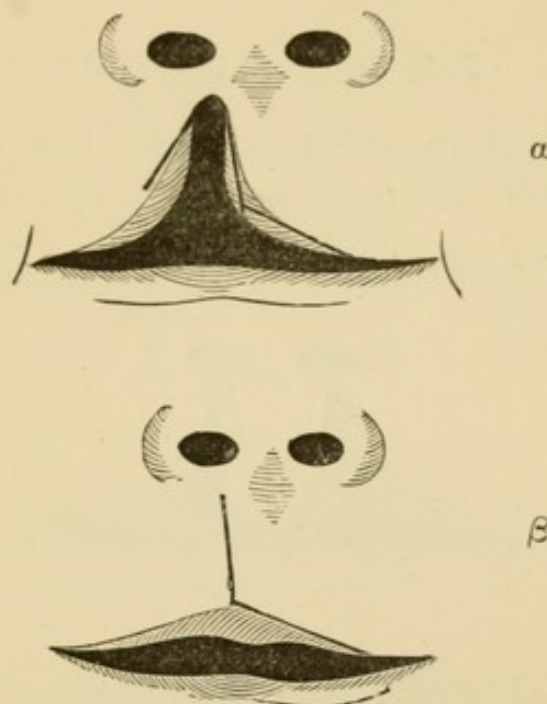


FIG. 27.—SINGLE HARE-LIP. (Second method.)

a, Left margin pared, flap to cover the latter made from the right border ;
β, flap in position ready for suture.

of the new lip. It is secured as above (*vide* fig. 27 *β*). Besides these two methods there is that of simply paring the edges of the cleft on both sides and drawing them together, but this is apt to leave a slight notch where the two lower borders come together, which is absent after both the other operations.

If in addition to the hare-lip the bone be also cleft and the intermaxillary process be somewhat displaced forwards, it may usually be twisted back into position without much

difficulty by inserting the blades of a sequestrum-forceps into the nostril and mouth, and may then be secured to the opposite side of the bony cleft by a wire passed deeply through both bones and twisted up closely. At the end of a month or so this wire can be removed, when it will be found in some cases that the cleft has been much narrowed, if not obliterated. In the last few cases operated on by the author he has adopted this practice with very encouraging results.

FOR DOUBLE HARE-LIP.

If this condition exist without the complication of fissured bone, the operations for its closure are simple in plan and easy of execution. The easiest of all consists in

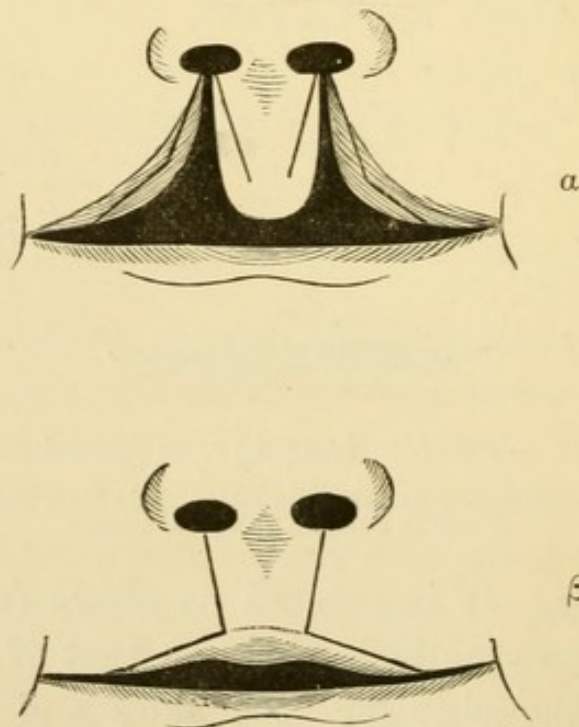


FIG. 28.—DOUBLE HARE-LIP. (First method.)

- a* Margins of lateral portions pared and flaps on central portion marked out ;
β, flaps cut from the central portion turned down to cover the pared edges of the lateral margins.

paring the edges both of the central process of skin and of the lateral portions, and bringing the cut edges together. This will, however, almost always leave a notch in the

middle line of the lip, especially if the central process of skin be shorter than the two lateral margins. To obviate this deformity the margin of the clefts may be pared according to one or other of the methods figured in the subjoined figs. 28 and 29, which explain themselves, the other steps of the procedure following the plan given above.

When the intermaxillary portion of bone cannot be

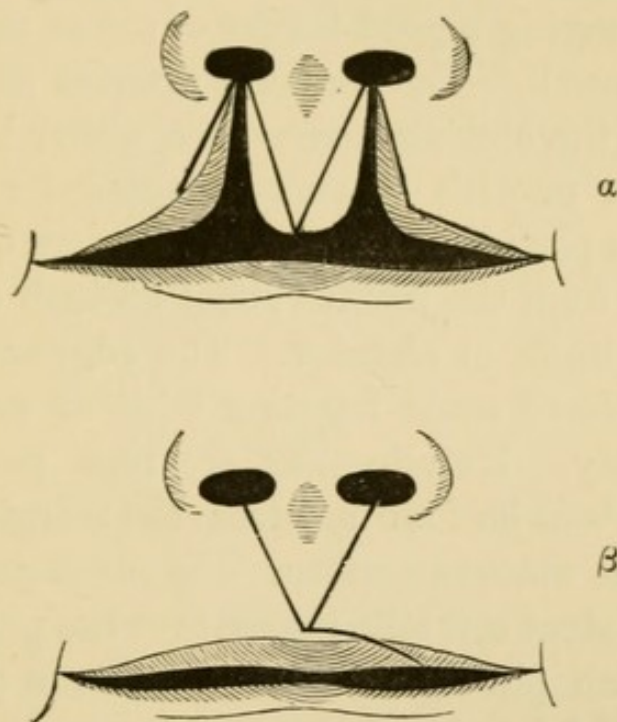


FIG. 29.—DOUBLE HARE-LIP. (Second method.)

a, Both margins of central and left lateral portions pared, flap made from the right to cover the pared edges; *β*, pared edges and flap in position.

forced back into position, and so fixed, it may be removed. In doing so the bone, with a little care, can be shelled out of its periosteum, which will subsequently furnish new osseous material (though of course without teeth), which will support the middle portion of the lip. The latter tends to sink in in the middle line if the bone be wholly taken away, and the result of the operation is spoiled to a considerable extent.

FOR NEW GROWTHS OF THE LIPS.

Operations for new growths are rarely or ever required for the upper lip, so that we may confine our attention to the lower. Here we have chiefly to do with epithelioma of greater or less extent. When fairly limited the tumour is best removed by a V-shaped incision, having its apex below more or less over the chin, the two limbs of the V running through all the tissues of the lip, and through its free margin, leaving a good border of sound tissue on either side of the growth. The coronary arteries should be controlled before the cutting commences, either by the fingers of an assistant or with specially adapted forceps. When the triangular portion is excised the borders of the incision are separated from the jaw for about an inch on either side either with a knife or elevator. The edges are then sufficiently movable to come together without undue traction being necessary. Harelip pins are now passed through the edges at about half an inch from the margin, but should not include the mucous surface. The cut edges are brought together with stout soft silk, passed over the pins in a figure-of-eight. Each pin should have a separate piece of silk. The first should be placed close to the margin of the lip, as many as are necessary being inserted below it. The red border of the lip should then be brought accurately together with one or two silk sutures. When accurate adjustment is completed the surface of the chin and lip should be dusted with iodoform and then covered with a thin layer of gauze or antiseptic wool, secured with a coating of collodion. The pins may be removed on the fourth day, or even on the third if there have been very little traction on the edges from the first, and the patient is careful. In some cases antiseptic silk or silver wire may be found more suitable for drawing the edges together than hare-lip pins.

When the whole lower lip has been removed by a V-shaped incision, it may be impossible to bring the edges of the wound together without some further operation. The difficulty is best met by Syme's modification of the above method. In this each limb of the V crossing its fellow is prolonged obliquely downwards and outwards, and then along the under border of the jaw (fig. 30). When the portion of the lip containing the growth has been removed




FIG. 30.—SYME'S OPERATION FOR REPLACING THE LOWER LIP.

The limbs of the V-shaped incision, between which the growth is included, are prolonged downwards to the edge of the jaw, and then outwards along the ramus of the latter.

the two flaps formed by the prolongation of the V incision are dissected off the jaw on either side and then slipped upwards until their ends meet in the middle line, where they are accurately adjusted (fig. 31), the gap below being, as a rule, to a large extent filled up by readjusting the cut edges on either side.

Memoranda.—In all cases of excision of the lip for epithelioma it is better to err on the side of taking away

too much than to remove too little. The edges of the wounds must be carefully cleansed of blood-clots before being brought together, and too much traction must not be put upon them.

Sometimes, when the upper border of the lip is widely but not deeply involved in disease, the latter may be swept off by a curved incision instead of one distinctly V-shaped. In this case it will be necessary to remedy the deficiency



FIG. 31.

The flaps fashioned as in the last figure are united in the middle line with hare-lip pins. The mucous membrane of the upper border of the flaps is united to the edge of the skin. The outer angles of the gaps left over the jaw may be drawn together with a few stitches.

of the lip. This may be done by the old method of Buchanan, which consists in forming two flaps from the side of the chin on either side, raising them and bringing their ends together in the middle line with hare-lip pins. The gaps in the skin below them are left to fill up by granulation. Syme's method, however, as given above, yields better results on the whole.

PLASTIC OPERATIONS ON THE FACE.

The operations designed from time to time for the remedy of deformities, congenital or acquired, about the face are almost countless, and a description of even a tithe of them would be beyond the limits of a work such as the present. It seems likely, moreover, that in the future the necessity for numerous modifications of plastic operations will cease with the increased success now attending the transplantation of large portions of skin, since the thorough recognition of antiseptic principles in surgery. Flaps fashioned in various ways from surrounding parts will no doubt be superseded in many cases by the simple insertion of portions of skin taken from distant parts. But whether we avail ourselves of the adjacent skin, or transplant separate portions from a distance, for the covering-in of defects, certain general rules have to be followed closely in order to ensure success.

1. In the first place a clean fresh surface must be prepared as a bed for the reception of the transplanted flap. This surface should be cut well into the deeper parts of the skin and not merely scraped on its surface.

2. The transplanted flap should consist of the full thickness of the skin, but should not carry with it any of the subcutaneous fat, which should be, as far as possible, left behind during the dissection. If not so, it should be subsequently snipped off with sharp scissors from the under surface of the flap.

3. All bleeding should be thoroughly stopped before stitching of the edges is begun. And not only this but every trace of blood-clot must be carefully wiped off the raw surfaces before the latter are brought together.

4. The edges of the raw surfaces must be united with great accuracy and with a close row of very fine stitches.

They must further be supported by careful padding with antiseptic wool so disposed as to protect the whole area of operation against alternations of temperature.

5. Finally, the most rigorous antiseptics must be observed throughout the operation and in the subsequent treatment of the wound. The best mode of dressing is probably to dust the united edges with fine iodoform powder after they have been thoroughly cleansed, and then cover them with salicylic or iodoform wool secured with collodion.

OPERATIONS ON THE EYELIDS.

For Ectropion.—This condition, whether affecting the upper or lower lid as the result of burn, will test all the skill of the surgeon, being most difficult to remedy.

If the upper lid is affected, a flap may be dissected off the forehead just above the root of the nose, being left attached by its lower end. This should be of the same shape as, but a little larger than, the defect in the skin left by dissecting down the cicatrix in the lid until the margin of the latter can be brought easily to lie in the normal position. The little frontal flap is then twisted into the wound and secured by numerous points of fine carbolised silk suture with the precautions mentioned above, and is then covered with antiseptic wool, the pressure of which ought to keep the lid closed until union has taken place. Then the pedicle of the flap may be cut through if necessary, and the ridge, due to its having been twisted, be adjusted.

There can be little doubt that for this deformity the plan of transplanting a flap from the inner side of the arm or forearm will yield better results in the future than the above method. In this case the lid having been dissected down, the size and shape of the resulting wound is gauged and marked out on the arm of the patient with a fine brush

dipped in tr. iodi. This is then carefully dissected off, without any of the subcutaneous fat, and, being thoroughly cleansed of any blood, is laid into the defect in the lid and secured and dressed as above.

For ectropion of the lower lid the flap of skin employed to fill up the defect is usually taken from the lax tissue of the cheek, and is glided into its new position and fixed there as described above. Or a portion of soft skin may be removed from the inner side of the arm and transplanted into the wound produced by dissecting up the lid. In either case the two eyelids should be united by a few fine carbolised silk sutures for a week or ten days, until the parts have united and have become accustomed to their new position.

FOR RESTORATION OF THE NOSE.

Assuming that the disease which originally destroyed the nose has ceased, and that the tissues around are now in a healthy state, several operations may be performed for the repair of the deformity. Formerly the choice, in cases where the whole organ had been destroyed, lay between the Tagliocotian and the Indian methods. The first of these is now universally abandoned and will not be here described; the second yields very good results in selected cases and claims our first attention. But besides this method the actual transplantation of portions of skin from other distant parts will probably give in the future as good results here as in the case of the eyelids, although so far there does not appear to be a large experience of the method.

The Indian Method.

This consists in taking a flap of skin from the forehead without detaching it at the root of the nose, and forming

a new organ by twisting it down into a bed prepared for it by dissection around the seat of the old organ.

One of the most important points in operating by this method is the shape of the frontal flap. The figure given in fig. 32 is that most usually chosen. But to ensure accuracy in its shape and that of the bed in which it is to be fixed, both should be traced out, before the operation,

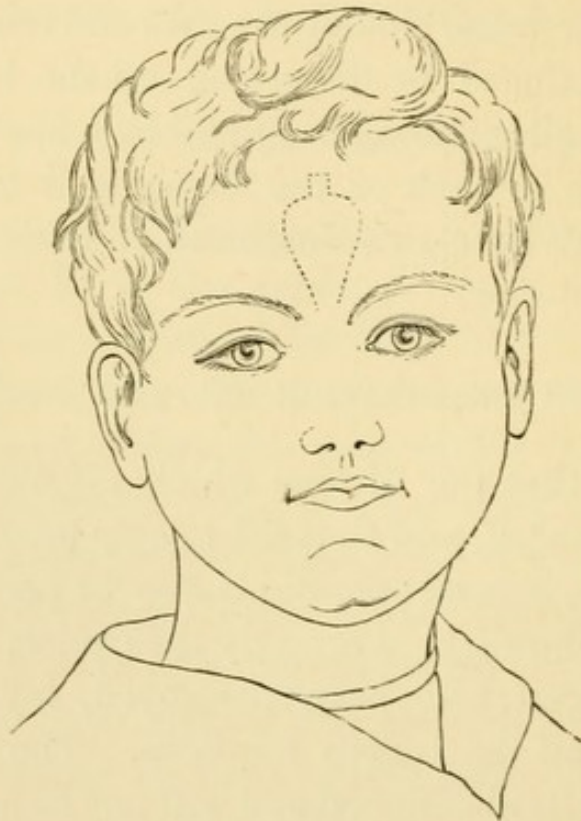

FIG. 32.

Flap of skin marked out on the forehead to be turned down to form a new nose.

with a fine paint-brush dipped in *tr. iodi*. When the outline of the wound in the face has thus been sketched, the amount of material necessary for the formation of the new nose may be estimated by fashioning a model of it in wash-leather, guided by the outline traced on the face. This is then spread out on the forehead and its outline is in turn traced with iodine. The frontal flap should be a little

larger than the bed prepared for it on the face, in order to allow for a little shrinking.

When both figures have been clearly traced, the operation is begun by dissecting out a fresh surface round the seat of the old member for the reception of the frontal flap. In doing this, care should be taken to cut well into the skin, without scoring it, in different directions, and to leave a well-defined margin. It will not do simply to scrape a fresh surface; the true skin must be cut into. All bleeding must now be stopped by torsion and pressure. When this has been done, a carbolised sponge should be kept firmly pressed upon the wound, while the flap is dissected from the forehead. The latter must consist of the whole thickness of the skin, and may be taken either from the middle of the forehead or from one side. It is best, however, to keep to the middle line. The periosteum has been removed by some operators on the theory that it would form a bony framework for the new nose, but this is not recommended by those who have given most attention to the subject. All bleeding having been checked from the under-surface of this flap, it is twisted round to the left and brought to lie smoothly in the bed prepared for it on the face, from which the sponge is now removed. Here it is fixed with a number of fine carbolised silk sutures. The openings for the nostrils are kept patent with plugs of lint or wool dipped in carbolic oil and secured from escape either inwards or outwards by strapping. There will probably be some difficulty in keeping the new nostrils from closing up, but with patience this may be prevented by careful plugging.

When the whole flap is secured accurately, and the field of operation has been cleansed, it is dusted with iodoform and dressed with antiseptic wool and collodion. This dressing need not be taken off for a week, when the

stitches should be removed if they show any signs of irritation ; otherwise they may be left for some days longer. The root of the frontal flap is cut through as soon as it is clear that the flap has contracted firm adhesion with the face. It may be sunk in a bed dissected for it in the adjacent skin, so as to remove all unevenness which would otherwise be present.

The wound in the forehead may be much diminished by being drawn together from each side. If dressed antiseptically it will heal rapidly and leave comparatively little disfigurement.

By Transplantation from the Arm.

The steps in this operation are practically the same as in the last, except that the skin-flap is taken from the front of the arm or forearm, and requires to be more carefully divested of its fat than in the last case.

Besides these two modes of restoring the whole nose there are minor operations for the repair of smaller deficiencies by taking flaps from the cheeks and gliding them into position on the stump of the damaged organ, a fresh surface having been prepared for them there. But for these no definite rules can be laid down : the principles which guide us here are the same as above.

STAPHYLOGRAPHY AND URANOPLASTY—OPERATIONS FOR THE
CLOSURE OF A CLEFT PALATE.

For the successful performance of these operations, attention to the following rules is necessary.

The general health of the patient should be good, and special care should be taken to guard against any irritation

of the air-passages likely to produce coughing or sneezing during the process of healing.

The great irritability of the palate and fauces should be blunted by repeated touching of them with the fingers or instruments for some days before the operation. This may be done by the mother or nurse if the patient is young, or in the case of an older patient by himself, very gently at first and freely after a little practice. It is remarkable how tolerant these parts become after a short treatment in this way.

In paring the edges of the cleft good broad surfaces should be provided for union, without too extensive cutting.

In drawing the pared edges together the stitches should not be tied too tightly, or there will be strangulation of the tissues opposite to each, and consequent failure of union: they should merely bring the surfaces into light contact.

All tension on the stitches should be relieved, either before or after suture, by division, if necessary, of the levator palati and palato-pharyngeus, either from behind with a curved knife, or from before by transfixion.

No solid food should be taken for four or five days by the mouth, but milk, beef-tea, and stimulants, if necessary, may be given from the first.

Staphyloraphy should not be performed before the third year, but after this has been reached the sooner it is undertaken the better.

STAPHYLORAPHY.

Instruments.—A long-handled, sharp-pointed knife; long, curved scissors; long, toothed forceps; long-handled needles with eye near the point, or the special hollow needle with a reel for wire on the handle; long, abruptly-

curved knives (Fergusson's); a gag (Smith's or Fergusson's); a narrow, curved elevator; a wire-twister.

Position of Patient.—Supine, with head and shoulders raised.

Position of Operator and Assistant.—The operator stands on the right side of the patient, an assistant at the opposite side steadying the head.

Operation.—The mouth having been fixed open with a gag, the tip of one lateral half of the uvula is seized in the long forceps and drawn forwards until the edge of the cleft is well on the stretch. The point of the knife is then entered exactly in the middle line above the angle of the cleft, and is thrust through the palate and then made to cut a strip of mucous membrane from the whole border of the cleft quite down to the tip of the uvula. The same manœuvre is repeated on the other side, a little shred of mucous membrane, however, being left uncut above until both edges have been deprived of their mucous covering. This little shred, connecting the two parings above, is then cut through and the latter are removed. If the cleft is a wide one, and the edges cannot now be brought together without undue strain, the chief muscles acting on the palate must be divided. As a rule it is not necessary to sever more than the levator palati and palato-pharyngeus, but in some cases the palato-glossus requires division too. The first of these muscles may be divided, either from behind forwards or from before backwards through the palate. If the former method, that of Fergusson, be chosen, it should be done after the paring of the cleft; if the latter, that of Pollock, it may be deferred until the cleft has been stitched. To divide the levatores palati from behind, the velum is drawn forwards on one side after the other, and the curved blade of a Fergusson's knife is laid upon their posterior surface about half-way between the

Eustachian tube and the free edge of the cleft. The blade is then made to cut downwards and forwards into the pterygoid fossa. The palato-pharyngei may be severed at the same time by a snip with the scissors on either side, and, if necessary, the palato-glossi. To divide the levatores from the front it is only necessary to transfix the palate above, just internal to the hamular process, which may be felt through the soft velum and cut downwards for about a quarter of an inch. If in transfixing the palate the point be aimed upwards and inwards, and then the hand be raised so as to make the point descend while cutting, the wound in the front of the soft palate may be but little longer than the breadth of the blade of the knife, while on the posterior surface it is much longer. When the palate is on the stretch, either before or after its suture, this is very simple. The author prefers to make this cut when the sutures are in position and have been tied, as in this case it is possible to see exactly how much requires to be divided to thoroughly relax the stitches. The latter are introduced in various ways according as they are of wire or silk. If the former, nothing can be better than the hollow needle on a handle known as Smith's. By means of this, fine silver wire is passed on one side from before backwards, and on the other from behind forwards at once through the edges of the velum, concealed in the needle, and is thrust out at the point where the latter emerges on the front of the palate. Here it is seized with forceps and drawn through the needle for the requisite length while the latter is withdrawn. Each side of the palate should be steadied with the forceps as the needle is thrust through at about a quarter of an inch from the pared margin. Three or four wires may be introduced in this way, but should not be tightened until all are in place. Then, commencing with the upper one, they are twisted until the edges are brought lightly

together. They are then cut short and the operation is completed. If silk thread is used, a loop is passed through on each side at corresponding points, from before backwards, with a common long needle on a handle. Then one of the loops is run through the other, which is withdrawn, carrying its fellow through, from behind forwards. When three or four stitches have been introduced in this way, they are tied as follows. One side of each suture is included in a plain knot made with the other run round it. It is then drawn upon until this knot runs up close to the closed wound. If properly applied, the knot will prevent any slipping until a second tie is made to keep the whole secure. The knots should be drawn close at one side rather than directly over the wound. Of the two materials wire and silk, the former is to be preferred. These stitches may be left alone until they work their way out, but if they appear to cause any irritation, which they should not do if clean material be used, they must be taken out on the third or fourth day. The patient should be kept quietly in bed until union is firm. If it be found that part of the wound have not united, the surgeon should wait before resorting to any further interference. Small deficiencies frequently close subsequently if let alone, and if slow in doing so may be touched with nitrate of silver, the actual cautery, or nitric acid, at intervals of four or five days. If after some weeks have elapsed union is plainly not going to take place, the edges of the defect may be again pared and brought together as before.

URANO- OR URANISCO-PLASTY. CLOSURE OF CLEFTS IN THE HARD PALATE.

There are two methods of closing fissures in the hard palate. In one the soft mucous membrane and periosteum

of the bone on either side are used, in the other the actual bone tissue.

The **Instruments, Position of Patient and Surgeon, &c.**, as for the last operation.

Landmarks for Incision and Operation.—The mouth being held open with a gag, an incision is made just within the alveolar margin of the hard palate from before backwards, commencing at the root of the canine tooth and ending behind the last molar. Through this incision a curved elevator or ordinary aneurism-needle is introduced, and is made to strip off the periosteum and mucous covering intimately fused with it from the hard palate, which lies between the cleft and the incision. The flap thus formed is left attached at both ends, and should be as gently dealt with as possible, so that its nutrition may be in no way impaired. When the posterior edge of the hard palate is reached, the flap must be separated from it, but not of course from the soft palate, with which it remains continuous. This stripping off from the bone behind should be effected with a scissors or knife, and not with the elevator, which may seriously bruise the part. A similar flap is loosened from the opposite side of the cleft in the same way. The borders of the cleft are now pared from the point of union of the flaps in front to the tip of the uvula on each side, if this part of the operation have not preceded the stripping off of the soft parts. Then fine silver stitches are introduced as in the last operation, and the cut edges of the flaps are brought evenly together from before backwards. The lateral incisions, now widely gaping, are left to granulate up. The after-treatment is carried out as in the last operation.

Memoranda.—The bleeding during this operation is often relatively severe, but may generally be stopped with a dry cold sponge without much difficulty. It used to be

the practice of surgeons to leave the cleft in the soft palate to be closed by a subsequent operation. This is, however, unnecessary, and both soft and hard may be dealt with at one sitting. If cleft palate co-exist with hare-lip the latter should be operated on at a much earlier date than the palate. Hare-lip is best closed in about the third month, at which age uranoplasty would be a rather severe procedure in view of the usually free bleeding. Besides this, the nutrition of the child will probably be much improved by the closure of the cleft in the lip, and this will tell very favourably on the result of the uranoplasty.

CLOSURE OF CLEFTS IN THE HARD PALATE BY OSTEO-PLASTY.

In this operation a similar incision is made on either side of the hard palate as in the last case. But here a chisel is used to divide the hard palate itself as well as its coverings, and to lever its inner border towards the middle line so as to close the cleft. The rest of the operation consists in paring the edges of the cleft and introducing wire stitches, which should in this case include the bone as well as its coverings. The procedure offers no special advantages over the last operation, and is apt to be followed by more or less necrosis of the palate.

OPERATIONS ON THE TONGUE.

Operations for the removal of parts of the tongue, which are of very early origin, have become so numerous and have been so variously modified that even a brief description of them all would be impossible in a work like the present. Nothing more than a brief notice of the objects aimed at in each will be given here, arranged in a table, and this

will be followed by a short description of those methods of dealing with tumours of the tongue now most in use.

As to the propriety of operating at all for the removal of cancer of the tongue there can be no doubt at the present day. The question turns upon two points.

First, is it possible to rid a patient permanently of his disease who once has cancer of the tongue? This question is answered distinctly in the affirmative, as regards a certain proportion of cases, by statistics (*vide* author's article on 'Dis. of Tongue,' in Holmes's 'System of Surgery,' vol. ii. p. 596 *et seq.*).

But there is another question hardly less important than that of the complete extirpation of the cancerous disease, and this is: 'Can nothing be done by operation to relieve patients afflicted thus, even though the disease be not permanently eradicated?' This, too, may be answered without hesitation in the affirmative. It is now an established fact that after removal of a cancerous tongue, even though recurrence may take place sooner or later, the cancer rarely or ever reappears within the mouth, and thus the patient is saved by the operation from all the pain and suffering incidental to the presence of a putrid mass in the track of the food and respired air. Again, it is shown by statistics (*loc. cit.*) that life is considerably prolonged by excision of the tongue, even where the disease is comparatively advanced.

Operations on the tongue for the removal of cancer should always be thorough. Even small masses of growth should be given a very wide berth. But though this is urged it must further be insisted on that the hope of the future lies quite as much in improved and more generally diffused powers of diagnosis of commencing cancer of the tongue as in developing elaborate operations for its removal.

What the difficulties and dangers of excision of the

tongue are, whether for cancer or benign growths, cannot be better illustrated than by the following table (Woelfler¹), showing their history and development very briefly. Minor modifications of the chief methods are not noticed here, and yet the list is a long one, showing by the very number of the operations it contains that no one in particular has hitherto proved altogether satisfactory.

They may be divided into two groups—1. The earliest irregular procedures; 2. The definitely designed operations—as follows:

EARLIEST IRREGULAR OPERATIONS.

1. Pimpernelle, died 1658. Was probably the first to excise the tongue with success.
2. Marchetti, 1664. Extirpated a cancer of the tongue by actual cautery: probably the first recorded extirpation for this disease.
3. Valens Hoffmann, 1692. Removed a tongue affected with macroglossia.
4. Ruysch, } 1737. Excised with a knife and cauterised with a
5. Memnista, } hot iron.
6. Heister, 1743. Gave the first methodical description of operative treatment of cancer of the tongue.
7. Buxdorf, 1754. Excised a true cancer of the tongue with the knife.
8. Guthrie, 1756. Was probably the first English surgeon to excise a cancer of the tongue, using the knife, followed by cauterisation of the cut surface.
9. Louis, 1759. Ligatured a 'fungus' of the organ, and later (1774) spoke at length and clearly in favour of total excision for cancer.

DEFINITELY DESIGNED OPERATIONS.

Ligature.

10. Inglis, 1803. Introduced ligature of the tongue from the mouth for cancer, the cords being drawn with needles through the tongue and round the tumour.
11. Major, 1827. Split the organ down centre to apply the ligature to the diseased half from the mouth.

¹ *Archiv. f. klin. Chir.* 1880, Bd. xxvi. p. 314.

12. Cloquet, 1827. Also split the organ, but introduced the ligature by a supra-hyoid incision, and strangled the diseased half.

Wedge-shaped Excision.

13. C. J. Langenbeck, 1819. Introduced wedge-shaped excision of diseased part of tongue, with careful suture of the resulting flaps.

Preliminary Ligature of the Lingual Artery.

14. Mirault, 1833. Introduced preliminary ligature of the lingual artery to give a clear bloodless field for extensive excisions. He was followed by Roux, and later by Roser.

Ecrasement.

15. Chassaignac, 1854. Introduced the *écraseur*, employing Cloquet's supra-hyoid method, and defining it more exactly, *i.e.* using puncture in above spot instead of incision.
16. Middeldorpf, 1854. Introduced the galvanic *écraseur*.
17. Nunneley, 1866. Introduced the supra-hyoid use of the *écraseur* into this country, adopting Chassaignac's modification.
18. Girouard, 1857. Employed circum-puncture with rods of caustic.

Division of the Cheeks.

19. Jaeger, 1831. Was the first to divide the cheek for free access to tongue.
20. Maisonneuve, 1858. Divided both cheeks from angle of mouth for the same purpose.
21. Collis, 1867. Re-introduced Jaeger's operation, using the *écraseur*.

Division of the Lower Jaw.

22. Roux, 1836. Was the first to divide the lower jaw and lip in mid-line, in order to gain free access to the floor of the mouth and tongue.
23. Sédillot, 1844. Improved this method by dividing the bone by a serrated cut.
24. Syme, 1857. Divided the jaw in mid-line, and excised with the knife.
25. Billroth, 1862. Divided the jaw and soft parts at the side in two places, and turned down the flap of skin and bone so formed, replacing and wiring the bone afterwards ('osteoplastic operation').

26. B. v. Langenbeck, 1875. Divided the jaw and soft parts opposite the first molar tooth on one side, in order to gain access to side of the mouth for removal of the tongue, glands, and part of the palatal arch and tonsil.

Infra-maxillary Operations.

27. Regnoli, 1838. Opened the floor of the mouth from below by an incision from middle of hyoid bone to chin, ending in another semilunar incision along the border of the jaw. The tongue, being drawn downwards and forwards through the opening thus formed, was excised.
28. Czerny, 1870. Modified this procedure considerably, forming lateral flaps.
29. Billroth, 1871-6. Modified it still further, extending both ends of the curved incision much further backwards, and omitting the incision in mid-line.
30. Kocher, 1880. Introduced a method of opening the mouth from behind and below the angle of the jaw to reach the base of the tongue and remove it with all the lymphatic glands there situated.

From the above short review we see that the first aim of the earliest operators was the avoidance of hæmorrhage in dealing with the tongue; hæmorrhage which, from its position, would be both difficult to control and particularly dangerous on account of the proximity of the air passages; hence the use of the actual cautery (2), the strangulating ligature (8, 9, 10, 11), the preliminary ligation of the lingual artery (14), the *écraseur* simple or galvanic (15, 16, 18).

When this danger had been more or less met, the more radical extirpation of the disease claimed attention, it having been found that recurrence beyond the root of the organ was frequent. Freer access to the deeper parts of the mouth was therefore sought either by splitting the cheek (19) or cheeks (20), or division of the jaw at one spot or other (22-26), or by various submental or submaxillary incisions.

Then when this requirement had been fulfilled and

access to all parts of the root of the organ and mouth had been provided for, and the number of operations increased, the attention of surgeons became urgently drawn towards the necessity of guarding against the risk of septic infection, which was found to be very frequent after these free operations. This was observed to take place either in the ordinary way from the wounded surfaces, or by the reception into the lungs of the products of putridity in the mouth during the separation of sloughs. To guard against these dangers, various modes of effectually draining and disinfecting the mouth were designed. And then access of pure air to the lungs was provided for by means of a preliminary tracheotomy opening, not to be closed until the wound was cleanly granulating, the mouth and nose being closed in the meantime. This prophylactic tracheotomy had already been introduced by Trendelenburg to obviate the risks of hæmorrhage into the larynx during the operation; but the idea of utilising the opening for breathing during this healing process, and thus increasing the facilities for antiseptic treatment of these cases, occurred apparently to the author and Professor Kocher of Bern simultaneously, and were put to a practical test by both at the same period according to the latter writer.¹

Finally the question of removing with the tongue all the lymphatic glands in and about the sublingual and submaxillary space, whether diseased or not, as a precaution against recurrence, has been raised lately, and an operation (30) designed to that end.

Of these various procedures it may be said generally that strangulation of the whole or part of the tongue by ligature is now abandoned almost entirely. The immunity from hæmorrhage which it gave was more than counterbalanced by the tediousness of the separation of the part, the distress

¹ *Deutsche Zeitschr. f. klin. Chir.* Bd. xiii. 1880, p. 147.

to the patient meanwhile, and the great danger of sepsis during the sloughing process. The galvanic *écraseur*, too, although still used by some, is less and less employed in this country, and especially in London, by those who have much experience of operations on the tongue. It is found not to give immunity from hæmorrhage, to leave a more foetid sloughing surface than any other operation, and thus to increase the danger of sepsis, while it is troublesome and uncertain in use. By far the largest number of extirpations of the tongue of any magnitude are now performed either with the knife, scissors, or simple *écraseur*, either chain, single wire, or twisted wire-cord. And the results have improved, though probably not altogether owing to the less frequent use of the galvanic *écraseur*. At University College Hospital there would appear, however, to be some relation between the abandoning of this last instrument and the improvement. Thus from our tables I learn that of 16 cases operated on in former years by the galvanic *écraseur* 8 died; while out of 17, where the wire *écraseur* was used during about the same period, only 2 were lost.

Any of these instruments may be applied to the tongue in numerous ways. But to describe all these would lead us too far, and only the most usual methods will now be mentioned.

They divide themselves naturally into three groups: *first*, operations from the mouth, with or without division of the cheek or cheeks; *secondly*, through openings made by section of the lip and jaw; and *thirdly*, through openings made by incisions beneath the jaw without division of the latter.

1. *Excisions from the mouth*.—For macroglossia, nævus, papillomata, or other benign growths, usually affecting the anterior part of the tongue, removal can usually be accomplished through the mouth. The part to be taken away can

be included in a single loop of an *écraseur* and so divided very slowly; or, two chains or wires having been passed through the middle line from below upwards, the organ may be severed in two planes. Or, again, the knife or scissors may be employed either to sweep it off in one or more cuts, or, what is better, to remove it by two converging incisions (C. F. Langenbeck, *l. c.*) meeting in the middle line of the tongue, the resulting lateral flaps being brought together and stitched so as to form a pointed stump. In a case in which I removed a tongue recently for macroglossia by this method the resulting stump was most shapely, being well pointed and not too thick. This cut may be combined, in the case of very thick tongues, with two horizontal incisions, meeting in the same point (Boyer).

If the disease reach further back, the mucous membrane of the anterior attachments of the tongue, and the geniohyoglossi muscles, may be divided with scissors at their insertion into the jaw (Paget); the organ thus freed may be drawn upwards and forwards out of the mouth to a considerable distance, and then dealt with, as just described, at a point much further back, the tongue being transfixed with a stout needle if necessary to keep the *écraseur* from slipping forwards. In this case, if only one half of the organ be but slightly diseased, it may in addition be split down its centre, and the side alone be taken away—an operation performed as early as 1827 by Major and Cloquet¹ using the ligature. This latter method of splitting the tongue into two halves has lately been revived and extensively practised by various surgeons.

Again, a method of excision has lately been advocated by Mr. W. Whitehead of Manchester² which offers several advantages as far as it goes. It consists simply in excising

¹ *Archiv. gén. de Médecine.* Tome xiv. 1^{re} série, 1827.

² *Trans. Internat. Med. Cong.* 1881, vol. ii. p. 460.

the tongue from the mouth at its root with a curved scissors, snip by snip, commencing at the anterior attachments of the organ, while the latter is drawn forwards and upwards out of the mouth, the insertion of the palatal folds being also snipped through in turn. The chief advantage claimed for this method is the small tendency to bleeding

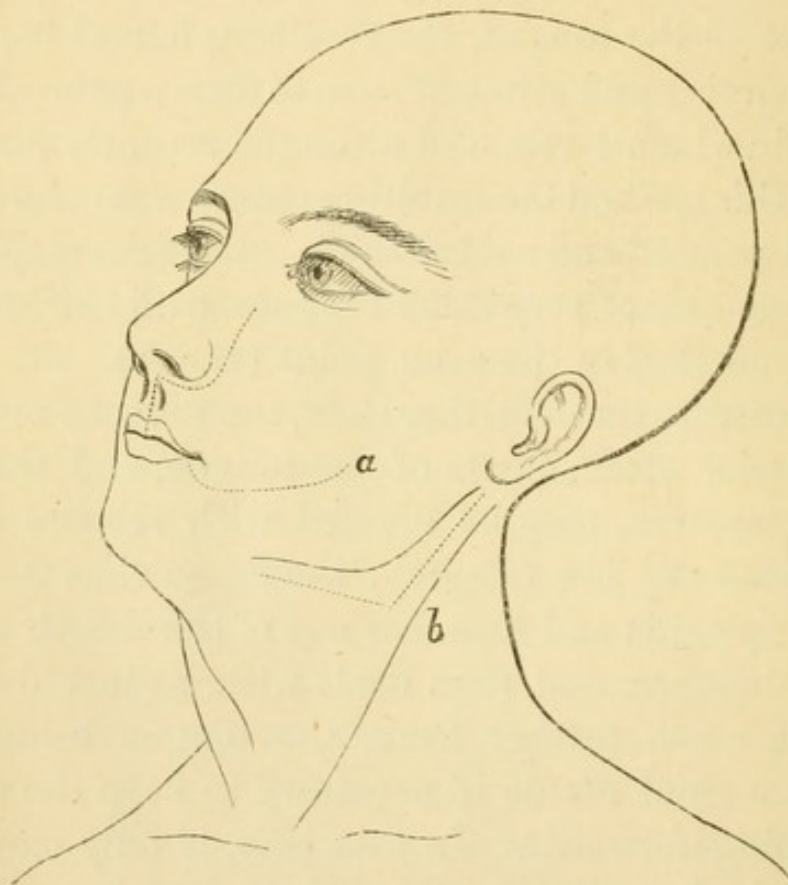


FIG. 33.

a, Incision through cheek for removal of the tongue by Jager's method, modified by Collis; *b*, incision for removal at the base of the tongue by Kocher's method. The curved dotted line round the ala of the nose indicates the incision in the cheek for partial resection of the upper jaw, *vid. infra*.

from the vessels thus cut slowly with the scissors. It sometimes happens that no vessel requires to be tied from beginning to end of the operation, but not unfrequently the lingual arteries bleed smartly. It has of course the disadvantage that it is not directed against the glands which are so frequently the seat of infiltration.

The scissors have also been in use in the same way for

some years past elsewhere, and notably in Professor Billroth's Klinik, with very good results. But this operator generally takes the extra precaution of extirpating all the glands at the angle of the jaw by an incision at the side of the neck, sometimes ligaturing the lingual artery besides.

But the belief that even this measure of cutting the anterior attachments of the tongue does not afford sufficient access to its deepest parts, has led many surgeons to enlarge the oral opening by incision of the cheek backwards from the angle of the lips. This was first done by Jaeger¹ in 1857 on one side, and later by Maisonneuve in 1858 on both. Jaeger's operation was revived a few years ago by Collis of Dublin,² and is still employed by some, Sir William Stokes of that city being a warm advocate of this method slightly modified.³ The incision in this case should be a curved one running from the last molar tooth downwards and forwards and at last upwards, to terminate on the border of the lower lip a quarter of an inch from the angle of the mouth. It no doubt gives very free access to the tongue, but it is fairly open to question whether, with disease so far advanced, some of the operations mentioned below will not be preferable as giving more room on the floor of the mouth for wider excision of the part with the submaxillary and sublingual lymphatic glands, then usually infiltrated. This has been felt by many surgeons, and they have resorted to other measures included in our second group.

2. *Excisions after section of lip and jaw.*—Thus Roux in 1836 and Sédillot in 1844 divided the lower lip and *symphysis menti* in the middle line, and separating the two halves of the jaw, removed the tongue freely. This operation was introduced into this country by Syme⁴ in 1857 and modi-

¹ *De extirpatione Linguae.* Erlangen, 1831, p. 9.

² *Dub. Quart. Journ.* 1867, vol. xliii. p. 1.

³ *Trans. Clin. Soc.* 1881, p. 188.

⁴ *Lancet*, 1857 and 1858.

fied by him. In his first operation, beside section of the jaw, he divided the attachments of all the muscles running to the symphysis, whereby the larynx lost much of its support, and the patient became unable to keep it out of the way of the discharges trickling backwards from the floor of the mouth. In his second method the genio-hyoglossi

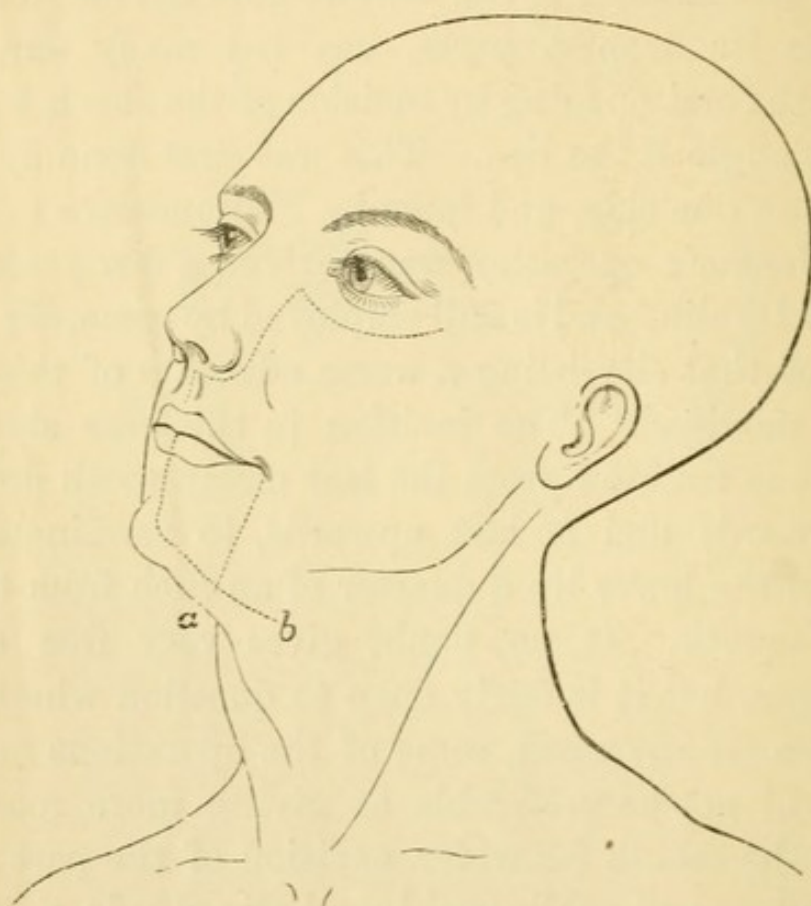


FIG. 34.

a, Incision for removal of the tongue after section of the jaw in mid-line by Roux, Sédillot, or Syme's methods; *b*, incision for removal of tongue after section of jaw opposite the first molar tooth by von Langenbeck's method. The dotted line round the ala of the nose indicates the incision for complete excision of the upper jaw on one side, *vid. infra*.

and hyo-glossi alone were divided anteriorly, the mylo- and genio-hyoidei remaining. He believed that in this way more power was left to the patient to raise his larynx and keep it out of the way of the putrid matters passing backwards into the air-passages, which had been the cause of death, as he believed, in three out of his four cases. The operation,

though a comparatively easy one, is very severe, and can only be necessary where the floor of the mouth anteriorly (with or without the bone) is engaged in the disease. The soft parts are divided in the middle line from the border of the lower lip to the hyoid bone, and then the jaw, first drilled through from before backwards on either side of the symphysis, is sawn through vertically either in a straight or slightly serrated line (Sédillot), so that in the latter case they may interlock to a certain extent when brought together again. The insertions of the genio-glossi muscles being now divided with scissors, as well as the mucous membrane along the ramus of the jaw, the whole tongue is drawn well upwards and forwards and removed either by one sweep of a knife at its base, or half at a time, which is better, giving but one lingual artery to deal with for the moment, or by the *écra-seur*, preceded or not by splitting the organ down its centre. The greatest immediate danger here is hæmorrhage with consequent suffocation. This, however, can be controlled with comparative ease in the wide gap provided by the division of the bone, and the vessel can be secured in the usual way with a ligature. If there be any difficulty in seizing it, the finger should be passed down the pharynx by the side of the epiglottis, and the root of the tongue hooked by it well forwards and outwards against the angle of the jaw, when the vessel will be compressed until its orifice is seen and secured. This manœuvre, which I believe originated with my colleague Mr. Heath, is simple and effectual in such cases and gets over a great difficulty. In three or four cases in which I operated by Sédillot's or Syme's method myself, I found division of half the base of the tongue at a time remove all the difficulty of securing the lingual artery, which was found on the cut face of the half stump as easily as could be wished, the organ being held forward by the uncut portion. When the latter was then divided, the

finger in the pharynx, pulling the root forwards as above, brought the second vessel well within reach. The only real difficulty arises when both vessels are allowed to spout at the same time, each thus obscuring the other. After the tongue has been removed the two ends of the jaw are wired together by means of the holes previously drilled, and then the soft parts are brought together as for hare-lip, the lower angle alone being kept open by a drain tube.

Syme's operation being deemed defective in some particulars, especially in not giving a clear view of the deeper lateral parts of the root of the tongue, another mode of dividing the jaw was devised and practised by Billroth in 1867; but it offers few advantages which simpler operations do not possess to counterbalance its severity. It consists in dividing the soft parts of the lip and face and the jaw at the side in two places by vertical incisions, and turning down the flap thus made, so as to gain access to the side of the mouth. The lingual artery glands and the tongue itself are thus easily reached: when these have been dealt with the flap containing the side of the jaw is replaced and secured by wire sutures in the usual way. But the disadvantages of this very severe operation led Billroth to abandon it, and I do not think that it was practised to any extent by other surgeons. In 1875 von Langenbeck, on the other hand, divided the soft parts and jaw from opposite the first molar tooth downwards and forwards to the hyoid bone, and thus reached the most important aspect of the diseased region. On the removal of the latter, the bone was wired as in Syme's operation, and the soft parts united with sutures, provision being made for drainage. This procedure has not yet found much favour in this country, though I have heard of it being used lately. Nor does it appear to be employed extensively abroad. It would, however, be suitable in

certain severe cases in which the disease lay far back and close to the floor of the mouth or jaw itself.

3. *Excisions through openings below the jaw.*—This leads us to the consideration of our third group of operations, including those by which the tongue and floor of the mouth are reached by incisions below the jaw. The first to plan an operation of this kind was Regnoli in 1838.¹ He commenced by making a curved incision under the border of the chin for about 3 inches, and another from the middle of this to the body of the hyoid bone. Through these the floor of the mouth was opened up and all the anterior attachments of the tongue were divided. The organ was then drawn well forwards and downwards through the wound, and removed with the knife. But it was found that Regnoli's method gave really but very limited access to the most important part of the mouth, in cases of cancer—namely, the base and lateral aspect of the tongue where the infiltration usually spreads. It was suitable, no doubt, for the removal of the large non-malignant growths not reaching far back, as in Regnoli's case, which was that of a girl of 15 years, whose tongue was the seat of what he described as a large, tubercular mass. Whatever this was, it most probably was not cancerous, in view of the age of the patient and the description of the tumour, and consequently the control of the base of the organ was of less importance except as far as the vessels were concerned. This first submental operation was then improved upon by another, devised by Czerny with the aim of better reaching the side and root of the tongue. This consisted in opening the mouth from the side, a large triangular flap of the soft parts being formed with its base along the ramus of the jaw, and its apex at the hyoid bone. This flap was turned upwards on the cheek, and then, after preliminary ligature

¹ Schmidt's *Jahrbuch*, 1839, Bd. xxiv. No. 2.

of the lingual artery, the tongue and all the glands in and about the digastric space were extirpated, after which the triangle of skin and soft parts was replaced and sutured, due provision being made for drainage of the cavity of the mouth.

Billroth again modified Regnoli's operation by omitting the vertical cut, but prolonging the curved submental incision much further backwards on both sides, so as to be able to ligature one or both lingual arteries before extirpating the tongue and its neighbouring lymphatic glands.

Finally, an infra-maxillary operation has lately been devised and practised by Kocher,¹ which appears to promise considerable advantages over the last two, and has hitherto given very good results. This consists in making an incision commencing a little below the tip of the ear, down the anterior border of the sterno-mastoid muscle as low as the hyoid bone, then forwards to the body of the latter, and so upwards along the anterior belly of the digastric muscle. The resulting flap is turned up upon the cheek, and the lingual artery ligatured before it passes under the hyoglossus muscle. Then, commencing from behind, the glands and all the structures at the postero-inferior aspect of the tongue are removed, together with the latter, the opposite lingual artery, if necessary, being tied first from a separate incision. All this is performed under the antiseptic spray, and the large wound is filled either with Listerian gauze, or a sponge wrung out of carbolic acid solution, and is left to granulate up without being stitched, the secretions, in the meantime, escaping into a loose external antiseptic dressing. This operation is usually preceded by a preliminary tracheotomy proposed by Trendelenburg several years ago for such cases, but first practised by von

¹ *Deutsche Zeitschr. f. klin. Chir.* Bd. xiii. 1880, p. 147.

Langenbeck. This is the first step in the procedure, after which the pharynx is carefully stuffed with a sponge wrung out of carbolic solution and held by a string. All fear of choking from blood being now over, the formation of the flap and excision are undertaken carefully and deliberately, chloroform being administered by the tracheal opening. Moreover, the patient is compelled to breathe solely by the latter, until the excision wound is healing well and cleanly. This last precaution was advocated and put in practice, as Kocher says, independently by him and the writer at the same time. And, from the experience I have had of it in several cases, I can speak very favourably of it, the patient breathing pure air all the time the wound is healing. But of the preliminary tracheotomy in any extensive operation on the tongue, I would venture to speak still more highly. Having been, I believe, the first to adopt the practice in this country, I have watched it with special interest, and am satisfied, after the experience of several cases in which I have adopted it, that the measure will take its place in surgery for certain cases. The comfort of operating when there is no risk of the patient being suffocated by his own blood, and when the state of the suspected tissues can consequently be examined without hurry, and any vessels easily controlled, can only be appreciated by those who have used both methods—*i.e.* with and without tracheotomy. The latter operation is comparatively easy when the patient is breathing quietly under chloroform, and does not itself, when thus done, materially add to the patient's danger. It will allow, too, of the wound being treated antiseptically from beginning to end if we follow Kocher's method.

Choice of operations.—Among all the operations above enumerated the surgeon has a large choice for any particular case. And yet, as a rule, each appears to

have a special liking for some one method as his routine practice. And here we find the greatest variety of likes and dislikes, one author advocating this measure and deprecating that as fervently and honestly as another will take the very opposite view. But, if we read the bulk of the most recent literature on the subject, we cannot help feeling that the origin of this diversity of choice lies probably in the different conceptions of the aims of the operation which exist in the minds of surgeons. Many appear to deal with epithelioma of the tongue as though to remove the purely local condition with immediate safety to the patient were their only object. Either this, or they are hopeless of doing more. Others, viewing the matter in the light of the experience that all ordinary operations for this disease upon the tongue alone are followed by almost inevitable recurrence in the neck (if the affection be anything more than just commencing), go a step further and, while admitting that even to remove the local disease alone is a most desirable object, contend that, as long as there is any hope of freeing the patient from all danger of future recurrence, our operations should aim at this, even though they be much more extensive, and involve considerable immediate risk to life. Now, if the first object alone be had in view, many of the operations upon the tongue itself from the mouth will be quite adequate; the local cancerous disease will be removed with but little risk on the whole, and will not recur, *in the mouth at all events*, except in rare instances. But it will recur in the lymphatic glands in an enormous proportion of cases. This last is no loose statement, but appears from an examination of a very large mass of recorded facts as well as from the observation of a considerable number of cases operated on by my colleagues and myself at University College Hospital. This being so (as may be seen from an examination of the

statistics of the operation), surely we are justified in undertaking very extensive operations on the tongue and its surroundings, and in running considerable risk in the hope not only of removing what is palpably diseased, but also those tissues around, of which we know that in ninety-nine cases out of a hundred, if they are left, they will develop the disease later on. That the whole tongue should be removed, except in cases where there is but a small nodule clearly localised in one border of the organ, is quite decided. The risk of leaving a little disease behind in the remaining half is too great to justify such conservatism. And the results to the patient as regards eating and speaking are as good, if not better, after total extirpation, as after removal of one half. It has been noticed that the scar down the centre of the mouth, where half is left behind, often interferes materially with the movements of the latter. Still, with disease of small extent, limited to the border of the organ as far as the fear of recurrence is concerned, we need not go far beyond the middle line; for the track of the lymphatics is for the most part away from the latter towards the root.

Memoranda.—The after-treatment in cases of removal of the tongue is fully as important as the operation. It consists first in drying the stump of the organ carefully and then dusting it over with iodoform. As the latter is washed away by the secretions of the mouth it should be replaced by being blown in in a light cloud. Washes are not necessary, and indeed should be avoided. For the first day or so small pieces of ice may be allowed to melt in the mouth. Food is best given with a long soft rubber tube introduced gently into the stomach, and having a funnel at the other end through which nourishing fluids are poured two or three times a day. All decomposition in the floor of the mouth is in this way prevented, and all movements of the jaw and muscles of the

base of the tongue avoided. The mortality of this operation is more influenced by attention to after-treatment than by the mode of operation. Treated as above, these cases have nowadays a low mortality. Where for any reason the soft stomach tube cannot be used, the patient must be fed at first by the rectum. It is most important to avoid feeding by the mouth in the usual way if it can be possibly prevented; the fragments of food which remain in the cavity of the mouth are certain to decompose and render the risks of septic infection very much greater. If a wound is made beneath the angle of the jaw, as in Kocher's operation, the operator may pass a tube through its upper angle into the stomach, and leave it there for feeding purposes for the first ten days or so. In this way the author has fed several patients on whom he has performed extensive excisions either of the tongue or pharynx. Whenever necessary, a funnel was attached to the free end of the tube and they were given as much fluid food as was wanted. The presence of the tube gave no inconvenience and the patient's strength was perfectly maintained during convalescence, while the mouth was kept in a thoroughly aseptic condition.

EXCISION OF THE UPPER JAW.

This operation is frequently required for the removal of new growths starting in one or other part of the bone on one side. Very rarely, both halves have to be excised completely. This the author has only seen once in a case under the care of a colleague at University College Hospital. The operation was successful. It is to be hoped, however, that improved knowledge of pathology and powers of early diagnosis throughout the profession will render in the future such very severe procedures rarer and rarer, all cases being

submitted to the operator at a stage of the disease in which only limited resections are called for. It is quite possible to remove the lower portions of the jaw leaving perfectly sound tissue above, but the formal operation will now be described.

Instruments.—A strong scalpel ; dissecting and artery forceps ; Fergusson's lion forceps ; a narrow-bladed saw ; a steel elevator ; strong bone-forceps.

Position of Patient.—Supine, with the head and shoulders well supported on pillows (Heath), or hanging back over the end of the table as recommended by the German surgeon Rose.

Position of Operator and Assistant.—Standing on the right side of the patient, having his assistant standing opposite to him on the patient's left side.

Landmarks for Incision and Operation.—Various incisions have been planned from time to time for reaching the surfaces of the jaw and removing it. But at the present time most surgeons prefer the following, which is a slight modification of that designed and practised by Fergusson : The middle line of the upper lip, the groove between the ala nasi and the cheek, and the lower border of the orbit are our guides for excision of the entire half of the lower jaw (fig. 35). When this is determined on the incisor tooth on the affected side is first extracted ; then the scalpel is carried exactly through the middle line of the lip round the ala of the nose as high as the border of the orbit, and then outwards along the latter as far as the middle line of the malar bone. If the complete excision is from the first determined on, the incision may be made in the reverse direction, commencing over the malar bone. The flap thus marked out is dissected outwards from the bone and folded back, the infra-orbital nerve being divided at the same time. A narrow saw is then introduced into the nostril and is made

to cut the hard palate and alveolar border directly downwards (fig. 35). The malar bone is now sawn through in a line with the speno-maxillary fissure. Then the nasal process of the inferior jaw is divided with bone-forceps, one blade being introduced into the nostril, the other carefully inside the orbit (fig. 35). Grasping the bone firmly with the lion forceps, the surgeon is now able in most cases to break the

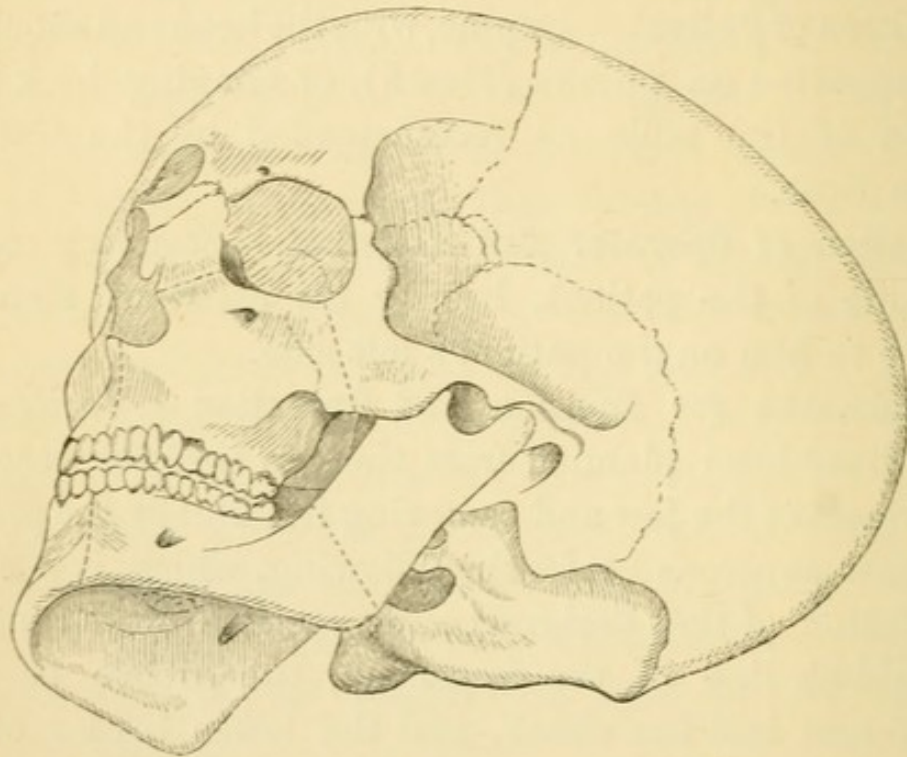


FIG. 35.—EXCISIONS OF THE JAWS.

Lines of section of bones of upper and lower jaw marked for operations of excision.

whole mass clear of any further attachments and remove it entire. Posteriorly alone it will require to be freed with a knife from its connection with the soft palate so far as this is left intact by the disease. The bleeding is usually smart along the line of the first incision, and should be checked at once. It is often severe also as the bone is broken away; but if this part of the operation is done firmly and quickly, it is easily controlled by thrusting a dry sponge into the cavity and exercising firm pressure with it until the vessels are taken

up one by one in the catch forceps. When this is accomplished the wound is carefully examined for any remains of new growth which may have escaped excision, and these are now removed freely. Then the whole cavity is cleansed of all clots and dried as far as possible, after which it is dusted with iodoform. The edges of the facial wounds are now brought together accurately either with silver or silk sutures, commencing at the border of the lip. The dressing preferred by the author out of the number of antiseptic materials employed is a pad of iodoform wool cut to the shape of the depression in the face and covering in the eye. The facial wound is dusted with iodoform before this is applied, and ought to heal by first intention in the course of four or five days, after which the dressing may be changed and the stitches removed, the same dressing being re-applied.

If on throwing back the flap after division of the lip and cheek as far as the nasal process (fig. 33) the growth appear to be limited to the lower part of the bone, the skin incision outward along the lower margin of the orbit may be omitted, as there will be room enough for excision of the affected part without it. This may be accomplished perhaps also without division of the malar bone and removal of the floor of the orbit, by first dividing the jaw in the middle line, and then making (instead of division of the malar) a horizontal saw-cut along the lower border of the latter and breaking away the bone downwards. The succeeding steps of the operation are completed as in the first instance. This procedure is most suited to those cases of malignant growth starting in or about the alveolar border which spread upwards towards the antrum.

If both maxillæ are to be removed the same facial incisions are made on both sides, the subsequent steps of the operation being practically the same except that the

median division of the bone may perhaps be omitted. Where the lower parts of both bones alone are to be excised, a median incision in the lip branching on either side into the nostril will give free enough access to the parts, especially if the septum of the nose be divided. It must however be noted here again, that where such an operation seems called for, a grave mistake has been committed by some one in not recognising the disease at an earlier stage.

Memoranda.—The first great aim of this operation is of course to get rid of the growth as completely as possible, the next is to do so with a minimum of bleeding. A loss of blood which in another part of the body would be insignificant may prove very serious here, as it may be drawn into the air passages and there give rise to serious troubles immediate and remote. Rapidity of execution will not always prevent the bleeding from proving troublesome in this way, and it is better thoroughly to control the vessels in the flaps before excision of the bone; the latter however cannot be done too rapidly.

In order to prevent the blood from gaining access to the larynx, some surgeons prefer to operate with the patient's head hanging well back over the edge of the table, so that the blood may run back into the upper part of the pharynx where it can be sponged away, rather than straight over the back of the tongue into the larynx. This plan, which was proposed by Prof. Rose in Germany, has been found to answer very well. Others again have thought it well to perform a preliminary tracheotomy a few days before the excision is undertaken, so that during the latter a sponge may be placed in the pharynx while the patient takes chloroform through the artificial opening. The advantages of this measure are very great for unusually large tumours, but for the removal of those of ordinary size it is not necessary.

EXCISION OF THE LOWER JAW.

The removal of the whole of the lower jaw is a rare operation, but excision of one half of the bone is often called for on account of new growths. The latter operation alone need be described, as the procedure only differs in degree from the more extensive one which can be carried out by a simple symmetrical extension of the same incision made for the excision of one half of the bone. Removal of portions of the alveolar margin can in every case be carried out through the mouth without any external incision.

Instruments, Position of Patient, &c., as for the last operation.

Landmarks for Incision and Operation.—The lower border of the jaw is the first line to be taken. Along this a curved incision is carried down to the bone reaching from just above the angle to half an inch above the symphysis. This divides the facial artery, which should be at once secured at both ends. The proximal end of the vessel, it should be remembered, is prone to retract under the bone and may give a little trouble if not looked after at once. When this is done the cheek is dissected upwards and the opposite edge downwards from the diseased mass. The latter should be cleared as far as possible in this way before the cavity of the mouth is opened up, so that no blood may gain access to the latter until the last moment. When quite cleared the symphysis is sawn nearly through in front and then the ramus behind, in sound tissue beyond the growths, but also only partially. The portions remaining unsevered under these two saw-cuts are finally divided with a bone-forceps. If it be thought necessary to disarticulate, which is rare, the symphysis may be cut through first and the skin

incision be prolonged upwards nearly to the zygoma, after which, partly by the knife and partly with the elevator, the bone is cleared up to the coronoid process, from which the muscle is cut away forthwith.

Then by moderate twisting, combined with touches of the knife or scissors carried close to the bone to avoid the internal maxillary artery, or with the help of an elevator, the condyle is dislodged from its bed. But every effort consistent with removal of the whole growth should be made to spare the coronoid process and condyle, which should, wherever possible, be divided with bone forceps and left *in situ*, and also to avoid opening up the mouth until the last moment. In this way the blood is kept from embarrassing the respiration.

When the whole mass is removed all bleeding is arrested, and a search is made for any diseased glands, which if found must be taken away. If the symphysis itself have to be included in the portion excised, it will be necessary to pass a thread through the tip of the tongue to prevent its falling backwards when its anterior attachments are divided. This thread must be secured to one of the remaining teeth for a few days. The whole wound having been carefully cleansed of clot, and oozing having been checked, is dusted with iodoform and closed with wire or carbolised silk sutures, preferably the latter. No drain is required in most cases.

Memoranda.—This operation, though severe, is relatively a simple one whether limited or extensive. Special care must be taken to keep as close to the bone and growth as is safe, and open up the mouth as late as possible. The incision should not reach high enough on the ramus to sever the facial nerve. The object of only partially dividing the bone with the saw and completing its division with bone-forceps is to prevent it losing its support from the

opposite half until ready to be finally released at either end. If one end is cut completely through with the saw, the instrument is apt to lock in making the second cut. A small plug of wood or catgut should be at hand to thrust into the dental foramen in those cases in which the dental artery gives trouble after the saw has done its work. A fine pointed cautery may also be needed if this fail to arrest the hæmorrhage. The after-treatment is conducted on the same lines as that after excision of the tongue (*q. v.* MEMORANDA, p. 229).

CHAPTER X.

OPERATIONS ON THE RESPIRATORY ORGANS.

I. OPERATIONS ON THE AIR PASSAGES.

THE operations to be noticed in this chapter are Thyrotomy, Laryngotomy, Tracheotomy, Excision of the Larynx, and the several modes of evacuating fluid from the pleura. The first three have so much in common that they may be described in some respects together.

Instruments.—A narrow-bladed scalpel; blunt-hooks; sharp-hooks; dissecting and artery-forceps; aneurism-needle; silver tubes of various sizes; tapes for the latter; a Trendelenburg's tampon cannula; Paquelin's cautery.

Position of Patient.—Supine, with the arms by the sides and the shoulders raised. A small hard thin bolster of about three inches in diameter, or the arm of an assistant, is placed immediately behind the neck, so as to throw the latter forward and the head back. The head must be held exactly in the middle line.

Position of Operator and Assistants.—The operator stands on the right side of the patient; one assistant on his left at the end of the table steadying the patient's head with a hand on each cheek, and subsequently using the blunt-hooks on either side; another assistant stands on the patient's left-hand side. The anæsthetist in this case

also places himself on the patient's left side, opposite to the operator.

LARYNGOTOMY.

This operation, if performed on a patient lying quietly under the influence of an anæsthetic, is one of the easiest in surgery, but when called for to relieve intense dyspnoea in one who is struggling for breath, is very far from easy. When undertaken formally, a short vertical incision an inch long is made in the middle line having its centre over the cricothyroid membrane. This is carried through the skin, and then the areolar tissue is picked up and unravelled, so that the membrane may be reached without damage to the small vessels which cross the latter. If there is time, the larynx should not be opened until every trace of bleeding has ceased. The knife is then thrust through the membrane with its blade transversely to the axis of the trachea, and when a sufficient opening has been made, a cannula is introduced. In some cases it will greatly facilitate the entrance of the latter if a crucial incision in the membrane is made, or if the upper edge of the cricoid cartilage is caught with a small sharp-hook and a narrow crescentic portion of its upper border is cut away in the middle line, leaving a round opening. When the tube is introduced it is secured by tapes passed through its shield and carried round the back of the neck from both sides.

Where suffocation is imminent from blocking of the larynx there is no time for the above formal operation, and a more rapid procedure must be resorted to. This consists in feeling for the lower border of the thyroid cartilage and cricoid in the middle line, and simply thrusting a sharp-pointed knife straight through both skin and membrane at once, and enlarging the opening by cutting a little on both sides as the knife is withdrawn. Through this

opening the tube is at once inserted, and a little pressure is made on the skin against it if necessary, until the bleeding has ceased.

Memoranda.—The utmost care must be taken to keep to the middle line, especially in children, and also not to thrust the knife so far as to wound the posterior wall of the trachea.

TRACHEOTOMY.

This, too, may be an exceedingly simple operation when performed on a patient lying quietly under the influence of chloroform, or, on the other hand, very difficult where dyspnoea is marked and there is no time for giving the latter. Two points may be chosen for opening the trachea, namely, immediately above and immediately below the isthmus of the thyroid body. In the first situation the operation is much easier than lower down, the tube being more superficial and the danger of meeting arteries or veins less; but it has the disadvantage that in many cases it is too close to the disease, and also to the thyroid isthmus with its numerous veins. Lower down, the tube lies much deeper and the vessels met with are larger and more likely to be numerous, besides which the thymus gland in children is more difficult to avoid, especially in a short neck.

The vessels likely to be in the way above the isthmus are almost entirely venous, i.e. a small twig or twigs uniting the thyroid veins. Over the isthmus itself, too, is a plexus of venules which converge rapidly to form two or more inferior thyroid veins. In addition to these, sometimes, in the low operation, a small artery is endangered, the *thyroidea ima*, a branch of the innominate artery. If the dissection be not carefully limited to the middle line, the common carotid arteries are also in danger, or even the

innominate in the child, and below the innominate vein might be wounded by incautious dissection.

Observing the preliminaries above given, tracheotomy above the isthmus is thus performed, following Bose's formula, which is perhaps the best of all.¹ An incision is first made exactly in the middle line, commencing over the middle of the thyroid cartilage (fig. 36, *a*) and running

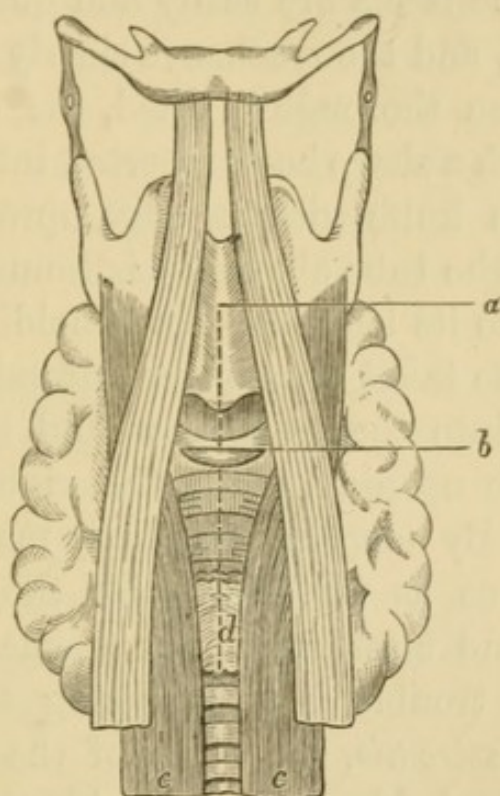


FIG. 36.—TRACHEOTOMY, BOSE'S METHOD.

a, Line of skin incision, from middle of thyroid cartilage downwards; *b*, transverse incision in fascia covering the cricoid cartilage; *c c*, sterno-thyroid muscles; *d*, isthmus of the thyroid body.

downwards from one to one and a half inch. This is to be carried down rapidly to the deep fascia lying beneath the sterno-thyroid muscles (*c c*). This fascia is attached to the thyroid cartilage above, and splits below and laterally to invest the thyroid body and isthmus (*d*) with their vessels. The isthmus of the thyroid body usually lies across the third and fourth rings of the trachea (Quain), and the simplest way

¹ *Archiv f. klin. Chir.* Bd. xiv. p. 137.

to carry it downwards without wounding its delicate vessels is to make a transverse incision (*b*) a third of an inch long through the deep fascia at the upper border of the cricoid cartilage, and then pass a director or blunt-hook well behind it and peel it off the front of the tracheal rings until enough of the latter have been exposed. In this way the isthmus and its vessels lying between the two layers of the fascia are easily and quickly moved without any injury, and the trachea is clearly seen. When the wound has been thoroughly dried, the operator steadies the trachea with a sharp hook inserted into its second ring, and thrusts his knife with its edge upwards through the middle line of the tube above the isthmus and cuts towards the hook, but to its left side. Still holding the hook with his left hand, he takes up a silver cannula with his right and inserts it into the tracheal wound by depressing the left edge of the opening, while the right is held forward by the hook. By adopting this little manœuvre, which is known among us as Mr. Marshall's, the difficulty due to the mobility and elasticity of the trachea is avoided. If there is much trouble in introducing the tube, and the patient is *in extremis*, the edges of the tracheal opening may be simply held apart with blunt-hooks until the dyspnoea has been relieved, when the introduction of the tube will be found a matter of much greater ease. If any force is used there is danger of the cannula being thrust down between the trachea and soft parts without entering the air passage at all. Sometimes it may be necessary to divide the cricoid cartilage as well as the rings just below it, but if this can be avoided the larynx has a much better chance of escaping damage, both during and after the operation.

If tracheotomy below the isthmus is required, an incision two inches long is made downwards in the middle line

commencing above this structure. When the fascia between the sterno-thyroidei is reached it is carefully divided on a director if there is time. The veins which present are drawn aside or divided between two fine silk ligatures. If the thymus gland is seen it is pressed downwards and the isthmus upwards with the pulp of the finger, both being held out of the way with blunt-hooks. The trachea now exposed is caught with a sharp-hook a little to the right of the middle line and steadied while the point of the knife is thrust through its rings below with the edge upwards, and a median incision is made, large enough to admit a full-sized cannula, introduced as described above. Here great caution is necessary lest the tube be pushed between the trachea and sternum without entering the former. The surgeon, too, should be on the look-out for any deviations from the normal in the course of the arteries, which, in some instances, have given rise to serious trouble both during and after operation. In all cases, so far as time will allow, bleeding should be completely arrested before the final opening of the trachea is proceeded with. When properly adjusted the tube is fixed with tapes tied behind the neck.

Memoranda.—The chief dangers connected with this operation are, in the first place, hæmorrhage into the air-passages and consequent suffocation. This is generally due to haste in operating and neglect to see that all vessels are closed before the trachea is opened. The surgeon then should operate as deliberately as is necessary to secure the patient against this danger. Haste may also endanger the carotid vessels if the surgeon errs from the middle line. Another danger is wound of the pharynx through the posterior wall of the trachea. This must be guarded against by avoiding too strong a thrust with the knife in opening the trachea, and amongst young operators

by holding only about half an inch of the knife-blade projecting beyond the fingers when piercing the tube. In children, the trachea may be missed at first altogether by a nervous operator, and serious damage be done to adjacent parts before it is found. Finally the silver cannula must be handled with much care and without force, lest it be forced to one side of or in front of the trachea, without reaching it at all.

THYROTOMY.

This operation, though simple in performance, is now rarely called for, and will probably fall eventually into disuse as our manipulative skill in removing bodies from the larynx through the mouth or a tracheal opening improves, and the seriousness of the procedure is more fully recognised. That the operation is a serious one in the young and old as regards risk to life has been abundantly shown (P. Bruns): that the danger of permanent injury to the voice is great has also been proved, and that it possesses no great advantages over other simpler methods for reaching bodies in the larynx has been demonstrated over and over again lately.

If called for, the operation is done as follows, the preliminaries being as above given. An incision is made exactly in the middle line, commencing at the lower border of the hyoid bone and running downwards over the *pomum Adami* to the lower border of the cricoid cartilage. This incision divides everything down to the cartilage, which is now fully exposed by drawing the soft parts asunder on each side with blunt-hooks. When all bleeding has been perfectly arrested, the edge of the knife is placed in the mesial notch in the upper border between the alæ, and is carried steadily downwards exactly in the middle line, the larynx being steadied with the left thumb and index finger.

In the young it is an easy matter to divide the cartilage, but where calcification of the latter has taken place a fine saw or bone-forceps has been used. When the alæ have been severed from one another they are drawn apart and the foreign body or growth is removed. To extract a growth various slender forceps, sharp-spoons, and fine-pointed cauteries should be at hand, but these must be used with as much care for the preservation of the mucous membrane of the part as is compatible with thorough removal of the neoplasm. When this has been effected the edges of the wound in the cartilage are brought together with as perfect accuracy as possible, and are secured with one or two stitches if necessary, every precaution being taken to keep the whole wound aseptic by cleansing and dusting with iodoform.

In some cases it has been considered desirable to perform a preliminary laryngo-tracheotomy for the introduction of a 'ballon tampon' into the trachea in order to prevent blood from finding its way into the air passages during the extraction of the growth. This latter part of the operation is usually accompanied by very free bleeding, which may lead to considerable embarrassment if the precaution of stopping the trachea beforehand be not taken. The tracheal tampon may be removed at the end of six hours and an ordinary cannula substituted. The latter must be worn until the intra-laryngeal wounds are quite healed and all tendency to contraction and stenosis about the cords has ceased. For it must not be forgotten that anything short of very free removal is almost certain to be followed by recurrence, and such free removal, especially if caustics have been employed, is very likely to result in the formation of adhesions or great contraction of the interval between the vocal chords.

RESECTION OF THE LARYNX.

This operation was first performed on the living human subject in 1873, by Billroth of Vienna, for malignant disease of the larynx. The patient lived for about one year after the operation, and died of recurrence in the glands of the neck. Thus the feasibility of the operation was demonstrated, and also the fact that, with an artificial larynx, a patient might be enabled to talk intelligibly if monotonously. Billroth's success led to the repetition of this operation in a comparatively long series of cases, with varying results. Thus, from Schüller's statistics¹ it appears that down to the end of 1878 nineteen extirpations of the larynx had been completed, with eight deaths and eleven recoveries. The disease in three cases was sarkoma, and of these, one patient lived in good health for four years, the next for more than a year, being with the third alive at the time Schüller wrote. Of the remaining sixteen the operation was performed for perichondritis in one case, with a fatal result on the fifth day, and for carcinoma in fifteen cases. Of these latter seven died within the first fortnight—five of pneumonia, two of exhaustion. The remaining five succumbed to recurrence in the lymph glands in four cases, in the root of the tongue in one. They lived after operation four, six, nine, nine, and twelve months respectively. From these statistics it would appear that the gravity of the operation consists chiefly in the risk of septic pneumonia from entrance of the discharges of the wound into the air passages, and if we exclude those cases which have died of this affection the mortality is not high. Judging from recent improved results obtained by various operators in excising the tongue by the use of antiseptics,

¹ *Deutsche Chirurgie*, Lieferung 37, 1880.

and especially of iodoform, it appears not improbable that the results in excision of the larynx will be similarly improved, and that this operation will, in the future, come to be regarded with more favour, especially as the artificial larynx has been much simplified and rendered more perfect in its action in recent cases. Nevertheless the great risks will only be recognised and properly avoided by those who have had experience of operations on the tongue and pharynx, almost everything depending upon attention to details in the after-treatment.

Instruments, Position of Patient, &c., as for the last operation.

Landmarks for Incision and Operation.—The only landmarks necessary to bear in mind here are the hyoid bone above the cricoid cartilage below, and the middle line between these two. In most cases a tracheotomy will have been previously performed for the relief of dyspnoea, and if so, a Trendelenburg's tampon cannula will first be placed in the opening and inflated. Through this chloroform will be administered. Then an incision is made exactly in the middle line from the body of the hyoid bone to the cricoid cartilage, the skin being steadied on either side with the left forefinger and thumb of the operator. Separating the edges of this wound with sharp-hooks, which are entrusted to an assistant, the surgeon now clears the thyroid cartilage on either side as far as possible with an elevator, aided here and there by a few touches of the knife. This is an easy matter where the disease is limited to the interior of the larynx, but if the new growth has perforated the cartilages, the dissection must be carried outside of it into healthy tissue. In clearing the larynx the sterno-hyoid and sterno-thyroid muscles are, if possible, turned aside with the skin, the latter being divided near their insertion into the larynx. If invaded with growth,

both of course must be freely cut away. In the dissection the superior laryngeal vessels or their branches must be ligatured with double ligatures and cut between these, and every means taken to prevent oozing of blood. The presence of the latter obscures the field of operation, and it may possibly be sucked into the air passages and embarrass the breathing. When all bleeding has been stopped the thyro-hyoid membrane is divided transversely, together with the muscle, and then, the larynx being drawn as far forwards as possible with the forefinger or a sharp-hook in its superior opening, the stylo- and palato-pharyngeus muscles are severed close to their insertion, and the inferior constrictor behind. With as little damage to the pharynx as possible the dissection is carried down behind the larynx to the cricoid cartilage. If the limitation of the disease admit, the lower border of the latter is left intact when the transverse cut is made to complete the removal of the larynx; but if there is any suspicion of the growth having encroached too far, not only the whole of the cricoid must be removed, but also one or two rings of the trachea as well. If this is necessary the edges of the remainder of the trachea should be stitched to the skin to prevent its sinking down, as it always has a tendency to do when severed from the larynx above. Before the larynx is cut away below, every trace of bleeding should be arrested.

In some cases in which no preliminary tracheotomy has been performed the dissection has been begun below by division of the trachea transversely, and then when the tampon cannula has been inserted and inflated the separation of the larynx from its connections has been continued from below upwards. This has some advantages, but the method described above has been that most frequently employed, on account chiefly of the ease with which blood may be prevented from entering the air passages during

the whole operation. Whether it is desirable to attempt extirpation of the larynx in those cases in which the disease extends beyond its cartilaginous walls is perhaps open to question, but it has been done more than once. Thus B. von Langenbeck removed not only the larynx, but also the root of the tongue, the hyoid bone, the anterior and lateral portions of the pharynx, and the pharyngo-palatine arch, the submaxillary lymph glands on both sides, and a portion of the œsophagus, the patient making a rapid and good recovery. This case is mentioned here, not to encourage others to attempt the same thing, but to show how wide-reaching operations in this direction may be without extreme immediate risk. If it be necessary to provide more working room than the above incision affords for the complete dissection of the diseased larynx, it is best secured by a two-inch transverse cut along the upper border of the hyoid bone, forming with the first a T-shaped incision. When the triangular flaps thus formed are turned back, sufficient space is provided for any operation which ought to be attempted.

The mode of dressing after this operation is of immense importance. In the first place, it is better not to put in any stitches to draw the edges of the wound together. The latter must be left to close by itself by granulation, so that all its surfaces can be watched and cleansed. Through this wound a stout feeding tube passing into the stomach is retained for some days. When this has been introduced and secured, the cavity is dusted over lightly with iodoform and is carefully packed with antiseptic gauze, a tracheotomy tube, replacing the tampon cannula, being left in for some days. A thick pad of antiseptic wool is then adjusted over the exterior of the wound, leaving the feeding tube and cannula free. When it is necessary to change the dressing a tampon cannula may be replaced for the occasion, if it is necessary

to wash out the wound, and again changed for an ordinary tube before the re-packing with gauze is begun. But with an irritable patient this need not be done, and the wound may be thoroughly cleansed without irrigation in the majority of cases where iodoform has been used. In a few

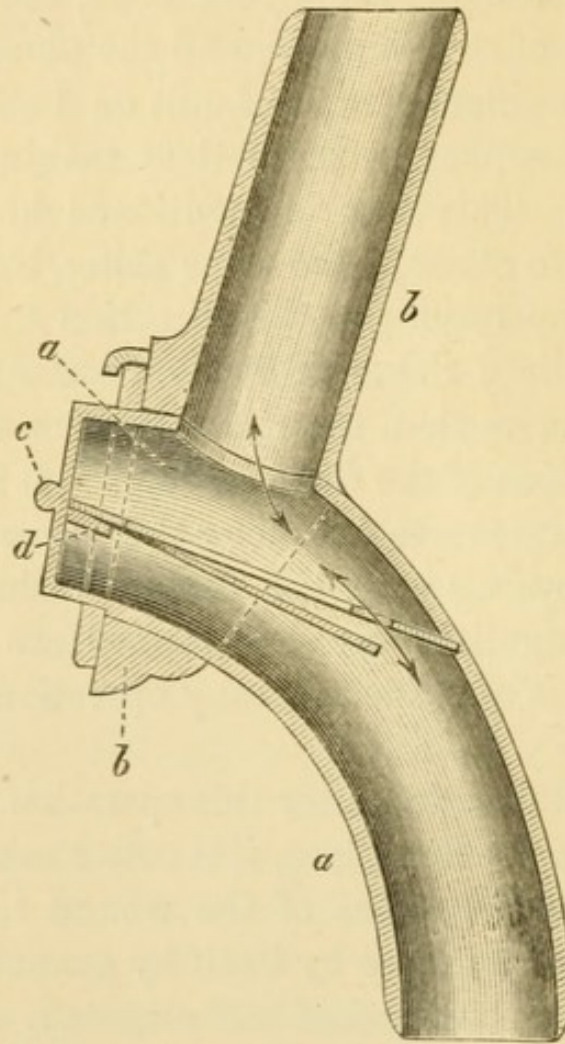


FIG. 37.—FOULIS' ARTIFICIAL LARYNX. (Natural size, after Foulis.)

a, Tracheal cannula; *b*, laryngeal cannula, into which *a* fits through a collar; *c*, sliding plate, carrying the flexible tongue *d*, which vibrates opposite the opening through which the air passes up and down in the directions of the arrows.

instances, notably those of *Foulis* and *Bruns*, a thick bent tube of pewter large enough to fit the trachea accurately has been used instead of an ordinary cannula, and has been found to have some advantages over the latter. It is most suited for those cases in which no preliminary tracheotomy has

been performed. Besides the careful cleansing of the wound, the mouth must also be frequently washed out with some disinfectant, one of the best being a solution of chlorate of potash. The feeding tube should not be dispensed with until granulation is well advanced, when it may be withdrawn and conveyed into the stomach by the mouth two or

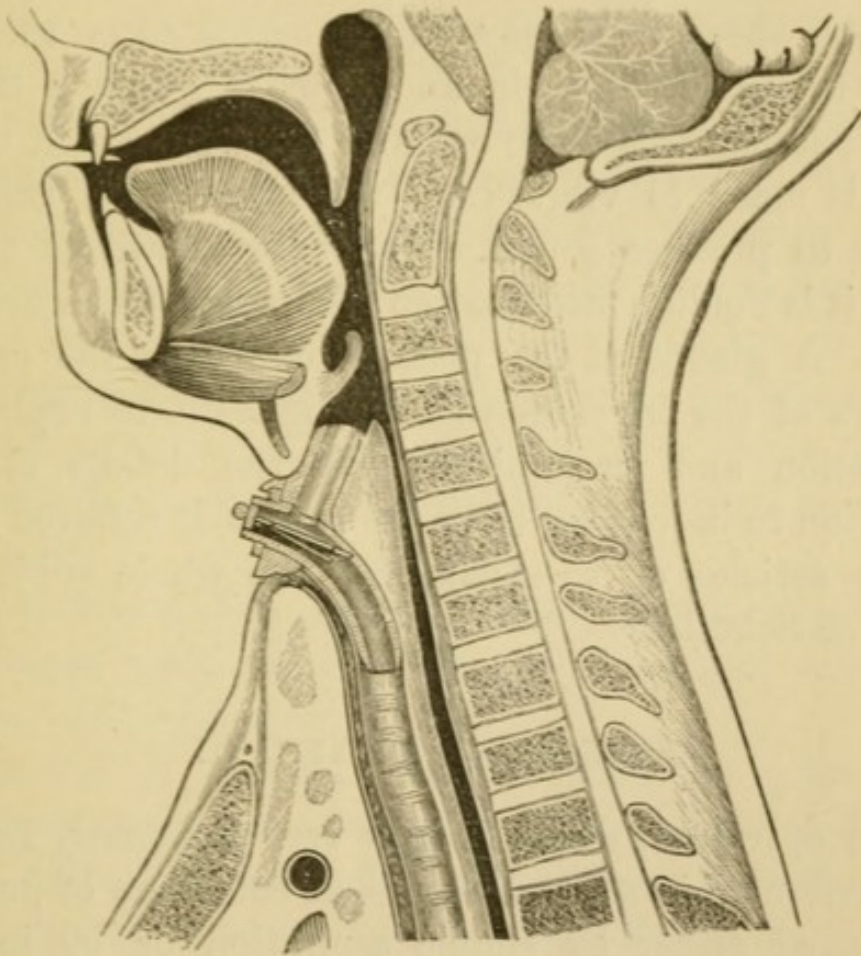


FIG. 38.—FOULIS' ARTIFICIAL LARYNX IN SITU. (After Foulis.)

The upper part is first placed in position, then the lower is pushed through its collar into the trachea.

three times a day for the introduction of fluid but nutritious food. It is remarkable how soon patients begin to swallow for themselves without difficulty, even though the epiglottis have been removed with the larynx. Nutrient enemata may also be employed in these cases with much benefit.

The introduction of an artificial larynx usually takes

place about the third week, on the one hand before contraction of the wound has progressed very far, and, on the other, not before a considerable amount of healing has taken place.

Various forms of apparatus have been devised to replace the larynx and supply a sound capable of being modulated by the movements of the tongue and lips so as to produce intelligible speech. These are all constructed on the principle of the 'reed pipes' in an organ, in which a flexible tongue passing across the opening through which the air rushes is made to vibrate by the latter with sufficient rapidity to produce sound. The best known is figured above; it is Foulis's modification of Gussenbauer's artificial larynx. A glance at the plate copied from the original drawings of the inventor will be sufficient to explain its construction and mechanism. For the details of their application in individual cases the reader is referred to the original articles or to *résumés* of the whole subject by Foulis¹ or Schüller.²

DRAINAGE OF EMPYEMATA.

This operation, which is now very frequently resorted to, is performed in several ways. A collection of pus may be removed either by simple aspiration or by incision through the wall of the thorax at one point or another.

For aspiration no special rules are required so long as it be fully understood that absolute cleanliness be attended to throughout. The point selected is that at which percussion and auscultation indicate that the fluid is most abundant, and here the needle is cautiously thrust through the soft parts exactly between two ribs, the vacuum having

¹ *Lancet*, vol. ii. 1877; vol. i. 1878.

² *Deutsche Chirurgie*, Lieferung 37, 1880.

been made previously and opened to the needle the moment the eyes of the latter are buried in the superficial soft parts. Care must be taken only to thrust the needle so far in that its eyes just reach the fluid, and also to withdraw it so soon as the latter becomes streaked with blood, lest the expanding lung be pierced by its point or the granulations lining the cavity be torn and bleed freely.

When the thorax has to be opened by incision, the first question which arises is what is the best point to select. This again is more or less determined by the position of the accumulation, but when the latter is general throughout the whole pleura, the spot which will be found best to meet the requirements of thorough drainage is one a little below and in front of the angle of the scapula when the arm is at right angles with the body (fig. 4, *i*), or at about the level of the eighth rib. Other points a little above or below this may be occasionally chosen, but that given is the most favourable.

Instruments.—A scalpel; artery-forceps; a curved, leaf-shaped periosteal elevator; bone-forceps; sequestrum forceps; sinus-forceps.

Position of Patient.—Supine, with the affected side projecting over the edge of the table and the arm held at right angles with the body. All rolling of the patient towards the opposite side of the body should be avoided as far as possible in view of the greatly embarrassed respiration.

Position of Operator and Assistant.—The surgeon stands or sits facing the affected side. In those cases in which, exceptionally, for one reason or another the patient is placed on the sound side, it is more convenient for him to stand. The assistant always stands leaning over the patient from the sound side.

Landmarks for Incision and Operation.—At the point indicated above, the direction of the ribs is felt for with the

fingers and an incision is made for about two inches directly across them, or, in case a portion of rib is to be excised, directly down the centre of the bone in question. The soft parts are then drawn aside with blunt-hooks until two adjacent ribs are clearly seen. Most operators now prefer to remove a portion of rib so as to secure the drain tube from pressure as the adjacent bones fall in. This has the extra advantage that the deeper incision may be made in the position of a rib, and thus there will be no danger to the intercostal vessels. To remove the rib the periosteum is first stripped off its outer side with the elevator for an inch or two. This is a very easy matter in children, and even with adults offers no special difficulties. From the pleural aspect of the bone the periosteum is separated with great ease, being with the pleura somewhat thickened and congested. As soon as the curved elevator has done its work behind and in front for about an inch or so, it is left under the bare portion of rib to protect the soft parts, and the latter is nipped across in two places with a bone-forceps and is removed. The scalpel is now thrust cautiously through the middle of the periosteal bed of the excised rib, with its blade in the direction of the latter. The pus will then well out, and a dressing forceps is introduced through the resulting opening with which to tear the hole larger. If the pus is thick it is well to introduce the finger into the cavity of the thorax to feel if there be any adherent masses of fibrinous material which would not readily flow through the tube. If such be present they are broken down, while the size and shape of the cavity are ascertained at the same time. A large rubber tube with a shield is now placed in the opening, reaching well into the deeper parts of the cavity: the shield and parts around are lightly sprinkled with iodoform, and the side is covered in the usual way with a Listerian dressing.

Sometimes it is considered desirable to remove two or

three inches from several ribs overlying the cavity, so that the wall of the latter may sink in and help to fill up the space. For this procedure no definite rules can be given except that the size and shape of the cavity should be made out as accurately as possible with the finger and a long probe, and then so much of the ribs be removed over its widest part as appears necessary. The incisions requisite for this purpose may be variously placed, and may run either in the direction of the bones to be excised or obliquely across them. The author has found that an incision directly over one rib will suffice for its excision and that of its fellows on either side. It is better to remove the outer wall of such a cavity by stages at intervals than to attempt the excision of too large a number of ribs at a time.

Memoranda.—In removing the portions of ribs as above every care should be taken not to lacerate the underlying pleura. This is easily avoided by working the elevator as close to the bone as possible. In the same way the intercostal vessels and nerves are preserved from injury.

CHAPTER XI.

OPERATIONS FOR ABDOMINAL TUMOURS.

OVARIOTOMY.

IN dealing with this operation I have thought it better to give Sir Spencer Wells's description, somewhat epitomised, as that of the surgeon whose name is most identified with its origin and development.

PRELIMINARY ARRANGEMENTS.

The patient should have a bath the night before, and the bowels should be relieved by an aperient, followed by an enema on the morning of operation. The latter is best done in the afternoon, only a light meal having been taken in the morning. The temperature of the room chosen for the operation must not be much above 60° F.; it should never be below this, and there should be a bright cheerful fire burning in the room. The patient is to be clad in loose warm night-clothes and long woollen stockings.

Two dressing-tables, one placed crosswise to the end of the other, answer very well for the patient to lie upon. They should be so arranged close to a window that the light falls upon the surgeon's right hand. On these tables the patient lies, with her feet towards the light and her

shoulders on the crossed table, the operator being of course on her right side. The abdomen, carefully washed and, if necessary, shaved beforehand, is covered with a waterproof sheet, having a hole about eight inches long and six inches wide in its middle. The edges of this opening are spread on their under-surface for an inch or so with a coating of adhesive plaster, which adheres to the skin, and protects the body clothing and blankets from chill and wetting during the exposure of the field of operation. Under the table a pail or footbath is placed to catch the fluid contents of the tumour, and the steam spray stands to the left of the patient's feet. Two assistants are required, one standing opposite to the operator on the patient's left, the other at the surgeon's left hand. On a table to the right of the latter are placed his instruments. Of these not many are required for a simple case, but for complications many may be needed and should be at hand. The list will include: one scalpel; one probe-pointed bistoury; one scissors; twelve catch-forceps; one Nélaton's vulsellum forceps; one Wells's trochar with elastic tubing; one double-hook; Wells's clamps and cautery; ligatures; needles; drainage tubes of glass and rubber; perchloride of iron; a hand mirror or 'bull's-eye lantern'; flat trays filled with carbolic lotion, $2\frac{1}{2}$ per cent.; twenty soft sponges; carbolic lotion, $2\frac{1}{2}$ per cent., a gallon.

Operation.—The only guide needed for the first incision is the middle line of the body, which is chosen by the majority of operators. The linea semilunaris has also been selected in a few cases, and some surgeons have made various oblique incisions through different parts of the abdominal walls. In all Sir S. Wells's cases the linea alba has been chosen. The length of the incision will vary with the size of the tumour, but usually reaches from below the umbilicus to within two inches of the symphysis pubis.

It is well not to go below this point lest the bladder be wounded, and at every stage of the incision the possible expansion of this organ should be borne in mind. If the incision has to be carried above the umbilicus it should be made on the left side, in order to avoid an unobliterated umbilical vein where such is present. The skin is divided either by a direct cut, or by transfixion of a fold held transversely, which is the better mode where the operation is done after tapping. Then the superficial fascia and fat are cut through and the linea alba is exposed; this is then divided by steady cautious strokes of the knife until the fat underlying the muscles and covering the peritoneum is reached. The serous coat will now probably bulge out, especially if there be fluid in the abdomen. In this case the membrane is opened and the fluid is allowed to flow off into the foot-pan under the table. When all has escaped, the membrane is slit up to the full extent of the skin wound, and here the flat director may prove most useful if the finger cannot be used as a guide for a blunt-pointed curved bistoury. The double hook is also of use in many cases for holding up the edge of the membrane from the ovarian cyst during the incision. Much care is necessary lest at this point the cyst be punctured and its contents escape into the abdominal cavity. But before the peritoneum is opened all bleeding must be carefully arrested by catch-forceps or torsion, and too much care cannot be taken in this respect. If, on dividing the linea alba, any difficulty be experienced in defining the boundary between the peritoneum and cyst, it is better to puncture the latter and empty it before going further, rather than run the risk of stripping off the peritoneum from the abdominal wall, as has been done more than once where the peritoneum was mistaken for the cyst wall. Any firm adhesions to the intestine or omentum should

also be left until the cyst has been emptied. When adhesions are loose or not extensive, and the cyst has been distinctly made out after division of the peritoneum, the adhesions may be easily separated as a rule by one or two fingers, or by inserting the whole hand between the abdominal wall and the tumour, with its palmar surface towards the latter, over which it is swept from side to side. Sometimes very extensive adhesions yield before a very slight force, but at other times considerable effort is required to break them down. Adhesions are rarely so firm as to require the use of knife or scissors, but if they are so it is better to cut away a portion of the cyst wall and leave it behind than to run the risk of injuring the viscus to which it is attached. If by any accident the bowel or bladder is torn, it should be at once sutured by Lembert's or Czerny's method of suture with fine carbonised silk (*vide* figs. 39 and 42).

When the tumour is found non-adherent, or after the separation of slight adhesions, the next step is to empty the cyst. For this the syphon trochar with spring hooks is held in the right hand and pushed sharply into the most prominent part of the tumour, if the latter is simple: if multilocular, into that compartment which appears to contain the largest quantity of fluid. The sharp point is then to be drawn back with the thumb into the cannula.

After a portion of the fluid has been drawn off and the cyst has become more or less flaccid, it is drawn up further upon the cannula, and fixed between the prongs of the spring-hooks, which, if properly adjusted, will hold the cyst wall tightly round the cannula. When the first cavity has been thus drained, a second and third or more may be tapped if necessary without removing the instrument, simply by pushing the trochar forward and thrusting it through the septum which separates the empty from the full cavity

adjacent. In this manner the whole tumour may be emptied, and its bulk so reduced that it may be drawn through the abdominal opening without undue force. In cases where there are several cysts which cannot be tapped one through the other, they must be emptied singly, either by the same trochar or by a fresh one. Great care must be taken if the same trochar is used not to puncture the main cyst wall a second time, lest some fluid should escape into the abdominal cavity.

Having succeeded in reducing the size of the tumour the surgeon draws it through the incision, at the same time breaking down any adhesions which may have escaped him before. The assistant opposite now places his hands on either side of the incision and prevents the prolapse of the intestines by carefully keeping its edges in close approximation. He does this best by placing the middle finger of his right hand inside the abdomen, hooking up the wall, and then, with the thumb on one side of the opening and the forefinger on the other side, he holds the edges close together. He should not allow his attention to be diverted from this very important part of his duty. The assistant on the operator's left hand supports the cyst until it is completely separated, and receives it in a towel or basin. No traction whatever is permitted, and the greatest caution ought to be observed in this respect when the pedicle is short and when undivided adhesions remain. In order to lessen the weight of the tumour, cysts which had not been emptied before may be punctured, and secondary cysts, if the septa are thin, may be broken down by the hand introduced through an opening into the first cavity. But it will not be always possible to reduce the bulk of the mass sufficiently to bring it through the original incision. Tumours are sometimes met with which consist of solid or semi-solid unyielding masses, or they are divided

by trabeculae into small cavities filled with viscid colloid substance which cannot be broken down sufficiently to pass through the cannula. It will therefore become necessary to enlarge the incision upwards. This is less dangerous than any attempt to squeeze a large tumour through a narrow outlet, during which either the cyst may burst and its contents enter the abdomen, or the edges of the wound be bruised and fail consequently to unite by first intention, or the peritoneum may be so injured that fatal peritonitis or gangrene may result. As the cyst is drawn out a large warmed flat sponge, 6 x 4 inches, is passed into the abdomen and left between the intestines and the open abdominal wall. This serves the double purpose of preventing the escape of the intestines and protecting the cavity from the entrance of anything from without and from chill.

The cyst or tumour having been drawn out of the abdomen, any omentum or intestine adhering to its peritoneal coat separated, and any bleeding vessel secured, the intestines and peritoneal cavity being protected as just described, the next step is to secure the pedicle. This is done either by the extra- or intra-peritoneal method, the latter being now almost exclusively employed. In the first the tumour is held up by one of the assistants, the clamp is passed round the pedicle and is pressed together, with one hand grasping the forceps firmly while the screw is closed with the other. When the tumour is now cut away the clamp may be again tightened with the screw, while the assistant keeps the wound tightly closed around the pedicle which alone fills it. It is necessary to look closely to see that no intestine be included in the clamp or escape beside the pedicle. The latter should be fixed as near to the lower end of the incision as is possible without producing traction upon it. It should not be cut off quite close to the clamp lest it retract and slip through the

latter, but about a quarter of an inch deep of tissue may be left beyond the instrument. This should be touched with solid perchloride of iron, which both checks oozing and prevents putrefaction.

When operating by the intraperitoneal method, which is now done almost invariably, it is never safe to trust to a ligature which does not transfix the pedicle unless the latter be very long and slender. Many cases are on record where, on cutting away the tumour, a simple encircling ligature has slipped off, and dangerous or even fatal hæmorrhage has followed. It should be the rule therefore always to transfix the pedicle and to tie it in two or more portions according to its size before the cyst is cut away. An ordinary long needle double-threaded, or a long-handled blunt needle, straight or curved, will answer our purpose here very well. The latter is safer and more convenient if the pedicle cannot be brought well out of the abdomen. The threads are tied one below and the other above the Fallopian tube. For additional security a separate ligature may be applied on the uterine side of those first tied. When the threads are about to be tightened the forceps or clamp holding the pedicle should be loosened somewhat in order that there shall be no slipping of the ligature when tied after the forceps has been taken off. This loosening of the instrument and drawing close of the ligatures should be simultaneous, and the latter should be made very secure.

If the case be a simple one, nothing now remains but to cut the silk ligatures short, allow the pedicle to sink back into the abdomen, and close the outer wound. But supposing there is no true pedicle, that the cyst is more or less completely encapsuled in a layer of the broad ligament or an expansion of the peritoneum, this capsule may be divided and the cyst shelled out of it, or the base of the cyst with its enveloping capsule may be transfixed and tied

in two or more portions before cyst and covering are cut away. This is what many operators have termed a very short broad pedicle. In some cases the Fallopian tube, more or less elongated, is so closely involved in the capsule that it is better to include it in the ligatures and cut away all the attached part. In others it is unaltered and quite free from the capsule; in such a case it is better not to interfere with it. The ovary may also be either free or attached. If normal and free, it is better to leave it untouched, but if closely applied to, or, as sometimes occurs, if stretched into a cordlike or flattened outer layer of the cyst wall and capsule, its removal is almost inevitable. In cases of doubt as to its soundness it is better to remove it than to leave it, even if separation is not difficult.

If after enucleating a cyst any considerable part of the capsule remain, and especially if any oozing of blood continues from the inner surface, all the loose part of the sac should be drawn up, its base transfixed and tied, and all mass beyond the ligature cut away. In the very rare cases where a cyst cannot be enucleated from the capsule or broad ligament, or from the retroperitoneal attachments, we must either be content with removing the fluid contents and closing the abdominal cavity, or to employ drainage. The choice between the two methods must be determined by the character of the contents of the cyst. If clear watery fluid only, the safer practice is to close the abdomen. But if colloid, purulent, or dermoid, drainage is certainly preferable.

When dividing the pedicle and separating the cyst, the utmost caution must be observed to prevent any of the contents of the latter entering the abdominal cavity. Should this happen, the cavity must be sponged out with the greatest care with sponges wrung out of warm carbolic acid lotion.

The omentum, the mesentery, and the situations of the adhesions to the anterior abdominal, will often be found the seat of hæmorrhage either from the orifices of large vessels or from capillary oozing. This bleeding must be stopped by ligature or torsion in the first place, or by pressure, with or without a needle, in the last, before the abdomen is stitched up.

As soon as the pedicle has been tied, the tumour removed, and the bleeding has been controlled, the state of the second ovary and uterus should be examined into, and if found diseased they too can be dealt with.

Before being closed, the peritoneal cavity must be most thoroughly cleansed from any fluid or clot which it may contain. A good deal of fluid may be pressed out or scooped out with the hand, but absolute cleanliness can only be attained by using many soft carbolised sponges in succession, passing them well down behind and in front of the uterus, along each flank in front of the kidneys, and over the abdominal wall, especially where adhesions have been separated, and also well in among the intestines. This 'toilet of the peritoneum' should be very thorough. One may regret incomplete sponging, but never having been too careful. And it is also desirable to insert a large flat sponge just within the wound, and leave it there resting upon the viscera all the time that the sutures are being introduced into the edges of the wound. It catches any drops of blood which may escape from the needle punctures, and protects the cavity from cold or the entrance of carbolic acid or other antiseptic while the stitching is taking place.

In closing the wound the most convenient method to adopt is the following. Silk sutures about eighteen inches long are threaded at either end on strong straight needles. Each needle is introduced by a holder from within out-

wards through the peritoneum and the whole thickness of the abdominal wall, at about one-third of an inch from the edges of the wound on either side, the surgeon pinching up both together, so that the silk may be carried through without perforation of the recti muscles. The ends of the sutures are held by the assistant, who draws up the lips of the wound until all the sutures have been introduced. Then the edges of the opening are once more held apart so that the surgeon may satisfy himself that no further oozing of blood has taken place into the abdominal cavity. When this has been ascertained, the latter may now, if necessary, be finally wiped out and the protecting flat sponge removed. This done, the sutures are tied carefully, the edges of the skin being adapted to one another without eversion or inversion, and the ends of the threads are cut off. If the abdominal wall be very thick, superficial sutures may be required between the deep ones. If the pedicle has been secured by the clamp, the sutures should be passed so close to it that the peritoneal cavity is perfectly closed.

The surface of the abdomen is now carefully cleaned and dried, the rubber cloth removed, and the wound covered by some non-irritating antiseptic dressing, such as salicylic or iodoform wool, supported by long strips of plaster. In some cases the false ribs having been pressed outwards by the tumour, a deep hollow is left after its removal, which must now be filled up with wool covered by a broad flannel binder. When all is secure the patient is gently lifted into the bed previously prepared and warmed for her. She is kept upon her back with the knees supported on a pillow, and is covered with light but warm blankets, and is provided with hot bottles, if cold.

The after-treatment is conducted on general principles.

MYOMYOTOMY, OR EXCISION OF UTERINE FIBROIDS.

In the description of this operation I have again followed Sir S. Wells.

All the preparations and precautions are here the same as for ovariectomy, and the patient is placed upon the table in the same position as for the latter operation. The additional instruments required in this case are: long pins; a wire constrictor or large clamp for use if the extraperitoneal method is adopted; cautery irons, or Paquelin's cautery; a cautery clamp; elastic ligatures of different sizes.

Except for cases of small solid tumours, or cases in which considerable cyst-like cavities may be emptied, the incision will usually be much longer than for ovariectomy, probably extending two or three inches above the umbilicus or even up to the ensiform cartilage. Even more caution is necessary here than in the last operation when making the lower angle of the incision, as the bladder is very apt to be pushed or drawn up towards the umbilicus. Sir S. Wells has never followed the practice of what Péan calls 'morcellement,' or dividing the tumour into several parts before extraction, in order to render the long incision unnecessary. This is a long and tedious process, and the prolongation of the operation and loss of blood entailed seem far to outweigh any advantages gained by diminishing by a few inches the length of the incision.

On opening the abdomen, adhesions are dealt with precisely as in ovariectomy, and when the tumour has been protruded through a long incision, it is a good plan to pass two or three sutures near and above the umbilicus through the edges, to draw them together and so prevent escape of the bowels during the rest of the operation. The mode of

removing the fibroid will of course depend upon its connections. When there is a distinct pedicle this may be secured exactly as in ovarian operations. But if there is no pedicle many plans of treatment are open to us. In some cases the growth may be enucleated out of the folds of the broad ligament and the surfaces of the latter be brought together by suture. In others, if not too bulky, the base is clamped with several large catch-forceps specially made for the purpose, and when thus secured is transfixed behind the latter with ligatures which are tied securely. Again, the connecting tissue between the uterus and tumour may be transfixed and tied in two or more portions without being held in forceps. In many cases the clamp appears the most suitable means of removing the mass, and being firmly applied the latter is cut away and the instrument and stump are fixed outside the wound. This method is best adapted for those cases in which the cavity of the uterus has to be opened. In some cases, where there is a bulky attachment between the growth and the uterus, one or more elastic ligatures may be used to arrest bleeding while the stump is being cut through, and may be left *in situ* and sunk in the abdomen. The after-treatment of the case is conducted on the same principles as after ovariectomy.

Submucous ingrowths into the uterine cavity, which are very common, are treated in various ways. Sometimes the os uteri is more or less dilated, and if the growth be pedunculated it may be pulled out into the vagina by a hook or instrument like a corkscrew. Here it is either divided with a scissors or crushed with an ordinary lithotrite or *écraseur*, or one or two pairs of forceps may be put on the pedicle and left hanging out of the vagina for an hour or two, the growth having been cut away. Sometimes in the case of submucous growths the membrane over them

may be divided and ergot be given to excite contraction of the uterus and expulsion of the mass which may be thus brought about, being helped by the finger or forceps. In other less favourable cases the tumour has to be taken away piecemeal with scissors and forceps, the bleeding being stopped with perchloride of iron.

OÖPHORECTOMY, OR BATTEY'S OPERATION FOR THE REMOVAL OF THE OVARY OR OVARIES.

This operation may be performed either through the vagina or through the abdominal wall, the latter method being preferred by Sir S. Wells. Great care is necessary however in opening the abdomen lest the intestine be wounded, for the conditions for which the operation is required are quite different here to those met with in ovariectomy, where the bowels are not in contact with the abdominal wall in the line of incision. In Battey's operation too the intestines have a greater tendency to protrude and are more difficult to replace after protrusion, the abdominal walls not being in this case relaxed by the removal of a large mass from within. The preparations for the operation are the same as for ovariectomy, as are also practically the various steps of the procedure, which need not therefore be given here again in detail. But it is not necessary in this procedure to make as large an opening in the abdominal wall as for the major operation.

An incision large enough to admit two fingers alone is required in the *linea alba* between the umbilicus and pubis. Through this the uterus is to be felt for, and one finger is placed behind and the other in front of its fundus. Then by carrying the fingers outwards, first on one side and then on the other, an ovary may be felt and brought out of the opening in the abdominal wall. Its connections

with the uterus are then transfixed and tied in two parts with a silk ligature, a third ligature being placed round the whole mass behind the other two. The ends of all are to be cut close to the knots, after which the ovary is stripped off, not too near the point of ligature, and the stump is allowed to slip back into the abdomen. It is not yet agreed amongst surgeons whether the fimbriæ and part of the Fallopian tube had better be removed with the ovary or not. If not quite healthy, they certainly should be so. After the second ovary has been similarly removed, the wound is closed as usual after ovariectomy, but requires the sutures to be placed closer to one another than after the latter operation, in order to obviate the greater tendency to prolapse of the omentum and intestines in those cases where the abdominal wall is healthy and has not been relaxed by the removal of a large tumour from within. The dressing and after-treatment should be precisely the same as after ordinary ovariectomy.

PORRO'S OPERATION, OR CÆSARIAN SECTION COMBINED WITH
REMOVAL OF THE UTERUS.

This operation was first performed as a premeditated procedure in 1876 by Porro, and both mother and child were saved. Since then it has been repeated more than 150 times, and with considerable success. The first case successful as regards both mother and child operated on in this country was that of Dr. Godson, in November 1882, and is thus described by Sir S. Wells.

‘Precisely similar arrangements as for ovariectomy were made. An incision from just below the umbilicus to about two inches above the symphysis exposed the uterus. As low down as possible on its anterior wall, or at about the junction of the lower with the middle third, a short incision

was made, just large enough to admit the finger. A gush of venous blood occurred and the membranes were seen. Dr. Godson inserted the tips of both forefingers and tore the uterus open transversely. The membranes were not ruptured by this manipulation. He then thrust his hand through them, extracted the child, tied the cord in two places and severed it. While he was thus engaged, Mr. K. Thornton, who was assisting him, grasped the neck of the uterus with his left hand and applied the wire of Koeberle's serre-nœud with the right, so as to include both ovaries and tubes as well as the uterus at about the level of the internal os. The wire was then tightened and the uterus with the contained placenta was cut away. Solid perchloride of iron was then applied to the stump. Two guarded pins were then passed through the latter above the wires, and a strong silk ligature was carried round beneath them for greater security. The abdominal wall was then closely united around the pedicle as in ovariectomy. The serre-nœud was not released until the thirteenth day. The patient regained perfect health, her abdomen showing hardly any scar, and no depression where the pedicle was secured.

‘ In performing Porro's operation it is not advisable to make an incision sufficiently long to admit of the uterus being turned out entire before opening it. The rent in the uterine wall should be out of the way of the placenta, and Dr. Godson's mode of dealing with the uterus by tearing it transversely just above the internal os is probably the best. The child should be extracted in the readiest way possible, and without any attempt to separate the placenta. The operator should firmly grasp the neck of the uterus with his left hand, and carry an elastic ligature round it with his right. Perhaps this might in some cases be done before the uterus is opened, as soon as any bleeding in the

abdominal wound has been stopped, but without making any strong constriction until after the child has been removed. The tying of the cord and any necessary attentions to the child should be entrusted to an assistant. The elastic ligature may then be fastened by a knot, or by being passed through a leaden ring which is squeezed upon it, or by being compressed with a catch-forceps. The uterus, with its placenta undisturbed, and the parts enclosed in the ligature, may then be cut away. Of course all the precautions described in the chapter on ovariectomy and uterine tumours for preventing the escape and exposure of the intestines, and for holding the edges of the opening in the abdominal wall together during the manipulation of the uterus and pedicle, should be observed. The uterus having been cut away and a few sutures passed through the edges of the upper part of the wound in the abdominal wall (supposing the extraperitoneal treatment of the stump to be preferred), two strong guarded pins are made to transfix the stump from side to side about half an inch above the elastic ligature. If the operator is unwilling to trust to the latter alone, the wire of Koeberle's *serre-nœud* may be placed immediately behind the pins, and as it is tightened the indiarubber can be removed or left as an additional precaution. As a rule the elastic ligature is sufficient. In either case perchloride of iron should be applied freely to the stump as soon as the peritoneal edges of the opening in the abdominal wall have been sewn closely round its serous coat. One suture below the latter, and the lowest of those above it, should pass through not only both edges of the abdominal wound but also the peritoneum of the pedicle. When these sutures are tightened it is almost impossible for any product of the decomposition of the stump or any liquefied perchloride of iron to run down into the abdominal cavity.

The skin and lower part of the wound are now carefully packed with iodoform wool, and the dressings applied as in ovariectomy. Careful daily dressings, changing the wool, tightening the wire, if one be used, removing portions of dead tissue, and the fresh application of perchloride of iron and iodoform are required until the pedicle separates.'

SHORTENING OF THE ROUND LIGAMENT FOR PROLAPSE OF THE UTERUS.

This operation has been of late performed on many occasions with considerable success. It is only resorted to in severe cases of prolapse, where other means have failed to keep the uterus in place.

Instruments.—A scalpel; dissecting forceps; blunt-hooks; needles; carbolised silk sutures; a uterine sound.

Position of Patient.—Supine, with the thighs apart and slightly flexed.

Position of Operator and Assistants.—The surgeon stands on the left side of the patient, with one assistant opposite to him, and another at the right knee of the patient to replace the uterus.

Landmarks for Incision and Operation.—The spine of the pubis is the only guide needed. An incision two inches long, having the spine of the pubis just below its centre, is made over the external abdominal ring in the direction of the fibres of the external oblique muscle. This should at once divide the skin and fat and expose the ring. The edges of the wound being held apart with blunt-hooks, a little dissection will now define the round ligament, which is to be caught up with a blunt-hook and drawn forwards. The finger is then inserted under it and it is drawn well out of the ring, the peritoneum being peeled off it, and pushed

back into the abdomen with the other hand. While this is being done on both sides of the body the second assistant reduces the prolapsed uterus, and retains it in place by means of a sound introduced into its cavity, and with the finger in the vagina. When both round ligaments have been cleared and drawn out sufficiently to fix the uterus behind the symphysis pubis, they are secured by a few stitches to the pillars of the external ring. The redundant loop of ligament is then folded up external to the latter, and laid in the floor of the wound, which is either allowed to granulate up from the bottom, or is at once closed. In the first case the stitches may be of silver wire, in the latter of carbolised silk or catgut. An antiseptic dressing completes the procedure, which is very simple.

SPLENECTOMY, OR EXCISION OF THE SPLEEN.

This operation, which had been frequently performed with perfect success for the removal of the organ when wounded or prolapsed through the abdominal wall, has been of late years advocated for disease of the spleen, and has been practised for the latter, but with results far less satisfactory. The whole question is well discussed in articles by Franzolini, Zesas, and Cr  d  , in Langenbeck's 'Archiv.' vol. xxviii. 1883, and by Sir S. Wells in his work on 'Abdominal Tumours,' 1885.

Cr  d   has collected thirty cases, including one successfully operated on by himself, in which the spleen has been removed for diseased conditions of various kinds. Of these splenectomies sixteen were for leuk  mia, and were all fatal. Among the remaining fourteen there were nine recoveries. The latter are made up as follows. One operation was for abscess round the organ, which had to be taken away as damaged; four were for simple hyper-

trophy; two were for 'wandering spleen'; two for cystic disease of the organ. In those cases which were watched for a long time after operation, the recovery of general health appeared to be complete, after a longer or shorter period of extreme anæmia.

Thus observations of cases operated on prove clearly that patients bear the loss of an enlarged spleen very well, and may live many years afterwards without showing any signs of serious constitutional derangement. But, on the other hand, it is equally clear that the general condition usually associated with great splenic enlargement strongly contra-indicates every operation. If anything is to be done for splenic disease it must be undertaken early, before the constitution has suffered, or not at all.

The operation itself in suitable cases offers no special difficulties. Every preliminary precaution is observed as for ovariectomy (*q.v.* p. 256). The incision in the abdominal wall may be made in the middle line, but is better placed at the outer border of the left rectus muscle. It should commence just below the ribs, and will vary in length according to the size of the organ. All bleeding must be stopped before the peritoneum is divided. The enlarged spleen will then present in the wound, but it may be overlaid by omentum or intestines. If adherent to other viscera to any considerable extent it is best to desist from further interference, but slight adhesion is not a barrier to the removal of the organ. This is effected by drawing the spleen through the wound with great care so as to pull as little as possible on the splenic vein, then transfixing and tying the pedicle with antiseptic silk before dividing it. In some cases it may be well to seize the pedicle in one or more catch-forceps, and then cut away the tumour before tying the vessels. This has the advantage of allowing the latter to be better seen and more accurately tied than when

covered and obscured by the tumour. In any case the vessels require the greatest care, and the silk used should be of the strongest and purest. The stump is returned into the abdomen after the ligatures have been cut short and it is certain that all bleeding has been controlled. Then the peritoneum is cleansed in the usual way and the incision is stitched and dressed as in ovariectomy.

The chief dangers here appear to be bleeding from adhesions, tearing of the splenic vein during extraction and division of some of the branches of the artery without having secured them. It is recommended that the splenic artery should be tied before its division. Special care is also necessary to avoid wounding the pancreas.

CHOLECYSTOTOMY.

In certain cases in which the cystic duct becomes obstructed by a gall-stone or from other causes, the gall-bladder may become greatly over-distended and the general health suffer; moreover, a patient thus affected runs considerable risk of rupture of the sac into the abdominal cavity, an accident almost invariably fatal. It is under such circumstances that the above operation is performed, with the object of relieving the over-distended gall-bladder without risk to the peritoneum. It has been done successfully a great many times within the last few years, but it would be impossible at present to give any reliable statistics as to the risks incidental to the operation.

Instruments, Position of Patient and Operator.—Practically as for ovariectomy (*q.v.* p. 256).

Landmarks for Incision and Operation.—The best guide to the position of the gall-bladder is the outer border of the right rectus muscle as it approaches the end of the cartilage of the tenth rib. An incision from two to three

inches long from this point directly downwards is that most usually resorted to to expose the viscus. This incision should be rapidly carried down to the peritoneum, but before the latter is opened every trace of bleeding must be arrested. When this has been done the peritoneum is divided to nearly the full extent of the external opening, and is drawn forward over the edges of the latter and fixed to the skin by a few points of suture. If the gall-bladder is now found greatly distended and thickened, it may be fixed by a row of stitches to the peritoneum, the stitches only passing through its serous and areolar coats, but leaving the mucous coat intact for the present. The whole area of operation is then thoroughly cleansed, dusted with iodoform, and covered with an antiseptic dressing which should be left undisturbed for a couple of days if possible, until adhesion of the peritoneal surfaces has become pretty firm. It can then be aspirated or opened without much risk of the bile becoming extravasated into the peritoneal cavity. But if it be decided not to delay the thorough opening up of the gall-bladder, it is aspirated before being stitched to the peritoneal surface of the abdomen, and as it collapses is seized with catch-forceps above and below the needle and drawn well into the wound. Here it is now carefully stitched all round to the peritoneum reflected over the edges of the abdominal wound, the sutures standing about a quarter of an inch apart. When quite secure in every part, especially at the angles of the wound, the gall-bladder is opened with scissors and explored as to the cause of obstruction of the cystic duct. If this is due to calculi the latter may often be removed by manipulation, either through the abdominal wall or of the sac itself; or they may be broken up with forceps and extracted, but this requires very great caution. When quite empty, the gall-bladder is covered with a

loose gauze dressing, having been first dusted over with iodoform. This dressing will require to be very frequently changed for the first few days on account of the copious discharge of bile, but the latter may be expected to diminish before long, and if the cystic duct be pervious the artificial opening will gradually shrink up and possibly close completely. If it does not do so spontaneously it may be closed by a plastic operation, or the operation of cholecystectomy may be performed.

CHOLECYSTECTOMY.

This operation is performed in every way as the last, except that when the gall-bladder has been separated from the parts around and emptied, it is wiped dry and cleansed of all traces of bile, and then cut away as close to the cystic duct as possible. The serous surfaces of the cut edges are then turned inwards one against the other and firmly sutured together with fine silk. The wound in the parietes is then closed after thorough cleansing of the neighbourhood of the gall-bladder.

The danger of leakage of bile into the peritoneal cavity is considerable in these cases, and the operation is not in much favour.

CHAPTER XII.

OPERATIONS ON THE ALIMENTARY TRACT.

PRELIMINARY REMARKS.

IN all operations upon the abdominal viscera the special liability to shock must be borne in mind and guarded against in every way possible. One of the chief factors in the production of this condition is chill, first of the surface of the body, next of the peritoneum. To guard against this all parts of the body except the front of the abdomen must be warmly clothed. Perhaps the best way of doing this is to wrap the limbs, pelvis, and chest in cotton wadding secured with roller bandages. For children I know of no better method. Then over the whole abdomen is spread an apron either of macintosh or oil-silk, with a hole in its centre sufficiently large to give access to the incision. The edges of this hole may be secured to the skin by adhesive plaster. With this apron the front of the abdomen, the sides, and the back are protected from wetting and currents of cold air throughout the operation, and if the spray be used it is of special value. To protect the peritoneum from chill it must be exposed as little and for as short a time as possible. All fluids brought into contact with it must be kept at a little above blood heat, and all sponges, compresses, &c., must be wrung out of hot antiseptic solutions before use.

But besides protection against cold, much may be done to save the patient from shock by gentle manipulation of the abdominal viscera. Whenever these require to be handled it should be done with the utmost delicacy and care, all dragging upon the intestines and other movable parts being particularly avoided.

Lastly, every trace of fluid must be removed from the cavity of the abdomen before it is closed. This is done first by pressing on the sides and so squeezing out the bulk of the fluid through the incision, and then by careful wiping with small sponges thrust down into the flank on either side and into the pelvis. The tendency to gravitation of fluid into these three situations must always be borne in mind. And when all fluid has been thus removed, a flat sponge should be left lying upon the intestines until the sutures have been inserted from the top to the bottom of the incision, and should only be removed at the moment that these are about to be drawn upon and knotted. Every possible source of delay should be foreseen and provided against as far as possible.

SUTURE OF WOUNDS OF THE ALIMENTARY TRACT.

Various methods have been devised from time to time for suturing wounds of the different parts of the alimentary tract, but all have had the same object in view, namely, the close and accurate adaptation of the edges by their *serous* surfaces. The importance of mastering the principles and details of these various methods cannot be overstated at the present day, in view of the increasing frequency of operations upon the contents of the abdominal cavity. I have therefore illustrated the best of these methods fully in the order of their development (figs. 39 to 45). But it should not be forgotten that no amount of study of diagrams

will suffice, to one who may be called on to operate upon the stomach or intestines, to render him proficient in suturing the bowel without practice upon the dead body or on animals.

In the figures below are represented the three layers of the stomach or intestine, the serous, muscular, and mucous. The direction in which the threads should traverse these is represented, but the effect of drawing the threads tight is not given in every case, being quite obvious. In Gussenbauer's method, for instance, the cut edges would be folded in one against the other if the threads were tightly drawn on.

The material now almost universally employed for suture of the intestine is the finest carbolised silk (*vide* p. 5), introduced by means of fine ordinary *round* sewing needles, which do not cut the coats of the intestine, but form a round hole, which closes on the thread without bleeding.

The earliest method definitely described on the sound principle of bringing the serous surfaces of the wounded intestine into close apposition was that of Lembert. He also aimed at passing the thread through serosa and muscularis alone, and not through the mucous layer, so that the contents of the intestine should not enter the track of the thread, and so risk contamination of the peritoneum. In the case of the stomach this has specially to be avoided, in view of the digesting properties of its secretions and their effects upon all but mucous surfaces. In Lembert's hands the needle was passed first through the serous and muscular coverings of the bowel at a little distance from the edge of the wound, and back again through the latter and out on the serous surface again; it was then entered at a corresponding point on the serous surface of the opposite edge of the wound, and carried in the same way through muscular and serous layers again as it emerged at

a point opposite to that at which it first entered (fig. 39) on the opposite side of the wound. The two ends being now drawn together and knotted, the effect was to double in the two opposed margins, and bring them flat together by their serous surfaces (fig. 40), the knot lying upon the junction of the latter.

This method possessed great advantages, but had the

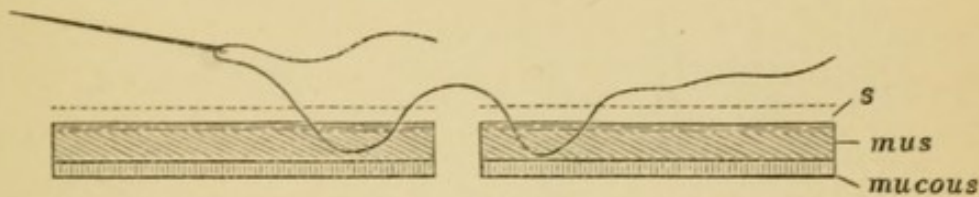


FIG. 39.—LEMBERT'S SUTURE (I.)

Two edges of intestinal wound about to be drawn together. *s*, serous; *mus*, muscular; *mucous*, mucous coats of bowel. The thread dips through the two outer layers only.

defect that the *edges* of the cut were not in perfect contact, and were exposed to the solvent and contaminating influences of the secretions of the viscus. It was therefore modified by Gussenbauer in such a way as to remove these objections while preserving its good points. He entered his

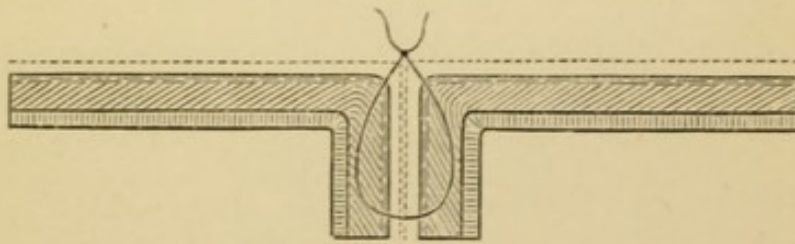


FIG. 40.—LEMBERT'S SUTURE (II.)

Threads drawn close, adapting the serous surfaces to one another.

needle on the serous aspect as before, at a little distance from the cut edge, and brought it out again after traversing the serosa and muscularis; he then dipped it a second time into the serous coat and passed it through the muscularis and out on the cut edge of the wound, between muscularis and mucosa; it was then entered at a corre-

sponding point of the opposite cut edge, and carried back in the same way through the various coats in a reversed direction.

When this thread was now drawn upon, it produced the effect of Lembert's suture, with the addition that the edges of the wounded bowel were brought together by the cut surfaces of their muscularis and mucosa besides (fig. 41).

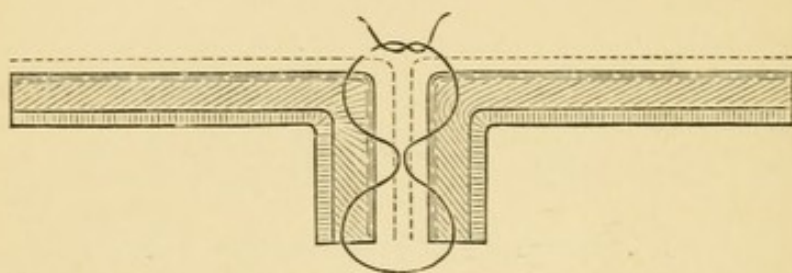


FIG. 41.—GUSSENBAUER'S SUTURE.

Threads drawn together for tying, adapting the serous surfaces to one another, and tending to bring the cut edges together when tightened.

This method, being somewhat cumbrous and difficult to carry out evenly, was further modified by Czerny, who divided it into two separate acts (fig. 42). He first brought the cut edges of the serous and muscular surfaces together

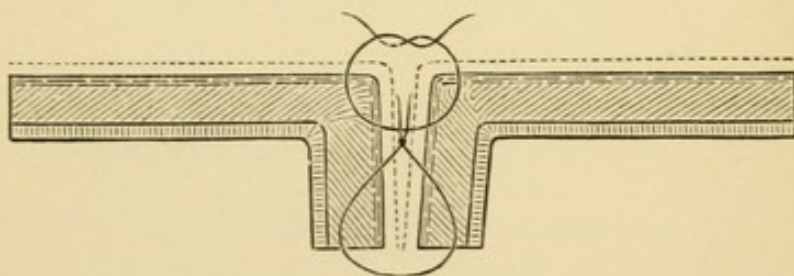


FIG. 42.—CZERNY'S SUTURE.

Two-stage suture. The first row of stitches is tied, the second is in position.

by one row of stitches, and then united the serous alone by a second and separate row further out. His first set passed through the serosa and muscularis 2 or 3mm. from the cut edge, then out on the surface of the latter between muscularis and mucosa, then entered the opposite cut edge and passed out on the serosa again in the reversed direc-

tion. This thread drew both cut edges and peritoneal surfaces together, and was knotted. The second row was placed a little further from the edge of the wound, and followed Lembert's method: each stitch was placed opposite an interval between two of the first row. When drawn tight and knotted externally, the second row reinforced the first, and brought a considerable area of the serous surfaces together (fig. 42).

Finally, in order to get over the difficulty of applying this double row of stitches on the posterior aspect of the viscus, Woelfler has so far modified Czerny's method as to enter his needle for the first row from within the bowel, between the muscular and mucous coat on the cut surface, and tie the knots along the opposed edges, including, however, as in Czerny's method, only the two outer layers of

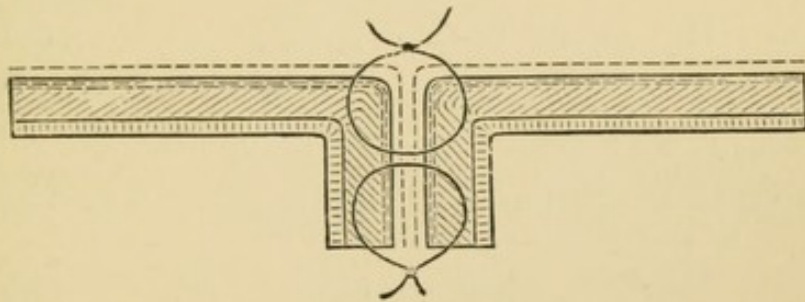


FIG. 43.—WOELFLER'S SUTURE.

Two-stage suture, like Czerny's, except that the first row of stitches is knotted on the intestinal aspect of the bowel wall.

each edge (fig. 43). The second row is applied in the same way as Czerny's second row (fig. 42). This modification has been found very serviceable for securing the mesenteric aspect of the cut edges of the bowel, and especially in excision of the pylorus (*q. v.* p. 285).

Another method has lately been advocated by Mr. C. S. Bishop, of Manchester, which offers some advantages, though perhaps a little complicated in execution. He brings the two cut edges together by their serous surfaces

with forceps, commencing at the mesenteric aspect of the bowel, and then passes a double-threaded needle through both, from mucous coat to mucous coat, from right to left, and then back again in the reverse direction, with a little interval between from left to right (fig. 44). One of the

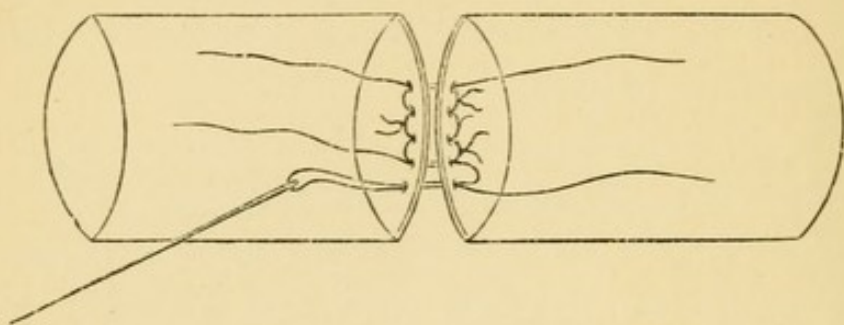


FIG. 44.—BISHOP'S SUTURE.

Threads introduced from mucous to mucous surface, knotted alternately on one side and the other, including the whole thickness of the walls of the bowel.

loops on the left is cut, and the ends lie loose and long for the present; the other is drawn tight, and tied with one of the first ends on the right. Then the needle is passed again through both edges in the same way from right to left, and one of its threads is again cut. The end, which

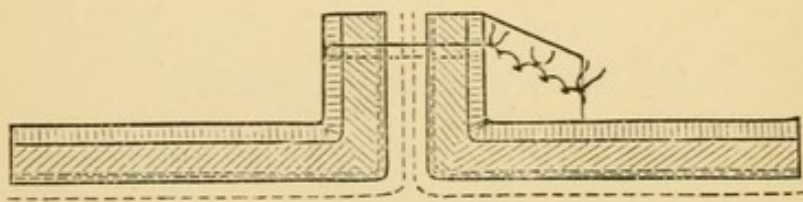


FIG. 45.—BISHOP'S SUTURE.

Threads introduced from mucous to mucous surface of the approximated edges of the bowel, and knotted alternately on one side and the other.

forms a loop on the right, is now drawn tight and knotted with the thread left free on the left after the first stitch, and so on until the whole circumference of the bowel is sutured (fig. 45).

PYLORECTOMY.

This operation, performed for the first time by Billroth, and moreover with success, on January 29, 1881, has since then been frequently repeated both by this surgeon and others in Germany. In this country only a few cases in which the operation has been done are on record, and so far as I know all have had an immediately fatal termination. We must therefore look abroad for any statistics available for conclusions as to the danger of the operation and the duration of life after its successful completion. Probably a better estimate on these points may be made from the experience in Billroth's Klinik alone, where the operations were all done under the same conditions and by one or two surgeons, than from lists of cases collected here and there from the medical periodicals.

Billroth and his assistants¹ have, between January 1881 and March 1885, performed pylorotomy 18 times, with 10 deaths and 8 recoveries. Of these 18 operations, 15 were for cancer of the pylorus, with 7 deaths; 3 for inflammatory stenosis of the same, with 2 deaths—one of these latter was a partial resection of the pyloric ring. In one of the cancer cases gastro-enterostomy had been done as a preliminary to pylorotomy. Of the 7 cancerous cases which survived the operation, the first lived four months and then died of recurrence; the second, a case of scirrhus, was alive, without any signs of local recurrence, four years and three months later, but had suspicious nodules about the pelvis; the third died of the disease ten months after operation; the fourth was alive in July 1885, two years and a month after operation; the fifth succumbed a year

¹ Woelfler, *Ueber die Resectionen des carcin. Pylorus*, 1881, and von Hacker, *Magenoperationen*, 1886.

after the first operation, gastro-enterostomy having been performed in the mean time to give relief;¹ the sixth died 8½ months after pylorotomy, the seventh four months after. The case in which excision was done for stenosis of the pylorus due to ulcer was completely cured.

With the figures in view it may be said that the operation is still on its trial, at all events as regards cancerous cases; but there can be little doubt that with careful selection of patients and improvement in methods of operation, the results might be greatly improved.

Instruments.—A scalpel and dissecting forceps; a dozen catch-forceps; one vulsellum forceps; one large and one small pair of scissors; four broad spatulæ; blunt-hooks; three dozen of small, round, straight glover's needles, threaded with the finest twist silk thoroughly carbolised (*vide* p. 5); two sets of sponges, also perfectly carbolised, one set to be reserved for wiping out the mucous surfaces of the viscera, the other for the various wounds, both to be kept quite separate; small soft napkins, prepared by boiling and steeping in warm five per cent. carbolic acid solution, to be used for slipping under and over the pylorus as guards when the latter is drawn out of the abdomen; stout silk ligatures for the abdominal wall, with a needle at both ends; antiseptic wool dressings and bandages to encircle the body. The preliminary remarks at the commencement of this chapter apply with special force to this operation.

Position of Patient.—Supine, with limbs extended.

Position of Operator.—Standing on the right side of the patient.

Position of Assistants.—One on the left side of the patient, the other on the right, to the left of the operator.

Landmarks for Incision and Operation.—In an ordinary case where the pylorus is not displaced, an incision four

¹ Von Hacker, *Archiv f. klin. Chir.*, Bd. xxxii. p. 616.

and a half inches long is made obliquely downwards and from left to right between the right costal margin and the umbilicus, having its upper third to the left of the middle line. The middle line above the umbilicus may also be chosen, or an oblique incision on the left side; the position of the tumour is in all cases the best guide, for the pylorus has been found in almost every part of the abdomen between the border of the ribs and the pubis. The abdominal wound is rapidly carried down to the peritoneum, but before the latter is reached all bleeding must be controlled. When this is effected the serous lining is opened and the relations and condition of the growth are fully explored. If it be regarded as sufficiently limited to be removed, it is drawn out of the abdominal incision as far as possible, and is grasped in one of the warm carbolised napkins. This is the first stage of the operation. The next consists in freeing the pylorus and growth, first from the great omentum below, and then from the lesser above. This is done by taking up portions of the omental tissues with forceps or aneurism-needles, tying them with double ligatures of fine carbolised silk, and cutting between the latter. This is the most tedious part of the operation. It has to be done with the greatest caution so as to secure perfect bloodlessness, and, on the other hand, to avoid dividing more of the omenta than is absolutely necessary for the thorough removal of the growth and any suspicious glands (*vide* Memoranda). When completed, a carbolised napkin is placed beneath the isolated part of the pylorus, thus rendering the rest of the procedure practically extra-peritoneal. In some cases a flat, soft sponge is, perhaps, more suitable for this purpose. The third stage of the operation commences by the division of the stomach at about three-quarters of an inch from the border of the growth, at all events in sound tissue. This is done by

one or two bold strokes of a large sharp pair of scissors, cutting obliquely from above and from left to right. This cut only divides about two-thirds of the depth of the organ and leaves a wide-gaping opening in the lesser curvature (fig. 46). The latter is now closed by a double row of stitches according to Czerny's method (*vide* fig. 42, p. 282). These stitches are placed about a tenth or an eighth of an inch apart, and when they are all in place the end of the stomach is reduced to about the size of the lumen of the duodenum. The ends of these stitches are not cut short

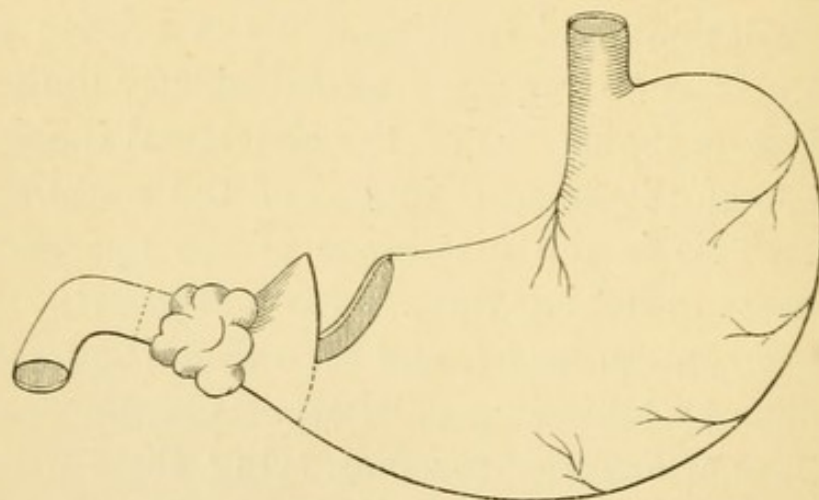


FIG. 46.—PYLORECTOMY (First Stage).

Incision in the smaller curvature of the stomach, two-thirds through the depth of the organ.

at once, but are massed together and secured with catch-forceps, and thus held serve to steady the end of the stomach during and after the division of its remaining third (fig. 46). This division now takes place with an even stroke of the scissors in the same line as the first incision, the growth meanwhile being grasped in the vulsellum forceps. The stomach being in this way detached from the diseased pylorus, its inner surface should be carefully cleansed with the carbolised sponges set apart for this purpose, each being thrown aside as used. Next the duodenum is half severed from the diseased mass by an

oblique incision with the scissors from above downwards, and from left to right, corresponding to that in the

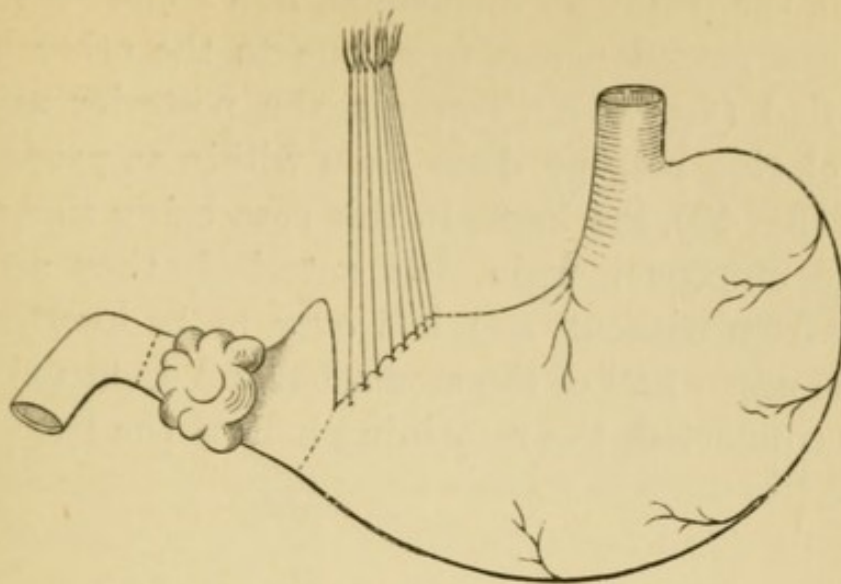


FIG. 47.—PYLORECTOMY (Second Stage).

Closure of first incision reducing the future pyloric opening of the stomach, the sutures not yet cut short.

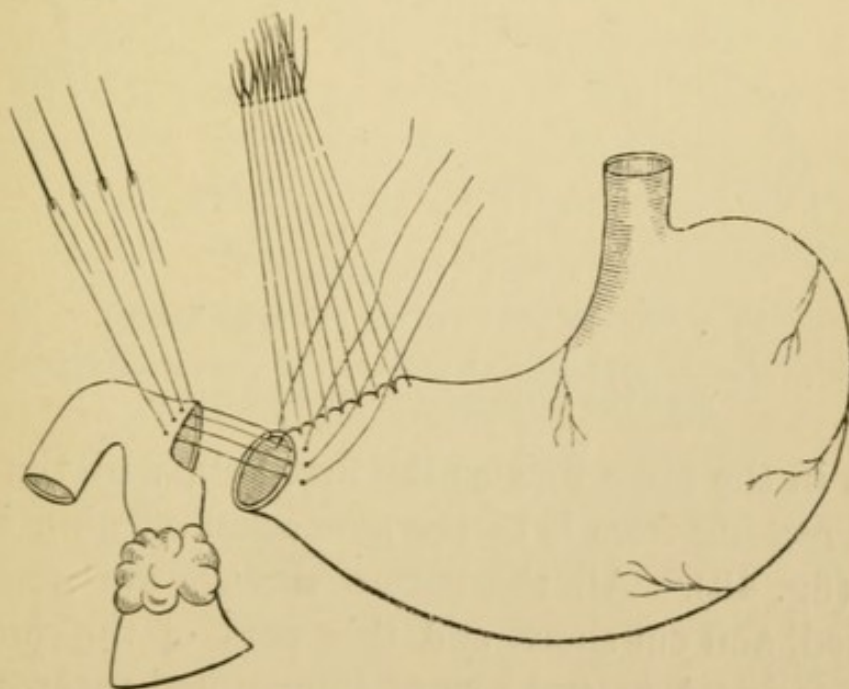


FIG. 48.—PYLORECTOMY (Third Stage).

Complete division of stomach, and partial division of duodenum. Suture of the upper half of the stomachal opening to the upper segment of the duodenum.

stomach (fig. 48). The lower half of its circumference is left for the present undivided and serves to steady the

bowel, being held by means of the growth. Then the reduced orifice of the stomach is adapted at its upper border to that of the fresh-cut duodenum, and a close-set row of stitches are passed across from one to the other but are not yet tied (fig. 48). Towards the posterior aspect of the bowel this may be done from within as proposed by Woelfler (fig. 43), the knots in this case being tied at once along the mucous margin, but anteriorly they are made as usual from without and left over to be knotted later. When the upper half of the stomachal and duodenal orifices are thus connected, the remaining half of the bowel is cut

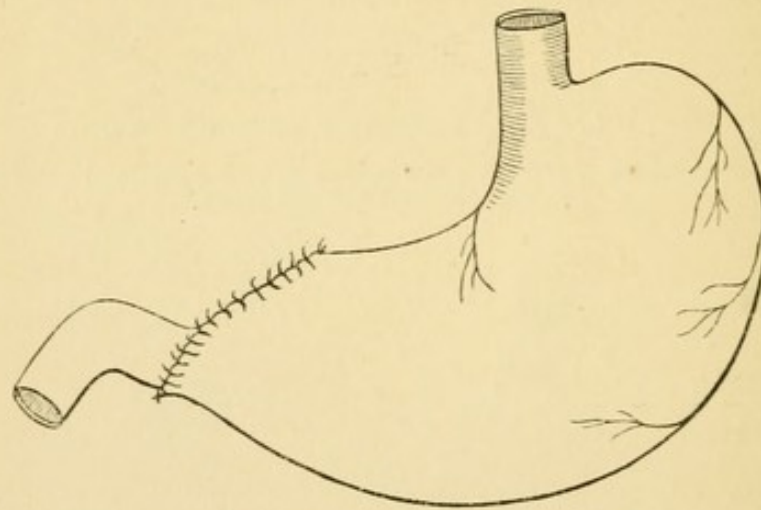


FIG. 49.—PYLORECTOMY (Fourth Stage).

Division of duodenum completed, and suture of whole circumference of duodenum to the reduced stomachal orifice.

through in the same line as the first half, and the row of stitches passing from it to the stomachal opening is completed (fig. 49). All the suture threads are now drawn close, tied, and cut short, and this part of the procedure is at an end. A second row of interrupted sutures placed opposite the intervals between those of the first row and at a little distance from the latter are necessary throughout the whole wound, and are in fact included in Czerny's method of suture. When they are in place the line of union ought to be watertight if accurately adjusted (fig.

49). The whole field of operation is next carefully cleansed and sponged, and the edges of the omenta are united to the edges of the reduced stomach by a few points of suture. Then, after a final cleansing, the viscus is replaced in the abdomen and adjusted so as to give the new opening in the stomach the best direction. The 'toilet of the peritoneum' is now looked to, and finally the abdominal walls are brought together in the usual way with deep and superficial sutures. A dressing of antiseptic wool secured by firm bandaging completes the operation, which is usually a long and tedious one, often only completed in two to three hours. It must be remembered, however, that to be successful, every minutest detail must receive the closest attention, and hurried work is likely to lead to a fatal result, while on the other hand all unnecessary delay increases the danger of shock.

Memoranda.—The preliminary preparation of the patient for this operation has such an important bearing upon its result that it may be described as part of the procedure. In the first place the bowels must be thoroughly opened for days beforehand by suitable medicines and by high-reaching enemata. Then the stomach is to be washed out repeatedly for several days, and for the last time about an hour or so before the operation. This is a most disagreeable matter for the patient, but is indispensable, and is borne well after a little practice. It is effected by passing an ordinary indiarubber tube of about half an inch inside diameter down into the stomach, having the other end attached to a glass funnel. Through this about a quart of warm water is slowly poured into the organ from a little height. It is then allowed to return by depressing the funnel, and this manœuvre is repeated until the fluid runs away quite clear. Some operators have thought it desirable to finally wash out the organ with a solution of

salicylic acid, but it is a question whether this is necessary. The stomach should be left empty for the operation.

The washing of the abdominal wall with warm water and soap, and then with a five per cent. carbolic acid solution, should also be most carefully attended to.

The diet best borne by the stomach before operation is also a point to be noted, as it will guide us in the after-treatment of the case.

As the immediate union of the serous surfaces of the divided viscera depends upon the non-interference with their vascular and nervous supply, it is necessary to be most cautious, in dividing the omenta from the stomach, not to disturb their attachments laterally more than is absolutely necessary. Nerves and arteries must be divided of course, but the separation and ligation of parts should be done as gently as possible, otherwise there is a great risk of sloughing of the edges of the duodenal and gastric wounds, or of the transverse colon. The pyloric, gastro-duodenal, and gastro-epiploica dextra arteries are almost certainly divided, but there is still an abundant vascular supply if the omenta are spared as much as possible.

GASTROENTEROSTOMY.

The formation of a permanent opening between the greater curvature of the stomach and the jejunum to replace a diseased pylorus.

In bad cases of cancer of the stomach and pylorus, unsuited on account of the position or extent of the disease for pylorotomy, this operation has been frequently done with considerable advantage since first designed and performed with success by Woelfler in 1881. It seems not improbable that it will for a time take the place of excision of the pylorus until the necessity for the very earliest performance of the latter is fully recognised. For

bad stenosis of the pylorus due to simple ulceration, it seems to have at least an equal right to consideration as pylorotomy, in view of the greater ease of its performance and the smaller risks it involves. For milder cases of stenosis, however, digital dilatation of the pylorus is to be always preferred to either of these operations.

Gastroenterostomy has been performed abroad in several very desperate cases of cancer of the pylorus, in which the idea of excision had to be abandoned, and this has materially influenced the statistics of the operation. Thus, out of sixteen gastroenterostomies for malignant disease, ten succumbed from the immediate effects of the procedure, while of four for non-malignant conditions, only one died.¹ Of eight cases of this operation in Billroth's Klinik, five died and three were relieved.² The longest survival after gastroenterostomy for cancer up to the present was in a case operated on by the author, where the patient lived one year and one week.³

For gastroenterostomy, the **Preliminary Treatment, Instruments, Position of Operator, &c.**, and **Landmarks** for the first incision down to the stomach, are the same as for Pylorotomy (*q. v.* p. 285).

When the stomach is reached, and the growth (fig. 50, *a*) has been exposed, its anterior surface is brought out of the abdominal wound, and is so held by an assistant. The nearest loop of small intestine to its cardiac end is then sought for by pushing the omentum aside, and is also drawn out a little. This loop is emptied of its contents by pressure of the fingers, and is kept empty by two india-rubber bands passed through the mesentery and round the bowel at either side, and tied loosely or held close to the bowel in catch-forceps. An incision an inch and a half long

¹ *Centralblatt*, 1885, No. 31.

² Von Hacker, *loc. cit.*

³ *Brit. Med. Journ.*, Feb. 17, 1886; *ibid.* April 9, 1887.

is now made in the long axis of the stomach on its anterior surface, about two inches from the greater curvature; then a corresponding cut is made along the free border of the loop of intestine. When the bleeding has been arrested, the edges are carefully cleansed with sponges specially prepared and kept apart for the purpose. The lower edge of the stomachal opening is now united to the corresponding margin of the intestinal incision by a row of stitches

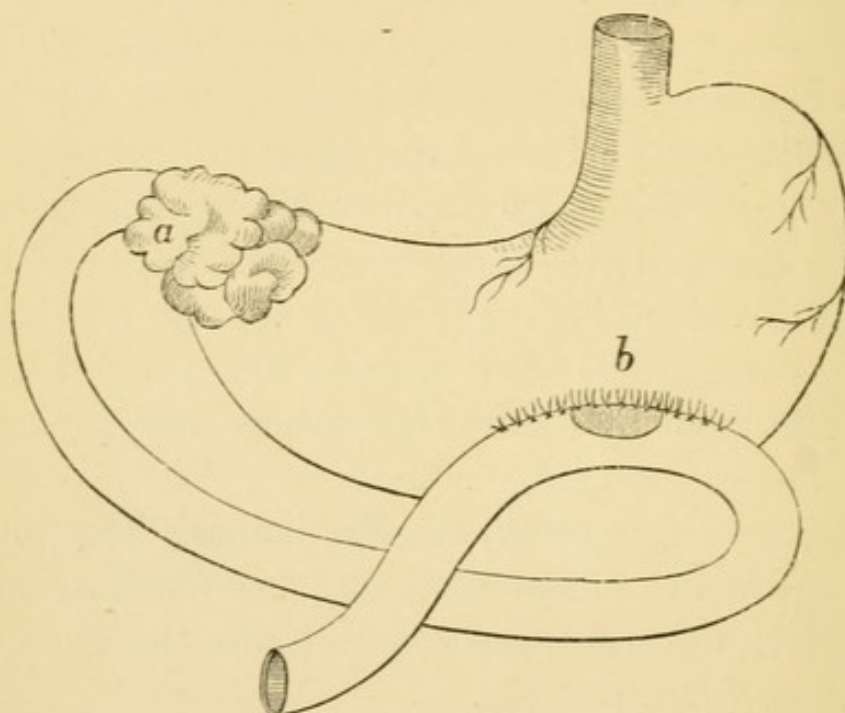


FIG. 50.—GASTROENTEROSTOMY.

a, Growth closing the pylorus; *b*, new opening formed between the jejunum and the stomach; the stitching is carried beyond the opening on either side.

introduced from the cut edges, according to Woelfler's modification of Czerny's suture (*vide* p. 283). The remaining portion of the circumference is then brought together by Czerny's suture, applied in the usual way from without. Finally, the posterior edges receive their second row from without by turning over the intestine. The whole is now united by a double row of stitches, including only the serous and muscular coats. Woelfler and Rydygier recommend that the mucous borders should also first be brought

together by a separate line of stitches, so as to protect the wounded surfaces as far as possible from the action of the gastric juices, but this is not necessary.

Besides the union of the two orifices, it is necessary to stitch the loop of bowel to the stomach wall for some distance on each side of the opening, in order to prevent kinking of the gut at the weakened spot, and consequent obstruction.

When all is secure the field of operation is washed and wiped dry with carbolised sponges, and the parietal wound is closed in the usual way (*vide* p. 264).

Memoranda.—In performing this operation the author has found it desirable to modify the above procedure as follows. When the point for opening the stomach and loop of intestine have been selected as above, both are pinched up together between the left forefinger and thumb in longitudinal folds. With a sharp knife two parallel incisions for an inch and a half are made along the axes of these two folds, each dividing the serous and muscular coats, but not yet opening either intestine or bowel, the mucous membrane being left intact. Still grasping the two viscera as before, a fine, ordinary round sewing needle armed with silk is taken up in the right hand, and, commencing to the left of the incision, the surgeon stitches first about an inch of the unbroken serous and muscular coats of both together by a *continuous* suture, and carries the same along the contiguous cut edges of the serous and muscular coats in the incision, and so for an inch beyond the end of the latter to his right. Both bowel and stomach are now opened by dividing their mucous tunic to the same extent as the two others, and then the anterior edges are united together by a row of Czerny's sutures. These may be reinforced by a second row, after which the bowel is turned over and the first continuous suture is

further strengthened by a second row of interrupted stitches. The advantage of not opening either viscus until the two edges are secured one to the other is obvious, and the operation is much simplified as well as time saved. In the case alluded to in which this operation was performed by the author,¹ the simplicity of this method was proved most satisfactorily.

DIGITAL DILATATION OF THE PYLORUS FOR NON-MALIGNANT STRICTURE.

This operation was first suggested by Richter² of Breslau in June 1881, but was not definitely formulated and practised until Prof. Loreta³ of Bologna undertook his first case in September 1882. This was successful, and was soon followed by several others which equally demonstrated its simplicity and usefulness. It should be clearly understood that it is only employed in cases of non-malignant stricture of the pylorus such as may follow the action of violent corrosives or the contraction of ordinary ulcers which are so frequently seated near that orifice.

The Preliminary Treatment, Instruments, &c., are the same as for pylorotomy (*q. v.* p. 285). But when the stomach is reached the proceeding becomes much simpler than the latter operation. The narrow end of the organ is first drawn out of the aperture in the abdominal wall, and is opened by an incision large enough to admit two fingers at a spot as clear of vessels as possible. Into this opening the right index finger is thrust and is slowly insinuated into the contracted pylorus. When this has been effected by a boring movement, the left index finger is similarly

¹ *Brit. Med. Journ.*, Feb. 13, 1886; Sequel, *ibid.*, April 9, 1887.

² *Deutsche med. Wochenschr.* 1882, p. 381.

³ Winslow, *Amer. Journ. Med. Sci.*, April 1885.

introduced by the side of its fellow and then both are separated by steady traction until the pylorus is dilated to about three inches. The opening in the stomach is then cleansed, and closed by a row of Czerny's sutures of fine carbolised silk, introduced by means of round sewing needles. Then when the 'toilet' of the peritoneum has been completed, the parietal wound is closed with deep and superficial stitches in the usual way (p. 264).

Memoranda.—Out of the first six cases in which this operation was performed, three recovered and were completely cured, one was doing well some days after operation, and two died of collapse within a few hours. The time occupied in the whole procedure ought not to be more than from twenty to fifty minutes. The only case, so far as I am aware, in which this operation has been performed in this country was successful: it is that of Mr. Haggard¹ of Hull.

ENTERECTOMY.

When on account of new-growth, intussusception, or gangrene of the bowel, it is determined to resect a portion of the latter completely, the surgeon has to face an operation requiring as much judgment, patience, and manipulative skill as any in the whole range of our art. He must therefore be prepared beforehand by every means in his power for all the details of the procedure. In the first place he should practise the suture of the bowels on the dead body and familiarise himself with all its difficulties. This should also be practised on the inferior animals if possible. He should pay particular care to the selection of needles and fine sutures, every one of which latter should be tested as to its freedom from flaws and

¹ *Brit. Med. Journ.*, Feb. 19, 1887.

knots. He should be prepared with abundance of absolutely pure sponges of various sizes and shapes, some of which should be set apart to receive any traces of its contents left in the gut when divided, and then be thrown aside not to be used again in this operation. A careful review of such matters will secure greater accuracy of manipulation and save time in operating. This latter is a most important consideration where the mere operation must be very deliberate and where the liability to shock is so great. Three points then have to be kept particularly clearly in view throughout the whole procedure. First an absolute antisepsis; secondly, accuracy in the adaptation of the serous surfaces to one another; thirdly, the saving of time and exposure of the contents of the abdomen as far as possible.

Numerous instances are on record in which considerable portions of the small and large intestine have been resected and the cut ends united successfully.¹ These cases should encourage surgeons to develop the operation in every way, even though the recoveries at present are probably only the exception, for it must never be forgotten that the conditions for which enterectomy is performed are almost inevitably fatal unless the operation be undertaken.

Instruments, &c., as for pylorotomy (*q. v.* p. 285).

Position of Patient.—Supine, the thighs being partly flexed over a pillow.

Position of Operator and Assistant.—The surgeon stands best on the right side of the patient, his assistant on the opposite side.

Landmarks for Incision and Operation.—Wherever possible the bowel should be dealt with through a median incision. But it is probable that for some time to come the operation will be more frequently required for sloughing

¹ Kocher, Julliard, and Author. *Trans. Med. Chir. Soc.*, 1887.

bowel, the result of strangulated hernia, about the groin, than for any other condition. The description here given, then, will have such a case as its basis.

The abdomen, at the seat of the constriction, is first laid open sufficiently freely to enable the bowel to be drawn out far enough to reach perfectly sound tissue on either side of the gangrenous part. And it must be remembered that it is better to sacrifice a little healthy bowel rather than run the risk of approaching the damaged area. The whole loop exposed must then be flushed freely with a warm antiseptic solution, a large perfectly pure sponge having been previously stuffed into the abdominal wound behind the protruded bowel.

The healthy bowel on either side of the spots selected for the resection is emptied by being drawn through the fingers. Then pieces of rubber tubing are pushed through a hole in the mesentery at either side, and are drawn round the bowel with sufficient strain to prevent regurgitation of its contents. Instead of being tied the tubing may be fastened with a Wells's catch-forceps on either side. The points of the bowel which are to be united are now made to approach one another, and this will of course bring the surfaces of the fold of mesentery belonging to the damaged portion into contact. Commencing at the free margin this fold is now cut with scissors towards the healthy portions of intestine, lying in each case close to the rubber clamps. This division of the mesentery should take place at some distance from the diseased tissue, but the line of section should approach gradually to the edge of the healthy bowel at the spot selected for the division of the latter.

As the section proceeds, the free margins of the mesentery must be stitched together from side to side in such a way that the sutures will secure the vessels of the part.

These sutures are left long for the present. When this stitching and cutting has reached the spot where the bowel is to be divided, the true axis of the latter must be made out and the scissors must be applied to it in such a way as to sever it so that its free margin shall be a little shorter on both sides than its mesenteric margin. Before the single snip of the scissors on either side, which is all that is necessary to complete the removal of the damaged loop, is made, a sponge is placed underneath the intestine, and the diseased intestine is caught in catch-forceps close to the line of section, so that none of its contents shall escape. Then a clean cut is made on each side, and the whole mass is removed with the attached forceps. But before division the abdominal wound beneath the loop should be freshly plugged with warm carbolised sponges to protect the peritoneal cavity from any trace of the contents of the bowel which might escape. The whole area of operation is now flushed again with warm antiseptic fluid, especially the ends of the divided bowel, and after this fresh sponges are placed in the abdominal wound.

Nothing now remains to be done but the approximation of the cut ends of the bowel and their union. This latter is begun at the mesenteric attachment of the tube, and is carried on both sides gradually towards the free margin. The suture most in favour is that of Czerny, p. 282, carried out with fine hard twist carbolised silk in round needles. A double row of sutures about an eighth of an inch apart should be carried round the gut, the stitches of the second row being opposite the intervals between those of the first. Both sets of course only include the serous and muscular coats of the viscus. It is necessary to be very careful at the mesenteric side of the bowel to make the serous surfaces secure.

The whole of the sutured area is now examined to see

that it is accurately closed, on which the rubber clamps are released and the contents of the bowel are allowed to flow through the restored lumen. If all is watertight it only remains to wash the parts thoroughly once again, cut the sutures short, and allow the bowel and mesentery to slip into the abdomen. The wound in the parietes is then closed in the usual manner, a drain tube having been placed in its lower angle for a few days. An antiseptic dressing completes the procedure. Iodoform may be dusted freely over the sutured bowel before it is replaced, and also about the wound.

GASTROSTOMY.

The formation of an artificial opening for the stomach on the abdominal wall in cases of obstructed œsophagus.

This procedure was first proposed by a Norwegian surgeon named Egeberg in the year 1841, but was not put in practice until 1849, when Sédillot employed it for the relief of a man suffering from cancerous stricture of the œsophagus, and proposed for it the above name, under which it has ever since been known.

It has now become an established procedure for the relief of patients afflicted with impassable stricture of the œsophagus of one kind or another. It is clear, however, from accumulated experience, that it has too often been postponed so long that the patient's powers have been lowered to a degree contra-indicating any severe surgical operation, and also until the stomach had undergone atrophic changes to an extent sufficient to render it incapable of digesting food introduced by the new artificial mouth. For the future, then, it ought to be our aim to interfere in these cases early, so soon as alimentation through an œsophageal tube becomes impossible, or insufficient to maintain the patient in fair health. As long, however, as a patient

can be fed by a tube, no matter how small, passed down through the stricture, he is much better off than with an artificial opening into the stomach, and gastrostomy should not be done.

Any statistics of this operation must be received with much caution as a basis of action. Those hitherto collected are, however, interesting as showing the diminution in mortality which has followed the introduction of antiseptic measures. From a collection of all the published records of gastrostomy recently made by Zesas,¹ it appears that of the first 31 cases belonging to the period before antiseptic treatment was the rule, only one survived the operation. Out of the remaining 132 cases operated on under the antiseptic régime 29 recovered. Among these 132 cases were 28 in which the operation was done for simple inflammatory or syphilitic contraction of the œsophagus, and of these 12 recovered and were much relieved. These statistics cannot be said to be encouraging, but it must not be forgotten that the conditions for which gastrostomy is performed are hopelessly doomed to a painful death unless we interfere by this operation.

The **Instruments, Position of Patient, of the Operator and his Assistants**, and the general preparations for the operation are the same as for pylorotomy (*q. v.* p. 285).

Landmarks for Incision and Operation.—The costal border on the left side is our best guide. About three-quarters of an inch from, and parallel to this, an oblique incision three inches long is made downwards and from right to left opposite the seventh, eighth, and ninth ribs. When the peritoneum is reached all bleeding is stopped, and then the membrane is opened, partly everted, and stitched to the edge of the skin on both sides. The stomach is now drawn into the opening and a row of stitches

¹ Zesas, *Archiv f. klin. Chir.*, Bd. xxxii., Hft. i. 1885.

round a circular area the size of a halfpenny-piece is passed through the serous and muscular coats and out through the skin.

When these are drawn close and knotted, the serous coat is everywhere brought into contact with the peritoneum of the abdominal wall. Then a second row of stitches placed opposite the intervals between the first is made to include a circular area within the previous set of about the size of a sixpenny-piece. In this case the stomach is brought into close union with the everted peritoneum covering the edges of part of the incision in the abdominal wall. Previous to this the latter has been drawn together somewhat, at one or both ends, to reduce its size. In the first instance it was made long to enable the surgeon to reach the stomach, which is in many cases a matter of much difficulty. The wall of the stomach, being now securely fixed to the reduced opening, should be punctured with a very sharp, medium-sized aspirator needle in the centre of the exposed area. Through this needle a couple of ounces of beef-tea or other nourishing fluid should be at once introduced, on which the instrument is withdrawn. It will now be seen that the puncture does not leak, and this method of feeding the patient may be repeated every few hours. Each time the exposed area of the stomach should be dusted with iodoform and covered with a fresh dressing of antiseptic gauze or wool. At the end of two or three days (feeding by puncture having in the meantime been steadily carried out) the organ now firmly adherent to the abdominal wall is opened by a sharp thrust of a keen-edged pointed knife, care being taken that the mucous membrane be not pushed before the latter without division. The opening thus made should not be larger than a No. 12 catheter, and in it an india-rubber tube with a shield is placed for the regular introduction of food.

Memoranda.—The incision as given above generally exposes the liver, which is in ordinary cases a good guide to the stomach immediately below it. But when this viscus is greatly shrunken, as is often the case, it is extremely difficult to find and bring up to the abdominal opening. This difficulty is best overcome by grasping the colon and drawing it forward and then following up the gastrocolic omentum to the stomach.

DUODENOSTOMY.

The formation of a permanent opening into the duodenum through the abdominal wall in cases of pyloric cancer.

This is an operation which is probably destined to pass out of favour very soon. It is difficult to imagine any condition in which gastroenterostomy would not be preferable; and as the latter operation is not more difficult, it will probably always be chosen for the future as the palliative for pyloric cancer and in preference to duodenostomy.

The operation itself consists in opening the abdomen as for pylorotomy, *q. v.*, and with similar precautions, and having drawn the anterior wall of the duodenum into the wound, stitching it there in the manner just detailed in describing gastrostomy. When adhesion has taken place after a couple of days, the bowel is opened and the patient is fed through the new mouth, either with peptonised fluids or with food chewed by himself.¹

LUMBAR COLOTOMY.

This operation consists in making an opening into the colon in either loin for the formation of an artificial anus which is to be temporary or permanent. The left side is

¹ Winslow, *Amer. Journ. (Med.)*, 1885, April, and G. Bird, *Clin. Soc. Trans.*, 1886.

usually chosen where choice is possible, the obstruction being situated low down in the large intestine, but the steps of the operation whether on the right or left side are practically the same.

The special preparation for this operation includes washing out of the rectum with high-reaching enemata, and distension of the bowel with air from below if it be not already distended with gas and fæces from above.

Instruments.—A scalpel; artery forceps; scissors; copper retractors and blunt-hooks; two large curved needles; four fine curved needles; stout and fine carbolised silk.

Position of the Patient.—Lying on the side opposite to that to be operated on, with a hard pillow or sand-bag under the flank, and the thighs well flexed.

Position of Operator and Assistants.—The operator stands behind the patient with an assistant on either side of him.

Landmarks for Incision and Operation.—A line is drawn in ink from the last rib to the crest of the ilium, midway between the anterior and posterior iliac spines. This gives the position of the colon. An incision is now made midway between the last rib and crest of the ilium, commencing two inches in front of this line and running either directly across it or a little obliquely from below upwards, to terminate two inches behind it (fig. 19, *f*). This first cut should at once divide the skin and fat down to the muscles. Then by successive strokes of the knife as their fibres contract, the edge of the latissimus dorsi, the external and internal oblique muscles, and the tendon of the transversalis or fascia lumborum are in turn quickly severed. Underneath the latter we come upon the transversalis fascia, which is now notched with a knife and then torn open with a director or the fingers. Under this is usually a good deal of fat covering the posterior surface of the colon.

The latter is now seized in the fingers and drawn into the wound. Then one of the large needles armed with thick silk is passed through one edge of the skin-wound, half an inch in front of the line marked on it, then transversely across the nearest part of the bowel, and again out through the skin, this time half an inch behind the same line. Another needle is similarly carried through the other border of the skin-wound and bowel, about an inch lower down the latter. The colon is now drawn towards the operator by means of the two loops passed transversely through it, and is opened by a small incision with knife or scissors, either transversely or in its long axis. The finger is then introduced into the bowel, and the two loops of silk passing across its lumen are caught and drawn out. Each of these being divided, the edges of the opening in the bowel are held by four points of suture and are accurately adjusted and secured to the skin by them. At this time, and before opening the bowel, every care should be taken to prevent access of the fæces to the wound in the soft parts. The edges of the latter are now brought together with a few points of suture reaching deeply through the cut muscles, and a few extra stitches of fine silk are inserted in the edges of the intestinal opening in order to lessen the strain on the first four and also to prevent any entrance of fæces into the deeper parts of the wound. Occasionally a drain-tube is required in the posterior part of the latter, but should be avoided if possible, as it is apt to conduct the fæces to the deeper parts as they pour out of the bowel. The whole field of operation having been dusted with iodoform, is best dressed with a square of lint dipped in carbolic oil having a hole in its centre corresponding to the new anus. Pads of oakum are secured over this.

Memoranda.—Whenever it is possible to postpone the actual opening of the colon for forty-eight hours or longer

it is well to do so, the surgeon simply stitching it by its muscular coat to the skin in the usual way, but without carrying the threads quite into its lumen. The bowel may then be punctured with a sharp medium-sized aspirator-needle, and any liquid fæces or flatus be allowed to escape. A puncture thus made may entirely relieve distension for a time, and may be repeated without any risk of leakage of the contents, as proved by the author in one of his cases. When the edges of the large wound have united and the surface of the colon is firmly adherent to the skin by plastic matter, the risk of opening the bowel and allowing the escape of the acrid fæces it contains is reduced to a minimum. In other respects this mode of procedure does not differ from that just described.

Intrinsically, lumbar colotomy is not a dangerous practice, if great care is taken to keep the field of operation clean. It has fallen to the writer's lot to perform it nine or ten times with only one death, which was not due to the operation, but to a perforation, as it turned out, of the transverse colon, which had taken place some hours before the latter was undertaken. Far larger series of cases show, I believe, equally good results.

INGUINAL COLOTOMY.

Littre's Operation.

This operation has the same end in view as the last, namely, the establishment of an artificial anus in the lower part of the colon. It differs, however, from the latter in that the opening is made in the abdominal wall in front of the anterior superior spinous process of the ilium instead of in the loin. This method undoubtedly possesses the great advantage that the patient is much better able to attend personally to the daily evacuations from the bowel when the latter opens on the front of the abdomen rather

than far back in the flank. It has, however, the disadvantages that the peritoneum is necessarily opened and runs a considerable risk of being contaminated, and also that in many cases the artificial anus would lie in a portion of bowel close to the growth which blocked it, and therefore be apt to be ulcerated and otherwise unsound. But in many cases where the cause of obstruction lies low down in the sigmoid flexure of the colon or the rectum, the formation of an artificial anus in the groin would be a more desirable operation than lumbar colotomy; moreover, with the improvements in antiseptic surgery the peritoneum can be safely interfered with even in the most trying cases.

Instruments as for lumbar colotomy.

Position of Patient.—Supine, with the head and shoulders raised, and the knees bent over a pillow.

Position of Operator and Assistants.—The surgeon stands on the right side of the patient; his assistant on the opposite side.

Landmarks for Incision and Operation.—The anterior superior iliac spine and the centre of Poupart's ligament are the only guides needed. An incision is made, starting an inch to the inner side of the first and terminating an inch above and a little external to the latter. This is rapidly carried by steady strokes of the knife through the skin, fat, superficial fascia, external and internal oblique and transversalis muscles, until the transversalis fascia is reached. The latter is opened on a director and the peritoneum is exposed. Before this is opened, however, all bleeding should be arrested, and the wound should be thoroughly cleansed of clots. Then the peritoneum is cautiously incised for about an inch and a half, and its edges are drawn out over the borders of the incision and stitched to the margin of the skin wound. If the distended bowel now bulges out, a circular row of stitches about an eighth of an inch apart,

but only passing through its serous and muscular coats, is made to unite its walls to the everted parietal peritoneum all round the opening in the latter, special attention being given to the security of the angles. If the patient's general condition admits, and it is safe to wait for a day or so, nothing further now remains to be done but to unite the angles of the wound in the skin and muscles, dust the part well over with iodoform, and apply a dressing of dry antiseptic wool. Then, when firm adhesion has taken place all round between the serous surfaces, an opening is made in the centre of the exposed portion of bowel, and the edges of this opening are further stitched to the sides of the wound. But if the patient's condition demands immediate evacuation of the contents of the colon, it must be opened, the edges of the stitched bowel being protected from fouling, and constantly washed with a strong antiseptic solution and dusted with iodoform. In some cases, where the retained fæces are fluid, they may be allowed to run off through a fine trochar thrust into the centre of the area stitched round to the peritoneum. When the bowel has thus been emptied, the instrument is withdrawn, and the puncture is seen to be closed at once by the soft mucous membrane from within. In this way the peritoneal surfaces can be kept quite clean until adhesion has taken place. The broad surface of contact between the parietal and visceral layers of peritoneum secured by the eversion of the former before the bowel is stitched to it will probably ensure the protection of the cavity of the peritoneum from the fæculent discharge under any circumstances, but if this method of occasional puncture for a few days can be adopted, there will be but little risk of the latter.

If on opening the peritoneal cavity the sigmoid flexure do not present in the wound, being held back by more or less of a mesentery, it is well to pass under it and through

the latter by means of an aneurism-needle a couple of stout silk threads about an inch apart, and by means of these draw the bowel into the wound. When this is done they can be secured through the skin and left in position for several days, until adhesion between the bowel and peritoneum is sound, when they can be withdrawn. Indeed it is possible that the use of these steadying stitches might be an advantage in all cases of Littré's operation.

Memoranda. — Where obstruction has become acute after more or less chronic difficulty in defæcation, the contents of the bowel will be for the most part fluid, and the method mentioned above of drawing off this fluid through a temporary puncture in the centre of the part of the bowel exposed and stitched should always be resorted to. In one of the last cases operated on by the author by Littré's method, this was done for several days before a permanent opening was established, and all this time the peritoneal surfaces could be kept perfectly clean. The patient made an excellent recovery. In cases where the fæces are solid, there is less chance of the wound being thoroughly contaminated, even if an opening is made at once, but in almost all such cases it will be possible to wait for sound adhesion between the serous surfaces to take place before establishing the anus finally.

ŒSOPHAGOTOMY.

Œsophagotomy, for the removal of foreign bodies from the gullet, has hitherto proved a very successful operation. And although it may at first sight appear a very formidable procedure, it is found anything but that either in its execution or its results. It may be performed on either side of the neck, according to the position of the foreign body impacted in the gullet, but the left side is to be preferred where there is a choice.

Instruments.—A scalpel; artery forceps; œsophageal forceps; a long curved sound; a director; sequestrum forceps; broad copper retractors; curved needles.

Position of Patient.—Supine, with the shoulders and head raised on pillows, the latter turned a little to the opposite side to that chosen for the incision.

Position of Operator and Assistant.—The operator stands on the left of his patient, the assistant being placed at the opposite side of the body.

Landmarks for Incision and Operation.—The sterno-clavicular articulation, the upper border of the thyroid cartilage, and the anterior border of the sterno-mastoid muscle, are our guides.

An incision is made from three-quarters of an inch above the sterno-clavicular articulation to the upper border of the thyroid cartilage, following the inner border of the sterno-mastoid muscle. This is carried steadily and rapidly down in the interval between the sheath of the great vessels and the trachea. The omohyoid muscle is drawn aside or divided. The outer fibres of the sterno-hyoid and thyroid muscles may also require division, but should if possible be pushed inwards. The sheath of the vessels is drawn outwards and guarded with the retractors which hold the sterno-mastoid muscle outwards, and the thyroid body is drawn inwards. The whole of the deeper dissection may be done with blunt instruments. The larynx is now pushed to the right, and the foreign body is felt for with the fingers. The long œsophageal forceps or a long curved sound introduced from the mouth will also aid greatly in finding the exact situation of the gullet and steadying it for the incision. The latter is made with a very sharp knife cutting on the point of the sound, which steadies the flaccid tube. It should be very limited at first, and afterwards opened up by the finger if necessary. When

large enough a sequestrum forceps is introduced and the foreign body is extracted.

Great care should be taken to avoid cutting in the deeper dissection, as by this means all risk to the thyroid arteries and inferior laryngeal nerve is avoided.

If the operation is done with every antiseptic precaution, and early, before the walls of the œsophagus have been damaged by inflammation, the opening in the latter may be carefully brought together with a few points of silk or catgut suture, otherwise it is best left open. The rest of the wound is treated according to the same rule.

For some days after operation the patient must be fed by a tube passed through the mouth well down to the lower part of the œsophagus.

ŒSOPHAGOSTOMY.

This operation is performed precisely as the last, with the addition that the edges of the wound in the gullet are stitched to the external opening and retained there as well as possible until a permanent opening is established. But œsophagostomy occupies a very different position in surgical favour to its fellow. It is strongly advocated by some as a palliative measure in cases of cancer of the gullet, but has not yet made a very secure place for itself among our surgical procedures. Nevertheless, in cases of impassable cancerous stricture high up in the gullet, this operation is much to be preferred to gastrostomy.

EXCISION OF THE RECTUM.

As commonly employed, this term is made to include removal of portions of the wall of the rectum as well as

complete excision of the whole circumference of the lower part of the bowel. And while it is still a matter of debate in what cases the latter operation ought to be performed, there can be no doubt as to the propriety of removing portions of the bowel for limited new growths. Excision of the whole girth of the rectum will therefore in all probability become rarer and rarer as attention to the affections of the part becomes more and more general, and diseases there are recognised *early*, and their importance is duly estimated.

In the operation now to be described, it will be assumed that only a portion of the wall of the rectum requires excision. If in certain cases wide-reaching growths are to be dealt with, the same principles will guide us and the lines of procedure will be practically the same. The cases most suited for operation are those in which a small patch of epithelioma is seated not far within the anus, and within reach of the finger on all its aspects—a patch freely movable on the structures beneath, and unaccompanied by any infiltration of glands. Such a case will give us our type.

The preparations for this operation are simple. The patient, who has usually suffered a good deal from the irritation in the rectum, should rest in bed for some days beforehand, and have his diet regulated so as to produce soft stools as far as possible. He should also have mild laxatives to make sure that there is no accumulation of fæces in any part of the large intestine, and copious enemata on the morning of operation. Immediately before the latter, the author has considered it desirable to administer an enema of brandy for the double purpose of acting as a general stimulant and an antiseptic.

Instruments.—A curved sharp-pointed bistoury; long curved scissors; pile forceps; artery forceps; two long

curved-handled needles; a cautery (Paquelin's); strong twisted carbolised silk.

Position of Patient.—As for lateral lithotomy, *q. v.*

Position of Operator and Assistants.—As for lateral lithotomy, *q. v.*

Landmarks for Incision and Operation.—The tip of the coccyx and the middle line of the posterior margin of the anus are the only points that need be kept in view at first. But in working within the bowel we must not forget the proximity of the urethra, the back of the bladder, and the recto-vesical pouch of peritoneum. The latter varies in the distance to which it descends, from three to five inches from the anus, and while a wound of it is not necessarily fatal if every antiseptic precaution be adopted, the greatest care should be taken to avoid encroaching on it. If only those growths are attacked, all parts of which can be easily reached with the forefinger and can be easily moved on the subjacent structures, there is little risk to the peritoneum. When the anterior wall of the rectum is the seat of the growth, it is well to keep a large catheter in the urethra during the operation (if a male case) as a guide to the situation of the passage. If a female is operated on, the wall of the vagina can be easily defined with the finger, and a portion of it removed if necessary. But supposing a patch of epithelioma of the size of a crown-piece to be seated just within the sphincter on the posterior wall, the operation is performed as follows.

The surgeon, placing his left index finger in the rectum, enters the point of the curved knife in the middle line just within the margin of the bowel and divides the skin, sphincter, and subcutaneous structures directly back to the tip of the coccyx by transfixion or a single stroke. The limits of the growth can now be easily defined, and it can be removed either with scissors, cautery, or ligature. If by

the former, nothing is necessary but to draw upon the mass with pile forceps, and cut round the growth in healthy tissue, securing vessels as they are divided. But this method, as a rule, gives rise to much bleeding, and is only suited for very limited growths. If the cautery knife is employed, the bowel is drawn down with pile forceps into the posterior wound, the parts around are protected from scorching, and the diseased mass is cleanly isolated by the cutting edge of the instrument at a dull red heat. But the safest mode of removing considerable portions of the bowel is undoubtedly that of ligaturing the surrounding wall and snipping away the part containing the new growth with a pair of curved scissors below the line of ligature. It is done thus. Through the posterior incision a long-handled needle armed with stout carbolised silk is thrust, and is made to enter the rectum an inch or more above the margin of the growth in the middle line. Here the silk is caught and a loop of it is drawn out of the anus: the needle is then withdrawn still threaded, and is again thrust through into the rectum about an inch to one side of the first puncture. A second loop is here caught up and similarly drawn out, while the needle is withdrawn and used to carry a third loop an inch or so from the last. A second needle threaded on the other end of the same piece of silk surrounds the opposite half of the growth with a similar series of loops. The latter are then cut, and the portions of bowel included between the several punctures are ligatured as securely as possible. The isolated portion of bowel may now be clipped away without fear of hæmorrhage, and the ligatures cut short and left to slough off in due time. The part of the bowel attached to the margin of the anus does not require to be ligatured, but may be simply cut through with the scissors. When all bleeding has ceased the operation is completed. The wounded surfaces are dusted with iodo-

form and the patient is put to bed, having some loose dressing over the wound to receive discharge and fæces. No sutures are required in the posterior wound, which must granulate up from the bottom, and the edge of the cut bowel also is left unsutured. Unless there be much oozing from the wound it should not be plugged in any way, but should be well syringed at short intervals and dusted with iodoform. The great aim in the after-treatment is to keep the parts clean and to provide free escape for all matters gravitating into the posterior wound, the greatest immediate dangers in these cases being pelvic cellulitis and pyæmia.

Memoranda.—It may be possible in some cases where the whole circumference of the bowel has been removed, to bring the cut edges of the tube down to the margin of the anus and secure them there. But this practice has been condemned by many who have had experience of it as tending to confine discharges within the ischio-rectal fossa to a dangerous extent, and they have preferred to leave the wounded surface to granulate up, and the mucous membrane to be drawn down to the anus by the contraction of the granulations. There can be no doubt however that if the whole wound during the operation can be kept in an aseptic condition, there ought not to be any discharges in the ischio-rectal fossa, in which case it would be a decided gain to bring the mucous edges of the divided rectum down to the anus and suture them there accurately. This would probably obviate the great tendency to stricture of the rectum which exists after the wound has been allowed to granulate up as described above. But the difficulty of keeping a wound of the rectum from contamination with ferments of one kind or another is very great, and will in most cases prevent union of the cut surfaces, in which case great care should be taken to give exit

to all discharge. Where very small portions of the rectal wall are excised, it is quite possible to unite the edges of the wound closely enough to ensure union by first intention, and this should always be done. In the author's cases the open method has been followed hitherto.

FOR PROLAPSUS ANI.

When operations for this condition are demanded, which is rare if great care is directed to the general health, diet, and the regulation of the bowels combined with the use of astringents locally, we have a choice of several procedures. The simplest of these is often the most effectual. This consists in scoring the prolapsed bowel and margin of the anus with the actual cautery in lines parallel with its axis and starting from the skin of the anus. These lines of cauterisation should be at least three quarters of an inch apart and should be tolerably deep. They cause a contraction of the redundant mucous membrane and condensation of its tissue, together with slight shrinking of the anus. It is well to be cautious in the use of the cautery lest too much contraction be produced, and it is better to have to repeat the operation than to do too much at first.

Another simple operation for prolapsus ani consists in removing two or three elliptical portions of skin and mucous membrane from the margin of the anus and the bowel immediately above it, and drawing their edges together so as to promote union by first intention as far as possible. The most rigid care as to cleanliness is here necessary to attain the latter object, and the bowels should be prevented from acting as long as possible. When it is necessary that they should be relieved, large non-stimulating enemata are given.

It seems probable that in the future an operation resembling that known as Whitehead's for the cure of piles,

vide infra, will be frequently performed for prolapsus ani. The conditions in both affections are so closely allied that it is not too much to expect that the good results achieved in the case of piles may be equally obtained in that of prolapse.

STRETCHING THE SPHINCTER ANI.

This operation has been largely practised in some schools of surgery for the relief of several very common diseases at and about the anus. The most important of these are ulcers and fissures of the margin, and the smaller fistulæ. The great obstacle to the successful treatment of these affections is recognised by all to be the difficulty of securing rest for the part, and the action of the powerful sphincter of the anus in a state of chronic irritation and spasm dragging upon tissues otherwise inclined to heal. To meet this difficulty several operations have been designed, all having for their immediate object the stretching or division in part or wholly of the fibres of the sphincter, so that on the one hand it may be temporarily thrown out of action, and on the other that the fæces may be expelled without extraordinary effort from above.

The simplest of all these operations is the above, which is thus performed.

The patient having been thoroughly anæsthetised is placed either in the lithotomy position or on his left side, with the thighs fully flexed. The operator's thumbs, well oiled, are then inserted back to back into the anus, and are forcibly separated until the fibres of the sphincter are felt to give way and the anus is left soft and patulous. In some cases it will be found more convenient to stretch the sphincter by the gradual insinuation of the fingers, well oiled, made up into a cone and slowly twisted backwards and forwards as they enter the anus. Occasionally the

muscle is so hypertrophied by prolonged irritation, that even the strongest hands are unable to stretch it sufficiently. In such a case a tenotome may be inserted at one or two points through the skin at the margin of the anus, underneath the mucous membrane, and the muscle may be notched slightly. Dilatation with the thumbs will then produce the necessary subcutaneous or submucous tearing of the muscle which is desired. In no case should the mucous membrane itself be injured, and consequently there is none of the inflammatory irritation of the tissues around which often accompanies the cutting operations employed for the cure of the same affections.

But if such an operation does not prove successful for the cure of fissures or ulcers of the anus, the following may be tried.

The ulcer or fissure having been exposed by a speculum, a curved knife is introduced within the anus and its point is sunk into the tissues at its upper margin and is made to cut deeply through its base as it is drawn out. The clean incised wound left thereby has far greater tendency to heal, being in a state of comparative rest from division of the muscular fibres underlying it, than the original fissure.

FOR FISTULA IN ANO.

For fistula in ano, whether blind external, blind internal, or complete, no doubt the commonest operation is division of the tissue which lies between the fistulous track and the bowel. This is done as follows. In each case the fistula must first be made complete either with a knife or director thrust forcibly through the uncompleted track. Then the director is introduced through the external aperture and passed into the rectum through the internal. Here it is caught by the finger introduced into the bowel,

and is drawn out at the anus. A curved sharp-pointed bistoury is now run along the groove of the director, and all the tissue lying upon the latter is severed at one stroke. Bleeding vessels should then be looked for and secured, the part dusted with iodoform, covered with a pad of antiseptic wool, and a morphia suppository left in the bowel. The wound will usually granulate up from the bottom without much delay, but may need to be occasionally stimulated with nitrate of silver.

Sometimes, if the tissues are very rigid, the director cannot be made to bend out at the anus, in which case a probe-pointed bistoury is introduced up the fistulous track, and having met the tip of the left index finger in the rectum, both are drawn downwards with a sawing movement, the intervening tissue being fully divided.

It should not be forgotten that after either of these operations on fistulæ there may be internal bleeding into the bowel which gives no sign externally. The patient's sensations should therefore be inquired after for some time subsequent to operation, and his pulse and colour noted. If he experiences a feeling of weight and tenesmus in the rectum and becomes blanched, with a feeble pulse, no time should be lost, but the wound should be examined for bleeding points, which if found should be attended to with the utmost care. If special bleeding points cannot be found, but there is a general oozing, the wound should be plugged with antiseptic lint or pressure be made on it by means of a ballon tampon covered with gauze and inflated in the rectum. The use of iodoform in all these cases has much diminished the risks of inflammation and septic absorption occasionally noticed in former times.

FOR PILES.

For piles we have a choice of several operations. Those which lie within the bowel, if few and of moderate size, are best treated by simple ligature or excision, those which are external either by clamping and removal with the actual cautery, by cutting them away after subcutaneous ligature of their pedicles, or by removing them together with a complete ring of mucous membrane within the margin of the anus (*vide* Whitehead's operation, p. 322).

In all cases the patients should be prepared for operation by having the bowels well cleared out by enemata, and by being placed sitting over a pan of hot water for about an hour before, so that the piles may be well brought down and clearly defined.

When the ligature is to be applied to an internal pile, the patient is placed on his left side with the thighs flexed strongly. The piles, having been brought into view by means of the finger, are seized in a ring forceps and are then tightly ligatured round their bases with strong carbolic silk, the mucous membrane having been first divided so as to allow the ligature to slip on to the base. The ends of these ligatures being cut away and the part dusted with iodoform, the piles are returned into the rectum and are allowed to slough off. The patient should have a morphia suppository immediately after operation, and at the end of four or five days should be given a large warm-water enema, so as to bring away the fæces with the least possible disturbance to the parts.

When external or intermediate piles are to be removed by clamp and cautery they are caught in pile forceps and drawn well down: the Smith's clamp is then made to tightly embrace their bases, and they are divided with the

cautery, just external to the clamp. The operator should be very careful to leave tracts of skin untouched by the hot iron between the bases of the piles if several are removed, otherwise great contraction of the anus is likely to follow such an operation. The after-treatment is conducted in the same way as in the last case.

When external piles are tied, the skin should never be included in the ligature. Having been caught one by one in pile forceps, an incision is made round the base of each, dividing only the soft delicate skin with which they are covered. Then a carbolised silk ligature is firmly tied around the vessels and connective tissue forming their pedicle, after which they may be either cut away or left to slough off, but it is better to excise them at once. The loose skin around them soon shrinks up to its normal condition.

*Whitehead's Operation.*¹

This operation, as it is the most radical and extensive, offers also the best prospect of a permanent cure. Mr. Whitehead's experience of it in more than three hundred cases shows it to be devoid of risk, and to give the best results immediate and remote. Its aim and object is to remove not only visible piles, but also the whole 'pile area' of the mucous membrane of the lower part of the rectum, i.e. that portion of the bowel in which most or all of the venous radicles have become dilated and weakened. No permanent cure, Mr. Whitehead thinks, can be expected so long as this diseased area is left to reproduce piles over and over again. In his three hundred cases operated on by this method there were no deaths, not a single instance of secondary hæmorrhage, or one where any complication such as abscess, stricture, or incontinence of fæces occurred, nor

¹ *Brit. Med. Journ.*, Feb. 26, 1887.

did any of the cases cause a moment's anxiety. All, so far as was known, were permanently cured.

Instruments, &c.—Blunt-pointed scissors; dissecting-forceps; torsion do. or Wells's catch-forceps.

Position of Patient.—Supine, with the knees drawn up. The table should be high.

Position of Operator.—Seated opposite the anus. The only assistant necessary is one to steady the patient as he lies.

Landmarks for Incision and Operation.—Before any incision is made the sphincters are thoroughly paralysed by digital stretching (p. 318) so that the hæmorrhoidal area may prolapse. This stretching may either be done with the thumbs thrust into the anus back to back, and then separated, or by means of the fingers formed into a cone and well oiled. Then the line of junction of the mucous membrane with the skin is carefully looked for, and along it the former is cut all round the anus and dissected with scissors and forceps from the external and part of the internal sphincters, which should be cleanly exposed, until the whole hæmorrhoidal area of bowel can be drawn down external to the anus. The mucous membrane above the hæmorrhoids is now cut away in stages transversely snip by snip with the scissors, the divided edge being at once stitched to the skin after each cut by means of silk sutures. In this way a complete ring of mucous membrane with its piles is removed. All bleeding vessels are treated by torsion at once. Before closing the wound finally, iodoform is dusted over its surfaces, and when all is completed a suppository of two grains of extract of belladonna is introduced into the rectum. Then the anus is dusted again with iodoform and covered by a piece of oiled lint secured with a T bandage. The silk sutures are not disturbed throughout the after-treatment, but are allowed to work

themselves free. The cut edge of the mucous membrane of the bowel generally unites to the skin all round the margin of the anus by first intention, if the wound has been kept aseptic during the operation, and if the stitching has been accurate, and all bleeding has been thoroughly arrested before closure of the circular wound.

Memoranda.—In dividing the pile-bearing mucous membrane from the healthy tissue above, it is well to work from behind forwards, by which means the area of operation is less obscured by blood than if the reverse direction were followed. The separation of the mucous membrane from the muscles is usually easy if the dissection with the fingers or scissors is carried close to the latter. At this stage of the operation the bleeding is slight, but when the ring of membrane is divided above, many small arteries are cut. But as this division only takes place by stages, these little vessels are easily seen and closed by torsion or forcipressure or by the suturing of the edges of the bowel to the margin of the anus, which proceeds as each snip of the scissors is made. Thorough digital dilatation of the anus is absolutely necessary for the complete success of this procedure.

HERNIOTOMY.

The more promptly this operation is performed the better. If the case is seen very early, taxis will usually be successful, aided by the previous application to the tumour of ice, and the use of chloroform. But when a hernia has been strangulated for many hours or days taxis ought to be employed, if at all, with the greatest caution; and if not followed by easy reduction, no time should be lost, and the strangulation should be released by operation. As to the question whether the sac of the hernia should be opened or not, each case must be judged on its own merits.

Where a case is seen soon after strangulation has taken place, opening the sac is rarely necessary if the aim of the operation is only the relief of the constriction. But it must not be forgotten that nowadays, in the case of children and people under middle age, most surgeons are not content merely with releasing a hernia, but usually at once follow this up where possible by one or other of the operations for the radical cure of the condition. For this to be safe and successful it is necessary that the patient should be strong and healthy, and at a time of life when such an operation is not superfluous. But above all things it is necessary, before an operation for the closure of a hernial opening be performed in a case of strangulated hernia, that we should feel quite certain as to the state of the included bowel or omentum. It is impossible to be quite sure upon this point unless the sac be opened and its contents carefully inspected. If, then, the parts appear too much congested to justify their being returned completely into the abdomen and closure of the ring, the constriction can be divided and they can be left *in situ* while the sac is carefully drained externally. If, on the other hand, they are found sound, they can be returned and the ring can be closed permanently. Except, then, in the most recent cases, there appears a direct gain in every way in opening the sac, especially as with the use of antiseptics little or no risk is run in doing so. And even in the most recent cases, where a radical cure is aimed at, we can often diminish the difficulty of defining the sac by opening it and using the inner surface of its neck to guide us in isolating it externally from the cord. The author has made it a practice of late years, therefore, in all cases of strangulated hernia to open the sac, and unless the condition of the contents contra-indicate it, or the patient be too old or feeble to render any prolongation of the operation undesirable,

to follow up the release of the constriction by suturing the abdominal ring securely. The modes of accomplishing this closure of hernial openings have been of late much simplified, and have probably lost nothing in efficiency thereby, although it is perhaps too soon to judge of the relative values of the latest improvements (*vide* Radical Cures, p. 333).

FOR STRANGULATED INGUINAL HERNIA.

Instruments.—A scalpel and hernia knife; dissecting and artery forceps; a steel director; a flat hernia director; blunt-hooks; scissors; half-curved needles.

In view of the possibility of a rent in the intestine during manipulation, or the necessity of resection of a portion of damaged gut, small round sewing-needles and fine carbolised silk should always be at hand.

Position of Patient.—Supine, with the head and shoulders somewhat raised.

Position of Operator and Assistants.—The surgeon is always best placed on the right side of the patient, no matter where the hernia is. An assistant stands on the opposite side.

Landmarks for Incision and Operation.—The best guide to look for in all cases is the axis of the upper part of the tumour, bearing in mind of course the direction of the natural openings through which herniæ usually make their escape. Thus in the inguinal varieties we should note the position of the internal ring, i.e. half to two-thirds of an inch above the middle of Poupart's ligament, and of the external—namely, immediately outside the spine of the pubis. When we have made out these points, a large fold of skin is pinched up at right angles to the axis of the last opening and is transfixed at its base and cut out-

wards. The wound thus formed in the axis of the inguinal canal can be lengthened if necessary to three inches or so for an adult if a radical cure is contemplated. And indeed in all cases it is well to have abundance of room for the deeper part of the dissection. This is rapidly carried through the several layers of tissue covering the sac, either by cutting directly on to them by steady strokes of the knife, or by raising them successively upon a director. No attempt need be made to distinguish one from the other until the sac is reached. This is recognised by the presence of a more or less distinct covering of fat in many cases, by the vessels ramifying in its walls, and in cases of very tight strangulation by the movements of fluid underneath it and around the gut or omentum. If the sac is not to be opened nothing further need be done except to clear the neck of the tumour and slip the knife, with or without a director, between it and the constricting structures and divide the latter. This is done in all cases by cutting upwards, the edge of the constriction being defined by the finger-nail and the sac and its contents protected by the finger. As little as possible of the ring should be divided compatible with reduction of the bowel without force. When the sac is to be opened it is pinched up at one spot with the forceps and divided here with a knife held on the flat and cutting towards the forceps. The director is then introduced, and it is freely slit up from below to the ring. The contents are now carefully examined, the further steps of the procedure being determined by the condition in which they are found. Four points should be specially noticed—(1) the presence or absence of gangrenous or faecal odour; (2) the thickness of the wall of the bowel; (3) the colour of the latter; (4) whether it preserves its normal lustre. 1. If there is a distinctly gangrenous or faecal odour, the protruded bowel and interior

of the sac should be carefully washed with a strong antiseptic solution, dusted with iodoform, and secured in its position by two or three silk stitches passed through its serous and muscular coat and tied to the skin. Then, and not before the parts have been absolutely cleansed, the constriction is cautiously divided so that none of the fluid contents of the sac shall run back into the abdomen. The bowel is not disturbed, but is simply dusted with iodoform and covered with a loose antiseptic dressing. If it recovers itself, well and good, it can be subsequently freed from its attachments and replaced in the abdomen; but if, as is most likely, it sloughs away, it will before this have contracted adhesions around the neck of the sac and its contents will be discharged on the surface of the body. It is better not to slit open the gangrenous gut at once if it can be avoided, but either postpone this for twenty or thirty hours, or leave it entirely to itself to slough away.

2. The thickness of the wall of the bowel is also a fair gauge of the amount of inflammatory exudation which has taken place in it. 3. Its colour too may be much altered without irretrievable damage to the gut; thus it may be deeply ecchymosed, and brown or nearly black, and yet recover, but when it shows patches of ash-grey with greenish or yellow spots interspersed with black, it is almost certain to slough. 4. We are confirmed in this prognosis if the bowel have lost its lustre and has become dull and is covered with flakes of dirty lymph.

But it is not only the body of the protruded mass of bowel or omentum which should be examined for these signs of injury. In all cases where there is the slightest uncertainty the mass should be drawn a little downwards, so that the part immediately under the constricting structures may be specially examined. It is here that most damage is likely to be found, and not unfrequently a dan-

gerous degree of sphacelus is observed at the neck of the tumour while its body is comparatively sound. If the surgeon is satisfied that the bowel cannot recover itself he may deal with it as just described, or if the patient's general condition justify a prolongation of the operation the damaged portion may be excised, and the ends of the intestinal tube carefully sutured to one another so as to restore the continuity of the gut (*vide* Enterectomy, p. 297).

If the bowel is reduced it must in all cases be pushed only just within the ring in case it should later give way. In such a case it would discharge most readily through the latter, and the abdominal cavity would probably escape.

In uncomplicated cases the rest of the operation only consists in thoroughly cleansing the parts and in suturing the wound, a drain-tube being left in the lower angle leading into the sac. Then a firmly applied antiseptic dressing is laid over all.

The mode of suturing the rings for radical cure is described below.

If much omentum is found within the sac it is better to remove it in all cases. This is easily done by tying its pedicle with one or more ligatures, by transfixion and cutting away all the mass below. Any adhesions to the sac are, as a rule, easily torn through, but if firm had better also be ligatured before division. Small portions of non-adherent omentum may be easily reduced.

Should any large vessel be injured in dividing the constriction, a ligature may be passed deeply through all the tissues on either side of the cut and tied temporarily on the surface of the skin, when the artery is sure to be included. These ligatures can be cut and removed after a few hours.

FOR STRANGULATED FEMORAL HERNIA.

Instruments, Position of Patient, Operator, and Assistants as for the last operation.

Landmarks for Incision and Operation.—Here we are dealing with a tumour as a rule below Poupart's ligament, just internal to the femoral vessels, and these structures are our guide for the first incision. It must not be forgotten that, in enlarging, a femoral hernia always ascends after passing the saphenic opening and may even overlap Poupart's ligament. But in such a case a line an inch or so internal and parallel to the great vessels, and crossing the tumour and ligament, will be chosen for incision. The skin is pinched up here too at right angles to this line, and divided by transfixion. The deeper structures in this case must be dissected with more caution than in inguinal hernia, being fewer and thinner. The body of the tumour will also require to be drawn down in order to reach the neck, after which the rest of the operation differs little in execution from that for inguinal hernia (*q. v.*). The incision of the constriction is upwards and a little inwards in this case. The treatment of the wound is that just described for the inguinal operation. The radical cure suitable for these cases will be described below.

Memoranda.—The chief dangers to be avoided in this operation are wound of the bowel in dissecting through the very thin coverings and sac, and wound of an irregular obturator artery. The first danger may be avoided by the use of the director at doubtful points and by keeping the knife on the flat in cutting. The second danger arises from the well-known irregularity of the obturator artery. This vessel arises in 2 out of 3 cases from the internal iliac artery, in about 1 in $3\frac{1}{2}$ cases from the epigastric, in 1 in

72 by two roots from the epigastric and internal iliac, and in the same proportion of cases from the external iliac. In either case its course is usually on the outside of the neck of the hernia, but occasionally, perhaps in 1 case in 60, it runs over and then internal to it, and is thus right in the way of the necessary incision. It has been thus wounded in some cases with more or less harm, but this is not an occurrence of much gravity, to judge by recorded cases. This accident once occurred to the author in making the usual cut to a very limited extent, but was not productive of any serious mischief, and this has been the experience of others.¹

FOR STRANGULATED UMBILICAL HERNIA.

This operation is rarely or ever called for in young children, although umbilical hernia is very common in infancy. This fact is due to the inherent tendency in the umbilical opening to close in childhood. It is in the later decades of life that strangulation at the umbilicus is most frequently met with, and then mostly among females who have borne large families. The real difficulties in dealing with the condition depend rather upon secondary complications likely to be present as the result of the chronic prolapse of the gut, than from any intrinsic difficulty in the operation. Thus adhesions are very likely to form within the sac of an old umbilical hernia, and there may be also entanglement of coils of the intestine with folds of the protruded omentum or strangulation through rents in the latter. In such a case mere division of the fibrous constriction, external to the peritoneal sac, would be quite insufficient to relieve the gut, and a very careful examination of all

¹ *Vide* Paper by Author, *Clin. Soc. Transactions*, vol. xi. p. 180.

the contents of the hernia might be required before the exact cause of the obstruction was discovered. There is one factor in strangulated umbilical hernia, however, which is more dangerous than in strangulated hernia about the groin, namely, the dependent position of the opening connecting the sac with the abdomen. As the result of this any inflammatory products accumulating in the former are extremely likely, indeed almost certain, to flow back into the peritoneum when the hernia is reduced either without or with operation. But with our present system of anti-septic surgery, this danger is reduced to a minimum by opening the sac in all cases and cleansing its contents before dividing the constriction and reducing them. It seems probable that before long this will be recognised generally to be the proper routine practice.

When a recent umbilical hernia becomes strangulated and it is determined to effect its release without opening the sac, it is only necessary to make a vertical incision about three inches long over the upper border of the ring, either in the middle line or somewhat to one side. This must be cautiously carried through the skin above the ring and only a little way on to the tumour, which should be drawn downwards as much as possible. The edge of the opening will then be easily made out and raised on the nail of the left index finger. A hernia knife is then slipped under it, and is made to cut upwards to a small extent. If this is not sufficient to liberate the hernia, some surgeons prefer to make one or more lateral cuts into the edge of the ring, rather than to extend the first far upwards. When reduced, the skin wound is closed in the usual way and firmly supported by padding and bandages.

Where the sac is to be opened, the same incision may be made, but the author has found it more convenient to cut from the middle line above downwards with a curve

over the side of the tumour. This, besides giving access to the upper border of the ring, allows any fluid which may be in the sac to run out at once at the most dependent point, and has, moreover, the advantage that if a radical cure is to be attempted, part of the necessary incision is already made (*vide infra*). The sac being opened and the state of the bowel ascertained, the forefinger of the left hand is thrust into the neck, and the hernia knife along this, by means of which the constriction is divided to an extent sufficient for reduction. If the strangulation be produced by bands or omental rents, the whole contents of the sac will require to be exposed and unravelled, after which they are carefully sponged and replaced in the abdomen if sufficiently sound. It is well in these cases, while operating with all antiseptic precautions, to remove all the omentum which is in the sac after securing its pedicle with one or more ligatures at the ring. The stump should be left just within the latter, unless a radical cure is to be attempted, as will be the case in most instances in the future, when the condition is recognised early (*vide infra*).

OPERATIONS FOR THE RADICAL CURE OF HERNIA.

Many more or less complicated operations for the radical cure of hernia have been proposed and practised from time to time, but since the introduction and perfecting of the antiseptic treatment of wounds, these have been much simplified. It is proposed here first to describe the simplest forms of operation as suitable to the conditions, whether congenital or acquired. The simplification of the procedures consists in the possibility of, and freedom from risk in exposing the neck of the sac and the structures around the aperture of exit, for the purpose of accurate

closure of both. By the best of the older methods attempts were made to close the rings by stitches passed through the skin and directed through the edges of the hernial openings and back again by the sense of touch alone. They were therefore necessarily more or less uncertain in their effects, and dangerous; while in the newer methods, in which the deeper structures are freely exposed by division of the skin, there is less risk of wounding important parts, and more certainty in closing the hernial opening. Again, the use of antiseptics obviates the necessity of removing the sutures employed for the latter purpose, and the external wounds may be allowed to close over them. In reference to this point it is unnecessary here to enter upon the discussion as to the best material to use for suture. Surgeons differ much in their views upon this point, some using ordinary silver wire, some carbolised or chromic catgut, others carbolised silk or prepared kangaroo tendon ligature, while others prefer that made from the aorta of the ox. These substances are all good, provided they are rendered thoroughly aseptic before use and have sufficient durability. To the author it appears likely that fine hard twisted silk will finally win the day for many reasons, and he has, after many trials of catgut, kangaroo tendon, &c., confined himself to the use of silk almost exclusively for these operations.

The procedure first to be described is that which has gradually come into use of late in the author's practice at University College Hospital for radical cure of inguinal hernia.

Instruments.—As for herniotomy, with the addition of two curved handled needles and an aneurism-needle.

Position of Patient, of Operator, Assistants, and Landmarks for Incision and Operation, as for herniotomy, *q. v.*

When the sac of the hernia (fig. 51, *s*) has been reached

and opened, and its contents have been reduced into the abdomen in the usual way, the next point is to separate the structures of the cord (*c*) from the neck of the sac. This is best done by inserting the index finger into the opening in the latter, and catching its edge between finger and thumb, while with the other thumb-nail the structures

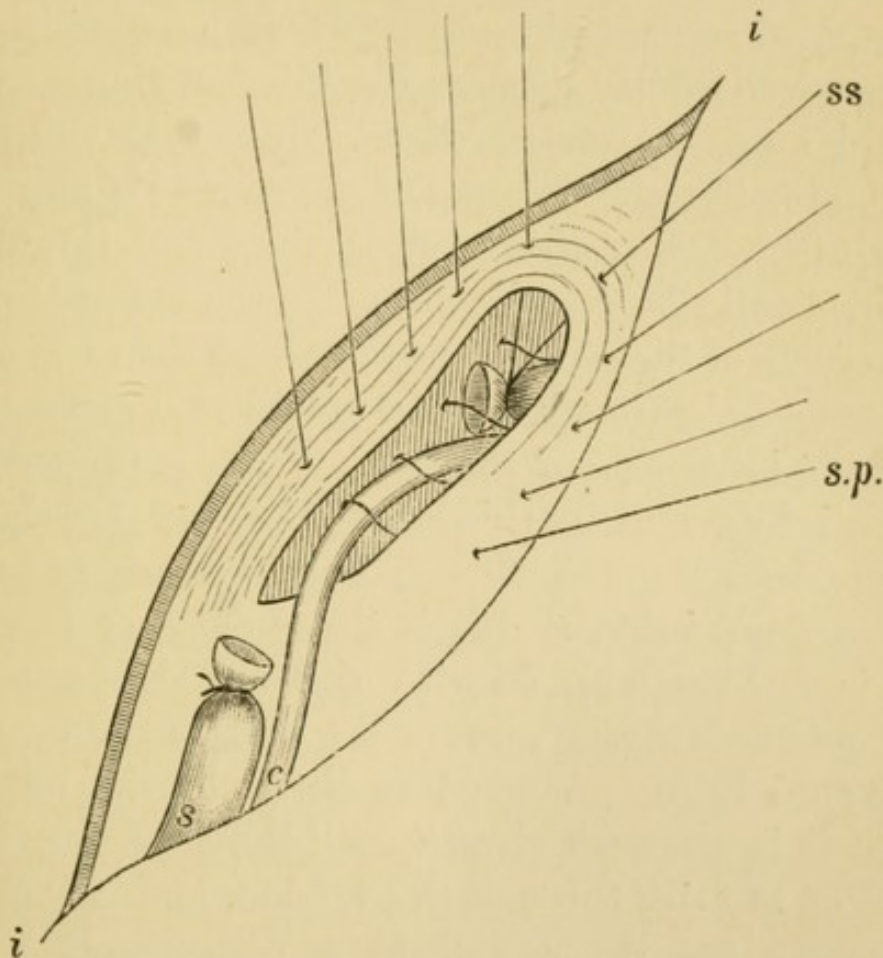


FIG. 51.—RADICAL CURE OF INGUINAL HERNIA.

ii, Incision in the skin ; *c*, spermatic cord ; *s*, sac of hernia ; *ss*, suture for the sac ; *s.p.* sutures for drawing the walls of the canal together. All the sutures are represented *in situ*, ready to be drawn close and knotted.

of the cord are peeled off the sac for a limited distance. In doing this all disturbance of the structures of the cord should be avoided as far as possible. Sometimes the thumb-nail may be replaced by the blunt point of an aneurism-needle. Be this as it may, eventually the latter instrument is carried under and close to the neck of the sac, and

when it is quite certain that it does not include anything but the latter, it is threaded with strong fine carbolised silk, and withdrawn. The two ligatures so introduced are now separated for about half an inch above and below the opening in the sac, and the upper pair are tightly tied as high up as possible, but not cut short; then the sac is divided between them. The pillars of the ring having been exposed by dissection, the left forefinger is introduced into the canal, and so through the internal ring, and made to press its anterior wall forwards. One of the silk threads belonging to the upper stump of the sac (*ss*) is now carried up the canal, inside the internal ring, and through the abdominal wall above and external to the external ring by means of one of the handled needles, and then the other is similarly passed through the abdominal wall about half an inch to the inner side of the first. These sutures are then knotted tightly, and by this means the stump of the sac is drawn up into the abdomen and fixed there, and at the same time the internal ring is closed more or less. The needle is now again armed with silk, and is passed from within outwards through one of the walls of the canal high up, the cord being protected as before by the left index finger. It is then withdrawn, still threaded, but leaving one end of the silk through the tendon, and is then made to puncture the other wall at a corresponding point, where it is unthreaded and withdrawn. The piece of silk so introduced is not knotted yet, but is used to draw forwards the two pillars and act as a guide for the introduction of three or four similar stitches lower down. All of these (*s.p.*) should if possible include a portion of the conjoined tendon (fig. 51) as well as the two pillars of the external ring. They should of course all pass across in front of the cord (*c*), and the lowest should not close the ring too tightly upon the latter. When all are in place they are

firmly knotted, beginning at the highest, and thus the canal is closed firmly throughout. The lower part of the sac is by some operators now removed by dissection off the cord and scrotal tissues, but this is quite unnecessary and may prove very mischievous, as during the dissection the nervous and vascular supply may be seriously damaged. If the sac be very thick and tough there may appear to be some justification for its removal, but even here little is gained. Those who make a practice of dissecting out the sac speak of the frequent occurrence of suppuration in the scrotal tissues, but without bad results. In my own operations, over forty in number, in which I almost always leave the sac, I think I have only seen anything approaching to this twice, and then only to the smallest extent. The presence of the sac is said by some to favour the re-descent of the hernia, but upon what grounds this view is based when nothing is left of it in the ring it is hard to discover. Nothing now remains but to suture the skin neatly, and to insert a drain tube in the lower angle of the wound in such a way that its inner end may lie as close to the external inguinal ring as possible. The part being dusted with iodoform is best dressed with antiseptic wool laid on in cut strips in abundance. This adapts itself better to these parts than gauze, and is more comfortable to the patient, and as there is usually but little oozing, its absorbent powers are not largely drawn upon. Of late the author has dispensed almost invariably with drainage tubes for this operation, and has relied in most cases upon healing throughout *per primam*. In some, where there is a little tendency to oozing, a strand of silk left between the lips of the wound at its lower angle provides quite enough drainage.

Memoranda.—This operation performed in early life for hernia which trusses will not completely retain seems destined to play an important part in surgery. It seems

likely to make a resort to trusses for long periods less and less frequent. It is simple and not dangerous, and makes but little demand upon the strength even of the youngest child. Out of over forty cases on which the author has performed this and allied operations for radical cure of hernia, he has not had a single untoward result. After the patient gets up he should wear a spica bandage or an elastic band for a time, applied over a pad of wool resting on the wound. Trusses in my opinion are not required in many cases of inguinal hernia, and may lead to chafing and irritation about the deeper stitches.¹

Macewen's Operation.

Since the above was written another operation has been described by Dr. Macewen of Glasgow and deserves a full trial, as it has yielded the best results in his hands.² The procedure differs but little in general plan from that just detailed, but has two points upon which especial stress is laid. In the first place the sac (fig. 52, *a*), freed from all its surroundings, is gathered up into a folded plug (*a*) by a running stitch (*b*), and is drawn thus within the *internal* abdominal ring so as to act as a buttress within the abdomen opposite that opening. In the next the outer edge of the conjoined tendon is drawn by stitches (fig. 53, *b b*) towards the outer border of the internal ring, so as to reproduce as far as possible the valve-like arrangement of parts which exists in a well-developed individual in the normal state. After this the pillars of the external ring are drawn together by the usual stitches (fig. 53, *c c*). In this operation Dr. Macewen uses catgut for the latter and decalcified bone drain tubes. He relies upon complete union of the deep parts having taken place before the

¹ *Proceedings of the Brit. Med. Association*, 1887.

² *Annals of Surgery*, Aug. 1886.

catgut is absorbed. In the operation last described the author uses carbolised silk, and relies not only upon plastic adhesion, but upon the silk supporting the deeper structures in their new position for months, perhaps years, and so preventing the recurrence of the rupture.

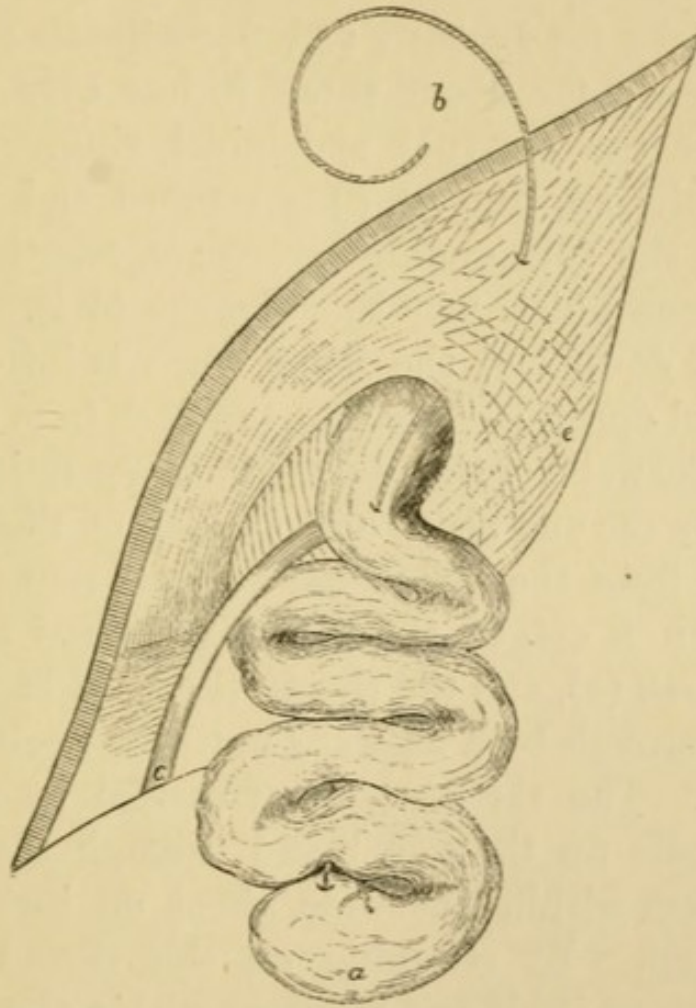


FIG. 52.—RADICAL CURE OF INGUINAL HERNIA.
(Macewen's Operation.)

a, Hernial sac; *b*, suture gathering up the sac; *c*, spermatic cord;
e, aponeurosis of ext. oblique.

Instruments.—In addition to those enumerated for the last procedure two long curved handled needles with the eye near the point, and having for the last inch or so a second curve, from right to left in the one case and from left to right in the other, are recommended.

Position of the Patient.—Supine, with the thigh semi-flexed and abducted, and lying on a pillow placed under the knee.

Position of the Surgeon and Assistant.—The surgeon stands on the affected side, his assistant on the other ready to retract the edges of the skin, &c.

Landmarks for Incision and Operation.—The first incision is made for about three inches over and in the direction of the external abdominal ring. By a little dissection the sac (fig. 52, *a*) is reached and is raised *en masse* from the surrounding structures, together with any adipose tissue which may be adherent to it. The sac is then pulled down and the index finger is introduced into the inguinal opening separating the neck from the cord (*c*) and from the walls of the canal. This separation is carried on until the sac and about half an inch of the peritoneum is loosened from the abdominal wall all round inside the ring. Then a catgut stitch (*b*) is secured to the lower end of the sac (*a*), and the thread is passed backwards and forwards through both its walls until the neck at the ring is reached. The thread is then carried by means of a curved needle up the canal and through the abdominal wall (*e*) from within outwards about an inch above the internal ring. By straining on this thread the sac is puckered up on itself and is drawn within the ring, where it forms a folded pad over the latter. The thread is then or later secured either by tying (fig. 53, *a*), or over a piece of decalcified bone tubing.

A second stout catgut thread (fig. 53, *b b*) is then passed through the conjoined tendon from below upwards by means of one of the curved needles, so that both ends appear on its anterior surface. These are then carried through the outer border of the internal ring and Poupart's ligament from within, and are tied tight so as to draw the

conjoined tendon and the opposite border of the opening together (fig. 53). The pillars of the external ring are then stitched together by stout threads (*cc*) in the usual way, but Dr. Macewen does not attach much importance to their closure, relying more upon the valve-like action of

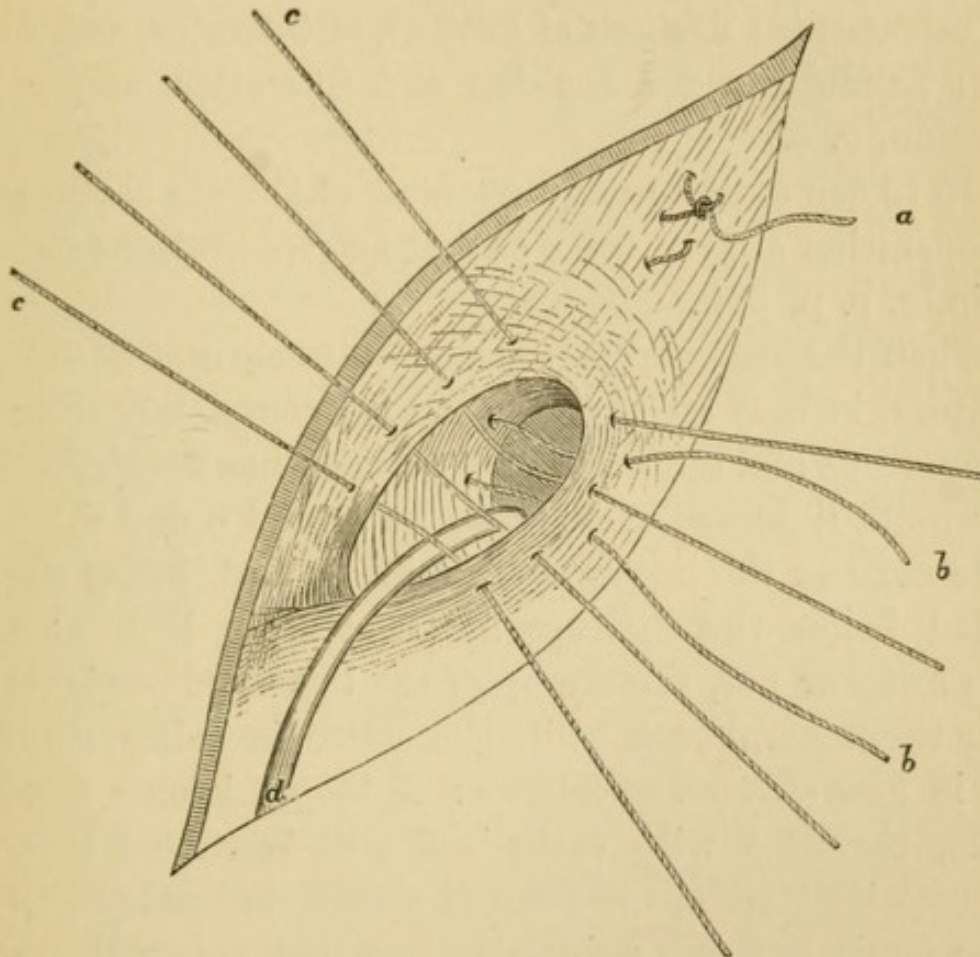


FIG. 53.—MACEWEN'S OPERATION.

a, Suture drawing the puckered sac within the abdomen; *b*, suture drawing the conjoined tendons down to Poupart's ligament; *cc*, sutures closing the external ring; *d*, spermatic cord.

the conjoined tendon in its new position. But if the ring be very large a second stitch similar to the first may be placed in the conjoined tendon.

If the hernia be congenital the sac is divided in the middle and the lower part is closed by a stitch or two to form a tunica vaginalis. The upper part is then slit up

behind to allow the cord to escape, and is then closed by stitching. It is subsequently treated as above described for the acquired form of hernia.

FOR RADICAL CURE OF FEMORAL HERNIA.

Instruments ; Position of Patient, of Operator, and Assistants ; Landmarks for Incision and Operation, as for last operation, *q. v.*

Up to the exposure and opening of the sac the steps of this operation are the same as that for strangulated femoral hernia, *q. v.* p. 330.

When the sac is opened and is quite clear of bowel and omentum, it may either be separated completely from its surroundings and removed after its neck has been closed by a stout silk ligature, or this may be passed round the neck of the sac and the latter be left in its bed, being simply divided below the ligature at the ring. But whether taken away or not, the stump of the ligatured sac is thrust under the femoral arch while the latter is being sutured. This is now effected as follows : A long Liston's handled needle, threaded with carbolised silk, is passed through the posterior layer of the femoral sheath and pubic portion of the fascia lata at a point about an inch below Poupart's ligament and a little internal to the femoral vein which is protected by the index finger ; it is then thrust upwards nearly as far as the pectineal ridge and is there made to emerge, cross the crural opening, and pass through the lower border of Poupart's ligament. The thread is now withdrawn from the eye of the needle and the latter is removed, threaded afresh, and made to traverse the same structures in a similar manner, about a quarter of an inch internal to the first stitch. This is repeated until a sufficient number of threads have been introduced to draw the

structures together and completely close the femoral ring. Sometimes one such stitch is quite enough for a permanent closure. The sutures are now drawn tight and knotted, one after the other. Then the skin wound is united carefully, a drain-tube or strand of catgut being left in its lower angle. An antiseptic dressing, secured by firm bandaging, completes the operation.

It would be possible, indeed easy, in some cases of small femoral herniæ, to clear the sac from its surroundings and push it bodily within the ring, after having reduced its contents, and without opening it. It is questionable whether this should ever be done, in view of the uncertainty as to the condition of the contents. We should be quite certain as to the state of both the bowel and omentum before we suture the ring, and as the risk of opening the sac with antiseptic precautions is very small, this ought always to be done.

FOR THE RADICAL CURE OF UMBILICAL HERNIA.

This operation, which would be unjustifiable without antiseptics, is now likely to become a common one in the hands of those familiar with all the details of safeguarding the peritoneum from septic infection, either with or without the spray. There will always, of course, be an element of risk about it, but with forethought and care this can be reduced almost to vanishing point. But even though there were considerable risk in the operation, many patients would be willing to incur it to get rid of the extremely troublesome and dangerous condition from which they suffer. The cases which appear so far to be best within reach of cure are those small or medium-sized umbilical herniæ occurring in people about middle age, which cannot be completely controlled by a truss, and in which

little or no great adhesion of the bowel within the sac has taken place. Adhesions of the omentum to any extent do not contra-indicate the operation, inasmuch as the sac itself is excised and with it the omentum.

Instruments, Position of Patient, of Operator, and Assistants, as in the last case.

Landmarks for Incision and Operation.—The chief points to be made out, if possible, are the position and size of the aperture in the abdominal wall through which the hernia is protruded. This may usually be done without much difficulty on reducing the whole or part of the contents of the sac. Having thus defined the opening, or, failing this, having fixed in the eye the centre of the base of the tumour, an incision is made commencing above the latter in the middle line and running along its neck as it is held on one side with the left hand, to terminate below it, also in the middle line. This incision, as it crosses the neck of the tumour, should be distant from the abdominal wall about half the diameter of the hernial opening in the latter. A similar incision is ultimately made on the other side of the tumour, commencing and ending as in the first case, and between the two lines thus marked out the bulk of the hernia will be included. The first stroke is only made skin-deep in both instances. Then that first made is deepened by careful dissection at its upper end until the sac is freely opened. If the gut and omentum are reducible they should be now put back, and a small flat sponge held by a strong ligature passed through its centre is thrust into the abdomen and drawn outwards against the opening. Then the latter is closed by a row of stout silk sutures, including about half an inch of the margins of the ring on both sides. The edges of the opening should be everted so as to bring the peritoneal surfaces well into contact before these are knotted one by one, and at the last moment the

sponge is withdrawn. But if adhesions exist between the bowel and sac, these must first be divided or carefully torn through, and the gut put back. In the majority of cases, however, suitable for operation the bowel is reducible, but the omentum is extensively adherent. Where this condition is present, after putting back the gut the omentum is drawn down, tied with one or more fine silk ligatures by transfixion at its base, and severed, the stump being returned into the abdomen. Then the sponge is introduced and left in until the sutures are inserted as above. When the sponge has been removed and the opening has been drawn together, the rest of the operation is practically extra-abdominal. It consists in separating the sac from the skin around the base of the tumour and cutting through its neck about two-thirds of an inch from the row of stitches just knotted and cut short, and then removing it *en bloc* with its contained omentum and the elliptical portion of skin included between the first two incisions. This skin is intimately adherent to the front of the sac, and is often excoriated or even ulcerated. Then what remains of the neck of the sac is united over the first line of sutures by a second row which should include a little of the sheath of the rectus besides. Nothing now remains to be done but to unite the skin in the middle line, leaving a drain tube in the lower angle of the wound. This is then sprinkled with iodoform and covered by strips of salicylic wool firmly secured by ordinary bandages passed round the whole abdomen.

Memoranda.—Our first and greatest aim in this operation is to reach the neck of the sac as quickly as possible and clear it of bowel and omentum. Our next is to close the hernial opening as soon and as firmly as we can, so as to prevent access to the peritoneal cavity of all matters from without. Then the removal of the bulk of the tumour

is proceeded with as an extraperitoneal operation, and is done *en masse* as it were. Finally we add strength to the line of suture by including as much tissue as possible in the second row of stitches which pass through the edges of the divided neck of the sac. A fine catgut drain may be placed in the line between the first row of sutures in addition to the tube in the subcutaneous space. Too much wool dressing should not be applied to the surface of the wound, as we want all the firm pressure that can be obtained and not much oozing is to be expected. The patient should lie in bed with the shoulders raised and the thighs flexed until sound union has taken place, and should then wear a well-fitting hernia binder constantly.

The above description is based upon the author's own experience in three cases, in which the result was very good.¹ It is impossible to add much from the work of other surgeons in this field, for comparatively few operations for the radical cure of umbilical hernia have been performed, and fewer published. Mr. Wood, with his very large experience, appears only to have operated for umbilical hernia five times, and in each by a subcutaneous method without incisions.²

¹ Vide *Brit. Med. Journal*, Dec. 12, 1885.

² *Ibid.*, June 13, 1885.

CHAPTER XIII.

OPERATIONS ON THE URINARY TRACT.

OPERATIONS ON THE KIDNEY.

It would be quite foreign to the scope of this work to discuss in detail the conditions of the kidney which require surgical interference with the organ itself, or to contrast the merits of the various operations designed for their relief. It must be assumed therefore that this aspect of the subject has been studied, and that one or other procedure has been determined on which simply requires description. As there is some little variety in the details adopted by different surgeons, it is necessary to remark here that each operation will be described as practised by the author, with those improvements which he has been led to make use of after a considerable personal experience in this branch of surgery and observation of the practice of others. It will be assumed that a typical case requires the particular operation chosen, and the latter will be described as for a typical case. The dangers to be avoided generally are the same practically in all operations on the kidney :

- (1) Wound of the peritoneum and infection of its cavity.
- (2) Hæmorrhage, especially from the renal vessels.
- (3) Septic processes in and about the kidney, or general infection of the system.

NEPHROTOMY.

This operation simply consists in making an incision into an enlarged kidney, usually on account of retained fluid, and for drainage of the latter, whether urine or pus.

Instruments.—A large scalpel; dissecting and artery-forceps; broad retractors; a hollow aspirator needle; a long, slender, handled aneurism-needle; a steel sound; stout silk ligatures and needles.

Position of Patient.—Lying on the sound side, with the thighs somewhat flexed. A long thick sandbag should be placed transversely to the axis of the body under the sound flank in order to bend the spinal column laterally and so increase the distance between the last rib and crest of ilium on the affected side.

Position of Operator and Assistants.—The surgeon stands behind the patient, steadying the skin of the loin with his left hand. One assistant is placed to the right and left of the operator, also behind the patient.

Landmarks for Incision and Operation.—The crest of the ilium and last rib, together with the border of the erector spinæ muscle, are the points to be kept in view. The first incision is made by one firm stroke midway between the rib and crest and parallel with the former (fig. 19, *f*. p. 127). It should be four inches long and terminate about an inch behind the margin of the erector spinæ, and should divide the skin and subcutaneous fat at once. The posterior part of this incision is rapidly deepened by firm steady strokes of the knife, as the fibres of the latissimus dorsi, external and internal oblique muscles, are successively divided. Then the tendon of the transversalis or fascia lumborum is exposed and is cautiously divided on a director, and in some cases the anterior border of the quadratus lumborum muscle will also require to be incised to

give room. Nothing now intervenes between the perinephral fat and the wound but the transversalis fascia, which must be notched with the knife and then torn open with a director or the fingers. The kidney will now be found easily with the latter, if it be not actually bulging into the wound from enlargement. To bring it closer to the surface, an assistant should press steadily on the abdominal wall at its distal side. Having made quite sure that the organ is not overlapped by the colon, and having arrested all bleeding from the parietes, the aspirator-needle is thrust into the renal substance perpendicular to its surfaces and is used to explore its condition. A stone is thus often struck, or urine wells out. In either case a knife may now be boldly pushed into the parenchyma of the organ along the needle, with its edge directed downwards, and an incision be made large enough to admit the finger. The latter will suffice to arrest the bleeding, which is free at first, and is used at the same time to dilate the opening. When fully explored the organ is emptied of its contents, whether fluid or solid. In the case of a moderate sized stone, an ordinary lithotomy or bullet forceps will help much in extraction, but where the stone is large and branched, it may require to be broken with a lithotrite or bone-forceps before it can be removed. If the contents are only fluid, it is merely necessary in incising the organ to make sure that the incision in the cortex will drain the whole diseased cavity, and then introduce a large drain tube with a flange at its outer end. But in some cases there may be several sacs within the organ containing fluid, and if this be so, the finger must be thrust through the intervening septa from the first cavity until a way of escape is provided for the contents of each through the external opening. When, on exposing the organ, it is found that the pelvis alone is distended, an opening should be made directly into

it without encroaching on the parenchyma at all. The incision should be made in the anterior wall of the dilated pelvis from within outwards, and be small at first, but dilated with fingers or forceps if necessary.

When the drain tube is well placed and all bleeding has been controlled, the anterior part of the wound should be closely united by deeply placed silk sutures including the divided muscles as well as the skin. It is better to leave the posterior angle of the wound open for drainage except in special cases. An antiseptic dressing of some loose absorbent tissue, used in large quantity, completes the operation.

Memoranda.—Before this operation is commenced the colon should be completely emptied of faeces by high-reaching enemata, and its relations to the tumour be determined by palpation and percussion under different conditions, i.e. when distended by air or fluid and with the body in varying positions.

No structures of any importance are necessarily divided in the parietes. Usually one or two small arterial twigs require attention, and more rarely the lumbar artery accompanying the last dorsal nerve may be large and bleed freely on division. The peritoneum is, as a rule, easily avoided if the wound is deepened mostly behind. If opened it should be carefully stitched before the operation is further proceeded with, and the line of suture should be well covered with iodoform and a carbolised sponge before and while the fluid is being evacuated from the kidney. When the latter has been emptied the whole wound must be most scrupulously cleansed, especially over the suture of the peritoneum. Excessive bleeding from the renal tissues, if present, may be checked by the insertion of a carbolised sponge well into the wound in the organ.

It is impossible to show by figures what the risks of

this operation are. It has been done for such varying conditions, and on patients in such widely different states as to general health, that any statistics derived from collections of recorded cases would be distinctly misleading. We have, however, learned this much from long series of observations, that in cases in which the general health is good and the local disease is limited, there are no very serious dangers necessarily attendant on simple incision of the kidney. The organ bears very free handling, incision, &c., without any shock to the system, and provided its fellow opposite be healthy we need have no hesitation in dealing with disease here, whether calculous or suppurative, in cases which have not been allowed to run down to great weakness.

NEPHROLITHOTOMY.

This operation is defined as the removal of a stone from a kidney, not sensibly enlarged, and with no evidence of accumulation of pus within it. The procedure only differs from nephrotomy in the fact that being performed on an organ not sensibly enlarged we must place our first incision a little higher up than in the latter operation, i.e. nearer to the last rib, and remember throughout the operation that a kidney of normal size lies partly covered by the costal margin behind. It may be necessary indeed to draw up the last rib forcibly with the fingers after our incision in the soft parts has been made, in order to expose the organ for the purpose of sounding it by acupuncture or incising it for the removal of the stone. Again, the drain tube may be dispensed with earlier in many of these cases. In this operation, too, the point of incision into the kidney is determined by the position of the stone within as found by acupuncture. The incision should be made from within outwards, from the lesser to the greater

curvature of the organ, as a rule, if the stone lies in the parenchyma, if in the pelvis always from within outwards. Beyond these few points it is not necessary to add to the description given above of nephrotomy, which will answer equally well for nephrolithotomy.

The statistics of this operation are very favourable. As it is performed on a comparatively healthy organ, it entails little risk to the patient beyond those of any surgical wound, and these may for the most part be avoided by rigid antiseptic precautions. To quote figures in support of this view would mislead at present, for it would be difficult to keep apart cases of simple nephrolithotomy from cases of removal of a stone from a suppurating kidney.

NEPHRORAPHY.

This operation has been planned for the fixation of kidneys so movable as to drag upon the vessels and nerves running into the hilus, and so give rise to much pain, vomiting, and other general discomfort. It is not often called for, but in certain cases is capable of affording much relief. So far, experience shows it to be devoid of any risk, and the only hesitation which the surgeon need feel as regards its performance in any particular case will be on account of its occasional failure to fix the organ permanently and relieve the symptoms. If a mesonephron be present it will of course be impossible to perform the operation without opening the peritoneum, but with due antiseptic precautions it is questionable whether this should be a barrier to the operation in the future. Hitherto, however, the measure has only been resorted to in those cases in which the kidney has slipped about behind the peritoneum, and where the latter consequently was not particularly endangered.

Operation.—As far as the stage at which the kidney is reached, the procedure is in no way different from that of nephrotomy (*q. v.* p. 348). The adipose tissue around the organ and the capsule of the latter are now caught up with eight or ten catgut or silk sutures and drawn thereby into the wound and fastened to its deeper edges. Then one or two strong stitches are passed through the abdominal wall at one side of the wound through the cortex and capsule of the kidney, and out through the abdominal wall on the other. These last sutures are fastened with buttons and are only left in for a week or so. A drain tube is now laid in the wound and the latter is closed. There is little or no bleeding throughout the operation except at the moment at which the cortex of the kidney is pierced, and this ceases very soon. The drain tube may be left *in situ* for a week or ten days, and the slight amount of irritation it produces will probably tend to increase the firmness of the adhesion which it is the object of the operation to produce around the outer border of the kidney.

The after-treatment consists in keeping the patient in the recumbent position long after the operation, so that the fresh adhesions may not be stretched by the weight of the kidney. The bowels must be carefully attended to, and when the patient gets up an abdominal belt, furnished with a pad to press firmly over the renal region in front, must be worn. Only the gentlest exercise should be indulged in for a long time after the operation.

It seems probable that in the future this procedure will be resorted to more freely the more fully its simplicity and immunity from risk are known. Writing in June 1883, Dr. Newman says that he had collected eight cases in which it had been done. Five at least were cured of their troubles, the other three were too short a time under observation to judge of the effects; none died.

NEPHRECTOMY.

This procedure was unknown as a formal operation until August 1869, when G. Simon of Heidelberg removed the kidney from the human subject for the first time. He had previously demonstrated the feasibility of the measure on dogs. Before Simon's case the whole kidney had been twice removed on a mistaken diagnosis in America, and once incompletely in Germany. Simon's monograph, published in 1871, was, however, the first attempt to place the operation in its true light. Within the last few years the kidney has been frequently excised for various morbid conditions in England and elsewhere,¹ and the knowledge of the details of the operation has increased rapidly with the publication of every case successful and unsuccessful. But, in spite of the long array of nephrectomies now before us, the exact method to be followed and the selection of suitable cases for operation are still matters of grave consideration.

Nephrectomy has been performed up to the present for renal calculus, for neoplasms, for pyo- and hydro-nephrosis, tubercular kidney, injury such as rupture of the organ, for floating and painful kidney, and for renal or ureteral fistula. It is quite manifest when we consider the wide differences between these various conditions, that the mode of performing nephrectomy must be considerably influenced by the state of things for which it is required.

The kidney has been removed at three points in the abdominal walls: 1, in the loin at the outer border of the erector spinæ muscle; 2, at the outer edge of the rectus abdominis muscle; 3, in the linea alba. By the first of these three methods the peritoneal cavity is not opened,

¹ Author, *Trans. Med. Chir. Soc.*, 1880 and 1881.

and no important structure is wounded in reaching the kidney; moreover, the wound is easily drained. By the second method the kidney and its pedicle are easily reached through the posterior layer of the mesocolon, which contains far fewer vessels of importance than the anterior layer. Again, the wound in the perinephral tissues may be made practically extraperitoneal by stitching the outer layer of the mesocolon to the anterior lip of the incision in the abdominal wall early in the operation, thus shutting off the general cavity of the peritoneum from that left by the removal of the kidney. By the third method freer access to the diseased kidney is gained, and also the condition of the opposite organ can be ascertained by passing the hand into the flank and actually feeling it with the fingers.

The chief objections raised to the first or lumbar method are that the organ is more difficult to reach from here, and especially its pedicle; that the space between the last rib and iliac crest is too limited for the removal of large tumours; and, finally, that in many conditions the state of the opposite kidney cannot be ascertained by direct manual examination.

The objections taken by some to the second or lateral incision are that in the first place the peritoneal cavity is opened, and that if it turns out that the tumour cannot be removed and must be drained, there is greater risk of contamination of the peritoneum, both during and after the operation, than in the lumbar method.

The same objections have also been urged against the third, or median method, with more or less cogency.

All these procedures have their proper place in surgery, and it remains for future experience to determine the exact conditions under which each shall be adopted. For the present it may be said generally that for the larger solid

and non-inflammatory tumours, median or lateral, abdominal section is to be preferred, while for the fluid tumours of the kidney and inflammatory conditions, the lumbar incision is best suited.

1. *By Lumbar Incision.*

Instruments, Position of Patient, of Surgeon, and Assistants, &c., as for nephrotomy (*q. v.* p. 348).

Landmarks for Incision and Operation.—These may be considered as identical with those for nephrotomy (*q. v.*), as far as the moment at which the surface of the kidney is reached. The subsequent steps of the procedure are determined by the condition of the organ. If its surface be but little or not at all affected by bygone inflammation, it is easily and rapidly separated by sweeping the finger round it until the pedicle is reached. But if at any time the perinephral fat have been inflamed and condensed, so that it forms a tough investing mass intimately united with the capsule of the organ, it is better to enucleate the latter at once out of its capsule. Indeed, it is almost impossible to do otherwise in many cases without very great risk from loss of time, bleeding, and shock. The separation of the kidney, on the other hand, from within its capsule is, as a rule, an easy matter until the pedicle is reached. Now the most difficult part of the operation begins, namely, the ligation of the latter. This is effected by means of an aneurism with a long handle, and made of stouter metal than usual. Armed with strong twisted silk, this is passed through the pedicle of the kidney, guided by the fingers in most cases, for it is rarely possible in so deep a wound to see clearly the part to be traversed. When the blunt eye of the instrument has been worked through the pedicle slowly, the double silk is caught and

drawn out, and the needle too is withdrawn. Then each half of the pedicle is securely tied with one of the threads, after which one of the latter is carried round the whole on the proximal side of the first point of ligature, and knotted firmly. In placing these threads, the organ must be turned to and fro, but all dragging upon it should be carefully avoided. The pedicle of the kidney is now cut through with a scissors as close to the hilus as possible. Indeed, unless the operation be done for new growth, some of the organ may be left, at least sufficient to obviate all risk of slipping of the ligatures. The latter are now cut short, and the stump of the pedicle is dried, dusted with iodoform, and sunk in the lumbar wound. The ureter is either tied in with the vessels or is secured by a separate ligature. It may also be dropped into the wound, or, better still, its cut surface may be drawn into the lips of the skin incision and stitched there, so that it may not contaminate the fresh cut surfaces by regurgitation or leakage of foul urine or mucus.

Nothing now remains but to insert a drain tube into the wound, which has been previously cleansed of all blood-clots. A loose antiseptic dressing is then applied over all.

Memoranda.—The occasional presence of an aberrant renal artery entering any part of the concave border of the kidney must not be forgotten in cutting away the organ. If it were divided without being seen, it would probably retract into the loose areolar tissues around and be very difficult to find. When recognised early there is no difficulty in securing it and dividing it between two ligatures.

2. *By Median Abdominal Section.*

In nephrectomy by median abdominal section, the steps of the operation, as far as the actual enucleation of the

organ, are generally almost the same as in ovariectomy (*q. v.*). The division of the abdominal muscles and peritoneum, and the precautions to be observed throughout as to bleeding, treatment of the intestines, &c., are all alike in both procedures. But when the bowels have been thrust aside and the anterior layer of the ascending mesocolon has been exposed, the special difficulties of nephrectomy commence. First, a transverse incision is made in the anterior layer of the mesocolon, great care being taken to avoid wounding the large veins which run as a rule transversely across the diseased organ. If necessary these must be secured with double ligatures and divided, which is better than running any risk of tearing them in enlarging the rent or getting out the kidney.

Then the organ is separated from its surroundings by the finger swept either inside or outside the capsule according to the amount of destruction of fat by inflammatory sclerosis or the absence of this process. Sometimes, as in the case of renal new growths, enucleation is very easy and accompanied by but little bleeding,¹ sometimes it is extremely difficult, especially where chronic inflammation has caused the perinephral tissue to sclerose. When the kidney is reached it can be lifted out of the abdominal wound and the pedicle and ureter be secured as in the lumbar operation just described. The kidney is then cut away and the stump of tissue containing the vessels is allowed to slip back into the abdominal cavity and the perinephral space. The latter are then thoroughly cleansed of blood-clots, &c., and the rent in the mesocolon is closed with a few catgut stitches. After a final cleansing of the

¹ In a case operated on by the author for sarcoma of the kidney, the whole organ shelled out through the opening in the anterior layer of the mesocolon, without the loss of more blood than could be taken up in a few small sponges.

peritoneum the abdominal wound is closed in the usual manner (*vide* Ovariectomy), and dressed with loose antiseptic dressing firmly bandaged. If there be any indication that fluid, e.g. blood or serum, is likely to accumulate in the post-peritoneal space left by the removal of the kidney, a knife may be thrust from it through the loin external to the erector spinæ muscle for the insertion of a drain tube, the cavity being then shut off from the peritoneum by being stitched closely. In this case, too, the cut end of the ureter may be secured in the angle of the abdominal wound if considered advisable.

3. *By Lateral Abdominal Section.*

Langenbuch's Method.

Nephrectomy by this method is performed as follows: The patient is placed supine, and a free incision is made along the outer border of the rectus muscle through the tendinous fibres of the linea semilunaris. Bleeding is then stopped, and the peritoneum is opened to the extent of the skin wound. Some part of the colon now probably presents and is gently pushed inwards, exposing the *external* layer of the mesocolon. In this few or no vessels are found, and it may be divided in the most suitable direction for the removal of the organ; a vertical incision is, however, to be preferred. If the tumour contain fluid, whether urine, pus, or blood, it is now well to unite the anterior lip of the wound in the mesocolon with the anterior lip of the peritoneal layer of the abdominal wound, so as to shut off the perinephral space from the general cavity of the abdomen. By this measure, if the fluid in the tumour should burst its coverings, it is prevented from contaminating the whole abdomen and can be drained out of the parietal wound, both immediately and

subsequently by a drain tube. In other respects the operation is completed as in the last method just described. Access to the kidney is much easier in the lateral than in the lumbar or median operations, but an examination of the opposite kidney is not so easy as with a median incision.

Memoranda.—Any comparison of the results of these three methods of performing nephrectomy, and their relative mortality, would be quite unreliable at present as a guide to the selection of one or other for a given case. The diseases for which they have been employed are so various, and the stages of the affections at which nephrectomy has been performed so very different, that no reliable conclusions on this point can be drawn from mere statistics. The author's attention to the whole subject has been very close for several years, and his personal experience of the operations considerable, yet at the present moment he is unable to profess any decided leaning to one method more than another, speaking of the removal of the kidney generally. Perhaps there is a slight tendency amongst surgeons to prefer the lumbar operation for the commoner affections of the organ. But the whole question can only be decided when we are able to group our cases more accurately and have a far larger material to judge from than at present.

SUPRA-PUBIC LITHOTOMY.

This old operation has lately been revived and largely practised in this country by many surgeons. Sir H. Thompson, whose large experience in the removal of stone from the bladder entitles him to speak with authority upon the subject, has given it his cordial approval, and by his practice has contributed largely to its development in its newer form. While it has been shown to be clearly a most

suitable operation for the removal of large stones in adults, it appears likely to come into very general use also among male children as a means of avoiding the large wound in the prostatic region, its immediate risks, and the chances of ultimate injury to the functions of the seminal vesicles and ducts.

The introduction of vesical distension and rectal dilatation combined, as a means of raising the bladder above the symphysis pubis and increasing the distance between the latter and the reflexion of the peritoneum, has rendered the operation much safer for the patient and easier for the surgeon than formerly.

The adult patient is prepared for operation by shaving the pubis and the introduction into his bladder of from eight to ten ounces of tepid water or boracic lotion which is retained by pressure on the penis with an elastic band. Then a soft rubber bag is introduced into the rectum and distended with from ten to fourteen ounces; by these means combined the bladder is brought well within reach. The pubis must then be carefully cleansed with one or other of the antiseptic solutions now in use. If the urine has been foul the bladder should be carefully disinfected by frequent washing before its final distension.

Instruments.—A scalpel; a ‘sonde à dard,’ which consists of an instrument like a catheter containing a sharp-pointed grooved stylet to be projected through its eye and withdrawn at pleasure—this is not always necessary; an ‘aponeurotome,’ which is simply a short curved probe-pointed bistoury; two blunt-hooks, one sharp do., lithotomy forceps, copper retractors.

Position of Patient.—Supine, with thighs extended, the head and shoulders being slightly raised.

Position of Operator and Assistant.—The surgeon stands on the right of his patient, the assistant at the opposite side.

Landmarks for Incision and Operation.—The pubic symphysis and the middle line are the only guides necessary. Commencing three inches above the bone, a straight incision is made through skin and fat directly in the middle line down to the symphysis. Then the linea alba is divided either on a director or by direct stroke of the knife. When the transversalis fascia has been exposed it is notched, raised on a director, and slit up to the extent of two inches or so. Then the fat in front of the bladder is cleared to one side with the finger-nail, and the tense wall of the organ is caught up with the sharp-hook. Thus steadied it is punctured vertically with a knife to an extent sufficient to admit the index finger, which is at once thrust in and dilates the opening. The operator's second index finger is then pushed in along its fellow, and the rent in the bladder is gently dilated to a size sufficient to admit of the extraction of the calculus, the dimensions of which can be easily gauged by the fingers. Sir H. Thompson prefers to remove the calculus with his fingers used like the blades of a forceps, the other fingers being locked together to give a purchase in the case of a heavy calculus. When this same operation is performed for the removal of a tumour of the bladder it is well to pass loops of silk through the lips of the vesical wound on either side in order to hold it forward during the extraction of the growth. During the whole operation there should be little or no bleeding if the dissection be carried directly through the middle line and the last part of it be completed by the fingers tearing carefully through the fat. If a knife is used here some of the large veins which ramify over the anterior part of the bladder are apt to be injured and the field of operation is obscured.

In the case of the female bladder, or where in the male a perineal opening has already been made for exploration,

the above operation requires to be modified on account of the impossibility of distending the bladder with fluid. Here it is necessary to use some guide from within to the apex of the bladder, and this is found in the 'sonde à dard' or in a grooved sound designed by Sir H. Thompson. The rectum having been dilated as above, one of these instruments is introduced through the urethra, and is depressed between the patient's legs until the point presses the apex of the bladder upwards close to the back of the symphysis. The bladder having been exposed as described, the point of this blunt instrument (sonde à dard) is felt for, and the stilet is then thrust through the bladder wall. When fully exposed a knife is placed edge downwards in the grooved posterior surface of the stilet, and the bladder wall is incised downwards behind the symphysis to an extent necessary for the removal of the foreign body.

No force should ever be used in thrusting the finger into the vesical opening, lest the anterior attachments of the bladder be disturbed and a space be formed into which infiltration of urine can take place.

The abdominal incision is not sutured in cases where there is foul urine in the bladder, but is left to close spontaneously, a soft rubber tube being introduced and left in the wound of the bladder to favour complete drainage. The patient is laid on his side with the same object in view, and should be changed from side to side about every six hours. Some light loose antiseptic dressing, such as a pad of iodoform wool, is the only covering needed for the wound. But in cases in which the interior of the bladder is perfectly healthy and the urine is sweet, especially among children, the wound in the viscus should be carefully closed with silk sutures in such a way as to bring the cut edges or their external surfaces into perfect apposition, and not the mucous surfaces. The abdominal wound is then cleansed,

dried, and also completely closed so as to aim at union by first intention.

Memoranda.—The cleansing of the interior of the bladder is of the utmost importance. It may best be accomplished by frequent washings with boracic lotion up to the moment of operation.

Excellent results have been obtained by this procedure, and we shall hear more and more of it daily. In those cases in which it has been done on children with healthy bladders, both the wounds in the latter and in the abdominal wall have often healed by first intention in a few days, and the patients have been practically well in a week or so. But if there is any doubt as to the cleanness of the wounds, or if there has been any bruising of the edges of the incision, it is better to leave in a small drain tube reaching into the bladder, the wound, except where this lies, being carefully closed.

LATERAL LITHOTOMY.

This ancient operation is becoming rarer and rarer every year with the improvements in lithotrity and increased knowledge of the pathology and treatment of lithiasis. It is also likely to give way to the suprapubic operation in cases of very large stone or of very much enlarged prostate, where the incision to reach the bladder would have to be very extensive, and the extraction of the calculus more than usually difficult. Still, for children and young adults it will probably still be employed largely, although here, too, the suprapubic operation is coming into vogue.

The preparations for this operation should be carefully attended to, for on them much of the success of the issue depends. The patient should rest in bed for some days

before, and only have a light nutritious diet during this time. He should also be given laxatives to ensure a thorough unloading of the bowels, and on the morning of operation should have his rectum specially emptied with a stimulating enema. The perineum must be shaved and thoroughly cleansed with some strong antiseptic fluid. Finally, the patient should be told to retain his water for a couple of hours before the operation.

Instruments.—A lithotomy knife; artery forceps; a syringe; grooved staff of the full size of the urethra; lithotomy forceps, straight and curved; lithotomy scoop; a 'tube en chemisette'; a short-beaked sound; a probe-pointed bistoury; a bag tampon. These should all be placed on a small table on the operator's right hand, immersed in carbolic lotion 1 in 20.

Position of Patient.—Supine, with both thighs flexed and abducted, the knees flexed, and the soles of the feet grasped by the hands and so fixed with a bandage, or the wrists and ankles connected by Pritchard's straps; the buttocks should be brought a little over the end of the table.

Position of Operator and Assistants.—The surgeon is seated facing the perineum, the skin of which he steadies with his left hand, the knife being held in the other in the writing position. An assistant stands facing the operator on the patient's left, his right hand holding the staff in the middle line steadied by being hooked up against the pubis, and with the thumb on the flat end of the handle, his left hand grasping the scrotum and penis and drawing them up out of the way. The left arm will also serve to steady the patient's left thigh, another assistant steadying the right.

Landmarks for Incision and Operation.—A point an inch in front of the anus in the raphé of the perineum, and

linea ano-ischiatrica

another point midway between the anus and the left tuber ischii, should be kept in view, as well as the direction of the staff. The latter is introduced by the surgeon first of all before the thighs are flexed as above, and is given into the charge of assistant No. 1, who keeps it in the middle line firmly, its point resting upon the stone, which should have been touched by the surgeon immediately before. The operator then thrusts the point of the knife, with its blade turned a little towards his right hand, straight in towards the groove in the staff at the first point indicated, and then depressing his hand a little, cuts downwards and outwards through the second point for about two inches. As he does this he slips his left index finger into the upper angle of the wound, and seeks with its nail the groove in the staff. Having found this the knife is thrust through the remaining tissues into the groove, and when the metal is clearly felt on either side of its point, is pushed on into the bladder. As it is withdrawn the hand is depressed, and it is made to enlarge the incision a little downwards and outwards. A gush of urine indicates that the neck of the bladder has been sufficiently incised. Through the opening thus formed the left index finger is slipped into the bladder along the staff, and when the organ is fairly entered, the latter is withdrawn. The finger is now rotated on its axis and pushed further inwards to dilate the deeper part of the incision, and should at the same time be made to estimate the size and shape of the stone by touch. If this appear to be too large for extraction through the opening as it now is, it is better to enlarge the latter somewhat with a knife rather than trust to dragging the stone through it forcibly. When considered large enough the blades of a lithotomy forceps are introduced into the bladder either closed or one along each side of the finger, and the latter is withdrawn. The forceps is now turned

so as to sweep one of its blades over the floor of the bladder from side to side, which will almost certainly secure the stone. The latter is then withdrawn, by a steady pull in the axis of the pelvis, together with slight movement from side to side if necessary. Search should now be made with the sound for any further calculi, which if present are removed in the same way. The bladder is then washed out with iced water introduced by means of a syringe and flexible tube passed deeply into it. If there is much oozing of blood after this, either the catheter 'en chémi-sette' or the 'ballon tampon' may be inserted and fully distended. When a scoop is employed instead of forceps, it is slipped into the bladder along the index finger and the stone is caught between it and the latter, both finger and scoop being then withdrawn with the stone in their grasp. In the case of very large calculi it is probably better practice to remove them by the suprapubic operation, *q. v.*, as recommended lately by Sir H. Thompson, than to run the risks of making a very large wound in the prostate for their extraction.

Memoranda.—The objects to be kept constantly in view throughout this operation are as follows: (1) To make a free opening into the bladder through the membranous and prostatic urethra by a clean incision which shall not infringe the capsule of the prostate. The urine should come freely away on completion of this incision. (2) To avoid wounding the bulb of the urethra or artery of the bulb by raising the point of the knife too much in the first part of the incision. (3) To make the outer part of the wound free enough, first, to reach the deeper parts easily, and then to provide free escape for fluids from the bladder. (4) To avoid lateralising the knife so much as to imperil the pudic artery. (5) To avoid cutting too far backwards, and thus wounding the rectum.

The stone should be examined for facets or abrasions indicating the presence of other calculi or chipping of the one extracted. If it lie behind an enlarged prostate the curved forceps will be needed to reach it, and this will be aided by tilting up the posterior wall of the bladder with the finger in the rectum. Again, it may lie above the pubis on the anterior wall of the bladder, and will require pressure over the hypogastrium to bring it within reach even of the curved forceps. Some surgeons make it a practice to insert a straight tube into the bladder through the wound and tie it in all cases, others avoid leaving anything in the wound, and certainly for children this is the best practice. Again, it may be found convenient to use the thumb-nail, instead of that of the index finger, as a guide for the knife into the groove of the staff in the first incision, as recommended by Surgeon-Major F. C. Barker, of Rajkot Kathiawar, who has had a large experience of lithotomy in India.

BILATERAL LITHOTOMY.

This operation has never been greatly in favour, and will in the future probably give way to the modernised high operation, i.e. above the pubis, as it is only needed for large stones, and these are more safely extracted by the latter procedure.

The preliminaries here are the same as for lateral lithotomy.

Instruments.—As for lateral lithotomy, with the addition of a ‘lithotome caché.’

Landmarks for Incision and Operation.—Two points midway between the tubera ischii and the anus on each side, and one point an inch in front of the anus in the middle line, are our guide. These are united by one curved incision through skin and fat and some fibres of the

sphincter. Through this opening the index finger of the left hand is inserted and the groove of the staff sought. Then the membranous portion of the urethra is opened along the front of the finger, and a lithotome caché is introduced and thrust along the groove of the staff into the bladder, with its curve upwards and its blades closed. When it has certainly entered, its beak is turned downwards, its blades are opened, and it is withdrawn, thus dividing the two halves of the prostate downwards and outwards. The extraction of the stone and the rest of the procedure is carried out precisely as in lateral lithotomy.

MEDIAN LITHOTOMY.

Allarton's Operation.

The improvement of lithotrity has left little room for this operation, which was designed for the removal of small stones; but the same median incision practised in this procedure has lately come into vogue for the removal of new growths from the bladder and for drainage of the organ in obstinate cystitis. The operation is performed on a curved staff with a dorsal groove, which is introduced into the bladder and hooked well up under the pubis by an assistant. Then the left index finger of the operator, placed in the rectum, feels for the front of the prostate and staff. A long straight bistoury with its edge upwards is then thrust from a point about half an inch in front of the anus directly into the membranous part of the urethra at the front of the prostate, where it should enter the groove of the staff and nearly reach the bladder. It is then made to cut upwards along the latter for about an inch, and as it is withdrawn the skin is incised for about an inch and a half in the middle line towards the root of the scrotum. A steel director or narrow gorget is now made to enter the bladder

along the staff, and the latter is withdrawn. Along this instrument the left index finger is steadily insinuated into the organ, the neck of which it is made to dilate to a size sufficient for the extraction of the foreign body, if of moderate size, with forceps or other instruments. If the foreign body or growth be large the supra-pubic operation described above will be preferable.

INTERNAL URETHROTOMY.

Two distinct methods of performing this operation have been in practice for a long time past, and numerous instruments have been devised for use whichever method is adopted. Thus we distinguish between operations which divide the stricture from behind forwards, and those which cut from before backwards. As a type of instrument adapted to accomplish the first of these objects, Civiale's urethrotome may be specially selected from among a number of others, and for the second Berkeley Hill's modification of Otis' urethrotome. The advantages claimed for the first method are that it is safer to cut from behind forwards, and easier because no special guide is required for the cutting blade as it is drawn out across the constricting bands—but then it requires that the stricture should be passable; for the second, that it can be employed in cases of very bad stricture, where only the very finest bougies can be made to pass the narrowed portion of the urethra, and that the toughened tissue to be severed is put strongly on the stretch during the act of cutting, so that no part of the morbid material is likely to escape division, while healthy urethral tissue is carried out of the way of the cutting blade by the process of stretching. Both modes of operating have their warm supporters, but it may be remarked here that, after a large experience, the latter is

most employed by the surgical staff at University College Hospital at the present time, 1887.

As in the case of other operations on the urinary organs, a great deal of the success of the undertaking depends upon the preliminary treatment of the patient. He should have rest in bed for some days before; the diet should be light and his bowels should be well opened with some saline purge; he should also use diluents in large quantity, and avoid all alcoholic drinks.

When a stricture lies within the first two inches of the urethra, nothing can be simpler than its division. It is simply necessary to thrust a sharp, narrow-bladed knife, tenotome, or bistouri caché down the passage and through the stricture, and then cut freely along the floor as the blade is withdrawn. A No. 13 or 14 catheter should then be passed into the bladder, and having drawn off the water be removed, and not passed again for two or three days. After this it should be introduced every couple of days for a few weeks, and then about once a week.

But when the stricture is in the deeper parts of the urethra, Civiale's instrument is well suited for this method of operating, provided the stricture can be dilated up to No. 5. It consists of a long slender sound with an oval bulb at the end of about the calibre of a No. 5 English catheter. Within this bulb a small blade is concealed which can be protruded by means of a screw acting at the other end of the instrument. The stricture having been enlarged to the size of No. 5 by 'continuous dilatation' for a few days, the patient is ready for the operation. This consists simply in introducing the instrument into the urethra, and passing it inwards until its bulbous end is felt to slip through the narrowed portion. Beyond this it need not travel more than half an inch, when the blade is made to protrude and the whole urethrotome is

withdrawn, cutting the cicatricial structures freely through along the floor of the passage. Then the large catheter is introduced as above, taking care that its point is kept along the roof of the urethra and enters the bladder so as to draw off all the water. Here, too, the wound is not disturbed for two or three days, at the end of which time it is again dilated with a No. 13 or 14 catheter, and this is repeated every two days until the end of the third week, when the intervals are lengthened.

When cutting from before backwards, Hill's urethrotome is very convenient. It consists of a slender double-bladed steel guide, to the end of which a very fine catgut bougie can be attached by a screw. Between the blades of the guide a wedge-shaped traveller is made to pass, having dovetailed slots corresponding to the guides on either side, and a stem by which it is pushed forwards. In this a triangular knife is concealed, which can be thrust out at need by means of pressure on the handle of the stem, and which recoils on the pressure being removed.

The patient having had the usual preliminary treatment, the fine catgut bougie is passed through the stricture, and this is, as a rule, the only difficult part of the whole procedure. When it has once entered the narrowed area, it is pushed on until only an inch or so is left external to the meatus. Here it is held in a forceps while the end of the double-bladed guide is being screwed on to it. When this has been securely done, the catgut bougie is pushed still further into the urethra by means of the steel guide now continuous with it, and which follows it up to and through the stricture, the soft fine bougie curling up within the bladder as it is replaced in the passage and stricture by the instrument. The wedge-shaped traveller is now placed between the blades of the portion of the

guide which is external to the urethra, its cutting edge being concealed and turned downwards. Then the penis is drawn well up over the guide, and the urethra thus stretched fully. The traveller is now pushed down the urethra, separating the blades of the guide and stretching the tissue of the stricture to the fullest extent. When it has reached the latter the blade is made to protrude, and the traveller is forced on its way for an inch or so. The blade is now allowed to recoil within the traveller, which will probably be found to move easily forwards in the guide. If it does not, the blade is again protruded, and any extra division of the stricture is made that is necessary. Both parts of the instrument are now withdrawn one after the other, and a No. 14 silver catheter is passed down the urethra, keeping close to the roof of the passage. If it passes freely in, nothing remains but to draw off the urine and remove it. But if it is held at any point the urethrotome may be again introduced, and an extra cut through the narrowed part be made. In this case the catgut guide will not be necessary, and its place at the end of the instrument is taken by a small bulb of metal which renders any catching of the point in the previous incision less likely to occur. It seems better as a rule to make all the incisions on the floor of the urethra rather than in the roof, but in certain cases this too may be done.

After this operation the patient is told, as in all other cases of internal urethrotomy, to retain his urine as long as possible, so that the surface of the wound in the urethra shall have time to glaze over with lymph, and thus the risks of entrance of the urine into the periurethral tissues be diminished as far as possible. No instrument need be passed for three days or so, as the divided structures will be sufficiently dilated in the meanwhile by each act of micturition. Then a large well-oiled catheter is passed

into the bladder, and this is repeated every few days until the part is healed, when it need only be done once a week or so.

EXTERNAL URETHROTOMY.

This operation is only called for in those comparatively rare cases in which a deep-seated stricture is either quite impassable to the finest bougies, or only occasionally so, and where the patient's condition seriously demands early relief.

In almost every method of external urethrotomy now in use the aim is the same, namely, to cut down into the urethra through the perineum just in front of the stricture, slit up the latter until the dilated part of the passage behind it is reached, and then trust to keeping the passage open with instruments while the perineal wound is cicatrising. Of the various methods which have from time to time been devised to accomplish these objects, none is so simple and safe as that introduced into practice by Mr. Wheelhouse of Leeds. It embodies all the good points of the procedures in vogue before it without their drawbacks, and it gives remarkably good results.

Wheelhouse's Operation.

Instruments.—A straight steel staff, grooved to within half an inch of its point, which terminates in a comma-shaped tip with an abrupt shoulder turned from the grooved side; two pairs of fine pointed catch-forceps; a narrow-bladed scalpel; a grooved fine probe-pointed director; a small probe-pointed gorget, known as 'Teale's dilator'; a No. 13 silver catheter; soft English ditto.

Position of Patient and other preliminaries as for median lithotomy.

Landmarks for Incision and Operation.—The middle line of the perineum, and the spot (usually in the bulbous

portion of the urethra) at which the tip of the staff is arrested by the stricture and forms a prominence when forced downwards, are the points to be kept in view. The operator, seated opposite the perineum, introduces the staff into the urethra and thrusts it downwards with the groove towards himself until its point bulges in the middle line of the perineum at the stricture. In this position it is firmly held by an assistant while the surgeon, steadying the skin with his left hand, the forefinger of which should rest on the staff, enters his knife in the middle line and thrusts it straight into the termination of the groove in the instrument. In withdrawing the knife the skin wound is enlarged to about an inch and a half. The urethra being now opened for about half an inch, the staff is pushed out of the hole, is then turned round and drawn a little upwards until the shoulder of its terminal bulb hitches against the upper angle of the incision in the urethral wall. The cut edges of the latter are now seized on either side with the fine pointed catch-forceps and held apart. If well sponged the interior of the urethra is now clearly seen, and in favourable cases the narrow orifice of the stricture at the bottom of a little pocket as it were. Through this narrow opening the probe-pointed director is insinuated with the groove downwards, and when through the stricture the blade of the knife is run along it from before backwards and the stricture is divided; the dilated urethra behind being freely opened. Along the groove in the director the beak of the slender gorget is now passed until it reaches the bladder by gentle dilatation of its neck. A large soft catheter is now passed down the urethra in place of the staff, and its beak is carried along the groove of the gorget into the bladder and is tied in for a day or so. The after-treatment will be determined by the ease or difficulty with which the catheter can be

passed along the new channel into the bladder. If there is much trouble in finding the way, the instrument should be allowed to remain in and only be changed for cleansing. If the way is easily found—and this is usually the case with a soft olivary French catheter, or an English catheter with a well curved stylet—it is only necessary to introduce it into the bladder once a day or so at first, and then at longer intervals. All irritation of the part is thus avoided.

This operation often requires much patience, and should never be performed without a good light or in a hasty way. A little care in the first incision into the urethra and cautious examination of its walls will usually lead to early detection of the track of the stricture. No force is to be applied to the searching probe, or false passages will be made which it will be very difficult to distinguish from the track of the strictured urethra.

In the after treatment of cases of urethrotomy it is well to use the largest catheter that can be introduced through the urethra without undue force, so that the new passage at the seat of the former stricture may be as wide as possible in case of any tendency to shrinking at this spot. In this way a No. 30 French catheter may be used with advantage in many cases.

CHAPTER XIV.

OPERATIONS ON THE MALE GENERATIVE
ORGANS.

AMPUTATION OF THE PENIS.

Sir J. Lister's Method.

THE patient lying supine, and the genitals having been rendered aseptic by shaving and careful washing with soap and water and carbolic lotion, two short, semilunar, antero-posterior flaps are made in the sound skin of the body of the penis. The integument is then retracted and the corpora cavernosa and spongiosa are severed transversely by a stroke of the knife. After bleeding has been arrested as far as possible, a short median slit is made in the lower flap corresponding to the end of the divided urethra, and the latter is passed through it. Here the end of the urethra is cut obliquely from below upwards and forwards so as to correspond to the orifice in the skin, to which its edges are closely united by several fine sutures. The two flaps are then sutured over the face of the stump, a small horsehair or silk drain being inserted at one point for the escape of blood, which is apt otherwise to distend the skin to a considerable extent and retard the healing of the wounds.

When last performing this operation it occurred to the

author that the oozing from the divided corpora cavernosa might be arrested by a temporary subcutaneous ligature *en masse* of the latter with silk or catgut, the ligature being prevented from slipping forwards by the introduction of a hare-lip pin transversely between corpora cavernosa and spongiosa. Both pin and ligature were withdrawn in a couple of days, having completely controlled all bleeding.

When the flaps have been accurately adjusted the whole end of the stump is dusted over with iodoform, then covered with a thin layer of iodoform wool which is fixed to the skin with collodion. The orifice of the urethra should of course be left free. When the collodion is dry the part should be covered with an extra layer of wool, only to be removed for the act of micturition.

More complete extirpation of the organ than the above may be accomplished by slitting the scrotum along its median raphé and stripping the crura from the rami of the pubis with a raspatory. When the whole body of the organ has been thus removed, the urethra is united in the posterior angle of the wound as described above.

CIRCUMCISION.

The simplest way of performing this operation is as follows. Having controlled the vessels by tying the root of the penis with a tape, a director is passed between the dorsum of the glans and the prepuce, and a sharp-pointed curved bistoury is run along it and made to transfix the latter in the middle line opposite the corona glandis. The two halves of the prepuce are then cut evenly off on either side as far as the edge of the frænum with scissors. The tape being now removed from the root of the organ, any vessels are secured which may require attention. Then the mucous membrane is everted and carefully adjusted to

the edge of the skin by continuous or interrupted suture. The parts are now finally cleansed with carbolic solution, which should also have been freely used before the commencement of the operation and during its performance. Then the whole end of the penis is dusted with iodoform, and a thin layer of antiseptic wool is laid around the glans and wound, leaving the meatus free. This wool is secured in place by the free use of collodion, which should form a hard covering for the wool. If the operation have been done with strict attention to cleanliness, this dressing will not require to be removed for several days. The wound will then probably be found united everywhere by first intention, and the stitches can be removed. The patient should keep quiet until all cicatrisation is complete, but need not necessarily remain in bed.

Circumcision may also be done by drawing the prepuce well forward and removing it by a sweep of a knife; then slitting up the mucous membrane on the dorsal aspect, and completing the operation as above. In either case the result depends on the accuracy with which the two edges are brought into contact by the sutures and the absence of septic matter at all stages of the procedure.

CASTRATION.

Instruments.—A sharp scalpel; artery-forceps; dissecting forceps.

Position of Patient.—Supine, with legs extended.

Position of Operator.—The surgeon stands on the patient's right side, his assistant opposite to him. With his left hand he grasps the scrotum from behind and draws it together in such a way as to render the skin in front of the testicle and cord as tense as may be. He then makes a three-inch vertical incision over the latter, commencing

at the external abdominal ring and terminating over the body of the organ. Through this the cord is rapidly cleared, and is then tied *en masse* with carbolised silk or catgut as high as possible. The testicle is then separated by a little traction and a few touches of the knife from its surroundings, and the cord is severed with one stroke just below the ligature. Any bleeding points are then attended to and the skin is stitched from above downwards, a drain being left in the lower angle.

Memoranda.—Some operators prefer to divide the cord first and then pick up the vessels separately, but this involves loss of time and possesses but few advantages over the ligature *en masse*.

FOR HYDROCELE OF THE TUNICA VAGINALIS.

The operative treatment of hydrocele of the tunica vaginalis is usually divided into *palliative* and *curative* or *radical*.

The Palliative Treatment.

Instruments.—A medium-sized trochar and cannula; some clean wool and collodion.

Position of Patient.—Standing with his back against the edge of a table, or against the wall.

Position of the Operator.—Sitting or kneeling before the patient. With his left hand he grasps the scrotum from behind and renders it tense in front by squeezing it.

Operation.—The surgeon holds the trochar in his right hand between the thumb and middle finger, and with the handle resting in the hollow of the hand. The tip of the forefinger should be placed firmly on the instrument at about half an inch from its point to act as a 'stop' during puncture. A spot is now chosen clear of all veins on the

front of the tense scrotum at about the junction of the middle and inferior thirds, and the point of the trochar being placed on this is suddenly forced through it until stopped by the tip of the finger. Still pressing the collar of the cannula inwards and upwards a little, the trochar is withdrawn and the fluid is allowed to escape. When the sac is quite empty the puncture is closed with a little wool dipped in collodion, and a suspensory bandage is worn for some days. This operation will probably have to be repeated every two or three months as the sac fills and becomes uncomfortable.

Memoranda.—The position of the testis should always be made out before operation by means of palpation and the translucency test. If it be found below and in front, as is in some rare instances the case, the sac must be punctured from the side. Care should always be taken to force the instrument well through the walls of the sac and to keep the cannula from slipping out of the tunica vaginalis while the trochar is being withdrawn. The instruments used should be very sharp and most carefully cleansed beforehand with some antiseptic; the scrotum also should be similarly cleansed.

The Radical Treatment.

In this case the object of operation is not only to withdraw the fluid from the tunica vaginalis, but also to provoke in the latter such an amount of aseptic inflammation as shall either modify its secreting power so that no excess of fluid shall be poured out, or actually obliterate the cavity altogether by inflammatory adhesion or granulation.

Two ways of attaining these objects are usually spoken of—(a) introduction of various irritants into the tunica

vaginalis, or the use of a seton ; and (β) laying open the sac freely. As the seton is now rarely used, the mode of employing it need not be described. The materials introduced into the tunica vaginalis are very many, only a few of which need be mentioned, the method of employing them being practically the same. Tincture of iodine stands first on the list as the most widely used of all ; next, solutions of sulphate of zinc, \mathfrak{zj} . ad Oj . ; and, again, port wine. Certain solids too are in favour more or less, and among these may be mentioned nitrate of silver, iodoform or red oxide of mercury, and carbolic acid.

a. The mode of using these substances is as follows : The tunica vaginalis having been emptied as above, a half-ounce glass syringe, with a slender nozzle either of glass or platinum to fit the cannula, is filled with one or other of the fluids alluded to. The syringe is then fitted to the cannula, care being taken that the point of the latter lies well within the sac, and its contents are steadily injected into the latter. The external orifice of the cannula is now closed with a wooden plug, and the scrotum is manipulated so as to bring the injected fluid into contact with the whole serous surface. At the end of ten minutes or so the plug is withdrawn from the cannula and the fluid is allowed to escape, after which the cannula is withdrawn and a small portion of cotton-wool dipped in collodion is fixed over the puncture. After this the patient may stay on his feet for a few hours, but should then go to bed and remain recumbent for some days. When the swelling and tenderness are declining he may get up, using a suspensory bandage. If the operation requires to be repeated, as is not uncommon, the mode of procedure is the same, but the surgeon must be careful to make out the exact seat of the testicle, which may have contracted anterior adhesion as the result of the first operation. If carbolic acid is

used it should be liquified by admixture with half its bulk of glycerine or by the addition of about one per cent. of water; a drachm of it is then injected as above.

Where powdered substances are used to excite inflammation in the tunica vaginalis, they are introduced through the cannula on the end of a probe slightly moistened with glycerine. When the end of the probe is felt in the scrotum, the latter is manipulated freely so as to spread out the powder over the inner surface of the sac. Then the probe is withdrawn, and subsequently the cannula and the wound is closed with wool and collodion, as in the last case. This is a very convenient way of treating hydroceles in out-patient practice. The patients are able to go home so soon as the puncture is closed with collodion, and without feeling so much pain at once. When this comes on after a few hours they should take to bed and remain there until the inflammation is on the decline, when they may be allowed to get about again, wearing a suspensory bandage.

β . The radical operation by laying open the tunica vaginalis is a very old one, and though dangerous in former times on account of the severe septic inflammation which so frequently followed it, is now considered almost free from risk when antiseptic precautions are observed, and is coming again into use. It is well suited for cases in which there is a thickened sac, or where injection has failed, or, on the other hand, has been followed by effusion of blood into the tunica vaginalis.

All hair having been removed from about the genitals, the latter are thoroughly cleansed, first with soap and water, then with carbolic lotion or solution of bichloride of mercury. The scrotum is now seized in the operator's left hand from behind, and the front is rendered tense by squeezing. It is then laid open by one firm stroke of a

sharp scalpel from top to bottom. The sac should then be searched for any abnormality such as encysted hydrocele or loculi. These, if found, must be laid open into the general cavity. The edges of the serous sac are now stitched to the skin at two or three points, and the cavity is either partially filled with carbolised lint, portions of drainage tube, or both. In a short time the sac will commence to contract and the small space left gradually to fill up with plastic matter, nothing but a superficial wound remaining after a little. Whatever is placed in the wound after the first incision should not distend the sac so as to interfere with its contraction. More or less orchitis may always be expected after this operation, but with rest, restricted diet, and the use of saline purges if necessary, it will give little trouble.

CHAPTER XV.

*OPERATIONS ON THE SKULL AND PARTS
WITHIN IT.*

TREPHING OR TREPANNING.

THIS operation, which had for a time become somewhat more restricted in its application for injuries of the head than was the case in former years, is now coming into wider use again with the increased powers of localising the lesions within the skull, and the great diminution of risk in the operation due to the perfecting of antiseptic methods of treatment. The use of antiseptics, too, has brought with it a modification of the procedure which is likely somewhat to influence the ultimate results in those cases which survive the operation. This is the re-implantation of portions of those pieces of bone which have been removed. This, which under the old *régime* would have led to nothing but increased liability to suppuration and all its consequences, is now followed in some cases, if carefully done, by reunion of those portions of bone, and a more or less perfect restoration of the original condition of parts. By those who have confidence in their powers of securing completely aseptic wounds, this addition to the operation will probably always be made in the future.

But it must not be forgotten that the difficulties of

preserving a fresh wound from septic influences are perhaps greater in the case of the scalp than in any other part of the body, with the exception of the region about the genitals. The fatty matter always present in abundance on the former renders it peculiarly difficult to cleanse absolutely, especially as the hairs and their follicles tend to retain dirt of all kinds. Bearing these points in mind, we must give special attention to the preliminary treatment of the scalp. The head is first shaved closely as long as possible before operation. It is then washed several times over with soft soap and warm water. Ether may also be used in the intervals to get rid of all traces of fatty matter from the orifices of the sebaceous follicles. Then the skin is soaked in carbolic acid lotion 1 to 20 by means of a cloth completely enveloping the head, and kept wet if possible for some hours. Finally, the field of operation may be washed over with a solution of bichloride of mercury 1 to 1000. The carbolic spray is subsequently used throughout the whole procedure.

The operation will of course vary somewhat according to the condition for which it is performed; it is described here as if called for on account of fracture of the skull.

Instruments.—A scalpel; dissecting and artery forceps; a periosteal elevator; trephines of different sizes; a Hey's saw; a tenaculum.

Position of Patient.—Supine, with the shoulders slightly raised, and the head turned away from the side to be operated on.

Position of Operator and Assistant.—The operator stands so that the head shall be a little on his left hand; his assistant is placed opposite to him.

Operation.—Supposing the case to be one of depressed fracture with unbroken skin, the first step is to make either a crucial, a semilunar, or a T-shaped incision through

the latter down to the bone, a little to one side of the depression. The soft parts, including the periosteum, are now stripped off the skull around to the full extent of the flaps defined by the incisions, which should be very free. The best incision is one which forms a semilunar flap whose base includes the arterial trunks of the region operated on. When all bleeding vessels have been closed, the fracture is examined, and if there is room for the introduction of an elevator under the edge of the depressed portion, the latter is raised by leverage in preference to any other method. Where this cannot be done, the pin of the trephine pushed out beyond the crown is set upon the edge of the undepressed part of the skull, and the instrument is rotated on it until the crown has entered the outer table of the bone. When this is felt, the pivot-pin is withdrawn and the crown is carried deeper and deeper, with all caution, until the inner table is reached. If there is any doubt as to the depth of the cut in the bone, it should be sounded all round from time to time with a fine probe, and at the same time the bone should be tested as to its mobility. Great caution is necessary when the instrument has penetrated deeply, lest it slip suddenly through the dura mater; also lest it be placed at an angle with the inner table of the bone instead of perfectly perpendicular, and so enter the skull at one point while the bone remains undivided at another. When it is felt that the trephine has been carried to a sufficient depth, and that the disk of bone is nearly loose, an elevator is inserted at one point and the disk is removed. Then the elevator is further inserted under the edge of the depressed fragment, and it is raised to the level of the rest of the bone around. The portion of bone removed with the trephine is meanwhile wrapped in a warm carbolised sponge or cloth. After elevation of the depressed portion, the wound

is thoroughly cleansed of all débris and blood, any vessels in the dura mater being secured. When quite dry and clean, a few small fragments, carefully chipped off the disk previously removed, are laid here and there over the dura mater, and then the flap or flaps are adjusted carefully upon the latter. They will probably not require any sutures if carefully padded, but if they do not come nearly together should be steadied with one or two stitches, a drain of horsehair or catgut being inserted at the most dependent angle. A loose gauze dressing secured lightly with a triangular bandage will be the most suitable application for the after-treatment.

Memoranda.—Free drainage for a few days is more than usually necessary in this case to avoid any pressure upon the brain or spread of fluid throughout the arachnoid space if the dura mater has been opened.

OPERATIONS ON THE BRAIN.

Until within the last few years operations on the brain have been limited to remedying the effects of injury to the organ, *e.g.* laceration and abscess, the result of injury with or without fracture. But quite recently the great discoveries as to the localisation of cerebral functions have been utilised by surgeons, and formal operations have been planned for the removal of growths and cicatrices from the brain with the object of saving life, of permanently curing some of the more serious nervous disorders, such as epilepsy, and of giving relief from intolerable pain. Abscesses in the brain too, unconnected with injury, and dependent for the most part upon disease in the middle ear, have been opened and drained with perfect success, and thus an inevitably fatal result has been averted. A great deal, however, remains to be learned by experiment

before such operations are likely to become at all general. But so far the results obtained are very encouraging. Thus, out of ten cases operated on by Mr. V. Horsley for various morbid conditions of the brain and cerebellum, only one died, and the rest were most materially benefited.¹ And of six published cases in which cerebral abscess depending on disease of the temporal bone was sought for and evacuated in this country, three were perfectly successful.²

The first matter to be considered is how to find the different sulci and convolutions underneath the surface of the skull.

For a long time to come it is probable that the surgery of the brain, apart from the opening of abscesses, will be limited in the main to operations upon the motor areas grouped around the fissure of Rolando (figs. 55 and 56), and fortunately, to localise this latter and the convolutions on either side of it is not a matter of great difficulty. Probably the best primary guide to this important sulcus is a 'base line' (first proposed, I believe, by Dr. Reid),³ which runs from the lower border of the orbit through the centre of the bony meatus of the ear (figs. 54, 58, 59, and 61 *aa*). From this line others can be drawn at right angles through certain bony points which it touches, and the brain be thus mapped out without much difficulty. The following are the rules given by Dr. Reid for finding the chief sulci and convolutions of the brain. A line from the glabella or depression between the two nasal eminences at the root of the nose to the external occipital protuberance indicates the great longitudinal fissure. The transverse fissure is found by drawing a line from the centre of the bony meatus of the ear along the superior curved line of the occipital

¹ *Brit. Med. Journ.*, April 23, 1887.

² *Ibid.* Dec. 11, 1886; Feb. 12, 1887; April 2, 1887; *Lancet*, 1886.

³ *Lancet*, 1884, p. 539.

bone (fig. 54 *a, g*). To find the fissure of Sylvius draw a line from a point an inch and a quarter behind the ext. angular process of the frontal bone to a point three-quarters of an inch below the most prominent part of the parietal eminence (fig. 54 *Sy. fis.*). Measuring from before backwards the first three-quarters of an inch of this line will

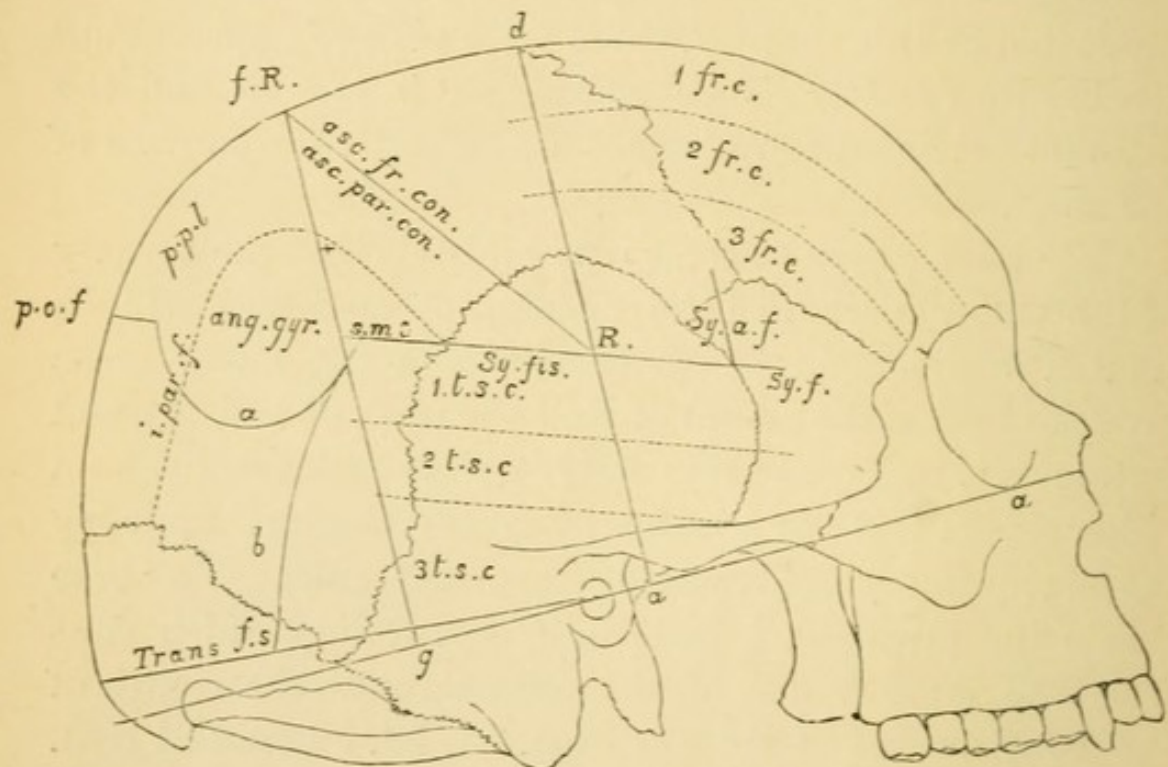


FIG. 54.—DIAGRAM OF CRANIO-CEREBRAL RELATIONS (Reid.)
(From a Photograph kindly made for me by Mr. Marriott.)

a, a, g, Base line; *trans. fis.* transverse fissure; *p.o.f.* parieto-occipital fissure; *Sy. fis.* Sylvian fissure; *Sy. a.f.* ascending limb of Sylvian fissure; *f. R. R.* fissure of Rolando; *asc. fr. con.* ascending frontal convolution; *asc. par. con.* ascending parietal convolution; 1 2 3 *fr. c.* 1st, 2nd, and 3rd frontal convolutions; 1 2 3 *t. s. c.* 1st, 2nd, and 3rd temporo-sphenoidal convolutions; *p.p.l.* postero-parietal lobule; *ang. gyr.* angular gyrus; *s. m. c.* supramarginal convolution; *i. par. f.* intra-parietal fissure; *a.* boundary of parietal lobe; *b.* boundary of temp.-sphenoidal lobe.

represent the main fissure, and the rest of the line the horizontal limb. The ascending limb starts at the point indicating the termination of the main fissure, i.e. two inches behind the ext. ang. process, and runs from this vertically upwards for about an inch (fig. 54 *Sy. a.f.*). The fissure of Rolando is found by drawing two lines from and

perpendicular to the base line (*a a*) to the top of the head *a.d.* and *g.R.*, one passing through the depression in front of the ear, and the other through the posterior border of the mastoid process. A line, *R.R.*, is now drawn from the point at which *a.d.* intersects the line marking the Sylvian fissure to the point at which *g.R.* intersects the sagittal suture or middle line of the head. This line, *R.R.*, indicates the direction of the fissure of Rolando, and the position consequently of the ascending frontal and parietal convolutions on either side of it.

The external parieto-occipital fissure (*p.o.f.*) is usually found under the posterior inch or so of the line indicating the Sylvian fissure, if the latter is prolonged to the middle line behind.

The first frontal fissure corresponds as nearly as possible to a line drawn parallel to the longitudinal fissure backwards from the supraorbital notch to about three-quarters of an inch from the line marking the fissure of Rolando. The second frontal fissure corresponds to the frontal part of the temporal ridge. We have thus a guide to the position of the first, second, and third frontal convolutions.

The ascending frontal and parietal convolutions occupy a space about three-quarters of an inch broad on either side of the fissure of Rolando.

The parietal lobe is bounded by the middle line behind the fissure of Rolando in front, and the lines for the parieto-occipital and Sylvian fissures below, united by a curved line with its convexity downwards. The intraparietal fissure *i.par.f.* is indicated by a line curved in the opposite direction, drawn from a point half an inch external to the lower end of the parieto-occipital fissure, and in its anterior third running parallel with the fissure of Rolando three-quarters of an inch behind it. Above, and in front of this curved

line, lies the ascending parietal convolution, and above and behind it the postero-parietal lobule, *p.p.l.* Below the line lies the supramarginal convolution in front and part of the angular gyrus behind. The supramarginal gyrus, *s.m.c.*, corresponds to the most prominent part of the parietal eminence.

The temporo-sphenoidal lobe is seen to be defined above by the Sylvian fissure and below by a line marking the upper border of the zygoma, and continued backwards to a point midway between the occipital protuberance and the posterior border of the mastoid process. In front it reaches as far as the posterior superior border of the malar bone. Behind it is bounded by a line slightly curved, *b*, with its convexity backwards extending from the posterior end of the Sylvian line to the point midway between the posterior border of the mastoid process and the occipital protuberance already indicated.

The three temporo-sphenoidal convolutions are marked out by two lines parallel with the Sylvian fissure, one about an inch below the latter, the second three-quarters of an inch lower down.

The occipital lobe is defined by the lines already given, the space covering it occupying the lower and back part of the scalp.

The most important cerebral centres related to the fissures and convolutions alluded to above are indicated in the accompanying figs. 55 and 56, for the permission to use which I am indebted to the kindness of Dr. Ferrier, from whose work on the Functions of the Brain they are taken. The numbers are the same in both figures.

“(1) On the superior or postero-parietal lobule.

The opposite hind limb is advanced as in walking—the thigh being flexed on the pelvis, the leg extended, with dorsal flexion of the foot, and spreading, or extension, of the toes.

Occasionally the action is limited to the foot, this being dorsally flexed and the toes expanded.

(2) On the upper extremity of the ascending parietal, and adjoining portion of the ascending frontal convolution.

Flexion with outward rotation of the thigh, rotation inwards

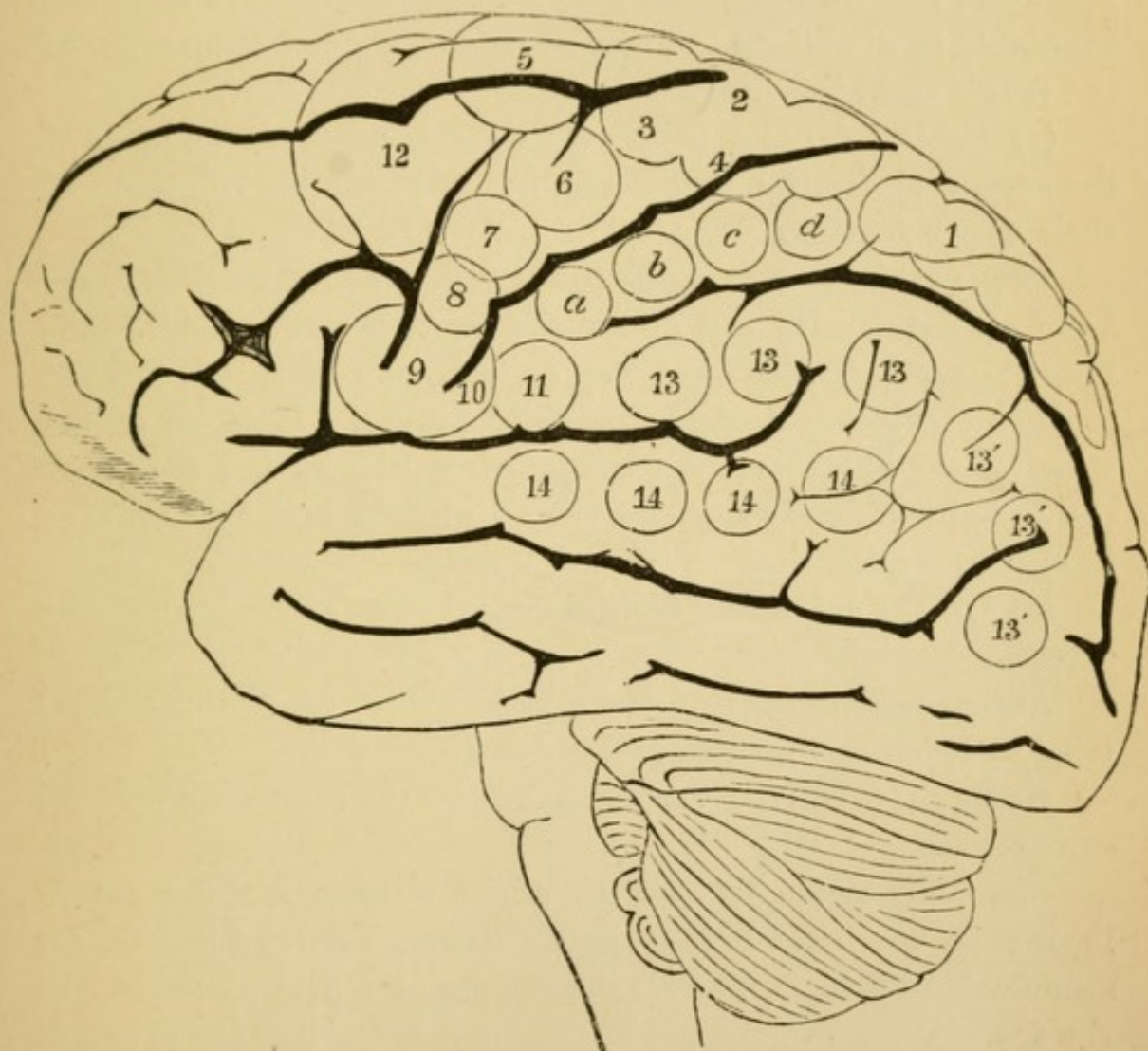


FIG. 55.—CORTICAL CENTRES OF THE BRAIN. (After Ferrier.)

of the leg, with flexion of the toes—the action being such as is seen when a monkey makes a grasping movement, or scratches its chest or abdomen with its foot. Various degrees of this action may be seen according to the strength and duration of the stimulus; but the above is the complete action uncomplicated by other movements, except certain synergic movements of the trunk necessary to the full execution of the action

in question. The action is similar to that caused by stimulation of the sixth lumbar root of the crural plexus (fifth in man).

(3) Close to the semilunar sulcus at the upper extremity of the ascending frontal convolution.

Here movements similar to those under (1) and (2) are produced, and in some cases also *the tail is moved*. I have not been able to dissociate the movements of the tail from those of the trunk and hind limb.

(4) Behind (3) and below (2) on the adjacent margins of the ascending frontal and ascending parietal convolutions at their upper portion.

The opposite arm is adducted, extended, and retracted, the hand pronated. By this action the hand is struck backwards almost exactly in the same way as occurs on stimulation of the seventh cervical root of the brachial plexus. It is an action which if the hand were a fixed point would by the action of the latissimus dorsi raise the body upwards and forwards, as in climbing a trapeze.

(5) On the ascending frontal convolution at the base of the superior frontal.

Extension forwards of the opposite arm, as if the animal tried to reach or touch something in front.

Areas (a) (b) (c) (d), various points on the ascending parietal convolution.

Clenching of the fist.—With slight stimulation the action begins in the thumb and index finger, followed on longer stimulation by flexion of all the fingers and firm clenching of the fist. With the closure of the fist is associated the synergic action of the extensors, of the wrist and fingers, but centres for the individual flexors and extensors could not be differentiated.

(6) On the ascending frontal convolution at the bend or knee of the præcentral sulcus.

Flexion and supination of the forearm—the completed action bringing the hand up to the mouth. The movement is essentially the same as that which occurs on stimulation of the sixth cervical root of the brachial plexus.

The action is apt to be associated with (7) and occasionally, when the irritation is near the fissure of Rolando, with clenching of the fist.

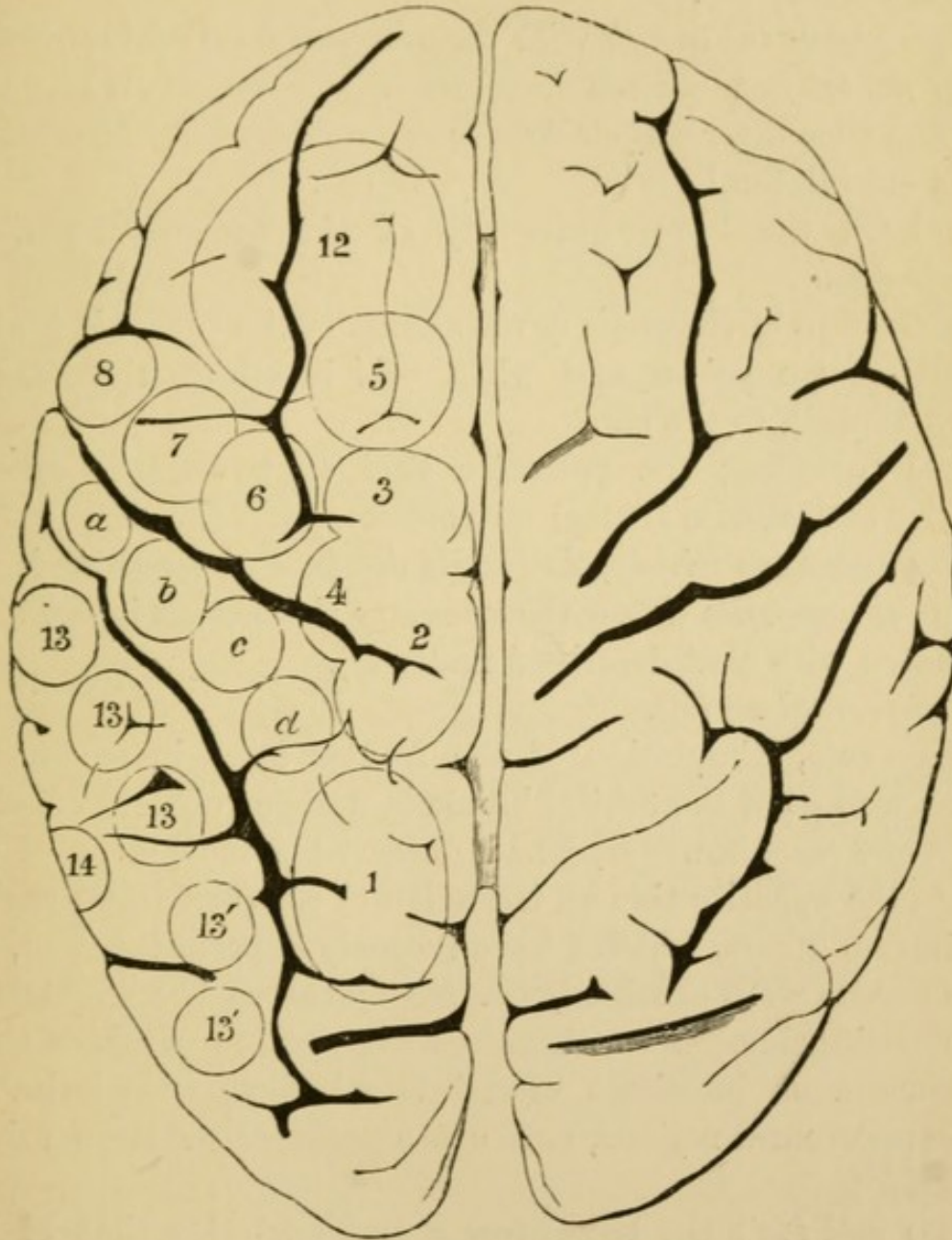


FIG. 56.—CORTICAL CENTRES OF THE BRAIN. (After Ferrier.)

(7) On the ascending frontal convolution below (6).

Retraction and elevation of the angle of the mouth—the action of the zygomatic muscles.

(8) On the ascending frontal convolution below (7).

Elevation of the ala of the nose and upper lip—associated

with depression of the lower lip, so as fully to expose the canine teeth.

(9) and (10) On the lower extremity of the ascending frontal convolution.

Opening of the mouth with the protrusion (9) and retraction (10) of the tongue.—These movements are occasionally repeated for some time after the electrodes are withdrawn. The movements are bilateral.

(11) On the lower extremity of the ascending parietal convolution.

Retraction of the angle of the mouth.—The action is that of the platysma myoides, and when this is strong the head is drawn slightly to the side.

(12) Including the posterior half or two-thirds of the superior and middle frontal convolutions.

The eyes open widely, the pupils dilate, and head and eyes turn to the opposite side.—Occasionally this action is apt to be associated with that described under (5).

Præfrontal region.

As a rule, stimulation of the frontal lobes in advance of (12) as well as of the orbital lobule is without obvious effect.

In one case, however, I had observed a movement of the eyes to the opposite side on irritation of the præfrontal region, and in two others, which I have recently experimented on, the same results were obtained, viz. movement of the eyeballs to the opposite side. I am therefore disposed to consider these movements as in direct causal relationship with irritation of the præfrontal regions, and not accidental or mere coincidences.

(13) and (13') On the anterior and posterior limb of the angular gyrus respectively.

The eyes move to the opposite side, with an upward or downward deviation, according as the electrodes are on (13) or (13') respectively. Usually also the pupils become contracted, and there is occasionally a tendency to closure of the eyelids, if the eyes are already open at the time of stimulation, as if under the stimulus of a strong light. Luciani and Tamburini

have occasionally seen the pupils dilate instead of contract, but differences of this kind are unimportant, as the pupils will vary according to the condition of the animal at the time. It is well known that during sleep the pupils are contracted, but dilate upon the individual being suddenly awakened, and then again contract under the influence of the light which falls on them. In like manner the sudden stimulation of the angular gyrus may in a monkey at the time fully awake cause contraction of the pupil; while in another, asleep or nearly so, the first effect will be dilatation from roused attention.

Sometimes the head turns with the eyes to the opposite side.

(14) On the superior temporo-sphenoidal convolution

Pricking of the opposite ear, head and eyes turn to the opposite side, pupils dilate widely."

The urgent need of special preparation of the surface of the scalp for the operation by the most elaborate cleansing is insisted on at p. 386, and the routine methods of effecting thorough cleansing are described.

Turning now to the operation on the brain itself, our first care is the selection of an anæsthetic. For guidance in this matter we are dependent on Mr. Horsley's experience, as indeed for most of the facts at present known regarding the newer formal operations on the brain for non-inflammatory disease.

Immediately before operation the patient should have a quarter of a grain of morphia, which not only obviates the necessity of using much chloroform, but has the effect also of contracting the arterioles of the central nervous system and thus diminishing the bleeding from the substance of the brain when this is cut into. Then chloroform is given in the usual manner.

In all operations it is considered better to use the Listerian formulæ of wound treatment, i.e. carbolic steam spray and gauze dressings, &c., than any of the modifica-

tions which are so frequently found convenient for wounds of other parts.

Instruments, &c.—A stout scalpel; artery-forceps; periosteal elevators; a large one-inch trephine; a Hey's saw; a surgical engine with a circular saw; well-curved needles; catgut of varying thickness; a probe-pointed scissors.

Position of Patient.—Supine, with the shoulders slightly raised and the head turned to the opposite side from that operated on.

Position of Operator and Assistants.—The operator stands on the affected side, his assistant opposite to him on the other side.

Landmarks for Incision and Operation.—The bone should be exposed over the diseased area by a curved incision planned so that its posterior end will be dependent when the patient is lying down. In mapping out such a flap the direction of the arteries supplying it must be borne in mind, and every care taken not to divide their trunks. The skin is cut straight down to the bone with one bold stroke of the knife, held vertically, and the periosteum is reflected in the flap with as little disturbance as possible. The bone is first trephined over the affected spot in order to ascertain its thickness, and then cut with a circular saw driven by a surgical engine, to an extent sufficient for free access to the brain. Those portions uncut by the circular saw are to be divided with a powerful bone-forceps. Portions of the bone removed should be placed between warmed carbolised sponges, and preserved for planting between the dura mater and skin at a further stage of the procedure.

The dura mater is incised with a knife at first, then with probe-pointed scissors, round four-fifths of the opening in the bone and at about an eighth of an inch from its border, so that there may be room for suturing it sub-

sequently if found to be healthy. The meningeal vessels may usually be seen before division of the dura mater, and secured with ligature by transfixing the membrane.

When the brain has been exposed, all alteration in its colour and consistency and the presence or absence of bulging into the trephine opening must be noticed, as well as changes in the walls of the vessels of the pia mater. In incising the brain the knife should be held vertically to its surface, so as to wound as few of its vessels as possible. In some cases the pia mater can be lifted out of the sulci and turned aside with advantage.

After the operation on the brain has been completed, and all oozing has been arrested by pressure with a soft sponge, the dura mater is turned down and fixed by catgut sutures, and then the large flap is laid over it and stitched at short intervals with silk. Small portions of bone may be planted here and there between the flap and the dura mater, but this is not necessary. About an inch of the posterior end of the wound is left unstitched for the escape of serum during the first twenty-four hours, but no drain tube need be inserted. Then the usual carbolic gauze dressing is applied over all with even pressure. Union everywhere by first intention is aimed at throughout this whole procedure, but if there is any undue distension of the flap with serum, on or about the second day, a little may be let out by insinuating a probe into the posterior angle of the wound and so dilating it. The stitches may be removed at the end of the first week, and the Listerian dressing changed for one of salicylic wool secured with collodion.

Memoranda.—Throughout this whole procedure the first and greatest object to be kept in view is the absolute cleanliness of the field of operation. If this is secured the exposure, manipulation, and excision of portions of the brain may be very free. The removal of large portions of

the skull does not lead to much inconvenience, as has long been known from the experience of military surgeons. Even if the periosteum does not furnish new bone, enough tough fibrous material is formed to protect the brain underneath; moreover, the weak spot can be protected if necessary with a shield of metal or some lighter material, such as vulcanite or celluloid.

FOR ABSCESS IN THE TEMPORO-SPHENOIDAL LOBE OF THE
BRAIN.

Abscess of the temporo-sphenoidal lobe of the brain is not infrequently a consequence of suppuration in the middle ear. This suppuration may or may not be associated with caries of the petrous portion of the temporal bone, but is in every case putrid. The cerebral abscess is usually in such a case found somewhat behind the middle of the lobe, or between two lines at right angles to the 'base line' (fig. 58 *a a*), about an inch and a quarter apart, one passing vertically through the centre of the meatus (fig. 57 *a*), the other about an inch and a quarter behind it (*c*). The distance above the base line to which the abscess may extend is of course variable, but after careful study of cases the author is led to conclude that the spot to be selected for opening a collection of the kind should be an inch and a quarter above the base line. If an aspirator needle then (fig. 57 *d*) be made to penetrate the brain at a point at this distance behind the centre of the meatus and the same above the base line, and be thrust inwards, forwards, and a little downwards towards the roof of the tympanum at (*a*), it can hardly fail to enter an abscess depending on ear disease if in the temporo-sphenoidal lobe. The pathological data from which these conclusions are drawn would be out of place here. They

are alluded to in a paper describing a case in which such an abscess was successfully opened by the author. ('Brit. Med. Journal,' Dec. 11, 1886.)

Instruments.—Scalpel; artery-forceps; trephine two-thirds of an inch diameter; elevator; an aspirator needle,

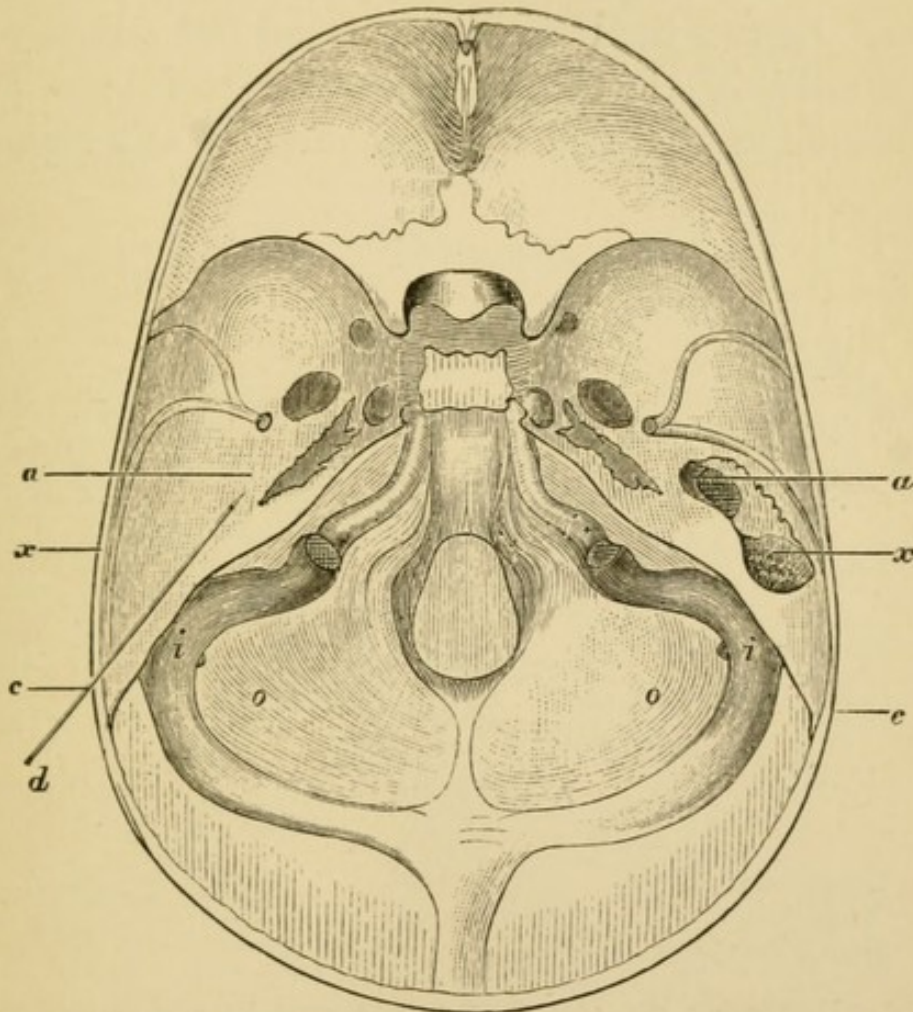


FIG. 57.—DRAWING OF THE BASE OF A SKULL TO ILLUSTRATE THE RELATIONS OF ABSCESS OF THE TEMPORO-SPHENOIDAL LOBE AND OF THE CEREBELLUM TO EAR DISEASE.

a a, tympanic cavity; *c c*, posterior border of mastoid process; *x x*, spot for trephining the mastoid antrum; *i i*, foramen for the mastoid vein; *o o*, spot for trephining for cerebellar abscess.

size of No. 4; English catheter; a silver drain tube, size of No. 8; English catheter; fine Volckmann's spoons.

Position of Patient.—Supine, with the head slightly raised and a little turned towards the sound side.

Position of Operator and Assistant.—The operator stands on the affected side of the head, with his assistant on the opposite one.

Landmarks for Incision and Operation.—The point to be chosen for the application of the trephine, which should be of medium size, is given above. At this spot the bone is laid bare by two incisions, one vertical immediately behind the insertion of the pinna, the other horizontal, crossing the mastoid process and meeting the first at a right angle,

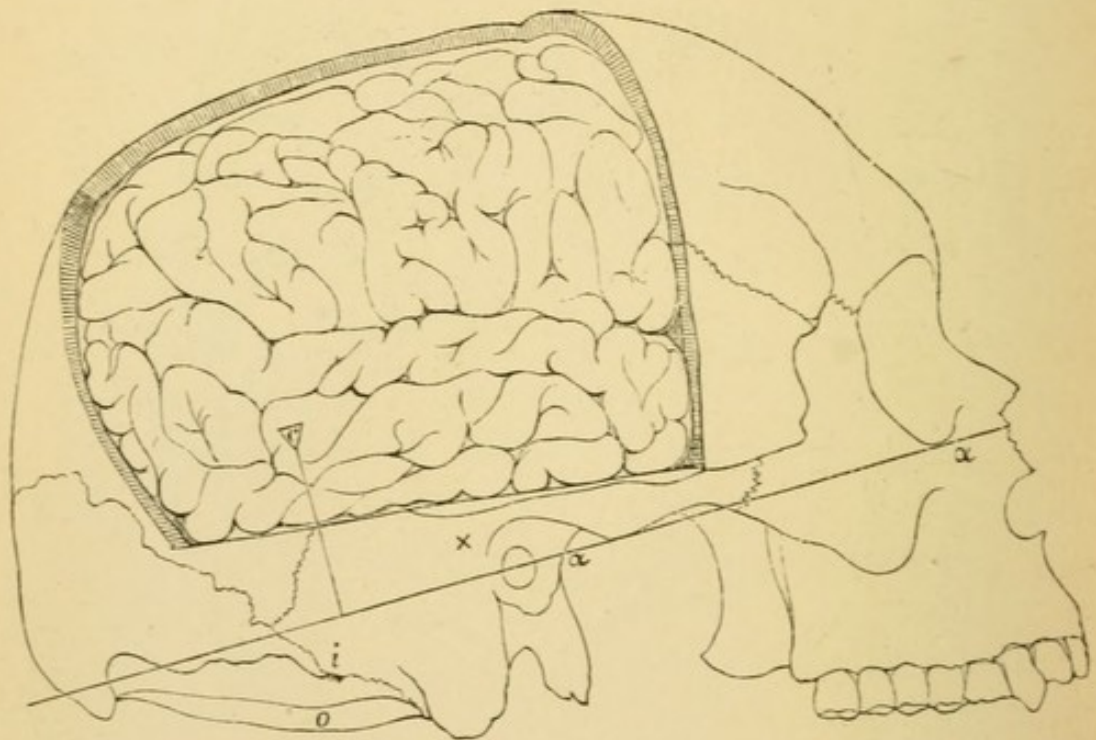


FIG. 58.—DRAWING OF A SKULL WITH THE BRAIN *in situ* TO ILLUSTRATE THE OPERATION OF TREPHINING FOR ABSCESS OF THE TEMPORO-SPHENOIDAL LOBE. (From a Photograph kindly taken for me by Mr. Marriott.)

thus forming a triangular flap with its base behind and above. Each of these incisions will be about an inch and a half long. This flap being turned upwards and backwards with the periosteum, the pin of the trephine is fixed at a point (fig. 58 *c*) an inch and a quarter above the base line (*a a*), and the same distance behind the centre of the

auditory meatus. The trephine is then put in motion, the surgeon remembering that the bone is here thicker below than above, and consequently directing the instrument a little upwards so that the upper edge of its crown shall not cut through the thin squamous portion before the lower edge has reached the dura mater. When the latter is laid bare it is divided by a crucial incision, and the brain is exposed. The whole area of operation should now be thoroughly cleansed with antiseptic sponges and dusted

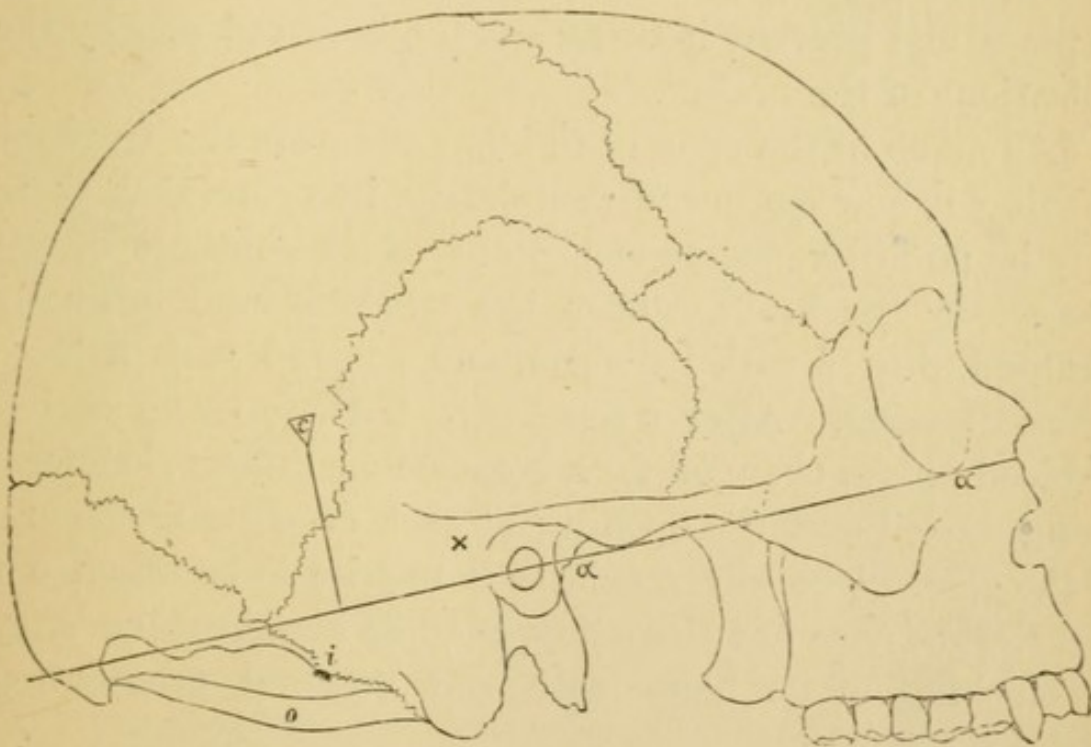


FIG. 59.—SAME SKULL AS IN LAST FIGURE BEFORE EXPOSURE OF THE BRAIN.

with iodoform. Then the aspirator needle is thrust into the brain in a direction inwards and a little downwards and forwards (fig. 57, *d a*). If pus is not struck when one and a half inch has been traversed in this direction, search in other directions, but not beyond an inch, may be tried. If pus is met with it is emptied through the needle, and on the withdrawal of the latter a sinus forceps

is at once introduced along its track for dilatation until a sharp spoon can be inserted. With this the cortex of the brain is cautiously scraped away until the opening has been considerably enlarged. Then a silver drain tube is introduced until about an inch lies within the skull. This is conveniently made from a portion of No. 8 silver catheter, split at the outer end so that the two halves can be turned out and hammered flat to form a flange resting on the skin. This flange can be pierced at either end to hold a thread, which, being carried round the head, will secure the tube in place and prevent it being gradually forced out by the pulsations of the brain.

As much of the apex of the flap as covers the trephine opening is now cut away completely, in order that there may be no hindrance to the escape of the contents of the abscess in the brain. Then the whole wound is finally cleansed, dusted with iodoform, and covered with a loose gauze dressing. After a few hours, if there be no oozing of blood, this is changed for a boracic fomentation, iodoform being dusted over the opening at each dressing to the end of the case. The silver tube will require to be taken out and cleaned once or twice a day, as there is a great tendency to blocking of its holes with soft cerebral granulation tissue.

Memoranda.—If the posterior branch of the middle meningeal artery is exposed in the trephine opening at the spot selected as above, it may easily be secured before the dura mater is incised. The utmost care should be taken in thrusting in the hollow needle, or later the silver tube, not to push away the cortex of the brain from the dura mater, otherwise septic matter may escape into the arachnoid space and set up general meningitis. If the surface of the cortex bulge a little into the trephine opening so much the better, as adhesion between the two surfaces will probably

take place in a few hours and prevent all extension of the inflammation over the meninges.

This operation has been done successfully at least three times. First by the author,¹ then by Mr. Caird of Edinburgh at the request of Dr. Greenfield,² and then by Dr. Macewen in a case under the care of Dr. Barr of Glasgow.³ Two other cases allied to these, but in both of which external bone disease and sinuses gave evidence of the situation of the cerebral abscess, have also been reported. The first was by Schondorff,⁴ the other, recorded by Truckenbrod,⁵ was operated on by Schede of Hamburg; both recovered. In the London, Edinburgh, and Glasgow cases referred to above there was little or no evidence in the condition of the bone to indicate the position of the abscess, the diagnosis being based upon other grounds. Three unsuccessful cases are also recorded by Mr. Hulke.⁶

FOR ABSCESS IN THE CEREBELLUM.

Abscess in the cerebellum is occasionally met with as the result of suppuration in the middle ear of more or less septic character. It is usually situated in the anterior and external part of the lateral lobe. The best spot to select for opening such an abscess is, in the adult, an inch and a half behind the centre of the meatus and an inch below the base line (*a a*). At this spot (figs. 57 to 59, *o*) there will be no danger of injury to the lateral sinus, and the most accessible part of the abscess, if present, will be reached.

¹ *Brit. Med. Journ.*, Dec. 11, 1886. ² *Ibid.* Feb. 12, 1887.

³ *Monatsschrift für Ohrenheilkunde*, 1885, No. 2.

⁴ *Archives of Otolaryngology*, vol. xv. Nos. 2 and 3, 1886.

⁵ *Brit. Med. Journ.*, April 2, 1887.

⁶ *Lancet*, 1886.

Instruments, Position of Patient, &c., as in the last operation.

Incision and Operation.—An incision, parallel with and about half an inch below the base-line, is made from the posterior edge of the mastoid process backwards for about two inches. This should reach at once to the periosteum, and will thus expose the superior curved line of the occipital bone. The soft structures, including the periosteum, are then peeled downwards with an elevator until the inferior curved line is exposed. The spot indicated above as best for exploring the cerebellum will be found to lie just below this line, a little behind and below the foramen for the mastoid vein (*i*). The skull is now opened at this point either with a trephine or a gouge, the surgeon bearing in mind the great thinness of the bone and the course of the lateral sinus (figs. 57, *i*, and 59, *c*), opposite the superior curved line above and the mastoid process in front. When the dura mater is exposed it should be cautiously divided by a crucial incision and turned back. Then the cortex of the cerebellum is closely inspected for any evidence of discoloration or bulging; if either is seen, the rest of the procedure is simple: the diseased area, having been dusted with iodoform, is simply punctured with a large hollow needle and the pus is allowed to escape into a vessel. This is better than a simple incision into the abscess, as it carries the foul pus clear of the surface of the arachnoid and the incision in the soft parts. When the collection has been thus emptied as far as possible, the needle is withdrawn and the opening is at once dilated with sinus forceps; it is then further enlarged by scraping *outwards* with a small Volckmann's spoon introduced along the forceps as the latter are withdrawn. Throughout the whole operation the parts should be frequently wiped with carbolised sponges or irrigated and dusted with iodoform. When

the abscess has been emptied completely, a drain tube, well dusted with iodoform, is inserted. This is best made of silver with a closed end like a catheter; a metal tube is more easy to remove and replace without disturbing the edges of the opening in the cortex than a rubber one. Then the whole area of operation is lightly dusted over with iodoform and a gauze dressing is applied, the wound being left open except at the ends. If the skin and soft parts, on being released, are found to overlap the trephine opening, they must be cut away sufficiently to leave the latter quite clear for drainage: should this be incomplete, the operation will of course be fruitless.

Memoranda.—When the bone is exposed it is well to examine the foramen for the mastoid vein (figs. 57 to 59, *i*, and 61, *d*). This, opening into the groove for the lateral sinus as it courses down the inner aspect of the mastoid process, any fluid pus lying in the latter ought to escape as soon as the foramen is exposed. If this occurs, as was the case in one of the author's operations, it will be well to pause for a few days, trying the effect of free drainage after the foramen has been enlarged, so as to give exit to the pus around the lateral sinus, but outside the arachnoid cavity. The symptoms of this condition are so similar to those which may be present with cerebellar abscess that it is well to see whether free drainage of the groove for the lateral sinus (part of which forms the posterior wall of the middle ear) may not relieve the patient's condition before running the risk of exploring the cerebellum through a possibly foul, inflamed patch of dura mater.

OPERATIONS ON THE AUDITORY APPARATUS.

The number of different operations which the surgeon will be called upon to practise on the auditory apparatus is

small, but such as there are should be familiar to all, being of the utmost importance and likely to crop up in every kind of practice. Much serious and even fatal disease may constantly be staved off by early resort to them.

Ordinary operations may be divided into those done within the meatus and those done on the external parts of the auditory apparatus.

INCISION OF THE MEMBRANA TYMPANI.

This operation is one very frequently called for on account of pent-up fluid in the middle ear. It is very simple, and, in the hands of any one familiar with the appearance of the middle ear, quite devoid of risk. The author has performed it many scores of times for all kinds of disease of the middle ear, and has never seen the slightest approach to an untoward accident, or anything but the best results from it. It is to be noted that the membrana tympani has the most remarkable powers of repair, so that this operation may require to be repeated unless the surgeon remembers to keep the aperture in the membrane open by the daily use of a fine probe separating the edges of the incision.

Instruments.—A forehead mirror with about an eight- or ten-inch focus; a set of silver specula; whalebone probes; a long narrow-bladed knife.

Position of Patient. --Lying down or sitting up, with the affected ear turned away from the light and the head in either case firmly supported and held steady.

Position of Operator.—Seated facing the affected ear, and the light from a bright window or lamp.

Landmarks for Incision and Operation.—The ear having been gently dried out, if moist, with salicylic wool rolled on probes so as to expose the membrana tympani fully, that

portion is selected at which the greatest bulging is apparent. This is usually noticed in the posterior segment. Here, then, the point of the long knife, held in the writing position, is to be entered a little above the equator, and a cut is at once quickly made straight downwards to the periphery of the membrane. If this does not seem to give free enough exit to the pent-up fluid, a second transverse incision below the equator may be made from the first forwards.

Memoranda.—The point of the knife should not be thrust too far through the membrana tympani at the outset, lest the stapes be struck and injured. Otherwise the danger of the operation is trifling when done by a steady hand, and the surgeon is more likely to make too small an incision than too large a one.

THE REMOVAL OF POLYPI FROM THE EAR.

Polypi may be removed either by snare, by forceps, by curette, or by hook. If low sized and almost sessile, as is most frequently the case, it is plain that the two first of these instruments will fail to grasp them, and that their removal must be effected by scraping away with a curette if they are to be removed at all. Again, if the polypi are pedunculated, it is very frequently quite possible to break the pedicle across with a small sharp hook passed over it, and then withdraw the polyp. This is by far the least painful process, and should be resorted to whenever possible. As a matter of fact, the snare and forceps are very rarely suitable for the removal of polypi, and for years past they have been almost entirely discarded at University College Hospital in favour of the curette and hook.

Given a sessile polyp, then, seated in the deepest part of the tympanum or on the wall of the meatus, the mode of

removing it is as follows. The whole of the meatus is first carefully wiped out with probes covered with salicylic wool, until the surface of the polyp is dry everywhere and it can be well seen. This cleansing must be done with all gentleness, so that the delicate vessels on the surface of the growth be not torn, and so give rise to oozing, which would obscure the field of operation and cause delay. When the whole of the mass is well seen, the sharp-edged little spoon is passed steadily in until its cutting edge is beyond the base of the growth: it is then withdrawn with a scraping movement, bringing away as much of the soft tissue from the very base as possible. In many cases where the root of the polyp is narrow, one stroke of the curette will be enough to complete the extirpation. But if not so, the part must be thoroughly dried of all blood, and when fully exposed the base must be scraped until no more of the growth remains. A probe covered with salicylic wool is then pressed upon the raw surface until the bleeding is arrested, and the latter is covered with iodoform when quite dry. At the next dressing, which should take place as soon as the meatus becomes moist (usually within the first twenty-four hours), the raw surface, after having been dried, should be touched with strong tincture of perchloride of iron, then dried carefully, and again dusted over with iodoform.

Memoranda.—The chief difficulty in this operation depends upon the great vascularity of the growth. After the first stroke of the curette the meatus fills up at once with blood, and nothing should ever tempt the surgeon to endeavour to remove any of the polyp remaining without first getting rid of this blood and obtaining a clear view of the mass. It is far better to wait even for a second sitting than to run the great risk of operating with a sharp instrument, the movements of which cannot be seen in the depths of the ear. After trying numerous methods, the above

seems to the author most suited of all as the routine treatment for polypi of the ear.

FOR ABSCESS IN THE WALL OF THE MEATUS.

It should be remembered in preparing for this operation that abscesses primarily starting in the wall of the meatus are only found in the outer third of tube. They are therefore always well within view and within reach of an ordinary Syme's abscess knife, which is the only instrument required in addition to those named above.

Position of Patient and Surgeon as for the last operation.

Operation.—The most swollen and tender spot of the meatus having been made out with a speculum, the point of the knife is gently inserted between it and the opposite wall, and well to the inner side of the abscess. The hand is then elevated and the point of the instrument depressed until it pierces the soft structures, when it is sharply drawn outwards, cutting through the whole abscess right to its base. When the pus has been gently pressed out of the sac the incision is wiped clean and dusted with iodoform, a pad of salicylic wool being placed over all. If there is much shreddy material to be discharged, a boracic fomentation will be a better dressing than the dry wool.

FOR SUPPURATION IN THE MASTOID REGION.

In certain cases in which there is pus pent up within the temporal bone as the result of ear disease, and unable to escape through the external meatus or Eustachian tube for one cause or another, it becomes necessary to provide an opening for its escape behind the auricle. This is often spoken of as trephining the mastoid cells, but this descrip-

tion is likely to mislead and to be a source of great danger in many instances. There is no doubt that in some cases in adults suppuration does take place primarily in the mastoid cells, and an opening into the mastoid process is the proper treatment for this. But it should never be forgotten that in children and in many adults there are no well developed mastoid cells, and that trephining over the situation of the mastoid process will not evacuate the pus

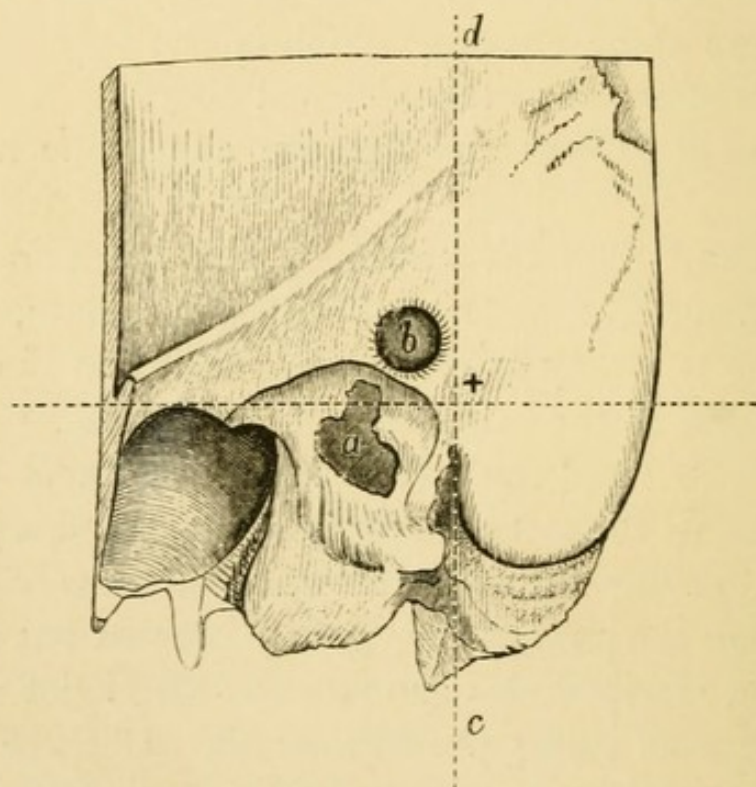


FIG. 60.—OPERATIONS ON THE MASTOID REGION.

(From a specimen in the Author's possession.)

a, Meatus of ear ; *b*, opening due to caries leading into the mastoid antrum ;
c, *d*, line crossing vertically the posterior border of the cartilaginous
 meatus, and crossed by another running horizontally over the roof ;
 +, spot at which mastoid antrum is to be opened.

pent up in the tympanum, and if persisted in will open up the lateral sinus (fig. 61, *c*). What really should be aimed for is the antrum of the mastoid, i.e. an offshoot posteriorly of the tympanic cavity, in which lies the suppuration. This is always present both in children and adults, and if opened

will drain both the mastoid cells (if present) and the tympanum.

In children the opening should never be below a line level with the roof of the meatus (fig. 60, *a*), and only just behind a line drawn perpendicularly through its posterior wall (*c d*). In adults the point chosen should only be a little

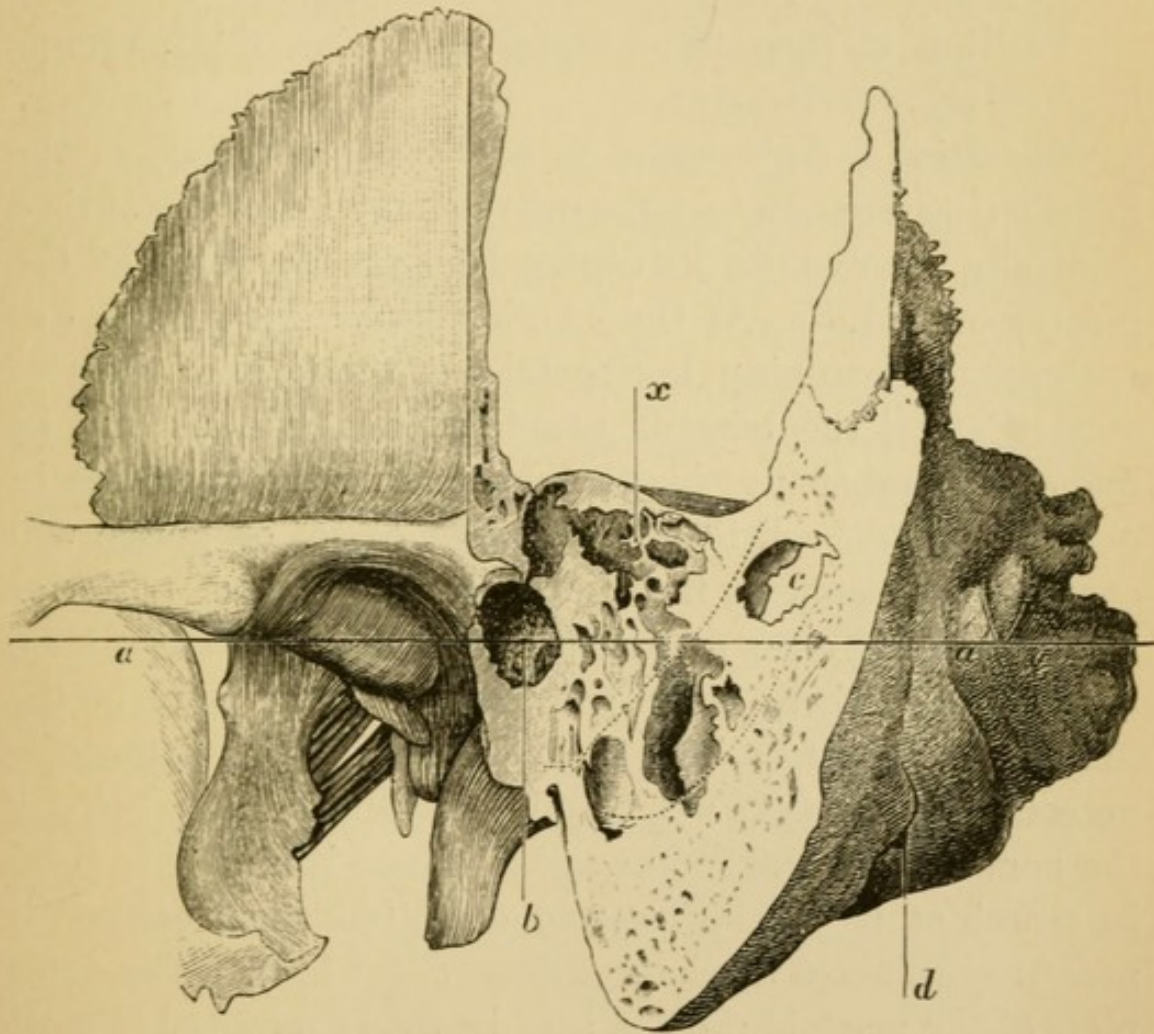


FIG. 61.—OPERATIONS ON THE MASTOID REGION.

(From a specimen in the Author's possession.)

a a, Base line running through the centre of the bony meatus; *b*, centre of the meatus; *c*, the lateral sinus; *d*, the foramen for the mastoid vein; *x*, spot over the mastoid antrum at which the latter should be opened.

below and behind this. In both cases the gouging should take place in a direction forwards as well as inwards (fig. 61, *x*). The arguments in favour of this rule would carry us too far in a work like the present, but they are

based upon a large clinical experience of ear diseases and numerous dissections of morbid specimens as well as by a careful study of the literature of the subject.

Instruments.—A strong scalpel; a narrow chisel; a narrow gouge; artery-forceps; a probe; sharp spoons.

Position of Patient.—Supine, the head inclined to the sound side.

Position of Operator.—Standing beside the patient's head on the affected side.

Operation.—An incision is first made reaching to the bone, a quarter of an inch behind the insertion of the auricle vertically downwards, its centre being at the level of the meatus (fig. 61, *b*). At the junction of this line (fig. 60, *c d*) with another running horizontally at the level of the roof of the latter, the bone is examined and will usually be found soft and spongy in cases demanding the operation in question; if so, a little cutting with chisel or gouge will open up the cavity of the middle ear at its most posterior and upper part, often called the mastoid antrum (fig. 61, *x*). Very often the bone is so soft here that the point of the knife actually sinks into it, and no other instrument is necessary. If pus be not found here in an adult, a little of the bone may be gouged away below and behind this point in search of it in the mastoid cells, but great caution is necessary to avoid the lateral sinus (fig. 61, *c*). The outer plate of the mastoid process may be freely removed in most cases, but deep cutting in this situation is to be done with much caution, though it is quite possible to open up the groove in the bone for the lateral sinus without doing any damage to the latter.


When the pus is evacuated the cavity is to be carefully scraped out with sharp spoons, and washed out with some strong antiseptic, and well dusted with iodoform. A boracic fomentation is the most suitable dressing and should

be frequently changed. As the opening soon tends to close it will require a small drainage tube constantly. This is best made of lead or a portion of silver catheter slightly curved to prevent its slipping out.


Memoranda.—There are few operations about the head more useful than the above. The condition to be relieved is a very common and a very grave one, and cannot be dealt with, as a rule, satisfactorily in any other way. The same rules which lead us to give exit to pus pent up in bone elsewhere must guide us here. The fear of opening up the groove for the lateral sinus or exposing the dura mater must not weigh too much with the surgeon. As the conditions demanding the operation are very grave, it is quite justifiable to run certain risks. These may be easily avoided by care and a study of the relations of parts in the mastoid and petrous region. That the operation may be done without undue risk is proved by statistics. I need only quote one series of cases in support of this. As they occurred in the practice of one surgeon and were operated on under the same conditions, they give a more accurate idea of the gravity of the procedure than a longer list made up from various sources. Hessler¹ gives a series of forty consecutive cases of opening up the mastoid cavities by operation. Of these thirty-five were cured of their disease, in two the course of the disease could not be followed quite to the end, but the result was probably good; death occurred in three, but was in no way due to the operation. In most of these cases the condition of the patient was most critical before the operation.

The author has only performed the operation seven or eight times. Two had pyæmic symptoms before operation and died of this disease eventually. All the rest were cured.

¹ *Archiv f. Ohrenheilkunde*, Bd. xxi. xxii.



INDEX.



ABD

- A**BDOMINAL tumours, 256
Abernethy, 17, 21
Alexander on ligature of vertebral artery, 44
Alimentary tract, 278
 suture of wound of, 279
Allarton on lithotomy, 369
Ammusat's colotomy, 304
Amputations, 113
 above knee, 142
 ankle, 134
 arm, 126
 Baudens on, 183
 Bell, B., on, 142
 breast, 147
 Bryant on, 138
 Brinton on, 138
 Carden's, 140
 Chopart's, 133
 circular, 115
 Dubreuil's, 124
 elbow joint, at, 125
 fingers, of, 120
 flaps, by, 117
 forearm, of, 125
 Fort's, Le, 136
 hand, of, 120
 Hardie's, 140
 Hey's, 132
 hip joint, at, 145
 knee joint, at, 138
 leg, of, 136
 Lister's, Sir J., at knee, 141
 at wrist, 124
 Markoe on, 138
 Nathan Smith on, 138

ART

- Amputations, oval, 117
 penis, of, 374
 Pirogoff's, 135
 Pollock on, 138
 'seat of election' at, 137
 Sédillot on, 138
 shoulder, at, 126
 Spence's, 143
 Stephen Smith, 138
 Syme's, at ankle, 134
 modified circular, 143
 Teale's, 118
 toes, of, 130
 wrist, at, 123
Ankle, amputation at, 134
Ankylosis of hip, 87
 knee, 93
Antisepsis, 2
Aorta, 15-17
Arm, amputation of, 126
Arteries, ligature of, 10
 aorta, 15-17
 axillary, 45-48
 carotid, external, 34-38
 dorsalis pedis, 33
 facial, 40
 femoral, 25-28
 iliac, common, 18
 iliac, external, 21, 23
 iliac, internal, 21
 innominate, 34
 lingual, 39
 popliteal, 29
 radial, 52
 subclavian, 41
 tibial anterior, 32

ART

Arteries, tibial posterior, 30
 ulnar, 51
 vertebral, 44
 Arthrectomy, 153
 Astley Cooper, Sir, 14, 23
 Auditory apparatus, operations on, 407
 Auditory meatus, operations on, 410
 Axillary artery, 45-48

BARR on cerebral abscess, 404
 Battey's operation, 268
 Baudens on amputation, 138
 Bell, B., on amputation, 142
 Billroth on excision of larynx, 246
 excision of tongue, 215, 224, 226
 on pylorotomy, 285
 Bird, G., on duodenostomy, 304
 Bishop on suture of intestine, 283
 Bones, operations on, 80
 suture of, 93
 transplantation of, 109
 Bose on tracheotomy, 241
 Boyer on excision of tongue, 219
 Brachial artery, 49
 Brain, operations on, 388
 Breast, amputation of, 147
 Brinton on amputation, 138
 Brunns, P., on thyrotomy, 244
 Bryant on amputation, 138
 Buxdorf on excision of tongue, 214

CAIRD on cerebral abscess, 404
 Carden on amputation, 140
 Carotid artery, 34-38
 Castration, 379
 Catgut, 4, 10
 Cerebellar abscess, 405
 Cerebral topography, 389
 abscess, 400
 Chassagnac on excision of tongue, 215
 Cholecystectomy, 277
 Cholecystotomy, 275
 Chopart on amputation, 133
 Circular amputations, 115

EXC

Circumcision, 378
 Cleft palate, 206
 Cloquet on excision of tongue, 215, 219
 Collis on excision of tongue, 215, 221
 Colotomy, inguinal, 307
 lumbar, 304
 Cooper, Sir A., 14
 Cooper (San Francisco), 34
 Cr  de on splenectomy, 273
 Cutter and Norris tables, 23
 Czerny on suture of intestine, 282
 excision of tongue, 216, 225

DAVIES-COLLEY on talipes, 101
 Davy on talipes, 100
 Deligation, *see* Ligature
 Didot on webbed fingers, 75
 Digital dilatation of pylorus, 296
 of anus, 318
 Dorsalis pedis artery, 23
 Drainage of knee, 98
 Dressings, 6
 permanent, 8
 Dubreuil on amputation, 124
 Duodenostomy, 304

ECTROPION, operation for, 201
 Egeberg on gastrostomy, 301
 Elbow, amputation at, 125
 Elevation of limbs to prevent bleeding, 114
 Empy  ma, drainage of, 252
 Enterectomy, 297
 Erasion *vel* arthrectomy, 153
 Esmarch's tourniquet, 114
 Excision of joints, 152
 of ankle, 170
 of astragalus, 174
 of elbow, by straight posterior incision, 179; by T-shaped incision, 181
 of hip, by anterior incision, 157; by posterior incision, 162; by superior incision, 161

EXC

- Excision of knee, 165; by oval anterior flap, 166; by H-shaped incision, 169
 of os calcis, 173
 of shoulder, by anterior incision, 175; by deltoid flap, 177
 of wrist, 182; Sir J. Lister's method, 182; Langenbeck's method, 188
- External carotid artery, 38
 External iliac artery, 21

FACE, operations on, 190

- Facial artery, 43
 False joint, 93
 Femoral artery, 25
 Ferrier on cerebral centres, 392
 Fibroids, uterine, 266
 Fingers, amputation of, 120
 Fistula in ano, 320
 Flap amputations, 117
 Forearm, amputation of, 125
 Foulis, artificial larynx, 250
 Fracture, badly united, osteotomy for, 92
 ununited wiring for, 93
 Fractured patella, wiring for, 94
 Franzolisi on splenectomy, 273

GASTROENTEROSTOMY, 292

- Gastrostomy, 301
 Genu valgum, operations for, 80
 Gibson, 20
 Girouard on excision of tongue, 215
 Godlee on nerve stretching, 67
 Godson on Porro's operation, 269
 Golding Bird on duodenostomy, 304
 Greenfield on cerebral abscess, 404
 Gussenbauer on artificial larynx, 252
 suture of intestine, 281
 Guthrie on excision of tongue, 214

HACKER, von, on pylorotomy, 285

KIT

- Haggard on digital dilatation of pylorus, 297
 Hallux valgus, operation for, 99
 Hamstrings, section of, 73
 Hand, amputation of, 120
 Hardie on amputation, 140
 Hare-lip, operations for, 190
 Heath on bleeding from lingual artery, 233
 Heister on excision of tongue, 214
 Herniotomy, 324
 Hessler on opening the mastoid antrum, 415
 Hey's amputation, 132
 Hip, amputation of, 145
 Hip, ankylosed, operation for, 87
 Hip, excision of, 157
 by anterior incision, 157
 posterior incision, 162
 superior incision, 161
 Hoffman on excision of tongue, 214
 Holmes, 23
 Horsely, V., on operations on the brain, 389
 Hulke on cerebral abscess, 405
 Hunter's canal, ligature of, femoral artery in, 28
 Hydrocele, palliative operation for, 380
 radical cure of, 381

ILIAC artery, common, 18

- external, 21
 internal, 21
 Indian operation on the nose, 203
 Inglis on excision of tongue, 214
 Innominate artery, 34

JAEGER on excision of tongue, 215

- James of Exeter, 16
 Jaw, excision of lower, 235
 upper, 230
 Julliard on enterectomy, 298

KANGAROO tendon, 10

- Kidney, operations on, 347
 Kite-shaped director, 101

KNE

- Knee, amputation at, 138
 ankylosis of, 90
 arthrectomy of, 153
 excision of, 165; by oval anterior flap, 166; by H-shaped incision, 169
 Kocher on excision of tongue, 206, 226
 on enterectomy, 298
- L**ANGENBECK, C. J., on excision of tongue, 215, 219
 Langenbeck, B. von, on excision of larynx, 249
 on excision of tongue, 216, 224
 on excision of wrist, 187
 Langenbuch on nephrectomy, 359
 Laryngotomy, 239
 Larynx, artificial, 250
 resection of, 246
 Le Fort on amputation, 136
 Leg, amputations of, 136
 Lembert on suture of intestine, 280
 Ligature of arteries, 10
 of abdominal aorta, 14-17
 axillary, 45-48
 brachial, 49-50
 carotid, common, 34
 external, 38
 dorsalis pedis, 33
 facial, 40
 femoral, common, 25
 superficial, 25
 in Scarpa's triangle, 25
 Hunter's canal, 28
 iliac, common, 18
 external, 21-23
 internal, 21
 innominate, 34
 lingual, 39
 radial, 52
 subclavian, 41
 tibial, anterior, 32
 posterior, 30
 ulnar, 51
 vertebral, 44
 Ligatures, silk, 5
 preparation of, 5
 Lips, operations on, 190
 removal of growths on, 198

NEP

- Lister, Sir J., amputation at knee, 141
 of penis, 377
 at wrist, 124
 on wiring the patella, 95
 Lithotomy, bilateral, 368
 lateral, 364
 median, 369
 suprapubic, 360
 Littré's colotomy, 307
 Loreta on digital dilatation of the pylorus, 296
 Louis on excision of tongue, 214
 Lumbar caries, operation for, 111
- M**ACEWEN on cerebral abscess, 404
 on genu valgum, 80
 on radical cure of hernia, 338
 Maisonneuve on excision of tongue, 215
 Major on excision of tongue, 214, 219
 Marchetti on excision of tongue, 214
 Markoe on amputation, 138
 Marshall on tracheotomy, 242
 Mastoid process, operation on, 311
 Membrana tympani, incision of, 408
 Memnista on excision of tongue, 214
 Middeldorpf on excision of tongue, 215
 Mirault on excision of tongue, 215
 Modified circular amputation, 143
 Monteiro on ligature of abdominal aorta, 18
 Murray on ligature of abdominal aorta, 17
 Myomyotomy, 266
- N**ATHAN SMITH on amputation, 138
 Nephrectomy, 354
 by lateral abdominal section, 359
 by lumbar incision, 356

NEP

- Nephrectomy, by median abdominal section, 357
 Nephrolithotomy, 351
 Nephroraphy, 352
 Nephrotomy, 348
 Nerves, operations on, 64
 Nerve stretching, 66
 of sciatic, 66
 of facial, 67
 Newman on nephroraphy, 352
 Norris and Cutter's tables, 23, 29
 Nose, operations on, 203
 Nunneley on excision of tongue, 215

EŒSOPHAGOSTOMY, 312

- Œsophagotomy, 310
 Ogston's operation, 85
 Ollier on excision of hip, 161
 on osteoplastic operations, 105
 Oöphorectomy, 268
 Osteoplastic operations, 104
 on palate, 212
 Osteotomy for badly united fracture, 92
 for bent tibia, 87
 for ankylosed knee, 90
 hip, 88
 for genu valgum, 80
 for talipes equino varus, 101
 for talipes equinus, 103
 Oval amputations, 117
 Ovariectomy, 256

PAGET, Sir J., on excision of tongue, 219

- Palate, operations on, 190
 Palmar fascia, division of, 72
 Parallel wire director, 101
 Parker on excision of hip, 157
Par approche, osteoplastic, 108
 glissement, 105
 renversement, 107
 Patella, wiring of, 94
 statistics of, 99
 Penis, amputation of, 377
 Phlebotomy, 55

SCH

- Piles, operations for, 321
 Whitehead's operation for, 322
 Pimpernelle on excision of tongue, 214
 Pirogoff on amputation, 135
 Plantar fascia, division of, 72
 Pollock on amputation, 138
 on cleft palate, 208
 Polypus of ear, removal of, 409
 Porro's operation, 269
 Prolapsus ani, operations for, 317
 of uterus, operation for, 272
 Pylorus, digital dilatation of, 296
 resection of, 285
 Pylorotomy, 285

RADIAL artery, 52, 53

- Radical cure of hernia, 333
 author's method, 334
 Macewen's method, 338
 inguinal, 334
 femoral, 342
 umbilical, 343
 hydrocele, 381
 varicocele, 57

- Rectum, excision of, 312
 Regnoli on excision of tongue, 216, 225
 Reid on cerebral topography, 389
 Respiratory tract, 238
 Richter on digital dilatation of pylorus, 296
 Rose of Marburg on operations on mouth and jaws, 234
 Round ligament, operation on, 272
 Roux on excision of tongue, 215, 221
 Ruysch on excision of tongue, 214

SCARPA'S triangle, 25

- Seat of election, amputation at, 137
 Schede on cerebral abscess, 405
 Schondorff on cerebral abscess, 405
 Schuller on excision of larynx, 246

SED

Sédillot on ligature of common carotid, 37; on amputation, 138; on excision of tongue, 215, 221; on gastrostomy, 301

Shoulder, amputations at, 126

Silk ligatures, preparation of, 5

Silver wire, sizes of, for wiring bones, 94

Simon on nephrectomy, 354

Skull, trephining of, 385

Smith, Nathan, 138

Smith, Stephen, 133

Smyth, 44

Spence on amputation, 143

Sphincter ani, stretching, 318

Splenectomy, 273

Sponges, preparation of, 4

Staphylophary, 206

Stephen Smith, 138

Sterno-mastoid muscle, division of, 74

Stokes, Sir W., on excision of tongue, 221

Strangulated hernia, 326
femoral, 330
inguinal, 326
umbilical, 331

Stretching of sphincter ani, 313

Sturge and Godlee on nerve stretching, 67

Subclavian artery, 41

Syme on amputation of ankle, 134
on circular amputation at knee, 143
on excision of tongue, 215, 221
on plastic operation on the lips, 200

TAGLIOCOTIAN operation, 203

Talipes, operations for, 72
equinus, 72
equino varus, 70
valgus, 72
osteotomy for, 100

Teale's amputation, 118

Temporo-sphenoidal abscess, 400
cases of, 404

Tendons and fasciæ, 69

Tenotomy for club-foot, 69

WHI

Tenotomy of hamstrings, 73

Thompson, Sir H., on suprapubic lithotomy, 362

Thyrotomy, 244

Tibial arteries, anterior, 32
posterior, 30

Toes, amputation of, 130

Tongue, operations on, 212

Tracheotomy, 240

Transfusion of blood, 62
of saline solutions, 63

Transplantation of bone, 109

Trepanning, 285

Trephining, 285

Treves's operation for lumbar caries, 111

ULNAR artery, 51, 52

Uraniscoplasty, 210

Uranoplasty, 210

Urethretomes, Hill's, 370
Civiale's, 371

Urethrotomy, external, 374
internal, 377

Uterine fibroids, removal of, 266

VARICOCELE, operations for, 57, 59

Varicose veins, operations for, 56

Veins, operations on, 55

Venesection, 55

Vertebral artery, 44

WEBBED fingers, operations for, 75
Didot's, 75
Zeller's, 77

Wells, Sir G., on myomyotomy, 266
on ovariectomy, 256
on Porro's operation, 269
on splenectomy, 273

Wheelhouse on internal urethrotomy, 374


Whitehead on excision of tongue, 219
excision of piles, 322

WIN

- Winslow on digital dilatation of
pylorus, 296
on duodenostomy, 304
- Wiring bones, 93
patella, 94
statistics, 99
- Woelfler on gastroenterostomy, 292
excision of tongue, 214
pylorectomy, 285

ZES

- Woelfler on suture of intestine, 283
- Wood, J., on radical cure of hernia,
346
- Z**ELLER'S operation on webbed
fingers, 77
- Zesas on gastrostomy, 302
splenectomy, 273



AUGUST 1887.

GENERAL LISTS OF WORKS

PUBLISHED BY

MESSRS. LONGMANS, GREEN, & CO.

39 PATERNOSTER ROW, LONDON, E.C.; AND

15 EAST 16th STREET, NEW YORK.



HISTORY, POLITICS, HISTORICAL MEMOIRS, &c.

Abbey's The English Church and its Bishops, 1700-1800. 2 vols. 8vo. 24s.

Abbey and Overton's English Church in the Eighteenth Century. Cr. 8vo. 7s. 6d.

Arnold's Lectures on Modern History. 8vo. 7s. 6d.

Bagwell's Ireland under the Tudors. Vols. 1 and 2. 2 vols. 8vo. 32s.

Ball's The Reformed Church of Ireland, 1537-1886. 8vo. 7s. 6d.

Boulton's History of the Church of England, Pre-Reformation Period. 8vo. 15s.

Buckle's History of Civilisation. 3 vols. crown 8vo. 24s.

Cox's (Sir G. W.) General History of Greece. Crown 8vo. Maps, 7s. 6d.

Creighton's History of the Papacy during the Reformation. 8vo. Vols. 1 and 2, 32s. Vols. 3 and 4, 24s.

De Tocqueville's Democracy in America. 2 vols. crown 8vo. 16s.

D'Herisson's The Black Cabinet. Crown 8vo. 7s. 6d.

Doyle's English in America: Virginia, Maryland, and the Carolinas, 8vo. 18s.

— — — The Puritan Colonies, 2 vols. 8vo. 36s.

Epochs of Ancient History. Edited by the Rev. Sir G. W. Cox, Bart. and C. Sankey, M.A. With Maps. Fcp. 8vo. price 2s. 6d. each.

Beesly's Gracchi, Marius, and Sulla.

Capes's Age of the Antonines.

— Early Roman Empire.

Cox's Athenian Empire.

— Greeks and Persians.

Curteis's Rise of the Macedonian Empire.

Ihne's Rome to its Capture by the Gauls.

Merivale's Roman Triumvirates.

Sankey's Spartan and Theban Supremacies.

Smith's Rome and Carthage, the Punic Wars.

Epochs of Modern History. Edited by C. Colbeck, M.A. With Maps. Fcp. 8vo. price 2s. 6d. each.

Church's Beginning of the Middle Ages.

Cox's Crusades.

Creighton's Age of Elizabeth.

Gairdner's Houses of Lancaster and York.

Gardiner's Puritan Revolution.

— Thirty Years' War.

— (Mrs.) French Revolution, 1789-1795.

Hale's Fall of the Stuarts.

Johnson's Normans in Europe.

Longman's Frederick the Great and the Seven Years' War.

Ludlow's War of American Independence

M'Carthy's Epoch of Reform, 1830-1850.

Moberly's The Early Tudors.

Morris's Age of Queen Anne.

— The Early Hanoverians.

Seebohm's Protestant Revolution.

Stubbs's The Early Plantagenets.

Warburton's Edward III.

Epochs of Church History. Edited by the Rev. Mandell Creighton, M.A. Fcp. 8vo. price 2s. 6d. each.

Brodrick's A History of the University of Oxford.

Carr's The Church and the Roman Empire.

Overton's The Evangelical Revival in the Eighteenth Century.

Perry's The Reformation in England.

Plummer's The Church of the Early Fathers.

Tucker's The English Church in other Lands.

* * * Other Volumes in preparation.

LONGMANS, GREEN, & CO. London and New York.

- Freeman's Historical Geography of Europe. 2 vols. 8vo. 31s. 6d.
- Froude's English in Ireland in the 18th Century. 3 vols. crown 8vo. 18s.
- History of England. Popular Edition. 12 vols. crown 8vo. 3s. 6d. each.
- Gardiner's History of England from the Accession of James I. to the Outbreak of the Civil War. 10 vols. crown 8vo. 60s.
- History of the Great Civil War, 1642-1649 (3 vols.) Vol. 1, 1642-1644, 8vo. 21s.
- Greville's Journal of the Reign of Queen Victoria, 1837-1852. 3 vols. 8vo. 36s. 1852-1860, 2 vols. 8vo. 24s.
- Historic Towns. Edited by E. A. Freeman, D.C.L. and the Rev. William Hunt, M.A. With Maps and Plans. Crown 8vo. 3s. 6d. each.
- London. By W. E. Loftie. | Bristol. By the Rev. W. Hunt.
Exeter. By E. A. Freeman. | Oxford. By the Rev. C. W. Boase.
- * * * Other volumes in preparation.
- Lecky's History of England in the Eighteenth Century. Vols. 1 & 2, 1700-1760, 8vo. 36s. Vols. 3 & 4, 1760-1784, 8vo. 36s. Vols. 5 & 6, 1784-1793, 36s.
- History of European Morals. 2 vols. crown 8vo. 16s.
- — — Rationalism in Europe. 2 vols. crown 8vo. 16s.
- Longman's Life and Times of Edward III. 2 vols. 8vo. 28s.
- Macaulay's Complete Works. Library Edition. 8 vols. 8vo. £5. 5s.
- — — Cabinet Edition. 16 vols. crown 8vo. £4. 16s.
- History of England :—
- Student's Edition. 2 vols. cr. 8vo. 12s. | Cabinet Edition. 8 vols. post 8vo. 48s.
People's Edition. 4 vols. cr. 8vo. 16s. | Library Edition. 5 vols. 8vo. £4.
- Macaulay's Critical and Historical Essays, with Lays of Ancient Rome In One Volume :—
- Authorised Edition. Cr. 8vo. 2s. 6d. | Popular Edition. Cr. 8vo. 2s. 6d.
or 3s. 6d. gilt edges.
- Macaulay's Critical and Historical Essays :—
- Student's Edition. 1 vol. cr. 8vo. 6s. | Cabinet Edition. 4 vols. post 8vo. 24s.
People's Edition. 2 vols. cr. 8vo. 8s. | Library Edition. 3 vols. 8vo. 36s.
- Macaulay's Speeches corrected by Himself. Crown 8vo. 3s. 6d.
- Malmesbury's (Earl of) Memoirs of an Ex-Minister. Crown 8vo. 7s. 6d.
- May's Constitutional History of England, 1760-1870. 3 vols. crown 8vo. 18s.
- Democracy in Europe. 2 vols. 8vo. 32s.
- Merivale's Fall of the Roman Republic. 12mo. 7s. 6d.
- General History of Rome, B.C. 753-A.D. 476. Crown 8vo. 7s. 6d.
- History of the Romans under the Empire. 8 vols. post 8vo. 48s.
- Nelson's (Lord) Letters and Despatches. Edited by J. K. Laughton. 8vo. 16s.
- Pears' The Fall of Constantinople. 8vo. 16s.
- Saintsbury's Manchester : a Short History. Crown 8vo. 3s. 6d.
- Seebohm's Oxford Reformers—Colet, Erasmus, & More. 8vo. 14s.
- Short's History of the Church of England. Crown 8vo. 7s. 6d.
- Smith's Carthage and the Carthaginians. Crown 8vo. 10s. 6d.
- Taylor's Manual of the History of India. Crown 8vo. 7s. 6d.
- Todd's Parliamentary Government in England (2 vols.) Vol. 1, 8vo. 24s.
- Vitzthum's St. Petersburg and London, 1852-1864. 2 vols. 8vo. 30s.
- Walpole's History of England, from 1815. 5 vols. 8vo. Vols. 1 & 2, 1815-1832, 36s. Vol. 3, 1832-1841, 18s. Vols. 4 & 5, 1841-1858, 36s.
- Wylie's History of England under Henry IV. Vol. 1, crown 8vo. 10s. 6d.

LONGMANS, GREEN, & CO., London and New York.

BIOGRAPHICAL WORKS

- Armstrong's (E. J.) Life and Letters. Edited by G. F. Armstrong. Fcp. 8vo. 7s. 6d.
 Bacon's Life and Letters, by Spedding. 7 vols. 8vo. £4. 4s.
 Bagehot's Biographical Studies. 1 vol. 8vo. 12s.
 Carlyle's Life, by J. A. Froude. Vols. 1 & 2, 1795-1835, 8vo. 32s. Vols. 3 & 4, 1834-1881, 8vo. 32s.
 — (Mrs.) Letters and Memorials. 3 vols. 8vo. 36s.
 Doyle (Sir F. H.) Reminiscences and Opinions. 8vo. 16s.
 English Worthies. Edited by Andrew Lang. Crown 8vo. 2s. 6d. each.
 Charles Darwin. By Grant Allen. | Steele. By Austin Dobson.
 Shaftesbury (The First Earl). By | Ben Jonson. By J. A. Symonds.
 H. D. Traill. | George Canning. By Frank H. Hill.
 Admiral Blake. By David Hannay. | Claverhouse. By Mowbray Morris.
 Marlborough. By Geo. Saintsbury.
 *** Other Volumes in preparation.
- Fox (Charles James) The Early History of. By Sir G. O. Trevelyan, Bart. Crown 8vo. 6s.
 Froude's Cæsar: a Sketch. Crown 8vo. 6s.
 Hamilton's (Sir W. R.) Life, by Graves. Vols. 1 and 2, 8vo. 15s. each.
 Havelock's Life, by Marshman. Crown 8vo. 3s. 6d.
 Hobart Pacha's Sketches from my Life. Crown 8vo. 7s. 6d.
 Macaulay's (Lord) Life and Letters. By his Nephew, Sir G. O. Trevelyan, Bart. Popular Edition, 1 vol. crown 8vo. 6s. Cabinet Edition, 2 vols. post 8vo. 12s. Library Edition, 2 vols. 8vo. 36s.
 Mendelssohn's Letters. Translated by Lady Wallace. 2 vols. cr. 8vo. 5s. each.
 Mill (James) Biography of, by Prof. Bain. Crown 8vo. 5s.
 — (John Stuart) Recollections of, by Prof. Bain. Crown 8vo. 2s. 6d.
 — — Autobiography. 8vo. 7s. 6d.
 Müller's (Max) Biographical Essays. Crown 8vo. 7s. 6d.
 Newman's Apologia pro Vitâ Suâ. Crown 8vo. 6s.
 Pasteur (Louis) His Life and Labours. Crown 8vo. 7s. 6d.
 Shakespeare's Life (Outlines of), by Halliwell-Phillipps. 2 vols. royal 8vo. 10s. 6d.
 Southey's Correspondence with Caroline Bowles. 8vo. 14s.
 Stephen's Essays in Ecclesiastical Biography. Crown 8vo. 7s. 6d.
 Wellington's Life, by Gleig. Crown 8vo. 6s.

MENTAL AND POLITICAL PHILOSOPHY, FINANCE, &C.

- Amos's View of the Science of Jurisprudence. 8vo. 18s.
 — Primer of the English Constitution. Crown 8vo. 6s.
 Bacon's Essays, with Annotations by Whately. 8vo. 10s. 6d.
 — Works, edited by Spedding. 7 vols. 8vo. 73s. 6d.
 Bagehot's Economic Studies, edited by Hutton. 8vo. 10s. 6d.
 — The Postulates of English Political Economy. Crown 8vo. 2s. 6d.
 Bain's Logic, Deductive and Inductive. Crown 8vo. 10s. 6d.
 PART I. Deduction, 4s. | PART II. Induction, 6s. 6d.
 — Mental and Moral Science. Crown 8vo. 10s. 6d.
 — The Senses and the Intellect. 8vo. 15s.
 — The Emotions and the Will. 8vo. 15s.
 — Practical Essays. Crown 8vo. 4s. 6d.

LONGMANS, GREEN, & CO., London and New York.

- Buckle's (H. T.) Miscellaneous and Posthumous Works. 2 vols. crown 8vo. 21s.
 Crump's A Short Enquiry into the Formation of English Political Opinion. 8vo. 7s. 6d.
 Dowell's A History of Taxation and Taxes in England. 4 vols. 8vo. 48s.
 Green's (Thomas Hill) Works. (3 vols.) Vols. 1 & 2, Philosophical Works. 8vo. 16s. each.
 Hume's Essays, edited by Green & Grose. 2 vols. 8vo. 28s.
 — Treatise of Human Nature, edited by Green & Grose. 2 vols. 8vo. 28s.
 Ladd's Elements of Physiological Psychology. 8vo. 21s.
 Lang's Custom and Myth : Studies of Early Usage and Belief. Crown 8vo. 7s. 6d.
 Leslie's Essays in Political and Moral Philosophy. 8vo. 10s. 6d.
 Lewes's History of Philosophy. 2 vols. 8vo. 32s.
 Lubbock's Origin of Civilisation. 8vo. 18s.
 Macleod's Principles of Economical Philosophy. In 2 vols. Vol. 1, 8vo. 15s. Vol. 2, Part I. 12s.
 — The Elements of Economics. (2 vols.) Vol. 1, cr. 8vo. 7s. 6d. Vol. 2, Part I. cr. 8vo. 7s. 6d.
 — The Elements of Banking. Crown 8vo. 5s.
 — The Theory and Practice of Banking. Vol. 1, 8vo. 12s. Vol. 2, 14s.
 — Economics for Beginners. 8vo. 2s. 6d.
 — Lectures on Credit and Banking. 8vo. 5s.
 Mill's (James) Analysis of the Phenomena of the Human Mind. 2 vols. 8vo. 28s.
 Mill (John Stuart) on Representative Government. Crown 8vo. 2s.
 — — on Liberty. Crown 8vo. 1s. 4d.
 — — Examination of Hamilton's Philosophy. 8vo. 16s.
 — — Logic. Crown 8vo. 5s.
 — — Principles of Political Economy. 2 vols. 8vo. 30s. People's Edition, 1 vol. crown 8vo. 5s.
 — — Subjection of Women. Crown 8vo. 6s.
 — — Utilitarianism. 8vo. 5s.
 — — Three Essays on Religion, &c. 8vo. 5s.
 Mulhall's History of Prices since 1850. Crown 8vo. 6s.
 Müller's The Science of Thought. 8vo. 21s.
 Sandars's Institutes of Justinian, with English Notes. 8vo. 18s.
 Seebohm's English Village Community. 8vo. 16s.
 Sully's Outlines of Psychology. 8vo. 12s. 6d.
 — Teacher's Handbook of Psychology. Crown 8vo. 6s. 6d.
 Swinburne's Picture Logic. Post 8vo. 5s.
 Thompson's A System of Psychology. 2 vols. 8vo. 36s.
 — The Problem of Evil. 8vo. 10s. 6d.
 Thomson's Outline of Necessary Laws of Thought. Crown 8vo. 6s.
 Twiss's Law of Nations in Time of War. 8vo. 21s.
 — — in Time of Peace. 8vo. 15s.
 Webb's The Veil of Isis. 8vo. 10s. 6d.
 Whately's Elements of Logic. Crown 8vo. 4s. 6d.
 — — Rhetoric. Crown 8vo. 4s. 6d.
 Wylie's Labour, Leisure, and Luxury. Crown 8vo. 6s.
 Zeller's History of Eclecticism in Greek Philosophy. Crown 8vo. 10s. 6d.
 — Plato and the Older Academy. Crown 8vo. 18s.
 — Pre-Socratic Schools. 2 vols. crown 8vo. 30s.
 — Socrates and the Socratic Schools. Crown 8vo. 10s. 6d.
 — Stoics, Epicureans, and Sceptics. Crown 8vo. 15s.
 — Outlines of the History of Greek Philosophy. Crown 8vo. 10s. 6d.

LONGMANS, GREEN, & CO., London and New York.

MISCELLANEOUS WORKS.

- A. K. H. B., The Essays and Contributions of. Crown 8vo.
 Autumn Holidays of a Country Parson. 3s. 6d.
 Changed Aspects of Unchanged Truths. 3s. 6d.
 Common-Place Philosopher in Town and Country. 3s. 6d.
 Critical Essays of a Country Parson. 3s. 6d.
 Counsel and Comfort spoken from a City Pulpit. 3s. 6d.
 Graver Thoughts of a Country Parson. Three Series. 3s. 6d. each.
 Landscapes, Churches, and Moralities. 3s. 6d.
 Leisure Hours in Town. 3s. 6d. Lessons of Middle Age. 3s. 6d.
 Our Homely Comedy; and Tragedy. 3s. 6d.
 Our Little Life. Essays Consolatory and Domestic. Two Series. 3s. 6d.
 Present-day Thoughts. 3s. 6d. [each.
 Recreations of a Country Parson. Three Series. 3s. 6d. each.
 Seaside Musings on Sundays and Week-Days. 3s. 6d.
 Sunday Afternoons in the Parish Church of a University City. 3s. 6d.
- Armstrong's (Ed. J.) Essays and Sketches. Fcp. 8vo. 5s.
 Arnold's (Dr. Thomas) Miscellaneous Works. 8vo. 7s. 6d.
 Bagehot's Literary Studies, edited by Hutton. 2 vols. 8vo. 28s.
 Beaconsfield (Lord), The Wit and Wisdom of. Crown 8vo. 1s. boards; 1s. 6d. cl.
 Evans's Bronze Implements of Great Britain. 8vo. 25s.
 Farrar's Language and Languages. Crown 8vo. 6s.
 Froude's Short Studies on Great Subjects. 4 vols. crown 8vo. 24s.
 Lang's Letters to Dead Authors. Fcp. 8vo. 6s. 6d.
 — Books and Bookmen. Crown 8vo. 6s. 6d.
- Macanlay's Miscellaneous Writings. 2 vols. 8vo. 21s. 1 vol. crown 8vo. 4s. 6d.
 — Miscellaneous Writings and Speeches. Crown 8vo. 6s.
 — Miscellaneous Writings, Speeches, Lays of Ancient Rome, &c.
 Cabinet Edition. 4 vols. crown 8vo. 24s.
 — Writings, Selections from. Crown 8vo. 6s.
- Müller's (Max) Lectures on the Science of Language. 2 vols. crown 8vo. 16s.
 — — Lectures on India. 8vo. 12s. 6d.
- Proctor's Chance and Luck. Crown 8vo. 5s.
 Smith (Sydney) The Wit and Wisdom of. Crown 8vo. 1s. boards; 1s. 6d. cloth.

ASTRONOMY.

- Herschel's Outlines of Astronomy. Square crown 8vo. 12s.
 Proctor's Larger Star Atlas. Folio, 15s. or Maps only, 12s. 6d.
 — New Star Atlas. Crown 8vo. 5s.
 — Light Science for Leisure Hours. 3 Series. Crown 8vo. 5s. each.
 — The Moon. Crown 8vo. 6s.
 — Other Worlds than Ours. Crown 8vo. 5s.
 — The Sun. Crown 8vo. 14s.
 — Studies of Venus-Transits. 8vo. 5s.
 — Orbs Around Us. Crown 8vo. 5s.
 — Universe of Stars. 8vo. 10s. 6d.
- Webb's Celestial Objects for Common Telescopes. Crown 8vo. 9s.

THE 'KNOWLEDGE' LIBRARY.

Edited by RICHARD A. PROCTOR.

- | | |
|---|--|
| How to Play Whist. Crown 8vo. 5s. | Pleasant Ways in Science. Cr. 8vo. 6s. |
| Home Whist. 16mo. 1s. | Star Primer. Crown 4to. 2s. 6d. |
| The Borderland of Science. Cr. 8vo. 6s. | The Seasons Pictured. Demy 4to. 5s. |
| Nature Studies. Crown 8vo. 6s. | Strength and Happiness. Cr. 8vo. 5s. |
| Leisure Readings. Crown 8vo. 6s. | Rough Ways made Smooth. Cr. 8vo. 6s. |
| The Stars in their Seasons. Imp. 8vo. 5s. | The Expanse of Heaven. Cr. 8vo. 5s. |
| Myths and Marvels of Astronomy.
Crown 8vo. 6s. | Our Place among Infinities. Cr. 8vo. 5s. |

LONGMANS, GREEN, & CO., London and New York.

CLASSICAL LANGUAGES AND LITERATURE.

- Æschylus*, The *Eumenides* of. Text, with Metrical English Translation, by J. F. Davies. 8vo. 7s.
- Aristophanes*' The *Acharnians*, translated by R. Y. Tyrrell. Crown 8vo. 2s. 6d.
- Aristotle*'s The *Ethics*, Text and Notes, by Sir Alex. Grant, Bart. 2 vols. 8vo. 32s.
- The *Nicomachean Ethics*, translated by Williams, crown 8vo. 7s. 6d.
- The *Politics*, Books I. III. IV. (VII.) with Translation, &c. by Bolland and Lang. Crown 8vo. 7s. 6d.
- Becker*'s *Charicles* and *Gallus*, by Metcalfe. Post 8vo. 7s. 6d. each.
- Cicero*'s Correspondence, Text and Notes, by R. Y. Tyrrell. Vols. 1 & 2, 8vo. 12s. each.
- Homer*'s *Iliad*, Homometrically translated by Cayley. 8vo. 12s. 6d.
- — Greek Text, with Verse Translation, by W. C. Green. Vol. 1, Books I.-XII. Crown 8vo. 6s.
- Mahaffy*'s Classical Greek Literature. Crown 8vo. Vol. 1, The Poets, 7s. 6d. Vol. 2, The Prose Writers, 7s. 6d.
- Plato*'s *Parmenides*, with Notes, &c. by J. Maguire. 8vo. 7s. 6d.
- Virgil*'s Works, Latin Text, with Commentary, by Kennedy. Crown 8vo. 10s. 6d.
- *Æneid*, translated into English Verse, by Conington. Crown 8vo. 9s.
- — — — — by W. J. Thornhill. Cr. 8vo. 7s. 6d.
- *Poems*, — — — — Prose, by Conington. Crown 8vo. 9s.
- Witt*'s Myths of Hellas, translated by F. M. Younghusband. Crown 8vo. 3s. 6d.
- The Trojan War, — — — — Fcp. 8vo. 2s.
- The Wanderings of Ulysses, — — — — Crown 8vo. 3s. 6d.

NATURAL HISTORY, BOTANY, & GARDENING.

- Allen*'s Flowers and their Pedigrees. Crown 8vo. Woodcuts, 5s.
- Decaisne* and *Le Maout*'s General System of Botany. Imperial 8vo. 31s. 6d.
- Dixon*'s Rural Bird Life. Crown 8vo. Illustrations, 5s.
- Hartwig*'s Aerial World, 8vo. 10s. 6d.
- Polar World, 8vo. 10s. 6d.
- Sea and its Living Wonders. 8vo. 10s. 6d.
- Subterranean World, 8vo. 10s. 6d.
- Tropical World, 8vo. 10s. 6d.
- Lindley*'s Treasury of Botany. 2 vols. fcp. 8vo. 12s.
- Loudon*'s Encyclopædia of Gardening. 8vo. 21s.
- — — — — Plants. 8vo. 42s.
- Rivers*'s Orchard House. Crown 8vo. 5s.
- Miniature Fruit Garden. Fcp. 8vo. 4s.
- Stanley*'s Familiar History of British Birds. Crown 8vo. 6s.
- Wood*'s Bible Animals. With 112 Vignettes. 8vo. 10s. 6d.
- Common British Insects. Crown 8vo. 3s. 6d.
- Homes Without Hands, 8vo. 10s. 6d.
- Insects Abroad, 8vo. 10s. 6d.
- Horse and Man. 8vo. 14s.
- Insects at Home. With 700 Illustrations. 8vo. 10s. 6d.
- Out of Doors. Crown 8vo. 5s.
- Petland Revisited. Crown 8vo. 7s. 6d.
- Strange Dwellings. Crown 8vo. 5s. Popular Edition, 4to. 6d.

LONGMANS, GREEN, & CO., London and New York.

PRIZE AND PRESENTATION BOOKS.

Jameson's Sacred and Legendary Art. 6 vols. square 8vo.

Legends of the Madonna. 1 vol. 21s.

— — — Monastic Orders 1 vol. 21s.

— — — Saints and Martyrs. 2 vols. 31s. 6d.

— — — Saviour. Completed by Lady Eastlake. 2 vols. 42s.

Macaulay's Lays of Ancient Rome, illustrated by Scharf. Fcp. 4to. 10s. 6d.

The same, with *Ivry* and the *Armada*, illustrated by Weguelin. Crown 8vo. 3s. 6d.

New Testament (The) illustrated with Woodcuts after Paintings by the Early Masters. 4to. 21s.

By Dr. G. Hartwig.

Sea Monsters and Sea Birds (from 'The Sea and its Living Wonders'). With 75 Illustrations. Crown 8vo. 2s. 6d. cloth extra, gilt edges.

Denizens of the Deep (from 'The Sea and its Living Wonders'). With 117 Illustrations. Crown 8vo. 2s. 6d. cloth extra, gilt edges.

Dwellers in the Arctic Regions (from 'The Sea and its Living Wonders'). With 29 Illustrations. Crown 8vo. 2s. 6d. cloth extra, gilt edges.

Winged Life in the Tropics (from 'The Tropical World'). With 55 Illustrations. Crown 8vo. 2s. 6d. cloth extra, gilt edges.

Volcanoes and Earthquakes (from 'The Subterranean World'). With 30 Illustrations. Crown 8vo. 2s. 6d. cloth extra, gilt edges.

Wild Animals of the Tropics (from 'The Tropical World'). With 66 Illustrations. Crown 8vo. 3s. 6d. cloth extra, gilt edges.

By the Rev. J. G. Wood.

The Branch Builders (from 'Homes without Hands'). With 28 Illustrations. Crown 8vo. 2s. 6d. cloth extra, gilt edges.

Wild Animals of the Bible (from 'Bible Animals'). With 29 Illustrations. Crown 8vo. 3s. 6d. cloth extra, gilt edges.

Domestic Animals of the Bible (from 'Bible Animals'). With 23 Illustrations. Crown 8vo. 3s. 6d. cloth extra, gilt edges.

Bird Life of the Bible (from 'Bible Animals'). With 32 Illustrations. Crown 8vo. 3s. 6d. cloth extra, gilt edges.

Wonderful Nests (from 'Homes without Hands'). With 30 Illustrations. Crown 8vo. 3s. 6d. cloth extra, gilt edges.

Homes Under the Ground (from 'Homes without Hands'). With 28 Illustrations. Crown 8vo. 3s. 6d. cloth extra, gilt edges.

CHEMISTRY ENGINEERING, & GENERAL SCIENCE.

Arnott's Elements of Physics or Natural Philosophy. Crown 8vo. 12s. 6d.

Barrett's English Glee and Part-Songs: their Historical Development. Crown 8vo. 7s. 6d.

Bourne's Catechism of the Steam Engine. Crown 8vo. 7s. 6d.

— Handbook of the Steam Engine. Fcp. 8vo. 9s.

— Recent Improvements in the Steam Engine. Fcp. 8vo. 6s.

Buckton's Our Dwellings, Healthy and Unhealthy. Crown 8vo. 3s. 6d.

Clerk's The Gas Engine. With Illustrations. Crown 8vo. 7s. 6d.

Crookes's Select Methods in Chemical Analysis. 8vo. 24s.

Culley's Handbook of Practical Telegraphy. 8vo. 16s.

Fairbairn's Useful Information for Engineers. 3 vols. crown 8vo. 31s. 6d.

— Mills and Millwork. 1 vol. 8vo. 25s.

Ganot's Elementary Treatise on Physics, by Atkinson. Large crown 8vo. 15s.

— Natural Philosophy, by Atkinson. Crown 8vo. 7s. 6d.

Grove's Correlation of Physical Forces. 8vo. 15s.

Haughton's Six Lectures on Physical Geography. 8vo. 15s.

LONGMANS, GREEN, & CO., London and New York.

- Helmholtz on the Sensations of Tone. Royal 8vo. 28s.
- Helmholtz's Lectures on Scientific Subjects. 2 vols. crown 8vo. 7s. 6d. each.
- Hudson and Gosse's The Rotifera or 'Wheel Animalcules.' With 30 Coloured Plates. 6 parts. 4to. 10s. 6d. each. Complete, 2 vols. 4to. £3. 10s.
- Hullah's Lectures on the History of Modern Music. 8vo. 8s. 6d.
- Transition Period of Musical History. 8vo. 10s. 6d.
- Jackson's Aid to Engineering Solution. Royal 8vo. 21s.
- Jago's Inorganic Chemistry, Theoretical and Practical. Fcp. 8vo. 2s.
- Jeans' Railway Problems. 8vo. 12s. 6d.
- Kolbe's Short Text-Book of Inorganic Chemistry. Crown 8vo. 7s. 6d.
- Lloyd's Treatise on Magnetism. 8vo. 10s. 6d.
- Macalister's Zoology and Morphology of Vertebrate Animals. 8vo. 10s. 6d.
- Macfarren's Lectures on Harmony. 8vo. 12s.
- Miller's Elements of Chemistry, Theoretical and Practical. 3 vols. 8vo. Part I. Chemical Physics, 16s. Part II. Inorganic Chemistry, 24s. Part III. Organic Chemistry, price 31s. 6d.
- Mitchell's Manual of Practical Assaying. 8vo. 31s. 6d.
- Noble's Hours with a Three-inch Telescope. Crown 8vo. 4s. 6d.
- Northcott's Lathes and Turning. 8vo. 18s.
- Owen's Comparative Anatomy and Physiology of the Vertebrate Animals. 3 vols. 8vo. 73s. 6d.
- Piesse's Art of Perfumery. Square crown 8vo. 21s.
- Richardson's The Health of Nations; Works and Life of Edwin Chadwick, C.B. 2 vols. 8vo. 28s.
- The Commonwealth; a Series of Essays. Crown 8vo. 6s.
- Schellen's Spectrum Analysis. 8vo. 31s. 6d.
- Sennett's Treatise on the Marine Steam Engine. 8vo. 21s.
- Smith's Air and Rain. 8vo. 24s.
- Stoney's The Theory of the Stresses on Girders, &c. Royal 8vo. 36s.
- Tilden's Practical Chemistry. Fcp. 8vo. 1s. 6d.
- Tyndall's Faraday as a Discoverer. Crown 8vo. 3s. 6d.
- Floating Matter of the Air. Crown 8vo. 7s. 6d.
- Fragments of Science. 2 vols. post 8vo. 16s.
- Heat a Mode of Motion. Crown 8vo. 12s.
- Lectures on Light delivered in America. Crown 8vo. 5s.
- Lessons on Electricity. Crown 8vo. 2s. 6d.
- Notes on Electrical Phenomena. Crown 8vo. 1s. sewed, 1s. 6d. cloth.
- Notes of Lectures on Light. Crown 8vo. 1s. sewed, 1s. 6d. cloth.
- Sound, with Frontispiece and 203 Woodcuts. Crown 8vo. 10s. 6d.
- Watts's Dictionary of Chemistry. 9 vols. medium 8vo. £15. 2s. 6d.
- Wilson's Manual of Health-Science. Crown 8vo. 2s. 6d.

THEOLOGICAL AND RELIGIOUS WORKS.

- Arnold's (Rev. Dr. Thomas) Sermons. 6 vols. crown 8vo. 5s. each.
- Boulton's Commentary on the 39 Articles. Crown 8vo. 6s.
- Browne's (Bishop) Exposition of the 39 Articles. 8vo. 16s.
- Bullinger's Critical Lexicon and Concordance to the English and Greek New Testament. Royal 8vo. 15s.
- Colenso on the Pentateuch and Book of Joshua. Crown 8vo. 6s.
- Conder's Handbook of the Bible. Post 8vo. 7s. 6d.

LONGMANS, GREEN, & CO., London and New York.

- Conybeare & Howson's *Life and Letters of St. Paul*:—
 Library Edition, with Maps, Plates, and Woodcuts. 2 vols. square crown 8vo. 21s.
 Student's Edition, revised and condensed, with 46 Illustrations and Maps. 1 vol. crown 8vo. 7s. 6d.
- Cox's (Homersham) *The First Century of Christianity*. 8vo. 12s.
- Davidson's *Introduction to the Study of the New Testament*. 2 vols. 8vo. 30s.
- Edersheim's *Life and Times of Jesus the Messiah*. 2 vols. 8vo. 24s.
 — *Prophecy and History in relation to the Messiah*. 8vo. 12s.
- Ellicott's (Bishop) *Commentary on St. Paul's Epistles*. 8vo. *Corinthians I*. 16s. *Galatians*, 8s. 6d. *Ephesians*, 8s. 6d. *Pastoral Epistles*, 10s. 6d. *Philippians*, *Colossians and Philemon*, 10s. 6d. *Thessalonians*, 7s. 6d.
 — *Lectures on the Life of our Lord*. 8vo. 12s.
- Ewald's *Antiquities of Israel*, translated by Solly. 8vo. 12s. 6d.
 — *History of Israel*, translated by Carpenter & Smith. 8 vols. 8vo. Vols. 1 & 2, 24s. Vols. 3 & 4, 21s. Vol. 5, 18s. Vol. 6, 16s. Vol. 7, 21s. Vol. 8, 18s.
- Hobart's *Medical Language of St. Luke*. 8vo. 16s.
- Hopkins's *Christ the Consoler*. Fcp. 8vo. 2s. 6d.
- Jukes's *New Man and the Eternal Life*. Crown 8vo. 6s.
 — *Second Death and the Restitution of all Things*. Crown 8vo. 3s. 6d.
 — *Types of Genesis*. Crown 8vo. 7s. 6d.
 — *The Mystery of the Kingdom*. Crown 8vo. 3s. 6d.
- Lenormant's *New Translation of the Book of Genesis*. Translated into English. 8vo. 10s. 6d.
- Lyra Germanica: *Hymns translated by Miss Winkworth*. Fcp. 8vo. 5s.
- Macdonald's (G.) *Unspoken Sermons*. Two Series, Crown 8vo. 3s. 6d. each.
 — *The Miracles of our Lord*. Crown 8vo. 3s. 6d.
- Manning's *Temporal Mission of the Holy Ghost*. Crown 8vo. 8s. 6d.
- Martineau's *Endeavours after the Christian Life*. Crown 8vo. 7s. 6d.
 — *Hymns of Praise and Prayer*. Crown 8vo. 4s. 6d. 32mo. 1s. 6d.
 — *Sermons, Hours of Thought on Sacred Things*. 2 vols. 7s. 6d. each.
- Monsell's *Spiritual Songs for Sundays and Holidays*. Fcp. 8vo. 5s. 18mo. 2s.
- Müller's (Max) *Origin and Growth of Religion*. Crown 8vo. 7s. 6d.
 — *Science of Religion*. Crown 8vo. 7s. 6d.
- Newman's *Apologia pro Vitâ Suâ*. Crown 8vo. 6s.
 — *The Idea of a University Defined and Illustrated*. Crown 8vo. 7s.
 — *Historical Sketches*. 3 vols. crown 8vo. 6s. each.
 — *Discussions and Arguments on Various Subjects*. Crown 8vo. 6s.
 — *An Essay on the Development of Christian Doctrine*. Crown 8vo. 6s.
 — *Certain Difficulties Felt by Anglicans in Catholic Teaching Considered*. Vol. 1, crown 8vo. 7s. 6d. Vol. 2, crown 8vo. 5s. 6d.
 — *The Via Media of the Anglican Church, Illustrated in Lectures, &c.* 2 vols. crown 8vo. 6s. each
 — *Essays, Critical and Historical*. 2 vols. crown 8vo. 12s.
 — *Essays on Biblical and on Ecclesiastical Miracles*. Crown 8vo. 6s.
 — *An Essay in Aid of a Grammar of Assent*. 7s. 6d.
- Overton's *Life in the English Church (1660-1714)*. 8vo. 14s.
- Supernatural Religion*. Complete Edition. 3 vols. 8vo. 36s.
- Youngehusband's *The Story of Our Lord told in Simple Language for Children*. Illustrated. Crown 8vo. 2s. 6d. cloth plain; 3s. 6d. cloth extra, gilt edges.

TRAVELS, ADVENTURES, &c.

- Baker's Eight Years in Ceylon. Crown 8vo. 5s.
 — Rifle and Hound in Ceylon. Crown 8vo. 5s.
 Brassey's Sunshine and Storm in the East. Library Edition, 8vo. 21s. Cabinet Edition, crown 8vo. 7s. 6d. Popular Edition, 4to. 6d.
 — Voyage in the 'Sunbeam.' Library Edition, 8vo. 21s. Cabinet Edition, crown 8vo. 7s. 6d. School Edition, fcp. 8vo. 2s. Popular Edition, 4to. 6d.
 — In the Trades, the Tropics, and the 'Roaring Forties.' Library Edition, 8vo. 21s. Cabinet Edition, crown 8vo. 17s. 6d. Popular Edition, 4to. 6d.
 Froude's Oceana; or, England and her Colonies. Crown 8vo. 2s. boards; 2s. 6d. cloth.
 Howitt's Visits to Remarkable Places. Crown 8vo. 7s. 6d.
 Riley's Athos; or, The Mountain of the Monks. 8vo. 21s.
 Three in Norway. By Two of Them. Illustrated. Crown 8vo. 2s. boards; 2s. 6d. cloth.

WORKS OF FICTION.

- Beaconsfield's (The Earl of) Novels and Tales. Hughenden Edition, with 2 Portraits on Steel and 11 Vignettes on Wood. 11 vols. crown 8vo. £2. 2s. Cheap Edition, 11 vols. crown 8vo. 1s. each, boards; 1s. 6d. each, cloth.
- | | |
|-------------------|---------------------|
| Lothair. | Contarini Fleming. |
| Sybil. | Alroy, Ixion, &c. |
| Coningsby. | The Young Duke, &c. |
| Tancred. | Vivian Grey. |
| Venetia. | Endymion. |
| Henrietta Temple. | |
- Brabourne's (Lord) Friends and Foes from Fairyland. Crown 8vo. 6s.
 Caddy's (Mrs.) Through the Fields with Linnæus: a Chapter in Swedish History. 2 vols. crown 8vo. 16s.
 Gilkes' Boys and Masters. Crown 8vo. 3s. 6d.
 Haggard's (H. Rider) She: a History of Adventure. Crown 8vo. 6s.
 — — Allan Quatermain, Illustrated. Crown 8vo. 6s.
 Harte (Bret) On the Frontier. Three Stories. 16mo. 1s.
 — — By Shore and Sedge. Three Stories. 16mo. 1s.
 — — In the Carquinez Woods. Crown 8vo. 1s. boards; 1s. 6d. cloth.
 Lyall's (Edna) The Autobiography of a Slander. Fcp. 1s. sewed.
 Melville's (Whyte) Novels. 8 vols. fcp. 8vo. 1s. each, boards; 1s. 6d. each, cloth.
- | | |
|-----------------|---------------------|
| Digby Grand. | Good for Nothing. |
| General Bounce. | Holmby House. |
| Kate Coventry. | The Interpreter. |
| The Gladiators. | The Queen's Maries. |
- Molesworth's (Mrs.) Marrying and Giving in Marriage. Crown 8vo. 2s. 6d.
 Novels by the Author of 'The Atelier du Lys':
 The Atelier du Lys; or, An Art Student in the Reign of Terror. Crown 8vo. 2s. 6d.
 Mademoiselle Mori: a Tale of Modern Rome. Crown 8vo. 2s. 6d.
 In the Olden Time: a Tale of the Peasant War in Germany. Crown 8vo. 2s. 6d.
 Hester's Venture. Crown 8vo. 2s. 6d.
 Oliphant's (Mrs.) Madam. Crown 8vo. 1s. boards; 1s. 6d. cloth.
 — — In Trust: the Story of a Lady and her Lover. Crown 8vo. 1s. boards; 1s. 6d. cloth.

LONGMANS, GREEN, & CO., London and New York.

- Payn's (James) *The Luck of the Darrells*. Crown 8vo. 1s. boards; 1s. 6d. cloth.
 — — *Thicker than Water*. Crown 8vo. 1s. boards; 1s. 6d. cloth.
- Reader's *Fairy Prince Follow-my-Lead*. Crown 8vo. 2s. 6d.
 — *The Ghost of Brankinshaw; and other Tales*. Fcp. 8vo. 2s. 6d.
- Sewell's (Miss) *Stories and Tales*. Crown 8vo. 1s. each, boards; 1s. 6d. cloth; 2s. 6d. cloth extra, gilt edges.
- | | |
|--------------------------|----------------------------|
| Amy Herbert. Cleve Hall. | A Glimpse of the World. |
| The Earl's Daughter. | Katharine Ashton. |
| Experience of Life. | Laneton Parsonage. |
| Gertrude. Ivors. | Margaret Percival. Ursula. |
- Stevenson's (R. L.) *The Dynamiter*. Fcp. 8vo. 1s. sewed; 1s. 6d. cloth.
 — — *Strange Case of Dr. Jekyll and Mr. Hyde*. Fcp. 8vo. 1s. sewed; 1s. 6d. cloth.
- Sturgis' *Thralldom: a Story*. Crown 8vo. 6s.
- Trollope's (Anthony) *Novels*. Fcp. 8vo. 1s. each, boards; 1s. 6d. cloth.
The Warden | *Barchester Towers*.

POETRY AND THE DRAMA.

- Armstrong's (Ed. J.) *Poetical Works*. Fcp. 8vo. 5s.
 — (G. F.) *Poetical Works*:—
- | | |
|--|---|
| <i>Poems, Lyrical and Dramatic</i> . Fcp. 8vo. 6s. | <i>King Saul</i> . Fcp. 8vo. 5s. |
| <i>Ugone: a Tragedy</i> . Fcp. 8vo. 6s. | <i>King David</i> . Fcp. 8vo. 6s. |
| <i>A Garland from Greece</i> . Fcp. 8vo. 9s. | <i>King Solomon</i> . Fcp. 8vo. 6s. |
| | <i>Stories of Wicklow</i> . Fcp. 8vo. 9s. |
- Bowen's *Harrow Songs and other Verses*. Fcp. 8vo. 2s. 6d.; or printed on hand-made paper, 5s.
- Bowdler's *Family Shakespeare*. Medium 8vo. 14s. 6 vols. fcp. 8vo. 21s.
- Dante's *Divine Comedy*, translated by James Innes Minchin. Crown 8vo. 15s.
- Goethe's *Faust*, translated by Birds. Large crown 8vo. 12s. 6d.
 — — translated by Webb. 8vo. 12s. 6d.
 — — edited by Selss. Crown 8vo. 5s.
- Ingelow's *Poems*. Vols. 1 and 2, fcp. 8vo. 12s.
 — *Lyrical and other Poems*. Fcp. 8vo. 2s. 6d. cloth, plain; 3s. cloth, gilt edges.
- Macaulay's *Lays of Ancient Rome, with Ivry and the Armada*. Illustrated by Weguelin. Crown 8vo. 3s. 6d. gilt edges.
- The same, *Popular Edition*. Illustrated by Scharf. Fcp. 4to. 6d. swd., 1s. cloth.
- Nesbit's *Lays and Legends*. Crown 8vo. 5s.
- Reader's *Voices from Flowerland, a Birthday Book*, 2s. 6d. cloth, 3s. 6d. roan.
- Southey's *Poetical Works*. Medium 8vo. 14s.
- Stevenson's *A Child's Garden of Verses*. Fcp. 8vo. 5s.
- Virgil's *Æneid*, translated by Conington. Crown 8vo. 9s.
 — *Poems, translated into English Prose*. Crown 8vo. 9s.

AGRICULTURE, HORSES, DOGS, AND CATTLE.

- Fitzwygram's *Horses and Stables*. 8vo. 5s.
- Lloyd's *The Science of Agriculture*. 8vo. 12s.
- Loudon's *Encyclopædia of Agriculture*. 21s.
- Steel's *Diseases of the Ox, a Manual of Bovine Pathology*. 8vo. 15s.

LONGMANS, GREEN, & CO., London and New York.

- Stonehenge's Dog in Health and Disease. Square crown 8vo. 7s. 6d.
 — Greyhound. Square crown 8vo. 15s.
 Taylor's Agricultural Note Book. Fcp. 8vo. 2s. 6d.
 Ville on Artificial Manures, by Crookes. 8vo. 21s.
 Youatt's Work on the Dog. 8vo. 6s.
 — — — — Horse. 8vo. 7s. 6d.

SPORTS AND PASTIMES.

- The Badminton Library of Sports and Pastimes. Edited by the Duke of Beaufort and A. E. T. Watson. With numerous Illustrations. Cr. 8vo. 10s. 6d. each.
 Hunting, by the Duke of Beaufort, &c.
 Fishing, by H. Cholmondeley-Pennell, &c. 2 vols.
 Racing, by the Earl of Suffolk, &c.
 Shooting, by Lord Walsingham, &c. 2 vols.
 Cycling. By Viscount Bury.
 * * * Other Volumes in preparation.
- Campbell-Walker's Correct Card, or How to Play at Whist. Fcp. 8vo. 2s. 6d.
 Ford's Theory and Practice of Archery, revised by W. Butt. 8vo. 14s.
 Francis's Treatise on Fishing in all its Branches. Post 8vo. 15s.
 Longman's Chess Openings. Fcp. 8vo. 2s. 6d.
 Pease's The Cleveland Hounds as a Trencher-Fed Pack. Royal 8vo. 18s.
 Pole's Theory of the Modern Scientific Game of Whist. Fcp. 8vo. 2s. 6d.
 Proctor's How to Play Whist. Crown 8vo. 5s.
 Ronalds's Fly-Fisher's Entomology. 8vo. 14s.
 Verney's Chess Eccentricities. Crown 8vo. 10s. 6d.
 Wilcocks's Sea-Fisherman. Post 8vo. 6s.

ENCYCLOPÆDIAS, DICTIONARIES, AND BOOKS OF REFERENCE.

- Acton's Modern Cookery for Private Families. Fcp. 8vo. 4s. 6d.
 Ayre's Treasury of Bible Knowledge. Fcp. 8vo. 6s.
 Brande's Dictionary of Science, Literature, and Art. 3 vols. medium 8vo. 63s.
 Cabinet Lawyer (The), a Popular Digest of the Laws of England. Fcp. 8vo. 9s.
 Cates's Dictionary of General Biography. Medium 8vo. 28s.
 Gwilt's Encyclopædia of Architecture. 8vo. 52s. 6d.
 Keith Johnston's Dictionary of Geography, or General Gazetteer. 8vo. 42s.
 M'Culloch's Dictionary of Commerce and Commercial Navigation. 8vo. 63s.
 Maunder's Biographical Treasury. Fcp. 8vo. 6s.
 — Historical Treasury. Fcp. 8vo. 6s.
 — Scientific and Literary Treasury. Fcp. 8vo. 6s.
 — Treasury of Bible Knowledge, edited by Ayre. Fcp. 8vo. 6s.
 — Treasury of Botany, edited by Lindley & Moore. Two Parts, 12s.
 — Treasury of Geography. Fcp. 8vo. 6s.
 — Treasury of Knowledge and Library of Reference. Fcp. 8vo. 6s.
 — Treasury of Natural History. Fcp. 8vo. 6s.
 Quain's Dictionary of Medicine. Medium 8vo. 31s. 6d., or in 2 vols. 34s.
 Reeve's Cookery and Housekeeping. Crown 8vo. 7s. 6d.
 Rich's Dictionary of Roman and Greek Antiquities. Crown 8vo. 7s. 6d.
 Roget's Thesaurus of English Words and Phrases. Crown 8vo. 10s. 6d.
 Willich's Popular Tables, by Marriott. Crown 8vo. 10s. 6d.

LONGMANS, GREEN, & CO., London and New York.

A SELECTION OF EDUCATIONAL WORKS.

TEXT-BOOKS OF SCIENCE

FULLY ILLUSTRATED.

- Abney's Treatise on Photography. Fcp. 8vo. 3s. 6d.
Anderson's Strength of Materials. 3s. 6d.
Armstrong's Organic Chemistry. 3s. 6d.
Ball's Elements of Astronomy. 6s.
Barry's Railway Appliances. 3s. 6d.
Bauerman's Systematic Mineralogy. 6s.
— Descriptive Mineralogy. 6s.
Bloxam and Huntington's Metals. 5s.
Glazebrook's Physical Optics. 6s.
Glazebrook and Shaw's Practical Physics. 6s.
Gore's Art of Electro-Metallurgy. 6s.
Griffin's Algebra and Trigonometry. 3s. 6d. Notes and Solutions, 3s. 6d.
Holmes's The Steam Engine. 6s.
Jenkin's Electricity and Magnetism. 3s. 6d.
Maxwell's Theory of Heat. 3s. 6d.
Merrifield's Technical Arithmetic and Mensuration. 3s. 6d. Key, 3s. 6d.
Miller's Inorganic Chemistry. 3s. 6d.
Preece and Sivewright's Telegraphy. 5s.
Rutley's Study of Rocks, a Text-Book of Petrology. 4s. 6d.
Shelley's Workshop Appliances. 4s. 6d.
Thomé's Structural and Physiological Botany. 6s.
Thorpe's Quantitative Chemical Analysis. 4s. 6d.
Thorpe and Muir's Qualitative Analysis. 3s. 6d.
Tilden's Chemical Philosophy. 3s. 6d. With Answers to Problems. 4s. 6d.
Unwin's Elements of Machine Design. 6s.
Watson's Plane and Solid Geometry. 3s. 6d.

THE GREEK LANGUAGE.

- Bloomfield's College and School Greek Testament. Fcp. 8vo. 5s.
Bolland & Lang's Politics of Aristotle. Post 8vo. 7s. 6d.
Collis's Chief Tenses of the Greek Irregular Verbs. 8vo. 1s.
— Pontes Græci, Stepping-Stone to Greek Grammar. 12mo. 3s. 6d.
— Praxis Græca, Etymology. 12mo. 2s. 6d.
— Greek Verse-Book, Praxis Iambica. 12mo. 4s. 6d.
Farrar's Brief Greek Syntax and Accidence. 12mo. 4s. 6d.
— Greek Grammar Rules for Harrow School. 12mo. 1s. 6d.
Geare's Notes on Thucydides. Book I. Fcp. 8vo. 2s. 6d.
Hewitt's Greek Examination-Papers. 12mo. 1s. 6d.
Isbister's Xenophon's Anabasis, Books I. to III. with Notes. 12mo. 3s. 6d.
Jerram's Græcè Reddenda. Crown 8vo. 1s. 6d.

LONGMANS, GREEN, & CO., London and New York.

- Kennedy's Greek Grammar. 12mo. 4s. 6d.
 Liddell & Scott's English-Greek Lexicon. 4to. 36s.; Square 12mo. 7s. 6d.
 Mahaffy's Classical Greek Literature. Crown 8vo. Poets, 7s. 6d. Prose Writers, 7s. 6d.
 Morris's Greek Lessons. Square 18mo. Part I. 2s. 6d.; Part II. 1s.
 Parry's Elementary Greek Grammar. 12mo. 3s. 6d.
 Plato's Republic, Book I. Greek Text, English Notes by Hardy. Crown 8vo. 3s.
 Sheppard and Evans's Notes on Thucydides. Crown 8vo. 7s. 6d.
 Thucydides, Book IV. with Notes by Barton and Chavasse. Crown 8vo. 5s.
 Valpy's Greek Delectus, improved by White. 12mo. 2s. 6d. Key, 2s. 6d.
 White's Xenophon's Expedition of Cyrus, with English Notes. 12mo. 7s. 6d.
 Wilkins's Manual of Greek Prose Composition. Crown 8vo. 5s. Key, 5s.
 — Exercises in Greek Prose Composition. Crown 8vo. 4s. 6d. Key, 2s. 6d.
 — New Greek Delectus. Crown 8vo. 3s. 6d. Key, 2s. 6d.
 — Progressive Greek Delectus. 12mo. 4s. Key, 2s. 6d.
 — Progressive Greek Anthology. 12mo. 5s.
 — Scriptorum Atticorum, Excerpts with English Notes. Crown 8vo. 7s. 6d.
 — Speeches from Thucydides translated. Post 8vo. 6s.
 Yonge's English-Greek Lexicon. 4to. 21s.; Square 12mo. 8s. 6d.

THE LATIN LANGUAGE.

- Bradley's Latin Prose Exercises. 12mo. 3s. 6d. Key, 5s.
 — Continuous Lessons in Latin Prose. 12mo. 5s. Key, 5s. 6d.
 — Cornelius Nepos, improved by White. 12mo. 3s. 6d.
 — Eutropius, improved by White. 12mo. 2s. 6d.
 — Ovid's Metamorphoses, improved by White. 12mo. 4s. 6d.
 — Select Fables of Phædrus, improved by White. 12mo. 2s. 6d.
 Collis's Chief Tenses of Latin Irregular Verbs. 8vo. 1s.
 — Pontes Latini, Stepping-Stone to Latin Grammar. 12mo. 3s. 6d.
 Hewitt's Latin Examination-Papers. 12mo. 1s. 6d.
 Isbister's Cæsar, Books I.-VII. 12mo. 4s.; or with Reading Lessons, 4s. 6d.
 — Cæsar's Commentaries, Books I.-V. 12mo. 3s. 6d.
 — First Book of Cæsar's Gallic War. 12mo. 1s. 6d.
 Jerram's Latinè Reddenda. Crown 8vo. 1s. 6d.
 Kennedy's Child's Latin Primer, or First Latin Lessons. 12mo. 2s.
 — Child's Latin Accidence. 12mo. 1s.
 — Elementary Latin Grammar. 12mo. 3s. 6d.
 — Elementary Latin Reading Book, or Tirocinium Latinum. 12mo. 2s.
 — Latin Prose, Palæstra Stili Latini. 12mo. 6s.
 — Latin Vocabulary. 12mo. 2s. 6d.
 — Subsidia Primaria, Exercise Books to the Public School Latin Primer.
 I. Accidence and Simple Construction, 2s. 6d. II. Syntax, 3s. 6d.
 — Key to the Exercises in Subsidia Primaria, Parts I. and II. price 5s.
 — Subsidia Primaria, III. the Latin Compound Sentence. 12mo. 1s.
 — Curriculum Stili Latini. 12mo. 4s. 6d. Key, 7s. 6d.
 — Palæstra Latina, or Second Latin Reading Book. 12mo. 5s.

- Millington's Latin Prose Composition. Crown 8vo. 3s. 6d.
 — Selections from Latin Prose. Crown 8vo. 2s. 6d.
 Moody's Eton Latin Grammar. 12mo. 2s. 6d. The Accidence separately, 1s.
 Morris's Elementa Latina. Fcp. 8vo. 1s. 6d. Key, 2s. 6d.
 Parry's Origines Romanae, from Livy, with English Notes. Crown 8vo. 4s.
 The Public School Latin Primer. 12mo. 2s. 6d.
 — — — Grammar, by Rev. Dr. Kennedy. Post 8vo. 7s. 6d.
 Prendergast's Mastery Series, Manual of Latin. 12mo. 2s. 6d.
 Rapier's Introduction to Composition of Latin Verse. 12mo. 3s. 6d. Key, 2s. 6d.
 Sheppard and Turner's Aids to Classical Study. 12mo. 5s. Key, 6s.
 Valpy's Latin Delectus, improved by White. 12mo. 2s. 6d. Key, 3s. 6d.
 Virgil's Æneid, translated into English Verse by Conington. Crown 8vo. 9s.
 — Works, edited by Kennedy. Crown 8vo. 10s. 6d.
 — — translated into English Prose by Conington. Crown 8vo. 9s.
 Walford's Progressive Exercises in Latin Elegiac Verse. 12mo. 2s. 6d. Key, 5s.
 White and Riddle's Large Latin-English Dictionary. 1 vol. 4to. 21s.
 White's Concise Latin-Eng. Dictionary for University Students. Royal 8vo. 12s.
 — Junior Students' Eng.-Lat. & Lat.-Eng. Dictionary. Square 12mo. 5s.
 Separately { The Latin-English Dictionary, price 3s.
 { The English-Latin Dictionary, price 3s.
 Yonge's Latin Gradus. Post 8vo. 9s.; or with Appendix, 12s.

WHITE'S GRAMMAR-SCHOOL GREEK TEXTS.

- | | |
|--|--|
| Æsop (Fables) & Palæphatus (Myths).
32mo. 1s. | Xenophon, Book I. without Vocabulary. 3d. |
| Euripides, Hecuba. 2s. | St. Matthew's and St. Luke's Gospels.
2s. 6d. each. |
| Homer, Iliad, Book I. 1s.
— Odyssey, Book I. 1s. | St. Mark's and St. John's Gospels.
1s. 6d. each. |
| Lucian, Select Dialogues. 1s. | The Acts of the Apostles. 2s. 6d. |
| Xenophon, Anabasis, Books I. III. IV.
V. & VI. 1s. 6d. each; Book II. 1s.;
Book VII. 2s. | St. Paul's Epistle to the Romans. 1s. 6d. |
- The Four Gospels in Greek, with Greek-English Lexicon. Edited by John T. White, D.D. Oxon. Square 32mo. price 5s.

WHITE'S GRAMMAR-SCHOOL LATIN TEXTS.

- | | |
|--|--|
| Cæsar, Gallic War, Books I. & II. V.
& VI. 1s. each. Book I. without
Vocabulary, 3d. | Nepos, Miltiades, Simon, Pausanias,
Aristides. 9d. |
| Cæsar, Gallic War, Books III. & IV.
9d. each. | Ovid. Selections from Epistles and
Fasti. 1s. |
| Cæsar, Gallic War, Book VII. 1s. 6d. | Ovid, Select Myths from Metamor-
phoses. 9d. |
| Cicero, Cato Major (Old Age). 1s. 6d. | Phædrus, Select Easy Fables, |
| Cicero, Lælius (Friendship). 1s. 6d. | Phædrus, Fables, Books I. & II. 1s. |
| Eutropius, Roman History, Books I.
& II. 1s. Books III. & IV. 1s. | Sallust, Bellum Catilinarium. 1s. 6d. |
| Horace, Odes, Books I. II. & IV. 1s. each. | Virgil, Georgics, Book IV. 1s. |
| Horace, Odes, Book III. 1s. 6d. | Virgil, Æneid, Books I. to VI. 1s. each. |
| Horace, Epodes and Carmen Seculare.
1s. | Book I. without Vocabulary, 3d. |
| | Virgil, Æneid, Books VII. VIII. X.
XI. XII. 1s. 6d. each. |


THE FRENCH LANGUAGE.


- Albités's How to Speak French. Fcp. 8vo. 5s. 6d.
 — Instantaneous French Exercises. Fcp. 2s. Key, 2s.
 Cassal's French Genders. Crown 8vo. 3s. 6d.
 Cassal & Karcher's Graduated French Translation Book. Part I. 3s. 6d.
 Part II. 5s. Key to Part I. by Professor Cassal, price 5s.
 Contanseau's Practical French and English Dictionary. Post 8vo. 3s. 6d.
 — Pocket French and English Dictionary. Square 18mo. 1s. 6d.
 — Premières Lectures. 12mo. 2s. 6d.
 — First Step in French. 12mo. 2s. 6d. Key, 3s.
 — French Accidence. 12mo. 2s. 6d.
 — — Grammar. 12mo. 4s. Key, 3s.
 Contanseau's Middle-Class French Course. Fcp. 8vo. :—
 Accidence, 8d. | French Translation-Book, 8d.
 Syntax, 8d. | Easy French Delectus, 8d.
 French Conversation-Book, 8d. | First French Reader, 8d.
 First French Exercise-Book, 8d. | Second French Reader, 8d.
 Second French Exercise-Book, 8d. | French and English Dialogues, 8d.
 Contanseau's Guide to French Translation. 12mo. 3s. 6d. Key 3s. 6d.
 — Prosateurs et Poètes Français. 12mo. 5s.
 — Précis de la Littérature Française. 12mo. 3s. 6d.
 — Abrégé de l'Histoire de France. 12mo. 2s. 6d.
 Féval's Chouans et Bleus, with Notes by C. Sankey, M.A. Fcp. 8vo. 2s. 6d.
 Jerram's Sentences for Translation into French. Cr. 8vo. 1s. Key, 2s. 6d.
 Prendergast's Mastery Series, French. 12mo. 2s. 6d.
 Souvestre's Philosophe sous les Toits, by Stièvenard. Square 18mo. 1s. 6d.
 Stepping-Stone to French Pronunciation. 18mo. 1s.
 Stièvenard's Lectures Françaises from Modern Authors. 12mo. 4s. 6d.
 — Rules and Exercises on the French Language. 12mo. 3s. 6d.
 Tarver's Eton French Grammar. 12mo. 6s. 6d.

THE GERMAN LANGUAGE.

- Blackley's Practical German and English Dictionary. Post 8vo. 3s. 6d.
 Buchheim's German Poetry, for Repetition. 18mo. 1s. 6d.
 Collis's Card of German Irregular Verbs. 8vo. 2s.
 Fischer-Fischart's Elementary German Grammar. Fcp. 8vo. 2s. 6d.
 Just's German Grammar. 12mo. 1s. 6d.
 — German Reading Book. 12mo. 3s. 6d.
 Longman's Pocket German and English Dictionary. Square 18mo. 2s. 6d.
 Naftel's Elementary German Course for Public Schools. Fcp. 8vo.
 German Accidence. 9d. | German Prose Composition Book. 9d.
 German Syntax. 9d. | First German Reader. 9d.
 First German Exercise-Book. 9d. | Second German Reader. 9d.
 Second German Exercise-Book. 9d.
 Prendergast's Mastery Series, German. 12mo. 2s. 6d.
 Quick's Essentials of German. Crown 8vo. 3s. 6d.
 Selss's School Edition of Goethe's Faust. Crown 8vo. 5s.
 — Outline of German Literature. Crown 8vo. 4s. 6d.
 Wirth's German Chit-Chat. Crown 8vo. 2s. 6d.

LONGMANS, GREEN, & CO., London and New York.





RD32

B24

Darke

Surgical Operations

COLUMBIA UNIVERSITY LIBRARIES (hsl, stx)

RD 32 B24 C.1

A short manual of surgical operations.



2002110601

