

Is appendicitis a surgical disease? / by Carl Beck.

Contributors

Beck, Carl, 1856-1911.
Augustus Long Health Sciences Library

Publication/Creation

New York : Appleton, 1898.

Persistent URL

<https://wellcomecollection.org/works/vbreyxfx>

License and attribution

This material has been provided by This material has been provided by the Augustus C. Long Health Sciences Library at Columbia University and Columbia University Libraries/Information Services, through the Medical Heritage Library. The original may be consulted at the the Augustus C. Long Health Sciences Library at Columbia University and Columbia University. where the originals may be consulted.

This work has been identified as being free of known restrictions under copyright law, including all related and neighbouring rights and is being made available under the Creative Commons, Public Domain Mark.

You can copy, modify, distribute and perform the work, even for commercial purposes, without asking permission.

**wellcome
collection**

Wellcome Collection
183 Euston Road
London NW1 2BE UK
T +44 (0)20 7611 8722
E library@wellcomecollection.org
<https://wellcomecollection.org>

COLUMBIA LIBRARIES OFFSITE
HEALTH SCIENCES STANDARD



HX64067017

RD542 B38

Is appendicitis a su

RECAP

Carl Beck

Is Appendicitis a Surgical Disease?


FD542

B.38

Columbia University
in the City of New York

COLLEGE OF
PHYSICIANS AND SURGEONS
LIBRARY





Digitized by the Internet Archive
in 2010 with funding from
Open Knowledge Commons

IS APPENDICITIS
A SURGICAL DISEASE?

BY
CARL BECK, M. D.,
NEW YORK.

REPRINTED FROM THE
New York Medical Journal
for November, 12, 19, and 26,
and December 10, 1898.

LIBRARY
UNIVERSITY
MEDICAL LIBRARY

RD542
B38

*Reprinted from the New York Medical Journal
for November 12, 19, and 26, and December 10, 1898.*

IS APPENDICITIS A SURGICAL DISEASE?

BY CARL BECK, M. D.,

NEW YORK.

APPENDICITIS is an inflammation of the vermiform process due to infection. Is such infection due to the invasion of a specific bacterium, or to the cooperation of two or more different species? The question is not yet settled; but the majority of observations point toward the ubiquitous *Bacterium coli commune* as playing the main part in the infection. Other species are found in the colon: the *Streptococcus lanceolatus*, the *Bacillus pyogenes*, the different varieties of proteus, the *Bacillus subtilis*, and sometimes staphylococci. Streptococci are found more frequently, the liquefying as well as the non-liquefying type. Regarding the repute of the streptococcus, it is no more than natural that there is an inclination to hold it responsible to a great extent for originating appendicitis, especially in its highly virulent forms.

Welch maintains that it is the combined influence of the colon bacterium and streptococcus which causes appendicitis, and that the failure to discover streptococci on the artificial soil does not necessarily prove

their absence. The colonies of the *Bacterium coli commune* grow so rapidly, and are so overshadowed, that they are overlooked. So it might be that from the standpoint of the companionship of two different types of bacteria the higher toxic potency of the various types of appendicitis could be explained.

Whether each of these bacterial species alone will originate appendicitis, or whether two or more associated species together are required, has as yet not been practically demonstrated. Theoretically, there seems to be no reason why each pathogenic species alone could not produce the infection. It is a well-known fact that the virulence of the *Bacterium coli commune* sometimes may become enormous. According to Lesage and Maçaigne (*Archives de méd. expériment. et d'anatom. pathol.*, 1892), it produces but insignificant effects if grown on a healthy surface, but causes the most intense reaction when isolated from tissues which have undergone pathological changes. Thus its virulence is the higher as the disease is graver in which this bacterium is found. The fact that cultures taken from a case of cholera showed a high virulence, while those taken from a pus focus were weak, is in entire accord with this theory. It will be reserved for the cooperation of surgeons possessing bacteriological knowledge to appreciate these different theories so far that practical results can be deduced from them.

One of the greatest difficulties in estimating the toxic dignity of the *Bacterium coli commune* is caused by its not representing a distinct uniform species, but a whole series of different subspecies, which, while alike in many respects, still show a few small but nevertheless well-marked diversities. The great difficulties of

differentiation may best be illustrated by the fact that Park goes even as far as to maintain that the *Bacterium coli commune* should probably be identical with the *Bacillus neapolitanus* Escherich, the *Bacillus fætidus* Passet, the *Bacillus aerogenes*, and a variety of other forms.

It is well known that the much-debated *Bacterium coli commune* is the most common inhabitant of the intestines of man, as well as of many animals, such as the dog, cat, goat, hog, cow, mouse, rabbit, etc. Thorough examination reveals the presence of this ubiquitous bacterium in the oral cavity of almost every healthy person. As long as the mucous membrane of the intestine is normal, it causes no disturbance whatsoever. But as soon as there is the slightest erosion of the epithelium, it will readily be absorbed. This will happen so much the easier when there are other disturbances in the intestinal tract.

According to Gilbert, Roger, and others, it forms very virulent tissue-change products, which are probably rendered innocuous by the liver, or more so by the bile. There is no better proof for the fact that disturbances of circulation offer a most provoking moment for infection than the experience that in hernial incarceration it is found, having advanced as far as to the serosa. That abrasions of the mucous membrane are the avenue for the invasion is evidenced also by the frequent presence of the *Bacterium coli commune* in dysentery, typhoid fever, and cholera. And there is hardly any other organ of the human body where the chances of a circulatory disturbance and of the abrasion of the mucous membrane are offered with such frequency as in the vermiform process. We need only to consider its situa-

tion above the ileo-psoas, a muscle so extensively used, the length of its channel, which is in no proportion to its small calibre; furthermore, the shortness of its mesenterium, and last, but not least, its low power of expulsion. Remembering the scantiness of its muscular tissue—there is but a small circular layer—this lack of expelling power can be well appreciated (Fig. 1).

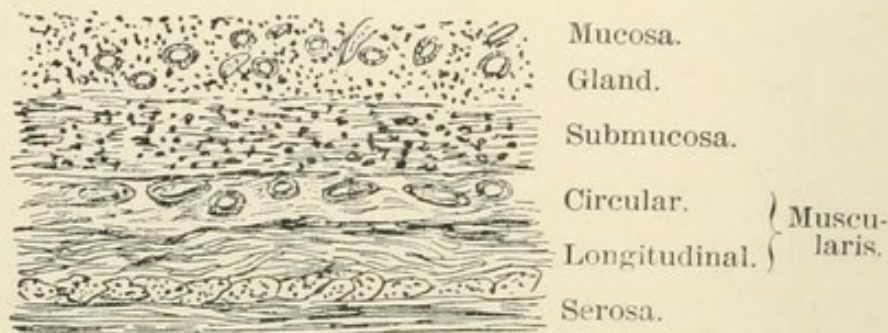


FIG. 1.—Section through normal appendicular wall.

A certain amount of circulation, however, in the vermiform process must be possible. I have made it a rule for several years (see *Journal of the American Medical Association*, December 28, 1895) to examine the vermiform process in each case of abdominal section. I have repeatedly found masses of moderate hardness, probably fæcal concretions, in individuals who had never up to that time and have not since then shown any symptoms of disease of this organ. Slight pressure sufficed to void such contents into the cæcum.

Appreciating the fact that in the majority of cases the vermiform appendix reaches as far as the true pelvis, it can easily be explained how kinks and twists are caused, which are apt to prevent mechanically the evacuation of the appendicular contents into the cæcum. The limits of this work forbid my entering into the various occasional causes more particularly. I shall only re-

mark that, regarding my own experience in two hundred and seven cases of appendicitis, I feel justified in emphasizing the rarity of real foreign bodies. Only twice have I found real foreign bodies in the appendix—once the traditional grapeseed, and another time a few cumin seeds. Fæcal concretions are frequently found—I have seen them forty-two times—almost always in the gangrenous form.

There is another ætiological factor the pathological significance of which has, so far as my knowledge goes, as yet not been studied—namely, the right floating kidney pressing the appendix, if directed backward toward the ileum.

In the case of two men, one being thirty-three and the other nineteen years of age, slight pain existed for years, the intensity of which increased gradually. In both cases it was located partially in the lumbar and hip-joint region, and partially in the right iliac fossa, so that lumbago as well as coprostasis was repeatedly diagnosed. In the case of the nineteen-year-old patient even coxitis had been thought of, because the right leg appeared to be slightly shortened. In both cases a skiagraph had been taken, which illustrated the integrity of the bones. Having been able to palpate a slight resistance in the depth of the iliac fossa, I thought of chronic appendicitis, and opened the abdomen. In both cases a movable kidney was discovered, which reached down into the fossa, pressing the appendix against the ilium at each inspiration. After their removal, both appendices, which appeared normal on the outside, showed strictures and contained a small quantity of discolored



FIG. 2.—Fæcal concretion from a gangrenous appendix.

and decomposed fæces. Nephropexy was performed at the same time and up to date, fifteen and ten months after the operation, no pain was noticed by either of the two patients.

In the case of a lady, thirty years of age, on whom I operated in the second attack I found the appendix buried by the side of the cæcum in such a manner that at first sight there seemed to be no appendix at all. It was only after some search that its structure could be identified, for it had almost become an integral part of the cæcum. Close examination revealed a deep-seated kidney pressing the cæcum down against the ilium. The appendix, which was directed backward, had been pressed against the ilium so that it had become flattened, and at the time of the first attack the serous surfaces of the appendix and cæcum were fused together, the appendix being imbedded in a groovelike depression on the cæcum. By careful dissection with a grooved director it was enucleated. At its tip there was a small perforation containing thick, yellow pus. It was removed, the stump was tied, and the wound was treated by the open method. The patient recovered. In this case there had been digestive disturbances for years, and at one time cholelithiasis had been suspected.

Edebohls, to whom we are so very much indebted for the discovery of the means of palpating the appendix, mentions the frequent occurrence of appendicitis in connection with floating kidney in general, attributing the pathological change of the appendix to the dislocation of the duodenum and pancreas and compression of the superior mesenteric vessels between the head of the pancreas and the bodies of the spinal vertebræ. But it seems to me that the deeply situated movable kidney

exerts its pathogenic influence directly upon the appendix.

Thus disturbances of circulation may be produced which, while in themselves of a slight nature, are still sufficient to cause swelling and obstruction, even after the original cause, the twist, the kink, or the compression have again ceased to exist. The swelling of the mucous membrane is usually at the spot where its circular duplicatures are found, as, for instance, above Gerlach's valve, which corresponds to the ostium of the appendix at the cæcum. Naturally, the appendicular secretion is apt to be retained below there. The further consequences are its decomposition and irritation. The presence of fæcal concretion may represent an additional ætiological factor as a mechanical insult. As alluded to, the contractility of the appendix is slight under ordinary conditions. How much more its contractility will be impaired, if there be a swelling, and a swelling means the presence of œdema, can easily be imagined.

And, moreover, how fruitful a field for the development of bacteria is this hollow organ, which resembles a cæcum in miniature. Its comparison with the tonsil in view of its glandular richness, unequaled by any other portion of the intestinal tract, is quite obvious. To appreciate the analogy, there is no need to go as far as Golouboff (*Berliner klinische Wochenschrift*, 1897, No. 5) did, who regards appendicitis as of epidemic origin, just like a tonsillar angina. But by considering that the appendix is in itself a large blind alley, while the tonsil is a conglomeration of many small blind alleys, by further realizing that both organs touch the two body cavities abounding more with bacteria than any other, the comparison can not be helped. There are a

few other factors pointing to the similarity—namely, the well-pronounced predilection for an early age, especially in the male, and the early manifestation of the inefficiency of their expulsive power against bacteria invasion, according to their anatomical structures.

For a better understanding, the anatomical relations,

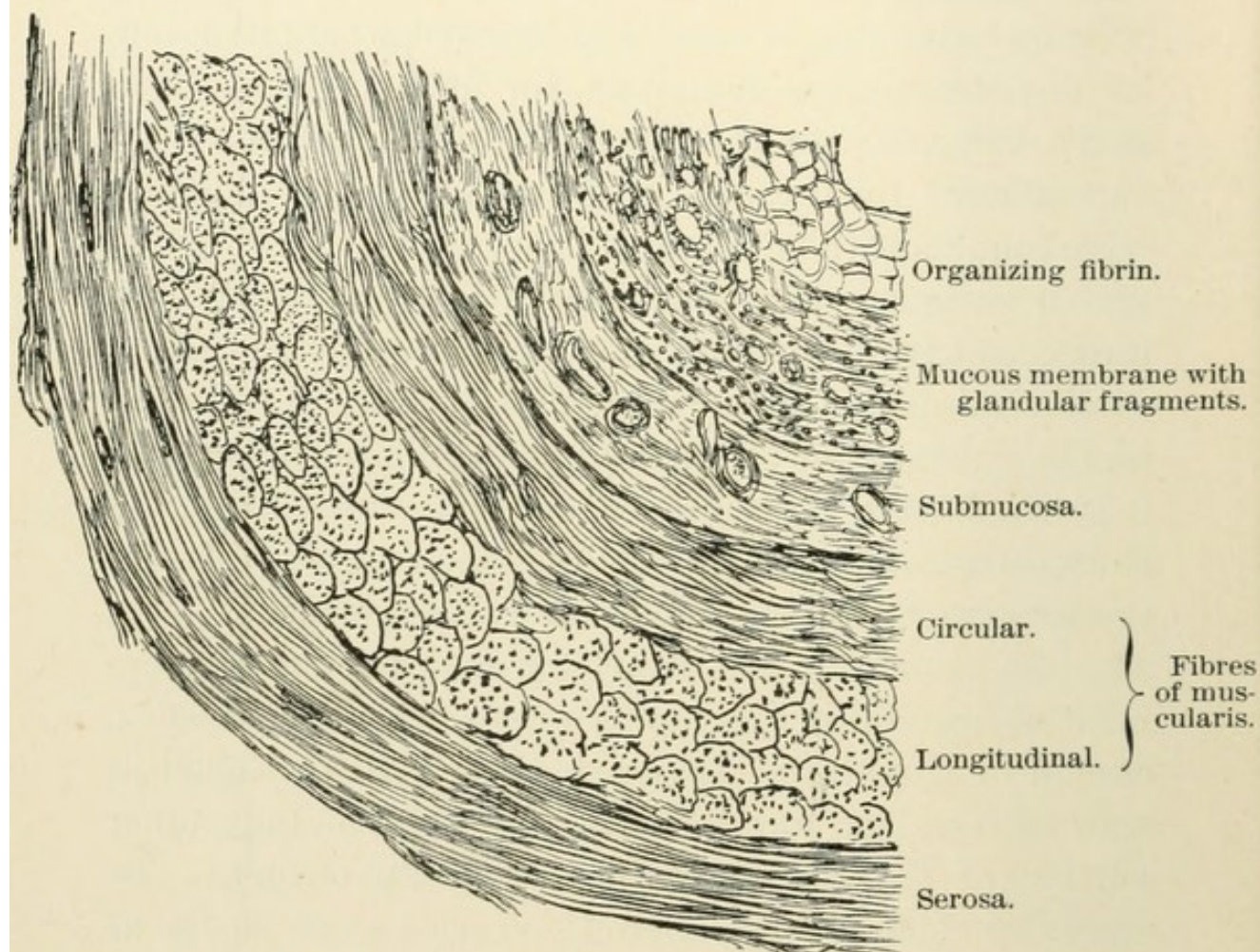


FIG. 3.—Appendix wall in simple appendicitis.

as shown in Fig. 1, should be recalled. There we have to deal with a mucous membrane containing little epithelium and a glandular and submucous layer, the latter showing traces of a muscularis mucosæ. Then follow the circular and longitudinal stratum, which are protected by the subserosa and serosa.

There can be no doubt that once in a while the irritating contents force their escape into the cæcum, and it is then that from a clinical standpoint the diagnosis "colic of the appendix" will be made. But in far the greater majority of cases the invasion of bacteria into the submucosa means the breach being shot, and then there is no further halt to the progression of the infection.

The muscularis rapidly being permeated, the subserosa and serosa are attacked soon. Accordingly the wall of the appendix becomes thickened. The contents of the channel become mucopurulent. This anatomical condition corresponds to what from a clinical standpoint is usually called "*appendicitis simplex*."

Microscopically the vessels of mucosa and submucosa appear to be dilated and filled with red blood-corpuscles. In the tubular glands there is an accumulation of large cells and in the interstitial tissues there is an infiltration of embryonic cells. The infiltration with small cells proceeds to the muscular stratum and forces its fibres asunder, thereby causing complete paresis of the muscularis. Now the subserosa and serosa participate, too, showing considerable multiplication of their endothelial cells. There also fibrinous exudate may organize, laying the foundation for partial obliteration. The muscular tissue, originally so scanty, may also participate in the proliferation and hypertrophy (Fig. 3).

In this stage resolution takes place frequently—that is to say, the *acute process subsides*. But, according to my mind, *restitution to perfect integrity seldom occurs*. Sometimes the serosa may remain intact, but in most cases it will become adherent to the adjoining intestine, or to the omentum, or to the abdominal wall.

The mucosa may, except at a few cicatricial points, the sequelæ of erosions, appear to be normal. But these scars are the originators of strictures (Fig. 4), which cause stagnation, and stagnation again may cause dilatation on other points. Thick mucous plugs, tightly crammed in, and organizing fibrinous exudates, obstructing the lumen, are then found there (Fig. 3). The submucosa and mucosa become thickened and hypertrophic, thus enlarging the dimensions of the whole appendix.

Sometimes there results a progressive tendency to obliteration. This has been described most pictorially by N. Senn as *appendicitis obliterans*.*

It goes without saying that all these conditions must necessarily provoke recurrence of an inflammatory process sooner or later. It is only when total shrinking of the appendix takes place, so that it is degraded to a simple, bandlike, functionless appendage, that such recurrence will fail to set in again. Thus the spontaneous cures are explained.

In periappendicitis there is an adhesive peritonitis, combined with the formation of fibrino-plastic exudation. There a resolution may take place in the same way as described in simple appendicitis—namely, the exudation may be absorbed and the acute inflammatory symptoms subside. The appendix of course remains in the same condition as if there had been an *appendicitis simplex* which had advanced as far as to the serosa, plus the adhesion of its serous coat to the neighborhood, in which it sometimes appears like a mummy baked in lava. It does not need urging that under such circumstances recurrence of inflammation is provoked to a higher de-

* *Journal of the American Medical Association*, March 24, 1894.

gree than in simple appendicitis, mechanical causes now also being added.

But very frequently resolution does not take place at all and the inflammatory process proceeds further. This can take place in different ways:

The inflammation may encroach upon the tissues situated nearest to the serosa, and the exudation, originally having been of a serous character, becomes purulent. It may safely be assumed, however, that the exudation, which microscopically appears to be of a serous character, contains pyogenic bacteria *a priori*, the same as in serous pleuritic effusion, which "turns over into pyothorax" (*perpendicular abscess*).

Or, the inflammation reaches the peritonæum by way of the lymph vessels as a true lymphangitis. I used to term this variety, in proportion to its propagation, either *circumscribed* or *progressive phlegmonous appendicitis*.

Or, the secretion of the appendix becomes purulent (*pyappendix*). Then in the vast majority of cases perforation takes place under successive distention of the walls and pressure necrosis. The perforated area may at first not be larger than the head of a pin and may enlarge gradually. Accordingly the pus may enter the peritoneal cavity slowly or rapidly.

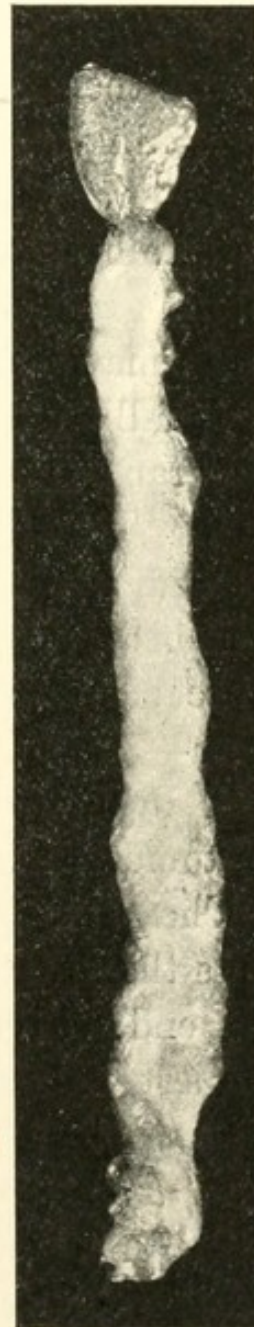

FIG. 4.—Long strictured appendix removed in chronic appendicitis.

Naturally, the peritoneal area adjoining the nearest perforated spot is highly irritated by the preceding inflammation, and therefore most susceptible to the further reception of the infections (*appendicitis suppurativa perforativa*).

But there may also be a suppurating nucleus, which, by forming adhesions and pushing them before itself, at last generates a partition-like, shut-off pus focus. Then the membranes, originally very thin, have a chance to distend gradually and gain strength by additional adhesive formation (*encysted, isolated appendicular abscess*).

Finally, there may ensue ulceration of the mucous membrane, which deepens gradually in a funnel-like shape. The blood-vessels, possessing but scant anastomosis, are only too readily inclined to the formation of thrombi or emboli, so that there results an anæmic infarct; in other words, necrosis of the muscularis and serosa—*i. e.*, a perforation hole. Great credit belongs to G. R. Fowler for having studied the significance of anastomosis formation in this most important relation.

The experience of many authors, my own included, shows the great predilection for perforation at the proximal end of the appendix—that is, where there is the scantiest arterial supply. Kinks and adhesion with the adjacent tissues are factors favoring inflammation. Fæcal concretions are to be regarded as the results rather than the causes of preceding pathological processes in the appendix.

This type, which is to be called *gangrenous appendicitis*, can be the direct consequence of the perforation form. But it can also encroach upon the appendix in its whole extent at once. Then the organ is found in the midst of decomposed pus, mutilated into a greenish-

black band-shaped fragment, the connection of which with the cæcum is entirely severed.

In all these various types of a suppurative character a spontaneous favorable termination may occur, just the same as it occurs in infectious processes in other parts of the body. But it can not be disputed that such occurrences are extremely rare. The abscess may be evacuated through the abdominal wall, as well as through the intestine, the latter possibility being the most frequent. It may also happen that pus foci, especially if encysted, are absorbed after being thickened and having undergone fatty degeneration. This can be expected so much easier if the bacteria contained by the pus died out, so that the pus lost its virulence. If the appendix be gangrenous, however, such possibilities can but very rarely be expected.

It is evident that these various types can not always be kept asunder, but that one often passes into another. This consideration leads us to the most important point, that the difference of type mainly depends upon the stage in which the appendix is made accessible to ocular inspection. This being possible only after the abdomen is opened, it is self-understood that the different pathological conditions vary in proportion as they develop upon an advocate of early or late surgical interference.

If the abdomen is opened at an early stage, the following state is often found:

The cæcal surface, as well as the adjacent intestines, show absolutely normal conditions. After the caput coli is lifted off, the appendix is found to be a rigid, firmly outstretched organ of the circumference of an index finger. It may properly be called an appendix in a state

of erection. By thin fibrinous exudations it becomes adherent to its vicinity. Its general color is dark red, but in some places there are yellow-grayish foci, just like those seen in panaritium which is near perforation, the appendix wall having become so thin by ulceration that it is translucent, and the intra-appendicular pus is visible. But there are no well-pronounced external signs of perforation (Fig. 5).

Such an appendix, after being removed, shows its interior filled with a decomposed pulp of an offensive odor, which mainly consists of pus, blood coagula, and necrotic fragments from the mucous membrane. The muscularis is necrotic in various spots and the serosa is extensively inflamed. This condition represents a true empyema, or, as we may properly term it, *pyappendix*, analogous to pyothorax, pyosalpinx, etc. (Fig. 6).

If in such cases operative steps are omitted the lapse of an hour may cause a small-calibred perforation, followed by fulminant sepsis, or slow-forming gangrene may come on, with the same final result.

On the other hand, the increase of the intra-appendicular pressure may have succeeded in extruding the appendicular contents into the cæcum. But even under such apparently favorable circumstances it certainly often happens that the appendicular walls being so much infected, the near tissues have absorbed so much virus that further peritoneal infection can not be stopped even by eliminating the original noxiousness.

We have to consider, in conclusion, what is called "*chronic appendicitis*," the frequent result of an appendicitis which took a "favorable course" after internal treatment.

This type, which is also frequently termed relapsing appendicitis, is characterized by a thickening of the whole sac, which is filled with a copious quantity of viscid mucus, sometimes mixed with pus. At some points there are ampulla-like dilatations, due to the presence of turns, kinks, or strictures in the canal. Thus the expulsive power, so small in itself, on account of the scantiness of muscular elements, is so much more

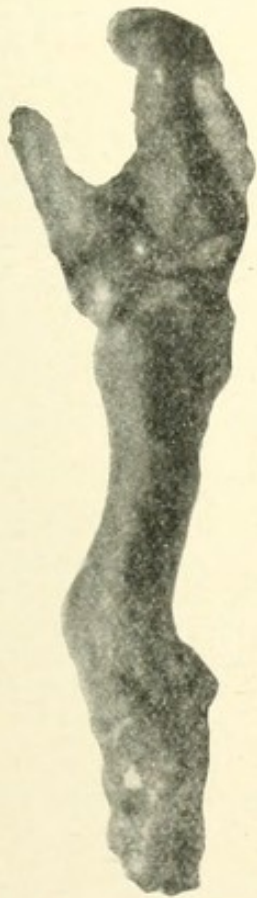

FIG. 5.—Pyappendix, removed during an acute attack.



FIG. 6.—Beginning perforation in pyappendix; extensive necrosis of mucosa and muscularis eleven hours after the beginning of the first clinical symptoms.

diminished that decomposition of the contents and renewed inflammatory manifestations must necessarily follow.

It is customary to theoretically distinguish this type from recurrent appendicitis, defining recurrent appen-

dicitis to mean that after an acute attack and the disappearance of symptoms, a second attack takes place after

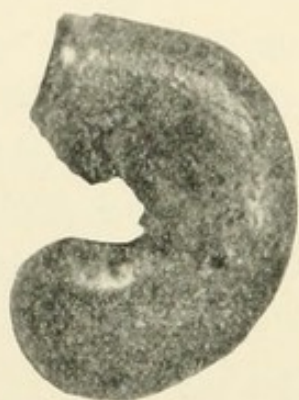

FIG. 7.—Fibrous degeneration of appendix. Tubercular ulcer. (Caseous focus on the tip.)

a free interval, while in relapsing appendicitis there is no free interval, the patient never being completely normal and there being a tendency to numerous exacerbations.

This differentiation, however, is a rather arbitrary one, and while it seems to be justified clinically, it can not be upheld from the standpoint of

pathology; and the term "chronic appendicitis" may properly cover both conditions.

Among the rarer types there may be mentioned the *actinomycotic* and the *tuberculous* appendicitis. The latter undoubtedly represents a much more frequent variety than is generally assumed. Tuberculous appendicitis has not infrequently been demonstrated on the autopsy table as a participating manifestation of general tuberculosis. In connection with peritoneal tuberculosis it has not been observed so often (Fig. 7).

The following cases of this type seem to me deserving mention:

CASE I.—A boy, eight years of age, suffering from the caseous form of peritoneal tuberculosis, which was extensive and well marked. I found a retroperitoneal caseous stratum of the thickness of an index finger; and laparotomy revealed diffuse tuberculosis of the peritonæum, intestine, and mesentery. On the basis of the appendix, which was deeply imbedded in adhesions, there was a cheesy focus of the size of a cherry. The patient recovered from the effects of the extensive opera-

tion, which consisted in the thorough removal of the foci, but four weeks thereafter he succumbed to general tuberculosis.

CASE II.—In a girl of thirteen years, in whom exploratory laparotomy had revealed tuberculosis peritonei (light ascitic form), a tuberculous appendix was discovered. The patient, being of a rather delicate constitution, had complained of pain in the hypogastric region more than a year before the operation. Various members of the fraternity had diagnosticated dyspepsia, stomachal catarrh, chlorosis, endocarditis rheumatica, etc. Six months before the operation was undertaken the patient was taken sick, having swallowed a large quantity of lemon kernels. According to the statement of a most reliable colleague, the patient's symptoms had then consisted in nausea, pain in the right iliac fossa, fever, and meteorism, so that the diagnosis of appendicitis had been made. The treatment was expectant. After two weeks the acute symptoms disappeared, but an exudation of the size of a man's fist remained in the right iliac fossa. Pressure there yielded a slight painful sensation. The abdomen was distended; there was constipation; nausea and fever were absent. The explorative laparotomy, performed in the linea alba, showed an innumerable quantity of nodules, ranging from the size of a pinhead to that of a pea, disseminated over the peritonæum. The apex of the appendix, which was thickly adherent to the right ovary as well as to the colon, showed three nodules. In the small pelvis were a few teaspoonfuls of light serum. Recovery took place without reaction. Six years have elapsed since, and the patient has remained perfectly well.

But there is undoubtedly a primary form of tuberculous appendicitis, and I trust that the daily progressing capacity for recognizing the various types of appendicitis, which is gained and trained by the autopsy *in vivo*, will soon furnish much more abundant knowledge of it. I can not help thinking that in former years,

when my experience in appendicitis was more limited, I have operated upon cases which gave me a suspicion in this direction; but various unfavorable circumstances prevented a sufficiently thorough examination into the possibilities of tuberculosis. Recently, however, I had a chance to examine and to operate upon two well-marked cases, which seem to me of interest.

CASE III.—A girl of two years was seized with slight peritoneal symptoms on October 27, 1897. According to the family physician's report, the ileo-cæcal region had been particularly sensitive on touch. Treatment consisted in opium and ice bag. The elevation of temperature, as well as the meteorism and the tympanic sound, soon disappeared again, but a slight nausea persisted. Finally, the patient had nearly fully recovered, when suddenly, on November 17th, she became seriously affected with peritoneal symptoms. There was intense vomiting and persistent obstipation, as well as an elevation of temperature. Soon thereafter collapse supervened, so that intestinal constriction caused by adhesions, such as often develop after peritonitis, was thought of.

November 18th I found the following state present: Poorly nourished child, showing the well-marked symptoms of collapse. Pulse, 160; temperature normal; meteorism. A dull area, comprising the whole right iliac fossa, was clearly distinguished from that of the tympanic abdominal sound.

Diagnosis.—Gangrenous appendicitis after previous simple appendicitis. Immediate operation at St. Mark's Hospital. After having opened the abdomen in the ileo-cæcal region the intestine was found to be of a dark-red color and covered partially with fibrinous exudation. Between the anterior surface of the cæcum and a loop of the jejunum was a fresh adhesion, which caused the jejunum to bend in to such an extent that it could easily explain the obstruction. The adhesions were

loosened under great difficulties, the surfaces bleeding profusely. Now, between this area a thick string, reaching from the cæcum to the spinal column, having about the size of a man's thumb, was brought into view. After being shelled out from the surrounding tissue, this string proved to be the appendix, surrounded by numerous glands. In the adjacent portion of the jejunum small nodules, from the size of a pinhead to that of a lentil, were found. The anæmic, yellowish appearance of these nodules contrasted strongly with the dark red tint of the intestine. Iodoform gauze packing. Fatal termination, five hours after operation, under symptoms of grave collapse. Examination of the lacerated appendix revealed the presence of a small caseous focus in the thickened wall. Altogether, fourteen glands had been removed, three of which had undergone cheesy degeneration. The presence of tuberculous bacilli was not demonstrated, but the macroscopical conditions were so well developed that there could hardly be any doubt as to the presence of tuberculosis. No abnormalities were found in any other organ of the body:

CASE IV.—A man, twenty-six years of age, of a very delicate constitution, highly anæmic, suffered from disturbances of the stomach and intestine for years. Last year one of his two brothers died from pulmonary tuberculosis; the other one has recently had hæmoptysis. The painful attacks, which could be localized above the large curvature, and which took place spontaneously as well as on pressure, together with the presence of pyrosis, nausea, hyperacidity, and obstipation, pointed toward the existence of a stomachal ulcer, although hæmatemesis was absent. All these symptoms yielded pretty quickly after the usual treatment for gastric ulcer was instituted. At the end of November, 1897, there were renewed pain in the right iliac fossa, fever, vomiting. The family physician diagnosticated catarrhal appendicitis. The treatment consisted in ice bag and opium. Two weeks later the patient was again

able to get up, but he failed to recover completely. There were also slight symptoms characteristic of stomachal ulcer. In the middle of December he had a second violent attack of the same kind as in November. Medicamentous therapeusis again. After a few days apyrexia, with renewed disturbances in stomach and intestine.

On December 25, 1897, after being admitted to St. Mark's Hospital, the patient showed a moderately distended abdomen, tenderness in the pyloric region, and well-marked pain in the right iliac fossa. Resistance and dullness correspondingly.

Diagnosis. — Chronic appendicitis. On December 26th oblique incision in the symphysis-rib line. The omentum, which is found covered with small nodules, tightly adheres to the cæcum, so that it must be divided to permit access to the appendix. Situated crosswise toward the spine the appendix is found imbedded in glandular tissue, indiscriminably changed into a hard band. Great technical difficulties presented themselves in shelling out the glands, which had partially undergone caseous degeneration. The microscopical examination, while in favor of tuberculosis, did not discover bacilli, nor did the fæces contain any tubercular bacilli. I availed myself of the opportunity of the intra-abdominal examination of the stomach to make a careful search, but neither by inspection nor palpation could I find anything abnormal. The patient recovered slowly.

Now, four months after operation, he has a moderate appetite, and is free from fever and pain. He is still very anæmic, but there are no positive objective signs of any disturbance.

Whether *ulcus ventriculi* really existed in this case I do not regard as proved. Without denying the possibility of it, I am inclined to consider all the more or less vague stomachal symptoms as indirect expressions of the diseased appendix, the ulcerative process perhaps

having existed for a long time without causing well-marked local manifestations.

In regard to the study of *actinomycotic appendicitis*, which I never had a chance to observe, I refer to the excellent essays of Barth, on abdominal actinomycosis (*Verhandlung der freien Vereinigung der Chirurgen Berlins*, 1890, Jahrg. 32, S. 29); Partsch, on human actinomycosis (*Sammlung klinischer Vorträge*, S. 306, 307); Lanz, on perityphlitis actinomycotica (Bern, 1893); Braun (*Correspondenzblätter des ärztlichen Vereins von Thüringen*, 1897); and Israel (*Verhandlungen der freien Vereinigung der Chirurgen Berlins*, 1895, S. 115).

Wherever mixed infection with pyogenic bacteria has taken place the picture of the disease is veiled, and the chances are that thus the character of this type is generally overlooked, the clinical picture of it not essentially differing from that of common appendicular suppurative processes.

There are also carcinomatous or sarcomatous affections of the appendix. In a case of intra-abdominal adenocarcinoma I was able to detect secondary nodules attached to the serosa of the appendix.

In a case of fibrocarcinoma I noticed a retrograde perforation caused by carcinomatous ulceration, the latter having corroded serosa and muscularis, so that the mucosa could be lifted up by a probe introduced from without.

On considering now the manner in which the anatomical changes described express themselves clinically, we at once touch the sorest point of the controversies on appendicitis. There can be no doubt that it is the anatomical basis alone on which a scientific standard fun-

dament, the symptomatology of a disease, can be built. A classification of appendicitis into light, moderate, and grave cases, as is suggested by some, must therefore, even from the strictly clinical standpoint, be rejected. The law is that there must be in general a clinical expression for any tissue change. The circumstance that in many cases such expressions fail to be perceived or explained properly by us is no proof of their non-existence. In spite of the difficulties of diagnosis we must endeavor again and again to interpret the various complex symptoms that present themselves more or less confusedly. It will be only after such patient, thoughtful, and repeated effort that we shall draw in our minds any adequate picture of the anatomical condition of the appendix. Only thus shall we be able to further the understanding of this immensely important disease. It can hardly be assumed that the anatomical changes as they were described would show a marked clinical expression from the very beginning. On the contrary, must it be imagined that this intra-appendicular crater has been silently working for a period of time before it came to the explosion of the first attack. So there is actually a more or less symptomless chronic appendicitis, the acute exacerbation of which leads our attention to the existence of the disease. By considering, however, the many vague symptoms, often protracted during years, which a number of histories reveal, we should not feel justified in speaking of the absolute absence of symptoms of this preliminary process. We should, on the contrary, realize that we have not as yet learned to interpret these symptoms properly. How often do we find complaints of disturbances of the stomach and intestine, or of diseases of the liver, kidneys, or bladder! (Compare, for instance, the history of Case IV.)

If women are concerned, such complaints are often disposed of as being of hysterical origin, and treatment of the adnexa might be undertaken, with no result of course. Likewise may a number of nervous disturbances, not only of the intestine, but also of the circulatory apparatus, being caused by reflex irritation, be derived from a diseased appendix. If we compel ourselves to think of the possibility of a diseased appendix in all cases of abdominal disorder, there can be no doubt but that we shall frequently detect some clues, no matter how meagre they may be, in this state. Palpation and percussion oftentimes fail, but there is frequently tenderness, felt spontaneously as well as on pressure. Thus, according to greater knowledge, we could cease to speak of a kind of latent appendicitis in favor of a really existing chronic appendicitis showing but scanty symptoms.

We are accustomed to use the term appendicitis as soon as there is a typical chain of symptoms, as they mark themselves more or less distinctly already in the simplest form of appendicitis (appendicitis simplex), the most predominant of them being the sudden accession of intense pain, either in the midst of perfect euphoria or after a short period of indisposition. In the greater majority of cases this pain is gradually located in the right iliac fossa. But there are cases where in the beginning it is concentrated in the epigastrium or the umbilical region. As a rule, it first occurs on the so-called McBurney's point, or at the exterior margin of the rectus muscle in the middle of a line drawn from the umbilicus to the anterior superior spine of the ilium. This most constant symptom is accompanied by abdominal tenderness and very frequently by nausea and vomiting. Slight elevation of temperature is also fre-

quently present, but it may also be absent, just the same as vomiting or nausea. The pulse may be but little accelerated. Vomiting and nausea usually do not precede the pain, as in indigestion, but follow it. There is obstipation in the majority of cases, but diarrhœa is also frequently observed.

In most cases a more or less marked resistance in the appendicular region can be palpated. There is frequently the sensation of pressing a rigid formation of the shape of a small sausage. A most constant symptom is the more or less marked dullness, which corresponds to the thickening of the swollen tissues and which does not at all necessarily imply fœcal stasis as a cause.

In many cases these symptoms subside after the first three or four days. But in the great majority of cases there remains much tenderness of the appendicular region, and sooner or later a second attack follows, which may end in resolution again, like the first one, but may just as well assume the circumappendicular, phlegmonous, or perforative character.

In periappendicitis there are virtually the same symptoms as in simple appendicitis, but they are much more pronounced. There being in fact a circumscribed peritonitis, a palpable tumor can generally be defined in the right iliac fossa. The inflammatory exudations and the serous infiltration of the sphere immediately surrounding the appendix naturally make the dullness more pronounced than in simple appendicitis. The stasis of the cœcal contents, caused by the compression, may further enlarge the extent of the dullness. But even if the cœcum be entirely evacuated, the dullness will persist.

The tumor may undergo resolution in three or four

days, just as in simple appendicitis, but there may as well be suppuration.

In phlegmonous appendicitis we may be confronted with the same symptoms during the first thirty-six hours as in appendicitis simplex or periappendicitis, so that a differential diagnosis at this period is entirely impossible. The temperature may also oscillate between 98.6° and 102.2° F., and the pulse need not necessarily exceed 90. There is a real chill sometimes. On account of the well-marked meteorism the tumor sometimes can not be palpated. But the reliable guide—dullness—is never absent. I am confident that in most cases the presence of appendicitis can be diagnosed without relying on the dullness, but it should always be taken into consideration as an additional proof, and if the question of differentiation should turn up it will be of the greatest importance. I am sure that sometimes it was only the dullness that led me into the right direction. Particularly where the appendix reached far down into the pelvis, a small but distinct dull area above Poupart's ligament indicated the character of the disease, which, as was corroborated always by the subsequent operation, has so far never misled me.

There is sometimes only half a tablespoonful of pus present, and in such cases it happened to me repeatedly that, after having exposed the upper surface of the cæcum, on a superficial view apparently normal intra-abdominal conditions presented themselves, so that at first the impression prevailed as if the operation had been entirely uncalled for. But after going further down and lifting off the cæcum a fibrinous membrane of moderate thickness was found, which ended on the

psoas muscle. These fibrinous deposits often tell of an underlying exudate, palpation of which is prevented by the overlapping cæcum, which, on account of its containing quite an amount of air, prohibits the palpating fingers from feeling a resistance. But the dull sound could not be suppressed by the tympanitic area. By pulling off the posterior cæcal surface carefully and introducing a grooved director gently into the fibrinous stratum, a small amount of pus was discharged from a cavity the walls of which were created by the agglutination of intestine, omentum, and the inflamed non-perforated appendix.

In appendicitis perforativa suppurativa the same chain of symptoms may be present as in simple appendicitis. In the majority of cases the vomiting may be more constant and intense, and the meteorism more developed. A distinct resistance can be felt, which, however, if the meteorism becomes extensive, may cease to be palpable. But in such an event the presence of an exudate, no matter how small it is, can be proved as projecting from the meteoristic area.

Chills are more frequently observed than in the other varieties, and furthermore the general disturbances of the body are more pronounced from the beginning. The fever is atypical, and might as well be moderate as high. In virulent cases it might be normal in the beginning, and in benign cases at the later period. The pulse is generally accelerated, but need not necessarily exceed 90 at the early stage.

All these manifestations may also subside, and protecting adhesions may form around the burst appendix, which shut off the purulent contents from the abdominal cavity. If these adhesions are firm and solid, pulse and

temperature may be entirely normal, because there is no absorption of pus products. Such accumulations may thus exist for a long time, the inconvenience caused by them being so insignificant sometimes that patients thus afflicted may go about for weeks, deplorable witnesses of the curative power of expectant therapy, until either a scalpel or Nature, by perforating through the point of least resistance, shows mercy.

But often the seemingly incorrect manifestations are followed by those of grave sepsis with such rapidity that the fate of the patient may be sealed inside of a few hours.

The appendicitis gangrænosa in its initial stage may begin just the same way as the other varieties, so that, unfortunately, during the first twenty-four or thirty-six hours there is entire ignorance as to the significance of the process. I say unfortunately, because this ignorance generally costs the patient's life.

When the peritoneal sepsis manifests itself by abdominal swelling, when there is constant vomiting, sometimes of a fæcal character, when fæces and urine are retained, the pulse goes up and the temperature down, then, of course, there is no more doubt as to the fatal significance of the case. Then it is generally not long before the face shows the Hippocratic expression, the nose and extremities become cold and clammy, and the compressible pulse points to the intoxication of the heart muscle. The tongue is usually of an intensely red color and sometimes coated. Unquenchable thirst and singultus torment the patient, and in two or three days after the onset of the attack the tragedy ends.

But in the gangrenous form, as well as in the phlegmonous or perforative variety, it need not neces-

sarily come to the physical signs of peritonitis. The abdomen may remain flat, and rapid death may occur through foudroyant sepsis. But only in a small number of cases of this kind does this plexus of symptoms mark itself so early as during the first few hours. Nothing has ever taught me the insufficiency of our diagnostic means so impressively as these terribly rapid cases, in which the clinical symptoms were in no proportion to the pathological changes, for which the surgical operation could do no more than to expose the fatal intra-abdominal lesions.

In honor of the medical fraternity in the native city of the appendix science, be it said here that there is a not inconsiderable number of physicians, increasing every year, who appreciate this gloomy state of affairs to its full extent. Their experience gained in surgical operations for appendicitis has taught them the danger of a delaying policy. They fear bacteria more than they do the scalpel, and consequently they have more confidence in operative interference than in palliative treatment. It happens even not too infrequently nowadays that in the holy ardor for the good cause there is too much good done in this direction, and that surgeons sometimes are called upon to operate when coprostasis only is present, a condition which, of course, readily yields to the most unsurgical treatment. Such hyperactivity need not disturb us. An early operation is illustrated in the following case:

CASE V.—A slenderly built girl of twenty-five years, who had suffered from slight attacks twice before during last year, was attacked suddenly in the morning of April 7, 1898, with moderate pain in the right iliac fossa, which later on radiated toward the whole abdo-

men. The physician, who was called a few hours after the onset of the pain, insisted upon the immediate removal of the appendix. The patient was transferred to St. Mark's Hospital, where the following state was present at 5 P. M. of the same day: The patient shows apparently few signs of disease. There is slight nausea and obstipation. Spontaneous pain of considerable intensity sometimes occurs. The rectal temperature registers 37.8° , and the regular pulse is 92. Inspection of the abdomen reveals nothing abnormal. Palpation states slight indistinct resistance in the appendicular region. The same area is very tender to touch. The patient declines the operation, claiming not to be sick enough. She sits erect in bed, as it is impossible for the nurses to keep her recumbent. This position does not seem to discomfort her as long as there is interval from pain. She threatens to get up, but, impressed by the implorations of her intelligent relatives, she at last consents to the operation, which was performed at 6 P. M., and revealed the following state: The abdominal cavity is entirely normal. The empty cæcum has even a pale-red color. While trying to lift it off, a thin, fibrinous stratum is discovered, which adheres to the posterior cæcal surface on one side and to the peritonæum of the right iliac fossa of the other, thus surrounding the rigidly erected appendix, which has a dark-red, and on some points a grayish-yellow appearance. The thickness, as well as the length, corresponds to the index finger of a man. There are no distinct external signs of perforation, but there is a well-marked foetid odor of the appendix even before its removal. After being removed, the canal shows a pulpy mass, consisting of pus, necrotic tissue, and blood-corpuscles, filling up its interior. The mucous membrane appears lacerated through ulceration, and a probe pushed against the lacerated points can be seen from without, the great translucency of the appendix wall indicating the cobweblike thinness of the portion of the serosa which still prevented perforation.

The stump was not sewed up in its entirety. After having been dusted with iodoform powder it was sur-

rounded with small strips of iodoform gauze. Three quarters of the abdominal wound were closed. There having been no further symptoms of infection, and the patient complaining of nothing else than hunger, the gauze is removed two days later. The small gape in the abdominal wall is drawn together above a piece of gauze by means of aseptic adhesive-plaster strings. Recovery was uninterrupted.

In view of the high pressure under which the thin and extremely translucent wall of the ulcerated appendix was, it could be fairly assumed that the perforation might have taken place inside of a few hours. So it was the energy of the family physician which prevented the highly virulent contents from flowing into the free abdominal cavity.

I suppose that *a priori* a number of colleagues would have been inclined to blame this family physician because he proposed operating in this early stage. Here we are confronted with the most delicate and important point of the appendicitis question. On this obscure point, the uncertainty of the diagnosis in reference to the stage and the toxic potency of the inflammatory process, hinge all the bitter controversies as to therapy; which show an increasing rather than decreasing harshness in condemning the early operation. On the basis of my own comparative clinical anatomical experience, I am forced to assume that in about half of the cases the clinical picture of appendicitis is not so well marked that any decisive conclusion can be drawn as to the status of the pathological change. That we should reach such perfection of diagnosis is most desirable, but cruel experience teaches that we have not attained it. The surgeon who, before opening the abdominal cav-

ity, will try to picture to himself its true condition, and who afterward has a chance to compare his imagined picture with the facts, must agree with me in this confession of ignorance.

Now the surgeon at last is compelled, in observing the return of cases insufficiently judged before operation, to the conviction that from the presence of apparently mild symptoms a decisive conclusion as to the relative innocence of the inflammation can hardly ever be drawn during the first twenty-four hours. On the surgeon the conviction is forced that in every case of appendicitis there must be an infection, and that if the infecting material has not trespassed beyond the appendix, yet it may do so at any moment. And after it has done so the power of the knife is limited. The following, being one among many, is a typical case of this kind:

CASE VI.—A very strong laborer thirty-six years of age suddenly noticed at 6 A. M. on January 12, 1898, in getting up, a pain in the umbilical region, which radiated toward the right iliac fossa in the course of the afternoon. The patient had always been well before, particularly so the previous evening. During the night he had slept well as usual. It was only in the afternoon of the day he was attacked that he felt unable to work. During the night, from the 12th to the 13th, he had a sensation of augmented discomfort and intermittent colicky attacks of moderate intensity. On January 13th, at 4 P. M., a physician was called in, who, in view of finding a nearly normal pulse and temperature, felt justified in diagnosing indigestion. To the administration of opium and pepsin the pain yielded promptly. On the morning of January 14th suddenly intense vomiting and distention of the abdomen set in, and only then was the suspicion of appendicitis entertained. After a consultation the patient was transferred to St. Mark's Hospital late in the afternoon of

January 14th. It had not been intended to operate on the patient on the same day. Merely by accident I had a chance to see this patient shortly after his arrival. The state present at that time was the following: A very strong man, an expression of suffering, vomiting moderately often; temperature, 37.4° ; pulse, 112. Abdomen distended and painful to touch. The presence of meteorism prevented palpation of either tumefaction or resistance, but the distinct dullness, emanating well defined from the tympanitic area, pointed to the presence of an exudate. I advised immediate operation. After washing out the stomach and administering a hypodermic saline infusion the abdomen was opened in the ileo-cæcal region by an extensive oblique incision. At once there sprang forth several dark-red loops of the ileum, which were covered with flocks of fibrin and cohered loosely by fibrinous membranes. On slight touch the intestine bled. Sero-pus of fœtid odor pours forth between the loops. After having pulled forward the intestine, which was flooded with hot salt water, while fibrinous flocks were wiped off by means of sterile-gauze mops, the adhesions were severed. Then the intestine was protected with hot compresses. The cæcum, in order to search for the appendix, is drawn out widely, and a small focus, containing about one tablespoonful of grayish-yellow stinking pus, is evacuated from the cavity to the right of the lumbar vertebral column. Now the greenish-black appendix, transversely situated toward the iliac bone, is recognized. Up to its cæcal junction it is smashed with the branches of a forceps, so that ligation of it is out of question. So it is carefully removed, and the vicinity packed with iodoform gauze, after another careful revision of the cæcum, done under permanent hot irrigation. Anæsthesia, administered after Schleich No. 1, was excellent. Great improvement followed the operation. Pulse even, of good quality, till the following morning showed the well-marked picture of peritoneal sepsis. Fatal termination on the same evening.

Could this patient have been saved? Probably, provided he could have been submitted to operation on January 12th, because on the 14th it was far too late, as the condition at the operation showed. But on the 12th the patient did not yet feel obliged to send for a physician. And on the 14th, half an hour before the opening of the abdomen, which revealed so grave an anatomical condition, several colleagues were undetermined whether the indication for an operation was yet present. In view of this anatomical condition it can be fairly assumed that gangrene and peritoneal infection had been developed as early as January 13th.

The question arises now: Is the first physician to be blamed? I say, No. It is by no means necessary that a gangrenous process should manifest itself by well-marked clinical symptoms at its beginning. Why should it? Until the death of the cells is completed twelve or twenty-four hours may elapse, and even after necrosis of the cells is complete it is not at all safe to assume that the toxic elements absorbed by the lymph channels should at once make themselves conspicuous in well-marked clinical manifestations. Thus it can be seen that from the surface we can not know the gloomy mole work that culminates in the infection of the peritonæum. *Vice versa*, there is no conclusion to be drawn from slight clinical manifestations as to the presence of an innocent simple form of appendicitis, when we could safely wait until the rise of temperature and other aggravations of the symptoms would indicate that a stage of higher virulence has come now. How beautiful, if such were the real facts! But it is an utter fallacy. Then it is true that the carrier of the infection can be removed, but the infection of the abdominal cavity itself can not be un-

done. To expect that after the elimination of the septic appendix the septic peritonitis should also cease to exist, would be like the wounded warrior, who, after the bullet is extracted, is triumphant, and cares nothing for the shot canal, nor for the tissue destruction caused by the bullet.

In some cases the comparison with panaritium, where the patient, besides his pain, does not necessarily feel any general disturbance, can not be helped.

For this diagnostic deficiency not the medical man but medical science is responsible. No man can give more than he has. But it can be demanded that the internists should give more attention to the knowledge gained by the surgeons during their autopsies *in vivo*. It is not the technique of the surgeon which I have in view. No, it is the experienced surgical observer, who watches the appendix in all its ways and doings so much more closely, who sees it in all its different forms and stages, who touches and inspects it intra-abdominally. The same standpoint would then force itself upon many internes, and they would cease to hold that "appendicitis in general is a light disease, the treatment of which consists in ice and opium. If exceptionally peritoneal manifestations should present, operative treatment might be considered." I do not have in view those colleagues who disavow the surgeon *à tout prix*, and who extol themselves with a smile of superiority that they have cured all their cases of appendicitis by their nihilistic *modus operandi*. But how many such cases terminate fatally without being diagnosticated properly! What would these antisurgeons say if in all these cases they had been cited before the pitiless autopsy forum?

No, I have in view those unprejudiced colleagues

who collect notable experience from sufficient clinical material. There can be no question that such colleagues see a not inconsiderable number of cases of appendicitis recover. The statistics on such recoveries are simply overwhelming, and in some clinics even the enormous percentage of ninety is spoken of.

If, however, those so-called recoveries are closely analyzed, it will be found that most of these patients who overcame simple appendicitis were not observed any further. But it can well be assumed that the appendix in all those "cured" cases had undergone pathological changes, which sooner or later caused a second or third attack. Then such a case might figure in the statistics as a case "which was cured three different times." Or the patient might have succumbed to the second attack just as well.

Sonnenburg alone observed recurrence of the inflammatory process thirty-two times in fifty-one cases, which gives a percentage of sixty-three.

It seems to me that in patients who report a first, well-overcome attack, the physician is particularly ready to resort to the expectant treatment. It is only when a grave toxæmic picture develops that in his anxiety he may at last advise an operation as an ultimate resort. But then it is much too late, and the operation being unsuccessful, the internist believes he has added further proof to the theory that operative interference in appendicitis is a fraud.

The surgeon, of course, will hold altogether differently, and very properly makes the procrastinator responsible for the fatal outcome. But this case now swells the surgical list of casualties and the internist goes out unconcerned, while virtually the mortality

number of this case belongs to his account. There is to be considered furthermore the large number of patients, occupying the wards of hospitals, who are admitted under the vague diagnosis of peritonitis, internal obstruction, etc. How often would appendicitis be demonstrated if an autopsy were always performed! If such cases terminate fatally under internal treatment they will not be credited to the appendicitis list of casualties. And if such desperate cases drift into the hands of a surgeon, who, adhering to the principle that such patients have nothing to lose and everything to gain, run the great risk of an operation, there will naturally be a very small number of recoveries. So all the surgeon could do was to swell the mortality account of appendicitis by his diagnosis, which was defined at, or rather by the operation. Suppose such a patient had died without being subjected to operation; the diagnosis of appendicitis would probably not have been made at all. It is a fact greatly to be deplored that in this country the permission of an autopsy is granted but exceptionally by the relatives of the deceased. Thus it appears no more than natural that the case should be put in the column of peritonitis instead of burdening internal medicine as a fatal case of appendicitis.

To refer to Case VI, in opening the peritonæum the conviction could not be suppressed that there was no hope. Up to that date I did not see a single case recover in which the presence of serum of foul odor was noted in connection with the absence of protecting adhesions. Thus I am inclined to regard such occurrences as a kind of criterion for further revelations in the peritoneal cavity. It seems to me as if there is a particularly high

virulence, which manifests itself partially by this macroscopical state.

Were aspiration undertaken in such a case, it might be that before operating a conclusion might be drawn from the aspirated serum to the extreme gravity of the case. But such cases take such a rapid course that there is no time for bacteriological investigation. Still, conclusions should be drawn from the direct macroscopical state as to the dignity of the toxon. There is only one drawback against aspiration—namely, the possibility of further inoculation with the tip of the needle, which should not be underestimated, as it can not at all be compared with the aspiration of an empyema or similar condition. An exploratory incision in the appendicular region is much less apt to spread infection than aspiration.

Regarding further dates and reports, considering the difficulties to find an adequate clinical expression for the grave anatomical lesions, I refer to my previous publications on this subject—viz., *On Some Difficulties in Reference to the Early Surgical Treatment of Appendicitis*.* I may be permitted to add that the experience gained since these articles were published has only corroborated my views about the unreliability of the symptoms.

Most cases of appendicitis do not come under the observation of the surgeon during the first forty-eight hours. Procrastination to the utmost limit before the surgeon with all his terrors is called upon is the too

* *Journal of the American Medical Association*, December 28, 1895, and *Zur Therapie, insbesondere dem Werthe der Frühoperation bei der Entzündung des Processus vermiformis*, *Berliner klinische Wochenschrift*, 1896, Nos. 37 and 38

frequent practice. And it is not only the layman; no, sometimes it is a hyperæsthetically disposed colleague who dreads the sight of steel more than the abominable appearance of a bloody tinged intestine bathed in fœtid secretion. This horrid intra-abdominal picture, of course, is veiled from his eyes, and therefore even from his imagination; so that he can give no attention to it. How often have I thought of the simple words of the peerless Henoeh, which he spoke in reference to the treatment of dysentery: "Whoever has seen on the autopsy table the immense destruction which the dysenteric ulcers cause will realize why so often our whole therapy sinks into nothingness." Furthermore, it is to be remembered that from a pyappendix sometimes emanates a subphrenic abscess. Cases of this sort are described in my publication on subphrenic abscess (*Medical Record*, February 15, 1896, and *Langenbeck's Archiv*, Bd. lii, Heft 3).

Abscesses in the liver, the pleura, the brain, may also be derived from appendicitis, the same as pyæmia and some lung affections, which figure as causes of death *per se*, while, in fact, appendicitis should be registered as such. So the statistics on appendicitis, as they are offered nowadays, can not be regarded as other than most unreliable. Only the most careful criticism of the cases and their further observation after a so-called well-overcome attack can do justice to the surgeon.

The following *résumé* may now be made:

1. The fate of patients operated upon unsuccessfully by the surgeon on account of extremely high virulence or undue procrastination is sealed beforehand.

2. The patients who were "cured" under medical treatment would also have recovered had they submitted

to operation. For the small number of deaths after operation, of which reports are given once in a while, rather the surgical novice than surgery itself is responsible.

3. Regarding the practice of delaying, even among most of those who advocate surgical interference, to recommend operation until abscess or gangrene is demonstrated, it must be realized that with few exceptions all such cases would finally have proved fatal under the pursuance of medical treatment.

According to the calculation of some of the most eminent surgeons in the country, there are about five thousand annual deaths from appendicitis in the United States alone which could have been prevented by early operation; and this enormous number does not seem to me to be exaggerated. We thus arrive at entirely different conclusions from those drawn from many internal statistics which were collected *bona fide*. I trust that I do not exaggerate if I calculate that the percentage of the fatal cases, treated expectantly or internally, if followed up *ad ultimum*, is about thirty. This percentage could be forced down to ten, or even to five, if the custom was adopted of operating early. Is it not strange that of all the patients whom I have operated upon as early as twelve hours after the onset of the attack, none have died? Unfortunately, this chance was given to me but twenty-seven times, while among those of my patients on whom I operated forty-eight hours after the onset there is a mortality of twenty-four per cent. Why do the internists not take to heart the excellent words of Strümpell, "Better too early than too late." Such golden words, coming from a distinguished internist, do more for the popularization of the surgical

standpoint than all efforts of the surgeons themselves; just as it was only after rib resection in pyothorax was indorsed by so popular a man as Gerhardt that this operation was fully recognized by the family physician.

There are yet to be considered those cases of appendicitis which are sent to the hospital under the diagnosis of internal obstruction, ileus, etc., from the standpoint of euthanasia. Such cases being far advanced, differentiation is almost impossible without operation.

But there are still a number of other diagnostic errors which are made by the most experienced internists and surgeons, and which are also cleared up by the operation only.

Empyema of the gall bladder, for instance, is a frequent source of such error. A striking case of this kind was published by me in the *New York Medical Journal*, May 8, 1897. (Compare also *Centralblatt für Chirurgie*, 1897, No. 42.)

The character of the pain is regarded as one of the most valuable points of distinction in this connection. In appendicitis the pain will often be localized around the umbilicus and epigastrium to establish itself at last at the right iliac fossa, while in cholelithiasis the pain remains fixed in the epigastrium and radiates at the same time toward the scapula. Thus the point which is found sensitive on palpation would correspond to the respective regions where the anatomical change has taken place. But to this reflection the objection has to be raised that the subjective localization of pain and the localization of the anatomical lesion do not always correspond, as it has often been proved in similar clinical observations which were followed by operation and revealed the pathological derangement at a

distance from the painful region. Considering the pain as trustworthy, it must be remembered, as explained above, how different the situation of the appendix is. It is found far down in the true pelvis and so high up that in an inflamed state it can well be taken for a deeply situated gall bladder, the latter possibility not being so very rare (compare case mentioned above) that, on the other hand, a diseased gall bladder could not be taken for a thickened appendix. Adding to this the fact that in cholelithiasis icterus is more frequently absent than present, we have to confess that in the majority of cases we have to relinquish this symptom, which otherwise is of such immense value for the distinction.

The type of the vomiting is also unreliable. It is regarded, as a rule, that in the early stage of appendicitis there are vomiting attacks, which decrease again after a while and later on increase again, while in gall-stone colic there is continuous and frequent vomiting. Taking it for granted that this is so in the majority of cases, it can not be denied that all the points described are not determining, and the ultimate decision in such cases will only be reached by opening the abdomen.

Pyosalpinx is also sometimes confounded with appendicitis. As both affections indicate laparotomy, a diagnostic confusion is fortunately not of great practical significance. There is, however, a difference of opinion as to whether such confusion is excusable or not. Some say that nothing is easier than to ascertain the presence of a swelling situated laterally from the fornix by bimanual palpation. Such swelling in connection with the immobility of the uterus and a history of disturbances in the sexual sphere could only be interpreted as

pyosalpinx. Reliable differential conclusions could also be drawn from the character of the temperature as well as from that of the pains and their radiation. I do not hesitate to confess that this error has happened to me twice, when I have been unable to palpate the pyosalpinx even after an anæsthetic was administered, the uterus having been slightly movable and the annexa having appeared to be normal. The explanation was that the tumor had been pushed upward.

On the other hand, it can easily be conceived that in a case where the appendix reaches far down a pyosalpinx is diagnosticated and a pyappendix is found at the operation. And it also happened to me several times that I was asked to perform an operation for appendicitis where salpingitis could well be distinguished without performing an abdominal section. (Compare cases in my article on Appendicitis, *Berliner klinische Wochenschrift*, 1896, No. 38.)

In five laparotomies performed for pyosalpinx I have found the appendix adherent to the tube or ovary. There the appendix was always removed also. On examination, cicatricial strictures were found in each of these appendices, from which fact it can certainly be assumed that it had participated in the inflammation of the annexa. It is also not excluded that an appendicitis had been the original cause of the inflammation of the annexa.

Three times I have found tube, ovary, and appendix glued together in a colloid mass, undoubtedly the late consequence of old inflammatory processes. There I was compelled to remove a considerable portion of the much-thickened peritonæum in order to be able to proceed radically.

CASE VII.—In the case of a woman of fifty years of age on whom I performed resection for intestinal carcinoma the following peculiar condition was found (see Fig. 8): A tumor originating from the cæcum, of the size of a man's fist, and easily palpated from without, reached from the median margin of the cæcum to the end of the ileum. Above this tumor there was a dermoid cyst (Cy.), a little larger than an apple, and attached to the tubal wall; it adhered tightly to the peritonæum above and toward the renal region. It contained the characteristic pulpy mass and hairs, cartilage, and teeth. The lower end of the appendix as well as the tube on the opposite surface of the cyst, as is evident from Fig. 8, adheres extensively to the dermoid cyst. (T represents the fragment of the tube and A the fragment of the ovary.) By performing a circular resection I succeeded in removing the different

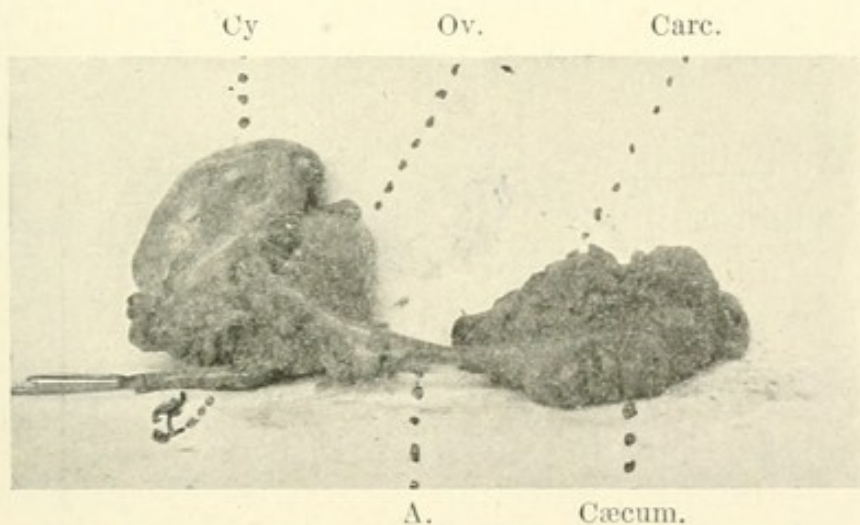


FIG. 8.—Appendix adherent to dermoid cyst, tube, and ovary.

masses in their coherence, as illustrated by Fig. 8. In this case strictures could be demonstrated in the appendix also. Considering the adhesions, it could safely be assumed that inflammatory processes had been present in and around the appendix. To these probably could be traced the attacks of pain which the patient suffered once in a while, and which had urged her to the operation. During an attack of this kind the picture of her

cæcal tumor would have been veiled, and so the thought of appendicitis could well have arisen. The carcinoma itself did not seem to have caused any direct disturbances, the tumor neither having narrowed the intestinal lumen nor had signs of breaking down manifested themselves. It may further deserve mention that, in view of being able to displace the carcinoma upward and backward, and also considering the good appearance of the patient, the possibility of the presence of a floating kidney had been borne in mind.

In this connection it should be remembered that periodical hydronephrosis, caused by a right floating kidney, which may exist together with fever, vomiting, and pain in the right side, could give rise to confusion with appendicitis. In comparing with this case the views of Osler,* I think that the mobility of the tumor should decide the question in favor of the affection of the kidney.

I have twice been guilty of a confusion with a right-sided hæmatosalpinx. In both cases the disease had begun with sudden pain in the side and with moderate fever and vomiting in women of middle age. Both patients recovered and have certainly not noticed any disadvantage from the wrong diagnosis.

Extra-uterine pregnancy also presents itself sometimes, and, after peritonitis has manifested itself, makes the meteorism answer to the question of inceptive causes just as difficult as in the diseases of the gall bladder, described above, in which laparotomy had to give the last word of explanation. In extra-uterine pregnancy the absence of menstruation, in connection with the general symptoms of pregnancy, the bloody vaginal secretion,

* *Principles and Practice of Medicine*, New York, 1894, p. 720.

and the sensitive tumor in the fornix have to be mainly considered.

In general, it may be said in reference to the distinction between appendicitis and diseases of the annexa, that the pain, the fever, and the signs of peritonitic irritation are common to both, but that in the latter the progressive tendency of extension to the peritonæum is usually lacking. Thus the consensus of symptoms in diseases of the annexa is not so grave. But we must not forget that sometimes, as already said, in the early stage of even the gravest forms of appendicitis there are no reliable signs of peritonitic irritation. For the disease of the annexa the gonococcus is mainly responsible. The gonococcus is a bacterium of comparatively low virulence. This becomes evident by the fact that gonococcus pus, finding its way into the peritoneal cavity, fails to produce general infection. This explains why the peritonitis, caused by it, generally takes a favorable course. If, during a laparotomy performed for pyosalpinx, the misfortune of the bursting of the pus sac happens, so that pus is freely discharged into the peritoneal cavity, it can be positively ascertained by microscopical examination in a few minutes whether there is gonococcus or streptococcus or staphylococcus pus. (See my *Manual of the Modern Theory and Technique of Surgical Asepsis*. Saunders, Philadelphia, 1895.) If the innocuous gonococcus diplococci are found, the abdominal cavity may safely be closed, while in the latter case the iodoform-gauze tampon is to be preferred.

But all these points are of only a general nature and in a special case appearances are often deceitful. It is also to be considered that the proof of benignity

is often furnished only after the process has taken its course. But in appendicitis there is no time for delay. Immediate action is required here; the patient not profiting after the lapse of a few days, we find that there is no hope for him any more. Had we given him the practical benefit of our diagnostic doubt in time, he would probably have been saved by an operation.

As said above, the surgeon is not infrequently requested to operate for alleged *internal obstruction*, for *invagination*, *intussusception*, *volvulus*, or for *adhesions* of inflammatory or congenital origin, in which the intestine is caught as in a mouse-trap. In such cases appendicitis is often found. Considering the great similarity of the symptoms—viz., the suddenness of the attack and of the pain, the vomiting, and the subsequent peritonitis—the confusion is obvious. Here it must also be considered that in internal obstruction the pain concentrates nearly never to the right iliac fossa, but more or less to the region from which the lesion in question itself originated. Furthermore, it should be borne in mind that in these cases the vomiting is nearly constant from the early stage on, and soon assumes a fæculent character, which hardly ever happens at the early stage of any type of appendicitis. Meteorism also supervenes only late in appendicitis.

In intussusception, a painless tumor can usually be palpated. Fever is generally absent.

In volvulus, digital exploration by the rectum often gives the desired information.

In mouse-trap cases there is generally a history of a preceding peritonitis.

The difficulty of distinguishing between internal obstruction, gallstone ileus, and appendicitis was illus-

trated by me in a fatal case, described in the *New-Yorker medicinische Wochenschrift*, February issue, 1897, p. 113.

Sometimes, also, it is difficult to differentiate between appendicitis, renal and gallstone colic. In renal colic it is important to know that the pain on pressure is mainly limited to the lumbar region, there is hardly ever any vomiting, and the pain gravitates toward the scrotal and rectal region. Vesical tenesmus and hæmaturia are also frequently present.

Ureteritis may also be confounded with appendicitis, especially if it becomes combined with cystitis and nephrolithiasis or tuberculous kidney. The presence of blood and pus in the urine and the chronic course should, however, be conclusive in favor of ureteritis. My experience in a recent case of nephrolithiasis, which caused ureteritis shows, however, how these symptoms may be veiled.

CASE VIII.—A well-built man, thirty-five years of age, who had always been well until about a year ago, began to suffer slightly from occasional digestive disturbances. On October 1, 1898, while at work, he noticed a pain of moderate intensity in the right iliac fossa. When, a few hours later, nausea and fever set in, medical treatment was obtained, which, so far as could be ascertained, was of a palliative character. On the following day the pain and nausea disappeared and on October 3d the patient resumed work. On the 10th, after having passed a whole week without discomfort, he was suddenly attacked with intense pain in the same region. Under the administration of opium and the use of an ice-bag he was relieved again for a short time, until, on the 11th, the symptoms assumed a grave character. The presence of a tumefaction was discovered then by the attending physicians, and the diagnosis of appendicitis made.

On the 14th, when the patient was referred to St. Mark's Hospital for operation, the following state was found: The emaciated patient's general condition made a grave impression. Little pain was complained of. Its character was by no means colicky, and it radiated somewhat toward the umbilicus. This was not regarded as a pathognomonic symptom, since the absence of intense pain could be explained by the narcotizing influence of the toxines present. The bowels were constipated, but the passage of the urine was normal. Vomiting was moderately frequent. The pulse was 130 and feeble; the temperature was 101.2° F.; and the respirations were 36. The abdomen was distended and slightly painful to the touch. In the right iliac fossa tumefaction and corresponding dullness were found, which filled the iliac fossa and extended anteriorly to the mamillary line. The lumbar region showed nothing particular. Examination of the highly saturated urine showed nothing abnormal; especially were no blood casts or pus detected.

It is obvious that, in view of the presence of these symptoms, so characteristic of appendicitis, the diagnosis was positive. The operation was performed on the same day, after saline infusions had been liberally administered. The incision was made in the symphysis-rib line. When the peritonæum was divided, slightly odorous pus of thick consistence and gray-yellowish color was discharged. Now a large cavity could be inspected, the median wall of which was formed by the cæcum, to which a normal-appearing appendix was attached by loose adhesions. In the bottom of the cavity a mass of necrotic tissue was found in which a hard stone of the size of a large filbert was discovered. Its shape was elliptic and its surface granular. Examination showed it to consist of a nucleus of uric acid with oxalate layers around it and a superficial coat of earthy phosphates. The situation of the ureter could not be made out distinctly among the detritus. Examination of the pus revealed nothing particular. The cavity was drained with iodoform gauze. Recovery was uninter-

rupted, and the patient was discharged from the hospital a month after the operation. No urine ever escaped through the wound.

It seems to me that the calculus had found its way from the renal pelvis into the right ureter, where, on account of its large size, it was arrested. There it caused considerable irritation and inflammatory changes, producing the formation of adhesions in which the calculus became impacted. This happened probably at the time the patient noticed the first pains, on October 1st. A few days later, probably synchronously with the second attack, perforation with abscess-formation took place, the adhesions then being so dense that they protected the ureteral perforation, thus preventing the escape of urine from there.

In regard to the absence of hæmaturia, the possibility should not be excluded that during the first epoch it might have been present unnoticed. During the second attack it was certainly absent. The normal passing of the urine and the absence of real paroxysms of renal colic are most remarkable in this case. Especially in septic cases the signs of nephritis are often found if the urine is carefully examined. Pus in the urine was observed by me seven times, undoubtedly the consequence of septic absorption. Only three of these cases recovered.

How coxitis can be taken for appendicitis has been explained above. If there is any doubt, the Röntgen rays will always throw light.

There are reports on typhoid fever in the first week, when moderate fever, slight pain in the right iliac fossa, and meteorism were present, having been confounded with appendicitis. But the history, the general charac-

ter of typhoid fever, the typical temperature, should permit of no doubt. Regarding perforation of a typhoid ulcer, it can be maintained that the symptoms of a perforation peritonitis are similar to those produced by a perforative appendicitis. But such an event never happens before the third week in typhoid fever, so that from the further course conclusions can be drawn from this fact.

Since it became known that with few exceptions all the forms of inflammation, vaguely termed typhlitis, perityphlitis and paratyphlitis, were identical with the different types of appendicitis, the impression has prevailed among some ultra-radically inclined colleagues that typhlitis has gone out of fashion entirely. But that there are real cases of stercoral typhlitis can not be doubted, the rarity of the cases being of course admitted. At the early stage the diagnosis is difficult, since the symptoms are identical with those of appendicitis. The only distinguishing diagnostic factor would be furnished by the doughy consistence of the tumor. Shrady* has sometimes been able to produce indentation, which phenomenon can be plausibly explained from the faecal composition of the contents of the tumor. They should, of course, not be confounded with cases of simple coprostasis, as happens frequently. That such cases of coprostasis are always easily cured, be they treated under their proper name or under the false diagnosis of appendicitis, by the omnipotent laxative, does not need further argument.

A most remarkable case which had been operated upon for appendicitis originally, and in which I found

* *Medical Record*, January 6, 1897.

an intact appendix by performing laparotomy later, is the following:

CASE IX.—A strong man of forty years of age fell ill on January 15, 1896, with intense pain in the region of the umbilicus and of the right iliac fossa. Nausea and fever were also present. In spite of the gravity of the symptoms the patient walked about until January 29th without consulting a physician. In a septic condition he was then admitted to St. Mark's Hospital. There a small, frequent pulse, high temperature, tumefaction, and a corresponding dullness in the right iliac fossa were noted. The diagnosis was appendicitis perforativa. The operation, which was performed at once, revealed partial gangrene of the cæcum. There was grayish-yellow pus of an offensive odor, but without a serous admixture. The appendix was not found. After the operation the patient recovered somewhat, but soon fell into a state of somnolence. The temperature wavered constantly, and the pulse remained between 120 and 150. Repeatedly abscesses, which formed near the cæcum between intestinal loops, were opened. Then there was always slight temporary improvement, soon followed again by the recurrence of septic symptoms, so that we gave the patient up at last. In the meanwhile an ectropion of the extent of the palm of the hand had formed (Fig. 9). Risking a last effort under ether anæsthesia, I, in exposing the upper wound margin, detected a small abscess, which reached upward to the liver. After having discharged the abscess, the presence of which had not at all been suspected by me, the patient recovered rapidly, so that I could proceed to the closure of the enormous ectropion on March 20th. After having prepared the patient thoroughly for several days, and after having packed the afferent and deferent ostia prophylactically, I severed the intestine extensively from the adhesions, this being particularly difficult posteriorly. The freshened intestinal wound margins were coaptated minutely and

sewed up continuously after the Lembert-Czerny method. There was perfect union, which seems to be mainly due to the most extensive separation of the adhesions. Many surgeons warn us against resection, as in most cases a little, promising procedure, and recommend entero-anastomosis instead.

The patient had defæcated through his abdominal opening ever since the operation on January 29th. Af-

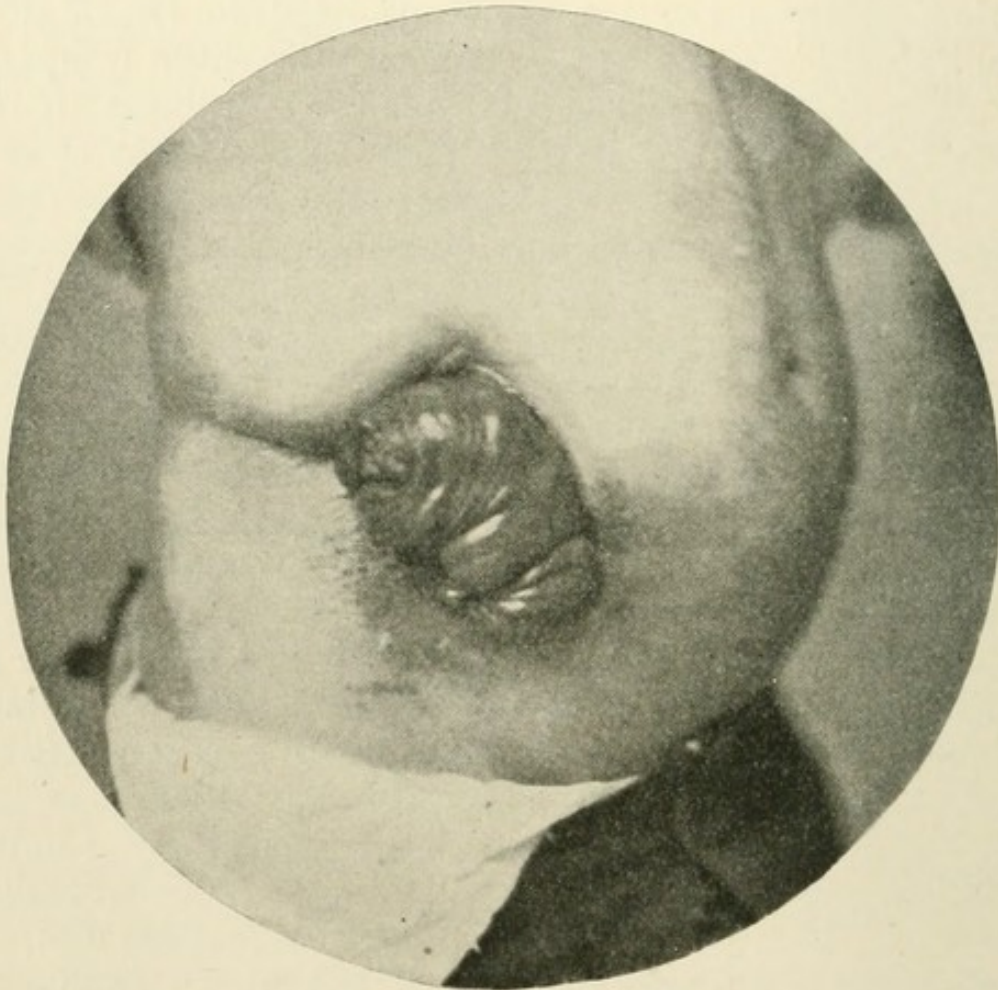


FIG. 9.—Intestinal ectropion after gangrenous typhlitis.

ter the enteroplasty he defæcated by the rectum. Only once, ten days after the last operation, transitorily fæces were found in the wound. On the following day perfect obliteration had taken place and the patient enjoys the best of health ever since. After the separation of the intestine was perfected, an intact appendix was dis-

covered slightly adherent to the peritonæum. Examination showed the mucosa to be normal. Therefore it may be assumed that originally the gangrenous process was confined to the wall of the cæcum.

Among other confusions, the psoas and lumbar abscesses may yet be borne in mind, the recognition of which should not cause much difficulty in view of their slow growth, the deformity, the absence of peritonitic manifestations as well as of grave initial symptoms, together with the history.

In regard to the diagnostic difficulties in peritoneal tuberculosis, I refer to history No. 2.

That diseases of the pancreas have been mistaken for appendicitis can be appreciated better than their confusion with malarial disease, influenza, or pneumonia.

Arriving now at the salient point of the appendicitis question, the therapy, we still hear the unceasing battle cry, "Here opium, here scalpel!" If we realize the infectious and progressive nature of appendicitis, as I tried to emphasize it in the introduction of my article, we shall not expect a cure from internal treatment; while by modern surgical technique we are able to reach the focus of disease and to render it innocuous at its early stage. I must therefore answer the question, "Is appendicitis a surgical disease?" in the clear affirmative. This does not mean that appendicitis should altogether be turned over from the hands of the internists to those of the surgeons. There is no fear of that, because the appendicitis public also has a word to say in this matter. In practice a case of appendicitis never goes directly to the surgeon, since the patient himself never makes the diagnosis appendicitis, but he suffers from the ominous pain, which, more than his feelings of general ma-

laise, causes him to see his family physician. What he demands from him first is that he should cure his "belly-ache."

Now, this family physician should realize that he is confronted with a disease of absolutely surgical character, and that, unless he can cure it surgically himself, he should immediately call in the aid of a surgeon. In this manner most surgical cases do not drift into the hands of the surgical specialist, but nearly always into those of the general practitioners, whose greater or lesser skill in surgery turns the scale, whether or not the case really requires further deliberation with a surgeon.

So we find it natural that in fractures the family physician is called in first. So long as he trusts he can master the case, he would be blamed for summoning a surgeon. But there would be much more reason for blaming him if he did not fully realize that he had to deal with a strictly surgical disease, which he must treat after true surgical principles. Should he encounter any difficulties in the treatment of the fracture, there is nearly always enough time to take a surgical specialist into council and to conduct further treatment according to his advice. But in appendicitis success is mainly determined by immediate interference, and the right to interfere is his only who is competent to execute the cure technically.

That there is plenty of space for cooperation of the family physician, who is conversant with a great many matters which the surgeon again does not know, and whose knowledge is to the surgeon's and the patient's greatest advantage, is beyond question.

It shall not be denied that immobilization of the intestine by opium, after a preceding evacuation of

the lower intestinal portion by an enema, will produce a perfect palliative success in a large number of cases of appendicitis. But a real cure can be expected as little as from the mere adoption of the splint in phlegmon of the hand. The administration of opium for the purpose of arresting intestinal peristalsis, agreeable as it is for the patient, has the most deplorable consequence that it lulls not only the patient but also the attending physician into a feeling of security, from which both are aroused most cruelly by the early appearance of peritonitic symptoms. Therefore the administration of opiates should be advised against most energetically before a distinct diagnosis is arrived at. After the diagnosis is made, the administration of opium is rational, even if immediately afterward the operation is performed.

However light the clinical expression of appendicitis may be, and how much it may appear to be in favor of a speedy temporary recovery, the operation is always justifiable. As the strength of the infection can never be known with certainty from the beginning, it appears to be wiser to take each appendicitis seriously. Among two evils the smaller should be chosen, and operation is the smaller evil.

The assumption of a simple appendicitis with a tendency to spontaneous resolution is mostly made by a comparatively untrained observer.

If there be nothing more than a simple appendicitis, I can not see how in the hands of an aseptically trained surgeon life should be jeopardized by simple appendectomy, even if it should prove to have been unnecessary. But if there is perforation or gangrene in the nascent stage, the early operation positively saves

the life of the patient, who otherwise would probably succumb to internal or expectant treatment.

Thus at the early stage the surgeon is the boss, so to say, while in the late stage he is an adventurer, who is successful, yet only once in a while, under extraordinary circumstances. But times have passed when celebrated surgeons found it expedient to write books on "luck in surgery."

If the attending physician does not care to be converted to this standpoint he should at least regard it his duty to explain the nature of the disease to his patient, and to leave it to him, whether, after he passed his attack, he had better have his appendix preserved in the alcohol bottle than in his iliac fossa, where it represents an explosive stuff which may lead to a catastrophe any moment. He can surely depend upon encountering a second or third attack after having been through one, and there is little doubt that he has to succumb to one of these attacks some day.

Considering that under the auspices of asepsis the mortality of simple appendectomy is nearly nil, every colleague should regard it his duty, no matter to what colors he has sworn, at least to communicate these facts to his patient. Up to date I have performed simple appendectomy seventy-four times without a single death. I know that there are several surgeons in this city who could report a much larger number of similar cases with the same gratifying result.

Even extensive adhesions should not cause disturbances in the course of the wound treatment. And these adhesions are, as a rule, only present if there has been more than one attack, as after one attack generally only slight adhesions are detected.

As alluded to above in the pathological part of this article, most patients who have gone over one attack of appendicitis suffer more or less from disturbances of stomach or intestine, which becomes worse on the slightest provocation. The fear of injuring themselves forces a regimen upon them which impairs their nutrition and becomes unendurable in the end. Thus, even when well-marked local symptoms fail to show themselves, a picture similar to hypochondriasis develops. If the appendix is removed in such patients, one is surprised to see how at one swoop all these symptoms disappear, and the patient becomes an entirely new man.

In drawing conclusions from what has been said we may condense them into the following theses:

1. Appendicitis is a surgical disease and should be treated surgically as soon as the diagnosis is made.

2. So long as no physician is able to ascertain the grade of bacterial virulence at its early stage, the safest therapy consists in the early removal of the appendix.

3. If the patient or his advisers should object to operation, the expectant immobilization treatment should be instituted, and, after the attack is over, the necessity of appendectomy thereafter should be made clear to the patient.

4. Should the conditions surrounding the patient be of an extremely unfavorable nature, should no competent surgeon be obtainable, and should there be other difficulties, the risk of the expectant treatment should be preferred to that of a badly performed operation in an acute attack. Then, if he should pass over the attack, the patient should submit to appendectomy later.

5. Considering that the mortality of simple appen-

dectomy is almost nil, its performance should be urgently recommended to the patient after the first attack.

I well realize that doing this will often cause the greatest difficulties to the family physician. So many prejudices, so many family considerations obtrude on him that he will often fail to have the courage to contend with the whole weight of his personality for these theses, although he is convinced of their scientific truth. Nor will I throw a stone at the family physician who, *jurans in verba magistri*, intoxicates himself with the sphere music of internist statistics, and shows the surgeon, who advises operation, sneeringly the list of dissuading internists. I simply deplore things as they are, and add my share to the better appreciation of a disease which, to its full extent, is recognized by none of us yet. But I may hope, with those who agree to my views, that the day will come when its surgical prospective will be everywhere acknowledged.

But what we are entitled to demand imperatively from every one who undertakes treating appendicitis is, that he learn enough of the pathology of the appendix to appreciate from the beginning the risk which the patient runs during his acute attack, and that information should be given accordingly. Penzoldt well says of appendicitis: "In none of these cases can a gloomy sensation of gravest responsibility be suppressed. The physician who does not know this sensation does not know the nature of this disease."

The technics of simple appendectomy, as I perform it in recent years, is the following:

First of all, I make it a principle to put the patient in bed for at least two days and to give him only fluid diet during this period. After admission to the hospital

he first takes one or two tablespoonfuls of castor oil; on the following day, and on the morning of the operation, an enema is applied. For thorough prophylactic disinfection the iliac and pelvic regions are shaved. While a warm bath is taken, a rigid scrubbing with green soap is done. Then a poultice of green soap is applied to the right lower abdomen, which remains twenty-four hours. I regard this an essential factor for the disinfection of the skin, because I do not believe that under ordinary circumstances the epidermis, which shelters a multitude of pathogenic bacteria, can be rendered sterile by the usual methods of disinfection, which generally are not carried out for more than from ten to fifteen minutes. A period of twenty-four hours gives the soap a chance to permeate the epidermis thoroughly, so that scrubbing on the following day is much more effective. Sometimes, indeed, the poultice macerates the epidermis so that it can be wiped off easily. Shortly before the operation the skin is scrubbed with gauze mops dipped in alcohol, the use of which is more important than that of any antiseptic drug, as it dissolves the fat of the skin. Bacteria so long as they are imbedded in fat will not be influenced at all by the strongest antiseptic medicament. I always attempt to have the protecting sterile napkins as near the wound margin as possible, fastening them there with small miniature forceps, so that all subsequent manipulations, especially ligation and suturing, can be done on a safe and sterile field. I have repeatedly seen surgeons who had taken minute care in their aseptic preparations wallow around the intestine on the abdominal skin in the roughest manner while manipulating it after it was taken from the abdominal cavity.

The operator, as well as the assistant engaged at the wound, and the one who hands the instruments, wear sterilized linen gloves. So long as we are not in possession of an absolutely reliable method of rendering the hands of the operator indisputably sterile, they should have a reliable aseptic protection, even though this may interfere with the elegance of the operation. After the abdomen is opened the gloves might be taken off for the minute work on the intestine. In pus cases they may be taken off after the abdomen is well cleaned. (On the employment of gloves, compare the writer's manual of the theory and technics of surgical asepsis, Saunders, Philadelphia, 1895, p. 94.)

The procedure of making the skin incision is of greatest importance. After having experimented with various methods, I found it most opportune to modify McBurney's method in making a long incision in the direction of the fibres of the external oblique muscle in such a manner that its centre fell into the middle of the line drawn from the symphysis to the anterior end of the eleventh rib. The incision begins about three fingers' breadth above the symphysis, and ends in the same distance from the anterior end of the eleventh rib in the line described (Fig. 10). Now the fatty superficial fascia and the fascia of the external oblique muscle are divided. The rectus muscle is not concerned, there being no fear of injuring its sheath, which would cause little, yet troublesome, hæmorrhage, and also a series of disturbances in the course of the wound treatment, inasmuch as the wound margins could only with difficulty be approximated to each other.

Now the fibres of the external oblique muscle are carefully separated, which can be done easily with the

handle of the scalpel, considering that the direction of the incision corresponds to that of the muscular fibres. If the margins are kept asunder by broad hooks, it is generally possible to separate the underlying fibres of the internal oblique and of the transverse muscle bluntly in the same manner—that is, corresponding to the direction of the fibres. The centre of this cross incision must be identical with the one of the oblique lon-

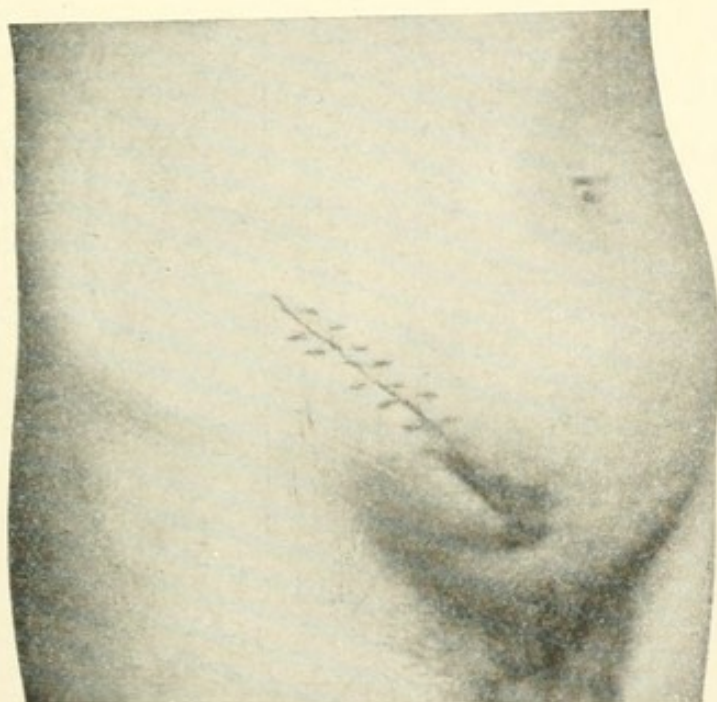


FIG. 10.—Direction of the incision in appendectomy.

gitudinal incision. It is true that there is a longitudinal as well as a crossed wound, but the size of the former, if the margins be kept well asunder, permits of considerable distention of the second incision, which, in emergencies, might be prolonged to the sheath of the rectus muscle on one side and to the crista ossis ilei on the other.

Nothing but the fatty subserous stratum, which partitions off the peritonæum, now remains; it must be

pushed out of the way. After having stopped each point of hæmorrhage thoroughly, no matter how scant it may be, the peritonæum is lifted by a small-toothed forceps and is carefully raised at its most elevated point just wide enough to permit the insertion of a grooved di-

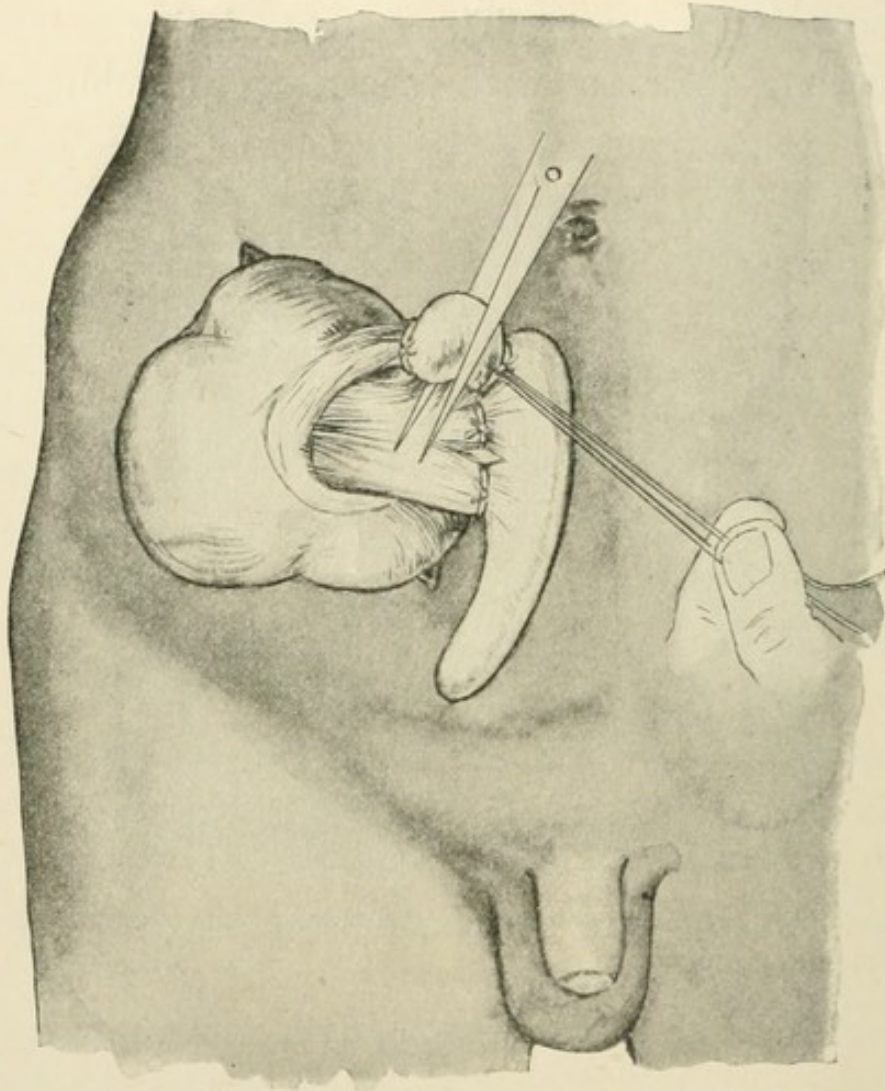


FIG. 11.—Removal of the appendix after securing the base by a ligature.

rector, upon which the further division of the peritonæum is completed. Now the index finger is introduced to get hold of the appendix. Sometimes it can be made to slip out like a little eel, so that the whole operation can at once be finished extra-abdominally. But in the major-

ity of cases the caput coli must first be drawn out; and even then the adhesions formed by previous inflammatory processes tighten it to such an extent that the abdominal wound must be enlarged transversely. But even then it frequently takes some time until the appendix, which has undergone pathological changes, can be brought into view. In order to get a landmark it is best to secure the ascending colon, which can be recognized by the longitudinal direction of its muscular fibres. By following the ascending colon downward the fundus of the appendix is reached anteriorly. If there be no adhesions of any account the appendix is removed after having ligated its mesenterium in three or more portions (Fig. 11).

For this purpose I use the formalin catgut exclusively, the sterility of this material, after it is boiled, being indisputable. After squeezing the contents of the appendix into the cæcum, the fundus of the appendix is tied with a catgut ligature. The same procedure is repeated about half a centimetre below (compare Fig. 11). Then with one stroke of the scissors the appendix is severed closely above the lower ligature. By previously having squeezed out the contents of the appendix and by tying doubly afterward, the exit of any faecal matter is prevented. The protruding mucous membrane of the appendix, after being disinfected with a strong solution of bichloride of mercury, is then seized with an artery forceps and pulled out as far as possible. Now it is cleanly cut off with the scissors (Fig. 12). There is then left a muscular serous flap, which can easily be united by three Lembert sutures (Fig. 13). After the removal of the mucous membrane some iodoform powder is dusted over the remainder of the mucous membrane in

the depth; but dusting the little wound margins, which are to be united, is to be very carefully avoided. All

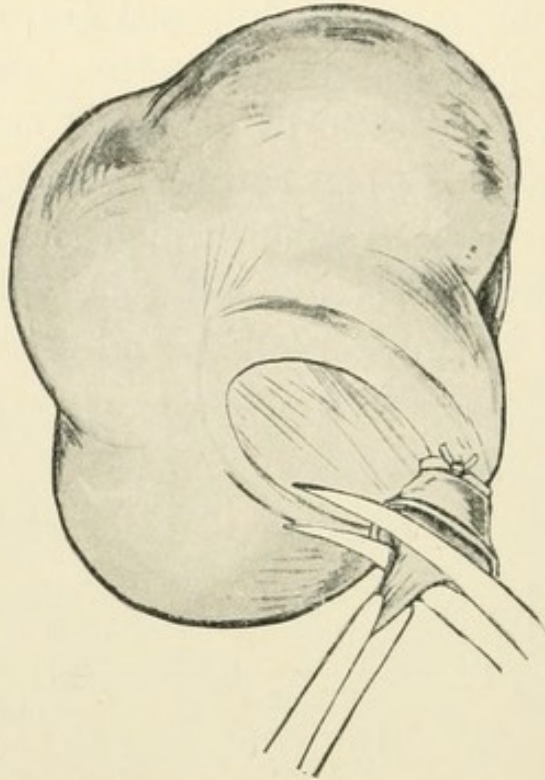


FIG. 12.—Removal of the mucous membrane.

these manipulations take place after the neighboring intestines, particularly the area situated directly below the appendix, are protected extensively with sterile compresses.

In some cases the appendix is so deeply imbedded in thick adhesions that it appears, as said above, like a mummy baked into lava. Its structure is then so much changed that it can only be identified after a long search. Then it is recommendable to separate the appendix at its cæcal end first, so that the colon can be pushed away from the operating field, after which removal of the appendix can be done much easier. It has happened to me repeatedly to have to proceed step by step by making very small incisions to shell out the appendix, which

sometimes reached crosswise up to the spinal column. After its removal its groovelike bed resembled the emptied husk of a bean pod.

In doubtful cases it is preferable to leave a serosa fragment rather than to extirpate too radically, in which cases the surface bleeding may become considerable.

After having stopped every little bleeding point minutely, whether by means of hot compresses or with the finest formalin catgut, the peritoneal margins can be united with the same catgut. Then follows the transverse fossa. The transverse and the external oblique muscle require but little suturing, as they approximate themselves by themselves as soon as the tenacula are withdrawn.

Hernia after this operation is an impossible sequel. It can occur only in cases where the great extent of

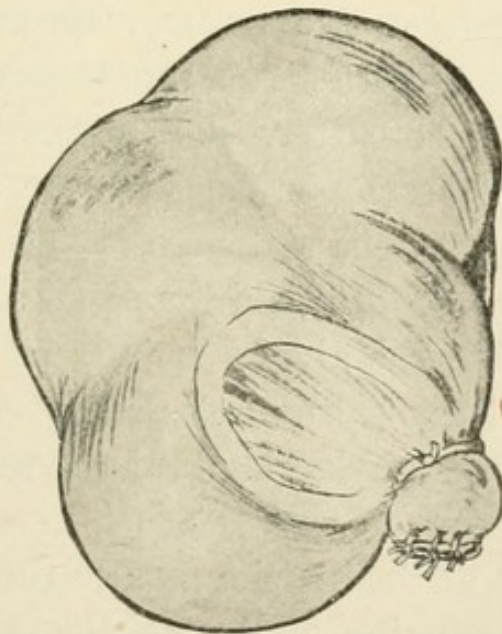


FIG. 13.—Suturing the stump.

adhesions necessitates enlarging the transverse wound to such an extent that the sheath of the rectus muscle

has to be injured. It is, of course, in the interest of the patient to enlarge the opening at the expense of a possible hernia rather than to restrict the liberty of intra-abdominal manipulations. Still, I have always succeeded so far in removing the appendix within the limits described without attacking the neighboring tissues.

The technics of appendicotomy (*sit venia verbo*) is the same in principle, be there an acutely inflamed, a perforated, or a gangrenous appendix. Virtually the preparations should be just as thorough as if there had to be done a simple appendectomy in a non-infected abdomen. The patient can not, of course, spend two days in making preparation; but the disinfecting procedures immediately preceding the operation should be carried out with great strictness, while the patient is anæsthetized.

From the time of the consultation up to the time of the operation at least two hours elapse, during which time there is a chance to scrub the abdomen with green soap, and alcohol thereafter. Up to the time when the anæsthesia is complete a poultice of green soap or formalin should be kept on the abdomen.

If the pulse is of a bad quality, a subcutaneous saline infusion should always be given. I am accustomed to administer a saline infusion shortly before each capital operation prophylactically if the pulse is not very good.

The direction of the incision is also the same. But if palpation or percussion indicates the presence of an exudate, the incision must be made as lateral as possible. Generally the line drawn from the symphysis up to the anterior end of the eleventh rib answers best. But if the exudate be situated far outward, the incision may be

made nearer to the spina anteriora superiora ossis ilei. It may easily happen that in incising above the so-called McBurney's point the partition walls, situated toward the median line and formed of protecting adhesions, should be cut. This deplorable accident has happened twice to me. Such a focus, secluded by adhesions from the abdominal cavity, becomes, in fact, extraperitoneal, and its opening is nearly as innocent as that of an abscess situated not too superficially on most other parts of the body.

The incision should not begin above the symphysis, as in simple appendectomy, but partly above it, as it is exceptional that the lower limits of the abscess can not be followed down to the true pelvis.

As demonstrated above, the formation of small abscesses directly above Poupart's ligament, which are often only demonstrated by percussion, is by no means of rare occurrence. In the last instance one may be guided as to the preference of the direction of the incision by the result of the palpation or percussion. By all means the principle should be obeyed: "Better too far outward than inward."

The external oblique muscle can also be separated bluntly. In regard to the fibres of the internal oblique and the transversalis, which run crosswise, it is not necessary to be as conservative in the case of the presence of an exudate as if there was a simple appendectomy to be performed. If speed is required, the fibres may be divided nearly transversely—that is, directly parallel to the skin incision. But in simple appendicitis or pyappendix the blunt method always holds good.

After having arrived at the peritonæum the way is best cleared, if there be an exudate, with the grooved

director. If pus appears on it, a small forceps is pushed along the groove of the instrument and the opening in there gradually dilated. Frequently the dark-red cæcum, covered with fibrinous flocks, presses forward, so that the greatest care has to be observed not to injure it with a cutting instrument. Therefore it is urgently advisable to use none but dull-pointed scissors or scalpels for the further division of the peritonæum.

Now careful wiping and inspection is done. Generally, only fresh adhesions are found, and in order to approach the appendix, tightly bound down, they have to be severed first by moderate pulling. During these procedures the neighboring organs must always be well protected by gauze mops which are pushed underneath.

If the appendix is closely attached to the wall, consisting of protecting adhesions, it is preferable to leave it there, provided it can not be removed without destroying the protecting wall. Then an iodoform gauze strip should be built around it or its fragments, which can be removed safely a few days thereafter. But if it can be shelled out without such difficulties, it should be done, and the tying and extirpation should be performed according to the methods of simple appendectomy. But every possible means should be tried before making the decision to leave an appendix, degenerated and infected, in the abdomen. It often happens that we are too conservative, and small abscesses, covered by the imbedded appendix, are overlooked, so that the patient may still die, the large abscess only having been discharged and one or more little foci upholding and spreading the infection.

If there is complete gangrene, the appendix can not be recognized as such any more. There its grayish-black

fragment must be removed with a blunt forceps. Even the slightest pull on its cæcal junction may cause the discharge of fæcal contents, and it is therefore of the greatest importance to push gauze compresses without delay underneath the endangered area just as soon as the appendix comes into view. Suturing is inadvisable; iodoform-gauze packing is to be preferred, after having cleaned the abdominal cavity thoroughly. Sometimes small fæcal fistulæ form, which usually close spontaneously.

If the mucous membrane protrudes, the attempt may be made to cauterize the ectropion by Paquelin's cautery. If this proves ineffectual, extensive post-operative means have to be resorted to (compare Case VIII, Fig. 9).

In gangrene, however, a protecting wall, consisting of adhesions, is hardly ever formed; in such cases we have to deal with peritonitis rather than with appendicitis. Sometimes it fortunately happens that the adhesive peritonitis agglutinates the intestinal loops adjoining the cæcal region, so that really extensive peritonitis is confined to a comparatively circumscribed area. This rare good fortune is explained by the careful evacuation of pus foci by the guarded boring index finger, and furthermore by the minute wiping off of all fibrinous flocks. (In my article on Appendicitis in the *Berliner klinische Wochenschrift*, 1896, No. 37, I described a very interesting case of this sort.)

After the inflammation has given up its circumscribed character then matters are much worse. Still, even in such desperate cases, results are obtained now and then, especially if one has the luck to discover encysted foci after external inspection and palpation of the peritoneal cavity. By exercising a great deal of patience

it is often astonishing how foci are discovered which were not suspected on a superficial examination. Anæsthesia should be employed in such cases. Such foci must, of course, be exposed thoroughly. The peritoneal cavity is washed with a hot saline infusion, the fibrinous flocks are wiped off carefully, and extensive drainage is effected by the use of iodoform wicks.

The thorough exposure of the suspicious peritoneal region first of all permits a complete evacuation of the pus accumulations from the edges and niches of the abdominal cavity. Adhesions, the results of preceding inflammatory processes, can be loosened easily, even though the thorough disinfection of the abdominal cavity still remains a pious desire rather than a surgical reality. Still, by these procedures a considerable amount of accumulated infectious material is got rid of, not to speak of the most beneficial lowering of the intra-abdominal pressure, and the consequent freeing of the respiration. There is a series of authentic reports, according to which a cure was effected in most desperate cases, to the treatment of which the surgeon proceeded without a spark of hope, where, for instance, the pulse was hardly perceptible. *Vice versa*, however, many cases have ended fatally where the prospects seemed entirely favorable.

If the gangrene has persisted for several days, the cæcum will naturally participate, considerable loss of substance then occurring sometimes. If the area thus affected is not thoroughly exposed and the necrotic tissue removed, the patient will surely succumb. I found that the best route from which such foci are exposed is by the lumbar region, a long, transverse incision being made from the abdominal incision backward, if necessary to the outer margin of the lumbo-dorsalis muscle.

Sometimes one is surprised at the extent of the necrotic process in this region, which escaped notice if inspected from the abdominal opening only. The latter should be sewed up after all necrotic fragments are removed and the wound cavity drained from the lumbar opening. In two of my most desperate cases recovery took place, although these rigorous procedures had to be undertaken while the patients were nearly conscious, respiration having stopped shortly after the anæsthetic had been administered. In both cases, one being of five and the other of seven days' standing, pus had been present in the urine.

It is no doubt depressing for a surgeon to proceed to heroic manipulations under such gloomy circumstances, where he must fear every moment that the small vital spark would become extinct. And, on the other hand, he can not forget that such a patient has nothing to lose and everything to gain, and that under these circumstances at all hazards this last chance should be offered to him. His permission is easily obtained, for such patients often suffer intensely, and are generally cognizant of the hopelessness of internal medication. Unfortunately, in most cases, the valuable span of time, which may eventually offer a chance for recovery, is sacrificed to aimless deliberation.

In infection of high virulence the prognosis is absolutely bad. When, on incising the peritonæum a serous exudation of a fæcal odor pours forth, I always say to myself: "Lasciate ogni speranza." Up to date I have lost all my cases of this kind. This form of exudation seems to point to an infection of high virulence. Treatment with antitoxine has also proved a failure in such cases.

Regarding the occlusion of the abdominal wall, primary union should always be striven for in simple inflammatory processes. Consequently the abdominal wall should be sewed up. In simple abscess formation the wound cavity is packed with iodoform gauze, and the abdomen is kept open and protected with a large piece of immobilizing moss board. The dressing is changed once in three days.

If virulent infection is assumed, the moist open-wound treatment is substituted for the dry open treatment by keeping the gauze filling in the wound cavity constantly moist with formalin. Instead of the moss board and the bandaging, only a compress, saturated with the formalin solution, is put over it. If the patients do well, a laxative is given twenty-four hours after the operation. As an anæsthetic, nearly always ether was employed. For the last six months Schleich's mixtures were tried, and while I have to acknowledge the ease with which some patients came under and out of their influence, I have failed to discover any material advantages over the usual methods of ether anæsthetization.

All patients in whom the open-wound treatment is tried have to wear an abdominal supporter, which has to be well padded on the right side.

Physicians————

who desire to keep *au courant* with the advances
of medicine and surgery should read


**The New York
Medical Journal**


Subscription price, *per annum*, \$5.00

Volumes begin in JANUARY and JULY

D. APPLETON AND COMPANY, Publishers

72 Fifth Avenue, New York





RD542

B38

Beck

COLUMBIA UNIVERSITY LIBRARIES (hsl, stx)

RD 542 B38 C.1

Is appendicitis a surgical disease? /



2002285681

