

Bismuth paste in chronic suppurations : its diagnostic importance and therapeutic value / by Emil G. Beck ... with an introduction by Carl Beck, M. D., and a chapter on the application of bismuth paste in the treatment of chronic suppuration of the nasal accessory sinuses and the ear, by Joseph C. Beck, M. D. With eighty-one engravings, nine diagrammatic illustrations, and a colored plate.

Contributors

Beck, Emil G., 1866-1932.
Augustus Long Health Sciences Library

Publication/Creation

St. Louis : C. V. Mosby company, 1914.

Persistent URL

<https://wellcomecollection.org/works/dbv2728m>

License and attribution

This material has been provided by This material has been provided by the Augustus C. Long Health Sciences Library at Columbia University and Columbia University Libraries/Information Services, through the Medical Heritage Library. The original may be consulted at the the Augustus C. Long Health Sciences Library at Columbia University and Columbia University. where the originals may be consulted.

This work has been identified as being free of known restrictions under copyright law, including all related and neighbouring rights and is being made available under the Creative Commons, Public Domain Mark.

You can copy, modify, distribute and perform the work, even for commercial purposes, without asking permission.



Wellcome Collection
183 Euston Road
London NW1 2BE UK
T +44 (0)20 7611 8722
E library@wellcomecollection.org
<https://wellcomecollection.org>

COLUMBIA LIBRARIES OFFSITE
HEALTH SCIENCES STANDARD



HX64052648

RD641 B38

Bismuth paste in chr

RECAP

RD641

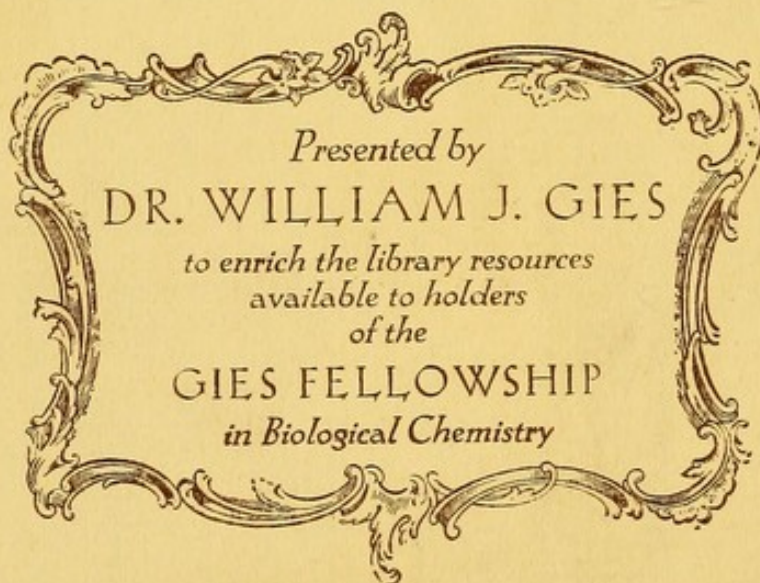
B38

Columbia University cop. 2
in the City of New York


College of Physicians and Surgeons

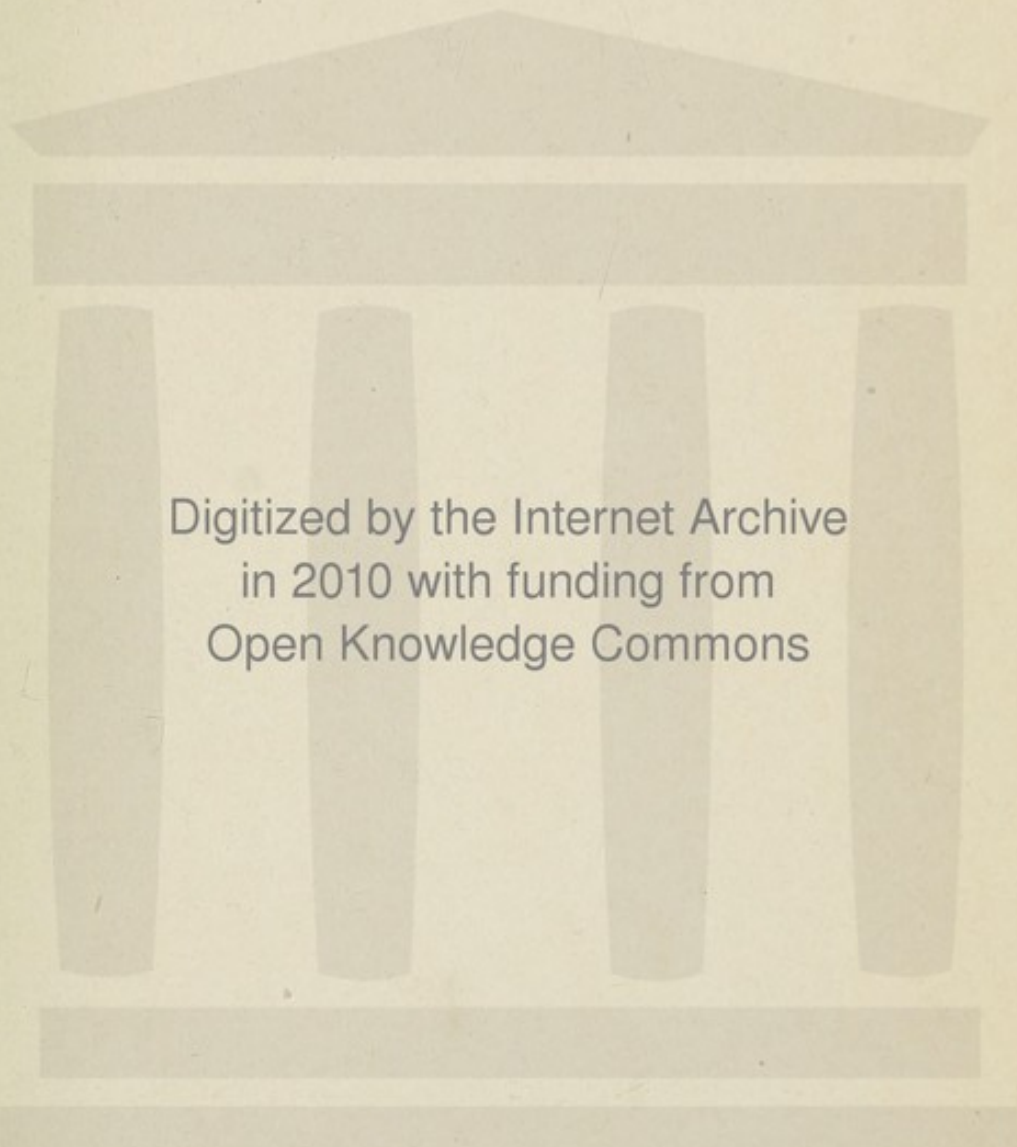


Reference Library











Digitized by the Internet Archive
in 2010 with funding from
Open Knowledge Commons



BISMUTH PASTE
IN
CHRONIC SUPPURATIONS



BISMUTH PASTE
IN
CHRONIC SUPPURATIONS

ITS DIAGNOSTIC IMPORTANCE AND
THERAPEUTIC VALUE

BY

EMIL G. BECK, M. D.

SURGEON TO THE NORTH CHICAGO HOSPITAL, CHICAGO, ILL.

WITH AN INTRODUCTION BY CARL BECK, M. D.

AND A

CHAPTER ON THE APPLICATION OF BISMUTH PASTE IN THE TREATMENT OF
CHRONIC SUPPURATION OF THE NASAL ACCESSORY SINUSES
AND THE EAR, BY JOSEPH C. BECK, M. D.

WITH EIGHTY-ONE ENGRAVINGS, NINE DIAGRAMMATIC
ILLUSTRATIONS, AND A COLORED PLATE.

ST. LOUIS
C. V. MOSBY COMPANY

1914

COPYRIGHT, 1910, BY C. V. MOSBY COMPANY


RD 641

B38

cop. 2

Press of
C. V. Mosby Company
St. Louis

DEDICATED TO
CLARA BECK
MY WIFE



PREFACE.

During the past year a number of my confreres have advised me to write a monograph on the uses of bismuth paste, believing that the subject was of vital importance and that the general practitioner was not sufficiently familiar with the method to apply it to the best advantage. My reluctance has rested on the belief that the subject was yet immature for such publication, but, yielding to persistent urging from various sources, I am prompted to bring forth the subject in its present state of development in the hope that in the meantime many may benefit by the experience thus far acquired in treating a large variety of cases by this new method.

Judging from the number of inquiries we have received from surgeons and physicians, as well as from specialists, I must conclude that the profession is sufficiently interested in this work to receive it at this time as a necessary aid to its proper and successful application.

I desire here to acknowledge the valuable aid received from my brothers, Dr. Carl Beck and Dr. Joseph C. Beck, whose suggestions have added a great deal to the development of this new method of treating chronic suppurative diseases.

No less do I appreciate the service rendered to the profession by Drs. Ochsner and Mayo, who in their daily clinics have spread the knowledge of this new method of treatment among a large number of the most active men in our profession.

I wish also to express my thanks to Drs. J. Ospray and F. Turley, as well as to Mr. W. F. Willis, for their assistance in executing the radiographic work and preparing the illustrations.

The publishers have executed their part of the work with promptness and exactness, for which I desire to express my appreciation.

EMIL G. BECK.

CONTENTS.

	PAGE
CHAPTER I.	
INTRODUCTION—By Carl Beck, M. D. (Chicago)	17
CHAPTER II.	
GENERAL CONSIDERATION	21
CHAPTER III.	
BISMUTH PASTE IN ANATOMICAL DIAGNOSIS	28
CHAPTER IV.	
DIAGNOSTIC ERRORS REVEALED BY BISMUTH PASTE INJECTIONS	35
CHAPTER V.	
THERAPEUTIC EFFECTS OF BISMUTH PASTE	44
CHAPTER VI.	
TREATMENT OF SINUSES DUE TO SPONDYLITIS	60
CHAPTER VII.	
TREATMENT OF SINUSES FOLLOWING OSTEOMYELITIS AND JOINT DIS- EASES	69
CHAPTER VIII.	
POST-OPERATIVE SINUSES FOLLOWING ABDOMINAL AND KIDNEY OPERA- TIONS	110
CHAPTER IX.	
RECTAL FISTULAE—DIAGNOSIS AND TREATMENT WITH BISMUTH PASTE	124
CHAPTER X.	
BISMUTH PASTE IN FECAL FISTULAE	132
CHAPTER XI.	
BISMUTH PASTE TREATMENT OF EMPYEMA AND LUNG ABSCESS	135
CHAPTER XII.	
BISMUTH PASTE IN THE CONSERVATIVE TREATMENT OF COLD ABSCESSSES	154

	PAGE
CHAPTER XIII.	
LIMITATIONS AND CAUSES OF FAILURE	171
CHAPTER XIV.	
BISMUTH POISONING AND ITS PREVENTION	180
CHAPTER XV.	
BISMUTH PASTE IN THE TREATMENT OF CHRONIC SUPPURATIVE DIS- EASES OF THE NOSE, ACCESSORY SINUSES, EARS, AND MASTOID PROCESS	199
CHAPTER XVI.	
THE USE OF BISMUTH PASTE IN DENTISTRY	218

ILLUSTRATIONS.

Colored Plate. Sequestrum of ulna—Reproduced from specimens in natural colors Frontispiece

FIGURE	PAGE
1. Types of syringes used for bismuth paste injections	29
2. Sinus after psoas abscess	30
3. Network of sinuses following tuberculosis of iliac bone	33
4. Bronchial tree of a cat injected with bismuth paste to show that the smallest channels can be reached	34
5. Osteomyelitis of femur, mistaken for hip joint disease	35
6. Tuberculous sinus originating in the sacrum, thought to be an abscess of hip	36
7. Bismuth paste remaining in focus of disease four months after closure—Hip shown to be normal	37
8. Tuberculosis of sacrum, mistaken for hip joint disease	38
8 A. Diagrammatic illustration of Fig. 8	39
9. Subphrenic abscess following appendicitis, suspected of being an empyema	40
9 A. Diagrammatic illustration of Fig. 9	41
10. Unsuspected renal sinus diagnosed by bismuth paste injection	42
10 A. Diagrammatic illustration of Fig. 10	43
11. Tuberculous knee joint, showing remnants of paste four months after closure	45
12. Spondylitis of the tenth dorsal vertebra, with communicating sinuses in supraclavicular and lumbar region	64
13. Spondylitis of tenth vertebra, showing course of sinus, opening in lumbar region at point of black dot, and then downward course into the pelvis	65
14. Sinus following psoas abscess, sixteen years' duration—Closed after third injection of bismuth paste	66
15. Bilateral psoas abscess without destruction of vertebræ—Each opening above Poupart's ligaments	67
16. Sinuses from nontuberculous osteomyelitis	70
17. Radiograph of humerus, showing sequestra	72
17 A. Diagrammatic illustration of Fig. 17	73
18. Three of the sequestra removed from humerus	73
19. Bismuth paste injected into cavity after sequestra were removed	74
19 A. Diagrammatic illustration of Fig. 19	75
20. Bismuth paste remaining after sinuses were closed	76
21. Complete closure of sinuses and perfect restoration of function of arm	77

FIGURE	PAGE
22. Typhoid osteomyelitis of tibia	78
23, 24. Blood supply in bones of infant, showing subdivisions of nutrient artery in metaphysial line	80
25. Villous growth of tuberculous knee joint	83
26. Rice bodies from tuberculous joint	84
27. Sinus openings, showing large pouting granulations after bis- muth injections	87
28. Radiograph showing sinuses within hip after sixteen years' suppuration—Closure in one month—No recurrence	90
29. Radiograph showing path of sinus into hip joint	91
30. Hip joint disease, nineteen years' duration	92
31. Nontuberculous osteomyelitis of femur	94
32. Bilateral tuberculosis—Tibia in right and femur in left limb affected	96
33, 34. Radiographs demonstrating bilateral tuberculosis	97
35. Demonstration of method of injection of bismuth paste into sinus of the knee	98
36. Tuberculous knee joint with forty-two sinuses, sixteen years' duration	99
37. Network of sinuses of femur	100
38. Hopeless condition of old tuberculous knee joint—Eight sinuses—Amputation required	101
39. Typical tuberculous ankle joint with sinuses	103
40. Destruction of ankle joint, with ankylosis (closed)	104
41. Tuberculosis of os calcis injected with bismuth paste	105
42. Sinuses supposed to have originated from ribs, found to be due to tuberculosis of sternum	107
43. Patient of radiograph shown in Fig. 42—Closure of all sinuses after removal of sternal focus	108
44. Sinus and fecal fistula in tuberculous peritonitis	111
45. Sinus following tuberculous peritonitis after removal of the adnexa	116
46. Tuberculous sinuses of kidney—Vertebral column unaffected .	120
46 A. Diagrammatic illustration of Fig. 46	121
47, 48. Patient with tuberculous kidney—Kidney not removed . .	122
49. Rectal fistula originating in coccyx, supposed to be of rectal origin	125
50. Method of injection of external rectal fistula	127
51. Dermoid cyst treated with bismuth paste	128
52. Supposed rectal fistula, shown to be a sinus resulting from disease of pelvic organs	129
53. Turtle-shaped sinus in perineal region, thought to be a straight rectal fistula	131
54. Method of reëxpansion of lung by suction pump	139
55. Cavity in pleura remaining after Estlander operation—Injected with bismuth paste	141

FIGURE	PAGE
56. Empyema of twenty-eight years' duration—Injected with bismuth paste—Closure in sixty days	143
57. Rubber coil showing against exposed pleura, demonstrating relation to lung abscess	148
58. Lung abscess cavity, viewed with stereoscope, will show four bronchial openings	149
59. Multilocular lung abscess injected with bismuth paste	150
59 A. Diagrammatic illustration of Fig. 59	151
60. Bronchial tree injected with bismuth paste for anatomical study	152
61. Psoas abscess, pointing in the lumbar region—Ready for spontaneous rupture	159
62. Abscess of hip joint injected with bismuth paste to prevent sinus	161
63. Normal pelvis of same age, for comparison with Fig. 62	162
64. Patient whose pelvis is shown in Fig. 62, standing on the diseased limb two weeks after injection of abscess	163
65. Tuberculous elbow joint with three abscesses before injection treatment	164
66. Reduction in size of arm shown in Fig. 65 after prophylactic, conservative treatment—Secondary infection avoided	164
67. Radiograph showing the three distinct cavities communicating with the elbow joint	166
67 A. Diagrammatic illustration of Fig. 67	167
68, 69. Tip of probe within the shaft of humerus as a cause of failure of bismuth injections—Cavity filled with bismuth paste after removal of foreign body	173
70. Sequestrum of the ulna, requiring removal before bismuth injection	175
71. Complete closure three weeks after operation and bismuth treatment—Removal of ulna from left arm	176
72. Incomplete injection of abscess cavity, demonstrating cause of failure of bismuth treatment	177
73. Injection of empyema after Estlander operation has failed to obliterate the cavity	178
74. Photomicrograph of section of liver about four micra thick—In the center of an interlobular vein, to the right and above a sublobular vein—The intima of both lined with bismuth	191
75. Large quantities of bismuth paste retained in pelvis, causing absorption—Complete recovery after washing out with olive oil	194
75 A. Diagrammatic illustration of Fig. 75	195
76. Empyema filled with bismuth paste, causing symptoms of absorption in two weeks—Prompt removal of paste resulted in complete recovery and cure	197

FIGURE	PAGE
77. Method of withdrawing mixture of paste and olive oil twenty-four hours after injection of the latter	198
78. Syringe and attachments for injection of bismuth paste in ear, nose, and throat cases	206
79. Frontal sinus injected with bismuth paste No. 2 by nasal route—Portion of the bismuth paste in the ethmoid region and antrum	211
80. Radical operation on antrum and filled with paste No. 2 . . .	213
81. Cyst of lower maxilla filled with bismuth paste	224

BISMUTH PASTE IN CHRONIC SUPPURATIONS.

CHAPTER I.

INTRODUCTION.

BY CARL BECK, M. D.

Ever since we have used aseptic methods in surgery, chronic suppurations have decreased in number. The difference between the old surgical ward of twenty-five years ago, reeking with the sweetish, repulsive odors of pus, mingled with the smell of carbolic acid, and the pure air of the modern hospital is a striking one. Most of our cases of operative surgery heal by primary union. Nevertheless, there are many victims of chronic suppurative conditions, and they are all the more disappointing because the surgeon demands more from his art nowadays; he expects healing by first intention where he was formerly well satisfied with the appearance of pus (*pus bonum et laudabile*). Rebellious and refractory cases become a source of disappointment to both surgeon and patient, particularly when they fail to heal after several operative attempts. It is then that the afflicted wander for years from surgeon to surgeon, to persons engaged in irregular methods, and then back to regular surgery, distressed and unhappy, or they often become resigned to the fate of a cripple who despairs of ever being helped. For a number of years I have been watching such cases, of which I saw many in hospital and private practice.

Many of them were affected with diseases of the bones, and had undergone a number of operations in the course of years. When the discovery of the x-ray was announced, it was taken up with enthusiasm. It was thought that it would help in diagnosis of bone lesions, and it seemed to me that a new ray of hope had come into the lives of these unfortunate patients. The early pictures of bone lesions were, however, rather imperfect, and helped little in diagnosis.

One of the most difficult problems in this connection seemed to me the question of how to make bone lesions distinct in the picture, and particularly how to follow those suppurative conditions to the focus of their origin. When I learned of the favorable results obtained by the use of bismuth in the stomach diagnosis, I immediately thought of the possibility of using it to outline the fistulous tracts and to follow them up to their origin. It took some experimenting before we found the right kind of vehicle which would allow liquefaction and then become solid in the tract, and which would enter into the smallest crevices and at the same time permit the substance to come out again. We first tried gelatin, then water, gum arabic, and other material, but they all proved failures until heated vaselin solved the problem. Our first case gives a beautiful picture. (Fig. 2.) When the injected mass failed to return, causing us to fear that we had stopped up the sinus and possibly infected the medullary canal, we felt great anxiety. When we observed, however, that, instead of fever and sepsis, a drying up and closure of the sinus followed, we were at first surprised, and then we began to experiment systematically on other cases. We studied the method from all points of view, and in all possible localities and varieties of cases. Dr. Emil Beck devoted a great deal of his time to

this study, and spared no efforts, first, to arrive at recognizable facts, and, second, to apply these facts and to show their application to others. He published a number of articles, demonstrated cases of different character, and tried the methods in different institutions and with other, often skeptical, surgeons. We may say with satisfaction that the method has aroused a great deal of general interest, and has elicited favorable comment from surgeons who are using it.

When the inquiries about the method became so numerous that we could not supply reprints, and we had gathered enough experience with the method to enable us to speak with some authority, we decided to condense this experience into a small book, which would contain the most important facts, points of technic, and results.

We are satisfied that the same results may be obtained by those following the procedure as given herein. Modifications of the method may yield good results, but we have found the technic and procedures described in this volume to give the most favorable results. One fact, however, is of importance, even in the simplest method of therapy—namely, that seeing a treatment applied is the best way to acquire a thorough knowledge of the procedure. No man should attempt to do surgery after having studied operative procedures merely from text books. He will be able to obtain good results only after witnessing or assisting in operations for some time. I remember very well one occasion, while I was still an assistant abroad, when a celebrated English gynecologist visited our clinic. In the visitor's honor our chief chose to perform one of the Englishman's methods of perineorrhaphy. When the operation was finished our visitor inquired whose method it was, and laughed heartily when he was informed that it was his own. This method

was, however, very simple, and had been well described in a journal, with illustrations, and our chief was a thorough reader of medical literature.

In our diagnostic work we make extensive use of bismuth paste. This book cites many instances in which errors in diagnosis have been revealed by it, and our records include many more which space does not permit to print. This phase of the method is almost universally recognized as the best aid to the surgeon, and I would regard any operation on a fistula or bone lesion with fistula without the previous use of bismuth injection as a mistake.

In giving this book to the profession we give the methods as we use them at present, but we are not using these methods to the exclusion of all the other scientific therapeutic methods which are universally recognized in the treatment of chronic suppuration.

There is no question that chronic suppurations must be analyzed as to their pathogenesis and must be treated with different methods. The injection of bismuth paste is a valuable aid in diagnosis and treatment, but only one of many, and in all probability its principle and technic will remain a therapeutic method, but it has its indications and also its limitations.

CHAPTER II.

GENERAL CONSIDERATION.

Suppurative sinuses, especially those of tuberculous origin, have always been most refractory to both medical and surgical treatment, proof of which may be found in the existing mass of invalids remaining uncured after the most skillful treatment has been employed. The extreme chronicity accounts for the accumulation of cripples all over the world. Several individuals in my series of cases have been afflicted with constant and extensive suppuration for from thirty to forty years, and managed to drag through life in their miserable condition.

A keynote to the prevalence of this scourge is given in his studies of cripples in Germany by Biesalsky,¹ in which he states that in Germany alone, excluding Bavaria, Baden, and Hessen, there exist 75,183 cripples. With the three above-named states included, their number is 89,048. Of every 10,000 children, 36 are cripples, of which number 6 are afflicted with tuberculous joints or bones. Other countries are no doubt equally, if not more greatly, burdened. I am informed by physicians practicing in China that the condition of suppurative sinuses is very much neglected in that country, and therefore very prevalent. They estimate that one in every four hundred Chinamen is afflicted with suppurative sinuses.

These sinuses and fistulæ, as we know, are sequelæ of infectious processes within the bones, joints, or parenchymatous organs. Fortunately, we are able to cure

¹ Biesalsky: *Zeitschrift für Orthopädische Chirurgie*, bd. 22, s. 323.

most cases of tuberculous infection in their early stages, either by immobilization or through hygienic or medical treatment, so that only a small percentage will terminate in sinus formation. When, however, this complication already exists, and the tendency to spontaneous closure is absent, only surgical treatment can be of any benefit. Even surgical treatment is here uncertain, and, if the sinus can not be traced to its origin, a cure by operation is almost impossible.

In all infections, whether acute or chronic, there exists a natural tendency to repair. Our system responds quickly to all infections—repelling the invading organism if possible, and, whenever it fails to repel it, calling into action all available resisting and fighting forces to check its progress.

The wonderful adaptation of the various types of cells to the needs of protection of the life of the individual has been aptly compared to a well-organized state, with its soldiers, its working and professional classes, etc., who in coöperation and perfect harmony render their services and are willing to perish in the fight for preservation of the whole organization. (Adami.)

The production within the body of various protective substances—such as **bacteriolysins**, **opsonins**, **antitoxins**, etc.—and also the well-known action of the white blood corpuscles called **phagocytosis**, are all contributing factors to the preservation of the life of the individual.

Our body can take care of a certain amount of injury or infection without in the least disturbing the health of the individual. In fact, mild and frequent infections create an immunity against the very poison produced by the microörganism which caused the infection. Only when our resisting forces are below par, and the invading microörganisms find us unprepared, will they be able

to get a foothold and develop into a powerful and destructive enemy.

Our resisting power is influenced by general and local conditions. Each individual inherits a certain degree of resisting power against diseases, which is either strengthened or weakened by various conditions. One may, for instance, inherit the tendency to tuberculosis, but may not contract it as long as he lives in favorable surroundings. Should he, however, suddenly change his environment and live among consumptives, he is more liable to contract it than one similarly predisposed, but who from childhood has lived in the midst of consumptives. The latter has by constant exposure, and probably by repeated and very mild tubercular infections, acquired an immunity against the tubercle bacillus.

Every person can increase his resisting power by proper hygienic life, by wholesome nutrition, and the physiologic exercise of all normal functions of the body. By disregarding these, especially through dissipation, alcoholism, etc., he is bound to produce the opposite—"a lowering of vitality." Conditions beyond his control—such as climate, constitutional diseases (diabetes, rheumatism, and various forms of anemia, etc.), and malnutrition—are other factors affecting his resisting power.

Mental influence upon resisting power is a factor probably much underestimated. Many patients have been scared into their graves, and many have escaped a premature death through their optimism. Worry and anger impair man's resisting power.

Local immunity as well as predisposition to infection are dependent upon several factors. Oft-repeated exposure or prolonged mild local infection will produce local immunity. The different types of cellular structures have different degrees of resistance, the highly organized cells

being less resistant than the coarser connective tissue cells. Denudation of the skin or mucous membrane and the lack of blood supply will also favor infection. Pathogenesis is, therefore, entirely dependent upon the strength of our resisting forces and the virulence and tenacity of the invading foe, "the pathogenic microbe."

In the struggle between the invading germs and the resisting forces, inflammation is always present. In most instances the inflammatory process terminates in **suppuration**. In very acute infections a diffuse cellulitis, also termed "**phlegmonous infiltration**," without pus formation, will be produced, while in the subacute or chronic conditions an abscess will form.

Formation of Abscess and Sinuses.

An **abscess** is a circumscribed accumulation of pus in one or more communicating pockets, formed by the products of inflammation.

The term **empyema** refers to an accumulation of pus within a cavity already existing, such as the pleura, pericardium, or antrum of Highmore, etc.

The character of the contents of abscesses varies according to the character of the infection. In acute cases, such as are due to the streptococcus, the pus is thin and scanty, while in the more chronic forms, such as follow the staphylococcus infection, the pus is thick and abundant. The contents of a tuberculous abscess, when originating from caries of bone or joints, is, as a rule, a watery fluid, containing the tuberculous debris, which consists of a quantity of whitish or gray curds and cheesy masses, and at times also contains small particles of bone. When the tuberculous abscess originates from a diseased lymph gland, a kidney, or other parenchymatous organ, the character of the pus is creamy and resembles that produced by staphylococcus infections.

The cytologic differences are likewise dependent upon the various types of infection. In acute forms the polymorphonuclear leucocytes predominate, while in the chronic forms the lymphocytes are more abundant. The fluid from tuberculous abscesses contains a small number of leucocytes and occasionally a few tubercle bacilli, but an abundance of granular material. While the bacilli are not frequently found in the fluid contents of the abscess, they are, as a rule, found in abundance within the abscess wall, which is called the **pyogenic membrane**. In the early stages this wall is somewhat ragged and congested, but with chronicity it becomes thickened and smooth, and assumes a much paler appearance, but still harbors the living tubercle bacilli.

These tuberculous abscesses have been named **cold abscesses** because they do not produce fever. They are apt to become very large (especially the so-called **psoas abscess**), and still may not give rise to any dangerous symptom. I have seen a child having an abscess nearly as large as its head, without rise of temperature or even much discomfort. These cold abscesses have a tendency to gravitation, or, rather, to undermine the tissues. The pressure within the abscess will force the pus along the fasciæ or muscles in the line of least resistance until it reaches a place so near the surface that spontaneous rupture may easily take place. The opening may be at such distance from the original focus of the disease as to mislead in the diagnosis. I report a case in which a spondylitis of the tenth dorsal produced a sinus opening in the neck, which up to the time of the bismuth injection was thought to be the result of tuberculous adenitis.

The spontaneous rupture or incision of these cold abscesses may terminate in closure and final cure, but their susceptibility to secondary infection after incision and

drainage has made this procedure almost prohibitive. Surgeons have learned from experience that it is dangerous to incise cold abscesses, as the majority of patients developed high fever and died as a result of secondary infection. Even though the fever subsides, it is very uncertain whether the suppuration will cease; it may continue, and a sinus or a fistula will result.

The terms sinus and fistula are often used synonymously. We shall in this work adopt the following definitions:

Fistula is an abnormal channel existing between hollow organs, such as the stomach, gall bladder, rectum, urinary bladder, etc., or between the skin and these organs.

Sinus is a suppurating channel which has its origin in connective tissue structures, such as bones, joints, muscles, etc., or in the parenchymatous organs, such as the liver, glands, kidney, etc.

A sinus has a granulating wall, which itself is not the source of the suppuration, but is simply the conducting channel for the flow of pus from the focus of infection, and is thus constantly bathed by the purulent secretions. The chronicity of the suppuration produces a thickening and hardening of the connective tissue wall. It is thus evident that these sinuses are nothing more than the shrunken remains of abscess cavities, and not, as is often supposed, an ulcerating process burrowing into the depth of the tissues. A sinus is practically always preceded by an abscess.

The pictures of the network of sinuses, as demonstrated by the radiographs with bismuth paste injections, teach us that the abscess is not always one globular sac of pus, but that the infected region is permeated by an irregular arrangement of a number of pus pockets,

communicating by either narrow or wide channels. They may open in several places, at some distance from one another, and still originate in the same focus. In one of my cases of knee joint tuberculosis forty-two sinuses existed before treatment was commenced—all communicating.

I trust that the preliminary remarks with reference to the origin, development, and anatomy of sinuses and abscesses will aid the reader in understanding the rational application of bismuth paste in the various forms of chronic suppurative diseases discussed in the succeeding chapters.

CHAPTER III.

BISMUTH PASTE IN ANATOMICAL DIAGNOSIS.

In the foregoing chapter we pointed out the fact that the sinuses frequently open at a distance from the seat of the disease, and that their course may be very tortuous and cause a labyrinth of suppurating channels. The truth of this assertion is at once evident when one of the radiographs of the sinuses which have been injected with bismuth paste is viewed.

Technic of Injections.

The bismuth paste consists of the following mixture:

FORMULA No. 1.

Bismuth subnitrate (arsen. free).....	33 percent.
Vaselin (yellow or white).....	67 percent.

It is prepared by first boiling the vaselin in an enameled jar and stirring in the bismuth powder before it becomes cool. Care should be taken not to spill any water into the mixture, as this will destroy its homogeneous consistency and thus prevent it from becoming firm. This forms a smooth, yellow paste, which, when heated over a water bath, becomes sufficiently liquefied to facilitate its being drawn into a glass syringe and then injected into a sinus.

Fig. 1 illustrates the various types of syringes used for the bismuth paste injections. The glass syringe A is the one most generally used, and may be had in various sizes from $\frac{1}{2}$ to 4 ounces. The glass syringe B has a

curved tip, which is preferable when injecting empyema. The metal syringes C, which have long nozzles and pointed tips, are used principally in rectal work, but I find them also practical for other sinuses where the opening is very small.

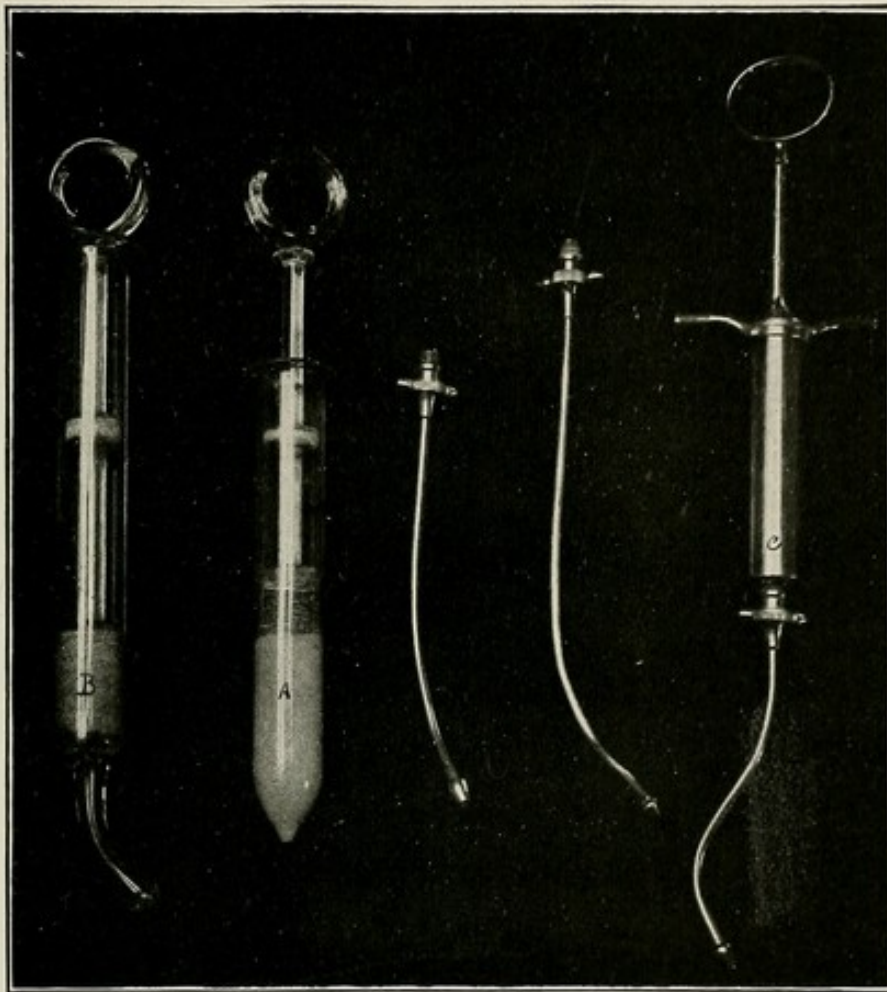


Fig. 1. Types of syringes used for bismuth paste injections. A, glass syringe for sinuses; B, glass syringe for empyema; C, metal syringe for rectal cases.

Without preliminary irrigation or curettage of the sinus, the external opening is cleansed with alcohol, and then the conical tip of the syringe is placed snugly against the opening, so as to fully occlude it. **Slowly and with gentle force** the liquefied paste is injected into the sinus until the patient begins to complain of pressure, or when

the surgeon feels a resistance and notes the overflow of the paste around the tip of the syringe.

The quantity injected varies with the character of the sinus. In narrow channels 1 or 2 drams will be all that the sinuses will hold, while in old empyema cavi-

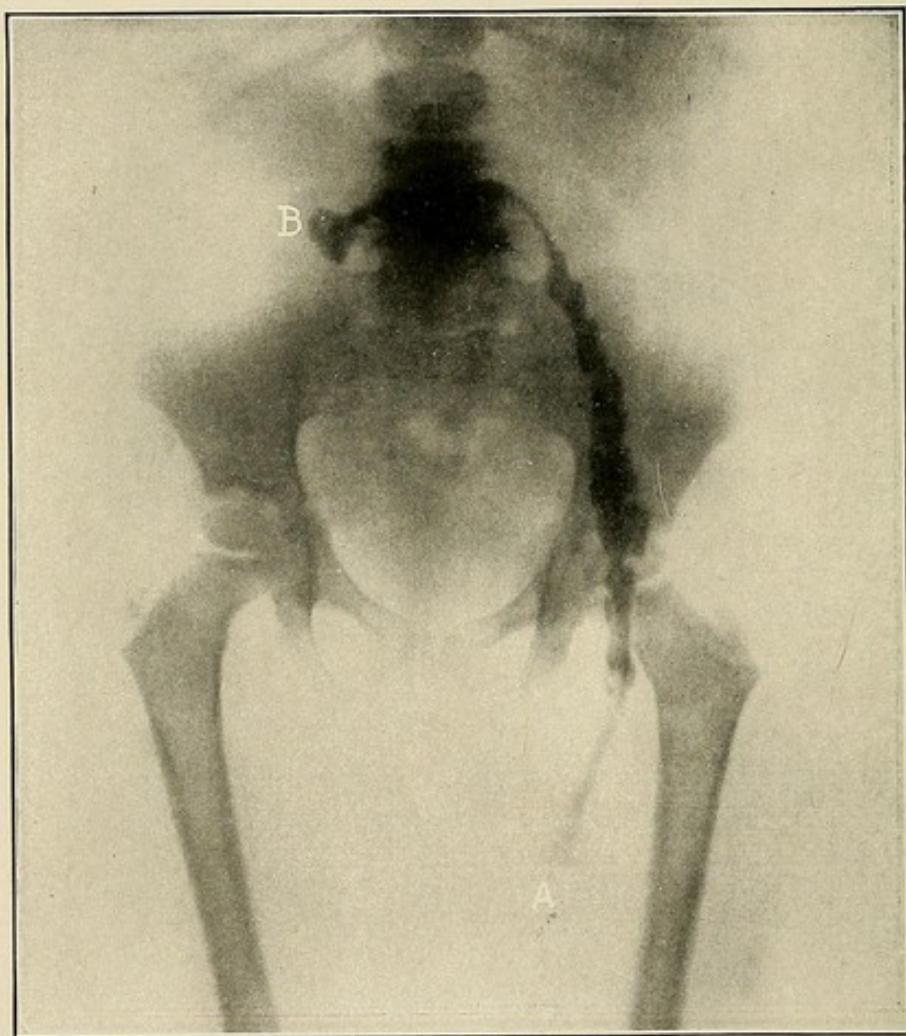

Fig. 2 Sinus after psoas abscess. A, sinus opening; B, small abscess cavity on the opposite side.

ties the quantity may reach as much as 20 ounces. It is, however, not advisable to inject more than 100 grams, except in empyema, where a large drainage opening exists. The liquefied paste will thus penetrate all ramifications of the sinuses, and on cooling will remain long

enough within them to permit the taking of a radiograph of the injected region. The radiograph thus produced will furnish a true picture of the condition existing within the diseased region. It will outline with perfect clearness the boundaries and ramifications of the sinuses, and in many instances will trace the path to the original focus of the disease.

Stereoscopic radiographs, which are obtained by taking two pictures of the same region from two different angles, and then fusing this pair of radiographs into one by means of a pair of prisms, are of the utmost value in establishing a correct anatomical diagnosis. They bring before one's eyes a picture in which all structures stand out in plastic effect, so that their relation to one another is easily estimated. We are then able to tell whether the injected paste runs in front of, behind, or through a bone.

It is well known that bismuth will produce a shadow on a sensitized plate when placed in the path of the x-ray. This principle was taken advantage of in tracing sinuses for anatomical diagnosis when, in March, 1906, my brother, Dr. Carl Beck, of Chicago, injected a sinus following spondylitis, illustrated in Fig. 2.

A. D., a girl, aged 4, was brought to the North Chicago Hospital in March, 1906, with a discharging sinus in Scarpa's triangle. History: spondylitis with psoas abscess at the age of 2 years, which ruptured spontaneously and persisted in discharging pus for two years, thus requiring daily dressing. The sinus was injected March, 1906, with bismuth paste and a radiograph taken. This picture (Fig. 2) clearly shows the sinus tract leading from the opening in Scarpa's triangle to the tuberculous focus, in the second and third lumbar vertebræ. At this point the paste fills out a space about three-fourths of an inch long and one and one-quarter inches wide. A small cavity leads to the other side of the spine, indicating that there existed a tendency to the formation of a double psoas abscess.

This case is instructive not only from the diagnostic standpoint, but from the therapeutic as well. A few days later the parents informed us that the sinus had for

the first time in two years stopped discharging. This stoppage was then considered to be only temporary, but now, after four years, there has been no recurrence, and the child, now 8 years old, is in perfect health.

The advantages of this advanced anatomical diagnosis are manifold. It enables us to study the topography of the sinuses before an operation is decided upon, and thus discriminate between operable and inoperable cases. We now see this class of diseased conditions in an entirely new light. Most of us will recall instances in which such pictures would have been of inestimable value, when they would have explained the causes of failure in operations. These operations at the time seemed to be most radical, but in the light of our recent knowledge of the complexity of these sinus tracts they must have been incomplete—some of the sinuses must have remained unexplored.

The older methods of diagnosis, such as the probe or the employment of colored fluids to stain the tracts, must, in the light of this new diagnostic method, appear unreliable. The probe may enter one of the sinuses and give us no idea whatever as to its depth. It may enter a blind pocket or a fold of the sinus, and leave us under the impression that it has reached its end, while, in fact, there may exist a network of sinuses beyond our conception. Such condition is well illustrated in Fig. 3, where the probe entered at A and reached down to B, and led us to repeated operations, all of which were failures, until the injection of bismuth paste revealed the existence of this extensive network of channels. This diagnostic injection resulted in a complete cure.

The injection of methylen blue to stain the walls of the sinuses, in order to facilitate tracing them during the operation, is likewise objectionable. In the first

place, it does not permit the study of the extent of the tracts before the operation. The sinuses may extend into inaccessible regions, and this may not be discovered until the patient has been subjected to the operation, and often after he has been an hour or two on the operating table. Furthermore, the stained sinuses are often lost track of by distortion and bloody discoloration of the tissues during the operation.

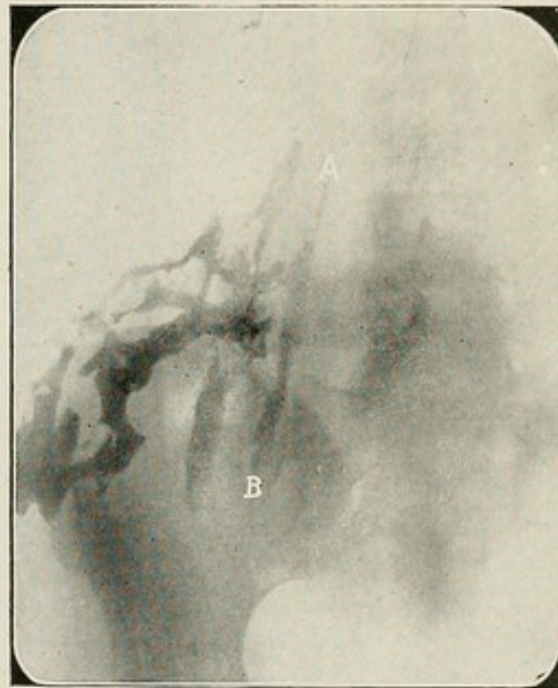


Fig. 3. Network of sinuses following tuberculosis of iliac bone. A, sinus opening; B, supposed bottom of sinus.

The employment of peroxide of hydrogen for diagnosis has no other value than to aid us in ascertaining whether a fistula communicates with a hollow organ or with another sinus.

By our new method, if properly carried out, it is almost impossible to miss any of the sinuses. That the paste may reach even the most minute tracts is amply demonstrated when we examine Fig. 4, which represents

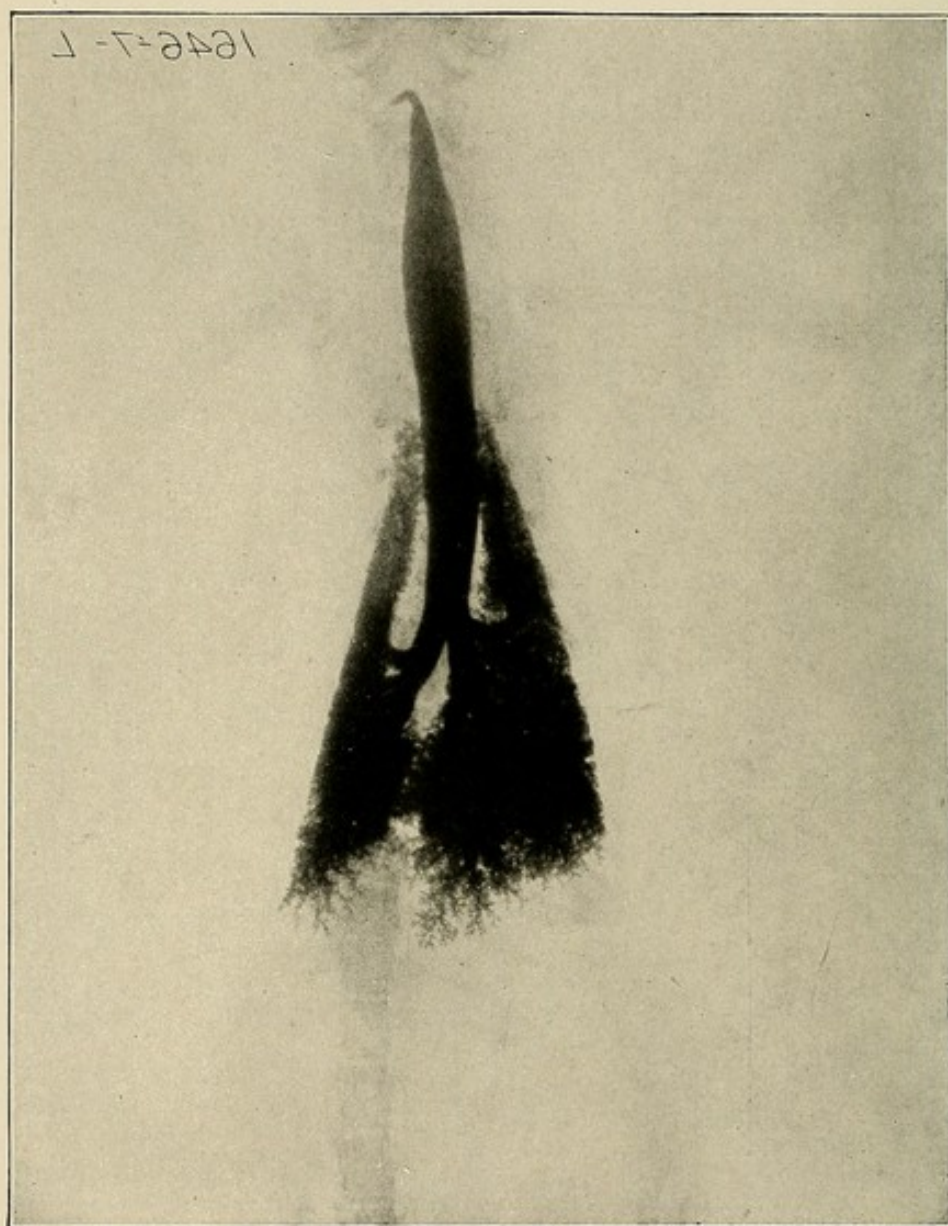


Fig. 4. Bronchial tree of a cat injected with bismuth paste to show that the smallest channels can be reached.

the bronchial tree of a cat, injected with the liquefied bismuth paste. We note that even the smallest bronchioles have been reached.

CHAPTER IV.

DIAGNOSTIC ERRORS REVEALED BY BISMUTH PASTE INJECTIONS.

We have demonstrated by means of the paste injections and radiographs that abscesses very often open at

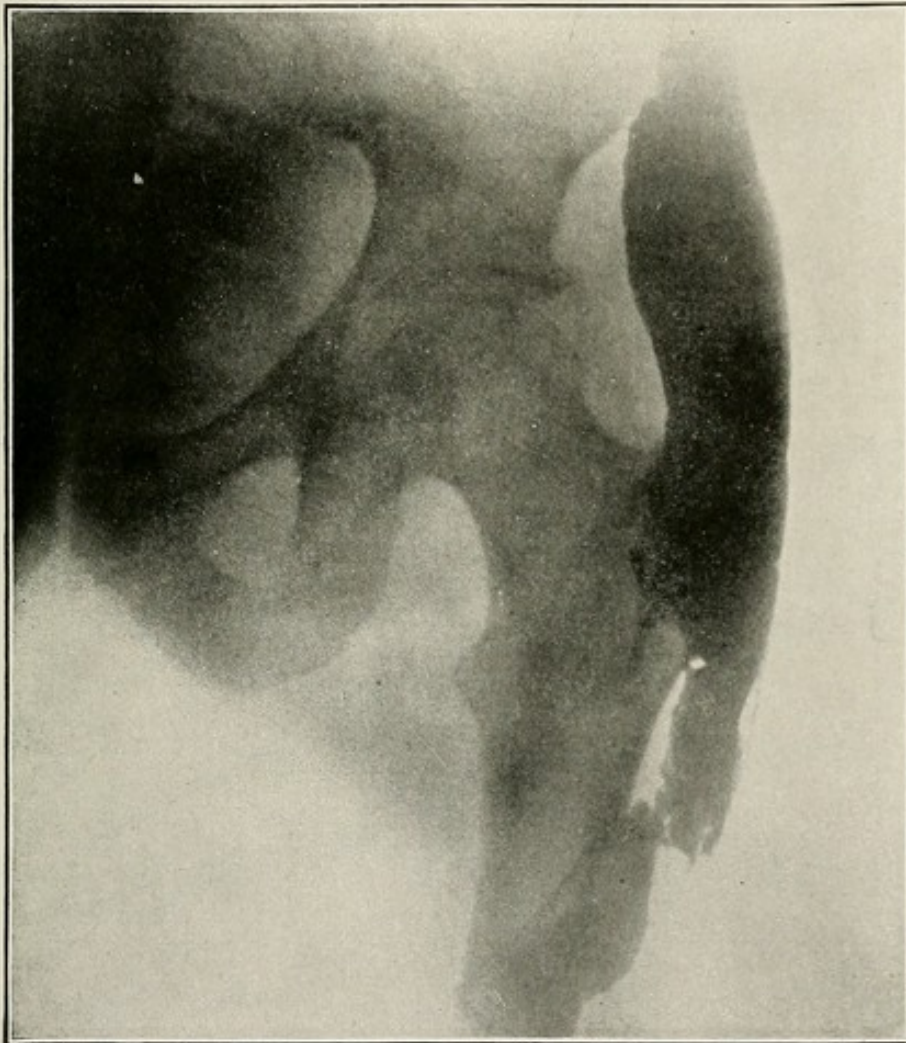


Fig. 5. Osteomyelitis of femur, mistaken for hip joint disease.

a distance from their origin, and thus the sinus opening is placed in a region which appears to have no anatomical

relation with the original focus of disease. Without the picture of the sinus tracts before us, this may lead to false diagnosis, and consequently to wrong treatment.

This is not at all theoretical. I will cite a variety of

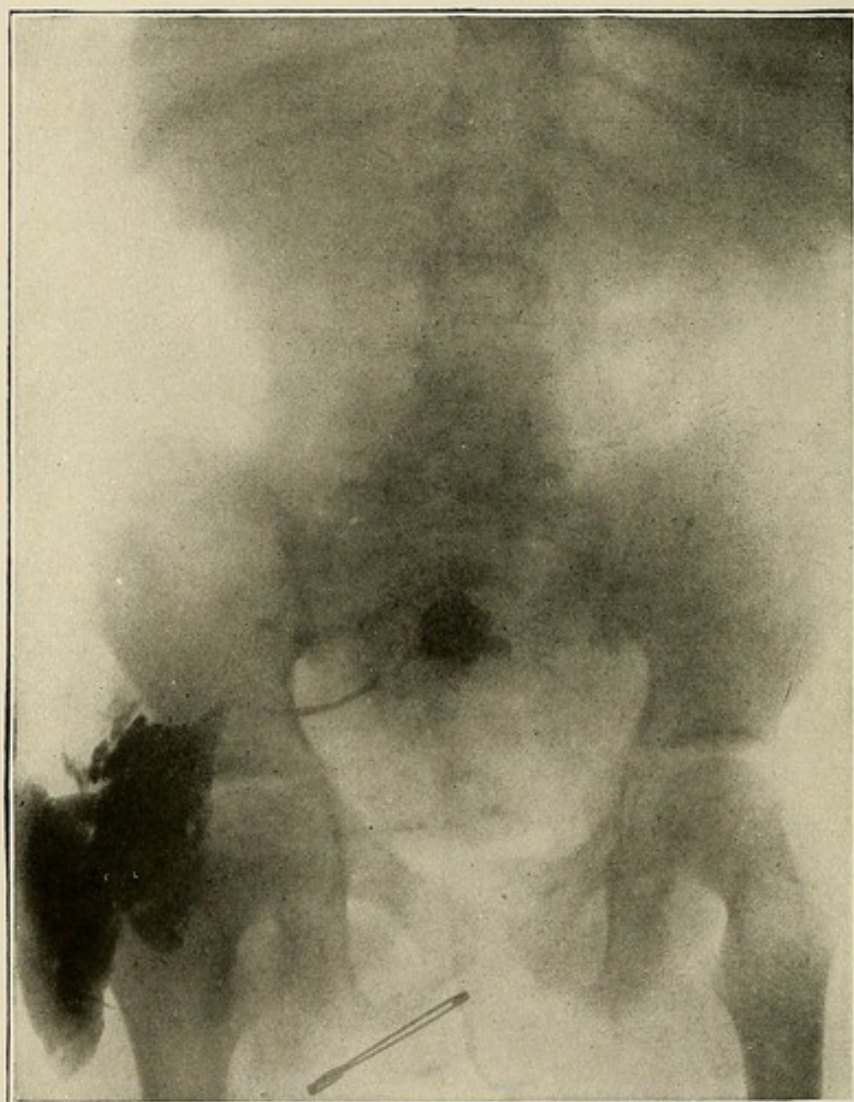


Fig. 6. Tuberculous sinus originating in the sacrum, thought to be an abscess of hip.

examples which illustrate most lucidly that faulty diagnosis was responsible for the failure in treatment, and that in most of the cases a cure was obtained as soon as the correct diagnosis was made.

Example 1. Osteomyelitis of Femur Treated for Hip Joint Disease.

—Mr. C., aged 26, farmer, gives the following history: at the age of 23 he developed a large abscess about his hip. An incision and drainage left a discharging sinus. A year later an operation for hip joint disease was performed, which failed to produce a cure. Later the area of suppuration was increased, so that four sinuses resulted. These sinuses were repeatedly curetted, but without avail. The radiograph

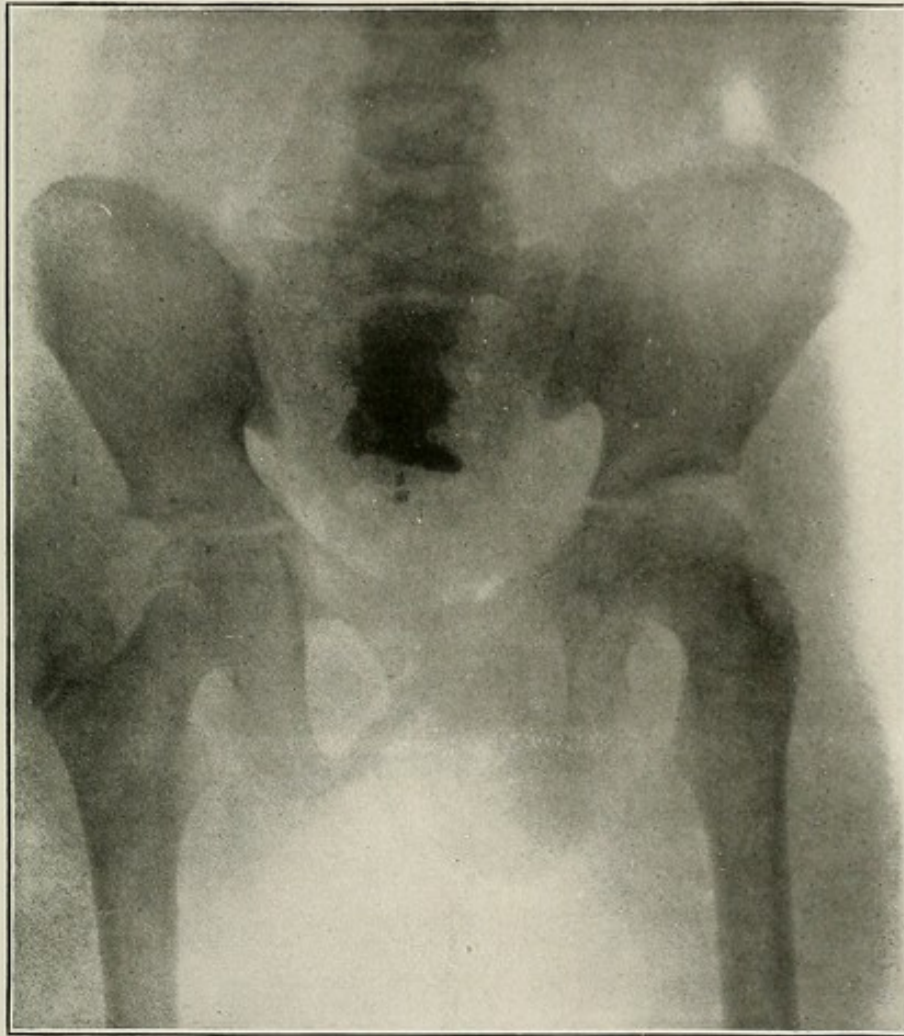


Fig. 7. Bismuth paste remaining in focus of disease four months after closure. Hip shown to be normal. (Case shown in Fig. 6.)

(Fig. 5), taken after injection of the paste for diagnostic purpose, revealed the fact that the hip joint was not affected at all, but that it was the shaft of the femur which was the original source of infection, and that at this source there was also a sequestrum, the removal of which produced a closure of three sinuses within a month. The fourth sinus kept on discharging some serous fluid, but otherwise caused no inconvenience. Patient gained forty-five pounds after the suppuration had ceased.

It is not surprising that this mistake in diagnosis was made by a number of competent physicians, because there existed severe lameness, and even some shortening of the affected limb, but our radiograph shows distinctly that the head of the femur and the acetabulum are intact, and no connection existed between the large abscess cavity and the hip joint.

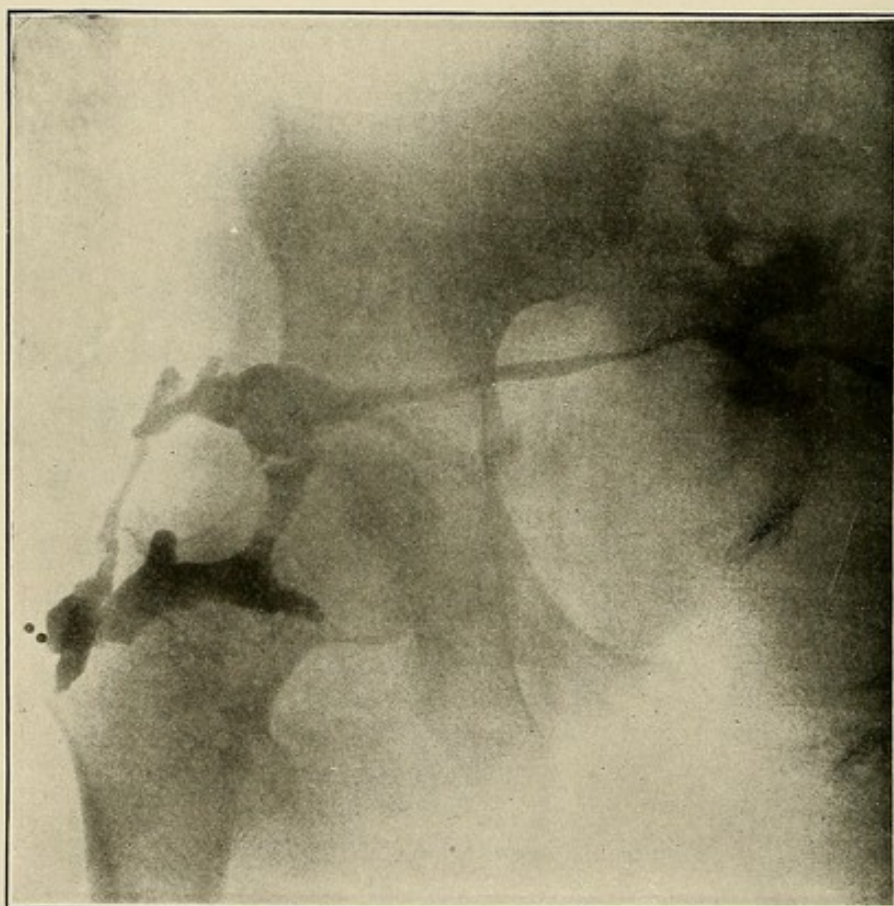


Fig. 8. Tuberculosis of sacrum, mistaken for hip joint disease.

Example 2. Abscess at the Hip, Originating in the Sacrum.—R. K., aged 13, with a tubercular family history, was well until the age of 5, when a swelling in his left hip, posterior to the greater trochanter, appeared. An abscess ruptured spontaneously and a copious purulent discharge persisted for seven years, which greatly debilitated the boy. In July, 1908, he was given the first injection of bismuth paste by Dr. Dahl, with whom I saw the case. The radiograph (Fig. 6) disclosed the fact that the abscess did not originate in the hip joint, as one would suspect from the location of the sinus, but that it communicated

with the original focus in the sacrum by a narrow channel. This case proved to be not only an interesting example of the diagnostic value of bismuth paste, but it likewise credited the therapeutic account with a cure of which both the doctor and patient are justly proud. A radiograph (Fig. 7) taken a few months after closure shows a small quantity of the paste still in the original focus.

Example 3. Tuberculosis of Sacrum Mistaken for Hip Joint Disease.

—J. F., aged 36, presented himself for treatment of a sinus about the trochanter of his right hip. This sinus had existed for several years, and had been treated with washes and cauterization, but no surgical

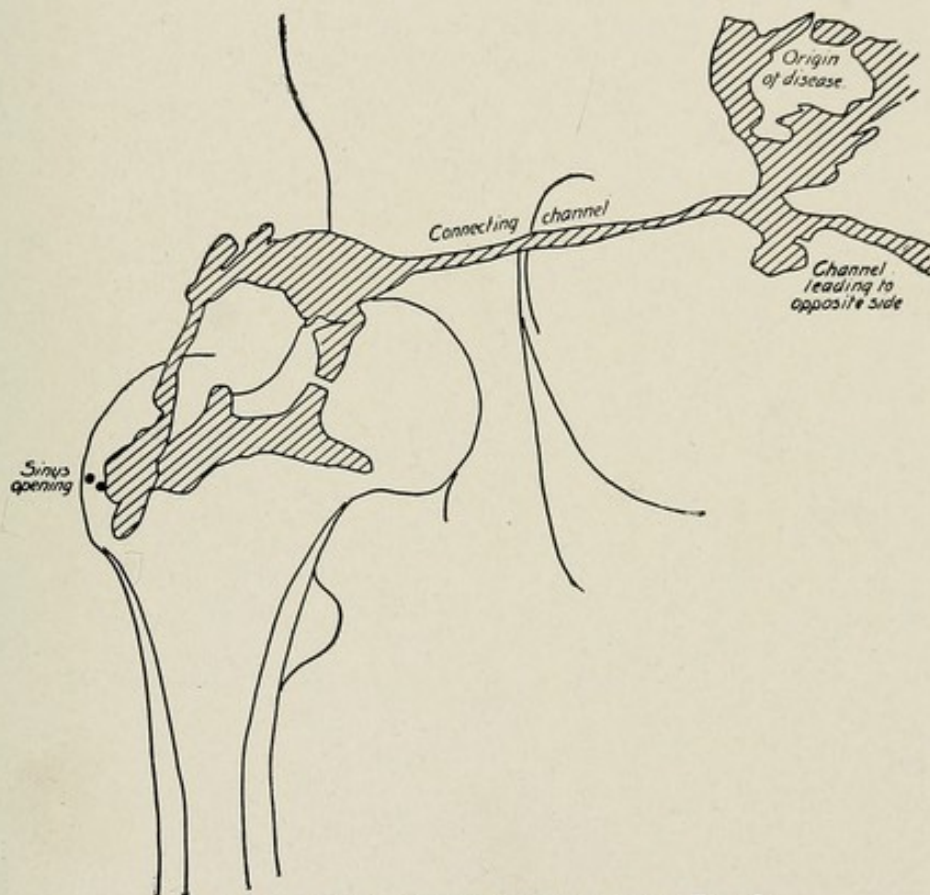


Fig. 8 A. Diagrammatic illustration of Fig. 8.

treatment. It was thought to originate from his hip joint. The radiograph (Fig. 8) clearly demonstrates that the hip is entirely free from disease, and that the sinus originates in the sacrum. The shadow of the injected paste traces the tract to the focus of infection—namely, the sacrum; there it fills out the ring around the diseased section and traces another tract running to the hip on the opposite side, which terminates in a blind end.

This case teaches us that a sinus opening near the hip does not necessarily mean hip joint disease, but that it

may exist as a result of a disease in the sacrum or the spine.

Example 4. Subphrenic Abscess Following Appendicitis.—A. L., a robust cab driver, aged 27, was suddenly attacked in July, 1909, with an acute appendicitis. An emergency operation consisted in removing a ruptured gangrenous appendix; diffuse peritonitis was present. With

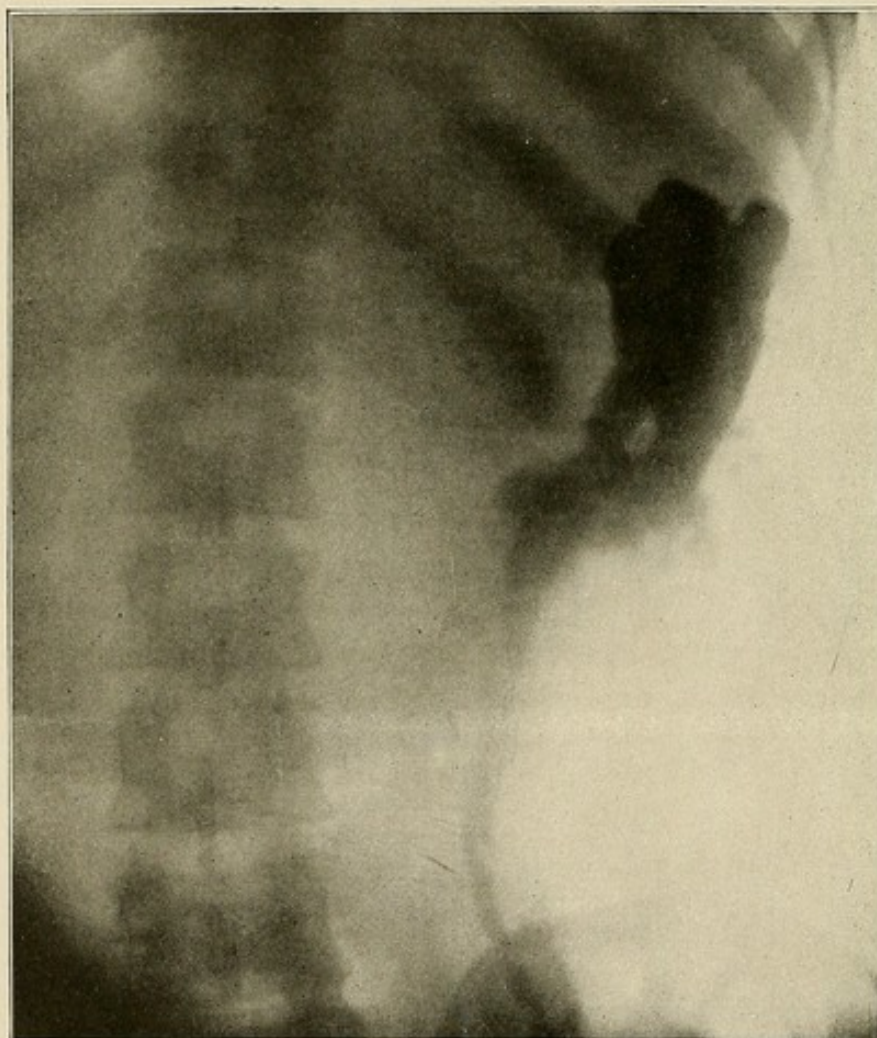


Fig. 9. Subphrenic abscess following appendicitis, suspected of being an empyema.

good drainage, in Fowler's position, and with continuous (Murphy) irrigation, I succeeded in carrying him over the shock, and four weeks later he left the hospital with the abdominal wound closed. His temperature, however, still rose to 100° or 101° every day, and he complained of pain in his chest. This condition became much aggravated, and within a week he developed a cough and suddenly expectorated large quantities of green, very fetid pus. At this time the abdominal wound also reopened and discharged the same character of pus. An

injection of the paste at the appendix incision proved that the original abscess of the appendix communicated with a subphrenic abscess, and that the latter had evidently ruptured into a bronchus, as he expectorated a portion of the injected paste. A radiograph (Fig. 9), taken a few days later, verified our diagnosis. The patient was treated with injections of the bismuth paste, of which he regularly coughed up a part. The lung is now entirely clear, cough has ceased, and the sinus is closed. The patient has gained thirty pounds.

Aside from the favorable therapeutic result obtained, the diagnosis

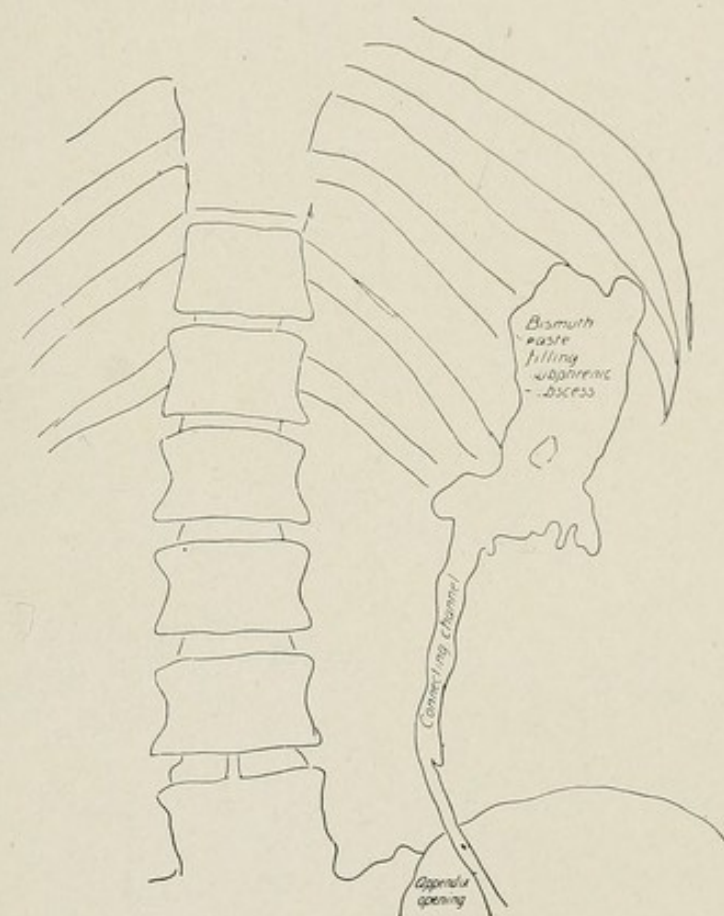


Fig. 9 A. Diagrammatic illustration of Fig. 9.

was greatly facilitated by the injection. The diagnosis rested between subphrenic abscess and empyema, but our radiograph removed all doubt as to the correctness of the diagnosis of subphrenic abscess.

Example 5. Unsuspected Renal Sinus.—R. P., boy, aged 10, has a sinus in his left lumbar region, which has persisted in discharging pus for about two years following an operation of an abscess within the pelvis. The radiograph (Fig. 10) brings out the surprising fact that the sinus extends not only downward into the pelvis, but that another channel exists and extends upward into the kidney, and there the paste maps out the contour of the pelvis of the kidney. This cleared up the

42 BISMUTH PASTE IN CHRONIC SUPPURATIONS.

diagnostic puzzle as to why the sinus secreted large quantities of watery secretions (as much as 10 ounces a day) in addition to occasional discharges of pus.

We could cite many similar examples, but these are sufficient to show the diagnostic possibilities of the paste in clearing for us diagnostic errors.

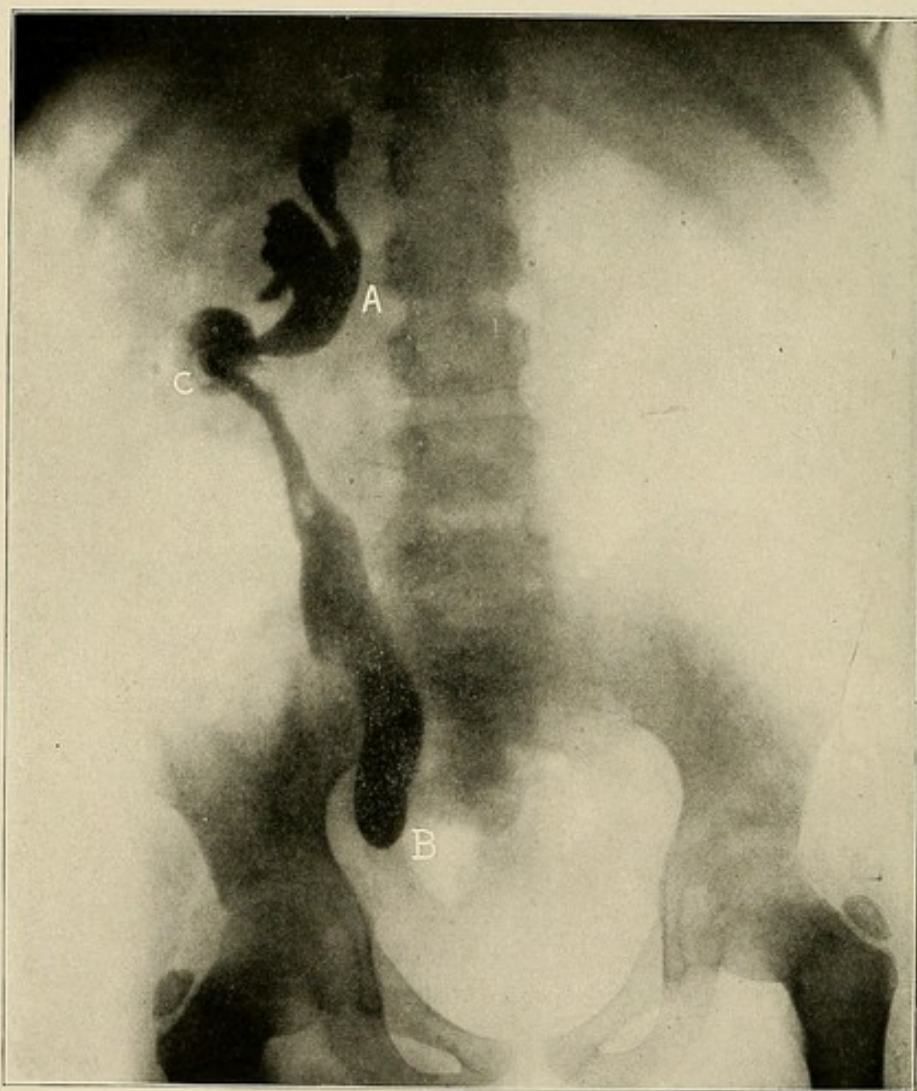


Fig. 10. Unsuspected renal sinus diagnosed by bismuth paste injection. A, renal pelvis; B, pelvic abscess; C, sinus opening for both.

In no other condition are the diagnostic errors more frequent than in rectal fistula. This will be elucidated in the chapter on treatment of that affection.

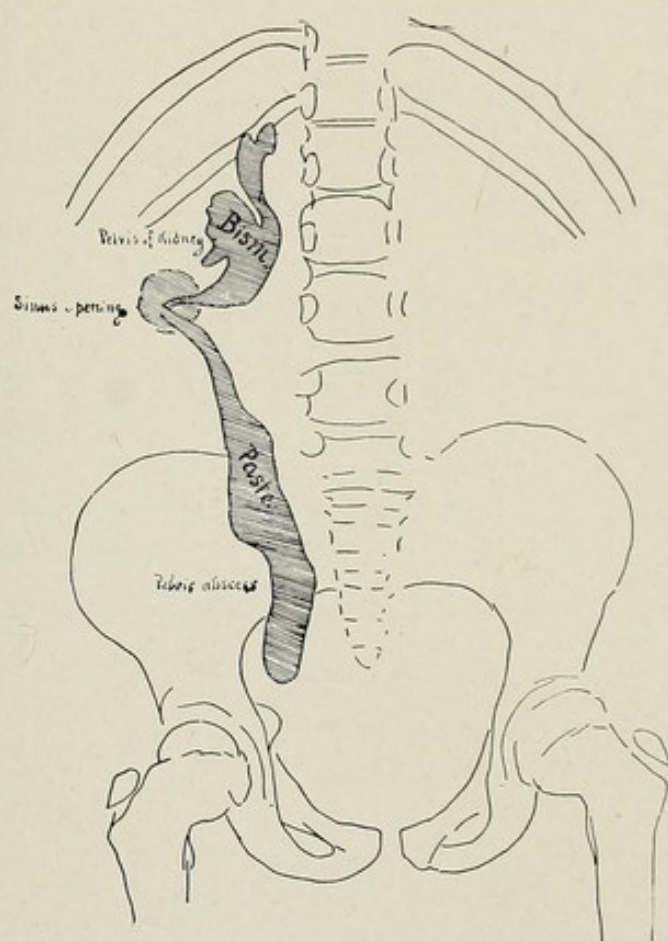


Fig. 10 A. Diagrammatic illustration of Fig. 10.

CHAPTER V.

THERAPEUTIC EFFECTS OF BISMUTH PASTE.

The technic employed in the therapeutic application of the paste is practically the same as that in the diagnostic method. The paste, formula 1, which consists of 1 part of bismuth subnitrate and 2 parts of vaselin, is employed in the first injection. Should it be desired to employ a firmer paste for longer retention, the following formula may be employed:

FORMULA No. 2.

Bismuth subnitrate	30 percent.
Vaselin	60 percent.
Paraffin (120° melting point).....	5 percent.
White wax	5 percent.

The minor details and rules for the frequency of injections will be fully treated in the description of typical cases.

Sufficient time has now elapsed, and an abundance of cases have been treated with bismuth paste in all parts of the world, to permit making an estimate of its therapeutic value. Let us review the literature, analyze the statistics, and then, by proper classification of cases, determine how this method compares with other forms of treatment.

The curative effects of bismuth paste were first observed in August, 1907, about one year after inception of its use for diagnostic purposes. The following case was the first in which the therapeutic effect was tested:

M. Y., aged 14; born in Germany; lived there until 1903; family history negative. He was healthy until he was 7 years old, when

he developed a painful swelling in his right knee. A cast was put on by his family physician for the purpose of immobilization. In a short time an abscess ruptured; the boy was transferred to the hospital at Freiburg, in Germany, and an operation was performed for tuberculosis of the knee joint. He left the hospital seven weeks later, with a sinus extending from the knee joint into the middle of the tibia, and two smaller ones near the joint.

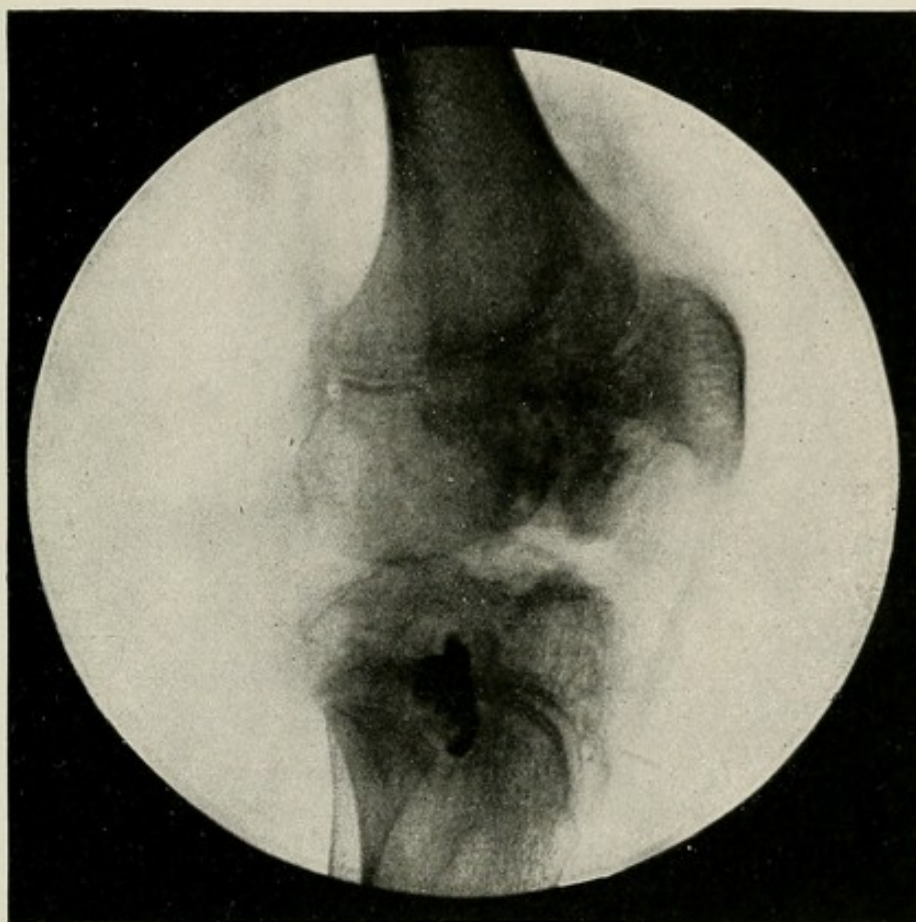


Fig. 11. Tuberculous knee joint, showing remnants of paste four months after closure.

A short time later he returned to the hospital for another operation, which, however, failed to close the sinuses, and a third operation was performed two months later, again with an unfavorable result. The parents then took the boy to Tübingen, where Professor Bruns performed the fourth operation. No improvement, however, resulted; the three fistulæ persisted as before. The family then moved to America, in June, 1903. They had abandoned all treatment; nothing more than daily dressing was done by the patient himself.

On March 21, 1907, at the age of 13, six years after the commence-

ment of the fistulæ, he came to me for treatment. A radiograph without bismuth injection was first taken. It shows the joint and the epiphyses of femur and tibia nearly destroyed, and a sequestrum is clearly visible in the tibia. I proposed the resection of the knee joint, which was refused, but the next best procedure, the removal of the sequestrum, was consented to. This was done March 29, 1907, but the three sinuses persisted.

The first bismuth paste injection was made October 3, 1907, and sinuses at once showed a tendency toward healing. After three injections, at intervals of one week, they nearly closed, and it was with difficulty that I made the fourth injection. Since that time all sinuses have remained healed, the boy has become stronger, and the pain entirely disappeared, so that he could discard his crutches, which he had used for seven years. He can now skip up and down stairs on the tuberculous limb, and can take part in all the athletic sports of his playmates. His weight and strength are those of a normal boy of his age. The radiograph (Fig. 11) presents the condition as it existed four months after closure of the sinuses, it showing a small portion of the paste still within the cavity which held the sequestrum, but the paste which had been in the epiphysis of the femur is nearly absorbed; only a few specks of it are visible in the picture.

Encouraged by this result, I tried the bismuth injection in a case of empyema, and, to my surprise, the cavity, which had suppurated for eight months, closed within one week (case reported in chapter on Empyema). Similar cases, such as sinuses following hip joint disease, tuberculous kidney, rectal fistulæ, and fecal fistulæ, were put to the test, and the results were uniformly favorable. Thereupon I traced the four cases which in the previous year were injected for diagnostic purposes, and found that these cases also had in the meantime healed. Thus I was able to report, in January, 1908, before the Chicago Medical Society,¹ 14 cases, 10 of which were then cured, 3 improved, and 1 unimproved. Ten of these cases were exhibited at the meeting. Now, after a lapse of two years, the present status of these 14 cases is as follows:

¹ E. G. Beck: A New Method of Diagnosis and Treatment of Fistulous Tracts, Sinuses, and Abscess Cavities.—*Journal American Medical Association*, March 14, 1908.

No. of case.	Number of sinuses.	Disease.	Duration, years.	Result.
1	1	Spondylitis	2	Closure, 4 years
2	18	Spondylitis	16	Died, 1 year after treating
3	1	Coxitis	9	Closure, 3½ years
4	2	Coxitis	16	Closure, 2½ years
5	3	Tuberculous knee	7	Closure, 2½ years
6	1	Tuberculous os ilium	3	Closure, 3 years
7	1	Tuberculous ulna	½	Closure, 2 years
8	1	Removal tuberculous kidney	1	Closure, 1½ years
9	1	Rectal fistula	2	Closure, 2½ years
10	1	Rectal fistula	1	Closure, 2½ years
11	1	Rectal fistula	½	Closure, 2 years
12	1	Abdominal fistula of the appendix	1	Closure, 2 years
13	1	Abdominal fistula after laparotomy	½	Closure, 2 years
14	1	Tuberculosis of metacarpal bone	1	Closure, 2 years

Total, 14 cases; cured, 13; died, 1.

Shortly after this first presentation the method was taken up by Drs. Ridlon and Blanchard at the Home for Crippled Children in Chicago. It was tested on 26 children, and after three months' treatment the following results were reported by them at the June, 1908, meeting of the American Orthopedic Association:¹

9 cases cured in which sinuses had existed from one to eight years.

4 cases cured in which an abscess was opened and only once injected.

7 cases were improved and were still under treatment in which the sinuses had existed from two to three years.

5 cases were only one week under treatment; result undetermined.

1 case unchanged; no deaths.

Total, 26 cases.

These cases were shown to the members of the association at the Home for Crippled Children.

¹ Ridlon and Blanchard: A New Method of Treating Old Sinuses.—*Journal of Orthopedic Surgery*, September, 1908.

Table of 26 Cases Treated by Ridlon and Blanchard.

TABLE 1. CASES OF TUBERCULOUS SINUSES CURED UNDER BISMUTH PASTE TREATMENT FROM FEBRUARY 3 TO JUNE 6, 1908.

No. of case.	Name.	Age, years.	Disease.	Duration, years.	Number of sinuses.	Number of injections.	Time of cure.
1	Thos. S.	13	Hip disease	8	2	15	1 month
2	Jake T.	5	Hip disease	1	1	7	1½ months
3	Eddie H.	7	Pott's and hip disease	2	1	1	7 days
4	John B.	9	Hip disease	4	3	11	33 days
5	Robert L.	11	Hip disease	1	1	6	1 month
6	Walter P.	7	Pott's and hip disease	4	2	7	18 days
7	James P.	5	Tuberculous finger	2	2	2	10 days
8	Loretta H.	8	Hip disease	4	2	13	1 month
9	Dorothy T.	1	Pott's disease	2	1	1	7 days

TABLE 2. CASES OF TUBERCULOUS ABSCESSSES OPENED AND INJECTED ONLY ONCE WITH BISMUTH PASTE.

No. of case.	Name.	Age, years.	Disease.	Duration, years.	Number of sinuses.	Number of injections.	Time of cure.
1	Elmer H.	5	Pott's disease, psoas abscess	9 days
2	Samuel J.	7	Hip disease, thigh	9 days
3	John S.	17	Pott's disease	20 days
4	Josef O.	5	Coxitis	18 days

TABLE 3. CASES OF TUBERCULOUS SINUSES STILL UNDER BISMUTH PASTE TREATMENT.

No. of case.	Name.	Age, years.	Disease.	Duration, years.	Number of sinuses.	Number of injections.	Duration of treatment.	Present condition.
1	Chas. T.	9	Hip disease	3	1	20	3 months	Unchanged
2	John K.	12	Hip disease	1½	3	13	3 months	Improved
3	William B.	6	Hip disease	1½	2	22	3 months	Unchanged
4	Martin S.	12	Hip disease	6	1	6	1 month	Improved
5	Fannie L.	15	Pott's disease	6	6	28	3 months	Improved
6	Annie M.	7	Pott's disease	1½	3	10	1 month	Improved
7	Samuel C.	11	Pott's disease	5	3	27	3 months	Improved
8	Henry R.	11	Pott's disease	8	3	11	1 month	Unchanged
9	Vincennes D.	7	Hip disease, excised head	4	2	1 week	Result awaited
10	Denny C.	8	Hip disease, excised head	3	2	1 week	Result awaited
11	Benj. B.	8	Tuberculous knee	2	2	1	1 week	Result awaited
12	Elizabeth B.	11	Hip disease, excised head	4	2	2	1 week	Result awaited
13	Louis R.	11	Hip disease	3	1	4	1 week	Result awaited

These 26 were not selected cases, but comprised practically the entire number of children who were then afflicted with sinuses at the institution; some of them had been inmates for years and many bedridden for months. A treatment which produced 50 percent of cures within a period of three months must certainly have been a welcome innovation in an institution of this character.

Their report, corresponding in its favorable results with that of my own series, served as a stimulus to other surgeons for its further application, and soon after my first publication reports began to appear in medical journals here and abroad. The usual conservatism with new methods was cast aside because the method was simple and appeared harmless, and, furthermore, material for testing it was willing and plentiful everywhere. To the unfortunate invalids who had nothing to lose and everything to gain, anything new in the way of treatment was welcome. Besides, there was no opposition to this treatment, no one having claimed any successful remedy for this class of cases.

Thus in October, 1908, I was able to present before the International Congress on Tuberculosis^{1 2} a collective report of 192 cases, which included histories of cases treated by such prominent men as Drs. Mayo, Ochsner, McGuire, Ridlon and Blanchard, and in two hospitals of the United States Navy. Of this number,

123 cases, or 64 percent, were cured.

55 cases, or 28.5 percent, were improved and still under treatment.

11 cases, or 6 percent, were unimproved and still under treatment.

3 cases, or 1.5 percent, died during the period of treatment.

¹ E. G. Beck: Surgical Treatment of Tuberculous Sinuses and Their Prevention.—Transactions Sixth International Congress on Tuberculosis.

² E. G. Beck: Diagnose, Chirurgische Behandlung, und Verhütung von Fistelgängen und Abscess Höhlen.—Beiträge zur Klinischen Chirurgie, 1909, bd. 62, h. 2.

The pathological classification of this series of cases is as follows:

- 143 cases were of tuberculous origin.
- 23 cases were of nontuberculous origin.
- 26 cases were of doubtful origin.

SUMMARY REPORT OF 192 CASES TREATED WITH BISMUTH PASTE METHOD.

Disease.	Total number treated.	Healed.	Im-proved.	Un-changed	Died.
Tuberculous spondylitis with sinuses .	26	13	9	3	1
Tuberculous hip joint with sinuses	43	21	19	2	1
Tuberculous sacrum and iliac syn-chondrosis with sinuses.....	7	7
Tuberculous knee joint with sinuses..	5	4	1
Tuberculous ankle joint with sinuses.	4	3	1
Tuberculous wrist joint and fingers with sinuses	4	4
Osteomyelitis of femur with sinuses...	12	6	6
Osteomyelitis tibia with sinuses.....	4	3	1
Osteomyelitis humerus with sinuses..	3	1	2
Osteomyelitis ulna with sinuses	2	2
Tuberculosis of fascia and muscle with sinuses	3	2	1
Empyema and tuberculous lung ab-scess.....	19	14	4	1
Tuberculosis of ribs with sinuses	6	4	2
Suppurative sinuses of head.....	6	3	3
Sinuses following tuberculous glands.	6	4	1	1
Osteomyelitis mandibulæ.....	1	1
Sinuses following abdominal opera-tions.....	16	13	1	1	1
Rectal fistulæ.....	18	13	5
Tuberculosis of kidney with sinuses...	7	5	2
Total.....	192	123 (1)	55 (2)	11 (3)	3 (4)

¹ Or 64 percent.

² Or 28½ percent.

³ Or 6 percent.

⁴ Or 1½ percent.

In a review of the literature on the uses of bismuth paste, Dr. Baer, of Johns Hopkins University, makes a comparative study of percentages of cures obtained by different surgeons. His report is as follows:

Name.	Number of cases.	Disease.	Percentage of cures.
Ochsner ¹	20	Tubercular sinuses	55
Ridlon and Blanchard ²	17	Tubercular sinuses	53
Beck, E. G. ^{3 4}	192	Collective report	64
Robitschek ⁵	9	Tubercular sinuses	55
Don (Edinburgh) ⁶	Tubercular sinuses	17
Rosenbach (Berlin) ⁷	4	Tubercular sinuses	50
Dollinger (Budapest) ⁸	16	Tubercular sinuses	12½
Beck, Jos. C. ⁹	319	Accessory sinuses	22
Pennington ¹⁰	17	Rectal fistulæ	76
Baer (Baltimore) ¹¹	12	Tubercular sinuses	33⅓

Since this review additional reports have appeared in the literature which show even larger percentages of cures:

Name.	Number of cases.	Disease.	Percentage of cures.
Stern (Cleveland) ¹²	4	Tubercular sinuses	100
Steinmann (München) ¹³	5	Tubercular sinuses	20
Bogardus ¹⁴	1	Tubercular sinuses	100
Vidakovich (Russia) ¹⁵	2	Empyema	100
Nemanoff (St. Petersburg) ¹⁶ ...	6	Empyema	100
Ochsner, A. J. ¹⁷	14	Empyema	85
Beck, E. G. (Chicago) ¹⁸	11	Empyema	82
Ely (New York) ¹⁹	14	Tubercular sinuses	43
Hines (Cincinnati) ²⁰	9	Tubercular sinuses	89
Cuthbertson (Chicago) ²¹	1	Intestinal fistulæ	100
Sandor, Sag (Budapest) ²²	2	Otologic	100
Heitz, Boyer, and Morens (Paris) ²³	11	Renal sinuses	73
Zollinger (Zurich) ²⁴	24	Tubercular sinuses	54
Schober (Philadelphia) ²⁵	5	Tubercular sinuses	80

¹ A. J. Ochsner: Michigan State Medical Society, August, 1908.

² Ridlon and Blanchard: A New Method of Treating Old Sinuses.—*Journal of Orthopedic Surgery*, September, 1908.

³ E. G. Beck: Surgical Treatment of Tuberculous Sinuses and Their Prevention.—*Transactions Sixth International Congress on Tuberculosis*.

⁴ E. G. Beck: Diagnose, Chirurgische Behandlung und Verhütung von Fistelgängen und Abscess Höhlen.—*Beiträge zur Klinischen Chirurgie*, 1909, bd. 62, h. 2.

⁵ Robitschek: Beck's Bismuth Paste Treatment of Sinuses.—*Northwestern Lancet*, February 15, 1909.

⁶ Don: *Edinburgh Medical Journal*, February, 1909.

⁷ Fr. Rosenbach: Zur Wismutbehandlung nach Beck.—*Berliner Klinische Wochenschrift*, February 15, 1909.

⁸ Dollinger: Gummos Eredetu Talyogok es Sipolyok Bismuth Pastaval, E. G. Beck.—*Orvosi Hetilap*, 1908.

⁹ Jos. C. Beck: Bismuth Paste in the Treatment of Suppuration of the Ear, Nose, and Throat.—*Journal American Medical Association*, January 9, 1909.

¹⁰ Pennington: Bismuth Paste in the Treatment of Rectal Fistula.—*Lancet Clinic*, December 26, 1908.

The results obtained vary from 12½ percent to 100 percent of cures in the hands of different surgeons. The majority, however, have obtained a cure in from 40 to 60 percent, except in empyema, where the average percentage in 31 cases reported by Nemanoff, Ochsner, Vidakovich, and Beck was 92 percent.

These reports of results obtained with bismuth paste by surgeons from different parts of the world should convince even the most skeptical that a remedy which cures such a large percentage of a class of cases formerly considered virtually hopeless is of practical value.

It is to be expected that, with the increasing experience and perfection in our technic, the failures will be reduced to a minimum, and thus the results obtainable will be more uniform. In the chapter on Causes of Failure I shall explain why some cases do not respond to this treatment.

The following rules apply to all cases:

A clear history of each case should be obtained, and a

¹¹ Baer: Some Results of the Injection of Beck's Bismuth Paste in the Treatment of Tuberculous Sinuses.—*Johns Hopkins Hospital Bulletin*, October, 1909.

¹² Stern: Bismuth Injection for the Treatment of Old Sinuses.—*Cleveland Medical Journal*, April, 1909, No. 203.

¹³ Steinmann: *Münchener Medizinische Wochenschrift*, December, 1908, No. 49, s. 2537.

¹⁴ Bogardus: Tuberculosis of Os Sacrum Treated with Bismuth Paste.—*Journal American Medical Association*, vol. 54, p. 701, February 26, 1910.

¹⁵ Vidakovich: *Centralblatt für Chirurgie*, 1908, No. 49, s. 1487.

¹⁶ N. J. Nemanoff: The Treatment of Fistulæ and Drainage Passages.—*Russki Vrach*, No. 7, p. 1568.

¹⁷ A. J. Ochsner: Treatment of Fistulæ of Old Empyema.—*Annals of Surgery*, July, 1909, p. 151.

¹⁸ E. G. Beck: Surgical Treatment of Tuberculosis, Pleurisy, Lung Abscess, and Empyema.—*Journal American Medical Association*, December 18, 1909.

¹⁹ Leonard Ely: Results of the Use of Bismuth Paste in Tuberculous Sinuses at the Sea Breeze Hospital, New York.—*American Journal of Surgery*, January, 1910.

²⁰ Hines: *Lancet Clinic*, September 26, 1908.

²¹ Cuthbertson: Intestinal Fistula Closed by the Use of Bismuth Paste.—*Illinois Medical Journal*, 1909, p. 348.

²² Sag Sandor: Ueber den Heilwert der Bismuth Paste in Otochirurgischen Fällen.—*Pester. Medizinische Chirurgische Presse*, 1909, No. 12.

²³ Heitz, Boyer, and Morens: Des Injections de Paté Bismuthée en Chirurgie Urinaire.—*Annales des Maladies des Organes Genito Urinaires*, June 1, 1910.

²⁴ Zollinger: Beiträge zur Frage der Wismuthpastenbehandlung Tuberculoher Fisteln nach Beck.—*Schweizer Rundschau für Medizin*, No. 20, May 21, 1910.

²⁵ Schober: Treatment of Chronic Tuberculous Sinuses by Beck's Bismuth Vaseline Paste Injections.—*Annals of Surgery*, No. 51, p. 716.

thorough physical examination—without any probing, however—of the sinuses should be made in order to determine whether the case is suitable for this treatment. All **chronic suppurative** sinuses, fistulæ, or abscess cavities, whether of tubercular or other infectious origin, with the exception of fistulæ of the gall bladder, pancreas, or those communicating with the cranium, are suitable for the bismuth paste treatment.

Very acute inflammatory conditions are not suitable for the injections, and, while some good results have been reported, I have noted even aggravation after the treatment.

After we have decided that a case is suitable for treatment, a culture and a smear of the pus should be made, and the sinuses are then injected in the same manner as described in the diagnostic method. When more than one sinus is present and the paste escapes from the various openings during the injection, it is best to press small pledgets of cotton against these openings and prevent the escape, and thus force the paste into all recesses of the fistulous tract.

I have made it a rule to take a radiograph also before the injection, in order to determine whether a sequestrum is at the seat of the trouble.

The dressings should be changed daily. If the discharge changes from a purulent to a serous, the injection need not be repeated, as this is an indication that the sinus has become sterile, and one may expect a closure without any further treatment. Should the discharge remain purulent, it is best to wait one week before giving the second injection.

The systematic examination of the secretion should be the guide for the frequency of injections. As long as the pus contains microorganisms, it is almost certain that

the focus of the disease has not been reached, and the injections should be continued for a reasonable length of time. If the case shows no tendency to healing, then the cause of failure must be determined. This will be treated in Chapter XIII.

Whether the chemical or mechanical action of the paste is instrumental in bringing about these striking results has been discussed by many, and various theories have been advanced, but, aside from plausible suggestions, no exhaustive report of investigation of this subject has as yet appeared in the literature.

Ridlon and Blanchard have drawn their conclusion from clinical observations, and state that they believe the beneficial effects from the paste are due to purely mechanical action.

Don, of Edinburgh, and Ryerson, of Chicago, made a suggestion similar to one advanced by Dr. Dunning, of Baltimore, which seems plausible. He says: "Is it not possible that, from the selective action of nitric acid on tuberculous and other pathological tissues, the subnitrate, when acted upon by organic acids, gives up its nitric acid, which attacks the tubercular wall of the cavity and forms a barrier to absorption, and to further growth of tubercle bacilli?"

Dr. Dunning tested samples of bismuth subnitrate from various manufacturers in order to determine whether there is any difference in the time they hydrolyze at a given temperature.

The results were striking; each preparation gave off a different quantity of nitric acid at the body temperature. Some preparations hydrolyzed from five to ten times as rapidly as others.

Dr. Baer, in studying this matter, made the deduction from these experiments that the results obtained will

vary according to the amount of nitric acid given off from a certain preparation of the subnitrate, and thus could explain some of the failures. His own experience would bear out his assertion. He used the same technic, but bismuth from different manufacturers at two different hospitals, and the results were as follows:

All his cured cases were at the Union Protestant Infirmary, while at the Johns Hopkins Hospital, in the service of Professor William Halsted, they could not obtain a single closure. Since then I have received personal information from Professor Halsted that they have obtained satisfactory results at their clinic.

From my personal observation and from the bacteriological studies of the secretions in over 500 cases we have formed an opinion as to which factors cause the rapid improvement following the injections of bismuth paste. I am ready, however, to change my opinion if more positive facts are offered in the solution of this problem.

We have noted that in most instances the secretions have changed after the first injection. The purulent, thick discharge assumes, as a rule, a seropurulent or a serous character. This is considered a favorable sign, since the sinuses usually close rapidly after this change in the secretion has taken place.

In each case we have made a smear preparation, a culture, and in some instances inoculated guinea pigs, to test the bactericidal action of the bismuth paste. Twenty-four hours after the first injection the secretions were again bacteriologically tested, and thereafter the test was made every third or fourth day. As a rule, the microorganisms disappeared in twenty-four hours after the first injection, but in a certain percentage of cases their number was only diminished, and cultures would grow a little slower. In many instances where the

growth was abundant prior to the injection we could obtain no growth subsequent to the first injection.

Tubercle bacilli are no exception to this rule. This fact was discovered in a case of tuberculous empyema (reported in my series of cases at the International Congress on Tuberculosis),¹ in which tubercle bacilli were found abundantly in the pus from the pleural cavity previous to the injection of bismuth. After the injection their number gradually diminished, and in five weeks they could not be found by microscopical examination. For illustration I cite this interesting case:

B. H., aged 23, law student, with negative family history as to tuberculosis, developed a pleurisy with effusion in his right chest in January, 1906. In May, 1906, the chest was aspirated three times in five days; each time a large quantity of clear fluid was withdrawn. His chest, however, continued to refill and was periodically aspirated. At the ninth aspiration 1,200 cubic centimeters of turbid fluid was removed. September 20, 1906, he went to Denver, where his chest was again aspirated three times by Dr. Bonney, who reported that tubercle bacilli were found in the fluid withdrawn. On his return to Chicago, in November, 1906, he consulted Dr. J. B. Herrick, his diagnosis likewise being tuberculous pleurisy with effusion.

On December 5, 1906, an operation was performed in Toledo, which consisted in the resection of five ribs, the removal of a large amount of fibrinous lymph, and establishment of drainage. The large cavity was irrigated daily with 0.5-percent iodine solution during his seven weeks' stay at the hospital, and thereafter continued at home. With the above history he was referred to me by Dr. Herrick for the bismuth treatment.

Physical examination revealed a hyperresonance over his entire right chest. A fistulous opening, discharging a dark-green pus, was in the center of an eczematous area, about two inches below the nipple. Smear preparations from the pus revealed the presence of tubercle bacilli, five to fifteen in each immersion field, and a moderate number of staphylococci.

A radiograph clearly showed the size of the cavity when empty, and another when injected to its full capacity with 620 grams of 33-percent bismuth paste. The drainage tube was at once left out, and the patient allowed to be outdoors. Every day or two thereafter the accumulation of pus was withdrawn by means of a glass tube and

¹ E. G. Beck: Surgical Treatment of Tuberculous Sinuses and their Prevention.—Transactions Sixth International Congress on Tuberculosis.

examined microscopically. Each time we noticed a diminution in the number of tubercle bacilli, and after eight weeks their final disappearance. The staphylococci had likewise disappeared. We also noticed that the tubercle bacilli which were found after the bismuth had been injected had lost their characteristic shape. They became granular, beaded, and took the fuchsin stain more readily.

Microscopical slides were submitted at different periods to Dr. Maximilian Herzog and Dr. A. Gehrmann, bacteriologists, whose reports coincided with our findings.

Eight guinea pigs were injected with the pus discharged during the period of treatment of this case.

Animal No. 4 was injected April 24 with 10 drops of a 10-percent solution of the pus taken from the chest before the bismuth treatment was instituted. Animal developed general tuberculosis and died six weeks later, showing tuberculosis of all parenchymatous organs and glands.

Animal No. 9 was injected May 1 exactly like No. 4; died June 24. Liver, lungs, and spleen tuberculous.

Animal No. 13 injected May 15 same as No. 4; killed July 15.

The report of findings by Dr. M. Herzog is as follows:

"Post-mortem examination of guinea pig No. 13, received alive July 10 and killed July 15, 1908, showed caseous enlarged axillary lymph glands on both sides and caseous enlarged inguinal lymph glands of the right side; very small young tubercles in the liver and spleen. Smears from these organs showed numerous typical tubercle bacilli.

"Animal No. 16, baby guinea pig, weighing 240 grams, was injected June 7 with 150 drops of 10-percent solution of pus from chest cavity. The animal has grown steadily, weighing 360 grams, and is very lively, but developed two lymph glands under the right axilla, which drained the injected point. One of the glands was excised for examination, and report of same is as follows:

"Sections of the gland of guinea pig No. 16, stained by various methods, show young, not very much degenerated, tubercles, with a moderate number of tubercle bacilli."

To test the toxicity of the discharge, two guinea pigs were injected. Each received an injection of 15 cubic centimeters of the discharge (not diluted) intraperitoneally, and both appeared well for three days, but were found dead on the fourth day. Post-mortem revealed acute peritonitis in both animals.

Animal No. 21 was injected with ten drops of a 10-percent dilution July 18, and kept for observation, and remained perfectly well for months. Post-mortem revealed no tuberculous disease.

The patient was cured with bismuth injections.

Another case quite similar to the one just quoted was subjected to the same experiment, and the results proved to be identical to those obtained in the former.

From these experiments we conclude that, while the tubercle bacilli can not be detected by the microscope soon after the institution of the bismuth treatment, the discharge must still contain some to produce tuberculous disease in guinea pigs, but the development of the disease is much slower and symptoms much milder in the animals last injected, which proves that the number of tubercle bacilli, as well as their virulence, diminishes as the treatment of the patient progresses.

If the rapid diminution and disintegration of tubercle bacilli noted in these two cases is not accidental, this disclosure is certainly of far-reaching importance.

Whether the bismuth destroys the bacilli by its chemical action, or whether its presence acts as a chemotactic, we have not yet determined, although the evidence predominates that its chemotactic property accounts for the destruction of the microorganisms.

Tubercle bacilli are not often found in the pus from tuberculous sinuses; more often, however, in tuberculous empyema. They lodge in the granulations and the walls of sinuses or abscess cavities in abundance. The bismuth paste coming in contact with the walls of these sinuses containing the bacilli, and thus inducing chemotaxis, is instrumental in the destruction of the bacilli. Whether the metallic bismuth or the liberation of the nitric acid from the subnitrate is the chemotactic factor, I do not know, but Baer's theory appeals to me as the most plausible. The chemotactic property of the paste is, then, considered the prime factor.

The mechanical action of the paste—namely, the distention of the collapsed sinuses, and filling them with a smooth, aseptic substance, instead of allowing acrid secretions to bathe their walls—is, no doubt, a favorable factor. The change in the granulating surfaces indi-

cates that the paste is an excellent aid for the formation of healthy granulations. It serves as a support for the formation of new granulations, which become so large that they bulge out from the sinus openings. The paste is displaced by the rapid growth of these granulations, and escapes through the external openings.

Very often the granulations are covered with a whitish membrane similar to the diphtheritic membrane, which, when peeled off, leaves a perfectly clean surface underneath. This coating is a deposit of fibrin which undergoes organization. We have examined sections of this membrane and found it infiltrated with leucocytes and some elongated connective tissue cells.

Another factor to which I have referred in my former publications is, no doubt, of some, but only secondary, importance. The exposure of tuberculous disease to the x-rays is known to be of great benefit, and many remarkable cures are recorded in the literature to support this. It is a known fact that bismuth subnitrate, as well as vaselin, when exposed to the x-rays, will become radioactive, and will retain this radioactivity for several hours. It seems reasonable to me that this property may accelerate the therapeutic action of the paste. I have taken advantage of this principle and exposed the most refractory cases to the action of the x-rays at intervals of three days, and am convinced that their action has been beneficial. It must be admitted that the exposure to the x-rays is not essential, since many surgeons have recorded excellent reports without them.

At present I consider these three factors as the principal agents in the therapeutic action of the paste:

1. The chemotactic quality of the paste, which induces the bactericidal action.
2. The mechanical action.
3. The exposure of the injected sinuses to the x-rays.

CHAPTER VI.

TREATMENT OF SINUSES DUE TO SPONDYLITIS.

The extreme frequency of Pott's disease and its serious consequences make it imperative that the physician should possess definite knowledge of its causes, development, and complications, and be also informed about the most advanced and safest methods of treatment. The physician's action in a given case of Pott's disease is of the utmost importance for the life of the patient. There is hardly another disease to which we can ascribe a larger percentage of therapeutic failures than spondylitis, in spite of the fact that we possess the means of saving nearly every case.

This disease is essentially a tuberculosis. This in itself relieves us of the task of searching for its cause. We know from the researches of many scientists (especially Koch) that without the tubercle bacillus there can be no tuberculosis, and thus we are certain that this germ has somehow found its way into the body of the affected individual.

The question must, however, be answered, Will the presence of the bacillus alone cause the disease in bony structures? The impression predominates that it requires a trauma to precipitate a tuberculous disease within the bones or joints by producing a **locus minoris resistentiæ**, and thus permit the tubercle bacilli circulating in the blood to get a foothold. Clinical facts support this view, but the question is not fully answered. Was the injured part perfectly healthy before the injury? Is it not possible that through the trauma a præexisting

latent, encapsulated tuberculous focus ruptured, and the bacilli thus liberated found in the traumatized bone a suitable soil for rapid development?

This latter view was propounded by Friedrich¹ and Hansel,² and has many plausible facts to support it. The bones are, as a rule, infected through the hematogenous route, unless the disease extends by continuity from a neighboring joint (König), but it is also possible to spread through the lymphatic channels. Usually the infection takes place through bacilli-carrying emboli, which lodge in the smallest branches of the arteries and there set up the tuberculous infection (Müller).

This, to a degree, explains why the disease selects for its victims small children. The rich and many-branched arrangement of the blood vessels in the young growing bones favors the lodgment of emboli, and thus the beginning of the disease. The source of the bacilli is usually a primary tuberculosis of the lymph glands, which in most cases can be clinically demonstrated.

It is important to know whether in a given case the localized tuberculosis in the spine is the only part of the body affected. Is there such disease as primary tuberculosis of the osseous system? To this question Professor König³ answers, "Yes." By very thorough investigation of 67 subjects who, during life, were afflicted with joint tuberculosis, he found 14 of the 67, or 21 percent, had no other tuberculous infection than that of the joints. This indicates that osseous tuberculosis may be primary, but it likewise shows that 79 percent of cases have multiple foci, and thus we must suspect in at least four-fifths of all cases tuberculous foci in other parts of the body to coexist.

¹ Friedrich: Experimentale Beiträge zur Tuberculose.—Deutsche Zeitschrift für Chirurgie, *bd.* 53, *s.* 512.

² Hansel: Ueber Trauma des Gelenke.—Beiträge zur Klinik der Tuberculose, *bd.* 28, *s.* 659.

³ König: Die Tuberculose der Menschlichen Gelenke, 1906.

This tuberculous infection within the bodies of the vertebræ causes a gradual destruction of the same, so that a gap on the anterior portion is soon established. What is the result? The body weight causes a collapse of the column at the weak point, and a more or less pointed projection backwards results, which is called **kyphus**. If the body weight is not supported by artificial means, the continuous weight upon the diseased and friable vertebra will increase the deformity, and change the shape of not only the spine, but also the chest and the relation of its viscera.

Fortunately, in all tuberculous infections there is a natural tendency to repair. The gap produced by the destruction of bone is soon filled with newly-formed bone tissue, although not of normal texture, but solid enough to establish a strong splint for the weight-bearing spine.

The majority of surgeons consider the formation of a kyphus as a necessary evil essential to a cure. This view is hotly opposed by Calot,¹ who for years has advocated a method for its prevention, and, even when the kyphus has already formed, he claims the spinal column may be straightened by proper redressment. He demonstrates the feasibility and success of this treatment by most convincing illustrations.

The complications of spondylitis are abscess, fistulæ, paralysis, and deformities. In this chapter we shall consider only one of these complications—namely, the resulting sinuses.

We have already described the process of formation of sinuses. We know that they are the shriveled abscess walls leading to the original focus of disease. The cold abscesses following spondylitis have three favorable

¹ Calot: Die Behandlung der Tuberculösen Wirbelentzündung, 1907.

locations for their rupture. In children they open most frequently into Scarpa's triangle, or above Poupart's ligament; in adults they usually select the lumbar region. The dorsal vertebræ are most frequently affected. In 538 cases, reported by Dollinger, 63 were in the cervical region, 321 in the dorsal, and 154 in the lumbar region. The disease is not frequent before the second year; 50 percent of all cases, however, occur between the third and sixth years, and the disease rarely starts after the twentieth year.

Spondylitis occurs oftener in males than in females. In Hoffa's analysis of 3,795 cases,¹ 2,045 were males and 1,750 females. Compared in frequency to tuberculosis of other joints, it stands first. At the Children's Hospital in Boston, of a total of 5,950 cases of joint tuberculosis, 2,867 affected the spine.

For the purpose of elucidating the finer points in the treatment with bismuth paste, the following types are cited:

Example 1. Spondylitis of Tenth Dorsal, with Supraclavicular and Lumbar Sinuses.—This case is cited to show that in extreme cases the sinuses may open at a great distance from their sources, in regions where their communication is not expected. This little girl, shown in Fig. 12, is 12 years old, and had, as a result of a spondylitis of five years' standing, three sinuses—one in the lumbar region, one near the eighth dorsal spinous process, and one in the supraclavicular region, all on the right side of her body. The suppuration was very profuse for years, with a varying daily temperature of from 98° to 102°, with extreme emaciation and amyloid degeneration of the organs. The supraclavicular sinus was thought to be due to a broken-down tubercular gland of the neck until the first bismuth injection, in July, 1909, proved that all three sinuses communicated. The paste was injected in the dorsal sinus, and escaped through the other two openings, the lumbar as well as the supraclavicular. The sinus in the neck closed after the first injection, but the two others persisted in discharging. Although the quantity of pus was diminished and its character changed to a seropurulent fluid, the prognosis in this case is, in view of the extreme marasmus, very unfavorable.

¹ Hoffa: Orthopedic Surgery, 5th edition, p. 239.

The radiograph (Fig. 13) was taken after the sinus in the neck was closed, and therefore shows the paste to reach only into the tenth dorsal vertebra.

Example 2. Spondylitis, Sixteen Years' Duration; Sinus Healed with Three Injections.—J. C., aged 18, with a tainted family history as to tuberculosis, was a strong baby until he had spinal meningitis when 18 months old. A year later a deformity of the spine, with all the symptoms of tubercular spondylitis, developed. A psoas abscess formed and

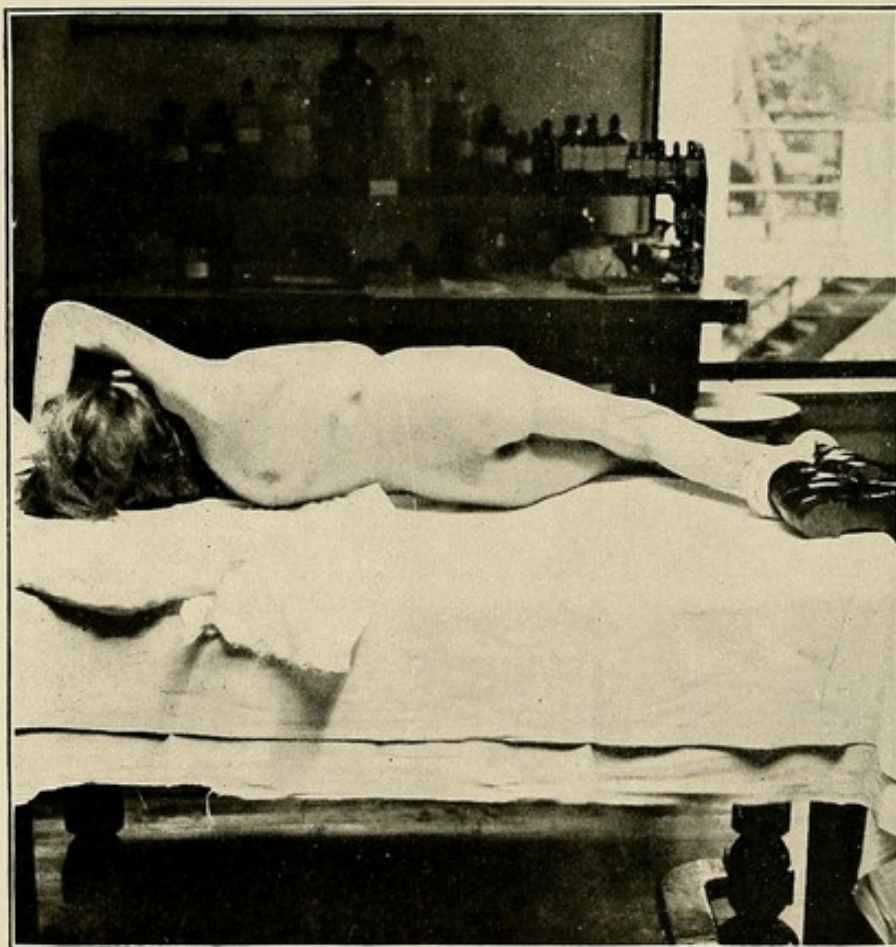


Fig. 12. Spondylitis of the tenth dorsal vertebra, with communicating sinuses in supraclavicular and lumbar region.

opened in the right Scarpa's triangle. An irritating pus discharge has persisted for the past twelve years. I made the first injection of bismuth paste in this case in May, 1909, and the radiograph taken (Fig. 14) disclosed a most tortuous fistula, the paste having reached the seat of the focus in the vertebra, and from there being forced into an existing channel on the opposite side, which had its blind end about two inches above the hip joint. There was not the slightest suspicion that this left sinus existed until it was discovered by means of the paste injections and radiography.

The most pleasing phase of this case, however, was the surprising therapeutic effect resulting from the bismuth paste. With only two subsequent injections the sinus closed, the patient gaining fourteen pounds in weight in four weeks.

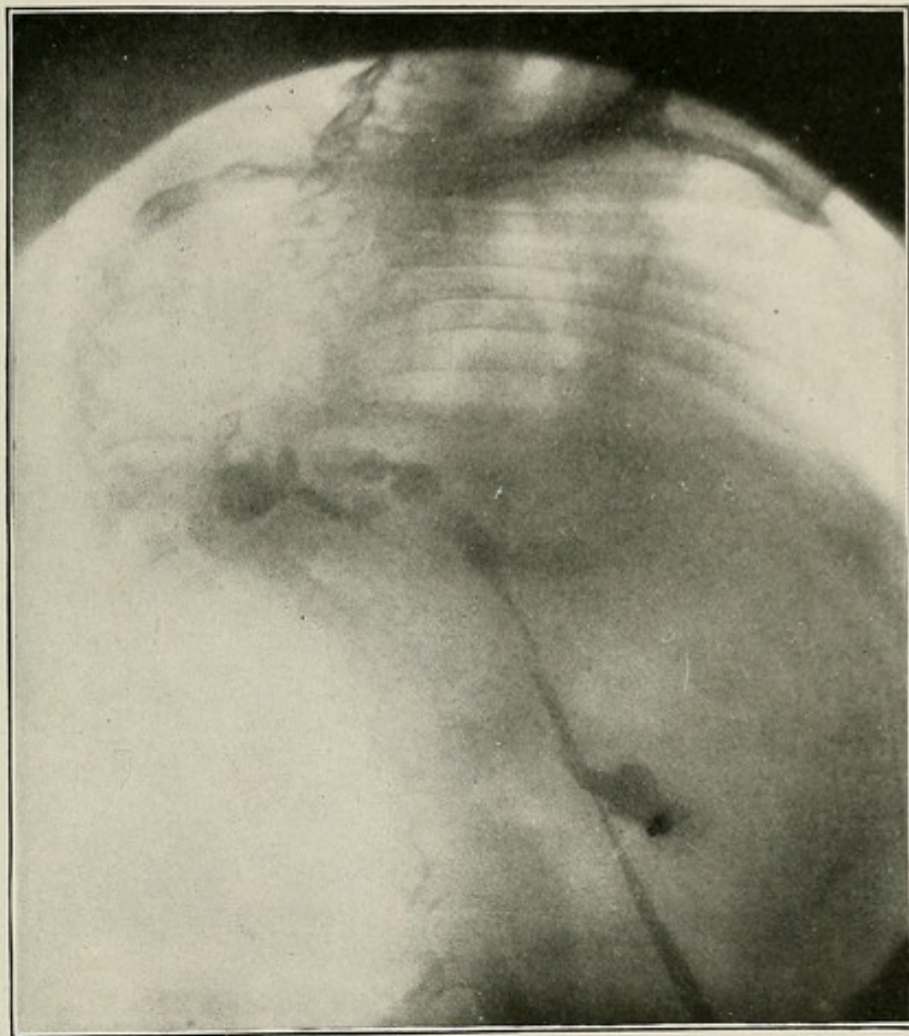


Fig. 13. Spondylitis of tenth vertebra, showing course of sinus, opening in lumbar region at point of black dot, and then downward course into the pelvis.

This case teaches several points:

First, it illustrates the fact that sinuses are formed by contraction of the abscess cavity.

Second, that even after twelve years' suppuration we may obtain a cure with a simple injection of the bismuth paste.

Third, that the absorption of small quantities of paste

will not cause any symptoms of intoxication. In this case all of the injected paste was absorbed.

Example 3. Bilateral Psoas Abscess Without Destruction of Vertebrae.—Miss M. K., aged 18, was in perfect health until two years ago. September, 1907, she fell and injured the tip of her coccyx. Thereafter she was constantly ill, and in December, 1908, an abscess developed

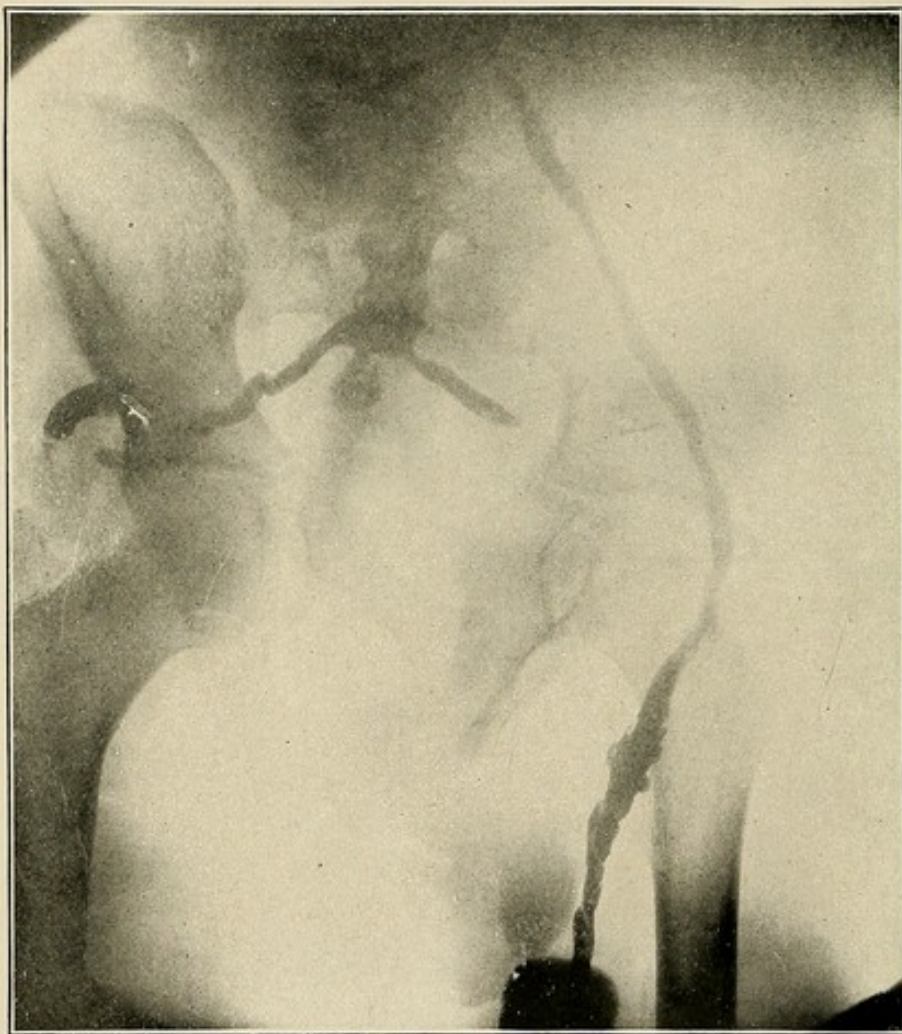


Fig. 14. Sinus following psoas abscess, sixteen years' duration (since infancy). Closed after third injection of bismuth paste.

above the right Poupart's ligament. Two weeks later the abscess was lanced by the attending physician and drainage established. In January, 1909, another abscess formed on the left side, in relatively the same region, and this was also incised and drained. Both resulting sinuses persisted in discharging profusely, so much so that in order to maintain a semblance of cleanliness the dressings had to be changed two to three times daily. Radiographs of the spine failed to

disclose any destruction of vertebræ, and a radiograph taken after an injection of bismuth paste furnished a remarkable picture. (Fig. 15.) The two abscess cavities are shown to be symmetrical, both triangular in form, having sharp borders, unlike those following psoas abscess. The diagnosis was for a time doubtful, but we have discovered that the intervertebral disc between the third and fourth lumbar vertebræ was missing, and in the absence of any other finding we concluded that in this space lay the focus of infection. The patient is still under treatment, and, while her condition is much improved, the discharge greatly diminished, and one sinus already closed, the final outcome is still uncertain.

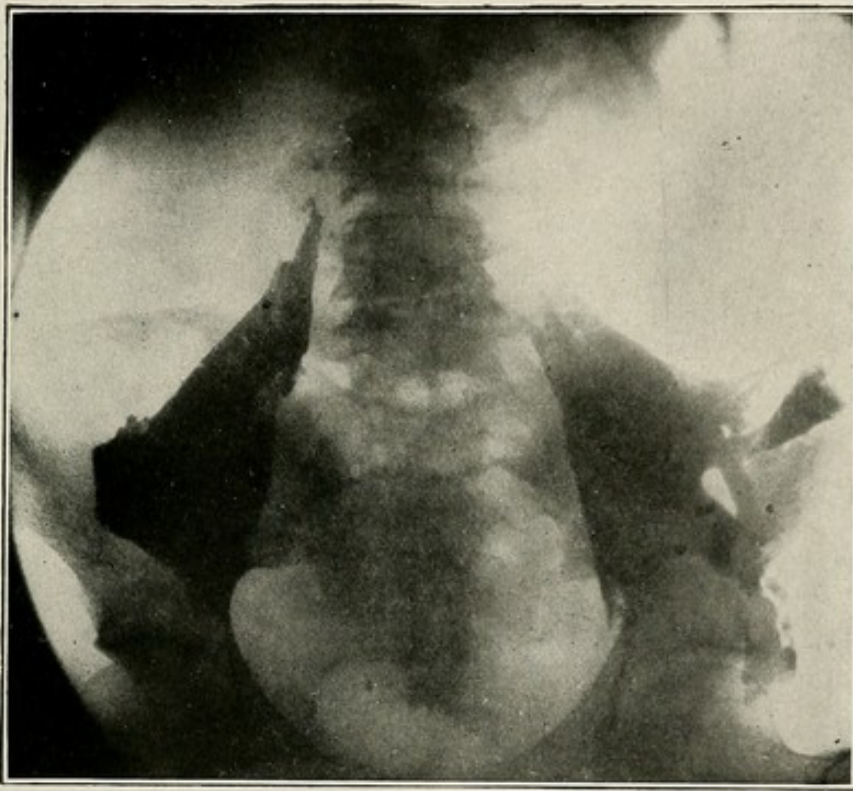


Fig. 15. Bilateral psoas abscess without destruction of vertebræ. Each opening above Poupart's ligaments.

The quantities of paste required for injection of the sinuses following spondylitis are usually very small, especially when the sinus has existed many years, such as example 2 here cited, which had existed twelve years, where only half an ounce of paste was sufficient to fill this long, narrow channel. In recent cases the abscess cavities have not yet shriveled down to narrow channels,

and thus may hold large quantities, and can, on account of the softness of their walls, be overdilated. For this reason I often use a 10-percent bismuth paste to prevent toxic effect from absorption.

In our series of cases of spondylitis with sinuses, 60 percent have healed subsequent to the injections. The remarkable fact is that the cases in which we least expected a cure—namely, those that had existed for the longest period—proved to be most favorable, and those of more recent origin were refractory.

I have reported¹ a case of spondylitis in a lady, aged 51, with sinuses in right and left lumbar regions, in which rubber drains had been kept for thirteen and eight years respectively, and nevertheless it took only two months for their permanent closure.

I must, however, warn against the premature declaration of a cure. There is no disease in which a cure is more often **only apparent** than tuberculous disease of the bones or joints. Recurrence or reopening of the sinuses, even after months, has taken place in a few cases, and thus we must be conservative and wait for a reasonable length of time before we assure our patient that he is permanently cured.

It must, however, be stated that, in patients who lived through the complications of abscess and sinuses and were finally cured, recurrence was much less frequent than in the cases in which the disease was checked in its incipiency.

¹ Beck: Beiträge zur Klinische Chirurgie, 1909, bd. 62, h. 2.

CHAPTER VII.

TREATMENT OF SINUSES FOLLOWING OSTEO-MYELITIS AND JOINT DISEASES.

Two principal varieties of osteomyelitis and arthritis are recognized—those of **pyogenic** and those of **tuberculous** origin.

The **pyogenic or nontuberculous osteomyelitis** originates in three different ways: **first**, in consequence of injuries, such as fractures, in which the bones were exposed or denuded of their periosteum; **second**, by extension of pyogenic infection from soft structures, such as phlegmon; and, **third**, through the circulation. All varieties of pus-producing microorganisms are liable to cause this form of infection.

In ectogenous infections the staphylococcus pyogenes aureus and streptococcus are the usual invaders, while through the hematogenous route the mixed infections of the staphylococcus pyogenes albus and the streptococcus pyogenes lead in frequency, and next in frequency occur the pneumococcus, the gonococcus, the bacillus typhosus, the colon bacillus, and bacillus influenzae. If the infection follows external injury, the periosteum is first attacked, it being lifted from the bone, and thus the disease may reach the bone marrow.

The nontubercular infection usually starts in the bone marrow of the long bones; less frequently in the cortical substance or the periosteum. From this primary focus it may spread in all directions, and may even break through the epiphysis into a joint, but most frequently it spreads through the Haversian canals toward the peri-

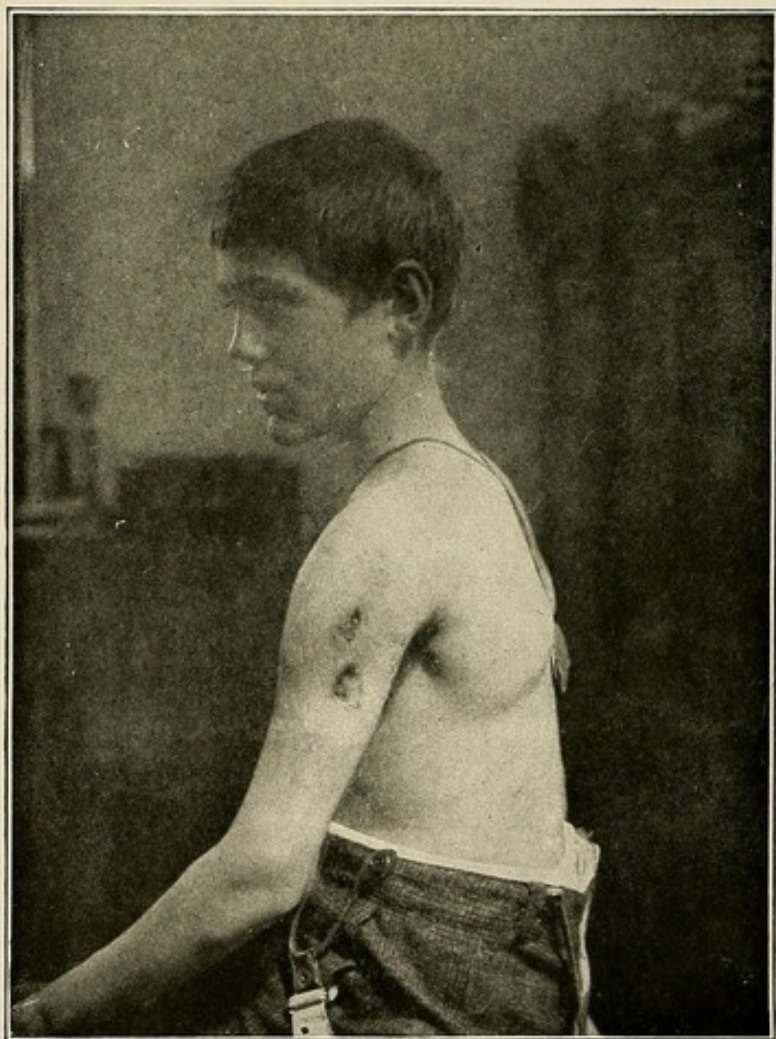


Fig. 16. Sinuses from nontuberculous osteomyelitis.

osteum, and causes a suppurative periostitis. The accumulation of pus will separate the periosteum from the bone shaft, deprive the underlying section of bone of its nutrition, and lead to its necrosis. A sequestrum is thus formed. This necrotic bone, now entirely detached, acts as a foreign body. Nature tries to either eliminate or encapsulate it. A liquefaction or crumbling of this bone will take place until only the hardest of its structure—a mere shell, perforated, grooved, with edges sharp and irregular—will remain. Such is the characteristic sequestrum of pyogenic osteomyelitis.

During the time of this destructive process a reactive **osteoplastic inflammation** takes place, in which the periosteum takes the principal part. This osteoplastic process surrounds the dead bone with a strong casing, and at the same time strengthens the shaft of the diseased bone. As a result of the disintegration of the bone and the suppuration of the tissues, an abscess is formed. At times the pressure of the pus breaks down the barriers, the abscess is ruptured toward the outside, and a sinus is formed.

The following case is typical of the facts just mentioned:

Nontubercular Osteomyelitis of Humerus.—G. W., a boy, aged 13, was brought to Dr. Carl Beck for operation in August, 1909. He had suffered from a suppurating sinus of his arm for over a year. Two operations had failed to cure the condition.

Examination revealed a very much thickened bone of irregular contour, extending from the head of the humerus to about the middle of the arm. On the external surface of the arm was a sinus, and a large scar as evidence of a former operation. (Fig. 16.) The first radiograph (Fig. 17) taken shows the presence of several large sequestra, imbedded in a mass of dense tissue. This skiagraph shows distinctly the darker shadows of the **sequestra** and a brighter zone around them, indicating a layer of **granulations**, in which they are imbedded. Another darker shadow outside of the light zone indicates the layers of reactive **ostitis**—**new formation of bone**.

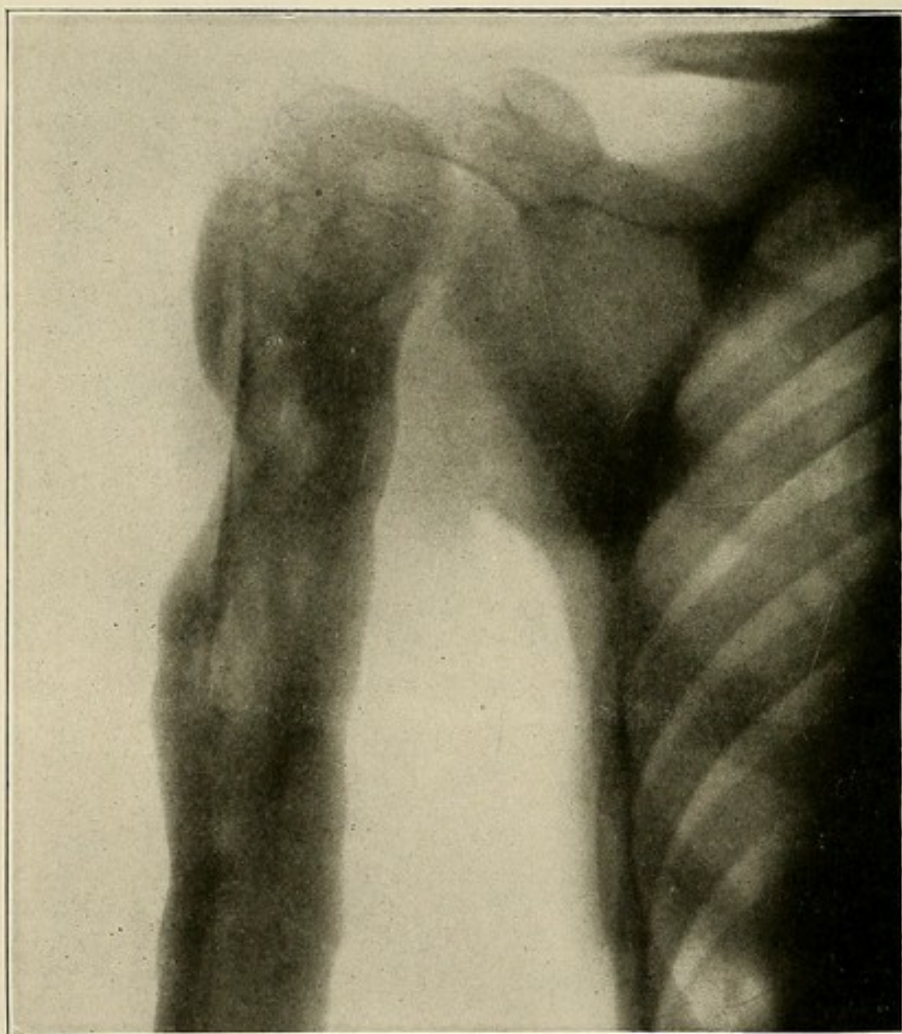


Fig. 17. Radiograph of humerus showing sequestra. (Case shown in Fig. 16.)

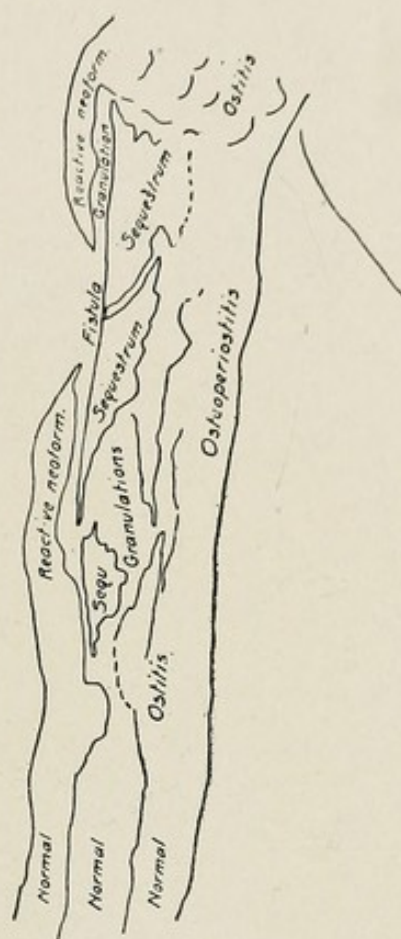


Fig. 17 A. Diagrammatic illustration of Fig. 17.




Fig. 18. Three of the sequestra removed from humerus. (Case shown in Fig. 16.)

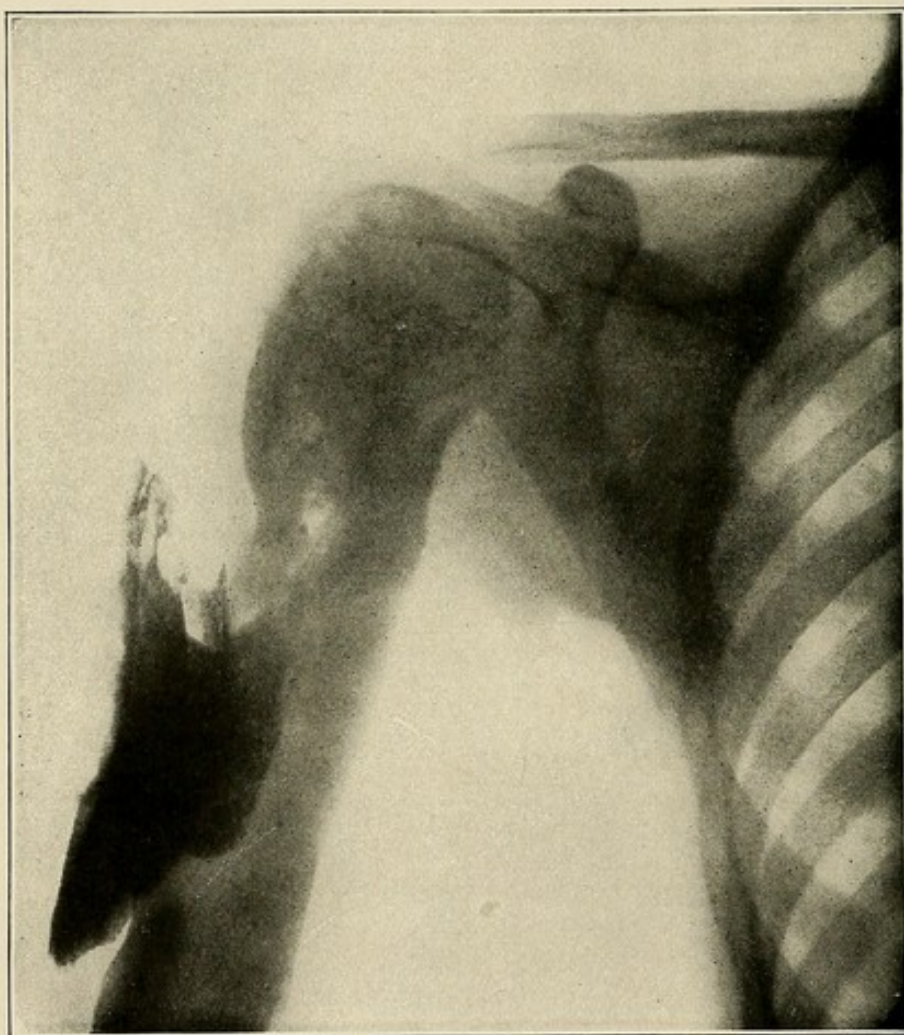


Fig. 19. Bismuth paste injected into cavity after sequestra were removed.
(Case shown in Fig. 16.)

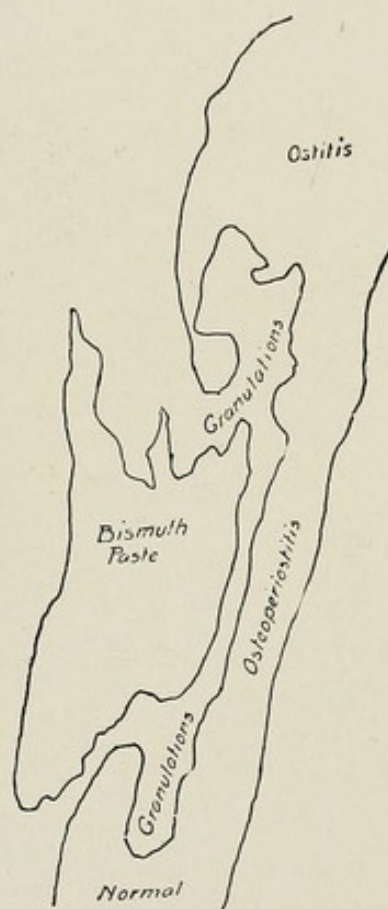


Fig. 19 A. Diagrammatic illustration of Fig. 19.

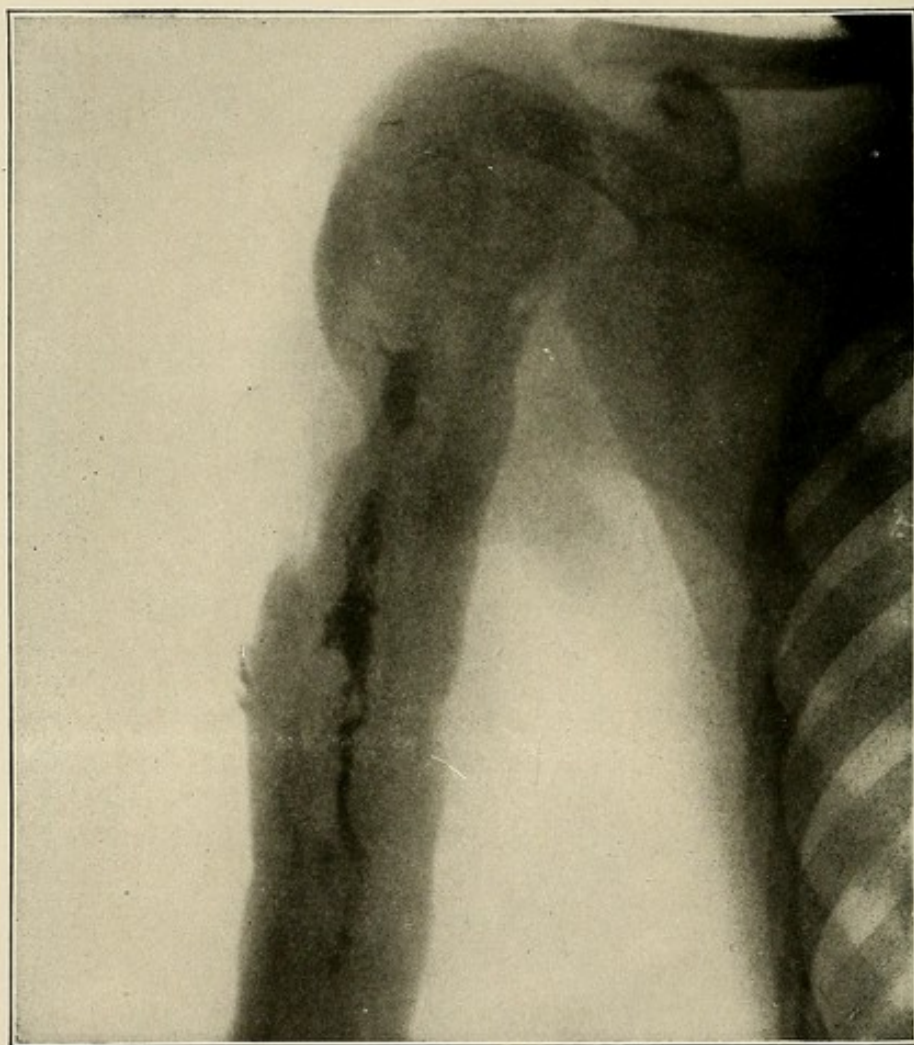

Fig. 20. Bismuth paste remaining after sinuses were closed. (Case shown in Fig. 16.)

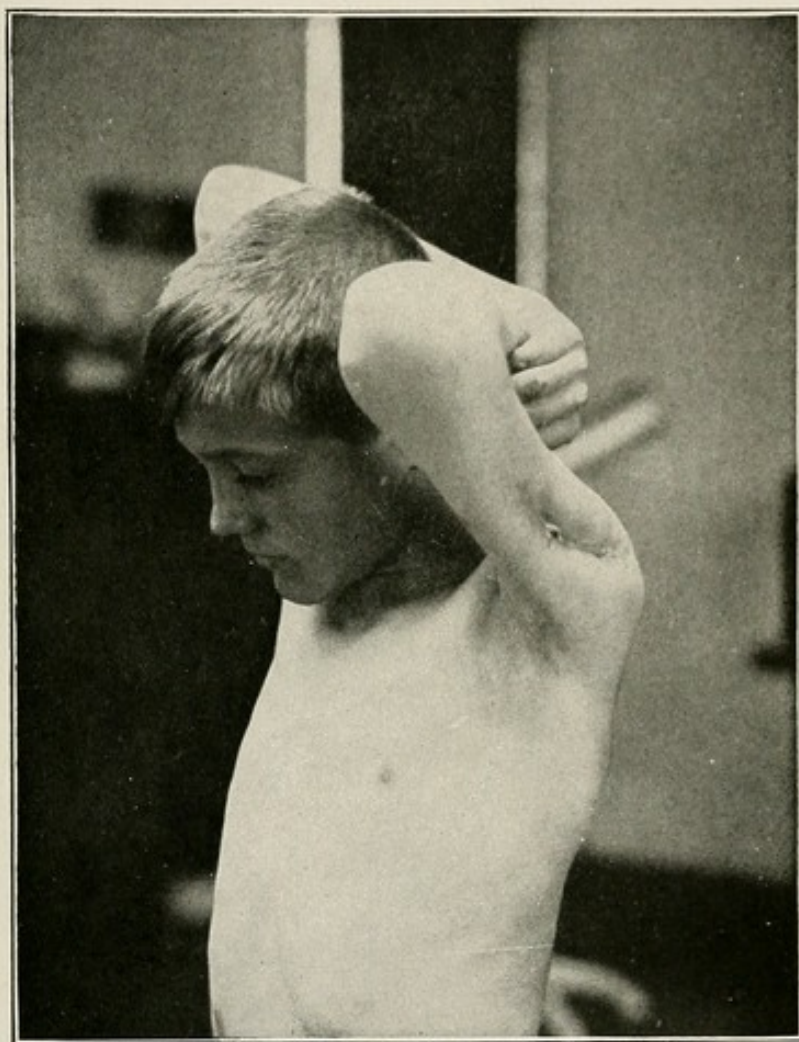


Fig. 21. Complete closure of sinuses and perfect restoration of function of arm. (Case shown in Fig. 16.)

78 BISMUTH PASTE IN CHRONIC SUPPURATIONS.

The accompanying tracings explain the various pathologic changes in the humerus shaft.

An operation was performed by Dr. Carl Beck, seven sequestra (Fig. 18) being removed, and the cavity packed with gauze. Twenty-four hours later the gauze was removed and the cavity filled with bismuth paste. A second radiograph (Fig. 19) was taken, which shows

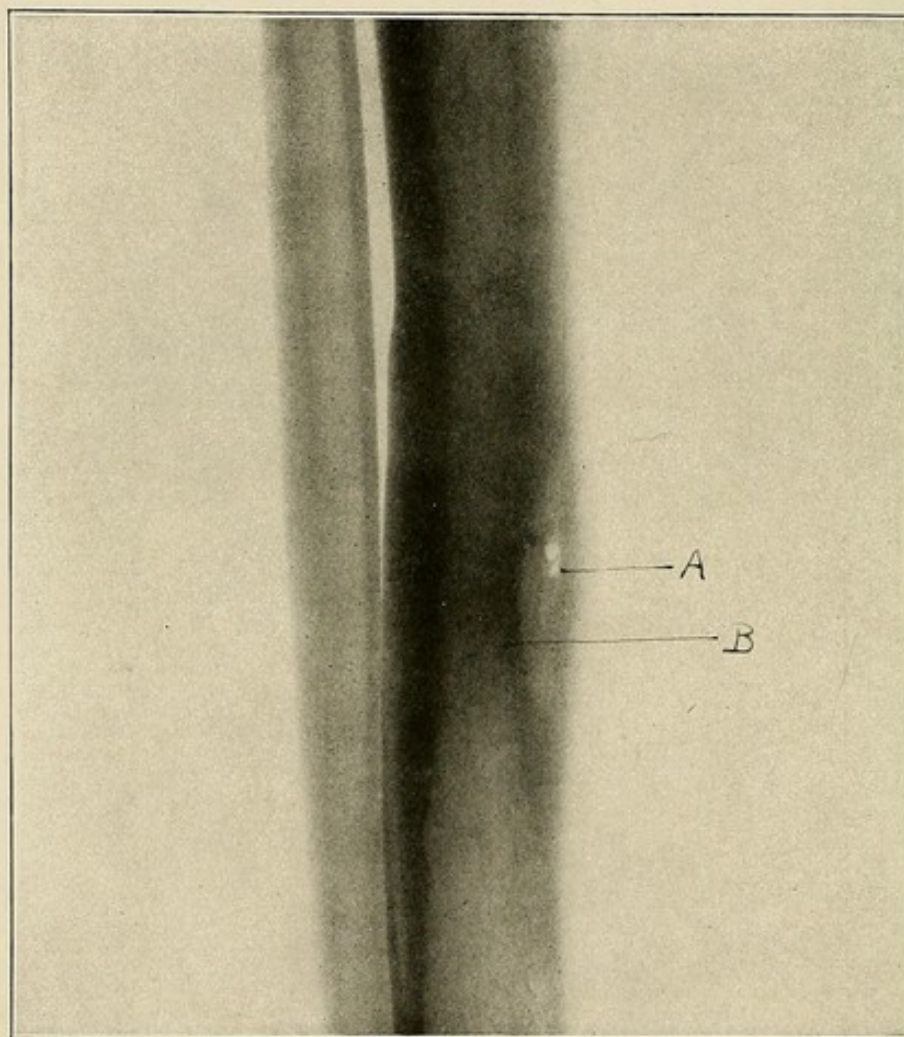


Fig. 22. Typhoid osteomyelitis of tibia. A, granulating cavity; B, hyperplastic sclerosis.

that all sequestra had been removed, and that the entire cavity had been filled with the paste, leaving only the lighter zone of the granulation tissue.

With few additional injections of the paste the cavity has entirely filled with healthy granulations and new formation of bone (Fig. 20); sinuses have closed within three weeks after the operation, and remained so.

The boy now has perfect motion of his arm, as shown in Fig. 21, and sufficient strength to do ordinary hard work.

A typical case of **typhoid osteomyelitis** of the tibia is shown in a radiograph. (Fig. 22.) The disease in the bone appeared four months after the typhoid fever subsided. The pus contained typhoid bacilli. The small area of infection is filled with granulation tissue (A), and the entire diseased process is surrounded by a layer of hyperplastic sclerosis (B), which acted as a barrier against spreading.

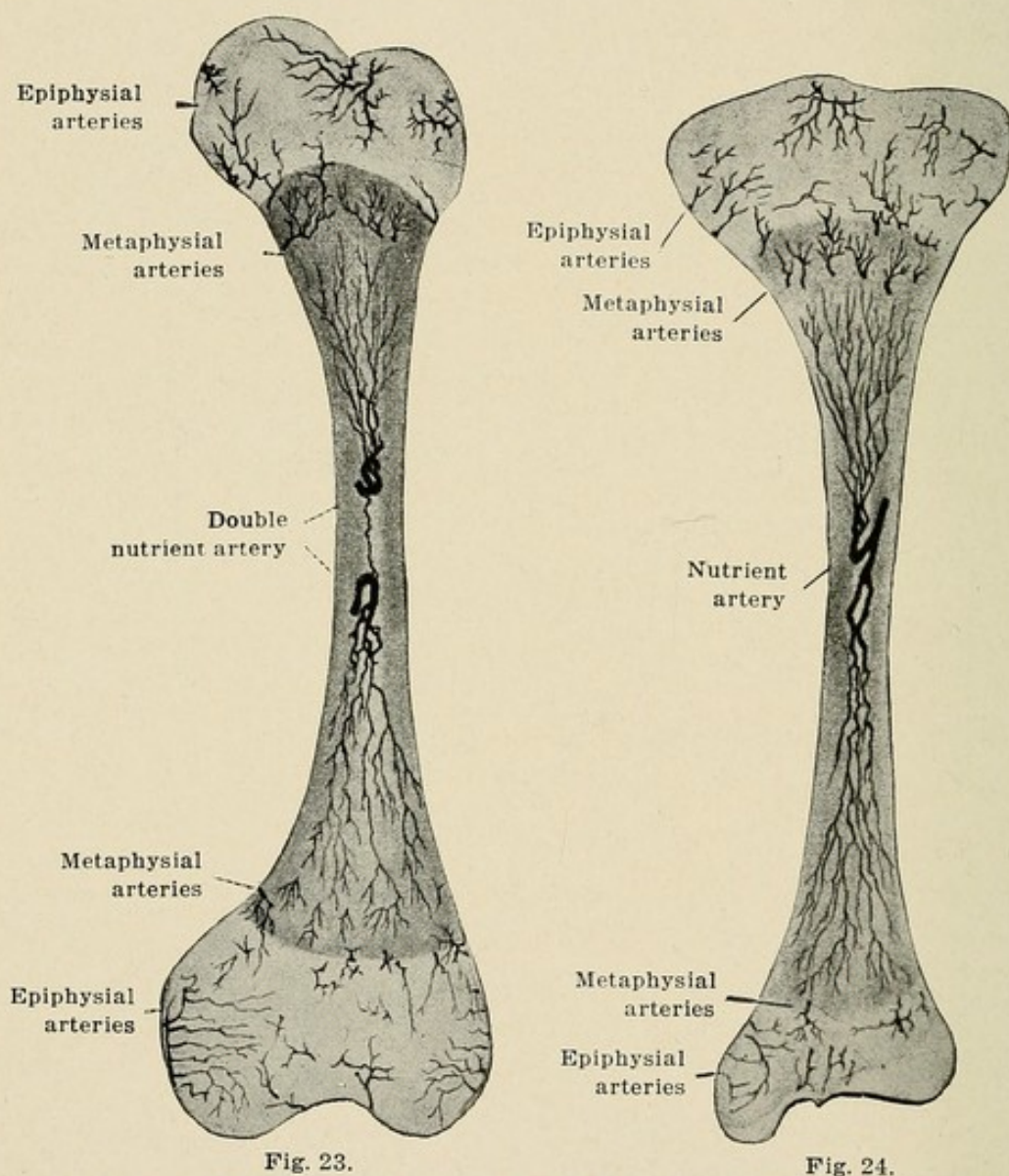
Pyogenic Arthritis.—The **nontubercular infection of joints** has the same etiology as that of the bones, and may likewise occur through the hematogenous route as a consequence of an acute general infection, such as scarlet fever, diphtheria, pneumonia, gonorrhea, erysipelas, and meningitis.

The synovial membrane is the structure first attacked. In consequence of its infection an exudate will at once be thrown out into the joint cavity. This exudate may be serous, serofibrinous, or from the start purulent, depending upon the virulence or type of the infective organism. The serous or serofibrinous variety represents the milder forms of infection, while the severer forms will, from the start, cause a suppuration within the joint, and may either destroy the same or cause a general septicemia or pyemia, unless proper surgical measures are taken.

In either the acute or chronic pyogenic arthritis the accumulation of pus within the joint may eventually lead to a sinus formation. The pus may reach the surface either by spontaneous rupture of the joint or through surgical intervention.

Tuberculous Osteomyelitis.—Except for anatomical differences, the formation of sinuses from tuberculous osteomyelitis is the same as that described in the chapter on spondylitis. The primary infection likewise takes place through the circulation or the lymphatics, and then ex-

tends to neighboring structures. The predominating opinion is that in the tuberculous type the epiphyses are in the vast majority of cases the primary focus of the in-



Figs. 23, 24. Blood supply in bones of infant, showing subdivisions of nutrient artery in metaphysial line. (Lexer.)

fection, and that from there the disease extends into the joint proper. Professor König has, however, pointed out that primary synovial tuberculosis is far more frequent than is supposed, and his experience is supported

by Lexer,¹ who states that the synovial form is at least as often primary as the osseous form.

In the **osseous form** the disease is, no doubt, of embolic origin. A study of the blood supply in the bones of growing children (Figs. 23, 24) teaches us why this disease selects the ends of the bones of young individuals. The smallest subdivisions of the nutrient artery take place at the metaphysial end, and the epiphysial arteries enter from all sides and meet in the center of the epiphysis. Small triangular infarcts, when present, are due to blocking of one of these end arteries with bacilli-carrying emboli, and from this focus the disease spreads into neighboring areas.

This primary infection causes an inflammatory reaction, with an area of infiltration, gradual formation of tubercles, and finally a cheesy degeneration of its center. The cancellous bone tissue is gradually destroyed, and a sequestrum of the harder portions of the bone may remain. The **tuberculous sequestrum** has certain characteristics. It is usually a small roundish or oblong body, resembling a rough gallstone, seldom reaching the size of a walnut, while the sequestrum in the nontuberculous form is usually flat and zigzag-edged.

Surrounding this diseased area we find a zone of new bone formation (**periostitis ossificans**), which forms a capsule around the sequestrum and the broken-down bone (**Knochensand—bone sand**). The process is liable to heal spontaneously. If, however, the disease has a tendency to further invasion, the limiting pyogenic membrane, or the osteosclerosis, will not form, but instead a **diffuse tuberculous ostitis** will take place. In this progressive form the tuberculous disease may spread upward and affect the entire shaft of the long bone, or it

¹ Lexer: Allgemeine Chirurgie, 1910, bd. 2, s. 378.

may extend to and break into the joint, and also affect the para-articular soft tissues. An abscess will then usually result, which may undermine the tissues and break through the skin in one or more places, and thus the tuberculous sinuses are formed.

Tuberculous Arthritis.—When this disease starts in the joint, the tubercle bacilli are primarily deposited in the capillaries of the synovia, and form miliary tubercles in this lining membrane. Inflammatory reaction is manifested by a serous or serofibrinous exudate and the formation of tuberculous granulations.

In the **milder forms** or in the beginning the exudate is of serous character (**hydrops articularis tuberculosis**, König) or may contain white flakes, which indicate an addition of fibrin to the fluid (**hydrops fibrinosus**, König). In the former the fluid is gradually absorbed; in the latter type the fibrin is deposited on the joint surfaces, and, through organization, causes their thickening, sometimes the formation of a villous growth (Fig. 25), or of free floating bodies. These free floating bodies, also called rice bodies (Fig. 26) (**corpora oryzoidea**), are always the result of a tuberculous infection, as they contain the tubercle bacilli, and when inoculated into guinea pigs will invariably produce tuberculosis.

In the **severe** forms the disease may still be arrested and the granulations undergo cicatrization. If cicatrization takes place, the synovia is studded with tubercles, which are covered by a pale, grayish-red, granular coating; if the disease progresses, the synovia is covered with a spongy mass of soft and mushy granulation. This condition is called **fungus** (Gliedschwamm), and causes a pseudo-fluctuation, and is therefore often mistaken for an abscess. In this latter form the parasynovial structures become edematous and swell, so as to put the over-

lying skin upon a tension, thus producing an anemic, "shining" swelling of the joint, which in the knee is familiarly known as **tumor albus**.

In the **most severe** form the masses of granulations within the joint undergo cheesy degeneration and small

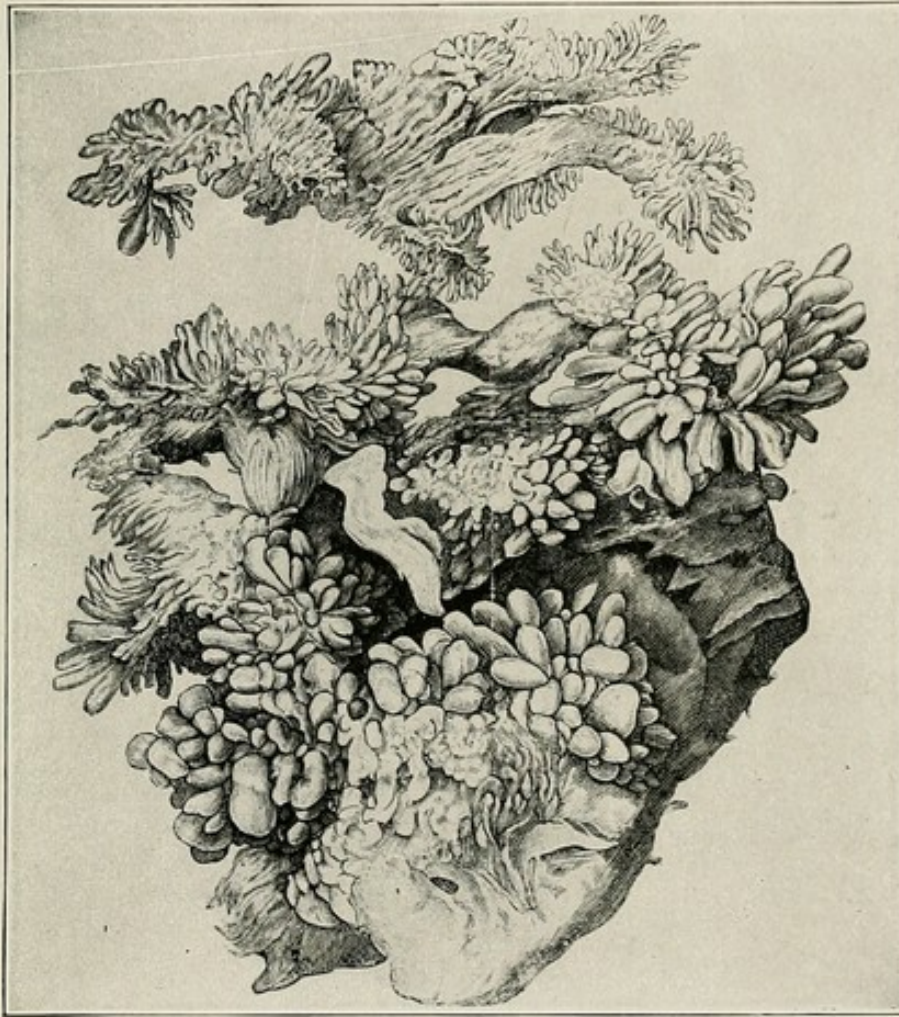

Fig. 25. Villous growth of tuberculous knee joint. (König.)

foci of suppuration. The latter are the forerunners of the abscess formation. Their number increases until they coalesce and form the "abscess." When the abscess is under great tension, the surrounding structures become undermined and pus will work its way toward the skin surface, and the abscess may finally rupture.

The disease may even lead to the destruction of the cartilages and the underlying bone surfaces, so that the entire joint is transformed into a mass of debris.

The **clinical course** of joint tuberculosis is variable, depending upon age of the patient, his resistance, and the joints affected. In general, the disease starts very insidiously, and the progress is gradual. Only in little

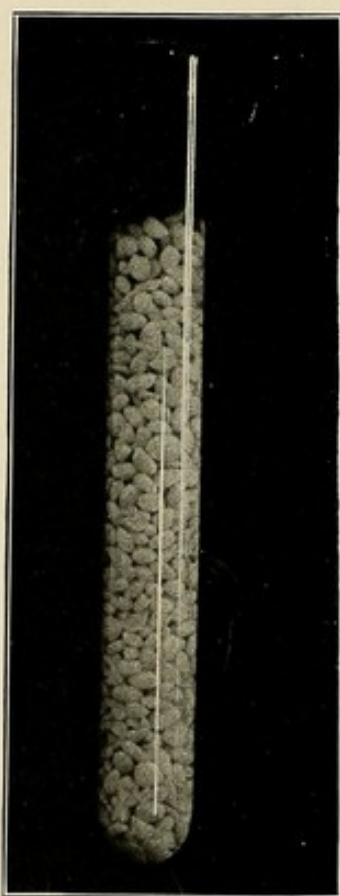


Fig. 26. Rice bodies from tuberculous joint. (Beck.)

babies do we encounter an acute onset of this disease. The diagnosis in its incipiency is very difficult, and many cases are treated weeks and months for rheumatism, sciatica, neuralgia, etc., before any characteristic symptoms arise. The usual forerunners are weakness in the affected limb, frequent lancinating pains, until the signs of the joint affection are manifest. When the character-

istic swelling and fixation of the joint are present, the diagnosis is easily established. A radiograph in doubtful cases is a most valuable aid. The early diagnosis is, of course, the salvation of the individual, because we possess the means of checking the disease only in its beginning.

Should an abscess form in spite of our efforts to prevent it, we may still prevent the formation of a sinus by proper conservative treatment, of which I shall speak in another chapter. When, however, the sinus is already present, then the treatment with bismuth paste will be of service.

Sinuses Following Hip Joint Disease.

Next in frequency to spondylitis, the hip is affected. Of 5,950 cases of joint tuberculosis treated at the Children's Hospital in Boston, 2,281 affected the hip and 2,867 the spine. In our series of cases, treated at the North Chicago Hospital during the past four years, the relative frequency of these two conditions was 41 cases of hip joint disease to 34 cases of spondylitis. These numbers, however, include only the cases in which sinuses were present. In the cases without sinuses the relative proportion was equal, 11 cases of each having come under our care. In only three instances did spondylitis and hip joint disease coexist.

In this series of 41 cases of hip joint disease with sinuses the right hip was affected in 26, the left in only 15 cases, none being bilateral. This disproportion seems to us more than accidental, as this same relative frequency has kept up each year since we first observed it.

Shortening of the affected limb existed in practically all cases, since the head of the femur was destroyed in nearly every case where the disease was so extensive as

to progress to sinus formation. In one case the shortening amounted to eight inches. In two cases there was no ankylosis, although the head of the femur was destroyed.

It is easy to make a correct diagnosis of hip joint disease when sinuses are already present. I have nevertheless encountered and cited in Chapter IV cases where sacral tuberculosis was mistaken for hip joint disease because the abscess happened to open directly over the hip.

Three principal complications result from hip joint disease—the **shortening**, the **ankylosis**, and **sinuses**. I shall here consider only the latter.

The number of sinuses which are liable to result from a tuberculous coxitis may vary extremely. In our series of 41 cases,

- 12 cases had 1 sinus.
- 8 cases had 2 sinuses.
- 9 cases had 3 sinuses.
- 1 case had 4 sinuses.
- 3 cases had 5 sinuses.
- 4 cases had 6 sinuses.
- 1 case had 8 sinuses.
- 2 cases had 16 sinuses.
- 1 case had 20 sinuses.

The sinuses usually open near the trochanter or in the gluteal region, but in extensive cases they may open at a distance from the hip joint.

Fig. 27 illustrates the type of hip joint disease in which the abscess formation resulted in numerous sinuses. In this case eight sinuses had existed for four years, three of these having recently closed. The open sinuses show the large, **pouting granulations** which follow the injections of the bismuth paste.

Not infrequently the sinuses open near the anus or scrotum, and thus may be mistaken for rectal fistulæ. In

one of my cases the abscess had ruptured into the bladder and thus the existing sixteen sinuses kept on discharging the urine for seven years.¹

At times the acetabulum is perforated and the abscess

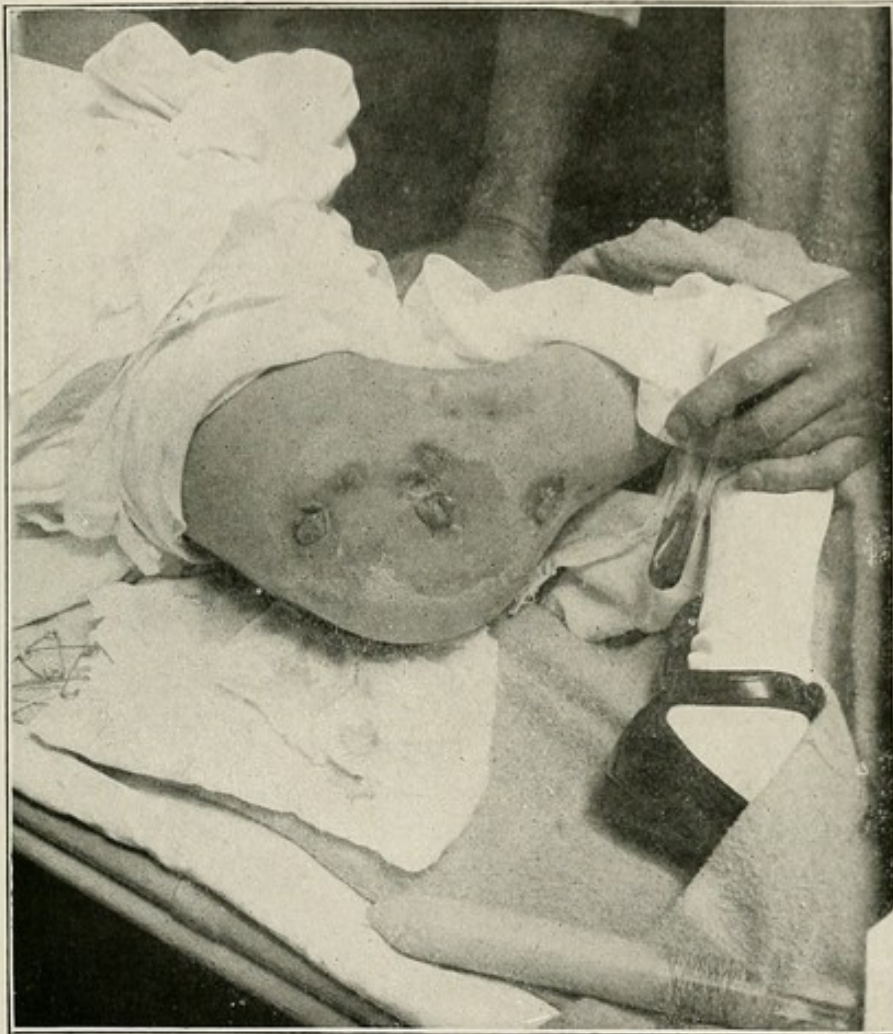


Fig. 27. Sinus openings showing large pouting granulations after bismuth injections.

will rupture into the pelvis, undermine the pelvic fascia, and open above or below Poupart's ligament. This complication, which increases the difficulty of treatment, was present in 5 cases in my series of 38. The radiographs after the bismuth injections have in every instance

¹ Beiträge zur Klinische Chirurgie, bd. 62, h. 2, s. 40.

cleared up the diagnosis as to the origin and distribution of these sinuses.

We are all familiar with the extreme chronicity of the affection. In our series of cases,

- 15 cases had sinuses from 1 to 3 years.
- 9 cases had sinuses from 3 to 10 years.
- 10 cases had sinuses from 10 to 15 years.
- 5 cases had sinuses from 15 to 20 years.
- 1 case had sinuses for 22 years.
- 1 case had sinuses for 41 years.

Most of these patients contracted their hip disease in early childhood, passed the acute stage of the disease, and after years of treatment, either operative or palliative, remained uncured.

The mortality in hip joint disease is probably lessened each year because of our improved methods and conservative treatment. Statistics compiled some years ago show an appalling mortality.

König placed the mortality at 40.3 percent.

Alexandria Hospital (384 cases), 26 percent.

Gibney reports 288 cases, with a mortality of 12.5 percent.

The mortality is lower in children than in adults.

A report of 100 cases from Kocher's clinic, by Lewiasch, gives the following mortality:

In 25 cases which had abscesses, mortality of 65 percent.

In 75 cases without abscesses, mortality of 13.3 percent.

The extreme chronicity and the resistance to simple treatment have forced the surgeons to adopt radical and often desperate methods. The most extensive and dangerous operations—such as excision of the hip joint, or even amputations—have been performed, but past experience has taught us that even these most radical proce-

dures have in a large measure resulted in failures. In the intervals between these operations the sinuses were irrigated with various antiseptic solutions, from the mildest boric acid to the corroding pure carbolic. The favorite irrigating fluid was a weak solution of iodine or permanganate of potash. Some cases in our series have given a history of many years' daily irrigation without any benefit. Most surgeons have now abandoned the irrigation of abscess cavities, and substituted more modern and effective methods.

In the light of our present knowledge of the anatomical distribution of sinuses, the injection of any watery fluid, whether corrosive or mild, no matter how effective its bactericidal action, can be of only temporary benefit, because the solution will not reach all channels and crevices of the infected tract, and, if it does, it will not remain in contact with the infected walls sufficiently long to exert a therapeutic action. The bismuth paste will accomplish this, and in this principle I believe lies the secret of its effectiveness. It possesses to a marked degree all the above requisite qualities. It is liquid when injected, so that it reaches all the branches of the sinuses, and on cooling becomes semi-solid, thus remaining in contact with every portion of the infected tract long enough to permit a slow chemical action.

Following are illustrations of the treatment of various types of hip joint disease:

Example 1. Hip Joint Disease, Sixteen Years' Duration; Fifteen Operations; Injection of Paste; Cure in Thirty Days.—Miss M. G., aged 21, developed a painful condition of her right knee and hip at the age of six. For one year she was treated symptomatically, and then a diagnosis of hip joint disease was made by aspirating pus from the hip. Incision and drainage (at that time considered the proper procedure) was made. Condition was thus aggravated, and after six months of extreme suffering, often requiring chloroformization during dressings, a radical operation was performed, consisting in the re-

section of the head of the femur. This radical procedure, however, resulted in the formation of many sinuses and persistence of fever. During the following ten years she submitted to thirteen more or less

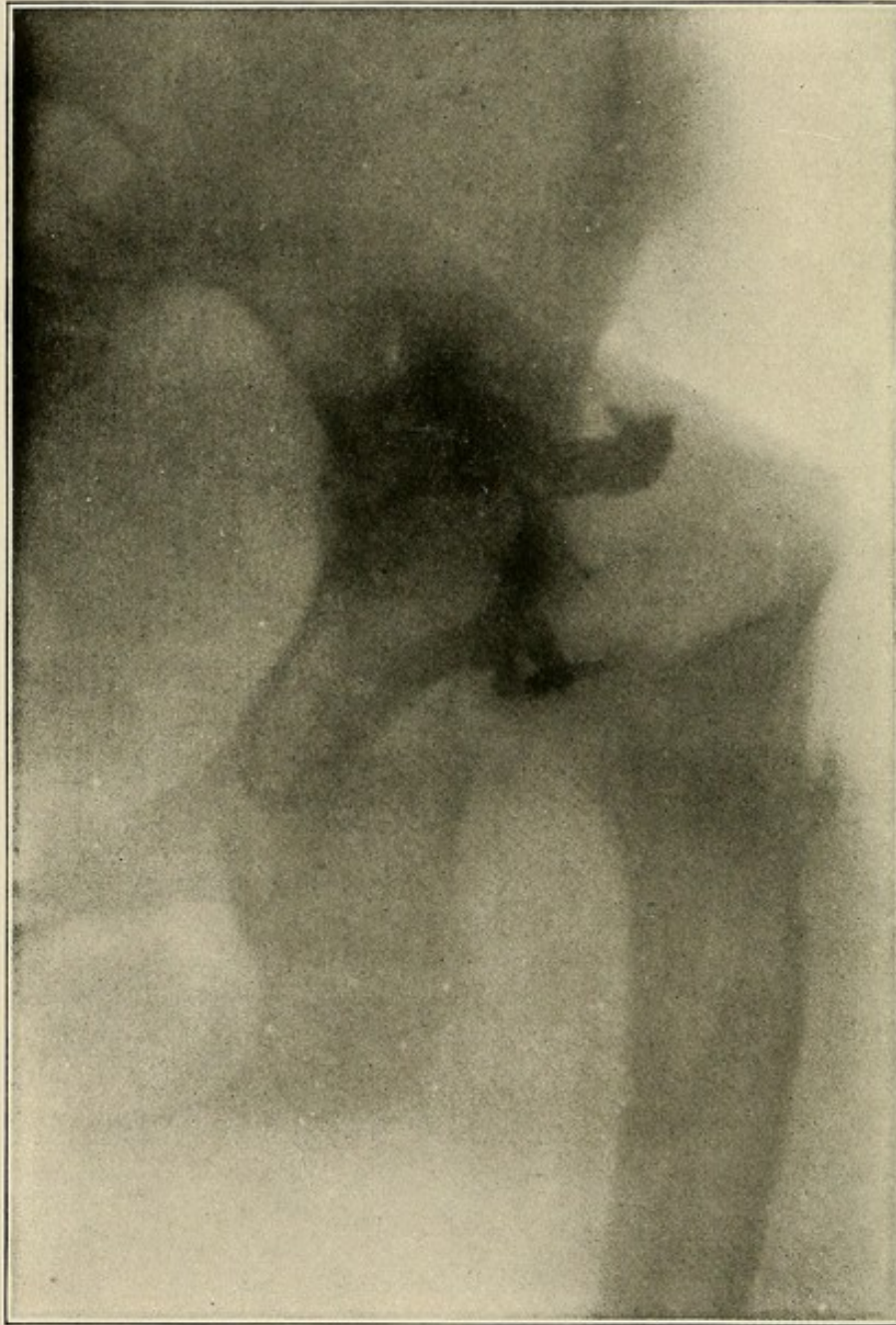


Fig. 28. Radiograph showing sinuses within hip after sixteen years' suppuration. Closure in one month; no recurrence.

radical operations, at intervals of from six months to three years, all of which, however, were of no avail. The discharge and pain persisted. The last operation was performed by the late Professor Senn

in June, 1907. It was the most radical procedure thus far undertaken; both trochanters were removed and the acetabulum was thoroughly curetted. The five sinuses, however, kept on discharging pus. In December, 1907, the first injection of bismuth paste was made, and repeated every two or three days, and on January 15 the sinuses were closed, and have remained thus to date. The radiograph (Fig. 28) shows the extreme destruction of the joint, the end of the femur, in-

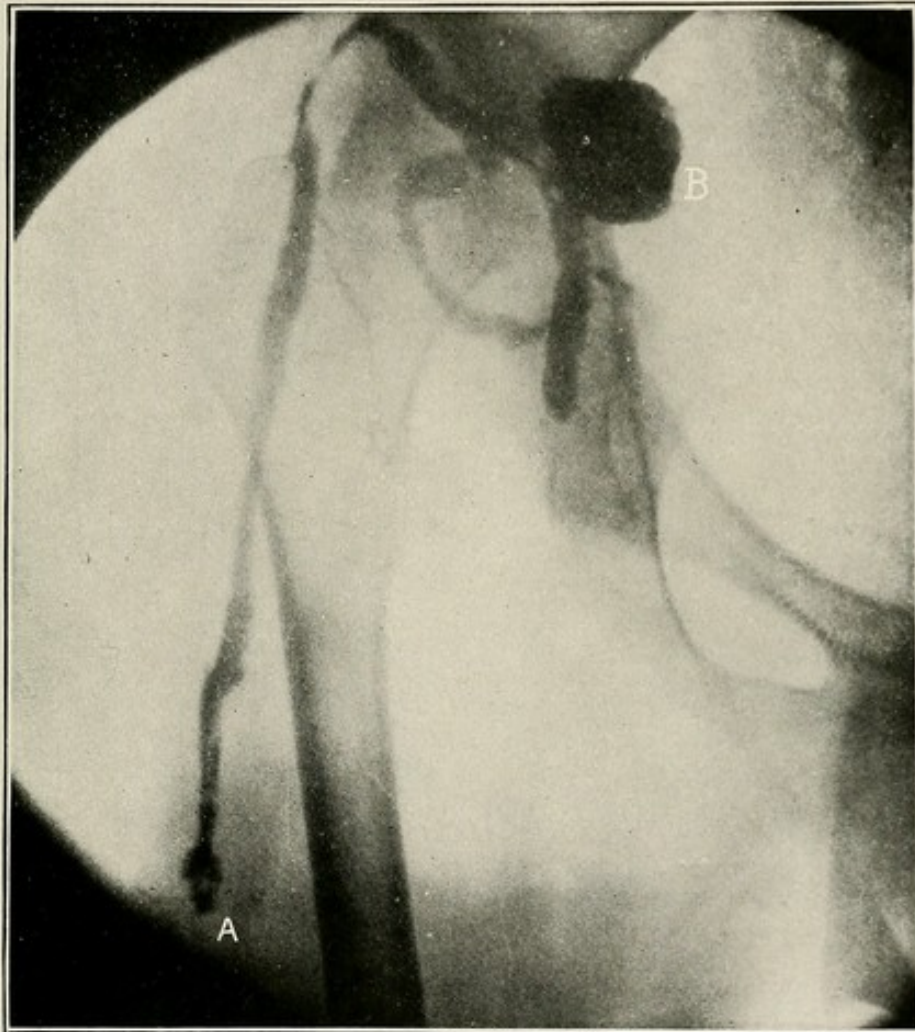


Fig. 29. Radiograph showing path of sinus into hip joint. A, sinus opening; B, small abscess cavity.

cluding both trochanters, having been removed. The rim of the acetabulum is filled with the bismuth paste, showing distinctly a collateral sinus.

Example 2. Hip Joint Disease, Six Years' Duration; One Sinus; Closure in Four Months.—Miss M. W., aged 13, was well until her seventh year, when she fell, striking her hip. No serious consequences were discovered until two years later. She was taken to

St. Joseph's Hospital in Chicago, where her case was diagnosed as tuberculosis of the hip; injected with a 10-percent iodoform-glycerin emulsion, and the limb put into a plaster of paris cast. Three months later the cast was removed, and from that time the injections of iodoform were repeated until nine had been given. An abscess, nevertheless, formed, which ruptured on the external side of her thigh, near the middle of the femur. The sinus resulting therefrom persisted in discharging large quantities of green, malodorous pus for three years, requiring daily dressing. She was unable to move about without the aid of crutches, owing to the tenderness in her hip.

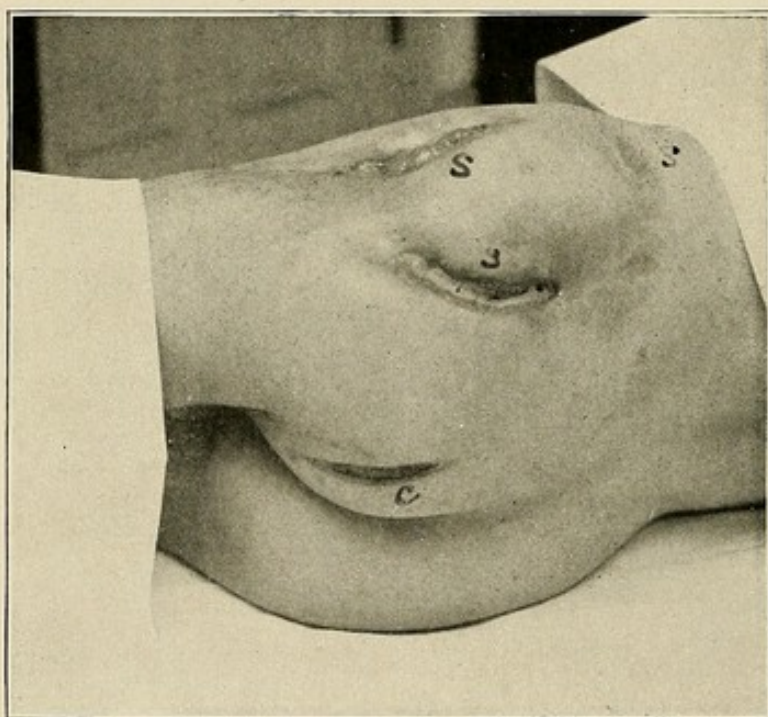


Fig. 30. Hip joint disease, nineteen years' duration. C, incision of abscess in gluteal region; S, S, S, sinus openings.

On February 28, 1908, when she first came for treatment, she was very much emaciated, pale, and weak, with a shortening of four inches of her left limb, and a sinus on the anterior surface of her left thigh, discharging pus.

A radiograph taken demonstrated the destruction of the head of the femur. A second stereoscopic radiograph (Fig. 29), taken after the first bismuth paste injection, demonstrated that the sinus extended from the opening on her thigh upward, in front of the trochanter, winding its way backward toward the acetabulum, and there filling a small cavity in front of the ramus of the ischium.

The discharge diminished after the first injection, and its character changed to a seropurulent fluid, resembling dish-water. After twenty

injections during a period of four months the sinus healed, and has remained so.

Example 3. Hip Joint Disease, Nineteen Years' Duration; Required Curettage Before Injection.—(Fig 30.) The patient is 26 years of age, and has had since his sixth year a hip joint disease, which resulted in the entire destruction of the head of the femur, and four sinuses, which latter continued to discharge for nineteen years. The radiographic examinations proved that a large sequestrum was at the bottom of the suppurating focus and that its removal would be required before a cure could be accomplished. This was done in May, 1909. Two large sequestra were removed, and an abscess, undermining the entire left gluteal region, was discovered during the operation. A large counter-incision (C) was made, and through this the abscess was traced into the pelvic cavity. After a few days' packing with gauze the cavities were filled with bismuth paste, and within four weeks all sinuses were closed. The temperature, which had constantly been high, became normal, and patient gained forty pounds in weight.

Sinuses from Pyogenic Osteomyelitis of the Femur.

The femur is the most frequent seat of nontuberculous osteomyelitis. During the past four years we have treated at the North Chicago Hospital 57 cases of **nontuberculous osteomyelitis**, occurring in the following parts:

- 20 in the femur.
- 12 in the tibia.
- 1 in the fibula (syphilitic).
- 6 in the humerus.
- 4 in the radius (3 syphilitic).
- 4 in the ulna (3 syphilitic).
- 2 in the ribs.
- 8 in the fingers.

Of the 20 femur cases,

- 9 occurred in the right and 11 in the left limb.
- 14 were males and 6 females.
- 15 were adults and 5 children.

The lower half of the femur is most frequently affected, the disease having occurred nineteen times below and only once above the middle. The cause of this unequal

distribution has not been determined, but is likely due to the anatomical difference in structure, the lower end having a much wider medullary canal than the upper

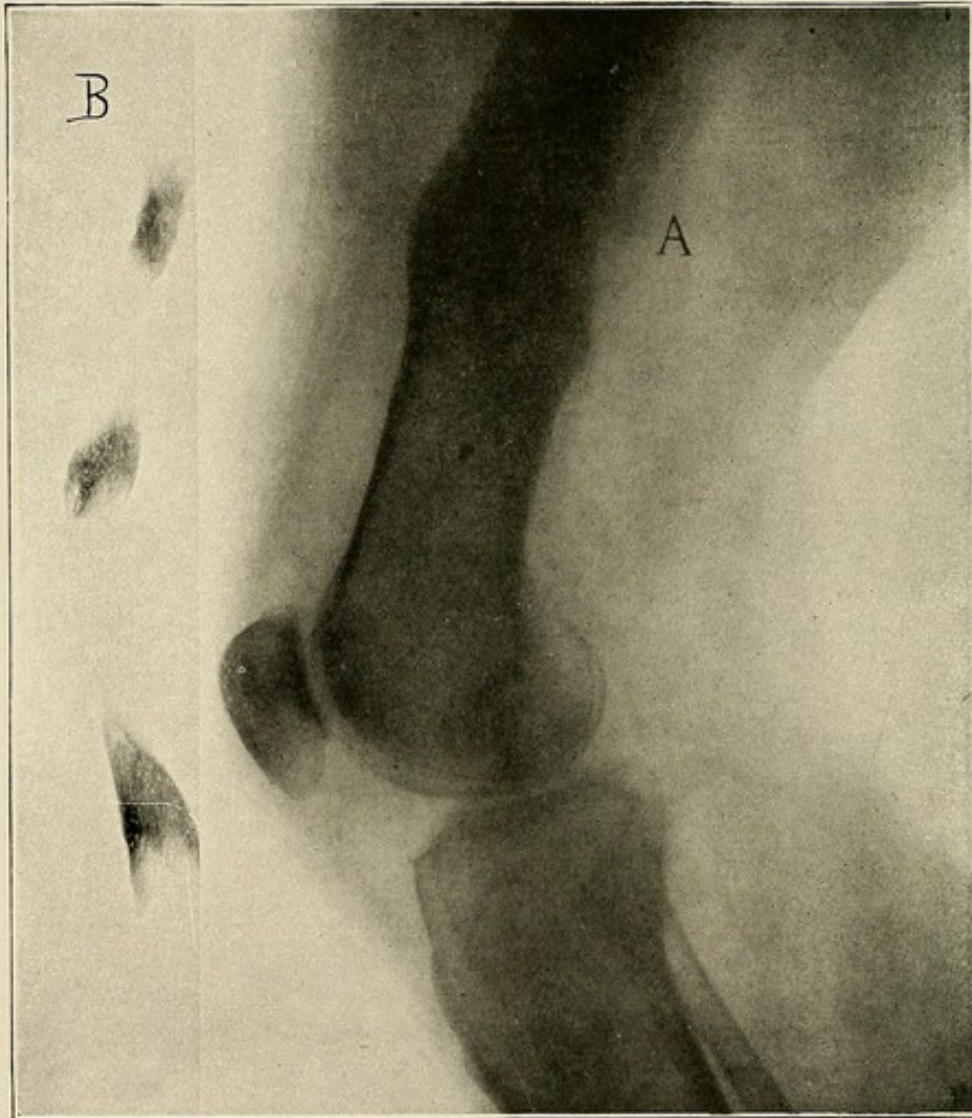


Fig. 31. Nontuberculous osteomyelitis of femur. A, density of bone; B, sequestra after removal.

portion of the femur, which predisposes the lower to the infection.

Nontuberculous sinuses in this location are usually two in number—one external, in the groove between the biceps femoris and the vastus lateralis, and the other on

the internal side, in the groove between the semi-tendinosus and semi-membranosus. Of our 20 cases, in only one instance has a sinus existed in the popliteal space. In most cases there exists a marked hypertrophic sclerosis, as plainly shown in the radiographs, where the part affected is at times nearly twice its normal thickness, and so vitrified that the medullary canal is obliterated and the entire width of the shaft gives a shadow of uniform density. This hardening of the bone structure is a result of chronic inflammation, and causes considerable difficulty during operations, it being almost impossible in some cases to cut the bone with a sharp chisel. At times there are foci of infection or small sequestra, encapsulated in such a hard shell of bone, and their removal thus becomes extremely difficult.

I cite a typical case of this variety for illustration.

A. H., aged 29, was always well until February, 1907, when a swelling appeared above his left knee, accompanied by chills, fever, and pain. Physician lanced the swelling and removed a quart of pus. Ten days later he was operated, and four sequestra from the femur were removed and the wound drained. A sinus persisted in discharging profusely an irritating pus.

In August, 1908, he was again operated; a radical curettage was performed, but again without result.

In November, 1908, I had a radiograph taken (Fig. 31), which explains the failure. The lower portion of the shaft is very much thickened and the cancellous tissue is entirely replaced by hard bone. Another sequestrum (A) is still in the femur. The four sequestra (B) previously removed are placed alongside the femur to show their relative size and shape. After the removal of the last sequestrum the bismuth paste was injected, and rapid improvement and closure of sinus followed.

Sinuses Resulting from Tuberculous Knee Joint.

The same pathologic processes as described in hip joint disease lead to the sinus formation in knee joint tuberculosis. Next to the hip, it is the most frequent seat of this disease. Young individuals are most frequently the

victims, one-third of all cases occurring before the tenth year. Men are more often affected than women. König's¹ series of 720 cases treated shows 60 percent were men.

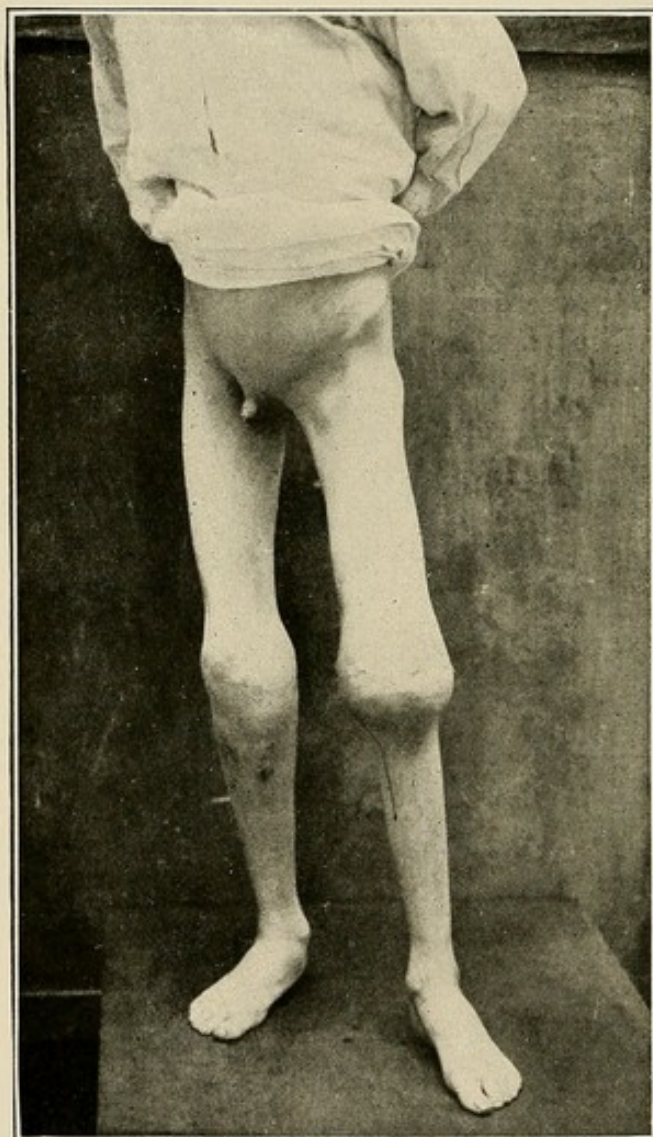


Fig. 32. Bilateral tuberculosis. Tibia in right and femur in left limb affected.

In our own series of 24 cases, treated at the North Chicago Hospital during the past four years, 19 occurred in men and only 5 in women. Of these 24, 7 affected the right and 17 the left limb, just the reverse ratio to what

¹ König: Die Tuberculose der Menschlichen Gelenke.

occurs in tuberculosis of the hip, where we encountered 26 cases affecting the right side against 15 the left.

König states that at least one-half of the cases begin with a primary synovial tuberculosis, and from there spread to the adjacent bones, while other authors (Tay-

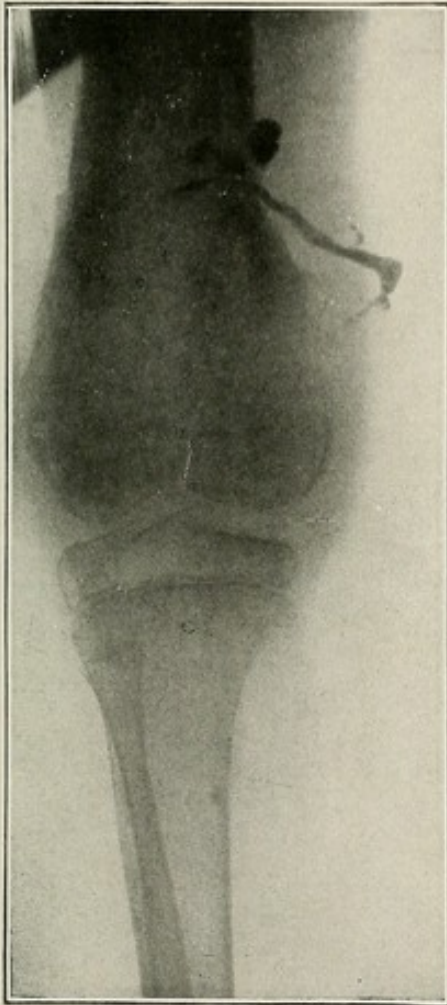


Fig. 33.

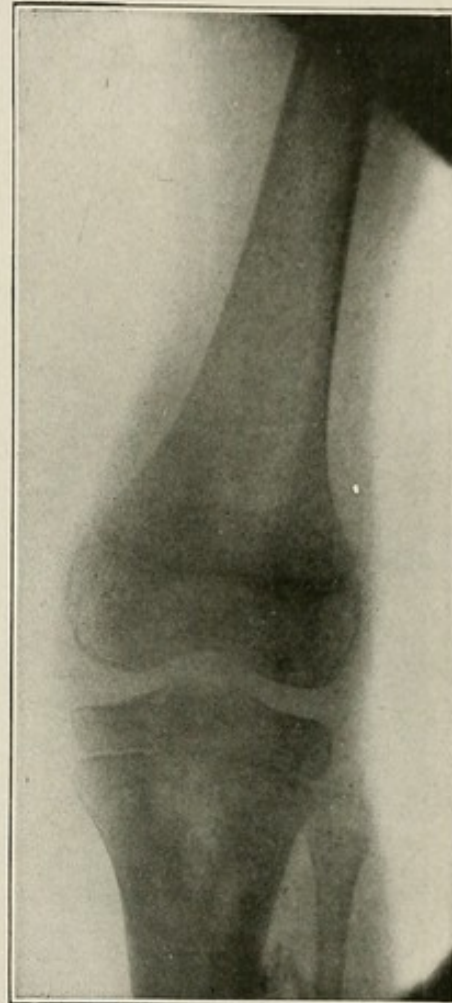


Fig. 34.

Figs. 33, 34. Radiographs demonstrating bilateral tuberculosis. (Case shown in Fig. 32.)

lor) assert that more frequently the disease starts in the bones and affects the joints secondarily.

Any of the four bones which make up the knee joint may be the primary seat of the disease. The lower end of the femur leads in frequency and is closely followed

by the upper end of the tibia. Primary tuberculosis in the patella is not as rare as is generally believed; only two cases, however, occurred in our series. In König's 720 cases it occurred 50 times, in 33 of which the patella was the only bone involved. The fibula is rarely affected; not a single case has occurred in our series.

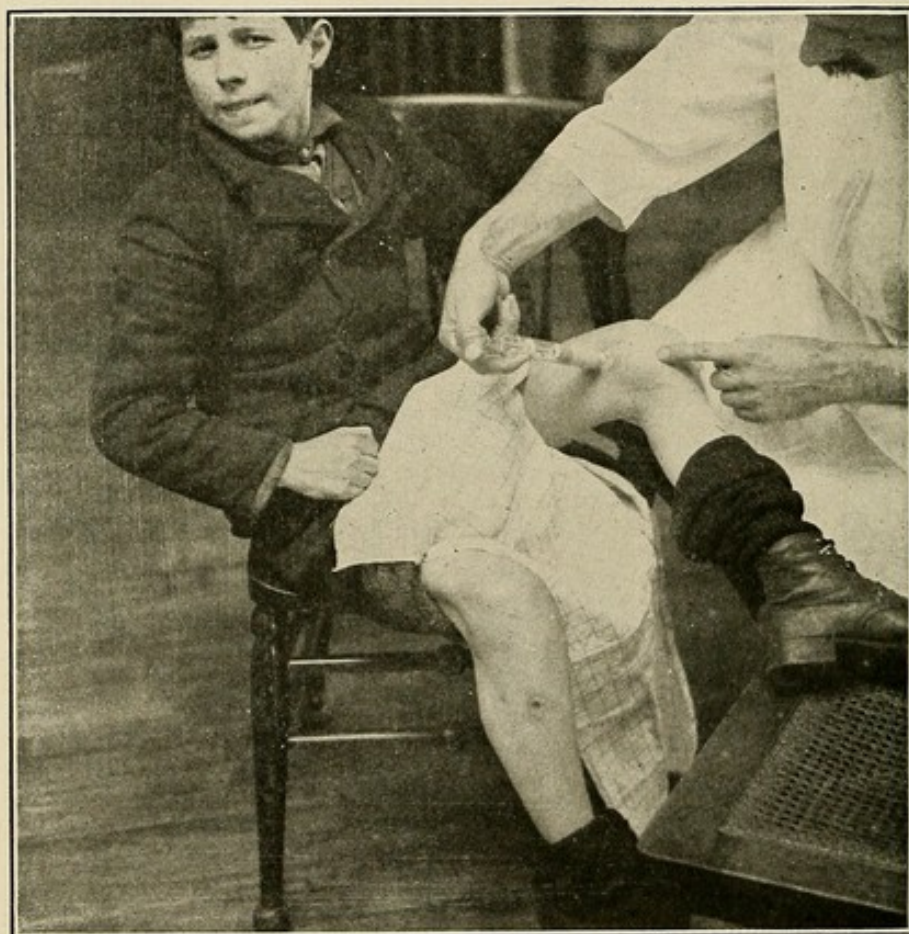

Fig. 35. Demonstration of method of injection of bismuth paste into sinus of the knee.

In one case the disease was bilateral. This case has so many interesting features that I desire to cite it:

Example 1. Bilateral Knee Joint Tuberculosis.—A boy, aged 13, developed bilateral tuberculosis (Fig. 32) at the age of 10. In both limbs the disease progressed until sinuses formed, which persisted in discharging purulent material, and also small spicula of bone. In the right limb only the tibia is affected, as shown by the large swelling below the

knee and the extreme atrophy above the knee. In the left limb the femur is diseased, the swelling being above and a contracting atrophy below the knee. The radiographs (Figs. 33, 34) demonstrate this condition most lucidly. It is remarkable that, in spite of this extensive destruction, neither the right nor the left joint is involved. The boy has no pain, can stand erect, walk fairly straight, and, moreover, he can bend both knees, as shown in Fig. 35, in which I demonstrate at the same time the method of injection of these sinuses with bismuth paste.

I have carried out this treatment in this case for the past eight

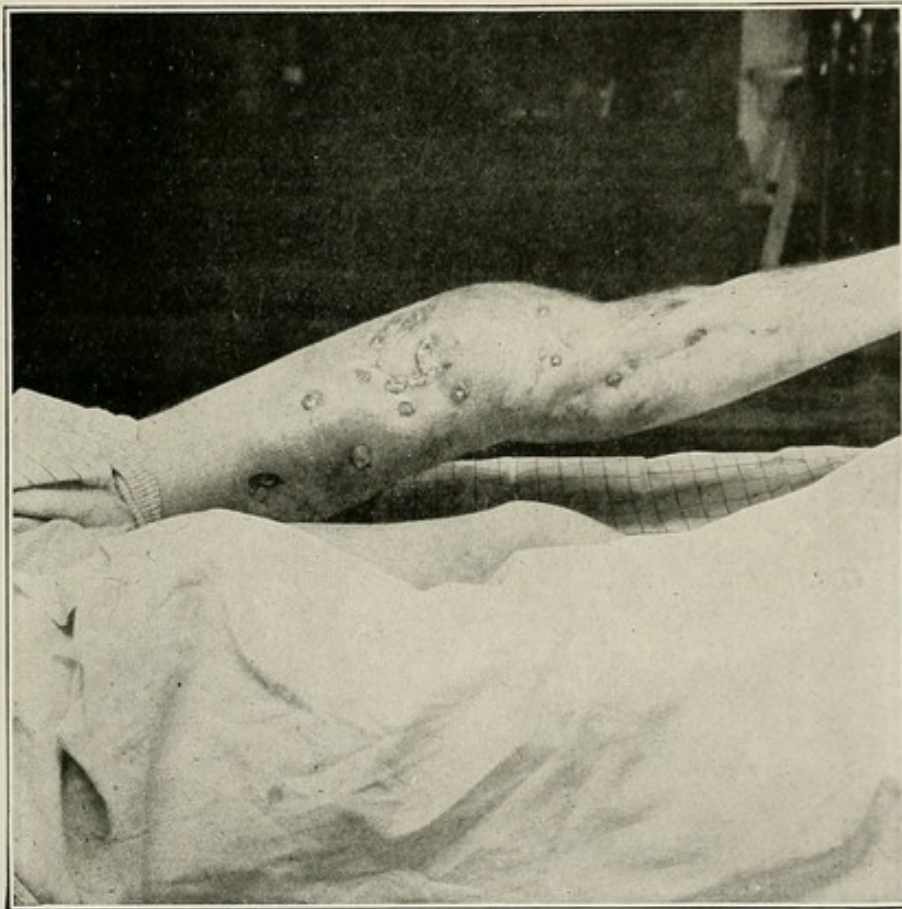

Fig. 36. Tuberculous knee joint with forty-two sinuses, sixteen years' duration.

months, injections having been given at ten days' intervals, but the sinuses continue discharging. A radical operation—namely, a complete exenteration of the end of the femur and tibia—is the indication under those circumstances, but the knee joints should not be opened.

For illustration as to what extent the soft structures may be undermined as a result of tuberculosis of the knee joint, I cite another case:

Example 2. Knee Joint Tuberculosis, with Forty-two Sinuses.—In this the disease started when the patient was 6 years old, and sinuses began to form until the entire area from the middle of the thigh down to the middle of the leg was studded with profusely discharging sinuses

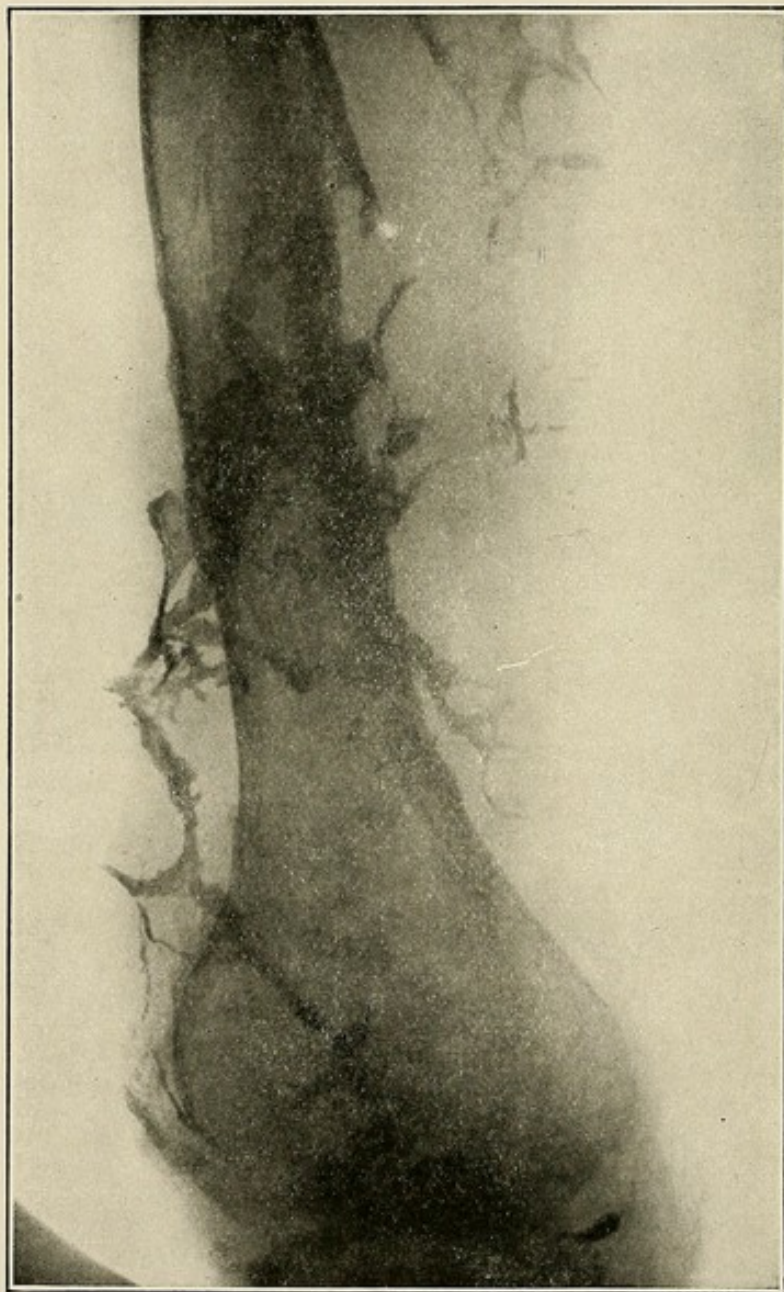

Fig. 37. Network of sinuses of femur. (Case shown in Fig. 36.)

(forty-two in number, Fig. 36). Multiple openings make it difficult of injection, as the paste escapes from the nearest counter-opening, thus failing to reach all portions of the network underneath. The patient's father, a physician, tried the bismuth paste, and, while it reduced the

amount of discharge, it failed to produce the closure of the sinuses. He believed that this was due to faulty technic, and brought his son to me for treatment.

While the case seemed hopeless, on account of the extent of the disease and the failures in the previous surgical treatment, we nevertheless decided to give it a trial. A stereoscopic radiograph of the knee joint was made, and demonstrates the causes of failure by showing a

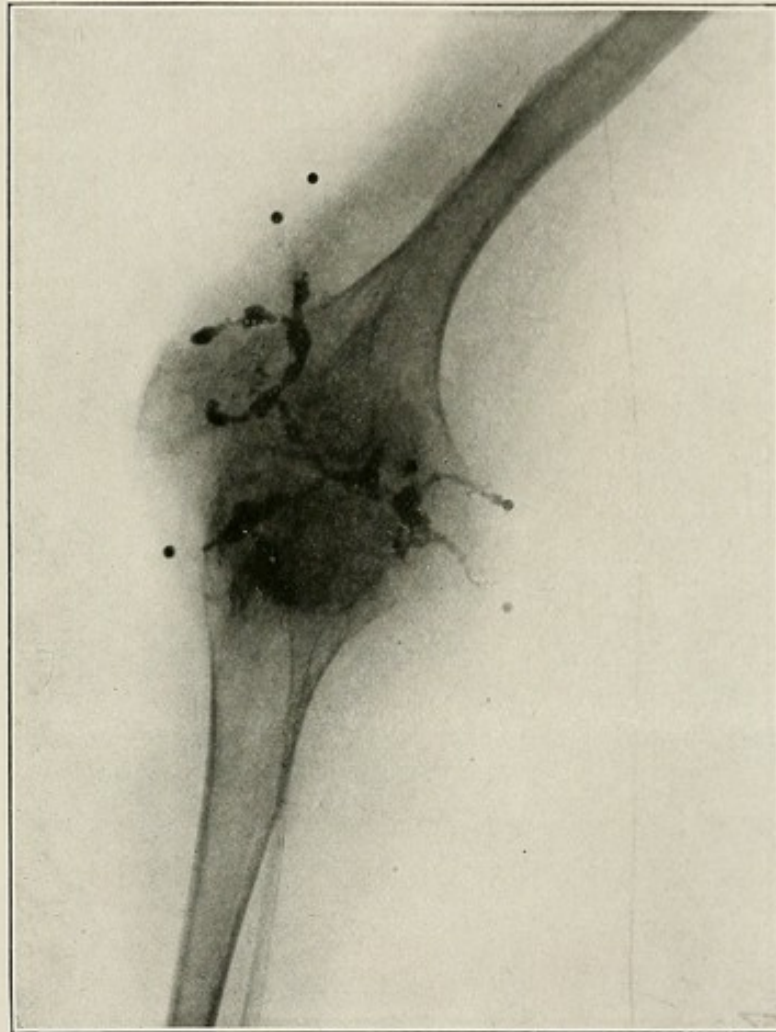


Fig. 38. Hopeless condition of old tuberculous knee joint. Eight sinuses. Amputation required.

large sequestrum in the tibia. This sequestrum was removed, and then all the sinuses were injected and another radiograph was taken. This picture (Fig. 37) demonstrates the complex arrangement of channels.

After this operation a rapid improvement followed, and the sinuses above the knee also began to close, indicating that the focus of the disease in the tibia was the fountain of the constant discharge. The case is still under treatment and the final outcome yet undecided.

It is needless to say that there are some cases which will not yield to the bismuth paste treatment. In our own series we found that 6 percent could not benefited after a persistent treatment of at least one year's duration. In no case do we give up hope of an ultimate cure until after at least one year's treatment.

Occasionally we encounter a case in which treatment is not even worth trying. The following case is an example:

M. F., aged 26, developed at the age of 10 a tuberculous knee. In spite of the most skillful treatment, the joint had undergone abscess formation, leaving it ankylosed, with eight suppurating sinuses, for sixteen years. The entire limb had undergone extreme atrophy and a shortening of six and one-half inches, so that, even if there had been no sinuses, the limb would have remained useless.

A radiograph, taken after an injection of the paste for diagnostic purposes (Fig. 38), discloses the hopelessness of a cure. I therefore amputated above the knee and had it replaced with a useful artificial limb. The discarding of crutches, a gain in general health, and a great improvement in appearance were the benefits derived from this procedure.

Sinuses from Bone and Joint Disease of the Foot.

The architecture of the foot is such that tuberculous disease rarely affects a solitary bone or joint. The os calcis is occasionally a solitary focus. The ankle joint is most frequently involved. In Fig. 39 we illustrate the typical shape of an advanced tuberculosis of the ankle. This case is of many years' duration, and was considered hopeless, an amputation having been advised by several surgeons after the radical operations had been of no avail. In 1908 the six sinuses were injected with bismuth paste and the treatment kept up for one year, and during this period the foot was reduced in size, three sinuses closed, and the three remaining have discharged only a few drops of serous fluid. He can walk without crutches, and returned to his work, which he had abandoned since the beginning of his disease.

Even the most extensive destruction in the ankle joint may ultimately heal, and the limb may become strong enough to carry the body weight. The radiograph (Fig. 40) illustrates such a case.

Tuberculous Ankle, Ten Years' Duration.—A young man, aged 19, developed at the age of 9 a typical tuberculosis of the ankle, in which

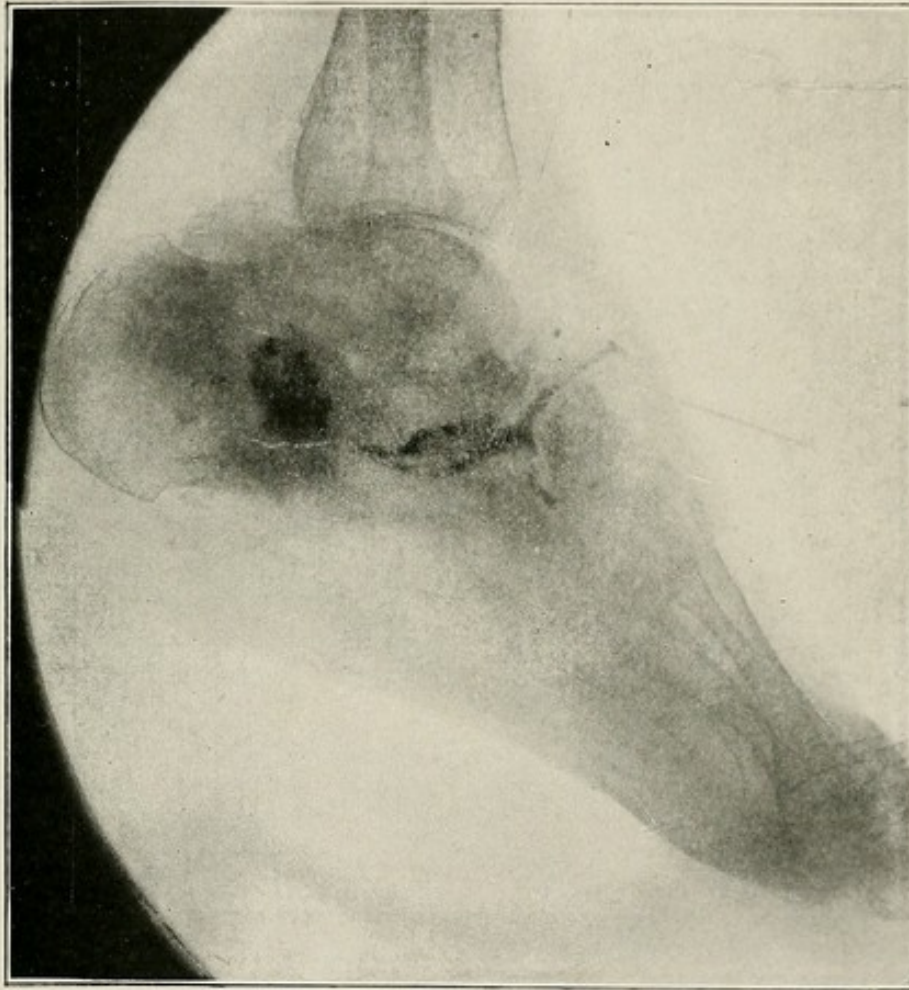


Fig. 39. Typical tuberculous ankle joint with sinuses.

the entire set of bones composing the ankle took part. The destruction of the joint was complete, abscess ruptured, and sinuses persisted for ten years, but the discharge became less profuse every year and the joint became small and painless.

In April, 1909, I injected the sinuses three times, and within a month they closed and remained so. The patient can support his body weight on the healed limb.

The radiograph (Fig. 40) has many instructive features. It shows

that after this extreme destruction of the joint nature has soldered the rough bony ends together, and produced a solid support. Callous deposits fill in all the gaps of missing bone.

Another pathological feature is here lucidly illustrated. It has been observed that the bones in the vicinity of tuberculous disease are frequently deficient in lime salts,

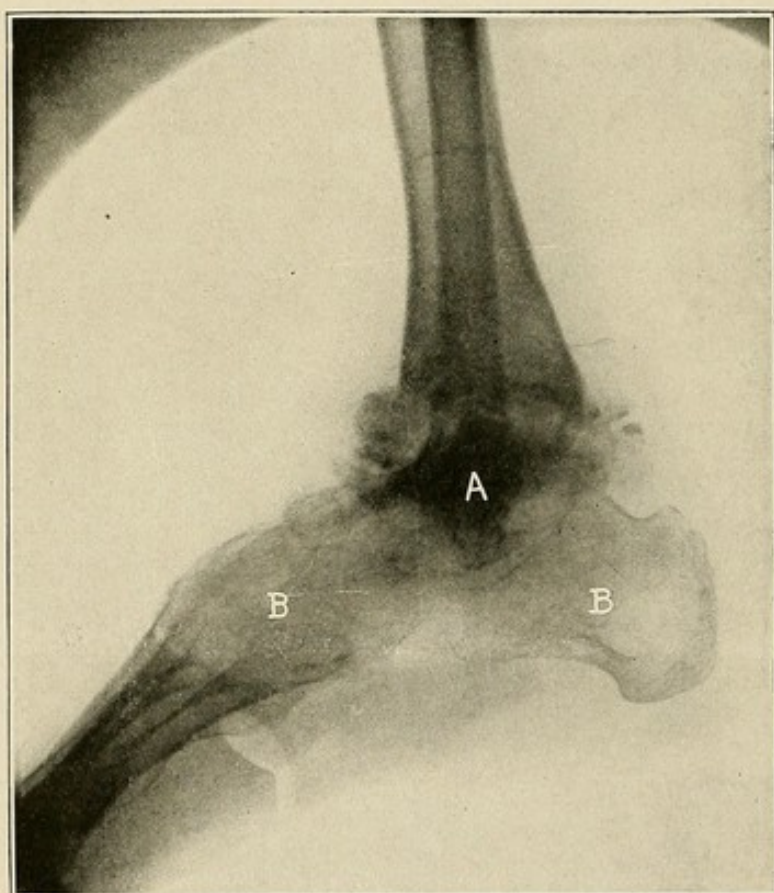


Fig. 40. Destruction of ankle joint, with ankylosis (closed). A, callus; B, B. absorption of calcium salts.

and therefore give a much lighter shadow than normal bone. We note that in this case the os calcis, all the tarsal bones, and the ends of the metatarsals show this characteristic deficiency of lime salts, while the tibia and fibula and the distal parts of the metatarsals are perfectly normal, and give a contrasted darker shadow.

Tuberculosis in the os calcis is not very rare. We illustrate a typical case in Fig. 41:

A young man of 20 developed a painful swelling of his right heel in 1907. After two months an abscess was lanced, but, instead of the expected healing, a sinus remained. A radiograph disclosed a sequestrum of a round shape, lodged in a well-formed cavity in the os calcis. Sequestrum was removed and a drainage on both sides of the heel established. The sinuses persisted and the disease extended upward, involving the sheath of the tendo Achillis, with formation of two more sinuses. In this condition he came to me for treatment. The first

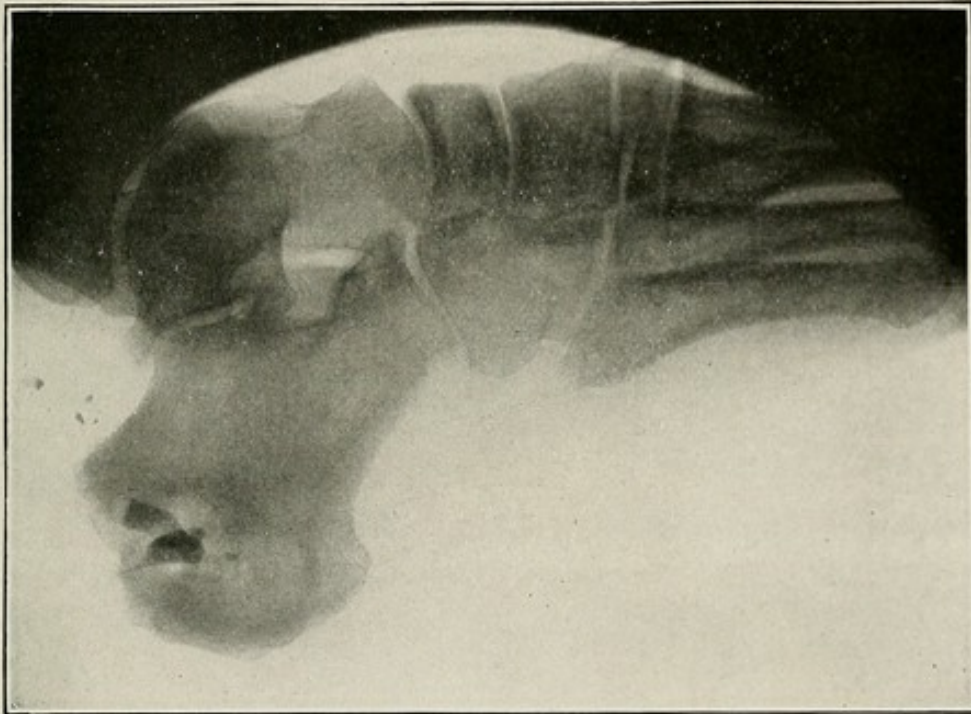


Fig. 41. Tuberculosis of os calcis injected with bismuth paste.

injection was made in March, 1909, and after three weeks' treatment the sinuses closed and remained so until January, 1910, when one of them reopened and a small amount of discharge returned. A few additional injections of the bismuth paste closed the last discharging sinus.

Sinuses from Tuberculosis of the Elbow Joint.

This disease shares the general characteristics of tuberculous infection in other joints. It occurs, however, more frequently in young girls than in boys; affects the

right arm at least 10 percent more often than the left. All three bones comprising the joint may be affected, but the humerus most frequently. Of 128 cases cited by König the radius was only twice affected, while the olecranon process was affected in 36 cases. The disease is primary in the bones in about 70 percent of cases, and invades the joint secondarily. If not arrested in its initial stages, it will progress as usual to abscess formation and rupture, with the ultimate sinus formation. In König's 128 cases 35 percent had abscesses, and in 53 percent sinuses were present. It must be remembered that his statistics comprise material of several decades, and therefore do not represent the proportion of sinuses of recent years. With the modern and conservative treatment introduced in the last few years, the formation of sinus has been reduced to a great extent, and, as will be shown in the chapter on the Conservative Treatment of Cold Abscesses, the sinus formation can be prevented in practically all cases. When, however, the sinuses already exist, the bismuth treatment is indicated, no special technic being required for this class of cases.

The **wrist** so resembles the ankle joint in architecture that the disease affects both in similar manner. The number of small bones and joint surfaces predispose to a rapid extension of the tuberculosis, and therefore it is rarely confined to one. In the wrist more than elsewhere the disease leads to abscess and sinuses, but these sinuses respond promptly to the bismuth paste treatment. Of 10 cases in our series, only 2 required curettage; the remainder healed after one or more injections without surgical interference.

The smaller bones and joints of the hand and foot are subject to the same infections, pyogenic or tuberculous, and the resulting sinuses yield to the same treatment as those of other joints.

Sinuses from Tuberculous Ribs and Sternum.

Tuberculous abscesses on the thorax wall rarely originate in the soft structures. Almost without exception they are the result of a bone tuberculosis. Leaving out sinuses resulting from empyema and those from spon-

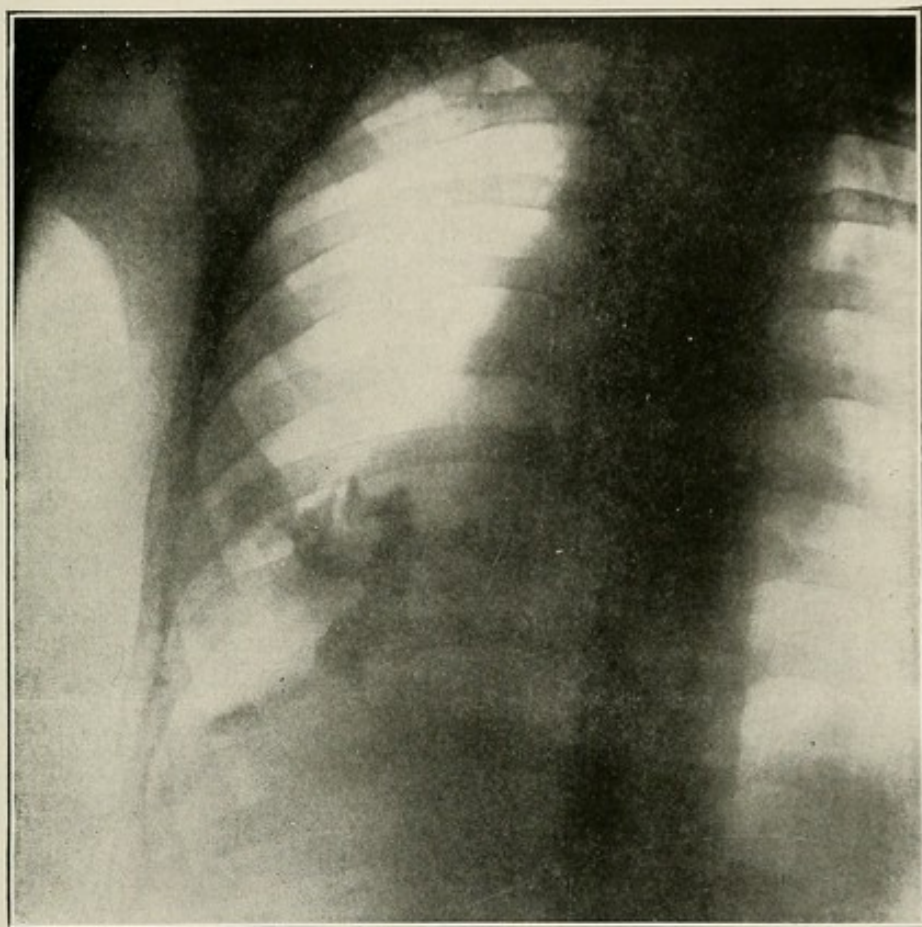


Fig. 42. Sinuses supposed to have originated from ribs, found to be due to tuberculosis of sternum.

dylitis, we may regard every sinus of the chest wall as that of a rib or sternum.

The ribs furnish about five times as many cases as the sternum, and most of them are of tuberculous origin, only a small fraction originating from typhoid or pyogenic infection. Men are more frequently affected than women, usually between 20 and 40 years of age. The

tuberculous foci are rarely larger than a cherry, usually affecting less than one inch of the rib. Their most favorite location is in the anterior curve of the third to the ninth rib. Tuberculosis of the ribs runs a very chronic

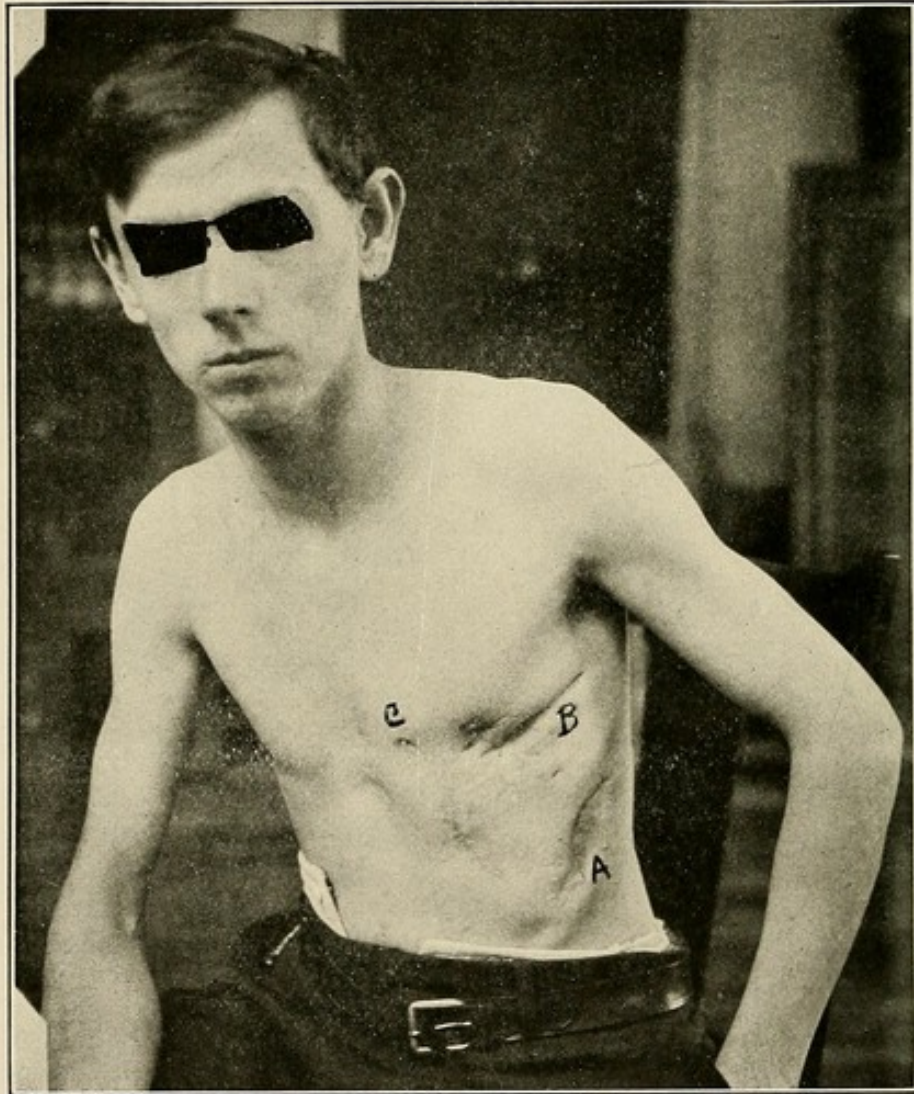


Fig. 43. Patient of radiograph shown in Fig. 42. A, incision of first operation; B, incision of second operation; C, incision for removal of sequestrum in sternum. Closure of all sinuses after removal of sternal focus.

course, often requiring months before an abscess forms, and the sinuses may open at quite a distance from the diseased focus. At times the disease originates in the sternum, and the abscess undermines the chest muscles

and opens clear over at the side of the chest wall, producing a sinus opening so far from the original focus as to mislead one in the diagnosis. The following case will illustrate this:

Tuberculosis of the Sternum Mistaken for Tuberculosis of Ribs.—

T. L., aged 21, developed when 16 multiple abscesses on the left side of his chest, below the nipple line. The same were drained, but, instead of spontaneous closure, they persisted discharging for a year. The diagnosis of tuberculosis of the rib was made and a part of the ninth rib was resected. This did not alter the condition, and a year later another radical operation was performed; the entire undermined area was curetted and a section of the fifth rib resected. Five sinuses remained after this operation, and persisted in discharging a purulent, very irritating pus for another three years.

With this history he came to me in the spring of 1909. My suspicion that this was a tuberculosis of the sternum and not of the ribs was verified by the radiograph (Fig. 42), in which it is shown that the sinuses led toward the sternum. Without opening any of the old sinuses, some of which were in the axillary line, I made an incision near the sternum, where I found some of the paste injected the day before. Following the tract of the paste toward the median line, I found a sequestrum the size of a silver quarter. This was removed and the cavity packed with gauze, followed by three injections of paste (33 percent). Subsequent to this operation, and without any surgical treatment to the other sinuses, the entire set of them closed within a month, as shown in Fig. 43, and remain so to date.

CHAPTER VIII.

POST-OPERATIVE SINUSES FOLLOWING ABDOMINAL AND KIDNEY OPERATIONS.

A decade ago, when it was customary to drain the abdomen after nearly all laparotomies for suppurative conditions, post-operative fistulæ were relatively frequent, especially when silk had been used for tying pedicles. At the present time of aseptic surgery, with our knowledge of the harmlessness of sterile pus and the acquired local immunity in chronic abscesses, we have been taught not to drain as frequently, and therefore post-operative fistulæ are rather uncommon. Nevertheless, there still exist quite a number of cases, carried over from the drainage period, some of which have lasted for many years.

Another variety of abdominal fistulæ are those resulting from the worst forms of tuberculous peritonitis, or rupture of subphrenic or appendiceal abscesses.

In these varieties of sinuses I have tested the efficacy of the bismuth paste treatment, and, while the number of cases is small, certain lessons can be drawn from my observations which may aid in the future treatment of this class of cases. Our experience is limited to thirteen abdominal cases, four of which were the results of tuberculous peritonitis and nine cases of post-operative sinuses after laparotomies.

Sinuses Following Tuberculous Peritonitis.

Two of the four cases in which tuberculous peritonitis was the cause of the sinuses were not in the least bene-

fited by the bismuth treatment, gradually wasted, and died. Both cases belonged to the most malignant type, and each had a fecal fistula besides the suppurating sinuses.

The **first case**, shown in Fig. 44 (a young man aged 23), took from the beginning a most violent course, simulating acute suppurative appendicitis, but a positive ophthalmic reaction and other symptoms convinced us that we had to deal with tuberculous peritonitis. Within six months the patient was emaciated to a skeleton, and a sinus

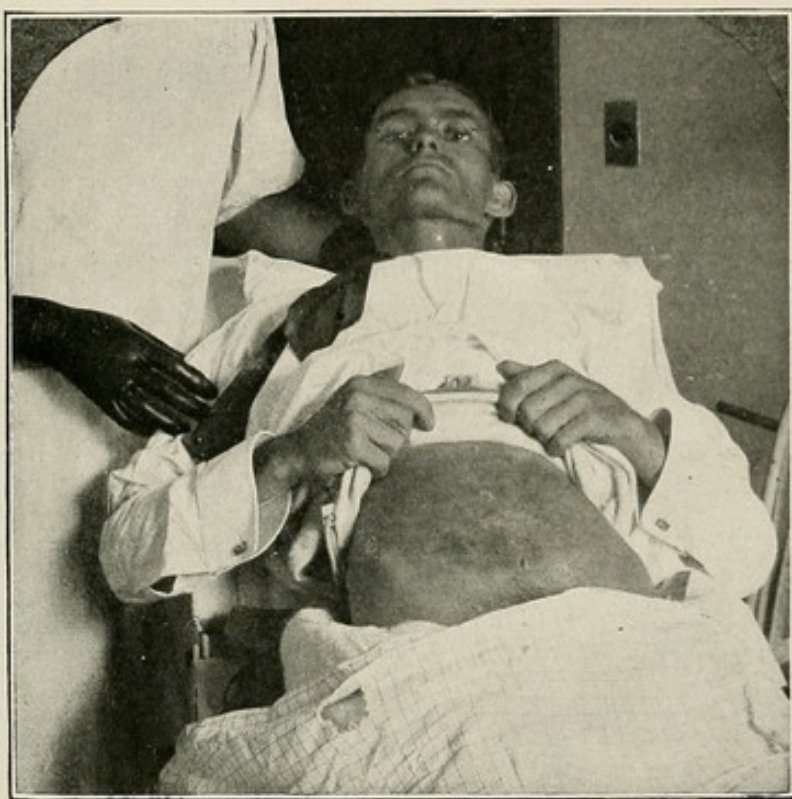

Fig. 44. Sinus and fecal fistula in tuberculous peritonitis.

formed just below the umbilicus, in the line of incision, and soon thereafter a fecal fistula complicated this condition. A violent eczema aggravated the already unbearable condition, and thus he succumbed to the disease. Six injections had been made into the sinuses without any effect.

The **second case** was that of a young man who was referred to us by his physician after the abdominal sinuses and fecal fistulae had already existed for several weeks. Following the first few bismuth injections he seemed to improve and began to walk, but soon after relapsed and gradually wasted away and died. A post-mortem was obtained. It proved to us the futility of this or any other treatment

in cases which have reached this stage. The disease had invaded the entire abdominal cavity to such an extent as to convert the intestines into a firm mass, in which were locked up hundreds of abscesses. The paste was seen to have reached only one of these abscess sacs. The duodenum showed a perforated ulcer. The cecum was evidently the primary focus of the disease, it having been transformed to a mass of tuberculous tissue.

With the experience in these two cases, I do not advise the use of the paste in tuberculous peritonitis when it has reached this malignant and hopeless stage.

Whether the paste will be of value in the earlier stages or the less malignant forms of tuberculous peritonitis is still a problem. There has always been something mysterious about the spontaneous cures of tuberculous peritonitis; nearly every remedy tried has been successful, and finally it was found that the simple opening of the abdominal cavity was all that was necessary to produce a cure. It has, however, been found that many of these mysterious cures were only apparent, and that recurrences took place. (Mayo.¹)

In St. Mary's Hospital at Rochester, Minnesota, where in a period of ten years (1894-1904) 89 cases of tuberculous peritonitis were operated upon by simply removing the fluid, most of them improved. It was noted, however, that a considerable percentage returned for further treatment, and thus it was shown that the improvement had been only temporary. Some were reoperated as many as four or five times without any permanent result. In 1902 Dr. J. B. Murphy called attention to the fact that when tuberculous peritonitis was present the mucosa of the fimbriated end of the Fallopian tube on one or both sides would usually be found everted and the tube considerably thickened. This fact was readily verified during the subsequent operations, and the majority of female

¹ Mayo: Surgical Tuberculosis in the Abdominal Cavity.—Journal American Medical Association, April 15, 1905.

patients with tuberculous peritonitis showed a thickening of the tubes. On removal of these tubes, typical tubercular ulcers of the mucous membrane, with cheesy deposits, were discovered, and in many instances the tubercle bacilli could be stained. In the minority of cases the tubes were normal.

This knowledge was at once taken advantage of, and in the subsequent laparotomies for tuberculous peritonitis the disease focus was radically removed whenever it could be located. Of 26 tubal resections for tuberculous peritonitis performed by Drs. Mayo, 25 recovered. Of these, 7 had been previously operated from one to four times. In not one single patient has a secondary operation been necessary thereafter.

This striking example from such a reliable source teaches us the lesson that tuberculous peritonitis is practically always secondary, and that by removing the primary focus the peritoneum will usually take care of itself and a permanent cure will be obtained. In other words, if the source of the constant reinfection could be eradicated, the peritoneum would undergo spontaneous healing.

The primary sources of tuberculous peritonitis are the Fallopian tubes, the appendix, the mesenteric glands, and ulcerations of the intestines. Since we know that this peritonitis is practically always secondary to tuberculous disease of other organs in the abdomen, it would be irrational to treat the peritonitis and ignore its source. Surgical treatment is the proper procedure, and, as shown by Mayo, the removal of the primary focus gives a splendid chance for permanent cure.

This remarkable fact has its analogy in other tuberculous conditions. For instance, in tuberculosis of the kidney there is frequently a coexisting tuberculosis of the

bladder. As soon as the kidney is removed, the bladder will usually heal spontaneously. Again, the removal of a tuberculous tonsil will frequently cure an infected chain of lymph glands. A similar, but not so well-established, example of this principle is that observed by Brauer, Forlanini, Murphy, and others—that when one tuberculous lung is collapsed (nitrous oxide gas injections into the pleural space), and healing has taken place, a coexisting focus in the other lung, when present, will also be favorably affected.

The regularity with which this spontaneous healing occurs precludes the possibility of coincidence, and requires an explanation. *Is it not possible that, through the removal of a large portion of the diseased tissue, our body, which has acquired such high degree of immunity during the gradual development of the disease, is suddenly relieved of the source of a large quantity of toxins, and the existing high degree of immunity is powerful enough to cope with the balance of microorganisms still operating in other parts of the body? In other words, is it not likely that during the development of the disease the degree of immunity keeps pace with the progress of the disease, and that the sudden removal of a part of the diseased tissue leaves the system a sufficient degree of immunity to combat the remaining quantity of disease in the body?* I have undertaken a series of experiments on lower animals, such as swine and guinea pigs, to prove this theory, but it is too early to permit of the publication of the results.

Surgical treatment, therefore, is the most rational in tuberculous peritonitis, and only when the removal of the original focus of the disease has failed to check the progress are other methods, such as injection of various oils and emulsions, to be employed.

I desire to warn the practitioner against injecting large

quantities of the bismuth paste into the peritoneal cavity, because the extensive surface for absorption may lead to bismuth poisoning. It may be permissible to inject a few drams of a 10-percent bismuth paste in the earlier stages, where the focus of the disease has already been removed. We have tried this in two cases, and, although we have obtained splendid results in both, I do not yet consider this a sufficient test for its advocacy.

A brief history of these cases may be of service:

Case 1. Tuberculous Peritonitis; Bismuth Treatment; Cure.—Miss L. M., aged 23, developed in 1907 symptoms of chronic appendicitis. An operation revealed a tuberculous peritonitis without adhesions, but the intestines and omentum were studded with tubercles. At the base of this was found a tuberculous appendix, which was removed.

Instead of gaining, she continued to lose in weight and strength, and was sent to California, where she remained for six months. Not improving, the physicians there advised her to return, pronouncing her case hopeless. Upon her return to Chicago, in 1909, I proposed to try the injection of a small quantity of paste into the peritoneal cavity. The parents consented and the procedure was as follows: through a small incision in the abdominal wall above the left inguinal ring three drams of a 10-percent paste were injected and the incision closed in the usual way. With the purpose of spreading the paste over the surface of the intestines, a gentle massage of the abdomen was made. For three weeks following this procedure she was rather ill, running a temperature of 100° every day, and apparently losing ground, but after that period she began to improve in every way, so that after one year she regained her health and is able to attend general household duties. Locally, there are no symptoms of peritonitis.

Case 2. Sinus Following Tuberculous Peritonitis; Bismuth Treatment; Cure.—Mrs. K. H. was treated in 1908 for tuberculosis of the glands of the neck. An extensive and radical operation was followed by a tedious process of suppuration, and deep-seated sinuses persisted until they healed with bismuth injections. Thereafter patient spent a year of perfect health in Colorado. Upon her return to Chicago she developed a large abdominal exudate and lost considerably in weight; ophthalmo reaction was positive. Exploratory laparotomy was performed by Dr. Carl Beck (my brother). The abdomen was studded with thousands of tubercles, and both Fallopian tubes were thick and tuberculous. He removed both tubes and closed the abdomen; primary union took place. Six weeks later the scar reopened and discharged a quantity of cheesy material and pus. The sinuses showed no tendency to closure, and the bismuth injections were then instituted.

116 BISMUTH PASTE IN CHRONIC SUPPURATIONS.

In the radiograph (Fig. 45) we can plainly trace the path of the sinus to the original focus in the region of the tubes. After one month's treatment with paste injections the sinus closed, and patient is now in good health.

Although the final result in these last two cases is very satisfactory, I advise the most extreme conservatism in

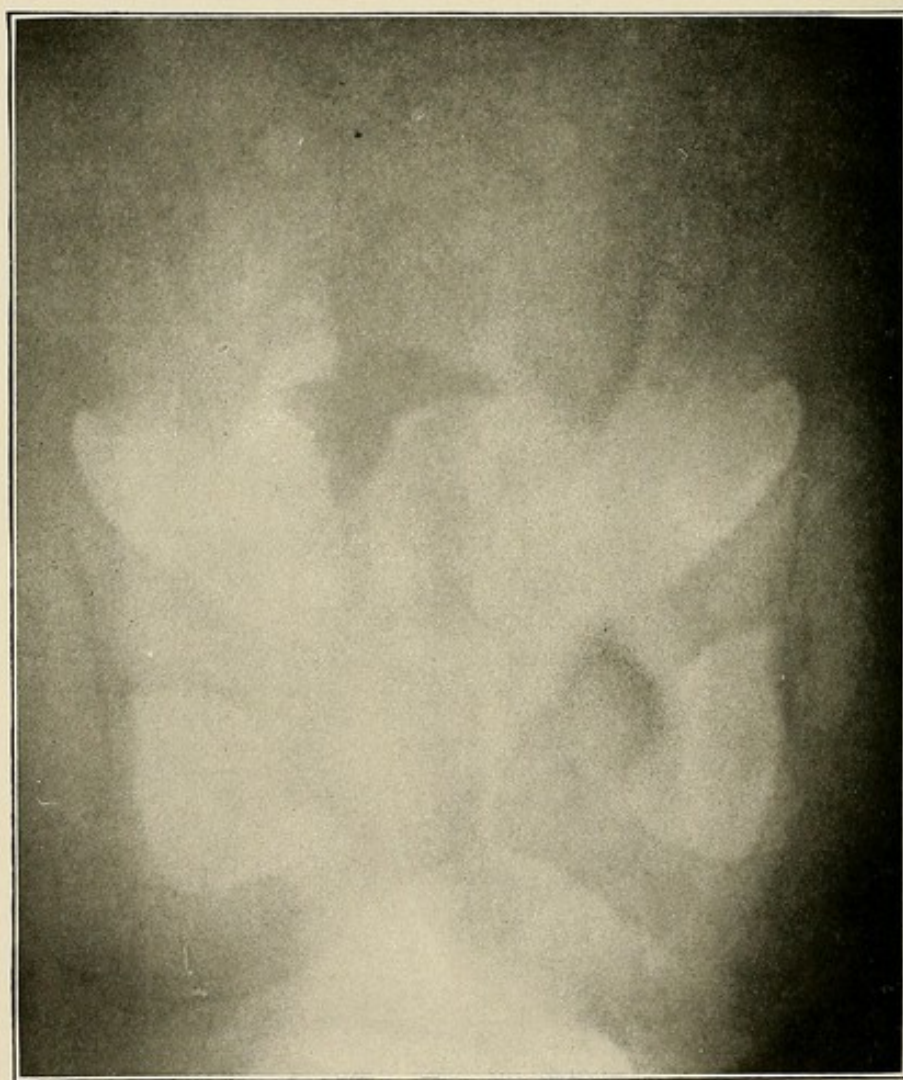


Fig. 45. Sinus following tuberculous peritonitis after removal of the adnexa.

the use of the paste in this class of cases, and would limit its use to those cases in which a fistula remains after a radical operation, barring the hopeless cases, such as I have cited in the beginning of this chapter.

Post-Operative Abdominal Fistula of Pyogenic Origin.

Nine cases of this variety were treated with bismuth paste. This series does not include post-operative fecal fistulæ, which are considered separately in another chapter. The sinuses in the above nine cases were of from two months' to three years' duration, all resulting from drainage following abdominal operations. In eight of these nine cases the treatment was effective, requiring from one to thirty injections for their closure; in the remaining case the bismuth treatment produced no effect.

The usual technic was applied in their treatment. I shall cite the case in which the treatment failed, because we can learn more from the failures than from the successful cases.

Case 9. This case, in which the bismuth treatment also failed, was a sinus occurring after a laparotomy performed two years ago. The radiograph shows a large cavity in the pelvis, and a tumor is present, which appears to be a pyosalpinx filling the left side of the pelvis. The abscess cavity evidently originates from a diseased tube, and thus we can not expect a closure of the sinus until the diseased mass is eradicated.

The remaining eight cases responded promptly to the treatment, especially those which were of long duration. I am certain that many physicians have had cases similar to those just cited, and their experiences will probably tally with those of mine.

I do not advise the use of the paste in recently operated cases in which a spontaneous healing may be expected in due time. Only in those cases where the healing is very much protracted, and where there is no tendency to spontaneous closure, are we justified in using the paste.

It must be remembered that the newly-formed adhesions of drainage channels are very thin and may tear at even moderate overdistention with the paste, and thus open fresh areas for infection. Moreover, we must bear in mind that fresh surfaces absorb the metallic bismuth much quicker than the hard fibrous walls of chronic

sinuses, and thus the excessive absorption may lead to bismuth intoxication. Again, I warn against the use of the paste when the abdominal wound is in a state of acute inflammation; here it may even aggravate the condition.

Sinuses from Tuberculous Kidneys.

Not all sinuses in the loin originate from the kidney. They may be the result of spondylitis or sacral tuberculosis. The latter two have already been discussed in the respective chapters, and their mention here is necessary only to point out that every sinus in the region of the kidney is not necessarily a kidney sinus. The history of the case and the entirely different symptoms in these two affections leave very little chance for diagnostic error; nevertheless, under unfavorable conditions a sinus from tuberculous disease of the kidney may be mistaken for one of spinal origin. I cite such a case on page 122.

When these sinuses lead from the bed of the kidney, they may have their origin in either the kidney substance or result from a perinephritic abscess—one which either ruptured spontaneously or had been incised and drained. Another variety is the post-operative sinus resulting from nephrotomy or nephrectomy.

The results obtained in this form of sinuses by means of the bismuth paste treatment have been most gratifying, because the prospects for a cure seemed scant and the results were surprisingly good. The most recent report on the therapeutic effects of bismuth paste on sinuses following nephrectomies is that of Heitz, Boyer, and Morens. They treated 11 most refractory cases in a Paris hospital, with the result of 8 complete and 1 relative cures, the two remaining cases being improved and still under treatment. The cases are reported in detail and illustrated with splendid radiographs, thus adding an in-

structive chapter to renal surgery.¹ My experience is limited to seven cases, six of which were cured and the seventh died subsequent to a surgical operation. For illustration, I will cite four of these cases, including the fatal one:

Case 1. Cystic Kidney with Calculi; Operation; Result, Fatal.—Mrs. H. J., aged about 50, mother of two healthy children, developed an abscess in the region of her left kidney when 35. The abscess was incised and supplicated for fifteen years. Besides the profuse, purulent, and malodorous discharge, she passed also a great deal of pus in the urine. December, 1907, she applied to me for treatment. At that time I had very little experience with the bismuth paste, but I decided to try it in this case. Following the injection, the discharge lessened, but the radiograph revealed the presence of calculi in the substance of the kidney. The patient was in many ways handicapped, having only one kidney, and was a poor subject for operation; nevertheless, nephrectomy was decided on and performed. It was very difficult to separate and remove this large sacculated kidney from its firm bed, which prolonged the operation. The kidney had been entirely destroyed and consisted of a large mass of multilocular abscesses studded with dark, irregular-shaped stones. The patient died on the fourth day from uremia. It is my belief that the ether anesthesia was partly responsible for the uremia. Bismuth paste treatment could have been of no value in this case on account of the infected calculi within the diseased tissue.

Case 2. Tuberculous Kidney; Nephrectomy; Sinuses One Year; Bismuth Treatment; Closure.—Mrs. H. R., aged 26, was operated upon January 7, 1907, by Dr. Carl Beck for tubercular right kidney. A tuberculous involvement of the bladder and urethra made it impossible to determine before the operation whether the left kidney was functioning normally and whether it was free from tuberculosis. For this reason the following procedure was followed:

The right kidney was brought forward and fixed outside of the body, split, and all the urine drained outward, whereupon the urine from the other kidney, which was voided through the bladder, was so clear that we could conclude that the nephrectomy could be performed with safety. It required a large incision, and the ragged cavity which remained after removal of the diseased kidney was packed with gauze. After long and tedious treatment, such as irrigation, the patient improved in general health, but the fistula showed no tendency to healing, and the patient left the hospital May 22, nearly six months after operation, with very little hope that her fistula would ever close.

¹Heitz, Boyer, and Morens: Des Injections de Paté Bismutée en Chirurgie Urinaire.—*Annales des Maladies des Organes Genito Urinaires*, June 1, 1910.

About three months later, when our experiments with bismuth injections became encouraging, I sent for her, intending to try this method, with the view of closing her fistula. She returned September 3, 1907, and the first bismuth injection was made, of which we have a skia-graph. It shows that the fistula reaches up to the diaphragm, about

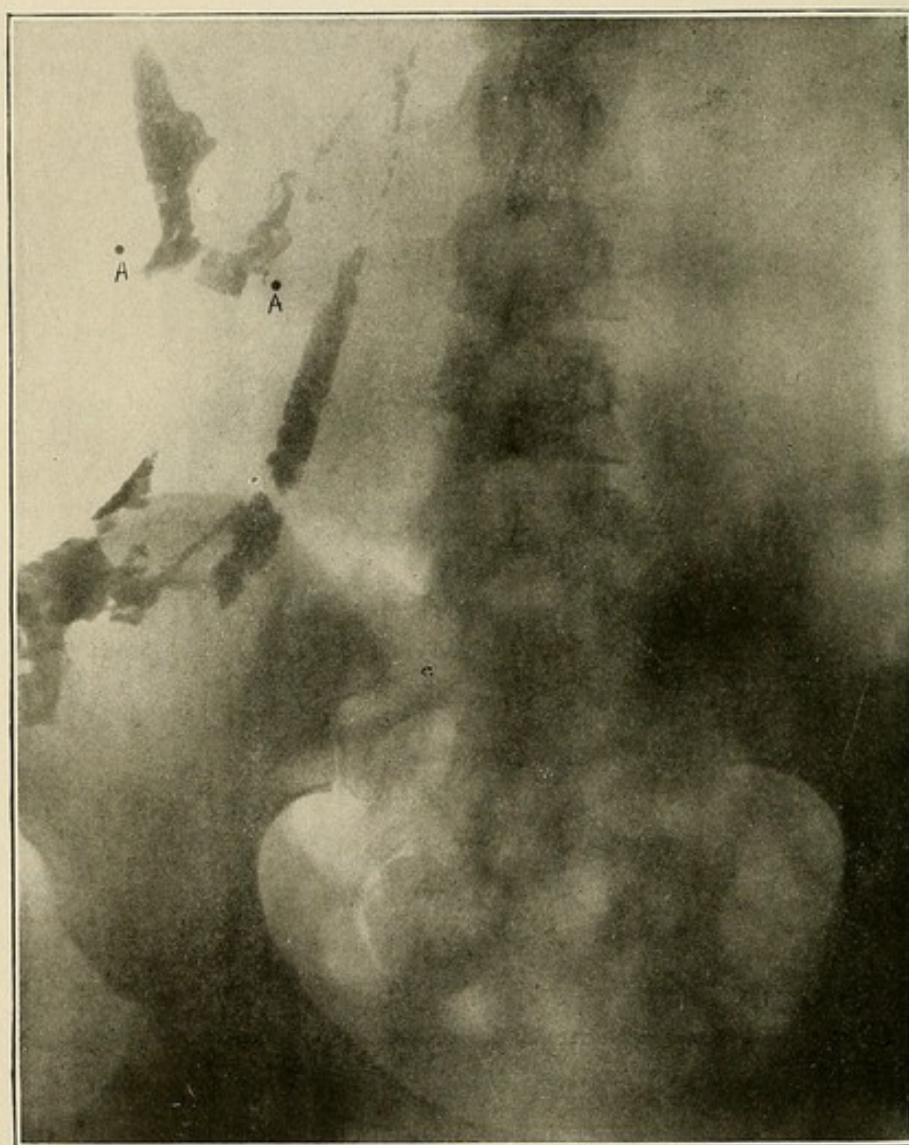


Fig. 46. Tuberculous sinuses of kidney. A, A (for tracing), openings of sinuses. Vertebral column unaffected.

four and one-half inches in length. From September 3 until November 13 only five injections were made, and a decided improvement followed. The patient did not, however, wish to remain longer at the hospital, and returned once a week for bismuth injections. By February 1, 1908, the sinus was closed and remained so. The closure of the sinus is not quite so remarkable a feature in this case as the most unusual

gain in weight. In her worst state, in September, 1907, she weighed ninety-one pounds, and within two years she has gained sixty-four pounds, and is in perfect health.

Case 3. Nephrectomy; Sinus Nine Years; One Injection; Closure in Twenty-four Hours.—Joe L. G., aged 46, developed an abscess in his left lumbar region. Incision and evacuation of one quart of pus relieved the symptoms, but sinuses remained. Two years later a nephrectomy was performed, during which he nearly lost his life from hemorrhage.

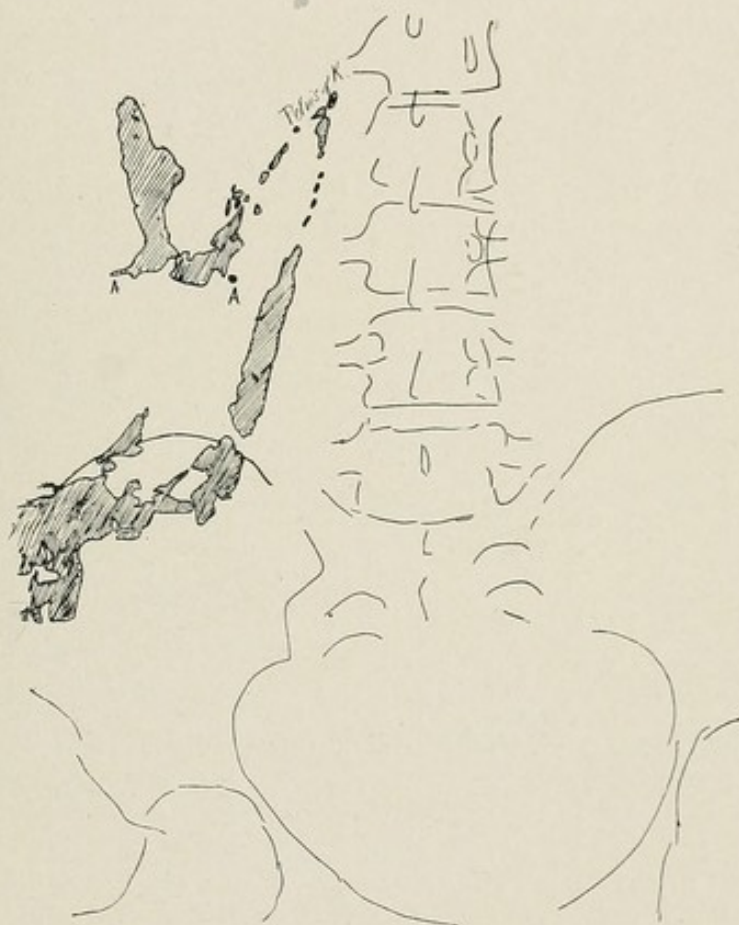


Fig. 46 A. Diagrammatic illustration of Fig. 46.

A suppurating sinus remained, and the drainage was kept up for nine years. The opening of the sinus was on the anterior wall of the abdomen, about three inches to the left of the umbilicus, but led subcutaneously to the kidney region. In October, 1908, he came for examination of the existing post-operative ventral hernia. I injected the suppurating sinus, which had then been open for nine years, and asked the patient to return next day. Within these twenty-four hours the sinus closed and never reopened. Patient gained very much in weight and strength.

The following case is instructive for diagnostic as well as for therapeutic reasons:

Case 4. Tuberculosis of Kidney; Sinus Treated Without Nephrectomy; Cure.—Miss C., aged 19, was well until 1907, when she fell from a buggy and slightly hurt her back. After two months' illness of fever, pain in the back, emaciation, an abscess formed in the lumbar region. The abscess was opened, whereupon secondary infection took place. For one year she was confined to bed, running a temperature from one

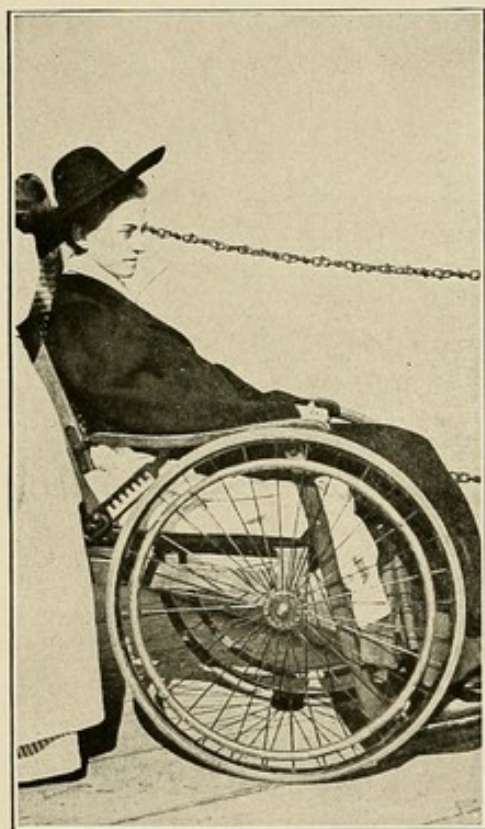

Fig. 47.



Fig. 48.

Figs. 47, 48. Patient with tuberculous kidney. Fig. 47, patient in most emaciated state; weight, 68 pounds. Fig. 48, patient one year later; weight, 129 pounds. Kidney not removed.

to three degrees every day, and thus was reduced to a mere skeleton, weighing only seventy-six pounds.

July 16, 1908, she was brought to me in this pitiable condition. In the eczematous lumbar region were two sinuses, secreting quantities of greenish pus. These two sinuses communicated, as proven by the bismuth injections. On account of the painful condition, I could inject only small quantities of the paste. A radiograph proved that this case was a tuberculosis of the kidney, the vertebral column being perfectly normal.

Between July 15 and September 9 the sinuses were injected sixteen times without the slightest effect upon the secretions or upon her general condition. The fever continued. On September 9 I used a little more force than usual during the injection, and felt as if something had given way, and I could inject three times the usual quantity. Another radiograph after this injection (Fig. 46) plainly shows that the paste reached into the kidney. From that day the temperature fell to normal, the secretion changed to a serous consistency, and after five subsequent injections the sinuses became entirely closed. The patient could be taken into the fresh air in a rolling-chair and began to gain rapidly. Fig. 47 shows her one week after closure of sinuses, when her weight was only sixty-eight pounds. Within one year her weight rose to one hundred and twenty-nine, which she has retained, and her perfect health can be discerned by her present photograph in Fig. 48.

Two cases similar to the one just cited were reported by Dr. A. J. Ochsner at the Chicago Medical Society, both recovering by this method of treatment.

These cases show that sinuses which remain after spontaneous rupture of kidney abscesses or after nephrectomy are not as hopeless a condition as formerly considered, and that with the bismuth treatment the outlook for a cure is most promising.

CHAPTER IX.

RECTAL FISTULÆ—DIAGNOSIS AND TREATMENT WITH BISMUTH PASTE.

The bismuth paste serves two purposes in rectal fistulæ. First, it reveals diagnostic errors, and, second, it heals the majority of cases which have not responded to surgical treatment. I have encountered several cases in which the radiographs of the injected fistulæ proved an incorrect diagnosis—they were sinuses resulting either from pelvic abscesses or tuberculous osteomyelitis of the hip or sacrum. These abscesses happened to rupture so near the anus that they were mistaken for a rectal fistula and operated upon, often with the disastrous result of adding an incontinence to the existing trouble, besides transposing the sinus opening from the skin into the rectum. Fig. 49 illustrates such a case.

The therapeutic results depend in a great measure upon correct diagnosis and proper technic. A fistula which has its origin in a tuberculous focus in the sacrum and a sequestrum at its root can not be expected to heal by simply injecting the paste. The focus of the disease must first be eradicated. If the fistula has a counter-opening in the rectum, the paste will flow into the rectum by the shortest route, and miss side branches if such exist.

The therapeutic possibilities of the paste in rectal fistulæ are illustrated in the following case:

Rectal Fistulae, Forty Years' Duration; One Injection; Closure.—J. P., aged 68, developed in 1868 a pararectal abscess. Being a cowboy, and living in a rural district where a physician was not within

reach, he performed his own surgical operation by plunging a jackknife into the abscess with the aid of a mirror. Within one year he had five sinuses around his anus, which discharged pus uninterruptedly for **forty years**. Although many times advised to undergo an operation, he refused, preferring daily dressing, to which he so accustomed himself that he did not mind their inconvenience.

In June, 1908, I first injected the fistulæ with bismuth paste (formula 1), and found that the five sinuses communicated. To my surprise, the discharge ceased after this first injection, and one month later all sinuses were closed and have remained so (two years).

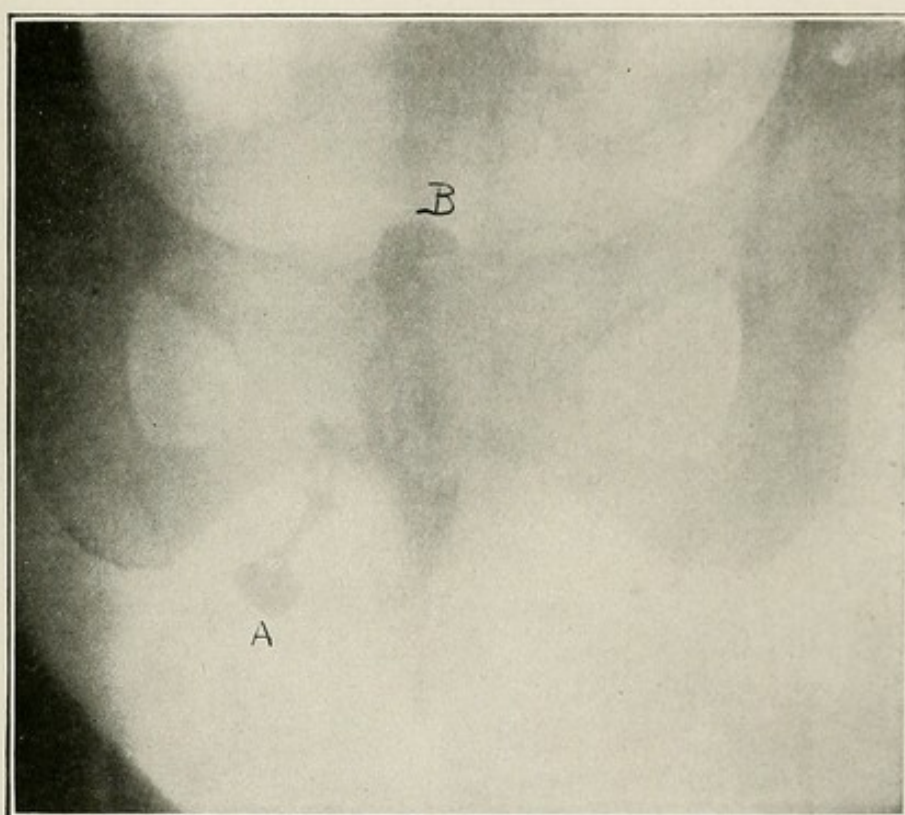


Fig. 49. Rectal fistula originating in coccyx, supposed to be of rectal origin. A, side branch; B, highest point, near coccyx.

The literature contains many scattered reports of cases of rectal fistula treated with bismuth paste, and the average results have been satisfactory. Failures in treatment could in nearly all cases referred to me be accounted for in two ways—first, faulty technic, and, second, incorrect anatomical diagnosis.

The only special report on rectal cases is that of Pen-

nington, who tested the method shortly after he saw my cases, brought before the Chicago Medical Society in January, 1908. His report relates to 17 cases which he treated with bismuth paste, most of which had been previously treated by other methods. After a period of four months he obtained a cure in 14 of the 17 cases (76.8 per cent). Dr. Pennington modestly attributes this high average to his good fortune in having favorable cases. My explanation would be that his large percentage of cures was due to following out the technic.

In my own series of 57 rectal cases 4 were given up as hopeless; 5 discontinued treatment, although improved; 48 were cured, 3 of which had recurrence and healed with resumed treatment. One patient died, three years after closure of the fistula, of a hemorrhage of his lung. There could be no relation established between the cause of his death and the former rectal trouble, except that the fistula had been of tuberculous nature.

Technic in Rectal Fistulæ.

The patient should be placed in the knee-chest position, and the sinus opening cleansed with 95-percent alcohol. The metal syringe shown in Fig. 1, filled with the paste, is then immersed in hot water, so as to keep the paste liquid. The tip of the nozzle is placed against the opening, and with steady, gentle pressure the paste is injected into the sinuses until the patient feels some distention. **No force should be used.** In order to ascertain whether the external sinus communicates with the rectum, the finger should be introduced, and, if it shows traces of the paste, we may conclude that we are dealing with a complete fistula. Should this be the case, the treatment will be somewhat difficult. It is then necessary to occlude the internal opening of the fistula with

the finger while the paste is being injected into the external opening. Thus the escape of the paste into the rectum is prevented and it is forced into the other direction, where it will fill other existing channels. At times it becomes necessary to employ a rectoscope in order to inject the fistula through the opening within the rectum.

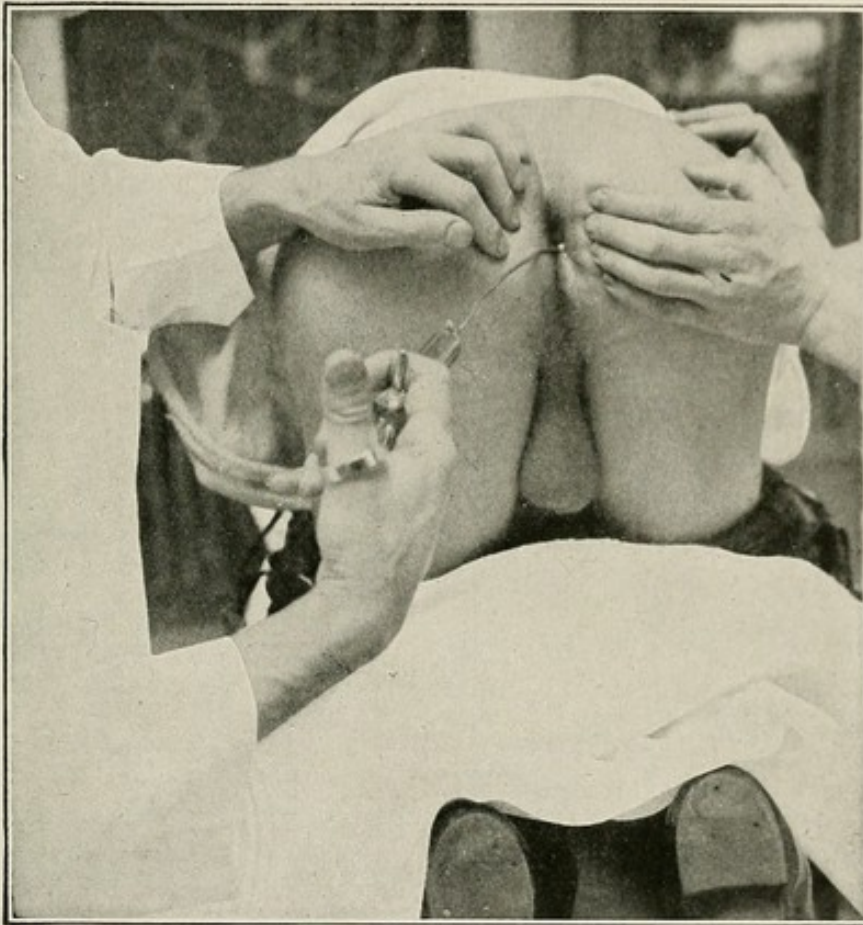


Fig. 50. Method of injection of external rectal fistula.

For this purpose the long nozzle of the metal syringe is used. It must be kept warm, so that the paste will not solidify and clog the narrow channel. When the fistula has a very small opening and is in the puckering folds of the anus, the spear-shaped tip is to be inserted, while an assistant stretches the folds. Fig. 50 illustrates this procedure.

After the injection is completed, a T-bandage is applied and the dressing changed daily. If after one week the discharge continues to be purulent, the fistula should be reinjected. If the secretion becomes serous, it should not be reinjected, as it will usually close within a short period. Fig. 50 illustrates the procedure.

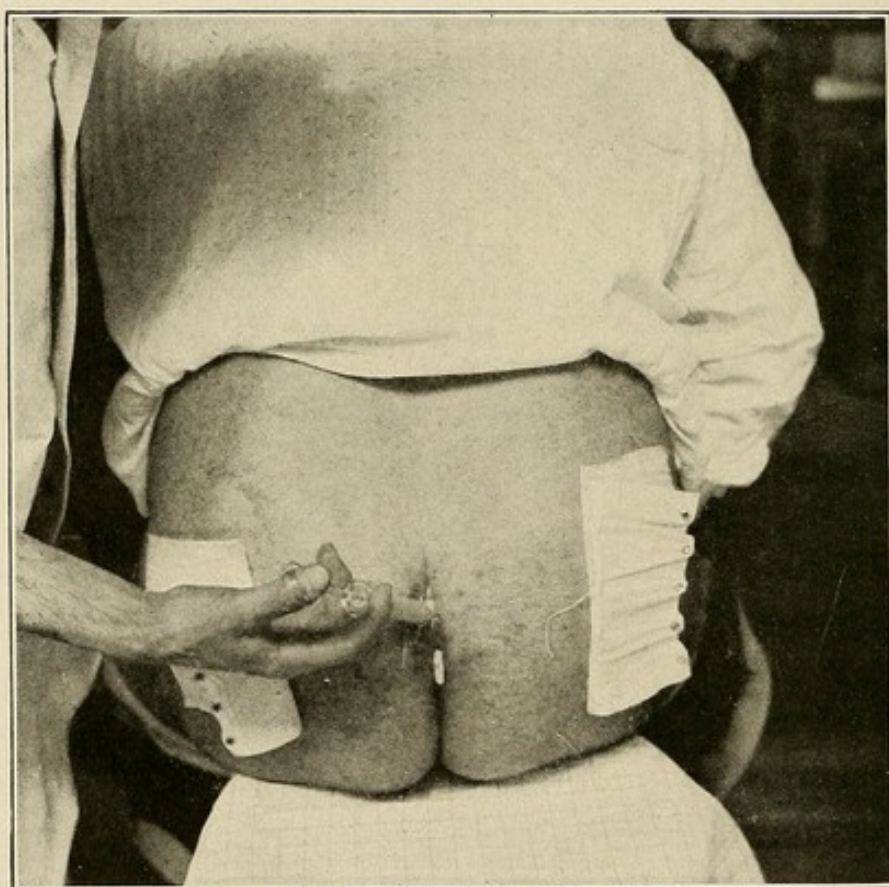


Fig. 51. Dermoid cyst treated with bismuth paste.

An infected dermoid cyst of the sacrum or coccyx may be mistaken for a rectal fistula. I illustrate such a case in Fig. 51.

In this picture there is shown the procedure of injecting a sinus resulting from a dermoid cyst. The patient is only 23 years old and weighs two hundred and sixty pounds. For the past five years he has had a foul discharge from four little openings, one-half inch apart, in the fold above the anus. The first injection proved that they communicated, because the paste injected in one at once escaped from

the mouths of the others. At one time a small quantity of jet-black hairs came out of one of the openings. This indicated that we had to deal with a dermoid cyst, and consequently an operation was advised and performed, which consisted in the complete eradication of the cyst. The cavity was drained and four days later an injection of the paste was made. The purulent and foul discharge changed into a yellowish, clear serum within three days, and healing progressed rapidly. This picture shows that a greater part of the incision is healed, and that the paste injected through the upper opening escapes through the lower. Within a period of six weeks the sinuses were closed.

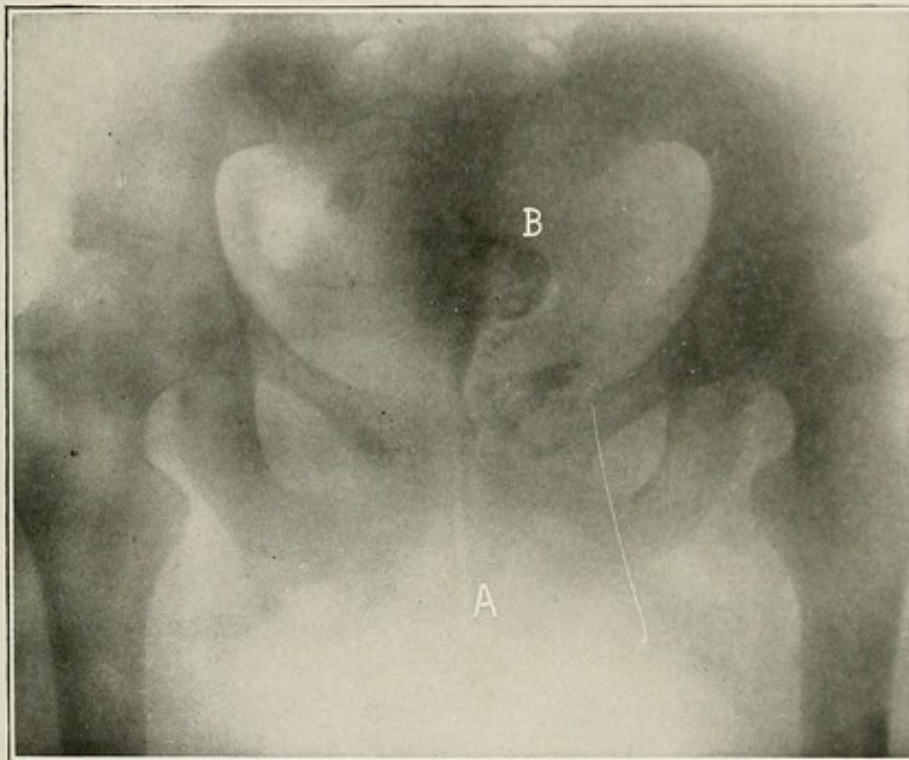


Fig. 52. Supposed rectal fistula, shown to be a sinus resulting from disease of pelvic organs. A, fistulous opening in the rectum; B, bi-paste in the pelvic cavity.

The following case is typical of those in which incorrect diagnosis led to futile operations:

Rectal Fistula Originating in the Pelvis.—The patient, a lady, aged 30, has since 1900 undergone six operations for rectal fistula, all of which failed to stop the profuse and irritating pus discharge. The last operation was very extensive and produced incontinence of feces. In this condition the patient came to me in January, 1908, when I made the first bismuth paste injection. A radiograph (Fig. 52) disclosed that the fistula had its origin high up in the pelvis. Several sinuses as high as the sacral prominence are plainly shown, the early discovery of which could have saved the patient the six operations and nine years

of invalidism. This fact was corroborated further by the most satisfactory result obtained from the bismuth paste injection. It required three months' treatment, but the sinuses healed. The sinus openings were intrarectal, and the large gaping rectal opening permitted their being easily reached and injected. A year after the cessation of discharge a plastic operation for the incontinence was tried, but was only partially successful. An abdominal operation six months later proved that the sinuses originated in the Fallopian tubes.

Examples as the one cited above must guard us against assuming that every suppurating sinus near the rectum is necessarily a rectal fistula.

In my collection of radiographs of bismuth-injected rectal fistulæ there are a number of examples in which the supposed rectal fistula was in fact a sinus originating in some distant part of the body, such as the hip joint or spine. In not a single one of them have I seen a straight fistula, similar to the schematic drawings of our text books. In the radiograph shown in Fig. 53 I illustrate a sinus in which the passing of a probe indicated that we had to deal with one single, straight fistula, and, behold, a turtle-shaped sinus, so different from what we expected, reveals itself.

This demonstrates the fallacy of relying upon the probe as an anatomical diagnostic guide. We can not rely upon its accuracy in showing us the direction, depth, and extent of a fistula. The mere fact that the probe will pass readily into a fistula is no proof that it has reached its depth, or that the sinus has no branches; and, on the other hand, if the probe is arrested in some fold or curve, it likewise fails as a diagnostic aid. In many instances its use is very deceptive, and has led to errors which have caused many a useless operation. The diagnostic method by means of the bismuth paste has, in my hands, entirely displaced the use of the probe for sounding fistulæ.

We must bear in mind the fact that a fistula is noth-

ing more than a shriveled old abscess cavity, and not, as is often supposed, a channel formed by an ulcerative process from the surface, burrowing into the depth of the tissues. At times the abscess is multilocular and will

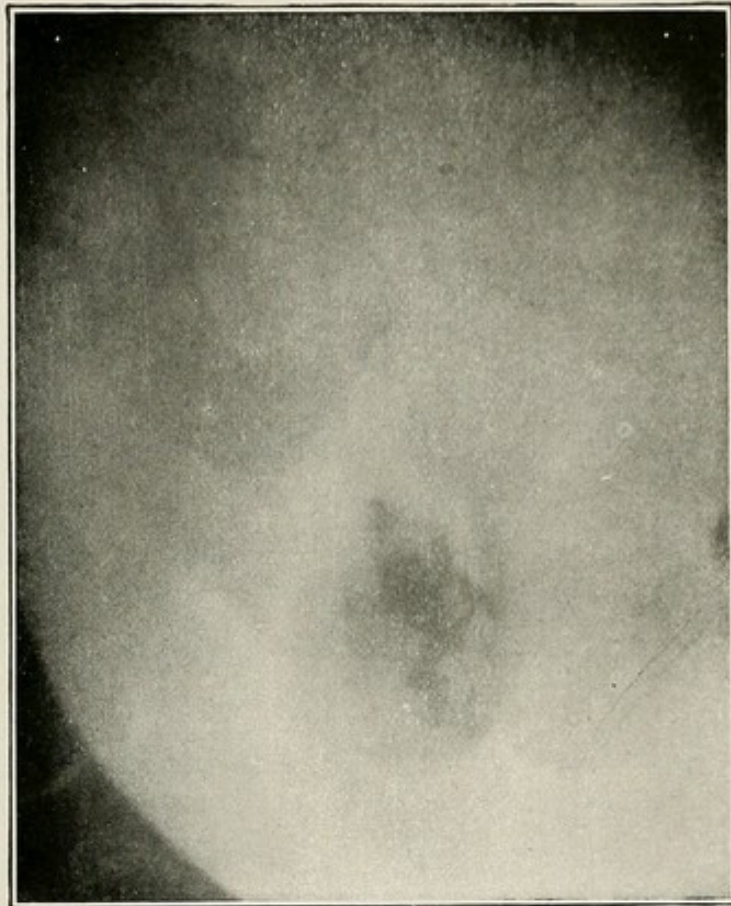

Fig. 53. Turtle-shaped sinus in perineal region, thought to be a straight rectal fistula.

undermine a large area in the perineum, and thus an irregular network of fistulous tracts may surround the rectum and form a number of sinus openings around the anus.

The stereoscopic radiographs, of which I have shown a number among my illustrations in Professor Kelly's Stereo-clinic, have shed a great deal of light upon the anatomical relations of the sinus tracts to the surrounding structure, and have cleared up for me many fallacies in both diagnosis and treatment of rectal fistulæ.

CHAPTER X.

BISMUTH PASTE IN FECAL FISTULÆ.

Fecal fistulæ, such as result from laparotomies, have the tendency to spontaneous closure. At times, however, their persistence causes the patient such misery that he is willing to submit to the most hazardous operations. It is, therefore, comforting to know that this class of fistulæ can also be successfully treated with bismuth paste. Besides several successful cases reported in medical literature by others, we have treated eight cases at the North Chicago Hospital, five of which were cured, one failed because of a coexisting intra-abdominal tumor, and two died as a result of tuberculous peritonitis, which was the cause of the fecal fistula.

The result obtained in the first case in which the paste was tried was so striking that I felt encouraged in its further application in similar cases. The history of this first case is as follows:

Fecal Fistulae; Bismuth Injection; Closure.—M. A., aged 25; family history nontubercular. In the fall of 1905 he was operated upon for gangrenous appendicitis. Fecal fistula resulted and persisted for four months. A second operation failed to close the fistula. He was then treated for six months with silver nitrate cauterization, without improvement. In August, 1906, we took a radiograph after an injection of bismuth paste. It demonstrated the uselessness of our silver nitrate treatment because of the existence of a cavity, which undermined the muscles to an area two inches in diameter. The first injection was sufficient to obliterate this fistula. Two years later finds the fistula still closed.

A second case with almost the identical history, in which the fecal fistula had persisted for one year, reacted also most favorably to the bismuth treatment.

The following case gives an idea of the possibilities of the bismuth paste in fecal fistulæ.

Fecal Fistula; Discharging Entire Bowel Contents.—Mrs. J., aged 29, was operated on July 17, 1909, for double pyosalpinx. The diseased tubes were so adherent to the intestines that during their removal the large bowel was torn. The sutures did not heal, the bowel reopened, and for three months the entire fecal contents discharged through the abdominal wound, no fecal matter or gas passing through the rectum. There being no natural tendency to closure, it was decided to resect a portion of the bowel, to which the patient, who was tired of her miserable existence, gladly consented. Before, however, resorting to this dangerous operation I decided to try a few injections of bismuth paste, and, although I did not expect very much from its use, the change was most surprising. The large opening gradually contracted to a narrow channel, the patient began to have a small evacuation from the rectum, and within ten weeks the fistula was entirely closed. Ten days later a pin-hole opening appeared and small amount of gas escaped. At present sinus is closed. Patient gained forty pounds.

This remarkable result in one case should not, however, create the impression that every fecal fistula can be cured by this method. The anatomical conditions in themselves make the prospects of a cure uncertain. I believe that the percentage of cases suitable for the bismuth treatment will be smaller than those of rectal fistulæ.

Dr. Cuthbertson, of Chicago, in reporting a case of post-operative fecal fistula cured with the paste, made a practical suggestion. He states: "It is absolutely necessary for the patient to remain in bed during the period of treatment. If he is allowed to walk about, the paste is immediately expelled either by the contraction of the abdominal muscles or the pressure of the bowel contents."

Our experience in treating these fecal fistulæ may be summed up as follows:

1. Where the fistula is the result of tuberculous peritonitis or intestinal tuberculosis, the bismuth treatment will be useless.
2. The post-operative fecal fistulæ are best suited for

this treatment, but a reasonable length of time should be allowed for spontaneous closure, and in no instance should the paste be poured into the fresh wound in the abdomen.

3. The cases in which the channel leading to the intestine is long and narrow respond most favorably to this treatment, as the paste blocks up the fistula, keeps the fecal masses from soiling it, and thus a most favorable condition for healing is produced. The fecal contents will then be propelled through the intestinal tract.

4. When the channel between the bowel and the skin surface is short, or when the intestines protrude, the paste is absolutely useless, a surgical operation then being the only means of producing a cure.

CHAPTER XI.

BISMUTH PASTE TREATMENT OF EMPYEMA AND LUNG ABSCESS.

Without dwelling upon the usual methods of treatment of empyema and lung abscess, I desire to describe this new method which is applicable especially to those cases in which other surgical treatment has failed.

The bismuth paste may be applied in chest cases for diagnostic and therapeutic purposes. As a **diagnostic aid** it has served most satisfactorily in outlining the contour and estimating the size of suppurative cavities within the pleural space. The radiographs showing the boundaries of these injected cavities aid in differentiating between an empyema of pleural origin and one resulting from a rupture of a lung abscess into the pleura.

As a **therapeutic agent** the paste has, in a certain class of cases, proven to be the remedy par excellence. Its chief value lies in producing rapid closure of old sinuses of empyema, some of which had persisted in discharging pus for many years in spite of the most radical surgical treatment, such as the Estlander or Schede operation.

Ample time has now elapsed and a sufficient number of reports from reliable sources in Europe and America have appeared in medical literature to justify the conclusions as to the real value of this new treatment.

In December, 1907, I first instituted this form of treatment in empyema, an abstract of a report of the first case being here cited:

Case 1. Empyema.—A. H., aged 19; family and personal history free from tuberculosis. January, 1907, attack of pleurisy with effusion,

soon changing into empyema. March 20, 1907, resection of two ribs, evacuation of pus, and drainage. A daily discharge of two or three ounces of fetid, green pus persisted in spite of all treatment. December 20, 1907, the patient was brought to me for treatment.

Bismuth Treatment.—Drainage tube was removed and 120 grams of bismuth-vaselin paste were injected into the suppurating cavity in the patient's chest. Two days later the injection was repeated, most of the previously injected paste having escaped with the discharging pus. After four days the discharge became serous, lost its foul odor, and greatly diminished in quantity. Injections were repeated daily, and on the twelfth day the sinus closed and has remained so. The patient has gained thirty pounds in weight and is in perfect health.

Skiagraphs had been taken at intervals of two months, which demonstrated the gradual absorption of the bismuth paste and the slow expansion of the lung where the abscess had existed.

This surprising result obtained by such simple means naturally encouraged its further application, and six months later I was able to include in my report to the Sixth International Congress on Tuberculosis nineteen cases of empyema and lung abscesses which had been treated by this method. Fourteen of these cases were then apparently cured, four improved and still under treatment, and one not improved—treatment discontinued.

The sources of this report were perfectly reliable, such competent surgeons as Mayo, Ochsner, McGuire, and others having contributed, in addition to the cases treated by myself.

Since the publication of these cases reports from many surgeons throughout this country and from abroad have convinced me that the application of the bismuth paste in the treatment of empyema surpasses even the good results obtained in treating other suppurative conditions by the bismuth paste method.

Nemanoff, for instance, reports from the clinic of Professor Kadjan, St. Petersburg, four cases of empyema in which one injection of bismuth paste in each case was sufficient to produce complete closure, whereas the same

patients had been treated at the clinic for six months by other methods without success. Vidakovich reports two cases of empyema, both with perfect result.

Dr. A. J. Ochsner, Chicago, reported to the American Surgical Association on June 4, 1909, fourteen cases of empyema, all of which had been previously operated (two by Estlander's operation), with sinuses in all cases persisting nevertheless. He applied the bismuth paste in each of these cases with the result that twelve cases healed completely, and two were still under treatment and very much improved.

My experience pertains to nineteen cases of empyema and eight cases of lung abscesses treated by the bismuth paste method.

At first I employed the paste in cases of drained empyema only, but later its usefulness was extended to cases of empyema still unopened and to abscesses within the lung tissue proper. Of these cases I shall cite a few, such as will illustrate some special points in the technic not mentioned in the general rules and aid in the selection of cases to which this form of treatment may be applied advantageously.

Technic in Chest Cases.

The technic of bismuth injections employed in abscess cavities in the chest differs somewhat from that applied in the sinuses. In the chest we have to deal with an infected cavity which has a rigid chest wall on one side, and the retracted, but more or less resilient, lung on the other.

A radiograph of the chest is first taken. The discharge should be examined microscopically, cultures made, and where tuberculosis is suspected a guinea pig should be inoculated. The cavity should then be filled by means

of a glass syringe with a 33-percent bismuth paste, but no drainage tube inserted, and then another radiograph taken, which will show the outline of the cavity.

It is not advisable to leave more than 100 grams of a 33-percent paste in the cavity longer than three days. When more than 100 grams are required to fill the cavity, and none of the injected paste has escaped during the following twenty-four hours, it is advisable to remove, either by suction or by flushing with olive oil, such quantity as will leave approximately 100 grams in the pleural cavity. In case the entire injected quantity has escaped into the dressings, a second injection should be made with a 10-percent bismuth paste in order to keep the hollow pleural space filled with a semi-solid sterile substance.

Gauze dressing is changed daily until the sinus closes. Should the temperature rise above 101° F., or the patient complain of severe pressure, the accumulated fluid should be drained off. If the temperature remains normal, and the amount of paste injected is not more than 100 grains, it may be left in for absorption, provided no signs of bismuth intoxication arise. Repetition of the injection is necessary only when the microorganisms are still present in the secretions, and therefore a systematic examination of same is necessary.

Negative Pressure for Re-expansion of the Lung.

At the suggestion of Dr. Carl Beck I have recently employed a means for reëxpansion of contracted lung. The technic is here illustrated:

M., aged 31, developed in 1900 acute pleurisy, terminating in empyema. After several tapplings of fluid, drainage with a rubber tube was established. The empyema proved to be of tubercular origin, the bacilli having constantly been found in the pleural discharge. For the past nine years the cavity had been flushed daily with antiseptic solutions and drainage maintained.

On January 10, 1910, the first bismuth paste injection was made, but the cavity was not entirely filled, only 240 grams being injected. The secretion, which up to this time had been purulent, soon became serous and sterile, but there was no indication of reëxpansion of lung.

The following method was applied and found satisfactory (Fig. 54):

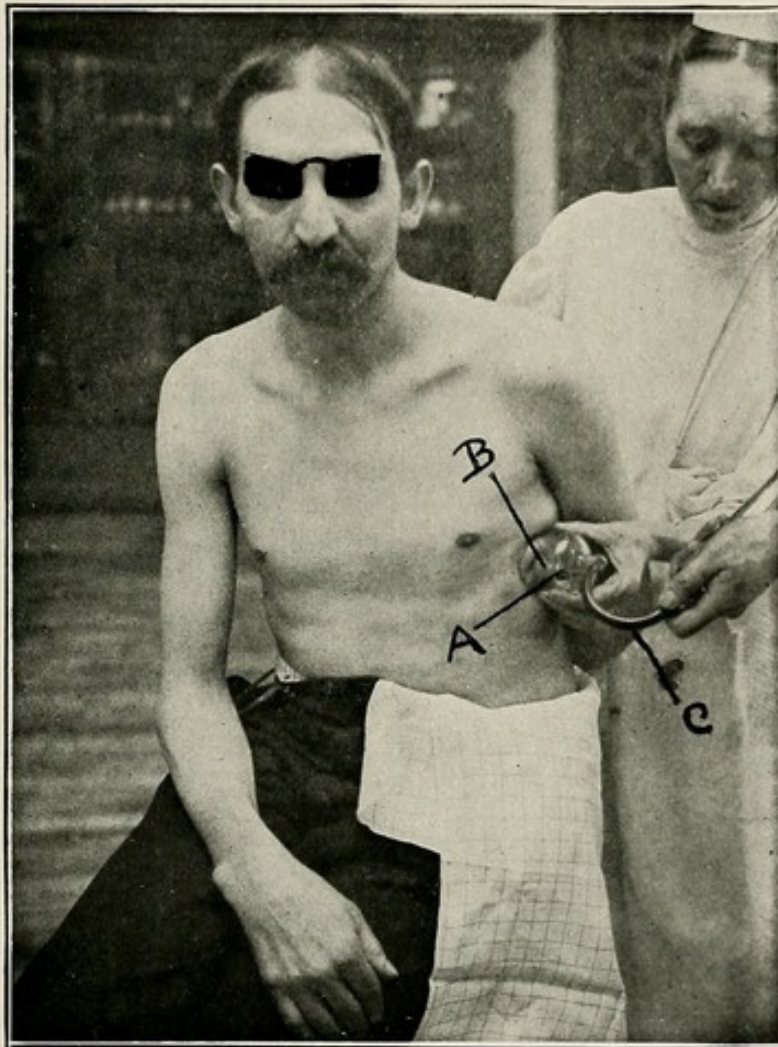


Fig. 54. Method of re-expansion of lung by suction pump.

The rubber tube (A), which is fastened to a rubber nipple (B), is inserted into the sinus and this is covered by a Bier's cup. To the outlet of the Bier's cup is attached the connecting tube (C) of a large suction syringe which has a release valve. Moderate suction is produced

and released in the rhythm of the patient's breathing. During inspiration we produce suction; during expiration we release the valve and allow the lung to collapse. This treatment is carried on systematically every day for five or ten minutes.

This is suitable in cases where the discharge is not profuse or bloody. In some cases the granulating surface is very apt to bleed when strong suction is applied, which fact should always be borne in mind.

In the case here illustrated we have watched the gradual expansion of the lung. When beginning the treatment the cavity would hold over 240 grams of the paste, while it now overflows when injecting but 45 grams. The physical signs and radiographs give evidence of the lung expansion.

Large Cavity Remaining After Estlander Operation.

In Fig. 55 we show the cavity left in the pleura after a secondary Estlander operation on a young man 26 years old. After two years of constant suppuration the bismuth paste treatment was instituted. The secretion became sterile, but the lung remained retracted. I employed the suction pump treatment described in this chapter, and within six weeks the cavity was reduced to half its size, holding only nine ounces at present.

The following cases are cited to illustrate the bismuth paste treatment of chest cases:

Case 4. Simple Empyema.—Chas. L., aged 18, had the grip in March, 1908; two weeks later pleurisy, with effusion; temperature, 105°. Four weeks later aspiration, resection of a rib, and evacuation of 2,000 cubic centimeters of pus, and drainage. For the next three months discharge profuse. July 20, 1908, 30 grams of bismuth paste were injected, and within twenty-four hours the discharge ceased and the sinus closed five days later. Patient gradually regained his health and sinus has not reopened.

Case 6. Empyema of Spontaneous Rupture, Leaving Three Sinuses.

—Mary H., aged 8, at the age of 6 developed an empyema, which, after several months of expectant medical treatment, ruptured spontaneously in two places on the anterior chest wall, leaving three sinuses discharging thick pus. Child was very much emaciated when brought to me in May, 1908. Fever rose to 101° or 102° daily. Patient coughed

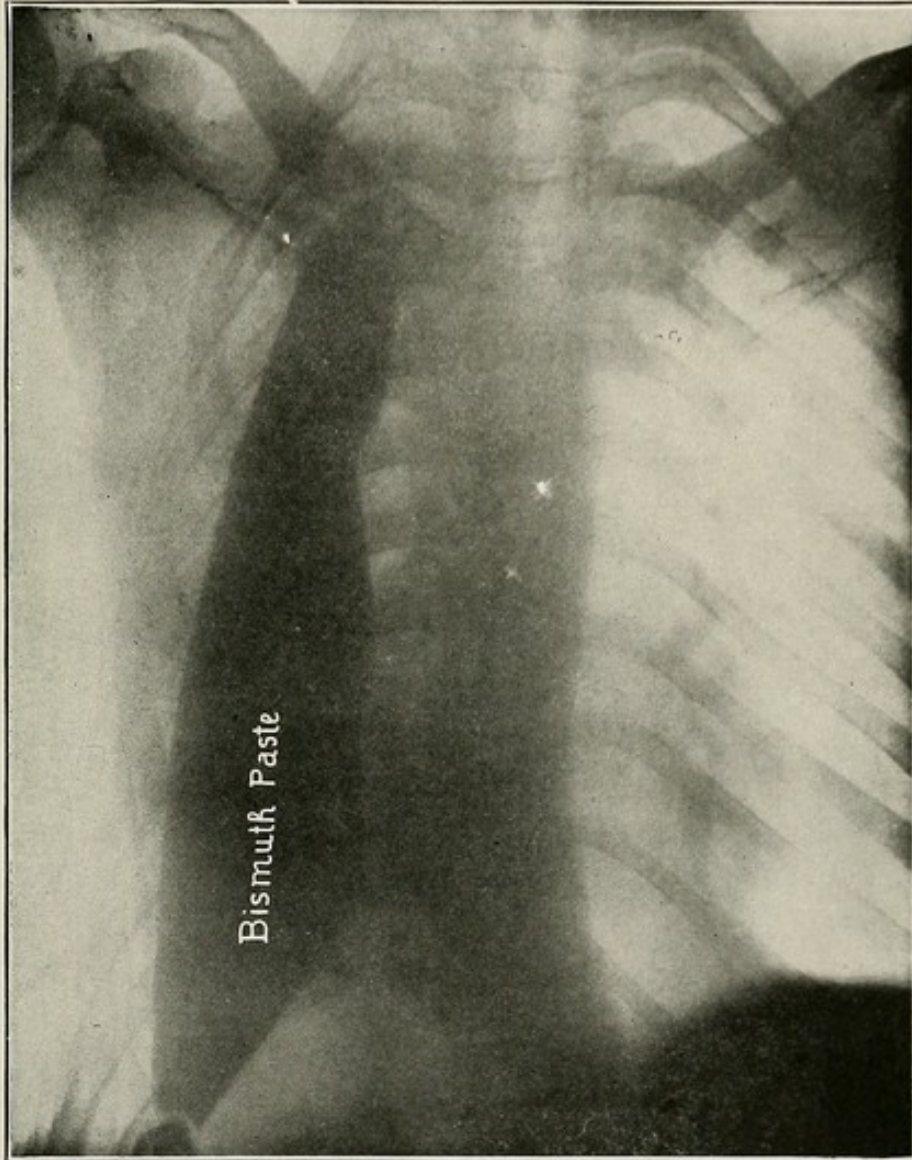


Fig. 55. Cavity in pleura remaining after Estlander operation. Injected with bismuth paste.

and had shortness in respiration (20 to 42). There was dullness over the entire left chest, radiograph distinctly showing the left side filled with fluid. Instead of the usual resection of ribs and drainage, I injected 60 grams of bismuth paste through one of the sinuses. Temperature and cough persisted in a milder form for three weeks; thereafter all symptoms disappeared and all sinuses closed. Two years have

elapsed, fluid has disappeared, child has gained thirty pounds, and is in perfect health.

Bacteriologic examination of pus, carried out systematically, proved that the pus discharge became sterile twenty days after first injection.

Case 7. Empyema; Two Years' Drainage; Permanent Closure After First Paste Injection.—Miriam D., a delicate child, aged 5½, at the age of 3 developed an acute lobar pneumonia. Empyema followed, and after aspiration of the pus two ribs were resected. Discharge of pus continued for one and one-half years, child gradually failing in health. As a last resort an Estlander operation was advised by the physician in charge, to which the parents did not consent. In October, 1908, the child was brought to me for treatment. Temperature from 99° to 101°. Extreme emaciation, cough with pain, as well as retraction of the chest wall, were the principal symptoms. The small opening in the chest secreted daily about 30 grams of creamy pus. Through this sinus I injected 30 grams of bismuth paste. A radiograph showed that the cavity contained a large quantity of pus, and that the paste merely floated therein. Although no further injections were made, I observed a gradual decrease in the fever and cough, cessation of the discharge, and closure of the sinus on the tenth day. The child gained four pounds in two weeks and now has regained perfect health. This patient was presented by Dr. Hartford at the session of the American Medical Association, Atlantic City, June, 1909.

The lesson learned from cases 6 and 7 is the following:

1. That it is not absolutely necessary to evacuate or drain off the pus from the pleural cavity before injecting the bismuth paste, and that small quantities (30 to 60 grams) are sufficient to produce the desired results.

2. Although the purulent exudate was not absorbed for several weeks after the bismuth injections, its presence caused no elevation of temperature, and sinuses closed in a comparatively short time.

3. While the discharge retained its purulent character after the bismuth injections, it was nevertheless found to be sterile.

Case 9. Empyema; Twenty-eight Years' Drainage; Closure with Bismuth Paste.—G. T., aged 39; engineer; family history negative. In 1881 he suffered from an attack of pneumonia, followed by an accumulation of pus in the left pleura. Drainage was established by intercostal incision (Dr. Favill, Sr., Madison, Wis.), and rubber tubing inserted. The purulent discharge had persisted since 1881, with only a

few days' intermission, a drainage tube being kept in the discharging sinus for twenty-eight years. Various methods, except radical operations, were tried in attempts to close the sinus, but all failed. In January, 1909, the patient was referred to me by Dr. H. B. Favill for treatment. His general health was very good, temperature and pulse

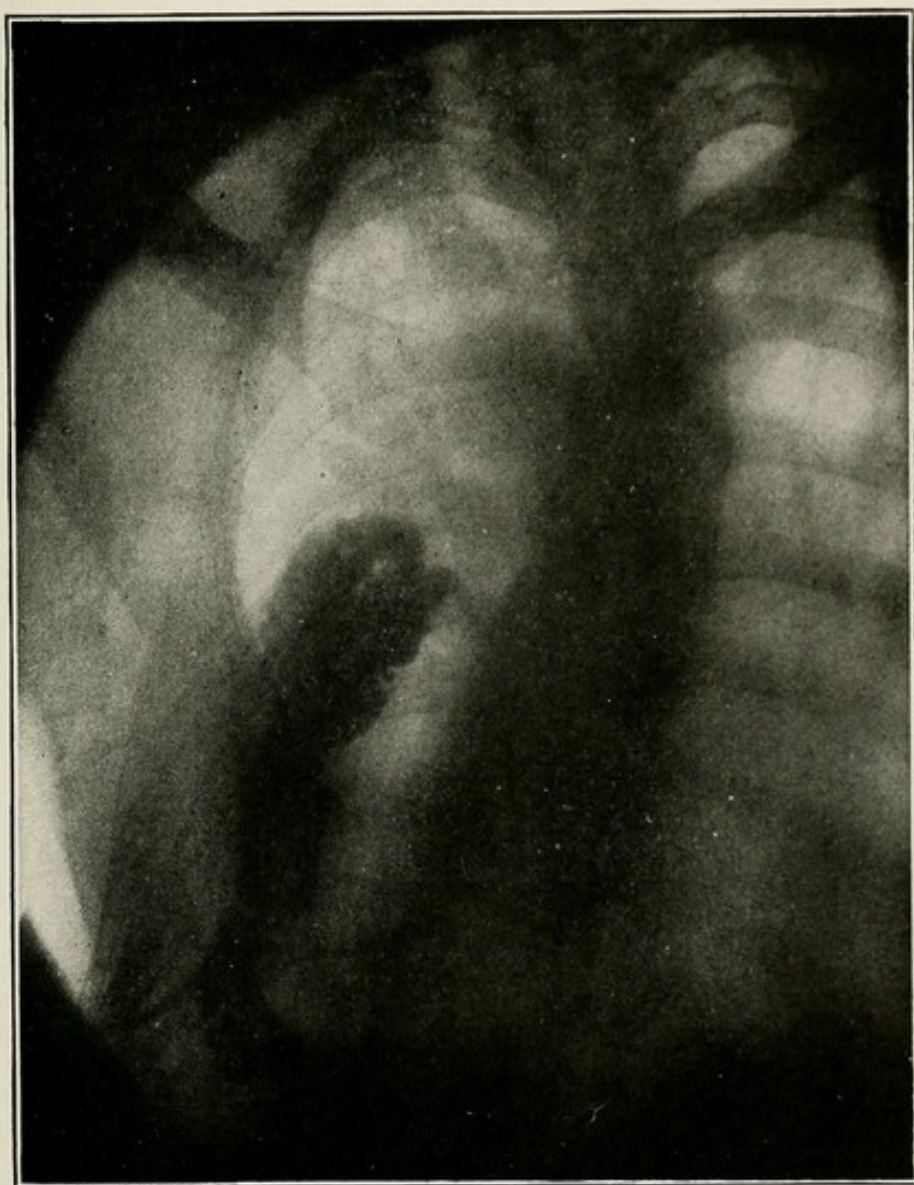


Fig. 56. Empyema of twenty-eight years' duration. Injected with bismuth paste. Closure in sixty days.

normal, right lung normal, left lung and chest cavity very much contracted; pus discharge thick and of dark-green color, containing staphylococci and a few streptococci.

Bismuth Treatment.—Injection of bismuth paste (formula No. 1), 60 grams filling out the entire contracted pus cavity. Temperature re-

mained normal, and discharge became serous on fifth day. After sixty days the sinus closed, and patient returned to Arizona to resume his work. There is no recurrence.

This case is very instructive, as it teaches that even after twenty-eight years' constant suppuration an empyema may be obliterated by injection of the paste. The radiograph (Fig. 56) shows the size and contour of the remaining pouch, and likewise illustrates the efforts of nature in her attempt to obliterate the pus cavity. The ribs are so much retracted that the intercostal spaces are nearly obliterated, the spinal column is markedly curved, with its convexity to the well side, the clavicle drawn downward and diaphragm drawn upward; all structure contracting toward one central point—the old suppurating cavity.

Case 12. Empyema of Infant Injected with Bismuth Paste.—M., aged 2, had a severe attack of pneumonia April 16, 1909; temperature, 105°; pulse, 136; respiration, 48; after ten days developed into an empyema. Resection of rib by Dr. Carl Beck; drainage. Temperature still rising to 100° to 102° daily; respiration, 38 to 48.

Bismuth Treatment.—On the eighth day after the operation an injection of 120 cubic centimeters of a 5-percent bismuth-vaselin paste was made, and two days later the same quantity was again injected. Temperature fell to 99.4° (rectal), respiration to 30. The pus became sterile after the first bismuth injection, but staphylococci reappeared a week later, and for this reason the opening was not allowed to close. The injections were continued for three weeks until the secretion became sterile. Sinus closed, and child is perfectly well.

Tuberculous Empyema.

It is noteworthy that the tuberculous empyema is far more resistant to any form of treatment than that of pneumococcus or other origin. Murphy states that a very large percentage of empyemas in adults is of the tuberculous form, and that these rarely undergo absorption or break into a bronchus.

From personal communication with Dr. Moore, medical

superintendent of the Dunning Hospital for Consumptives, an institution which takes care of an average of four hundred consumptives in the most advanced stages, I have the information that in the past four years he observed, in 5,000 cases treated, 25 cases of tuberculous empyema, and, whether operated on or not, all of the patients succumbed to the disease.

These cases usually start with serofibrinous pleurisy, which, either from frequent tapping or spontaneously, become secondarily infected and result in empyema. Operation is usually resorted to, and as a rule the subsequent treatment is very tedious and unsatisfactory.

In my series of cases of empyema three proved to be of tuberculous origin, and, while I do not consider them perfectly cured, they have regained their health sufficiently to permit of the resumption of their usual occupations.

Empyemas in children, or those following acute pleuritis in adults, give a much brighter outlook for recovery. In children the expansion of the lung and spontaneous closure of the sinus is rapid, and the majority of cases of the nontuberculous type in adults will yield to the simple drainage. A small percentage of cases, however, resist all medical and surgical treatment, and sinuses will persist in discharging pus indefinitely. The failures may be explained as follows:

1. As long as the walls lining the abscess cavity are the seat of living microorganisms, especially tubercle bacilli, an obliteration of the space can not be expected.

2. After years of suppuration the pleura has become hard and leathery, binding down the cicatrized lung, and thus the expansion of the lung is not possible.

The requirements, therefore, are: a cavity free from microorganisms and the lung still sufficiently resilient for expansion.

The method described and employed in my cases possesses, I believe, to a marked degree the means essential to obliteration of empyema. The introduction of bismuth paste has as a rule produced, by a process of local leucocytosis, a sterilization of the cavity, and in most cases softened the indurated pleura sufficiently to allow moderate expansion of the lung and the obliteration of the space.

Lung Abscess.

It is needless to say that, in order to cure lung abscess, an operation is necessary. I suggest two valuable aids in the procedure—namely, **the stereoradiograph for diagnosis, and the bismuth paste for the after-treatment.**

The **stereoradiograph** is a most valuable guide in the diagnosis. It will define, in plastic form, the boundaries of the abscess, thus enabling the surgeon to reach it by the shortest route. It will also locate foreign bodies, which, at times, are the cause of the abscess.

The **bismuth paste** is a valuable adjunct in the after-treatment. Instead of draining the abscess for weeks or months, or flushing it with various antiseptic solutions, it is filled with the paste the second day after the operation. This promotes the sterilization of the cavity, the odor soon disappears, and the cavity tends toward contraction and final obliteration.

It is noteworthy that such cases heal in a very short time, even when the cavity communicates with a bronchus. The following case illustrates this new method of treatment:

Case 5. M. M., aged 42. One year ago, after a short illness of cough and fever, he suddenly felt a large quantity of fluid rising in his throat, which almost strangled him. It was the rupture of a lung abscess. From that

time on he continually expectorated from ten to twelve ounces of very offensive pus every morning.

Diagnosis.—May 13, 1910. A stereoradiograph demonstrated the lung abscess to be located in the right lower lobe, corresponding to the posterior aspect of the eighth, ninth, and tenth ribs. The stereoscopic view showed plainly that the abscess was not superficial, and that at least a two-inch thickness of lung tissue existed between the pleura and the abscess wall. Physical examination by Professor Babcock corroborated the findings of the radiograph.

New Method of Treatment.—The following surgical, two-step operation, which I had previously carried out in two similar cases, was employed. Under general anesthesia, through a trap-door incision, three inches of each of the tenth and eleventh ribs in line with the abscess were resected. The costal pleura was cleared of all adherent tissue, so that a circular area three inches in diameter was exposed. Without incising the pleura, the exposed surface was swabbed with a small quantity of 95-percent carbolic acid. Into this cauterized area a flat coil of No. 14 red rubber tubing was placed, and the skin wound closed with temporary sutures. The object of the carbolic cauterization of the costal pleura was to produce its rapid adhesion to the opposite surface of the lung. By this procedure two important aims are attained:

1. The adhesion protects the pleural cavity from infection.

2. The inflammatory adhesion has the tendency to **draw the lung abscess toward the surface**, thus facilitating approach to the abscess. The rubber coil was placed in for the purpose of preventing adhesions of the muscles of the flap to the cauterized pleura, and thus preserve a clean field for the second operation.

After this procedure a second radiograph was taken to show the location of the rubber coil in its relation to the lung abscess. It was shown to be one inch lower

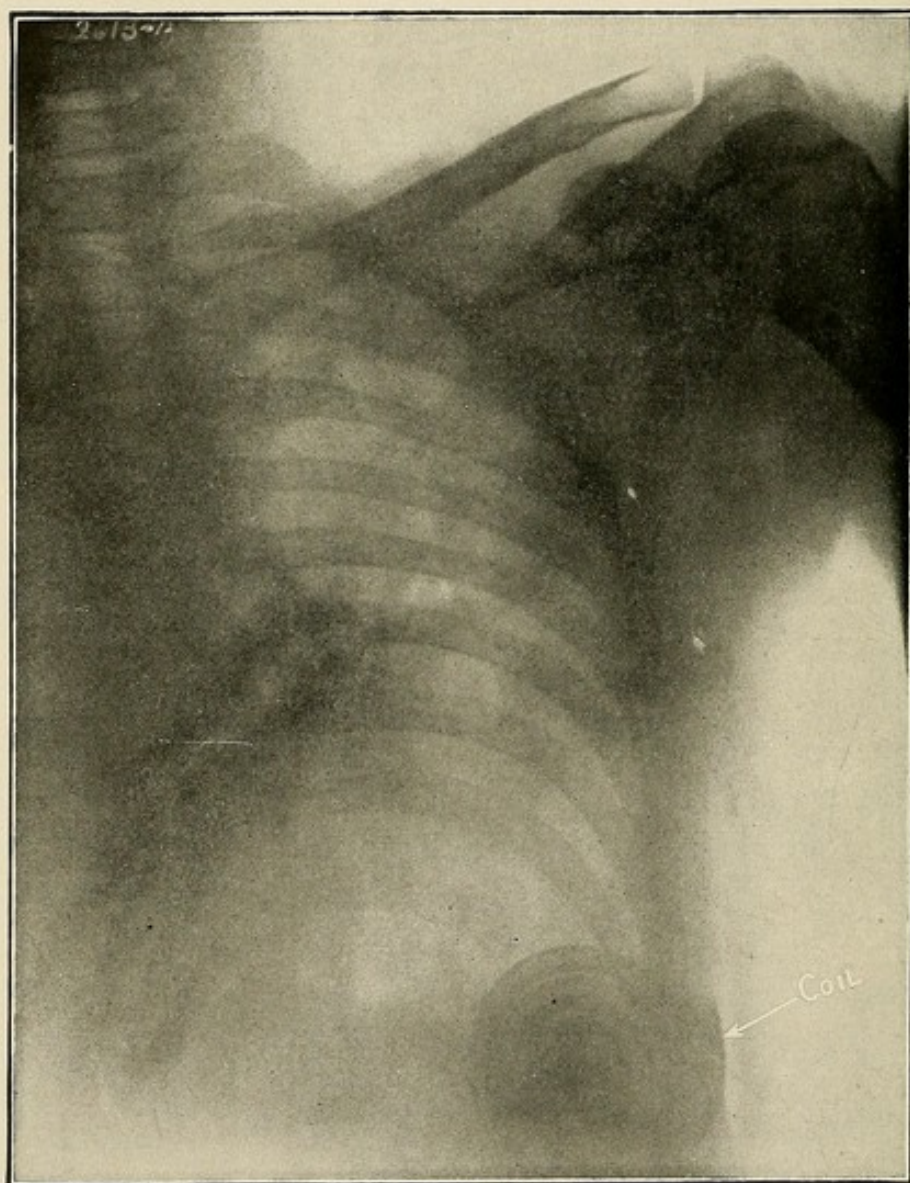


Fig. 57. Rubber coil showing against exposed pleura, demonstrating relation to lung abscess.

than the abscess, and therefore served as a valuable guide in the second operation. (Fig. 57.) Four days after the first operation the patient was again anesthetized, the wound reopened, the rubber coil lifted from its

bed, and the clean costal pleura exposed. An incision one inch in length was made in the upper angle of the exposed pleura, and then, with the index finger, the lung tissue was penetrated and the abscess wall immediately felt. A blunt forceps was then pushed into the abscess wall and widely spread. The cavity was explored with the index finger and found to consist of several compart-

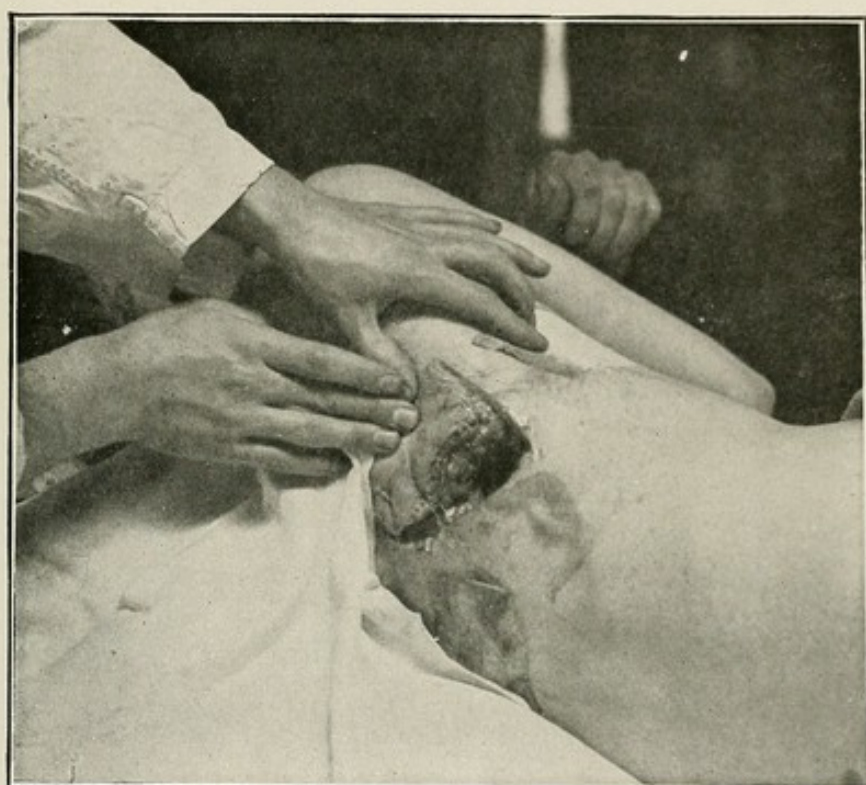


Fig. 58. Lung abscess cavity, viewed with stereoscope, will show four bronchial openings.

ments, which were separated by friable walls. These walls were broken up and two calcareous concretions removed. There was no hemorrhage. The procedure lasted only ten minutes. The cavity was packed with gauze for twenty-four hours, and then injected with 33-percent bismuth-vaselin paste, of which the patient coughed up a considerable quantity during the next few hours. Without reinjection, the pus secretion from the

abscess cavity disappeared within ten days, and only mucus could be forced out by intentional coughing. The depth of the abscess cavity could now be inspected by ordinary daylight, four bronchial openings being plainly

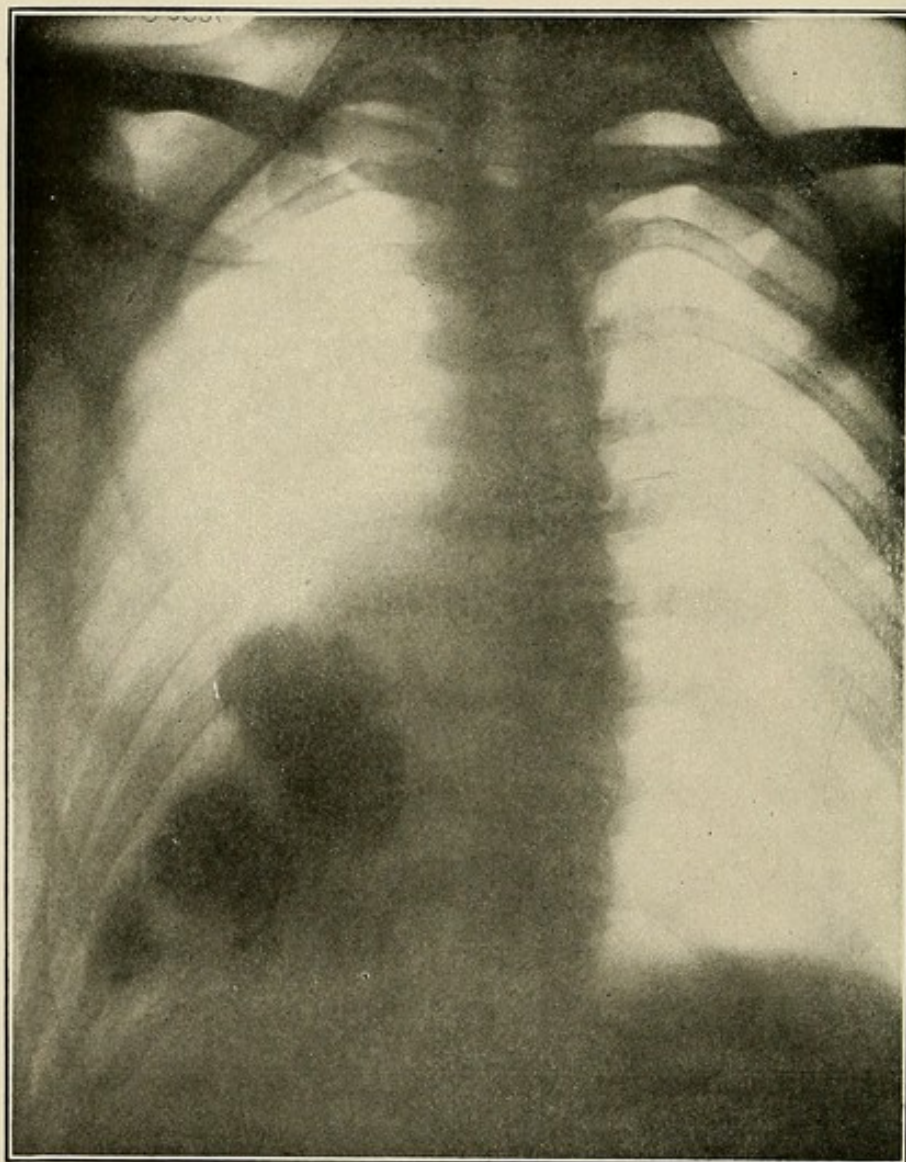


Fig. 59. Multilocular lung abscess injected with bismuth paste.

visible. (Fig. 58.) To insure the closure of the bronchial openings, their mucous lining was destroyed with electric cauterization. This procedure was painless, although the resulting smoke passing up through the bronchi and nostrils was irritating and disagreeable.

The cavity is now rapidly shrinking, and the indications for permanent closure are evident. In two cases previously treated in this manner the cavities closed in from two to four weeks after the operation.

Fig. 59 illustrates the multilocular condition of lung abscess in one of these cases treated in this same man-

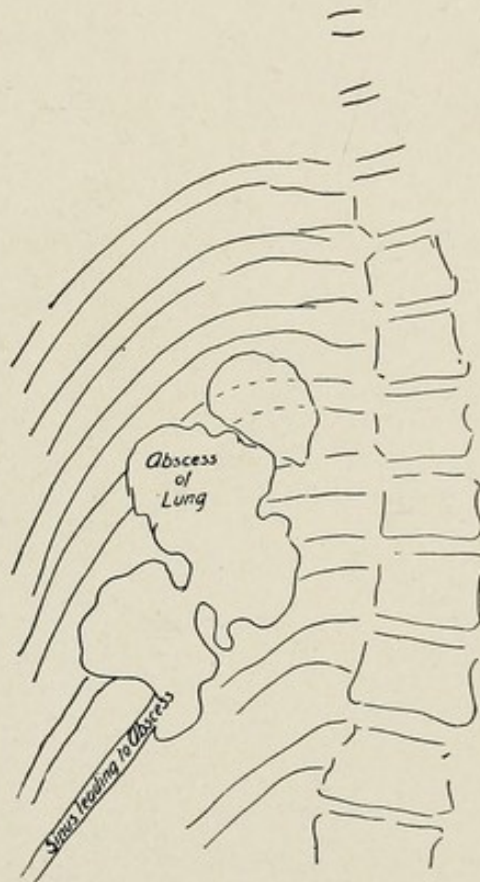


Fig. 59 A. Diagrammatic illustration of Fig. 59.

ner. While this procedure is comparatively new, and to my knowledge has not as yet been tried by others, I have employed it successfully in three cases, and have in each instance located the abscess without any difficulty and without causing a hemorrhage, and therefore anticipate that the method will be tested by other surgeons.

The task of definitely locating a lung abscess has al-

ways been considered rather difficult, and many an operation has had to be abandoned because of profuse hemorrhage in searching for the abscess. With the aid of the stereoradiograph and the subsequent surgical procedure

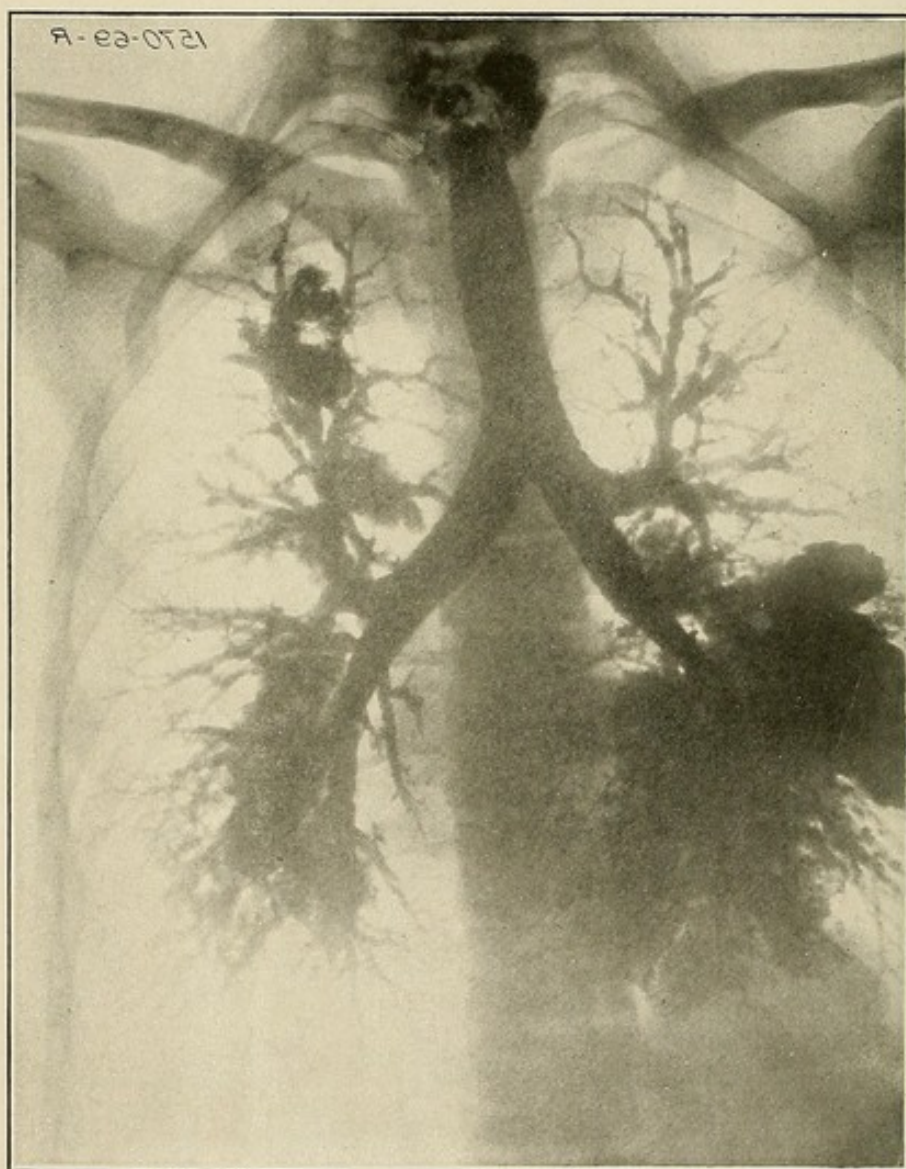


Fig. 60. Bronchial tree injected with bismuth paste for anatomical study.

which I advocate, the locating of the abscess is comparatively easy and almost certain, and the danger of the operation is reduced to a minimum.

In the diagnosis of lung abscesses knowledge of the

anatomy of the bronchial tree is essential. To assist in the study of this subject I have produced a radiograph of a bronchial tree (Fig. 60) which I believe will aid in the locating of abscesses.

This picture was produced by injecting into the trachea of a fresh cadaver a quantity of bismuth paste which penetrated the minutest ramifications of the bronchi, in some places even filling the alveoli and thus producing the cauliflower-like shadows.

The division of the trachea takes place opposite the sixth dorsal vertebra. It is generally assumed that the right bronchus is a continuation of the trachea. Practically this is the case, but our radiograph shows that the right bronchus deviates 17 degrees and the left 40 degrees from the axis of the trachea. The number of subdivisions in the bronchi vary from six to ten, those in the lower lobe having more subdivisions. The bronchioles appear somewhat beaded, due probably to overdistention by the paste. This picture also furnishes the true relations of the bronchi to other structures within the chest, as they actually exist in life, before the chest cavity is opened and the lung collapsed.

I trust that the employment of the stereoscopic radiograph and the anatomical illustration of the bronchial tree will add much to our diagnostic ability, and that the introduction of the simple and effective surgical operation here described will aid in simplifying the surgery of lung abscess.

CHAPTER XII.

BISMUTH PASTE IN THE CONSERVATIVE TREATMENT OF COLD ABSCESES.

Surgeons the world over are almost unanimous in their opinion that cold abscesses should neither be opened nor drained, but they have not yet agreed upon a method which would prevent the complications and dangers which usually follow the spontaneous rupture or incision of these abscesses. As long as a cold abscess is closed, it is comparatively harmless, but when opened it immediately becomes a source of danger. Secondary infection is then the rule, and sepsis and death the frequent consequences. Calot says: "To open a spondylitic abscess or allow it to open spontaneously means to open the gate through which death nearly always enters. A physician's viewpoint in the treatment of cold abscesses is, for the life of the patient, of the utmost importance."

In 1858 Bouvier said: "It is common to see both adults and children in whom large abscesses cause little inconvenience, but, when these abscesses are opened, acute pain and extensive inflammation gradually exhaust and may even kill the patient."

The last century has witnessed many changes in the treatment of cold abscesses, the methods in each period depending upon the prevailing opinions which were held at the time as to their pathology.

Before Pasteur's great discovery, when surgeons had no conception of asepsis, the treatment was, of course, irrational. Dupuytren, Larrey, and others treated cold abscesses with wide incisions, but many surgeons were

decidedly opposed to such procedures. The mortality at that time, according to Follin's figures, ranged from 56 to 70 percent in hip diseases and spinal caries. In the light of our present knowledge of the disease this high mortality was due to imperfect immobilization, bad hygiene, and the lack of knowledge regarding the necessity of sterilization of instruments and care in dressings.

With the introduction of asepsis and the modern teachings on tuberculosis of bones and joints by such men as König and Lannelongue, the treatment was radically changed. It was shown by Lannelongue that the cold abscess was the result of a primary tuberculous infection, and consequently he advocated the early **radical removal** of the primary focus. This certainly was rational treatment. The death rate, however, from shock in the extensive resections of hips and vertebræ was enormous, and the final results in the cases which survived were deplorable because of the resulting deformities.

For this reason this method soon lost its popularity, and a reaction to **less radical methods** took place. Thereafter the treatment was limited to the abscess, and the bony lesions from which it sprang were ignored. Curetment of the abscess lining or the excision of the abscess wall, under the most rigid aseptic precautions, were practiced apparently with favorable results. Wounds healed by primary union, and patients gained rapidly in health soon after the operations. The test of time, however, shattered the hopes of the advocates of this method, it having been observed that the cures in most cases were not permanent. The reason for recurrences with this semiradical method is apparent when the following facts are considered:

While it is true that the tuberculous debris within an abscess is usually sterile, we know that the wall itself is

the seat of living bacteria. At the same time the abscess wall furnishes the fortification against the spreading of the bacteria into neighboring tissues. Its connective tissue wall forms a barrier against further invasion. Would it, then, be rational to excise or scoop out these natural barriers, and thereby expose large surfaces to the implantation of the living bacteria, which were comparatively harmless when imbedded in the connective tissue of the abscess wall? Moreover, by removing the lining or the entire abscess wall we still leave the primary lesion intact, which still retains its activity. Of what advantage, then, is the excision of the abscess wall?

Unless the primary focus is already extinguished, or the virulence of the bacilli so much attenuated as to be harmless, the curetment or excision of the abscess wall can be of little avail.

Practically the final results confirm this assertion. The immediate effects in many of the operated cases seem excellent, and, no doubt, some lasting results are obtained, but most frequently the cavity refills with either tuberculous debris or purulent secretion; the wound reopens, and frequently secondary infection takes place. If the process is not so violent as to cause death, the condition becomes chronic and a sinus results.

While this semiradical procedure is still practiced in some countries, it has been largely supplanted by the **conservative method**.

The most desirable treatment is the nonoperative one. It consists in allowing the abscess to become absorbed. This is accomplished by complete rest in bed, immobilization, and giving the patient all the hygienic advantages that reinforce the natural resistance against disease. The conservative orthopedic surgeons have a great deal more patience with these cases than some of the aggres-

sive, restless, younger generation of surgeons, and, no doubt, have saved by their conservatism thousands of children; but, on the other hand, many a cripple with a discharging sinus hobbles from clinic to clinic who might have been spared much misery if his abscess had, **at the proper moment**, been treated by proper surgical method instead of having been permitted to rupture and to drain. The most effective and satisfactory method is that of aspiration of the abscess and injecting a modifying substance.

Calot¹ prescribes the following rules for treating cold abscess:

1. "It is **forbidden** to touch abscesses when they are not easily reached. There is no danger that these will rupture spontaneously."

2. "It is **permitted** to treat abscesses when they are easily reached, even if they do not threaten to rupture spontaneously."

3. "It is **our urgent duty to treat** abscesses when they threaten to rupture. In this case they are easily accessible. 'To treat them' means to aspirate and then inject some substance producing a healing effect."

I subscribe most decidedly to rules 1 and 3, but can not subscribe to rule 2, as it is my belief that **the non-operative treatment should be persisted in as long as possible**.

As long as the patient does not suffer extreme pain, and has very little fever, he should be given a chance of cure without surgical interference, but the abscess should be constantly watched, and as soon as signs of threatening rupture appear it is of the utmost importance that surgical methods be employed. If, however, there appear symptoms of pyrexia, or if the patient's health de-

¹ Calot: Die Behandlung der Tuberculösen Wirbelsäulenentzündung.

clines steadily, then it may be assumed that the abscess contains true pus, and surgical interference is not only permissible, but is urgently required. The surgical procedure should, however, not be too radical. It is not judicious to use a curet, nor is irrigation of the abscess indicated. The abscess should be located, aspirated, and filled with a modifying substance.

The aspiration and injection of modifying fluids is, at the present time, the most popular method in cases in which the abscess threatens to rupture. Various substances have been used at different periods for the injection of these cold abscesses, and it seems that nearly all of them have given satisfactory results. Silver nitrate, tincture of iodine, alcohol, corrosive sublimate, lactic acid, ether and iodoform, naphtholcamphor, trypsin, serums, guaiacol, formalin, and many others have been used at different periods of the development of this curative method, but in the last few years Calot's mixture—

Ol. olivarum	50 grams
Ether sulf.	50 grams
Kreosot	2 grams
Iodoform	5 grams

—or naphtholcamphor (1 gram in 5 grams of glycerin), and lately the 2-percent formalin-glycerin mixture of Murphy, have been most in favor.

Some surgeons do not employ modifying fluids, claiming good results with simple aspiration, repeating it as often as the abscess refills. (Gangolphe.)

Simple aspiration may be compared to the tappings of pleural exudates in tuberculous pleurisy. They do not often cure the underlying disease, although they usually benefit the patient temporarily. The aspiration of an abscess is an incomplete procedure, since it can not remove or disinfect the original focus of the disease, of

which the abscess is only a consequence. If the opening or aspiration of the abscess meant the eradication of the disease, the problem of curing spinal tuberculosis or hip joint disease would indeed be very simple. The necessity of frequent repetition of the aspiration, furthermore, predisposes to secondary infection, which is practically avoided by using modifying substances.

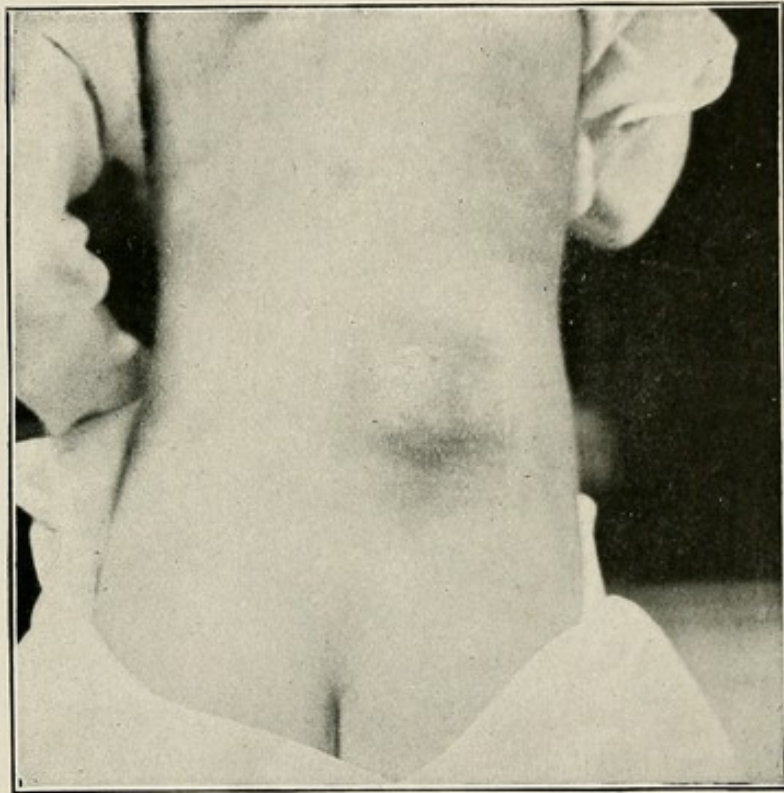


Fig. 61. Psoas abscess, pointing in the lumbar region. Ready for spontaneous rupture.

In January, 1908, I tested the value of **bismuth paste as a modifying substance** in the conservative treatment of cold abscesses, and, finding it very effective, I have since employed it in a large number of cases. Now, after two years' experience, I have no hesitation in recommending it as a most valuable addition to other modifying fluids.

Method of Application.—A cold abscess, when it has reached the stage of spontaneous rupture (Fig. 61), should, with the most aseptic measures, be opened by an incision one-half inch in length, at the fluctuating spot, and the contents allowed to escape, but not squeezed out forcibly. Vigorous manipulation is harmful. Then, through this small incision, a quantity of **not more than 100 grams of a 10-percent bismuth-vaselin paste** is injected into the cavity, and the **opening is not sealed or drained**. **Gentle massage** over the abscess area should then be made in order to spread the injected paste into all the folds of the collapsed abscess. A sterile gauze dressing is placed over the incision and a five-yard sterile gauze bandage is snugly put on and securely pinned, so that the patient, usually a child, can not displace it and can not infect the wound. This method, properly carried out, will prevent secondary infection. The gradual contracting of the cavity forces small quantities of the thick paste from within through the small incision, thereby blocking the opening and preventing the introduction of any infectious material. Dressings are to be changed daily under the most scrupulous asepsis. Should the fluid reaccumulate, the incision may be reopened, and the fluid contents, which have by this time become serous, allowed to escape, but the injection need not be repeated.

The first trial of this prophylactic method was made on January 17, 1908, at the North Chicago Hospital on a two-and-one-half-year-old boy, who had a tuberculous abscess about the middle of his tibia. I made only one injection, and the abscess was obliterated within one week and remained closed.

This favorable result encouraged me to try the treatment in the following case of psoas abscess:

A boy, aged $4\frac{1}{2}$, had a large psoas abscess pointing above Poupart's ligament, with a softened area at its summit. A quart of debris was evacuated and the cavity injected with 120 grams of a 10-percent bismuth-vaselin paste. The temperature remained absolutely normal after this injection, whereas previously it had risen from 99° to 100° every

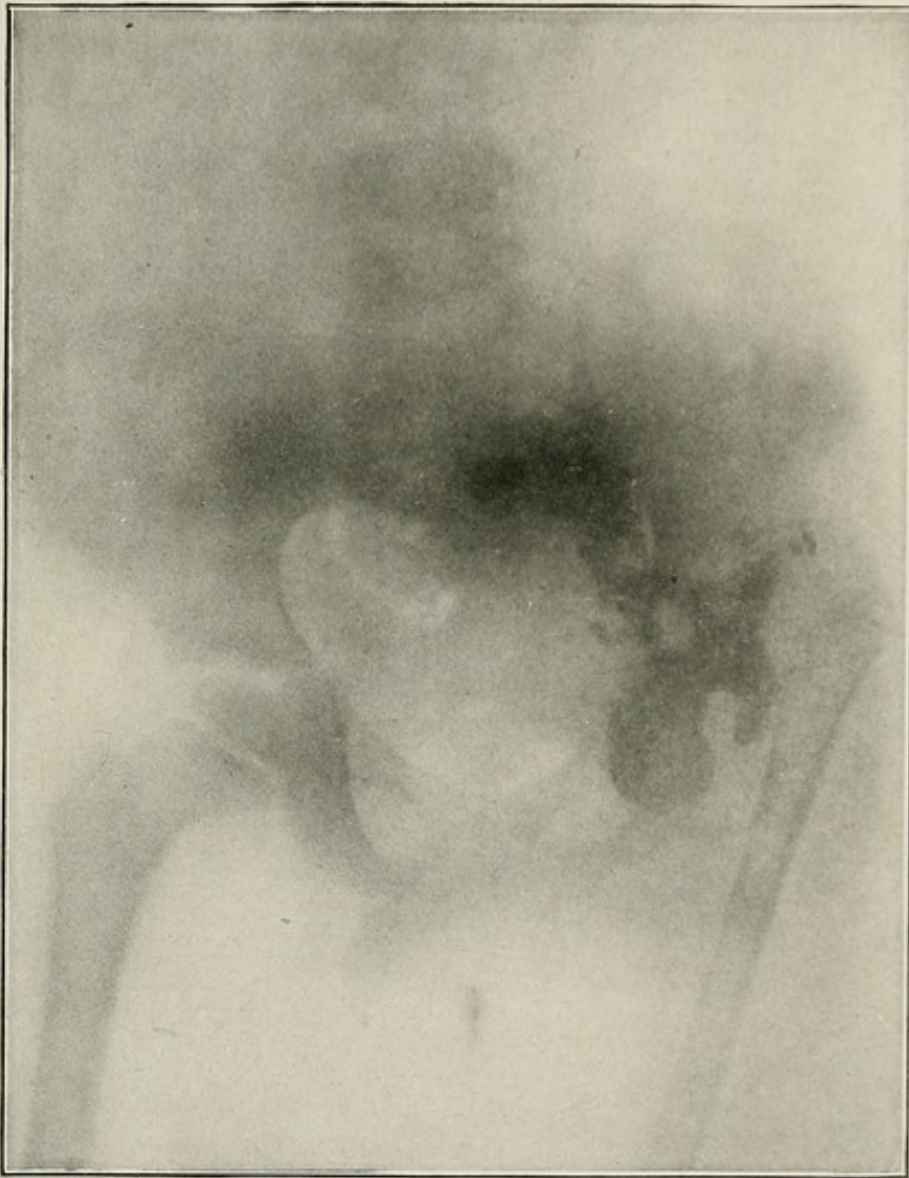

Fig. 62. Abscess of hip joint injected with bismuth paste to prevent sinus.

day. The incision closed in four days, and was intentionally reopened three days later and about three ounces of muddy, but sterile, liquid were removed, and 60 grams of a 33-percent bismuth-vaselin paste injected. The opening closed three days later, and the patient gained rapidly in general health.

This prophylactic method is applicable in treating cold abscesses in all parts of the body. Several cases are here cited for illustration:

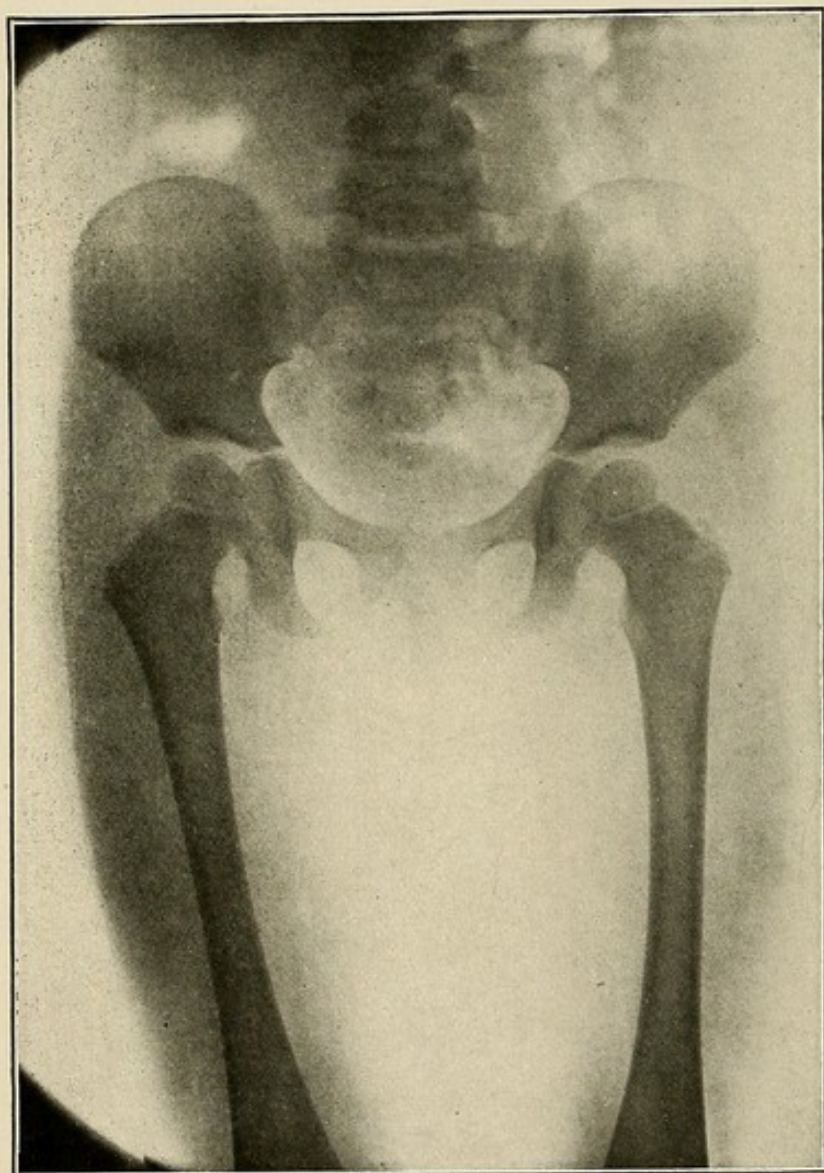


Fig. 63. Normal pelvis of same age, for comparison with Fig. 62.

Hip-joint Abscess.—Master E. T., aged 7, at the age of $2\frac{1}{2}$ years fell and soon after developed an abscess in his hip. One year later his physician incised and drained the abscess, and purulent discharge continued for two years. In April, 1908, I made the first injection of bismuth paste, whereupon the sinus closed. With the aid of a high shoe the boy could now run about as well as his healthy comrades, and was well until September, 1909 (sixteen months after closure),

when he fell downstairs, which accident was followed by chills and fever of 103° , and extreme tenderness of the hip. For three weeks his hip was treated with liniments, etc., without any relief, and a large abscess in the gluteal region appeared. In this condition he was again brought to me for treatment. On October 24, 1909, the prophylactic method of bismuth treatment was carried out as follows:

An incision two inches long was made through the gluteal muscles, reaching a deep abscess. The pus was allowed to escape without any scooping or the introduction of gauze, and the resulting cavity was

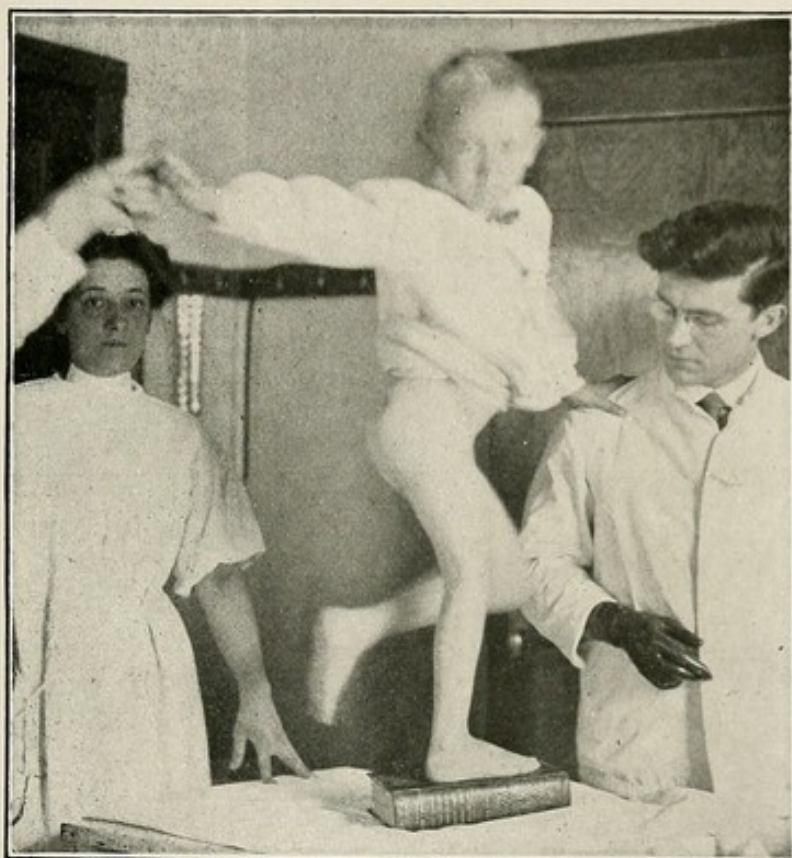


Fig. 64. Patient whose pelvis is shown in Fig. 62, standing on the diseased limb two weeks after injection of abscess.

filled with a 10-percent bismuth paste. The radiograph (Fig. 62) illustrates the size and shape of the cavity. The shadow of a buckshot represents the location of the opening of the sinus. This radiograph also illustrates the extreme tilting of the pelvis and the atrophy of the shaft of the femur, which occurs in some of the cases of hip joint disease. For comparison I show a radiograph (Fig. 63) of a normal pelvis of a child of the same age. Child has fully recovered and supports his body weight on the tuberculous limb. (Fig. 64.)

Tuberculosis of Elbow with Multiple Cold Abscesses.—L. R., aged 18, when 8 years old was operated upon for tuberculosis of the knee

164 BISMUTH PASTE IN CHRONIC SUPPURATIONS.

joint. Result, primary union, with considerable shortening. Since then the patient remained apparently well until four months ago, when a swelling in his left elbow began to form, which was first diagnosed as rheumatism. This swelling enlarged and the elbow became entirely immovable. Fluctuation was distinct at three different points. The

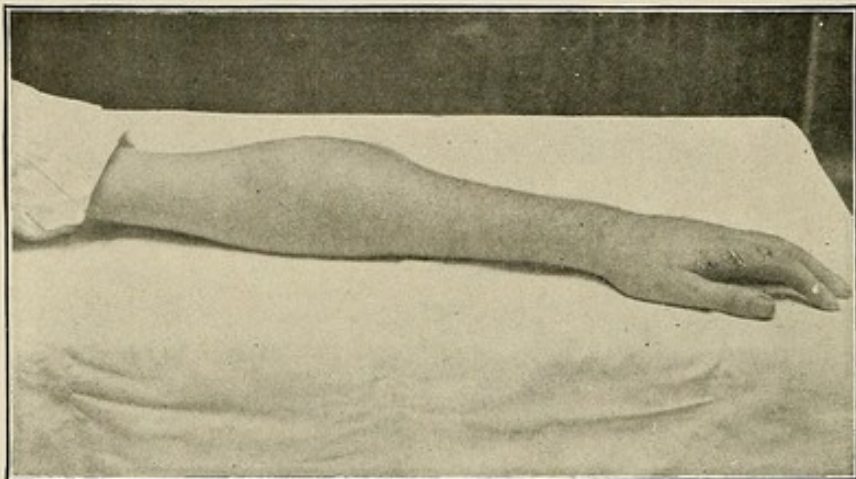


Fig. 65. Tuberculous elbow joint with three abscesses before injection treatment.




Fig. 66. Reduction in size of arm shown in Fig. 65 after prophylactic, conservative treatment. Secondary infection avoided.

photograph of the arm (Fig. 65) shows the size of the swelling before the prophylactic treatment was instituted. March 1, 1910, the three abscesses were incised at their softest points, and, according to the method described, were injected with bismuth paste No. 1, this 33-percent paste being employed because the quantities used were small.

The cloudy discharge changed within twenty-four hours to a clear

straw-colored fluid, which at first was very abundant, but gradually became scanty. The opening closed, and the elbow returned to its normal size. (Fig. 66.) Mobility was less impaired than we anticipated.

The radiograph (Fig. 67), which was taken after the abscesses were injected, shows distinctly the size of each abscess, and demonstrates the fact that these abscesses did not communicate, but all of them had their origin in one tuberculous focus in the external condyle of the humerus.

During the past two years I have applied this method of treating cold abscesses in nearly all parts of the body, including suppurating lymph glands and pararectal abscesses, and not in a single instance have I experienced a secondary infection and high fever. I have not trusted to simple aspiration, and have employed it in every case of cold abscess treated during the past two years.

Therapeutically the results have been all that could be desired; in fact, of twenty-six cases treated in this manner in only one did a sinus persist, and in this case a badly diseased hip joint was responsible for its failure to close.

This method has already been tried by others. Ridlon and Blanchard made a report in June, 1909, to the American Orthopedic Association of eight cases treated in this manner at the Home for Crippled Children, in Chicago, in which institution I had introduced this method a year previous to their report. Their results were as follows:

REPORT OF 8 CASES OF COLD ABSCESS TREATED BY RIDLON AND BLANCHARD WITH BISMUTH PASTE.

No. of case.	Name.	Age, years.	Disease.	Duration, years.	Abscess.	Cured in
1	Elmer H.	5	Pott's disease	3½	Psoas	21 days
2	Samuel J.	7	Hip disease	12	Thigh	13 days
3	John B.	9	Hip disease	2	Thigh	14 days
4	Joseph M.	8	Hip disease	12	Thigh	16 days
5	Josephine O.	5	Hip disease	12	Thigh	20 days
6	Hiram W.	17	Pott's disease	1	Lumbar	17 days
7	Maggie S.	10	Hip disease	12	Thigh	16 days
8	George T.	9	Hip disease	12	Thigh	15 days

One might ask why surgeons have shifted from one to another of these modifying substances when nearly all of them have fulfilled their purpose. New modifying fluids




Fig. 67. Radiograph showing the three distinct cavities communicating with the elbow joint. (Case shown in Fig. 65.)

were introduced, not because the older ones failed, but, rather, they were added because they were just as effective and, in addition, possessed other advantages, such as being less toxic, less irritating, or painless.

Action of Bismuth Paste as a Modifying Substance.

We have studied the effects of bismuth paste upon the secretions of these abscesses by cytologic tests in several hundred cases, and have made observations which, in a large measure, explain to us its favorable action upon the diseased abscess cavities and their contents. The con-

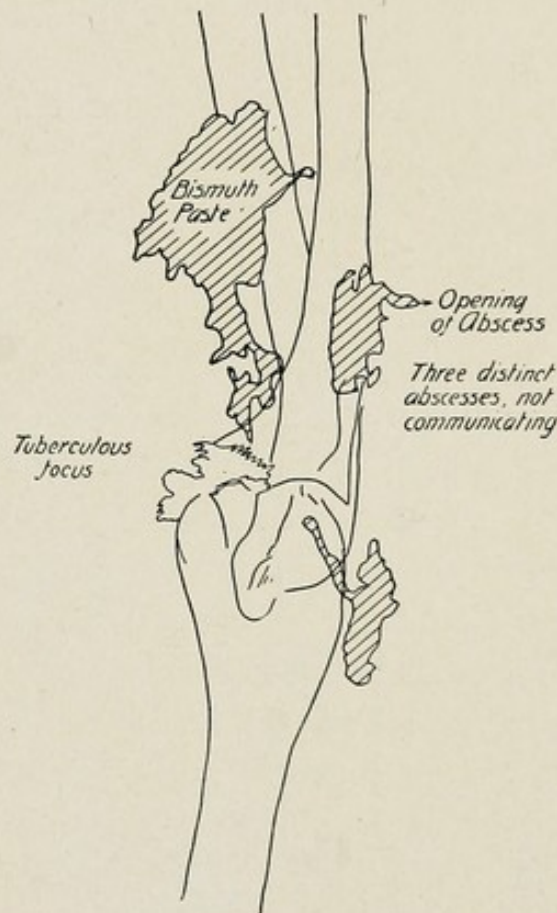


Fig. 67 A. Diagrammatic illustration of Fig. 67.

tents of tuberculous abscesses are usually sterile, and consist of debris with a very few white blood corpuscles. Within twenty-four hours after an injection of the bismuth paste the fluid will contain an abundance of polymorphonuclear leucocytes. A fibrinous network, in which are entangled a large number of these leucocytes and some red corpuscles, will appear. All these facts in-

dicating that there is an inflammatory reaction. The same cytologic changes have been noted by other observers when other modifying substances have been applied.

Coyon and Fiesenger (*Journal des Practiciens*, October 20, 1909) have advanced a theory which places the action of the various fluids on a chemical basis. They have shown that, in the more acute form of abscess, there exists a proteolytic ferment analogous to the tryptic ferment of the pancreas, which coagulates albumins and changes them into peptones and amido-acids. This ferment is produced by the destruction of the polymorphonuclear leucocytes.

In contradistinction, this ferment is not present in tuberculous abscesses because of the absence of the polymorphonuclear leucocytes in cold abscess. The injection of any of the modifying fluids will cause the appearance of the leucocytes.

Soon after the discovery of the tubercle bacillus it was believed that the curative action of modifying injections was due purely to their antiseptic power, but it was found that some of these substances exert very slight bactericidal power *in vitro*, while within an abscess their action upon bacteria is very powerful. Iodoform is a striking example. Its retarding action upon bacterial growth outside of the body is very weak, but within the living tissues it exerts a marked inhibition upon the growth of microorganisms, especially upon that of tubercle bacillus.

The bactericidal action of the paste does not depend upon the antiseptic power of the bismuth, but upon an underlying principle which governs all these modifying substances—namely, the production of a **local leucocytosis**. The bismuth has a **chemotactic action**—it attracts the leucocytes to those tissues with which it comes in

contact. Indirectly, then, the injection of the paste is responsible for the phagocytic action.

The following are the advantages of using bismuth paste instead of other modifying substances:

1. The paste is injected through a small incision instead of using a trocar, and thus the possibility of missing the abscess is eliminated.

2. By discarding the aspirating needle the danger of injuring underlying vital organs or entering blood vessels is avoided.

3. Through an incision it is possible to evacuate the larger clumps of the tuberculous debris, which could not pass through the aspirating needle.

4. The thick paste within the cavity will allow the escape of secretions along the walls of the abscess, but will not permit the entrance of infectious material; thus secondary infection is prevented.

5. Injections of other modifying fluids must, as a rule, be repeated, while with the paste the first injection usually attains the desired result.

6. The injection of bismuth paste is not painful or irritating. It is injected in a warm, semi-liquid state, and remains long enough in contact with the diseased tissues to produce its therapeutic effect. The vehicle (vaselin) does not macerate the walls of the abscess. Toxic effects from bismuth subnitrate can easily be prevented.

7. The therapeutic results are equal, if not superior, to those obtained by other modifying substances.

These advantages and the practical results obtained with the paste in treating cold abscesses naturally suggest the question: Why could it not be employed for the injection of tuberculous joints before abscess formation instead of iodoform emulsion, etc.? This question has

frequently been put to me. I have been reluctant in advising it, although I have employed it in several cases with success, but I encountered one failure which taught me the possibility of its producing harm.¹

In the past few months, however, I have renewed its application in tuberculous joints by a modified method, but the brief period which has elapsed does not permit drawing definite conclusions and its publication.

I do not as yet advise the general use of the paste when abscess is not formed; at least not until the reports from large clinics have established the safety of its application and its advantage over the methods now in vogue.

¹ Beck: Transactions of Sixth International Congress on Tuberculosis, vol. 2.

CHAPTER XIII.

LIMITATIONS AND CAUSES OF FAILURE.

To one who has the opportunity of treating many cases with the bismuth paste, new possibilities for its application constantly suggest themselves. Its application in the accessory sinuses of the nose and ear is so extensive, and its possibilities so great, that a special chapter is devoted to their consideration.

In dentistry the paste has likewise found a place of usefulness. A publication by Dr. R. Beck, including a collective report from several hundred dentists of America and Europe who have made use of it in pyorrhea alveolaris and sinuses within the mouth, indicates that in dentistry there are also great possibilities for its application. A special chapter is written on this feature.

There is no reason why the same beneficial results may not be obtained in lower animals affected with sinuses. In this branch of surgery the veterinaries have already taken advantage of its use. In the *American Veterinary Review* (February, 1910) Dr. C. A. Leslie published a report in which he gave histories of thirteen cases of various forms of fistulæ in horses in which he used bismuth paste, with complete recovery in every case. Some of these cases had been operated upon as many as four times without success, and with this simple method a complete cure was obtained within ten days. Similar reports not yet published have been made to me by other veterinaries. Should these reports be verified in veterinary colleges, where I am informed this method is being

tested, this treatment will certainly prove to be of immense value.

The wide range of application of bismuth paste must not, however, mislead to the belief that there are no limitations to its use. There are suppurative conditions in which it is of no benefit, and in some its application may even be harmful.

First of all, **it is contraindicated** in acute inflammatory conditions, such as acute sinusitis, acute phlegmon, freshly opened **acute** abscesses, etc. Although some gratifying results have been reported also in acute conditions, we have been conservative in its application, having occasionally noted an aggravation of the symptoms after its use in acute cases.

For obvious reasons it should never be injected into a fistula of the gall-bladder or the pancreas, and great care should be exercised when making injections in the vicinity of the cranium, where there is a possibility of the paste finding its way into the subdural space, as it would cause a compression of the brain similar to that of a blood clot.

A hypodermic needle should never be employed to make these injections, as it may enter a vein, and thus the paste may be injected into the circulation and cause death by blocking the branches of the pulmonary artery.

Causes of Failure.

We have had many cases referred to us in which the method had been applied and for some reason the desired results had not been obtained. Thus we were afforded a good opportunity to study the causes of failure in quite a variety of most interesting cases. The citation of a few examples will be instructive in showing the causes of failure.

Foreign Body.—W. W., aged 4. One month following an attack of croup, in December, 1907, became suddenly ill with chills and fever, and pain in the upper arm. Within two weeks of continued intermittent rise of temperature, up to 104.5° , a swelling midway between the shoulder and elbow appeared. Diagnosis: **osteomyelitis**. A half pint of pus was evacuated through three incisions from shoulder to elbow. The suppuration failed to cease within a reasonable time, and another operation was performed, in which a considerable amount of necrosed

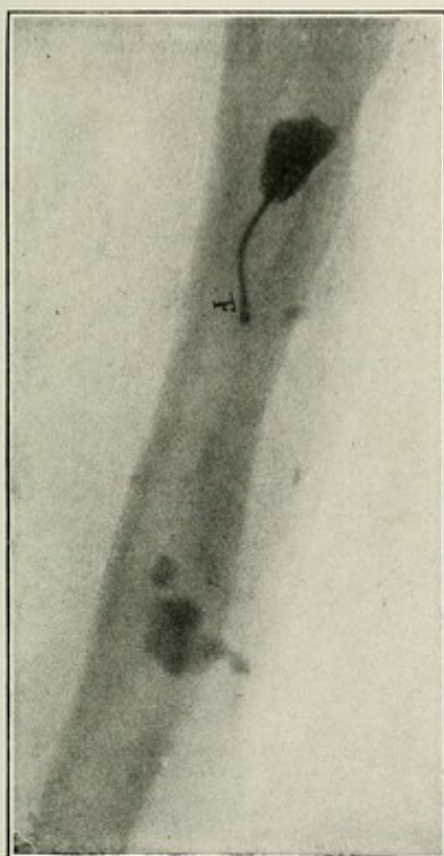


Fig. 68.

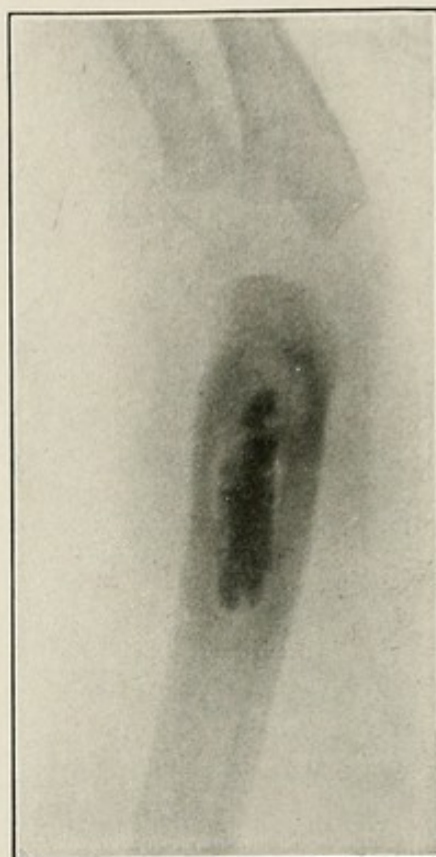


Fig. 69.

Figs. 68, 69. Tip of probe (Fig. 68, F) within the shaft of humerus as a cause of failure of bismuth injections. Cavity filled with bismuth paste (Fig. 69) after removal of foreign body.

bone was removed and the entire length of the medullary shaft of the humerus was curetted. Five weeks later the discharge still persisted. At this time the bismuth paste treatment was tried by the physician in charge, but with no benefit. Therefore another radical operation was undertaken and more necrosed bone removed. Bismuth paste was again injected, and after a sufficient trial it was discontinued. In July, 1908, the boy was brought to Chicago for the bismuth treatment. The radiographs here shown (Figs. 68, 69) explain the cause of failure. The tip of a probe, one and one-half inches long, was

lodged in the shaft of the humerus. After its removal the bismuth paste was injected and all sinuses promptly closed without a recurrence.

Foreign Body.—J. N., aged 14. Developed an osteomyelitis in the upper part of the humerus and the tibia four years ago. After the usual treatment at home, which included curettage and drainage of the bone cavities, there appeared to be no tendency to healing. The sinuses continued to discharge pus profusely. He was then brought to me for the bismuth treatment.

A radiograph of the humerus, taken before the injection of bismuth paste, shows a shadow resembling a sequestrum. In the presence of a sequestrum the paste would be of no avail, and I therefore proposed a thorough curettage before injection. During the operation I noticed a dark striated object lying within the shaft of the humerus. It was resilient, like a large blood vessel, and upon extraction proved to be a piece of rubber tubing two and one-half inches long. Bismuth paste would, no doubt, have been a failure had we not discovered the foreign body beforehand.

These two cases, however, represent accidents, and can not be taken as examples of frequent causes of failure; but the disease itself very often leaves a foreign body at the seat of trouble—namely, **the sequestrum**.

Sequestra are the most frequent causes of failure. Their diagnosis has been extensively studied by my brother, Dr. Carl Beck, who satisfied the members of the Surgical Society of Chicago that sequestra, when present, **can** be recognized by means of radiographs practically in all cases.¹ When a sequestrum is present we do not expect a cure until it has been removed. Nevertheless, a risky operation should be undertaken only as a last resort. I know of two instances in which sequestra have healed in during the bismuth treatment.

Large Sequestrum of Ulna.—L. B., aged 12, with congenital syphilis, was treated by me for this condition the first three years of his life. For seven years thereafter he enjoyed comparatively good health and normal growth. At the age of 10 he developed a remittent fever, which lasted six months, and debilitated the boy very much. With antiluetic treatment he gradually recuperated until he reached his

¹ Carl Beck, Chicago: Chronic Osteomyelitis—Diagnosis and Treatment.—Surgery, Gynecology and Obstetrics, February, 1910.

11th year. Thereafter he was sickly for one year, and returned for treatment at the age of 12. He had a daily temperature of from 100° to 103° , was extremely anemic and emaciated. His legs below the knees and his forearms were very much enlarged. Radiographs of these parts were taken, and it was found that suppurative osteitis had taken place in practically all of the bones of these parts, showing softened areas on the skin, which indicated the presence of abscesses. On the right forearm was a sinus, through the opening of which a portion of

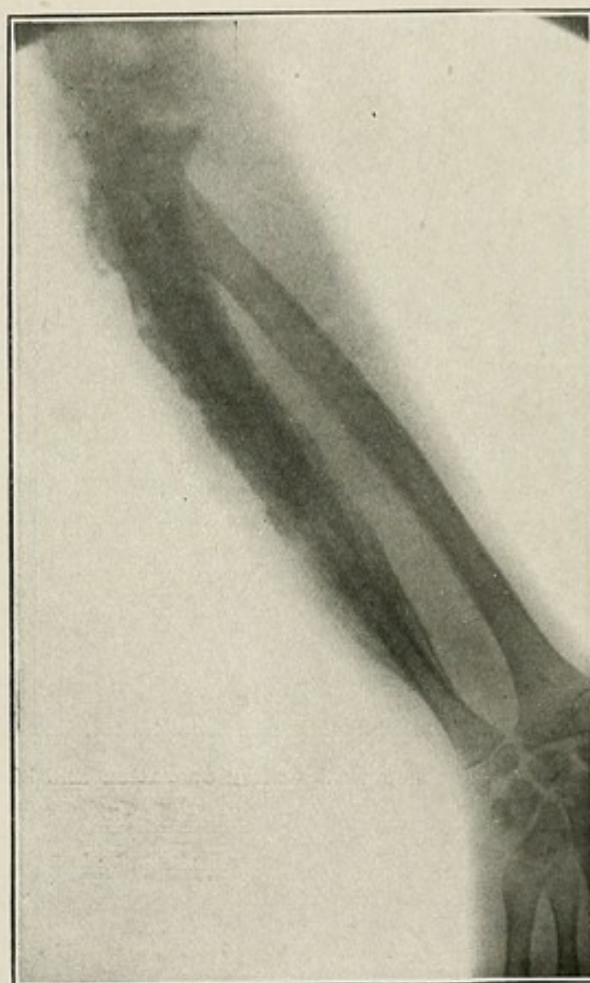

Fig. 70. Sequestrum of the ulna, requiring removal before bismuth injection.

dead bone protruded. The radiograph (Fig. 70) of this arm shows enormous destruction of the ulna and elbow joint. The entire ulna was practically a sequestrum, and the futility of any conservative treatment was evident. The sequestrum was removed under anesthesia, and its natural size and colors are shown in the colored plate. The cavity was packed with gauze, and the next day was filled with bismuth paste. The abscesses on the left arm were incised and injected, and closed without secondary infection within three days. Temperature

ceased after first injection. The healing progressed rapidly, and three weeks after the operation the wound was practically closed, the boy had gained twelve pounds, and had practically normal motion in both arms. (Fig. 71.) It must, however, be stated that he had at the same time received antiluetic treatment, which may, to a certain degree, account for the rapid improvement, although the same treatment before the operation did not have this effect.

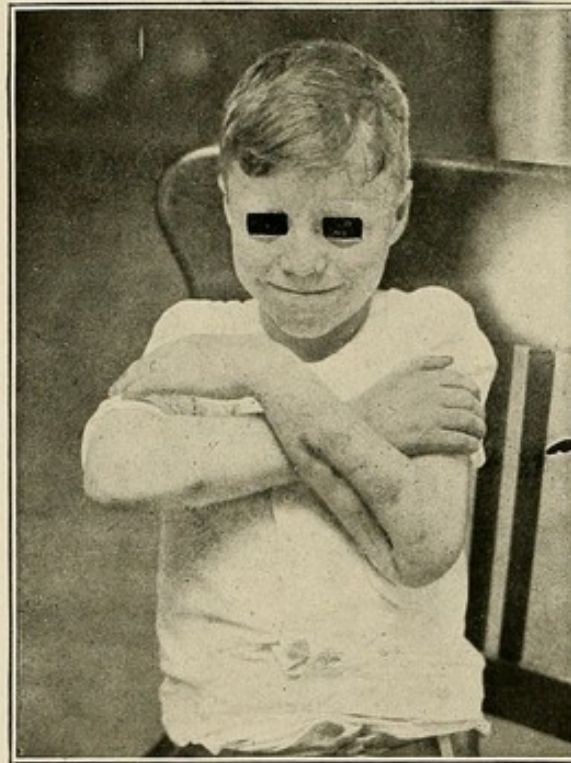

Fig. 71. Complete closure three weeks after operation and bismuth treatment. Removal of ulna from left arm.

Faulty Technic.

Faulty technic is, no doubt, the cause of many failures. I have often been surprised to find that cases referred to me, in which the paste had been used "faithfully" for months without success, responded to my first injection and closed.

The underlying principle must always be kept in mind that the bismuth paste must be soft enough to permit its flowing into the remotest parts of the channels and filling every one of them completely. In Fig. 72 we show a

bone cavity which was injected, but not filled completely. If a small side-pocket or branch of a sinus is missed, the suppuration will continue and in time the entire tract of the sinus become reinfected.

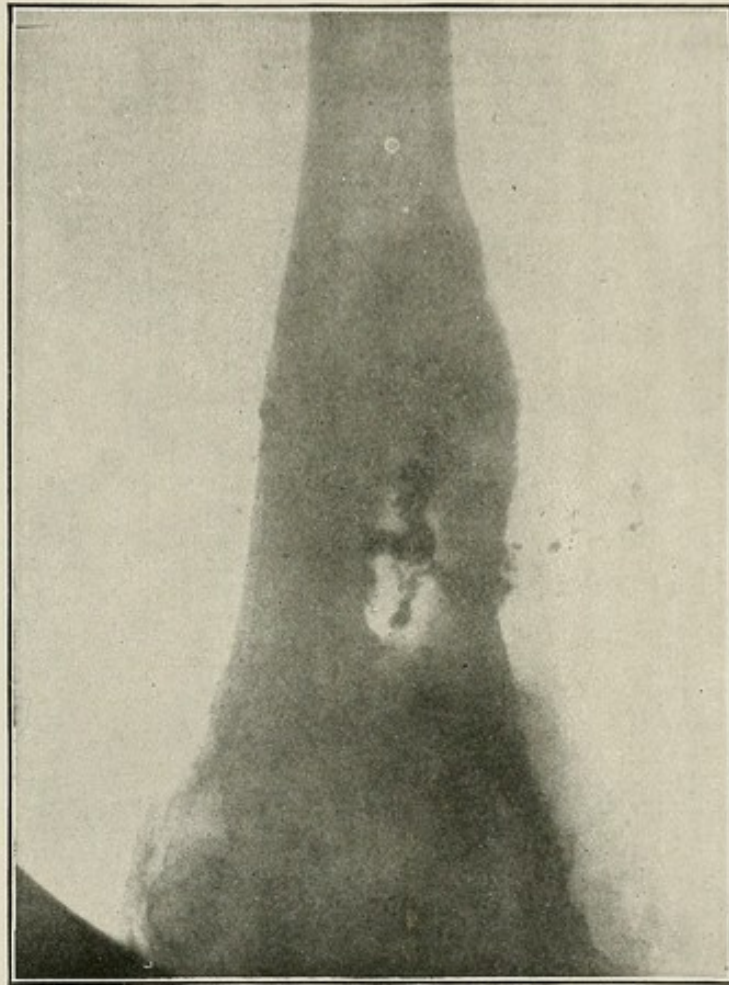


Fig. 72. Incomplete injection of abscess cavity, demonstrating cause of failure of bismuth treatment.

Unexplained Causes of Failure.

Empyema; Estlander Operation; Closure with Paste.—Miss L. E., aged 28. Her family and personal history are negative as to tuberculosis. Four years ago she developed an acute pleurisy, with effusion. Two weeks later purulent fluid was aspirated, whereupon a resection of one rib was performed and drainage instituted. For eighteen months a copious, purulent discharge persisted. A second operation was performed for the purpose of establishing a counter-drainage, but this also failed to stop suppuration. As a last resort

178 BISMUTH PASTE IN CHRONIC SUPPURATIONS.

an extensive Estlander operation was performed, but even this radical procedure did not suffice to stop the discharge. The bismuth injections were then tried at home, and, while the discharge became more scanty and less purulent, it did not cease. Retention, with fever, often occurred. With this history the patient arrived at our hospital

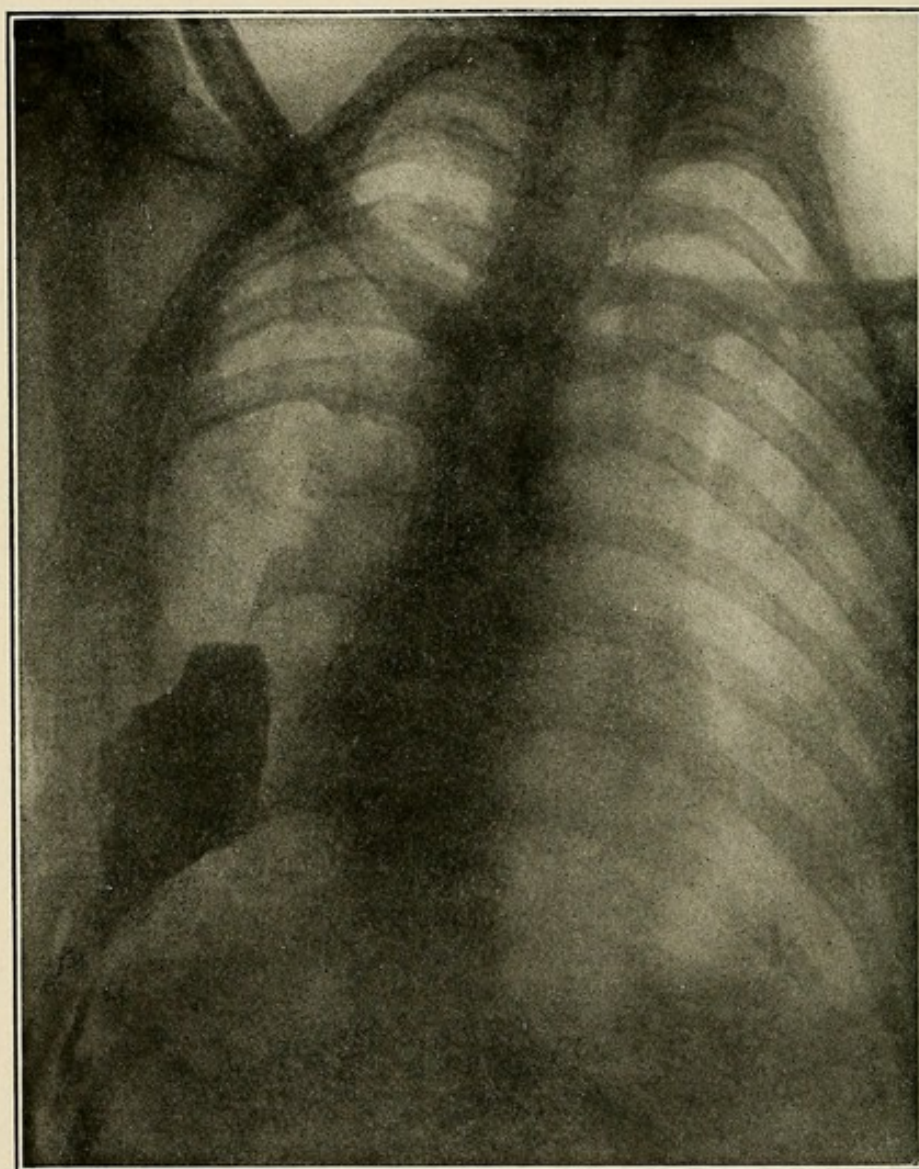


Fig. 73. Injection of empyema after Estlander operation has failed to obliterate the cavity.

in October, 1909. The radiograph here shown (Fig. 73) gives a vivid illustration of the true condition within the chest which existed after an Estlander operation. The paste occupies the remaining cavity. The upper part of the lung is perfect and functioning.

The paste, which was in the chest cavity, was washed out with

warm olive oil, and the following day a fresh injection of bismuth paste No. 1 was made. The secretion became sterile, and the sinus closed within one week and has remained so to date. There has been no elevation of temperature or discomfort, and a radiograph taken recently shows the absorption of the paste and the distention of the lung. These are signs most promising for the permanency of the cure, although recurrence is possible.

We have noticed that there are two classes of cases—one class responds promptly to the bismuth treatment, while the other is very refractory. To which class a case belongs is usually decided after the first injection. If the purulent discharge changes into a serous one, a good result is to be anticipated, and a closure usually follows the first injection. If the discharge remains purulent, the outlook is not so promising. The injection is not, however, repeated for at least one week. Only the daily dressings, with frequent microscopical examinations, are continued. Thereafter the sinus is reinjected every three or four days for a reasonable length of time—about a month. If no improvement is noticed, the cause of failure must be searched for, which in some cases remains inexplicable.

The limitations here prescribed may seem too strict and unnecessarily conservative to surgeons who have already tried the bismuth paste and obtained good results even in cases where I do not recommend its use. Nevertheless, I insist that it is far safer for the present to limit its use to such cases where our experience has assured us of its safety and usefulness.

CHAPTER XIV.

BISMUTH POISONING AND ITS PREVENTION.

The introduction of new remedies is usually met with skepticism, and the failures and possible dangers are pointed out first. This is, of course, most desirable, since it helps to eliminate the objectionable features from otherwise useful methods. The x-ray received its first blow when the reports of x-ray burns began to pour into the literature, but after fourteen years of its employment, when its use has been increased a hundredfold, reports of burns are comparatively rare.

Vaccination, antitoxins, and anesthetics passed through similar experiences until their true value was recognized. There is no remedy of any importance which has not some objectionable feature, and its true value depends only upon the relative amount of good to be accomplished by it. Chloroform may cause death, but nevertheless thousands of persons request anesthetics, knowing their usefulness.

Bismuth paste is no exception to the rule, and its objectionable features were brought forward shortly after the appearance of my first article on the subject. The objection advanced is the toxic effect following its administration. It is far safer to magnify this danger than to make too light of it, but an undue exaggeration of this complication may deter many from applying an otherwise useful method of treatment. Neither my brothers nor I have had a single case of poisoning in our experience with several hundred cases. I have, neverthe-

less, at every opportunity warned the profession against this possible danger.

It must be admitted that in the application of bismuth paste toxic effects may be produced. The slow absorption of the metallic bismuth from cavities where large quantities are retained for a long period causes symptoms of poisoning similar to those of mercurial intoxication.

The first symptom, a slight lividity of the skin, appears during the second or third week. Later we find small blue ulcerations of the gums and back of the wisdom teeth, and a black discoloration underneath the tongue. Soon thereafter patient complains of nausea, headache, and, frequently, diarrhea. The urine contains epithelial casts and some albumin. If the progress is not checked, the ulcerations will enlarge, the teeth become loose, and the patient become cyanotic and begin to lose considerably in weight, and finally may succumb to the effects of poisoning.

Administration of bismuth subnitrate in overdoses may produce two distinct varieties of poisoning:

1. The **acute nitrite poisoning**, which results from the rapid absorption of large quantities of nitrites liberated in the intestines from the bismuth subnitrate.

2. The slow but constant absorption of the metallic bismuth from either the intestinal tract or the serous cavities, or when injected into wounds—**bismuth poisoning**.

The instances of toxic effects from the use of bismuth subnitrate in medicine and surgery have been so rare that, until recently, physicians have regarded its administration as perfectly harmless. Schuler¹ and Von Bardeleben² have pronounced its action as nontoxic, the latter

¹ Schuler: Zeitschrift für Chirurgie, 1885.

² Von Bardeleben: Deutsche Medizinische Wochenschrift, 1901, No. 23, p. 544.

having treated one hundred cases of extensive burns by dusting with bismuth subnitrate, and observed no unpleasant symptoms therefrom. Professor Mühlig¹ administered 20 grams daily for a prolonged period without producing any poisonous effect.

It was, therefore, not surprising, when radiographers began to use bismuth subnitrate for the purpose of obtaining radiographs of the stomach and intestines, that they had no hesitancy in administering large doses, and boasted of the safety with which as much as 40 grams in one dose could be administered. The subject of bismuth poisoning has been revived only within the past three years, during which time radiographers have employed the drug more extensively.

Bismuth Poisoning Due to Dusting Powder.

The first authentic report of bismuth poisoning was made by Theodor Kocher² in 1882, who observed that the insoluble bismuth preparation, when applied to large wound surfaces, is capable of yielding enough bismuth to absorption to produce poisonous effects. Similar cases were reported by Professor Peterson.³ Thereafter the literature on the subject remained silent until 1901, when Professor Mühlig⁴ reported the following two cases:

Case 1. A man, aged 26, received burns on both arms, hand, and neck, which were dressed with oil for three days and the pure bismuth subnitrate applied. Two weeks later a black border around the teeth appeared, and within five more days the whole mouth and uvula were grayish-blue and slightly ulcerated. Urine remained normal; digestion normal. Recovery took place after wounds were curetted and freed from bismuth.

Case 2. A man, aged 34, was burned on both legs. Treatment the same as in case 1. Twelve days after first bismuth dressing symptoms identical with those in case 1 appeared. Urine and stool re-

¹ Mühlig: *Münchener Medizinische Wochenschrift*, 1901, No. 13, p. 592.

² Kocher: *Volkmann's Klinische Vorträge*, 1882, p. 224.

³ Peterson: *Deutsche Medizinische Wochenschrift*, June 20, 1883.

⁴ Mühlig: *Münchener Medizinische Wochenschrift*, 1901, No. 13, p. 592.

mained normal. The curettage of the wounds resulted in prompt remission of the symptoms. The bismuth used in these cases was free from impurities.

A similar case was reported by Dressman:¹

Case 3. A man, aged 30, received a burn of third degree. Five days later a 10-percent bismuth salve was applied. Three weeks later a black sediment was discovered in the urine. A severe stomatitis, with deglutition pains, followed. A bluish-green border around his teeth was noticed, and the mouth resembled the condition which exists after eating huckleberries. After the bismuth dressings were stopped the symptoms abated, but even six months later there were marks around the teeth.

These cases prove that absorption of bismuth subnitrate, when applied as dusting powder on burns, may produce symptoms of bismuth poisoning, which, however, subside as soon as the bismuth is removed. None of these cases were fatal.

Nitrite Poisoning Due to Bismuth Subnitrate.

The first fatal case directly traceable to the administration of bismuth subnitrate for diagnostic purposes is reported by Bennecke and Hoffman:²

Case 4. A baby, aged 3 weeks, suffering from enteritis, weak and emaciated. A mixture of three grams of bismuth subnitrate in 100 cubic centimeters of buttermilk was administered by stomach in order to diagnosticate a pyloric stenosis by röntgenograph. Twelve hours afterward cyanosis developed, collapse followed, and the child died three hours later. Post-mortem examination revealed bismuth in the bowel, and small quantities in the liver and blood. Methemoglobinaemia was present.

From the same clinic a similar case was reported by Böhme.³

Case 5. A child, aged 1½, markedly rachitic, artificially fed, and marasmic, received a few grams of bismuth subnitrate by stomach for

¹ Dressman: *Münchener Medizinische Wochenschrift*, 1901, No. 6, p. 238.

² Bennecke and Hoffman: *Münchener Medizinische Wochenschrift*, 1906, No. 19.

³ Böhme: *Archives für Experimentelle Pathologie und Pharmakologie*, p. 441, 1907.

radiographic purpose. Stomach was washed out, and no symptoms of poisoning appeared. Two days later a few grams of bismuth subnitrate were injected by rectum for the same purpose, and again the bismuth was washed out. Three hours later the child was suddenly seized with pain, became cyanotic, pale, skin cool, pulse small; it died in thirty minutes.

Section. Distinct methemoglobinemia, all mucous membranes were brownish discolored, marked rachitis, dilatation of the stomach, with stenosis of pylorus. Colon contained large quantities of black and white bismuth.

Professor Hefter suggested that death might have been caused by nitrite poisoning. The blood and pericardial fluids were tested, and in both nitrites were found. Bismuth could not be detected in the liver or blood. These chemical findings threw new light on both cases, and prompted Dr. Böhme to determine the true cause of bismuth subnitrate poisoning. The results of his experiments were as follows:

A number of pure cultures of the bacterium coli were found to liberate nitrites in every case when added to bouillon to which some bismuth subnitrate had been added. The controls of bouillon—treated the same way, but without the addition of bismuth—remained free from nitrites. This experiment was repeated by using a solution of children's stool instead of pure cultures, and in every instance the formation of nitrites was marked, while the same experiments with stools from grown persons showed nitrites absent in 40 percent, slight in 35 percent, and marked in only 25 percent of the cases. The character of food seemed not to influence the nitrite formation, as some of the adults received a milk diet.

The next question Böhme determined was whether the formation of nitrites would occur in feeding lower animals with bismuth subnitrate. Cats and rabbits were used for experiments, and, after finding their stools and urine free from nitric acid, they were given from three to

five grams of bismuth subnitrate in milk. **Nitrates** appeared in the urine after a few hours, and did not cease to be eliminated from the kidney for twenty-four hours. Reaction to **nitrites** was absent in the rabbits and only faintly marked in the cats.

To prove that children's feces mixed with bismuth subnitrate would liberate nitrites in the bowel of the rabbit, Böhme injected a mixture of five grams of each into a part of the bowel by first ligating the loop. Nitrates and nitrites were found in the urine, but not in the blood taken from the hearts of the animals. In the feces of the ligated part of the bowel a large quantity of nitrates and nitrites was found. In trying larger quantities by the same method, and testing the urine hourly, the quantity of nitrates and nitrites increased, but **not enough was absorbed to cause methemoglobinemia.**

By these experiments Böhme proved by test tube and animal experiments that the feces of children, when in contact with bismuth subnitrate, will liberate nitrites, which are quickly absorbed from the intestines and found in the urine. While methemoglobinemia was not produced by the absorption, it must be assumed that the absorption of larger quantities would produce methemoglobinemia. Experiments proved this to be a fact.

Collishon¹ reports two cases of accidental nitrite poisoning in which sodium **nitrite** instead of the sodium **nitrate** was given. The symptoms were cyanosis, extreme weakness, and a grayish-blue discoloration of the mucous membrane and the tongue; they were so severe as to produce collapse, but cleared up after the drug was discontinued.

Routenberg² reported a case in which a methemoglobin-

¹ Collishon: Deutsche Medizinische Wochenschrift, 1889, No. 41.

² Routenberg: Berliner Klinische Wochenschrift, 1906, No. 43, p. 1397.

emia, with the usual symptoms of nitrite poisoning, followed the rectal injection of 50 grams of bismuth subnitrate in 400 cubic centimeters of oil of sesame, and, while the author ascribes the poisoning to the contamination of the oil, the analogy to other similar cases leads one to suspect that it was a case of nitrite poisoning.

A recent report of fatal nitrite poisoning due to bismuth subnitrate is published by Novak and Gütig.¹

Case 6. A man, aged 44, who, a year after a retrocolic gastroenterostomy, suffered from symptoms of obstruction, received in July, 1908, a rectal injection of four tablespoonfuls of bismuth subnitrate suspended in two liters of water, to test the function of the anastomosis. Soon after the x-ray examination the bowels were washed out. He had a restless night. In the morning the nurse noticed a discoloration of the patient's skin. Gradually the patient became grayish-green, mucous membranes cyanotic, temperature 40° C., pulse 96, had stertorous breathing, and did not respond to treatment. Venesection revealed the blood to be of a chocolate color, due to methemoglobinemia. Patient died eighteen hours after rectal injection of bismuth subnitrate. Spectroscopic examination of the blood a few hours after death showed that it had returned to normal, the brown color having changed to red. Two days later the post-mortem examination proved that the methemoglobinemia, which was positive before death, had now disappeared and blood had assumed a normal color.

This case also gave further impetus to investigation. "The administration of 100 grams of bismuth subnitrate by mouth, then by rectum, and through a fistula into the small and large bowels of dogs and rabbits, failed to produce any symptoms of poisoning, while in cats much smaller quantities (20 grams) would cause death in ten hours. Seven hours after ingestion of this quantity the cat vomited, her mucous membranes became bluish-gray, blood assumed a chocolate color, and spectroscopic examination revealed the methemoglobin stripe in the red."

This proves that certain animals are susceptible to

¹ Novak und Gütig: Berliner Klinische Wochenschrift, 1908, No. 39, p. 1764.

nitrite poisoning, while others are not. It is not yet fully determined to which class the human belongs.

Maasen proved that certain bacteria in the bowel convert the nitrites into ammonia or into nitrogen. It is likely that the bismuth subnitrate ingested always causes a liberation of small quantities of nitrites, which are either absorbed (and owing to the small amount cause no toxic symptoms) or are changed in the intestine into ammonia or nitrogen.

When, however, large quantities of bismuth subnitrate are given, and the liberation of nitrites is abundant and can not be neutralized quickly, typical symptoms of nitrite poisoning will appear. Alcohol and glycerin accelerate the formation of nitrites in the intestines. This suggests to us a practical point—namely, when we encounter a case of nitrite poisoning, to withhold alcoholics and glycerin from ingestion and administer some form of iodine.

From these experiments and reports of fatal cases we must conclude that the poisonous effects of the bismuth subnitrate were **not due to the absorption of the metallic bismuth**, but to the absorption of nitrites, which caused the methemoglobinemia. This methemoglobinemia is the factor producing most of the clinical symptoms—the cyanosis, dyspnea, diarrhea, and cramps. The sudden change in the blood impairs the internal or tissue respiration, and the patient succumbs, with symptoms of suffocation.

It appears that the intestine, and especially the sigmoid and the rectum, are the laboratories for the liberation of nitrites. The bacteria in this part of the intestinal tract evidently are the nitrite-splitting factors, whereas those in the stomach and small intestines allow the bismuth subnitrate to pass into the large intestines

without liberation of quantities of nitrites sufficient to cause poisoning.

The fatal cases thus far reported were all suffering from intestinal diseases, especially diarrhea or constipation, which suggests that the intestinal putrefaction accelerated the nitrite formation and rapid poisoning.

During the past three years the author¹ has employed bismuth subnitrate quite extensively in the treatment of empyema, sinus, and abscess cavities by injecting a mixture containing 33-percent bismuth subnitrate incorporated in petrolatum into the cavities. The question as to what became of the bismuth paste after the injection arose. A study of the subject revealed the fact that if the paste did not discharge from the sinus soon after injection, but was retained, it became encapsulated and absorbed. In nonresilient cavities, such as bone cavities, the mass is penetrated from all sides by fibroblasts and gradually replaced by connective tissue, while in collapsible cavities, such as the pleura, the expanding lung gradually replaces the slowly absorbing bismuth paste. This can be proven by taking radiographs at certain intervals of the region injected. This, then, proves that the bismuth paste is absorbed, and the question arises, How is the bismuth excreted, and is its absorption harmful?

Harnack² states that bismuth subnitrate is slowly absorbed and slowly eliminated. Orfilla found bismuth subnitrate in the liver. M. M. Bergeret³ states that bismuth subnitrate is found in the urine and in the serous exudates a few hours after administration. In rabbits the administration of a few grains could be detected in the spleen, muscles, and blood. Professor E. S. Wood⁴

¹ Beck: Illinois Medical Journal, April and July, 1908.

² Harnack: *Arzneilehre*, 1883, p. 383.

³ Bergeret: *Journal de l'Anatomie*, 1873, p. 242.

⁴ Wood: *Transactions of American Neurological Association*, 1883, p. 23.

has detected bismuth in the urine four weeks after administration, proving its slow absorption. We may, therefore, conclude that the bismuth is slowly absorbed and slowly eliminated.

Before attempting to answer the question—Is the absorption of bismuth paste harmful?—we must decide whether the harmful effects noted in the reported cases are due to the absorption of the liberated nitrites or of the bismuth itself.

In my experience with the injection of bismuth petrolatum into sinus and abscess cavities I have not encountered a single case in which the train of symptoms would correspond to that of an acute nitrite poisoning. I have, therefore, concluded that the injection of the paste does not produce a nitrite poisoning.

The first case in which I observed symptoms of true bismuth intoxication as a result of bismuth paste was a case of empyema pleuræ, in which I injected into the pleural cavity 720 grams of 33-percent bismuth paste, which was retained there for six weeks. A desquamative nephritis developed, albuminuria was present, with rapid loss of previously gained weight, and the blue border around the teeth appeared. As soon as the bismuth paste was withdrawn by means of olive oil all the symptoms disappeared, and the patient regained his weight in a few weeks.

I desire to cite a case which I saw in consultation, and reported in the *New York Medical Journal*, January 2, 1909, in which the bismuth injections had caused severe bismuth intoxication, and after this abated the patient died. Post-mortem examination and complete analysis throw some light on the pathology of this affection.

Case 7. R., a lawyer, aged 57, for many years an invalid, had a tuberculosis of his hip since 1896. After extensive operations he re-

tained several sinuses, which discharged large quantities of foul pus. In March, 1908, his sinuses had been injected by the house physician twenty times in a period of sixty days with a 33-percent bismuth petrolatum paste, the total amount representing about 400 grams of pure bismuth subnitrate. While his general condition improved at first and his sinuses had healed up, all typical signs of bismuth intoxication gradually developed. The mucous membrane of the mouth and gums became bluish-black, with ulcerations; teeth became loose and lips edematous. He experienced great thirst, diarrhea, and had desquamative nephritis. The symptoms gradually abated, and he became well enough to resume his work as an attorney, and for two months was active in his vocation. A radiograph taken of his pelvis demonstrates that there were only small quantities of bismuth within the tissues.

August 1, 1908, he fell, injured his wrist, and a large abscess formed, which was operated on by Dr. V. Verity. A large area of necrosis followed. From this time his temperature varied from 99° to 101.5° F. He lost in strength, his urine was loaded with casts and albumin, his heart became weaker and irregular, and he died August 16, 1908.

Post-mortem examination, made by Dr. Gehrmann and myself, showed the following conditions:

Abdominal Cavity. A small amount of fluid present. No adhesions or evidence of tumors or inflammatory exudates.

Liver. Normal in size, dark-brownish in color. Section fails to show any noticeable changes.

Spleen. Normal size, but unusually dark; quite soft.

Pancreas. Negative.

Intestines. Somewhat distended with gas, but otherwise negative.

Vermiform Appendix. Negative.

Mucous Membrane of Intestines. Shows dark color, very marked.

Kidneys. Normal in size. External surface of both shows some evidence of beginning contraction, as the capsule is irregularly depressed. Sections show both kidneys to be of dark color, with the cortical markings not as distinct as in a normal organ.

Pelvis and Ureters. Free. On the right side in the perivis the retroperitoneal tissue appears gelatinous, of a whitish, glistening appearance, as if filled with a foreign substance. (No bismuth.)

Chest. Pericardium negative. Heart about the size of subject's fist. Heart muscle rather softer than normal. Valves negative and coronary arteries negative.

Lungs. Few adhesions about apices on both sides. Some hypostasis on both sides. Otherwise negative.

Bones of Thorax and Spine. Inspection, as far as possible, fails to show fractures, tumors, or inflammatory changes.

Head. Not posted.

The microscopical examination of the tissues from the liver, spleen, kidneys, heart muscle, and intestine, and the chemical analysis of tissues, were made by Dr. Maximilian Herzog, and his report is as follows:

Liver. The liver parenchyma cells in general do not show any marked pathological changes. Some cloudy swelling is noticeable here and there, but the process is not at all extensive; on the contrary, it is quite limited. There is very little fatty infiltration and fatty degeneration. Quite a number of parenchyma cells show bile granules in their paraplasm. Whether the latter also contain here and there bismuth is a question which can not be definitely decided, as we do not know of any microchemical reaction for bismuth. It appears, however, that we find frequently in liver cells granules darker than the bile granules and that they are bismuth granules. The latter can first

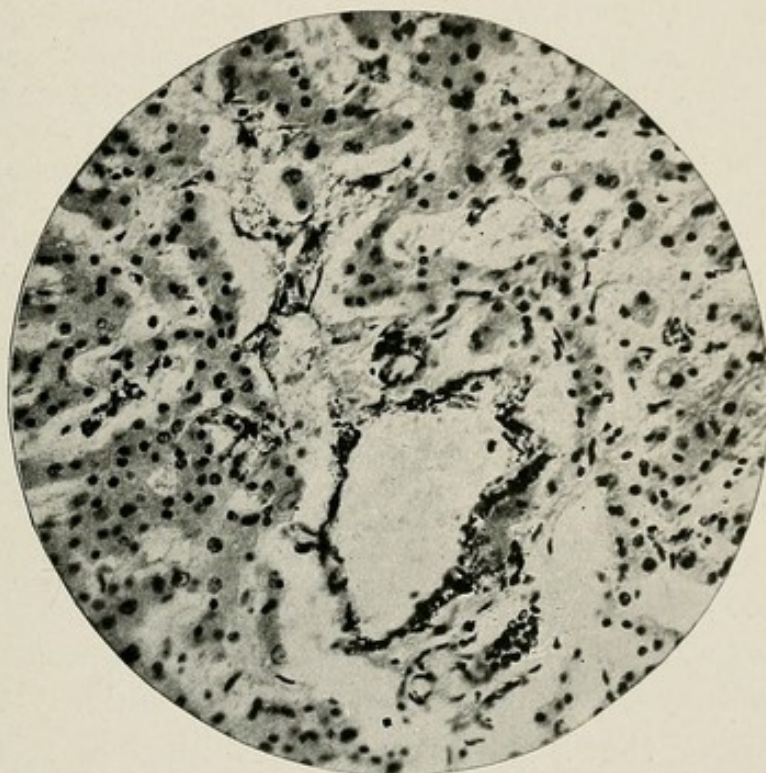

Fig. 74. Photomicrograph of section of liver about four micra thick. In the center of an interlobular vein, to the right and above a sublobular vein. The intima of both lined with bismuth. Magnification, 210 diameters.

be seen distinctly and beyond doubt in the interlobular capillaries. Here we see the dark granules in the lumen of the small vessels and crowded in fusiform cells, probably the star cells of Kupfer. In the interlobular veins bismuth is present to a large extent; it is found in the vascular endothelium and deposited in the form of fine granules on the free surface of the intima. Occasionally one sees in the interlobular connective tissue a vessel, apparently a sublobular vein, which likewise contains bismuth. (Fig. 74.) But this point is not clear beyond doubt, as is the presence of bismuth in the portal system. Bile capillaries containing bismuth can be distinguished here and there between the liver cells; bismuth is also occasionally found in the

small interlobular bile ducts, but the biliary ducts and capillaries are generally collapsed and empty.

Kidneys. The renal tissue shows chronic interstitial changes, with hyaline degeneration of a considerable number of glomeruli. A few of the degenerated hyaline spheres contain lime salts. Some tubules contain hyaline casts; besides, here and there the tubular epithelia show marked cloudy swelling. There is no bismuth present in the renal sections.

Spleen. There is some thickening of the capsule and of the trabeculae noticeable. The pulp spaces are not very distinct—well crowded with erythrocytes and leucocytes. The Malpighian bodies are not well defined. Some bismuth is present in the shape of amorphous granules, and denser masses in the pulp spaces.

Myocardium. Striation is not very distinct; there is here and there a fine vacuolation; also occasionally some cells which show the pigmentation of brown atrophy. But these pathological changes are very moderate in degree. A few subpericardial round cells foci are present.

Intestinal tissue. Nothing, except a very few thick, irregular sections were accessible for examination. These show an extensive infiltration of the mucosa with bismuth. The lymphoid tissue likewise shows bismuth, and much of the latter is found in the veins of the submucosa.

The chemical examination resulted as follows:

Heart Muscle. A faint trace of bismuth.

Spleen. Very small piece. Distinct reaction for bismuth.

Liver. Contained 0.13 percent of bismuth oxide. The tissue was pressed fairly dry between filter paper. Weight, 2,292 grams; total ash weight, 0.030 grams, in which bismuth weighed 0.003 grams.

From the above microscopical examination it might appear that the bismuth was first absorbed into the lymphatics—that it was transported to and excreted into the intestines. Much was, however, reabsorbed by the portal circulation and transported to the liver, to be there excreted into the bile passages. There is no evidence that any of the bismuth was excreted by the kidneys.

While this case presented the symptoms of bismuth intoxication, and its absorption was proven post-mortem by microscopical examination and chemical analysis, the question is still open as to whether the absorption and presence of metallic bismuth in the tissues was the direct cause of death. The pathological changes in the liver,

spleen, and heart muscle did not indicate that a severe destructive process, which would interfere with function, was going on. The interstitial nephritis was evidently not due to the bismuth absorption, as the renal tissue was free from deposits of the metal, and the pathological condition found could be expected in an old man who had for years suffered from a chronic suppurative disease. Dr. Verity reports that the patient was treated by him ten years ago for chronic nephritis.

Dr. H. Eggenberger,¹ from the clinic of Professor Wilms, of Basel, reports a fatal case of bismuth intoxication subsequent to the injection of a psoas abscess in a child 7 years old. Thirty grams of the paste were injected and retained for six weeks. Stomatitis developed, resembling mercurial intoxication; pulse rose to 130, and a picture of toxic cortex, such as is often observed in uremia, developed. The abscess cavity was evacuated, but the child died a few days later.

Autopsy revealed no anatomical changes, except a hyperemic condition of the central nervous system and small hemorrhagic spots in the mucous membrane of the stomach. The intestinal follicles were red and swollen, and on the valvula Bauhini a greenish-brown ulceration, 2 to 3 centimeters in circumference, was found.

In a résumé, Reich,² of Professor Bruns' clinic, has collected from the literature thirteen cases of bismuth intoxication, of which six terminated fatally and seven recovered. This series includes the three cases previously reported by me, which, however, occurred in the practice of other physicians who called me to see them. The remaining three cases were those of Kaufmann (Cook County Hospital), Eggenberger, and Reich.

¹ Eggenberger: *Centralblatt für Chirurgie*, 1908, No. 44.

² Reich: *Beiträge zur Klinische Chirurgie*, 1909, bd. 65, h. 1.

Since then Matsuoka,¹ of Japan, reported three cases, of which two were fatal and one recovered.

Most of these cases occurred in the early period of the

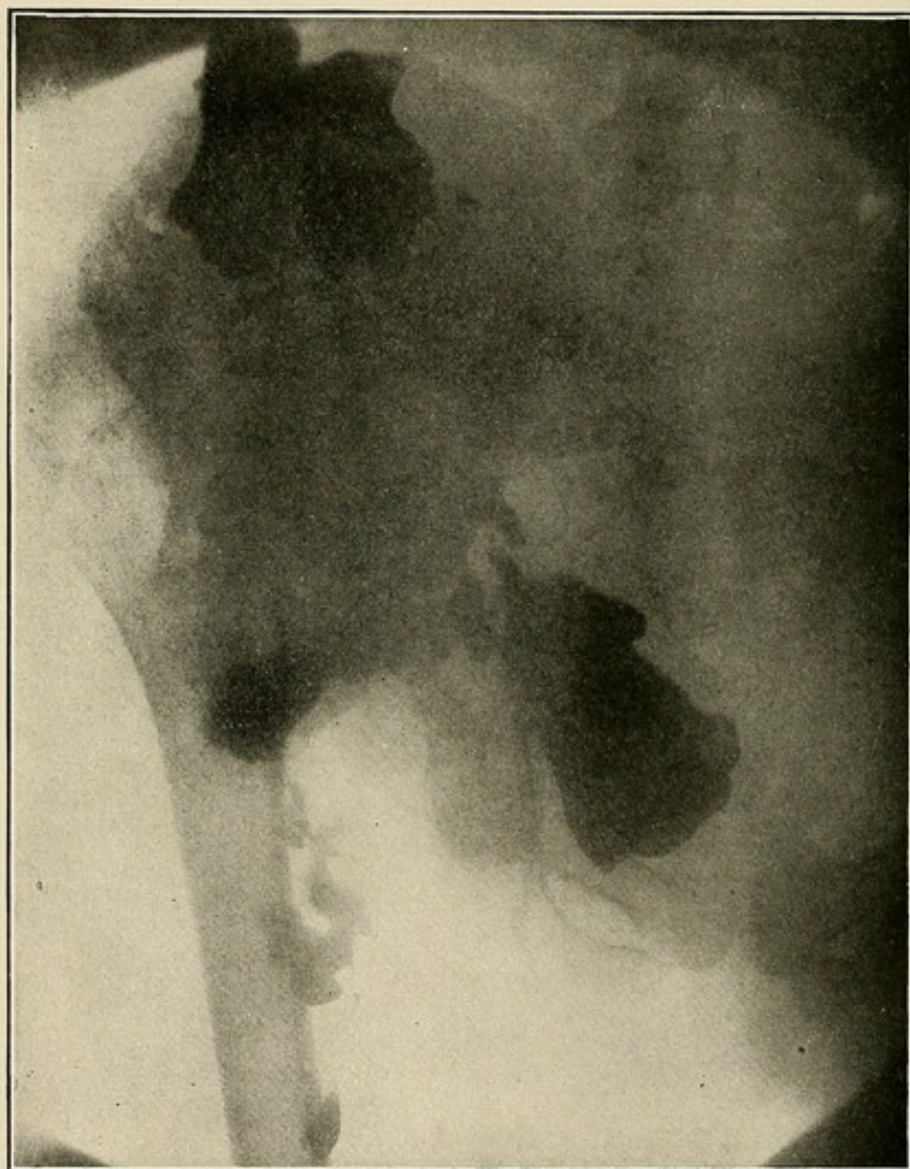


Fig. 75. Large quantities of bismuth paste retained in pelvis, causing absorption. Complete recovery after washing out with olive oil.

development of the bismuth paste treatment, and usually in one of the first cases in which it was tried. Since the various warnings and my publications as to its preven-

¹ Matsuoka: Deutsche Zeitschrift für Chirurgie, bd. 102, s. 508.

tion, the reports of bismuth poisoning ceased to appear in the literature, in spite of the fact that its use has been extended into all parts of the world. This indicates that the paste is used more judiciously and the intoxication is avoided, thus eliminating the one objectionable element.

My brothers and I consider ourselves fortunate in not

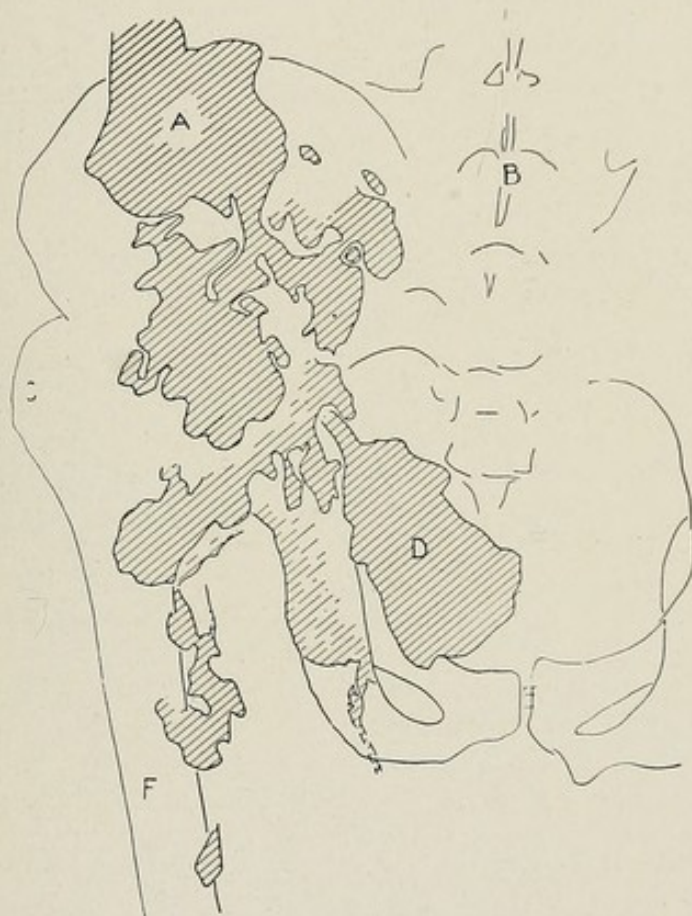


Fig. 75 A. Diagrammatic illustration of Fig. 75. A, bismuth paste in pelvic cavity; B, sacrum; C, greater trochanter; D, intrapelvic abscess, cavity close to rectum; E, symphysis pubis; F, femur.

having had a fatal case in our large series, especially so as we had no one to put us on our guard against such contingency. Fortunately I discovered the onset in the first case, an empyema, early enough to prevent a fatality, and from this lesson we learned to anticipate and prevent its occurrence.

Prevention of Bismuth Poisoning.

The prevention consists of not allowing large quantities of the paste to remain in the body for absorption. Should the symptoms appear, the paste must be removed by washing out the cavity with **warm olive oil**. The sterile oil is injected and retained for twelve to twenty-four hours, in order to produce an emulsion, which should be withdrawn by means of suction. After its removal all symptoms will promptly disappear. Scraping out the paste with a scoop is a dangerous procedure, because it opens fresh channels for absorption.

The following case illustrates the prevention of bismuth poisoning:

R. W., aged 33, fell from a horse at the age of 15, injuring his left hip. Three months later an abscess developed, which ruptured spontaneously. Within a year the limb shortened four and one-half inches, and five sinuses about the hip developed and persisted in discharging pus for the next seventeen years. In the fall of 1908 the bismuth injections were begun at his home. The first few injections were made by his physician, and thereafter (he living in a rural district) the treatment had to be continued at home by the patient's wife. She "faithfully" injected every day, and after thirty days he developed typical signs of bismuth absorption—namely, blue ulcers of the gums, headache, loss of weight, etc. The radiograph (Fig. 75) demonstrates that enormous quantities of paste have accumulated in pelvic cavities, with no outlet for their return, and thus their absorption.

The sinuses were immediately washed out with warm olive oil, and within twenty-four hours nearly all the paste was withdrawn by means of a suction pump. Symptoms of bismuth poisoning subsided within four days, but the sinuses continued to discharge. Four weeks later I injected 30 grams of paste. The secretion changed from that of pus to serum, and two weeks later the sinuses closed.

Another illustration is the following case of empyema:

B. had pneumonia, followed by empyema, in the fall of 1909. A resection of one rib was performed and drainage instituted. The suppuration continued, however, for several months, when he was brought to me for treatment. After estimating the size of the cavity by radiograph, I injected 16 ounces of the 33-percent bismuth-vaselin paste. Radiograph (Fig. 76) shows the size of the cavity. The paste was

retained for ten days, and during this time the patient felt absolutely well, but thereafter he began to complain of lassitude and loss of appetite. An examination of the mouth showed the first symptoms of bismuth absorption—i. e., a bluish discoloration at the margins of the gums and also bluish rings around the follicles of the tonsils. Within

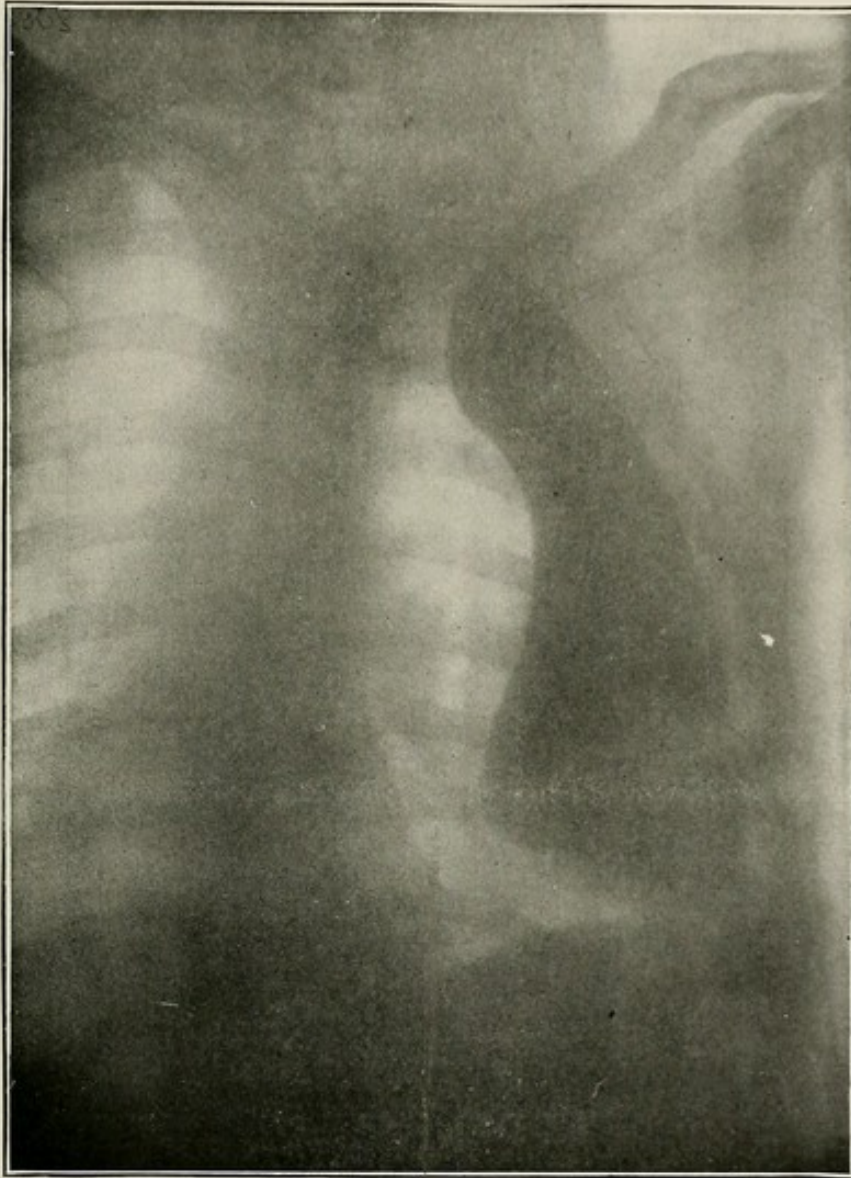


Fig. 76. Empyema filled with bismuth paste, causing symptoms of absorption in two weeks. Prompt removal of paste resulted in complete recovery and cure.

the next twenty-four hours small ulcerations began to appear back of the wisdom teeth. The chest cavity was at once washed out with warm olive oil and the paste withdrawn with suction pump. (Fig. 77.) The cavity was refilled with sterile vaselin in order to prevent the entrance of air. The secretions in the meantime had become abso-

198 BISMUTH PASTE IN CHRONIC SUPPURATIONS.

lutely sterile and reduced in quantity. The symptoms of bismuth absorption at once began to disappear, and within three weeks not a sign of them remained. The cavity was treated by repeated suction to expand the resilient lung. Two more injections of a 10-percent bismuth paste were given at intervals of ten days. Finally all the paste was withdrawn, the cavity closed, and now the contracted lung has ex-

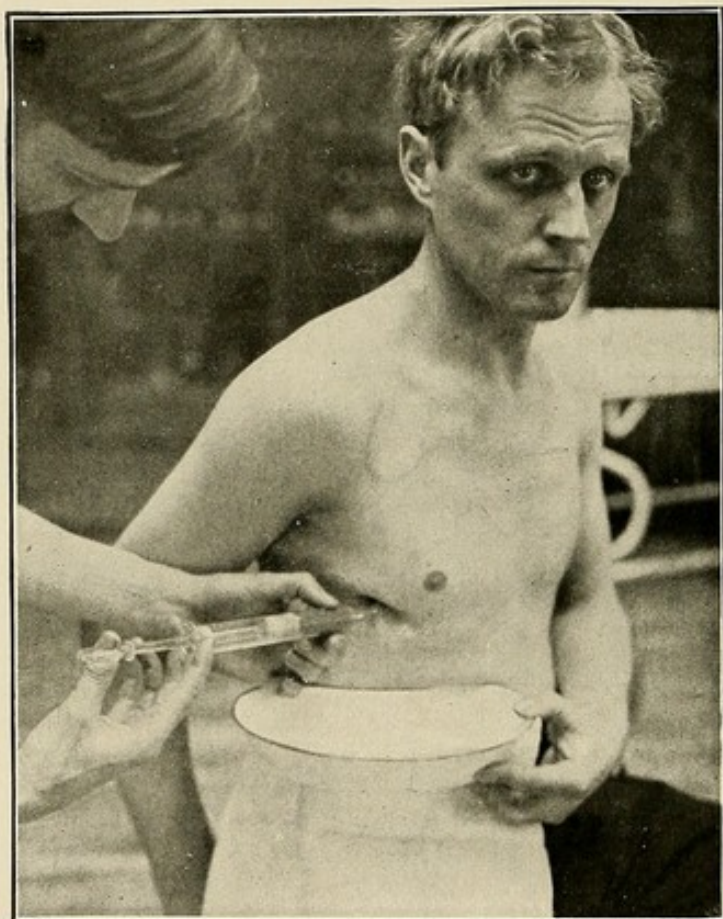


Fig. 77. Method of withdrawing mixture of paste and olive oil twenty-four hours after injection of the latter.

panded sufficiently to fill out the entire space first occupied by the bismuth paste. The sinus is closed, and the patient has gained greatly in weight and general health.

We have shown that **bismuth poisoning can be prevented**, and when it does appear it can be checked. Thus we are able to eliminate the objectionable feature of the bismuth paste treatment.

CHAPTER XV.

BISMUTH PASTE IN THE TREATMENT OF CHRONIC SUPPURATIVE DISEASES OF THE NOSE, ACCESSORY SINUSES, EARS, AND MASTOID PROCESS.

BY JOSEPH C. BECK, M. D.¹

One of the first cases of the head treated by means of bismuth paste, and subsequently reported by Dr. Emil Beck, was a tuberculous osteoperiostitis of the orbit, with abscess and fistulous formation, in a child, and so striking was the therapeutic result that I from that time—January 24, 1908—began to employ this method of treatment with great enthusiasm.

In order to determine the value and limitations of bismuth paste in chronic suppurations in the head and neck, I decided to experiment on every pathological condition in which the principles underlying the action of bismuth paste appeared to be indicated.

In May, 1908, I made a preliminary report before the Chicago Otolaryngological Society on the injection of bismuth paste in antrum suppurations, and in October, 1908, I made a complete report before the Chicago Medical Society of 319 cases of the following conditions and results obtained.

The results in this report were not final, as a large percentage of these cases were at the time still under treatment.

¹Surgeon to the North Chicago Hospital and Cook County Hospital; Clinical Professor of Otolaryngology, College of Physicians and Surgeons, Chicago; Professor of Otolaryngology, Eye, Ear, Nose, and Throat College, Chicago.

319 Cases of Chronic Suppurations About the Head and Neck Treated with Bismuth Paste.

Description of Series of Cases.	No. of cases.	Bilateral.	Unilateral.	Cured.	Improved.	Not improved.	Discontinued treatment.
SERIES 1. NASAL ACCESSORY SINUSES INJECTED WITH BISMUTH PASTE.							
Chronic suppuration of the accessory sinuses not operated on; bismuth paste injected in the region of the openings.....	43	19	24	2	10	27	4
Chronic suppuration of the frontal sinus, ethmoidal cells, antrum of Highmore, and sphenoidal sinus, in which a middle turbinectomy and ethmoidal exenteration had been performed; bismuth paste injected.....	4	3	1	1	3 (1)
Chronic suppuration of frontal sinus, anterior ethmoidal cells, and antrum of Highmore, in which a middle turbinectomy and ethmoidal exenteration had been performed; bismuth paste injected.....	20	14	6	8	9 (1)	1 (2)	2
Chronic suppuration of frontal sinus and anterior ethmoidal cells, in which a middle turbinectomy and ethmoidal exenteration had been performed; bismuth paste injected.....	9	5	4	2	1 (1)	1
Chronic suppuration of antrum of Highmore of dental origin and nasal origin; primary puncture at inferior meatus; bismuth paste injected.	4	1	3	4
SERIES 2. INTRANASAL CONDITIONS.							
Atrophic rhinitis; bismuth paste injected.....	5	4	1	4	1 (1)
Luetic ozena; bismuth paste injected.....	2	2	2 (1)
Pseudo-membranous rhinitis; bismuth paste injected.....	1	1	1
Maggot infection; bismuth paste injected	1	1	1
Suppuration associated with and following removal of foreign bodies from the nose; bismuth paste injected.....	1	1	1
Tuberculosis vestibulitis; bismuth paste injected.....	1	1	1
Middle turbinectomy in nonsuppurative condition; bismuth paste injected as dressing.....	19	12	7 (3)

Inferior turbinectomy; bismuth paste injected as dressing.....	14	14
Submucous resection of the septum; bismuth paste injected as dressing—bilateral.....	42 (4)
Hypertrophic rhinitis, principally of inferior turbinated body; bismuth paste injected.....	42	42	0	30	6	6
Ulceration of the septum; bismuth paste injected.....	6	2	4	2	4
Suppurative dacryocystitis; bismuth paste injected.....	3	3	3
SERIES 3. MASTOIDS AND EAR.								
Otitis, external, furunculosa; bismuth paste injected.....	4	1	3	4
Otitis, external, eczematosa; bismuth paste injected.....	2	1	1	2
Chronic otitis media suppurativa; bismuth paste injected either through external auditory canal or Eustachian tube.....	30	12	18	12	6	4	6 (3)
Chronic suppuration following the semiradical (Heath) mastoid operation; bismuth paste injected.....	4	4	2	1	1
Chronic suppuration after radical mastoid operation; bismuth paste injected.....	8	1	7	1	5	2
Scale formation; bismuth paste injected.....	3	2	1	3
Acute mastoid operation; filling defect with bismuth paste and complete immediate suture.....	7	7	7
Semiradical mastoid operation; bismuth paste injected instead of inflation as a subsequent dressing.....	3	3	1	2 (1)
Radical mastoid operation; bismuth paste used as a dressing instead of gauze packing and drainage.....	9	1	8	8	1 (1)
SERIES 4. TONSILLAR AFFECTIONS.								
Peritonsillar abscess; small incision and injection of bismuth paste.....	3	1	2 (6)
Chronic lacunar tonsillitis and supratonsillar infection; bismuth paste injected.....	29	8	21	5	20	2	2

¹ Still under treatment.² Operated on by external method.³ Besides 2 operated on.⁴ No bleeding, granulation, or crust formation.⁵ Checks bleeding; no suppuration or odor; no granulation or synechia following.⁶ No other return of abscess for one year.

After more than one year of observation of these cases, treated for finding the limitations of the bismuth paste in nose and ear work, I came to the following conclusions:

1. That in **atrophic rhinitis**, while scab-forming and odor were controlled during the period of treatment, the curative effect upon the atrophic condition was negative, and, as the injections were more disagreeable than other methods of treatment, I have discontinued their use in this affection.

2. As a **primary dressing following submucous resection** of the septum, I have discontinued its use, owing to the possibility of some of the paste getting in between the mucoperichondrial flaps and thus preventing union.

3. In **ethmoid suppurations** I have found that injections were of no avail, as the paste can not reach all the infected cells, and consequently I do not employ it in this affection; but as a primary dressing after exenteration I employ it regularly, as will be shown in this chapter.

4. In **chronic lacunar tonsillitis** I have come to the conclusion that no permanent results could be obtained, and therefore it is of no greater value than any other palliative treatment.

5. In **chronic suppuration of the antrum of Highmore**, and the **frontal** and **sphenoidal sinuses**, as a palliative treatment, I am convinced that the results are equally as good as from any other method of treatment. As a curative method the paste has produced the best results in the radical obliteration of the frontal sinus and the antrum, as will be shown later.

6. In **chronic suppurations of the middle ear** I continue to employ bismuth paste, and find that, while it does not cure more cases than other palliative means of treatment (the pathologic condition usually precluding such a pos-

sibility), I am nevertheless certain that in cases which are curable by nonoperative measures the paste treatment will stop the suppuration quicker and recurrences will be less frequent.

7. As a **primary dressing** (at the time of the operation) **in radical mastoid** with plastic I have discontinued the employment of bismuth paste, owing to the fact that some of the paste may find its way underneath the flaps and delay healing. **As a secondary dressing**, however, just as soon as union has taken place, I know of no better dressing to control the suppuration and stench, which we are accustomed to see in these cases, than the application of bismuth paste.

8. As a **framework for bone formation** in the simple mastoid operation, with primary closure of the wound, I employ it only in the selected cases, where the bony walls of the mastoid are absolutely intact, and when the character of the infection is not of a virulent type.

9. As a **secondary dressing** in the simple mastoid cases, I am certain there is no other method that will compare with the results in obtaining rapid and permanent closure of the retroauricular wound.

10. In **otitis externa eczematosa**, filling the external auditory canal with the paste is preferable to other methods of local application.

11. The simplest means of **controlling intranasal hemorrhage**, especially when it originates from the anterior or upper regions, is the injection of semi-solid bismuth paste No. 2. The difficulty of controlling bleeding from the posterior and lower portions of the nasal cavity is due to the inability to retain sufficient quantity to plug that region, as it usually drops into the throat.

Treatment of Suppurations of the Nose and Its Accessory Sinuses.

In considering the treatment of chronic suppurative diseases of the nose, I refer especially to the accessory sinuses, as suppuration of the cavity proper is usually secondary to the above-named structures, although ozena, atrophic rhinitis, and suppurations associated with foreign bodies are frequently met with. Before considering the treatment of the sinuses it will be well to mention some anatomical, physiological, and pathological points, so far as these bear relation to bismuth paste treatment.

Anatomical Points.—The nasal accessory sinuses are solid-walled cavities, oftentimes divided by partial septa, and irregular in shape, the ethmoidal labyrinth being multicellular. They are neither compressible nor distensible, and are lined by a modified mucous membrane.

The openings leading into them from the nasal cavity are so located as to make the introduction of a cannula or sound somewhat difficult, and thus the treatment can be carried out advantageously only by those who are familiar with the technic and the use of reflected light.

Physiological Points.—1. These cavities are resonators to the voice.

2. They impart warmth and moisture to the inspired air.

3. An accessory function of the sense of smell is attributed to them.

4. Their hollow construction serves the purpose of making the bones of the head very light.

5. The large surface of mucous membrane has a powerful absorptive function.

Pathological Points.—There exists usually the myxomatous degeneration of the mucous membrane with

polypoid formation. In very chronic cases there is frequently superficial osteitis, a necrosis with accompanying granulations.

These points must all be borne in mind in the treatment. Without a perfect knowledge of them, one will scarcely be able to explain the difficulties in the treatment of these cavities compared with the treatment in other parts of the body.

It must be stated at this time that only chronic suppurative conditions should be treated with bismuth paste—never acute ones.

The treatment is divided into two subdivisions—namely, (A) palliative and (B) radical, or obliterative.

The formulæ used in the treatment of the suppurative conditions of the nose and ear are the same as used in other parts of the body; the technic and instruments are, however, somewhat different.

Instruments.—In Fig. 78 are shown the syringes and cannulæ, the use of which is described in the technic of treating the various conditions.

(A.) PALLIATIVE METHOD.

Injection of Antrum of Highmore. Condition 1.—An antrum which has not previously been treated surgically. Position of patient—sitting. Cocaine anesthesia.

By means of trocar the antrum is punctured in the usual manner, and without previously irrigating it the syringe proper is adjusted by its bayonet joint and the cavity injected to distention.

The middle meatus is temporarily packed with cotton in order to prevent a too free escape of the paste while injecting. A small pad of cotton is placed against the opening created by the trocar, and the patient kept quiet

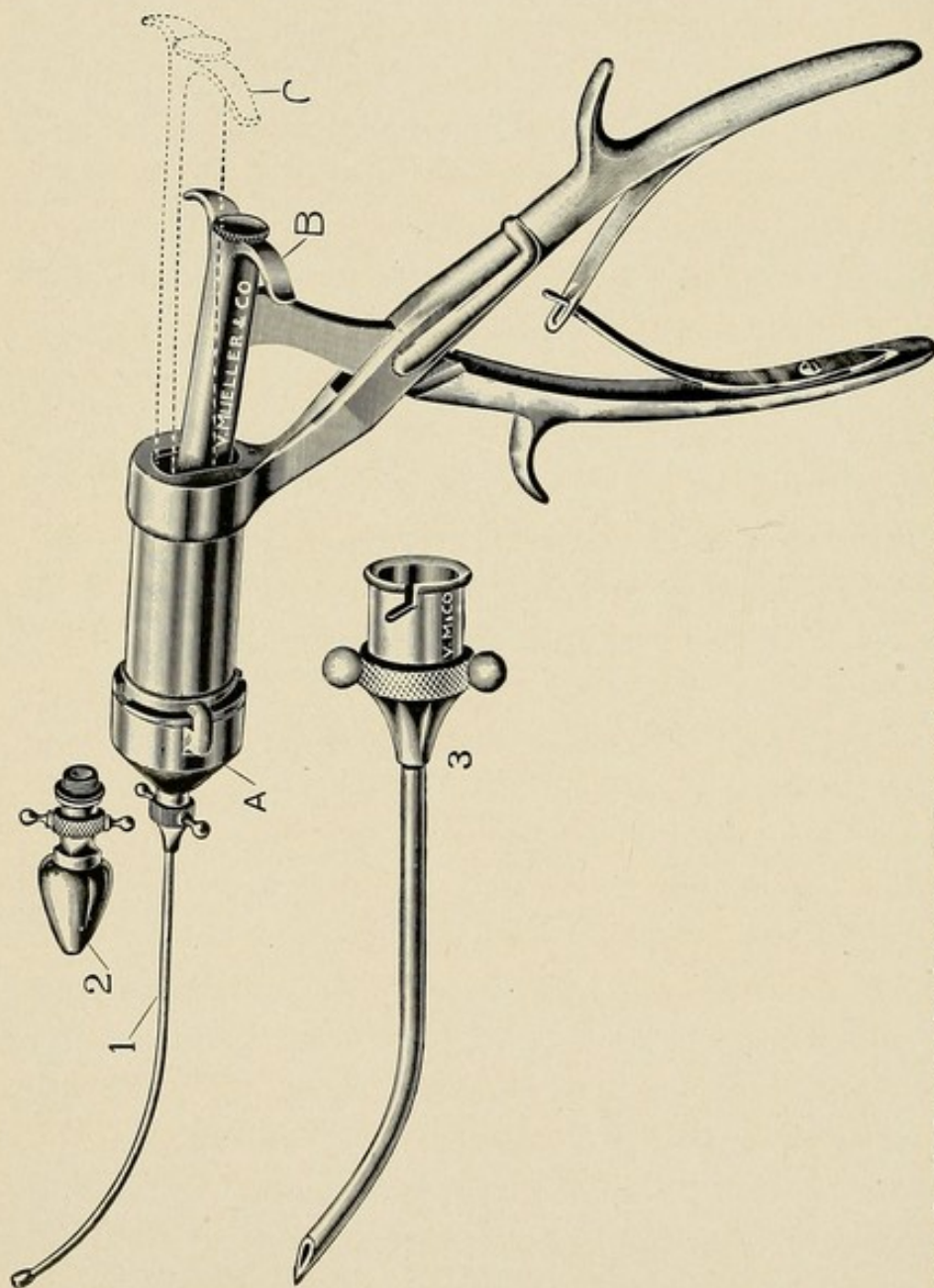


Fig. 78. Syringe and attachments for injection of bismuth paste in ear, nose, and throat cases. The syringe is filled with the paste by detaching the front cone and then filling the barrel by means of the regulation glass bismuth syringe shown in Fig. 1. Cannula, tip, and trocar are used as described respectively in the technic. 1, cannula, which may be bent to suit introduction into any sinus; 2, olive-shaped tip to fit nostril or external ear; 3, detachable trocar; A, cap, which is to be detached when filling the barrel with bismuth paste; B, piston, half-way drawn out; C, piston, fully drawn out.

for about ten minutes, to insure the paste remaining in the cavity.

Condition 2.—An antrum which has an opening in the canine fossa or socket of a tooth. Position of patient—sitting, head slightly reclining; lip retracted.

The middle meatus is firmly packed under the middle turbinal, so as to block the natural opening; then the olive tip of the syringe is put to the existing opening of the canine fossa or to the alveolar openings, and the cavity is injected. The cotton is then removed from the nose. It is well to pack the external openings either with a semi-solid rubber plug mounted on a partial dental plate or by cotton, to prevent the escape of the paste or entrance of food into the antrum.

Condition 3.—An opening exists in the lateral wall of the nose in the inferior meatus. The patient's head is placed on the side which is to be injected.

The cannula is passed into the antrum, cotton packed well about it in order to insure filling the cavity to distention, and the antrum injected until some of the paste returns along the cotton packing. The cannula is withdrawn, but the cotton packing is allowed to remain for about half an hour, until the paste has become set.

Injection of Ethmoidal Labyrinth.—These cells can not be treated by injections, as it is anatomically impossible to inject each individual cell. There is, however, a distinct use of the paste as a primary dressing in operations of middle turbinectomy and ethmoid curetment. This is accomplished as follows: As soon as the primary bleeding ceases, the patient is instructed to close the post-nasal space from the pharynx by having him repeat rapidly the word "kick." Simultaneously one applies the olive tip of the syringe to the nostril so as to obliterate it, and injects the cavity to the sensation of distention. Some of

the paste will return along the olive tip and into the nasopharynx when the soft palate is relaxed.

The paste employed for this purpose is formula No. 2, which is injected in as solid a form as is possible to force from the syringe. This dressing remains in the nasal cavity until the next morning, and by its presence prevents bleeding, adhesions, and decomposition of secretions. It is best if the patient does not walk very much immediately after the injection, so as not to dislodge the paste. It becomes fixed in the exenterated ethmoidal area. In this connection it may be stated that there is positively no such blocking of the nasal cavity as to cause any retention, and, in fact, it has been proven that the bismuth paste dressing is an excellent drain, the drainage taking place between the nasal wall and the bismuth dressing. There is no need of removing the paste; most of it will run out or will be blown out, and what remains is absorbed. In the use of this method of dressing it has been found that practically no after-treatment is necessary.

Injection of Frontal Sinus.—Patient semi-reclining. Cocaine and adrenalin anesthesia to naso-frontal duct.

The cannula is passed through the naso-frontal duct, and, if the passage is large, some cotton is firmly packed about the introduced cannula. The syringe is then attached and the cavity injected to the sensation of distention. Usually one observes the paste escaping along the cannula. Patient should remain quiet for about ten minutes, and a small cotton tampon remains for another hour to insure the retention of the paste in the sinus.

Injection of Sphenoidal Sinus.—Position of patient—same as for injection of frontal sinus.

Whether or not the middle turbinated body is removed, the cannula is passed into the sinus and the cavity in-

jected until there is an escape of the paste along the cannula. A tampon is pressed against the opening for half an hour after injection to help the retention of the paste until it has become set. Should the natural opening be too small to pass the cannula, it should be enlarged, but care should be exercised not to make it too large, else the paste will escape. In case the opening is too large to begin with, or an operation has previously been performed which left the large opening, it is well to pack some cotton firmly about the cannula to prevent the escape of the paste.

(B.) RADICAL METHOD OR PERMANENT OBLITERATION OF ACCESSORY SINUSES WITH THE AID OF BISMUTH PASTE.

The ideal results aimed at in the permanent cure of chronic suppurative cavities, especially nasal accessory sinuses, is, of course, a return to the normal. This is, however, precluded on account of the pathological changes that have taken place in the mucous membrane lining these cavities. Heretofore—in fact, at the present time—it has been the practice of the majority of specialists to resort to operations of enlarging the normal outlets of the sinuses, or making artificial openings, eventually curetting the diseased mucous membranes, and subsequently irrigating them by all sorts of astringents and antiseptics. The results from such treatment are very unsatisfactory, and in the majority of instances the supuration continues.

As we can not expect the ideal result—namely, complete resolution—the next best result obtainable is unquestionably the radical obliteration, or exenteration, of the sinuses.

Frontal Sinus.—Killian has contributed a boon to humanity by his radical frontal sinus operation. While

the Killian frontal sinus operation cures a large percentage of cases of chronic suppuration of the frontal sinus, it has some disadvantages: first, it creates a considerable amount of external deformity, and it also takes some time before obliteration takes place; second, frequently reinfection of the operated frontal sinus occurs following an acute attack of rhinitis; third, there are quite a number of cases thus operated which do not become obliterated and continue to suppurate.

In order to obviate some of these difficulties, the aid of the bismuth paste is a marked advantage.

Technic in Frontal Sinus.

After opening the frontal sinus externally sufficient to inspect the entire cavity, one will remove every vestige of mucous membrane of the entire sinus. Upon the thoroughness of this procedure depends the success of the obliteration. A probe is then passed through the nasofrontal duct into the nasal cavity and the duct curetted of its mucous membrane, but not enlarged by any operation on the bone of this duct. The upper region of the nose is now firmly packed temporarily with tampon to prevent the easy escape of the paste while filling the sinus. The sinus is now thoroughly dried of its blood by packing it with gauze saturated with peroxide of hydrogen or adrenalin, and filled completely with No. 2 bismuth paste. (Fig. 79.) The periosteum and skin are sutured without any drain, and about a half an hour later, while the patient is still in the recumbent position, the nasal tampon is removed. Should the paste escape and suppuration again occur from the frontal sinus, then one will reinject the cavity by the nasal route, as described in the palliative method of treatment of chronic frontal sinus suppuration.

The **antrum of Highmore**, even after the most radical measures, such as the Denker or Jansen operations, remains a suppurative cavity because it communicates with the general nasal cavity, although retention is obviated by these methods. The ideal result (aside from return to the normal) is unquestionably complete obliteration.

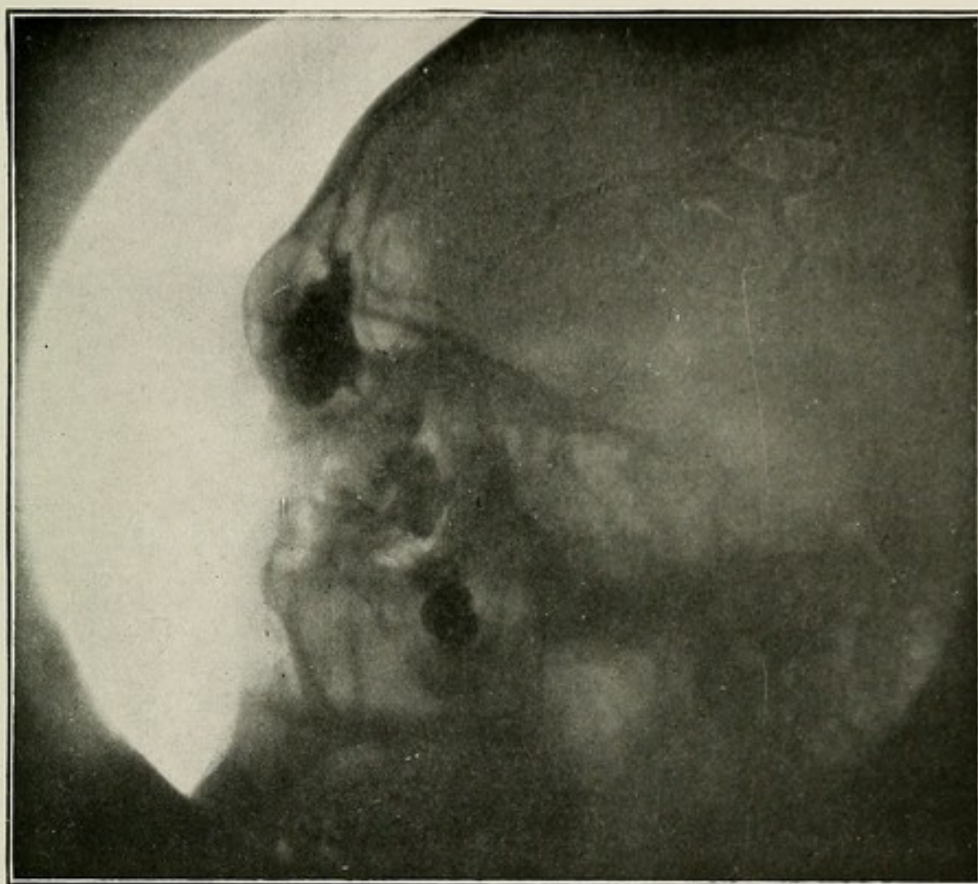

Fig. 79. Frontal sinus injected with bismuth paste No. 2 by nasal route. Portion of the bismuth paste in the ethmoid region and antrum.

tion, and to that end the aid of bismuth paste and certain technic in the operation are required.

Technic in Antrum of Highmore.

The most suitable cases for this mode of treatment are, of course, such as have had no great amount of operating done on the lateral wall of the nose or internal antral

wall, as any large communication into the nose prevents the retention of the paste within the cavity.

The usual opening into the antrum is made through the canine fossa, and as much as possible of the anterior and external wall of the antrum is removed. The mucous membrane is now very thoroughly removed by curet, great care being exercised in curetting the internal wall of the antrum, so as not to break into the nasal cavity. In some cases one can remove the bony part of this internal wall of the antrum, and then obliteration is much more rapid. The cavity is packed with peroxide or adrenalin gauze and the nasal cavity temporarily, but completely, tamponed. The packing is now removed from the antrum and the cavity filled either with bismuth paste No. 2 (Fig. 80) if the antrum is of small size, or, preferably, with packing of gauze strips which have been thoroughly impregnated with bismuth paste No. 1. The ends of these gauze strips are allowed to come out through the gingivo-labial margin after most of the incision has been sutured. The nasal tampon is removed, and the patient remains lying on the side of the operated antrum to prevent the paste from escaping. The subsequent treatment of the cavity filled with gauze strips is to remove them in about two or three days, and either refill with similar strips or inject bismuth paste No. 2. (It should be remembered that the paste is to be used in fairly cold or semi-solid consistency in this procedure.) After the injection with the paste, drainage is discontinued and the wound allowed to close.

Recently Citelli¹ has made several experiments on animals in filling their frontal sinuses with the Moorhof-Mosetig plug, and subsequently tried it on some chronic suppurative sinuses in the human, with the idea of oblit-

¹ Citelli: International Centralblatt der Ohrenheilkunde, April, 1910.

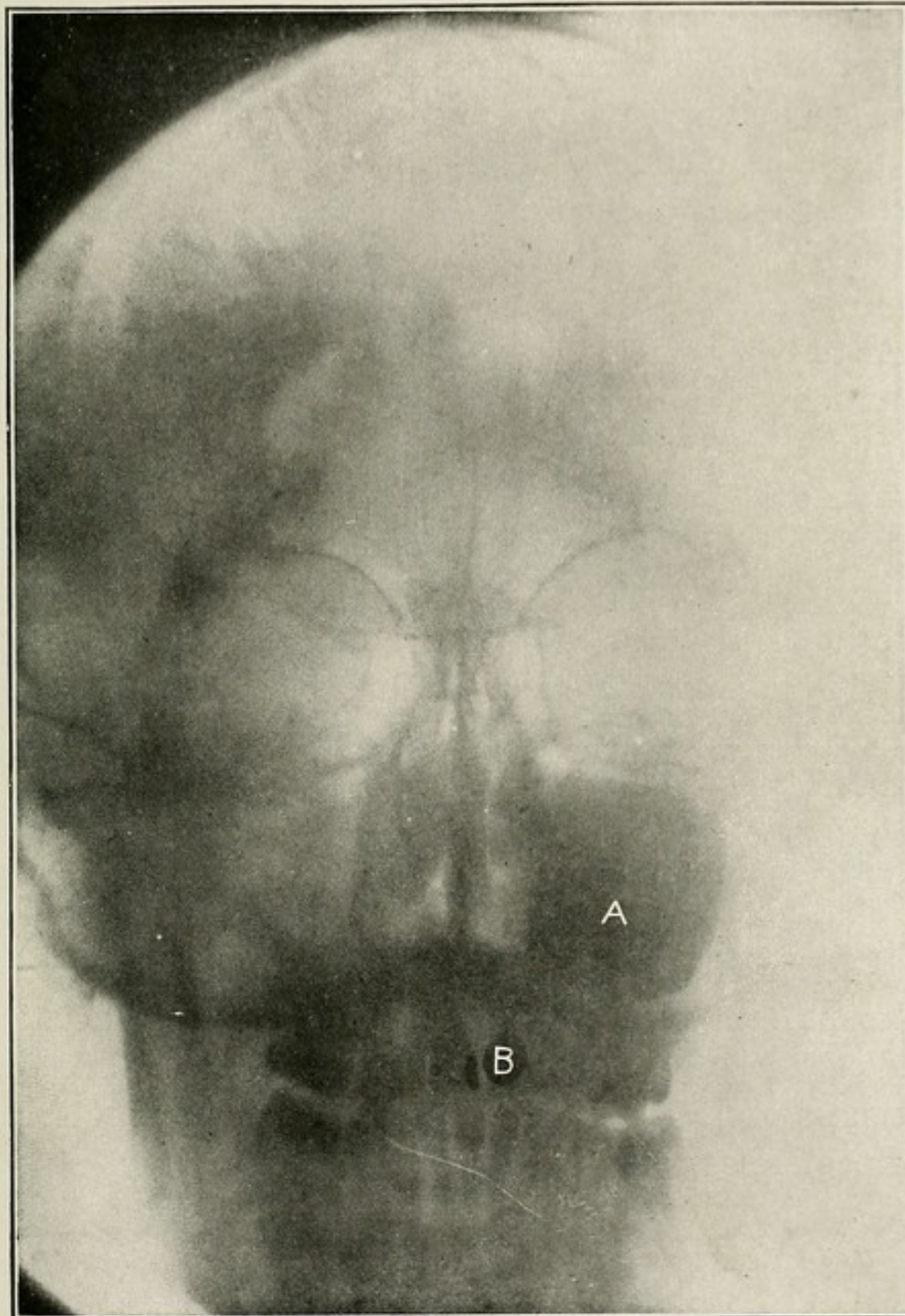


Fig. 80. Radical operation on antrum and filled with paste No. 2. A, antrum filled; B, gold tooth filling.

erating these cavities. No definite data are given as to results.

In chronic suppuration of the **sphenoid sinuses** the best one can do is to remove as much of the anterior wall as possible and curet the diseased mucous membrane. The obliteration of this cavity is impossible, as the retention of the paste is difficult, but it can be materially reduced in size by packing it with gauze impregnated with bismuth paste.

As to the **ethmoid labyrinth**, when chronic suppuration is present within it, there is no question that the complete exenteration of every cell insures the best chances for a permanent cure. Unfortunately this is not possible in the majority of instances on account of the anatomical conditions. When, however, during this complete exenteration at the time of operation an injection of bismuth paste is made as a primary dressing (as described in the previous chapter), the chances for a radical cure are increased.

Use of Paste in the Nose for Conditions Other than Sinus Disease.

1. After actual cautery of the inferior turbinated body.—To prevent too great a reaction, synechia formation, and easy loosening of the eschar, the cavity is filled with bismuth paste No. 2 and repeated until the cauterized surface is healed.

2. Post-operative dressing to the inferior turbinectomy.—In cases where one did not require splint or gauze packing, the cavity should be filled with bismuth paste No. 2. Should packing be necessary, then the impregnation of the material with bismuth paste No. 1 furnishes an excellent dressing.

3. Septal ulcer.—To control the scabbing and bleed-

ing, the filling of the anterior half of the nasal cavity with bismuth paste No. 2 once or twice daily gives the best results. Quite profuse bleeding can be checked by this method in these cases.

Use of Paste in Diseases of the Ear and Mastoid Process.

1. Chronic suppurative otitis media treated with bismuth paste.—The olive tip syringe, which has running through it a small rubber tubing, is fitted snugly into the external auditory meatus. The rubber tubing is pushed in as far as possible, and the cavity injected with bismuth paste No. 1. The purpose of the rubber tubing is to allow the air to escape, so that the paste can follow through the perforation into the middle ear and beyond it. A firm cotton plug is placed into the meatus to retain the paste. Examinations of mastoids in which the middle ear was thus injected just before a radical mastoid operation, as well as experiments on the cadaver, show that the paste never passed beyond the beginning of the aditus ad antrum. The attic as well as the entire middle ear are filled with the paste. The results from this treatment are no more satisfactory than any other local measure. One fact, however, is noticeable—that the odor is markedly reduced or completely destroyed. It has occurred that during the injections patients complained of dizziness, which, however, promptly disappeared as soon as one removed the tip of the syringe. Very small perforations or labyrinth symptoms are contraindications for the injection.

2. Otitis externa eczematosa.—The entire canal is injected with bismuth paste No. 1 in the same manner as in injecting the middle ear.

3. Primary dressing in simple mastoid operation by bismuth paste.—In cases of acute mastoiditis in which,

after complete exenteration of all the cells, the walls of the mastoid process remain intact—that is, where no exposure of either the lateral sinus, dura, horizontal semicircular canal, or facial nerve occurred—the following technic is employed:

Dry the cavity of all the blood and insert a few strands of silkworm gut within the antrum. Allow these to come out through a separate small incision below and posterior to the main one. Fill the cavity with bismuth paste No. 2 to the level of its margins, and unite the entire incision by carefully bringing the periosteum over the paste. The silkworm drain is removed as soon as the discharge ceases from the auditory canal, and the little stab wound is allowed to close. Radiographs taken six weeks after operation show about one-half of the paste absorbed, and two or three months later will show only traces of bismuth. The cavity has been replaced by much denser structure, as shown by comparing radiographs of mastoid cavities treated by allowing the cavity to fill with blood clot. Most of the cases treated by the above-mentioned method have healed in from one to three weeks, with practically no deformity.

4. Secondary dressing of the simple mastoid operation with bismuth paste.—In cases where one has allowed considerable drainage through the main incision the following technic is employed:

After a week or ten days' drainage with rubber tube, gauze, etc., and when the discharge from the external auditory canal has ceased, the remaining granulating cavity is filled with bismuth paste No. 2, a gauze pad placed over it to retain it, and bandage applied. The injection is repeated every other day until the cavity is obliterated. Frequently, especially if the cavity is not too large, the wound will close after one or two injec-

tions. The paste should never be wiped or washed out, nor is the cavity previous to the injection cleansed or washed in any way.

In injecting these mastoid cavities it may occur that some paste finds its way into the middle ear, and even into the external auditory canal and pharynx through the Eustachian tube. This is not desirable, and need not occur if one does not use too much pressure in filling the cavity, or if one just fills it with a small spatula. In the cases in which it occurred it caused no untoward symptoms. If the wound does not heal after these injections, one may conclude that there is necrosis or an unexplored infected area somewhere within the mastoid or middle ear. In such cases reoperation is usually necessary.

5. Secondary dressing of a radical mastoid operation.
—After about one or two weeks of drainage by gauze, one will substitute it by the filling of the exenterated cavity with bismuth paste No. 2. This is simpler for the physician and very much easier for the patient, and hastens the granulation and healing of the exposed bone. The granulations grow very rapidly and the injection must be at times interrupted, the granulations cauterized, and the cavity again packed with gauze, so as to obtain rapid epidermization.

CHAPTER XVI.

THE USE OF BISMUTH PASTE IN DENTISTRY.

The teeth and alveolar process are subject to various chronic suppurative conditions, which the dentist is called upon to treat. Pyorrhea alveolaris, for instance, is a prevalent condition, especially of old people, and its etiology and treatment have created for years an animated discussion among dentists.

Alveolar abscesses and the resulting sinuses occur so frequently in the practice of the dentist that a new and promising remedy, such as bismuth paste, will no doubt be welcome to them.

Since the favorable results obtained with the paste in general surgery are not confined to tubercular sinuses, and especially satisfactory results are obtained in chronic suppuration of pyogenic origin or in mixed infections, there is no reason why the dentist can not obtain equally good results in chronic suppurative conditions of the jaws, where the anatomical conditions are even more favorable.

The first tests of its efficacy in dentistry were made by Dr. Rudolph Beck, who presented his first report in January, 1909, and published in the *Dental Review*.

His second report of his experience of more than two years with this method was read before the Illinois State Dental Society in May, 1910, the substance of which, with a collective report from about fifty dental surgeons of this country and Europe who have applied the method in their practice, comprise this chapter.

The following is an abstract of Dr. Rudolph Beck's report:

Pyorrhea Alveolaris.

Forty-four severe cases, of which 27 were men and 17 women, ages ranging from 25 to 68 years, were selected for a test, and in all of them the bismuth treatment was carried out in the same manner. The results were as follows:

Twelve cases were entirely cured with from one to twenty injections; 15 were only temporarily benefited; 17 were refractory, no improvement having been attained after sufficient trial.

An analytical study of these 44 cases helped in determining the cause of failure. Every case in which a complete cure was effected was free from any constitutional disorder, the affection being of only local origin, while in the cases in which the treatment failed there existed in nearly every instance some general constitutional disorder responsible for the pyorrhea. This fact corroborates our former assertion that whenever a constitutional disease—such as diabetes, nephritis, or faulty elimination—is associated with pyorrhea, the treatment of these constitutional diseases must either precede or accompany the local treatment if any results are to be expected. This fact also explains why only temporary benefit was obtained in the 15 cases which responded so slowly to treatment.

Example 1. Pyorrhea of Local Origin.—Victor B., aged 45, clerk, applied for treatment in February, 1909. First molar and one bicuspid were absent. Salivary deposits and profuse suppuration from the sockets of the incisors and molars were present.

The first treatment was as follows: Without any special preparation of the teeth, the blunt-pointed, flexible silver needle of a metal syringe, filled with bismuth paste No. 2, was inserted into the deepest part of the pus pockets, and then by gentle and steady pressure the

paste was forced into all recesses. The same procedure was followed in all sockets affected. The second treatment, two days later, consisted in removing the deposits around the necks and roots of the teeth, and again the paste was injected in the same manner. The discharge changed from a purulent to a muco-serous character. After each subsequent injection at intervals of two to three days the condition of the gingiva gradually improved, and after three weeks' treatment the case was entirely cured, there being no recurrence up to this date—one year.

The deposits were intentionally left undisturbed before the first injection because the scaling is apt to cause some laceration and thus produce new channels for infection in the already infected area. By injecting the paste previous to the scaling of deposits, this danger is obviated because the paste is known to possess a bactericidal action, and by its contact with diseased tissues for a time it places them in a condition favorable for the removal of the deposits.

Frequency of Injections.

The number and frequency of the injections are determined by the response to treatment in each individual case. If, after the first injection, the character of the discharge changes to a serous or a sero-purulent consistency, it is best to wait from three to four days before repeating the injections. In exceptional cases the pus discharge will entirely cease after the second injection, and the case remain cured, but, as a rule, it requires from five to fifteen injections to produce good results. If the discharge persists, the injections may be repeated daily for a period of thirty days, and if after that time no improvement has followed it may be assumed that the pyorrhea is due to some constitutional disease. The treatment is then discontinued. Before attempting to treat a case, it is well to inquire whether a constitutional disease—such as diabetes, rheumatism, or gout—exists, as in these cases the bismuth paste treatment will not be effective.

The combination of bismuth subnitrate and vaselin forms an excellent means of treatment for pyorrhea alveolaris. Since the bismuth is insoluble, it is not dis-

solved by the saliva, and the vaselin, being a semi-solid vehicle, keeps the bismuth in contact with the diseased tissues long enough to produce a curative effect.

Chronic Alveolar Abscess and Fistula.

A series of 58 cases of sinuses of the mouth were treated with bismuth paste by Dr. R. Beck. The period of the existence varied from six months to fifteen years. Some of the cases were previously treated by other methods, but their persistence speaks for the inefficiency of the former methods employed.

The treatment with bismuth paste produced the following results:

Six cases closed after the first injection; 3 cases after two injections; 2 cases after three injections; 4 cases after five injections; 6 cases after from five to ten injections, all without operative interference; 9 cases closed after more than ten injections, also without operative interference.

This is a total of 30 out of 58 cases in which the injection of paste produced a closure of the existing sinuses, without surgical aid, after other methods had failed in the majority of them.

The remaining 28 cases required surgical interference as follows: in 8 cases curettage of the sinuses or excision of the apices of the roots was necessary, and all cases closed thereafter.

In 16 cases even curettage failed to produce a cessation of the discharge, and thus the removal of the tooth involved was necessary for cure. While in the 16 cases the paste was used, it is fair to say that the sinus in them might have also closed after the extraction of the teeth without the use of the paste.

The remaining 3 cases had fistulous tracts not com-

municating with any tooth, and their origin was unknown. One case required operative interference, while the other 2 cases healed by means of the injection alone. It is obvious that the percentage of cures by this simple and painless method is much larger than by any means previously employed. Many of these cases have been treated for years by very competent and painstaking dental practitioners without any results, and were cured by means of the injection of the paste within a short time.

A suitable syringe is also of vital importance. The best is a metal syringe, with a flexible, blunt-pointed silver nozzle, so that the conical tip may be adjusted to the opening of the sinus, and enough pressure exerted to allow the paste to reach all the crevices before the overflow would return around the sides of the nozzle.

For the injection of sinuses, formula No. 1 is generally used, but at times, where it is desirable to retain the paste for a longer period, it may be of advantage to use formula No. 2, which, on account of the addition of wax and paraffin, becomes a little stiffer on cooling. It is not advisable, however, to allow large quantities of the paste, which contains paraffin, to remain permanently within a closed cavity on account of the irritating quality of the paraffin when retained for absorption.

The following case of chronic alveolar abscess, with a fistulous tract, serves as an illustration of this method of treatment:

Case 2. Chronic Alveolar Abscess with a Fistulous Tract.—Mrs. E. R., aged 61. Gives a history of developing about ten years ago an abscess above the second upper molar, which after rupture terminated in a chronic discharging sinus. The tooth was treated, the sinus closed, and the tooth then filled. Several months later the patient noticed a swelling on the buccal alveolar process. This proved to be a recurrence, and after the abscess ruptured pus kept on discharging for the

past year, with only occasional temporary closure. With this history she presented herself for treatment. Believing that this sinus originated in an imperfect root filling, I first removed the gutta-percha root filling, but found the canals dry and odorless. Thereupon I injected bismuth paste through the sinus opening to see if it would pass through the apical opening into the tooth, but it did not. The pulp chamber was then packed with cotton and the tooth sealed with gutta-percha. Two days later the packing was removed, but no pus was found, nor could any paste be forced into the tooth. I then enlarged the sinus opening by means of a sharp round bur and reinjected the sinus. Three days later another injection was made, after which the sinus closed, and has remained so up to date—one year. Permanent filling was then inserted.

At the present time he does not remove the fillings before injection, unless he is certain that an infected root is the cause of the sinus. The injection is made first, and if, after a reasonable length of time, the sinus shows no tendency to close, he seeks for the cause in the root canal.

To further illustrate the method of treating pyorrhea and sinuses of the mouth, I shall quote some typical cases from the report of Dr. Rudolph Beck:

Histories of Cases from Dr. Rudolph Beck's Series.

Case 4. Pyorrhea Alveolaris (Mild Case, Local Cause).—J. V., aged 52, merchant. Was treated by me for several years for pyorrhea alveolaris, with only temporary relief. In September, 1908, when I first began to experiment with bismuth paste, I decided to try it on this case. It required only five injections at intervals of four days to produce cessation of the discharge, and now, after two years, no recurrence has taken place. Result: cure.

Case 5. Pyorrhea Alveolaris (Severe Case, Local Cause).—J. R. B., aged 41, salesman. For more than a year has had a profuse pus discharge from the deep pockets of nearly all his badly neglected and many decayed teeth. Abundance of salivary and seruminous deposits were present. No treatment had been applied up to December, 1908, when I made the first injection of bismuth paste. A few days after this injection the deposits were removed, and injections repeated at three to four days' intervals for a period of six weeks. Improvement followed, but patient had to leave the city for two months. Upon his return the treatment was resumed, and after four months' treatment the discharge ceased. Decayed teeth were then filled, and up to this date not the slightest sign of recurrence has manifested itself. Result: cure.

Case 2. Double Alveolar Fistula.—Ed. M., aged 34, merchant. Presented himself in November, 1908, with two fistulous openings opposite the roots of the second upper molar. One opening was on the lingual and the other on the buccal surface. All the teeth on that side were sound and vital. An injection of bismuth paste was made, and the patient returned next day with severe pain in the right first upper molar. I exposed the pulp in this tooth, but found no pus. This indicated that the sinus did not originate in the first molar. A radiograph was taken, which clearly showed the tract of the sinus leading into the region of the root of this tooth, but not communicating with it. The

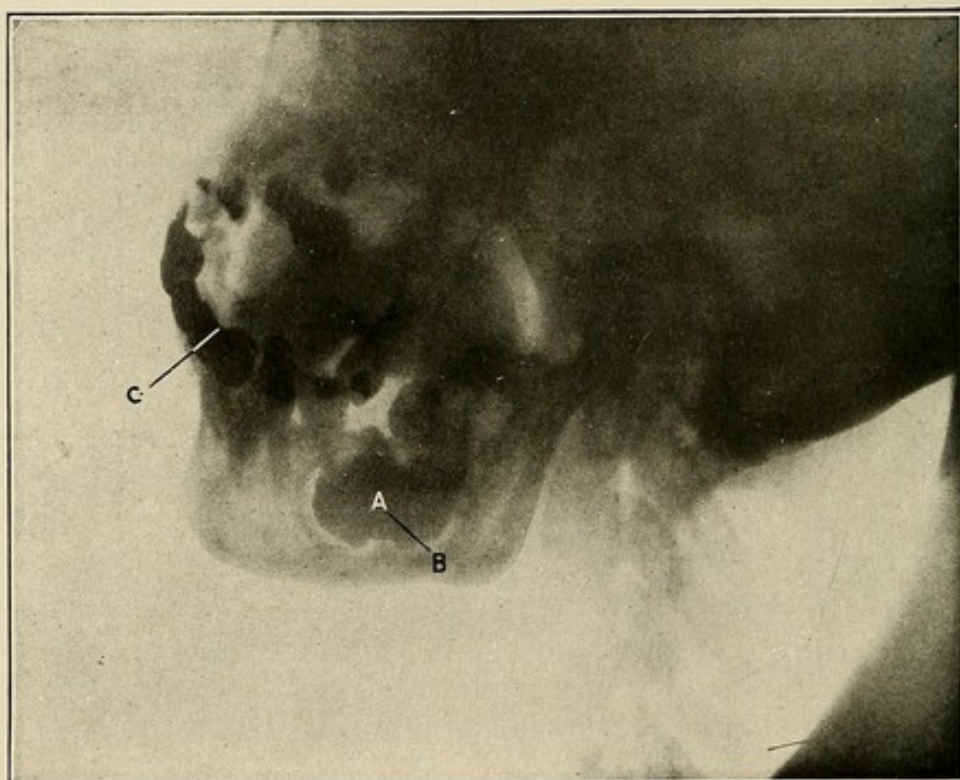


Fig. 81. Cyst of lower maxilla filled with bismuth paste. A, bismuth paste; B, light zone of granulations; C, gold crowns.

tooth was filled and injections continued. After four injections the buccal fistula closed, and two more injections sufficed to close the lingual. Six months later the lingual fistula reopened, but after two injections of paste closed again, and no recurrence has taken place since. Result: cure.

Cysts and Sinuses Following Fractures.


Another class of cases which sometimes come under the care of the dentist are sinuses of the jaws due to fractures or cysts. I desire to illustrate a case in radiograph

(Fig. 81), which shows a cyst in the lower maxilla. The cyst was opened and the cavity filled with bismuth paste, and the picture most graphically illustrates the contour of the bony cyst. Surrounding the borders of the injected paste we note a light zone, which represents the granulations lining this cavity. The darker margin of this light zone shows the osteitis which marks its boundaries.

The value of this diagnostic method must appeal to those who have had difficulty in estimating the size of these bone cysts.

Frequently the radiograph will show a sequestrum in the jaw, which, after removal, leaves a cavity which should be injected for therapeutic purposes.

While the introduction of the bismuth paste into dentistry is of recent origin, sufficient reports from some of the most prominent dental surgeons in the country indicate that its use also in dentistry will find many advocates.



REFERENCES.

- | | |
|-------------------------------------|---|
| Adami, 22 | Heitz, 51, 118 |
| Babcock, 147 | Herrick, 56 |
| Baer, 50, 51, 54, 58 | Herzog, 57 |
| Beck, Carl, 31, 78, 115, 174 | Hines, 51 |
| Beck, Emil G., 46, 49, 51, 188, 199 | Hoffa, 63 |
| Beck, Joseph C., 51, 199 | Hoffman, 183 |
| Beck, Rudolph, 171, 218, 221, 223 | |
| Bennecke, 183 | Kadjan, 136 |
| Bergeret, 188 | Kaufmann, 193 |
| Biesalsky, 21 | Kelly, 131 |
| Blanchard, 47, 49, 51, 54 | Killian, 209 |
| Bogardus, 51 | Koch, 60 |
| Bonney, 56 | Kocher, 88, 182 |
| Bouvier, 154 | König, 61, 80, 82, 88, 96, 97, 106, 155 |
| Boyer, 51, 118 | |
| Böhme, 183, 184, 185 | Lannelongue, 155 |
| Brauer, 114 | Larrey, 154 |
| Bruns, 45 | Lexer, 81 |
| | |
| Calot, 61, 154, 157 | Maasen, 187 |
| Collishon, 185 | Matsuoka, 194 |
| Coyon, 168 | Mayo, 49, 112, 113, 136 |
| Cuthbertson, 51, 133 | McGuire, 49, 136 |
| | Moore, 144 |
| Dahl, 38 | Morens, 118 |
| Dollinger, 51, 63 | Murphy, 112, 114, 144 |
| Don, 51, 54 | Mühlig, 182 |
| Dunning, 54 | Müller, 61 |
| Dupuytren, 154 | |
| | Nemanoff, 51, 136 |
| Eggenberger, 193 | Novak, 186 |
| Ely, 51 | |
| | Ochsner, 49, 51, 123, 136 |
| Favill, 143 | |
| Fiesenger, 168 | Pennington, 51, 126 |
| Follin, 155 | Peterson, 182 |
| Forlanini, 114 | |
| Friedrich, 61 | Reich, 193 |
| | Ridlon, 47, 49, 51, 54 |
| Gangolphe, 158 | Robitschek, 51 |
| Gehrmann, 57, 190 | Rosenbach, 51 |
| Gibney, 88 | Routenberg, 185 |
| Gütig, 186 | Ryerson, 54 |
| | |
| Halsted, 55 | Sandor, 51 |
| Hansel, 61 | Schober, 51 |
| Harnack, 188 | Schuler, 181 |
| Hartford, 142 | Steinmann, 51 |
| Hefter, 184 | Stern, 51 |

Taylor, 97

Verity, 190, 193

Vidakovich, 51, 137

Von Bardeleben, 181

Wilms, 193

Wood, 188

Zollinger, 51

INDEX.

A

- Abdominal fistula, post-operative, of pyogenic origin, 117
- operation, post-operative sinus following, 110
- Abscess as complication of spondylitis, 62
- at hip, originating in sacrum, 38
- bilateral psoas, 66
- cavity, bismuth subnitrate in, 188
- sinus formed by, 65
- cause of, 24
- chronic alveolar, 221
- cold, bismuth paste in treatment of, 154
- cause of, 25, 155
- danger of incising, 26
- hip joint, 162
- psoas, 161
- table of, cases treated, 165
- treatment, 157, 160
- kidney, sinus after, 123
- lung, 137, 146
- bismuth paste in aftertreatment of, 135
- multilocular, condition of, 151
- mistaken for rectal fistula, 124
- psas, cause of, 25
- subphrenic, following appendicitis, 40
- table of cold, cases treated, 165
- Accessory sinus, bismuth paste in, 199
- sinuses, suppuration of nose and, 204
- Action of bismuth paste as modifying substance, 167
- Acute nitrate poisoning, 181
- Adenitis, tuberculous, spondylitis mistaken for, 25
- Aid in diagnosis, 20
- in treatment, 20
- Alveolar abscess, chronic, 221
- fistula, chronic, 221
- Anatomical diagnosis, 28
- failure of bismuth paste due to incorrect, 125
- stereoradiograph as guide in, 31, 146

- Ankle joint, wrist affected same as, 106
- tuberculosis of, 103
- Antitoxins as protective factor, 22
- Antrum of Highmore, chronic suppuration of, 202
- injection of, 205
- technic in, 211
- Appendicitis, subphrenic abscess following, 40
- Application after cautery of inferior turbinated body, 214
- in septal ulcer, 214
- of bismuth paste, 29, 53
- rules for, 52
- Arthritis, pyogenic, 69, 79
- tuberculous, 69, 82
- Aspiration and injection of modifying fluids, 158
- Atrophic rhinitis, 202
- Avoidance of bismuth intoxication, 195

B

- Bacteriolysins as protective factor, 22
- Bilateral knee joint tuberculosis, 98
- psoas abscess, 66
- Bismuth intoxication, 193
- avoidance of, 195
- Bismuth paste, action of, as modifying substance, 159, 167
- application of, 29, 53
- as diagnostic aid, 135
- as therapeutic agent, 135
- bronchial tree injected with, 153
- causes of failure of, 171, 172
- chemotactic action of, 58, 168
- contraindication of, 172
- discovery of curative effects of, 44
- displaces probe, 130
- effect of, on tubercle bacilli, 56
- failure of, due to faulty technic, 125
- due to incorrect anatomical diagnosis, 125
- first test of, 44
- formula No. 1 of, 28

- Bismuth paste—cont'd.
 formula No. 2 of, 44
 in accessory sinus, 199
 in aftertreatment of lung abscess, 135
 in chronic disease of mastoid process, 199
 in chronic suppurative disease of ears, 199
 in chronic suppurative disease of nose, 199
 in dentistry, 171, 218
 in disease of ear, 215
 in disease of mastoid process, 215
 in empyema, 46
 in fecal fistula, 132
 in nose for other disease than sinus, 214
 in pyorrhea alveolaris, 171
 in sinus of ear, 171
 in sinus of mouth, 171
 in sinus of nose, 171
 in treatment of cold abscess, 154
 in veterinary cases, 171
 limitation of, 171
 in peritoneal cavity, 115
 mechanical action of, 58
 not cause of nitrate poisoning, 189
 preparation of, 28
 reliability of, 33
 reveals diagnostic errors, 35, 124
 rules for application of, 52
 therapeutic action of, 54
 therapeutic effects of, 44
 treatment, cases suitable for, 53
 of empyema, 135
 palliative method of, 205
 radical method of, 209
- Bismuth poisoning, 180
 due to dusting power, 182
 prevention of, 180, 196, 198
 symptoms of, 181
- Bismuth subnitrate, effect of, on animals, 184
 effect of x-rays on, 59
 in abscess cavities, 188
 in empyema, 188
 in sinus, 188
 nitrite poisoning due to, 183, 186
 nontoxicity of, 181
- Bismuth treatment, indication for, 177
- Bone disease of foot, sinus from, 102
 formation, framework for, 203
- Bronchial tree injected with bismuth paste, 153
- C
- Calot's mixture, formula for, 158
 Calculi, cystic kidney with, 119
 Cases cited—abscess at hip, originating in sacrum, 38
 bilateral knee joint tuberculosis, 98
 bilateral psoas abscess without destruction of vertebræ, 66
 bismuth paste not cause of nitrite poisoning, 189
 bismuth poisoning due to dusting powder, 182, 183
 chronic alveolar abscess with fistulous tract, 222
 cold hip joint abscess, 162
 cold psoas abscess, 161
 cystic kidney with calculi, 119
 double alveolar fistula, 223
 effect of bismuth paste on tubercle bacilli, 56
 empyema, 135, 142
 empyema after Estlander operation, 177
 empyema of infant, 144
 empyema of spontaneous rupture, 140
 fecal fistula, 132
 first test of bismuth paste, 44
 foreign body cause of failure, 173, 174
 hip joint disease, sixteen years' duration, 89
 hip joint disease, six years' duration, 91
 knee joint tuberculosis, 100, 102
 large sequestrum of ulna, 174
 lung abscess, 146
 mild pyorrhea alveolaris, 223
 nephrectomy, 121
 nitrite poisoning due to bismuth subnitrate, 183, 186
 nontubercular osteomyelitis of humerus, 71
 osteomyelitis of femur treated for hip joint disease, 37
 post-operative abdominal fistula of pyogenic origin, 117
 prevention of bismuth poisoning, 196
 pyorrhea alveolaris, 219
 rectal fistula, 124
 rectal fistula originating in the pelvis, 129
 re-expansion of lung, 138

- Cases cited—cont'd.
 severe pyorrhea alveolaris, 223
 simple empyema, 140
 sinus following tuberculous peritonitis, 111, 115
 sinus from dermoid cyst, 128
 sinus from pyogenic osteomyelitis of the femur, 95
 spondylitis of tenth dorsal, with supraclavicular and lumbar sinuses, 63
 spondylitis, sixteen years' duration, 64
 subphrenic abscess following appendicitis, 40
 tuberculosis in os calcis, 105
 tuberculosis of elbow with multiple cold abscess, 163
 tuberculosis of kidney, 122
 tuberculosis of sacrum mistaken for hip joint disease, 39
 tuberculosis of sternum mistaken for tuberculosis of ribs, 109
 tuberculous ankle, ten years' duration, 103
 tuberculous kidney, 119
 tuberculous peritonitis, 115
 unsuspected renal sinus, 41
 value of radiograph in diagnosis, 31
- Cases suitable for bismuth paste treatment, 53
 treated, table of, 47, 48, 49, 50, 51
- Cause of abscess, 24
 of cold abscess, 25, 155
 of empyema, 24
 of failure, faulty technic, 176
 of failure, foreign body, 173, 175
 of failure, sequestrum, 174
 of failure, unexplained, 177
 of failure of bismuth paste, 171, 172
 of fistula, 26, 130
 of methemoglobinemia, 187
 of psoas abscess, 25
 of sinus, 24, 26
 of sequestrum, 71
 of suppuration, 24
- Cautery, application after, of inferior turbinated body, 214
- Cavity after Estlander operation, 140
- Chemotactic action of bismuth paste, 58, 168
- Chest cases, technic in, 137
 x-ray in, 137
- Chronic alveolar abscess, 221
 fistula, 221
 lacunar tonsillitis, 202
 suppuration of antrum of Highmore, 202
 suppuration of middle ear, 202
 suppurations, table of cases of, about head and neck, 200
- Clinical course of joint tuberculosis, 84
- Coccyx, dermoid cyst of, mistaken for rectal fistula, 128
- Cold abscess, bismuth paste in treatment of, 154
 cases treated, table of, 165
 cause of, 25, 155
 danger of incising, 26
 treatment of, 157, 160
- hip joint abscess, 162
 psoas abscess, 161
- Colored fluids, unreliability of, 32
- Contraindication of bismuth paste, 172
- Curative effects of bismuth paste, discovery of, 44
- Cyst, dermoid, of coccyx mistaken for rectal fistula, 128
 of sacrum mistaken for rectal fistula, 128
 sinus of jaw due to, 224
- Cystic kidney with calculi, 119
- D
- Deficiency in lime salts, 104
- Deformity as complication of spondylitis, 62
 of spine in spondylitis, 64
- Dentistry, bismuth paste in, 171, 218
- Dermoid cyst of coccyx mistaken for rectal fistula, 128
 of sacrum mistaken for rectal fistula, 128
- Diagnosis, aid in, 20
 anatomical, 28
 failure of bismuth paste due to incorrect, 125
 stereoradiograph as guide in, 31, 146
 value of radiograph in, 31
- Diagnostic aid, bismuth paste as, 135
 errors, bismuth paste reveals, 35, 124
- Diffuse tuberculous ostitis, 81
- Discovery of curative effects of bismuth paste, 44
- Dressing, post-operative, in inferior turbinectomy, 214

Dressing—cont'd.

- primary, following submucous resection, 202
- in radical mastoid operation, 203
- in simple mastoid operation, 215
- secondary, in radical mastoid operation, 203, 217
- in simple mastoid operation, 203, 216

Dusting powder, bismuth poisoning due to, 182

E

- Ear, bismuth paste in chronic suppurative disease of, 199
- in disease of, 215
- in sinus of, 171
- chronic suppuration of middle, 202
- instruments for, 206
- Effect of bismuth paste on tubercle bacilli, 56
- of bismuth subnitrate on animals, 184
- of x-rays on bismuth subnitrate, 59
- on vaselin, 59
- Elbow joint, sinus from tuberculosis of, 105
- tuberculosis of, 163
- Empyema, 135, 136, 137, 142
- after Estlander operation, 177
- bismuth paste in, 46
- treatment of, 135
- bismuth subnitrate in, 188
- cause of, 24
- of infant, 144
- of spontaneous rupture, 140
- simple, 140
- tuberculous, 144
- Errors, bismuth paste reveals diagnostic, 35, 124
- Estlander operation, cavity after, 140
- empyema after, 177
- Ethmoidal labyrinth, injection of, 205
- technic of, 214
- Ethmoid suppuration, 202

F

- Failure, causes of, of bismuth paste, 171, 172
- faulty technic cause of, 176
- foreign body cause of, 173, 174
- of bismuth paste due to faulty technic, 125

Failure—cont'd.

- of bismuth paste due to incorrect anatomical diagnosis, 125
- sequestrum cause of, 174
- unexplained cause of, 177
- Faulty technic cause of failure, 176
- Fecal fistula, 132
- bismuth paste in, 132
- treatment of, 133
- Femur, sinus from pyogenic osteomyelitis of the, 93
- First test of bismuth paste, 44
- Fistula as complication of spondylitis, 62
- cause of, 26, 130
- chronic alveolar, 221
- fecal, 132
- bismuth paste in, 132
- treatment of, 133
- in horses, 171
- post-operative abdominal, of pyogenic origin, 117
- rectal, 124
- abscess mistaken for, 124
- dermoid cyst of coccyx mistaken for, 128
- originating in the pelvis, 129
- technic in, 126
- Fistulae sequelae of infectious processes, 21
- Fluids, modifying, aspiration and injection of, 158
- Foot, sinus from bone disease of, 102
- sinus from joint disease of, 102
- Foreign body cause of failure, 173, 174
- Formula for Calot's mixture, 158
- for Murphy's formalin mixture, 158
- No. 1 of bismuth paste, 28
- No. 2 of bismuth paste, 44
- Fracture, sinus of jaw due to, 224
- Framework for bone formation, 203
- Frontal sinus, injection of, 208
- operation, 209
- technic in, 210

G

- General consideration of sinuses, 21

H

- Head, table of cases of chronic suppurations about, 200
- Hemorrhage, intranasal, 203

- Hip, abscess at, originating in sacrum, 38
 joint abscess, cold, 162
 disease, 89, 91
 mortality in, 88
 osteomyelitis mistaken for, 37
 sinus following, 85
 tuberculosis of sacrum mistaken for, 39
 Horses, fistula in, 171
 Humerus, nontubercular osteomyelitis of, 71

I

- Incising, danger of, cold abscess, 26
 Indication for bismuth treatment, 177
 for surgical treatment, 22
 Infant, empyema of, 144
 Infectious processes, fistulæ sequelæ of, 21
 sinuses sequelæ of, 21
 Inferior turbinated body, application after cauterization of, 214
 turbinectomy, post-operative dressing in, 214
 Inflammation, osteoplastic, 71
 Injection in pyorrhea alveolaris, 220
 of antrum of Highmore, 205
 of ethmoidal labyrinth, 205
 of frontal sinus, 208
 of sphenoidal sinus, 208
 syringes for, 28
 technic of, 28
 Instruments for ear, 206
 for nose, 206
 for throat, 206
 Intoxication, bismuth, 193
 avoidance of, 195
 Intranasal hemorrhage, 203
 Introduction, 17

J

- Jaw, sinus of, due to cyst, 224
 due to fracture, 224
 Joint disease of foot, sinus from, 102
 treatment of sinus following, 69
 tuberculosis, clinical course of, 84

K

- Kidney abscess, sinus after, 123
 cystic, with calculi, 119

Kidney—cont'd.

- operation, post-operative sinus following, 110
 tuberculosis of, 122
 tuberculous, 119
 sinus from, 118
 Knee joint disease, primary seat of, 97
 tuberculosis, 100, 102
 bilateral, 98
 tuberculous, sinus resulting from, 95
 Kyphus resulting from tuberculous infection, 62

L

- Labyrinth, ethmoid, technic of, 214
 Lacunar tonsillitis, chronic, 202
 Lime salts, deficiency in, 104
 Limitation of bismuth paste, 171
 in peritoneal cavity, 115
 Limited value of peroxide of hydrogen, 33
 Lung abscess, 137, 146
 bismuth paste in aftertreatment of, 135
 multilocular condition of, 151
 negative pressure for re-expansion of, 138

M

- Mastoid operation, primary dressing in radical, 203
 primary dressing in simple, 215
 secondary dressing in radical, 203, 217
 secondary dressing in simple, 203, 216
 process, bismuth paste in chronic disease of, 199
 bismuth paste in disease of, 215
 Mechanical action of bismuth paste, 58
 Mental influence as resisting factor, 23
 Methemoglobinemia, cause of, 187
 Mixture, Calot's, formula for, 158
 Murphy's formalin, formula for, 158
 Modifying fluids, aspiration and injection of, 158
 substance, action of bismuth paste as, 159, 167
 Mortality in hip joint disease, 88
 Mouth, bismuth paste in sinus of, 171

- Multilocular condition of lung abscess, 151
 Murphy's formalin mixture, formula for, 158
- N
- Neck, table of cases of chronic suppurations about, 200
 Negative pressure for re-expansion of lung, 138
 Nephrectomy, 121
 Nitrite poisoning, acute, 181
 bismuth paste not cause of, 189
 due to bismuth subnitrate, 183, 186
 treatment of, 187
 Nontoxicity of bismuth subnitrate, 181
 Nontubercular osteomyelitis of humerus, 71
 Nontuberculous osteomyelitis, 69, 93
 Nose, bismuth paste in chronic suppurative disease of, 199
 in, for other disease than sinus, 214
 in sinus of, 171
 instruments for, 206
 suppuration of, and accessory sinuses, 204
- O
- Operation, empyema after Estlander, 177
 Estlander, cavity after, 140
 frontal sinus, 209
 post-operative sinus following abdominal, 110
 following kidney, 110
 radical mastoid, primary dressing in, 203
 secondary dressing in, 203, 217
 simple mastoid, primary dressing in, 215
 secondary dressing in, 203, 216
 Opsonins as protective factor, 22
 Os calcis, tuberculosis in, 105
 Osteomyelitis mistaken for hip joint disease, 37
 nontubercular, of humerus, 71
 nontuberculous, 69, 93
 pyogenic, 69
 sinus from, of the femur, 93
 treatment of sinus following, 69
 tuberculous, 69, 79
 Osteoplastic inflammation, 71
 Otitis, diffuse tuberculous, 81
 externa eczematosa, 203, 215
 media, suppurative, 215
- P
- Palliative method of bismuth paste treatment, 205
 Paralysis as complication of spondylitis, 62
 Pelvis, rectal fistula originating in the, 129
 Peritoneal cavity, limitation of bismuth paste in, 115
 Peritonitis, tuberculous, 115
 primary source of, 113
 sinus following, 110, 115
 surgical treatment in, 114
 Peroxide of hydrogen, limited value of, 33
 Phagocytosis as protective factor, 22
 Poisoning, acute nitrite, 181
 bismuth, 180
 due to dusting powder, 182
 prevention of, 180, 196, 198
 symptoms of, 181
 nitrite, bismuth paste not cause of, 189
 due to bismuth subnitrate, 183, 186
 treatment of, 187
 Post-operative abdominal fistula of pyogenic origin, 117
 dressing in inferior turbinec-tomy, 214
 sinus following abdominal operation, 110
 kidney operation, 110
 Powder, dusting, bismuth poisoning due to, 182
 Preparation of bismuth paste, 28
 Prevention of bismuth poisoning, 180, 196, 198
 Primary dressing following sub-mucous resection, 202
 in radical mastoid operation, 203
 in simple mastoid operation, 215
 seat of knee joint disease, 97
 source of tuberculous peritonitis, 113
 synovial tuberculosis, 80
 Probe, bismuth paste displaces, 130
 Protective factor, antitoxins as, 22
 bacteriolysins as, 22
 opsonins as, 22
 phagocytosis as, 22

- Psoas abscess, cause of, 25
cold, 161
Pyogenic arthritis, 69, 79
osteomyelitis, 69
of the femur, sinus from, 93
Pyorrhea alveolaris, 219
bismuth paste in, 171
injections in, 220

R

- Radical mastoid operation, primary dressing in, 203
secondary dressing in, 203, 217
method of bismuth paste treatment, 209
Radiographs, stereoscopic, in anatomical diagnosis, 31
Rectal fistula, 124
abscess mistaken for, 124
dermoid cyst of coccyx mistaken for, 128
originating in the pelvis, 129
technic in, 126
Re-expansion of lung, negative pressure for, 138
Reliability of bismuth paste, 33
Renal sinus, unsuspected, 41
Resection, primary dressing following submucous, 202
Resisting factor, mental influence as, 23
Rhinitis, atrophic, 202
Ribs, sinus from tuberculous, 107
tuberculosis of sternum mistaken for tuberculosis of, 109
Rice bodies, 82
Rules for application of bismuth paste, 52
Rupture, spontaneous, empyema of, 140

S

- Sacrum, abscess at hip originating in, 38
tuberculosis of, mistaken for hip joint disease, 39
Secondary dressing in radical mastoid operation, 203, 217
in simple mastoid operation, 203, 216
Septal ulcer, application in, 214
Sequestrum, cause of, 71
cause of failure, 174
of ulna, 174
tuberculous, 81
Simple empyema, 140
mastoid operation, primary dressing in, 215

- Simple mastoid operation—cont'd.
secondary dressing in, 203, 216
Sinus, accessory, bismuth paste in, 199
after kidney abscess, 123
bismuth paste in nose for other disease than, 214
bismuth subnitrate in, 188
cause of, 24, 26
due to spondylitis, treatment of, 60
following hip joint disease, 69
following joint disease, treatment of, 69
following osteomyelitis, treatment of, 69
following tuberculous peritonitis, 110, 115
formed by contraction of abscess cavity, 65
from bone disease of foot, 102
from joint disease of foot, 102
from pyogenic osteomyelitis of the femur, 93
from tuberculosis of elbow joint, 105
from tuberculous kidney, 118
from tuberculous ribs, 107
from tuberculous sternum, 107
frontal, injection of, 208
technic in, 210
in spondylitis of tenth dorsal, 63
of ear, bismuth paste in, 171
of jaw due to cyst, 224
due to fracture, 224
of mouth, bismuth paste in, 171
of nose, bismuth paste in, 171
post-operative, following abdominal operation, 110
following kidney operation, 110
resulting from tuberculous knee joint, 95
sphenoidal, injection of, 208
technic of, 214
unsuspected renal, 41
Sinuses from tuberculous coxitis, table of cases of, 86
general consideration of, 21
sequelæ of infectious processes, 21
Sphenoidal sinus, injection of, 208
technic of, 214
Spine, deformity of, in spondylitis, 64
Spondylitis a tuberculosis, 60
abscess as complication of, 62
deformity as complication of, 62

Spondylitis—cont'd.

- deformity of spine in, 64
- fistula as complication of, 62
- mistaken for tuberculous adenitis, 25
- of tenth dorsal, sinus in, 63
- paralysis as complication of, 62
- treatment of sinus due to, 60
- Spontaneous rupture, empyema of, 140
- Stereoradiograph as guide in anatomical diagnosis, 31, 146
- Sternum, sinus from tuberculous, 107
 - tuberculosis of, mistaken for tuberculosis of ribs, 109
- Submucous resection, primary dressing following, 202
- Subnitrate, bismuth, effect of, on animals, 184
 - in abscess cavities, 188
 - in empyema, 188
 - in sinus, 188
 - nitrite poisoning due to, 183, 186
 - nontoxicity of, 181
- Subphrenic abscess following appendicitis, 40
- Suppuration, cause of, 24
 - chronic, of antrum of Highmore, 202
 - of middle ear, 202
 - ethmoid, 202
 - of nose and accessory sinuses, 204
- Suppurations, chronic, table of cases of, about head and neck, 200
- Suppurative otitis media, 215
- Surgical treatment, indication for, 22
 - in tuberculous peritonitis, 114
- Symptoms of bismuth poisoning, 181
- Syringes for injection, 28

T

- Table of cases of chronic suppurations about head and neck, 200
 - of sinuses from tuberculous coxitis, 86
 - treated, 47, 48, 49, 50, 51
 - of cold abscess cases treated, 165
- Technic, faulty, cause of failure, 176
 - failure of bismuth paste due to faulty, 125
 - in antrum of Highmore, 211

Technic—cont'd.

- in chest cases, 137
- in frontal sinus, 210
- in rectal fistula, 126
- of ethmoid labyrinth, 214
- of injections, 28
- of sphenoid sinus, 214
- of therapeutic application, 44
- Therapeutic action of bismuth paste, 54
 - agent, bismuth paste as, 135
 - application, technic of, 44
 - effects of bismuth paste, 44
- Throat, instruments for, 206
- Tonsillitis, chronic lacunar, 202
- Treatment, aid in, 20
 - bismuth paste, of empyema, 135
 - of lung abscess, 135
 - palliative method of, 205
 - radical method of, 209
 - of cold abscess, 157, 160
 - bismuth paste in, 154
 - of fecal fistula, 133
 - of nitrite poisoning, 187
 - of sinus due to spondylitis, 60
 - of sinus following joint disease, 69
 - of sinus following osteomyelitis, 69
- Tubercle bacilli, effect of bismuth paste on, 56
- Tuberculosis, bilateral knee joint, 98
 - in os calcis, 105
 - of ankle, 103
 - of elbow, 163
 - of elbow joint, sinus from, 105
 - of kidney, 122
 - of ribs, tuberculosis of sternum mistaken for, 109
 - of sacrum mistaken for hip joint disease, 39
 - of sternum mistaken for tuberculosis of ribs, 109
 - primary synovial, 80
 - joint, clinical course of, 84
 - knee joint, 100, 102
 - spondylitis a, 60
- Tuberculous adenitis, spondylitis mistaken for, 25
 - arthritis, 69, 82
 - empyema, 144
 - infection, kyphus resulting from, 62
 - kidney, 119
 - sinus from, 118
 - knee joint, sinus resulting from, 95
 - osteomyelitis, 69, 71

Tuberculous—cont'd.

- ostitis, diffuse, 81
- peritonitis, 115
 - primary source of, 113
 - sinus following, 110, 115
 - surgical treatment in, 114
- ribs, sinus from, 107
- sequestrum, 81
- sternum, sinus from, 107
- Turbinectomy, inferior, post-operative dressing in, 214

U

- Ulcer, septal, application in, 214
- Ulna, sequestrum of, 174
- Unexplained cause of failure, 177
- Unreliability of colored fluids, 32
- Unsuspected renal sinus, 41

V


- Value of radiograph in diagnosis, 31
- Vaselin, effect of x-rays on, 59
- Veterinary cases, bismuth in, 171

W


- Wrist affected same as ankle joint, 106


X


- X-rays, effect of, on bismuth sub-nitrate, 59
 - on vaselin, 59
 - in chest cases, 137











COLUMBIA UNIVERSITY LIBRARIES (hsl.stx)
Rd 641 B38 C.2
Bismuth paste in chronic suppurations.



2002098318

RD641

B38

cop. 2

Beck

